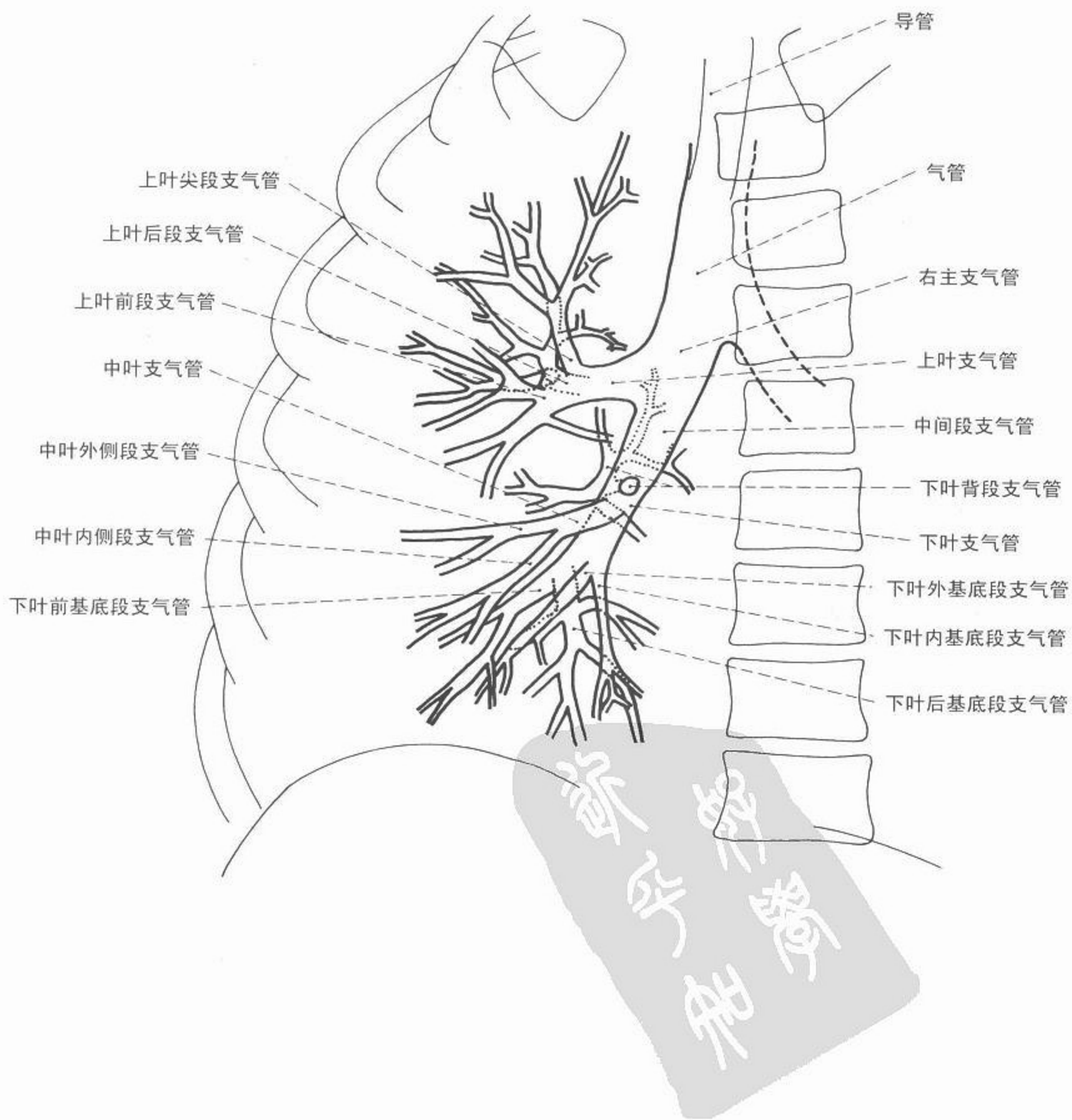




X线平片



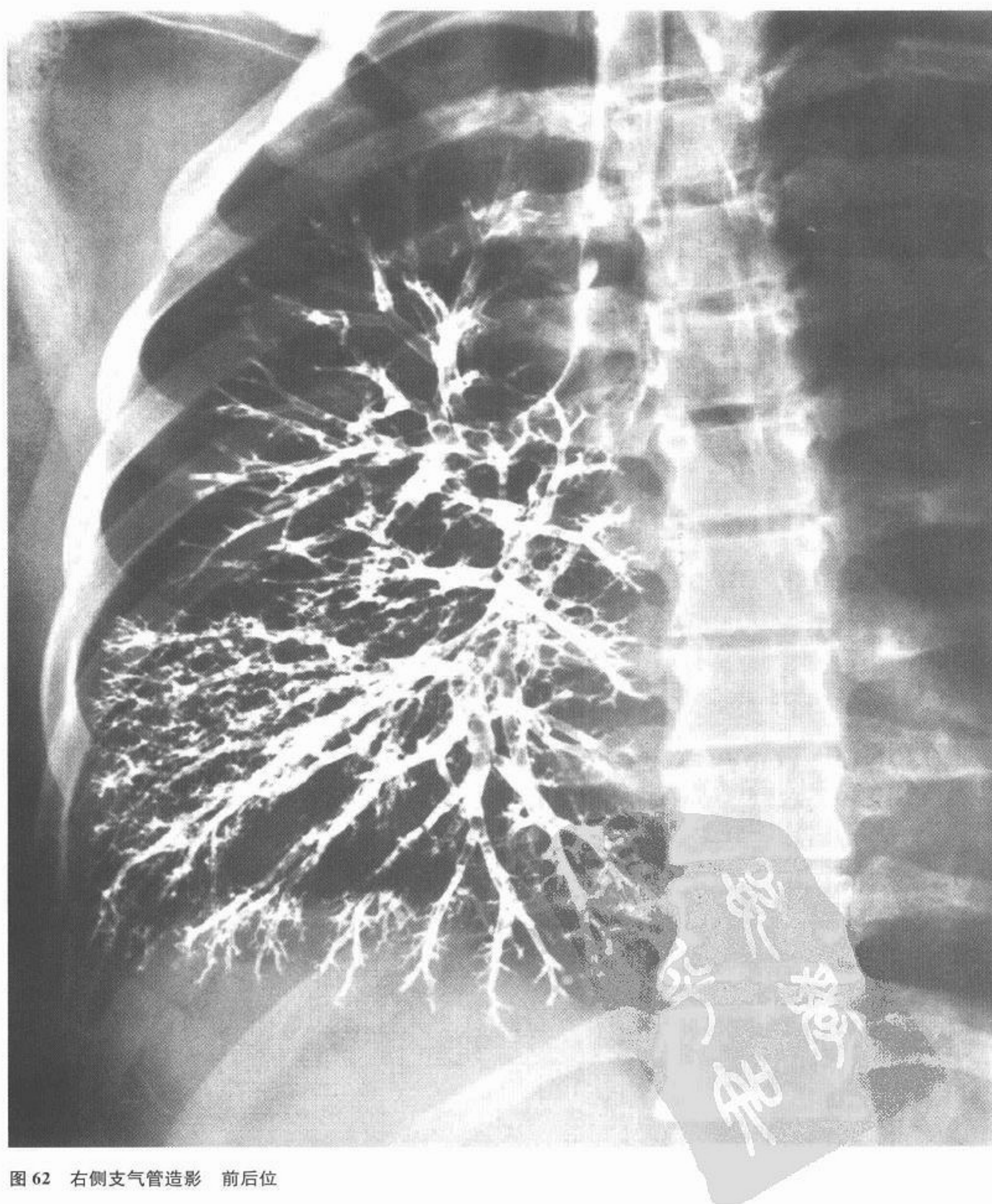
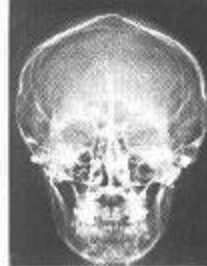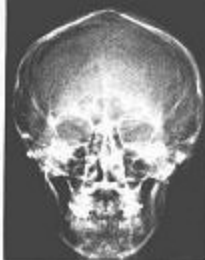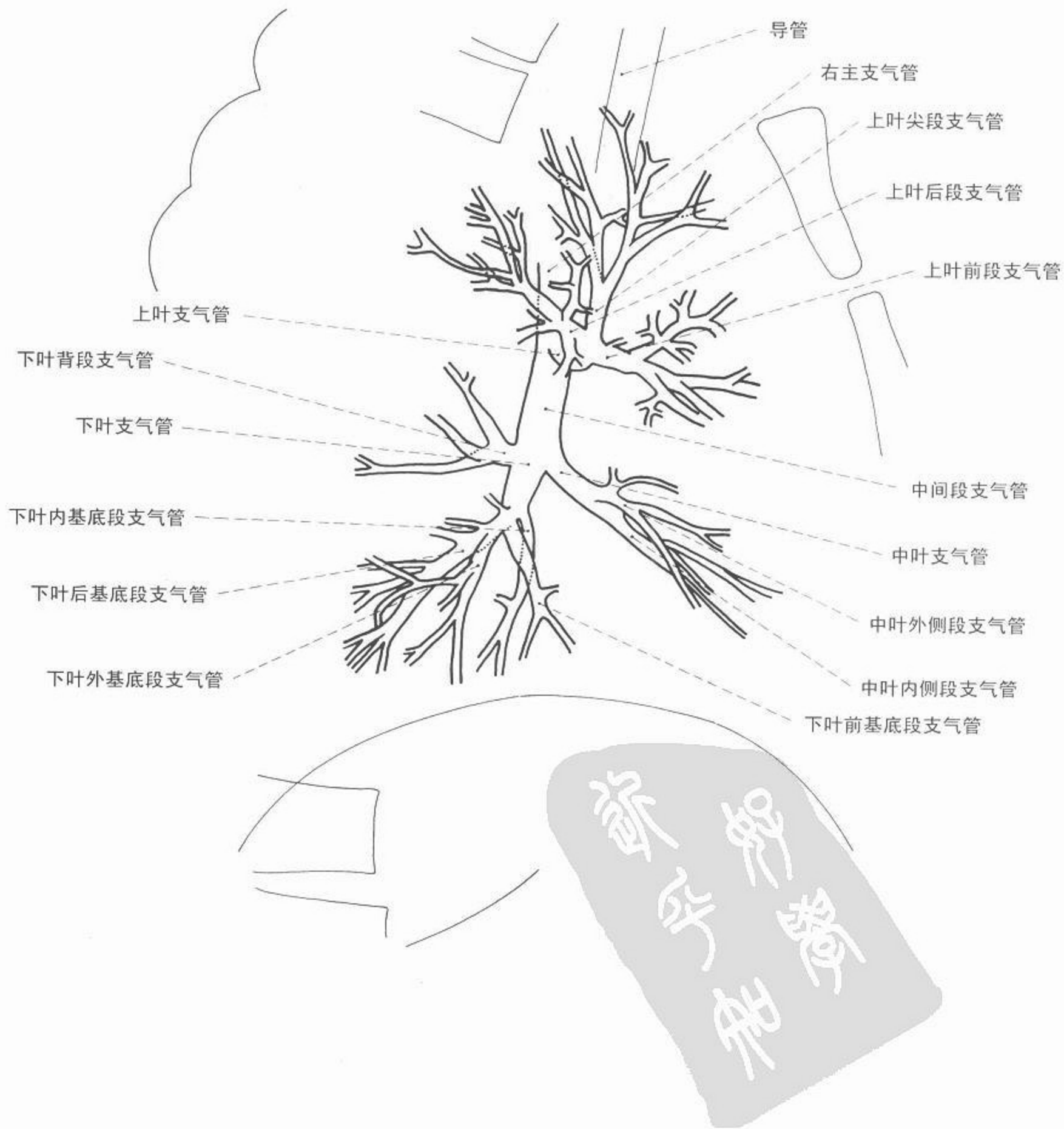


图 62 右侧支气管造影 前后位



X 线平片



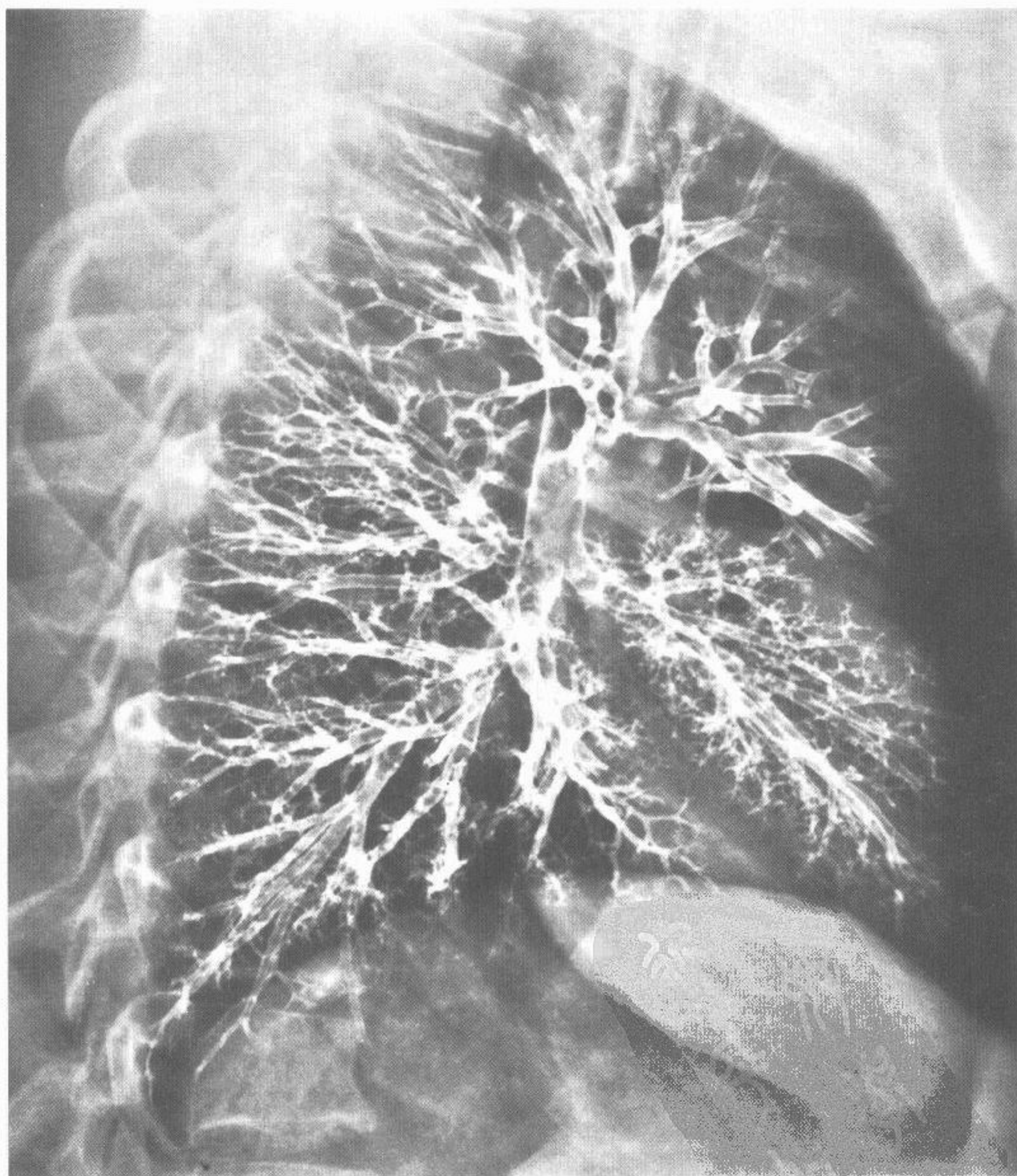
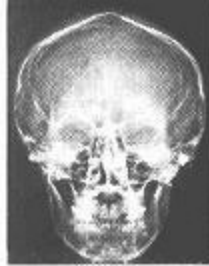
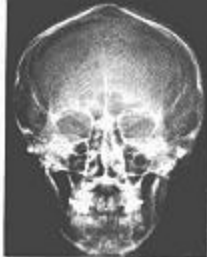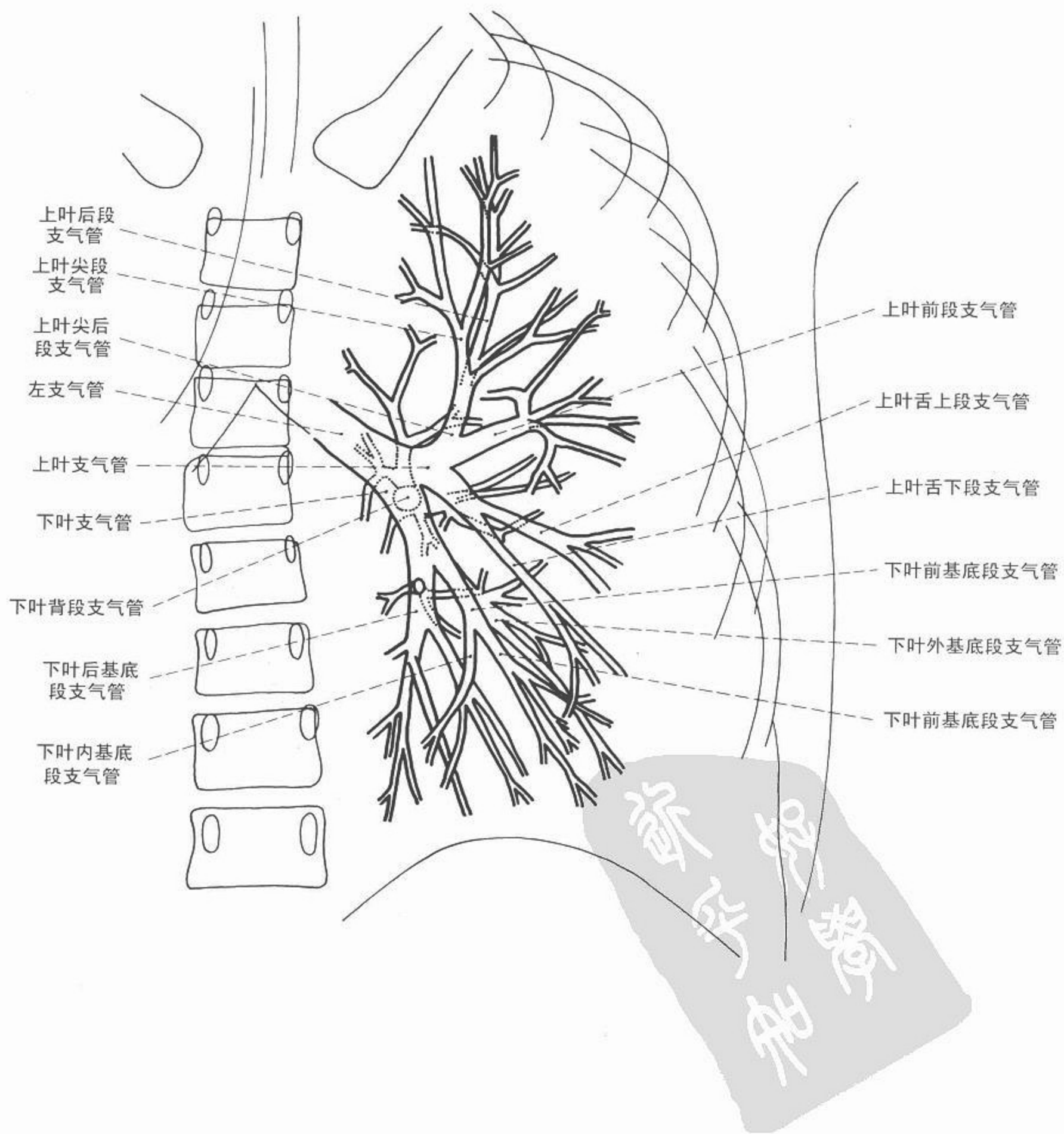


图 63 右侧支气管造影 侧位



X 线平片



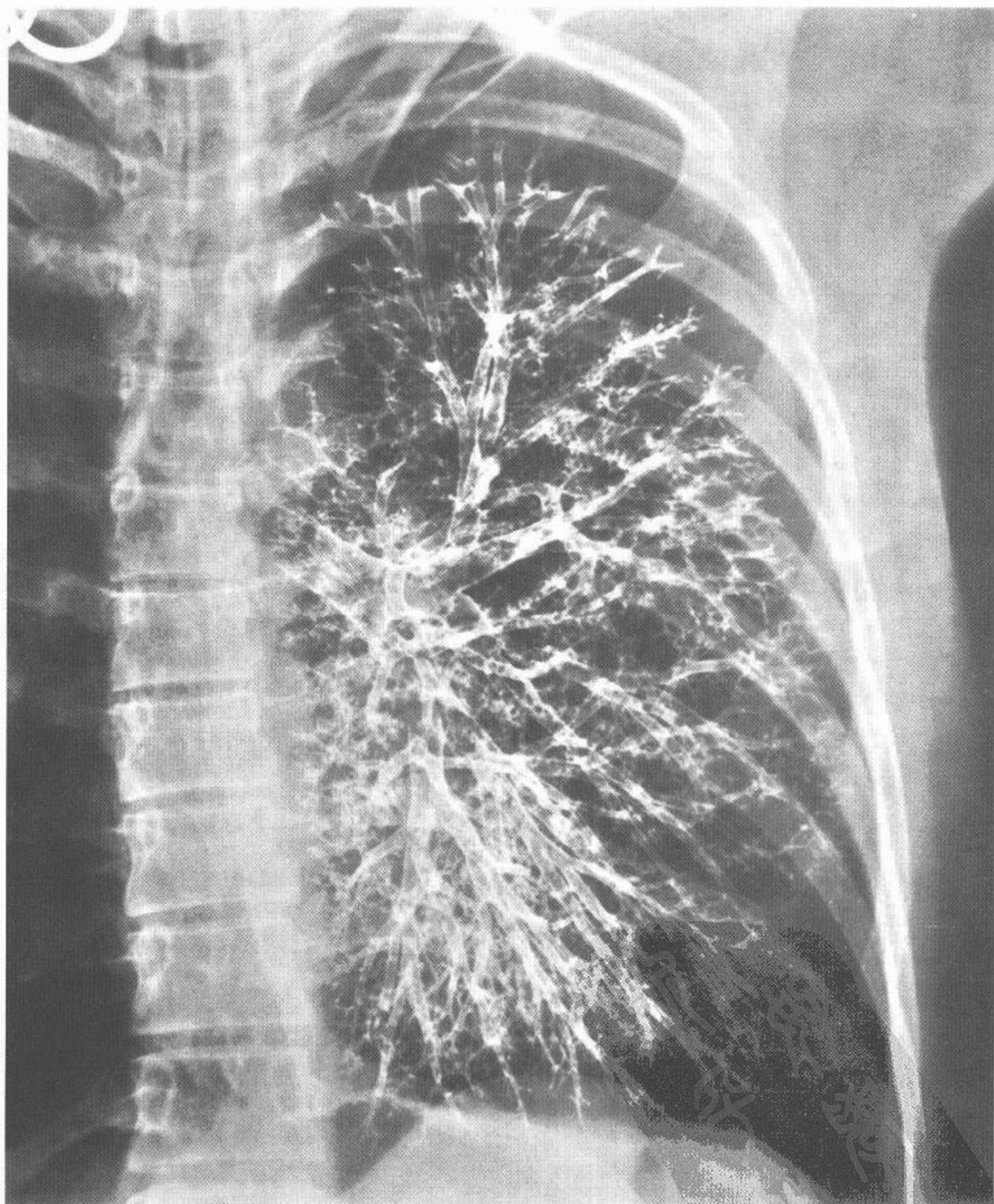
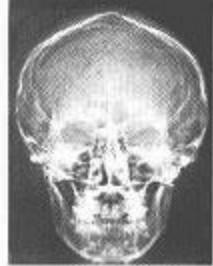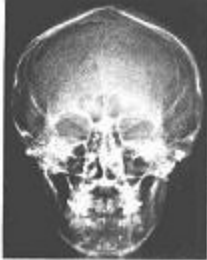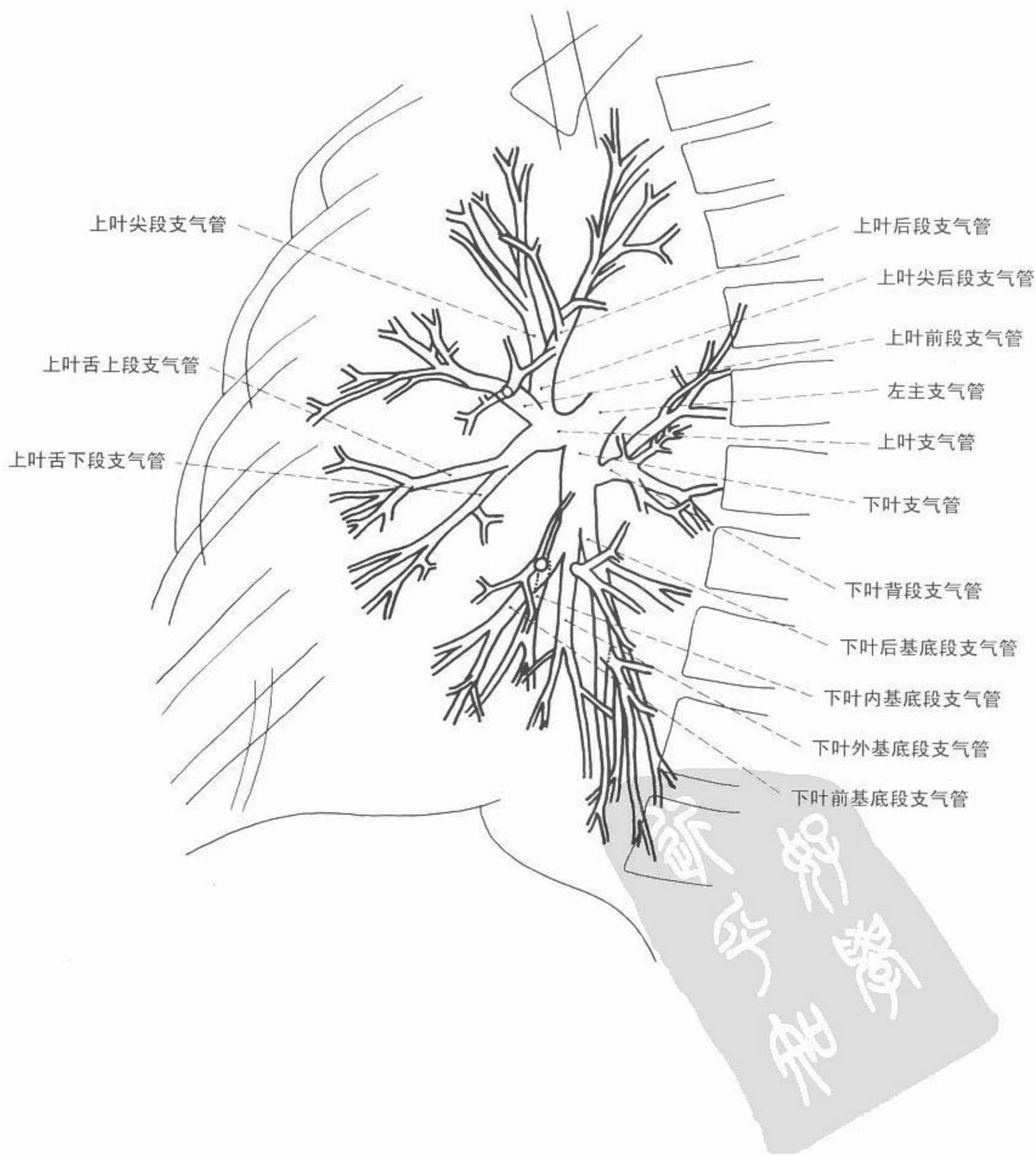


图 64 左侧支气管造影 前后位



X 线平片



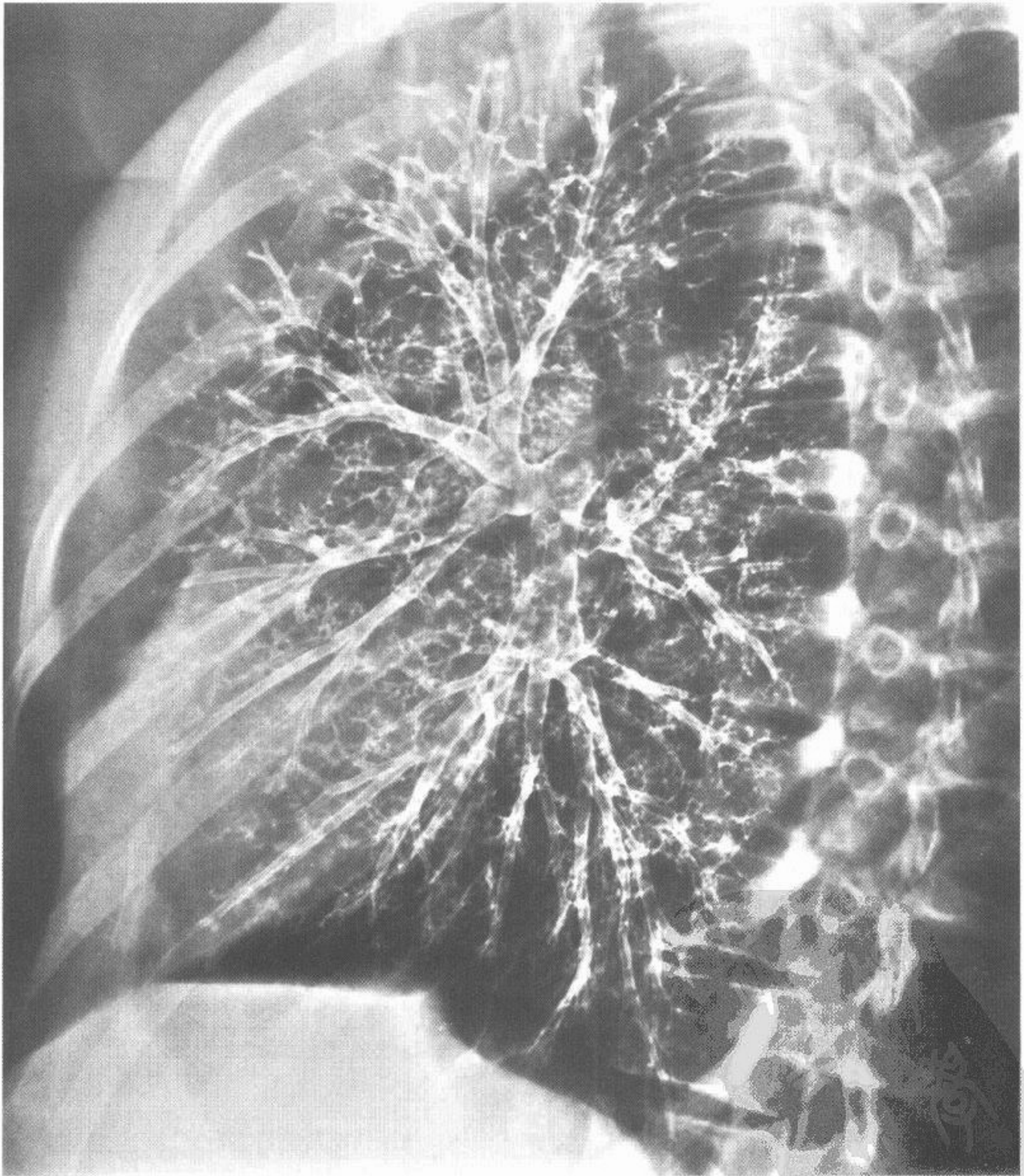
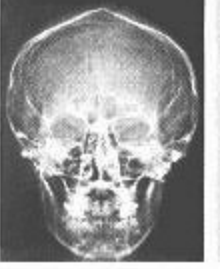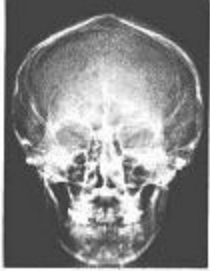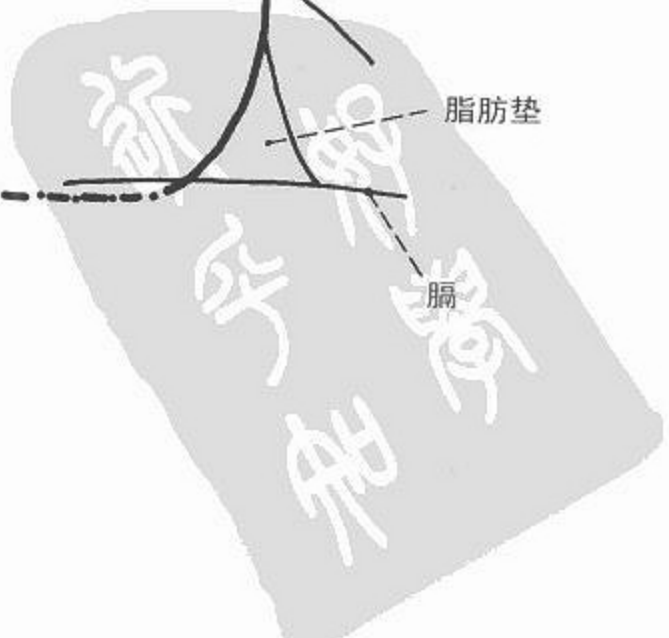
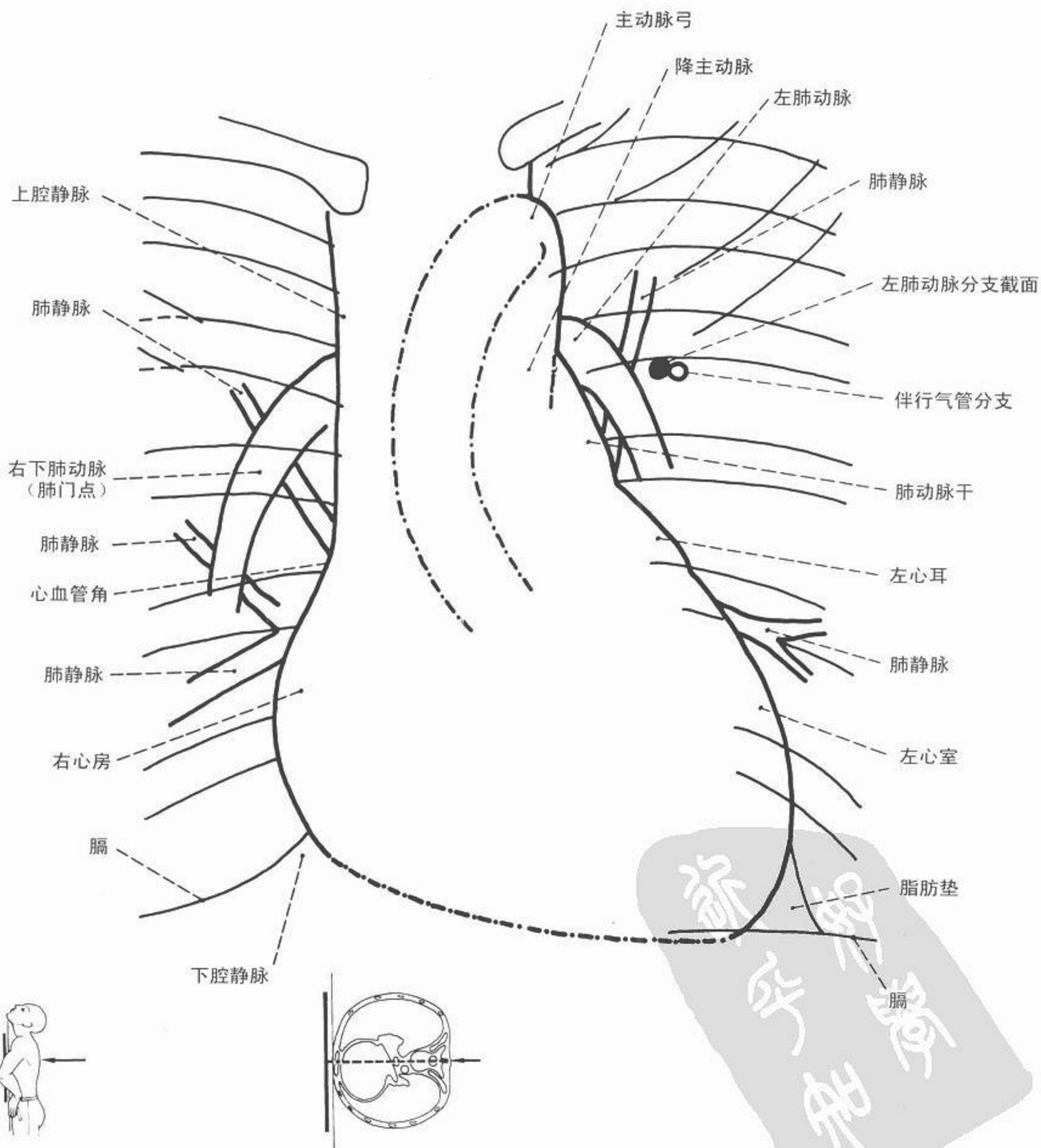


图 65 左侧支气管造影 侧位



X 线平片



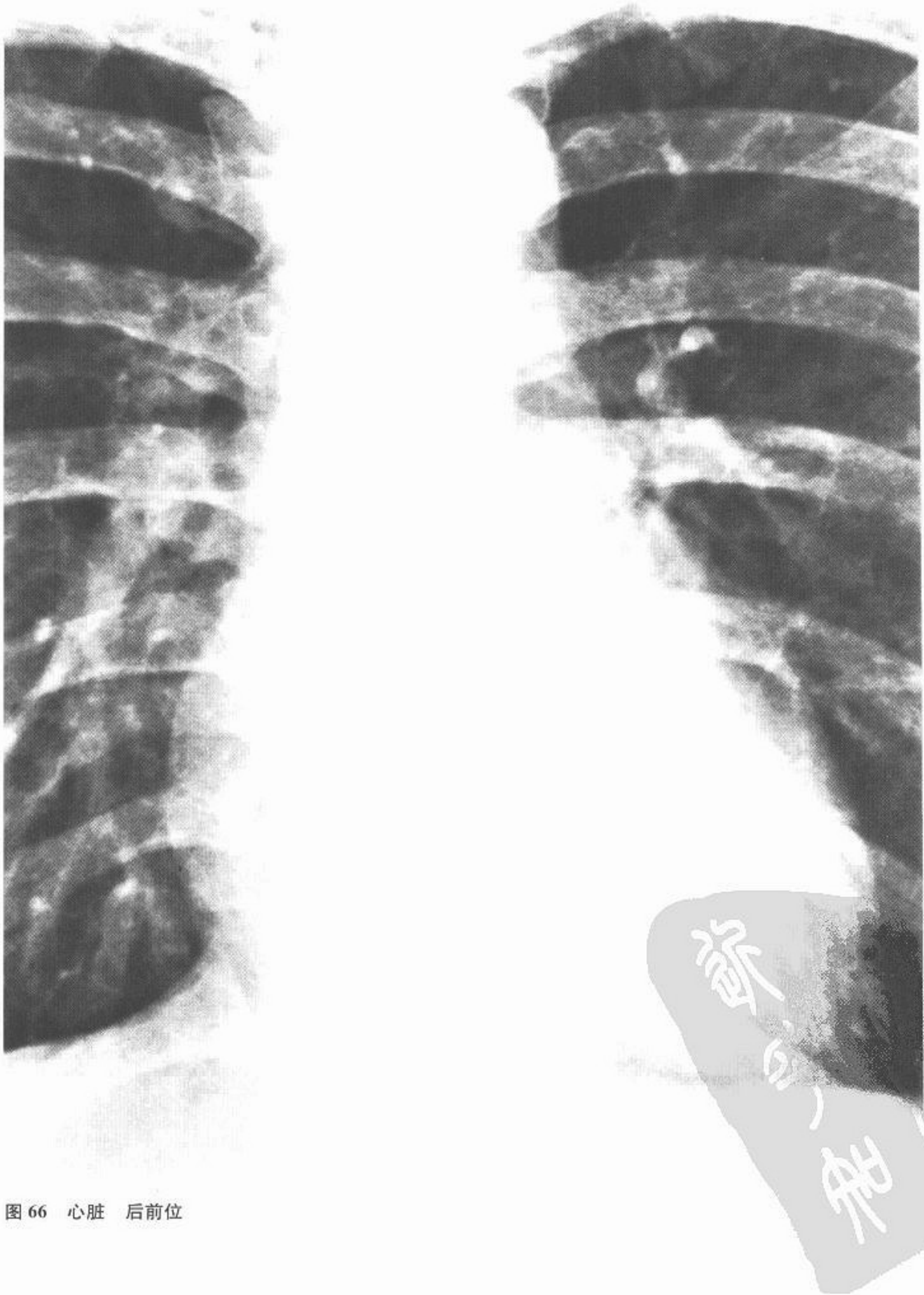
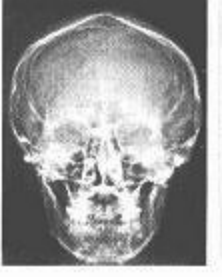
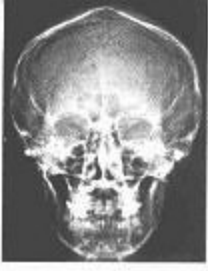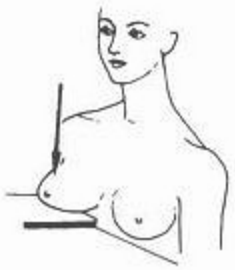
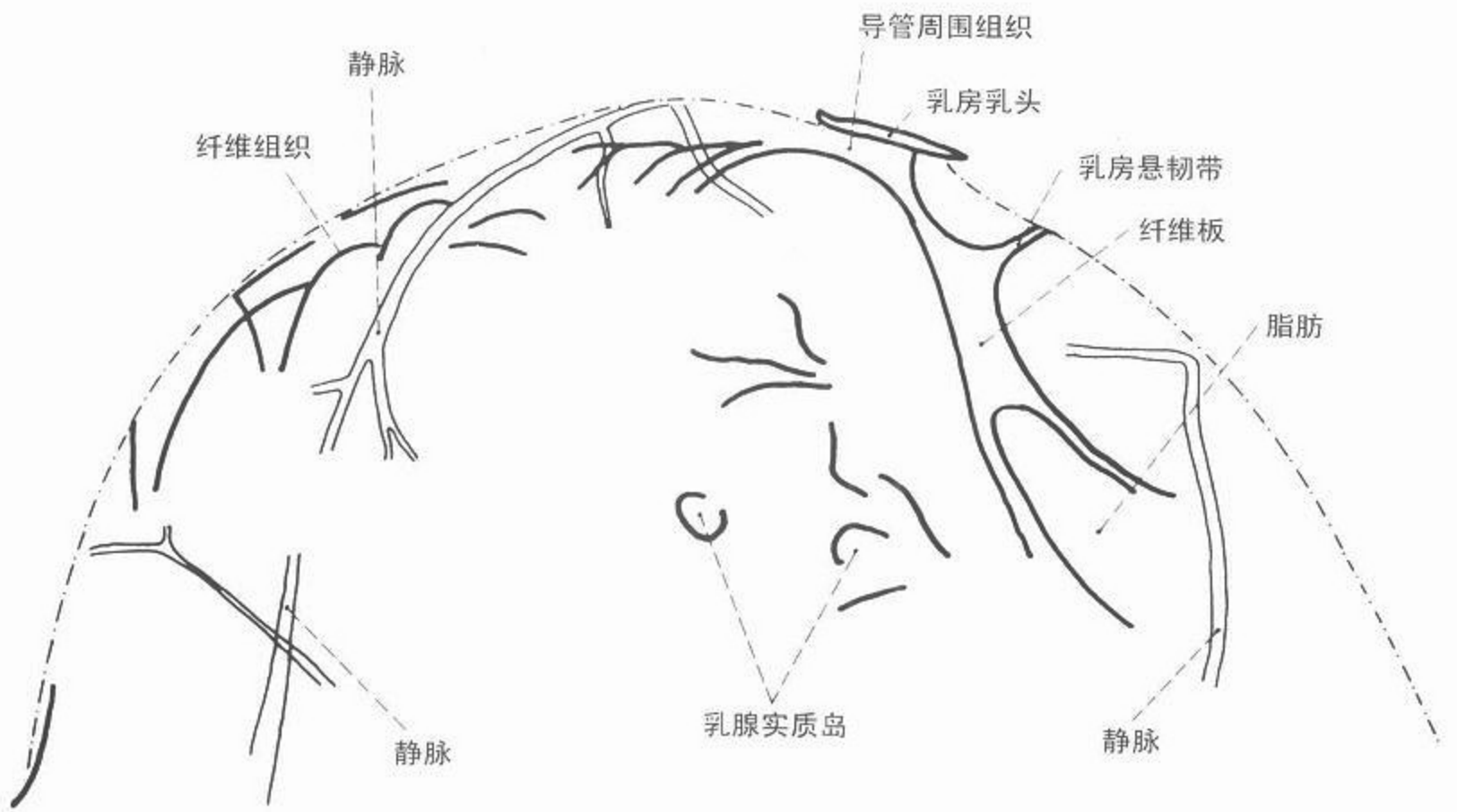


图 66 心脏 后前位



X 线平片



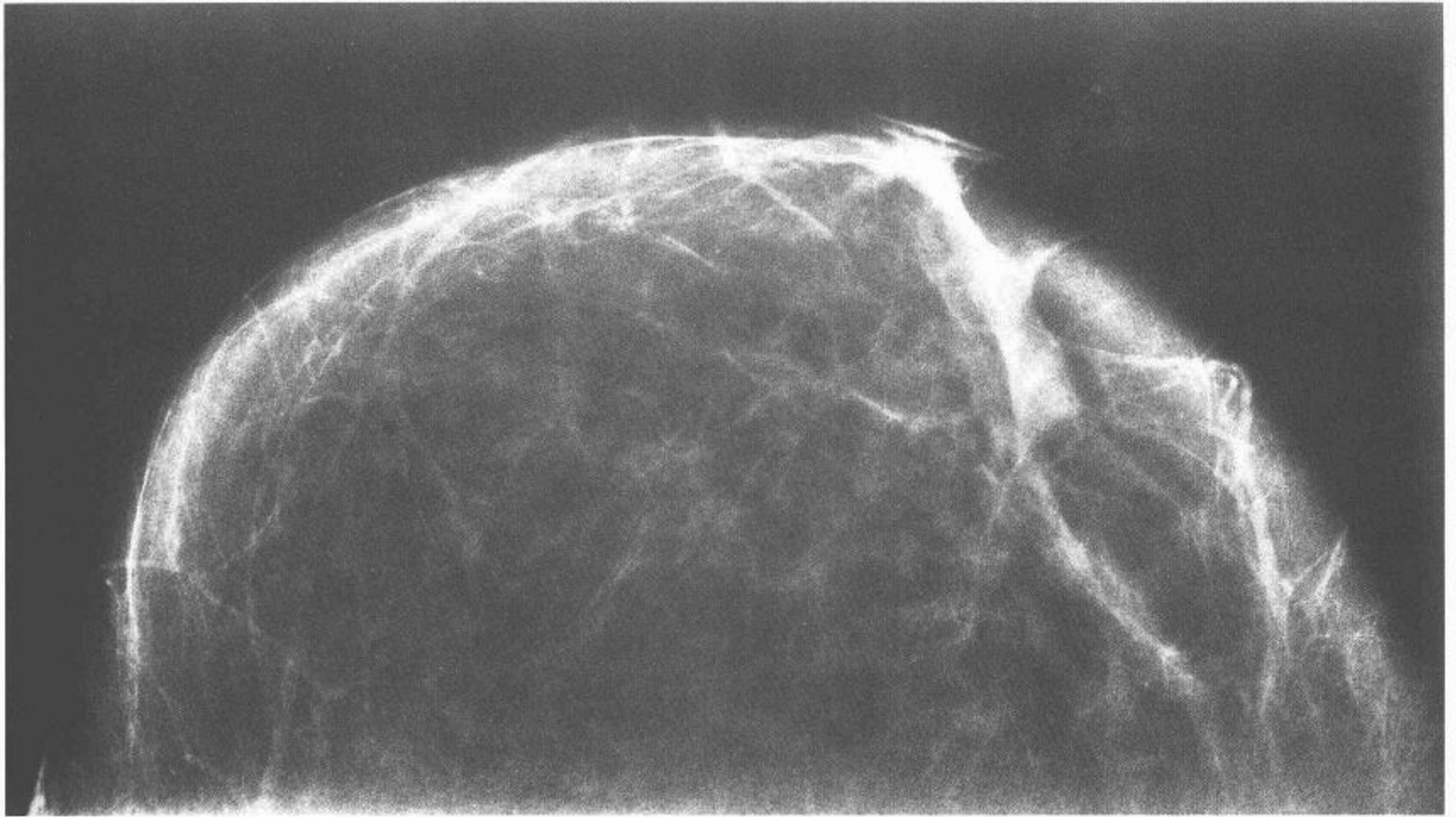
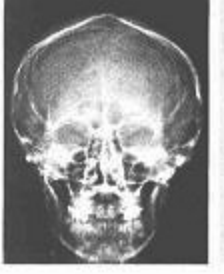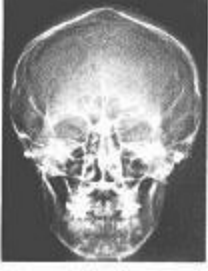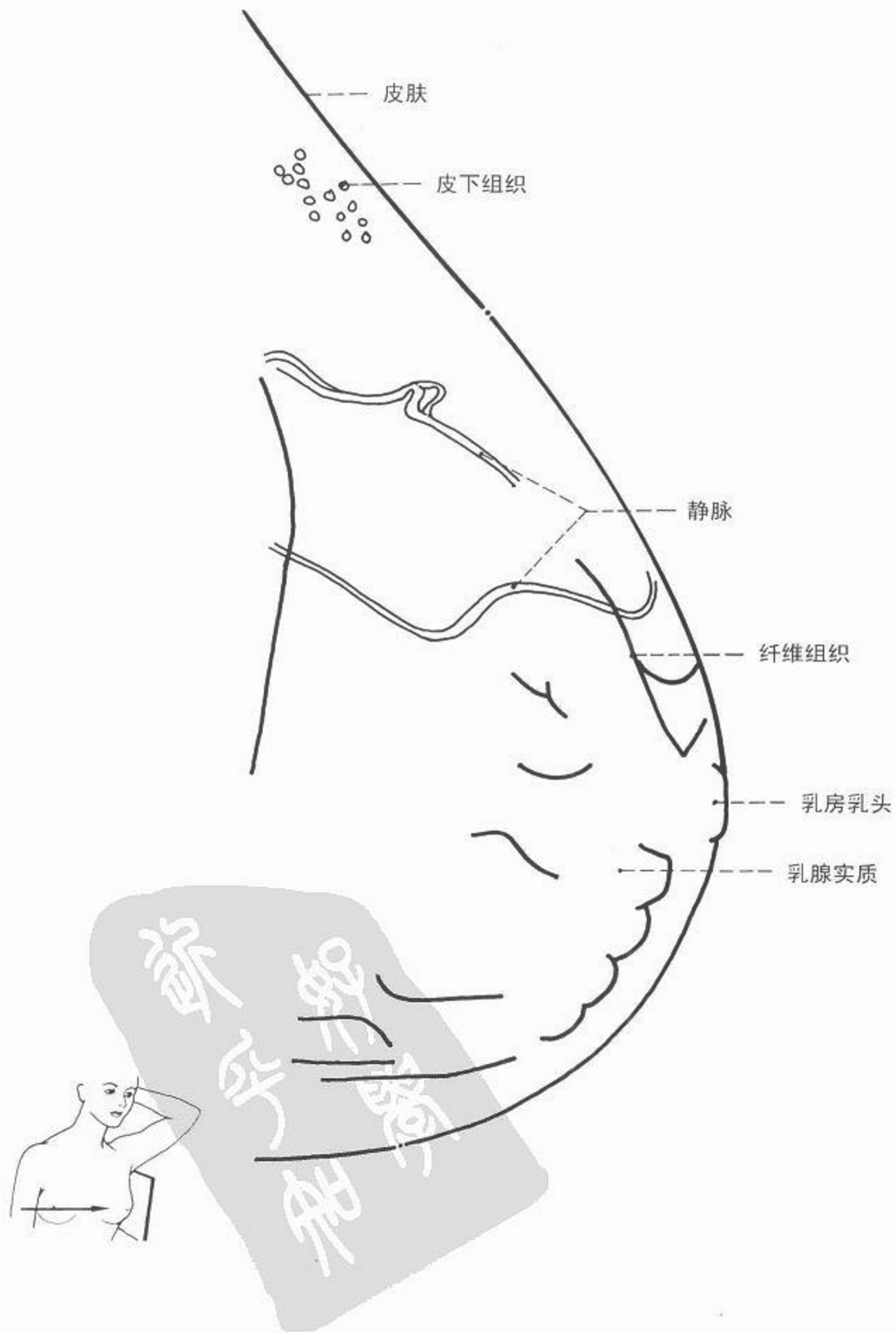


图 67 乳腺平片 从头侧到足侧





X 线平片



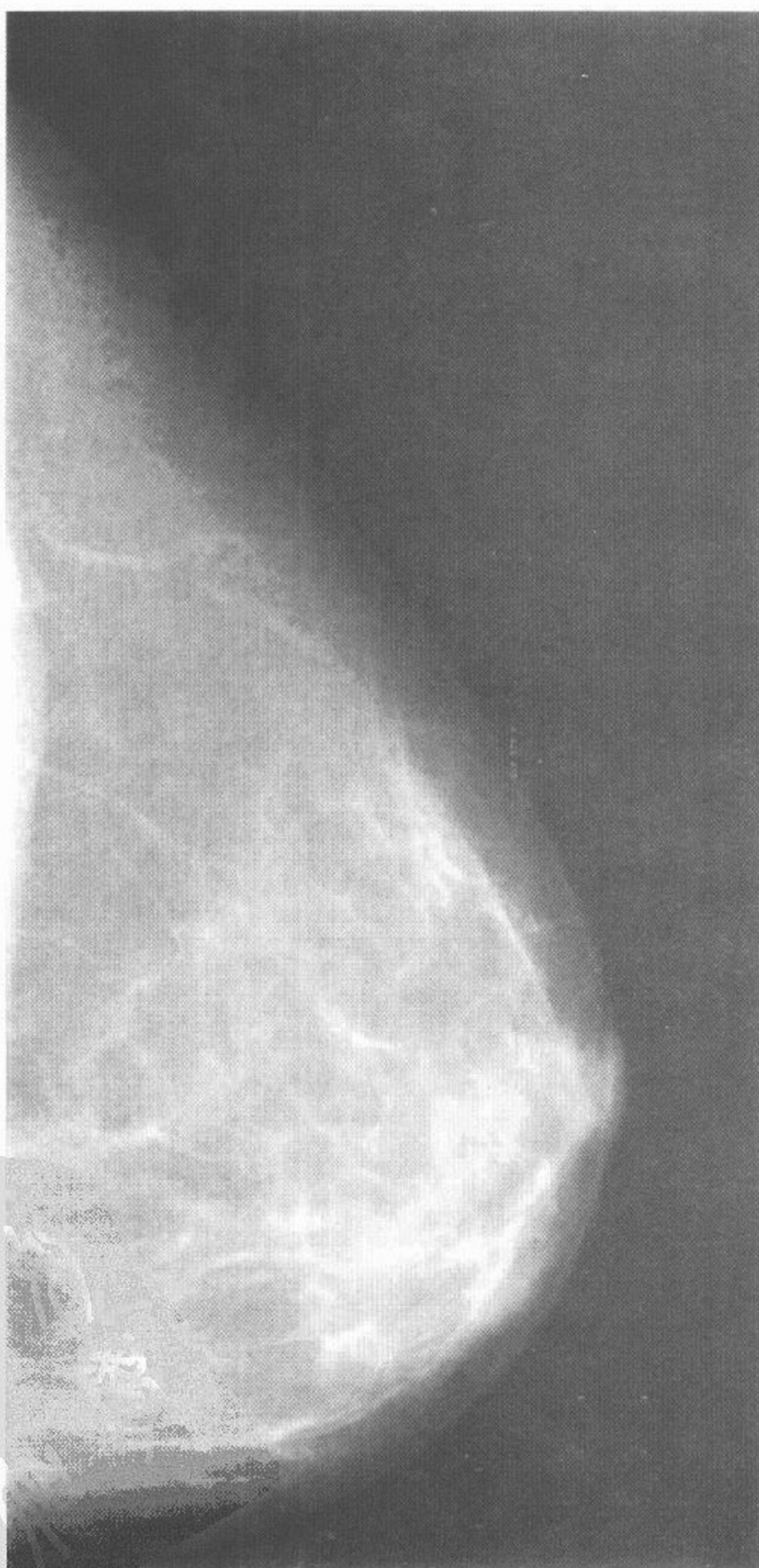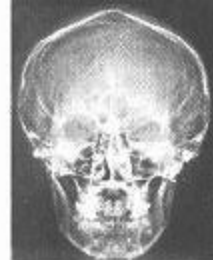
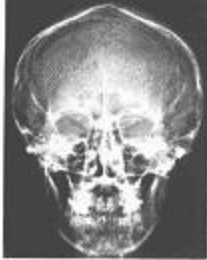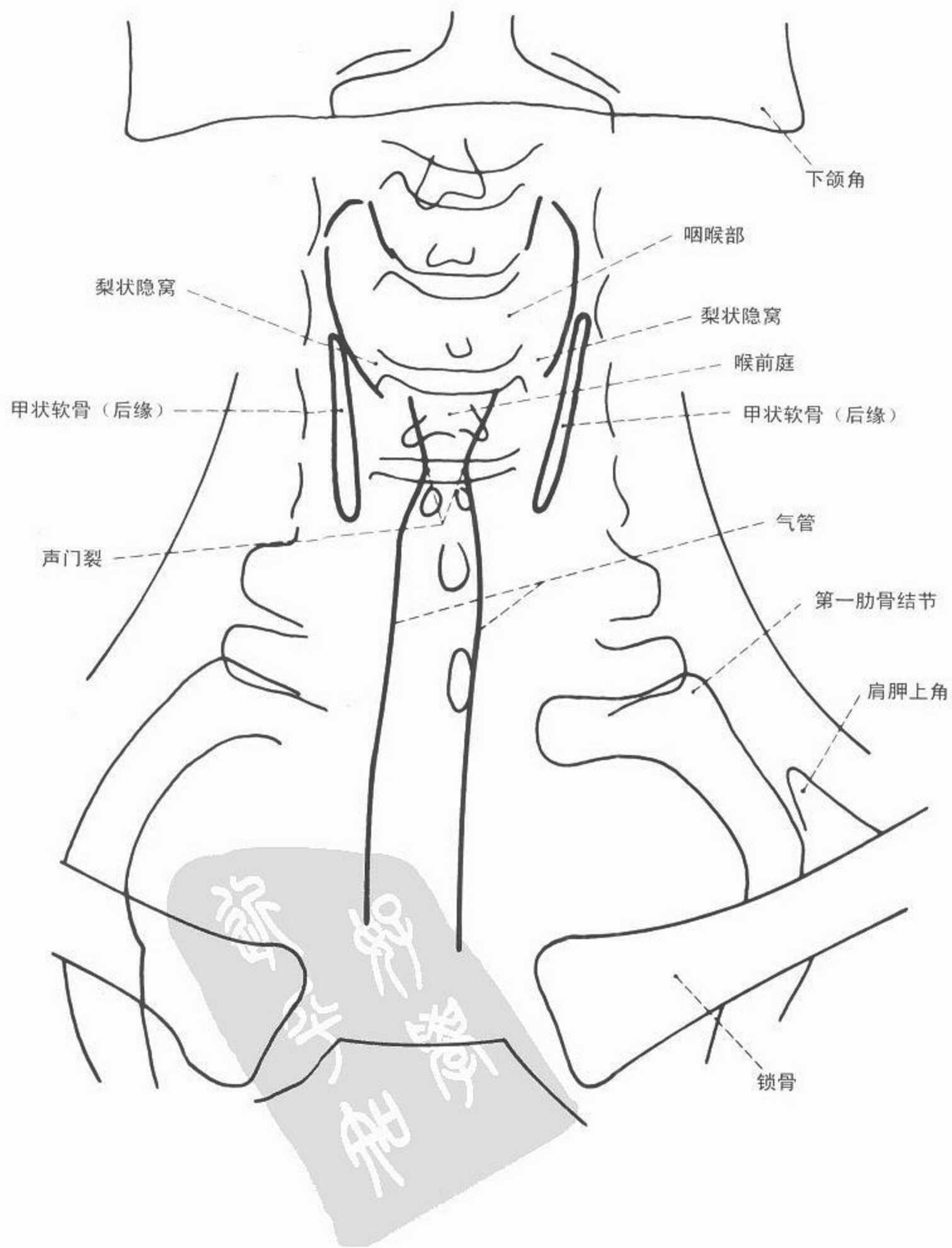


图 68 乳腺平片 侧位



X 线平片



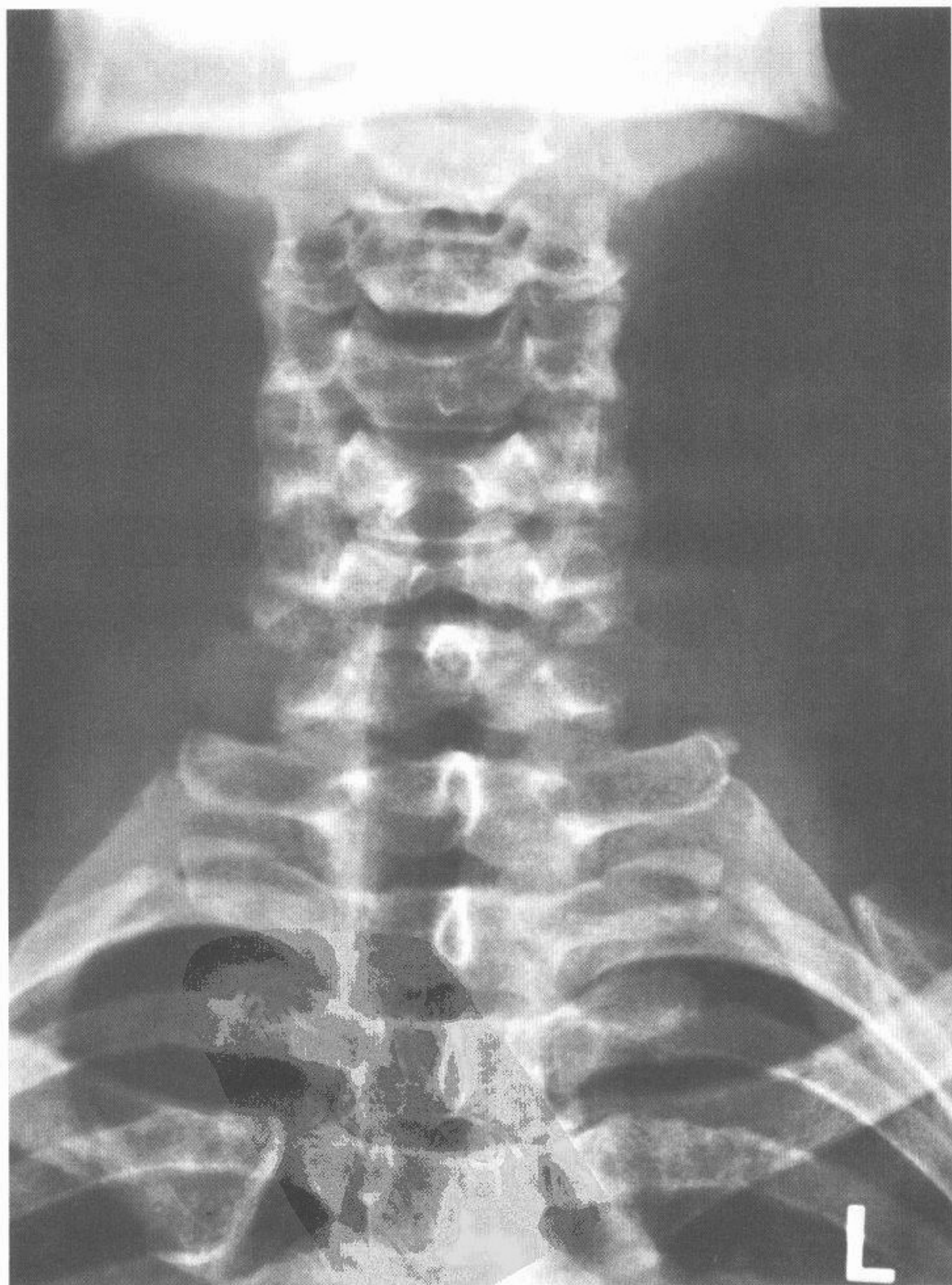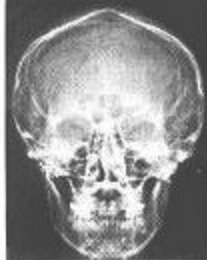

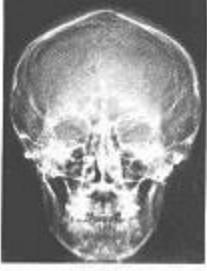
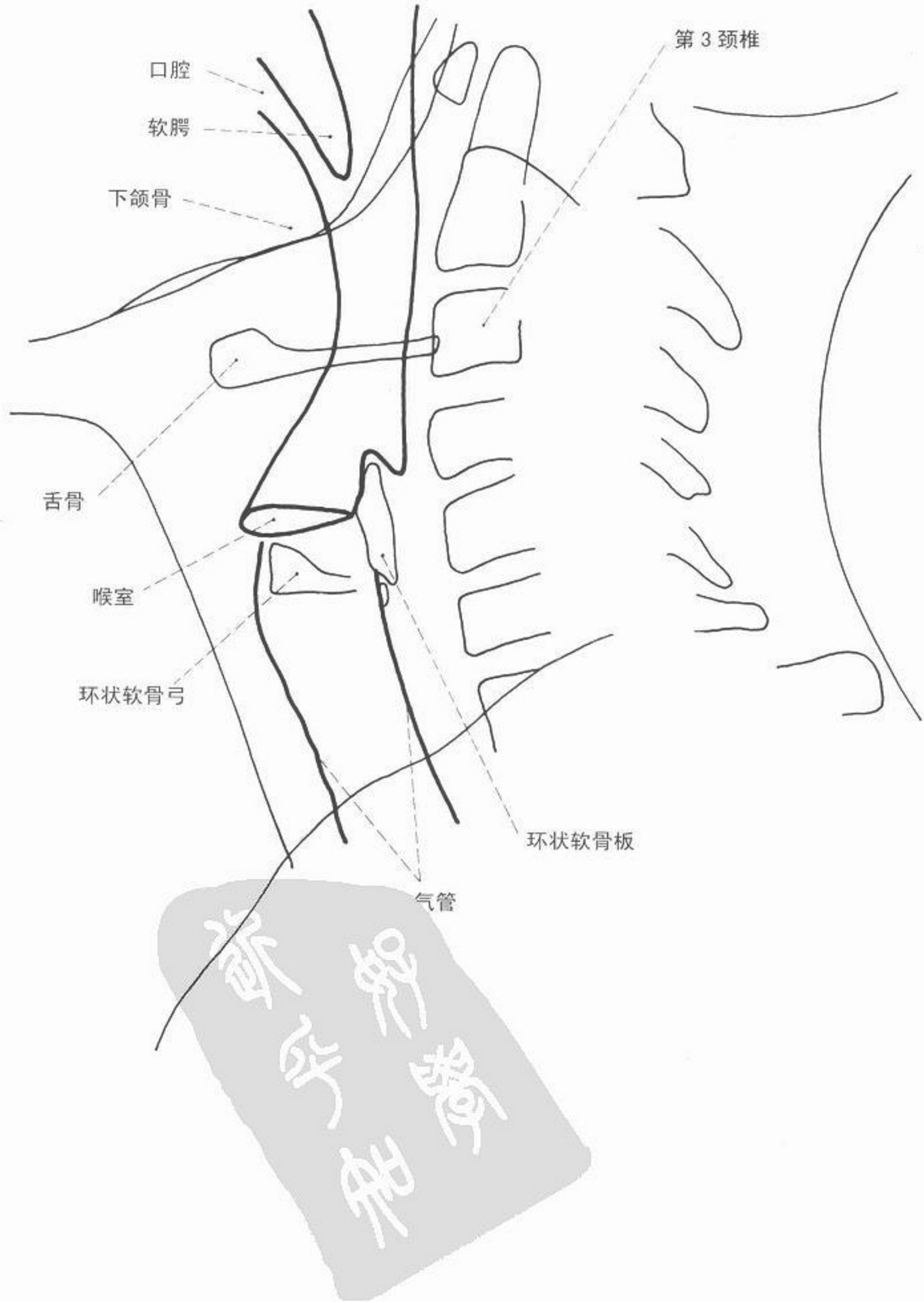图 69 气管 后前位



X 线平片

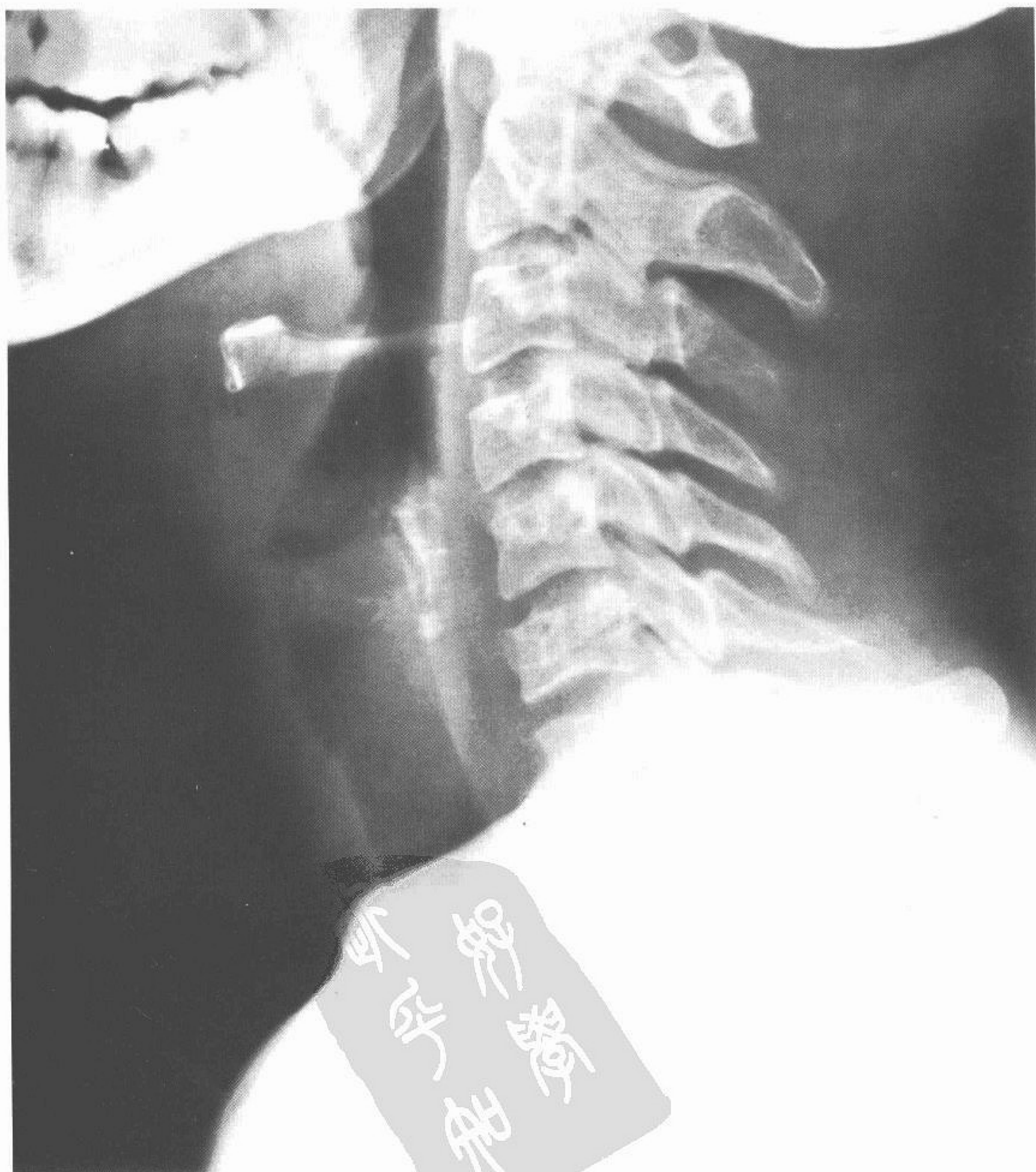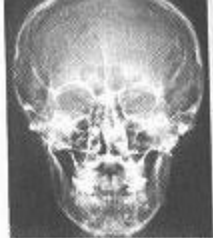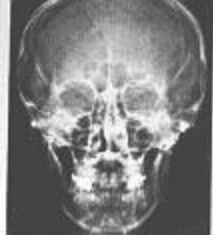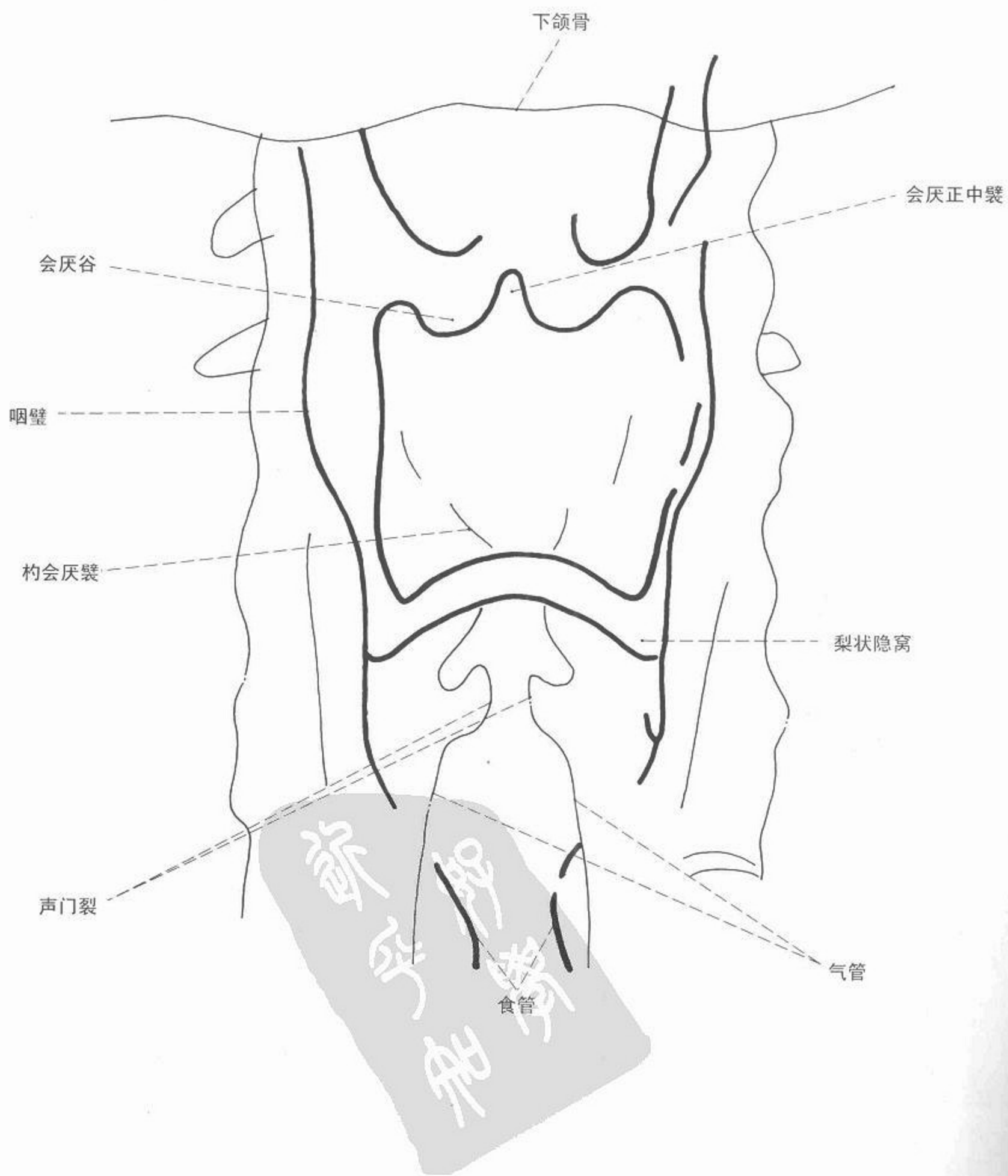




图 70 气管 侧位



X 线平片



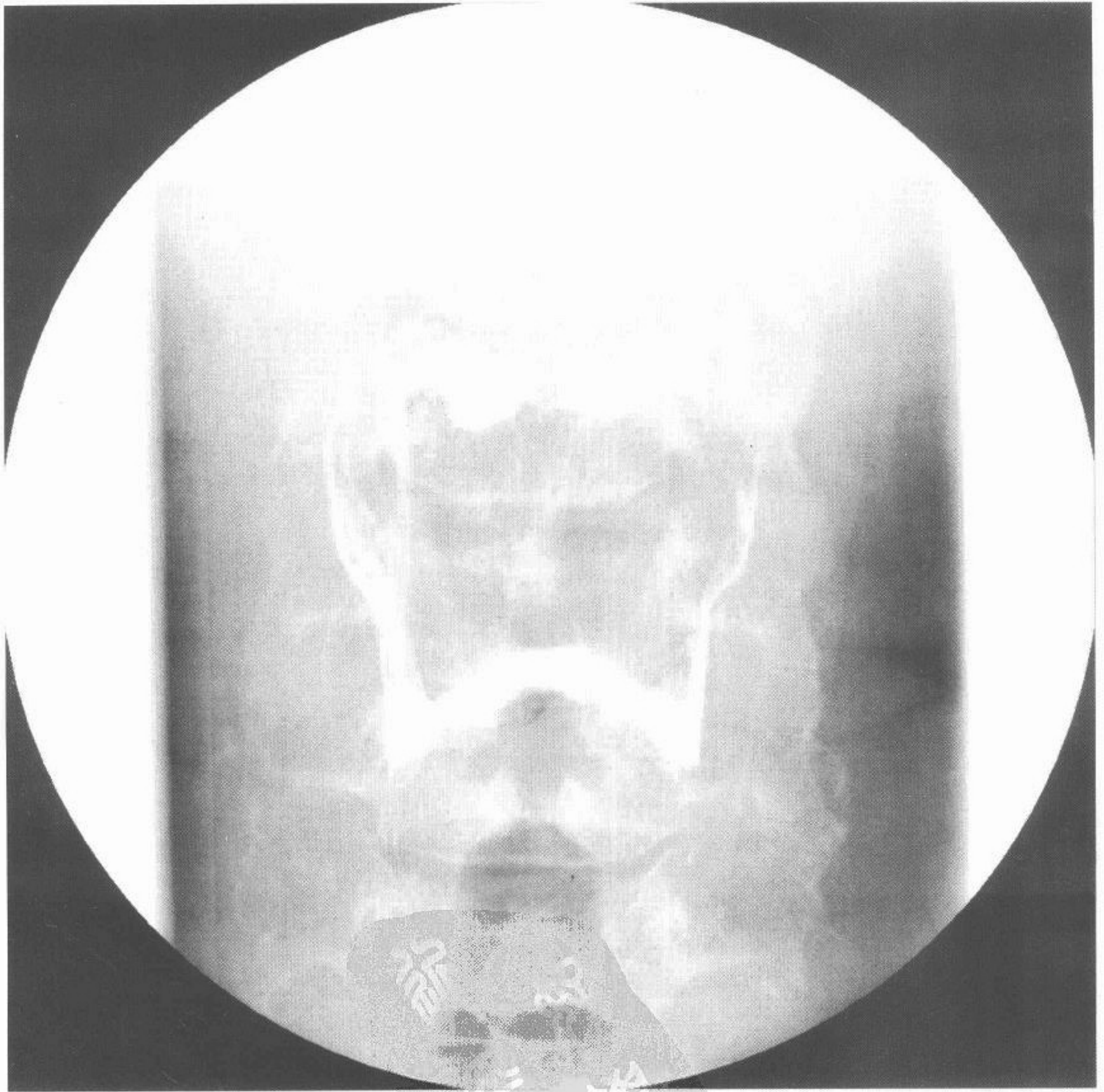
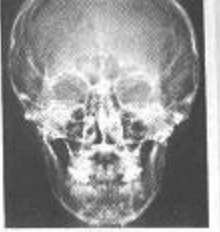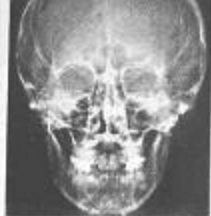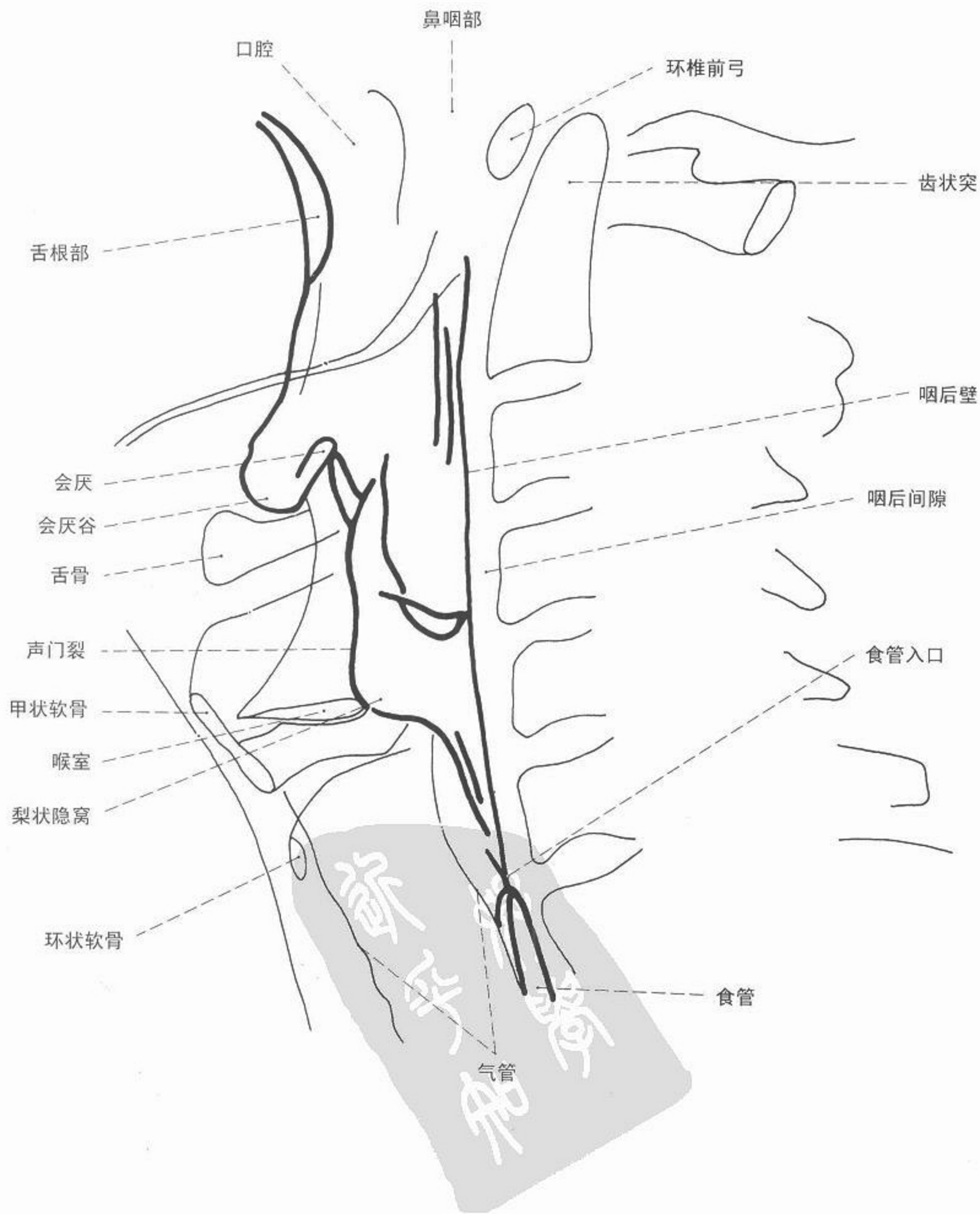


图 71 咽 X 线片 后前位



X线平片



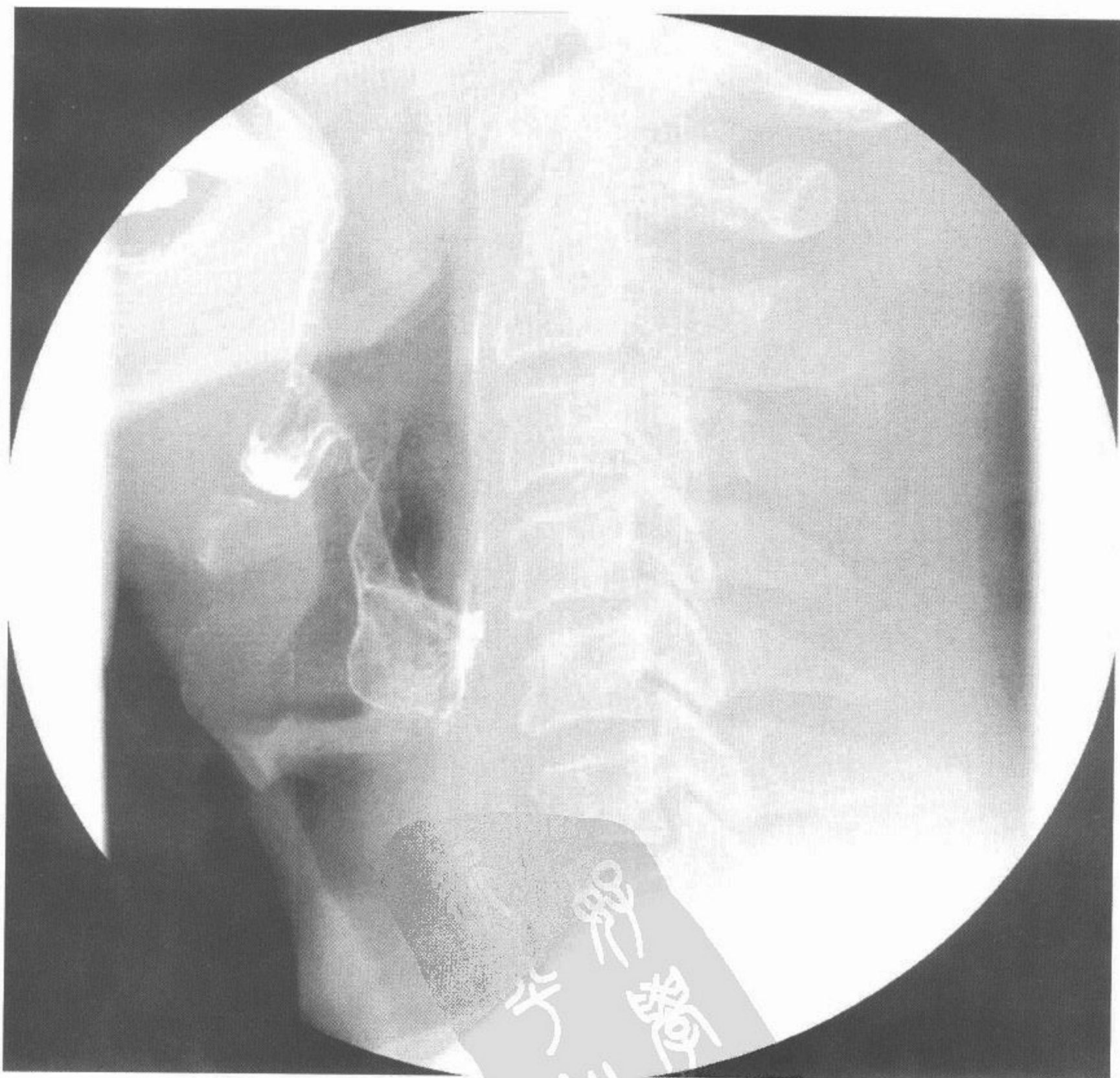
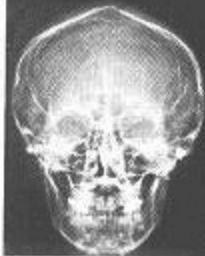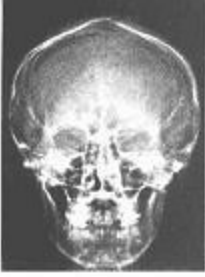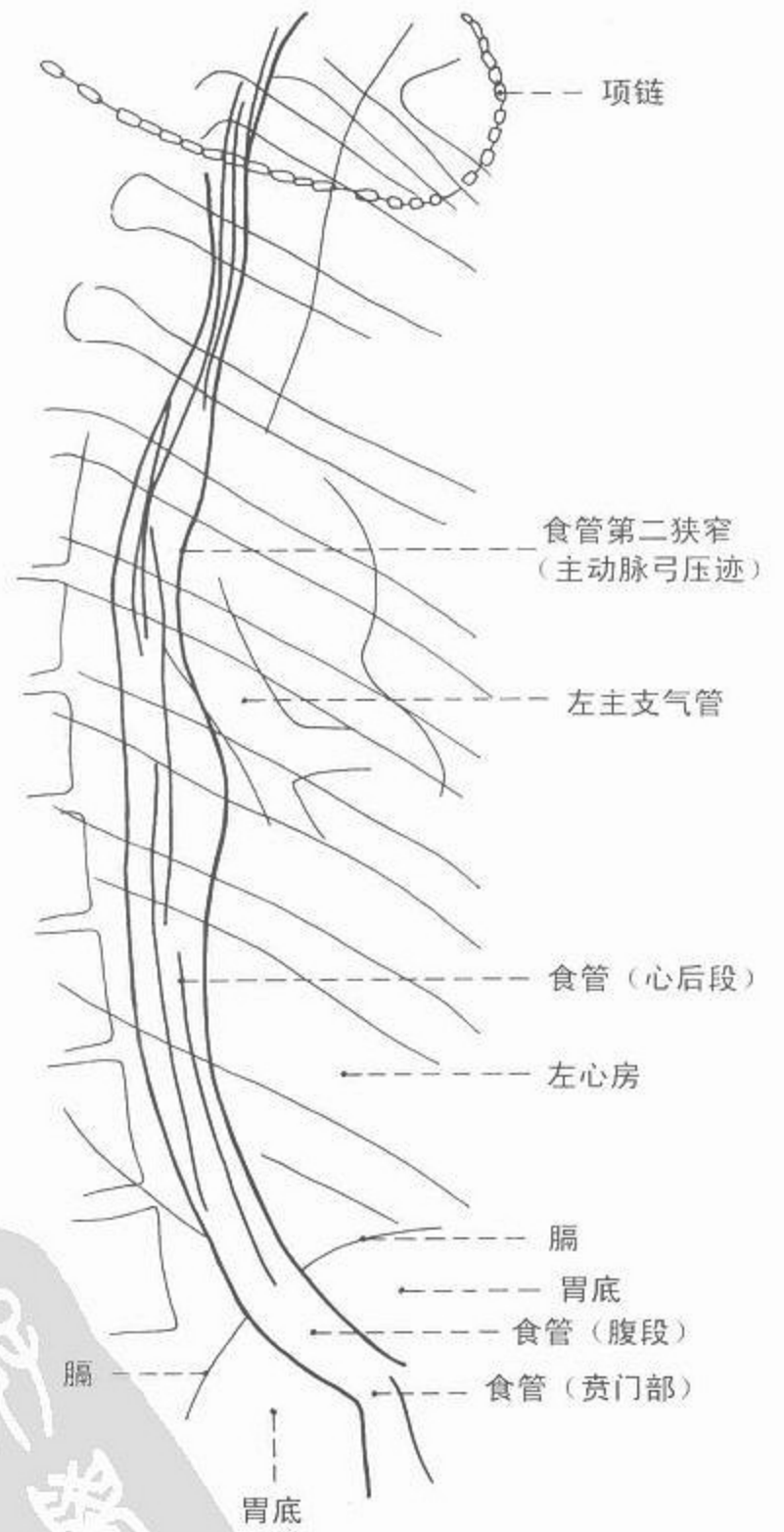
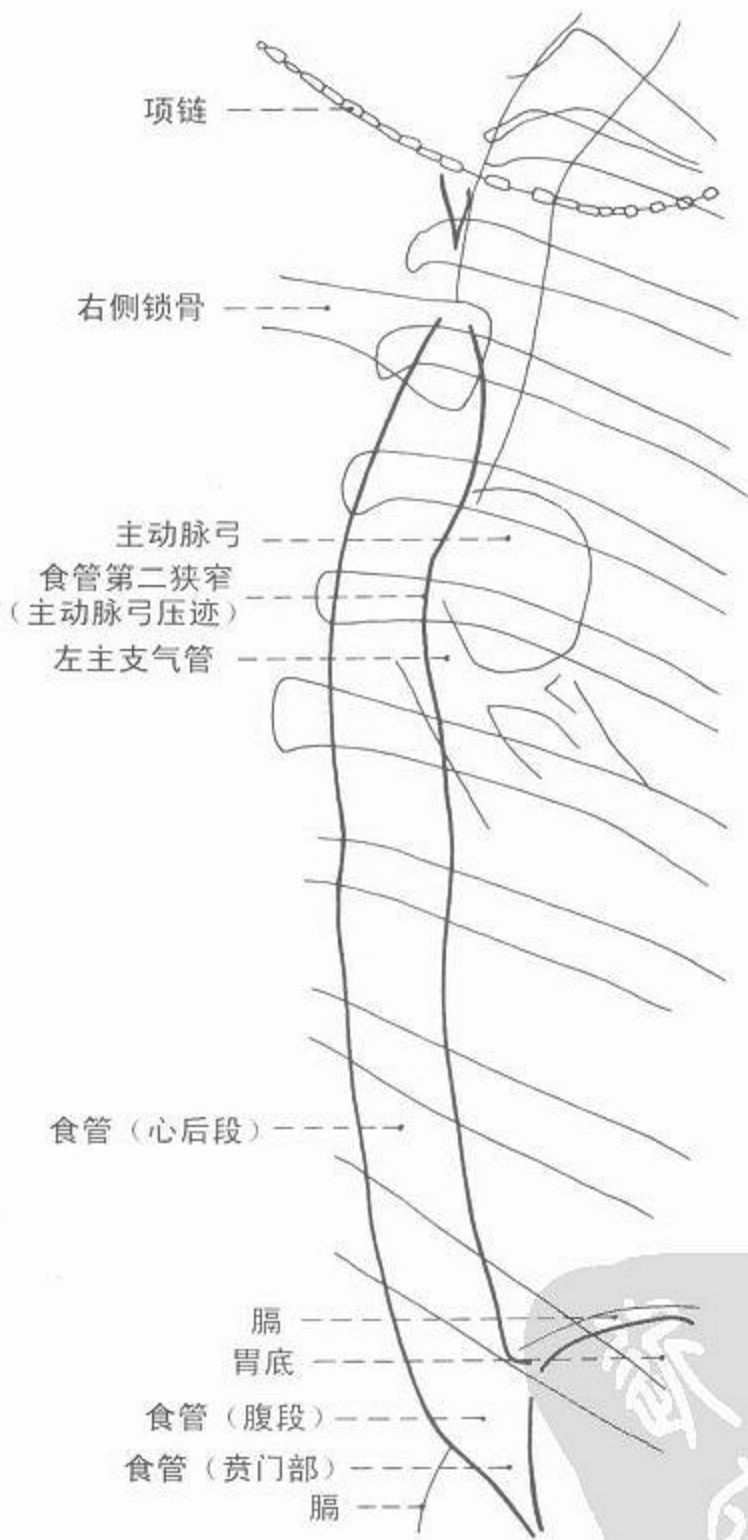


图 72 咽 X 线片 侧位



X 线平片



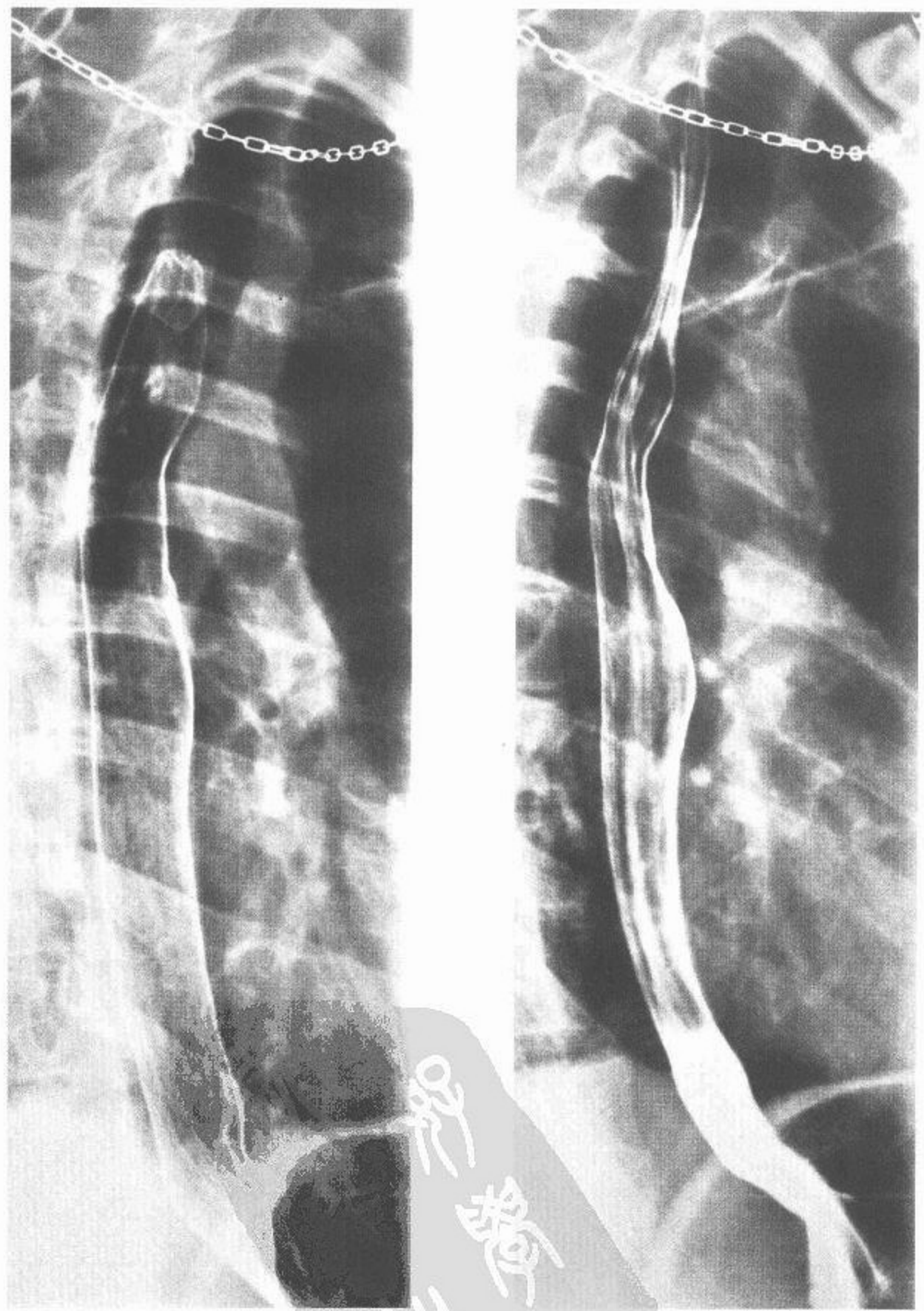
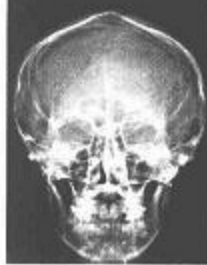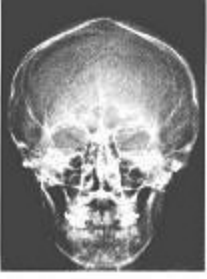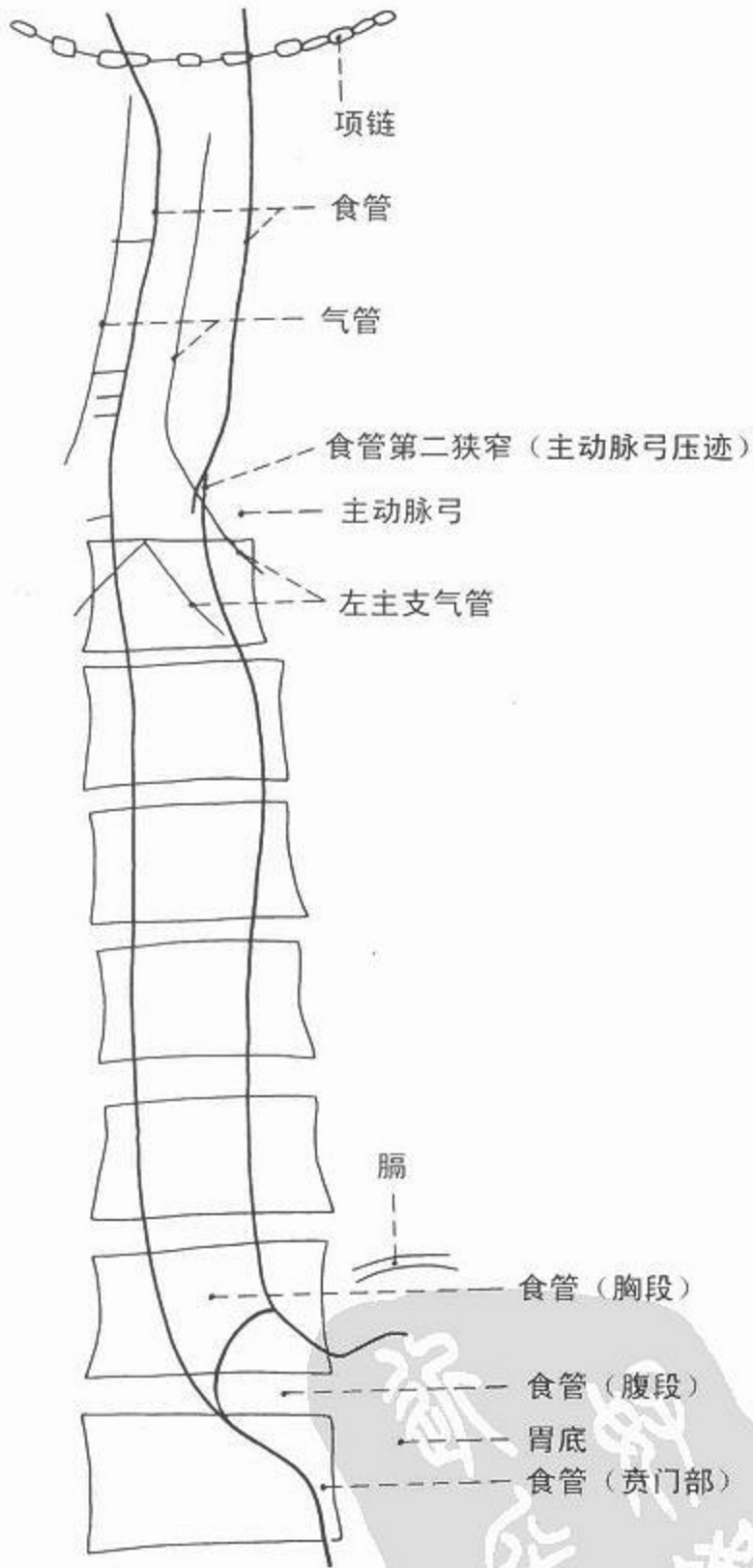


图 73 食管 前斜位



X 线平片



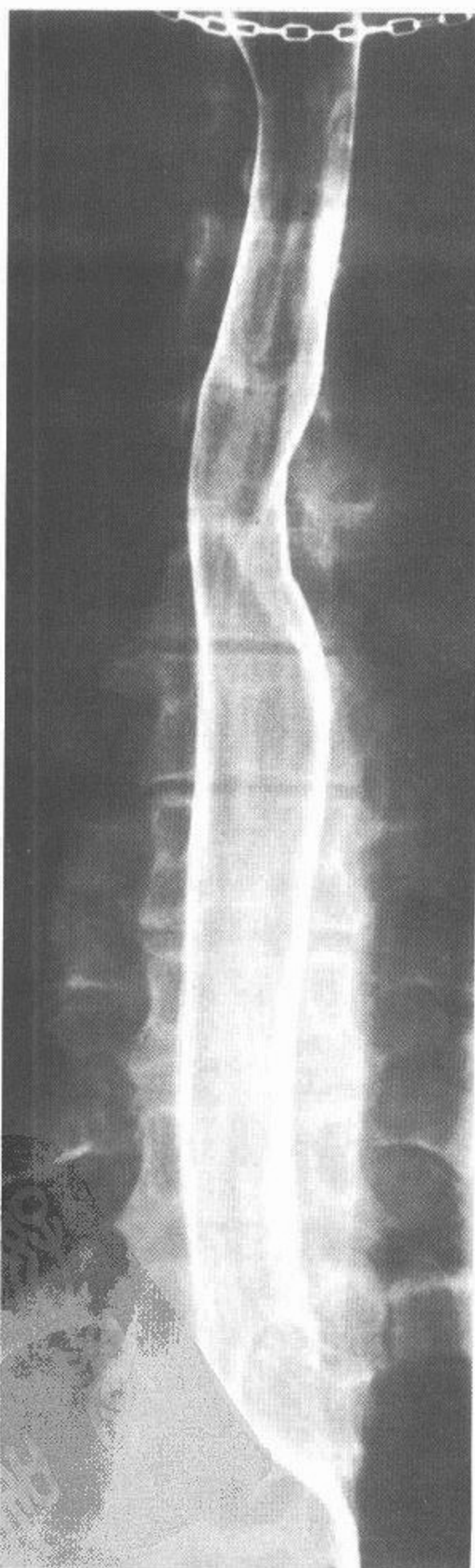
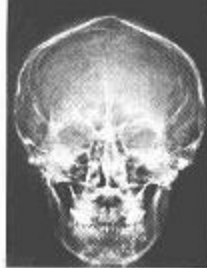
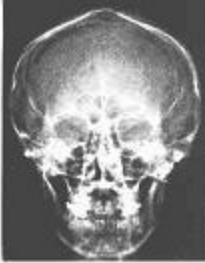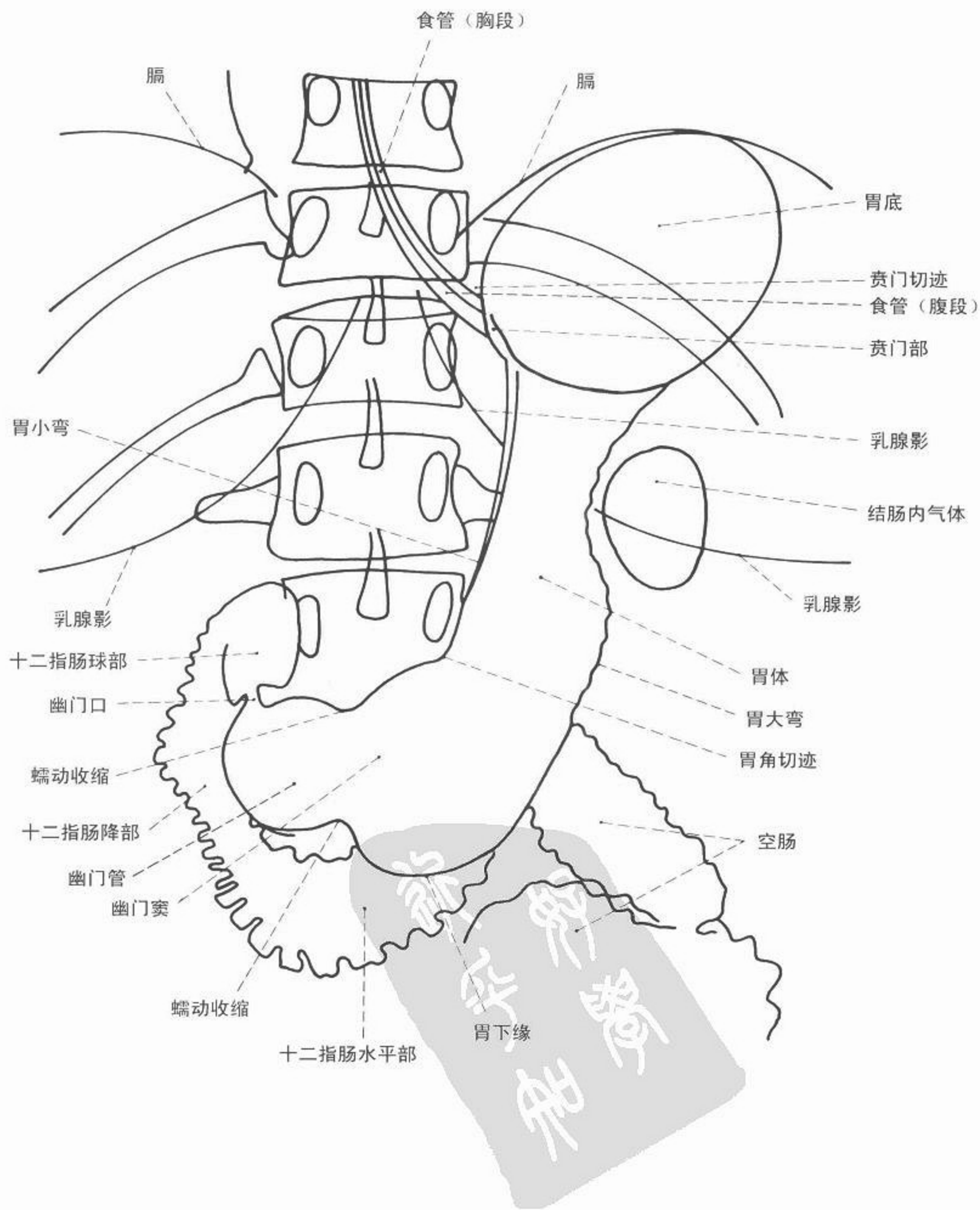


图 74 食管 后前位



X线平片



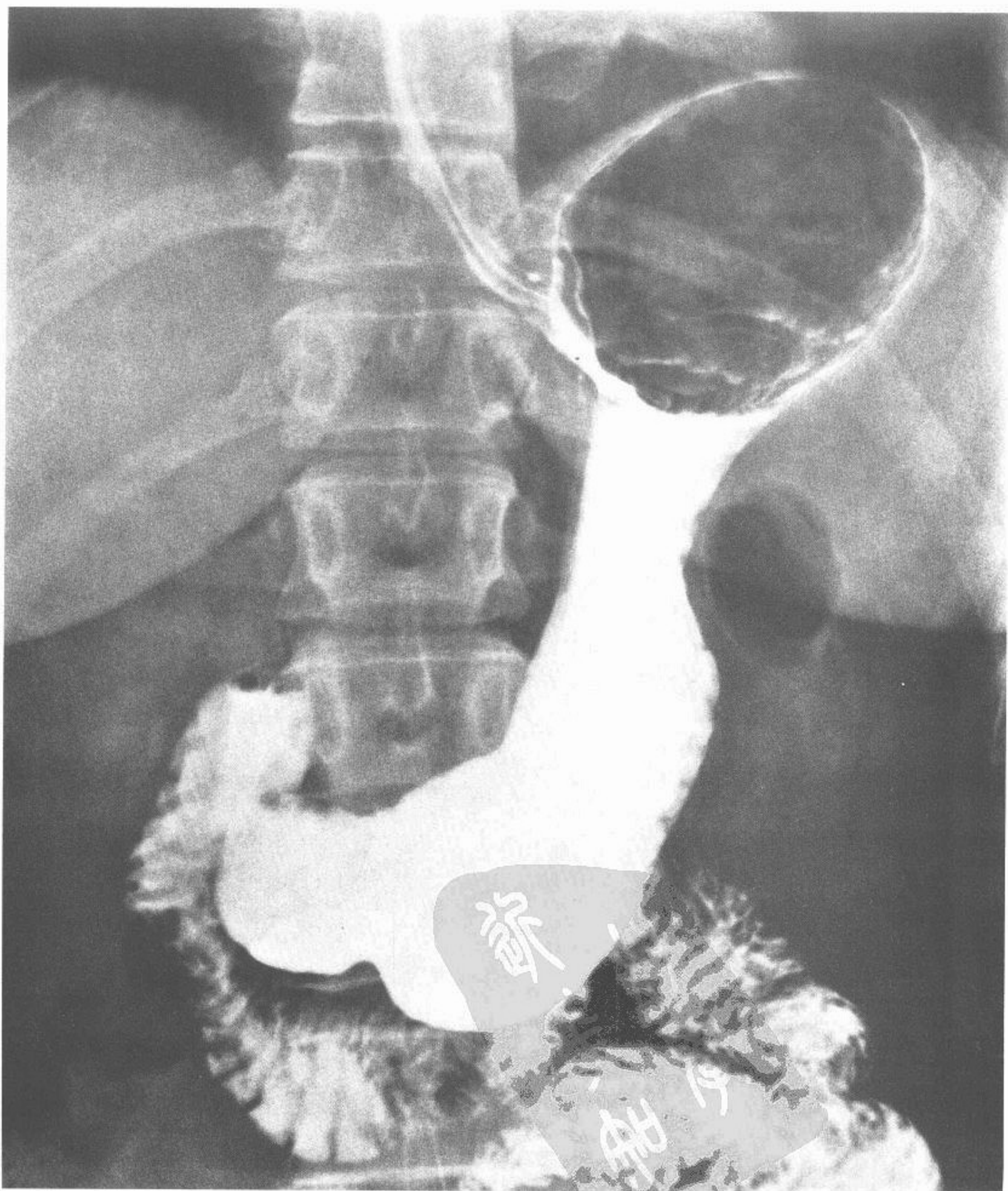
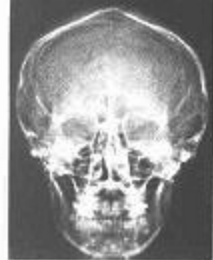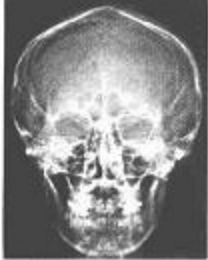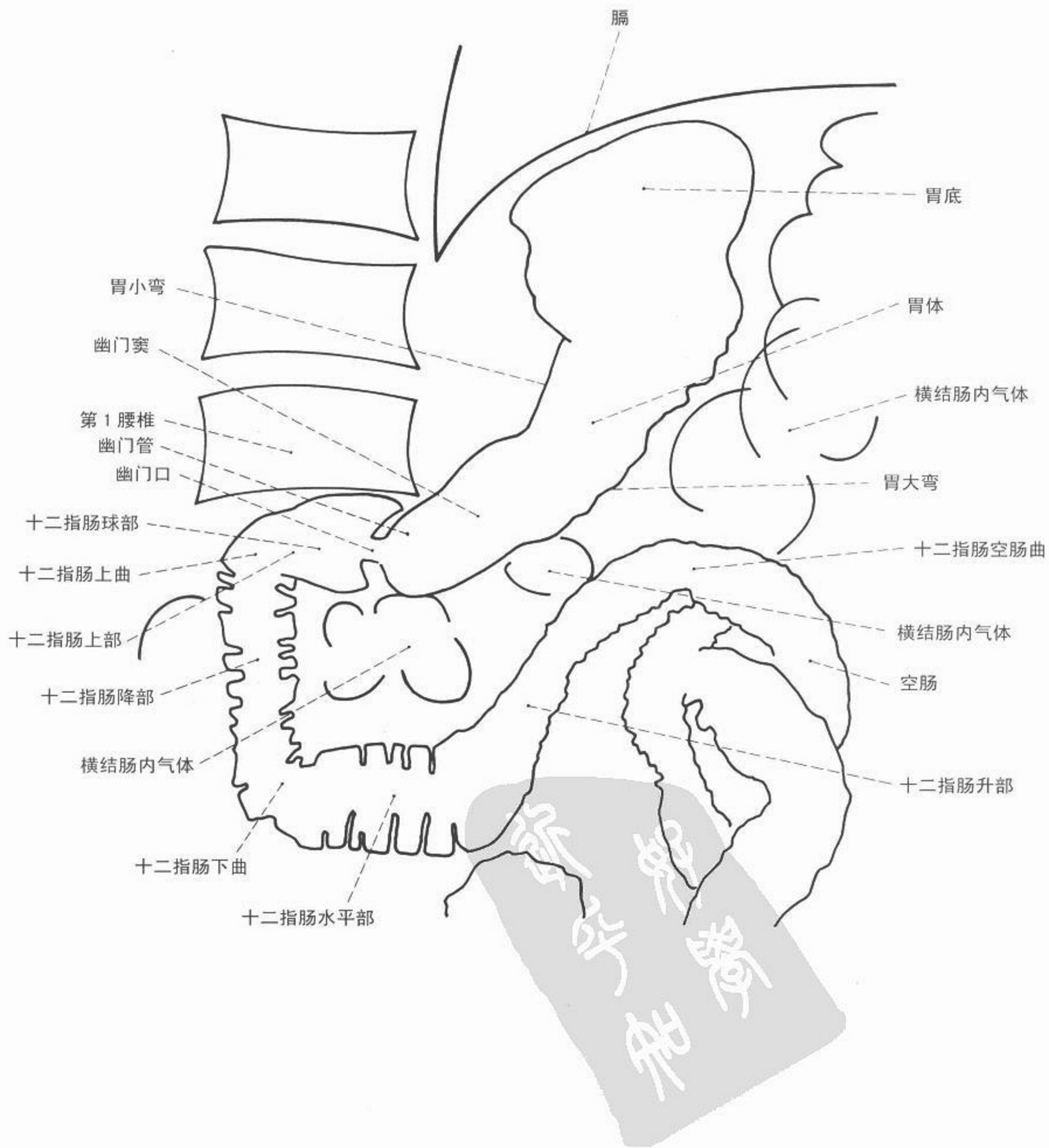


图 75 胃 站立后前位(钩形)



X 线平片



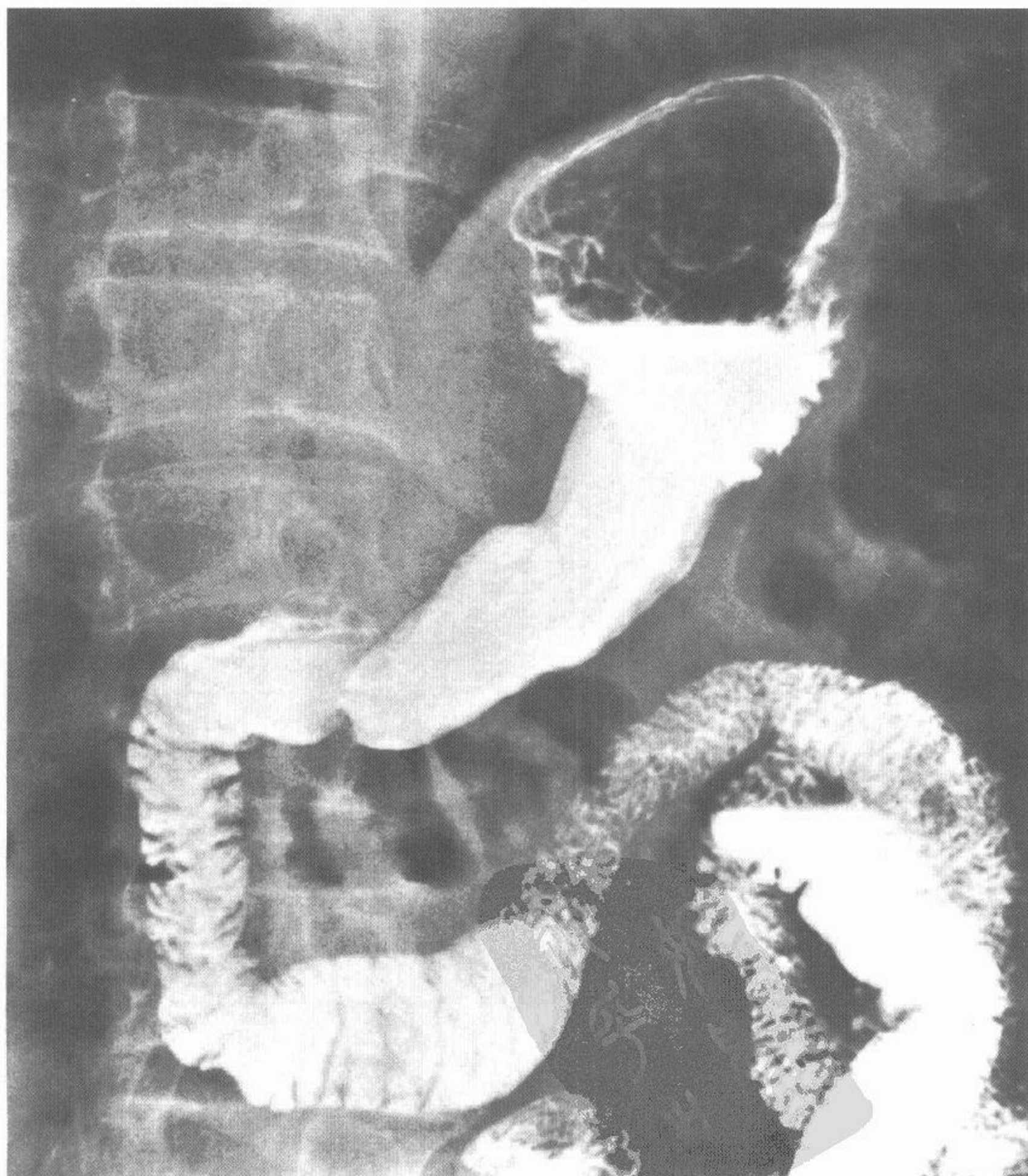
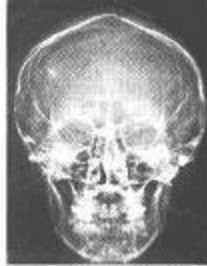
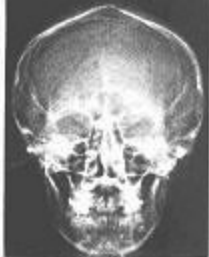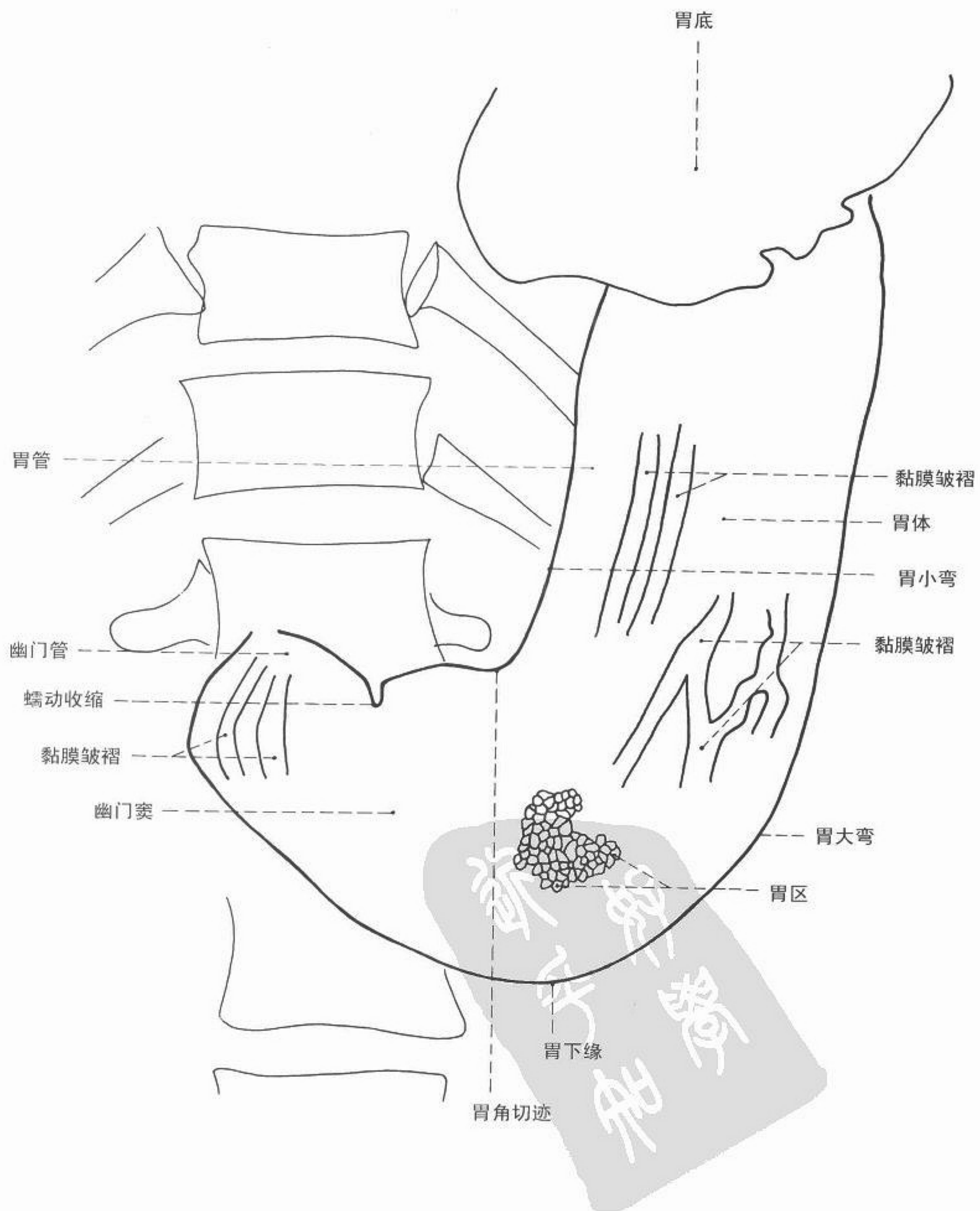


图 76 胃 仰卧后前位(头低脚高)



X 线平片



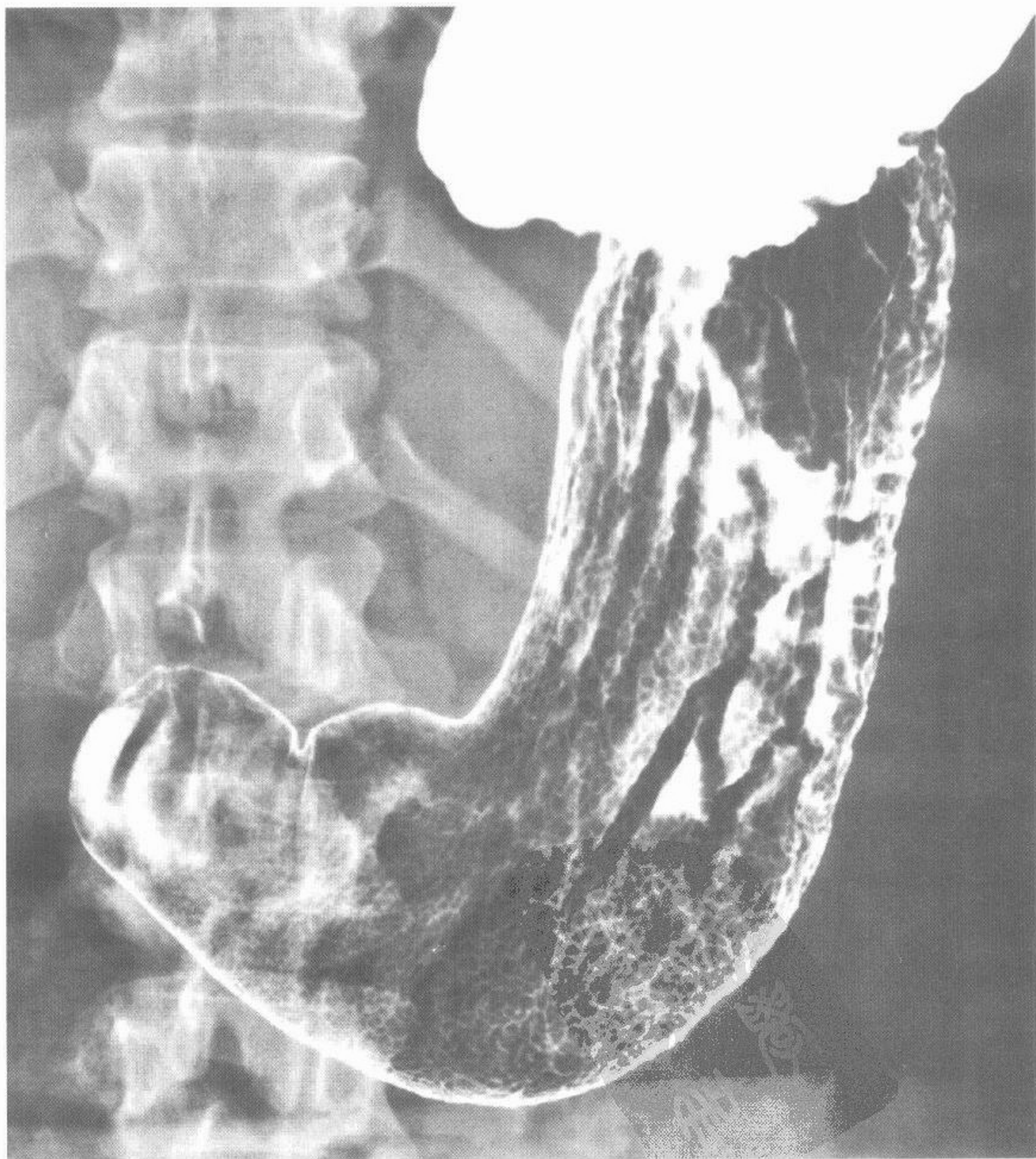
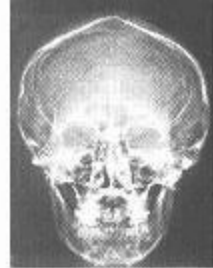
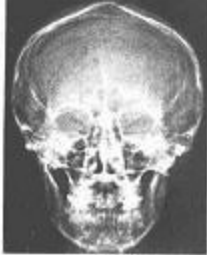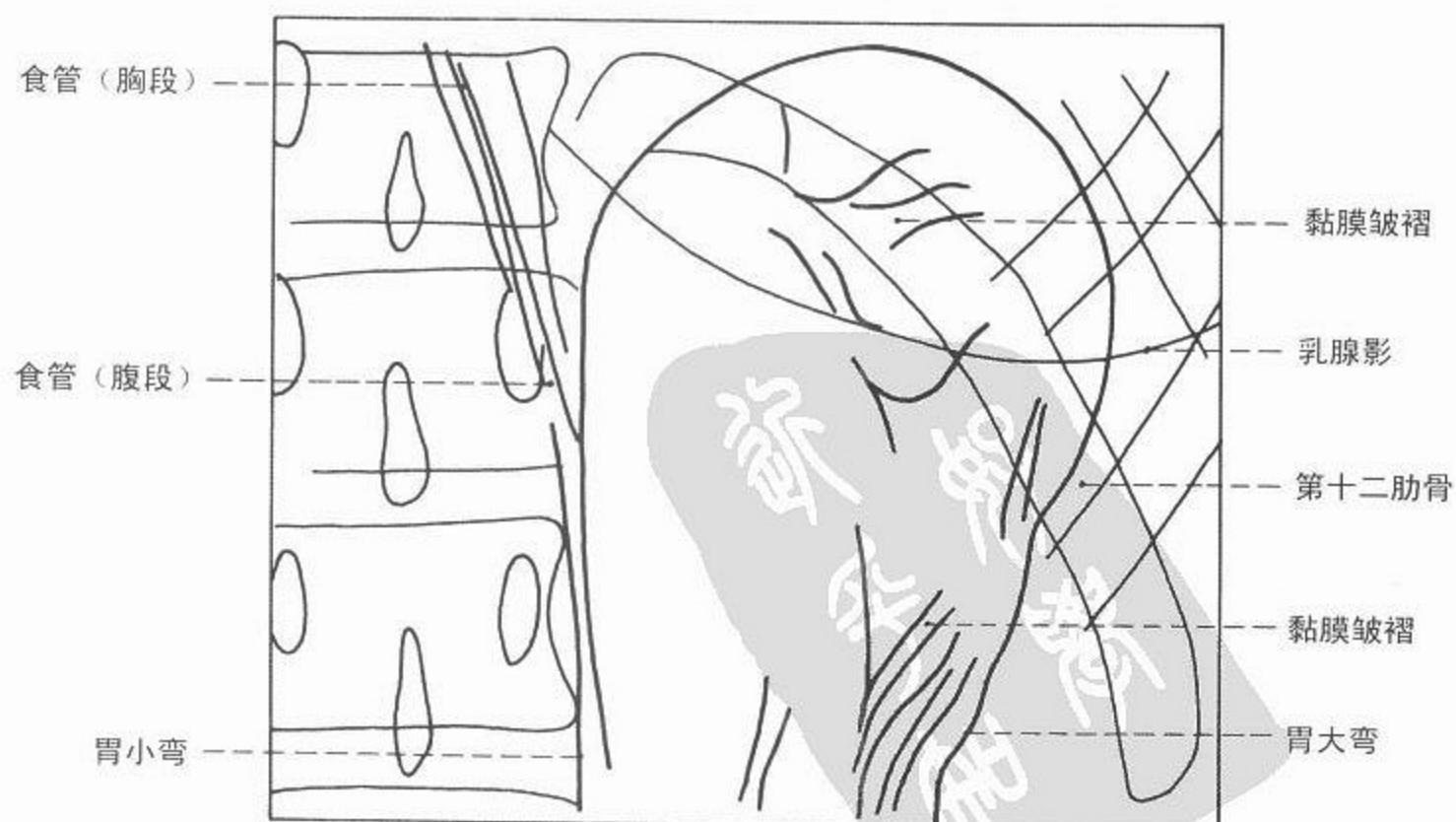

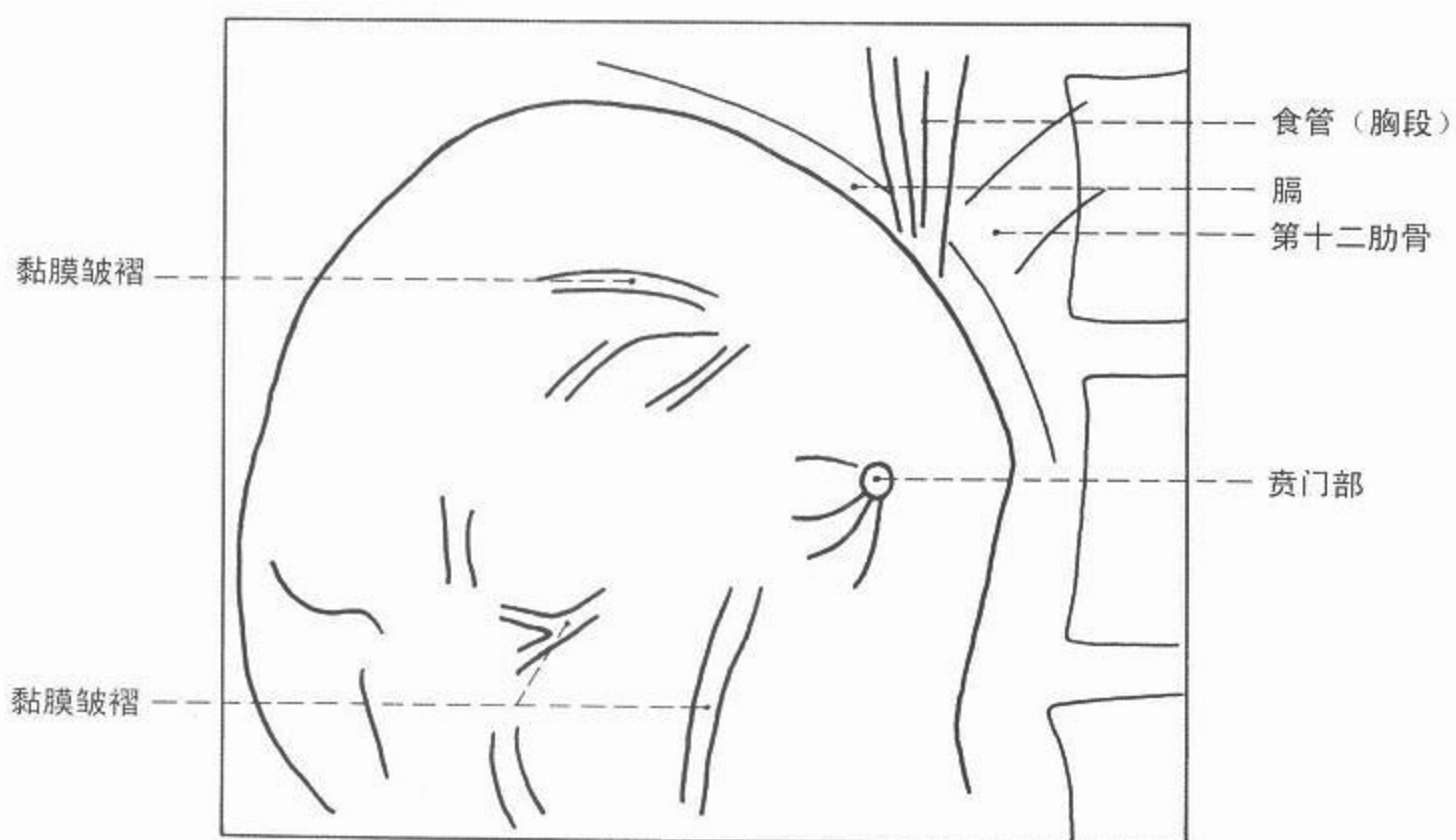
图 77 胃底点片 仰卧后前位(头低脚高)



X 线平片



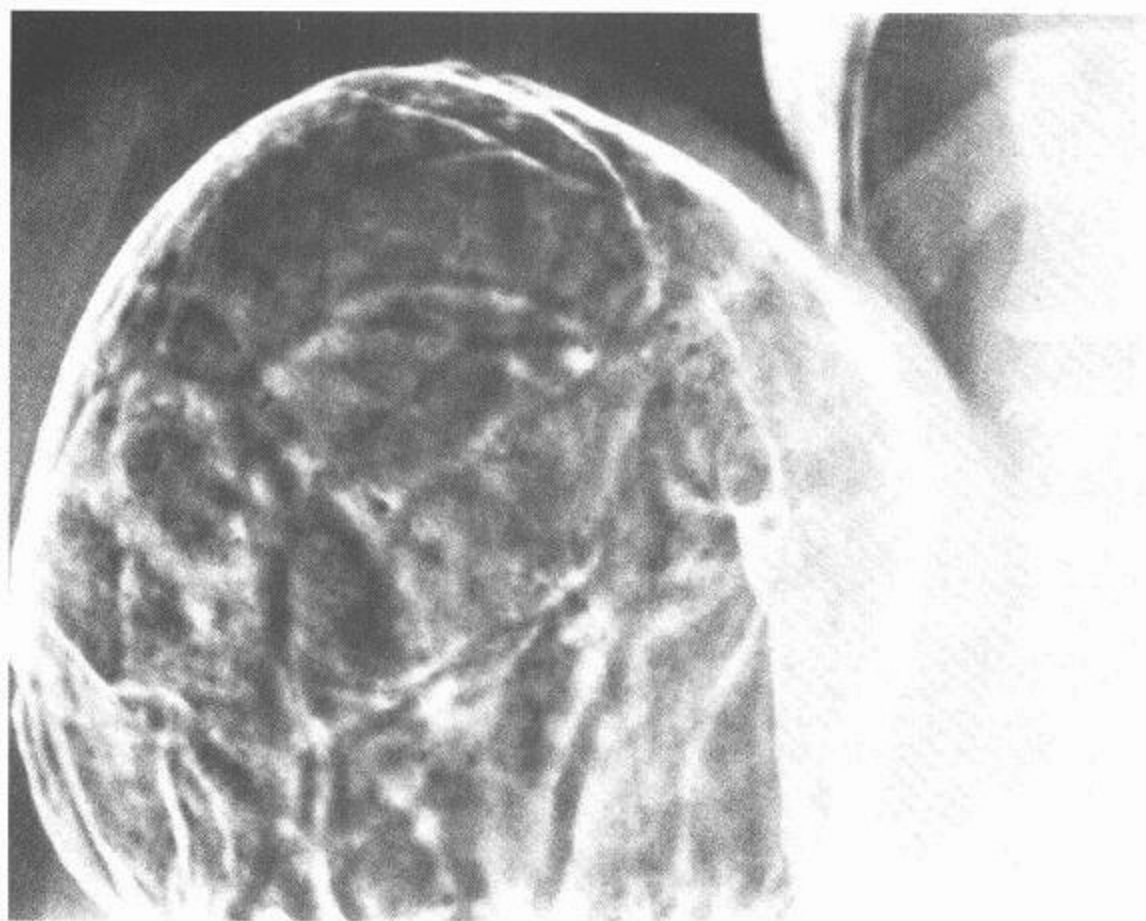
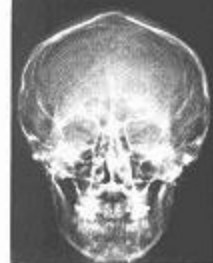

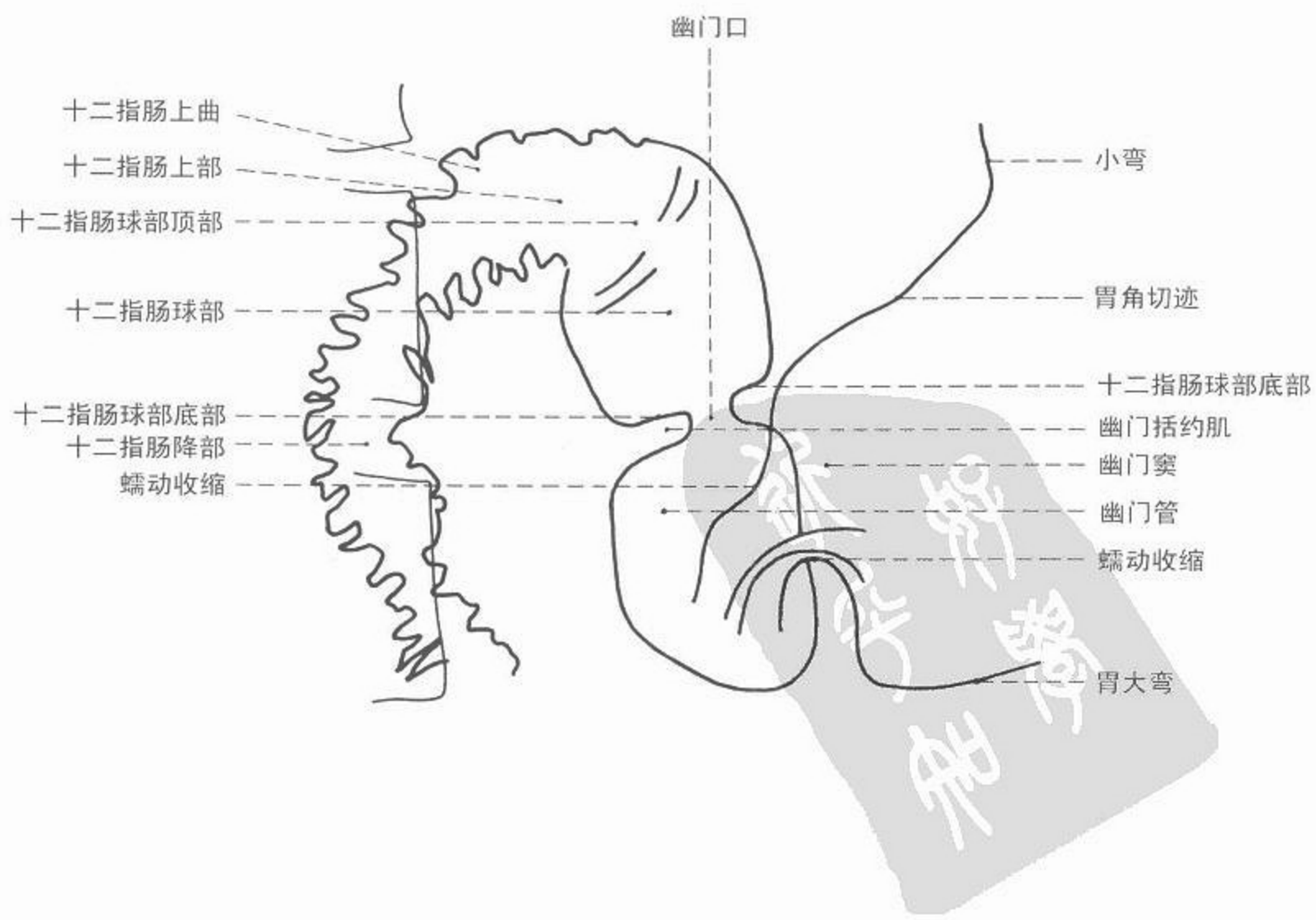
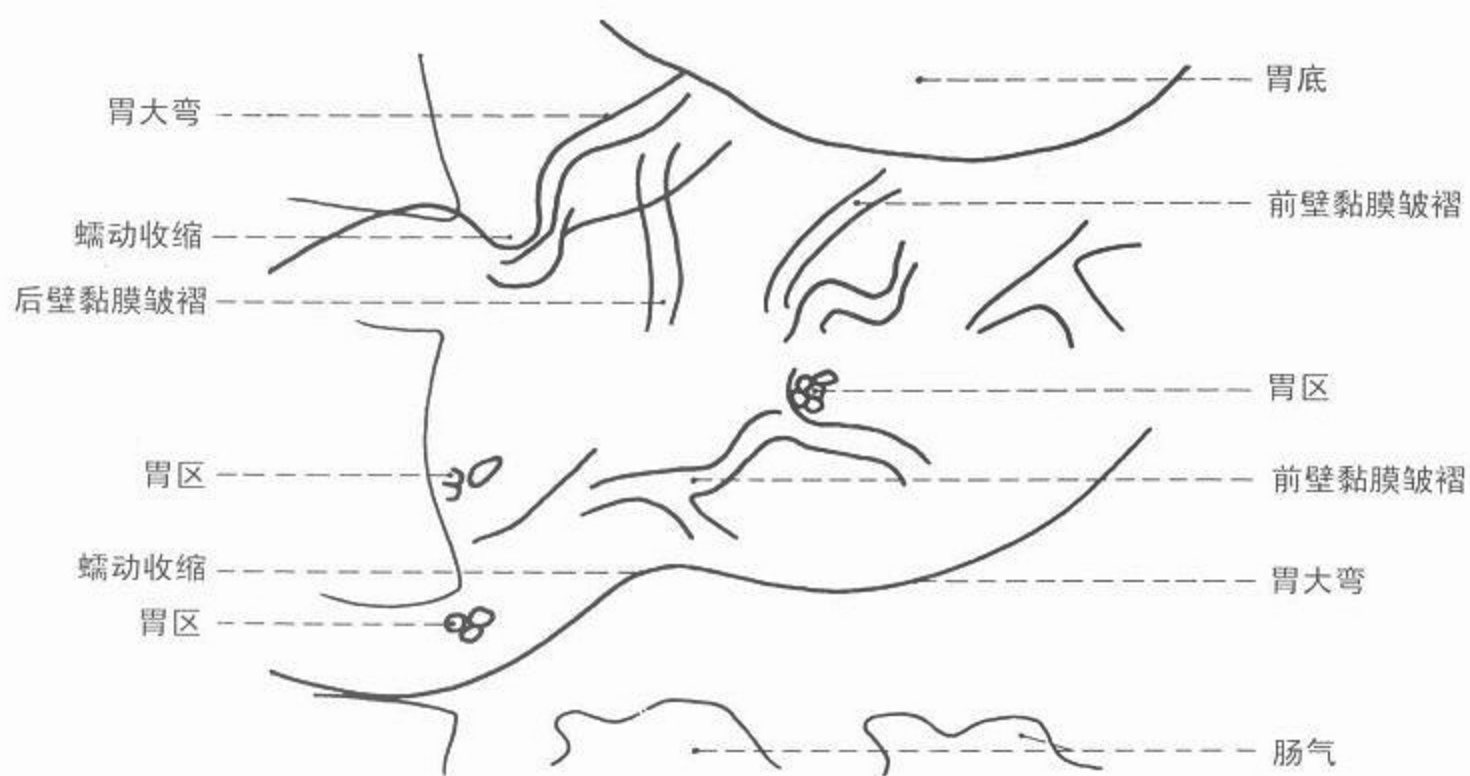
图 78 胃底点片 俯卧前斜位

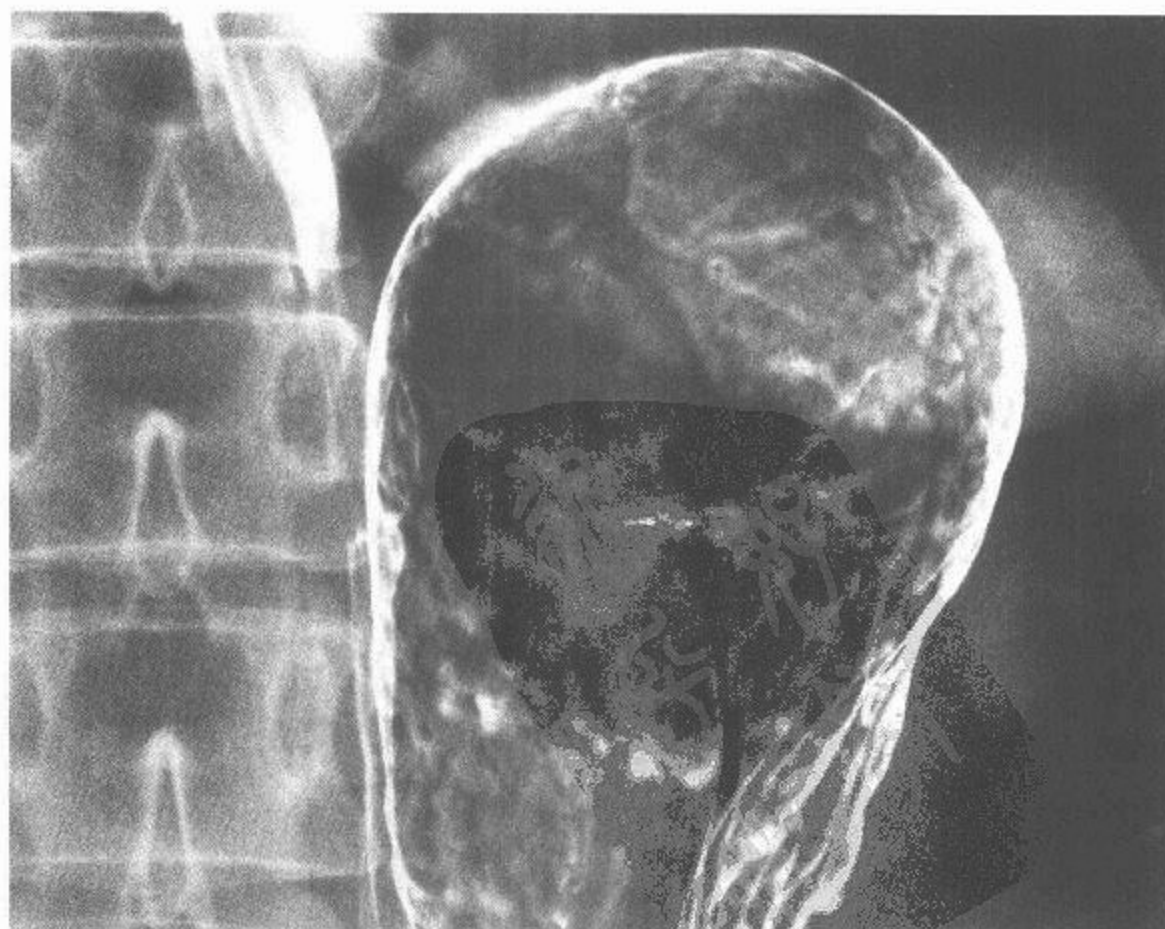
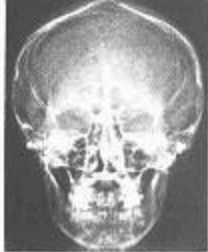
图 79 胃底点片 站立位



X 线平片



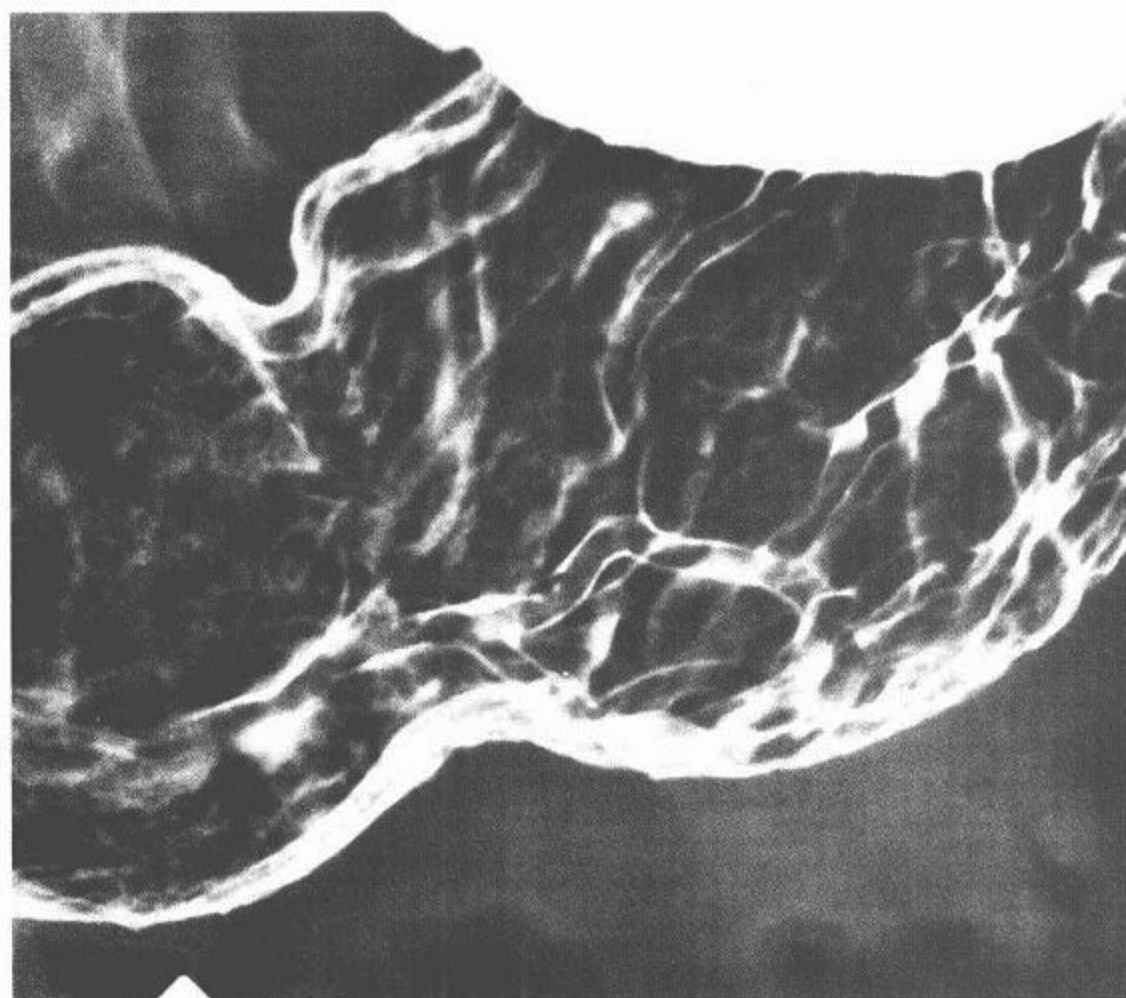
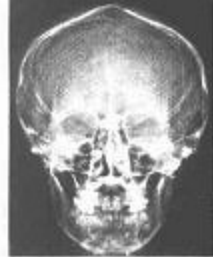

图 80 胃体点片 仰卧前斜位

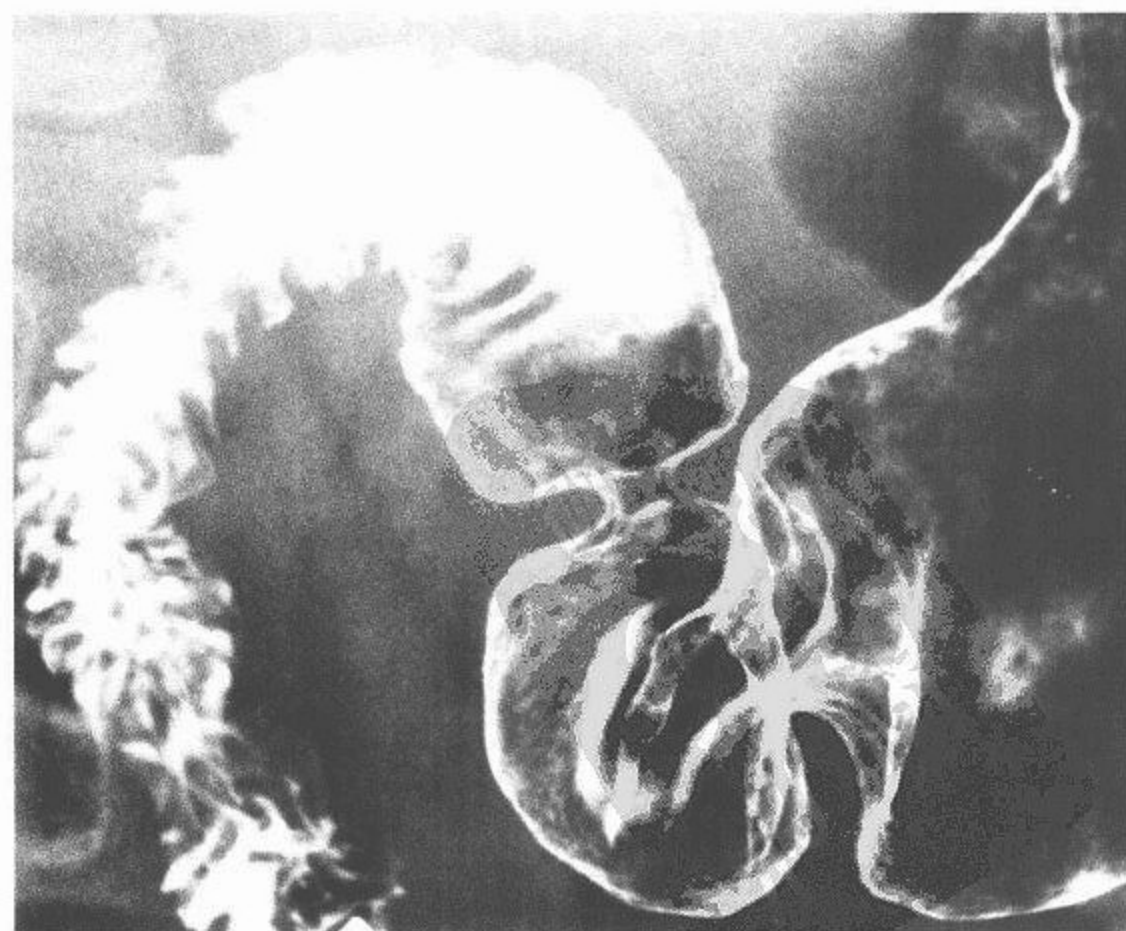
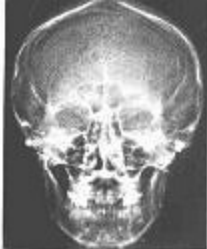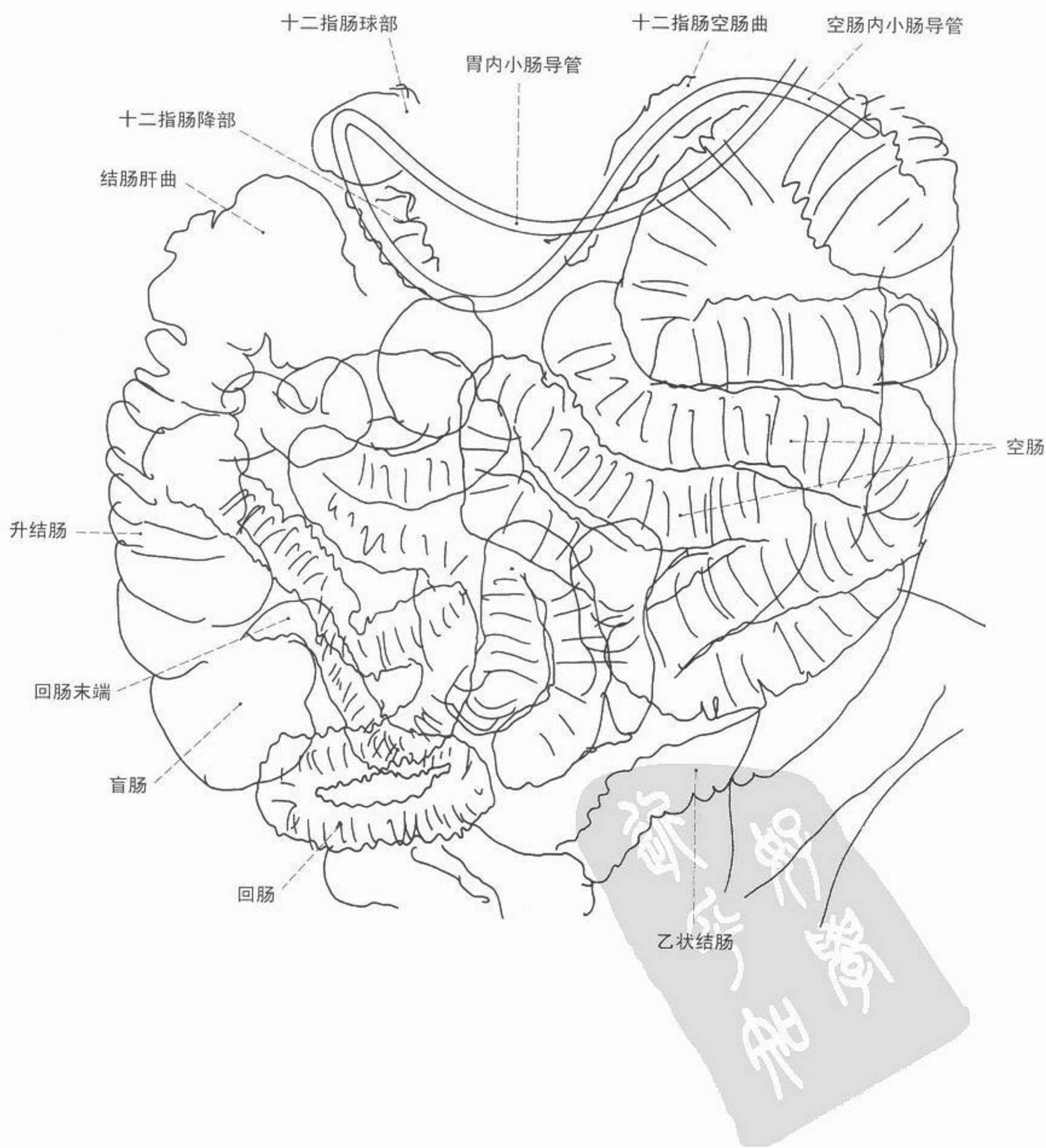


图 81 幽门部和十二指肠球部点片
仰卧后前位(前斜)



X 线平片



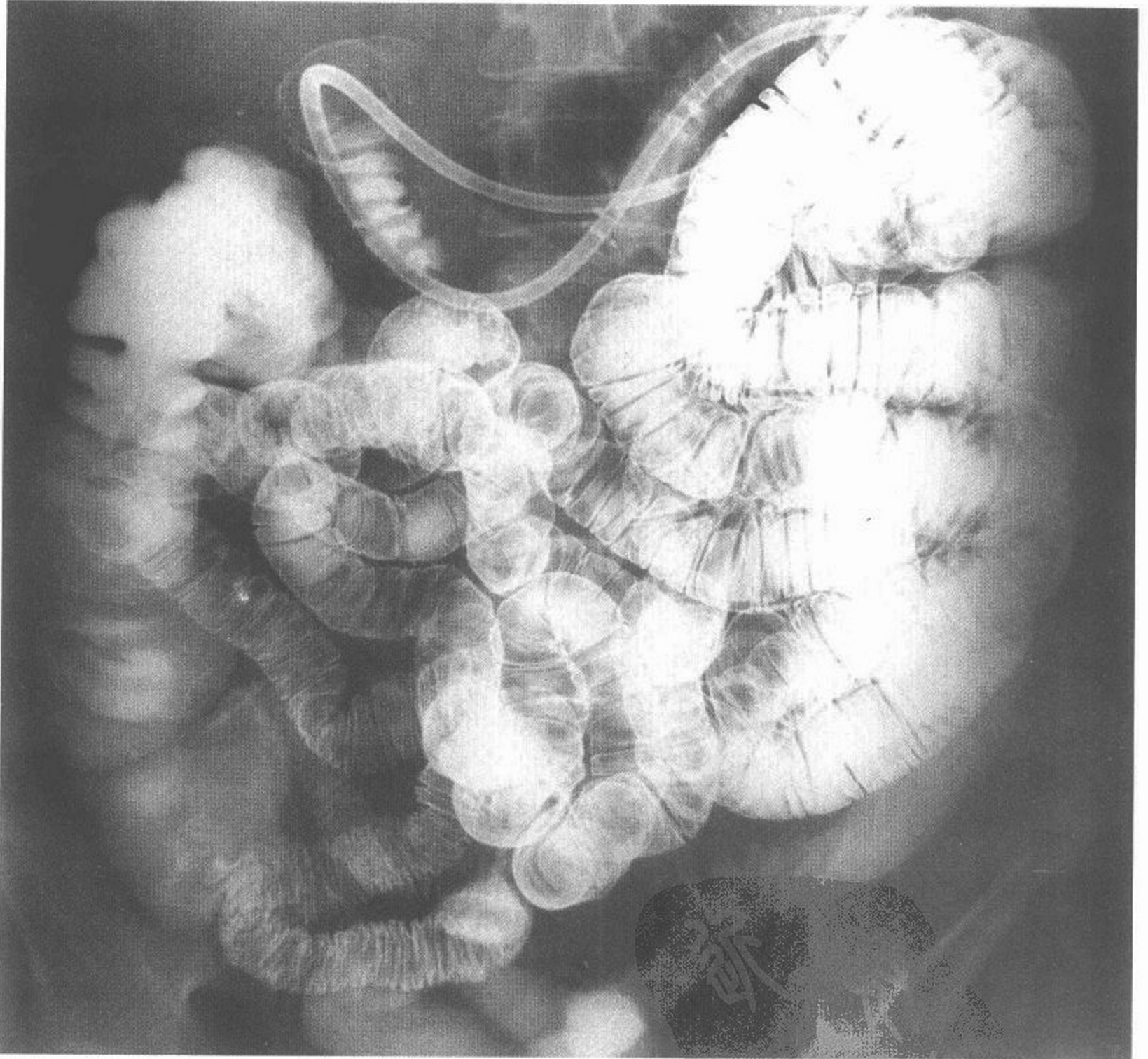
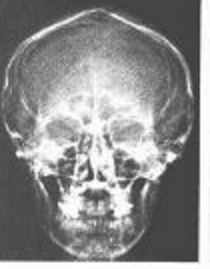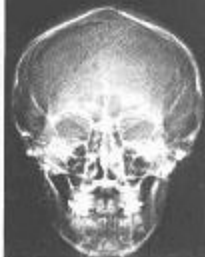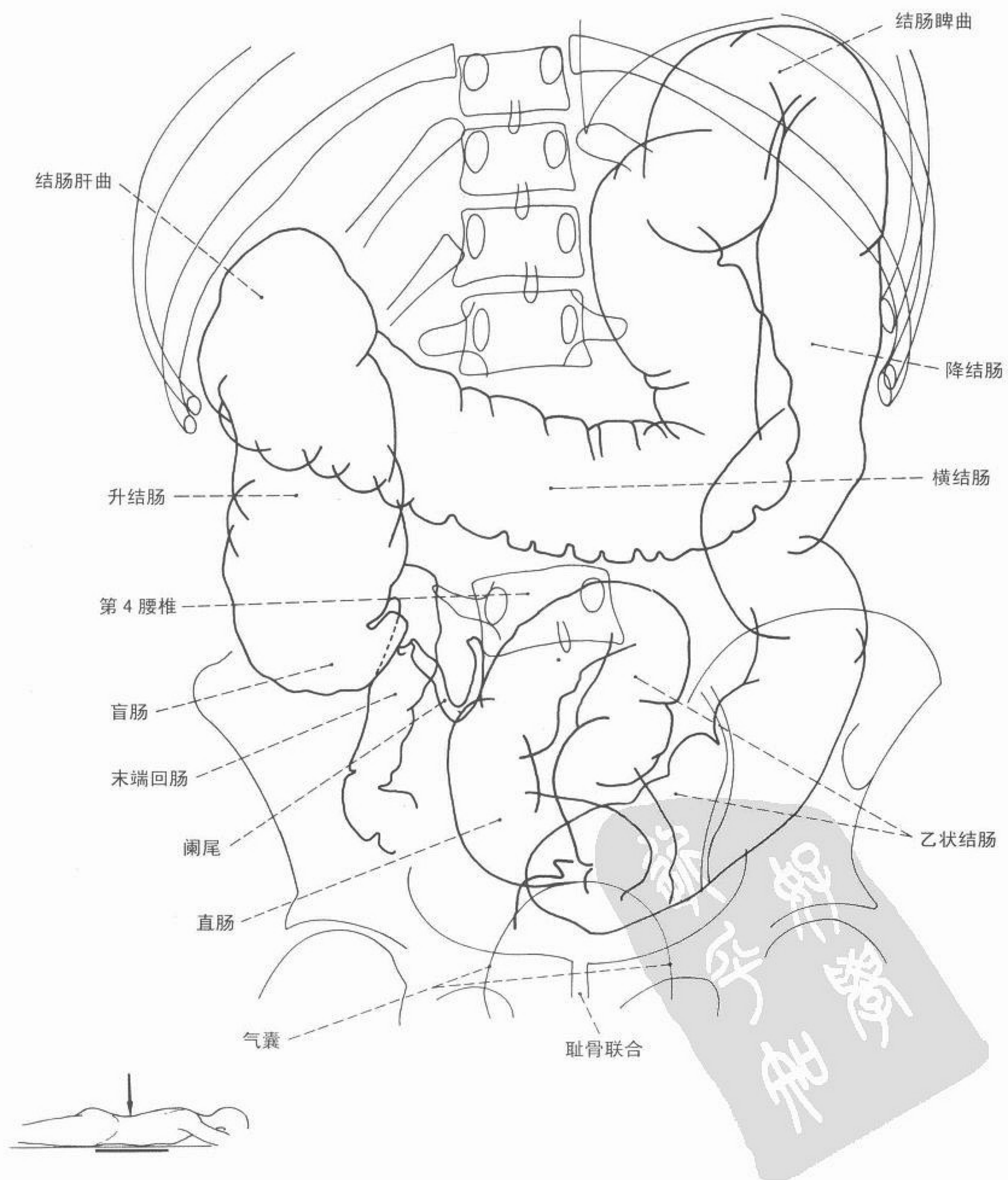


图 82 小肠 双重对比(灌肠)仰卧前后位



X 线平片



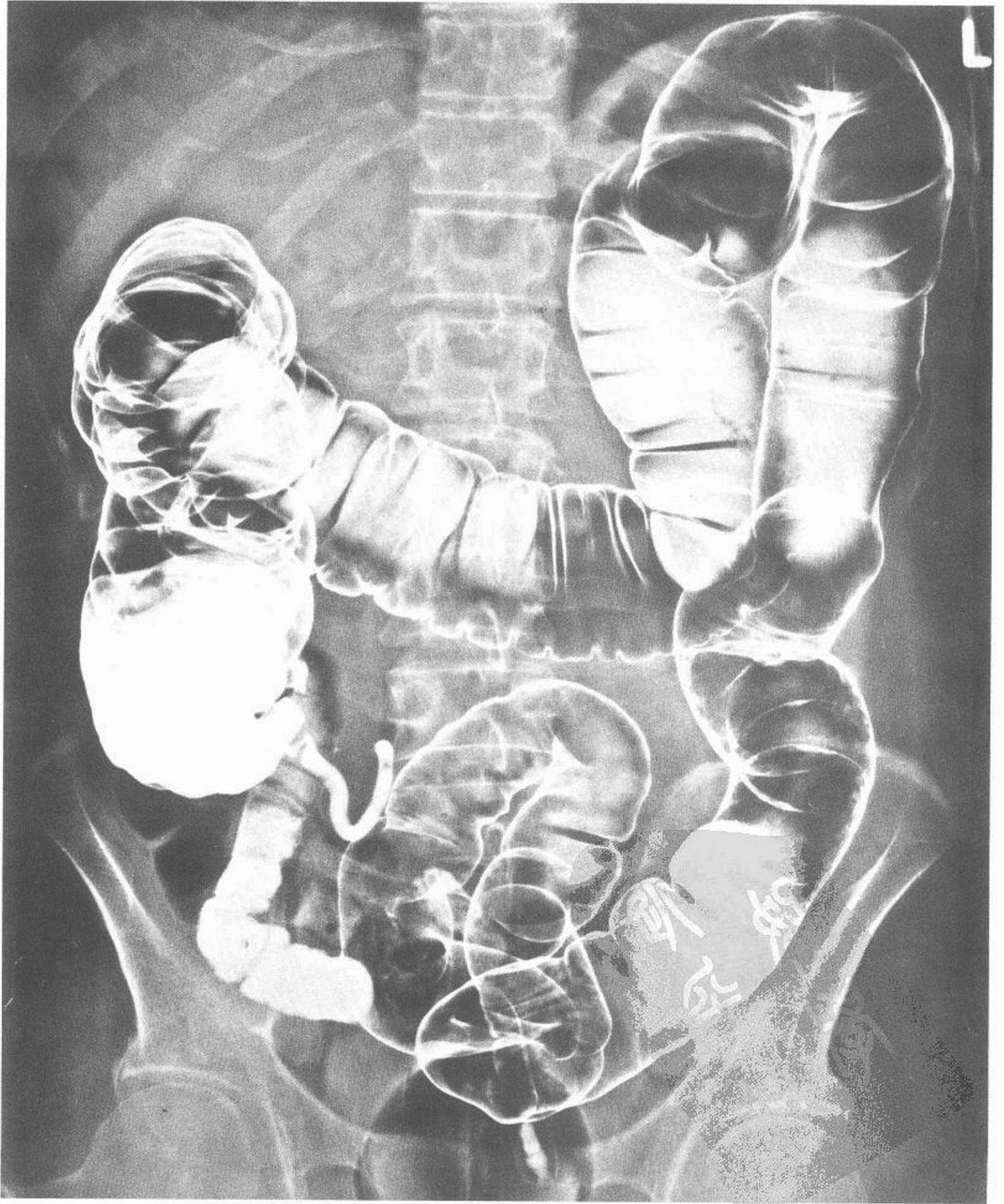
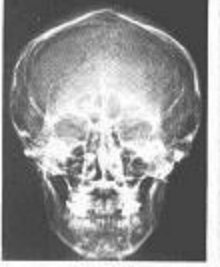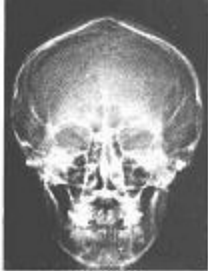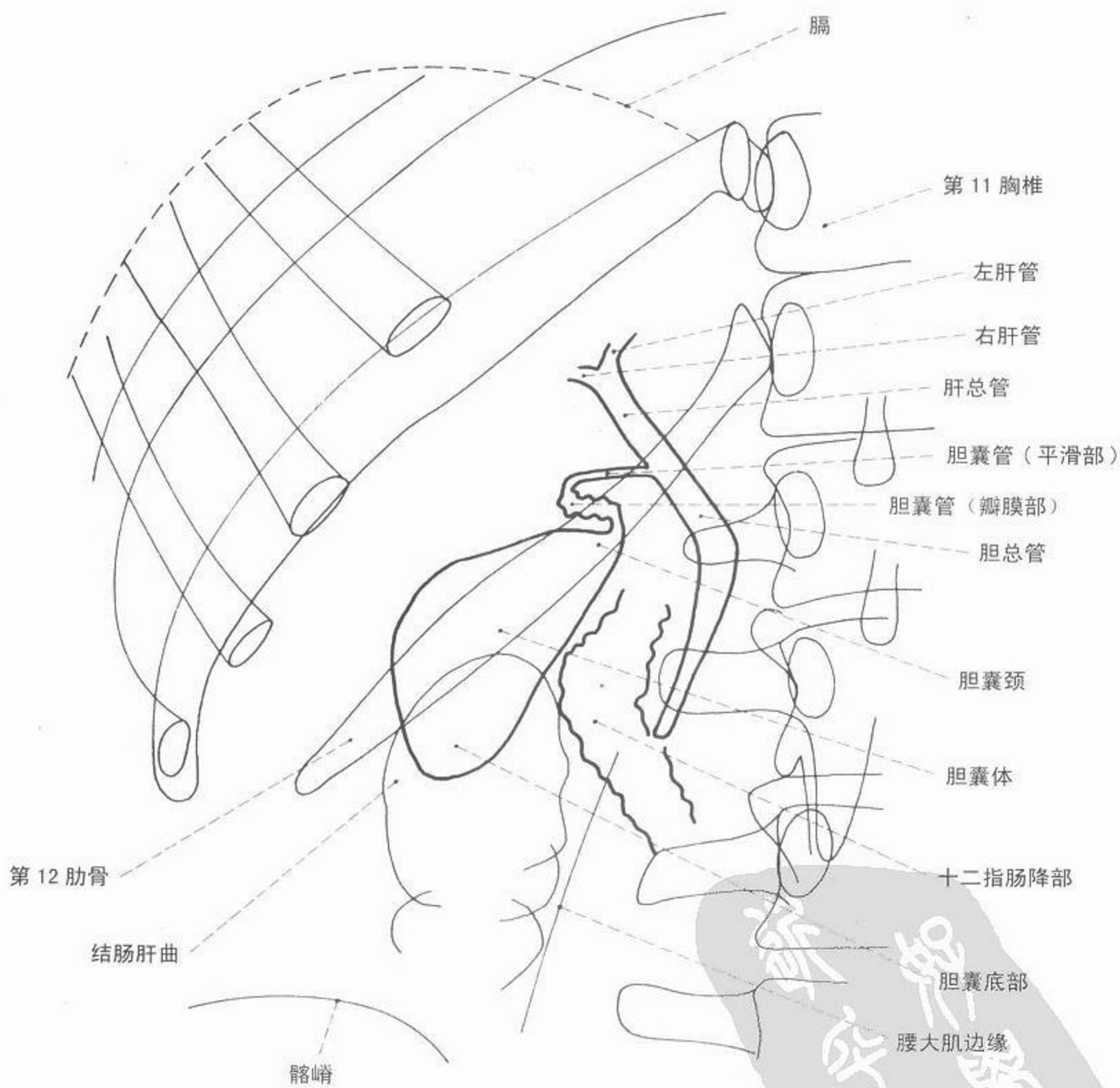


图 83 结肠 双重对比(灌肠)仰卧前后位



X 线平片



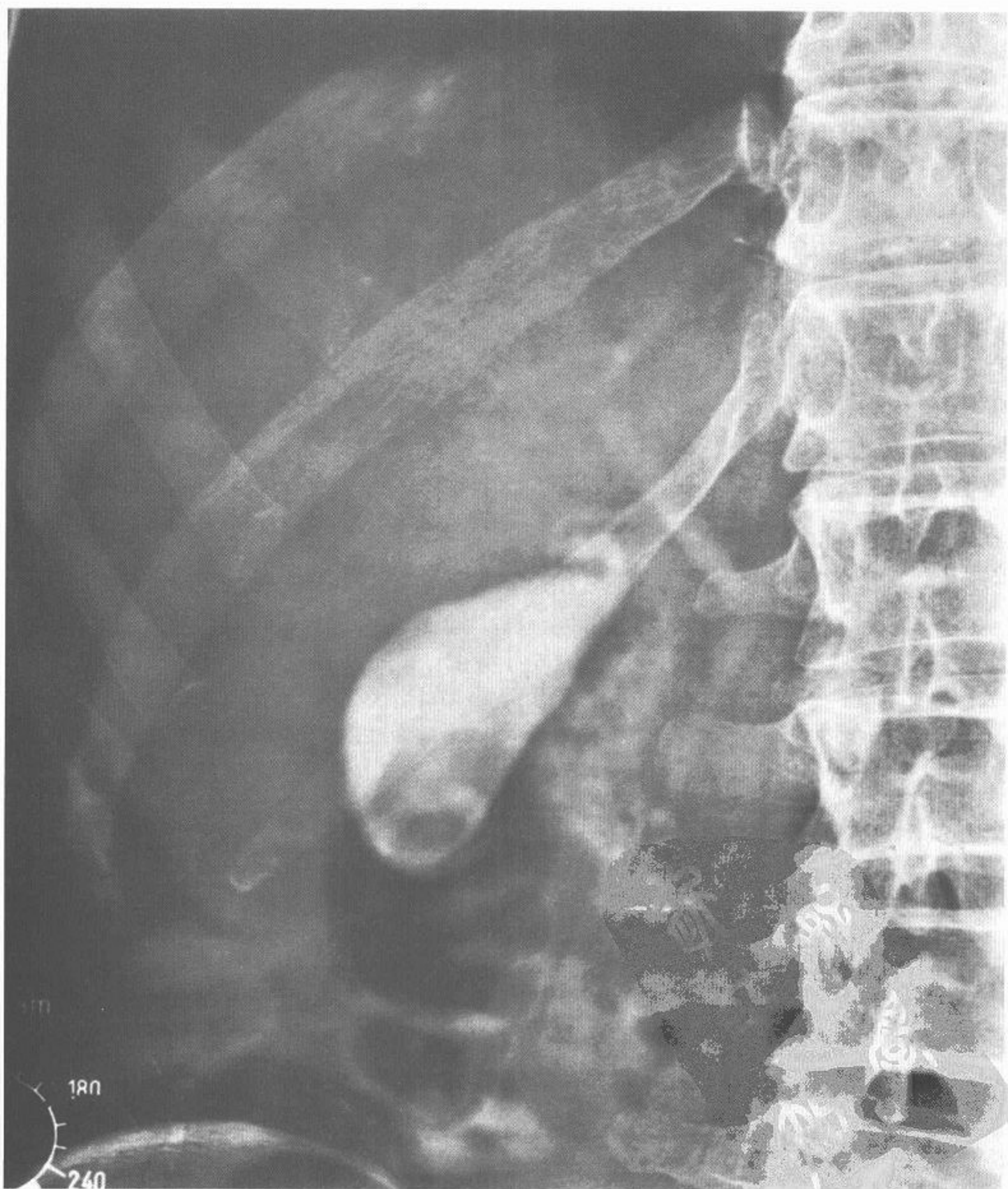
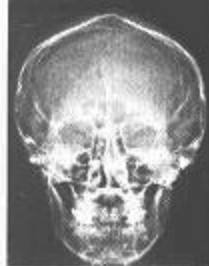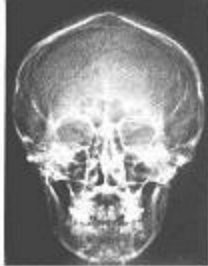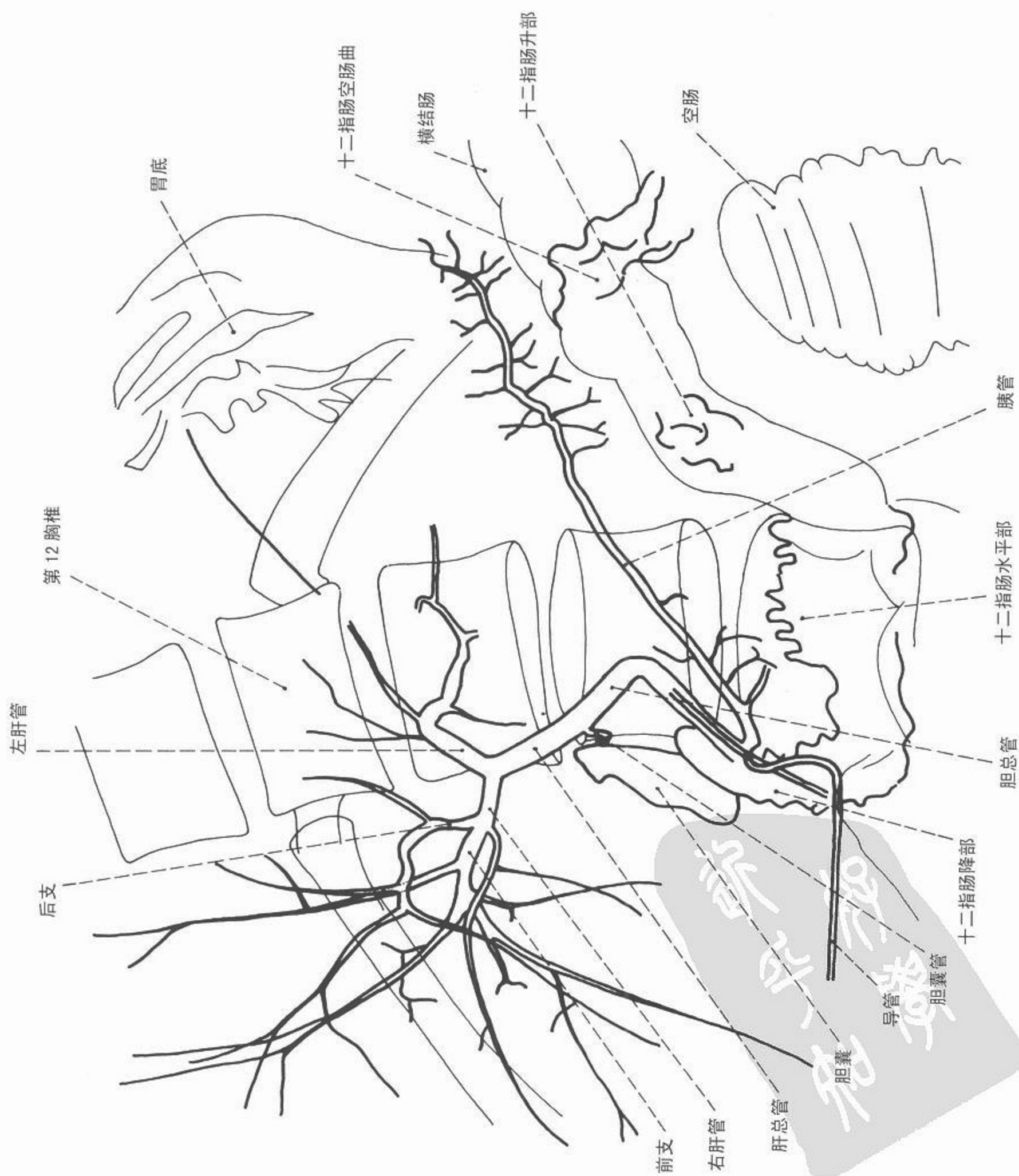


图 84 经静脉胆囊造影



X 线平片



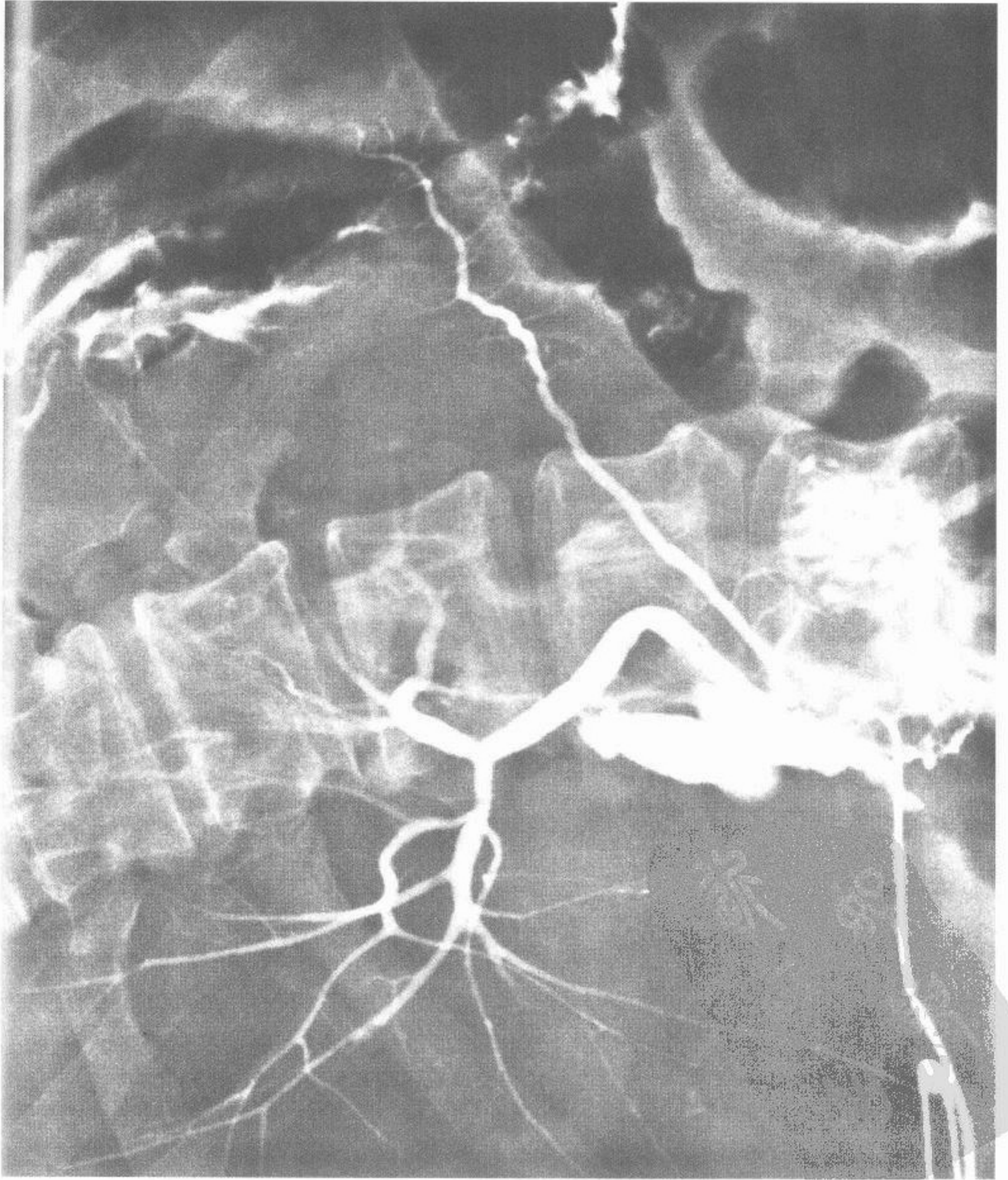
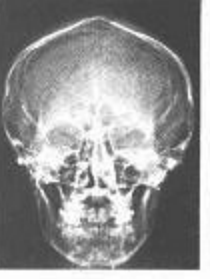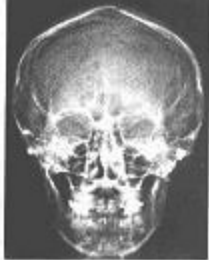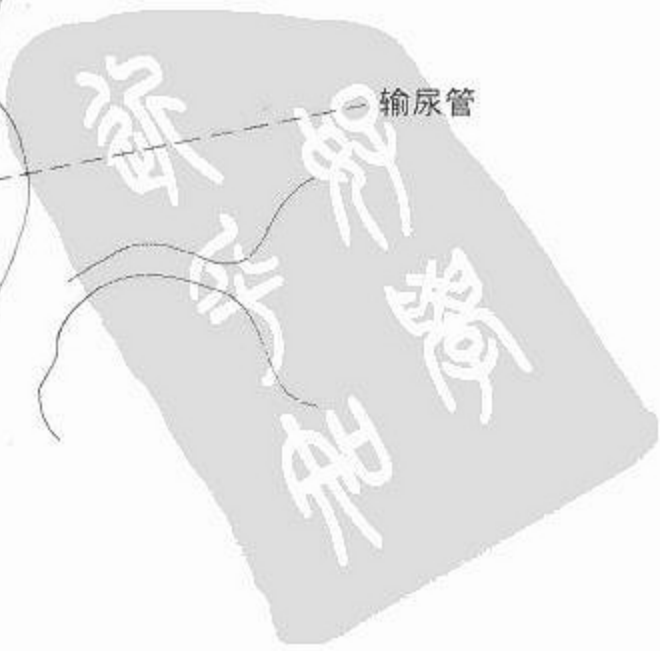
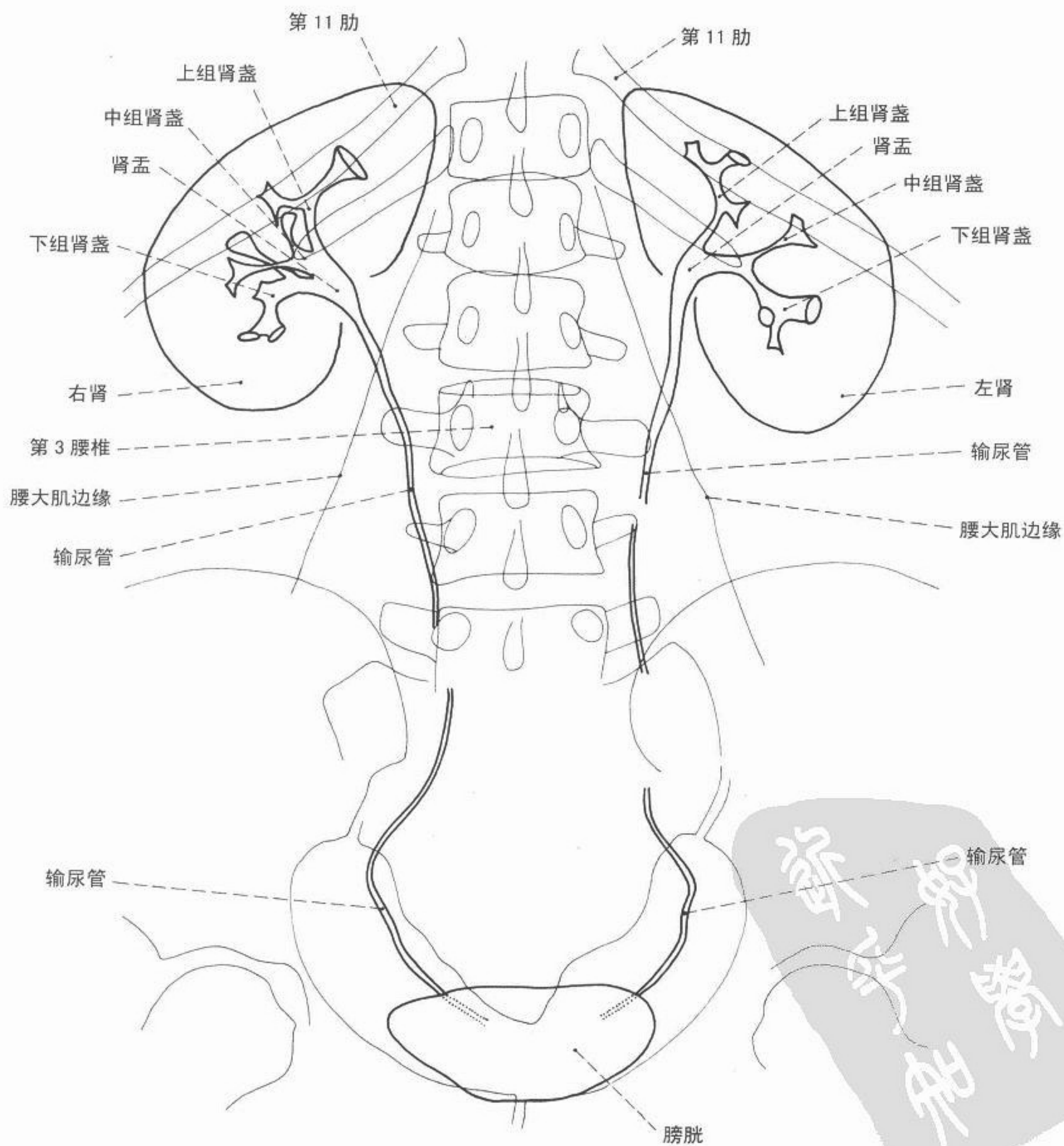


图 85 经 T 管逆行胰胆管造影



X 线平片



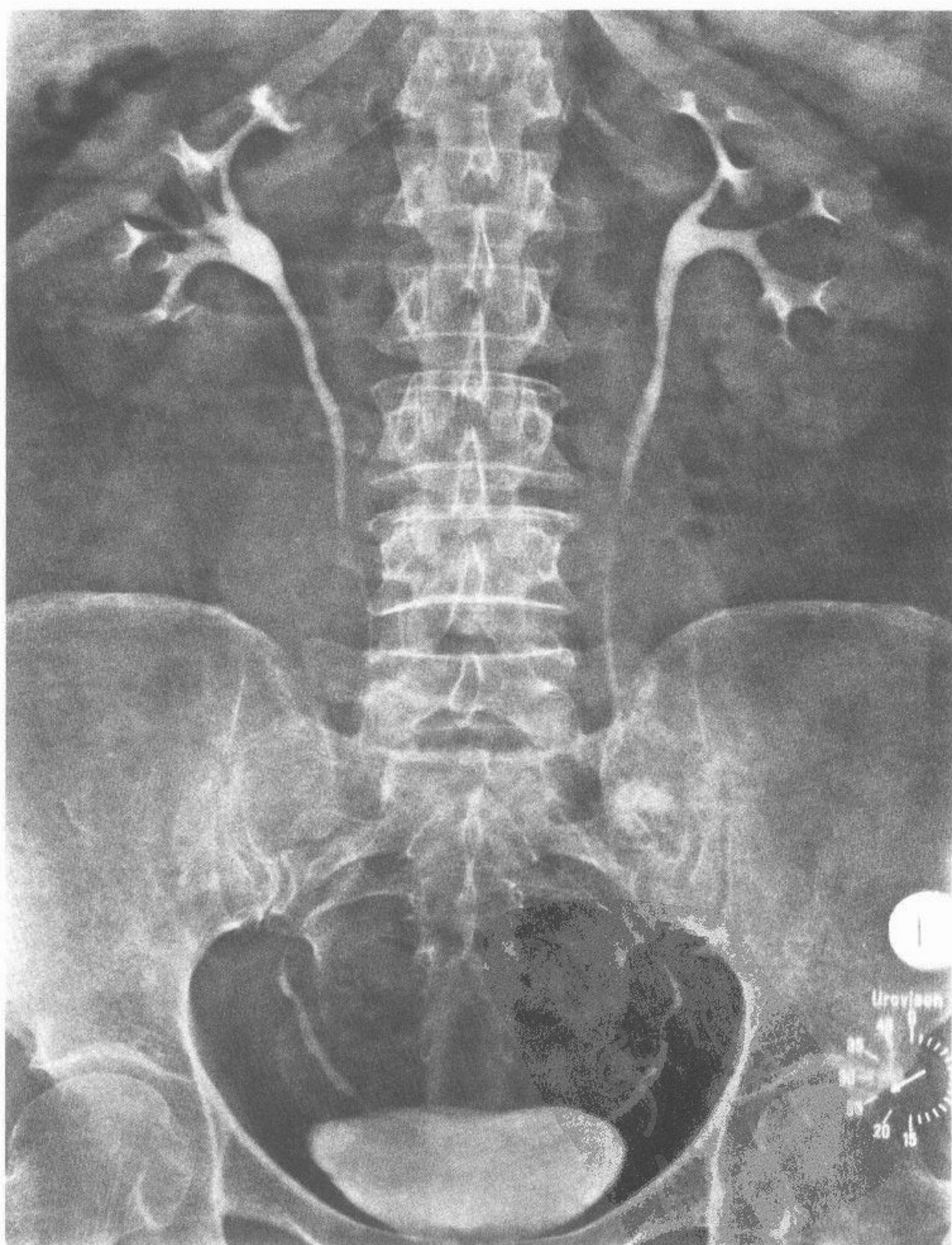
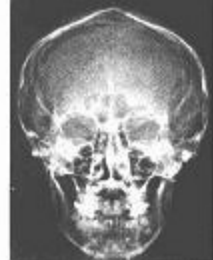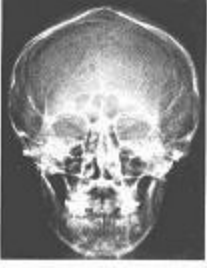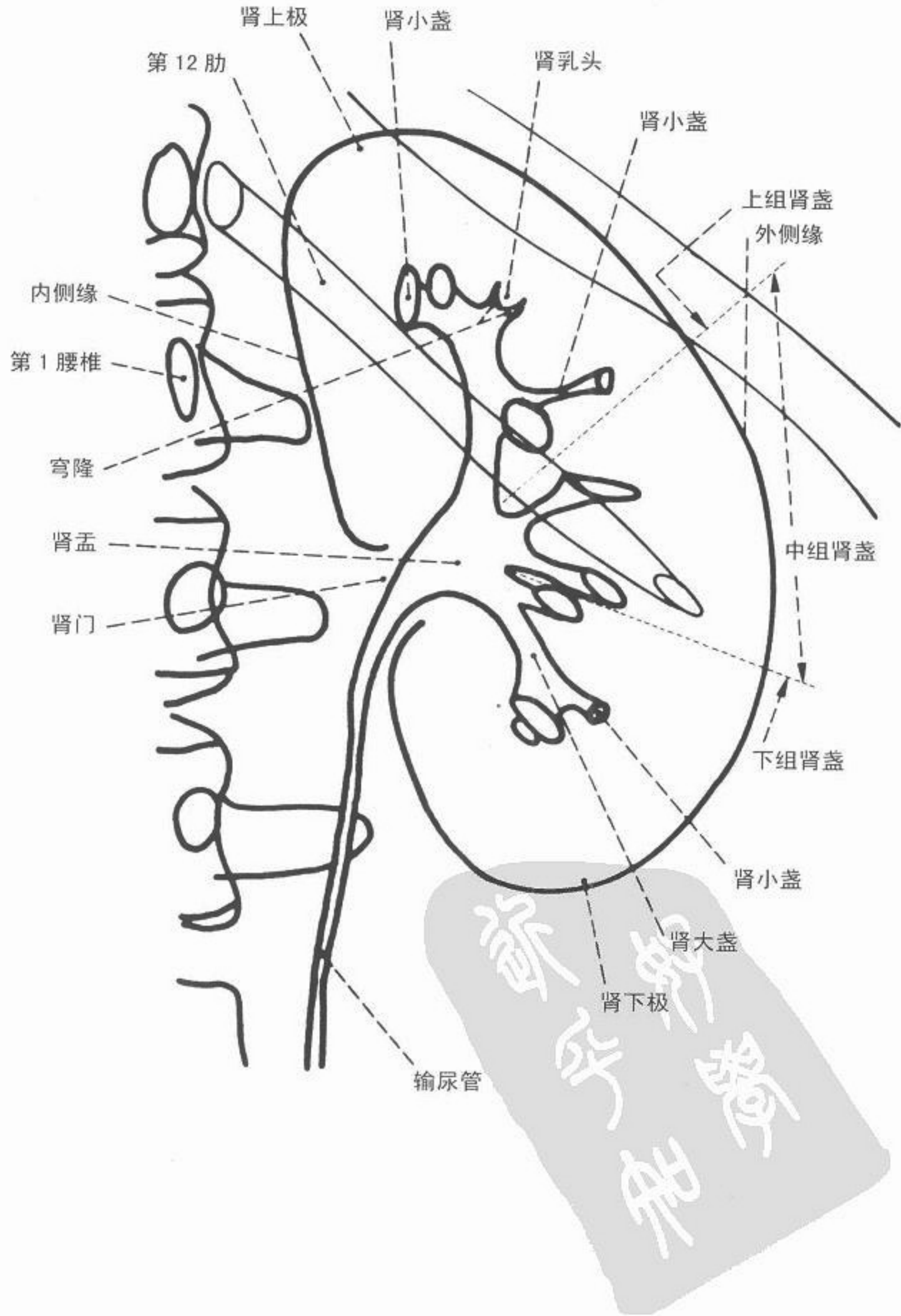


图 86 静脉尿路造影



X 线平片



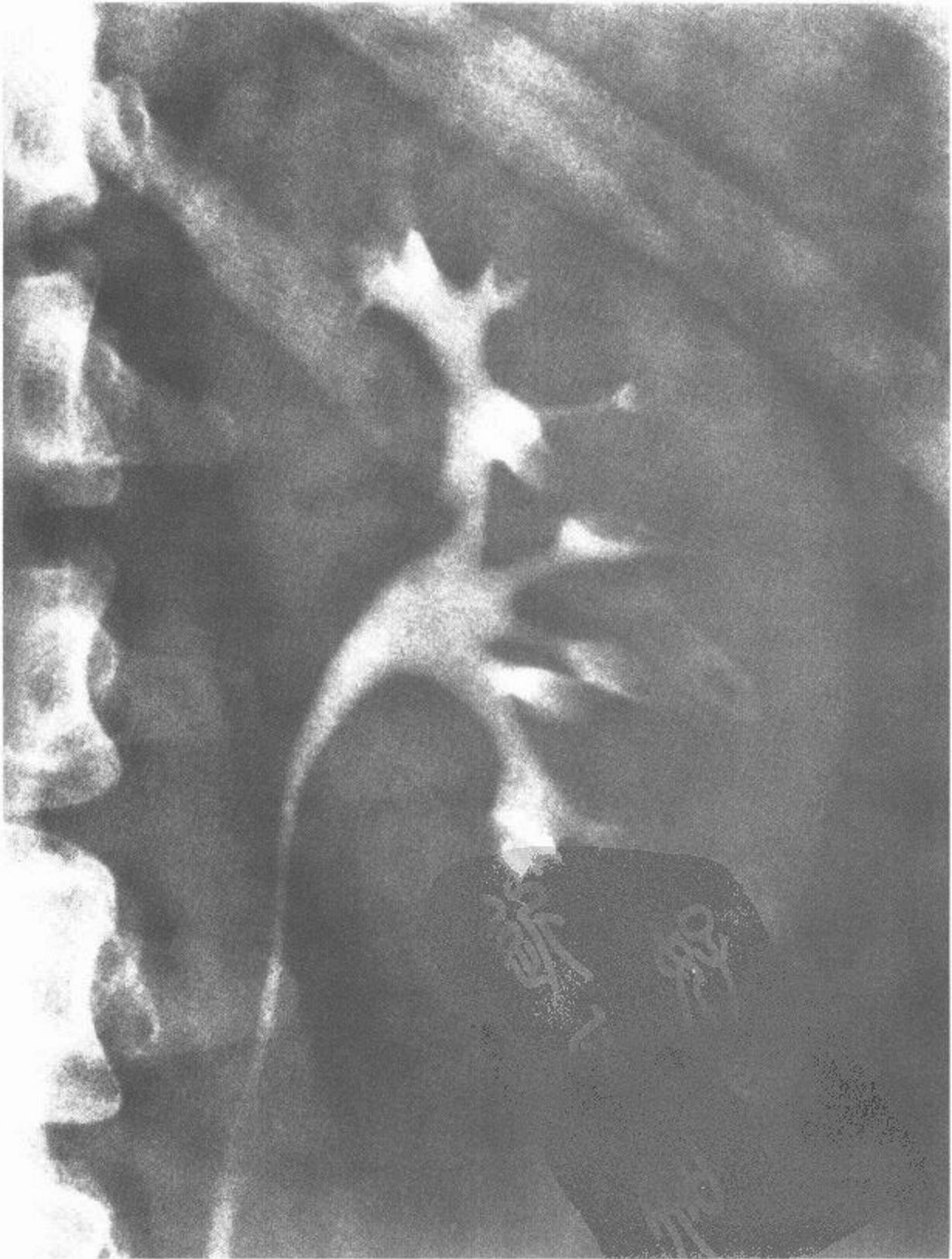
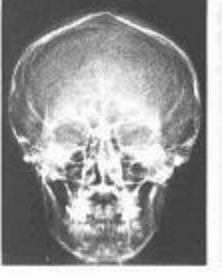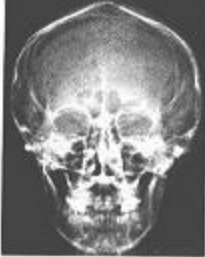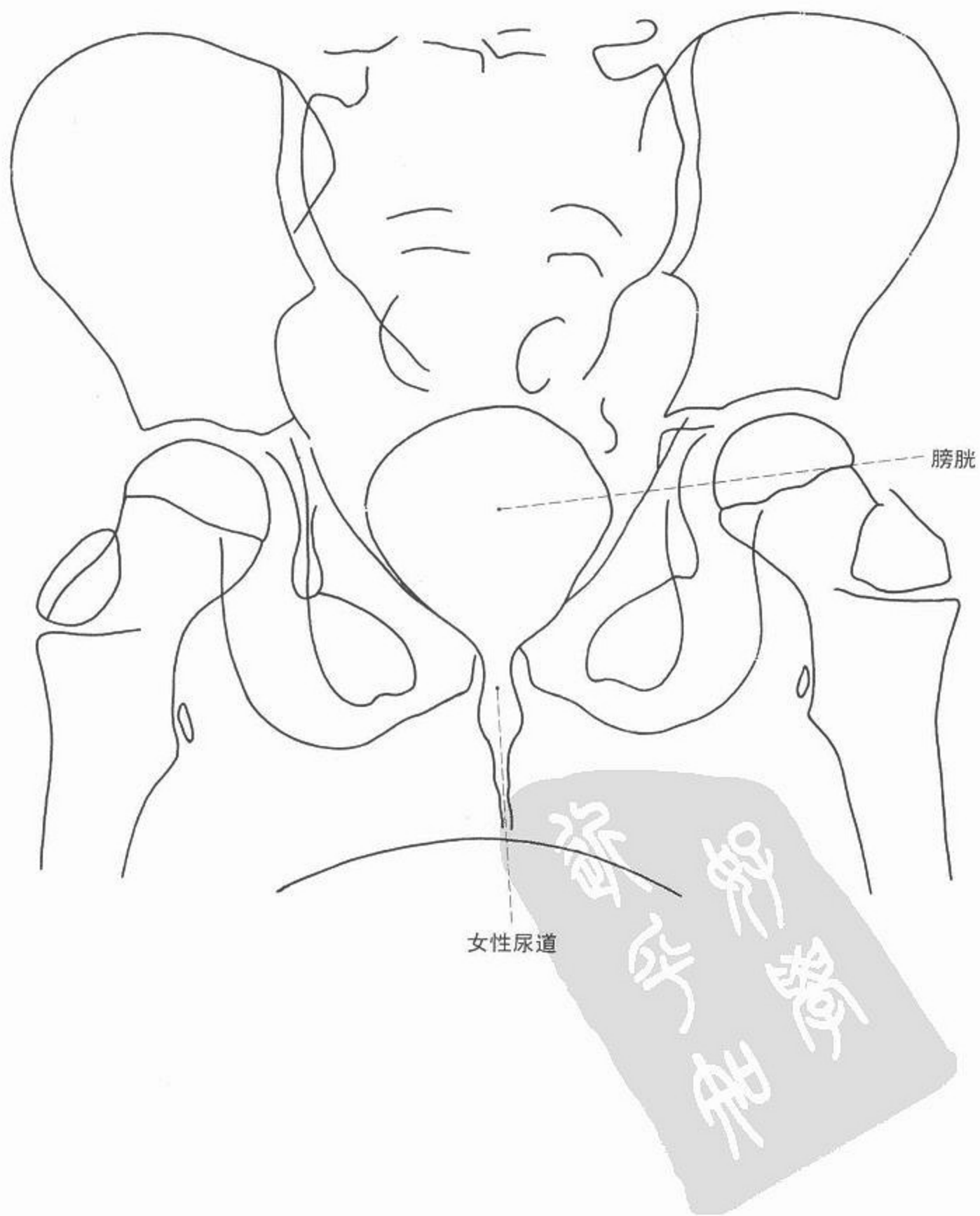


图 87 静脉尿路造影(左肾)



X 线平片



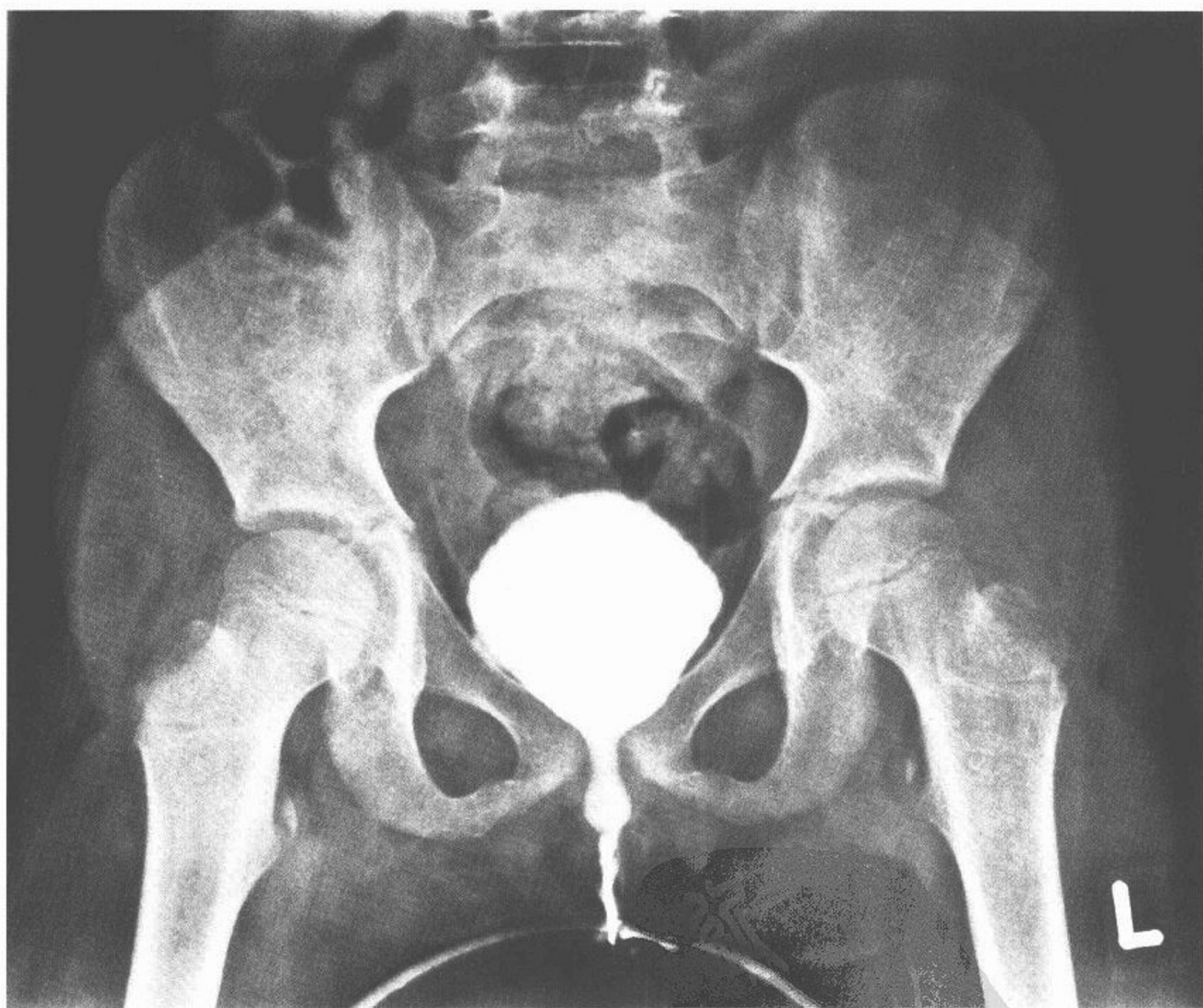
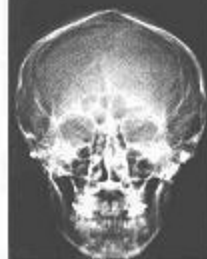
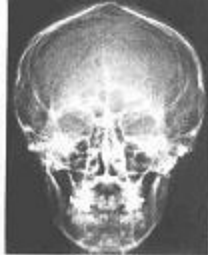
图 88 女性膀胱尿道逆行造影

医学影像



X 线平片

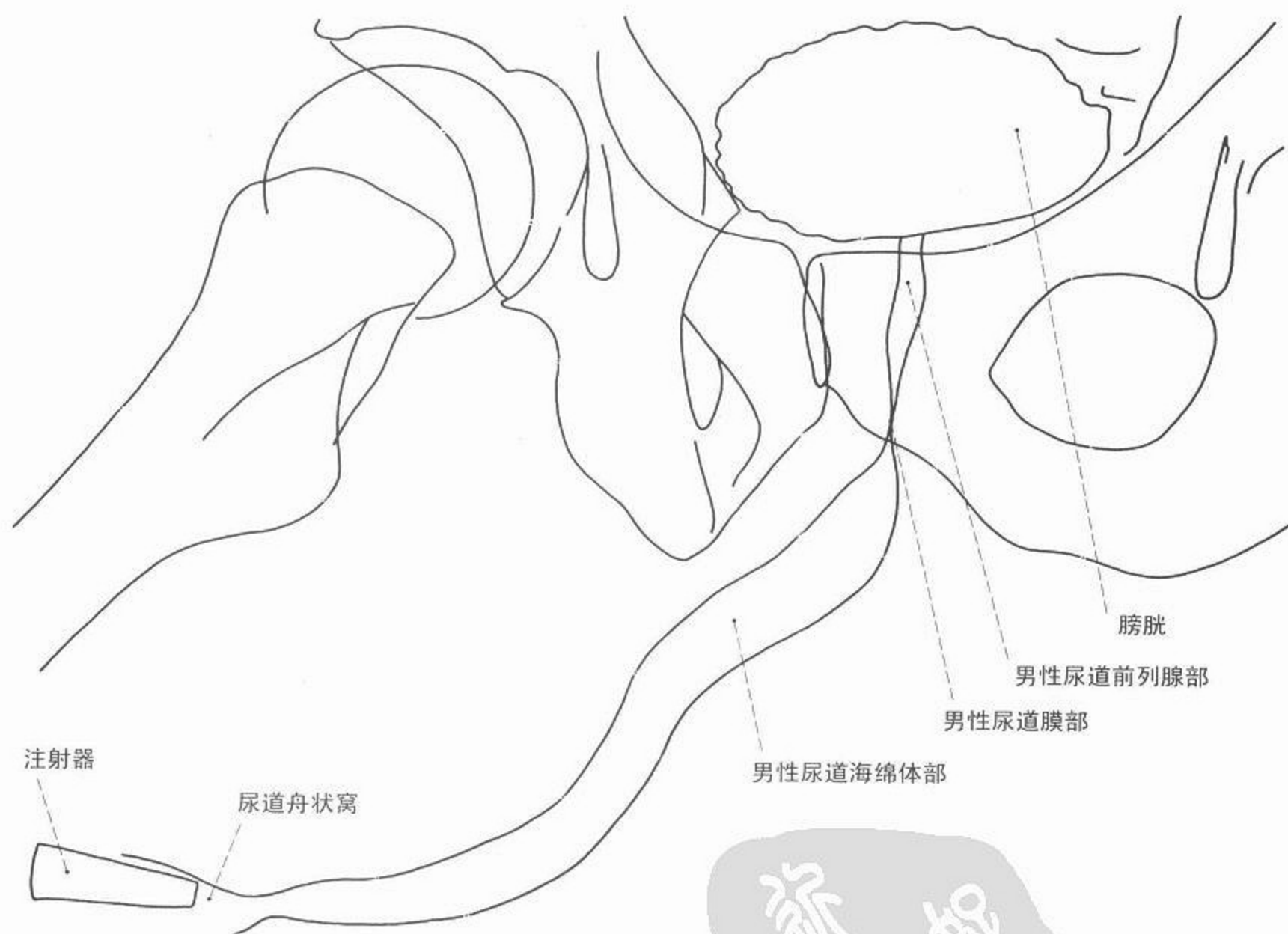

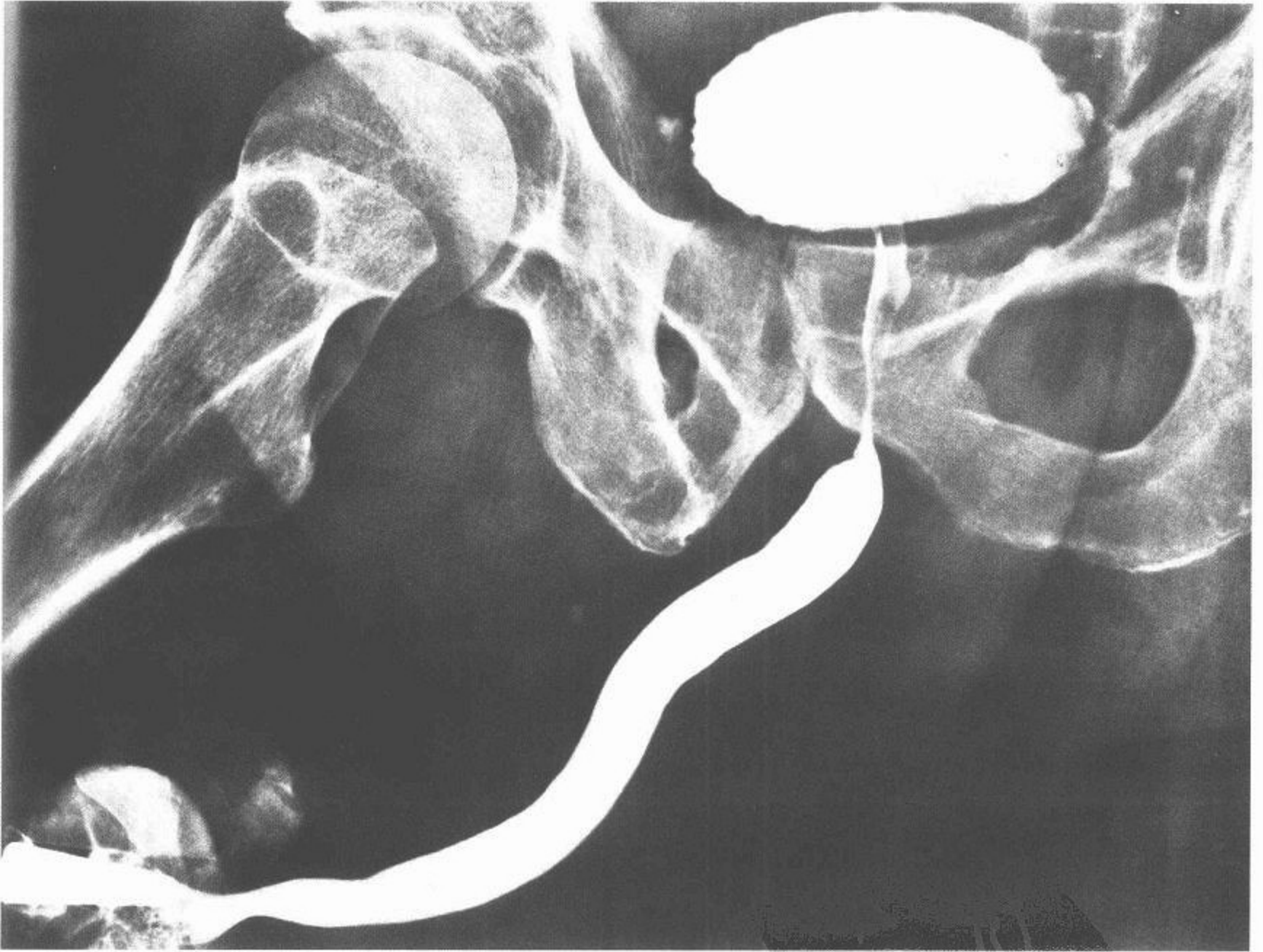
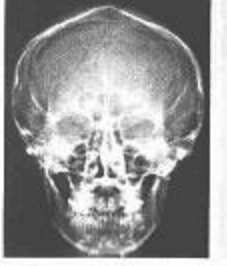
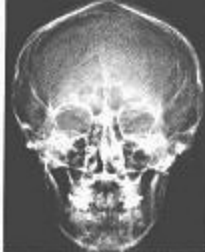
图 89 男性膀胱尿道逆行造影



血管造影

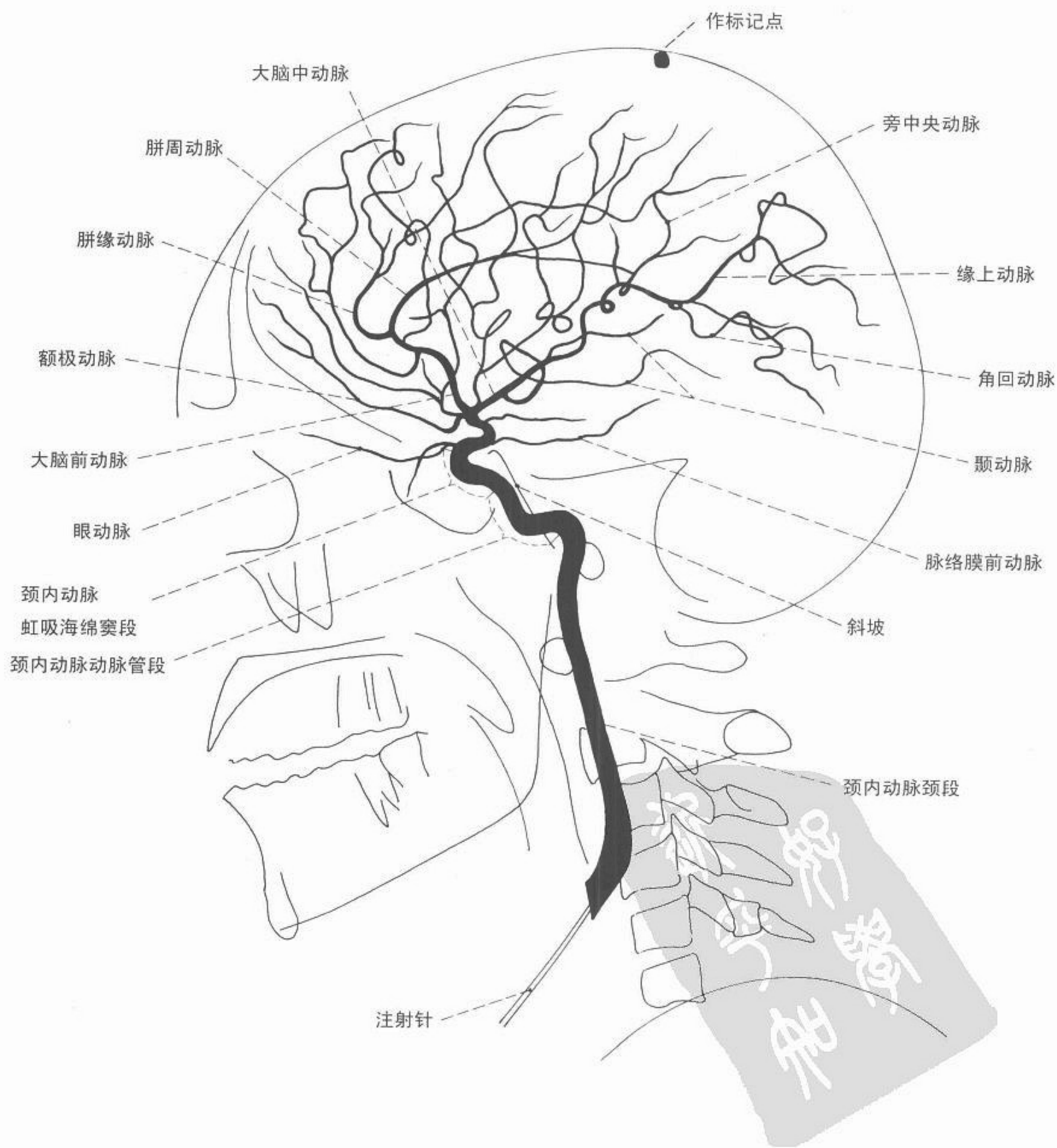

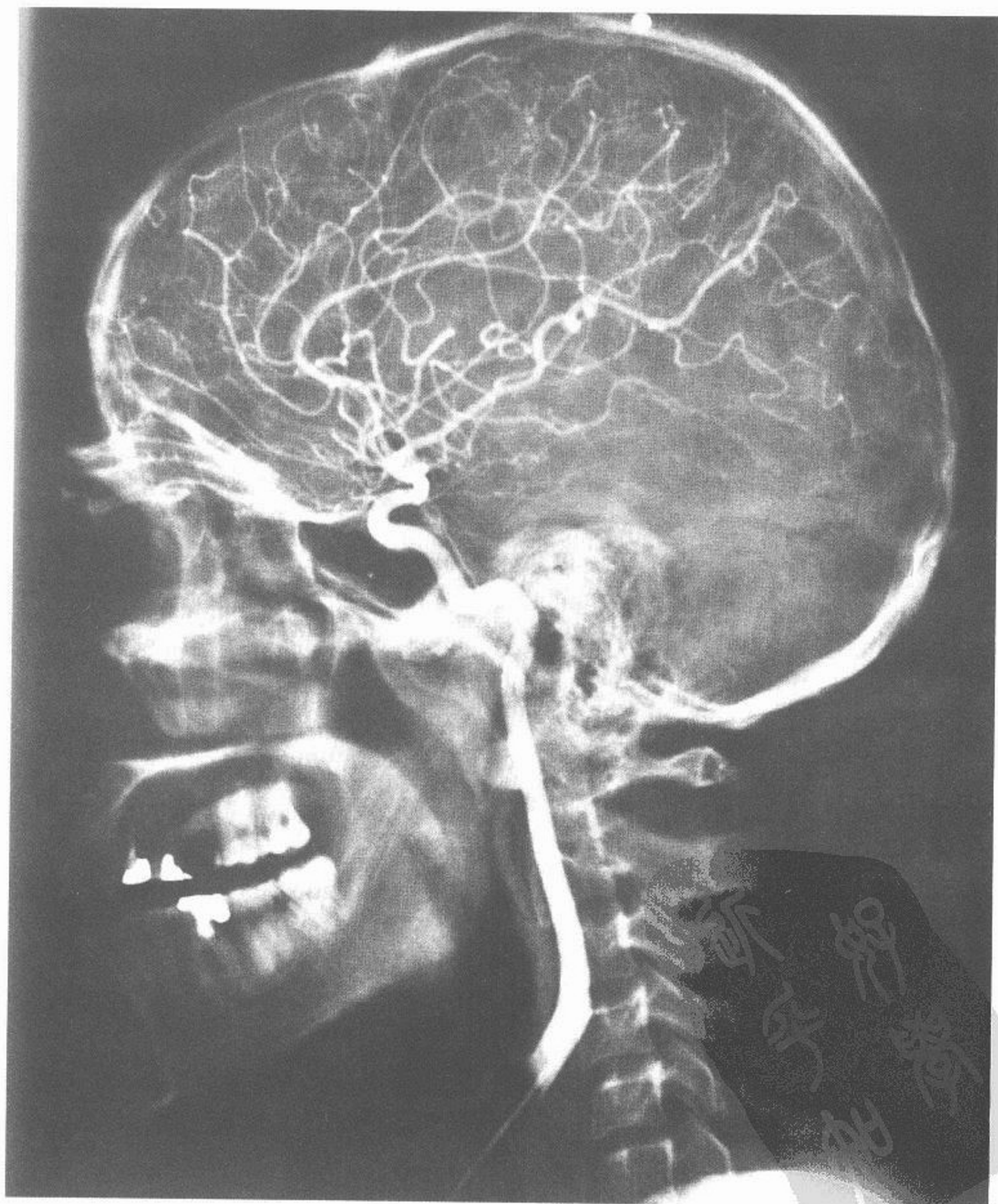
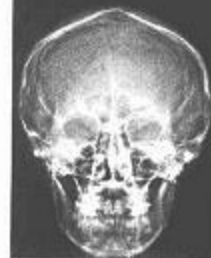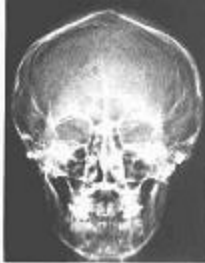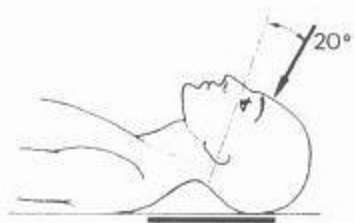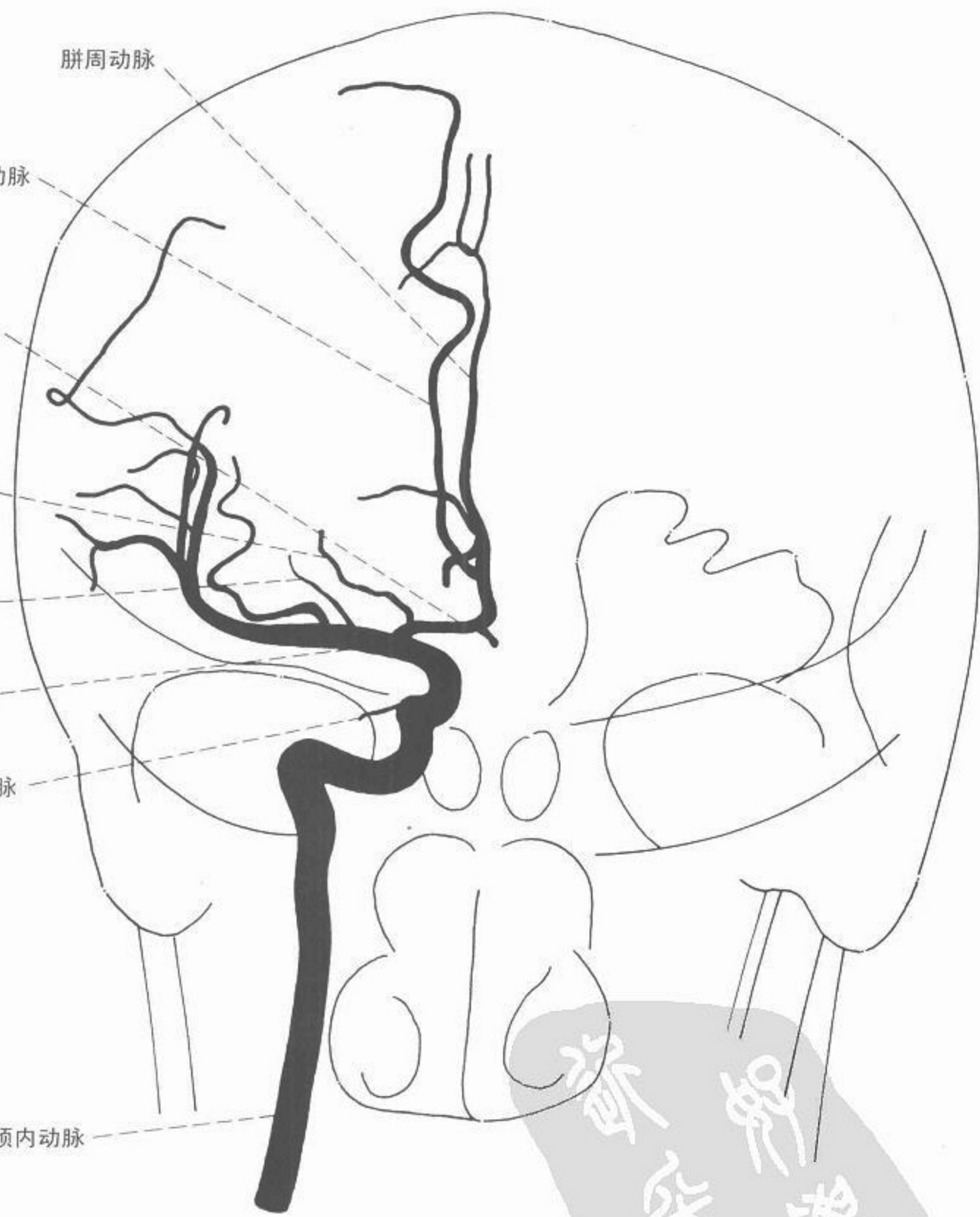


图 90 颈部血管造影 侧位

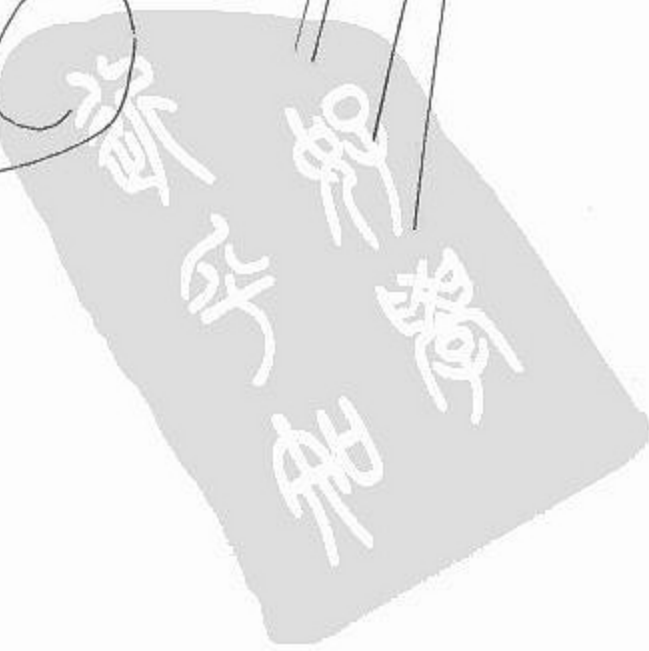

血管造影

- 胼周动脉
- 胼缘动脉
- 大脑前动脉
- 纹状体前动脉
- 豆状核动脉
- 大脑中动脉
- 眼动脉
- 颈内动脉



..... = 德国平面 (眼耳平面)



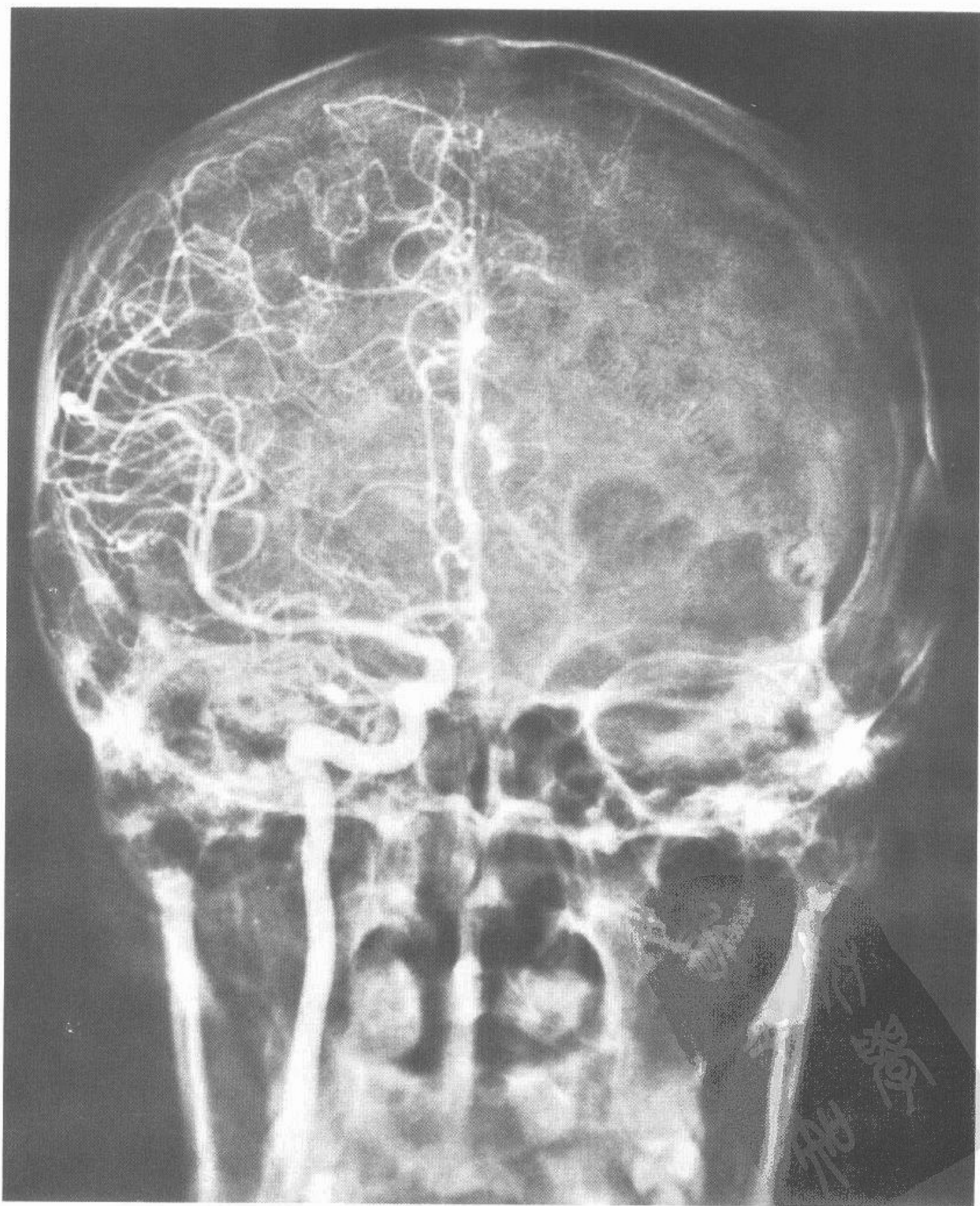
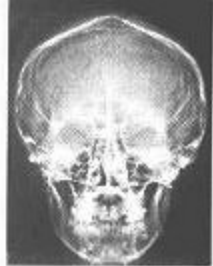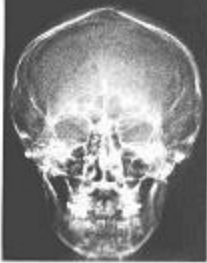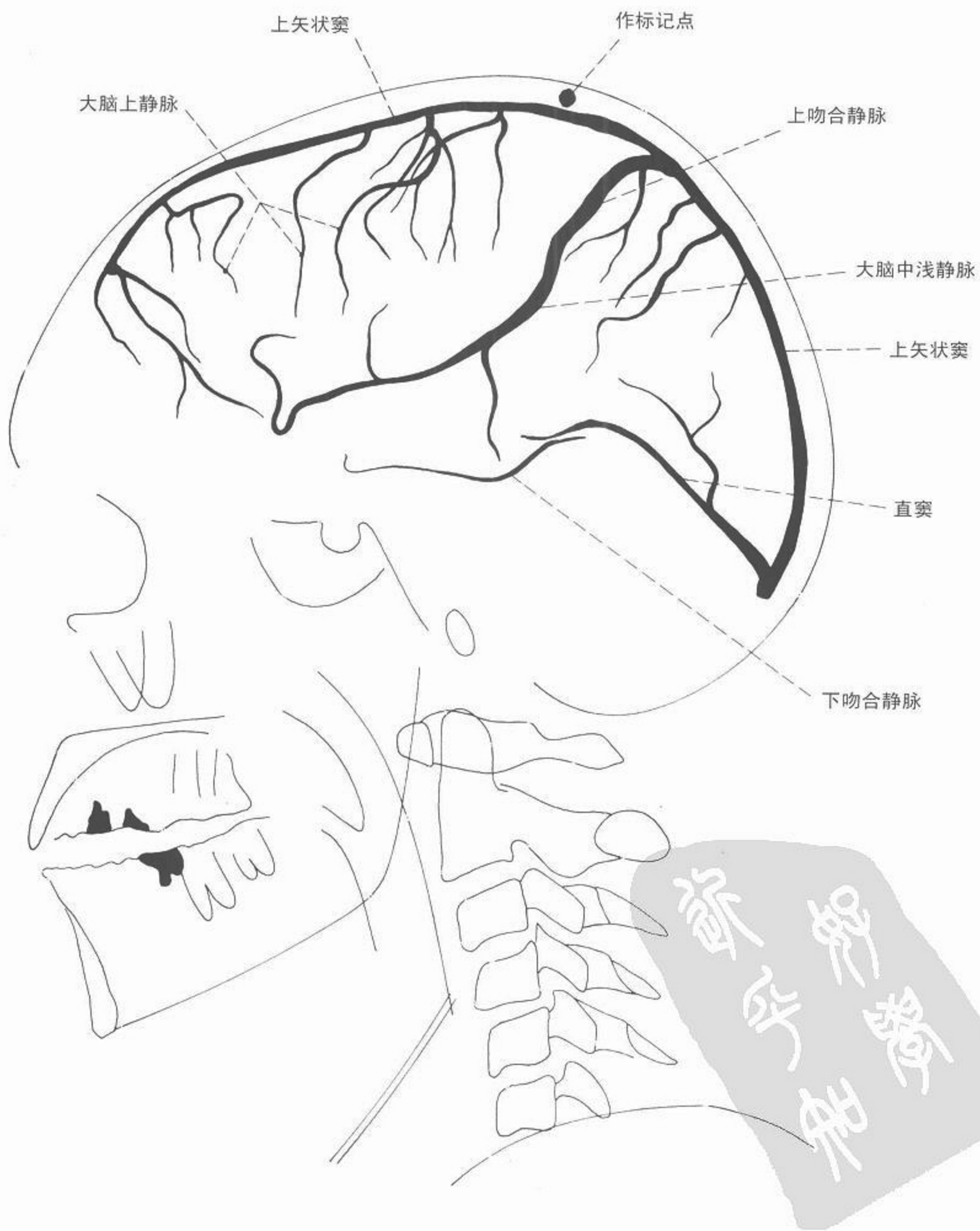


图 91 颈部血管造影 前后位



血管造影



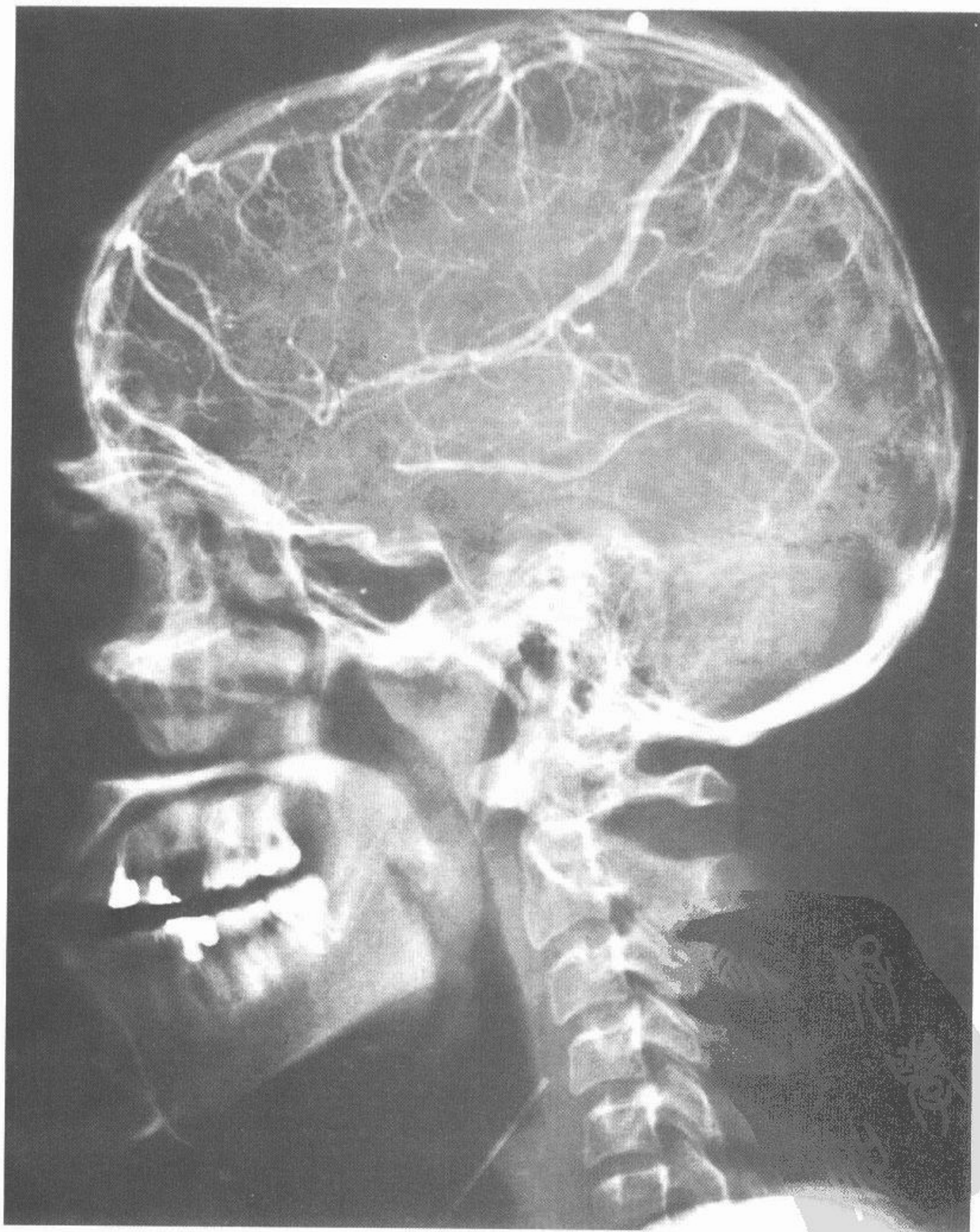
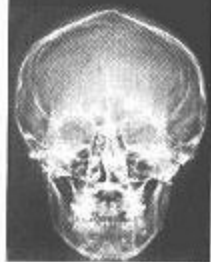
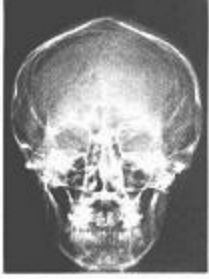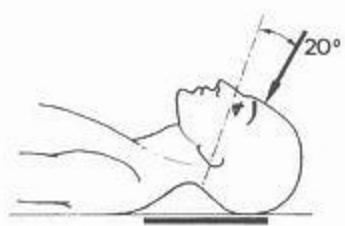
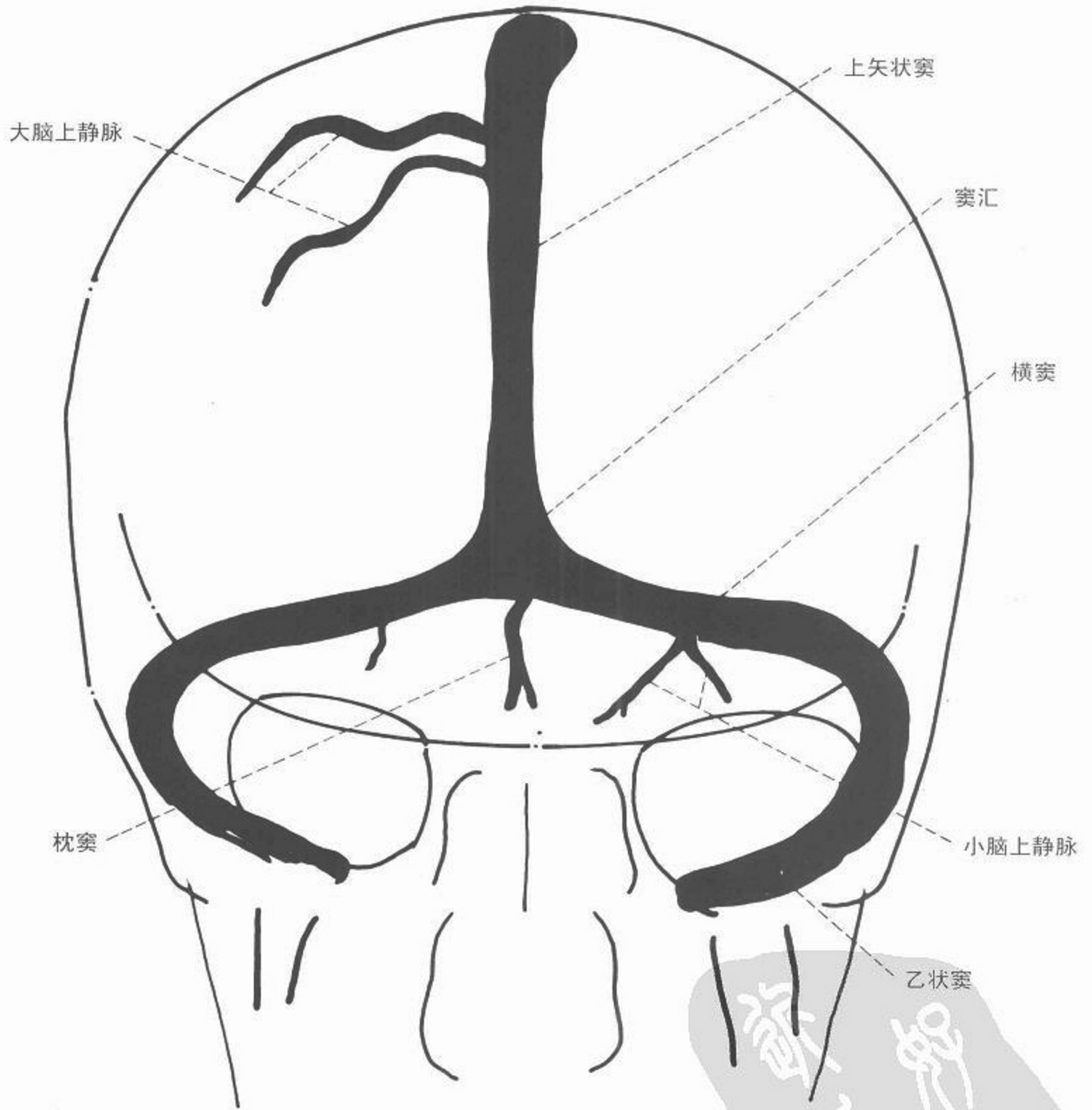



图 92 颈部血管造影 静脉期 侧位



血管造影



..... 德国平面 (眼耳平面)



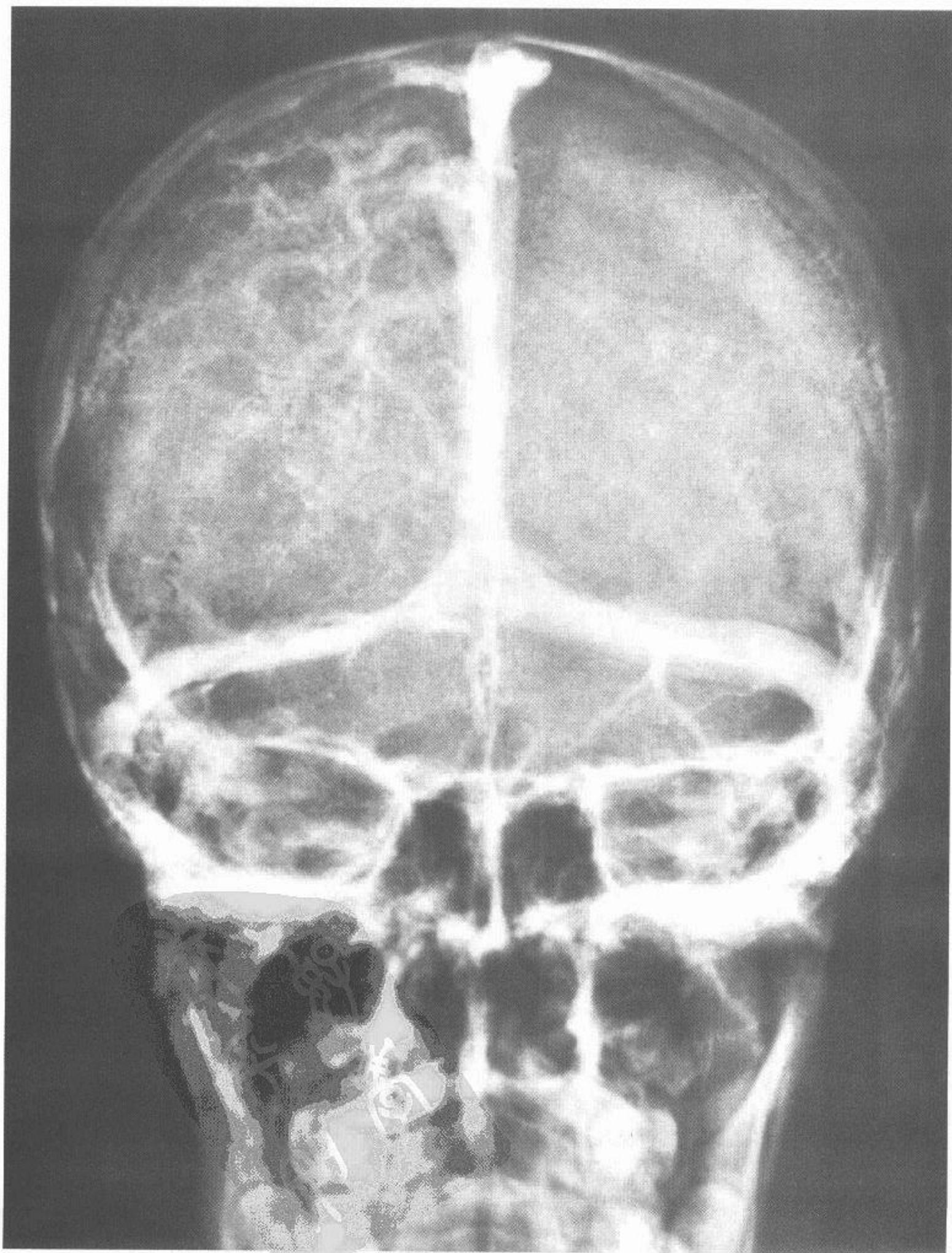
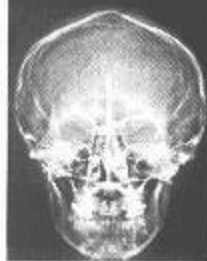
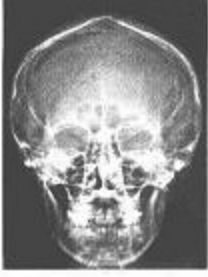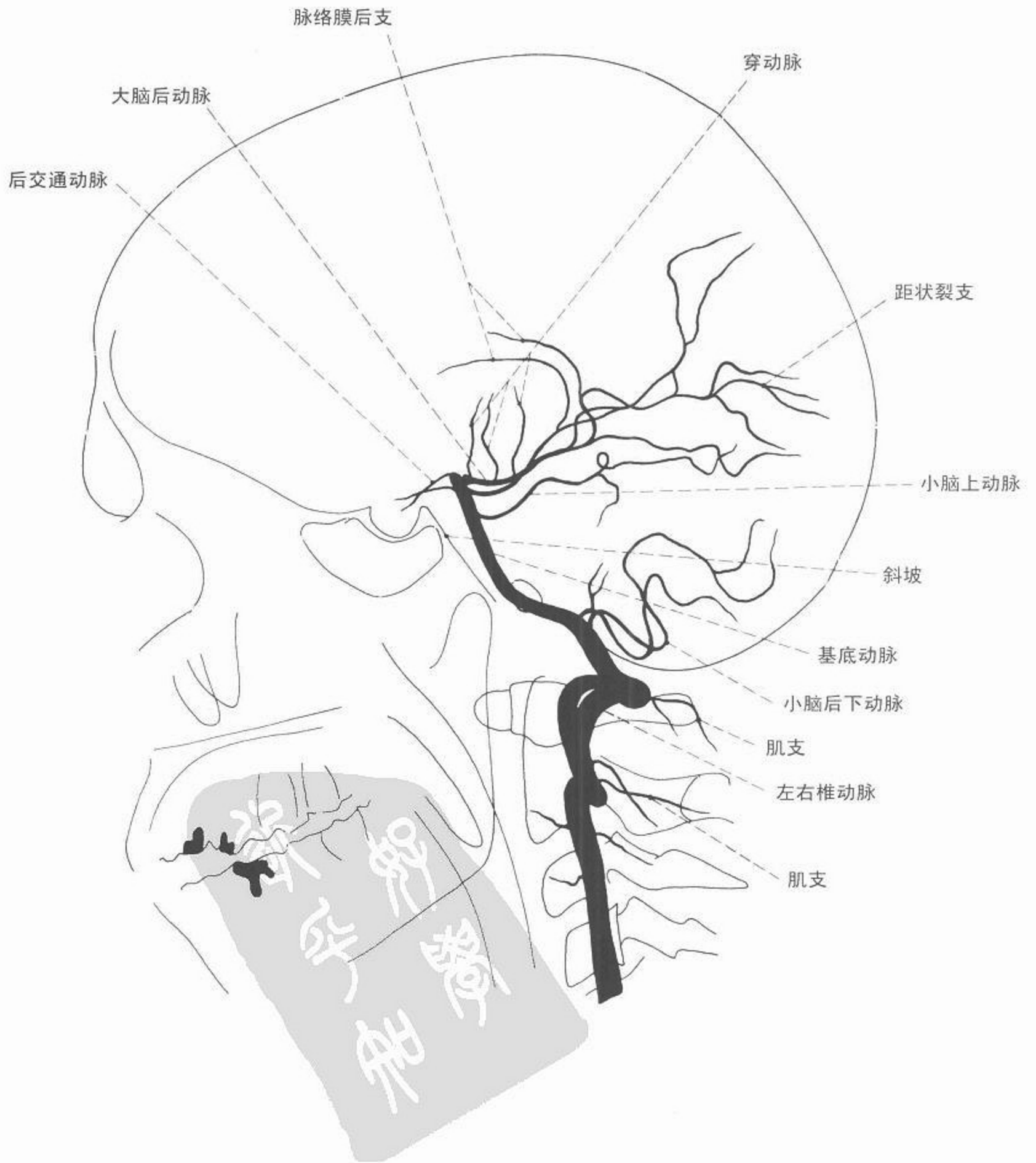


图 93 颈部血管造影 静脉期 前后位



血管造影



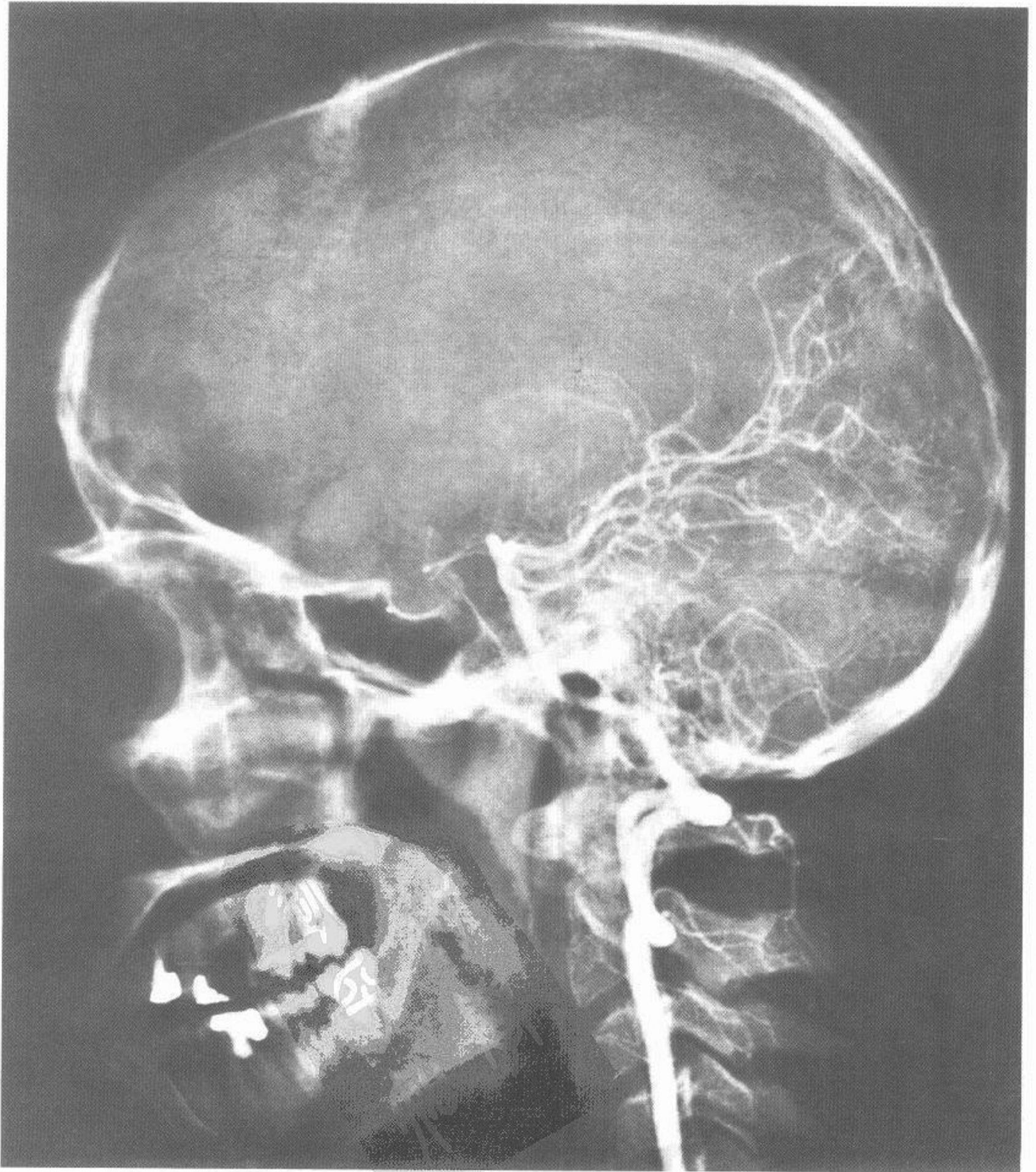
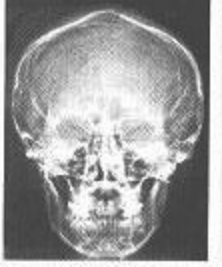
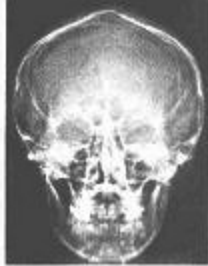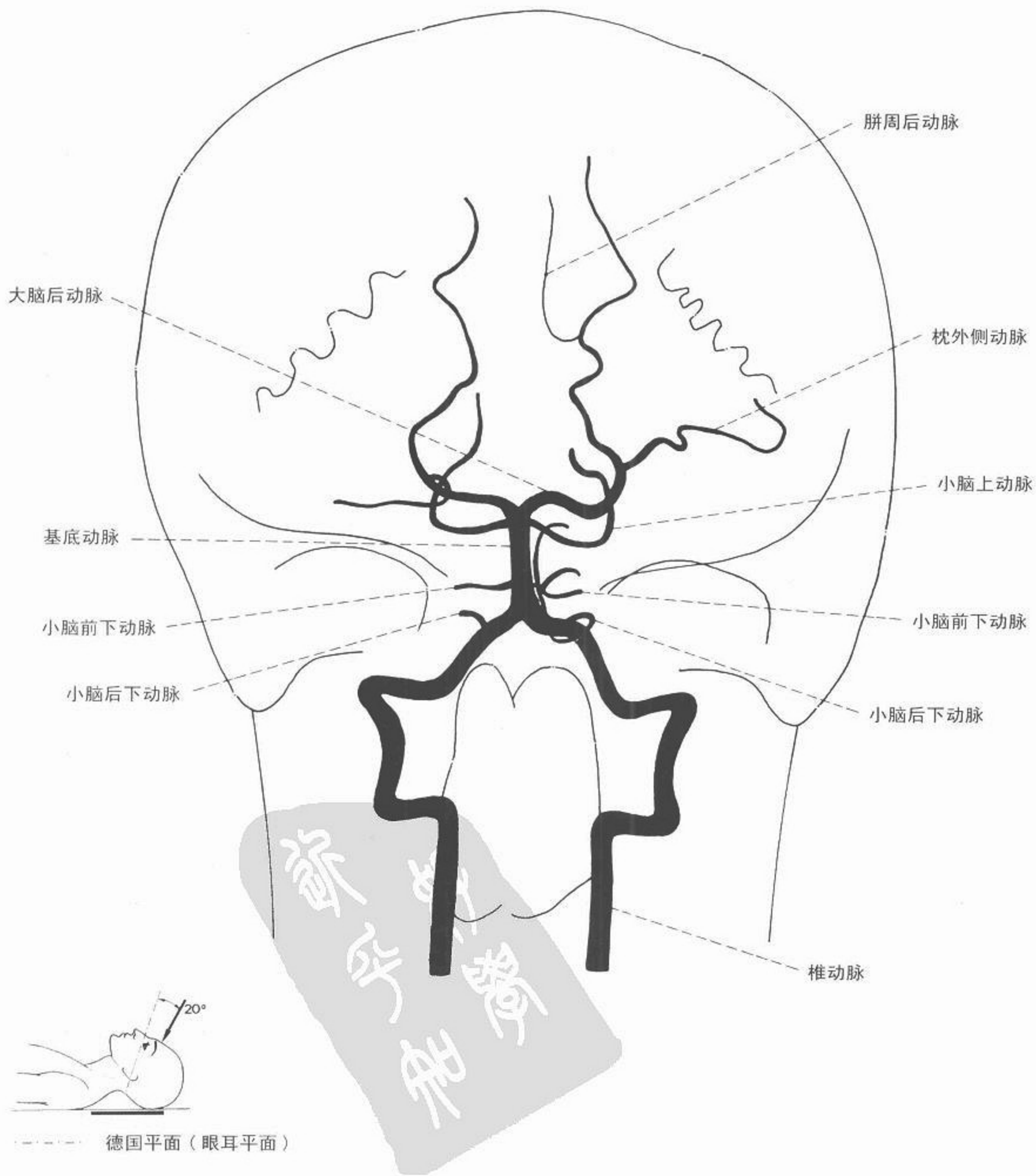


图 94 椎基底血管造影 侧位



血管造影



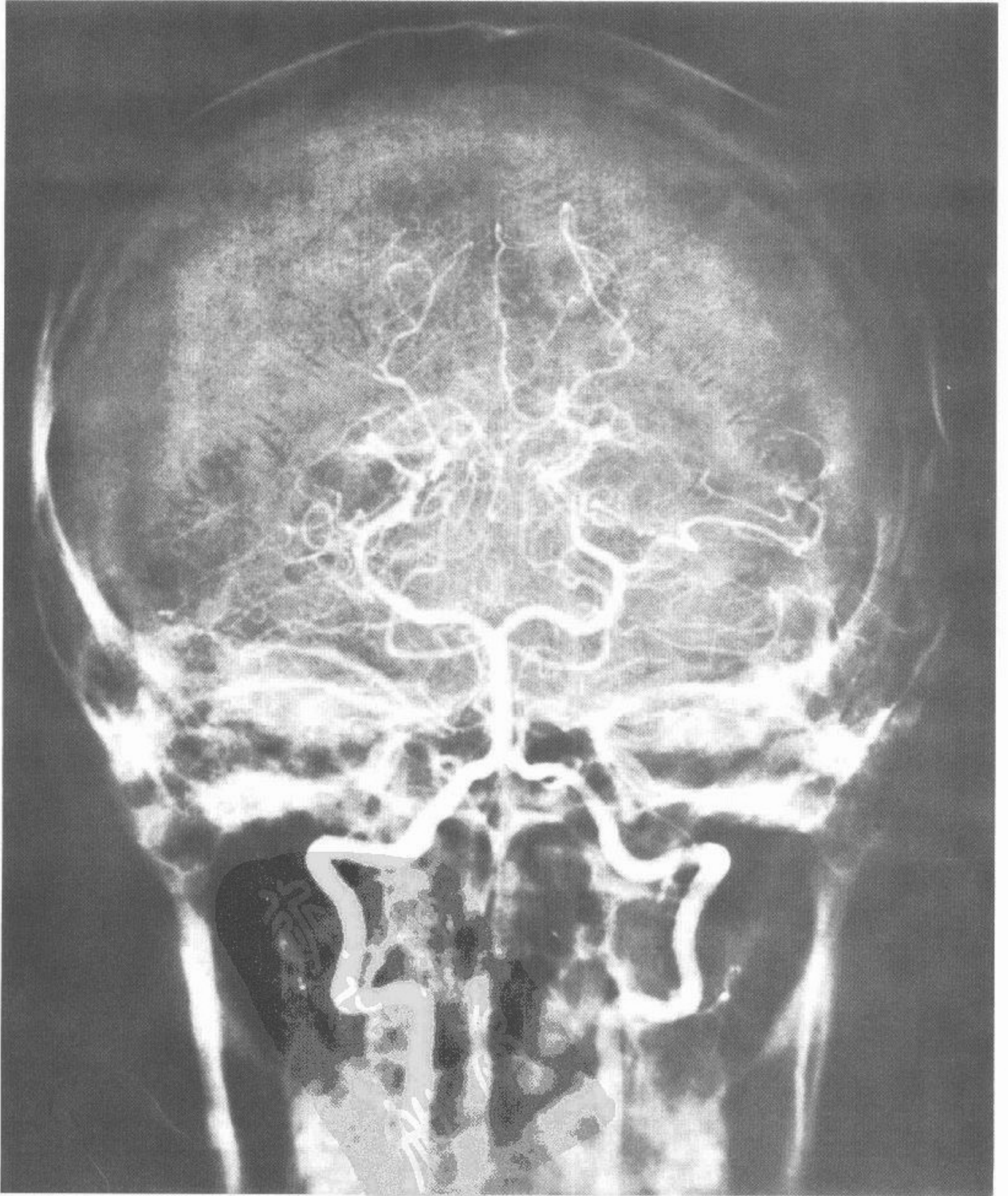
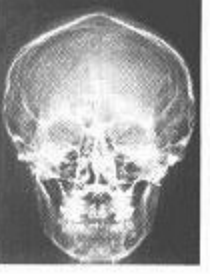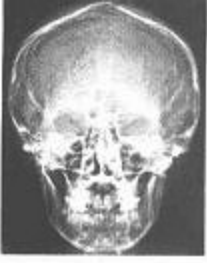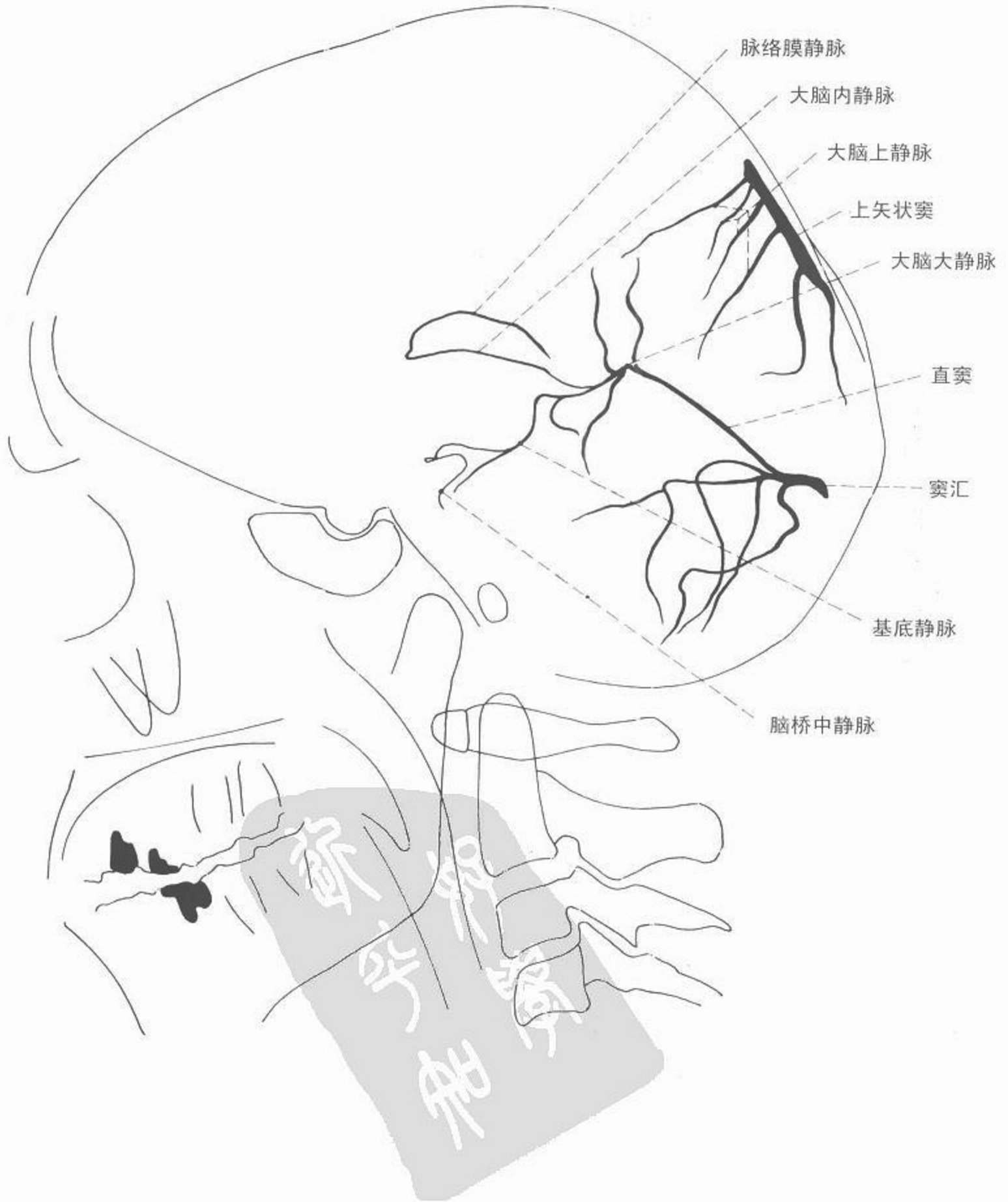


图 95 椎基底血管造影 前后位



血管造影



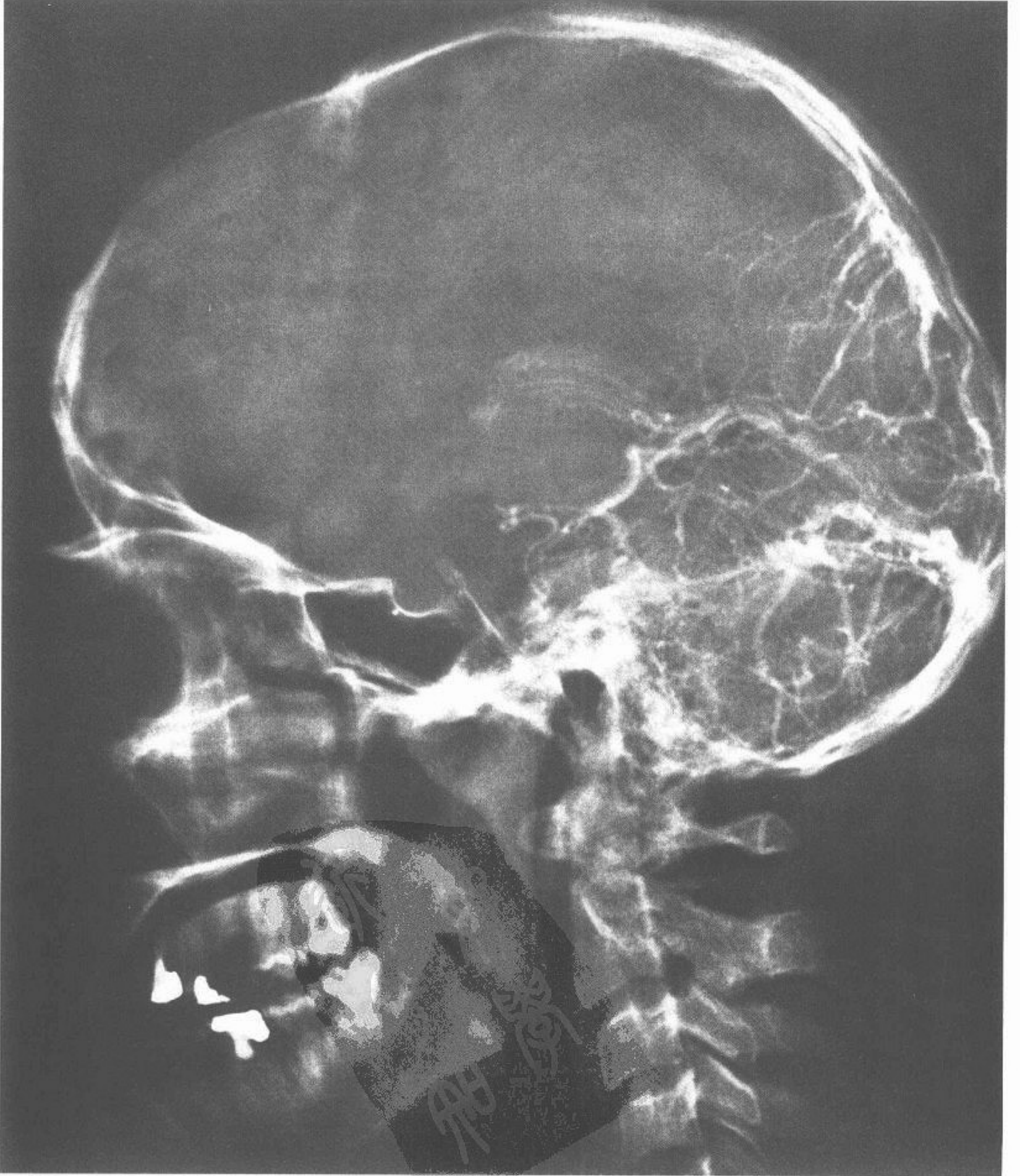
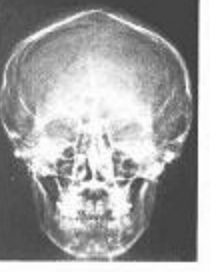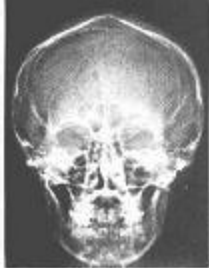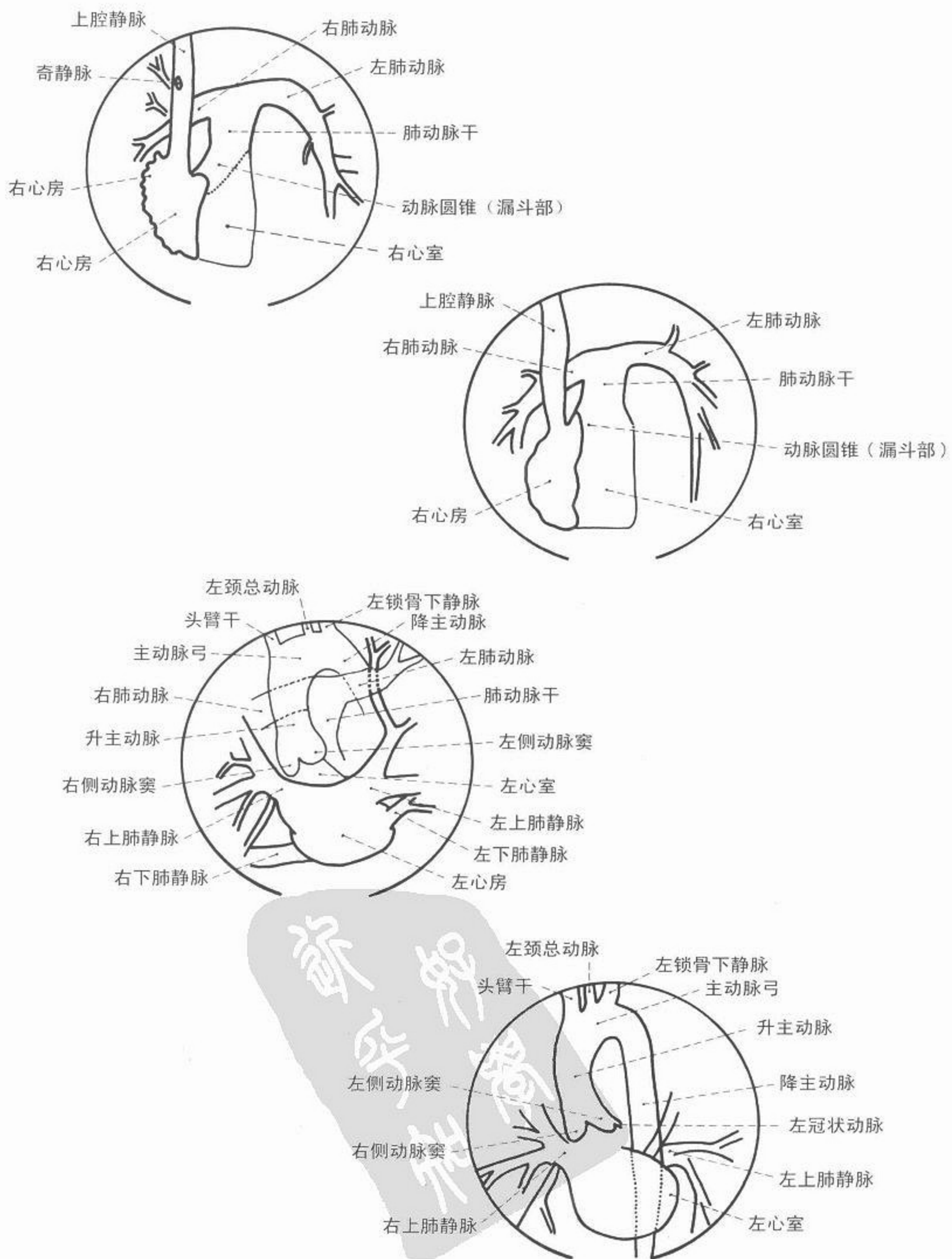


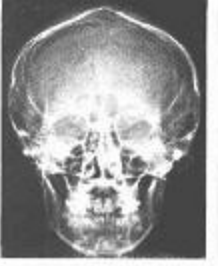图 96 椎基底血管造影 静脉期 侧位



血管造影





心血管造影

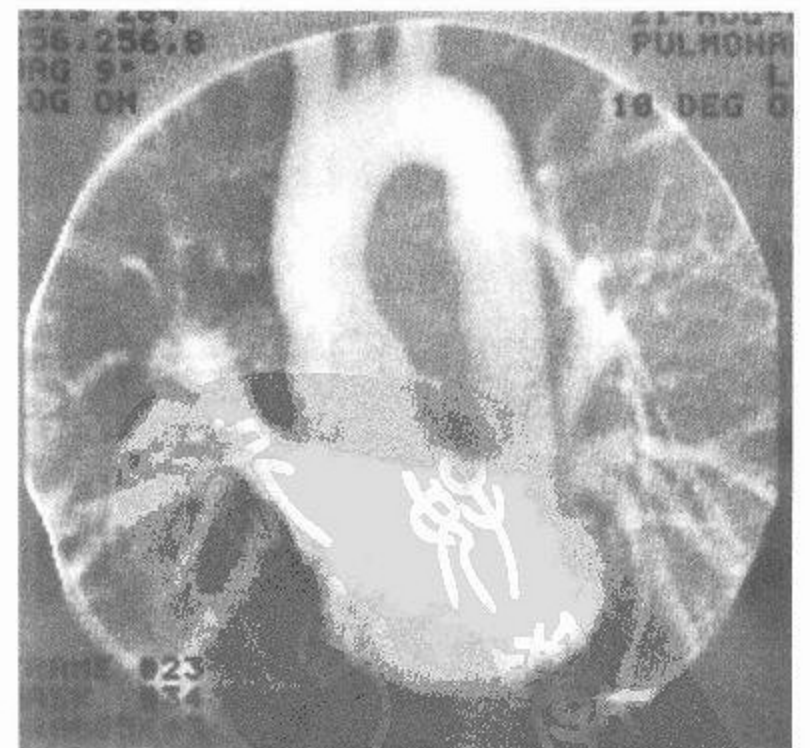
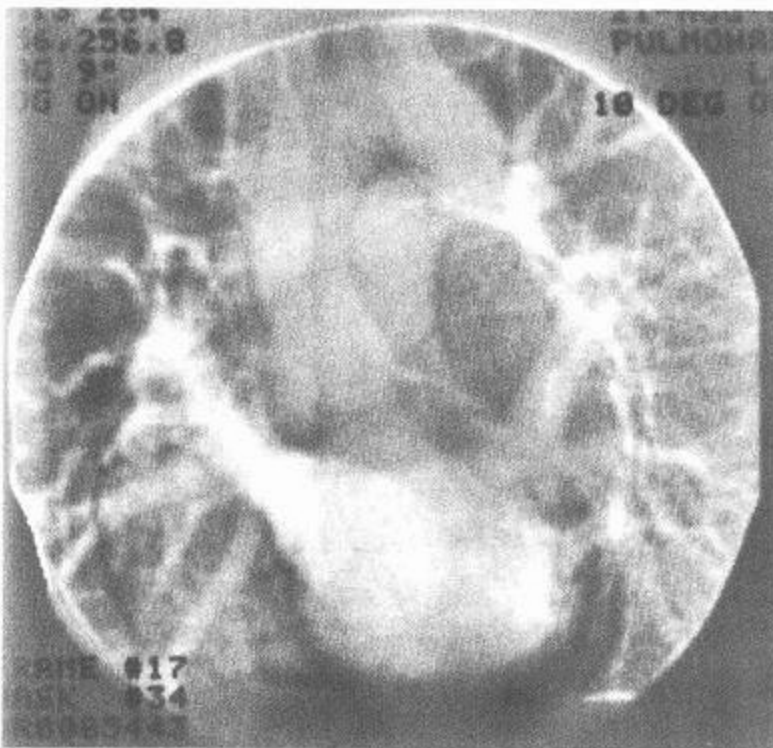
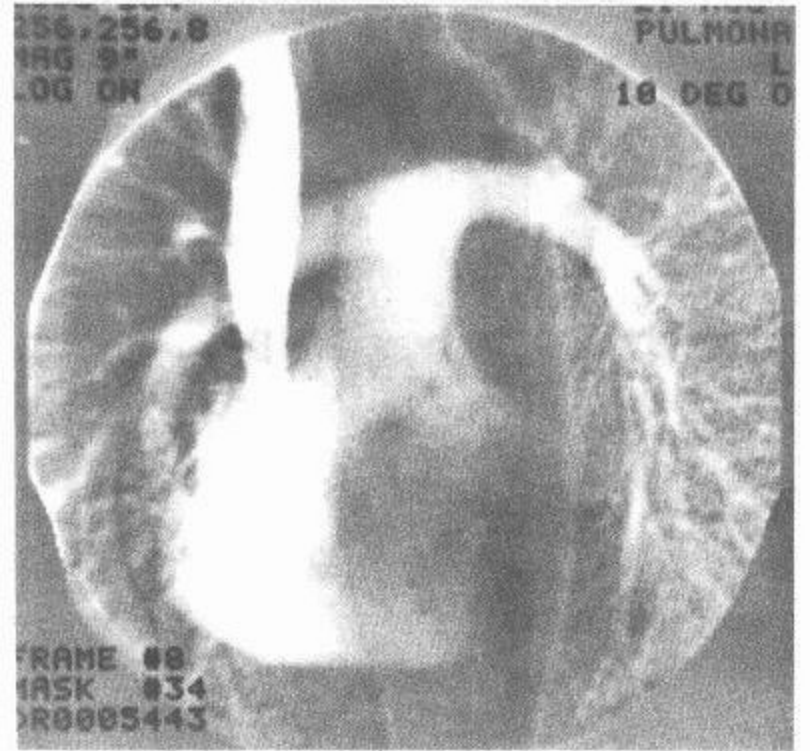
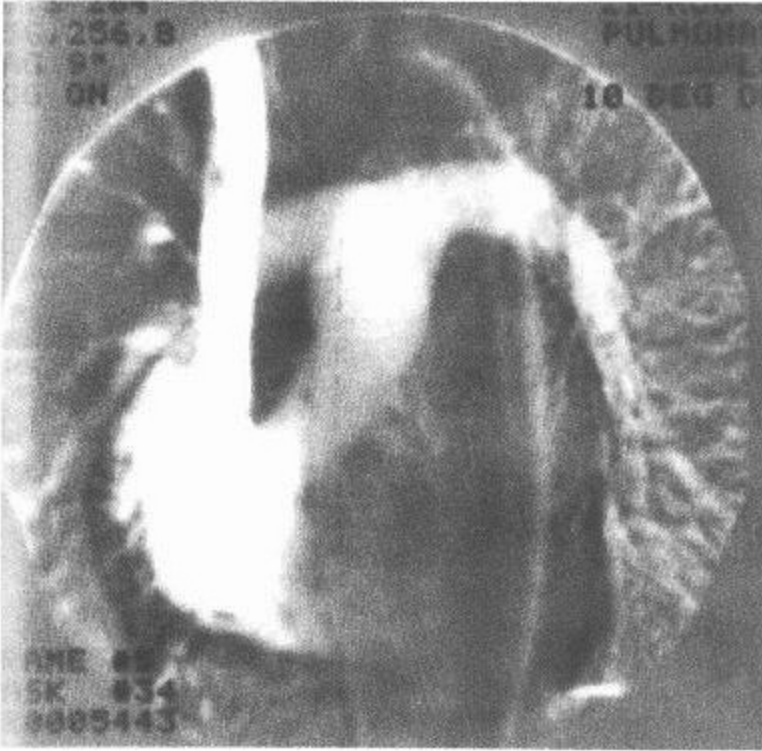
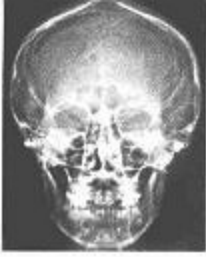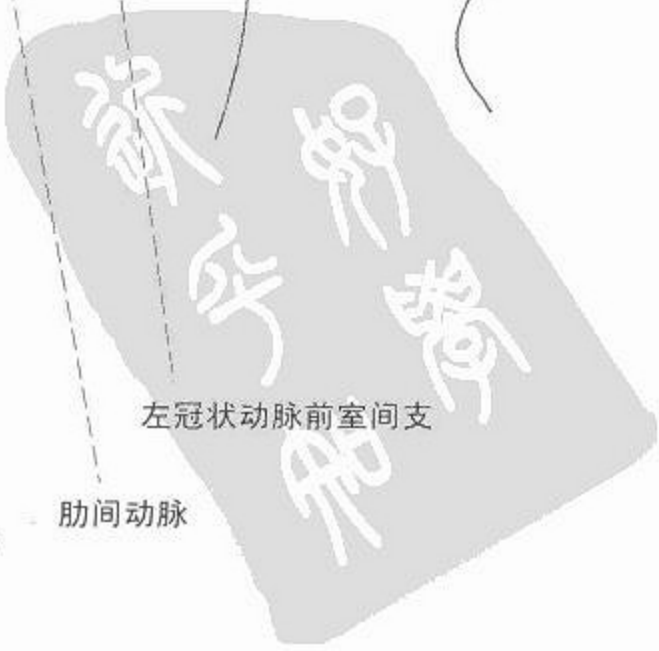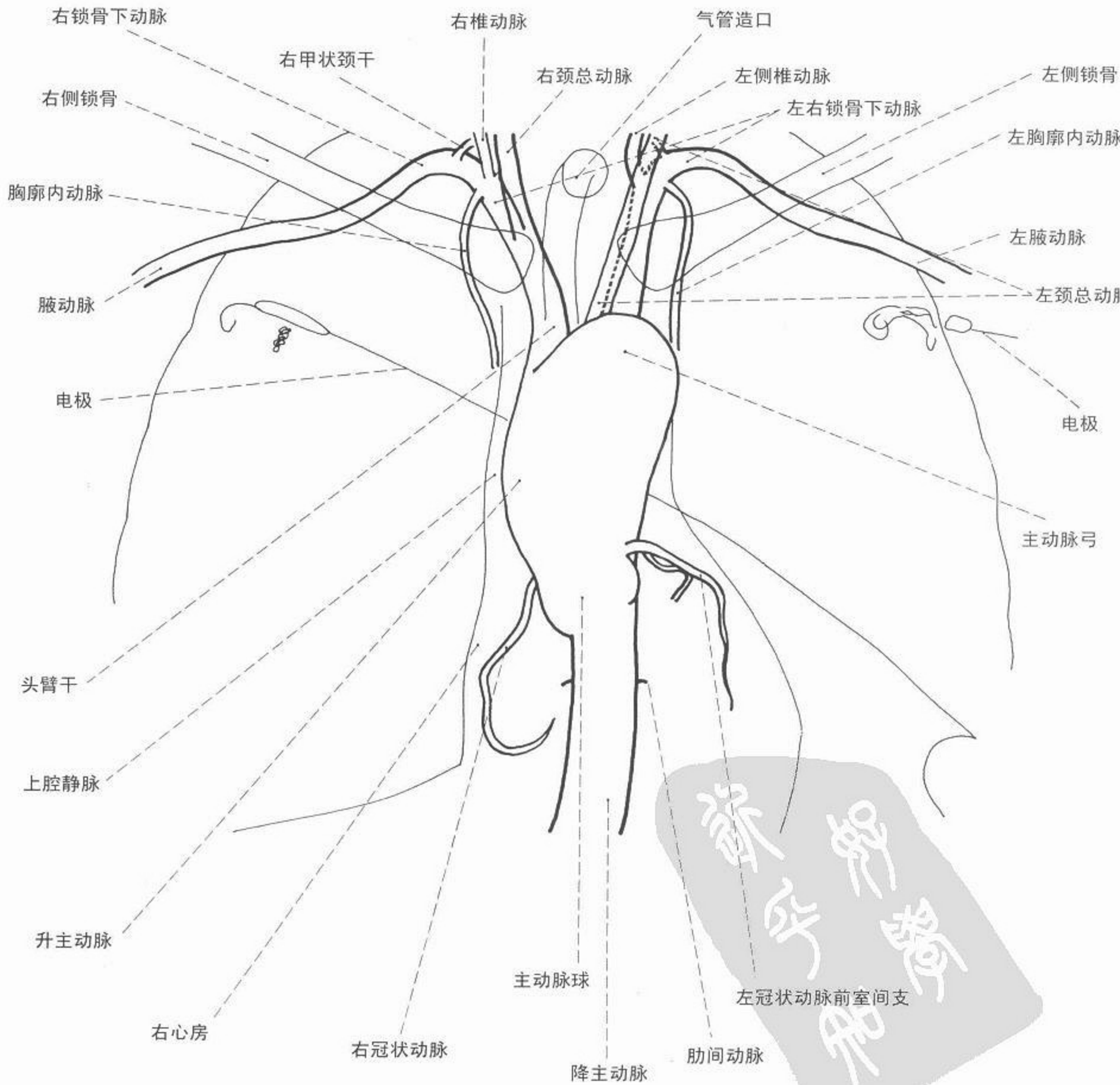


图 97 心脏数字减影血管造影 仰卧位



血管造影



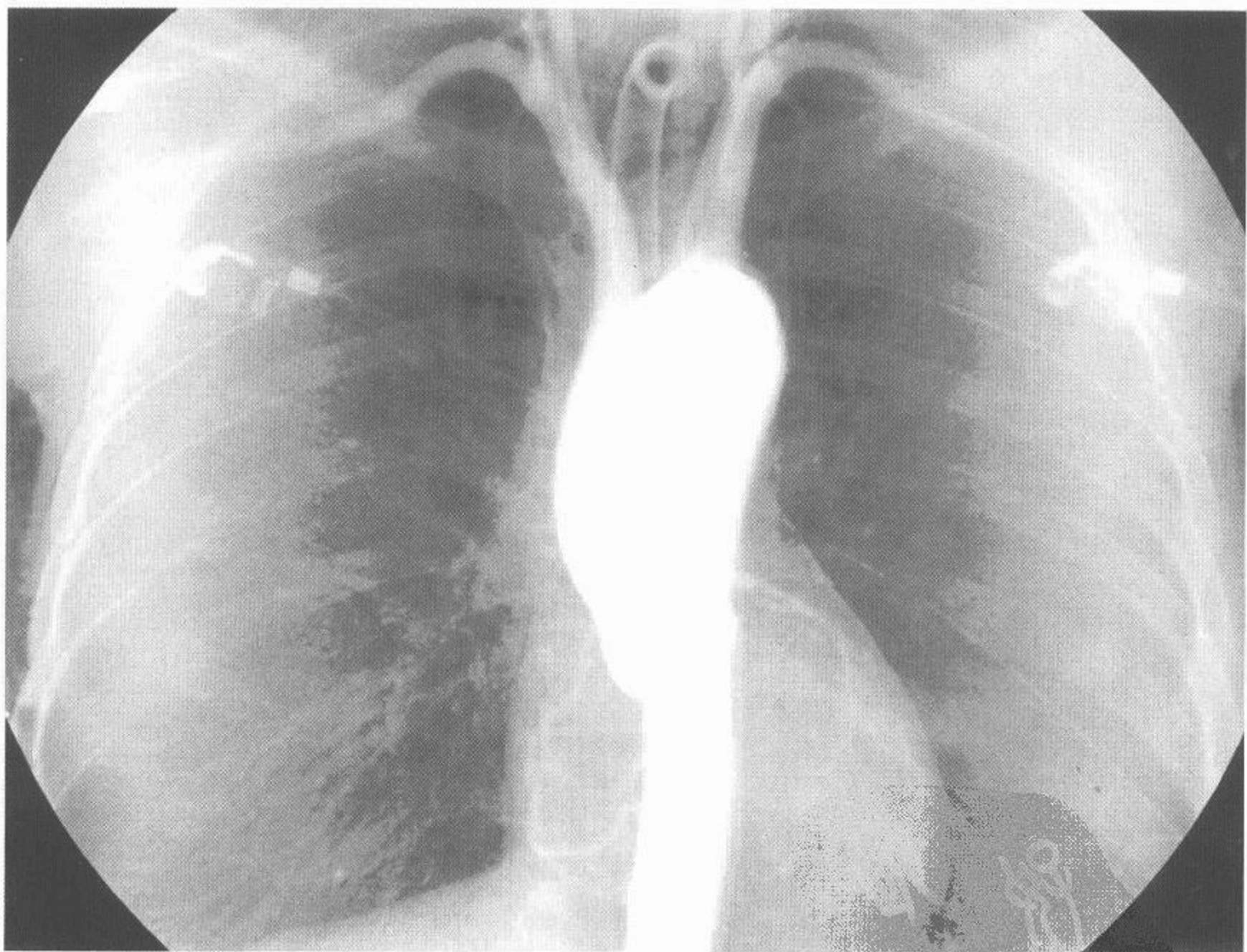
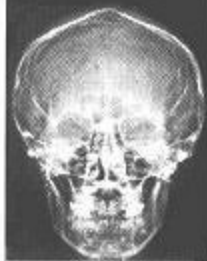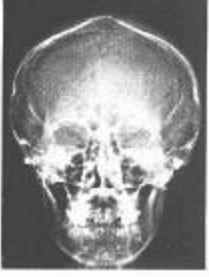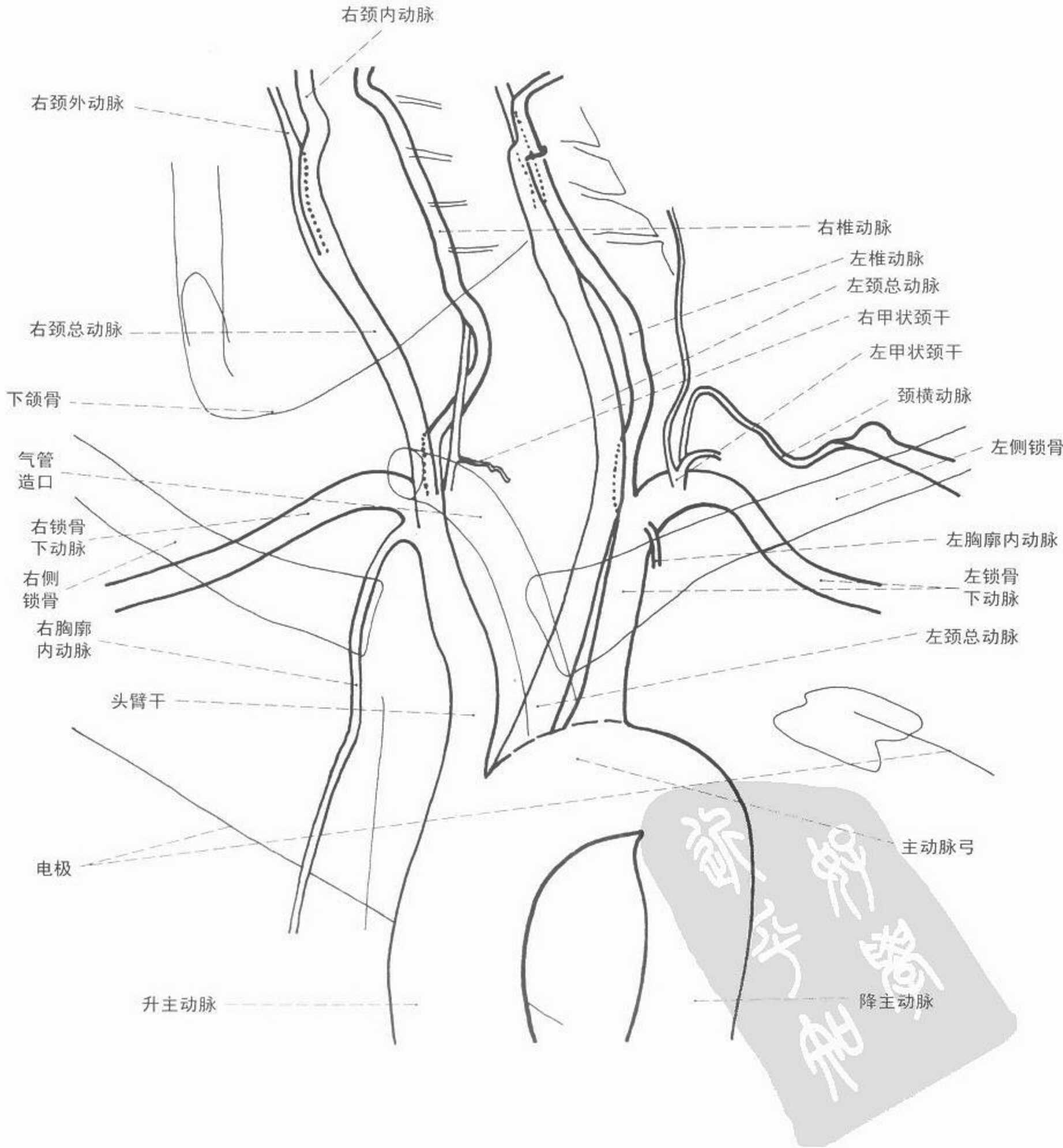


图 98 主动脉弓造影

采
集
器



血管造影



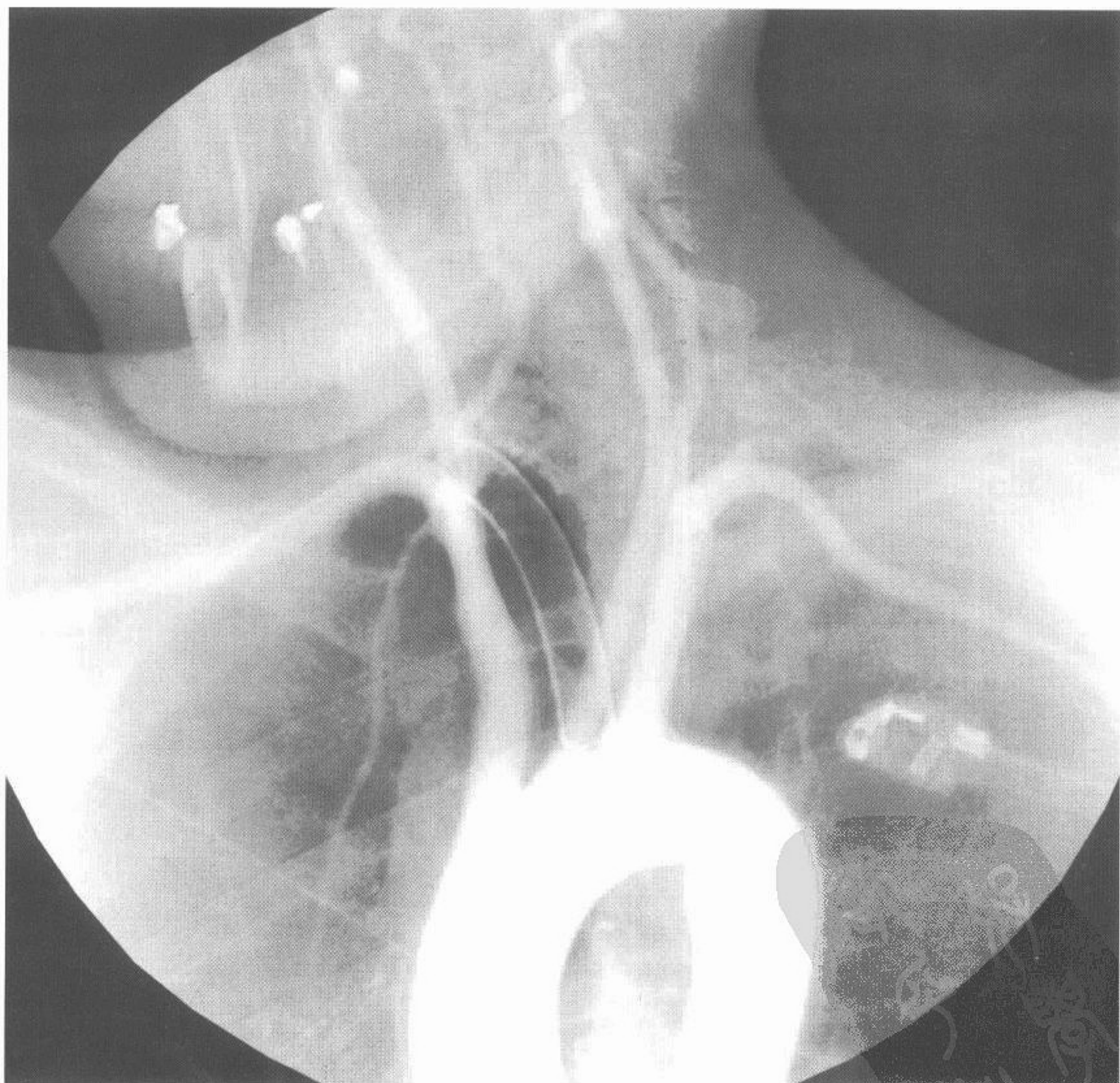
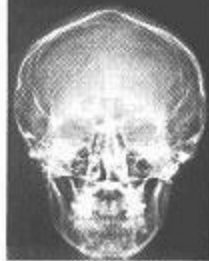
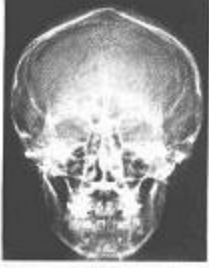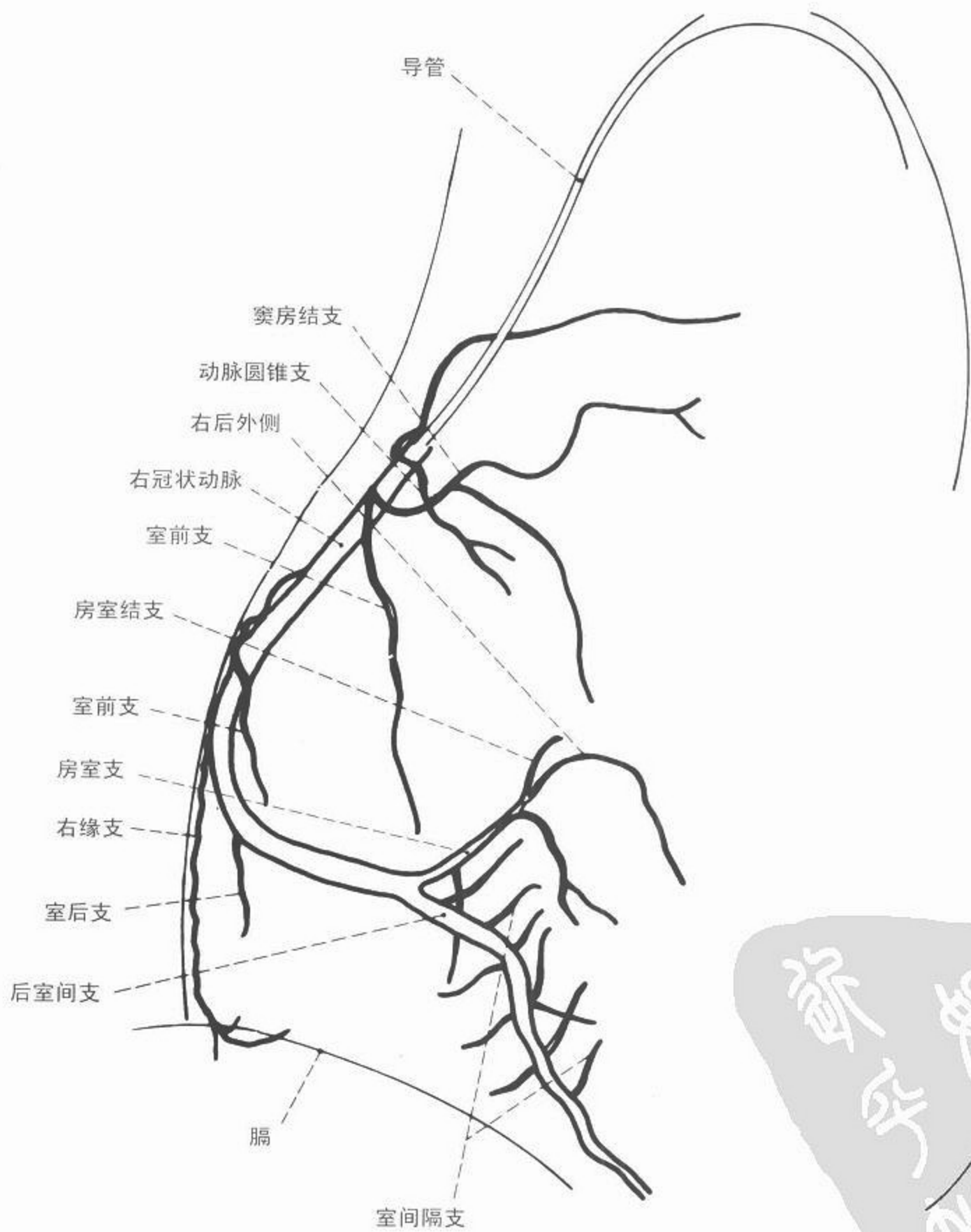


图 99 主动脉弓及其分支造影



血管造影



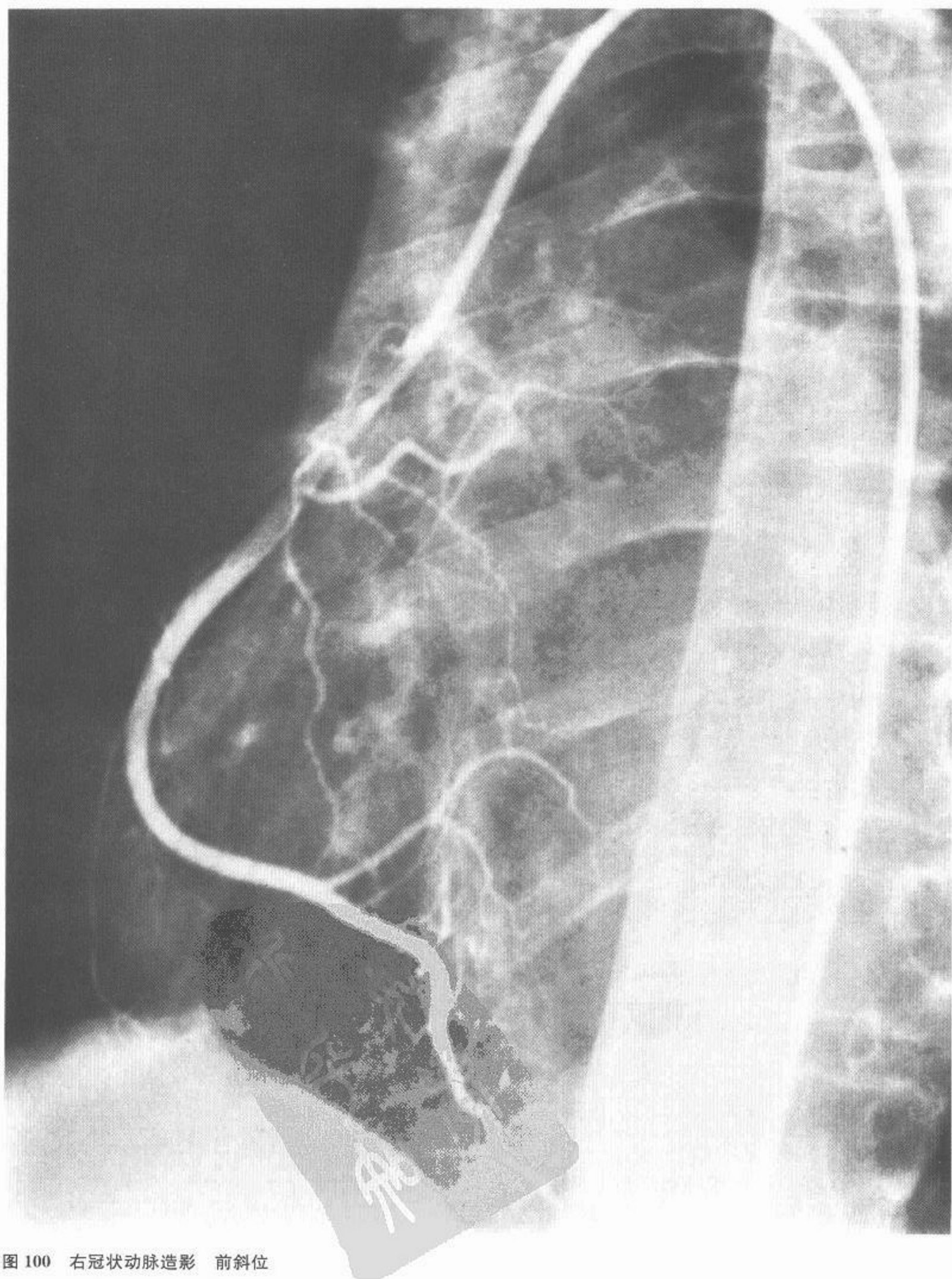
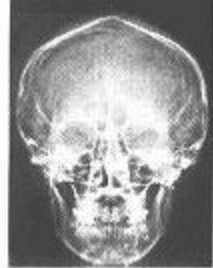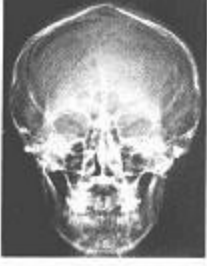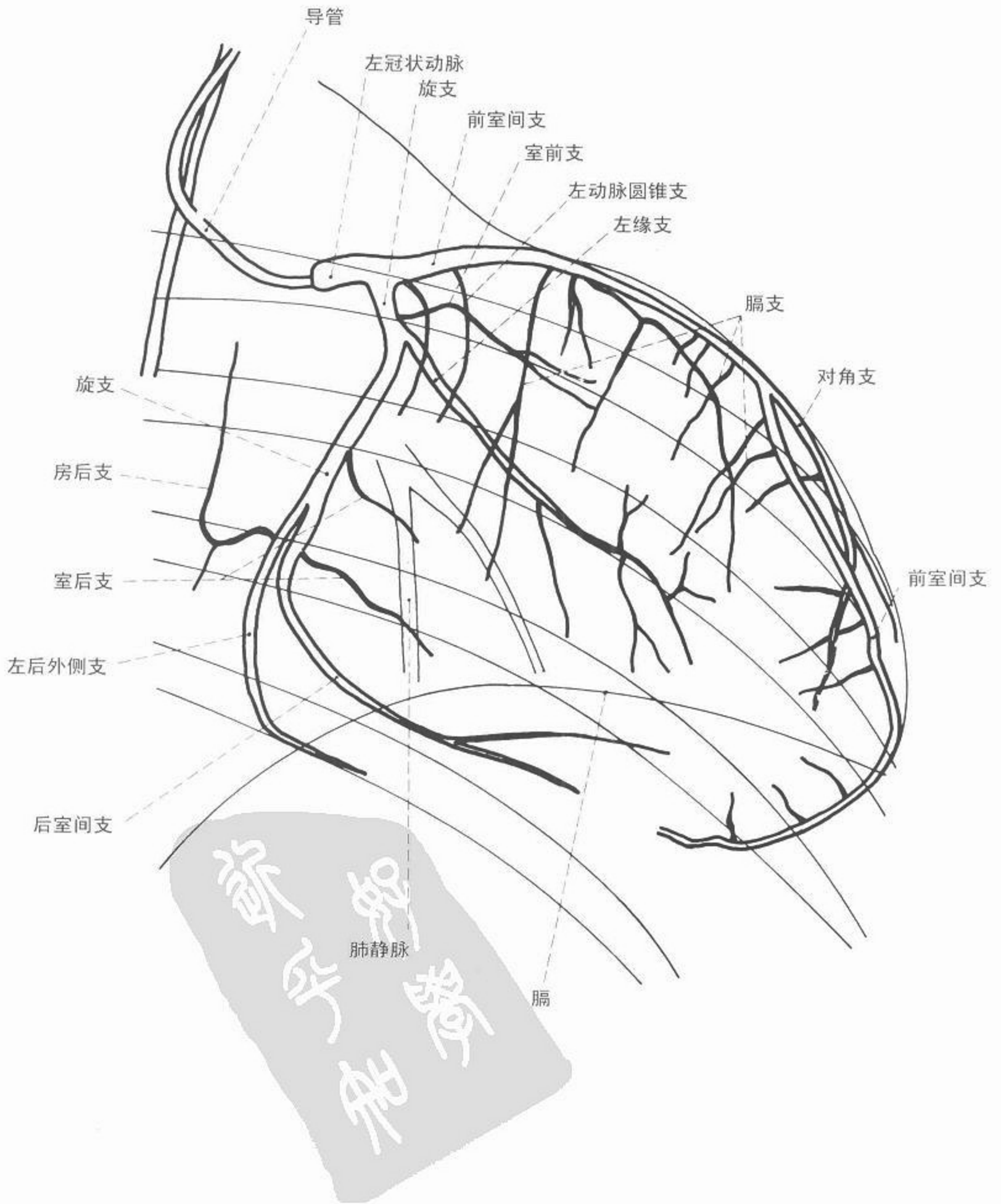


图 100 右冠状动脉造影 前斜位



血管造影



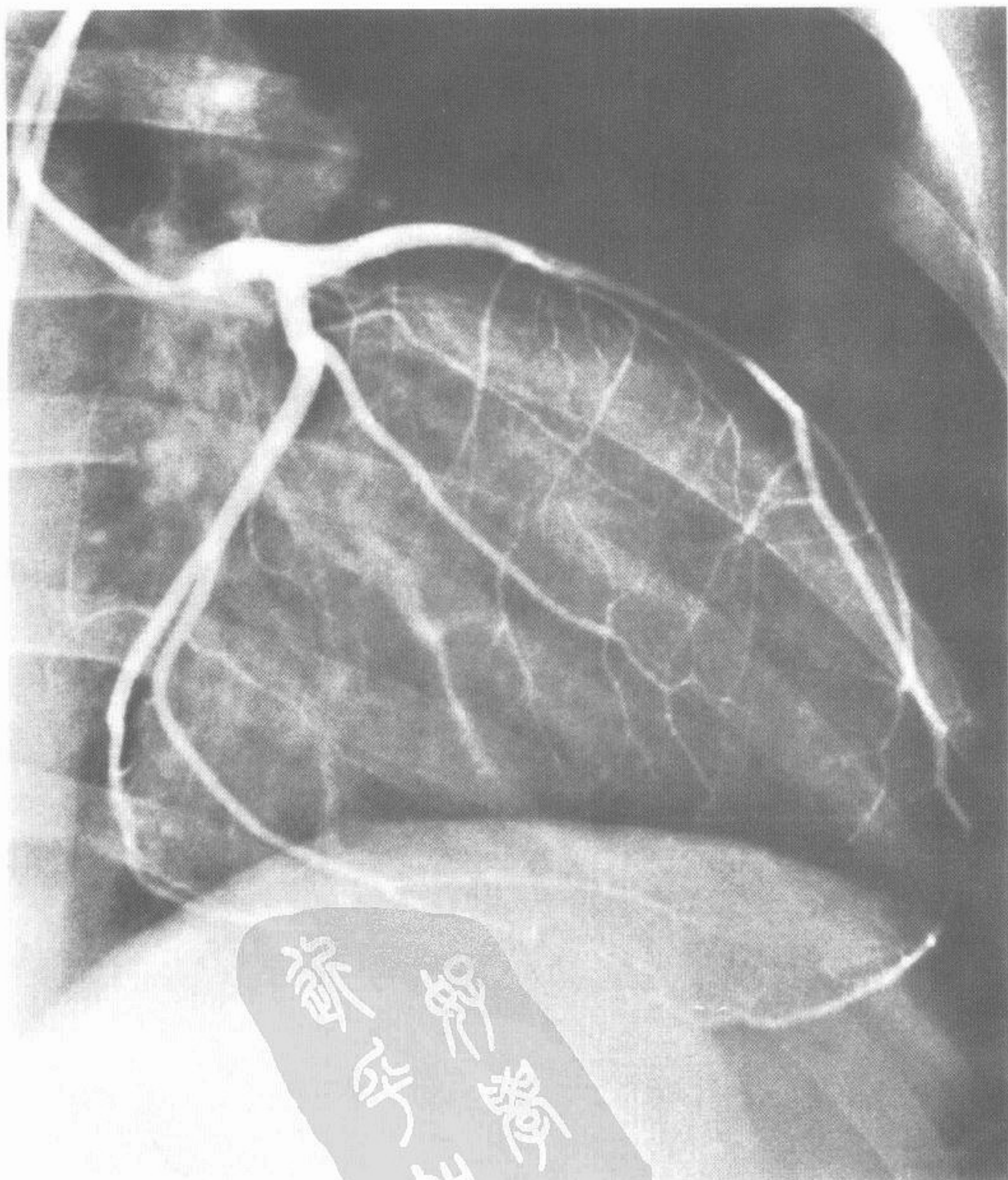
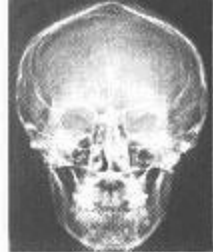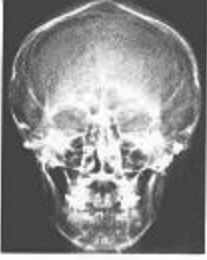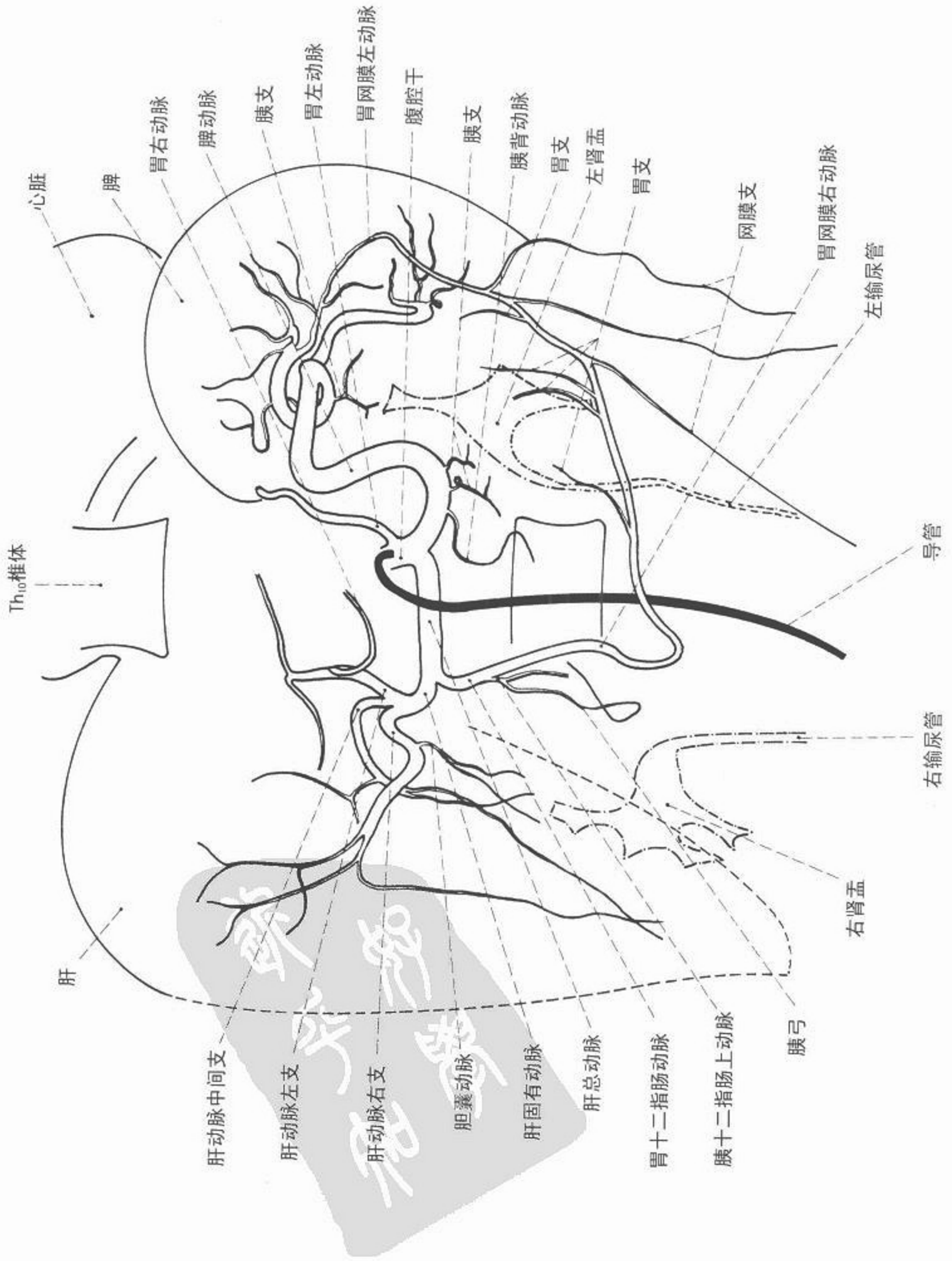


图 101 左冠状动脉造影 前斜位



血管造影



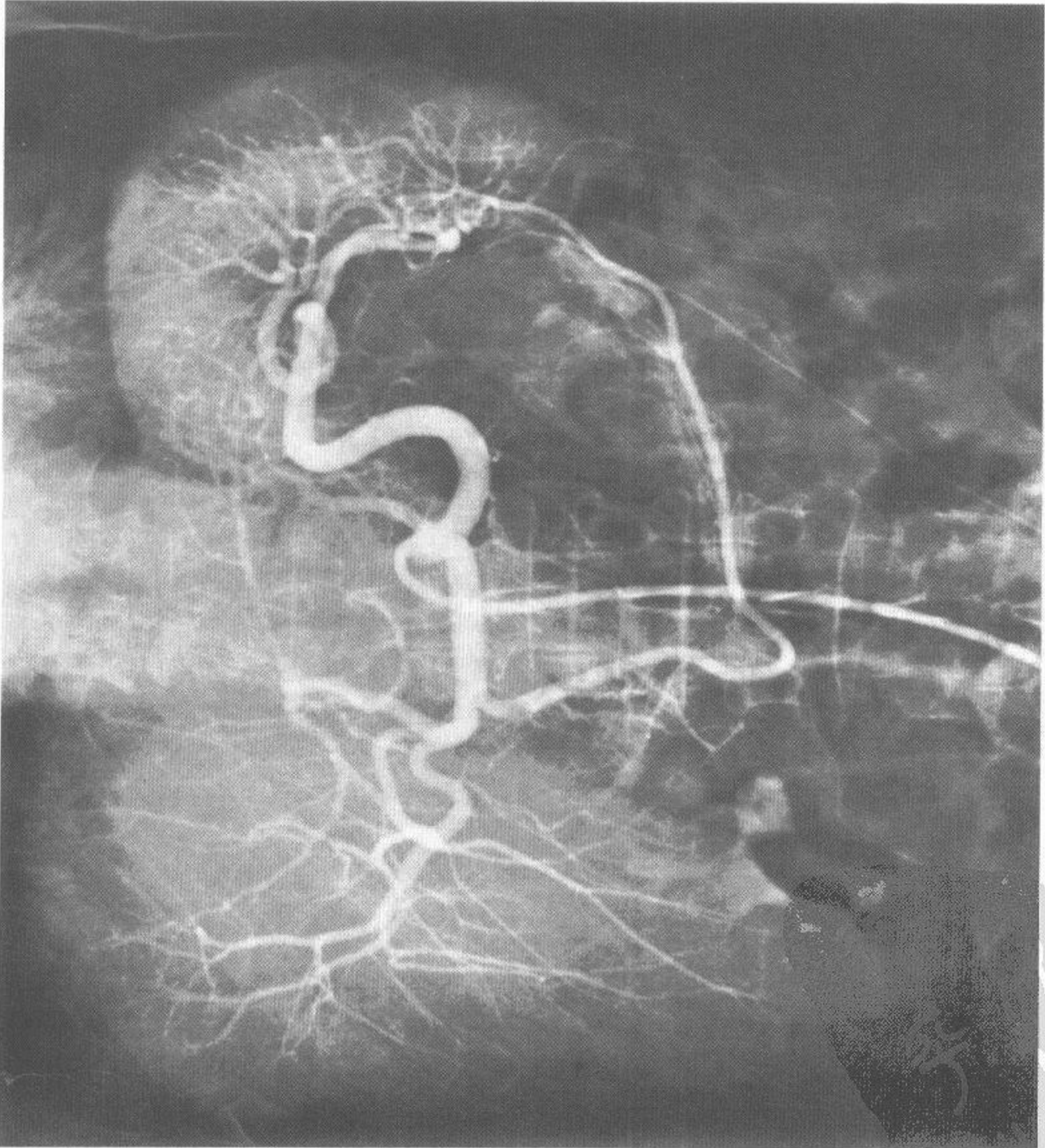
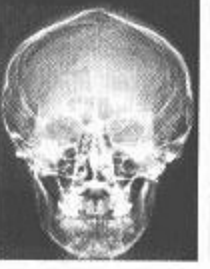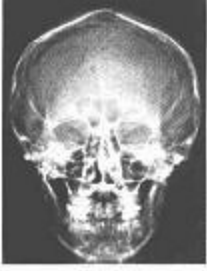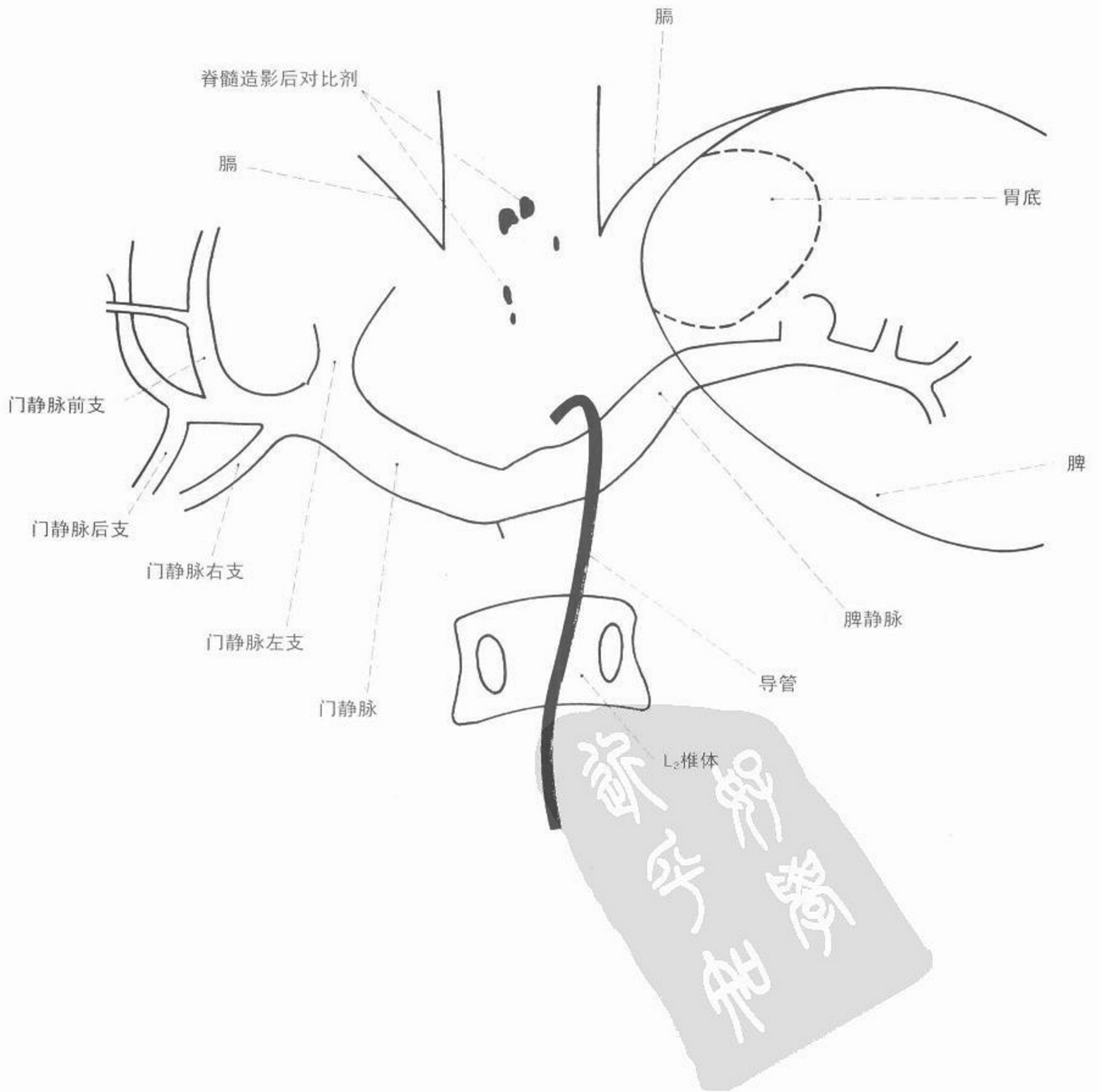


图102 腹腔干造影



血管造影



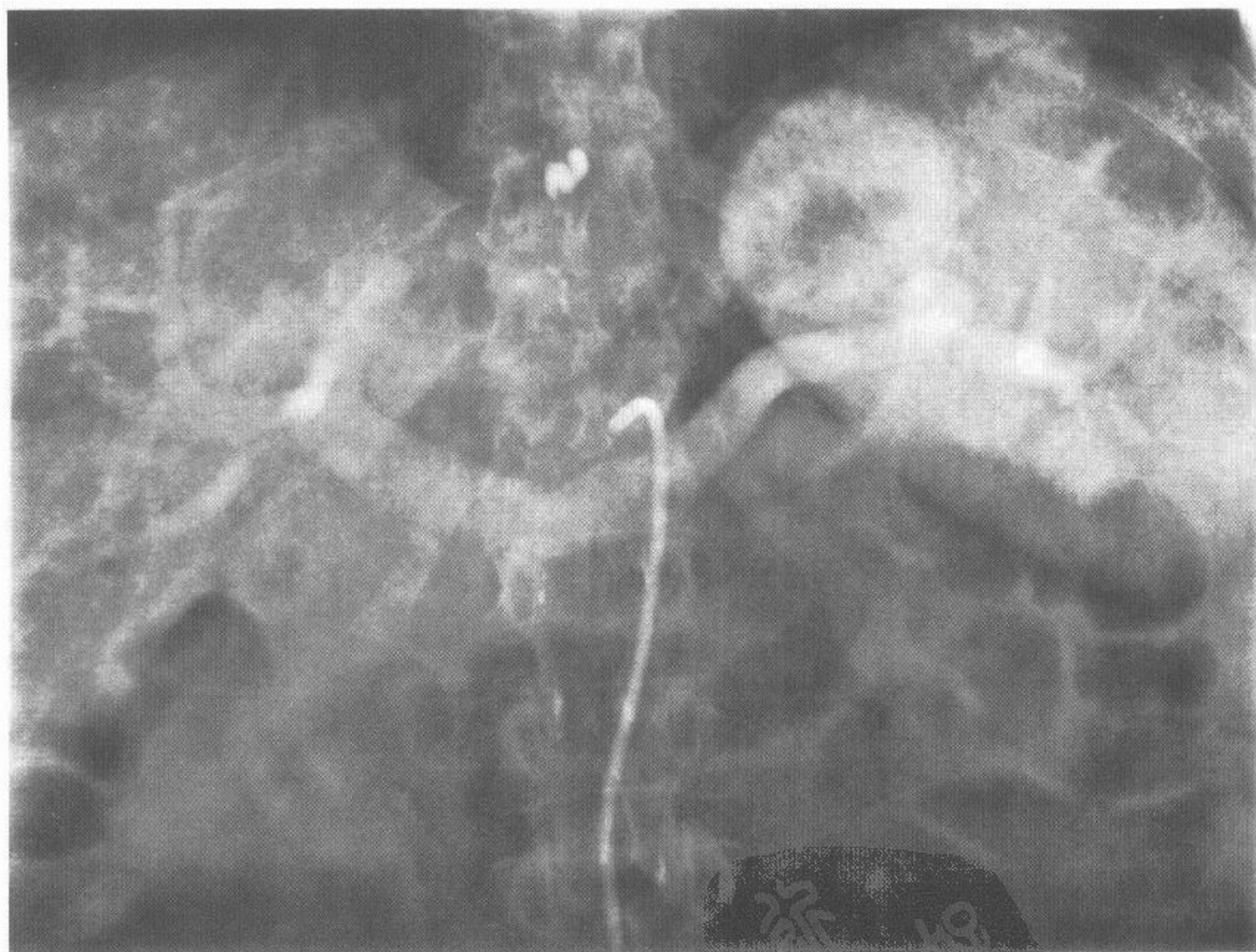
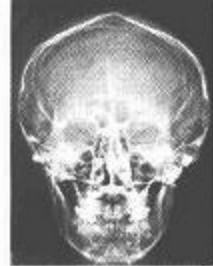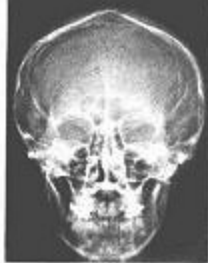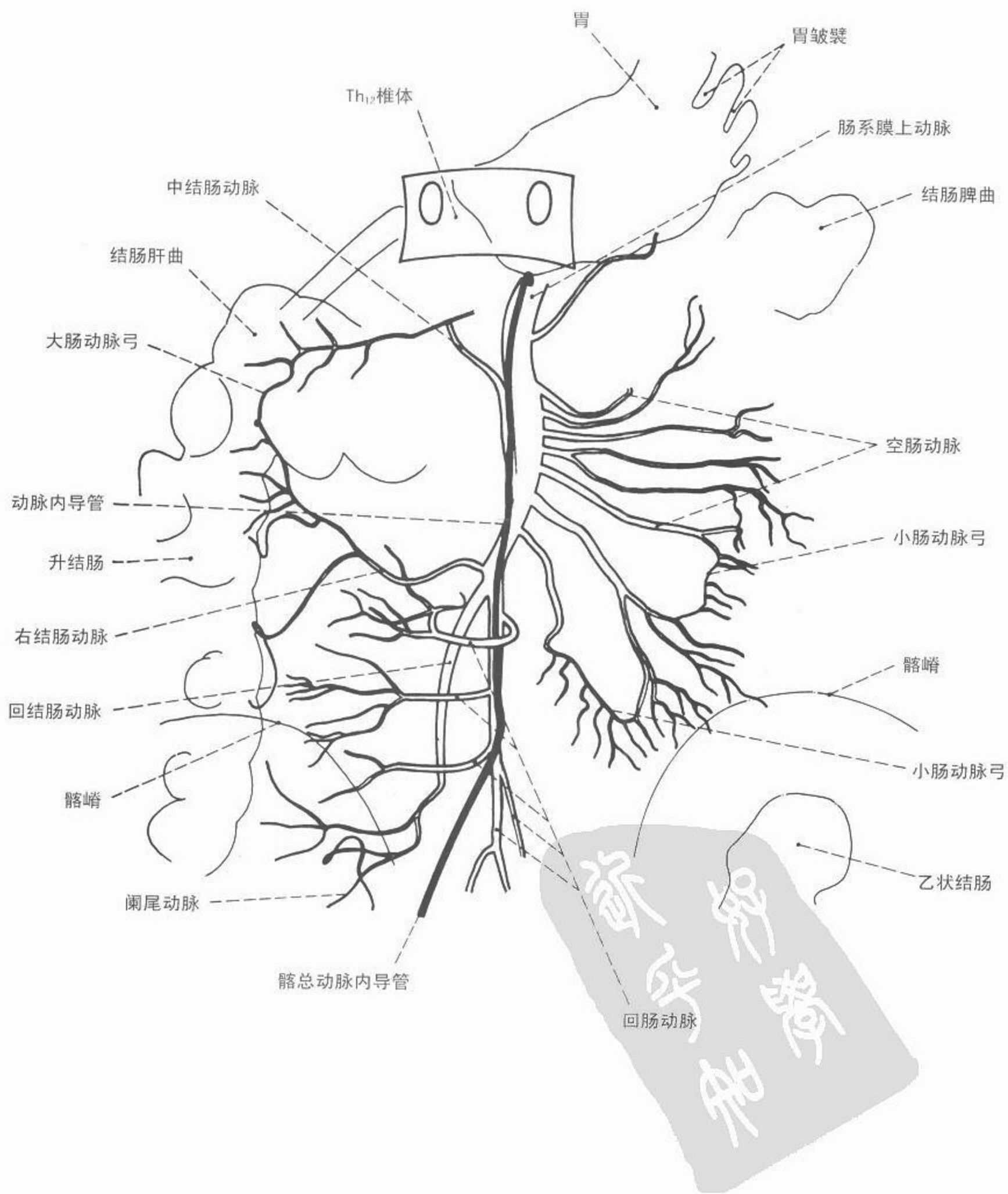


图 103 经脾门静脉造影

经脾门静脉造影



血管造影



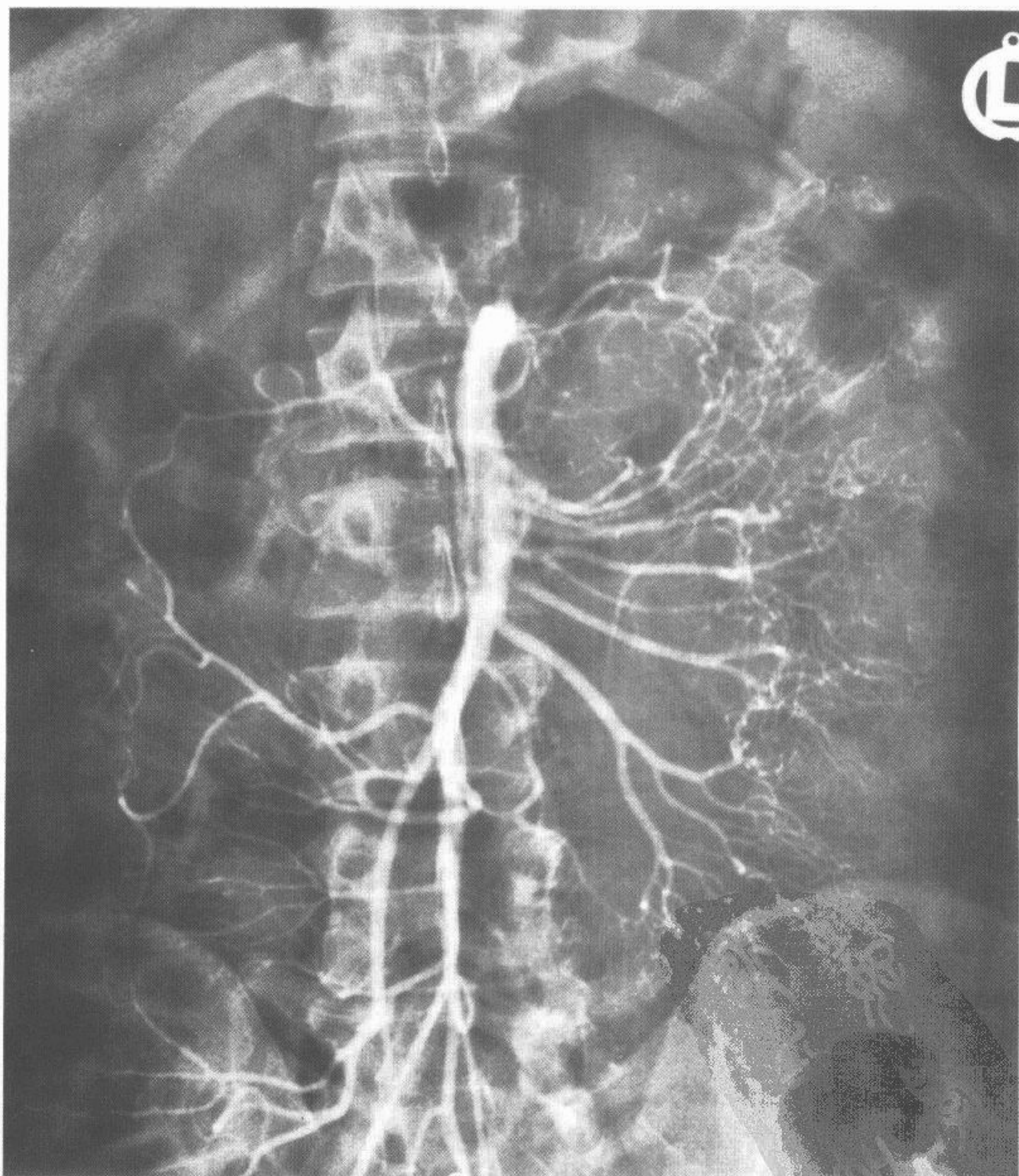
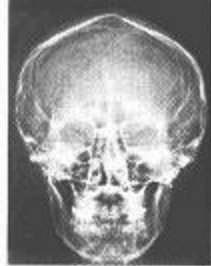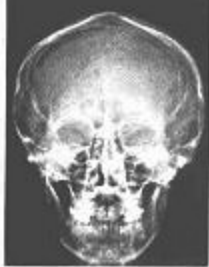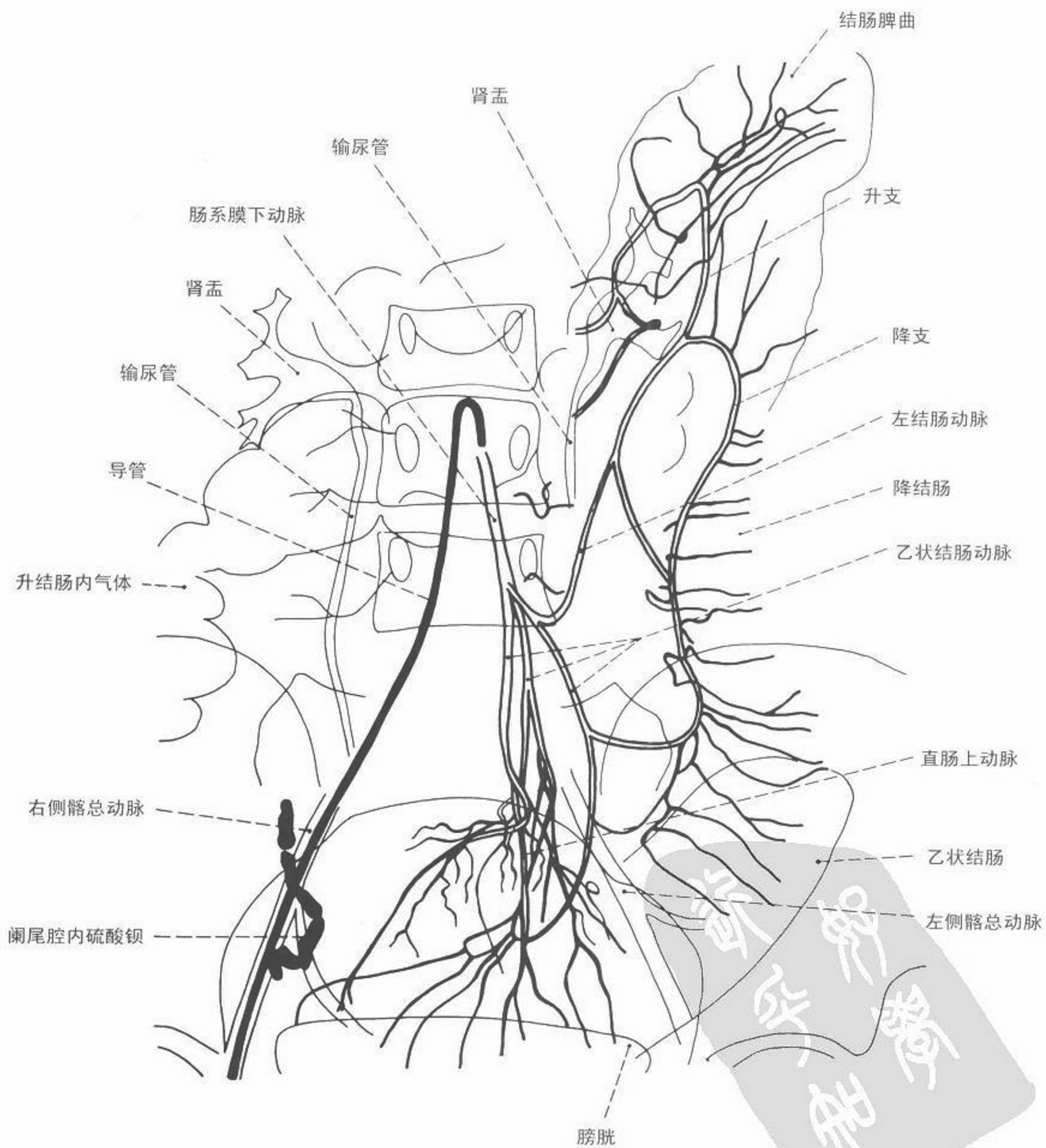


图 104 肠系膜上动脉造影



血管造影



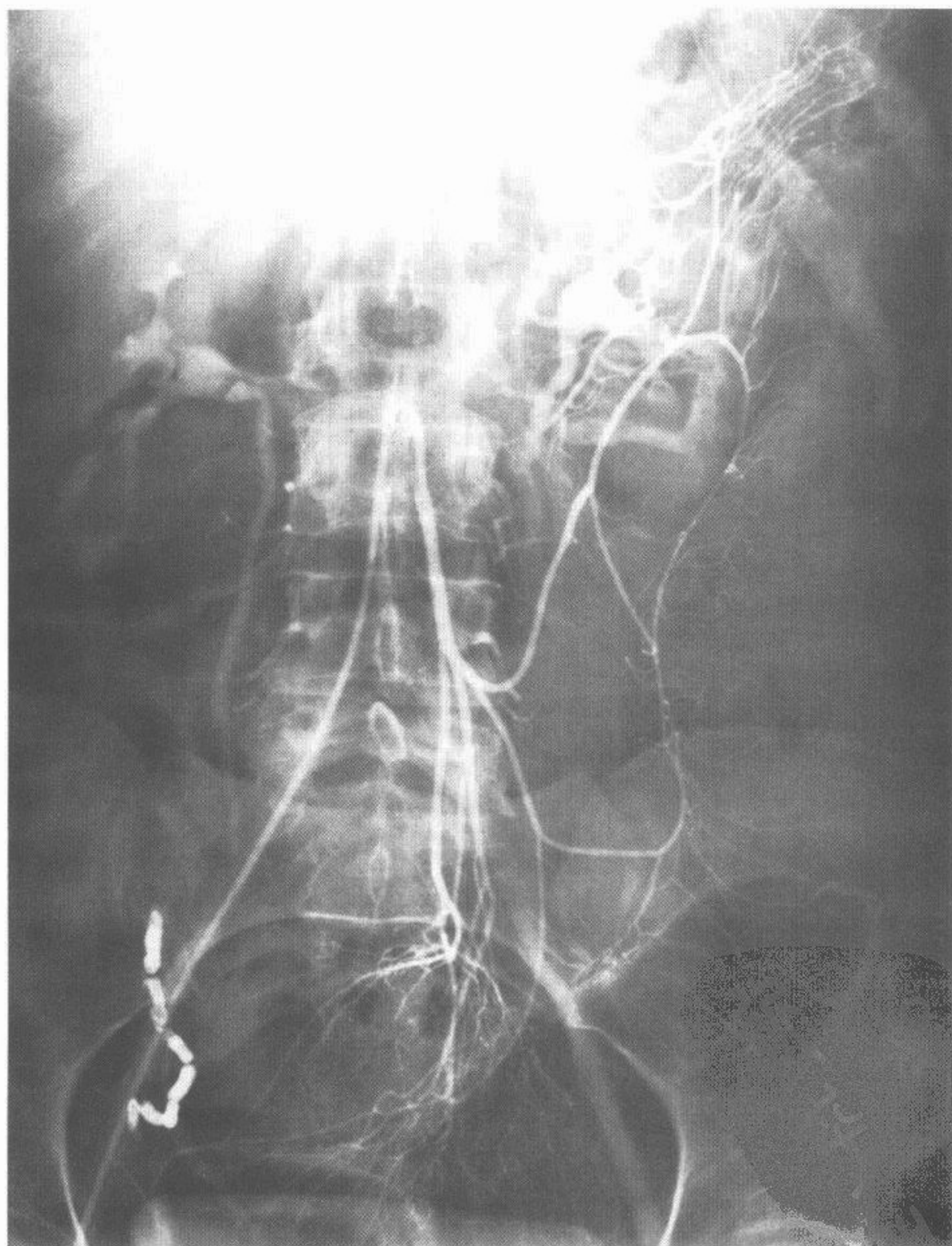
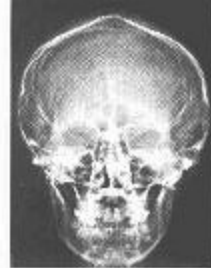
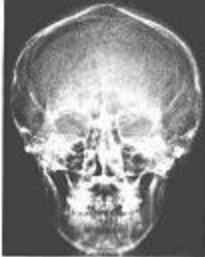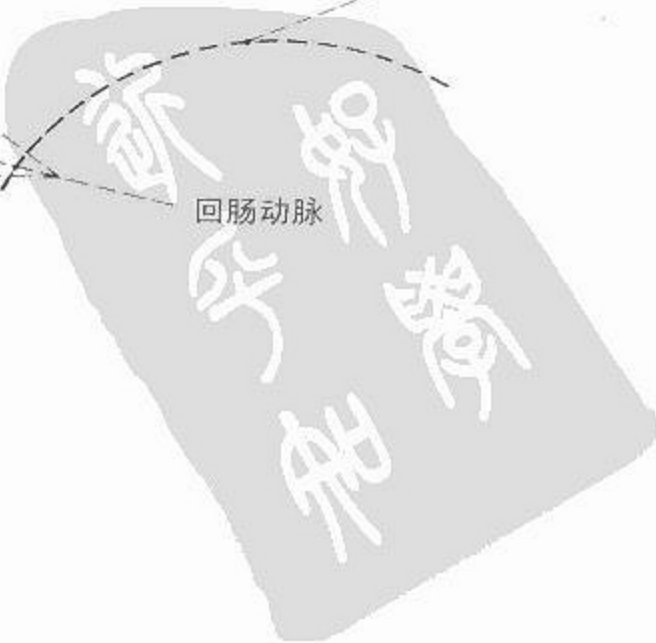
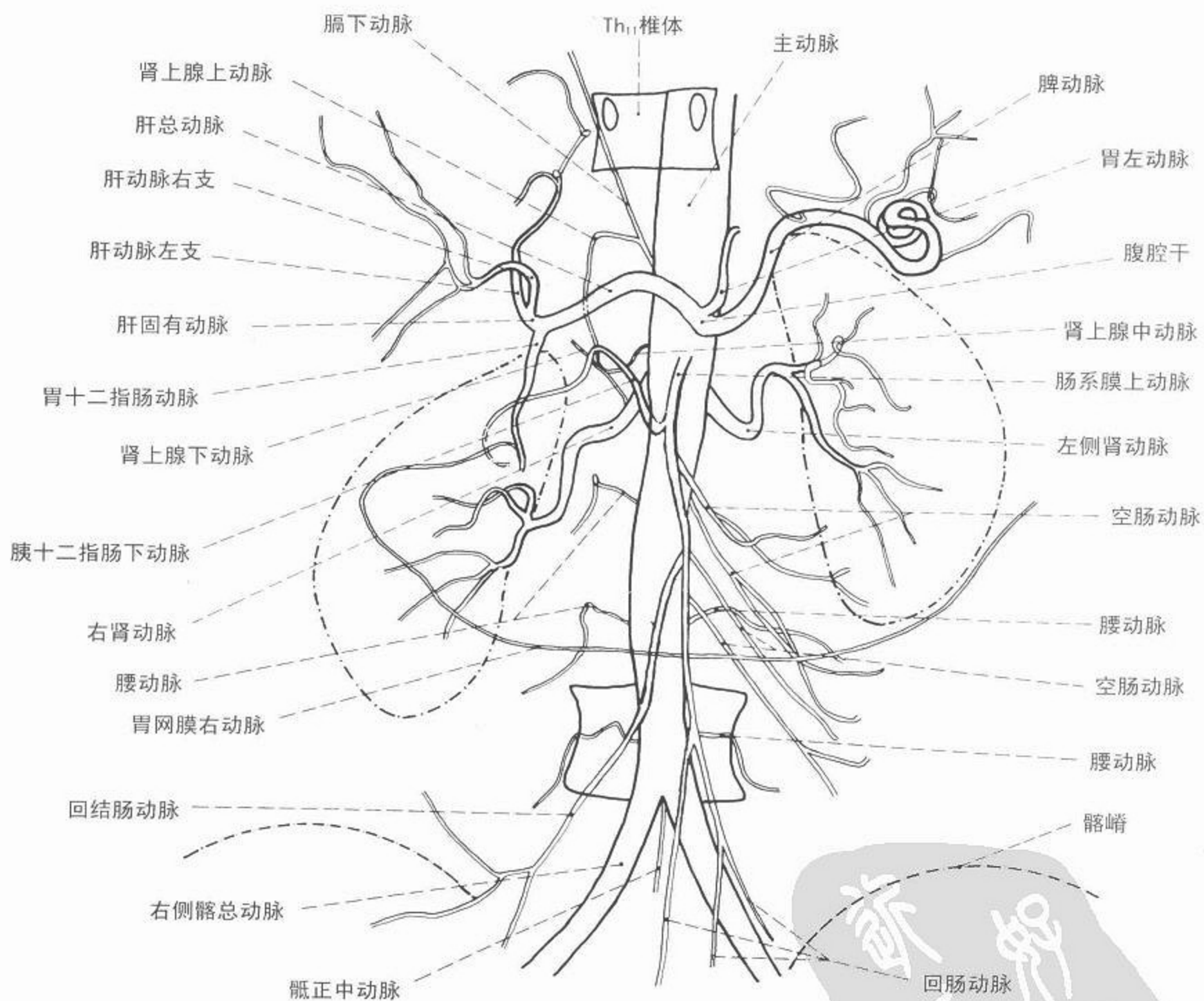


图 105 肠系膜下动脉造影



血管造影



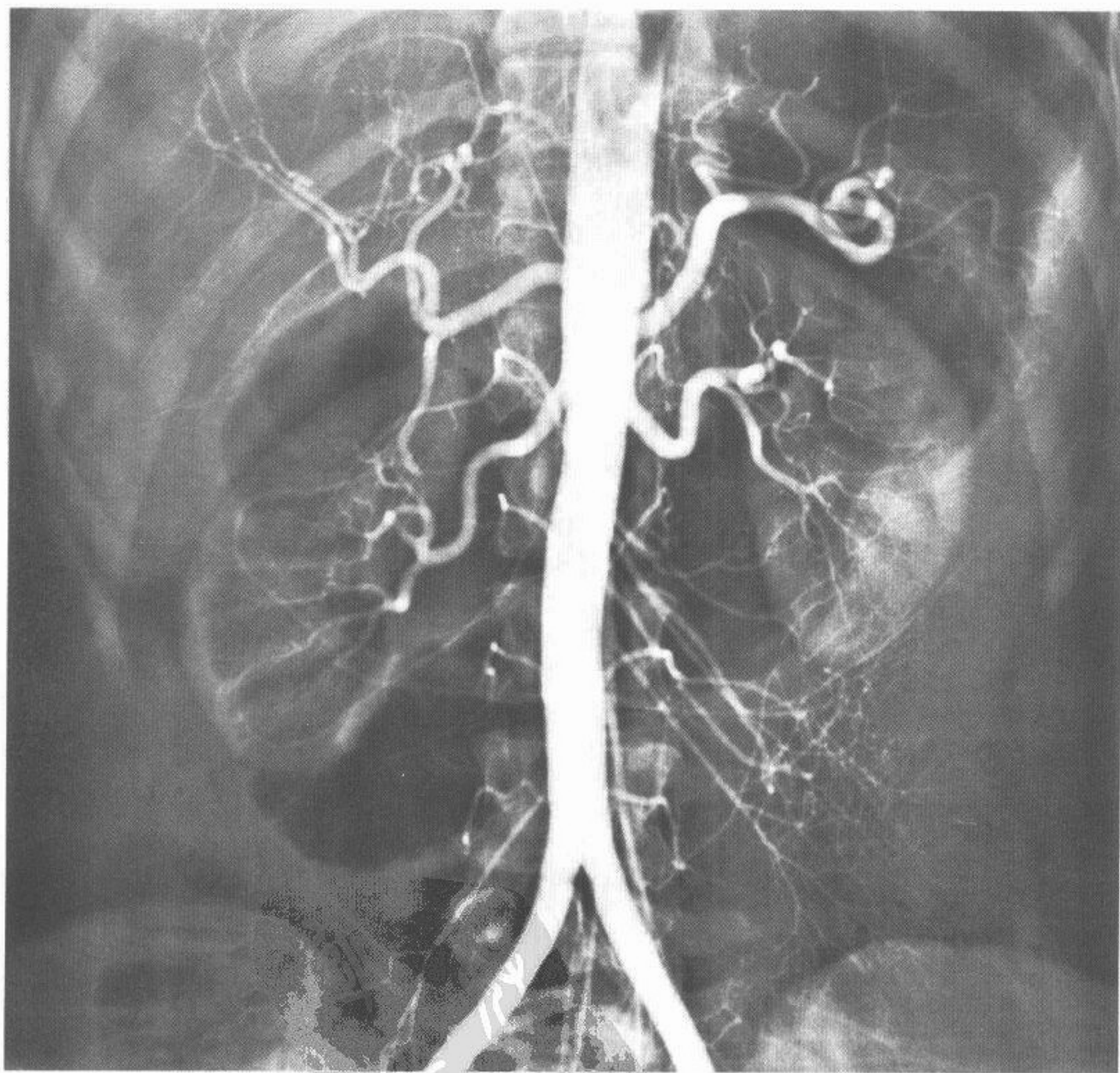
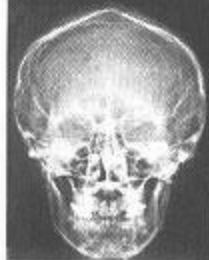
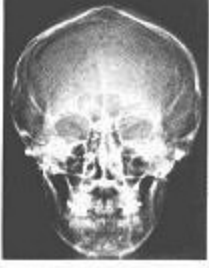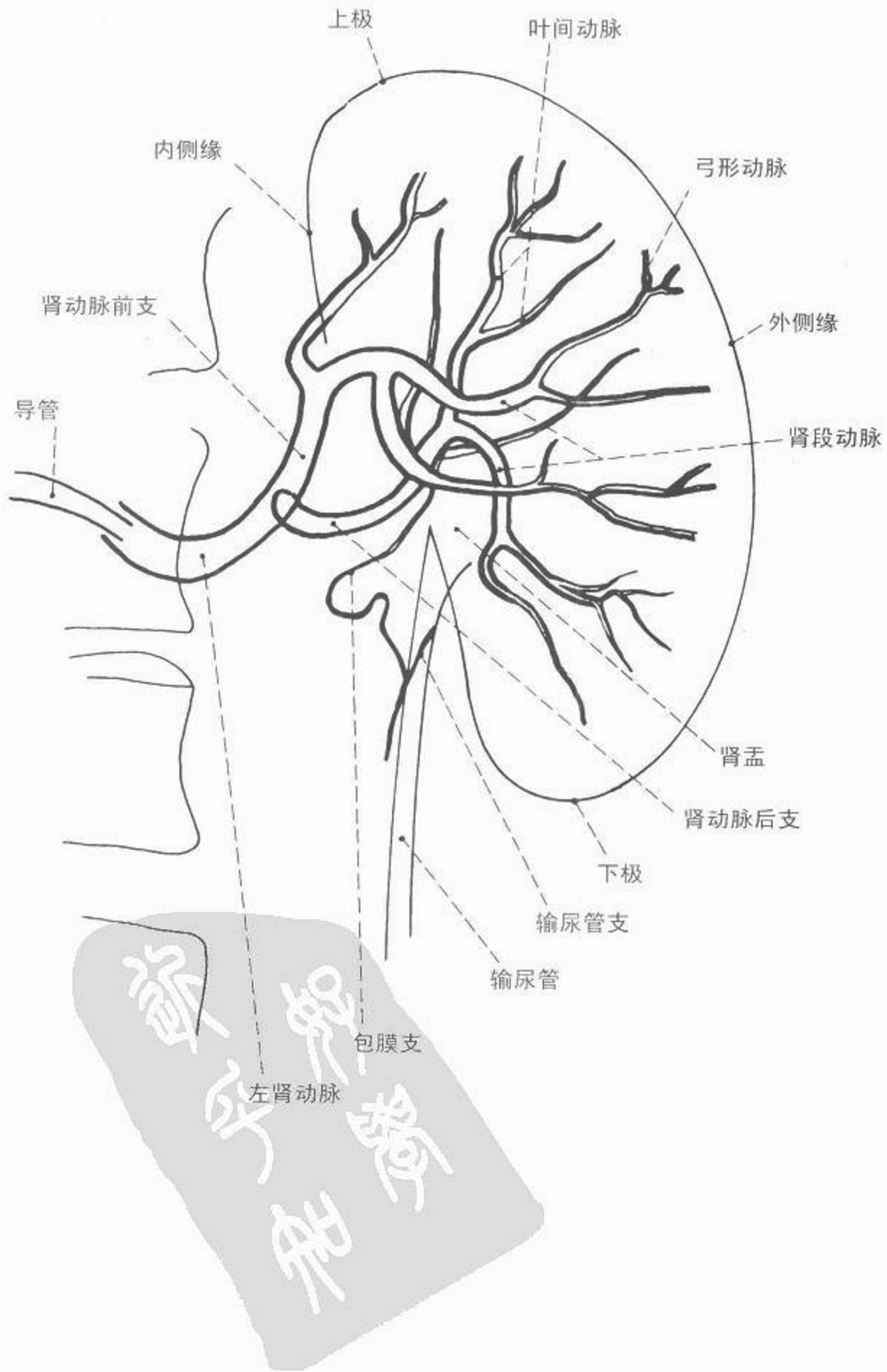


图 106 腹部动脉造影概貌



血管造影



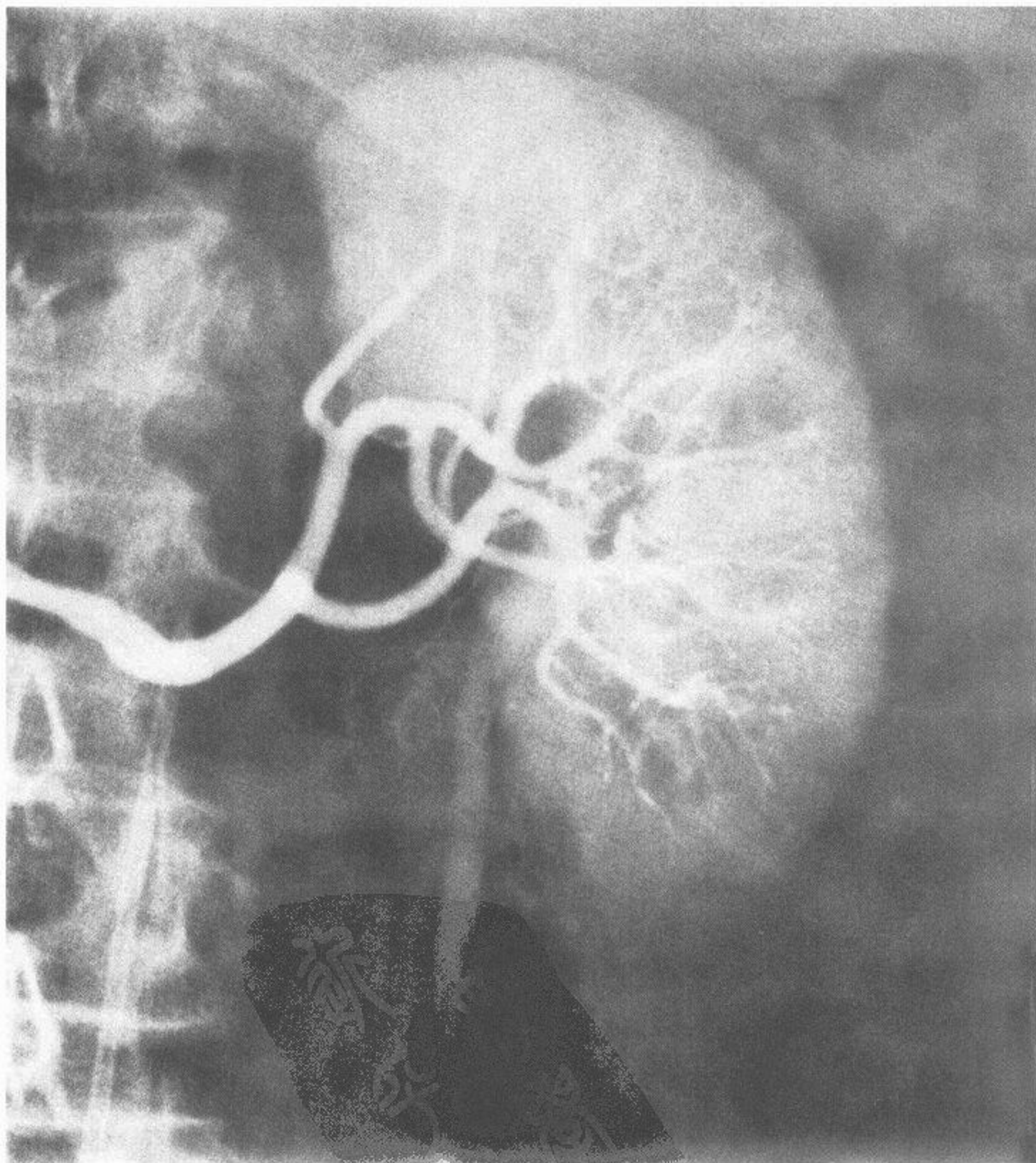
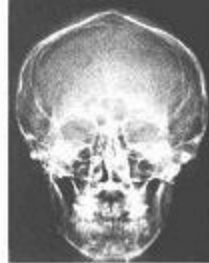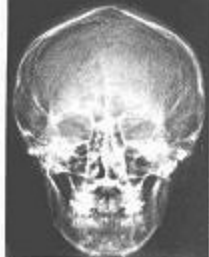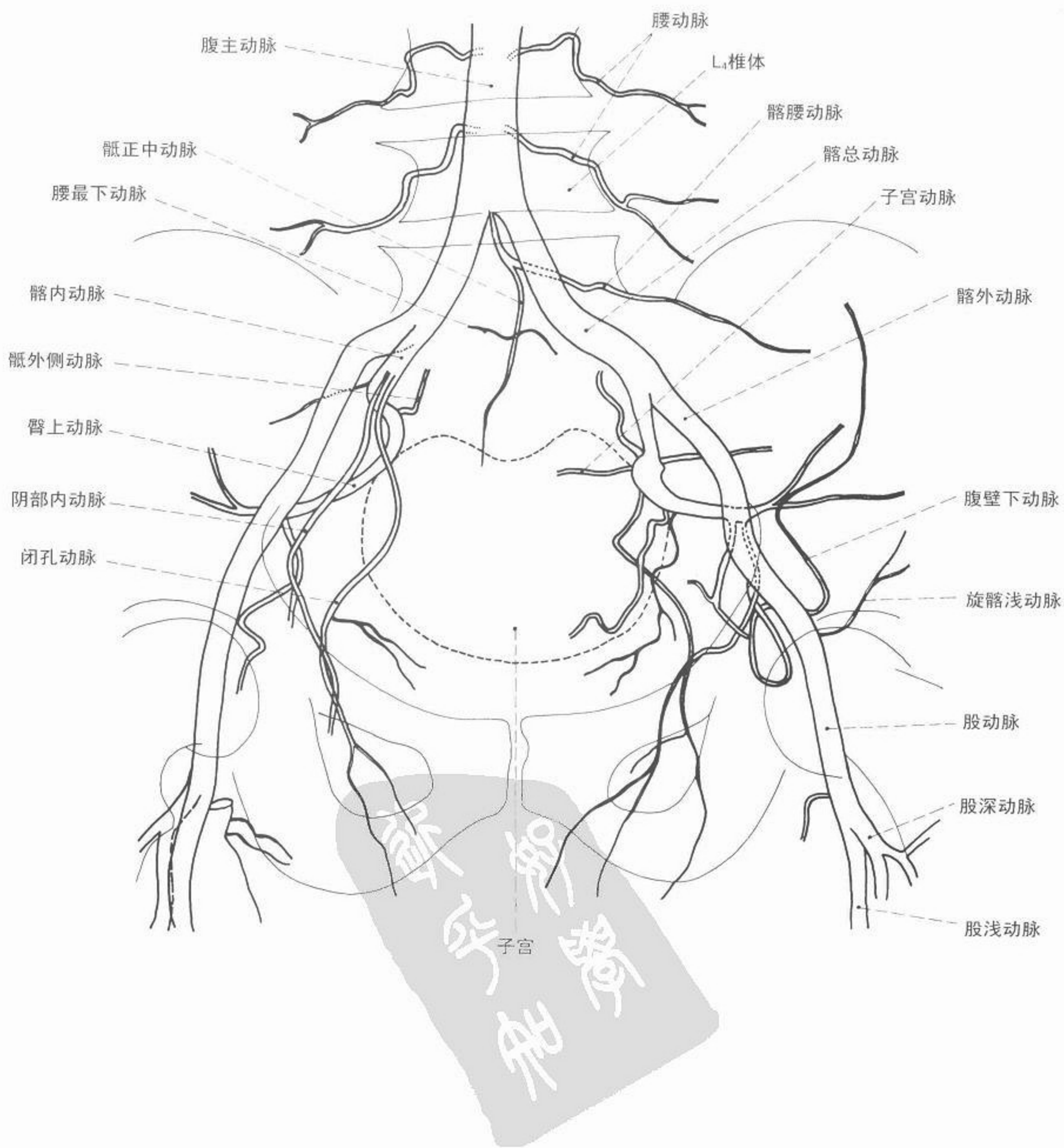


图 107 选择性左肾动脉造影



血管造影



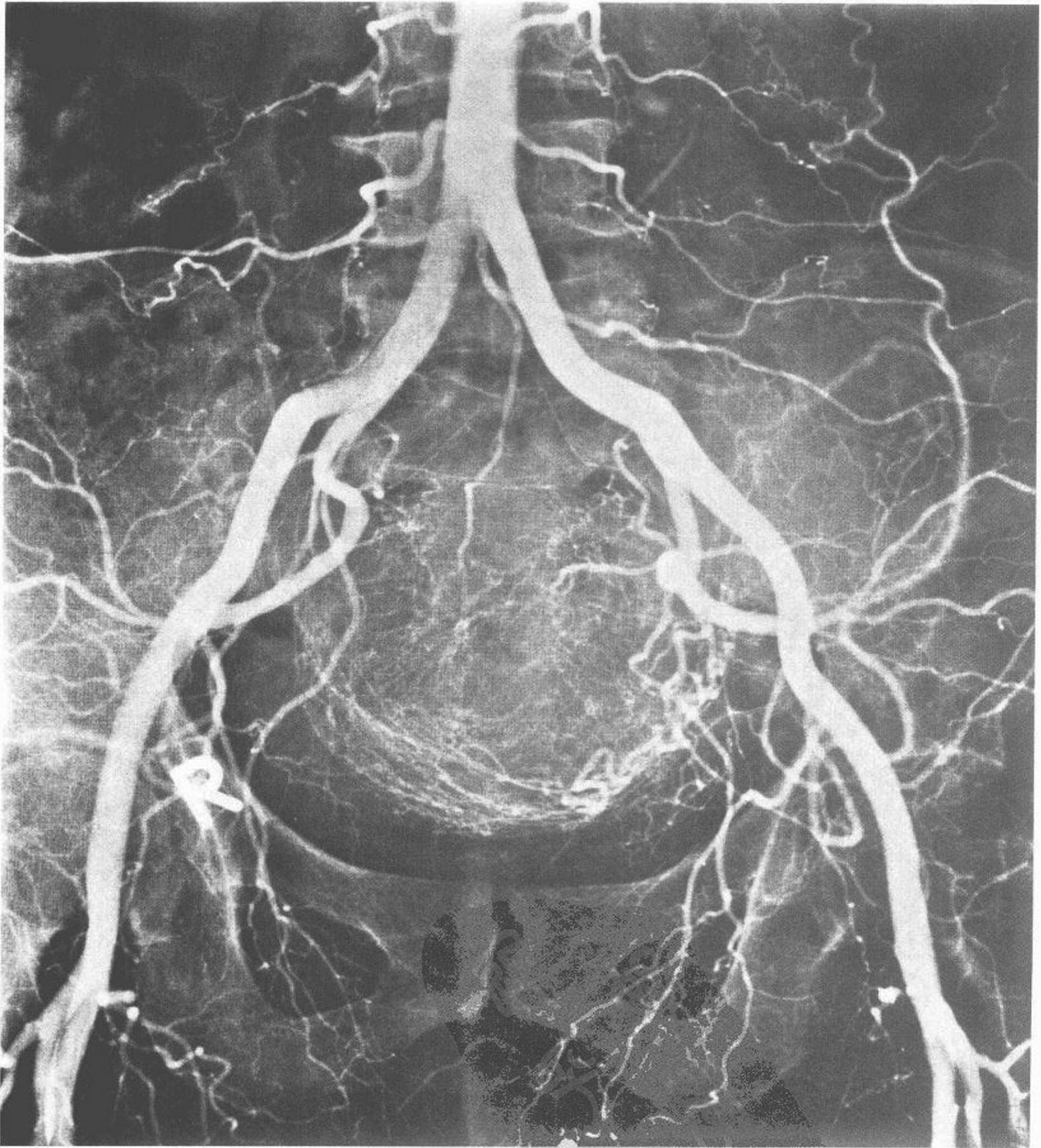
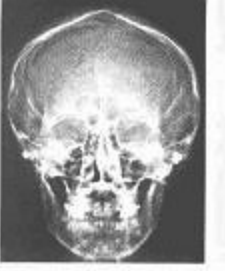
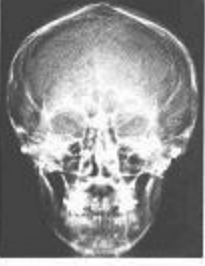
图 108 盆腔动脉造影



血管造影

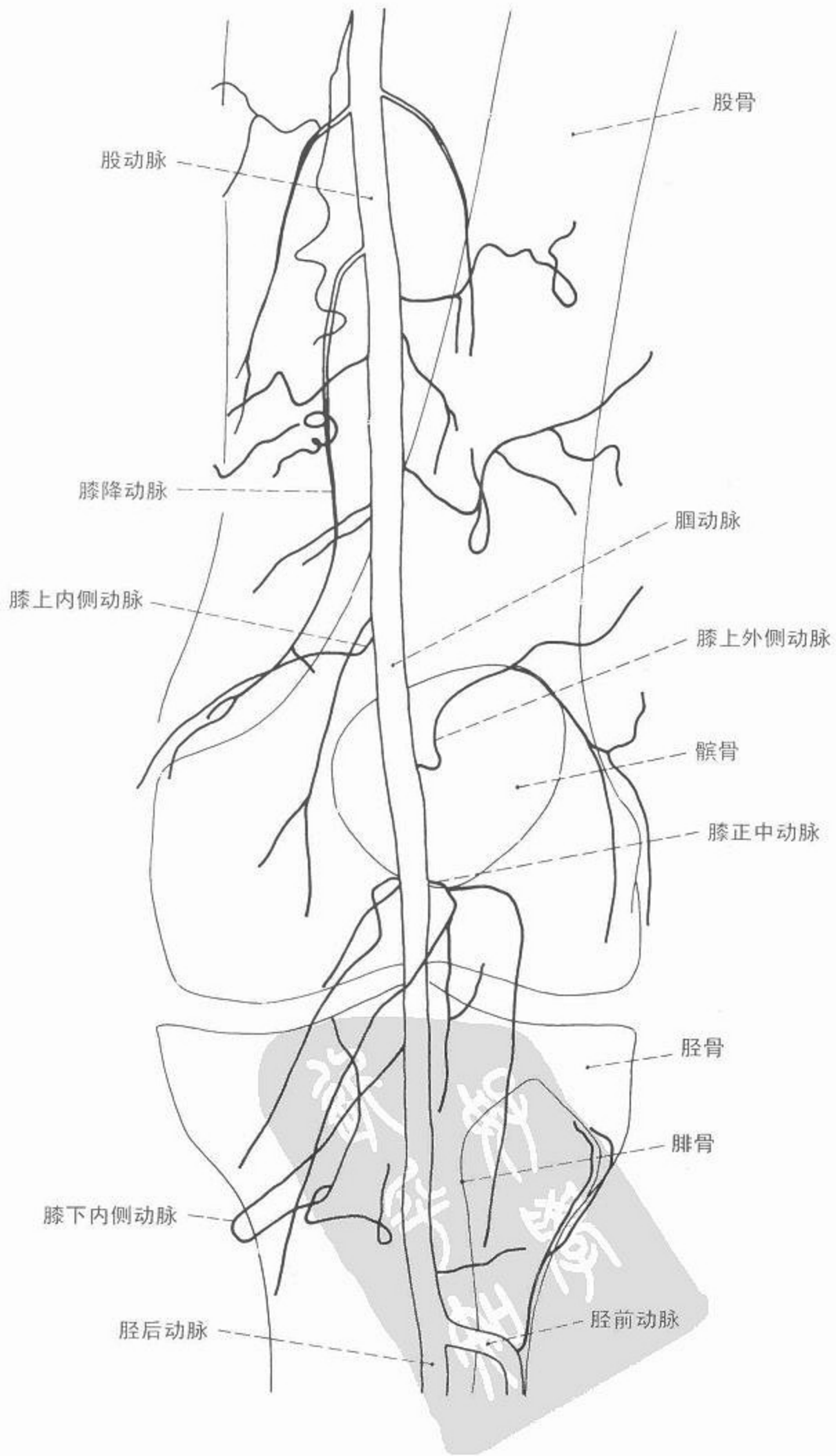
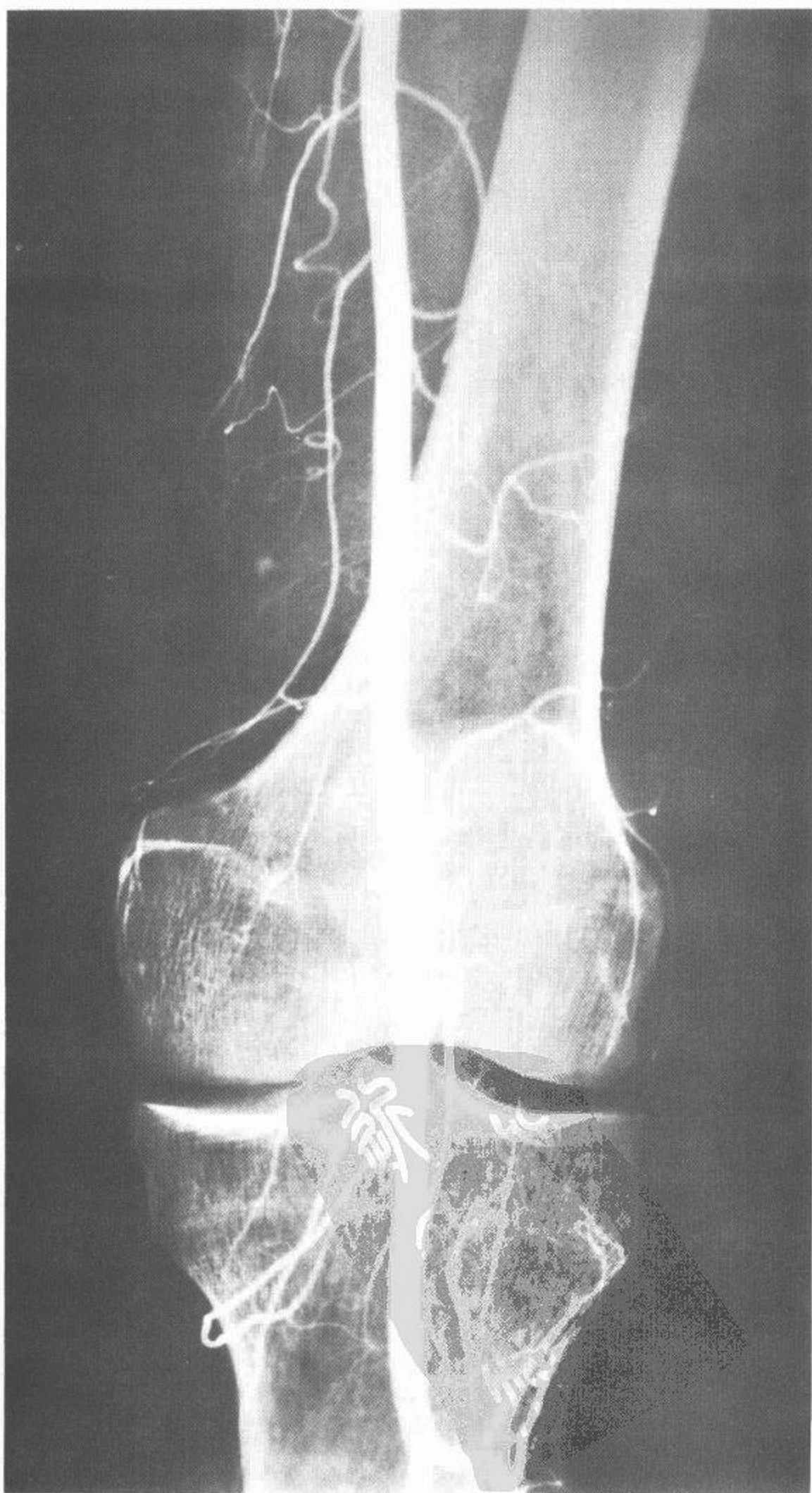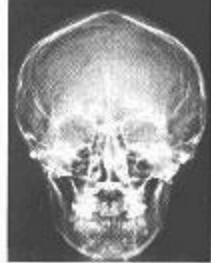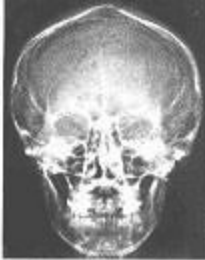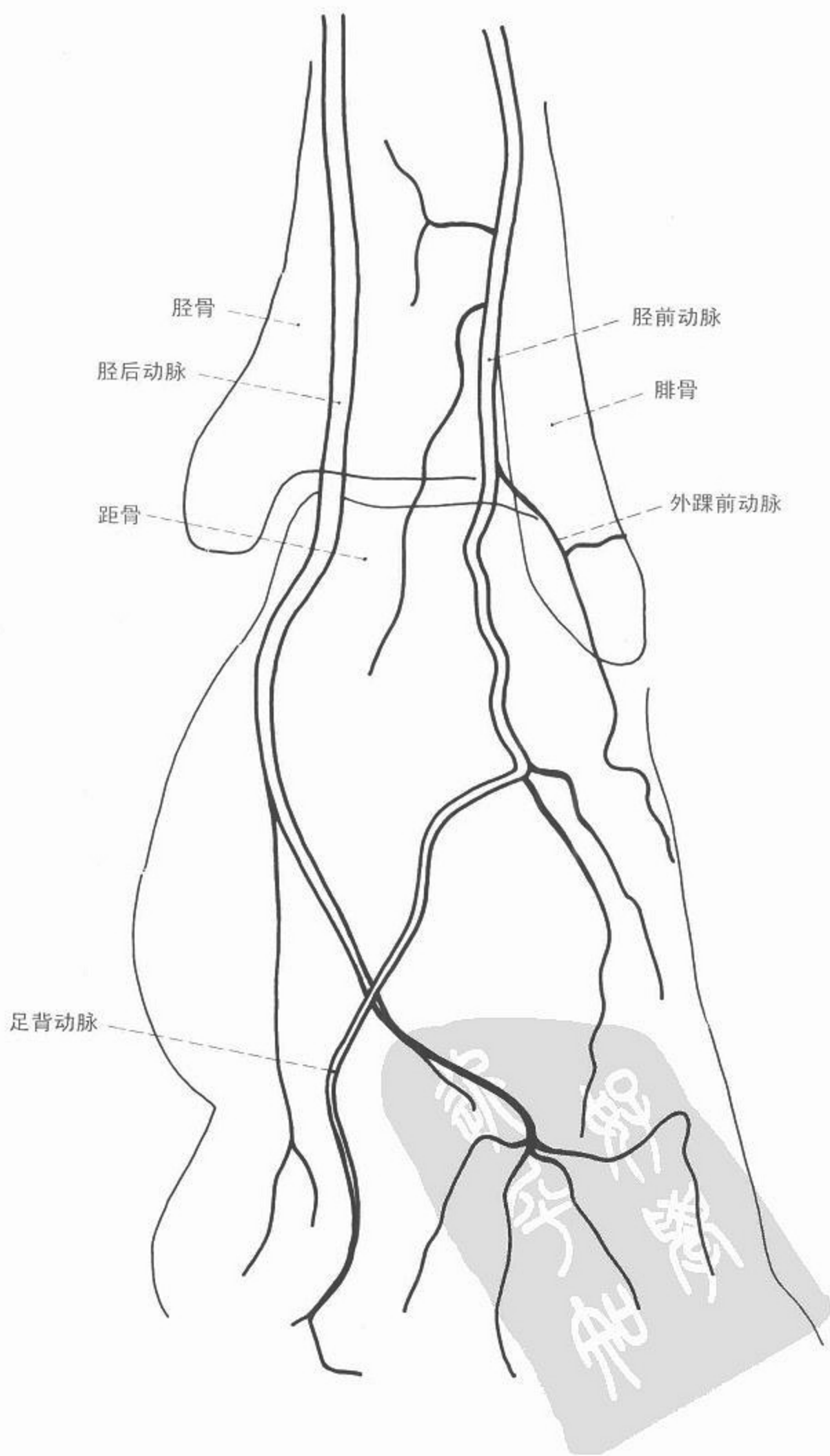




图 109 左膝关节血管造影



血管造影



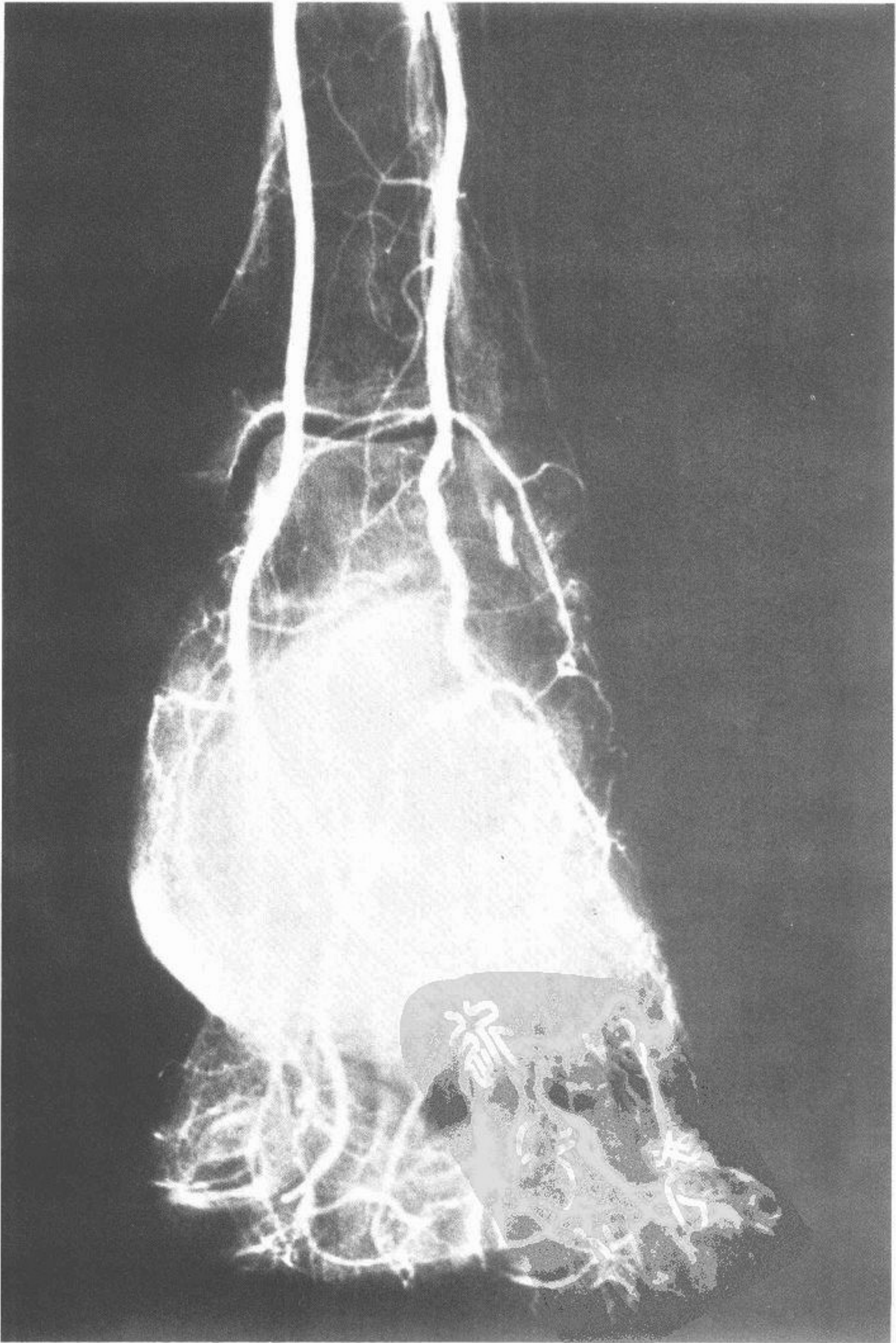
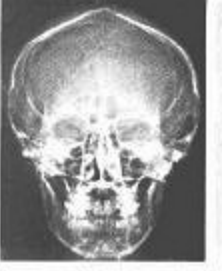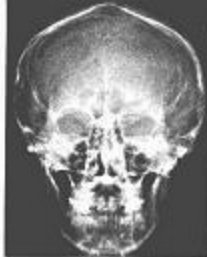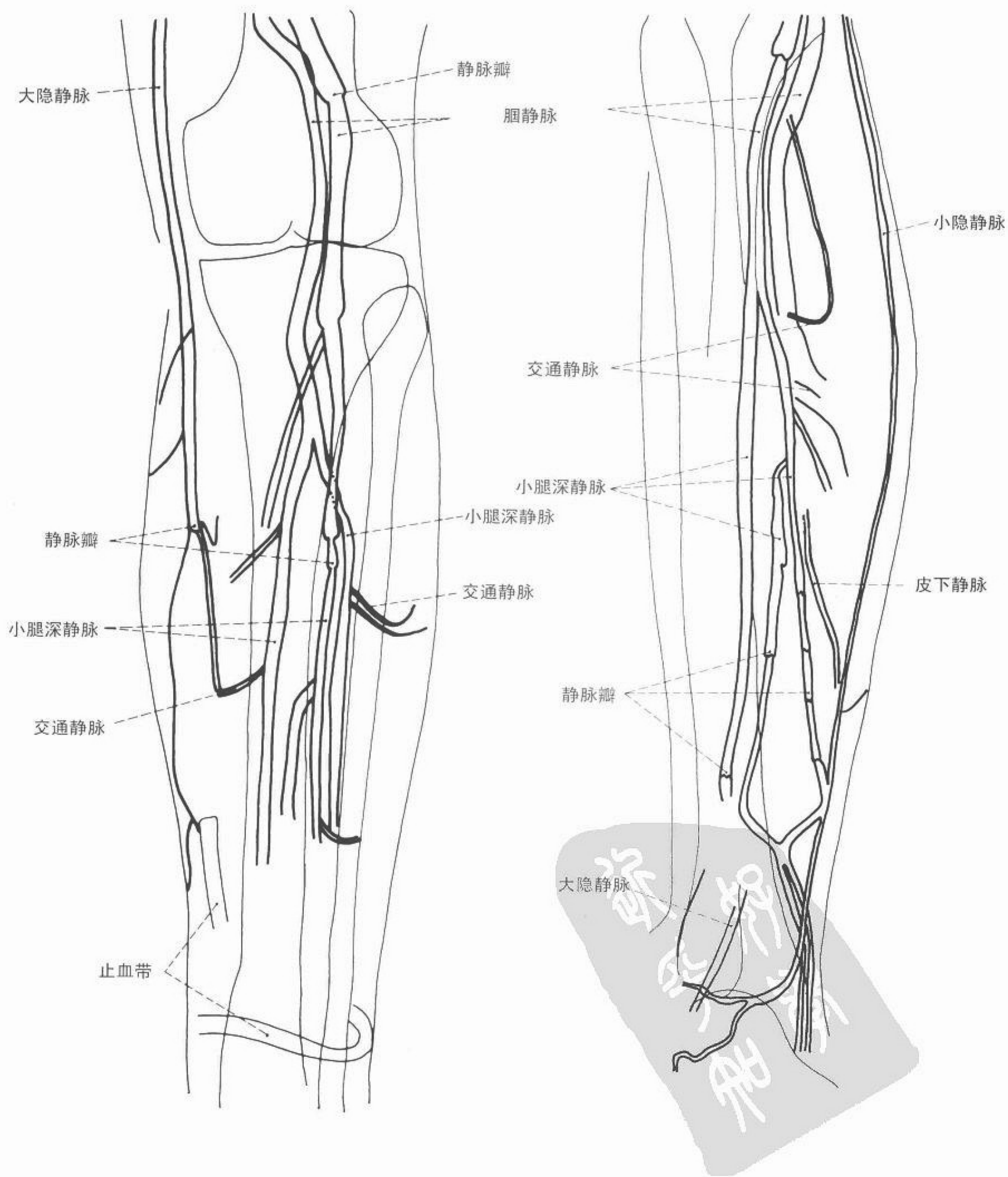


图 110
左踝关节
血管造影



血管造影



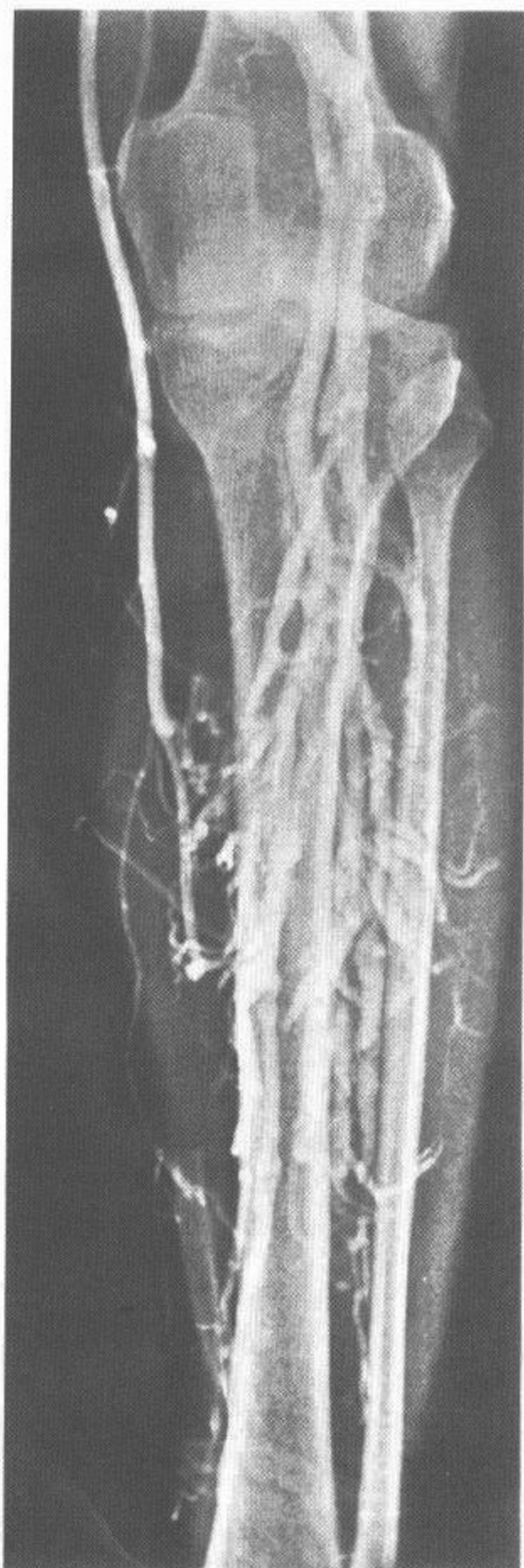
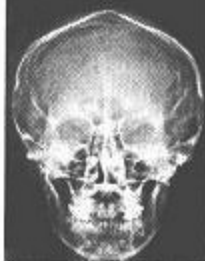


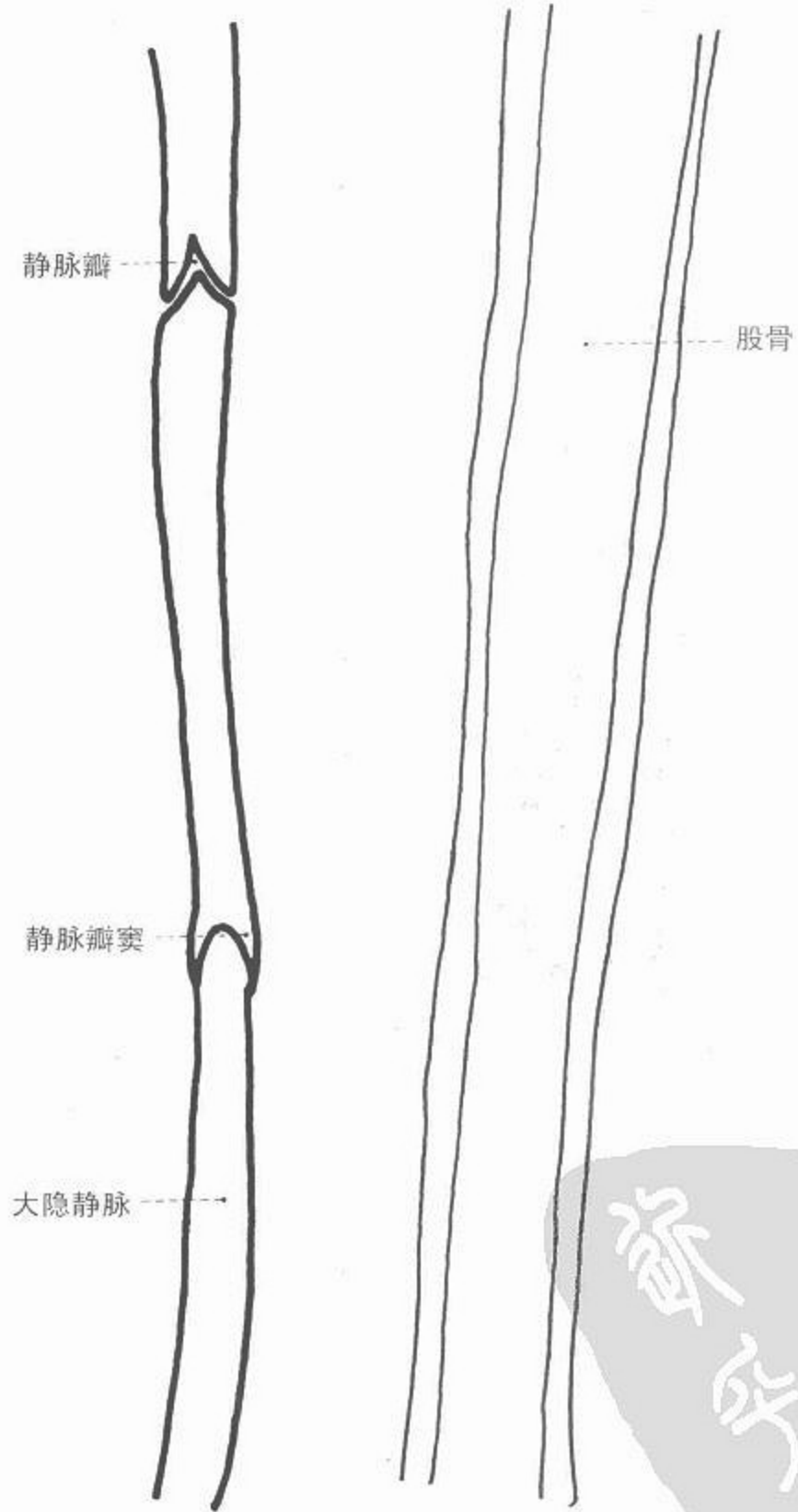
图 111 左小腿静脉造影 前后位

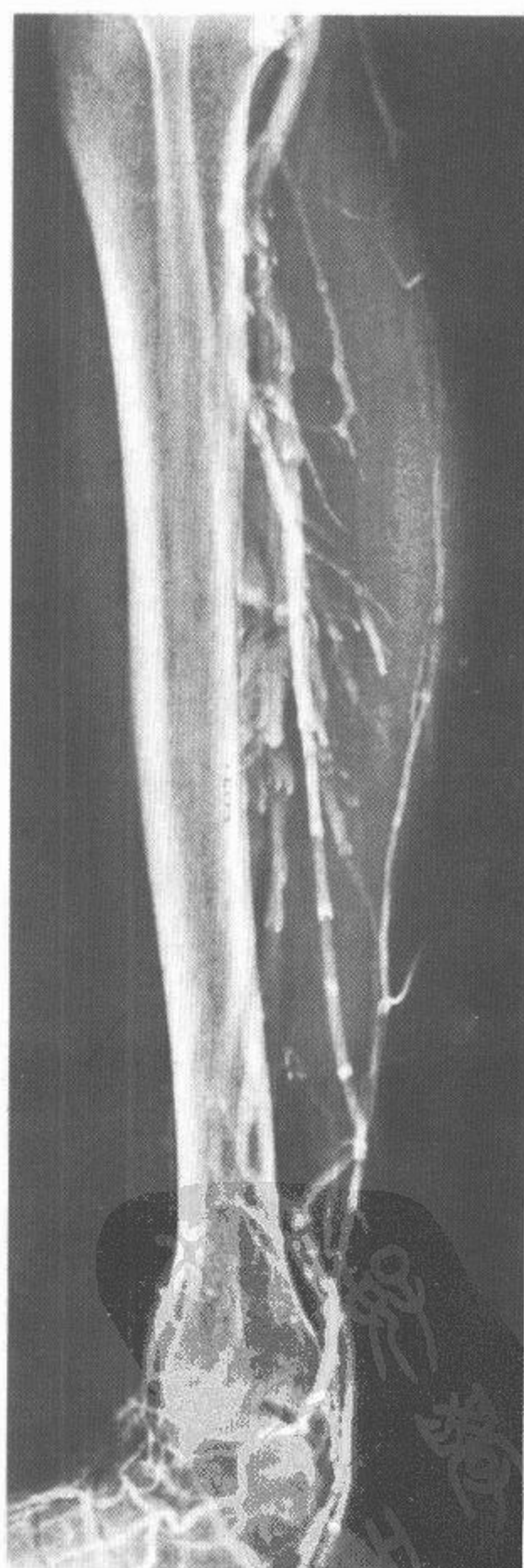
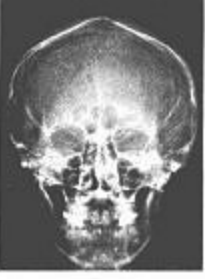
图 112 左小腿静脉造影 侧位



血管造影



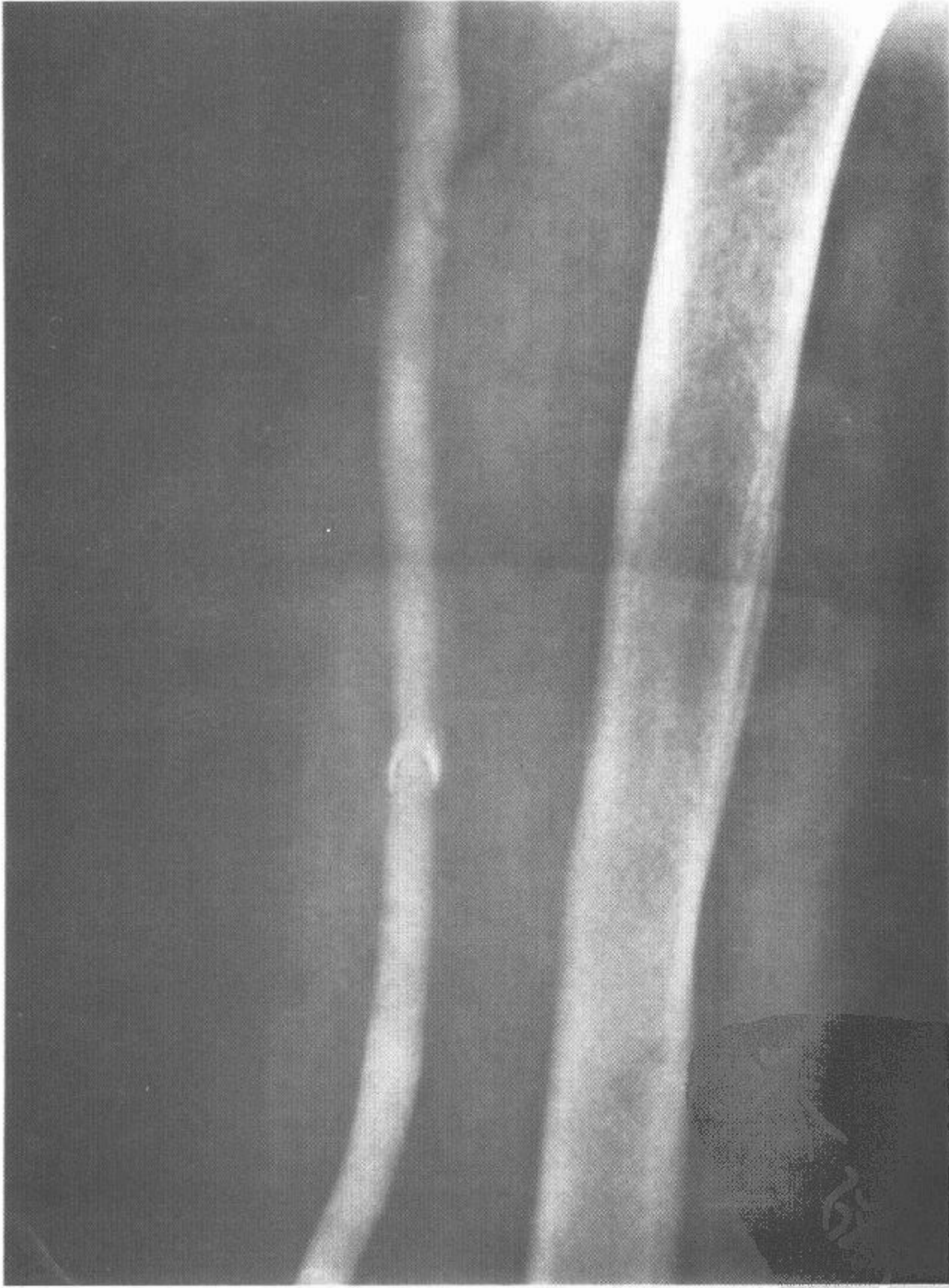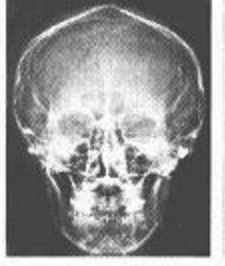
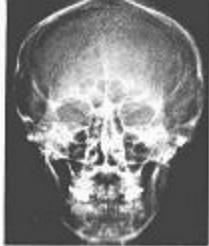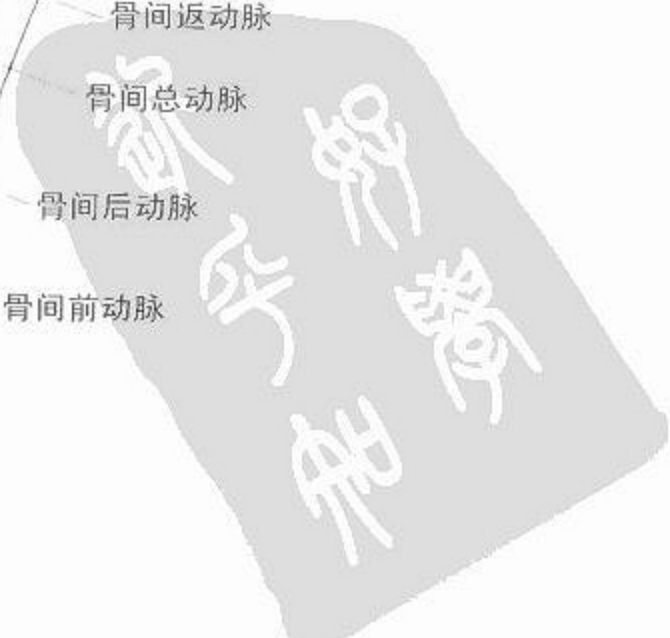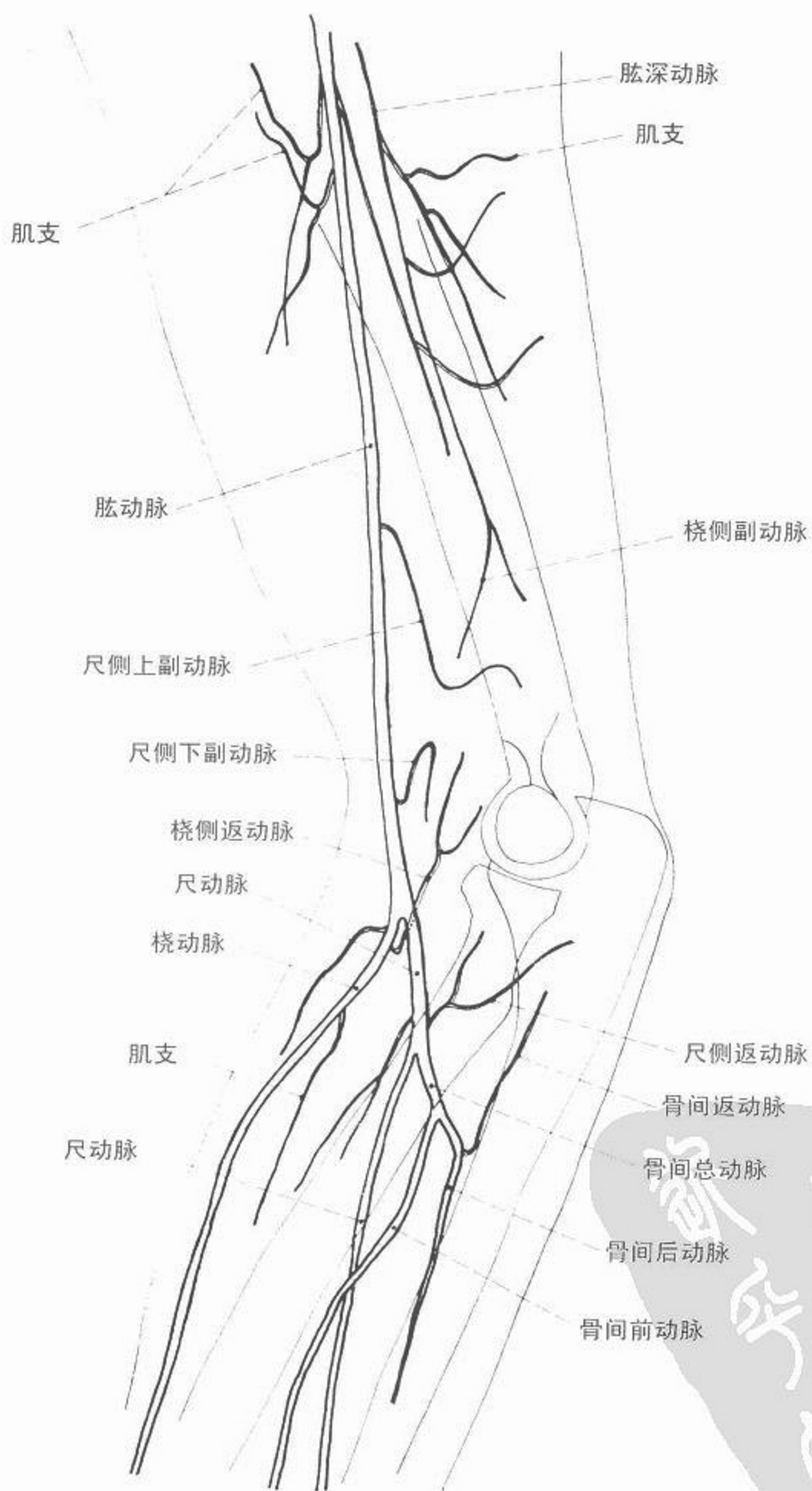


图 113 静脉瓣



血管造影



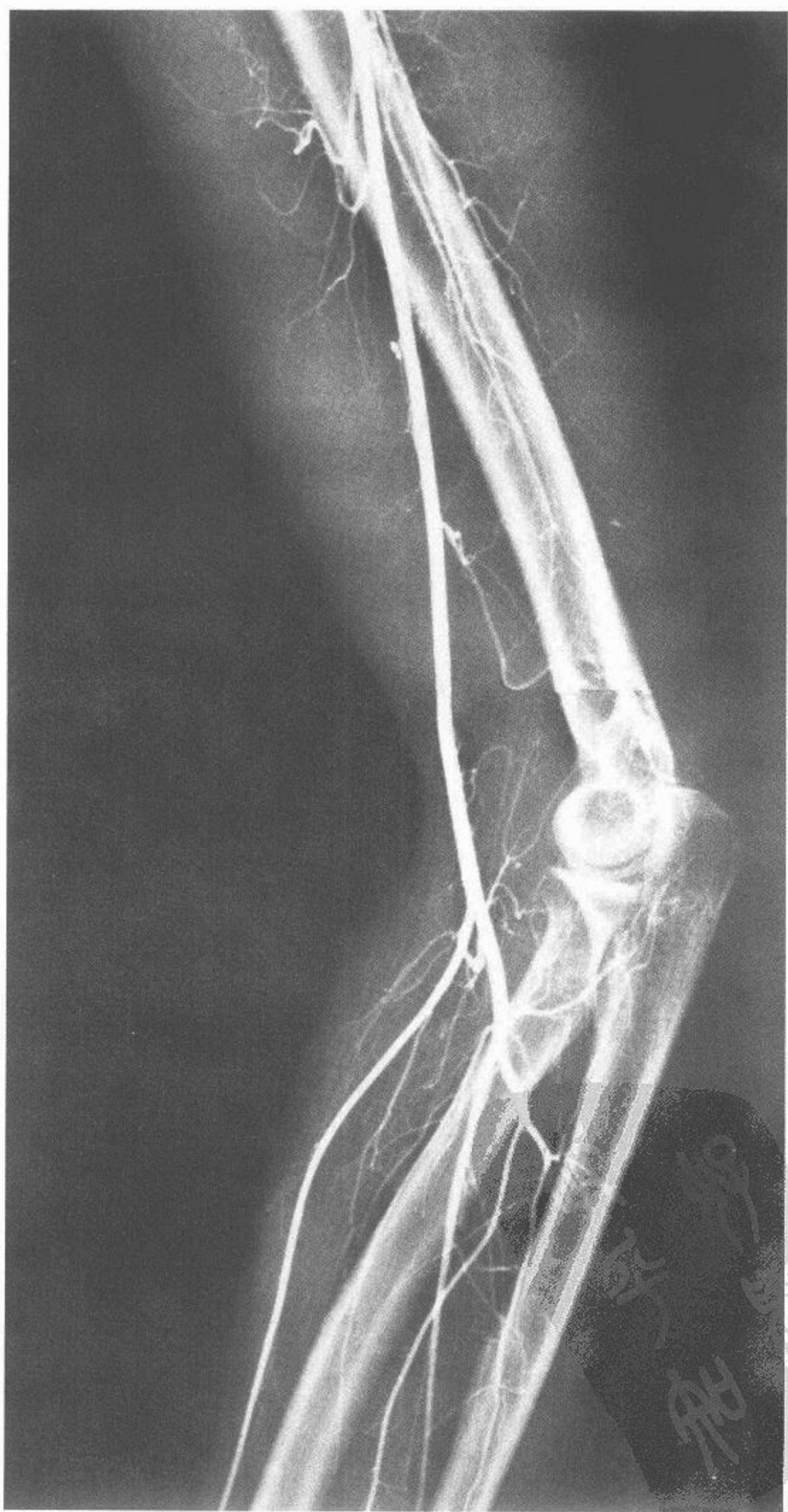
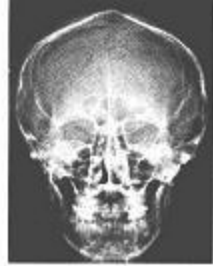

图 114 肘关节血管造影