

姜树学 马述盛 主编

断面解剖与

*MRI
CT
ECT*

对照图谱

辽宁科学技术出版社

109437

ATLAS OF SECTIONAL ANATOMY CORRELATED
WITH MRI CT AND ECT

姜树学 马述盛 主编

CHIEF EDITORS

JIANG SHUXUE

MA SHUSHENG

Professor of Department of Anatomy Professor of Department of Radiology

College of Basic Medical sciences The first clinical college

China Medical University China Medical University

辽宁科学技术出版社

中国·沈阳

Liaoning Science and Technology Publishing House

Shenyang, China



断面解剖与 MRI CT ECT 对照图谱

解放军医学图书馆(书)



C0203146

ANATOMY CORRELATED WITH MRI CT AND ECT
ATLAS OF SECTIONAL

图书在版编目 (CIP) 数据

断面解剖与 MRI CT ECT 对照图谱/姜树学, 马述盛
主编. - 沈阳: 辽宁科学技术出版社, 1998.5
ISBN 7-5381-2705-4

I. 断… II. ①姜… ②马… III. 影像-诊断学-图谱 IV. R445

中国版本图书馆 CIP 数据核字(97)第 28549 号

辽宁科学技术出版社出版

沈阳市和平区北一马路 108 号

邮政编码:110001

辽宁省新华书店发行

沈阳新华印刷厂印刷

开本:889×1194 1/16

印张:23 $\frac{3}{4}$ 插页:4

字数:532 千字

1998 年 5 月第 1 版

1999 年 3 月第 2 次印刷

责任编辑:宋纯智 倪晨涵

封面设计:邹君文

版式设计:李 夏

责任校对:丁东戈

印 数:3 001—6 000

定 价:198.00 元

断面解剖与

MRI CT ECT

对照图谱

- 主 编** CHIEF EDITORS
姜树学 Jiang Shuxue 马述盛 Ma Shusheng
- 副主编** VICE EDITORS
陈金宝 Chen Jinbao 吴振华 Wu Zhenhua
- 审 阅** REVISER
陈炽贤 Chen Chixian
- 编 者** EDITORS
姜树学 Jiang Shuxue 马述盛 Ma Shusheng
陈金宝 Chen Jinbao 吴振华 Wu Zhenhua
王振宇 Wang Zhenyu 李佩玲 Li Peiling
姜拥军 Jiang Yongjun 黎 庶 Li Shu
王书轩 Wang Shuxuan 苏惠群 Su Huiqun
王 顺 Wang Shun 姜爱民 Jiang Aimin
- 摄 影** PHOTOGRAPHER
邵 郢 Shao Ying
- 电子排版** ELECTRONIC COMPOSITION
陈树刚 Chen Shugang 杜龙梅 Du Longmei
刘克江 Liu Kejiang 姜树学 Jiang Shuxue



主编简介

ABOUT CHIEF EDITOR

姜树学 1939 年生于吉林省农安县, 1958 年考入中国医科大学医疗系, 1963 年毕业留校任教。现为系统解剖学和断面解剖学教授, 政府特殊津贴获得者。数十年来潜心钻研解剖学的教学和科研。1996 年断面解剖学教学, 获辽宁省教学成果二等奖。1985 年“侧胸皮瓣的研究”获卫生部科技成果乙级奖。1982 年“前臂皮瓣的研究”获辽宁省重大科技成果一等奖, 1988 年该项研究又获得国家发明三等奖。并参加编写了《显微外科解剖学》、《外科解剖学》及《皮瓣和肌皮瓣显微外科解剖学》等著作。1988 年被授予“辽宁省有突出贡献专家”的称号。

Jiang Shuxue, born in Nongan County, Jilin Province in 1939, admitted to the China Medical University in 1958 and became a teacher of the university after graduation in 1963. Now, he is a professor of systemic anatomy and sectional anatomy in China Medical University, and he is one of the winners of the government special allowance. For several decades, he has been working in the research and teaching of anatomy.

In 1996, he was rewarded the second prize of Liaoning Province teaching achievement for his "Sectional anatomic teaching". In 1985, he was rewarded for the second prize of scientific and technologic achievement of Health Ministry for his "Research of lateral thoracic skin flap". In 1982, he was rewarded the first prize of important scientific research of Liaoning Province for his "Research of forearm skin flap". In 1988, he was rewarded the third prize of national invention for his "Research work of forearm skin flap". Professor Jiang participated in compiling the books of "Microsurgical Anatomy", "Surgical Anatomy", "Microsurgical Anatomy of Skin Flap and Musculocutaneous flap". Professor Jiang Shuxue was conferred on the title of "Specialist having prominent contribution of Liaoning Province" in 1988.

前 言

随着医学检测手段的迅速发展, B 型超声、CT 已得到普及, MRI 与 ECT 设备相继出现于市级医院。传统的投影成像(X 线成像), 已变成二维或三维的断面成像, 如 CT、MRI 和超声成像。与此同时, 医学影像工作者的队伍逐年扩大, 各科医生都在积极学习和运用医学影像知识为患者服务。读 CT、MRI 片必须以断面解剖学知识为基础, 然而过去没有断面解剖学的教育, 临床工作的医生大都缺乏这方面的知识。为了满足临床医务工作者的诊断和医学院校影像教学的急需, 我们编写了这本《断面解剖与 MRI CT ECT 对照图谱》, 为读者提供了宝贵的图像资料。

本书精选出 180 幅断面解剖图、337 幅 MRI 图、105 幅 CT 图、40 幅 ECT 图和 3 幅 MRA 图。每两页为一单元, 一页为彩色断面解剖图、ECT 图及定位图。另一页为 CT 及 MRI 图。每一单元图都处于同一断面上, 切线相同, 结构相同, 便于读者学习和应用。本图谱不仅对从事医学影像的学者是一本不可缺少的读物, 而且对其它各科临床医生阅读 CT、MRI 图像也是极有价值的参考书。断面解剖标本是用健康国人尸体冰冻切片制成的。胸、腹、盆部的横断面(水平断面)及头颈部、膝关节的断面等层厚为 1cm; 胸、腹、盆部的冠状断面及矢状断面层厚为 2cm。CT、MRI 及 ECT 等各种影像图都是用健康国人扫描制成的。

CT 图是用第四代 CT 机扫描、激光照像制成。头颈部与胸部用平扫图像; 腹部与盆部用增强扫描图像。

MRI 图像(T₁WI、T₂WI 及 PDWI)是用 1.5T、2.0T 磁共振仪、自旋回波(SE)序列采集的。

名词以全国自然科学名词审定委员会 1991 年公布的人体解剖学名词为准, 中英文对照。

本图谱是断面解剖学与医学影像学相结合的产物, 经过几年的努力终于和读者见面了, 我们感到欣慰。本书在编著过程中得到王淀教授、曹郁琦教授等人的帮助, 特此表示衷心的感谢。

尽管诸位编者尽心尽力, 精益求精, 但是仍有不足之处, 敬请各位读者指正。

姜树学 马述盛
1997 年 9 月于沈阳

PREFACE

With the rapid development of modern sophisticated imaging modalities, the conventional projection imaging as radiography is now changed to sectional imaging such as B-mode US, CT and MRI. Now, in China most of hospitals are equipped with such imaging modalities. Doctors and technicians in the department of Radiology and physicians in other departments are interested in studying the fundamental knowledge of human sectional anatomy. However, in the past few medical school offered the course of sectional anatomy so that most of the radiologists and clinical physicians are not familiar with this. To meet the urgent need for the clinical medical workers and training of students, we compiled this book "Atlas of Sectional Anatomy Correlated with the MRI, CT and ECT" with hope that it would be easier for them to learn.

One hundred and eighty illustrations of sectional anatomy together with corresponding 337 MR images, 105 CT images and 40 ECT pictures were carefully chosen for the atlas. Each unit is composed of two pages, one shows the colored illustration of sectional anatomy and ECT image as well as a locator of section, while another page depicts the CT and MR images of the corresponding section. This atlas is not only indispensable for radiologists but also essential to all clinical physicians in interpreting CT and MR imaging.

All the anatomic sections were made from normal Chinese cadavers with frozen section method. The thickness of horizontal section for the thorax, abdomen, pelvis and the thickness of sections for head and neck, knee joint were 1.0 cm, and the thickness of frontal and sagittal sections was 2.0 cm for the thorax, abdomen and pelvis. The CT, MRI and ECT images were obtained from scanning normal Chinese volunteers.

All CT examinations were performed with PQ-2000 (Picker International, Cleveland, Ohio, U. S. A.) and laser printer. The images of head and neck, chest were non-enhanced, while the images of abdomen and pelvis were enhanced. The slice thickness was 1.0 cm.

MR images including T₁ weighted, T₂ weighted and proton density images were performed on 1.5T scanner (Signa, GE Medical Systems, Milwaukee, Wis., U. S. A.) and 2.0 T scanner (Prestige, Elscint Ltd. Israel) with spin echo (SE) sequence. The slice thickness was 1.0 cm.

Terms are used according to the Human Anatomic Terms published in 1991 by the National Examination and Approval Committee on Natural Scientific Terminology with corresponding English terms.

After several years, the authors appreciated very much that this book was eventually compiled and published. We hope that the readers will find this book interesting and helpful.

We would like to express our thanks to Prof. Wang Dian and Prof. Cao Yuqi, whose assistance and co-operation made this publication possible.

Shenyang September, 1997

Jiang Shuxue

Ma Shusheng

使用说明

一、本图谱分头颈部、胸部、腹部、盆部和四肢等五个部分。每两页为一单元，一页为彩色断面解剖图、ECT图及定位图。定位图的白色线为断面的切线，蓝色线为基准线。另一页为黑白的CT图、MRI T₁加权图、MRI T₂加权图及该单元的中英文名词。每一单元的所有图像都处于同一断面上。

二、参考平面

1. 头颈部水平断面的参考平面为眶下缘至外耳门的平面。
2. 头颈部额状断面的参考平面为垂直于眼耳平面的断面。
3. 头颈部矢状断面的参考平面为正中矢状断面。
4. 胸腹盆及四肢水平断面的参考平面为经过胸骨角或脐的水平断面。
5. 胸腹盆及膝关节的矢状断面的参考平面为躯干和膝关节的正中矢状面。
6. 胸腹盆及膝关节的额状断面的参考平面为经过腋中线和膝关节的侧中线的额状面。

三、英文名词缩写：

Fig.	Figure	H	Horizontal
C	Cephalo - cervical	S	Sagittal
F	Frontal	T	Thoracic Vertebrae
L	Lumbar Vertebrae	S	Sacral Vertebrae
CO	Coccyx	A	Abdomen
P	Pelvis	K	Knee
UL	Upper Limb	LL	Lower Limb
PD	Proton Density	f	female
m	male	a.	artery
v.	vein	n.	nerve

INSTRUCTIONS

1. There are five regions in this atlas including head and neck, thorax, abdomen, pelvis and limbs. Every unit is composed of two pages. One page shows a colored sectional anatomic picture, ECT image and a locator of sections in which the white line represents cutting plane, and the blue line represents basic plane. Another page shows CT and MRI (T₁WI and T₂WI) images with Chinese - English anatomical terms of this section. Pictures and images of one unit are all at the same plane.

2. The plane of reference

a. The plane of reference for horizontal sections of head and neck is at the eye - ear plane (Frankfurt horizontal, orbito - meatal line)

b. The plane of reference for frontal sections of head and neck is the plane perpendicular to the eye - ear plane (Frankfurt horizontal, orbitomeatal line)

c. The plane of reference for sagittal sections of head and neck is median sagittal plane.

d. The plane of reference for horizontal sections of thorax, abdomen, pelvis and limbs is the horizontal plane passing through sternal angle or umbilicus.

e. The plane of reference for sagittal sections of thorax, abdomen, pelvis or knee joint is the median sagittal plane of trunk or knee joint.

f. The plane of reference for frontal sections of thorax, abdomen, pelvis or knee joint is the plane passing through midaxillary line or lateral median line of knee joint.

3. Abbreviations

Fig.	Figure	H	Horizontal
C	Cephalo - cervical	S	Sagittal
F	Frontal	T	Thoracic Vertebrae
L	Lumbar Vertebrae	S	Sacral Vertebrae
CO	Coccyx	A	Abdomen
P	Pelvis	K	Knee
UL	Upper Limb	LL	Lower Limb
PD	Proton Density	f	female
m	male	a.	artery
v.	vein	n.	nerve

目 录

头颈部

水平断面 HC	2
额状断面 FC	44
矢状断面 SC	74
磁共振血管成像 MRA	100

胸部

水平断面 HT	102
额状断面 FT	136
矢状断面 ST	152
磁共振成像(气管、心脏)MRI	174

腹部

水平断面 HA	176
额状断面 FA	206
矢状断面 SA	222
磁共振成像(胆、胰管和输尿管)MRI	244

盆部

女盆水平断面 HPf	246
男盆水平断面 HPm	274
女盆额状断面 FPf	292
男盆矢状断面 SPm	304
磁共振成像(前列腺)MRI	316

四肢部

左上肢水平断面 HUL	318
左下肢水平断面 HLL	330
左膝关节额状断面 FK(L)	342
右膝关节矢状断面 SK(R)	356

CONTENTS

Head and Neck (Cephalic and Cervical regions)	
Horizontal Sections HC	2
Frontal Sections FC	44
Sagittal Sections SC	74
MR Angiography MRA	100
Thorax	
Horizontal Sections HT	102
Frontal Sections FT	136
Sagittal Sections ST	152
MRI (trachea, heart)	174
Abdomen (Abdomen and Pelvis)	
Horizontal Sections HA	176
Frontal Sections FA	206
Sagittal Sections SA	222
MRI (cystic, pancreatic duct and ureter)	244
Pelvis	
Horizontal Sections, female HPf	246
Horizontal Sections, male HPm	274
Frontal Sections, female FPf	292
Sagittal Sections, male SPm	304
MRI (prostate)	316
Limbs	
Horizontal Sections of the Left Upper Limb HUL	318
Horizontal Sections of the Left lower Limb HLL	330
Frontal Sections of the Left Knee FK(L)	342
Sagittal Sections of the Right Knee SK(R)	356

HEAD AND NECK

头颈部

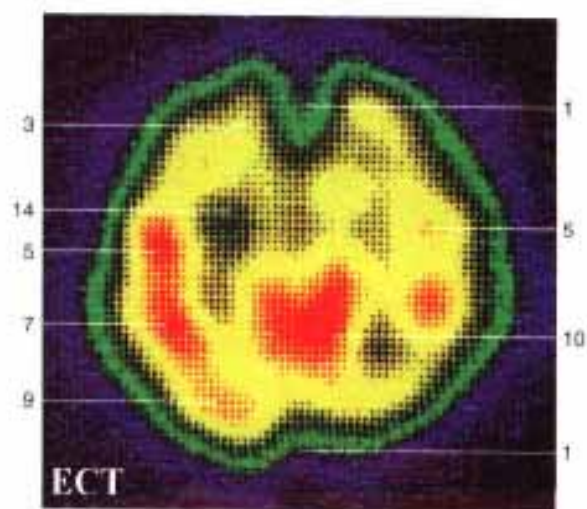
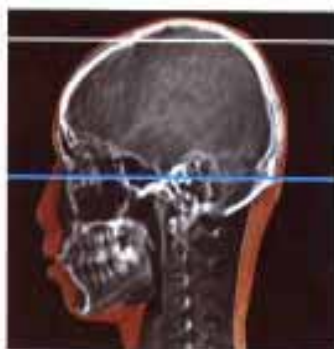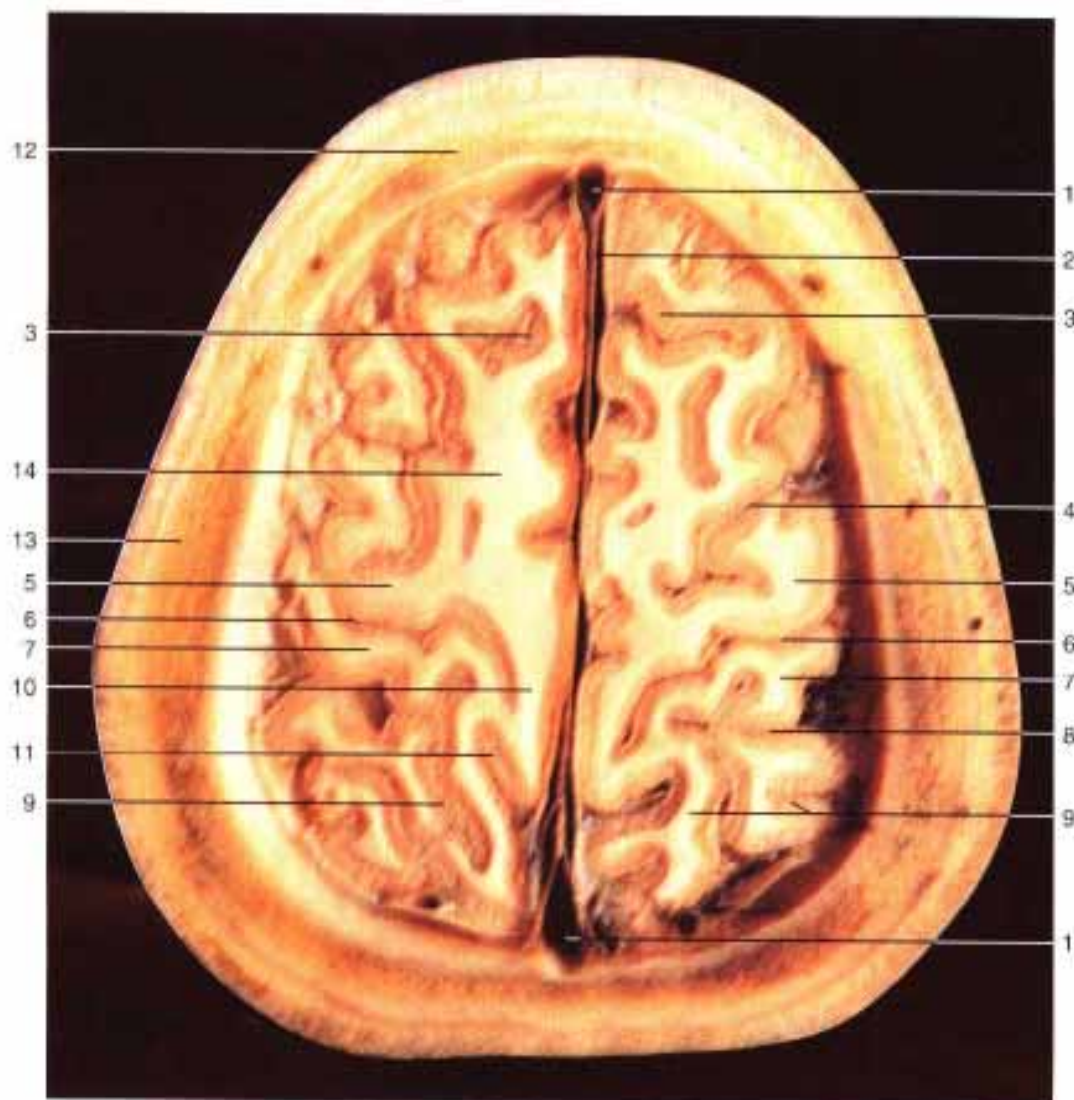
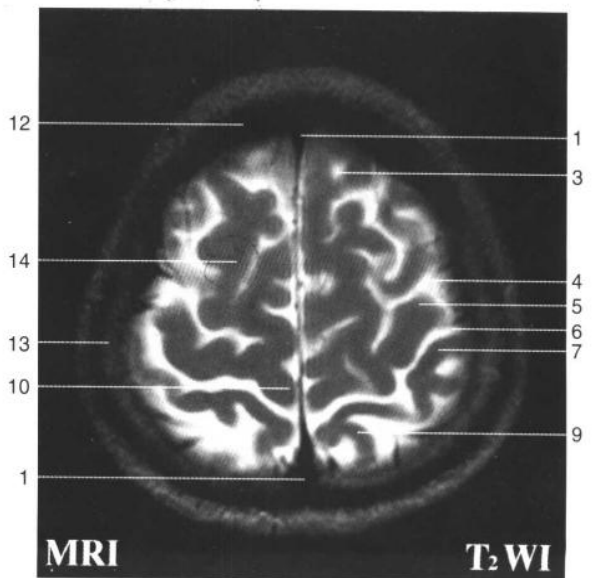
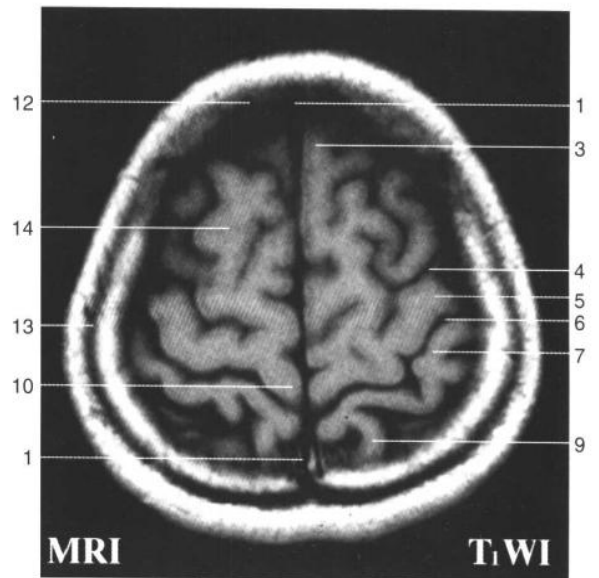
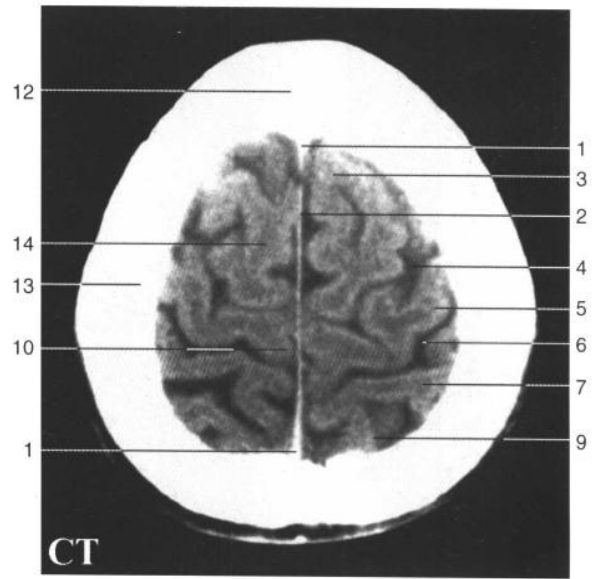


Fig. HC 1

Fig. HC 1

1. 上矢状窦 superior sagittal sinus
2. 大脑镰 cerebral falx
3. 额上回 superior frontal gyrus
4. 中央前沟 precentral sulcus
5. 中央前回 precentral gyrus
6. 中央沟 central sulcus
7. 中央后回 postcentral gyrus
8. 中央后沟 postcentral sulcus
9. 顶上小叶 superior parietal lobule
10. 中央旁小叶 paracentral lobule
11. 扣带沟缘支 marginal ramus of cingulate sulcus
12. 额骨 frontal bone
13. 顶骨 parietal bone
14. 辐射冠 corona radiata



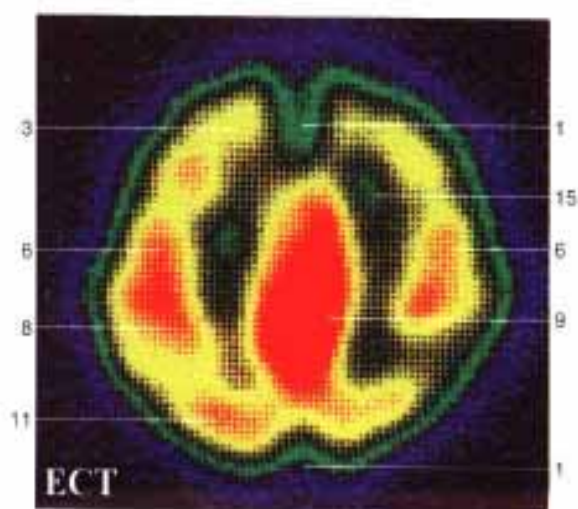
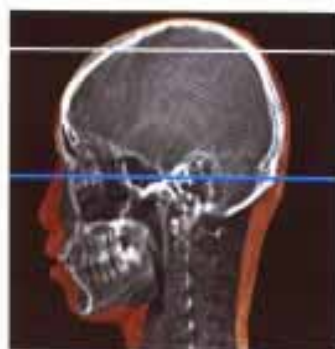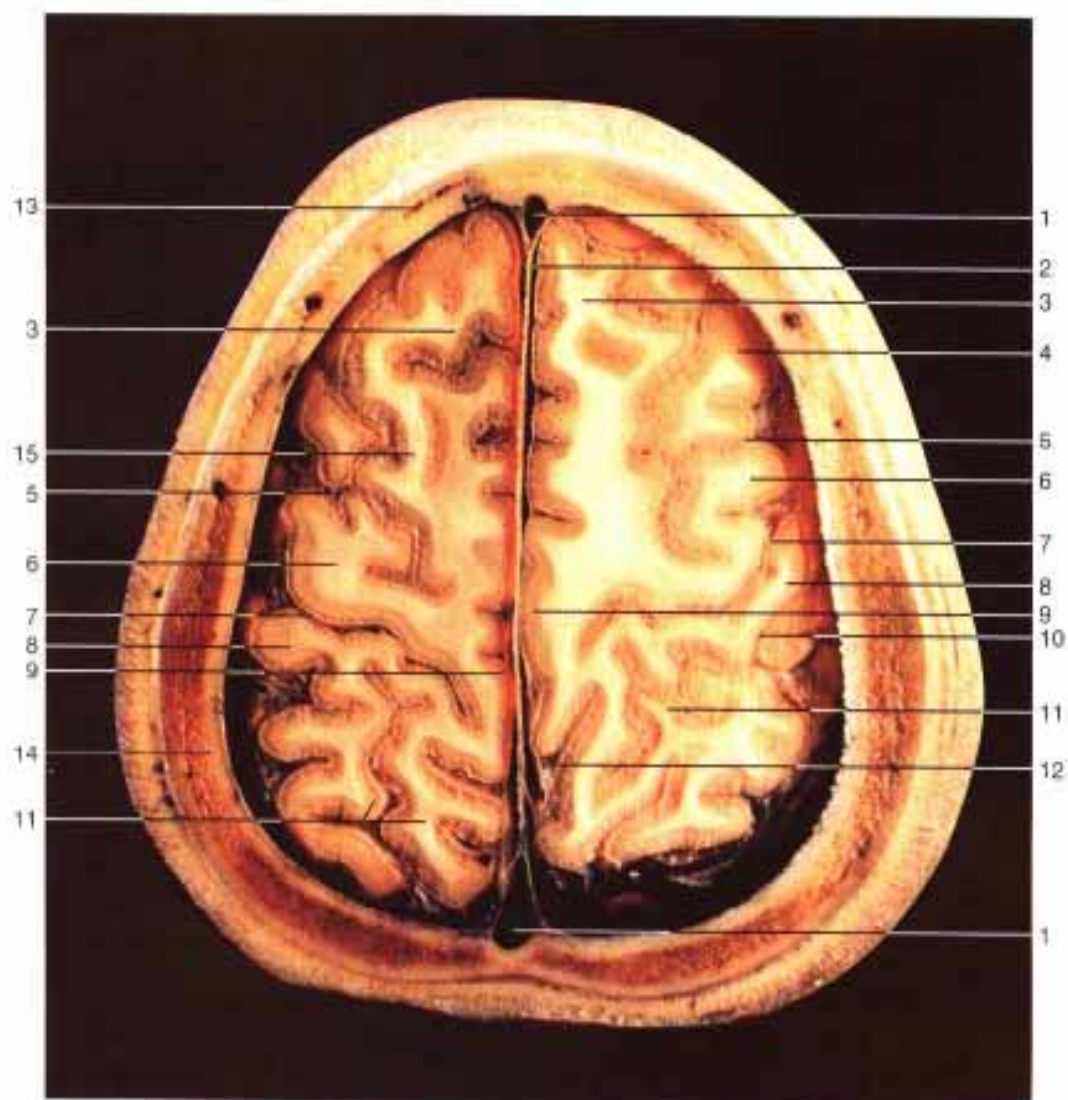
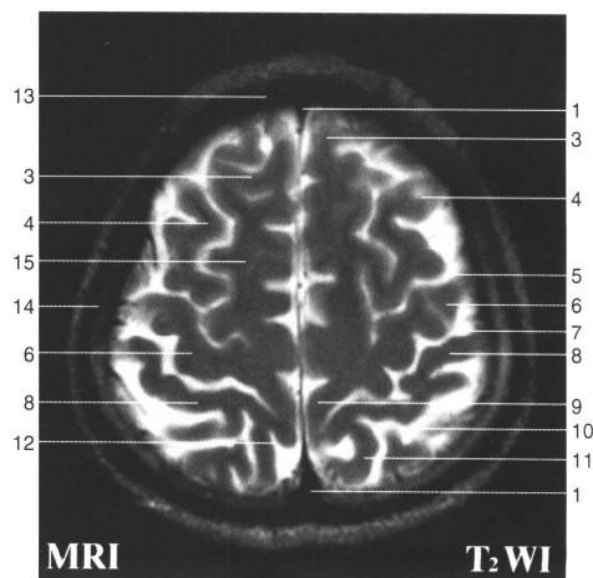
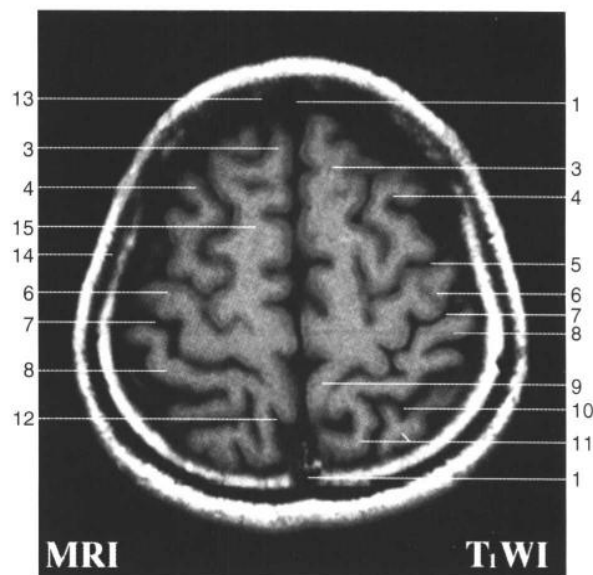
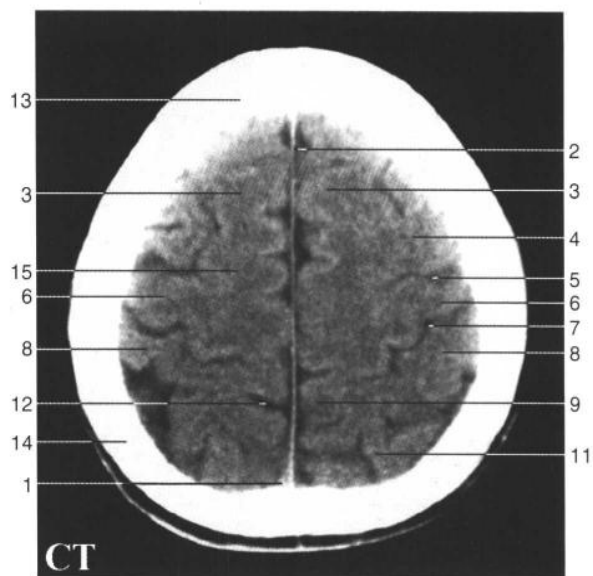


Fig. HC 2

Fig. HC 2

1. 上矢状窦 superior sagittal sinus
2. 大脑镰 cerebral falx
3. 额上回 superior frontal gyrus
4. 额中回 middle frontal gyrus
5. 中央前沟 precentral sulcus
6. 中央前回 precentral gyrus
7. 中央沟 central sulcus
8. 中央后回 postcentral gyrus
9. 中央旁小叶 paracentral lobule
10. 中央后沟 postcentral sulcus
11. 顶上小叶 superior parietal lobule
12. 扣带沟缘支 marginal ramus of cingulate sulcus
13. 额骨 frontal bone
14. 顶骨 parietal bone
15. 辐射冠 corona radiata



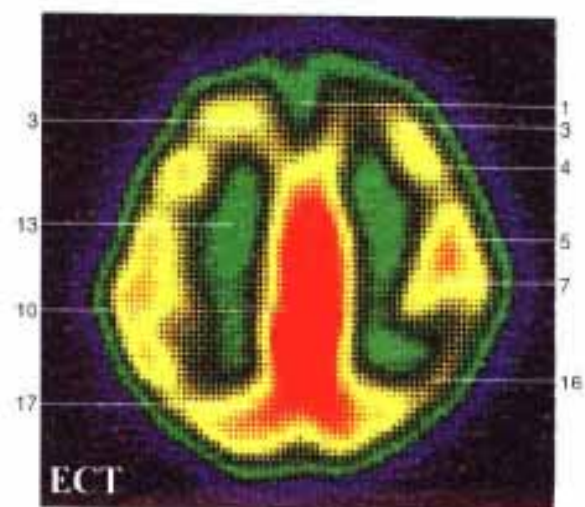
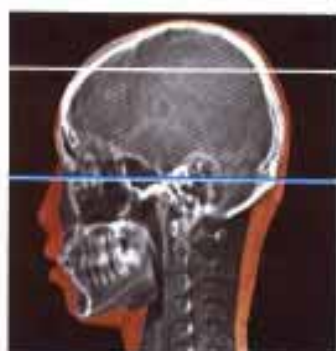
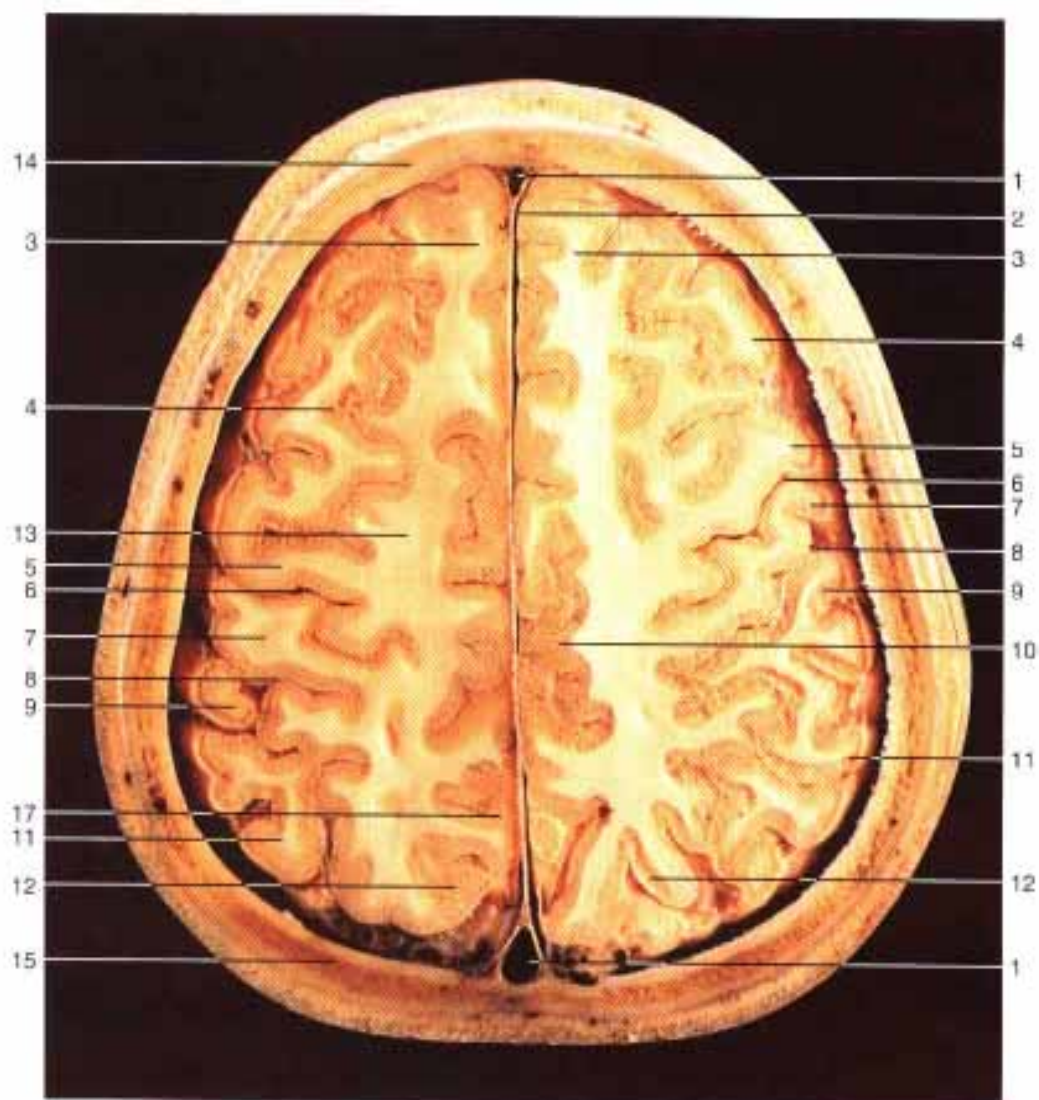
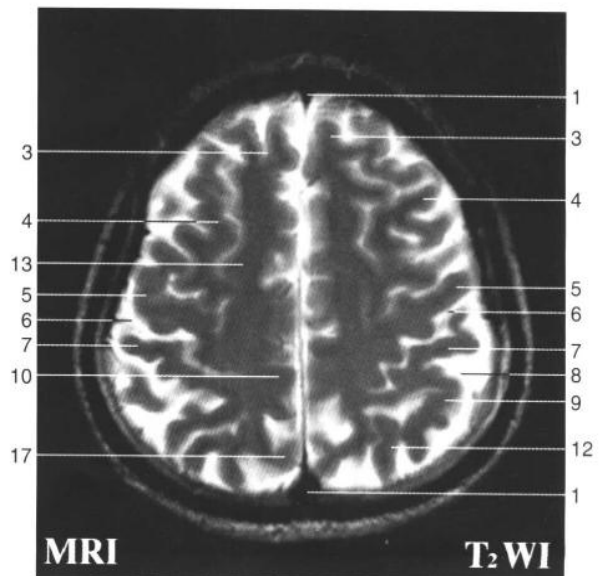
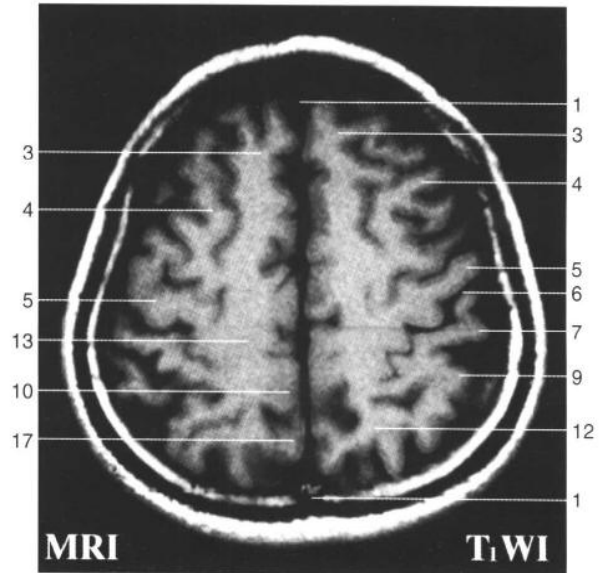
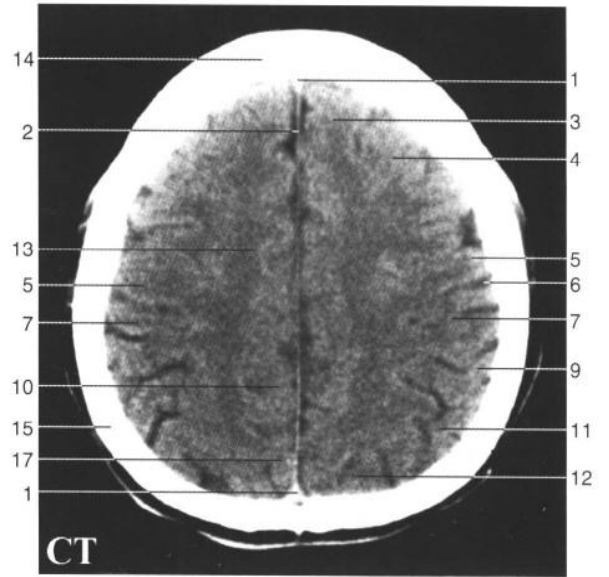


Fig. HC 3

Fig. HC 3

1. 上矢状窦 superior sagittal sinus
2. 大脑镰 cerebral falx
3. 额上回 superior frontal gyrus
4. 额中回 middle frontal gyrus
5. 中央前回 precentral gyrus
6. 中央沟 central sulcus
7. 中央后回 postcentral gyrus
8. 中央后沟 postcentral sulcus
9. 缘上回 supramarginal gyrus
10. 中央旁小叶 paracentral lobule
11. 角回 angular gyrus
12. 顶上小叶 superior parietal lobule
13. 辐射冠(半卵圆中心) corona radiata (centrum semiovale)
14. 额骨 frontal bone
15. 顶骨 parietal bone
16. 顶叶 parietal lobe
17. 楔前叶 precuneus



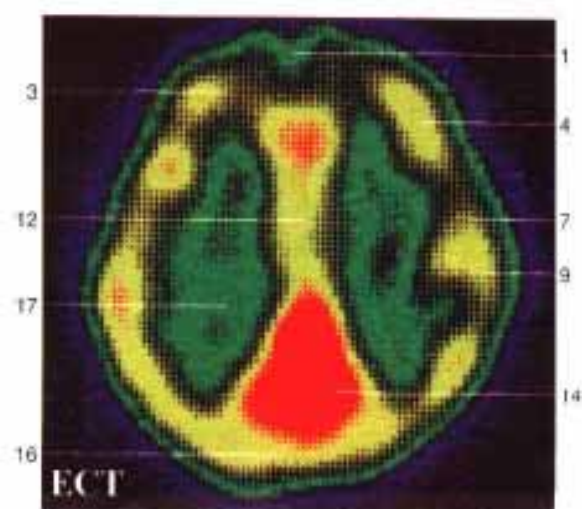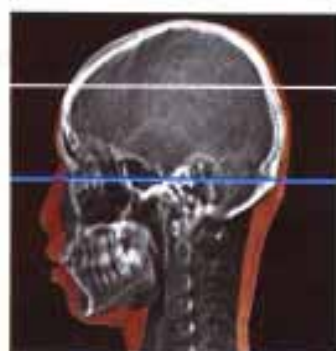
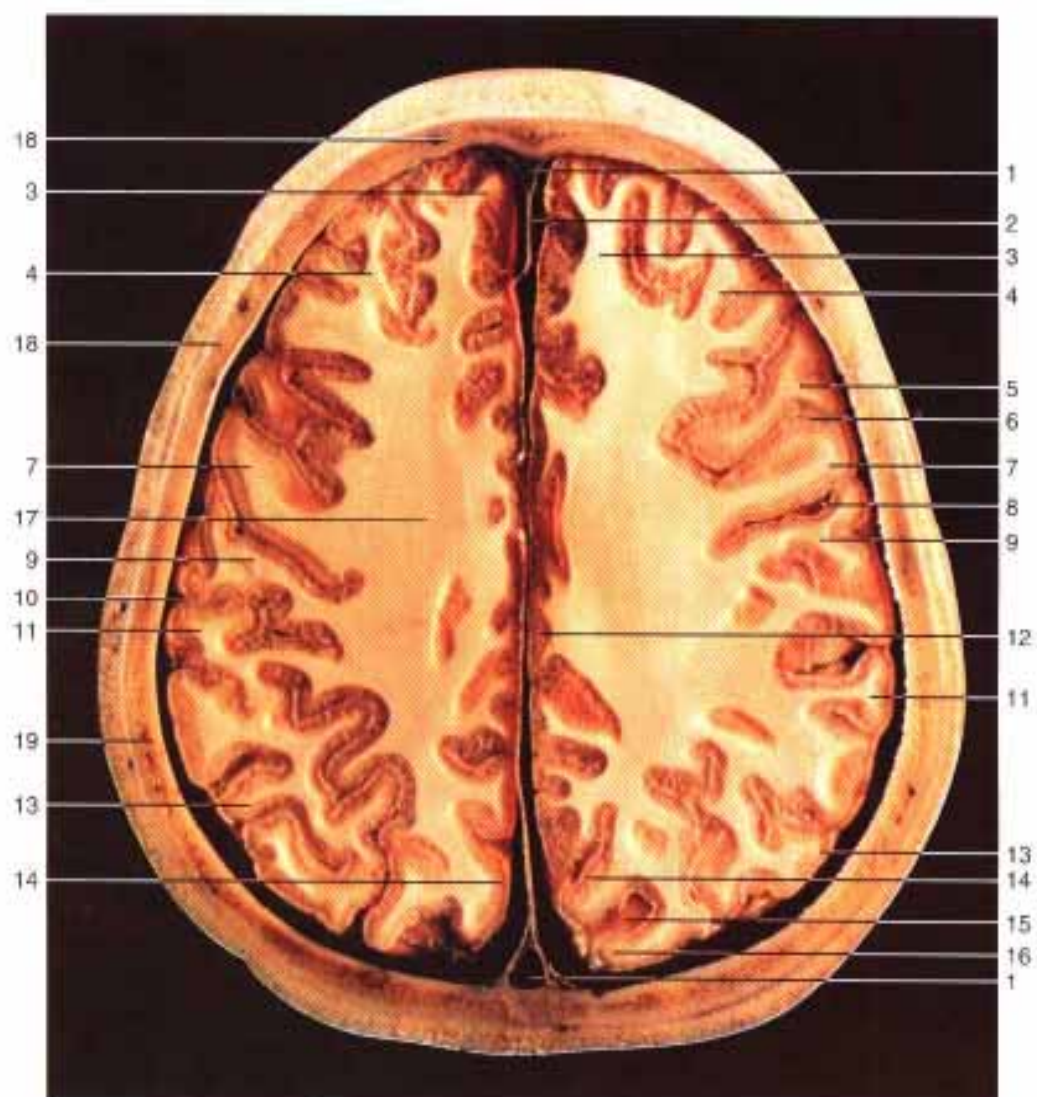
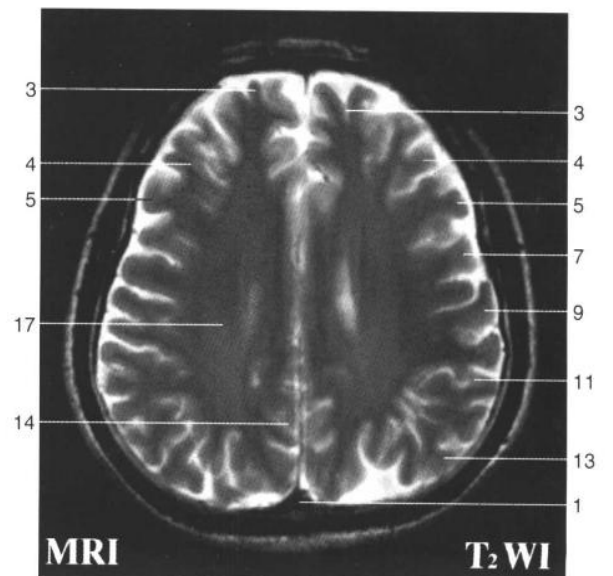
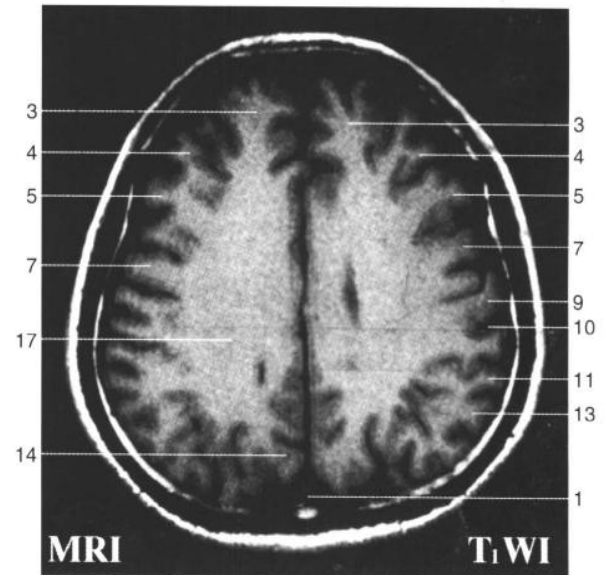
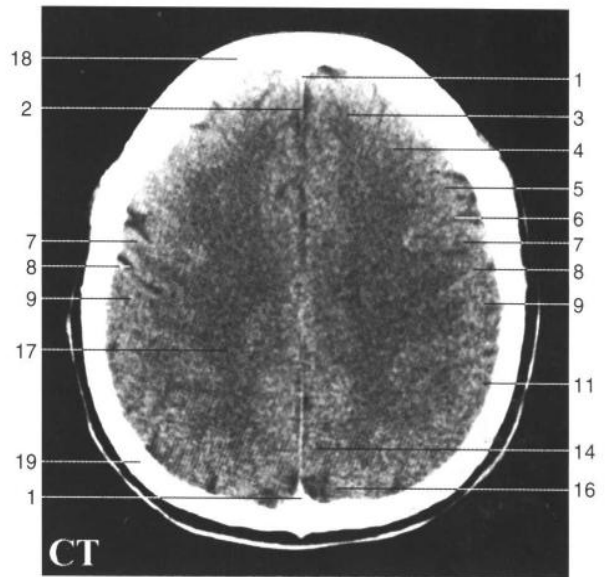


Fig. HC 4

Fig. HC 4

1. 上矢状窦 superior sagittal sinus
2. 大脑镰 cerebral falx
3. 额上回 superior frontal gyrus
4. 额中回 middle frontal gyrus
5. 额下回 inferior frontal gyrus
6. 中央前沟 precentral sulcus
7. 中央前回 precentral gyrus
8. 中央沟 central sulcus
9. 中央后回 postcentral gyrus
10. 中央后沟 postcentral sulcus
11. 缘上回 supramarginal gyrus
12. 扣带回 cingulate gyrus
13. 角回 angular gyrus
14. 楔前叶 precuneus
15. 顶枕沟 parietooccipital sulcus
16. 楔叶 cuneus
17. 辐射冠(半卵圆中心) corona radiata (centrum semiovale)
18. 额骨 frontal bone
19. 顶骨 parietal bone



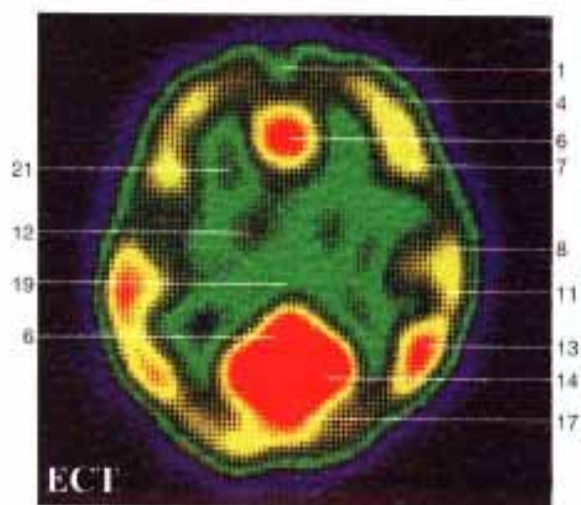
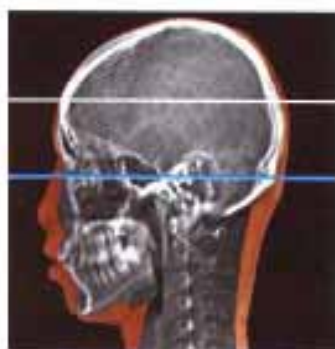
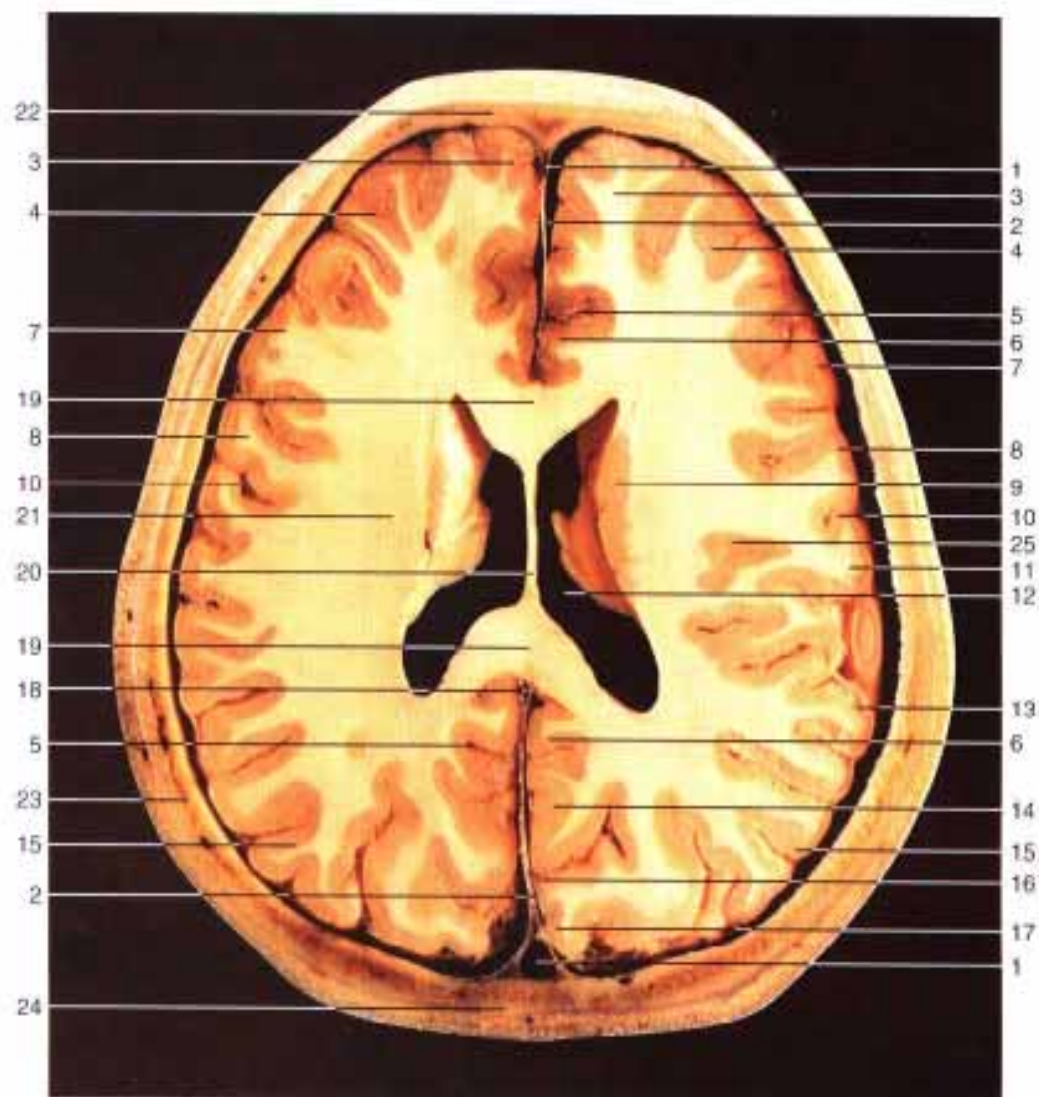
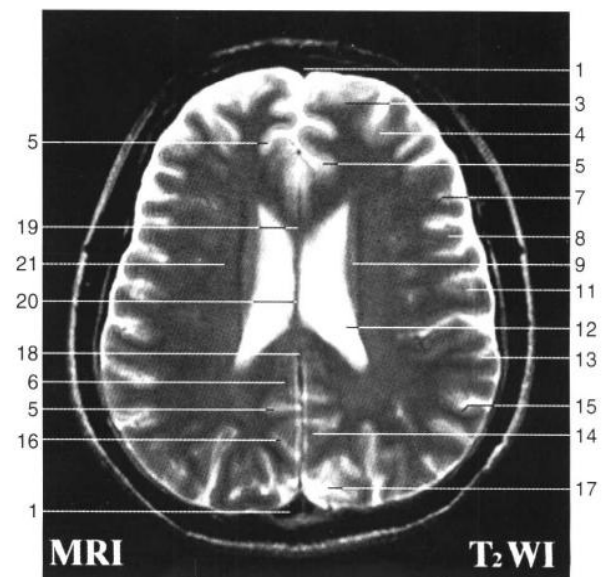
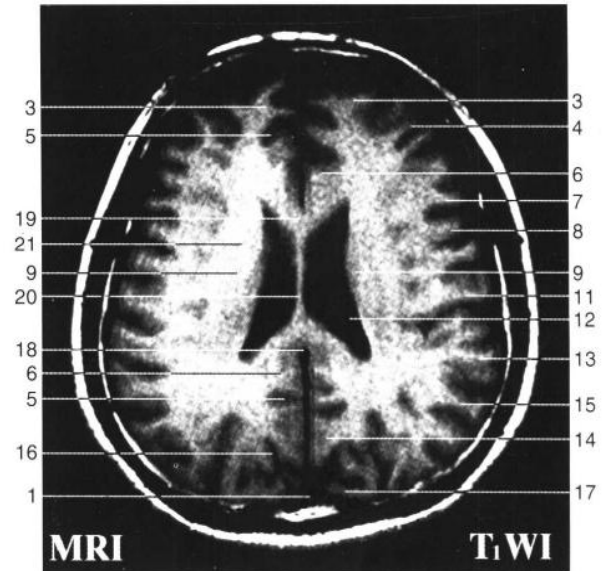
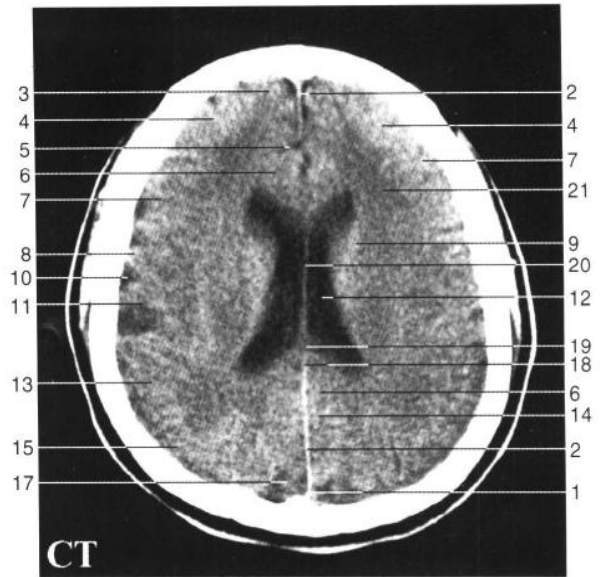


Fig. HC 5

Fig. HC 5

1. 上矢状窦 superior sagittal sinus
2. 大脑镰 cerebral falx
3. 额上回 superior frontal gyrus
4. 额中回 middle frontal gyrus
5. 扣带沟 cingulate sulcus
6. 扣带回 cingulate gyrus
7. 额下回 inferior frontal gyrus
8. 中央前回 precentral gyrus
9. 尾状核体 body of caudate nucleus
10. 中央沟 central sulcus
11. 中央后回 postcentral gyrus
12. 侧脑室中央部 central part of lateral ventricle
13. 缘上回 supramarginal gyrus
14. 楔前叶 precuneus
15. 角回 angular gyrus
16. 顶枕沟 parietooccipital sulcus
17. 楔叶 cuneus
18. 下矢状窦 inferior sagittal sinus
19. 胼胝体 corpus callosum
20. 透明隔 septum pellucidum
21. 辐射冠(半卵圆中心) corona radiata (centrum semiovale)
22. 额骨 frontal bone
23. 顶骨 parietal bone
24. 枕骨 occipital bone
25. 岛叶 insular lobe



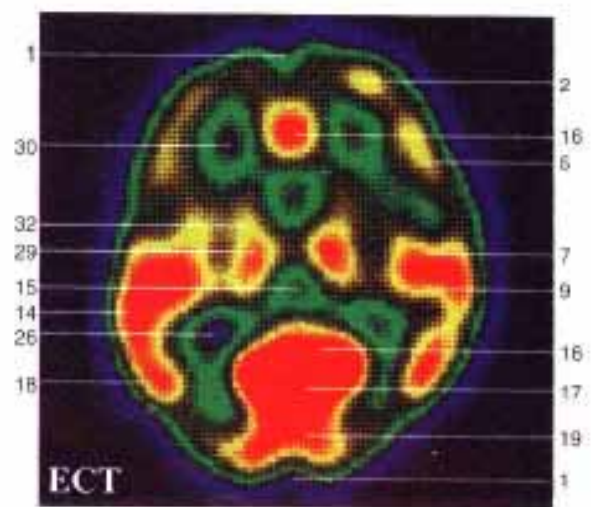
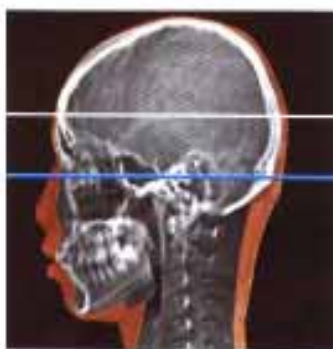
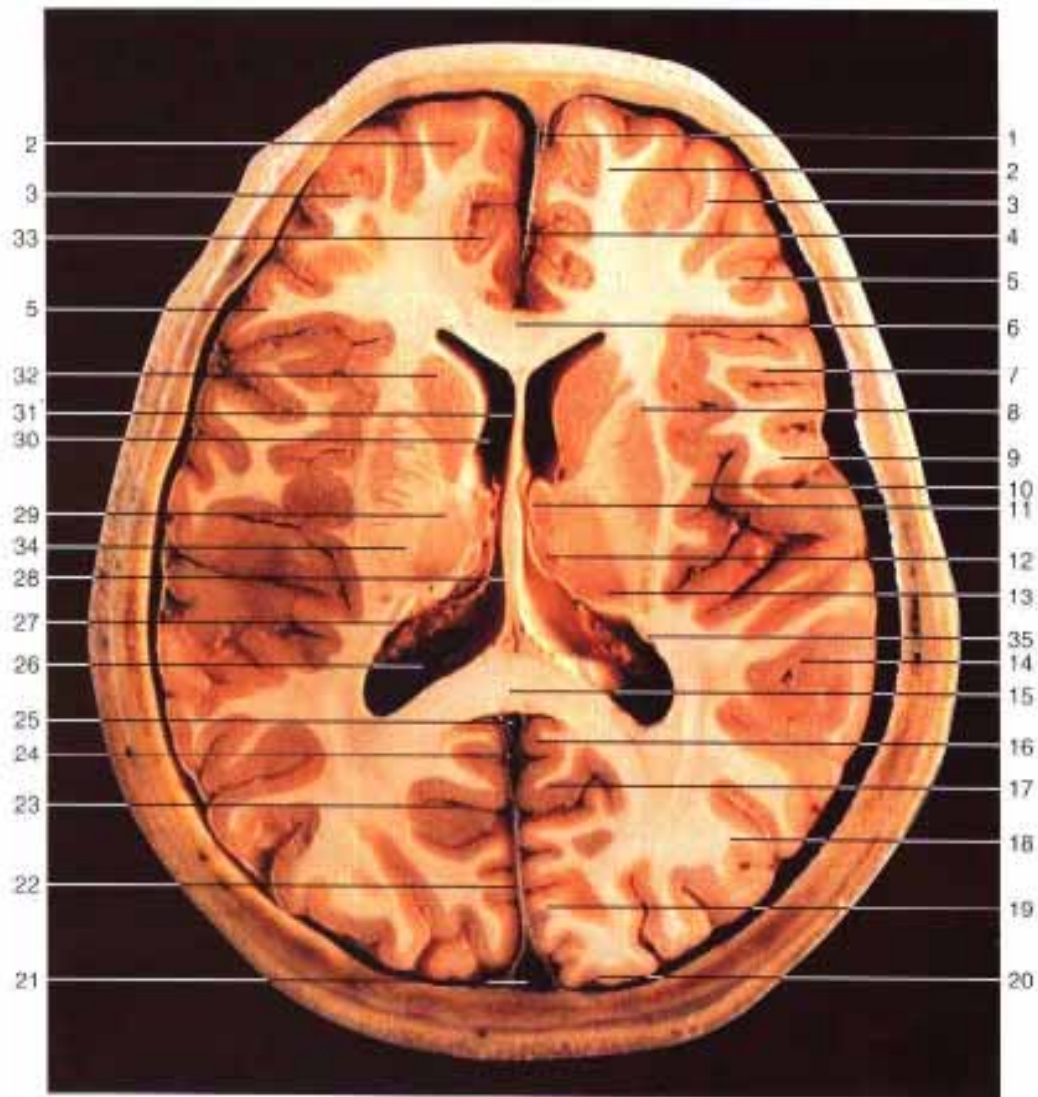
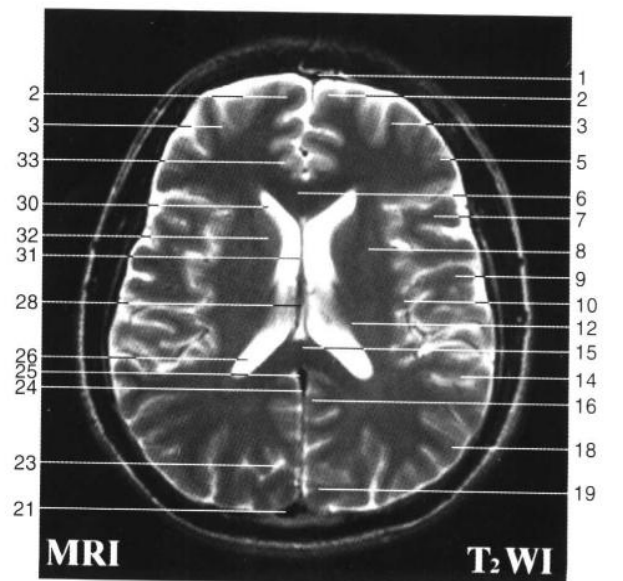
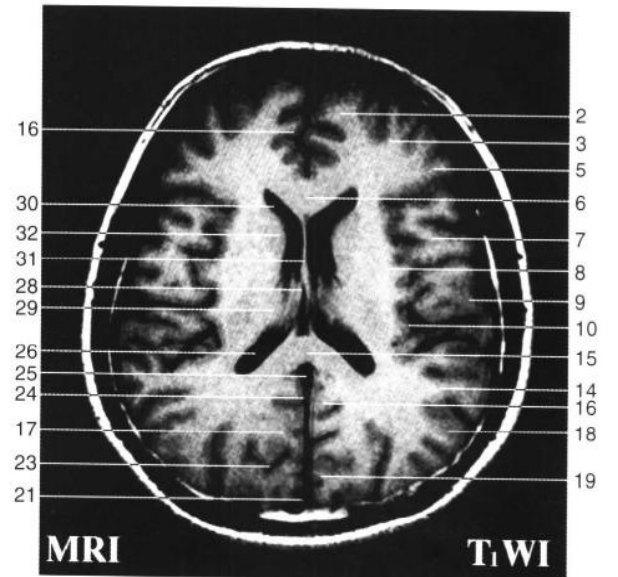
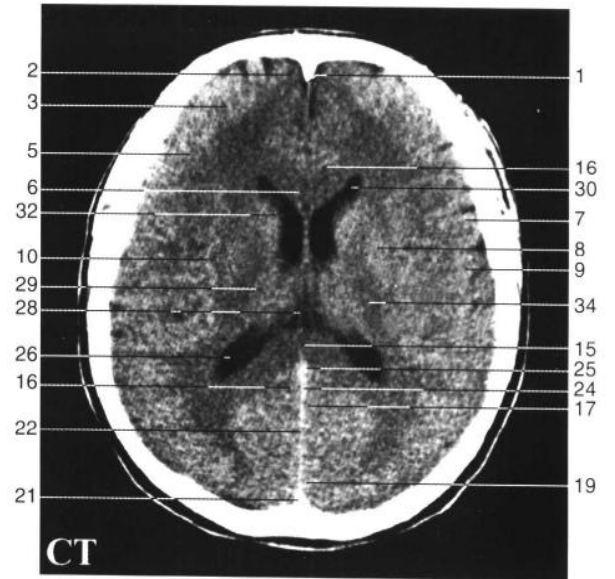


Fig. HC 6

Fig. HC 6

1. 上矢状窦 superior sagittal sinus
2. 额上回 superior frontal gyrus
3. 额中回 middle frontal gyrus
4. 大脑镰 cerebral falx
5. 额下回 inferior frontal gyrus
6. 胼胝体膝 genu of corpus callosum
7. 中央前回 precentral gyrus
8. 壳 putamen
9. 中央后回 postcentral gyrus
10. 岛叶 insular lobe
11. 丘脑前核群 anterior nuclear group of thalamus
12. 丘脑内侧核群 medial nuclear group of thalamus
13. 丘脑外侧核群 lateral nuclear group of thalamus
14. 缘上回 supramarginal gyrus
15. 胼胝体压部 splenium of corpus callosum
16. 扣带回 cingulate gyrus
17. 楔前叶 precuneus
18. 角回 angular gyrus
19. 楔叶 cuneus
20. 枕上回 superior occipital gyrus
21. 上矢状窦 superior sagittal sinus
22. 大脑镰 cerebral falx
23. 顶枕沟 parietooccipital sulcus
24. 直窦 straight sinus
25. 大脑大静脉 great cerebral v.
26. 侧脑室后角 posterior horn of lateral ventricle
27. 侧脑室脉络丛 choroid plexus of lateral ventricle
28. 穹窿体 body of fornix
29. 背侧丘脑 dorsal thalamus
30. 侧脑室前角 anterior horn of lateral ventricle
31. 透明隔 septum pellucidum
32. 尾状核头 head of caudate nucleus
33. 扣带回 cingulate gyrus
34. 内囊后肢 posterior limb of internal capsule
35. 尾状核尾 tail of caudate nucleus



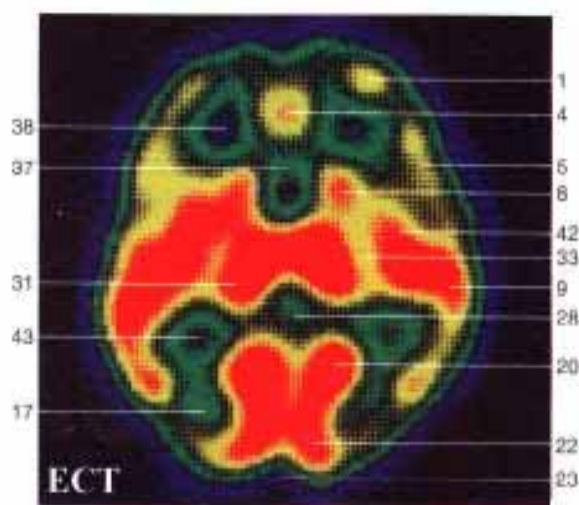
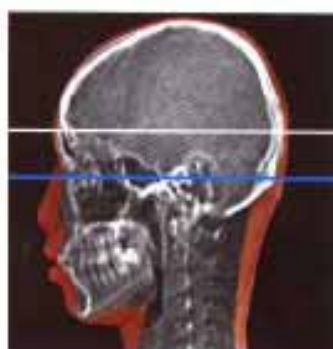
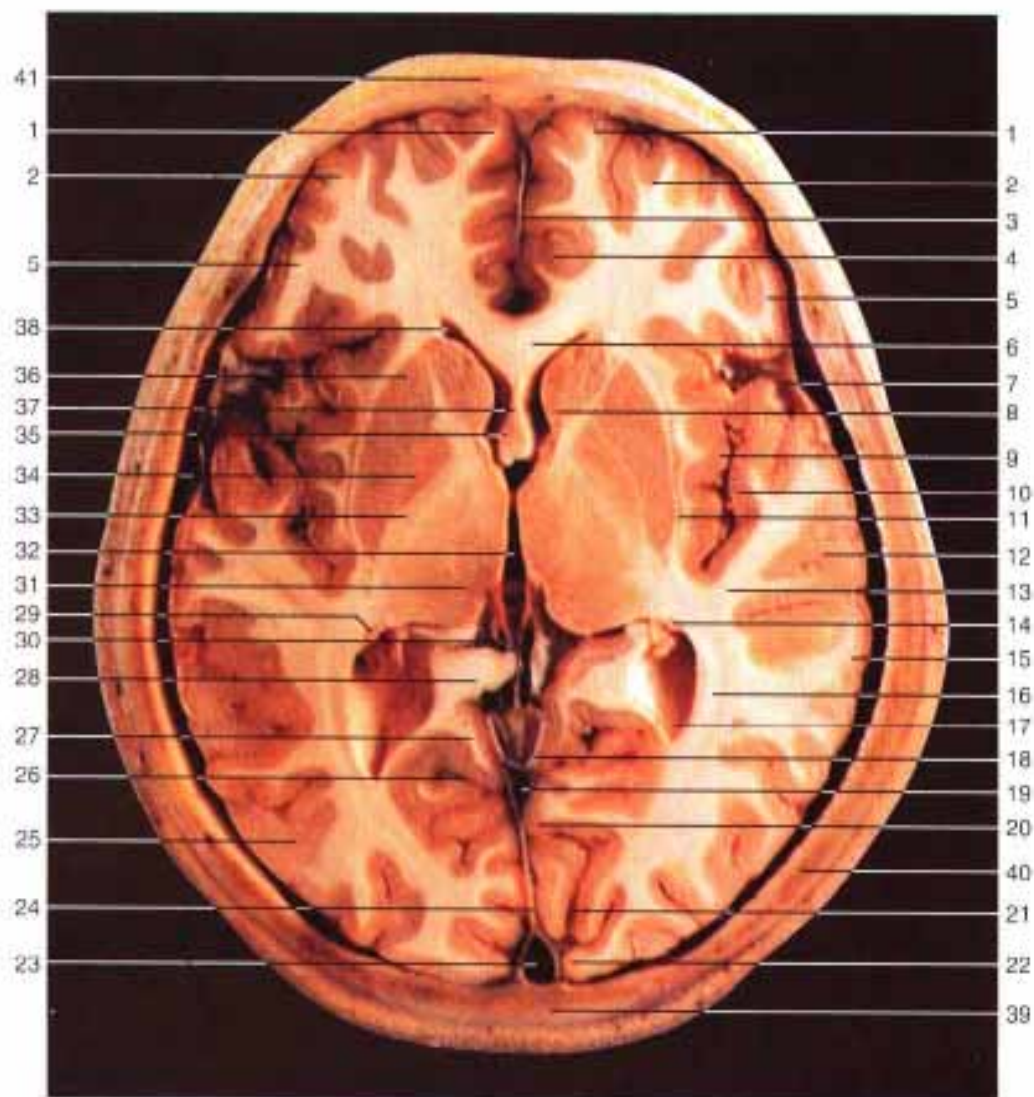
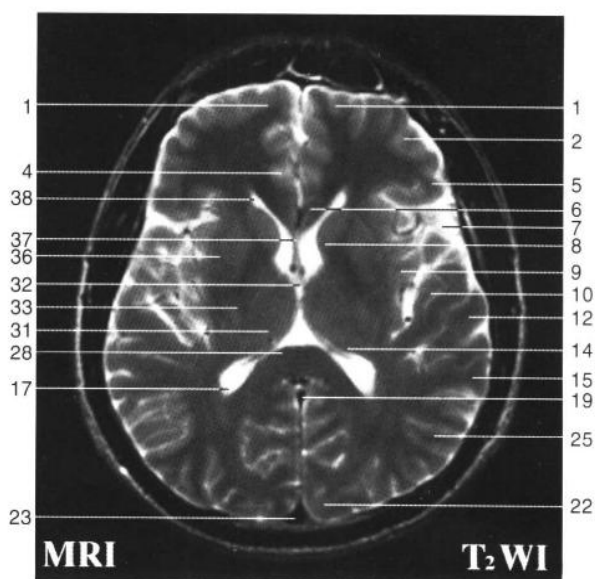
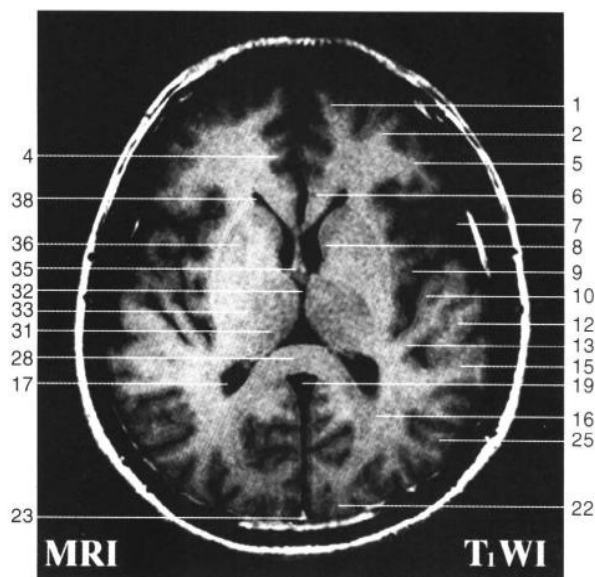
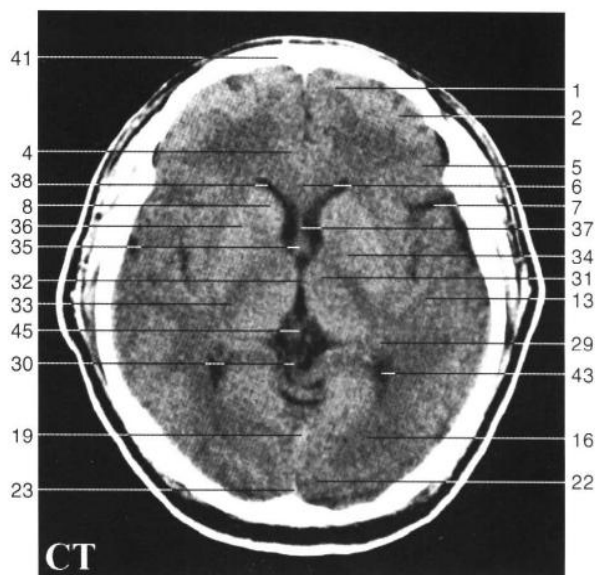


Fig. HC 7

Fig. HC 7

1. 额上回 superior frontal gyrus
2. 额中回 middle frontal gyrus
3. 大脑镰 cerebral falx
4. 扣带回 cingulate gyrus
5. 额下回 inferior frontal gyrus
6. 胼胝体膝 genu of corpus callosum
7. 大脑外侧窝池 cistern of lateral fossa of cerebrum
8. 尾状核头 head of caudate nucleus
9. 岛叶 insular lobe
10. 颞横回 transverse temporal gyri
11. 屏状核 claustrum
12. 颞上回 superior temporal gyrus
13. 听辐射 acoustic radiation
14. 尾状核尾 tail of caudate nucleus
15. 颞中回 middle temporal gyrus
16. 视辐射 optic radiation
17. 侧脑室后角 posterior horn of lateral ventricle
18. 小脑幕 tentorium of cerebellum
19. 直窦 straight sinus
20. 舌回 lingual gyrus
21. 距状沟 calcarine sulcus
22. 楔叶 cuneus
23. 上矢状窦 superior sagittal sinus
24. 大脑镰 cerebral falx
25. 颞下回 inferior temporal gyrus
26. 距状沟 calcarine sulcus
27. 扣带回峡 isthmus of cingulate gyrus
28. 胼胝体压部 splenium of corpus callosum
29. 尾状核尾 tail of caudate nucleus
30. 大脑内静脉 internal cerebral v.
31. 背侧丘脑 dorsal thalamus
32. 第三脑室 third ventricle
33. 内囊后肢 posterior limb of internal capsule
34. 苍白球 globus pallidus
35. 穹窿柱 column of fornix
36. 壳 putamen
37. 透明隔 septum pellucidum
38. 侧脑室前角 anterior horn of lateral ventricle
39. 枕骨 occipital bone
40. 顶骨 parietal bone
41. 额骨 frontal bone
42. 豆状核 lentiform nucleus
43. 侧脑室三角 trigone of lateral ventricle
44. 额窦 frontal sinus
45. 松果体 pineal body



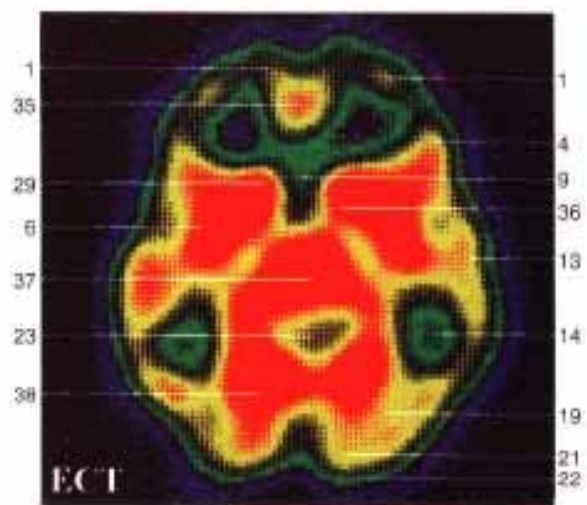
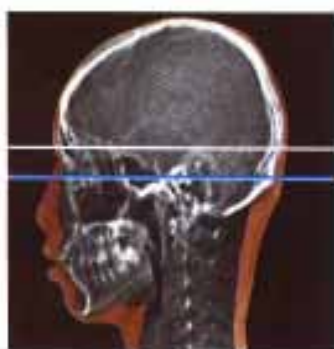
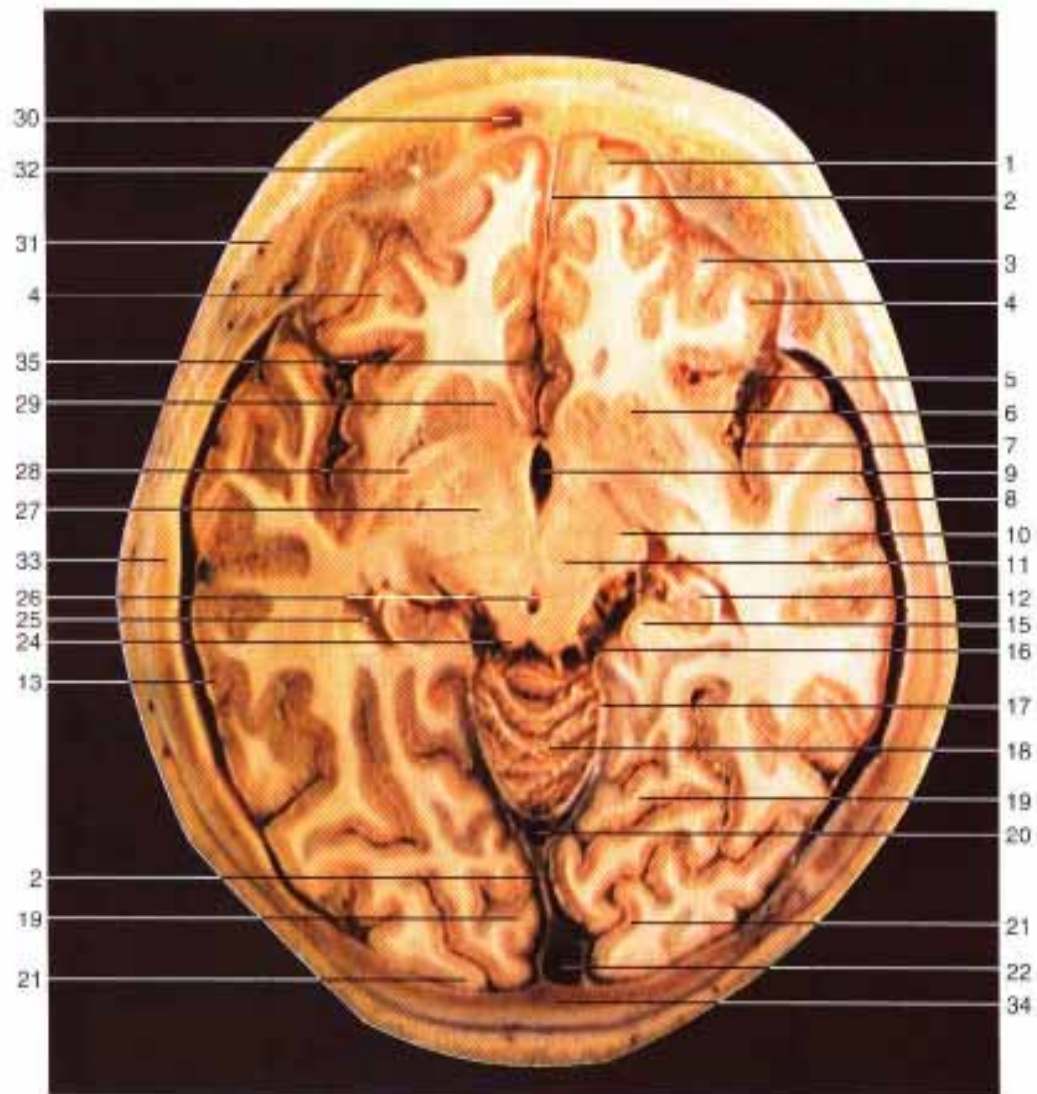
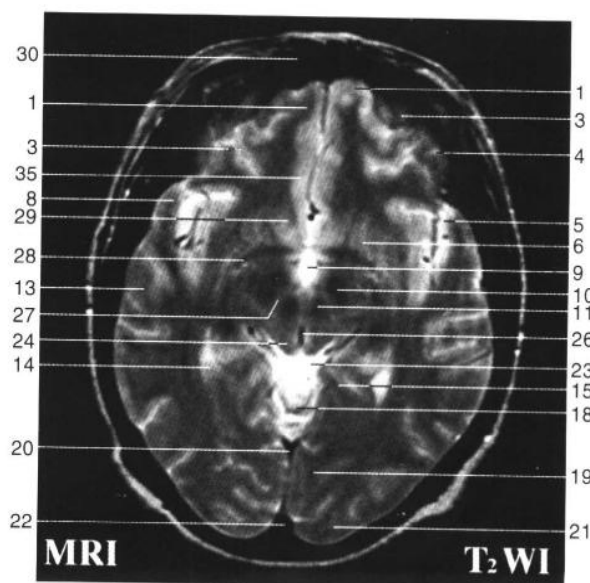
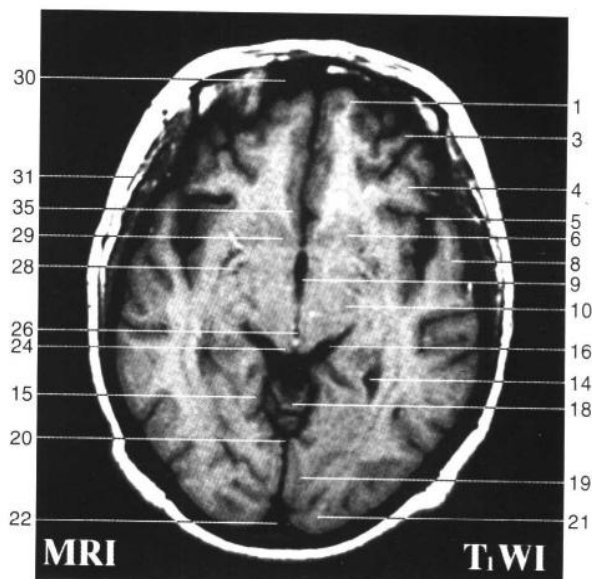
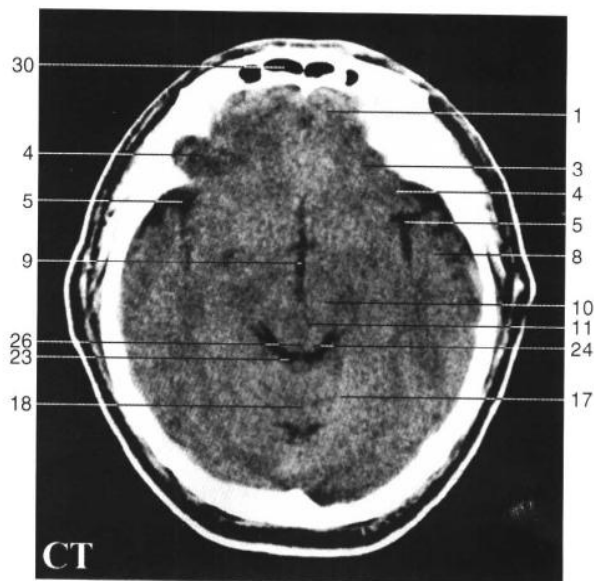


Fig. HC 8

Fig. HC 8

1. 额上回 superior frontal gyrus
2. 大脑镰 cerebral falx
3. 额中回 middle frontal gyrus
4. 额下回 inferior frontal gyrus
5. 大脑外侧窝池 cistern of lateral fossa of cerebrum
6. 壳 putamen
7. 大脑中动脉 middle cerebral a.
8. 颞上回 superior temporal gyrus
9. 第三脑室 third ventricle
10. 大脑脚底 crus cerebri
11. 红核 red nucleus
12. 海马 hippocampus
13. 颞中回 middle temporal gyrus
14. 侧脑室下角 inferior horn of lateral ventricle
15. 海马旁回 parahippocampal gyrus
16. 四叠体池 quadrigeminal cistern
17. 小脑幕 tentorium of cerebellum
18. 小脑蚓 vermis
19. 枕颞内侧回 medial occipitotemporal gyrus
20. 直窦 straight sinus
21. 枕颞外侧回 lateral occipitotemporal gyrus
22. 上矢状窦 superior sagittal sinus
23. 四叠体池 quadrigeminal cistern
24. 下丘 inferior colliculus
25. 侧脑室下角 inferior horn of lateral ventricle
26. 中脑水管 mesencephalic aqueduct
27. 黑质 substantia nigra
28. 前连合 anterior commissure
29. 尾状核头 head of caudate nucleus
30. 额窦 frontal sinus
31. 颞肌 temporalis
32. 额骨 frontal bone
33. 顶骨 parietal bone
34. 枕骨 occipital bone
35. 隔区 septal area
36. 下丘脑 hypothalamus
37. 中脑 midbrain
38. 小脑 cerebellum



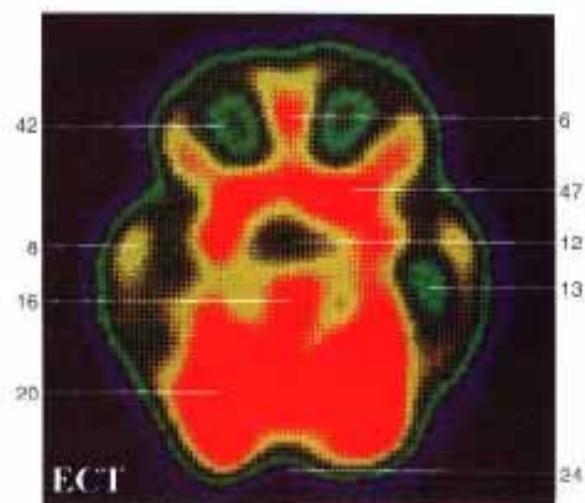
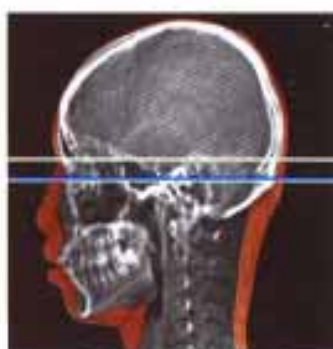
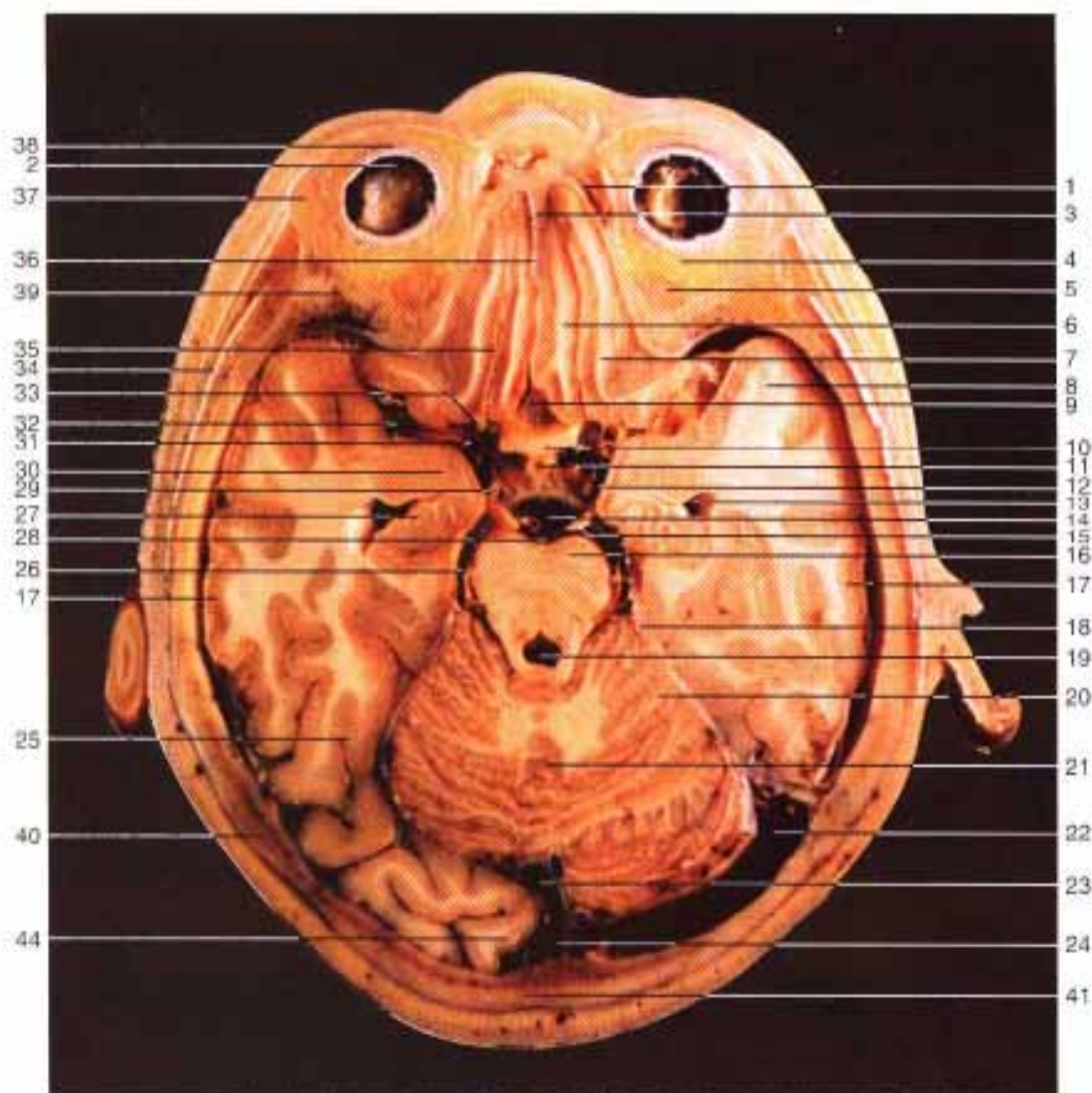
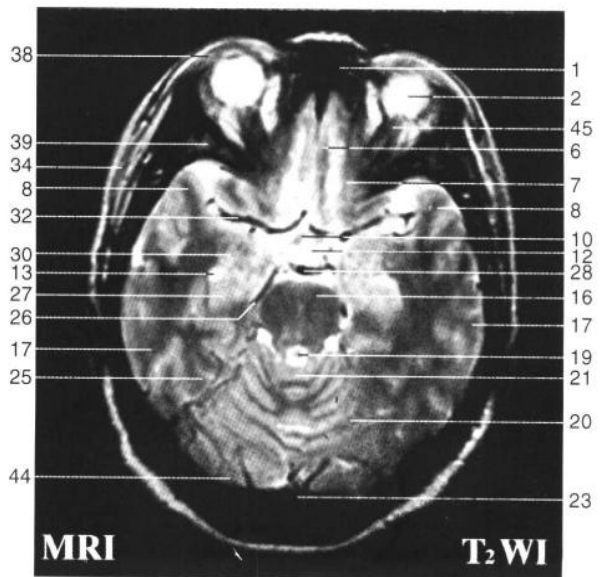
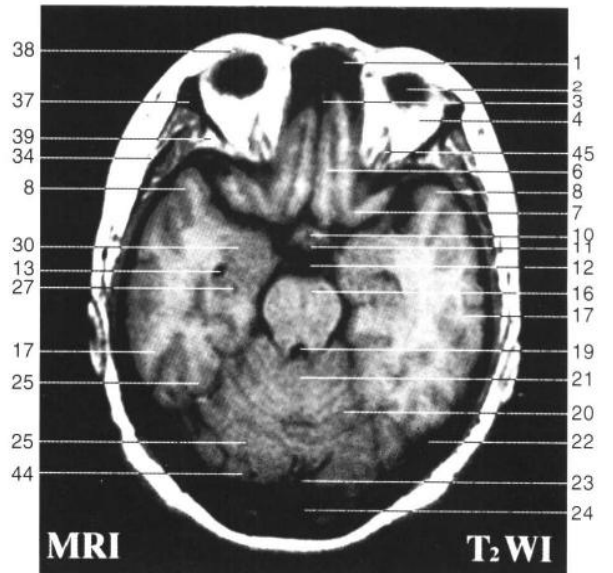
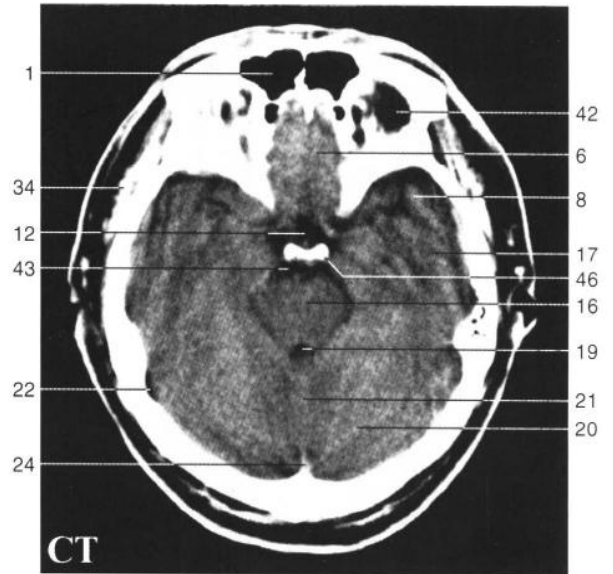


Fig. HC 9

Fig. HC 9

1. 额窦 frontal sinus
2. 眼球 eyeball
3. 鸡冠 crista galli
4. 眶脂体 adipose body of orbit
5. 上睑提肌 levator palpebrae superioris
6. 直回 gyrus rectus
7. 眶回 orbital gyri
8. 颞上回 superior temporal gyrus
9. 大脑前动脉 anterior cerebral a.
10. 视交叉 optic chiasma
11. 漏斗 Infundibulum
12. 鞍上池 supracellar cistern
13. 侧脑室下角 inferior horn of lateral ventricle
14. 鞍背 dorsum sellae
15. 动眼神经 oculomotor n.
16. 脑桥基底部分 basilar part of pons
17. 颞中回 middle temporal gyrus
18. 小脑幕 tentorium of cerebellum
19. 第四脑室 fourth ventricle
20. 小脑半球 cerebellar hemisphere
21. 小脑蚓 vermis
22. 横窦 transverse sinus
23. 直窦 straight sinus
24. 窦汇 confluence of sinuses
25. 枕颞内侧回 medial occipitotemporal gyrus
26. 大脑后动脉 posterior cerebral a.
27. 海马 hippocampus
28. 基底动脉 basilar a.
29. 后交通动脉 posterior communicating a.
30. 杏仁体 amygdaloid body
31. 颈内动脉 internal carotid a.
32. 大脑中动脉 middle cerebral a.
33. 嗅三角 olfactory trigone
34. 颞肌 temporalis
35. 嗅束 olfactory tract
36. 大脑镰 cerebral falx
37. 泪腺 lacrimal gland
38. 上睑板 superior tarsus
39. 蝶骨大翼 greater wing of sphenoid bone
40. 顶骨 parietal bone
41. 枕骨 occipital bone
42. 眶腔 orbital cavity
43. 桥池 pontine cistern
44. 枕颞外侧回 lateral occipitotemporal gyrus
45. 视神经 optic n.
46. 后床突 posterior clinoid process
47. 钩 uncus



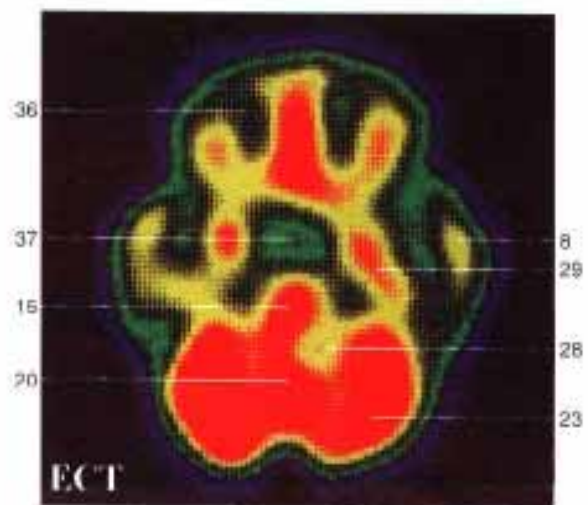
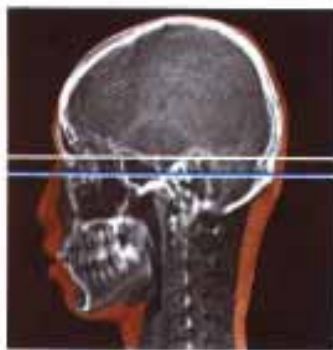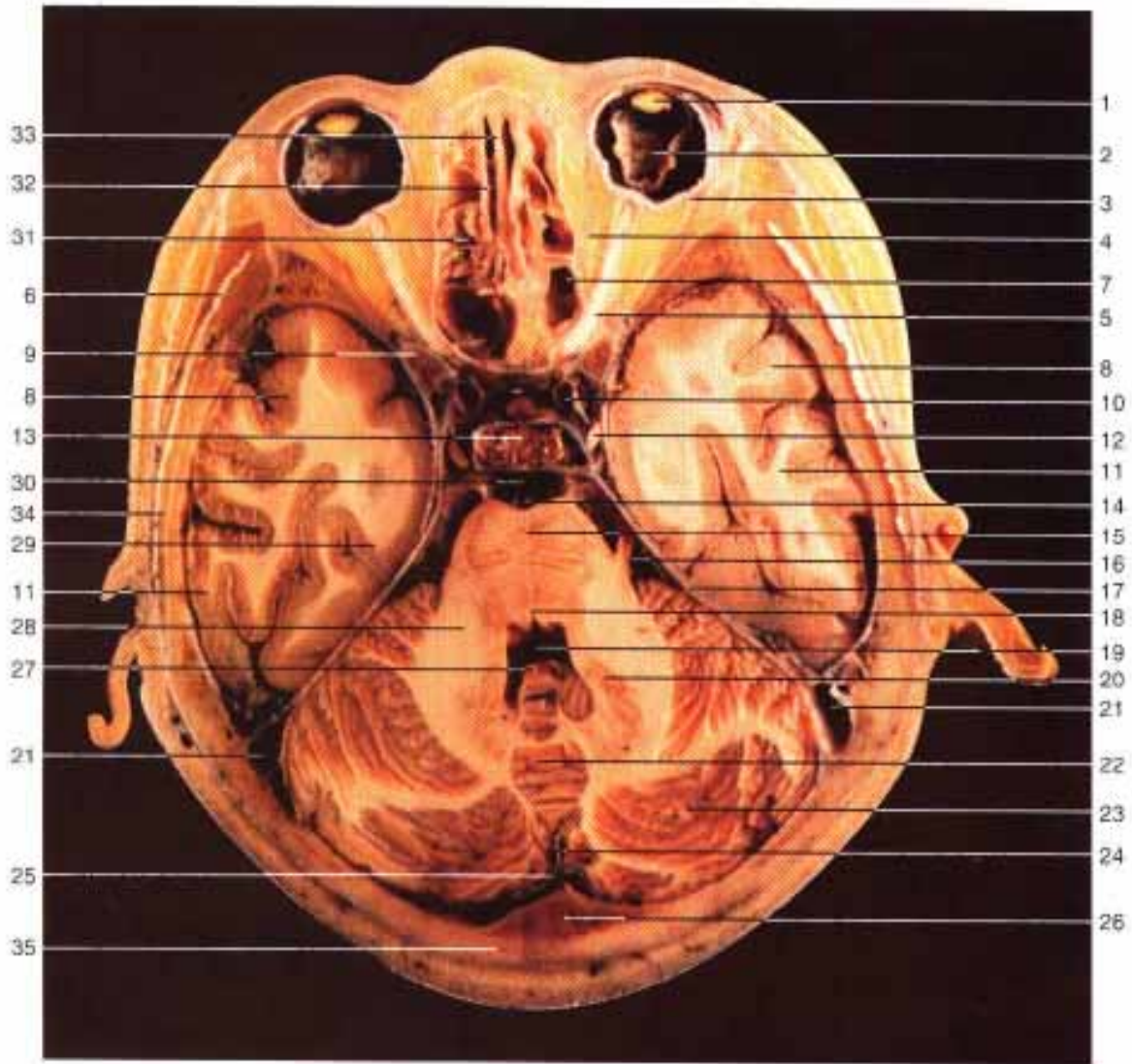
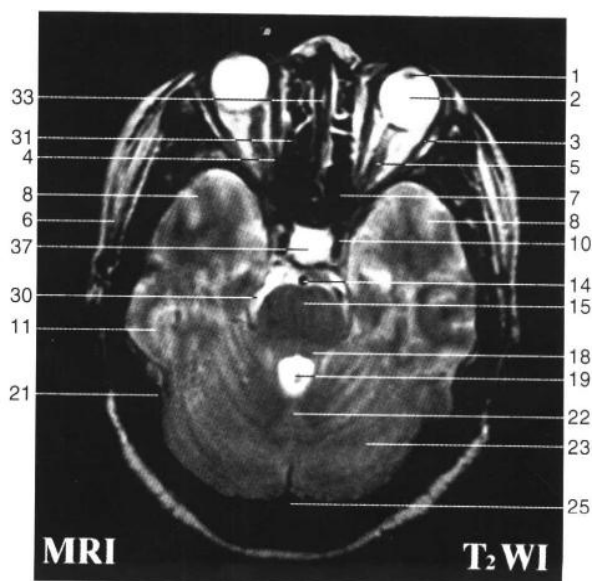
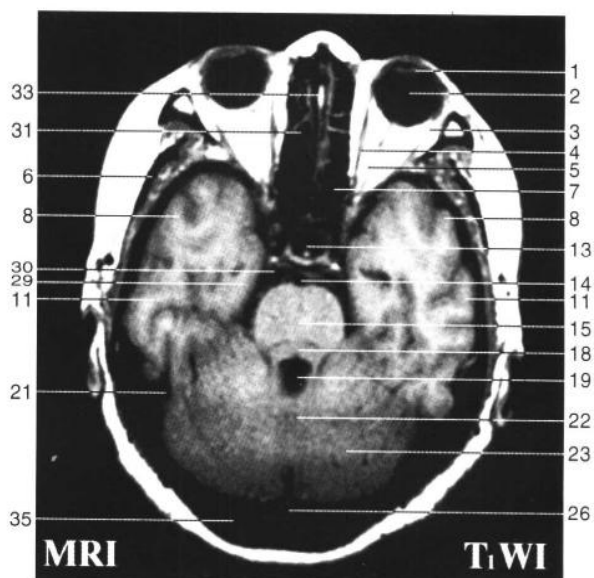
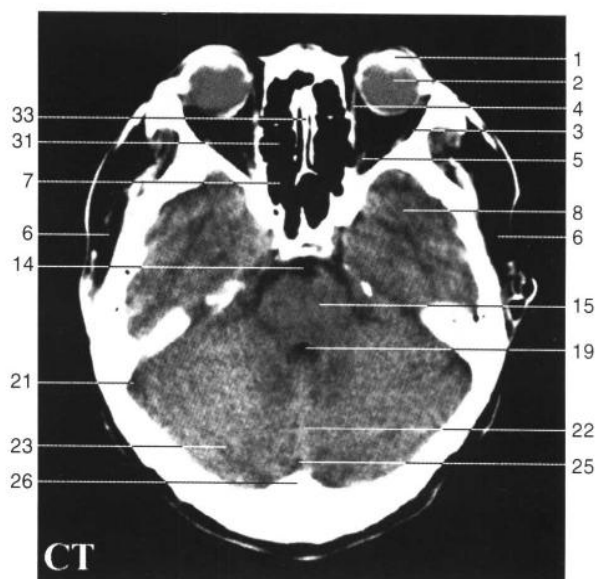


Fig. HC 10

Fig. HC 10

1. 晶体 lens
2. 眼球 eyeball
3. 外直肌 lateral rectus
4. 内直肌 medial rectus
5. 视神经 optic n.
6. 颞肌 temporalis
7. 后筛窦 posterior ethmoid sinuses
8. 颞中回 middle temporal gyrus
9. 前床突 anterior clinoid process
10. 颈内动脉 internal carotid a.
11. 颞下回 inferior temporal gyrus
12. 动眼神经 oculomotor n.
13. 垂体 hypophysis
14. 基底动脉 basilar a.
15. 脑桥基底部分 basilar part of pons
16. 三叉神经根 root of trigeminal n.
17. 小脑幕 tentorium of cerebellum
18. 脑桥被盖部 tegmentum of pons
19. 第四脑室 fourth ventricle
20. 齿状核 dentate nucleus
21. 横窦 transverse sinus
22. 小脑蚓 vermis
23. 小脑半球 cerebellar hemisphere
24. 小脑镰 cerebellar falx
25. 枕窦 occipital sinus
26. 枕内隆凸 internal occipital protuberance
27. 小结 nodule
28. 小脑中脚 middle cerebellar peduncle
29. 海马旁回 parahippocampal gyrus
30. 桥池 pontine cistern
31. 中筛窦 middle ethmoid sinuses
32. 鼻腔 nasal cavity
33. 鼻中隔 nasal septum
34. 颞骨 temporal bone
35. 枕骨 occipital bone
36. 眶腔 orbital cavity
37. 鞍上池 supracellar cistern



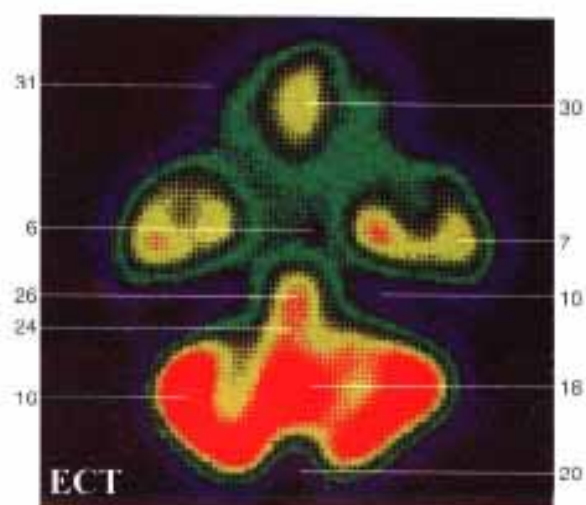
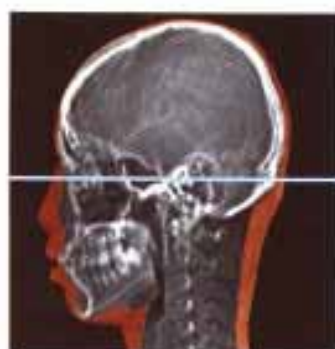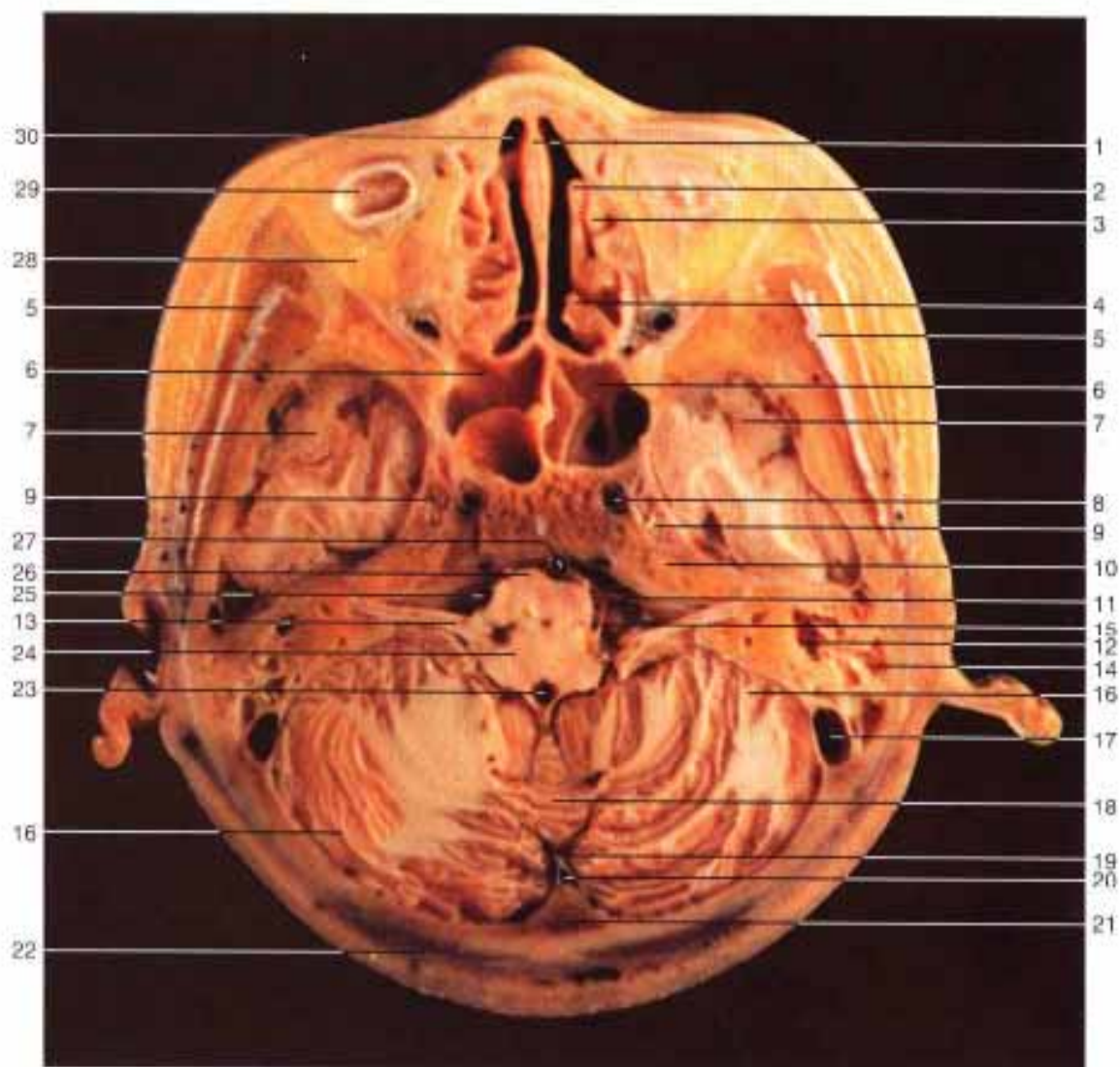
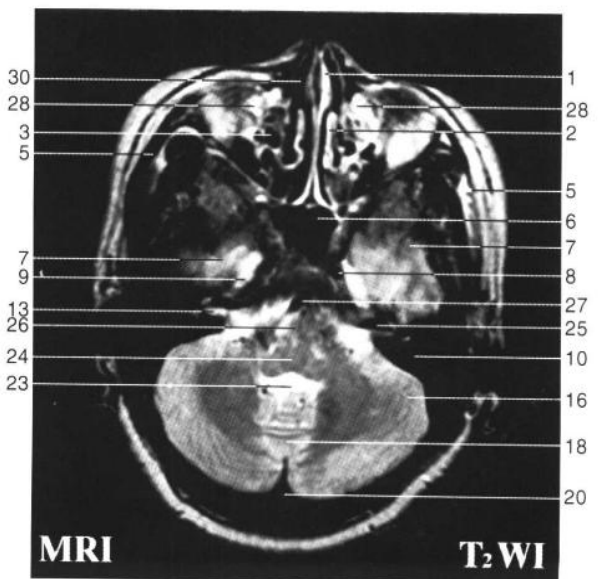
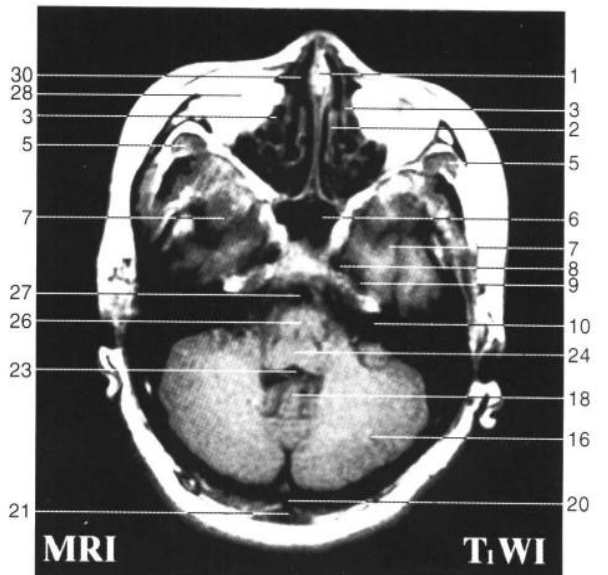
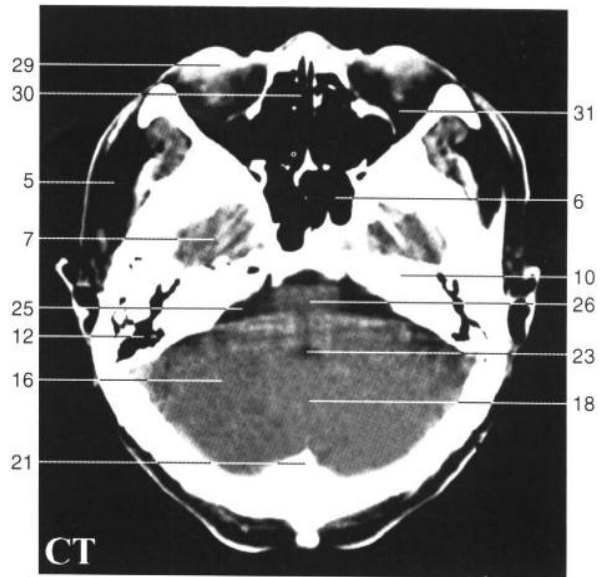


Fig. HC 11

Fig. HC 11

1. 鼻中隔 nasal septum
2. 中鼻甲 middle nasal concha
3. 筛泡 ethmoidal bulla
4. 上鼻甲 superior nasal concha
5. 颞肌 temporalis
6. 蝶窦 sphenoidal sinus
7. 颞下回 inferior temporal gyrus
8. 颈内动脉 internal carotid a.
9. 三叉神经节 trigeminal ganglion
10. 颞骨岩部 petrous part of temporal bone
11. 迷路动脉 labyrinthine a.
12. 鼓室 tympanic cavity
13. 面神经及前庭蜗神经 facial n. and vestibulocochlear n.
14. 乳突窦 mastoid antrum
15. 小脑下前动脉 anterior inferior cerebellar a.
16. 小脑半球 cerebellar hemisphere
17. 乙状窦 sigmoid sinus
18. 小脑蚓 vermis
19. 小脑镰 cerebellar falx
20. 枕窦 occipital sinus
21. 枕内隆凸 internal occipital protuberance
22. 头半棘肌 semispinalis capitis
23. 第四脑室 fourth ventricle
24. 延髓 medulla oblongata
25. 脑桥小脑三角池 cistern of pontocerebellar trigone
26. 脑桥 pons
27. 基底动脉 basilar a.
28. 眶脂体 adipose body of orbit
29. 眼球 eyeball
30. 鼻腔 nasal cavity
31. 眶腔 orbital cavity



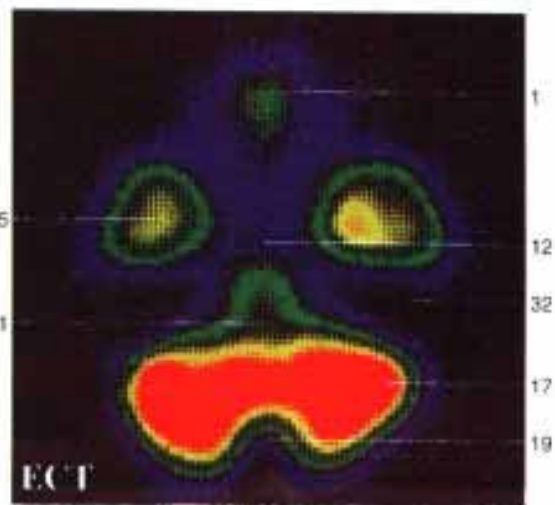
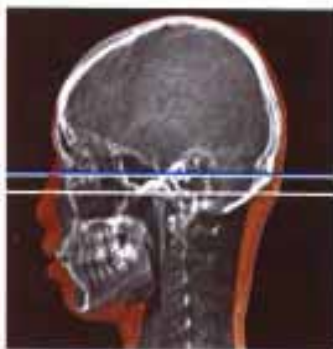
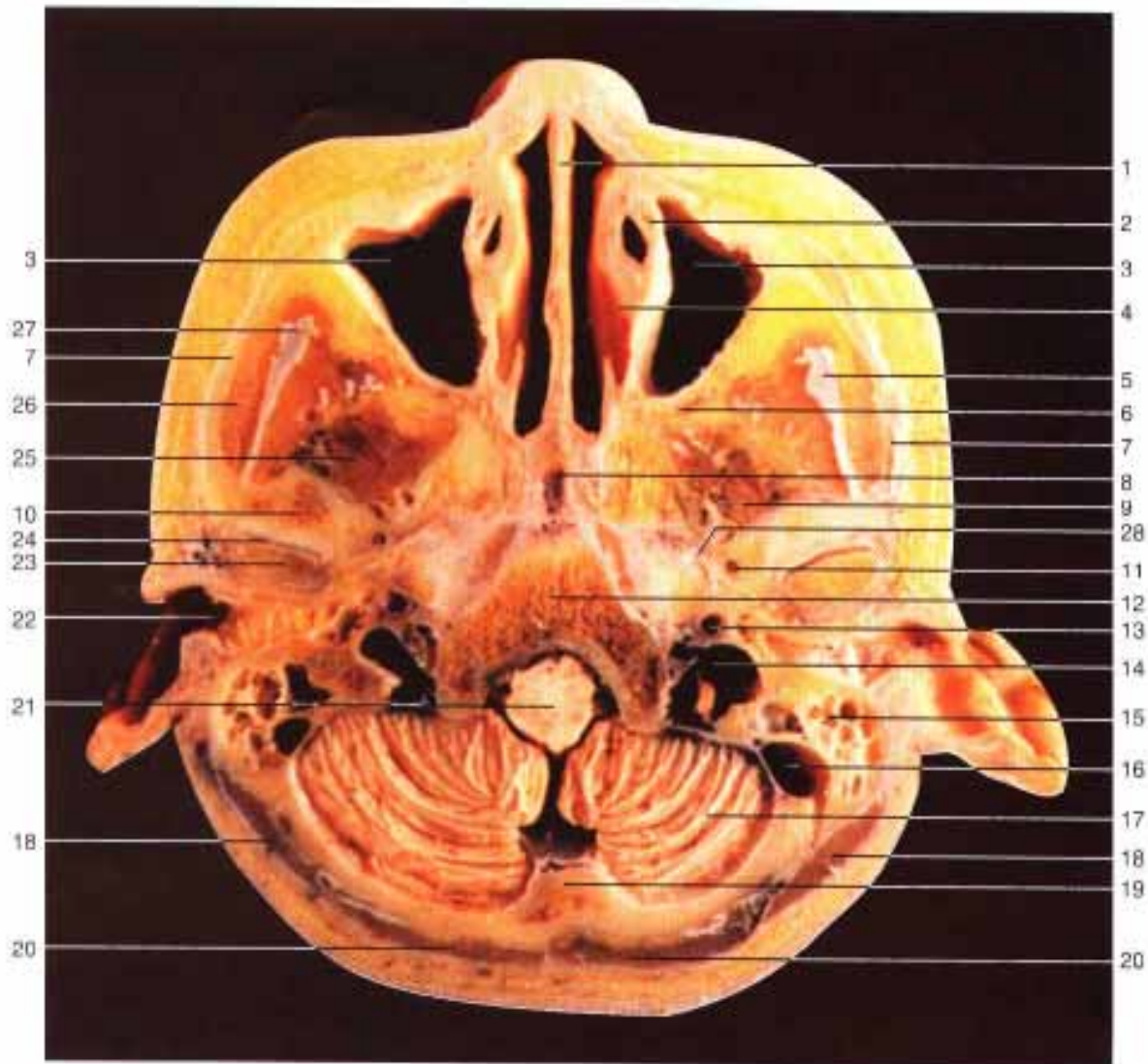
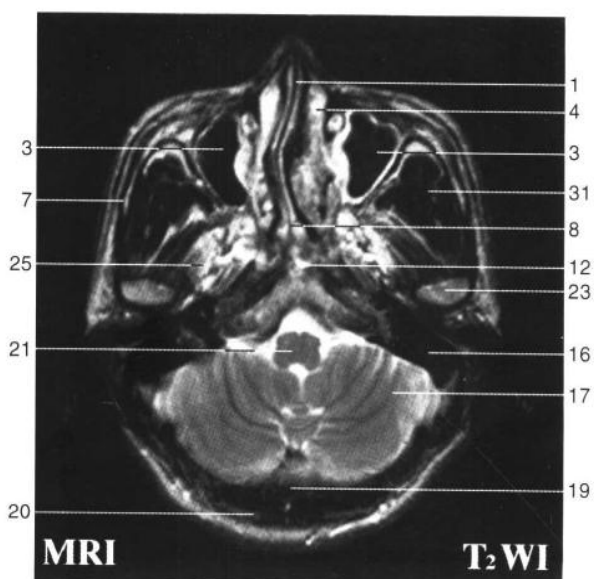
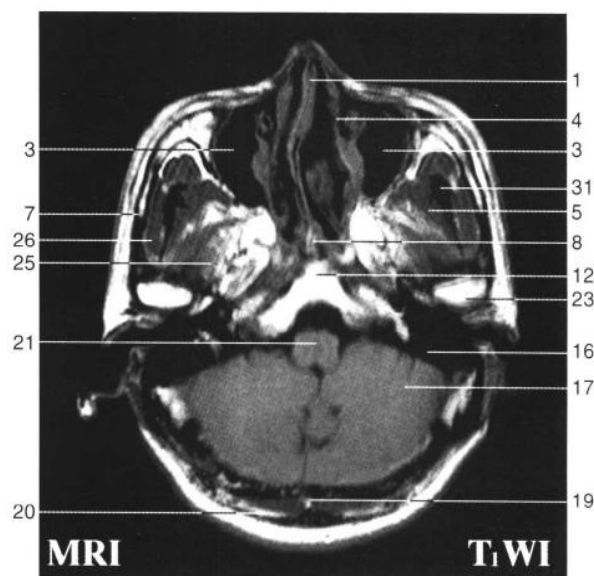
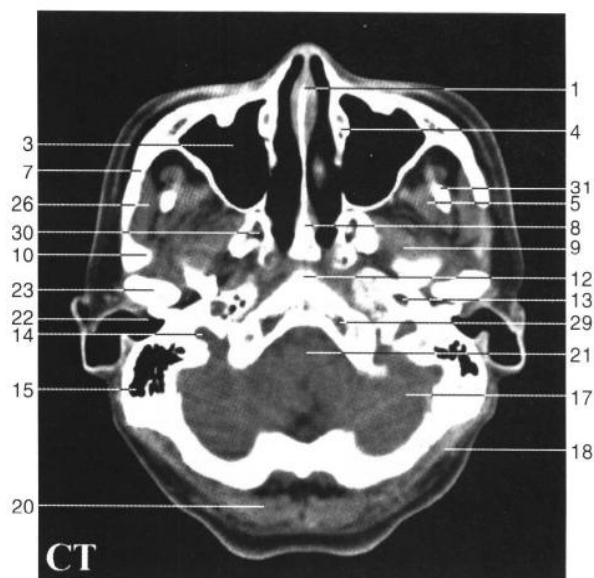


Fig. HC 12

Fig. HC 12

1. 鼻中隔 nasal septum
2. 鼻泪管 nasolacrimal duct
3. 上颌窦 maxillary sinus
4. 下鼻甲 inferior nasal concha
5. 颞肌 temporalis
6. 上颌动脉 maxillary a.
7. 颧弓 zygomatic arch
8. 梨骨 vomer
9. 翼外肌 lateral pterygoid
10. 关节结节 articular tubercle
11. 脑膜中动脉 middle meningeal a.
12. 枕骨底部部 basilar part of occipital bone
13. 颈内动脉 internal carotid a.
14. 颈内静脉 internal jugular v.
15. 乳突小房 mastoid cells
16. 乙状窦 sigmoid sinus
17. 小脑半球 cerebellar hemisphere
18. 头夹肌 splenius capitis
19. 枕内隆凸 internal occipital protuberance
20. 头半棘肌 semispinalis capitis
21. 延髓 medulla oblongata
22. 外耳道 external acoustic meatus
23. 下颌头 head of mandible
24. 颞下颌关节腔 articular cavity of temporomandibular joint
25. 翼外肌 lateral pterygoid
26. 咬肌 masseter
27. 颞肌 temporalis
28. 下颌神经 mandibular n.
29. 舌下神经管 hypoglossal canal
30. 翼腭窝 pterygopalatine fossa
31. 冠突 coronoid process
32. 颞骨岩部 petrous part of temporal bone



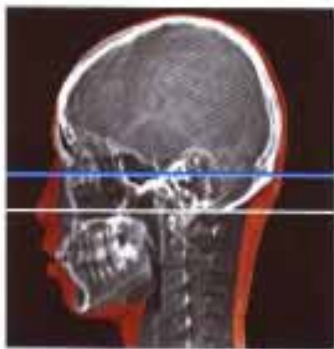
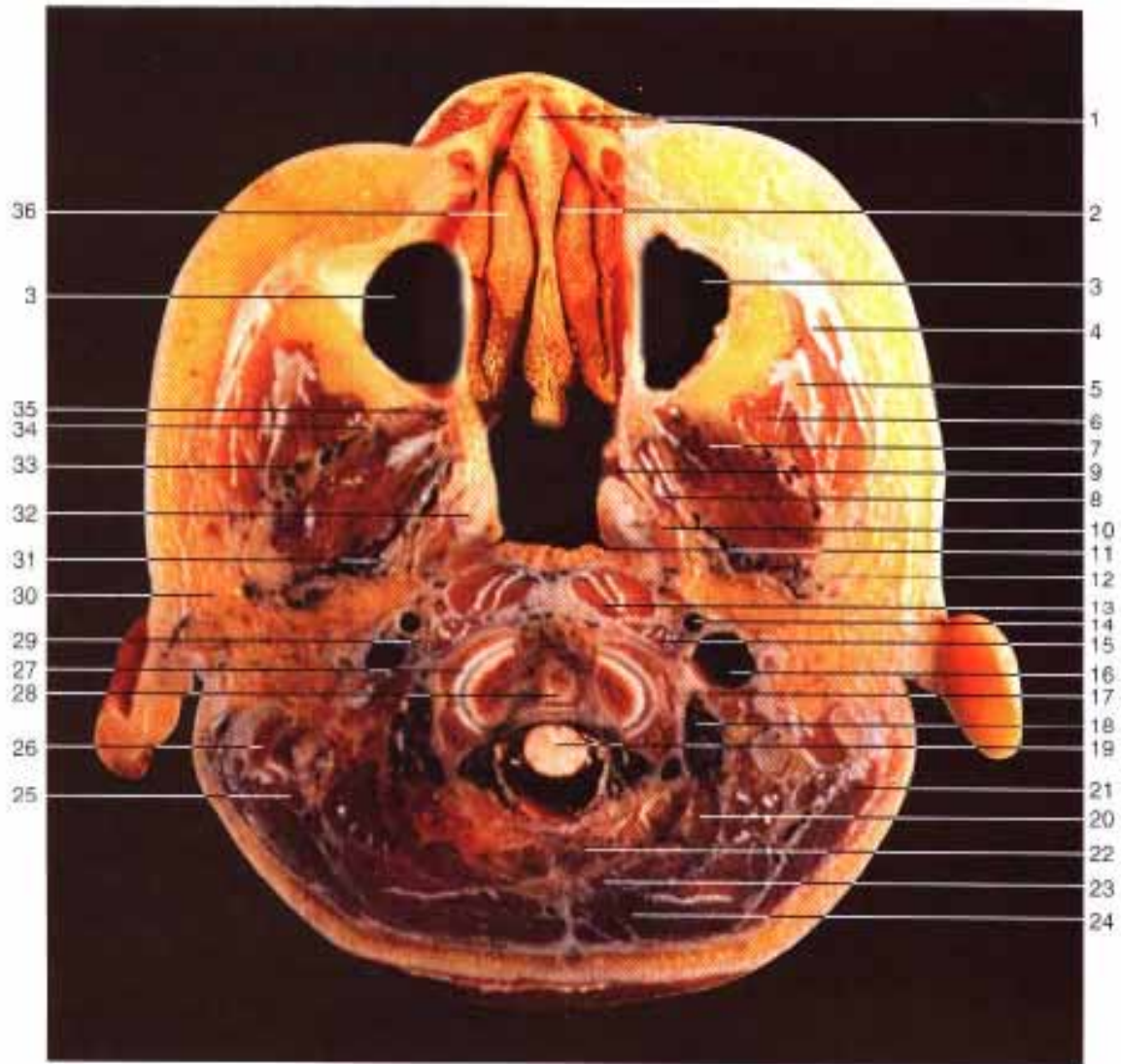


Fig. HC 13

Fig. HC 13

1. 鼻中隔软骨 septal cartilage of nose
2. 下鼻道 inferior nasal meatus
3. 上颌窦 maxillary sinus
4. 咬肌 masseter
5. 冠突 coronoid process
6. 颞肌 temporalis
7. 翼外肌 lateral pterygoid
8. 腭帆张肌 tensor veli palatini
9. 咽鼓管咽口 pharyngeal opening of auditory tube
10. 腭帆提肌 levator veli palatini
11. 咽隐窝 pharyngeal recess
12. 下颌颈 neck of mandible
13. 头长肌 longus capitis
14. 颈内动脉 internal carotid a.
15. 头前直肌 rectus capitis anterior
16. 颈内静脉 internal jugular v.
17. 头外侧直肌 rectus capitis lateralis
18. 椎动、静脉 vertebral a. and v.
19. 脊髓 spinal cord
20. 头上斜肌 obliquus capitis superior
21. 头夹肌 splenius capitis
22. 头后小直肌 rectus capitis posterior minor
23. 头后大直肌 rectus capitis posterior major
24. 头半棘肌 semispinalis capitis
25. 头最长肌 longissimus capitis
26. 二腹肌后腹 posterior belly of digastric
27. 寰枕关节 atlantooccipital joint
28. 齿突 dens
29. 舌咽神经、迷走神经和副神经 glossopharyngeal n., vagus n. and accessory n.
30. 腮腺 parotid gland
31. 下颌神经 mandibular n.
32. 咽鼓管软骨 cartilage of auditory tube
33. 上颌动、静脉 maxillary a. and v.
34. 颊神经 buccinator n.
35. 翼腭窝 pterygopalatine fossa
36. 下鼻甲 inferior nasal concha
37. 茎突 styloid process
38. 翼突外侧板 lateral pterygoid plate

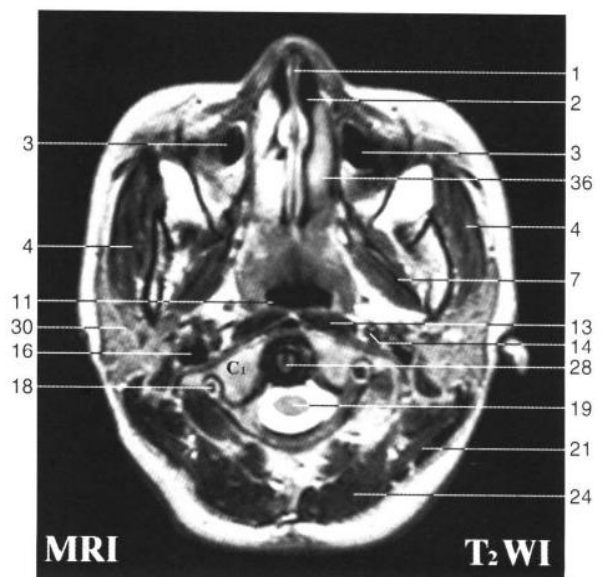
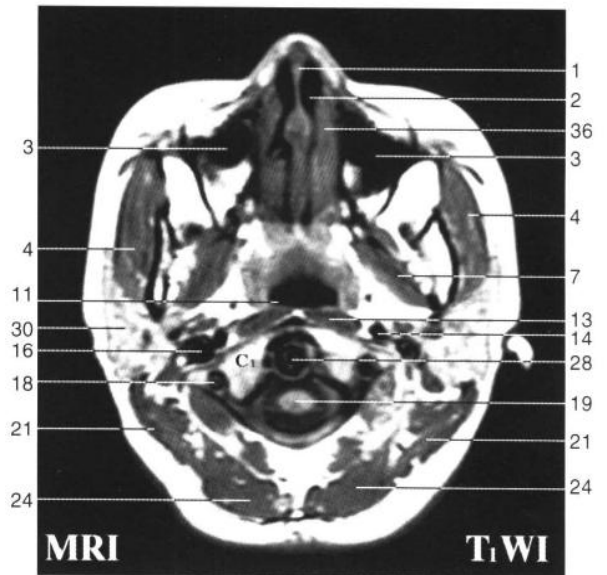
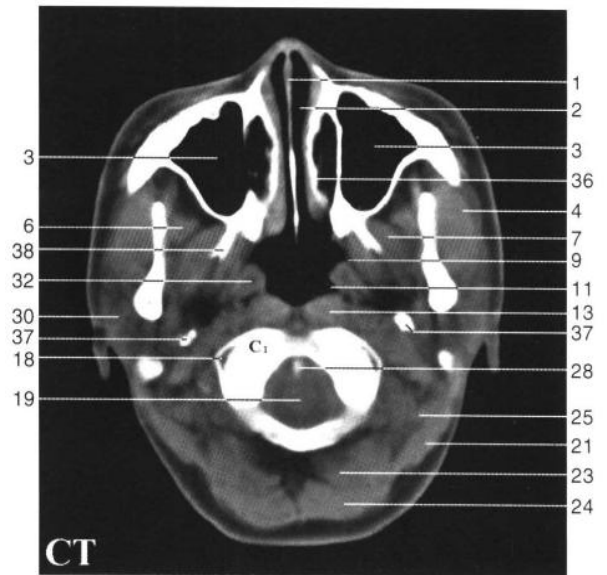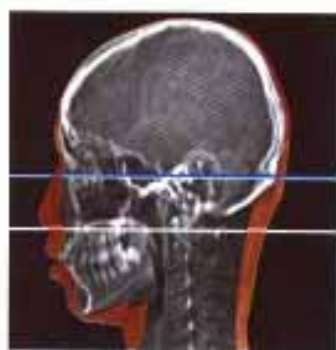
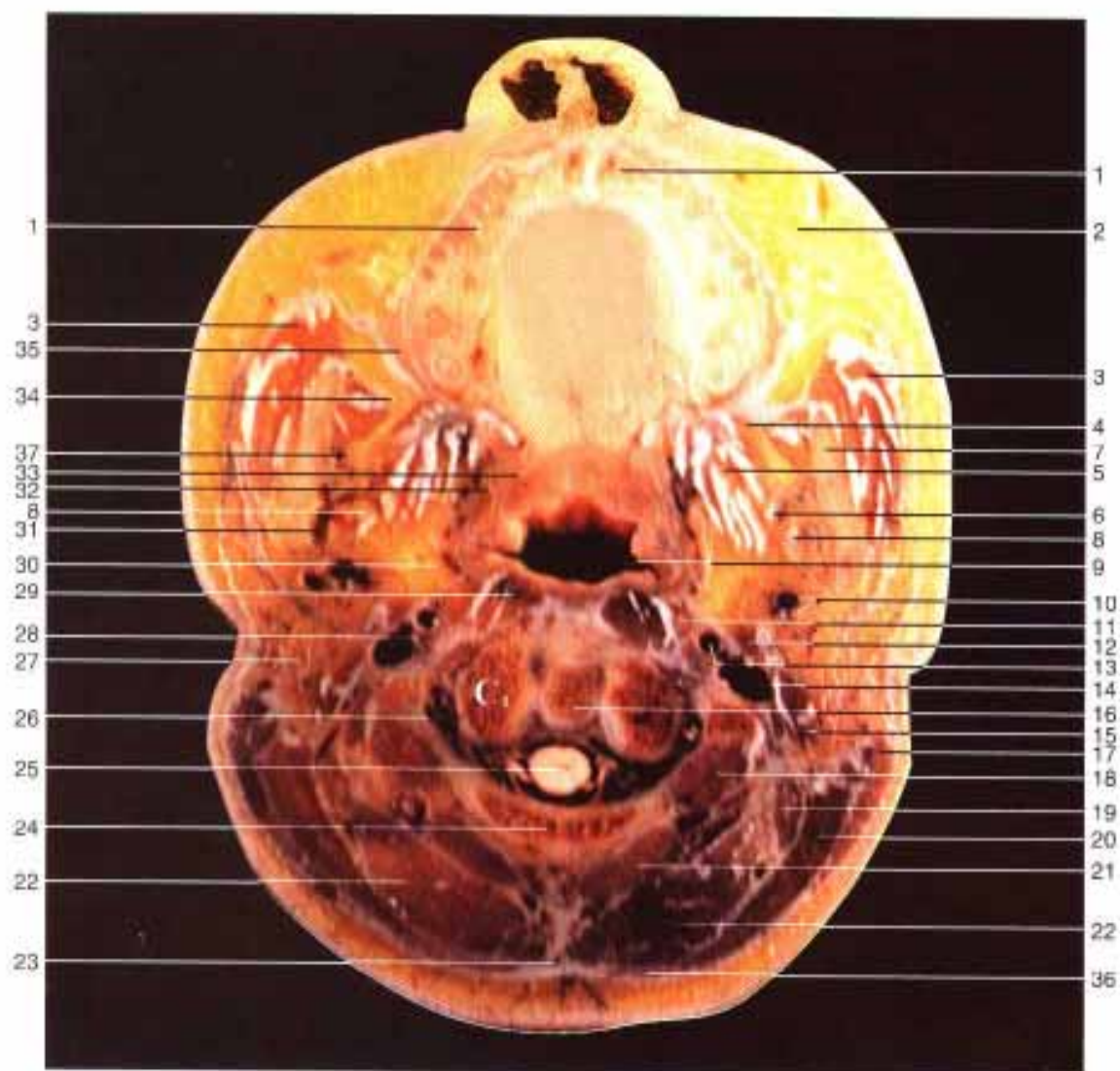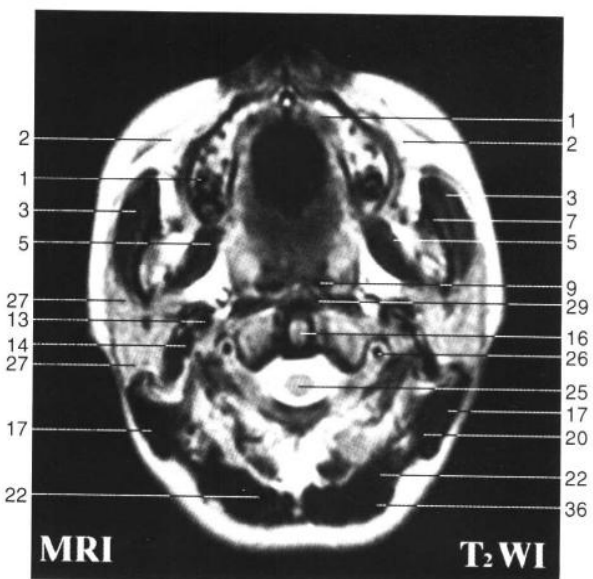
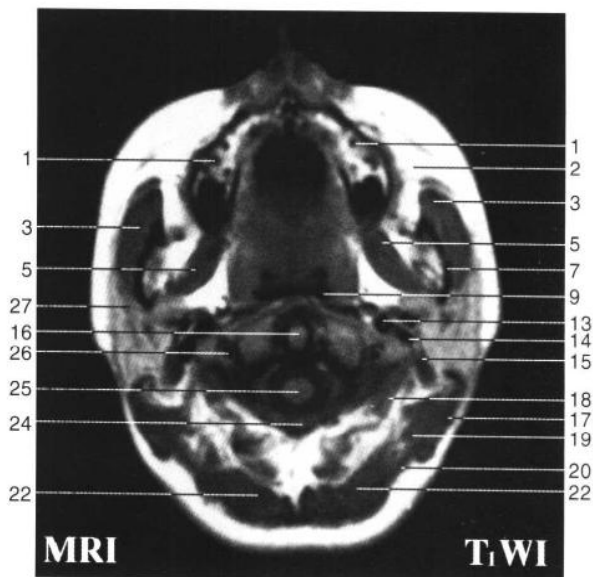
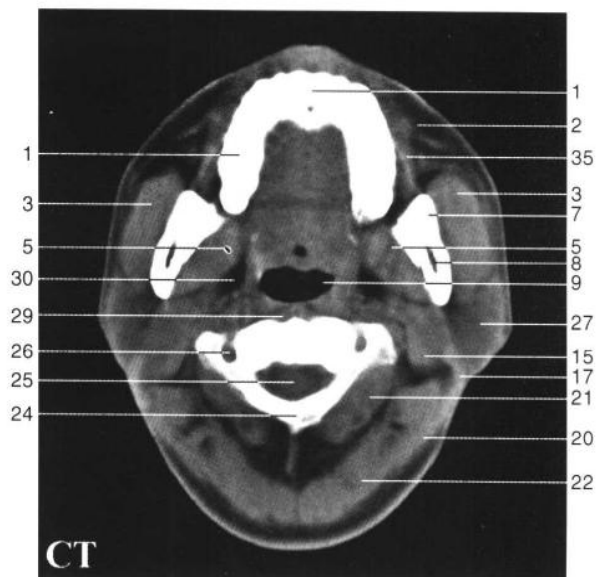




Fig. HC 14

Fig. HC 14

1. 上颌牙根 root of maxillary tooth
2. 颊脂体 buccal fat pad
3. 咬肌 masseter
4. 颊神经 buccinator n.
5. 翼内肌 medial pterygoid
6. 舌神经 lingual n.
7. 下颌支 ramus of mandible
8. 下牙槽神经 inferior alveolar n.
9. 咽腔 cavity of pharynx
10. 下颌后静脉及颈外动脉 retromandibular v. and external carotid a.
11. 颈上神经节 superior cervical ganglion
12. 茎突咽肌 stylopharyngeus
13. 颈内动脉 internal carotid a.
14. 颈内静脉 internal jugular v.
15. 二腹肌后腹 posterior belly of digastric
16. 齿突 dens
17. 胸锁乳突肌 sternocleidomastoid
18. 头下斜肌 obliquus capitis inferior
19. 头最长肌 longissimus capitis
20. 头夹肌 splenius capitis
21. 头后大直肌 rectus capitis posterior major
22. 头半棘肌 semispinalis capitis
23. 项韧带 ligamentum nuchae
24. 寰椎后弓 posterior arch of atlas
25. 脊髓 spinal cord
26. 椎动、静脉 vertebral a. and v.
27. 腮腺 parotid gland
28. 舌咽神经、迷走神经和副神经 glossopharyngeal n., vagus n. and accessory n.
29. 头长肌 longus capitis
30. 咽外侧间隙 lateropharyngeal space
31. 上颌动、静脉 maxillary a. and v.
32. 腭帆张肌 tensor veli palatini
33. 腭帆提肌 levator veli palatini
34. 颊神经 buccal n.
35. 颊肌 buccinator
36. 斜方肌 trapezius
37. 上颌静脉 maxillary v.



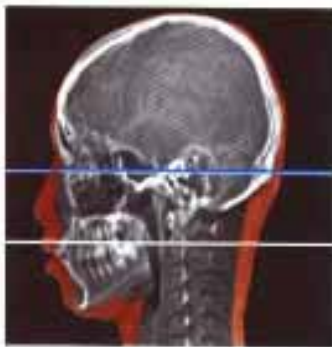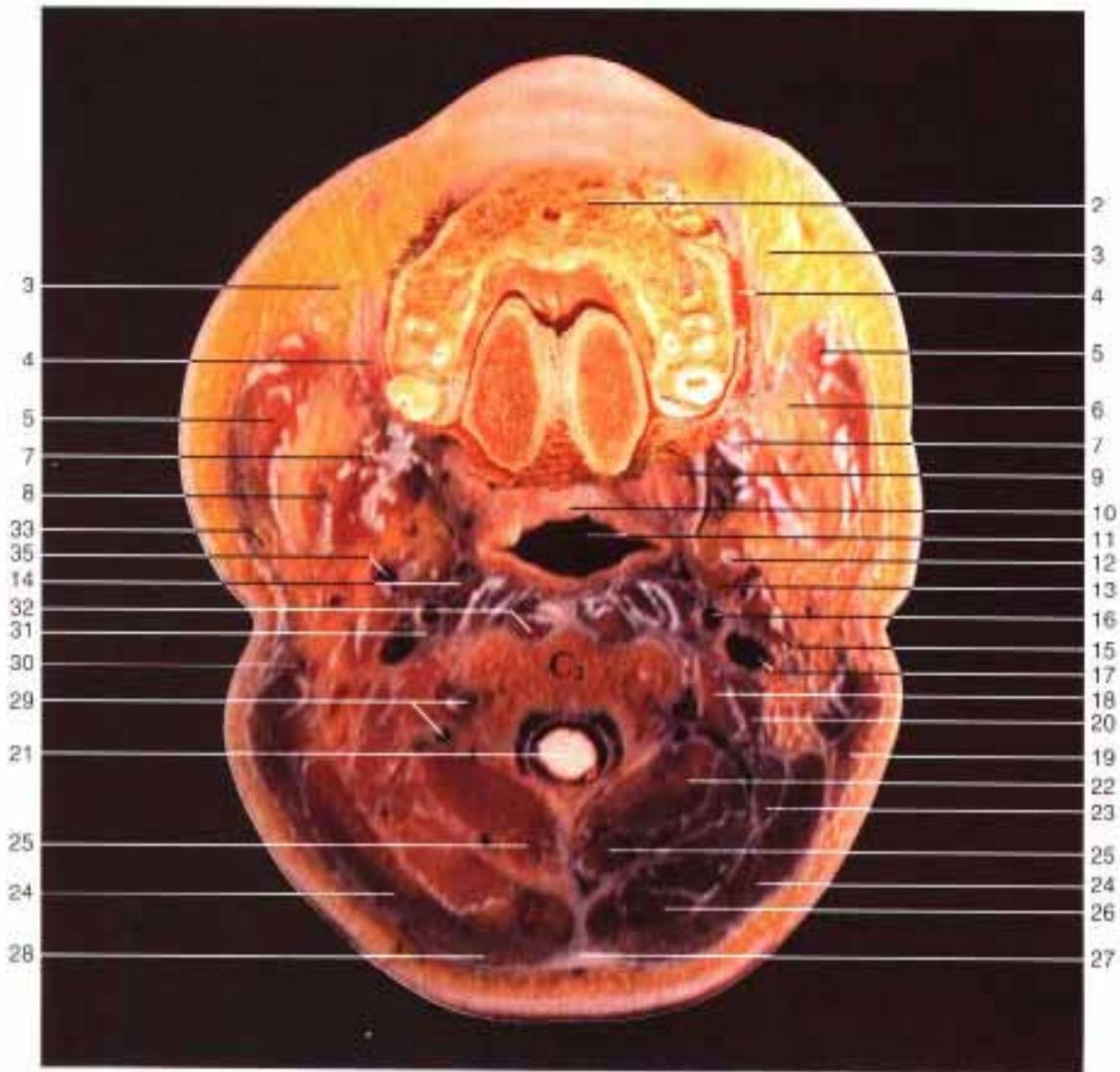
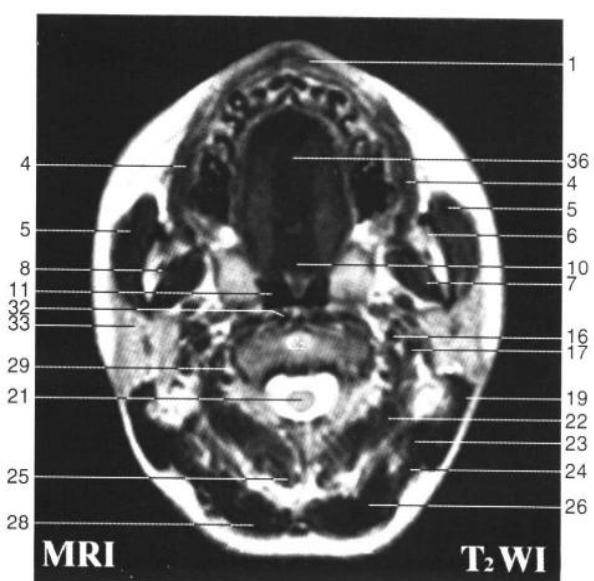
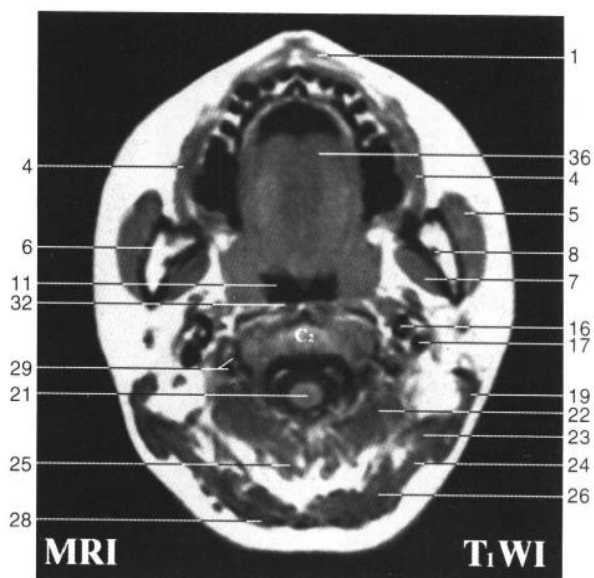
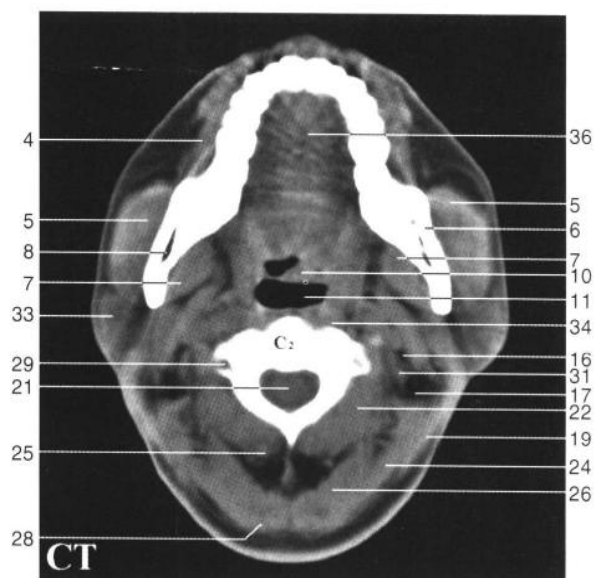


Fig. HC 15

Fig. HC 15

1. 口轮匝肌 orbicularis oris
2. 上颌牙槽突 alveolar process of maxilla
3. 颊脂体 buccal fat pad
4. 颊肌 buccinator
5. 咬肌 masseter
6. 下颌支 ramus of mandible
7. 翼内肌 medial pterygoid
8. 下牙槽动脉与神经 inferior alveolar a. and n.
9. 腭扁桃体 palatine tonsil
10. 软腭 soft palate
11. 咽腔 cavity of pharynx
12. 茎突舌肌 styloglossus
13. 茎突咽肌 stylopharyngeus
14. 颈上神经节 superior cervical ganglion
15. 二腹肌后腹 posterior belly of digastric
16. 颈内动脉 internal carotid a.
17. 颈内静脉 internal jugular v.
18. 中斜角肌 scalenus medius
19. 胸锁乳突肌 sternocleidomastoid
20. 肩胛提肌 levator scapulae
21. 脊髓 spinal cord
22. 头下斜肌 obliquus capitis inferior
23. 头最长肌 longissimus capitis
24. 头夹肌 splenius capitis
25. 头后大直肌 rectus capitis posterior major
26. 头半棘肌 semispinalis capitis
27. 项韧带 ligamentum nuchae
28. 斜方肌 trapezius
29. 椎动、静脉 vertebral a. and v.
30. 颈外静脉 external jugular v.
31. 舌咽神经、迷走神经和副神经 glossopharyngeal n.,
vagus n. and accessory n.
32. 颈长肌 longus colli
33. 腮腺 parotid gland
34. 头长肌 longus capitis
35. 颈外动脉 external carotid a.
36. 硬腭 hard palate



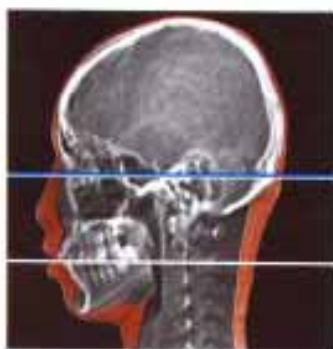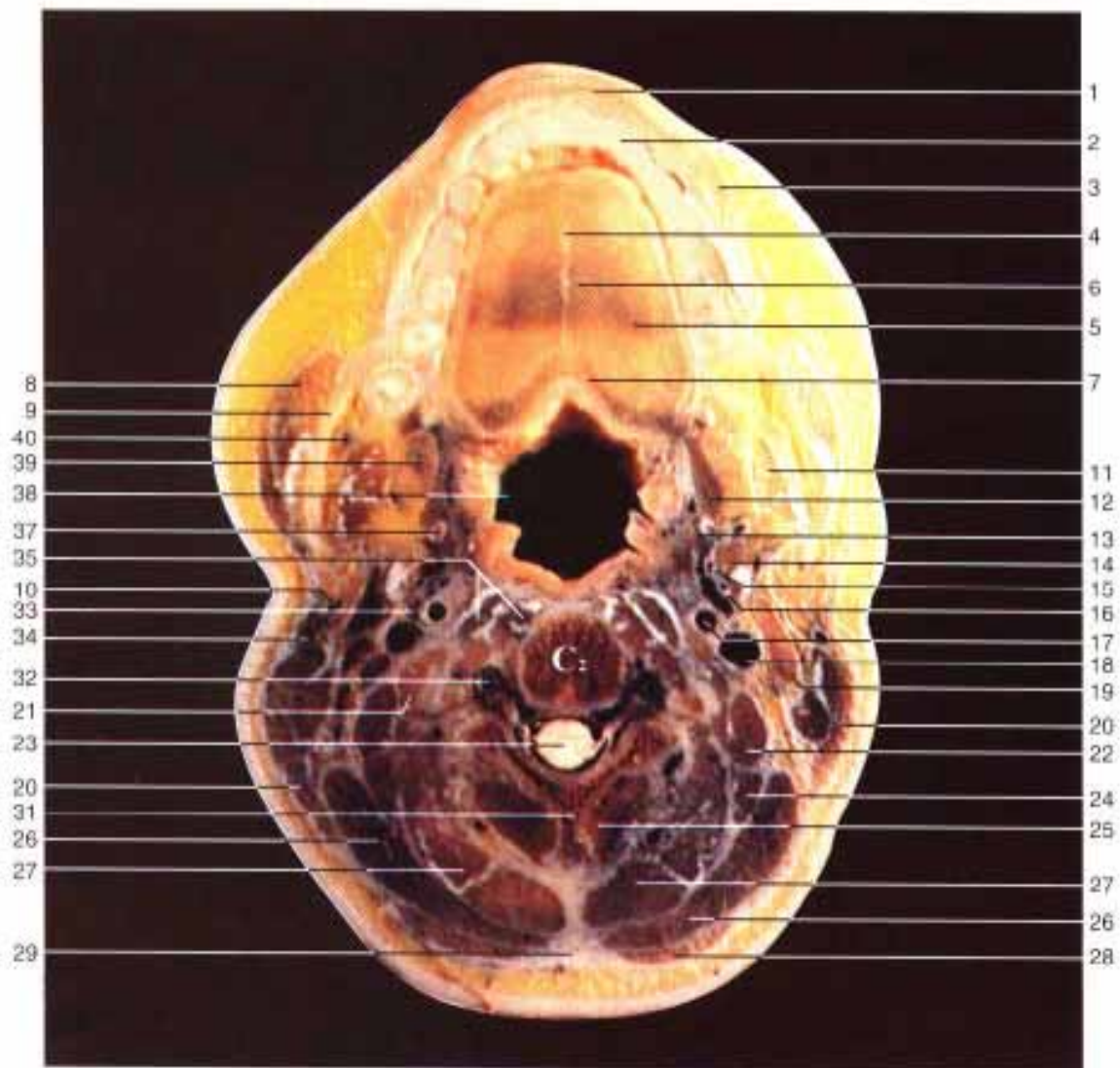
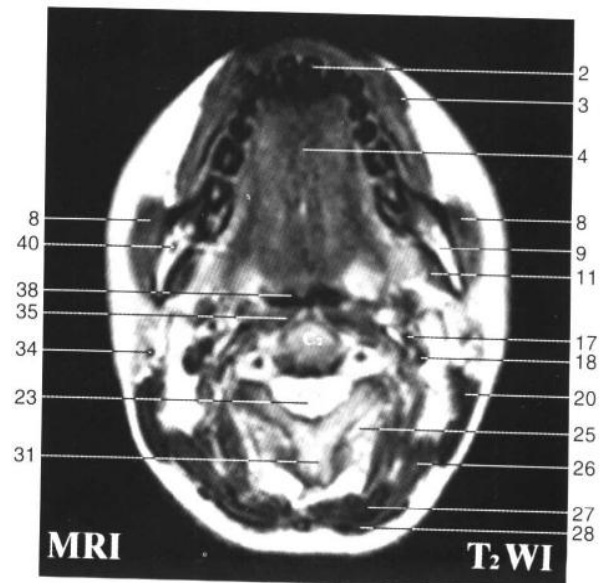
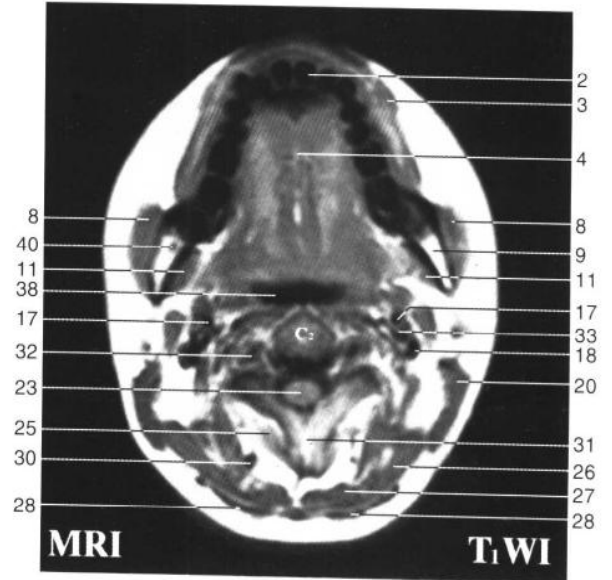
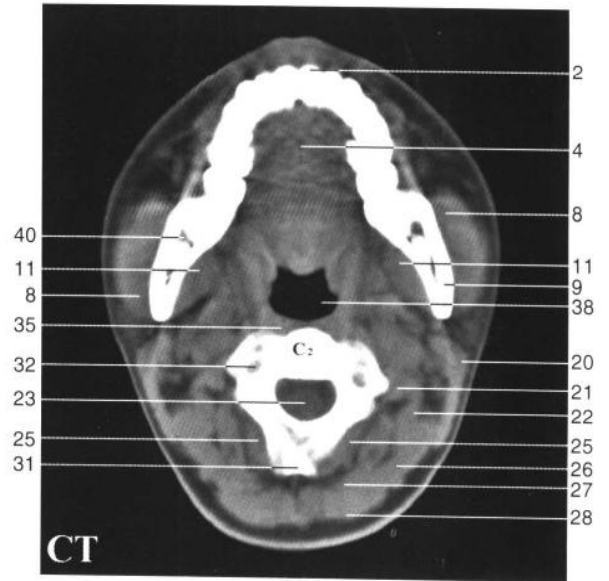


Fig. HC 16

Fig. HC 16

1. 口轮匝肌 orbicularis oris
2. 切牙 incisor
3. 降口角肌 depressor anguli oris
4. 舌中隔 septum of tongue
5. 舌动脉 lingual a.
6. 颞舌肌 genioglossus
7. 上纵肌 superior longitudinal muscle
8. 咬肌 masseter
9. 下颌支 ramus of mandible
10. 下颌后静脉 retromandibular v.
11. 翼内肌 medial pterygoid
12. 茎突舌肌 styloglossus
13. 茎突咽肌 stylopharyngeus
14. 二腹肌后腹与茎突舌骨肌 posterior belly of digastric and stylohyoid
15. 颈外动脉 external carotid a.
16. 枕动脉 occipital a.
17. 颈内动脉 internal carotid a.
18. 颈内静脉 internal jugular v.
19. 颈外侧上深淋巴结 superior deep lateral cervical lymph nodes
20. 胸锁乳突肌 sternocleidomastoid
21. 中斜角肌 scalenus medius
22. 肩胛提肌 levator scapulae
23. 脊髓 spinal cord
24. 头最长肌 longissimus capitis
25. 头下斜肌 obliquus capitis inferior
26. 头夹肌 splenius capitis
27. 头半棘肌 semispinalis capitis
28. 斜方肌 trapezius
29. 项韧带 ligamentum nuchae
30. 颈深动脉 deep cervical a.
31. 枢椎棘突 spinous process of axis
32. 椎动、静脉 vertebral a. and v.
33. 舌咽神经、迷走神经和副神经 glossopharyngeal n., vagus n. and accessory n.
34. 颈外静脉 external jugular v.
35. 头长肌与颈长肌 longus capitis and longus colli
36. 下颌后静脉与颈外动脉 retromandibular v. and external carotid a.
37. 茎突 styloid process
38. 咽腔 cavity of pharynx
39. 下颌下腺 submandibular gland
40. 下牙槽动脉与神经 inferior alveolar a. and n.



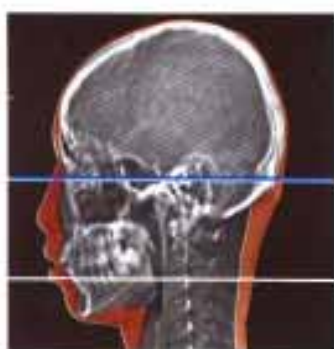
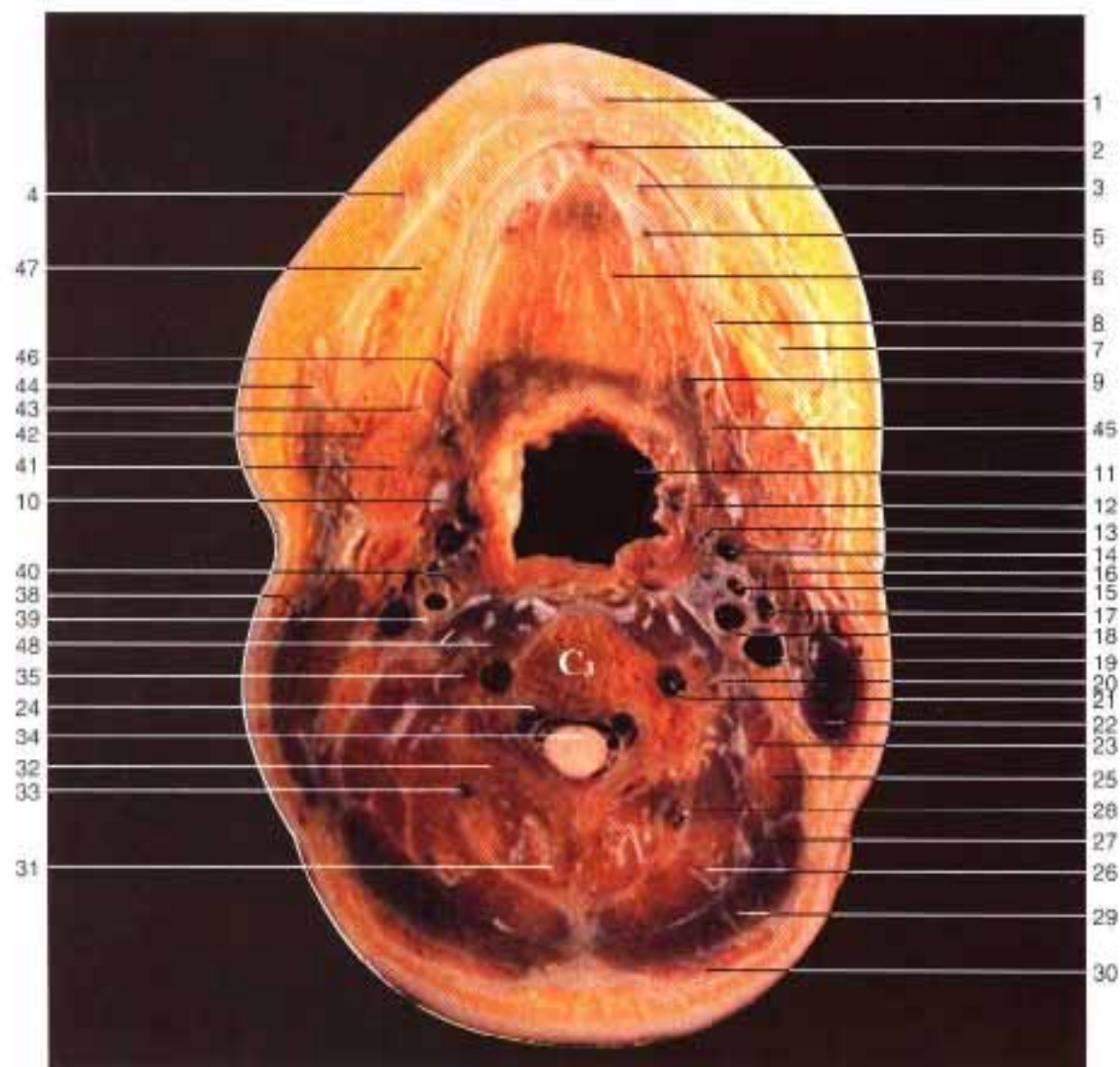
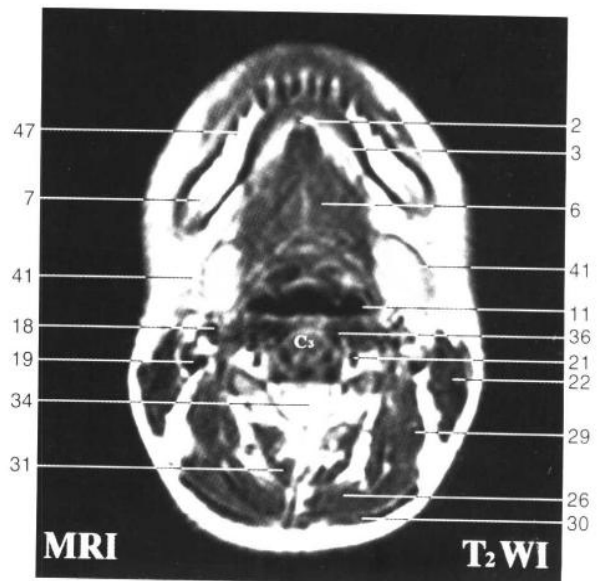
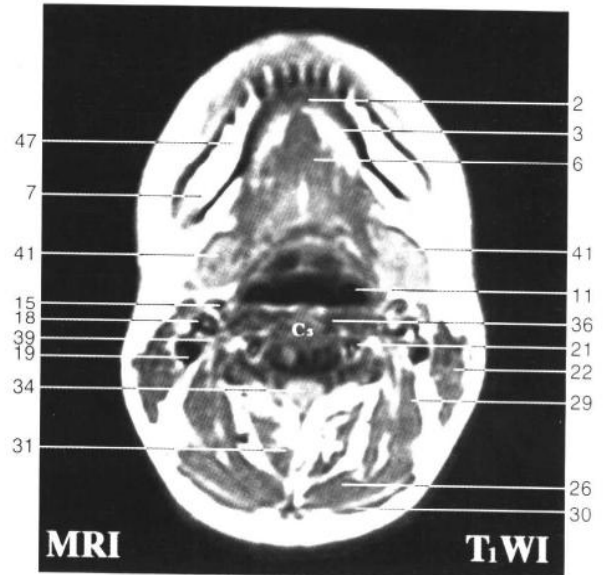
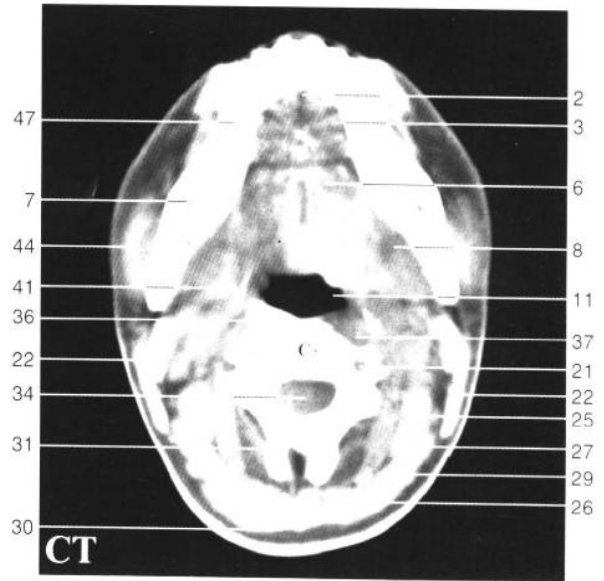


Fig. HC 17

Fig. HC 17

1. 颞肌 mentalis
2. 舌下动脉 sublingual a.
3. 舌下腺 sublingual gland
4. 降下唇肌 depressor labii inferioris
5. 舌深动脉 deep lingual a.
6. 颞舌肌 genioglossus
7. 下牙槽神经 inferior alveolar n.
8. 下颌舌骨肌 mylohyoid
9. 茎突舌肌 styloglossus
10. 二腹肌后腹与茎突舌骨肌 posterior belly of digastric and stylohyoid
11. 咽腔 cavity of pharynx
12. 咽中缩肌 middle constrictor of pharynx
13. 面动脉 facial a.
14. 面静脉 facial v.
15. 颈外动脉 external carotid a.
16. 颈内静脉外侧淋巴结 lateral jugular lymph nodes
17. 下颌后静脉 retromandibular v.
18. 颈内动脉 internal carotid a.
19. 颈内静脉 internal jugular v.
20. 第2颈神经 2nd cervical n.
21. 椎动脉 vertebral a.
22. 胸锁乳突肌 sternocleidomastoid
23. 中斜角肌 scalenus medius
24. 椎内前静脉丛 anterior internal vertebral venous plexus
25. 肩胛提肌 levator scapulae
26. 头半棘肌 semispinalis capitis
27. 头最长肌 longissimus capitis
28. 颈深动脉 deep cervical a.
29. 头夹肌 splenius capitis
30. 斜方肌 trapezius
31. 颈半棘肌 semispinalis cervicis
32. 头下斜肌 obliquus capitis inferior
33. 颈深静脉 deep cervical v.
34. 脊髓 spinal cord
35. 第2颈椎横突 transverse process (C₂)
36. 颈长肌 longus colli
37. 头长肌 longus capitis
38. 颈外静脉 external jugular v.
39. 迷走神经 vagus n.
40. 颈上神经节 superior cervical ganglion
41. 下颌下腺 submandibular gland
42. 下颌下淋巴结 submandibular lymph nodes
43. 舌下静脉 sublingual v.
44. 咬肌 masseter
45. 舌骨舌肌 hyoglossus
46. 舌下神经 hypoglossal n.
47. 下颌骨 mandible
48. 颈长肌与头长肌 longus colli and longus capitis



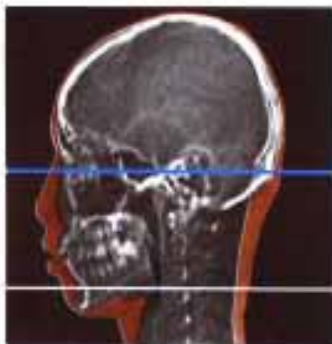
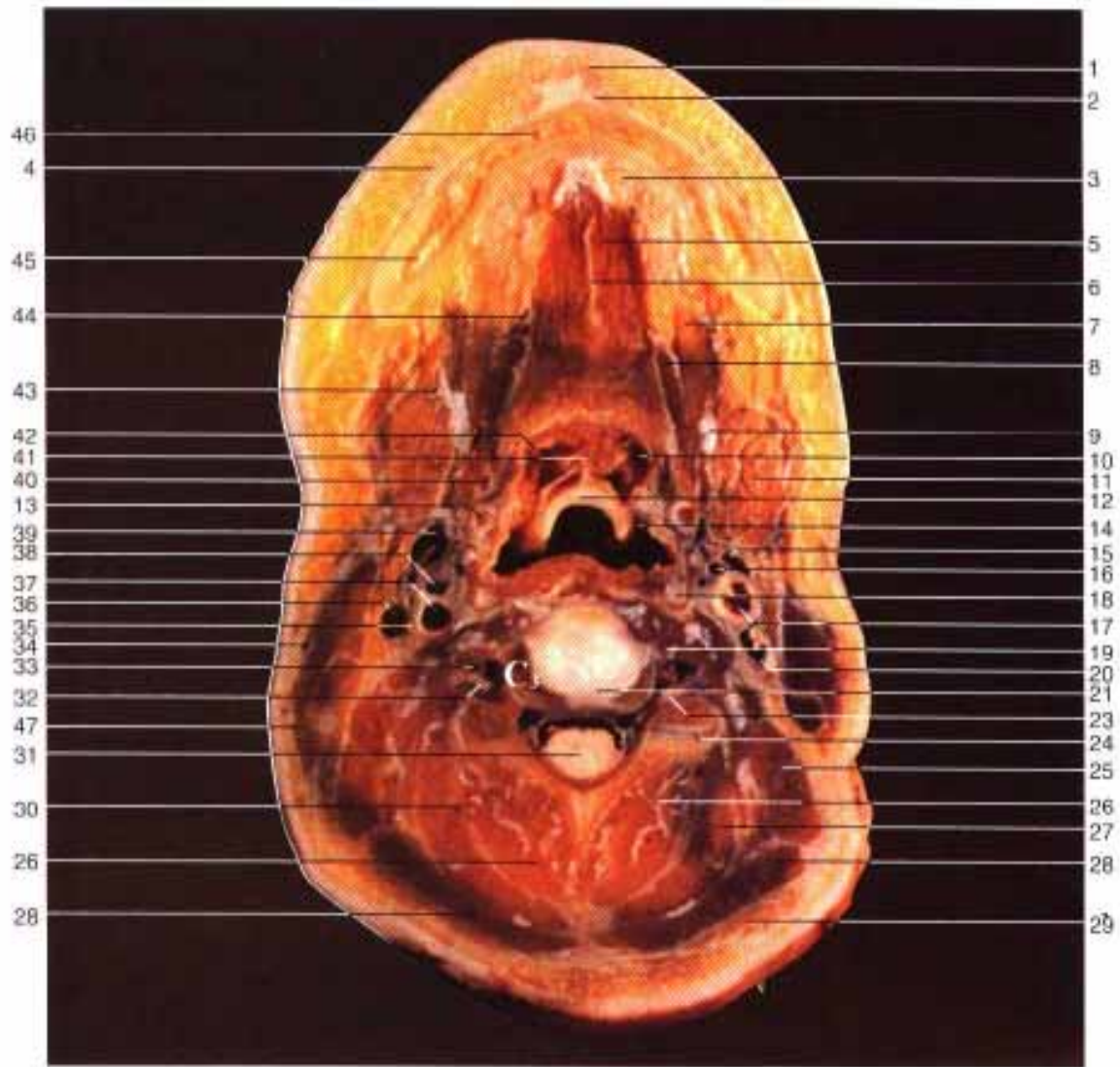
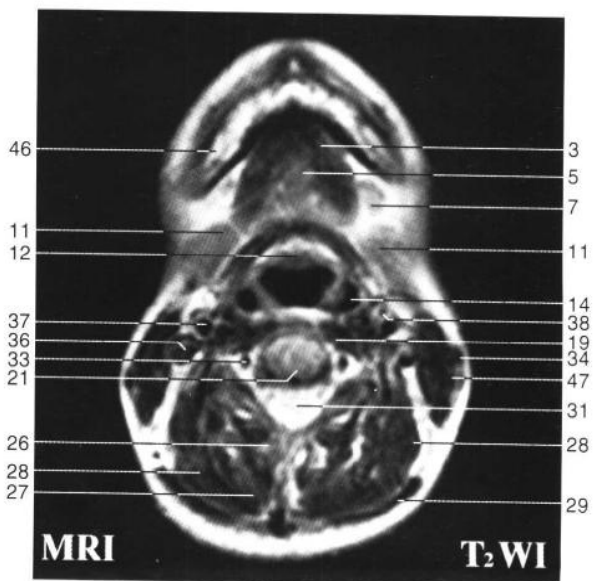
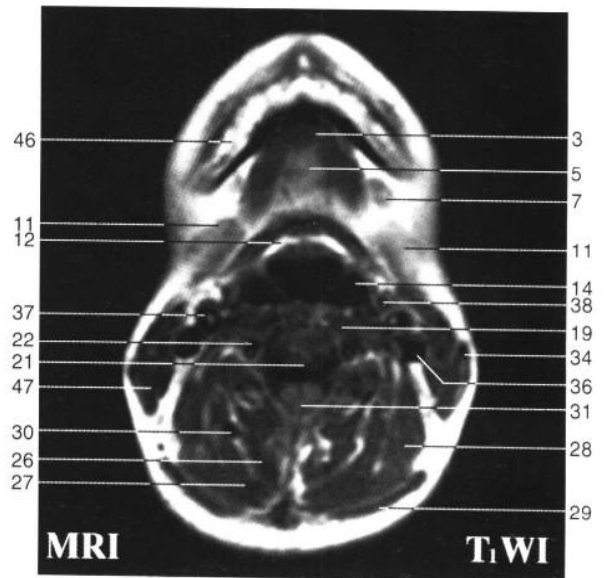
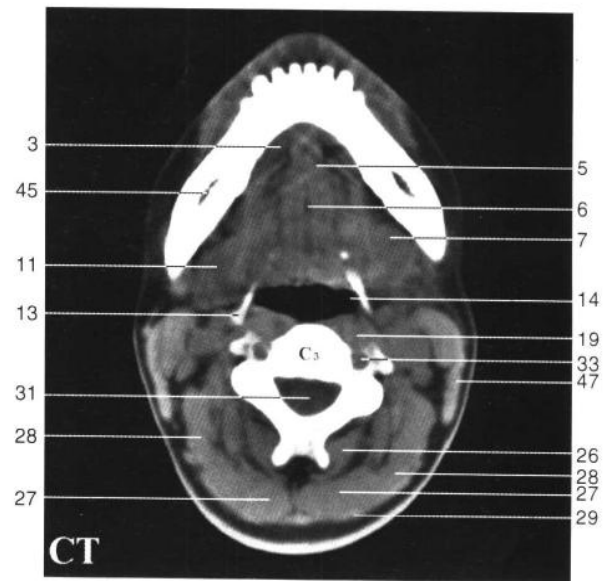


Fig. HC 18

Fig. HC 18

1. 口轮匝肌 orbicularis oris
2. 颏肌 mentalis
3. 舌下腺 sublingual gland
4. 降下唇肌 depressor labii inferioris
5. 颏舌肌 genioglossus
6. 舌中隔 septum of tongue
7. 下颌舌骨肌 mylohyoid
8. 舌骨舌肌 hyoglossus
9. 二腹肌后腹与茎突舌骨肌 posterior belly of digastric and stylohyoid
10. 会厌谷 epiglottic vallecula
11. 下颌下腺 submandibular gland
12. 会厌 epiglottis
13. 舌骨大角 greater horn of hyoid bone
14. 咽腔 cavity of pharynx
15. 面静脉 facial v.
16. 颈外动脉 external carotid a.
17. 颈总动脉 common carotid a.
18. 甲状软骨上角 superior horn of thyroid cartilage
19. 头长肌与颈长肌 longus capitis and longus colli
20. 颈内静脉 internal jugular v.
21. 3,4 颈椎间盘 intervertebral disc (C₃ - C₄)
22. 椎静脉 vertebral v.
23. 第3颈神经 3rd cervical n
24. 3,4 颈椎关节突关节 zygapophysial joint (C₃ - C₄)
25. 肩胛提肌 levator scapulae
26. 颈半棘肌 semispinalis cervicis
27. 头半棘肌 semispinalis capitis
28. 头夹肌 splenius capitis
29. 斜方肌 trapezius
30. 颈深动脉 deep cervical a.
31. 脊髓 spinal cord
32. 第3颈神经后支 posterior branch of 3rd cervical n.
33. 椎动脉 vertebral a.
34. 颈外静脉 external jugular v.
35. 迷走神经 vagus n.
36. 颈内静脉 internal jugular v.
37. 颈内动脉 internal carotid a.
38. 颈外动脉 external carotid a.
39. 面静脉 facial v.
40. 舌动脉 lingual a.
41. 舌会厌正中襞 median glossoepiglottic fold
42. 舌会厌外侧襞 lateral glossoepiglottic fold
43. 舌下静脉 sublingual v.
44. 舌深动脉 deep lingual a.
45. 下牙槽神经 inferior alveolar n.
46. 下颌骨 mandible
47. 胸锁乳突肌 sternocleidomastoid



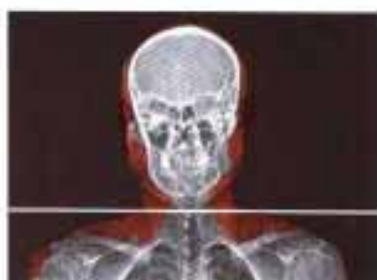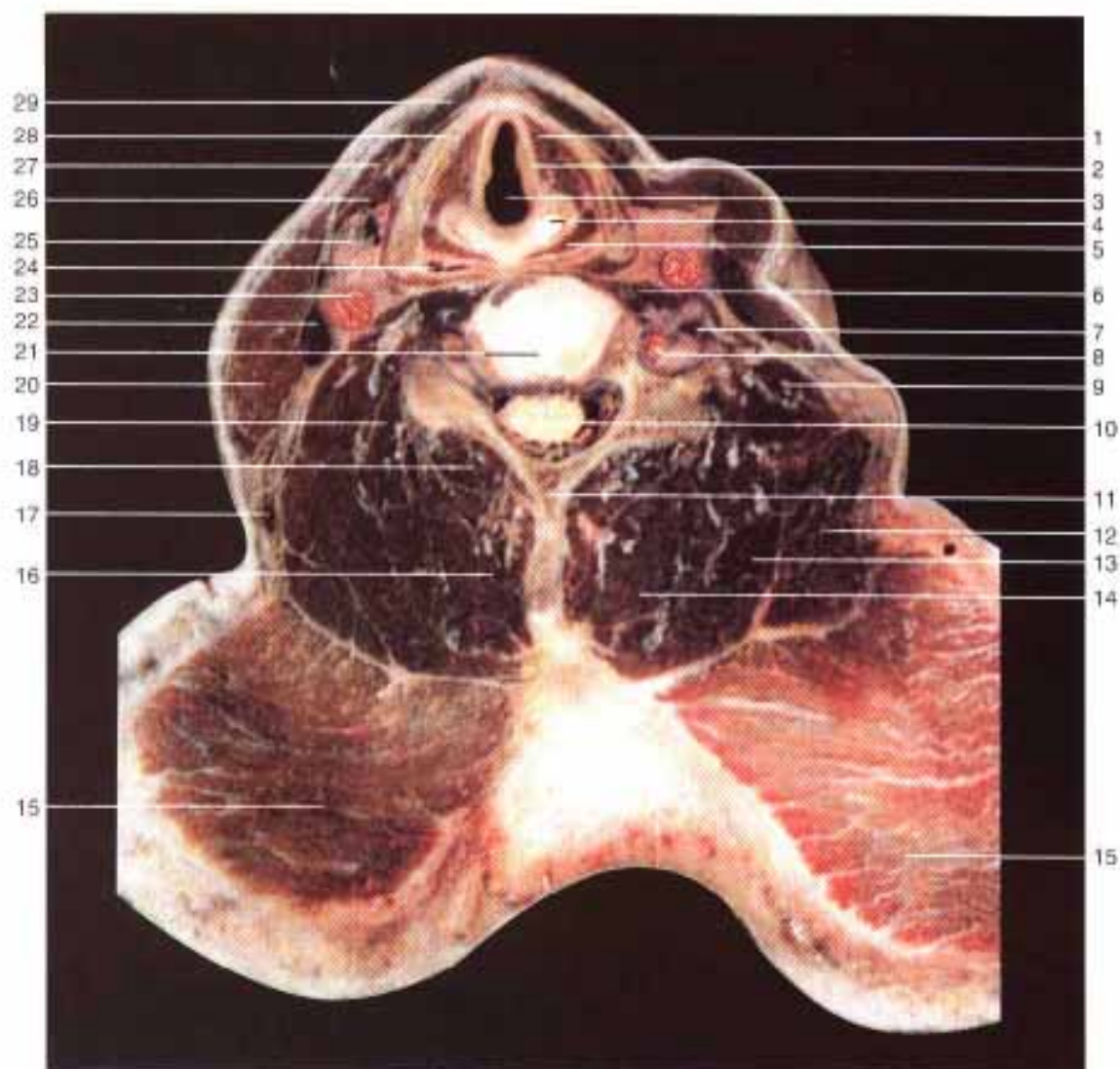
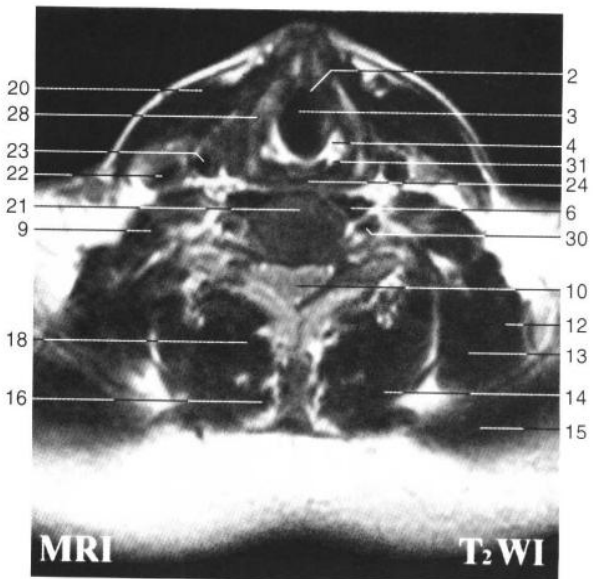
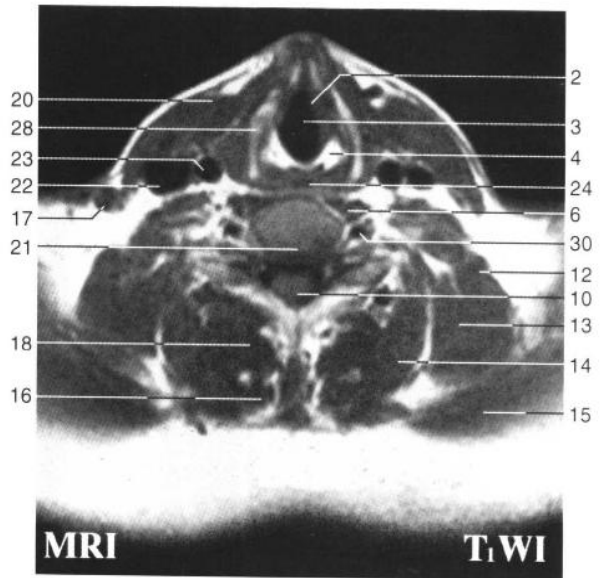
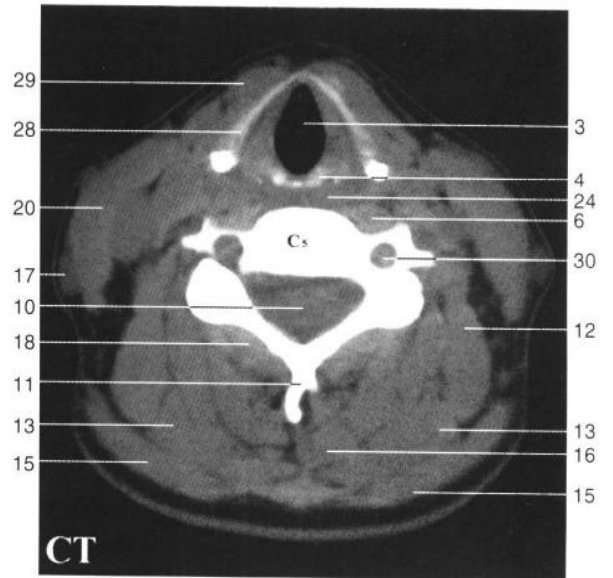


Fig. HC 19

Fig. HC 19

1. 甲杓肌 thyroarytenoid
2. 声襞 vocal fold
3. 喉腔 laryngeal cavity
4. 环状软骨 cricoid cartilage
5. 环杓后肌 posterior cricoarytenoid
6. 颈长肌 longus colli
7. 前斜角肌 scalenus anterior
8. 椎动脉与第5颈神经 vertebral a. and 5th cervical n.
9. 中、后斜角肌 scalenus medius and posterior
10. 脊髓 spinal cord
11. 第5颈椎棘突 spinous process (C₅)
12. 肩胛提肌 levator scapulae
13. 夹肌 splenius
14. 头半棘肌 semispinalis capitis
15. 斜方肌 trapezius
16. 颈半棘肌 semispinalis colli
17. 右颈外静脉 right external jugular v.
18. 多裂肌 multifidi
19. 最长肌 longissimus
20. 胸锁乳突肌 sternocleidomastoid
21. 4、5 颈椎间盘 intervertebral disc (C₄ - C₅)
22. 右颈内静脉 right internal jugular v.
23. 右颈总动脉 right common carotid a.
24. 喉咽 laryngopharynx
25. 甲状腺 thyroid gland
26. 胸骨甲状肌 sternothyroid
27. 肩胛舌骨肌 omohyoid
28. 甲状软骨右板 right lamina of thyroid cartilage
29. 胸骨舌骨肌 sternohyoid
30. 椎动脉 vertebral a.
31. 构状软骨肌突 muscular process of arytenoid cartilage



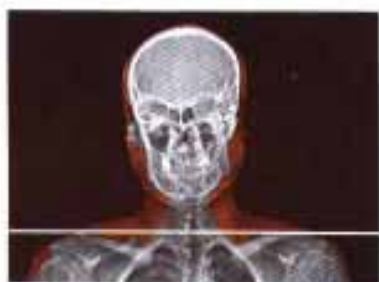
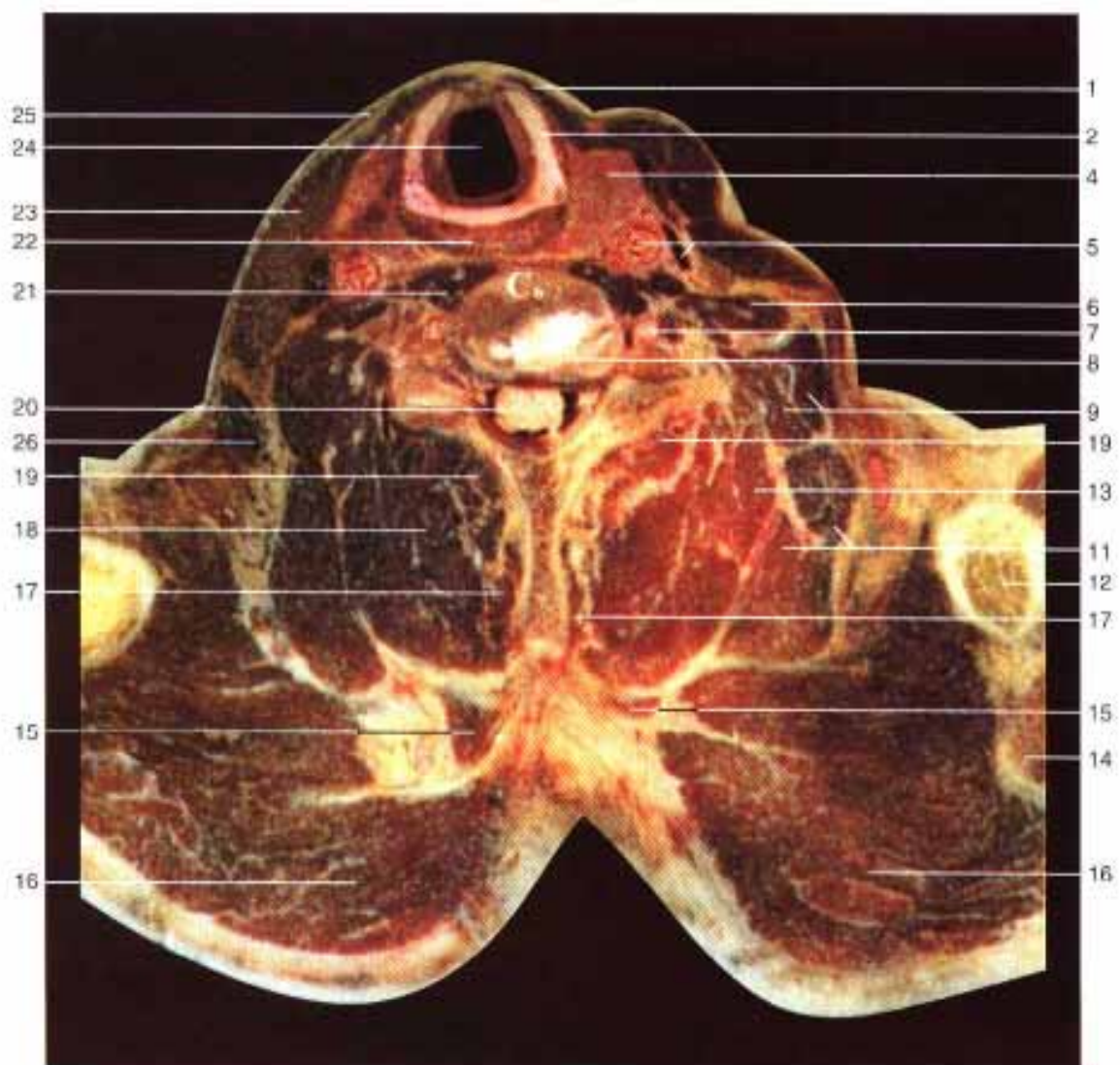
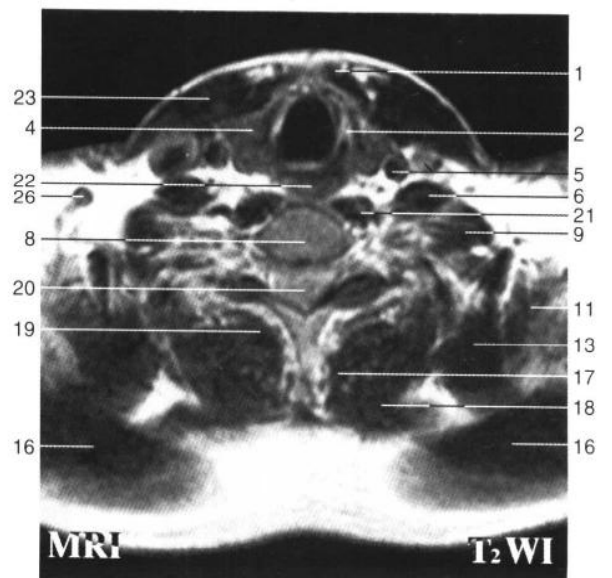
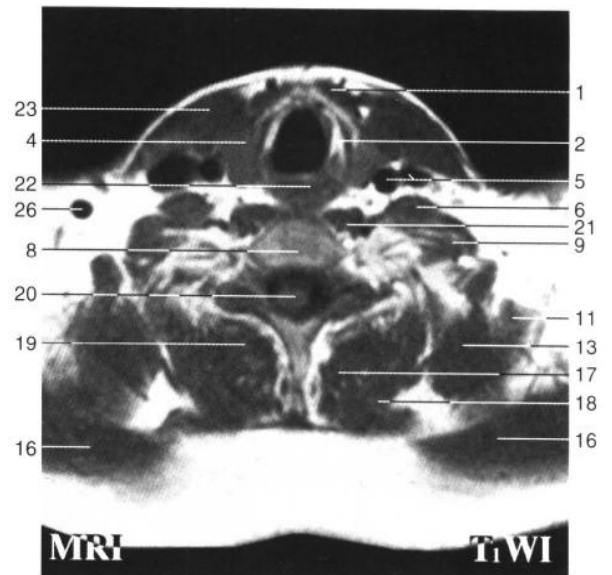
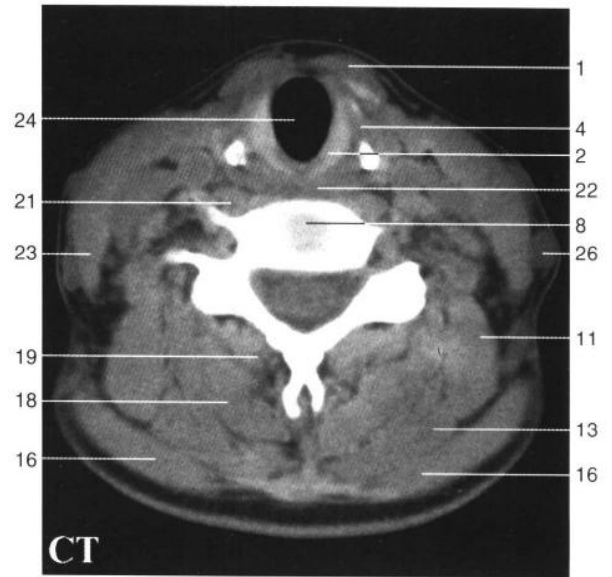


Fig. HC 20

Fig. HC 20

1. 胸骨舌骨肌 sternohyoid
2. 环状软骨 cricoid cartilage
3. 胸骨甲状肌 sternothyroid
4. 甲状腺 thyroid gland
5. 左颈总动脉与颈内静脉 left common carotid a. and internal jugular v.
6. 前斜角肌 scalenus anterior
7. 椎动脉与第 5 颈神经 vertebral a. and 5th cervical n.
8. 5,6 颈椎间盘 intervertebral disc (C₅ - C₆)
9. 中、后斜角肌 scalenus medius and posterior
10. 最长肌 longissimus
11. 肩胛提肌 levator scapulae
12. 锁骨 clavicle
13. 夹肌 splenius
14. 冈上肌 supraspinatus
15. 小菱形肌 rhomboideus minor
16. 斜方肌 trapezius
17. 颈半棘肌 semispinalis colli
18. 头半棘肌 semispinalis capitis
19. 多裂肌 multifidi
20. 脊髓 spinal cord
21. 颈长肌 longus colli
22. 喉咽 laryngopharynx
23. 胸锁乳突肌 sternocleidomastoid
24. 声门下腔 infraglottic cavity
25. 颈阔肌 platysma
26. 颈外静脉 external jugular v.



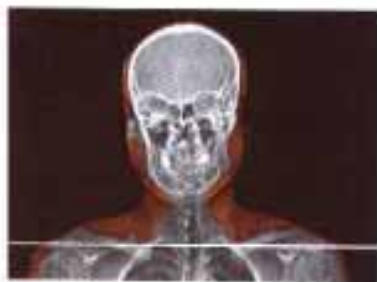
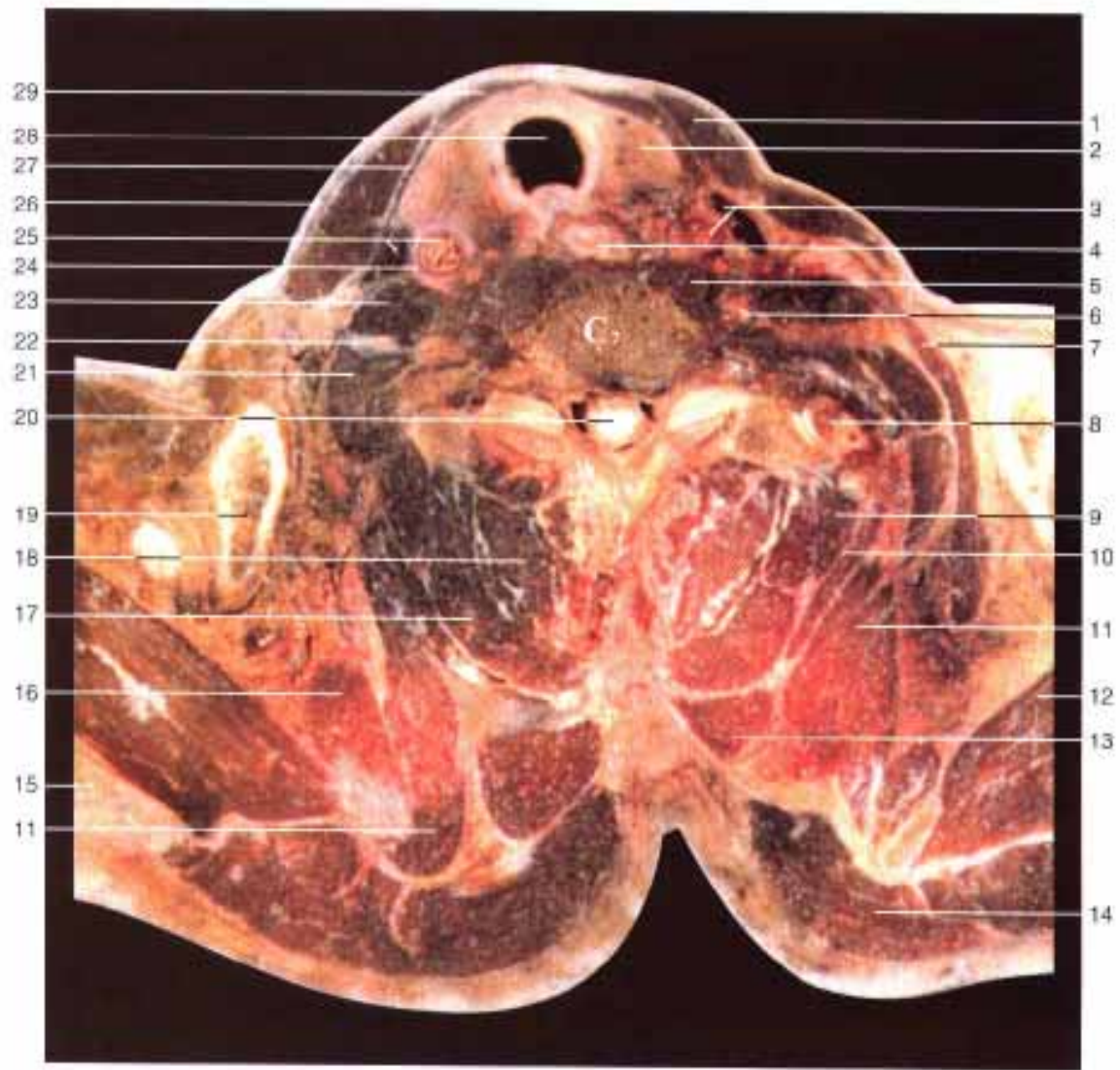
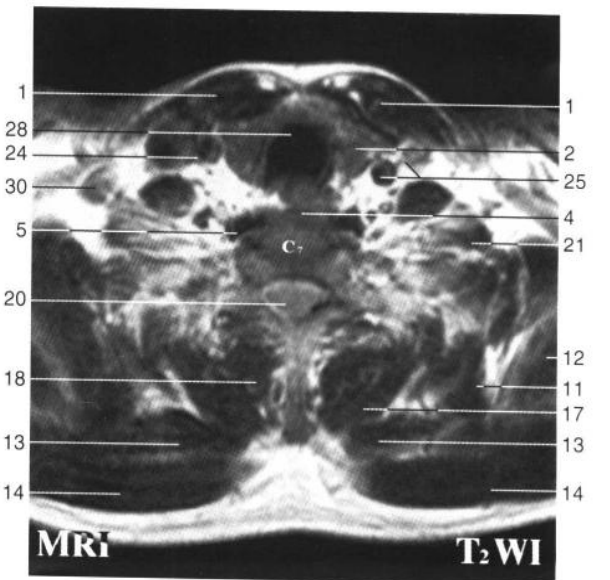
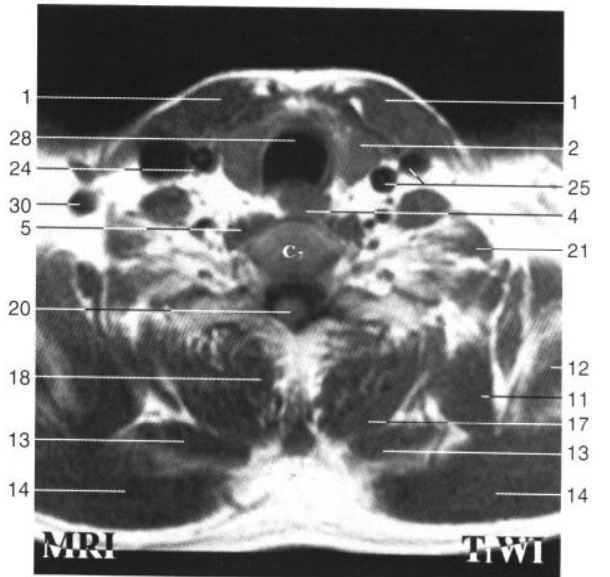
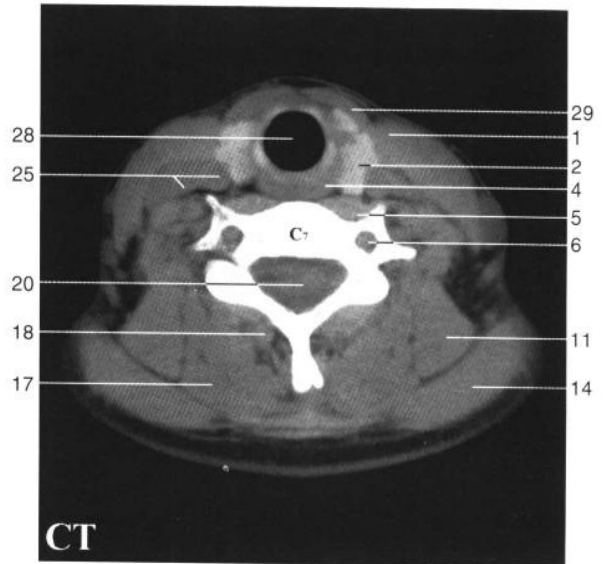


Fig. HC 21

Fig. HC 21

1. 胸锁乳突肌 sternocleidomastoid
2. 甲状腺 thyroid gland
3. 左颈内静脉与颈总动脉 left internal jugular v. and common carotid a.
4. 食管 esophagus
5. 颈长肌 longus colli
6. 椎动脉 vertebral a.
7. 肩胛舌骨肌下腹 inferior belly of omohyoid
8. 第1肋 1st rib
9. 最长肌 longissimus
10. 上后锯肌 serratus posterior superior
11. 肩胛提肌 levator scapulae
12. 冈上肌 supraspinatus
13. 小菱形肌 rhomboideus minor
14. 斜方肌 trapezius
15. 肩胛冈 spine of scapula
16. 前锯肌 serratus anterior
17. 夹肌 splenius
18. 颈半棘肌 semispinalis colli
19. 锁骨 clavicle
20. 脊髓 spinal cord
21. 中、后斜角肌 scalenus medius and posterior
22. 第6颈神经 6th cervical n.
23. 前斜角肌 scalenus anterior
24. 迷走神经 vagus n.
25. 颈总动脉与颈内静脉 common carotid a. and internal jugular v.
26. 颈阔肌 platysma
27. 胸骨甲状肌 sternothyroid
28. 气管 trachea
29. 胸骨舌骨肌 sternohyoid
30. 颈外静脉 external jugular v.



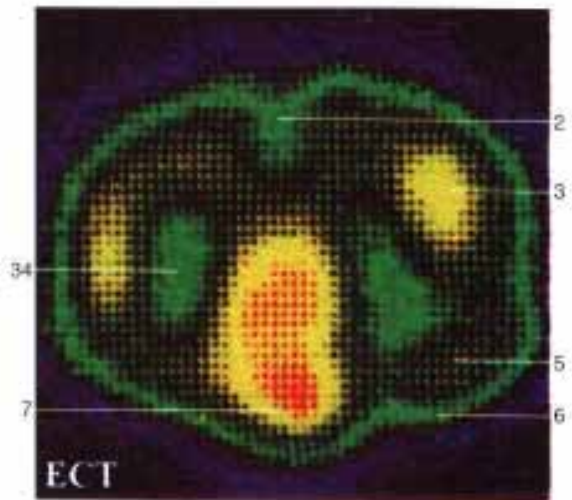
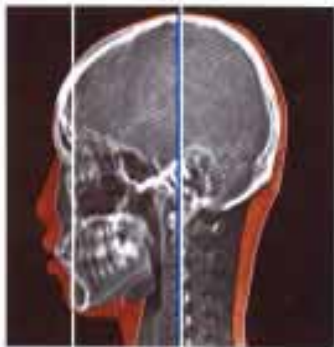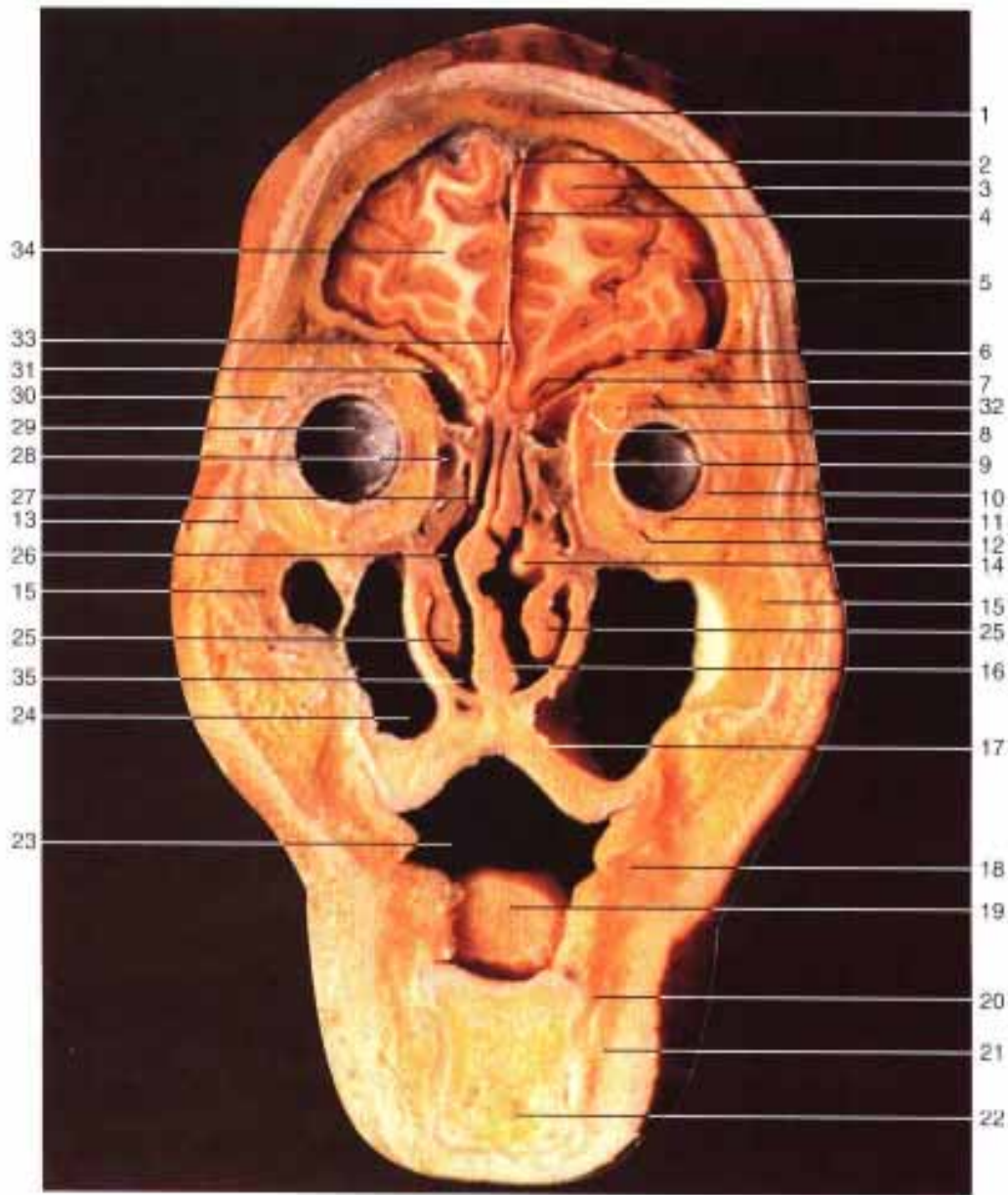
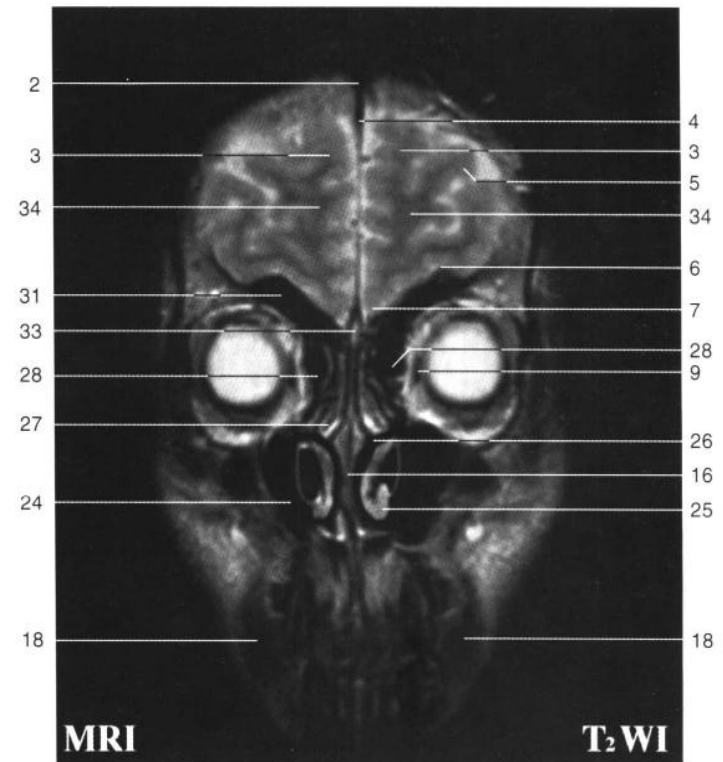
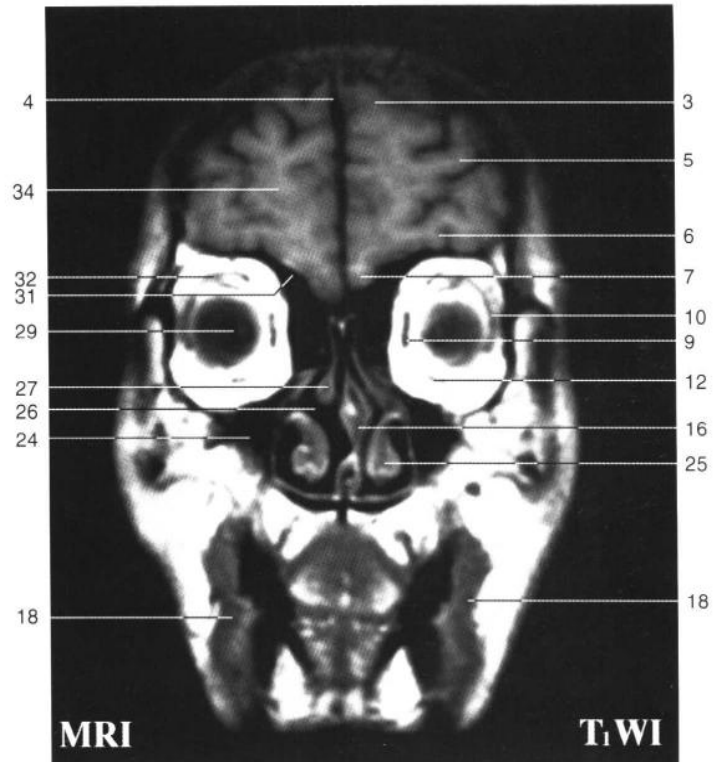


Fig. FC 1

Fig. FC 1

1. 额骨 frontal bone
2. 上矢状窦 superior sagittal sinus
3. 额上回 superior frontal gyrus
4. 大脑镰 cerebral falx
5. 额中回 middle frontal gyrus
6. 眶回 orbital gyrus
7. 直回 gyrus rectus
8. 上斜肌 superior obliquus
9. 内直肌 medial rectus
10. 外直肌 lateral rectus
11. 下斜肌 inferior obliquus
12. 下直肌 inferior rectus
13. 颧骨 zygomatic bone
14. 筛泡 ethmoidal bulla
15. 上颌骨 maxilla
16. 鼻中隔 nasal septum
17. 硬腭 hard palate
18. 颊肌 buccinator
19. 舌 tongue
20. 降下唇肌 depressor labii inferioris
21. 降口角肌 depressor anguli oris
22. 下颌骨 mandible
23. 口腔 oral cavity
24. 上颌窦 maxillary sinus
25. 下鼻甲 inferior nasal concha
26. 中鼻道 middle nasal meatus
27. 中鼻甲 middle nasal concha
28. 筛窦 ethmoidal sinuses
29. 眼球 eyeball
30. 泪腺 lacrimal gland
31. 额窦 frontal sinus
32. 上睑提肌及上直肌 levator palpebrae superioris and superior rectus
33. 鸡冠 crista galli
34. 辐射冠 corona radiata
35. 下鼻道 inferior nasal meatus



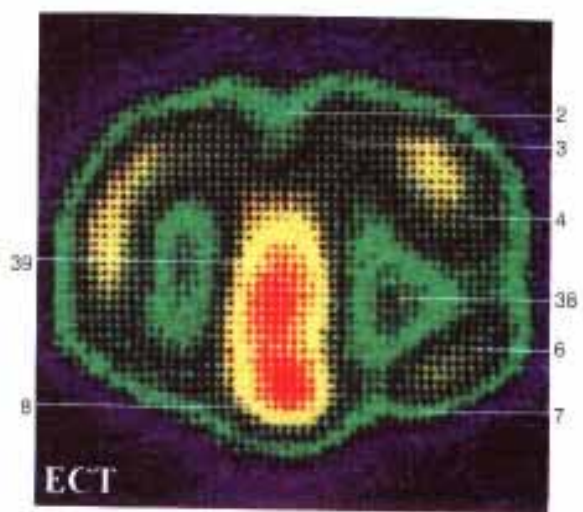
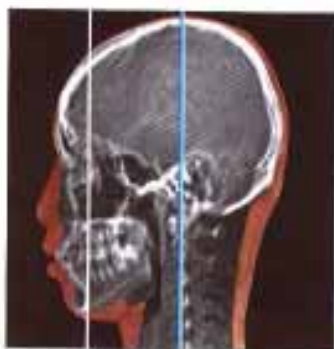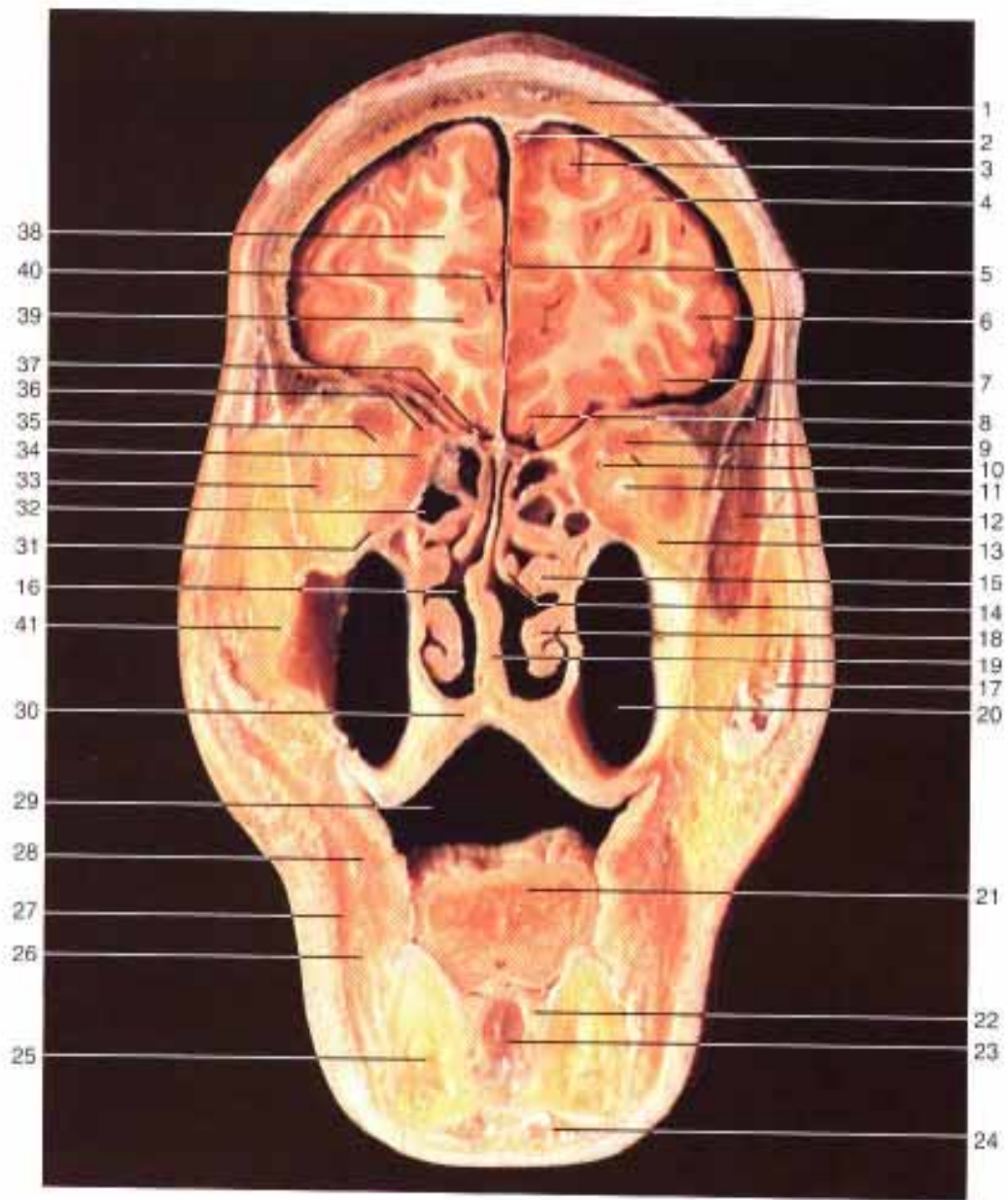
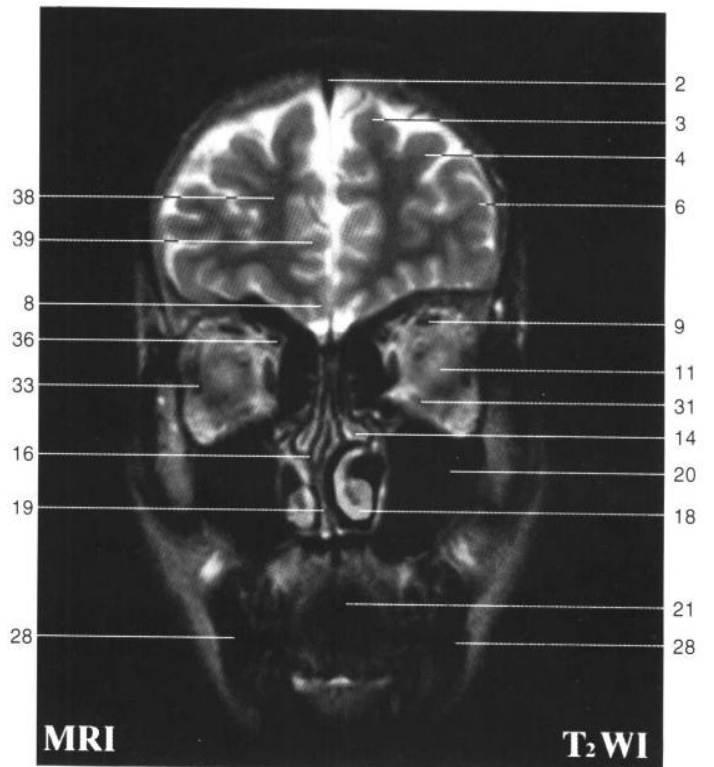
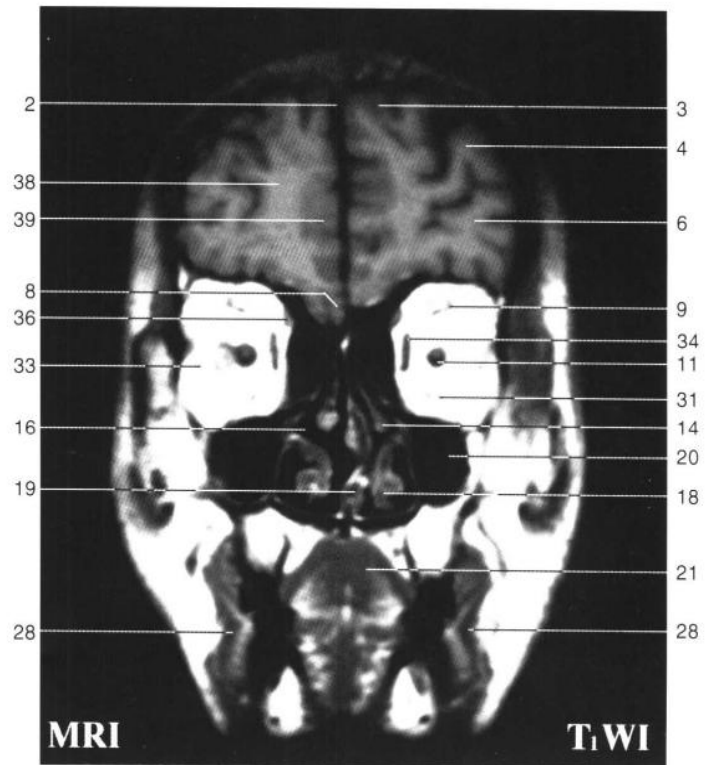


Fig. FC 2

Fig. FC 2

1. 额骨 frontal bone
2. 上矢状窦 superior sagittal sinus
3. 额上回 superior frontal gyrus
4. 额中回 middle frontal gyrus
5. 大脑镰 cerebral falx
6. 额下回 inferior frontal gyrus
7. 眶回 orbital gyrus
8. 直回 gyrus rectus
9. 上睑提肌及上直肌 levator palpebrae superioris and superior rectus
10. 眼动脉和眼上静脉 ophthalmic a. and superior ophthalmic v.
11. 视神经 optic n.
12. 颞肌 temporalis
13. 眼下静脉 inferior ophthalmic v.
14. 中鼻甲 middle nasal concha
15. 筛泡 ethmoidal bulla
16. 中鼻道 middle nasal meatus
17. 颧骨 zygomatic bone
18. 下鼻甲 inferior nasal concha
19. 鼻中隔 nasal septum
20. 上颌窦 maxillary sinus
21. 舌 tongue
22. 舌下腺 sublingual gland
23. 颏舌肌 genioglossus
24. 二腹肌前腹 anterior belly of digastric
25. 下颌骨 mandible
26. 降下唇肌 depressor labii inferioris
27. 降口角肌 depressor anguli oris
28. 颊肌 buccinator
29. 口腔 oral cavity
30. 硬腭 hard palate
31. 下直肌 inferior rectus
32. 筛窦 ethmoidal sinuses
33. 外直肌 lateral rectus
34. 内直肌 medial rectus
35. 动眼神经上支 superior branch of oculomotor n.
36. 上斜肌 superior obliquus
37. 嗅束 olfactory tract
38. 辐射冠 corona radiata
39. 扣带回 cingulate gyrus
40. 大脑前动脉 anterior cerebral a.
41. 上颌骨 maxilla



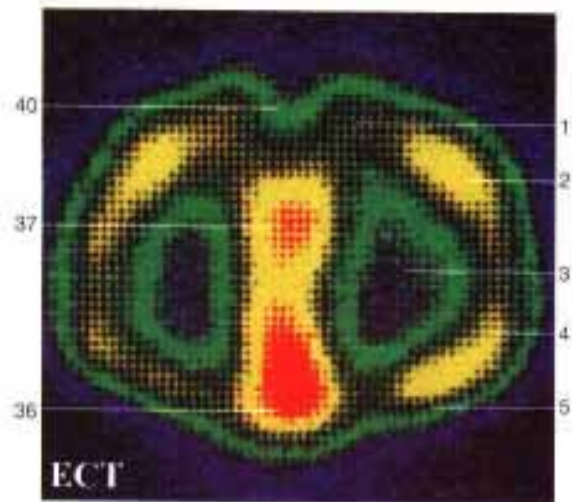
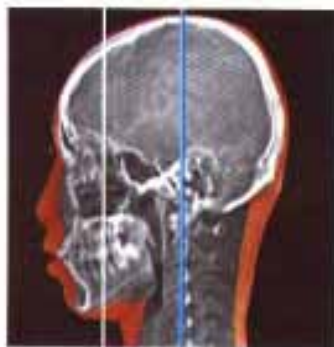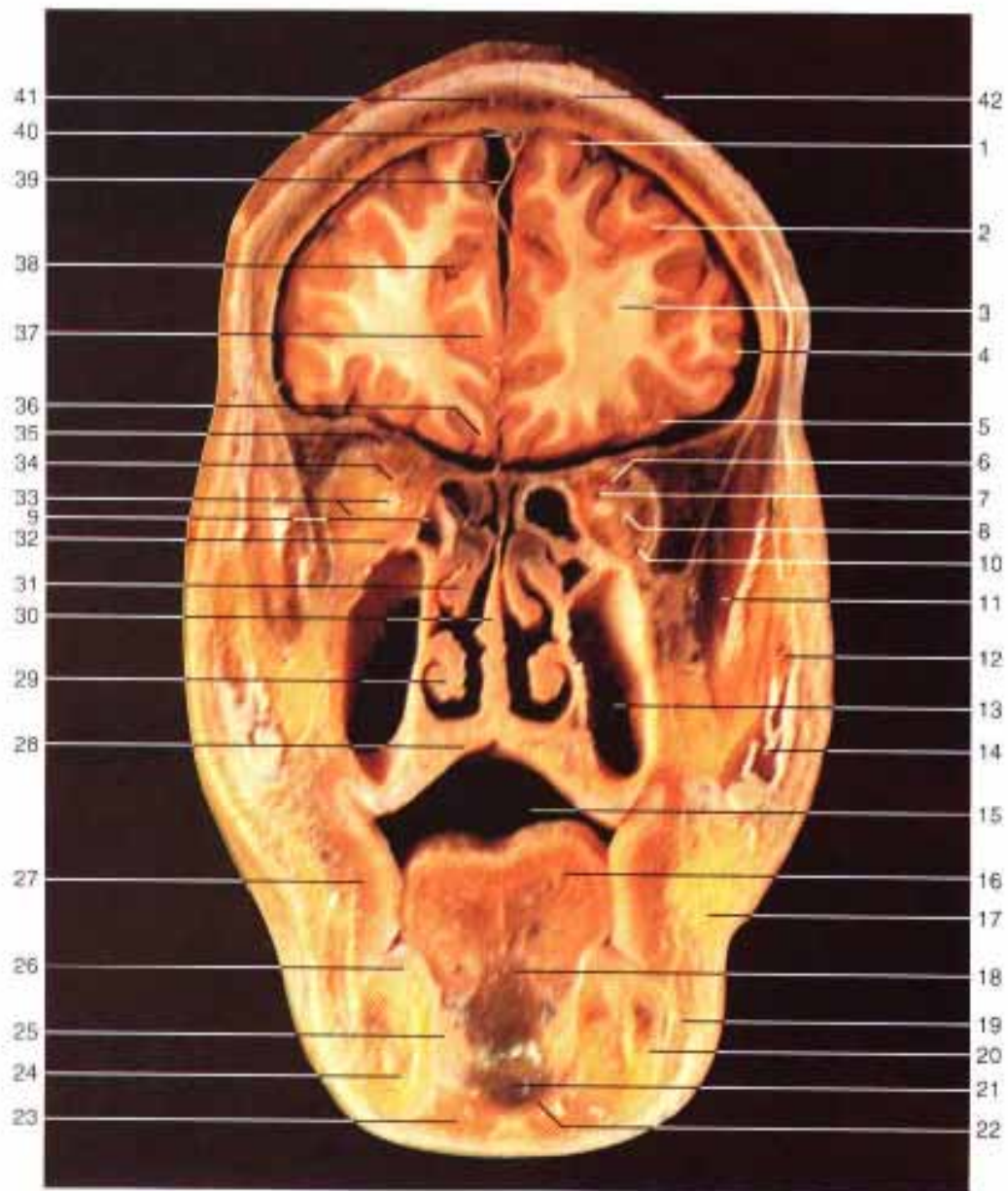
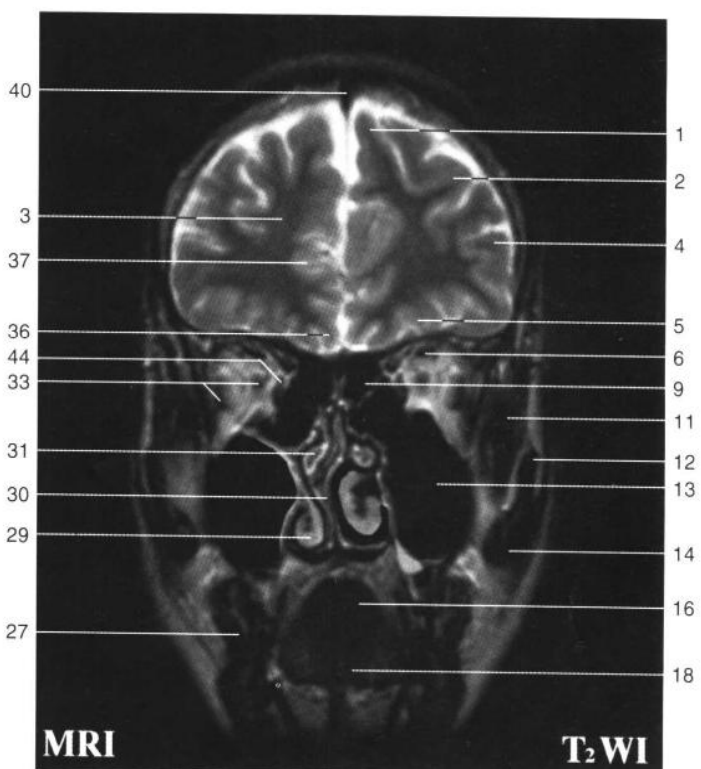
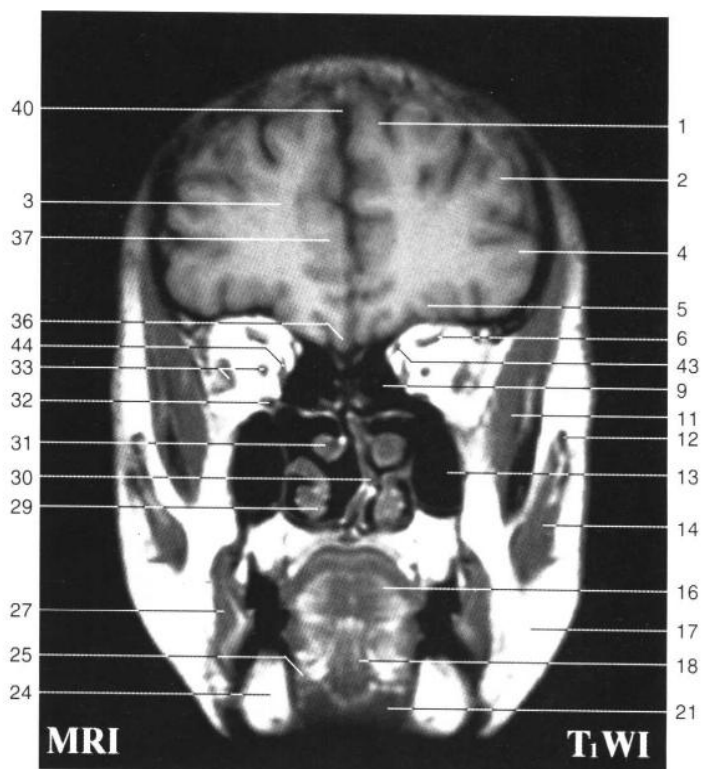


Fig. FC 3

Fig. FC 3

1. 额上回 superior frontal gyrus
2. 额中回 middle frontal gyrus
3. 辐射冠 corona radiata
4. 额下回 inferior frontal gyrus
5. 眶回 orbital gyrus
6. 上睑提肌及上直肌 levator palpebrae superioris and superior rectus
7. 眼动脉 ophthalmic a.
8. 动眼神经下支与睫状神经节 inferior branch of oculomotor n. and ciliary ganglion
9. 筛窦 ethmoidal sinuses
10. 眼下静脉 inferior ophthalmic v.
11. 颞肌 temporalis
12. 颧弓 zygomatic arch
13. 上颌窦 maxillary sinus
14. 咬肌 masseter
15. 口腔 oral cavity
16. 舌 tongue
17. 颊脂体 buccal fat pad
18. 颞舌肌 genioglossus
19. 降口角肌 depressor anguli oris
20. 下牙槽神经 inferior alveolar n.
21. 颞舌骨肌 geniohyoid
22. 下颌舌骨肌 myohyoid
23. 二腹肌前腹 anterior belly of digastric
24. 下颌骨 mandible
25. 舌下腺 sublingual gland
26. 下颌第二磨牙 2nd molar tooth of mandible
27. 颊肌 buccinator
28. 硬腭 hard palate
29. 下鼻甲 inferior nasal concha
30. 鼻中隔 nasal septum
31. 中鼻甲 middle nasal concha
32. 下直肌 inferior rectus
33. 视神经与外直肌 optic n. and lateral rectus
34. 动眼神经上支 superior branch of oculomotor n.
35. 额神经 frontal n.
36. 直回 gyrus rectus
37. 扣带回 cingulate gyrus
38. 大脑前动脉分支 branch of anterior cerebral a.
39. 大脑镰 cerebral falx
40. 上矢状窦 superior sagittal sinus
41. 额骨 frontal bone
42. 帽状腱膜 epicranial aponeurosis
43. 上斜肌 superior obliquus
44. 内直肌 medial rectus



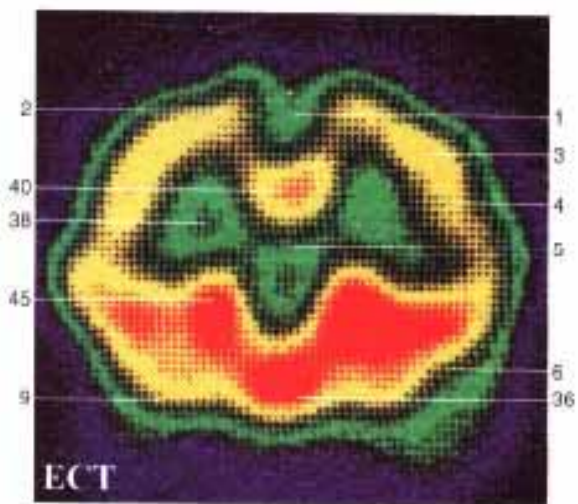
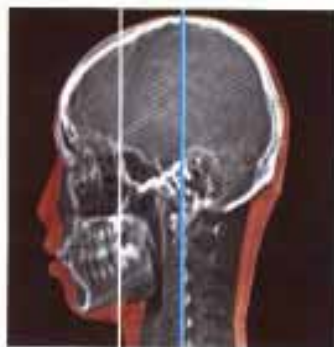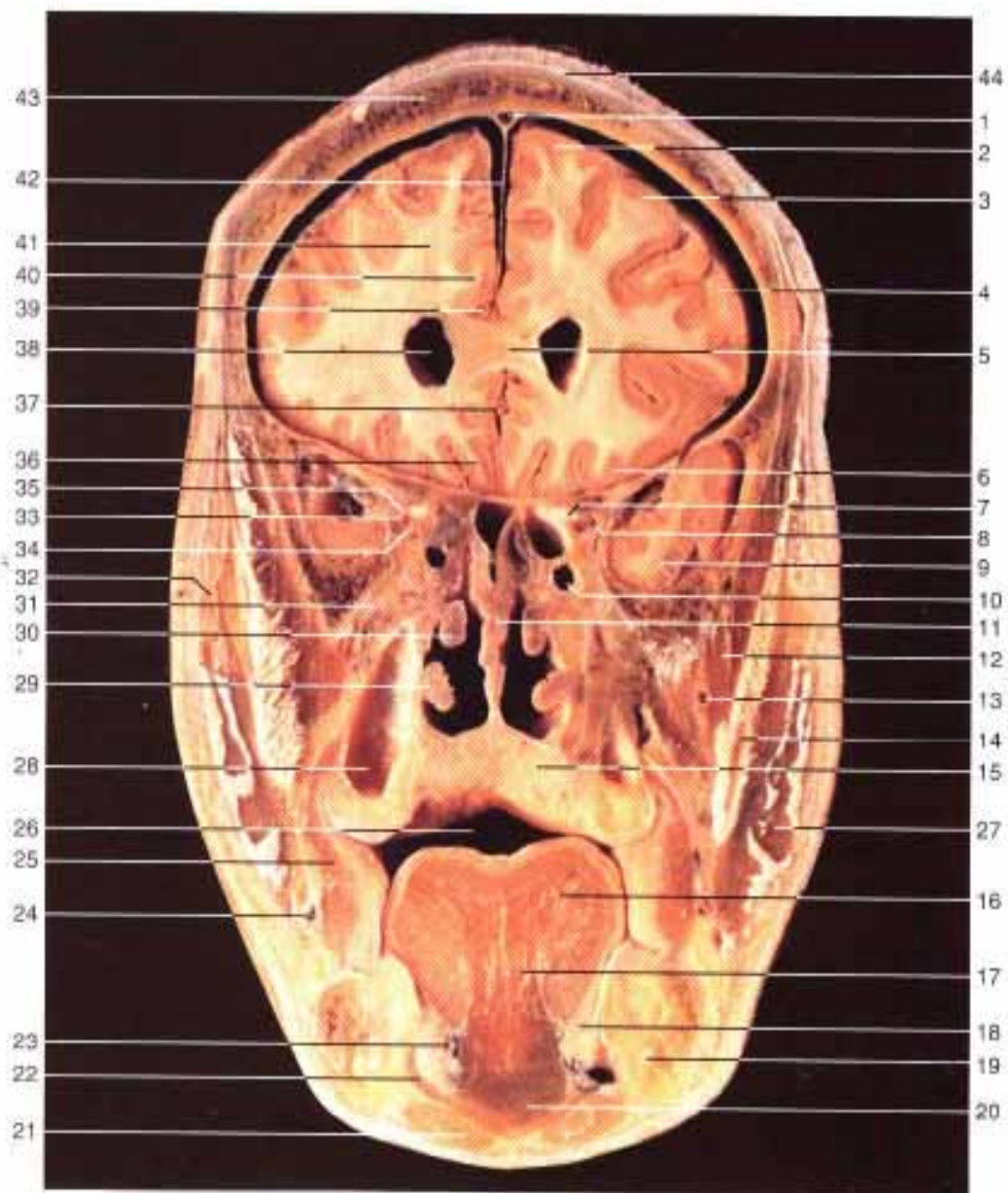
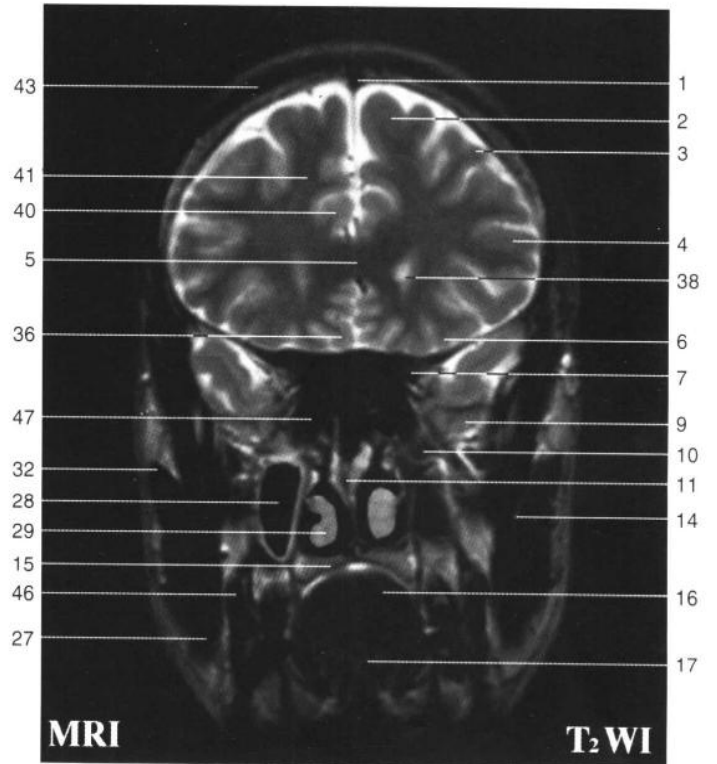
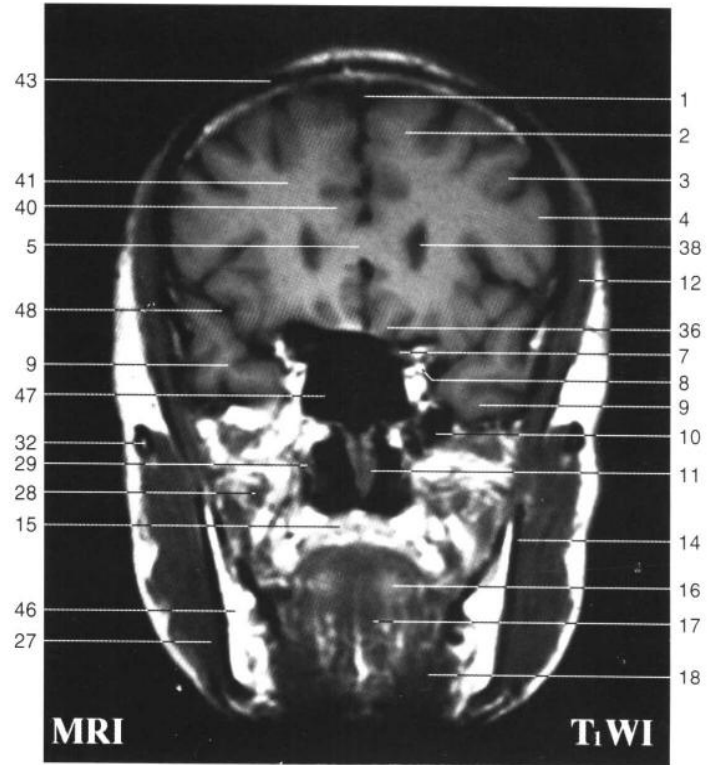


Fig. FC 4

Fig. FC 4

1. 上矢状窦 superior sagittal sinus
2. 额上回 superior frontal gyrus
3. 额中回 middle frontal gyrus
4. 额下回 inferior frontal gyrus
5. 胼胝体膝 genu of corpus callosum
6. 眶回 orbital gyrus
7. 视神经 optic n.
8. 眼动、静脉 ophthalmic a. and v.
9. 颞极 temporal pole
10. 筛窦 ethmoidal sinuses
11. 鼻中隔 nasal septum
12. 颞肌 temporalis
13. 上颌动脉 maxillary a.
14. 下颌骨冠突 coronoid process of mandible
15. 硬腭及腭腺 hard palate and palatine glands
16. 舌 tongue
17. 颞舌肌 genioglossus
18. 舌下腺 sublingual gland
19. 下牙槽神经 inferior alveolar n.
20. 颞舌骨肌 geniohyoid
21. 二腹肌前腹 anterior belly of digastric
22. 下颌舌骨肌 myohyoid
23. 舌下动、静脉 sublingual a. and v.
24. 面动、静脉 facial a. and v.
25. 颊肌 buccinator
26. 口腔 oral cavity
27. 咬肌 masseter
28. 上颌窦 maxillary sinus
29. 下鼻甲 inferior nasal concha
30. 中鼻甲 middle nasal concha
31. 上颌神经 maxillary n.
32. 颧弓 zygomatic arch
33. 展神经 abducent n.
34. 动眼神经 oculomotor n.
35. 眼神经 ophthalmic n.
36. 直回 gyrus rectus
37. 大脑前动脉 anterior cerebral a.
38. 侧脑室前角 anterior horn of lateral ventricle
39. 大脑前动脉 anterior cerebral a.
40. 扣带回 cingulate gyrus
41. 辐射冠(半卵圆中心) corona radiata (centrum semiovale)
42. 大脑镰 cerebral falx
43. 额骨 frontal bone
44. 帽状腱膜 epicranial aponeurosis
45. 尾状核头 head of caudate nucleus
46. 下颌骨 mandible
47. 蝶窦 sphenoidal sinus
48. 外侧沟 lateral sulcus



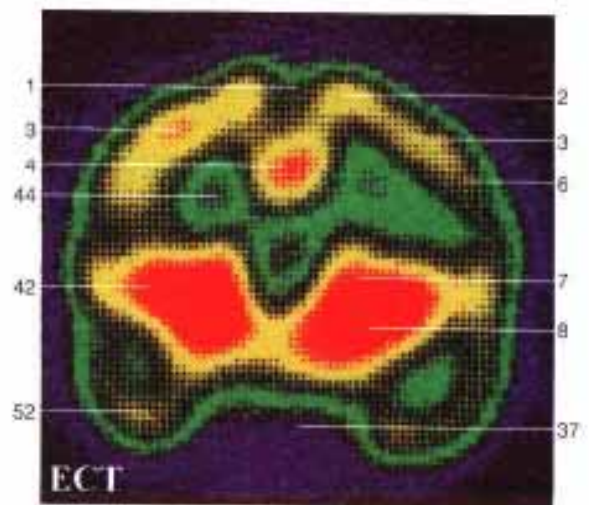
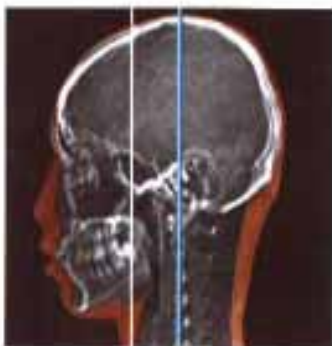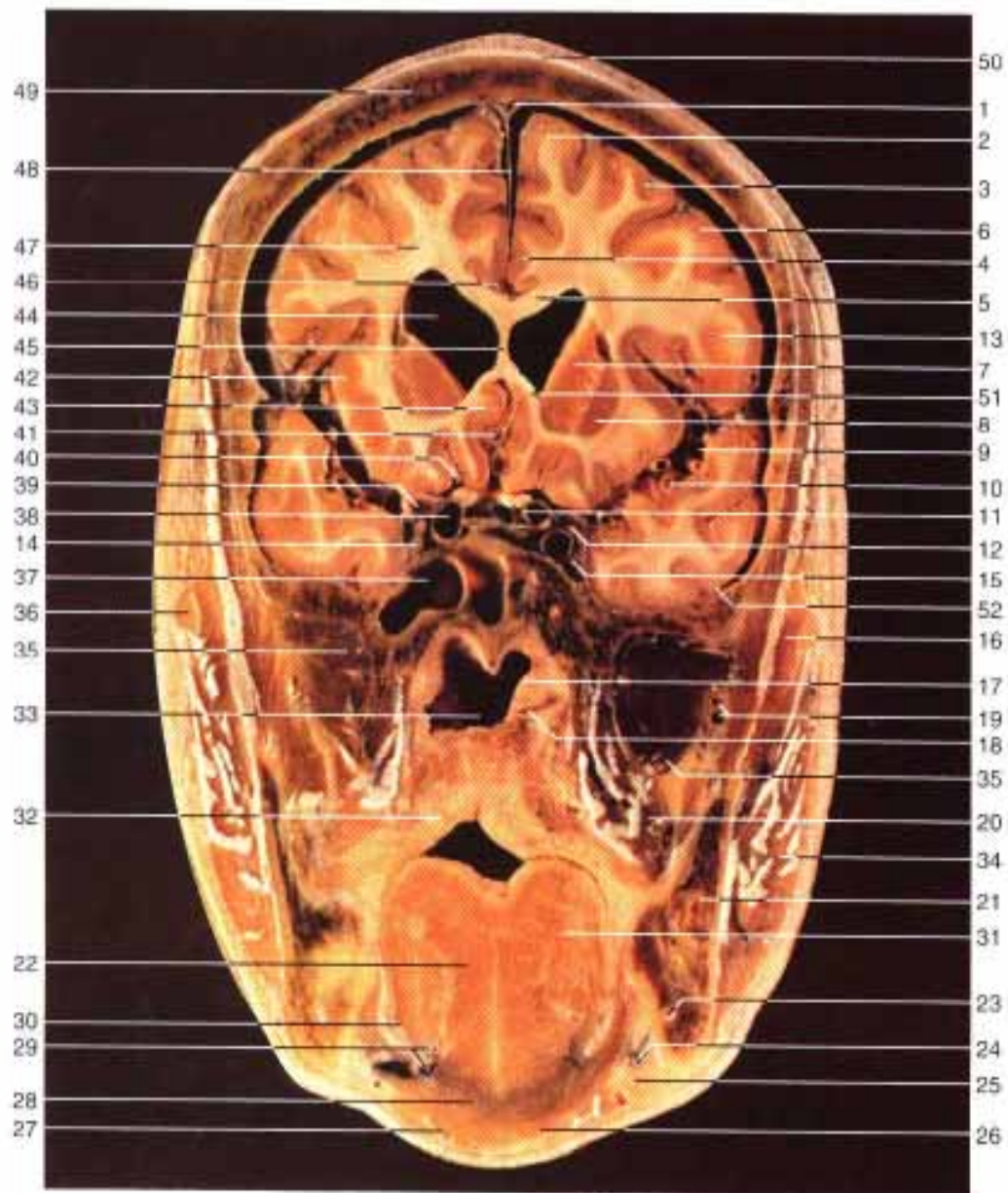
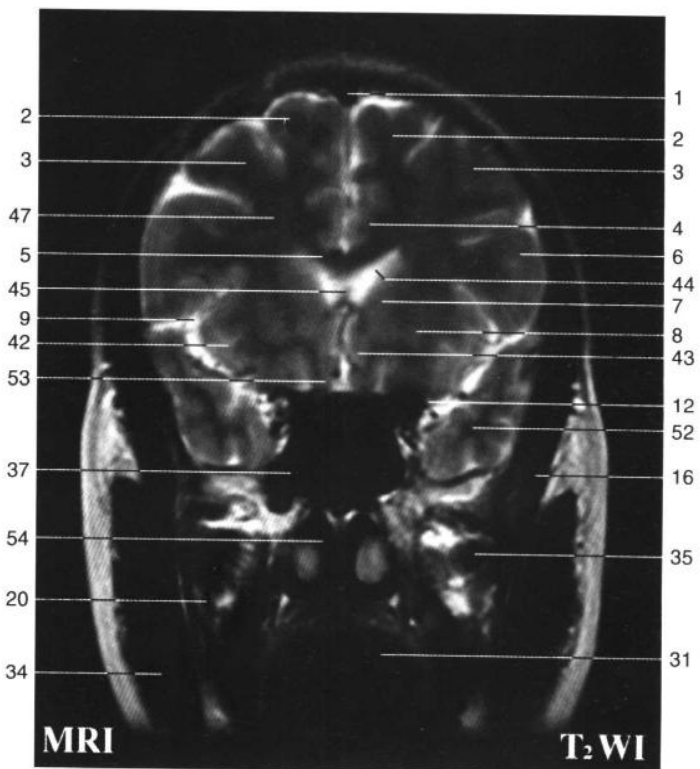
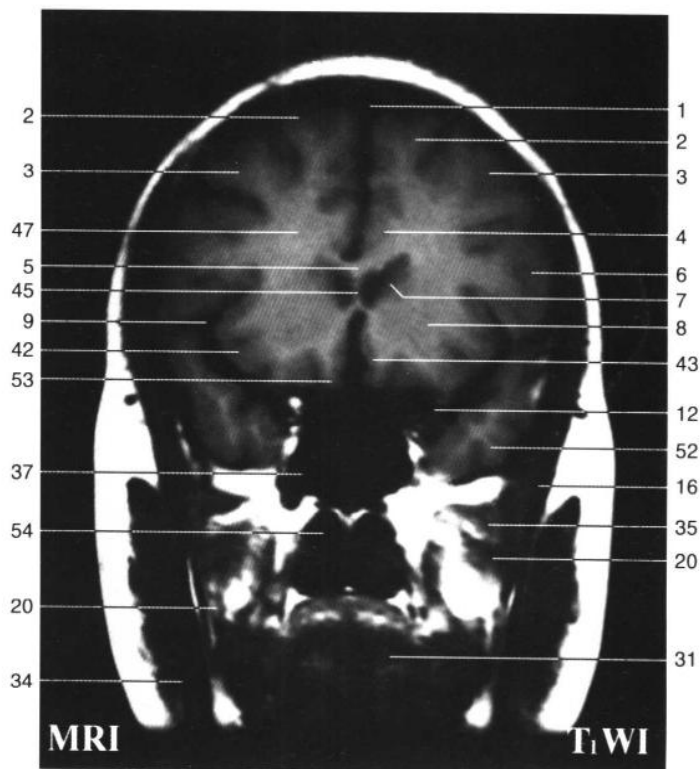


Fig. FC 5

Fig. FC 5

1. 上矢状窦 superior sagittal sinus
2. 额上回 superior frontal gyrus
3. 额中回 middle frontal gyrus
4. 扣带回 cingulate gyrus
5. 胼胝体 corpus callosum
6. 额下回 inferior frontal gyrus
7. 尾状核头 head of caudate nucleus
8. 壳 putamen
9. 大脑外侧窝池 cistern of lateral fossa of cerebrum
10. 大脑中动脉 middle cerebral a.
11. 视神经 optic n.
12. 动眼神经 oculomotor n.
13. 中央前回 precentral gyrus
14. 眼神经 ophthalmic n.
15. 展神经 abducent n.
16. 颞肌 temporalis
17. 咽鼓管圆枕 tubal torus
18. 咽鼓管咽口 pharyngeal opening of auditory tube
19. 上颌动、静脉 maxillary a. and v.
20. 翼内肌 medial pterygoid
21. 下颌骨 mandible
22. 颞舌肌 genioglossus
23. 下牙槽神经 inferior alveolar n.
24. 面动、静脉 facial a. and v.
25. 下颌下腺 submandibular gland
26. 下颌舌骨肌 myohyoid
27. 二腹肌前腹 anterior belly of digastric
28. 颞舌骨肌 geniohyoid
29. 舌下动、静脉 sublingual a. and v.
30. 舌下腺 sublingual gland
31. 舌肌 muscles of tongue
32. 软腭 soft palate
33. 咽腔 cavity of pharynx
34. 咬肌 masseter
35. 翼外肌 lateral pterygoid
36. 颧弓 zygomatic arch
37. 蝶窦 sphenoidal sinus
38. 颈内动脉 internal carotid a.
39. 前床突 anterior clinoid process
40. 嗅束 olfactory tract
41. 大脑前动脉 anterior cerebral a.
42. 岛叶 insular lobe
43. 终板旁回 paraterminal gyrus
44. 侧脑室前角 anterior horn of lateral ventricle
45. 透明隔 septum pellucidum
46. 大脑前动脉 anterior cerebral a.
47. 辐射冠(半卵圆中心) corona radiata (centrum semiovale)
48. 大脑镰 cerebral falx
49. 额骨 frontal bone
50. 帽状腱膜 epicranial aponeurosis
51. 胼胝体嘴 rostrum of corpus callosum
52. 颞叶 temporal lobe
53. 直回 gyrus rectus
54. 鼻腔 nasal cavity



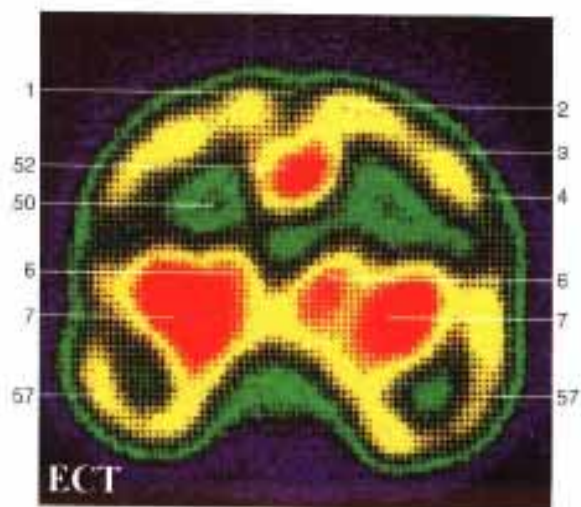
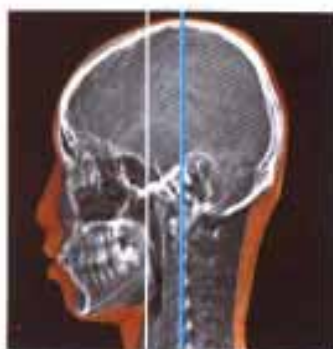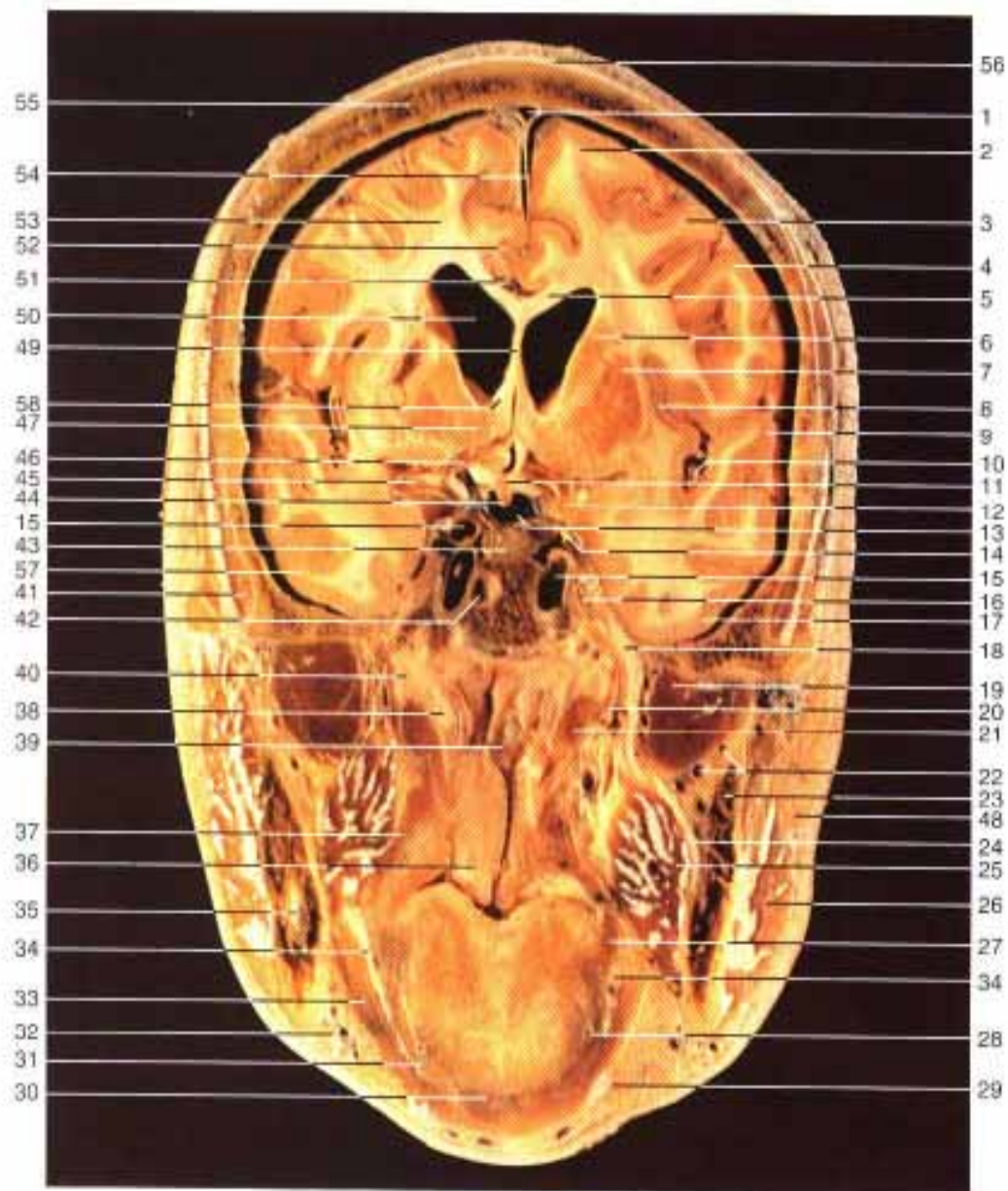
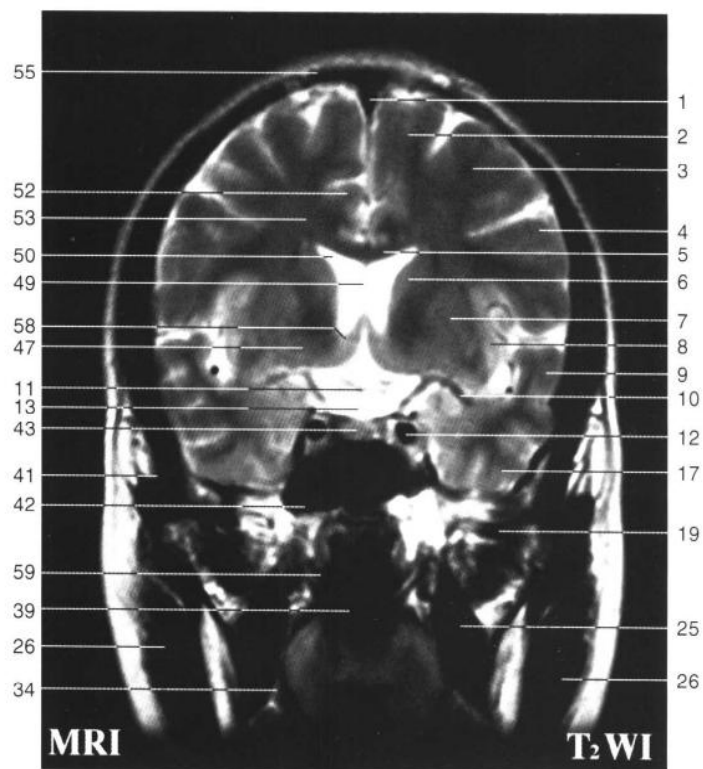
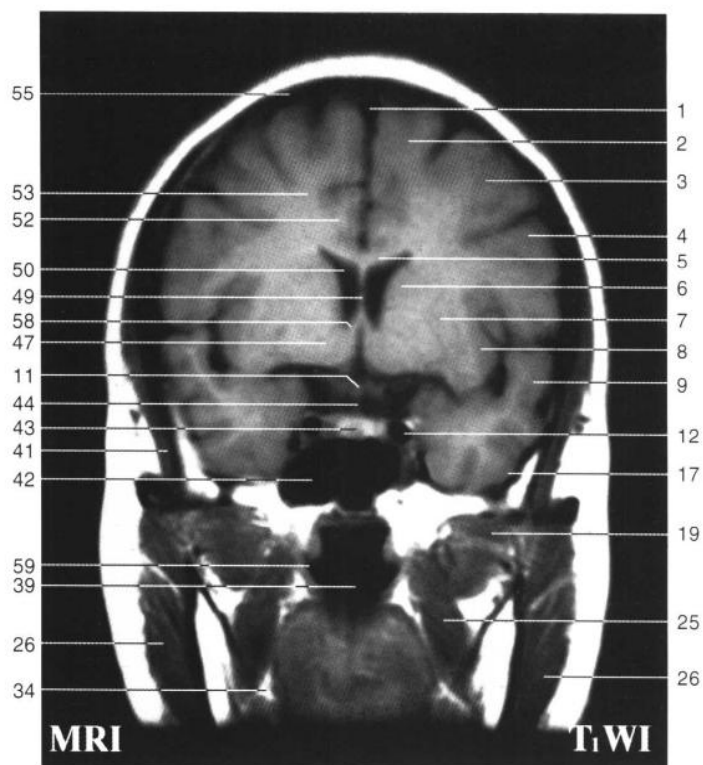


Fig. FC 8

Fig. FC 6

1. 上矢状窦 superior sagittal sinus
2. 额上回 superior frontal gyrus
3. 额中回 middle frontal gyrus
4. 中央前回 precentral gyrus
5. 胼胝体 corpus callosum
6. 尾状核头 head of caudate nucleus
7. 壳 putamen
8. 岛叶 insular lobe
9. 颞上回 superior temporal gyrus
10. 大脑中动脉 middle cerebral a.
11. 视交叉 optic chiasma
12. 颈内动脉 internal carotid a.
13. 鞍上池 supracellar cistern
14. 动眼神经 oculomotor n.
15. 颈内动脉与展神经 internal carotid a. and abducent n.
16. 三叉神经节 trigeminal ganglion
17. 颞下回 inferior temporal gyrus
18. 下颌神经 mandibular n.
19. 翼外肌 lateral pterygoid
20. 腭帆张肌 tensor veli palatini
21. 腭帆提肌 levator veli palatini
22. 上颌动、静脉 maxillary a. and v.
23. 下颌骨 mandible
24. 下牙槽神经 inferior alveolar n.
25. 翼内肌 medial pterygoid
26. 咬肌 masseter
27. 茎突舌肌 styloglossus
28. 舌动脉 lingual a.
29. 二腹肌 digastric
30. 颏舌骨肌 geniohyoid
31. 舌骨舌肌 hyoglossus
32. 下颌下腺 submandibular gland
33. 下颌舌骨肌 myohyoid
34. 舌神经 lingual n.
35. 下牙槽神经 inferior alveolar n.
36. 软腭 soft palate
37. 腭舌肌 palatoglossus
38. 咽鼓管软骨 cartilage of auditory tube
39. 咽腔 cavity of pharynx
40. 咽鼓管 auditory tube
41. 颞肌 temporalis
42. 蝶窦 sphenoidal sinus
43. 垂体 hypophysis
44. 漏斗 infundibulum
45. 大脑中动脉 middle cerebral a.
46. 大脑前动脉 anterior cerebral a.
47. 伏隔核 nucleus accumbens septi
48. 腮腺 parotid gland
49. 透明隔 septum pellucidum
50. 侧脑室中央部 central part of lateral ventricle
51. 大脑前动脉 anterior cerebral a.
52. 扣带回 cingulate gyrus
53. 辐射冠 corona radiata
54. 大脑镰 cerebral falx
55. 额骨 frontal bone
56. 帽状腱膜 epicranial aponeurosis
57. 颞叶 temporal lobe
58. 隔核 nuclei septi
59. 咽鼓管咽口 pharyngeal opening of auditory tube



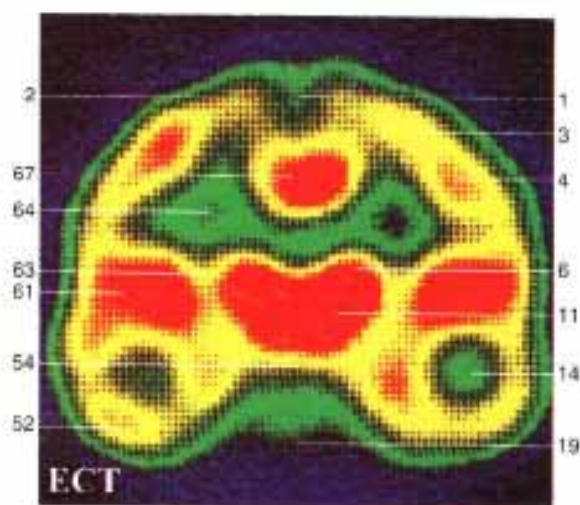
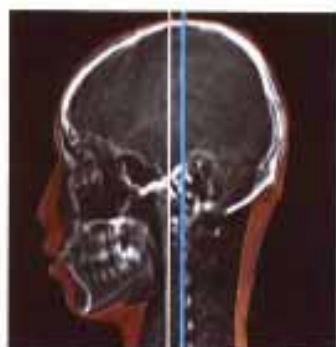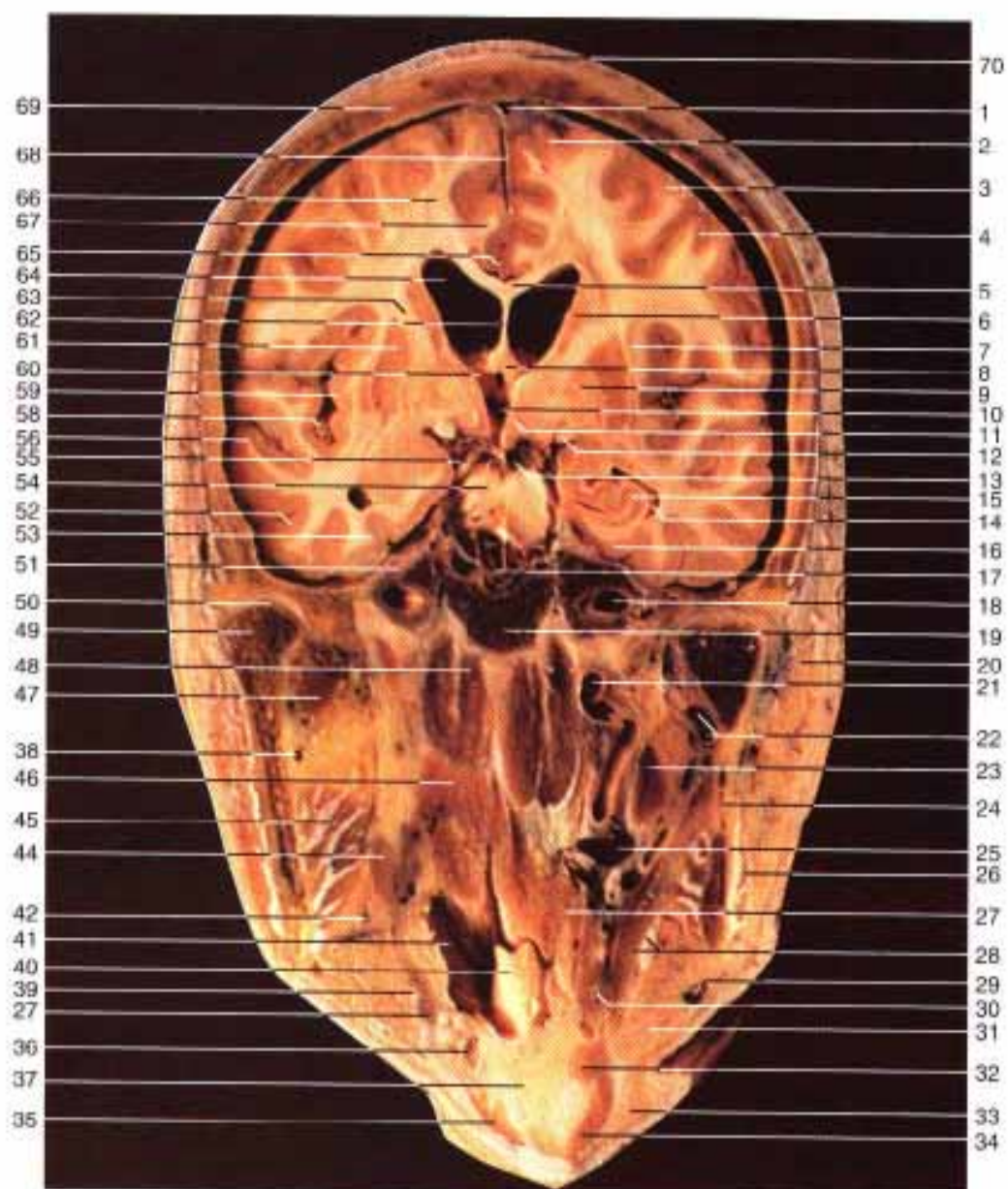
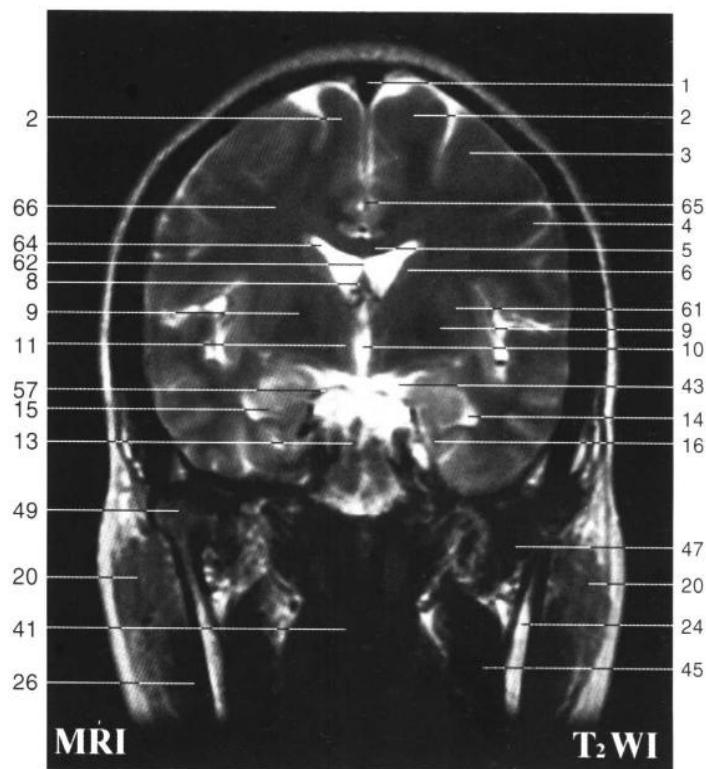
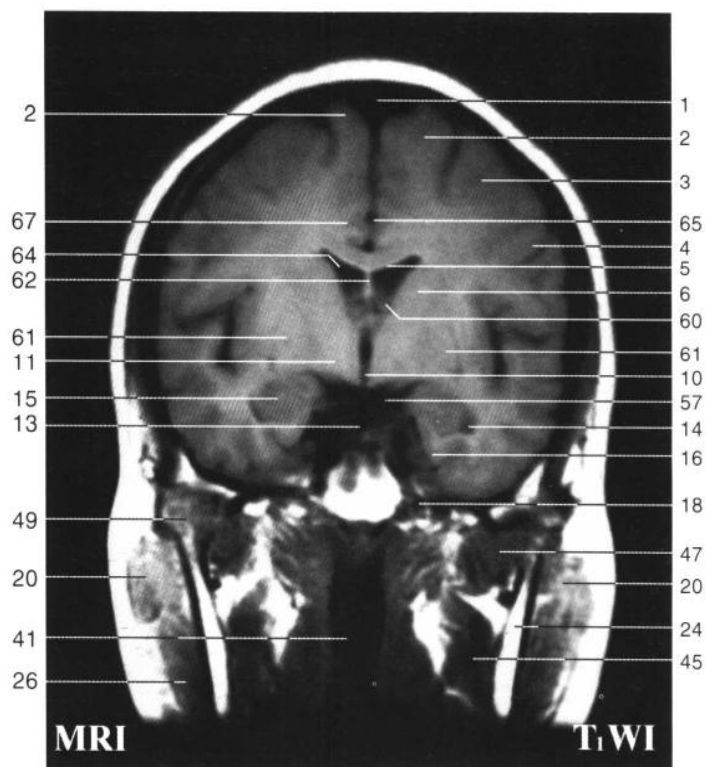


Fig. FC 7

Fig. FC 7

1. 上矢状窦 superior sagittal sinus
2. 额上回 superior frontal gyrus
3. 中央前回 precentral gyrus
4. 中央后回 postcentral gyrus
5. 胼胝体干 trunk of corpus callosum
6. 尾状核体 body of caudate nucleus
7. 屏状核 claustrum
8. 穹隆柱 column of fornix
9. 苍白球 globus pallidus
10. 第三脑室 third ventricle
11. 背侧丘脑 dorsal thalamus
12. 视束 optic tract
13. 基底动脉 basilar a.
14. 侧脑室下角 inferior horn of lateral ventricle
15. 海马 hippocampus
16. 海马旁回 parahippocampal gyrus
17. 基底动脉 basilar a.
18. 颈内动脉 internal carotid a.
19. 枕骨基底部 basilar part of occipital bone
20. 腮腺 parotid gland
21. 颈内动脉 internal carotid a.
22. 上颌动、静脉 maxillary a. and v.
23. 茎突舌肌 styloglossus
24. 下颌骨 mandible
25. 颈内静脉 internal jugular v.
26. 咬肌 masseter
27. 咽中缩肌 middle constrictor of pharynx
28. 二腹肌与茎突舌骨肌 digastric and stylohyoid
29. 面静脉 facial v.
30. 舌动脉 lingual a.
31. 下颌下腺 submandibular gland
32. 甲状舌骨肌 thyrohyoid
33. 颈阔肌 platysma
34. 胸骨舌骨肌 sternohyoid
35. 肩胛舌骨肌 omohyoid
36. 舌骨大角 greater horn of hyoid
37. 甲状软骨 thyroid cartilage
38. 上颌动脉 maxillary a.
39. 舌下神经 hypoglossal n.
40. 会厌 epiglottis
41. 咽腔 cavity of pharynx
42. 面动、静脉 facial a. and v.
43. 桥池 pontine cistern
44. 茎突咽肌 stylopharyngeus
45. 翼内肌 medial pterygoid
46. 咽后壁 posterior wall of pharynx
47. 翼外肌 lateral pterygoid
48. 头长肌 longus capitis
49. 下颌头 head of mandible
50. 下颌关节 mandibular joint
51. 三叉神经根 root of trigeminal n.
52. 颞下回 inferior temporal gyrus
53. 枕颞内侧回 medial occipitotemporal gyrus
54. 脑桥基底部 basilar part of pons
55. 动眼神经 oculomotor n.
56. 颞中回 middle temporal gyrus
57. 大脑后动脉 posterior cerebral a.
58. 大脑中动脉 middle cerebral a.
59. 岛叶 insular lobe
60. 室间孔 interventricular foramen
61. 壳 putamen
62. 透明隔 septum pellucidum
63. 内囊前肢 anterior limb of internal capsule
64. 侧脑室中央部 central part of lateral ventricle



65. 大脑前动脉 anterior cerebral a.
66. 辐射冠(半卵圆中心) corona radiata (centrum semiovale)
67. 扣带回 cingulate gyrus
68. 大脑镰 cerebral falx
69. 顶骨 parietal bone
70. 帽状腱膜 epicranial aponeurosis

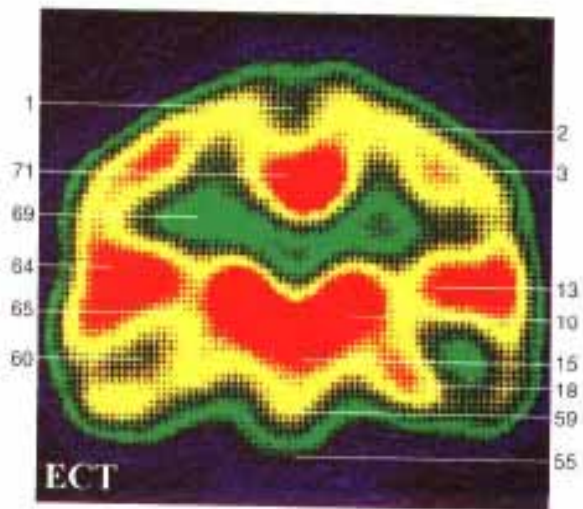
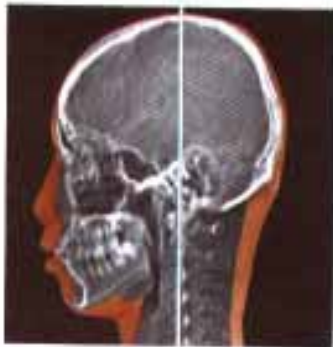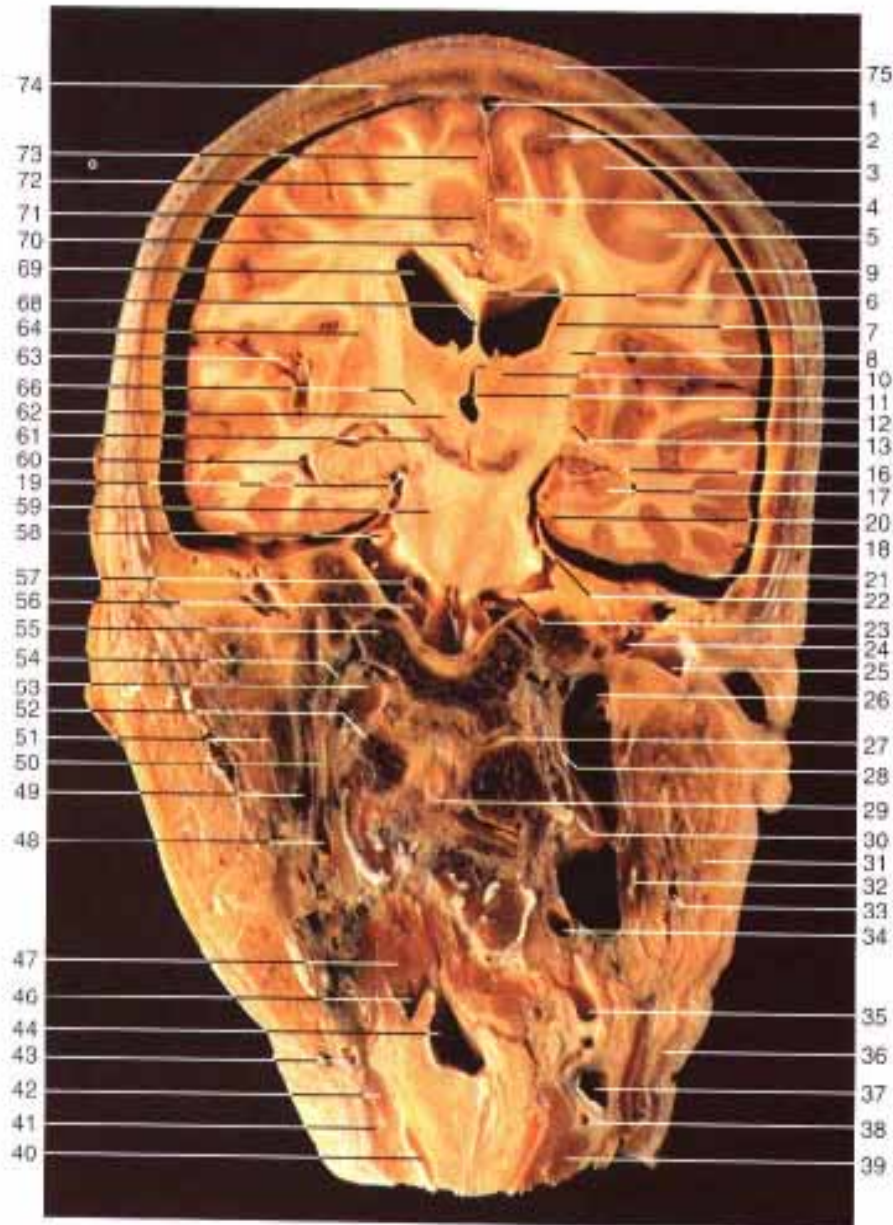
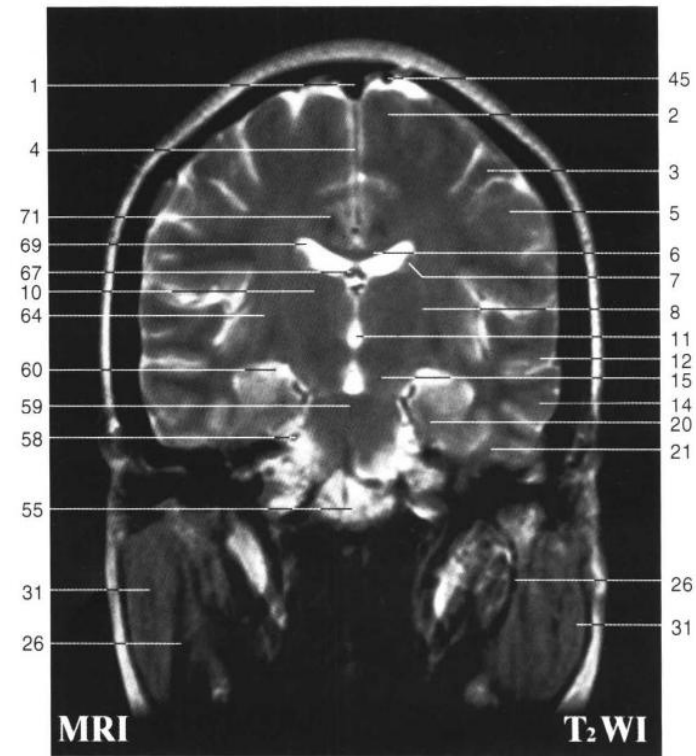
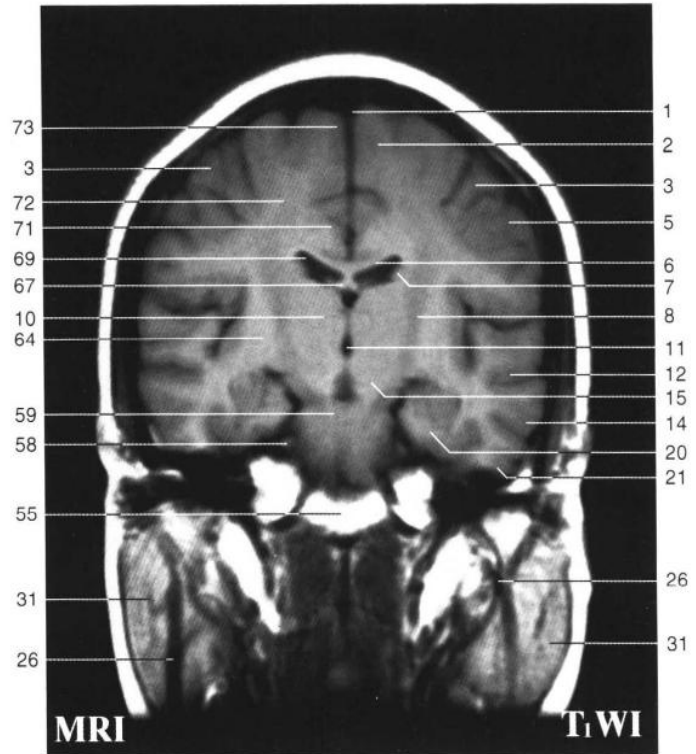


Fig. FC 8

Fig. FC 8

1. 上矢状窦 superior sagittal sinus
2. 中央前回 precentral gyrus
3. 中央后回 postcentral gyrus
4. 大脑镰 cerebral falx
5. 顶上小叶 superior parietal lobule
6. 胼胝体干 trunk of corpus callosum
7. 尾状核体 body of caudate nucleus
8. 内囊前肢 anterior limb of internal capsule
9. 缘上回 supramarginal gyrus
10. 背侧丘脑 dorsal thalamus
11. 第三脑室 third ventricle
12. 颞上回 superior temporal gyrus
13. 苍白球 globus pallidus
14. 颞中回 middle temporal gyrus
15. 中脑 midbrain
16. 尾状核尾 tail of caudate nucleus
17. 海马 hippocampus
18. 颞下回 inferior temporal gyrus
19. 大脑后动脉 posterior cerebral a.
20. 海马旁回 parahippocampal gyrus
21. 枕颞外侧回 lateral occipitotemporal gyrus
22. 小脑幕 tentorium of cerebellum
23. 面神经 facial n.
24. 鼓室 tympanic cavity
25. 外耳道 external acoustic meatus
26. 颈内静脉 internal jugular v.
27. 寰枕关节 atlantooccipital joint
28. 迷走神经 vagus n.
29. 齿突 dens
30. 舌下神经 hypoglossal n.
31. 腮腺 parotid gland
32. 二腹肌后腹 posterior belly of digastric
33. 下颌后静脉 retromandibular v.
34. 颈内动脉 internal carotid a.
35. 颈外动脉 external carotid a.
36. 颈阔肌 platysma
37. 面静脉 facial v.
38. 面动脉 facial a.
39. 胸锁乳突肌 sternocleidomastoid
40. 甲状软骨右板 right lamina of thyroid cartilage
41. 肩胛舌骨肌 omohyoid
42. 甲状舌骨肌 thyrohyoid
43. 面动、静脉 facial a. and v.
44. 喉前庭 laryngeal vestibule
45. 外侧陷窝 lateral lacunae
46. 咽腔 pharyngeal cavity
47. 咽后壁 posterior wall of pharynx
48. 颈内动脉 internal carotid a.
49. 颈内静脉 internal jugular v.
50. 迷走神经 vagus n.
51. 二腹肌后腹及茎突 posterior belly of digastric and styloid process
52. 寰椎侧块 lateral mass of atlas
53. 头前直肌 rectus capitis anterior
54. 舌咽神经 glossopharyngeal n.
55. 枕骨基底部 basilar part of occipital bone
56. 椎动脉 vertebral a.
57. 小脑下前动脉 anterior inferior cerebellar a.
58. 三叉神经根 root of trigeminal n.
59. 脑桥 pons
60. 侧脑室下角 inferior horn of lateral ventricle
61. 黑质 substantia nigra
62. 红核 red nucleus
63. 大脑中动脉 middle cerebral a.
64. 壳 putamen
65. 内囊后肢 posterior limb of internal capsule
66. 底丘脑核 subthalamic nucleus
67. 穹隆体 body of fornix
68. 透明隔 septum pellucidum



69. 侧脑室中央部 central part of lateral ventricle
70. 大脑前动脉 anterior cerebral a.
71. 扣带回 cingulate gyrus
72. 辐射冠 corona radiata
73. 中央旁小叶 paracentral lobule
74. 顶骨 parietal bone
75. 帽状腱膜 epicranial aponeurosis

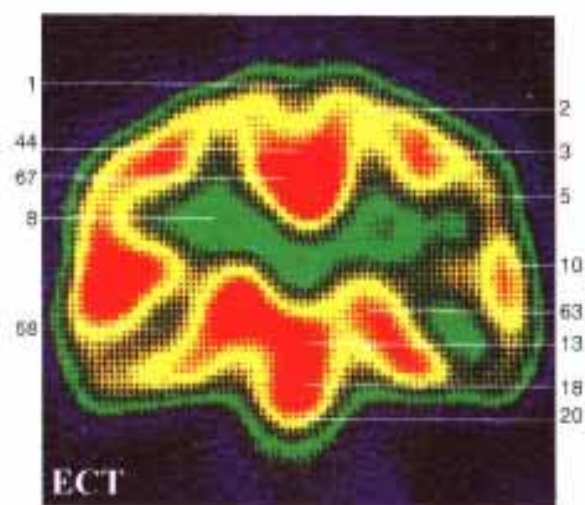
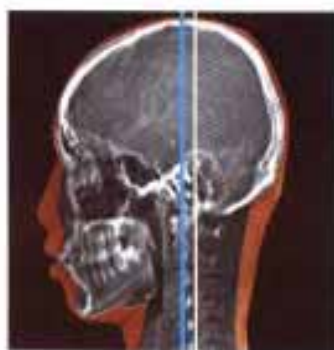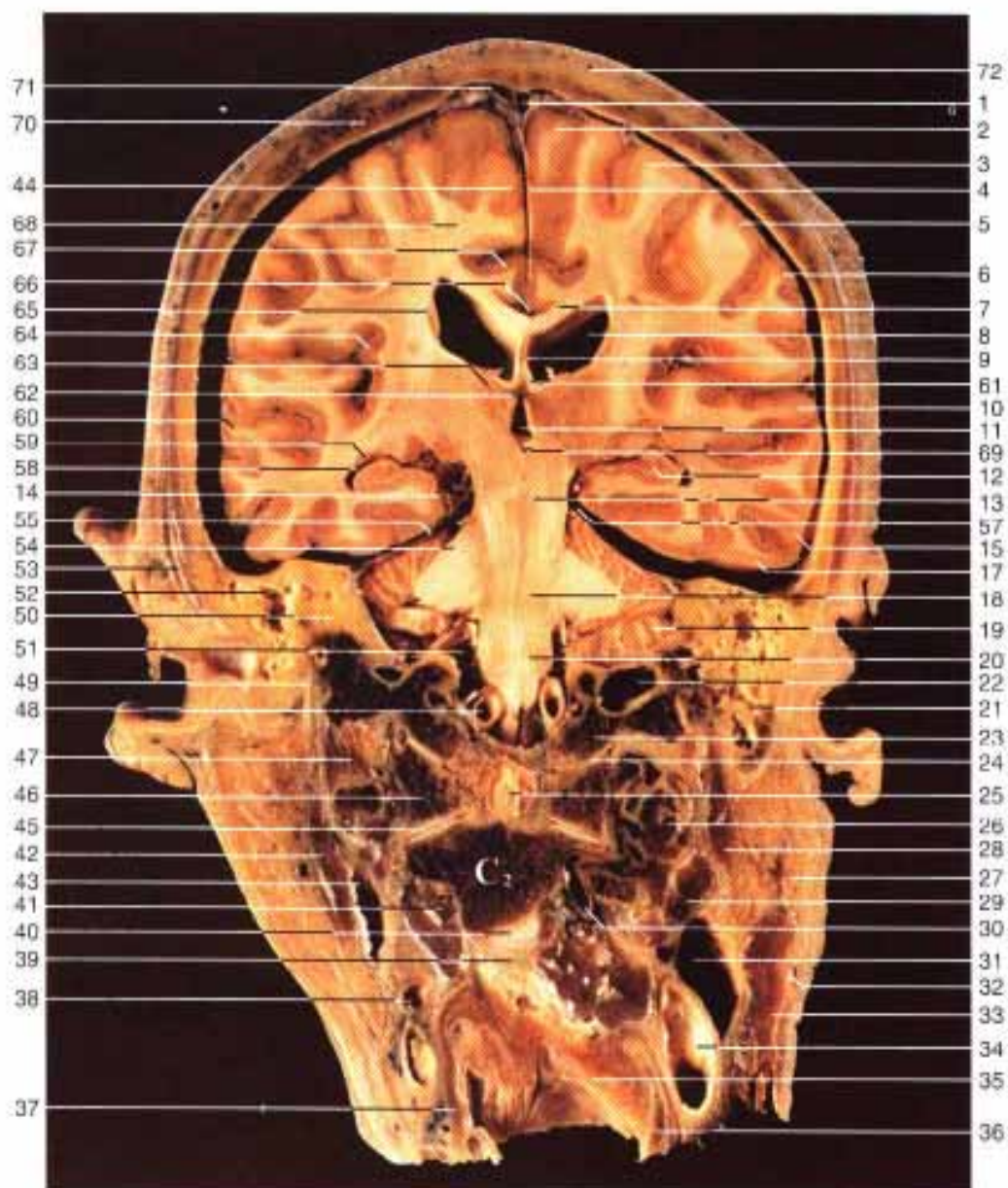
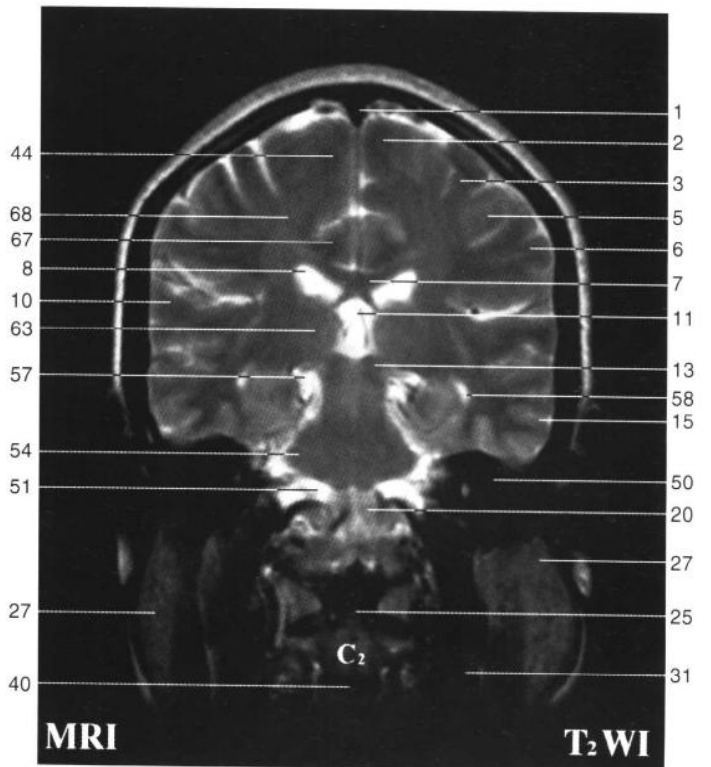
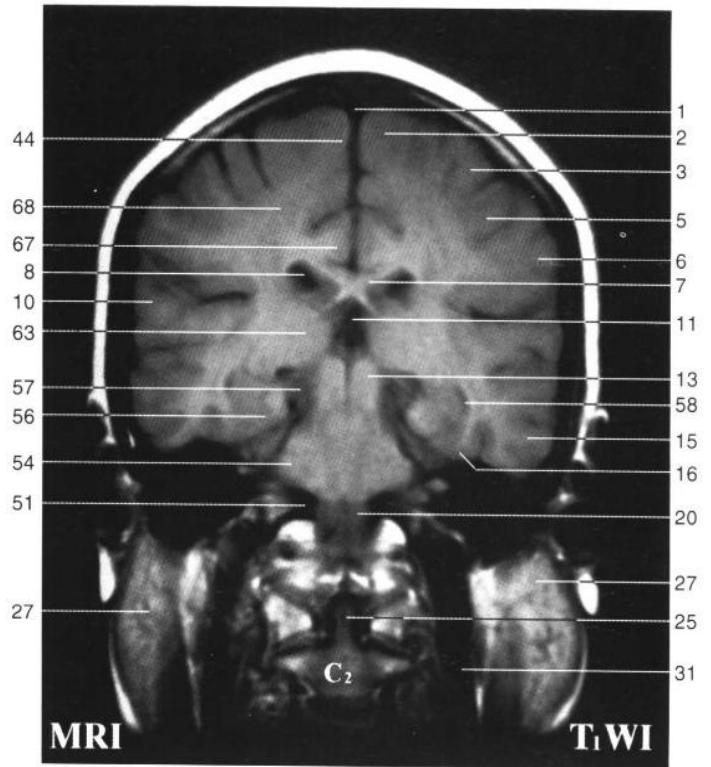


Fig. FC 9

Fig. FC 9

1. 上矢状窦 superior sagittal sinus
2. 中央前回 precentral gyrus
3. 中央后回 postcentral gyrus
4. 大脑镰 cerebral falx
5. 顶上小叶 superior parietal lobule
6. 缘上回 supramarginal gyrus
7. 胼胝体干 trunk of corpus callosum
8. 侧脑室中央部 central part of lateral ventricle
9. 透明隔及透明隔腔 septum pellucidum and cavity of septum pellucidum
10. 颞上回 superior temporal gyrus
11. 第三脑室 third ventricle
12. 海马 hippocampus
13. 大脑脚 cerebral peduncle
14. 大脑后动脉 posterior cerebral a.
15. 颞下回 inferior temporal gyrus
16. 枕颞内侧回 medial occipitotemporal gyrus
17. 枕颞外侧回 lateral occipitotemporal gyrus
18. 脑桥被盖部 tegmentum of pons
19. 小脑半球 cerebellar hemisphere
20. 延髓 medulla oblongata
21. 乳突小房 mastoid cells
22. 颈静脉窝 jugular fossa
23. 枕骨基底部 basilar part of occipital bone
24. 寰枕关节 atlantooccipital joint
25. 齿突 dens
26. 头下斜肌 obliquus capitis inferior
27. 腮腺 parotid gland
28. 茎突舌骨肌 stylohyoid
29. 肩胛提肌 levator scapulae
30. 椎动脉 vertebral a.
31. 颈内静脉 internal jugular v.
32. 颈外静脉 external jugular v.
33. 胸锁乳突肌 sternocleidomastoid
34. 颈总动脉 common carotid a.
35. 咽后壁 posterior wall of pharynx
36. 舌骨大角 greater horn of hyoid bone
37. 咽中缩肌 middle constrictor of pharynx
38. 颈内动脉 internal carotid a.
39. 前纵韧带 anterior longitudinal ligament
40. 2,3 颈椎间盘 intervertebral disc (C₂ - C₃)
41. 头长肌 longus capitis
42. 二腹肌后腹及茎突舌骨肌 posterior belly of digastric and stylohyoid
43. 颈内静脉 internal jugular v.
44. 中央旁小叶 paracentral lobule
45. 寰枢外侧关节 lateral atlantoaxial joint
46. 寰椎侧块 lateral mass of atlas
47. 头上斜肌 obliquus capitis superior
48. 椎动脉 vertebral a.
49. 面神经 facial n.
50. 颞骨岩部 petrous part of temporal bone
51. 脑桥小脑三角池 cistern of pontocerebellar trigone
52. 乳突窦 mastoid antrum
53. 颞肌 temporalis
54. 小脑中脚 middle cerebellar peduncle
55. 小脑幕 tentorium of cerebellum
56. 海马旁回 parahippocampal gyrus
57. 环池 cisterna ambiens
58. 侧脑室下角 inferior horn of lateral ventricle
59. 尾状核尾 tail of caudate nucleus
60. 颞中回 middle temporal gyrus
61. 穹窿体 body of fornix
62. 大脑内静脉 internal cerebral v.
63. 背侧丘脑 dorsal thalamus
64. 岛叶 insular lobe
65. 尾状核体 body of caudate nucleus
66. 大脑前动脉 anterior cerebral a.



67. 扣带回 cingulate gyrus
68. 辐射冠 corona radiata
69. 后连合 posterior commissure
70. 顶骨 parietal bone
71. 外侧陷窝 lateral lacunae
72. 帽状腱膜 epicranial aponeurosis

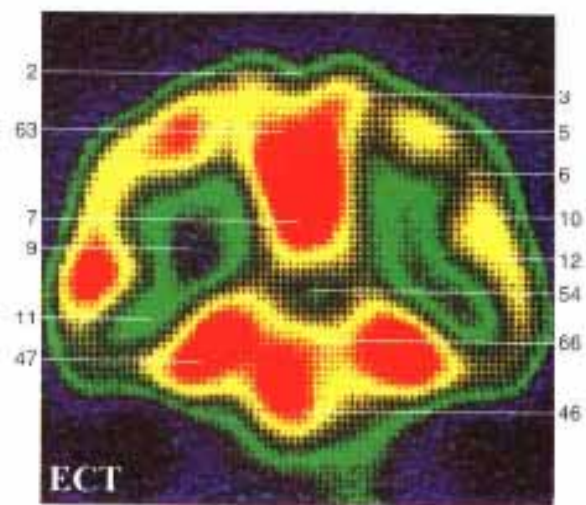
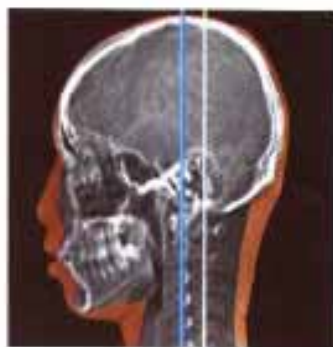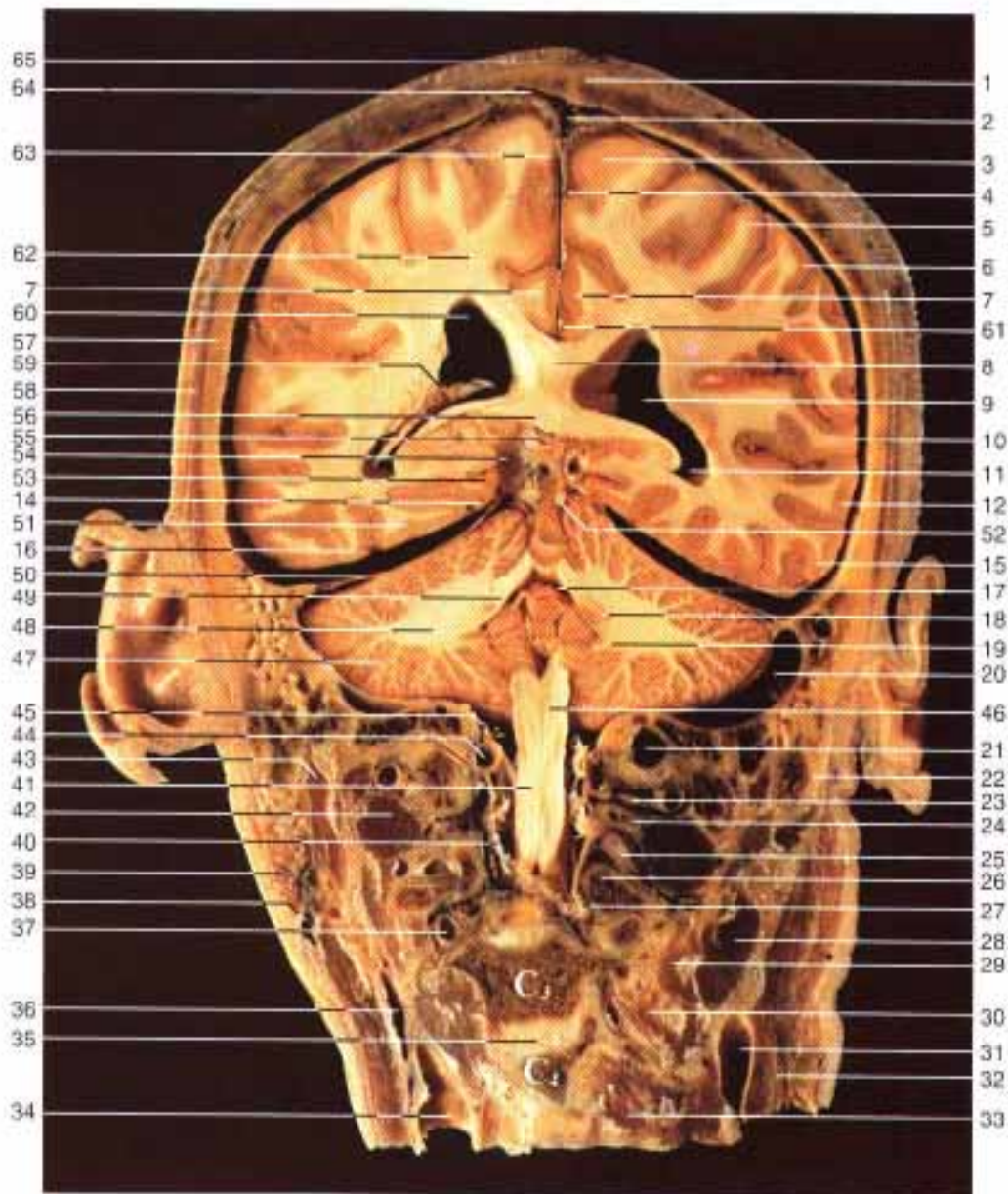
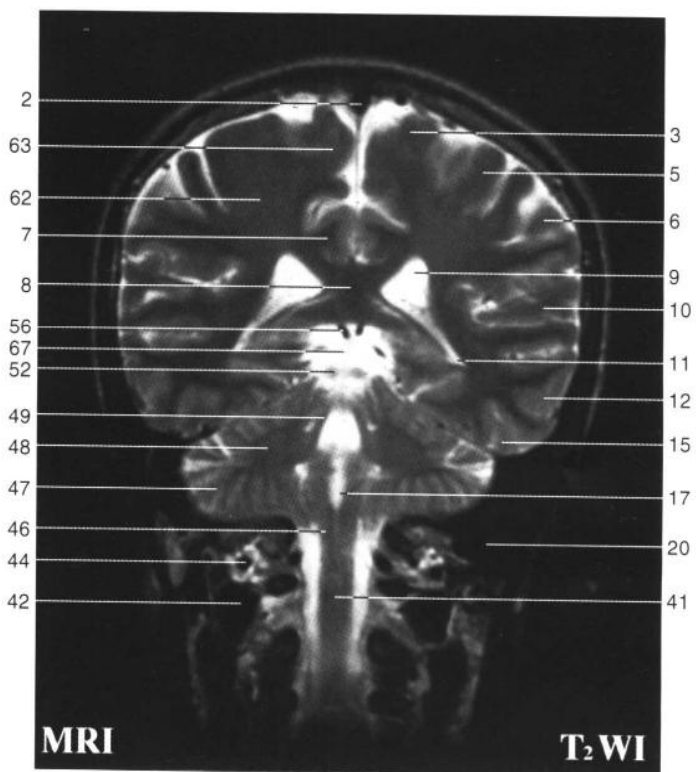
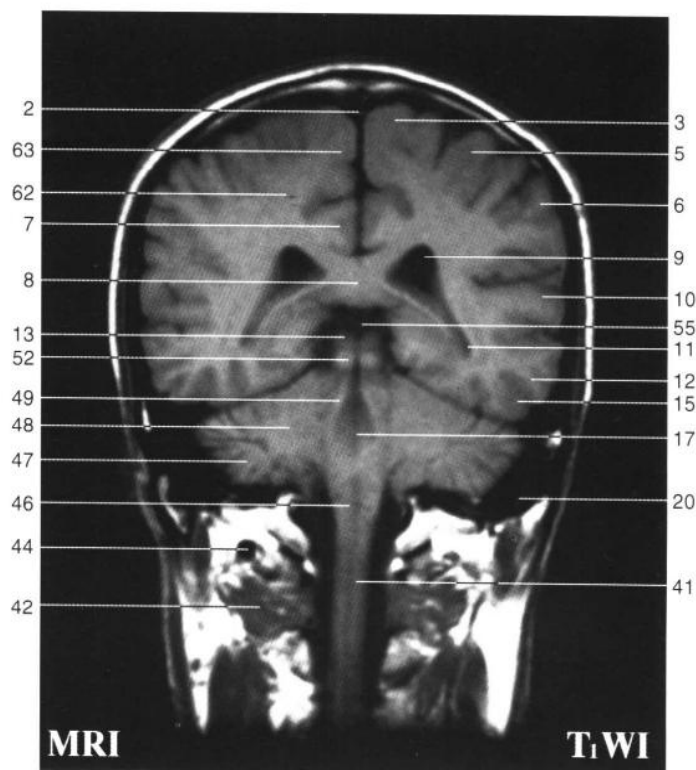


Fig. FC 10

Fig. FC 10

1. 顶骨 parietal bone
2. 上矢状窦 superior sagittal sinus
3. 中央后回 postcentral gyrus
4. 大脑镰 cerebral falx
5. 顶上小叶 superior parietal lobule
6. 缘上回 supramarginal gyrus
7. 扣带回 cingulate gyrus
8. 胼胝体压部 splenium of corpus callosum
9. 侧脑室三角 trigone of lateral ventricle
10. 颞上回 superior temporal gyrus
11. 侧脑室下角 inferior horn of lateral ventricle
12. 颞中回 middle temporal gyrus
13. 上丘 superior colliculus
14. 大脑后动脉 posterior cerebral a.
15. 颞下回 inferior temporal gyrus
16. 枕颞外侧回 lateral occipitotemporal gyrus
17. 第四脑室 fourth ventricle
18. 齿状核 dentate nucleus
19. 小脑下脚 inferior cerebellar peduncle
20. 乙状窦 sigmoid sinus
21. 颈静脉窝 jugular fossa
22. 乳突 mastoid process
23. 第1颈神经 1st cervical n.
24. 寰椎横突 transverse process of atlas
25. 第2颈神经 2nd cervical n.
26. 枢椎横突 transverse process of axis
27. 第3颈神经 3rd cervical n.
28. 肩胛提肌 levator scapulae
29. 中斜角肌 scalenus medius
30. 前斜角肌 scalenus anterior
31. 颈内静脉 internal jugular v.
32. 胸锁乳突肌 sternocleidomastoid
33. 头长肌 longus capitis
34. 颈总动脉 common carotid a.
35. 3,4 颈椎间盘 intervertebral disc (C₃ - C₄)
36. 颈内静脉 internal jugular v.
37. 椎动脉 vertebral a.
38. 颈外静脉 external jugular v.
39. 腮腺 parotid gland
40. 硬脊膜 spinal dura mater
41. 脊髓 spinal cord
42. 头下斜肌 obliquus capitis inferior
43. 二腹肌 digastric
44. 椎动脉 vertebral a.
45. 副神经 accessory n.
46. 延髓 medulla oblongata
47. 小脑半球 cerebellar hemisphere
48. 小脑中脚 middle cerebellar peduncle
49. 小脑上脚 superior cerebellar peduncle
50. 小脑幕 tentorium of cerebellum
51. 枕颞内侧回 medial occipitotemporal gyrus
52. 下丘 inferior colliculus
53. 海马旁回 parahippocampal gyrus
54. 环池 cisterna ambiens
55. 松果体 pineal body
56. 大脑内静脉 internal cerebral v.
57. 颞骨 temporal bone
58. 颞肌 temporalis
59. 侧脑室脉络丛 choroid plexus of lateral ventricle
60. 侧脑室后角 posterior horn of lateral ventricle
61. 大脑前动脉 anterior cerebral a.



62. 辐射冠 corona radiata
63. 中央旁小叶 paracentral lobule
64. 外侧陷窝 lateral lacunae
65. 帽状腱膜 epicranial aponeurosis
66. 中脑 midbrain
67. 四叠体池 quadrigeminal cistern

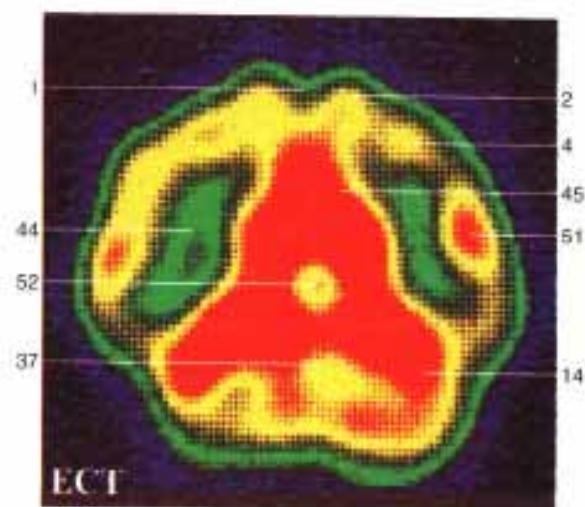
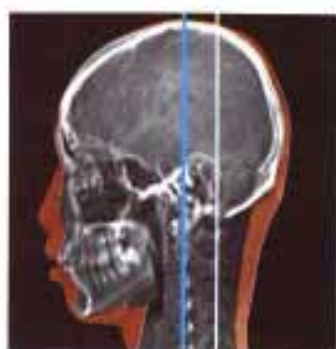
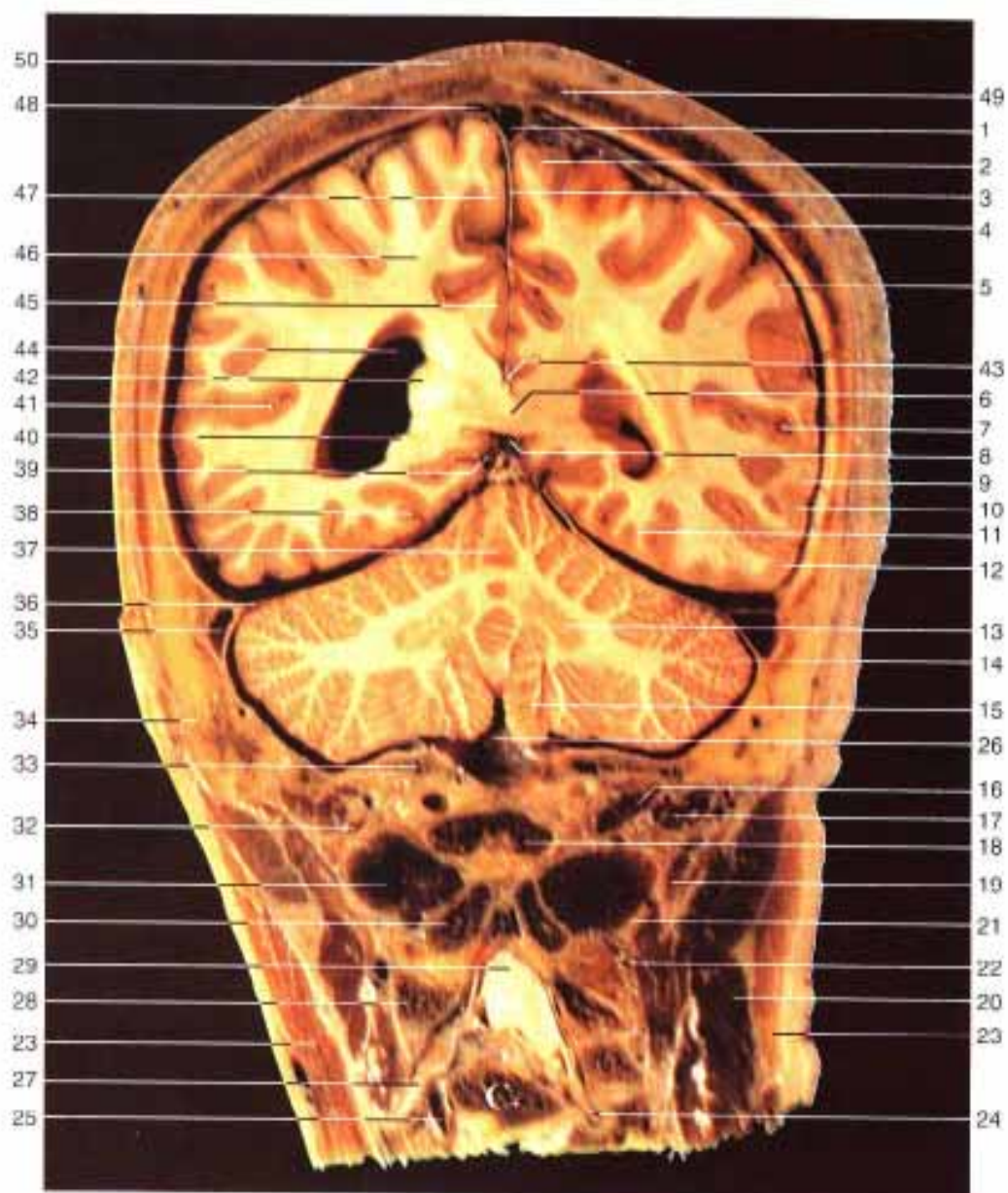
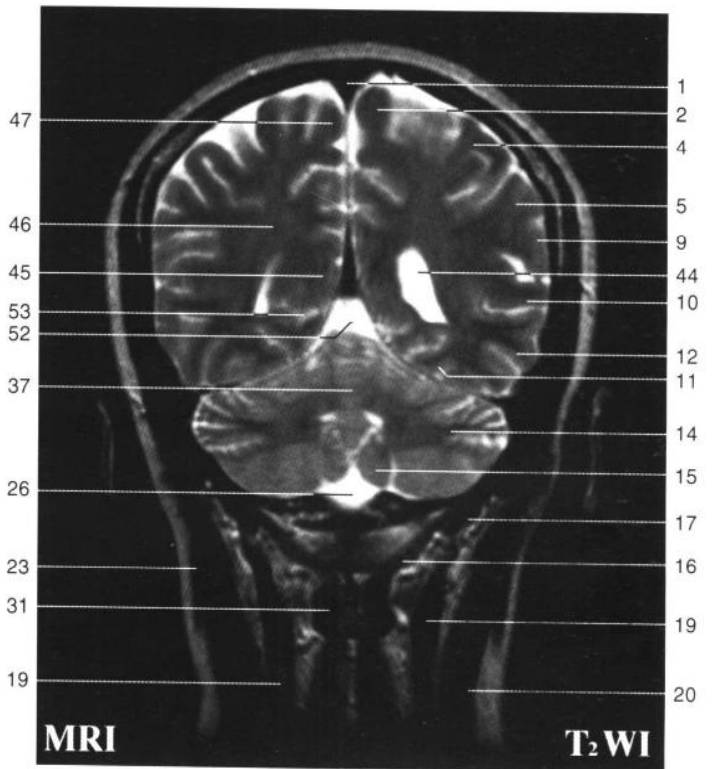
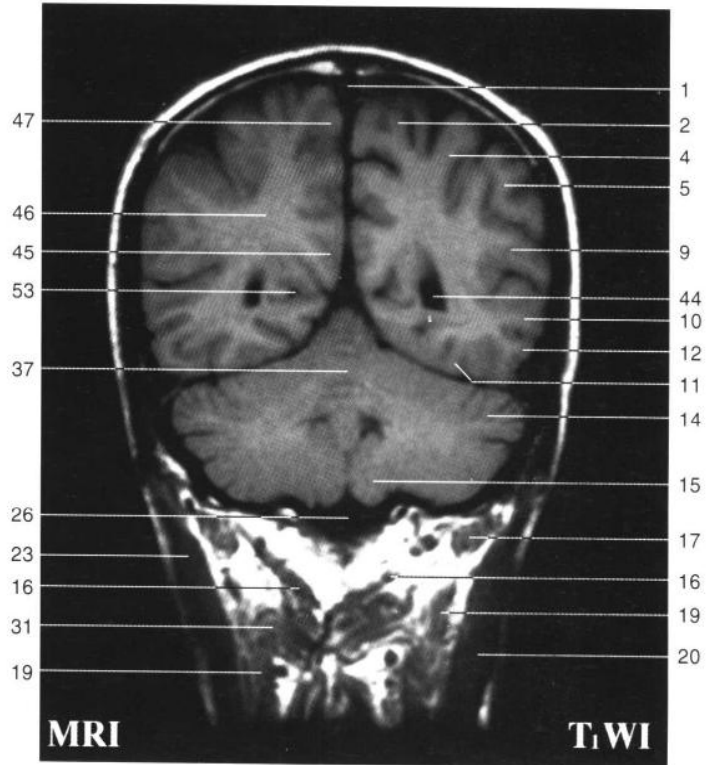


Fig. FC 11

Fig. FC 11

1. 上矢状窦 superior sagittal sinus
2. 中央后回 postcentral gyrus
3. 大脑镰 cerebral falx
4. 顶上小叶 superior parietal lobule
5. 缘上回 supramarginal gyrus
6. 胼胝体压部 splenium of corpus callosum
7. 大脑中动脉 middle cerebral a.
8. 大脑大静脉 great cerebral v.
9. 颞上回 superior temporal gyrus
10. 颞中回 middle temporal gyrus
11. 枕颞内侧回 medial occipitotemporal gyrus
12. 颞下回 inferior temporal gyrus
13. 齿状核 dentate nucleus
14. 小脑半球 cerebellar hemisphere
15. 小脑扁桃体 cerebellar tonsil
16. 头后大直肌 rectus capitis posterior major
17. 头上斜肌 obliquus capitis superior
18. 寰椎后弓 posterior arch of atlas
19. 头半棘肌 semispinalis capitis
20. 头夹肌 splenius capitis
21. 枕大神经 greater occipital n.
22. 颈深动脉 deep cervical a.
23. 胸锁乳突肌 sternocleidomastoid
24. 第5颈神经 5th cervical n.
25. 椎动脉 vertebral a.
26. 小脑延髓池 cerebellomedullary cistern
27. 第4颈神经 4th cervical n.
28. 第3颈椎横突 transverse process (C₃)
29. 脊髓 spinal cord
30. 枢椎棘突 spinous process of axis
31. 头下斜肌 obliquus capitis inferior
32. 枕动脉 occipital a.
33. 枕骨 occipital bone
34. 颞骨 temporal bone
35. 乙状窦 sigmoid sinus
36. 小脑幕 tentorium of cerebellum
37. 小脑蚓 vermis
38. 大脑后动脉 posterior cerebral a.
39. 小脑上动脉 superior cerebellar a.
40. 禽距 calcar avis
41. 大脑中动脉 middle cerebral a.
42. 后角球 bulb of posterior horn
43. 下矢状窦 inferior sagittal sinus
44. 侧脑室后角 posterior horn of lateral ventricle
45. 扣带回 cingulate gyrus
46. 辐射冠 corona radiata
47. 中央旁小叶 paracentral lobule
48. 外侧陷窝 lateral lacunae
49. 顶骨 parietal bone
50. 帽状腱膜 epicranial aponeurosis
51. 颞叶 temporal lobe
52. 小脑上池 supracerebellar cistern
53. 距状沟 calcarine sulcus



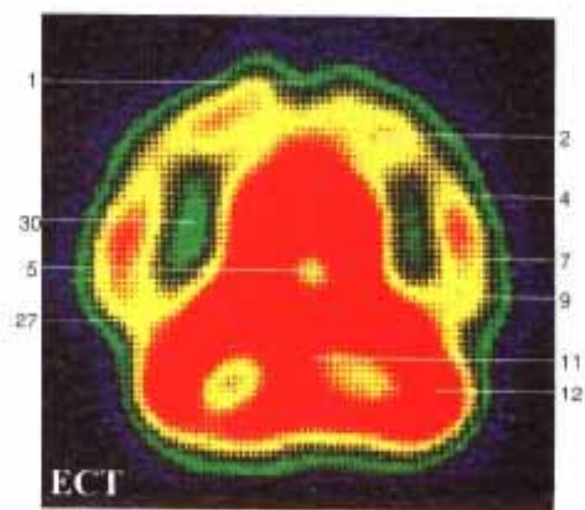
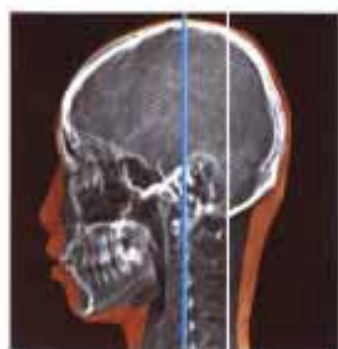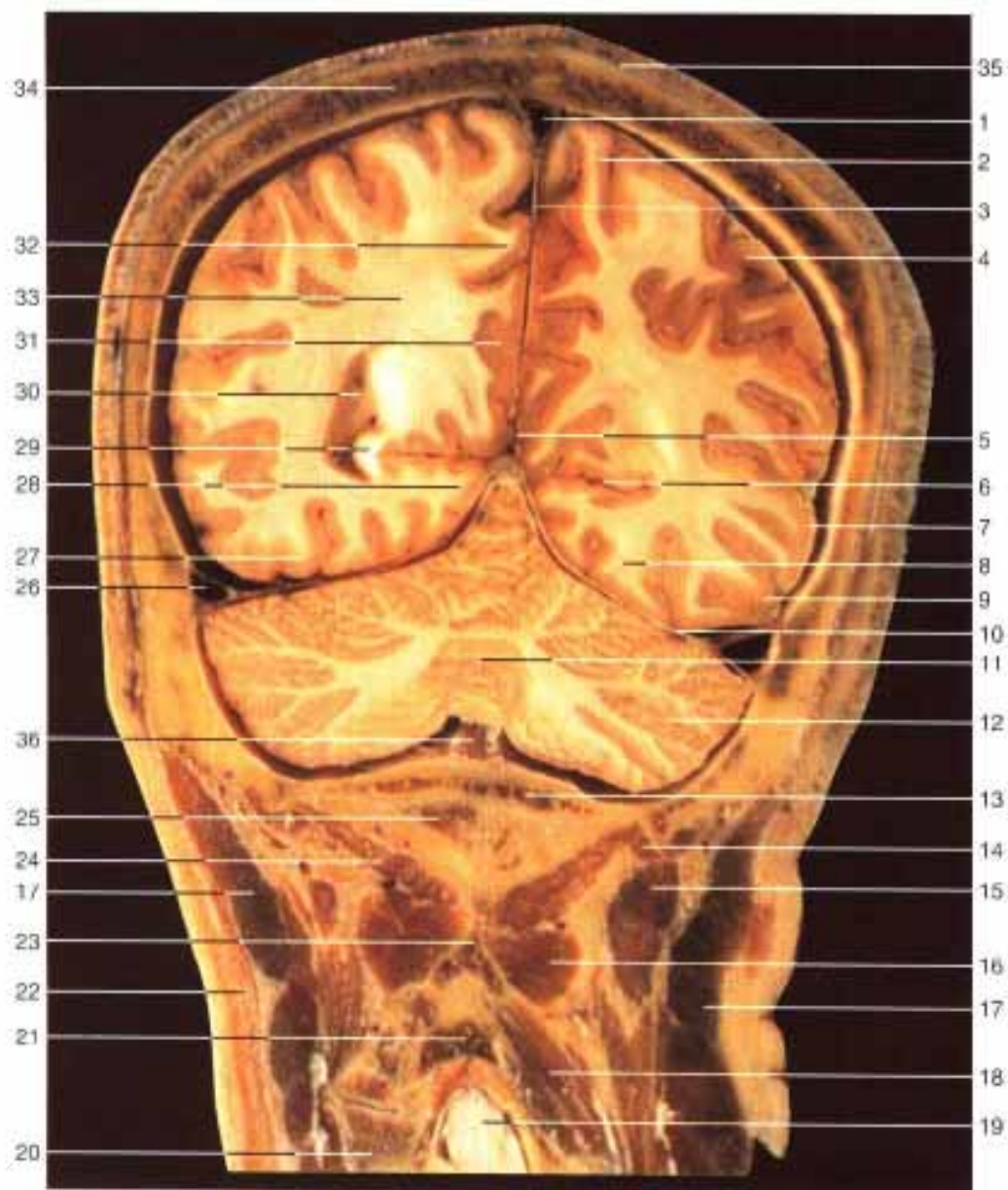
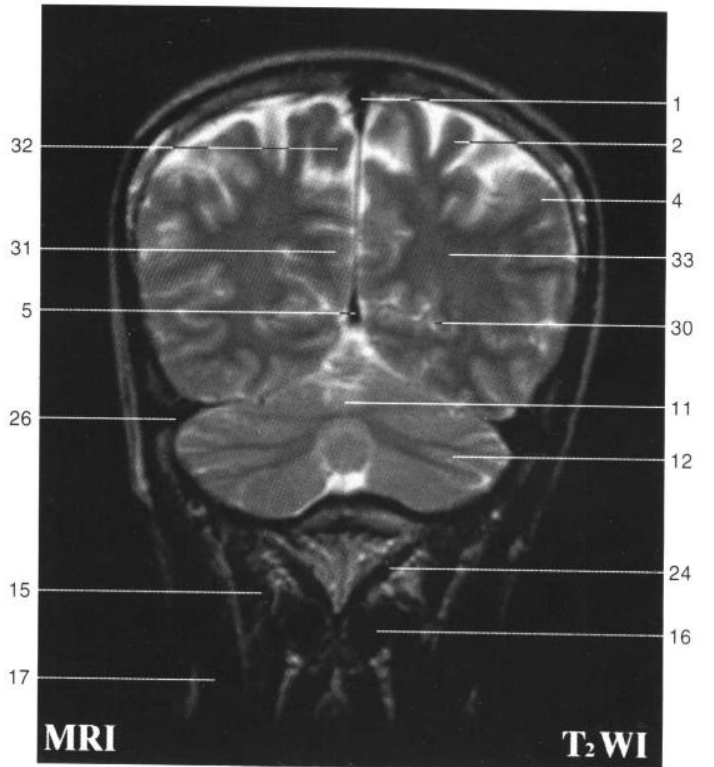
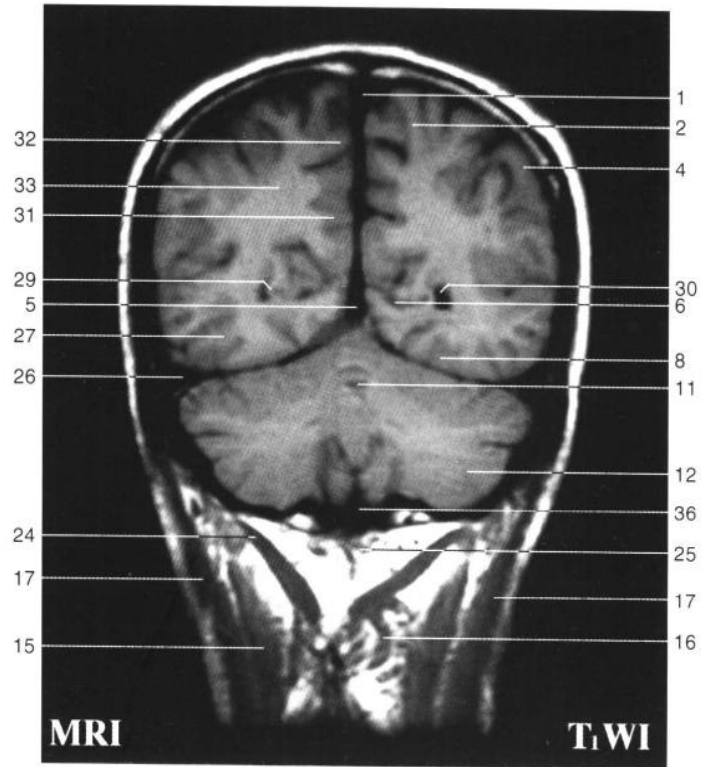


Fig. FC 12

Fig. FC 12

1. 上矢状窦 superior sagittal sinus
2. 顶上小叶 superior parietal lobule
3. 大脑镰 cerebral falx
4. 角回 angular gyrus
5. 直窦 straight sinus
6. 距状沟 calcarine sulcus
7. 颞中回 middle temporal gyrus
8. 枕颞内侧回 medial occipitotemporal gyrus
9. 颞下回 inferior temporal gyrus
10. 小脑幕 tentorium of cerebellum
11. 小脑蚓 vermis
12. 小脑半球 cerebellar hemisphere
13. 枕骨 occipital bone
14. 头上斜肌 obliquus capitis superior
15. 头半棘肌 semispinalis capitis
16. 头下斜肌 obliquus capitis inferior
17. 头夹肌 splenius capitis
18. 颈半棘肌 semispinalis cervicis
19. 脊髓 spinal cord
20. 第4颈椎上关节突 superior articular process (C₄)
21. 第3颈椎棘突 spinous process (C₃)
22. 胸锁乳突肌 sternocleidomastoid
23. 枢椎棘突 spinous process of axis
24. 头后大直肌 rectus capitis posterior major
25. 头后小直肌 rectus capitis posterior minor
26. 横窦 transverse sinus
27. 枕颞外侧回 lateral occipitotemporal gyrus
28. 舌回 lingual gyrus
29. 禽距 calcar avis
30. 侧脑室后角 posterior horn of lateral ventricle
31. 楔叶 cuneus
32. 楔前叶 precuneus
33. 辐射冠 corona radiata
34. 顶骨 parietal bone
35. 帽状腱膜 epicranial aponeurosis
36. 小脑延髓池 cerebellomedullary cistern



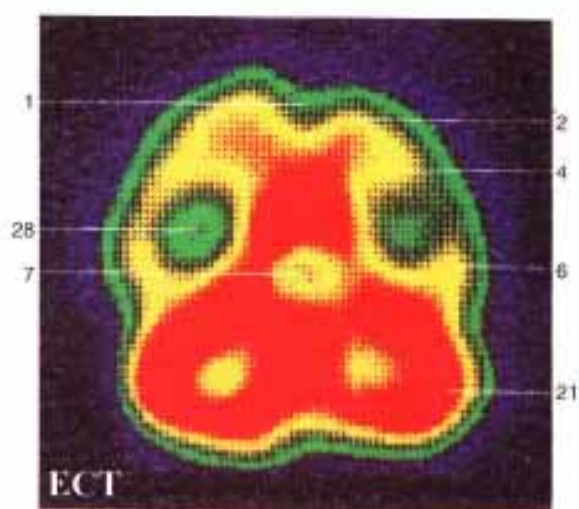
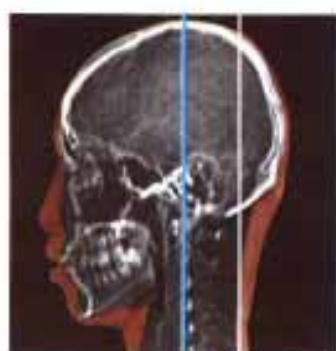
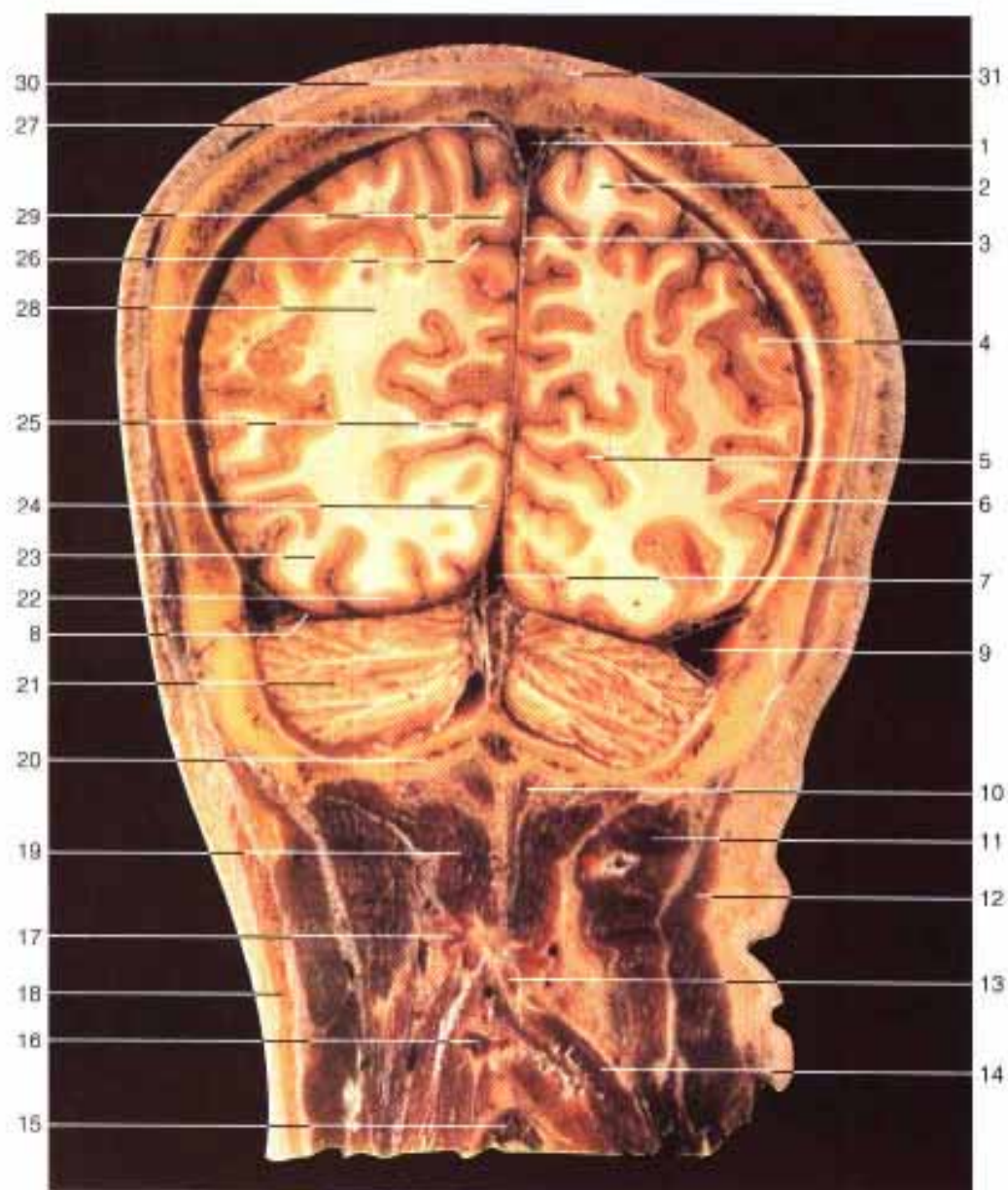
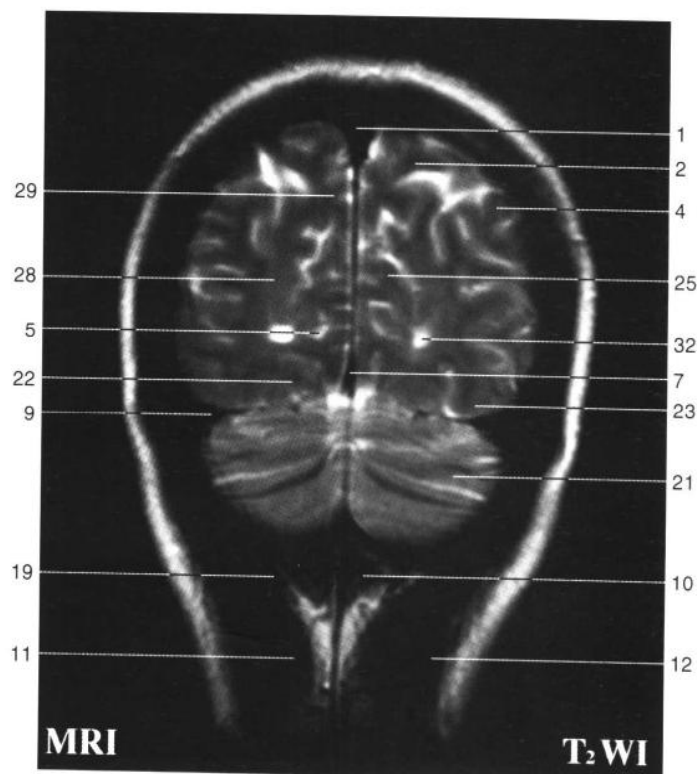
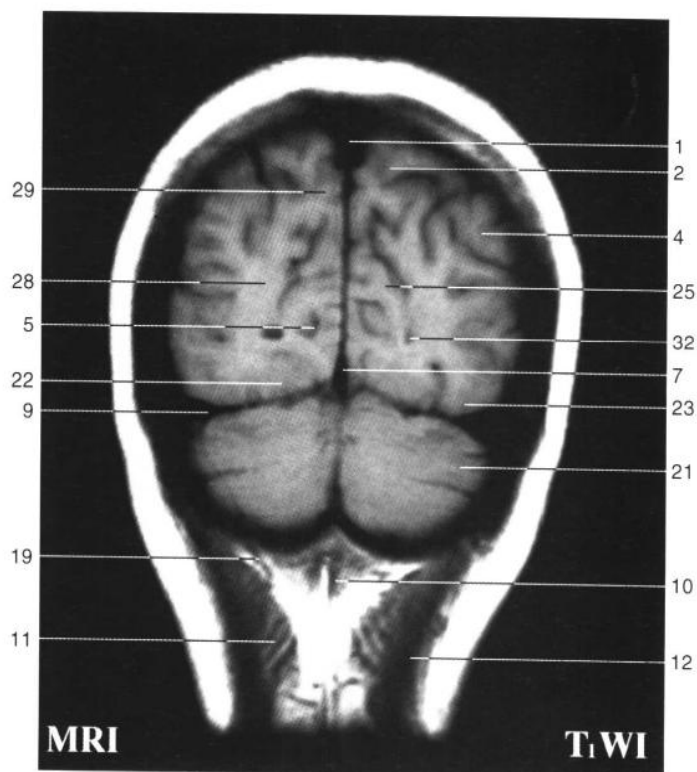


Fig. FC 13

Fig. FC 13

1. 上矢状窦 superior sagittal sinus
2. 顶上小叶 superior parietal lobule
3. 大脑镰 cerebral falx
4. 枕上回 superior occipital gyrus
5. 距状沟 calcarine sulcus
6. 颞中回 middle temporal gyrus
7. 直窦 straight sinus
8. 小脑幕 tentorium of cerebellum
9. 横窦 transverse sinus
10. 头后小直肌 rectus capitis posterior minor
11. 头半棘肌 semispinalis capitis
12. 头夹肌 splenius capitis
13. 枢椎棘突 spinous process of axis
14. 颈半棘肌 semispinalis cervicis
15. 第4颈椎棘突 spinous process (C₄)
16. 第3颈椎棘突 spinous process (C₃)
17. 头下斜肌 obliquus capitis inferior
18. 胸锁乳突肌 sternocleidomastoid
19. 头后大直肌 rectus capitis posterior major
20. 枕骨 occipital bone
21. 小脑半球 cerebellar hemisphere
22. 枕颞内侧回 medial occipitotemporal gyrus
23. 枕颞外侧回 lateral occipitotemporal gyrus
24. 舌回 lingual gyrus
25. 楔叶 cuneus
26. 顶枕沟 parietooccipital sulcus
27. 外侧陷窝 lateral lacunae
28. 辐射冠 corona radiata
29. 楔前叶 precuneus
30. 顶骨 parietal bone
31. 帽状腱膜 epicranial aponeurosis
32. 侧脑室后角 posterior horn of lateral ventricle



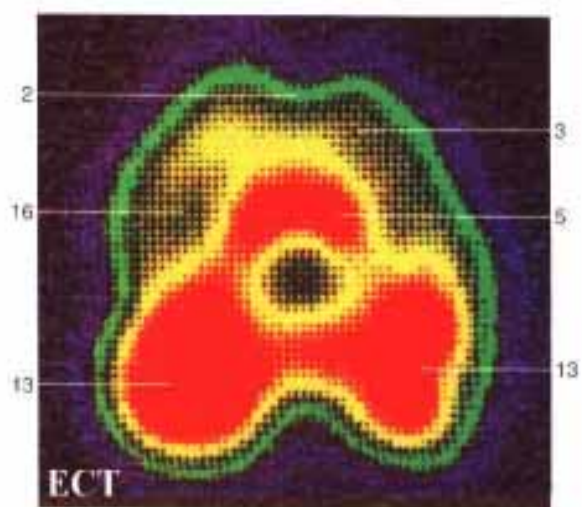
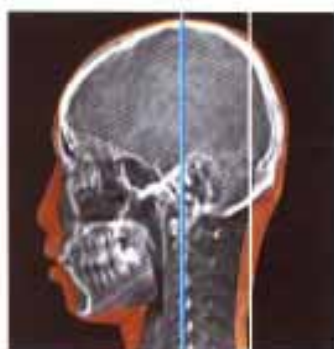
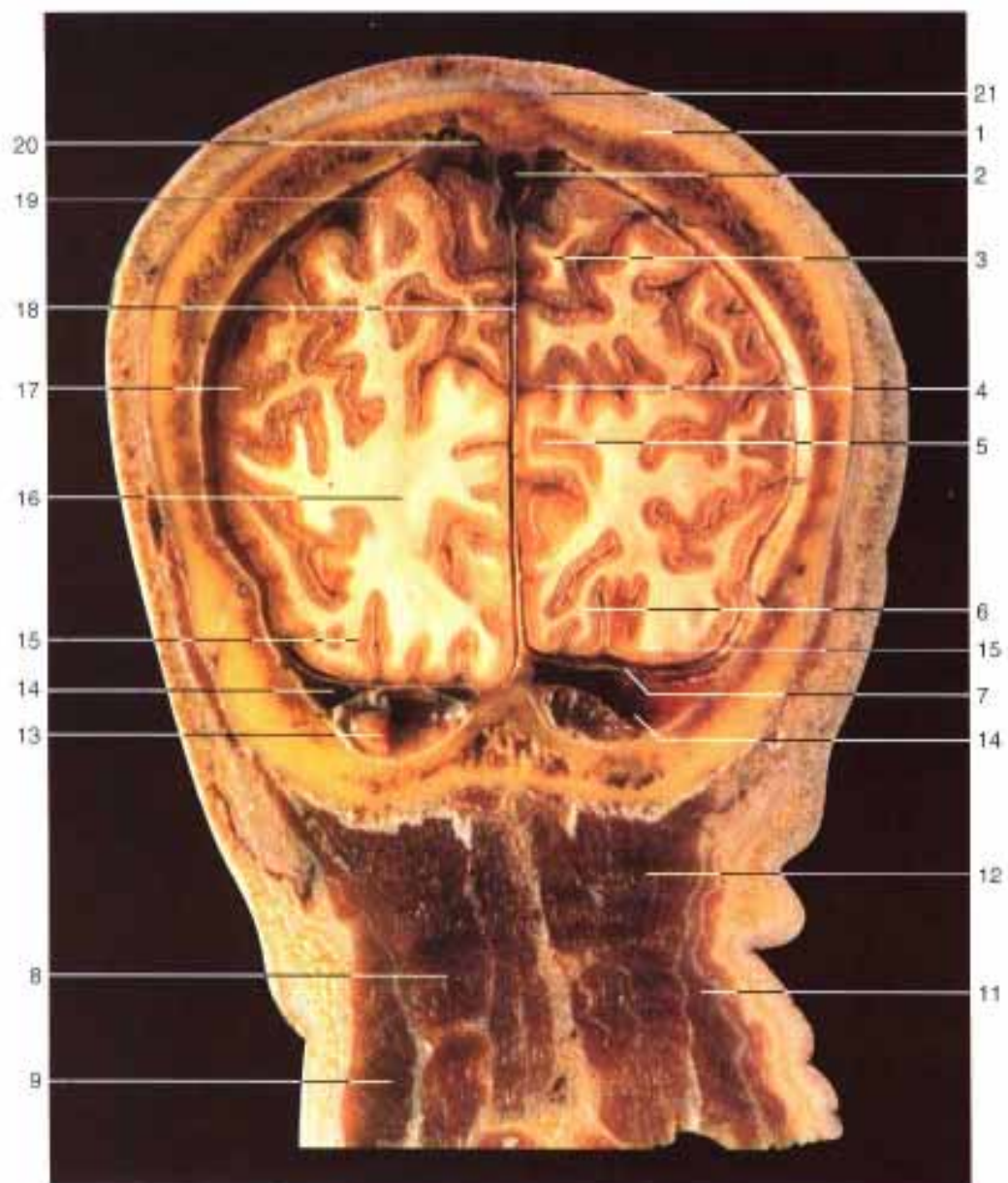
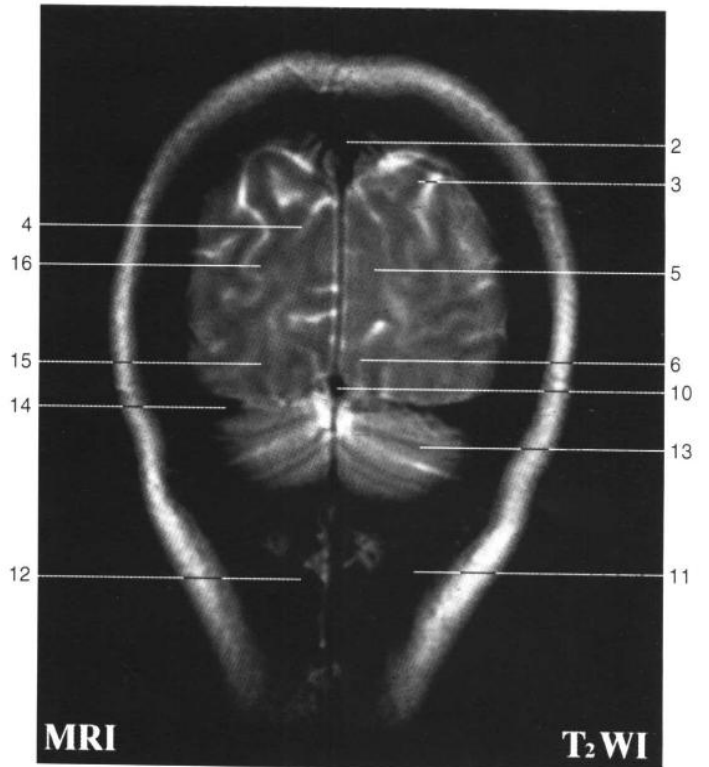
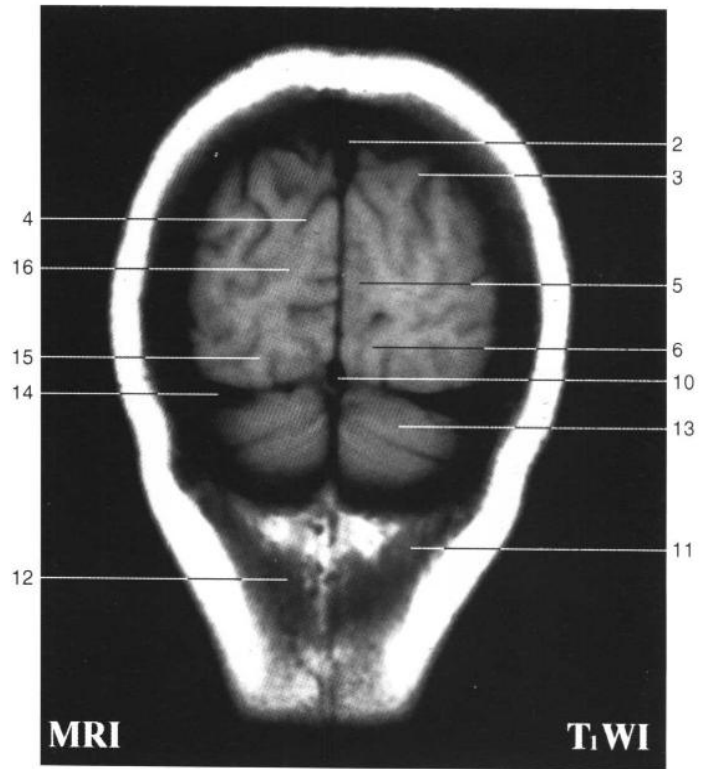


Fig. FC 14

Fig. FC-14

1. 顶骨 parietal bone
2. 上矢状窦 superior sagittal sinus
3. 楔叶 cuneus
4. 距状沟 calcarine sulcus
5. 舌回 lingual gyrus
6. 枕颞内侧回 medial occipitotemporal gyrus
7. 小脑幕 tentorium of cerebellum
8. 头半棘肌 semispinalis capitis
9. 头夹肌 splenius capitis
10. 直窦 straight sinus
11. 头夹肌 splenius capitis
12. 头半棘肌 semispinalis capitis
13. 小脑半球 cerebellar hemisphere
14. 横窦 transverse sinus
15. 枕颞外侧回 lateral occipitotemporal gyrus
16. 辐射冠 corona radiata
17. 枕外侧回 lateral occipital gyrus
18. 大脑镰 cerebral falx
19. 枕上回 superior occipital gyrus
20. 外侧陷窝 lateral lacunae
21. 帽状腱膜 epicranial aponeurosis



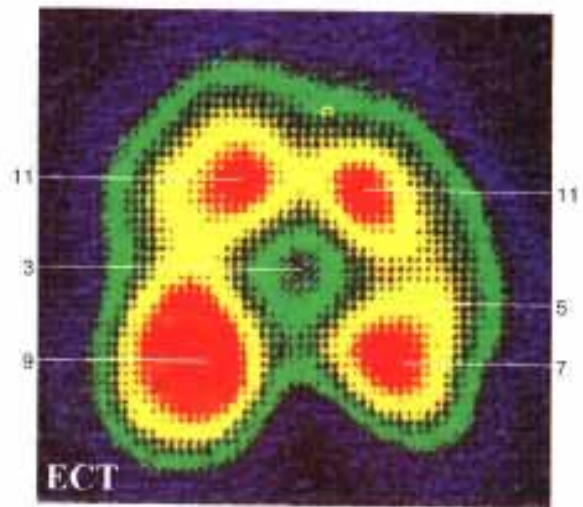
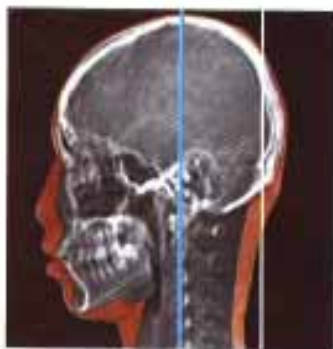
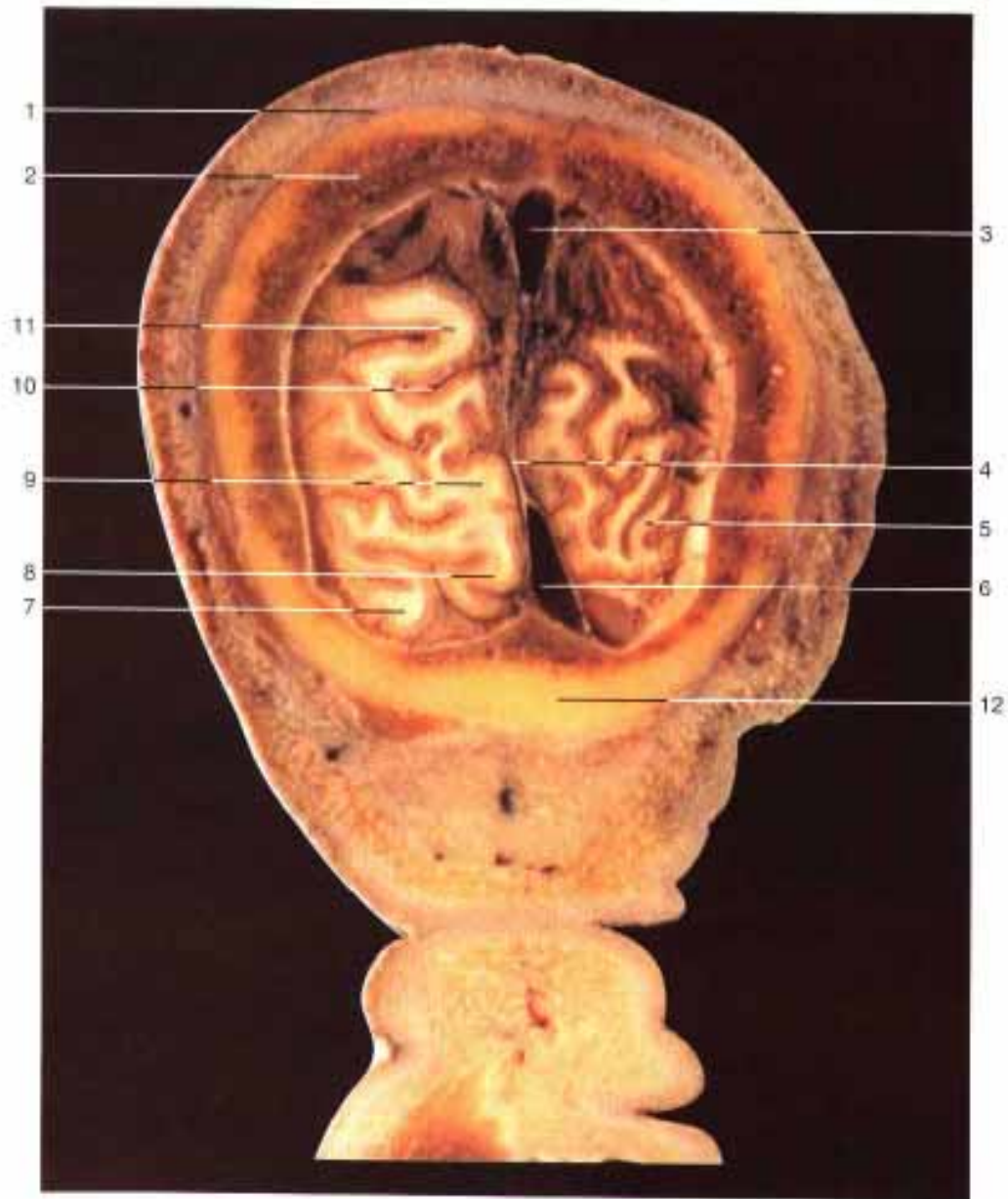
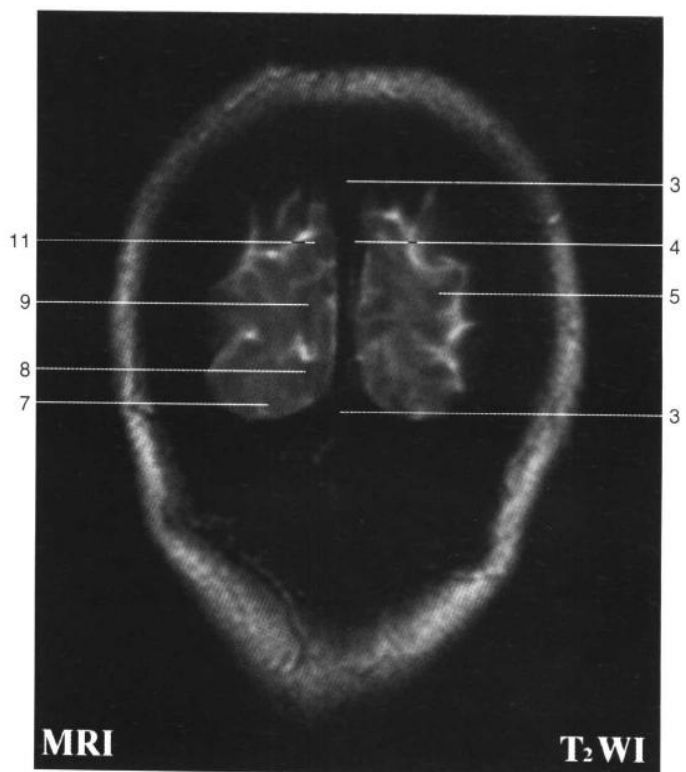
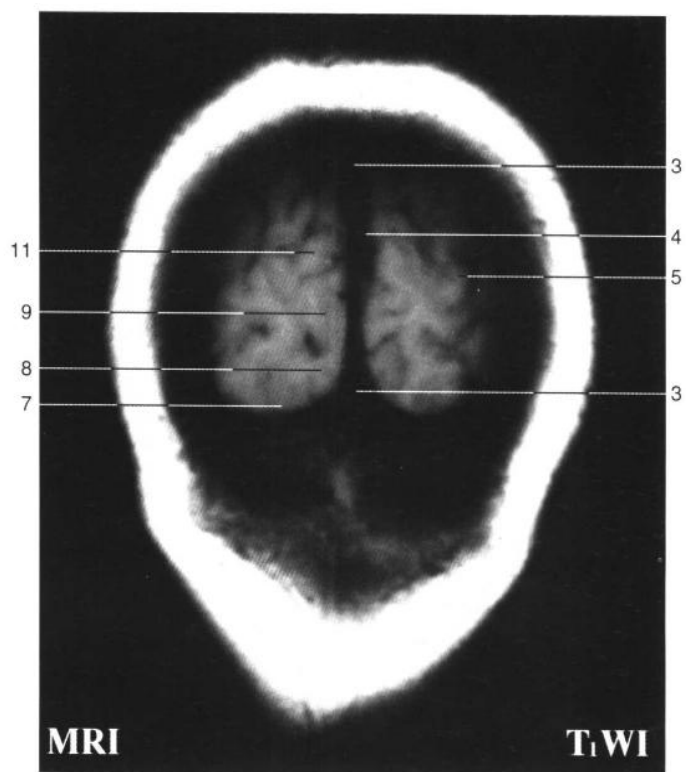


Fig. FC 15

Fig. FC 15

1. 帽状腱膜 epicranial aponeurosis
2. 顶骨 parietal bone
3. 上矢状窦 superior sagittal sinus
4. 大脑镰 cerebral falx
5. 枕外侧回 lateral occipital gyrus
6. 上矢状窦 superior sagittal sinus
7. 枕颞外侧回 lateral occipitotemporal gyrus
8. 枕颞内侧回 medial occipitotemporal gyrus
9. 舌回 lingual gyrus
10. 距状沟 calcarine sulcus
11. 楔叶 cuneus
12. 枕骨 occipital bone



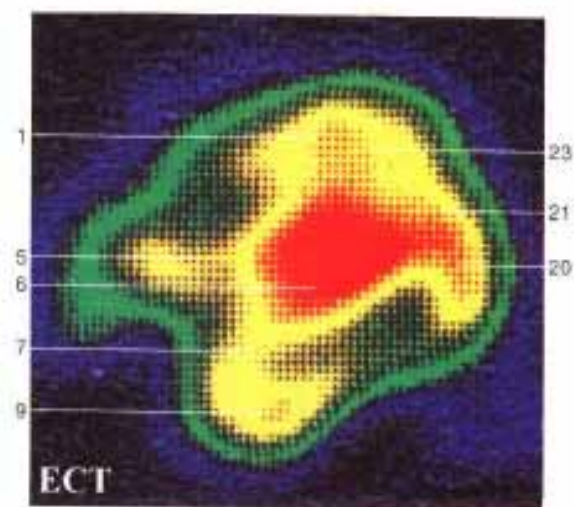
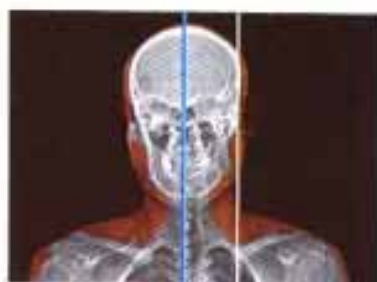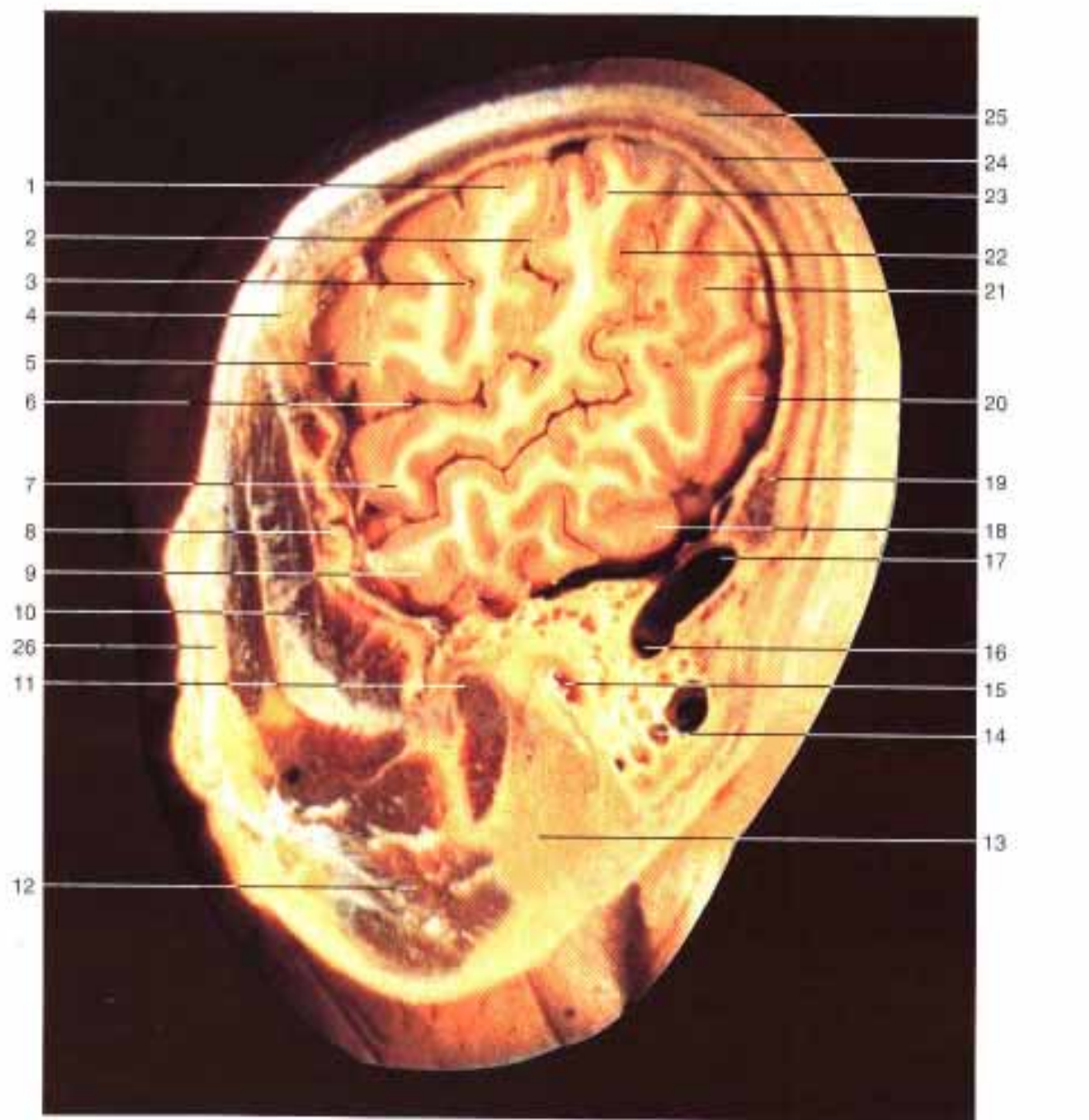
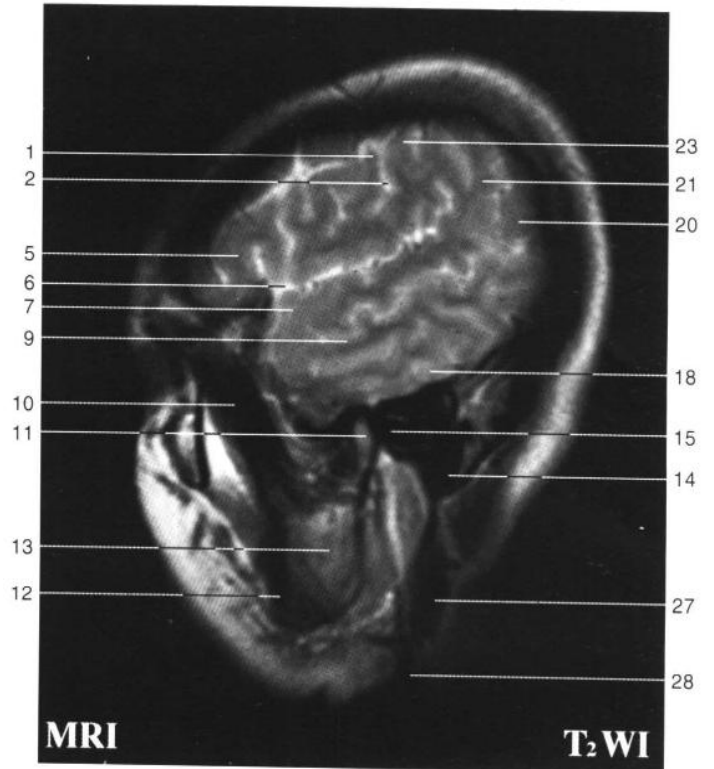
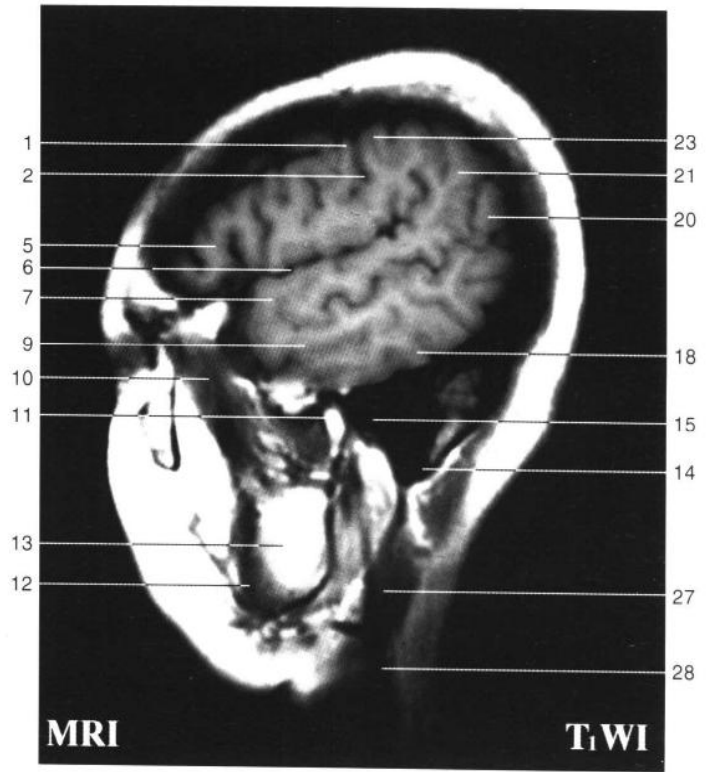


Fig. SC 1

Fig. SC 1

1. 中央前回 precentral gyrus
2. 中央沟 central sulcus
3. 中央前沟 precentral sulcus
4. 额骨 frontal bone
5. 额下回 inferior frontal gyrus
6. 外侧沟 lateral sulcus
7. 颞上回 superior temporal gyrus
8. 蝶骨大翼 greater wing of sphenoid bone
9. 颞中回 middle temporal gyrus
10. 颞肌 temporalis
11. 髁突 condylar process
12. 咬肌 masseter
13. 腮腺 parotid gland
14. 乳突小房 mastoid cells
15. 外耳道 external acoustic meatus
16. 乙状窦 sigmoid sinus
17. 横窦 transverse sinus
18. 颞下回 inferior temporal gyrus
19. 枕骨 occipital bone
20. 角回 angular gyrus
21. 缘上回 supramarginal gyrus
22. 中央后沟 postcentral sulcus
23. 中央后回 postcentral gyrus
24. 顶骨 parietal bone
25. 帽状腱膜 epicranial aponeurosis
26. 颧骨 zygomatic bone
27. 胸锁乳突肌 sternocleidomastoid
28. 颈外静脉 external jugular v.



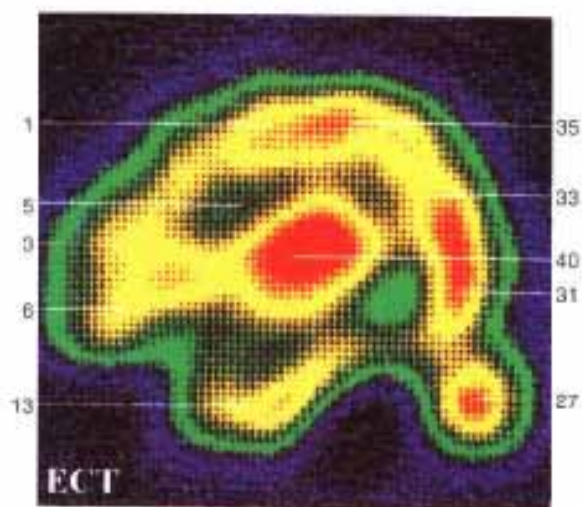
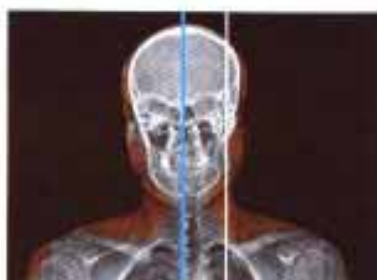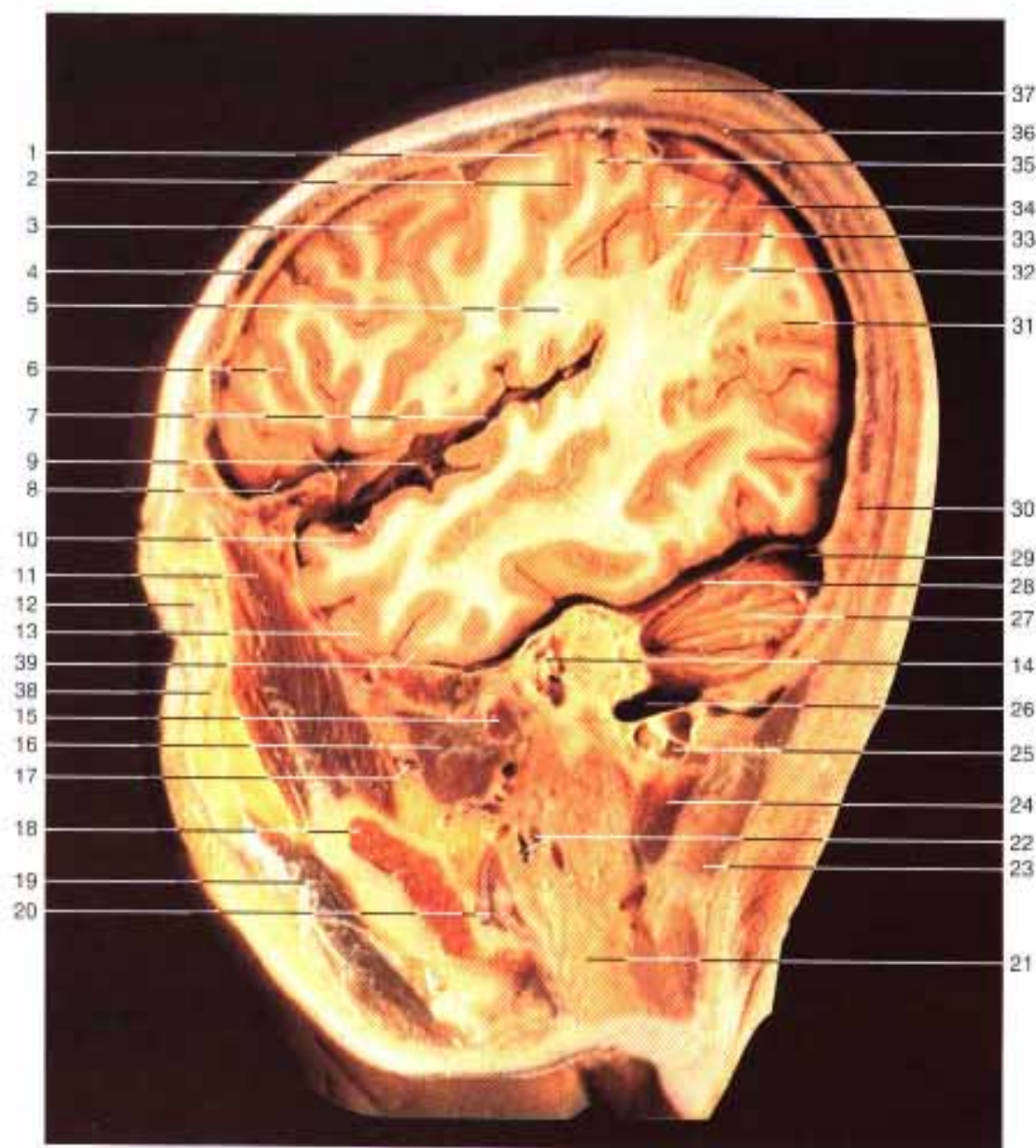
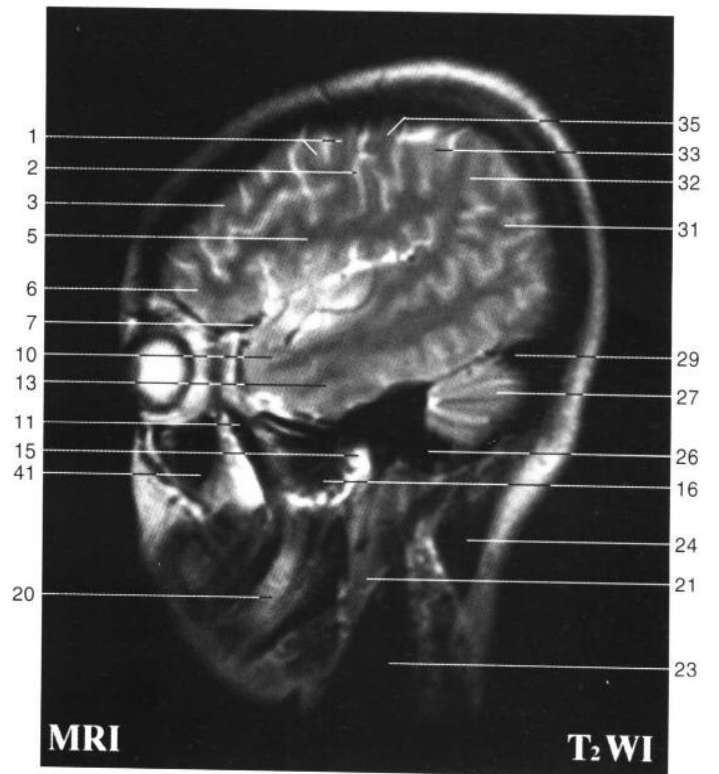
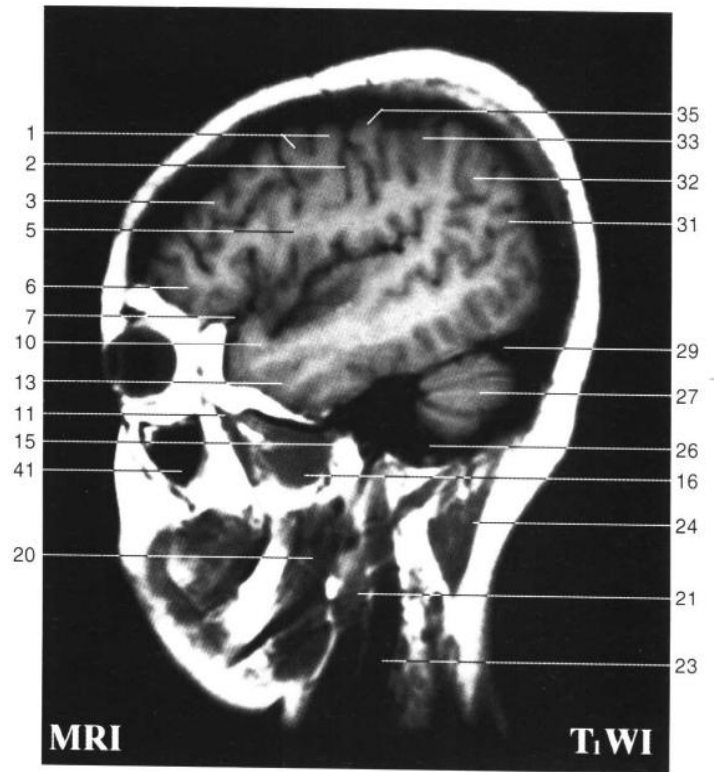


Fig. SC 2

Fig. SC 2

1. 中央前回 precentral gyrus
2. 中央沟 central sulcus
3. 额中回 middle frontal gyrus
4. 额骨 frontal bone
5. 辐射冠 corona radiata
6. 额下回 inferior frontal gyrus
7. 外侧沟 lateral sulcus
8. 眶回 orbital gyrus
9. 大脑中动脉 middle cerebral a.
10. 颞上回 superior temporal gyrus
11. 颞肌 temporalis
12. 泪腺 lacrimal gland
13. 颞中回 middle temporal gyrus
14. 鼓室及听小骨 tympanic cavity and auditory ossicles
15. 髁突 condylar process
16. 翼外肌 lateral pterygoid
17. 上颌动、静脉 maxillary a. and v.
18. 下颌骨 mandible
19. 咬肌 masseter
20. 翼内肌 medial pterygoid
21. 腮腺 parotid gland
22. 颈外动脉与下颌后静脉 external carotid a. and retromandibular v.
23. 胸锁乳突肌 sternocleidomastoid
24. 头夹肌 splenius capitis
25. 乳突小房 mastoid cells
26. 乙状窦 sigmoid sinus
27. 小脑半球 cerebellar hemisphere
28. 小脑幕 tentorium of cerebellum
29. 横窦 transverse sinus
30. 枕骨 occipital bone
31. 角回 angular gyrus
32. 缘上回 supramarginal gyrus
33. 顶上小叶 superior parietal lobule
34. 中央后沟 postcentral sulcus
35. 中央后回 postcentral gyrus
36. 顶骨 parietal bone
37. 帽状腱膜 epicranial aponeurosis
38. 颧骨 zygomatic bone
39. 颞下回 inferior temporal gyrus
40. 岛盖 operculum
41. 上颌窦 maxillary sinus



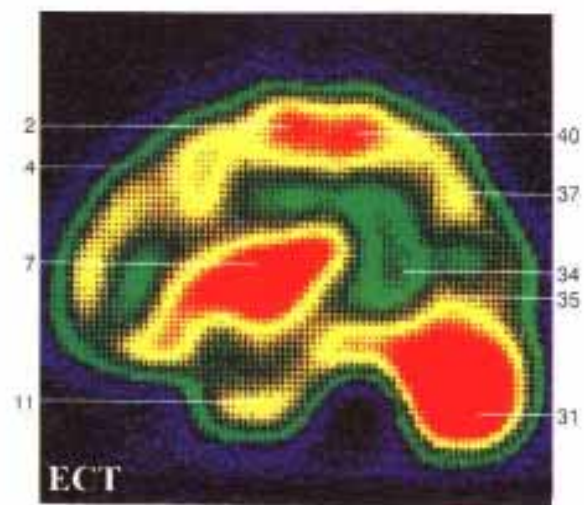
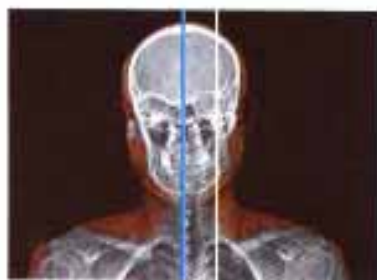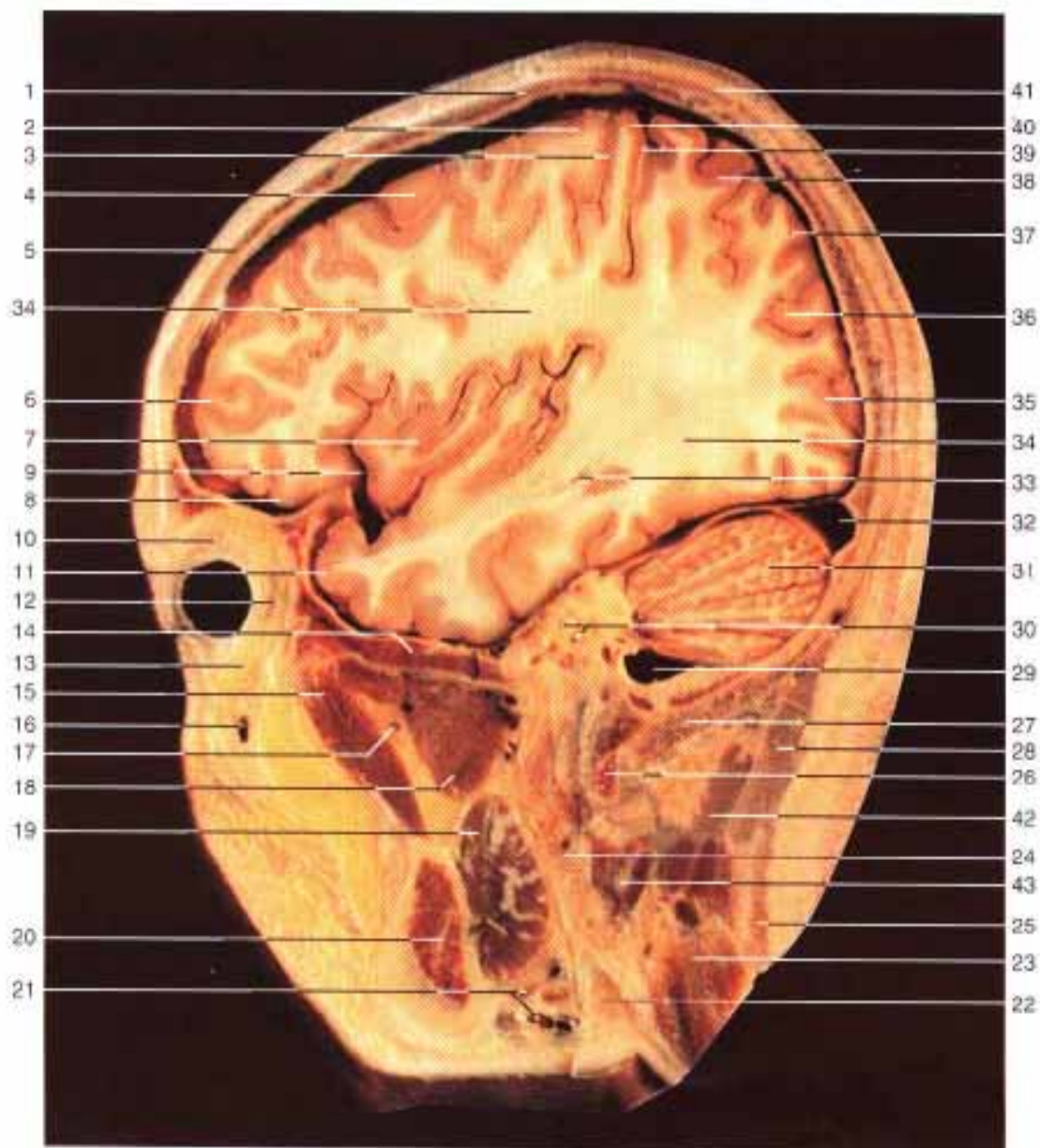
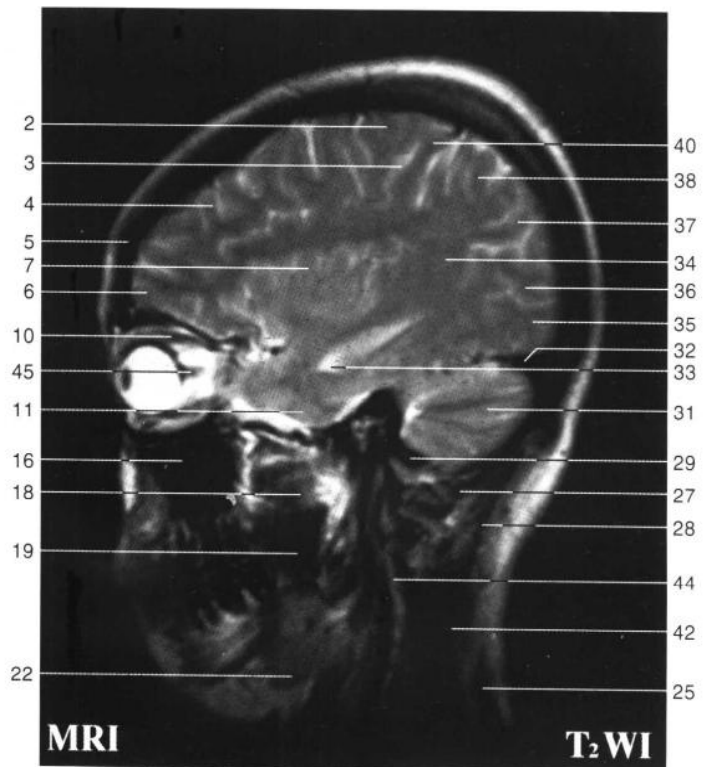
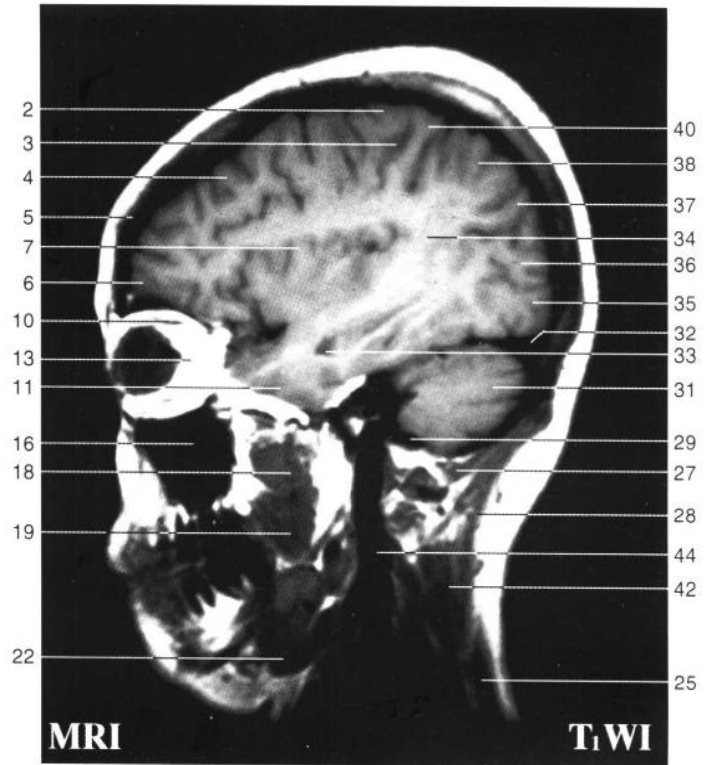


Fig. SC 3

Fig. SC 3

1. 顶骨 parietal bone
2. 中央前回 precentral gyrus
3. 中央沟 central sulcus
4. 额中回 middle frontal gyrus
5. 额骨 frontal bone
6. 额极 frontal pole
7. 岛叶 insular lobe
8. 眶回 orbital gyri
9. 外侧沟 lateral sulcus
10. 上睑提肌及上直肌 levator palpebrae superioris and superior rectus
11. 颞极 temporal pole
12. 外直肌 lateral rectus
13. 眶脂体 adipose body of orbit
14. 蝶骨大翼 greater wing of sphenoid bone
15. 颞肌 temporalis
16. 上颌窦 maxillary sinus
17. 上颌动脉 maxillary a.
18. 翼外肌 lateral pterygoid
19. 翼内肌 medial pterygoid
20. 下牙槽神经 inferior alveolar n.
21. 面动、静脉 facial a. and v.
22. 下颌下腺 submandibular gland
23. 胸锁乳突肌 sternocleidomastoid
24. 腮腺 parotid gland
25. 斜方肌 trapezius
26. 寰椎横突 transverse process of atlas
27. 头上斜肌 obliquus capitis superior
28. 头夹肌 splenius capitis
29. 乙状窦 sigmoid sinus
30. 半规管 semicircular canals
31. 小脑半球 cerebellar hemisphere
32. 横窦 transverse sinus
33. 侧脑室下角 inferior horn of lateral ventricle
34. 辐射冠 corona radiata
35. 枕叶 occipital lobe
36. 角回 angular gyrus
37. 缘上回 supramarginal gyrus
38. 顶上小叶 superior parietal lobule
39. 中央后沟 postcentral sulcus
40. 中央后回 postcentral gyrus
41. 帽状腱膜 epicranial aponeurosis
42. 头半棘肌 semispinalis capitis
43. 二腹肌与茎突舌骨肌 digastric and stylohyoid
44. 颈内静脉 internal jugular v.
45. 视神经 optic n.



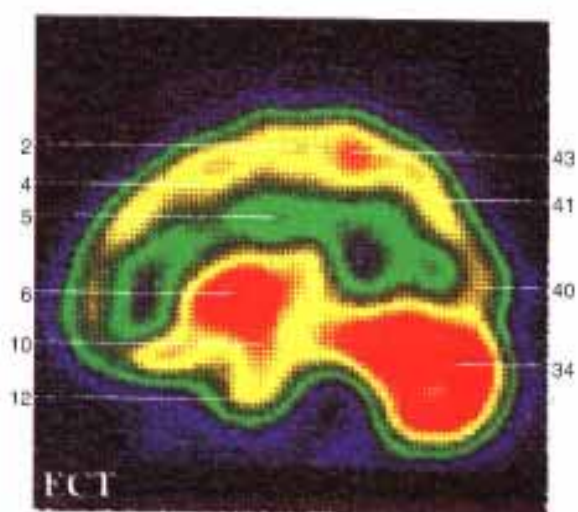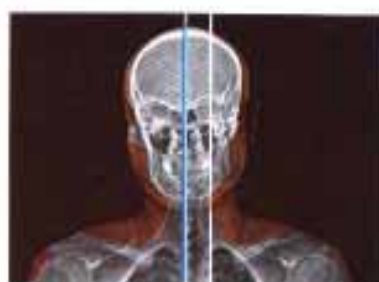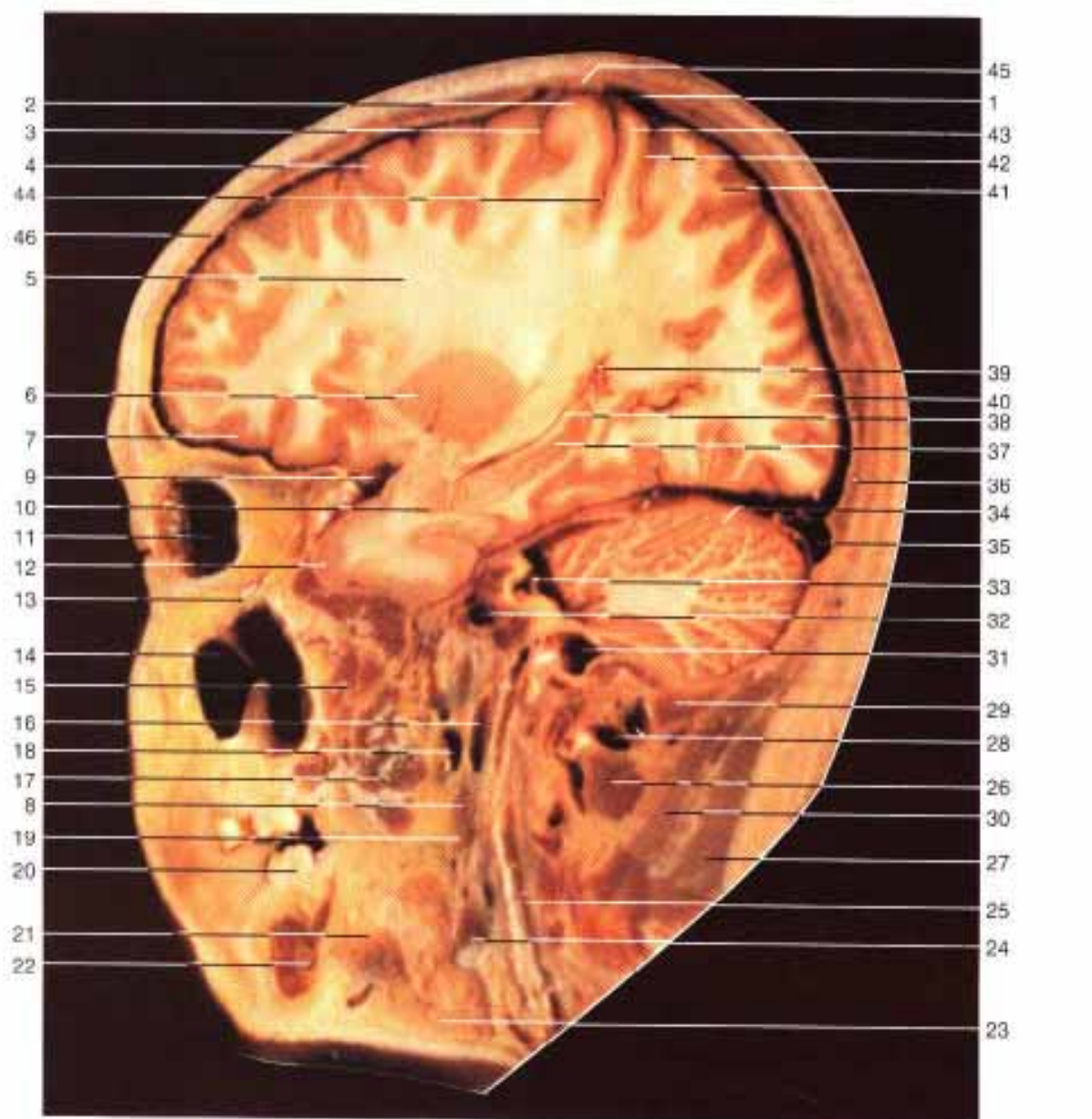
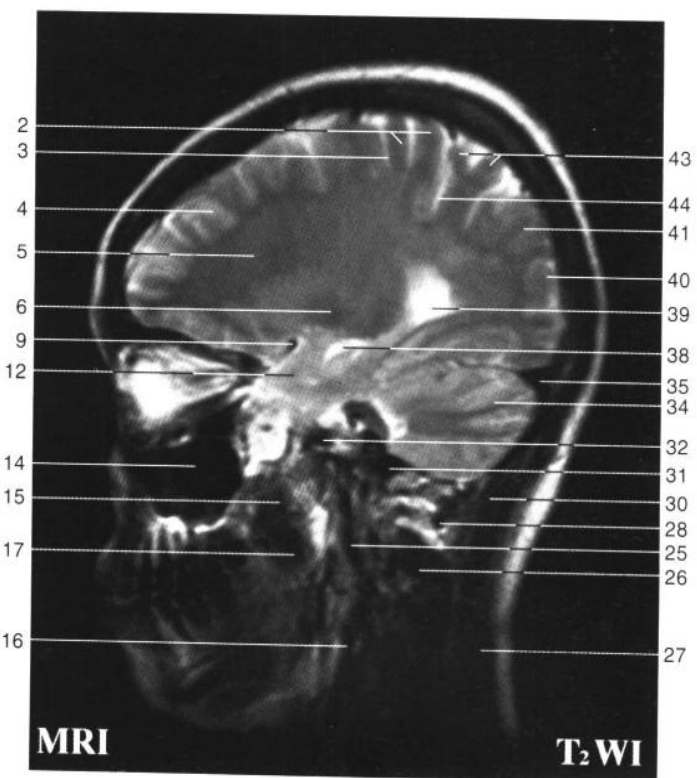
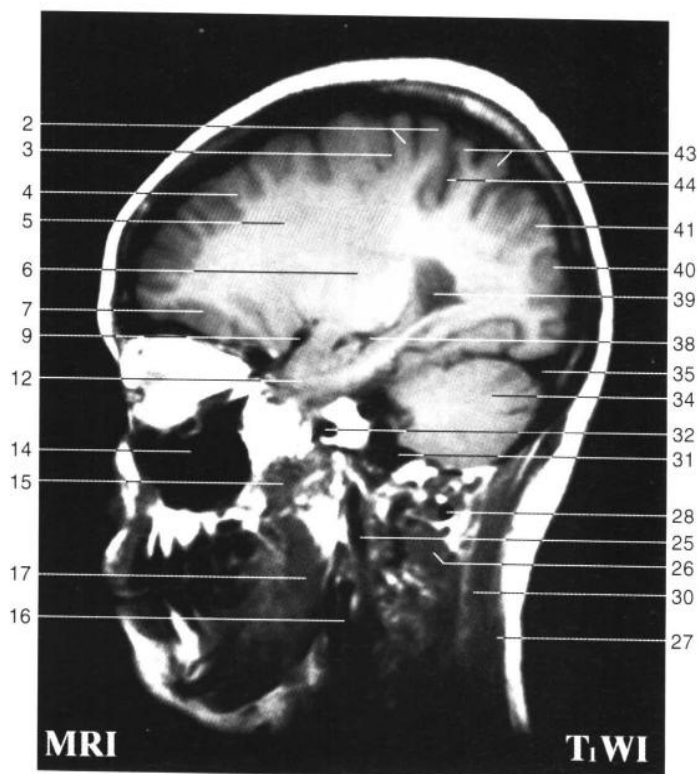


Fig. SC 4

Fig. SC 4

1. 外侧陷窝 lateral lacunae
2. 中央前回 precentral gyrus
3. 中央前沟 precentral sulcus
4. 额中回 middle frontal gyrus
5. 辐射冠(半卵圆中心) corona radiata (centrum semiovale)
6. 壳 putamen
7. 眶回 orbital gyri
8. 茎突舌肌 styloglossus
9. 外侧沟与大脑中动脉 lateral sulcus and middle cerebral a.
10. 杏仁体 amygdaloid body
11. 眼球 eyeball
12. 颞极 temporal pole
13. 下直肌 inferior rectus
14. 上颌窦 maxillary sinus
15. 翼外肌 lateral pterygoid
16. 颈内动脉 internal carotid a.
17. 翼内肌 medial pterygoid
18. 上颌静脉 maxillary v.
19. 茎突咽肌 stylopharyngeus
20. 第二磨牙 2nd molar
21. 下颌舌骨肌 mylohyoid
22. 下牙槽神经 inferior alveolar n.
23. 下颌下腺 submandibular gland
24. 二腹肌与茎突舌骨肌 digastric and stylohyoid
25. 颈内静脉 internal jugular v.
26. 头下斜肌 obliquus capitis inferior
27. 头夹肌 splenius capitis
28. 椎动、静脉 vertebral a. and v.
29. 头上斜肌 obliquus capitis superior
30. 头半棘肌 semispinalis capitis
31. 乙状窦 sigmoid sinus
32. 颈内动脉 internal carotid a.
33. 迷路动脉 labyrinthine a.
34. 小脑半球 cerebellar hemisphere
35. 横窦 transverse sinus
36. 枕骨 occipital bone
37. 海马 hippocampus
38. 侧脑室下角 inferior horn of lateral ventricle
39. 侧脑室三角 trigone of lateral ventricle
40. 楔叶 cuneus
41. 顶上小叶 superior parietal lobule
42. 中央后沟 postcentral sulcus
43. 中央后回 postcentral gyrus
44. 中央沟 central sulcus
45. 顶骨 parietal bone
46. 额骨 frontal bone



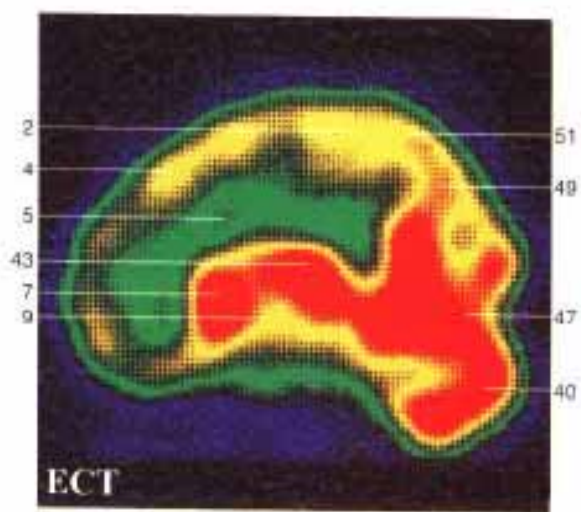
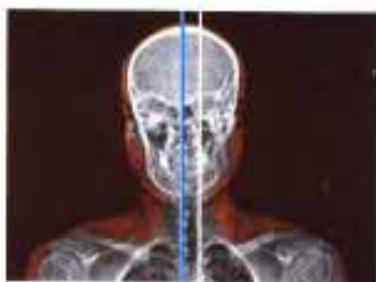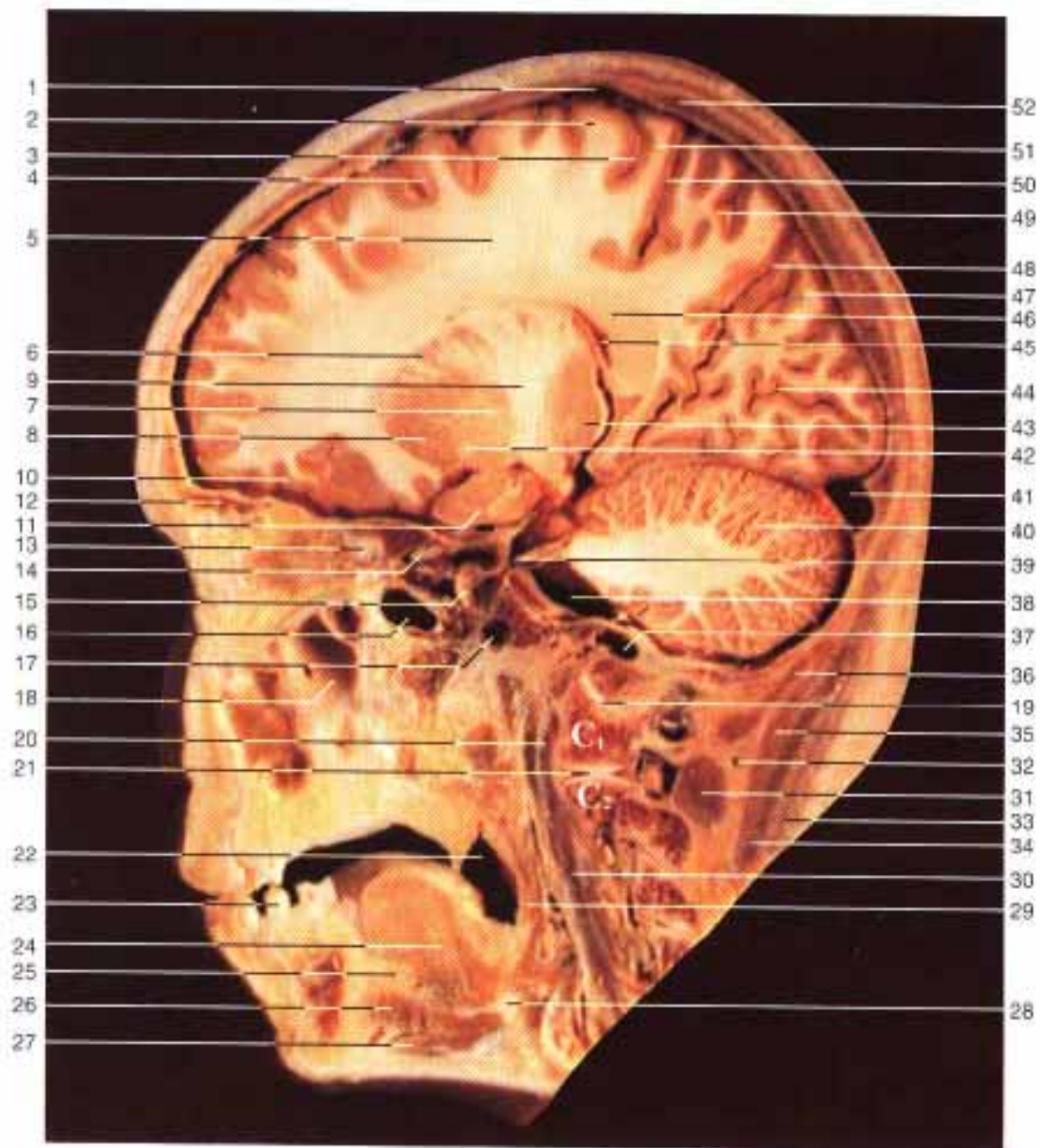
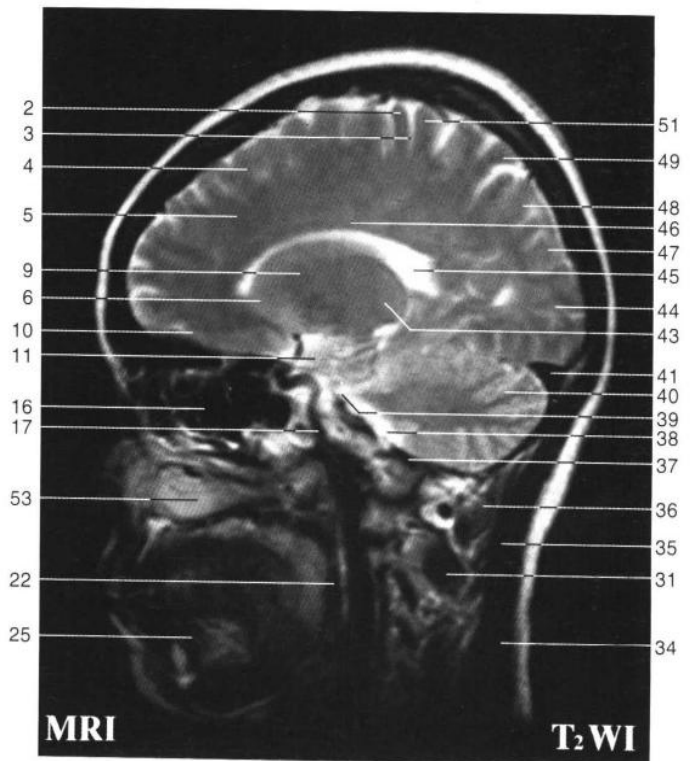
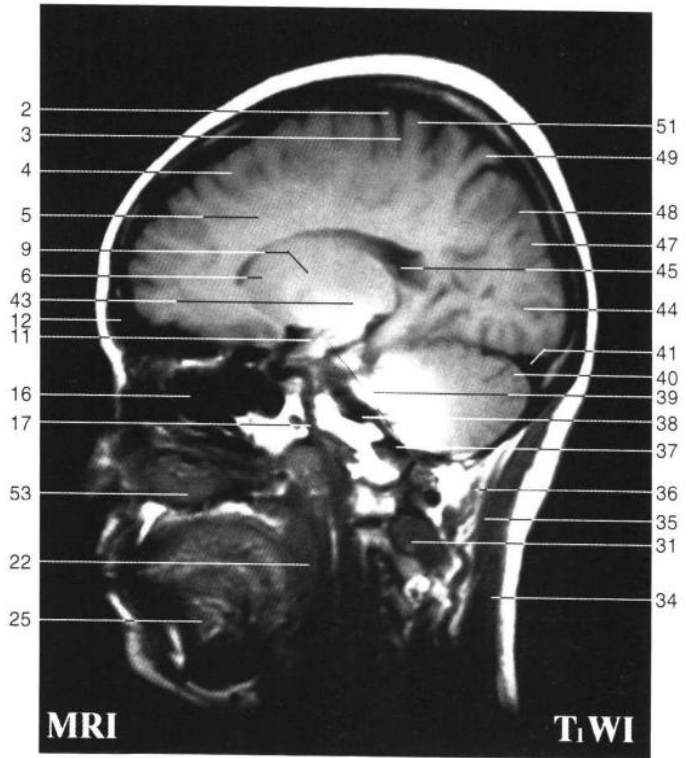


Fig. SC 5

Fig. SC 5

1. 外侧陷窝 lateral lacunae
2. 中央前回 precentral gyrus
3. 中央沟 central sulcus
4. 额上回 superior frontal gyrus
5. 辐射冠(半卵圆中心) corona radiata (centrum semiovale)
6. 尾状核头 head of caudate nucleus
7. 苍白球 globus pallidus
8. 壳 putamen
9. 内囊后肢 posterior limb of internal capsule
10. 眶回 orbital gyri
11. 杏仁体 amygdaloid body
12. 额窦 frontal sinus
13. 视神经 optic n.
14. 动眼神经 oculomotor n.
15. 三叉神经节 trigeminal ganglion
16. 筛窦 ethmoidal sinuses
17. 颈内动脉 internal carotid a.
18. 上颌窦 maxillary sinus
19. 寰枕关节 atlantooccipital joint
20. 头长肌 longus capitis
21. 寰枢关节 atlantoaxial joint
22. 口咽 oropharynx
23. 尖牙 canine tooth
24. 舌骨舌肌 hyoglossus
25. 舌下腺 sublingual gland
26. 下颌舌骨肌 mylohyoid
27. 二腹肌前腹 anterior belly of digastric
28. 舌骨 hyoid bone
29. 腭舌肌 palatoglossus
30. 颈长肌 longus colli
31. 头下斜肌 obliquus capitis inferior
32. 颈深动脉 deep cervical a.
33. 斜方肌 trapezius
34. 头夹肌 splenius capitis
35. 头半棘肌 semispinalis capitis
36. 头后大直肌 rectus capitis posterior major
37. 乙状窦 sigmoid sinus
38. 脑桥小脑三角池 cistern of pontocerebellar trigone
39. 三叉神经根 root of trigeminal n.
40. 小脑半球 cerebellar hemisphere
41. 横窦 transverse sinus
42. 前连合 anterior commissure
43. 背侧丘脑 dorsal thalamus
44. 距状沟 calcarine sulcus
45. 侧脑室 lateral ventricle
46. 胼胝体 corpus callosum
47. 楔叶 cuneus
48. 顶枕沟 parietooccipital sulcus
49. 楔前叶 precuneus
50. 中央后沟 postcentral sulcus
51. 中央后回 postcentral gyrus
52. 顶骨 parietal bone
53. 下鼻甲 inferior nasal concha



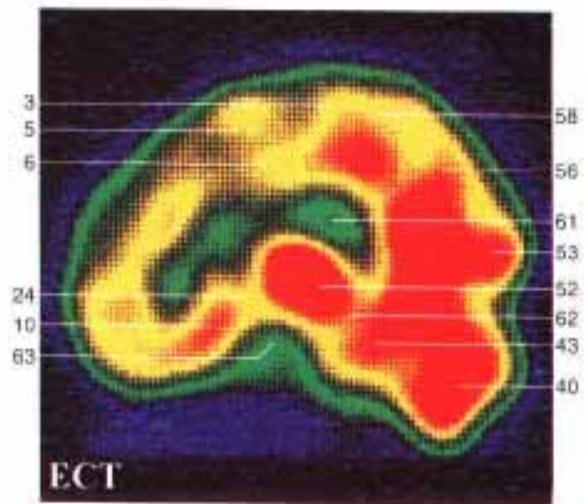
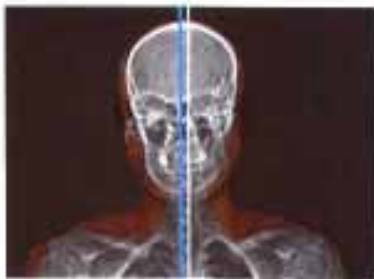
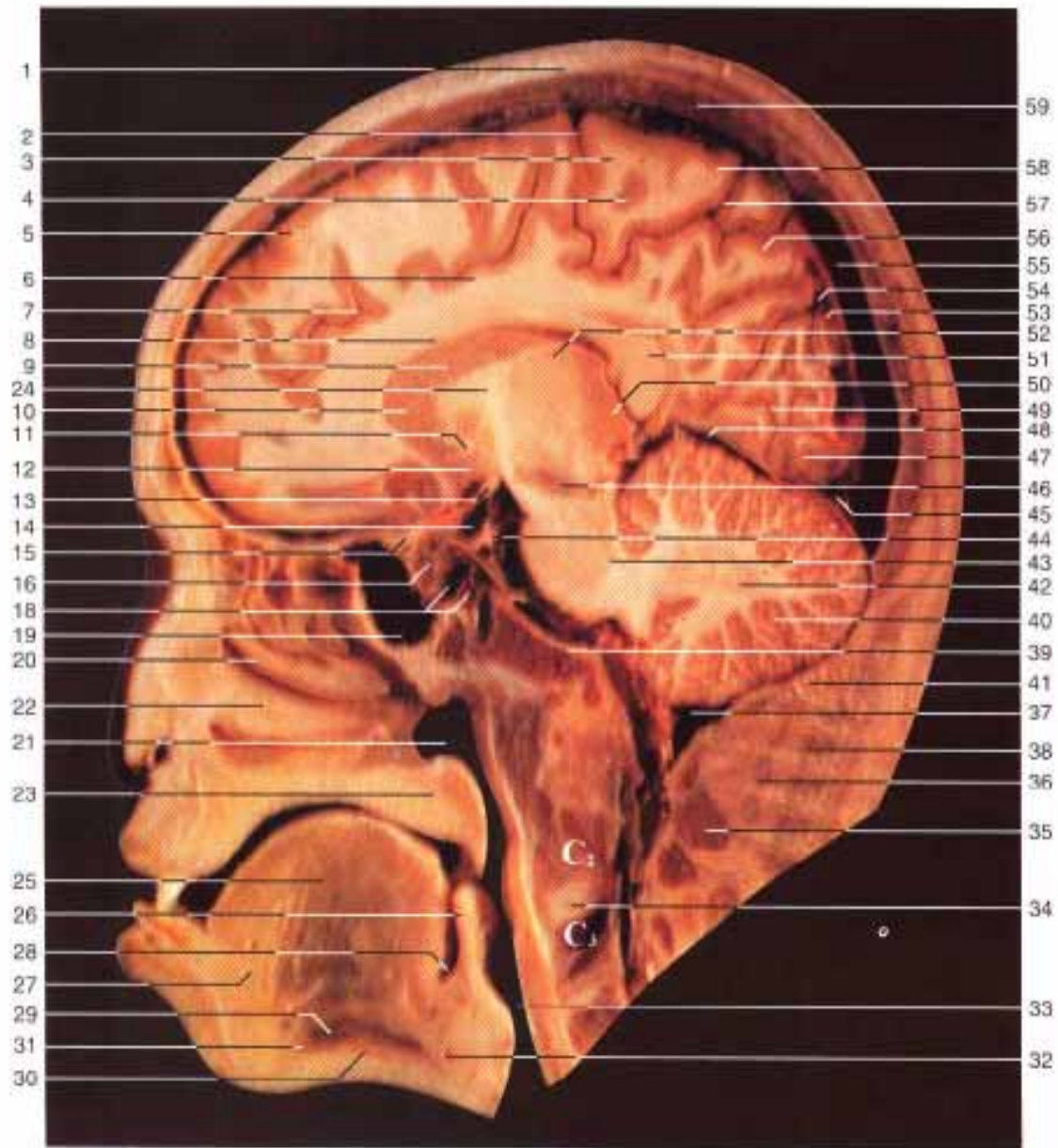
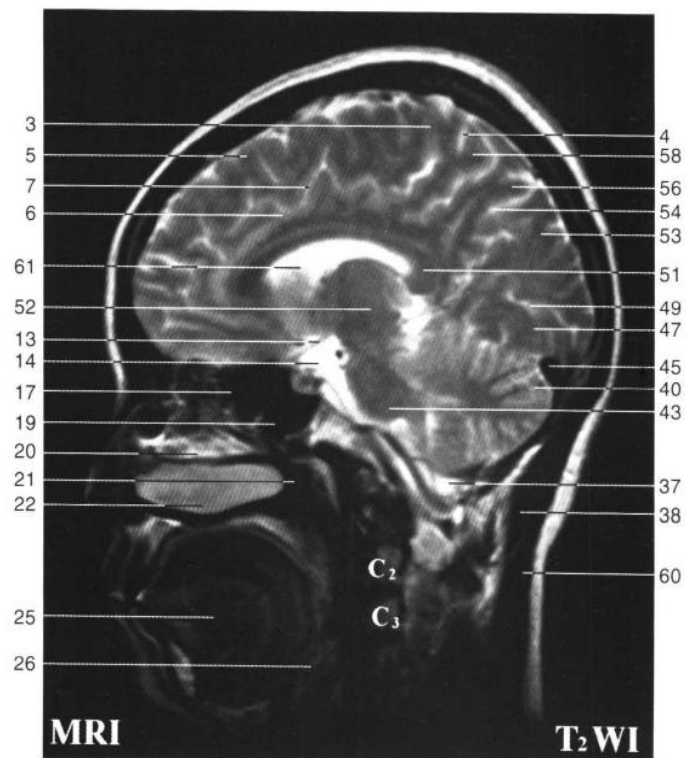
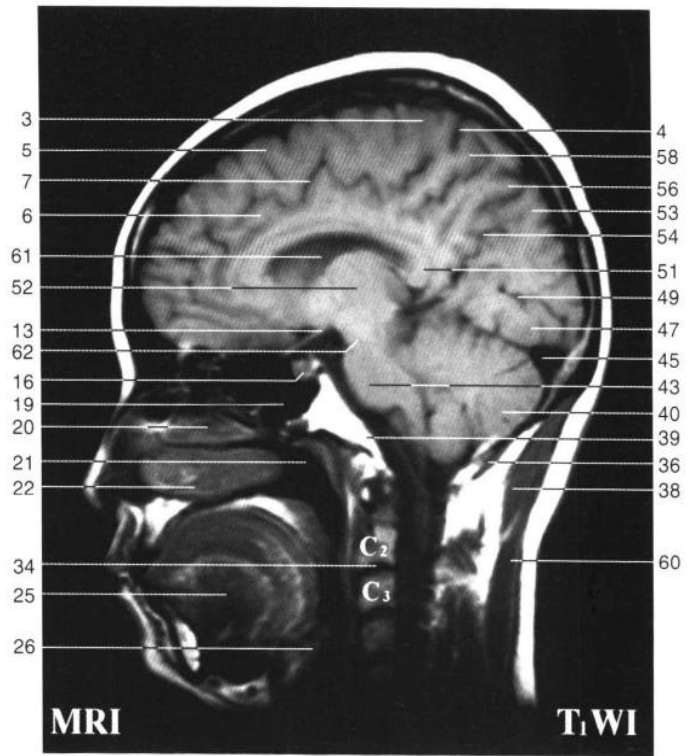


Fig. SC 6

Fig. SC 6

1. 帽状腱膜 epicranial aponeurosis
2. 中央前沟 precentral sulcus
3. 中央前回 precentral gyrus
4. 中央沟 central sulcus
5. 额上回 superior frontal gyrus
6. 扣带回 cingulate gyrus
7. 扣带沟 cingulate sulcus
8. 胼胝体干 trunk of corpus callosum
9. 尾状核体 body of caudate nucleus
10. 尾状核头 head of caudate nucleus
11. 前连合 anterior commissure
12. 隔核 nuclei septi
13. 视束 optic tract
14. 脚间池 interpeduncular cistern
15. 视神经 optic n.
16. 垂体 hypophysis
17. 筛窦 ethmoidal sinuses
18. 海绵窦与颈内动脉 cavernous sinus and internal carotid a.
19. 蝶窦 sphenoidal sinus
20. 中鼻甲 middle nasal concha
21. 鼻咽 nasopharynx
22. 下鼻甲 inferior nasal concha
23. 软腭 soft palate
24. 内囊膝 genu of internal capsule
25. 颞舌肌 genioglossus
26. 会厌 epiglottis
27. 舌下腺 sublingual gland
28. 会厌谷 epiglottic vallecula
29. 颞舌骨肌 geniohyoid
30. 下颌舌骨肌 mylohyoid
31. 二腹肌 digastric
32. 舌骨 hyoid bone
33. 喉咽 laryngopharynx
34. 2,3 颈椎间盘 intervertebral disc (C₂ - C₃)
35. 头下斜肌 obliquus capitis inferior
36. 头后大直肌 rectus capitis posterior major
37. 小脑延髓池 cerebellomedullary cistern
38. 头半棘肌 semispinalis capitis
39. 斜坡 clivus
40. 小脑半球 cerebellar hemisphere
41. 枕骨 occipital bone
42. 齿状核 dentate nucleus
43. 脑桥 pons
44. 动眼神经 oculomotor n.
45. 横窦 transverse sinus
46. 黑质 substantia nigra
47. 舌回 lingual gyrus
48. 小脑上池 supracerebellar cistern
49. 距状沟 calcarine sulcus
50. 丘脑枕 pulvinar
51. 胼胝体压部 splenium of corpus callosum
52. 背侧丘脑 dorsal thalamus
53. 楔叶 cuneus
54. 顶枕沟 parietooccipital sulcus
55. 上矢状窦 superior sagittal sinus
56. 楔前叶 precuneus
57. 中央后沟 postcentral sulcus
58. 中央后回 postcentral gyrus
59. 顶骨 parietal bone
60. 头夹肌 splenius capitis
61. 侧脑室 lateral ventricle
62. 大脑脚 cerebral peduncle
63. 鞍上池 suprasellar cistern



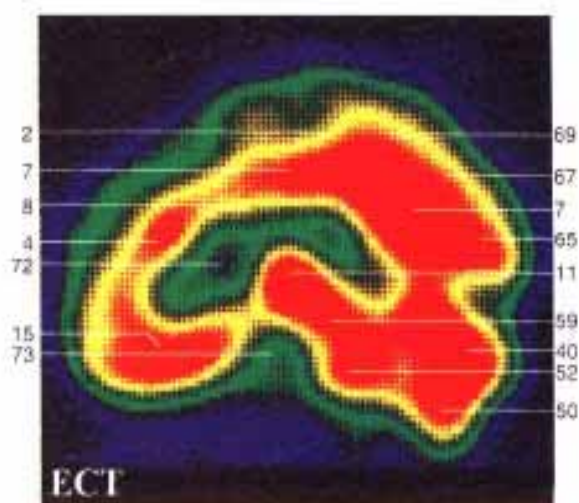
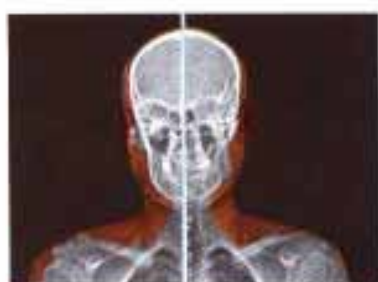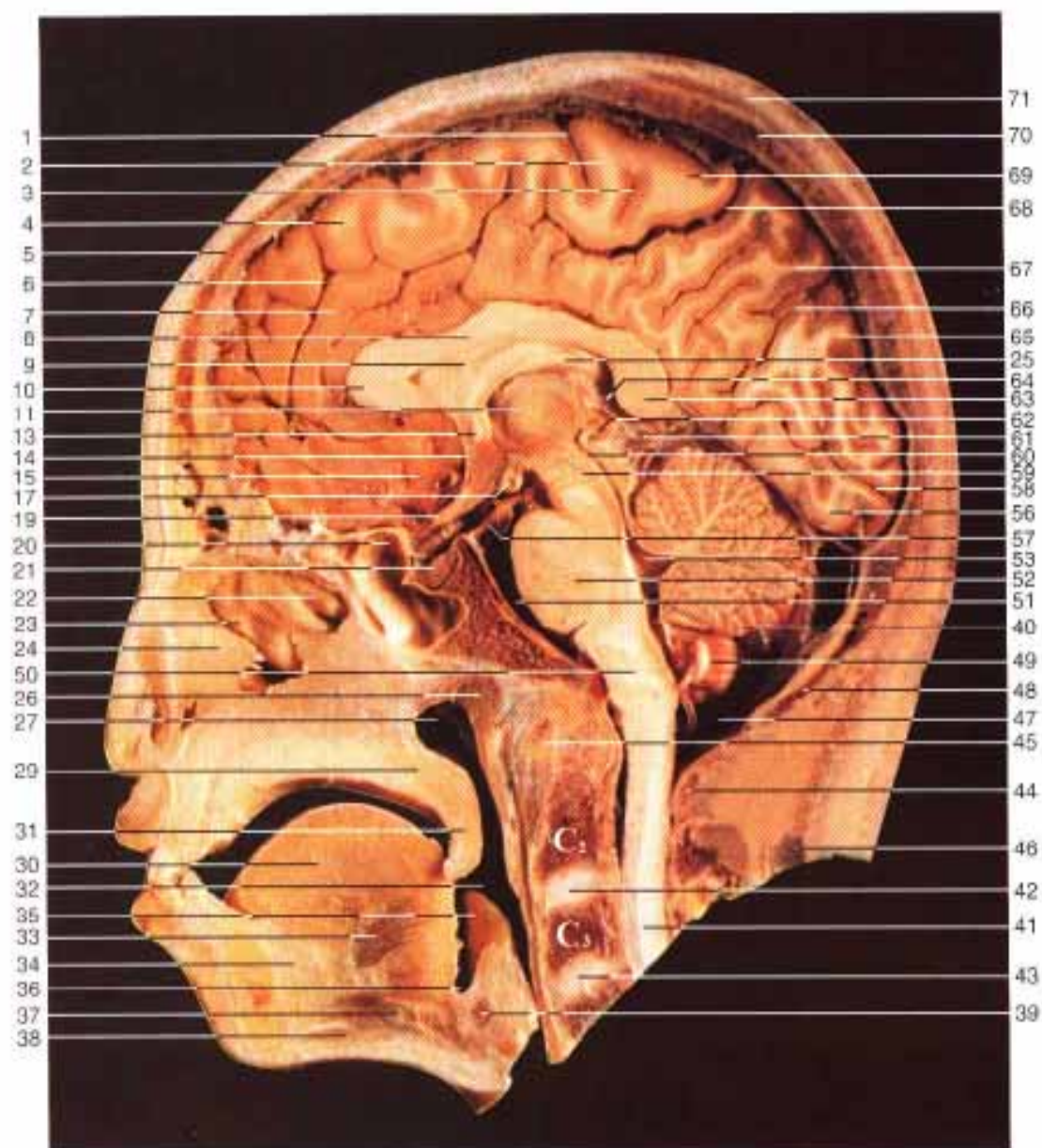
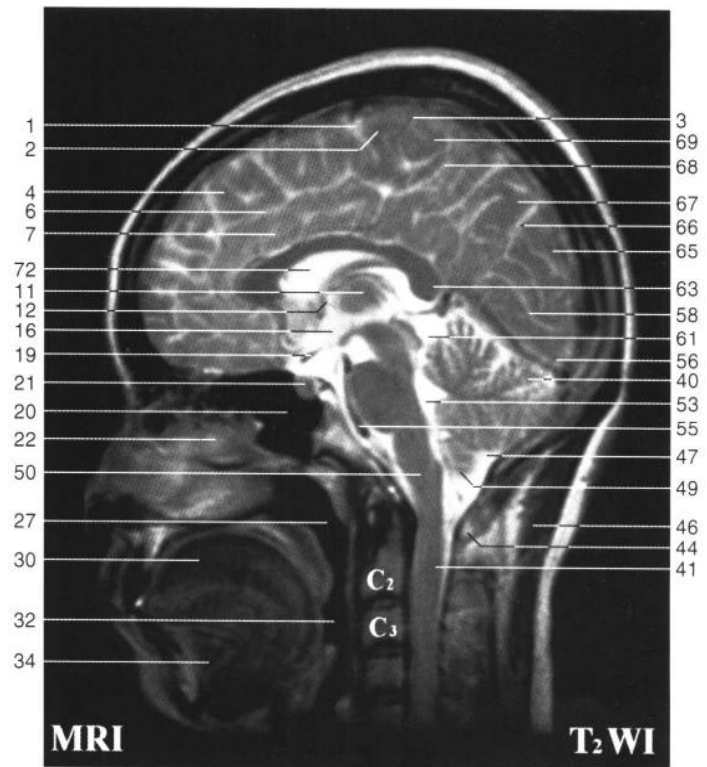
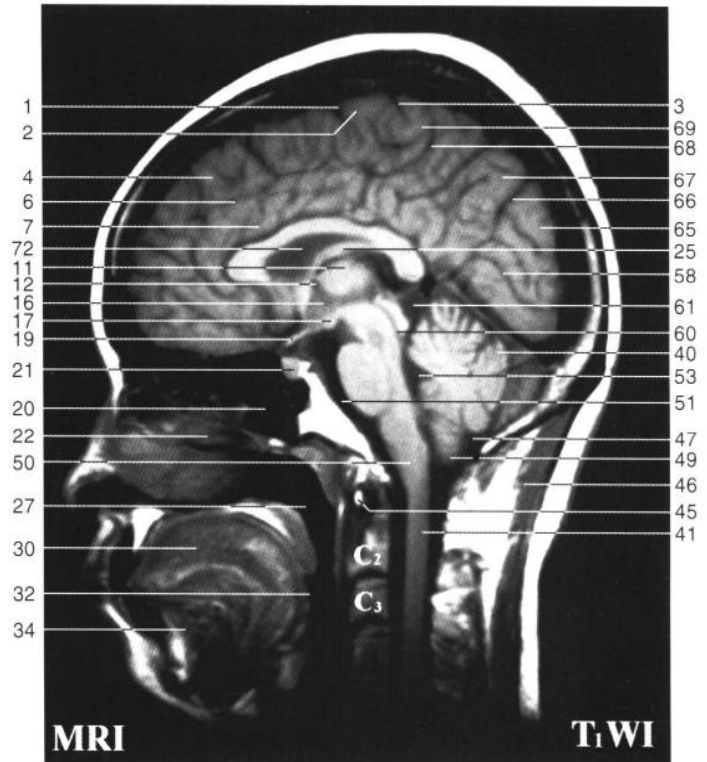


Fig. SC 7

Fig. SC 7

1. 中央前沟 precentral sulcus
2. 中央前回 precentral gyrus
3. 中央沟 central sulcus
4. 额上回 superior frontal gyrus
5. 额骨 frontal bone
6. 扣带沟 cingulate sulcus
7. 扣带回 cingulate gyrus
8. 胼胝体干 trunk of corpus callosum
9. 透明隔 septum pellucidum
10. 胼胝体膝 genu of corpus callosum
11. 背侧丘脑 dorsal thalamus
12. 室间孔 interventricular foramen
13. 前连合 anterior commissure
14. 终板 lamina terminalis
15. 隔区 septal area
16. 第三脑室 third ventricle
17. 乳头体 mamillary body
18. 额窦 frontal sinus
19. 视交叉 optic chiasma
20. 蝶窦 sphenoidal sinus
21. 垂体 hypophysis
22. 上鼻甲 superior nasal concha
23. 中鼻甲 middle nasal concha
24. 鼻中隔 nasal septum
25. 穹窿体 body of fornix
26. 咽扁桃体 pharyngeal tonsil
27. 鼻咽 nasopharynx
28. 硬腭 hard palate
29. 软腭 soft palate
30. 舌 tongue
31. 腭垂 uvula
32. 口咽 oropharynx
33. 颞舌肌 genioglossus
34. 舌下腺 sublingual gland
35. 会厌 epiglottis
36. 会厌谷 epiglottic vallecula
37. 颞舌骨肌 geniohyoid
38. 下颌舌骨肌 mylohyoid
39. 舌骨 hyoid bone
40. 小脑 cerebellum
41. 脊髓 spinal cord
42. 2,3 颈椎间盘 intervertebral disc(C₂-C₃)
43. 3,4 颈椎间盘 intervertebral disc(C₃-C₄)
44. 寰椎后弓 posterior arch of atlas
45. 寰椎前弓 anterior arch of atlas
46. 头半棘肌 semispinalis capitis
47. 小脑延髓池 cerebellomedullary cistern
48. 枕骨 occipital bone
49. 小脑扁桃体 tonsil of cerebellum
50. 延髓 medulla oblongata
51. 桥池 pontine cistern
52. 脑桥基底部 basilar part of pons
53. 第四脑室 fourth ventricle
54. 横窦 transverse sinus
55. 基底动脉 basilar a.
56. 舌回 lingual gyrus
57. 动眼神经 oculomotor n.
58. 距状沟 calcarine sulcus
59. 大脑脚 cerebral peduncle
60. 中脑水管 mesencephalic aqueduct
61. 四叠体池 quadrigeminal cistern
62. 松果体 pineal body
63. 胼胝体压部 splenium of corpus callosum
64. 松果体上隐窝 suprapineal recess
65. 楔叶 cuneus
66. 顶枕沟 parietooccipital sulcus



67. 楔前叶 precuneus
68. 扣带沟缘支 marginal ramus of cingulate sulcus
69. 中央后回 postcentral gyrus
70. 顶骨 parietal bone
71. 帽状腱膜 epicranial aponeurosis
72. 侧脑室 lateral ventricle
73. 鞍上池 suprasellar cistern

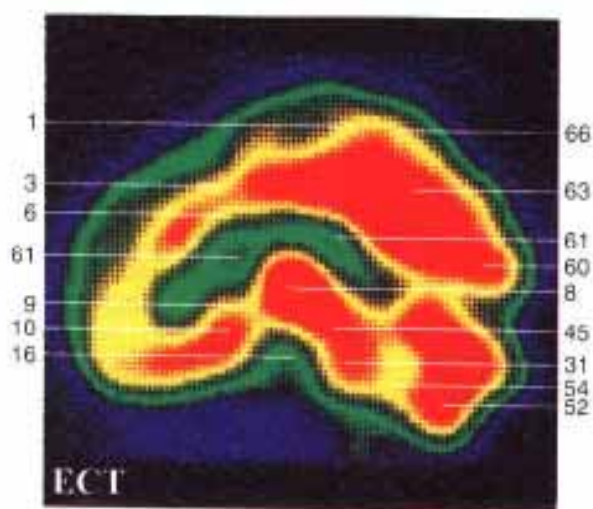
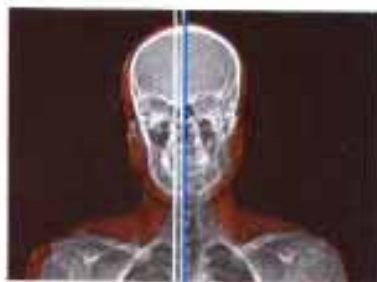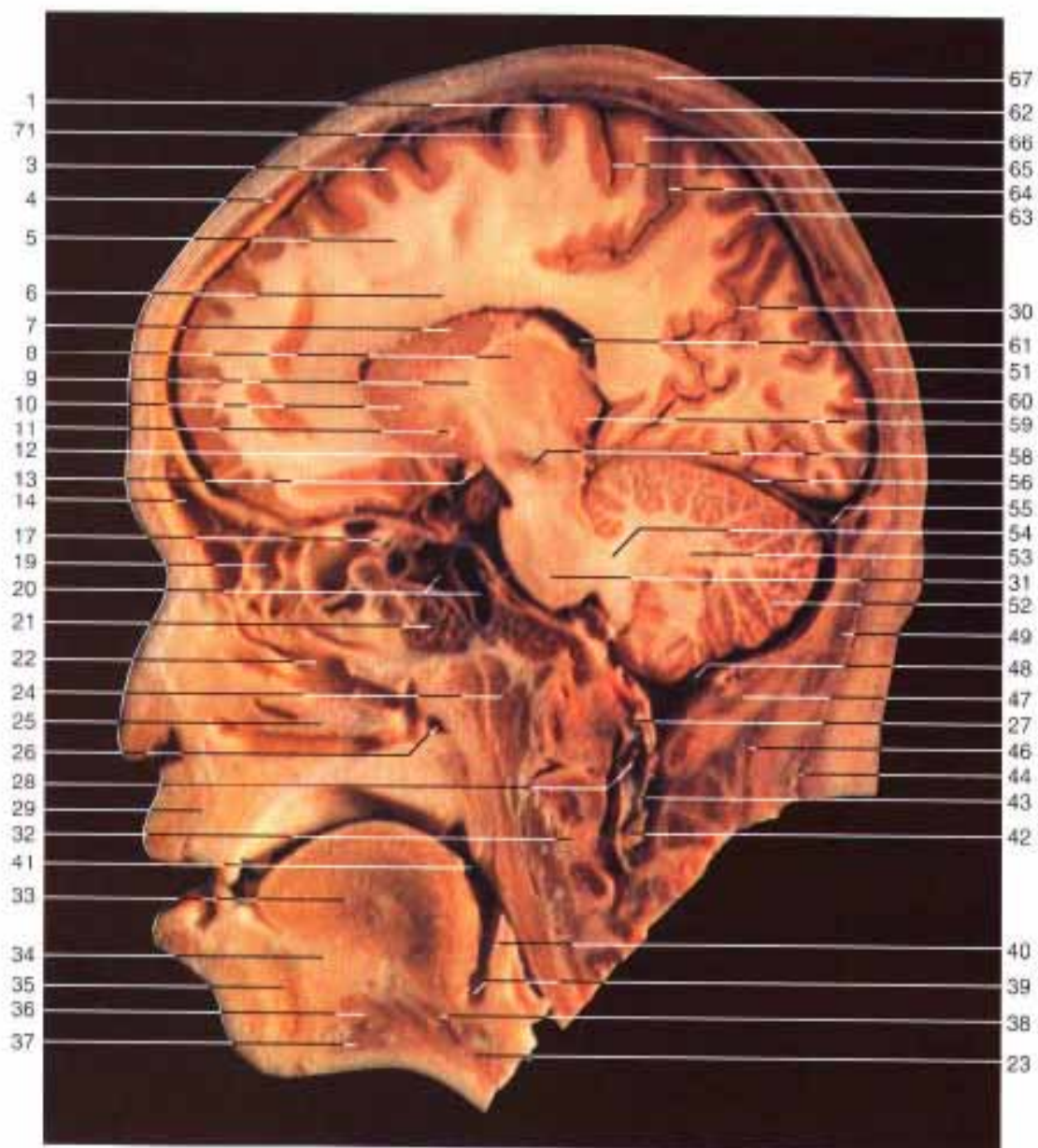
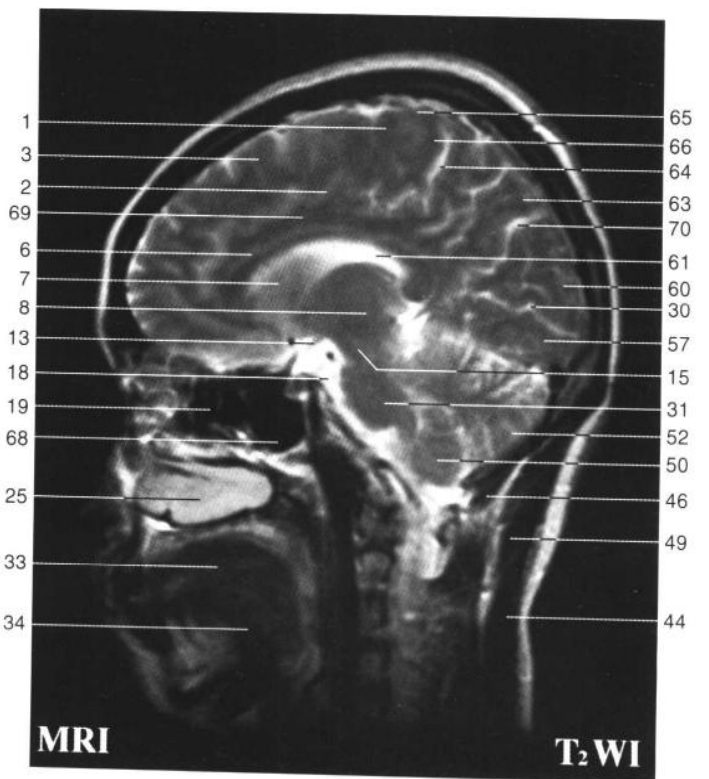
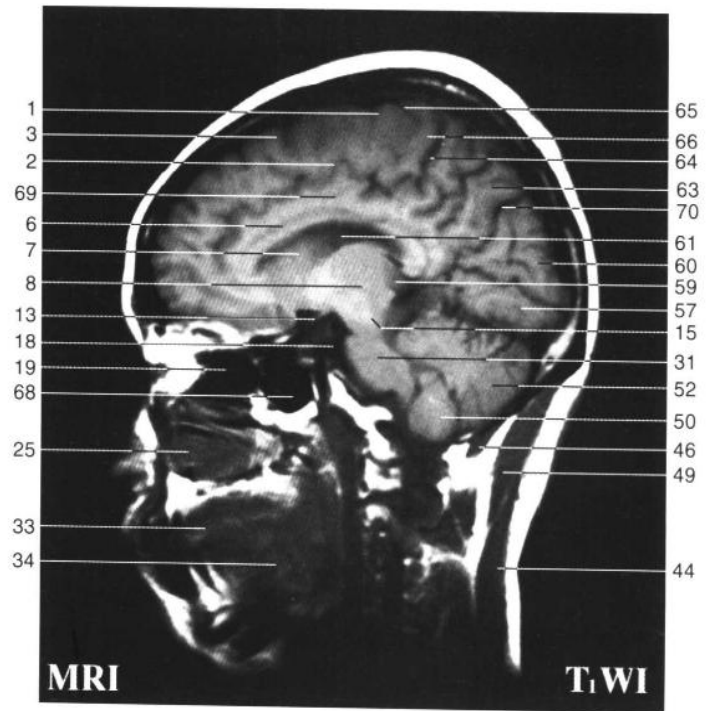


Fig. SC 8

Fig. SC 8

1. 中央前回 precentral gyrus
2. 扣带沟 cingulate sulcus
3. 额上回 superior frontal gyrus
4. 额骨 frontal bone
5. 辐射冠(半卵圆中心) corona radiata (centrum semiovale)
6. 胼胝体 corpus callosum
7. 尾状核体 body of caudate nucleus
8. 背侧丘脑 dorsal thalamus
9. 内囊膝 genu of internal capsule
10. 尾状核头 head of caudate nucleus
11. 前连合 anterior commissure
12. 隔核 nuclei septi
13. 视束 optic tract
14. 额窦 frontal sinus
15. 大脑脚 cerebral peduncle
16. 脚间池 interpeduncular cistern
17. 视神经 optic n.
18. 桥池 pontine cistern
19. 筛窦 ethmoidal sinuses
20. 海绵窦与颈内动脉 cavernous sinus and internal carotid a.
21. 蝶骨 sphenoid bone
22. 中鼻道 middle nasal meatus
23. 舌骨 hyoid bone
24. 头长肌 longus capitis
25. 下鼻甲 inferior nasal concha
26. 咽鼓管咽口 pharyngeal opening of auditory tube
27. 第1颈神经 1st cervical n.
28. 第2颈神经 2nd cervical n.
29. 上颌骨 maxilla
30. 距状沟 calcarine sulcus
31. 脑桥 pons
32. 2,3颈椎间盘 intervertebral disc (C₂ - C₃)
33. 舌 tongue
34. 舌下腺 sublingual gland
35. 下颌骨 mandible
36. 颞舌骨肌 geniohyoid
37. 下颌舌骨肌 mylohyoid
38. 舌骨舌肌 hyoglossus
39. 会厌谷 epiglottic vallecula
40. 会厌 epiglottis
41. 口咽 oropharynx
42. 第3颈神经 3rd cervical n.
43. 副神经脊髓根 spinal root of accessory n.
44. 头夹肌 splenius capitis
45. 中脑 midbrain
46. 头后大直肌 rectus capitis posterior major
47. 头后小直肌 rectus capitis posterior minor
48. 小脑延髓池 cerebellomedullary cistern
49. 头半棘肌 semispinalis capitis
50. 小脑扁桃体 tonsil of cerebellum
51. 枕骨 occipital bone
52. 小脑半球 cerebellar hemisphere
53. 齿状核 dentate nucleus
54. 小脑中脚 middle cerebellar peduncle
55. 横窦 transverse sinus
56. 小脑幕 tentorium of cerebellum
57. 舌回 lingual gyrus
58. 黑质 substantia nigra
59. 丘脑枕 pulvinar
60. 楔叶 cuneus
61. 侧脑室 lateral ventricle
62. 顶骨 parietal bone



63. 楔前叶 precuneus lobe
64. 扣带沟缘支 marginal ramus of cingulate sulcus
65. 中央沟 central sulcus
66. 中央后回 postcentral gyrus
67. 帽状腱膜 epicranial aponeurosis
68. 蝶窦 sphenoidal sinus
69. 扣带回 cingulate gyrus
70. 顶枕沟 parietooccipital sulcus
71. 中央前沟 precentral sulcus

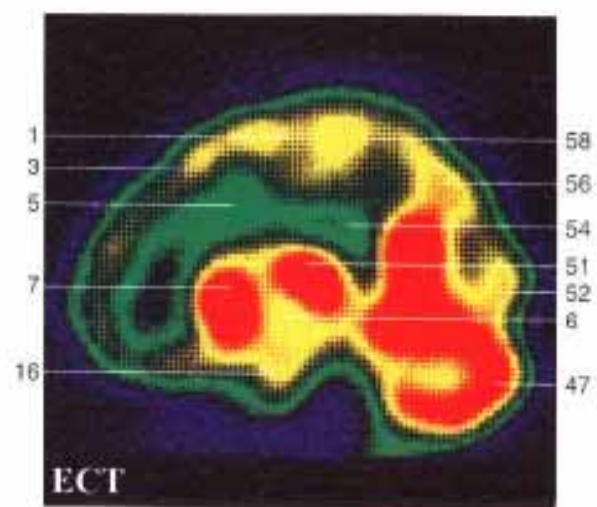
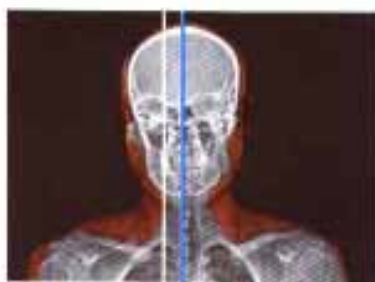
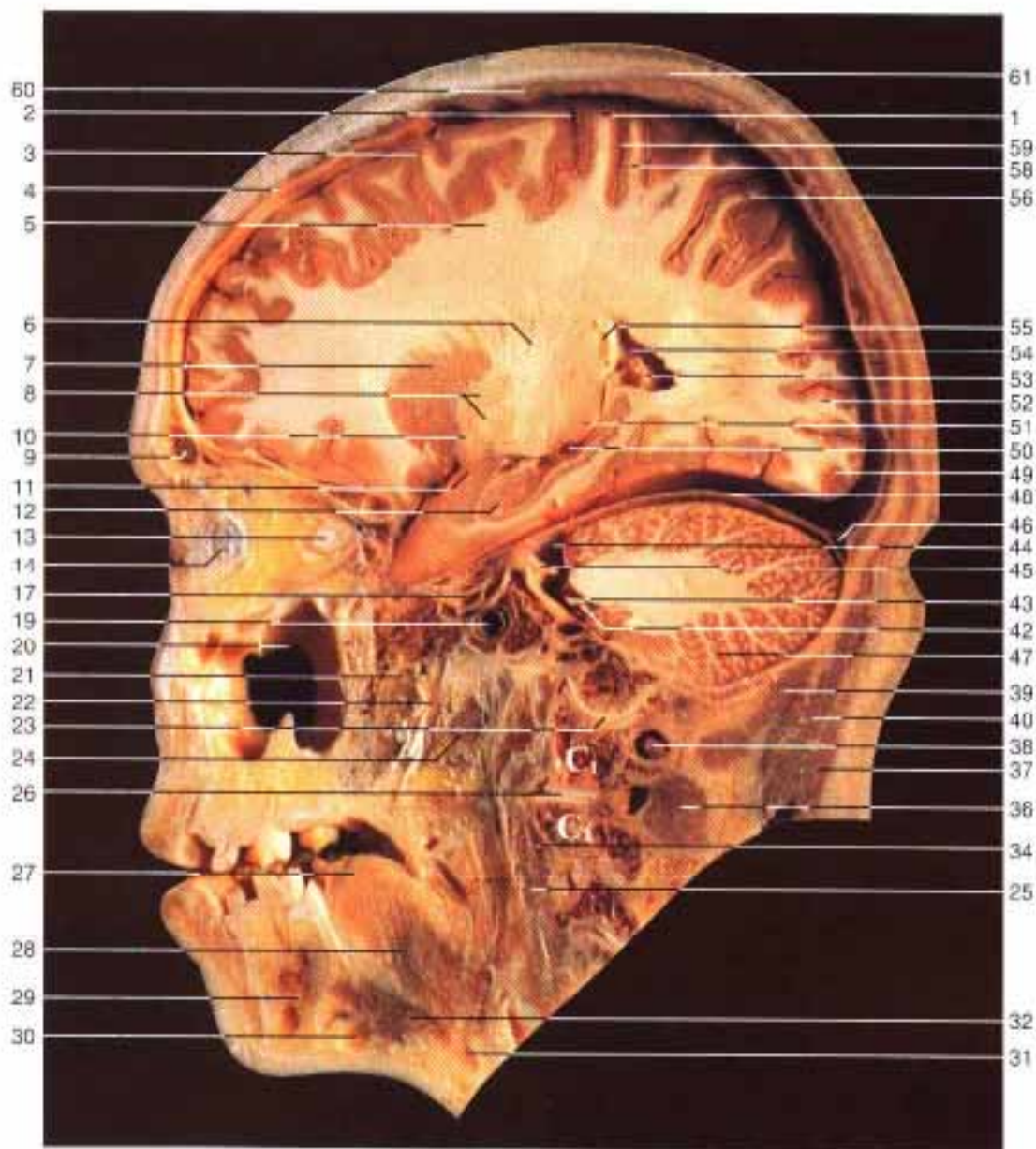
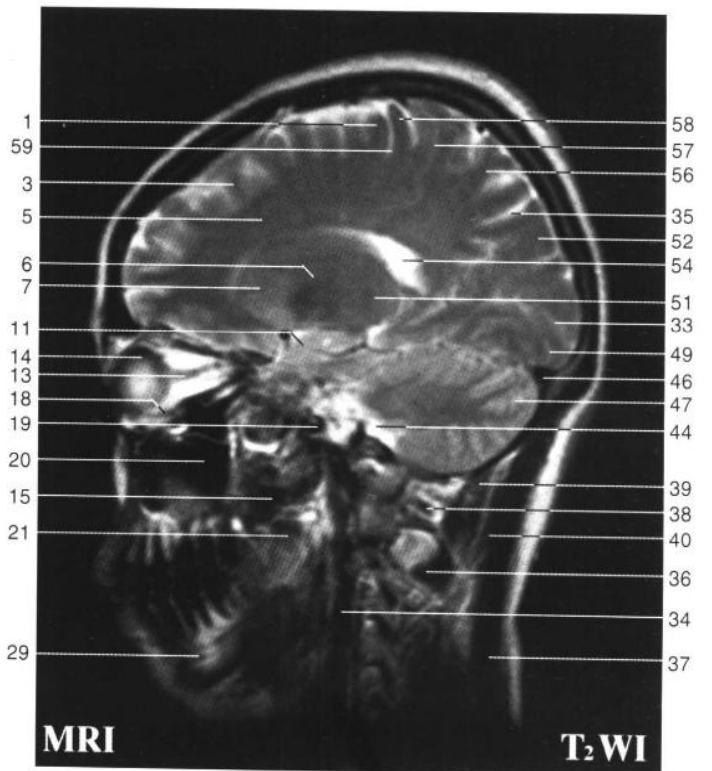
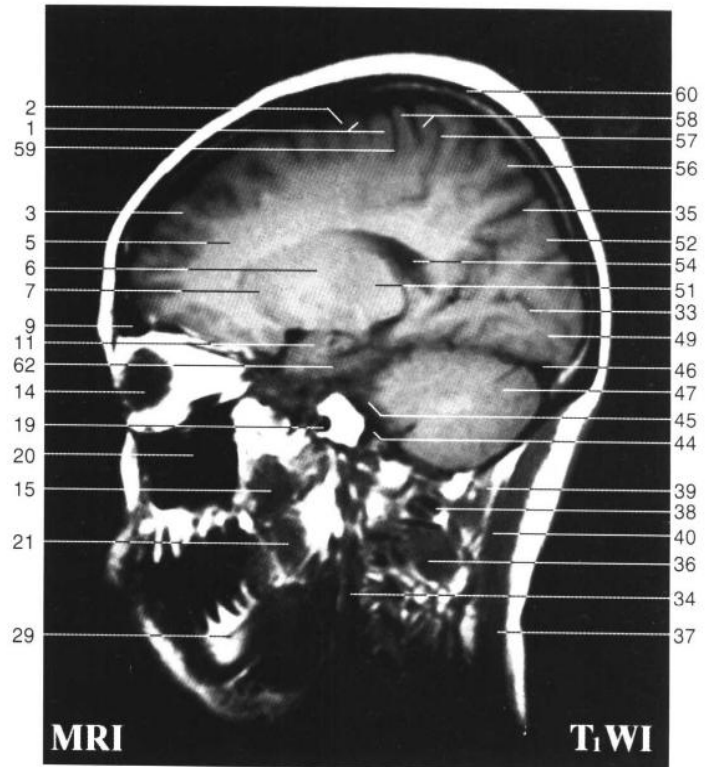


Fig. SC 9

Fig. SC 9

1. 中央前回 precentral gyrus
2. 中央前沟 precentral sulcus
3. 额上回 superior frontal gyrus
4. 额骨 frontal bone
5. 辐射冠(半卵圆中心) corona radiata (centrum semiovale)
6. 内囊后肢 posterior limb of internal capsule
7. 壳 putamen
8. 苍白球 globus pallidus
9. 额窦 frontal sinus
10. 前连合 anterior commissure
11. 杏仁体 amygdaloid body
12. 海马 hippocampus
13. 视神经 optic n.
14. 眼球 eyeball
15. 翼外肌 lateral pterygoid
16. 颞极 temporal pole
17. 三叉神经节 trigeminal ganglion
18. 下直肌 inferior rectus
19. 颈内动脉 internal carotid a.
20. 上颌窦 maxillary sinus
21. 翼内肌 medial pterygoid
22. 腭帆张肌 tensor veli palatini
23. 寰枕关节 atlantooccipital joint
24. 腭帆提肌 levator veli palatini
25. 头长肌 longus capitis
26. 寰枢关节 atlantoaxial joint
27. 舌 tongue
28. 舌骨舌肌 hyoglossus
29. 下牙槽神经 inferior alveolar n.
30. 二腹肌 digastric
31. 舌骨 hyoid bone
32. 颞舌骨肌 geniohyoid
33. 距状沟 calcarine sulcus
34. 颈长肌 longus colli
35. 顶枕沟 parietooccipital sulcus
36. 头下斜肌 obliquus capitis inferior
37. 头夹肌 splenius capitis
38. 横突孔与椎动脉 transverse foramen and vertebral a.
39. 头后大直肌 rectus capitis posterior major
40. 头半棘肌 semispinalis capitis
41. 岩下窦 inferior petrosal sinus
42. 前庭蜗神经 vestibulocochlear n.
43. 面神经 facial n.
44. 脑桥小脑三角池 cistern of pontocerebellar trigone
45. 三叉神经根 root of trigeminal n.
46. 横窦 transverse sinus
47. 小脑半球 cerebellar hemisphere
48. 小脑幕 tentorium of cerebellum
49. 舌回 lingual gyrus
50. 侧脑室下角 inferior horn of lateral ventricle
51. 背侧丘脑 dorsal thalamus
52. 楔叶 cuneus
53. 侧脑室脉络丛 choroid plexus of lateral ventricle
54. 侧脑室三角 trigone of lateral ventricle
55. 尾状核尾 tail of caudate nucleus
56. 顶上小叶 superior parietal lobule
57. 中央后沟 postcentral sulcus
58. 中央后回 postcentral gyrus
59. 中央沟 central sulcus



60. 顶骨 parietal bone
61. 帽状腱膜 epicranial aponeurosis
62. 海马旁回 parahippocampal gyrus

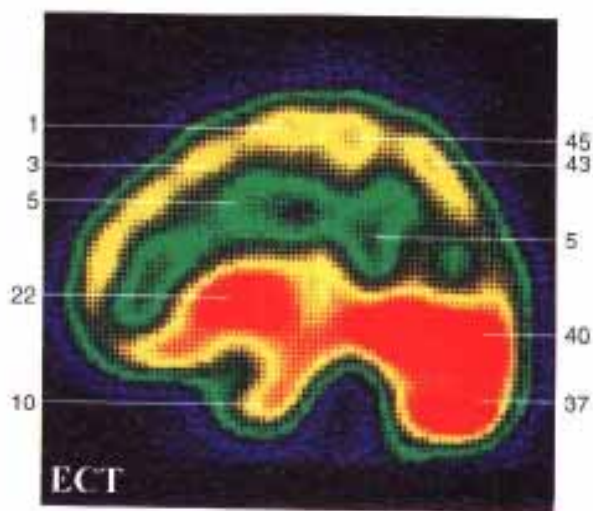
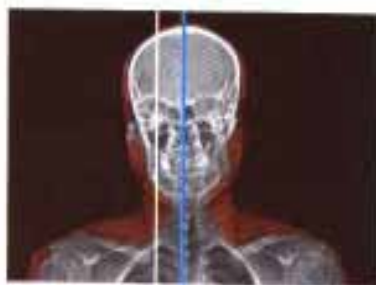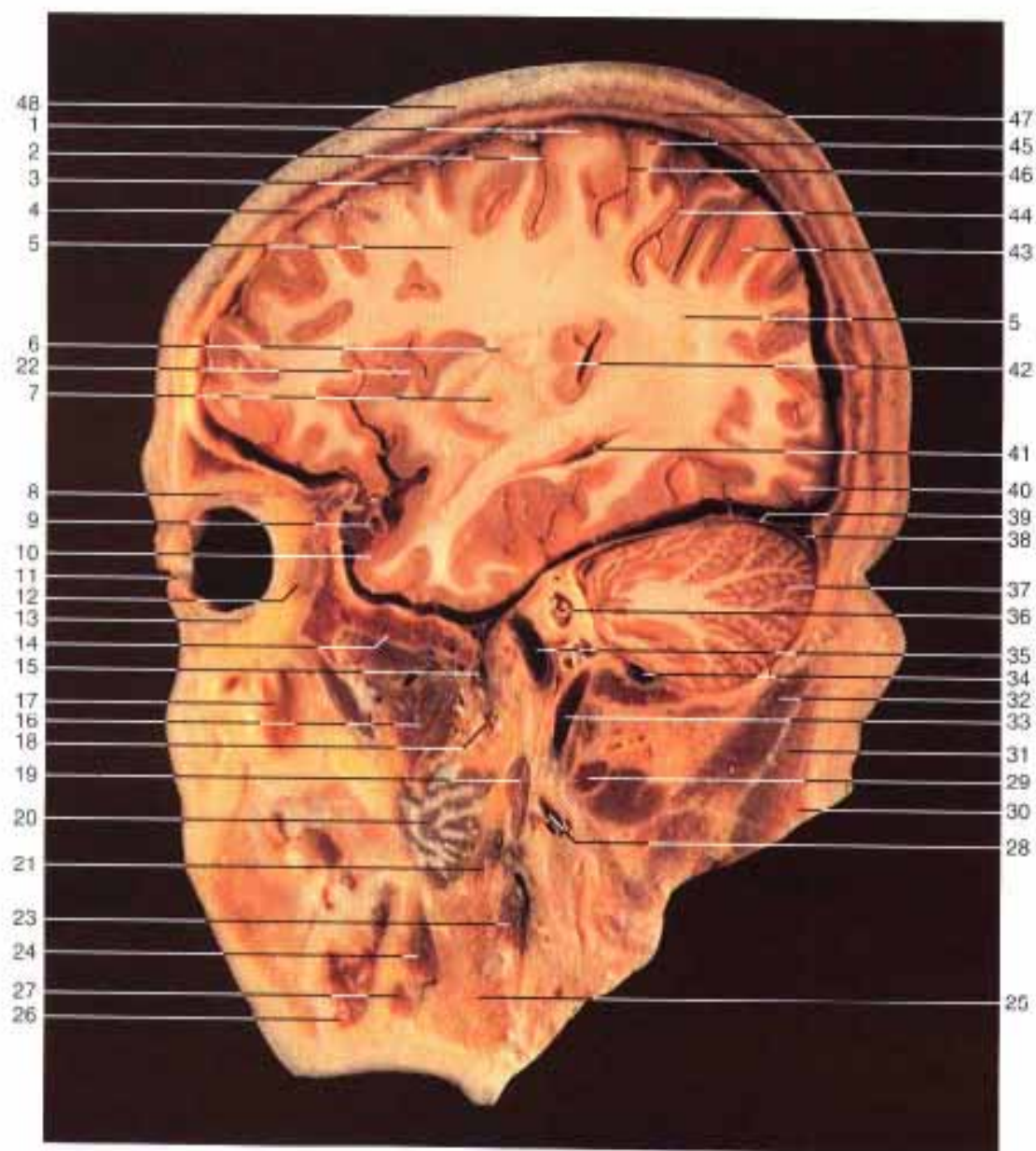
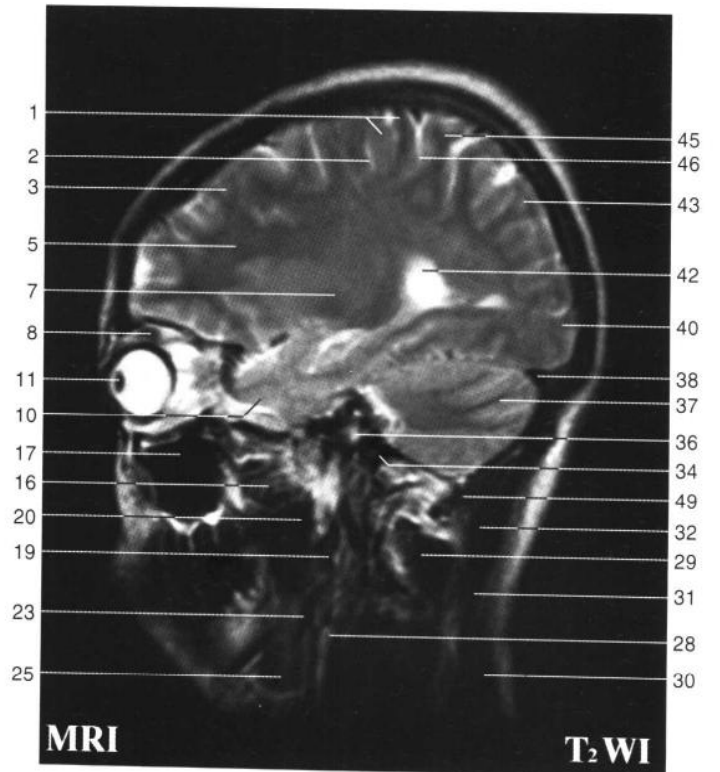
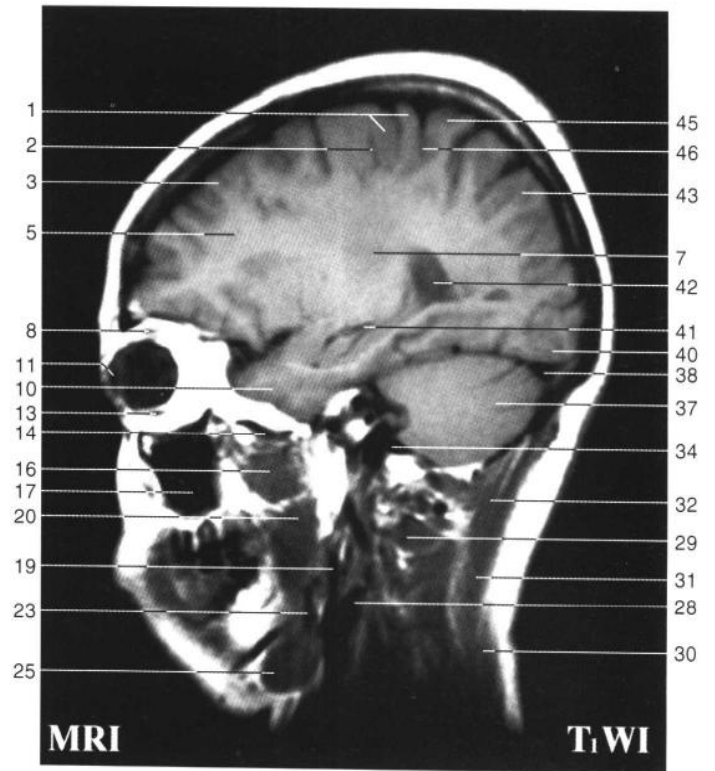


Fig. SC 10

Fig. SC 10

1. 中央前回 precentral gyrus
2. 中央前沟 precentral sulcus
3. 额中回 middle frontal gyrus
4. 额骨 frontal bone
5. 辐射冠(半卵圆中心) corona radiata (centrum semiovale)
6. 屏状核 claustrum
7. 壳 putamen
8. 上睑提肌与上直肌 levator palpebrae superioris and superior rectus
9. 大脑中动脉 middle cerebral a.
10. 颞极 temporal pole
11. 角膜 cornea
12. 外直肌 lateral rectus
13. 下直肌 inferior rectus
14. 蝶骨大翼 greater wing of sphenoid bone
15. 脑膜中动脉 middle meningeal a.
16. 翼外肌 lateral pterygoid
17. 上颌窦 maxillary sinus
18. 上颌动脉 maxillary a.
19. 茎突咽肌 stylopharyngeus
20. 翼内肌 medial pterygoid
21. 茎突舌肌 styloglossus
22. 岛叶 insular lobe
23. 二腹肌与茎突舌骨肌 digastric and stylohyoid
24. 下颌舌骨肌 mylohyoid
25. 下颌下腺 submandibular gland
26. 下颌骨 mandible
27. 下颌下淋巴结 submandibular lymph nodes
28. 颈内动脉 internal carotid a.
29. 头下斜肌 obliquus capitis inferior
30. 斜方肌 trapezius
31. 头夹肌 splenius capitis
32. 头半棘肌 semispinalis capitis
33. 颈内静脉 internal jugular v.
34. 乙状窦 sigmoid sinus
35. 颈内动脉 internal carotid a.
36. 面神经与前庭蜗神经 facial n. and vestibulocochlear n.
37. 小脑半球 cerebellar hemisphere
38. 横窦 transverse sinus
39. 小脑幕 tentorium of cerebellum
40. 枕叶 occipital lobe
41. 侧脑室下角 inferior horn of lateral ventricle
42. 岛叶 insular lobe
43. 顶上小叶 superior parietal lobule
44. 中央后沟 postcentral sulcus
45. 中央后回 postcentral gyrus
46. 中央沟 central sulcus
47. 顶骨 parietal bone
48. 帽状腱膜 epicranial aponeurosis
49. 头后大直肌 rectus capitis posterior major



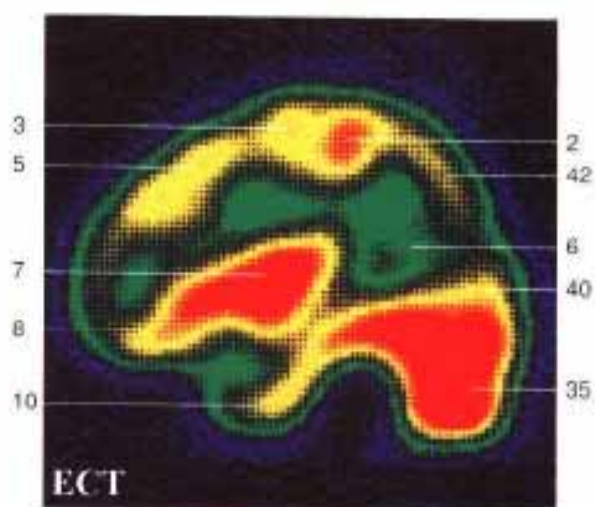
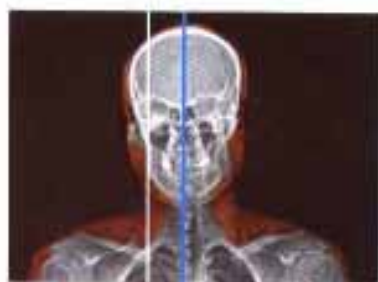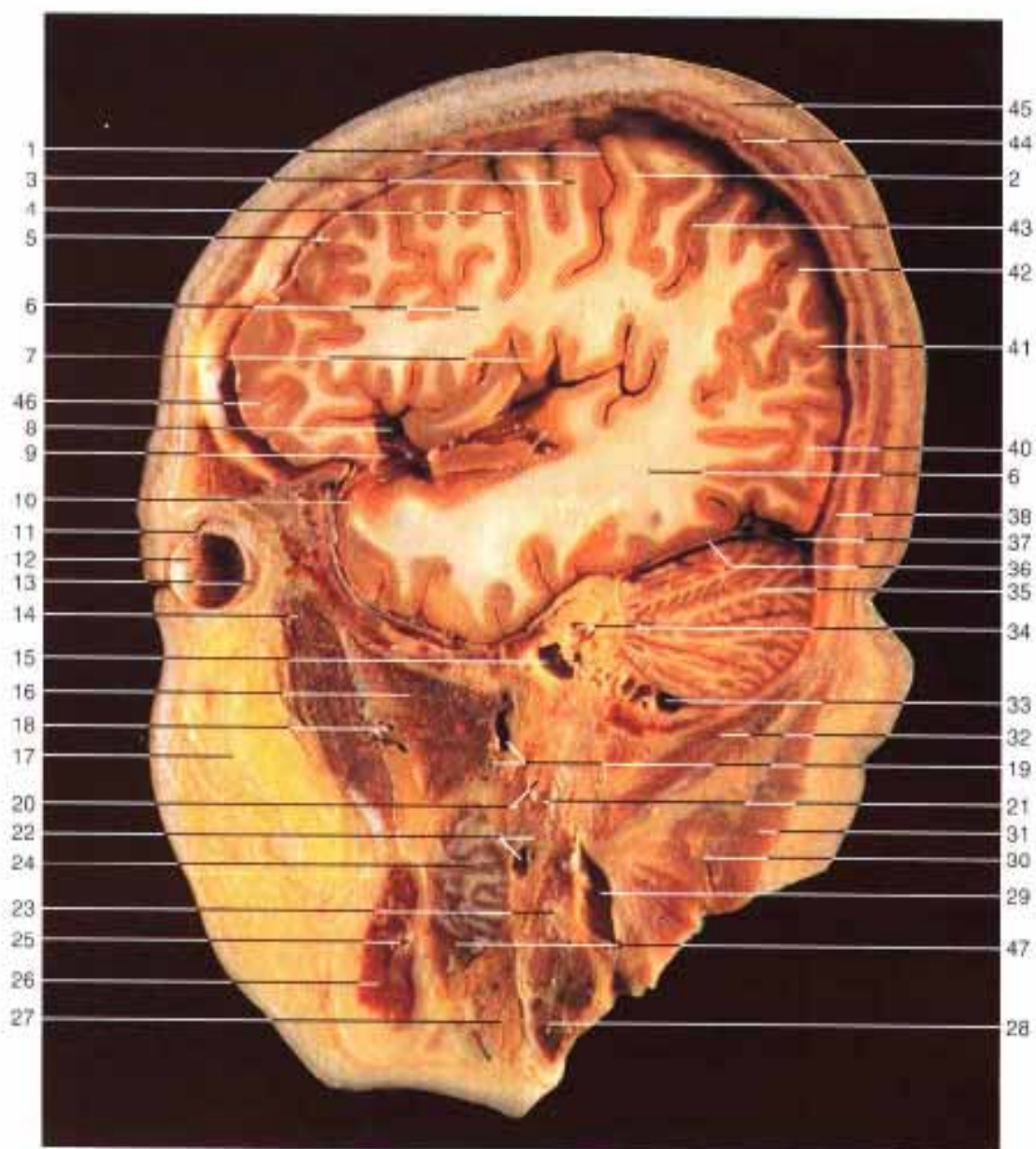
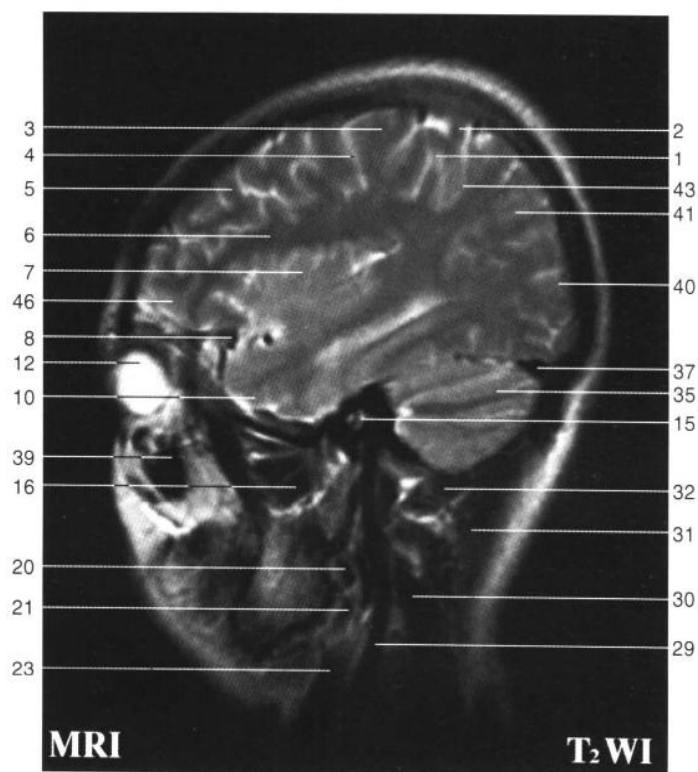
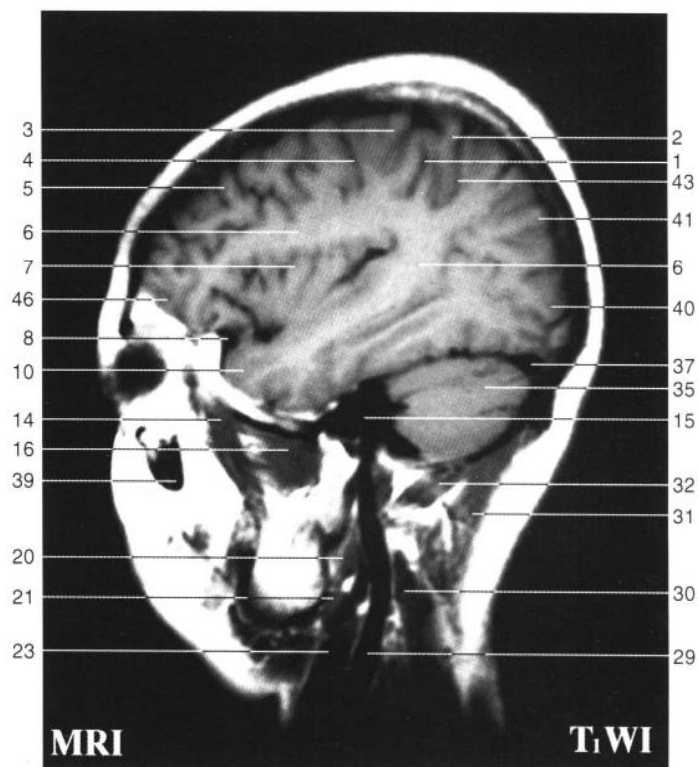


Fig. SC 11

Fig. SC 11

1. 中央沟 central sulcus
2. 中央后回 postcentral gyrus
3. 中央前回 precentral gyrus
4. 中央前沟 precentral sulcus
5. 额中回 middle frontal gyrus
6. 辐射冠 corona radiata
7. 岛叶 insular lobe
8. 外侧沟 lateral sulcus
9. 大脑中动脉 middle cerebral a.
10. 颞叶 temporal lobe
11. 上睑提肌及上直肌 levator palpebrae superioris and superior rectus
12. 眼球 eyeball
13. 外直肌 lateral rectus
14. 颞肌 temporalis
15. 鼓室 tympanic cavity
16. 翼外肌 lateral pterygoid
17. 上颌骨 maxilla
18. 上颌动、静脉 maxillary a. and v.
19. 脑膜中动、静脉 middle meningeal a. and v.
20. 茎突与茎突舌肌 styloid process and styloglossus
21. 茎突咽肌 stylopharyngeus
22. 腮腺与下颌后静脉 parotid gland and retromandibular v.
23. 茎突舌骨肌 stylohyoid
24. 翼内肌 medial pterygoid
25. 下牙槽神经 inferior alveolar n.
26. 下颌骨 mandible
27. 下颌下腺 submandibular gland
28. 下颌下淋巴结 submandibular lymph nodes
29. 颈内静脉 internal jugular v.
30. 头半棘肌 semispinalis capitis
31. 头夹肌 splenius capitis
32. 头上斜肌 obliquus capitis superior
33. 乙状窦 sigmoid sinus
34. 前庭与半规管 vestibule and semicircular canals
35. 小脑半球 cerebellar hemisphere
36. 小脑幕 tentorium of cerebellum
37. 横窦 transverse sinus
38. 枕骨 occipital bone
39. 上颌窦 maxillary sinus
40. 枕叶 occipital lobe
41. 角回 angular gyrus
42. 缘上回 supramarginal gyrus
43. 中央后沟 postcentral sulcus
44. 顶骨 parietal bone
45. 帽状腱膜 epicranial aponeurosis
46. 额下回 inferior frontal gyrus
47. 下颌舌骨肌 mylohyoid



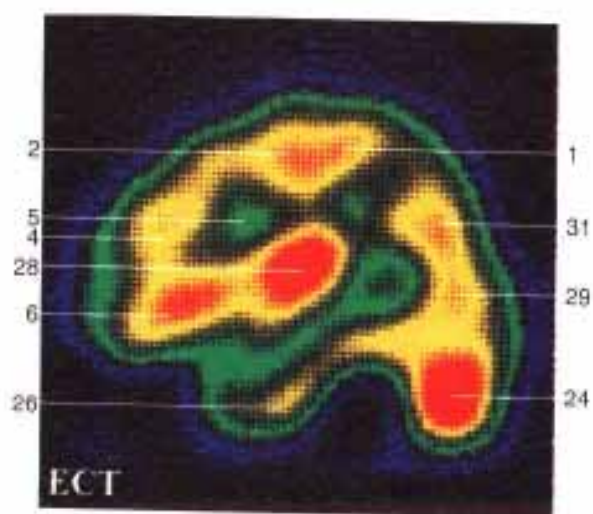
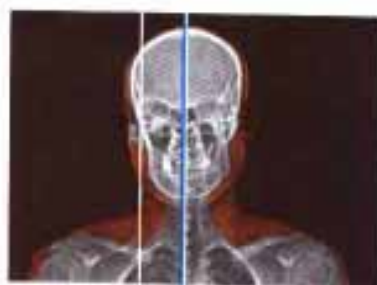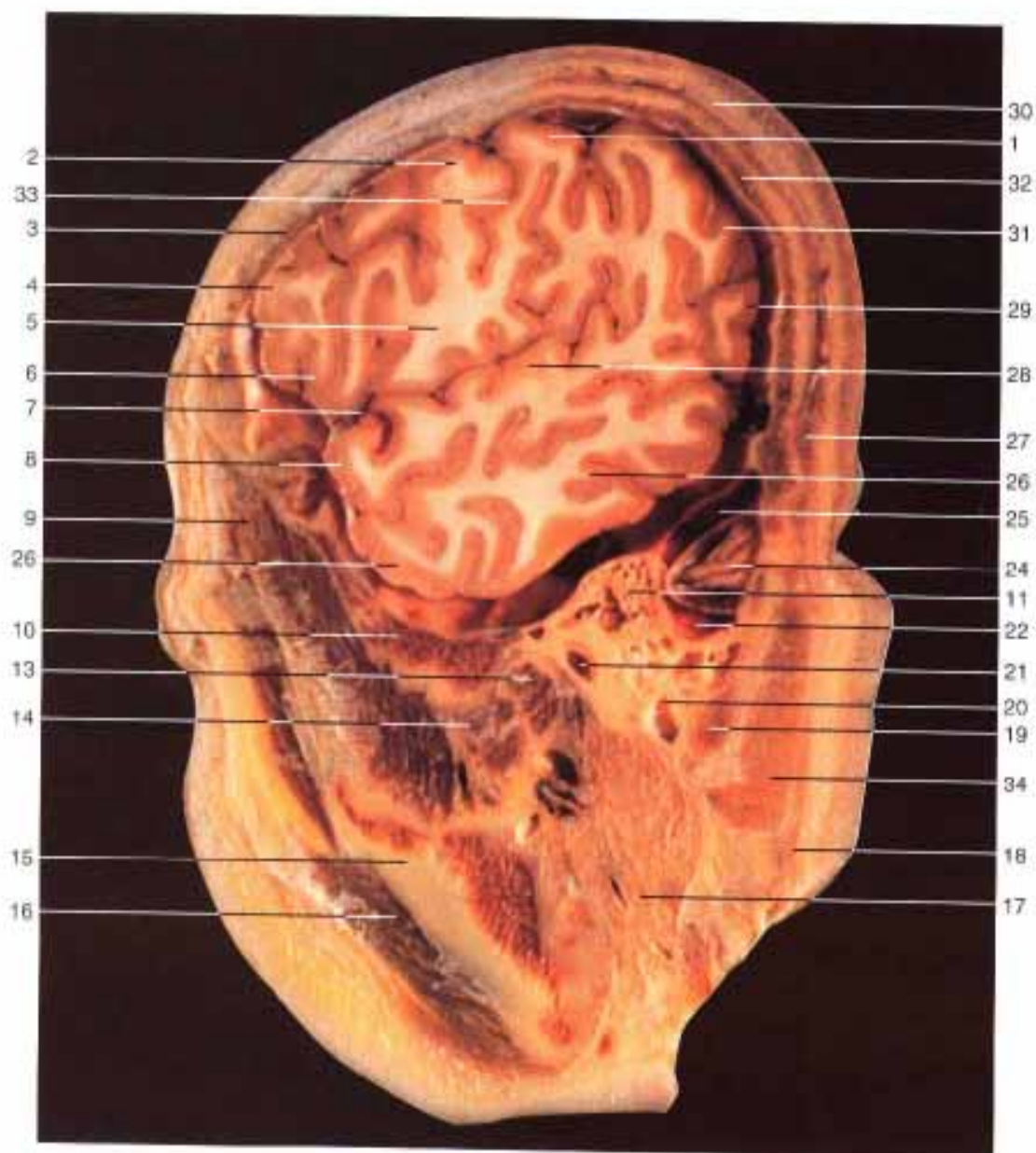
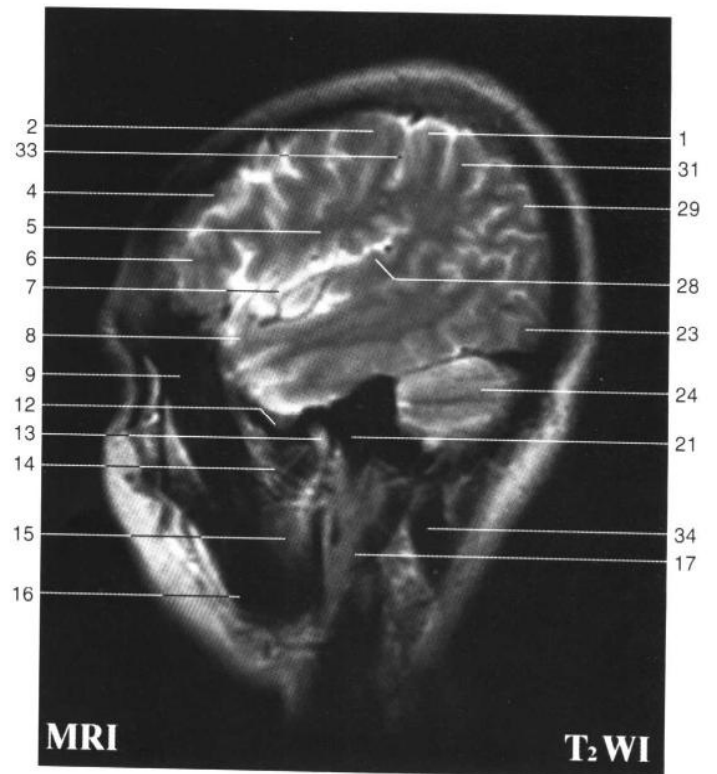
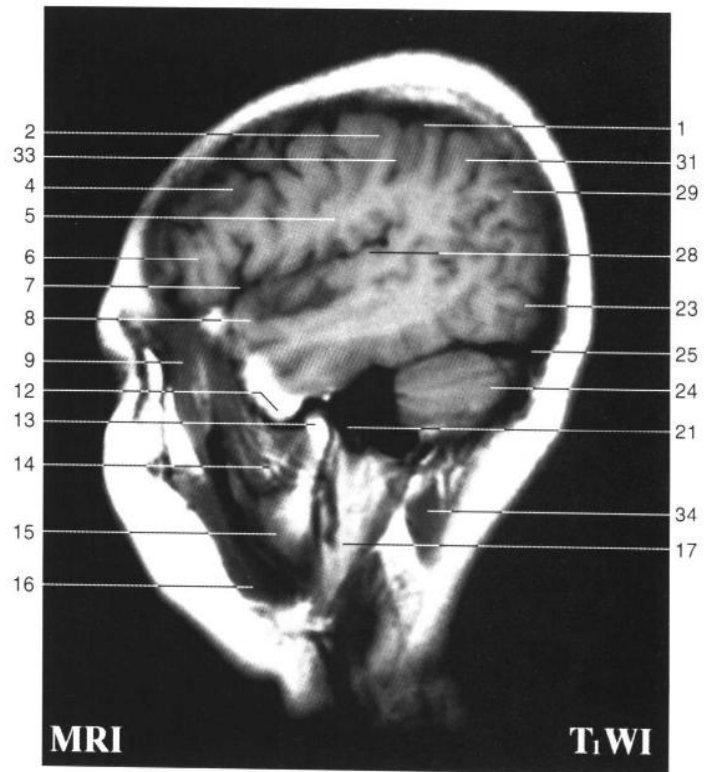


Fig. SC 12

Fig. SC 12

1. 中央后回 postcentral gyrus
2. 中央前回 precentral gyrus
3. 额骨 frontal bone
4. 额中回 middle frontal gyrus
5. 辐射冠 corona radiata
6. 额下回 inferior frontal gyrus
7. 外侧沟 lateral sulcus
8. 颞上回 superior temporal gyrus
9. 颞肌 temporalis
10. 蝶骨大翼 greater wing of sphenoid bone
11. 颞骨岩部 petrous part of temporal bone
12. 关节结节 articular tubercle
13. 下颌骨髁突 condylar process of mandible
14. 翼外肌 lateral pterygoid
15. 下颌骨 mandible
16. 咬肌 masseter
17. 腮腺 parotid gland
18. 胸锁乳突肌 sternocleidomastoid
19. 二腹肌后腹 posterior belly of digastric
20. 乳突小房 mastoid cells
21. 外耳道 external acoustic meatus
22. 乙状窦 sigmoid sinus
23. 枕叶 occipital lobe
24. 小脑半球 cerebellar hemisphere
25. 横窦 transverse sinus
26. 颞中回 middle temporal gyrus
27. 枕额肌 occipitofrontalis
28. 颞横回 transverse temporal gyri
29. 角回 angular gyrus
30. 帽状腱膜 epicranial aponeurosis
31. 缘上回 supramarginal gyrus
32. 顶骨 parietal bone
33. 中央沟 central sulcus
34. 头夹肌 splenius capitis



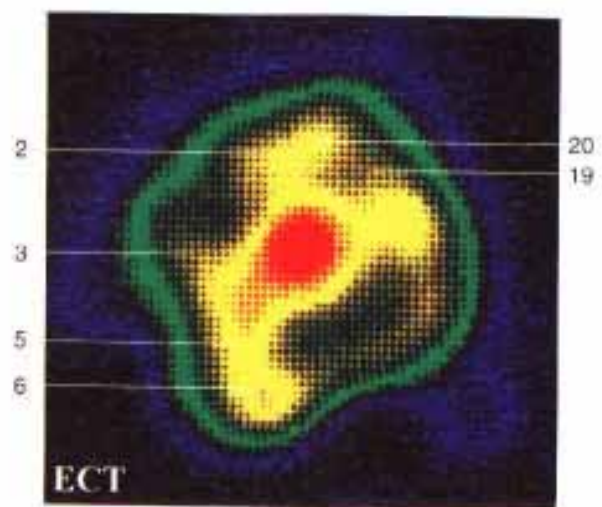
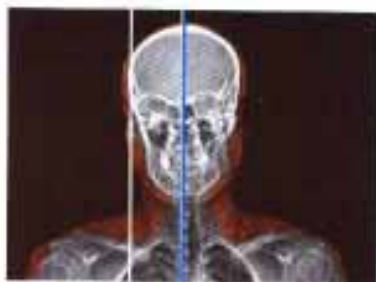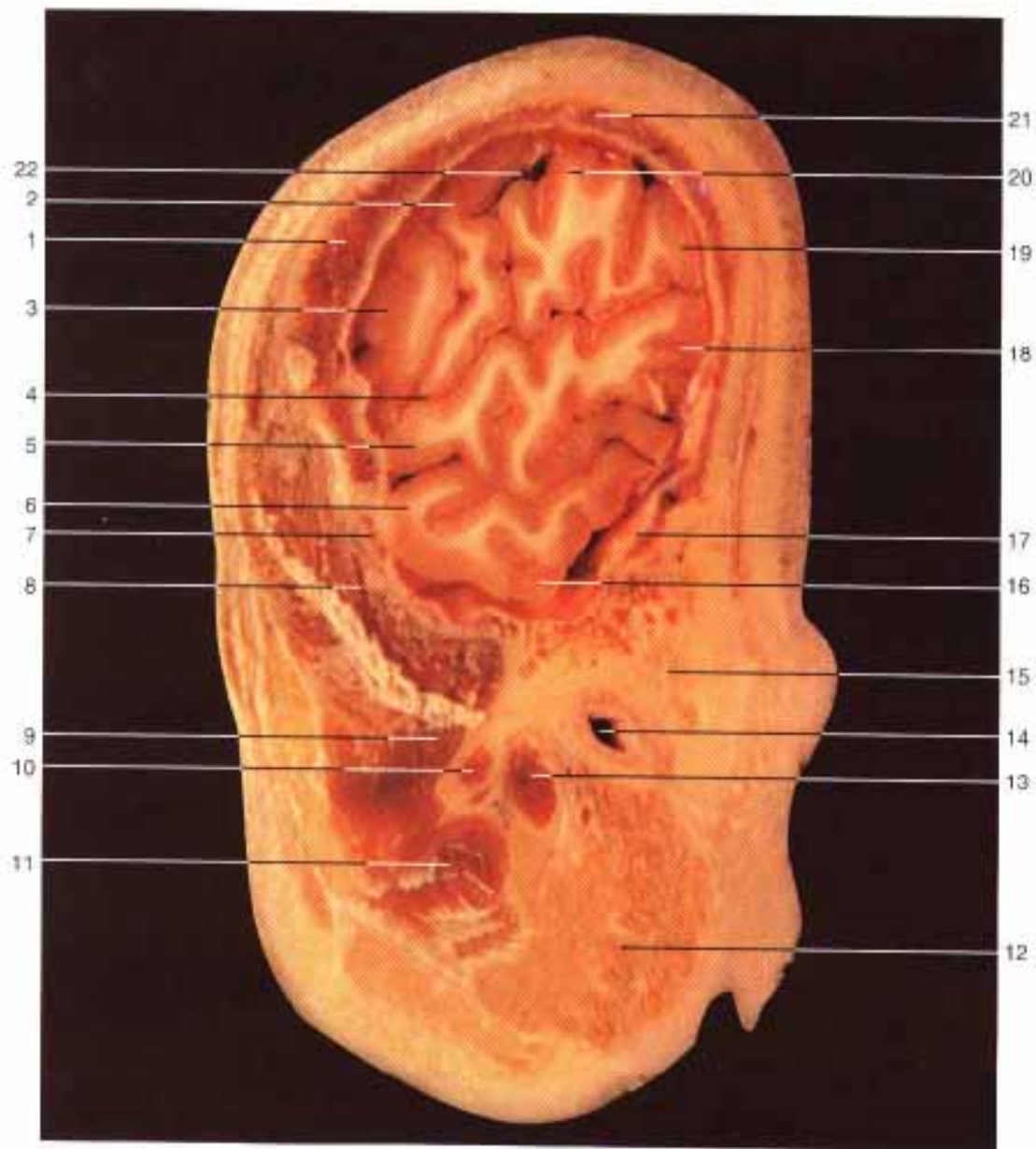


Fig. SC 13

Fig. SC 13

1. 额骨 frontal bone
2. 中央前回 precentral gyrus
3. 额下回 inferior frontal gyrus
4. 外侧沟 lateral sulcus
5. 颞上回 superior temporal gyrus
6. 颞中回 middle temporal gyrus
7. 蝶骨大翼 greater wing of sphenoid bone
8. 颞肌 temporalis
9. 颞肌 temporalis
10. 颧弓 zygomatic arch
11. 咬肌 masseter
12. 腮腺 parotid gland
13. 下颌骨髁突 condylar process of mandible
14. 外耳道 external acoustic meatus
15. 乳突小房 mastoid cells
16. 颞下回 inferior temporal gyrus
17. 颞骨 temporal bone
18. 角回 angular gyrus
19. 缘上回 supramarginal gyrus
20. 中央后回 postcentral gyrus
21. 顶骨 parietal bone
22. 中央沟 central sulcus

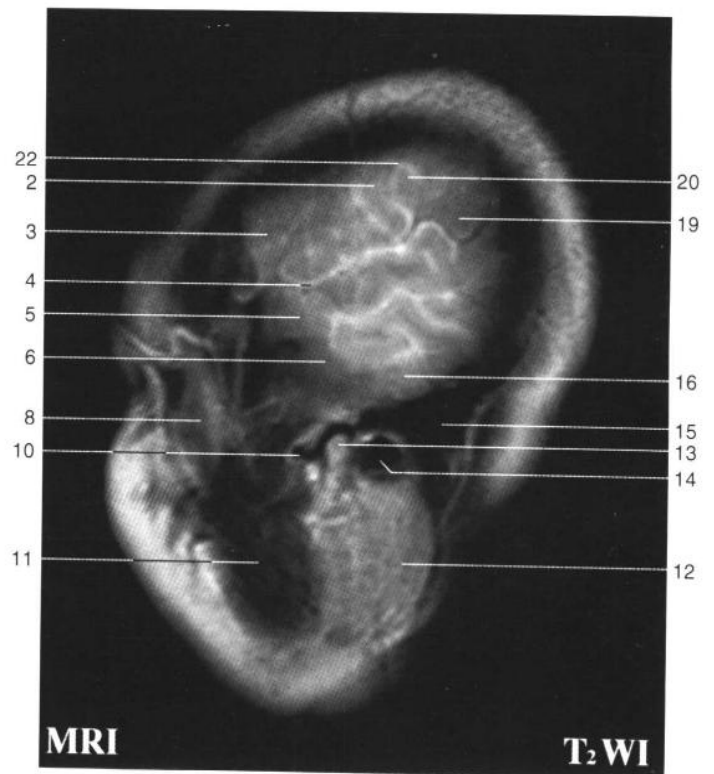
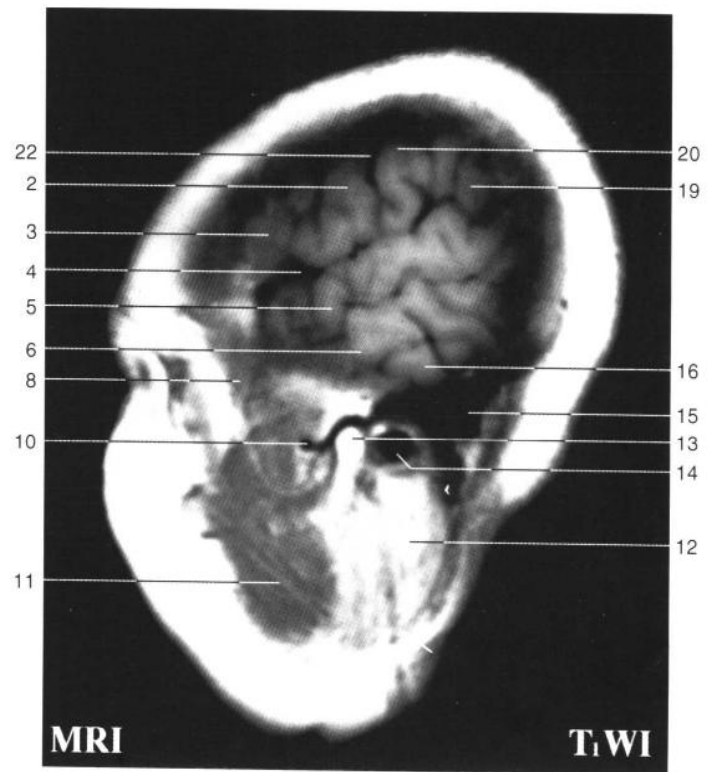


Fig. MRA

1. 颈内动脉 internal carotid a.
2. 颈外动脉 external carotid a.
3. 后交通动脉 posterior communicating a.
4. 颈内静脉 internal jugular v.
5. 脉络丛前动脉 anterior choroidal a.
6. 大脑前动脉 anterior cerebral a.
7. 大脑中动脉 middle cerebral a.
8. 大脑后动脉 posterior cerebral a.
9. 额叶前内侧支 anteromedial frontal branch
10. 小脑上动脉 superior cerebellar a.
11. 横窦 transverse sinus
12. 乙状窦 sigmoid sinus
13. 上矢状窦 superior sagittal sinus
14. 大脑上静脉 superior cerebral v.
15. 基底动脉 basilar a.
16. 直窦 straight sinus
17. 大脑大静脉 great cerebral v.
18. 中央沟动脉 artery of central sulcus
19. 角回动脉 artery of angular gyrus
20. 顶枕动脉 parietooccipital a.
21. 距状沟动脉 calcarine a.
22. 椎动脉 vertebral a.
23. 中央前沟动脉 artery of precentral sulcus
24. 中央后沟动脉 artery of postcentral sulcus
25. 额叶中内侧支 mediomedial frontal branch
26. 额叶后内侧支 posteromedial frontal branch
27. 旁中央动脉 paracentral a.
28. 楔前动脉 precuneal a.

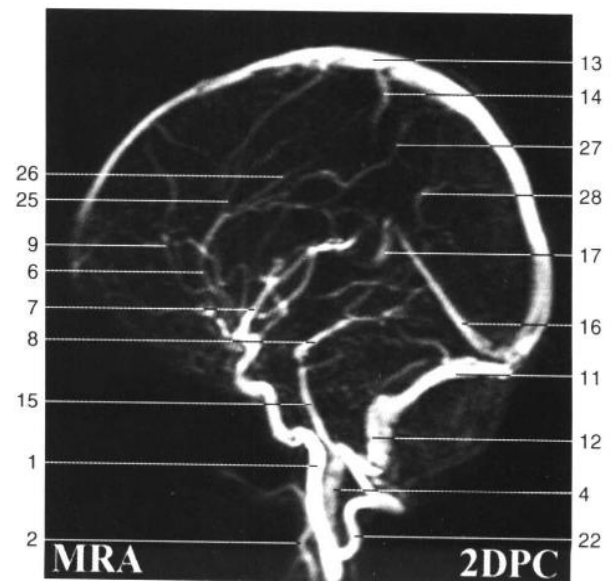
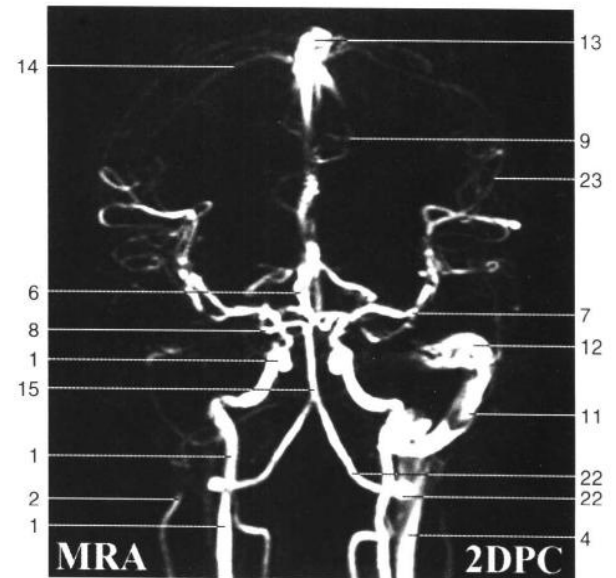
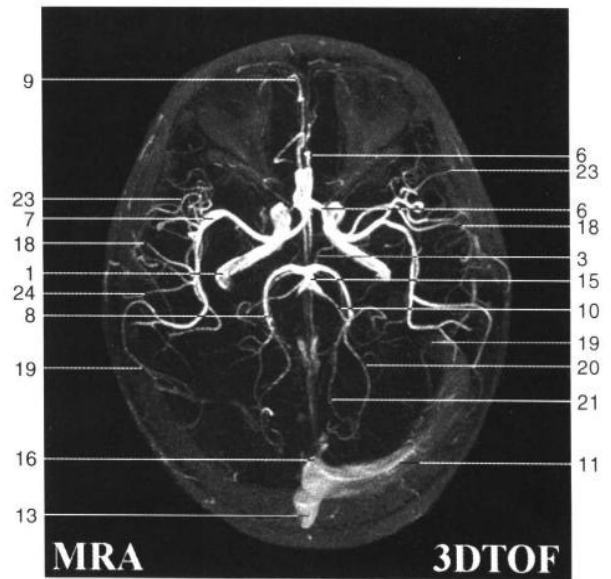


Fig. MRA

THORAX

胸部

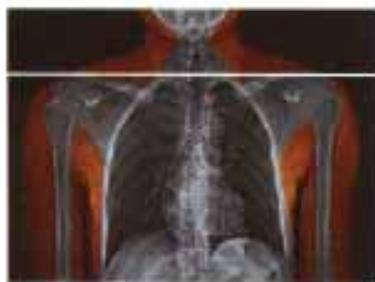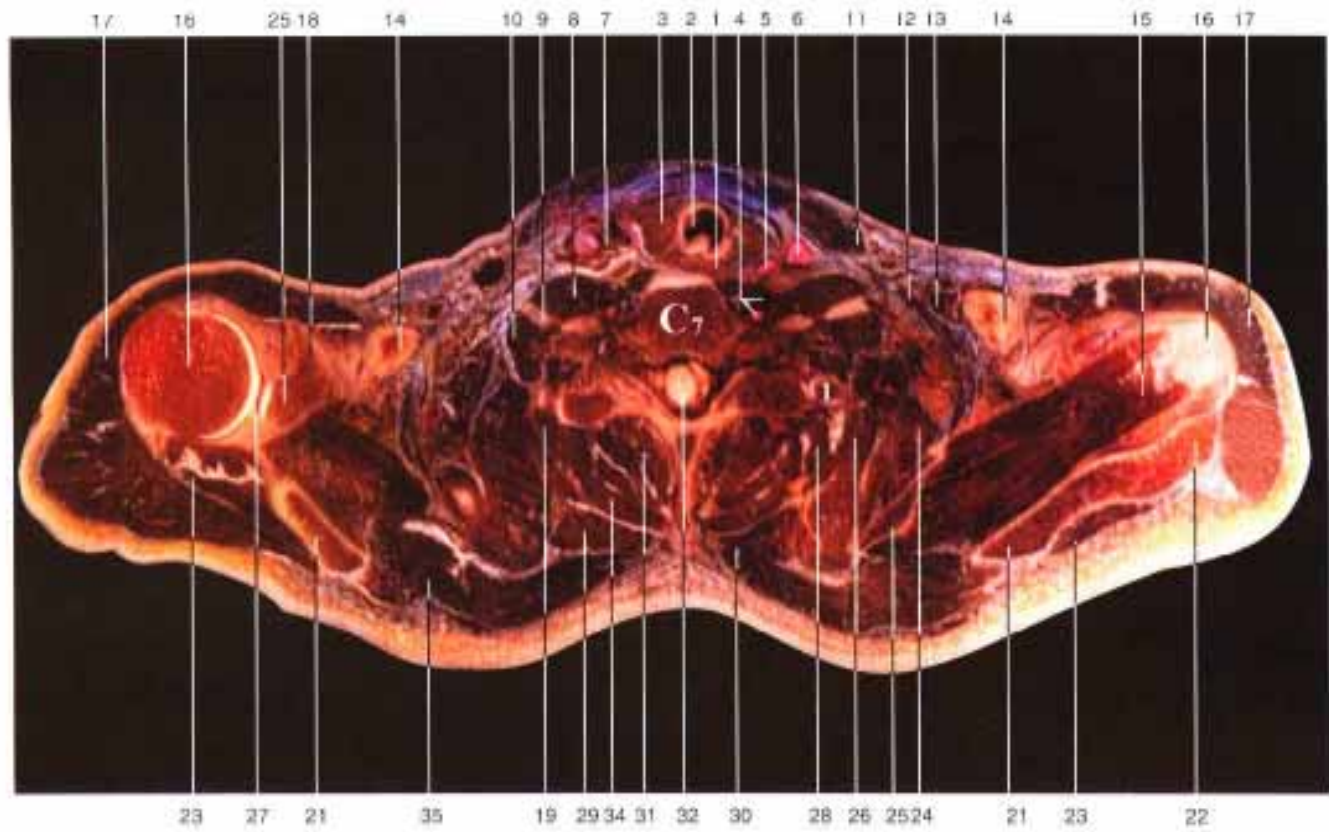
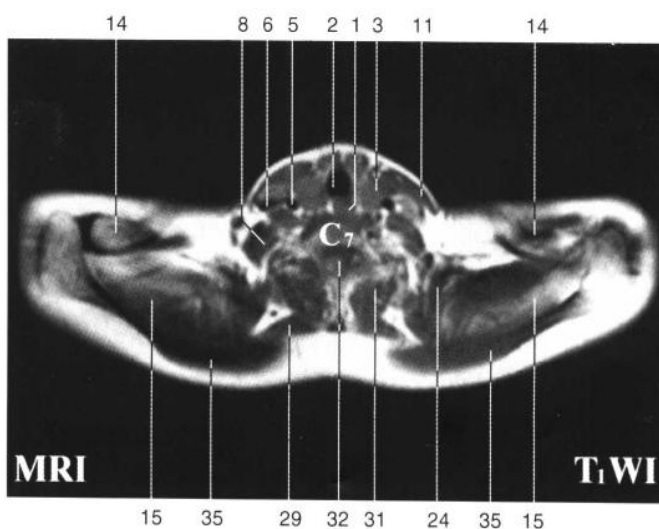
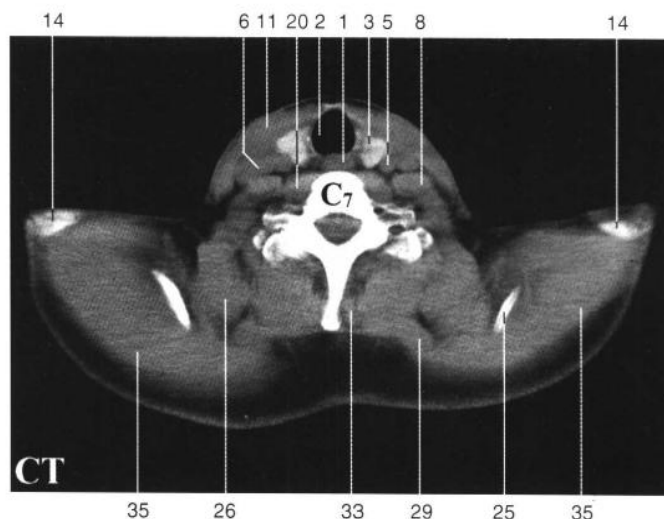


Fig. HT 1

1. 食管 esophagus
2. 气管 trachea
3. 甲状腺 thyroid gland
4. 椎动、静脉 vertebral a. and v.
5. 颈内动脉 internal carotid a.
6. 颈内静脉 internal jugular v.
7. 迷走神经 vagus n.
8. 前斜角肌 scalenus anterior
9. 臂丛 brachial plexus
10. 中斜角肌 scalenus medius
11. 胸锁乳突肌 sternocleidomastoid

Fig.HT 1

12. 肩胛舌骨肌 omohyoid
13. 颈外静脉 external jugular v.
14. 锁骨 clavicle
15. 冈上肌 supraspinatus
16. 肱骨头 head of humerus
17. 三角肌 deltoid
18. 喙突 coracoid process
19. 肋提肌 levatores costarum
20. 颈长肌 longus colli
21. 肩胛冈 spine of scapula
22. 肩峰 acromion
23. 冈下肌 infraspinatus
24. 肩胛提肌 levator scapulae
25. 肩胛骨 scapula
26. 前锯肌 serratus anterior
27. 肩关节 shoulder joint
28. 上后锯肌 serratus posterior superior
29. 小菱形肌 rhomboideus minor
30. 大菱形肌 rhomboideus major
31. 多裂肌与回旋肌 multifidi and rotatores
32. 脊髓 spinal cord
33. 颈半棘肌 semispinalis cervicis
34. 头夹肌 splenius capitis
35. 斜方肌 trapezius



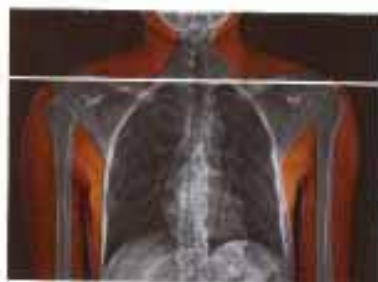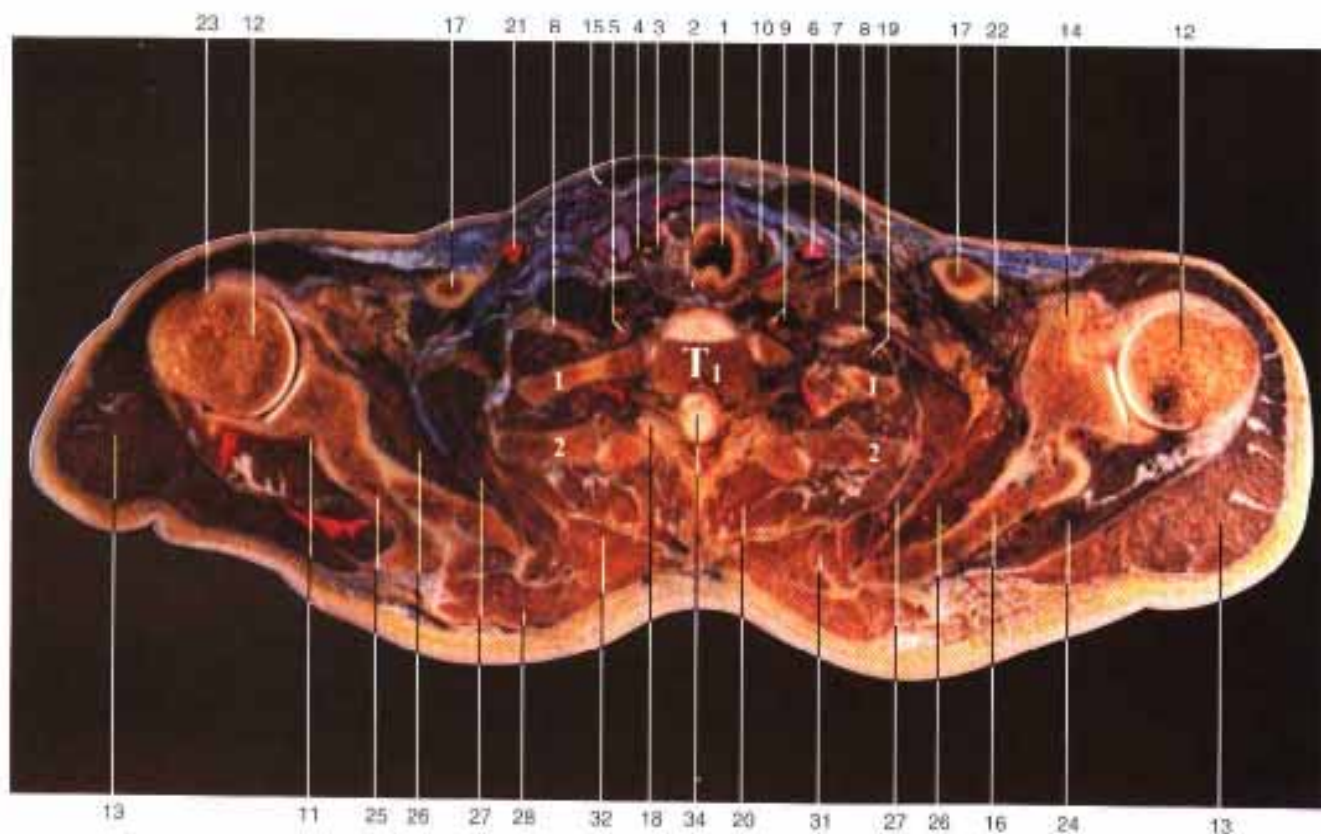
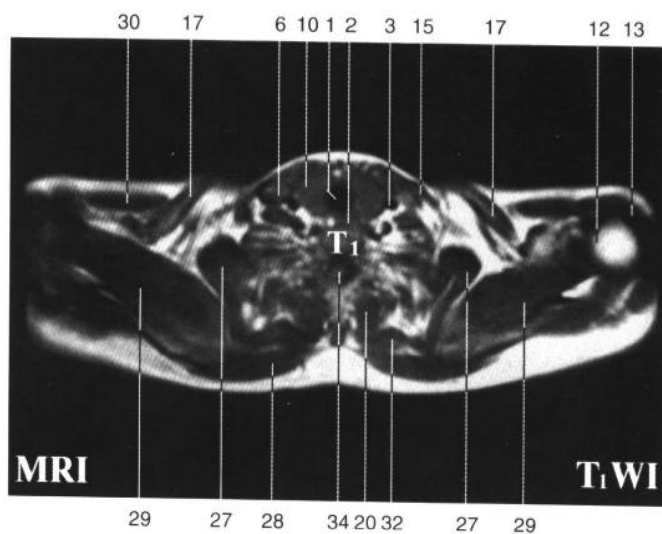
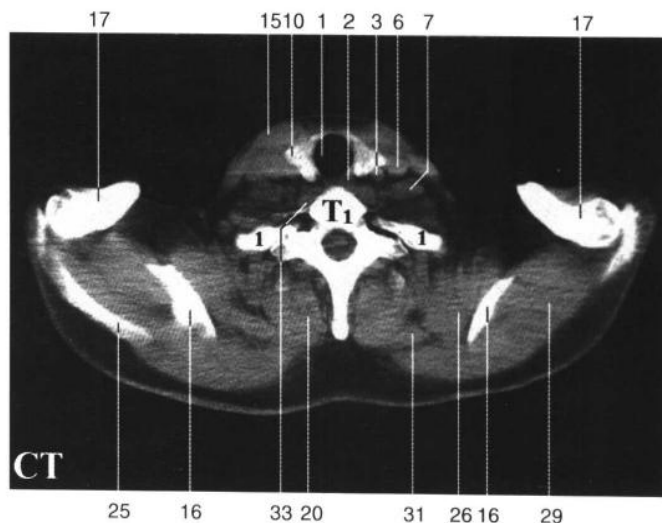


Fig. HT 2

1. 气管 trachea
2. 食管 esophagus
3. 颈总动脉 common carotid a.
4. 迷走神经 vagus n.
5. 肋间淋巴结 intercostal lymph node
6. 颈内静脉 internal jugular v.
7. 前斜角肌 scalenus anterior
8. 臂丛 brachial plexus
9. 椎动、静脉 vertebral a. and v.
10. 甲状腺 thyroid gland
11. 肩胛上动脉 suprascapular a.

Fig.HT 2

12. 肱骨头 head of humerus
13. 三角肌 deltoid
14. 喙突 coracoid process
15. 胸锁乳突肌 sternocleidomastoid
16. 肩胛骨 scapula
17. 锁骨 clavicle
18. 1、2 胸椎关节突关节 zygapophysial joint (T₁ - T₂)
19. 中斜角肌 scalenus medius
20. 竖脊肌 erector spinae
21. 右颈外静脉 right external jugular v.
22. 锁骨下肌 subclavius
23. 肱二头肌长头 long head of biceps brachii
24. 冈下肌 infraspinatus
25. 肩胛冈 spine of scapula
26. 肩胛下肌 subscapularis
27. 前锯肌 serratus anterior
28. 斜方肌 trapezius
29. 冈上肌 supraspinatus
30. 胸大肌 pectoralis major
31. 小菱形肌 rhomboideus minor
32. 大菱形肌 rhomboideus major
33. 颈长肌 longus colli
34. 脊髓 spinal cord



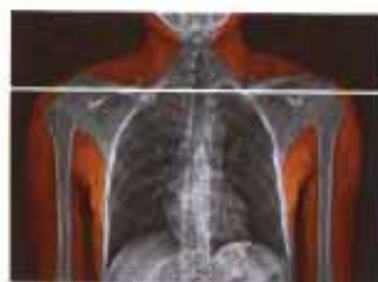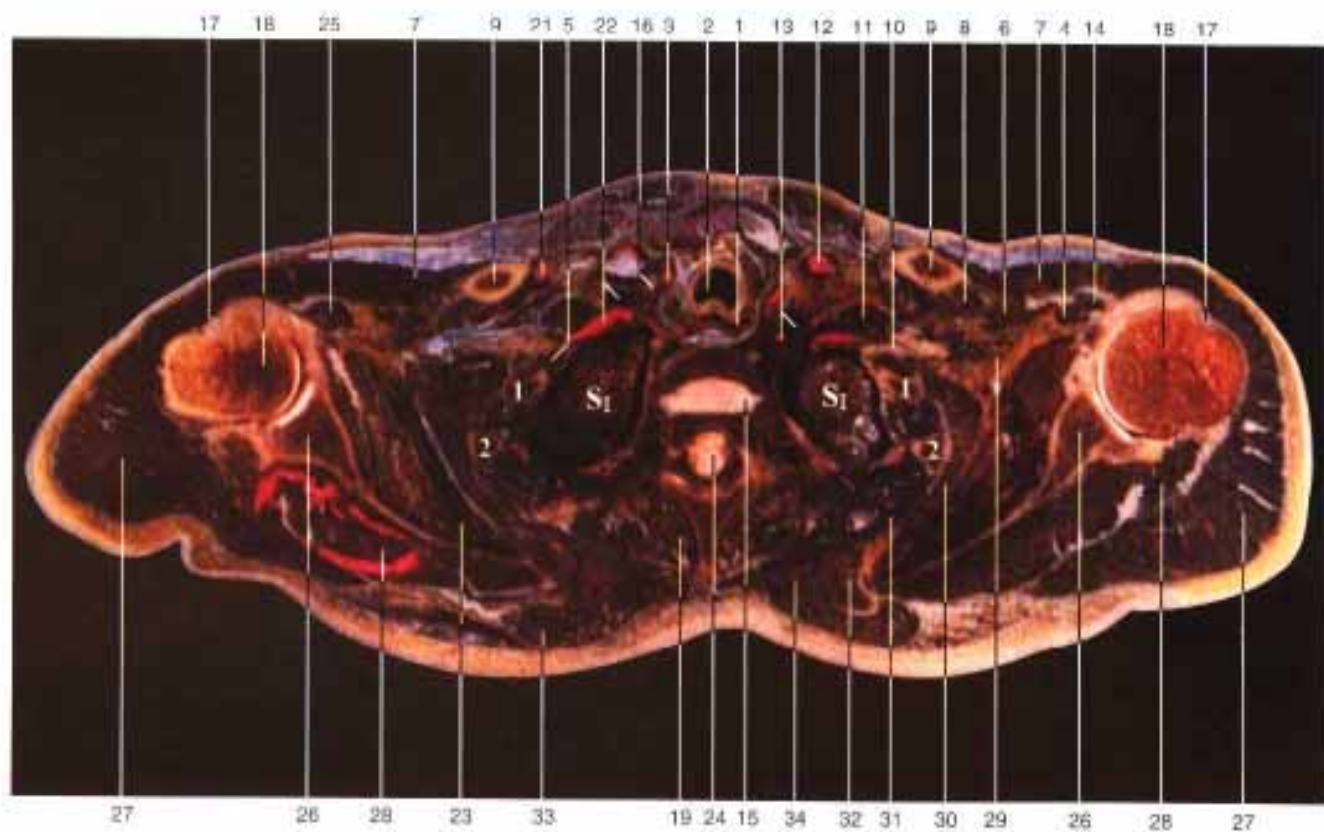
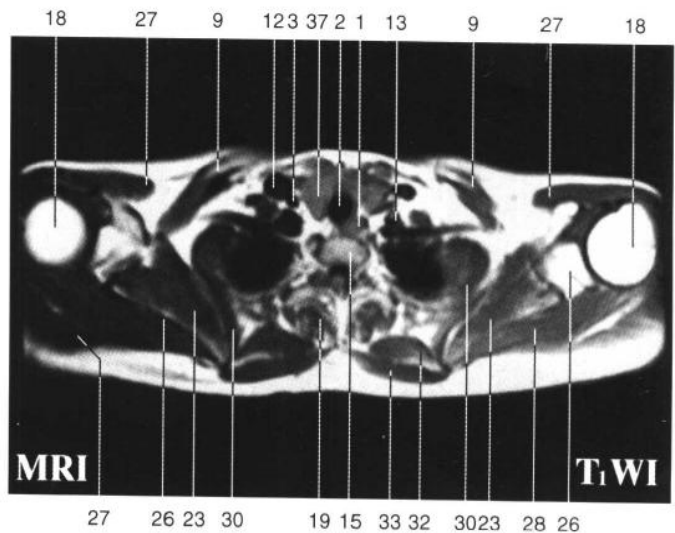
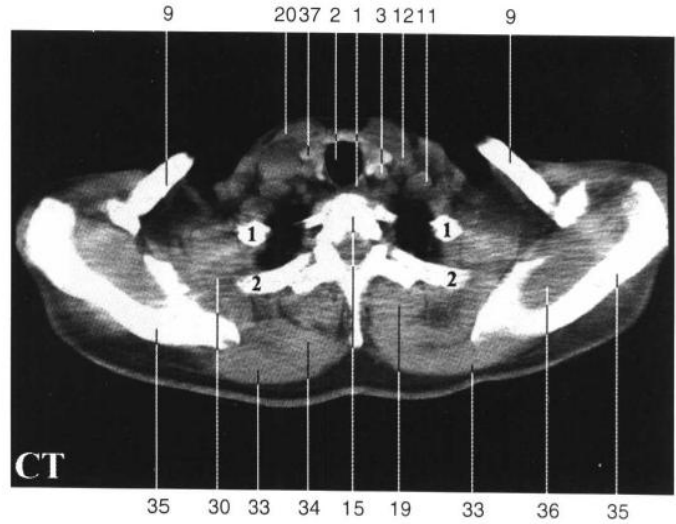


Fig.HT 3

Fig. HT 3

1. 食管 esophagus
2. 气管 trachea
3. 颈总动脉 common carotid a.
4. 喙肱肌 coracobrachialis
5. 中斜角肌 scalenus medius
6. 胸小肌 pectoralis minor
7. 胸大肌 pectoralis major
8. 锁骨下肌 subclavius
9. 锁骨 clavicle
10. 臂丛 brachial plexus
11. 前斜角肌 scalenus anterior

12. 颈内静脉 internal jugular v.
 13. 椎动、静脉 vertebral a. and v.
 14. 肱二头肌短头 short head of biceps brachii
 15. 1,2 胸椎间盘 intervertebral disc(T₁-T₂)
 16. 迷走神经 vagus n.
 17. 肱二头肌长头 long head of biceps brachii
 18. 肱骨头 head of humerus
 19. 竖脊肌 erector spinae
 20. 胸锁乳突肌 sternocleidomastoid
 21. 颈外静脉 external jugular v.
 22. 右锁骨下动、静脉 right subclavian a. and v.
 23. 肩胛下肌 subscapularis
 24. 脊髓 spinal cord
 25. 肱二头肌短头与喙肱肌 short head of biceps brachii and coracobrachialis
 26. 肩胛骨 scapula
 27. 三角肌 deltoid
 28. 冈下肌 infraspinatus
 29. 腋窝 axillary fossa
 30. 前锯肌 serratus anterior
 31. 上后锯肌 serratus posterior superior
 32. 小菱形肌 rhomboideus minor
 33. 斜方肌 trapezius
 34. 大菱形肌 rhomboideus major
 35. 肩胛冈 spine of scapula
 36. 冈上肌 supraspinatus
 37. 甲状腺 thyroid gland
- S₁: 尖段(S₁) apical segment(S₁)



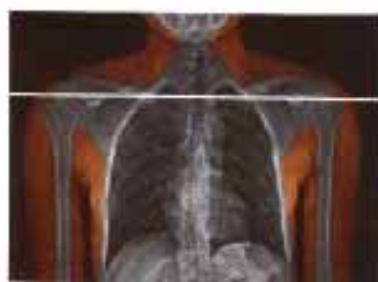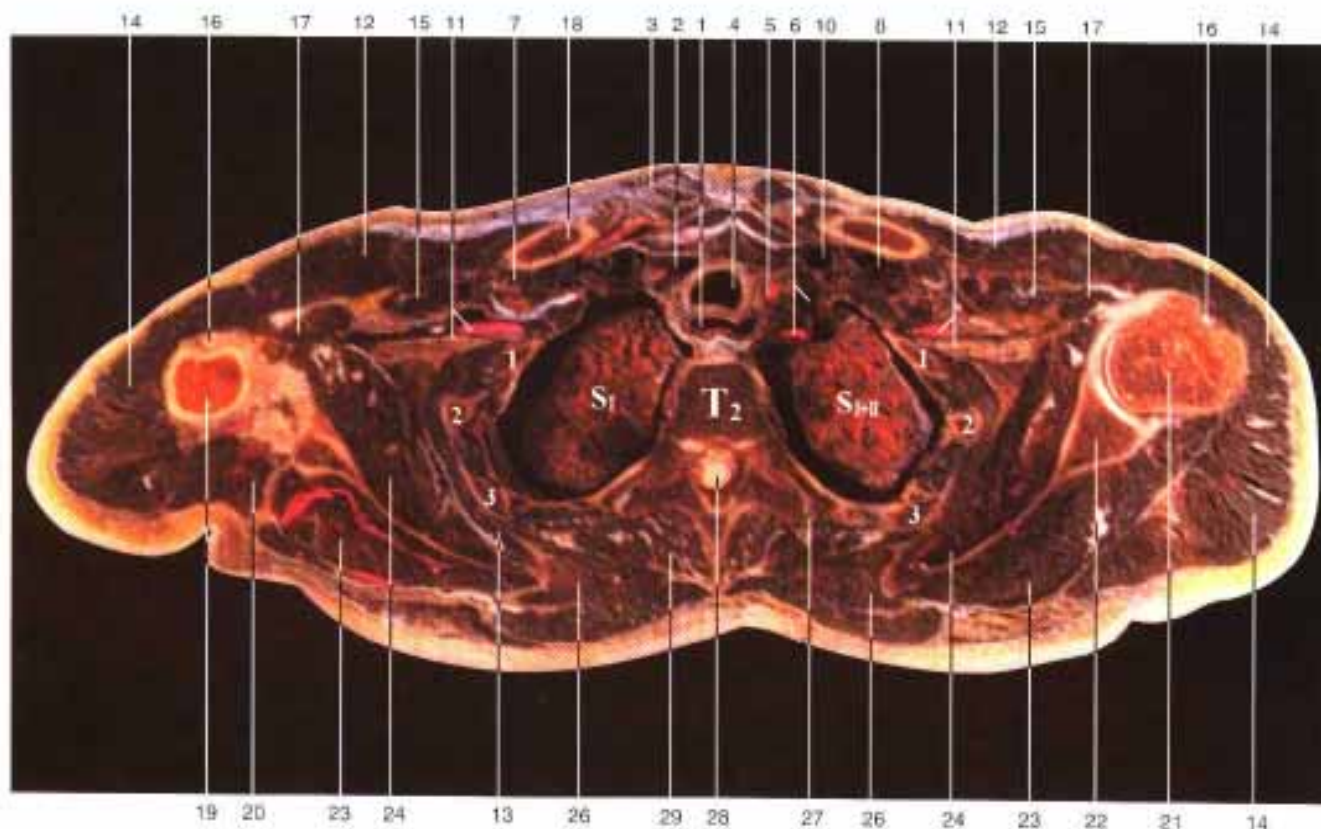
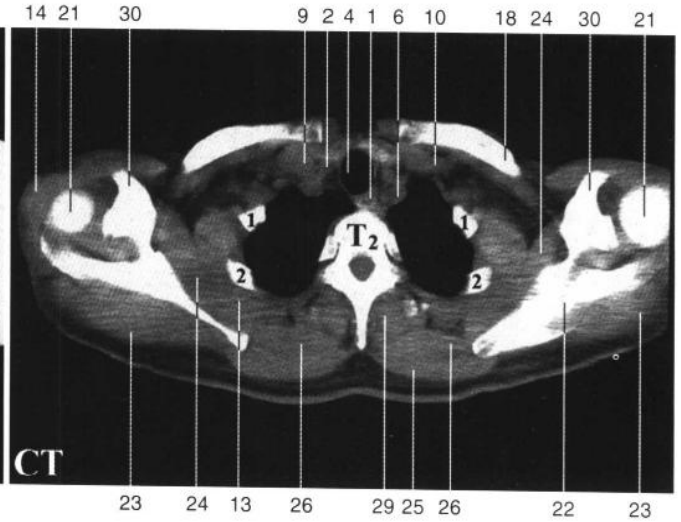
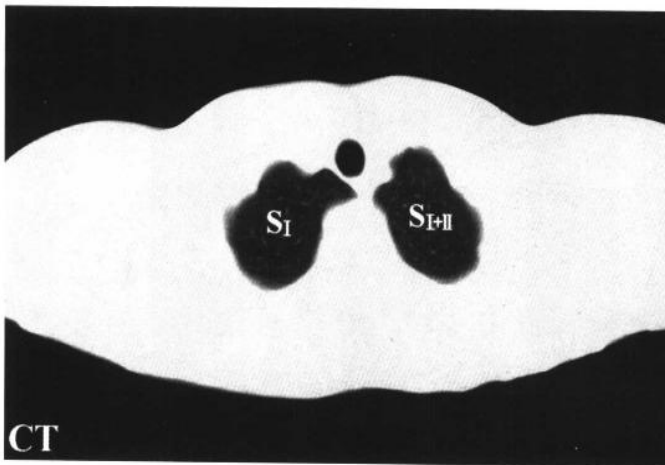


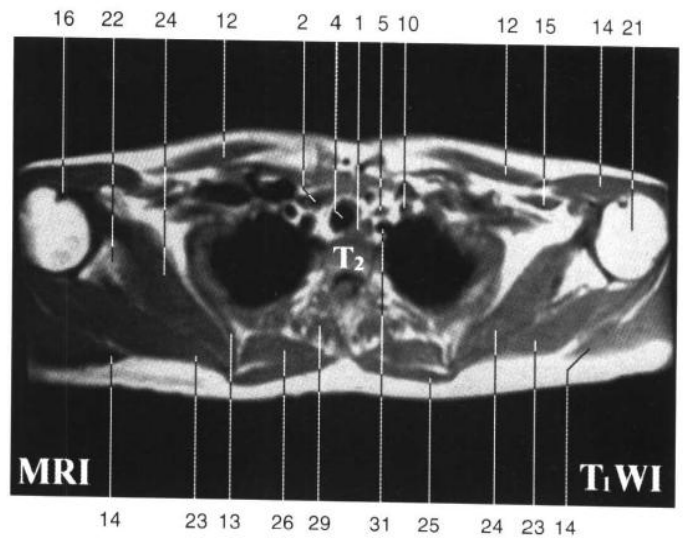
Fig.HT 4

Fig. HT 4

1. 食管 esophagus
2. 头臂干 brachiocephalic trunk
3. 胸锁乳突肌 sternocleidomastoid
4. 气管 trachea
5. 左颈总动脉 left common carotid a.
6. 左锁骨下动、静脉 left subclavian a. and v.
7. 锁骨下肌 subclavius
8. 颈外静脉 external jugular v.
9. 右头臂静脉 right brachiocephalic v.
10. 左头臂静脉 left brachiocephalic v.
11. 腋动脉与臂丛 axillary a. and brachial plexus



- 12. 胸大肌 pectoralis major
 - 13. 前锯肌 serratus anterior
 - 14. 三角肌 deltoid
 - 15. 胸小肌 pectoralis minor
 - 16. 肱二头肌长头 long head of biceps brachii
 - 17. 肱二头肌短头与喙肱肌 short head of biceps brachii and coracobrachialis
 - 18. 锁骨 clavicle
 - 19. 肱骨 humerus
 - 20. 大圆肌 teres major
 - 21. 肱骨头 head of humerus
 - 22. 肩胛骨 scapula
 - 23. 冈下肌 infraspinatus
 - 24. 肩胛下肌 subscapularis
 - 25. 斜方肌 trapezius
 - 26. 大菱形肌 rhomboideus major
 - 27. 肋横突关节 costotransverse joint
 - 28. 脊髓 spinal cord
 - 29. 竖脊肌 erector spinae
 - 30. 喙突 coracoid process
 - 31. 左锁骨下动脉 left subclavian a.
- S_I: 尖段(S_I) apical segment(S_I)
 S_{I+II}: 尖后段(S_{I+II}) apicoposterior segment(S_{I+II})



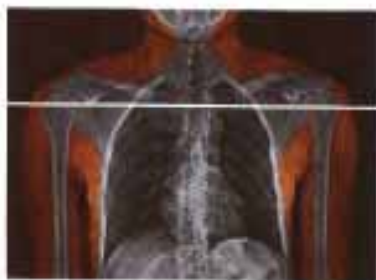
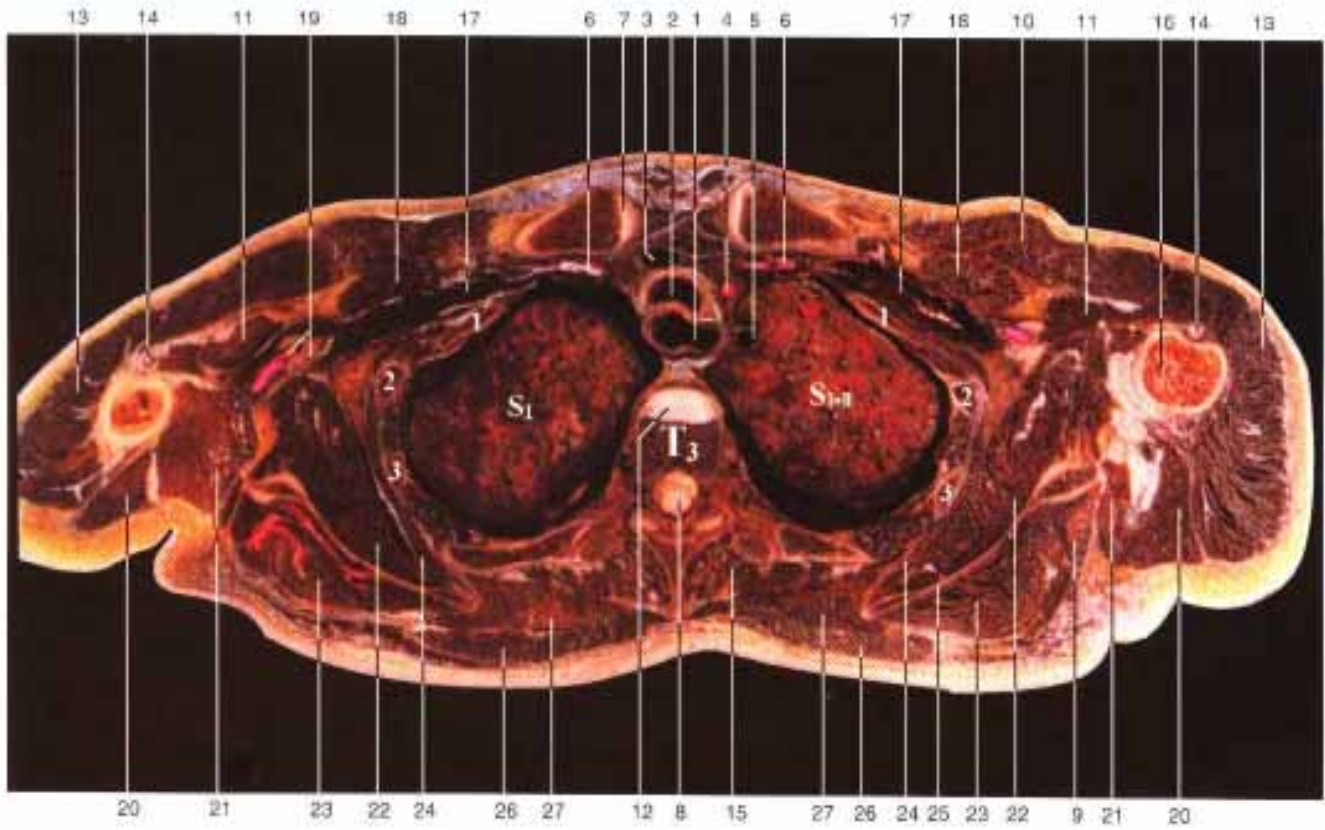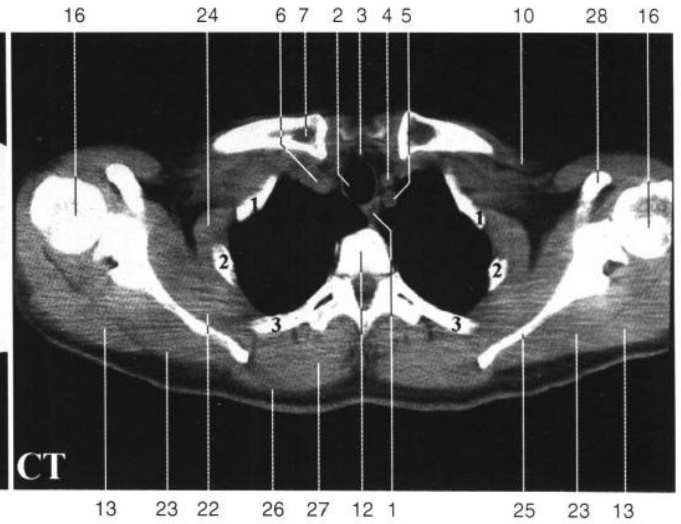
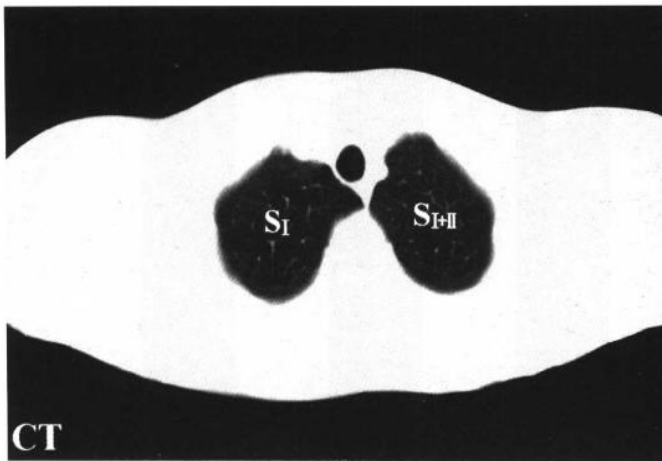


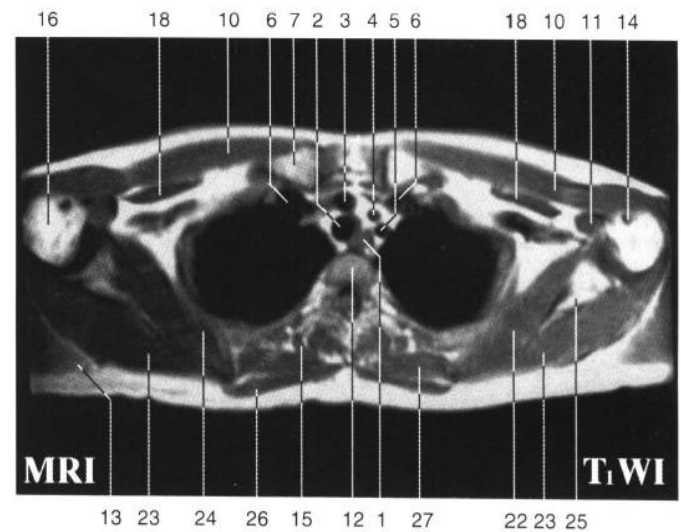
Fig. HT 5

Fig. HT 5

1. 食管 esophagus
2. 气管 trachea
3. 头臂干 brachiocephalic trunk
4. 左颈总动脉 left common carotid a.
5. 左锁骨下动脉 left subclavian a.
6. 头臂静脉 brachiocephalic v.
7. 锁骨胸骨端 sternal end of clavicle
8. 脊髓 spinal cord
9. 小圆肌 teres minor
10. 胸大肌 pectoralis major
11. 喙二头肌短头与喙肱肌 short head of biceps brachii and coracobrachialis



- 12. 2,3 胸椎间盘 intervertebral disc(T₂ - T₃)
- 13. 三角肌 deltoid
- 14. 肱二头肌长头 long head of biceps brachii
- 15. 竖脊肌 erector spinae
- 16. 肱骨头 head of humerus
- 17. 腋静脉 axillary v.
- 18. 胸小肌 pectoralis minor
- 19. 腋动脉与臂丛 axillary a. and brachial plexus
- 20. 肱三头肌长头 long head of triceps brachii
- 21. 大圆肌 teres major
- 22. 肩胛下肌 subscapularis
- 23. 冈下肌 infraspinatus
- 24. 前锯肌 serratus anterior
- 25. 肩胛骨 scapula
- 26. 斜方肌 trapezius
- 27. 大菱形肌 rhomboideus major
- 28. 喙突 coracoid process
- S₁: 尖段(S₁) apical segment(S₁)
- S_{1+II}: 尖后段(S_{1+II}) apicoposterior segment(S_{1+II})



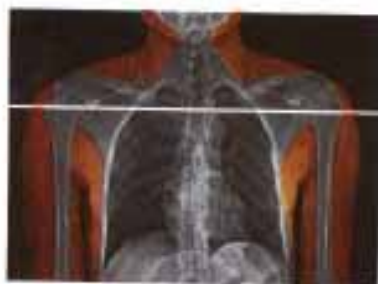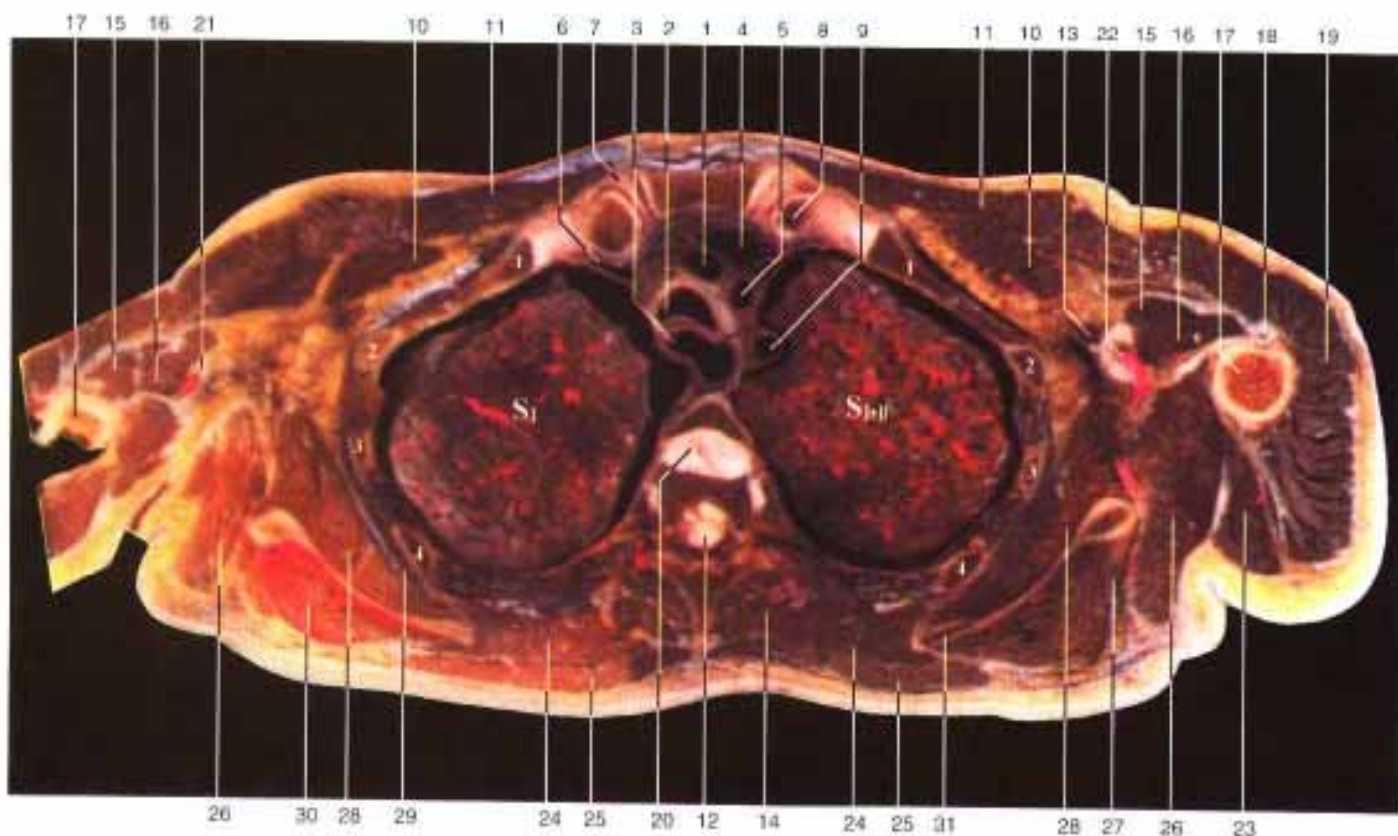
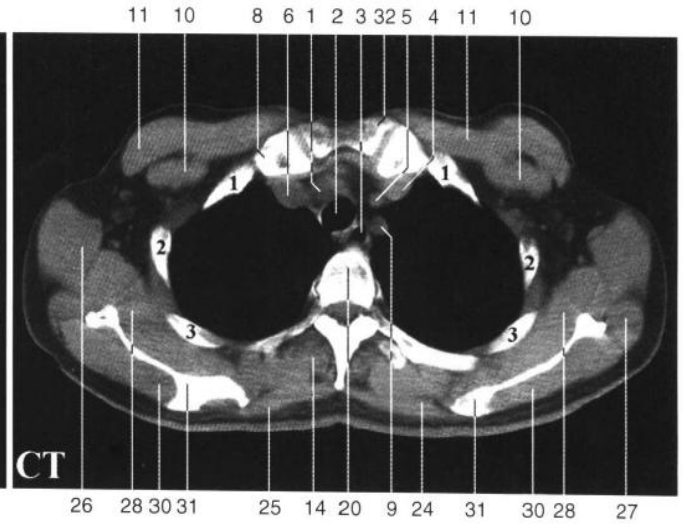

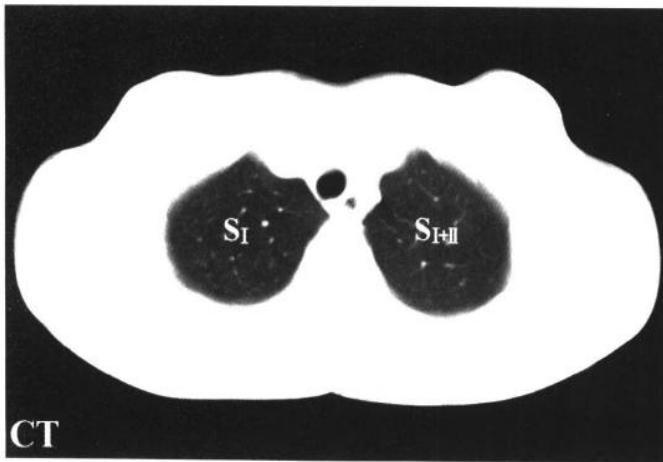
Fig. HT 6

1. 头臂干 brachiocephalic trunk
2. 气管 trachea
3. 食管 esophagus
4. 左头臂静脉 left brachiocephalic v.
5. 左颈总动脉 left common carotid a.
6. 右头臂静脉 right brachiocephalic v.
7. 胸锁关节盘 articular disc of sternoclavicular joint
8. 锁骨 clavicle
9. 锁骨下动脉 subclavian v.
10. 胸小肌 pectoralis minor
11. 胸大肌 pectoralis major

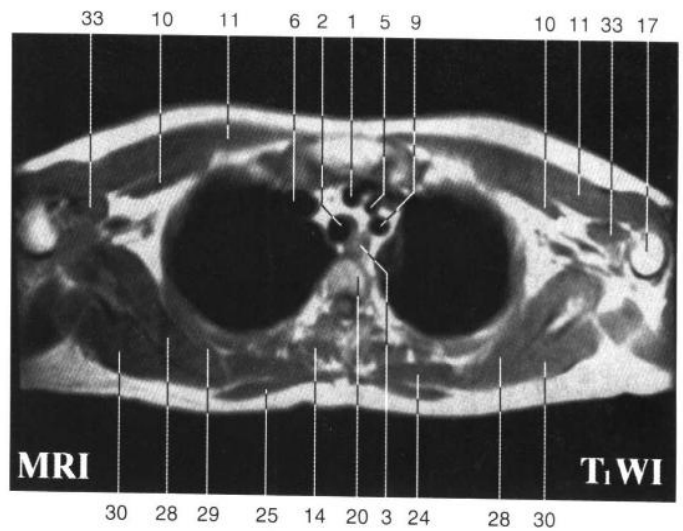
Fig.HT 6



12. 脊髓 spinal cord
13. 腋静脉 axillary v.
14. 竖脊肌 erector spinae
15. 肱二头肌短头 short head of biceps brachii
16. 喙肱肌 coracobrachialis
17. 肱骨 humerus
18. 肱二头肌长头 long head of biceps brachii
19. 三角肌 deltoid
20. 3,4 胸椎间盘 intervertebral disc(T₃ - T₄)
21. 臂丛 brachial plexus
22. 腋动脉 axillary a.
23. 肱三头肌长头 long head of triceps brachii
24. 大菱形肌 rhomboideus major
25. 斜方肌 trapezius
26. 大圆肌 teres major
27. 小圆肌 teres minor
28. 肩胛下肌 subscapularis
29. 前锯肌 serratus anterior
30. 冈下肌 infraspinatus
31. 肩胛骨 scapula
32. 胸骨柄 manubrium sterni
33. 肱二头肌 biceps brachii

S_I: 尖段(S_I) apical segment(S_I)

S_{I+II}: 尖后段(S_{I+II}) apicoposterior segment(S_{I+II})



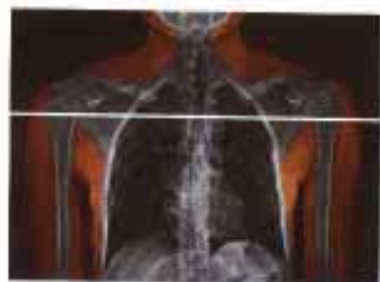
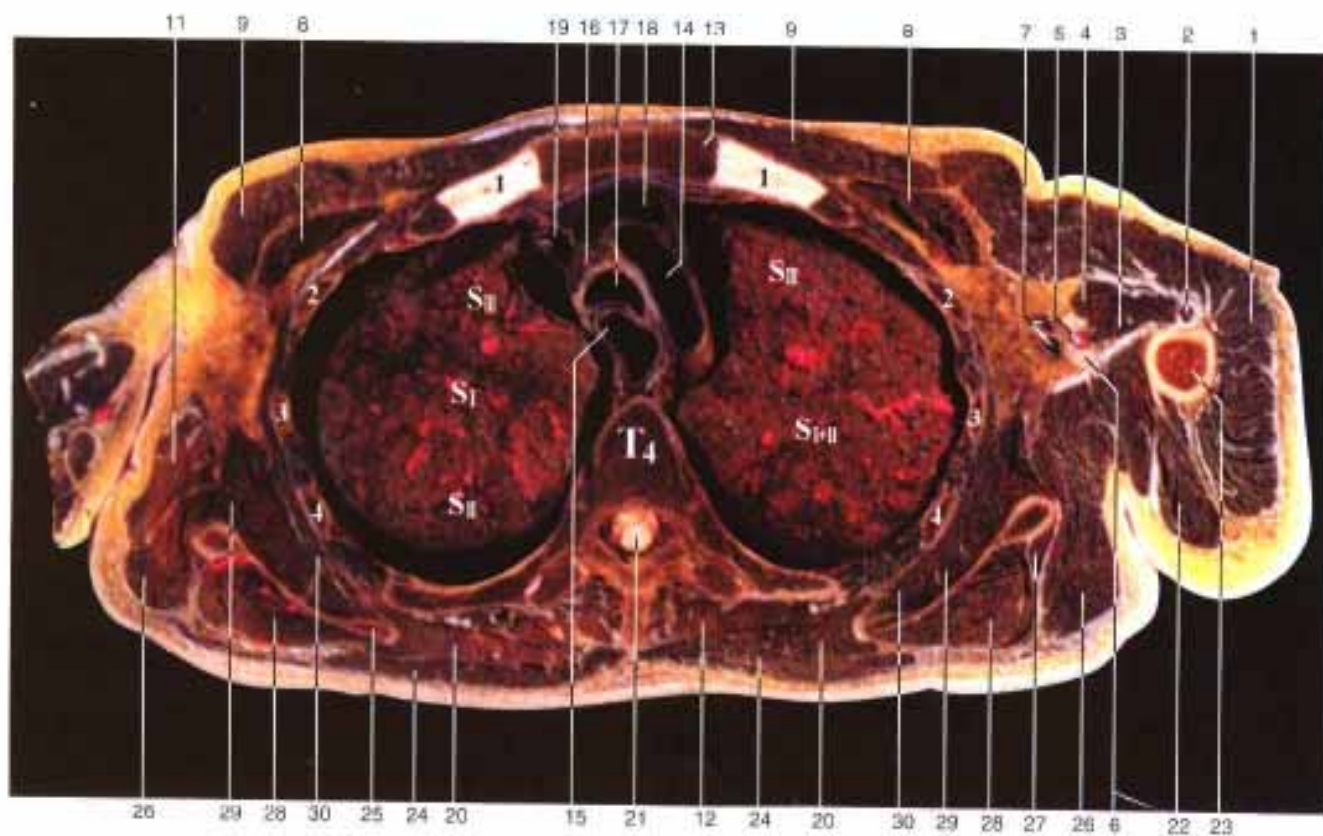
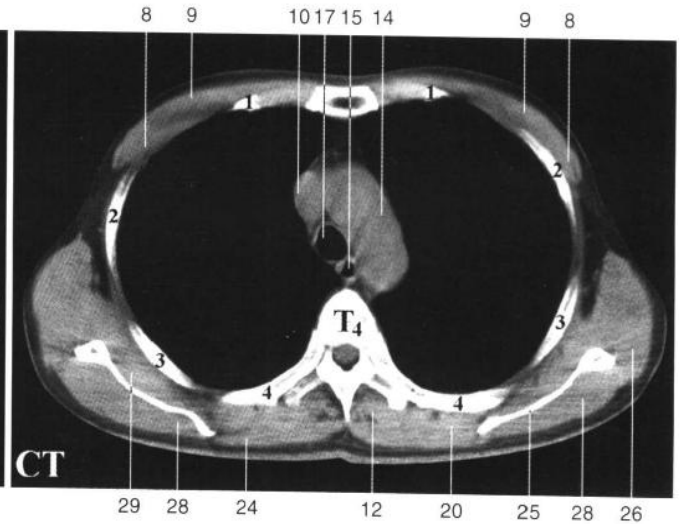
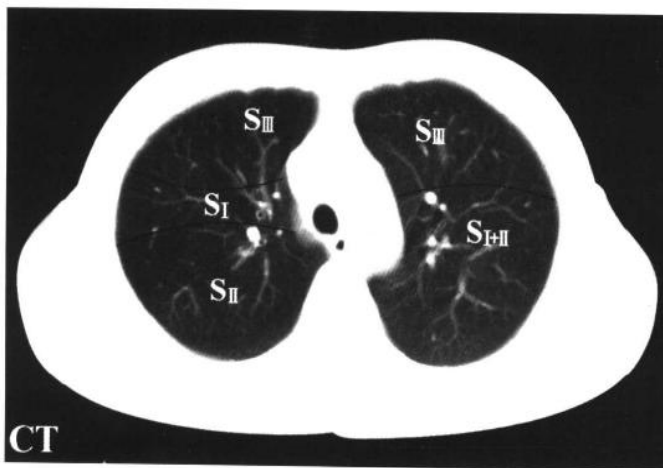


Fig. HT 7

1. 三角肌 deltoid
2. 肌二头肌长头 long head of biceps brachii
3. 喙肱肌 coracobrachialis
4. 肌二头肌短头 short head of biceps brachii
5. 腋动脉 axillary a.
6. 臂丛 brachial plexus
7. 腋静脉 axillary v.
8. 胸小肌 pectoralis minor
9. 胸大肌 pectoralis major
10. 上腔静脉 superior vena cava

Fig.HT 7



11. 背阔肌 latissimus dorsi
12. 竖脊肌 erector spinae
13. 胸骨柄 manubrium sterni
14. 主动脉弓 aortic arch
15. 食管 esophagus
16. 胸廓内动脉的气管支 tracheal branch of internal thoracic a.
17. 气管 trachea
18. 左头臂静脉 left brachiocephalic v.
19. 右头臂静脉 right brachiocephalic v.
20. 大菱形肌 rhomboideus major
21. 脊髓 spinal cord
22. 肱三头肌长头 long head of triceps brachii
23. 肱骨 humerus
24. 斜方肌 trapezius
25. 肩胛骨 scapula
26. 大圆肌 teres major
27. 小圆肌 teres minor
28. 冈下肌 infraspinatus
29. 肩胛下肌 subscapularis
30. 前锯肌 serratus anterior

- S_I: 尖段(S_I) apical segment(S_I)
 S_{I+II}: 尖后段(S_{I+II}) apicoposterior segment(S_{I+II})
 S_{II}: 后段(S_{II}) posterior segment(S_{II})
 S_{III}: 前段(S_{III}) anterior segment(S_{III})

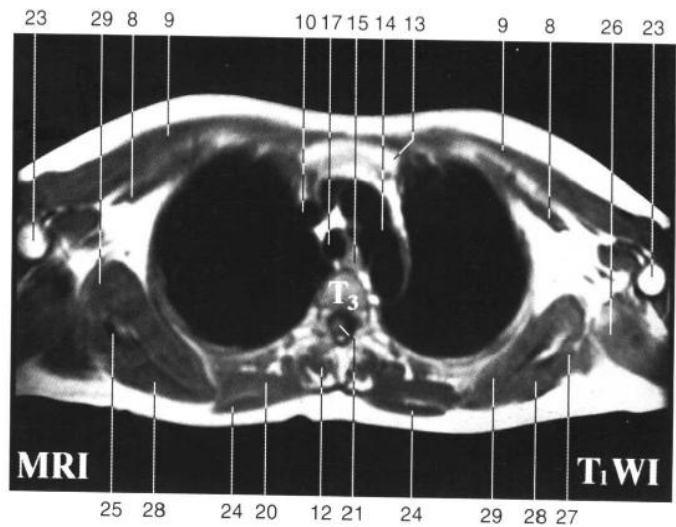
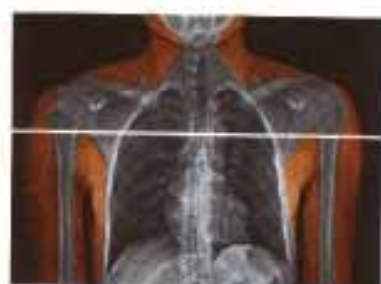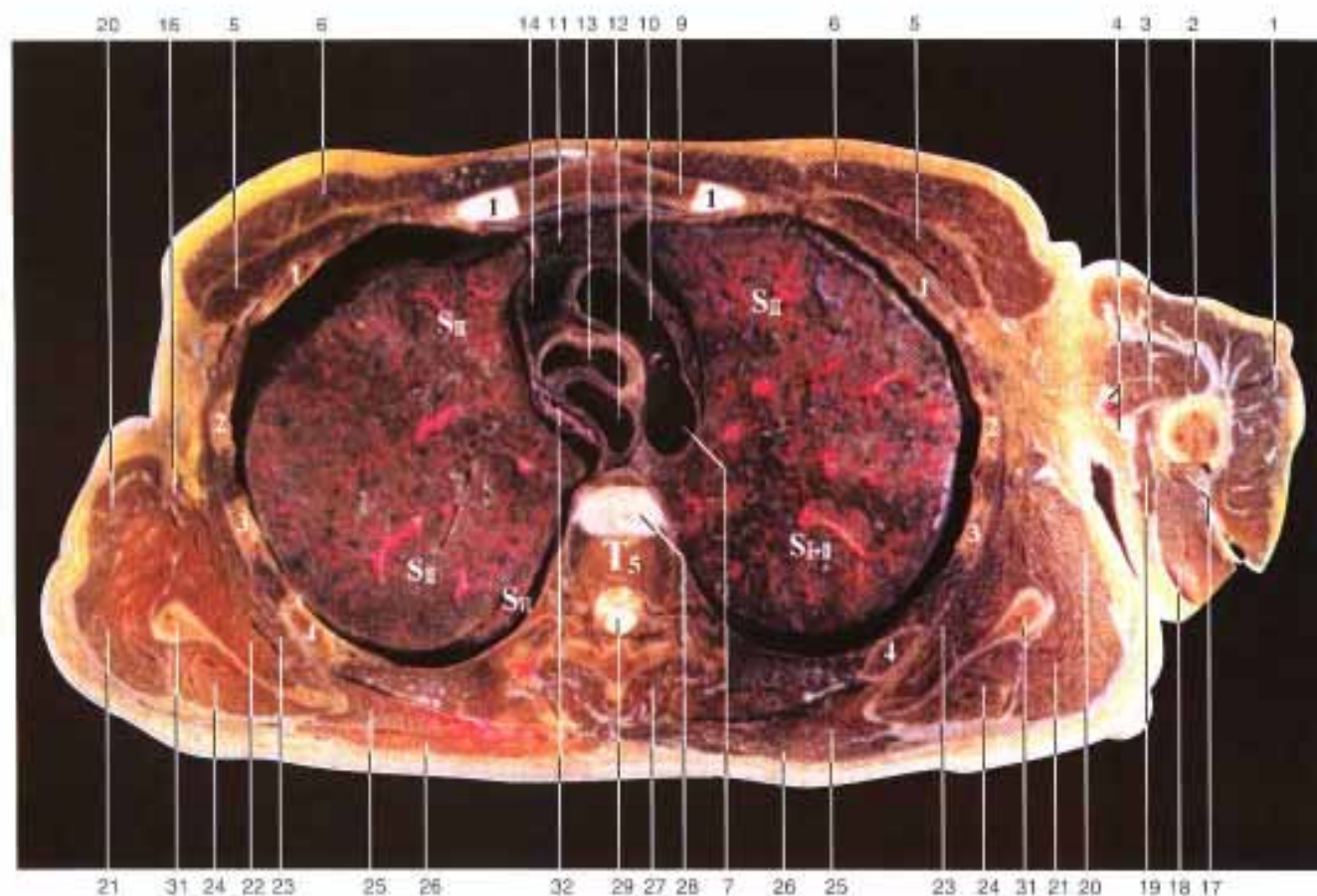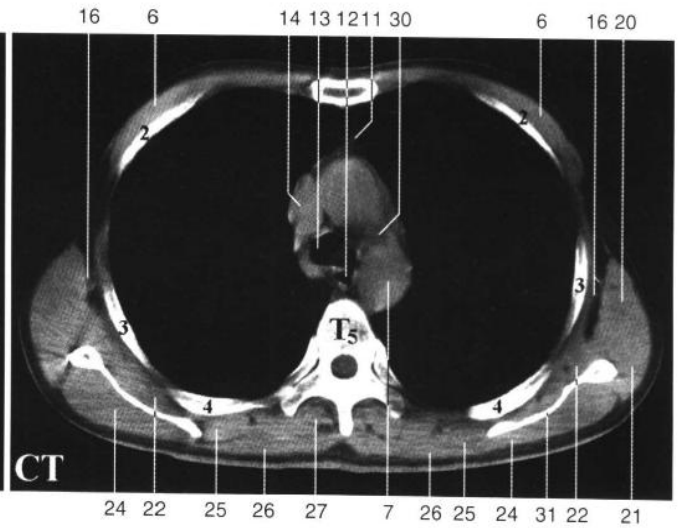
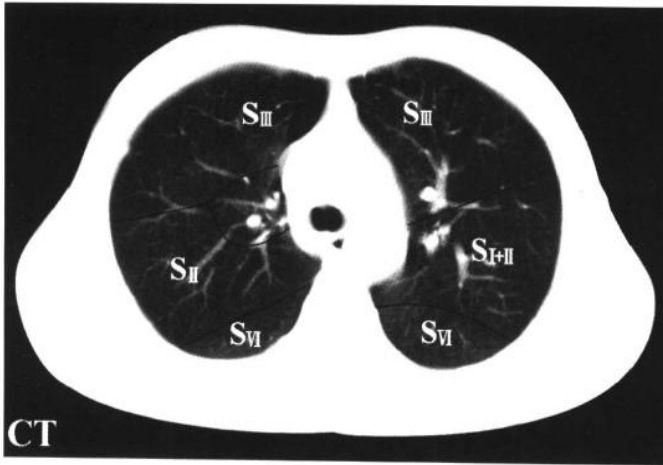




Fig. HT 8

1. 三角肌 deltoid
2. 腋二头肌长头 long head of biceps brachii
3. 喙肱肌 coracobrachialis
4. 腋动脉与臂丛 axillary a. and brachial plexus
5. 胸小肌 pectoralis minor
6. 胸大肌 pectoralis major
7. 胸主动脉 thoracic aorta
8. 升主动脉 ascending aorta
9. 胸骨柄 manubrium sterni
10. 主动脉弓 aortic arch
11. 胸腺 thymus

Fig.HT 8



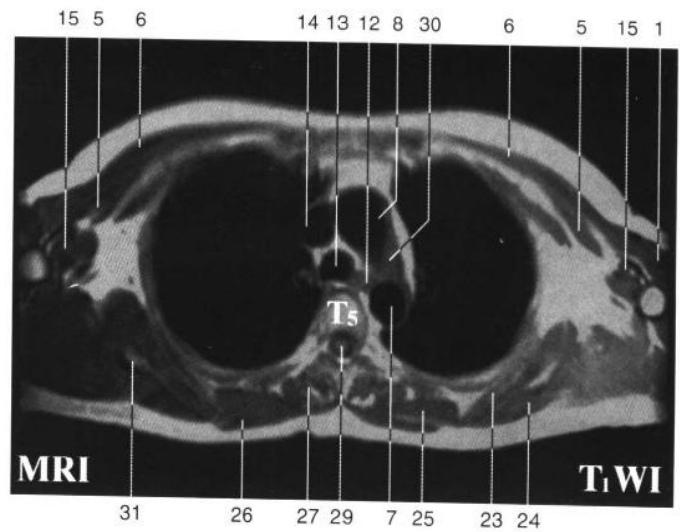
12. 食管 esophagus
13. 气管 trachea
14. 上腔静脉 superior vena cava
15. 肱二头肌 biceps brachii
16. 胸背动、静脉与胸背神经 thoracodorsal a.,v. and thoracodorsal n.
17. 肱三头肌外侧头 lateral head of triceps brachii
18. 肱三头肌长头 long head of triceps brachii
19. 肱三头肌内侧头 medial head of triceps brachii
20. 背阔肌 latissimus dorsi
21. 大圆肌 teres major
22. 肩胛下肌 subscapularis
23. 前锯肌 serratus anterior
24. 冈下肌 infraspinatus
25. 大菱形肌 rhomboideus major
26. 斜方肌 trapezius
27. 竖脊肌 erector spinae
28. 4,5 胸椎间盘 intervertebral disc (T₄ - T₅)
29. 脊髓 spinal cord
30. 主动脉肺动脉窗 aorto - pulmonary window
31. 肩胛骨 scapula
32. 奇静脉 azygos v.

S_{I+II}: 尖后段 (S_{I+II}) apicoposterior segment (S_{I+II})

S_{II}: 后段 (S_{II}) posterior segment (S_{II})

S_{III}: 前段 (S_{III}) anterior segment (S_{III})

S_{VI}: 上段 (S_{VI}) superior segment (S_{VI})



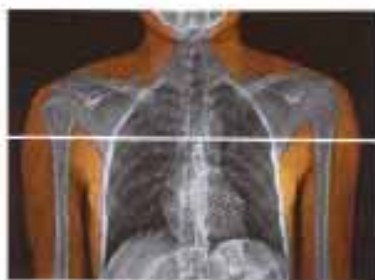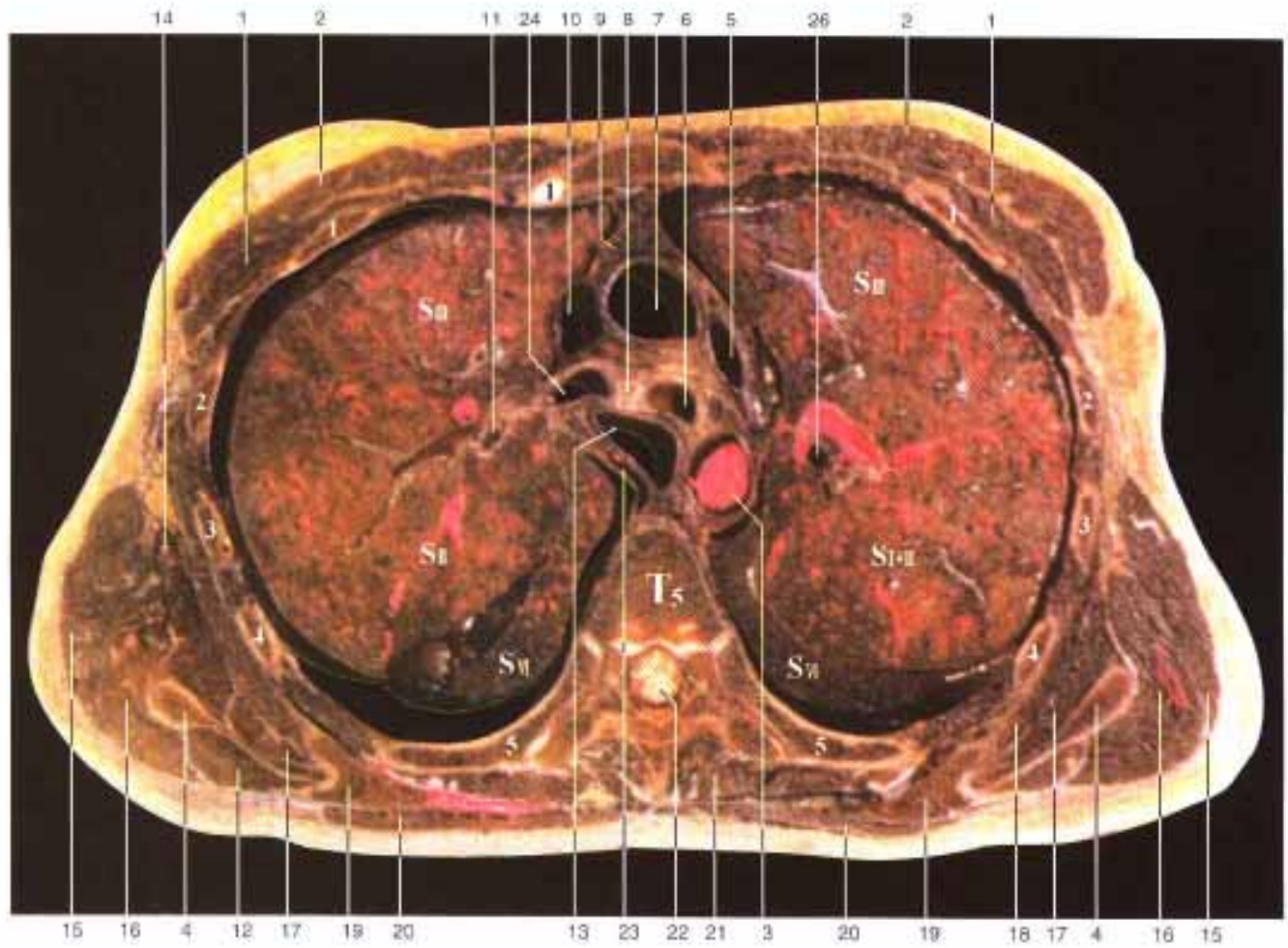
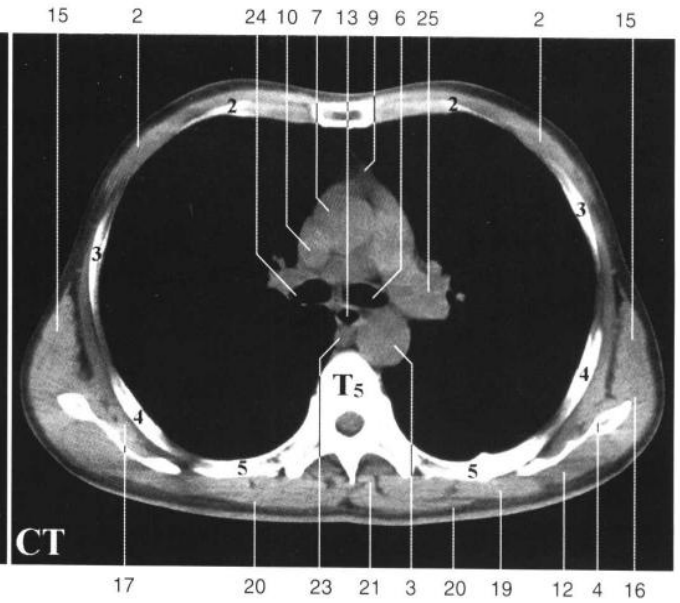
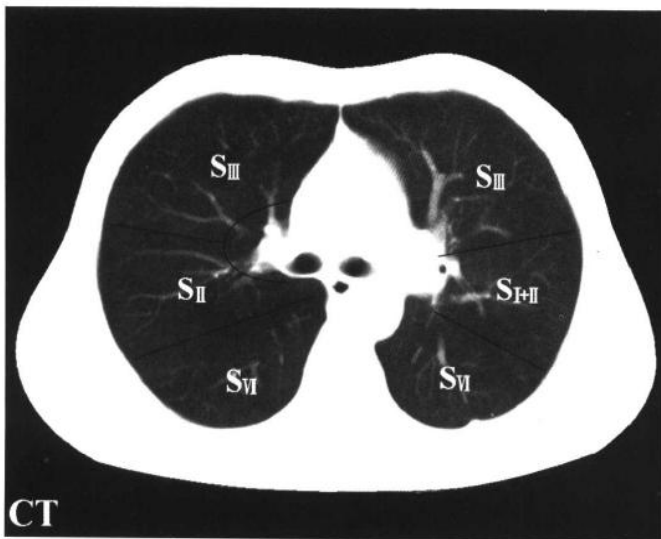


Fig.HT 9

Fig. HT 9

- 1. 胸小肌 pectoralis minor
- 2. 胸大肌 pectoralis major
- 3. 胸主动脉 thoracic aorta
- 4. 肩胛骨 scapula
- 5. 肺动脉 pulmonay a.
- 6. 左上支气管 left principal bronchus
- 7. 升主动脉 ascending aorta
- 8. 气管隆嵴 carina of trachea
- 9. 胸腺 thymus
- 10. 上腔静脉 superior vena cava
- 11. 右肺动脉上叶支 superior lobar branch of right pulmonary a.



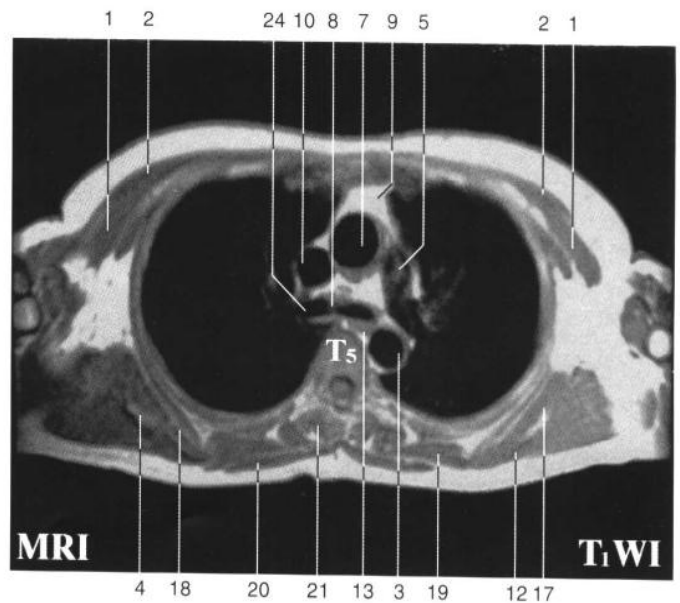
- 12. 冈下肌 infraspinatus
- 13. 食管 esophagus
- 14. 胸背动、静脉与胸背神经 thoracodorsal a., v. and thoracodorsal n.
- 15. 背阔肌 latissimus dorsi
- 16. 大圆肌 teres major
- 17. 肩胛下肌 subscapularis
- 18. 前锯肌 serratus anterior
- 19. 大菱形肌 rhomboideus major
- 20. 斜方肌 trapezius
- 21. 竖脊肌 erector spinae
- 22. 脊髓 spinal cord
- 23. 奇静脉 azygos v.
- 24. 右主支气管 right principal bronchus
- 25. 左肺动脉 left pulmonary a.
- 26. 左肺动脉上叶支 superior lobar branches of left pulmonary a.

S_{I+II}: 尖后段 (S_{I+II}) apicoposterior segment (S_{I+II})

S_{II}: 后段 (S_{II}) posterior segment (S_{II})

S_{III}: 前段 (S_{III}) anterior segment (S_{III})

S_{VI}: 上段 (S_{VI}) superior segment (S_{VI})



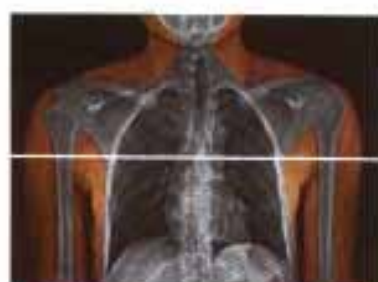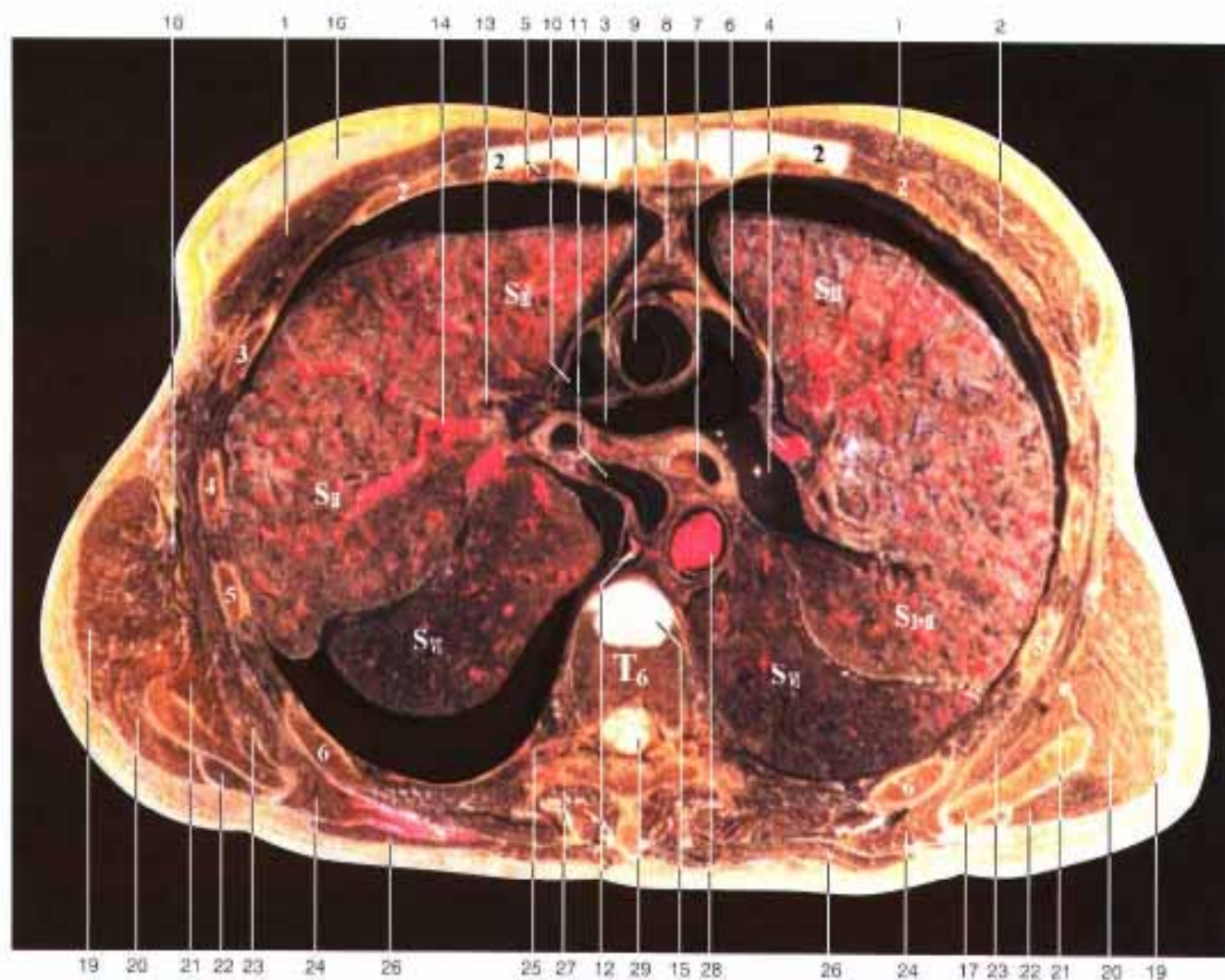
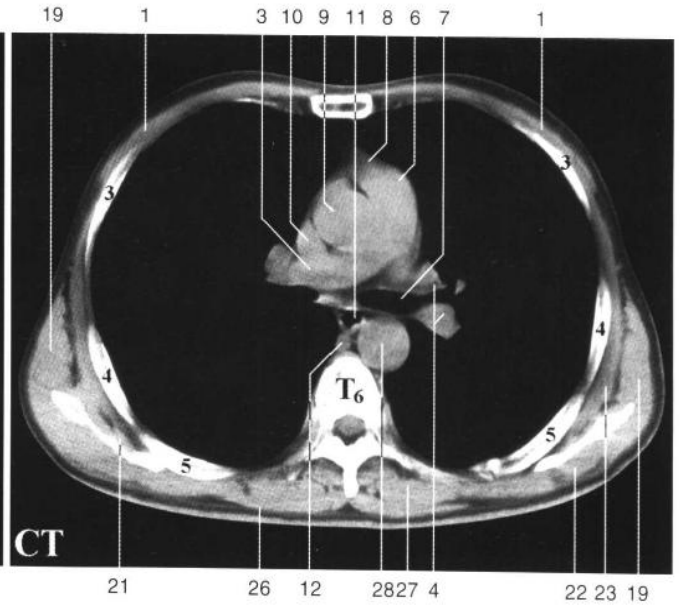
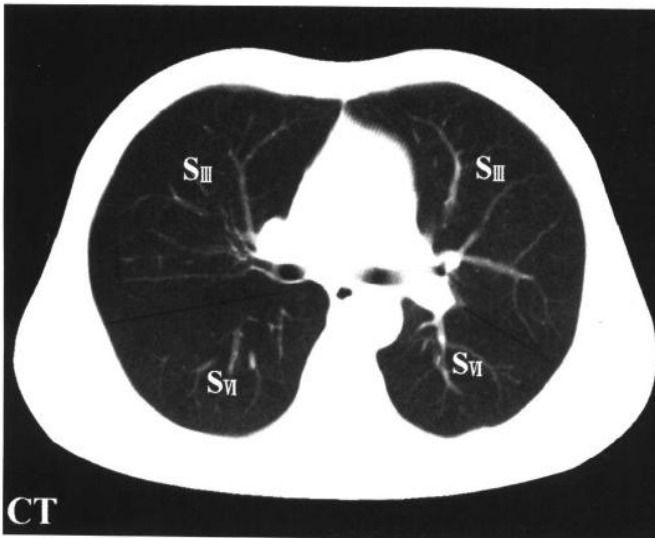


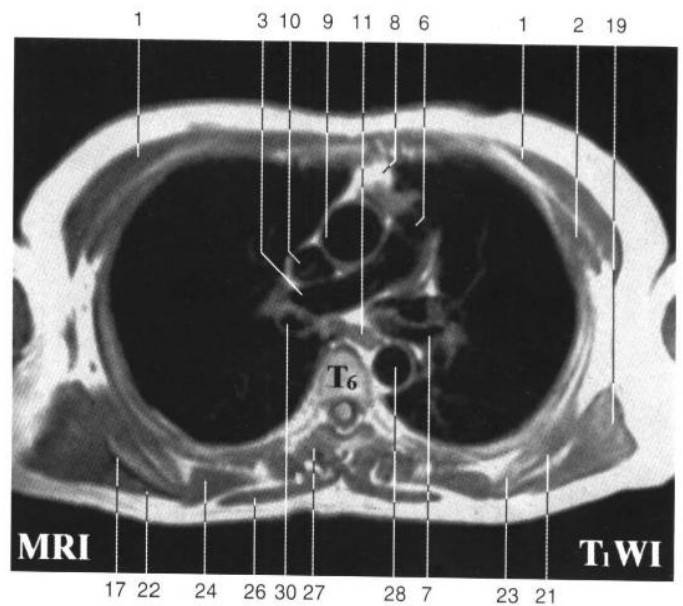
Fig. HT 10

1. 胸大肌 pectoralis major
2. 胸小肌 pectoralis minor
3. 右肺动脉 right pulmonary a.
4. 左肺动脉及左肺上静脉 left pulmonary a. and left superior pulmonary v.
5. 胸廓内动、静脉 internal thoracic a. and v.
6. 肺动脉干 pulmonary trunk
7. 左上支气管 left principal bronchus
8. 胸腺 thymus
9. 升主动脉 ascending aorta
10. 上腔静脉 superior vena cava

Fig. HT 10



11. 食管 esophagus
 12. 奇静脉 azygos v.
 13. 右肺上叶支气管 right superior lobar bronchus
 14. 右上肺静脉段间部 intersegmental part of right superior pulmonary v.
 15. 5,6 胸椎间盘 intervertebral disc (T₅ - T₆)
 16. 乳腺 mammary gland
 17. 肩胛骨 scapula
 18. 胸背动、静脉 thoracodorsal a. and v.
 19. 背阔肌 latissimus dorsi
 20. 大圆肌 teres major
 21. 肩胛下肌 subscapularis
 22. 冈下肌 infraspinatus
 23. 前锯肌 serratus anterior
 24. 大菱形肌 rhomboideus major
 25. 第4胸神经 4th thoracic n.
 26. 斜方肌 trapezius
 27. 竖脊肌 erector spinae
 28. 胸主动脉 thoracic aorta
 29. 脊髓 spinal cord
 30. 右主支气管 right principal bronchus
- S_{I+II}: 尖后段 (S_{I+II}) apicoposterior segment (S_{I+II})
 S_{II}: 后段 (S_{II}) posterior segment (S_{II})
 S_{III}: 前段 (S_{III}) anterior segment (S_{III})
 S_{VI}: 上段 (S_{VI}) superior segment (S_{VI})



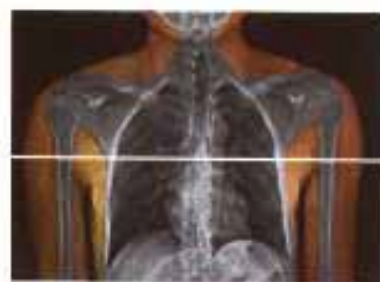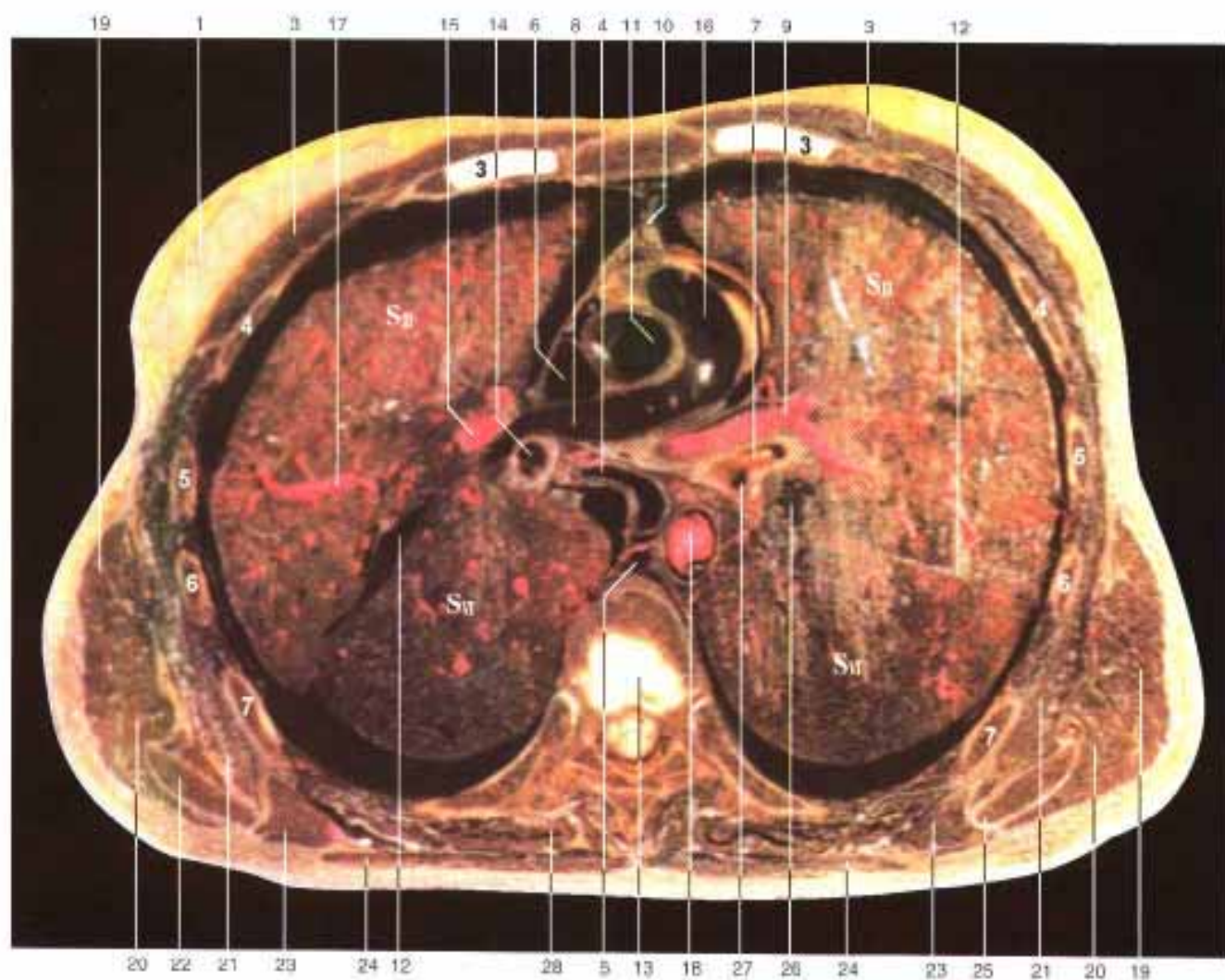
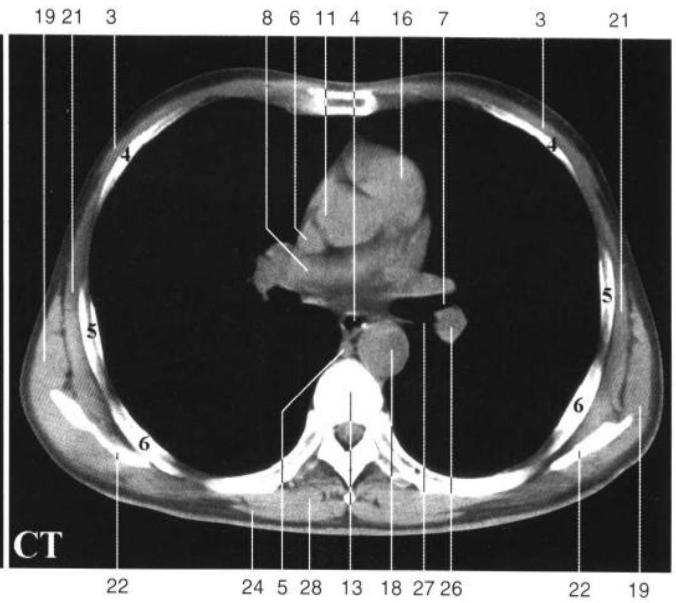
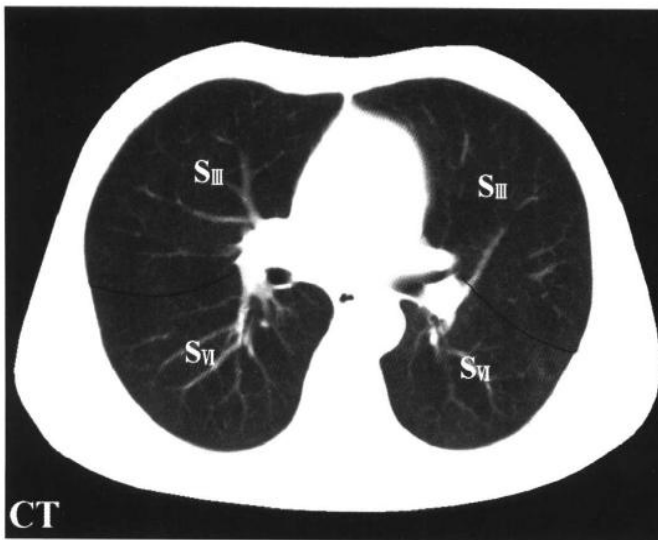


Fig. HT 11

1. 乳腺 mammary gland
2. 胸小肌 pectoralis minor
3. 胸大肌 pectoralis major
4. 食管 esophagus
5. 奇静脉 azygos v.
6. 上腔静脉 superior vena cava
7. 左肺上叶支气管 left superior lobar bronchus
8. 右肺动脉 right pulmonary a.
9. 左肺动脉 left superior pulmonary v.
10. 胸腺 thymus
11. 升主动脉 ascending aorta

Fig. HT 11



- 12. 斜裂 oblique fissure
- 13. 6,7 胸椎间盘 intervertebral disc (T₆ - T₇)
- 14. 右主支气管 right principal bronchus
- 15. 右上肺静脉 right superior pulmonary v.
- 16. 肺动脉干 pulmonary trunk
- 17. 右上肺静脉段间部 intersegmental part of right superior pulmonary v.
- 18. 胸主动脉 thoracic aorta
- 19. 背阔肌 latissimus dorsi
- 20. 大圆肌 teres major
- 21. 前锯肌 serratus anterior
- 22. 肩胛骨 scapula
- 23. 大菱形肌 rhomboideus major
- 24. 斜方肌 trapezius
- 25. 肩胛骨 scapula
- 26. 左肺动脉 left pulmonary a.
- 27. 左肺下叶支气管 left inferior lobar bronchus
- 28. 竖脊肌 erector spinae
- S_{III}: 前段 (S_{III}) anterior segment (S_{III})
- S_{IV}: 上段 (S_{IV}) superior segment (S_{IV})

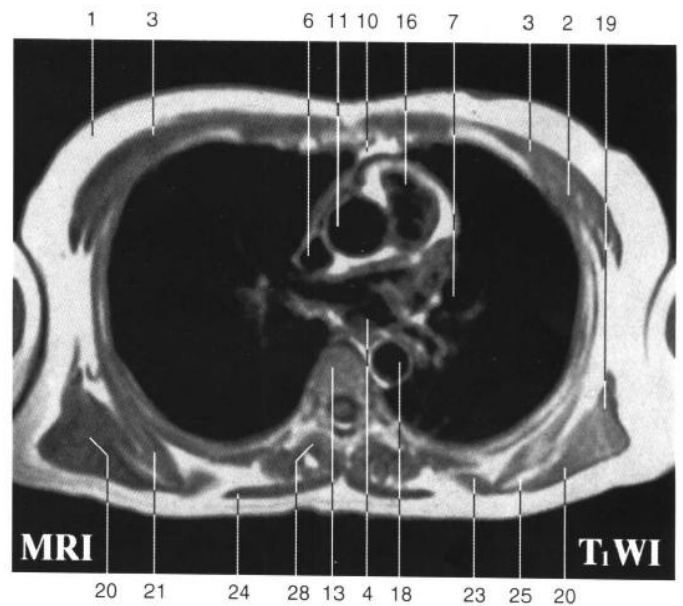
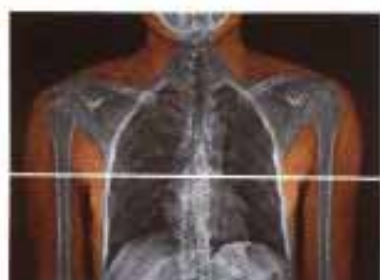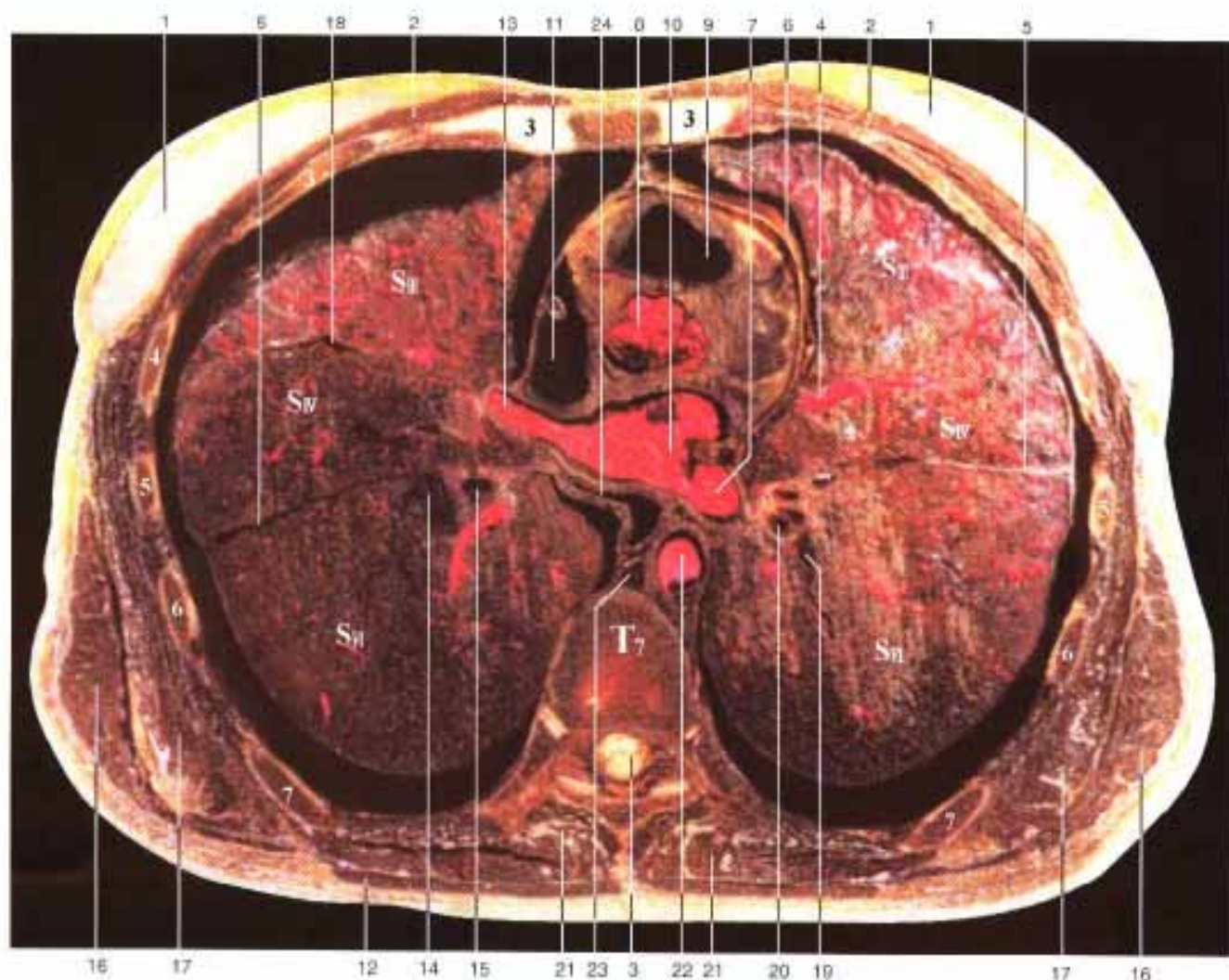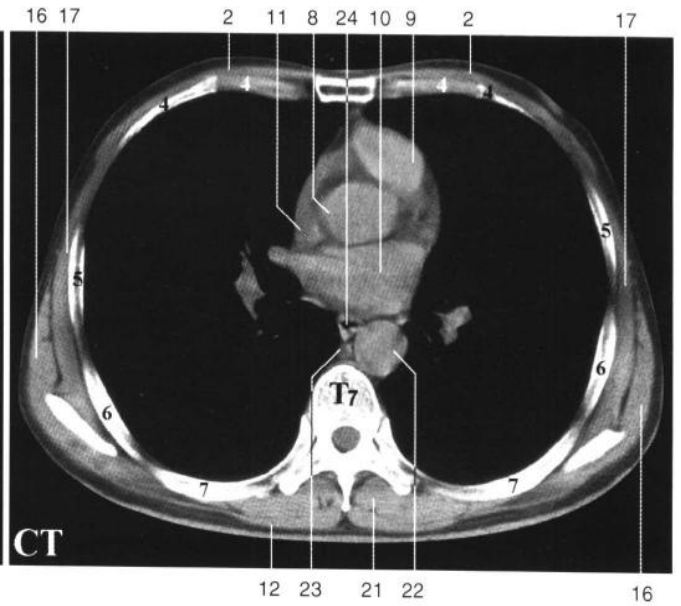
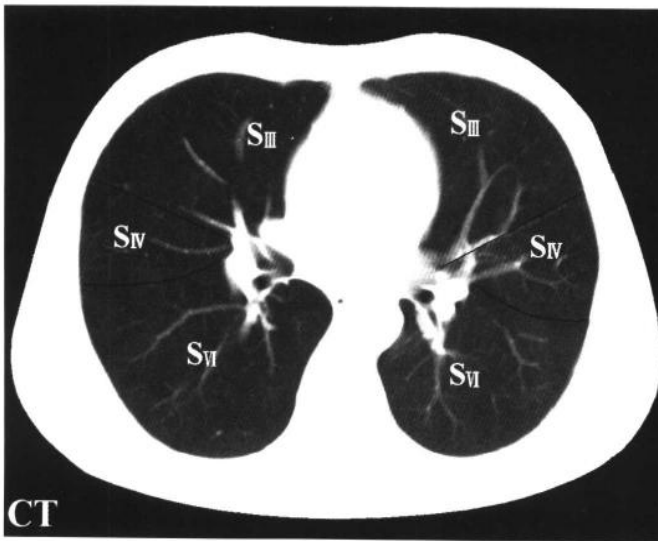




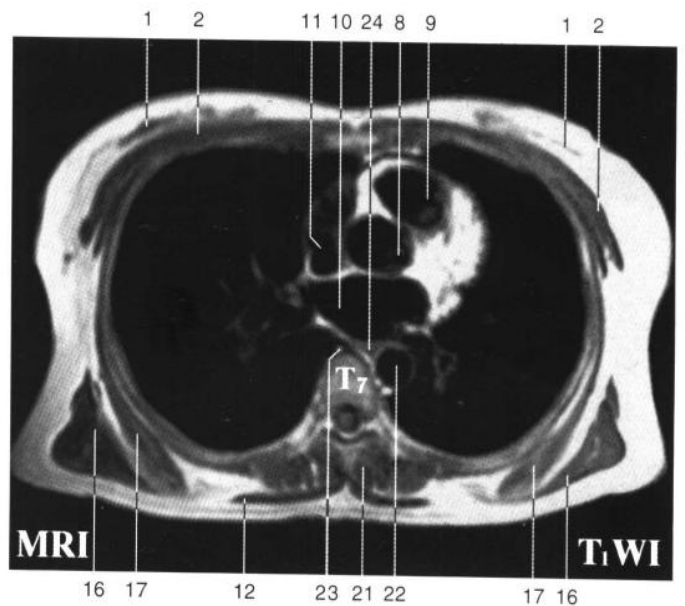
Fig. HT 12

1. 乳腺 mammary gland
2. 胸大肌 pectoralis major
3. 脊髓 spinal cord
4. 左上肺静脉段间部 intersegmental part of left superior pulmonary v.
5. 斜裂 oblique fissure
6. 心包 pericardium
7. 左下肺静脉 left inferior pulmonary v.
8. 升主动脉 ascending aorta
9. 右心室 right ventricle
10. 左心房 left atrium

Fig. HT 12



- 11. 右心房 right atrium
- 12. 斜方肌 trapezius
- 13. 右上肺静脉 right superior pulmonary v.
- 14. 右肺动脉下叶支 inferior lobar branch of right pulmonary a.
- 15. 上段支气管 superior segmental bronchus
- 16. 背阔肌 latissimus dorsi
- 17. 前锯肌 serratus anterior
- 18. 右肺水平裂 horizontal fissure of right lung
- 19. 左肺动脉下叶上支 superior branch of inferior lobe of left pulmonary a.
- 20. 上段支气管 superior segmental bronchus
- 21. 竖脊肌 erector spinae
- 22. 胸主动脉 thoracic aorta
- 23. 奇静脉 azygos v.
- 24. 食管 esophagus
- S_{III}: 前段(S_{III}) anterior segment(S_{III})
- S_{IV}: 外侧段(S_{IV}) lateral segment(S_{IV})
- S_V: 上舌段(S_V) superior lingual segment(S_V)
- S_{VI}: 上段(S_{VI}) superior segment(S_{VI})



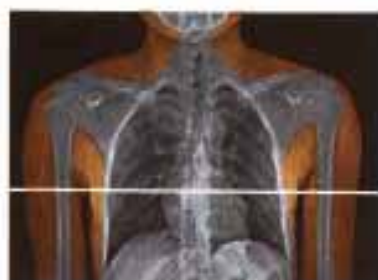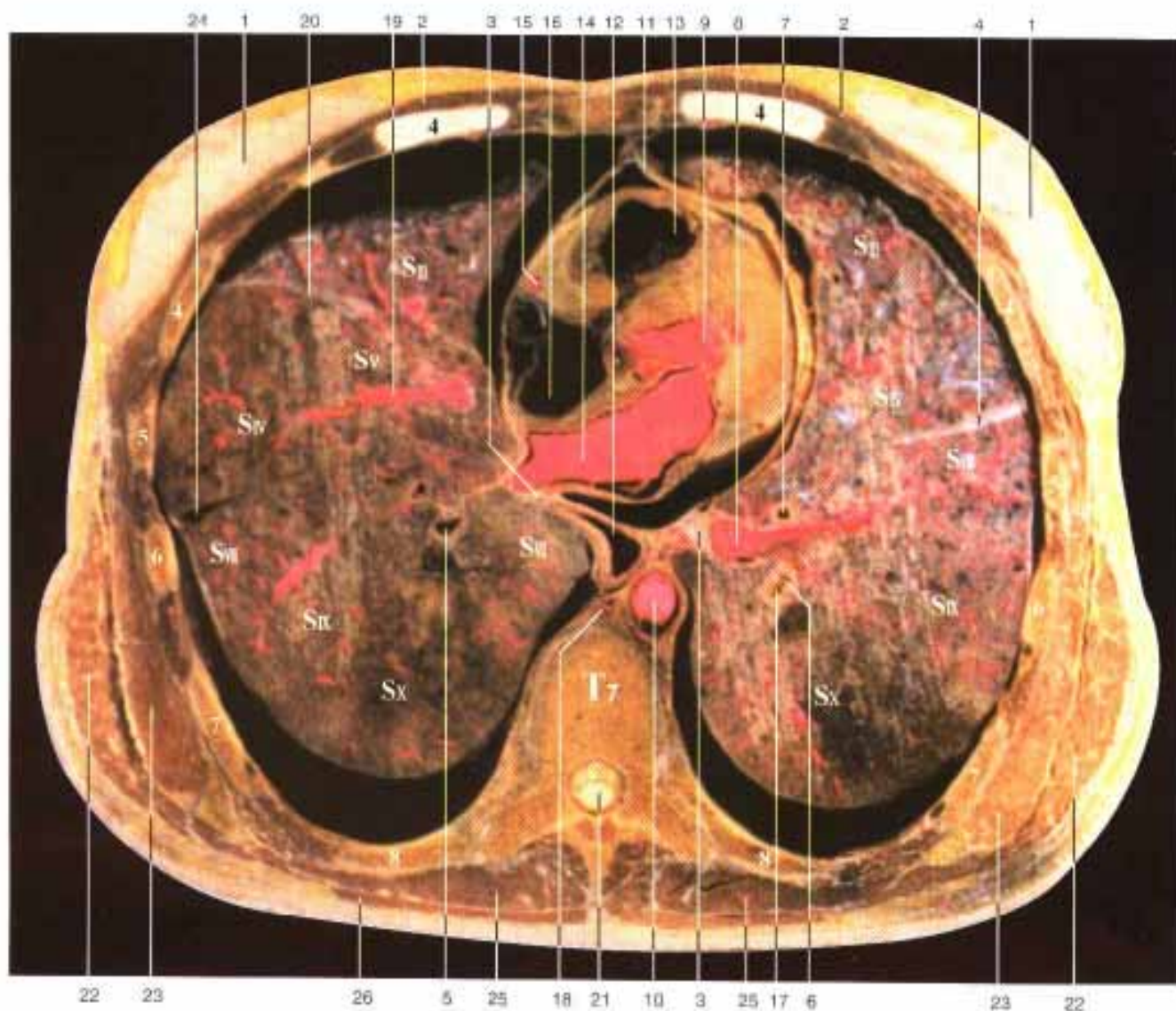
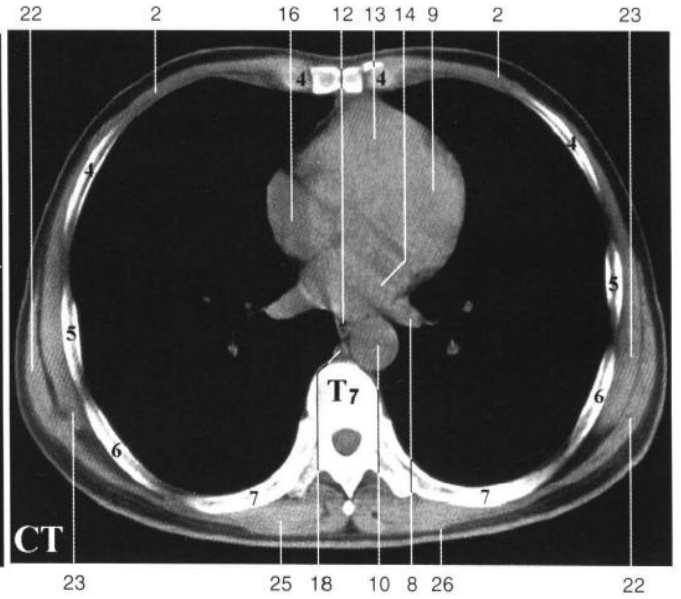

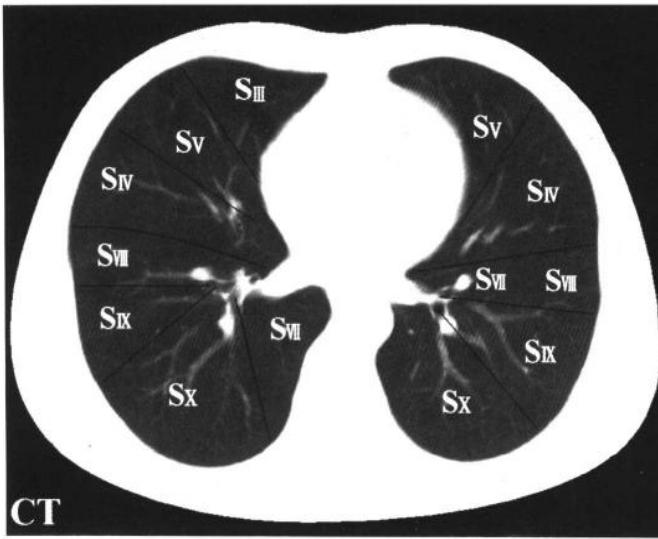
Fig. HT 13

1. 乳腺: mammary gland
2. 胸大肌: pectoralis major
3. 肺韧带: pulmonary ligament
4. 斜裂: oblique fissure
5. 右肺下叶支气管: right inferior lobar bronchus
6. 外侧基底段支气管(B₆): lateral basal segmental bronchus(B₆)
7. 前基底段支气管(B₇): anterior basal segmental bronchus(B₇)
8. 左下肺静脉: left inferior pulmonary v.
9. 左心室: left ventricle
10. 胸主动脉: thoracic aorta
11. 心包: pericardium
12. 食管: esophagus

Fig. HT 13



- 13. 右心室 right ventricle
- 14. 左心房 left atrium
- 15. 右冠状动脉 right coronary a.
- 16. 右心房 right atrium
- 17. 后底段支气管(B_X) posterior basal segmental bronchus(B_X)
- 18. 奇静脉 azygos v.
- 19. 右上肺静脉中叶支 branch of middle lobe of right superior pulmonary v.
- 20. 右肺水平裂 horizontal fissure of right lung
- 21. 脊髓 spinal cord
- 22. 背阔肌 latissimus dorsi
- 23. 前锯肌 serratus anterior
- 24. 斜裂 oblique fissure
- 25. 竖脊肌 erector spinae
- 26. 斜方肌 trapezius
- 27. 升主动脉 ascending aorta
- S_{III}: 前段(S_{III}) anterior segment(S_{III})
- S_N: 上舌段(S_N) superior lingual segment(S_N)
- S_L: 外侧段(S_L) lateral segment(S_L)
- S_V: 内侧段(S_V) medial segment(S_V)
- S_{IV}: 内侧底段(S_{IV}) medial basal segment(S_{IV})
- S_{VB}: 前底段(S_{VB}) anterior basal segment(S_{VB})
- S_{LB}: 外侧底段(S_{LB}) lateral basal segment(S_{LB})
- S_X: 后底段(S_X) posterior basal segment(S_X)

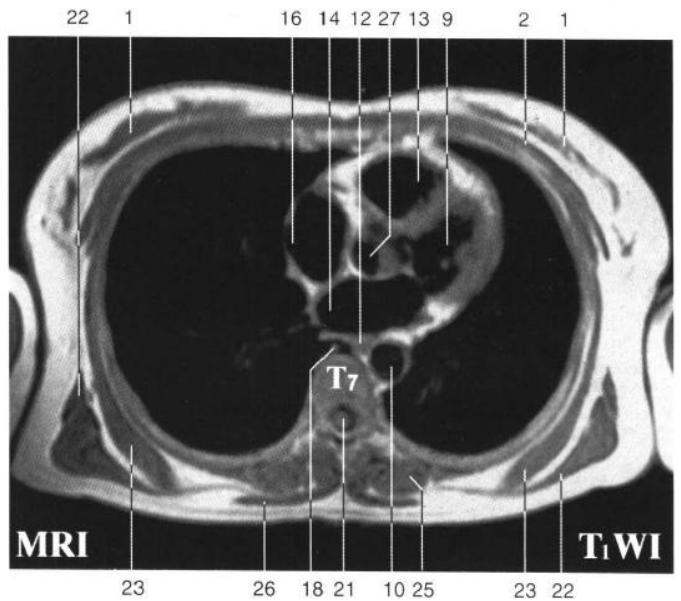
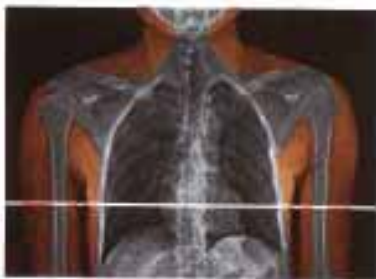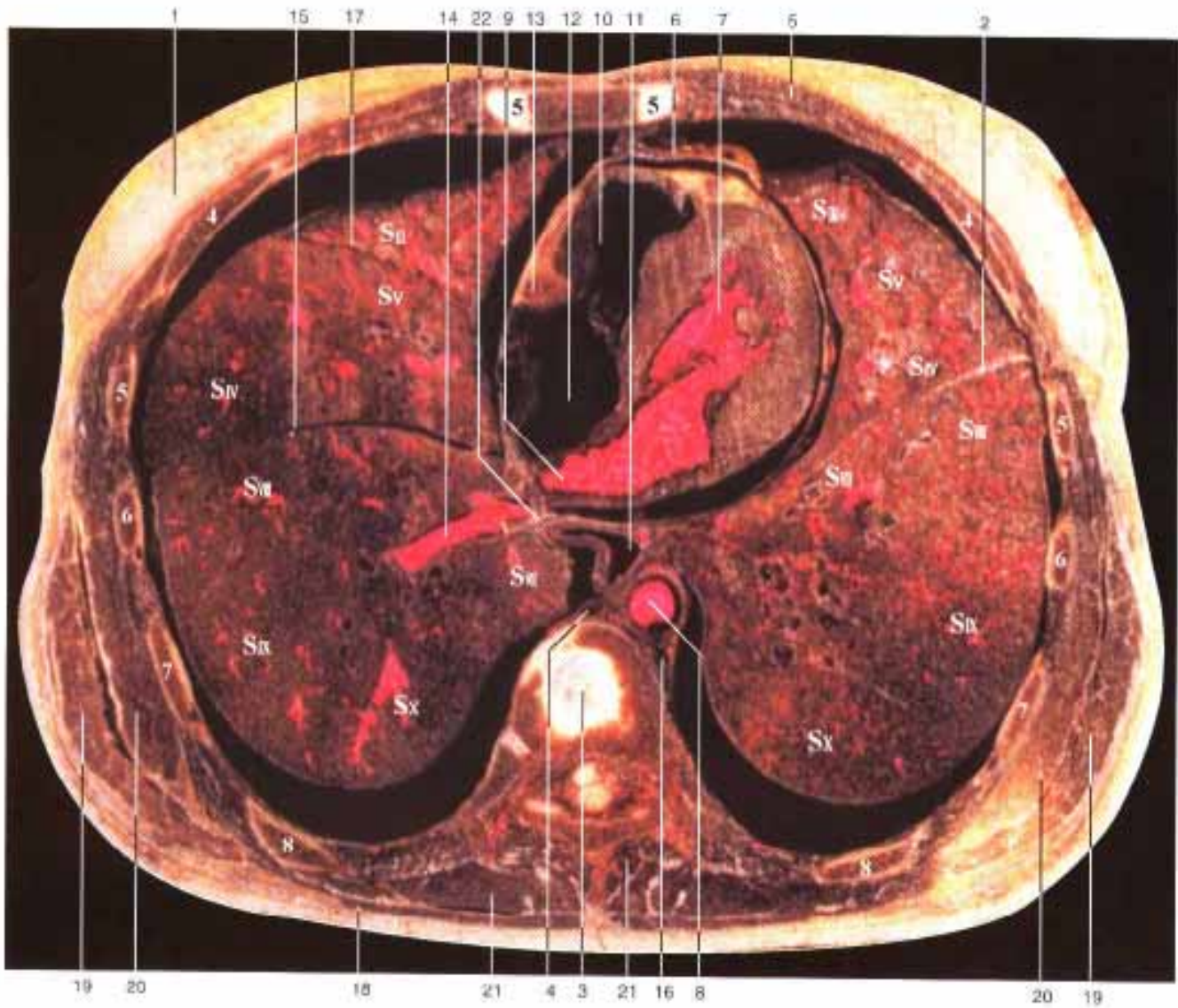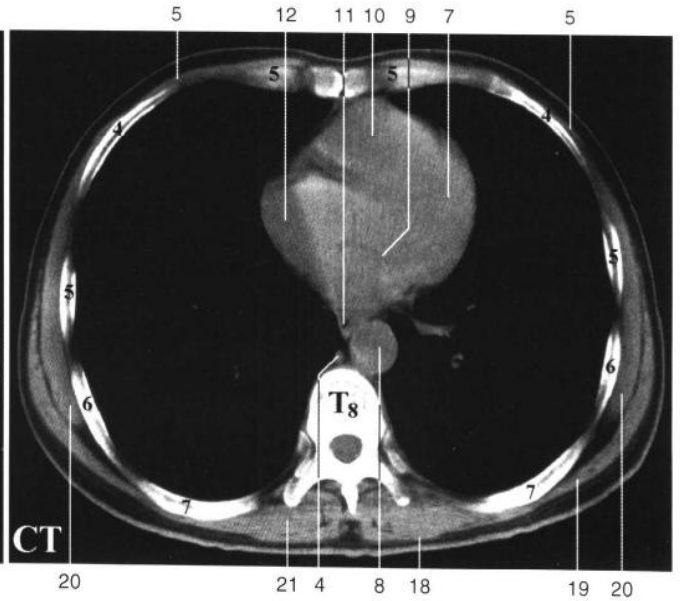



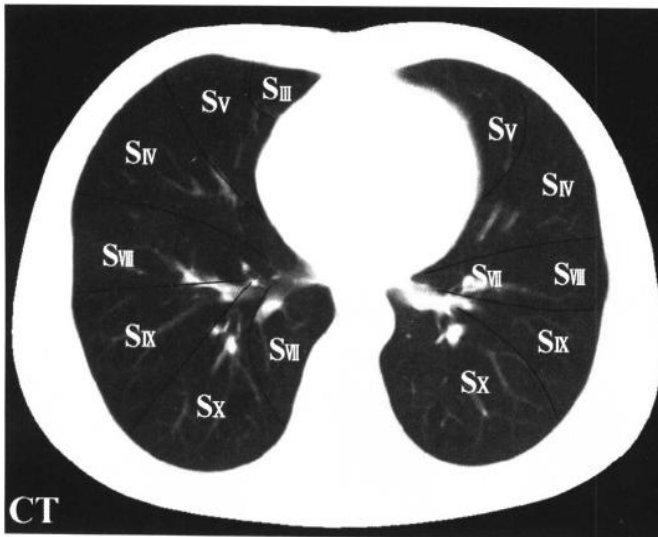
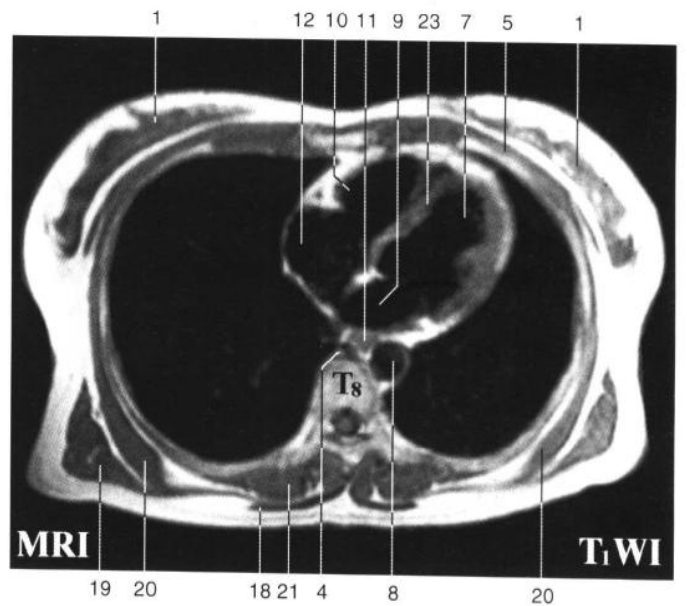
Fig. HT 14

1. 乳腺 mammary gland
2. 斜裂 oblique fissure
3. 7,8 胸椎间盘 intervertebral disc (T₇ - T₈)
4. 奇静脉 azygos v.
5. 胸大肌 pectoralis major
6. 心包 pericardium
7. 左心室 left ventricle
8. 胸主动脉 thoracic aorta
9. 左心房 left atrium
10. 右心室 right ventricle
11. 食管 esophagus

Fig. HT 14



- 12. 右心房 right atrium
- 13. 右冠状动脉 right coronary a.
- 14. 右下肺静脉 right inferior pulmonary v.
- 15. 斜裂 oblique fissure
- 16. 半奇静脉 hemiazygos v.
- 17. 右肺水平裂 horizontal fissure of right lung
- 18. 斜方肌 trapezius
- 19. 背阔肌 latissimus dorsi
- 20. 前锯肌 serratus anterior
- 21. 竖脊肌 erector spinae
- 22. 肺韧带 pulmonary ligament
- 23. 室间隔 interventricular septum
- S_{III}: 前段(S_{III}) anterior segment(S_{III})
- S_{IV}: 外侧段(S_{IV}) lateral segment(S_{IV})
- S_V: 上舌段(S_V) superior lingual segment(S_V)
- S_V: 内侧段(S_V) medial segment(S_V)
- S_V: 下舌段(S_V) inferior lingual segment(S_V)
- S_{VI}: 内侧底段(S_{VI}) medial basal segment(S_{VI})
- S_{VI}: 前底段(S_{VI}) anterior basal segment(S_{VI})
- S_{IX}: 外侧底段(S_{IX}) lateral basal segment(S_{IX})
- S_X: 后底段(S_X) posterior basal segment(S_X)



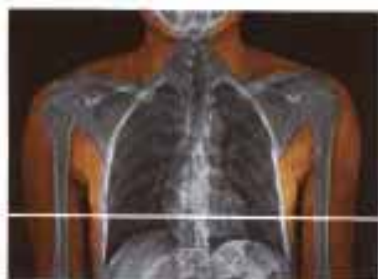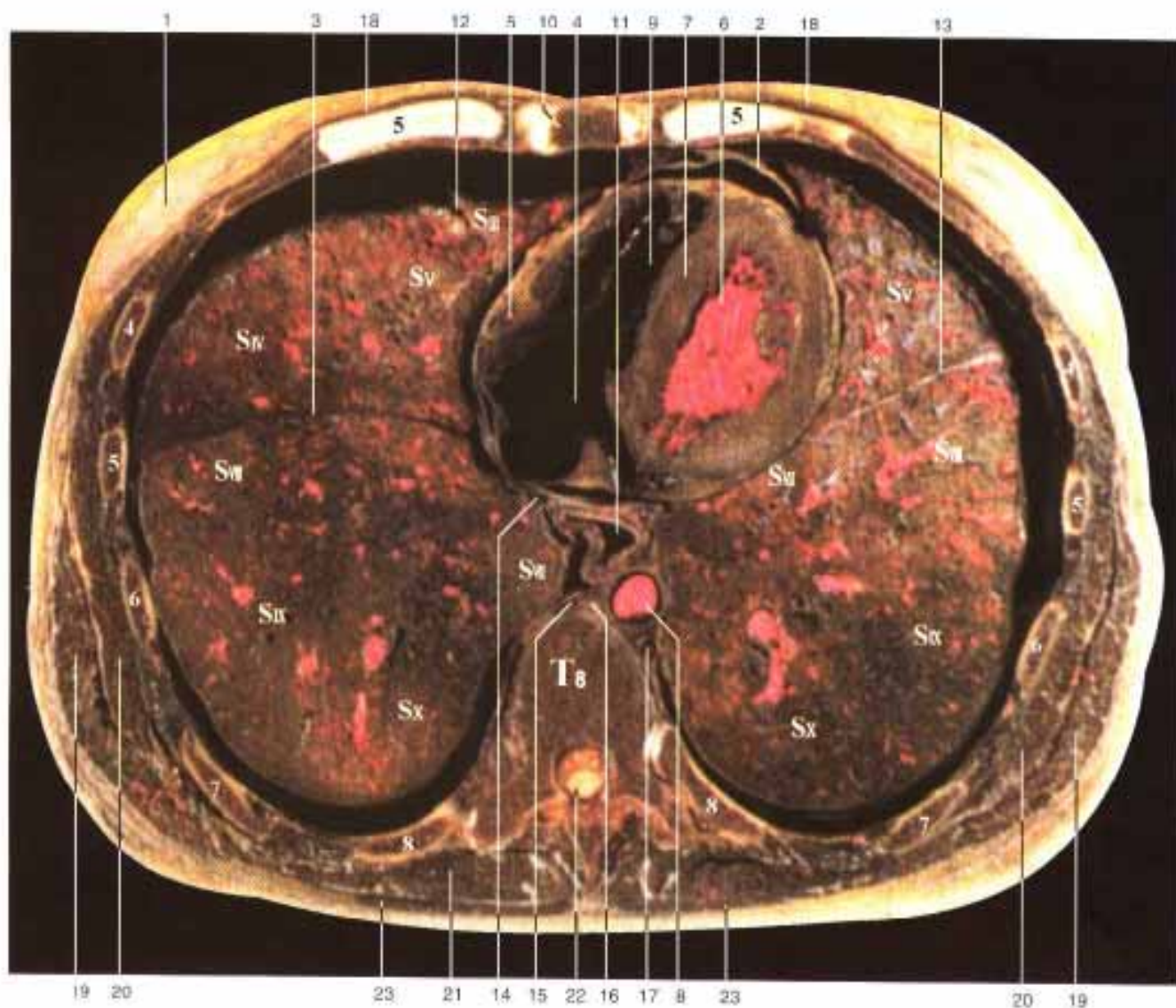
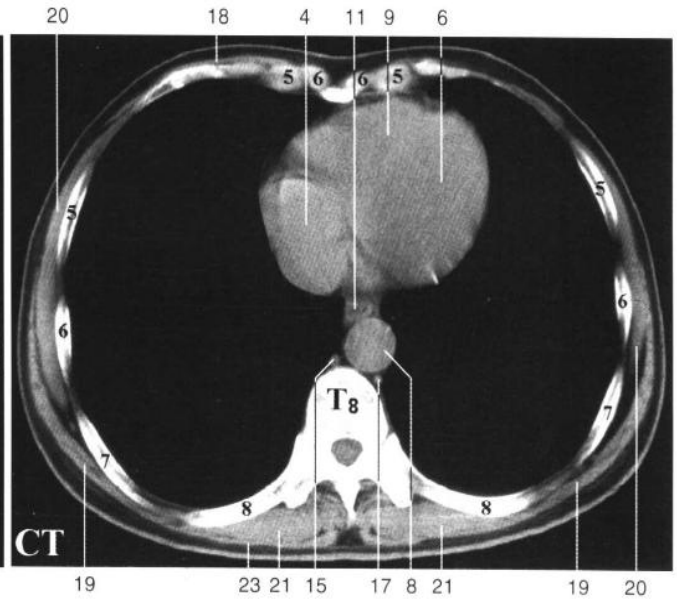

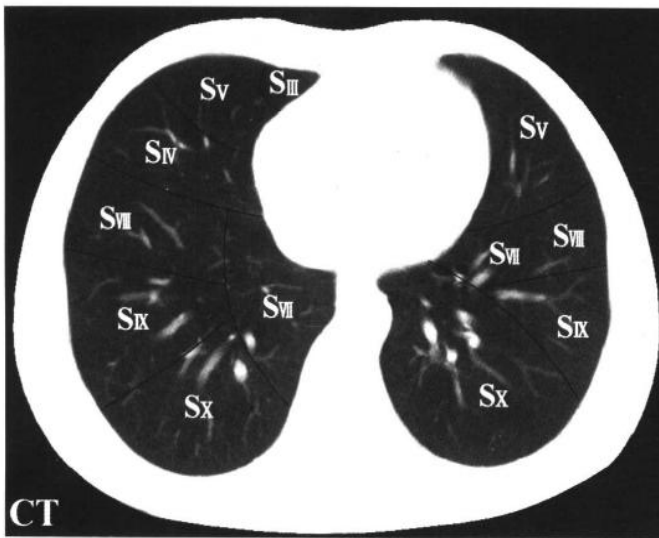
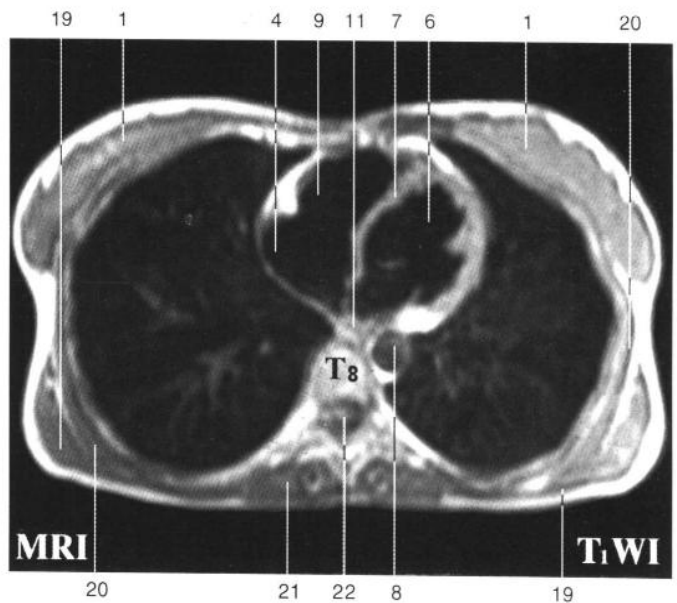
Fig. HT 15

1. 乳腺 mammary gland
2. 心包 pericardium
3. 斜裂 oblique fissure
4. 右心房 right atrium
5. 右冠状动脉 right coronary a.
6. 左心室 left ventricle
7. 室间隔 interventricular septum
8. 胸主动脉 thoracic aorta
9. 右心室 right ventricle
10. 胸骨体 body of sternum
11. 食管 esophagus

Fig. HT 15



- 12. 右肺水平裂 horizontal fissure of right lung
- 13. 斜裂 oblique fissure
- 14. 纵隔后淋巴结 posterior mediastinal lymph node
- 15. 奇静脉 azygos v.
- 16. 胸导管 thoracic duct
- 17. 半奇静脉 hemiazygos v.
- 18. 胸大肌 pectoralis major
- 19. 背阔肌 latissimus dorsi
- 20. 前锯肌 serratus anterior
- 21. 竖脊肌 erector spinae
- 22. 脊髓 spinal cord
- 23. 斜方肌 trapezius
- S_{III}: 前段(S_{III}) anterior segment(S_{III})
- S_N: 外侧段(S_N) lateral segment(S_N)
- S_V: 内侧段(S_V) medial segment(S_V)
- S_V: 下舌段(S_V) inferior lingual segment(S_V)
- S_{IV}: 内侧底段(S_{IV}) medial basal segment(S_{IV})
- S_{IV}: 前底段(S_{IV}) anterior basal segment(S_{IV})
- S_N: 外侧底段(S_N) lateral basal segment(S_N)
- S_X: 后底段(S_X) posterior basal segment(S_X)



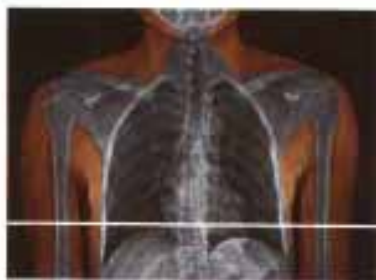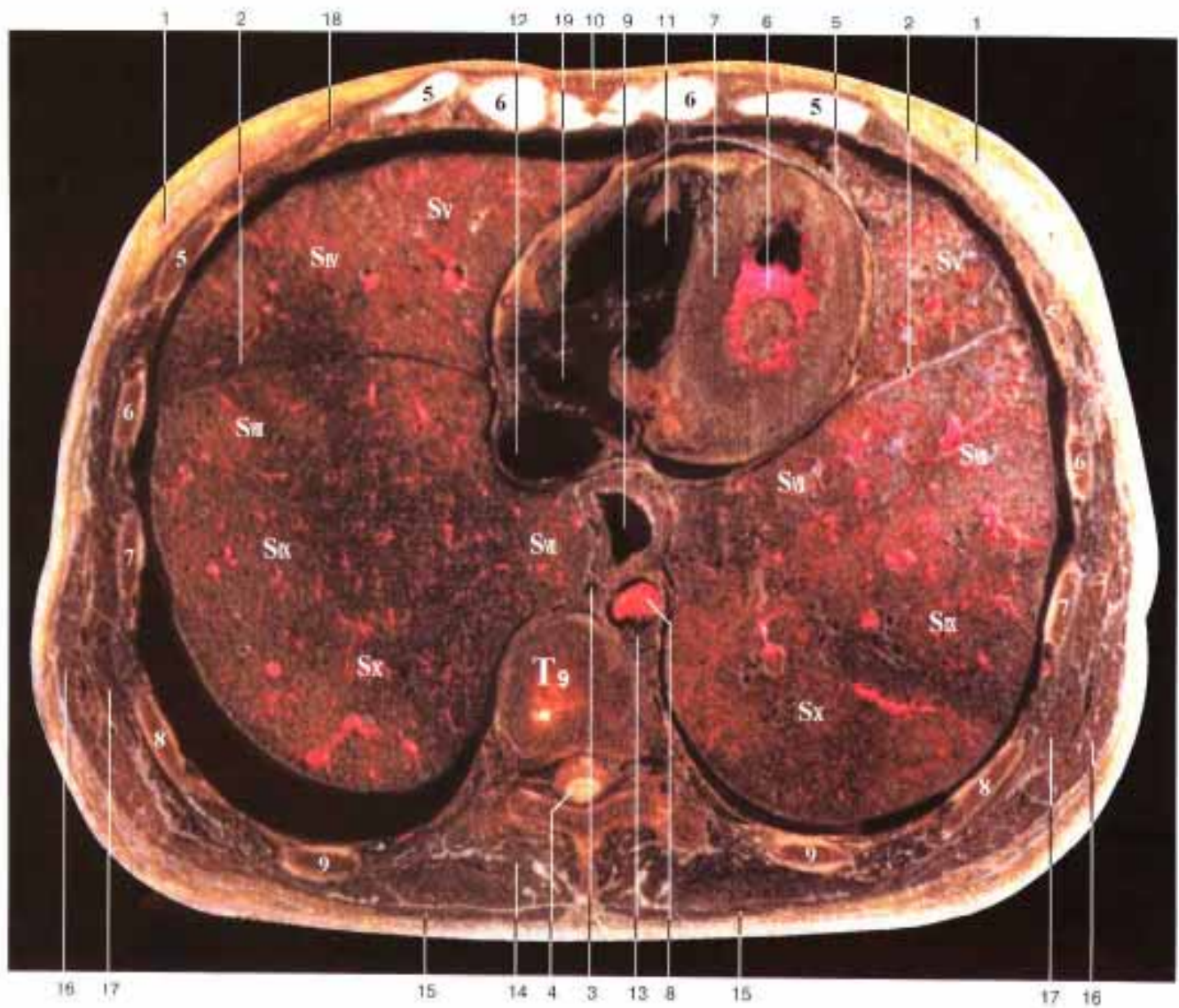
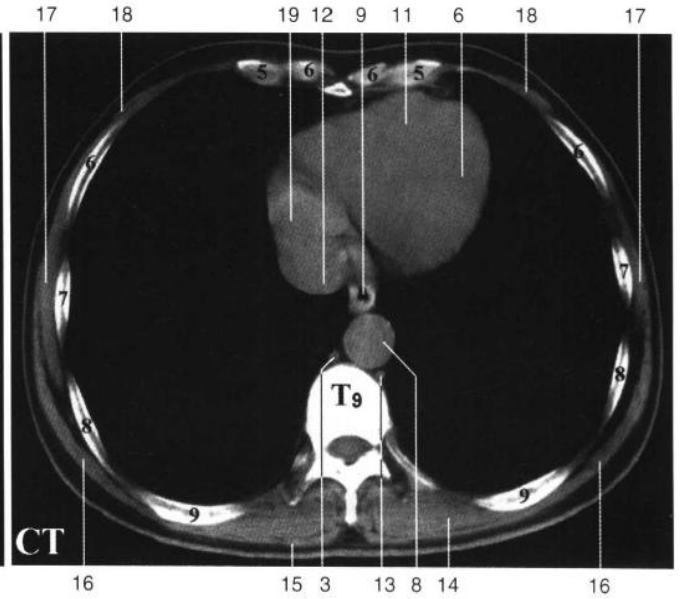

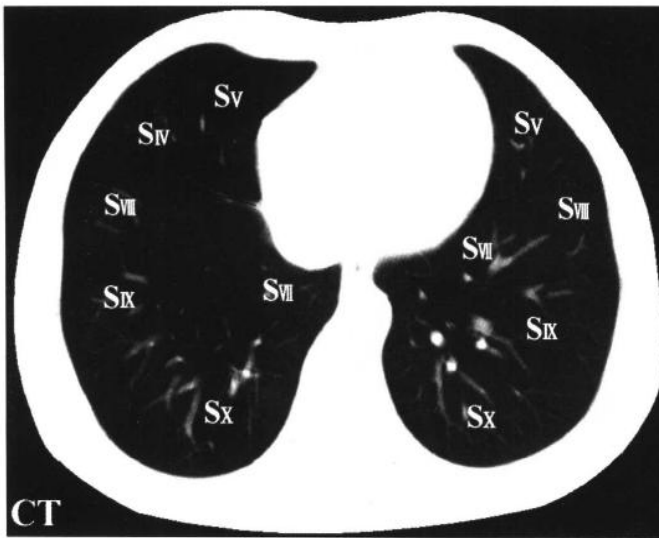
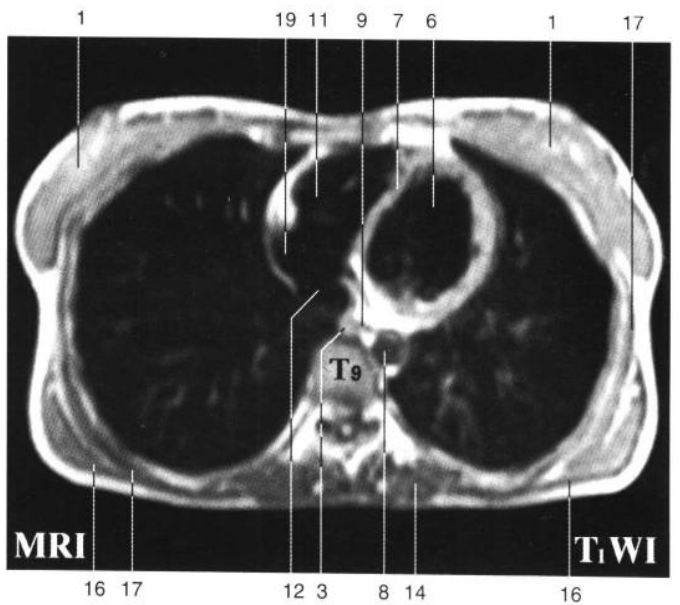
Fig. HT 16

1. 乳腺 mammary gland
2. 斜裂 oblique fissure
3. 奇静脉 azygos v.
4. 脊髓 spinal cord
5. 心包 pericardium
6. 左心室 left ventricle
7. 室间隔 interventricular septum
8. 胸主动脉 thoracic aorta
9. 食管 esophagus
10. 胸骨体 body of sternum
11. 右心室 right ventricle

Fig. HT 16



- 12. 下腔静脉 inferior vena cava
- 13. 半奇静脉 hemiazygos v.
- 14. 竖脊肌 erector spinae
- 15. 斜方肌 trapezius
- 16. 背阔肌 latissimus dorsi
- 17. 前锯肌 serratus anterior
- 18. 胸大肌 pectoralis major
- 19. 右心房 right atrium
- S_R: 外侧段(S_R) lateral segment(S_R)
- S_V: 内侧段(S_V) medial segment(S_V)
- S_V: 下舌段(S_V) inferior lingual segment(S_V)
- S_{IV}: 内侧底段(S_{IV}) medial basal segment(S_{IV})
- S_{VII}: 前底段(S_{VII}) anterior basal segment(S_{VII})
- S_R: 外侧底段(S_R) lateral basal segment(S_R)
- S_X: 后底段(S_X) posterior basal segment(S_X)



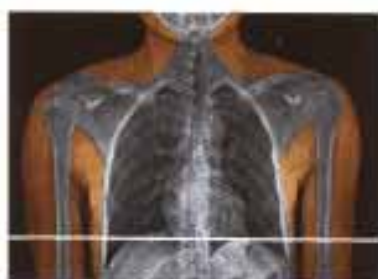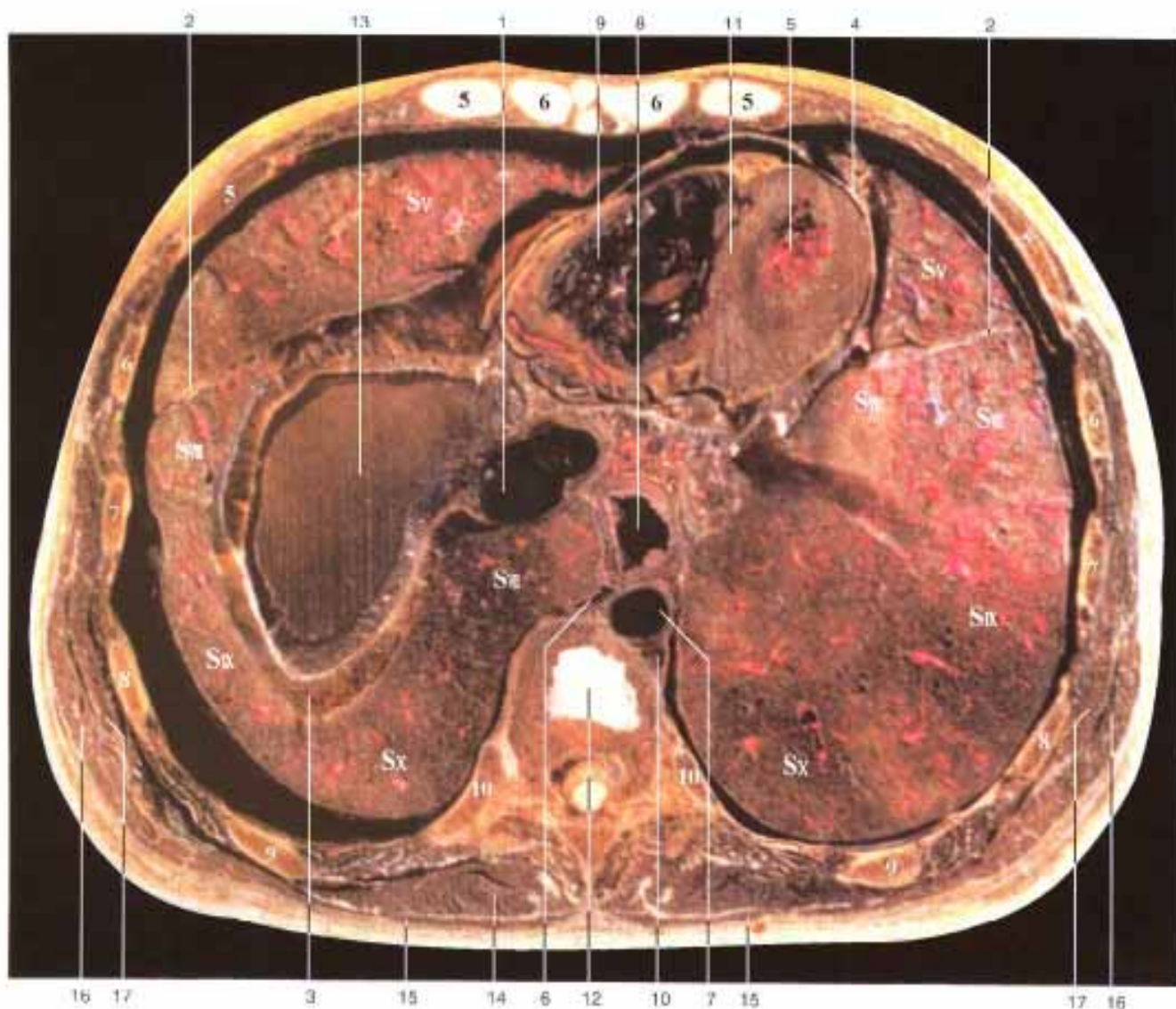
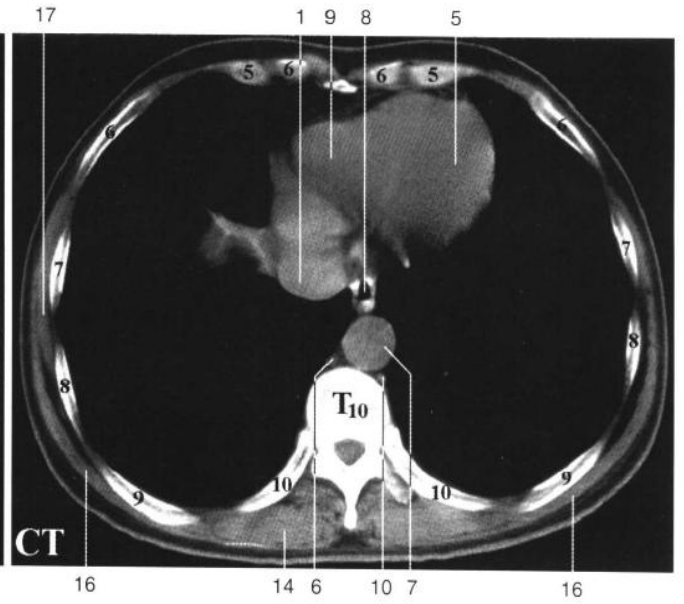
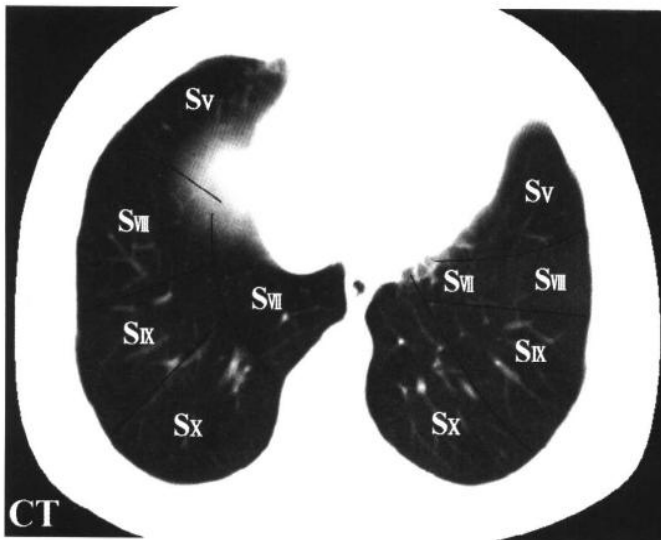


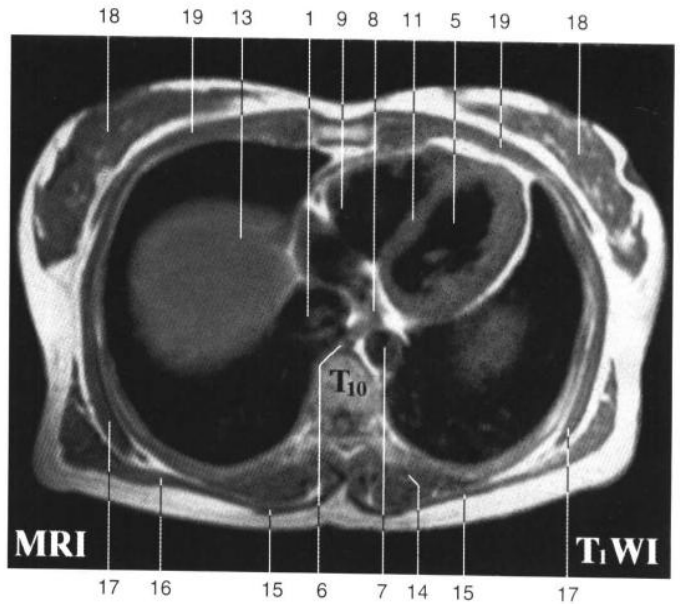
Fig. HT 17

1. 下腔静脉 inferior vena cava
2. 斜裂 oblique fissure
3. 膈 diaphragm
4. 心包 pericardium
5. 左心室 left ventricle
6. 奇静脉 azygos v.
7. 胸主动脉 thoracic aorta
8. 食管 esophagus
9. 右心室 right ventricle
10. 半奇静脉 hemiazygos v.
11. 室间隔 interventricular septum

Fig. HT 17



12. 9,10 胸椎间盘 intervertebral disc($T_9 - T_{10}$)
 13. 肝 liver
 14. 竖脊肌 erector spinae
 15. 斜方肌 trapezius
 16. 背阔肌 latissimus dorsi
 17. 前锯肌 serratus anterior
 18. 乳腺 mammary gland
 19. 胸大肌 pectoralis major
 S_V : 内侧段(S_V) medial segment(S_V)
 S_{V_i} : 下舌段(S_{V_i}) inferior lingual segment(S_{V_i})
 $S_{V_{iI}}$: 内侧底段($S_{V_{iI}}$) medial basal segment($S_{V_{iI}}$)
 $S_{V_{iII}}$: 前底段($S_{V_{iII}}$) anterior basal segment($S_{V_{iII}}$)
 $S_{V_{iL}}$: 外侧底段($S_{V_{iL}}$) lateral basal segment($S_{V_{iL}}$)
 S_X : 后底段(S_X) posterior basal segment(S_X)



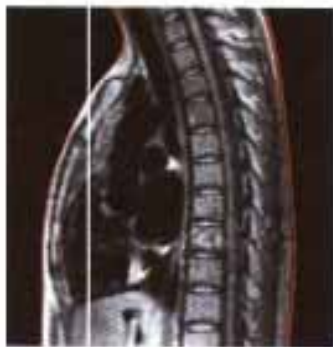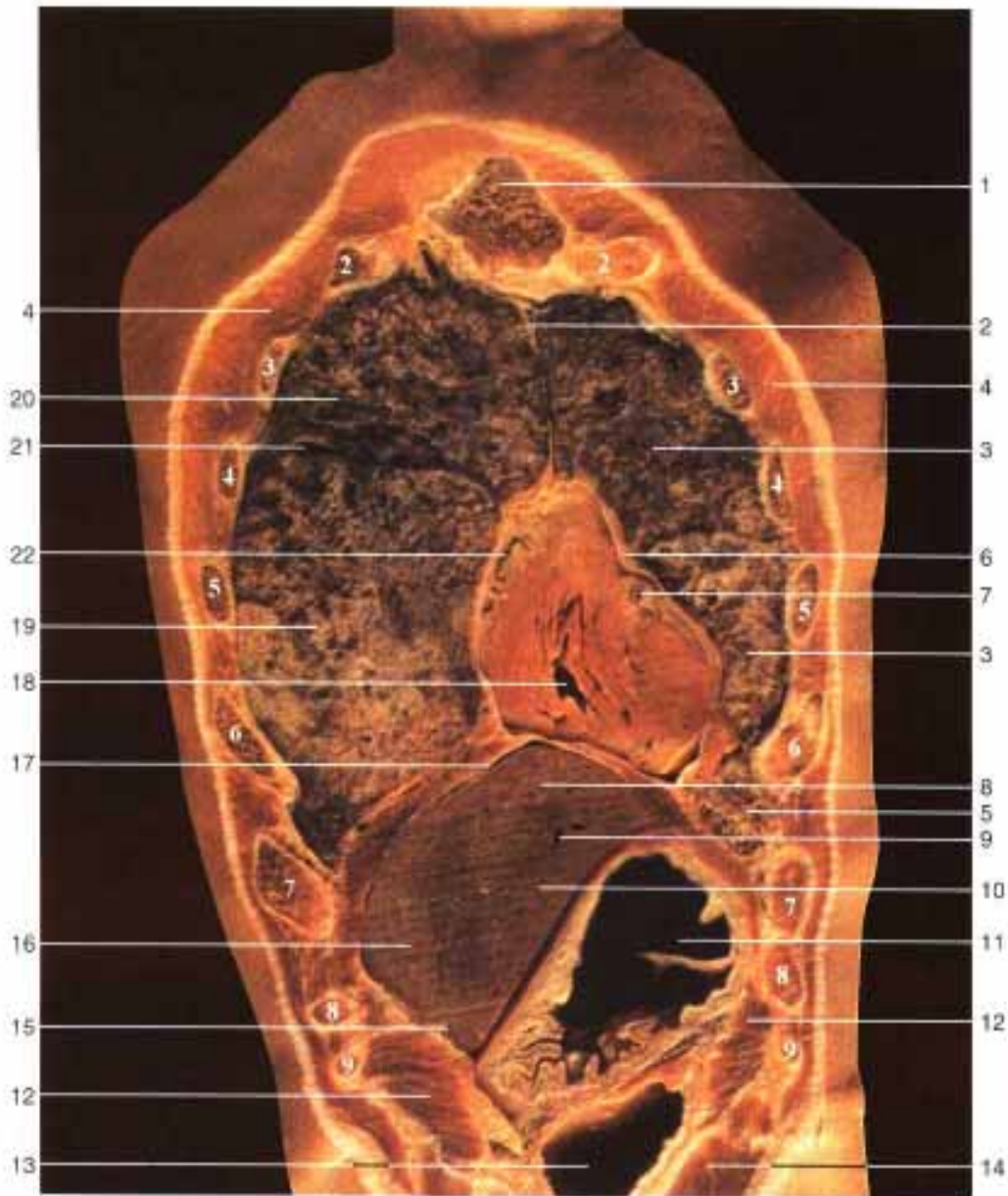
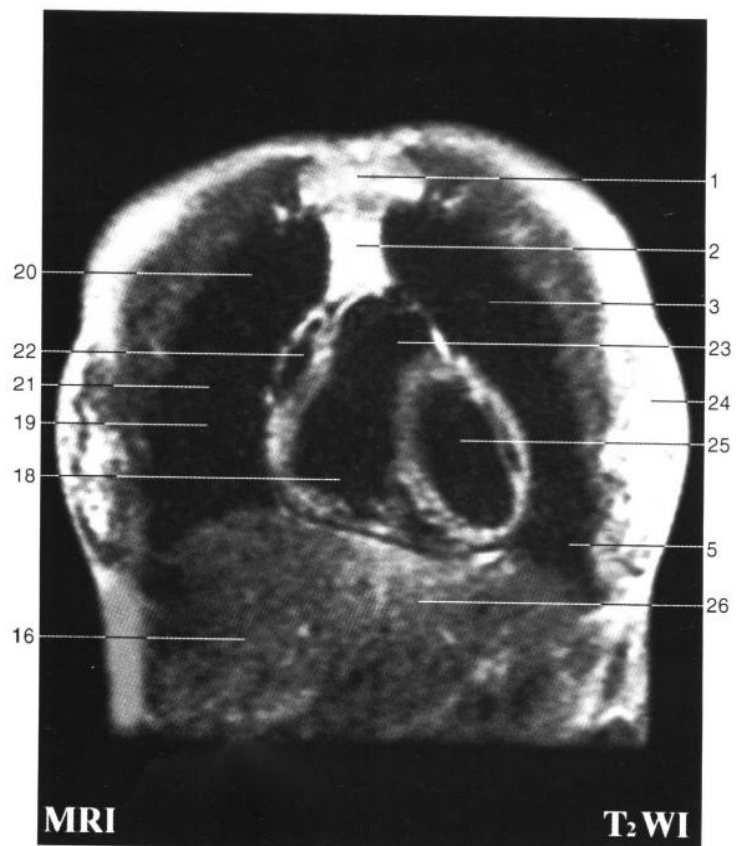
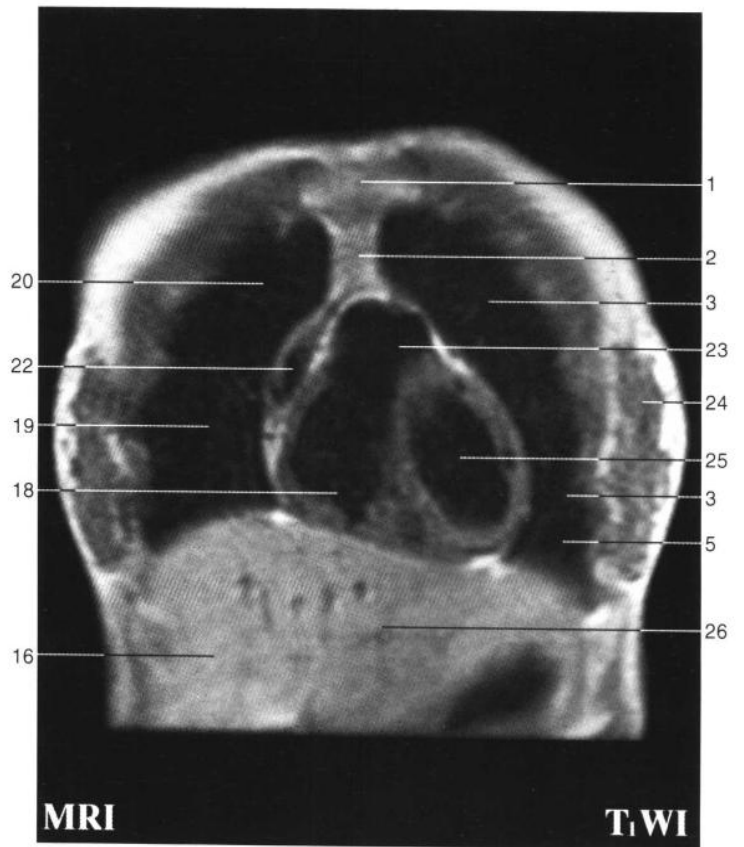


Fig. FT 1

1. 胸骨柄 manubrium sterni
2. 胸骨心包韧带 sternopericardial ligament
3. 左肺上叶 superior lobe of left lung
4. 胸大肌 pectoralis major
5. 左肺下叶 inferior lobe of left lung
6. 心包 pericardium
7. 左冠状动脉 left coronary a.
8. 左外叶上段 superior segment of left lateral lobe
9. 肝左静脉 left hepatic v.
10. 左外叶下段 inferior segment of left lateral lobe

Fig. FT 1

11. 胃 stomach
12. 腹横肌 transversus abdominis
13. 横结肠 transverse colon
14. 腹直肌 rectus abdominis
15. 肝圆韧带裂 fissure for ligamentum teres hepatis
16. 左内叶 left medial lobe
17. 膈 diaphragm
18. 右心室 right ventricle
19. 右肺中叶 middle lobe of right lung
20. 右肺上叶 superior lobe of right lung
21. 右肺水平裂 horizontal fissure of right lung
22. 右心耳 right auricle
23. 肺动脉干 pulmonary trunk
24. 乳腺 mammary gland
25. 左心室 left ventricle
26. 左外叶 left lateral lobe



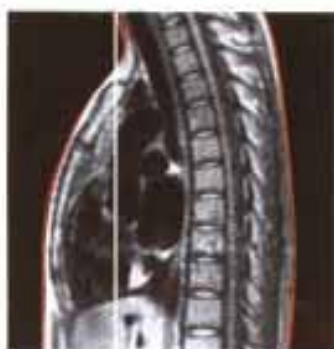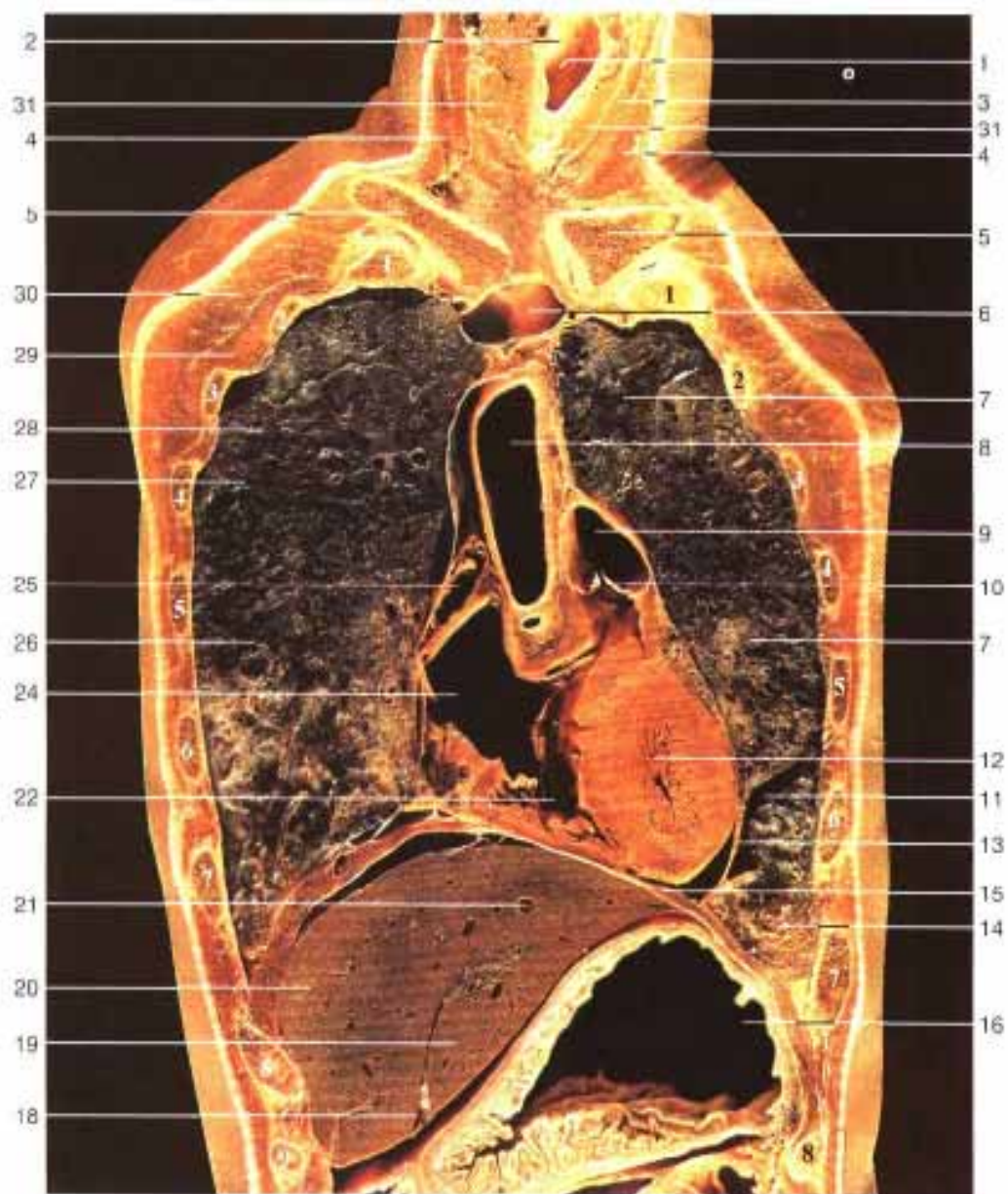


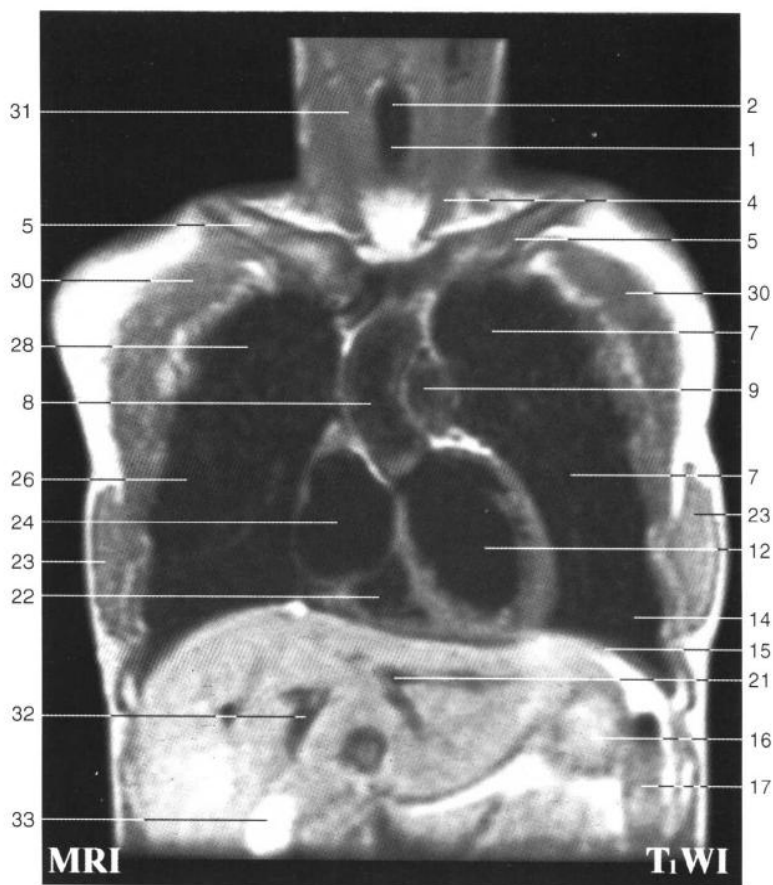Fig. FT 2

1. 气管 trachea
2. 喉下腔 infraglottic cavity
3. 胸骨舌骨肌 sternohyoid
4. 胸锁乳突肌 sternocleidomastoid
5. 锁骨 clavicle
6. 左头臂静脉 left brachiocephalic v.
7. 左肺上叶 superior lobe of left lung
8. 升主动脉 ascending aorta
9. 肺动脉干 pulmonary trunk

Fig. FT 2

10. 肺动脉瓣 valve of pulmonary trunk
11. 斜裂 oblique fissure
12. 左心室 left ventricle
13. 心包 pericardium
14. 左肺下叶 inferior lobe of left lung
15. 膈 diaphragm
16. 胃底 fundus of stomach
17. 脾 spleen
18. 肝圆韧带裂 fissure for ligamentum teres hepatis
19. 左外叶 left lateral lobe
20. 左内叶 left medial lobe
21. 肝左静脉 left hepatic v.
22. 右心室 right ventricle
23. 乳腺 mammary gland
24. 右心房 right atrium
25. 右心耳 right auricle
26. 右肺中叶 middle lobe of right lung
27. 右肺水平裂 horizontal fissure of right lung
28. 右肺上叶 superior lobe of right lung
29. 胸小肌 pectoralis minor
30. 胸大肌 pectoralis major
31. 甲状腺 thyroid gland
32. 肝中间静脉 intermediate hepatic v.
33. 胆囊 gallbladder

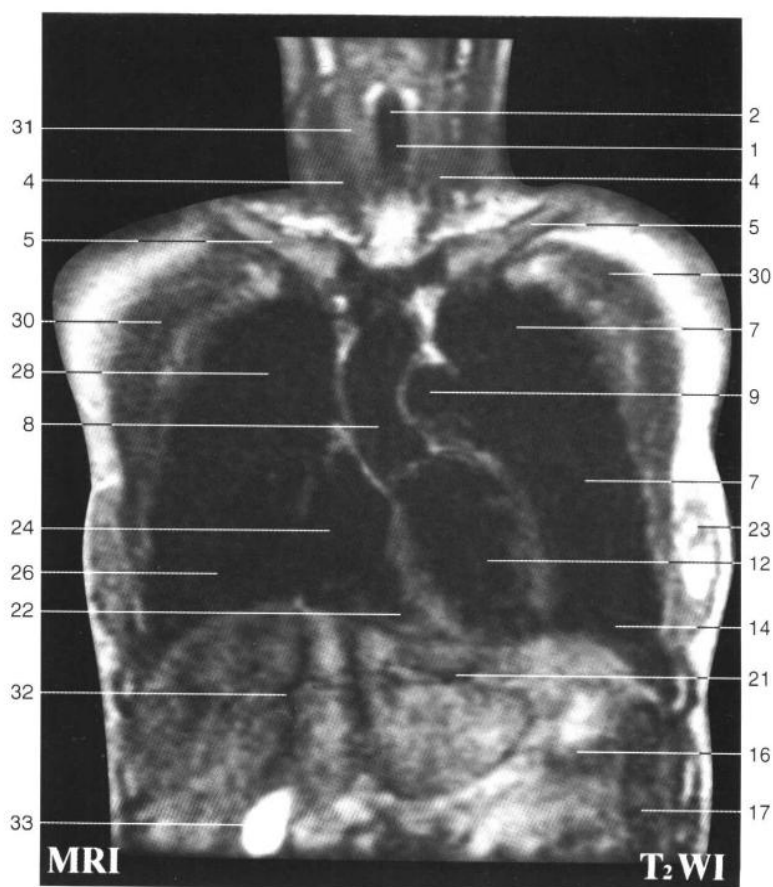

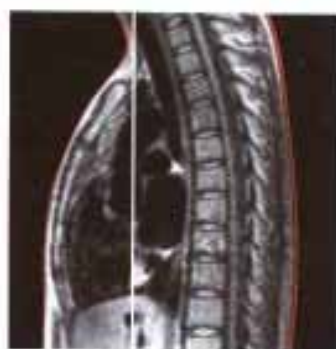
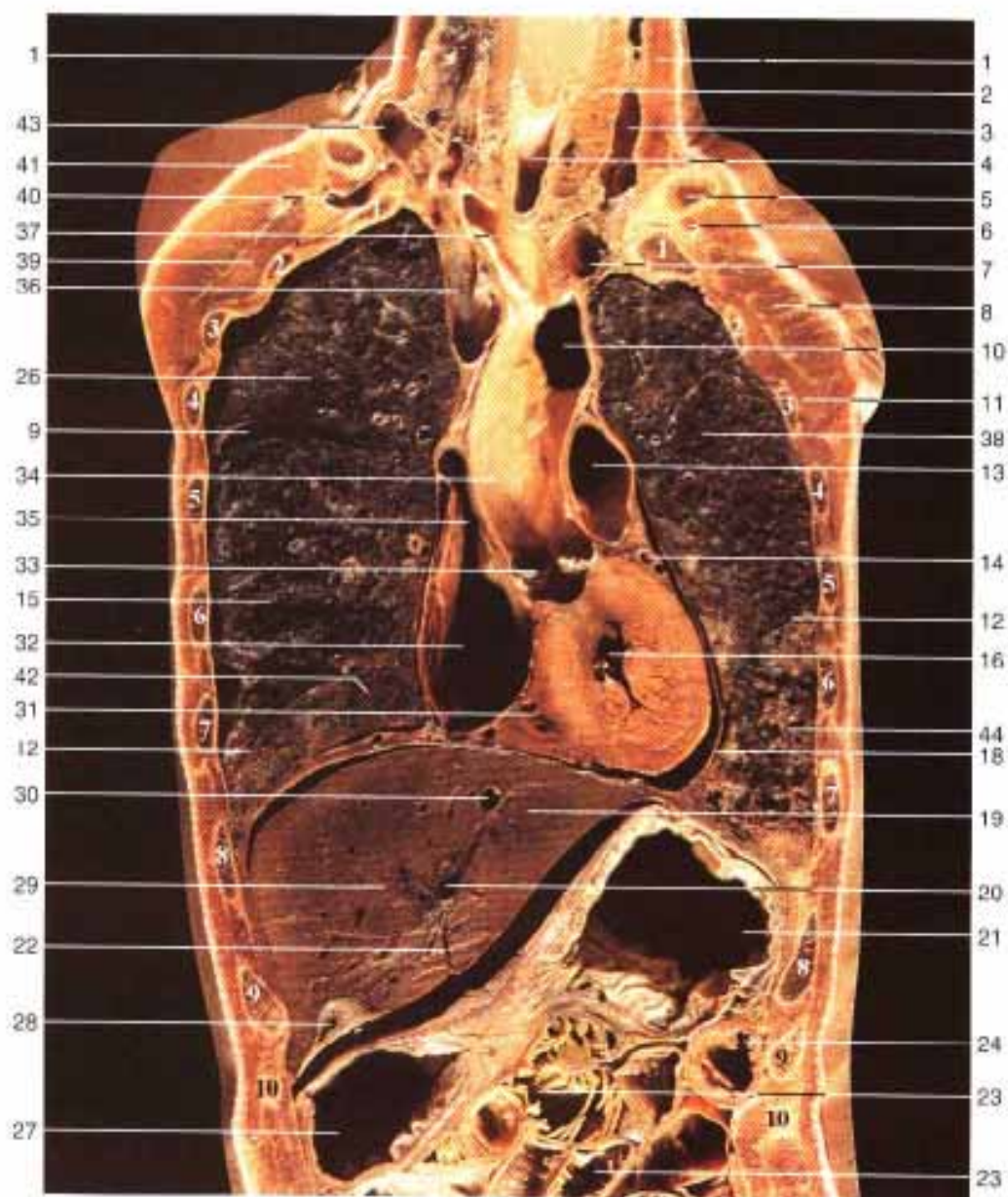
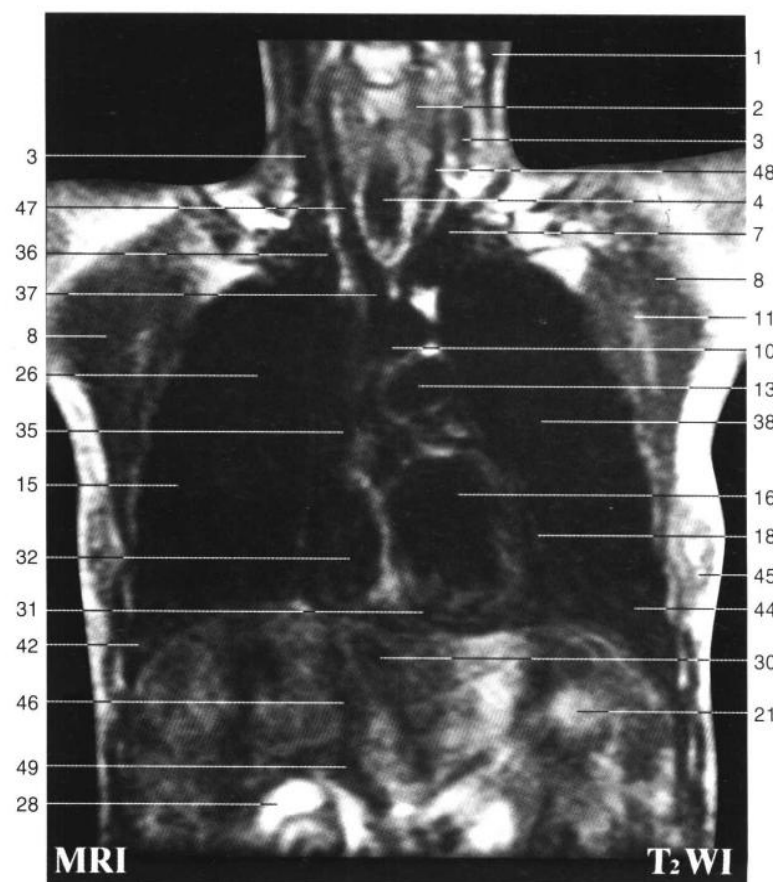
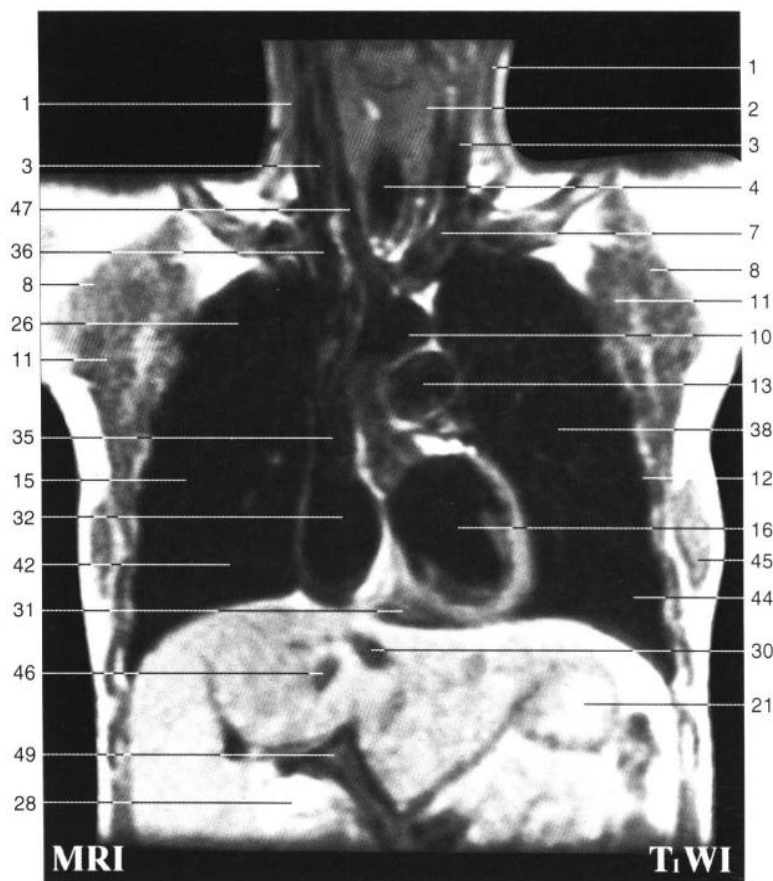Fig. FT 3

1. 胸锁乳突肌 sternocleidomastoid
2. 甲状腺 thyroid gland
3. 颈内静脉 internal jugular v.
4. 气管 trachea
5. 锁骨 clavicle
6. 锁骨下肌 subclavius
7. 左头臂静脉 left brachiocephalic v.
8. 胸大肌 pectoralis major
9. 右肺水平裂 horizontal fissure of right lung
10. 主动脉弓 aortic arch

Fig. FT 3

11. 胸小肌 pectoralis minor
12. 斜裂 oblique fissure
13. 肺动脉干 pulmonary trunk
14. 左冠状动脉 left coronary a.
15. 右肺中叶 middle lobe of right lung
16. 左心室 left ventricle
17. 左肺下叶 inferior lobe of left lung
18. 心包 pericardium
19. 左外叶 left lateral lobe
20. 肝门静脉左支脐部 umbilical part of left branch of hepatic portal v.
21. 胃底 fundus of stomach
22. 肝圆韧带裂 fissure for ligamentum teres hepatis
23. 空肠 jejunum
24. 横结肠 transverse colon
25. 空肠 jejunum
26. 右肺上叶 superior lobe of right lung
27. 幽门窦 pyloric antrum
28. 胆囊 gallbladder
29. 左内叶 left medial lobe
30. 肝左静脉 left hepatic v.
31. 右心室 right ventricle
32. 右心房 right atrium
33. 主动脉瓣 aortic valve
34. 升主动脉 ascending aorta
35. 上腔静脉 superior vena cava
36. 右头臂静脉 right brachiocephalic v.
37. 头臂干 brachiocephalic trunk
38. 左肺上叶 superior lobe of left lung
39. 胸小肌 pectoralis minor
40. 锁骨下静脉 subclavian v.
41. 胸大肌 pectoralis major
42. 右肺下叶 inferior lobe of right lung
43. 肩胛上静脉 suprascapular v.
44. 左肺下叶 inferior lobe of left lung
45. 乳腺 mammary gland
46. 肝中间静脉 intermediate hepatic v.
47. 右颈总动脉 right common carotid a.
48. 左颈总动脉 left common carotid a.
49. 肝门 porta hepatis



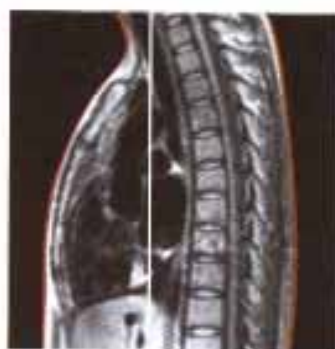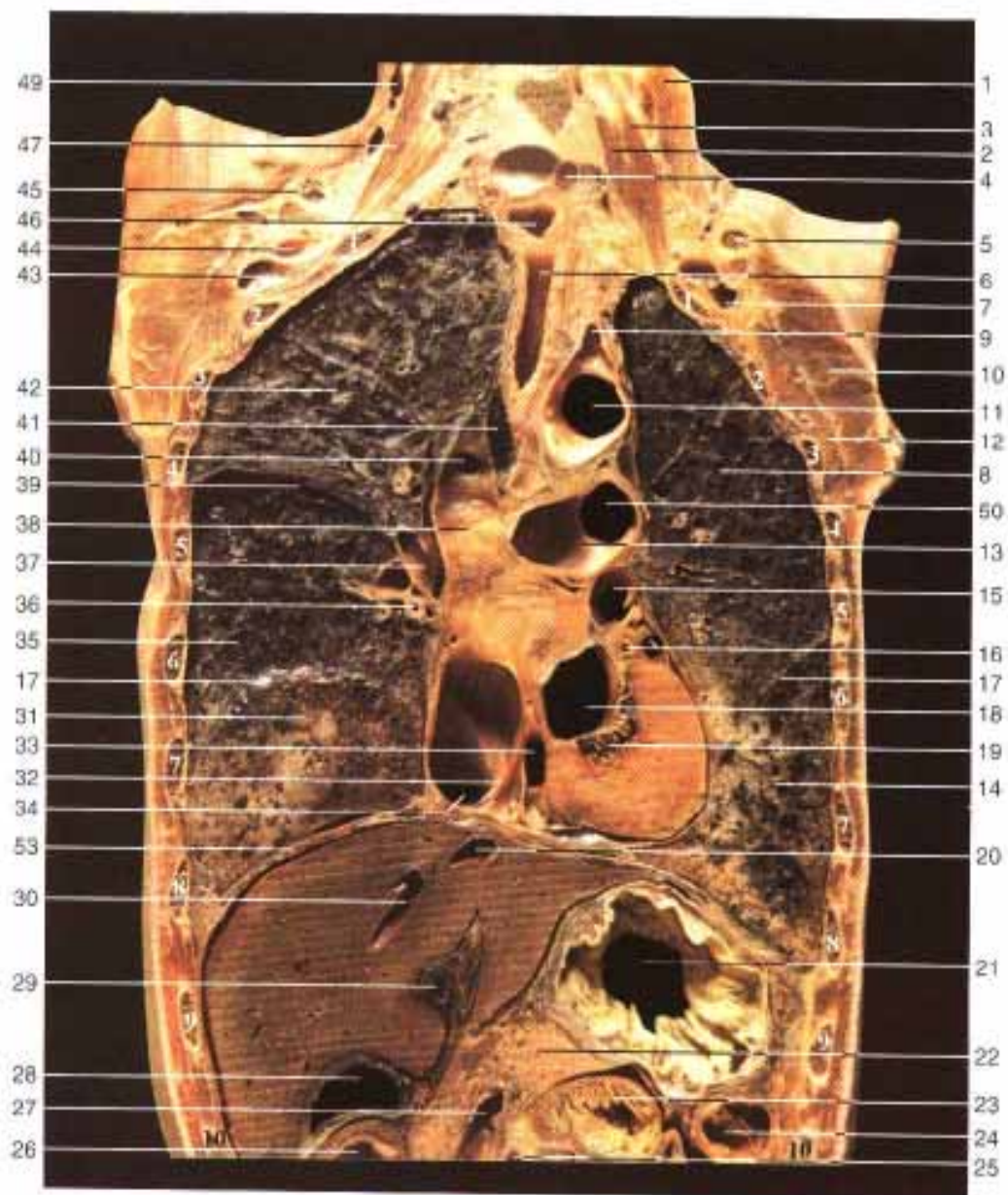

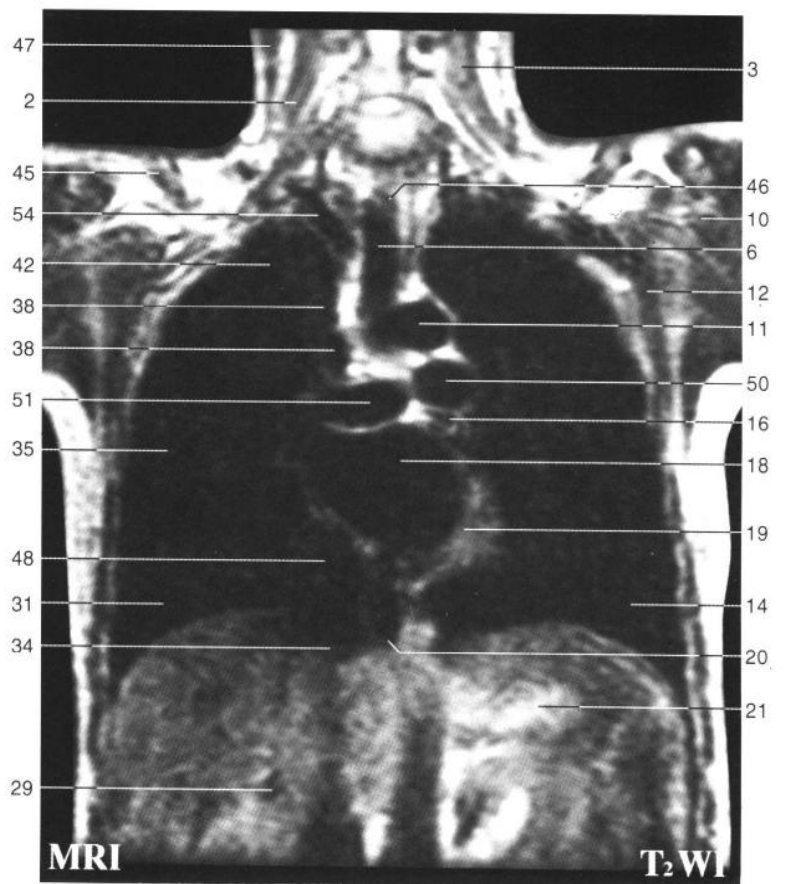
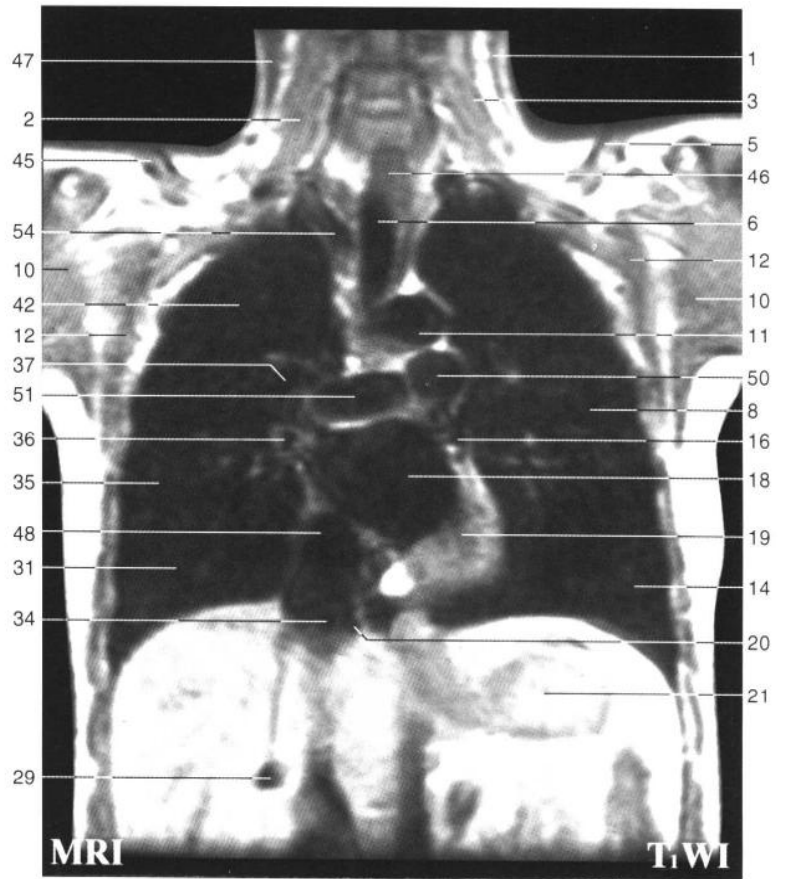Fig. FT 4

1. 胸锁乳突肌 sternocleidomastoid
2. 中斜角肌 scalenus medius
3. 前斜角肌 scalenus anterior
4. 颈长肌 longus colli
5. 锁骨 clavicle
6. 气管 trachea
7. 左锁骨下静脉 left subclavian v.
8. 左肺上叶 superior lobe of left lung
9. 左颈总动脉 left common carotid a.

Fig. FT 4

10. 胸大肌 pectoralis major
11. 主动脉弓 aortic arch
12. 胸小肌 pectoralis minor
13. 肺动脉干 pulmonary trunk
14. 左肺下叶 inferior lobe of left lung
15. 左心耳 left auricle
16. 左冠状动脉 left coronary a.
17. 斜裂 oblique fissure
18. 左心房 left atrium
19. 左心室 left ventricle
20. 肝左静脉 left hepatic v.
21. 胃底 fundus of stomach
22. 胰 pancreas
23. 空肠 jejunum
24. 横结肠 transverse colon
25. 肠系膜上动脉 superior mesenteric a.
26. 幽门窦 pyloric antrum
27. 肠系膜上静脉 superior mesenteric v.
28. 胆囊 gallbladder
29. 肝门静脉左支脐部 umbilical part of left branch of hepatic portal v.
30. 肝中间静脉 intermediate hepatic v.
31. 右肺下叶 inferior lobe of right lung
32. 下腔静脉瓣 valve of inferior vena cava
33. 冠状窦口 orifice of coronary sinus
34. 下腔静脉 inferior vena cava
35. 右肺中叶 middle lobe of right lung
36. 右肺中叶支气管 right middle lobar bronchus
37. 右肺动脉支 br. right pulmonary a.
38. 上腔静脉 superior vena cava
39. 右肺水平裂 horizontal fissure of right lung
40. 奇静脉口 orifice of azygos v.
41. 气管旁淋巴结 paratracheal lymph nodes
42. 右肺上叶 superior lobe of right lung
43. 锁骨下静脉 subclavian v.
44. 锁骨下动脉 subclavian a.
45. 锁骨 clavicle
46. 食管 esophagus
47. 胸锁乳突肌 sternocleidomastoid
48. 右心房 right atrium
49. 颈外静脉 external jugular v.
50. 左肺动脉 left pulmonary a.
51. 右肺动脉 right pulmonary a.
52. 头臂干 brachiocephalic trunk
53. 膈 diaphragm
54. 右头臂静脉 right brachiocephalic v.



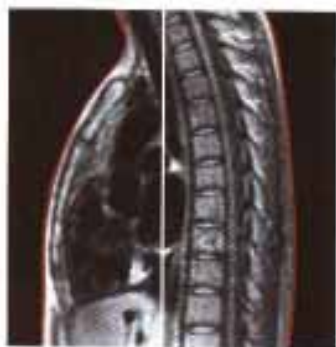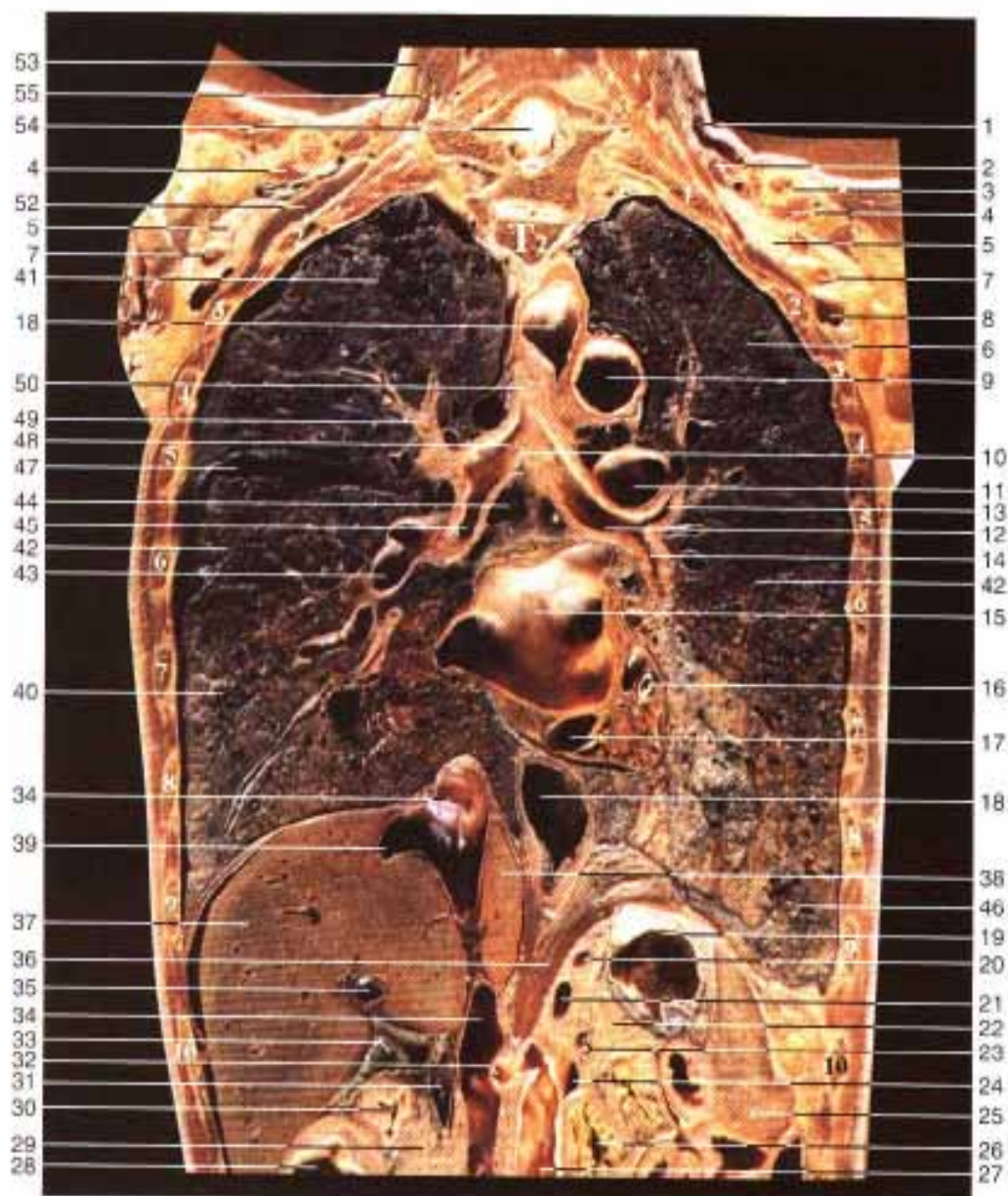

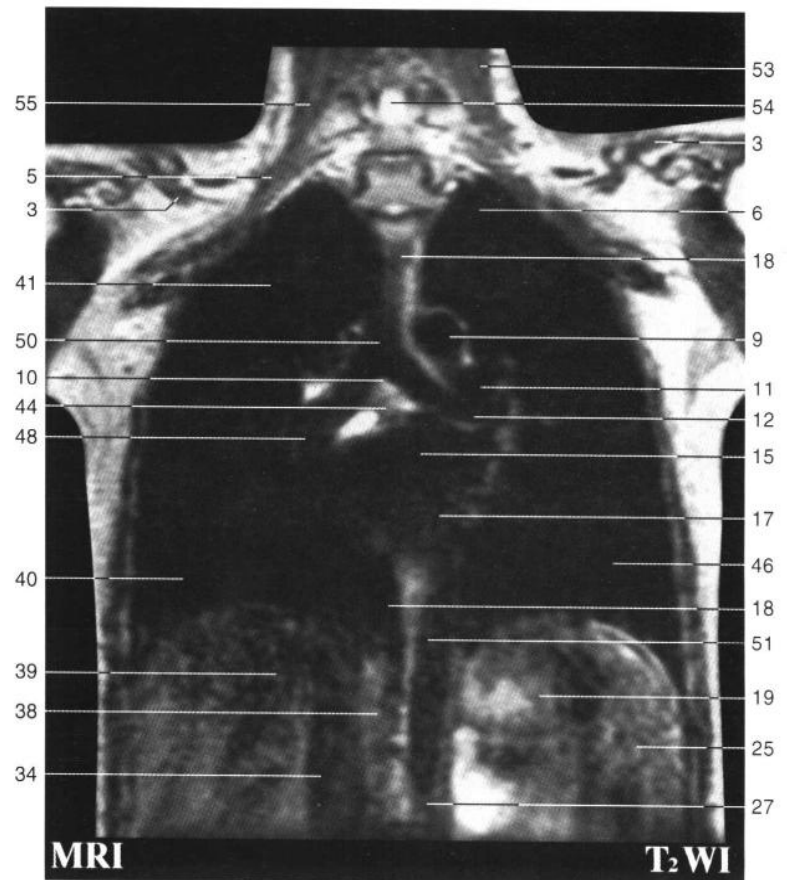
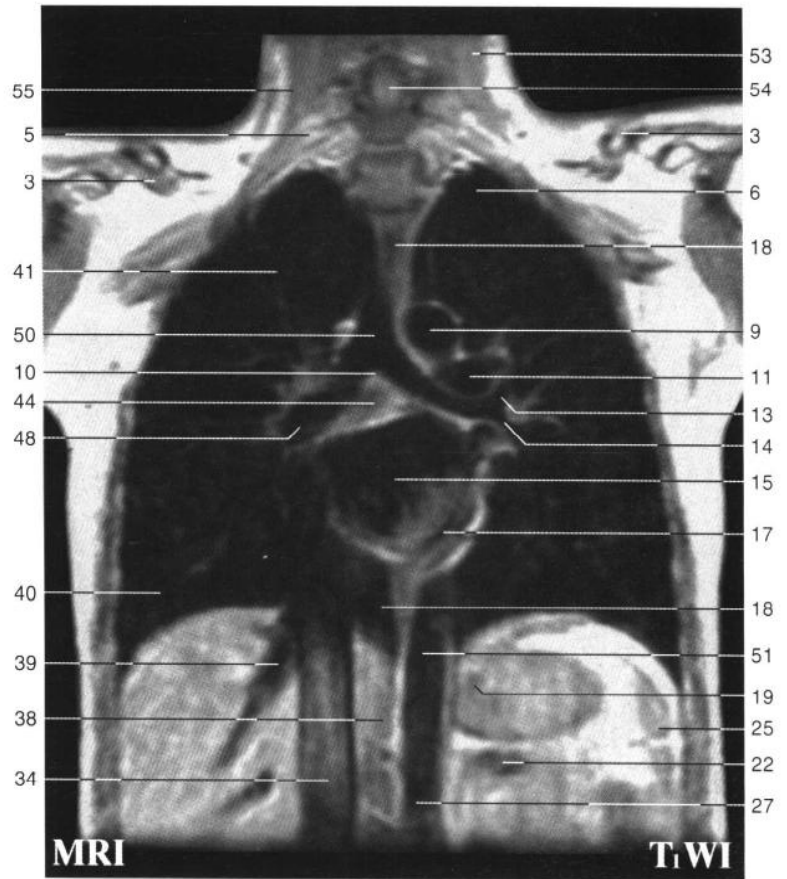Fig. FT 5

1. 颈外静脉 external jugular v.
2. 肩胛舌骨肌 omohyoid
3. 锁骨 clavicle
4. 锁骨下肌 subclavius
5. 臂丛 brachial plexus
6. 左肺上叶 superior lobe of left lung
7. 腋动脉 axillary a.
8. 腋静脉 axillary v.
9. 主动脉弓 aortic arch
10. 气管隆嵴 carina of trachea
11. 左肺动脉 left pulmonary a.
12. 左主支气管 left principal bronchus

Fig. FT 5

13. 左肺上叶支气管 left superior lobar bronchus
14. 左肺下叶支气管 left inferior lobar bronchus
15. 左心房 left atrium
16. 左冠状动脉 left coronary a.
17. 冠状窦 coronary sinus
18. 食管 esophagus
19. 贲门 cardia
20. 腹腔干 celiac trunk
21. 肠系膜上动脉 superior mesenteric a.
22. 胰 pancreas
23. 脾动、静脉 splenic a. and v.
24. 左肾静脉 left renal v.
25. 脾 spleen
26. 十二指肠水平部 horizontal part of duodenum
27. 腹主动脉 abdominal aorta
28. 幽门管 pyloric canal
29. 胰头 head of pancreas
30. 幽门 pylorus
31. 胆总管 common bile duct
32. 右肾动脉 right renal a.
33. 胆囊 gallbladder
34. 下腔静脉 inferior vena cava
35. 肝门静脉右支 right branch of hepatic portal v.
36. 膈左脚 left crus of diaphragm
37. 右后叶 right posterior lobe
38. 尾状叶 caudate lobe
39. 肝右静脉 right hepatic v.
40. 右肺下叶 inferior lobe of right lung
41. 右肺上叶 superior lobe of right lung
42. 斜裂 oblique fissure
43. 右肺动脉 right pulmonary a.
44. 气管支气管下淋巴结 inferior tracheobronchial lymph nodes
45. 中间支气管 intermediate bronchus
46. 左肺下叶 inferior lobe of left lung
47. 右肺水平裂 horizontal fissure of right lung
48. 右主支气管 right principal bronchus
49. 右上叶支气管 right superior lobar bronchus
50. 气管 trachea
51. 胸主动脉 thoracic aorta
52. 前锯肌 serratus anterior
53. 胸锁乳突肌 sternocleidomastoid
54. 脊髓 spinal cord
55. 肩胛提肌 levator scapulae



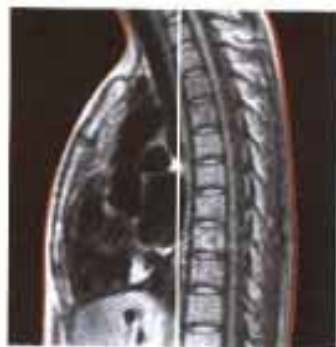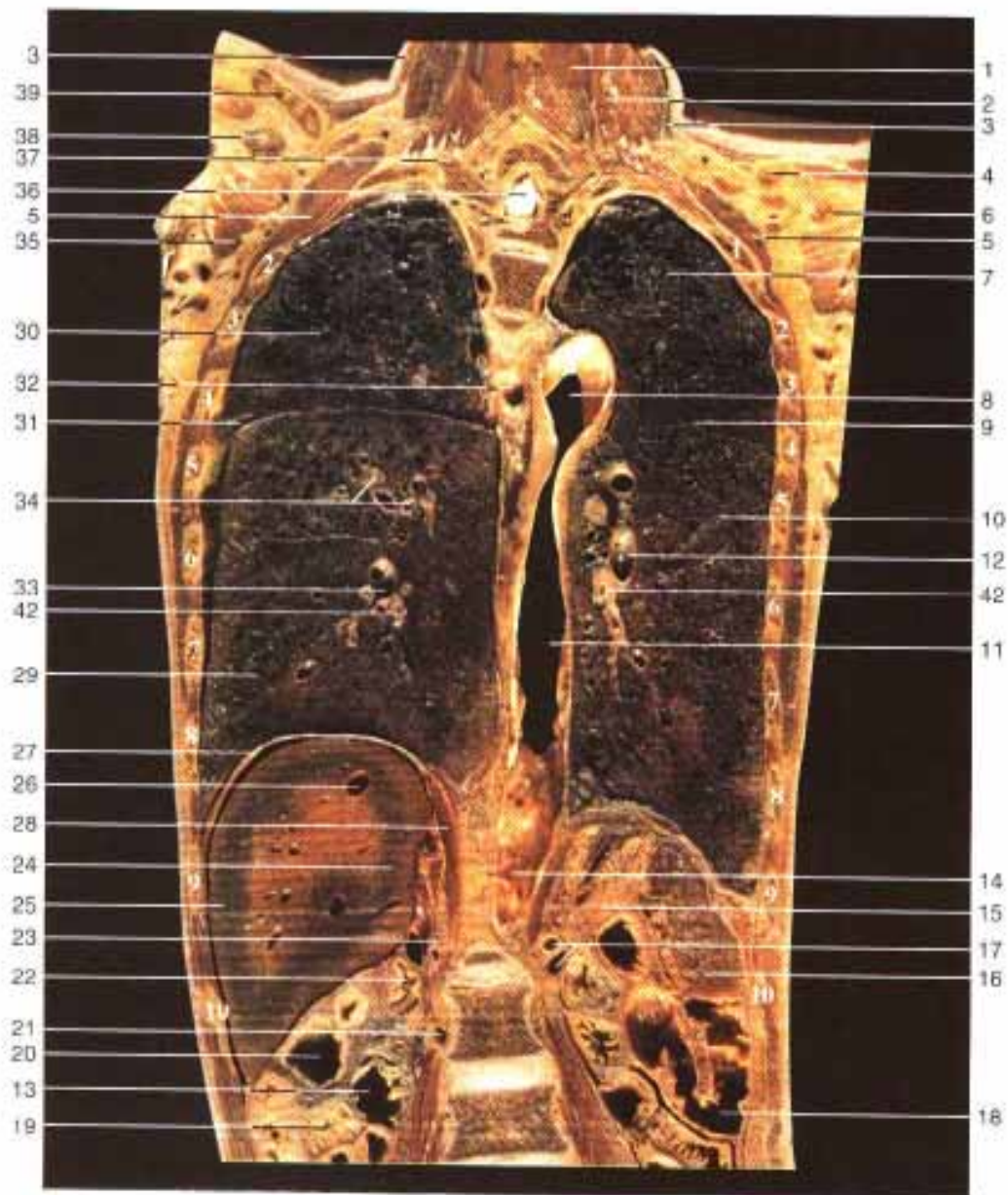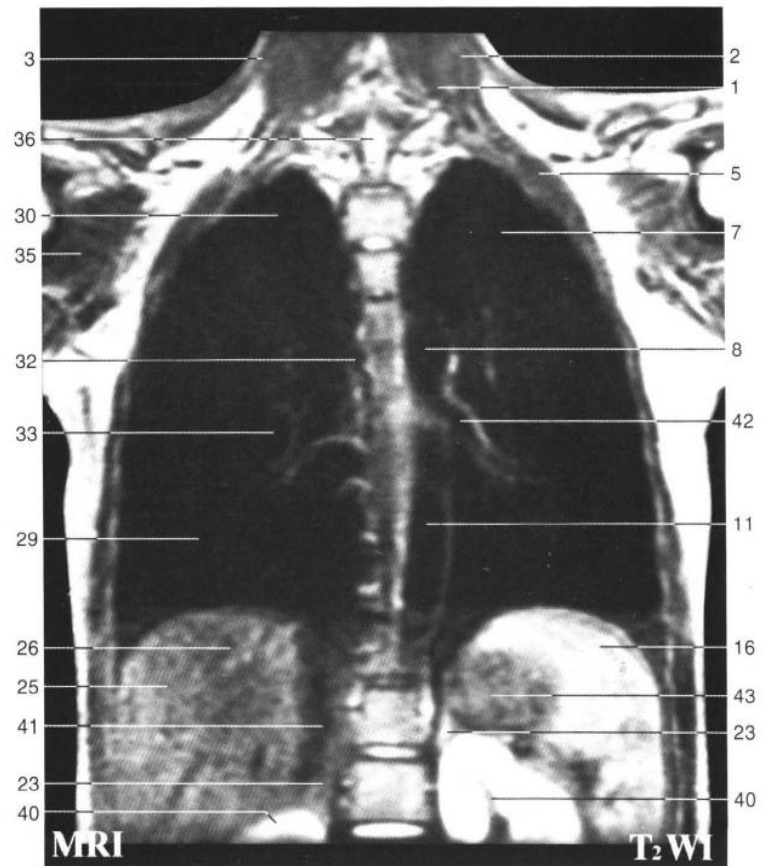
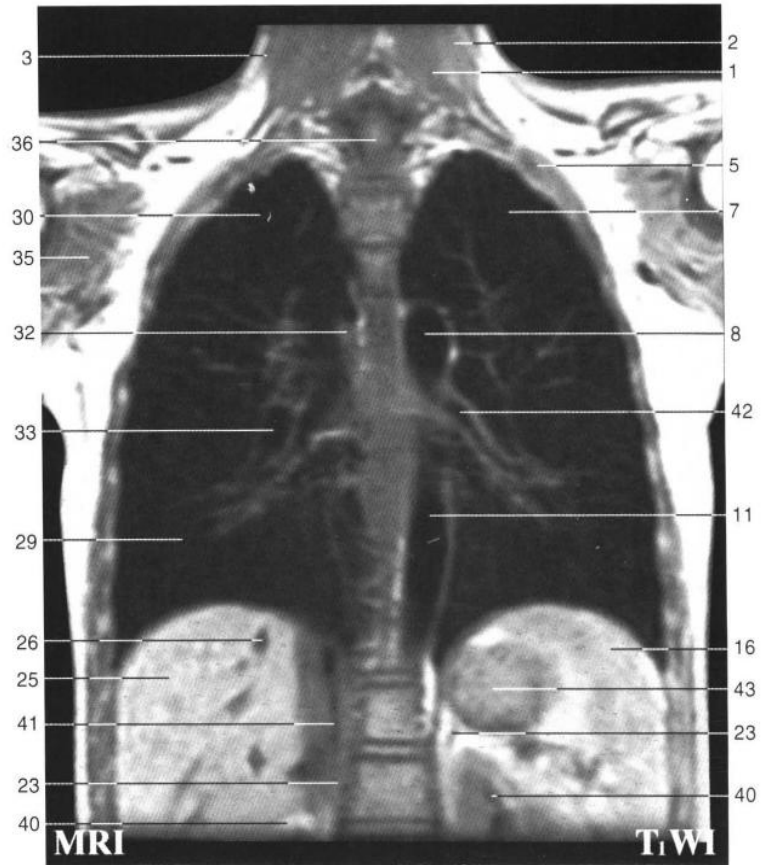


Fig. FT 6

- 1. 头半棘肌 semispinalis capitis
- 2. 头夹肌 splenius capitis
- 3. 斜方肌 trapezius
- 4. 锁骨 clavicle
- 5. 前锯肌 serratus anterior
- 6. 喙突 coracoid process
- 7. 左肺上叶 superior lobe of left lung
- 8. 主动脉弓 aortic arch
- 9. 斜裂 oblique fissure

Fig. FT 6

10. 左肺下叶 inferior lobe of left lung
11. 胸主动脉 thoracic aorta
12. 左肺动脉支 br., left pulmonary a.
13. 十二指肠降部 descending part of duodenum
14. 腹主动脉 abdominal aorta
15. 胰 pancreas
16. 脾 spleen
17. 左肾动、静脉 left renal a. and v.
18. 结肠左曲 left colic flexure
19. 回肠 ileum
20. 幽门管 pyloric canal
21. 腰动脉 lumbar a.
22. 幽门 pylorus
23. 肾上腺 suprarenal gland
24. 右前叶 right anterior lobe
25. 右后叶 right posterior lobe
26. 肝右静脉 right hepatic v.
27. 膈 diaphragm
28. 膈右脚 right crus of diaphragm
29. 右肺下叶 inferior lobe of right lung
30. 右肺上叶 superior lobe of right lung
31. 斜裂 oblique fissure
32. 奇静脉 azygos v.
33. 右肺动脉支 br., right pulmonary a.
34. 上段支气管(B_V) superior segmental bronchus(B_V)
35. 肩胛下肌 subscapularis
36. 脊髓 spinal cord
37. 第1胸椎横突 transverse process(T₁)
38. 喙突 coracoid process
39. 锁骨 clavicle
40. 肾 kidney
41. 下腔静脉 inferior vena cava
42. 后底段支气管(B_X) posterior basal segmental bronchus(B_X)
43. 胃 stomach



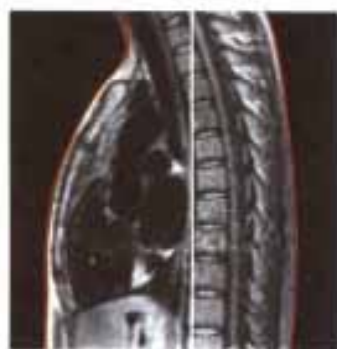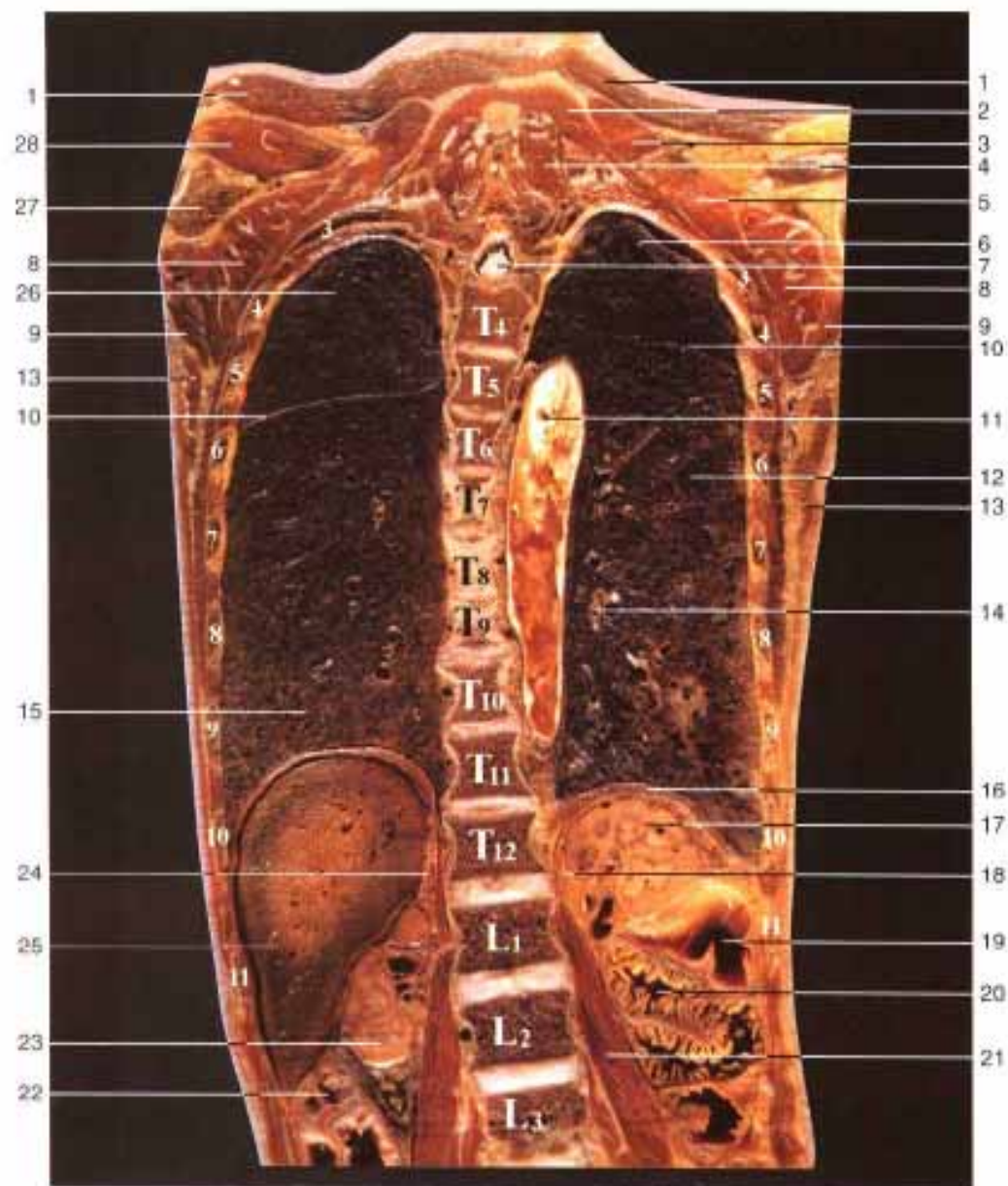
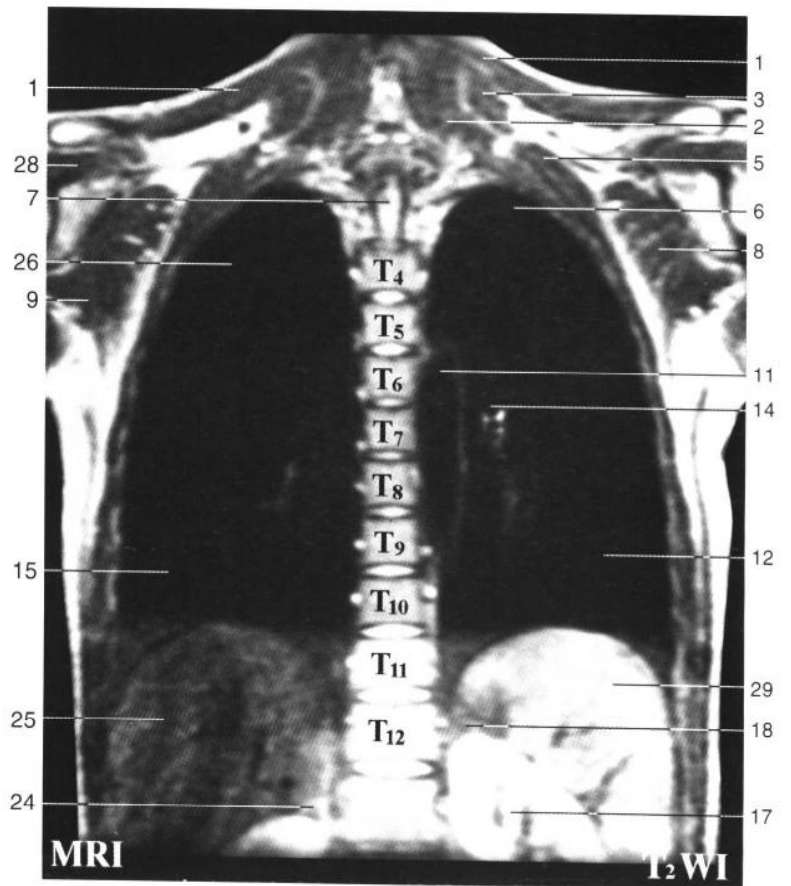

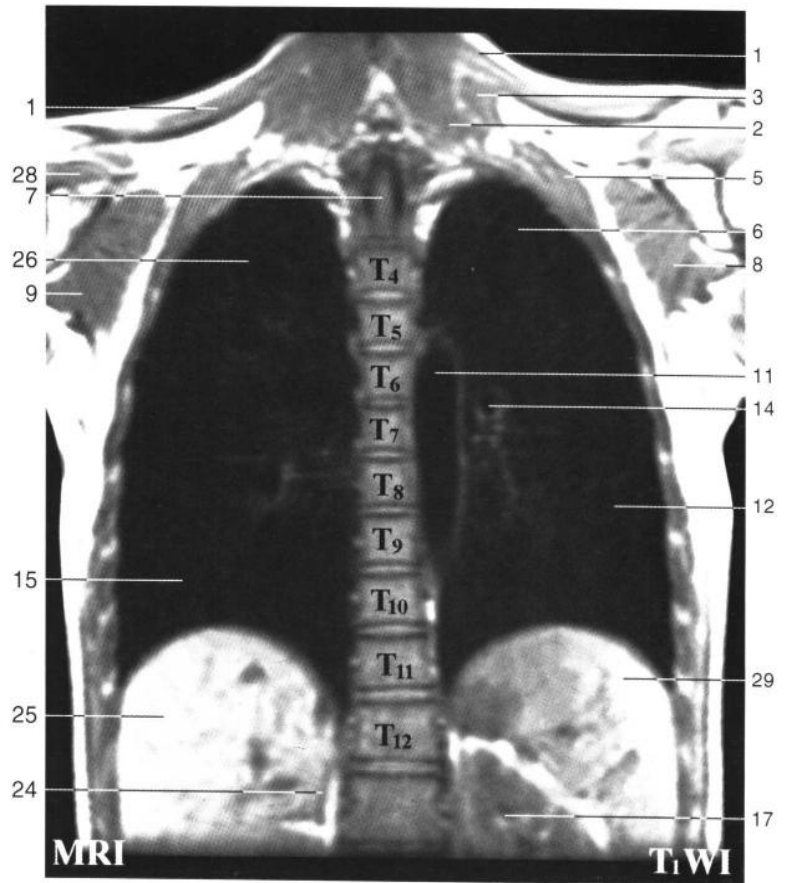
Fig. FT 7

1. 斜方肌 trapezius
2. 头夹肌 splenius capitis
3. 肩胛提肌 levator scapulae
4. 颈半棘肌 semispinalis cervicis
5. 前锯肌 serratus anterior
6. 左肺上叶 superior lobe of left lung
7. 脊髓 spinal cord
8. 肩胛下肌 subscapularis
9. 大圆肌 teres major

Fig. FT 7

10. 斜裂 oblique fissure
11. 胸主动脉 thoracic aorta
12. 左肺下叶 inferior lobe of left lung
13. 背阔肌 latissimus dorsi
14. 后底段支气管(B_x) posterior basal segmental bronchus(B_x)
15. 右肺下叶 inferior lobe of right lung
16. 膈 diaphragm
17. 左肾 left kidney
18. 左肾上腺 left suprarenal gland
19. 横结肠 transverse colon
20. 空肠 jejunum
21. 腰大肌 psoas major
22. 横结肠 transverse colon
23. 右肾 right kidney
24. 右肾上腺 right suprarenal gland
25. 右后叶 right posterior lobe
26. 右肺上叶 superior lobe of right lung
27. 肩胛冈 spine of scapula
28. 冈上肌 supraspinatus
29. 脾 spleen



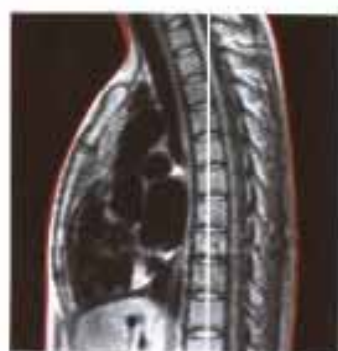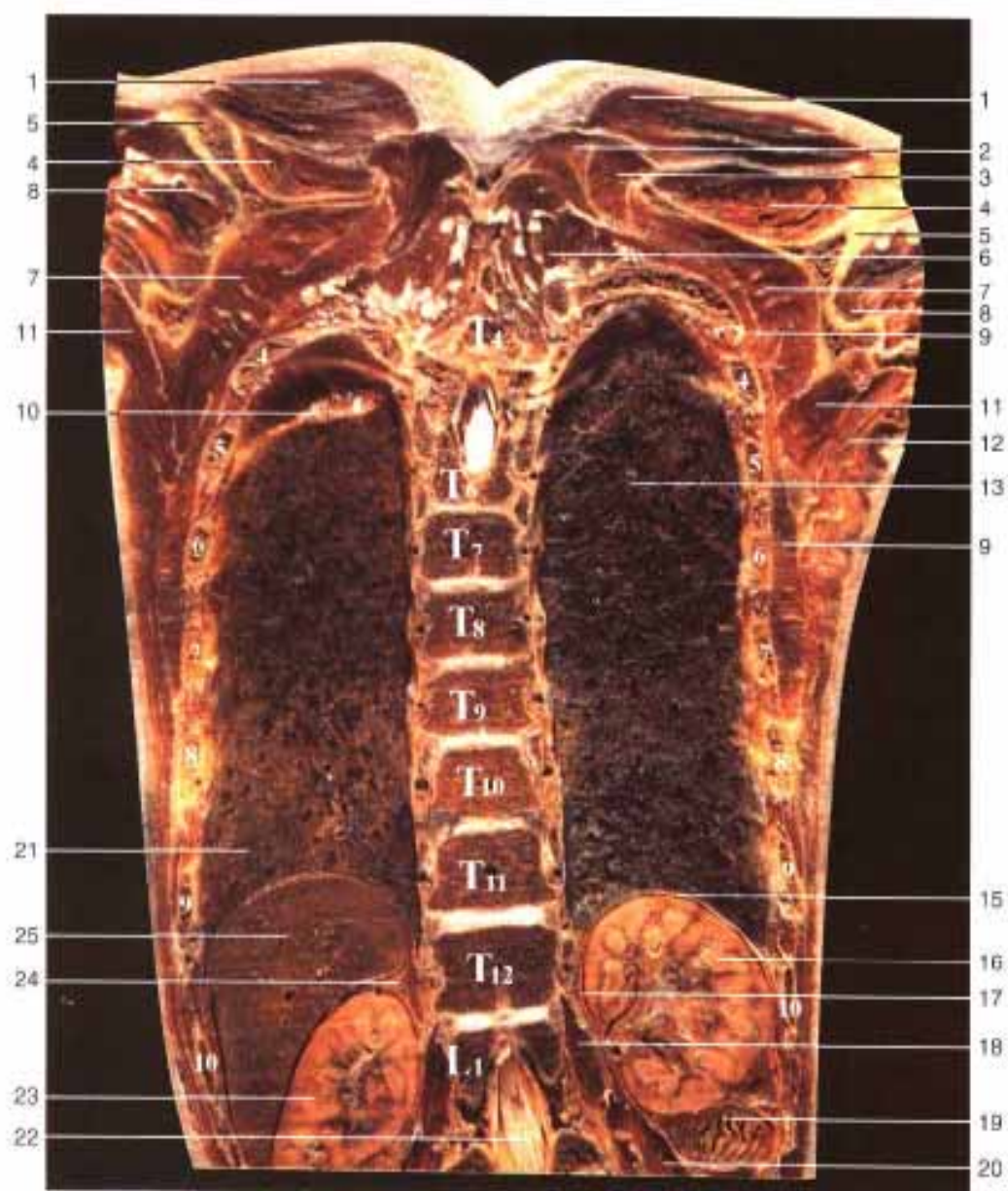
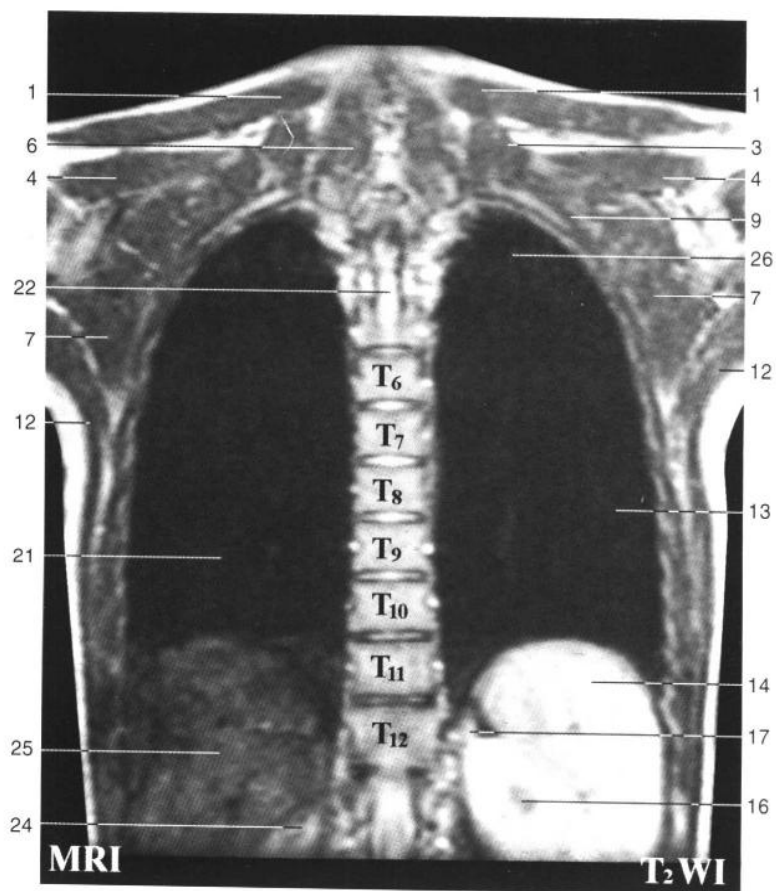

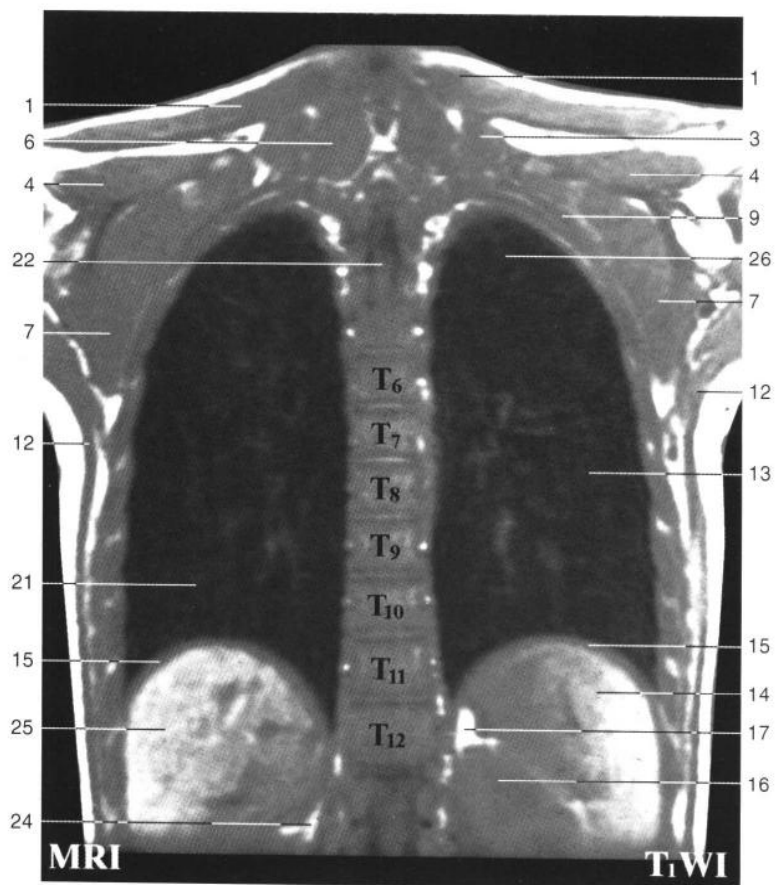
Fig. FT 8

1. 斜方肌 trapezius
2. 菱形肌 rhomboideus
3. 肩胛提肌 levator scapulae
4. 冈上肌 supraspinatus
5. 肩胛冈 spine of scapula
6. 竖脊肌 erector spinae
7. 肩胛下肌 subscapularis
8. 冈下肌 infraspinatus
9. 前锯肌 serratus anterior

Fig. FT 8

10. 斜裂 oblique fissure
11. 大圆肌 teres major
12. 背阔肌 latissimus dorsi
13. 左肺下叶 inferior lobe of left lung
14. 脾 spleen
15. 膈 diaphragm
16. 左肾 left kidney
17. 左肾上腺 left suprarenal gland
18. 腰大肌 psoas major
19. 空肠 jejunum
20. 腰方肌 quadratus lumborum
21. 右肺下叶 inferior lobe of right lung
22. 脊髓 spinal cord
23. 右肾 right kidney
24. 右肾上腺 right suprarenal gland
25. 右后叶 right posterior lobe
26. 左肺上叶 superior lobe of left lung



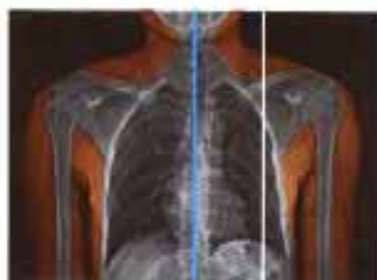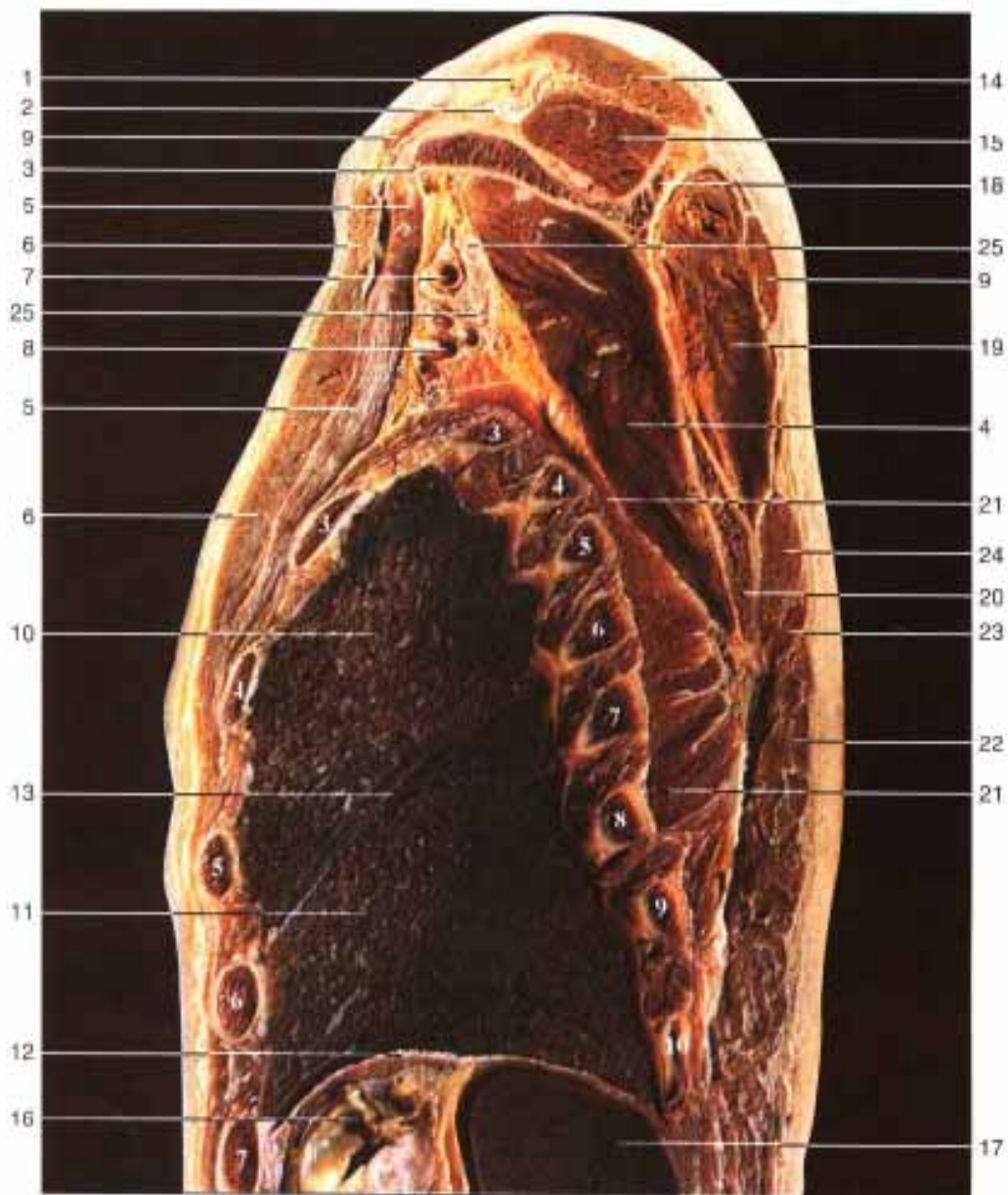
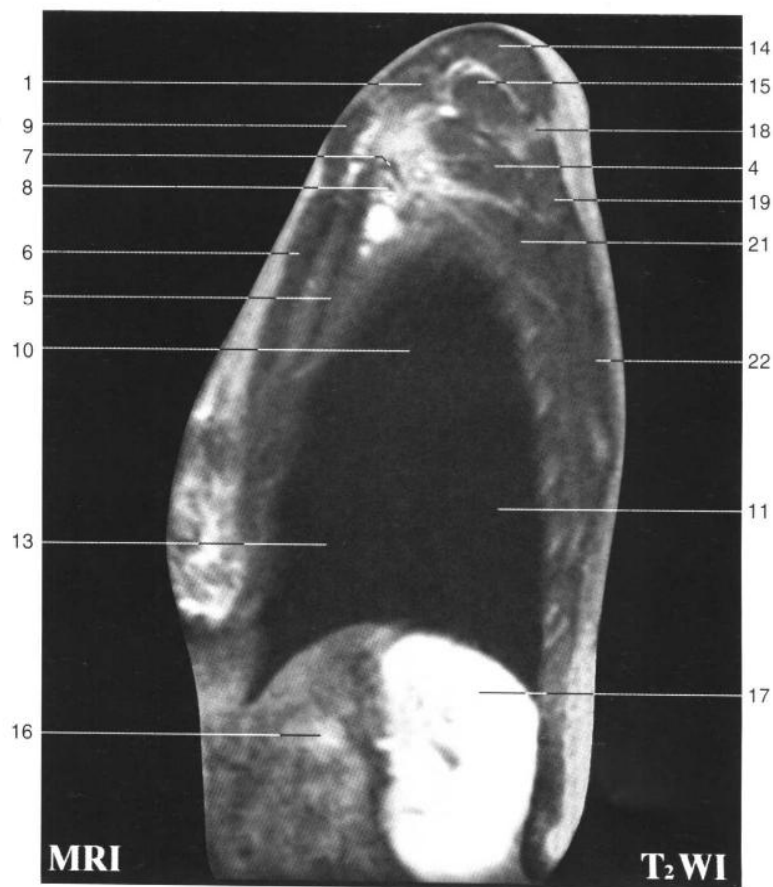

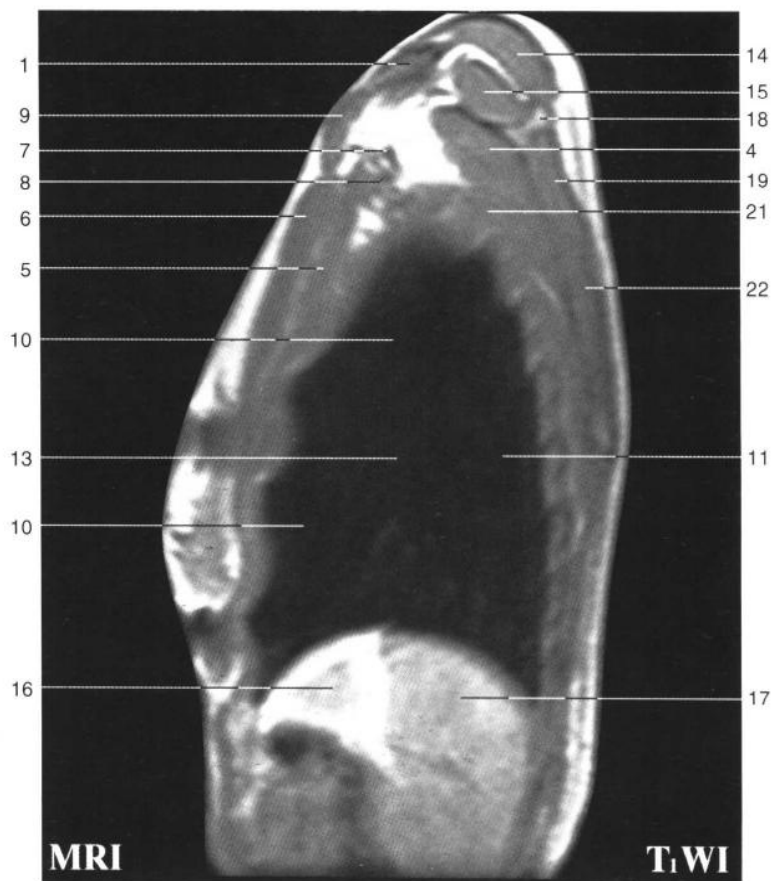
Fig. ST 1

1. 锁骨 clavicle
2. 喙锁韧带 coracoclavicular ligament
3. 喙突 coracoid process
4. 肩胛下肌 subscapularis
5. 胸小肌 pectoralis minor
6. 胸大肌 pectoralis major
7. 腋动脉 axillary a.
8. 腋静脉 axillary v.
9. 三角肌 deltoid

Fig. ST 1

- 10. 左肺上叶 superior lobe of left lung
- 11. 左肺下叶 inferior lobe of left lung
- 12. 膈 diaphragm
- 13. 斜裂 oblique fissure
- 14. 斜方肌 trapezius
- 15. 冈上肌 supraspinatus
- 16. 胃底 fundus of stomach
- 17. 脾 spleen
- 18. 肩胛冈 spine of scapula
- 19. 冈下肌 infraspinatus
- 20. 肩胛骨 scapula
- 21. 前锯肌 serratus anterior
- 22. 背阔肌 latissimus dorsi
- 23. 大圆肌 teres major
- 24. 小圆肌 teres minor
- 25. 臂丛 brachial plexus



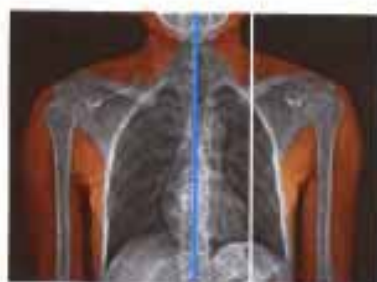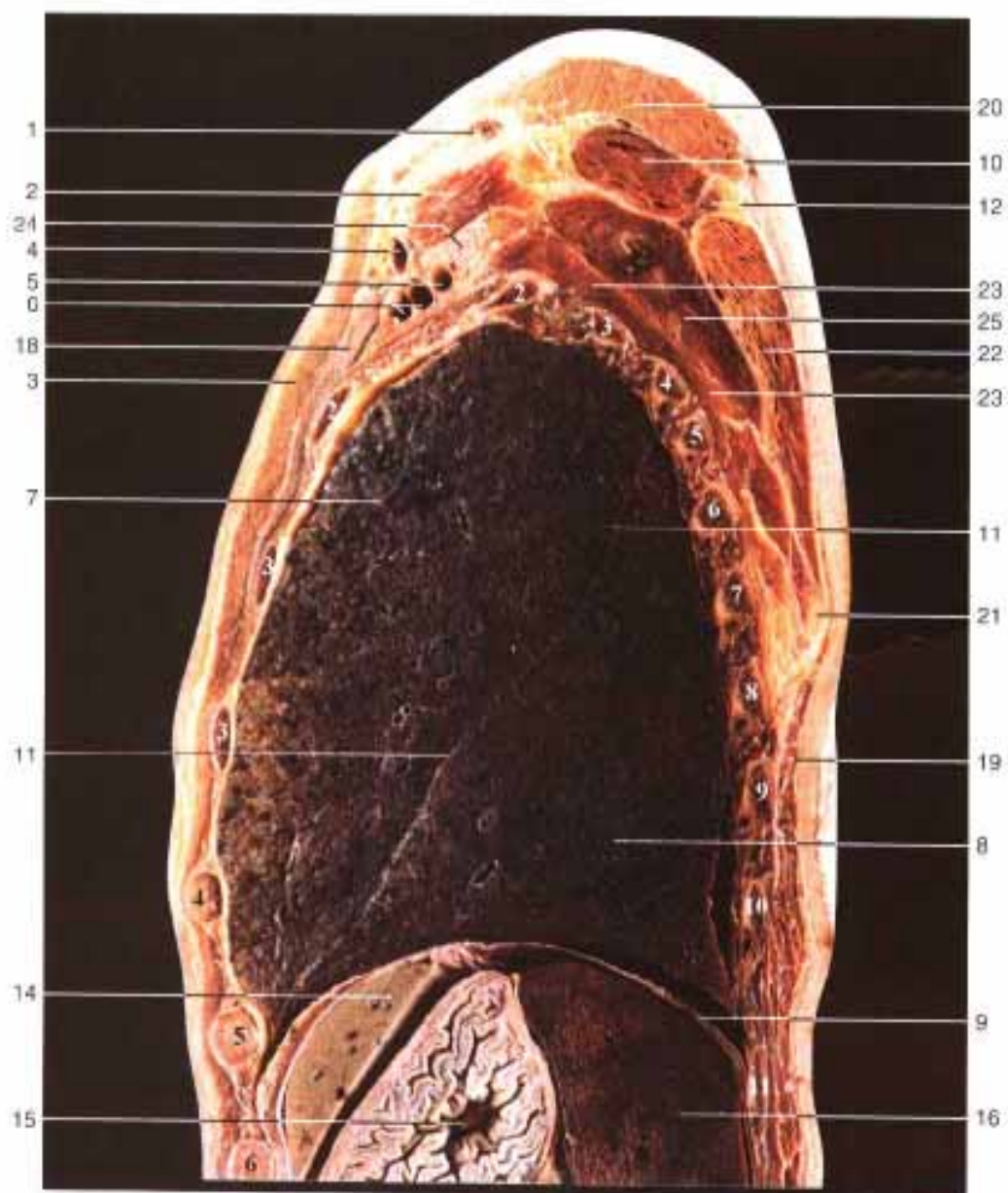

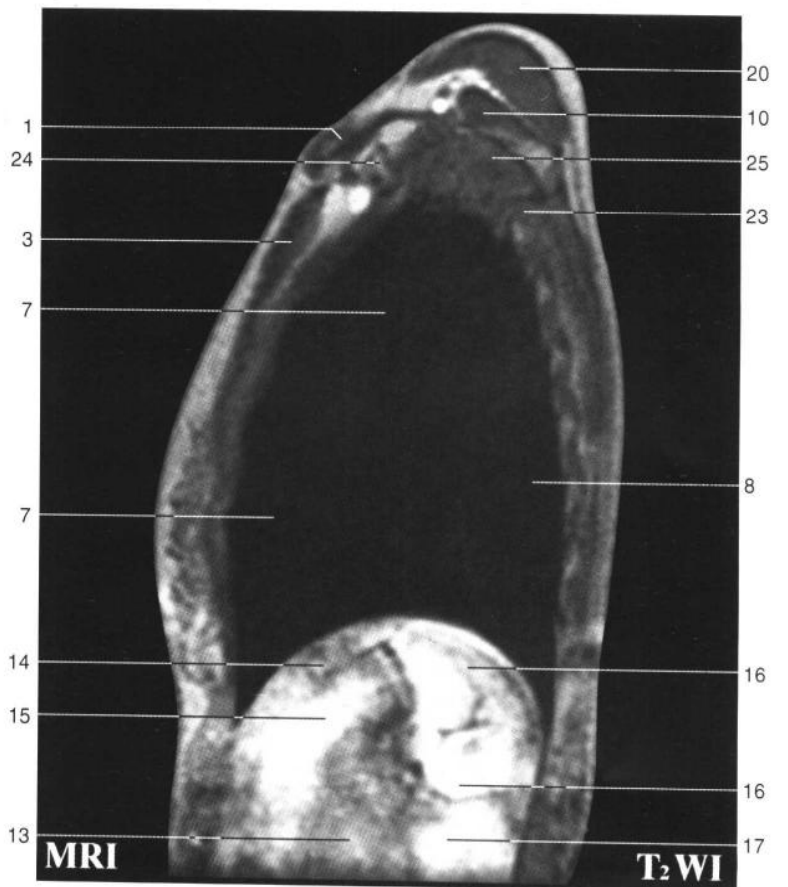
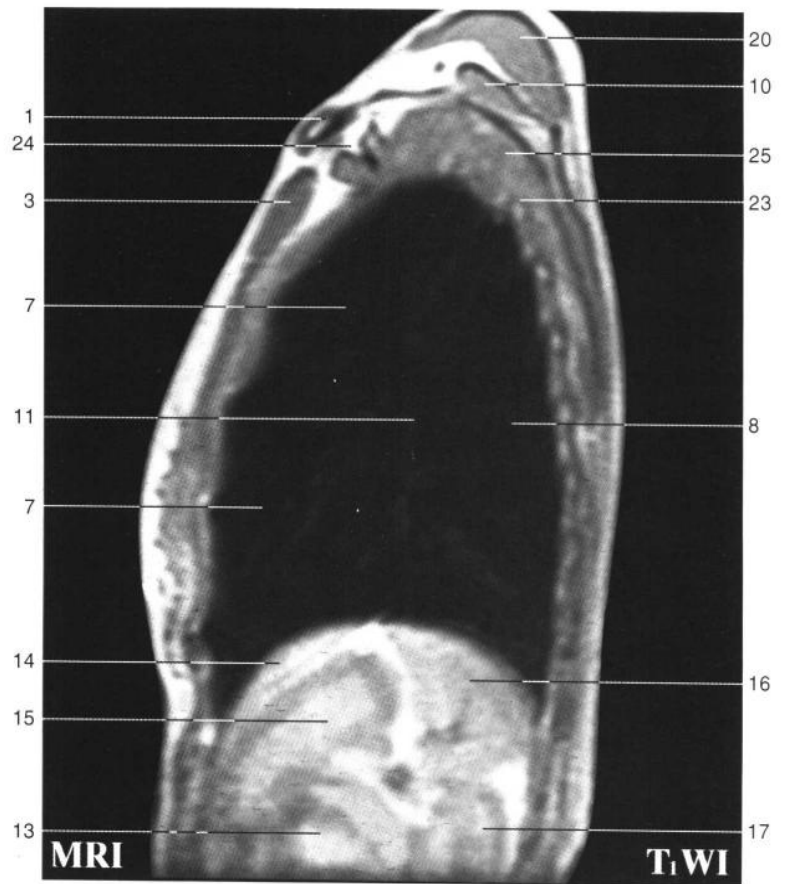Fig. ST 2

- 1. 锁骨 clavicle
- 2. 锁骨下肌 subclavius
- 3. 胸大肌 pectoralis major
- 4. 头静脉 cephalic v.
- 5. 腋动脉 axillary a.
- 6. 腋静脉 axillary v.
- 7. 左肺上叶 superior lobe of left lung
- 8. 左肺下叶 inferior lobe of left lung
- 9. 膈 diaphragm

Fig. ST 2

- 10. 冈上肌 supraspinatus
- 11. 斜裂 oblique fissure
- 12. 肩胛冈 spine of scapula
- 13. 空肠 jejunum
- 14. 左外叶 left lateral lobe
- 15. 胃底 fundus of stomach
- 16. 脾 spleen
- 17. 结肠左曲 left colic flexure
- 18. 胸小肌 pectoralis minor
- 19. 背阔肌 latissimus dorsi
- 20. 斜方肌 trapezius
- 21. 肩胛骨 scapula
- 22. 冈下肌 infraspinatus
- 23. 前锯肌 serratus anterior
- 24. 臂丛 brachial plexus
- 25. 肩胛下肌 subscapularis



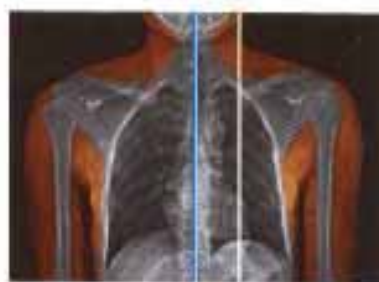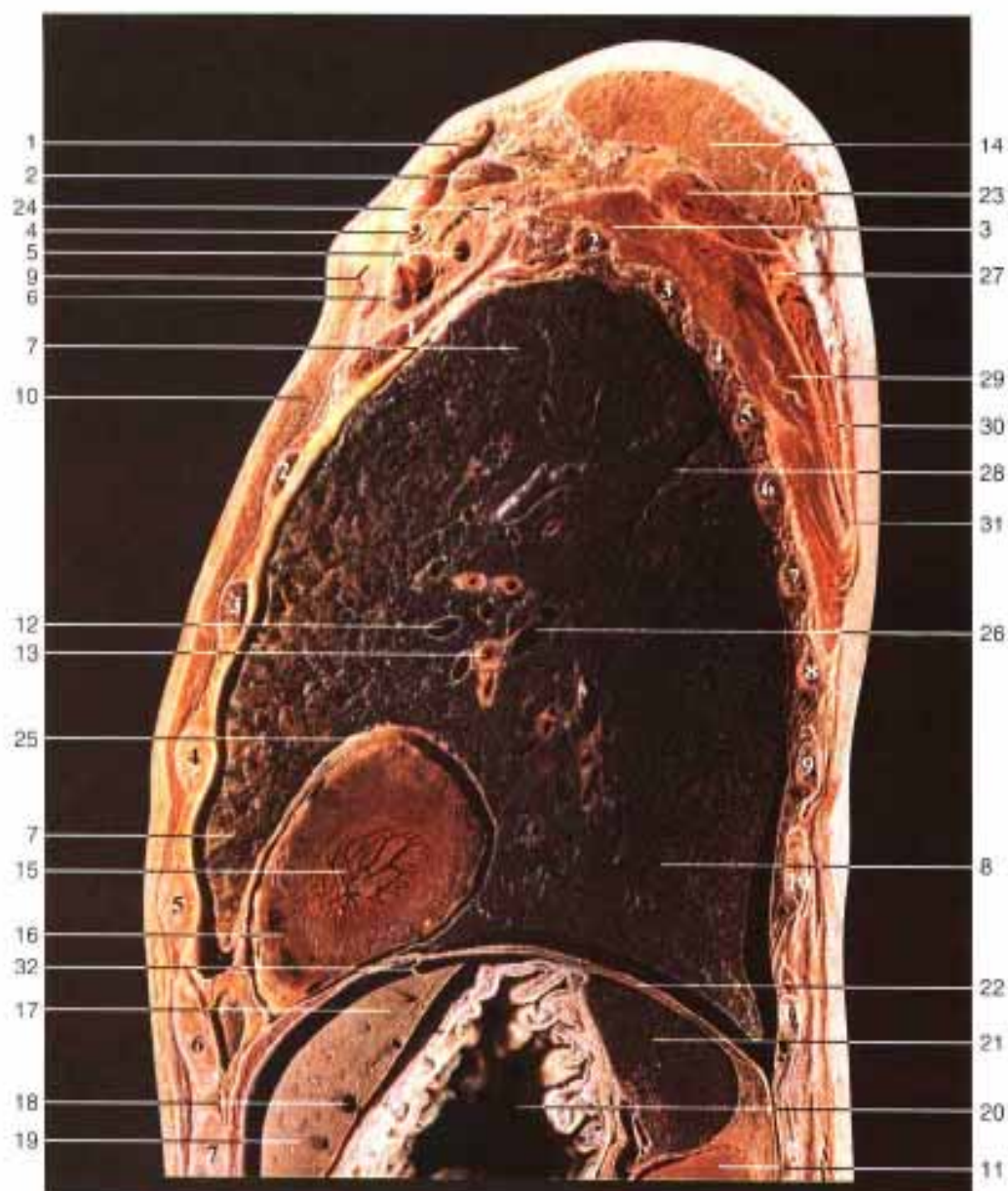

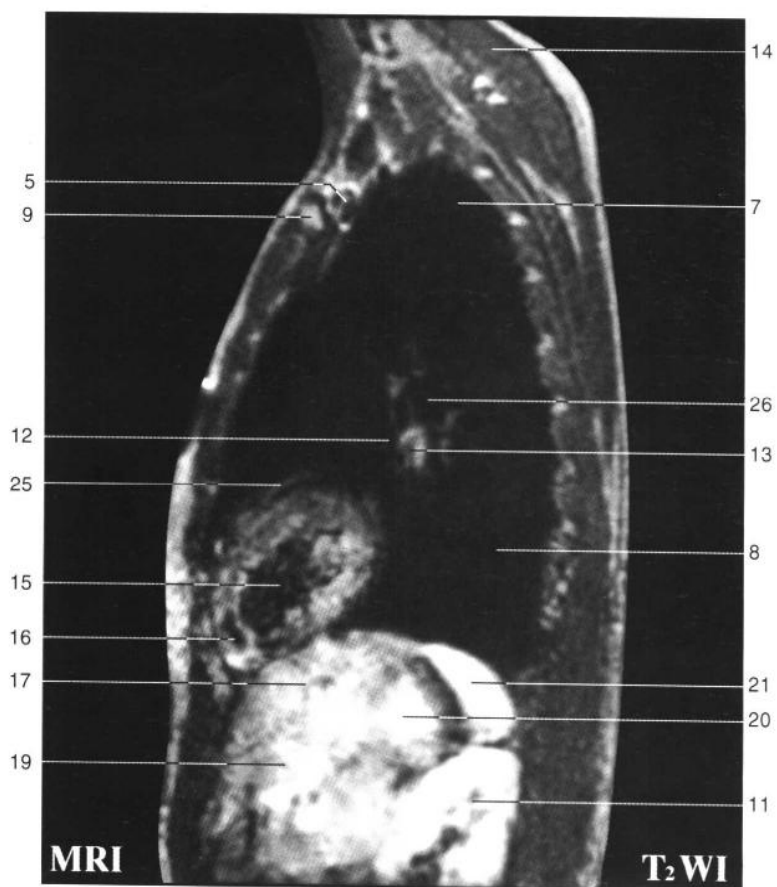
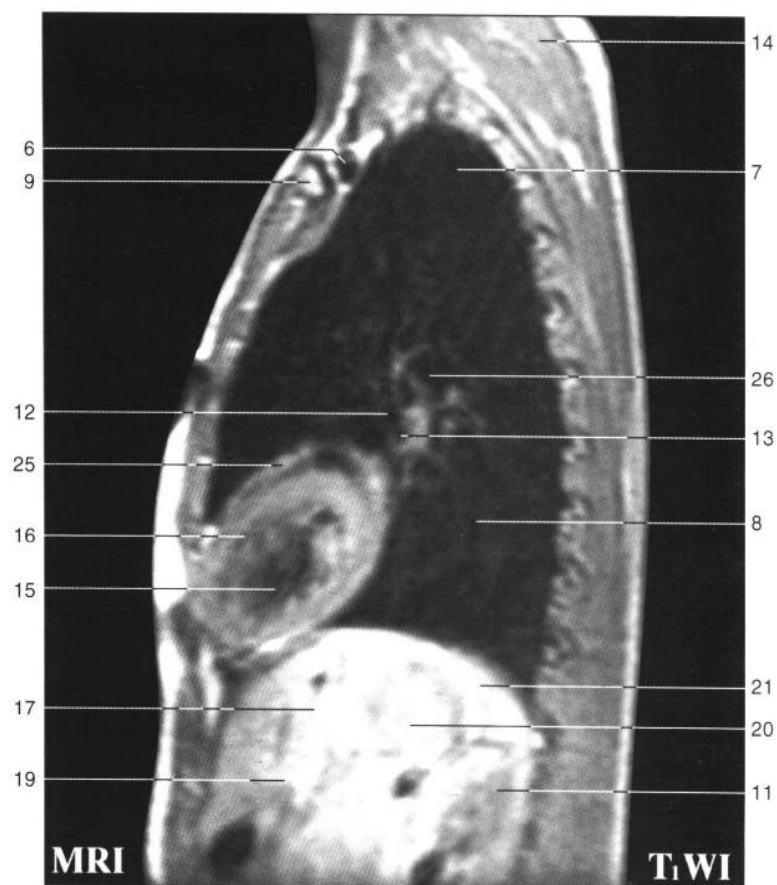Fig. ST 3

1. 颈外静脉 external jugular v.
2. 肩胛舌骨肌 omohyoid
3. 前锯肌 serratus anterior
4. 肩胛上动、静脉 suprascapular a. and v.
5. 左锁骨下动脉 left subclavian a.
6. 左锁骨下静脉 left subclavian v.
7. 左肺上叶 superior lobe of left lung
8. 左肺下叶 inferior lobe of left lung
9. 锁骨 clavicle

Fig. ST 3

10. 胸大肌 pectoralis major
11. 左肾 left kidney
12. 左上肺静脉 left superior pulmonary v.
13. 下舌段支气管(B_V) inferior lingual bronchus(B_V)
14. 斜方肌 trapezius
15. 左心室 left ventricle
16. 右心室 right ventricle
17. 左外叶上段 superior segment of left lateral lobe
18. 肝左静脉 left hepatic v.
19. 左外叶下段 inferior segment of left lateral lobe
20. 胃体 body of stomach
21. 脾 spleen
22. 膈 diaphragm
23. 冈上肌 supraspinatus
24. 臂丛 brachial plexus
25. 心包 pericardium
26. 左肺动脉上叶支 superior lobar branches of left pulmonary a.
27. 肩胛冈 spine of scapula
28. 斜裂 oblique fissure
29. 肩胛下肌 subscapularis
30. 冈下肌 infraspinatus
31. 肩胛骨 scapula
32. 冠状韧带 coronary ligament



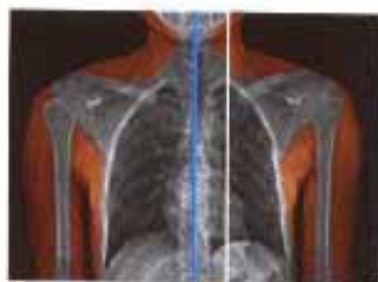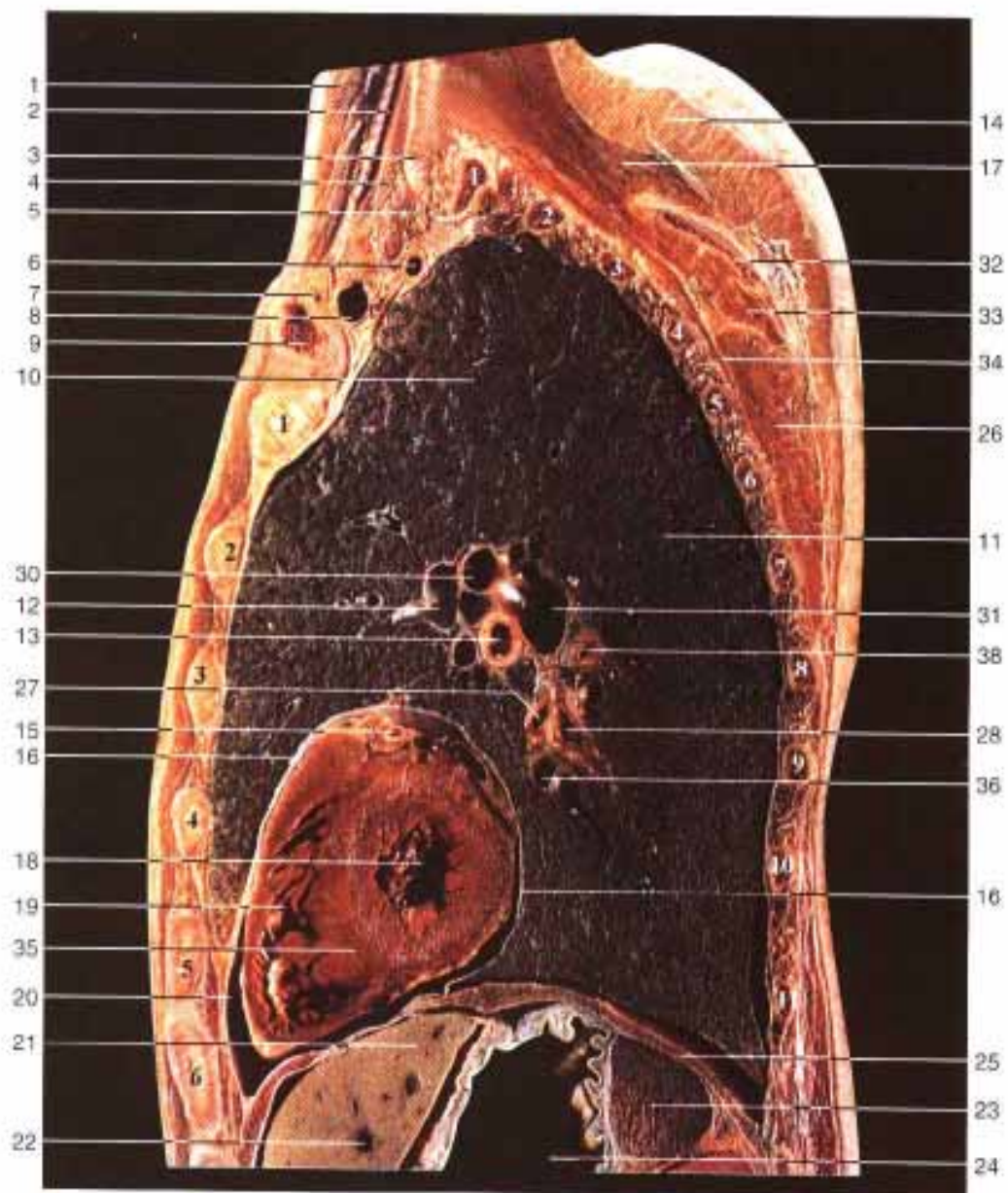

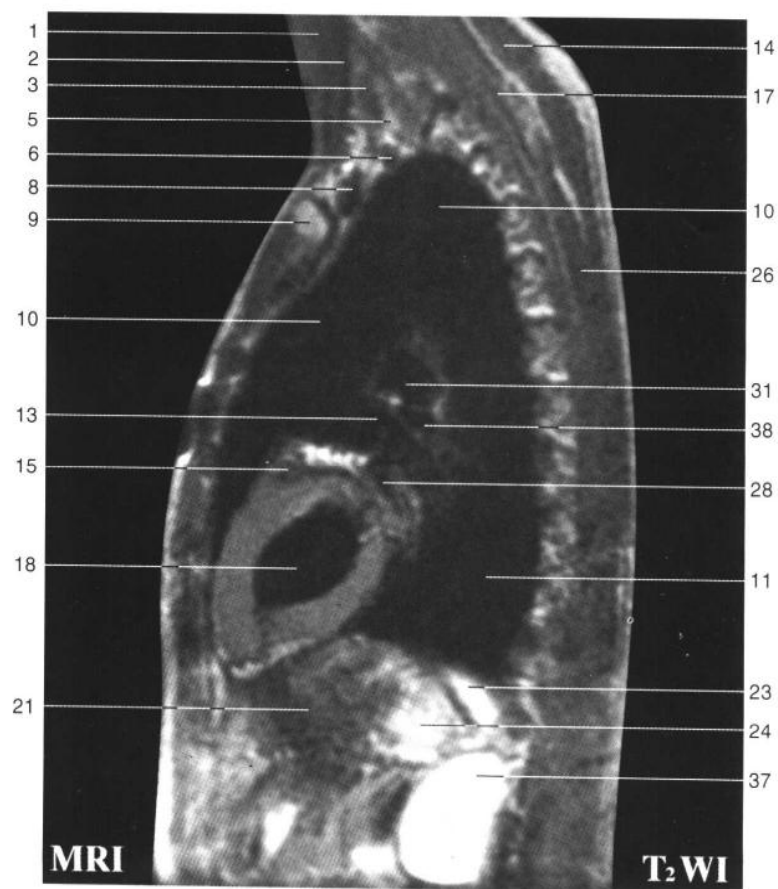
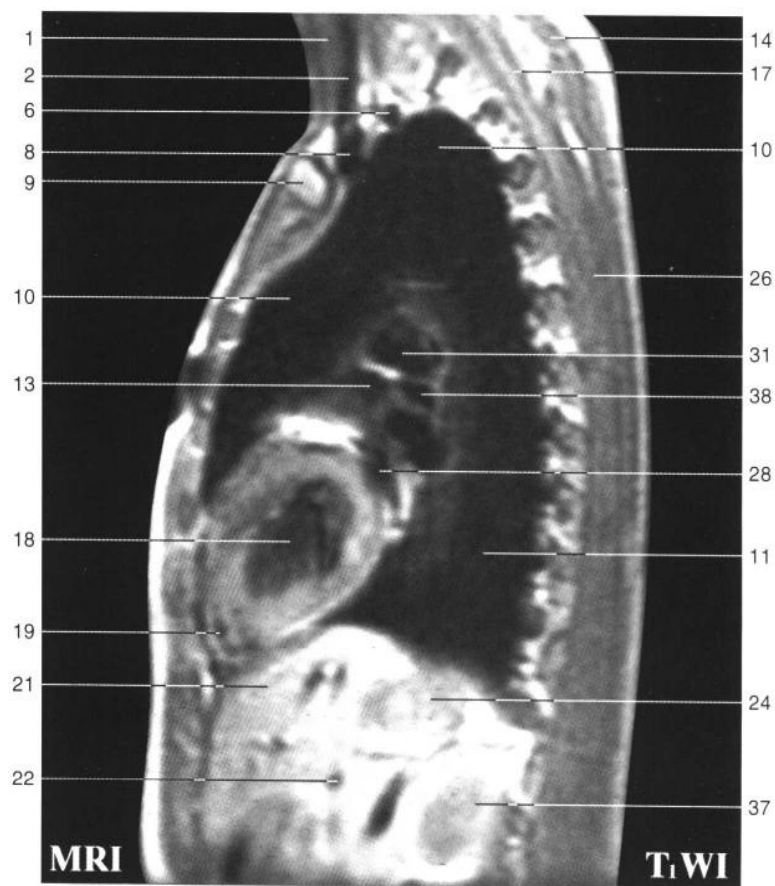Fig. ST 4

1. 胸锁乳突肌 sternocleidomastoid
2. 颈内静脉 internal jugular v.
3. 中斜角肌 scalenus medius
4. 前斜角肌 scalenus anterior
5. 臂丛(中干) brachial plexus(middle trunk)
6. 左锁骨下动脉 left subclavian a.
7. 颈静脉弓 jugular venous arch
8. 左锁骨下静脉 left subclavian v.
9. 锁骨 clavicle

Fig. ST 4

10. 左肺上叶 superior lobe of left lung
11. 左肺下叶 inferior lobe of left lung
12. 左上肺静脉 left superior pulmonary v.
13. 左肺上叶支气管 left superior lobar bronchus
14. 斜方肌 trapezius
15. 左冠状动脉 left coronary a.
16. 心包 pericardium
17. 肩胛提肌 levator scapulae
18. 左心室 left ventricle
19. 右心室 right ventricle
20. 心包腔 pericardial cavity
21. 左外叶上段 superior segment of left lateral lobe
22. 肝左静脉 left hepatic v.
23. 脾 spleen
24. 胃体 body of stomach
25. 膈 diaphragm
26. 菱形肌 rhomboideus
27. 内侧底段支气管(B_V) medial basal segmental bronchus(B_V)
28. 后底段支气管(B_X) posterior basal segmental bronchus(B_X)
29. 臂丛 brachial plexus
30. 左肺动脉 left pulmonary a.
31. 左肺动脉 left pulmonary a.
32. 肩胛骨 scapula
33. 前锯肌 serratus anterior
34. 上后锯肌 serratus posterior superior
35. 室间隔 interventricular septum
36. 左下肺静脉 left inferior pulmonary v.
37. 左肾 left kidney
38. 上段支气管(B_V) Superior segmental bronchus(B_V)



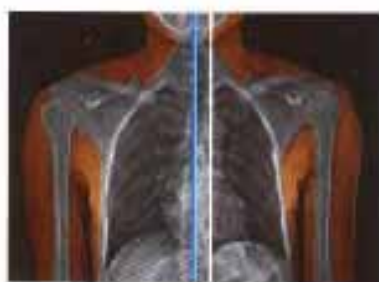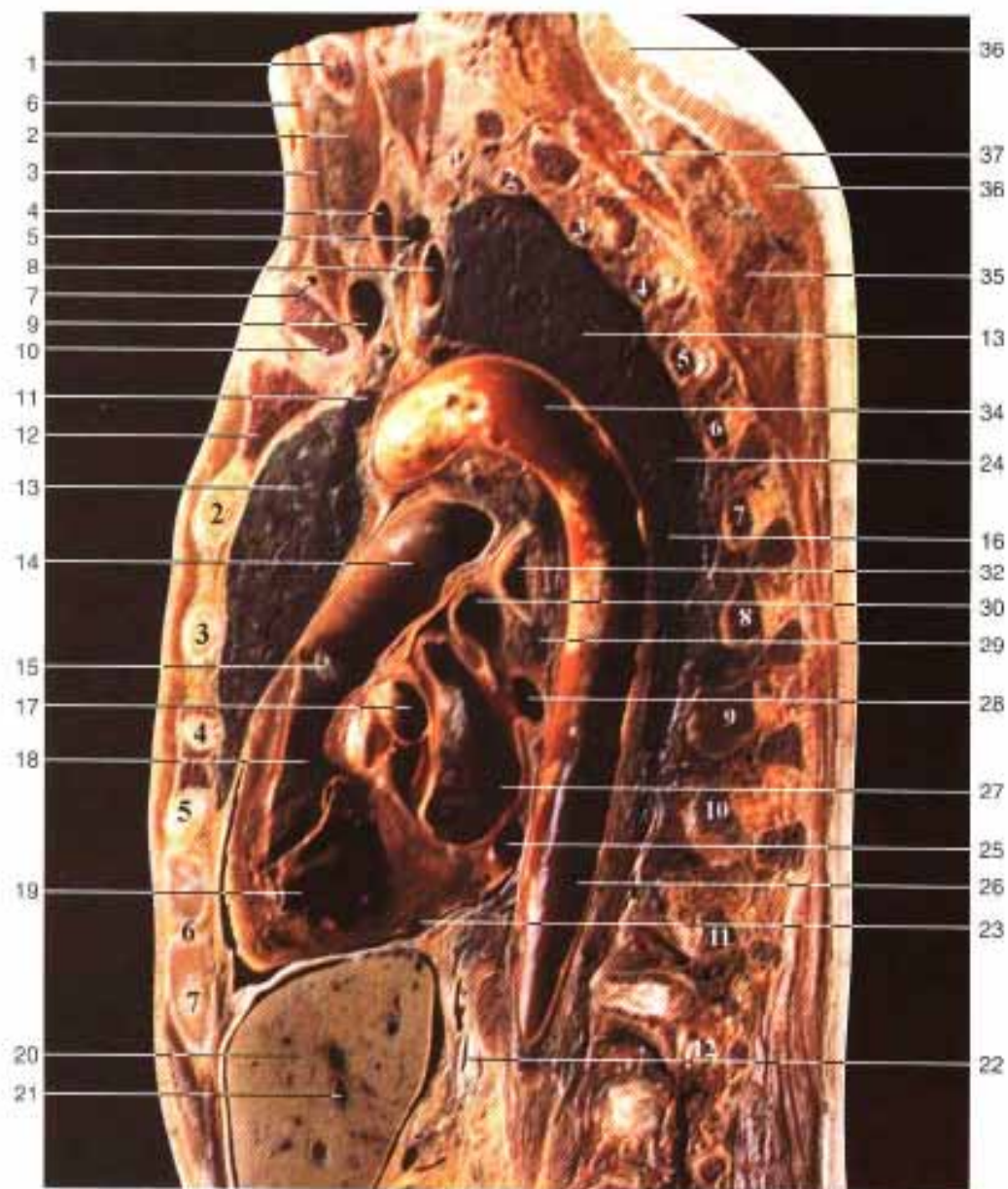

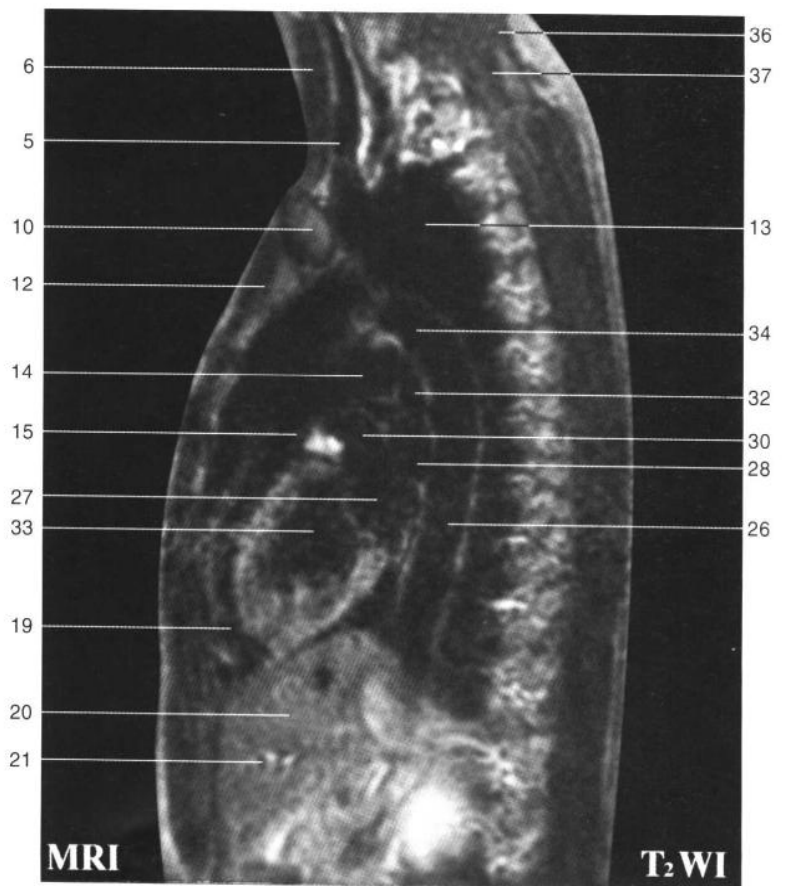
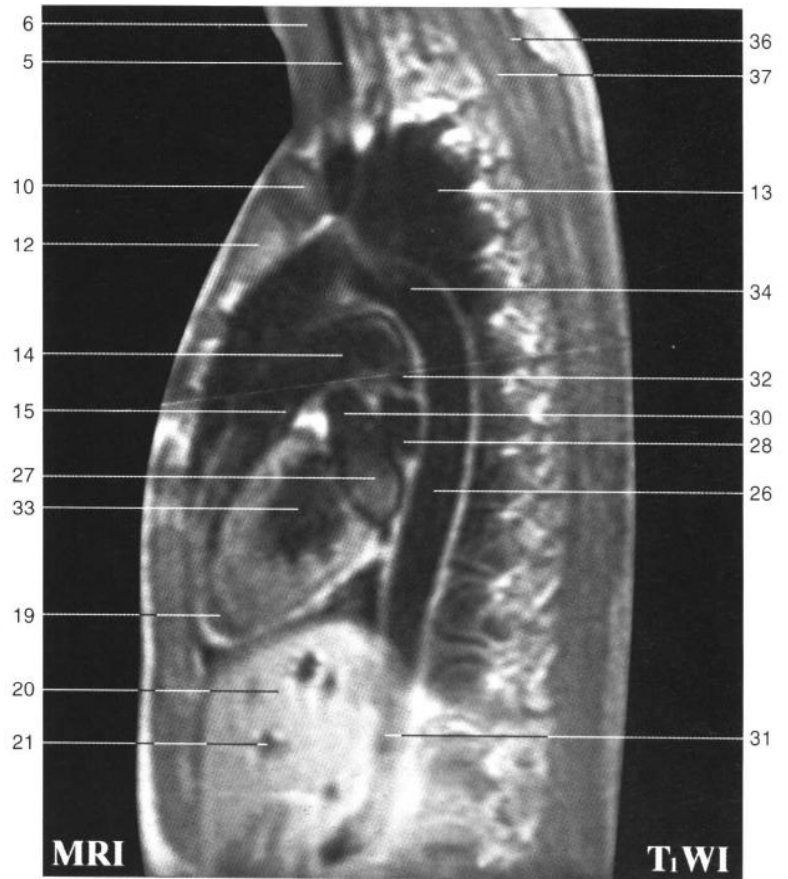Fig. ST 5

1. 甲状软骨 thyroid cartilage
2. 甲状腺 thyroid gland
3. 胸骨舌骨肌 sternohyoid
4. 左颈总动脉 left common carotid a.
5. 左颈内静脉 left internal jugular v.
6. 胸锁乳突肌 sternocleidomastoid
7. 颈静脉弓 jugular venous arch
8. 左锁骨下动脉 left subclavian a.
9. 左锁骨下静脉 left subclavian v.

Fig. ST 5

10. 锁骨 clavicle
11. 纵隔前淋巴结 anterior mediastinal lymph node
12. 胸骨柄 manubrium sterni
13. 左肺上叶 superior lobe of left lung
14. 肺动脉干 pulmonary trunk
15. 肺动脉瓣 valve of pulmonary trunk
16. 左肺下叶 inferior lobe of left lung
17. 主动脉瓣 aortic valve
18. 动脉圆锥 conus arteriosus
19. 右心室 right ventricle
20. 肝左叶 left lobe of liver
21. 肝左静脉 left hepatic v.
22. 食管 esophagus
23. 心中静脉 middle cardiac v.
24. 斜裂 oblique fissure
25. 冠状窦 coronary sinus
26. 胸主动脉 thoracic aorta
27. 左心房 left atrium
28. 左下肺静脉 left inferior pulmonary v.
29. 气管支气管下淋巴结 inferior tracheobronchial lymph nodes
30. 左上肺静脉 left superior pulmonary v.
31. 腹主动脉 abdominal aorta
32. 左主支气管 left principal bronchus
33. 左心室 left ventricle
34. 主动脉弓 aortic arch
35. 大菱形肌 rhomboideus major
36. 斜方肌 trapezius
37. 竖脊肌 erector spinae



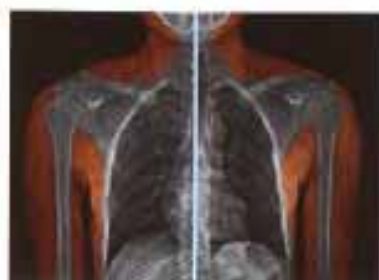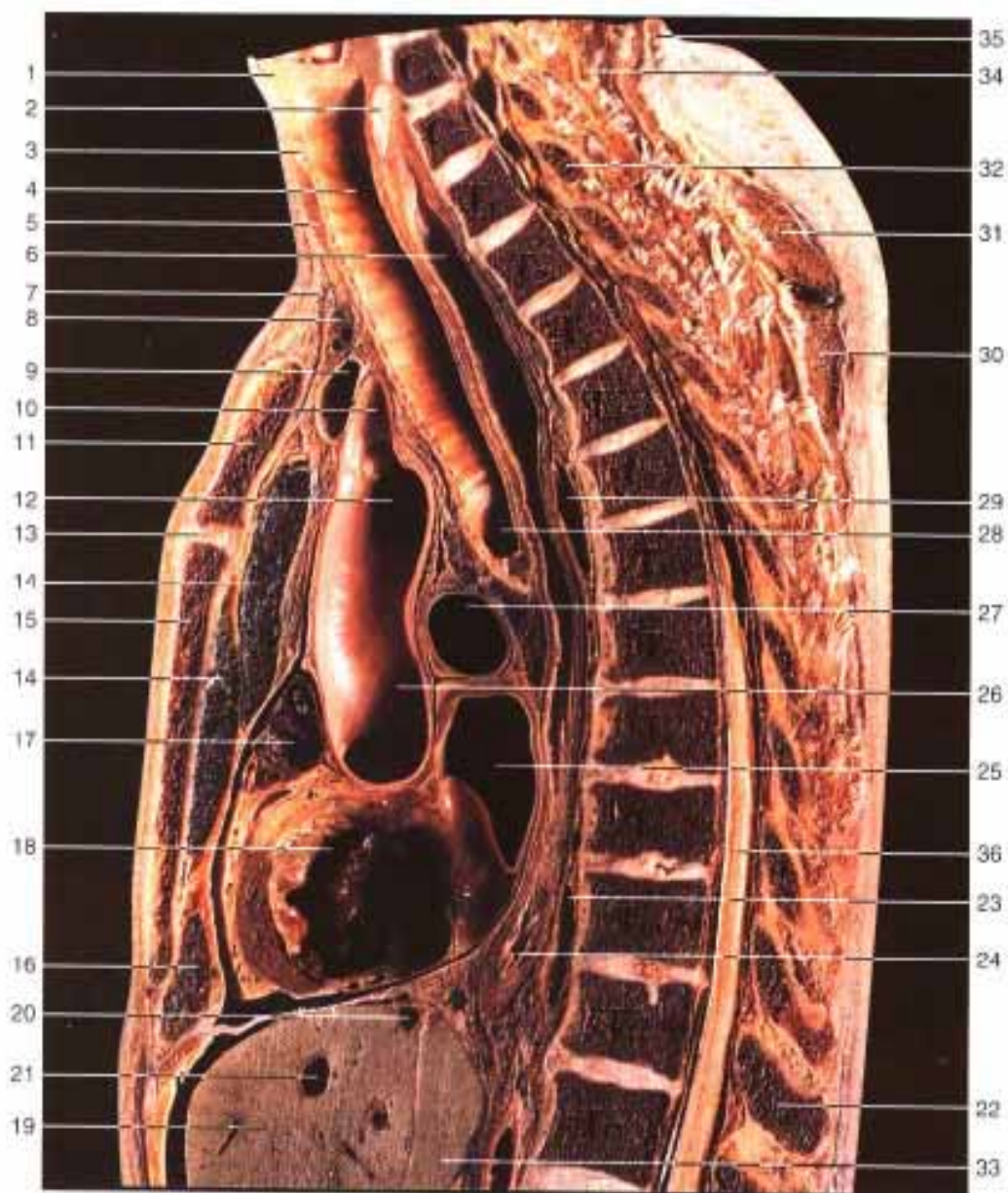

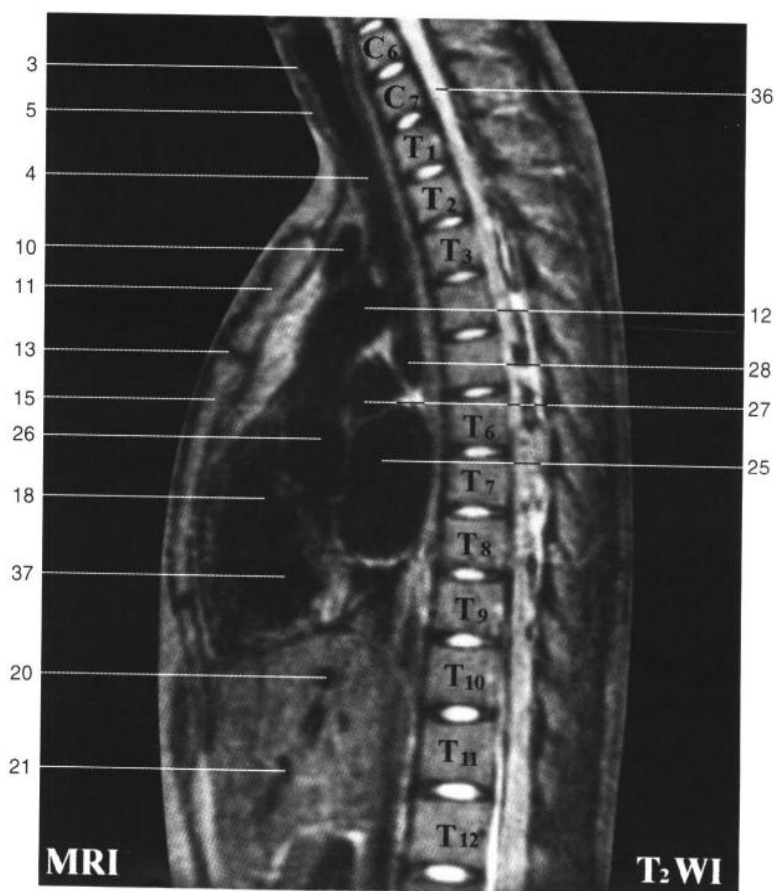
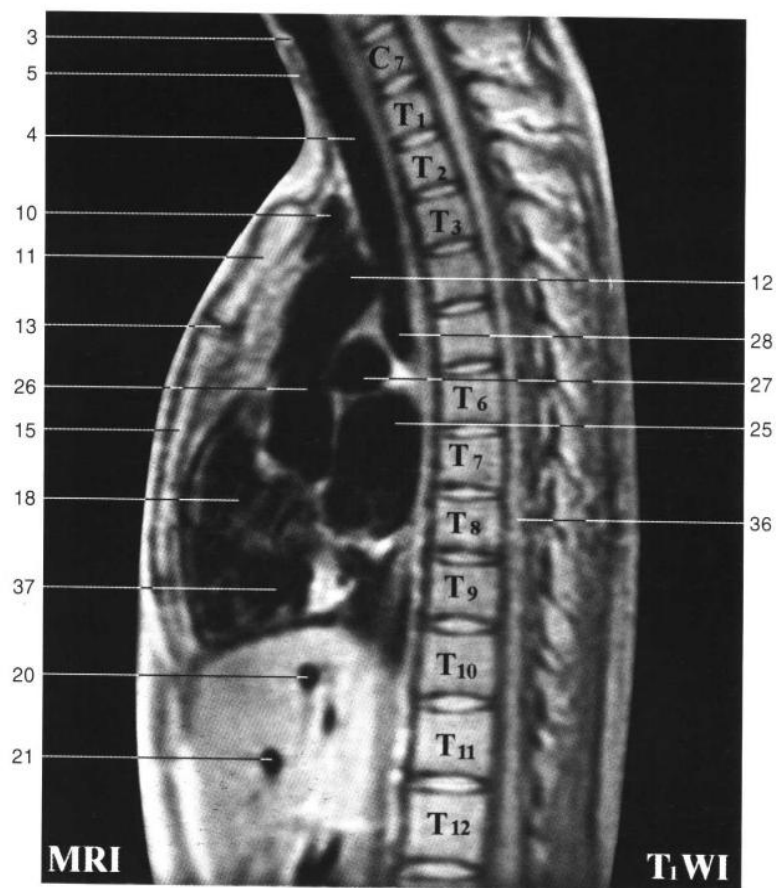Fig. ST 6

1. 甲状软骨 thyroid cartilage
2. 环状软骨板 lamina of cricoid cartilage
3. 环状软骨弓 arch of cricoid cartilage
4. 气管 trachea
5. 甲状腺峡 isthmus of thyroid gland
6. 食管 esophagus
7. 胸骨甲状腺 sternothyroid
8. 纵隔前淋巴结 anterior mediastinal lymph node
9. 左头臂静脉 left brachiocephalic v.

Fig. ST 6

- 10. 头臂干 brachiocephalic trunk
- 11. 胸骨柄 manubrium sterni
- 12. 主动脉弓 aortic arch
- 13. 胸骨角 sternal angle
- 14. 右肺上叶 superior lobe of right lung
- 15. 胸骨体 body of sternum
- 16. 右肺中叶 middle lobe of right lung
- 17. 右心耳 right auricle
- 18. 右心房 right atrium
- 19. 左外叶 left lateral lobe
- 20. 肝中间静脉 intermediate hepatic v.
- 21. 肝左静脉 left hepatic v.
- 22. 第 11 胸椎棘突 spinous process(T₁₁)
- 23. 奇静脉 azygos v.
- 24. 食管 esophagus
- 25. 左心房 left atrium
- 26. 升主动脉 ascending aorta
- 27. 右肺动脉 right pulmonary a.
- 28. 右主支气管 right principal bronchus
- 29. 奇静脉 azygos v.
- 30. 大菱形肌 rhomboideus major
- 31. 小菱形肌 rhomboideus minor
- 32. 第 1 胸椎棘突 spinous process(T₁)
- 33. 尾状叶 coudate lobe
- 34. 竖脊肌 erector spinae
- 35. 斜方肌 trapezius
- 36. 脊髓 spinal cord
- 37. 右心室 right ventricle



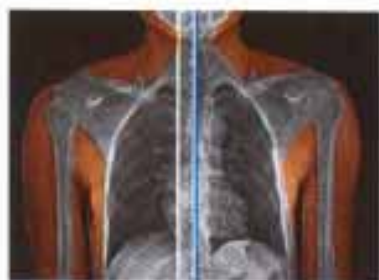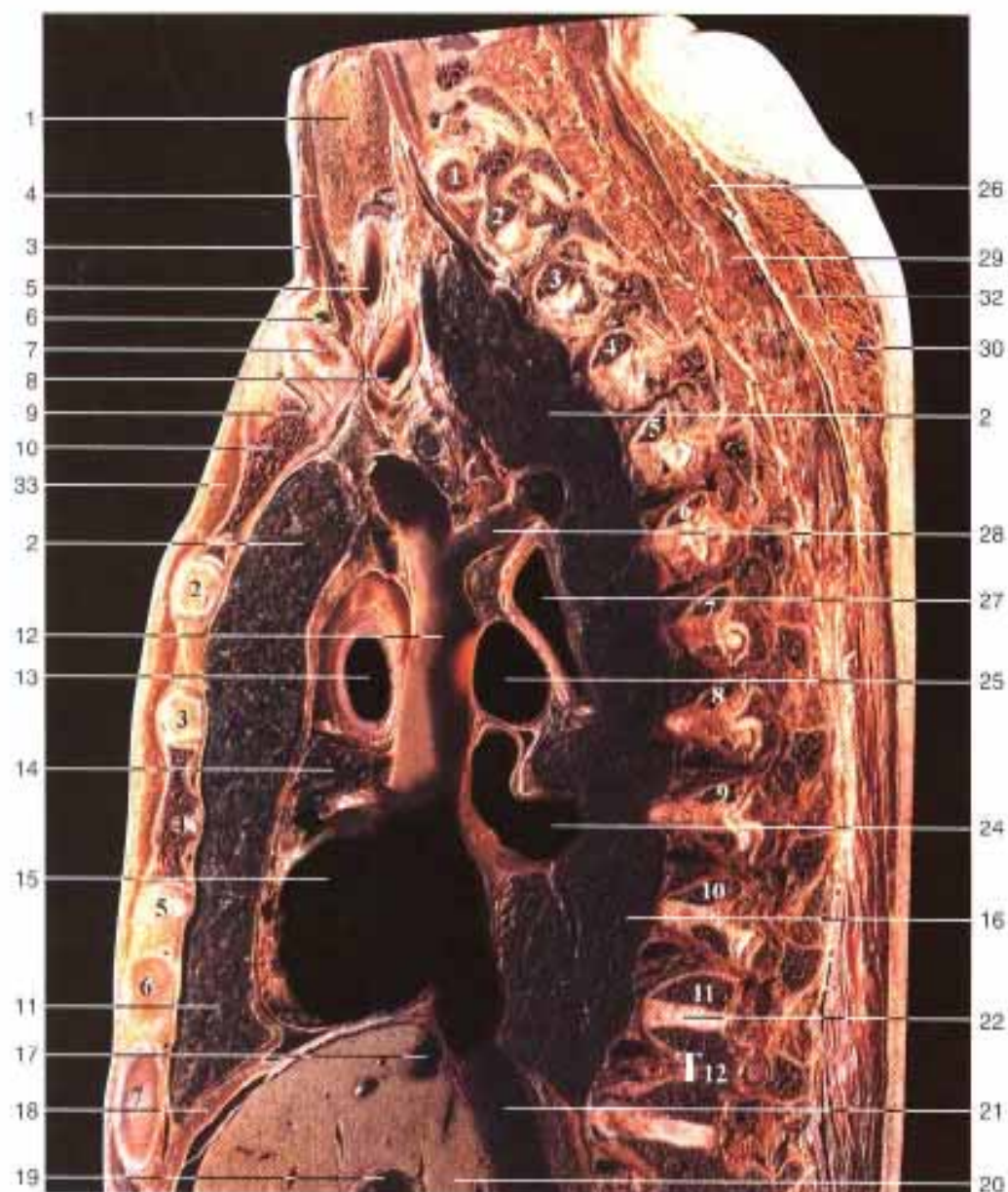
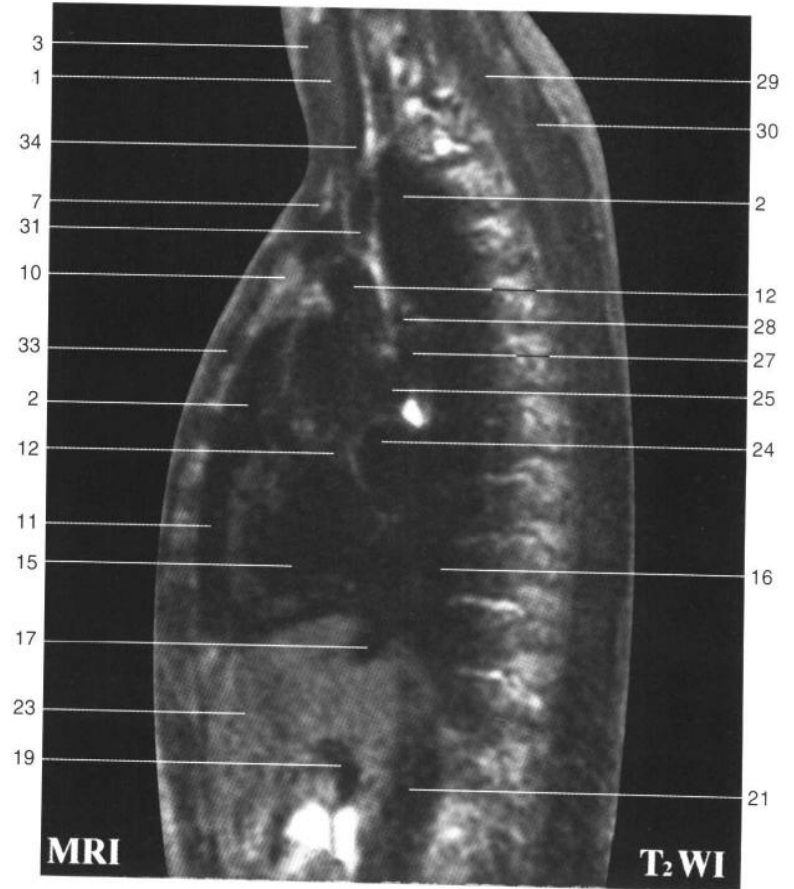

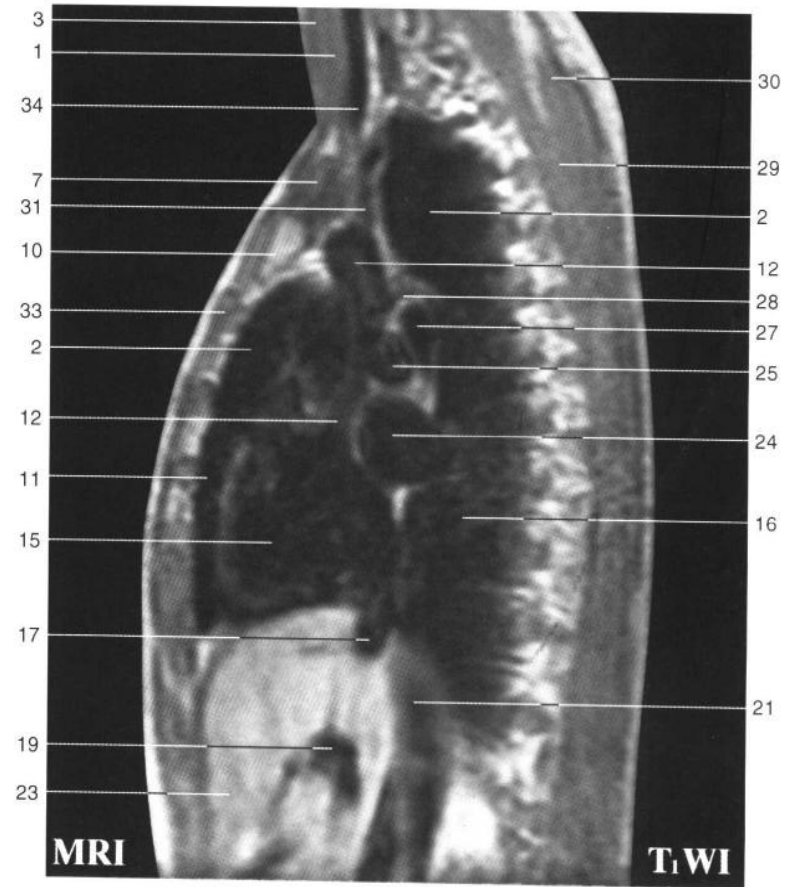
Fig. ST 7

1. 甲状腺 thyroid gland
2. 右肺上叶 superior lobe of right lung
3. 胸锁乳突肌 sternocleidomastoid
4. 胸骨舌骨肌 sternohyoid
5. 右颈总动脉 right common carotid a.
6. 颈静脉弓 jugular venous arch
7. 锁骨 clavicle
8. 右锁骨下动脉 right subclavian a.
9. 关节盘(胸锁关节) articular disc(sternoclavicular joint)

Fig. ST 7

- 10. 胸骨柄 manubrium sterni
- 11. 右肺中叶 middle lobe of right lung
- 12. 上腔静脉 superior vena cava
- 13. 升主动脉 ascending aorta
- 14. 右心耳 right auricle
- 15. 右心房 right atrium
- 16. 右肺下叶 inferior lobe of right lung
- 17. 肝中间静脉 intermediate hepatic v.
- 18. 膈 diaphragm
- 19. 肝门静脉左支 left branch of hepatic portal v.
- 20. 尾状叶 caudate lobe
- 21. 下腔静脉 inferior vena cava
- 22. 11、12 胸椎间盘 intervertebral disc(T₁₁ - T₁₂)
- 23. 左外叶 left lateral lobe
- 24. 左心房 left atrium
- 25. 右肺动脉 right pulmonary a.
- 26. 头夹肌 splenius capitis
- 27. 右主支气管 right principal bronchus
- 28. 奇静脉弓 arch of azygos v.
- 29. 竖脊肌 erector spinae
- 30. 斜方肌 trapezius
- 31. 右头臂静脉 right brachiocephalic v.
- 32. 大菱形肌 rhomboideus major
- 33. 胸大肌 pectoralis major
- 34. 颈内静脉 internal jugular v.



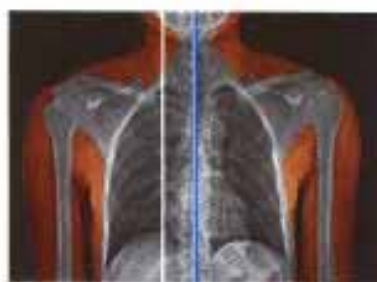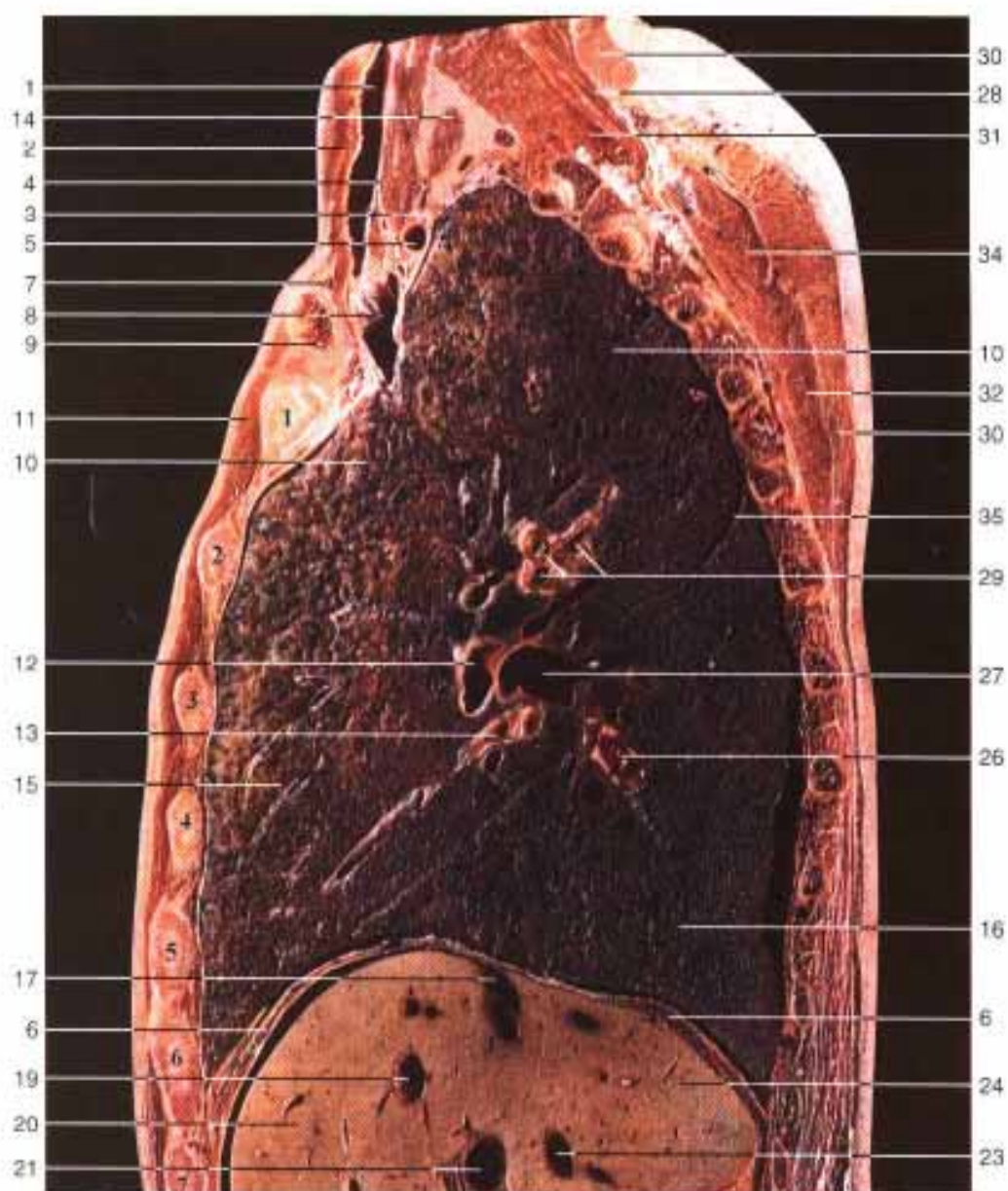
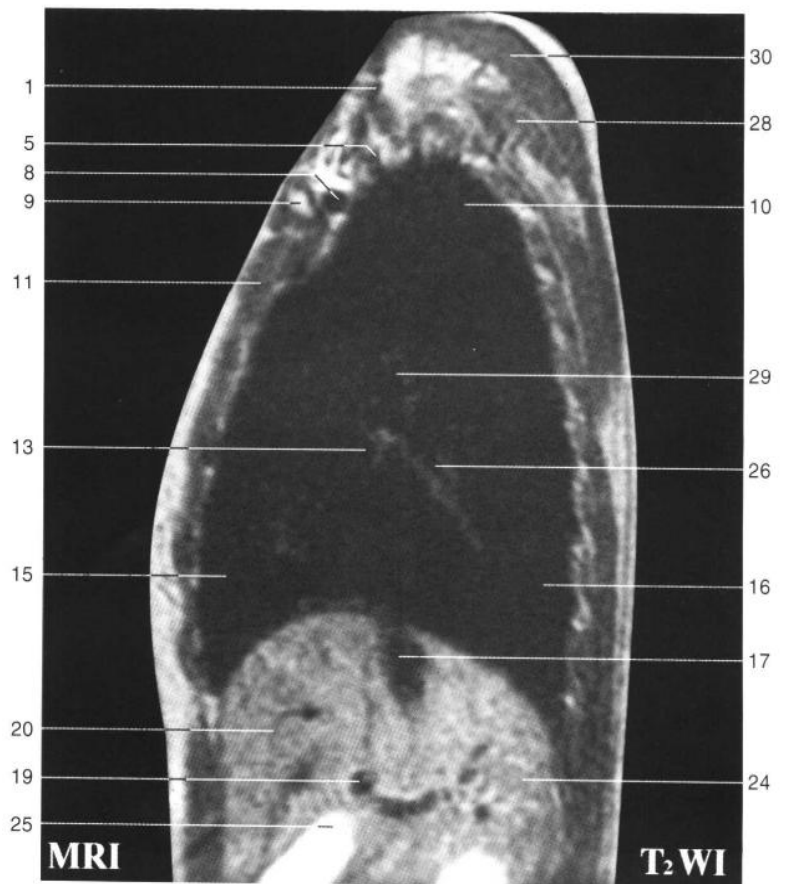
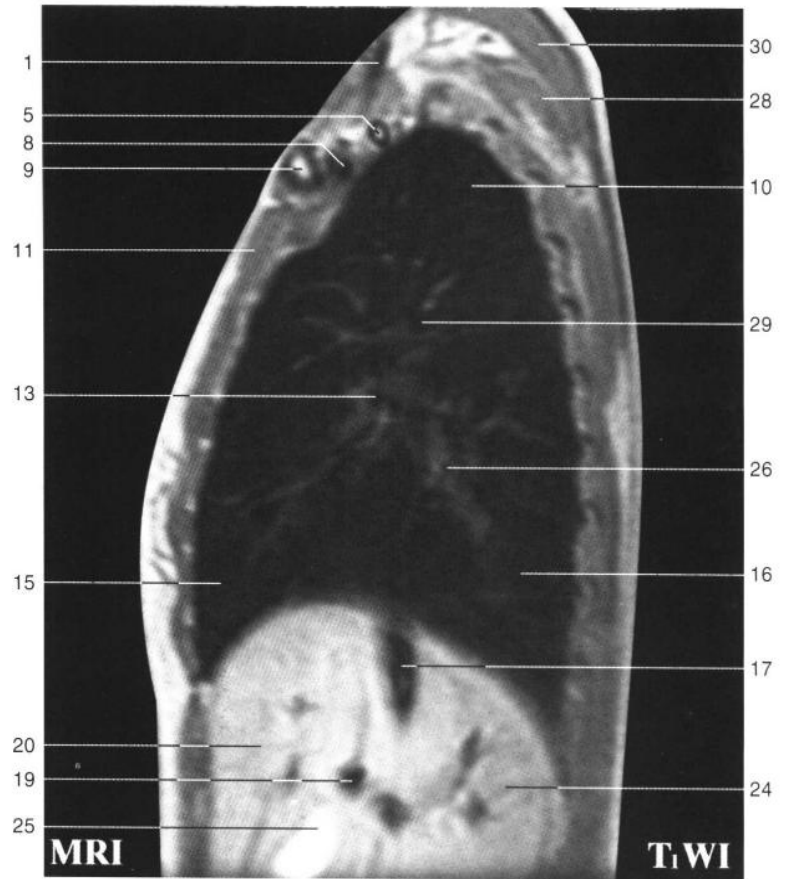


Fig. ST 8

1. 右颈内静脉 right internal jugular v.
2. 胸锁乳突肌 sternocleidomastoid
3. 臂丛 brachial plexus
4. 前斜角肌 scalenus anterior
5. 右锁骨下动脉 right subclavian a.
6. 膈 diaphragm
7. 颈静脉弓 jugular venous arch
8. 右锁骨下静脉 right subclavian v.
9. 锁骨 clavicle

Fig. ST 8

- 10. 右肺上叶 superior lobe of right lung
- 11. 胸大肌 pectoralis major
- 12. 右上肺静脉 right superior pulmonary v.
- 13. 右肺中叶支气管 right middle lobar bronchus
- 14. 后斜角肌 scalenus posterior
- 15. 右肺中叶 middle lobe of right lung
- 16. 右肺下叶 inferior lobe of right lung
- 17. 肝右静脉 right hepatic v.
- 18. 右前叶 right anterior lobe
- 19. 肝中间静脉 intermediate hepatic v.
- 20. 左外叶 left lateral lobe
- 21. 肝门静脉 hepatic portal v.
- 22. 左内叶 left medial lobe
- 23. 右肝后静脉 right posterior hepatic v.
- 24. 右后叶 right posterior lobe
- 25. 胆囊 gallbladder
- 26. 右肺下叶支气管 right inferior lobar bronchus
- 27. 右肺动脉 right pulmonary a.
- 28. 头夹肌 splenius capitis
- 29. 右肺上叶支气管 right superior lobar bronchus
- 30. 斜方肌 trapezius
- 31. 头半棘肌 semispinalis capitis
- 32. 大菱形肌 rhomboideus major
- 33. 中斜角肌 scalenus medius
- 34. 肩胛提肌 levator scapulae
- 35. 斜裂 oblique fissure



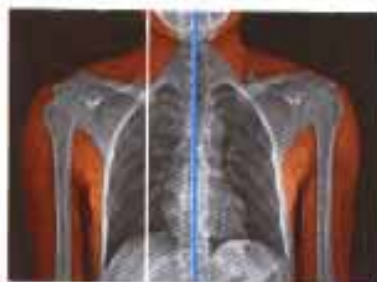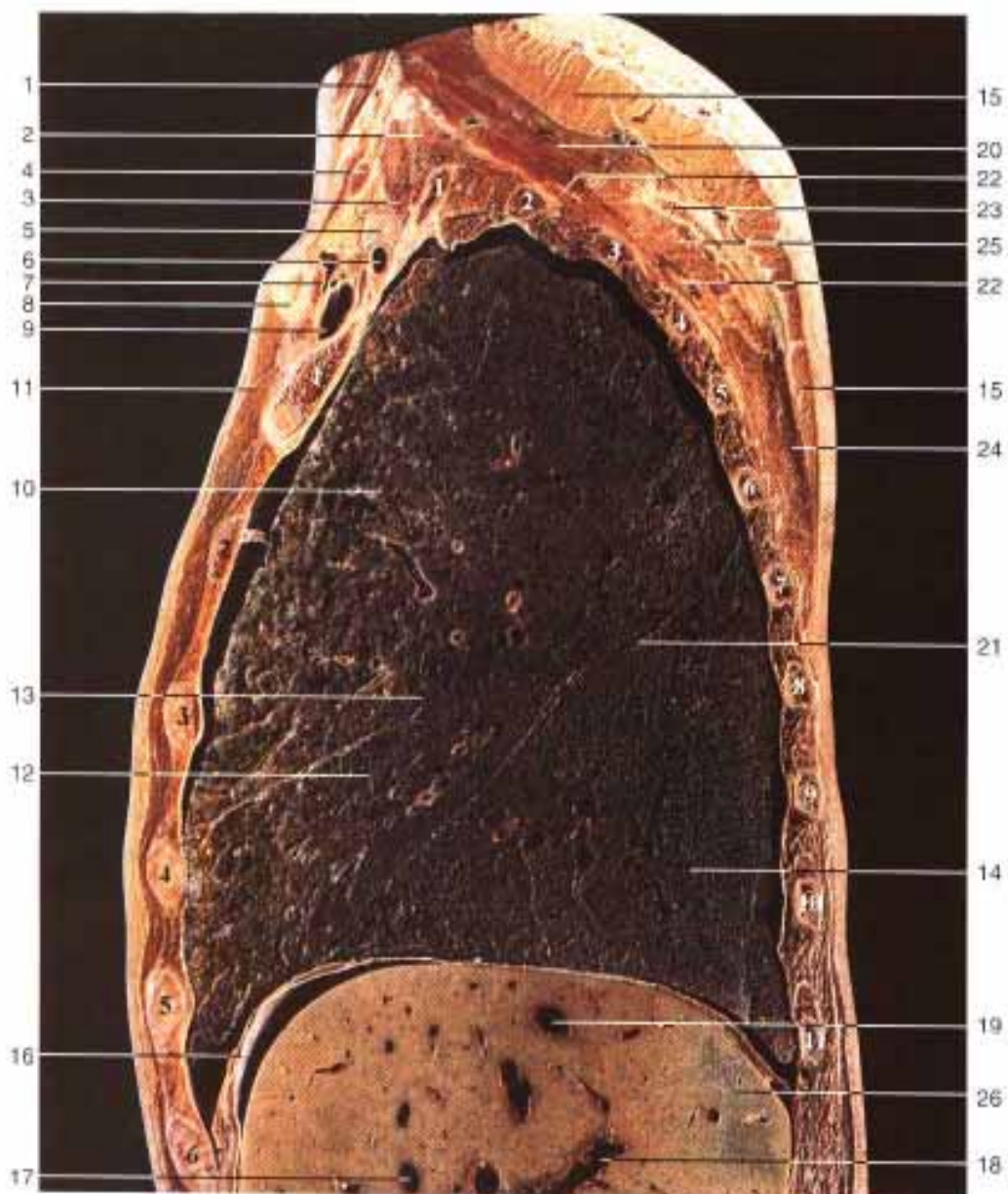
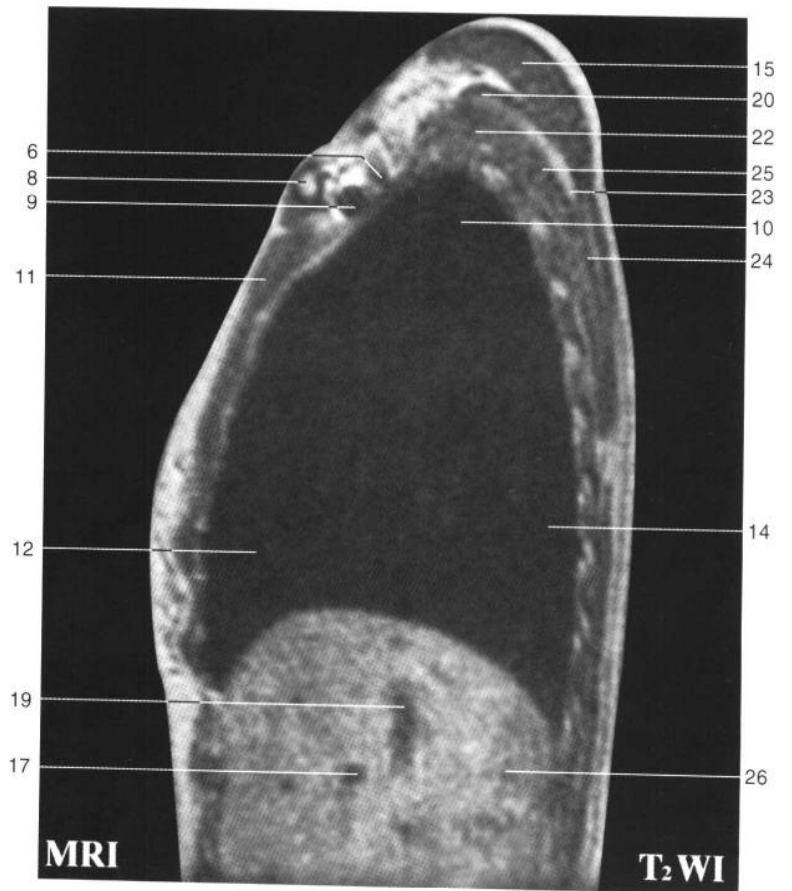

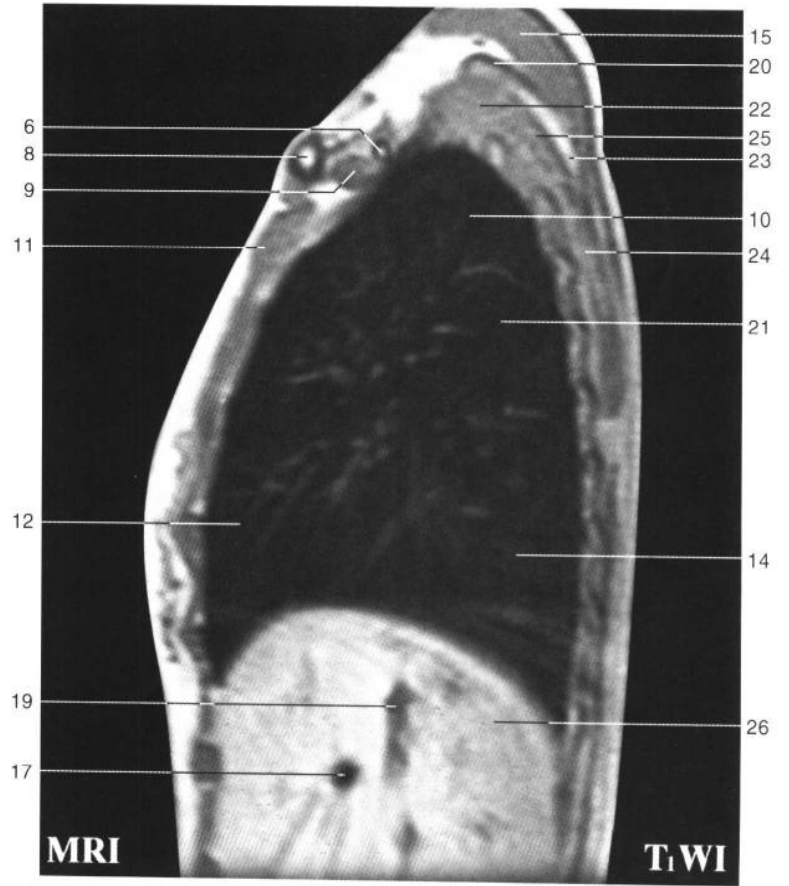
Fig. ST 9

1. 胸锁乳突肌 sternocleidomastoid
2. 后斜角肌 scalenus posterior
3. 中斜角肌 scalenus medius
4. 肩胛舌骨肌 omohyoid
5. 臂丛 brachial plexus
6. 锁骨下动脉 subclavian a.
7. 颈外静脉 external jugular v.
8. 锁骨 clavicle
9. 锁骨下静脉 subclavian v.

Fig. ST 9

- 10. 右肺上叶 superior lobe of right lung
- 11. 胸大肌 pectoralis major
- 12. 右肺中叶 middle lobe of right lung
- 13. 右肺水平裂 horizontal fissure of right lung
- 14. 右肺下叶 inferior lobe of right lung
- 15. 斜方肌 trapezius
- 16. 膈 diaphragm
- 17. 肝中间静脉 intermediate hepatic v.
- 18. 肝门静脉右支 right branch of hepatic portal v.
- 19. 肝右静脉 right hepatic v.
- 20. 肩胛提肌 levator scapulae
- 21. 斜裂 oblique fissure
- 22. 上后锯肌 serratus posterior superior
- 23. 肩胛骨 scapula
- 24. 大菱形肌 rhomboideus major
- 25. 前锯肌 serratus anterior
- 26. 右后叶 right posterior lobe



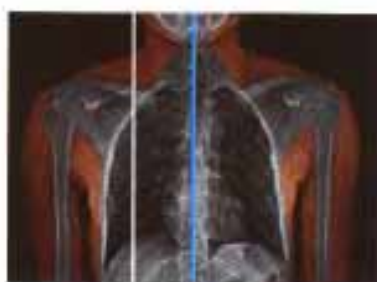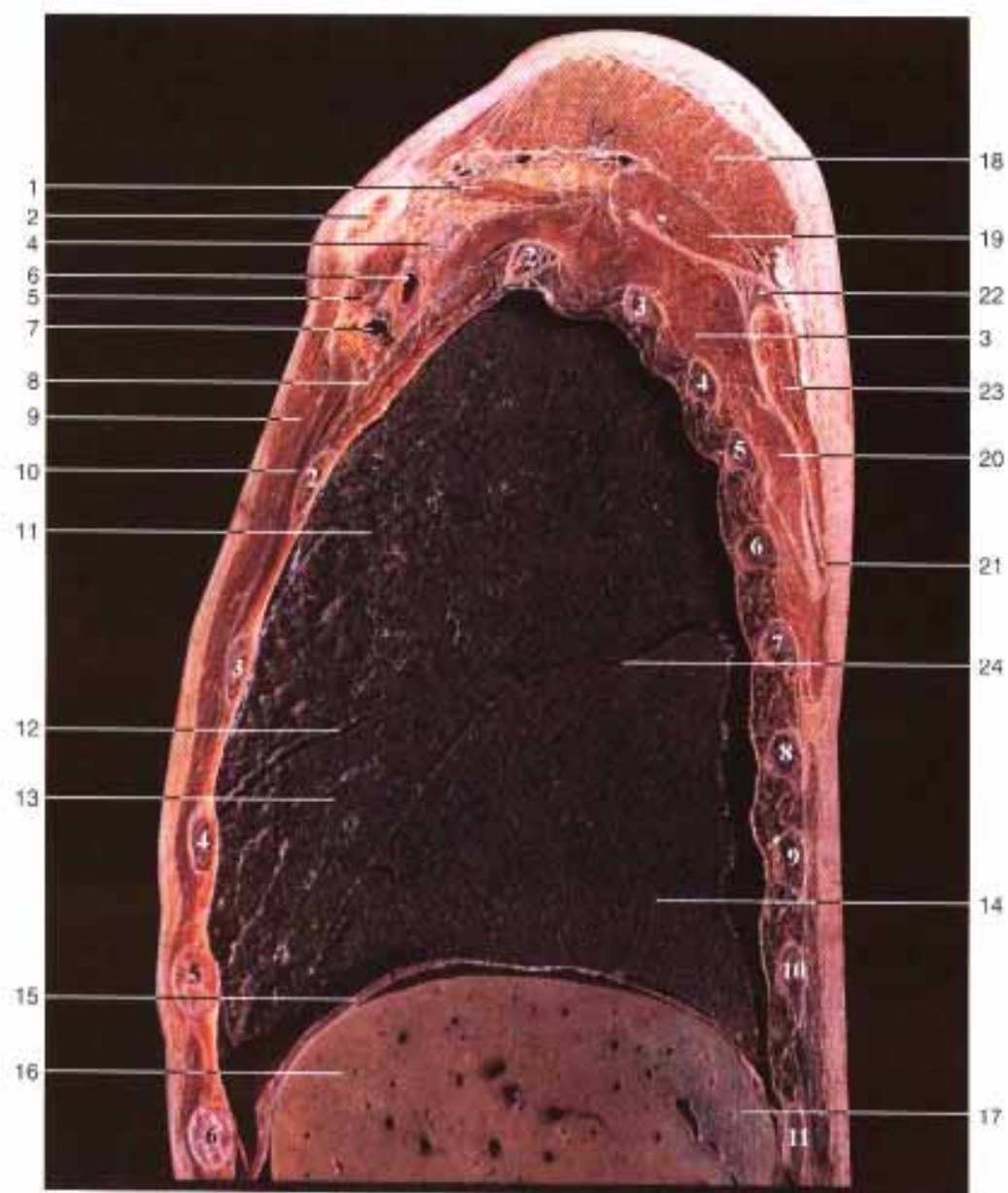
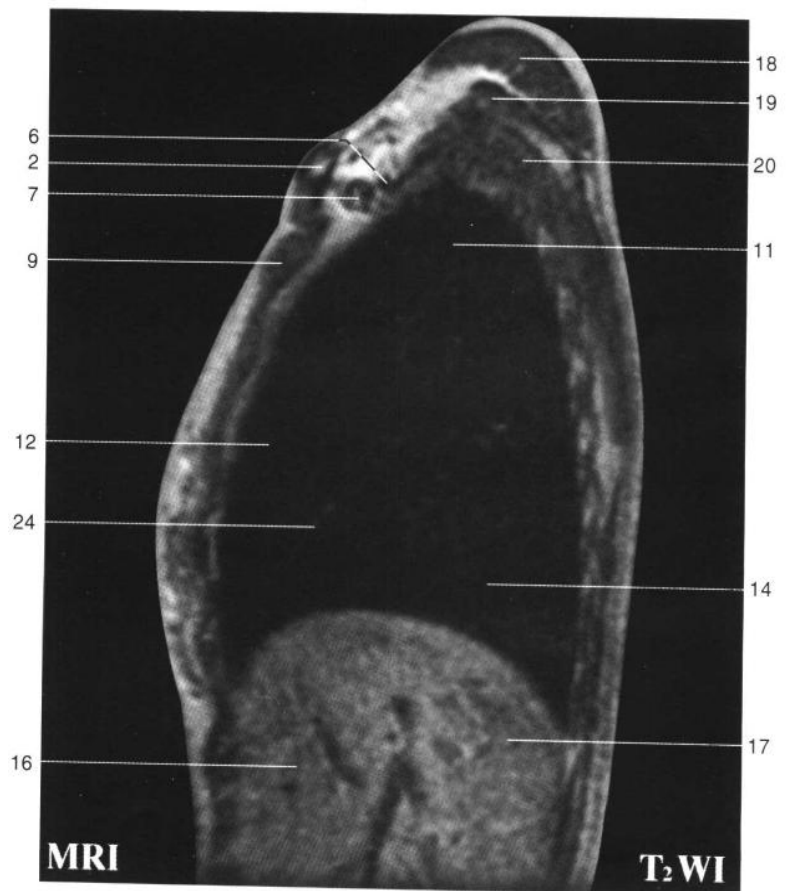

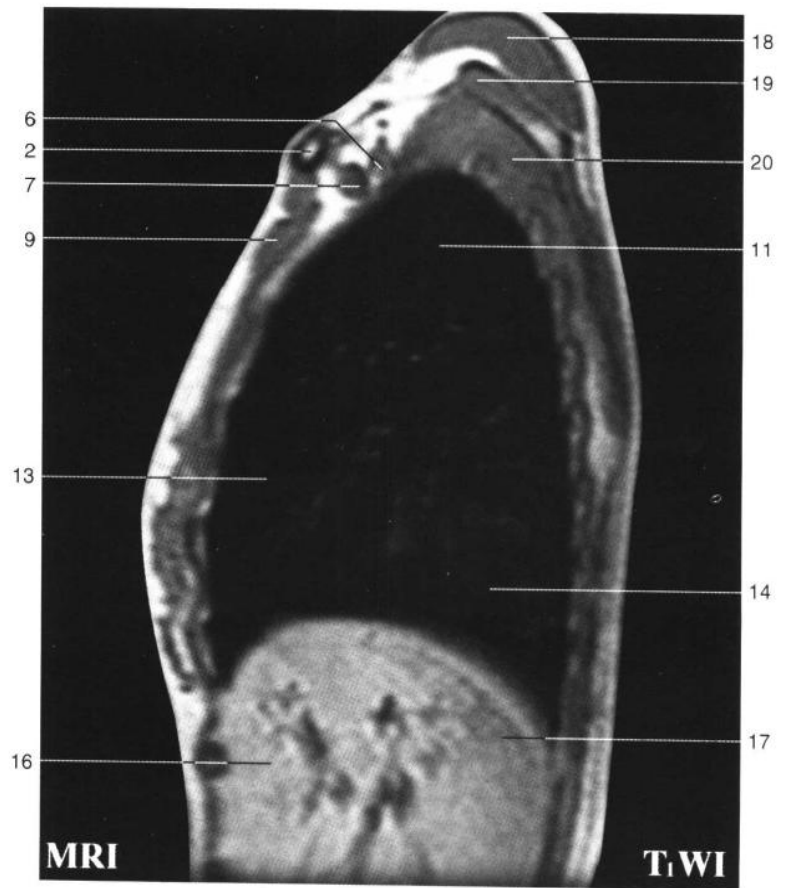
Fig. ST 10

1. 肩胛舌骨肌 omohyoid
2. 锁骨 clavicle
3. 前锯肌 serratus anterior
4. 臂丛 brachial plexus
5. 锁骨下肌 subclavius
6. 腋动脉 axillary a.
7. 腋静脉 axillary v.
8. 肋间肌 intercostales
9. 胸大肌 pectoralis major

Fig. ST 10

- 10. 胸小肌 pectoralis minor
- 11. 右肺上叶 superior lobe of right lung
- 12. 右肺水平裂 horizontal fissure of right lung
- 13. 右肺中叶 middle lobe of right lung
- 14. 右肺下叶 inferior lobe of right lung
- 15. 膈 diaphragm
- 16. 右前叶 right anterior lobe
- 17. 右后叶 right posterior lobe
- 18. 斜方肌 trapezius
- 19. 冈上肌 supraspinatus
- 20. 肩胛下肌 subscapularis
- 21. 肩胛骨 scapula
- 22. 肩胛冈 spine of scapula
- 23. 冈下肌 infraspinatus
- 24. 斜裂 oblique fissure



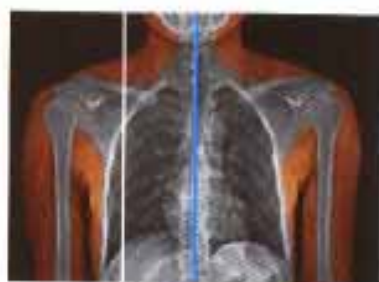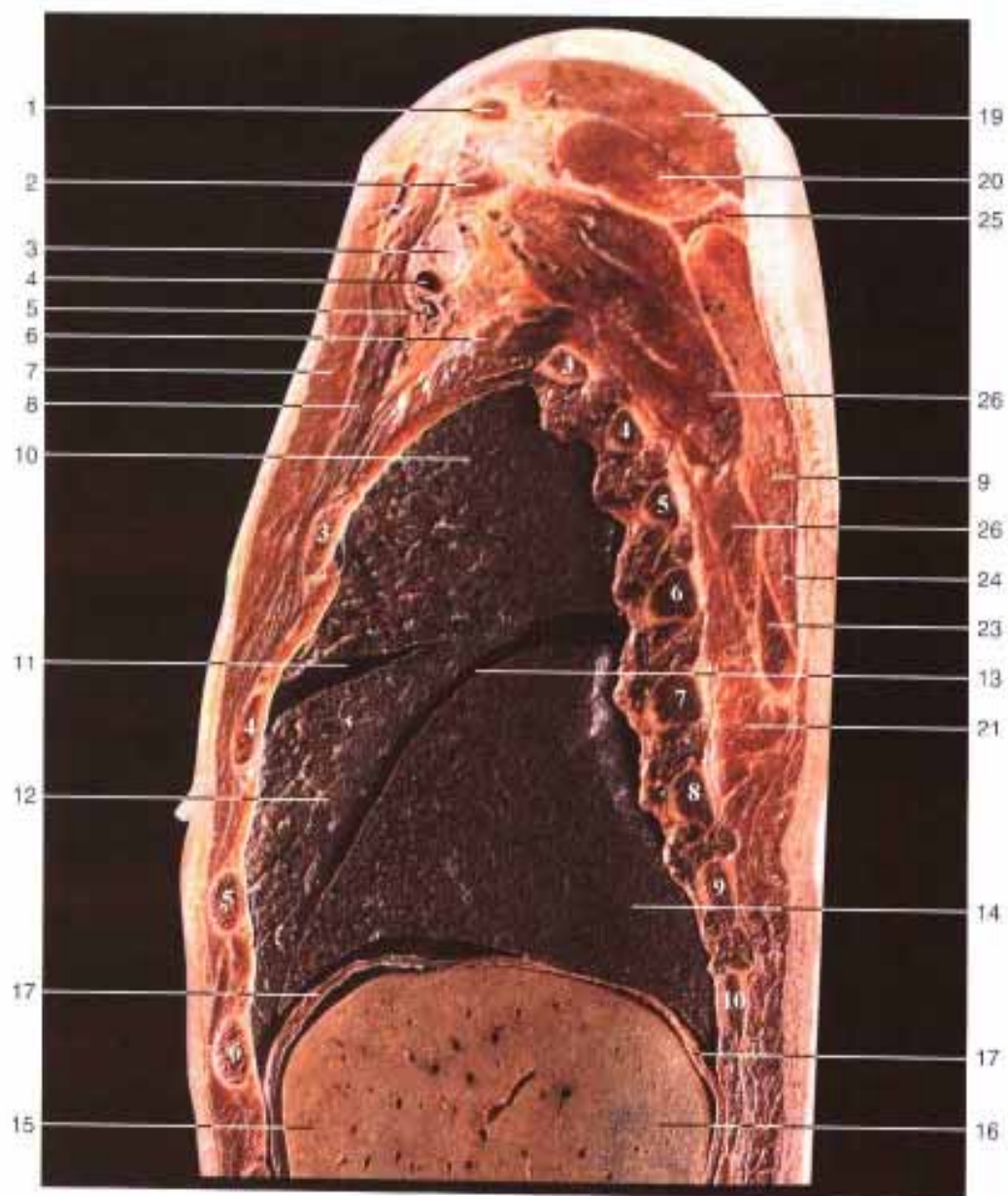


Fig. ST 11

1. 锁骨 clavicle
2. 肩胛舌骨肌 omohyoid
3. 臂丛 brachial plexus
4. 腋动脉 axillary a.
5. 腋静脉 axillary v.
6. 前锯肌 serratus anterior
7. 胸大肌 pectoralis major
8. 胸小肌 pectoralis minor
9. 冈下肌 infraspinatus

Fig. ST 11

- 10. 右肺上叶 superior lobe of right lung
- 11. 右肺水平裂 horizontal fissure of right lung
- 12. 右肺中叶 middle lobe of right lung
- 13. 斜裂 oblique fissure
- 14. 右肺下叶 inferior lobe of right lung
- 15. 右前叶 right anterior lobe
- 16. 右后叶 right posterior lobe
- 17. 膈 diaphragm
- 18. 三角肌 deltoid
- 19. 斜方肌 trapezius
- 20. 冈上肌 supraspinatus
- 21. 前锯肌 serratus anterior
- 22. 上段(S_V) superior segment(S_V)
- 23. 肩胛骨 scapula
- 24. 小圆肌 teres minor
- 25. 肩胛冈 spine of scapula
- 26. 肩胛下肌 subscapularis

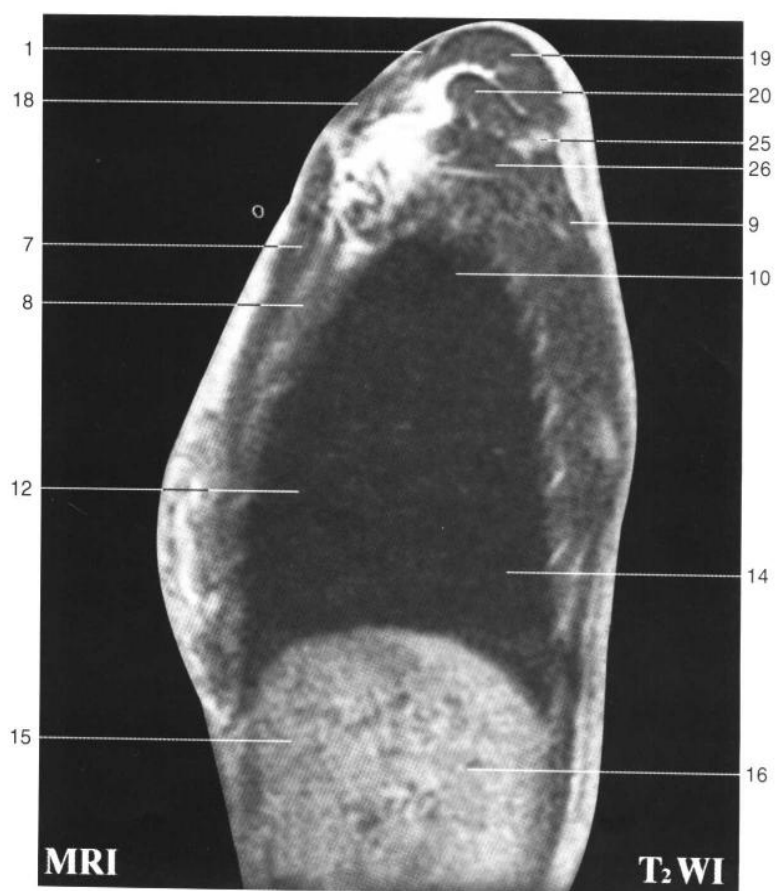
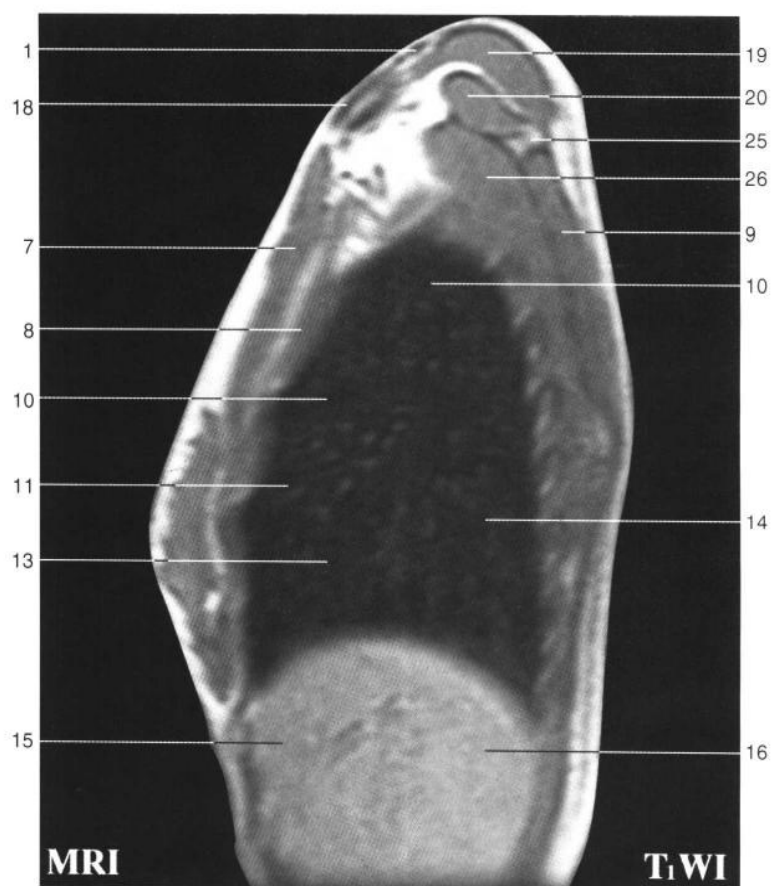
Fig. MRI

1. 气管 trachea
2. 主动脉弓 aortic arch
3. 左肺动脉 left pulmonary a.
4. 右主支气管 right principal bronchus
5. 上叶支气管 superior lobar bronchus
6. 左肺下叶支气管 left inferior lobar bronchus
7. 胸主动脉 thoracic aorta
8. 奇静脉弓 arch of azygos v.
9. 右锁骨下动脉 right subclavian a.
10. 中间支气管 intermediate bronchus
11. 肺动脉干 pulmonary trunk
12. 升主动脉 ascending aorta
13. 左心室 left ventricle
14. 头臂干 brachiocephalic trunk
15. 上腔静脉 superior vena cava
16. 右心房 right atrium
17. 右心室 right ventricle
18. 膈 diaphragm
19. 心包 pericardium
20. 左颈总动脉 left common carotid a.
21. 肝右叶 right lobe of liver
22. 肝门静脉 hepatic portal v.
23. 肝左叶 left lobe of liver
24. 左冠状动脉 left coronary a.

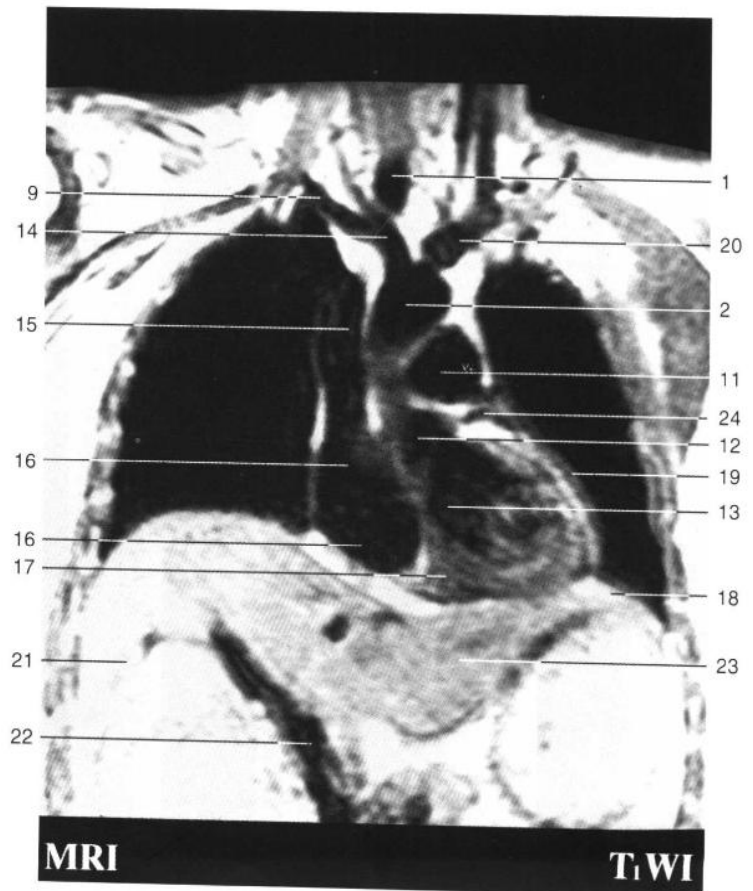
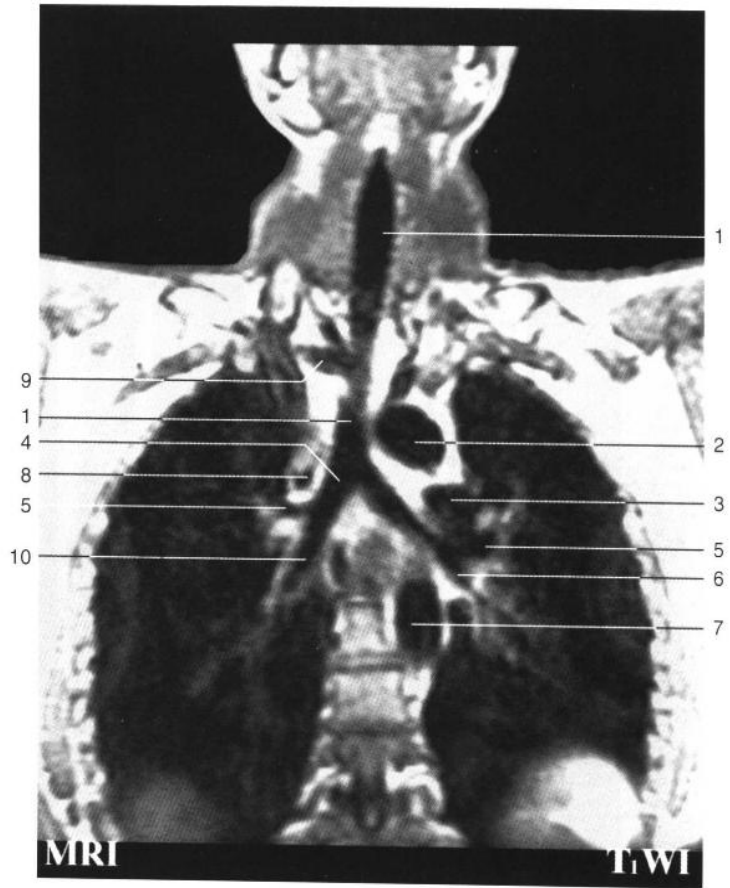

Fig. MRI

ABDOMEN

腹部

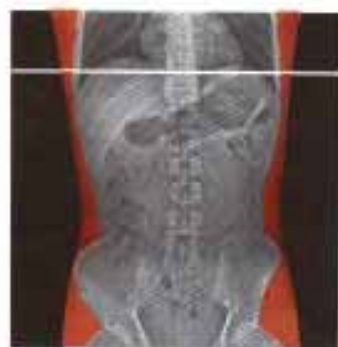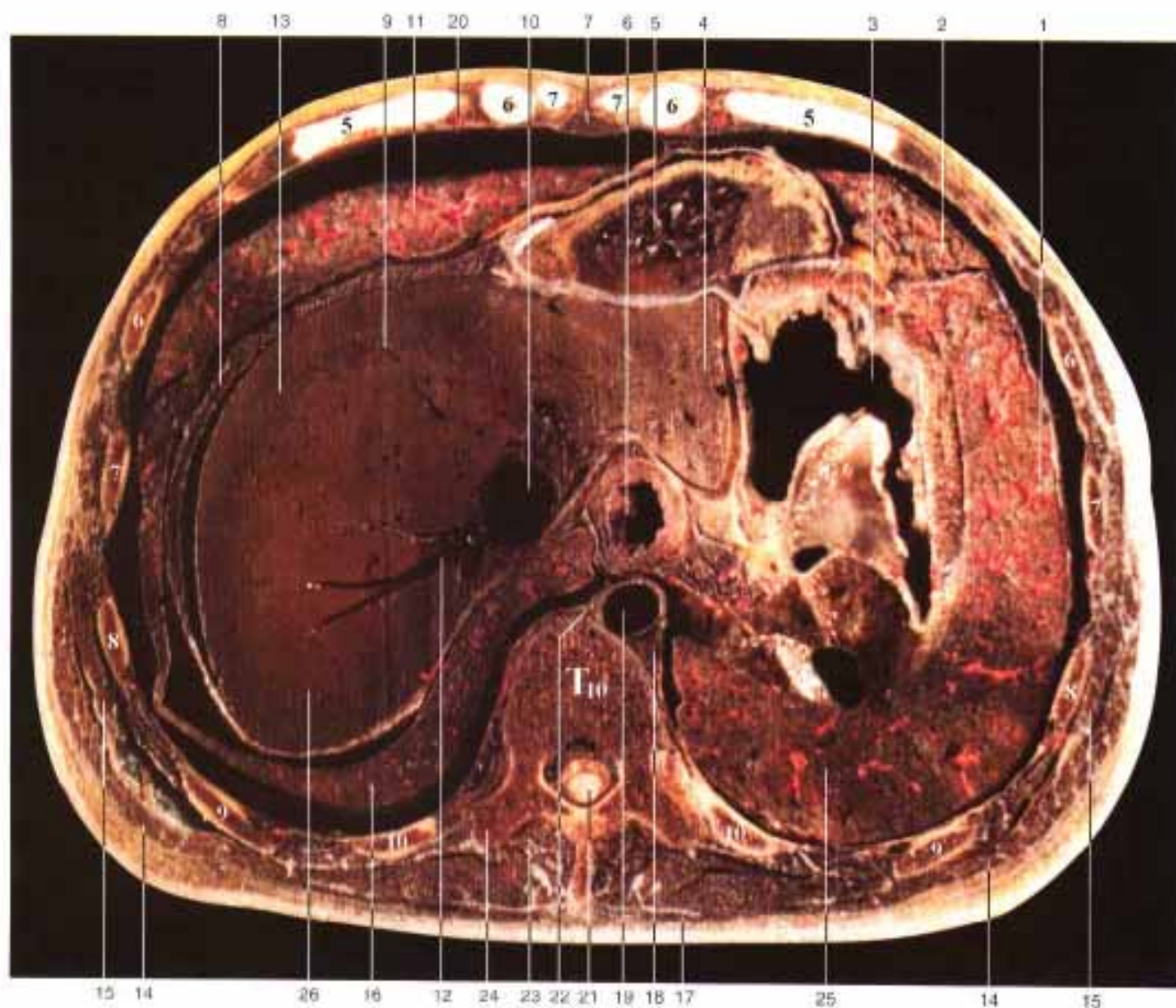
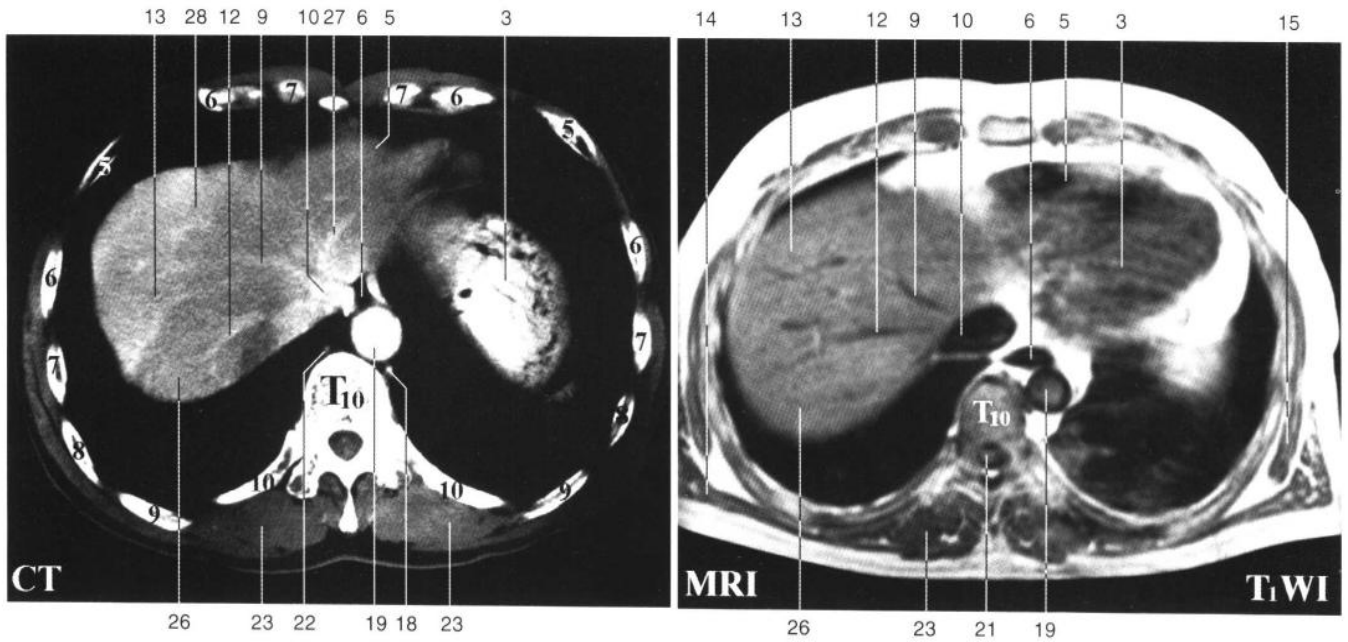


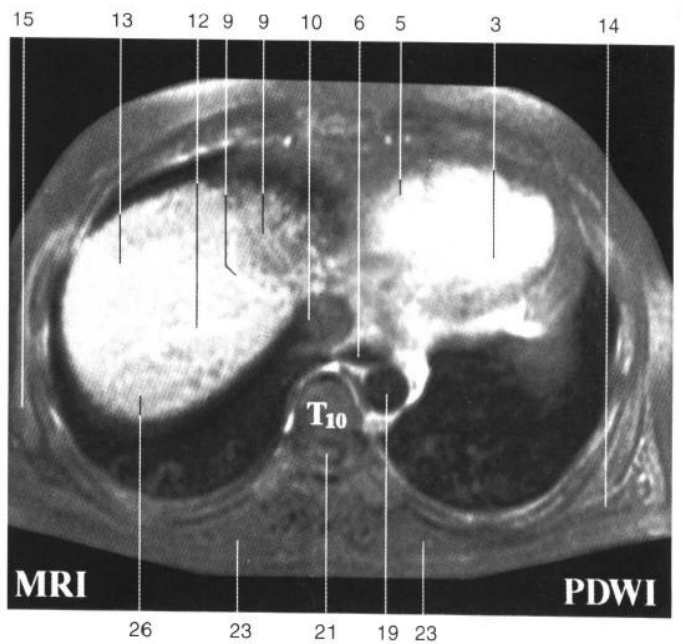
Fig. HA 1

1. 外侧基底段 (S_{lx}) lateral basal segment (S_{lx})
2. 下舌段 (S_v) inferior lingual segment (S_v)
3. 胃底 fundus of stomach
4. 左外叶 left lateral lobe
5. 右心室 right ventricle
6. 食管 esophagus
7. 剑突 xiphoid process
8. 膈 diaphragm
9. 肝中间静脉 intermediate hepatic v.
10. 下腔静脉 inferior vena cava

Fig.HA 1



- 11. 内侧段 (S_V) medial segment (S_V)
- 12. 肝右静脉 right hepatic v.
- 13. 右前叶 right anterior lobe
- 14. 背阔肌 latissimus dorsi
- 15. 前锯肌 serratus anterior
- 16. 后底段 (S_X) posterior basal segment (S_X)
- 17. 斜方肌 trapezius
- 18. 半奇静脉 semiazygos v.
- 19. 胸主动脉 thoracic aorta
- 20. 胸廓内动脉 internal thoracic a.
- 21. 脊髓 spinal cord
- 22. 奇静脉 azygos v.
- 23. 竖脊肌 erector spinae
- 24. 第 10 胸椎横突 transverse process (T₁₀)
- 25. 后底段 (S_X) posterior basal segment (S_X)
- 26. 右后叶 right posterior lobe
- 27. 肝左静脉 left hepatic v.
- 28. 左内叶 left medial lobe



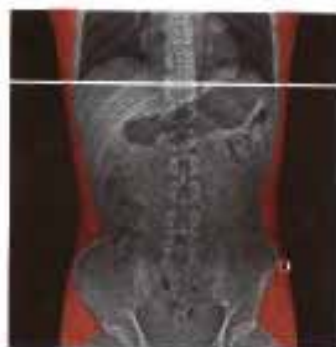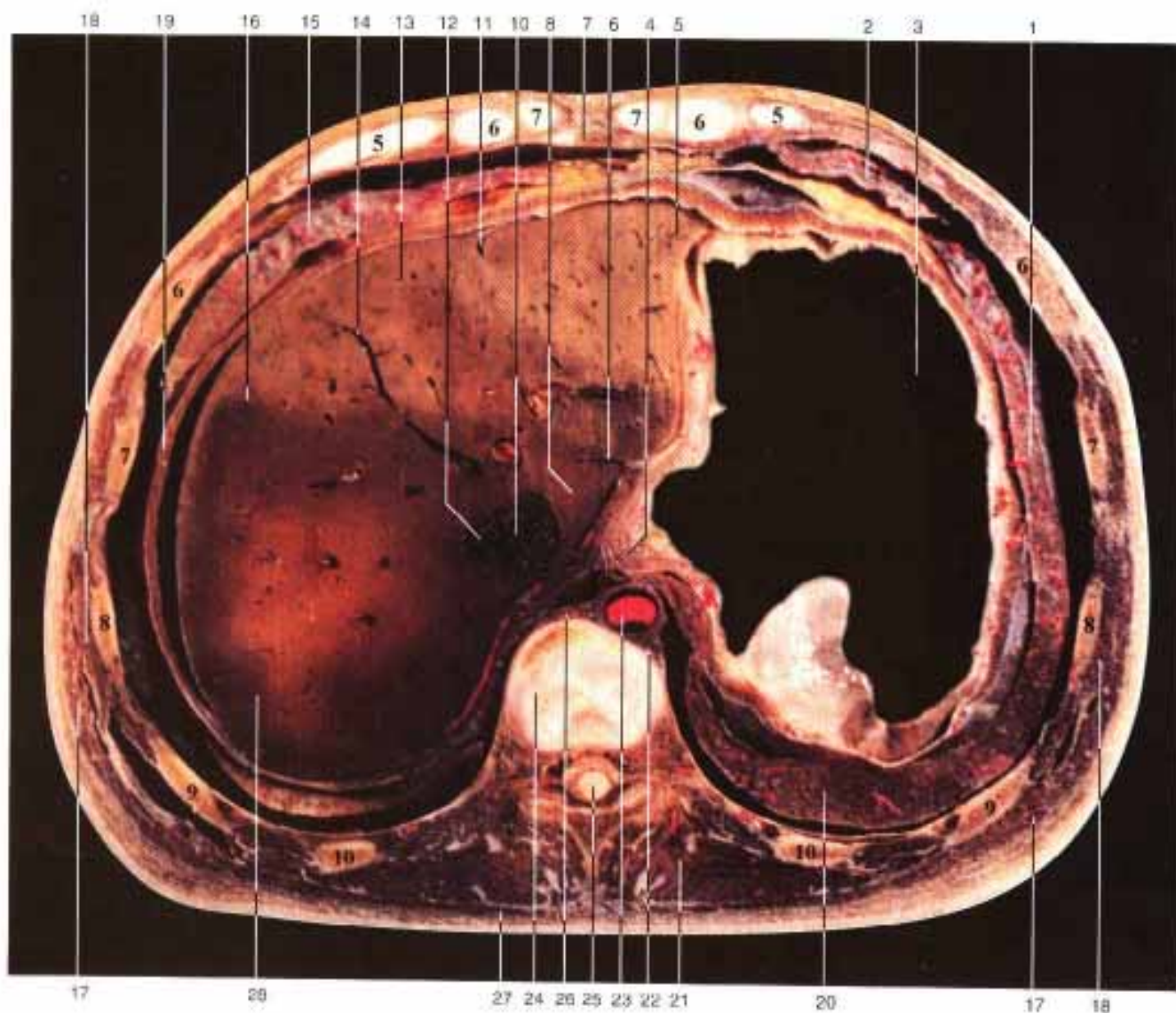
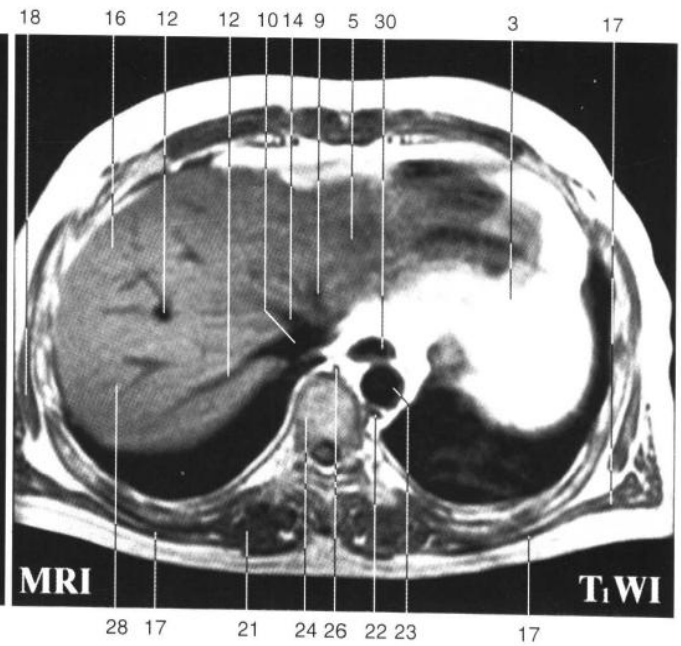
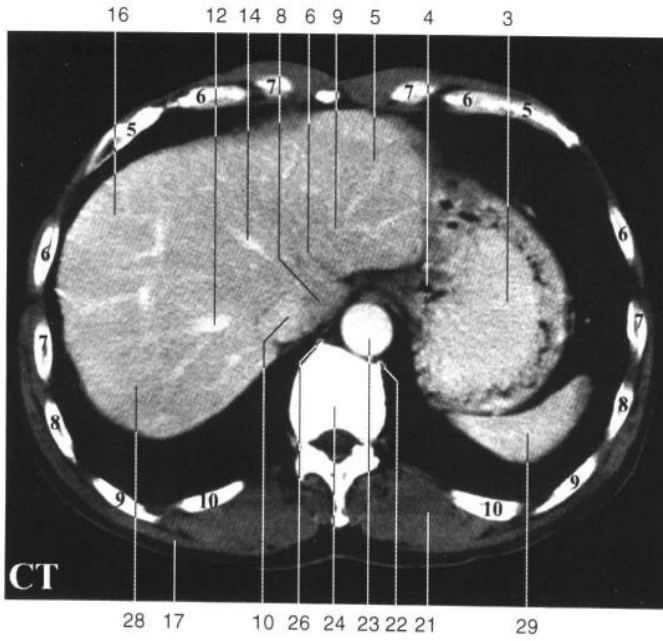


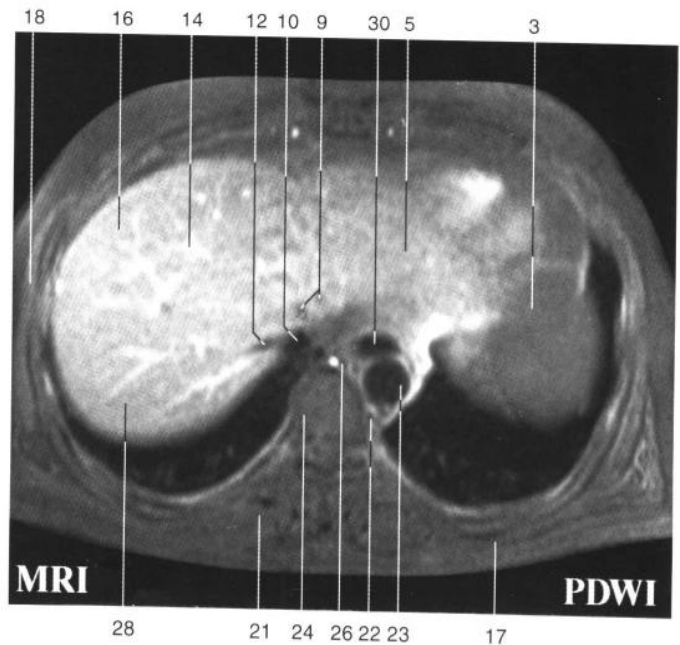
Fig. HA 2

1. 外侧底段 (S_w) lateral basal segment (S_w)
2. 下舌段 (S_v) inferior lingual segment (S_v)
3. 胃 stomach
4. 贲门 cardia
5. 左外叶 left lateral lobe
6. 静脉韧带裂 fissure for ligamentum venosum
7. 剑突 xiphoid process
8. 尾状叶 caudate lobe
9. 肝左静脉 left hepatic v.
10. 下腔静脉 inferior vena cava

Fig.HA 2



11. 肝圆韧带裂 fissure for ligamentum teres hepatis
12. 肝右静脉 right hepatic v.
13. 左内叶 left medial lobe
14. 肝中间静脉 intermediate hepatic v.
15. 内侧段(S_V) medial segment(S_V)
16. 右前叶 right anterior lobe
17. 背阔肌 latissimus dorsi
18. 前锯肌 serratus anterior
19. 膈 diaphragm
20. 后底段(S_X) posterior basal segment(S_X)
21. 竖脊肌 erector spinae
22. 半奇静脉 semiazygos v.
23. 胸主动脉 thoracic aorta
24. 10、11 胸椎间盘 intervertebral disc(T₁₀₋₁₁)
25. 脊髓 spinal cord
26. 奇静脉 azygos v.
27. 斜方肌 trapezius
28. 右后叶 right posterior lobe
29. 脾 spleen
30. 食管 esophagus



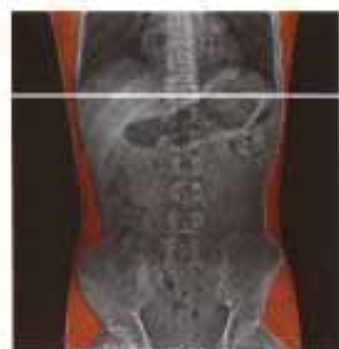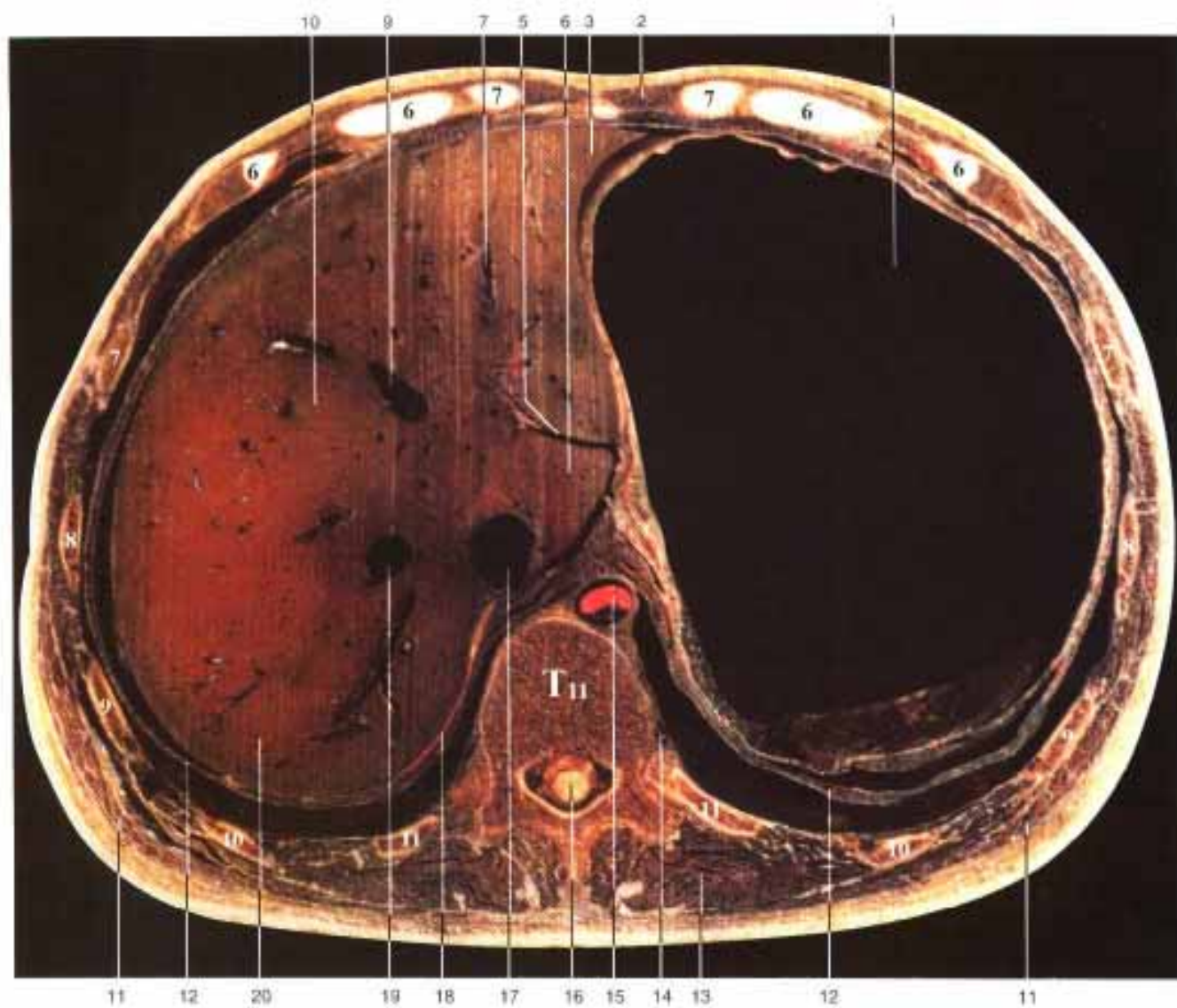
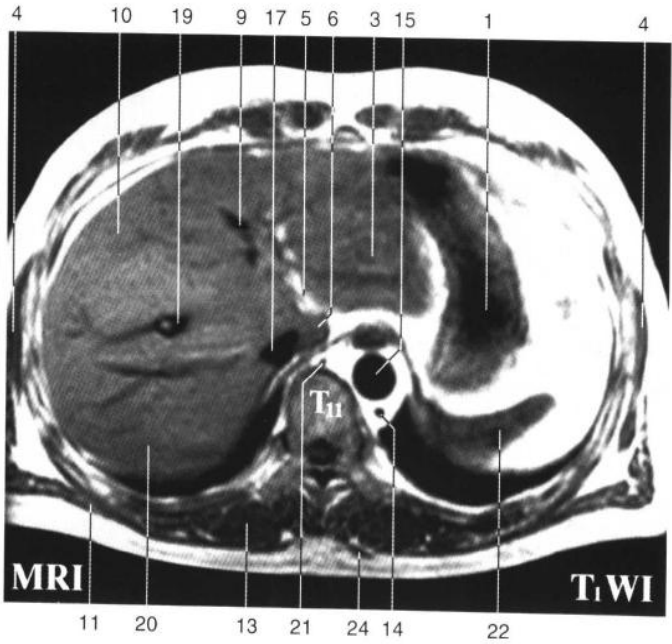
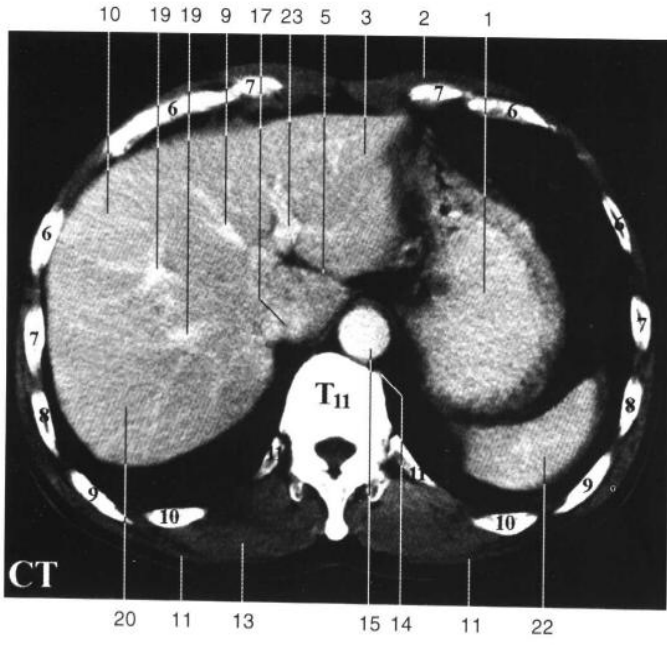


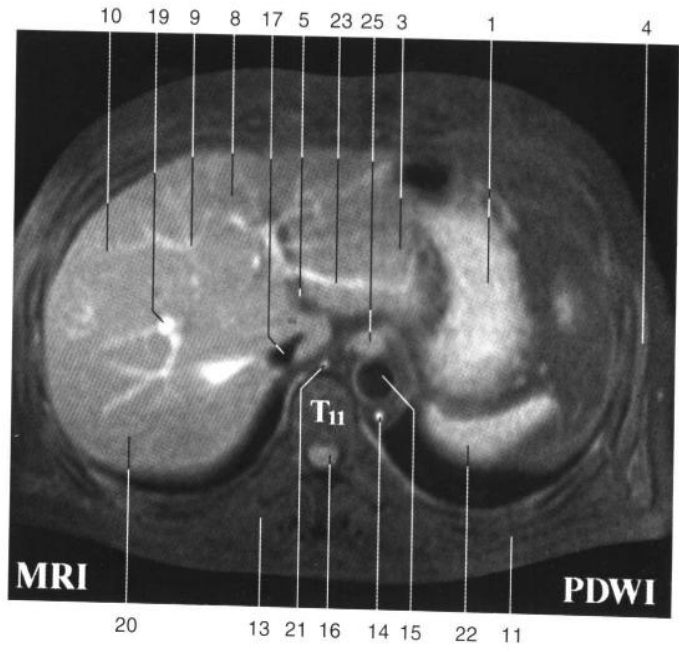
Fig. HA 3

1. 胃 stomach
2. 腹直肌 rectus abdominis
3. 左外叶 left lateral lobe
4. 前锯肌 serratus anterior
5. 静脉韧带裂 fissure for ligamentum venosum
6. 尾状叶 caudate lobe
7. 肝左静脉 left hepatic v.
8. 左内叶 left medial lobe
9. 肝中间静脉 intermediate hepatic v.
10. 右前叶 right anterior lobe

Fig. HA 3



11. 背阔肌 latissimus dorsi
12. 膈 diaphragm
13. 竖脊肌 erector spinae
14. 半奇静脉 semiazygos v.
15. 胸主动脉 thoracic aorta
16. 脊髓 spinal cord
17. 下腔静脉 inferior vena cava
18. 右肾上腺 right suprarenal gland
19. 肝右静脉 right hepatic v.
20. 右后叶 right posterior lobe
21. 奇静脉 azygos v.
22. 脾 spleen
23. 肝门静脉左支 left branch of hepatic portal v.
24. 斜方肌 trapezius
25. 食管 esophagus



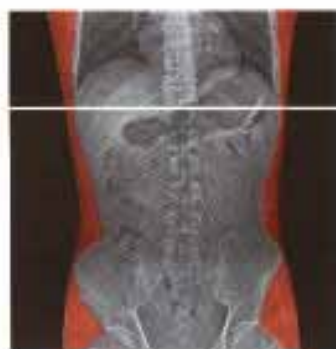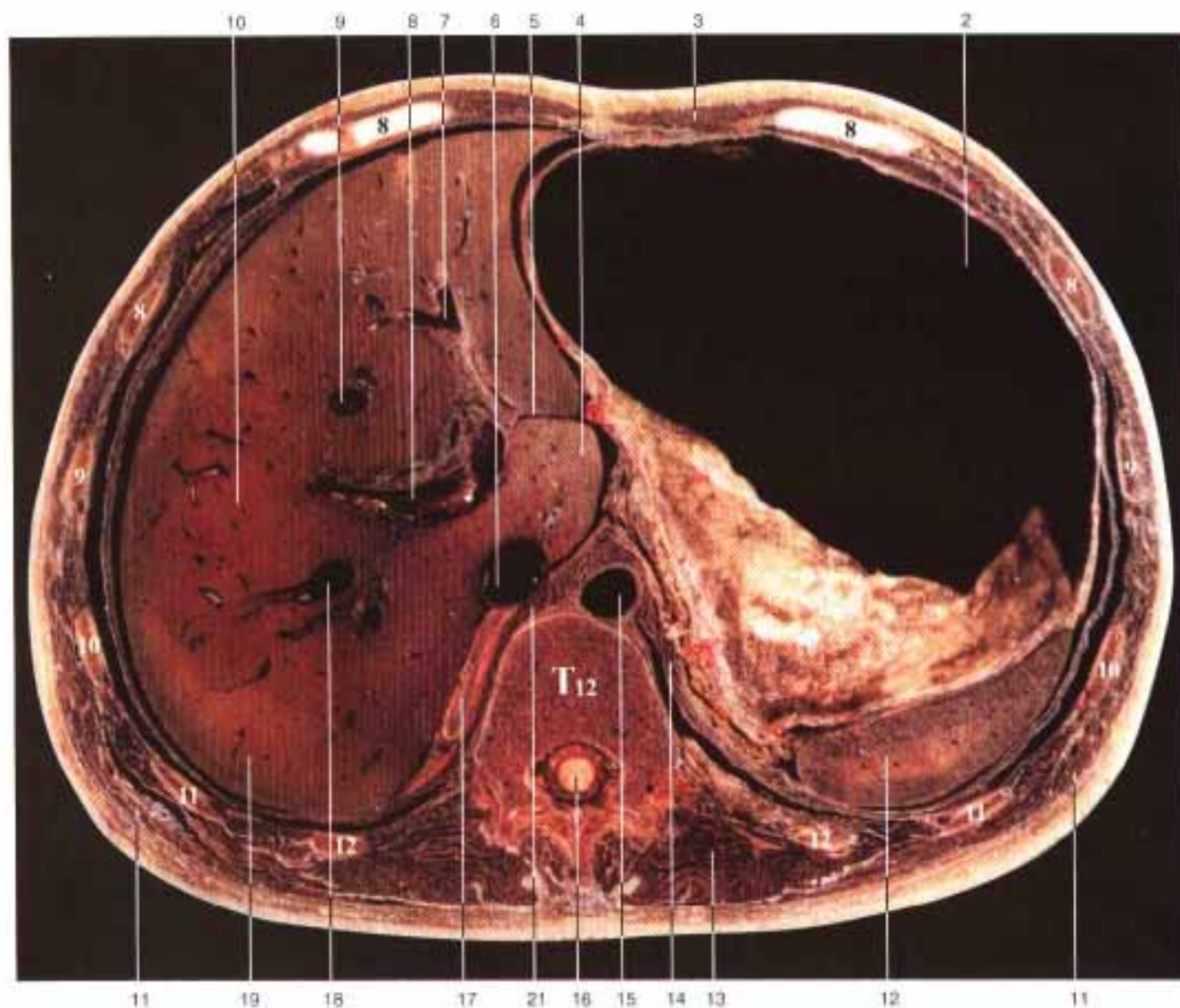
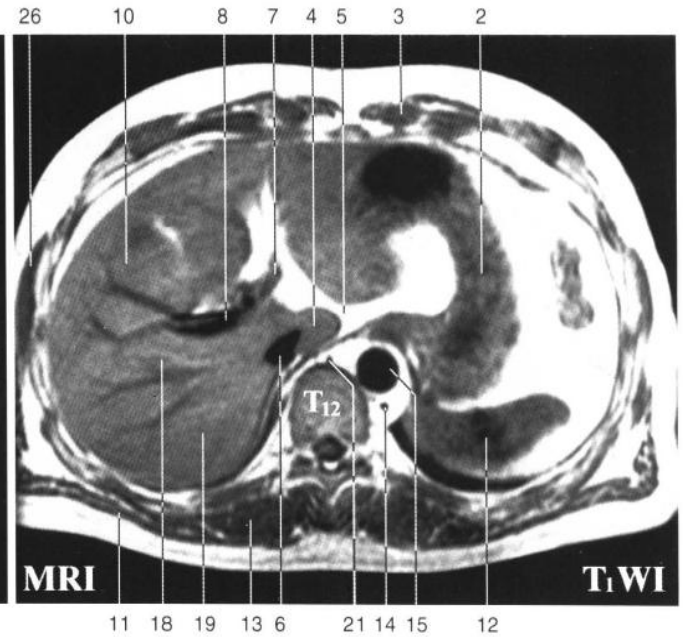
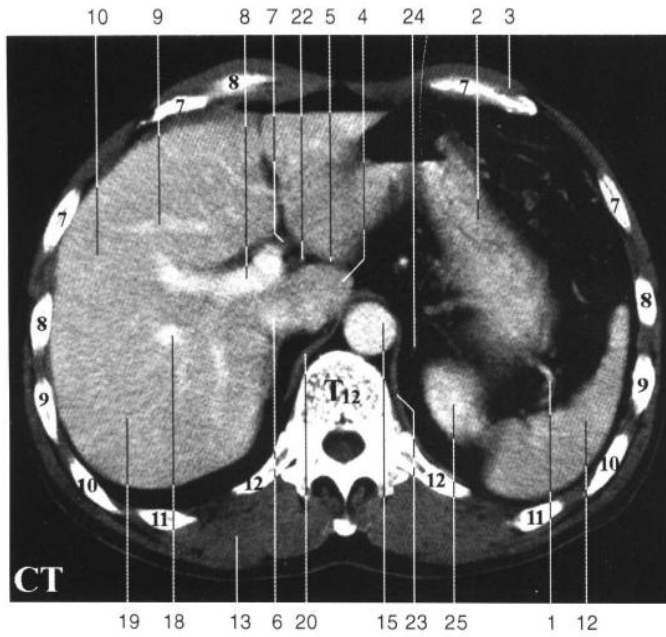


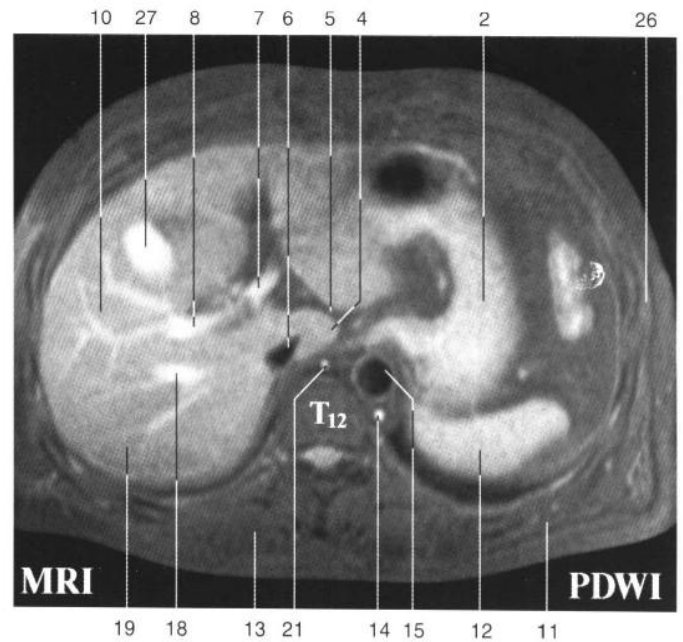
Fig. HA 4

1. 脾动脉 splenic a.
2. 胃 stomach
3. 腹直肌 rectus abdominis
4. 尾状叶 caudate lobe
5. 静脉韧带裂 fissure for ligamentum venosum
6. 下腔静脉 inferior vena cava
7. 肝门静脉左支 left branch of hepatic portal v.
8. 肝门静脉右支 right branch of hepatic portal v.
9. 肝中静脉 intermediate hepatic v.
10. 右前叶 right anterior lobe

Fig. HA 4



- 11. 背阔肌 latissimus dorsi
- 12. 脾 spleen
- 13. 竖脊肌 erector spinae
- 14. 半奇静脉 semiazygos v.
- 15. 胸主动脉 thoracic aorta
- 16. 脊髓 spinal cord
- 17. 右肾上腺 right suprarenal gland
- 18. 肝右静脉 right hepatic v.
- 19. 右后叶 right posterior lobe
- 20. 膈右脚 right crus of diaphragm
- 21. 奇静脉 azygos v.
- 22. 肝固有动脉 proper hepatic a.
- 23. 膈左脚 left crus of diaphragm
- 24. 左肾上腺 left suprarenal gland
- 25. 左肾 left kidney
- 26. 前锯肌 serratus anterior
- 27. 胆囊 gallbladder



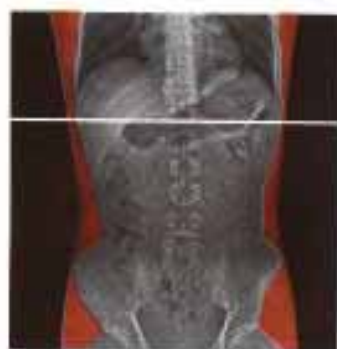
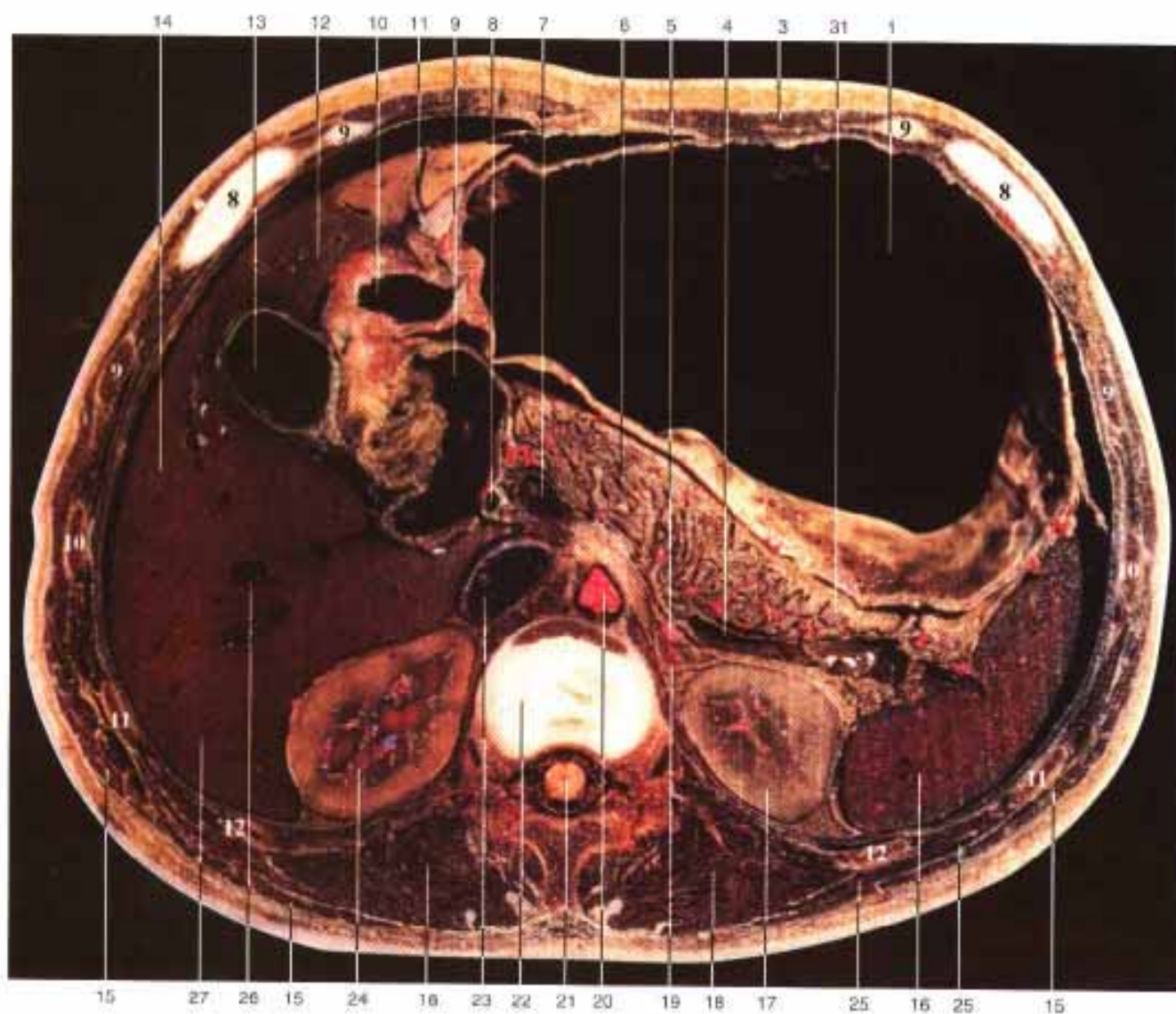
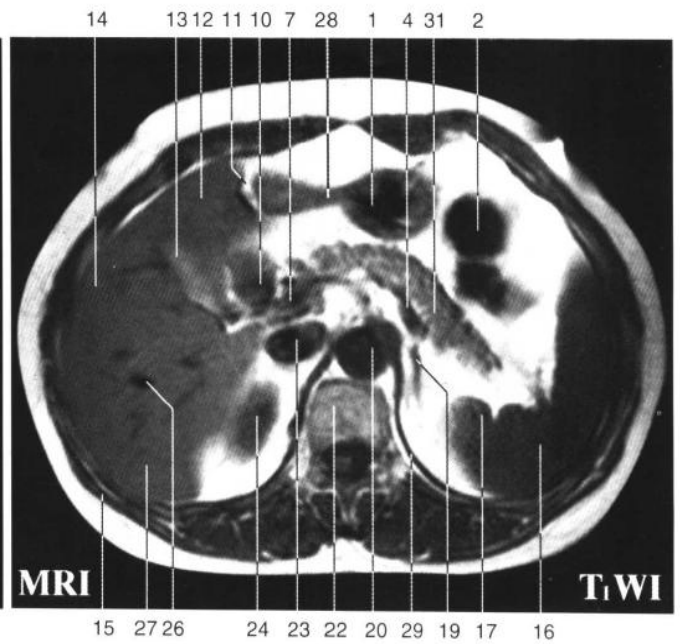
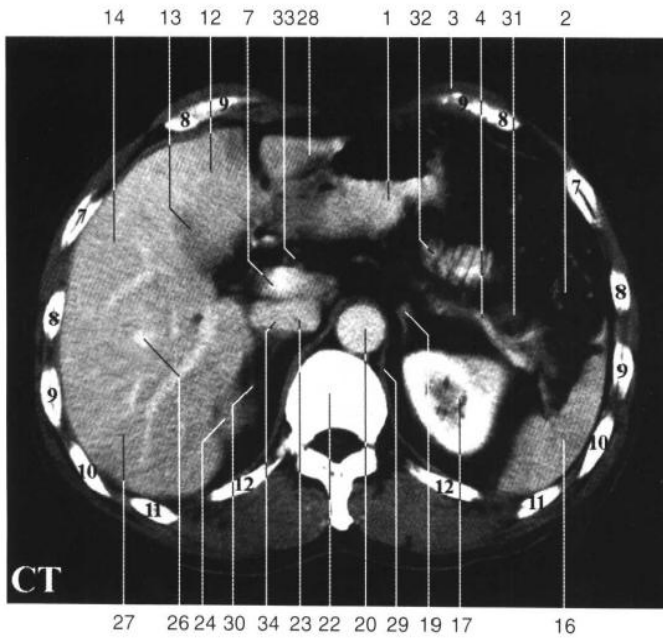


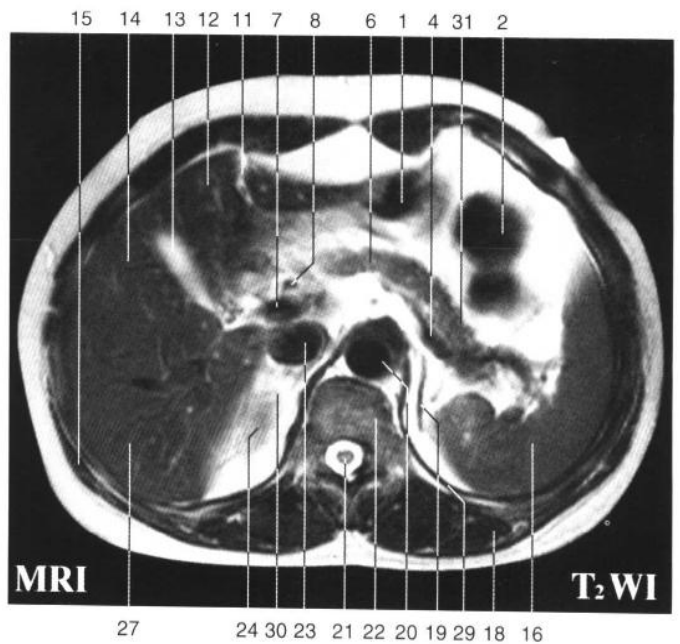
Fig. HA 5

1. 胃 stomach
2. 结肠左曲 left colic flexure
3. 腹直肌 rectus abdominis
4. 脾静脉 splenic v.
5. 左肾动脉 left renal a.
6. 胰体 body of pancreas
7. 肝门静脉 hepatic portal v.
8. 胆总管 common bile duct
9. 十二指肠降部 descending part of duodenum
10. 幽门窦 pyloric antrum

Fig.HA 5



11. 肝圆韧带裂 fissure for ligamentum teres hepatis
12. 左内叶 left medial lobe
13. 胆囊 gallbladder
14. 右前叶 right anterior lobe
15. 背阔肌 latissimus dorsi
16. 脾 spleen
17. 左肾 left kidney
18. 竖脊肌 erector spinae
19. 左肾上腺 left suprarenal gland
20. 腹主动脉 abdominal aorta
21. 脊髓 spinal cord
22. 第12胸椎与第1腰椎间盘 intervertebral disc (T₁₂ - L₁)
23. 下腔静脉 inferior vena cava
24. 右肾 right kidney
25. 下后锯肌 serratus posterior inferior
26. 肝右静脉 right hepatic v.
27. 右后叶 right posterior lobe
28. 左外叶 left lateral lobe
29. 膈左脚 left crus of diaphragm
30. 右肾上腺 right suprarenal gland
31. 胰尾 tail of pancreas
32. 十二指肠空肠曲 duodenojejunal flexure
33. 肝固有动脉 proper hepatic a.
34. 尾状叶 caudate lobe



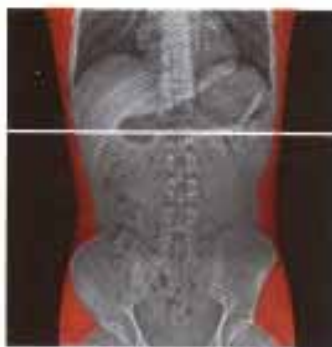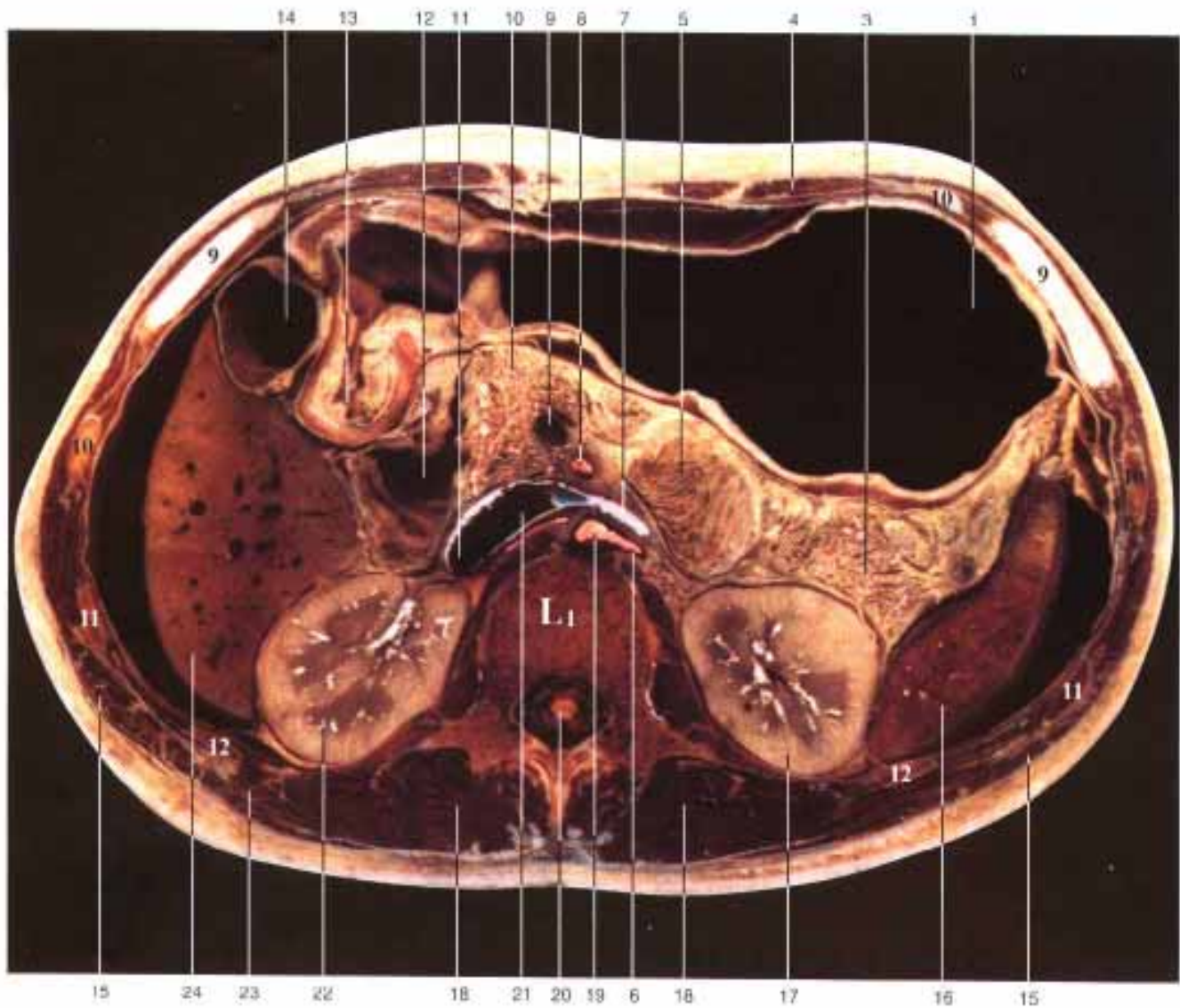
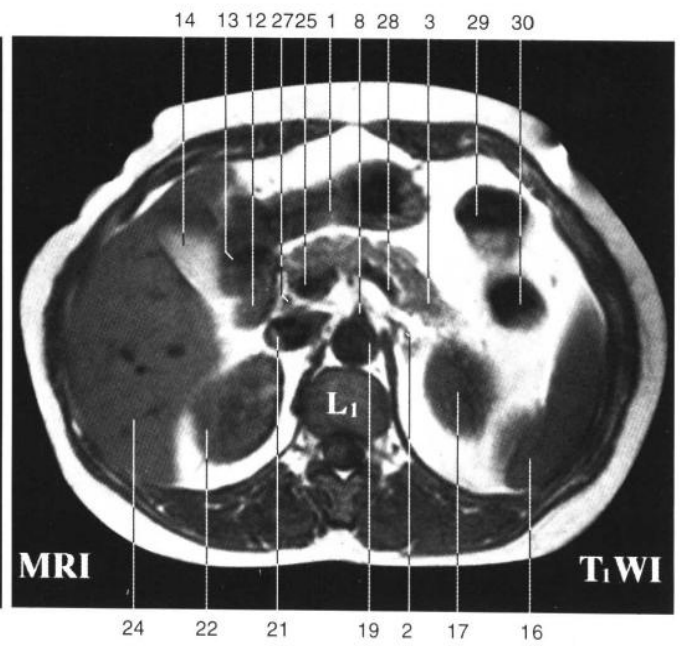

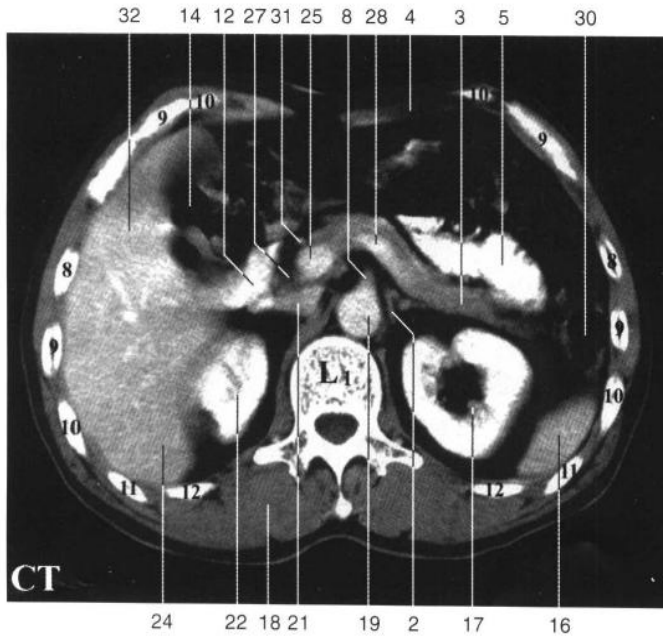
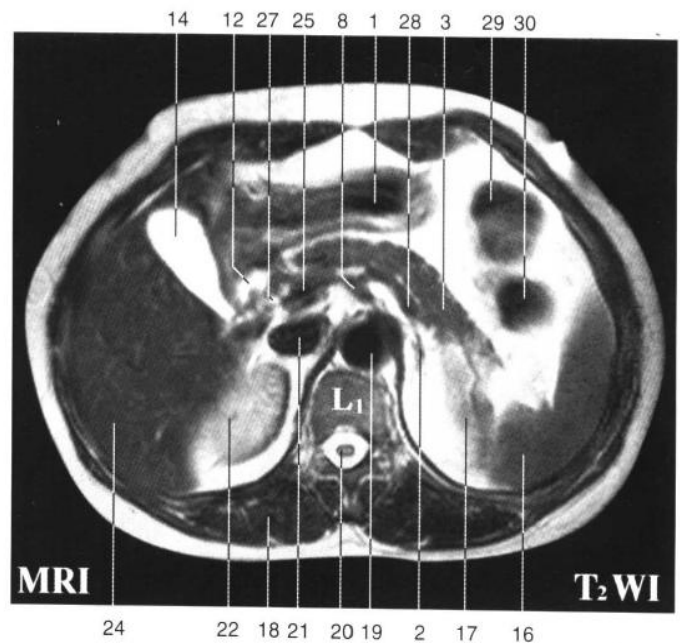
Fig. HA 6

1. 胃 stomach
2. 左肾上腺 left suprarenal gland
3. 胰尾 tail of pancreas
4. 腹直肌 rectus abdominis
5. 空肠 jejunum
6. 左肾动脉 left renal a.
7. 左肾静脉 left renal v.
8. 肠系膜上动脉 superior mesenteric a.
9. 肠系膜上静脉 superior mesenteric v.
10. 胰头 head of pancreas

Fig.HA 6



- 11. 右肾静脉 right renal v.
- 12. 12 指肠降部 descending part of duodenum
- 13. 幽门 pylorus
- 14. 胆囊 gallbladder
- 15. 背阔肌 latissimus dorsi
- 16. 脾 spleen
- 17. 左肾 left kidney
- 18. 竖脊肌 erector spinae
- 19. 腹主动脉 abdominal aorta
- 20. 脊髓 spinal cord
- 21. 下腔静脉 inferior vena cava
- 22. 右肾 right kidney
- 23. 下后锯肌 serratus posterior inferior
- 24. 右后叶 right posterior lobe
- 25. 肝门静脉 hepatic portal v.
- 26. 胰体 body of pancreas
- 27. 胆总管 common bile duct
- 28. 脾静脉 splenic v.
- 29. 横结肠 transverse colon
- 30. 降结肠 descending colon
- 31. 肝固有动脉 proper hepatic a.
- 32. 右前叶 right anterior lobe



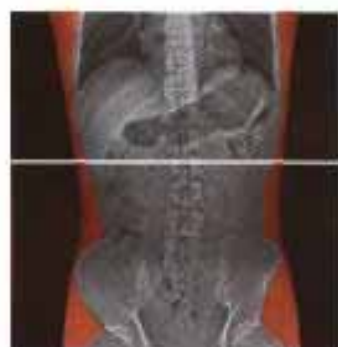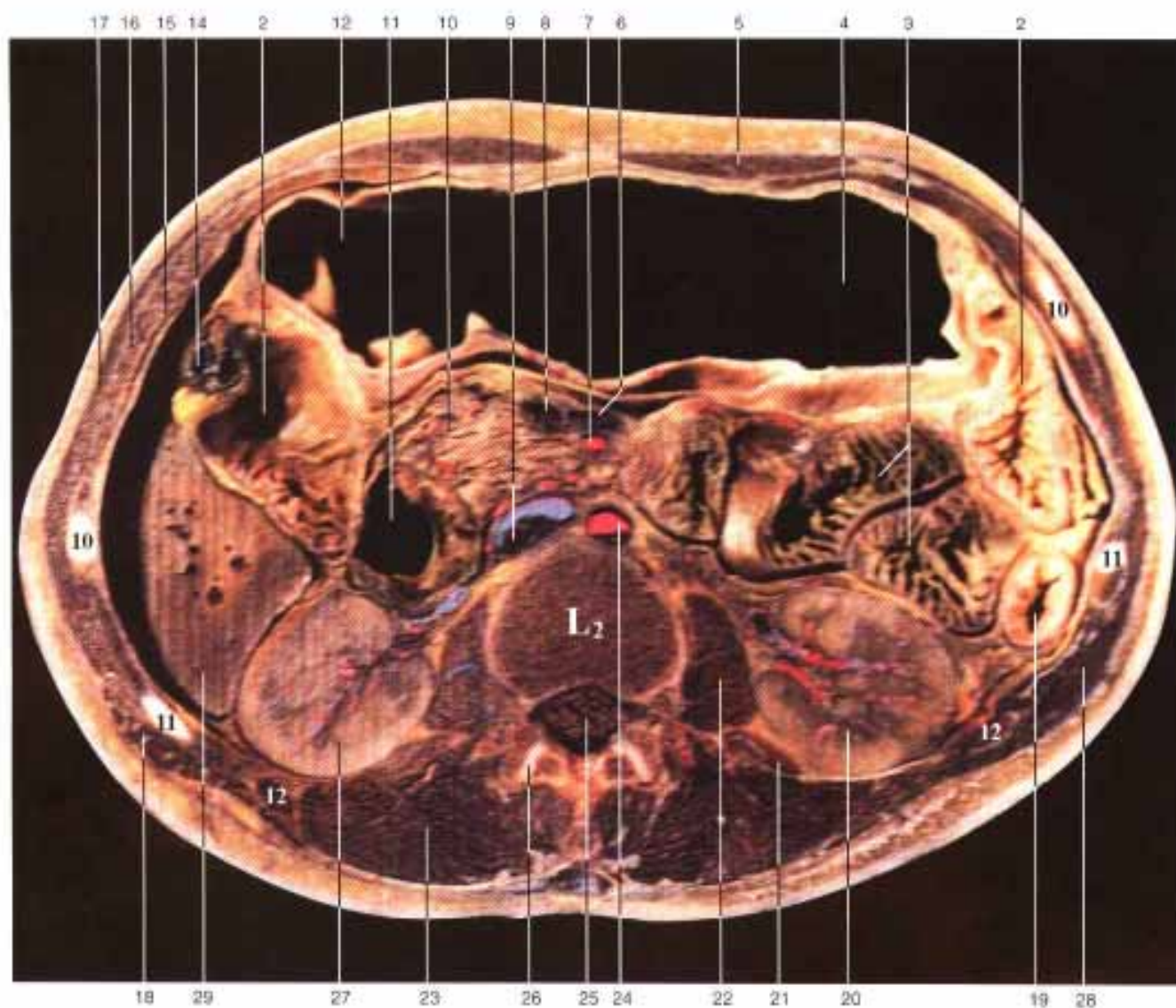
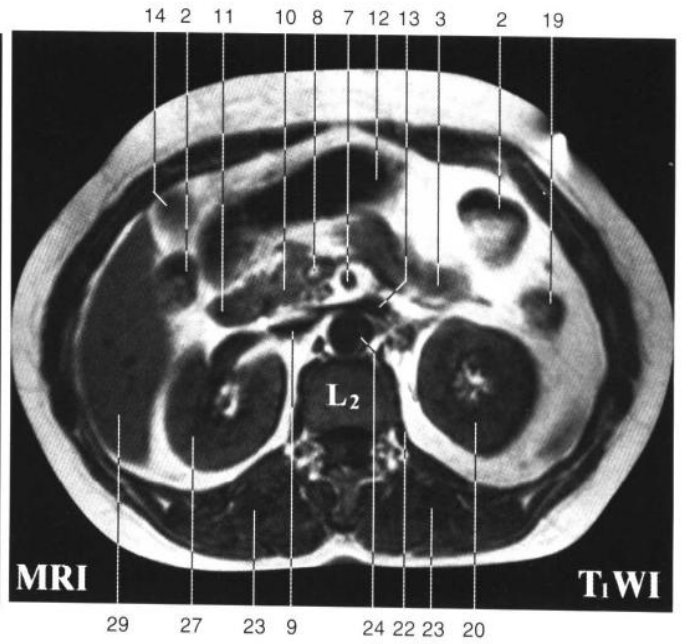
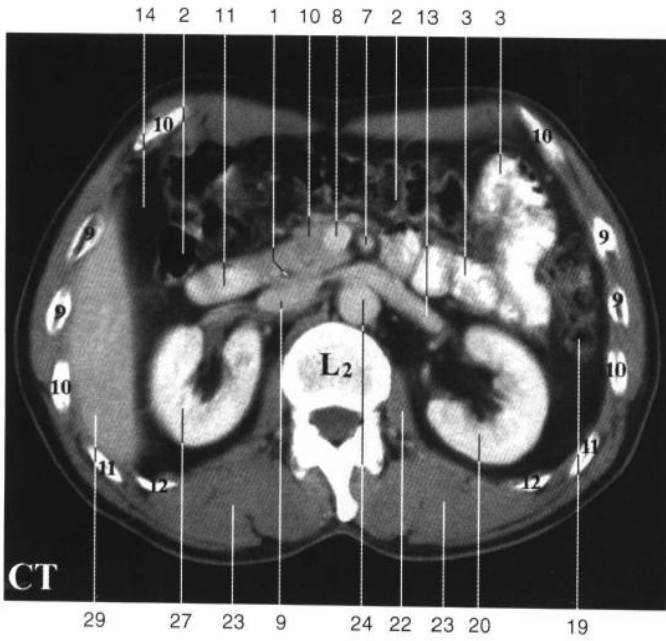


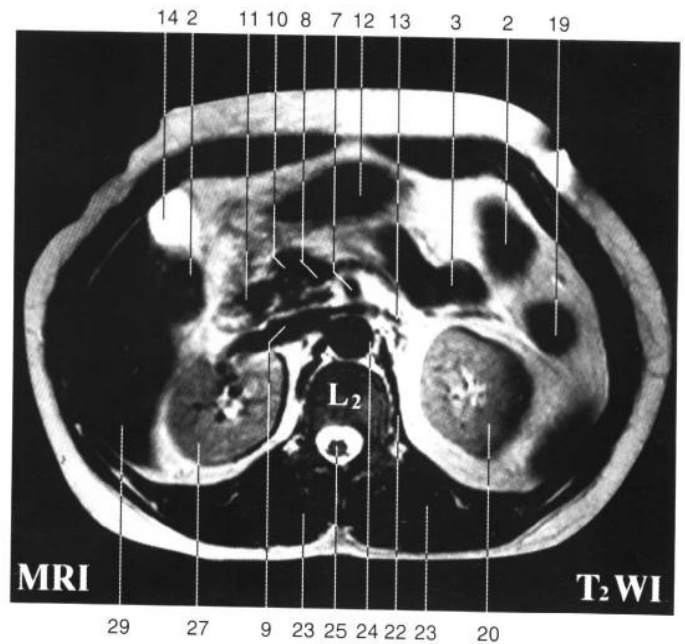Fig. HA 7

1. 胆总管 common bile duct
2. 横结肠 transverse colon
3. 空肠 jejunum
4. 胃 stomach
5. 腹直肌 rectus abdominis
6. 脾静脉 splenic v.
7. 肠系膜上动脉 superior mesenteric a.
8. 肠系膜上静脉 superior mesenteric v.
9. 下腔静脉 inferior vena cava
10. 胰头 head of pancreas

Fig.HA 7



- 11. 12 指肠降部 descending part of duodenum
- 12. 胃 stomach
- 13. 左肾静脉 left renal v.
- 14. 胆囊 gallbladder
- 15. 腹横肌 transversus abdominis
- 16. 腹内斜肌 obliquus internus
- 17. 腹外斜肌 obliquus externus
- 18. 背阔肌 latissimus dorsi
- 19. 降结肠 descending colon
- 20. 左肾 left kidney
- 21. 腰方肌 quadratus lumborum
- 22. 腰大肌 psoas major
- 23. 竖脊肌 erector spinae
- 24. 腹主动脉 abdominal aorta
- 25. 马尾 cauda equina
- 26. 1,2 腰椎关节突关节 zygapophysial joint(L₁-L₂)
- 27. 右肾 right kidney
- 28. 下后锯肌 serratus posterior inferior
- 29. 右后叶 right posterior lobe



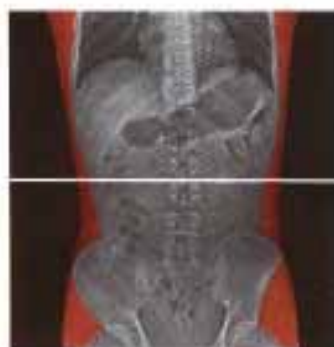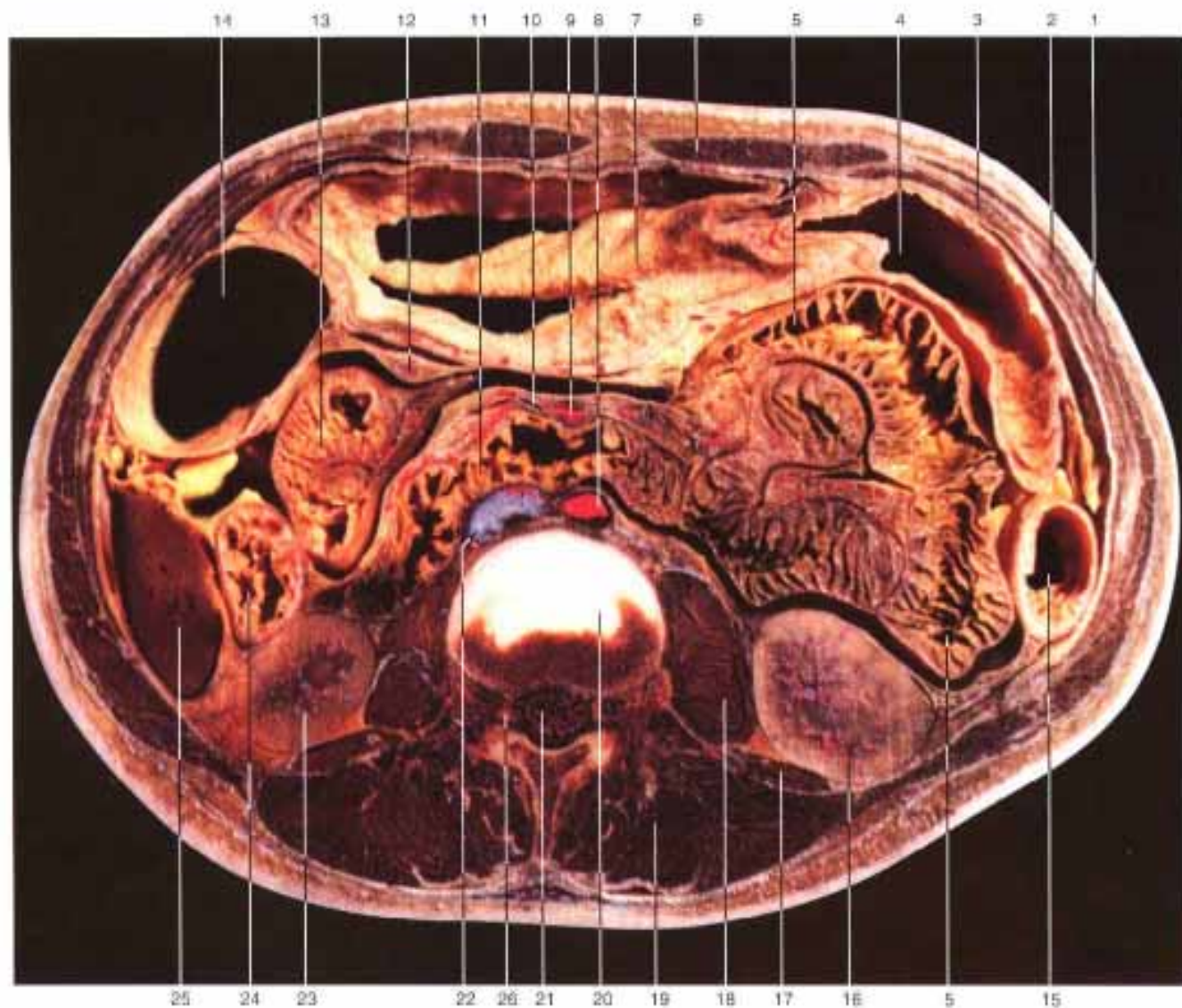
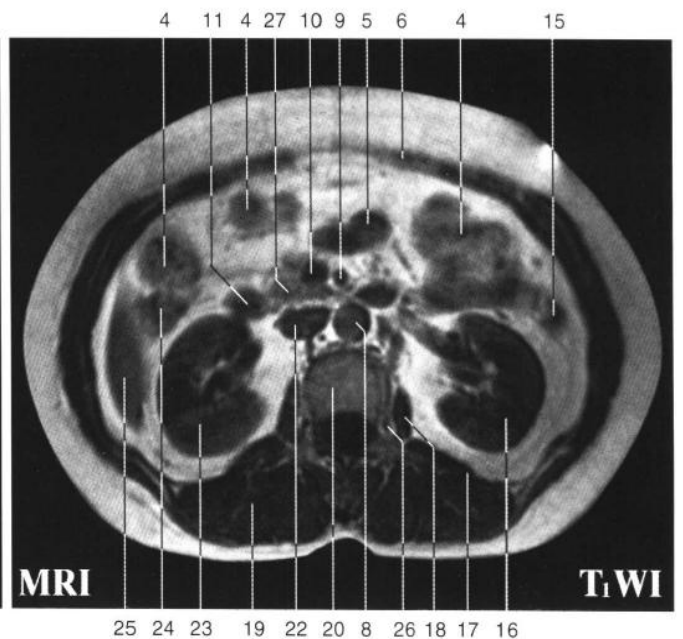
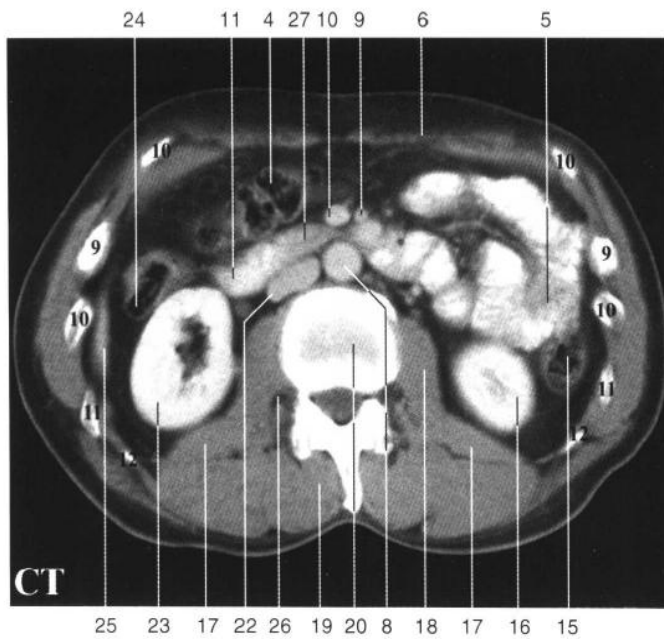


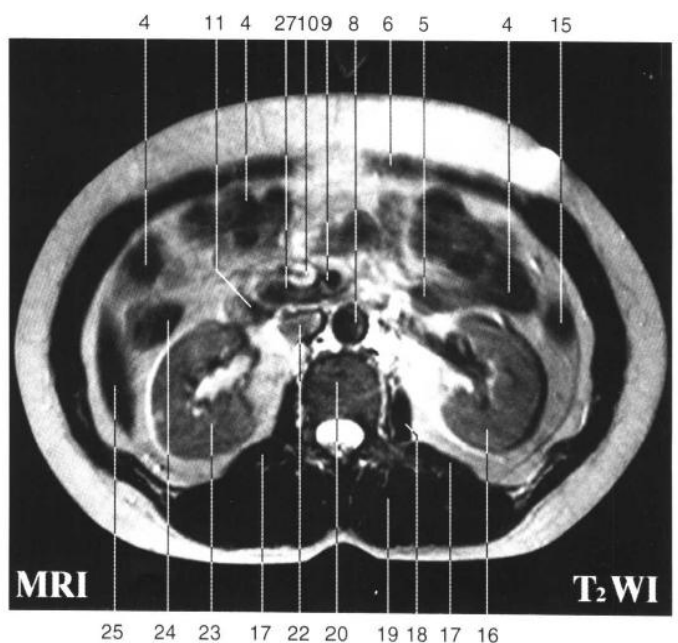
Fig. HA 8

1. 腹外斜肌 obliquus externus abdominis
2. 腹内斜肌 obliquus internus abdominis
3. 腹横肌 transversus abdominis
4. 横结肠 transverse colon
5. 空肠 jejunum
6. 腹直肌 rectus abdominis
7. 胃 stomach
8. 腹主动脉 abdominal aorta
9. 肠系膜上动脉 superior mesenteric a.
10. 肠系膜上静脉 superior mesenteric v.

Fig.HA 8



- 11. 12 指肠水平部 horizontal part of duodenum
- 12. 肠系膜 mesentery
- 13. 回肠 ileum
- 14. 横结肠 transverse colon
- 15. 降结肠 descending colon
- 16. 左肾 left kidney
- 17. 腰方肌 quadratus lumborum
- 18. 腰大肌 psoas major
- 19. 竖脊肌 erector spinae
- 20. 2,3 腰椎间盘 intervertebral disc(L₂ - L₃)
- 21. 马尾 cauda equina
- 22. 下腔静脉 inferior vena cava
- 23. 右肾 right kidney
- 24. 升结肠 ascending colon
- 25. 右后叶 right posterior lobe
- 26. 第 2 腰神经 2nd lumbar n.
- 27. 钩突 uncinat process



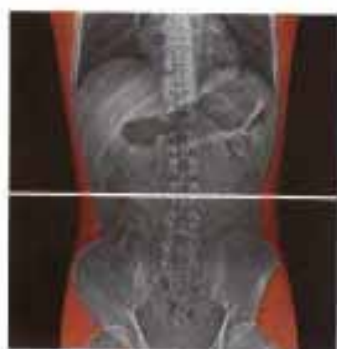
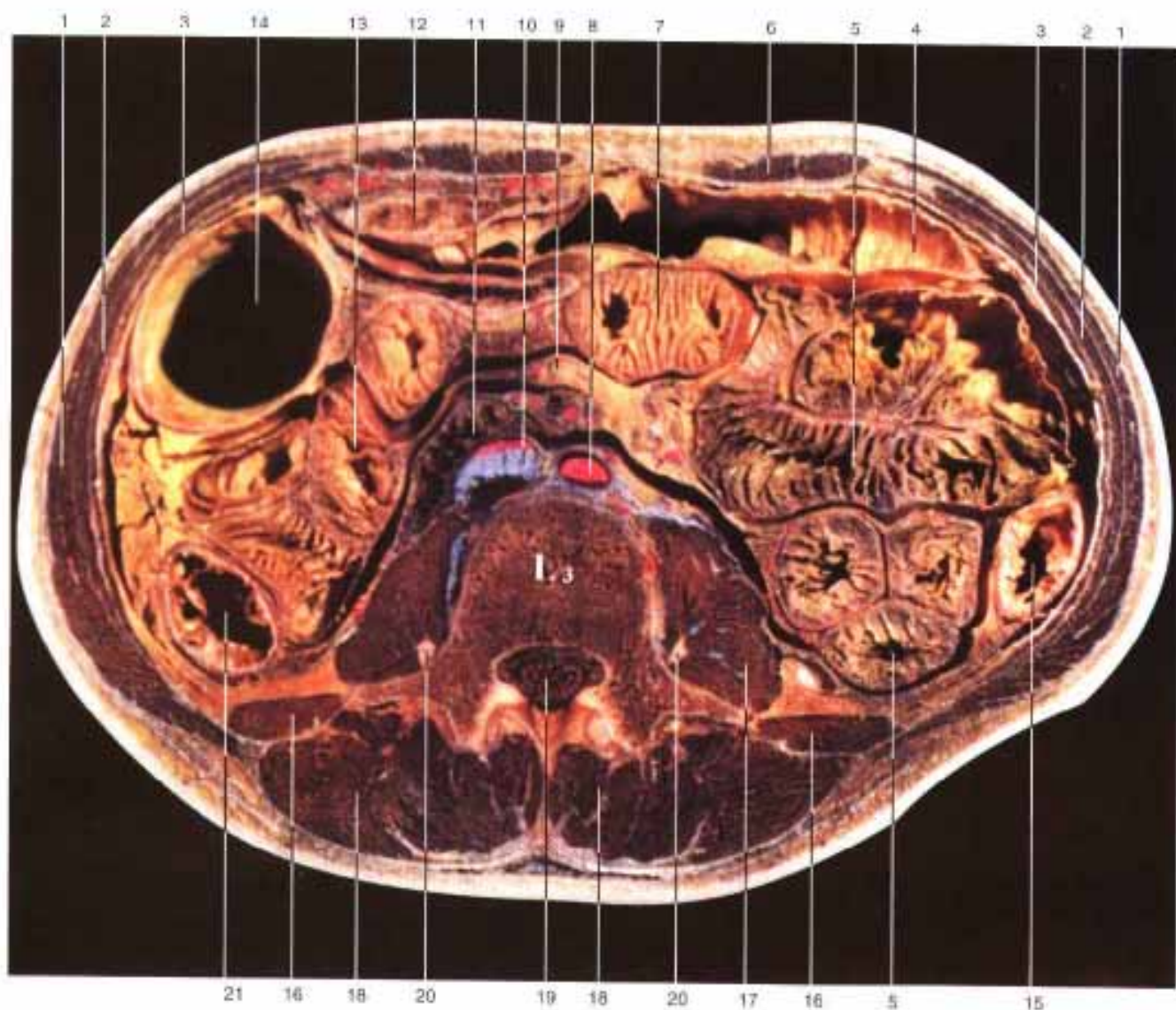
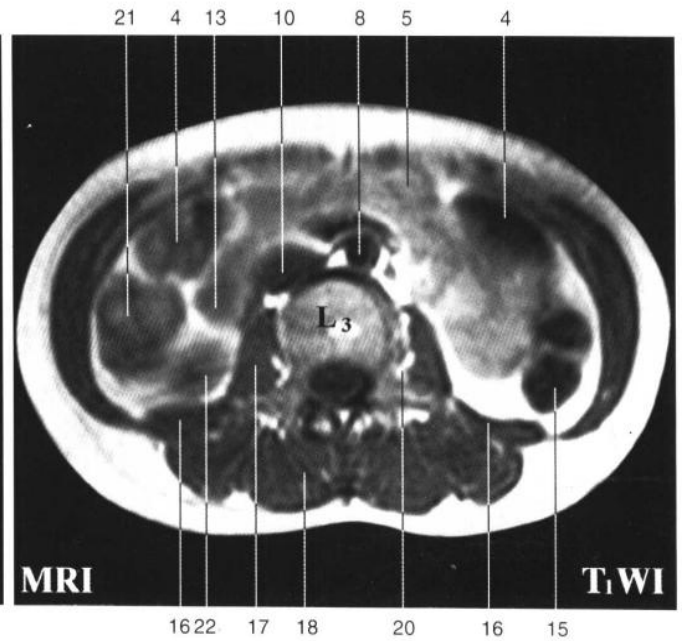
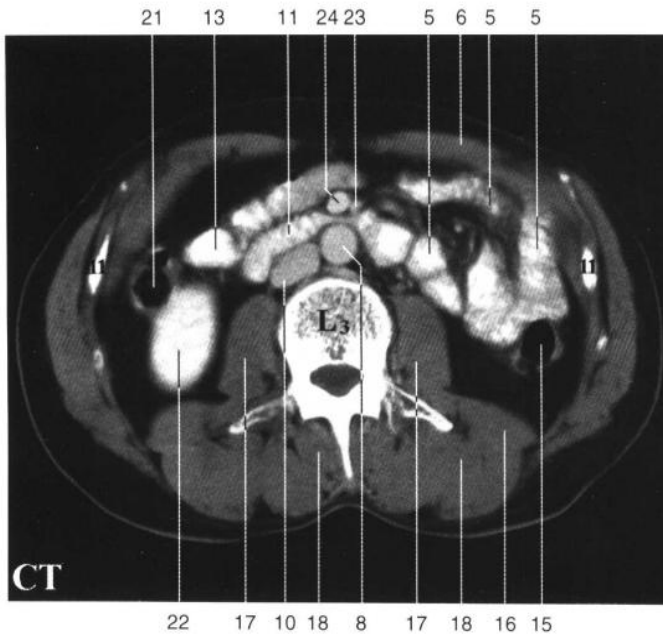


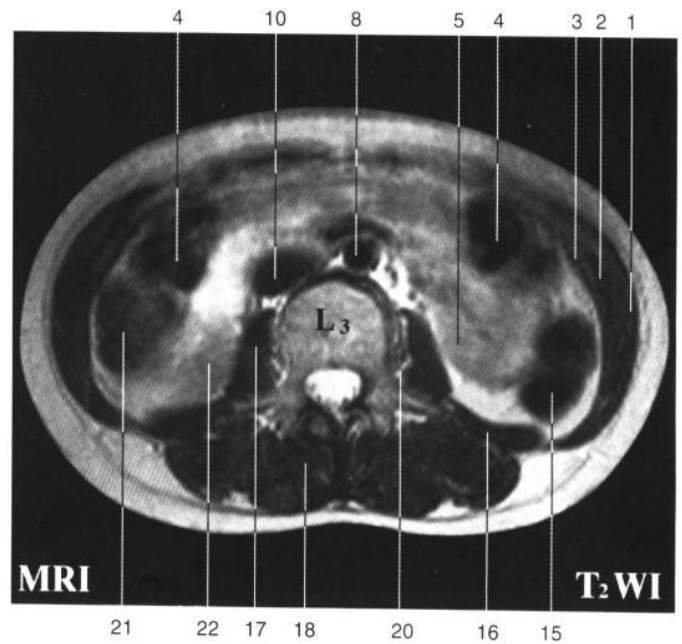
Fig. HA 9

1. 腹外斜肌 obliquus externus abdominis
2. 腹内斜肌 obliquus internus abdominis
3. 腹横肌 transversus abdominis
4. 横结肠 transverse colon
5. 空肠 jejunum
6. 腹直肌 rectus abdominis
7. 空肠 jejunum
8. 腹主动脉 abdominal aorta
9. 肠系膜 mesentery
10. 下腔静脉 inferior vena cava

Fig.HA 9



- 11. 十二指肠水平部 horizontal part of duodenum
- 12. 胃 stomach
- 13. 回肠 ileum
- 14. 横结肠 transverse colon
- 15. 降结肠 descending colon
- 16. 腰方肌 quadratus lumborum
- 17. 腰大肌 psoas major
- 18. 竖脊肌 erector spinae
- 19. 马尾 cauda equina
- 20. 第3腰神经 3rd lumbar n.
- 21. 升结肠 ascending colon
- 22. 右肾 right kidney
- 23. 肠系膜上动脉 superior mesenteric a.
- 24. 肠系膜上静脉 superior mesenteric v.



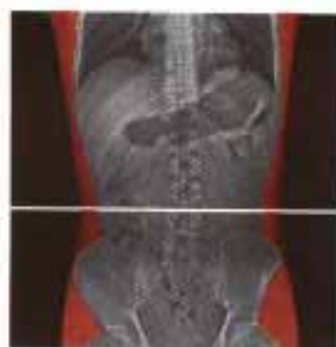
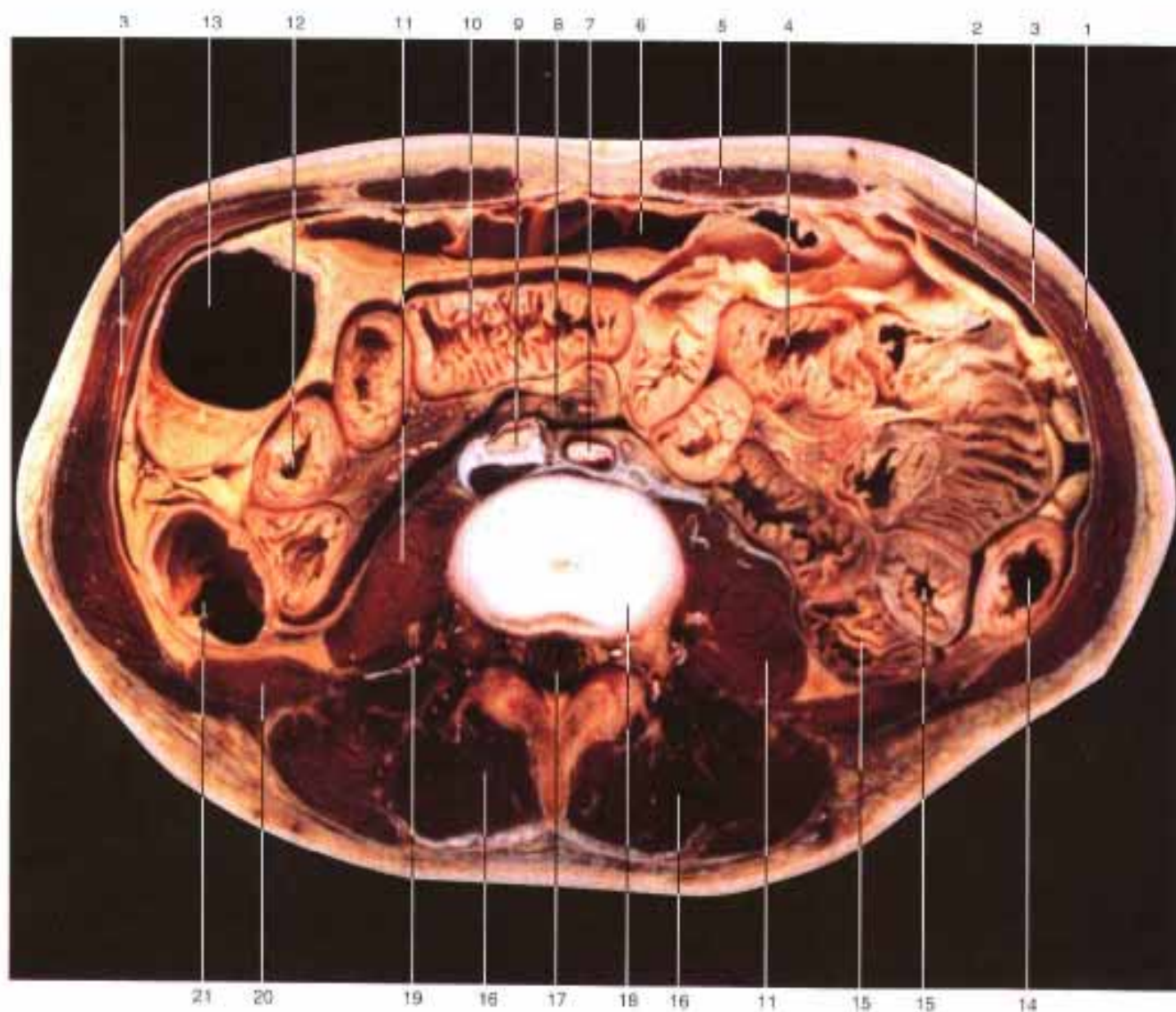
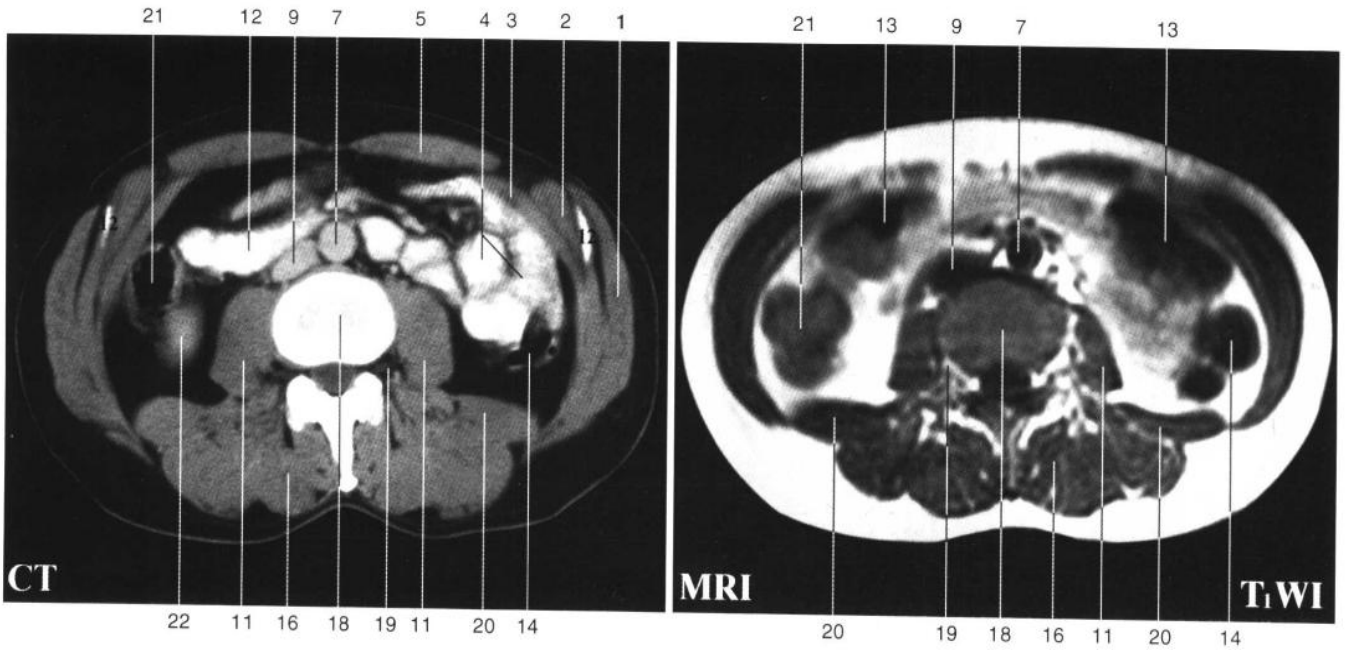


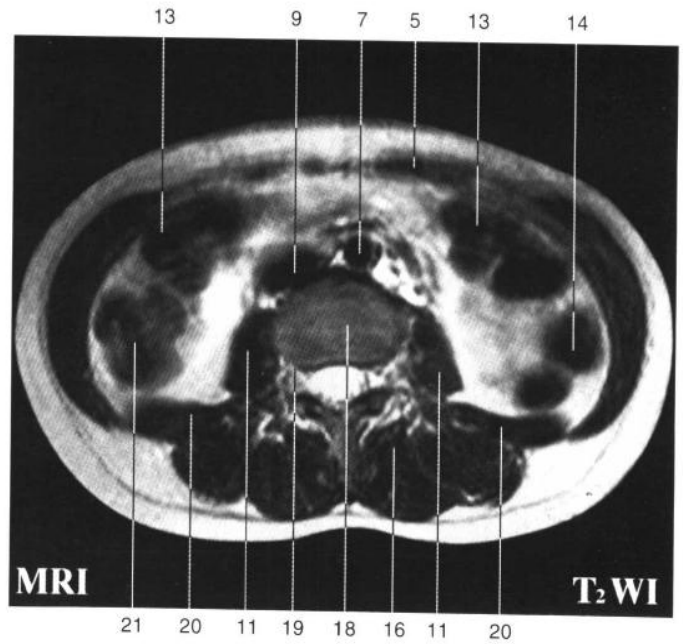
Fig. HA 10

1. 腹外斜肌 obliquus externus abdominis
2. 腹内斜肌 obliquus internus abdominis
3. 腹横肌 transversus abdominis
4. 空肠 jejunum
5. 腹直肌 rectus abdominis
6. 横结肠 transverse colon
7. 腹主动脉 abdominal aorta
8. 肠系膜 mesentery
9. 下腔静脉 inferior vena cava
10. 空肠 jejunum

Fig.HA 10



- 11. 腰大肌 *psoas major*
- 12. 回肠 *ileum*
- 13. 横结肠 *transverse colon*
- 14. 降结肠 *descending colon*
- 15. 空肠 *jejunum*
- 16. 竖脊肌 *erector spinae*
- 17. 马尾 *cauda equina*
- 18. 3、4 腰椎间盘 *intervertebral disc (L₃ - L₄)*
- 19. 第 3 腰神经 *3rd lumbar n.*
- 20. 腰方肌 *quadratus lumborum*
- 21. 升结肠 *ascending colon*
- 22. 右肾 *right kidney*



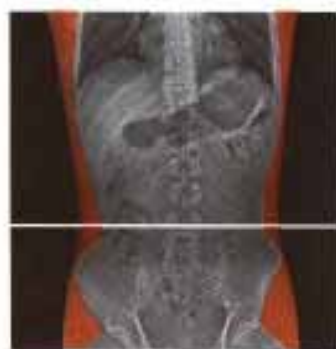
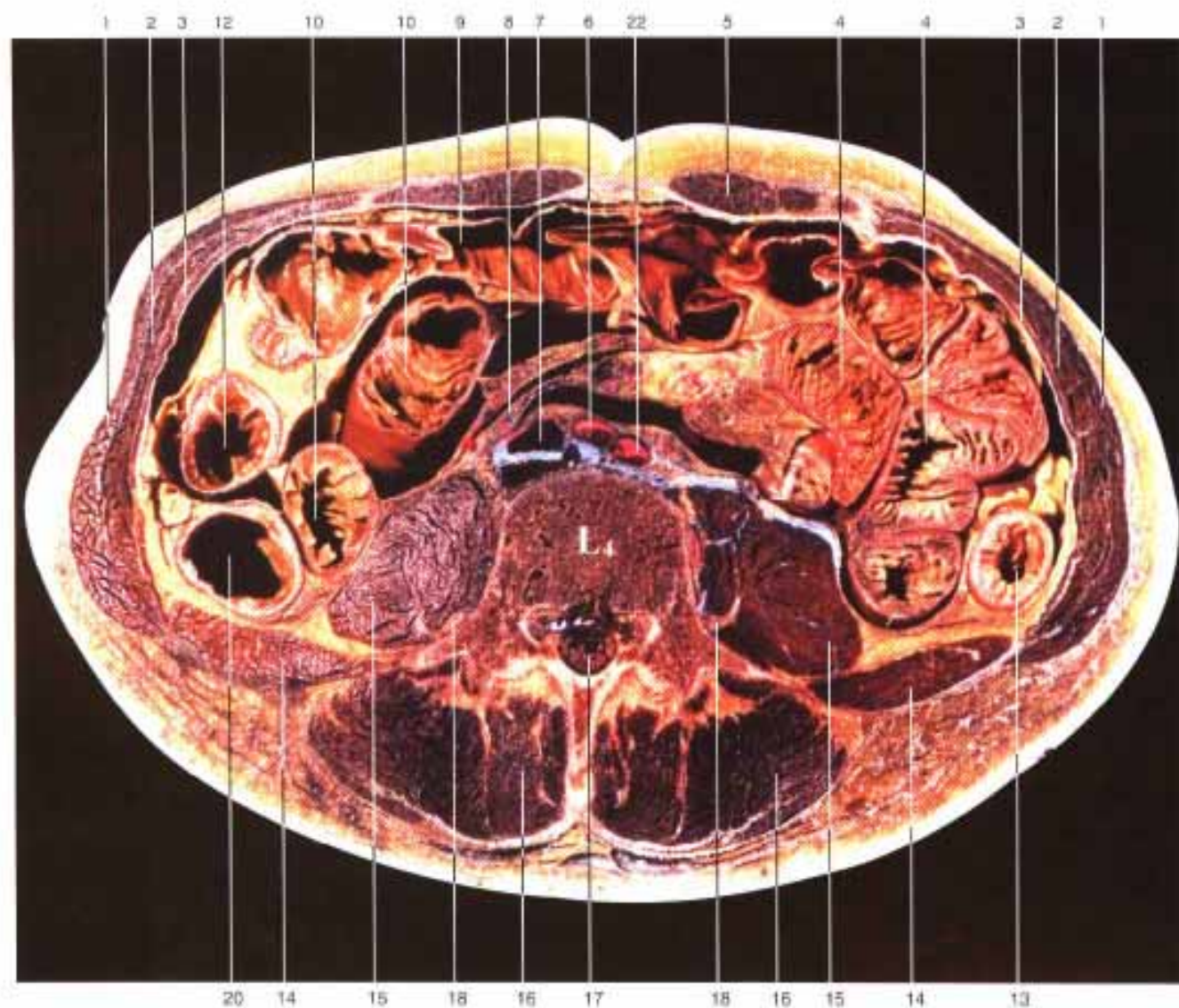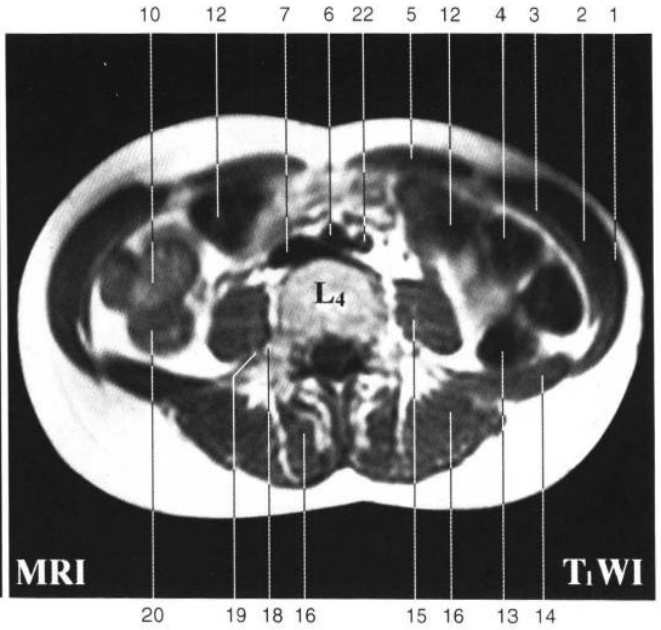
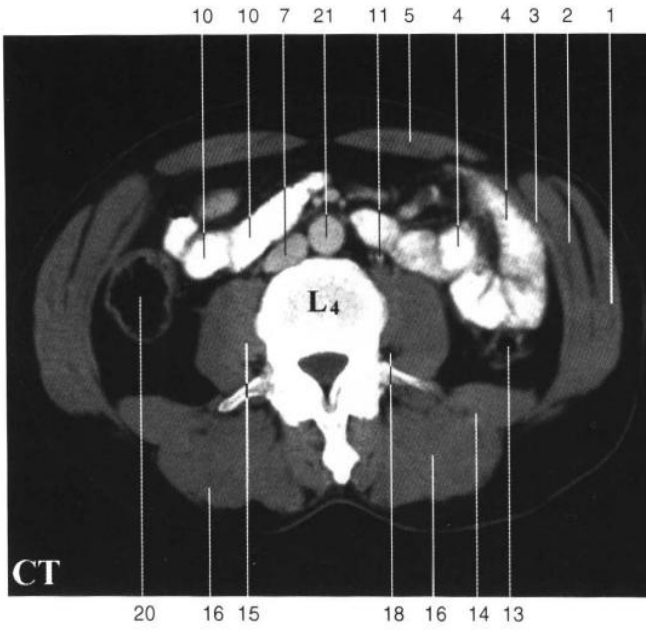


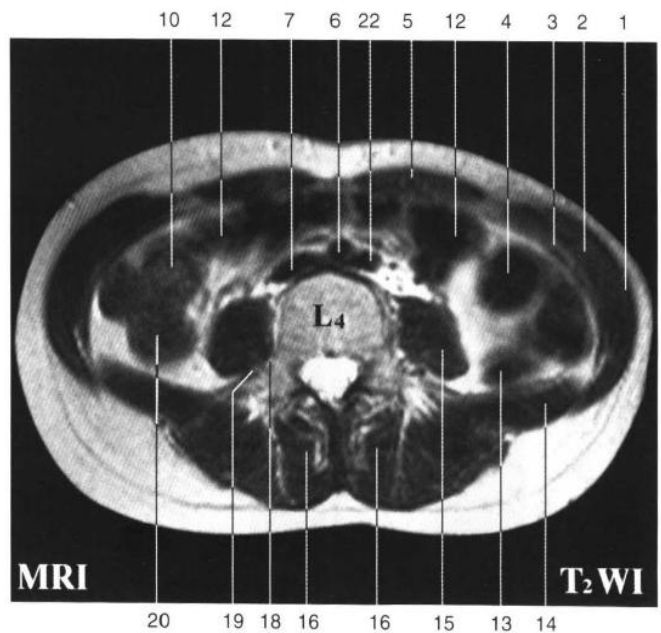
Fig. HA 11

1. 腹外斜肌 obliquus externus abdominis
2. 腹内斜肌 obliquus internus abdominis
3. 腹横肌 transversus abdominis
4. 空肠 jejunum
5. 腹直肌 rectus abdominis
6. 右髂总动脉 right common iliac a.
7. 下腔静脉 inferior vena cava
8. 肠系膜 mesentery
9. 横结肠 transverse colon
10. 回肠 ileum

Fig.HA 11



11. 输尿管 ureter
12. 横结肠 transverse colon
13. 降结肠 descending colon
14. 腰方肌 quadratus lumborum
15. 腰大肌 psoas major
16. 竖脊肌 erector spinae
17. 马尾 cauda equina
18. 第4腰神经 4th lumbar n.
19. 第3腰神经 3rd lumbar n.
20. 升结肠 ascending colon
21. 腹主动脉 abdominal aorta
22. 左髂总动脉 left common iliac a.



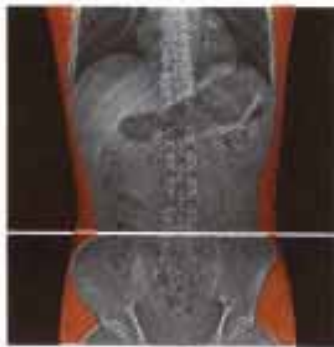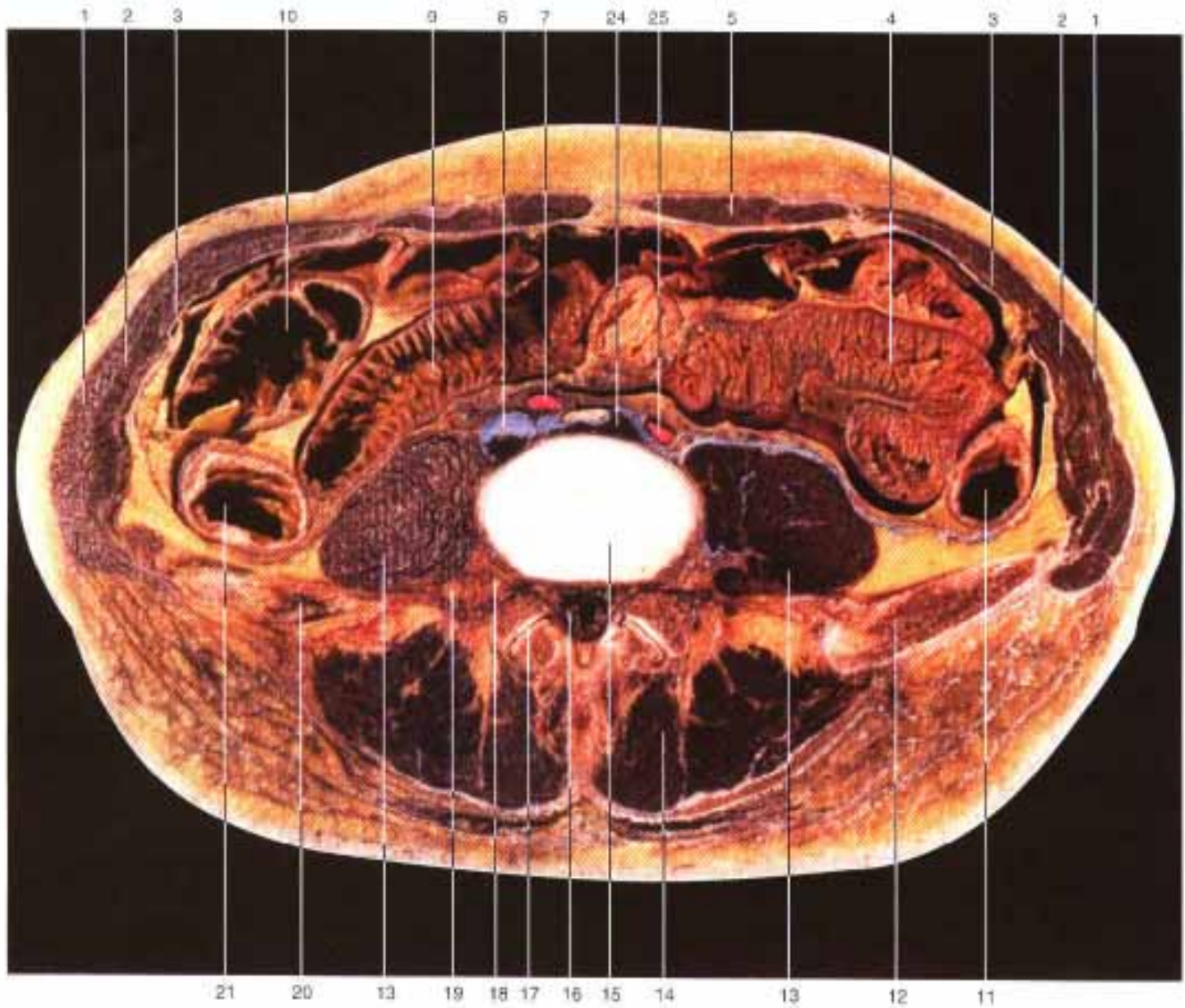
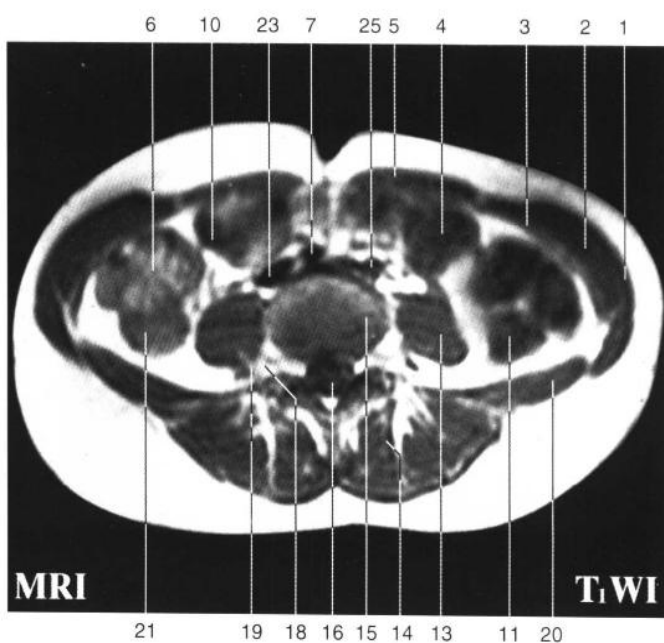
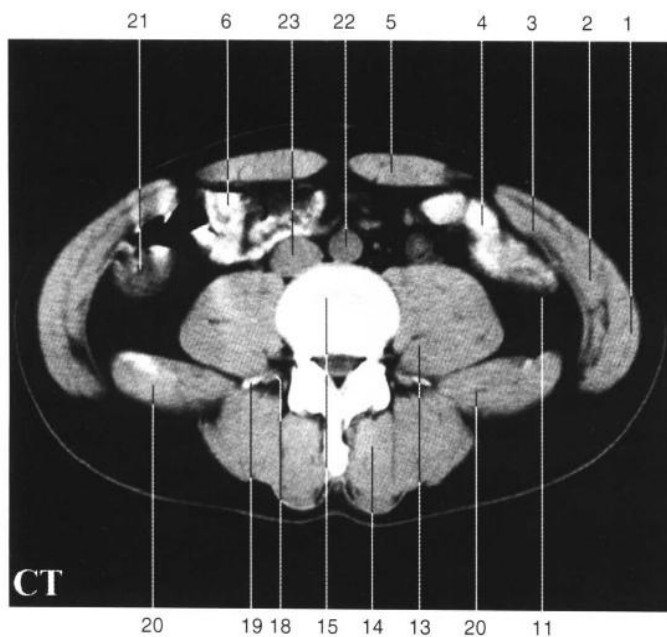


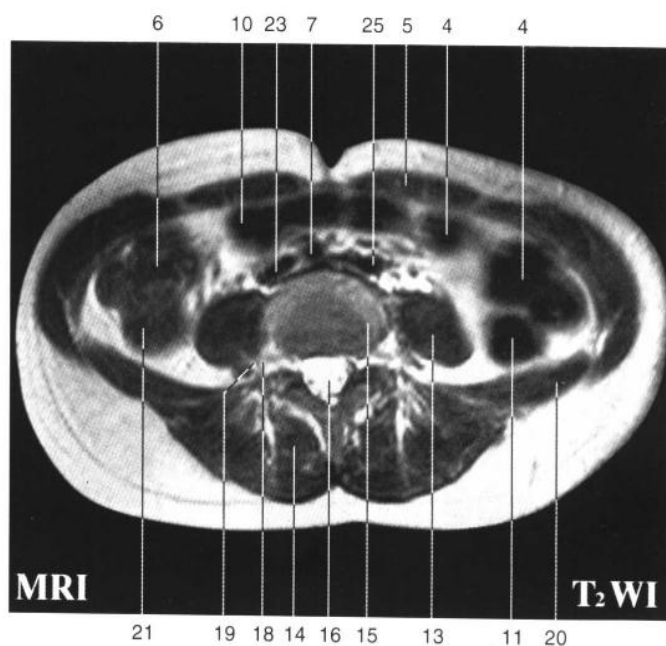
Fig. HA 12

1. 腹外斜肌 *obliquus externus abdominis*
2. 腹内斜肌 *obliquus internus abdominis*
3. 腹横肌 *transversus abdominis*
4. 空肠 *jejunum*
5. 腹直肌 *rectus abdominis*
6. 回肠 *ileum*
7. 右髂总动脉 *right common iliac a.*
8. 右髂总静脉 *right common iliac v.*
9. 空肠 *jejunum*
10. 横结肠 *transverse colon*

Fig. HA 12



11. 降结肠 descending colon
12. 髂嵴 iliac crest
13. 腰大肌 psoas major
14. 竖脊肌 erector spinae
15. 4,5 椎间盘 intervertebral disc(L₄-L₅)
16. 马尾 cauda equina
17. 4,5 腰椎关节突关节 zygapophysial joint(L₄-L₅)
18. 第4 腰神经 4th lumbar n.
19. 第3 腰神经 3rd lumbar n.
20. 腰方肌 quadratus lumborum
21. 升结肠 ascending colon
22. 腹主动脉 abdominal aorta
23. 下腔静脉 inferior vena cava
24. 左髂总静脉 left common iliac v.
25. 左髂总动脉 left common iliac a.



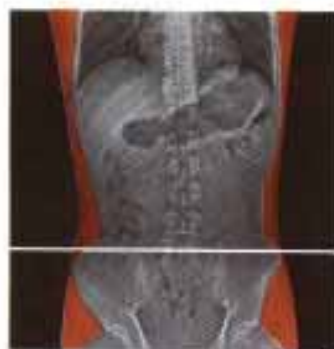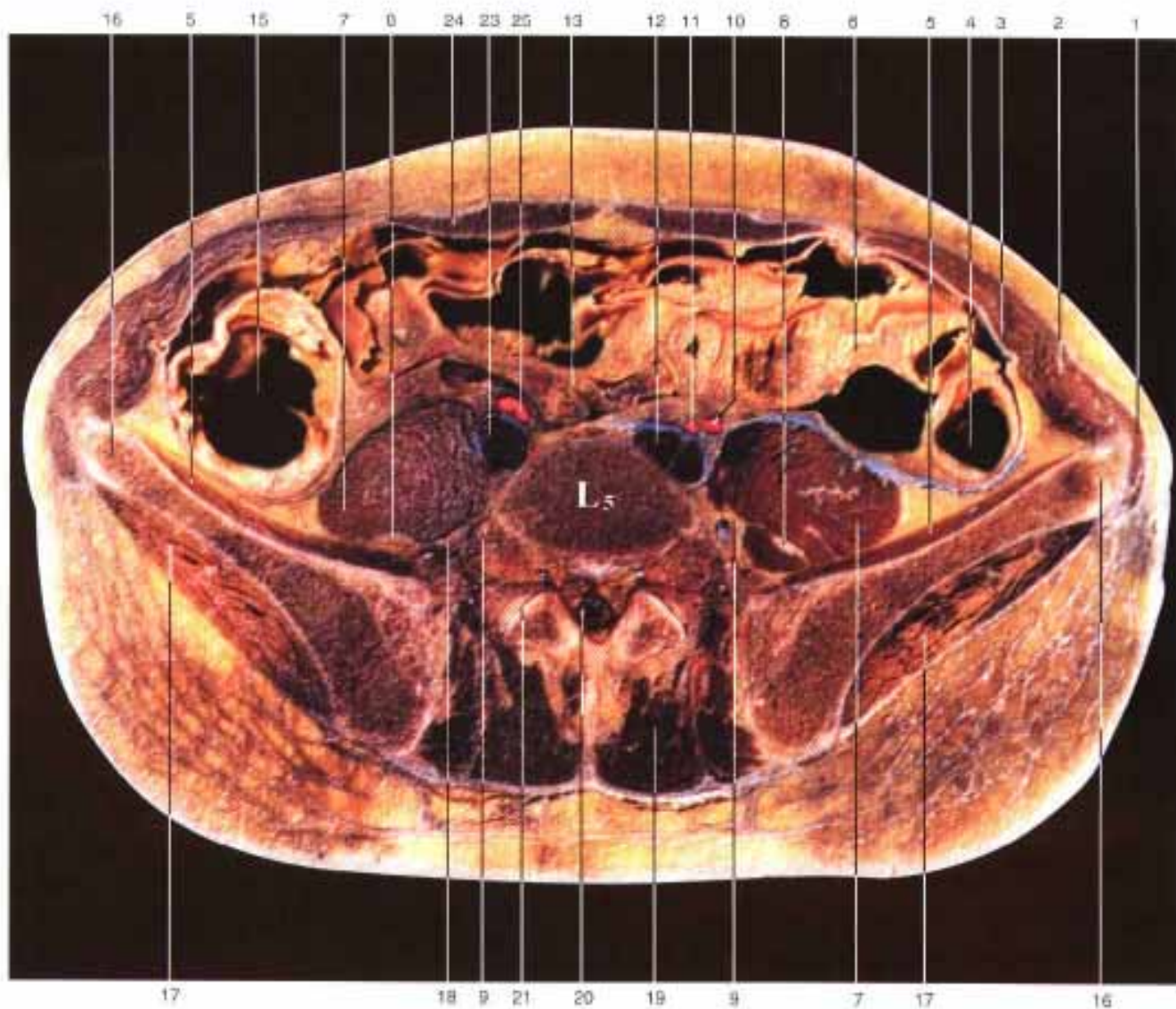
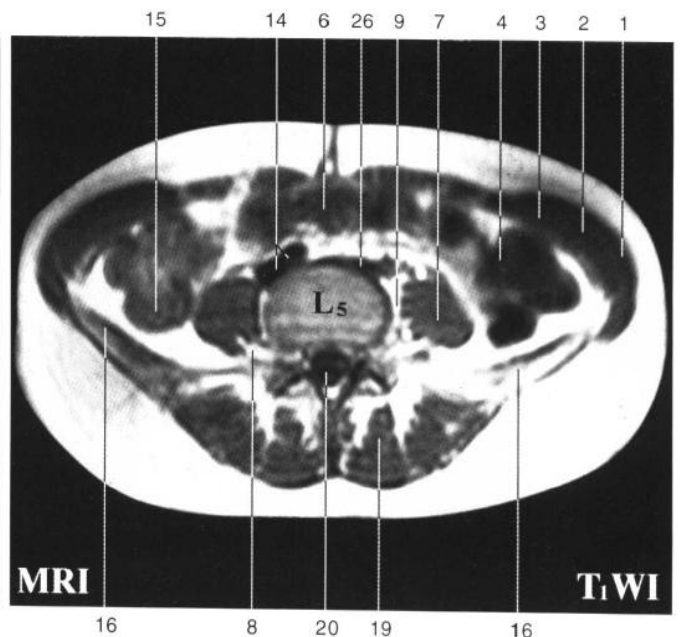
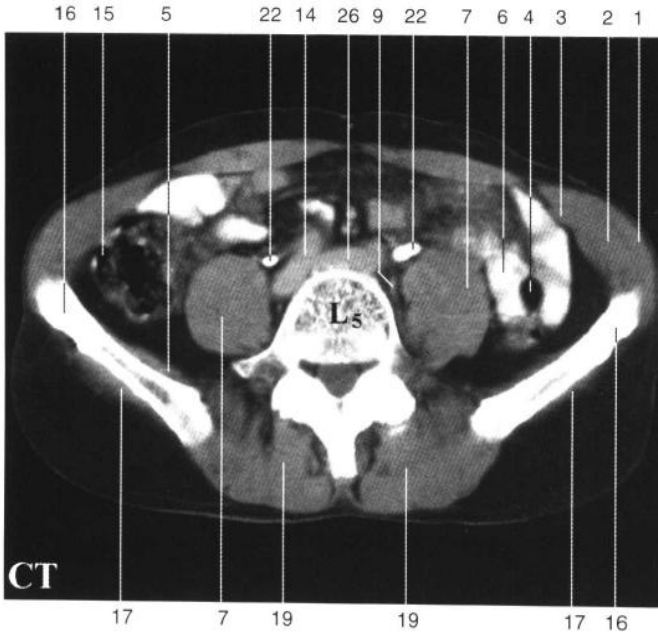


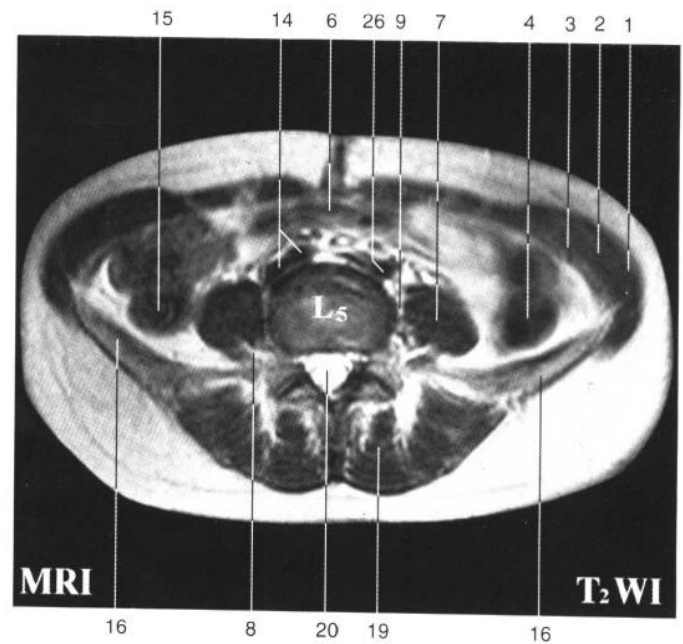
Fig. HA 13

1. 腹外斜肌 obliquus externus abdominis
2. 腹内斜肌 obliquus internus abdominis
3. 腹横肌 transversus abdominis
4. 乙状结肠 sigmoid colon
5. 髂肌 iliacus
6. 回肠 ileum
7. 腰大肌 psoas major
8. 股神经 femoral n.
9. 闭孔神经 obturator n.
10. 左髂外动脉 left external iliac a.

Fig.HA 13



11. 左髂内动脉 left internal iliac a.
12. 左髂总静脉 left common iliac v.
13. 肠系膜 mesentery
14. 右髂总动、静脉 right common iliac a. and v.
15. 升结肠 ascending colon
16. 髂骨翼 ala of ilium
17. 臀中肌 gluteus medius
18. 第4腰神经 4th lumbar n.
19. 竖脊肌 erector spinae
20. 马尾 cauda equina
21. 4,5 腰椎关节突关节
zygapophysial joint (L₄-L₅)
22. 输尿管 ureter
23. 右髂总静脉 right common iliac v.
24. 腹直肌 rectus abdominis
25. 右髂总动脉 right common iliac a.
26. 左髂总动、静脉 left common iliac a. and v.



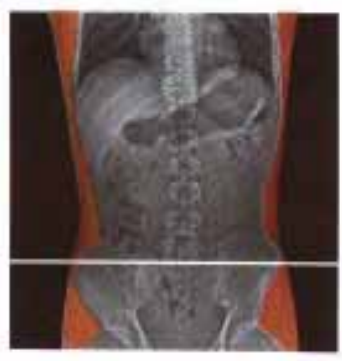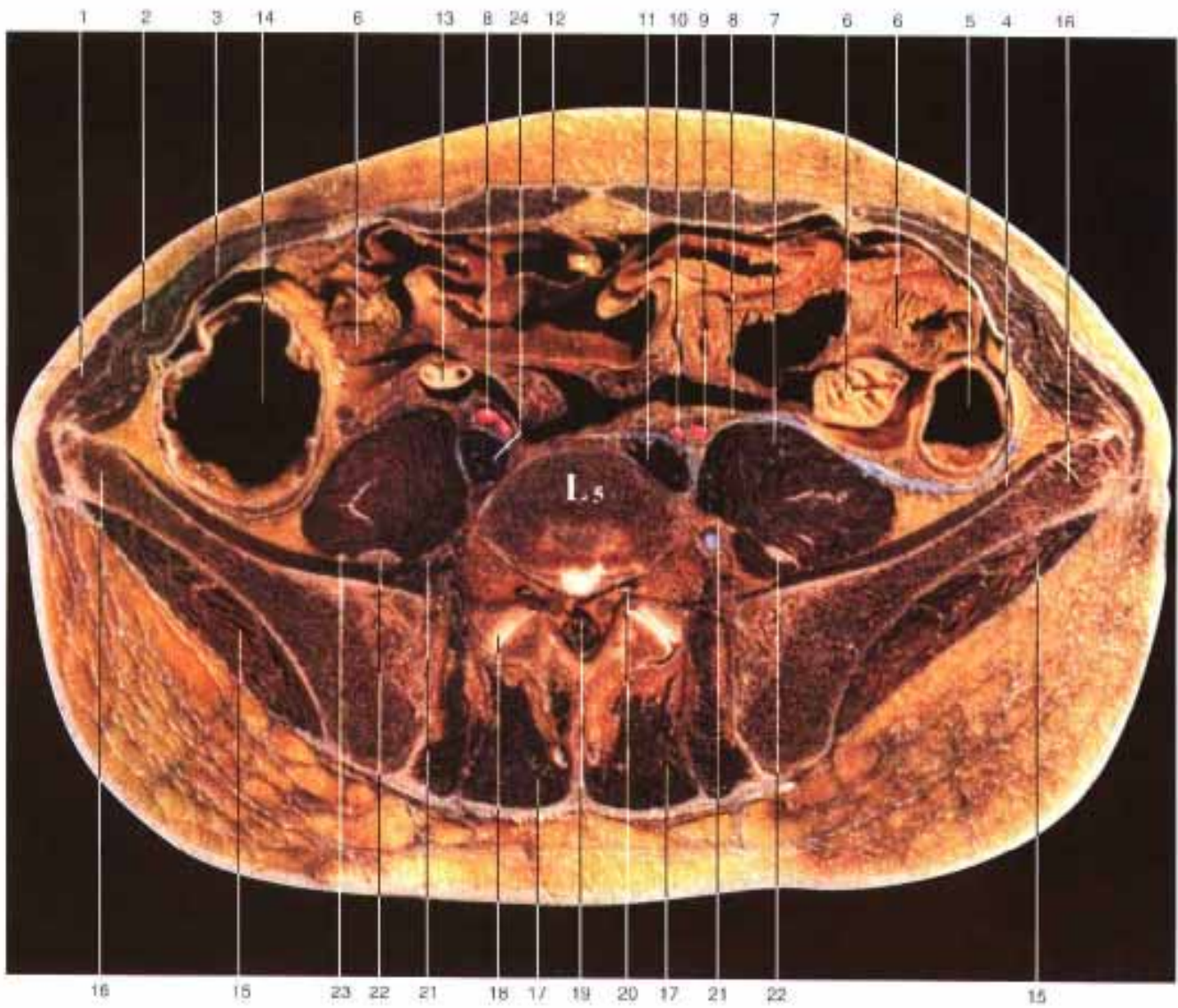
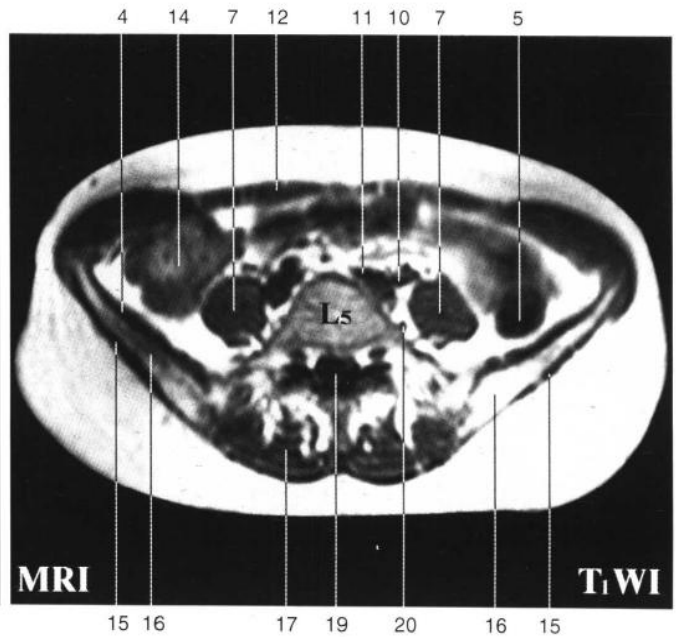
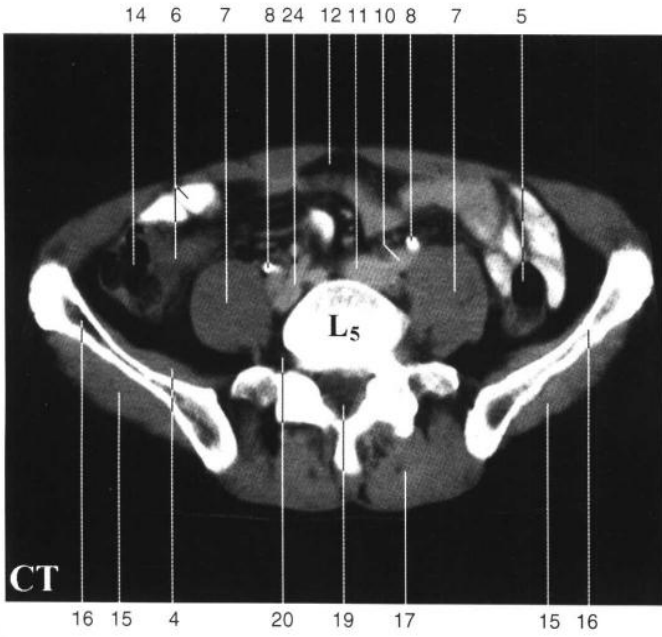


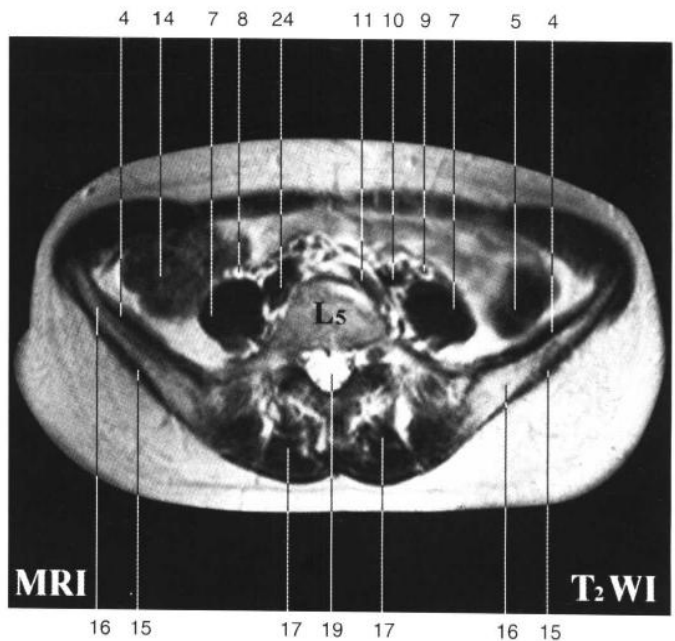
Fig. HA 14

1. 腹外斜肌 obliquus externus abdominis
2. 腹内斜肌 obliquus internus abdominis
3. 腹横肌 transversus abdominis
4. 髂肌 iliacus
5. 乙状结肠 sigmoid colon
6. 盲肠 ileum
7. 腰大肌 psoas major
8. 输尿管 ureter
9. 左髂外动脉 left external iliac a.
10. 左髂内动脉 left internal iliac a.

Fig.HA 14



11. 左髂总静脉 left common iliac v.
12. 腹直肌 rectus abdominis
13. 阑尾 vermiform appendix
14. 升结肠 ascending colon
15. 臀中肌 gluteus medius
16. 髂骨翼 ala of ilium
17. 竖脊肌 erector spinae
18. 第5腰椎与第1骶椎关节突关节 zygapophysial joint(L₅-S₁)
19. 马尾 cauda equina
20. 第5腰神经 5th lumbar n.
21. 第4腰神经 4th lumbar n.
22. 股神经 femoral n.
23. 第2腰神经 2nd lumbar n.
24. 右髂总静脉 right common iliac v.



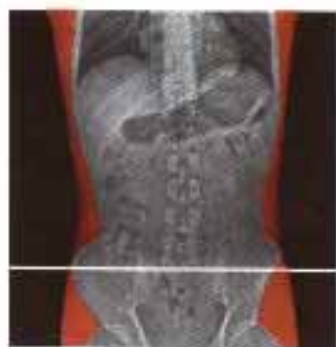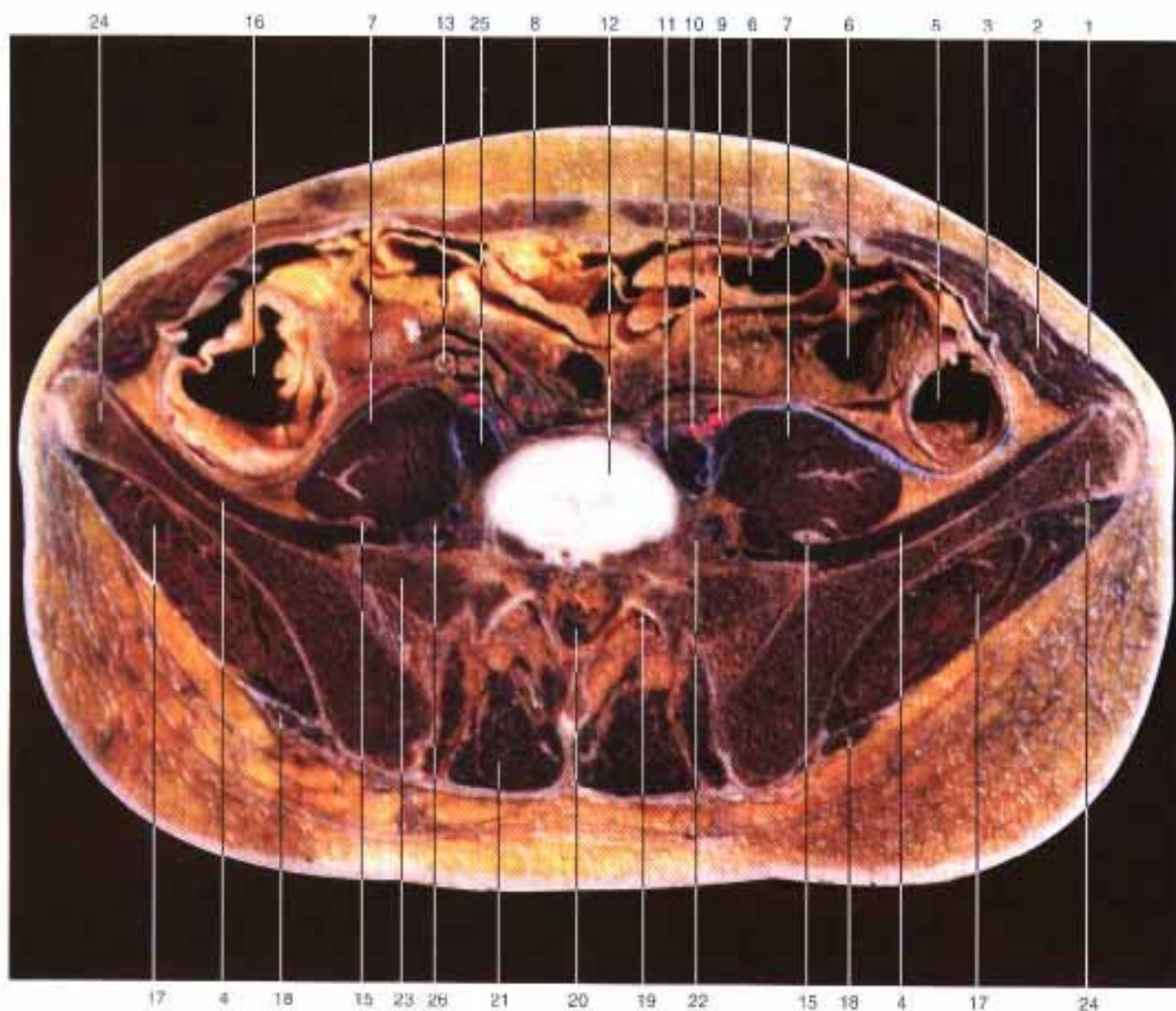
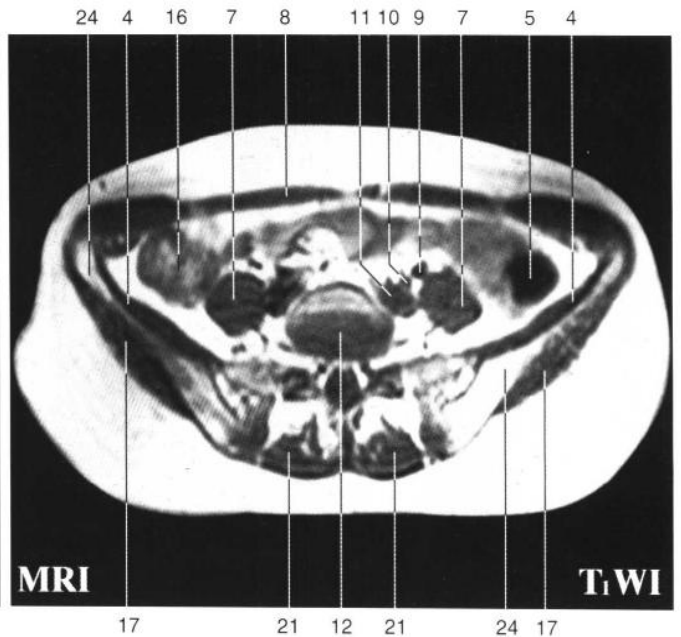
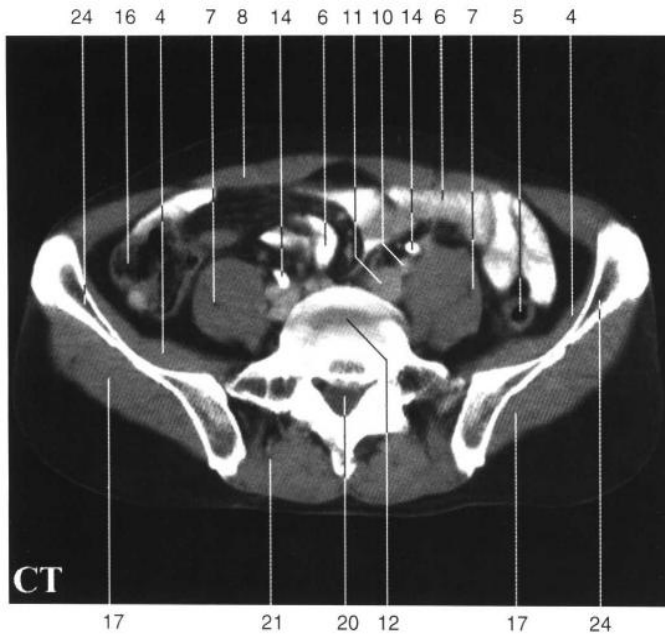


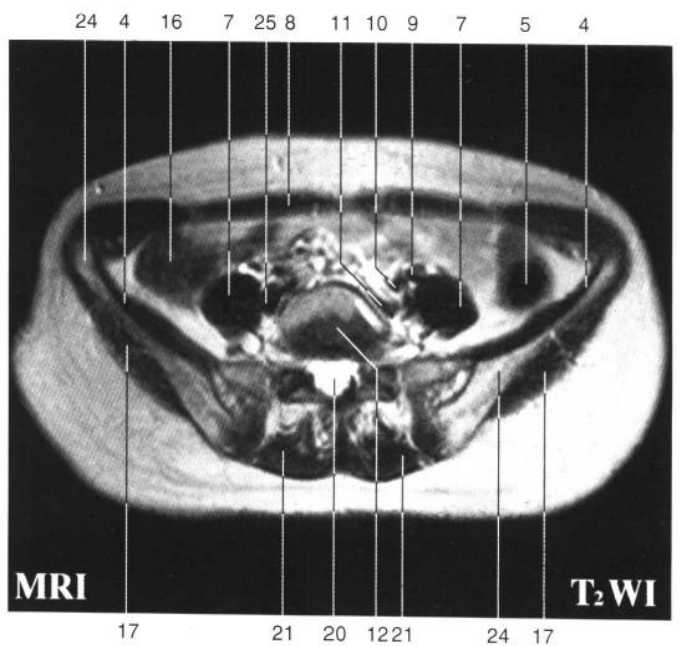
Fig. HA 15

1. 腹外斜肌 obliquus externus abdominis
2. 腹内斜肌 obliquus internus abdominis
3. 腹横肌 transversus abdominis
4. 髂肌 iliacus
5. 乙状结肠 sigmoid colon
6. 回肠 ileum
7. 腰大肌 psoas major
8. 腹直肌 rectus abdominis
9. 左髂外动脉 left external iliac a.
10. 左髂内动脉 left internal iliac a.

Fig.HA 15



11. 左髂总静脉 left common iliac v.
12. 第5腰椎与第1骶椎间盘 intervertebral disc (L₅-S₁)
13. 阑尾 vermiform appendix
14. 输尿管 ureter
15. 股神经 femoral n.
16. 升结肠 ascending colon
17. 臀中肌 gluteus medius
18. 臀大肌 gluteus maximus
19. 第5腰椎与第1骶椎关节突关节 zygapophysial joint (L₅-S₁)
20. 马尾 cauda equina
21. 竖脊肌 erector spinae
22. 腰骶干 lumbosacral trunk
23. 骶翼 ala of sacrum
24. 髂骨翼 ala of ilium
25. 右髂总静脉 right common iliac v.
26. 闭孔神经 obturator n.



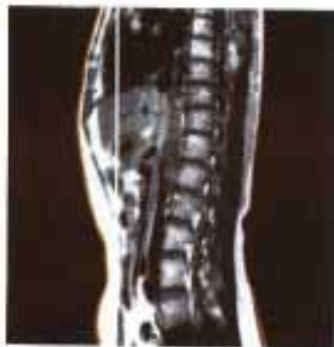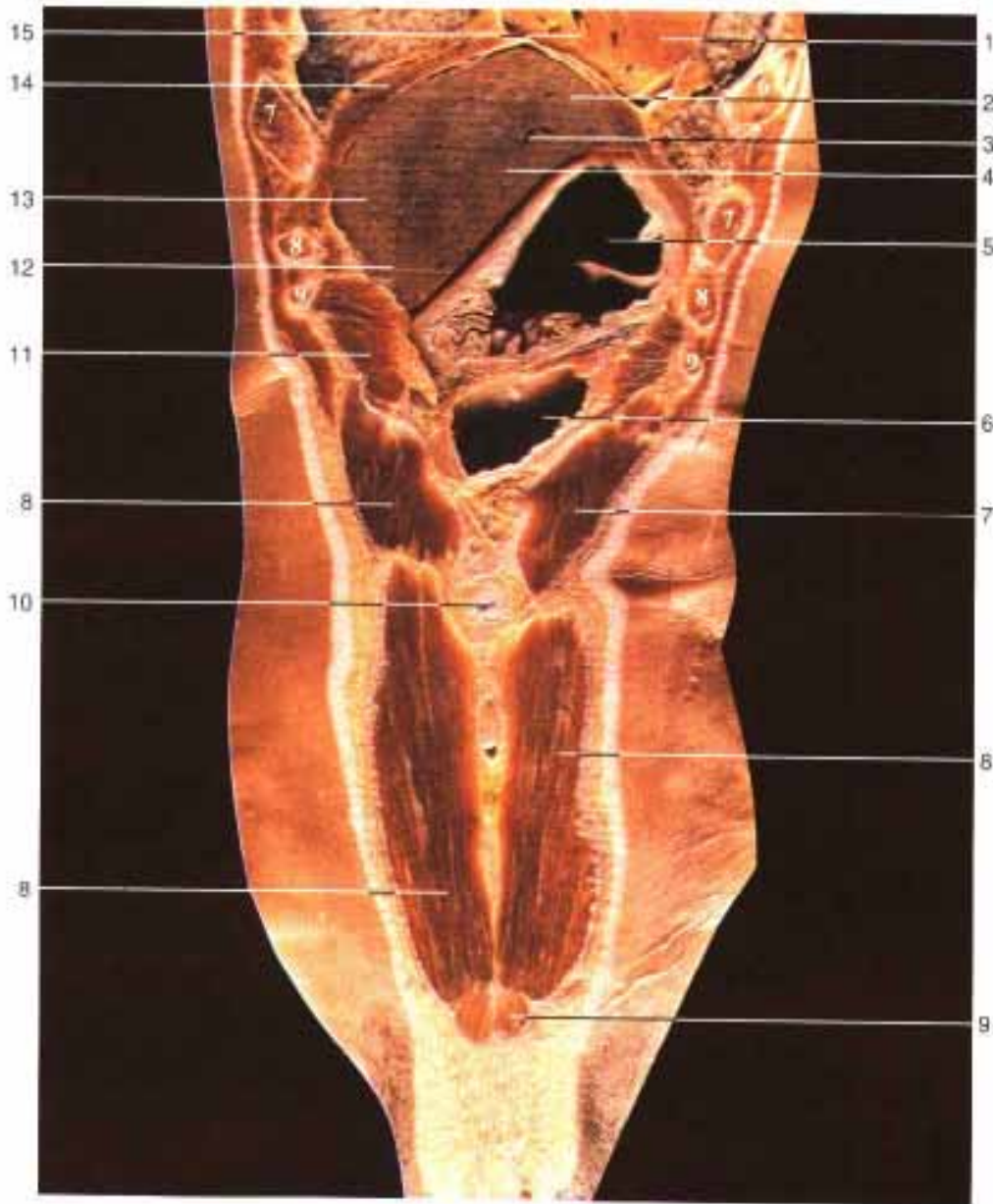
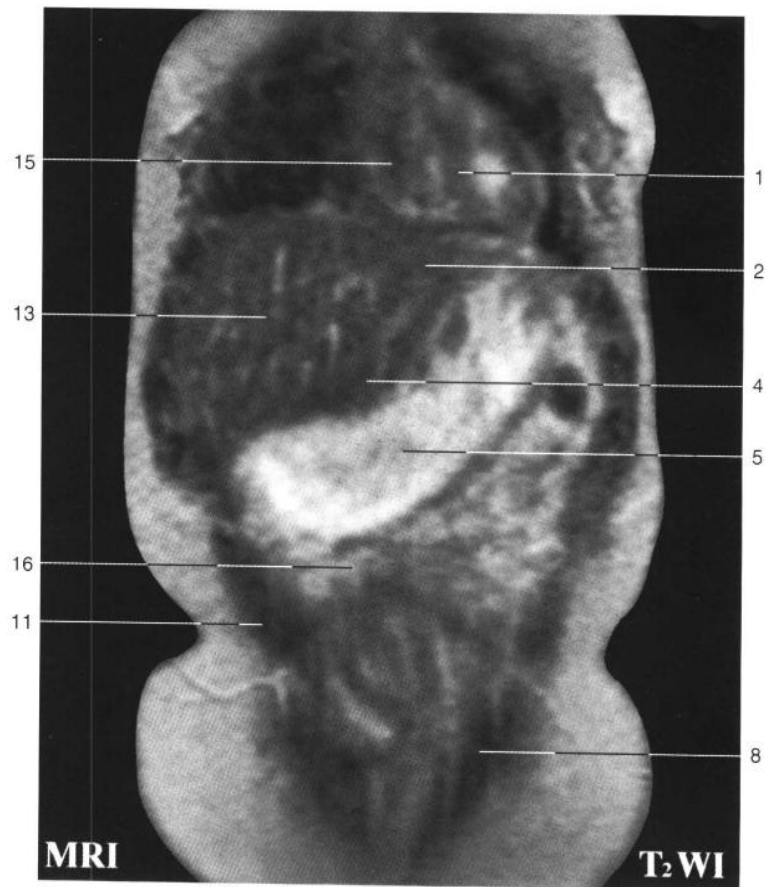

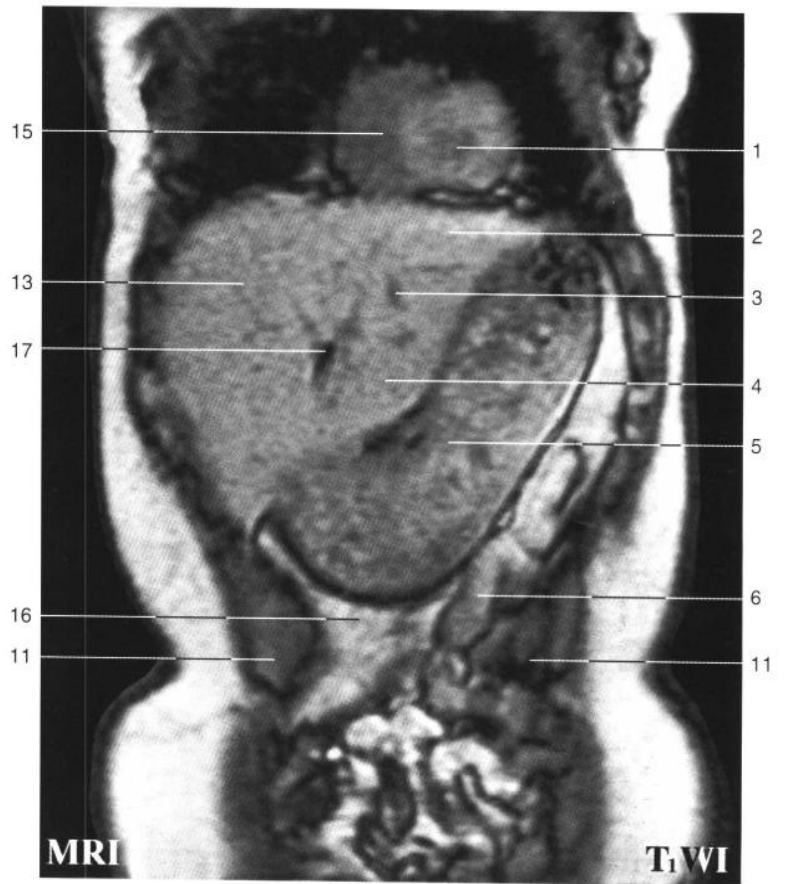
Fig. FA 1

1. 左心室 left ventricle
2. 左外叶上段 superior segment of left lateral lobe
3. 肝左静脉 left hepatic v.
4. 左外叶下段 inferior segment of left lateral lobe
5. 胃 stomach
6. 横结肠 transverse colon
7. 腹直肌 rectus abdominis
8. 腹直肌 rectus abdominis
9. 锥状肌 pyramidalis
10. 脐 umbilicus

Fig.FA 1

- 11. 腹横肌 transversus abdominis
- 12. 肝圆韧带裂 fissure for ligamentum teres hepatis
- 13. 左内叶 left medial lobe
- 14. 膈 diaphragm
- 15. 右心室 right ventricle
- 16. 大网膜 greater omentum
- 17. 肝门静脉左支 left branch of hepatic portal v.



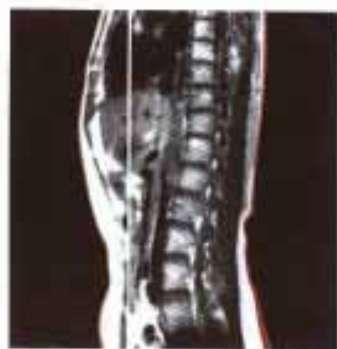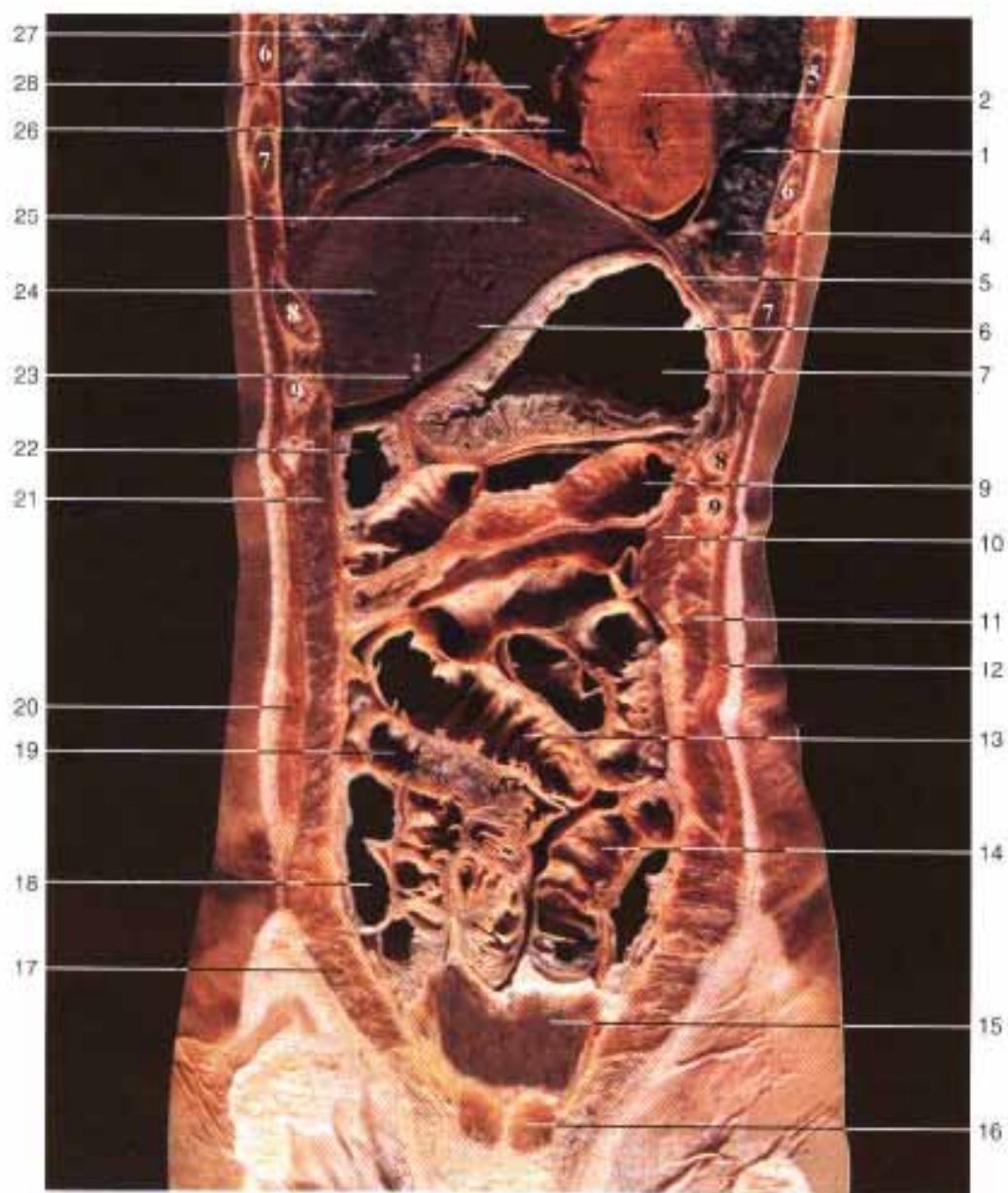
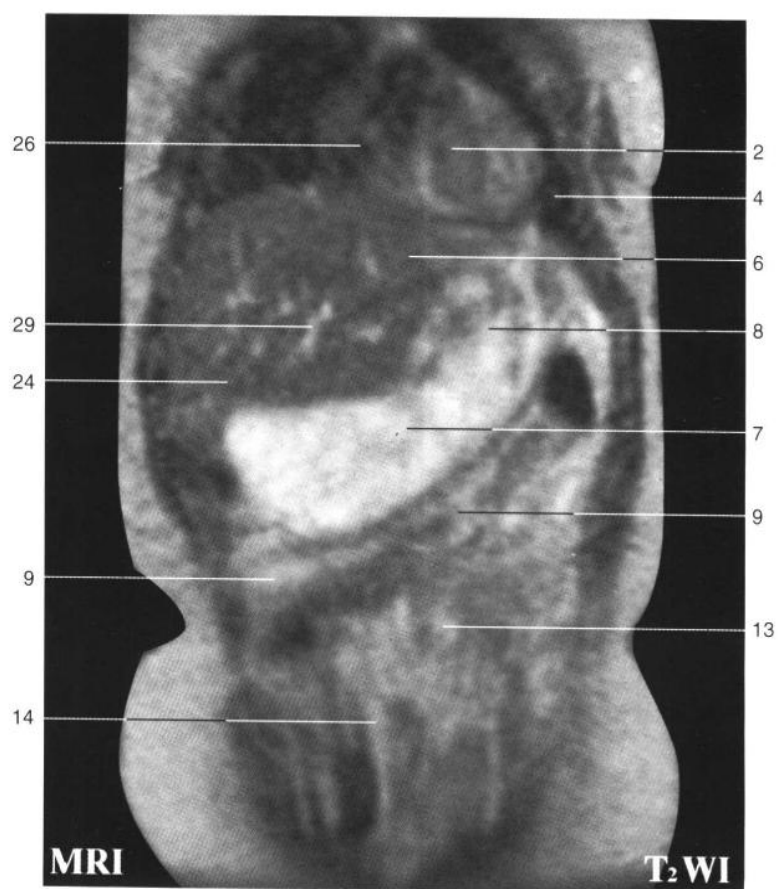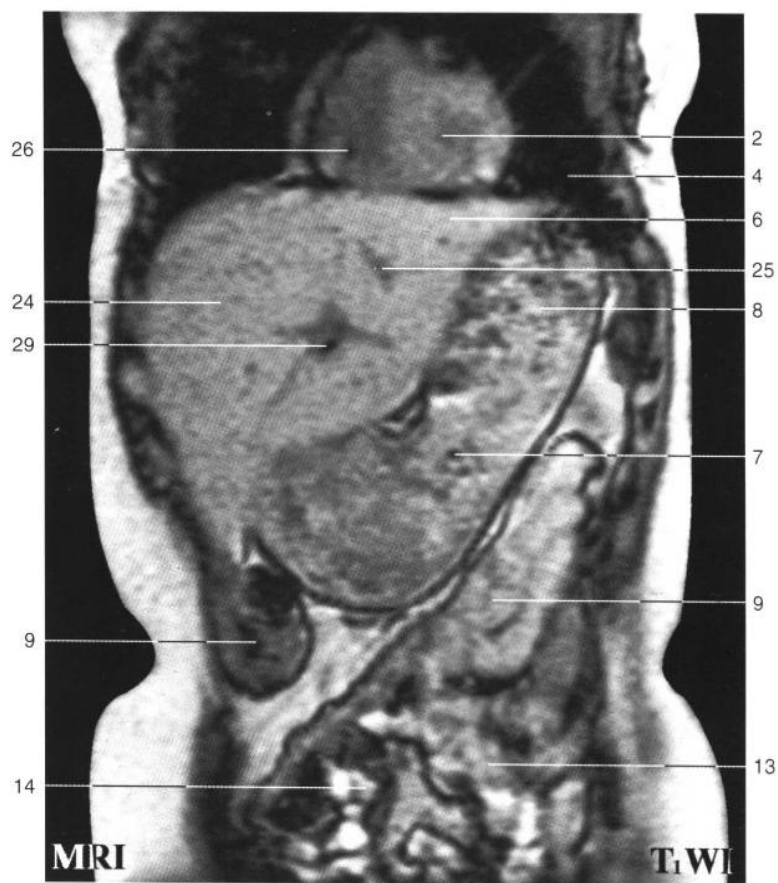


Fig. FA 2

1. 斜裂 oblique fissure
2. 左心室 left ventricle
3. 心包 pericardium
4. 左肺下叶 inferior lobe of left lung
5. 膈 diaphragm
6. 左外叶 left lateral lobe
7. 胃体 body of stomach
8. 胃底 fundus of stomach
9. 横结肠 transverse colon
10. 腹横肌 transversus abdominis

Fig.FA 2

11. 腹内斜肌 obliquus internus abdominis
12. 腹外斜肌 obliquus externus abdominis
13. 空肠 jejunum
14. 空肠 jejunum
15. 腹直肌 rectus abdominis
16. 锥状肌 pyramidalis
17. 腹内斜肌 obliquus internus abdominis
18. 升结肠 ascending colon
19. 回肠 ileum
20. 腹外斜肌 obliquus externus abdominis
21. 腹横肌 transversus abdominis
22. 幽门窦 pyloric antrum
23. 肝圆韧带裂 fissure
for ligamentum teres hepatis
24. 左内叶 left medial lobe
25. 肝左静脉 left hepatic v.
26. 右心室 right ventricle
27. 右肺中叶 middle lobe of right lung
28. 右心房 right atrium
29. 肝门静脉左支 left branch
of hepatic portal v.



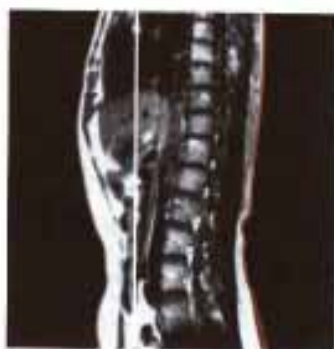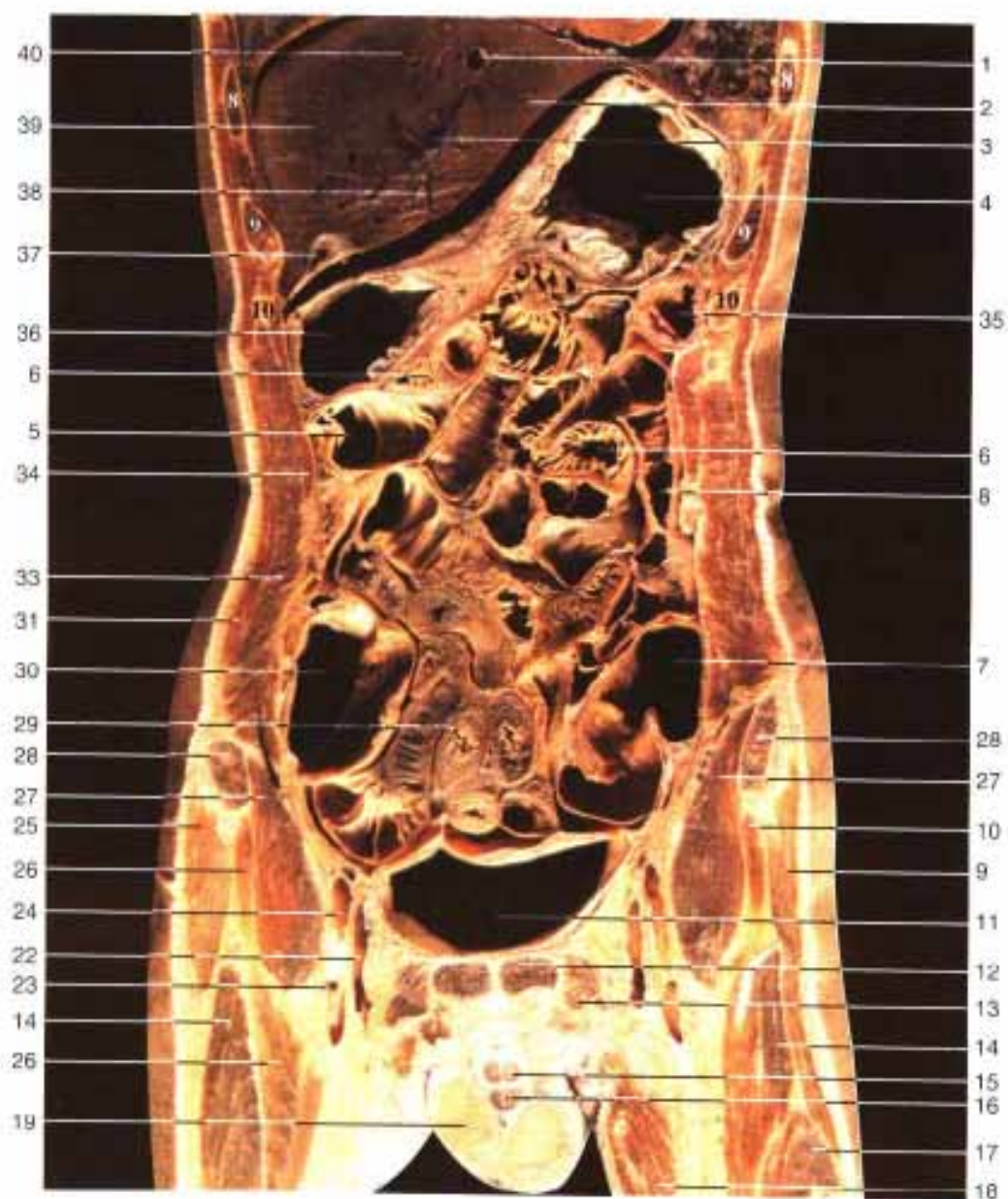
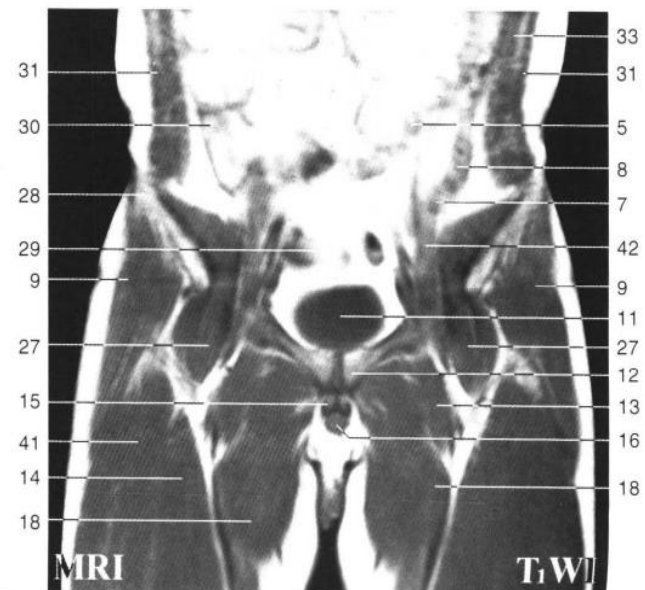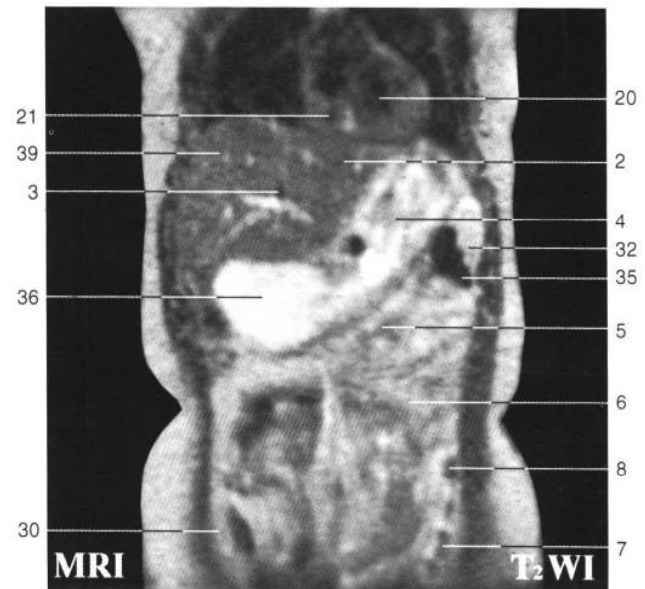
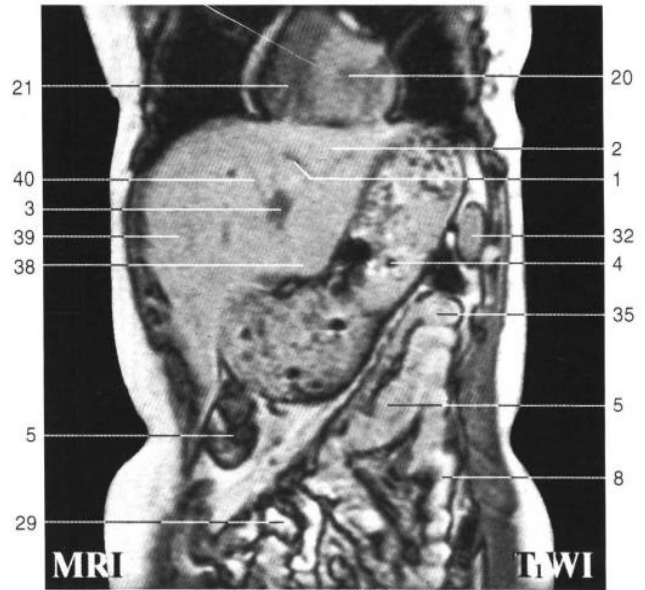


Fig. FA 3

1. 肝左静脉 left hepatic v.
2. 左外叶 left lateral lobe
3. 肝门静脉左支脐部 umbilical part of left branch of hepatic portal v.
4. 胃 stomach
5. 横结肠 transverse colon
6. 空肠 jejunum
7. 乙状结肠 sigmoid colon
8. 降结肠 descending colon
9. 阔筋膜张肌 tensor fasciae latae

Fig.FA 3

10. 缝匠肌 sartorius
11. 膀胱 urinary bladder
12. 耻骨 pubis
13. 耻骨肌 pectineus
14. 股直肌 rectus femoris
15. 阴茎脚 crus penis
16. 尿道海绵体 cavernous body of urethra
17. 股中间肌 vastus intermedius
18. 长收肌 adductor longus
19. 睾丸 testis
20. 左心室 left ventricle
21. 右心房 right atrium
22. 股静脉 femoral v.
23. 股深动脉 deep femoral a.
24. 股动脉 femoral a.
25. 阔筋膜张肌 tensor fasciae latae
26. 缝匠肌 sartorius
27. 髂腰肌 iliopsoas
28. 髂前上棘 anterior superior iliac spine
29. 回肠 ileum
30. 升结肠 ascending colon
31. 腹外斜肌 obliquus externus abdominis
32. 脾 spleen
33. 腹内斜肌 obliquus internus abdominis
34. 腹横肌 transversus abdominis
35. 结肠左曲 left colic flexure
36. 幽门窦 pyloric antrum
37. 胆囊 gallbladder
38. 肝圆韧带裂 fissure for ligamentum teres hepatis
39. 右前叶 right anterior lobe
40. 左内叶 left medial lobe
41. 股外侧肌 vastus lateralis
42. 腰大肌 psoas major



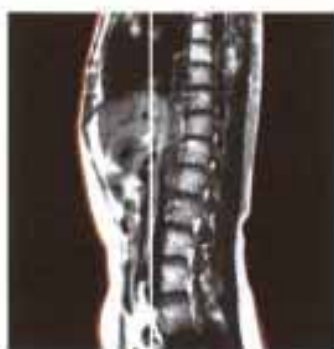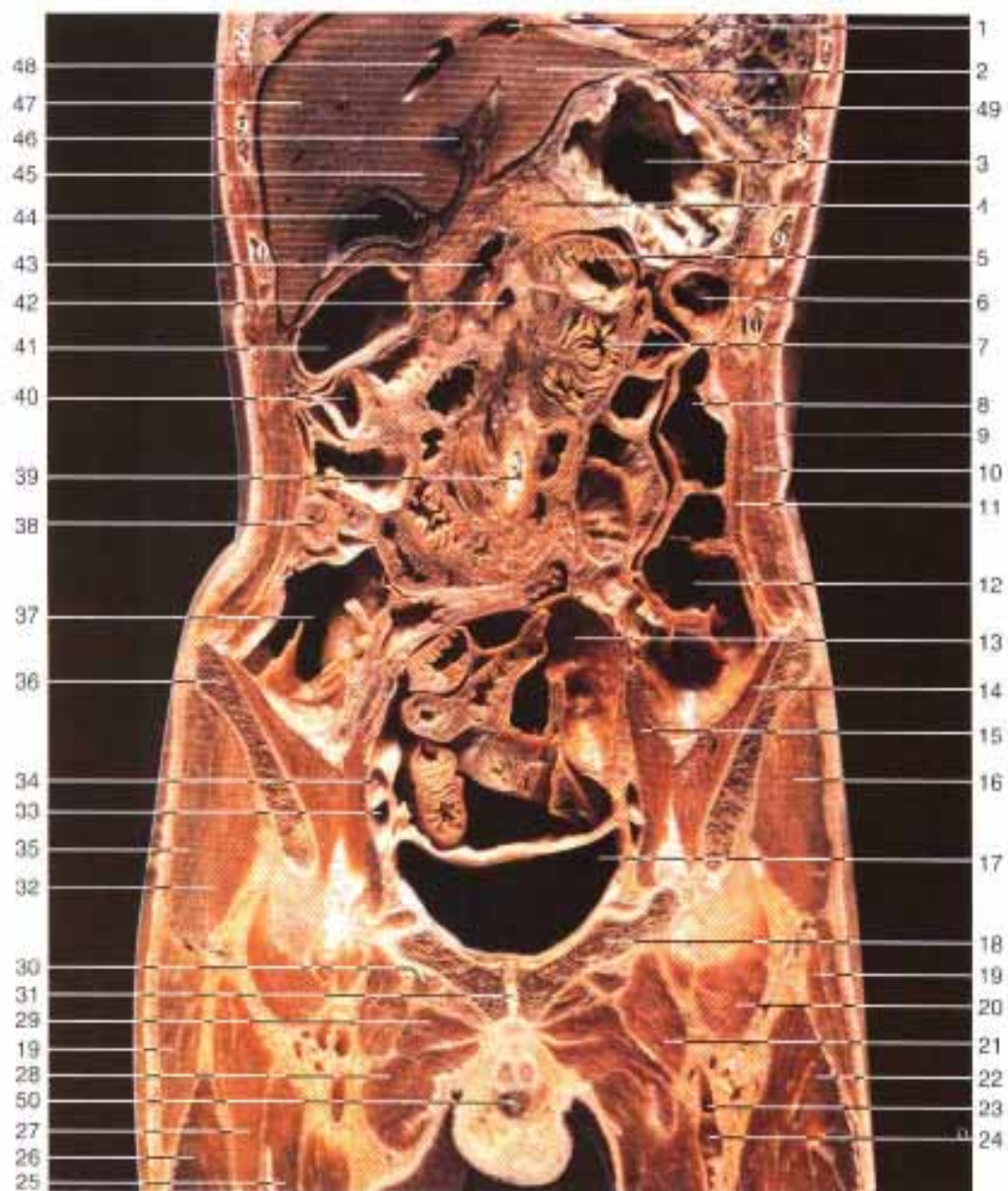
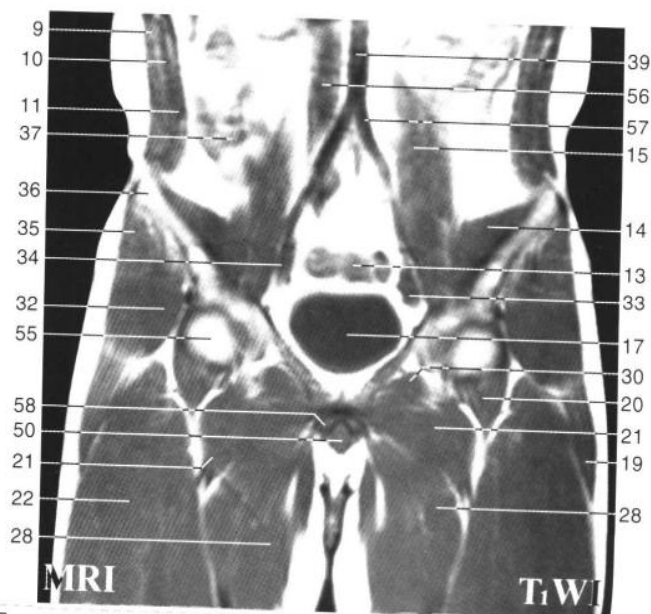
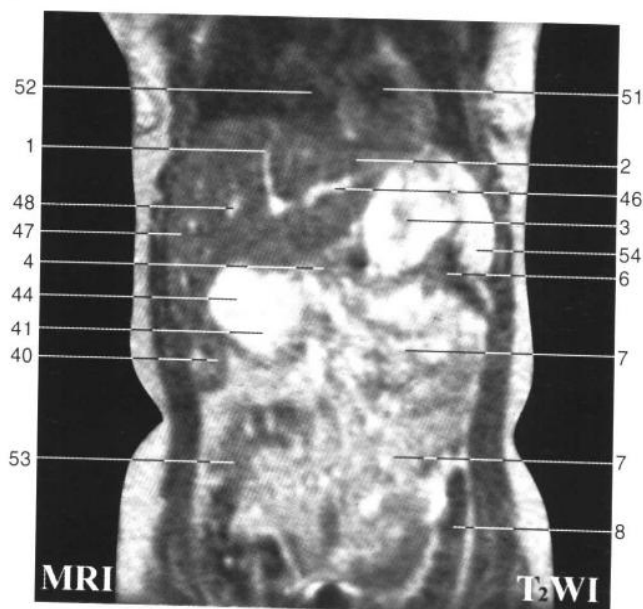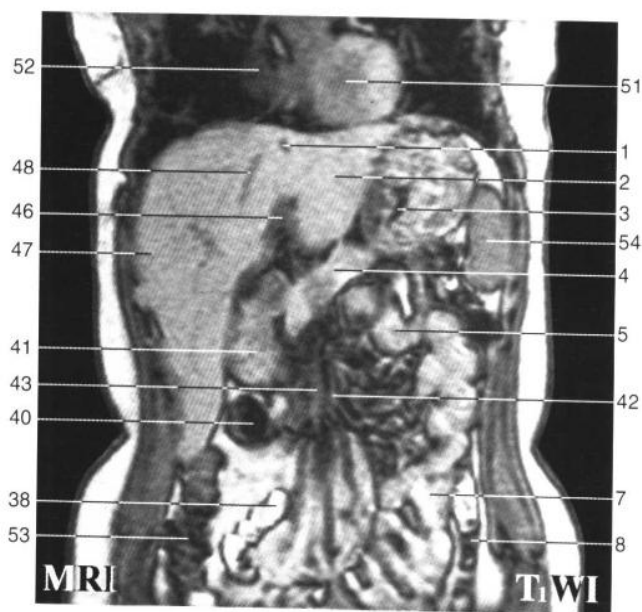


Fig. FA 4

1. 肝左静脉 left hepatic v.
2. 左外叶 left lateral lobe
3. 胃底 fundus of stomach
4. 胰 pancreas
5. 空肠 jejunum
6. 横结肠 transverse colon
7. 空肠 jejunum
8. 降结肠 descending colon
9. 腹外斜肌 obliquus externus abdominis
10. 腹内斜肌 obliquus internus abdominis

Fig.FA 4

11. 腹横肌 transversus abdominis
12. 乙状结肠 sigmoid colon
13. 乙状结肠 sigmoid colon
14. 髂肌 iliacus
15. 腰大肌 psoas major
16. 臀中肌 gluteus medius
17. 膀胱 urinary bladder
18. 耻骨上支 superior ramus of pubis
19. 阔筋膜张肌 tensor fasciae latae
20. 髂腰肌 iliopsoas
21. 耻骨肌 pectineus
22. 股直肌 rectus femoris
23. 股深动脉 deep femoral a.
24. 股动脉 femoral a.
25. 缝匠肌 sartorius
26. 股外侧肌 vastus lateralis
27. 股直肌 rectus femoris
28. 长收肌 adductor longus
29. 短收肌 adductor brevis
30. 闭孔外肌 obturator externus
31. 耻骨联合 pubic symphysis
32. 臀小肌 gluteus minimus
33. 髂外静脉 external iliac v.
34. 髂外动脉 external iliac a.
35. 臀中肌 gluteus medius
36. 髂嵴 iliac crest
37. 盲肠 cecum
38. 回肠 ileum
39. 腹主动脉 abdominal aorta
40. 横结肠 transverse colon
41. 幽门窦 pyloric antrum
42. 肠系膜上动脉 superior mesenteric a.
43. 肠系膜上静脉 superior mesenteric v.
44. 胆囊 gallbladder
45. 左内叶 left medial lobe
46. 肝门静脉左支脐部 umbilical part of left branch of hepatic portal v.
47. 右前叶 right anterior lobe
48. 肝中间静脉 intermediate hepatic v.
49. 膈 diaphragm
50. 尿道海绵体 cavernous body of urethra
51. 左心室 left ventricle
52. 右心房 right atrium
53. 升结肠 ascending colon
54. 脾 spleen
55. 股骨头 femoral head
56. 下腔静脉 inferior vena cave
57. 髂总动脉 common iliac a.
58. 阴茎脚 crus penis



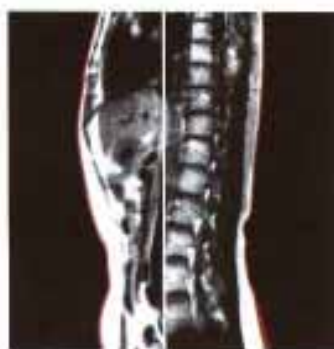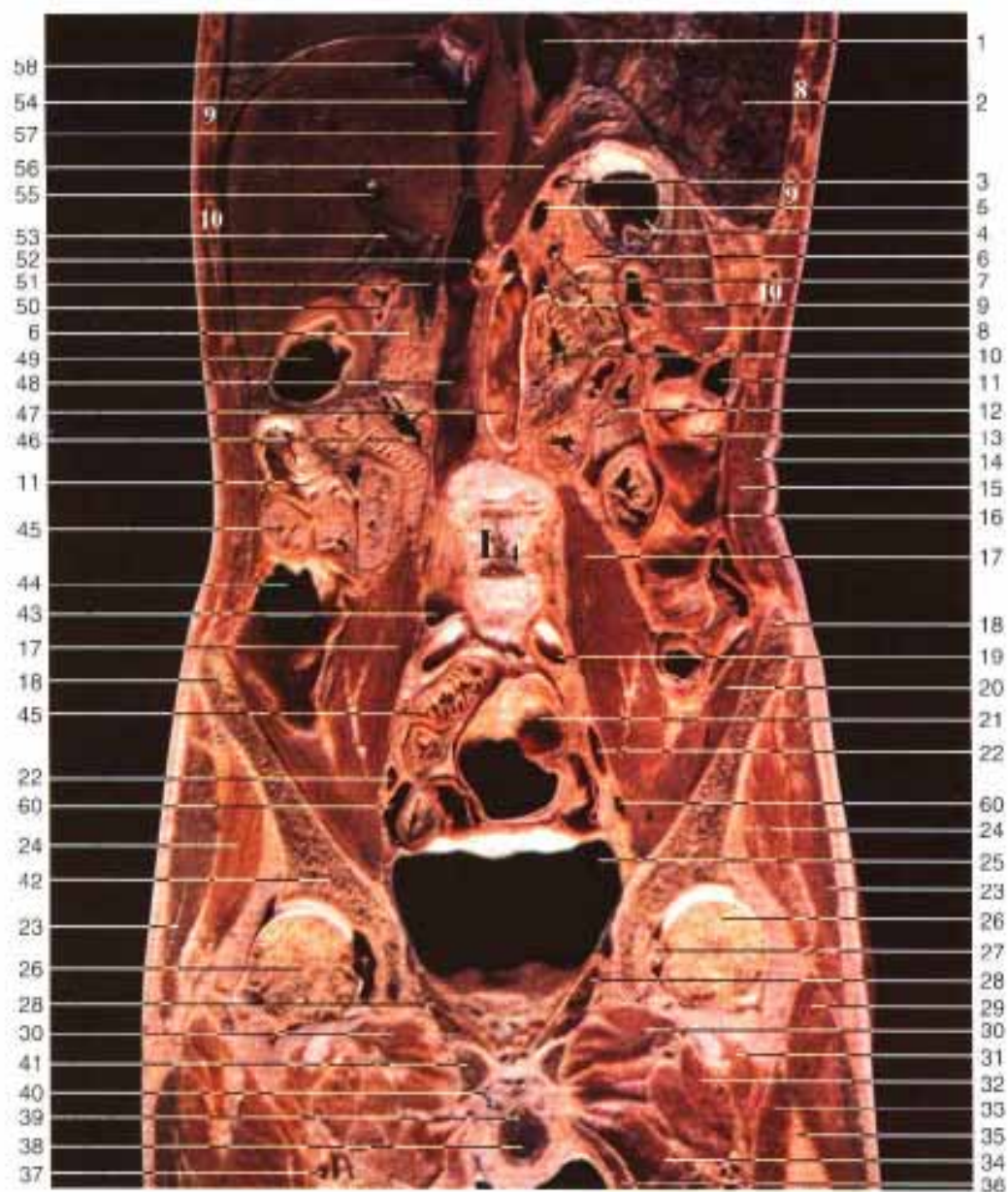
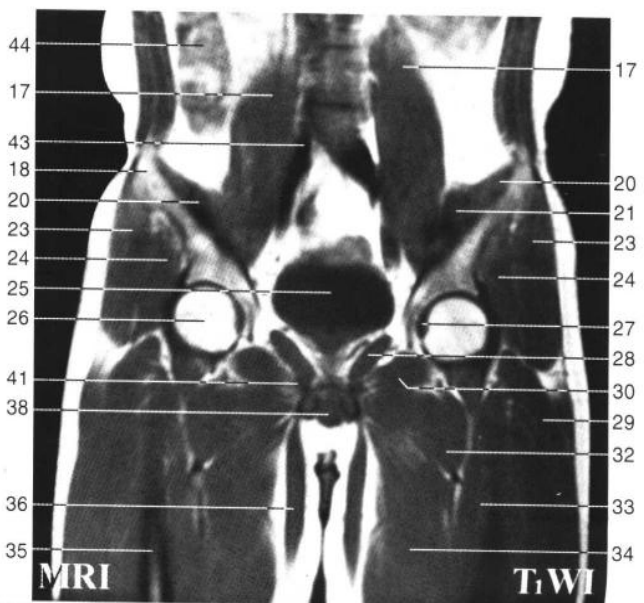
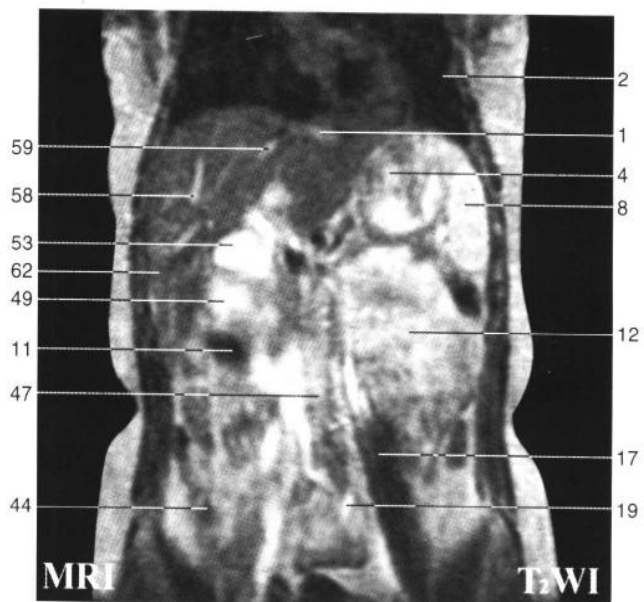

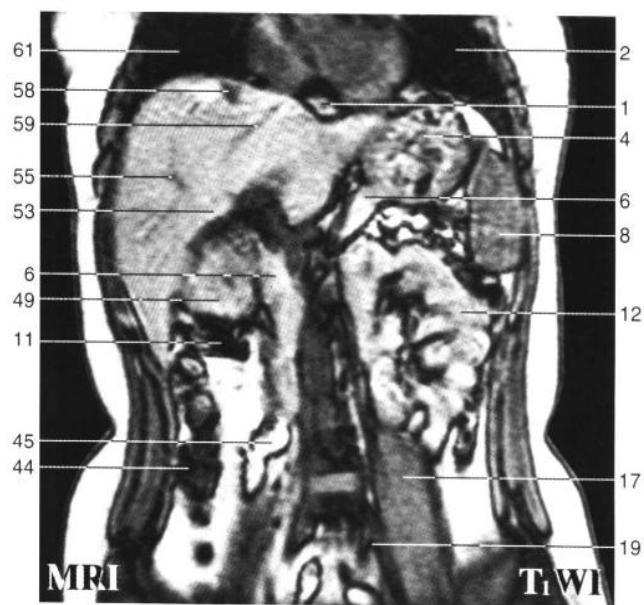
Fig. FA 5

1. 食管 esophagus
2. 左肺下叶 inferior lobe of left lung
3. 腹腔干 celiac trunk
4. 贲门 cardia
5. 肠系膜上动脉 superior mesenteric a.
6. 胰 pancreas
7. 脾动脉 splenic a.
8. 脾 spleen
9. 左肾静脉 left renal v.
10. 12 指肠水平部 horizontal part of duodenum
11. 横结肠 transverse colon

Fig.FA 5

12. 空肠 jejunum
13. 降结肠 descending colon
14. 腹外斜肌 obliquus externus abdominis
15. 腹内斜肌 obliquus internus abdominis
16. 腹横肌 transversus abdominis
17. 腰大肌 psoas major
18. 髭嵴 iliac crest
19. 髭总动脉 common iliac a.
20. 髭肌 iliacus
21. 乙状结肠 sigmoid colon
22. 髭外动脉 external iliac a.
23. 臀中肌 gluteus medius
24. 臀小肌 gluteus minimus
25. 膀胱 urinary bladder
26. 股骨头 femoral head
27. 股骨头韧带 ligament of head of femur
28. 闭孔内肌 obturator externus
29. 股外侧肌 vastus lateralis
30. 闭孔外肌 obturator externus
31. 髭腰肌 iliopsoas
32. 耻骨肌 pectineus
33. 股内侧肌 vastus medialis
34. 大收肌 adductor magnus
35. 股骨 femur
36. 股薄肌 gracilis
37. 股深动、静脉 deep femoral a. and v.
38. 尿道海绵体 cavernous body of urethra
39. 男尿道 male urethra
40. 阴茎脚 crus penis
41. 耻骨下支 inferior ramus of pubis
42. 髭骨体 body of ilium
43. 右髭总静脉 right common iliac v.
44. 升结肠 ascending colon
45. 回肠 ileum
46. 12指肠降部 descending part of duodenum
47. 腹主动脉 abdominal aorta
48. 下腔静脉 inferior vena cava
49. 幽门管 pyloric canal
50. 幽门 pylorus
51. 胆总管 common bile duct
52. 右肾动脉 right renal a.
53. 胆囊 gallbladder
54. 下腔静脉 inferior vena cava
55. 肝门静脉右支 right branch of hepatic portal v.
56. 膈左脚 left crus of diaphragm
57. 尾状叶 caudate lobe
58. 肝右静脉 right hepatic v.
59. 肝中间静脉 intermediate hepatic v.
60. 髭外静脉 external iliac v.
61. 右肺下叶 inferior lobe of right lung
62. 右后叶 right posterior lobe



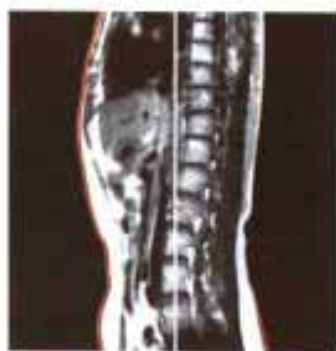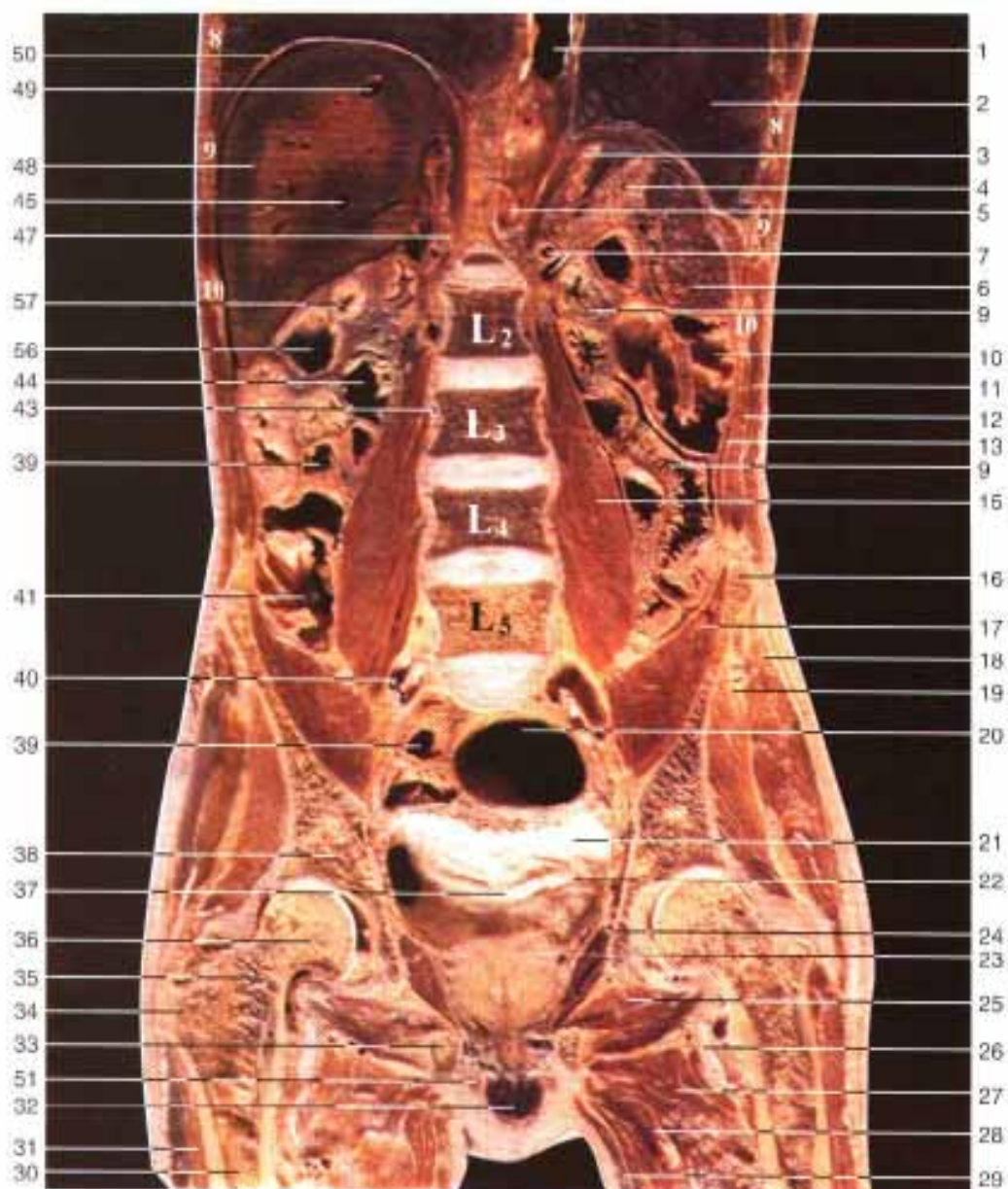
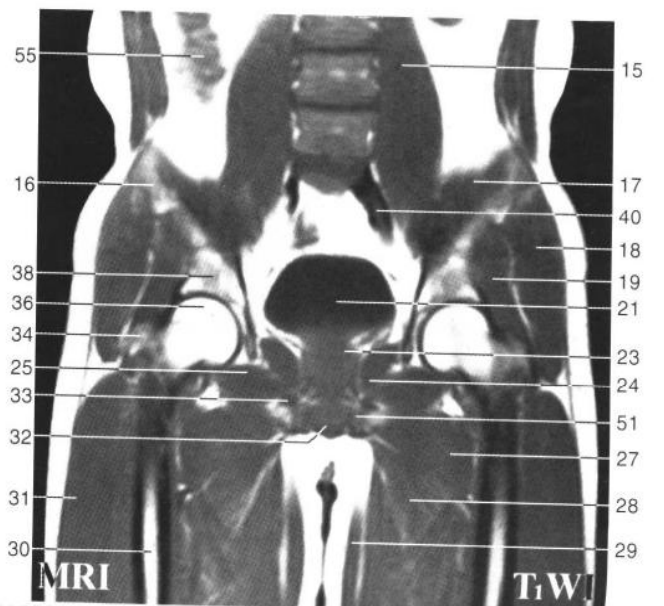
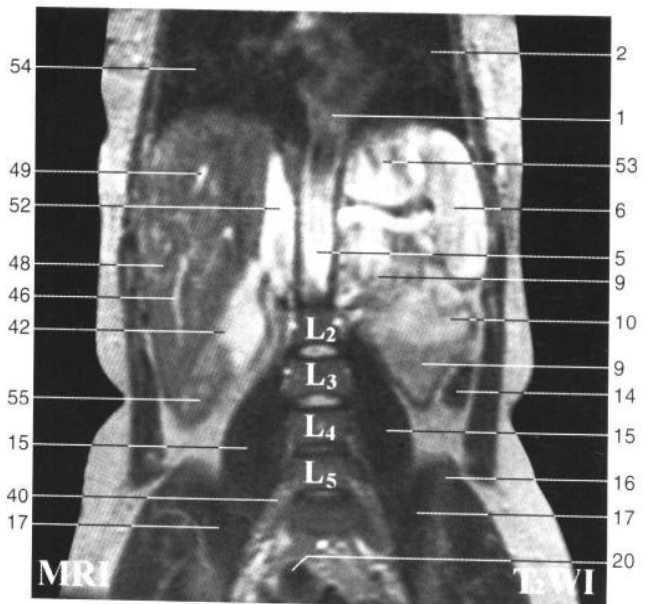
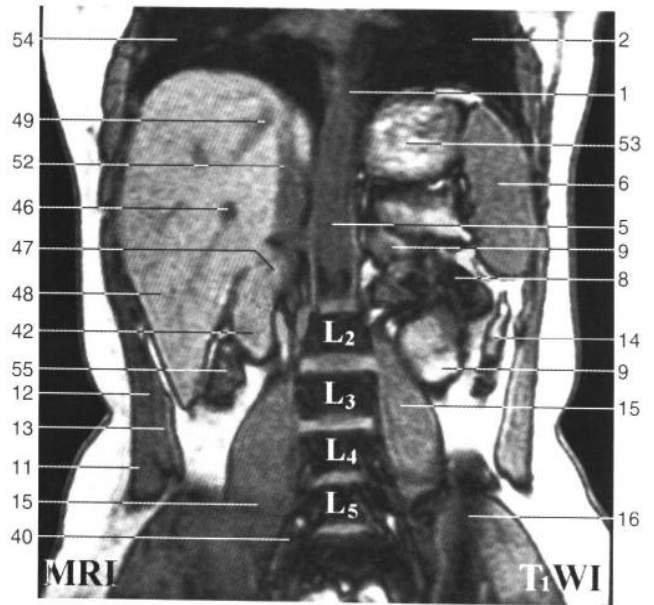


Fig. FA 6

1. 胸主动脉 thoracic aorta
2. 左肺下叶 inferior lobe of left lung
3. 左肾上腺 left suprarenal gland
4. 胰 pancreas
5. 腹主动脉 abdominal aorta
6. 脾 spleen
7. 左肾动脉、静脉 left renal a. and v.
8. 横结肠 transverse colon
9. 空肠 jejunum
10. 结肠左曲 left colic flexure

Fig.FA 6

11. 腹外斜肌 obliquus externus abdominis
12. 腹内斜肌 obliquus internus abdominis
13. 腹横肌 transversus abdominis
14. 降结肠 descending colon
15. 腰大肌 psoas major
16. 髂嵴 iliac crest
17. 髂肌 iliacus
18. 臀中肌 gluteus medius
19. 臀小肌 gluteus minimus
20. 乙状结肠 sigmoid colon
21. 膀胱 urinary bladder
22. 输尿管口 ureteric orifice
23. 前列腺 prostate gland
24. 闭孔内肌 obturator internus
25. 闭孔外肌 obturator externus
26. 髂腰肌腱 tendon of iliopsoas
27. 短收肌 adductor brevis
28. 大收肌 adductor magnus
29. 股薄肌 gracilis
30. 股骨 femur
31. 股外侧肌 vastus lateralis
32. 尿道球 bulb of urethra
33. 坐骨支 ramus of ischium
34. 大转子 greater trochanter
35. 股骨颈 neck of femur
36. 股骨头 femoral head
37. 输尿管间襞 interureteric fold
38. 髌骨体 body of ilium
39. 回肠 ileum
40. 右髂总动、静脉 right common iliac a. and v.
41. 盲肠 cecum
42. 右肾 right kidney
43. 腰动脉、静脉 lumbar a. and v.
44. 12指肠降部 descending part of duodenum
45. 肝右静脉 right hepatic v.
46. 右前叶静脉 right anterior lobar v.
47. 右肾上腺 right suprarenal gland
48. 右后叶 right posterior lobe
49. 肝右静脉 right hepatic v.
50. 膈 diaphragm
51. 阴茎脚 crus penis
52. 下腔静脉 inferior vena cava
53. 胃底 fundus of stomach
54. 右肺下叶 inferior lobe of left lung
55. 升结肠 ascending colon
56. 幽门管 pyloric canal
57. 幽门 pylorus



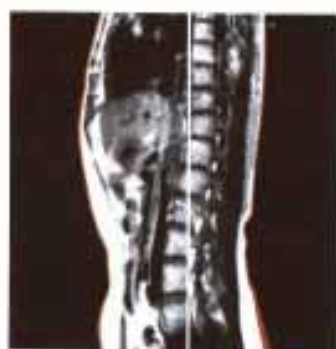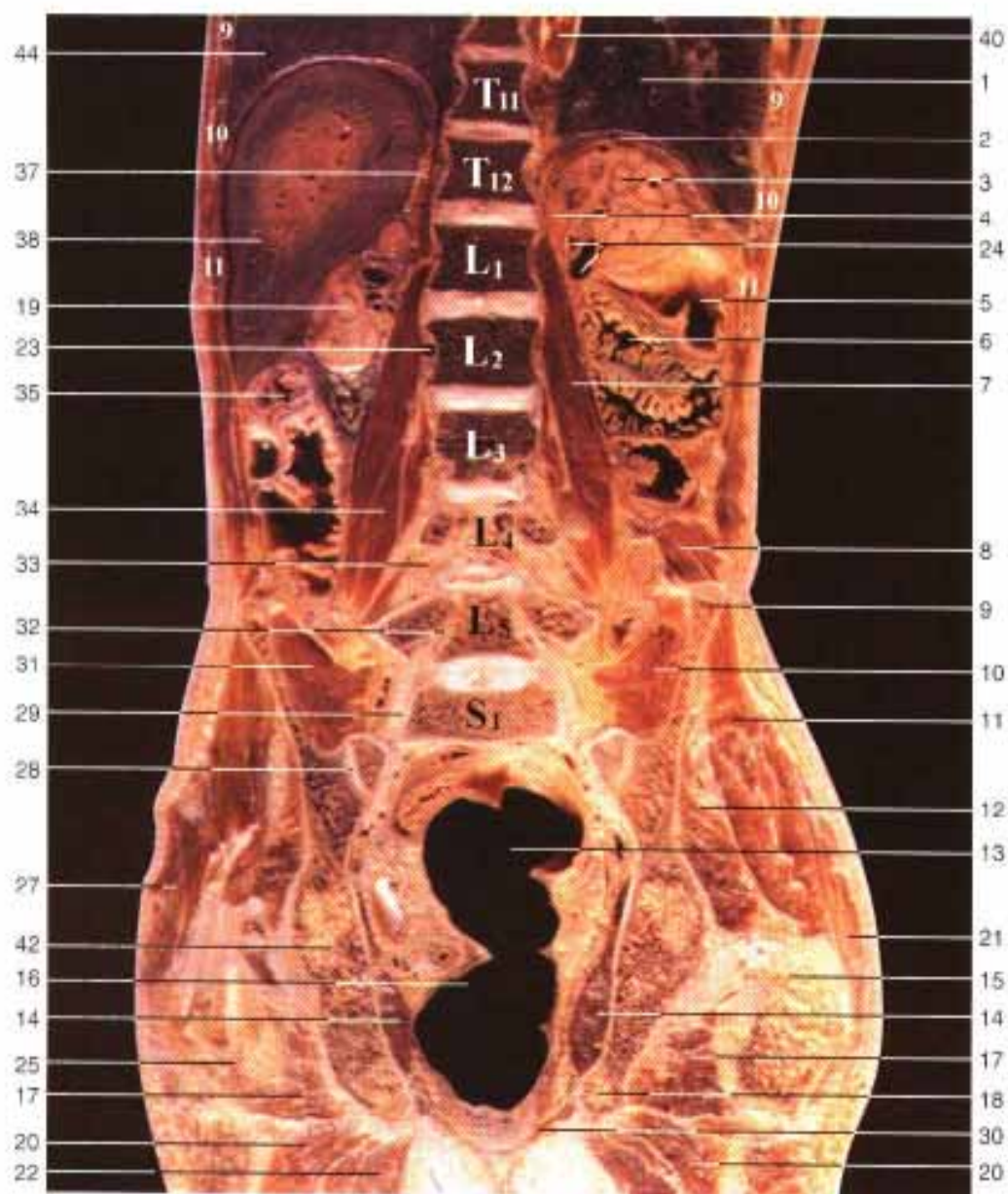


Fig. FA 7

1. 左肺下叶 inferior lobe of left lung
2. 膈 diaphragm
3. 左肾 left kidney
4. 左肾上腺 left suprarenal gland
5. 横结肠 transverse colon
6. 空肠 jejunum
7. 腰大肌 psoas major
8. 腰方肌 quadratus lumborum
9. 髂嵴 iliac crest
10. 髂肌 iliacus

Fig.FA 7

11. 臀中肌 gluteus medius
12. 臀小肌 gluteus minimus
13. 乙状结肠 sigmoid colon
14. 闭孔内肌 obturator internus
15. 大转子 greater trochanter
16. 直肠 rectum
17. 股方肌 quadratus femoris
18. 坐骨结节 ischial tuberosity
19. 右肾 right kidney
20. 半腱肌 semitendinosus
21. 臀大肌 gluteus maximus
22. 大收肌 adductor magnus
23. 腰动脉 lumbar a.
24. 左肾动脉、静脉 left renal a. and v.
25. 股骨 femur
26. 肝右静脉 right hepatic v.
27. 臀大肌 gluteus maximus
28. 骶髂关节 sacroiliac joint
29. 第1骶神经 1st sacral n.
30. 肛提肌 levator ani
31. 髂肌 iliacus
32. 第5腰神经 5th lumbar n.
33. 第4腰神经 4th lumbar n.
34. 腰大肌 psoas major
35. 横结肠 transverse colon
36. 右肾 right kidney
37. 右肾上腺 right suprarenal gland
38. 右后叶 right posterior lobe
39. 脾 spleen
40. 胸主动脉 thoracic aorta
41. 胃底 fundus of stomach
42. 坐骨 ischium
43. 脊髓 spinal cord
44. 右肺下叶 inferior lobe of right lung

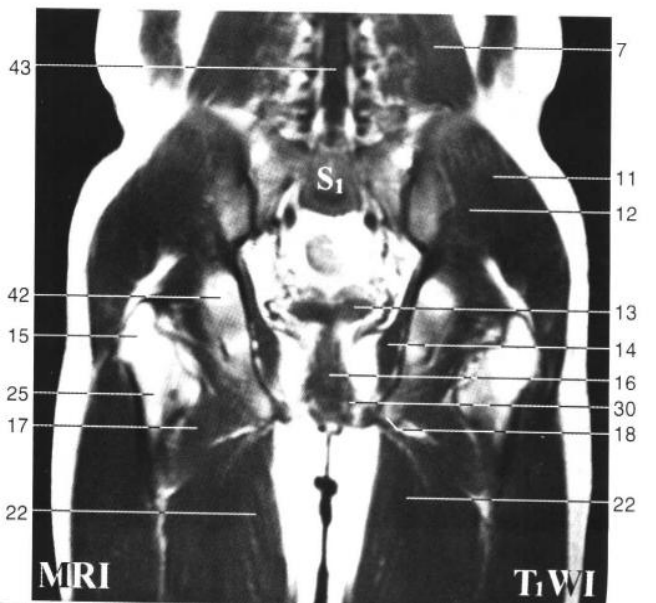
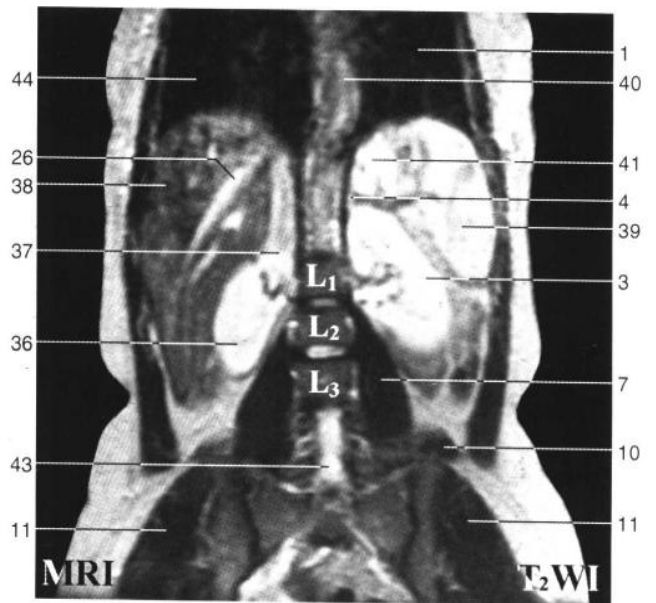
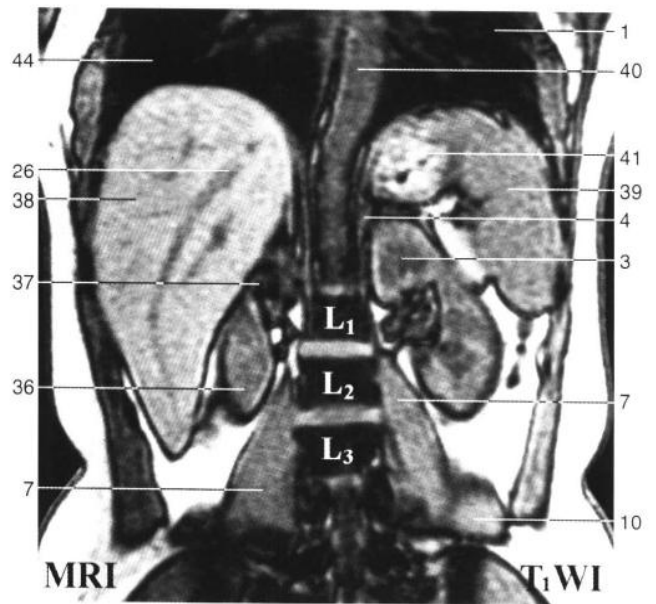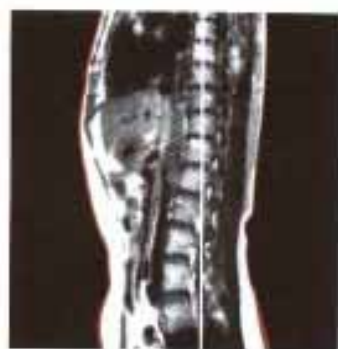
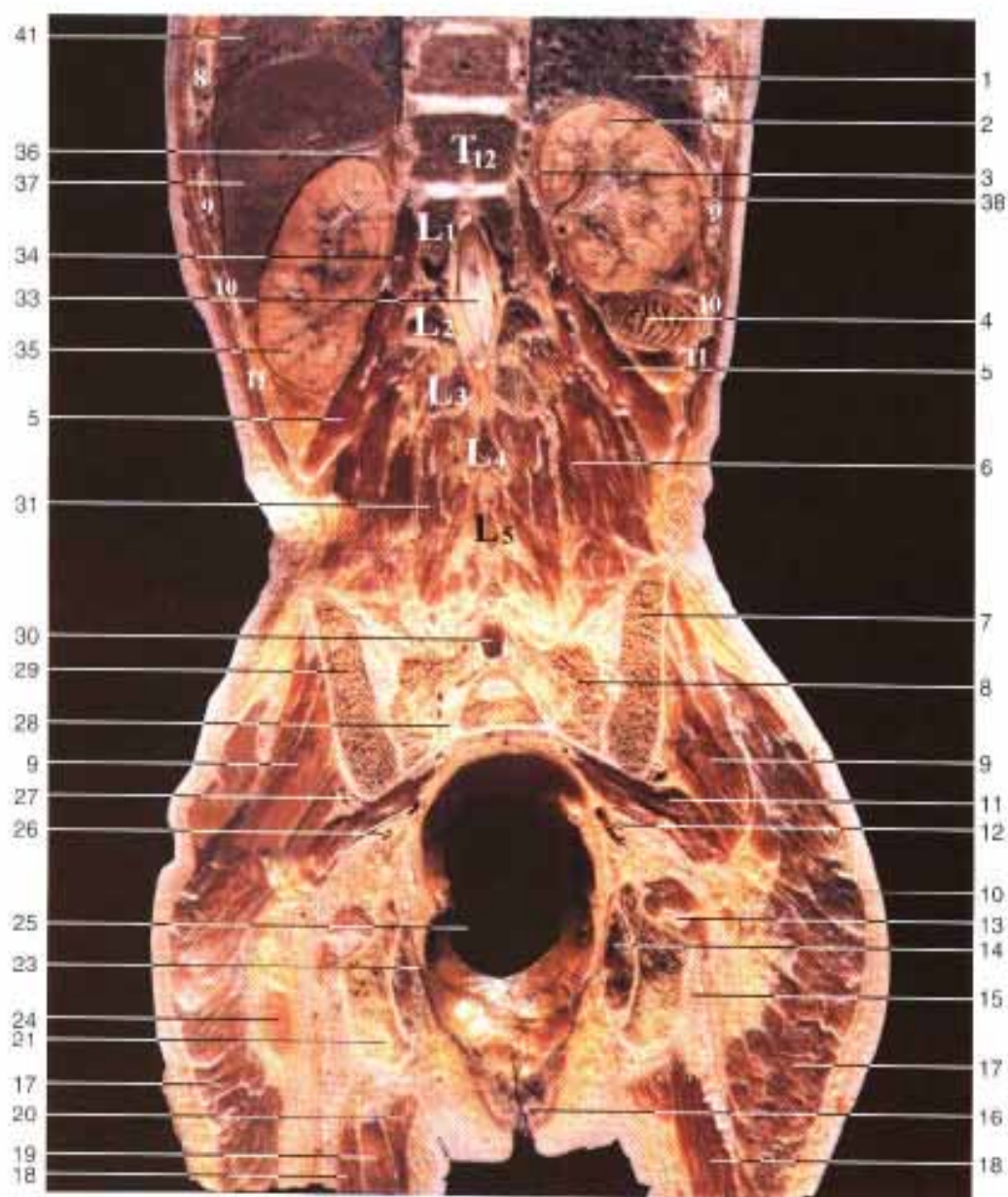

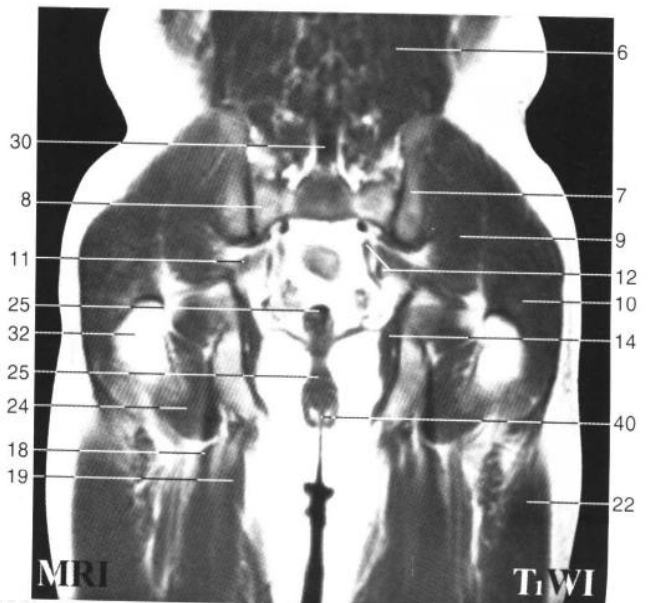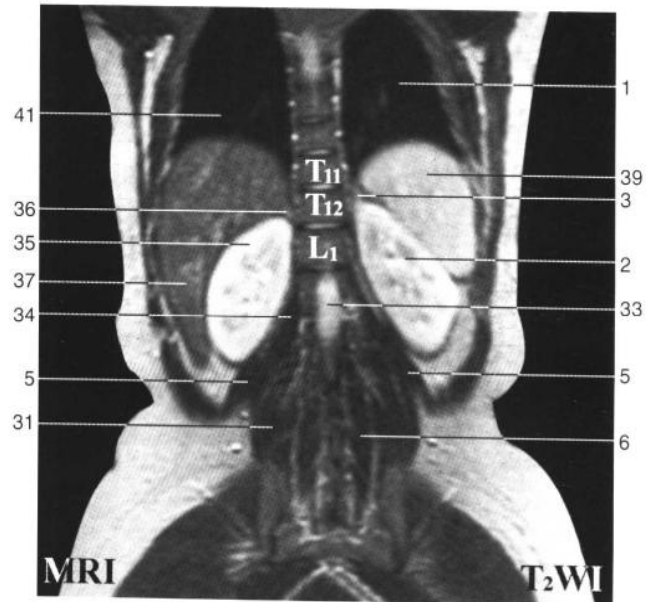
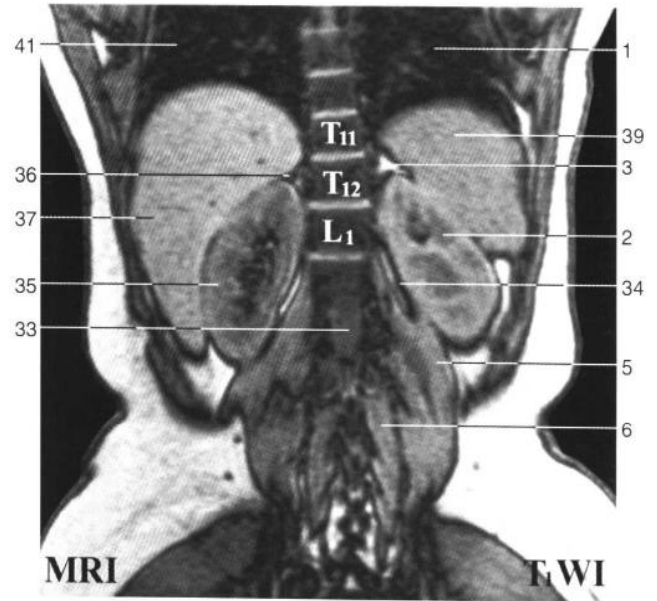


Fig. FA 8

1. 左肺下叶 inferior lobe of left lung
2. 左肾 left kidney
3. 左肾上腺 left suprarenal gland
4. 空肠 jejunum
5. 腰方肌 quadratus lumborum
6. 竖脊肌 erector spinae
7. 髂嵴 ala of ilium
8. 骶翼 ala of sacrum
9. 臀中肌 gluteus medius
10. 臀大肌 gluteus maximus
11. 梨状肌 piriformis

Fig.FA 8

12. 臀下动、静脉 inferior gluteal a. and v.
13. 闭孔内肌腱 tendon of obturator internus
14. 闭孔内肌 obturator internus
15. 坐骨神经 sciatic n.
16. 肛门 anus
17. 臀大肌 gluteus maximus
18. 股二头肌长头 long head of biceps femoris
19. 半腱肌 semitendinosus
20. 大收肌 adductor magnus
21. 坐骨 ischium
22. 股外侧肌 vastus lateralis
23. 肛提肌 levator ani
24. 股方肌 quadratus femoris
25. 直肠 rectum
26. 臀下动、静脉 inferior gluteal a. and v.
27. 臀上动、静脉 superior gluteal a. and v.
28. 骶前孔 anterior sacral foramen
29. 髂骨翼 ala of ilium
30. 骶管 sacral canal
31. 竖脊肌 erector spinae
32. 大转子 greater trochanter
33. 脊髓 spinal cord
34. 腰大肌 psoas major
35. 右肾 right kidney
36. 右肾上腺 right suprarenal gland
37. 右后叶 right posterior lobe
38. 膈 diaphragm
39. 脾 spleen
40. 肛门外括肌 sphincter ani externus
41. 右肺下叶 inferior lobe of right lung



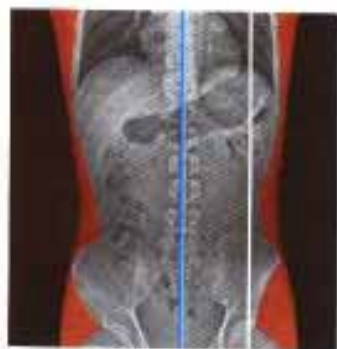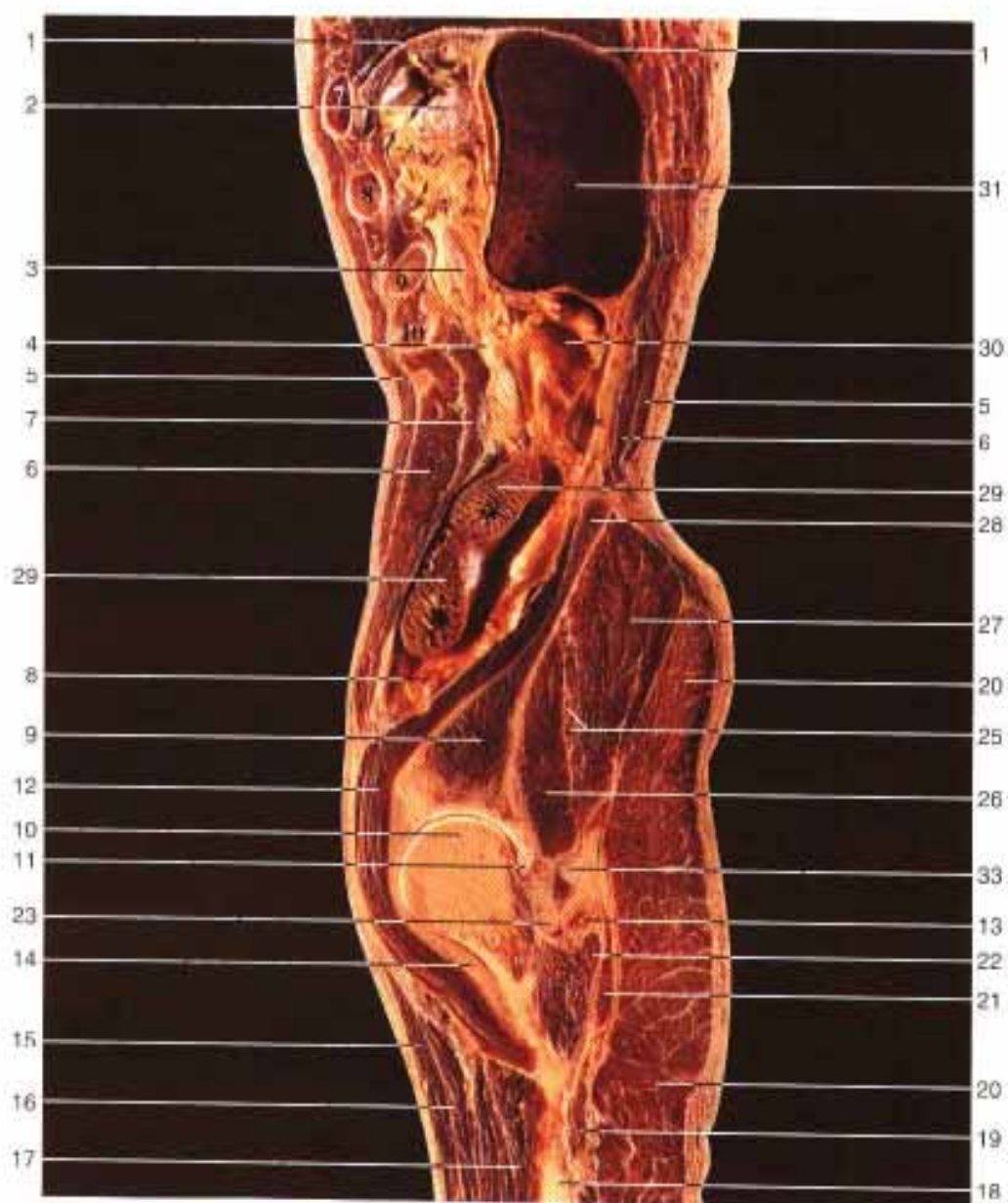
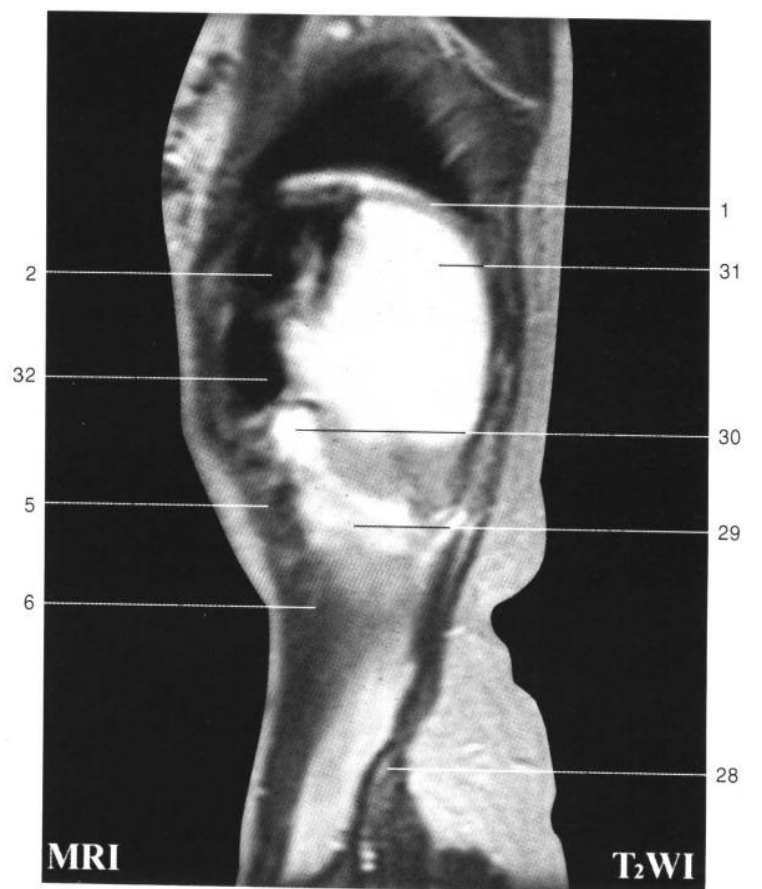
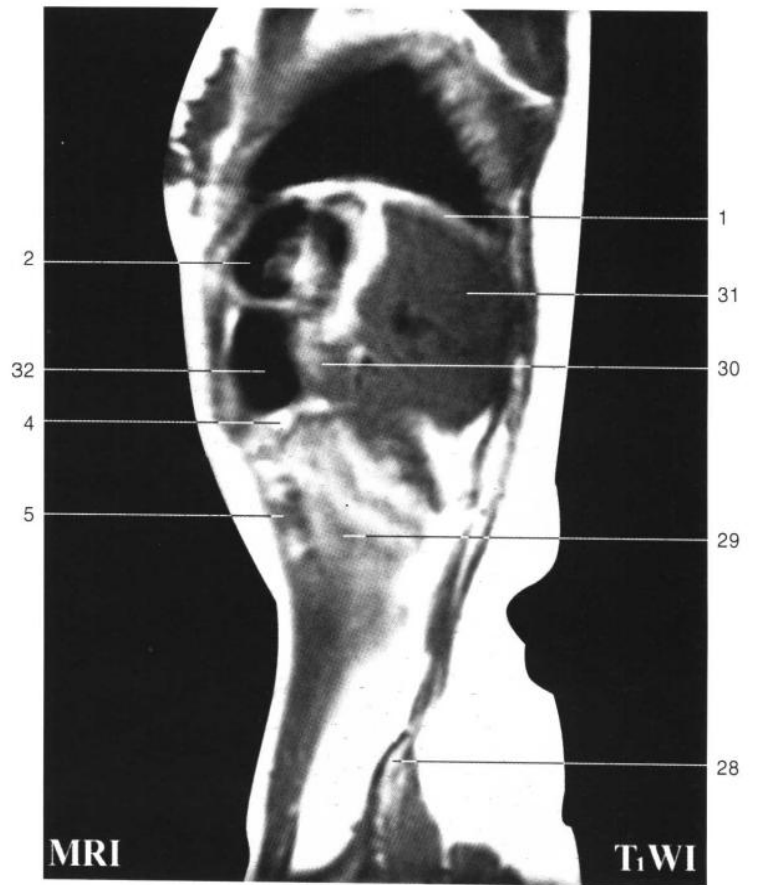


Fig. SA 1

1. 膈 diaphragm
2. 胃底 fundus of stomach
3. 横结肠 transverse colon
4. 大网膜 greater omentum
5. 腹外斜肌 obliquus externus abdominis
6. 腹内斜肌 obliquus internus abdominis
7. 腹横肌 transversus abdominis
8. 乙状结肠 sigmoid colon
9. 髂骨体 body of ilium
10. 股骨头 femoral head

Fig.SA 1

11. 髋臼唇 acetabular labrum
12. 髂腰肌 iliopsoas
13. 闭孔外肌腱 tendon of obturator externus
14. 关节囊 articular capsule
15. 缝匠肌 sartorius
16. 股直肌 rectus femoris
17. 股中间肌 vastus intermedius
18. 股骨 femur
19. 半腱肌 semitendinosus
20. 臀大肌 gluteus maximus
21. 股方肌 quadratus femoris
22. 大转子 greater trochanter
23. 闭孔内肌腱 tendon of obturator internus
24. 梨状肌 piriformis
25. 臀上动、静脉 superior gluteal a. and v.
26. 臀小肌 gluteus minimus
27. 臀中肌 gluteus medius
28. 髂嵴 iliac crest
29. 空肠 jejunum
30. 结肠左曲 left colic flexure
31. 脾 spleen
32. 胃体 body of stomach
33. 梨状肌腱 tendon of piriformis



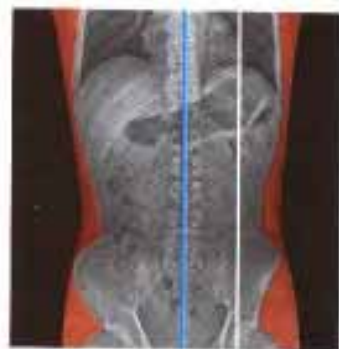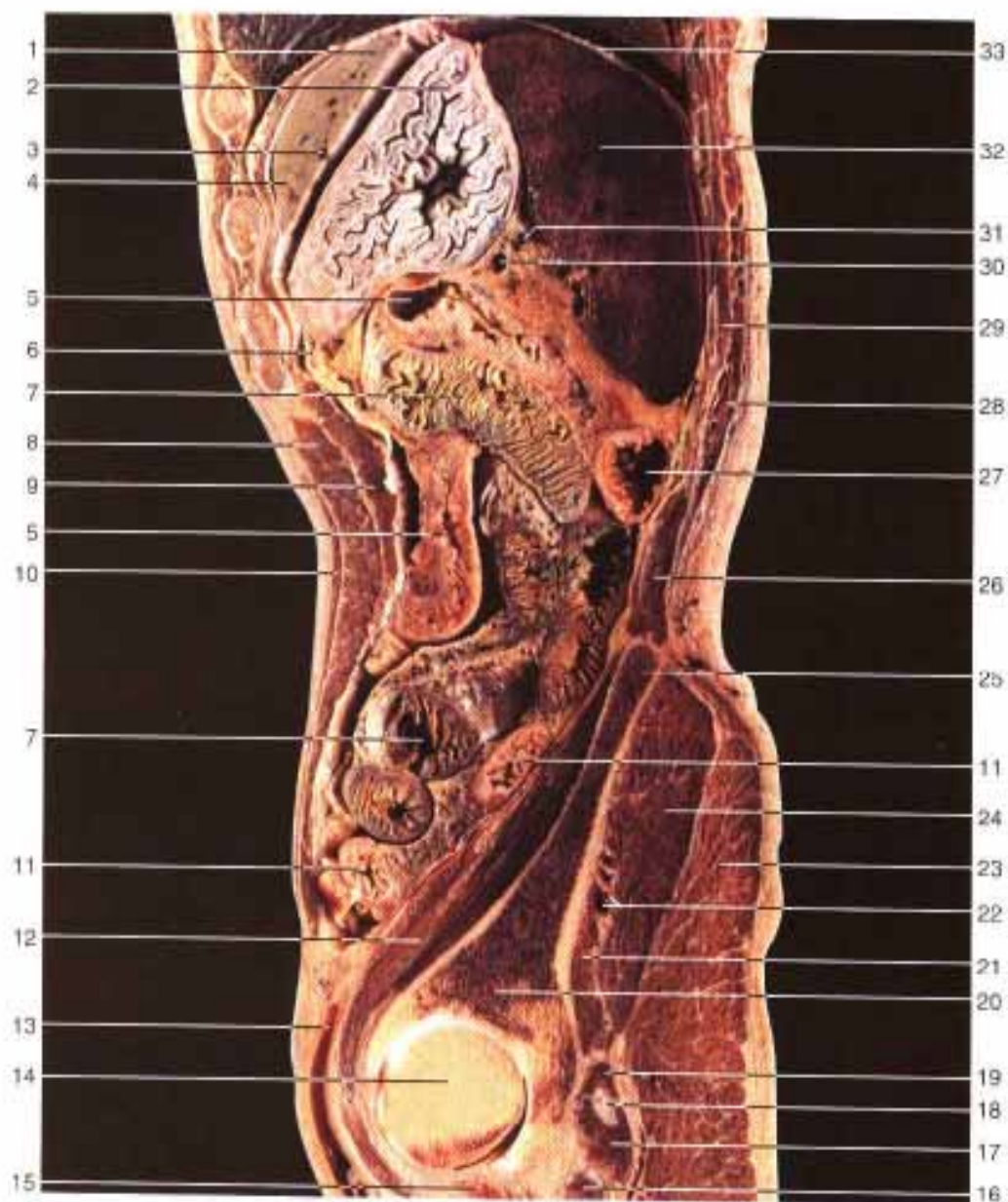

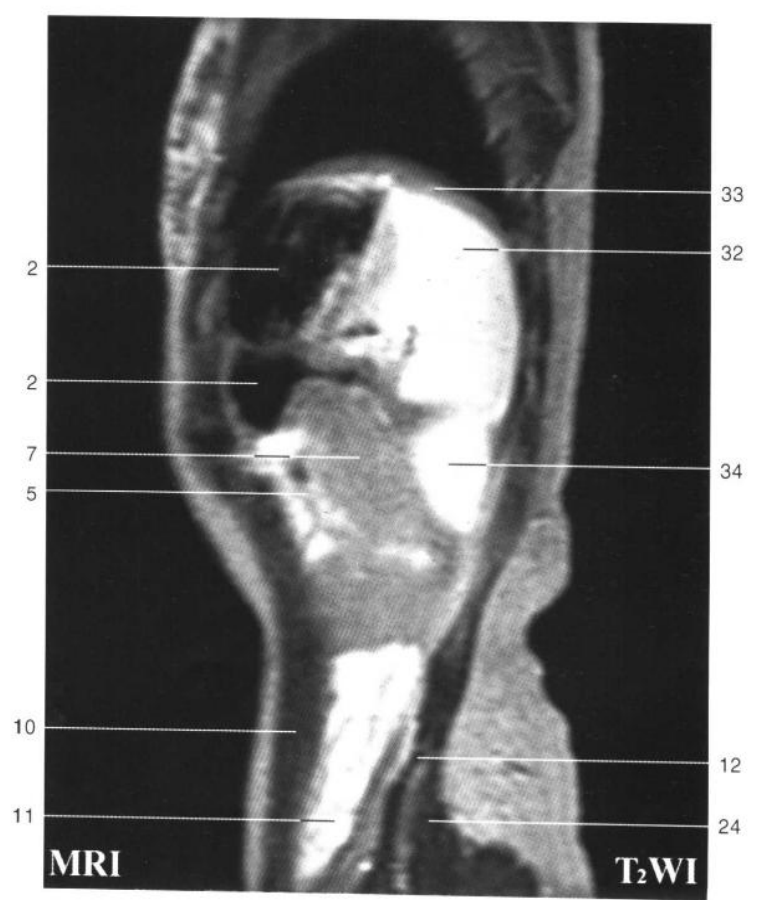
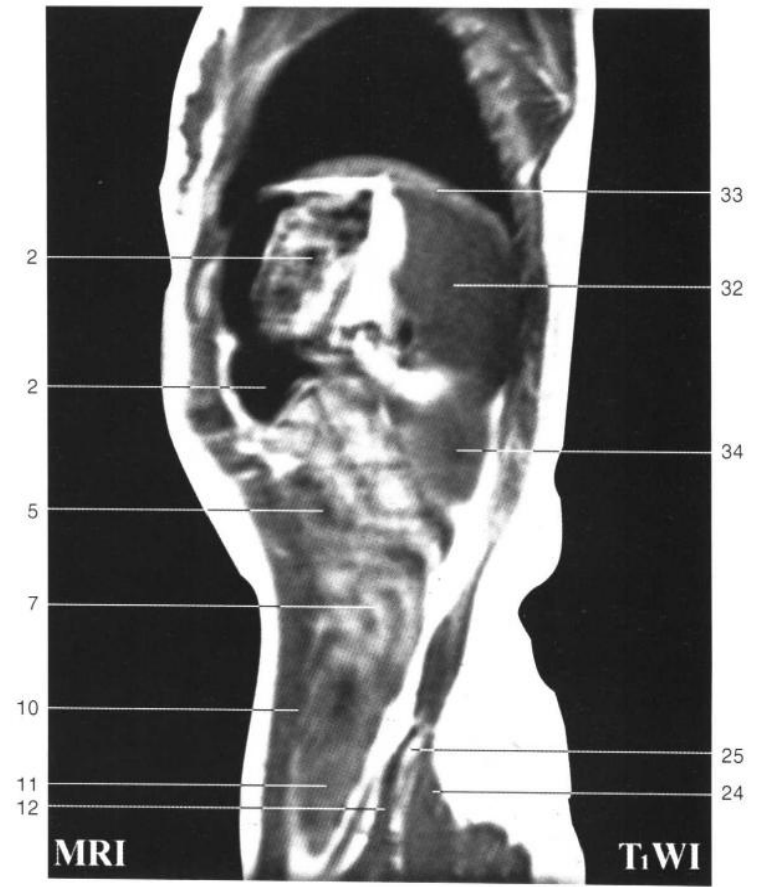Fig. SA 2

1. 左外叶上段 superior segment of left lateral lobe
2. 胃 stomach
3. 肝左静脉 left hepatic v.
4. 左外叶下段 inferior segment of left lateral lobe
5. 横结肠 transverse colon
6. 大网膜 greater omentum
7. 空肠 jejunum
8. 腹内斜肌 obliquus internus abdominis
9. 腹横肌 transversus abdominis

Fig.SA 2

- 10. 腹外斜肌 obliquus externus abdominis
- 11. 乙状结肠 sigmoid colon
- 12. 髂肌 iliacus
- 13. 股动脉 femoral a.
- 14. 股骨头 femoral head
- 15. 闭孔外肌 obturator externus
- 16. 股方肌 quadratus femoris
- 17. 下孖肌 gemellus inferior
- 18. 梨状肌腱 tendon of piriformis
- 19. 上孖肌 gemellus superior
- 20. 髌骨体 body of ilium
- 21. 臀小肌 gluteus minimus
- 22. 臀上动、静脉 superior gluteal a. and v.
- 23. 臀大肌 gluteus maximus
- 24. 臀中肌 gluteus medius
- 25. 髂嵴 iliac crest
- 26. 腰方肌 quadratus lumborum
- 27. 结肠左曲 left colic flexure
- 28. 腹外斜肌 obliquus externus abdominis
- 29. 腹内斜肌 obliquus internus abdominis
- 30. 脾静脉 splenic v.
- 31. 脾动脉 splenic a.
- 32. 脾 spleen
- 33. 膈 diaphragm
- 34. 左肾 left kidney



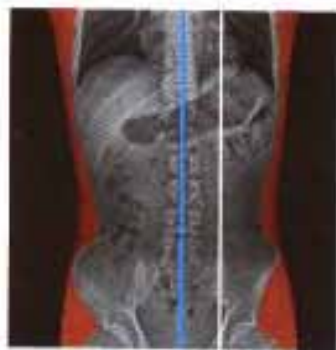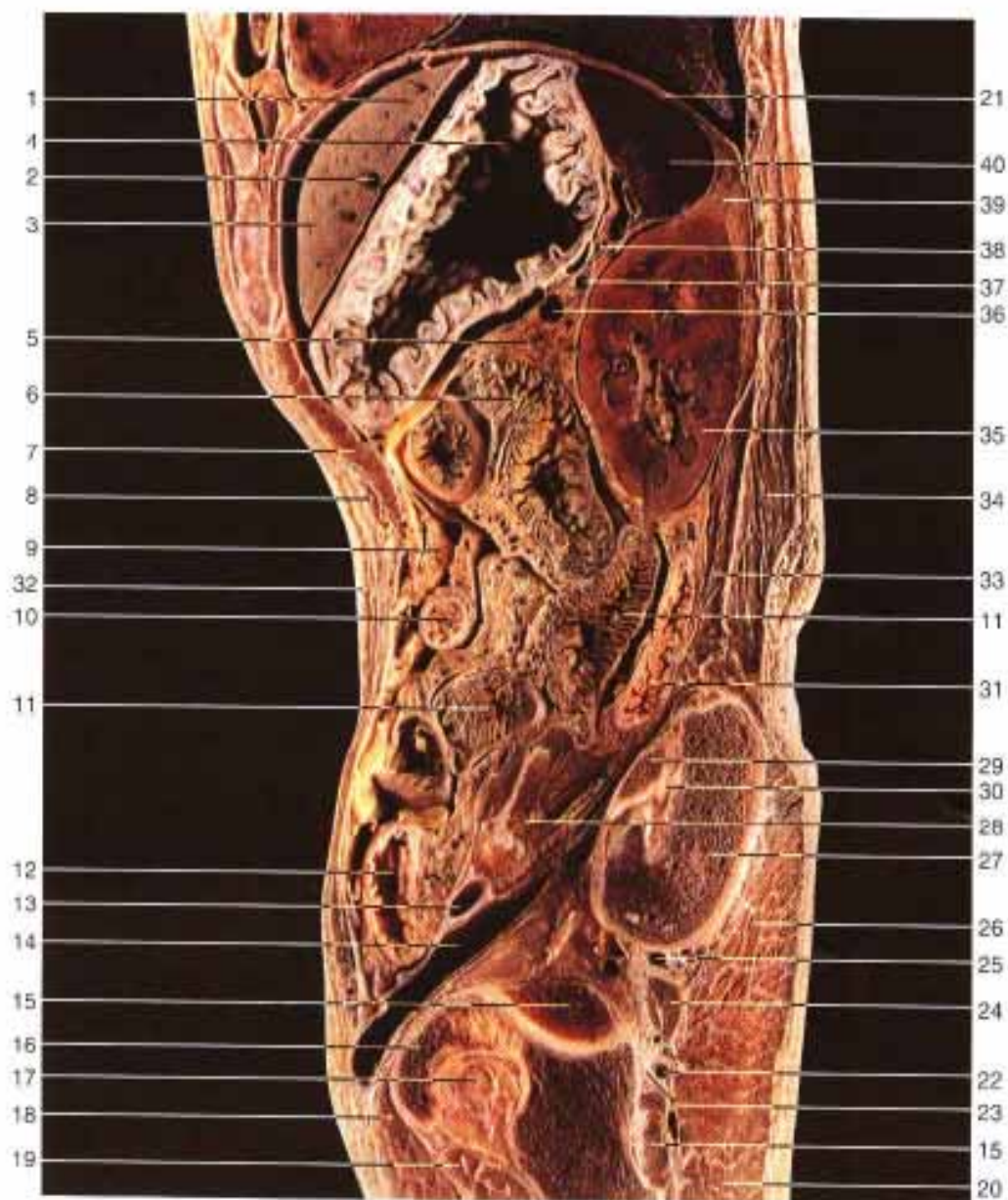

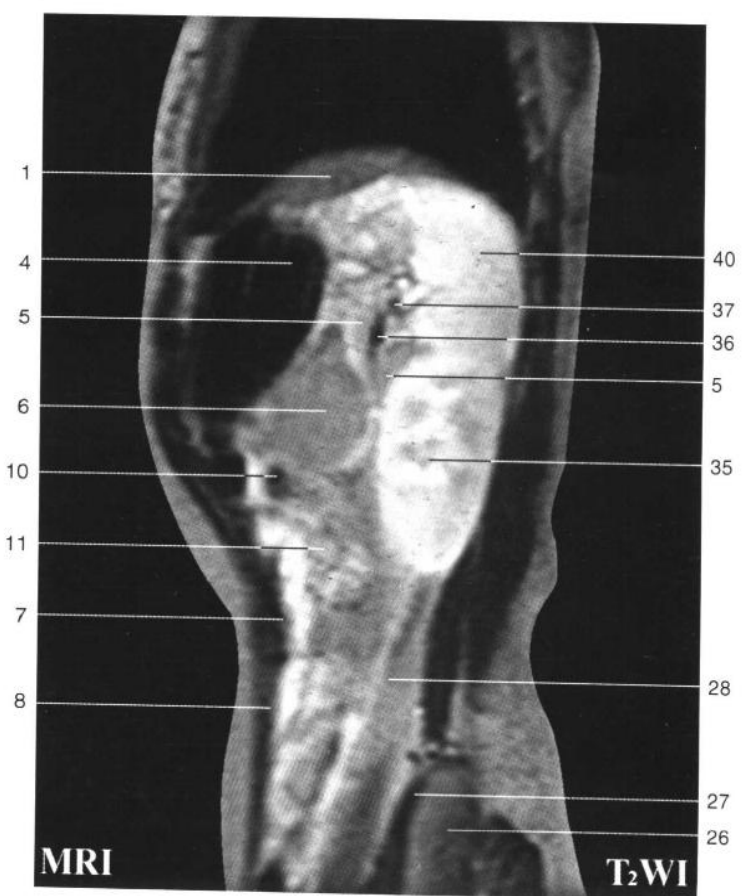
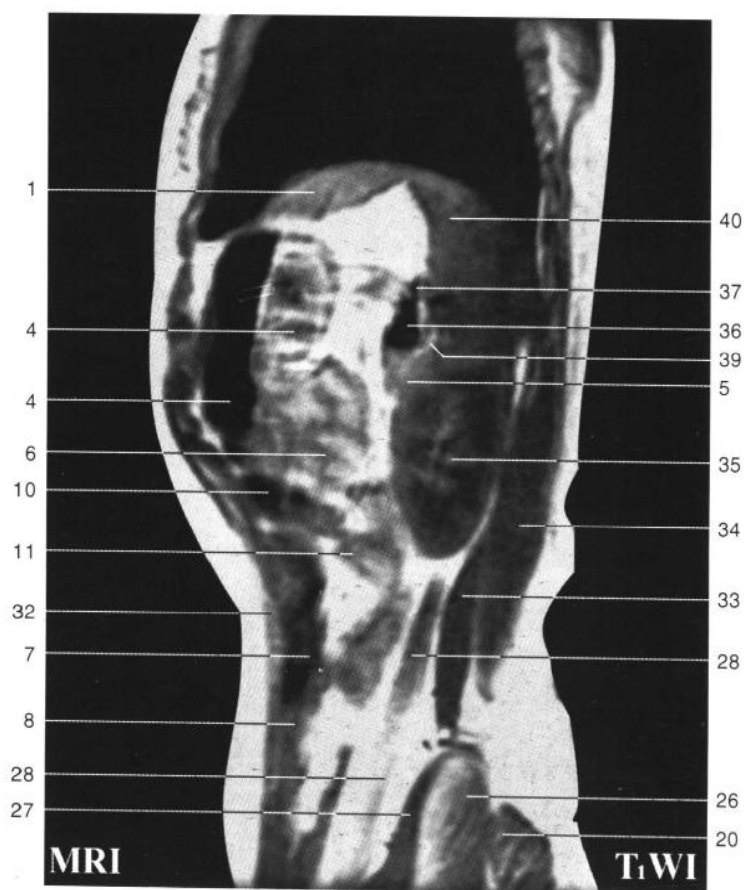Fig. SA 3

1. 左外叶上段 superior segment of left lateral lobe
2. 肝左静脉 left hepatic v.
3. 左外叶下段 inferior segment of left lateral lobe
4. 胃体 body of stomach
5. 胰 pancreas
6. 空肠 jejunum
7. 腹横肌 transversus abdominis
8. 腹内斜肌 obliquus internus abdominis
9. 大网膜 greater omentum

Fig.SA 3

10. 横结肠 transverse colon
11. 空肠 jejunum
12. 乙状结肠 sigmoid colon
13. 左髂外动脉 left external iliac a.
14. 左髂外静脉 left external iliac v.
15. 闭孔内肌 obturator internus
16. 耻骨体 body of pubis
17. 股骨头 femoral head
18. 耻骨肌 pectineus
19. 闭孔外肌 obturator externus
20. 臀大肌 gluteus maximus
21. 膈 diaphragm
22. 臀下动、静脉 inferior gluteal a. and v.
23. 坐骨神经 sciatic n.
24. 梨状肌 piriformis
25. 臀上动、静脉 superior gluteal a. and v.
26. 臀中肌 gluteus medius
27. 髌骨 ilium
28. 腰大肌 psoas major
29. 骶骨 sacrum
30. 骶髂关节 sacroiliac joint
31. 降结肠 descending colon
32. 腹外斜肌 obliquus externus abdominis
33. 腰方肌 quadratus lumborum
34. 竖脊肌 erector spinae
35. 左肾 left kidney
36. 脾静脉 splenic v.
37. 脾动脉 splenic a.
38. 胃短动脉 short gastric a.
39. 左肾上腺 left suprarenal gland
40. 脾 spleen



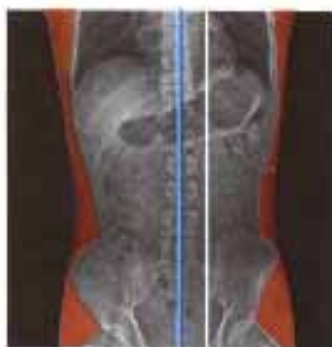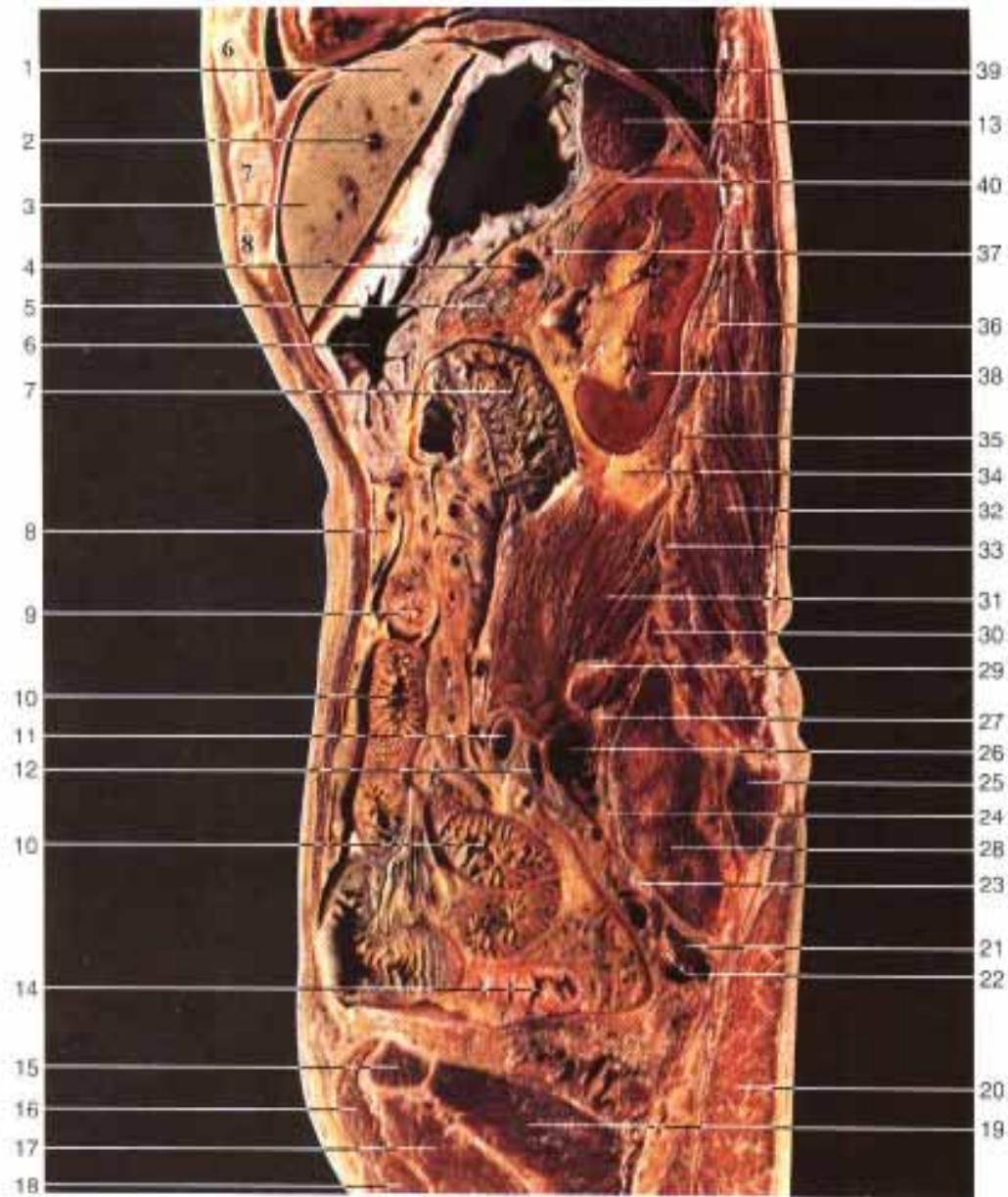

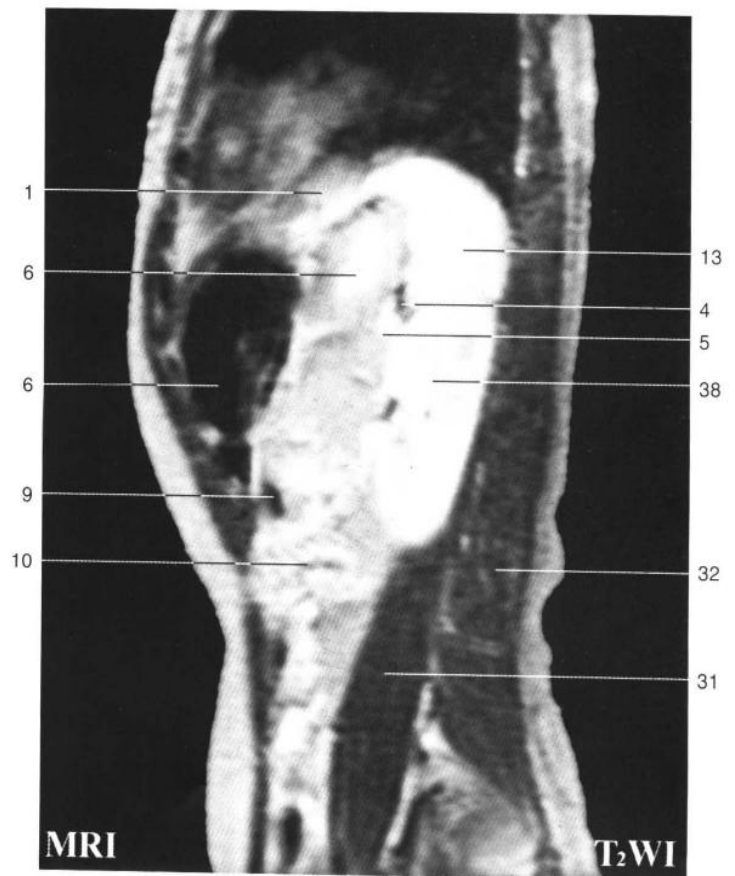
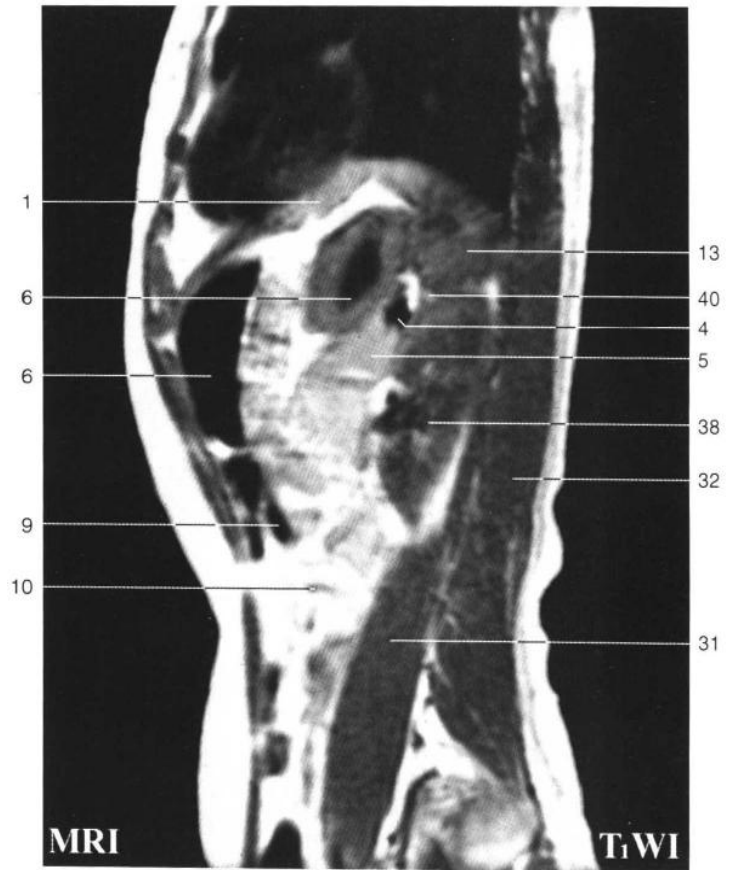Fig. SA 4

1. 左外叶上段 superior segment of left lateral lobe
2. 肝左静脉 left hepatic v.
3. 左外叶下段 inferior segment of left lateral lobe
4. 脾静脉 splenic v.
5. 胰 pancreas
6. 胃体 body of stomach
7. 空肠 jejunum
8. 大网膜 greater omentum
9. 横结肠 transverse colon
10. 空肠 jejunum

Fig.SA 4

11. 左髂外动脉 left external iliac a.
12. 左髂内动脉 left internal iliac a.
13. 脾 spleen
14. 乙状结肠 sigmoid colon
15. 耻骨上支 superior ramus of pubis
16. 耻骨肌 pectineus
17. 闭孔外肌 obturator externus
18. 长收肌 adductor longus
19. 闭孔内肌 obturator internus
20. 臀大肌 gluteus maximus
21. 梨状肌 piriformis
22. 第2骶神经 2nd sacral n.
23. 第1骶神经 1st sacral n.
24. 腰骶干 lumbosacral trunk
25. 髌骨 ilium
26. 左髂总静脉 left common iliac v.
27. 闭孔神经 obturator n.
28. 骶骨 sacrum
29. 股神经 femoral n.
30. 第4腰椎横突 transverse process(L₄)
31. 腰大肌 psoas major
32. 竖脊肌 erector spinae
33. 第3腰椎横突 transverse process(L₃)
34. 脂肪囊 fatty renal capsule
35. 第2腰椎横突 transverse process(L₂)
36. 第1腰椎横突 transverse process(L₁)
37. 脾动脉 splenic a.
38. 左肾 left kidney
39. 膈 diaphragm
40. 左肾上腺 left suprarenal gland



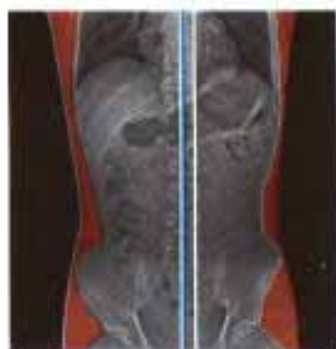
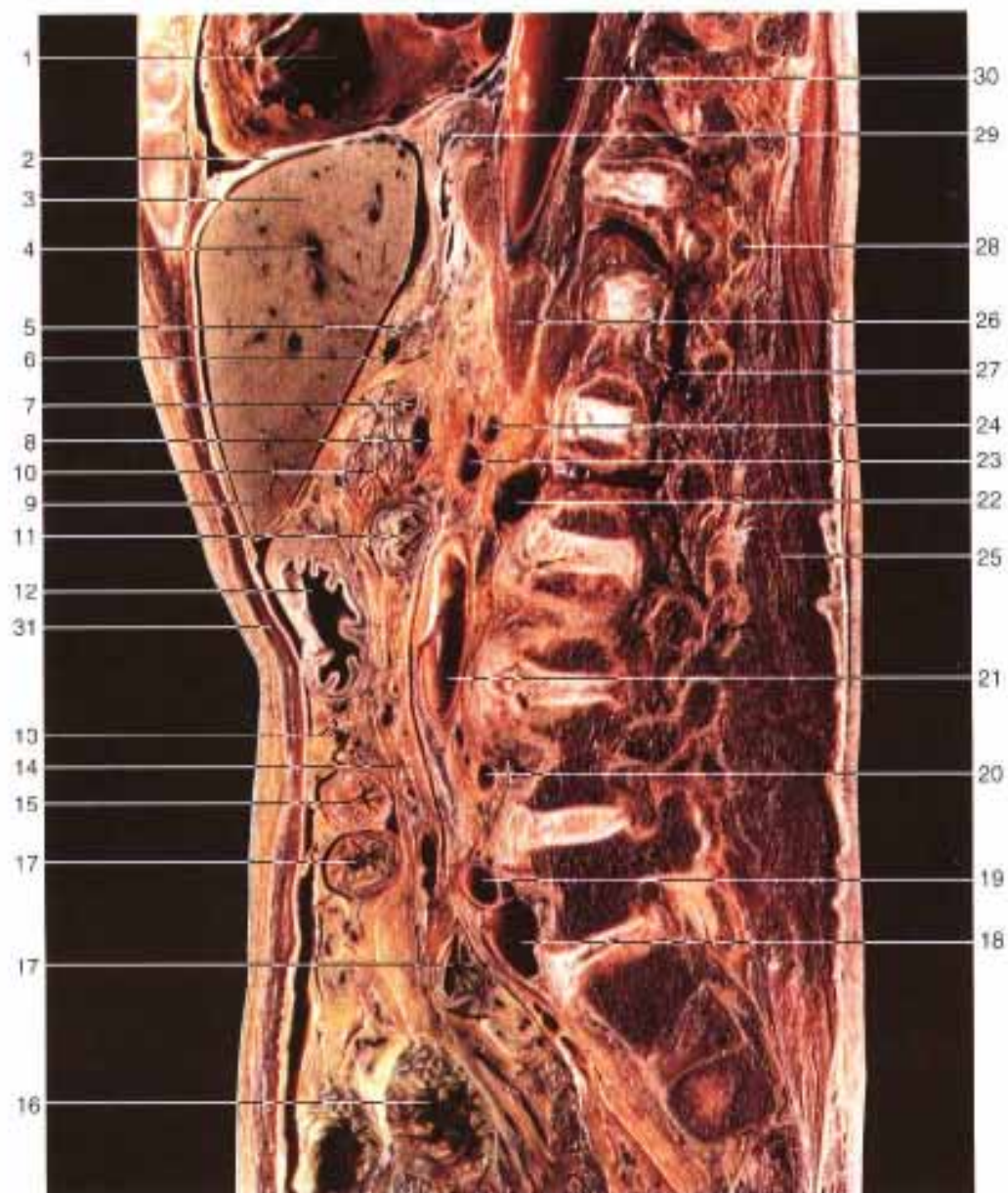

Fig. SA 5

1. 右心室 right ventricle
2. 膈 diaphragm
3. 左外叶 left lateral lobe
4. 肝左静脉 left hepatic v.
5. 胃左动脉 left gastric a.
6. 胃左静脉 left gastric v.
7. 脾动脉 splenic a.
8. 脾静脉 splenic v.
9. 左外叶下段 inferior segment of left lateral lobe

Fig.SA 5

10. 胰 pancreas
11. 十二指肠水平部 horizontal part of duodenum
12. 幽门窦 pyloric antrum
13. 胃网膜右动、静脉 right gastroepiploic a. and v.
14. 肠系膜 mesentery
15. 横结肠 transverse colon
16. 空肠 jejunum
17. 空肠 jejunum
18. 左髂总静脉 left common iliac v.
19. 左髂总动脉 left common iliac a.
20. 腰动脉 lumbar a.
21. 腹主动脉 abdominal aorta
22. 第3腰静脉 3rd lumbar v.
23. 左肾静脉 left renal v.
24. 左肾动脉 left renal a.
25. 竖脊肌 erector spinae
26. 膈左脚 left crus of diaphragm
27. 椎外静脉丛 external vertebral venous plexus
28. 第12胸椎横突 transverse process (T₁₂)
29. 食管 esophagus
30. 胸主动脉 thoracic aorta
31. 腹直肌 rectus abdominis
32. 胃体 body of stomach
33. 腹腔干 celiac trunk
34. 肠系膜上动脉 superior mesenteric a.

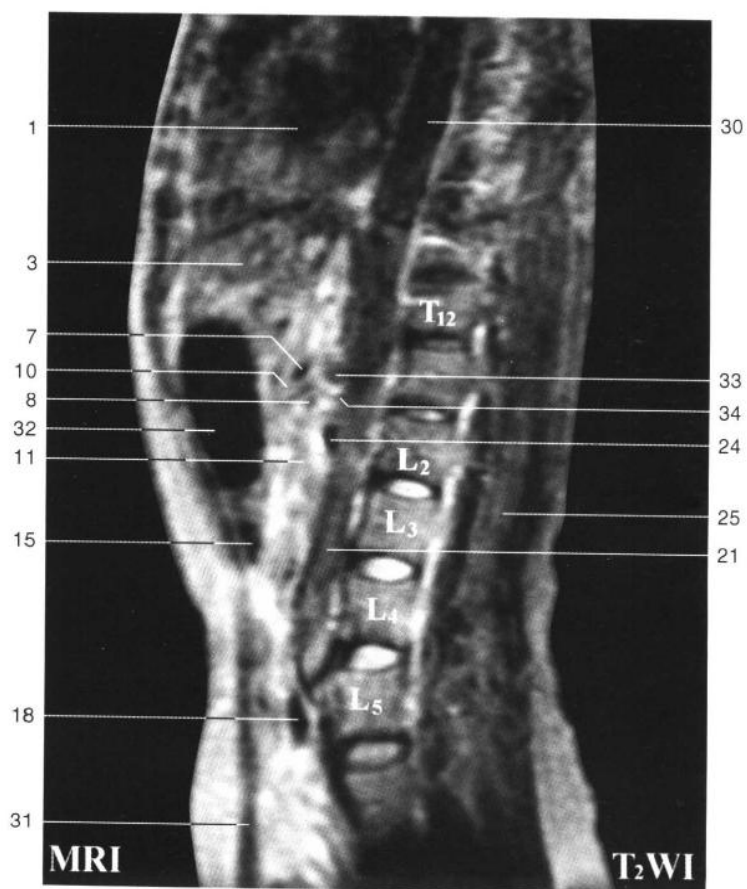
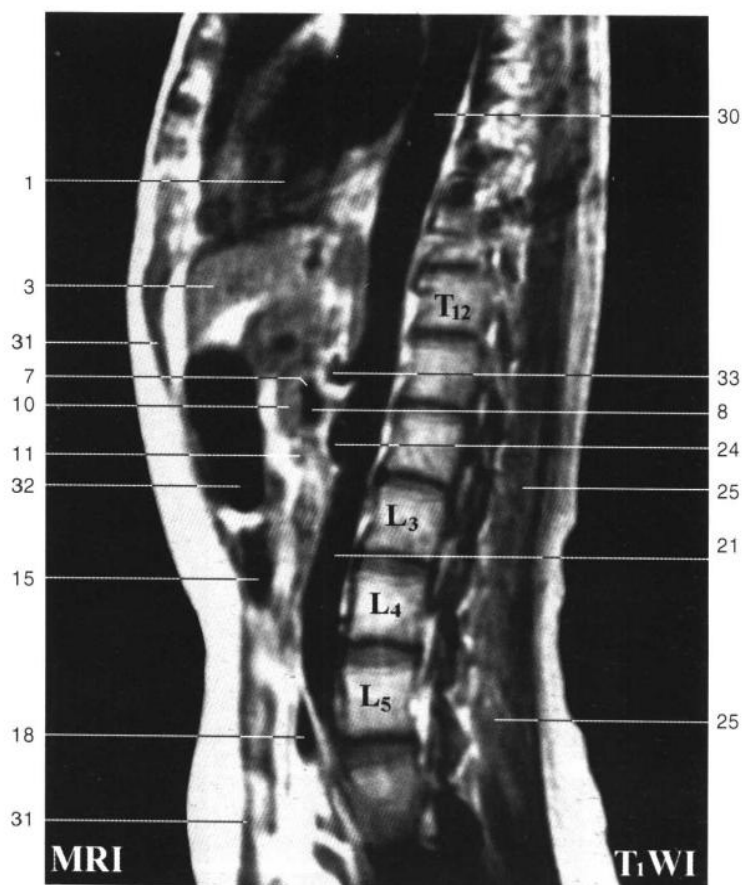
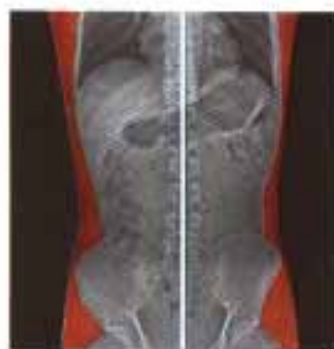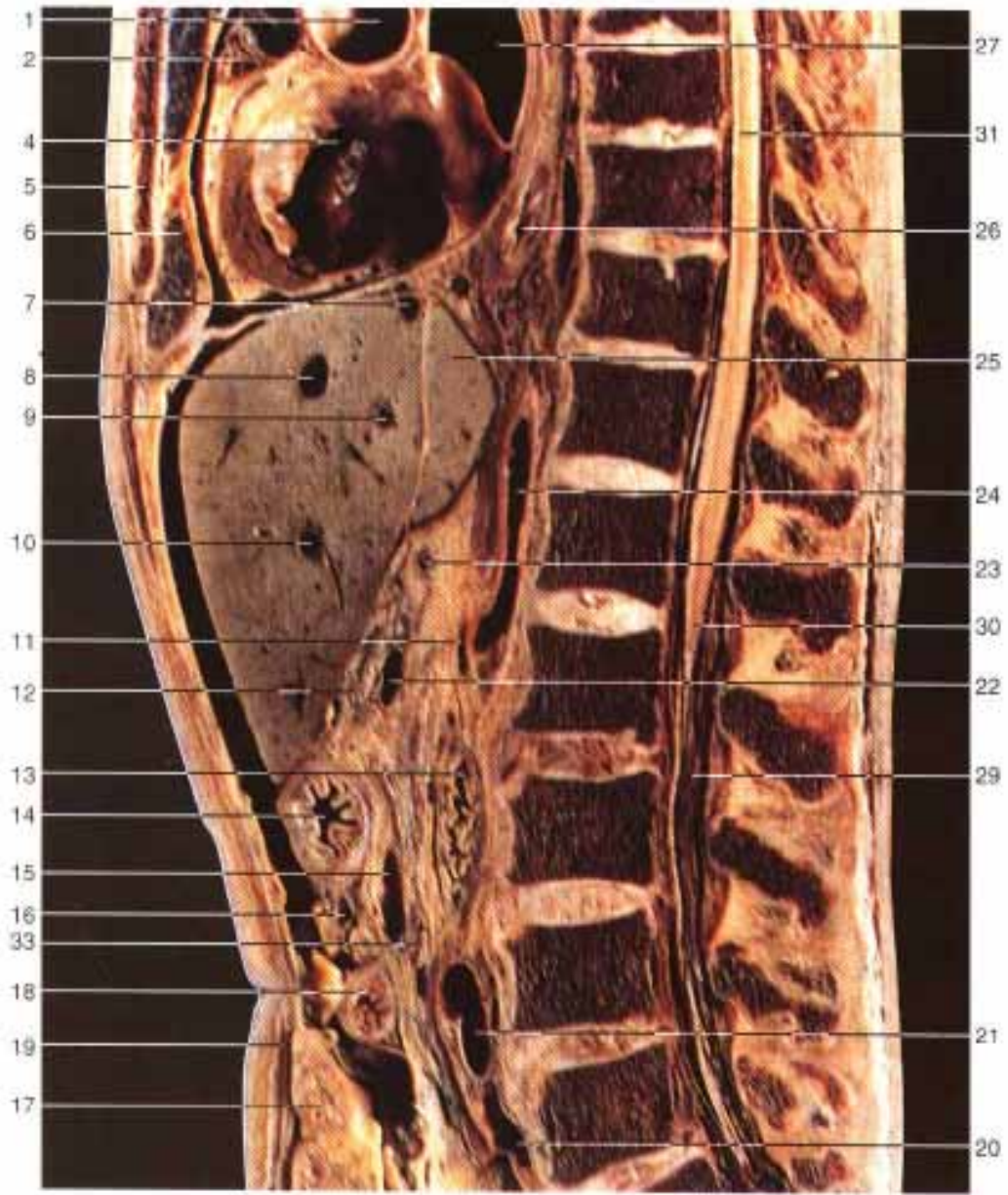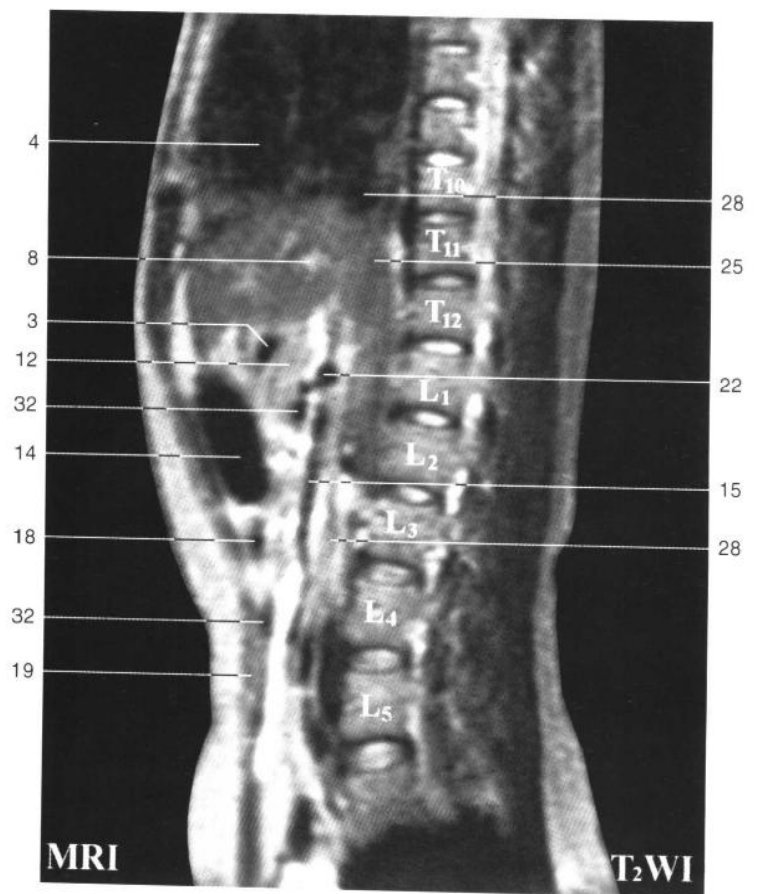
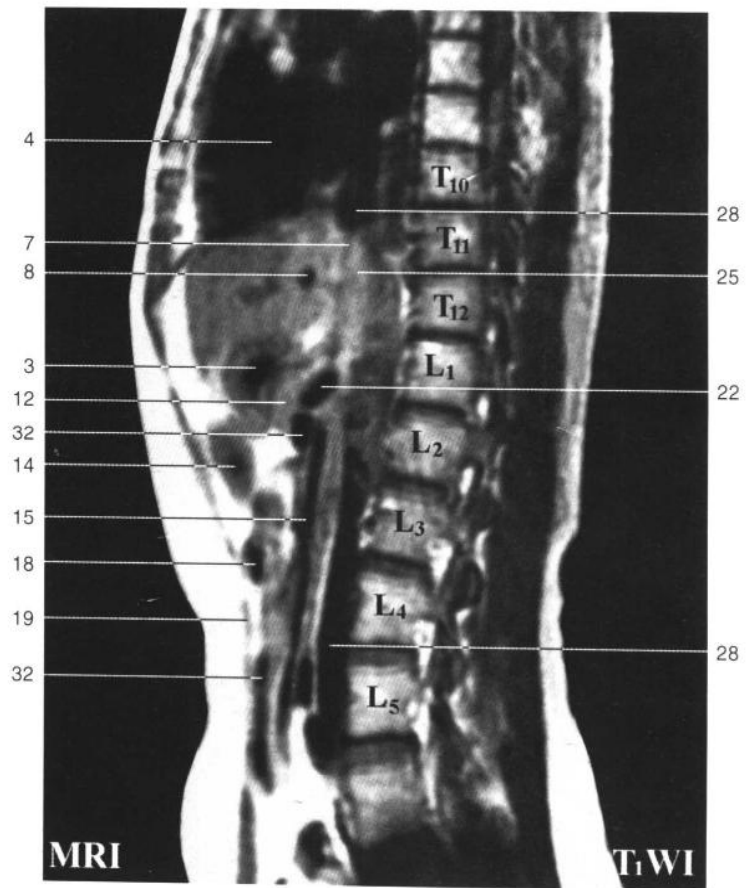




Fig. SA 6
 1. 升主动脉 ascending aorta
 2. 右心房 right auricle
 3. 胃 stomach
 4. 右心房 right atrium
 5. 胸骨体 body of sternum
 6. 左肺上叶 superior lobe of left lung
 7. 肝中间静脉 intermediate hepatic v.
 8. 肝左静脉 left hepatic v.
 9. 左外叶上段静脉 superior segmental v. of left lateral lobe

Fig.SA 6

10. 左外叶下段静脉 inferior segmental v. of left lateral lobe
11. 左肾静脉 left renal v.
12. 胰 pancreas
13. 十二指肠水平部 horizontal part of duodenum
14. 幽门管 pyloric canal
15. 肠系膜上静脉 superior mesenteric v.
16. 胃网膜右动、静脉 right gastroepiploic a. and v.
17. 大网膜 greater omentum
18. 横结肠 transverse colon
19. 腹直肌 rectus abdominis
20. 左髂总静脉 left common iliac v.
21. 左髂总动脉 left common iliac a.
22. 肝门静脉 hepatic portal v.
23. 肝总动脉 common hepatic a.
24. 腹主动脉 abdominal aorta
25. 尾状叶 caudate lobe
26. 食管 esophagus
27. 左心房 left atrium
28. 下腔静脉 inferior vena cava
29. 马尾 cauda equina
30. 脊髓圆锥 conus medullaris
31. 脊髓 spinal cord
32. 肠系膜上动脉 superior mesenteric a.
33. 空肠 jejunum



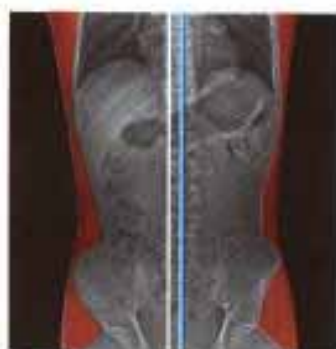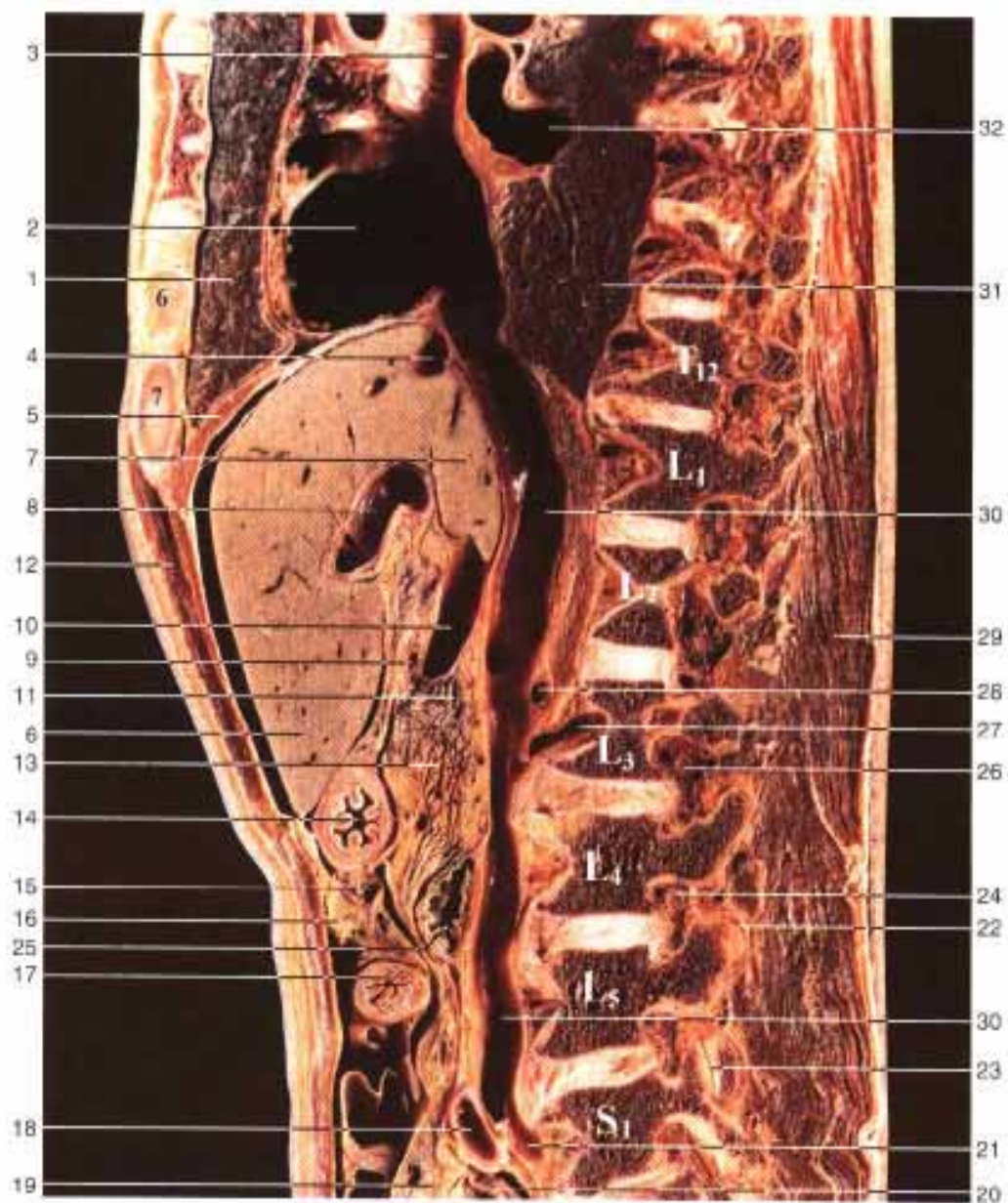
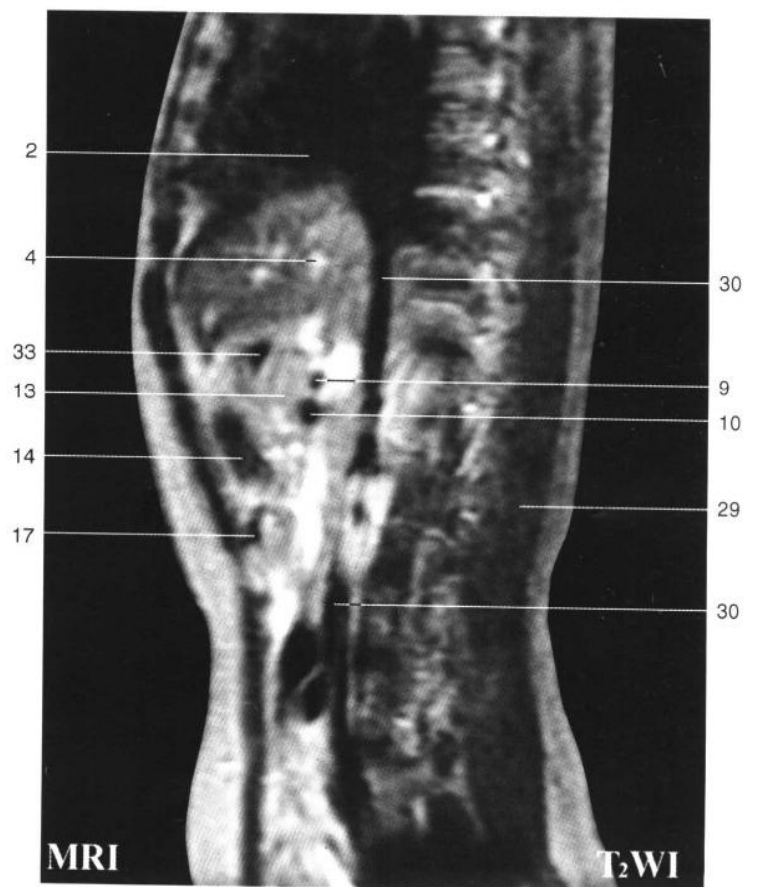

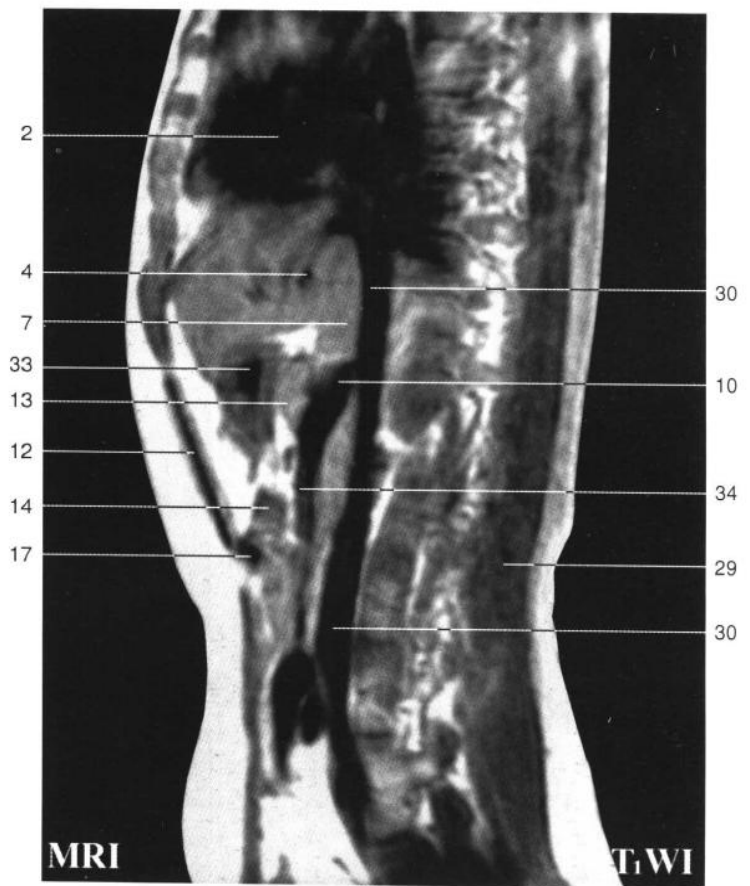
Fig. SA 7

1. 右肺中叶 middle lobe of right lung
2. 右心房 right atrium
3. 上腔静脉 superior vena cava
4. 肝中间静脉 intermediate hepatic v.
5. 膈 diaphragm
6. 左外叶 left lateral lobe
7. 尾状叶 caudate lobe
8. 肝门静脉左支脐部 umbilical part of left branch of hepatic portal v.
9. 肝固有动脉 proper hepatic a.

Fig.SA 7

10. 肝门静脉 hepatic portal v.
11. 胆总管 common bile duct
12. 腹直肌 rectus abdominis
13. 胰头 head of pancreas
14. 幽门管 pyloric canal
15. 胃网膜右动、静脉 right gastroepiploic a. and v.
16. 大网膜 greater omentum
17. 横结肠 transverse colon
18. 右髂总动脉 right common iliac a.
19. 肠系膜 mesentery
20. 空肠 jejunum
21. 右髂总静脉 right common iliac v.
22. 4,5 腰椎关节突关节 zygapophysial joint(L₄-L₅)
23. 第5腰椎、第1骶椎关节突关节 zygapophysial joint(L₅-S₁)
24. 第4腰神经 4th lumbar n.
25. 十二指肠水平部 horizontal part of duodenum
26. 第3腰神经 3rd lumbar n.
27. 第3腰静脉 3rd lumbar v.
28. 右肾动脉 right renal a.
29. 竖脊肌 erector spinae
30. 下腔静脉 inferior vena cava
31. 右肺下叶 inferior lobe of right lung
32. 左心房 left atrium
33. 胃 stomach
34. 肠系膜上静脉 superior mesenteric v.



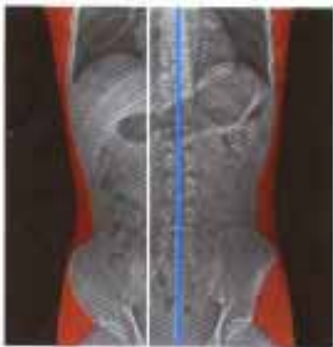
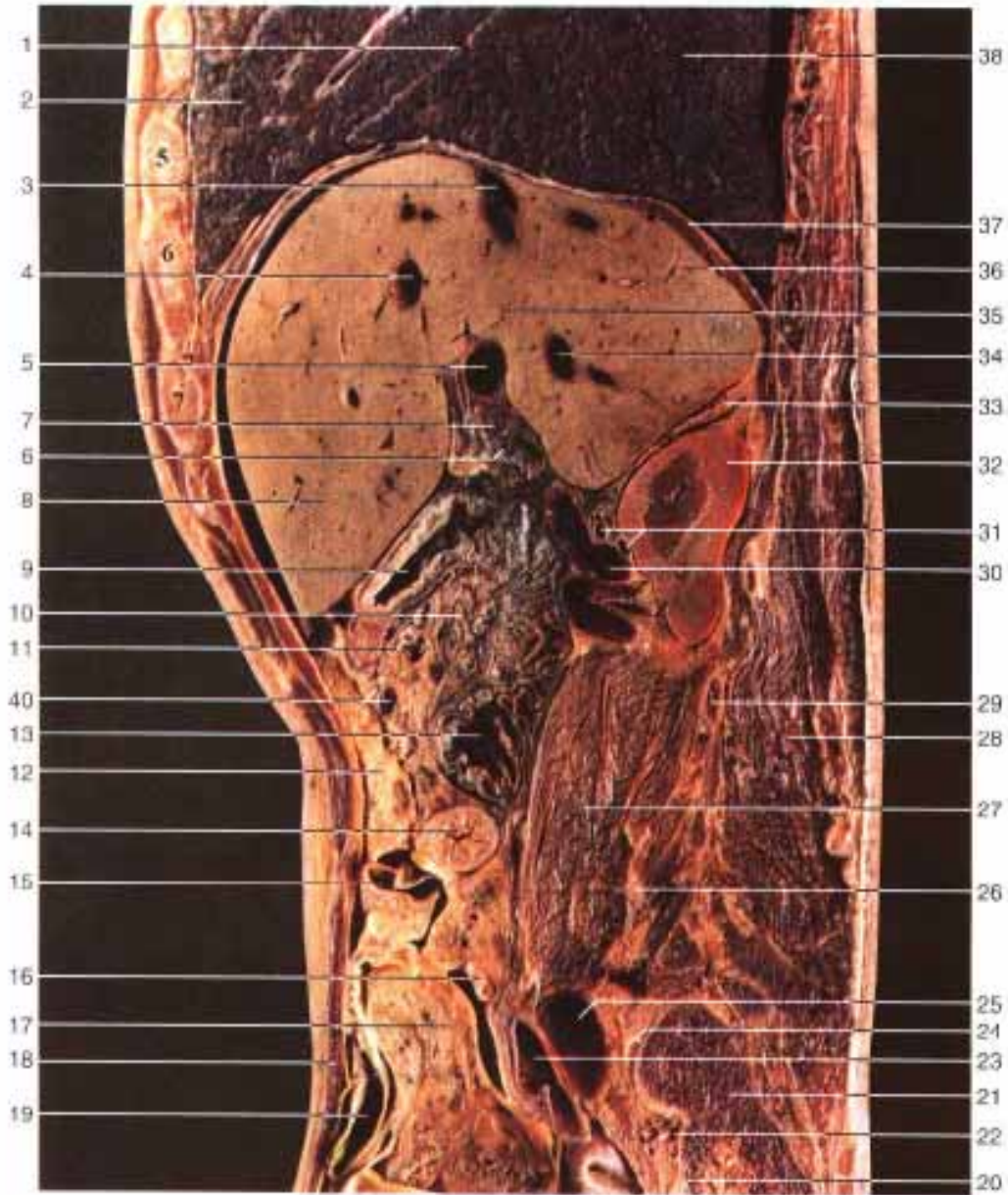
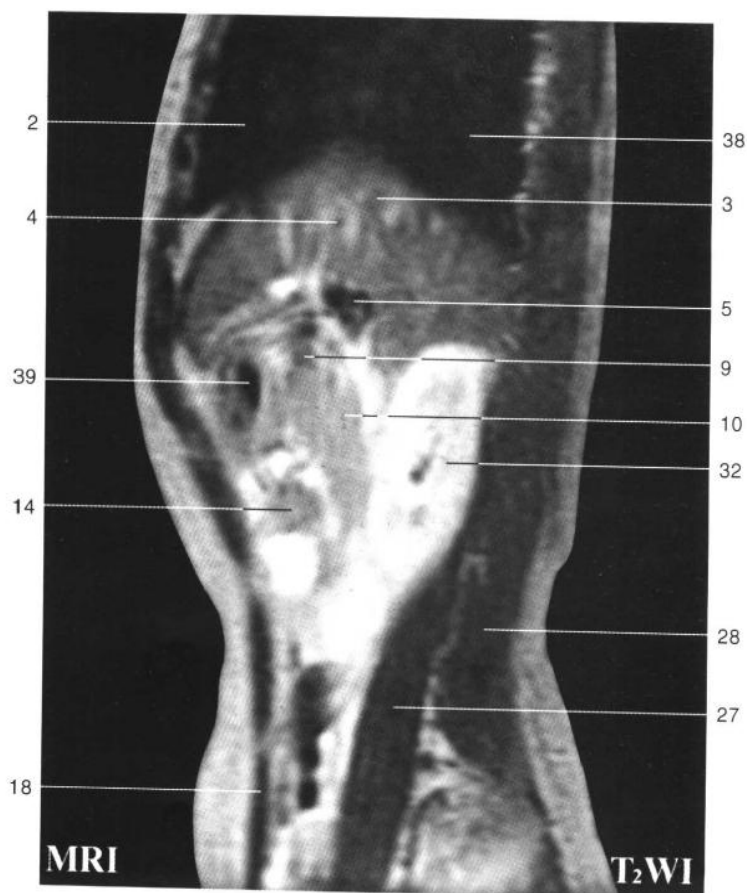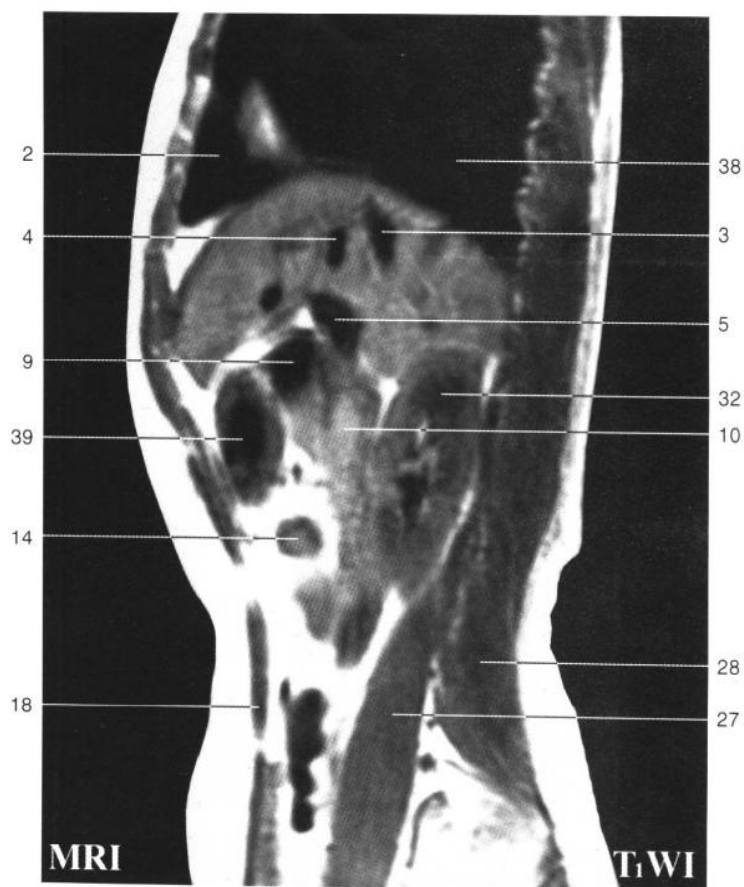


Fig. SA 8

1. 斜裂 oblique fissure
2. 右肺中叶 middle lobe of right lung
3. 下腔静脉 inferior vena cava
4. 肝中间静脉 intermediate hepatic v.
5. 肝门静脉 hepatic portal v.
6. 肝固有动脉 proper hepatic a.
7. 胆总管 common bile duct
8. 左内叶 left medial lobe
9. 十二指肠上部 superior part of duodenum
10. 胰头 head of pancreas

Fig.SA 8

11. 胰十二指肠动脉 pancreaticoduodenal a.
12. 大网膜 greater omentum
13. 十二指肠降部 descending part of duodenum
14. 横结肠 transverse colon
15. 回肠 ileum
16. 阑尾 vermiform appendix
17. 肠系膜 mesentery
18. 腹直肌 rectus abdominis
19. 空肠 jejunum
20. 骶丛 sacral plexus
21. 骶骨 sacrum
22. 骶外侧动脉 lateral sacral a.
23. 右髂总动脉 right common iliac a.
24. 第5腰椎神经 5th lumbar n.
25. 右髂总静脉 right common iliac v.
26. 股神经 femoral n.
27. 腰大肌 psoas major
28. 竖脊肌 erector spinae
29. 第3腰椎横突 transverse process(L₃)
30. 右肾静脉 right renal v.
31. 右肾动脉 right renal a.
32. 右肾 right kidney
33. 右肾上腺 right suprarenal gland
34. 右肝后静脉 right posterior hepatic v.
35. 右前叶 right anterior lobe
36. 右后叶 right posterior lobe
37. 膈 diaphragm
38. 右肺下叶 inferior lobe of right lung
39. 胃 stomach
40. 胃网膜右动、静脉 right gastroepiploic a. and v.



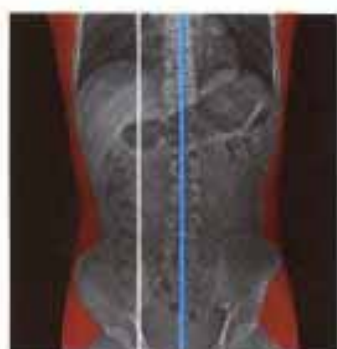
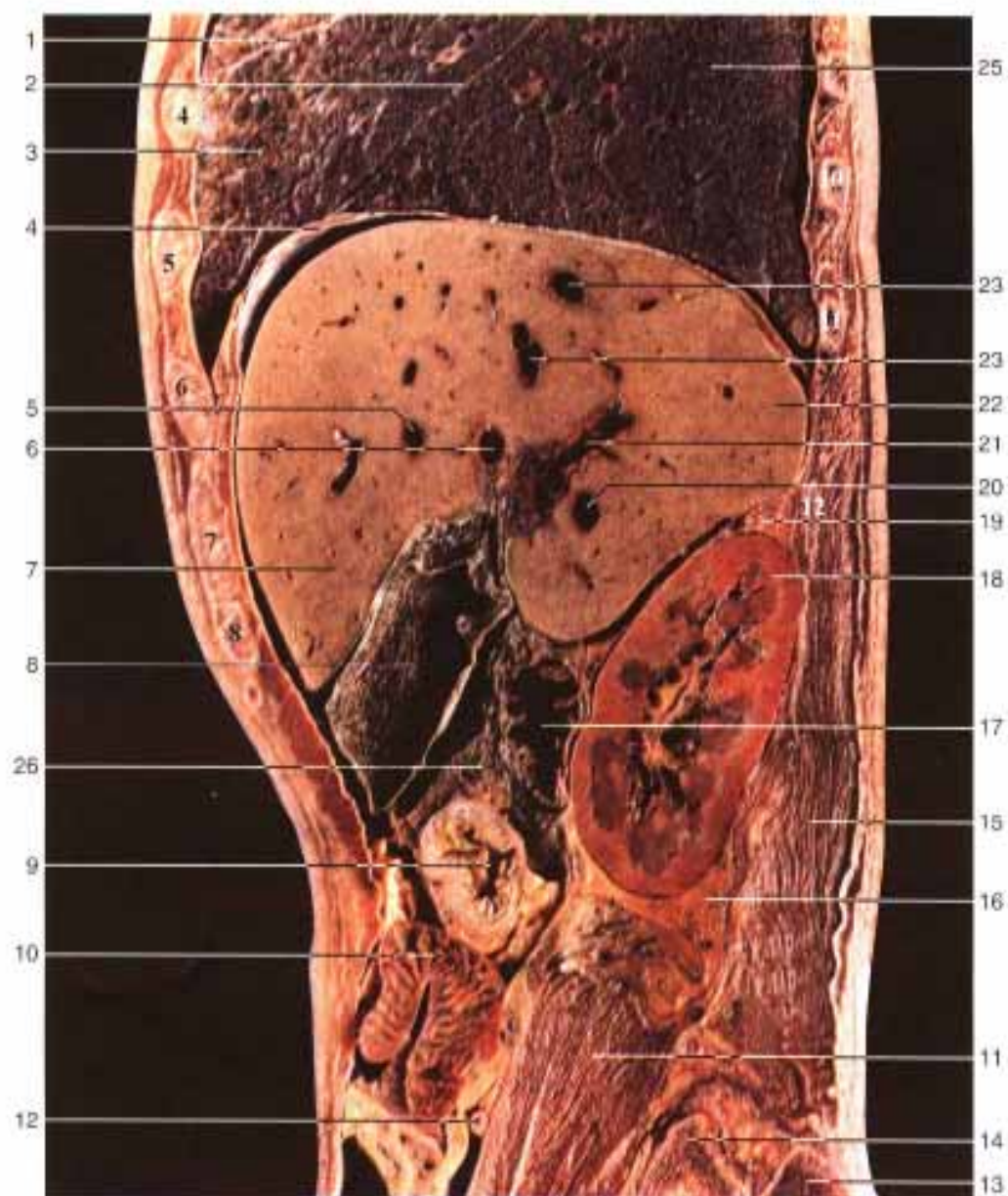
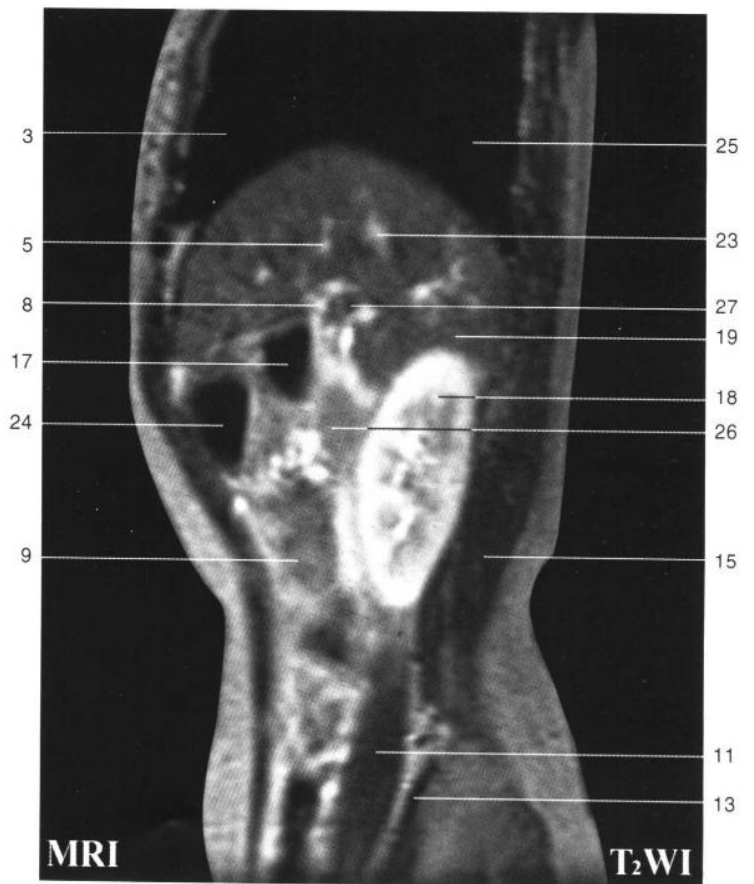
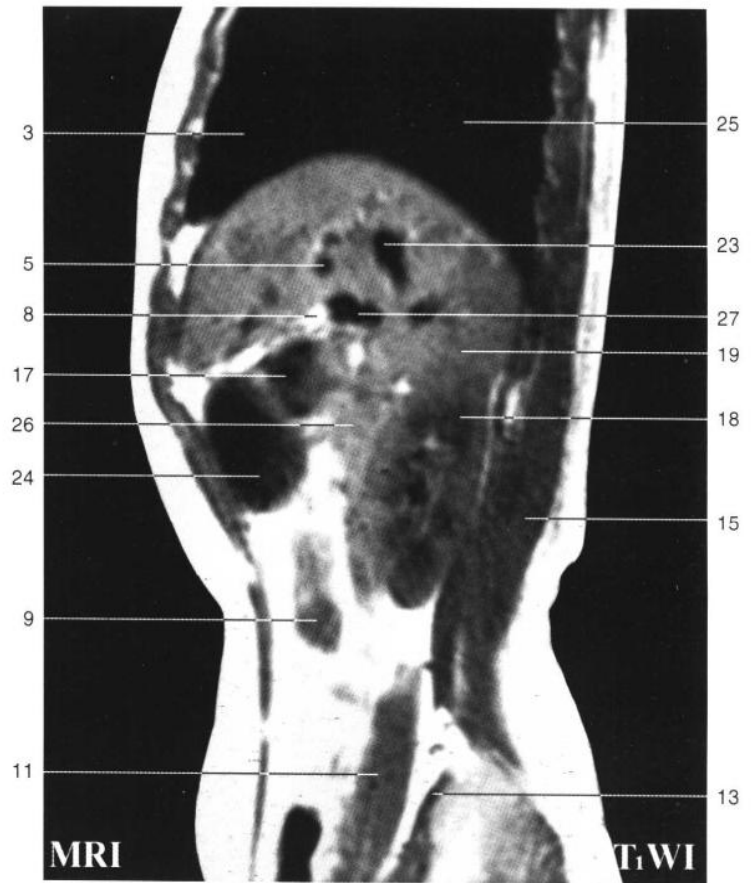
Fig. SA 9

1. 右肺水平裂 horizontal fissure of right lung
2. 斜裂 oblique fissure
3. 右肺中叶 middle lobe of right lung
4. 膈 diaphragm
5. 肝中间静脉 intermediate hepatic v.
6. 肝门静脉左支横部 transverse part of left branch of hepatic portal v.
7. 左内叶 left medial lobe
8. 胆囊 gallbladder
9. 横结肠 transverse colon

Fig.SA 9

10. 回肠 ileum
11. 腰大肌 psoas major
12. 阑尾 vermiform appendix
13. 髌骨 ilium
14. 骶骨 sacrum
15. 竖脊肌 erector spinae
16. 脂肪囊 fatty renal capsule
17. 十二指肠降部 descending part of duodenum
18. 右肾 right kidney
19. 右肾上腺 right suprarenal gland
20. 右后肝静脉 right posterior hepatic v.
21. 肝门静脉右支 right branch of hepatic portal v.
22. 右后叶 right posterior lobe
23. 肝右静脉 right hepatic v.
24. 胃 stomach
25. 右肺下叶 inferior lobe of right lung
26. 胰头 head of pancreas
27. 肝门静脉 hepatic portal v.



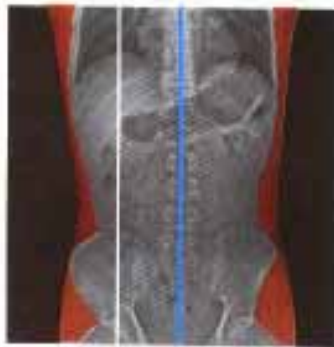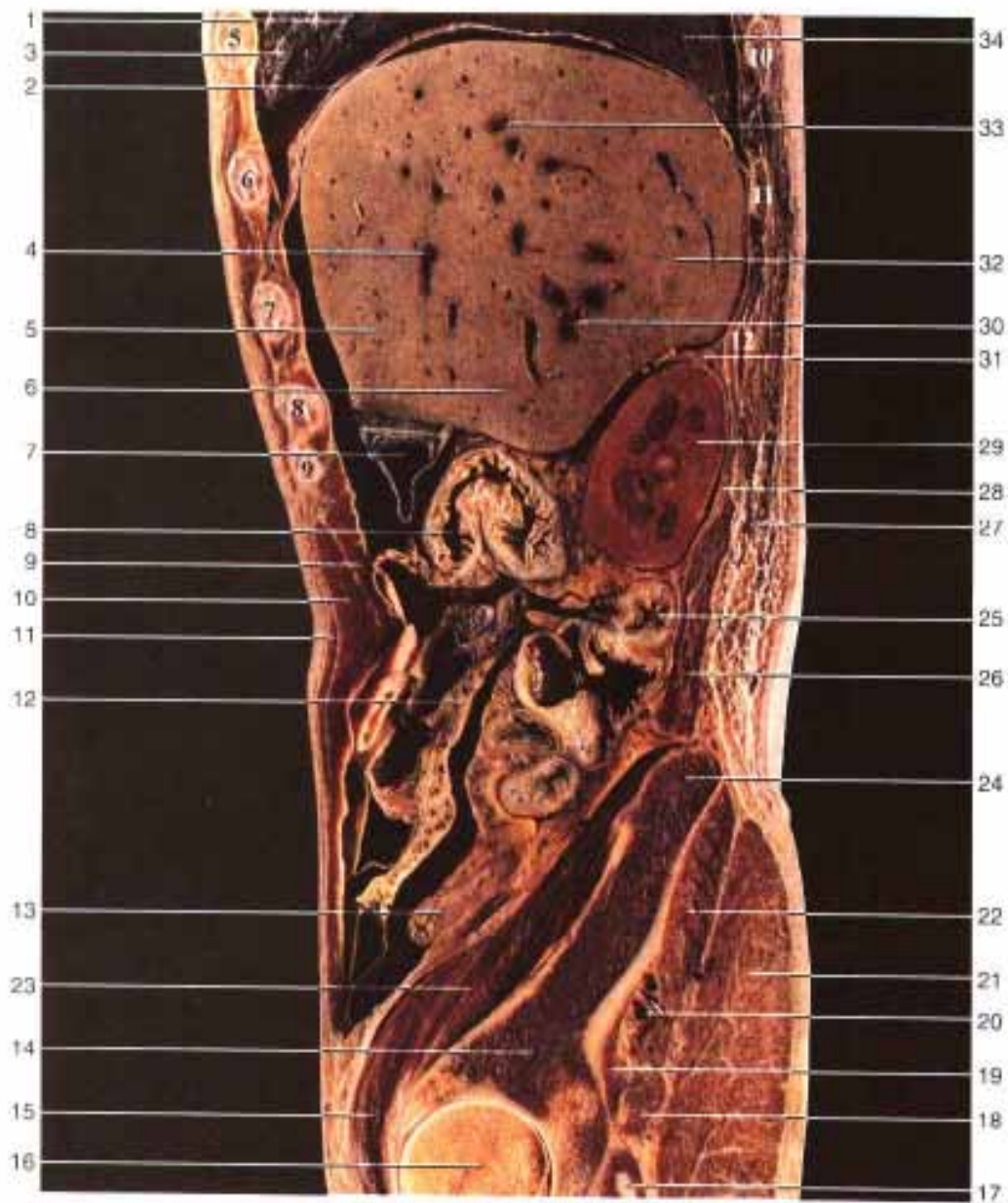

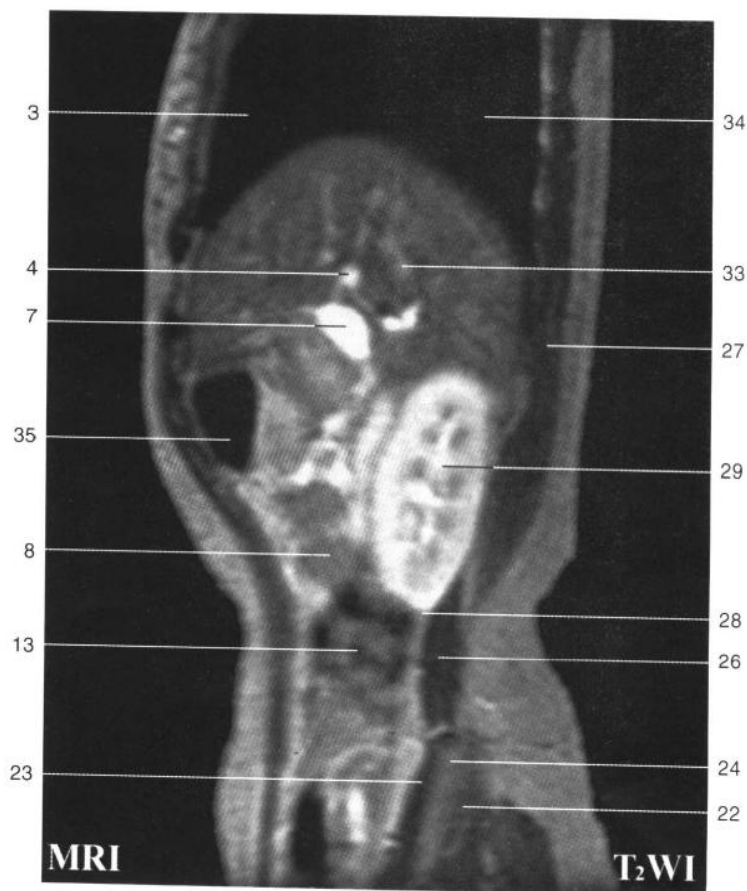
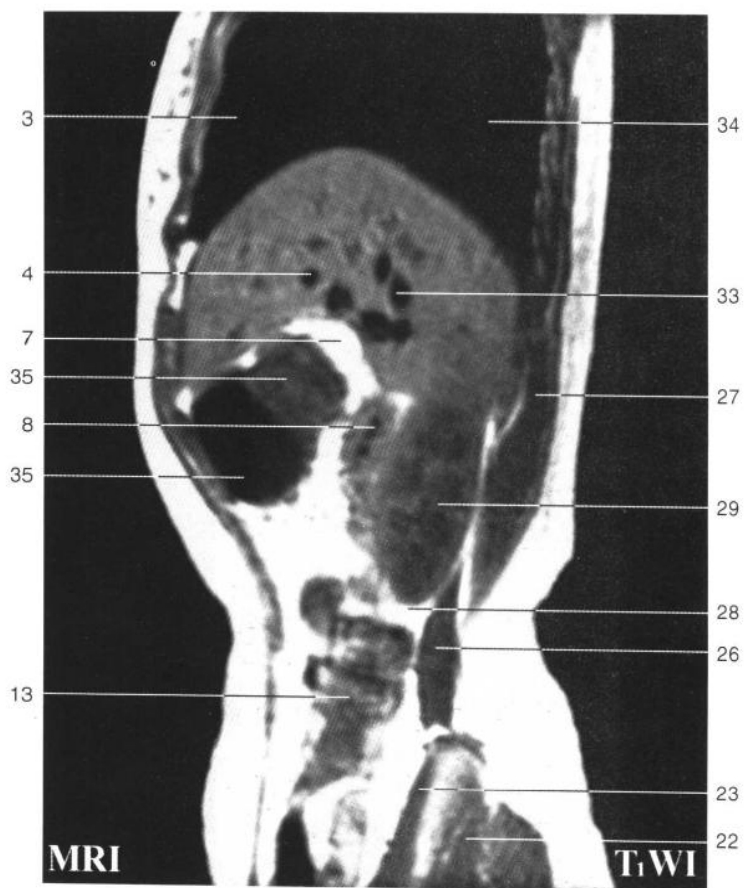Fig. SA 10

1. 斜裂 oblique fissure
2. 膈 diaphragm
3. 右肺中叶 middle lobe of right lung
4. 肝中间静脉 intermediate hepatic v.
5. 左内叶 left medial lobe
6. 右前叶 right anterior lobe
7. 胆囊 gallbladder
8. 横结肠 transverse colon
9. 腹横肌 transversus abdominis
10. 腹内斜肌 obliquus internus abdominis

Fig.SA 10

11. 腹外斜肌 obliquus externus abdominis
12. 肠系膜 mesentery
13. 回肠 ileum
14. 髌骨体 body of ilium
15. 髂腰肌 iliopsoas
16. 股骨头 femoral head
17. 闭孔内肌腱 tendon of obturator internus
18. 梨状肌 piriformis
19. 臀小肌 gluteus minimus
20. 臀上动、静脉 superior gluteal a. and v.
21. 臀大肌 gluteus maximus
22. 臀中肌 gluteus medius
23. 髂肌 iliacus
24. 髂嵴 iliac crest
25. 升结肠 ascending colon
26. 腰方肌 quadratus lumborum
27. 竖脊肌 erector spinae
28. 脂肪囊 fatty renal capsule
29. 右肾 right kidney
30. 右后叶静脉 right posterior lobar v.
31. 右肾上腺 right suprarenal gland
32. 右后叶 right posterior lobe
33. 肝右静脉 right hepatic v.
34. 右肺下叶 inferior lobe of right lung
35. 胃 stomach



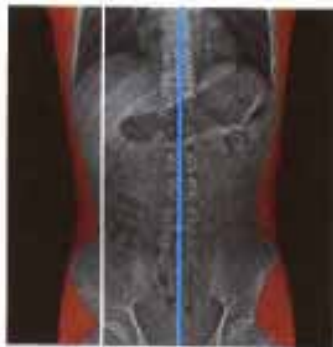
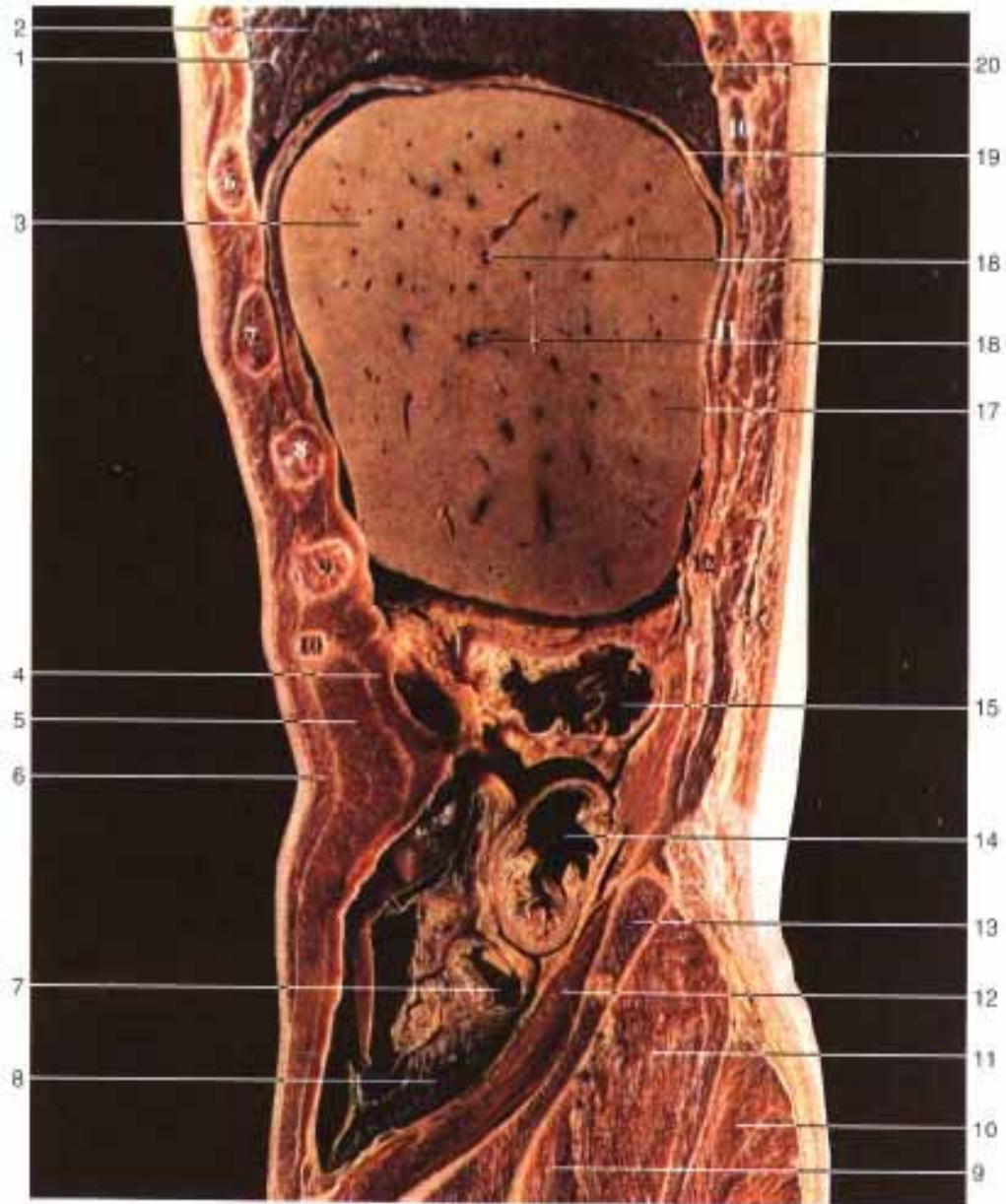


Fig. SA 11

1. 右肺中叶 middle lobe of right lung
2. 斜裂 oblique fissure
3. 右前叶 right anterior lobe
4. 腹横肌 transversus abdominis
5. 腹内斜肌 obliquus internus abdominis
6. 腹外斜肌 obliquus externus abdominis
7. 盲肠 cecum
8. 回肠 ileum
9. 臀小肌 gluteus minimus
10. 臀大肌 gluteus maximus

Fig.SA 11

- 11. 臀中肌 gluteus medius
- 12. 髂肌 iliacus
- 13. 髂嵴 iliac crest
- 14. 升结肠 ascending colon
- 15. 结肠右曲 right colic flexure
- 16. 胃 stomach
- 17. 右后叶 right posterior lobe
- 18. 肝右静脉 right hepatic v.
- 19. 膈 diaphragm
- 20. 右肺下叶 inferior lobe of right lung
- 21. 胆囊 gallbladder

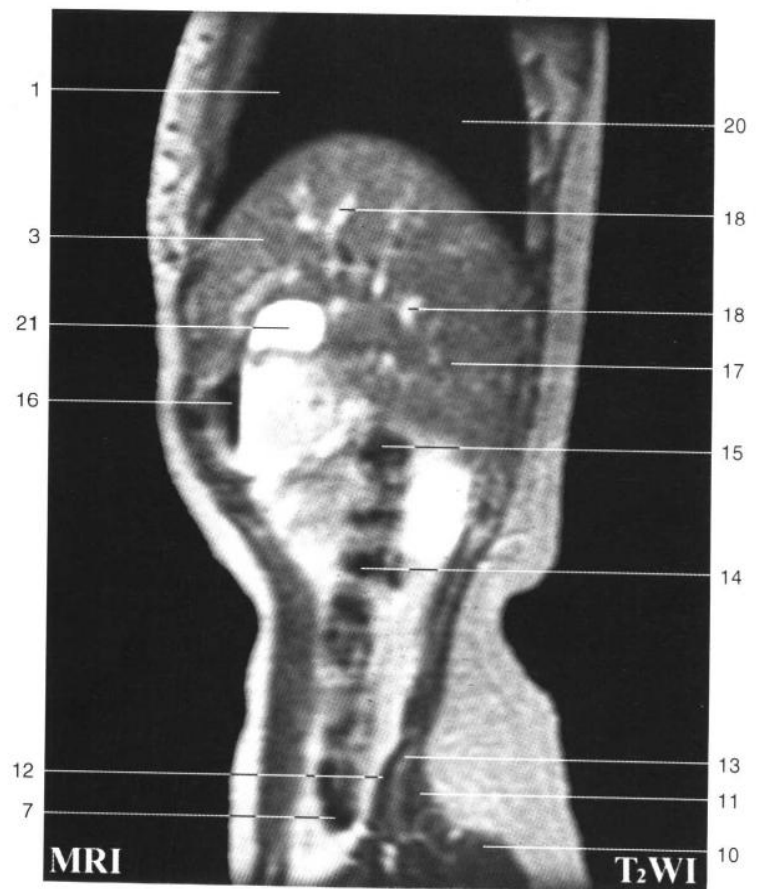
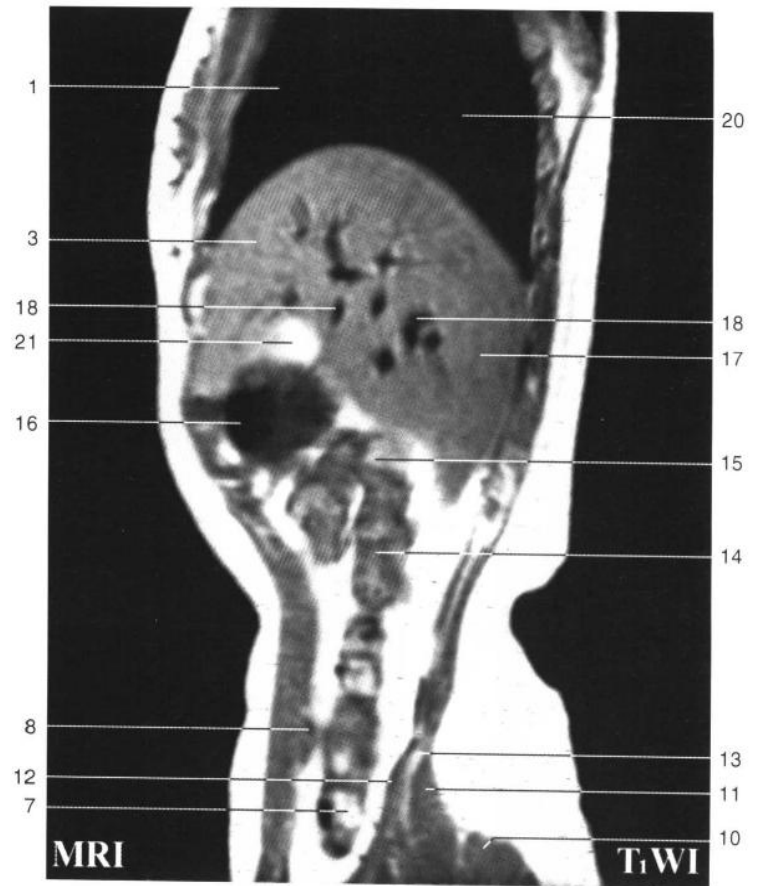
Fig. MRI

- 1. 肝左管 left hepatic duct
- 2. 肝右管 right hepatic duct
- 3. 肝总管 common hepatic duct
- 4. 胆囊 gallbladder
- 5. 胆结石 cholelith
- 6. 胰管 pancreatic duct
- 7. 胆囊管 cystic duct
- 8. 12指肠 duodenum
- 9. 胆总管 common bile duct
- 10. 肾 kidney
- 11. 肾盂 renal pelvis
- 12. 输尿管 ureter
- 13. 膀胱 urinary bladder
- 14. 精囊 seminal vesicle
- 15. 蛛网膜下隙 subarachnoid space
- 16. 横结肠 transverse colon
- 17. 坐骨支 ramus of ischium
- 18. 升结肠 ascending colon
- 19. 髌骨 ilium
- 20. 股骨头 femoral head
- 21. 肾大盏 major renal calices

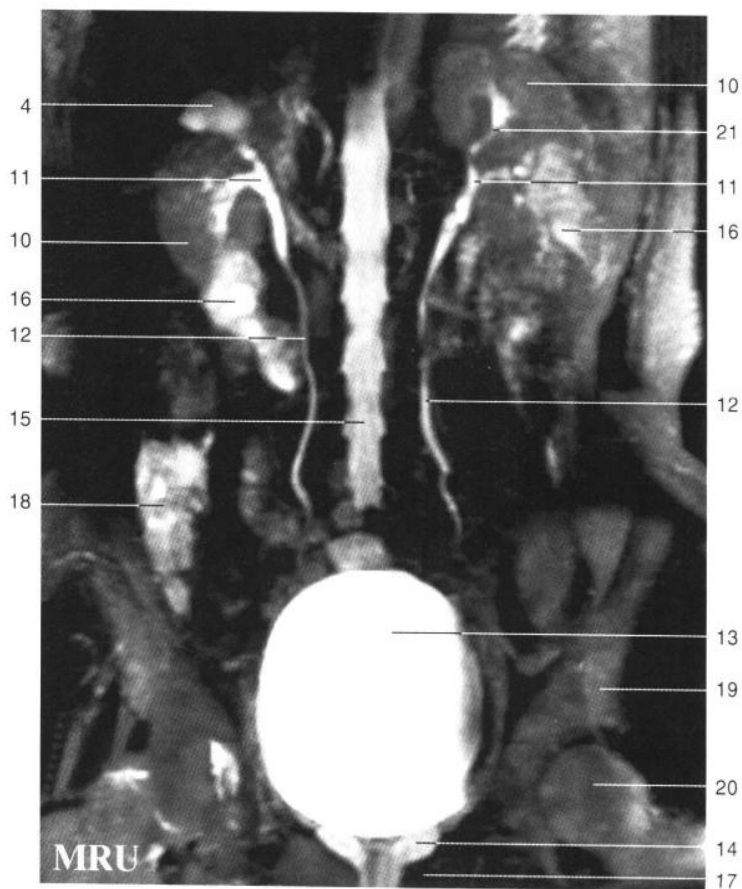
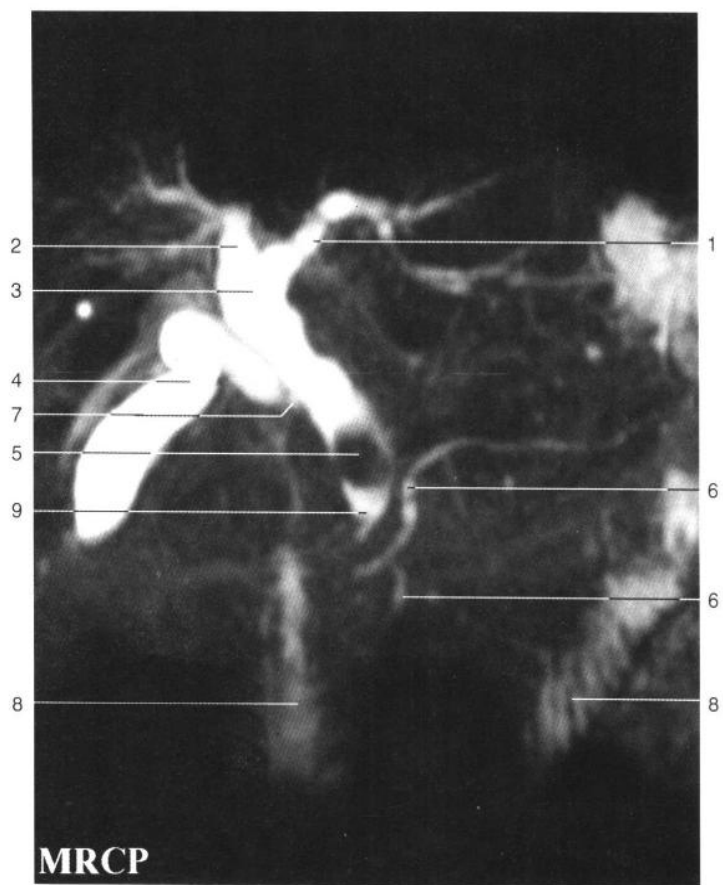

Fig. MRI

PELVIS

盆 部

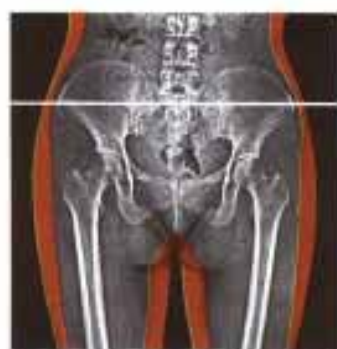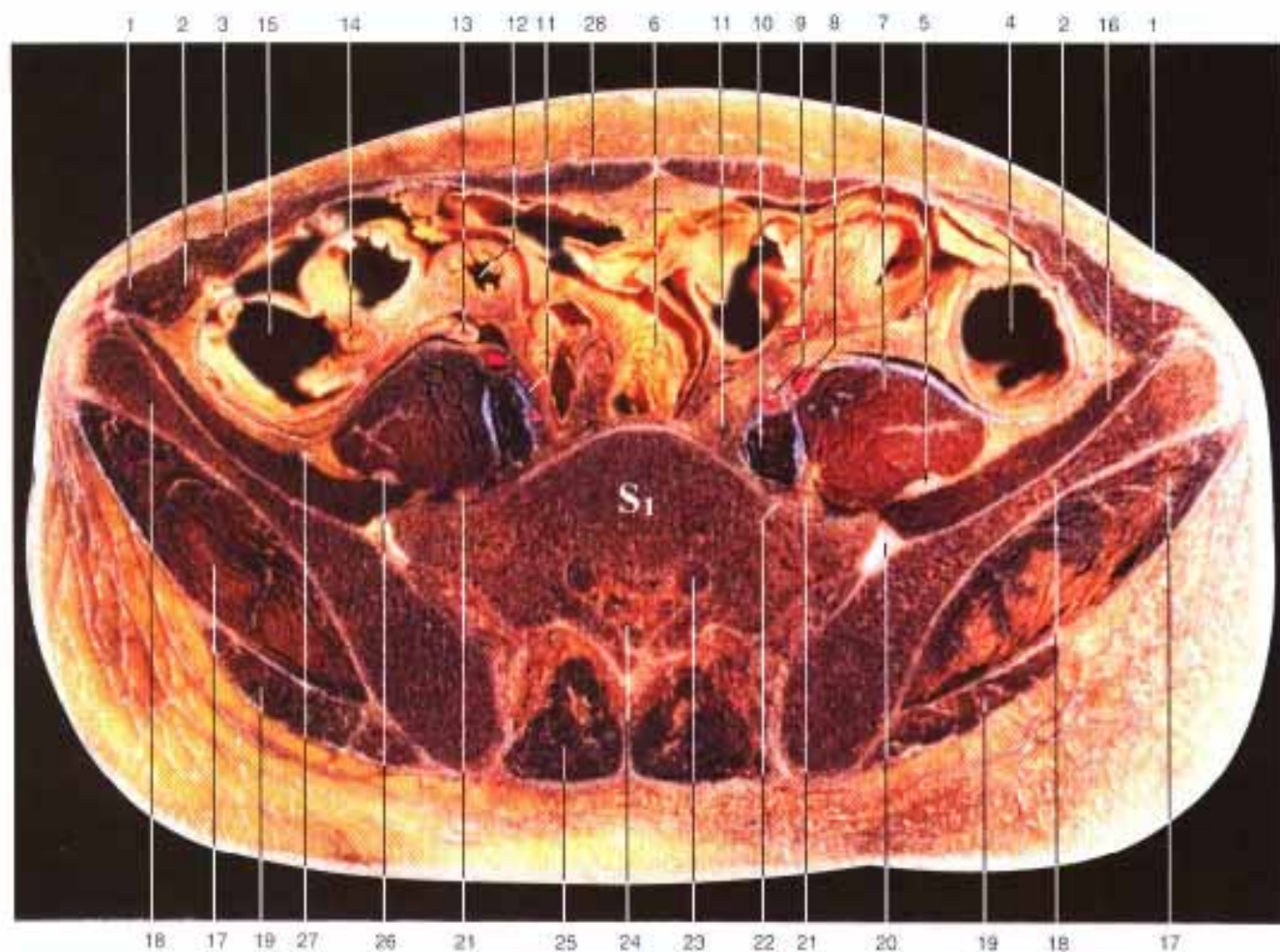
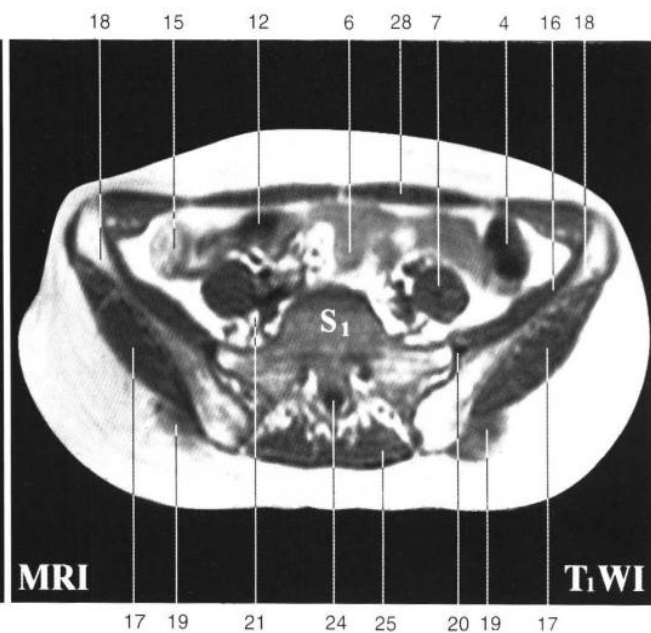
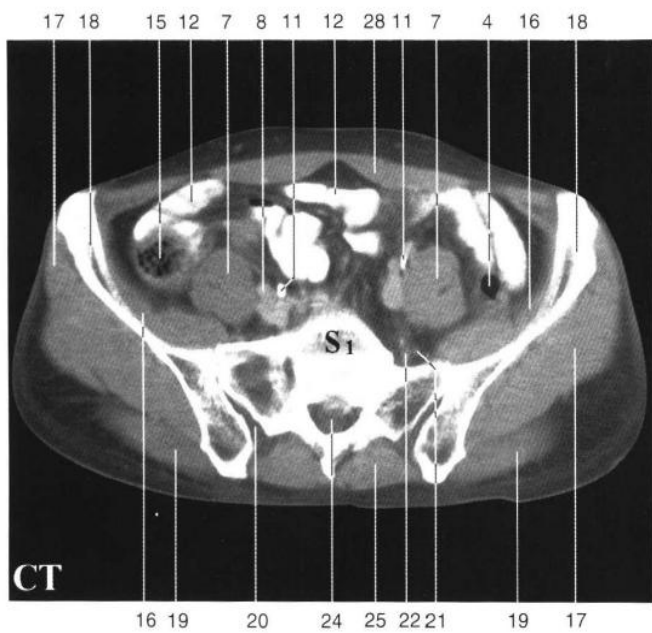


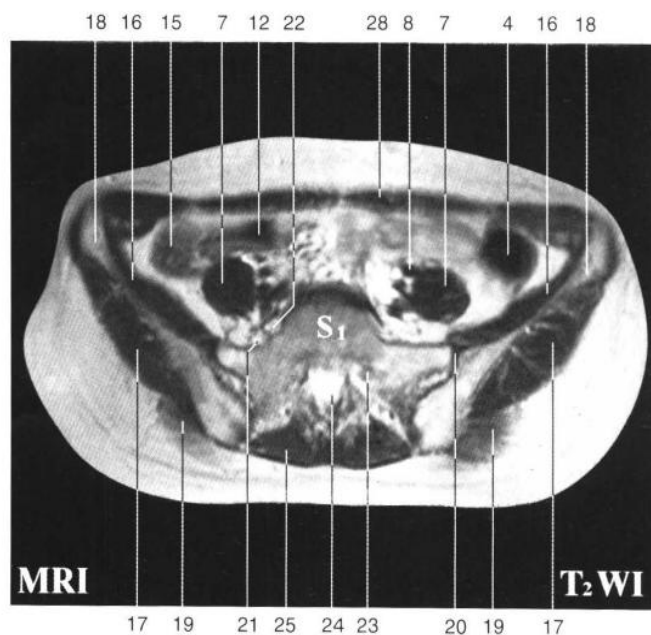
Fig. HP1 1

1. 腹内斜肌 obliquus internus abdominis
2. 腹横肌 transversus abdominis
3. 腹外斜肌 obliquus externus abdominis
4. 乙状结肠 sigmoid colon
5. 股神经 femoral n.
6. 回肠 ileum
7. 髂大肌 psoas major
8. 左髂外动脉 left external iliac a.
9. 左髂内动脉 left internal iliac a.
10. 左髂总静脉 left common iliac v.

Fig. HP1 1



11. 输尿管 ureter
12. 回肠 ileum
13. 阑尾 vermiform appendix
14. 回盲瓣 ileocecal valve
15. 盲肠 cecum
16. 髂肌 iliacus
17. 臀中肌 gluteus medius
18. 髂骨翼 ala of ilium
19. 臀大肌 gluteus maximus
20. 骶髂关节 sacroiliac joint
21. 闭孔神经 obturator n.
22. 腰骶干 lumbosacral trunk
23. 第1骶神经 1st sacral n.
24. 马尾 cauda equina
25. 竖脊肌 erector spinae
26. 股神经 femoral n.
27. 股外侧皮神经 lateral femoral cutaneous n.
28. 腹直肌 rectus abdominis



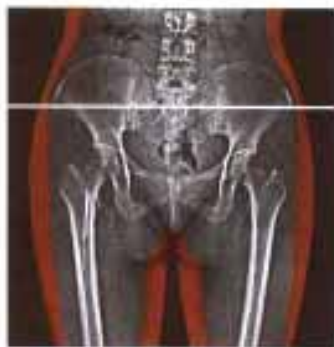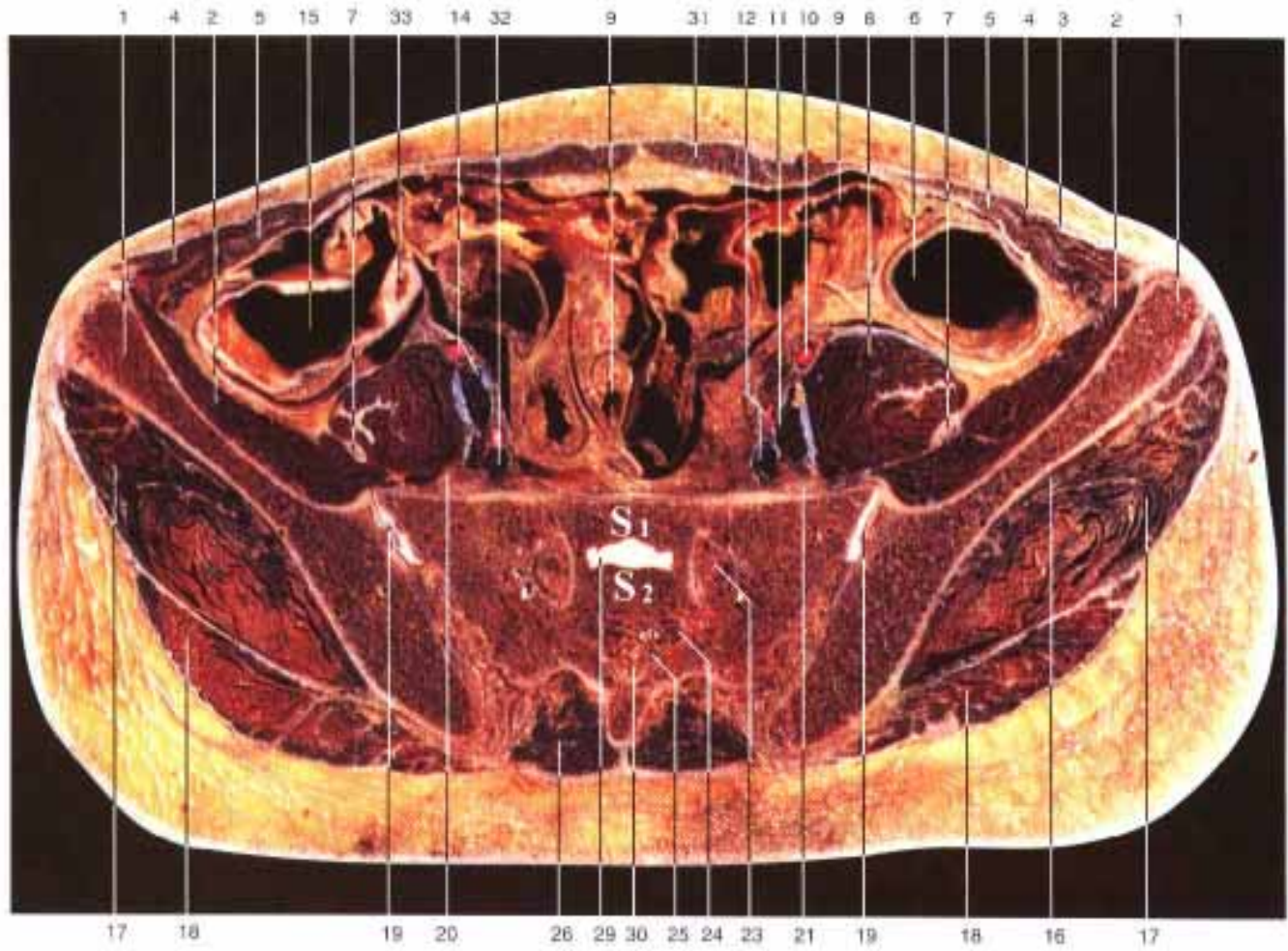
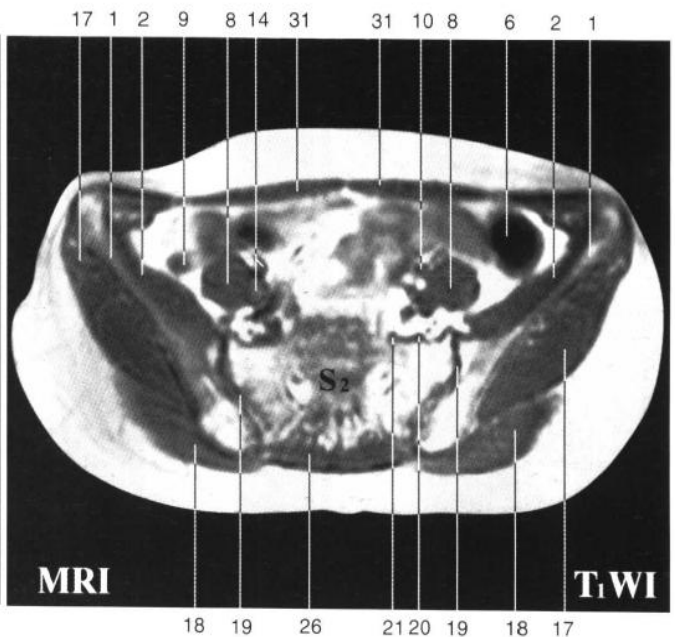
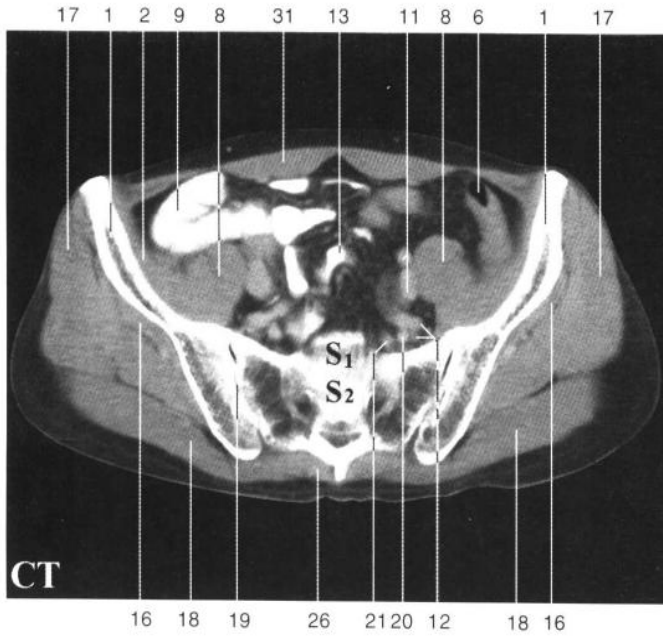


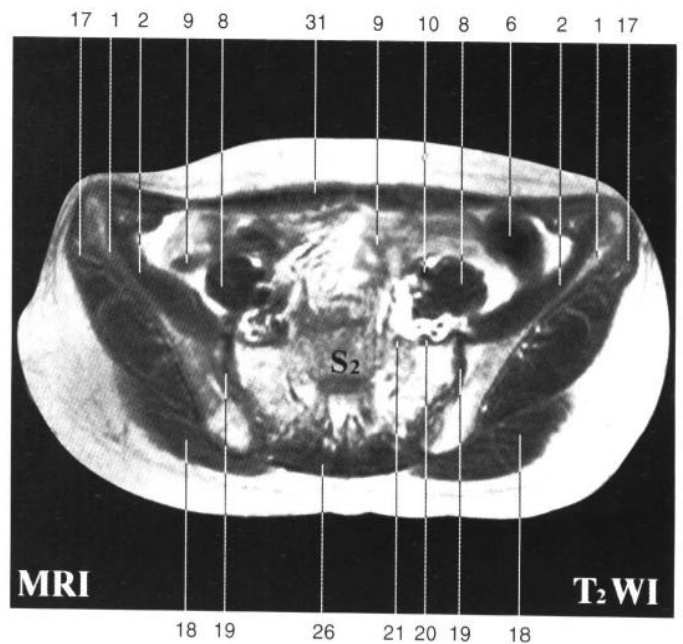
Fig. HPI 2

1. 髂骨翼 ala of ilium
2. 髂肌 iliacus
3. 腹外斜肌腱膜 aponeurosis of obliquus externus abdominis
4. 腹内斜肌 obliquus internus abdominis
5. 腹横肌 transversus abdominis
6. 乙状结肠 sigmoid colon
7. 股神经 femoral n.
8. 腰大肌 psoas major
9. 回肠 ileum

Fig.HPI 2



10. 左髂外动脉 left external iliac a.
11. 左髂外静脉 left external iliac v.
12. 左髂内动、静脉 left internal iliac a. and v.
13. 回肠 ileum
14. 右髂外动脉、静脉 right external iliac a. and v.
15. 盲肠 cecum
16. 臀小肌 gluteus minimus
17. 臀中肌 gluteus medius
18. 臀大肌 gluteus maximus
19. 骶髂关节 sacroiliac joint
20. 闭孔神经 obturator n.
21. 腰骶干 lumbosacral trunk
22. 阑尾 vermiform appendix
23. 第1骶神经 1st sacral n.
24. 第2骶神经 2nd sacral n.
25. 第3骶神经 3rd sacral n.
26. 竖脊肌 erector spinae
27. 股外侧皮神经 lateral femoral cutaneous n.
28. 髂腹股沟神经 ilioinguinal n.
29. 1,2 骶椎间盘 intervertebral disc (S₁ - S₂)
30. 第4骶神经 4th sacral n.
31. 腹直肌 rectus abdominis
32. 右髂内动、静脉 right medial iliac a. and v.
33. 回肠 ileum



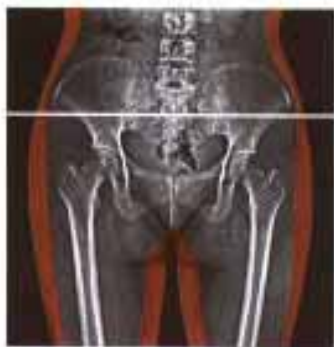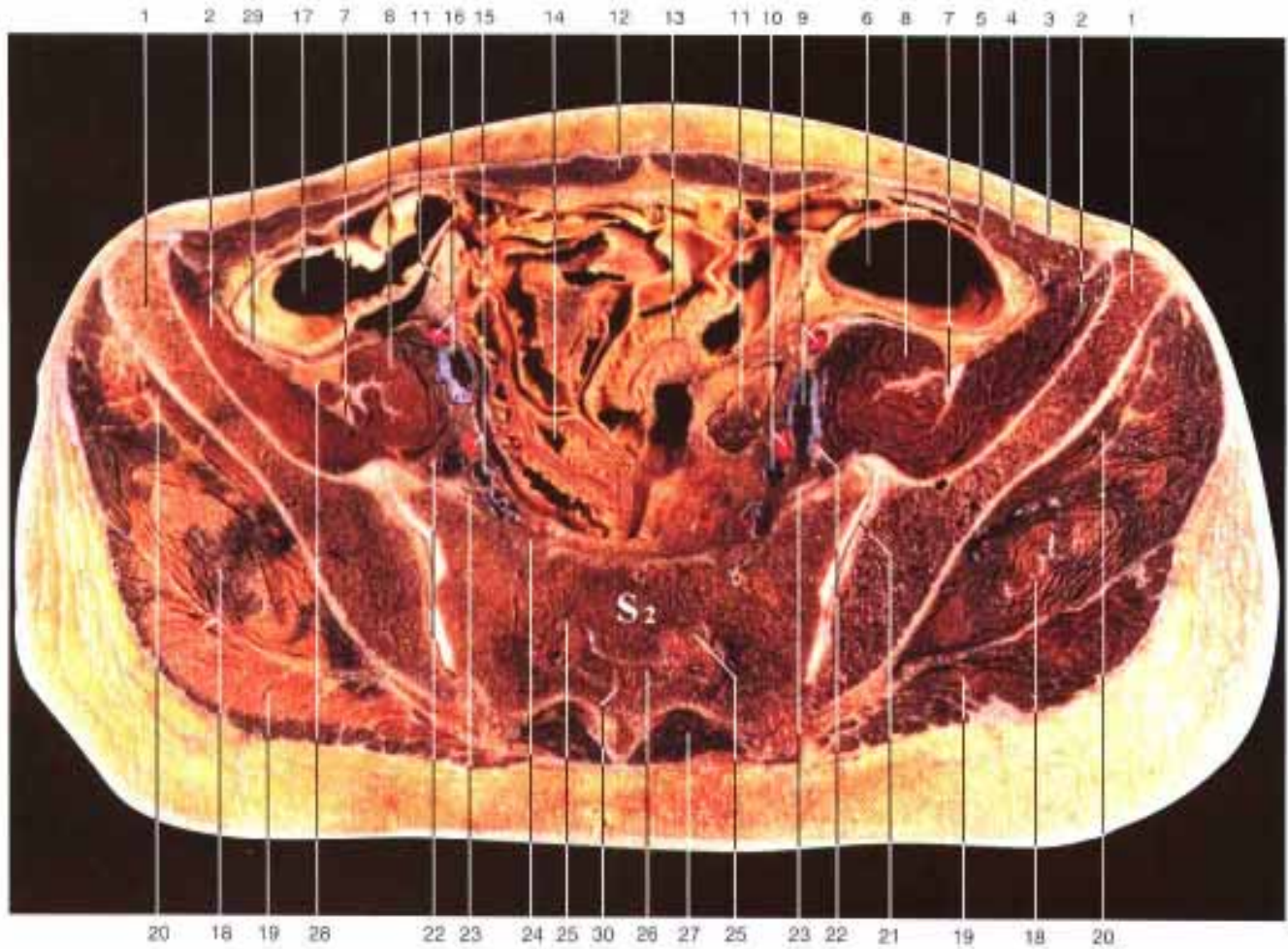
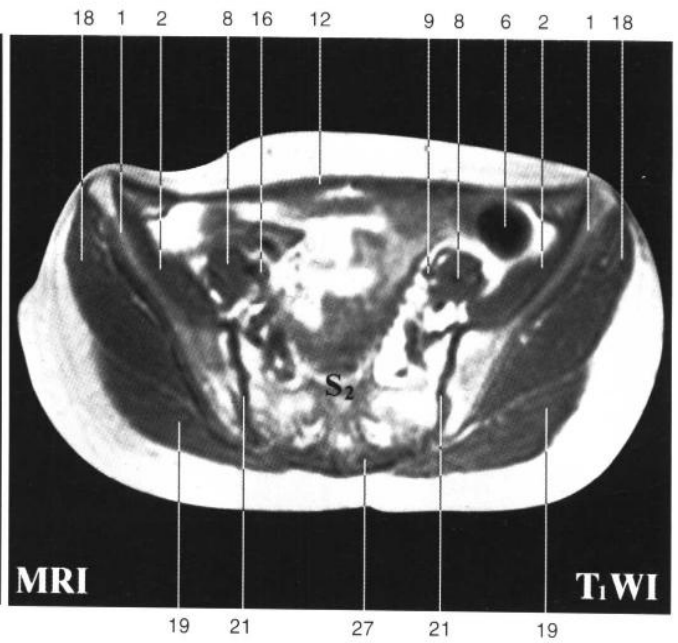
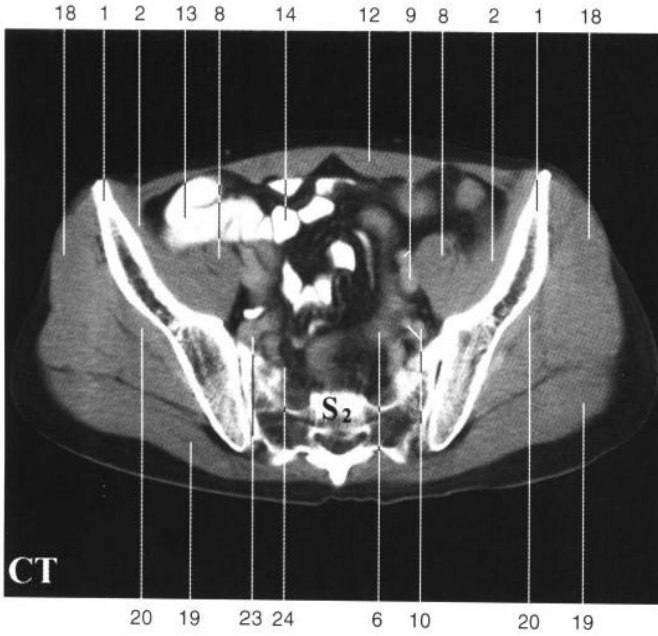


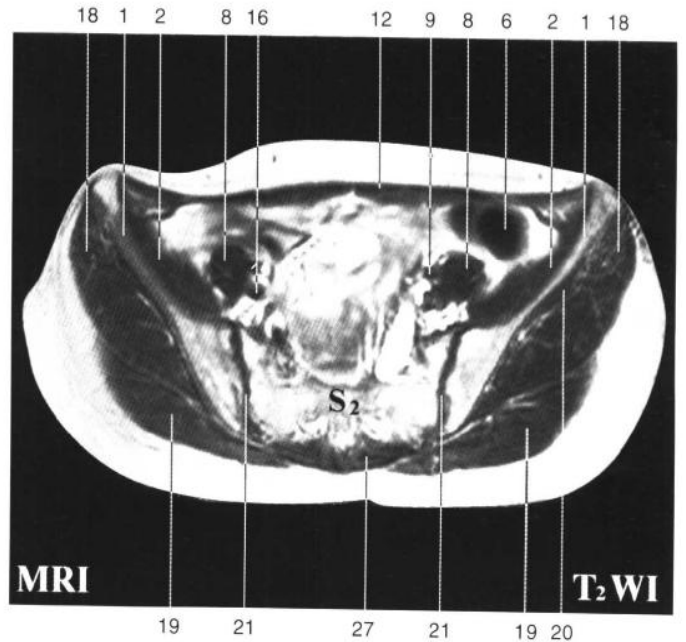
Fig. HPf 3

1. 髂骨窝 ala of ilium
2. 髂肌 iliacus
3. 腹外斜肌腱膜 aponeurosis of obliquus externus abdominis
4. 腹内斜肌 obliquus internus abdominis
5. 腹横肌 transversus abdominis
6. 乙状结肠 sigmoid colon
7. 股神经 femoral n.
8. 腰大肌 psoas major
9. 左髂外动、静脉 left external iliac a. and v.

Fig. HPf 3



10. 左髂内动、静脉 left internal iliac a. and v.
11. 卵巢 ovary
12. 腹直肌 rectus abdominis
13. 回肠 ileum
14. 回肠 ileum
15. 右髂内动、静脉 right internal iliac a. and v.
16. 右髂外动、静脉 right external iliac a. and v.
17. 盲肠 cecum
18. 臀中肌 gluteus medius
19. 臀大肌 gluteus maximus
20. 臀小肌 gluteus minimus
21. 骶髂关节 sacroiliac joint
22. 闭孔神经 obturator n.
23. 腰骶干 lumbosacral trunk
24. 第1骶神经 1st sacral n.
25. 第2骶神经 2nd sacral n.
26. 第3骶神经 3rd sacral n.
27. 竖脊肌 erector spinae
28. 股外侧皮神经 lateral femoral cutaneous n.
29. 髂腹股沟神经 ilioinguinal n.
30. 第4骶神经 4th sacral n.



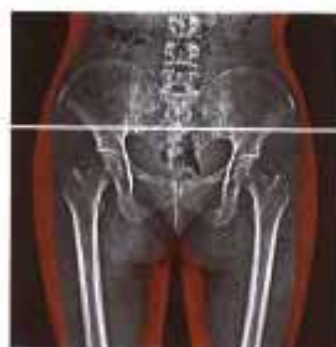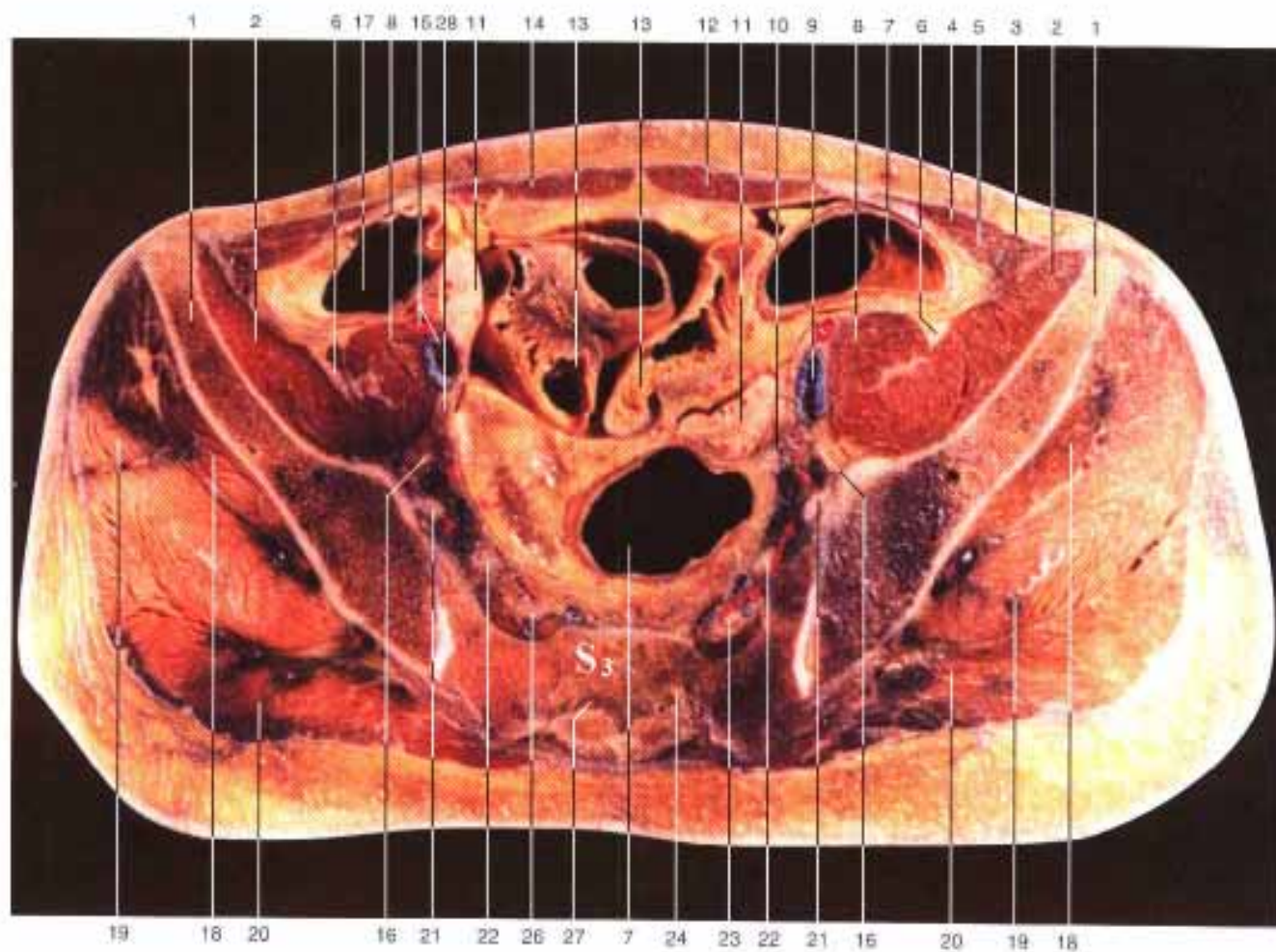
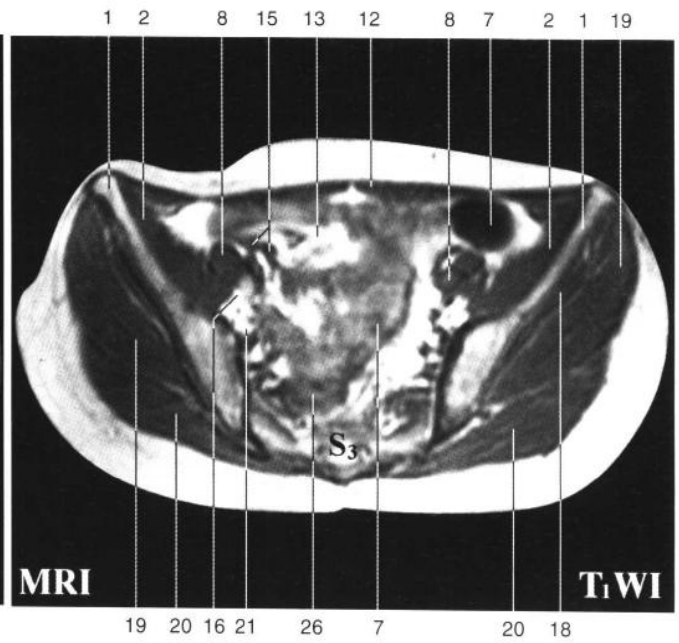
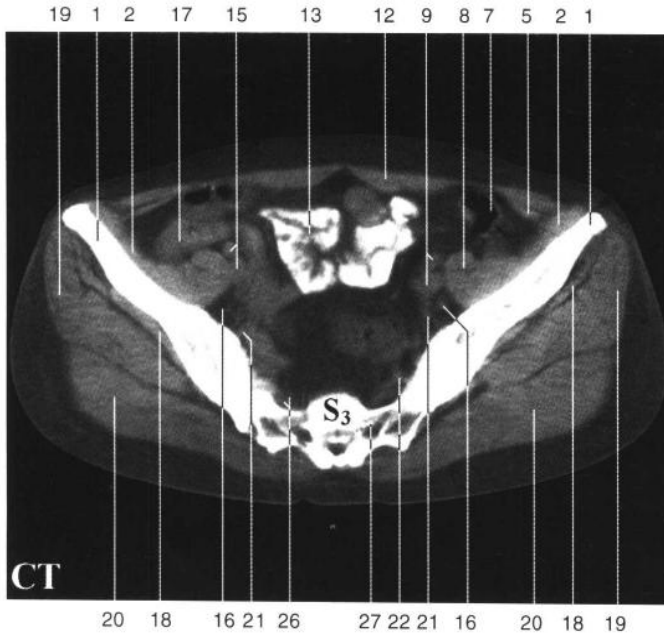


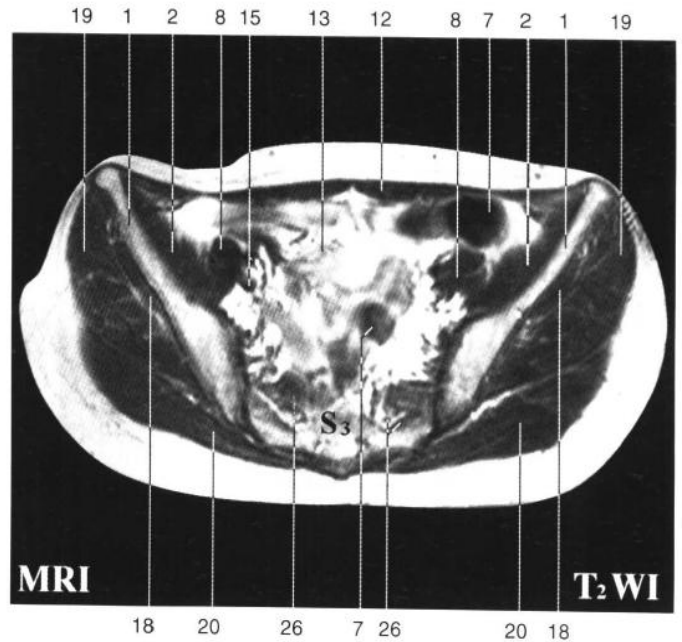
Fig. HPf 4

1. 髂嵴窝 ala of ilium
2. 髂肌 iliacus
3. 腹外斜肌腱膜 aponeurosis of obliquus externus abdominis
4. 腹内斜肌 obliquus internus abdominis
5. 腹横肌 transversus abdominis
6. 股神经 femoral n.
7. 乙状结肠 sigmoid colon
8. 髂大肌 psoas major
9. 左髂外动、静脉 left external iliac a. and v.

Fig. HPf 4



10. 输尿管 ureter
11. 卵巢 ovary
12. 腹直肌 rectus abdominis
13. 回肠 ileum
14. 腹直肌 rectus abdominis
15. 右髂外动、静脉 right external iliac a. and v.
16. 闭孔神经 obturator n.
17. 盲肠 cecum
18. 臀小肌 gluteus minimus
19. 臀中肌 gluteus medius
20. 臀大肌 gluteus maximus
21. 腰骶干 lumbosacral trunk
22. 第1骶神经 1st sacral n.
23. 第2骶神经 2nd sacral n.
24. 第3骶神经 3rd sacral n.
25. 乙状结肠 sigmoid colon
26. 第2骶神经与梨状肌 2nd sacral n. and piriformis
27. 第4骶神经 4th sacral n.
28. 右髂内动脉 right internal iliac a.



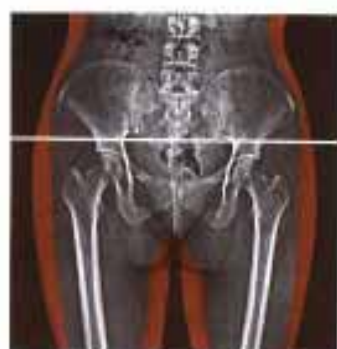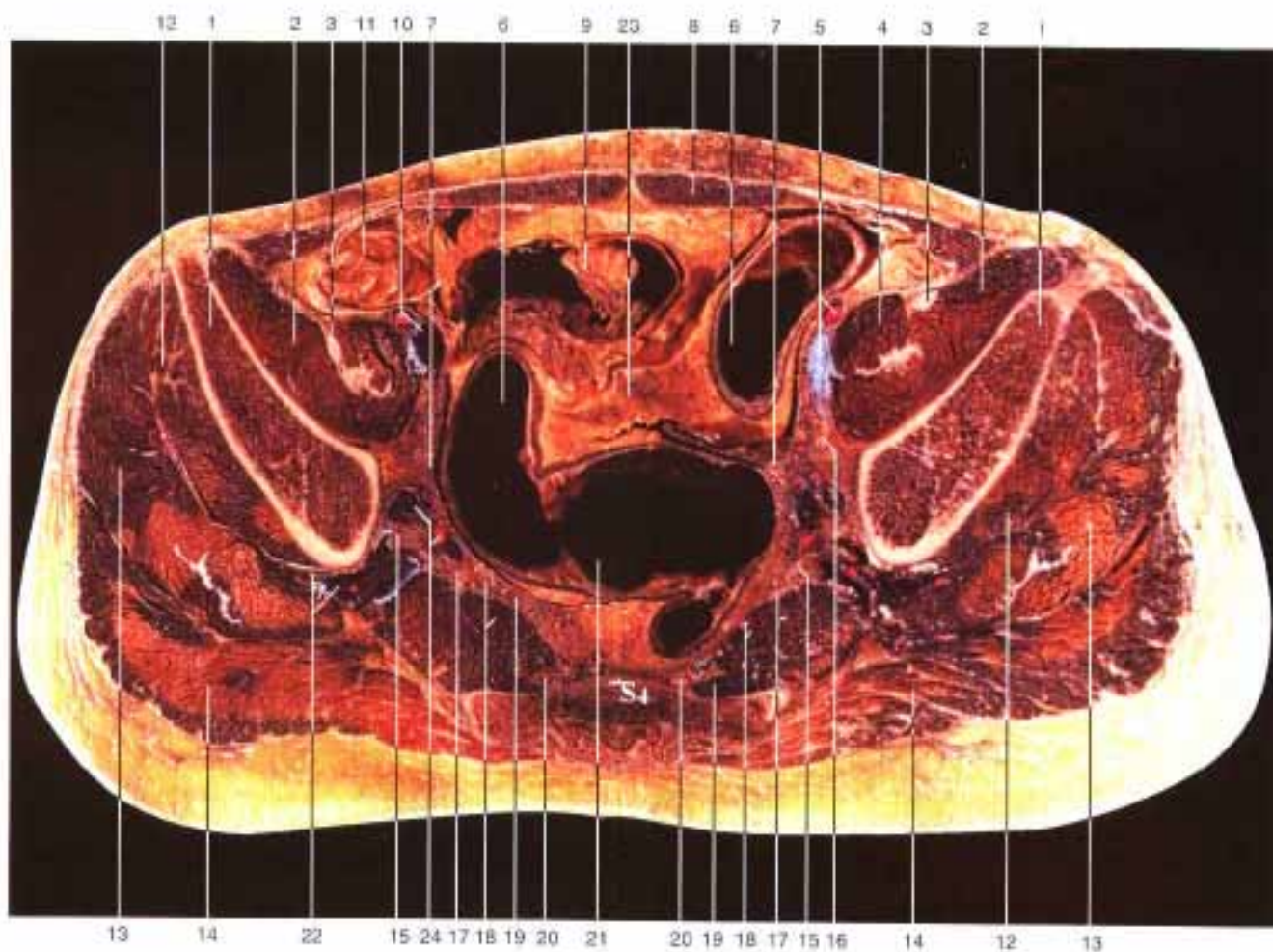
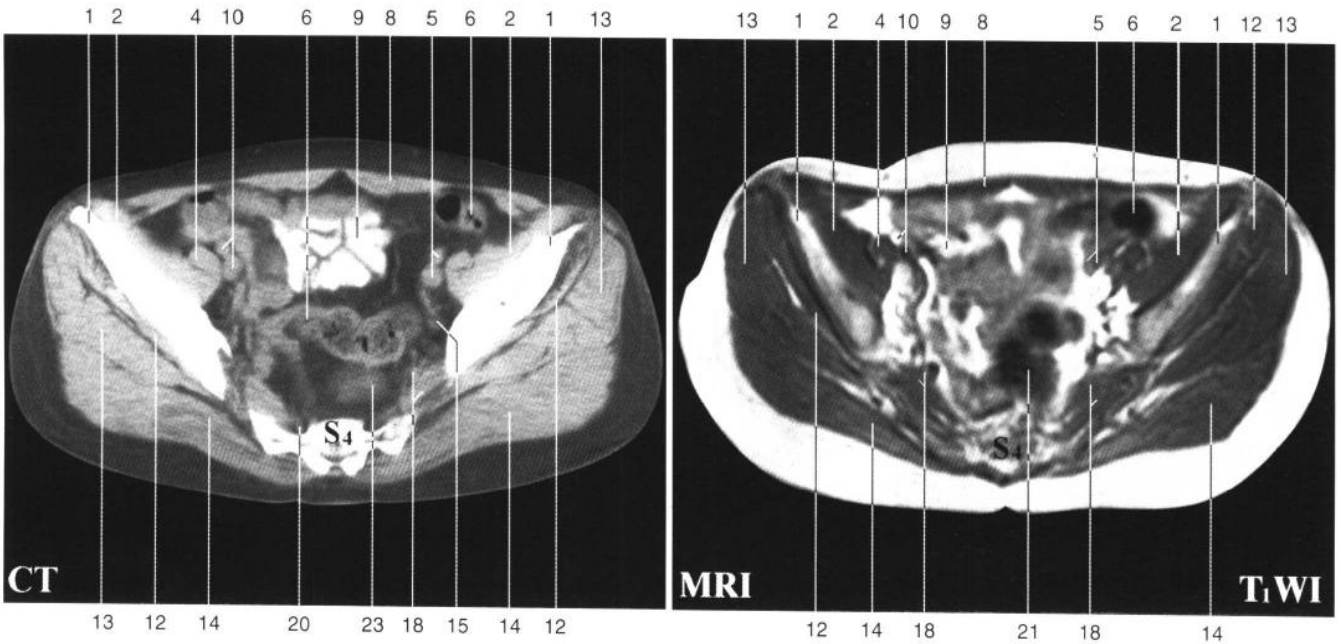


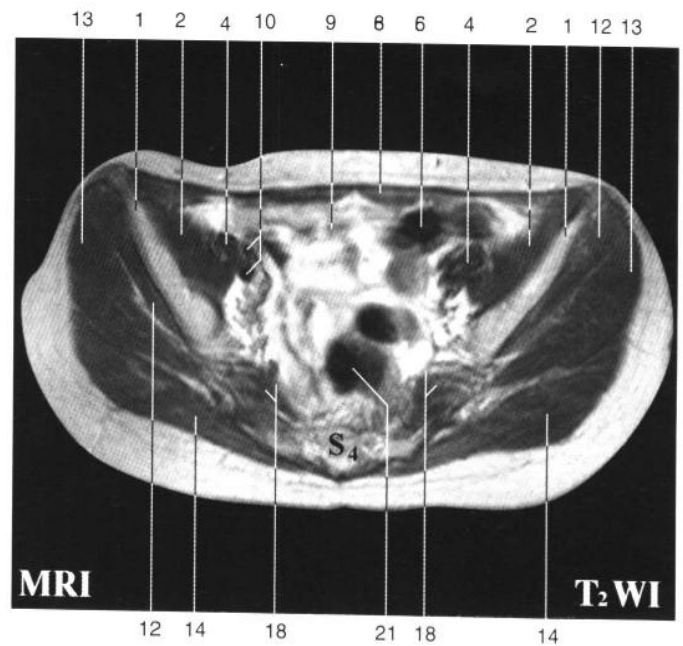
Fig. HPf 5

1. 髂骨翼 ala of ilium
2. 髂肌 iliacus
3. 股神经 femoral n.
4. 腰大肌 psoas major
5. 左髂外动、静脉 left external iliac a. and v.
6. 乙状结肠 sigmoid colon
7. 输尿管 ureter
8. 腹直肌 rectus abdominis
9. 回肠 ileum
10. 右髂外动、静脉 right external iliac a. and v.

Fig. HPf 5



11. 盲肠 cecum
12. 臀小肌 gluteus minimus
13. 臀中肌 gluteus medius
14. 臀大肌 gluteus maximus
15. 腰骶干 lumbosacral trunk
16. 闭孔神经 obturator n.
17. 第1骶神经 1st sacral n.
18. 第2骶神经与梨状肌 2nd sacral n. and piriformis
19. 第3骶神经 3rd sacral n.
20. 第4骶神经 4th sacral n.
21. 直肠 rectum
22. 臀上动、静脉 superior gluteal a. and v.
23. 子宫 uterus
24. 右髂内动脉、静脉 right internal iliac a. and v.



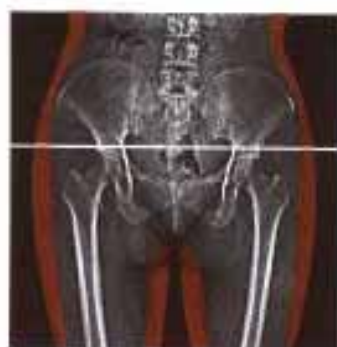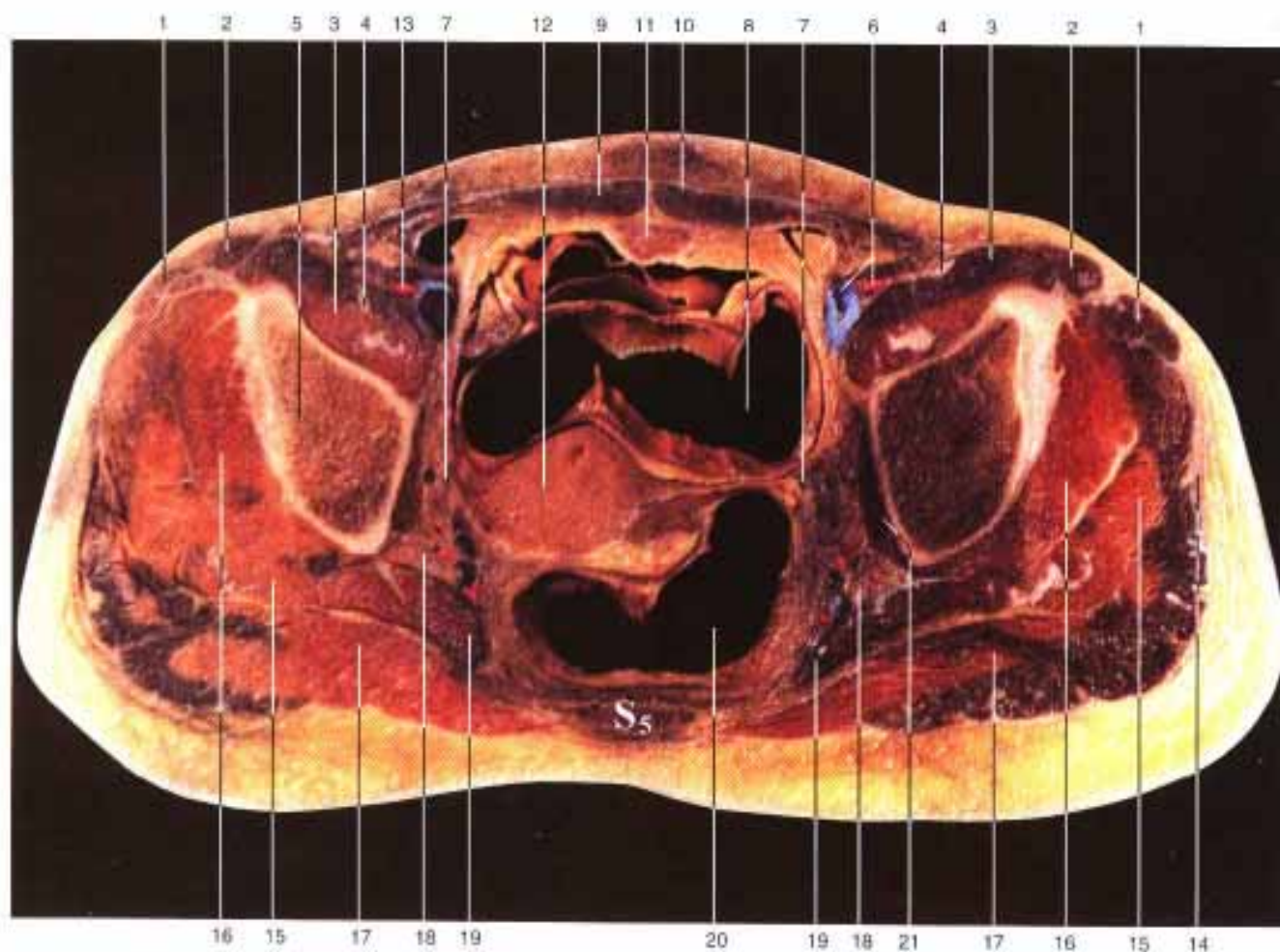
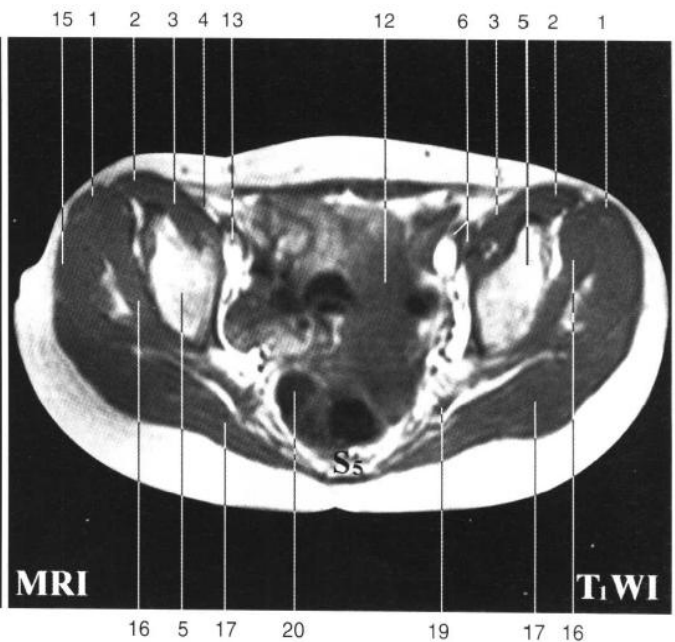
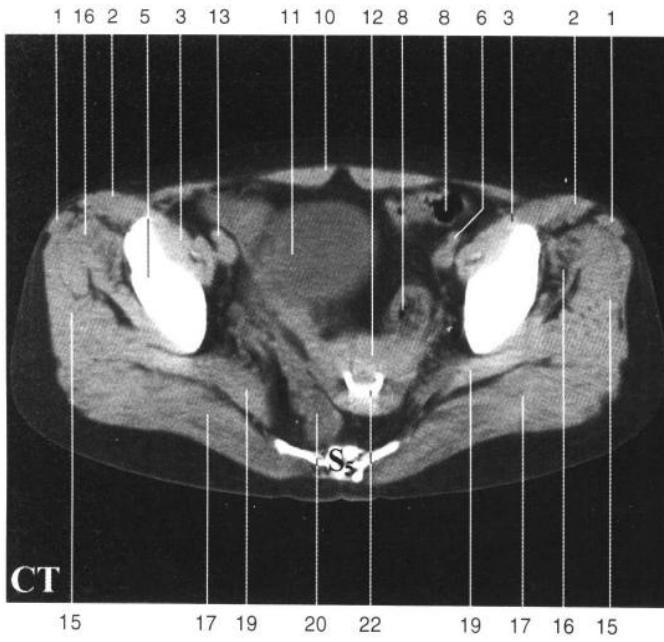


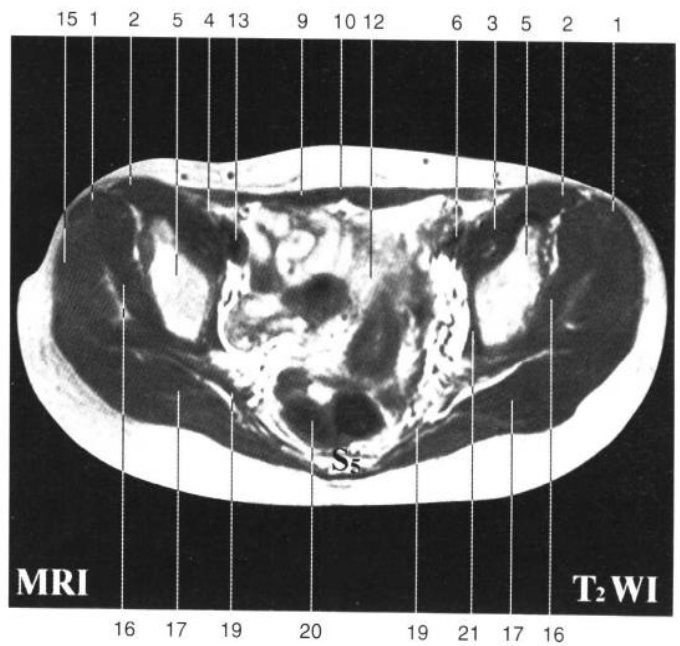
Fig. HPf 6

1. 阔筋膜张肌 tensor fasciae latae
2. 缝匠肌 sartorius
3. 髂腰肌 iliopsoas
4. 股神经 femoral n.
5. 髌骨体 body of ilium
6. 髂外动、静脉 external iliac a. and v.
7. 输尿管 ureter
8. 乙状结肠 sigmoid colon
9. 腹直肌 rectus abdominis

Fig. HPf 6



10. 锥状肌 pyramidalis
11. 膀胱尖 apex of bladder
12. 子宫底 fundus of uterus
13. 右髂外动脉 right external iliac a.
14. 髂胫束 iliotibial tract
15. 臀中肌 gluteus medius
16. 臀小肌 gluteus minimus
17. 臀大肌 gluteus maximus
18. 坐骨神经 sciatic n.
19. 梨状肌 piriformis
20. 直肠 rectum
21. 闭孔内肌 obturator internus
22. 节育环 contraceptive ring



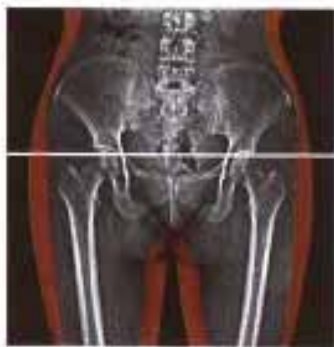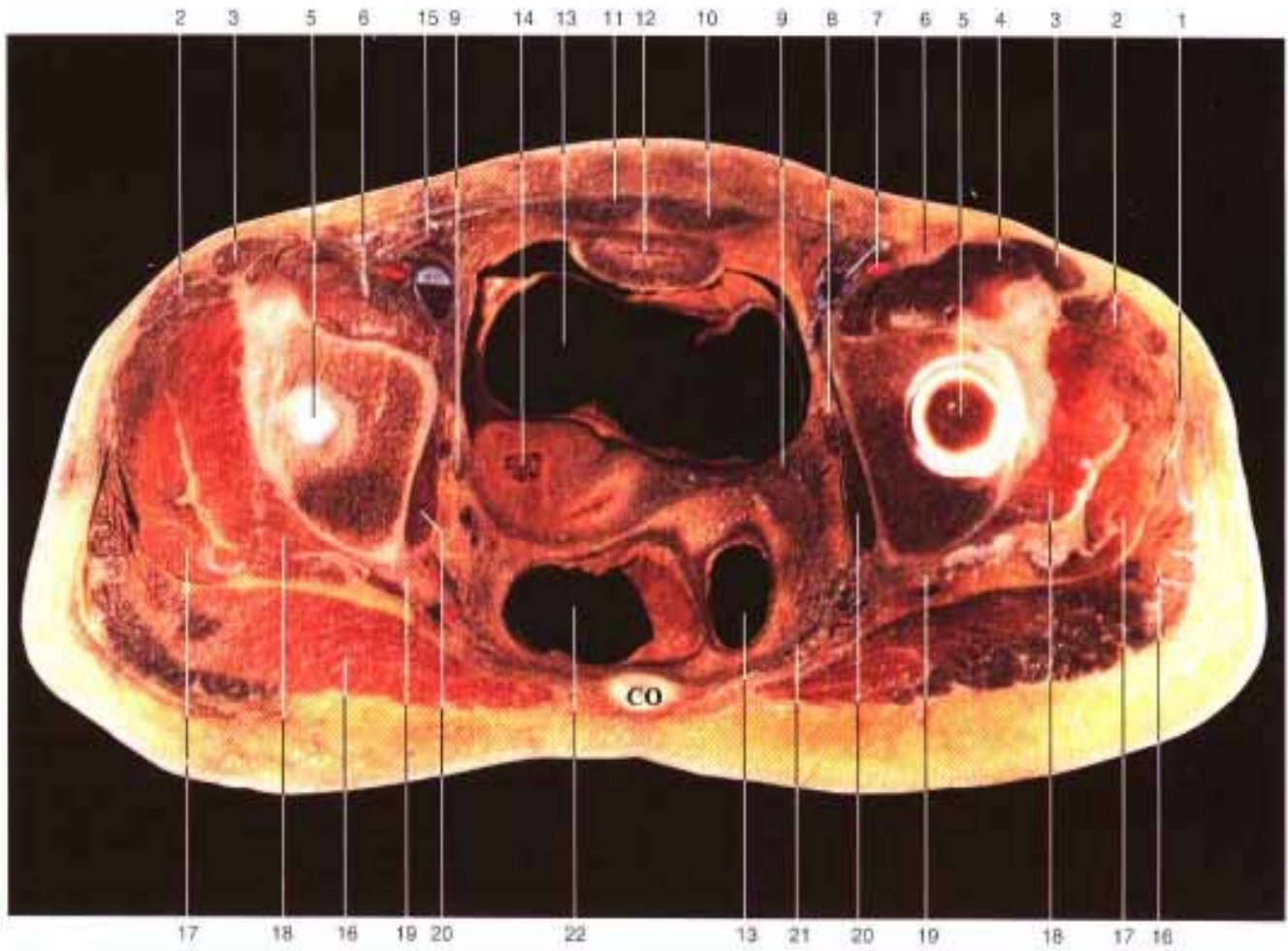
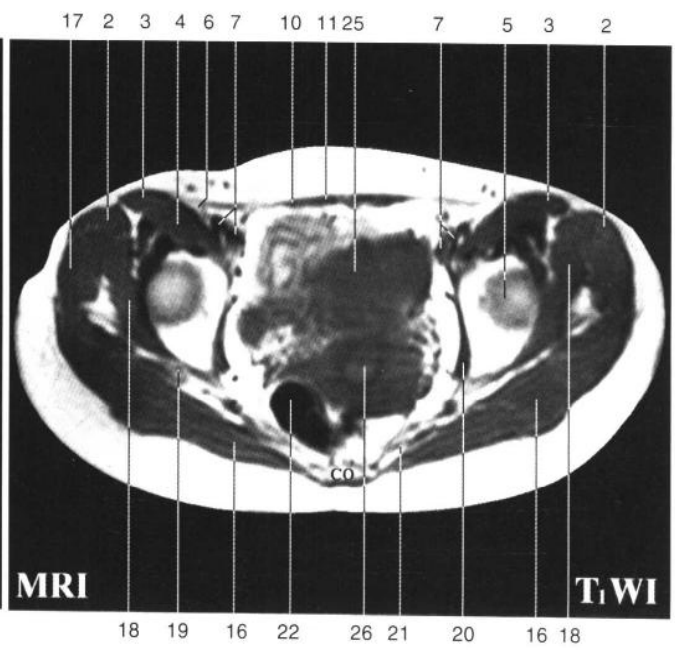
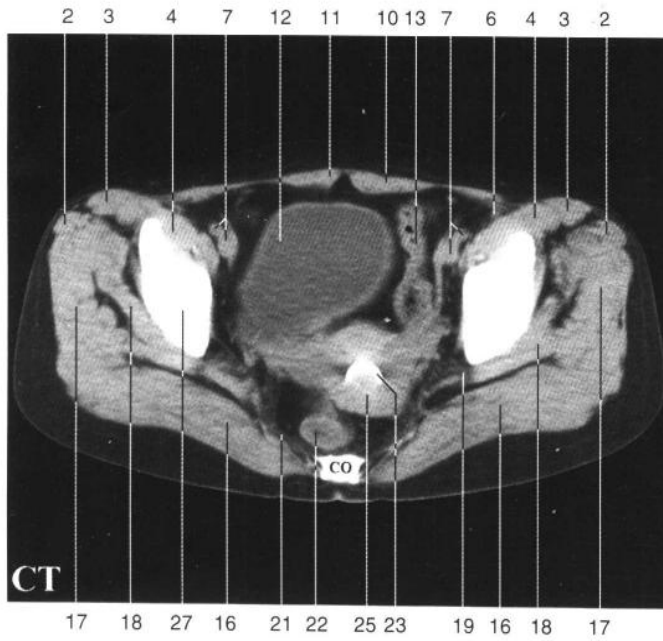


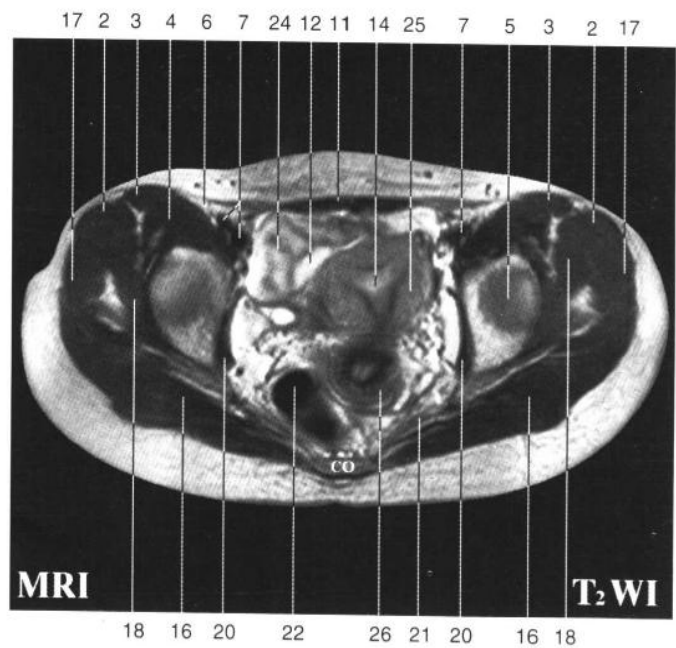
Fig. HP1 7

1. 髂胫束 iliotibial tract
2. 阔筋膜张肌 tensor fasciae latae
3. 缝匠肌 sartorius
4. 髂腰肌 iliopsoas
5. 股骨头 femoral head
6. 股神经 femoral n.
7. 髂外动、静脉 external iliac a. and v.
8. 闭孔神经 obturator n.
9. 输尿管 ureter

Fig. HP1 7



- 10. 腹直肌 rectus abdominis
- 11. 锥状肌 pyramidalis
- 12. 膀胱 urinary bladder
- 13. 乙状结肠 sigmoid colon
- 14. 子宫腔 cavity of uterus
- 15. 腹壁下动、静脉 inferior epigastric a. and v.
- 16. 臀大肌 gluteus maximus
- 17. 臀中肌 gluteus medius
- 18. 臀小肌 gluteus minimus
- 19. 坐骨神经 sciatic n.
- 20. 闭孔内肌 obturator internus
- 21. 尾骨肌 coccygeus
- 22. 直肠 rectum
- 23. 节育环 contraceptive ring
- 24. 回肠 ileum
- 25. 子宫体 body of uterus
- 26. 子宫颈 neck of uterus
- 27. 髌骨体 body of ilium



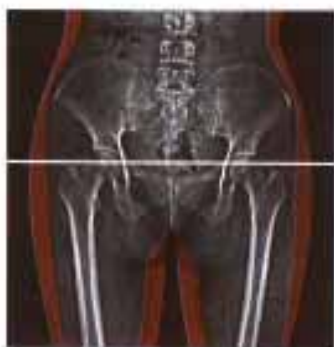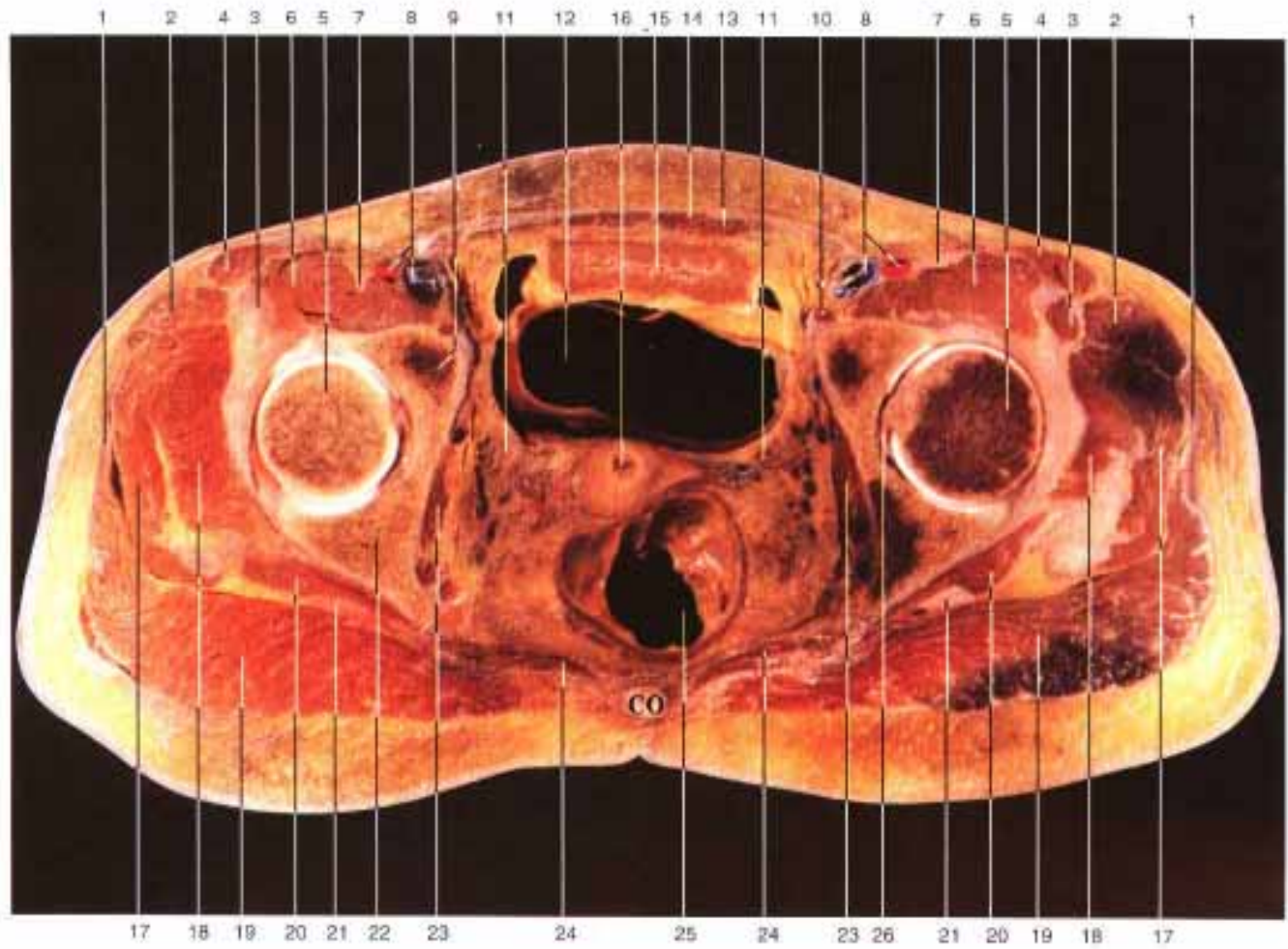
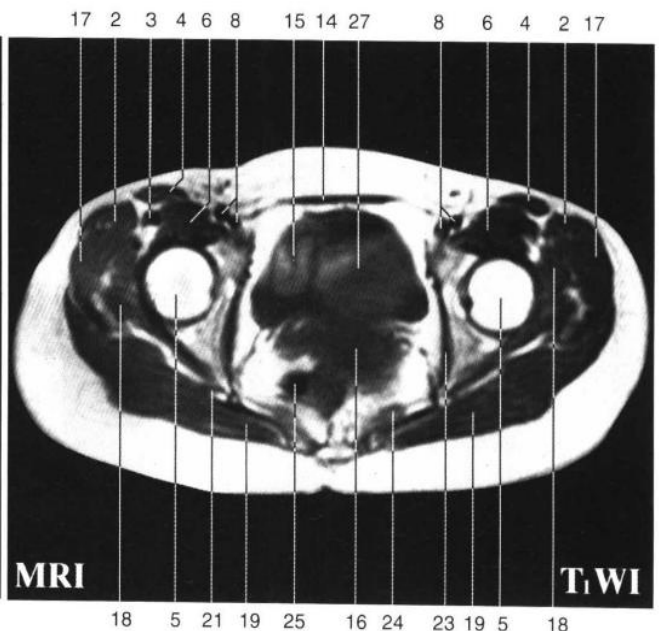
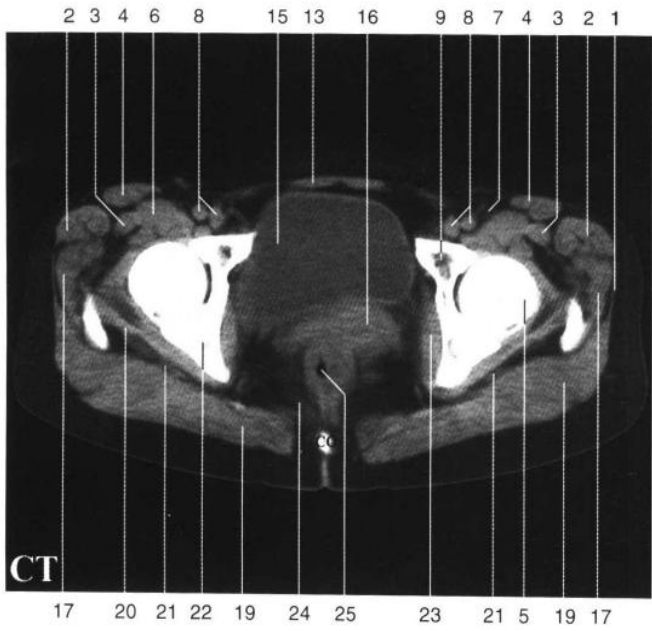


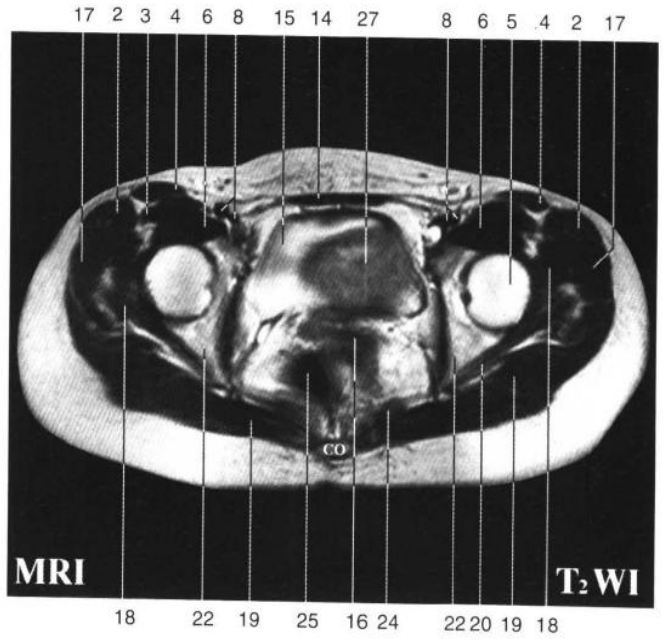
Fig. HPf 8

1. 髂胫束 iliotibial tract
2. 阔筋膜张肌 tensor fasciae latae
3. 股直肌 rectus femoris
4. 缝匠肌 sartorius
5. 股骨头 femoral head
6. 髂腰肌 iliopsoas
7. 股神经 femoral n.
8. 股动、静脉 femoral a. and v.
9. 耻骨体 body of pubis
10. 耻骨肌 pectineus

Fig. HPf 8



- 11. 输尿管 ureter
- 12. 乙状结肠 sigmoid colon
- 13. 腹直肌 rectus abdominis
- 14. 锥状肌 pyramidalis
- 15. 膀胱 urinary bladder
- 16. 子宫颈管 canal of cervix of uterus
- 17. 臀中肌 gluteus medius
- 18. 臀小肌 gluteus minimus
- 19. 臀大肌 gluteus maximus
- 20. 上孖肌 gemellus superior
- 21. 坐骨神经 sciatic n.
- 22. 坐骨体 body of ischium
- 23. 闭孔内肌 obturator internus
- 24. 尾骨肌 coccygeus
- 25. 直肠 rectum
- 26. 股骨头韧带 ligament of head of femur
- 27. 子宫体 body of uterus



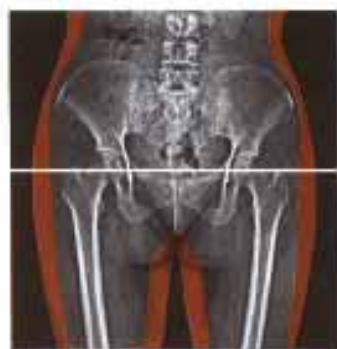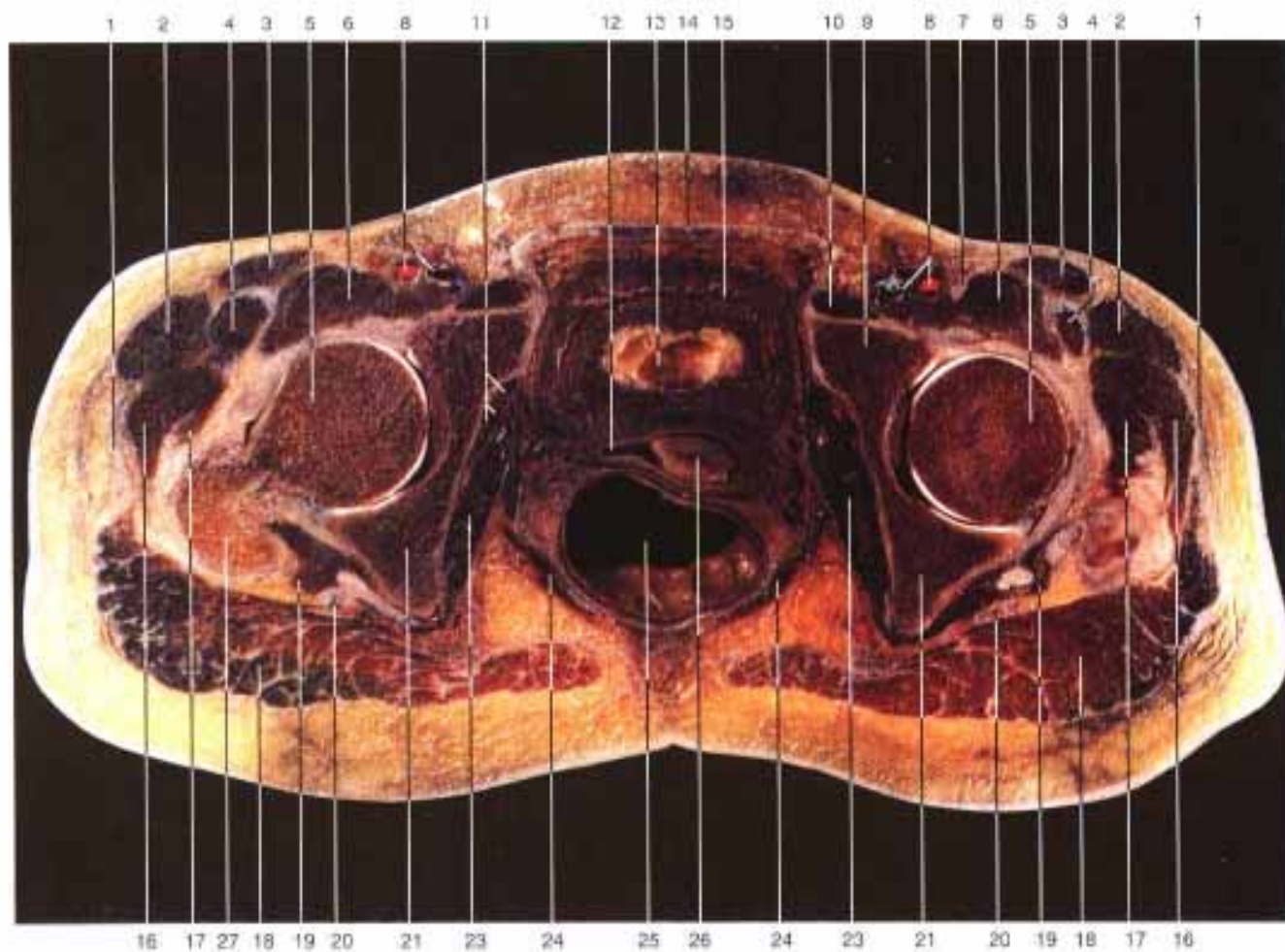
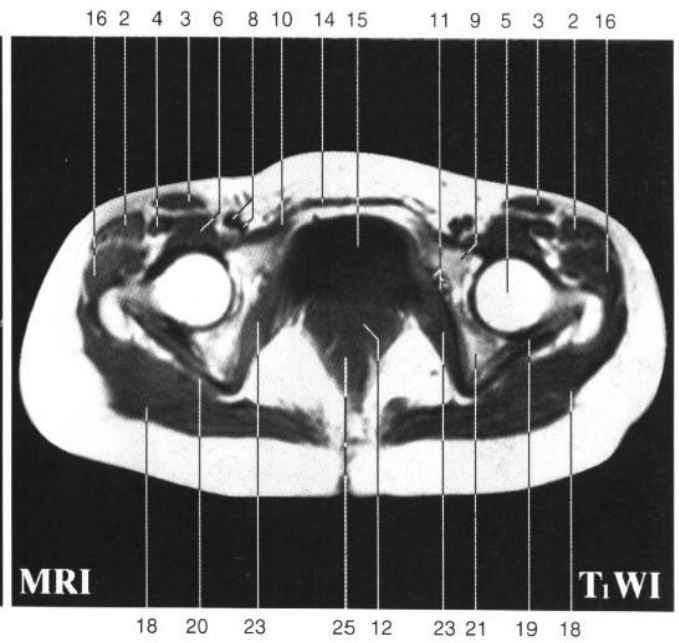
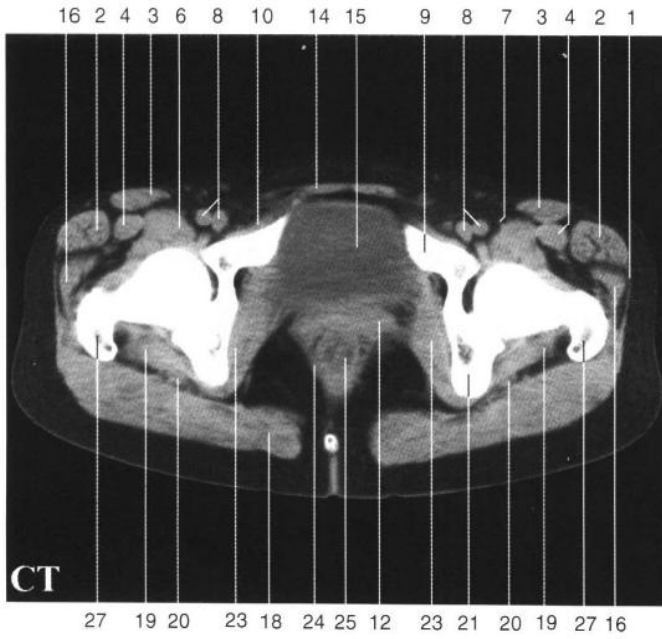


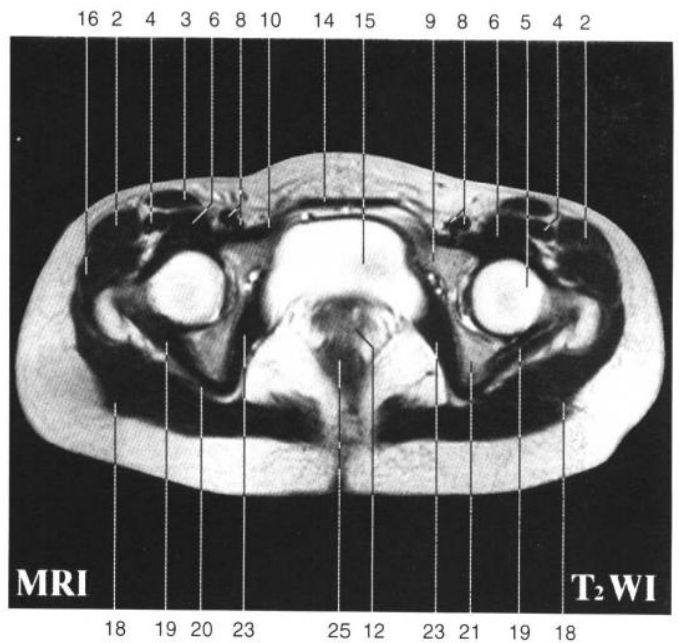
Fig. HPf 9

1. 髂胫束 iliotibial tract
2. 阔筋膜张肌 tensor fasciae latae
3. 缝匠肌 sartorius
4. 股直肌 rectus femoris
5. 股骨头 femoral head
6. 髂腰肌 iliopsoas
7. 股神经 femoral n.
8. 股动、静脉 femoral a. and v.
9. 耻骨体 body of pubis
10. 耻骨肌 pectineus

Fig. HPf 9



11. 闭孔动、静脉与闭孔神经 obturator
a. ,v. and obturator n.
12. 阴道 vagina
13. 乙状结肠 sigmoid colon
14. 锥状肌 pyramidalis
15. 膀胱 urinary bladder
16. 臀中肌 gluteus medius
17. 臀小肌 gluteus minimus
18. 臀大肌 gluteus maximus
19. 下孖肌 gemellus inferior
20. 坐骨神经 sciatic n.
21. 坐骨体 body of ischium
22. 股骨头韧带 ligament of head of femur
23. 闭孔内肌 obturator internus
24. 肛提肌 levator ani
25. 直肠 rectum
26. 子宫颈阴道部 vaginal part of cervix
27. 大转子 greater trochanter



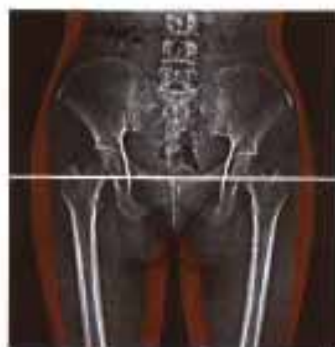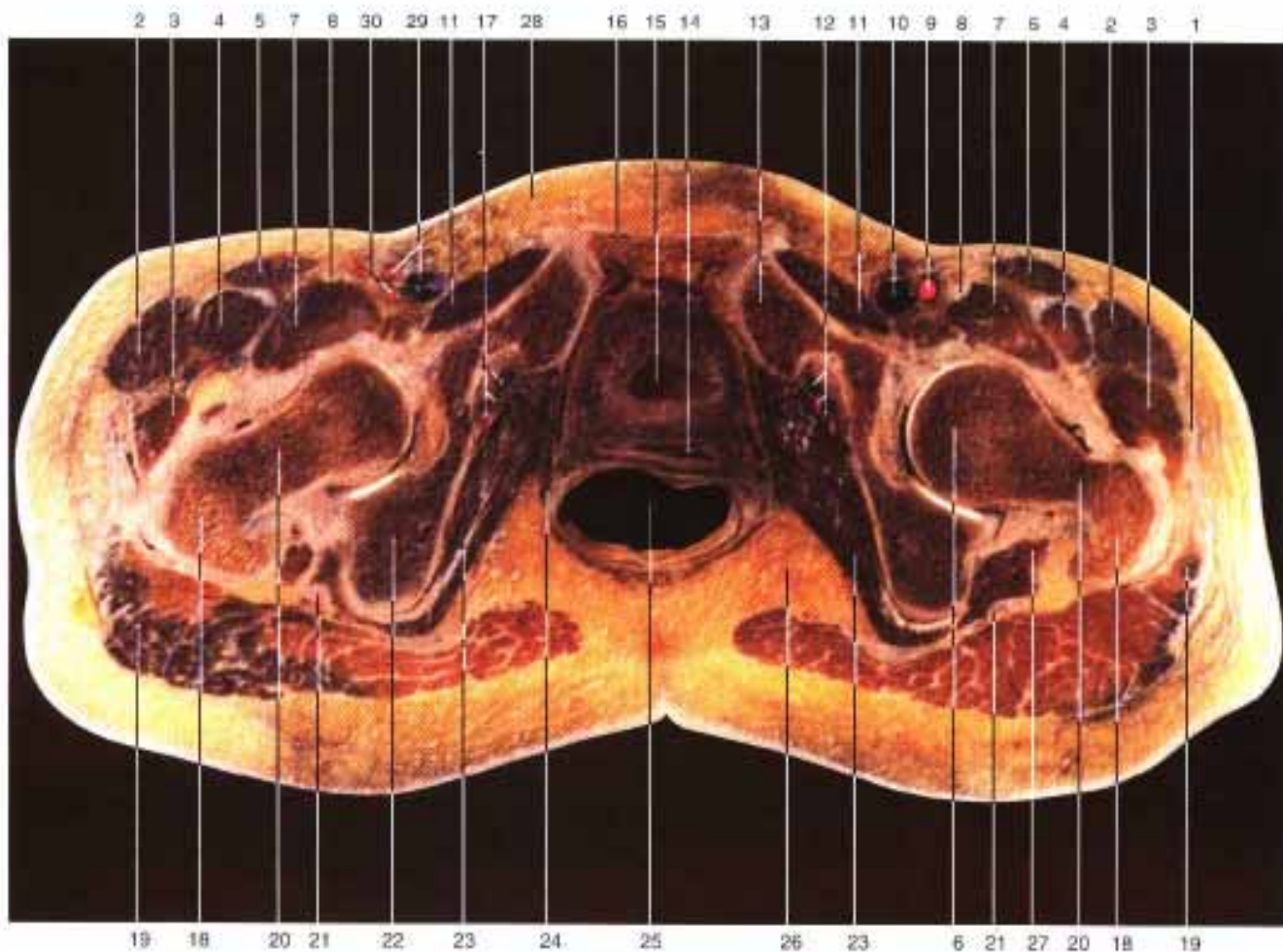
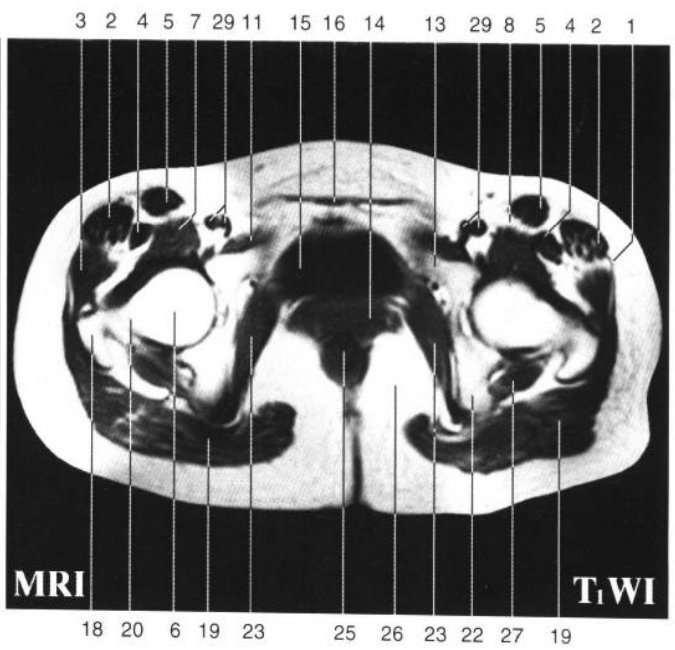
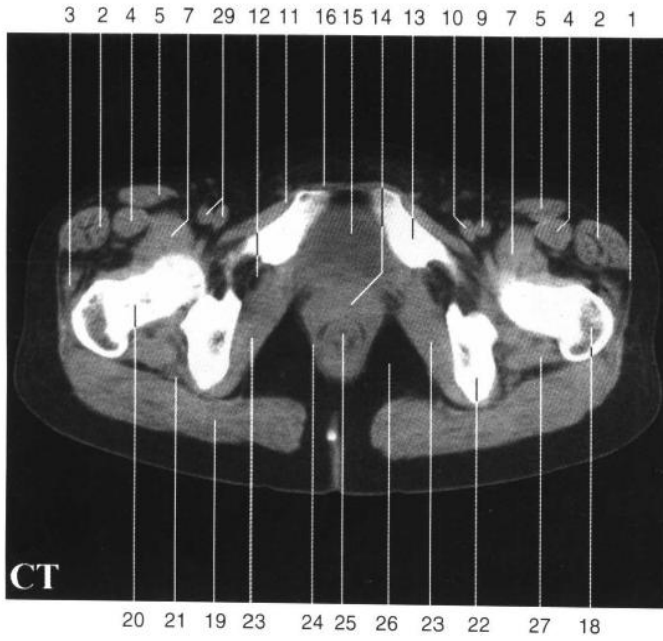


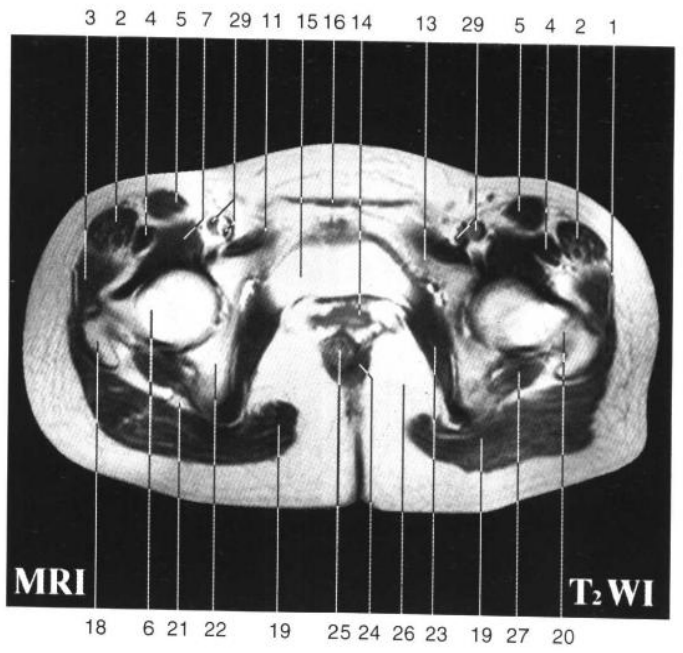
Fig. HPf 10

1. 髂胫束 iliotibial tract
2. 阔筋膜张肌 tensor fasciae latae
3. 臀中肌 gluteus medius
4. 股直肌 rectus femoris
5. 缝匠肌 sartorius
6. 股骨头 femoral head
7. 髂股肌 iliopsoas
8. 股神经 femoral n.
9. 股动脉 femoral a.
10. 股静脉 femoral v.

Fig. HPf 10



- 11. 耻骨肌 pectineus
- 12. 闭孔神经(闭膜管) obturator n. (obturator canal)
- 13. 耻骨上支 superior ramus of pubis
- 14. 阴道 vagina
- 15. 膀胱 urinary bladder
- 16. 锥状肌 pyramidalis
- 17. 闭孔动、静脉(闭膜管) obturator a. and v. (obturator canal)
- 18. 大转子 greater trochanter
- 19. 臀大肌 gluteus maximus
- 20. 股骨颈 neck of femur
- 21. 坐骨神经 sciatic n.
- 22. 坐骨体 body of ischium
- 23. 闭孔内肌 obturator internus
- 24. 肛提肌 levator ani
- 25. 直肠 rectum
- 26. 坐骨肛门窝脂体 adipose body of ischioanal fossa
- 27. 股方肌 quadratus femoris
- 28. 阴阜 mons pubis
- 29. 股动、静脉 femoral a. and v.
- 30. 股深动脉 deep femoral a.



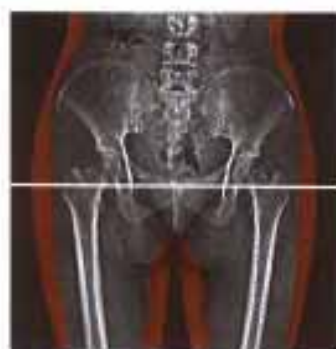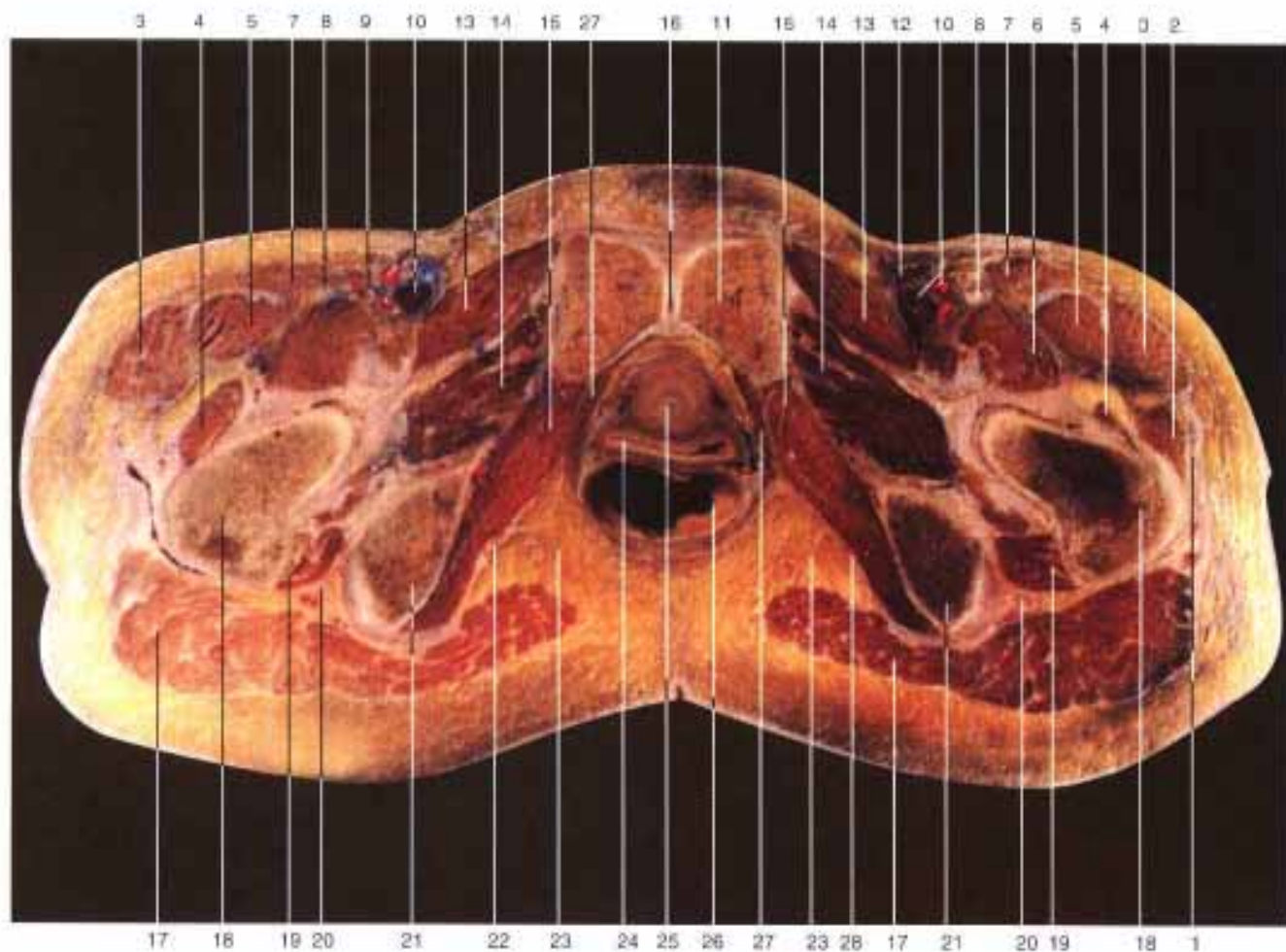
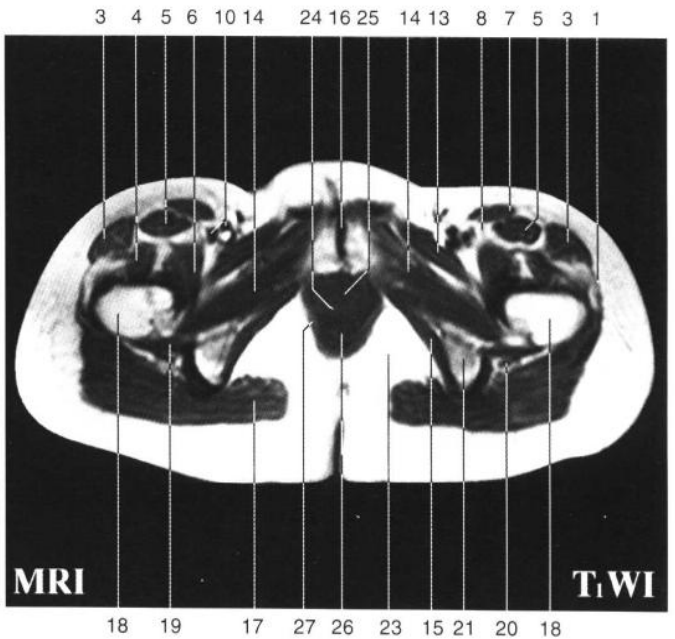
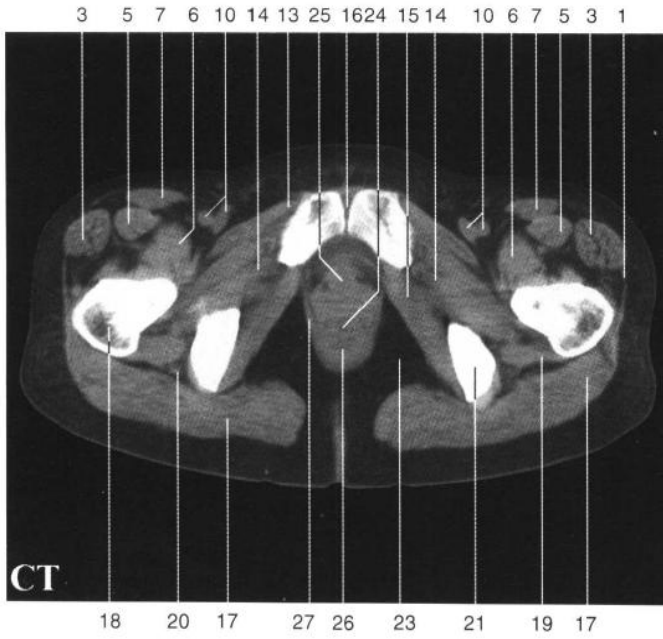


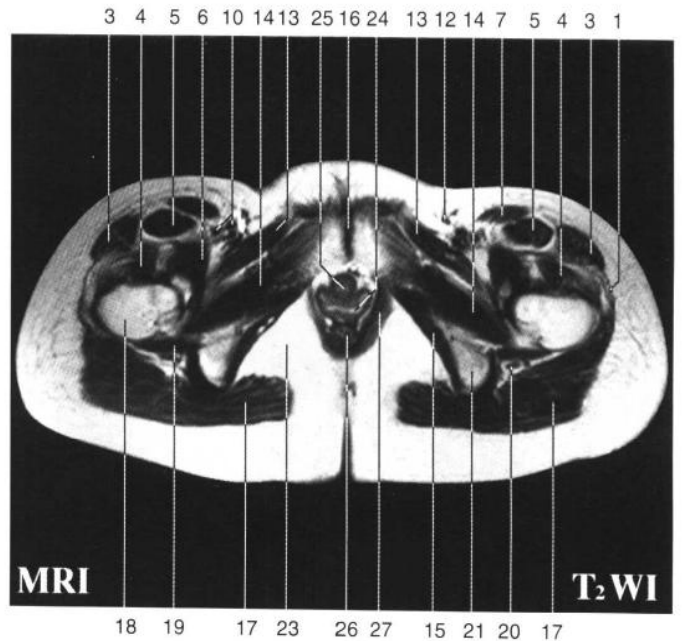
Fig. HPf 11

1. 髂胫束 iliotibial tract
2. 臀中肌 gluteus medius
3. 阔筋膜张肌 tensor fasciae latae
4. 股外侧肌 vastus lateralis
5. 股直肌 rectus femoris
6. 髂腰肌 iliopsoas
7. 缝匠肌 sartorius
8. 股神经 femoral n.
9. 股深动脉 deep femoral a.
10. 股动、静脉 femoral a. and v.

Fig. HPf 11



11. 耻骨上支 superior ramus of pubis
12. 大隐静脉 great saphenous v.
13. 耻骨肌 pectineus
14. 闭孔外肌 obturator externus
15. 闭孔内肌 obturator internus
16. 耻骨联合 pubic symphysis
17. 臀大肌 gluteus maximus
18. 大转子 greater trochanter
19. 股方肌 quadratus femoris
20. 坐骨神经 sciatic n.
21. 坐骨结节 ischial tuberosity
22. 阴部管 pudendal canal
23. 坐骨肛门窝脂体 adipose body of ischioanal fossa
24. 阴道 vagina
25. 女尿道 female urethra
26. 直肠 rectum
27. 肛提肌 levator ani
28. 阴部内动、静脉与阴部神经 internal pudendal a., v. and pudendal n.



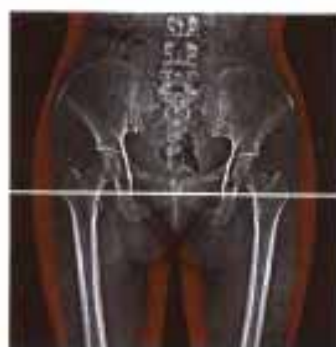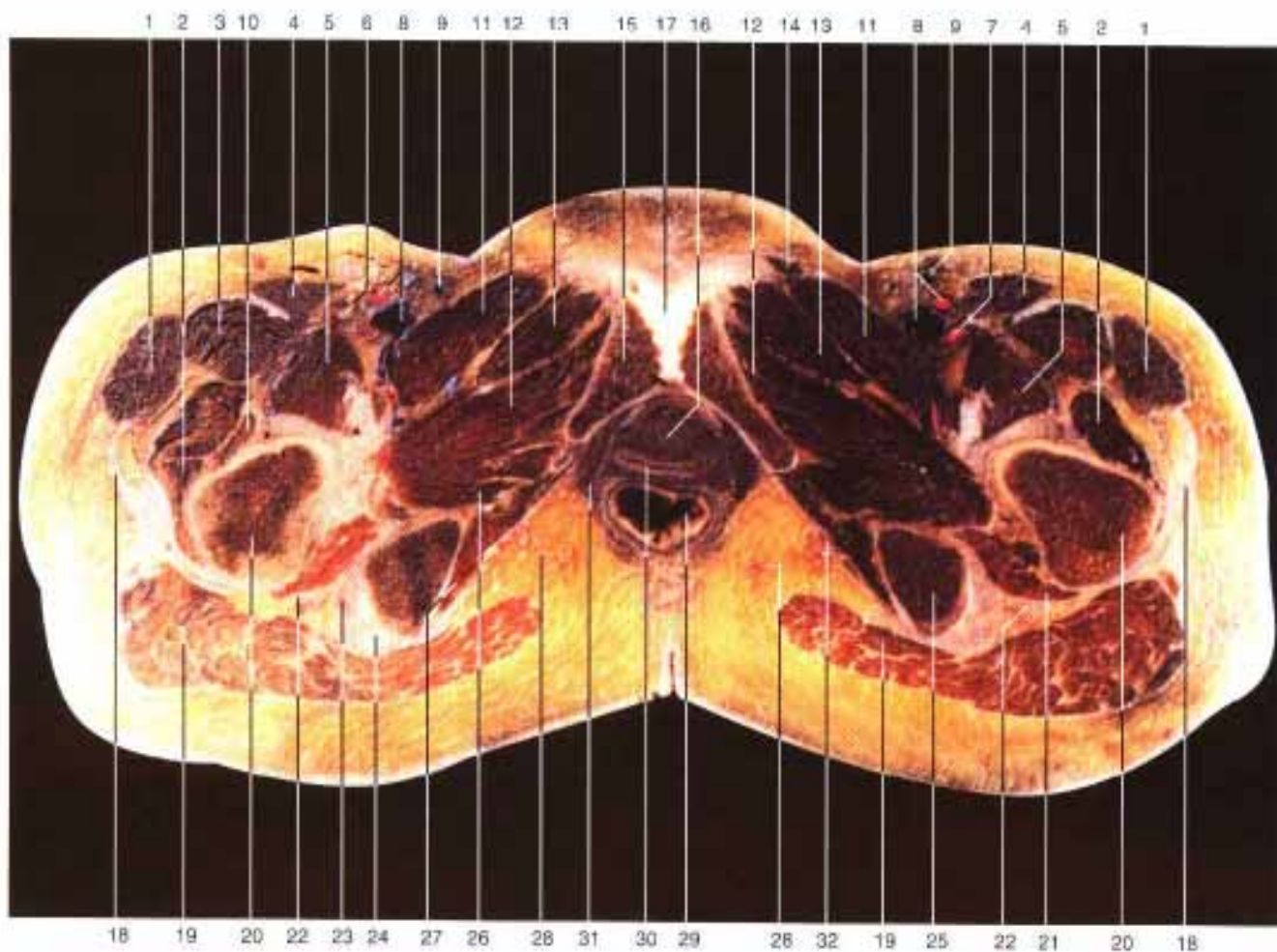
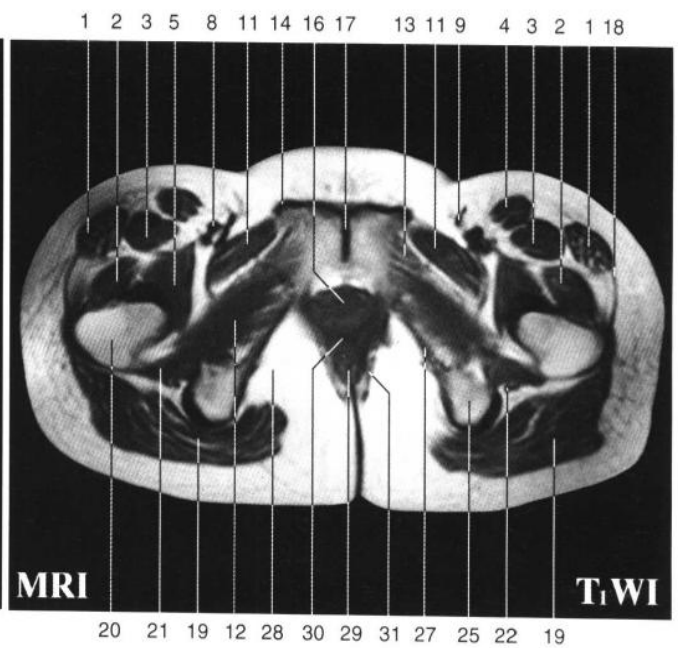
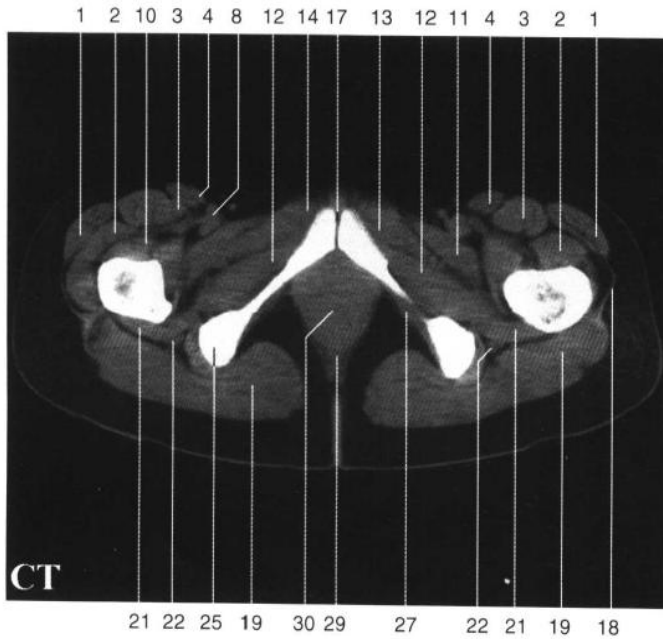


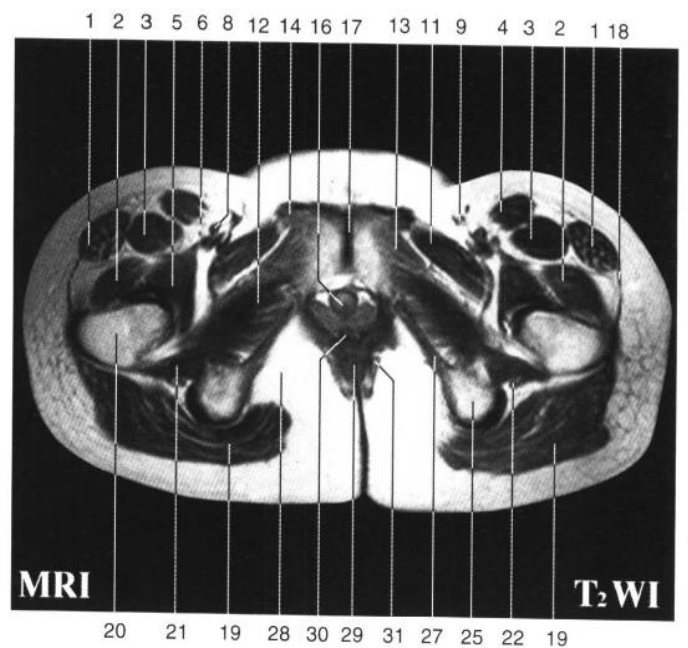
Fig. HPF 12

1. 阔筋膜张肌 tensor fasciae latae
2. 股外侧肌 vastus lateralis
3. 股直肌 rectus femoris
4. 缝匠肌 sartorius
5. 髂腰肌 iliopsoas
6. 股神经 femoral n.
7. 股深动脉 deep femoral a.
8. 股动、静脉 femoral a. and v.
9. 大隐静脉 great saphenous v.
10. 股中间肌 vastus intermedius

Fig. HPf 12



11. 耻骨肌 pectineus
12. 大收肌 adductor magnus
13. 短收肌 adductor brevis
14. 长收肌 adductor longus
15. 耻骨下支 inferior ramus of pubis
16. 女尿道 female urethra
17. 耻骨联合 pubic symphysis
18. 髂胫束 iliotibial tract
19. 臀大肌 gluteus maximus
20. 大转子 greater trochanter
21. 股方肌 quadratus femoris
22. 坐骨神经 sciatic n.
23. 半膜肌腱 tendon of semimembranosus
24. 半腱肌与股二头肌长头腱 tendon of semitendinosus and long head of biceps femoris
25. 坐骨结节 ischial tuberosity
26. 闭孔外肌 obturator externus
27. 闭孔内肌 obturator internus
28. 坐骨肛门窝脂体 adipose body of ischioanal fossa
29. 直肠 rectum
30. 阴道 vagina
31. 肛提肌 levator ani
32. 阴部管 pudendal canal



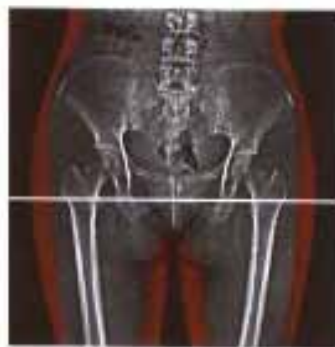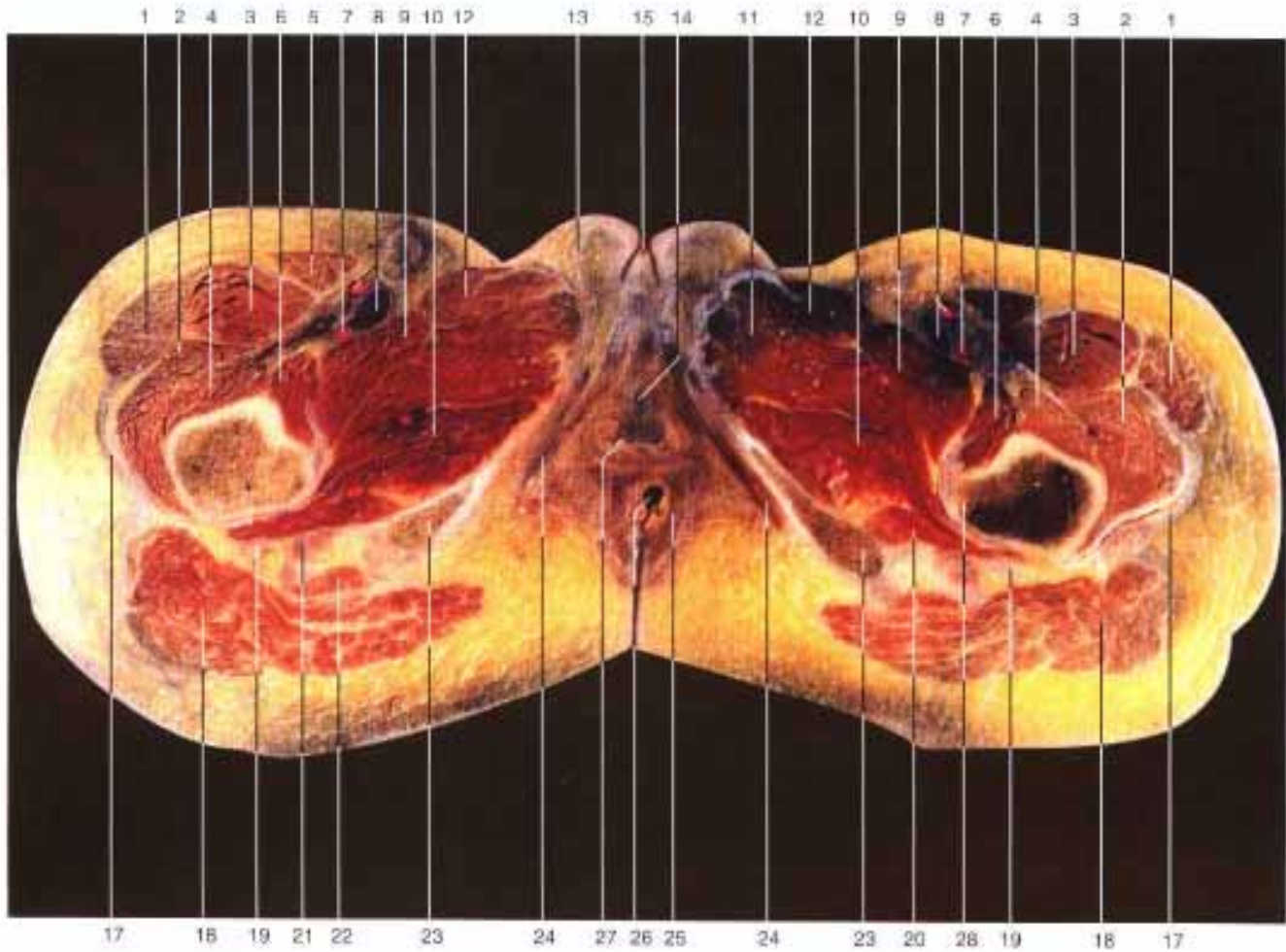
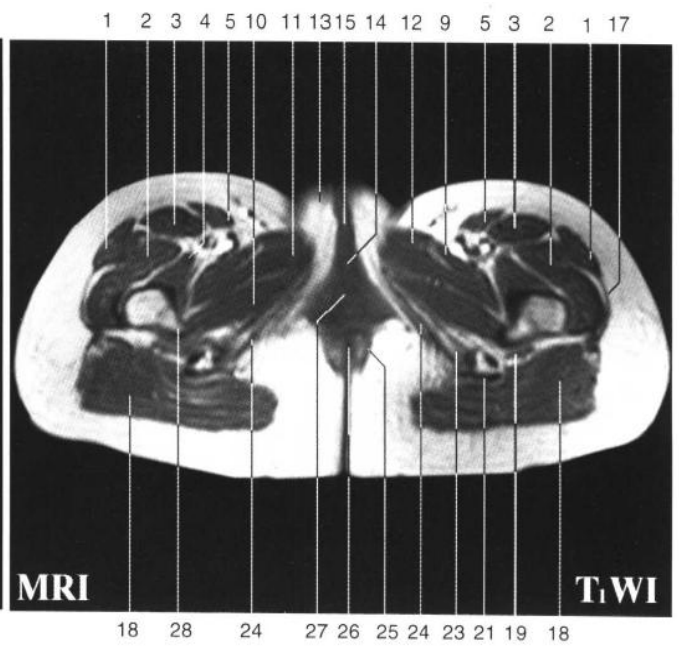
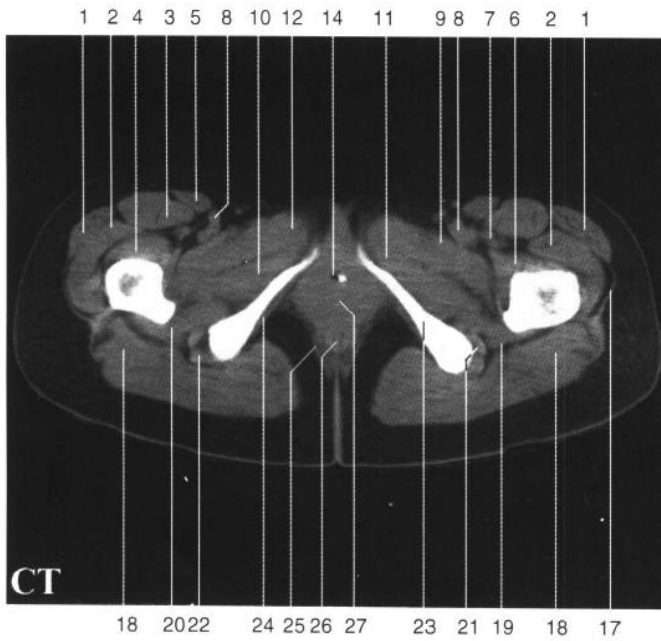


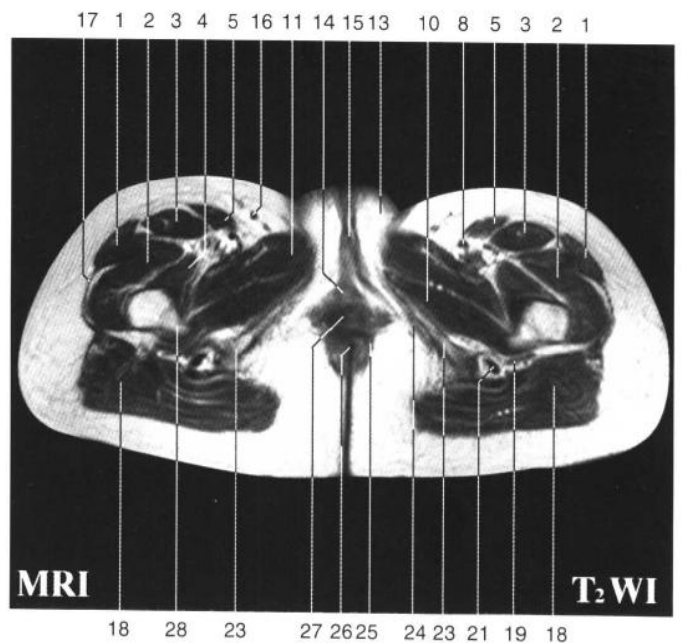
Fig. HPf 13

1. 阔筋膜张肌 tensor fasciae latae
2. 股外侧肌 vastus lateralis
3. 股直肌 rectus femoris
4. 股中间肌 vastus intermedius
5. 缝匠肌 sartorius
6. 髂腰肌 iliopsoas
7. 股深动脉 deep femoral a.
8. 股动、静脉 femoral a. and v.
9. 髂胫肌 pectineus

Fig. HPf 13



- 10. 大收肌 adductor magnus
- 11. 短收肌 adductor brevis
- 12. 长收肌 adductor longus
- 13. 大阴唇 greater lip of pudendum
- 14. 女尿道 female urethra
- 15. 阴蒂 clitoris
- 16. 大隐静脉 great saphenous v.
- 17. 髂胫束 iliotibial tract
- 18. 臀大肌 gluteus maximus
- 19. 坐骨神经 sciatic n.
- 20. 股方肌 quadratus femoris
- 21. 半膜肌腱 tendon of semimembranosus
- 22. 半腱肌与股二头肌长头腱 semitendinosus and tendon of long head of biceps femoris
- 23. 坐骨支 ramus of ischium
- 24. 坐骨海绵体肌 ischiocavernosus
- 25. 肛门外括约肌 sphincter ani externus
- 26. 肛门 anus
- 27. 阴道 vagina
- 28. 小转子 lesser trochanter



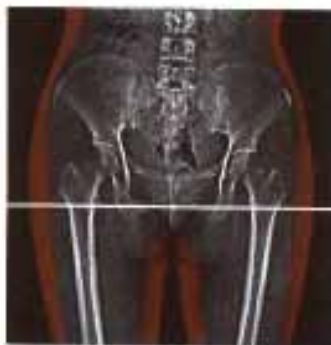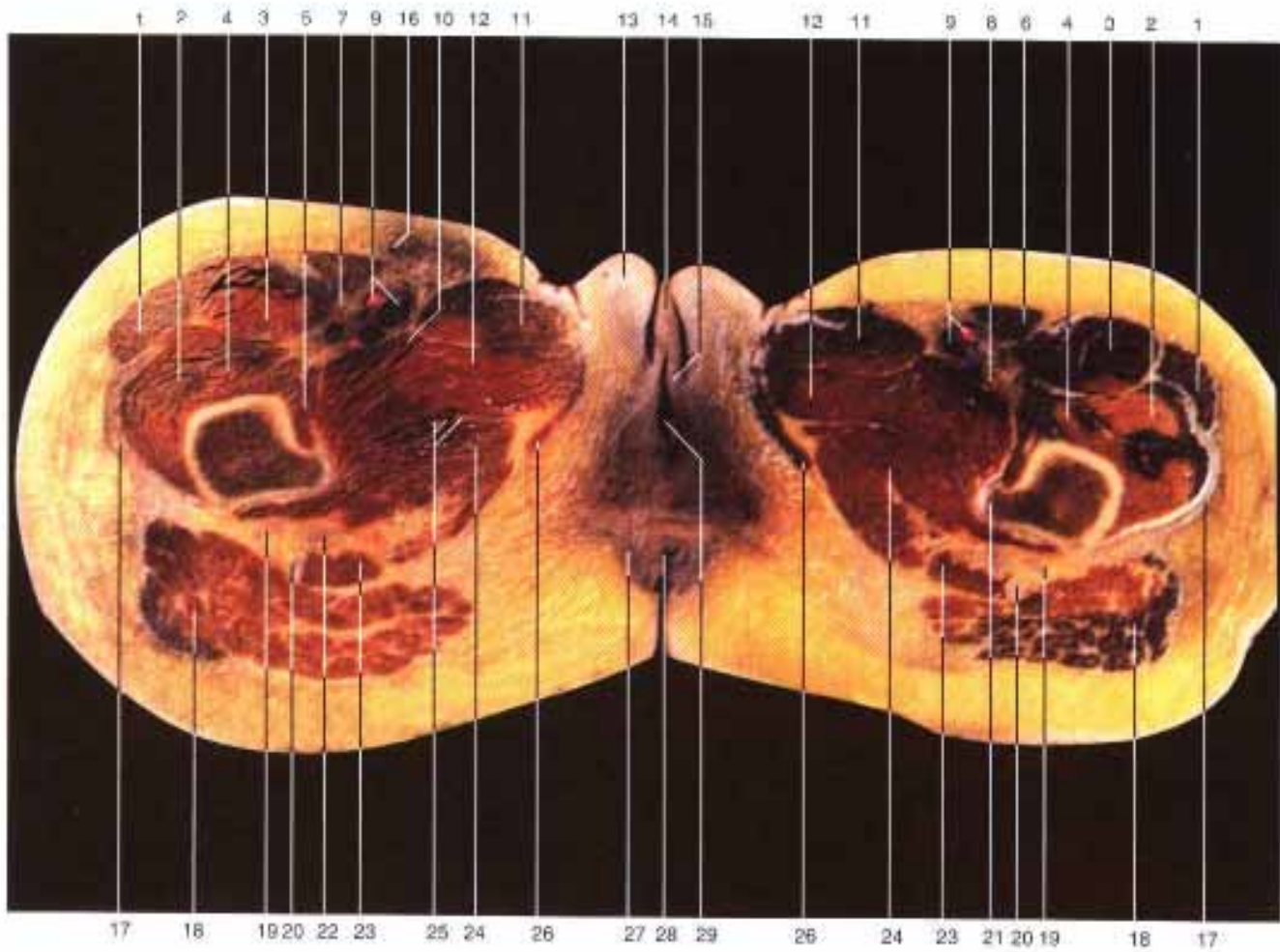
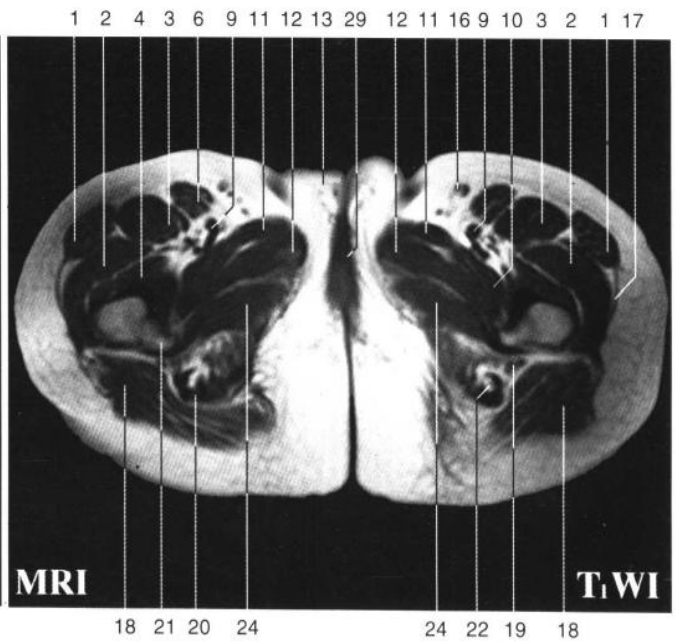

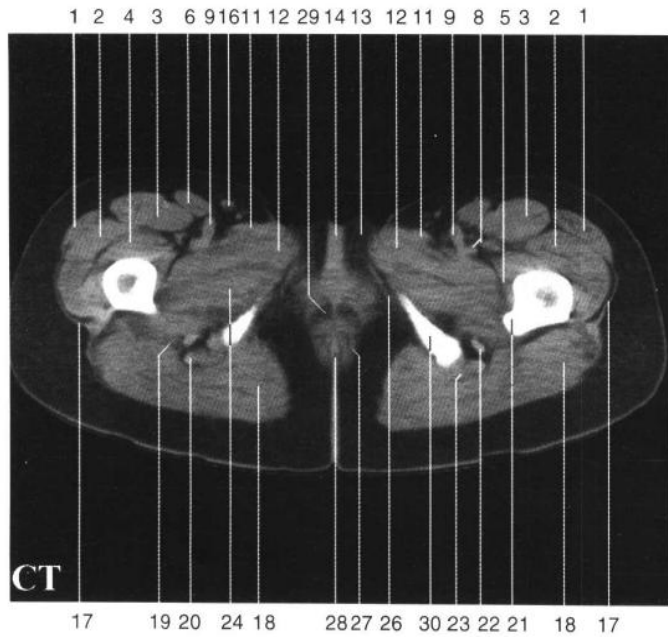
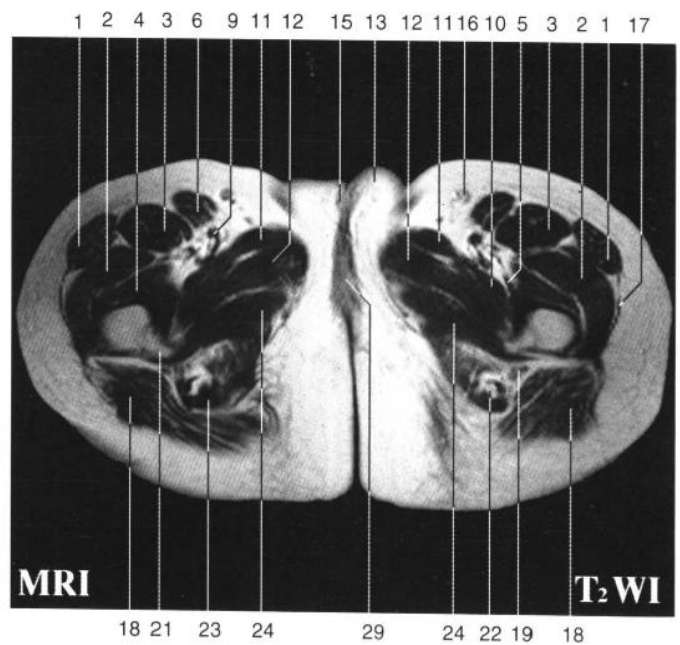
Fig. HPf 14

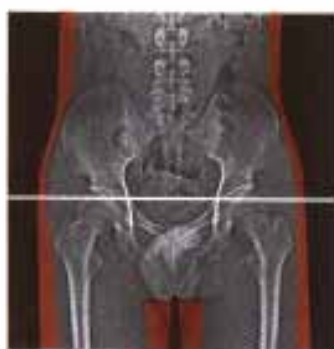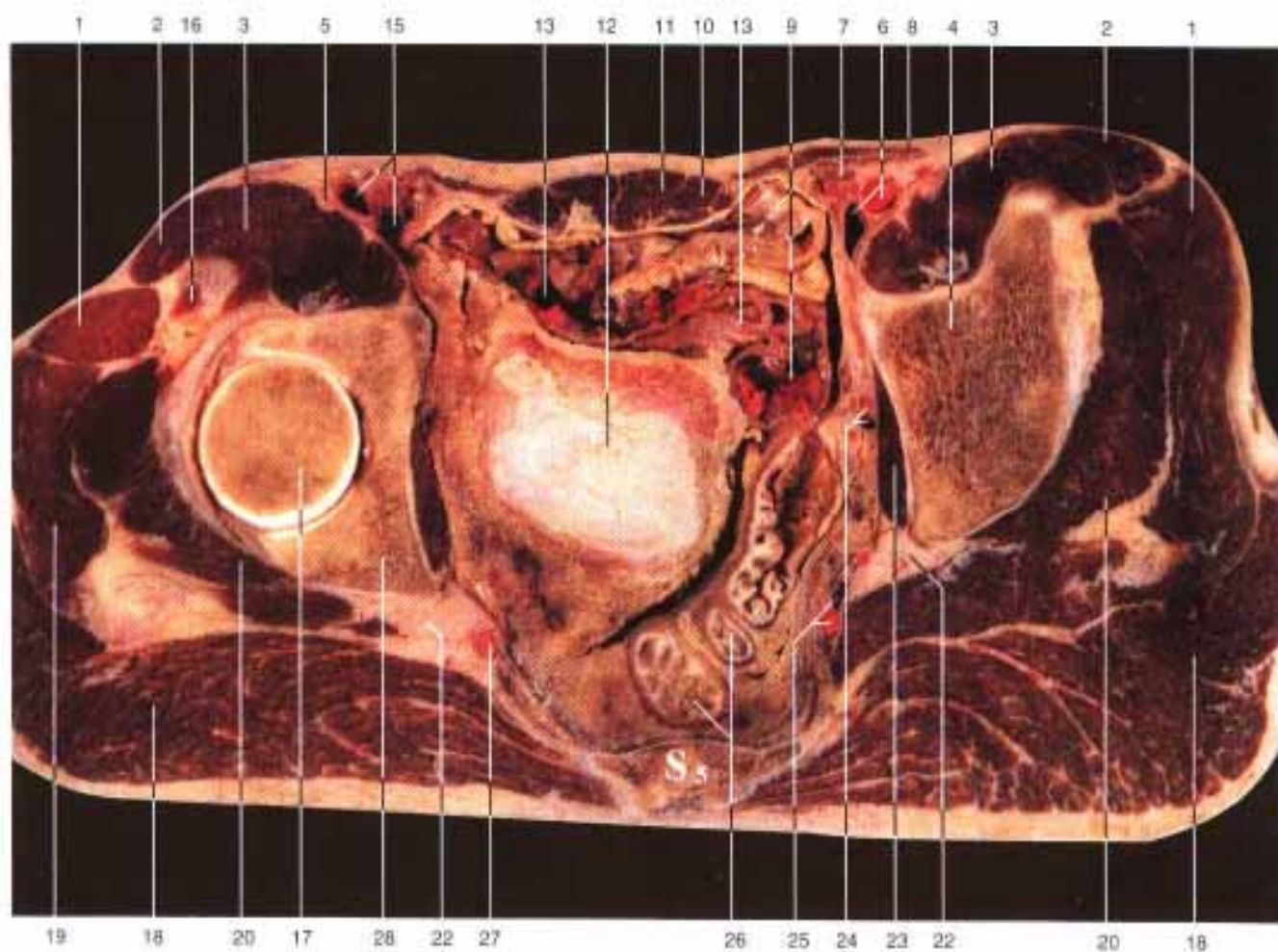
1. 阔筋膜张肌 tensor fasciae latae
2. 股外侧肌 vastus lateralis
3. 股直肌 rectus femoris
4. 股中间肌 vastus intermedius
5. 髂腰肌 iliopsoas
6. 缝匠肌 sartorius
7. 股神经 femoral n.
8. 股深动、静脉 deep femoral a. and v.
9. 股动、静脉 femoral a. and v.
10. 耻骨肌 pectineus

Fig. HPf 14



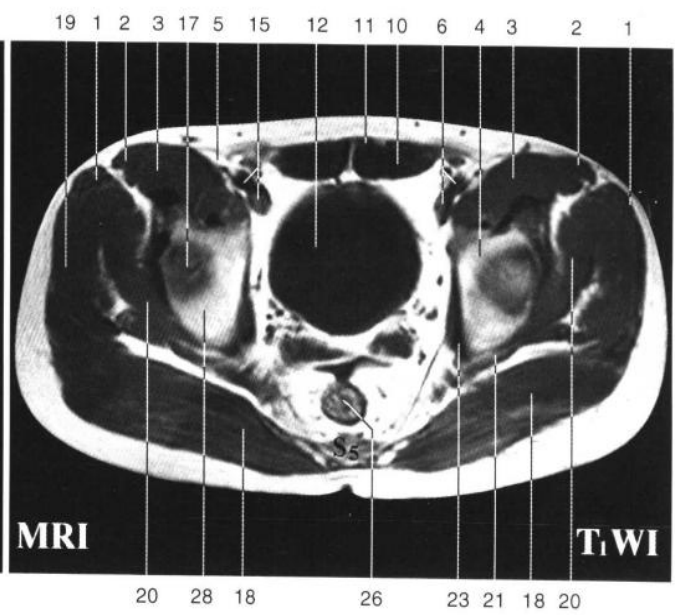
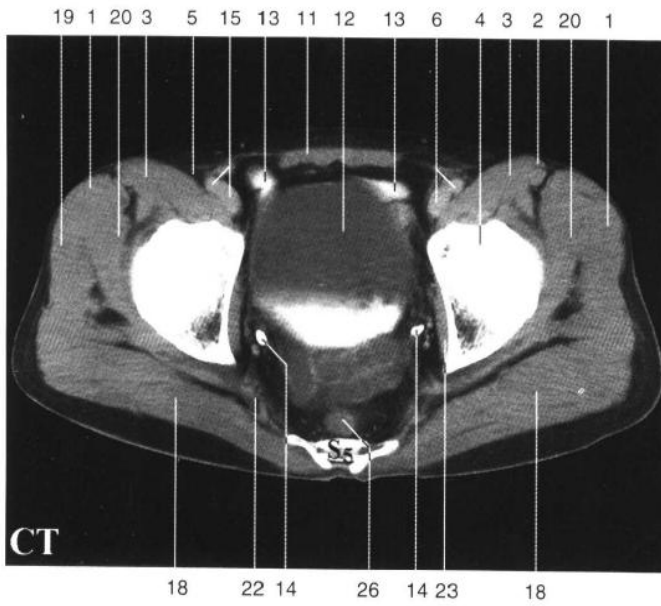
11. 长收肌 adductor longus
12. 短收肌 adductor brevis
13. 大阴唇 greater lip of pudendum
14. 阴蒂 clitoris
15. 小阴唇 lesser lip of pudendum
16. 大隐静脉 great saphenous v.
17. 髂胫束 iliotibial tract
18. 臀大肌 gluteus maximus
19. 坐骨神经 sciatic n.
20. 股二头肌长头腱 tendon of long head of biceps femoris
21. 小转子 lesser trochanter
22. 半膜肌腱 tendon of semimembranosus
23. 半腱肌 semitendinosus
24. 大收肌 adductor magnus
25. 闭孔动、静脉与神经 obturator a., v. and n.
26. 股薄肌 gracilis
27. 肛门括约肌 sphincter ani externus
28. 肛门 anus
29. 阴道前庭 vaginal vestibule
30. 坐骨支 ramus of ischium



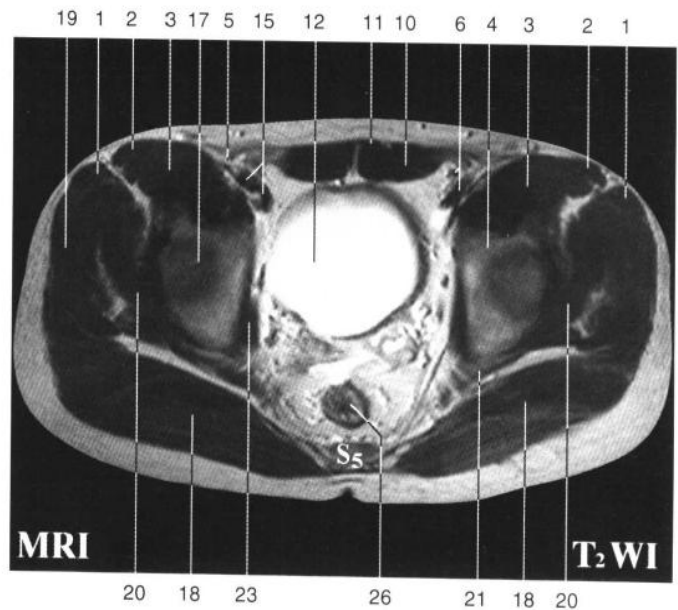


- Fig. HPm 1
1. 阔筋膜张肌 tensor fasciae latae
 2. 缝匠肌 sartorius
 3. 髂肌 iliopsoas
 4. 髌骨体 body of patella
 5. 股神经 femoral n.
 6. 左髂外动、静脉 left external iliac a. and v.
 7. 精索 spermatic cord
 8. 腹内斜肌 obliquus internus abdominis
 9. 乙状结肠 sigmoid colon
 10. 腹直肌 rectus abdominis

Fig. HPm 1



11. 锥状肌 pyramidalis
12. 膀胱 urinary bladder
13. 回肠 ileum
14. 输尿管 ureter
15. 右髂外动、静脉 right external iliac a. and v.
16. 股直肌 rectus femoris
17. 股骨头 femoral head
18. 臀大肌 gluteus maximus
19. 臀中肌 gluteus medius
20. 臀小肌 gluteus minimus
21. 梨状肌 piriformis
22. 坐骨神经 sciatic n.
23. 闭孔内肌 obturator internus
24. 闭孔动、静脉 obturator a. and v.
25. 臀下动、静脉 inferior gluteal a. and v.
26. 直肠 rectum
27. 阴部内动、静脉 internal pudendal a. and v.
28. 坐骨体 body of ischium



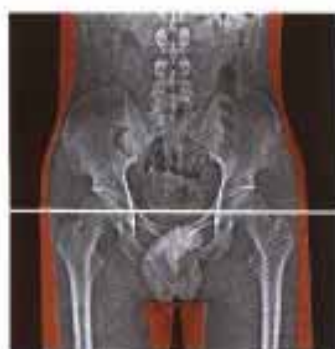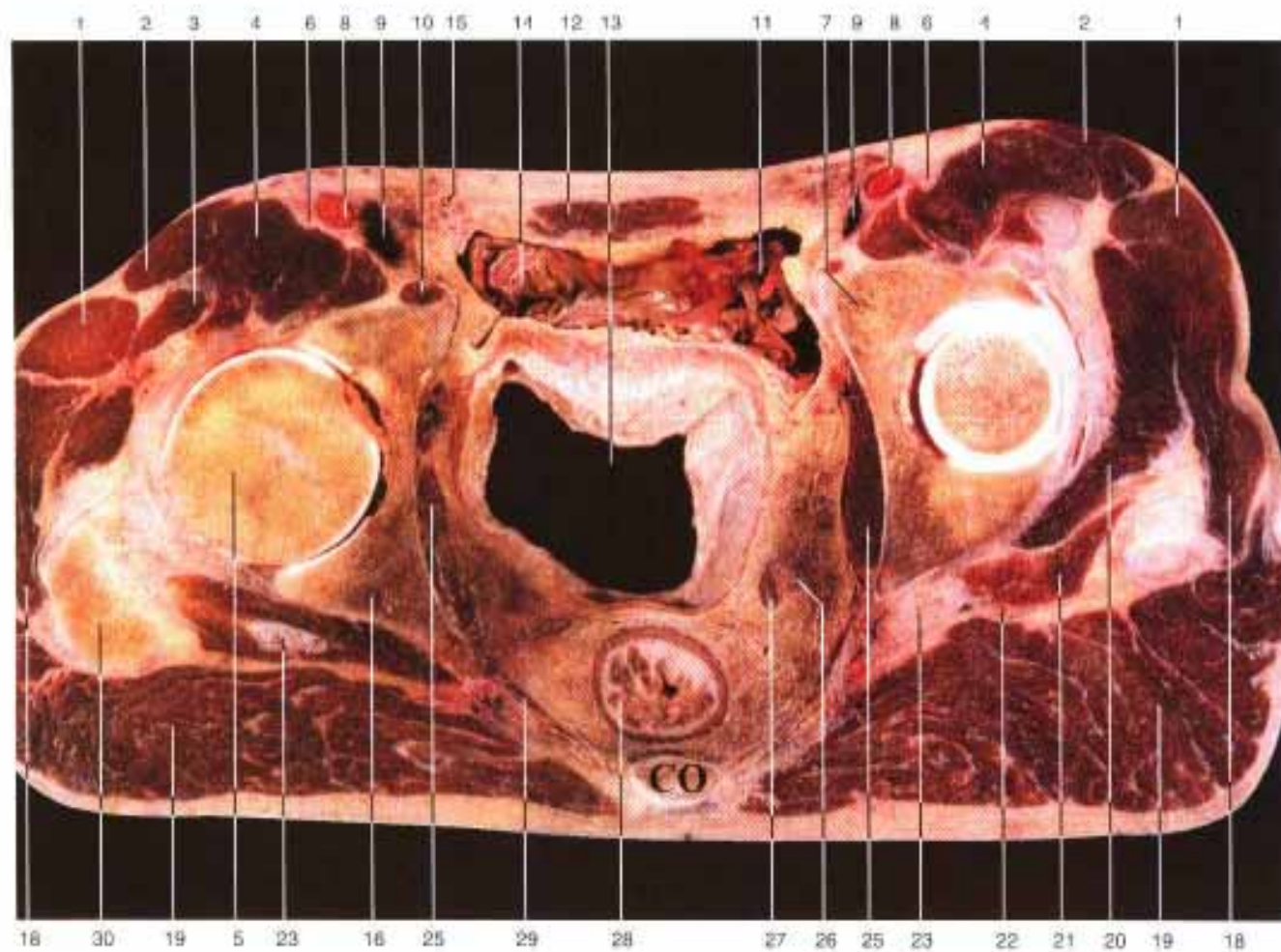
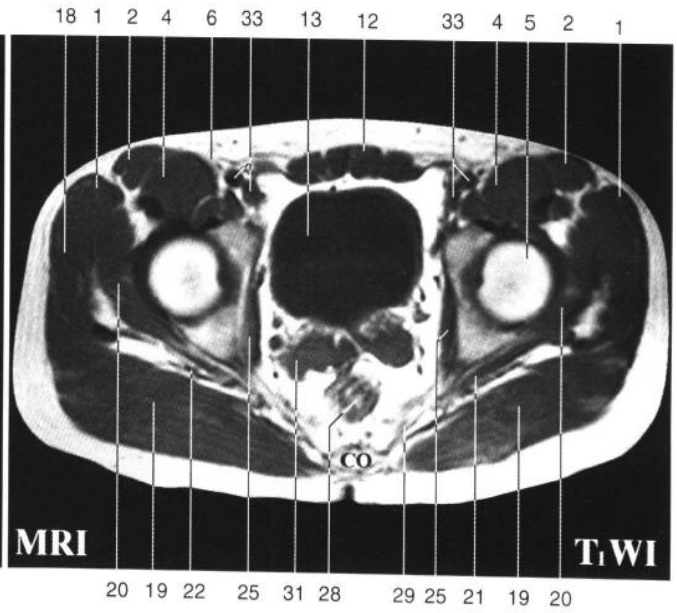
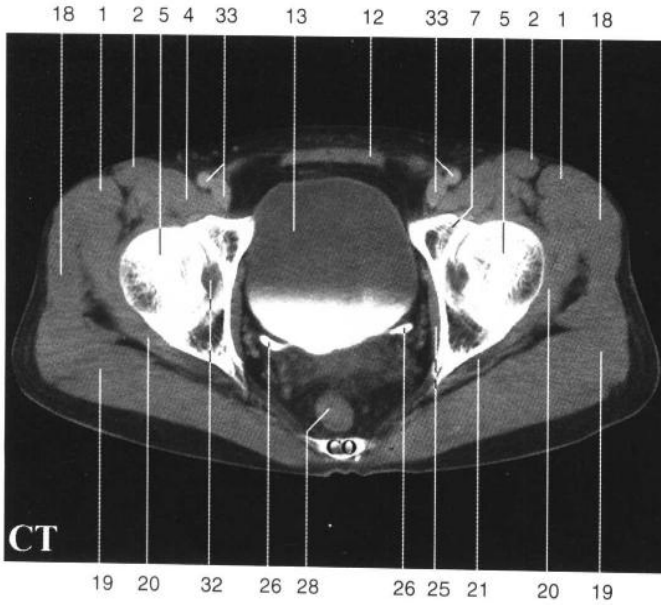


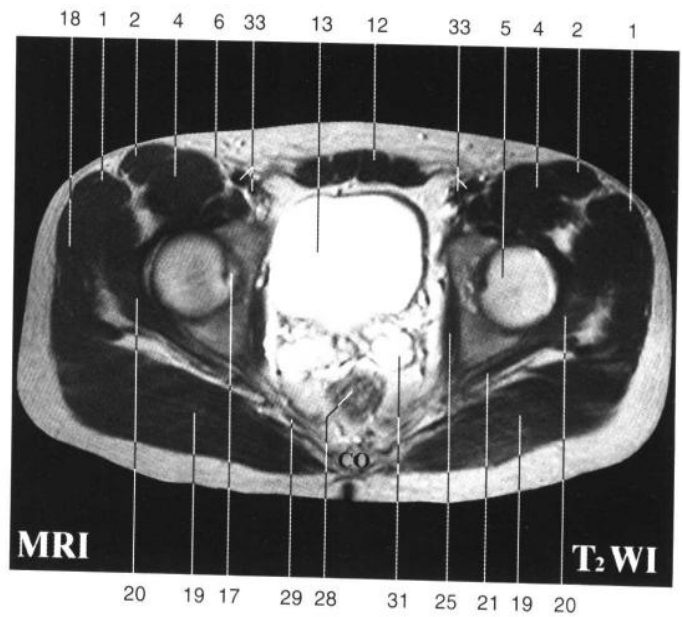
Fig. HPm 2

1. 阔筋膜张肌 tensor fasciae latae
2. 缝匠肌 sartorius
3. 股直肌 rectus femoris
4. 髂腰肌 iliopsoas
5. 股骨头 femoral head
6. 股神经 femoral n.
7. 耻骨体 body of pubis
8. 股动脉 femoral a.
9. 股静脉 femoral v.
10. 耻骨肌 pectineus

Fig. HPm 2



11. 乙状结肠 sigmoid colon
12. 锥状肌 pyramidalis
13. 膀胱 urinary bladder
14. 回肠 ileum
15. 精索 spermatic cord
16. 坐骨体 body of ischium
17. 股骨头韧带 ligament of head of femur
18. 臀中肌 gluteus medius
19. 臀大肌 gluteus maximus
20. 臀小肌 gluteus minimus
21. 上孖肌 gemellus superior
22. 坐骨神经 sciatic n.
23. 闭孔内肌腱 tendon of obturator internus
24. 臀下动、静脉 inferior gluteal a. and v.
25. 闭孔内肌 obturator internus
26. 输尿管 ureter
27. 输精管 ductus deferens
28. 直肠 rectum
29. 尾骨肌 coccygeus
30. 大转子 greater trochanter
31. 精囊 seminal vesicle
32. 股骨头韧带 ligament of head of femur
33. 股动、静脉 femoral a. and v.



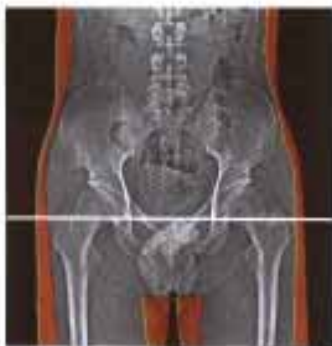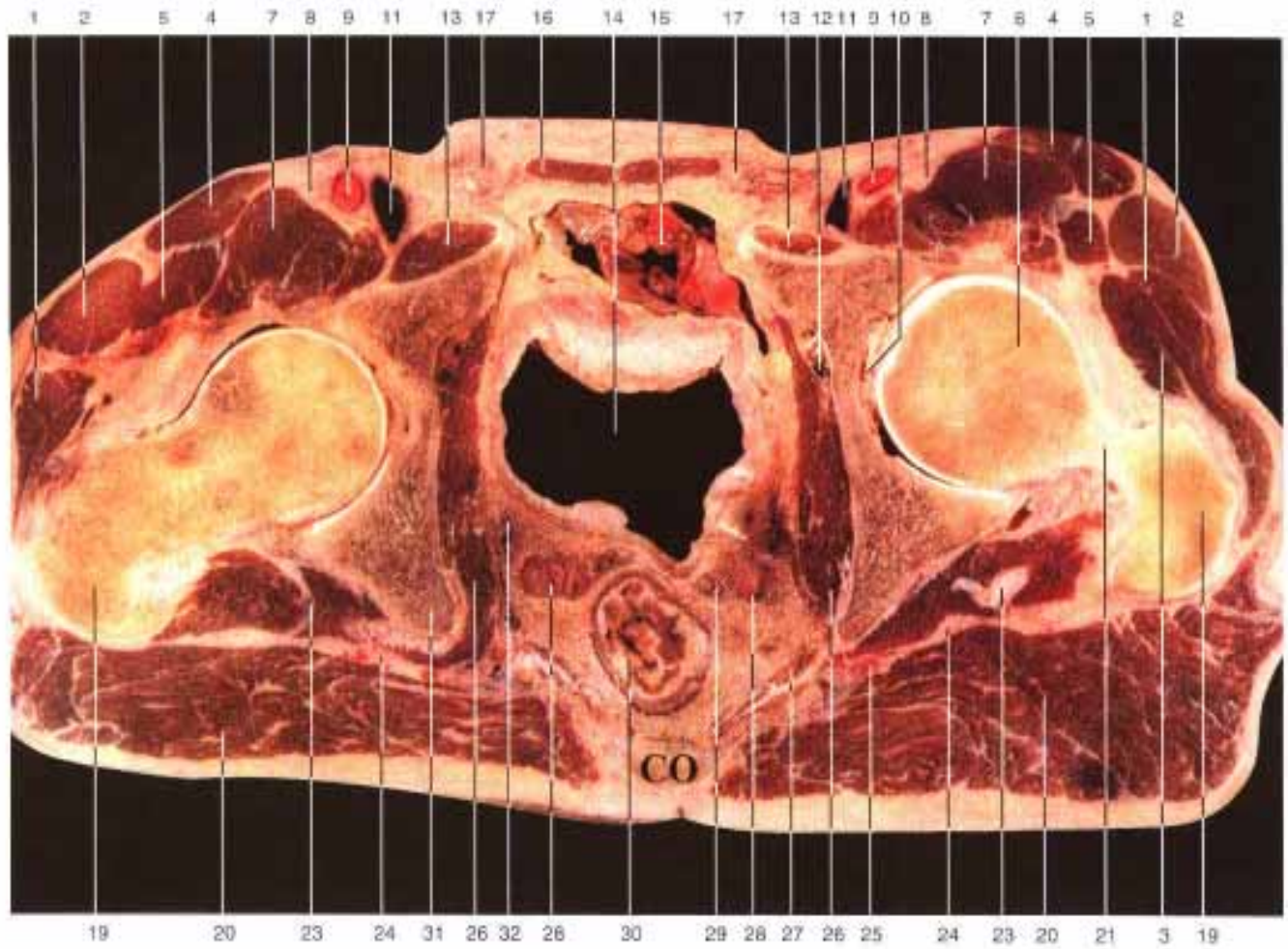
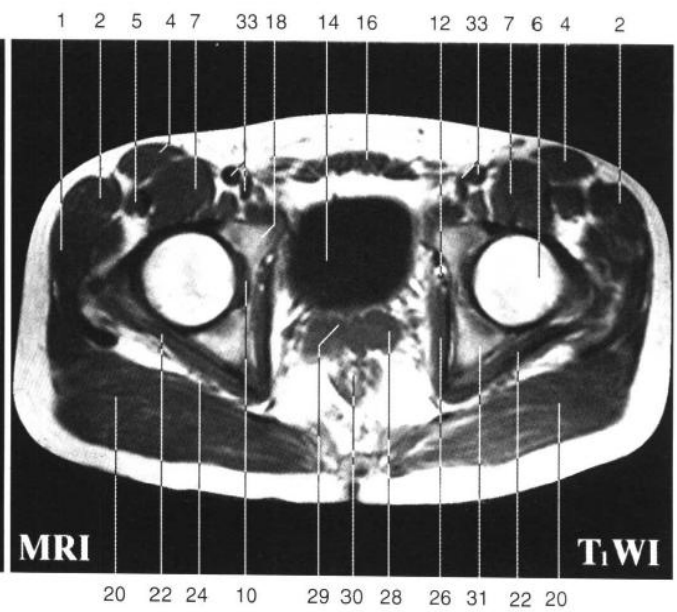

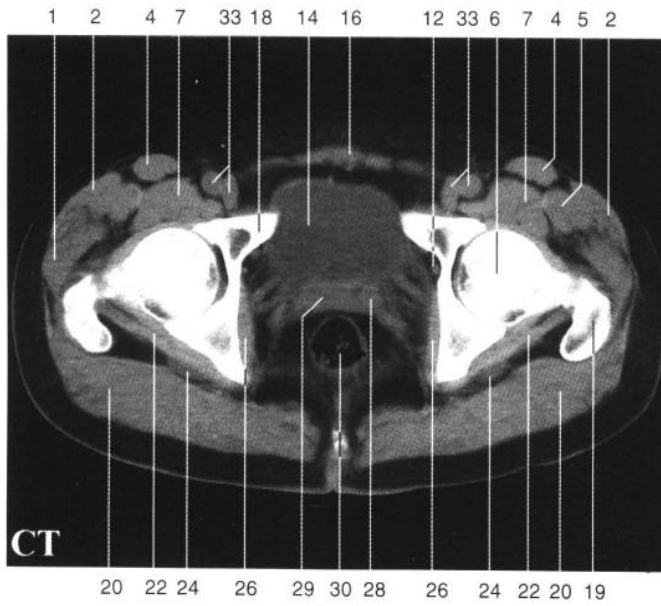
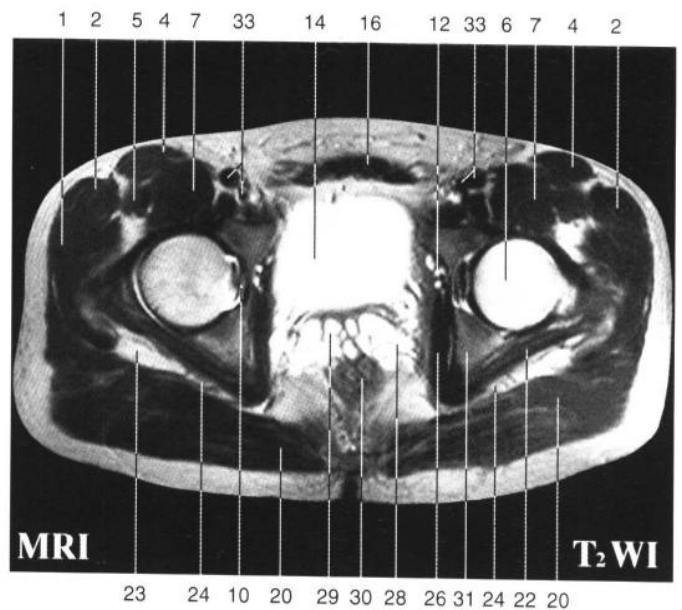
Fig. HPm 3

1. 臀中肌 gluteus medius
2. 阔筋膜张肌 tensor fasciae latae
3. 臀小肌 gluteus minimus
4. 缝匠肌 sartorius
5. 股直肌 rectus femoris
6. 股骨头 femoral head
7. 髂胫肌 iliopsoas
8. 股神经 femoral n.
9. 股动脉 femoral a.
10. 股骨头韧带 ligament of head of femur

Fig. HPm 3



- 11. 股静脉 femoral v.
- 12. 闭膜管 obturator canal
- 13. 耻骨肌 pectineus
- 14. 膀胱 urinary bladder
- 15. 乙状结肠 sigmoid colon
- 16. 锥状肌 pyramidalis
- 17. 精索 spermatic cord
- 18. 耻骨体 body of pubis
- 19. 大转子 greater trochanter
- 20. 臀大肌 gluteus maximus
- 21. 股骨颈 neck of femur
- 22. 下孖肌 gemellus inferior
- 23. 闭孔内肌腱 tendon of obturator internus
- 24. 坐骨神经 sciatic n.
- 25. 臀下动、静脉 inferior gluteal a. and v.
- 26. 闭孔内肌 obturator internus
- 27. 尾骨肌 coccygeus
- 28. 精囊 seminal vesicle
- 29. 输精管壶腹 ampulla ductus deferentis
- 30. 直肠 rectum
- 31. 坐骨体 body of ischium
- 32. 输尿管 ureter
- 33. 股动、静脉 femoral a. and v.



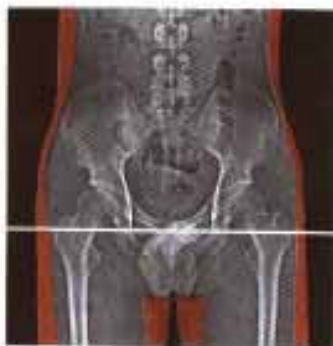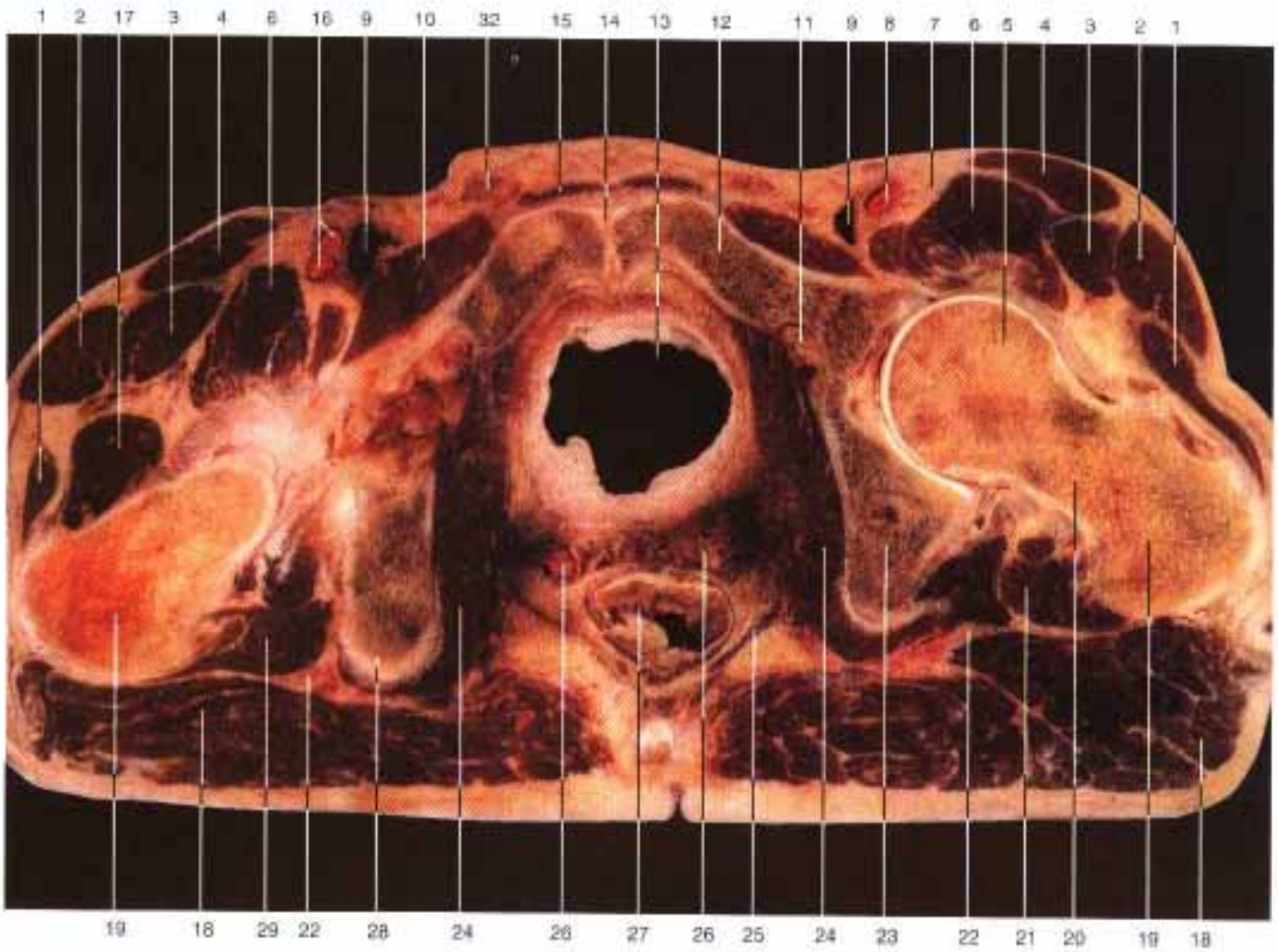
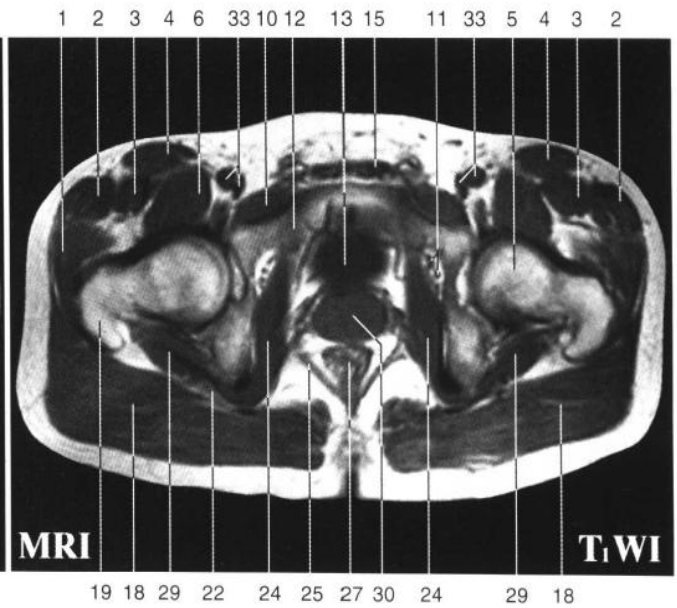
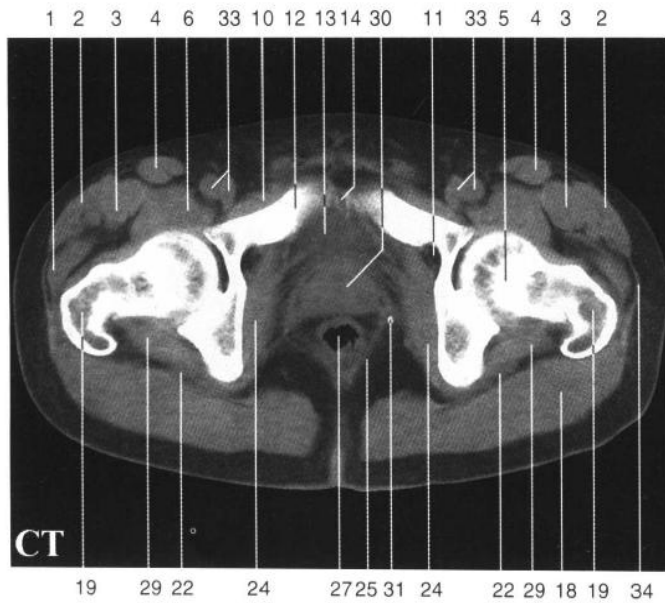


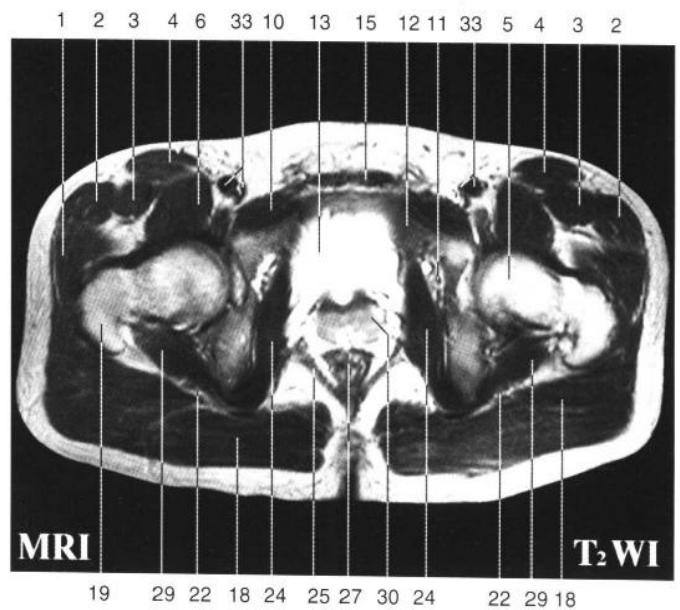
Fig. HPm 4

1. 臀中肌 gluteus medius
2. 阔筋膜张肌 tensor fasciae latae
3. 股直肌 rectus femoris
4. 缝匠肌 sartorius
5. 股骨头 femoral head
6. 髂腰肌 iliopsoas
7. 股神经 femoral n.
8. 股动脉 femoral a.
9. 股静脉 femoral v.
10. 耻骨肌 pectineus

Fig. HPm 4



11. 闭膜管 obturator canal
12. 耻骨上支 superior ramus of pubis
13. 膀胱 urinary bladder
14. 耻骨联合 pubic symphysis
15. 锥状肌 pyramidalis
16. 股动脉与股深动脉 femoral a. and deep femoral a.
17. 股外侧肌 vastus lateralis
18. 臀大肌 gluteus maximus
19. 大转子 greater trochanter
20. 股骨颈 neck of femur
21. 下孖肌 gemellus inferior
22. 坐骨神经 sciatic n.
23. 坐骨体 body of ischium
24. 闭孔内肌 obturator internus
25. 肛提肌 levator ani
26. 精囊 seminal vesicle
27. 直肠 rectum
28. 坐骨结节 ischial tuberosity
29. 股方肌 quadratus femoris
30. 前列腺 prostate
31. 静脉石 phlebolith
32. 精索 spermatic cord
33. 股动、静脉 femoral a. and v.
34. 髂胫束 iliotibial tract



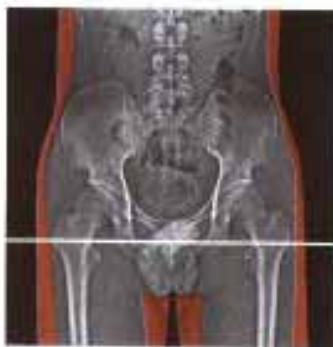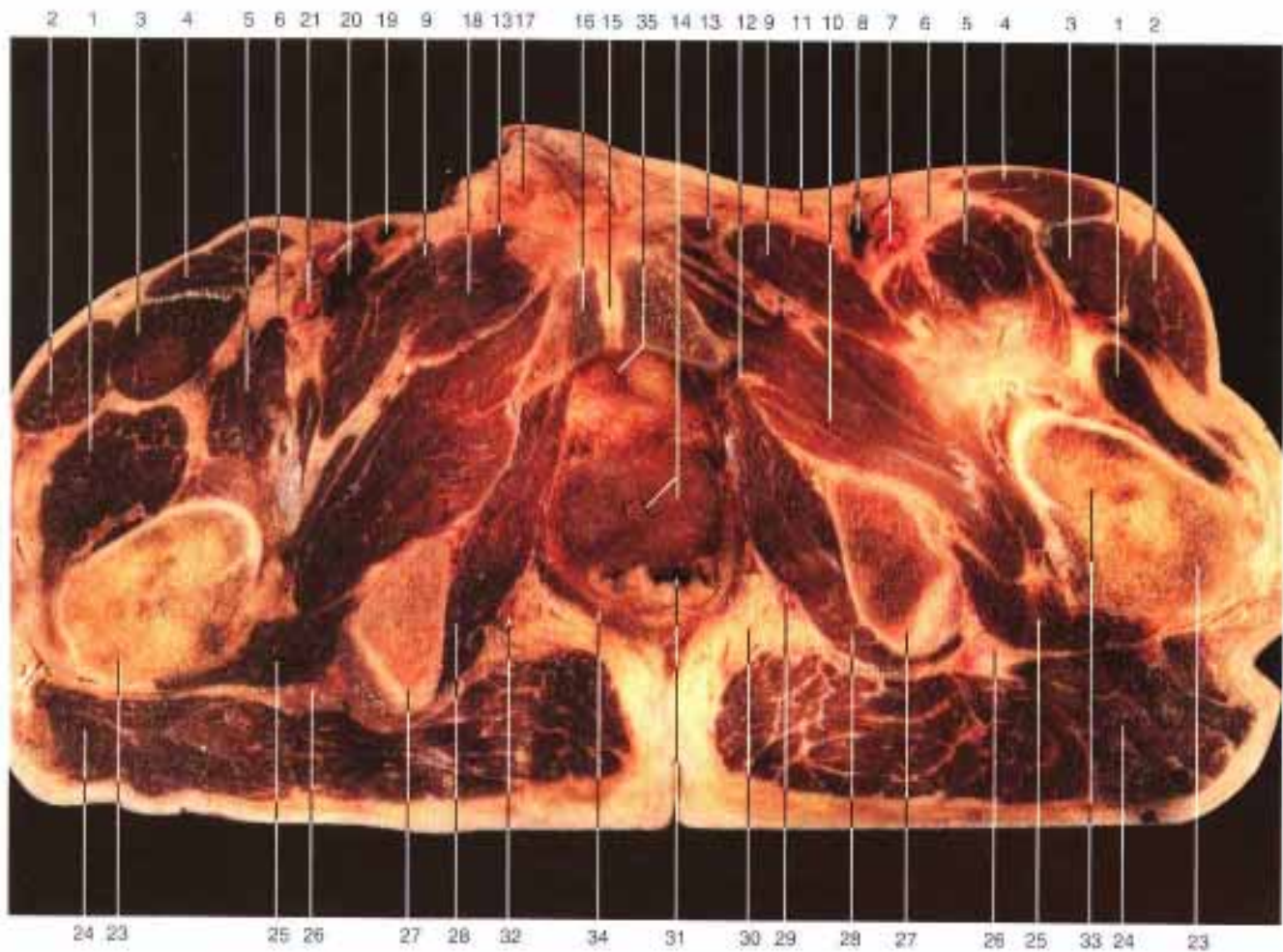
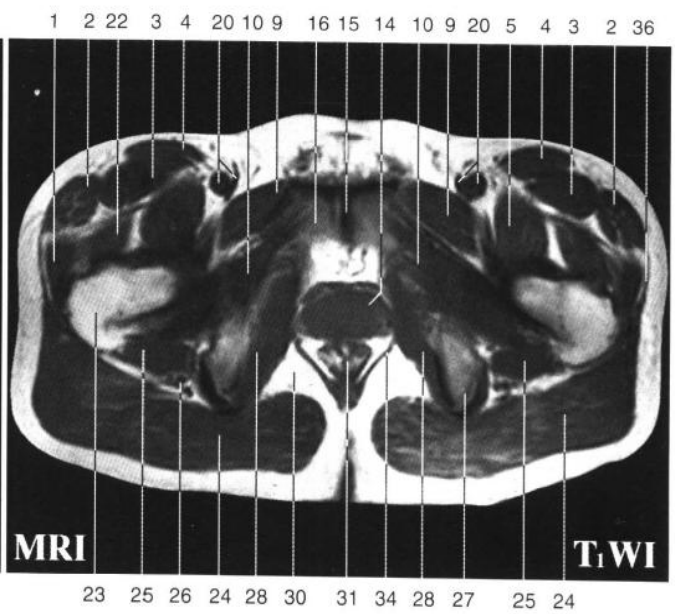
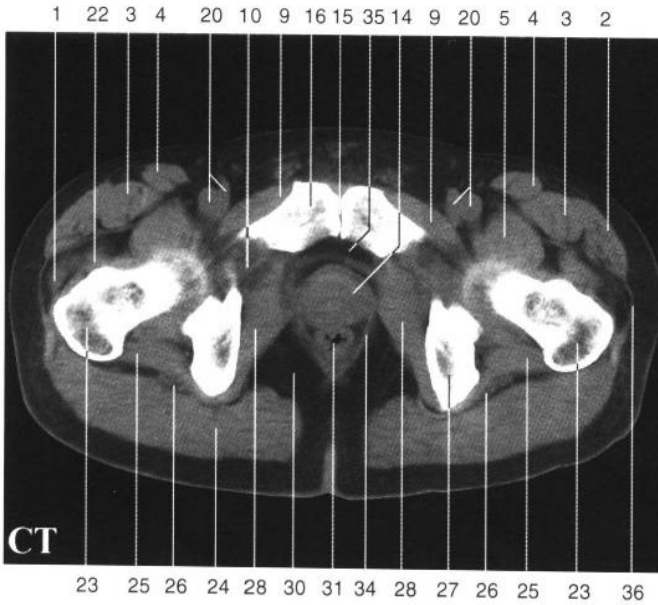


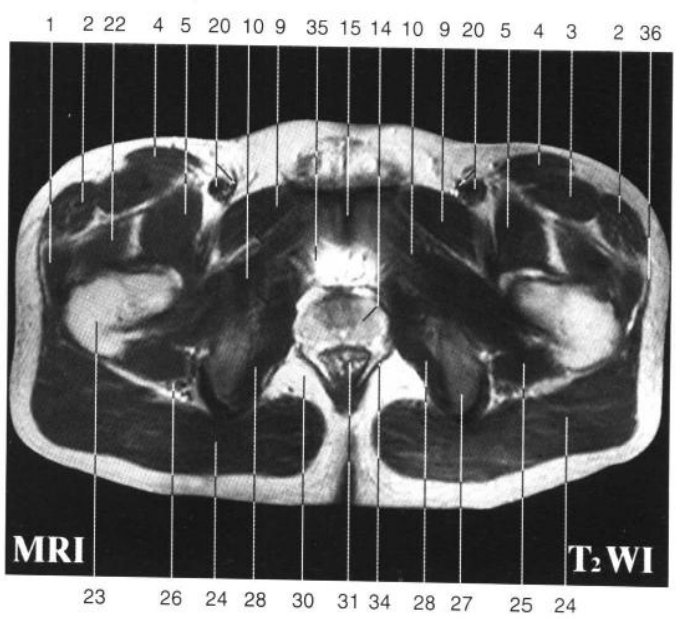
Fig. HPm 5

1. 股外侧肌 vastus lateralis
2. 阔筋膜张肌 tensor fasciae latae
3. 股直肌 rectus femoris
4. 缝匠肌 sartorius
5. 髂腰肌 iliopsoas
6. 股神经 femoral n.
7. 股动脉与股深动脉 femoral a. and deep femoral a.
8. 股静脉 femoral v.
9. 耻骨肌 pectineus
10. 闭孔外肌 obturator externus

Fig. HPm 5



11. 腹股沟浅淋巴结 superficial inguinal lymph node
12. 闭孔神经 obturator n.
13. 长收肌 adductor longus
14. 前列腺与尿道 prostate and urethra
15. 耻骨联合 pubic symphysis
16. 耻骨上支 superior ramus of pubis
17. 精索 spermatic cord
18. 短收肌 adductor brevis
19. 大隐静脉 great saphenous v.
20. 股动、静脉 femoral a. and v.
21. 股深动脉 deep femoral a.
22. 股中间肌 vastus intermedius
23. 大转子 greater trochanter
24. 臀大肌 gluteus maximus
25. 股方肌 quadratus femoris
26. 坐骨神经 sciatic n.
27. 坐骨结节 ischial tuberosity
28. 闭孔内肌 obturator internus
29. 阴部管 pudendal canal
30. 坐骨肛门窝脂体 adipose body of ischioanal fossa
31. 直肠 rectum
32. 阴部内动、静脉与阴部神经 internal pudendal a. , v. and pudendal n.
33. 股骨颈 neck of femur
34. 肛提肌 levator ani
35. 耻骨后〔间〕隙 retropubic space
36. 髂胫束 iliotibial tract



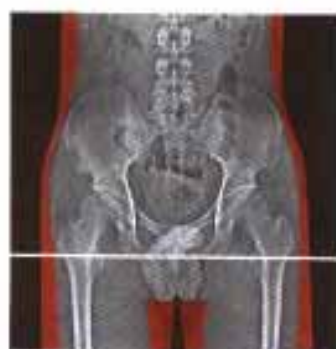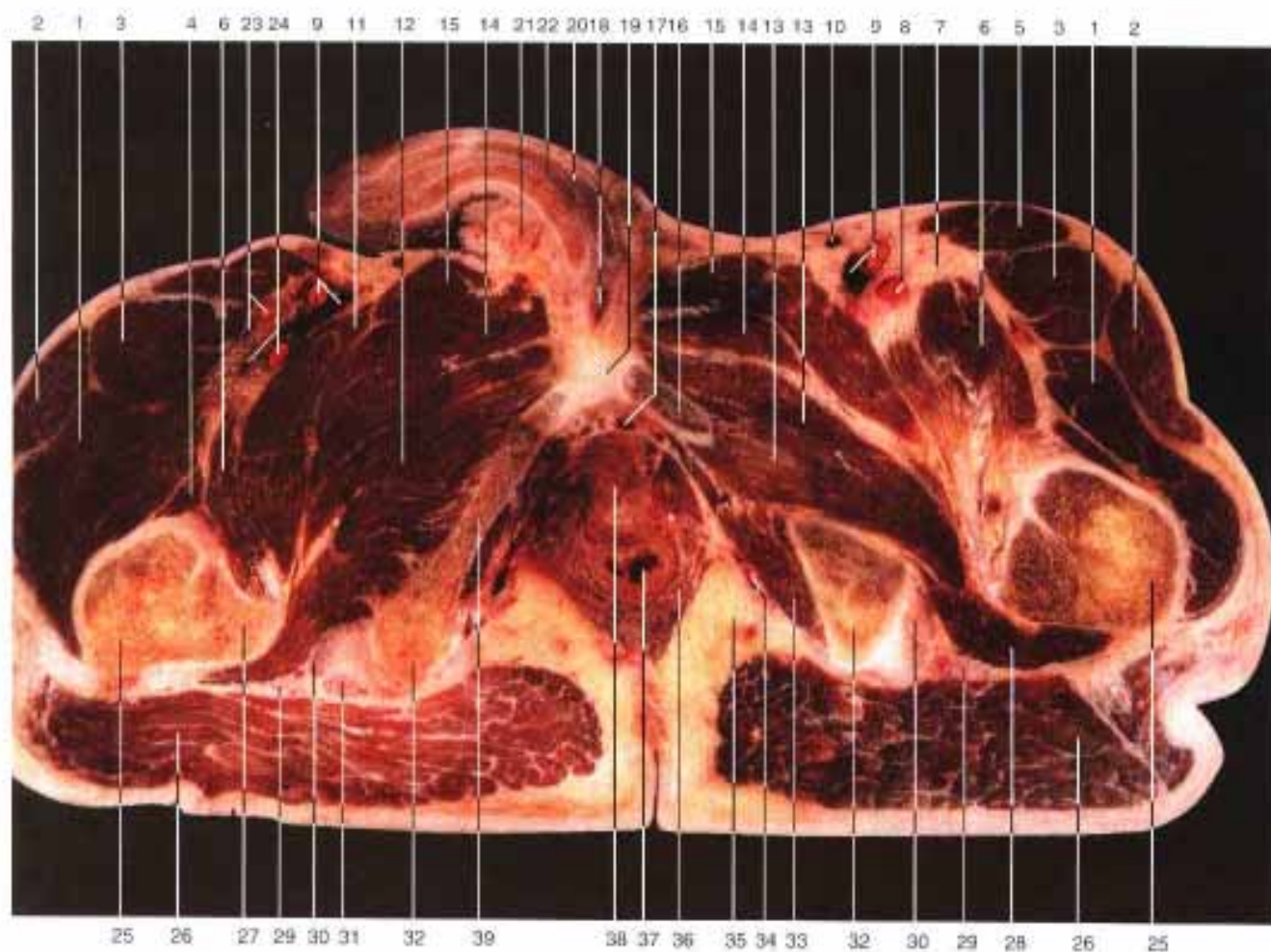
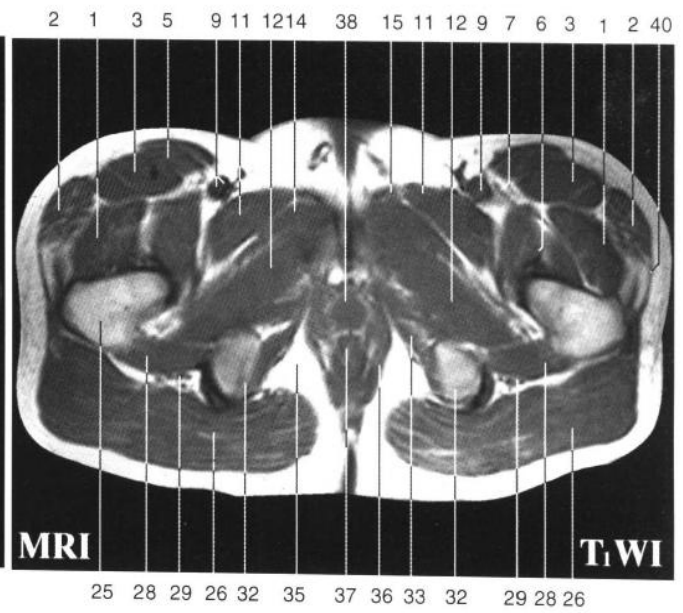

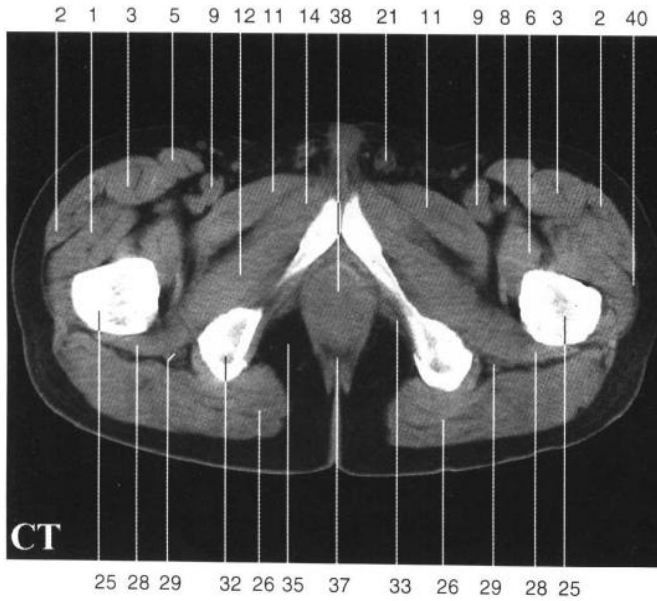
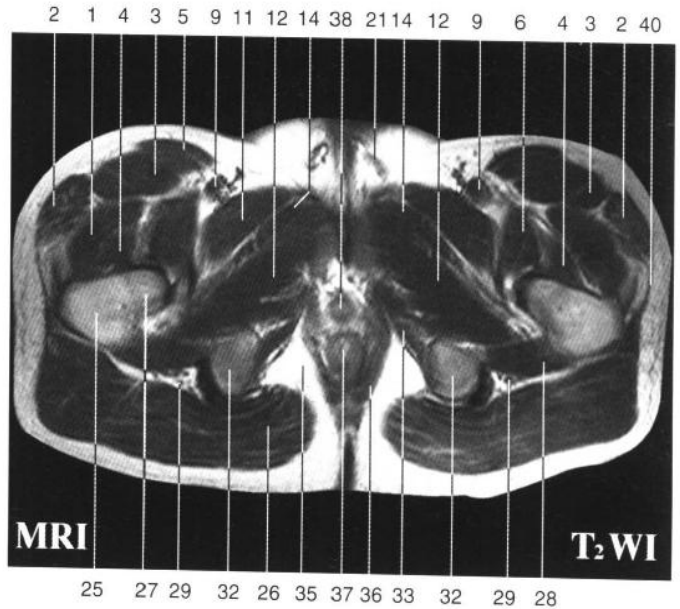Fig. HPm 6

1. 股外侧肌 vastus lateralis
2. 阔筋膜张肌 tensor fasciae latae
3. 股直肌 rectus femoris
4. 股中间肌 vastus intermedius
5. 缝匠肌 sartorius
6. 髂胫肌 iliopectineus
7. 股神经 femoral n.
8. 股深动脉 deep femoral a.
9. 股动、静脉 femoral a. and v.
10. 大隐静脉 great saphenous v.
11. 耻骨肌 pectineus
12. 大收肌 adductor magnus

Fig. HPm 6



13. 闭孔外肌 obturator externus
14. 短收肌 adductor brevis
15. 长收肌 adductor longus
16. 耻骨下支 inferior ramus of pubis
17. 前列腺静脉丛 prostatic venous plexus
18. 尿道 urethra
19. 耻骨联合 pubic symphysis
20. 阴茎海绵体 cavernous body of penis
21. 精索 spermatic cord
22. 尿道海绵体 cavernous body of urethra
23. 旋股外侧动、静脉 lateral femoral circumflex a. and v.
24. 股深动、静脉 deep femoral a. and v.
25. 股骨 femur
26. 臀大肌 gluteus maximus
27. 小转子 lesser trochanter
28. 股方肌 quadratus femoris
29. 坐骨神经 sciatic n.
30. 半膜肌腱 tendon of semimembranosus
31. 股二头肌长头腱与半腱肌腱 tendon of long head of biceps femoris and semitendinosus
32. 坐骨结节 ischial tuberosity
33. 闭孔内肌 obturator internus
34. 阴部管 pudendal canal
35. 坐骨肛门窝脂体 adipose body of ischioanal fossa
36. 肛提肌 levator ani
37. 直肠 rectum
38. 前列腺与尿道 prostate and urethra
39. 坐骨支 ramus of ischium
40. 髂胫束 iliotibial tract



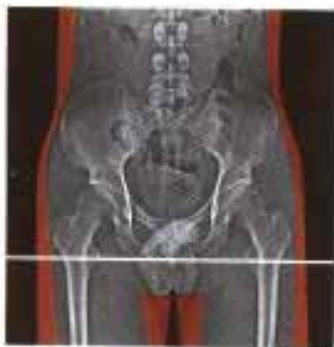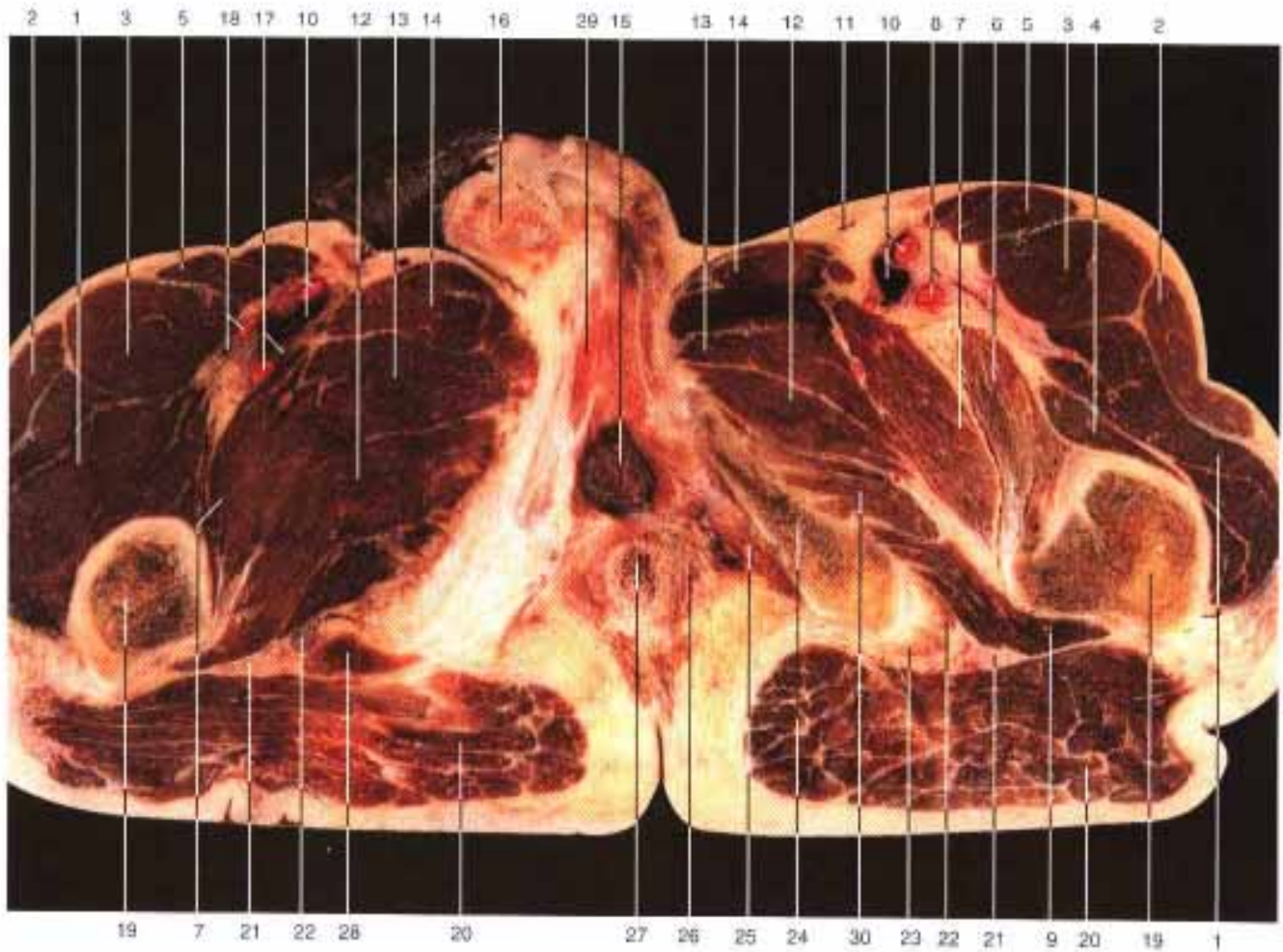
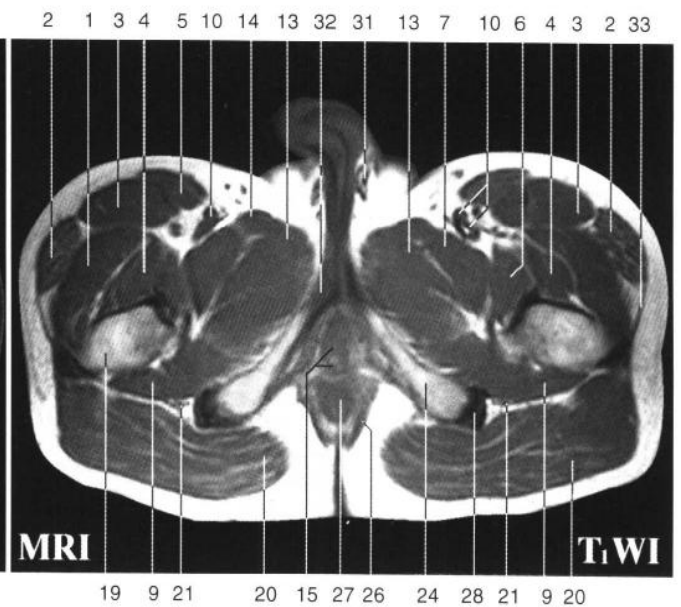

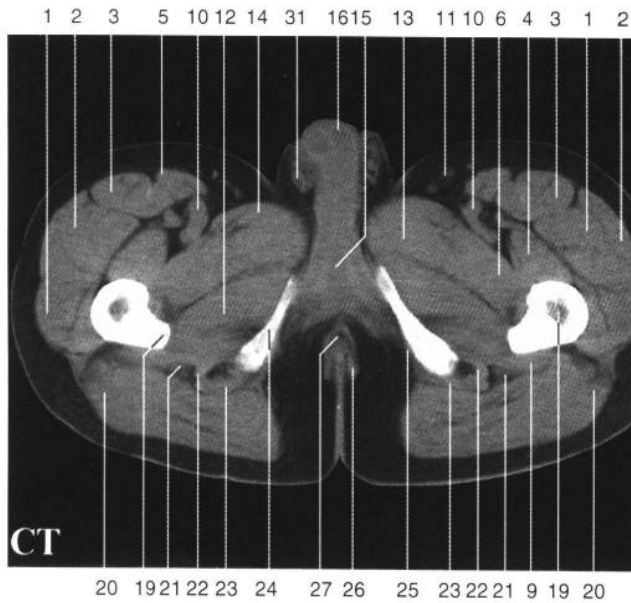
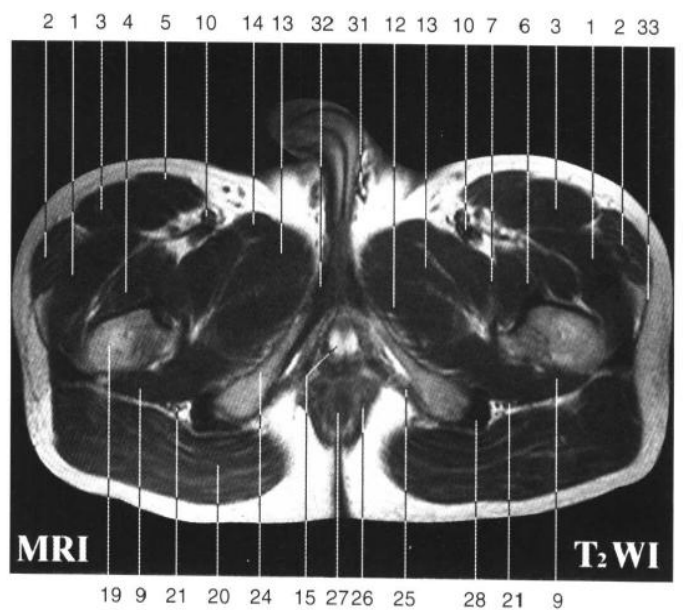
Fig. HPm 7

1. 股外侧肌 vastus lateralis
2. 阔筋膜张肌 tensor fasciae latae
3. 股直肌 rectus femoris
4. 股中间肌 vastus intermedius
5. 缝匠肌 sartorius
6. 髂腰肌 iliopsoas
7. 耻骨肌 pectineus
8. 股深动脉与股神经 deep femoral a. and femoral n.
9. 股方肌 quadratus femoris
10. 股动、静脉 femoral a. and v.

Fig. HPm 7



11. 大隐静脉 great saphenous v.
12. 大收肌 adductor magnus
13. 短收肌 adductor brevis
14. 长收肌 adductor longus
15. 尿道球 bulb of urethra
16. 睾丸 testis
17. 股深动脉、静脉 deep femoral a. and v.
18. 旋股外侧动、静脉 lateral femoral circumflex a. and v.
19. 股骨 femur
20. 臀大肌 gluteus maximus
21. 坐骨神经 sciatic n.
22. 半膜肌腱 tendon of semimembranosus
23. 股二头肌长头腱与半腱肌腱 tendon of long head of biceps femoris and semitendinosus
24. 坐骨支 ramus of ischium
25. 坐骨海绵体肌 ischiocavernosus
26. 肛门外括约肌 sphincter ani externus
27. 肛管 anal canal
28. 半腱肌 semitendinosus
29. 阴茎海绵体 cavernous body of penis
30. 大收肌 adductor magnus
31. 精索 spermatic cord
32. 球海绵体肌 bulbocavernosus
33. 髂胫束 iliotibial tract



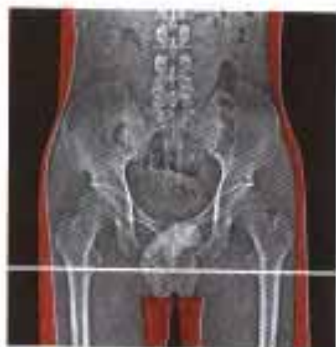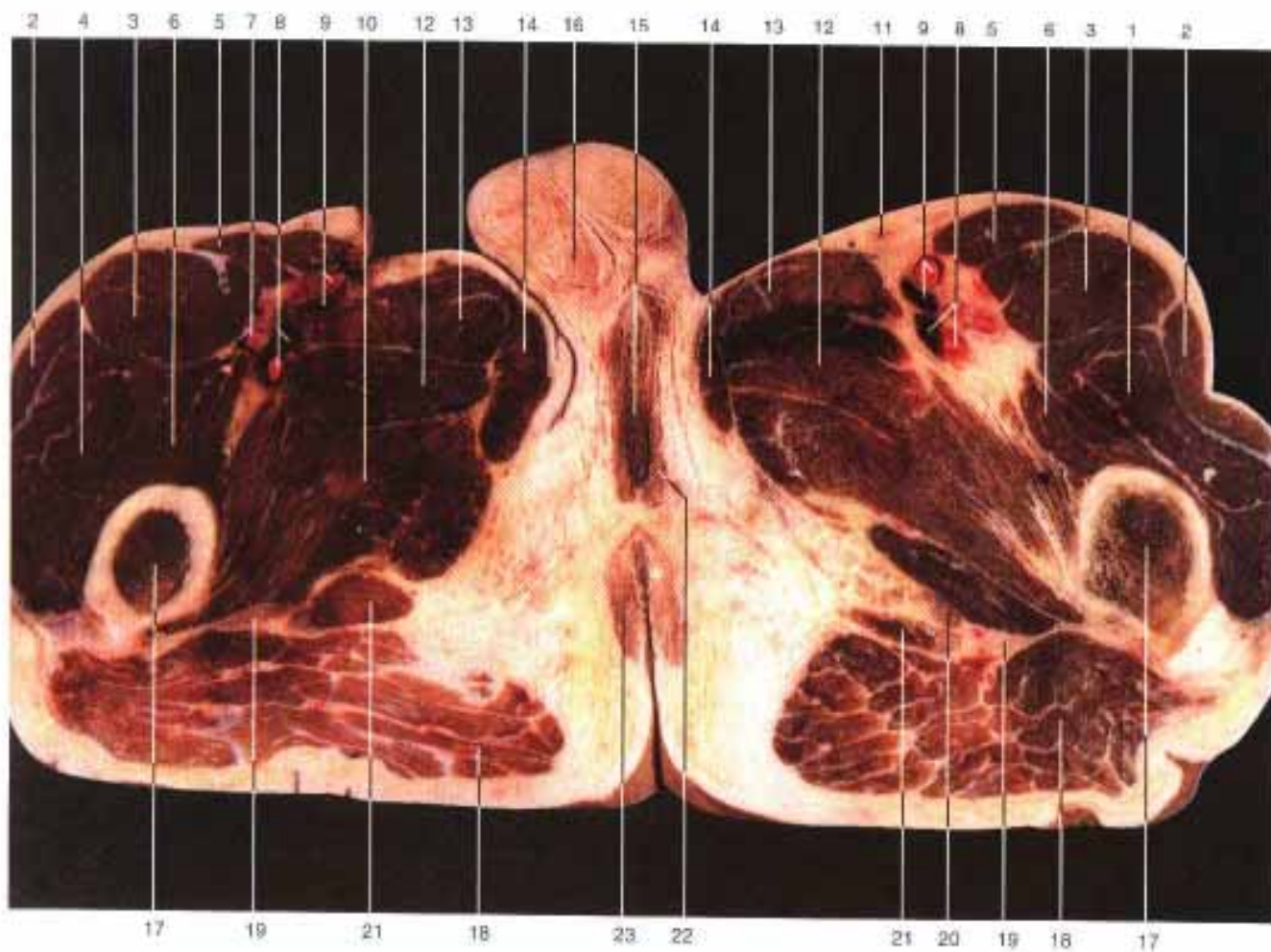
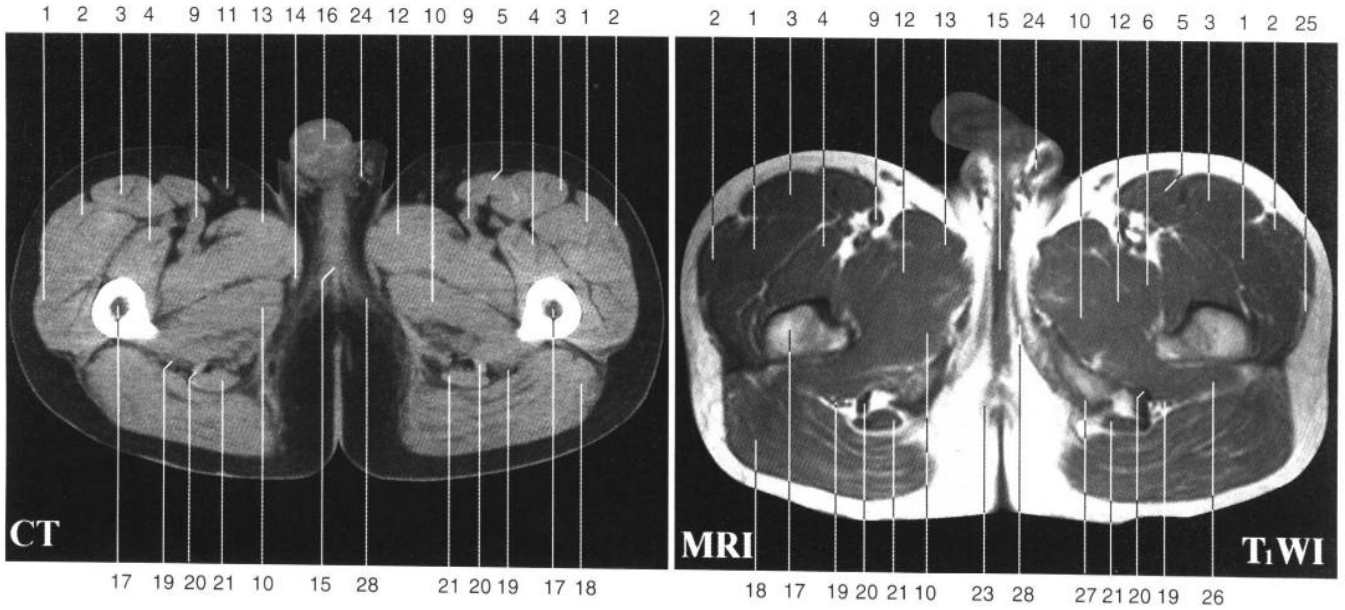


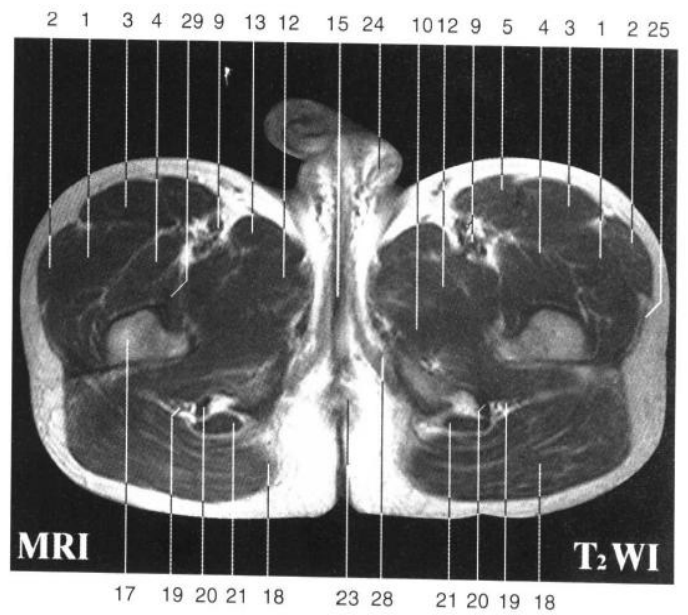
Fig. HPm 8

1. 股外侧肌 vastus lateralis
2. 阔筋膜张肌 tensor fasciae latae
3. 股直肌 rectus femoris
4. 股中间肌 vastus intermedius
5. 缝匠肌 sartorius
6. 耻骨肌 pectineus
7. 旋股外侧动、静脉 lateral femoral circumflex a. and v.
8. 股深动、静脉 deep femoral a. and v.
9. 股动、静脉 femoral a. and v.
10. 大收肌 adductor magnus

Fig. HPm 8



- 11. 大隐静脉 great saphenous v.
- 12. 短收肌 adductor brevis
- 13. 长收肌 adductor longus
- 14. 股薄肌 gracilis
- 15. 尿道海绵体 cavernous body of urethra
- 16. 睾丸 testis
- 17. 股骨 femur
- 18. 臀大肌 gluteus maximus
- 19. 坐骨神经 sciatic n.
- 20. 半膜肌腱 tendon of semimembranosus
- 21. 股二头肌长头腱与半腱肌 tendon of long head of biceps femoris and semitendinosus
- 22. 球海绵体肌 bulbocavernosus
- 23. 肛门外括约肌 sphincter ani externus
- 24. 精索 spermatic cord
- 25. 髂胫束 iliotibial tract
- 26. 股方肌 quadratus femoris
- 27. 坐骨支 ramus of ischium
- 28. 坐骨海绵体肌 ischiocavernosus
- 29. 髂腰肌 iliopsoas



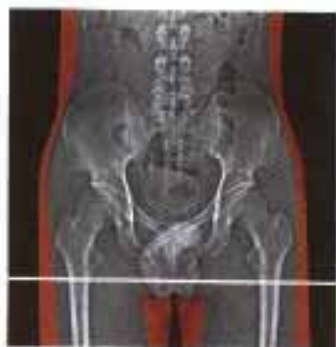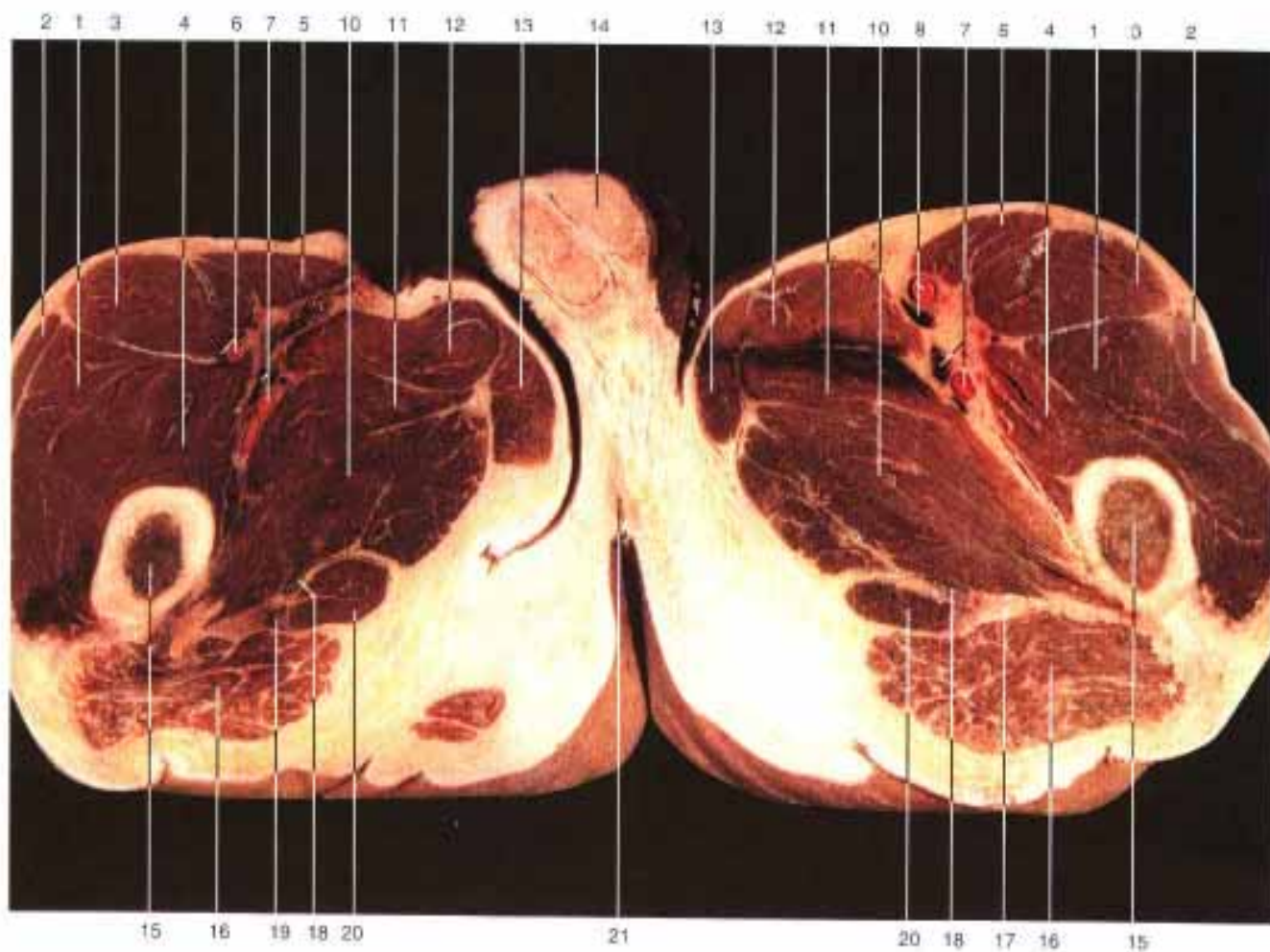
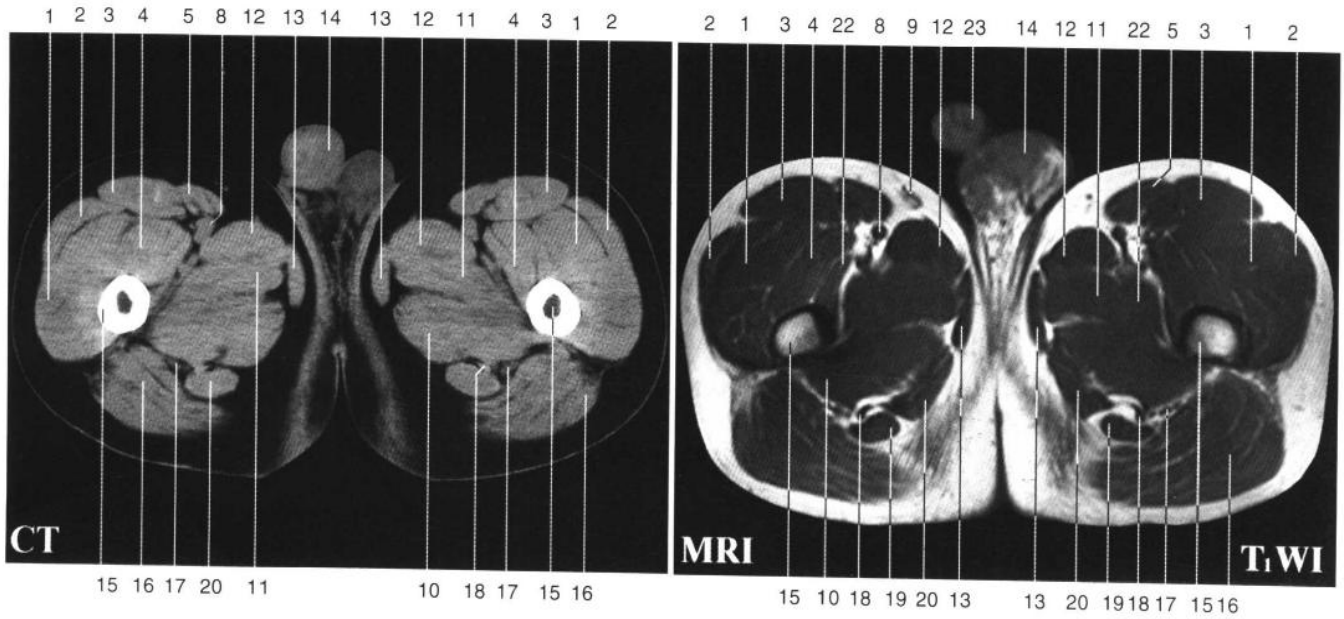


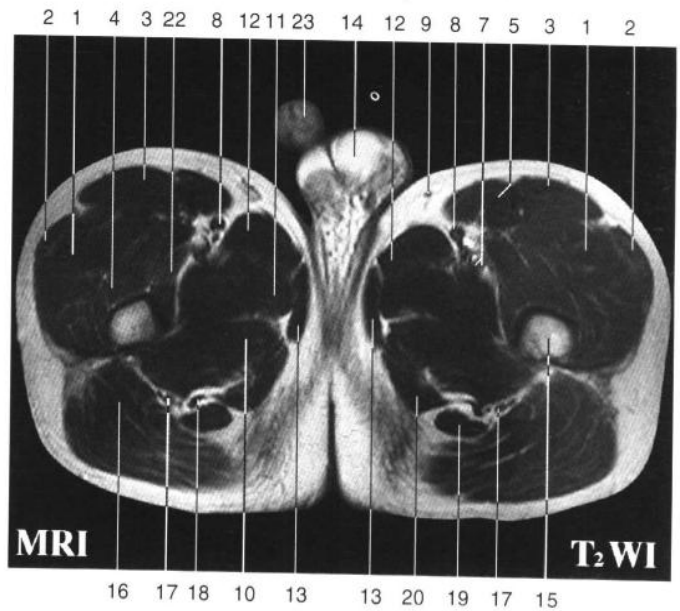
Fig. HPm 9

1. 股外侧肌 vastus lateralis
2. 阔筋膜张肌 tensor fasciae latae
3. 股直肌 rectus femoris
4. 股中间肌 vastus intermedius
5. 缝匠肌 sartorius
6. 旋股外侧动、静脉 lateral femoral circumflex a. and v.
7. 股深动、静脉 deep femoral a. and v.
8. 股动、静脉 femoral a. and v.
9. 大隐静脉 great saphenous v.
10. 大收肌 adductor magnus

Fig. HPm 9



- 11. 短收肌 adductor brevis
- 12. 长收肌 adductor longus
- 13. 股薄肌 gracilis
- 14. 睾丸 testis
- 15. 股骨 femur
- 16. 臀大肌 gluteus maximus
- 17. 坐骨神经 sciatic n.
- 18. 半膜肌 semimembranosus
- 19. 股二头肌长头腱 tendon of long head of biceps femoris
- 20. 半腱肌 semitendinosus
- 21. 球海绵体肌 bulbocavernosus
- 22. 耻骨肌 pectineus
- 23. 阴茎 penis



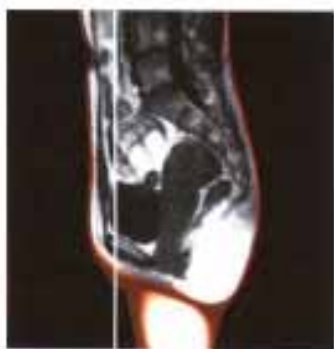
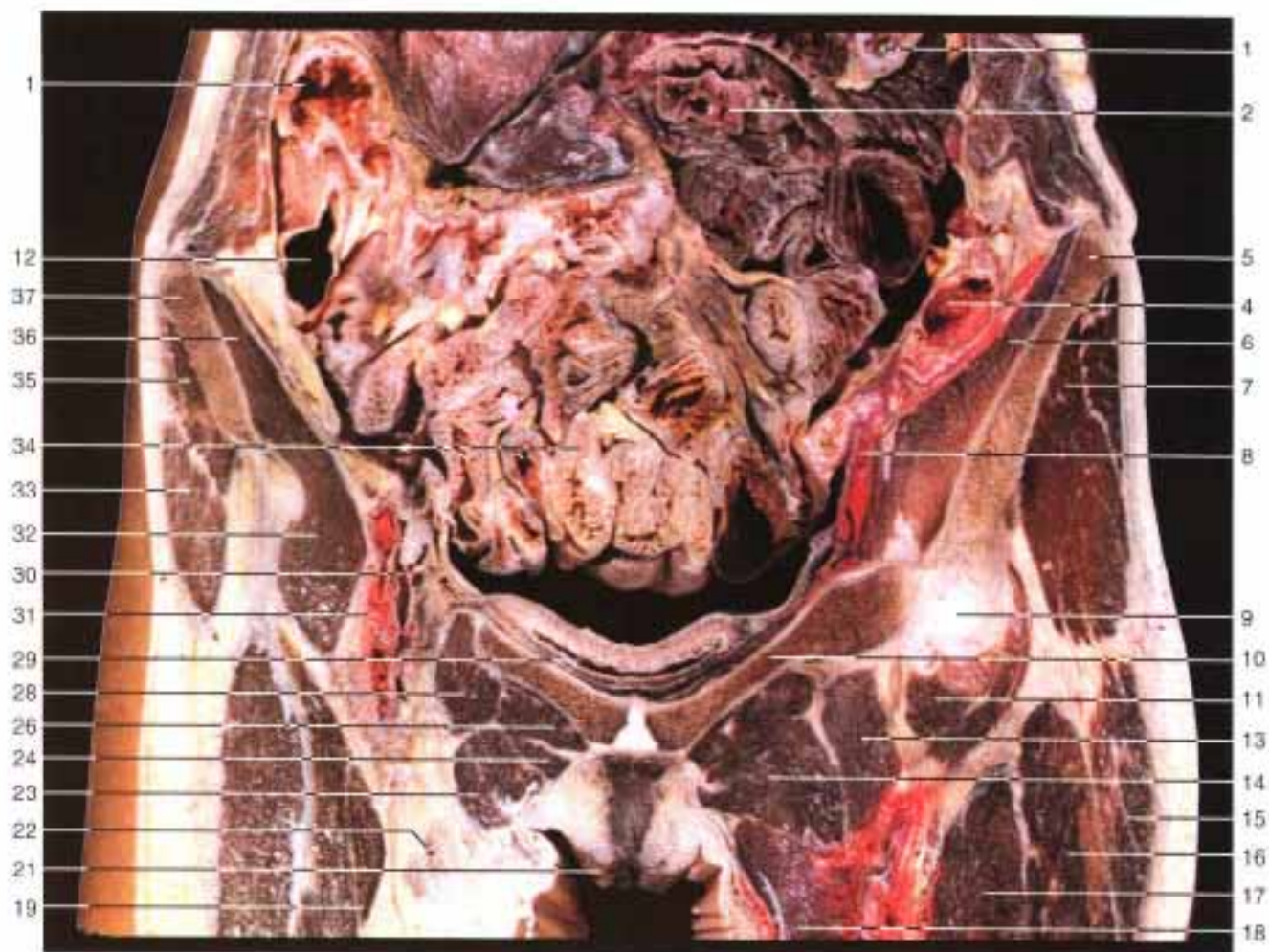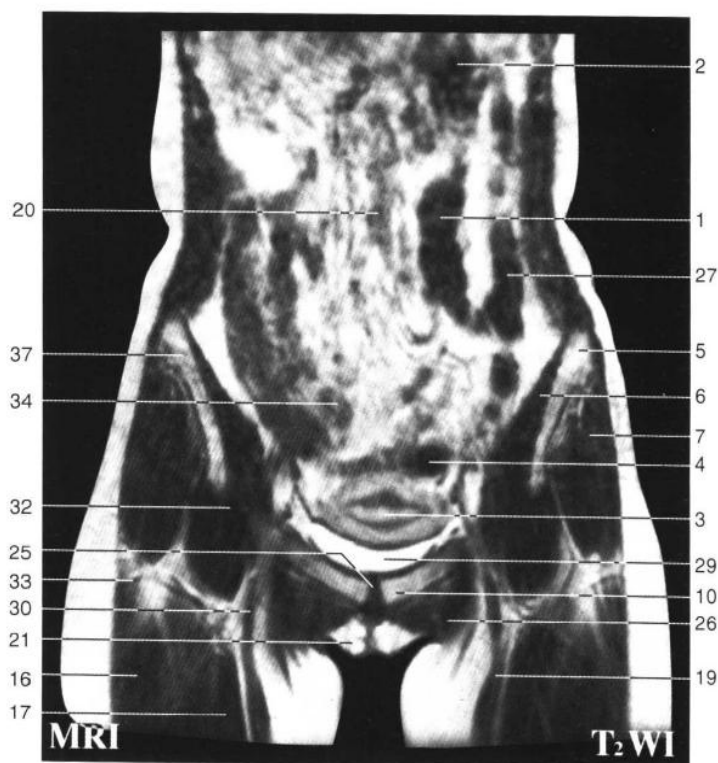

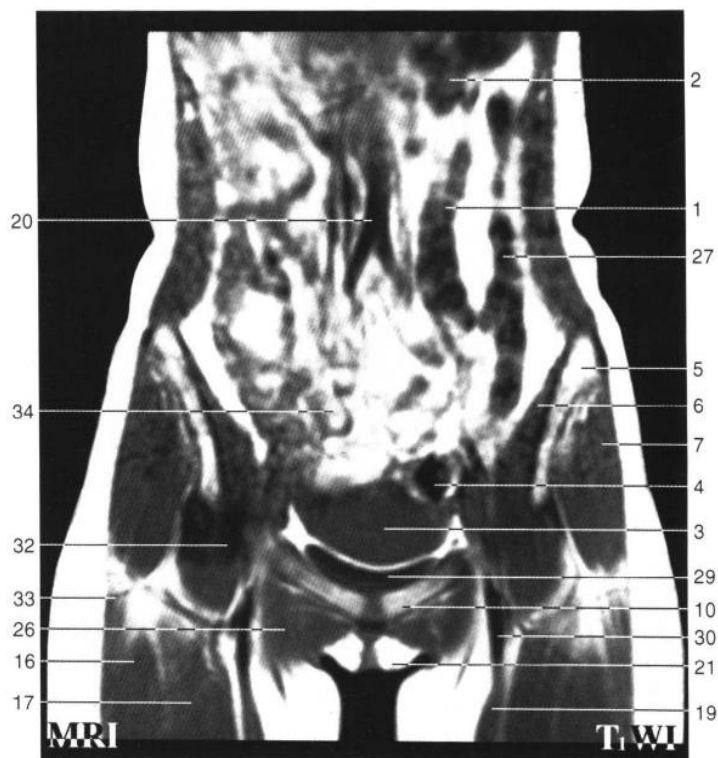
Fig. FPf 1

1. 横结肠 transverse colon
2. 空肠 jejunum
3. 子宫 uterus
4. 乙状结肠 sigmoid colon
5. 髂嵴 ala of ilium
6. 髂肌 iliacus
7. 臀中肌 gluteus medius
8. 髂外动脉 external iliac a.
9. 股骨头 femoral head
10. 耻骨上支 superior ramus of pubis

Fig. FPf 1

11. 髂腰肌 iliopsoas
12. 盲肠 cecum
13. 耻骨肌 pectineus
14. 短收肌 adductor brevis
15. 阔筋膜张肌 tensor fasciae latae
16. 股直肌 rectus femoris
17. 股内侧肌 vastus medialis
18. 长收肌 adductor longus
19. 缝匠肌 sartorius
20. 腹主动脉 abdominal aorta
21. 大阴唇 greater lip of pudendum
22. 大隐静脉 great saphenous v.
23. 长收肌 adductor longus
24. 短收肌 adductor brevis
25. 耻骨联合 pubic symphysis
26. 闭孔外肌 obturator externus
27. 降结肠 descending colon
28. 耻骨肌 pectineus
29. 膀胱 urinary bladder
30. 股静脉 femoral v.
31. 股动脉 femoral a.
32. 髂腰肌 iliopsoas
33. 阔筋膜张肌 tensor fasciae latae
34. 回肠 ileum
35. 臀中肌 gluteus medius
36. 髂肌 iliacus
37. 髂嵴 iliac crest



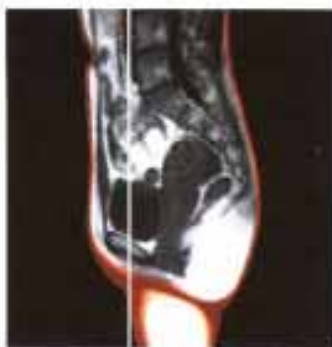
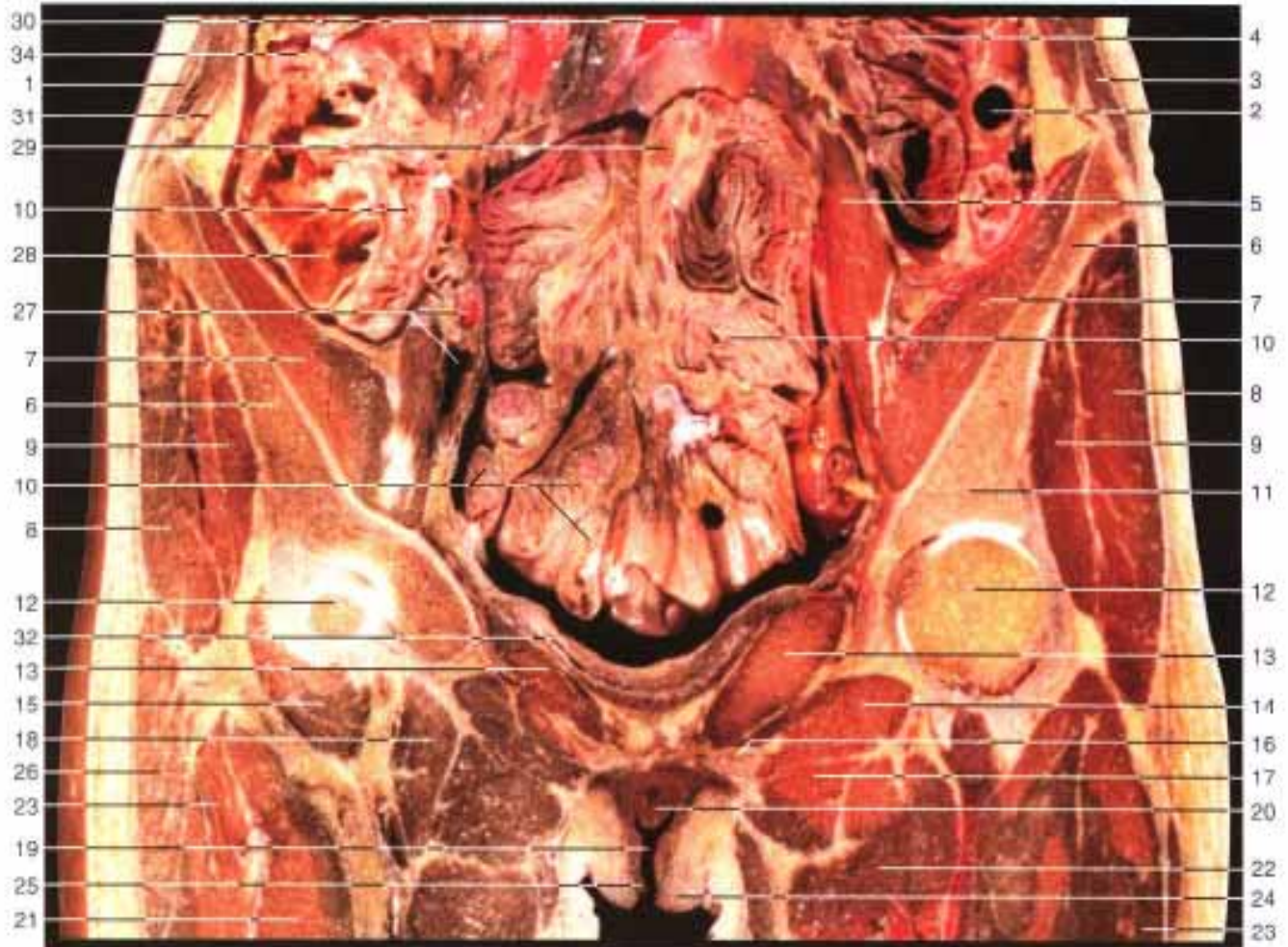
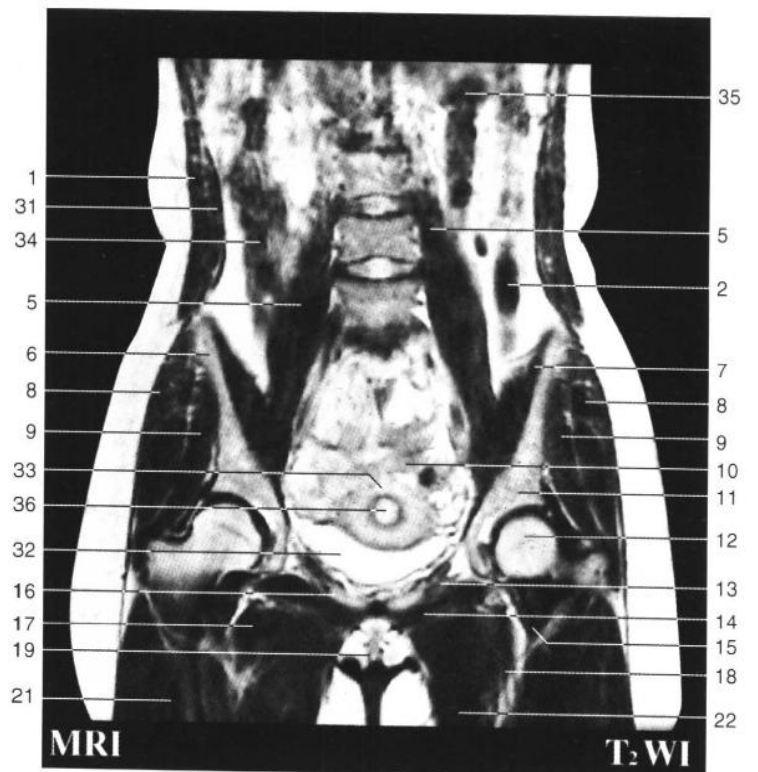
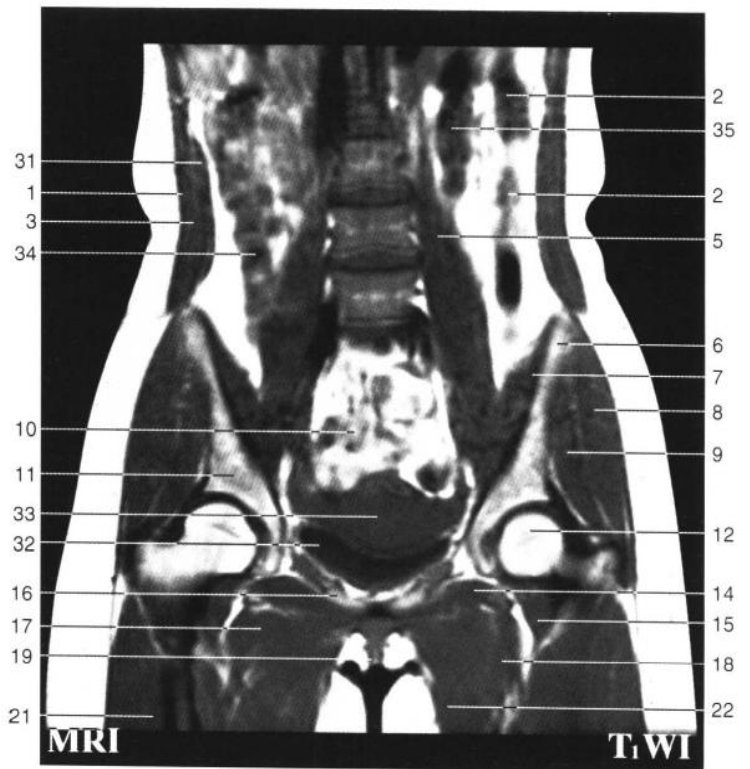
Fig. FPf 2

1. 腹外斜肌 obliquus externus abdominis
2. 降结肠 descending colon
3. 腹内斜肌 obliquus internus abdominis
4. 空肠 jejunum
5. 髂大肌 psoas major
6. 髂骨翼 ala of ilium
7. 髂肌 iliacus
8. 臀中肌 gluteus medius
9. 臀小肌 gluteus minimus
10. 回肠 ileum

Fig. FPf 2

11. 髂骨体 body of ilium
12. 股骨头 femoral head
13. 闭孔内肌 obturator internus
14. 闭孔外肌 obturator externus
15. 髂腰肌 iliopsoas
16. 耻骨下支 inferior ramus of pubis
17. 短收肌 adductor brevis
18. 耻骨肌 pectineus
19. 阴道前庭 vaginal vestibule
20. 阴道 vagina
21. 股中间肌 vastus intermedius
22. 长收肌 adductor longus
23. 股外侧肌 vastus lateralis
24. 大阴唇 greater lip of pudendum
25. 小阴唇 lesser lip of pudendum
26. 阔筋膜张肌 tensor fasciae latae
27. 右髂外动、静脉 right external iliac a. and v.
28. 盲肠 cecum
29. 肠系膜 mesentery
30. 腹主动脉 abdominal aorta
31. 腹横肌 transversus abdominis
32. 膀胱 urinary bladder
33. 子宫 uterus
34. 升结肠 ascending colon
35. 横结肠 transverse colon
36. 子宫腔 cavity of uterus



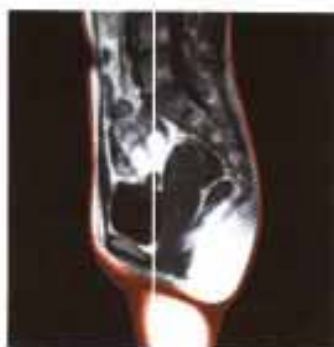
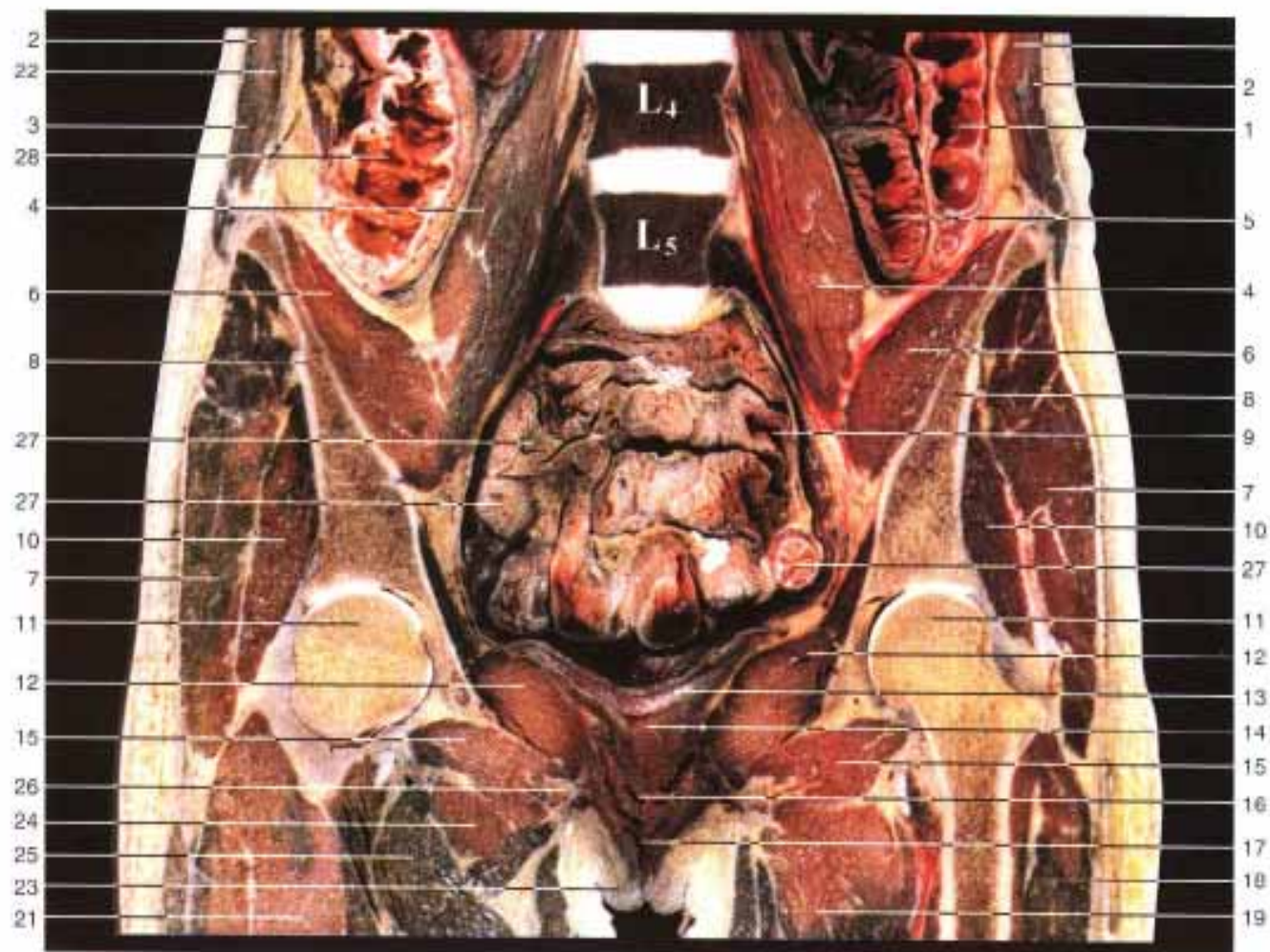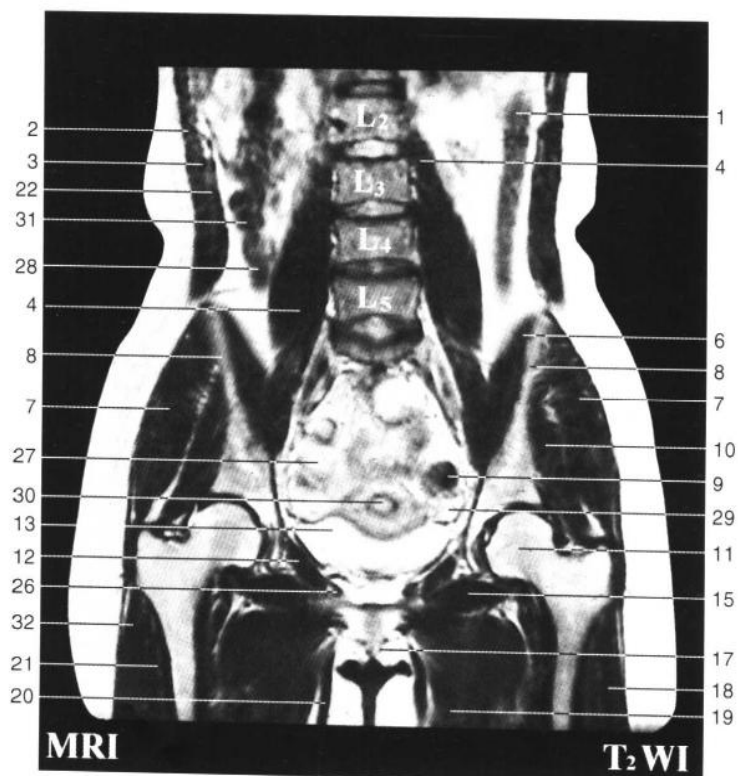
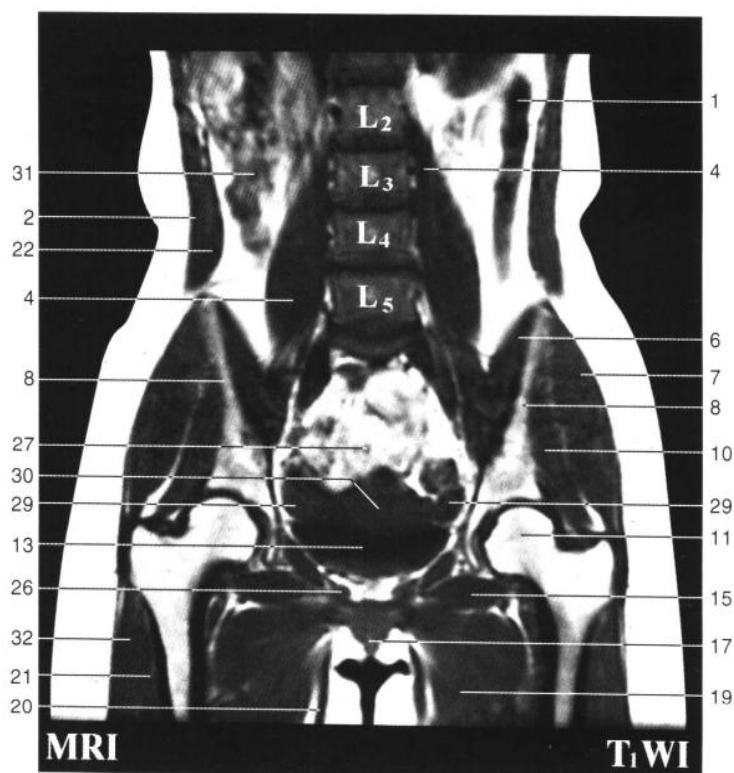


Fig. FPf 3

1. 降结肠 descending colon
2. 腹外斜肌 obliquus externus abdominis
3. 腹内斜肌 obliquus internus abdominis
4. 腰大肌 psoas major
5. 空肠 jejunum
6. 髂肌 iliacus
7. 臀中肌 gluteus medius
8. 髂骨翼 ala of ilium
9. 乙状结肠 sigmoid colon
10. 臀小肌 gluteus minimus

Fig. FPf 3

11. 股骨头 femoral head
12. 闭孔内肌 obturator internus
13. 膀胱 urinary bladder
14. 阴道前壁 anterior wall of vagina
15. 闭孔外肌 obturator externus
16. 阴道 vagina
17. 阴道前庭 vaginal vestibule
18. 股外侧肌 vastus lateralis
19. 大收肌 adductor magnus
20. 股薄肌 gracilis
21. 股中间肌 vastus intermedius
22. 腹横肌 transversus abdominis
23. 大阴唇 greater lip of pudendum
24. 短收肌 adductor brevis
25. 长收肌 adductor longus
26. 耻骨下支 inferior ramus of pubis
27. 回肠 ileum
28. 盲肠 cecum
29. 卵巢 ovary
30. 子宫 uterus
31. 升结肠 ascending colon
32. 股外侧肌 vastus lateralis



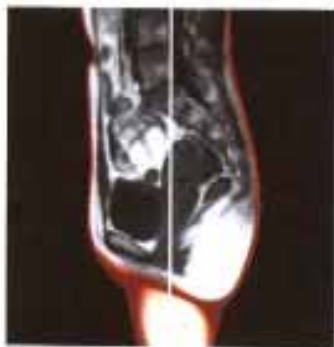
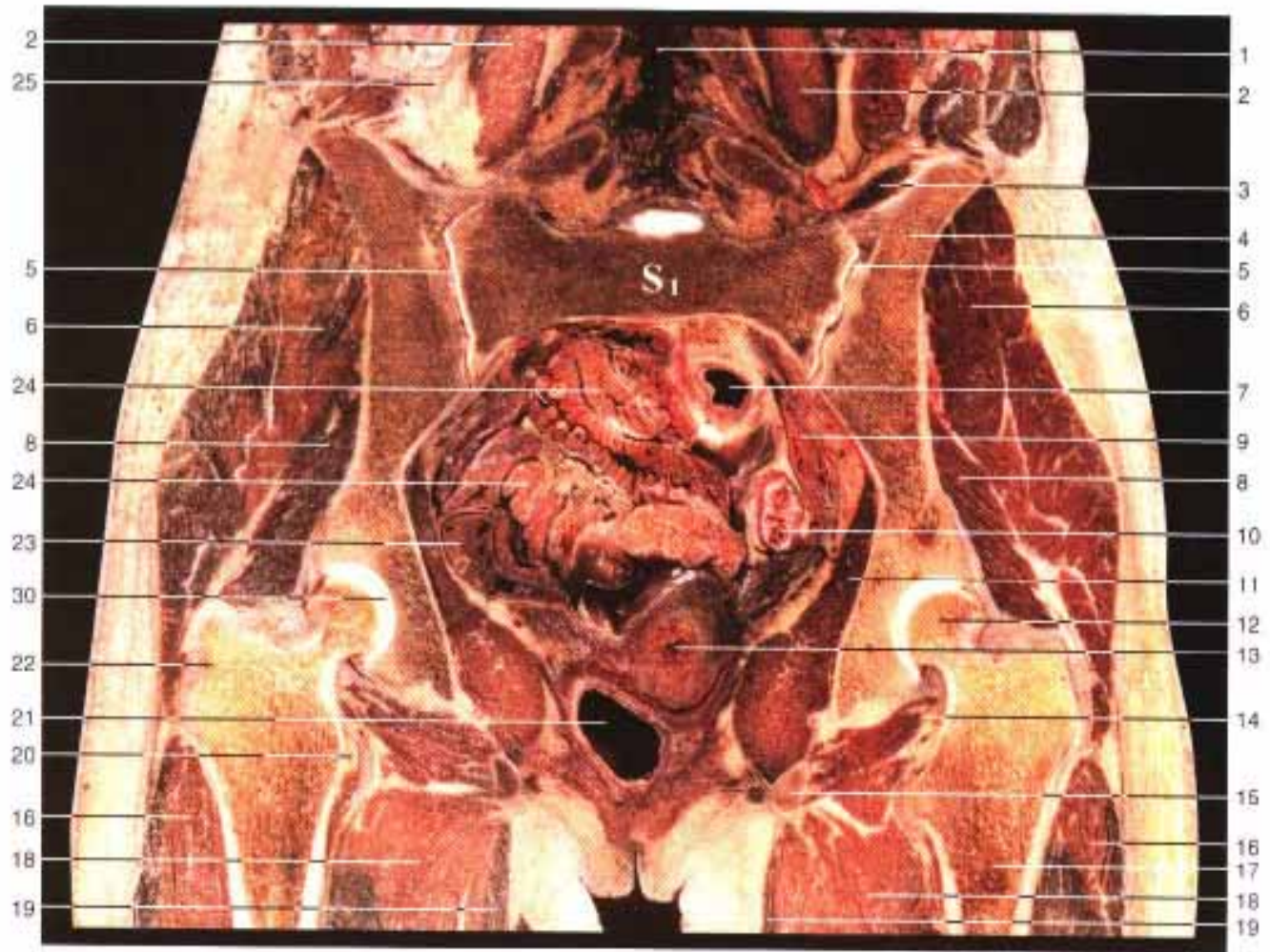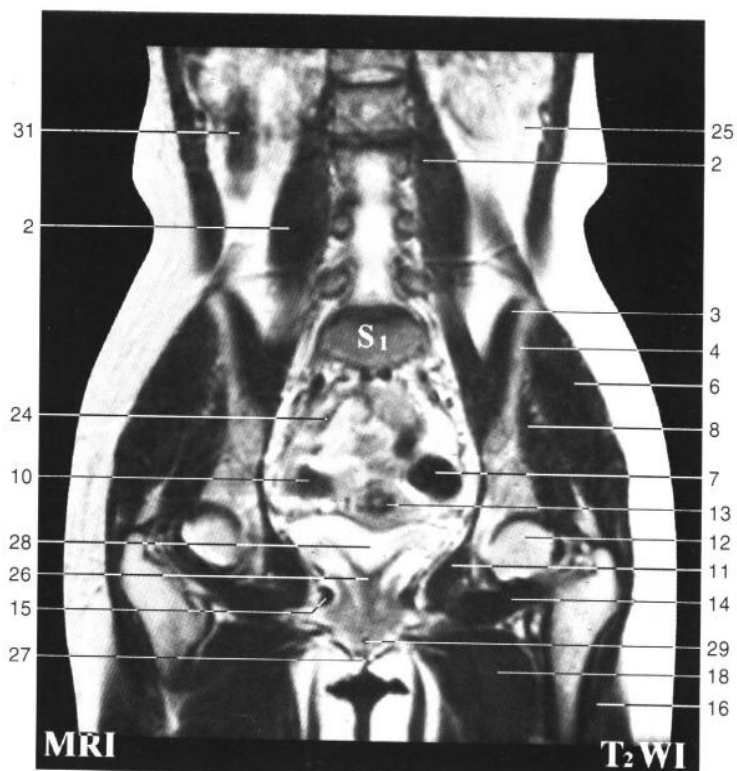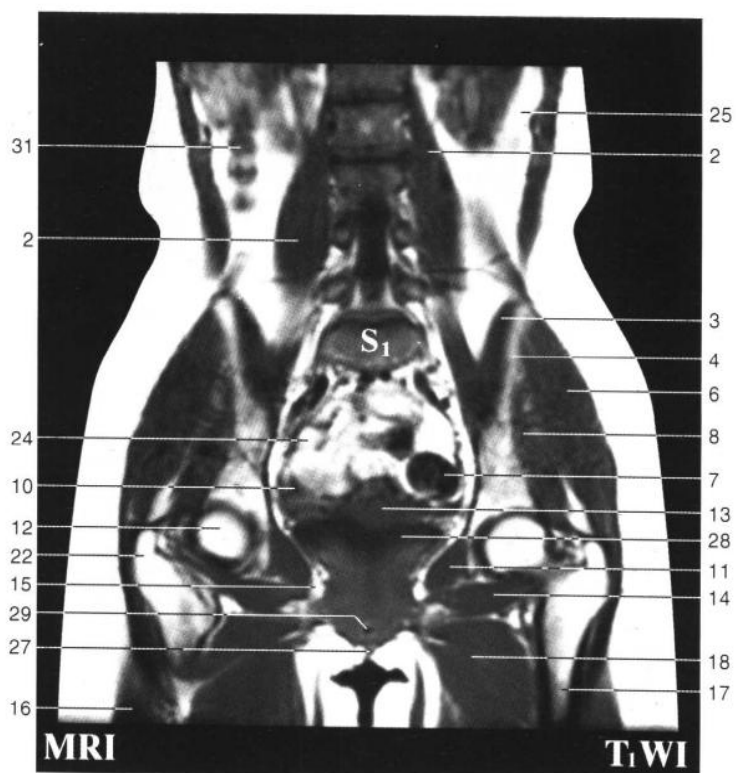


Fig. FPf 4

1. 后纵韧带 posterior longitudinal ligament
2. 腰大肌 psoas major
3. 髂肌 iliacus
4. 髂骨翼 ala of ilium
5. 骶髂关节 sacroiliac joint
6. 臀中肌 gluteus medius
7. 乙状结肠 sigmoid colon
8. 臀小肌 gluteus minimus
9. 卵巢 ovary
10. 回肠 ileum

Fig. FPf 4

11. 闭孔内肌 obturator internus
12. 股骨头 femoral head
13. 子宫 uterus
14. 闭孔外肌 obturator externus
15. 坐骨支 ramus of ischium
16. 股外侧肌 vastus lateralis
17. 股骨 femur
18. 大收肌 adductor magnus
19. 股薄肌 gracilis
20. 小转子 lesser trochanter
21. 直肠 rectum
22. 大转子 greater trochanter
23. 输卵管 uterine tube
24. 回肠 ileum
25. 脂肪囊 fatty renal capsule
26. 阴道 vagina
27. 阴道前庭 vaginal vestibule
28. 膀胱 urinary bladder
29. 尿道外口 external orifice of urethra
30. 髋关节 hip joint
31. 升结肠 ascending colon



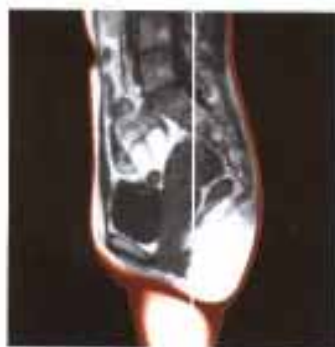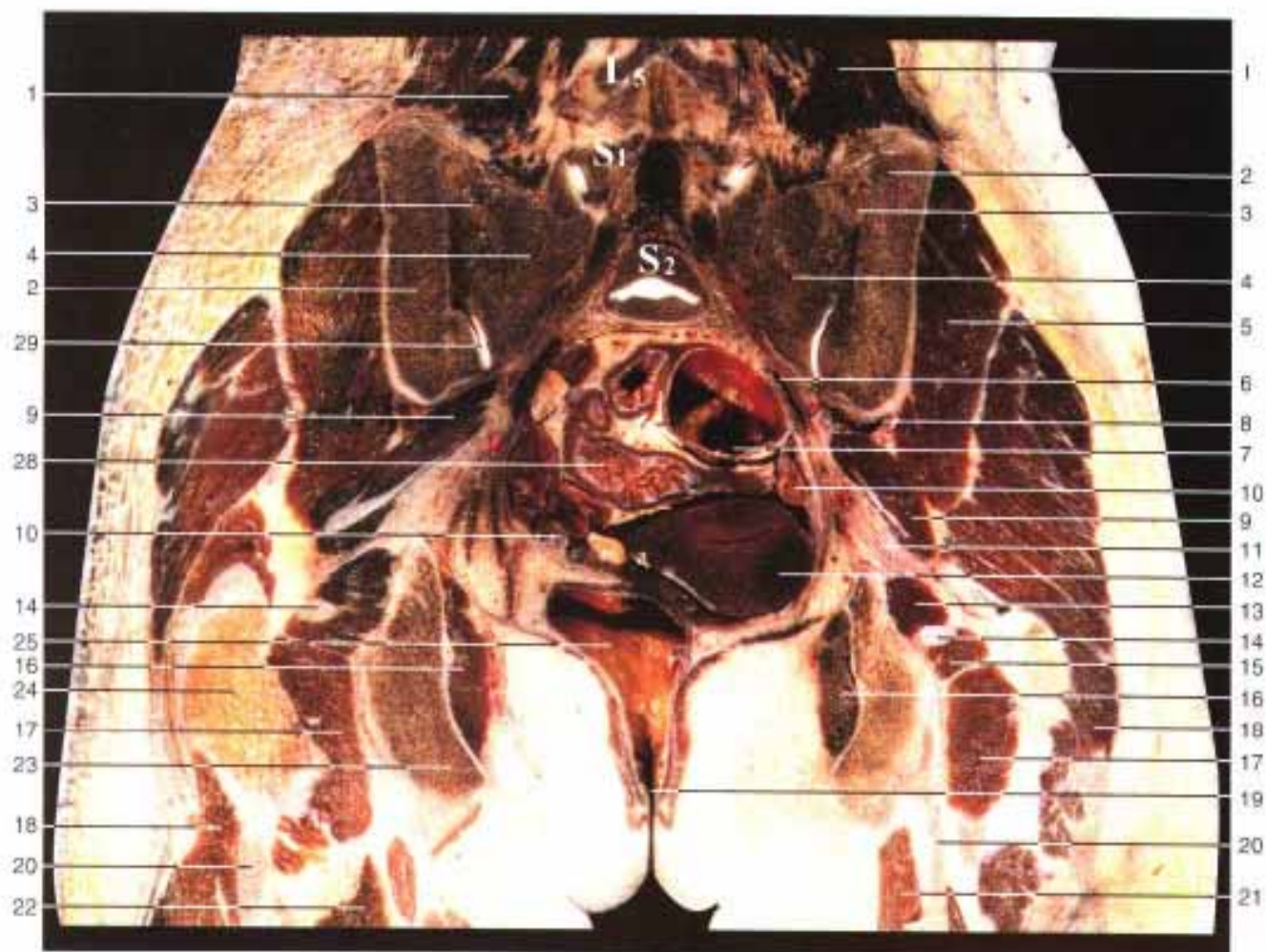
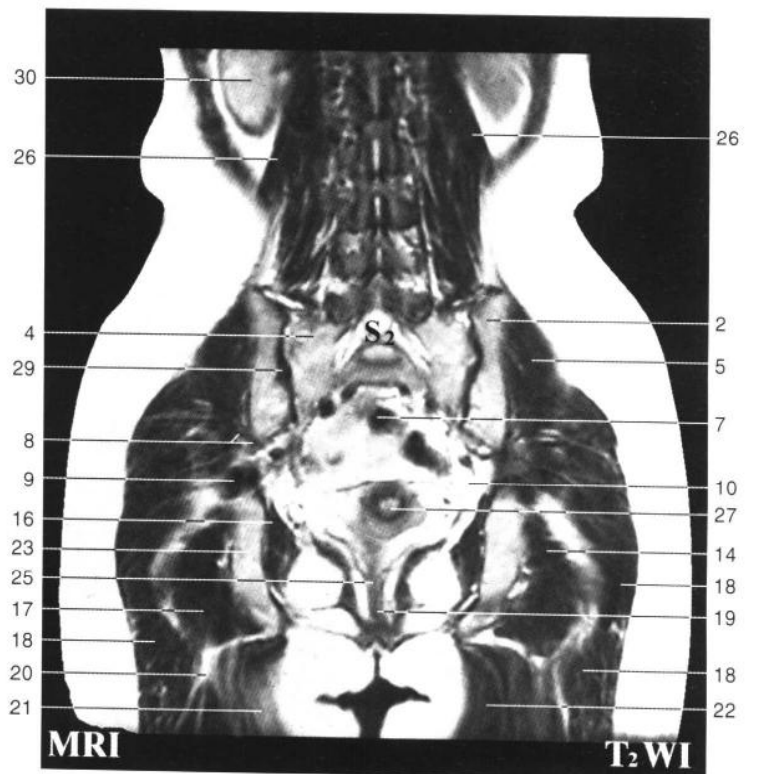
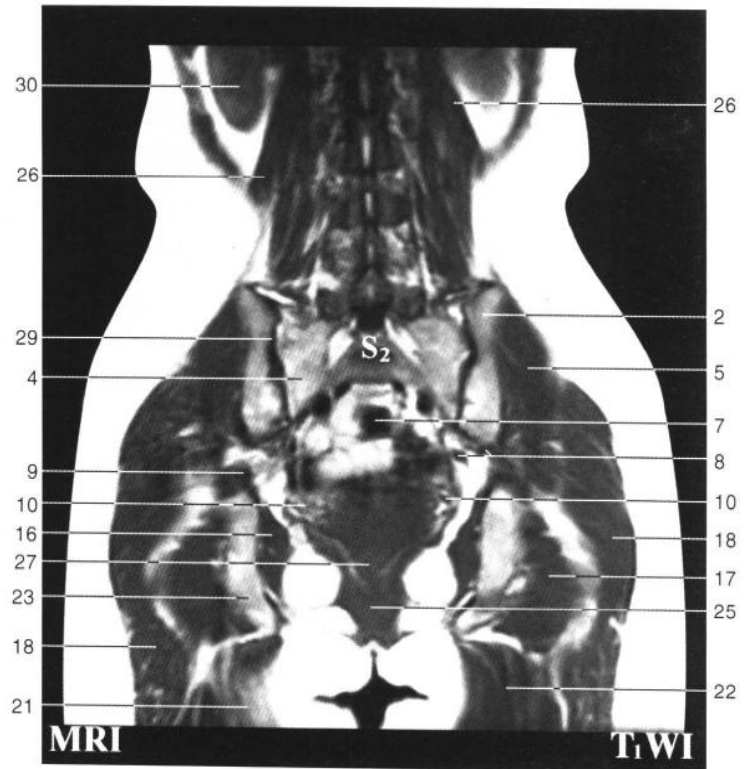


Fig. FP1 5

1. 横突棘肌 transversospinales
2. 髂骨翼 ala of ilium
3. 骶骨间韧带 interosseous sacroiliac ligaments
4. 骶粗隆 sacral tuberosity
5. 臀中肌 gluteus medius
6. 髂内静脉 internal iliac v.
7. 乙状结肠 sigmoid colon
8. 臀上动、静脉 superior gluteal a. and v.
9. 梨状肌 piriformis
10. 卵巢 ovary

Fig. FP1 5

11. 坐骨神经 sciatic n.
12. 子宫体 body of uterus
13. 上孖肌 gemellus superior
14. 闭孔内肌腱 tendon of obturator internus
15. 下孖肌 gemellus inferior
16. 闭孔内肌 obturator internus
17. 股方肌 quadratus femoris
18. 臀大肌 gluteus maximus
19. 肛管 anal canal
20. 坐骨神经 sciatic n.
21. 半腱肌 semitendinosus
22. 大收肌 adductor magnus
23. 坐骨 ischium
24. 大转子 greater trochanter
25. 直肠 rectum
26. 腰方肌 quadratus lumborum
27. 子宫颈 neck of uterus
28. 回肠 ileum
29. 骶髂关节 sacroiliac joint
30. 肾 kidney



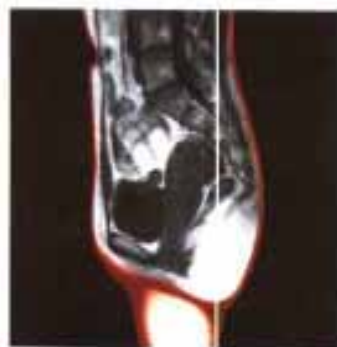
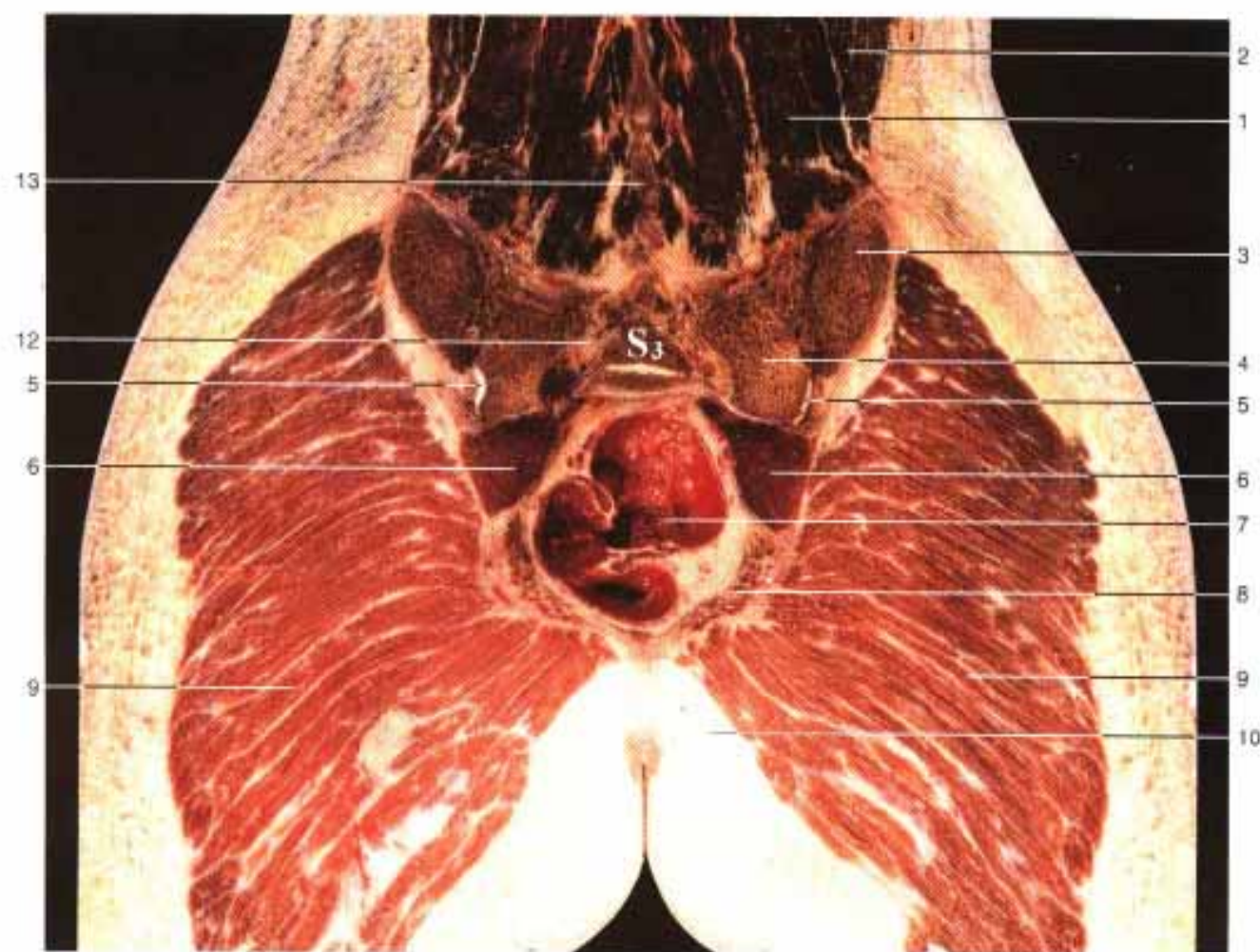
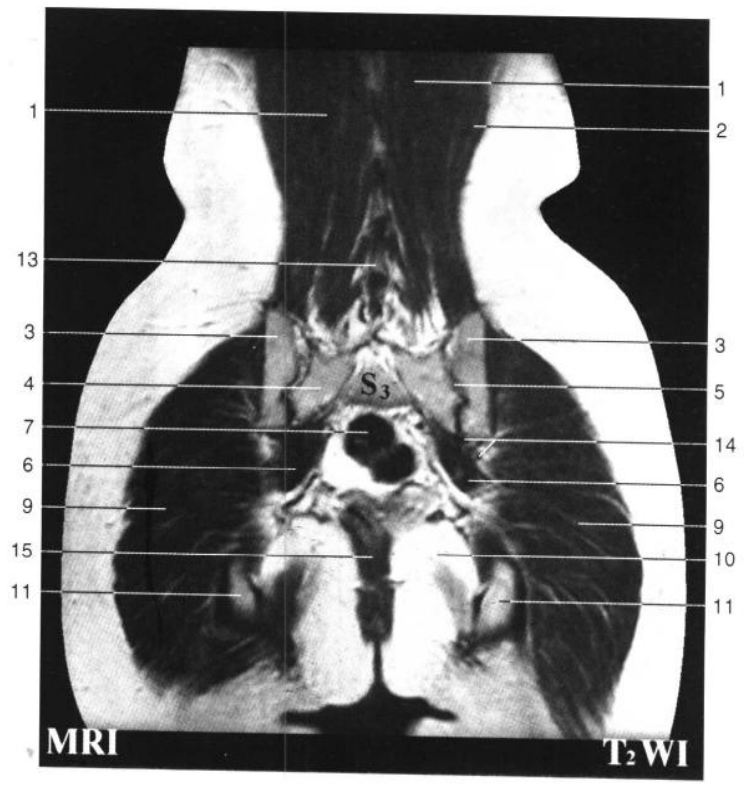
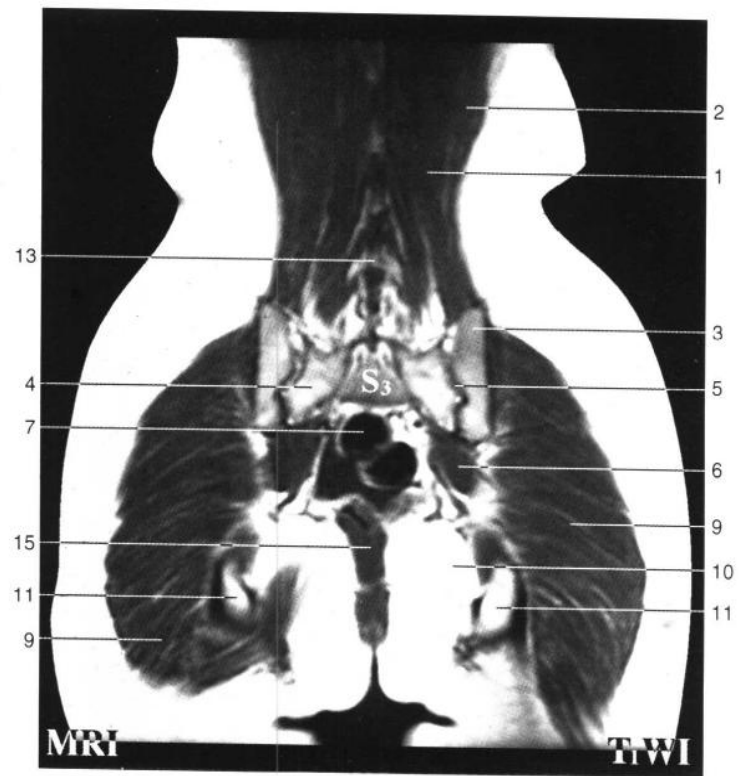
Fig. FPf 6

1. 竖脊肌 erector spinae
2. 背阔肌 latissimus dorsi
3. 髂骨翼 ala of ilium
4. 骶翼 ala of sacrum
5. 骶髂关节 sacroiliac joint
6. 梨状肌 piriformis
7. 直肠壶腹 ampulla of rectum
8. 肛提肌 levator ani
9. 臀大肌 gluteus maximus
10. 坐骨肛门窝 ischioanal fossa

Fig. FPf 6

- 11. 坐骨结节 ischial tuberosity
- 12. 第 2 骶神经 2nd sacral n. (ventral ramus)
- 13. 第 5 腰椎棘突 spinous proccoss (L₅)
- 14. 臀上动脉 superior gluteal a.
- 15. 直肠 rectum



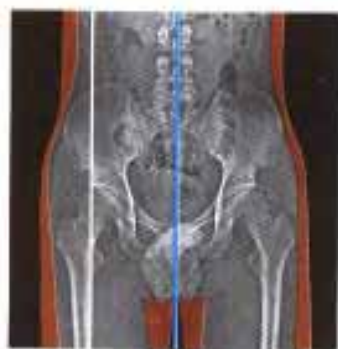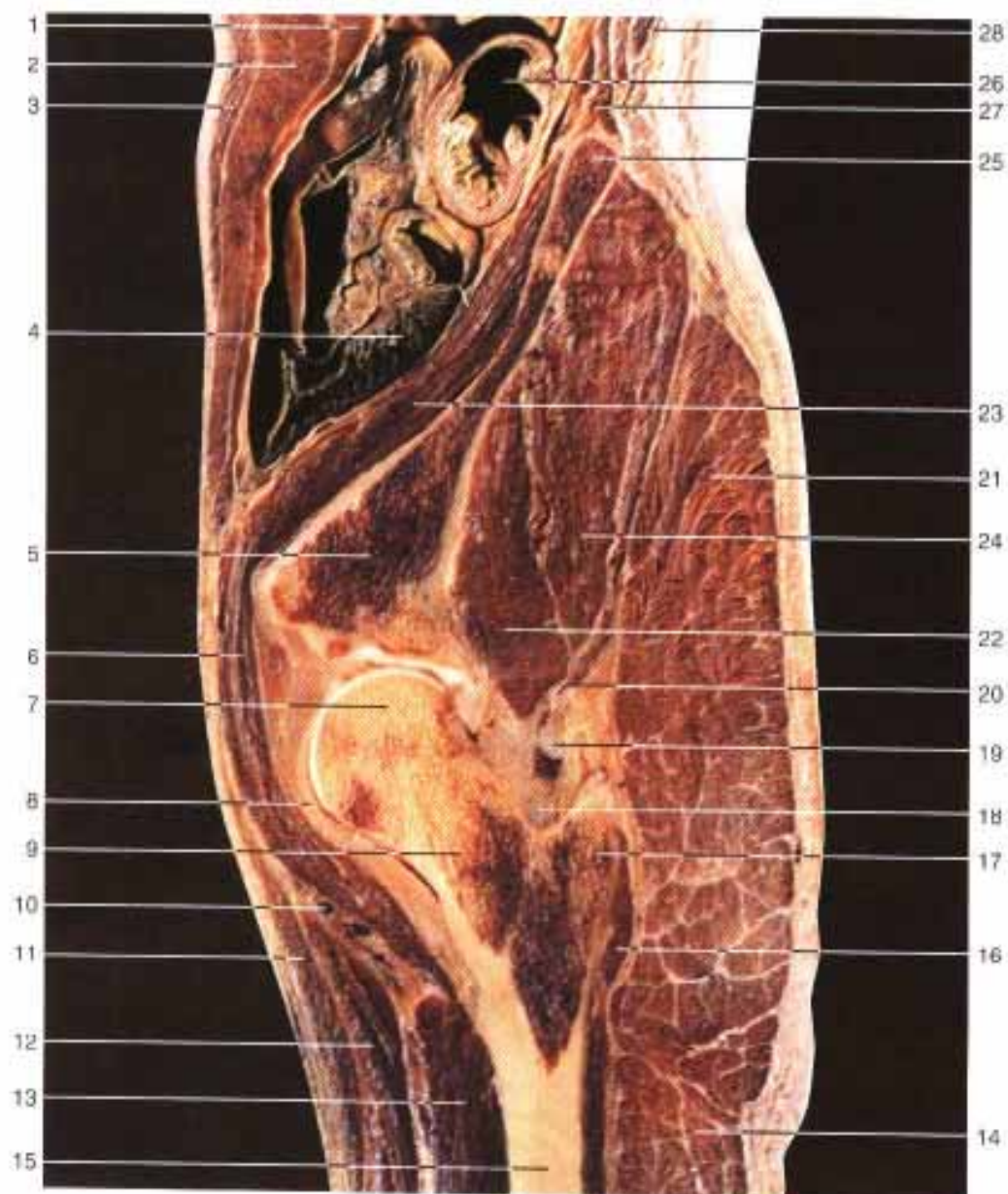
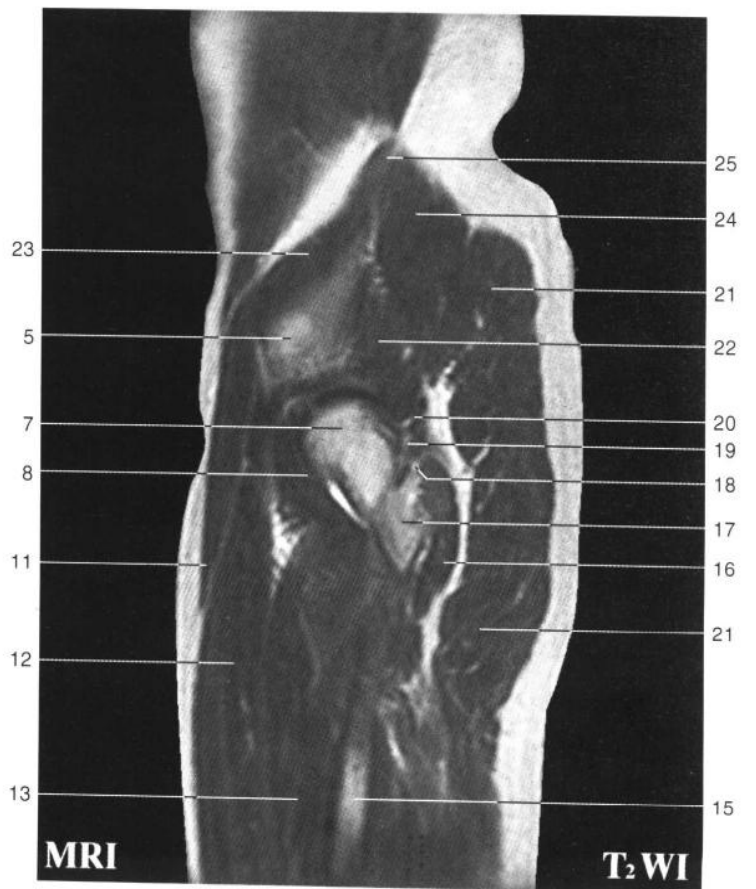
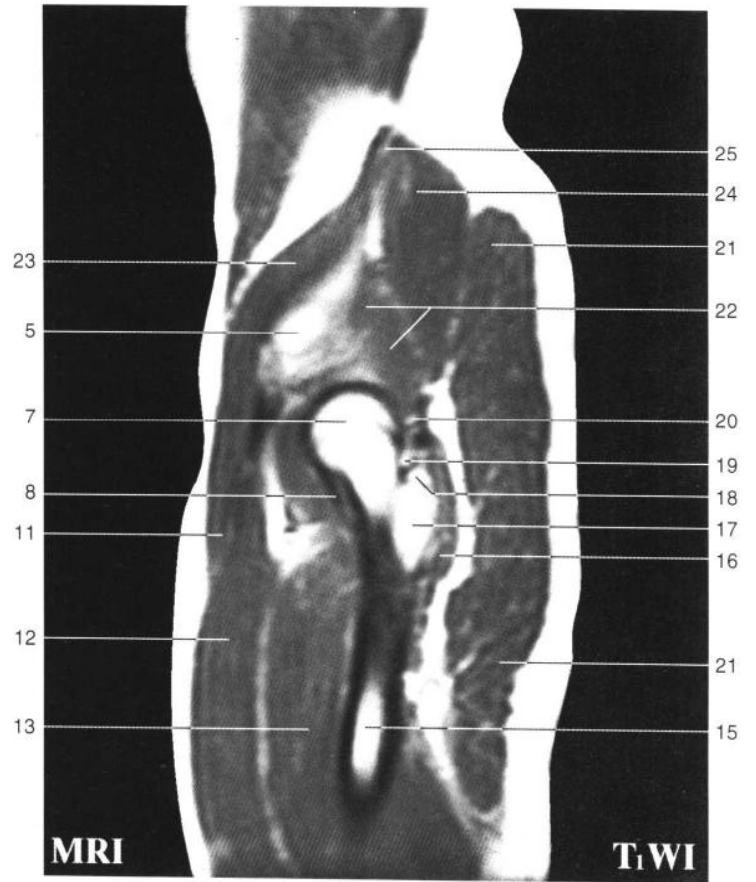


Fig. SPm 1

1. 腹横肌 transversus abdominis
2. 腹内斜肌 obliquus internus abdominis
3. 腹外斜肌 obliquus externus abdominis
4. 回肠 ileum
5. 髌骨体 body of ilium
6. 髂腰肌 iliopsoas
7. 股骨头 femoral head
8. 关节囊 articular capsule
9. 股骨颈 neck of femur
10. 股动脉 lateral femoral circumflex a.

Fig. SPm 1

11. 缝匠肌 sartorius
12. 股直肌 rectus femoris
13. 股中间肌 vastus intermedius
14. 臀大肌 gluteus maximus
15. 股骨体 shaft of femur
16. 股方肌 quadratus femoris
17. 大转子 greater trochanter
18. 闭孔外肌腱 tendon of obturator externus
19. 闭孔内肌腱 tendon of obturator internus
20. 梨状肌腱 tendon of piriformis
21. 臀大肌 gluteus maximus
22. 臀小肌 gluteus minimus
23. 髂肌 iliacus
24. 臀中肌 gluteus medius
25. 髂嵴 iliac crest
26. 升结肠 ascending colon
27. 腰方肌 quadratus lumborum
28. 背阔肌 latissimus dorsi



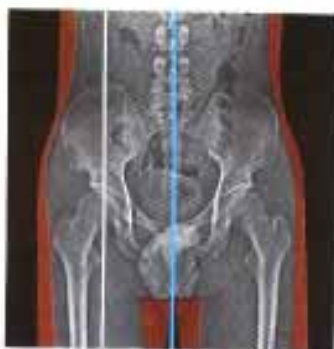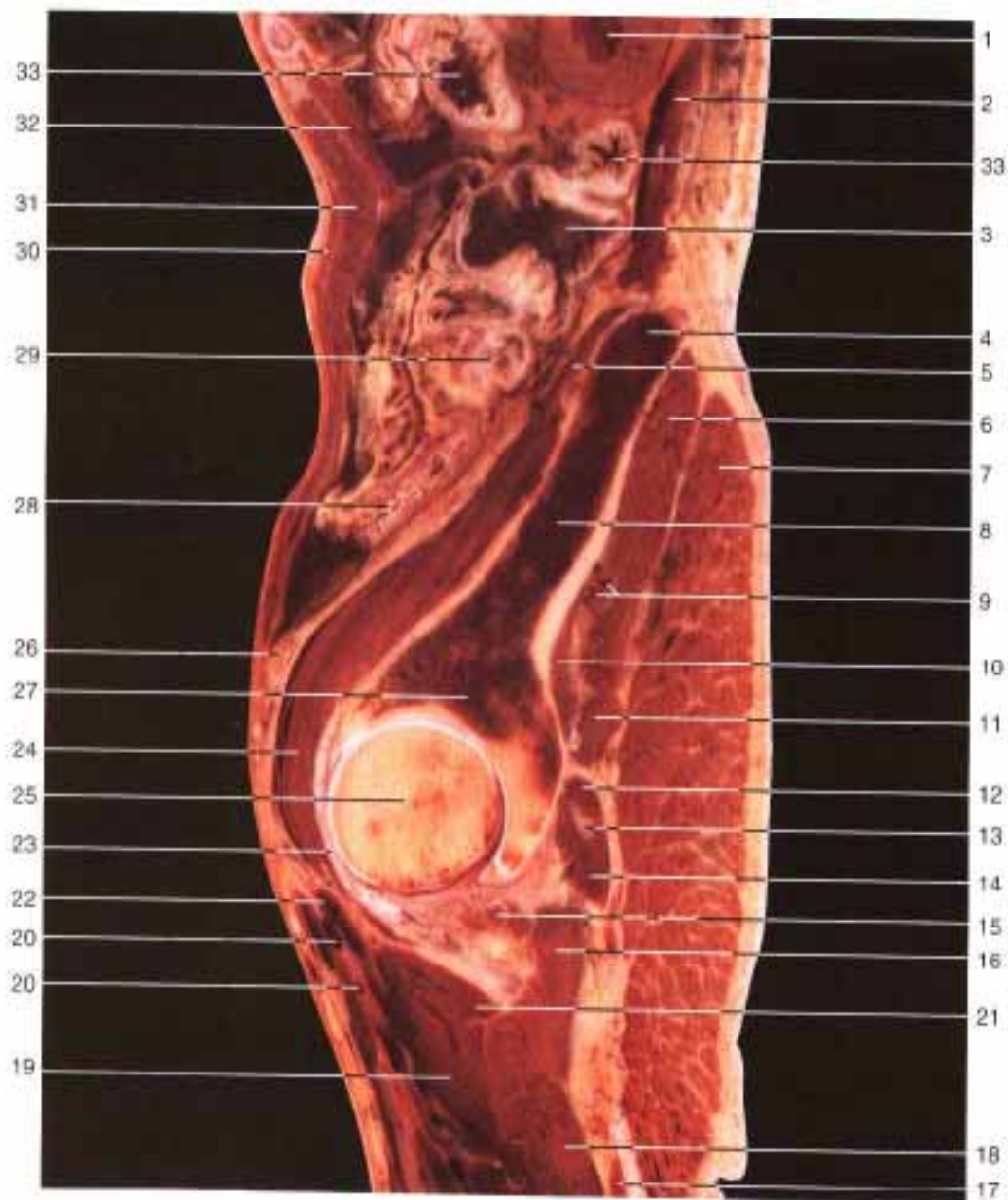
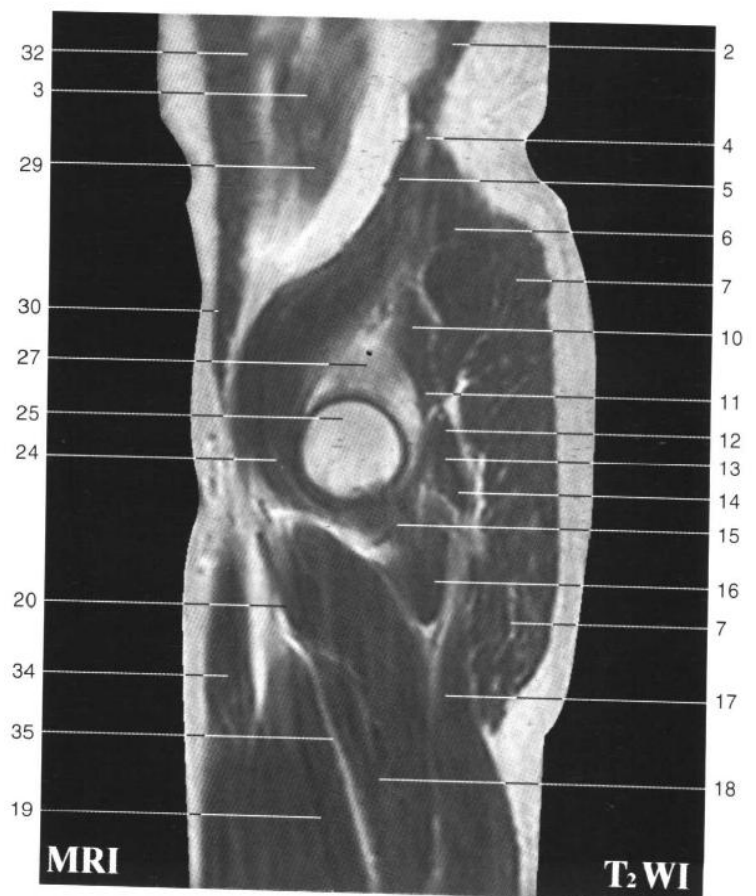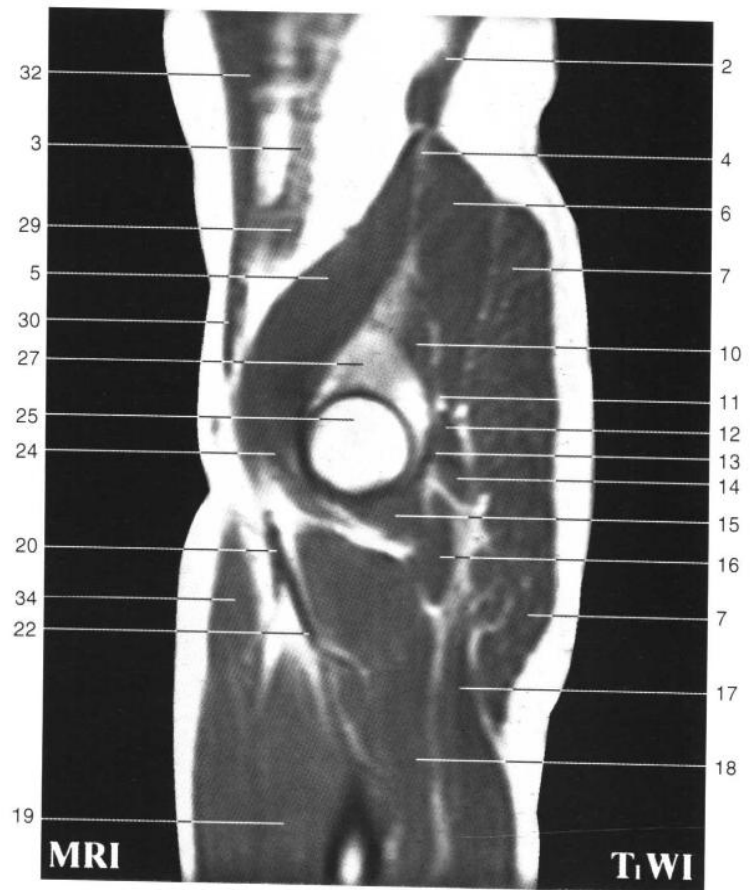


Fig. SPm 2

1. 右肾 right kidney
2. 腰方肌 quadratus lumborum
3. 升结肠 ascending colon
4. 髭嵴 iliac crest
5. 髂肌 iliacus
6. 臀中肌 gluteus medius
7. 臀大肌 gluteus maximus
8. 髂骨翼 ala of ilium
9. 臀上动脉 superior gluteal a.
10. 臀小肌 gluteus minimus

Fig. SPm 2

11. 梨状肌 piriformis
12. 上孖肌 gemellus superior
13. 闭孔内肌腱 tendon of obturator internus
14. 下孖肌 gemellus inferior
15. 闭孔外肌 obturator externus
16. 股方肌 quadratus femoris
17. 半腱肌 semitendinosus
18. 大收肌 adductor magnus
19. 长收肌 adductor longus
20. 股动脉 femoral a.
21. 短收肌 adductor brevis
22. 股深动脉 deep femoral a.
23. 关节囊 articular capsule
24. 髂腰肌 iliopsoas
25. 股骨头 femoral head
26. 腹股沟韧带 inguinal ligament
27. 髌骨体 body of ilium
28. 回肠 ileum
29. 盲肠 cecum
30. 腹外斜肌 obliquus externus abdominis
31. 腹内斜肌 obliquus internus abdominis
32. 腹横肌 transversus abdominis
33. 横结肠 transverse colon
34. 缝匠肌 sartorius
35. 肌间隔 intermuscular septum



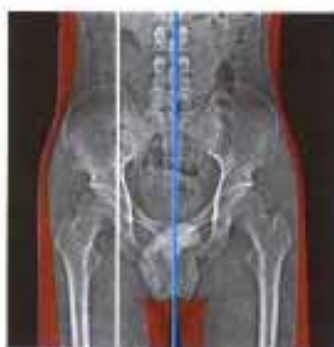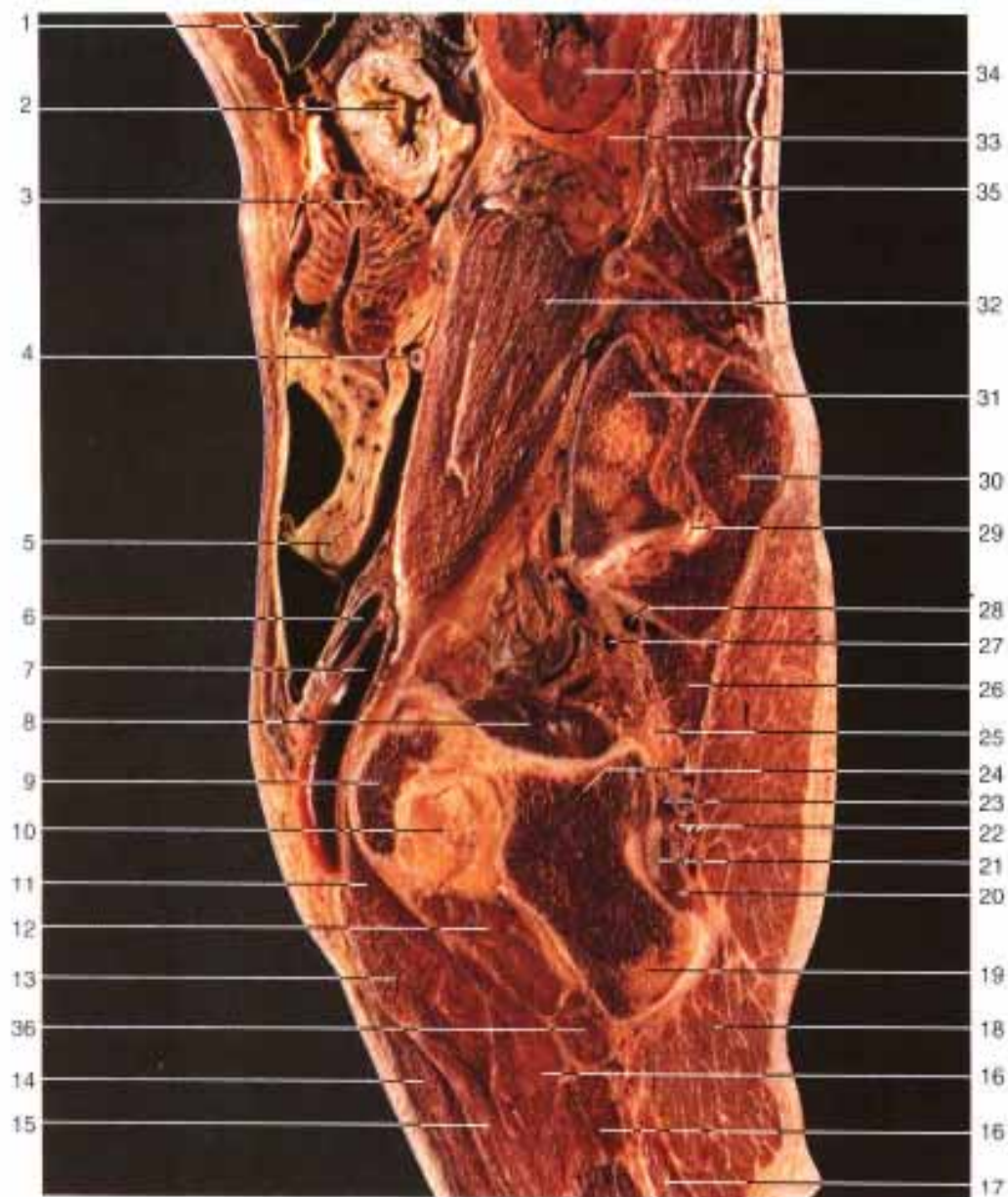
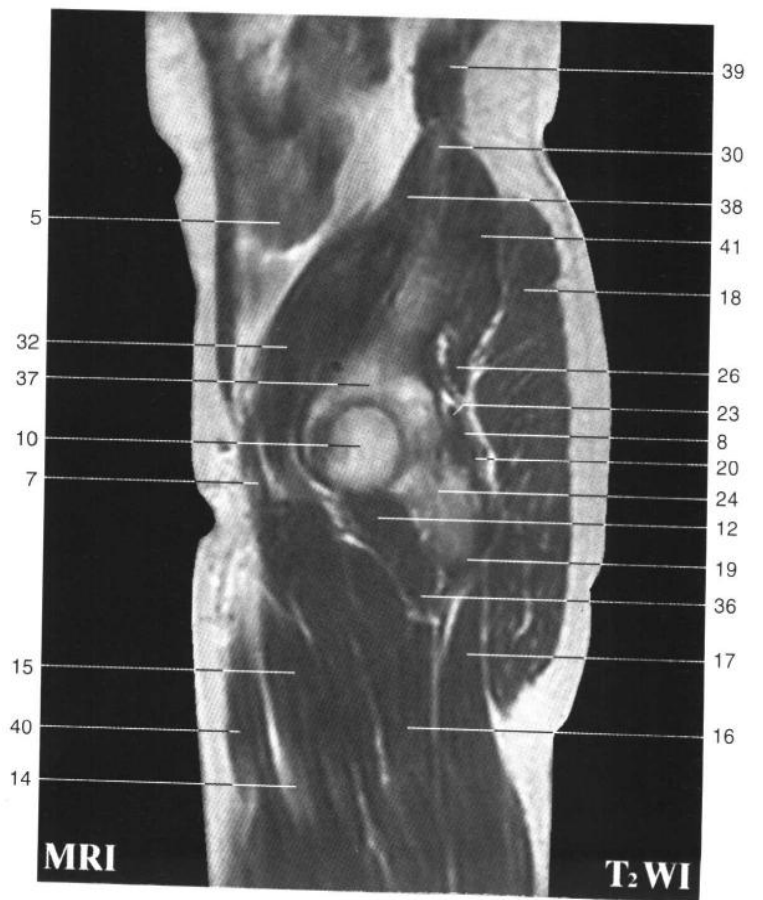
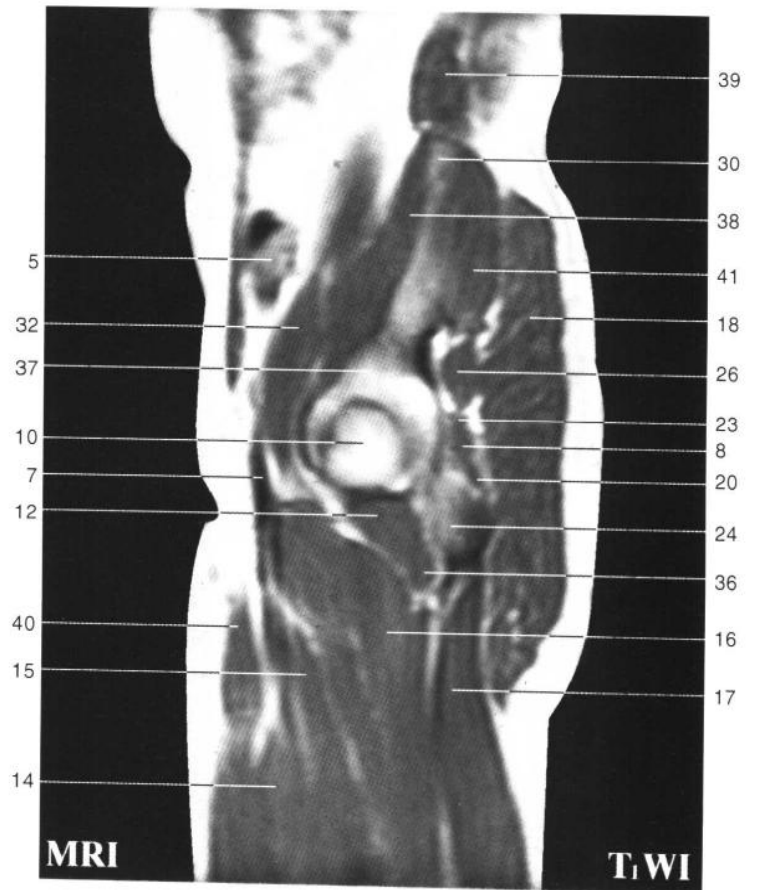


Fig. SPm 3

1. 胆囊 gallbladder
2. 横结肠 transverse colon
3. 回肠 ileum
4. 阑尾 vermiform appendix
5. 回肠 ileum
6. 右髂外动脉 right external iliac a.
7. 右髂外静脉 right external iliac v.
8. 闭孔内肌 obturator internus
9. 耻骨体 body of pubis
10. 股骨头 femoral head

Fig. SPm 3

- 11. 耻骨肌 pectineus
- 12. 闭孔外肌 obturator externus
- 13. 耻骨肌 pectineus
- 14. 长收肌 adductor longus
- 15. 短收肌 adductor brevis
- 16. 大收肌 adductor magnus
- 17. 半腱肌 semitendinosus
- 18. 臀大肌 gluteus maximus
- 19. 坐骨结节 ischial tuberosity
- 20. 下孖肌 gemellus inferior
- 21. 闭孔内肌腱 tendon of obturator internus
- 22. 臀下动脉、静脉 inferior gluteal a. and v.
- 23. 上孖肌 gemellus superior
- 24. 坐骨体 body of ischium
- 25. 坐骨神经 ischial n.
- 26. 梨状肌 piriformis
- 27. 臀下动脉 inferior gluteal a.
- 28. 臀上动脉 superior gluteal a.
- 29. 骶髂关节 sacroiliac joint
- 30. 髌骨 ilium
- 31. 骶骨 sacrum
- 32. 腰大肌 psoas major
- 33. 脂肪囊 fatty renal capsule
- 34. 右肾 right kidney
- 35. 竖脊肌 erector spinae
- 36. 股方肌 quadratus femoris
- 37. 髌骨体 body of ilium
- 38. 髌肌 iliacus
- 39. 腰方肌 quadratus lumborum
- 40. 缝匠肌 sartorius
- 41. 臀中肌 gluteus medius



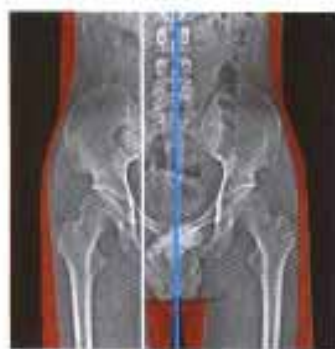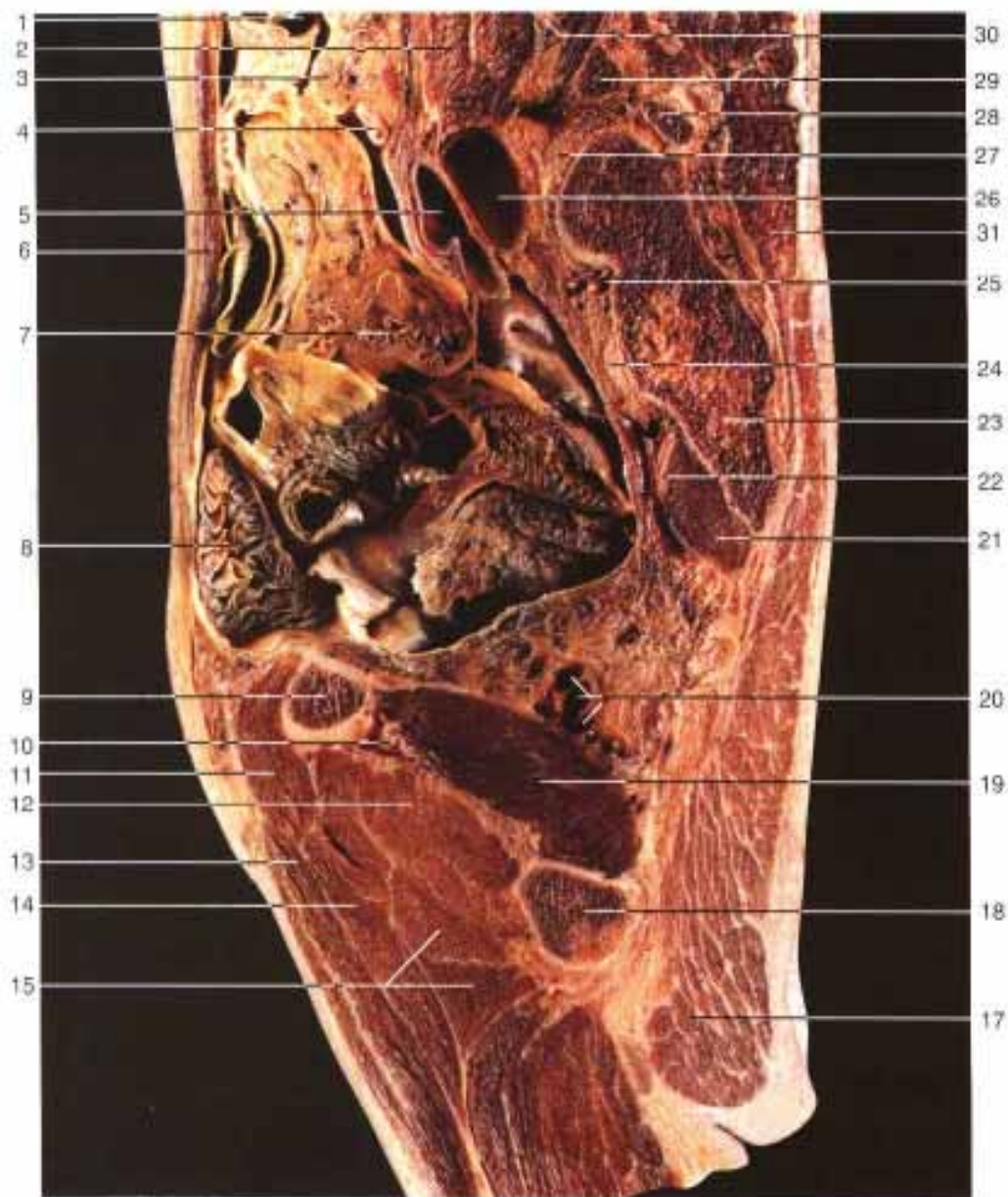

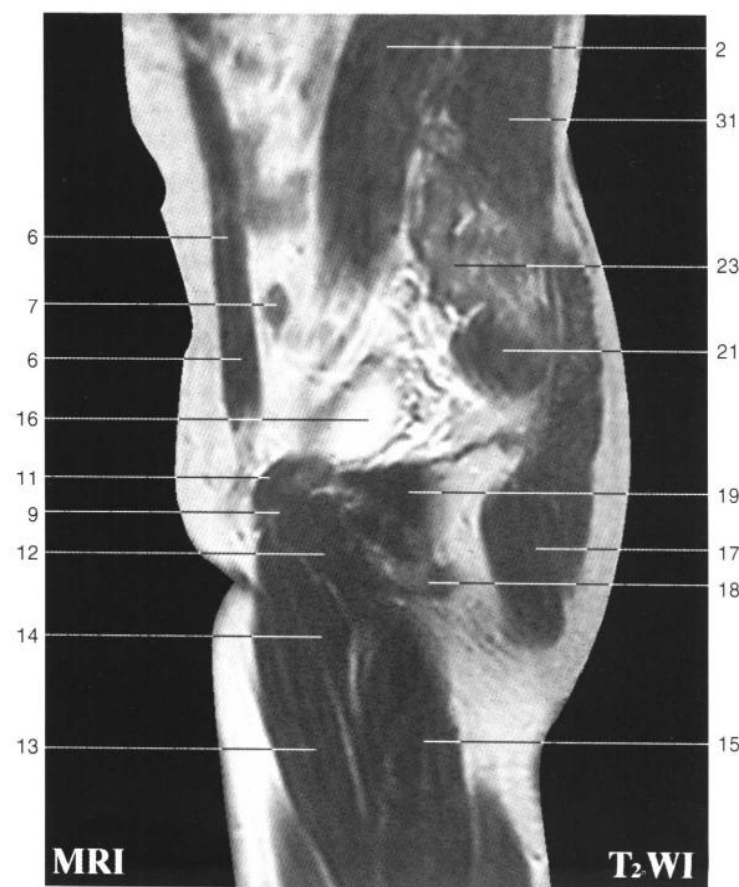
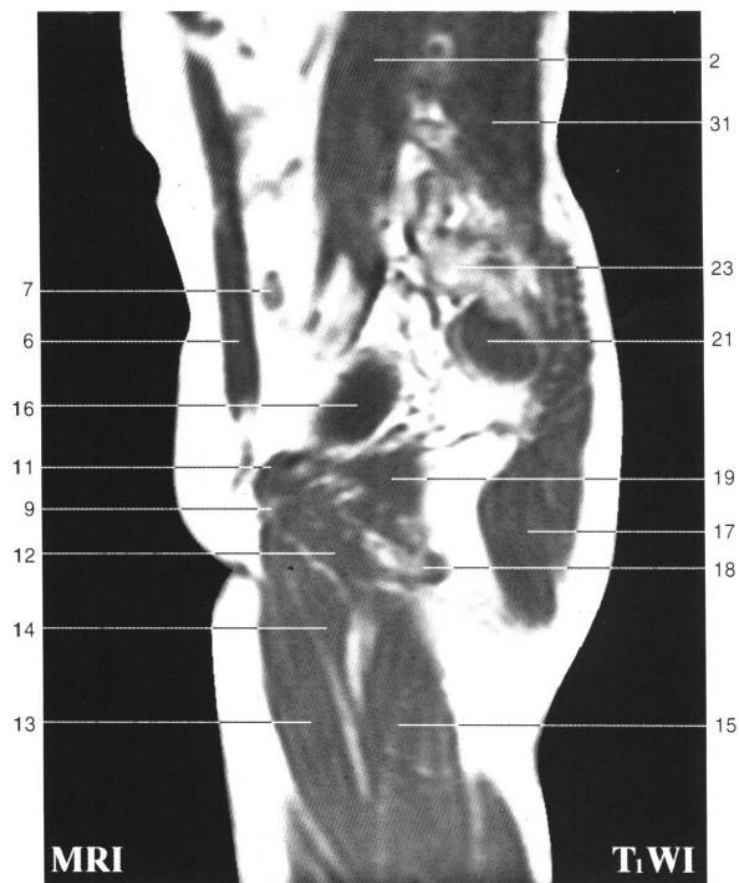Fig. SPm 4

1. 横结肠 transverse colon
2. 髂大肌 psoas major
3. 肠系膜淋巴结 mesenteric lymph nodes
4. 阑尾 vermiform appendix
5. 右髂总动脉 right common iliac a.
6. 腹直肌 rectus abdominis
7. 回肠 ileum
8. 回肠 ileum
9. 耻骨上支 superior ramus of pubis
10. 闭孔环, 静脉 obturator a. and v.

Fig. SPm 4

11. 耻骨肌 pectineus
12. 闭孔外肌 obturator externus
13. 长收肌 adductor longus
14. 短收肌 adductor brevis
15. 大收肌 adductor magnus
16. 膀胱 urinary bladder
17. 臀大肌 gluteus maximus
18. 坐骨支 ramus of ischium
19. 闭孔内肌 obturator internus
20. 膀胱静脉丛 vesical venous plexus
21. 梨状肌 piriformis
22. 第3骶神经 3rd sacral n.
23. 骶骨 sacrum
24. 第2骶神经 2nd sacral n.
25. 骶外侧动脉 lateral sacral a.
26. 右髂总静脉 right common iliac v.
27. 第5腰椎神经 5th lumbar n.
28. 髌骨 ilium
29. 第5腰椎横突 transverse process (L₅)
30. 股神经 femoral n.
31. 竖脊肌 erector spinae



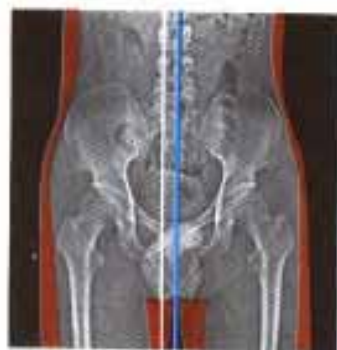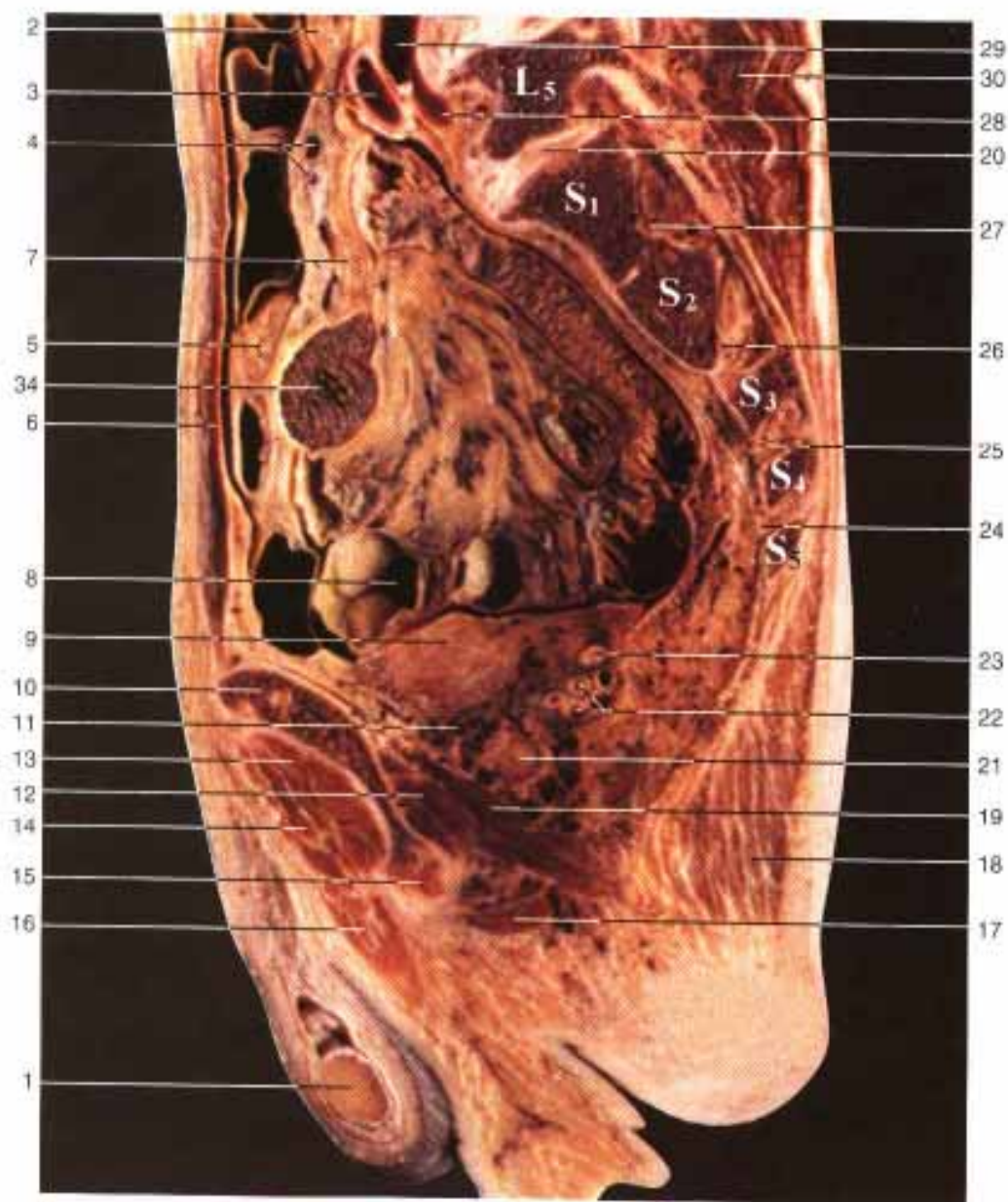


Fig. SPM 5

1. 睾丸 testis
2. 肠系膜淋巴结 mesenteric lymph nodes
3. 右髂总动脉 right common iliac a.
4. 肠系膜动脉, 静脉 mesenteric a. and v.
5. 回肠 ileum
6. 腹直肌 rectum abdominis
7. 肠系膜 mesentery
8. 乙状结肠 sigmoid colon
9. 膀胱 urinary bladder
10. 耻骨上支 superior ramus of pubis

Fig. SPm 5

11. 膀胱静脉丛 vesical venous plexus
12. 闭孔内肌 obturator internus
13. 闭孔外肌 obturator externus
14. 耻骨肌 pectineus
15. 耻骨下支 inferior ramus of pubis
16. 长收肌 adductor longus
17. 球海绵体肌 bulbocavernosus
18. 臀大肌 gluteus maximus
19. 肛提肌 levator ani
20. 椎间盘 intervertebral disc
21. 前列腺 prostate
22. 精囊 seminal vesicle
23. 输精管壶腹 ampulla ductus deferentis
24. 第4骶神经 4th sacral n.
25. 第3骶神经 3rd sacral n.
26. 第2骶神经 2nd sacral n.
27. 第1骶神经 1st sacral n.
28. 右髂总静脉 right common iliac v.
29. 下腔静脉 inferior vena cava
30. 竖脊肌 erector spinae
31. 直肠 rectum
32. 椎弓根 pedicle of vertebral arch
33. 椎间孔 intervertebral foramina
34. 空肠 jejunum

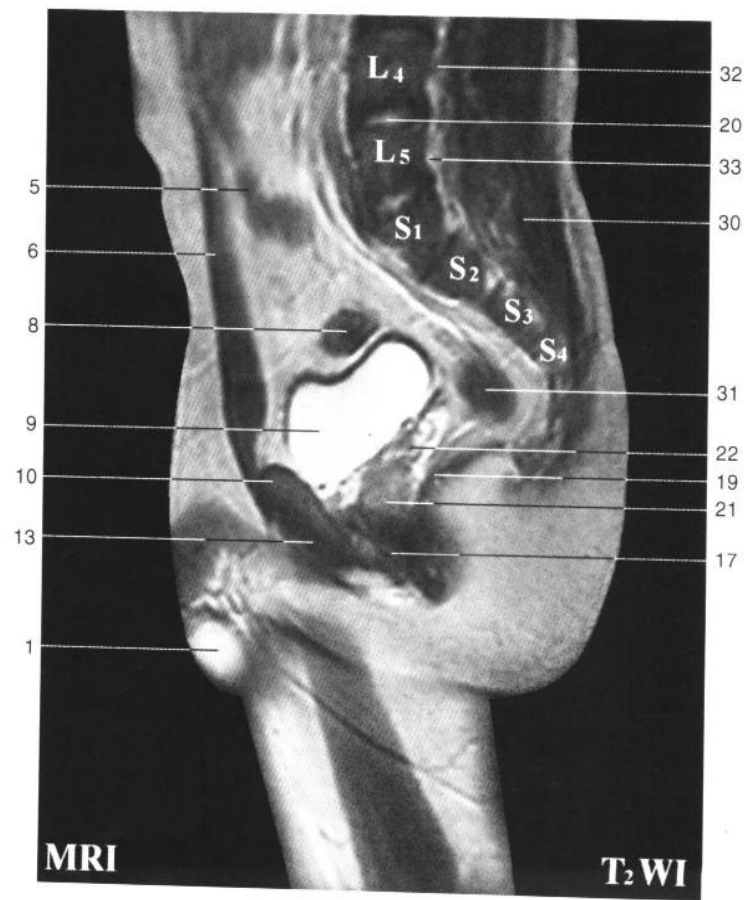
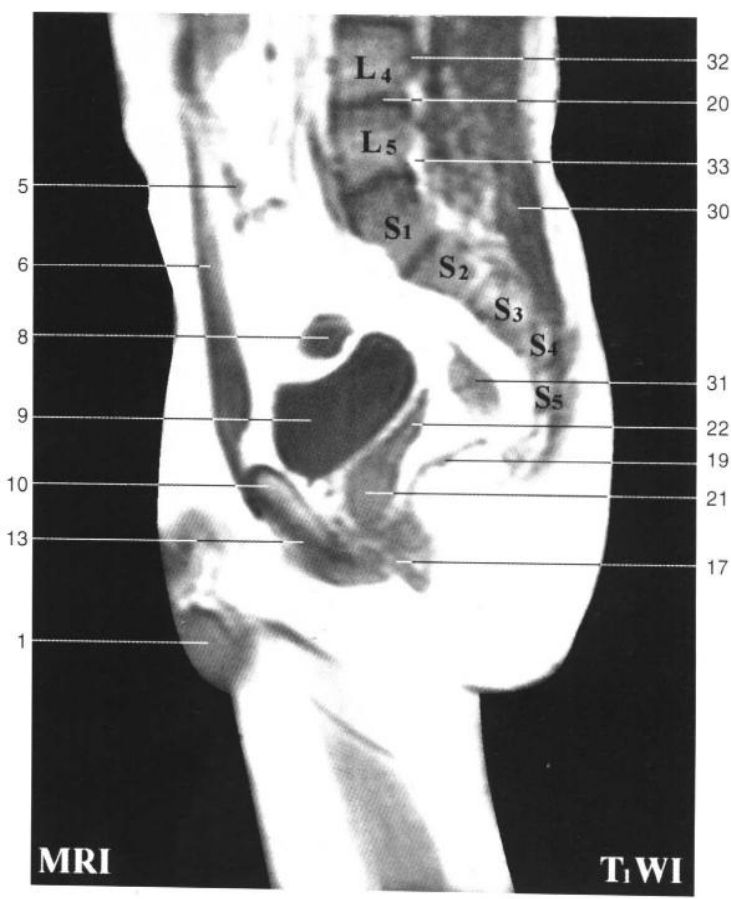
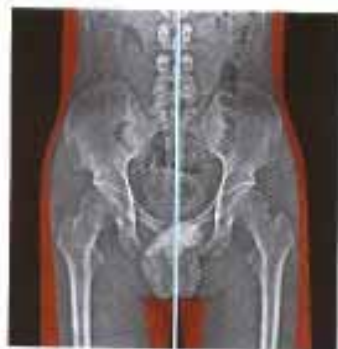
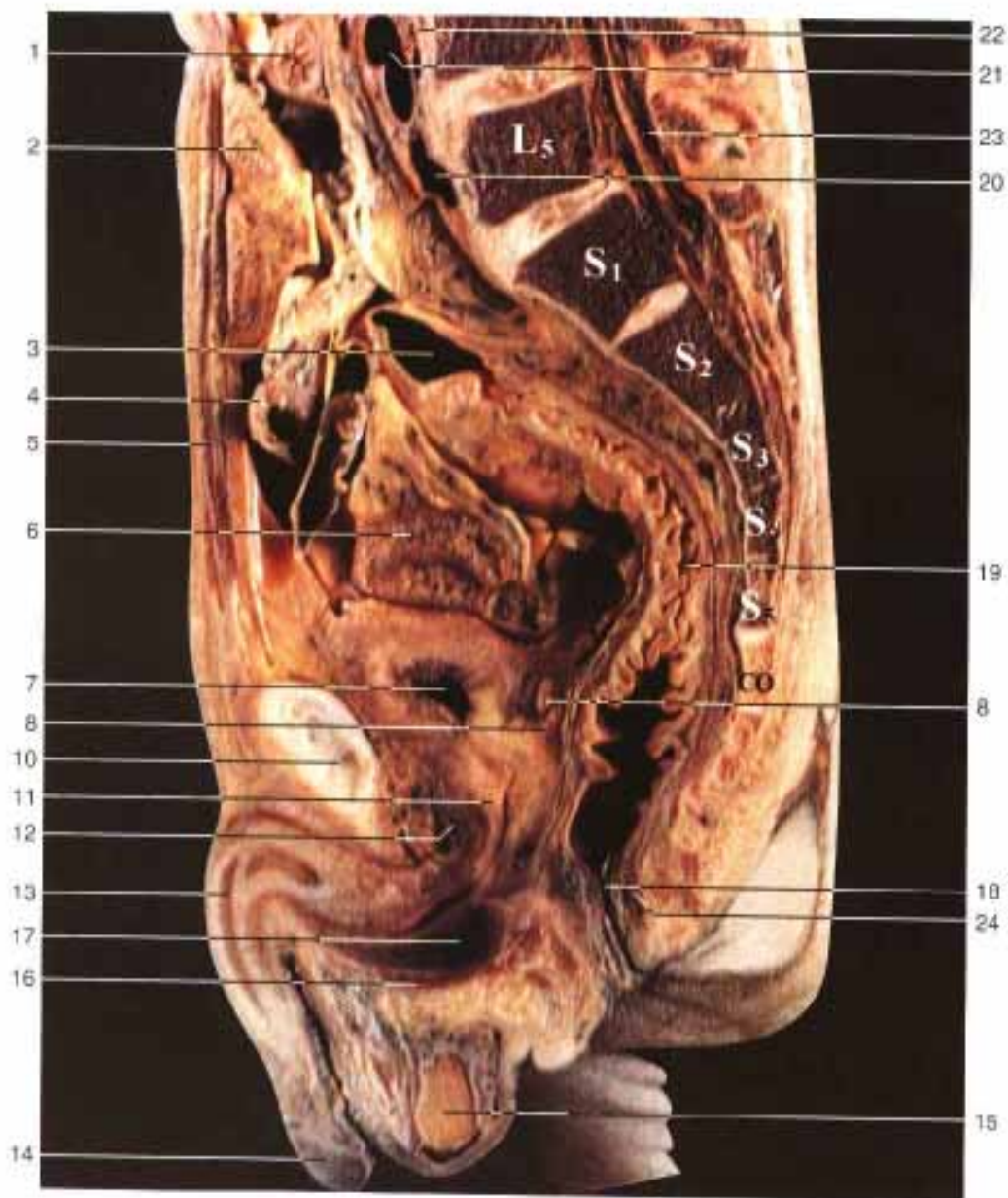
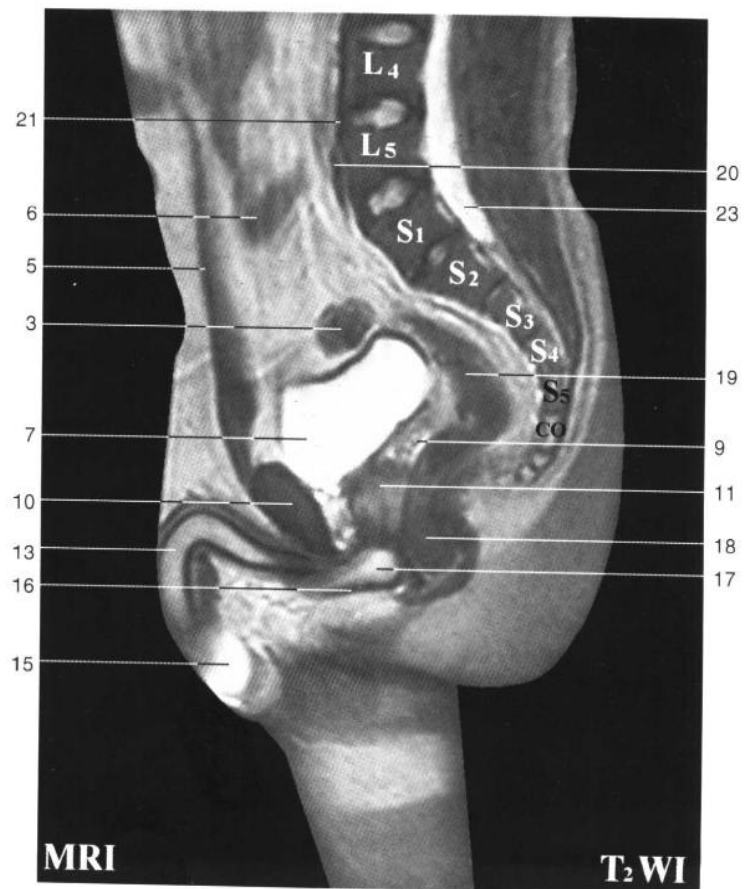
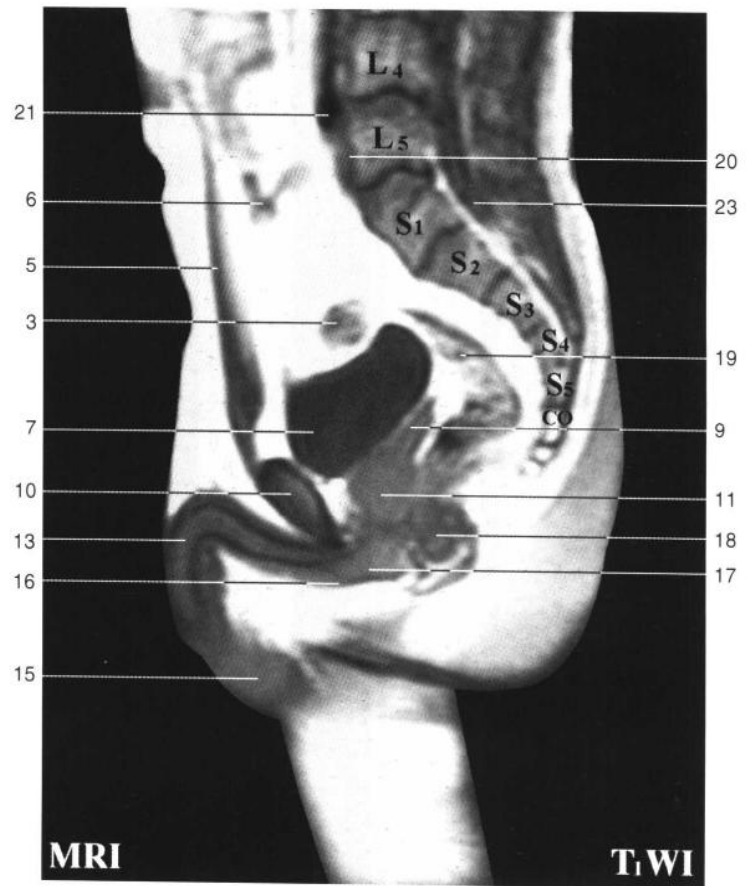


Fig. SPm 6

1. 空肠 jejunum
2. 空肠 jejunum
3. 乙状结肠 sigmoid colon
4. 大网膜 greater omentum
5. 腹直肌 rectus abdominis
6. 回肠 ileum
7. 膀胱 urinary bladder
8. 输精管壶腹 ampulla ductus deferentis
9. 精囊 seminal vesicle

Fig. SPm 6

10. 耻骨联合 pubic symphysis
11. 前列腺 prostate
12. 前列腺静脉丛 prostatic venous plexus
13. 阴茎 penis
14. 阴茎头 glans penis
15. 睾丸 testis
16. 球海绵体肌 bulbocavernosus
17. 尿道球 bulb of urethra
18. 肛管 anal canal
19. 直肠 rectum
20. 右髂总静脉 right common iliac v.
21. 右髂总动脉 right common iliac a.
22. 腰动脉 lumbar a.
23. 骶管 sacral canal
24. 肛门外括约肌 sphincter ani externus



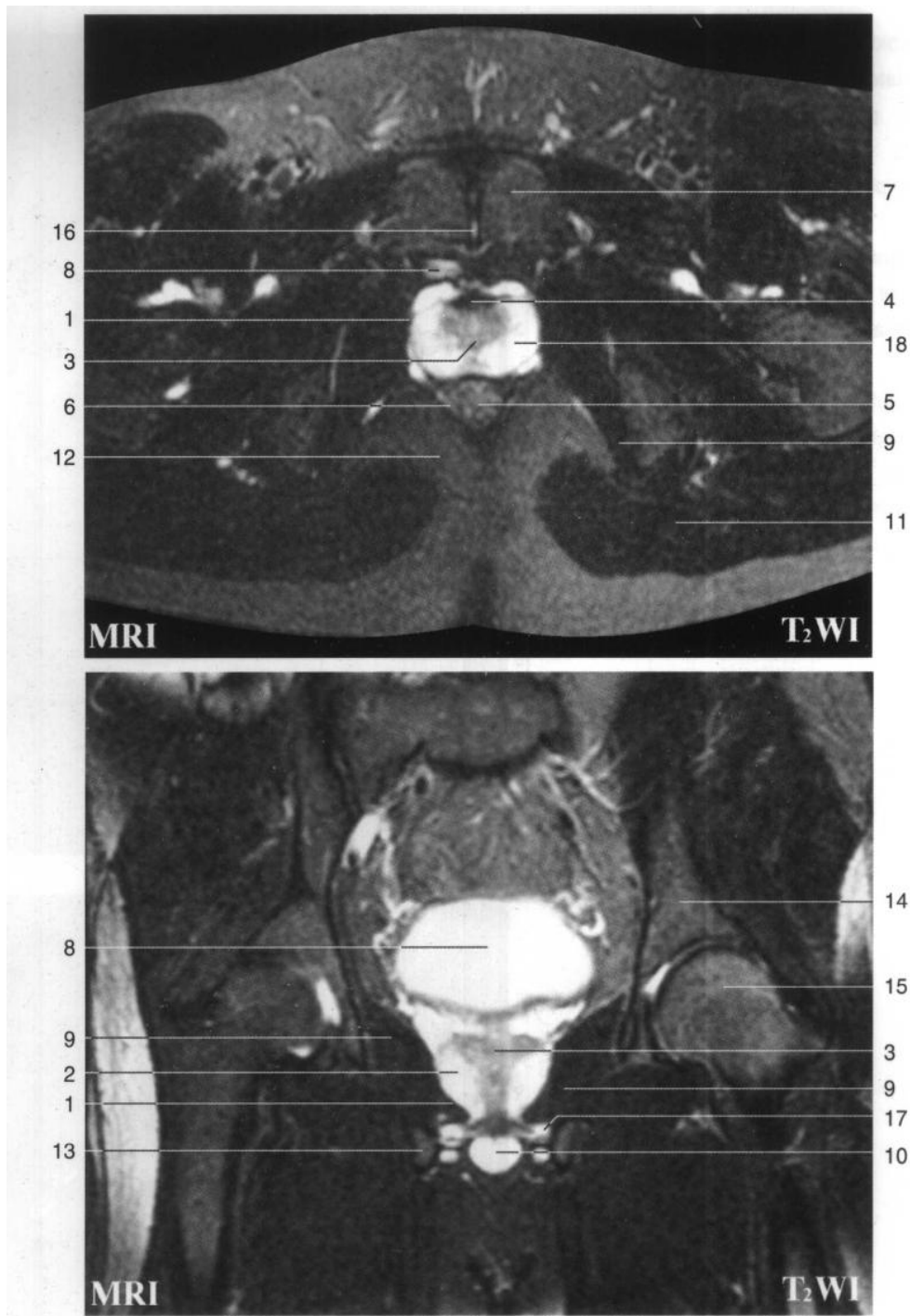


Fig. MRI

- 1. 前列腺[纤维]囊 prostatic capsule
- 2. 前列腺右叶 right lobe of prostate
- 3. 前列腺中叶 middle lobe of prostate
- 4. 前列腺肌质 muscular substance of prostate
- 5. 直肠 rectum
- 6. 肛提肌 levator ani
- 7. 耻骨 pubis
- 8. 膀胱 urinary bladder

- 9. 闭孔内肌 obturator internus
- 10. 尿道海绵体 cavernous body of urethra
- 11. 臀大肌 gluteus maximus
- 12. 坐骨肛门窝脂体 adipose body of ischioanal fossa
- 13. 坐骨支 ramus of ischium
- 14. 髌骨体 body of ilium
- 15. 股骨头 femoral head
- 16. 耻骨联合 pubic symphysis
- 17. 阴茎脚 crus penis
- 18. 前列腺左叶 left lobe of prostate

Fig. MRI

LIMBS

四肢部

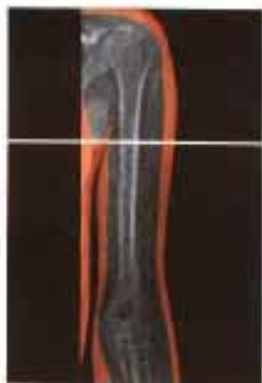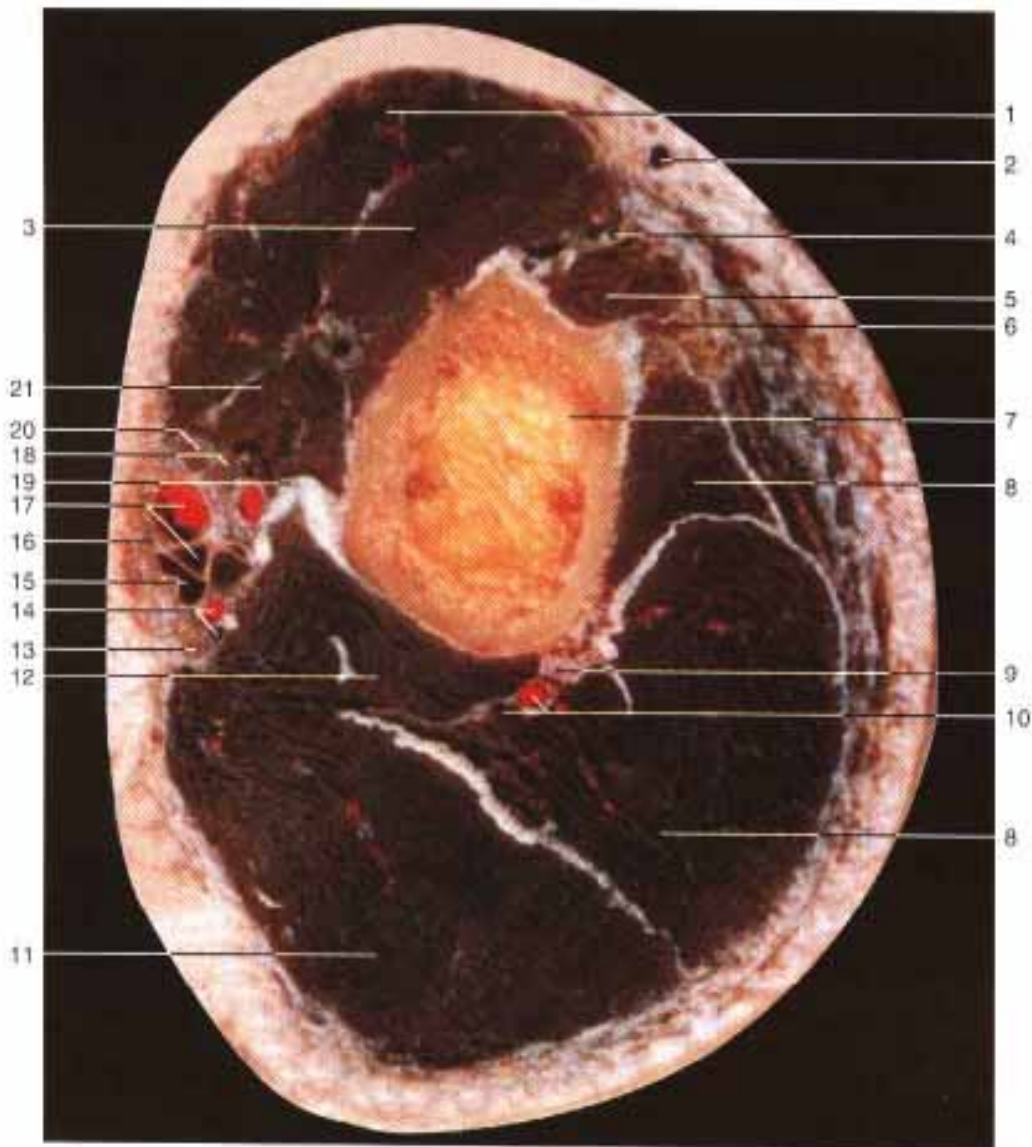
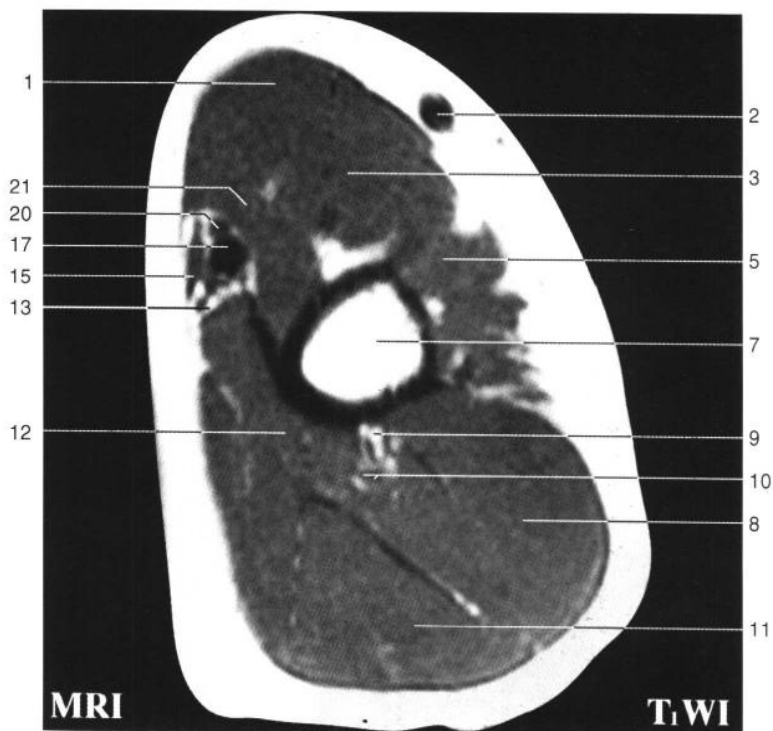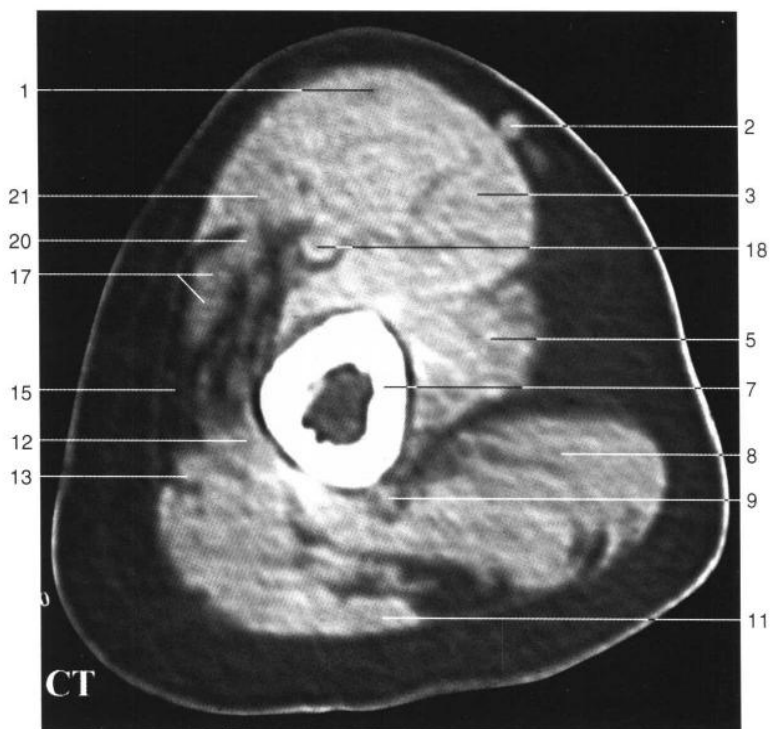


Fig. HUL 1

1. 肱二头肌短头 short head of biceps brachii
2. 头静脉 cephalic v.
3. 肱二头肌长头 long head of biceps brachii
4. 腋深动脉三角肌支 deltoid branch of deep brachial a.
5. 三角肌 deltoid
6. 臂外侧肌间隔 lateral brachial intermuscular septum
7. 肱骨 humerus
8. 肱三头肌外侧头 lateral head of triceps brachii
9. 桡神经 radial n.
10. 腋深动、静脉 deep brachial a. and v.

Fig. HUL 1

11. 肱三头肌长头 long head of triceps brachii
12. 肱三头肌内侧头 medial head of triceps brachii
13. 尺神经 ulnar n.
14. 尺侧上副动、静脉 superior ulnar collateral a. and v.
15. 贵要静脉 basilic v.
16. 前臂内侧皮神经 medial antebrachial cutaneous n.
17. 肱动、静脉 brachial a. and v.
18. 肌皮神经 musculocutaneous n.
19. 臂内侧肌间隔 medial brachial intermuscular septum
20. 正中神经 median n.
21. 喙肱肌 coracobrachialis



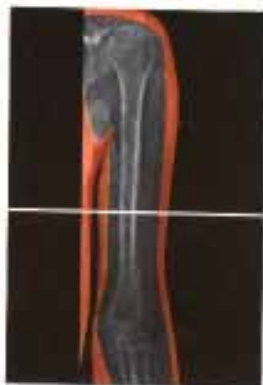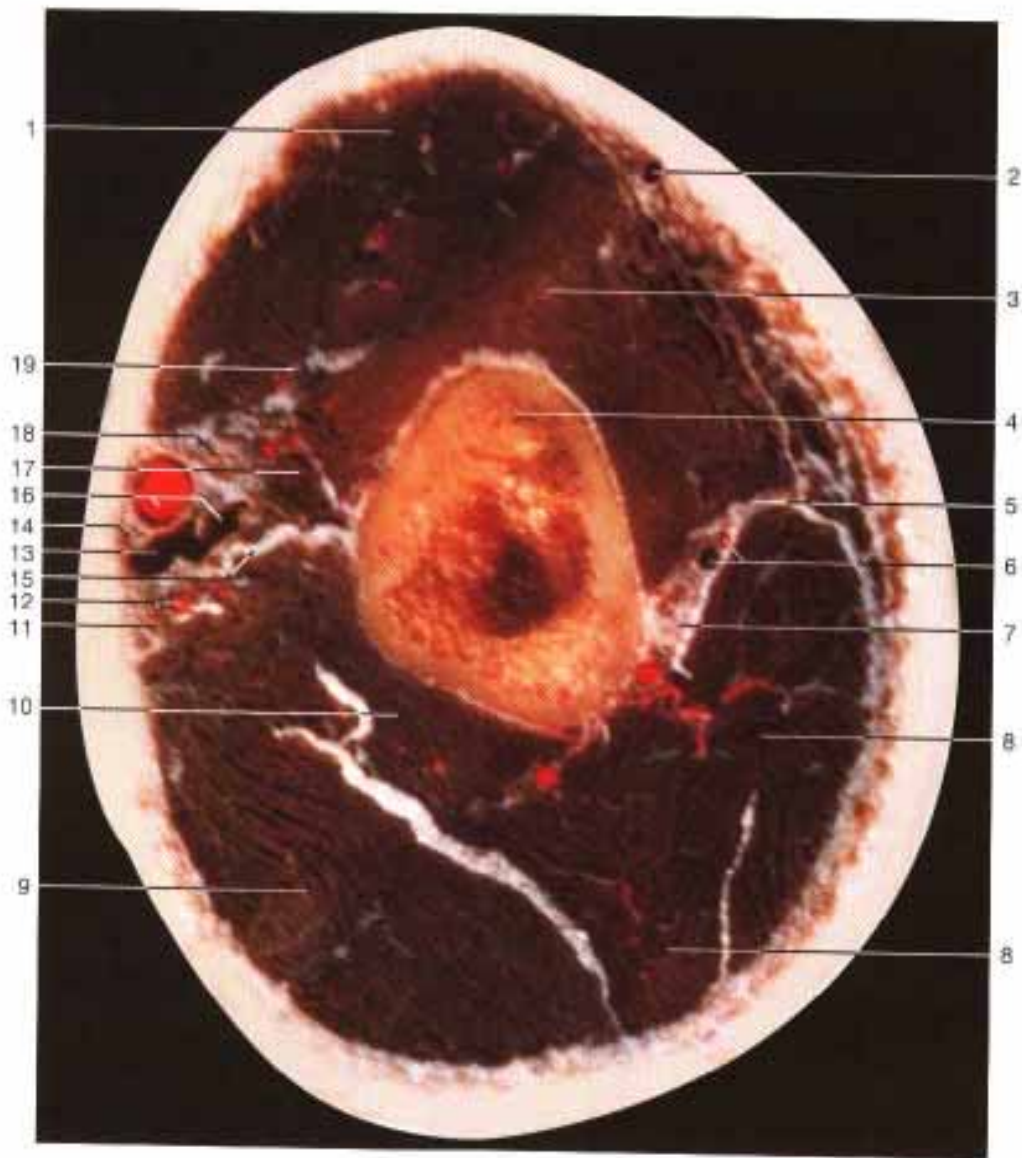
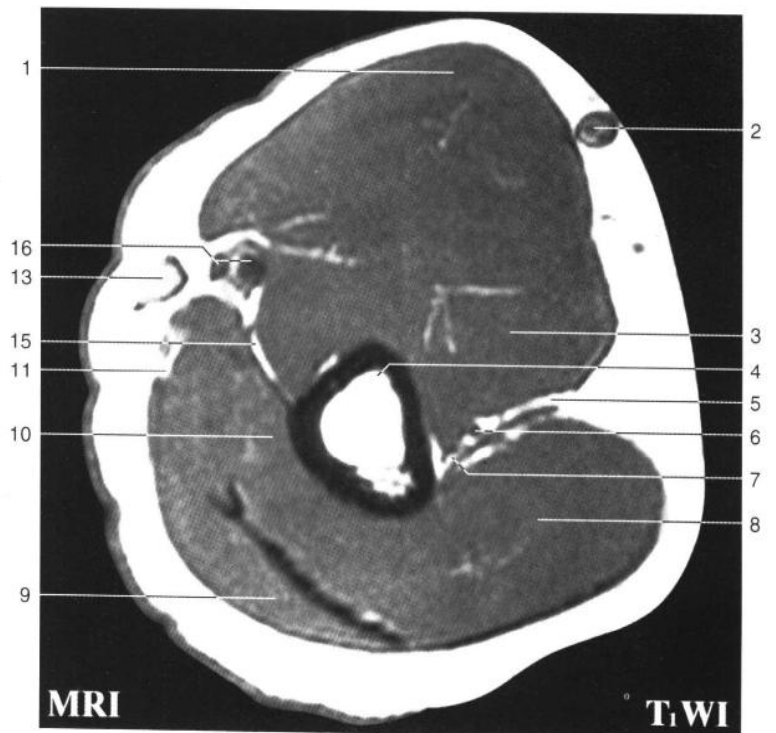
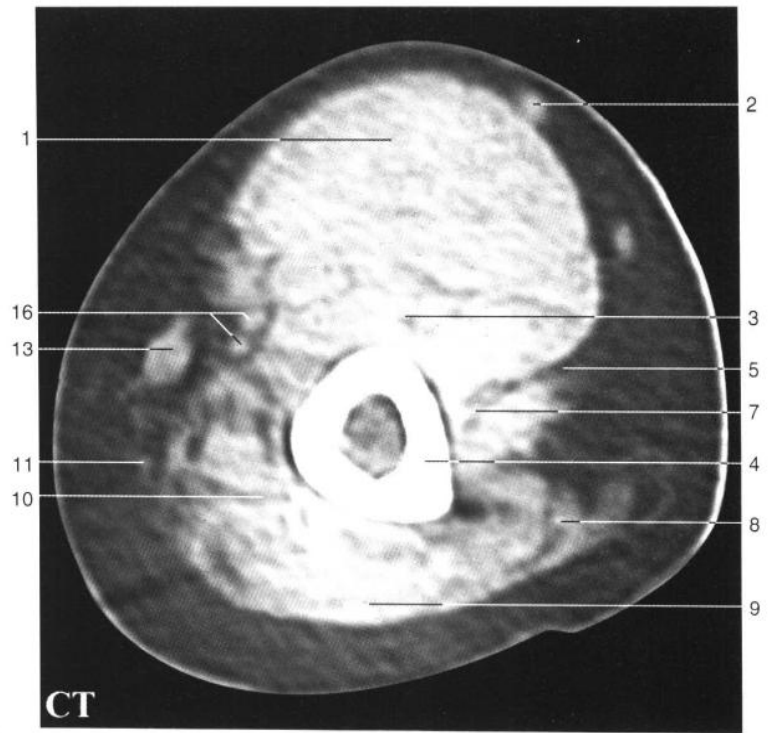


Fig HUL 2

1. 腋二头肌 biceps brachii
2. 头静脉 cephalic v.
3. 喙肌 brachialis
4. 肱骨 humerus
5. 臂外侧肌间隔 lateral brachial intermuscular septum
6. 腋深动、静脉 deep brachial a. and v.
7. 桡神经 radial n.
8. 腋三头肌外侧头 lateral head of triceps brachii
9. 腋三头肌长头 long head of triceps brachii
10. 腋三头肌内侧头 medial head of triceps brachii

Fig. HUL 2

- 11. 尺神经 ulnar n.
- 12. 尺侧上副动、静脉 superior ulnar collateral a. and v.
- 13. 贵要静脉 basilic v.
- 14. 前臂内侧皮神经 medial antebrachial cutaneous n.
- 15. 臂内侧肌间隔 medial brachial intermuscular septum
- 16. 肱动、静脉 brachial a. and v.
- 17. 喙肱肌 coracobrachialis
- 18. 正中神经 median n.
- 19. 肌皮神经 musculocutaneous n.



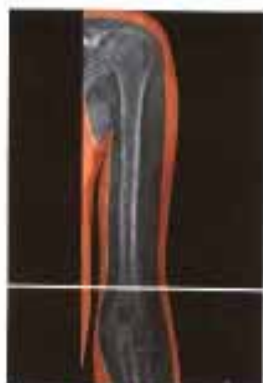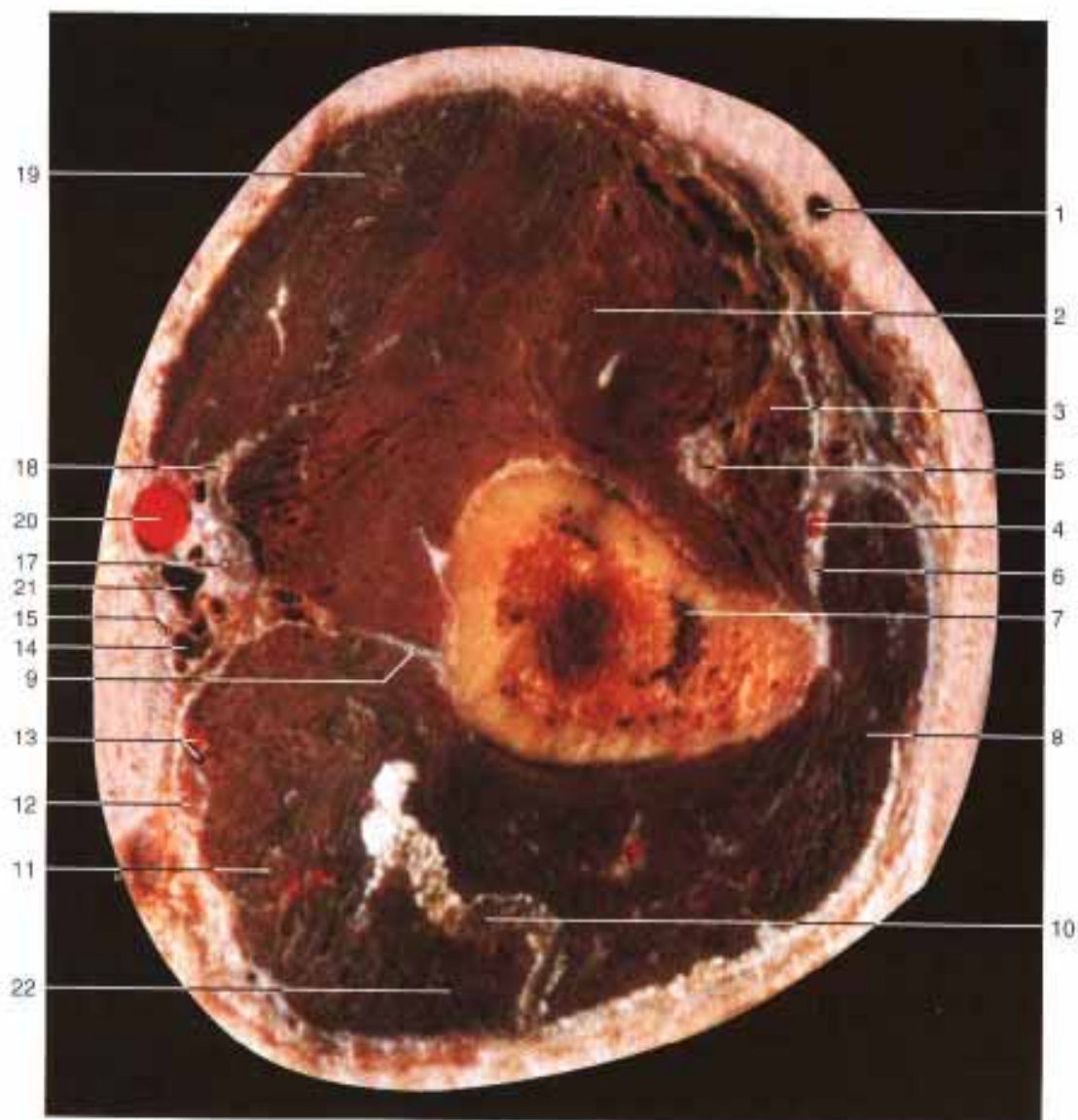
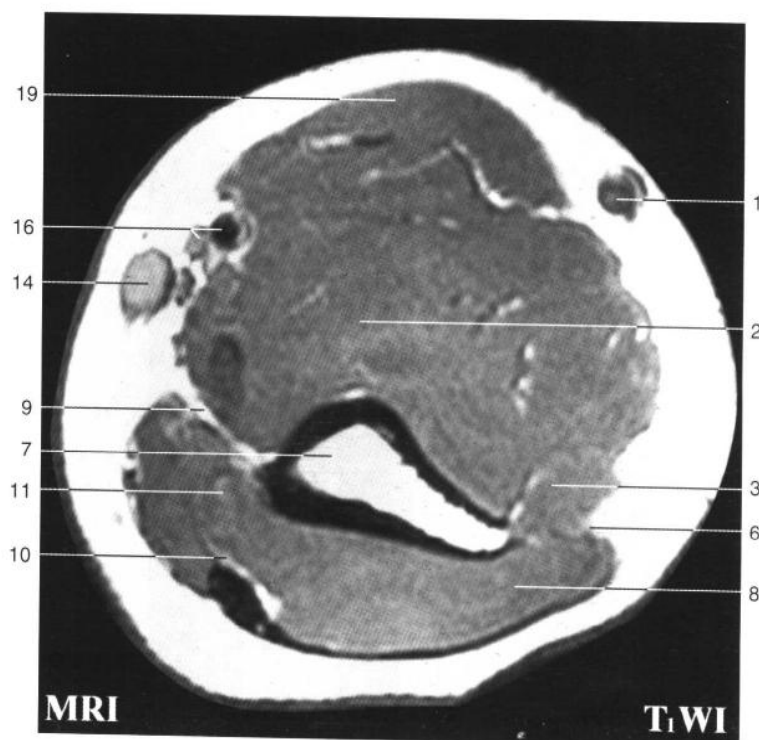
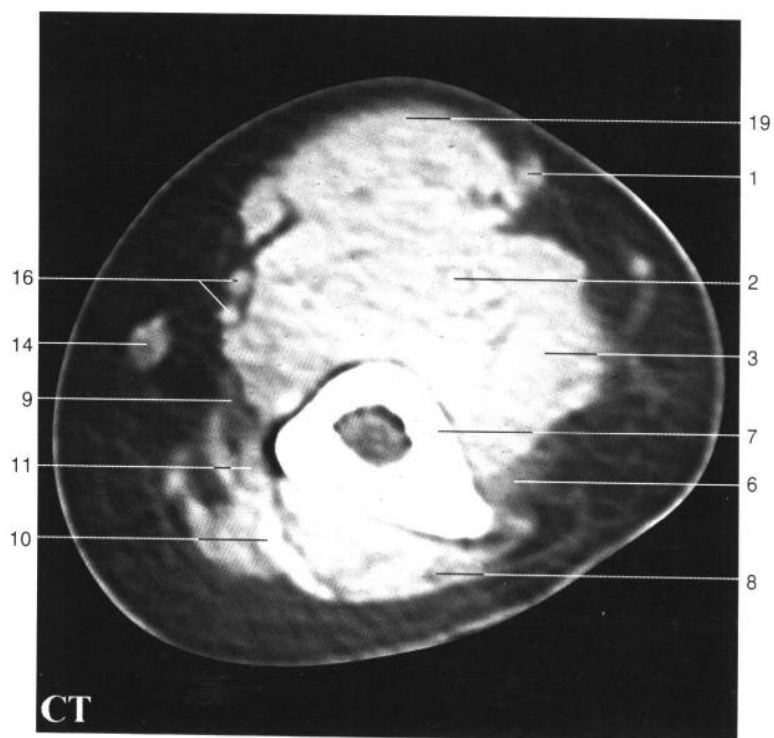


Fig. HUL 3

1. 头静脉 cephalic v.
2. 喙肌 brachialis
3. 旋前肌 brachioradialis
4. 桡侧副动、静脉 radial collateral a. and v.
5. 桡神经 radial n.
6. 臂外侧肌间隔 lateral brachial intermuscular septum
7. 肱骨 humerus
8. 喙三头肌外侧头 lateral head of triceps brachii
9. 臂内侧肌间隔 medial brachial intermuscular septum
10. 喙三头肌腱 tendon of triceps brachii

Fig. HUL 3

11. 肱三头肌内侧头 medial head of triceps brachii
12. 尺神经 ulnar n.
13. 尺侧上副动、静脉 superior ulnar collateral a. and v.
14. 贵要静脉 basilic v.
15. 前臂内侧皮神经 medial antebrachial cutaneous n.
16. 肱动、静脉 brachial a. and v.
17. 正中神经 median n.
18. 肌皮神经 musculocutaneous n.
19. 肱二头肌 biceps brachii
20. 肱动脉 brachial a.
21. 肱静脉 brachial v.
22. 肱三头肌长头 long head of triceps brachii



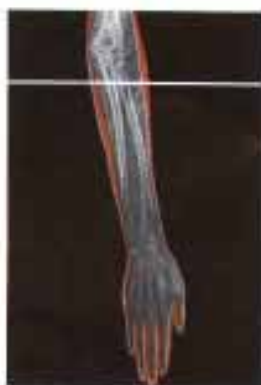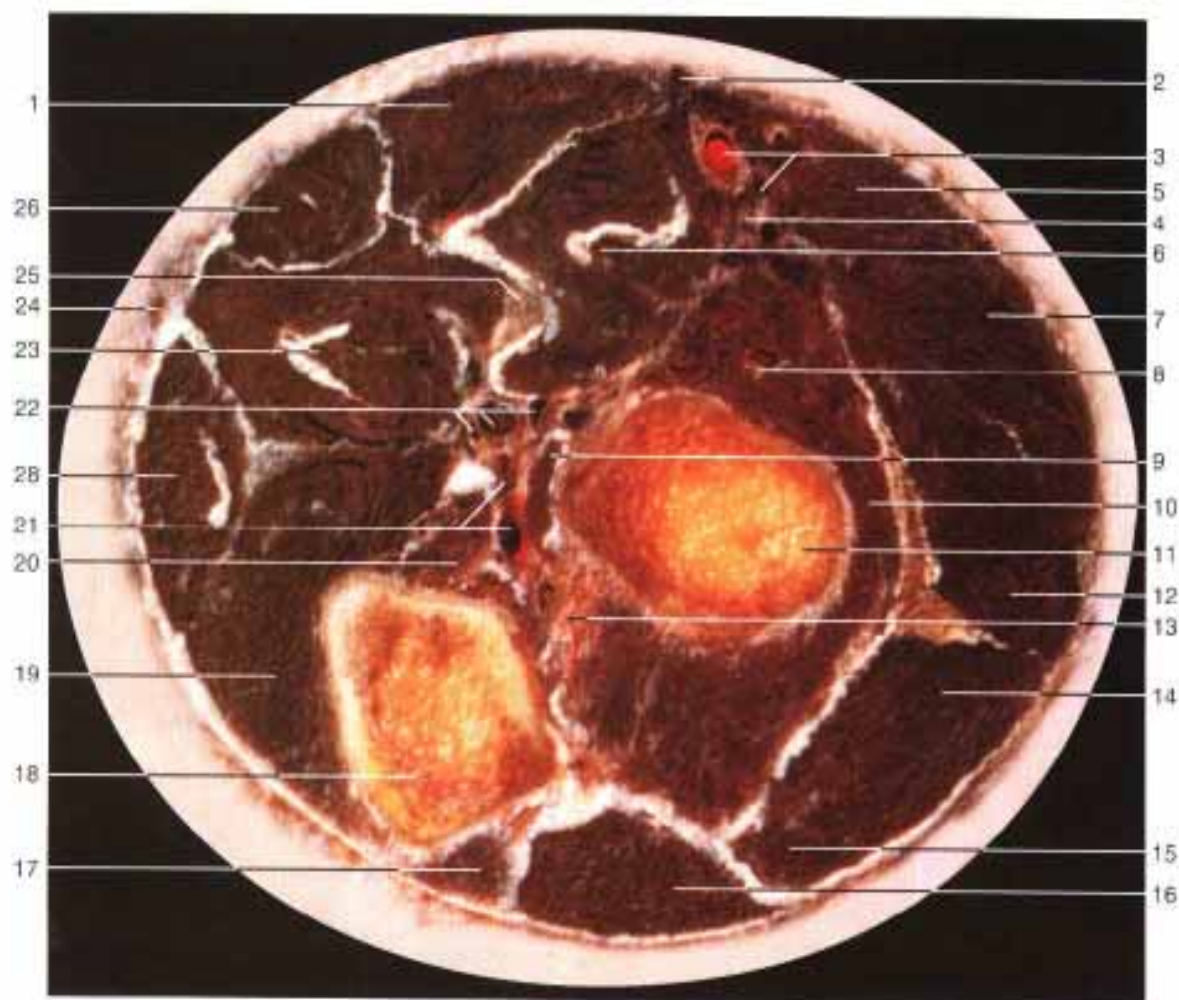
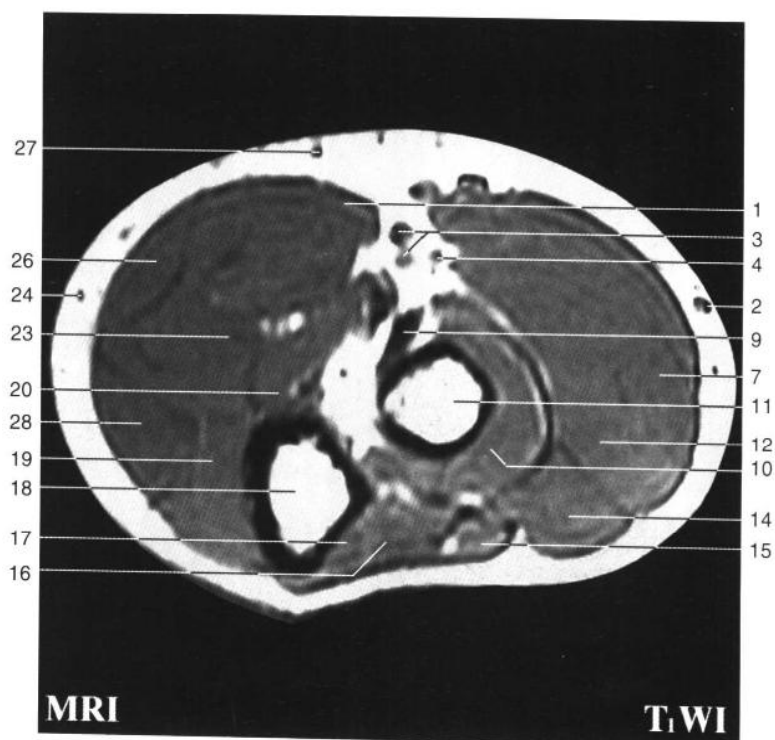
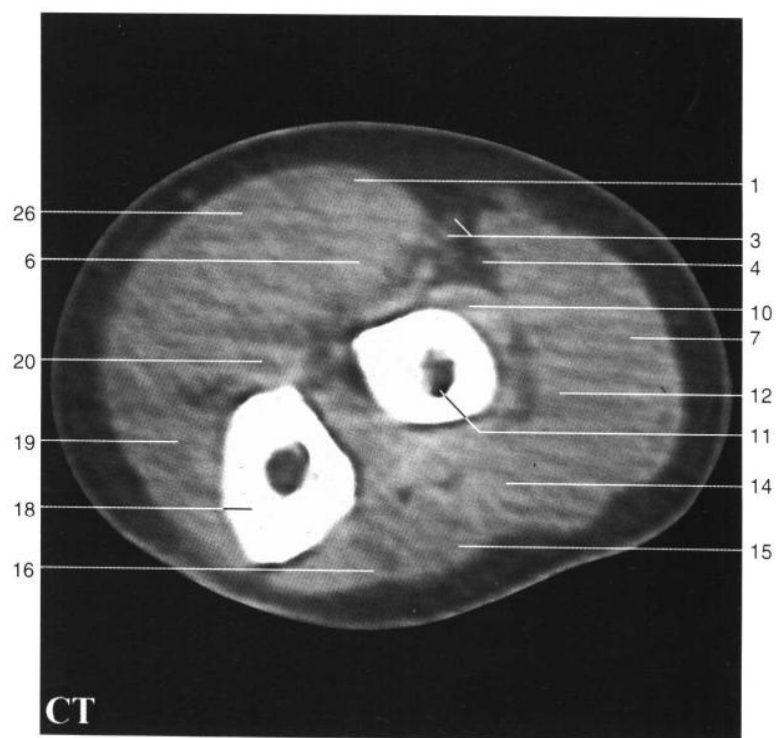


Fig. HUL 4

1. 桡腕屈肌 flexor carpi radialis
2. 头静脉 cephalic v.
3. 桡动脉、静脉 radial a. and v.
4. 桡神经浅支 superficial branch of radial n.
5. 肌桡肌 brachioradialis
6. 旋前圆肌 pronator teres
7. 桡腕伸肌 extensor carpi radialis longus
8. 桡神经深支 deep branch of radial n.
9. 肱二头肌 biceps brachii
10. 旋后肌 supinator

Fig. HUL 4

11. 桡骨 radius
12. 桡侧腕短伸肌 extensor carpi radialis brevis
13. 前臂骨间膜 interosseous membrane of forearm
14. 指伸肌 extensor digitorum
15. 小指伸肌 extensor digiti minimi
16. 尺侧腕伸肌 extensor carpi ulnaris
17. 肘肌 anconeus
18. 尺骨 ulna
19. 指深屈肌 flexor digitorum profundus
20. 肱肌 brachialis
21. 骨间总动、静脉 common interosseous a. and v.
22. 尺动、静脉 ulnar a. and v.
23. 指浅屈肌 flexor digitorum superficialis
24. 贵要静脉 basilic v.
25. 正中神经 median n.
26. 掌长肌 palmaris longus
27. 前臂正中静脉 median antebrachial v.
28. 尺侧腕屈肌 flexor carpi ulnaris



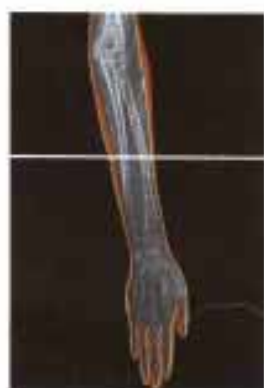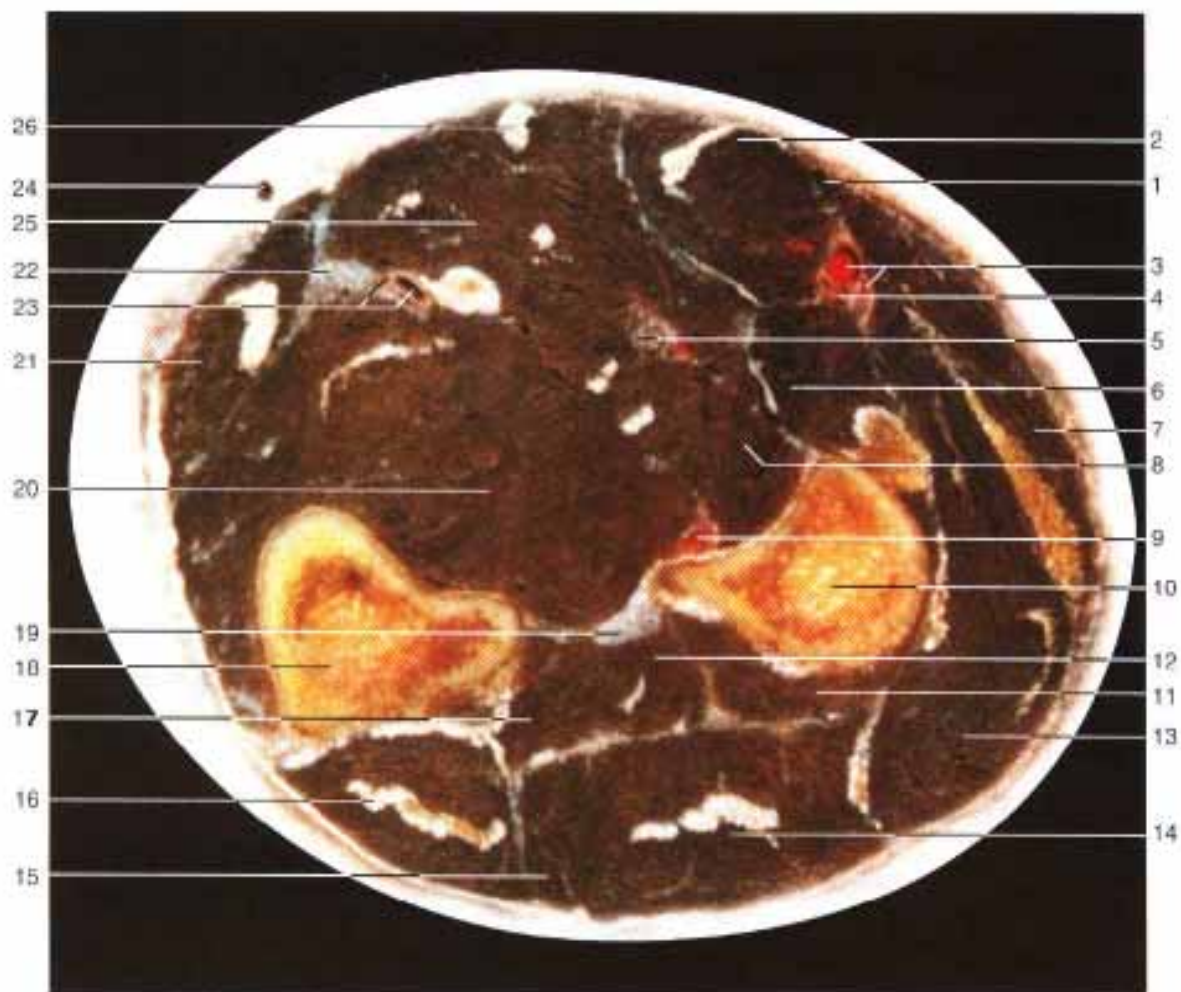
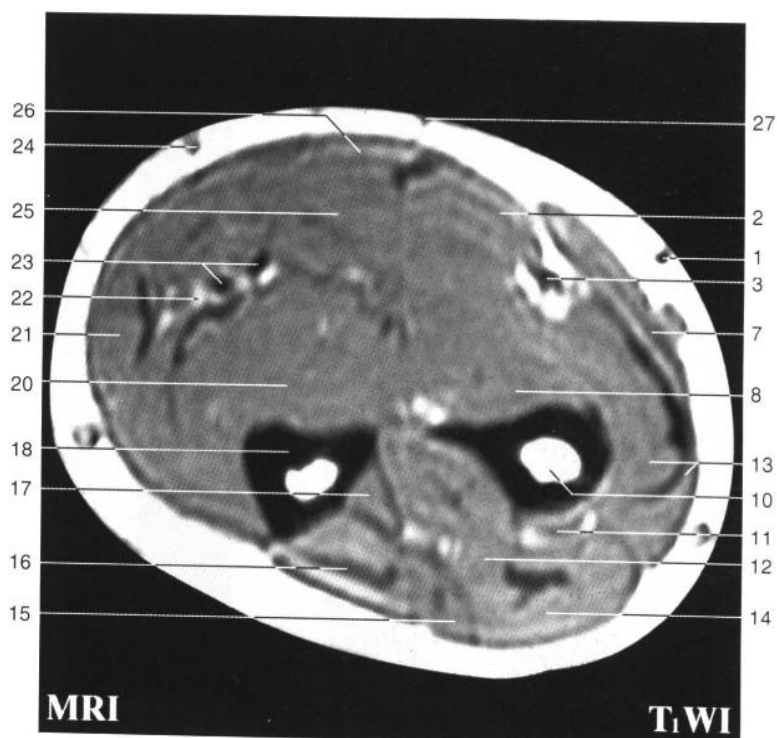
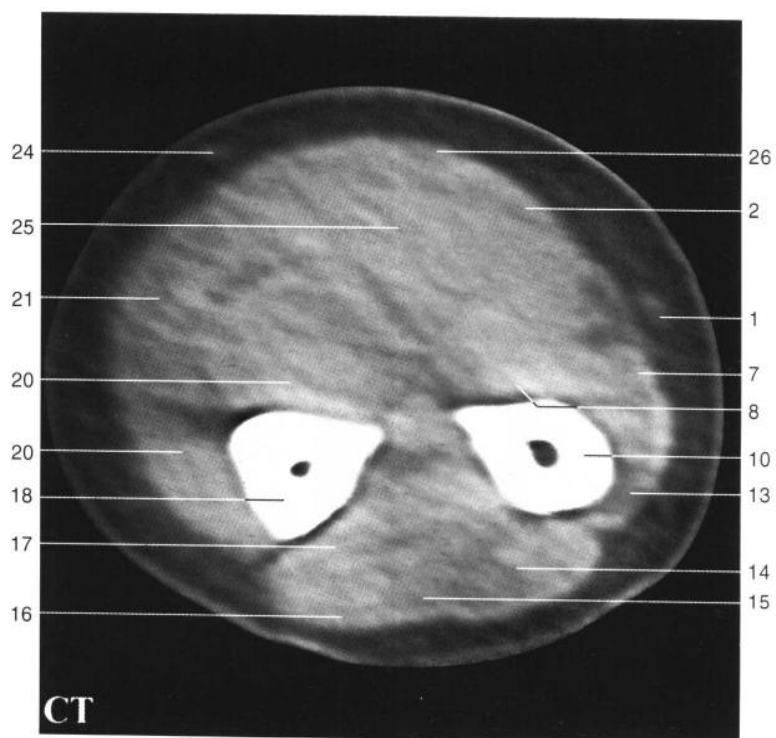


Fig. HUL 5

1. 头静脉 cephalic v.
2. 桡侧腕屈肌 flexor carpi radialis
3. 桡动, 静脉 radial a. and v.
4. 桡神经浅支 superficial branch of radial n.
5. 正中神经 median n.
6. 旋前圆肌 pronator teres
7. 肱桡肌 brachioradialis
8. 拇长屈肌 flexor pollicis longus
9. 骨间前动, 静脉 anterior interosseous a. and v.
10. 桡骨 radius

Fig. HUL 5

11. 旋后肌 supinator
12. 拇长展肌 abductor pollicis longus
13. 桡侧腕长、短伸肌 extensor carpi radialis longus and brevis
14. 指伸肌 extensor digitorum
15. 小指伸肌 extensor digiti minimi
16. 尺侧腕伸肌 extensor carpi ulnaris
17. 拇长伸肌 extensor pollicis longus
18. 尺骨 ulna
19. 前臂骨间膜 interosseous membrane of forearm
20. 指深屈肌 flexor digitorum profundus
21. 尺侧腕屈肌 flexor carpi ulnaris
22. 尺神经 ulnar n.
23. 尺动、静脉 ulnar a. and v.
24. 贵要静脉 basilic v.
25. 指浅屈肌 flexor digitorum superficialis
26. 掌长肌 palmaris longus
27. 前臂正中静脉 median antebrachial v.



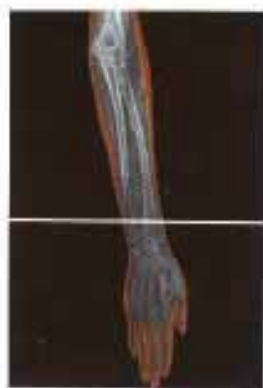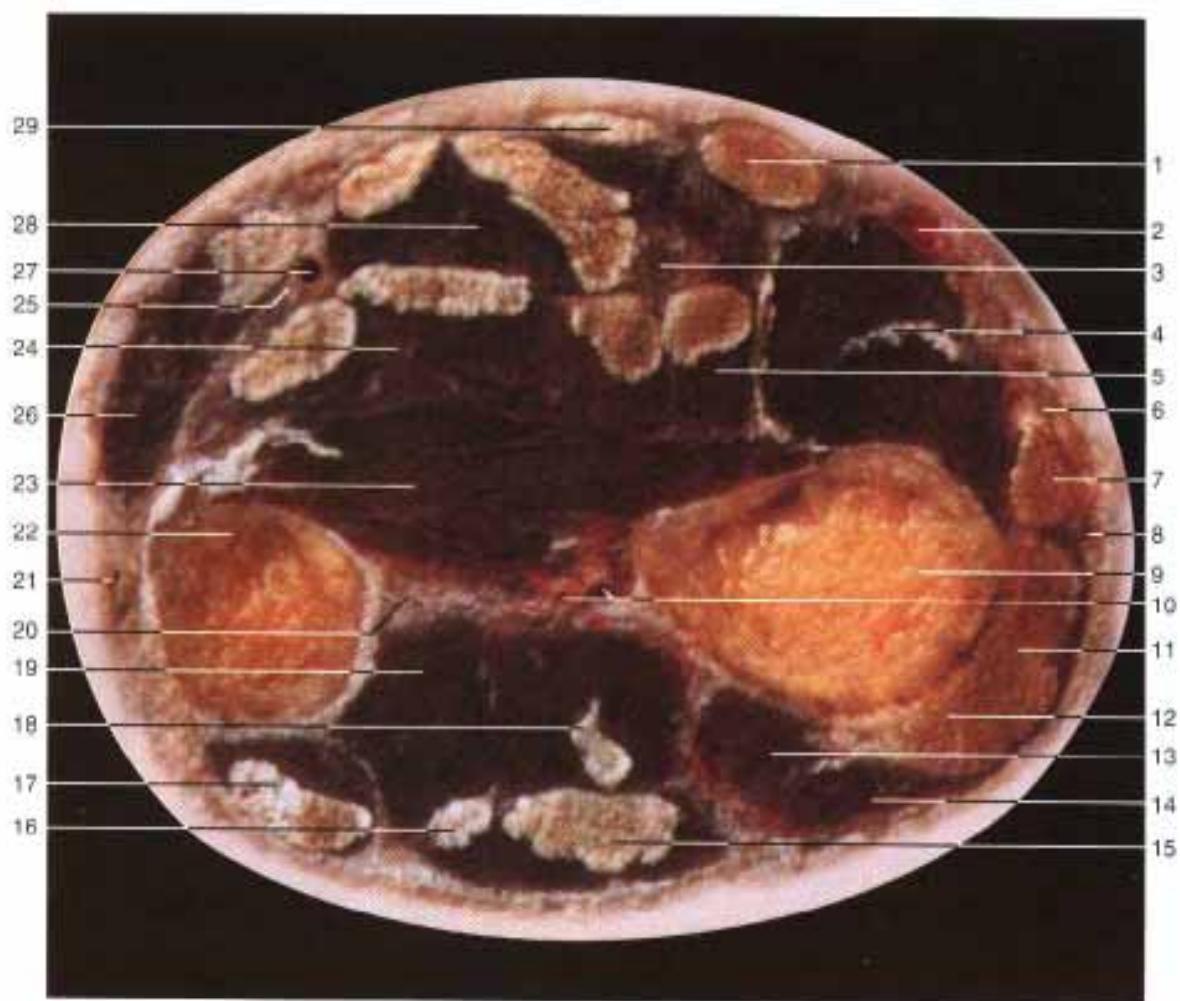
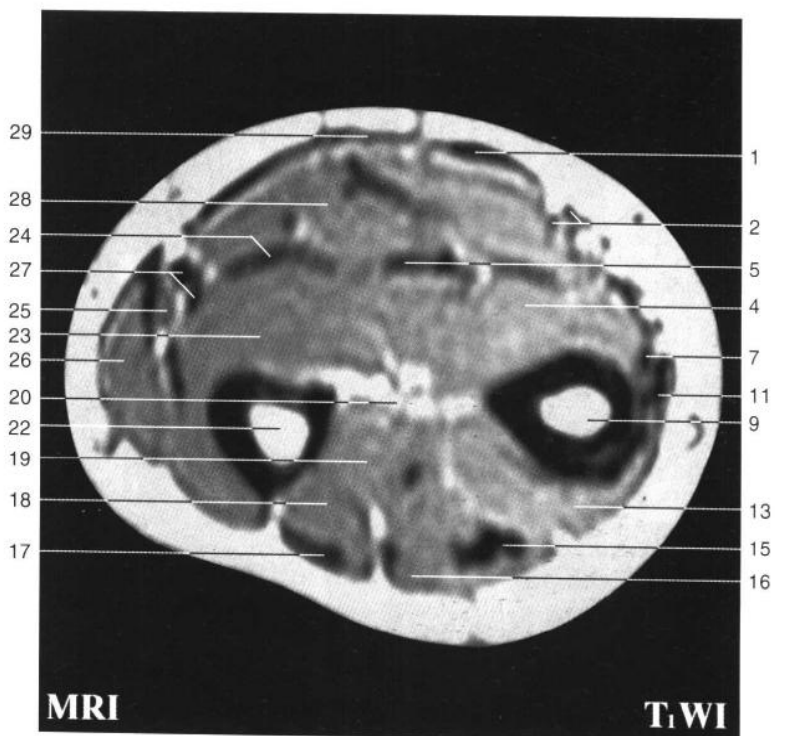

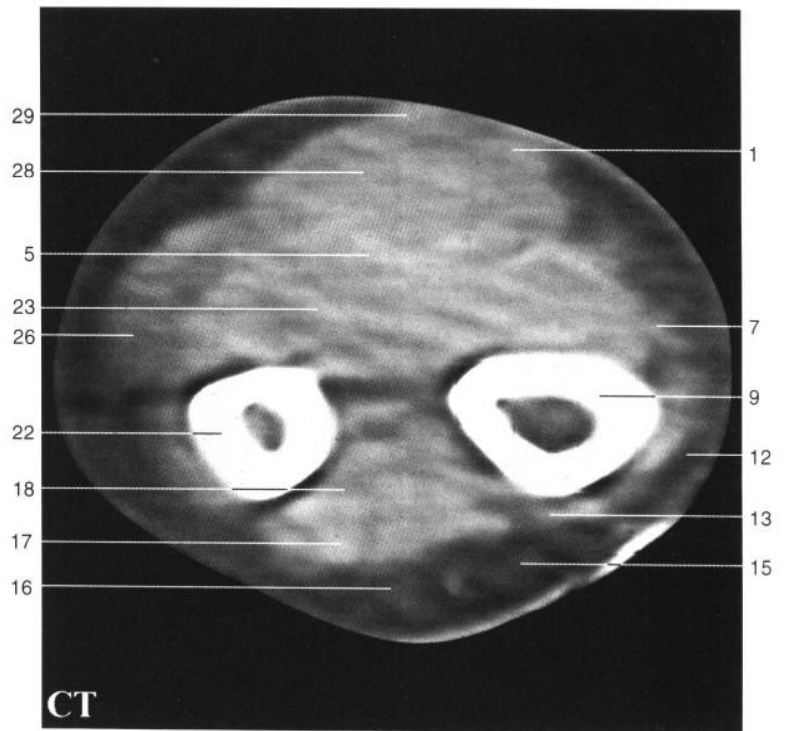
Fig. HUL 6

1. 桡侧腕屈肌 flexor carpi radialis
2. 桡动脉, 静脉 radial a. and v.
3. 正中神经 median n.
4. 拇长屈肌 flexor pollicis longus
5. 指深屈肌 flexor digitorum profundus
6. 桡神经浅支 superficial branch of radial n.
7. 旋前圆肌 tendon of brachioradialis
8. 头静脉 cephalic v.
9. 桡骨 radius
10. 骨间前动, 静脉 anterior interosseous a. and v.

Fig. HUL 6

11. 桡侧腕长伸肌腱 tendon of extensor carpi radialis longus
12. 桡侧腕短伸肌腱 tendon of extensor carpi radialis brevis
13. 拇长展肌腱 tendon of abductor pollicis longus
14. 拇短伸肌 extensor pollicis brevis
15. 指伸肌腱 tendon of extensor digitorum
16. 小指伸肌腱 tendon of extensor digiti minimi
17. 尺侧腕伸肌 extensor carpi ulnaris
18. 拇长伸肌 extensor pollicis longus
19. 食指伸肌 extensor indicis
20. 前臂骨间膜 interosseous membrane of forearm
21. 贵要静脉 basilic v.
22. 尺骨 ulna
23. 旋前方肌 pronator quadratus
24. 指深屈肌 flexor digitorum profundus
25. 尺神经 ulnar n.
26. 尺侧腕屈肌 flexor carpi ulnaris
27. 尺动、静脉 ulnar a. and v.
28. 指浅屈肌 flexor digitorum superficialis
29. 掌长肌腱 tendon of palmaris longus



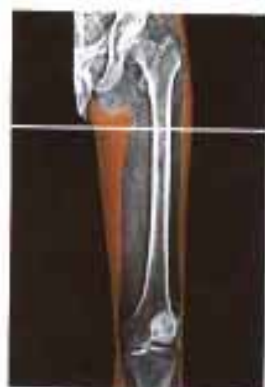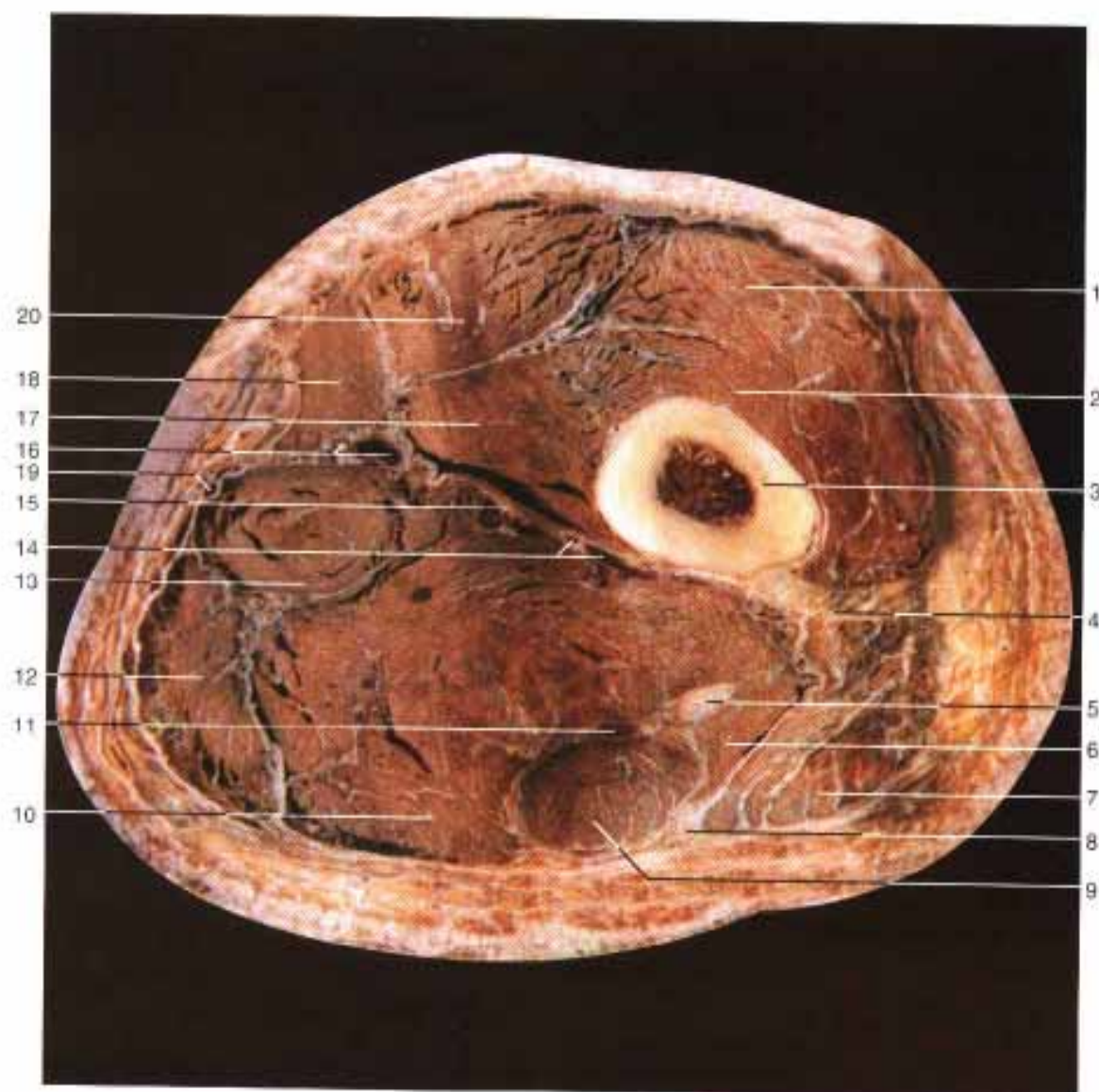
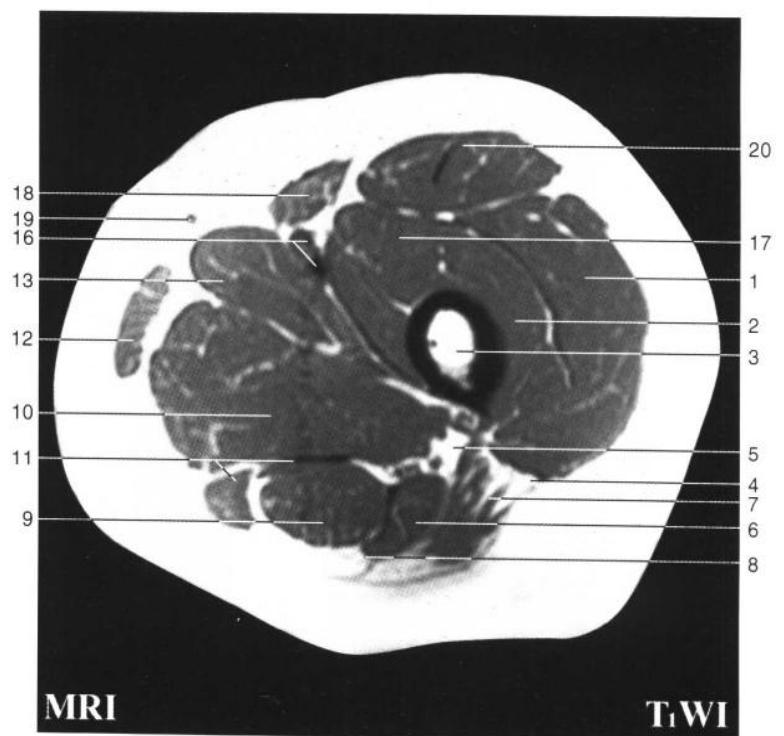
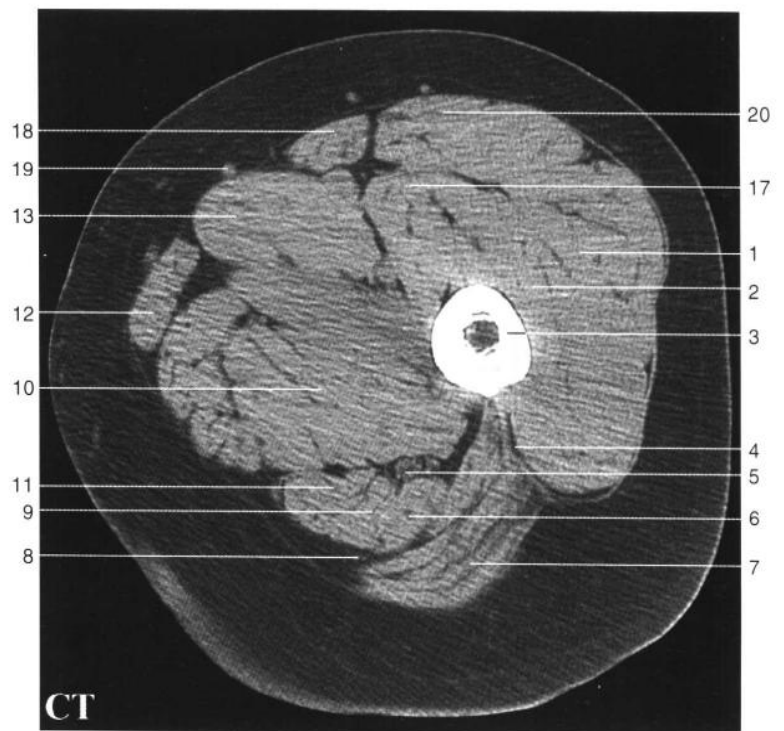


Fig. HLL 1

1. 股外侧肌 vastus lateralis
2. 股中间肌 vastus intermedius
3. 股骨 femur
4. 股外侧肌间隔 lateral femoral intermuscular septum
5. 坐骨神经 sciatic n.
6. 股二头肌长头 long head of biceps femoris
7. 臀大肌 gluteus maximus
8. 股后皮神经 posterior femoral cutaneous n.
9. 半腱肌 semitendinosus
10. 大收肌 adductor magnus

Fig. HLL 1

- 11. 半膜肌 semimembranosus
- 12. 股薄肌 gracilis
- 13. 长收肌 adductor longus
- 14. 股深动、静脉 deep femoral a. and v.
- 15. 股内侧肌间隔 medial femoral intermuscular septum
- 16. 股动、静脉 femoral a. and v.
- 17. 股内侧肌 vastus medialis
- 18. 缝匠肌 sartorius
- 19. 大隐静脉 great saphenous v.
- 20. 股直肌 rectus femoris



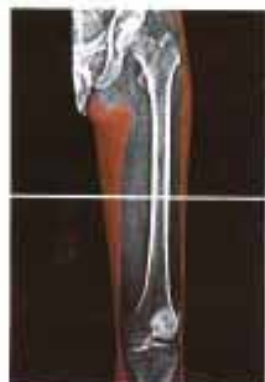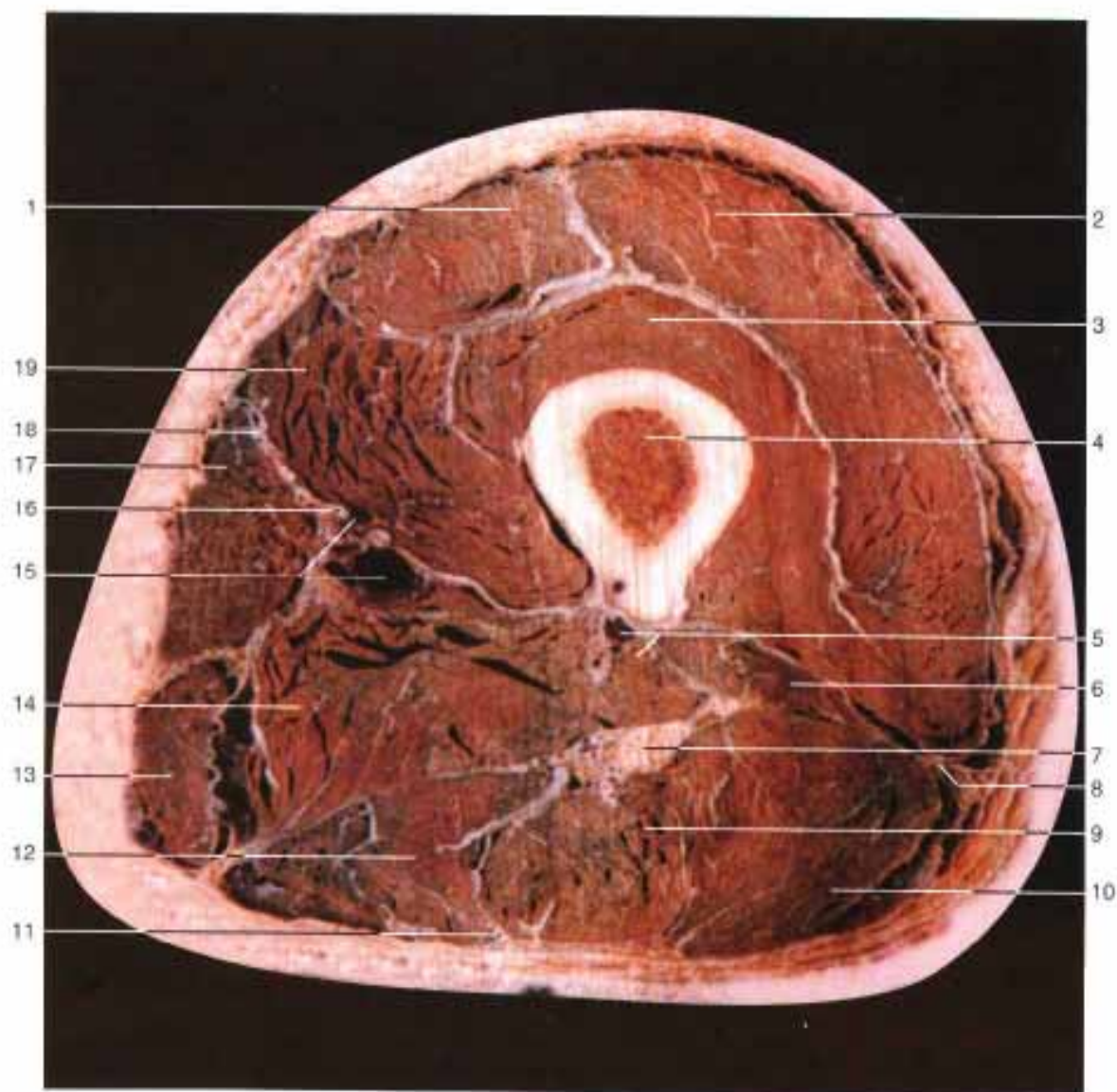
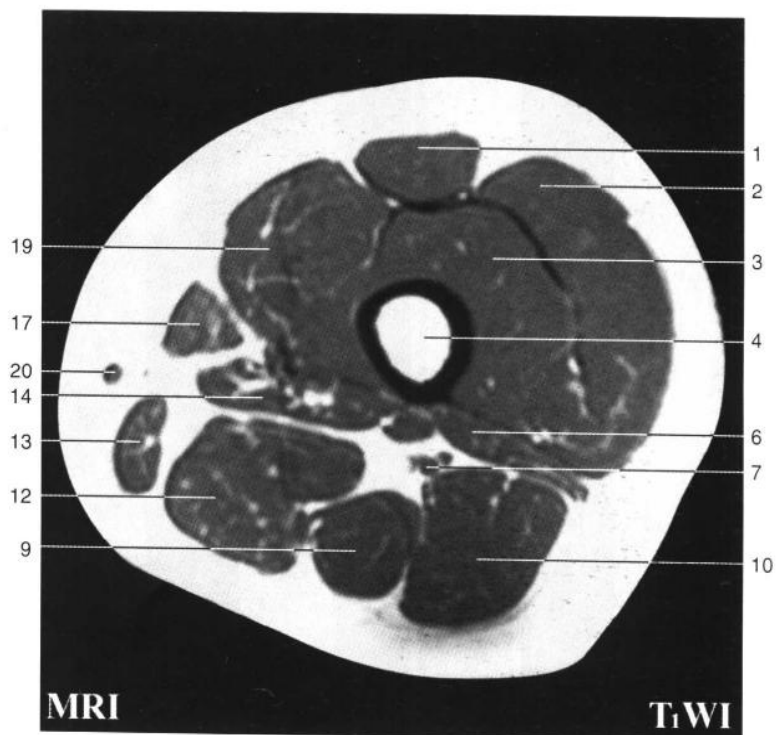
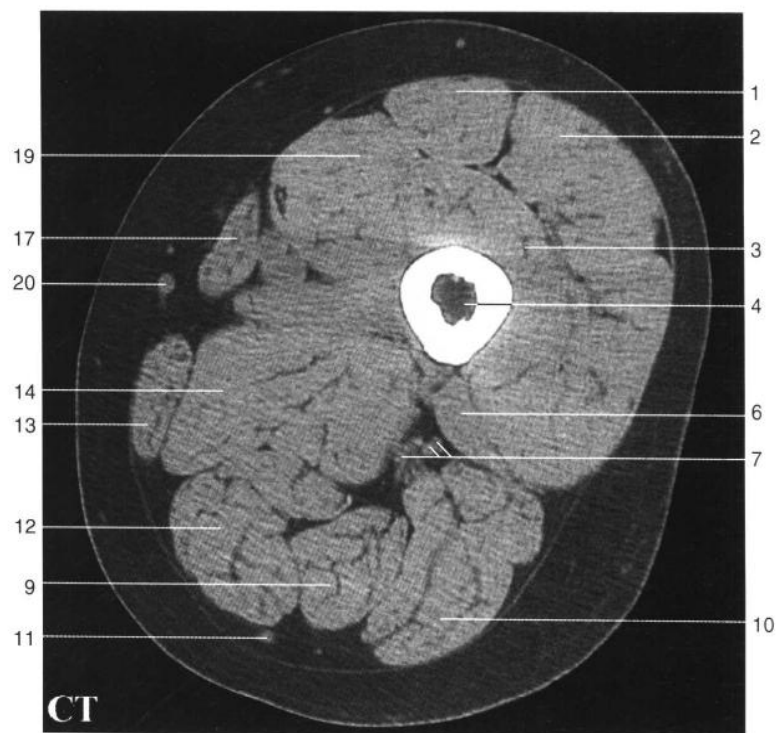


Fig. HLL 2

1. 股直肌 rectus femoris
2. 股外侧肌 vastus lateralis
3. 股中间肌 vastus intermedius
4. 股骨 femur
5. 股深动、静脉 deep femoral a. and v.
6. 股二头肌短头 short head of biceps femoris
7. 坐骨神经及坐骨神经伴行动、静脉 sciatic n. and accompanying a. and v.
8. 股外侧肌间隔 lateral femoral intermuscular septum
9. 半腱肌 semitendinosus

Fig. HLL 2

- 10. 股二头肌长头 long head of biceps femoris
- 11. 股后皮神经 posterior femoral cutaneous n.
- 12. 半膜肌 semimembranosus
- 13. 股薄肌 gracilis
- 14. 大收肌 adductor magnus
- 15. 股动、静脉 femoral a. and v.
- 16. 隐神经 saphenous n.
- 17. 缝匠肌 sartorius
- 18. 股内侧肌间隔 medial femoral intermuscular septum
- 19. 股内侧肌 vastus medialis
- 20. 大隐静脉 great saphenous v.



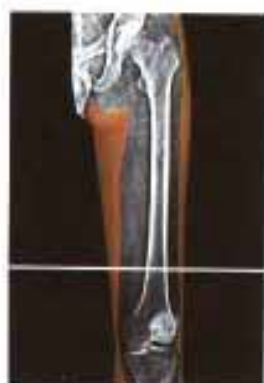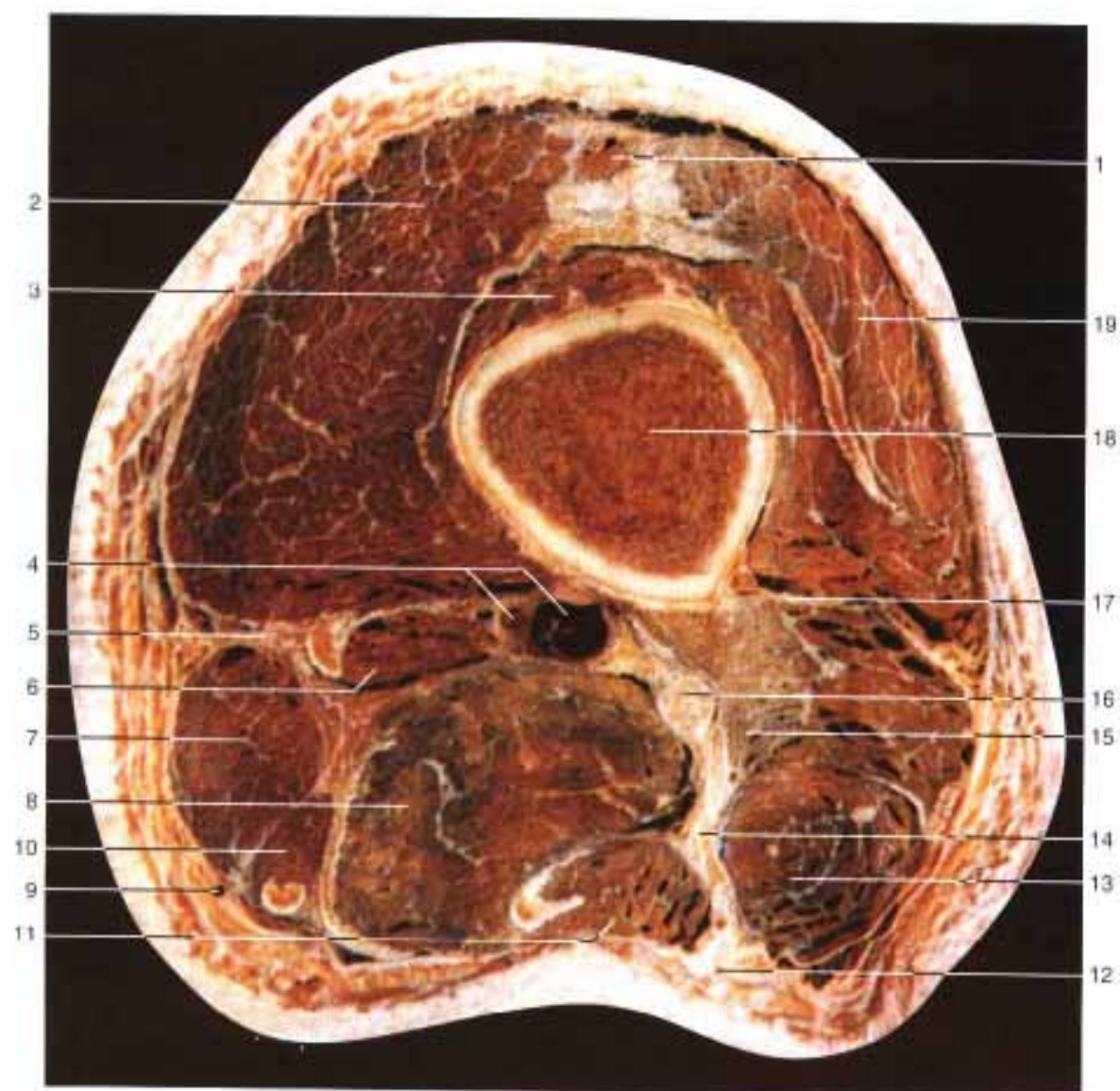
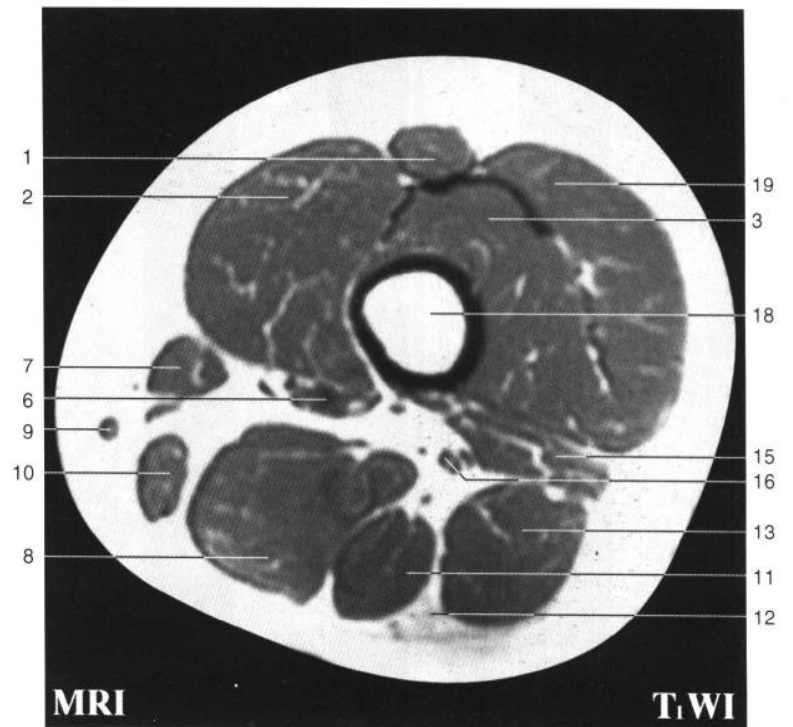
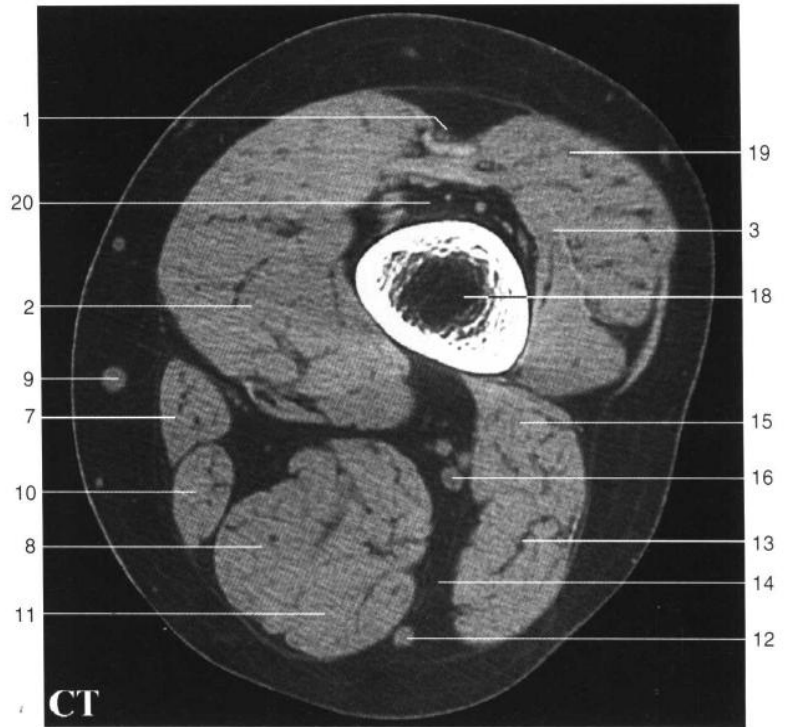


Fig. HLL 3

1. 股直肌 rectus femoris
2. 股内侧肌 vastus medialis
3. 股中间肌 vastus intermedius
4. 股动、静脉 femoral a. and v.
5. 股内侧肌间隔 medial femoral intermuscular septum
6. 大收肌 adductor magnus
7. 缝匠肌 sartorius
8. 半膜肌 semimembranosus
9. 大隐静脉 great saphenous v.

Fig. HLL 3

- 10. 股薄肌 gracilis
- 11. 半腱肌 semitendinosus
- 12. 股后皮神经 posterior femoral cutaneous n.
- 13. 股二头肌长头 long head of biceps femoris
- 14. 股后肌间隔 posterior femoral intermuscular septum
- 15. 股二头肌短头 short head of biceps femoris
- 16. 坐骨神经 sciatic n.
- 17. 股外侧肌间隔 lateral femoral intermuscular septum
- 18. 股骨 femur
- 19. 股外侧肌 vastus lateralis
- 20. 髌上囊 suprapatellar bursa



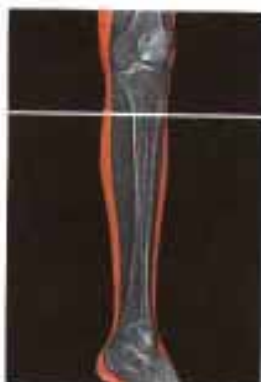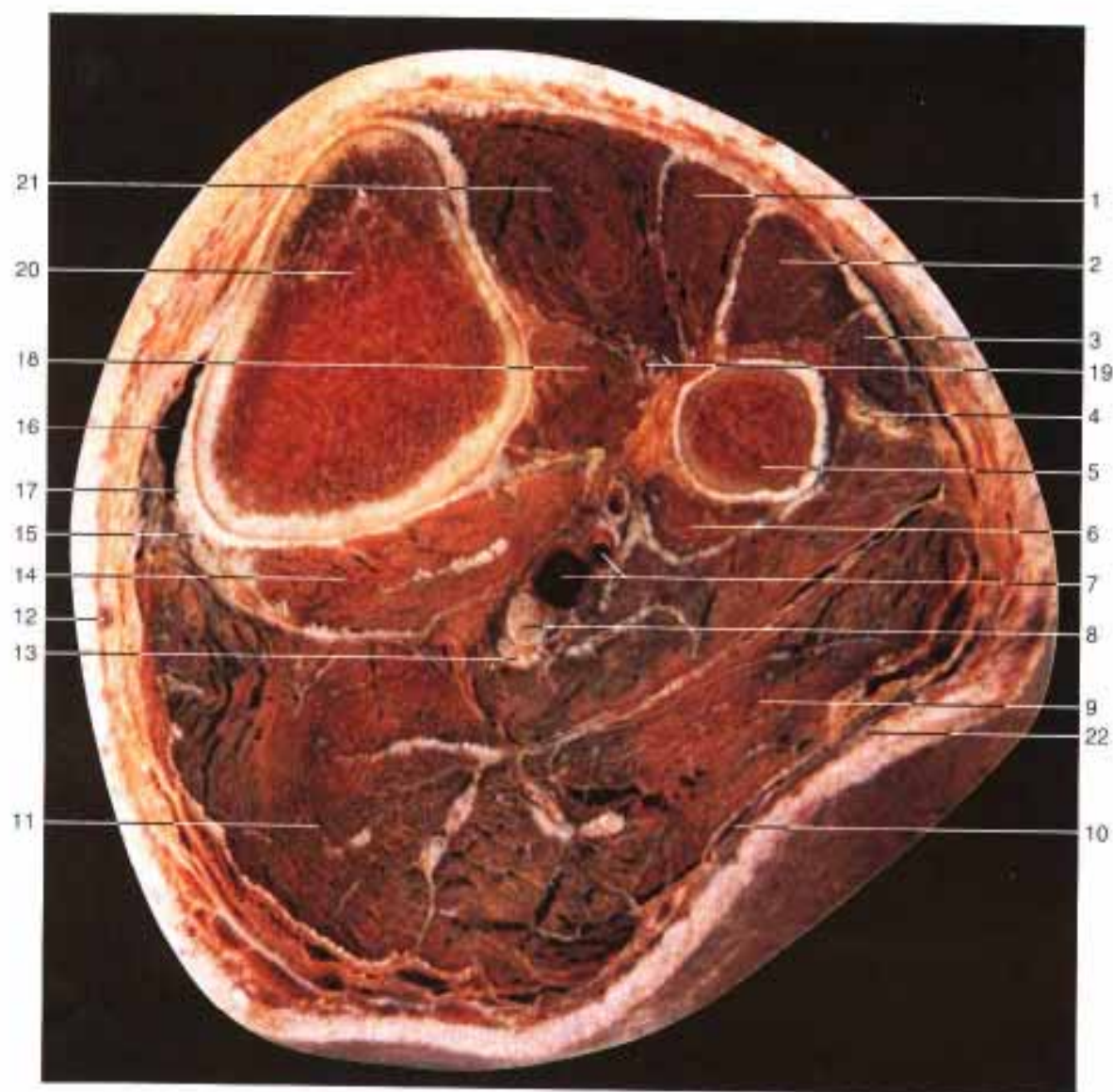
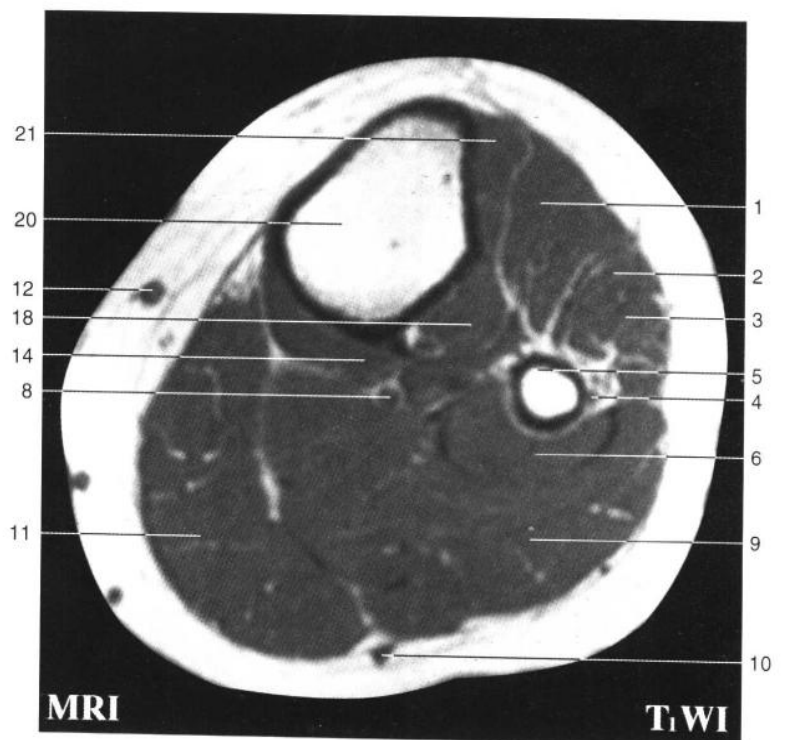
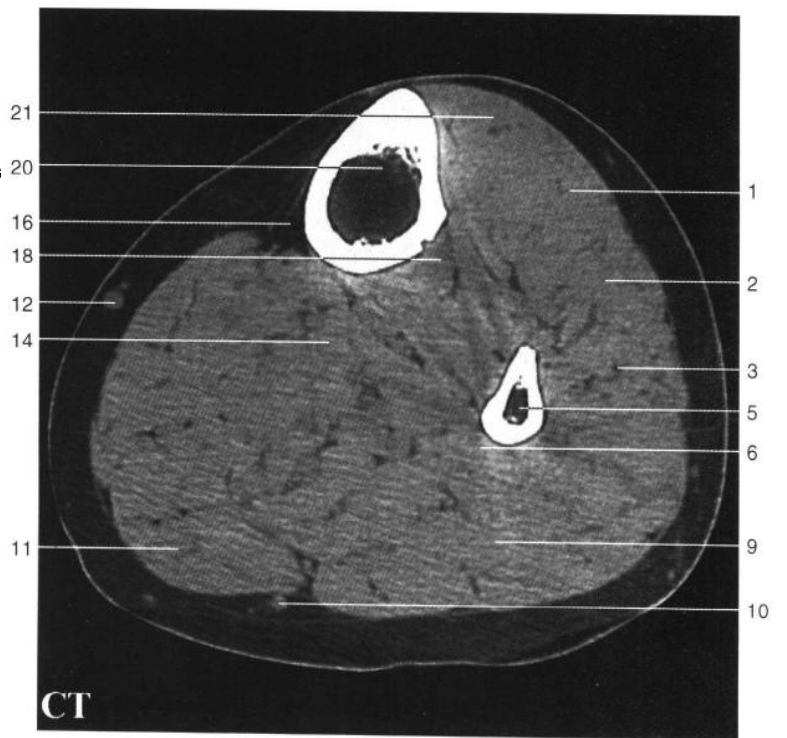


Fig. HLL 4

1. 趾长伸肌 extensor digitorum longus
2. 腓骨长肌 peroneus longus
3. 腓骨短肌 peroneus brevis
4. 腓总神经 common peroneal n.
5. 腓骨 fibula
6. 比目鱼肌 soleus
7. 胫后动、静脉 posterior tibial a. and v.
8. 胫神经 tibial n.
9. 腓肠肌外侧头 lateral head of gastrocnemius
10. 小隐静脉 small saphenous v.

Fig. HLL 4

- 11. 腓肠肌内侧头 medial head of gastrocnemius
- 12. 大隐静脉 great saphenous v.
- 13. 跖肌 plantaris
- 14. 腘肌 popliteus
- 15. 半膜肌、半腱肌腱 tendon of semimembranosus and semitendinosus
- 16. 鹅足囊 anserine bursa
- 17. 缝匠肌、股薄肌腱 tendon of sartorius and gracilis
- 18. 胫骨后肌 tibialis posterior
- 19. 胫前动、静脉 anterior tibial a. and v.
- 20. 胫骨 tibia
- 21. 胫骨前肌 tibialis anterior
- 22. 腓肠外侧皮神经 lateral sural cutaneous n.



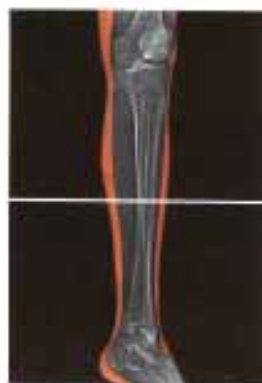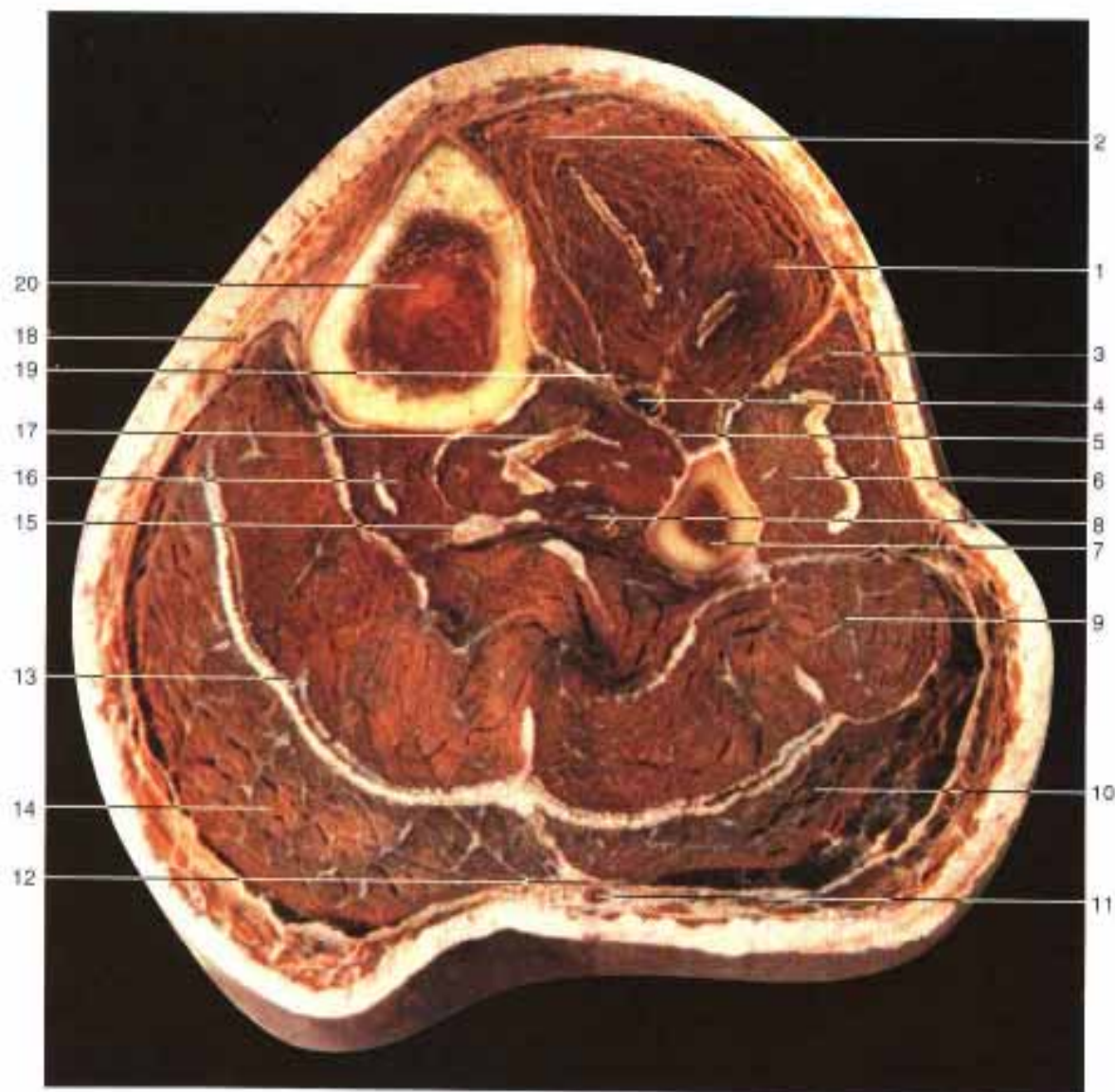
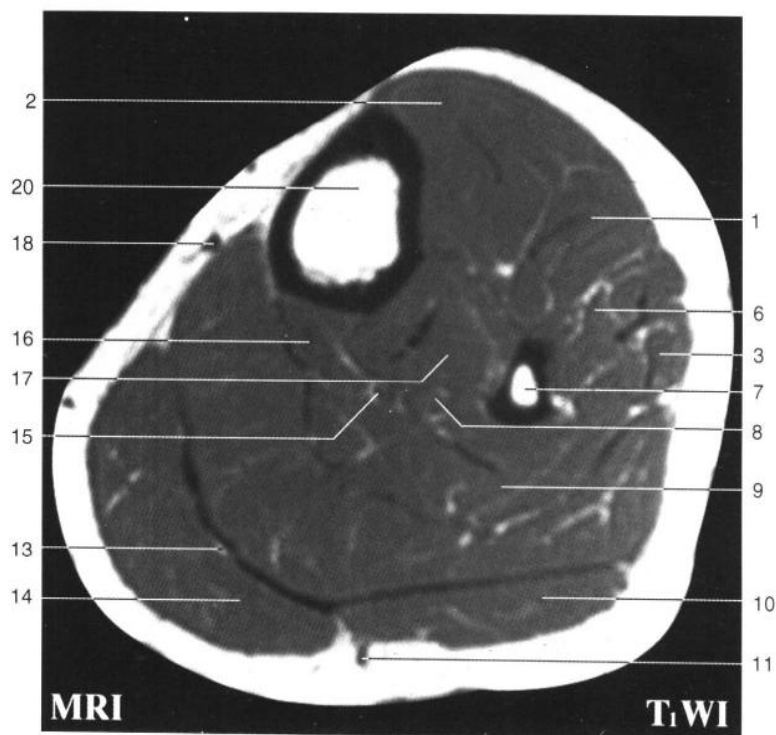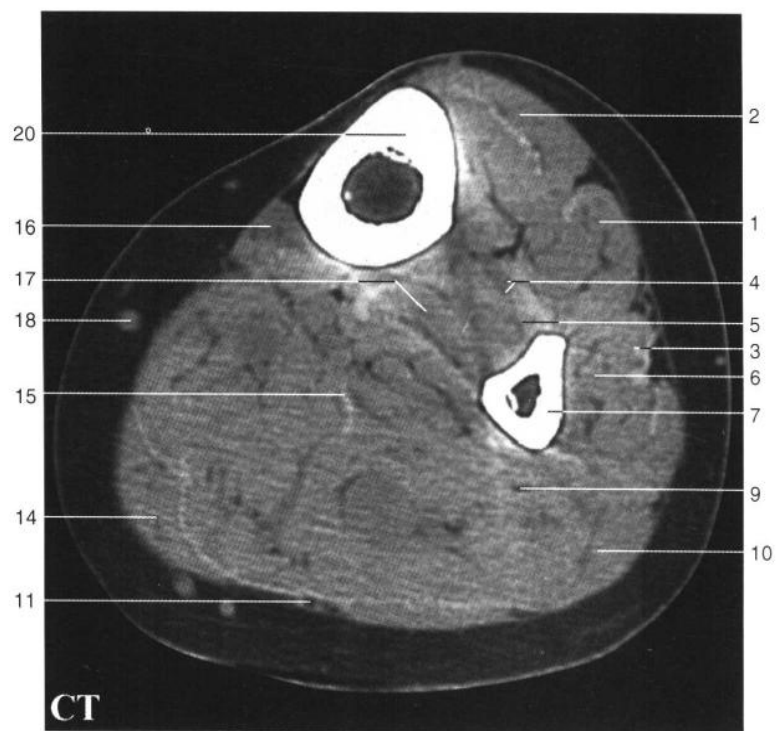


Fig. HLL 5

1. 趾长伸肌 extensor digitorum longus
2. 胫骨前肌 tibialis anterior
3. 腓骨长肌 peroneus longus
4. 胫前动、静脉 anterior tibial a. and v.
5. 小腿骨间膜 crural interosseous membrane
6. 腓骨短肌 peroneus brevis
7. 腓骨 fibula
8. 胫后动、静脉 posterior tibial a. and v.
9. 比目鱼肌 soleus
10. 腓肠肌外侧头 lateral head of gastrocnemius

Fig. HLL 5

- 11. 小隐静脉 small saphenous v.
- 12. 腓肠内侧皮神经 medial sural cutaneous n.
- 13. 跖肌腱 tendon of plantaris
- 14. 腓肠肌内侧头 medial head of gastrocnemius
- 15. 胫神经 tibial n.
- 16. 趾长屈肌 flexor digitorum longus
- 17. 胫骨后肌 tibialis posterior
- 18. 大隐静脉 great saphenous v.
- 19. 腓深神经 deep peroneal n.
- 20. 胫骨 tibia



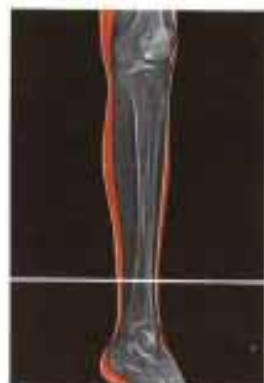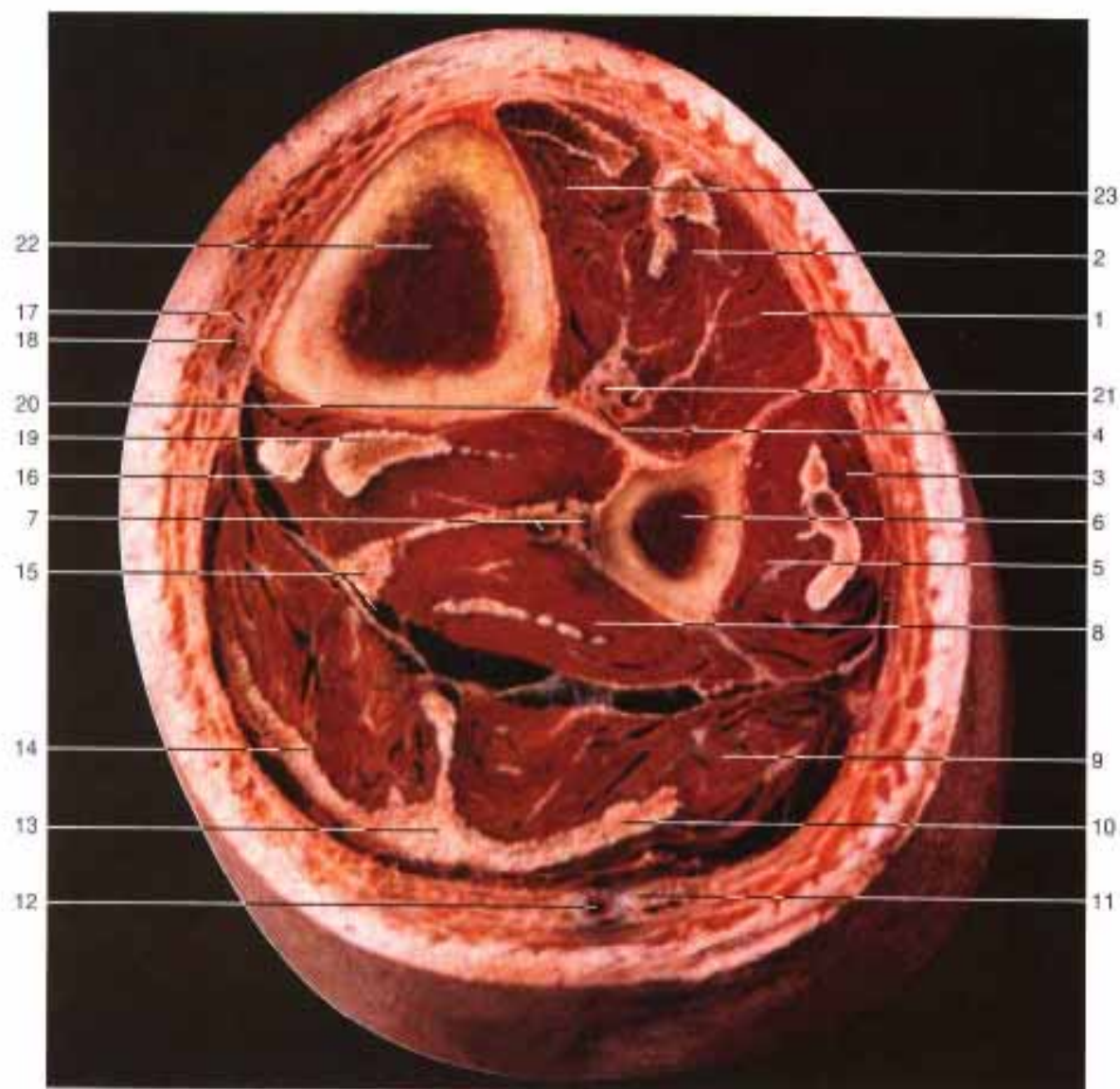
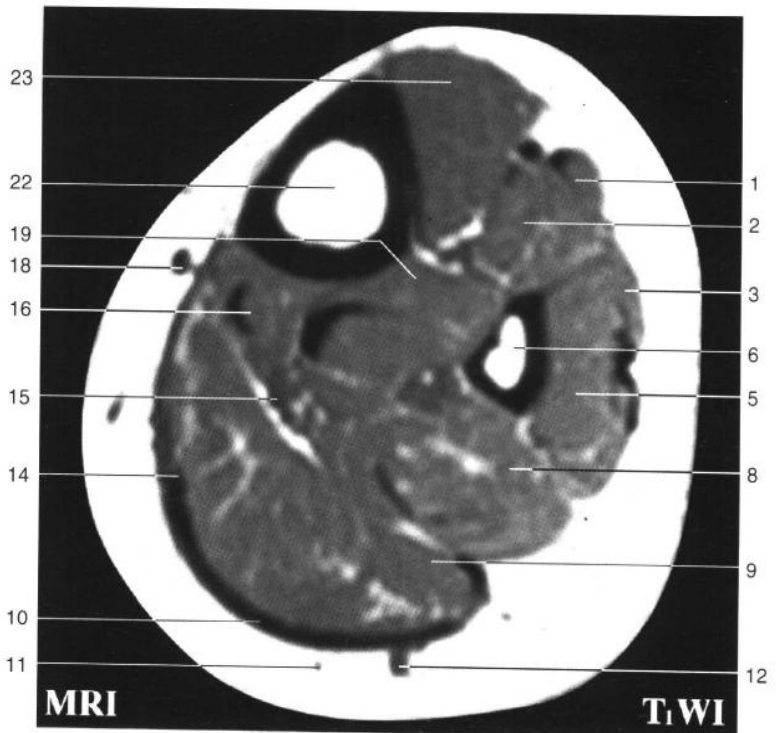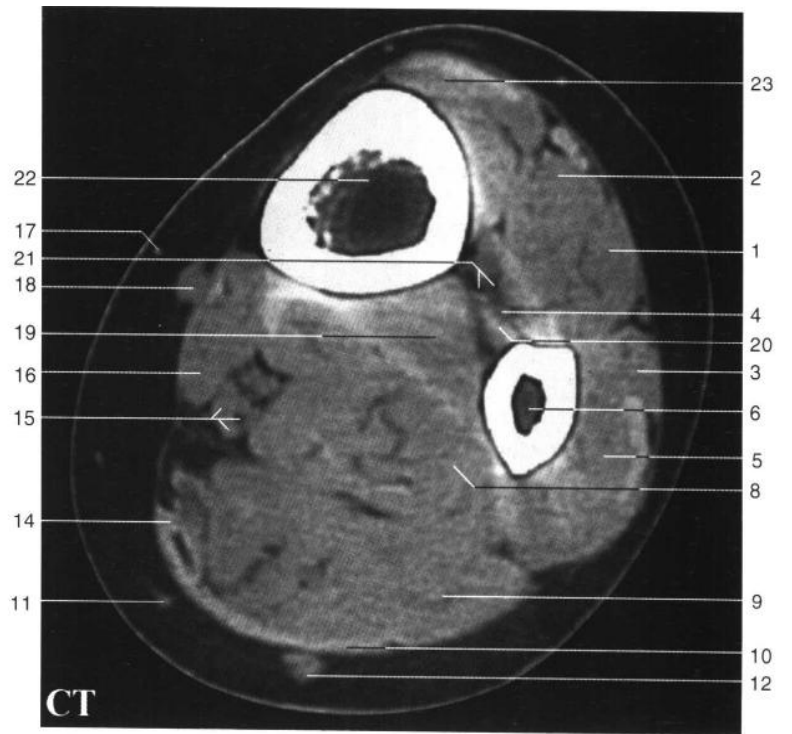


Fig. HLL 6

1. 趾长伸肌 extensor digitorum longus
2. 趾长伸肌 extensor hallucis longus
3. 腓骨长肌 peroneus longus
4. 腓深神经 deep peroneal n.
5. 腓骨短肌 peroneus brevis
6. 腓骨 fibula
7. 腓动、静脉 peroneal a. and v.
8. 趾长屈肌 flexor hallucis longus
9. 比目鱼肌 soleus
10. 腓肠肌腱 tendon of gastrocnemius

Fig. HLL 6

- 11. 腓肠神经 sural n.
- 12. 小隐静脉 small saphenous v.
- 13. 腓肠肌腱 tendon of gastrocnemius
- 14. 跖肌腱 tendon of plantaris
- 15. 胫神经与胫后动、静脉 tibial n. and posterior tibial a., v.
- 16. 趾长屈肌 flexor digitorum longus
- 17. 隐神经 saphenous n.
- 18. 大隐静脉 great saphenous v.
- 19. 胫骨后肌 tibialis posterior
- 20. 小腿骨间膜 crural interosseous membrane
- 21. 胫前动、静脉 anterior tibial a. and v.
- 22. 胫骨 tibia
- 23. 胫骨前肌 tibialis anterior



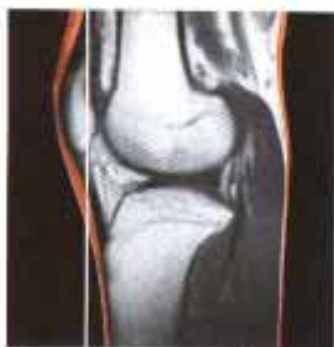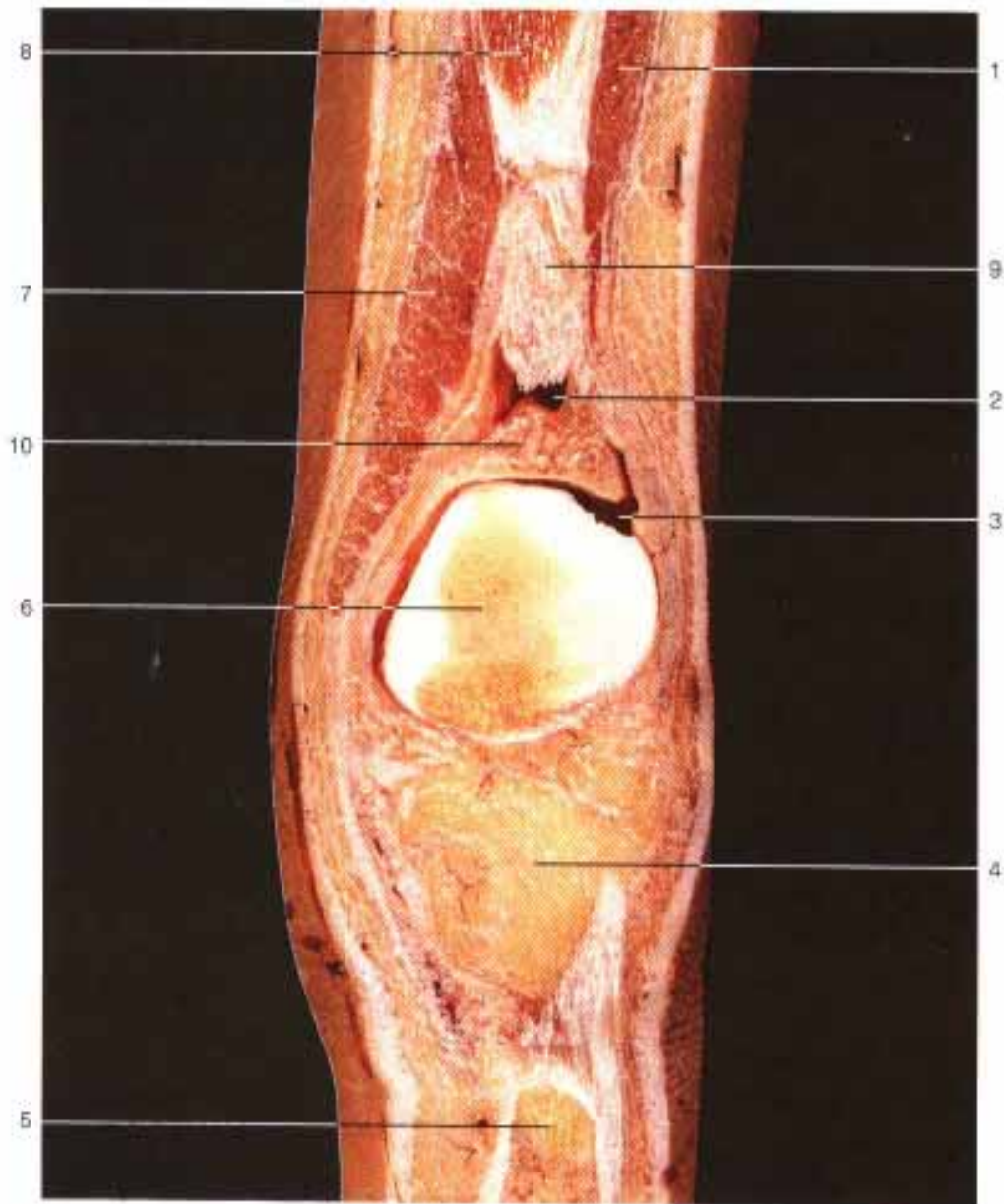
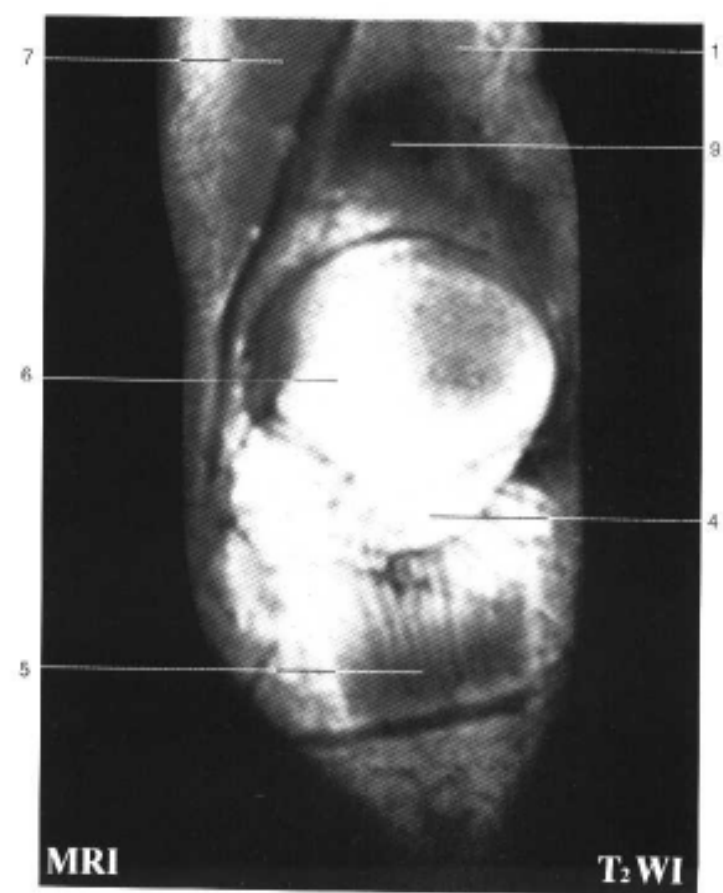
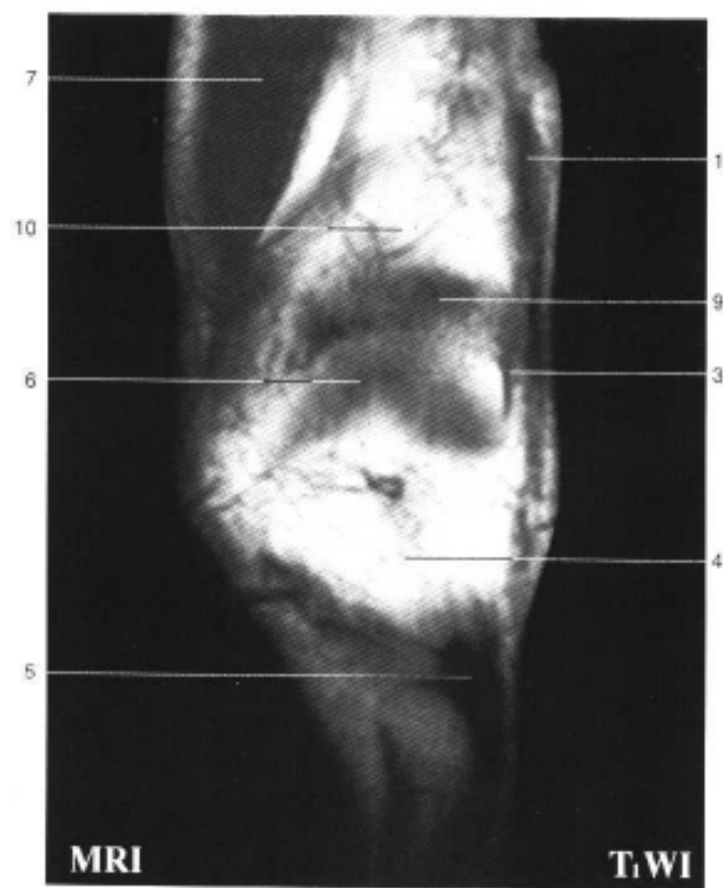


Fig. FK(L) 1

1. 股外侧肌 vastus lateralis
2. 膝上囊 suprapatellar bursa
3. 膝关节腔 articular cavity of knee joint
4. 膝下脂体 infrapatellar fat pad
5. 髌韧带 patellar ligament
6. 髌骨 patella
7. 股内侧肌 vastus medialis
8. 股直肌 rectus femoris
9. 股四头肌腱 tendon of quadriceps femoris
10. 膝上脂体 suprapatellar fat pad

Fig. FK(L) 1



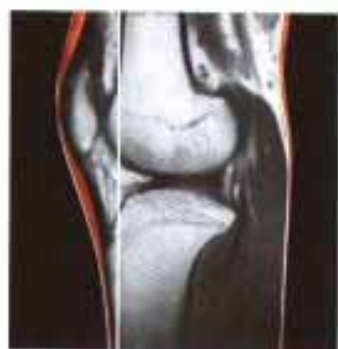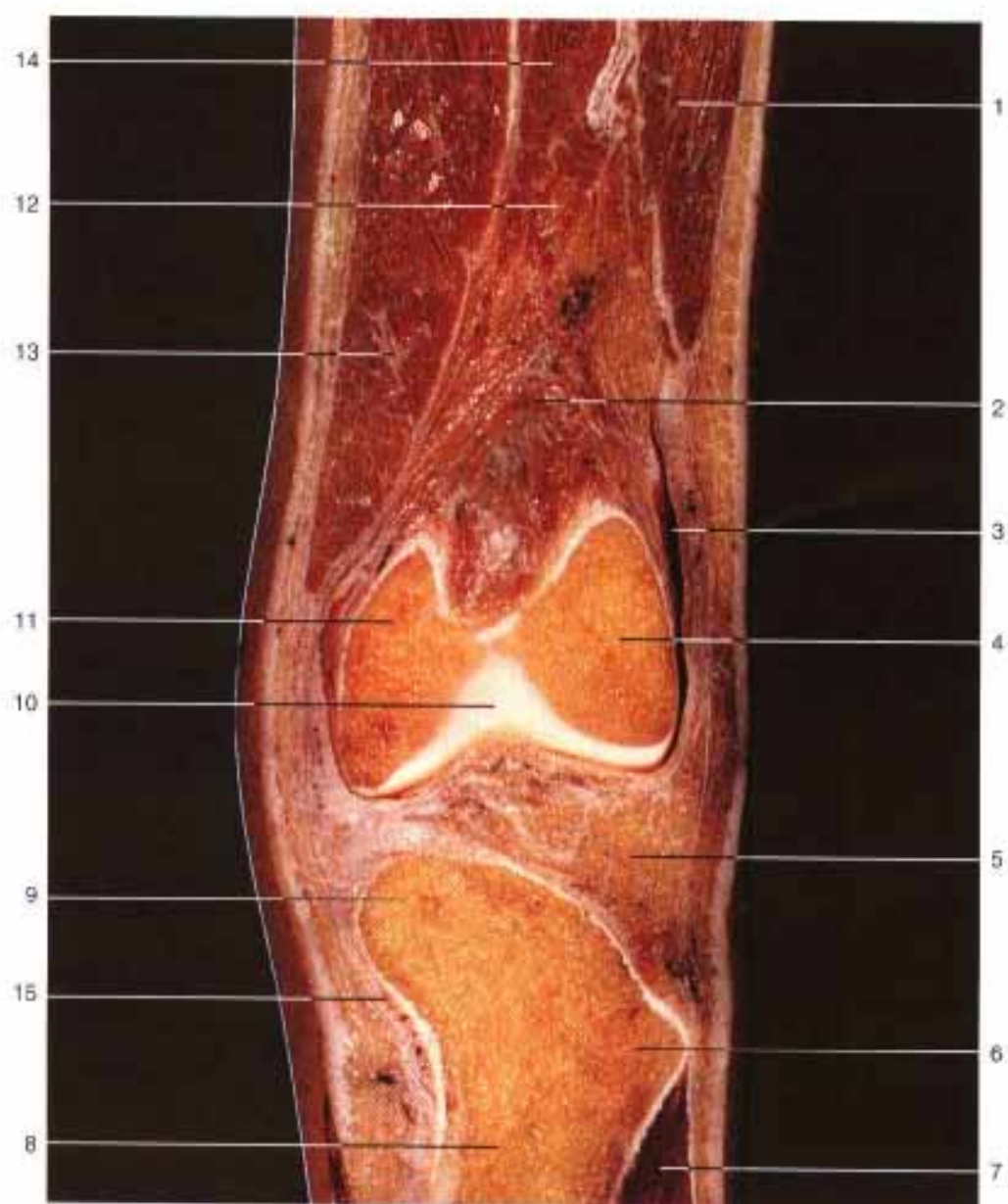
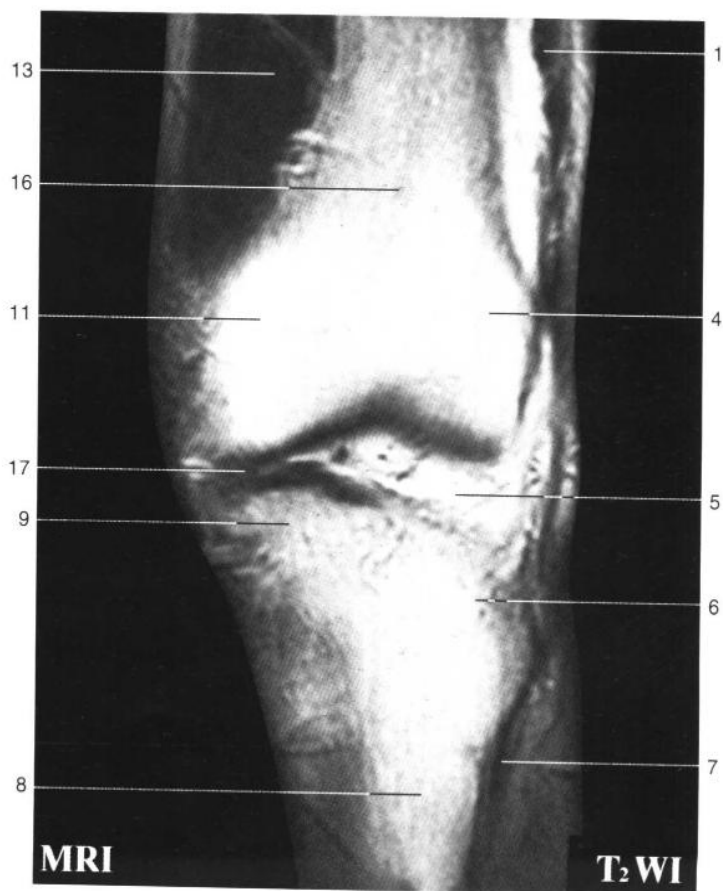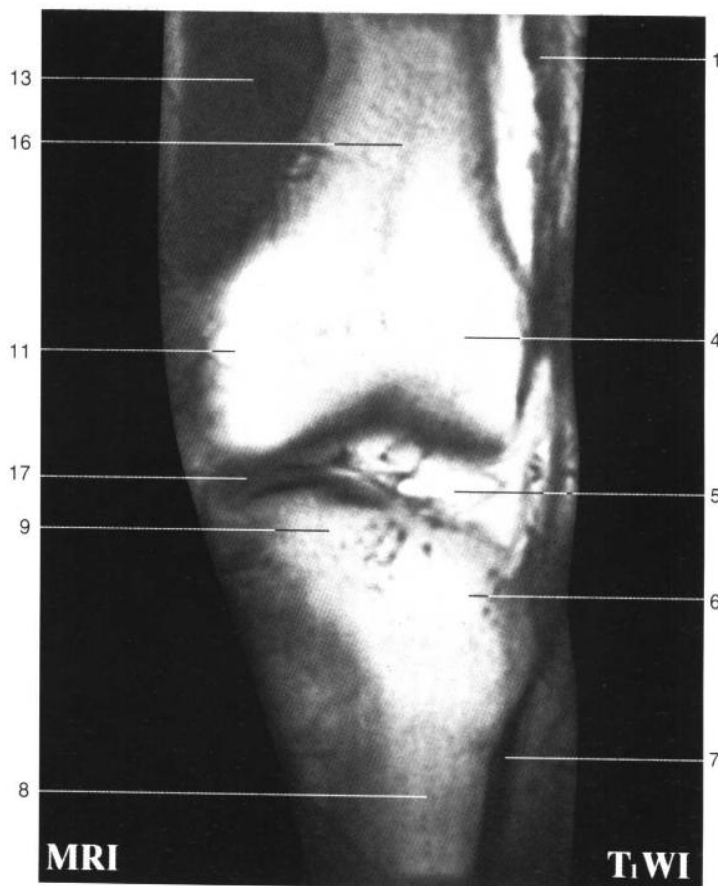


Fig. FK(L) 2

1. 股外侧肌 vastus lateralis
2. 膝关节炎 articularis genus
3. 关节腔 articular cavity
4. 股骨外侧髁 lateral condyle of femur
5. 膝下脂体 infrapatellar fat pad
6. 胫骨外侧髁 lateral condyle of tibia
7. 胫骨前肌 tibialis anterior
8. 胫骨 tibia
9. 胫骨内侧髁 medial condyle of tibia
10. 髌面 patellar surface

Fig. FK(L) 2

- 11. 股骨内侧髁 medial condyle of femur
- 12. 膝关节肌 articularis genus
- 13. 股内侧肌 vastus medialis
- 14. 股中间肌 vastus intermedius
- 15. 缝匠肌与股薄肌腱 tendon of satorius and gracilis
- 16. 股骨 femur
- 17. 内侧半月板 medial meniscus



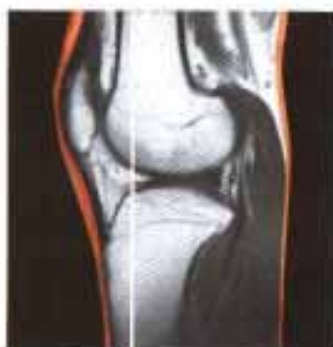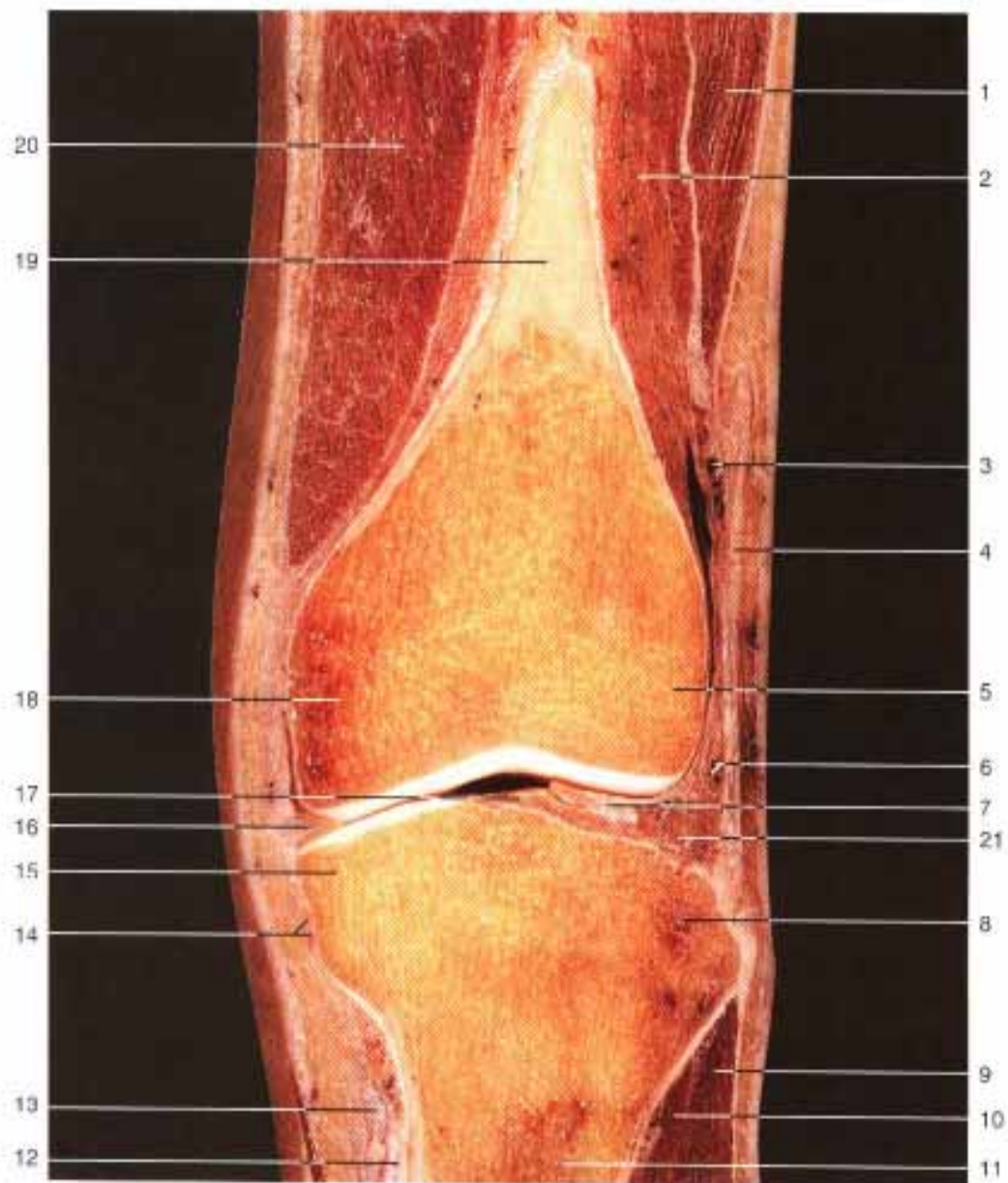
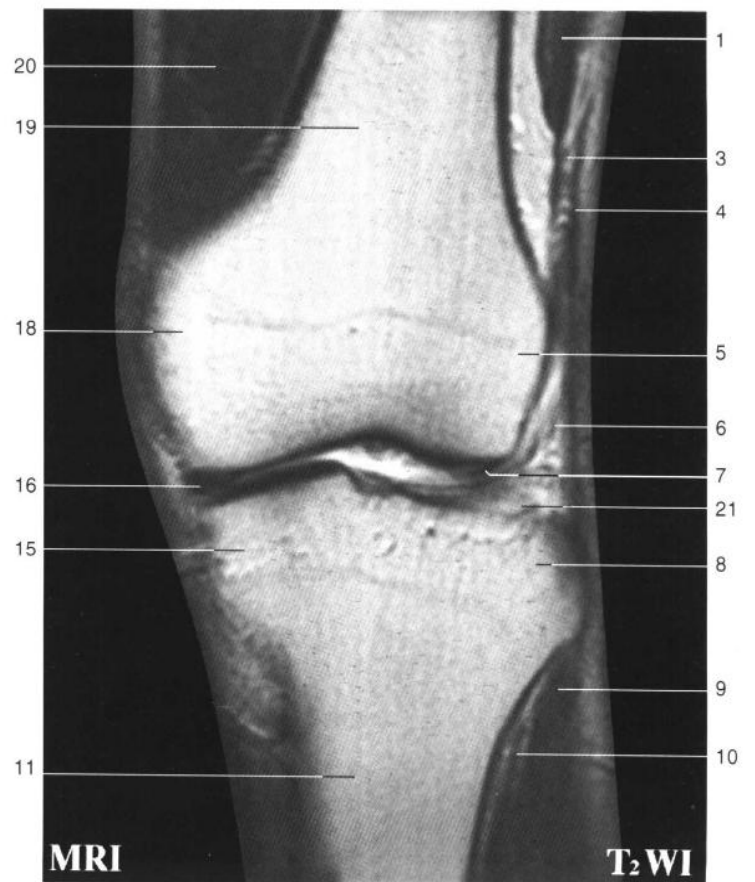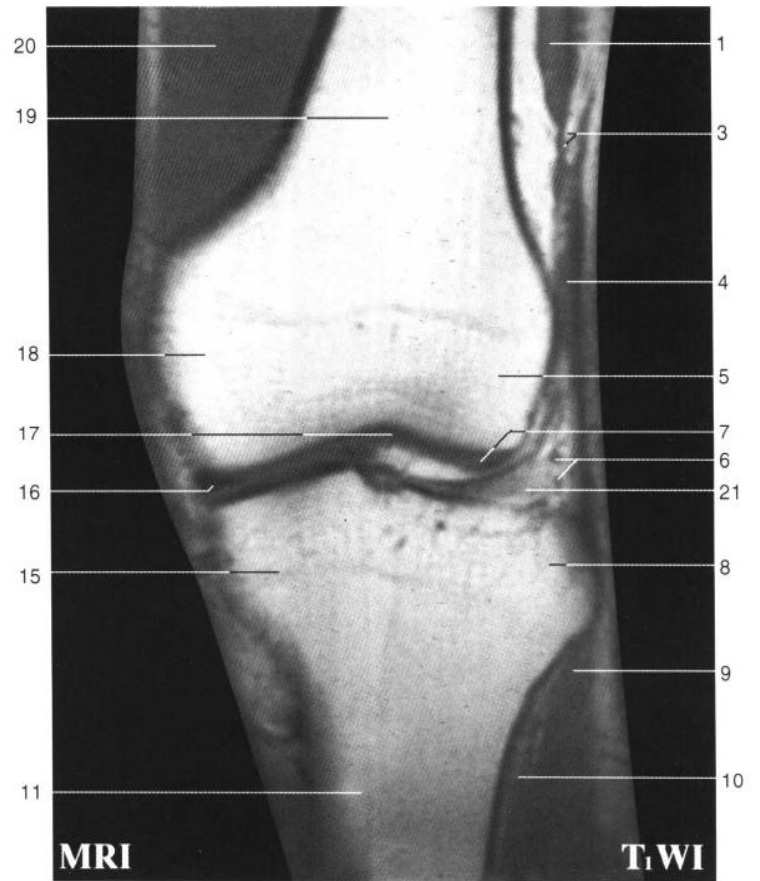


Fig. FK(L) 3

1. 股外侧肌 vastus lateralis
2. 股中间肌 vastus intermedius
3. 膝上外侧动、静脉 lateral superior genicular a. and v.
4. 髂胫束 iliotibial tract
5. 股骨外侧髁 lateral condyle of femur
6. 膝下外侧动、静脉 lateral inferior genicular a. and v.
7. 外侧半月板 lateral meniscus
8. 胫骨外侧髁 lateral condyle of tibia
9. 胫骨前肌 tibialis anterior

Fig. FK(L) 3

- 10. 趾长伸肌 extensor digitorum longus
- 11. 胫骨 tibia
- 12. 半腱肌腱 tendon of semitendinosus
- 13. 半膜肌腱 tendon of semimembranosus
- 14. 缝匠肌及股薄肌腱 tendon of sartorius and gracilis
- 15. 胫骨内侧髁 medial condyle of tibia
- 16. 内侧半月板 medial meniscus
- 17. 膝横韧带 transverse ligament of knee
- 18. 股骨内侧髁 medial condyle of femur
- 19. 股骨 femur
- 20. 股内侧肌 vastus medialis
- 21. 髌下脂体 infrapatellar fat pad



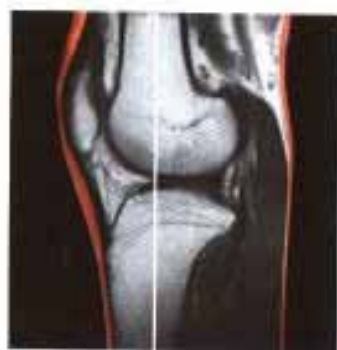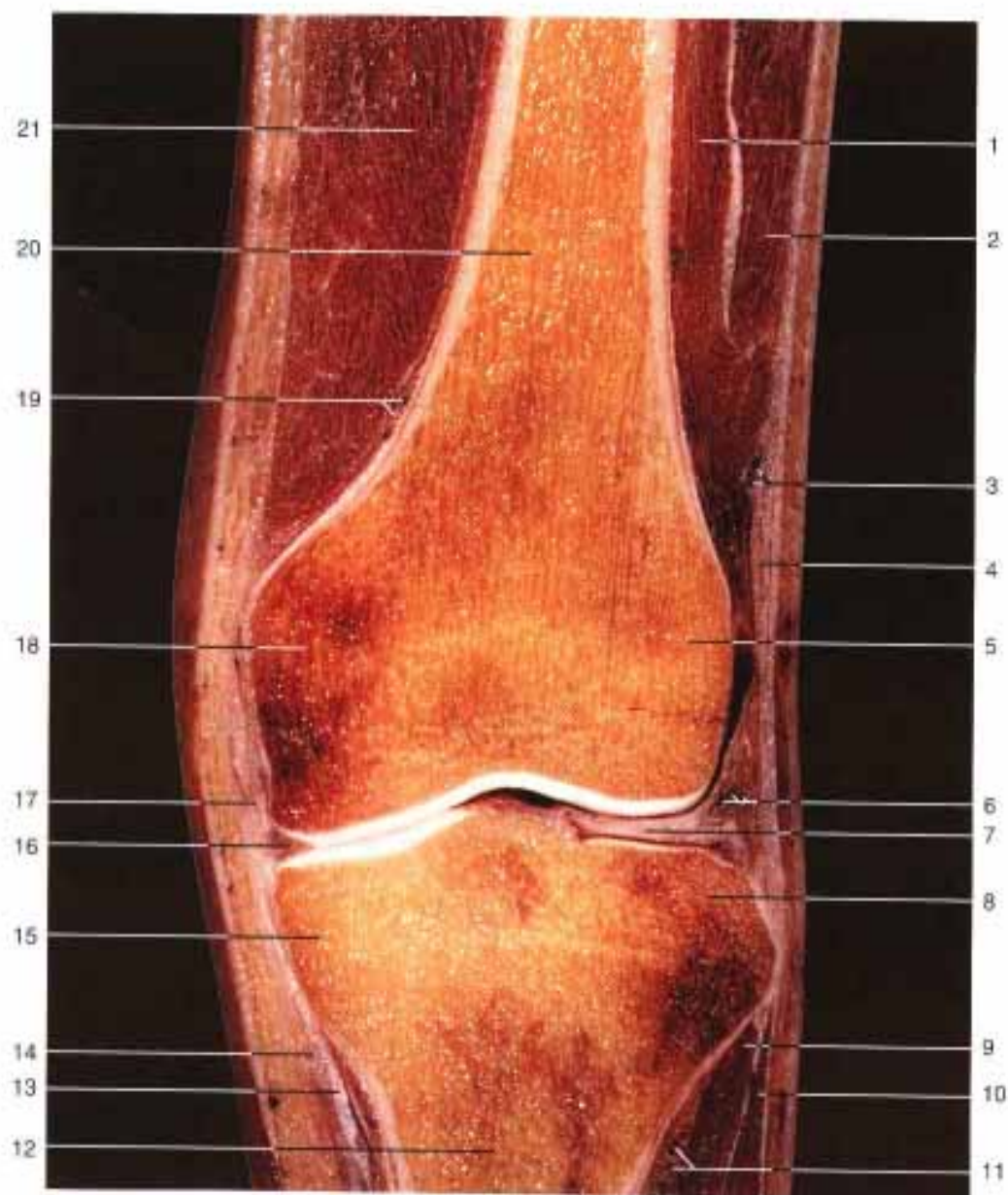


Fig. FK(L) 4

1. 股中间肌 vastus intermedius
2. 股外侧肌 vastus lateralis
3. 膝上外侧动、静脉 lateral superior genicular a. and v.
4. 髁胫束 iliotibial tract
5. 股骨外侧髁 lateral condyle of femur
6. 膝下外侧动、静脉 lateral inferior genicular a. and v.
7. 外侧半月板 lateral meniscus
8. 胫骨外侧髁 lateral condyle of tibia
9. 胫骨前肌 tibialis anterior
10. 趾长伸肌 extensor digitorum longus

Fig. FK(L) 4

- 11. 胫前动、静脉 anterior tibial a. and v.
- 12. 胫骨 tibia
- 13. 半膜肌与半腱肌腱 tendon of semimembranosus and semitendinosus
- 14. 缝匠肌腱 tendon of sartorius
- 15. 胫骨内侧髁 medial condyle of tibia
- 16. 内侧半月板 medial meniscus
- 17. 胫侧副韧带 tibial collateral ligament
- 18. 股骨内侧髁 medial condyle of femur
- 19. 膝上内侧动、静脉 medial superior genicular a. and v.
- 20. 股骨 femur
- 21. 股内侧肌 vastus medialis

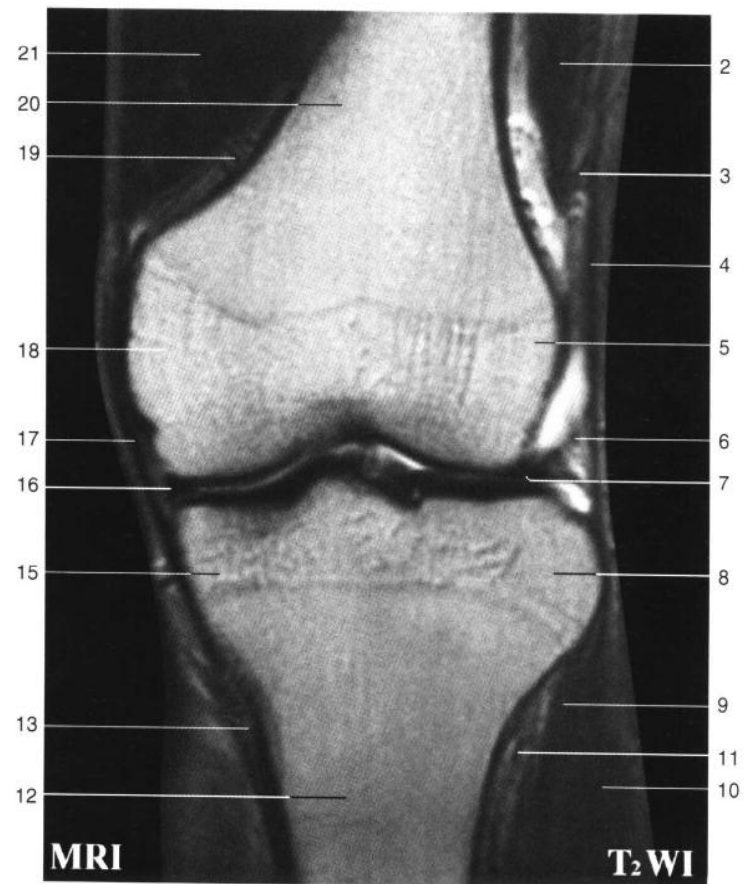
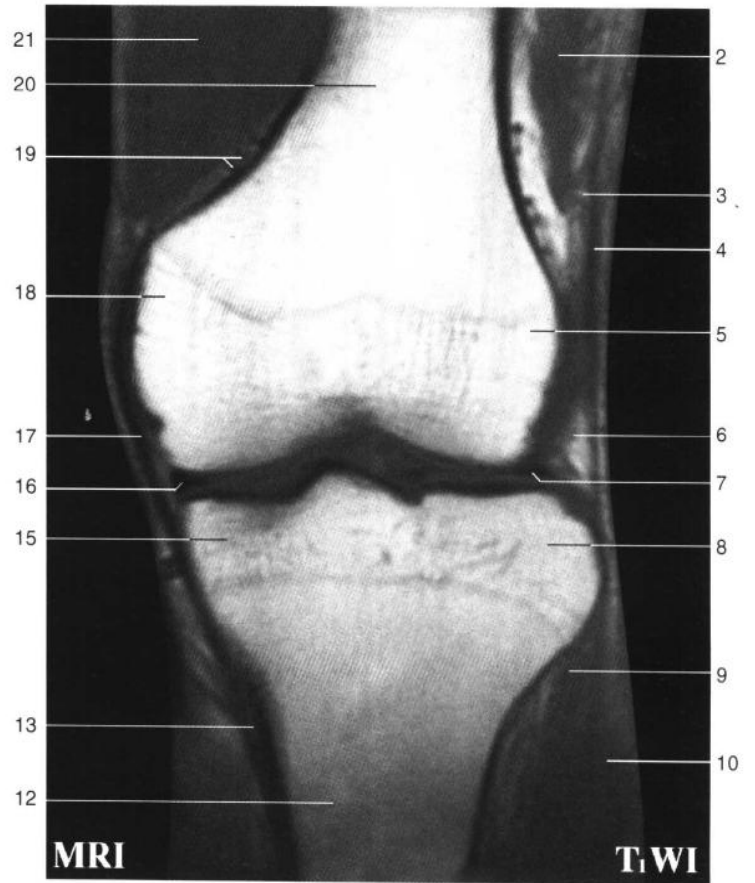
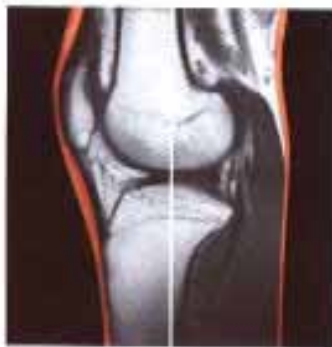
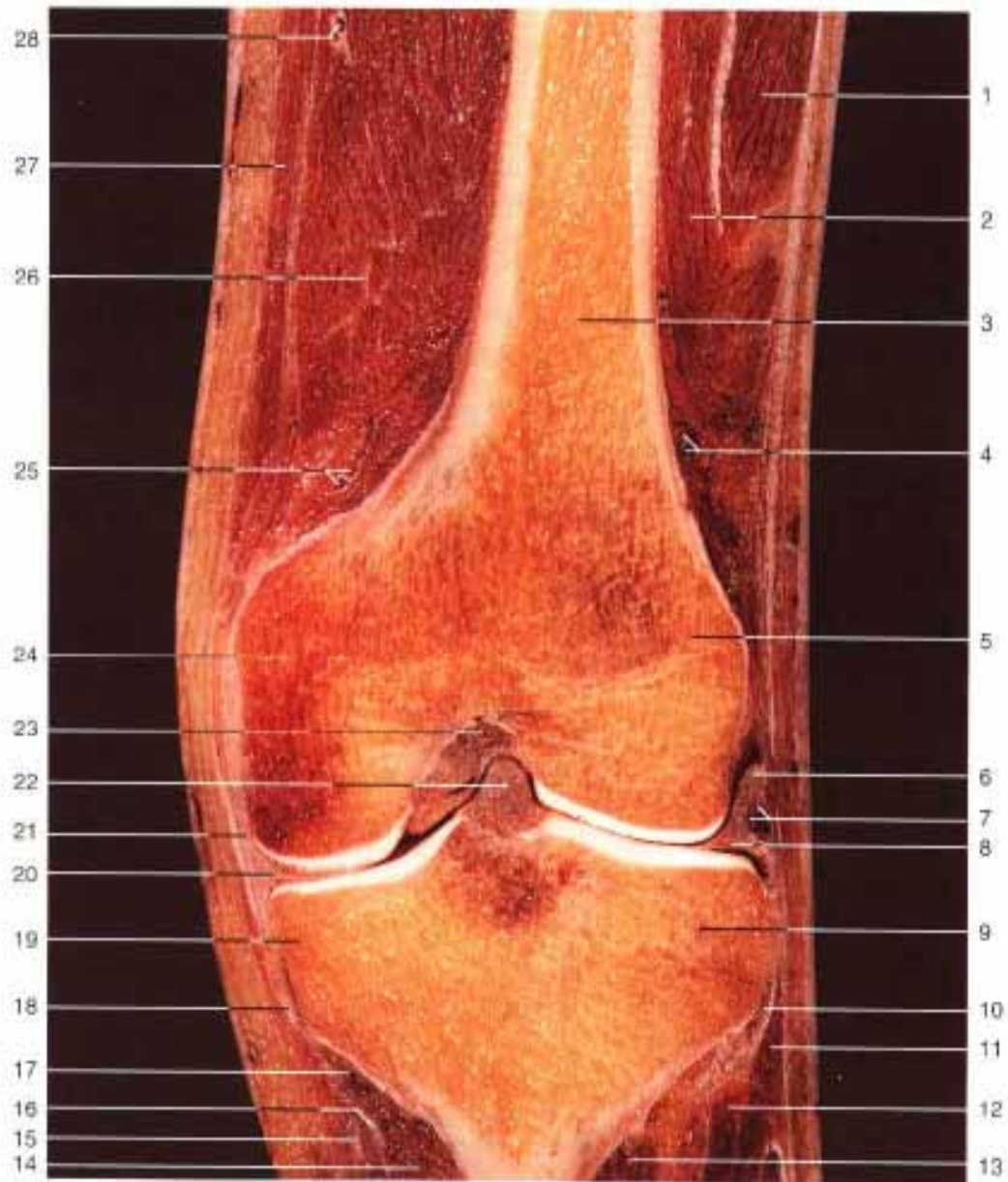
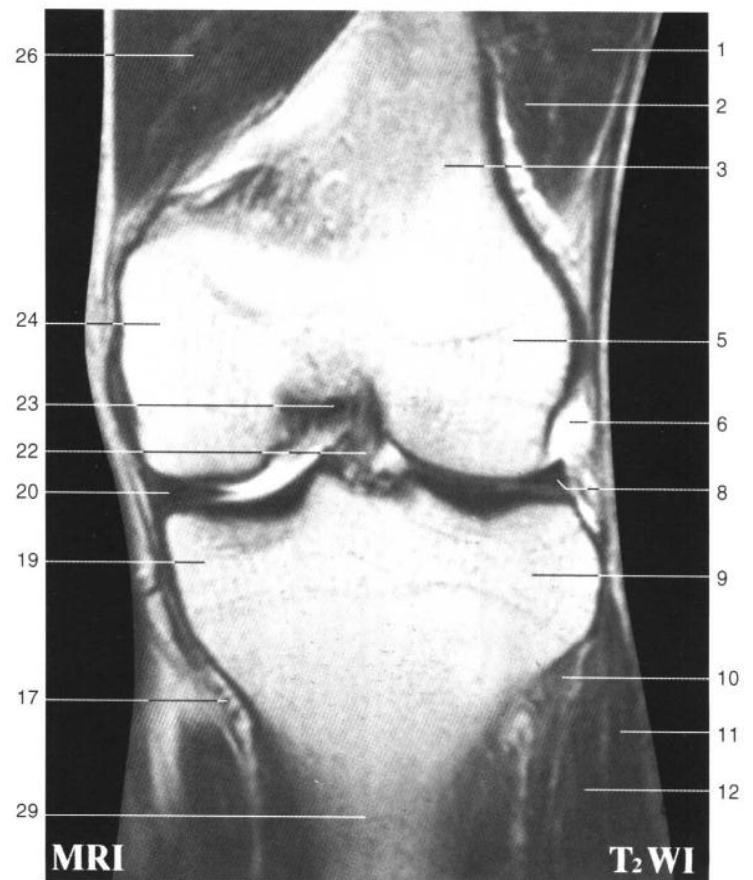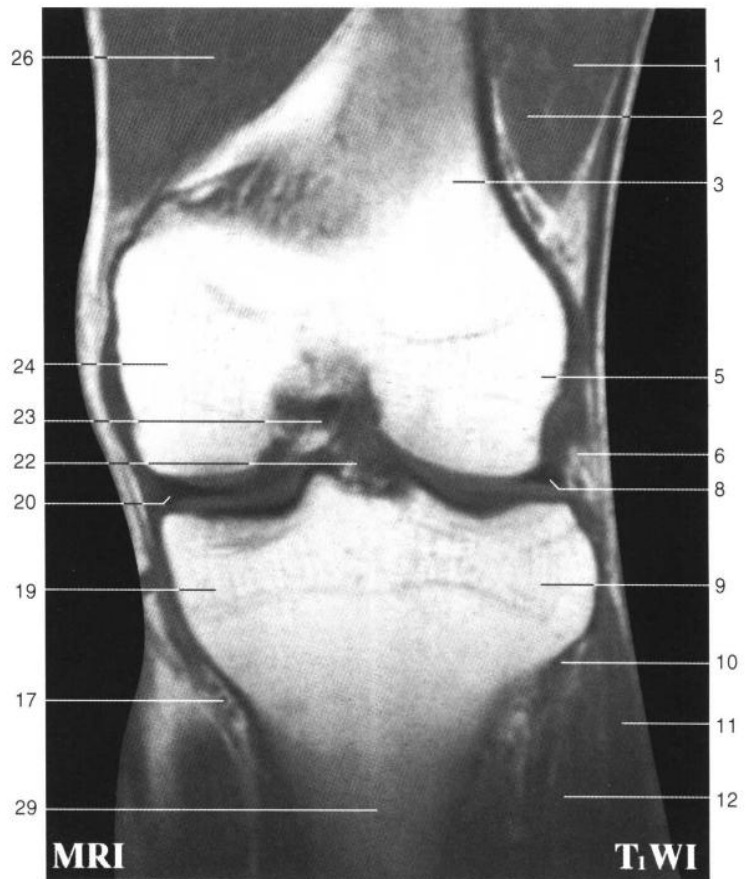


Fig. FK(L) 5

1. 股外侧肌 vastus lateralis
2. 股中间肌 vastus intermedius
3. 股骨 femur
4. 膝上外侧动、静脉 lateral superior genicular a. and v.
5. 股骨外侧髁 lateral condyle of femur
6. 腘肌腱 tendon of popliteus
7. 膝下外侧动、静脉 lateral inferior genicular a. and v.
8. 外侧半月板 lateral meniscus
9. 胫骨外侧髁 lateral condyle of tibia
10. 股二头肌腱 tendon of biceps femoris

Fig. FK(L) 5

11. 趾长伸肌 extensor digitorum longus
12. 胫骨前肌 tibialis anterior
13. 胫骨后肌 tibialis posterior
14. 腘肌 popliteus
15. 半腱肌腱 tendon of semitendinosus
16. 半膜肌腱 tendon of semimembranosus
17. 膝下内侧动、静脉 medial inferior genicular a. and v.
18. 缝匠肌腱 tendon of sartorius
19. 胫骨内侧髁 medial condyle of tibia
20. 内侧半月板 medial meniscus
21. 胫侧副韧带 tibial collateral ligament
22. 前交叉韧带 anterior cruciate ligament
23. 后交叉韧带 posterior cruciate ligament
24. 股骨内侧髁 medial condyle of femur
25. 膝上内侧动、静脉 medial superior genicular a. and v.
26. 股内侧肌 vastus medialis
27. 缝匠肌 sartorius
28. 降膝动、静脉 descending genicular a. and v.
29. 胫骨 tibia



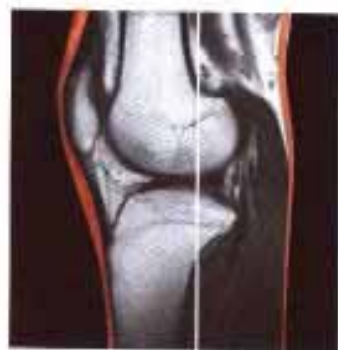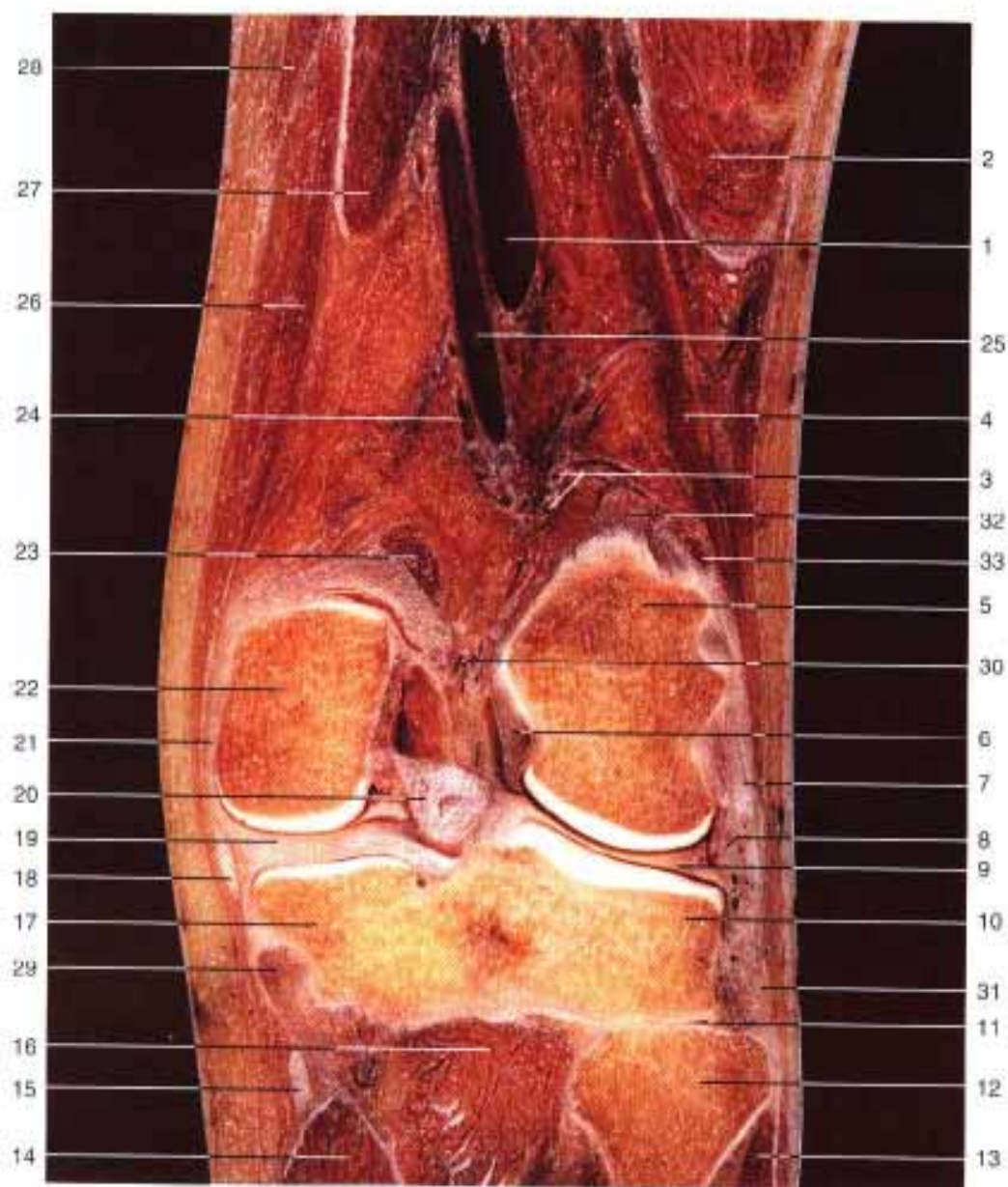
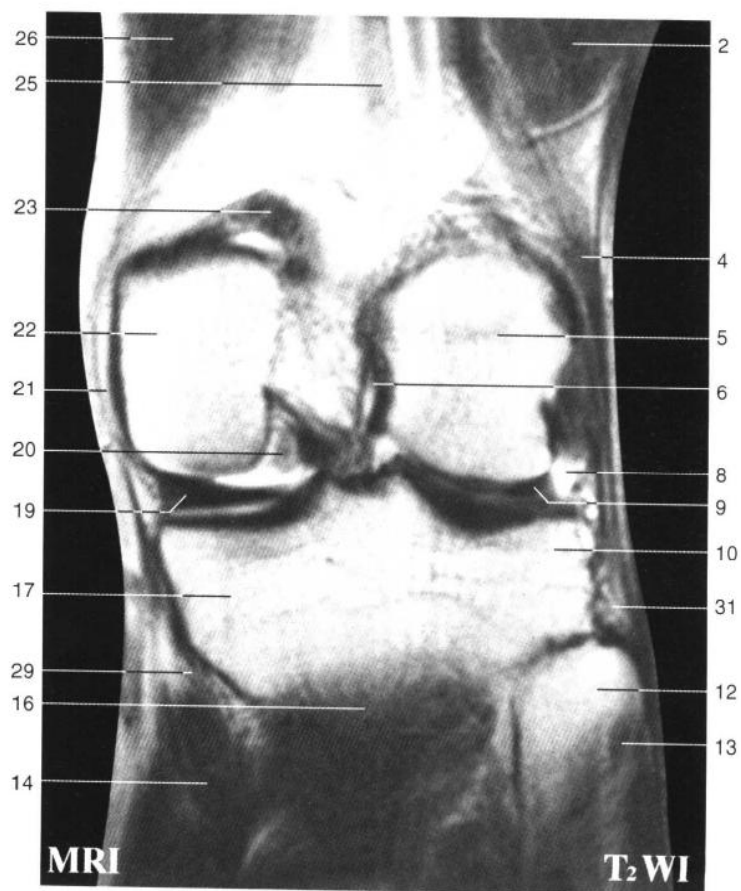
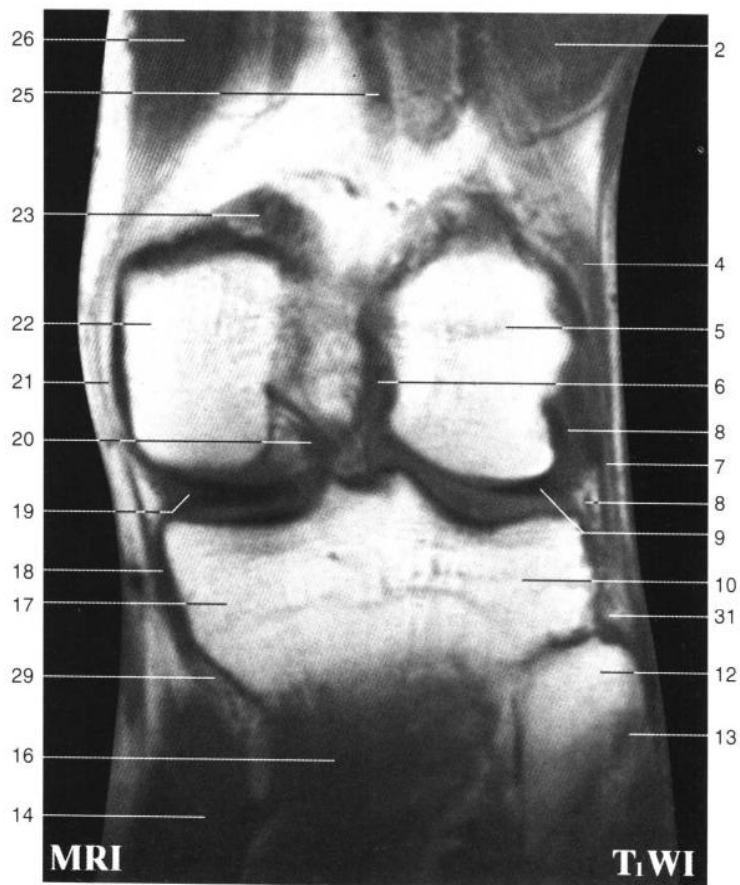


Fig. FK(L) 6

1. 腘静脉 popliteal v.
2. 股外侧肌 vastus lateralis
3. 膝上外侧动、静脉 lateral superior genicular a. and v.
4. 股二头肌 biceps femoris
5. 股骨外侧髁 lateral condyle of femur
6. 前交叉韧带 anterior cruciate ligament
7. 膝侧副韧带 fibular collateral ligament
8. 腘肌腱 tendon of popliteus
9. 外侧半月板 lateral meniscus

Fig. FK(L) 6

10. 胫骨外侧髁 lateral condyle of tibia
11. 胫腓关节 tibiofibular joint
12. 腓骨头 fibular head
13. 腓骨长肌 peroneus longus
14. 比目鱼肌 soleus
15. 半膜肌腱 tendon of semimembranosus
16. 腘肌 popliteus
17. 胫骨内侧髁 medial condyle of tibia
18. 缝匠肌腱 tendon of sartorius
19. 内侧半月板 medial meniscus
20. 后交叉韧带 posterior cruciate ligament
21. 胫侧副韧带 tibial collateral ligament
22. 股骨内侧髁 medial condyle of femur
23. 腓肠肌内侧头 medial head of gastrocnemius
24. 膝上内侧动脉 medial superior genicular a.
25. 腘动脉 popliteal a.
26. 缝匠肌 sartorius
27. 股内侧肌 vastus medialis
28. 股薄肌 gracilis
29. 半膜肌腱 tendon of semimembranosus
30. 膝下外侧动、静脉 lateral inferior genicular a. and v.
31. 股二头肌腱 tendon of biceps femoris
32. 跖肌 plantaris
33. 腓肠肌外头 lateral head of gastrocnemius



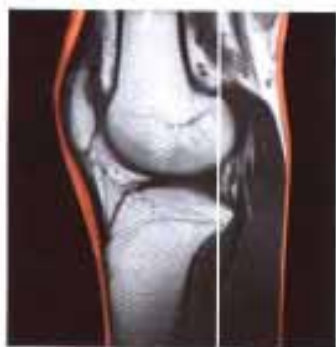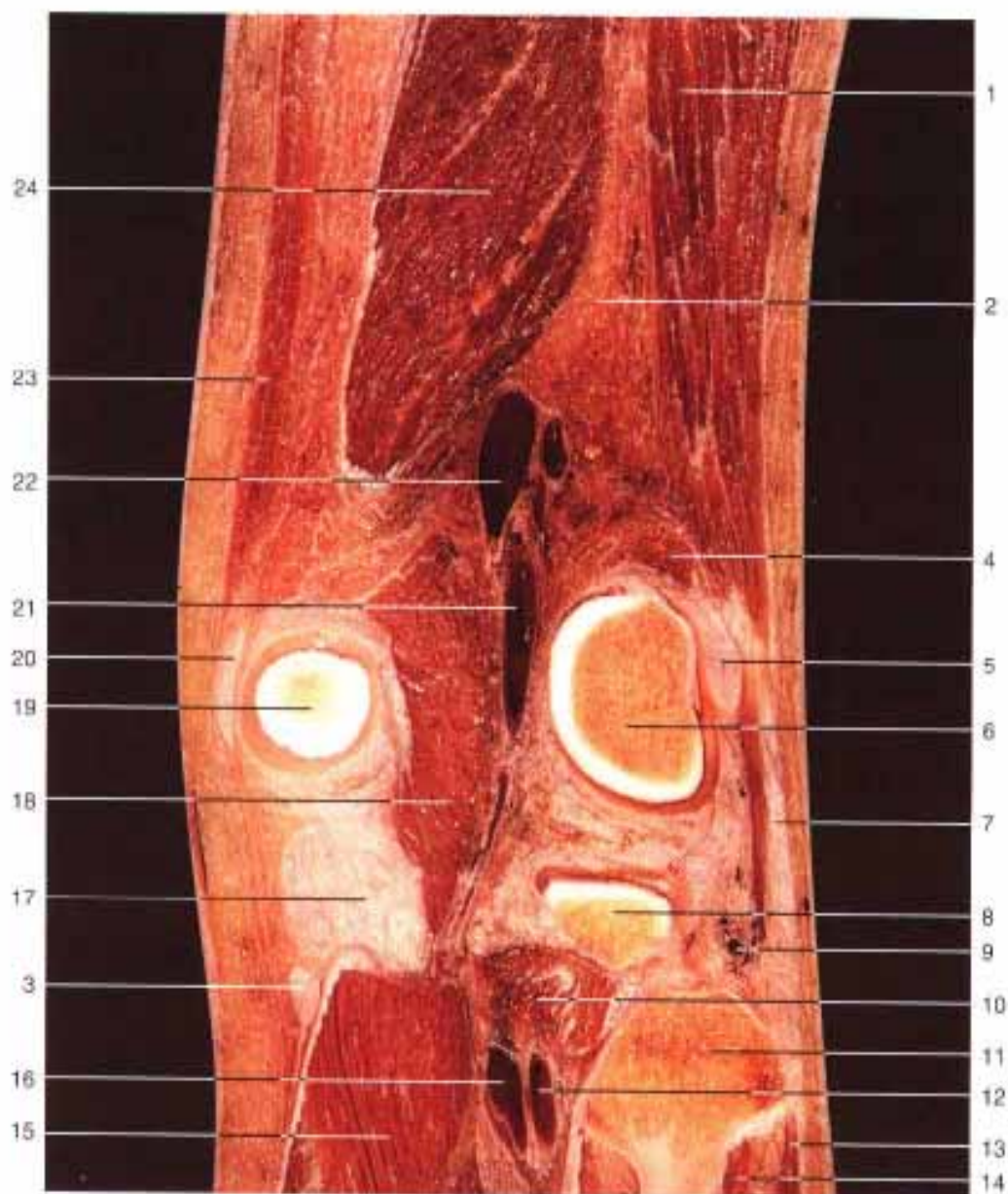
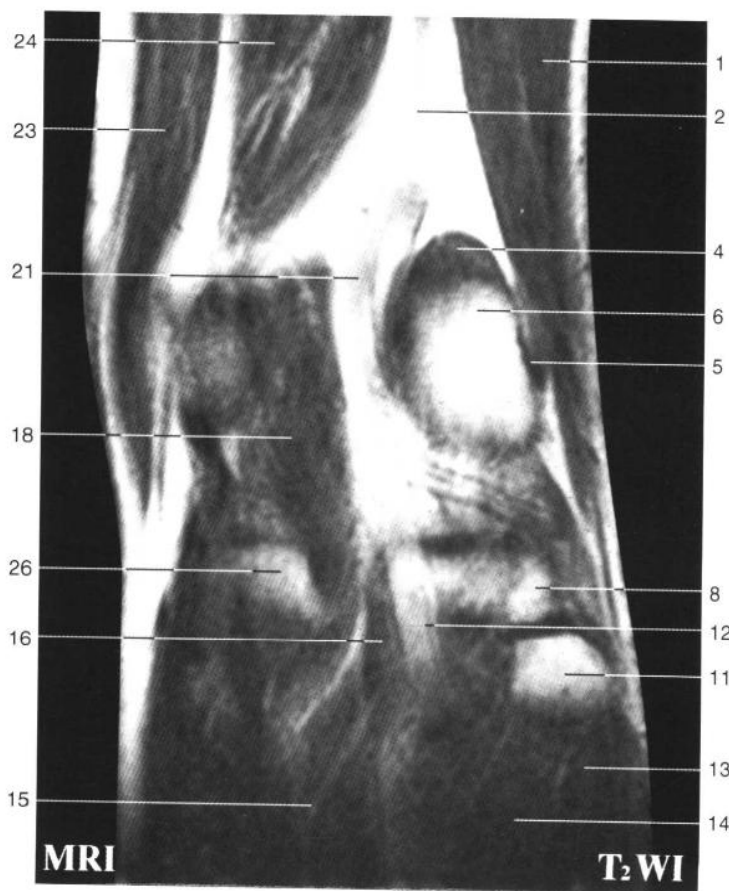
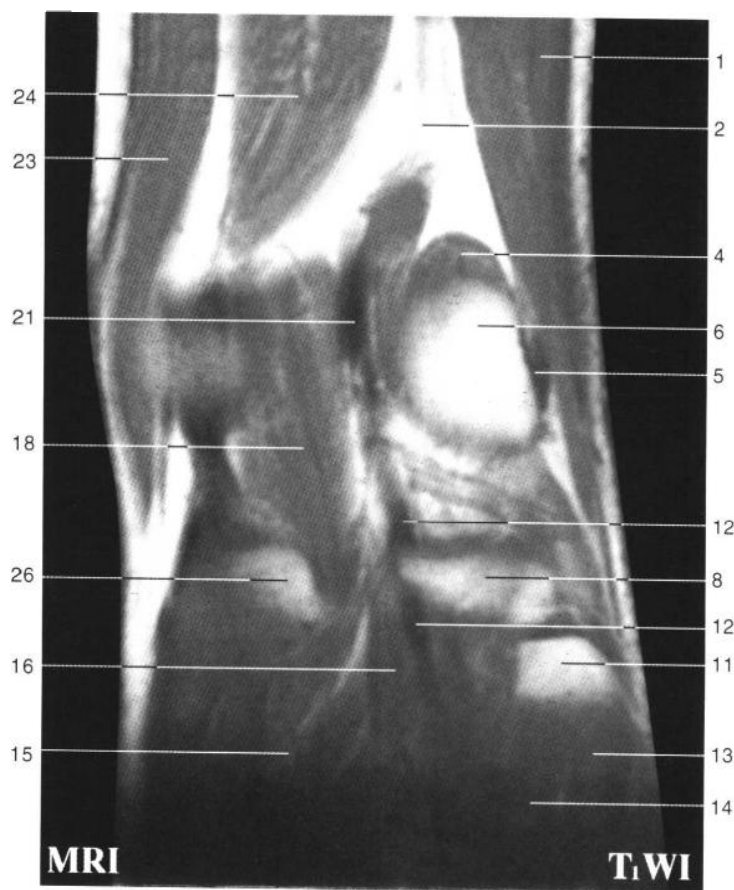


Fig. FK(L) 7

1. 股二头肌 biceps femoris
2. 腘窝 popliteal fossa
3. 半膜肌腱 tendon of semimembranosus
4. 腓肠肌外侧头 lateral head of gastrocnemius
5. 腓肌腱 tendon of popliteus
6. 股骨外侧髁 lateral condyle of femur
7. 腓侧副韧带 tibular collateral ligament
8. 胫骨外侧髁 lateral condyle of tibia
9. 腓下外侧动、静脉 lateral inferior genicular a. and v.
10. 跖肌 plantaris

Fig. FK(L) 7

- 11. 腓骨头 fibular head
- 12. 腘动脉 popliteal a.
- 13. 腓骨长肌 peroneus longus
- 14. 腓骨短肌 peroneus brevis
- 15. 腓肠肌 gastrocnemius
- 16. 腘静脉 popliteal v.
- 17. 关节囊 articular capsule
- 18. 腓肠肌内侧头 medial head of gastrocnemius
- 19. 股骨内侧髁 medial condyle of femur
- 20. 股薄肌与缝匠肌腱 tendon of gracilis and sartorius
- 21. 腘动脉 popliteal a.
- 22. 腘静脉 popliteal v.
- 23. 缝匠肌 sartorius
- 24. 大收肌 adductor magnus
- 25. 股薄肌 gracilis
- 26. 胫骨内侧髁 medial condyle of tibia



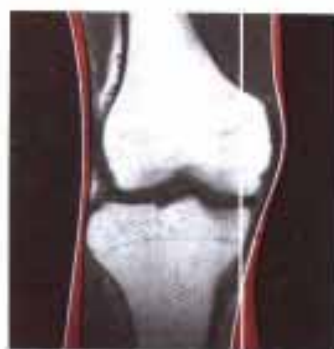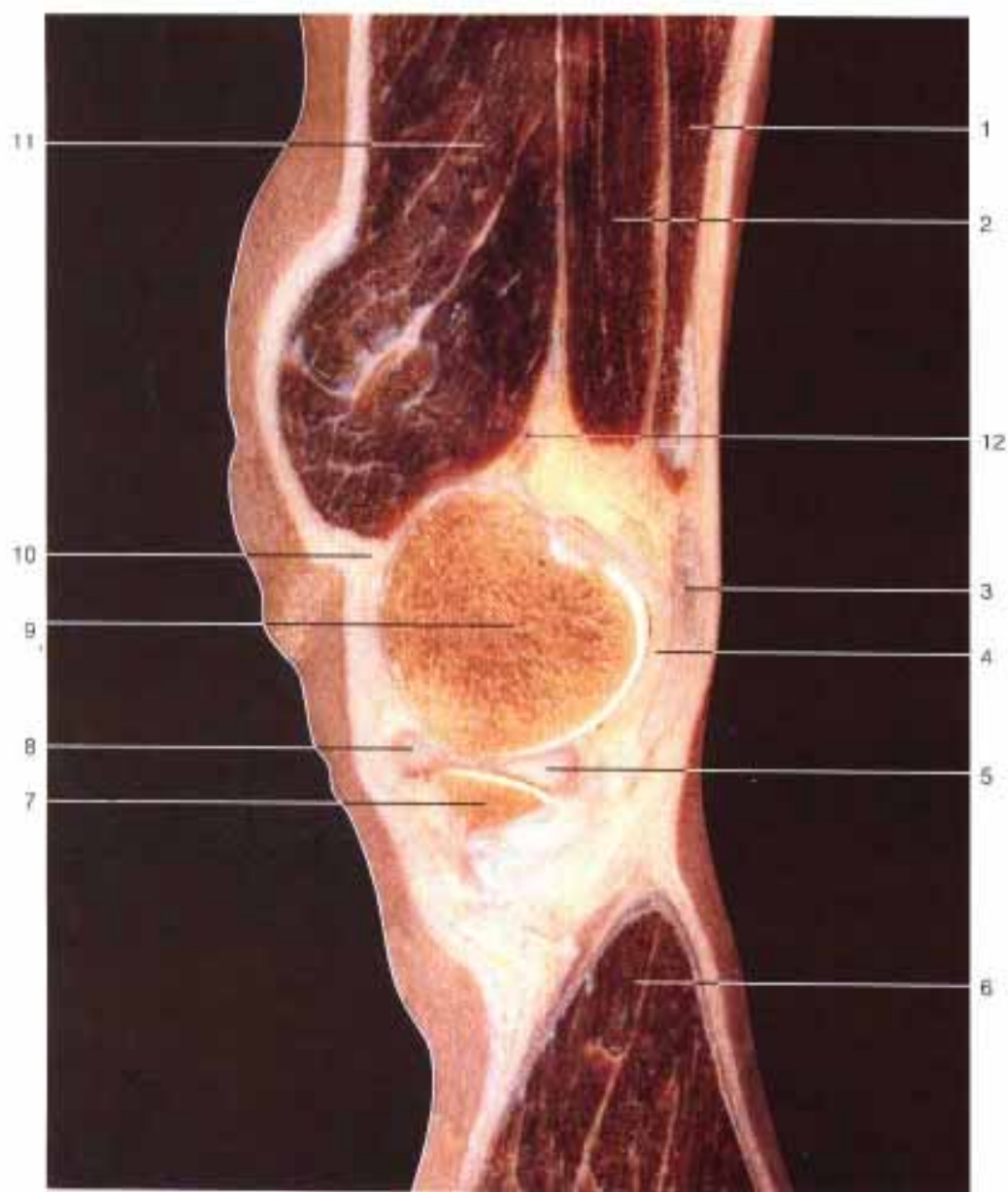
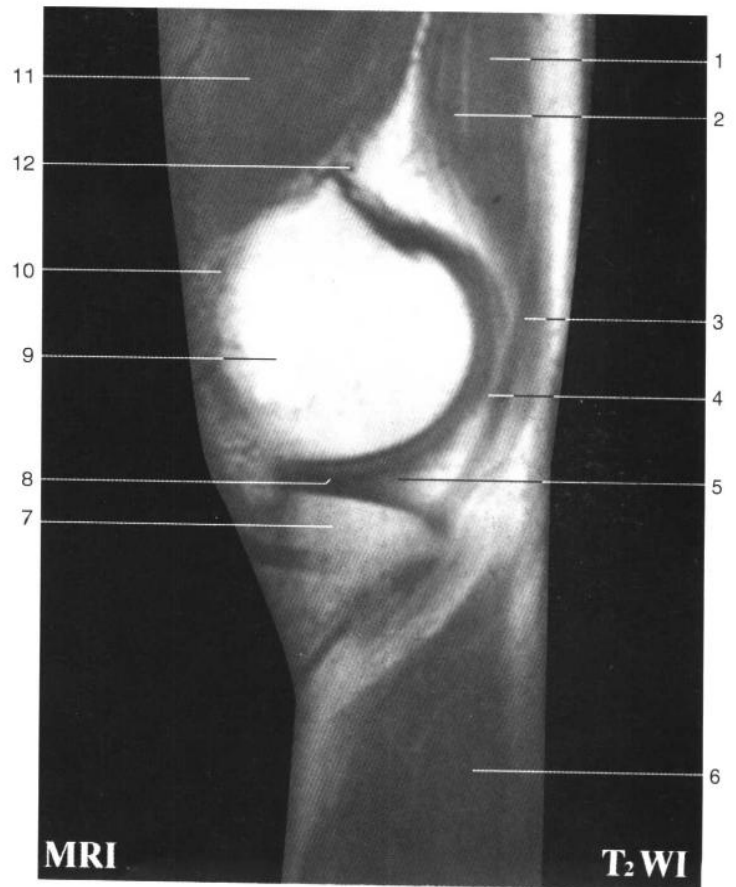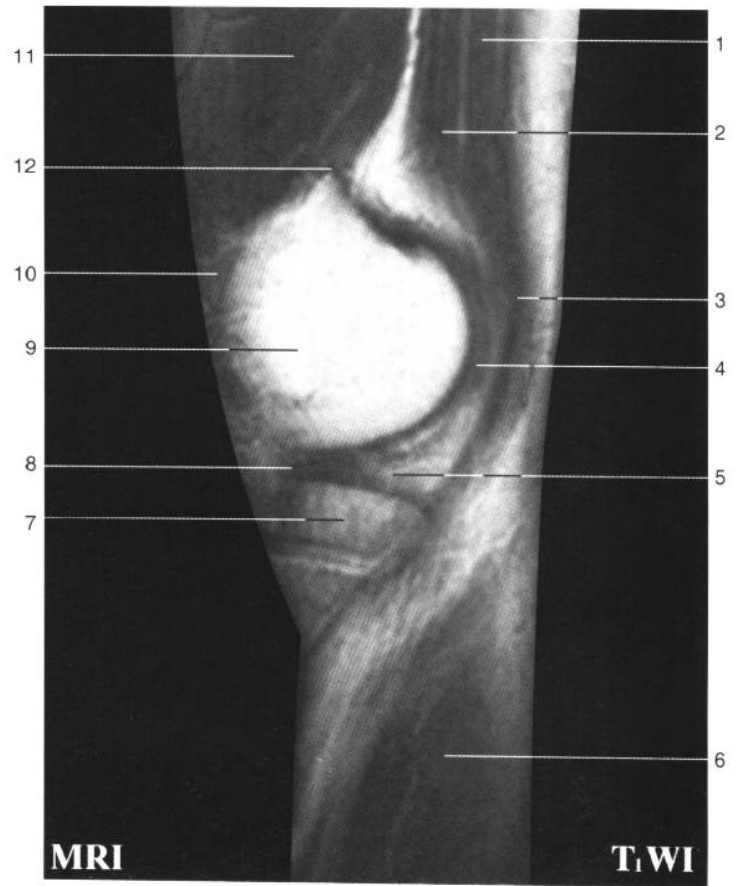


Fig. SK(R) 1

1. 股薄肌 gracilis
2. 缝匠肌 sartorius
3. 半腱肌腱 tendon of semitendinosus
4. 关节囊 articular capsule
5. 内侧半月板后部 posterior part of medial meniscus
6. 腓肠肌内侧头 medial head of gastrocnemius
7. 胫骨内侧髁 medial condyle of tibia
8. 内侧半月板前部 anterior part of medial meniscus
9. 股骨内侧髁 medial condyle of femur

Fig. SK(R) 1

- 10. 髌内侧支持带 medial patellar retinaculum
- 11. 股内侧肌 vastus medialis
- 12. 膝上内侧动脉 medial superior genicular a.



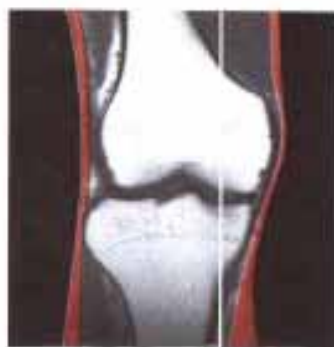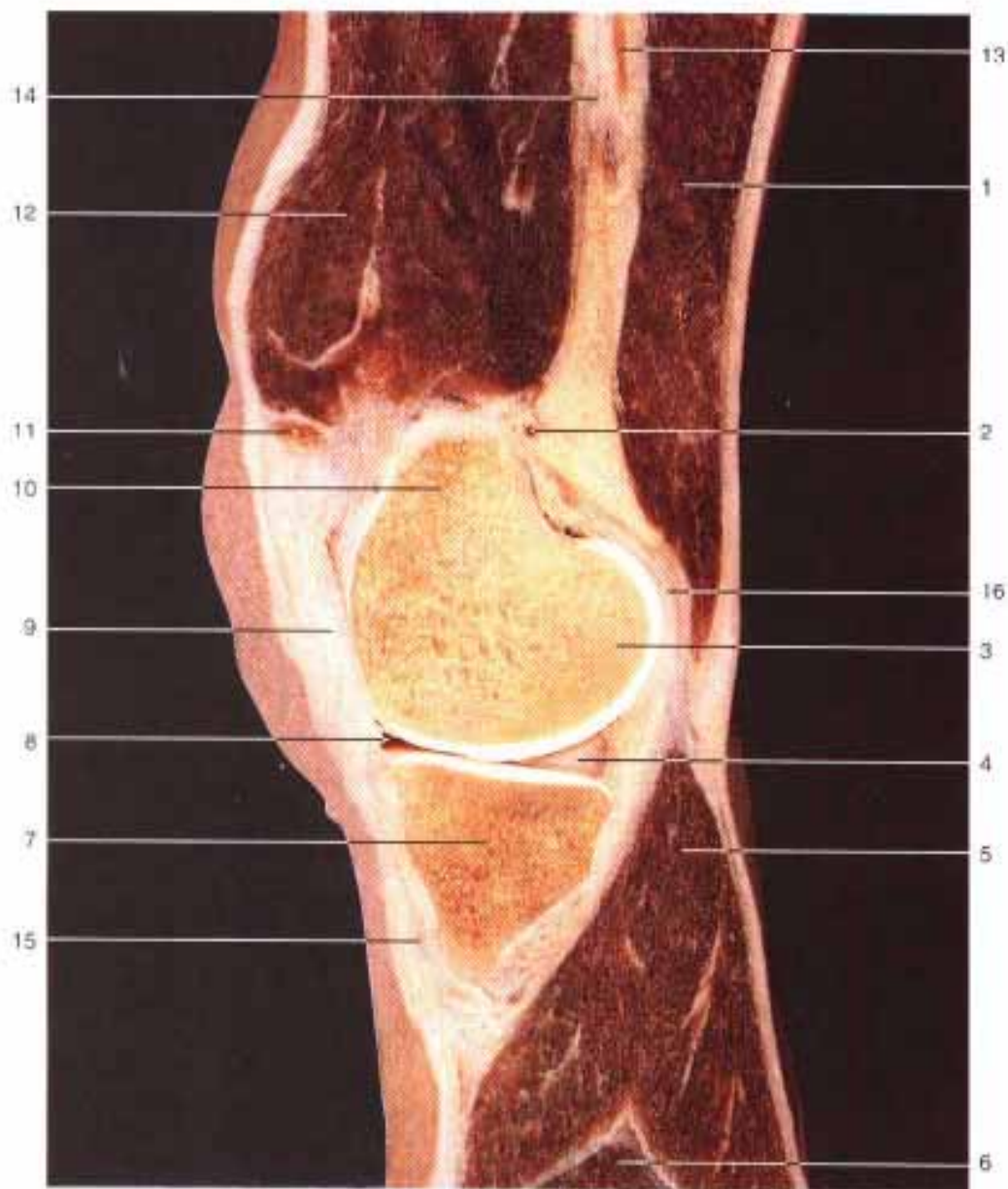

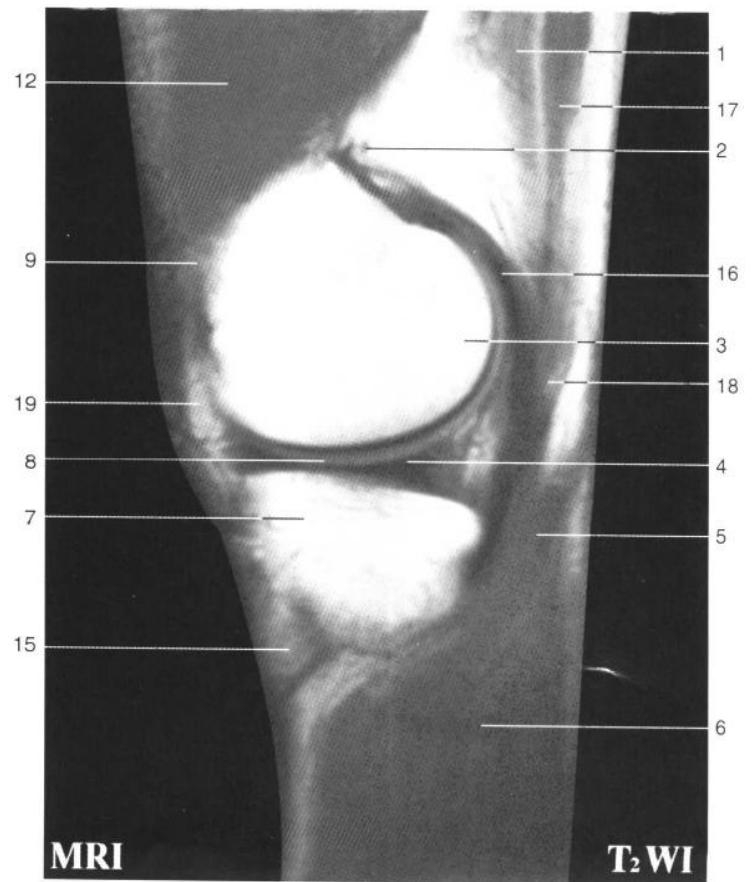
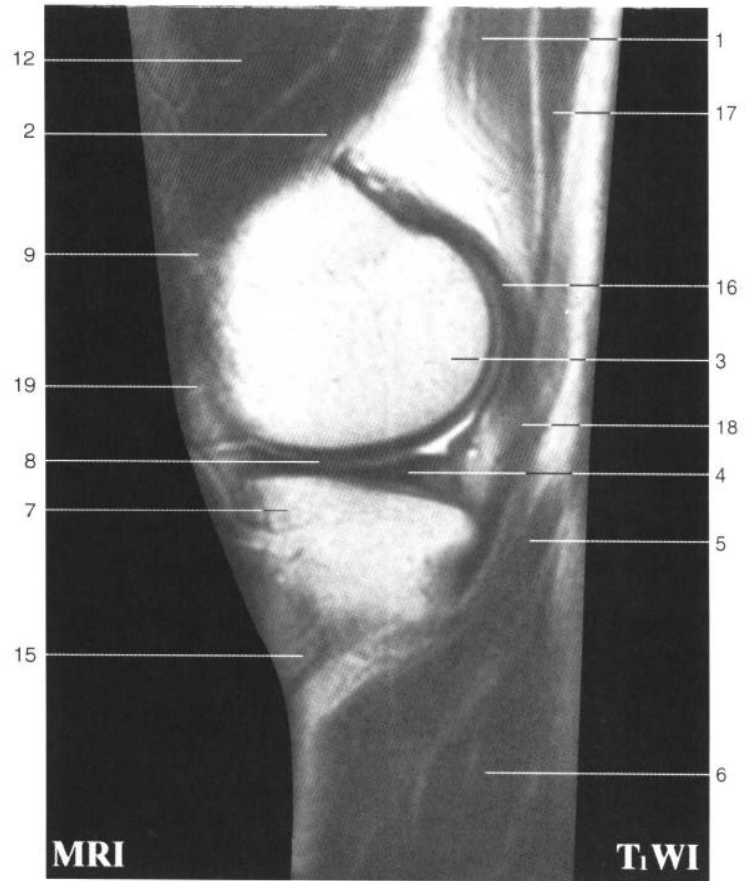Fig. SK(R) 2

1. 半膜肌 semimembranosus
2. 膝上内髁动脉 medial superior genicular a.
3. 股骨内髁髁 medial condyle of femur
4. 内侧半月板后部 posterior part of medial meniscus
5. 腓肠肌内侧头 medial head of gastrocnemius
6. 比目鱼肌 soleus
7. 胫骨内髁髁 medial condyle of tibia
8. 关节腔 articular cavity
9. 髌韧带 patellar ligament
10. 股骨 femur

Fig. SK(R) 2

- 11. 髌骨 patella
- 12. 股内侧肌 vastus medialis
- 13. 大收肌 adductor magnus
- 14. 股内侧肌间隔 medial femoral intermuscular septum
- 15. 缝匠肌腱 tendon of sartorius
- 16. 关节囊 articular capsule
- 17. 半腱肌 semitendinosus
- 18. 半膜肌腱 tendon of semimembranosus
- 19. 髌内侧支持带 medial patellar retinaculum



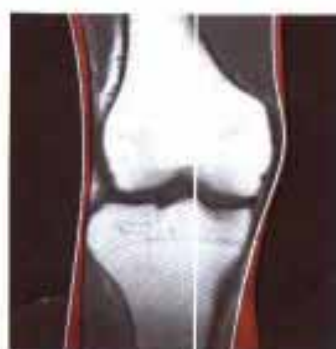
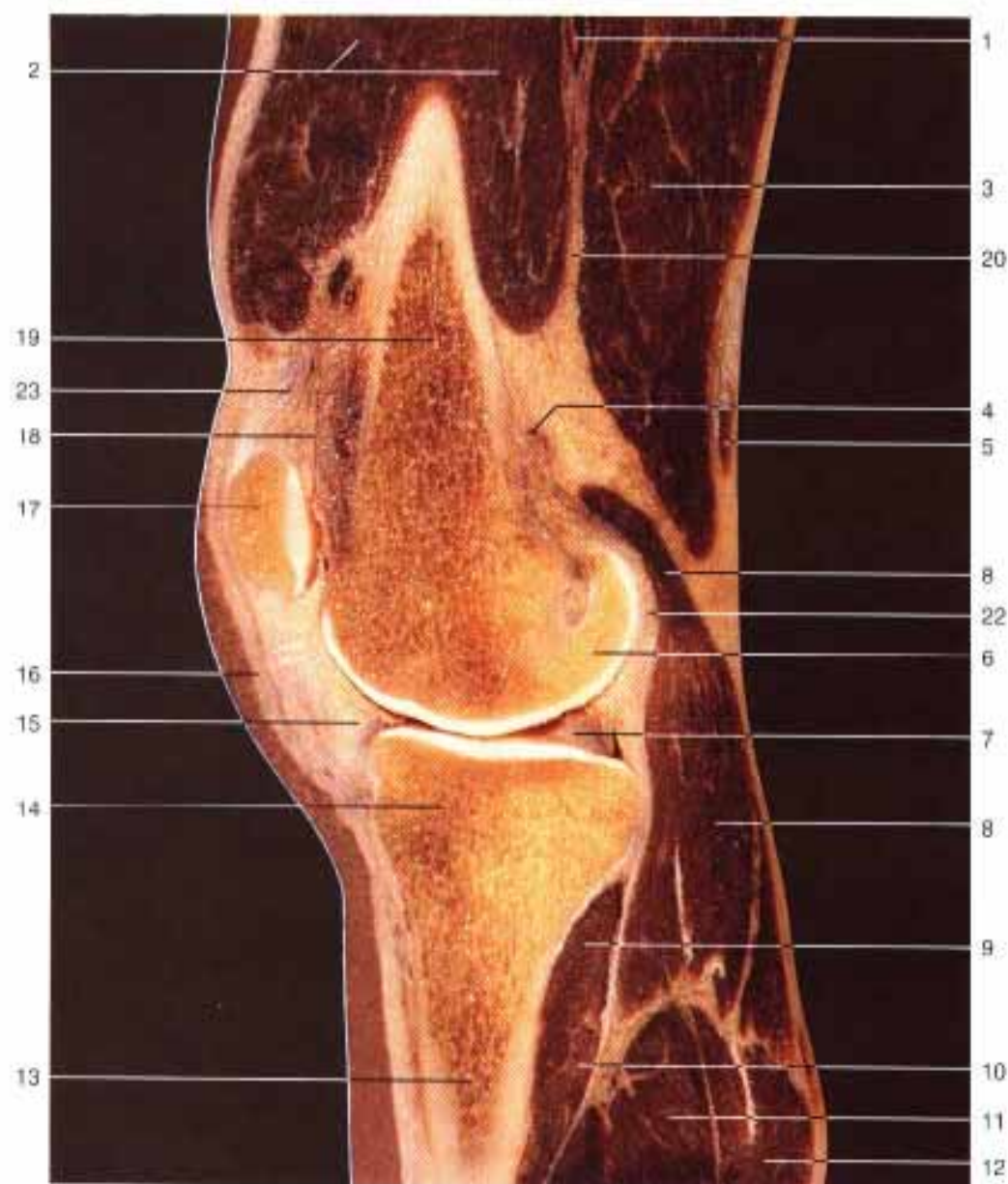
Fig. SK(R) 3

1. 股动脉 femoral a.
2. 股内侧肌 vastus medialis
3. 半膜肌 semimembranosus
4. 膝上内侧动脉 medial superior genicular a.
5. 半腱肌 semitendinosus
6. 股骨内侧髁 medial condyle of femur
7. 内侧半月板后部 posterior part of medial meniscus
8. 腓肠肌内侧面 medial head of gastrocnemius
9. 腓肌 popliteus

Fig. SK(R) 3

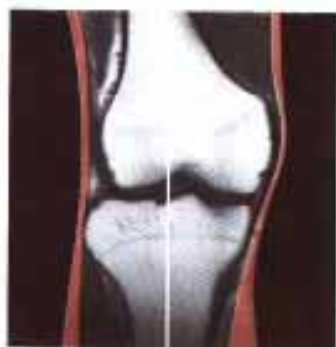
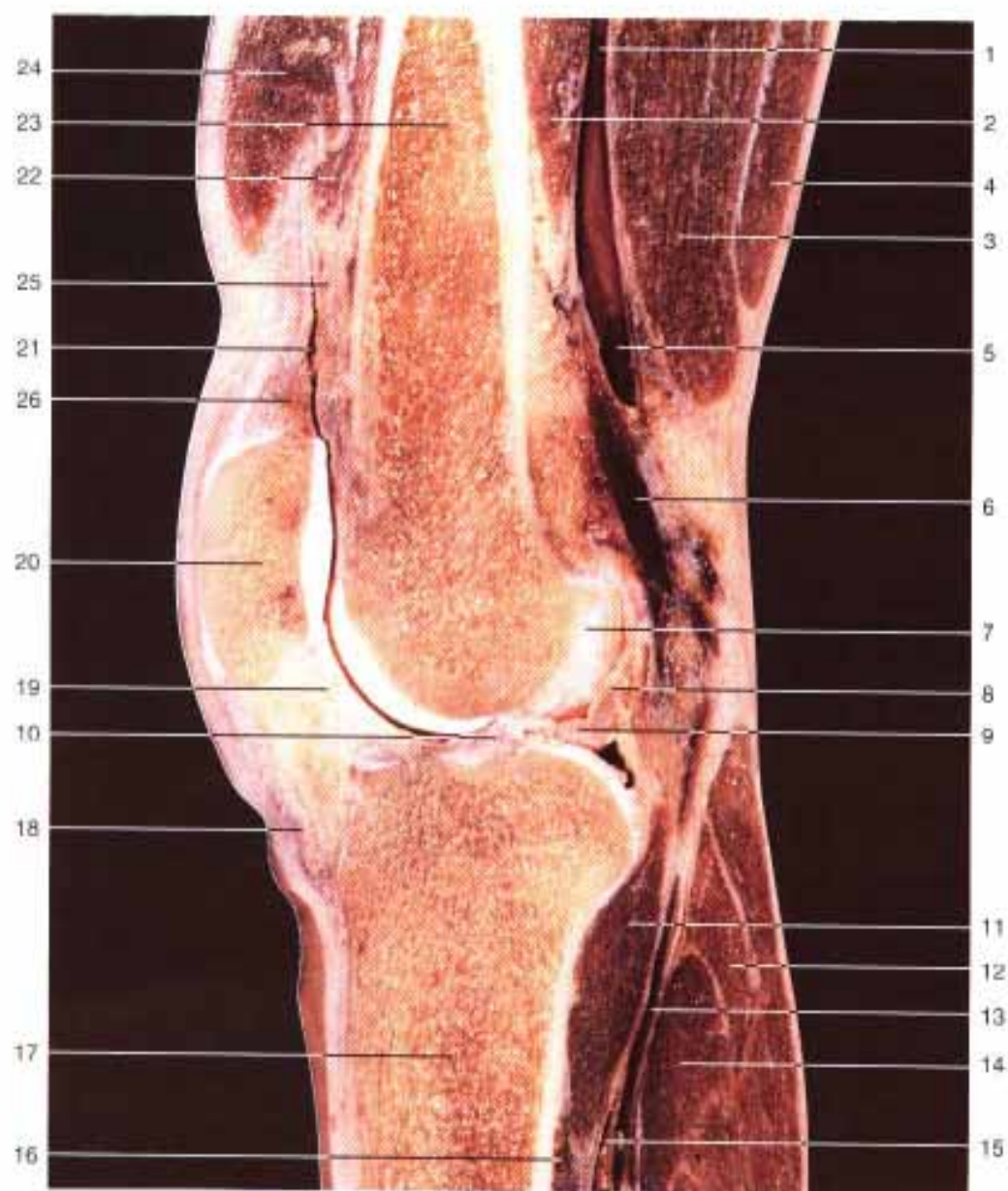
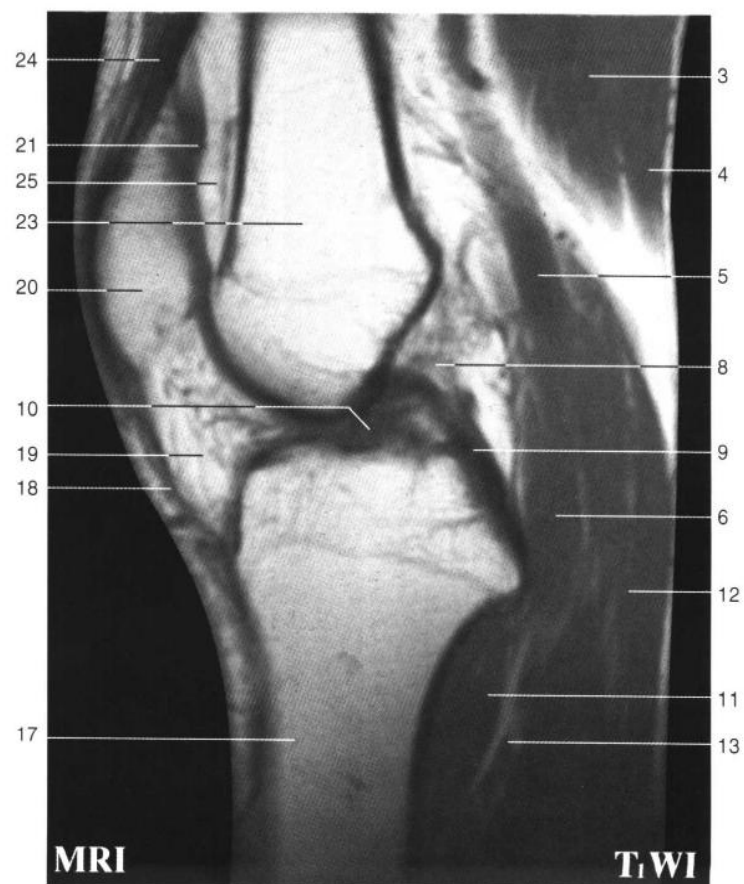
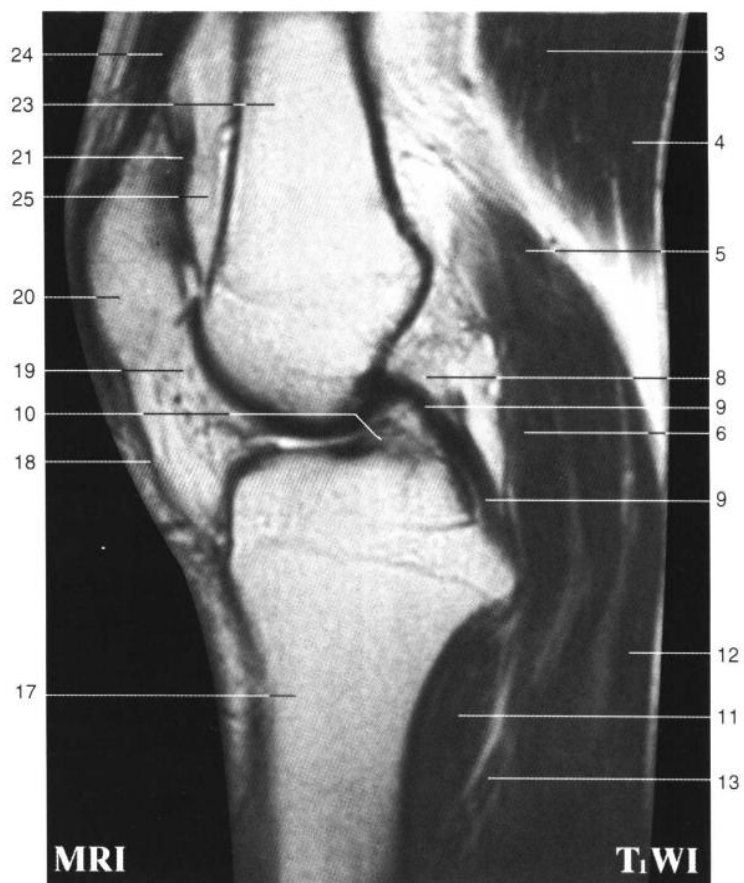


Fig. SK(R) 4

1. 股静脉 femoral v.
2. 股内侧肌 vastus medialis
3. 半膜肌 semimembranosus
4. 半腱肌 semitendinosus
5. 腓静脉 popliteal v.
6. 腓动脉 popliteal a.
7. 股骨外侧髁 lateral condyle of femur
8. 板股后韧带 posterior meniscolfemoral ligament
9. 后交叉韧带 posterior cruciate ligament

Fig. SK(R) 4

- 10. 前交叉韧带 anterior cruciate ligament
- 11. 腓肌 popliteus
- 12. 腓肠肌 gastrocnemius
- 13. 胫后静脉 posterior tibial v.
- 14. 比目鱼肌 soleus
- 15. 胫后动脉 posterior tibial a.
- 16. 胫骨后肌 tibialis posterior
- 17. 胫骨 tibia
- 18. 髌韧带 patellar ligament
- 19. 翼状襞 alar fold
- 20. 髌骨 patella
- 21. 髌上囊 suprapatellar bursa
- 22. 膝关节肌 articularis genus
- 23. 股骨 femur
- 24. 股直肌 rectus femoris
- 25. 股前脂体 prefemoral fat pad
- 26. 髌上脂体 suprapatellar fat pad



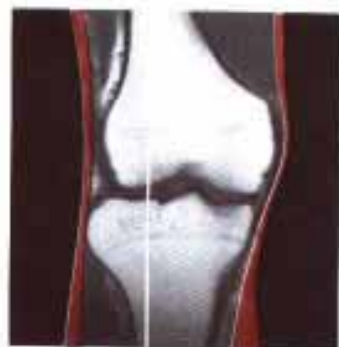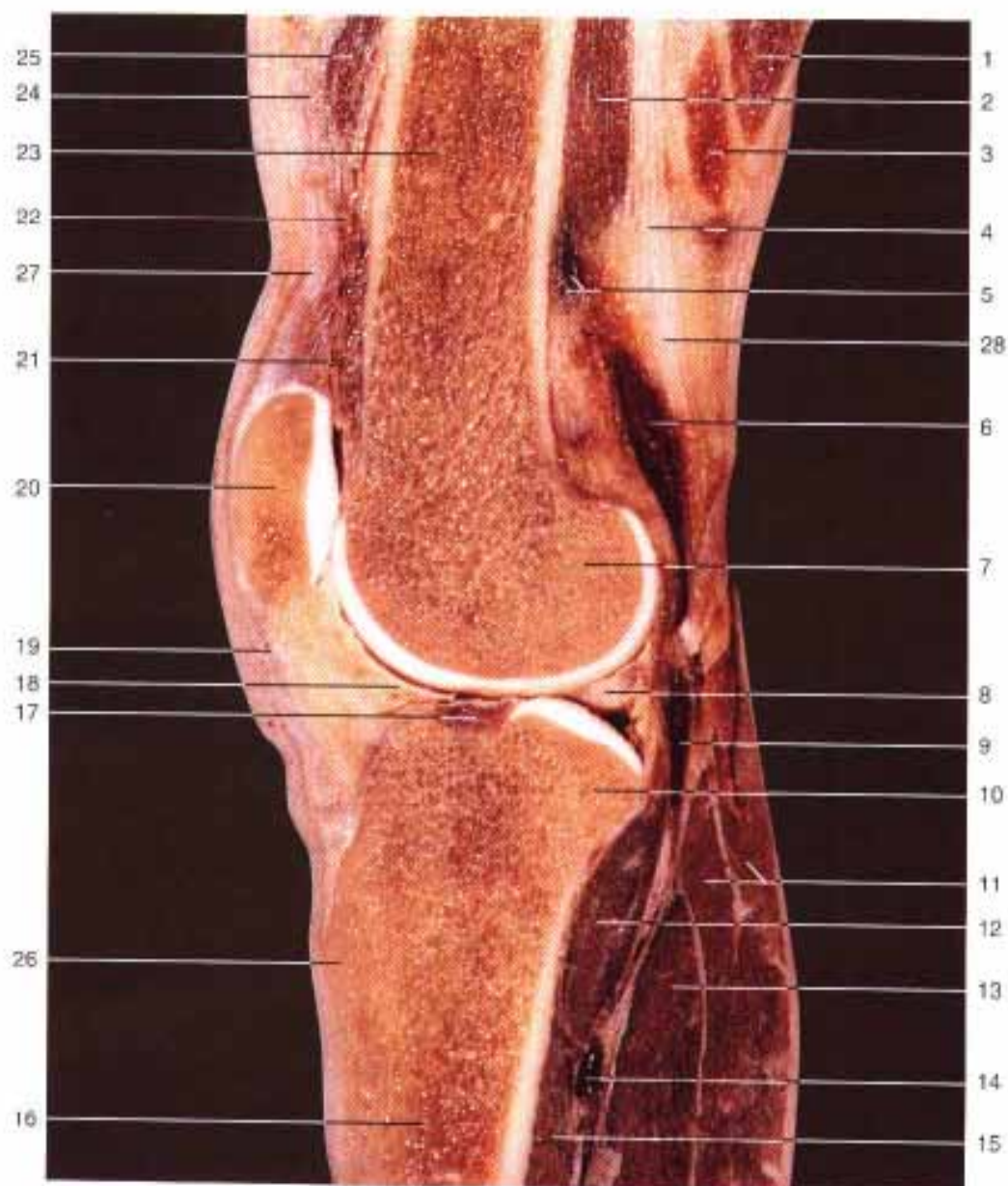
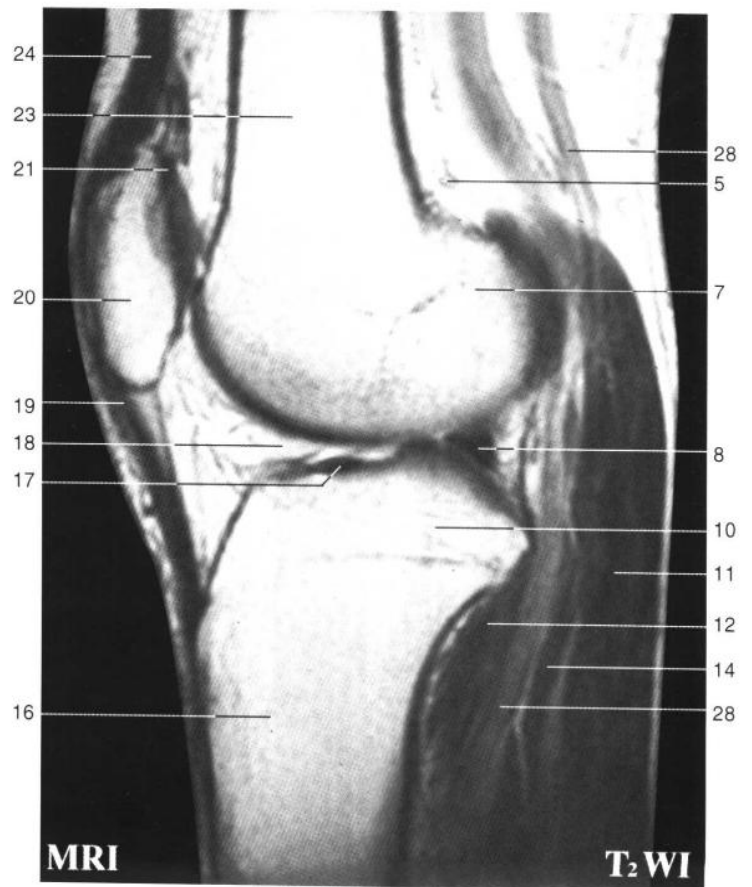
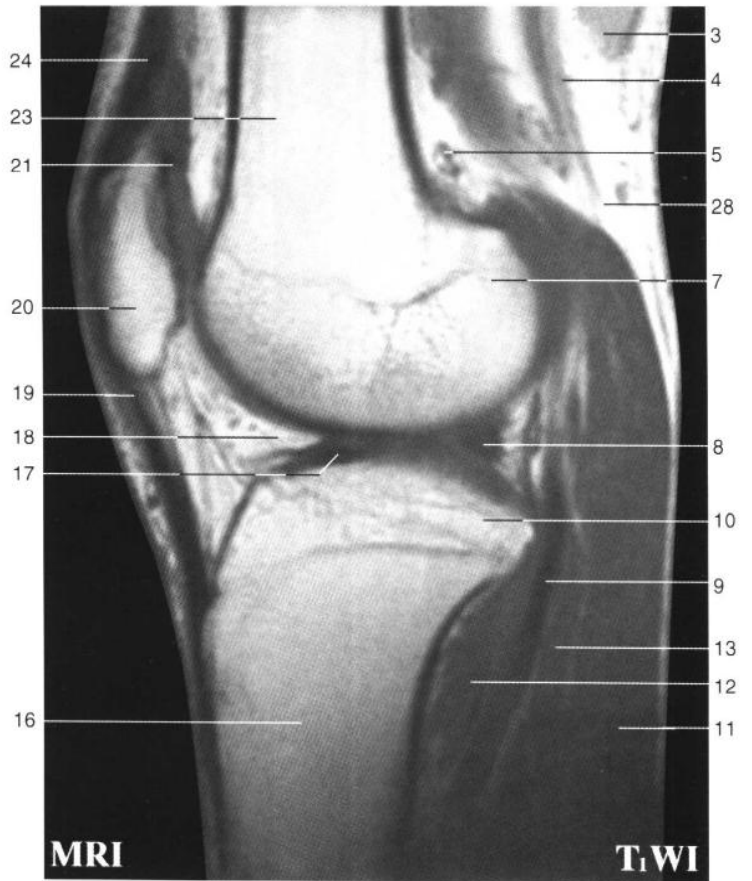


Fig. SK(R) 5

1. 股二头肌长头 long head of biceps femoris
2. 股二头肌短头 short head of biceps femoris
3. 半膜肌 semimembranosus
4. 坐骨神经 sciatic n.
5. 膝上外侧动脉、静脉 lateral superior genicular a. and v.
6. 腘静脉 popliteal v.
7. 股骨外侧髁 lateral condyle of femur
8. 外侧半月板后面 posterior part of lateral meniscus
9. 腘动脉 popliteal a.

Fig. SK(R) 5

10. 胫骨外侧髁 lateral condyle of tibia
11. 腓肠肌 gastrocnemius
12. 腘肌 popliteus
13. 比目鱼肌 soleus
14. 胫后动脉 posterior tibial a.
15. 胫骨后肌 tibialis posterior
16. 胫骨 tibia
17. 前交叉韧带 anterior cruciate ligament
18. 髌下滑膜襞 infrapatellar synovial fold
19. 髌韧带 patellar ligament
20. 髌骨 patella
21. 髌上囊 suprapatellar bursa
22. 膝关节肌 articularis genus
23. 股骨 femur
24. 股直肌腱 tendon of rectus femoris
25. 股中间肌 vastus intermedius
26. 胫骨粗隆 tibial tuberosity
27. 股四头肌腱 tendon of quadriceps femoris
28. 胫神经 tibial n.



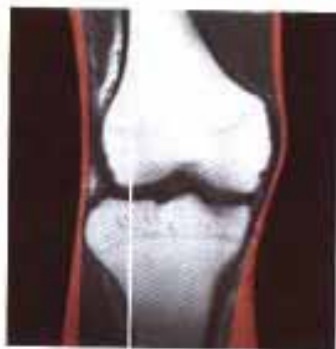
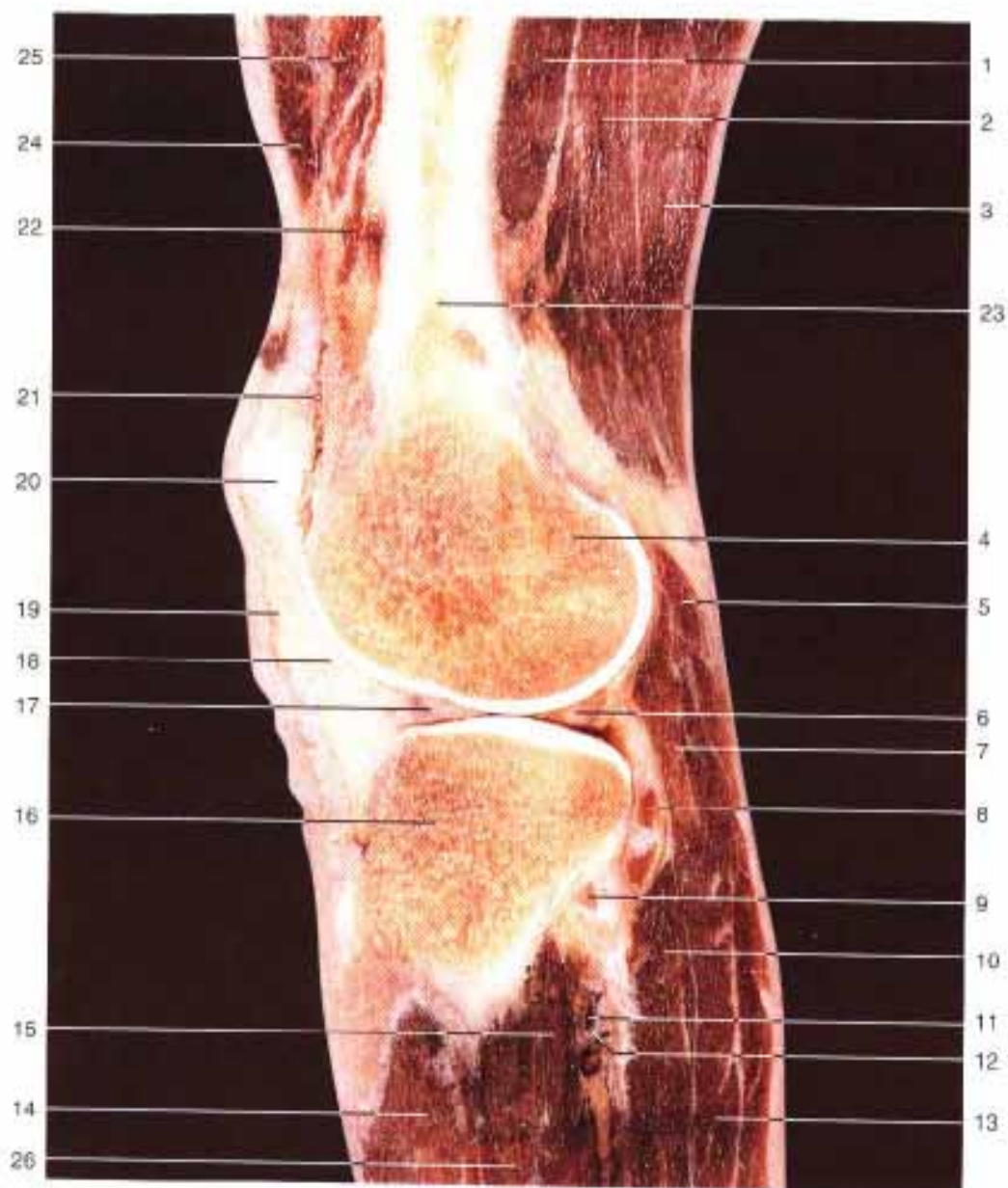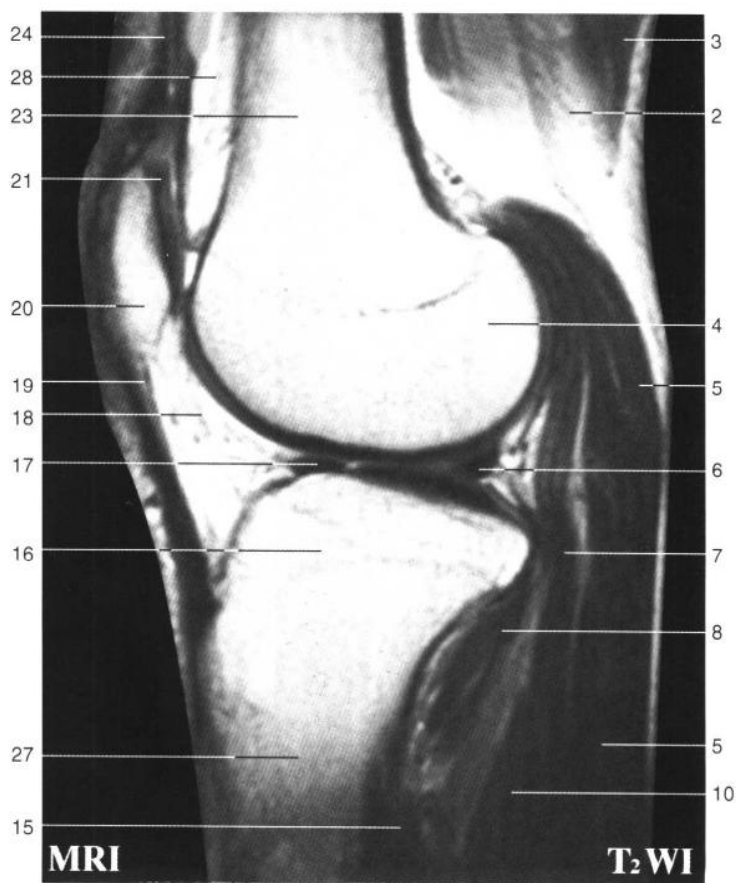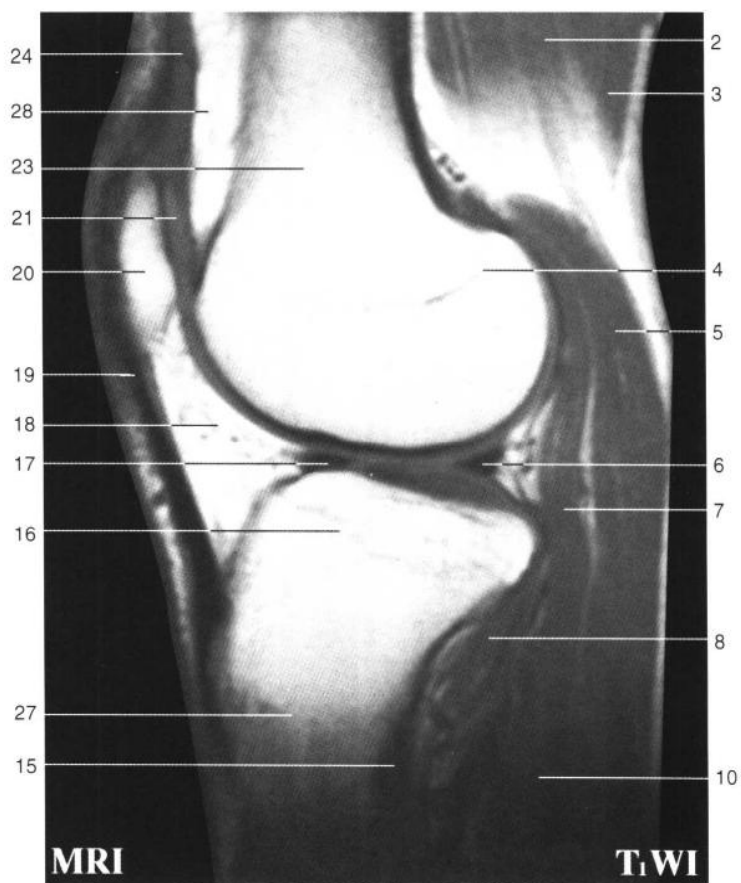


Fig. SK(R) 6

1. 股中间肌 vastus intermedius
2. 股二头肌短头 short head of biceps femoris
3. 股二头肌长头 long head of biceps femoris
4. 胫骨外侧髁 lateral condyle of femur
5. 腓肠肌外侧头 lateral head of gastrocnemius
6. 外侧半月板后部 posterior part of lateral meniscus
7. 腓肌 plantaris
8. 腓肌 popliteus
9. 腓骨头 fibular head
10. 比目鱼肌 soleus

Fig. SK(R) 6

11. 胫后动、静脉 posterior tibial a. and v.
12. 胫神经 tibial n.
13. 腓肠肌 gastrocnemius
14. 胫骨前肌 tibialis anterior
15. 胫骨后肌 tibialis posterior
16. 胫骨外侧髁 lateral condyle of tibia
17. 外侧半月板前部 anterior part of lateral meniscus
18. 翼状襞 alar fold
19. 髌韧带 patellar ligament
20. 髌骨 patella
21. 髌上囊 suprapatellar bursa
22. 膝关节肌 articularis genus
23. 股骨 femur
24. 股直肌 rectus femoris
25. 股中间肌 vastus intermedius
26. 趾长伸肌 extensor digitorum longus
27. 胫骨 tibia
28. 股前脂体 prefemoral fat pad



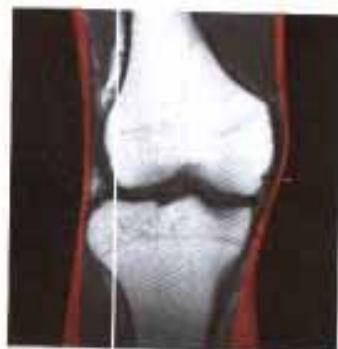
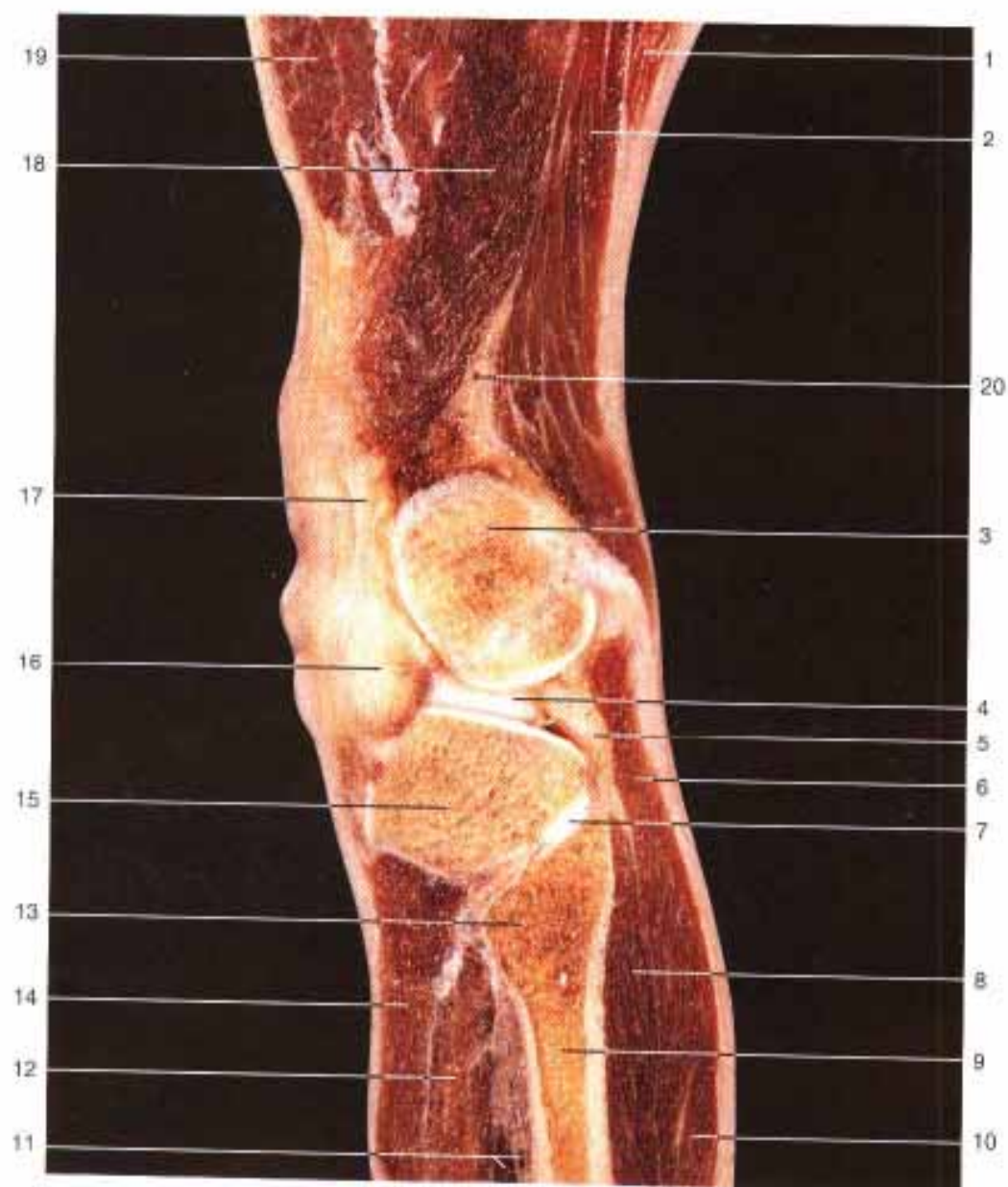


Fig. SK(R) 7

1. 股二头肌长头 long head of biceps femoris
2. 股二头肌短头 short head of biceps femoris
3. 股骨外侧髁 lateral condyle of femur
4. 外侧半月板 lateral meniscus
5. 腓肌腱 tendon of popliteus
6. 腓肠肌外侧头 lateral head of gastrocnemius
7. 腓腓关节 tibiofibular joint
8. 比目鱼肌 soleus
9. 腓骨 tibia
10. 腓肠肌 gastrocnemius

Fig. SK(L) 7

- 11. 胫前动、静脉 anterior tibial a. and v.
- 12. 趾长伸肌 extensor digitorum longus
- 13. 腓骨头 fibular head
- 14. 胫骨前肌 tibialis anterior
- 15. 胫骨外侧髁 lateral condyle of tibia
- 16. 翼状襞 alar fold
- 17. 髌外侧支持带 lateral patellar retinaculum
- 18. 股中间肌 vastus intermedius
- 19. 股外侧肌 vastus lateralis
- 20. 膝上外侧动、静脉 lateral superior genicular a. and v.
- 21. 髌骨 patella

