

内容提要

磁共振能帮助医师全面观察关节内部及周围的结构、病变,不管是影像科医师或者临床医师,在工作中都经常借助磁共振检查进行临床诊断和治疗,制定完善的治疗方案,而熟悉、掌握正常关节磁共振图像解剖是这一切的基础。本稿主要对正常关节,包括肩、肘、腕关节和髋、膝、踝关节的解剖结构,以磁共振图谱的方式,按照正常矢状位、横断位和冠状位予以显示并标明解剖结构的中英名称,便于医学生、青年医生学习、掌握正常关节的 MRI 解剖。

前 言

近年来随着计算机技术的迅猛发展,CT、磁共振成像(MRI)等医学影像手段已广泛应用于临床,并对临床诊治发挥着巨大作用。随着医疗经济水平的提高,骨关节病变的影像诊断越来越普遍,其中MRI和关节镜等对骨关节解剖学有进一步认识与发展。

骨关节系统包括肩、肘、腕、髌、膝及踝足等各个关节及四肢部位,断面影像解剖非常复杂,而诊断信息大都基于包括横断面、冠状面及矢状面的断面影像,因此作为一名医学工作者,必须充分掌握器官结构的断面解剖。MRI的应用能清晰全面地显示关节的内部周围情况,使医生对其能进行准确评估和诊断,进而制定完善的治疗方案和随访手段。本书主要着重于各个关节及肢体基本部位的磁共振断层解剖,采用了3.0T磁共振机器进行部位采集,采集现有最先进设备的图像来展示其断面解剖,同时每幅MR图像均附定位线以

说明图像的位置,使读者能够快速掌握其解剖关系。

本书以普及和提高临床医学工作者在影像检查临床应用方面的水平为目的,适用于骨科医师、研究生及放射影像诊断医师阅读使用。

李明华 姚伟武

2010年2月


目 录

1	踝关节磁共振图谱(冠状位)
15	踝关节磁共振图谱(横断位)
27	踝关节磁共振图谱(矢状位)
39	肩关节磁共振图谱(冠状位)
47	肩关节磁共振图谱(横断位)
59	肩关节磁共振图谱(矢状位)
71	髋关节磁共振图谱(冠状位)
81	髋关节磁共振图谱(横断位)
89	髋关节磁共振图谱(矢状位)
99	腕关节磁共振图谱(冠状位)
107	腕关节磁共振图谱(横断位)
115	腕关节磁共振图谱(矢状位)
125	膝关节磁共振图谱(冠状位)
137	膝关节磁共振图谱(横断位)
149	膝关节磁共振图谱(矢状位)
163	肘关节磁共振图谱(冠状位)
171	肘关节磁共振图谱(横断位)
179	肘关节磁共振图谱(矢状位)

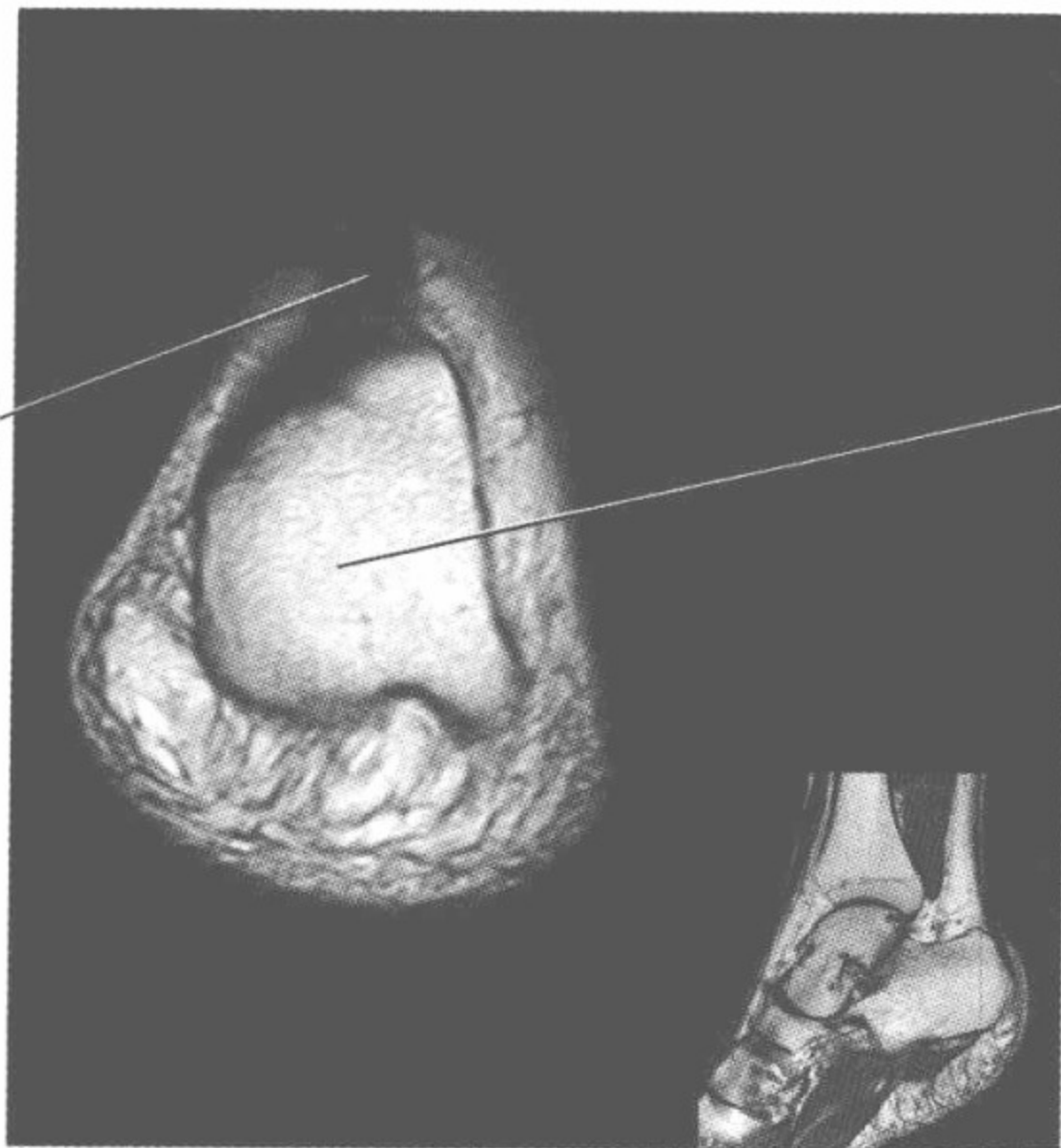

踝关节磁共振图谱

(冠状位)

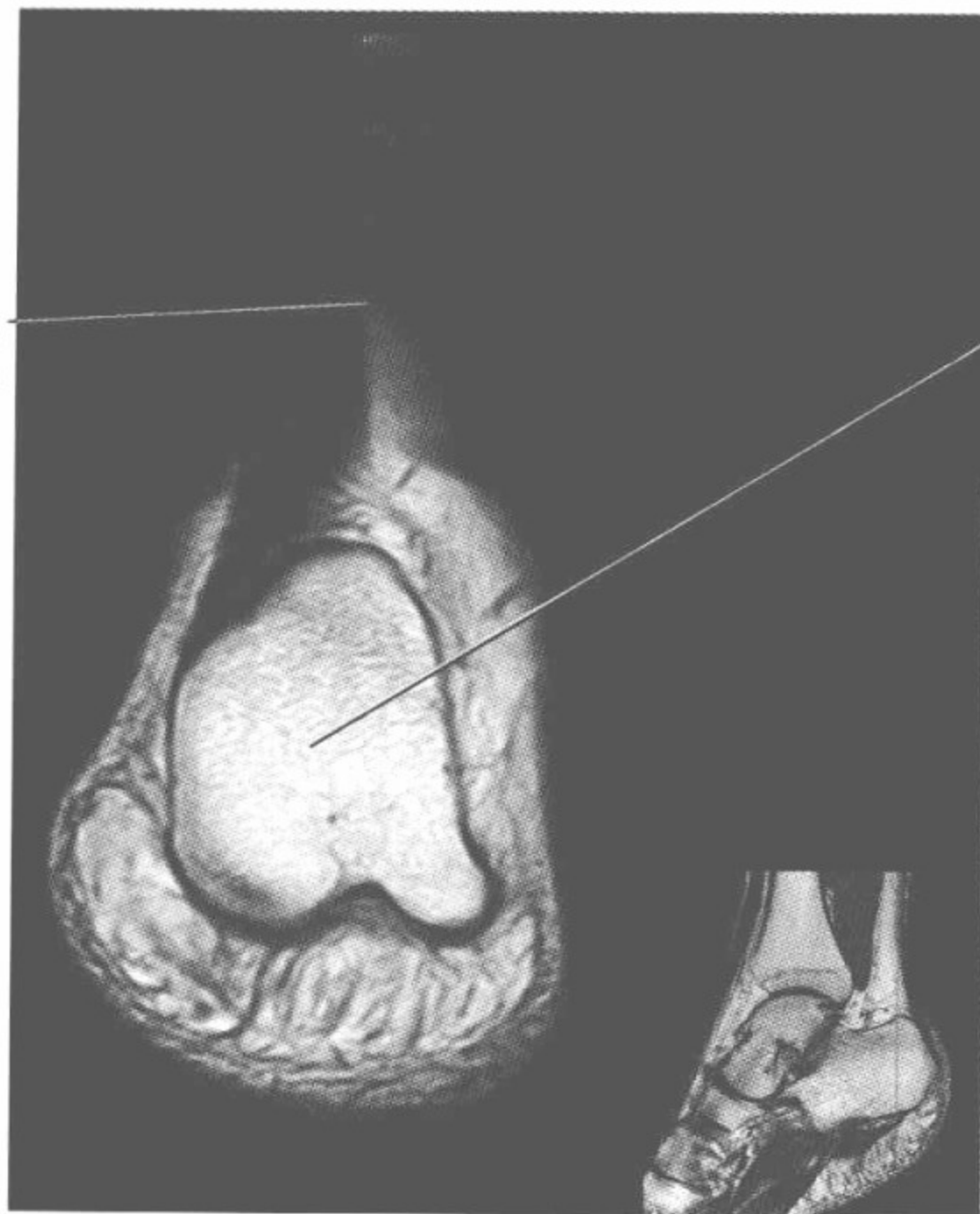


跟腱
Achilles tendon

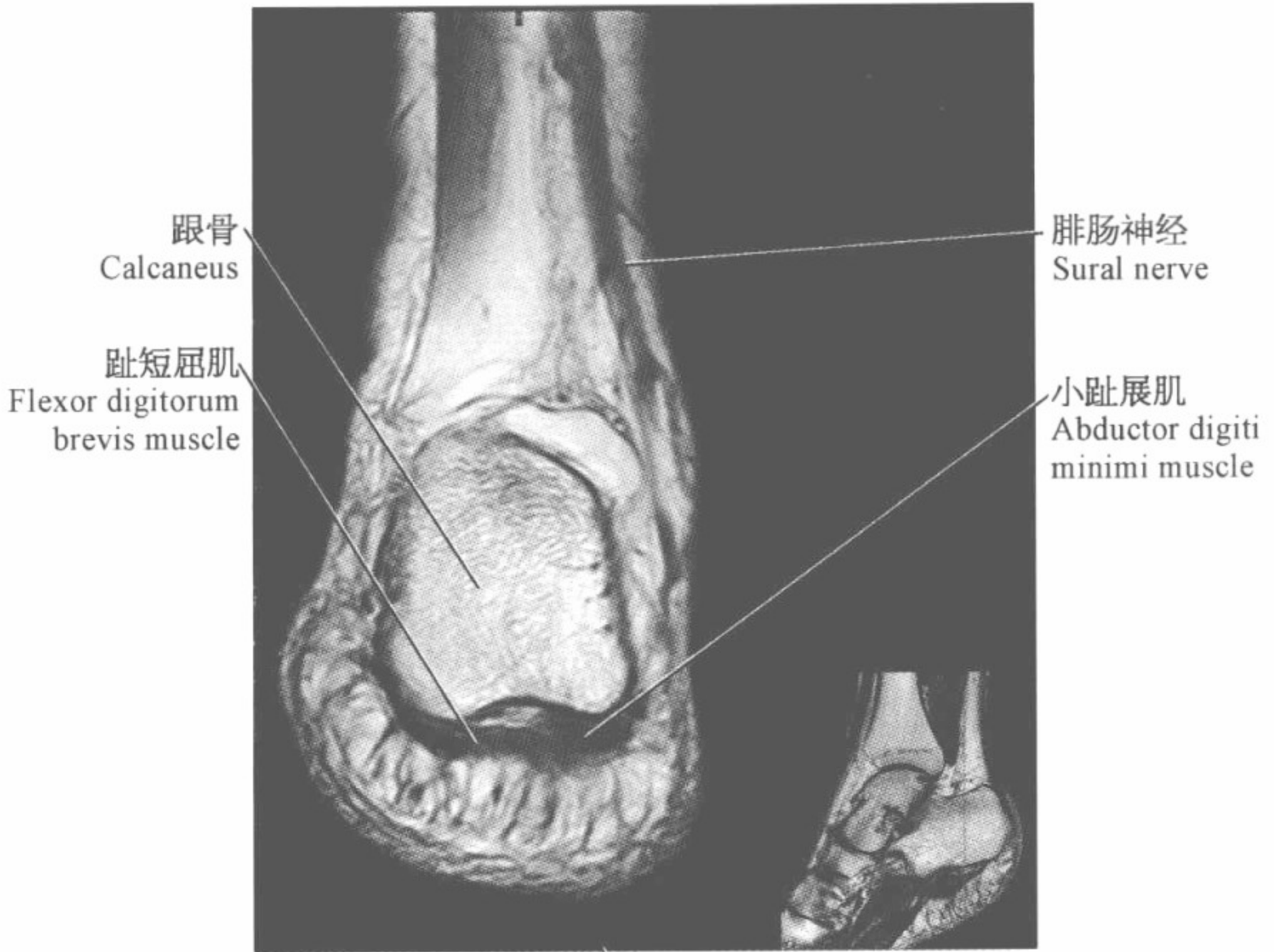
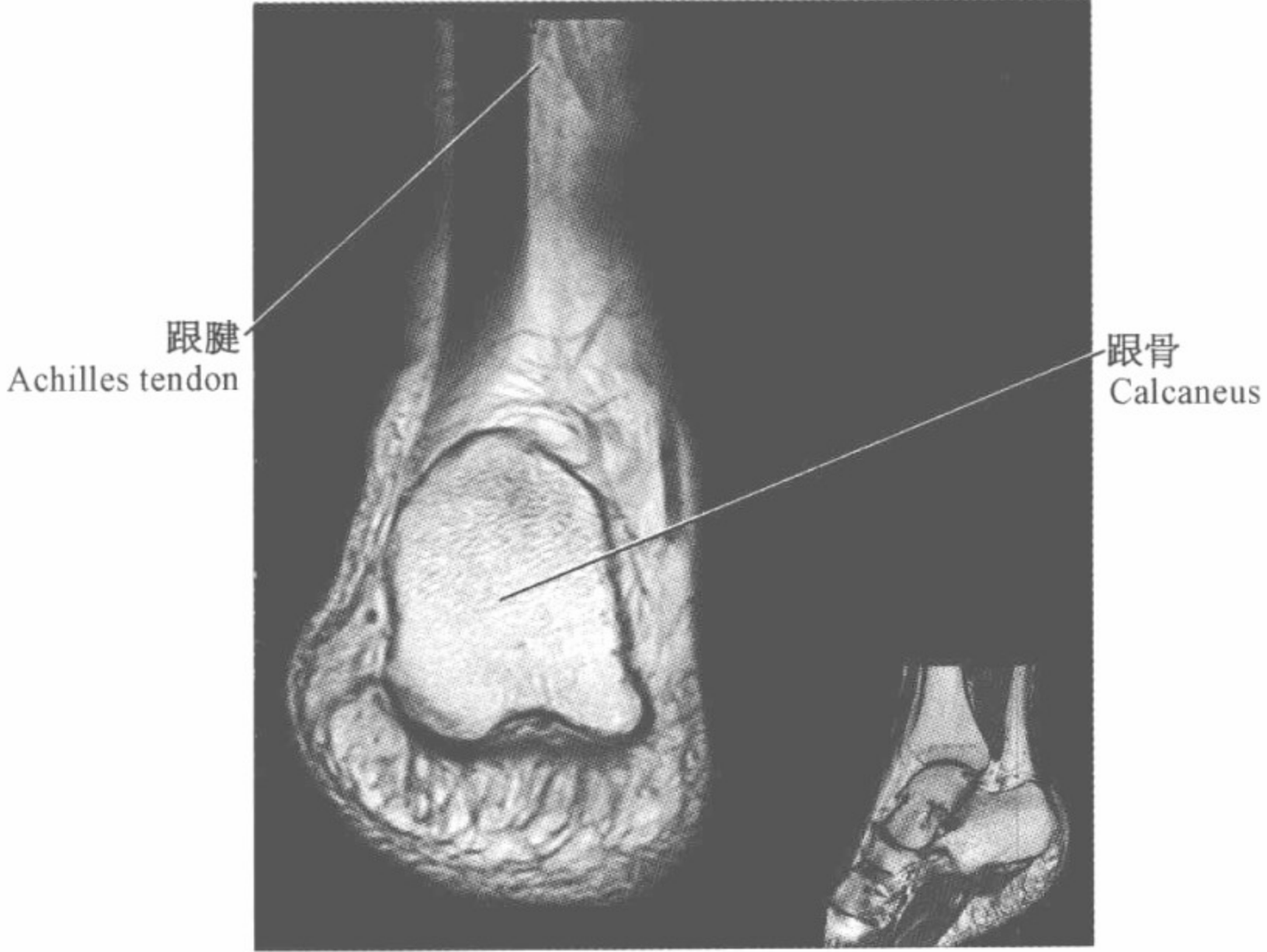

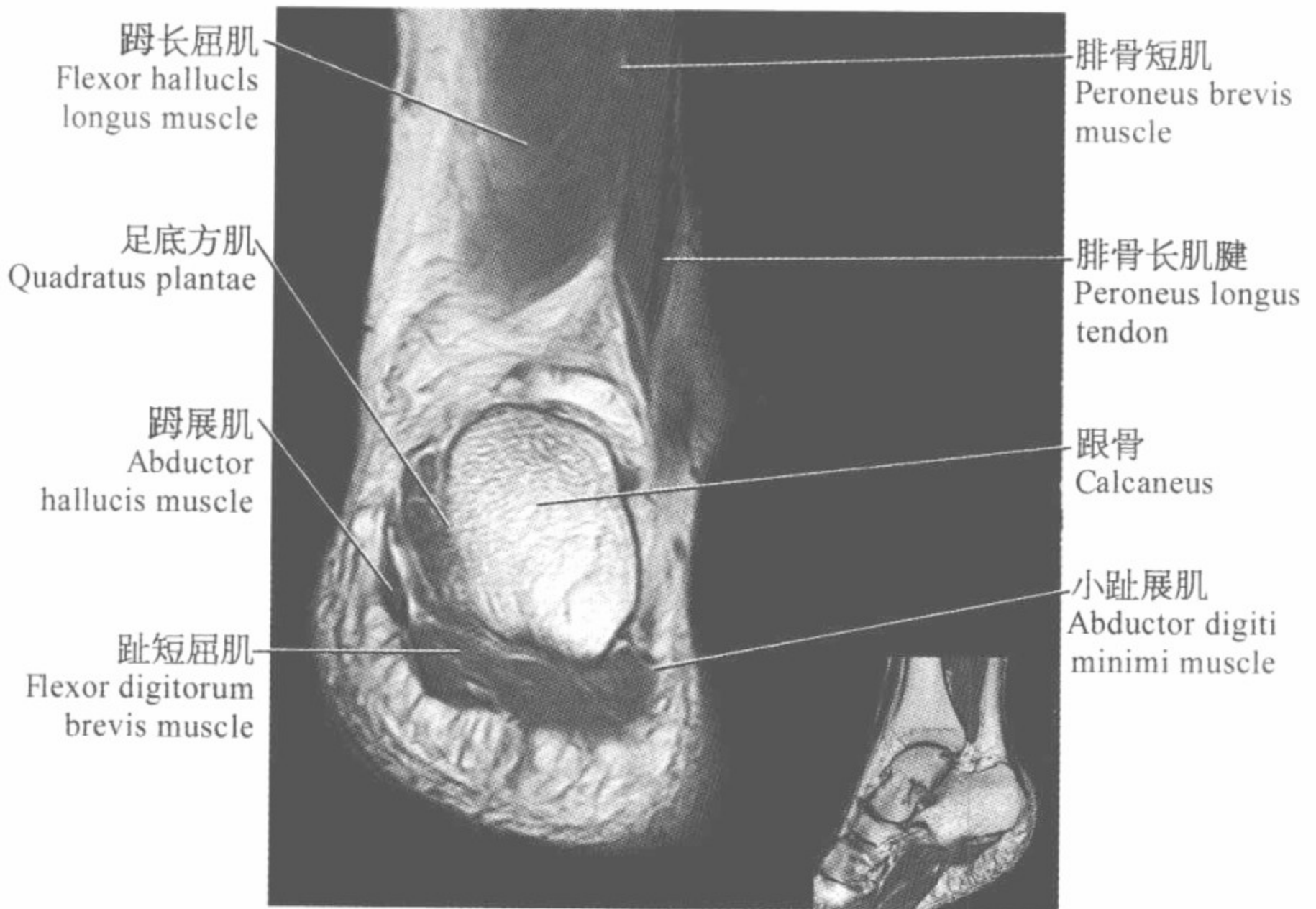
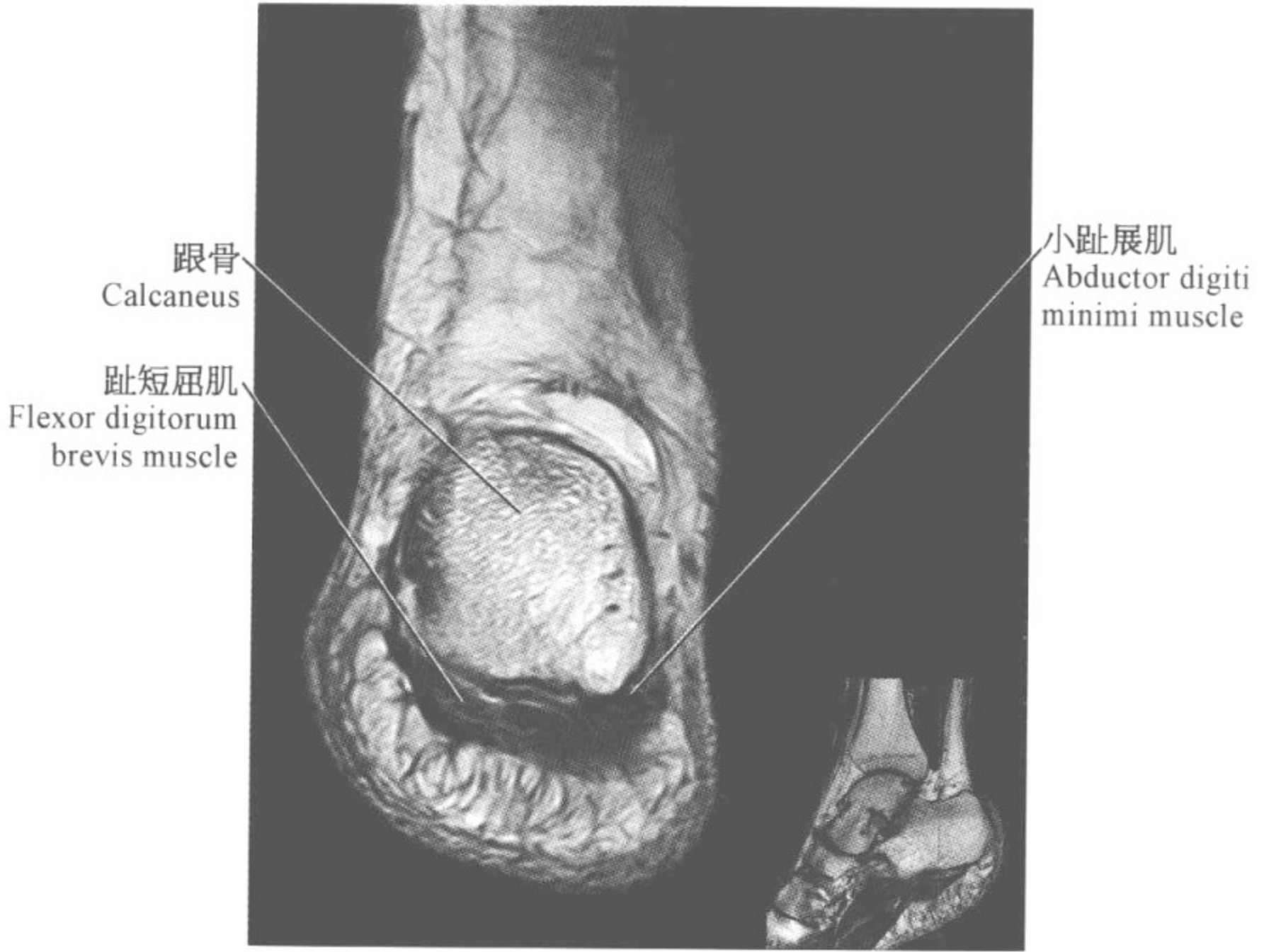
跟骨
Calcaneus

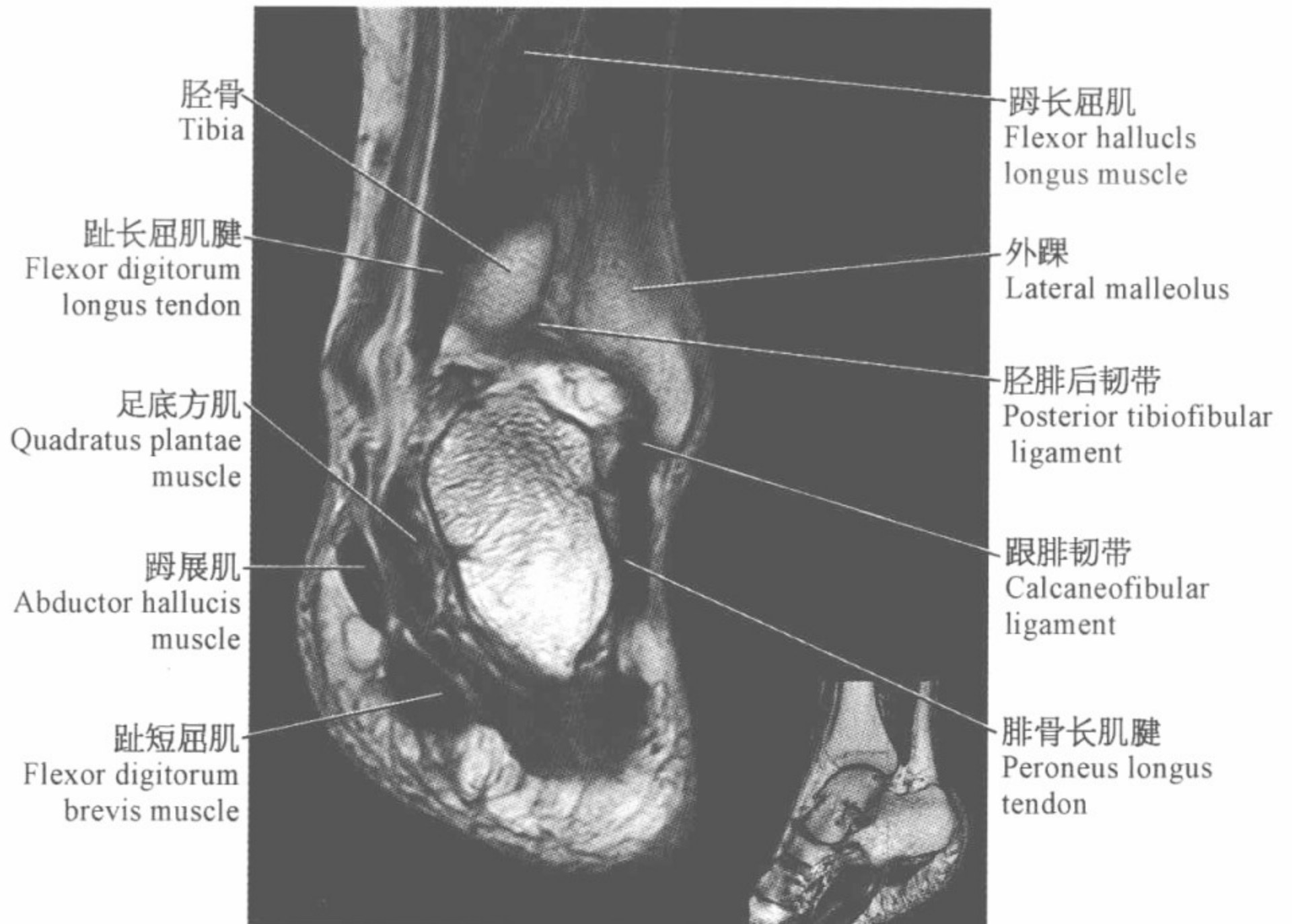
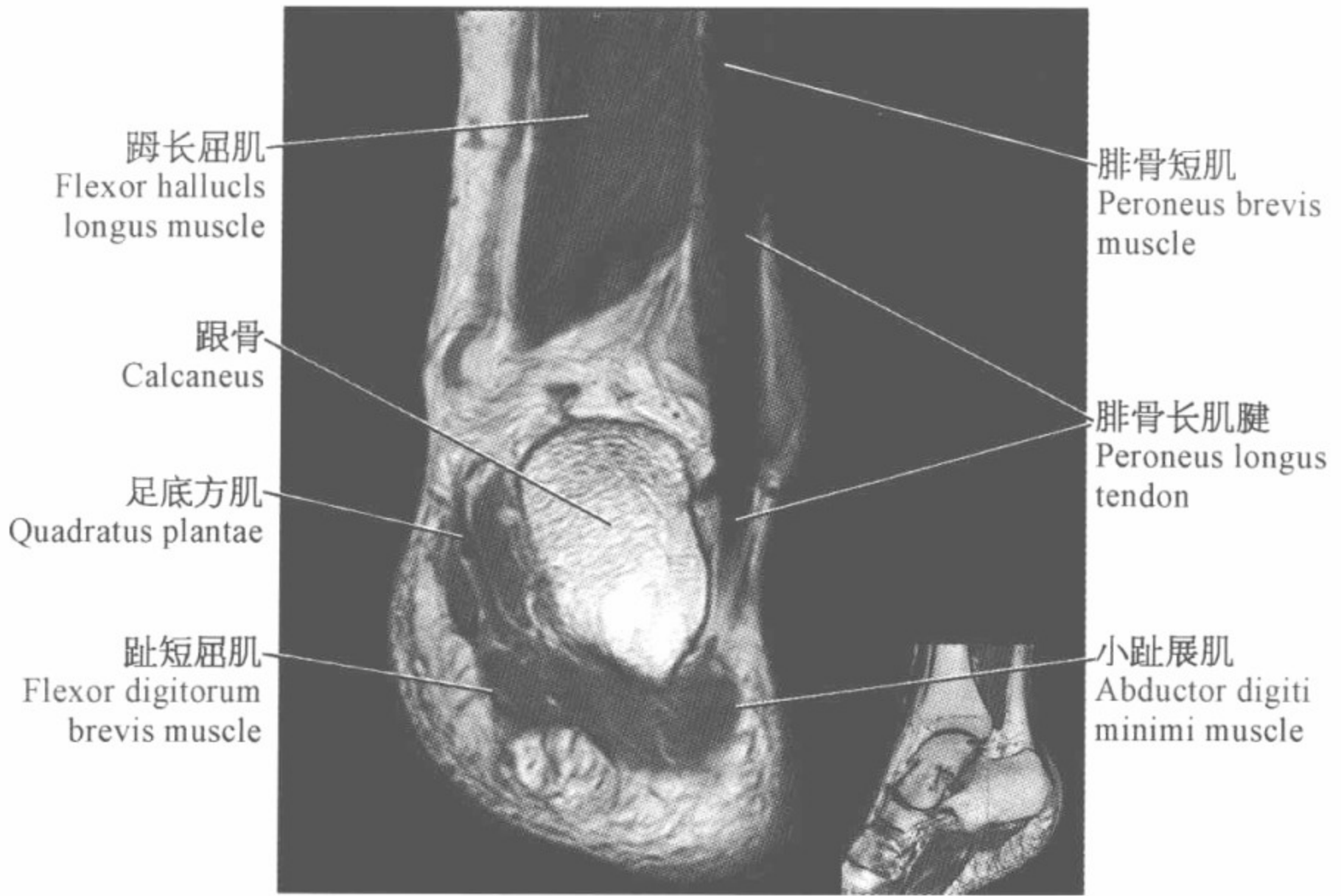
跟腱
Achilles tendon

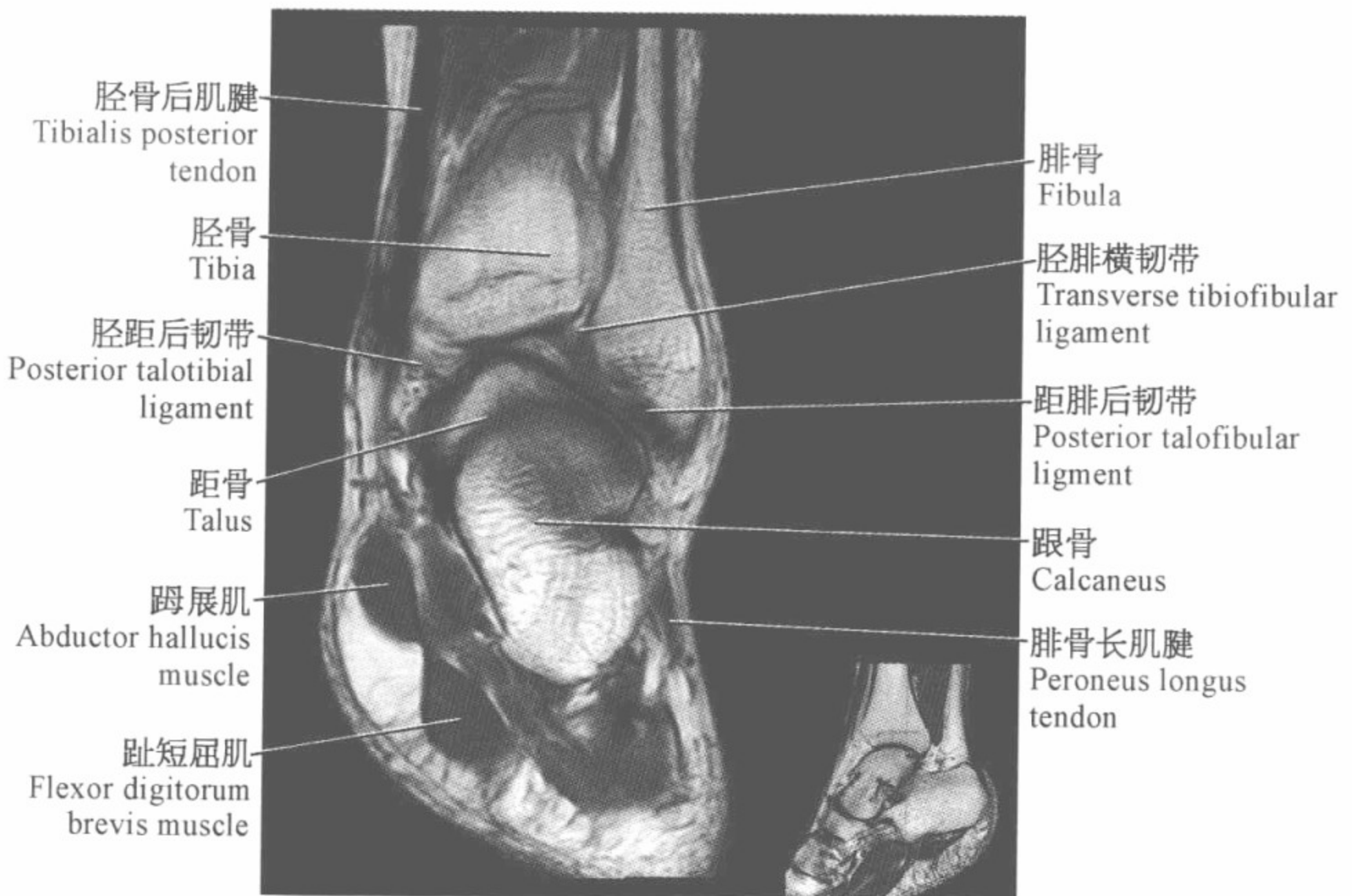
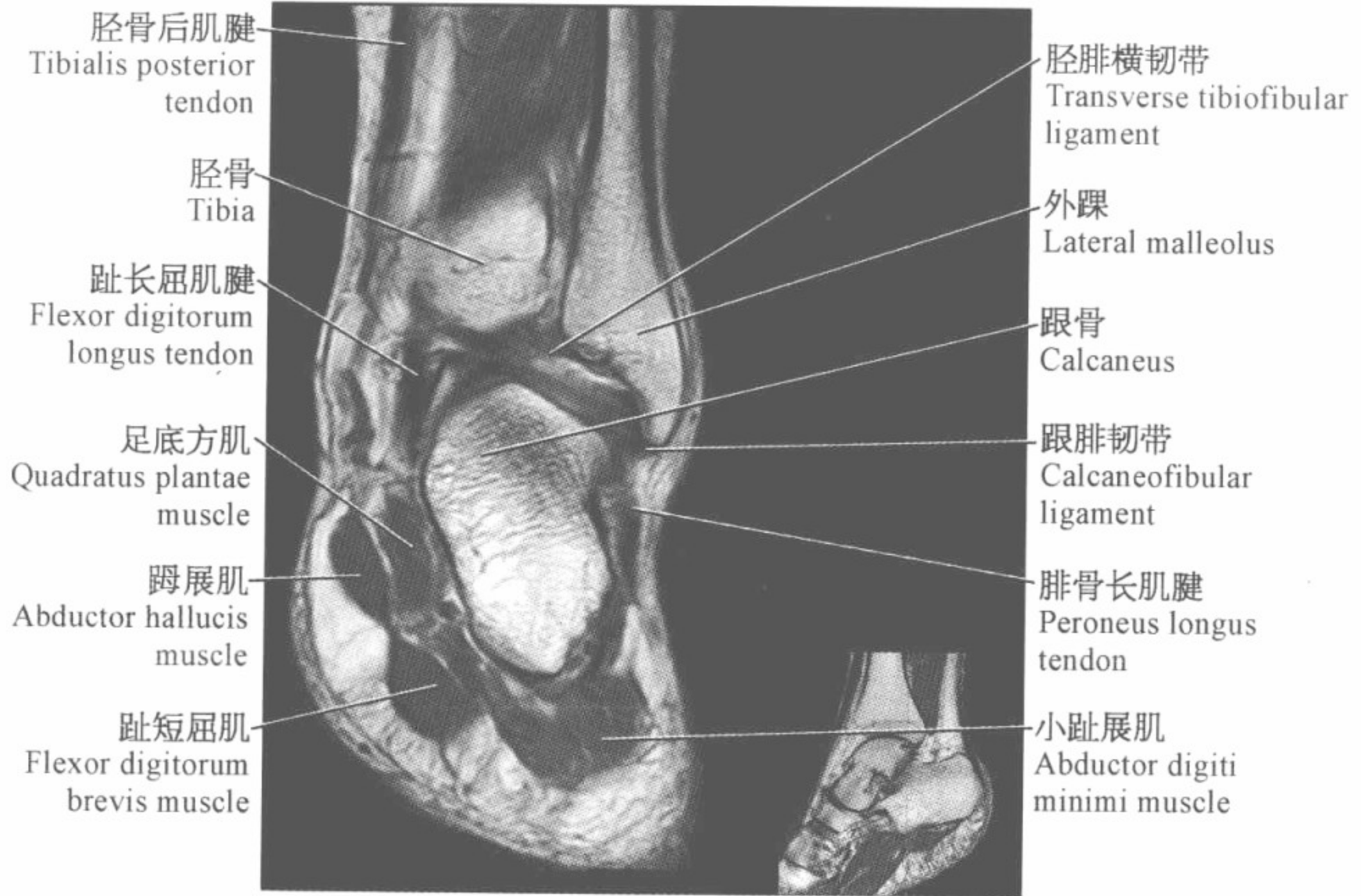


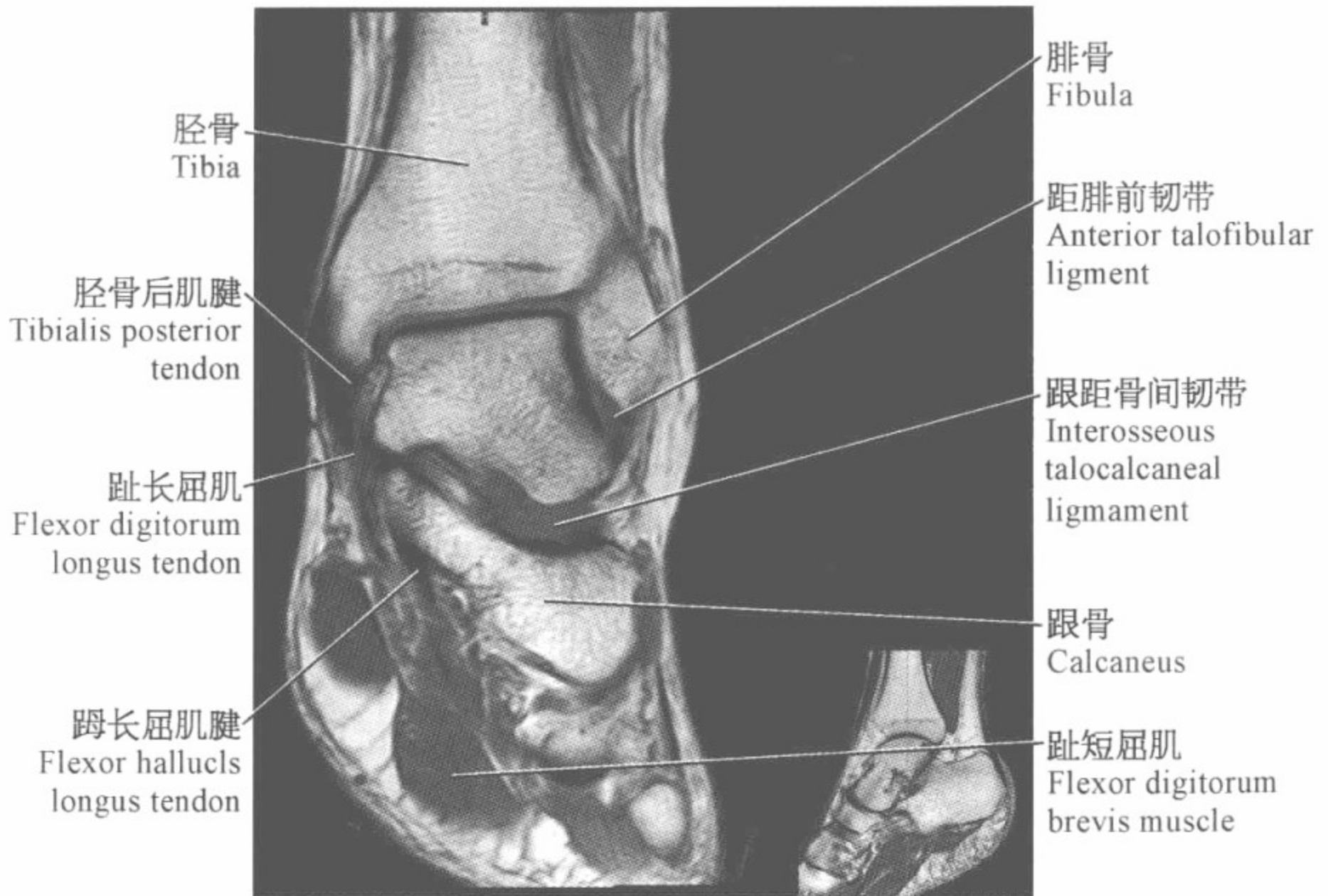
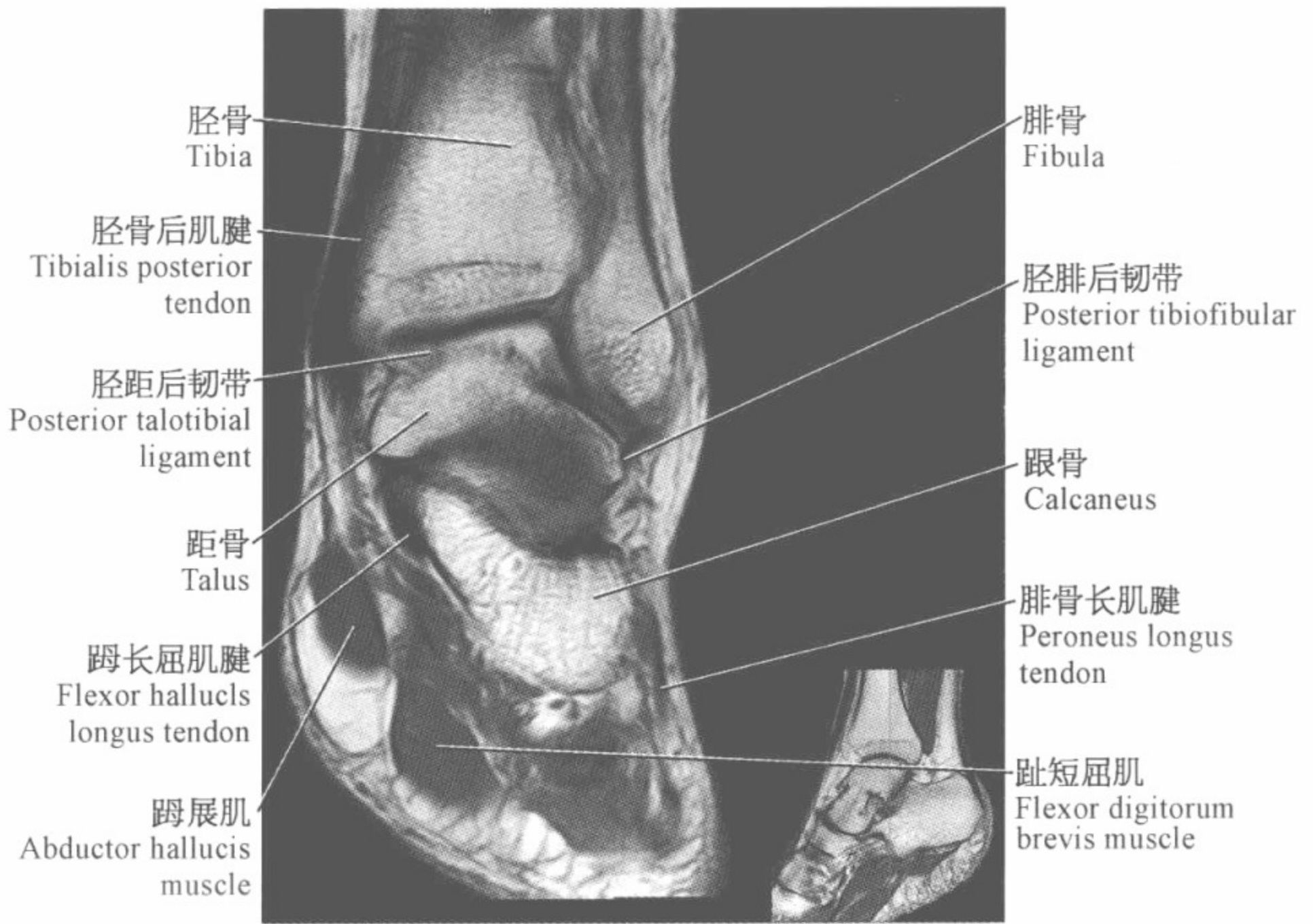
跟骨
Calcaneus

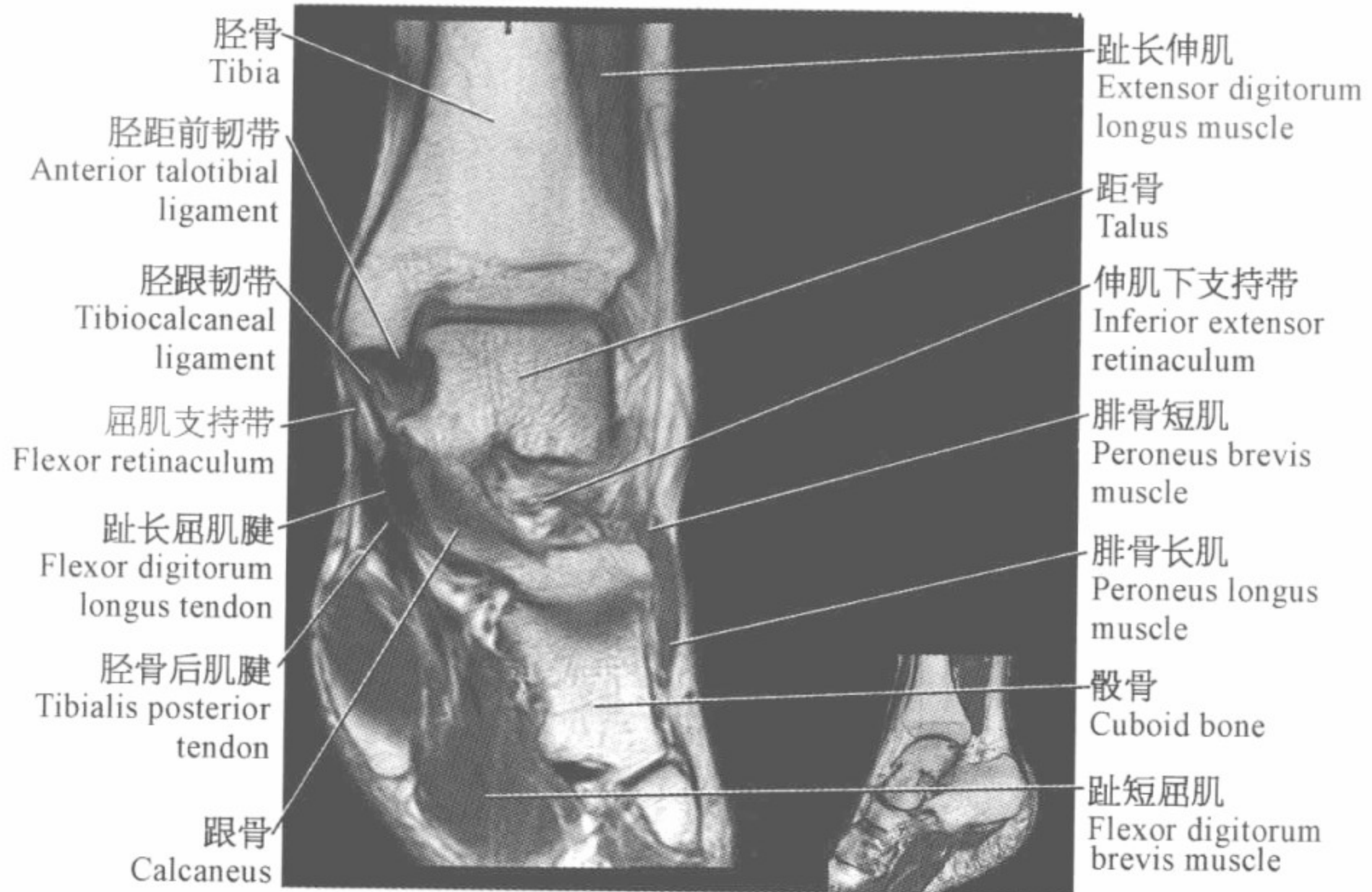
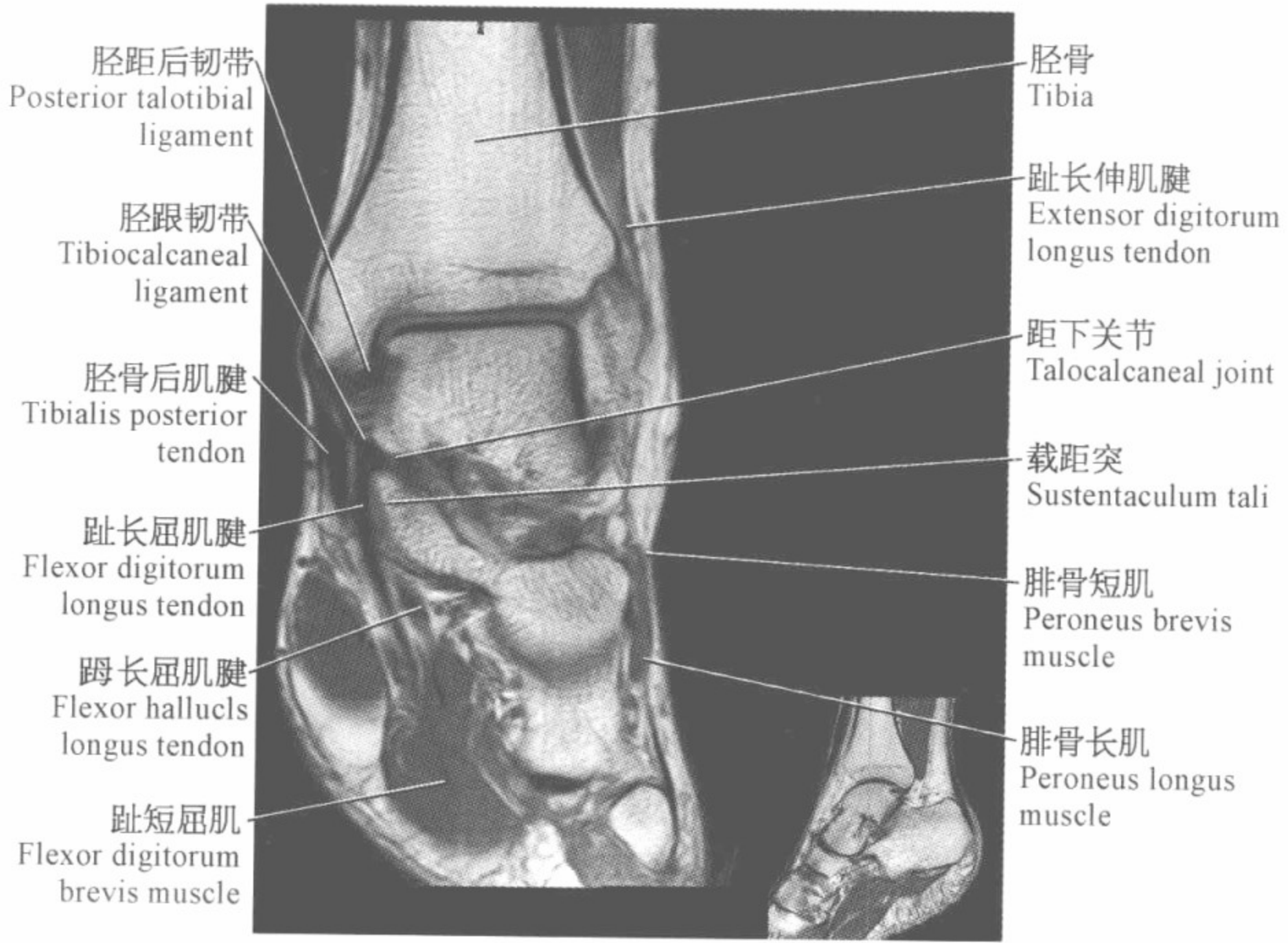


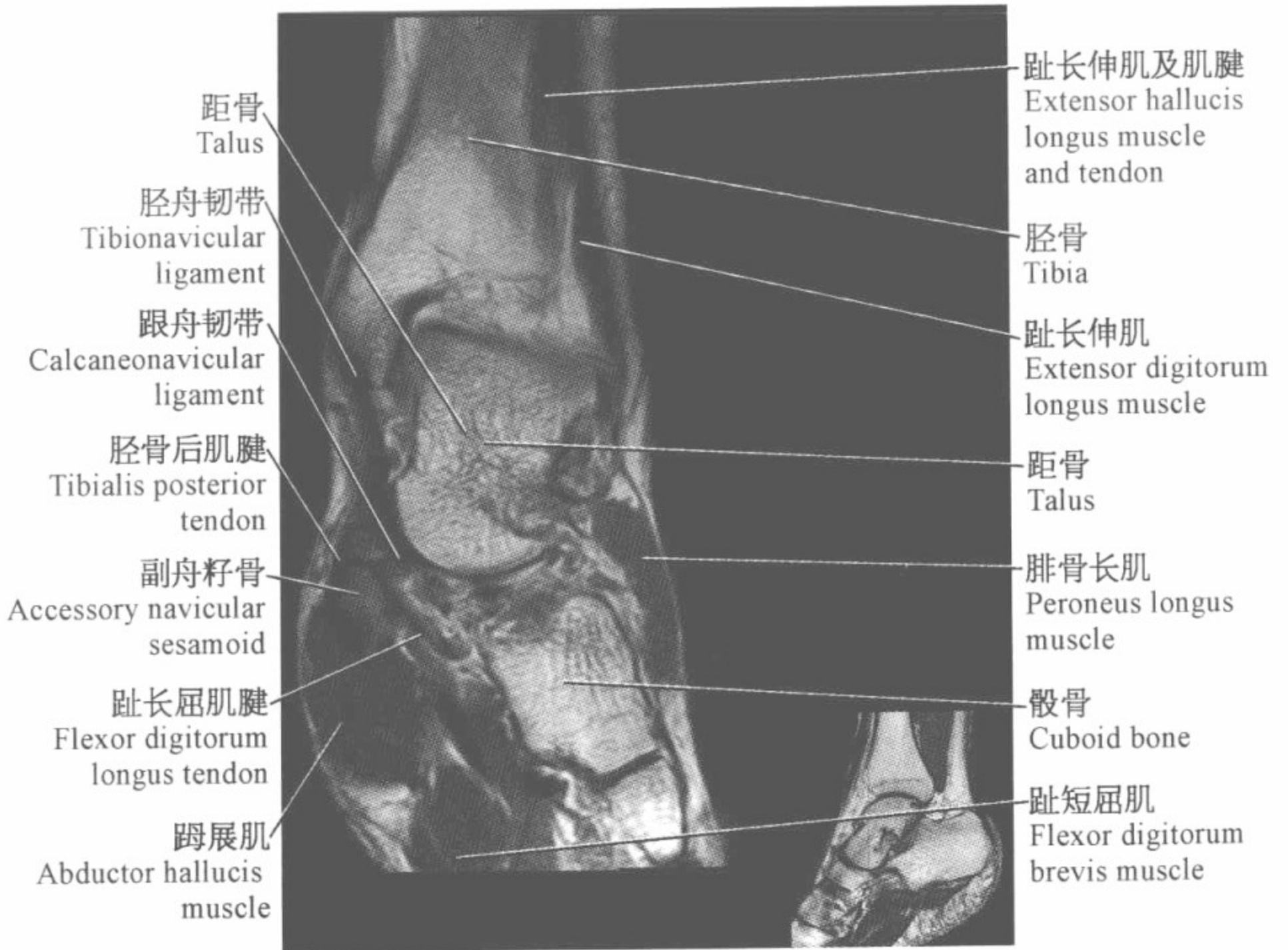
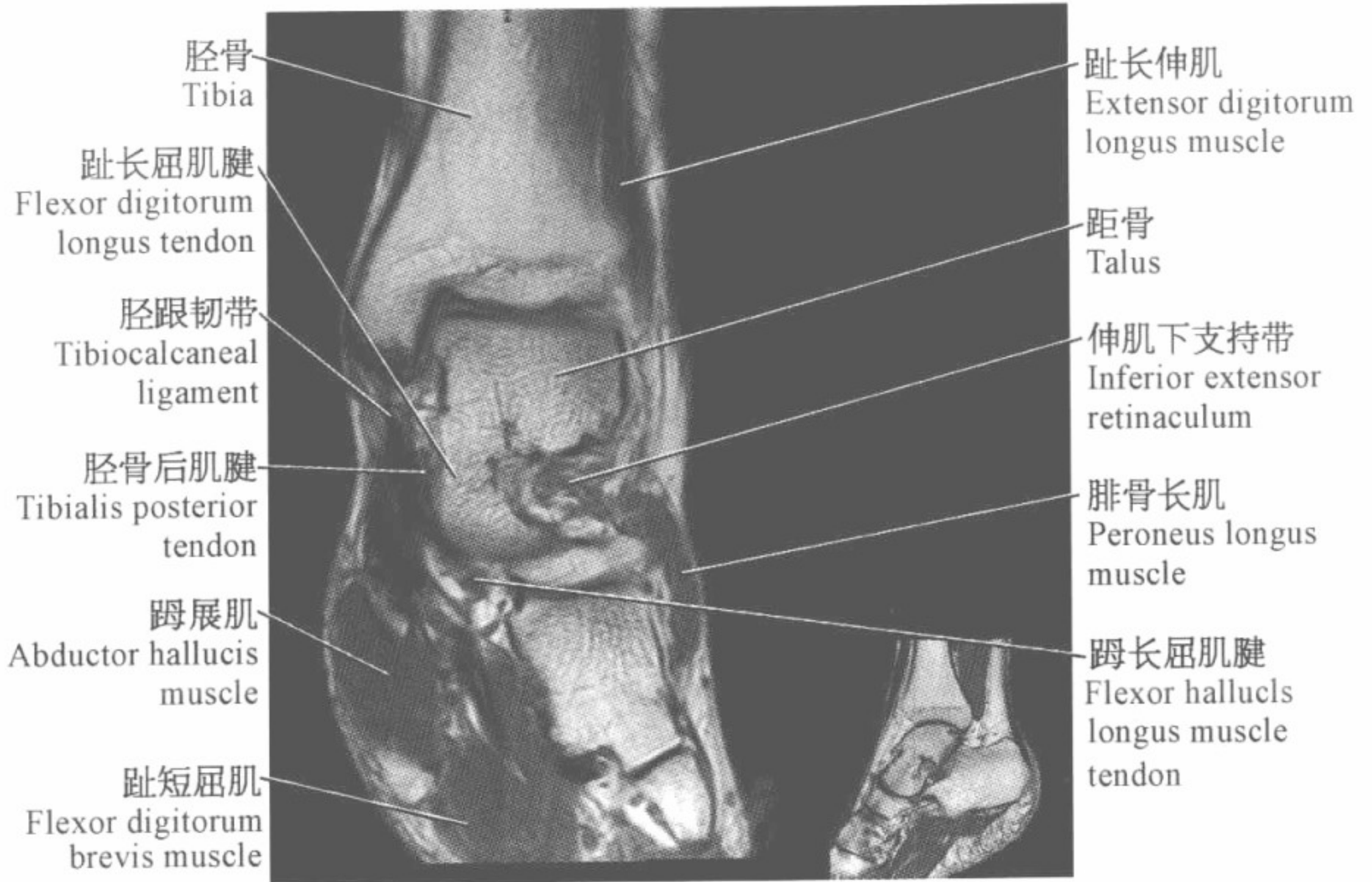


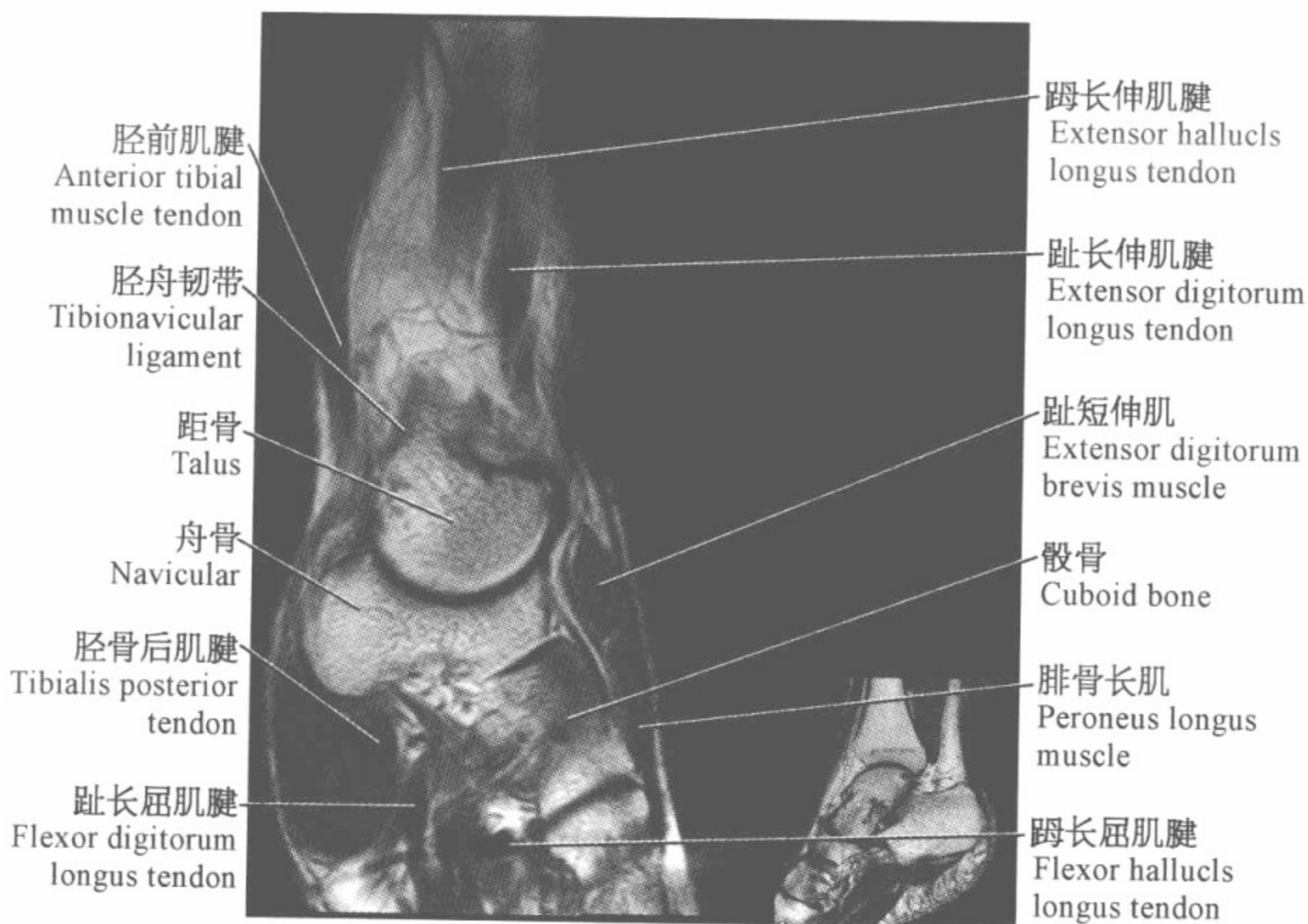
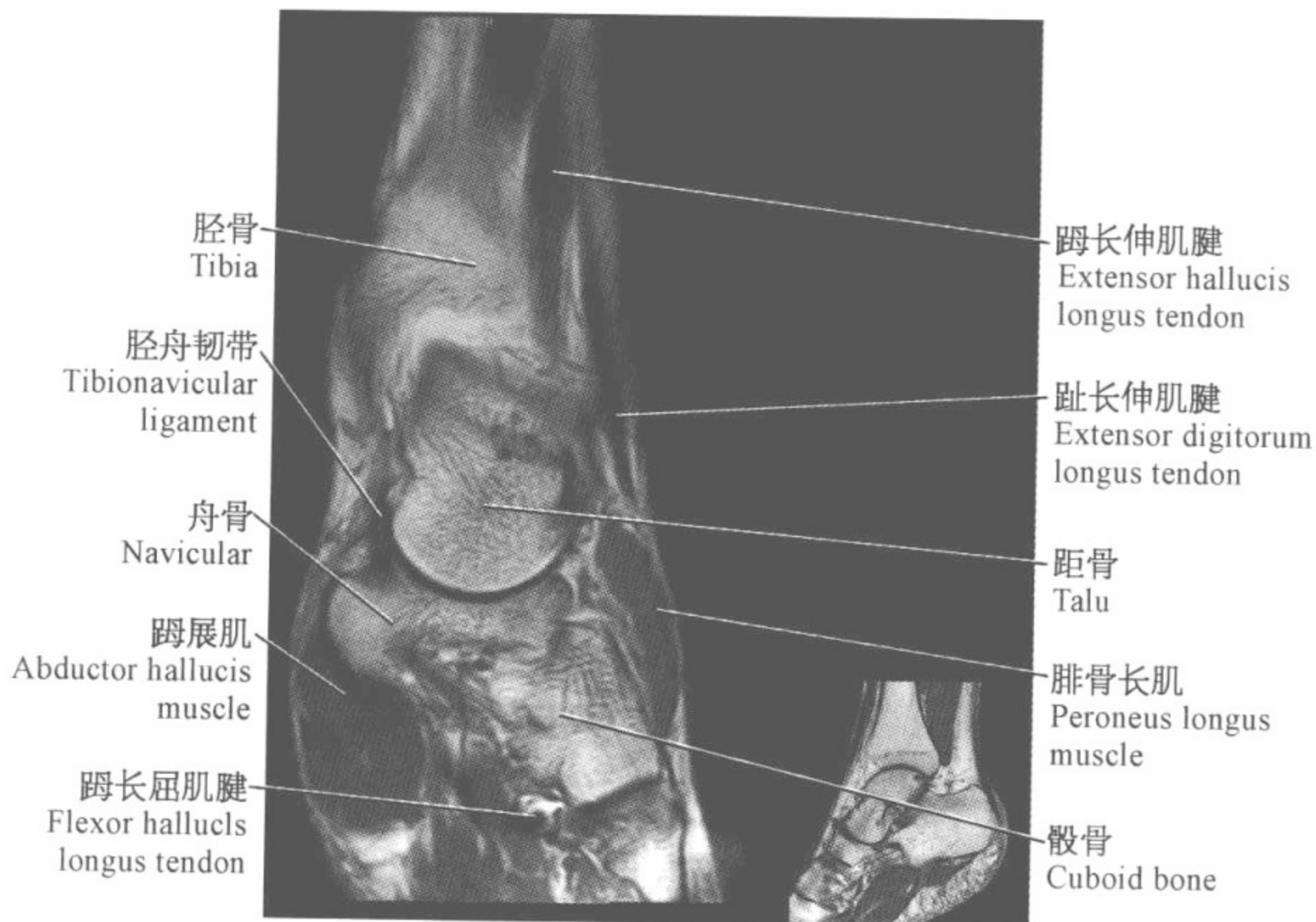


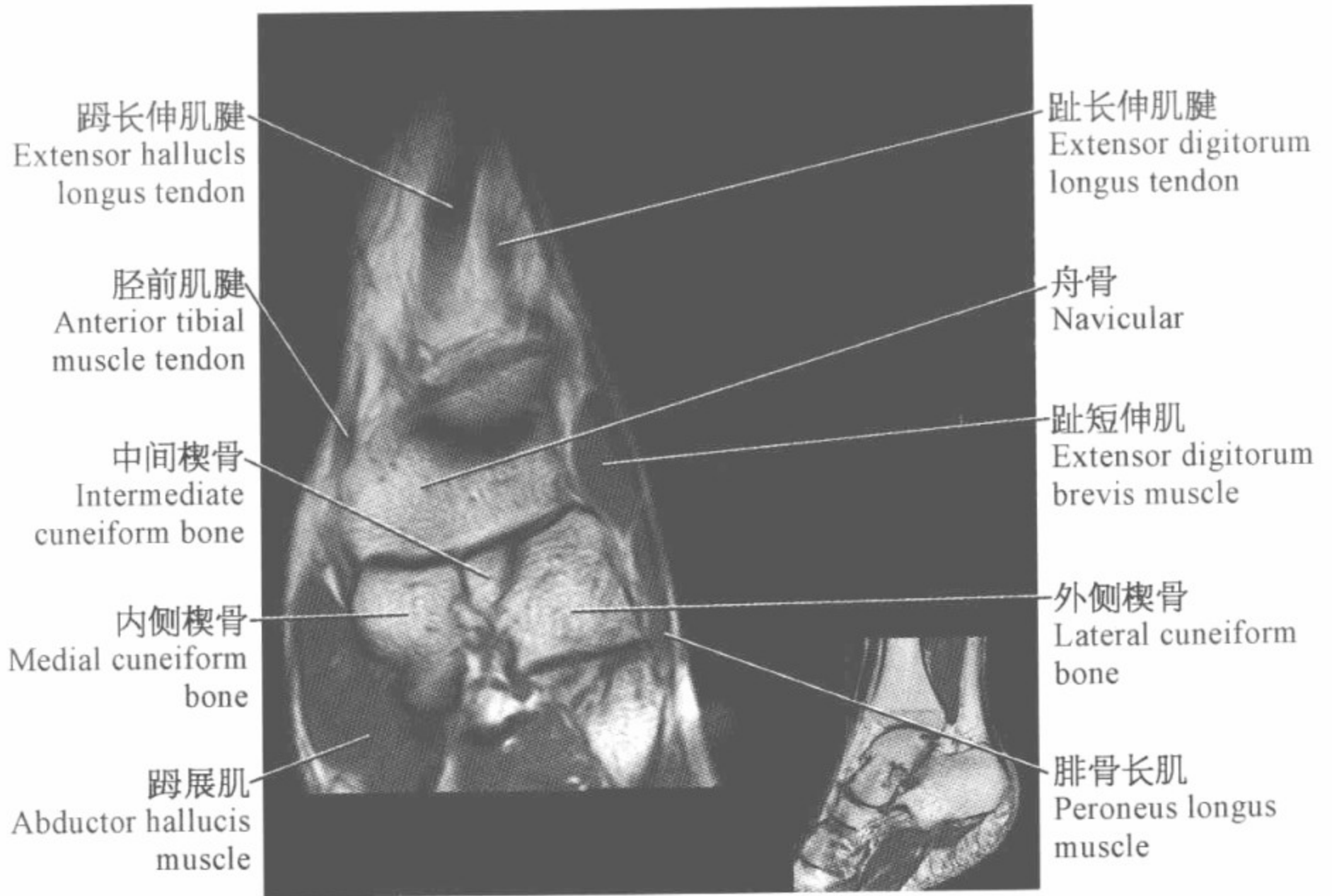
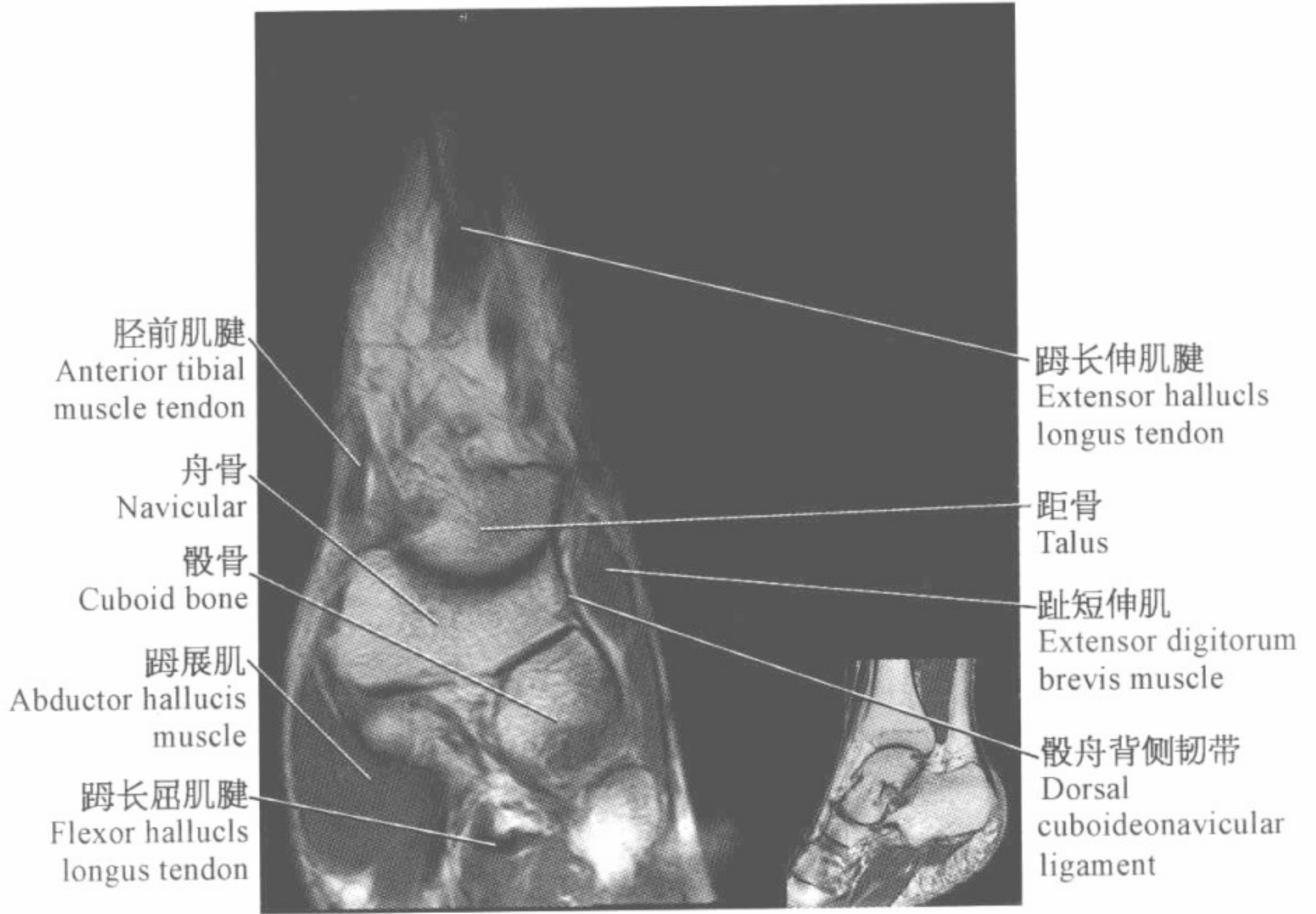


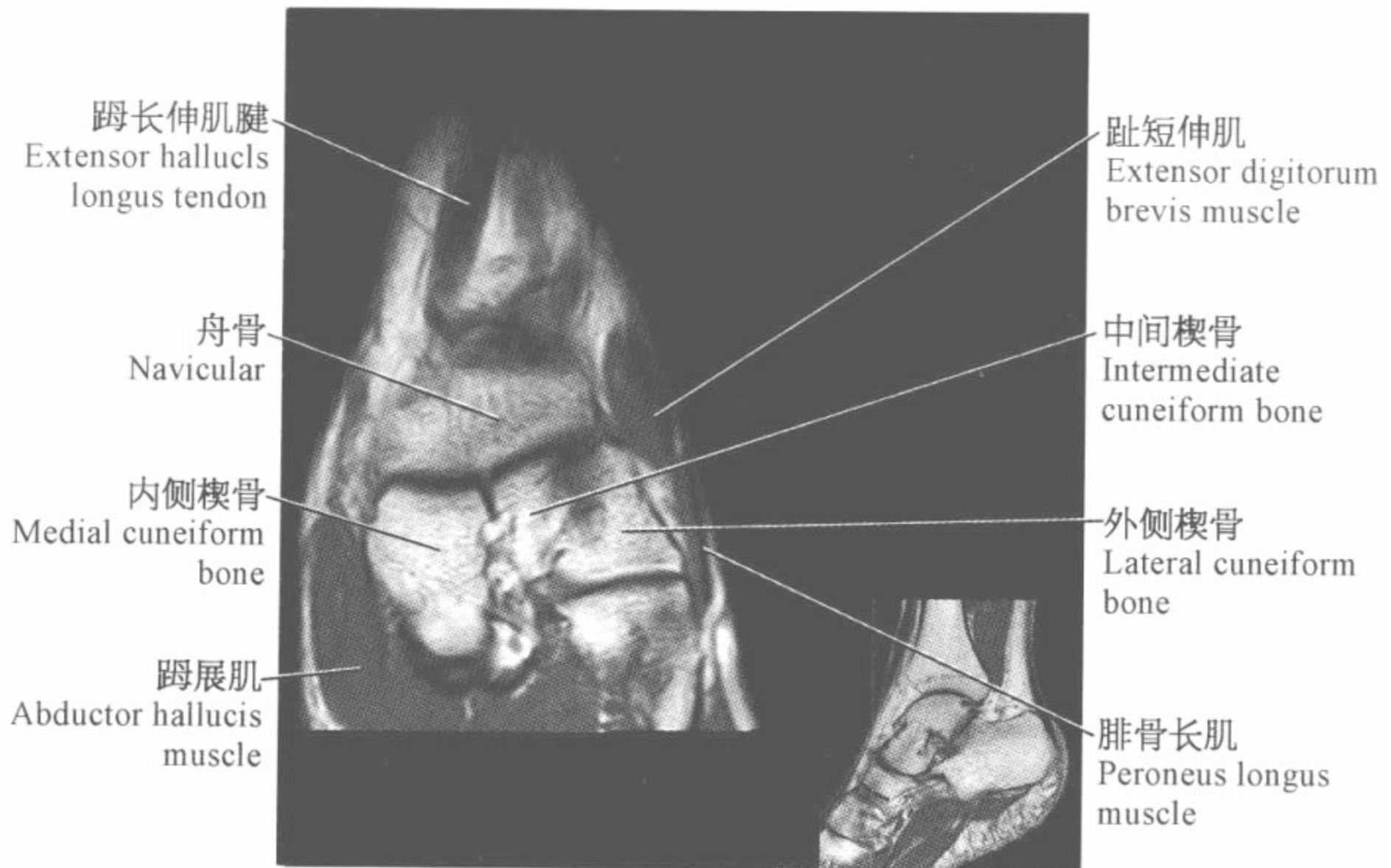








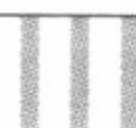

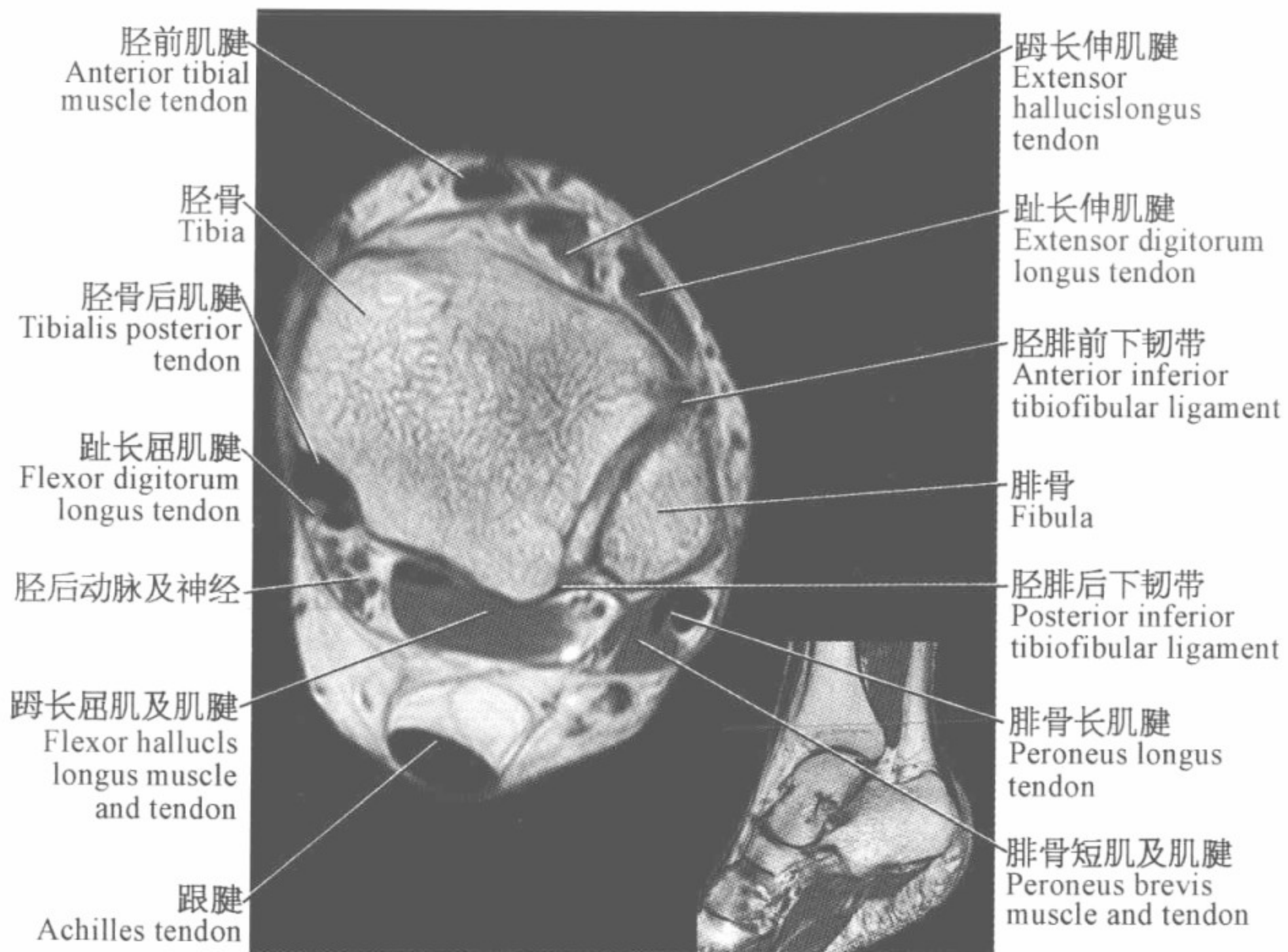
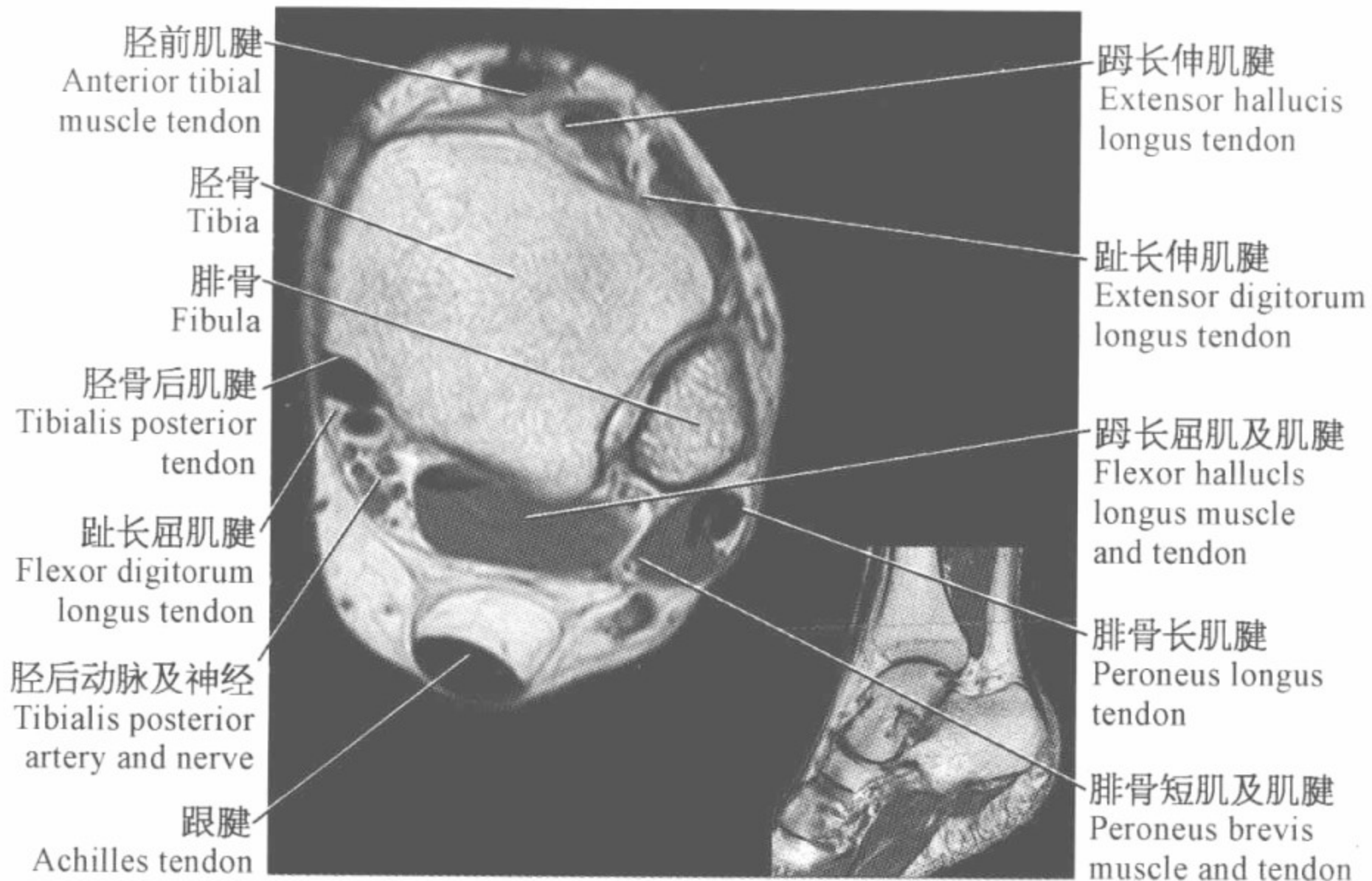


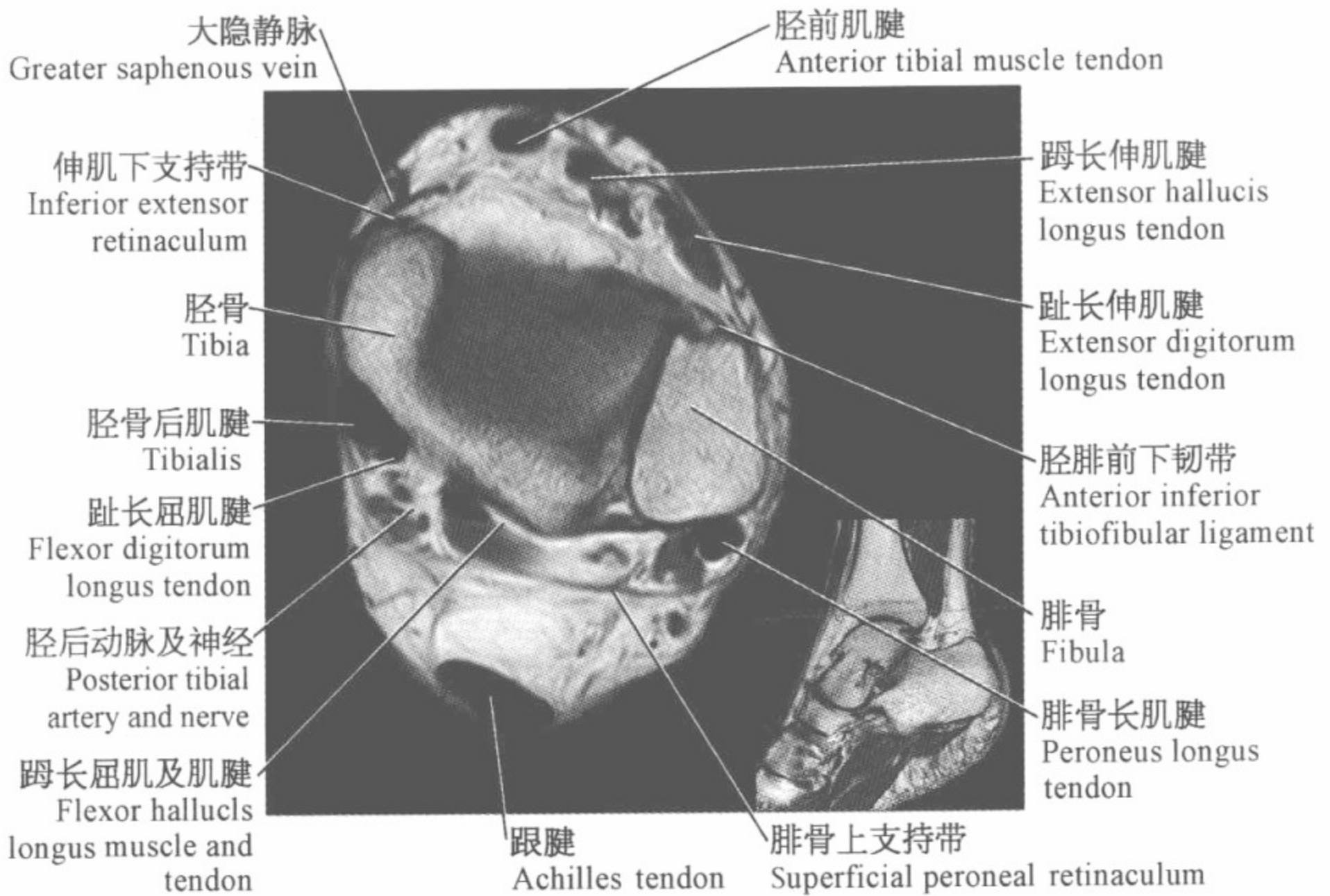
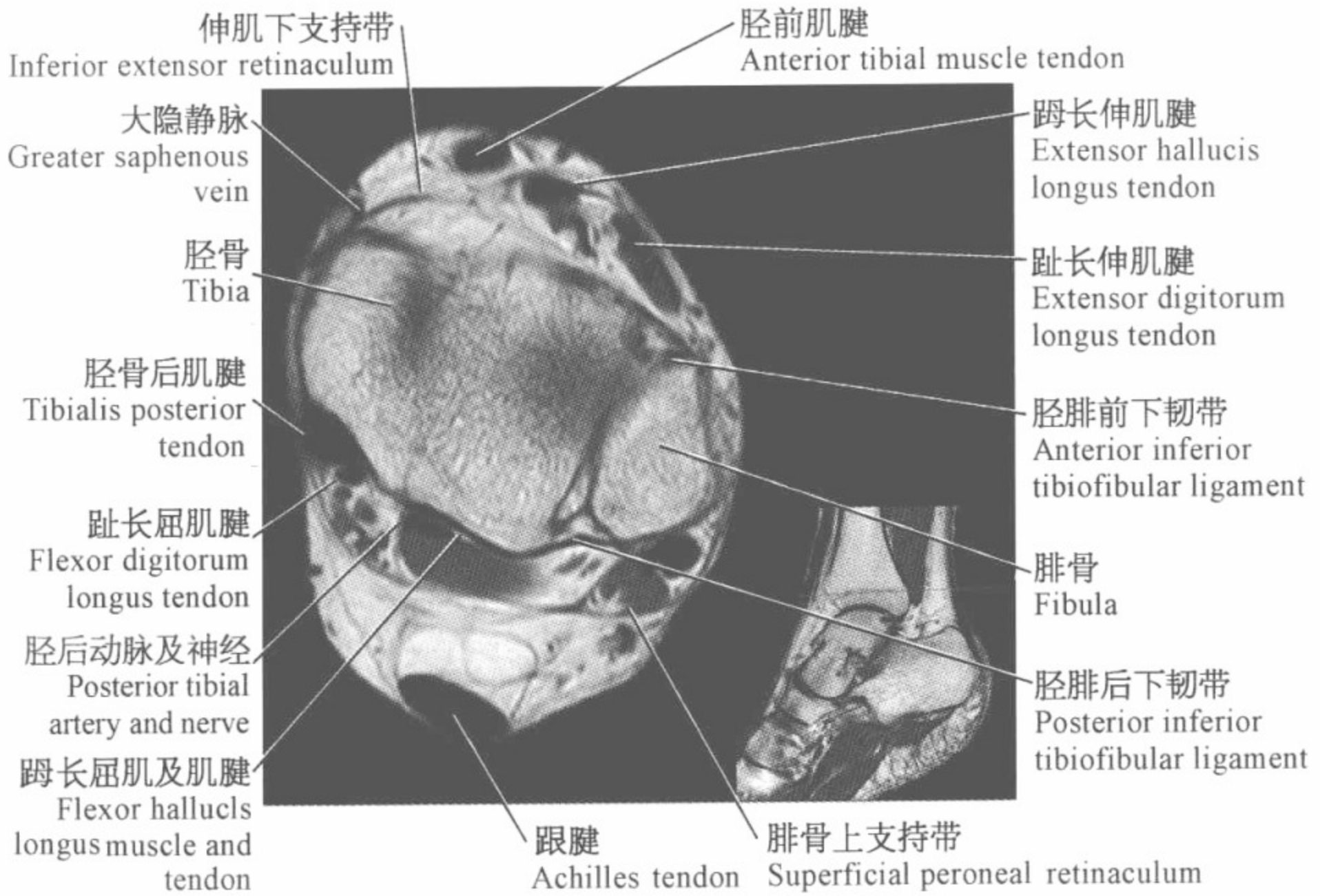


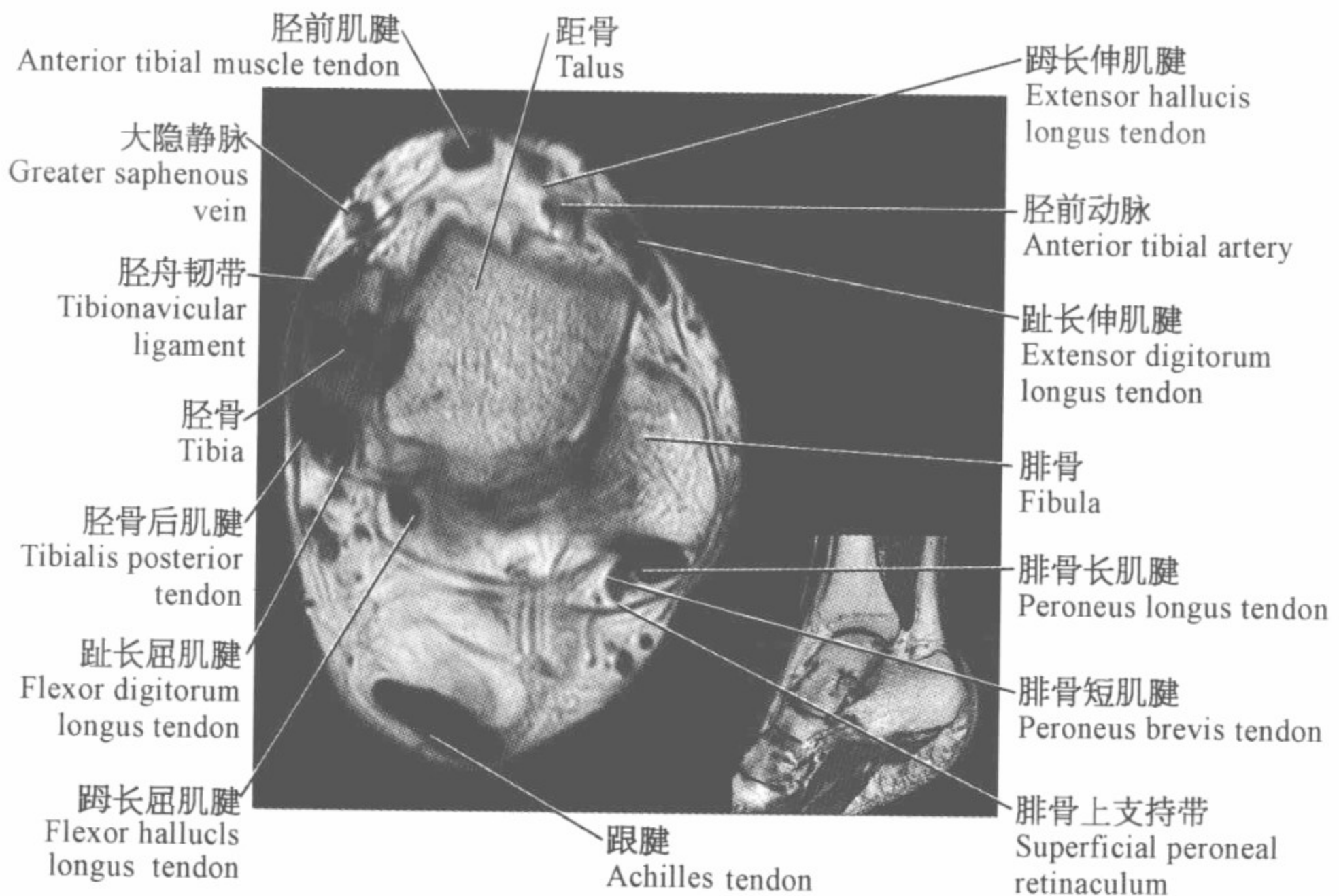
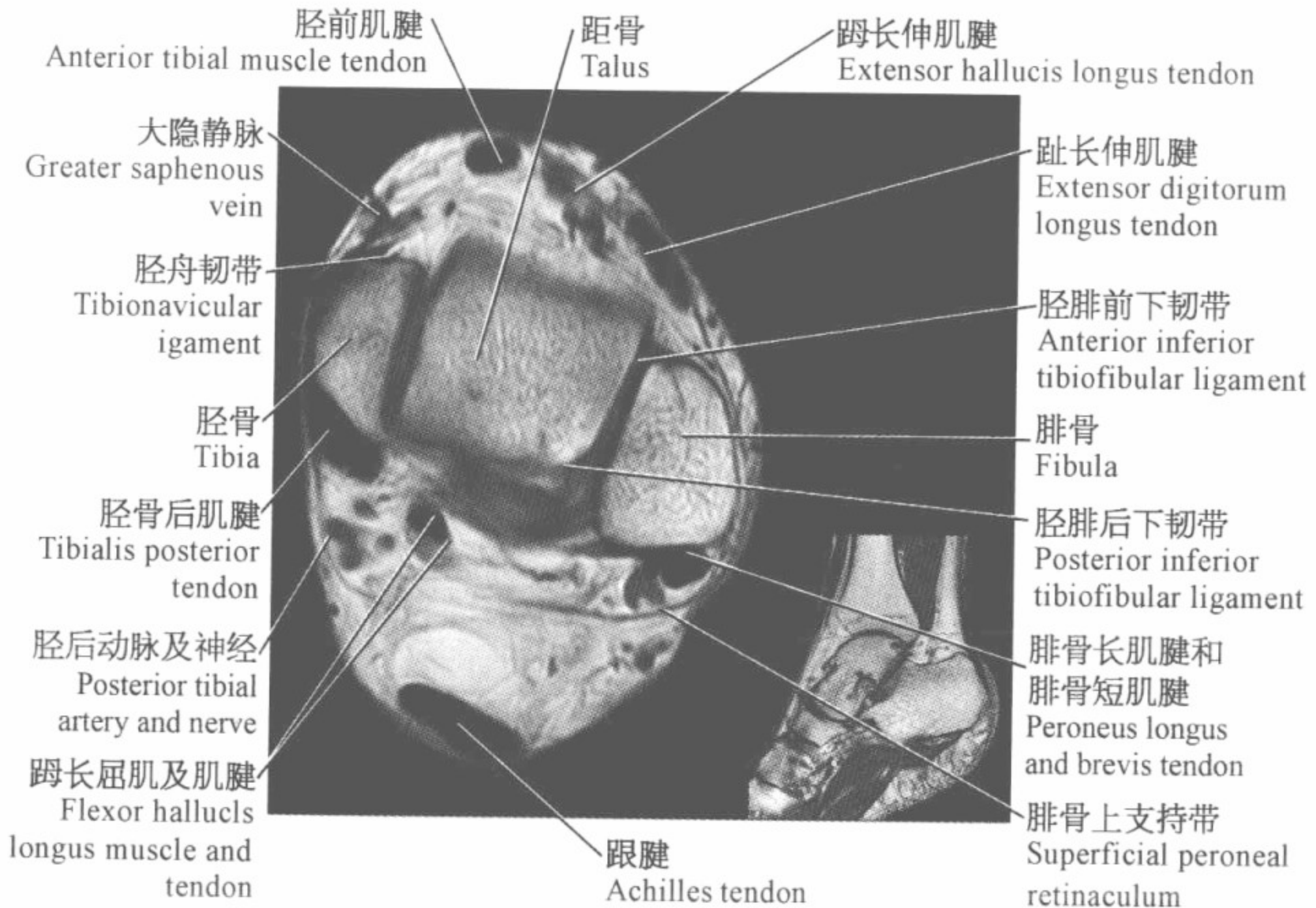
踝关节磁共振图谱

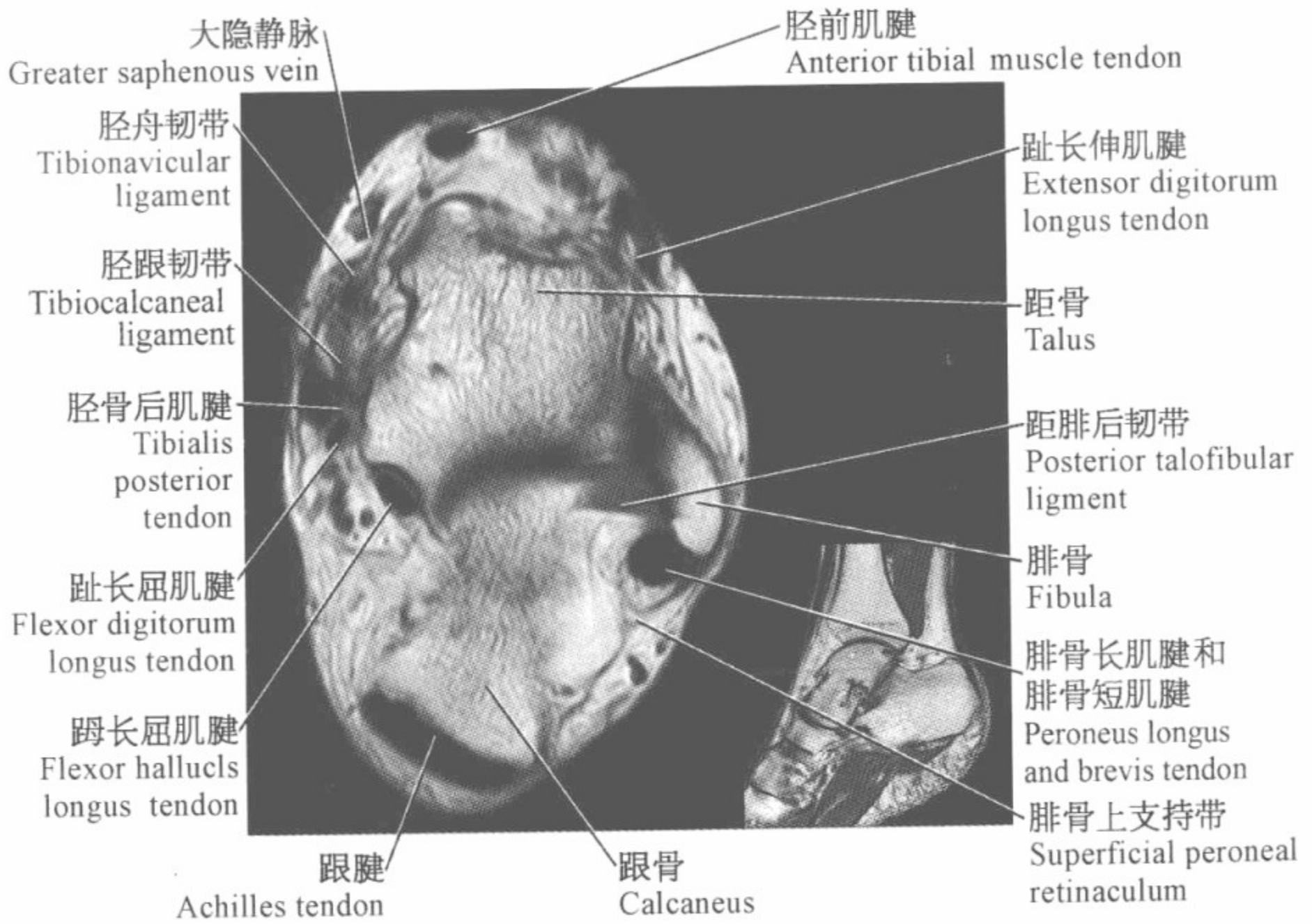
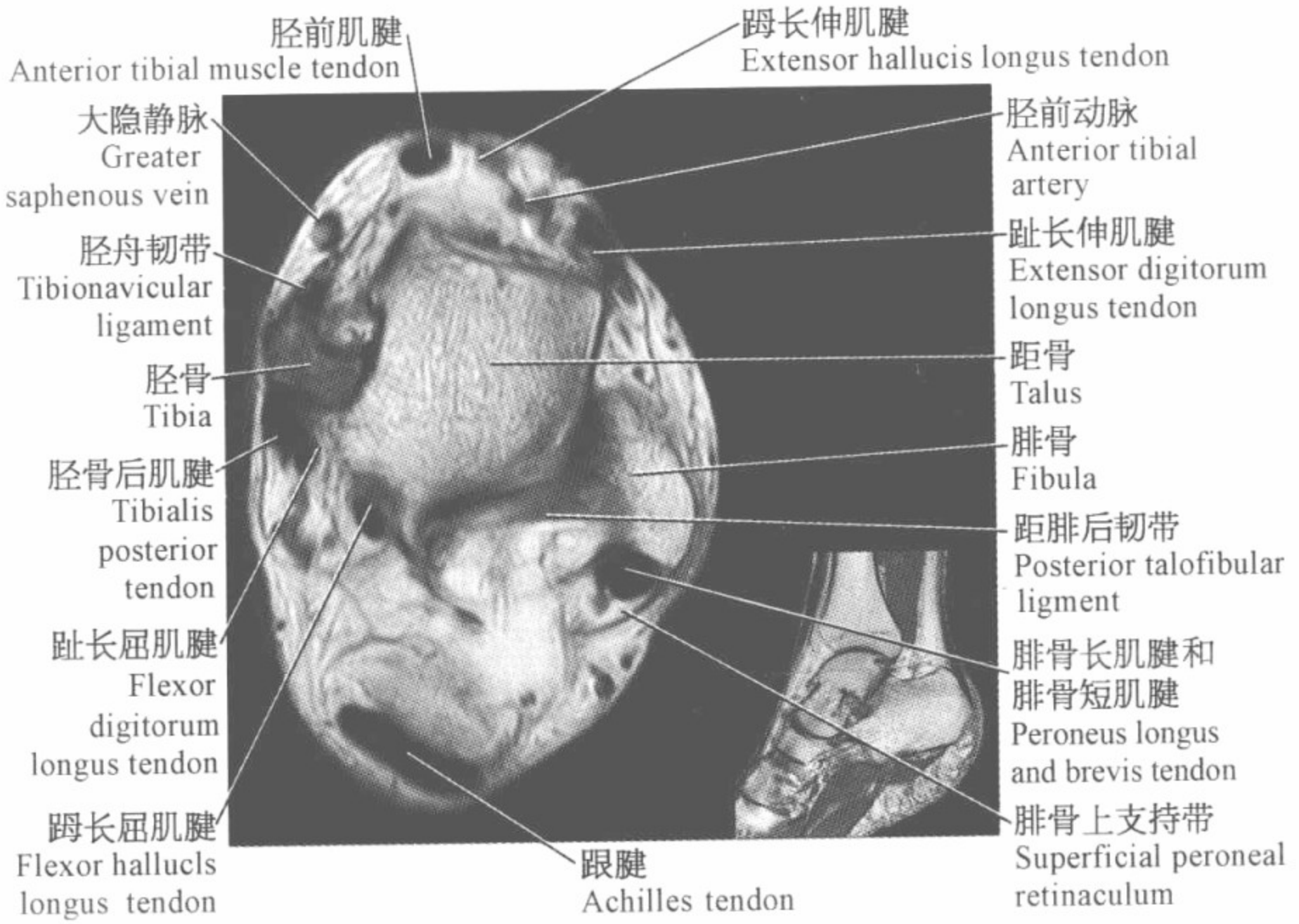
(横断位)

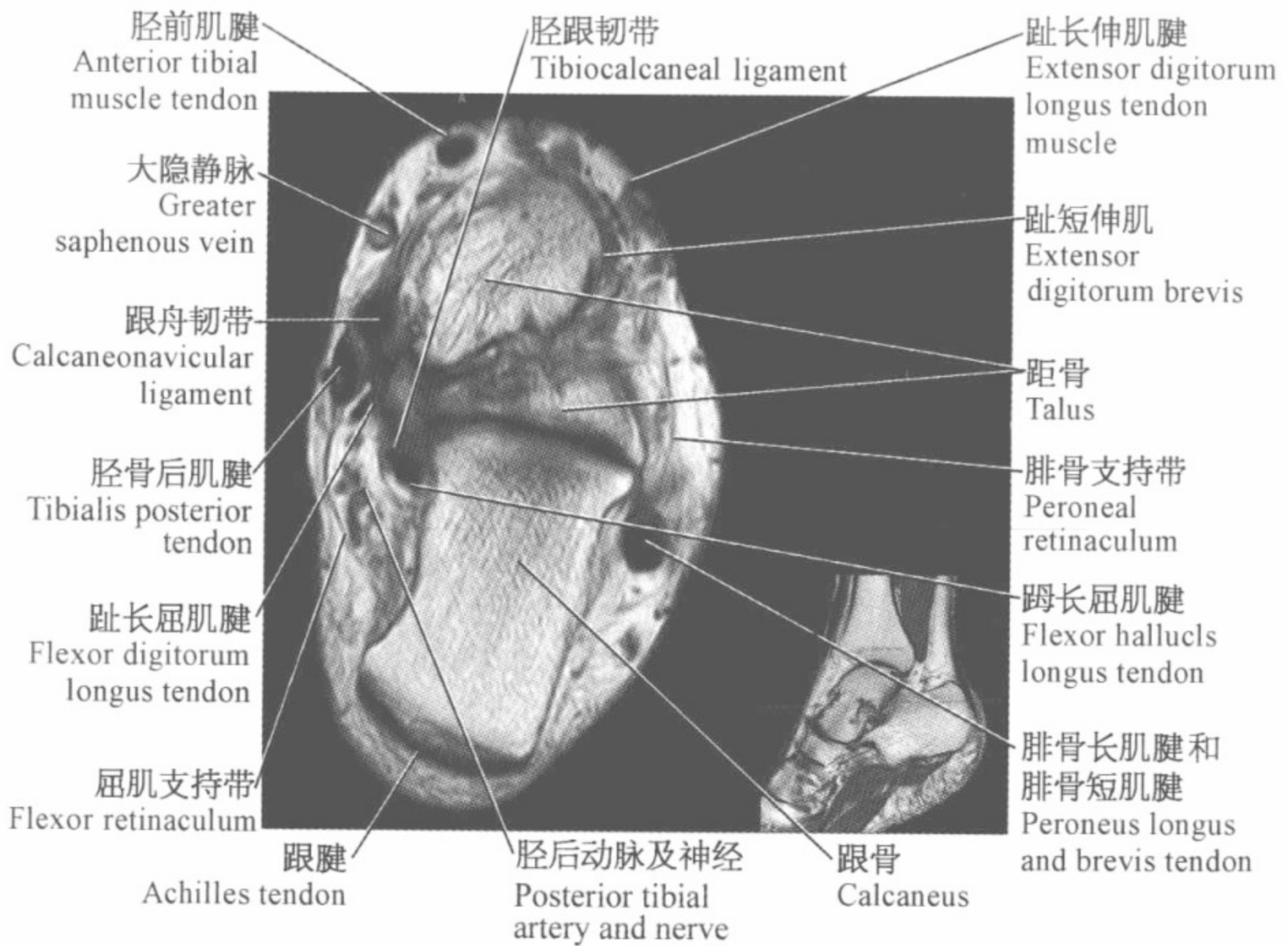
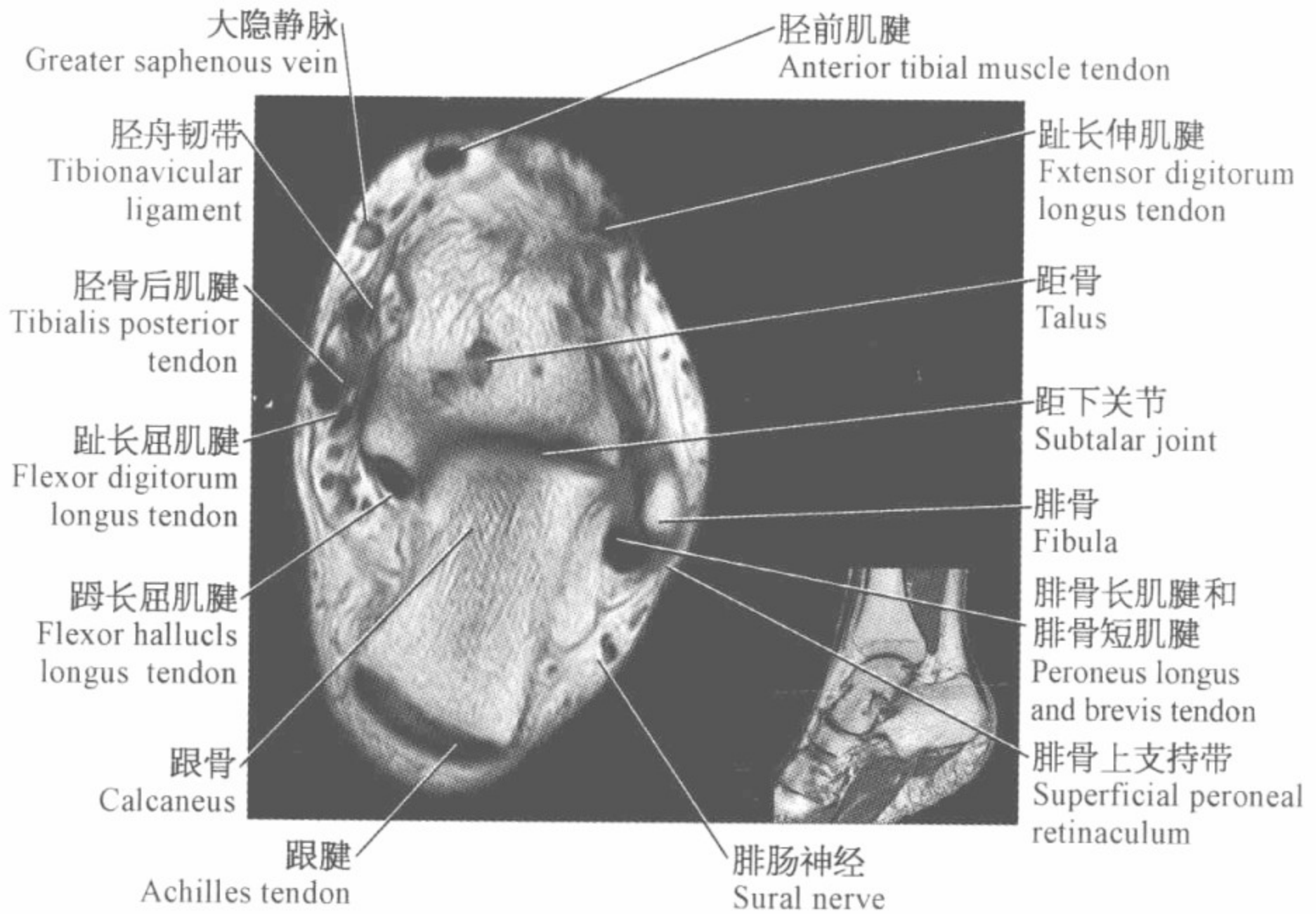


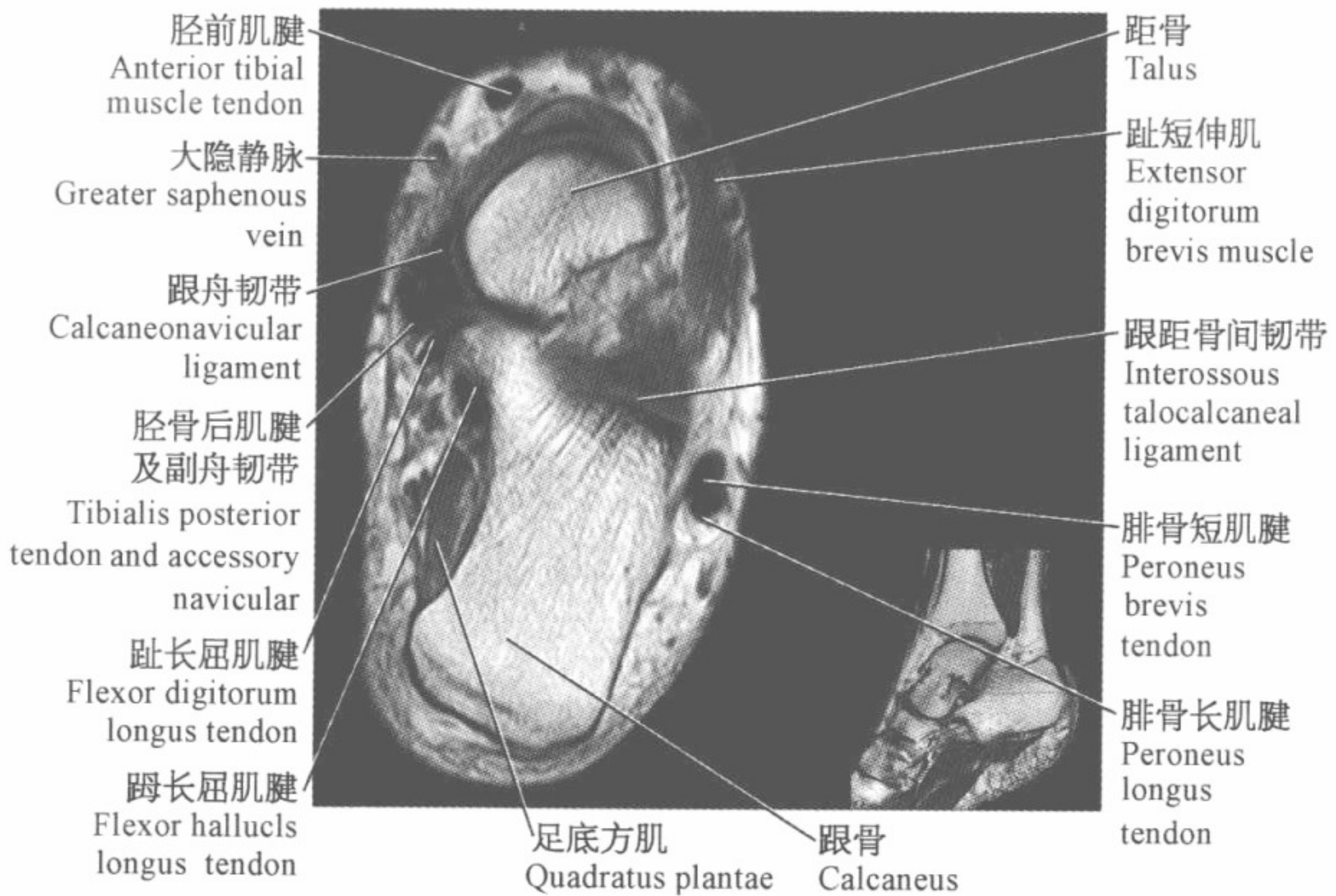
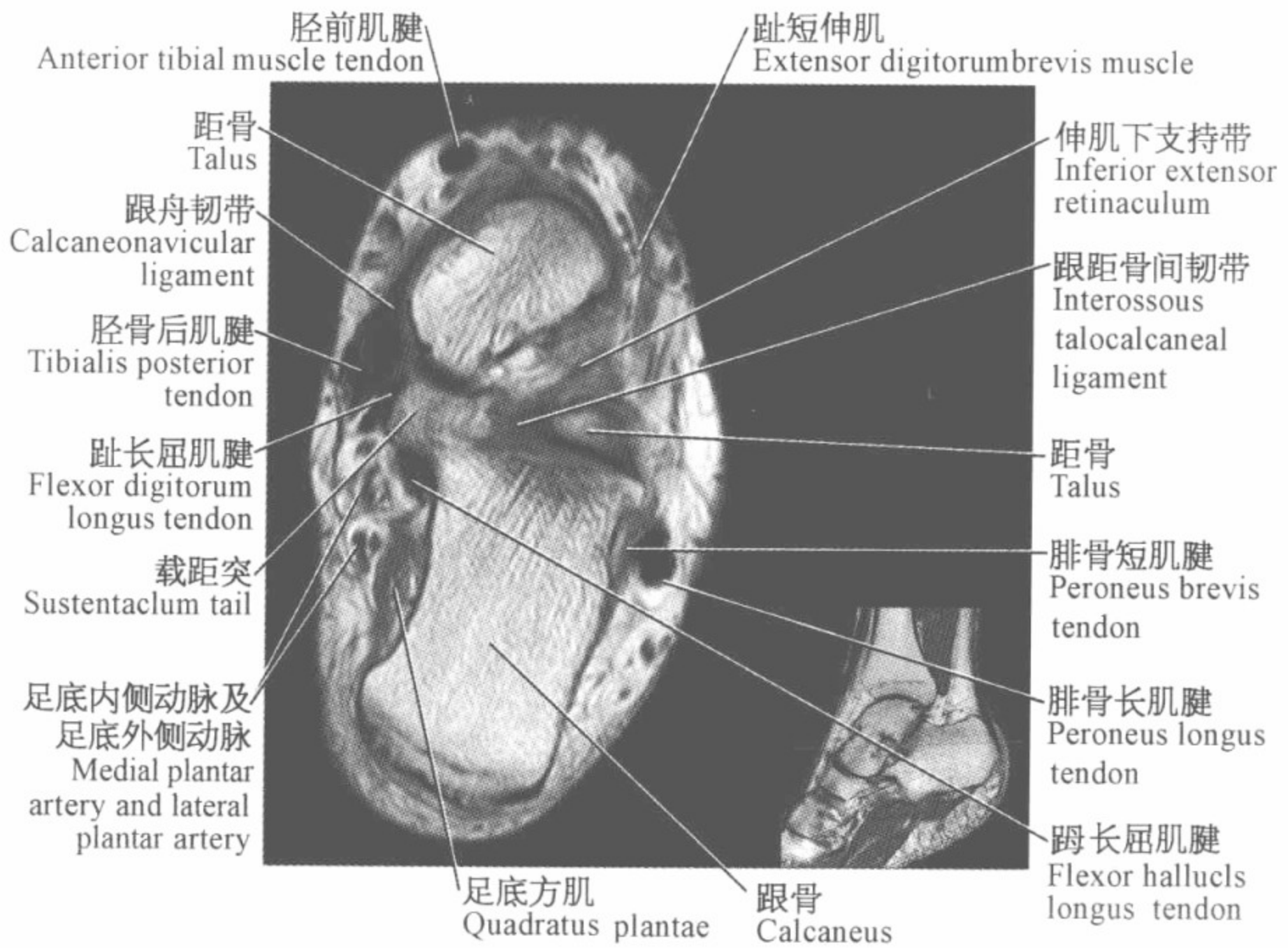


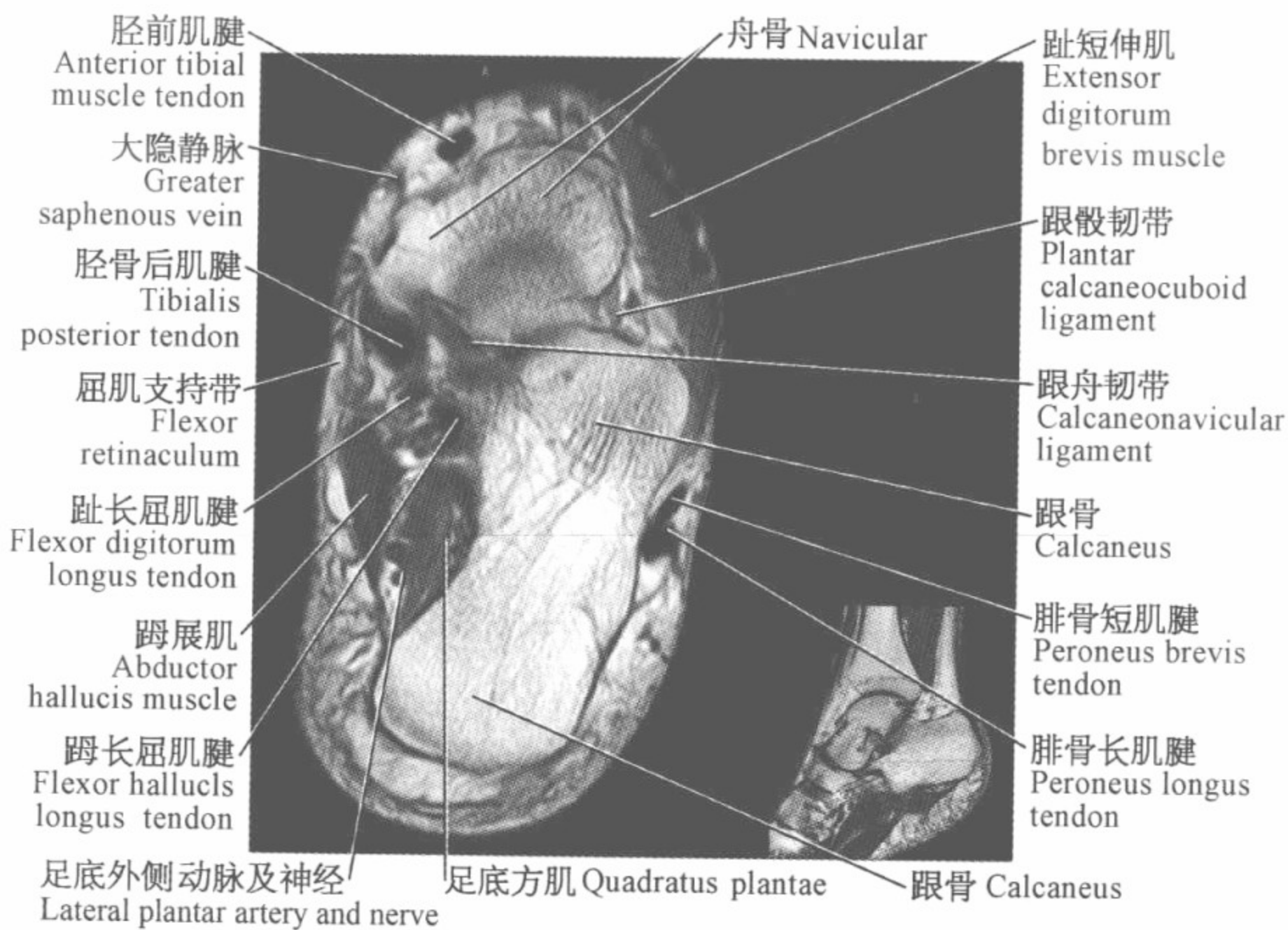
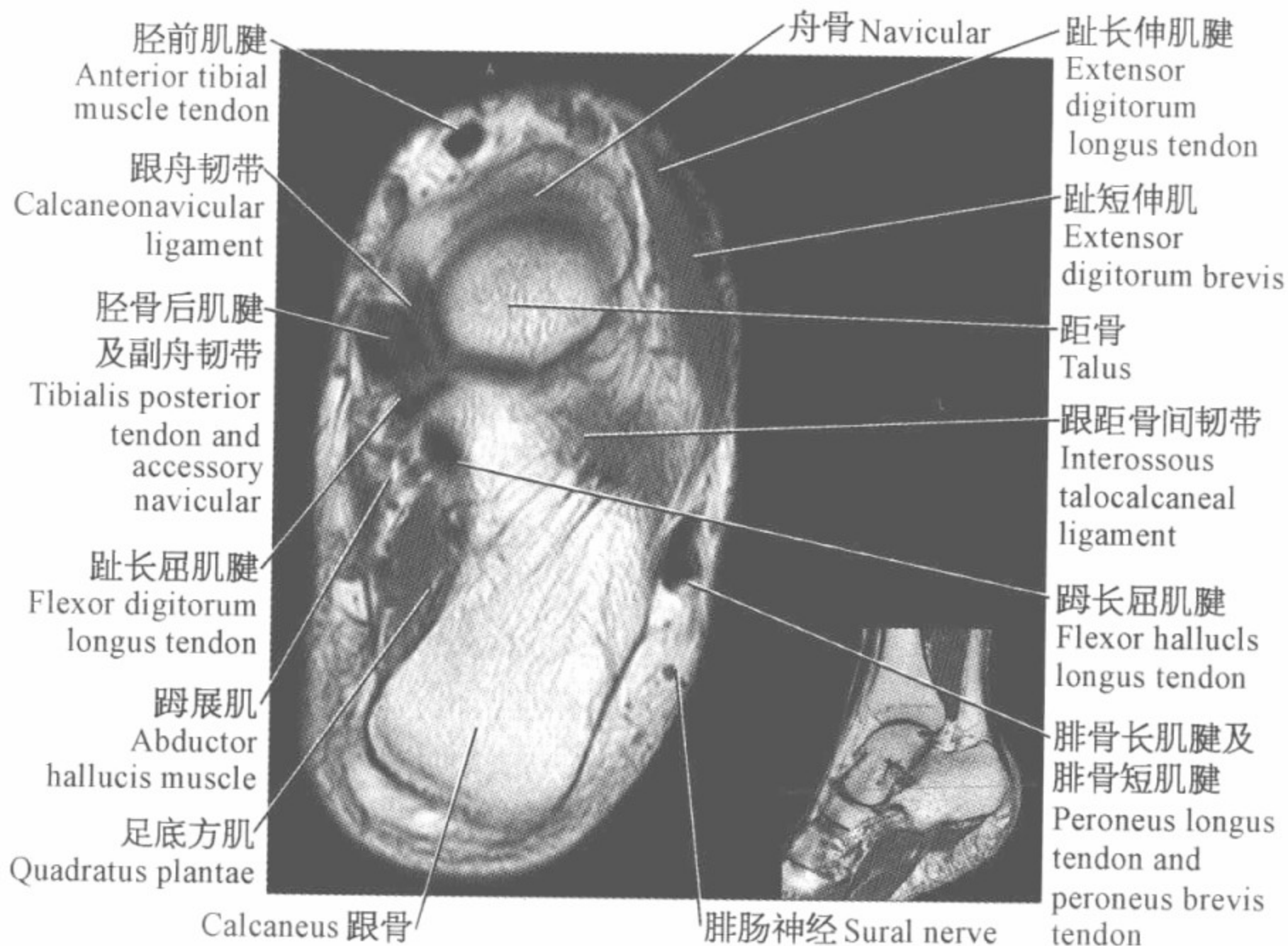


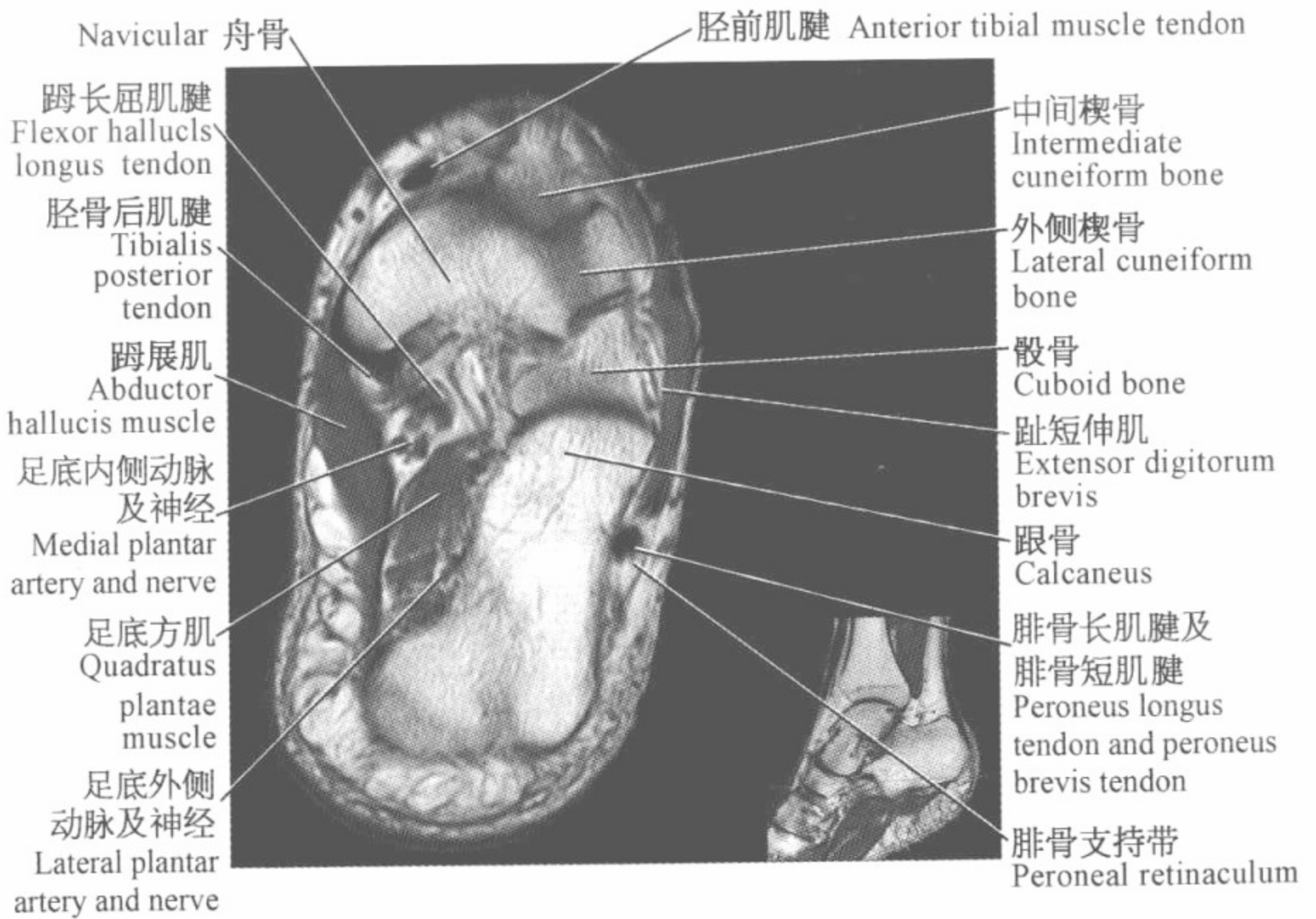
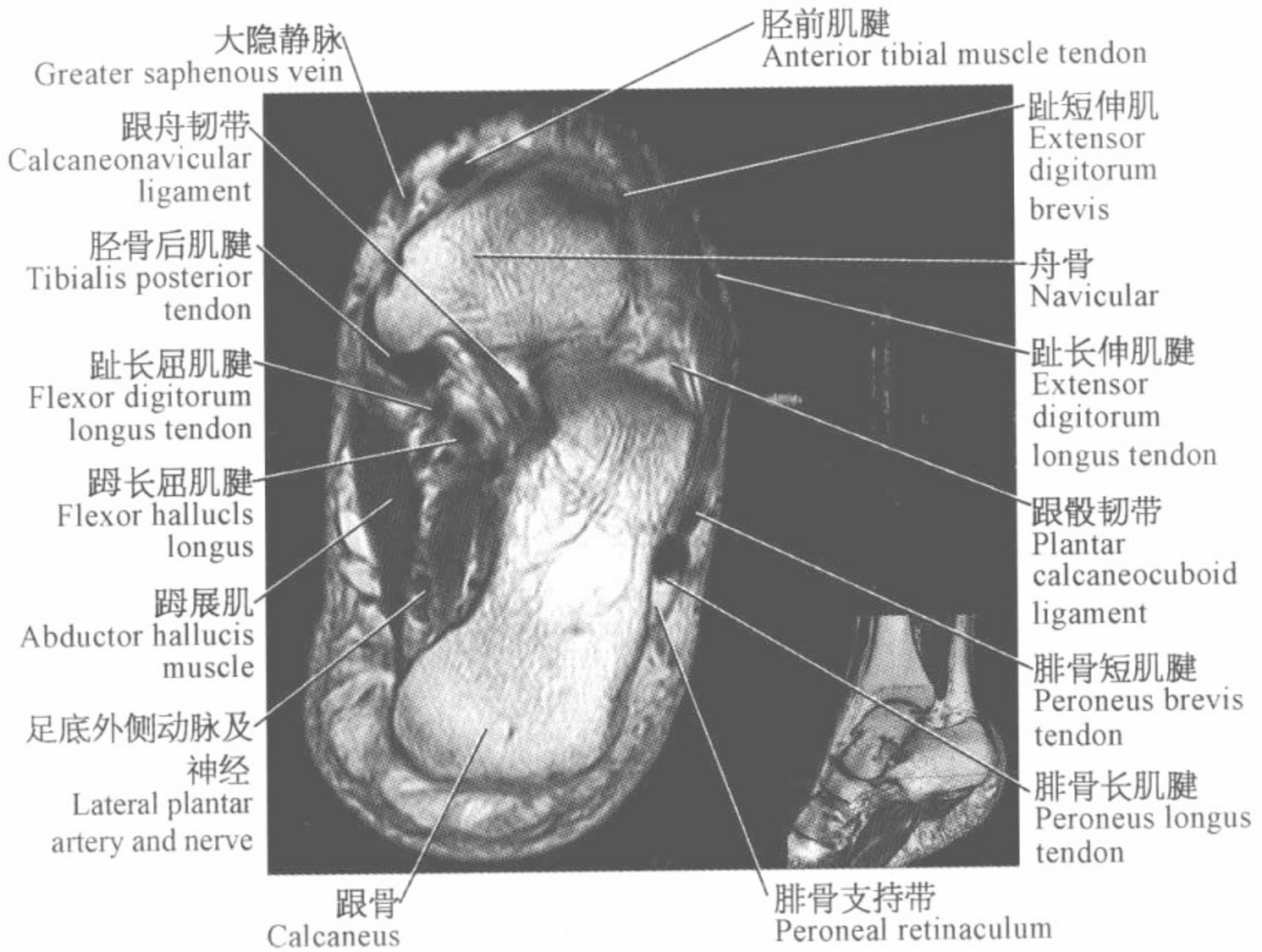


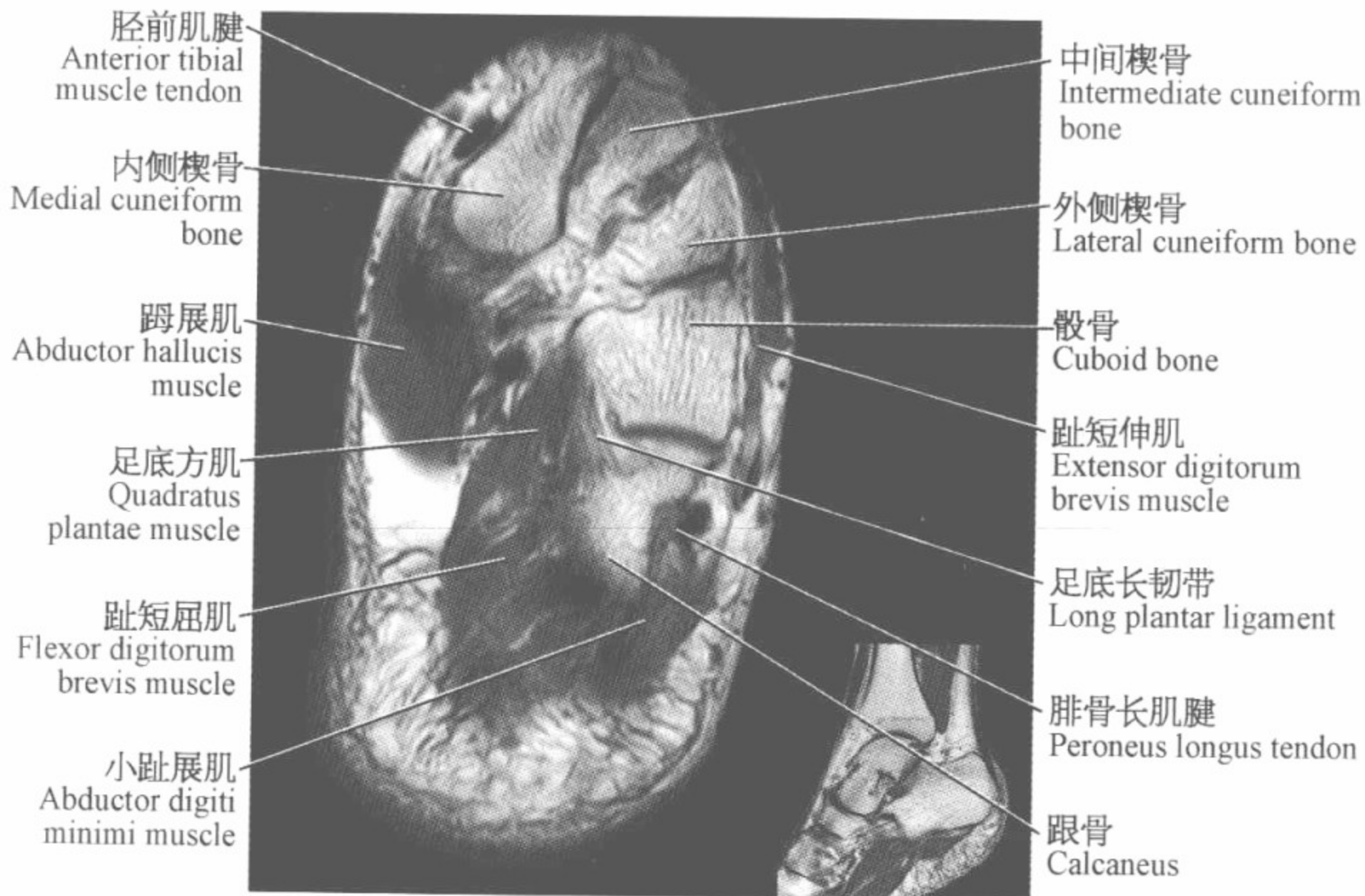
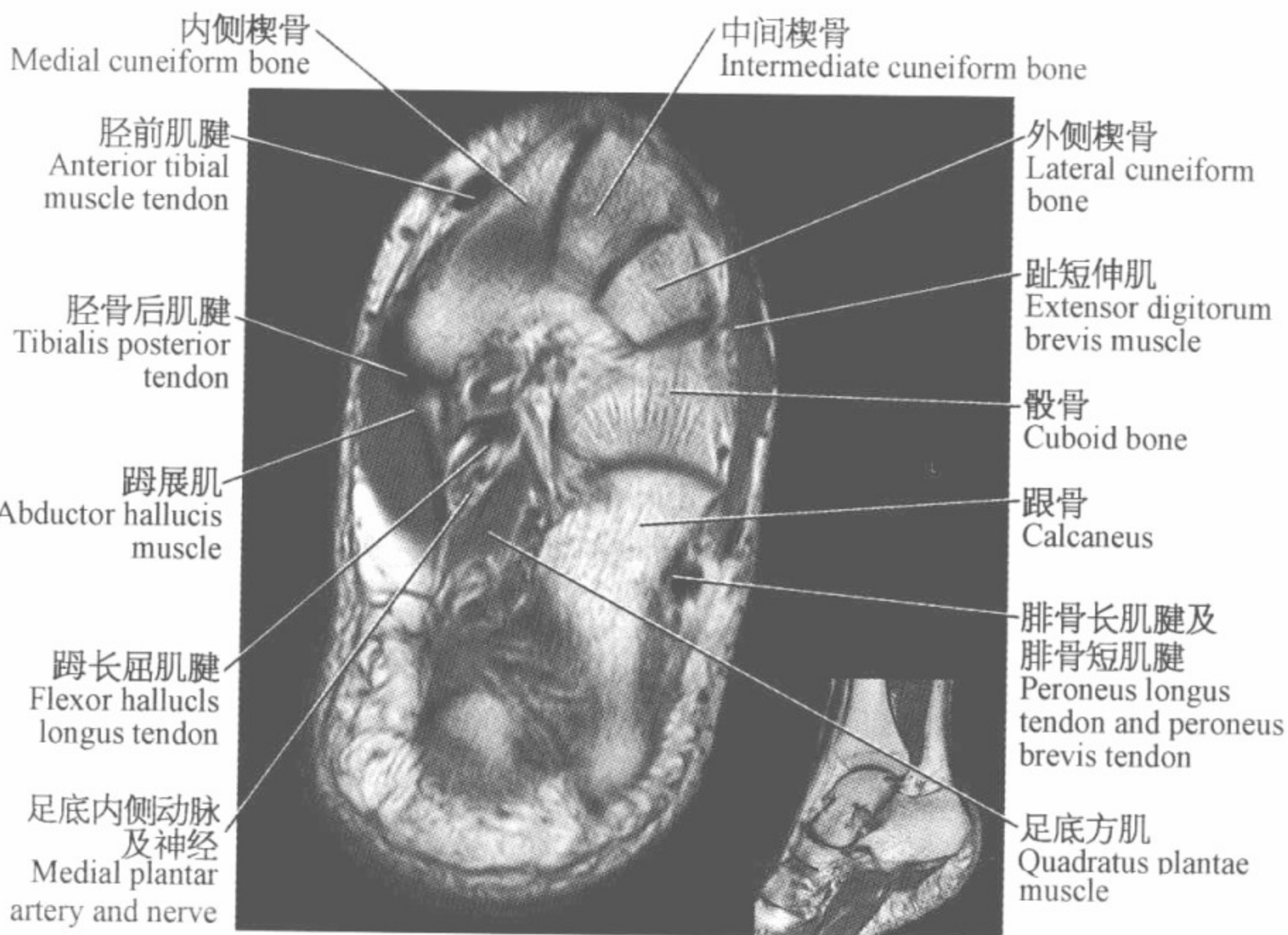


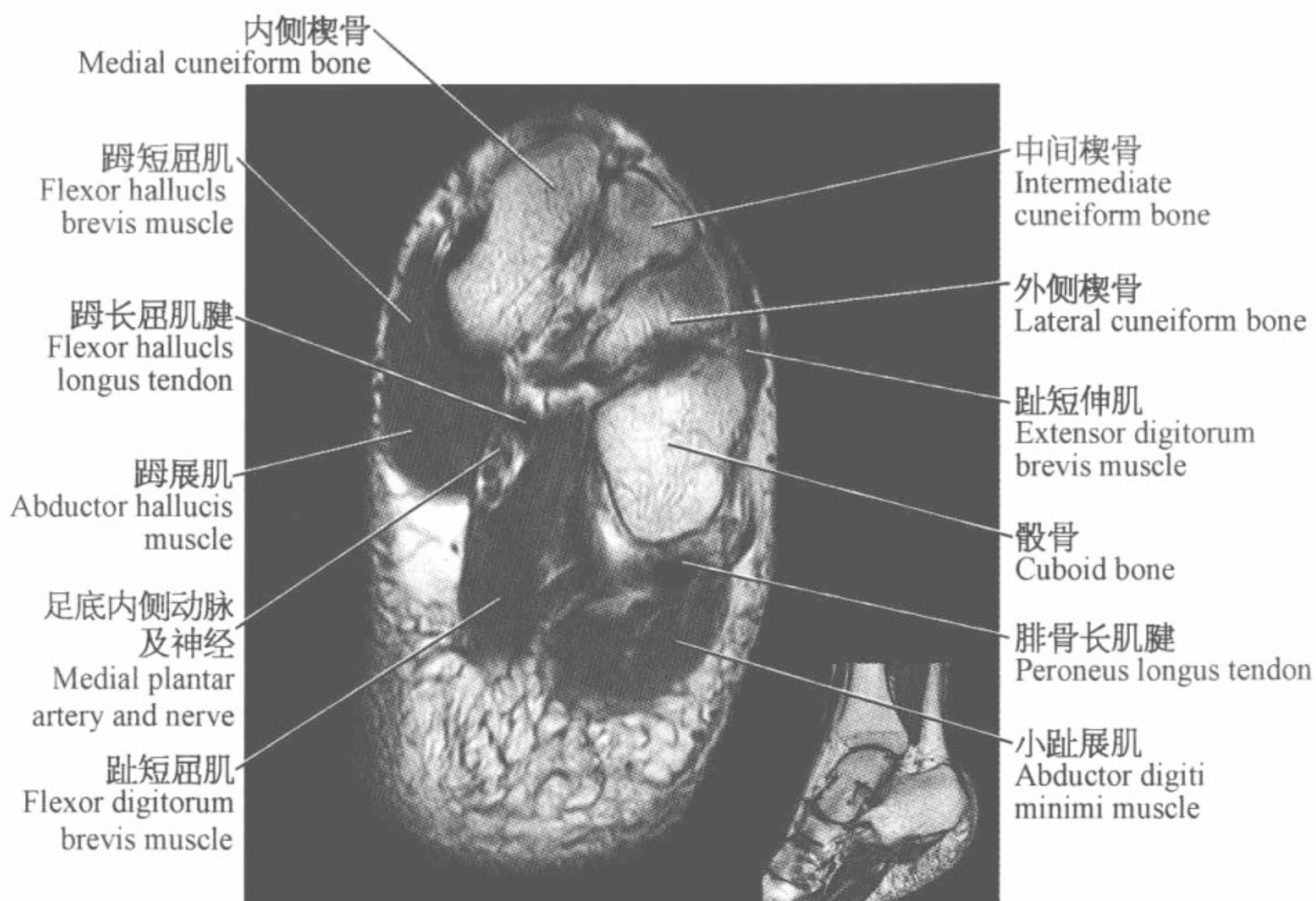
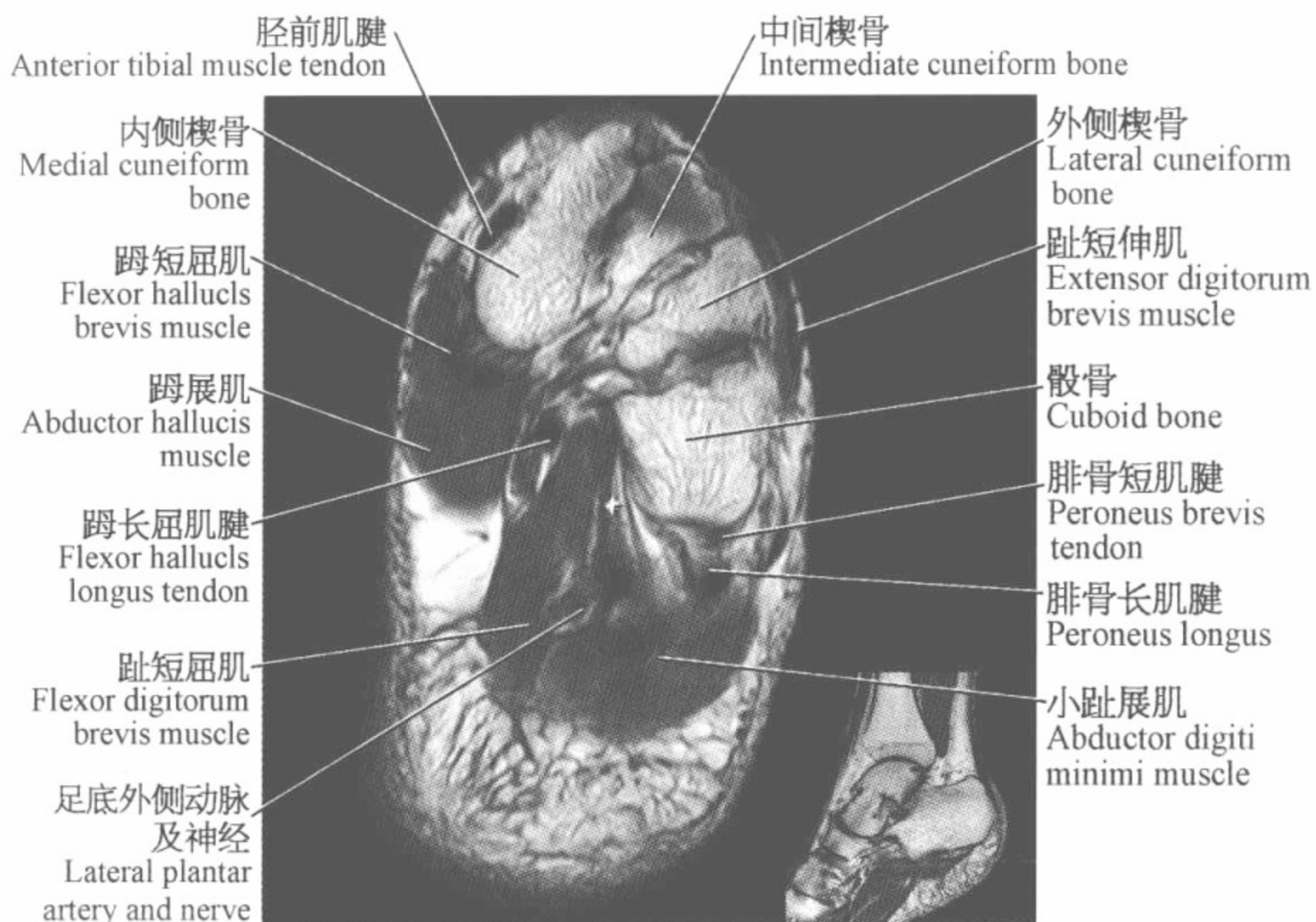








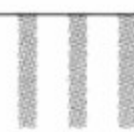


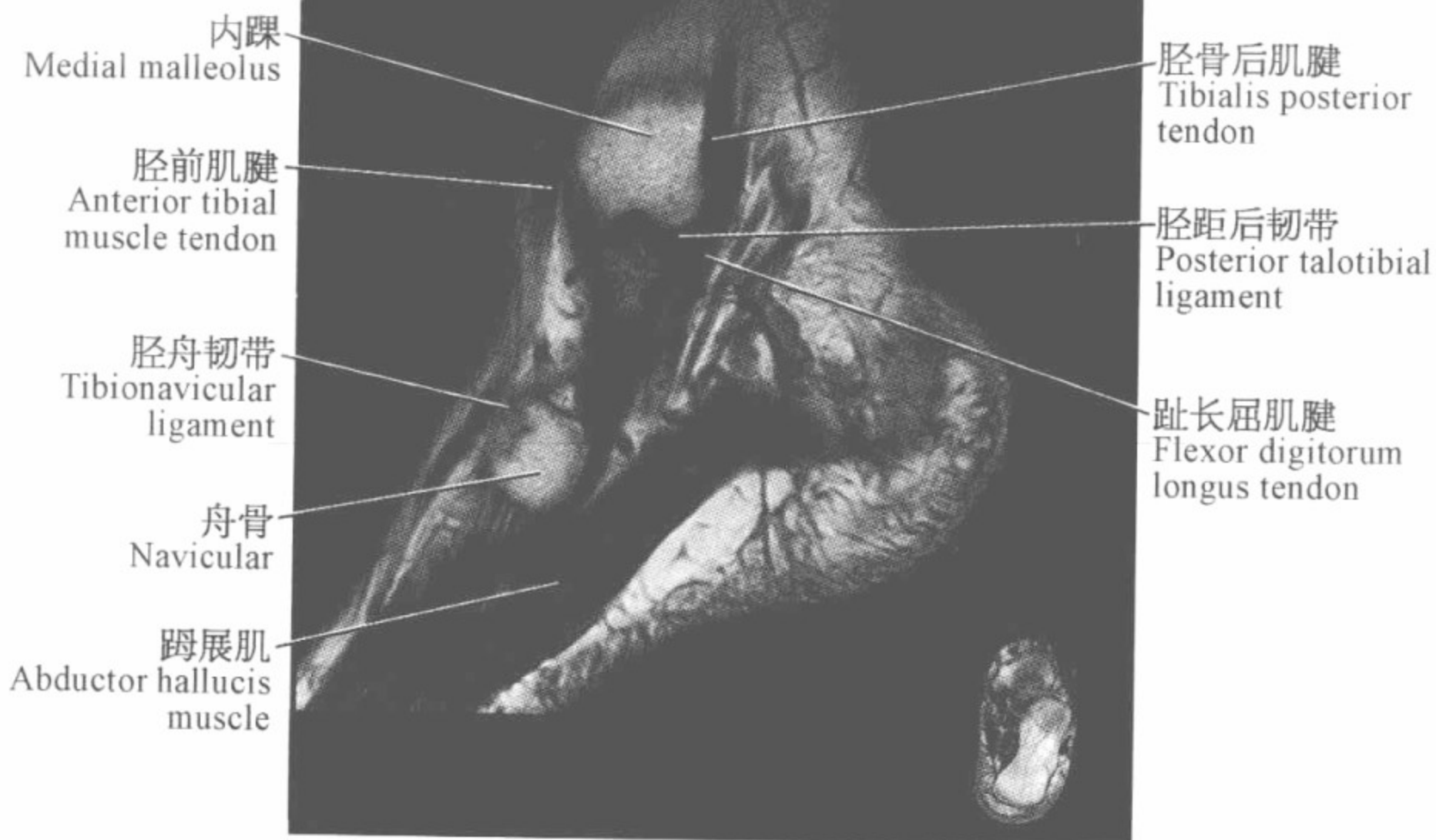
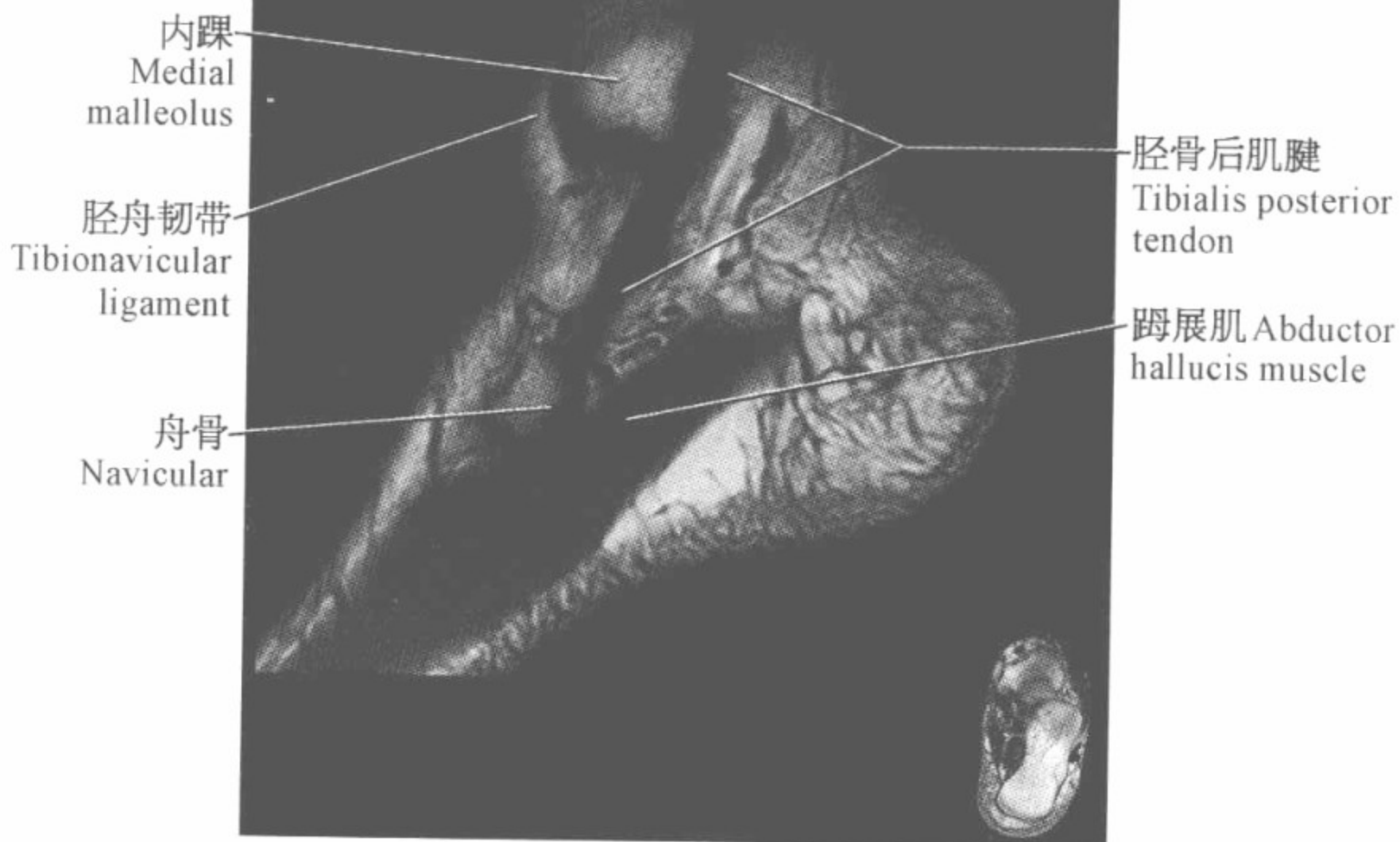


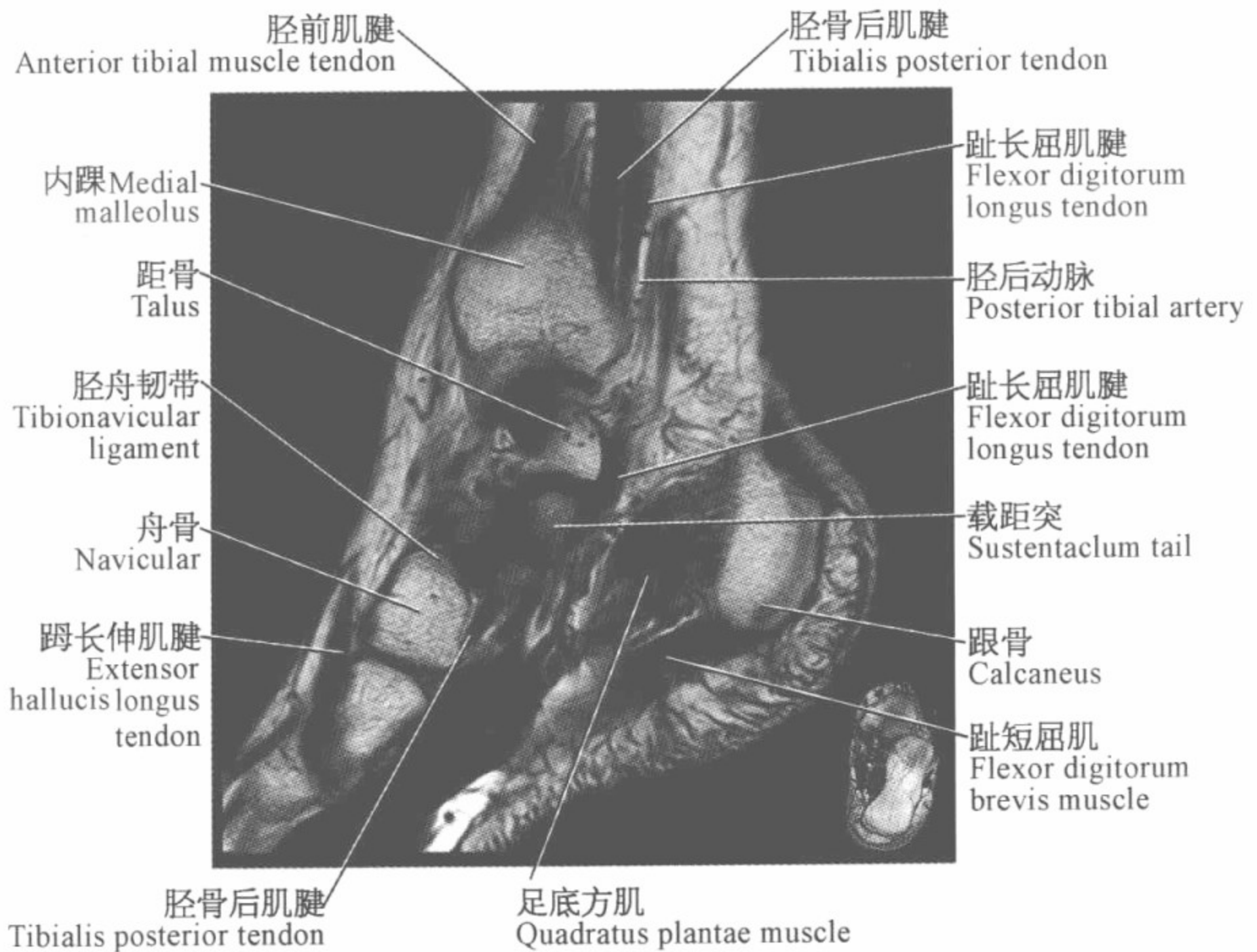
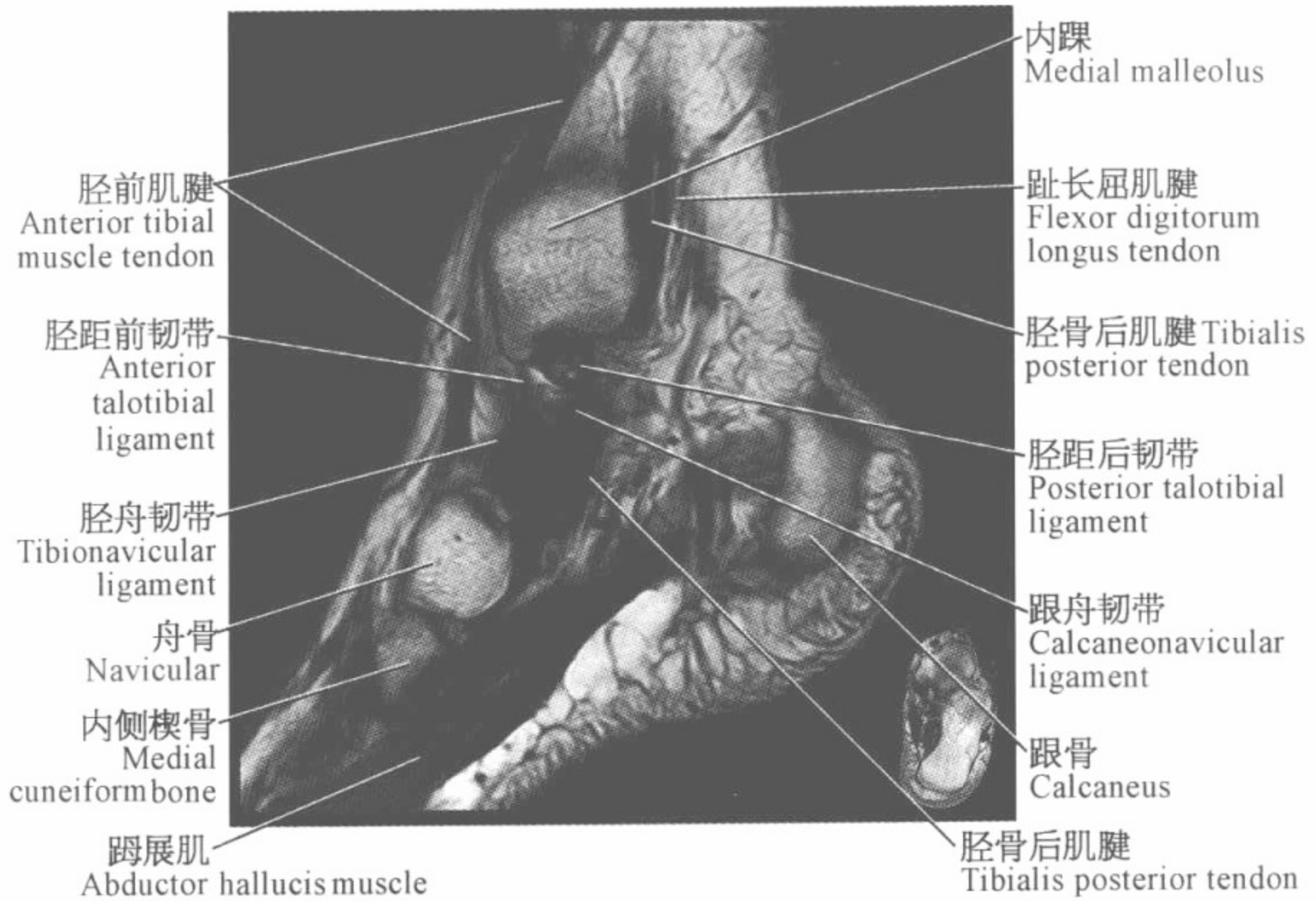


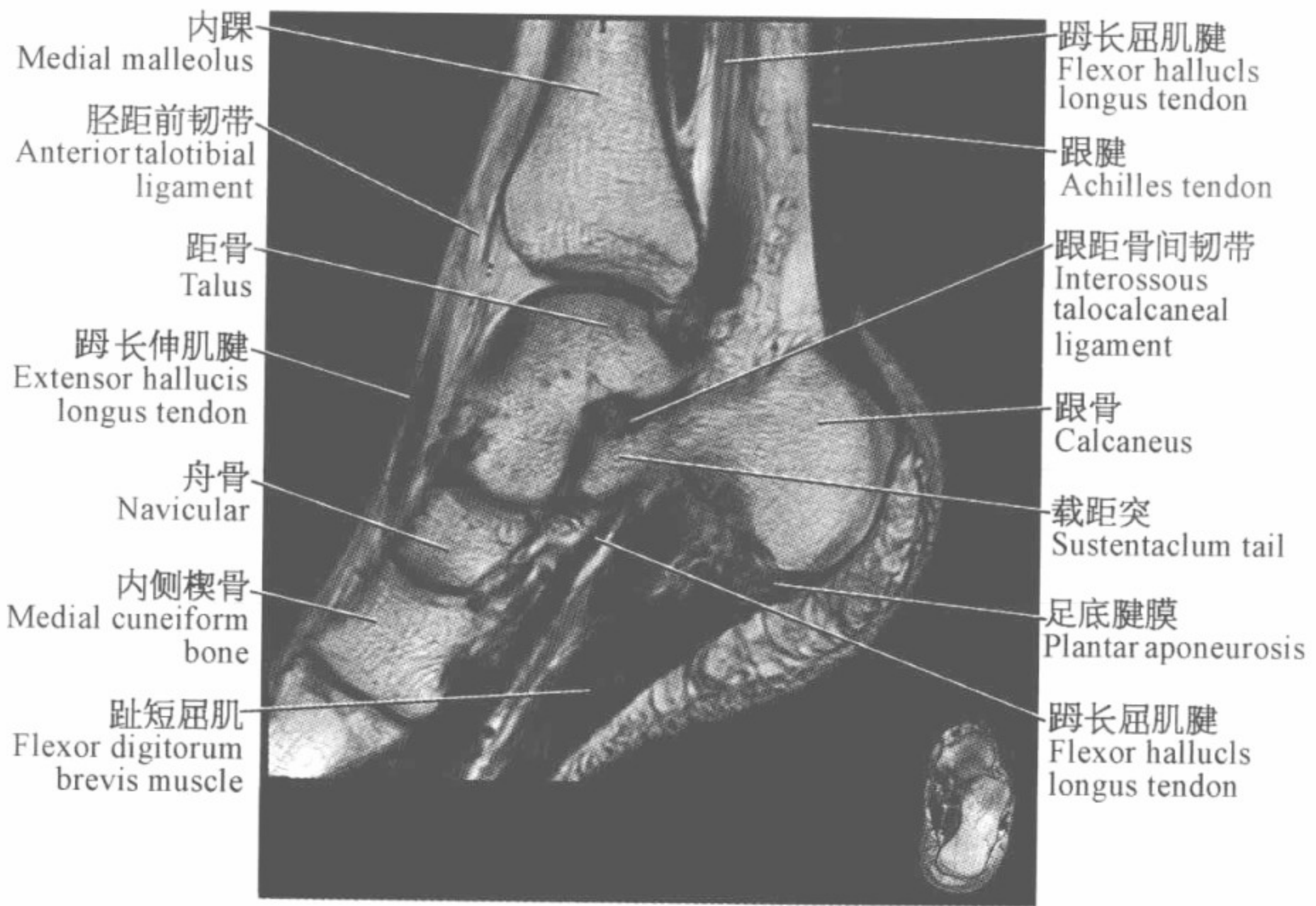
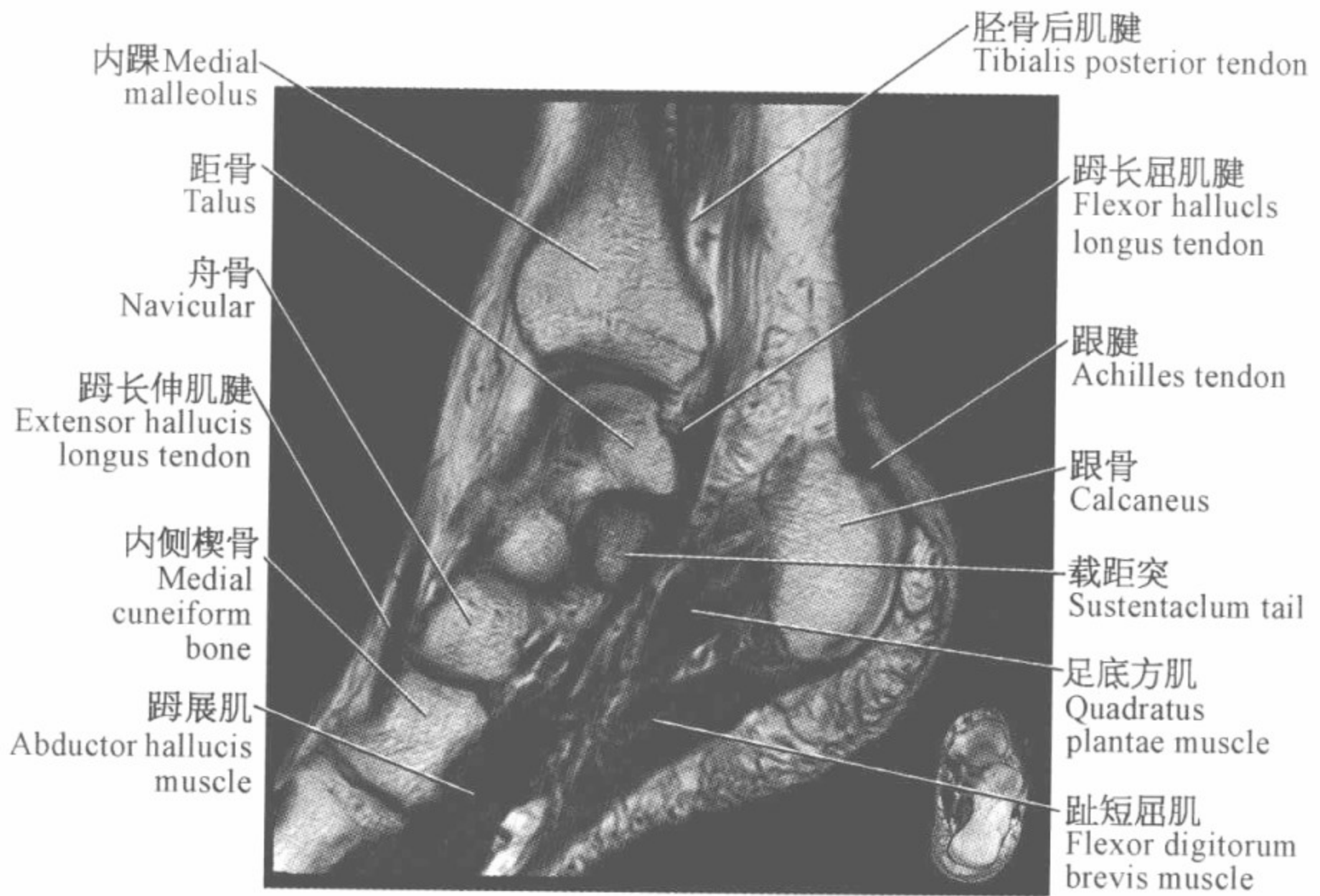
踝关节磁共振图谱

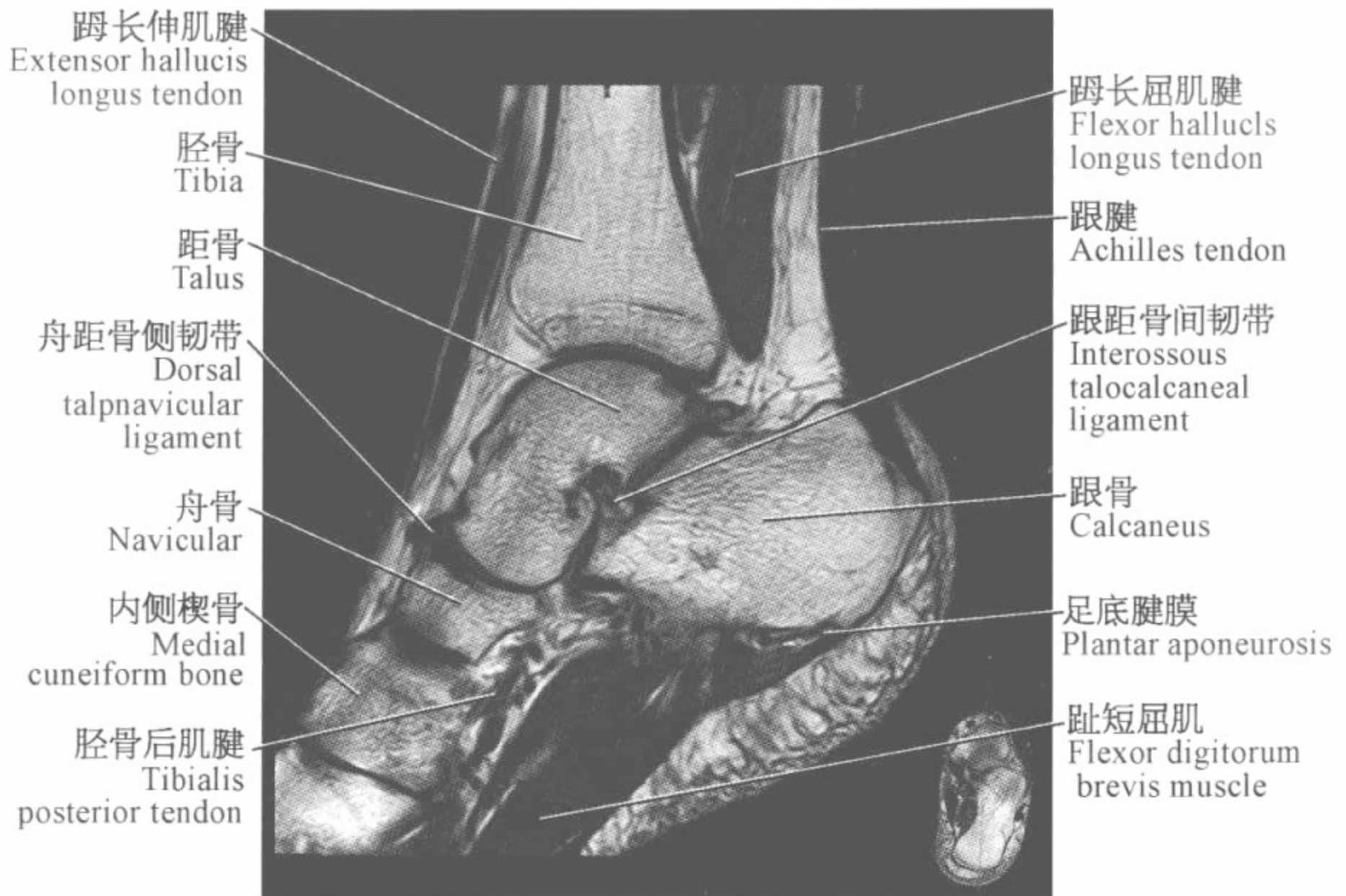
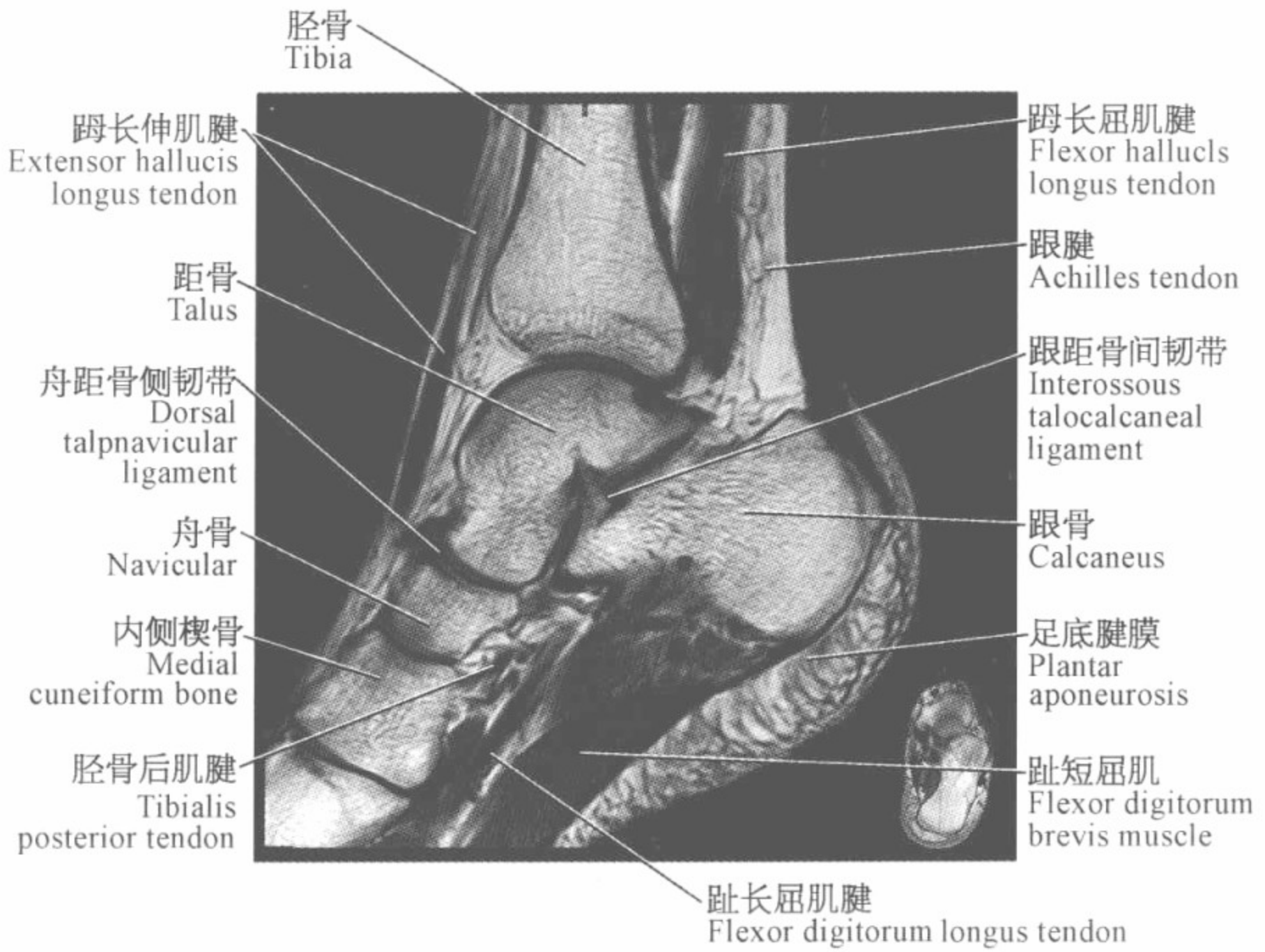
(矢状位)

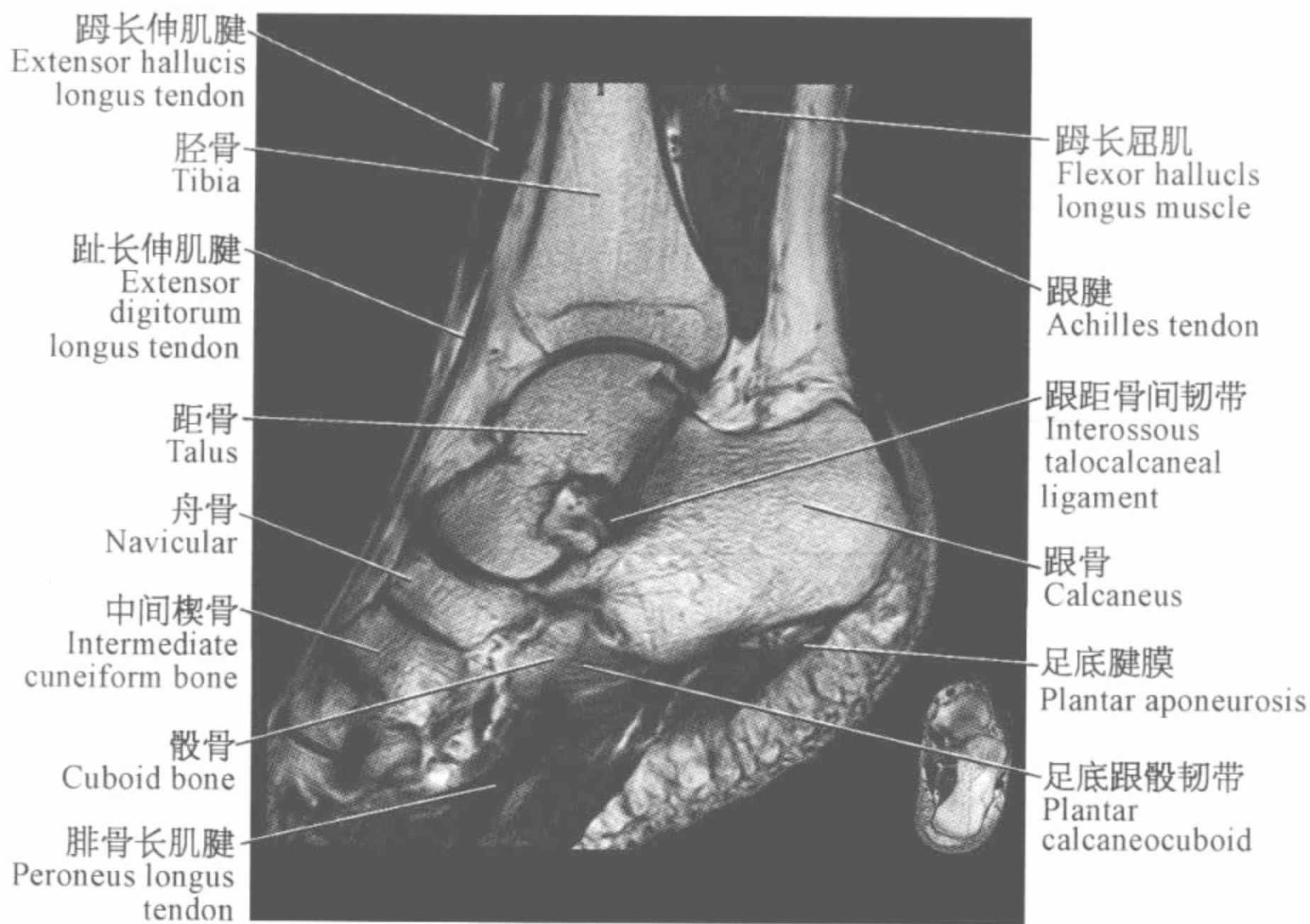
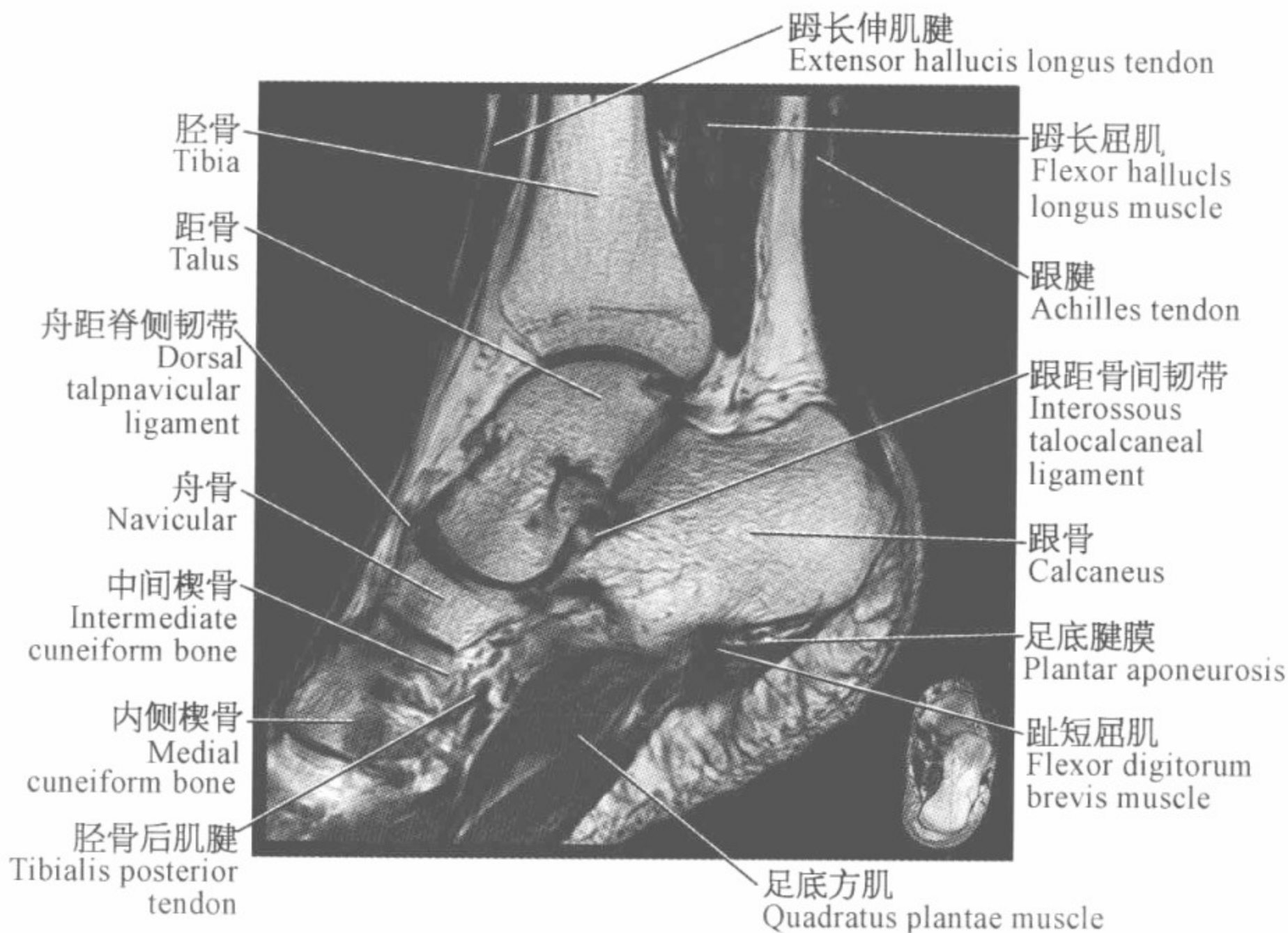


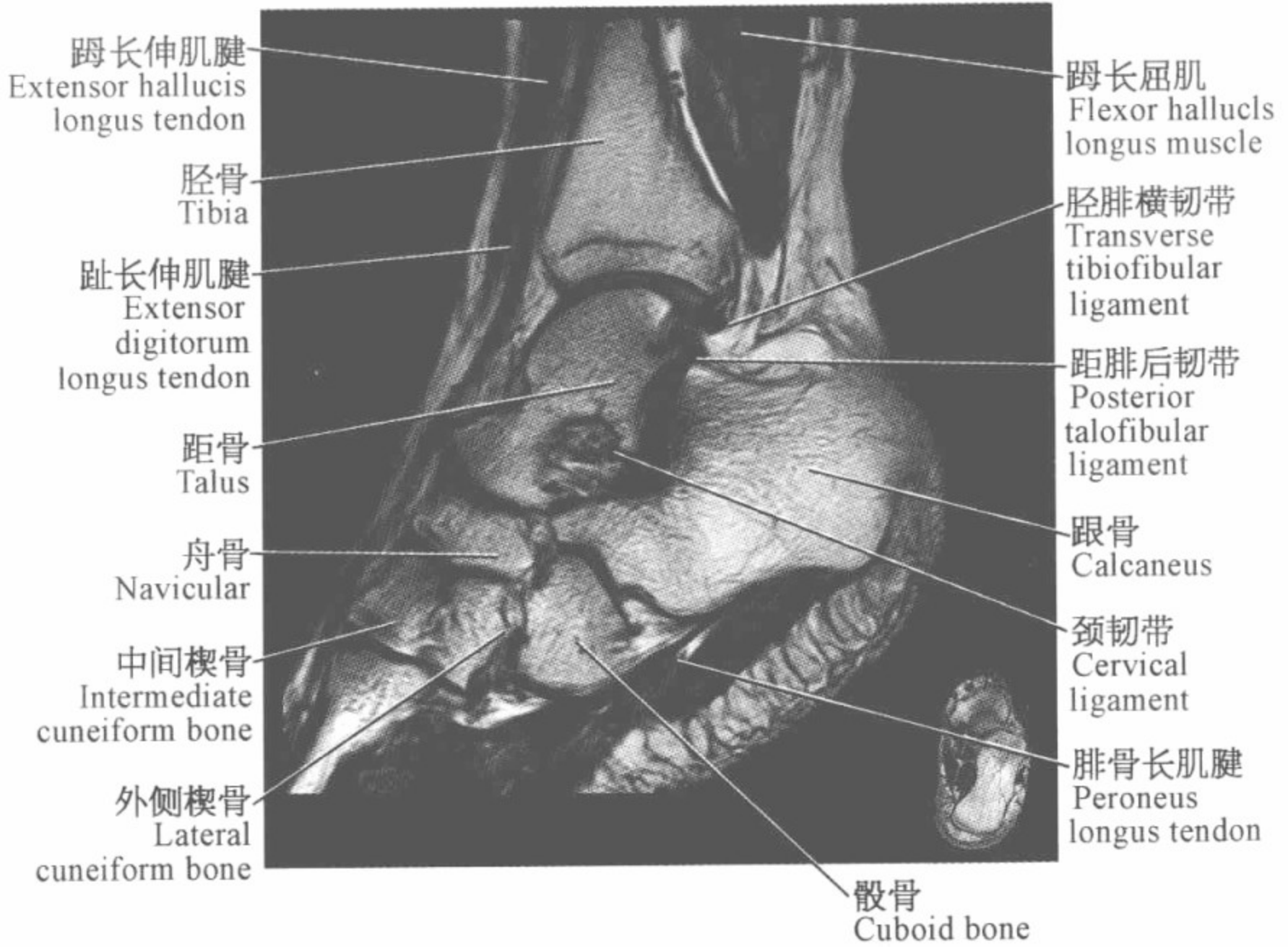
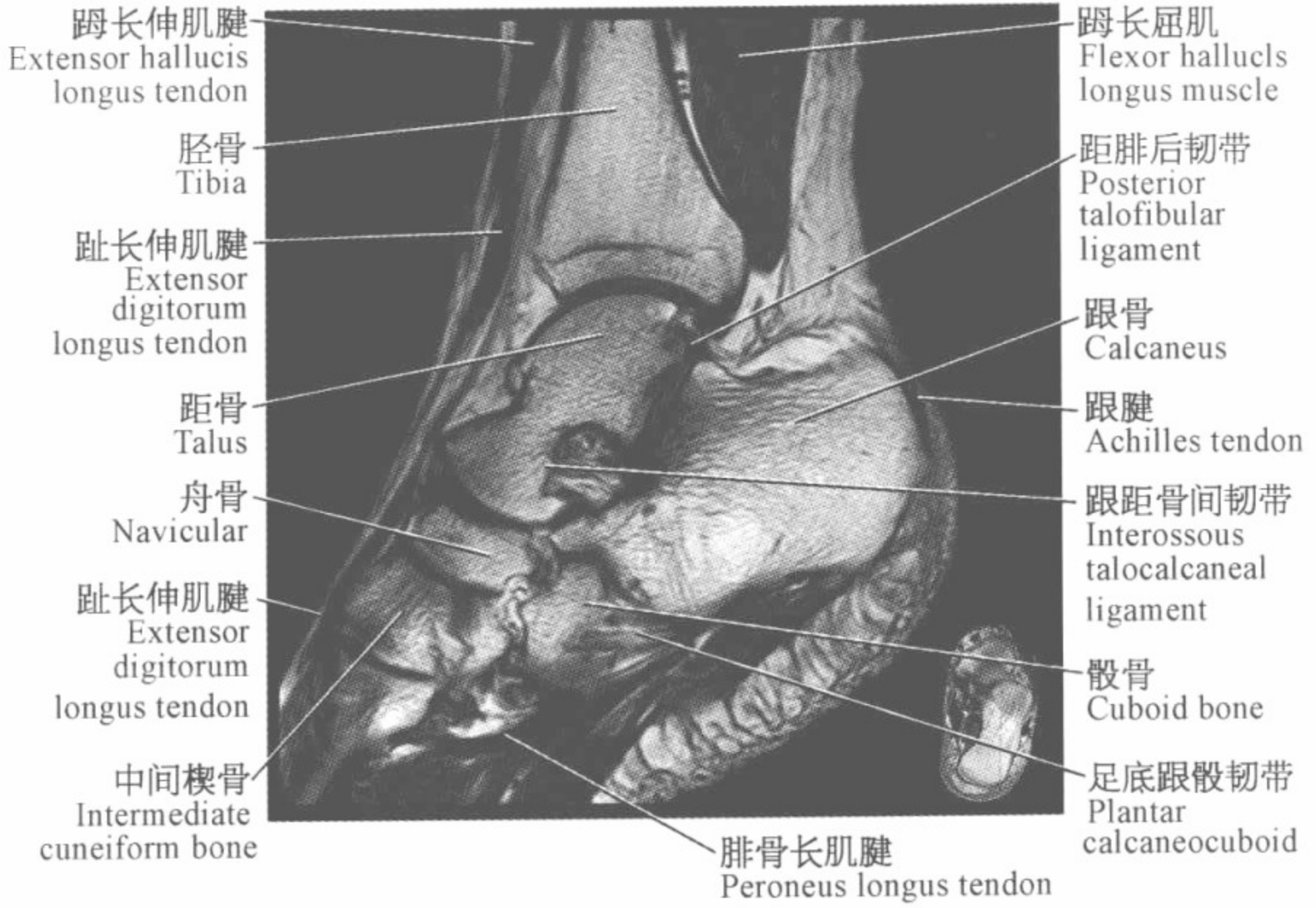


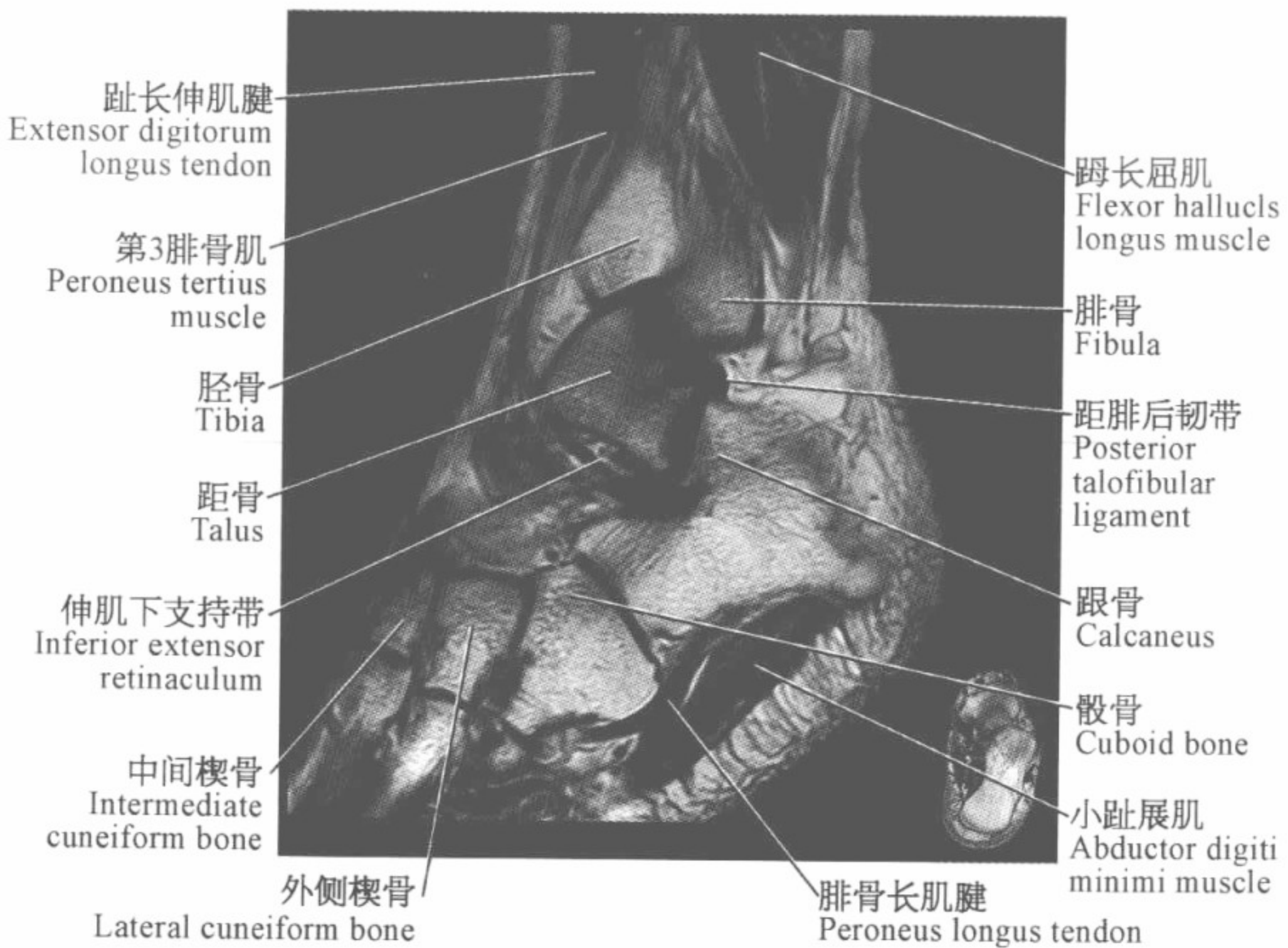
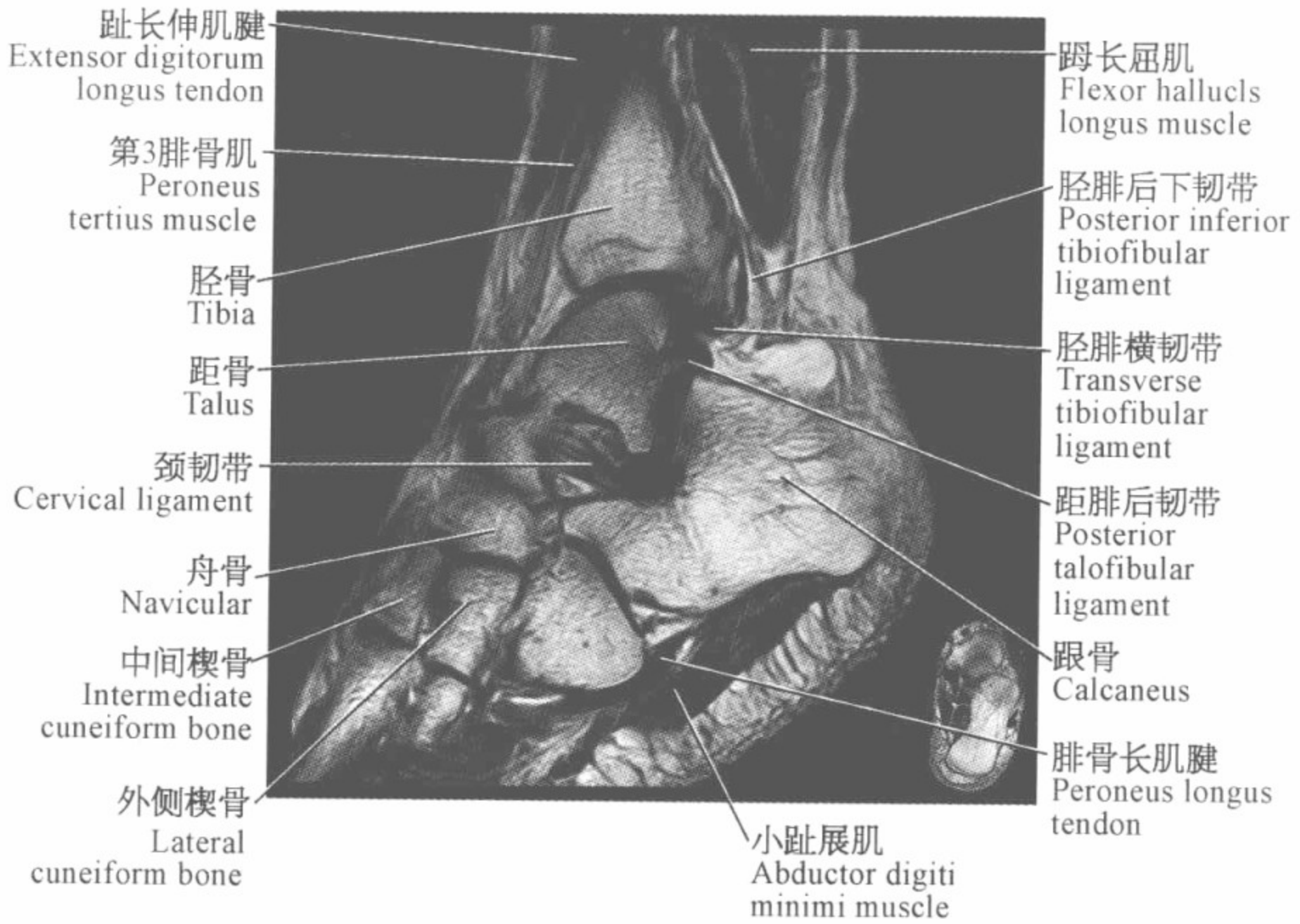


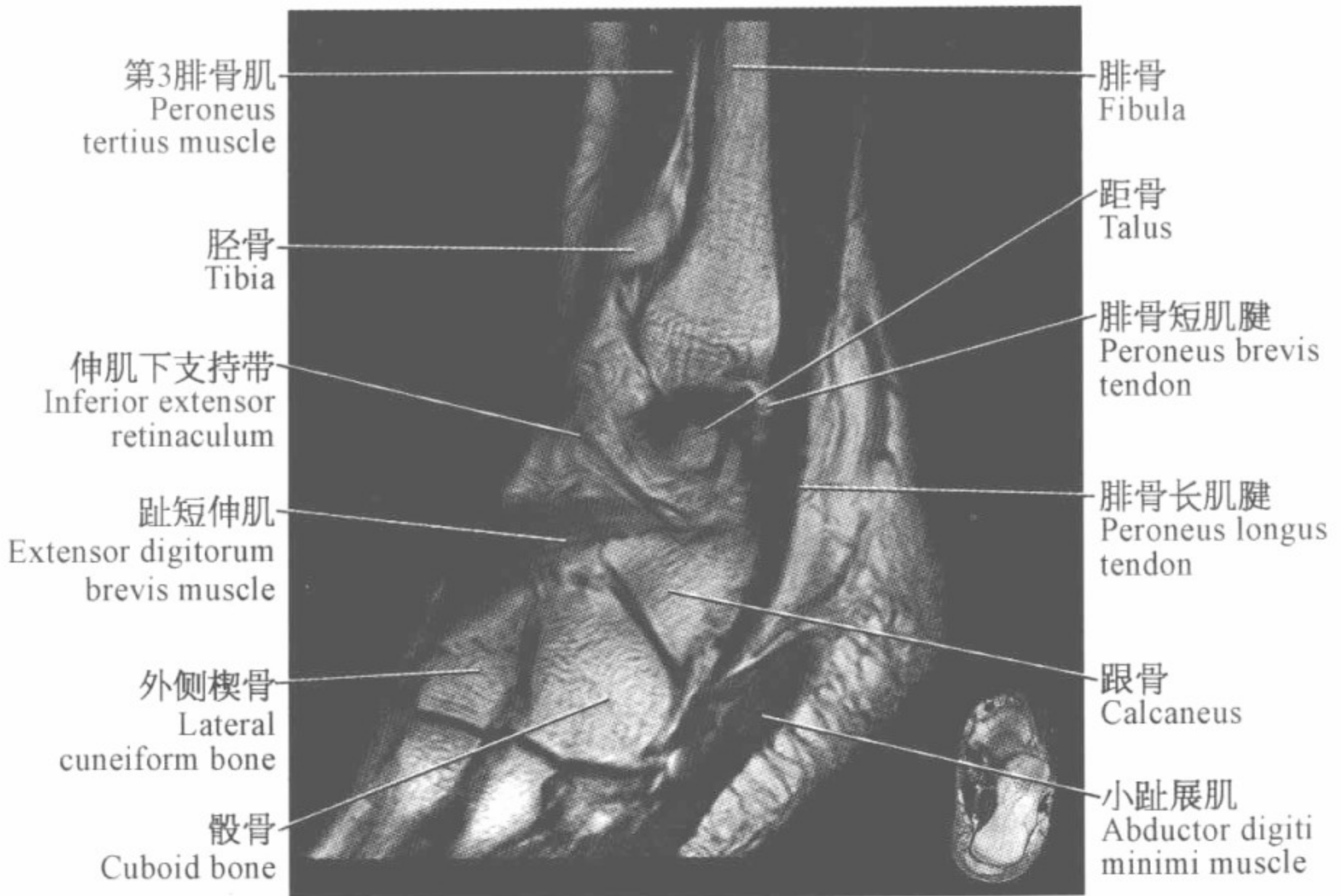
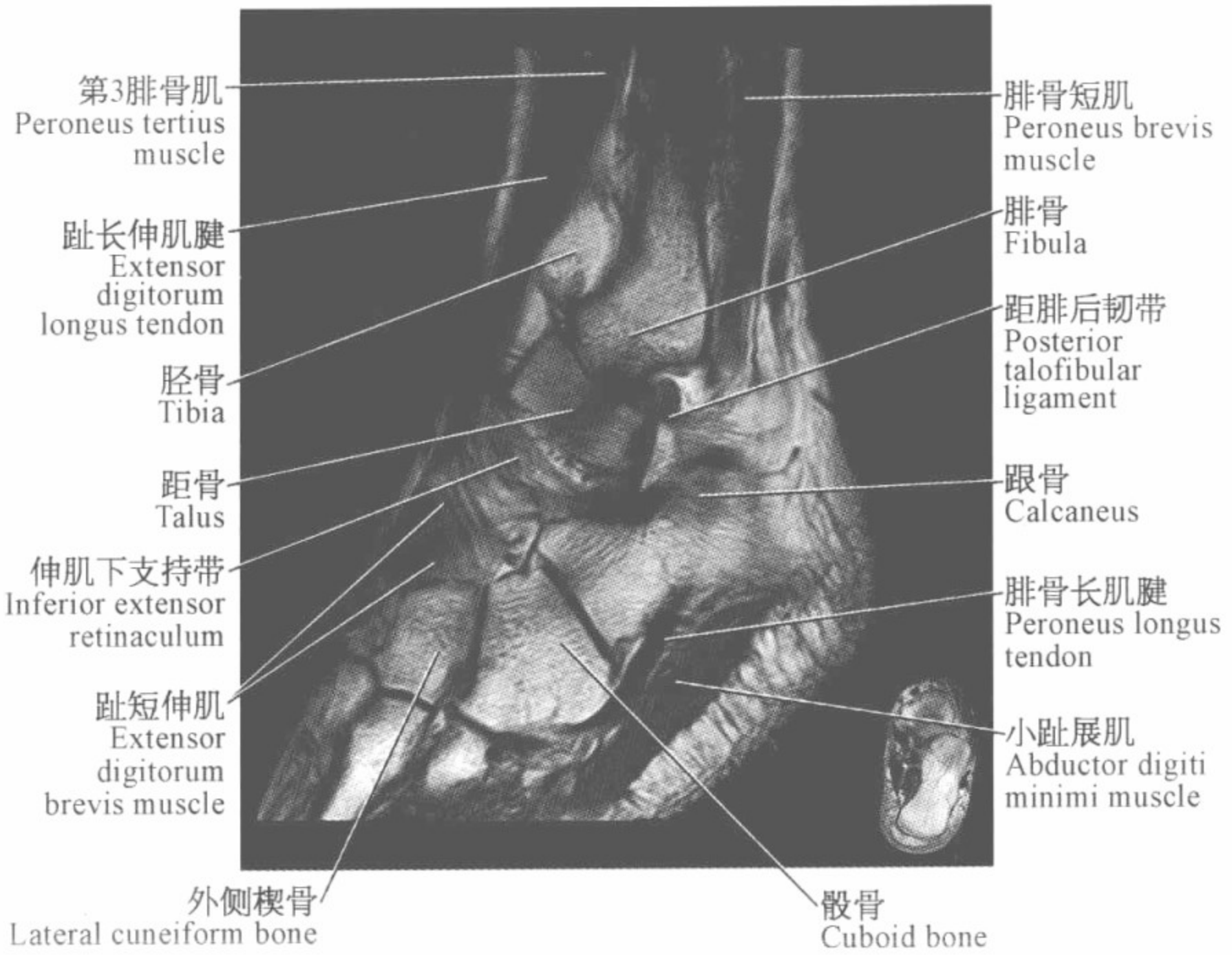


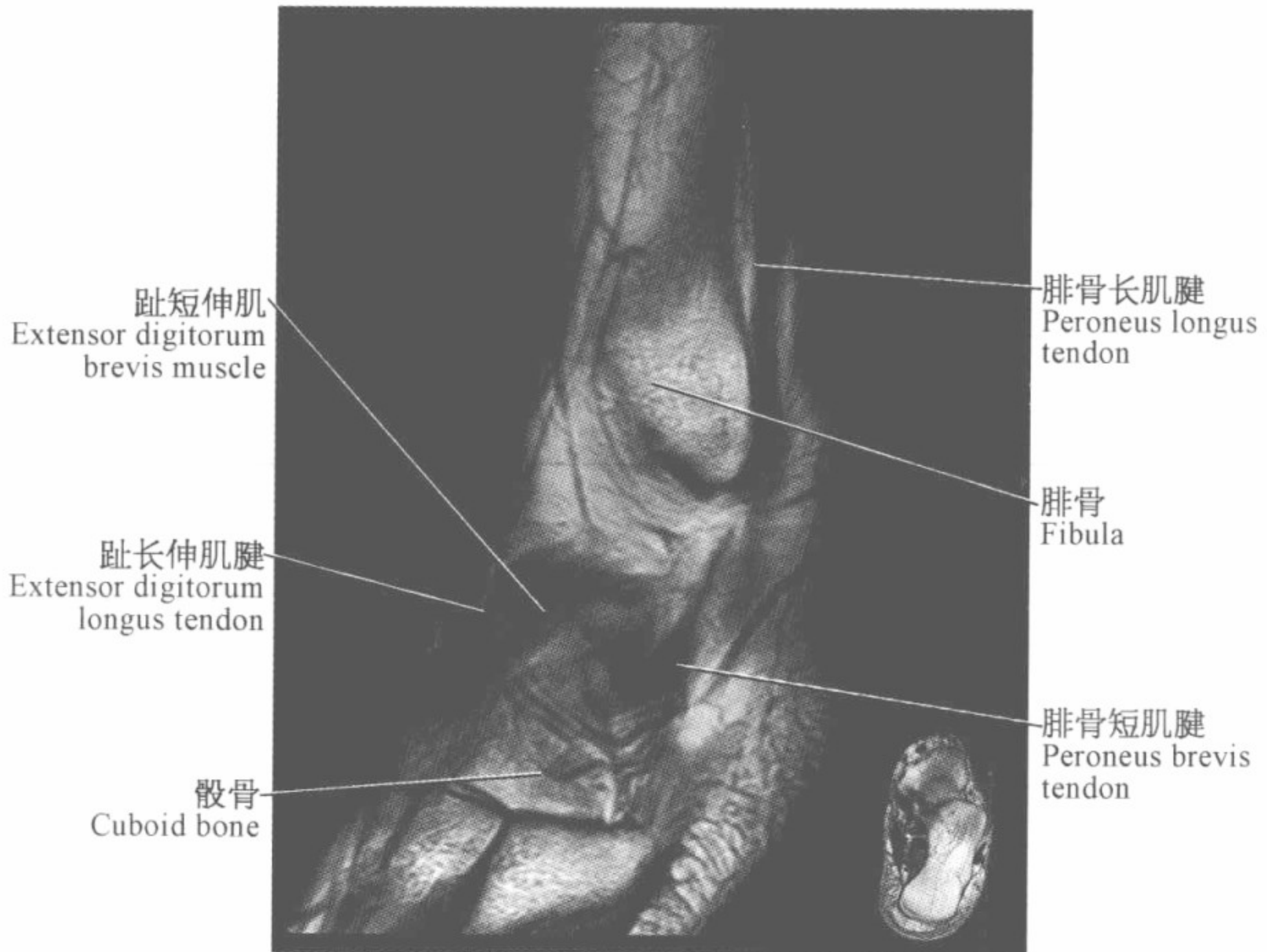
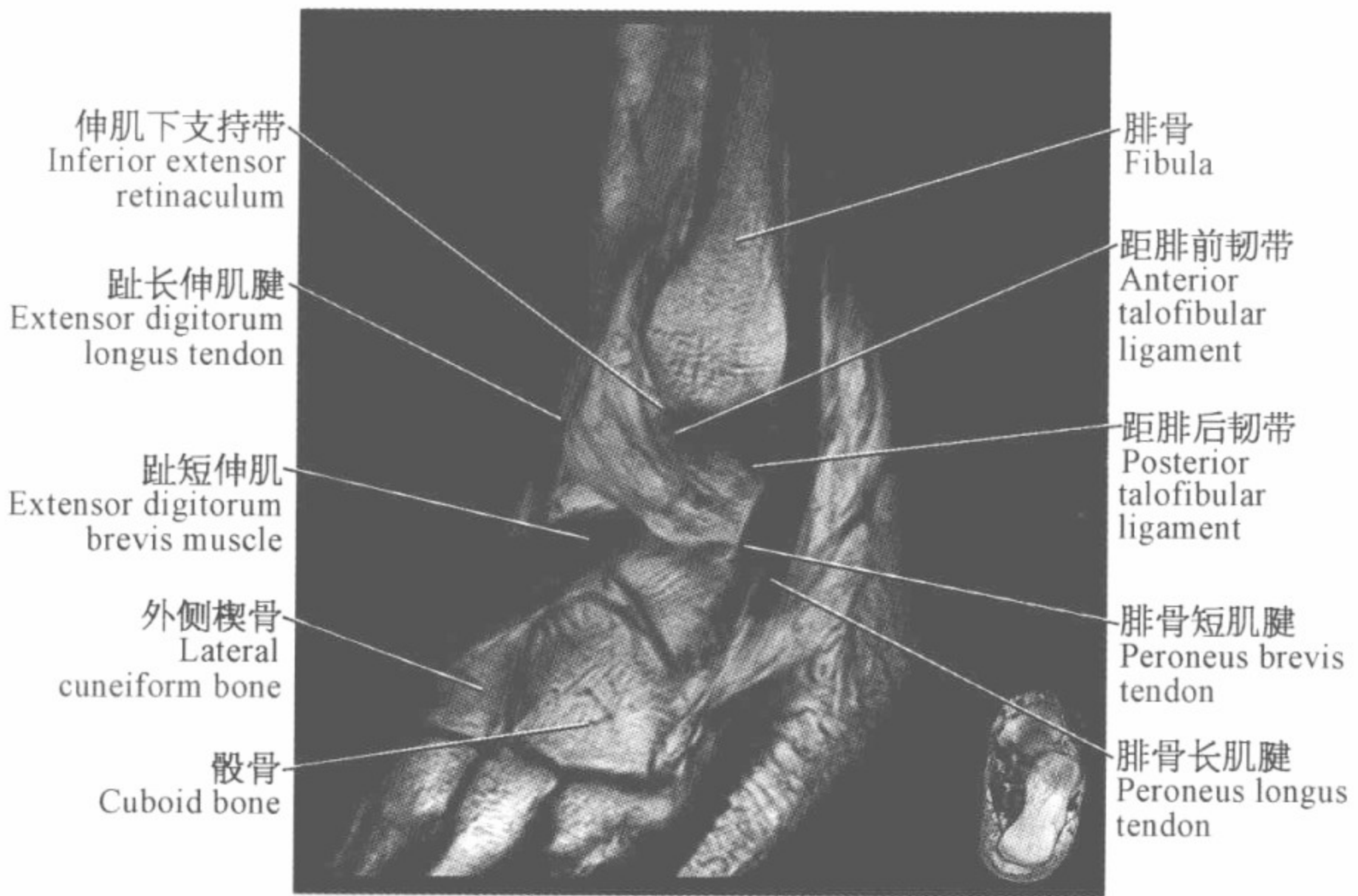








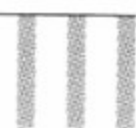


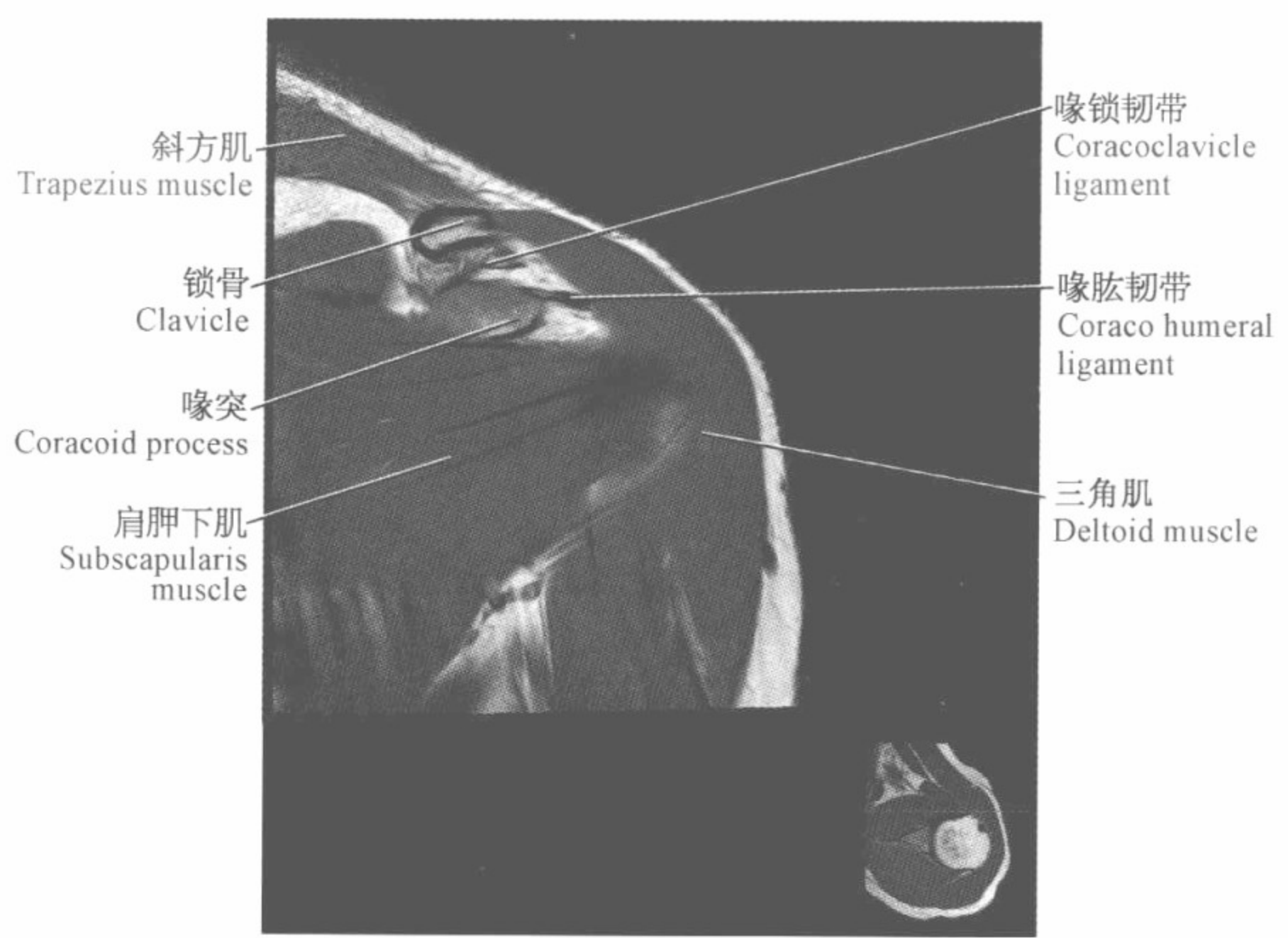
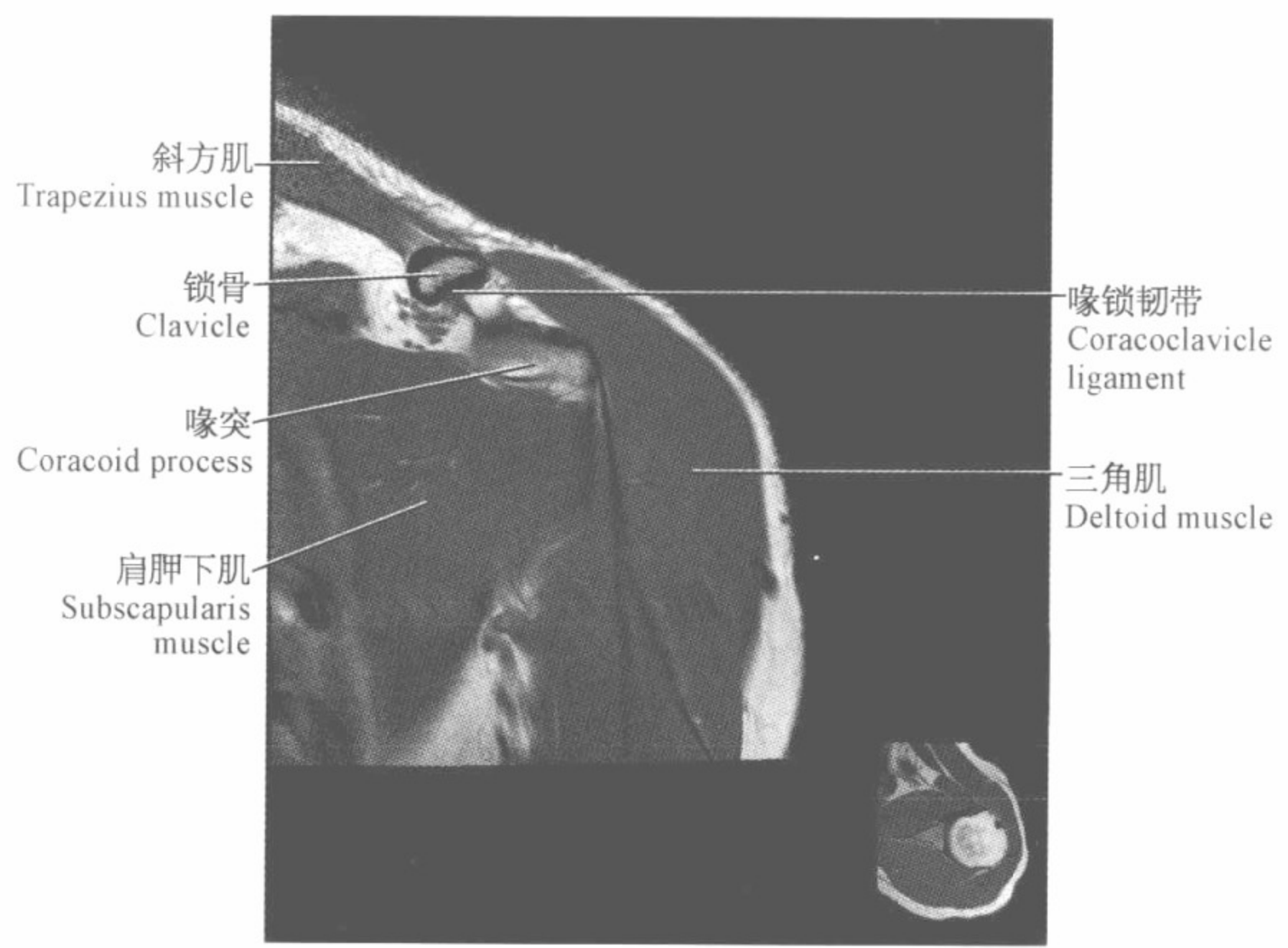


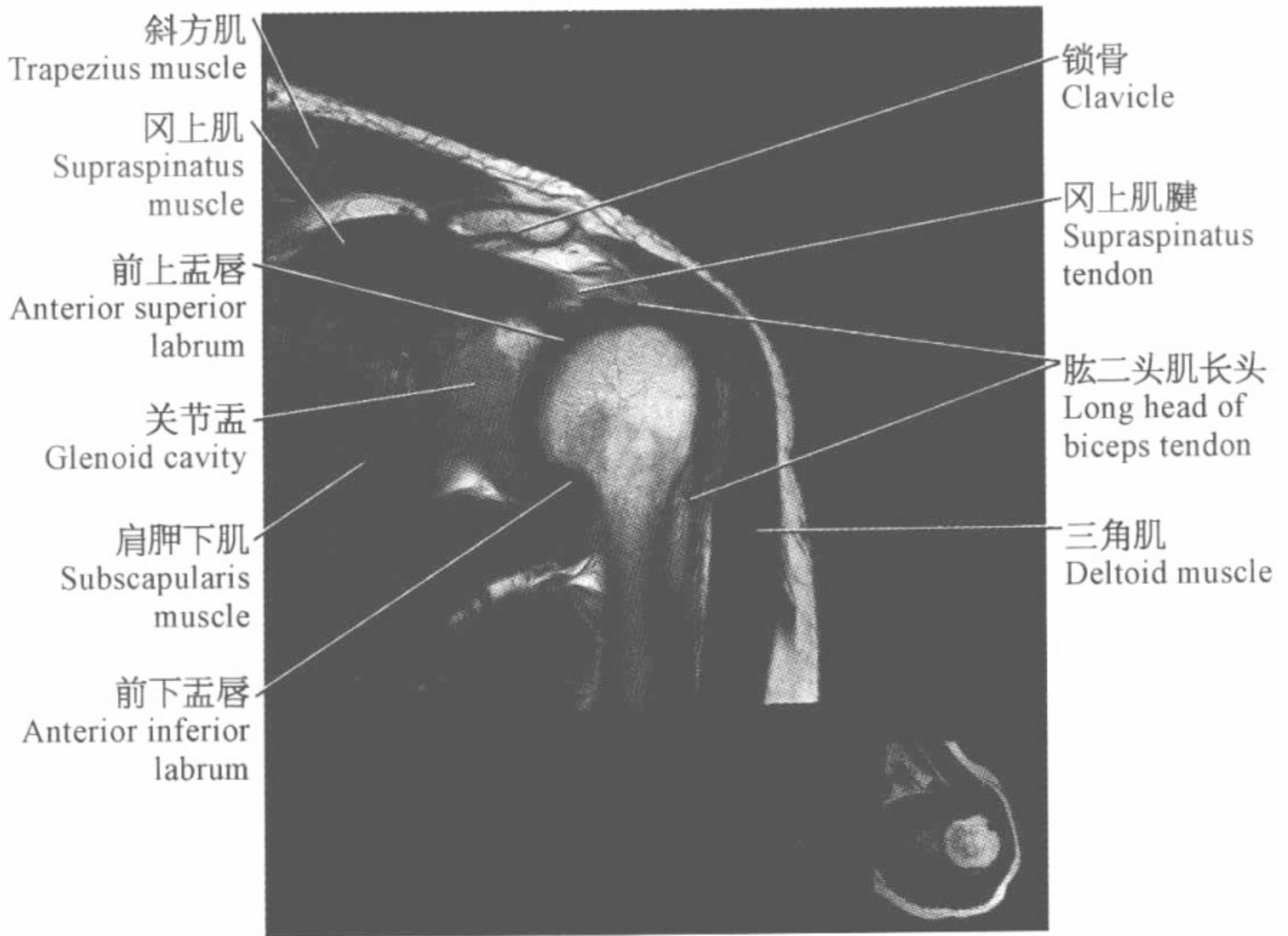
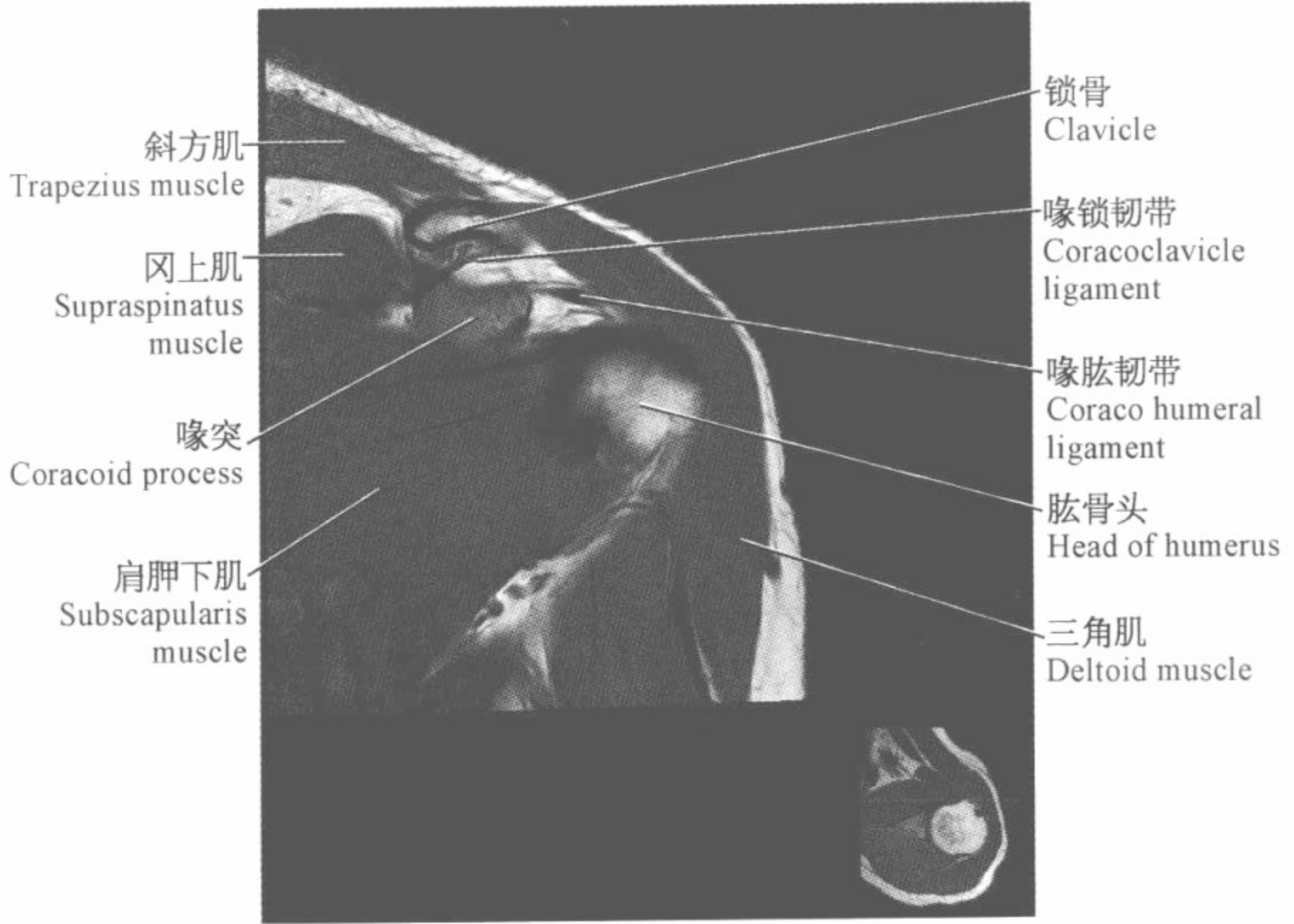


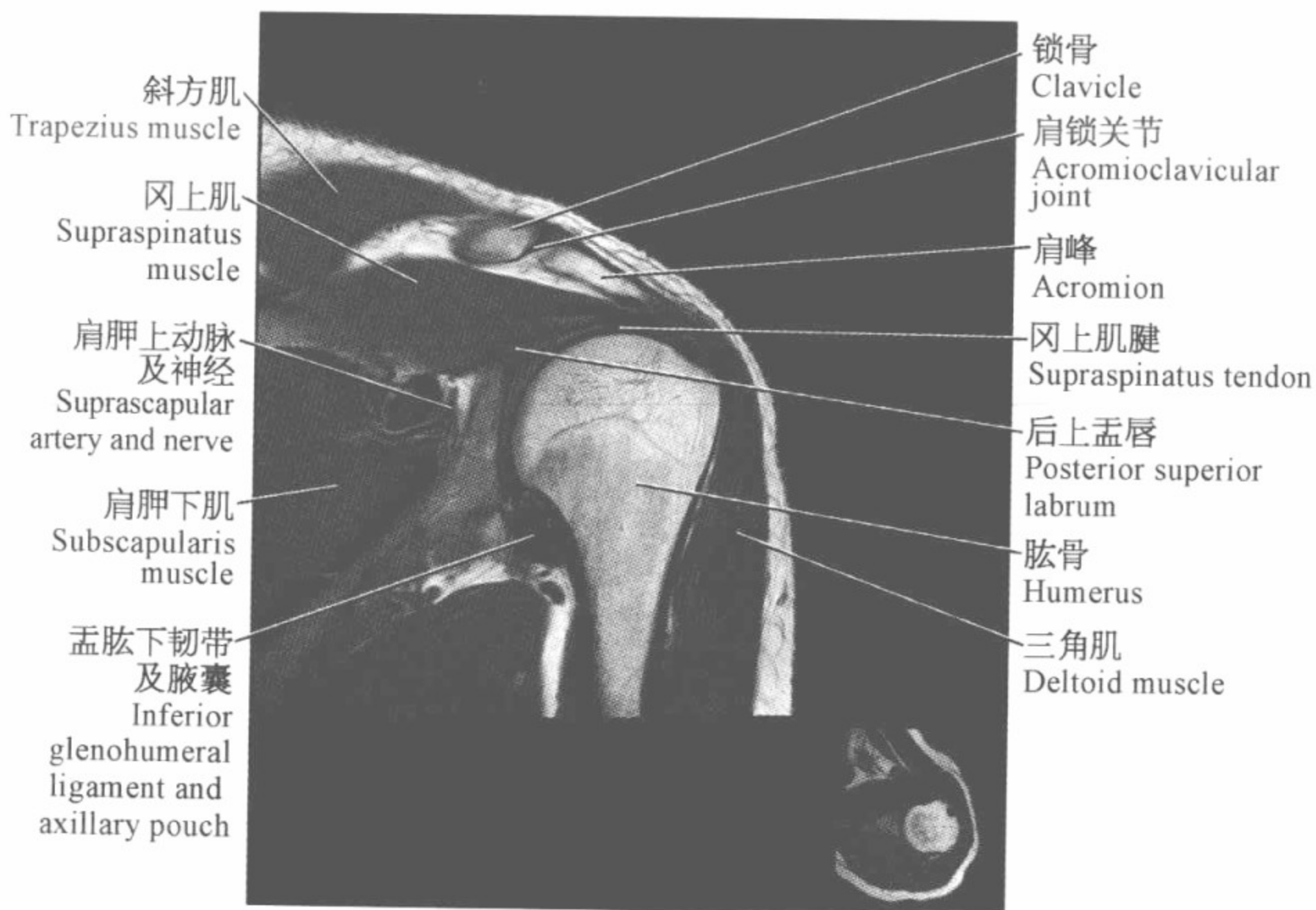
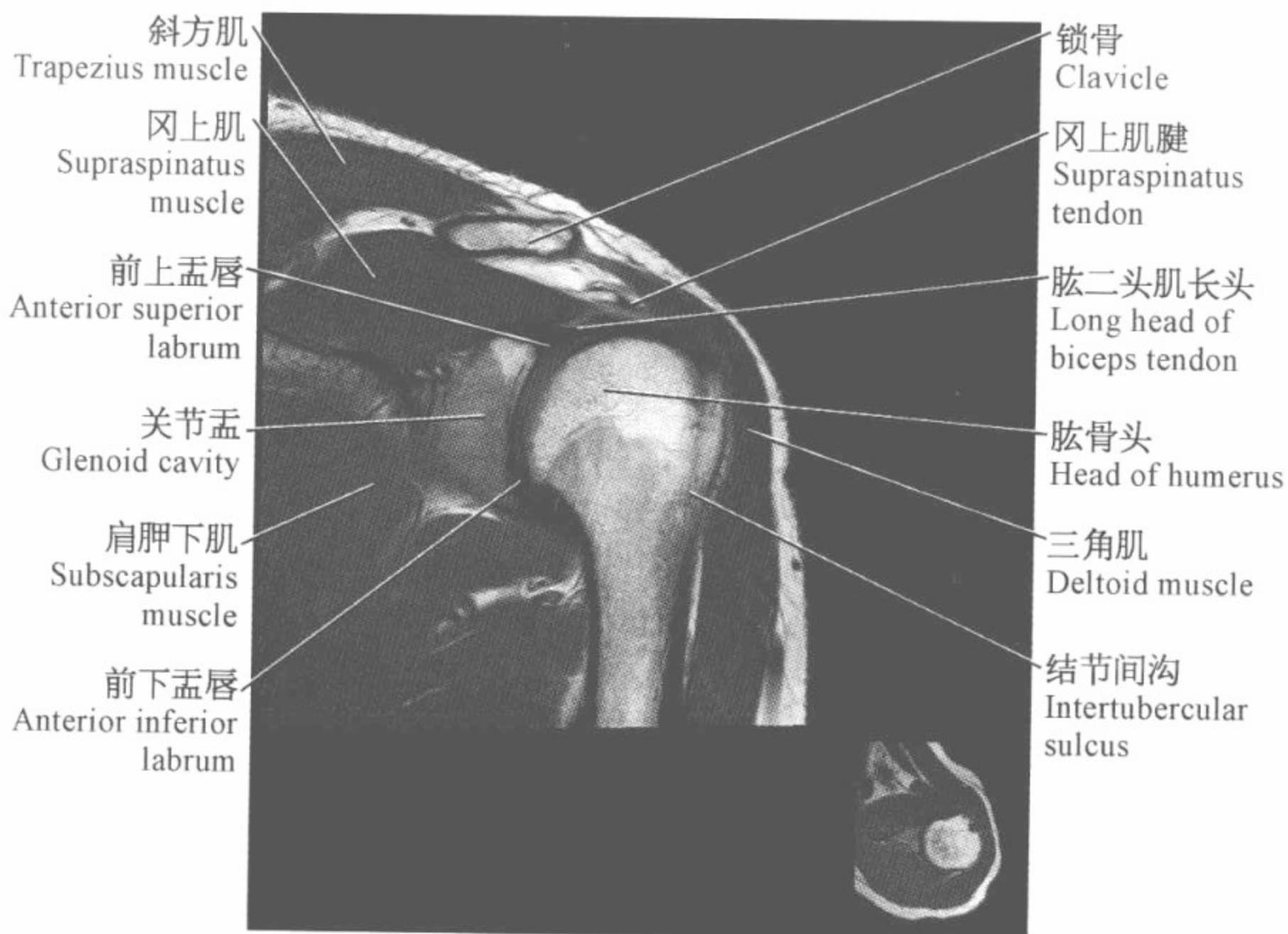
肩关节磁共振图谱

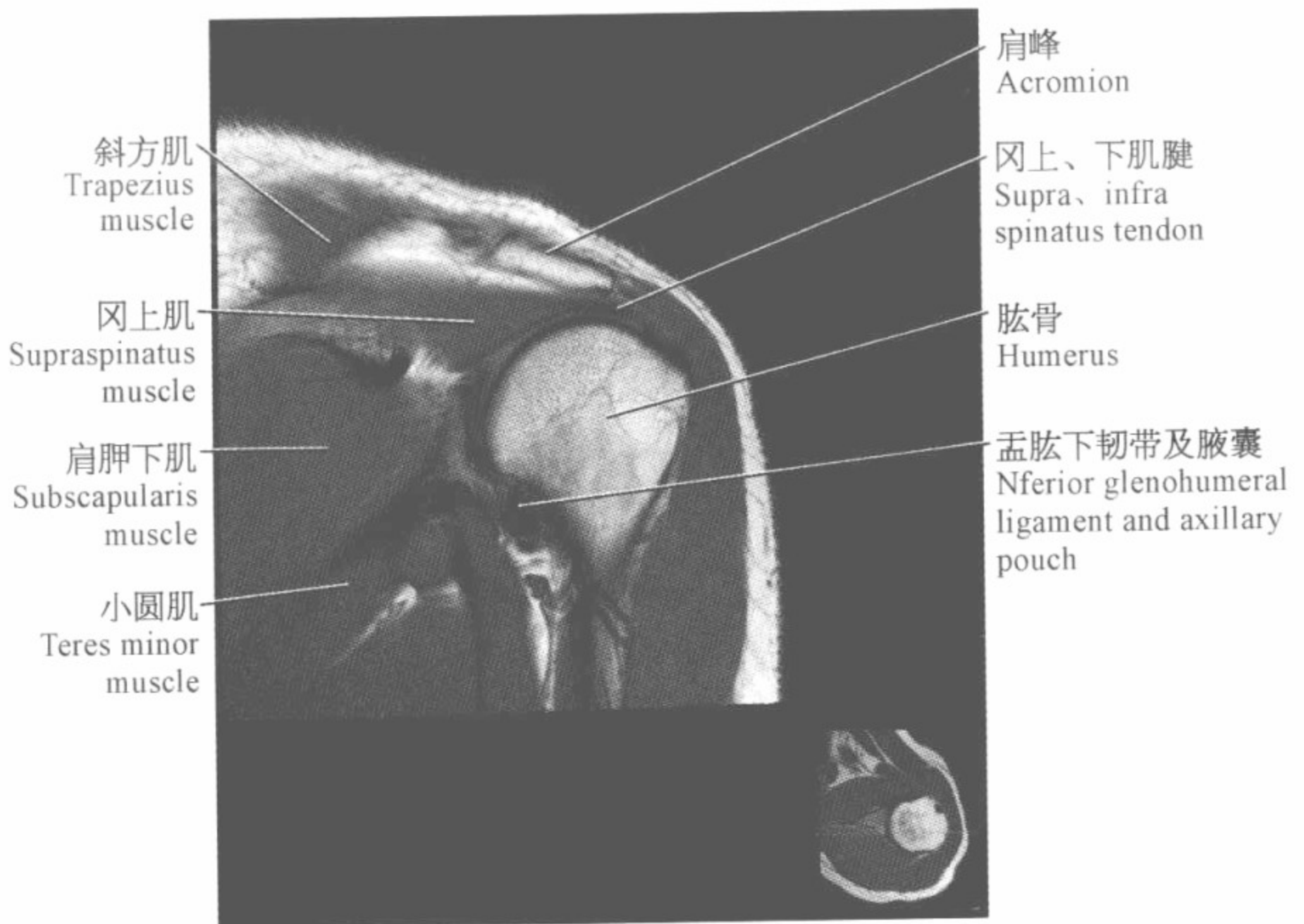
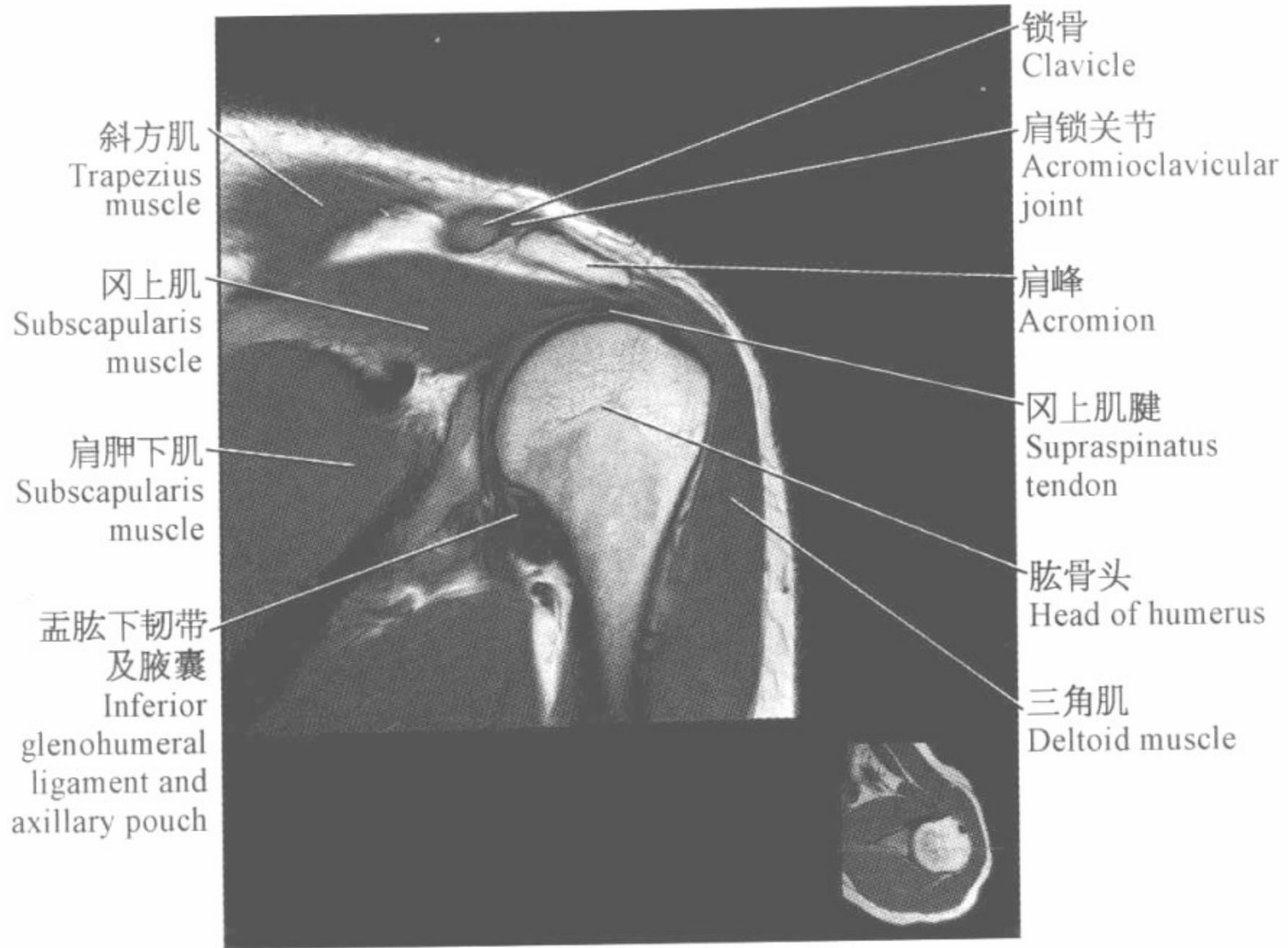
(冠状位)











肩胛冈
Spine of scapula

冈下肌
Infraspinatus
muscle

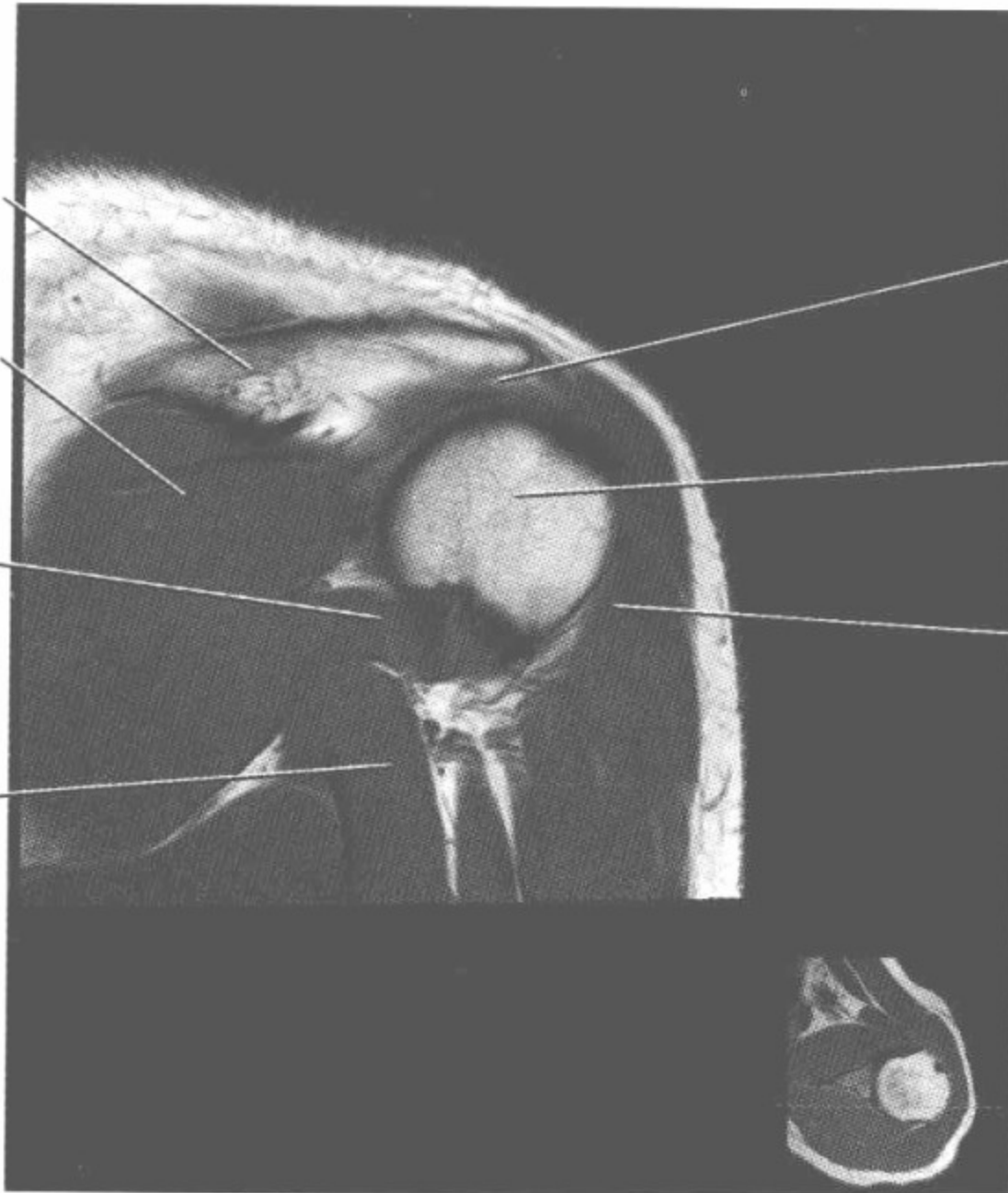
小圆肌
Teres minor
muscle

三头肌长头
Long head of
triceps muscle

冈下肌腱
Infraspinatus
tendon

肱骨头
Head of humerus

三角肌
Deltoid muscle



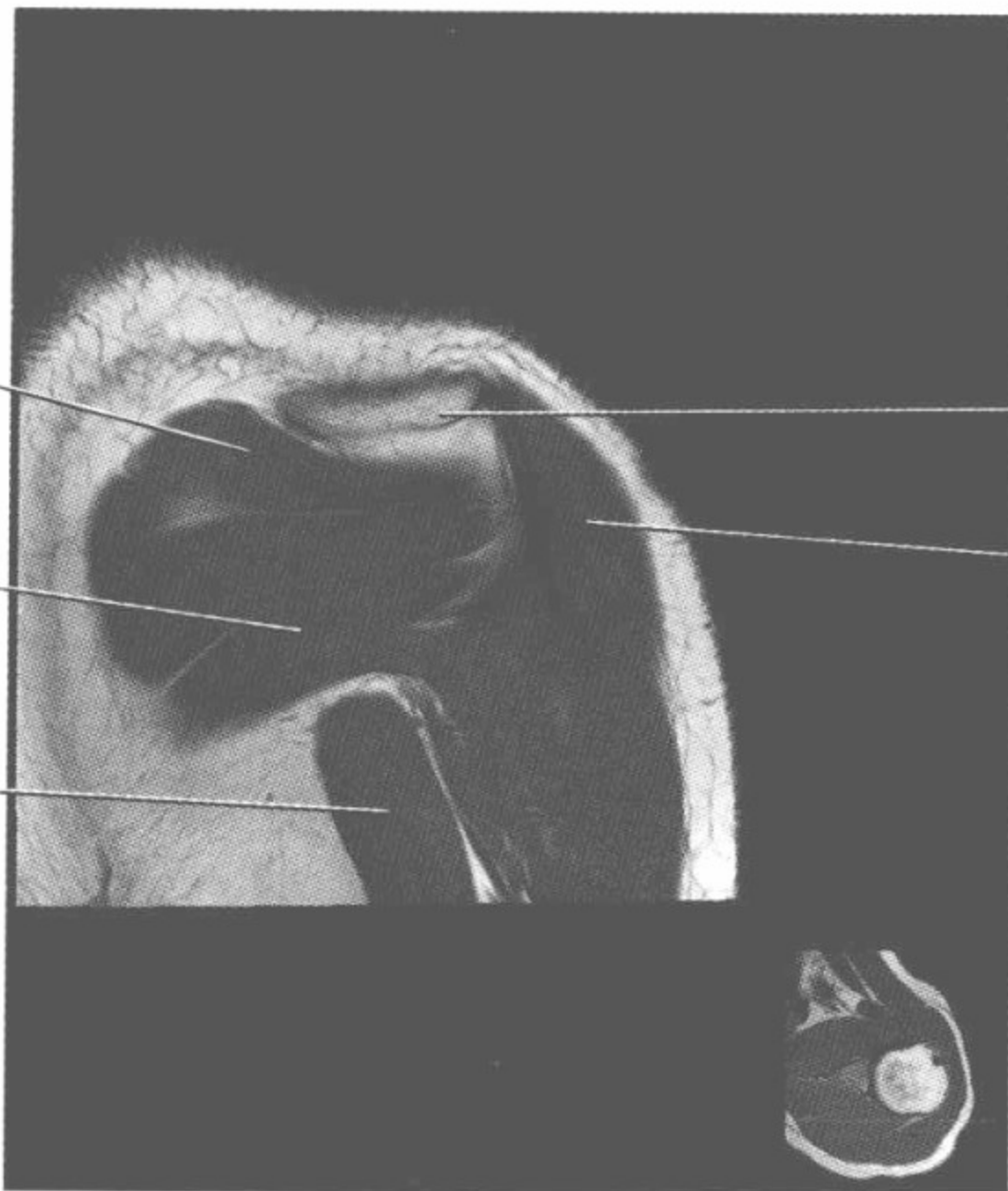
冈下肌
Infraspinatus
muscle

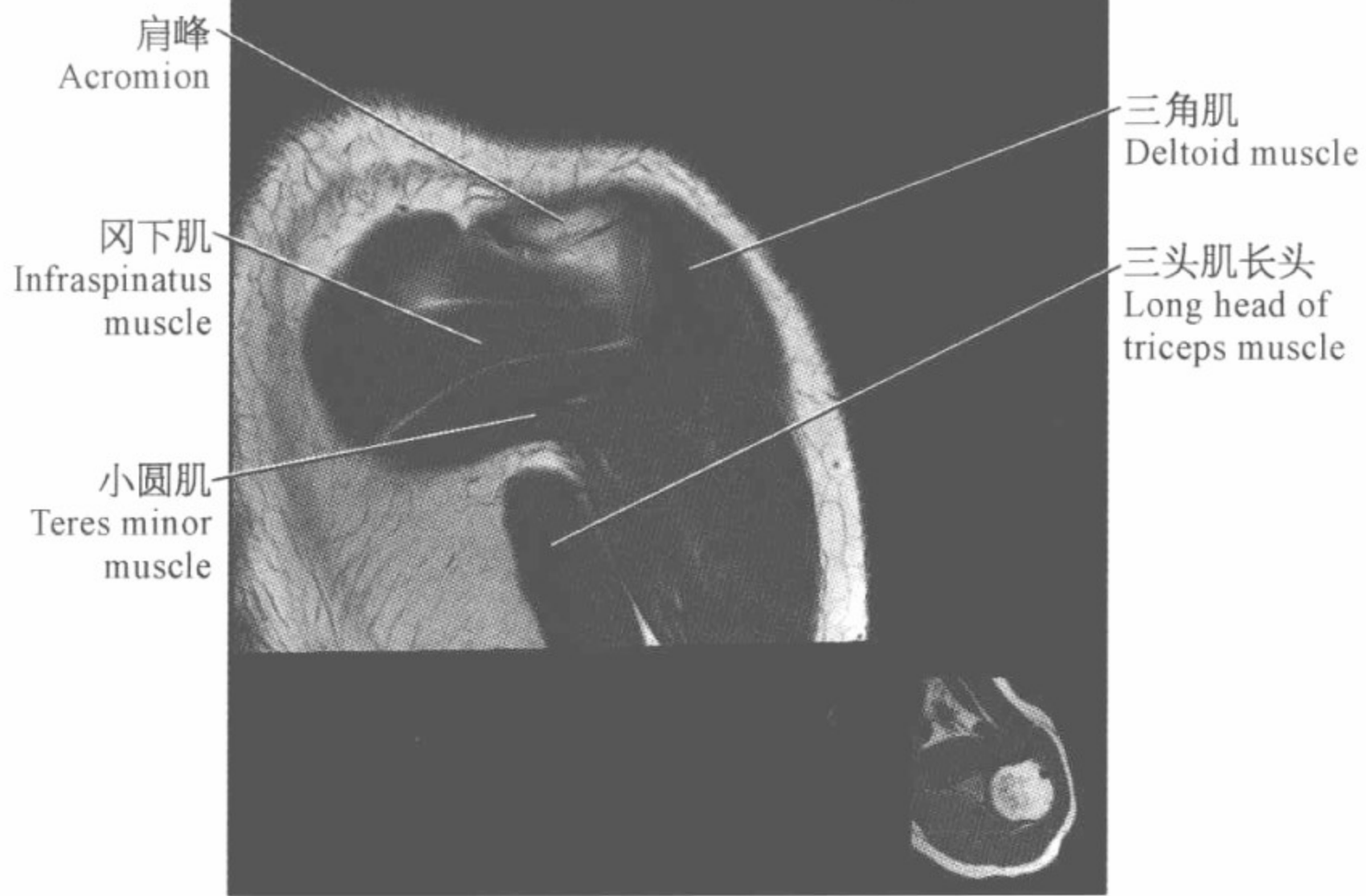
小圆肌
Teres minor
muscle

三头肌长头
Long head of
triceps muscle

肩峰
Acromion

三角肌
Deltoid muscle

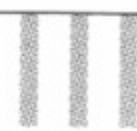




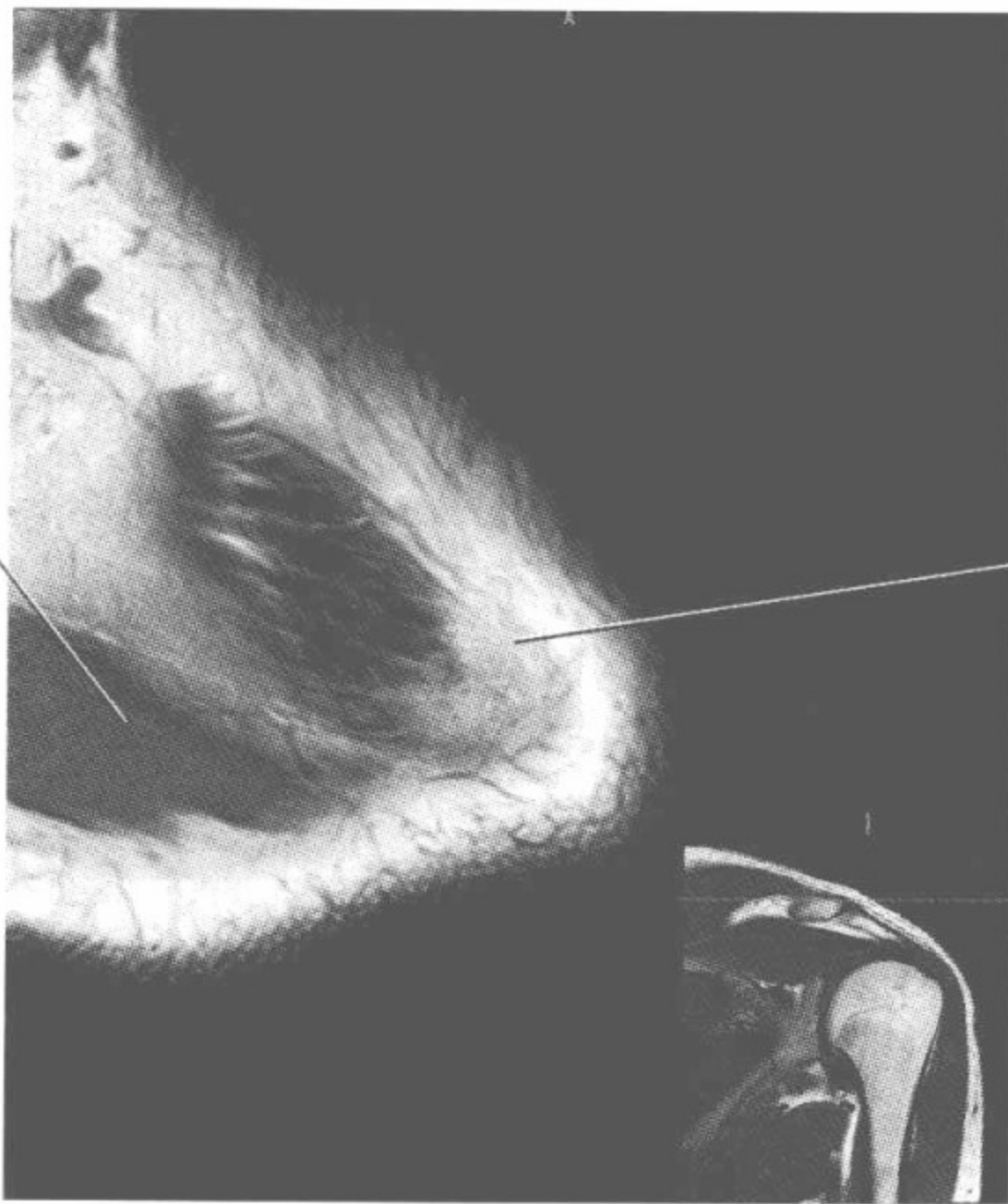


肩关节磁共振图谱

(横断位)

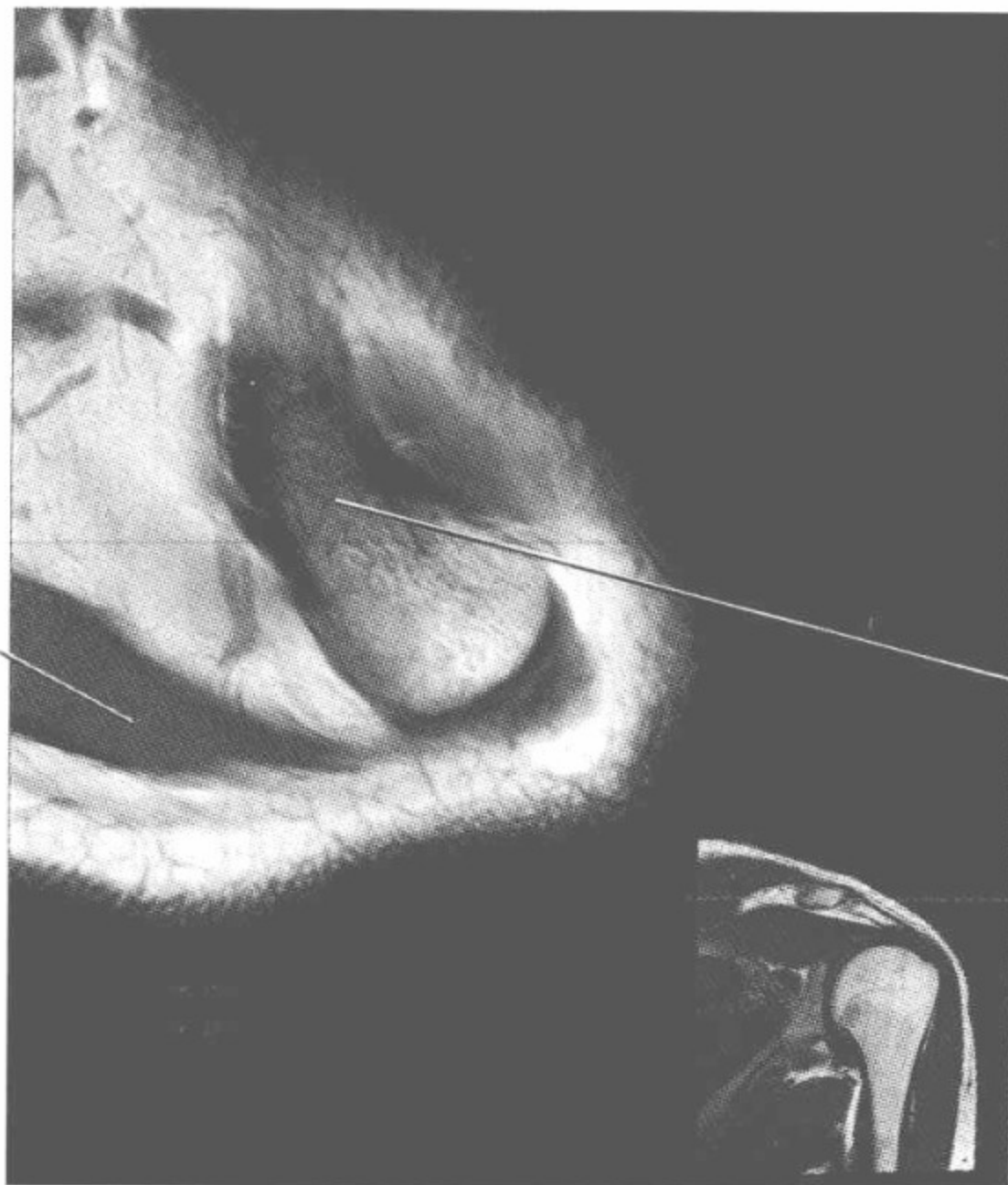

斜方肌
Trapezius muscle



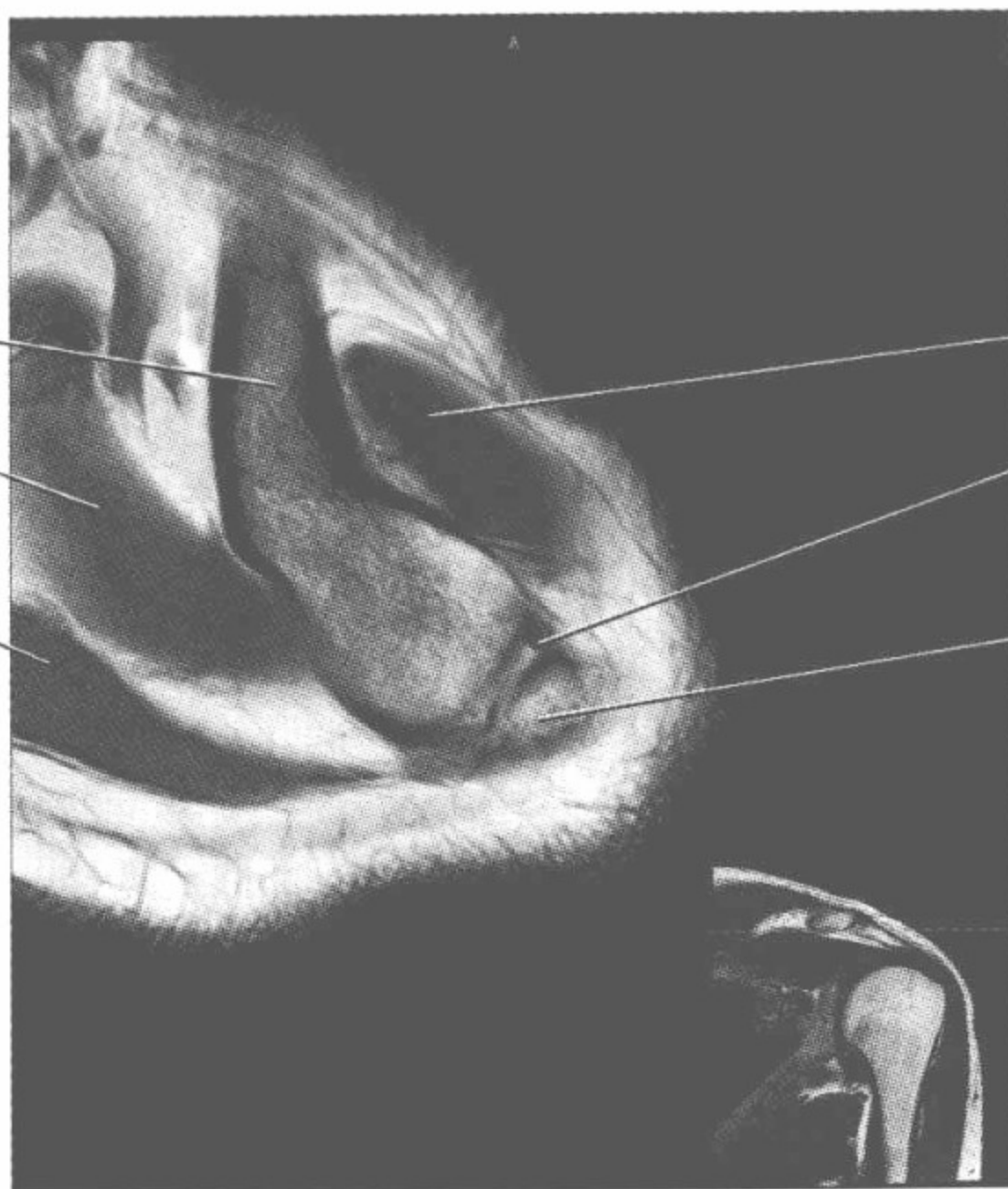
锁骨
Clavicle

斜方肌
Trapezius muscle



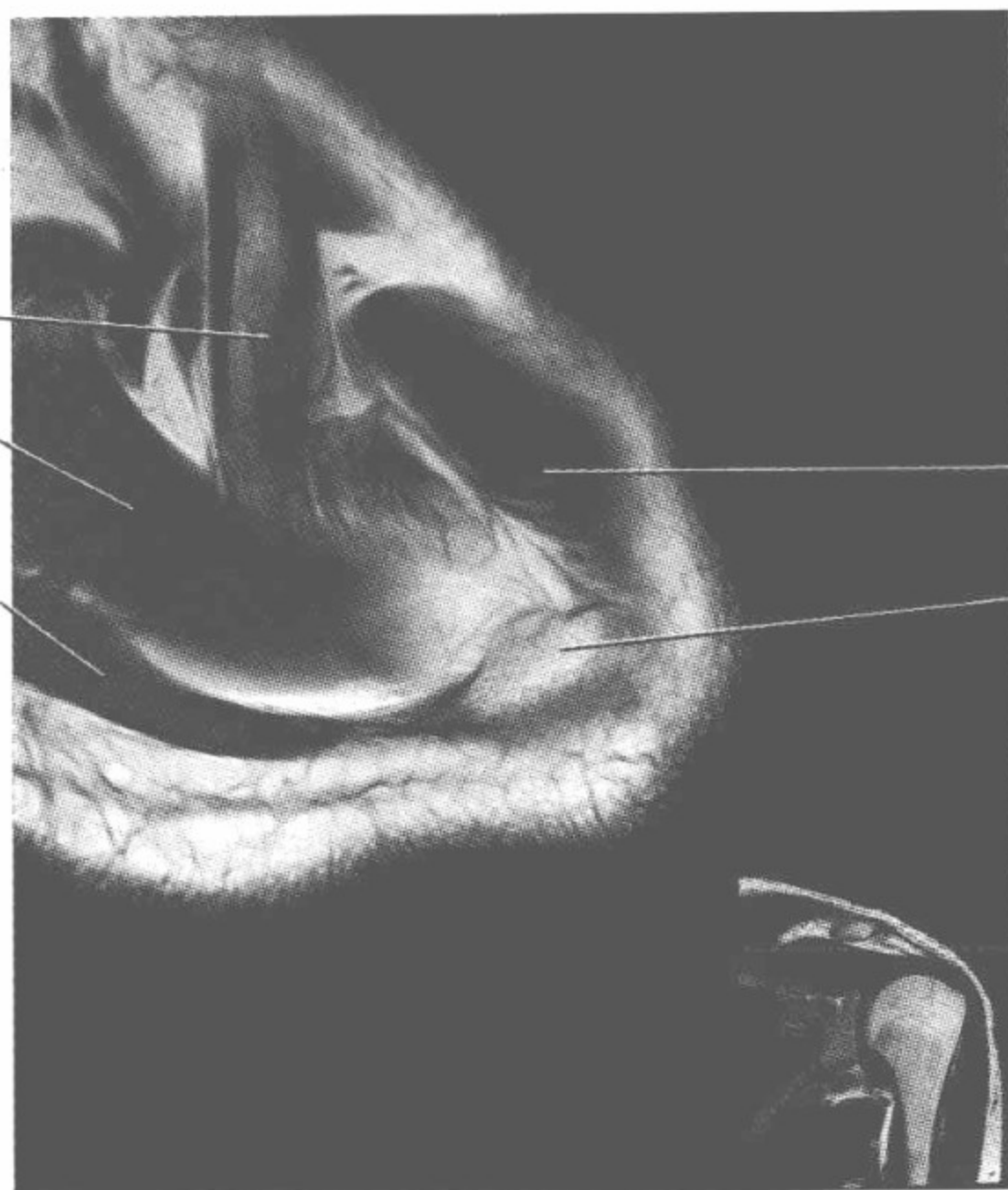
锁骨
Clavicle

锁骨
Clavicle
冈上肌
Supraspinatus
muscle
斜方肌
Trapezius muscle

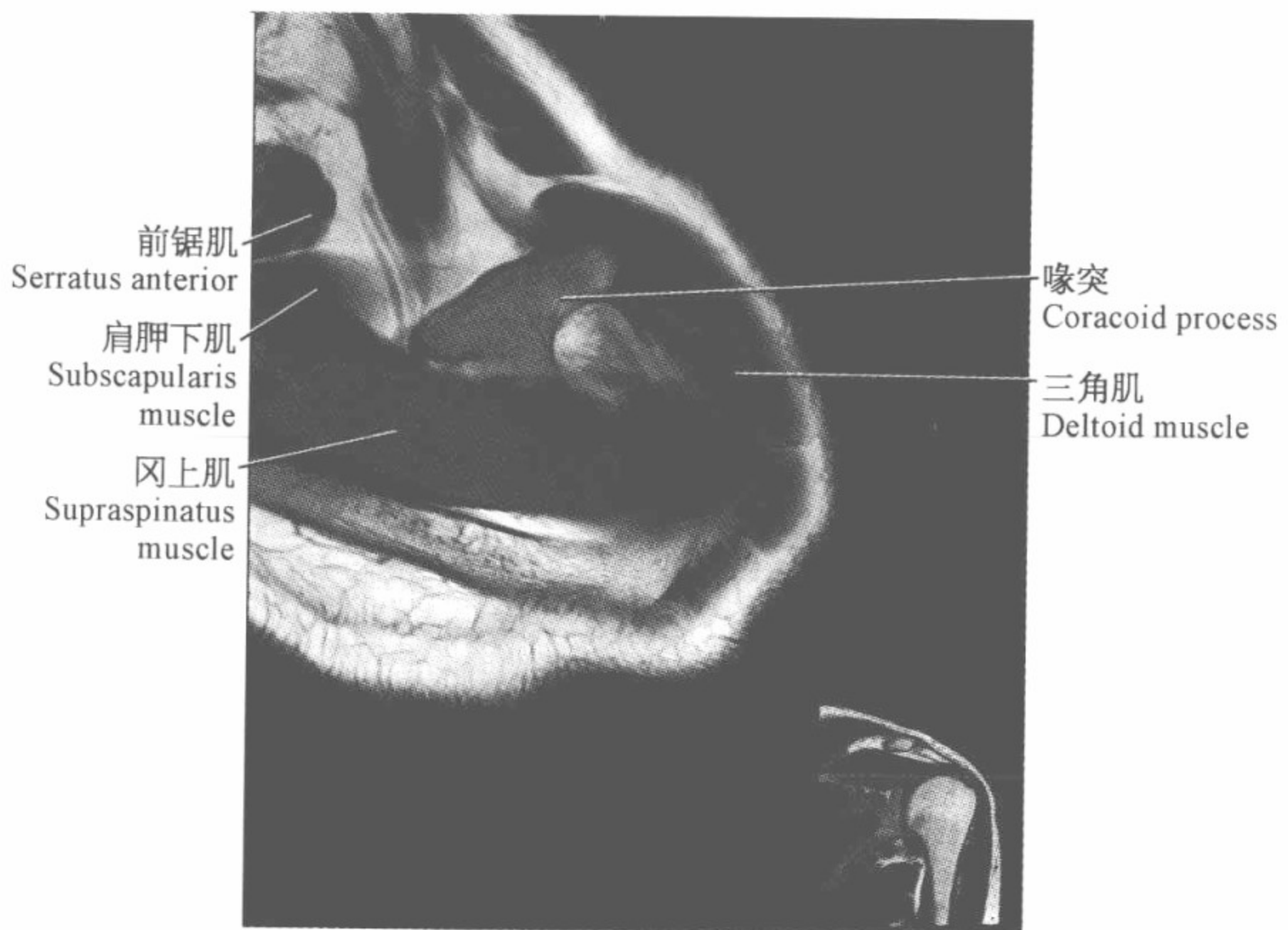
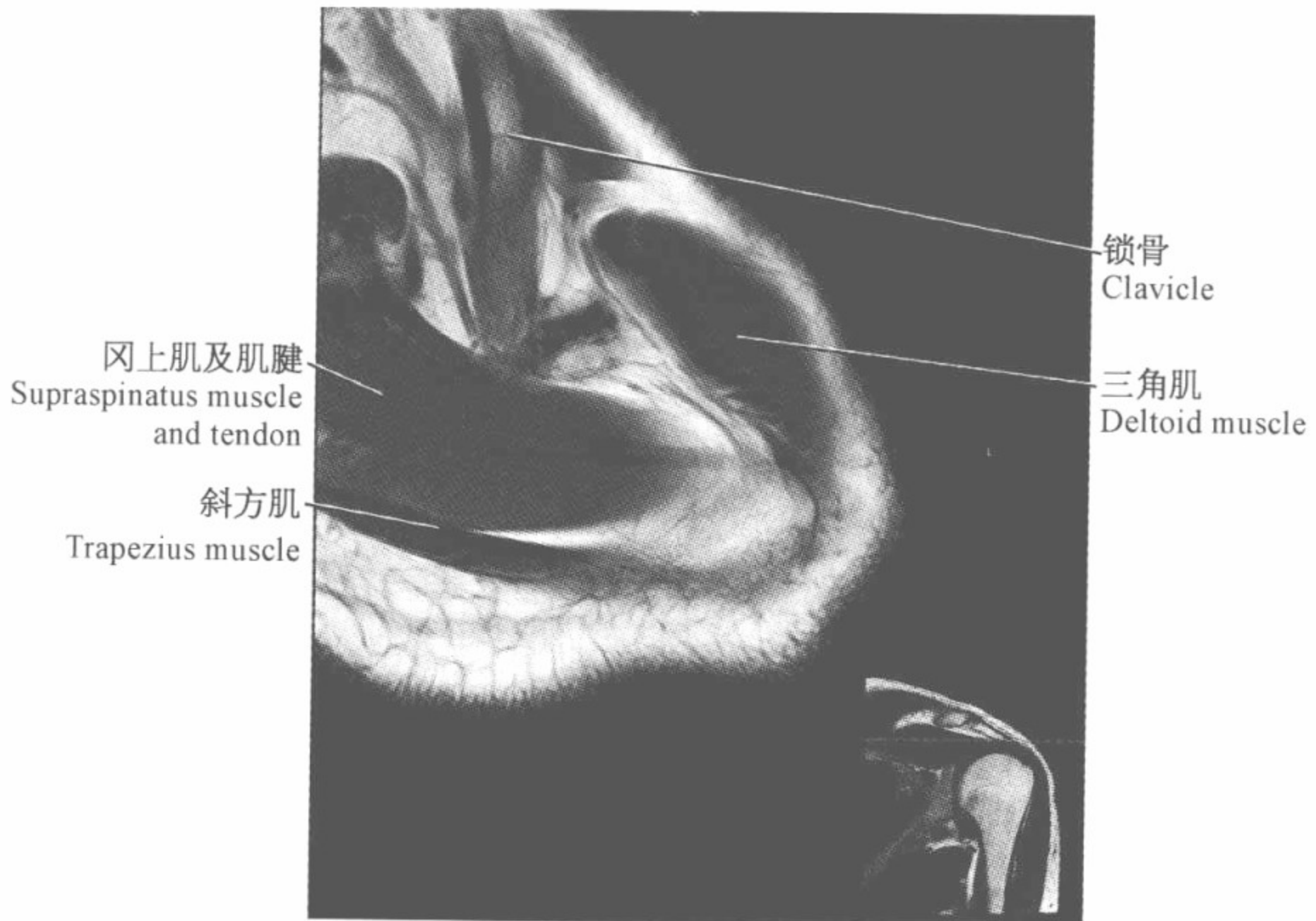


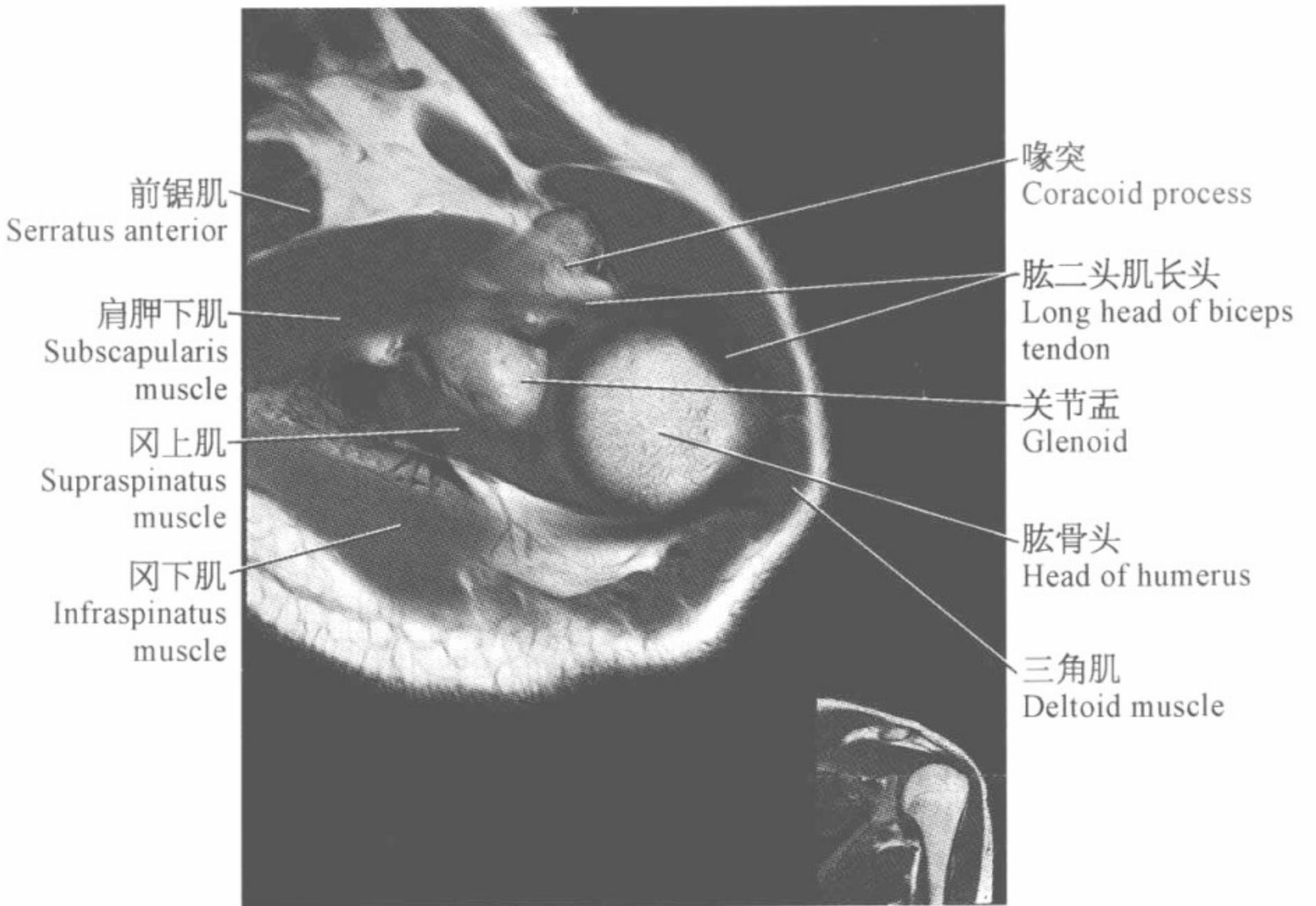
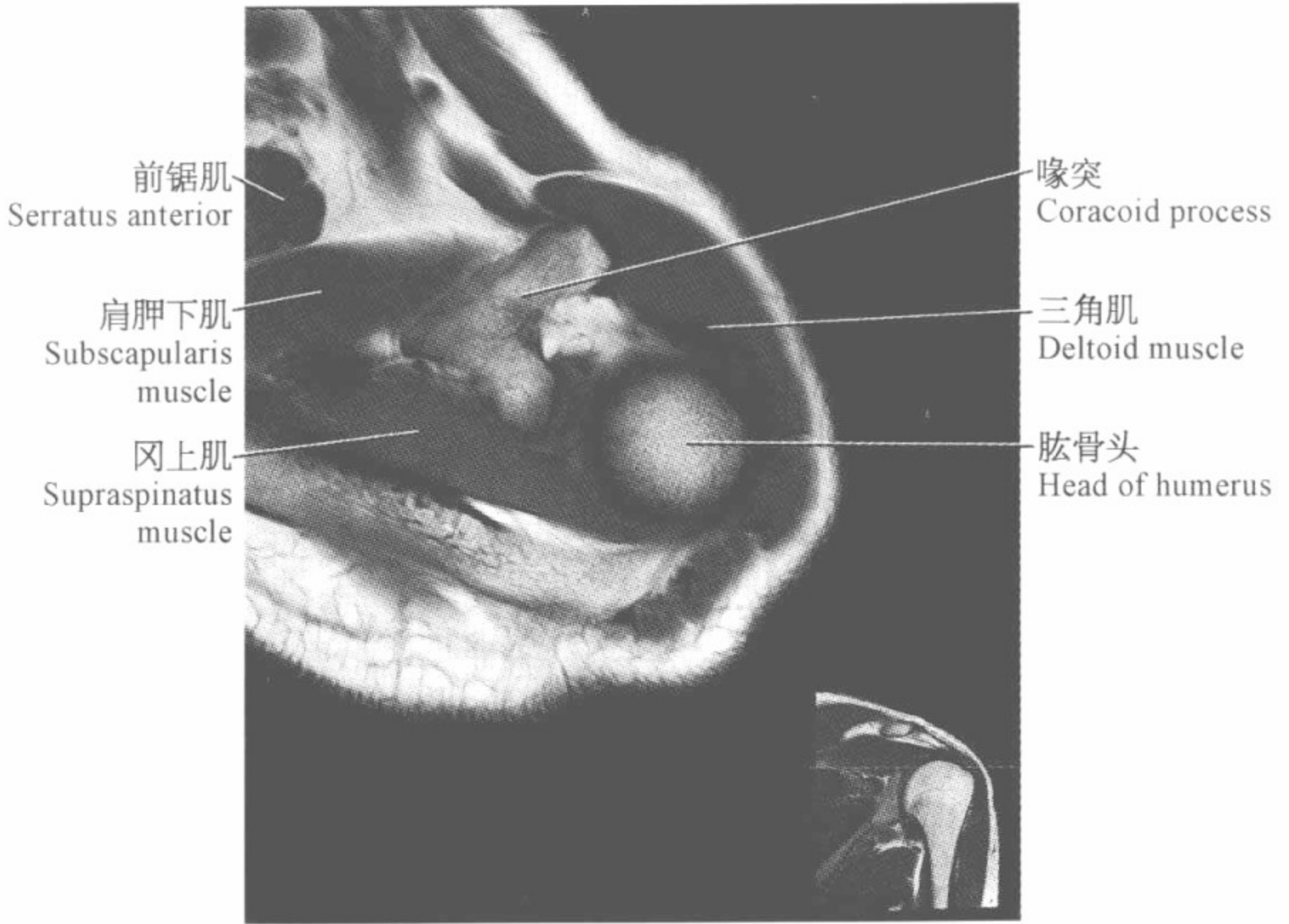
三角肌
Deltoid muscle
肩锁韧带
Acromionclavicular
ligament
肩峰
Acromion

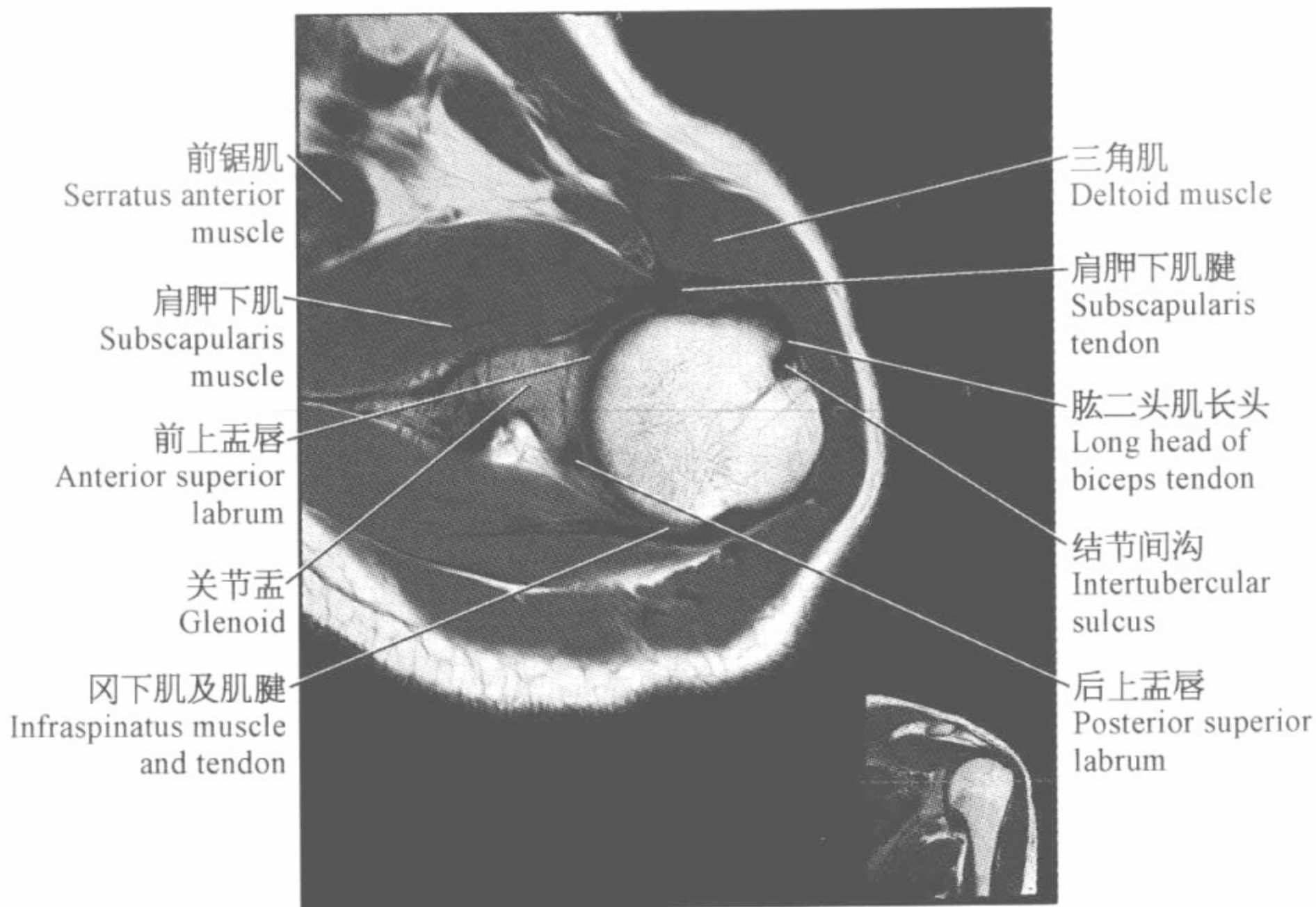
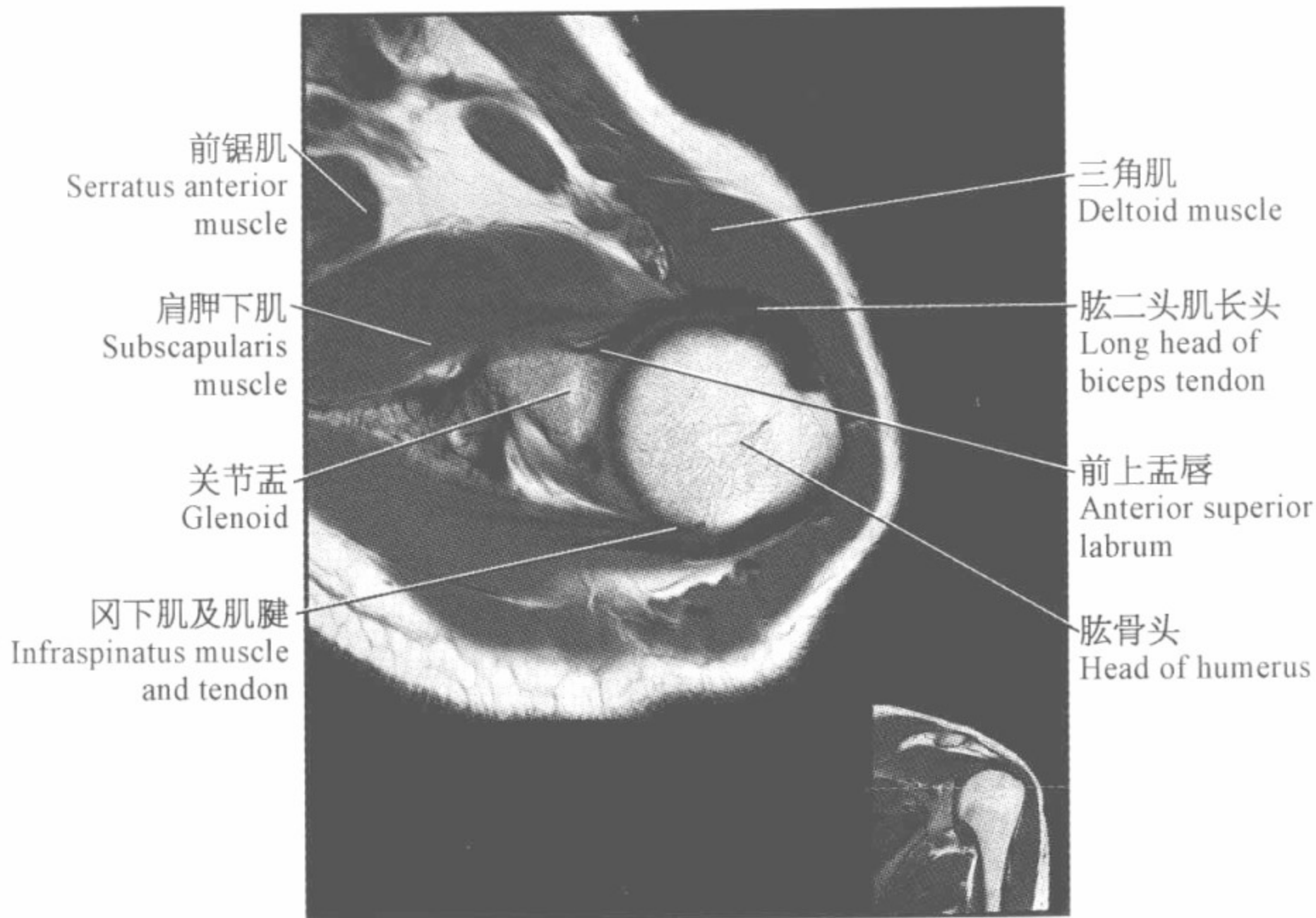
锁骨
Clavicle
冈上肌
Supraspinatus
muscle
斜方肌
Trapezius muscle

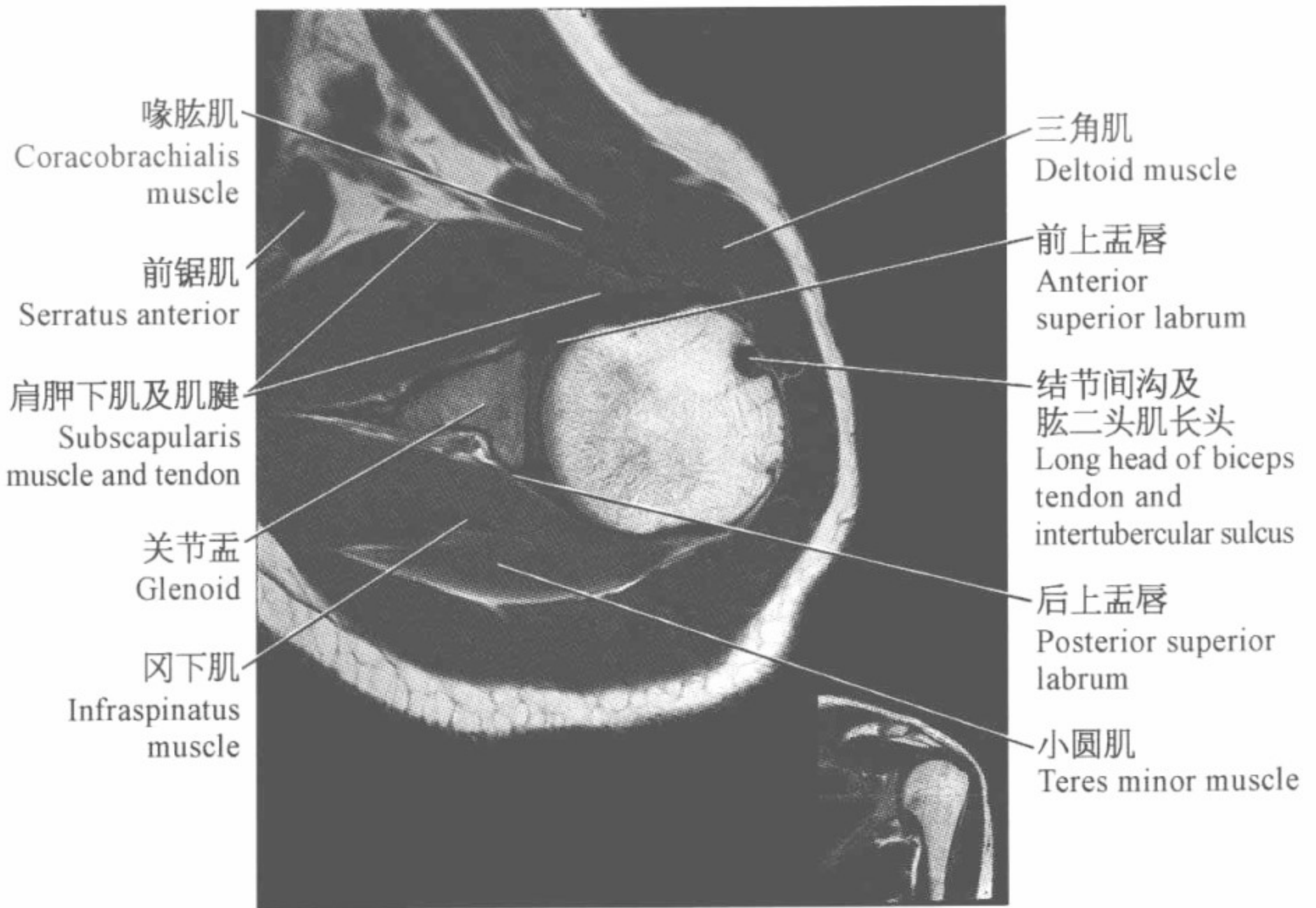
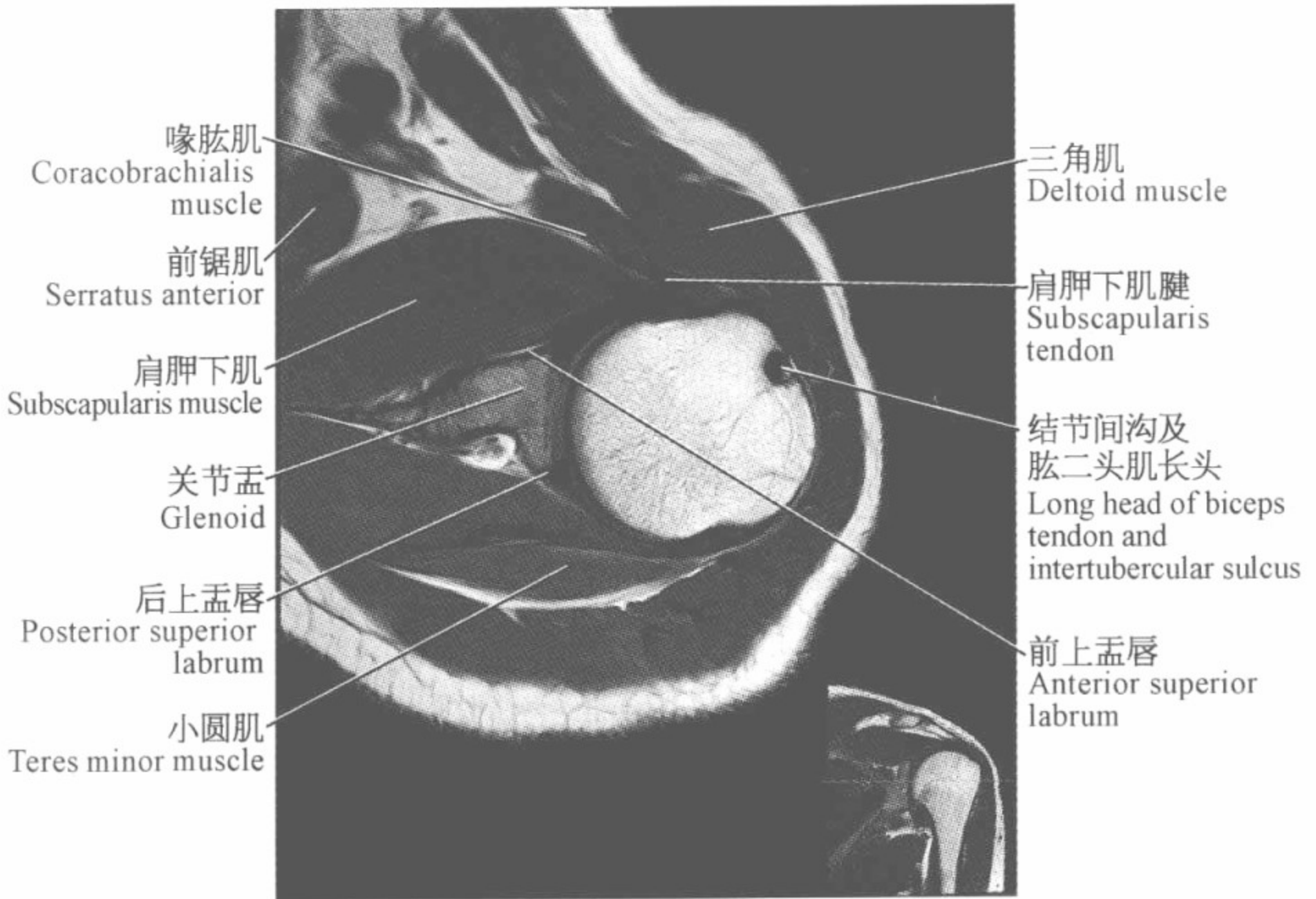


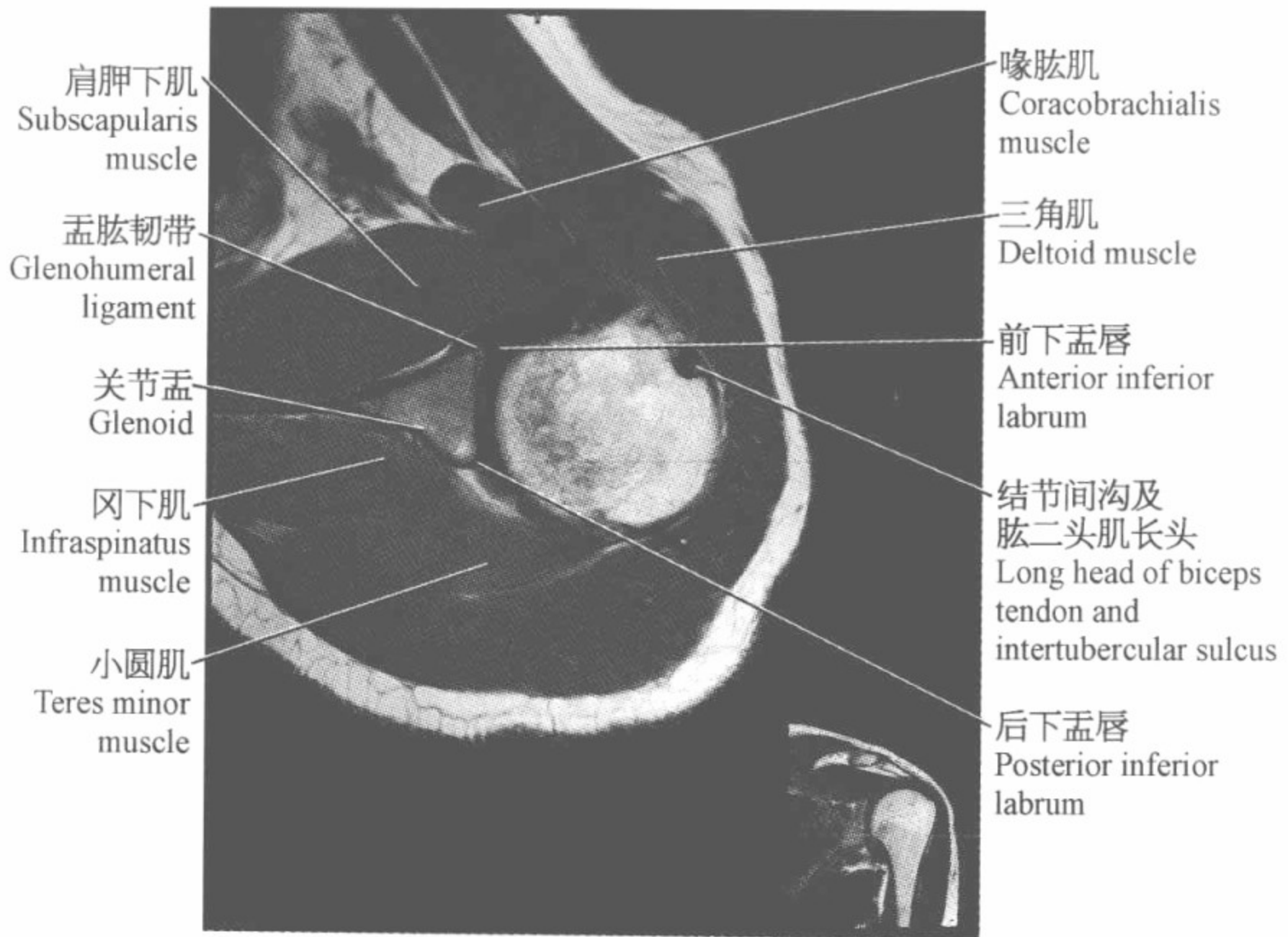
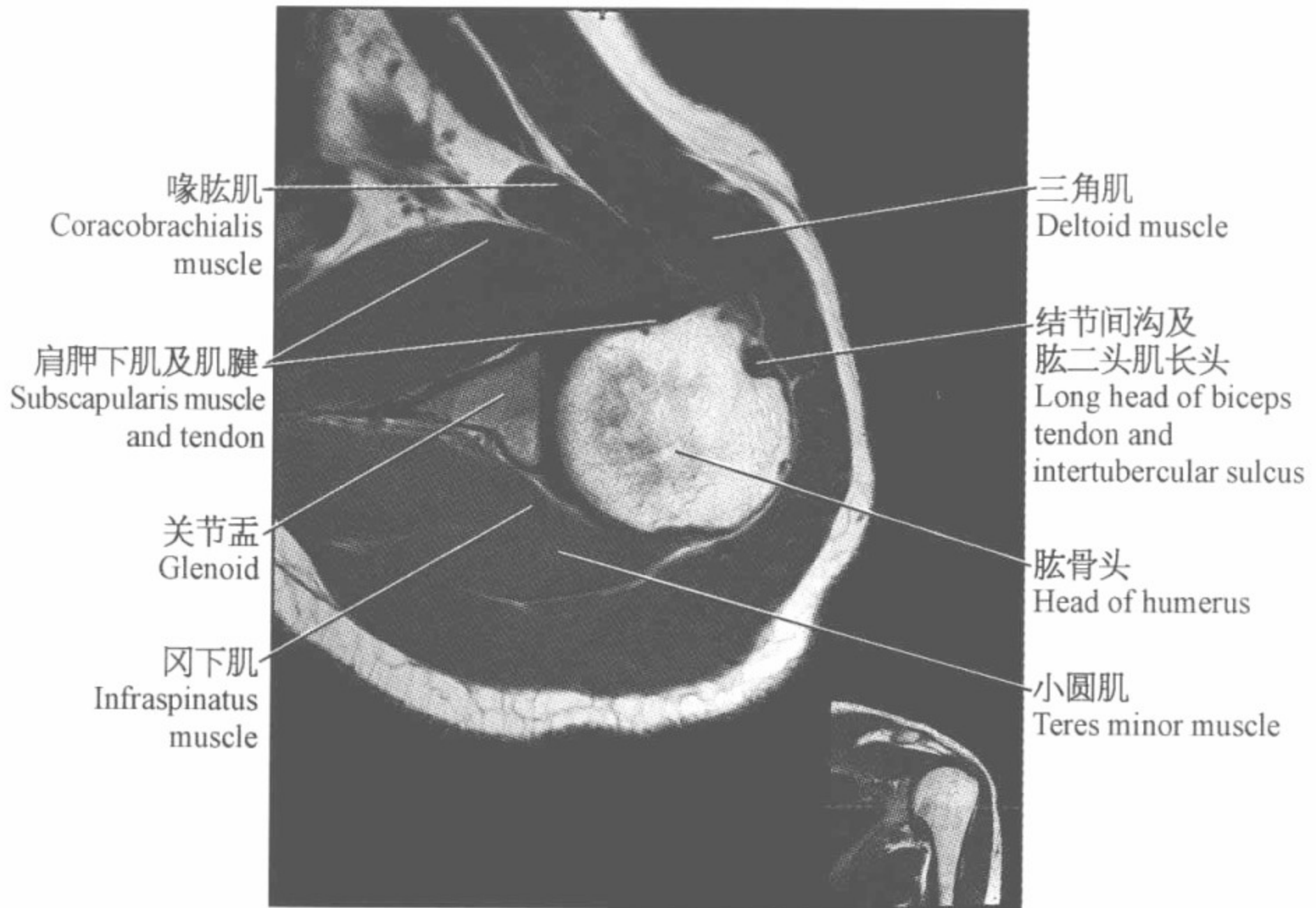
三角肌
Deltoid muscle
肩峰
Acromion

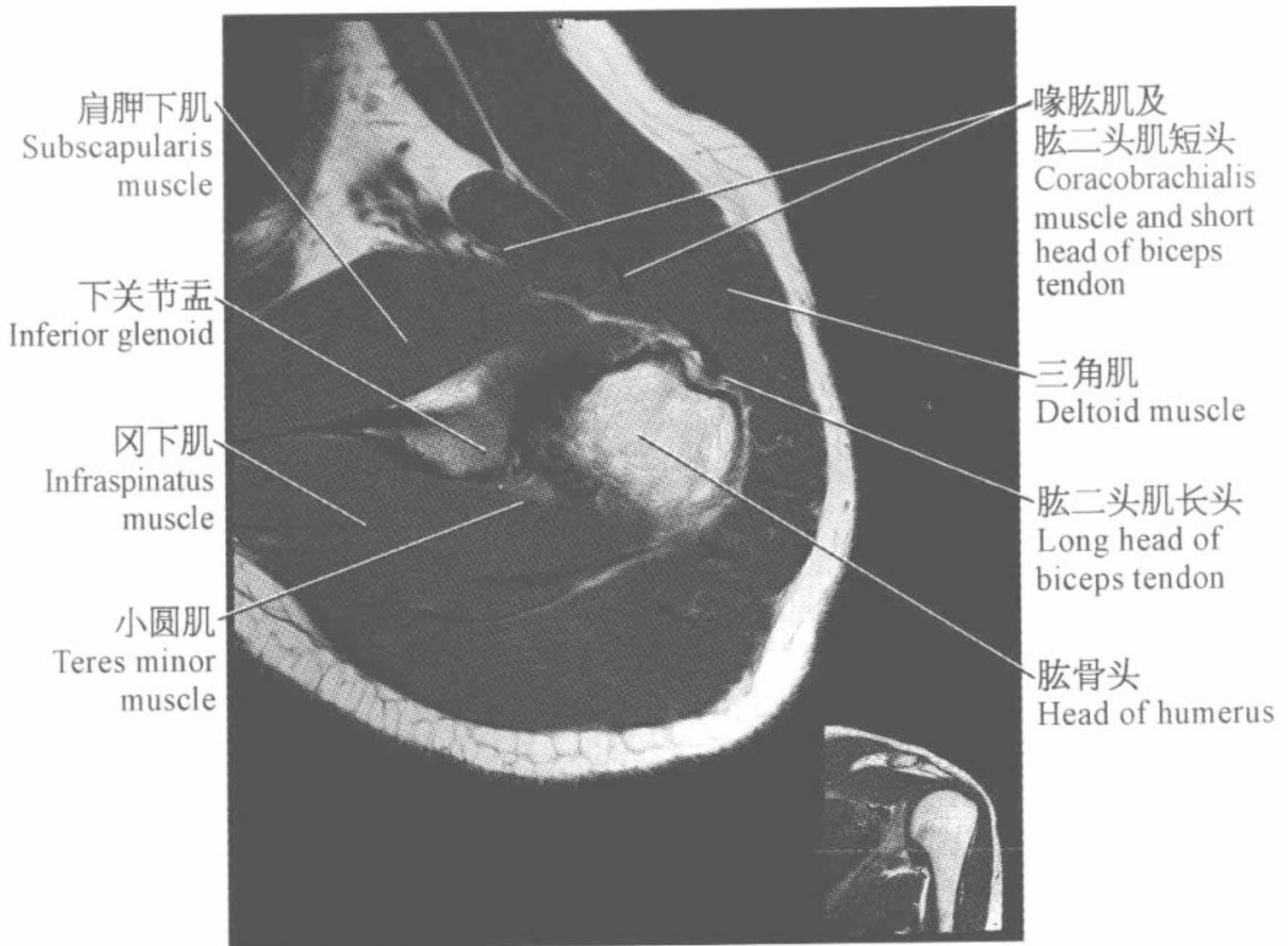
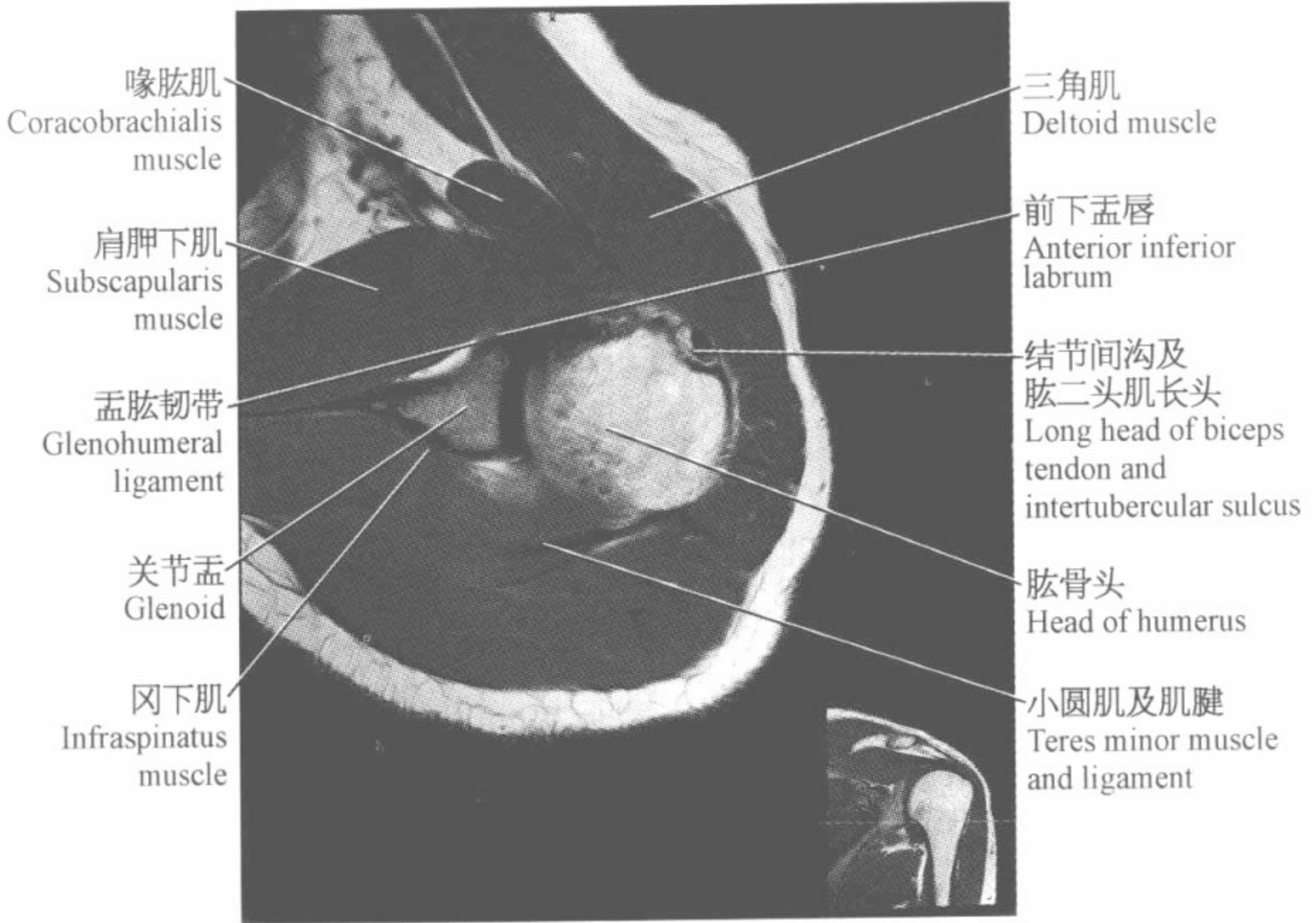


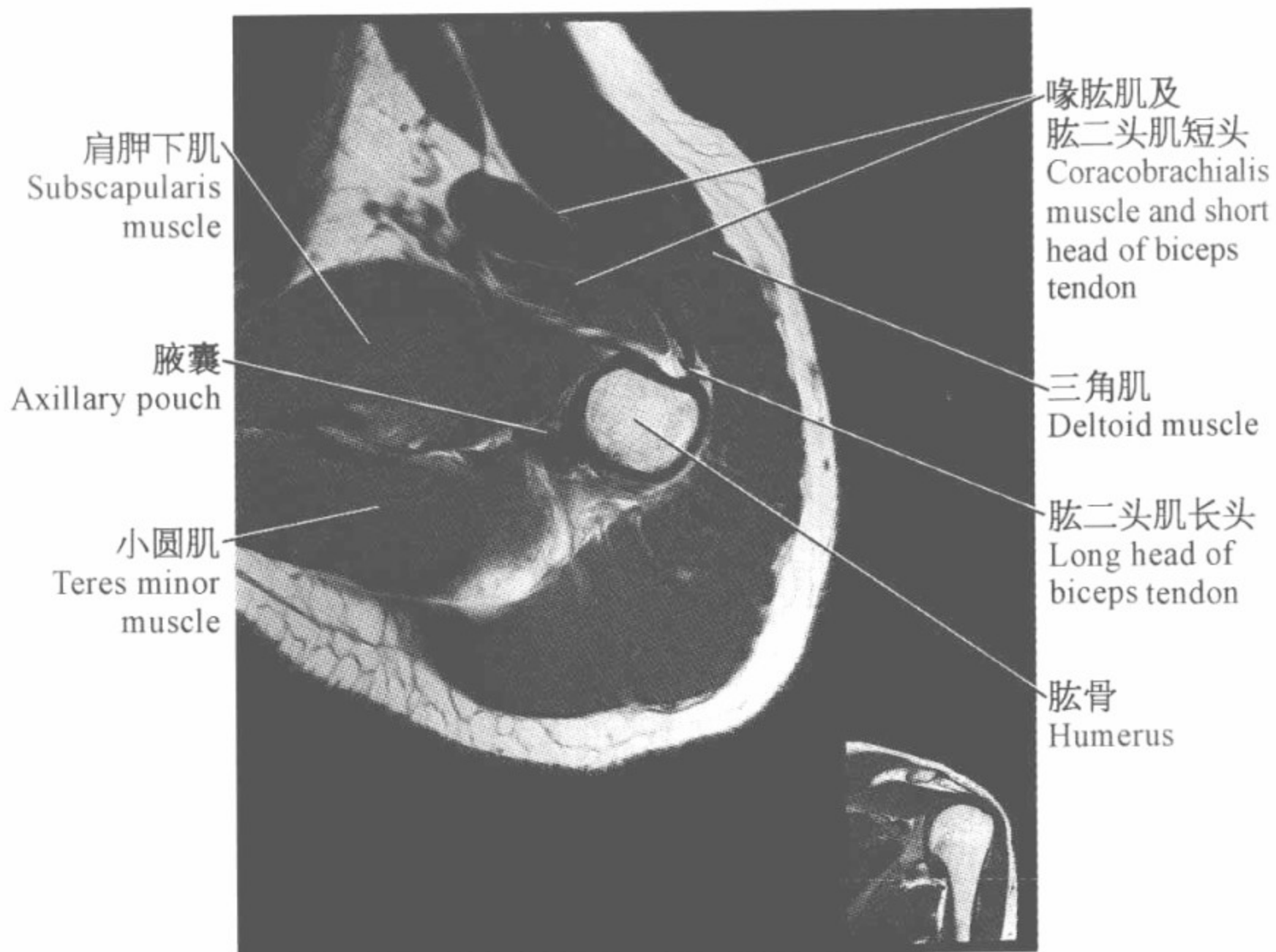
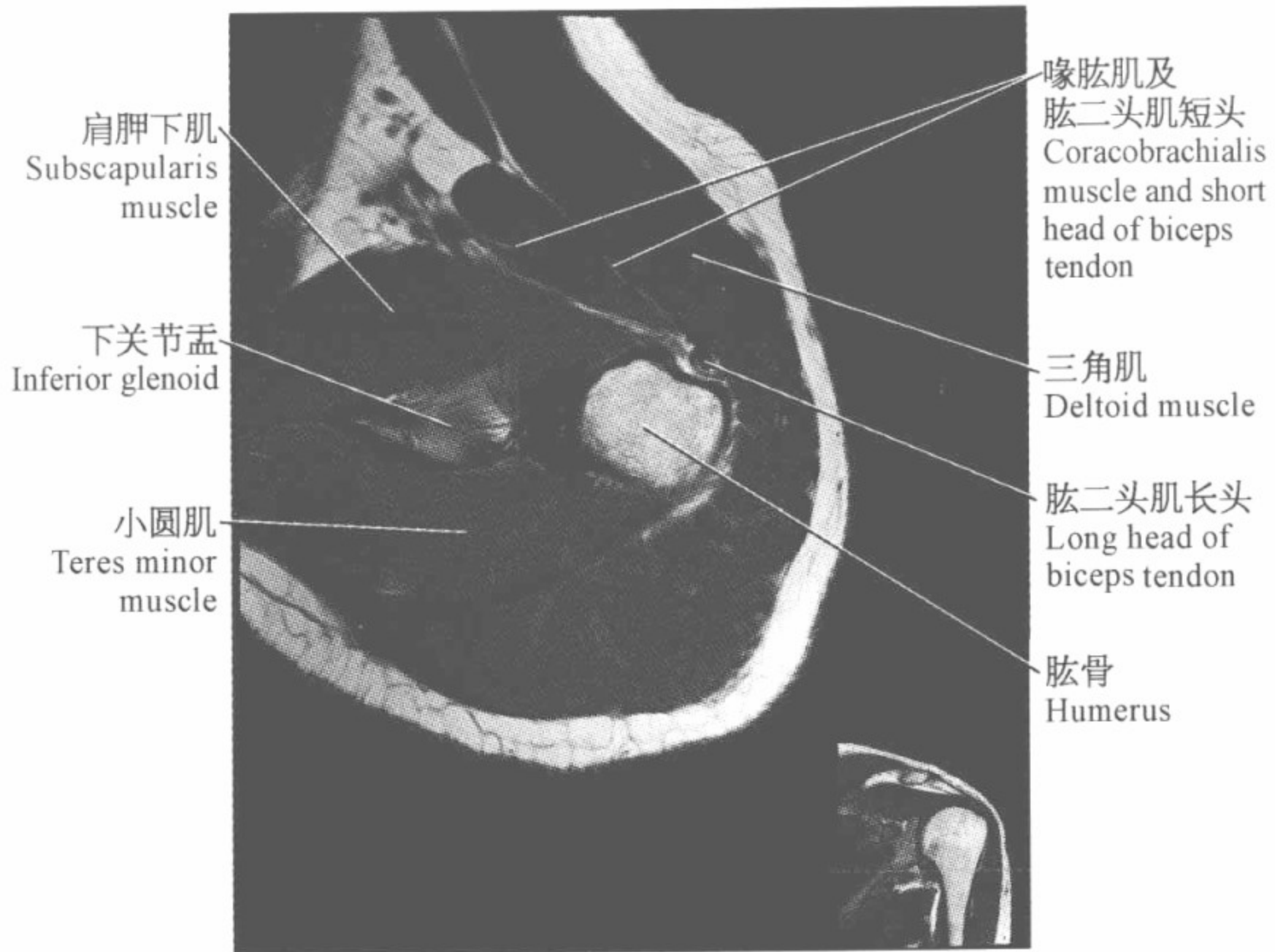






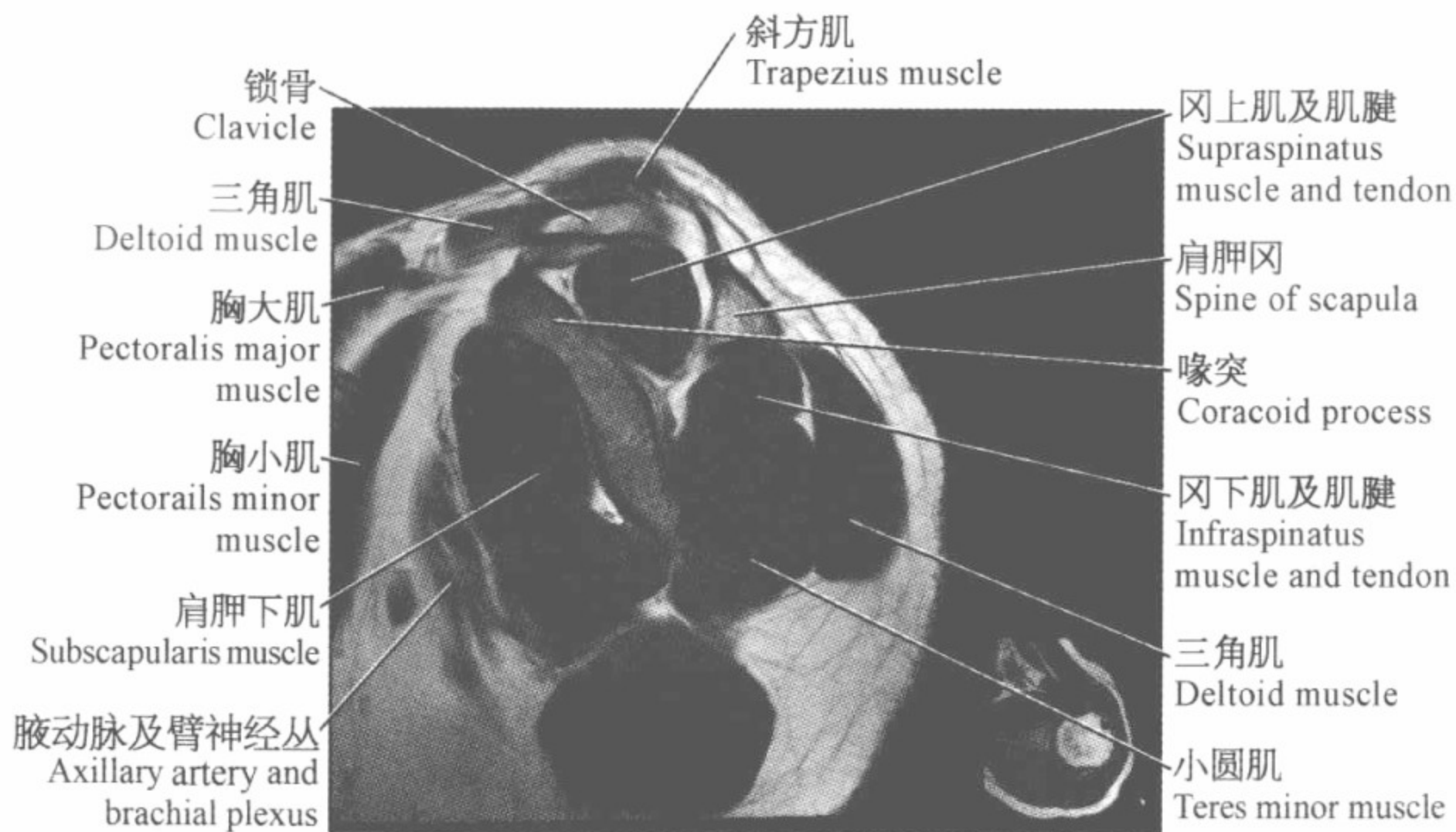
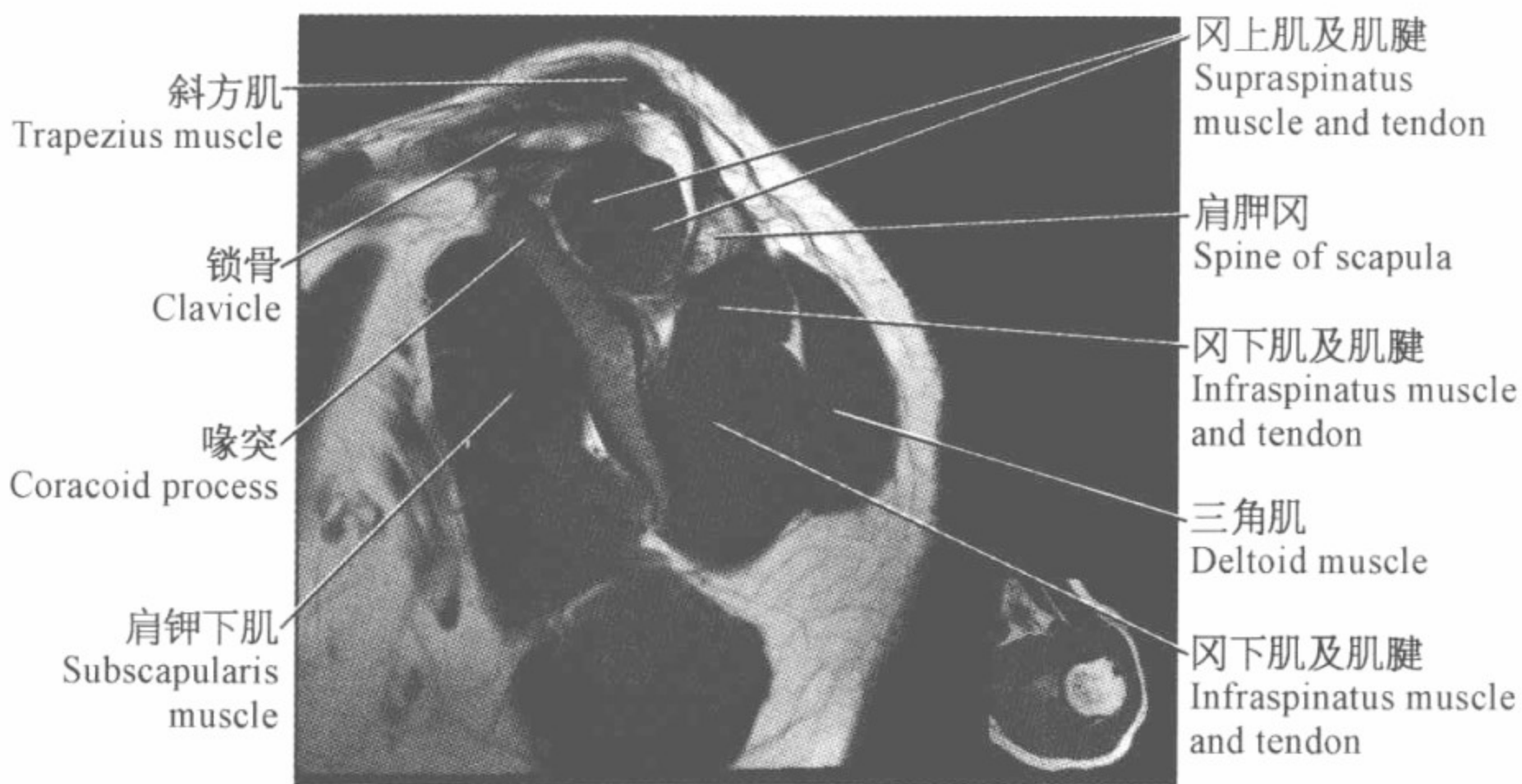



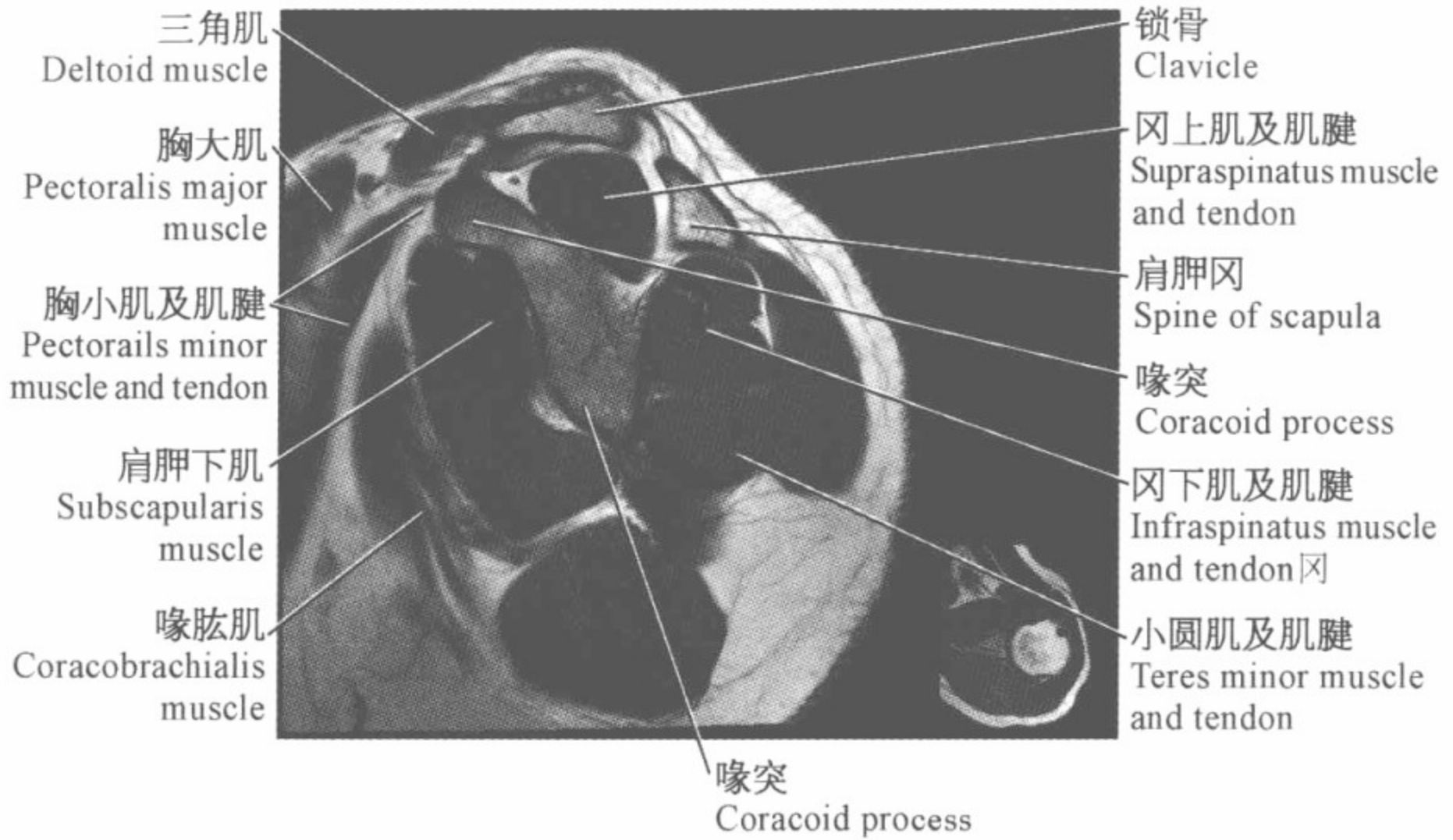


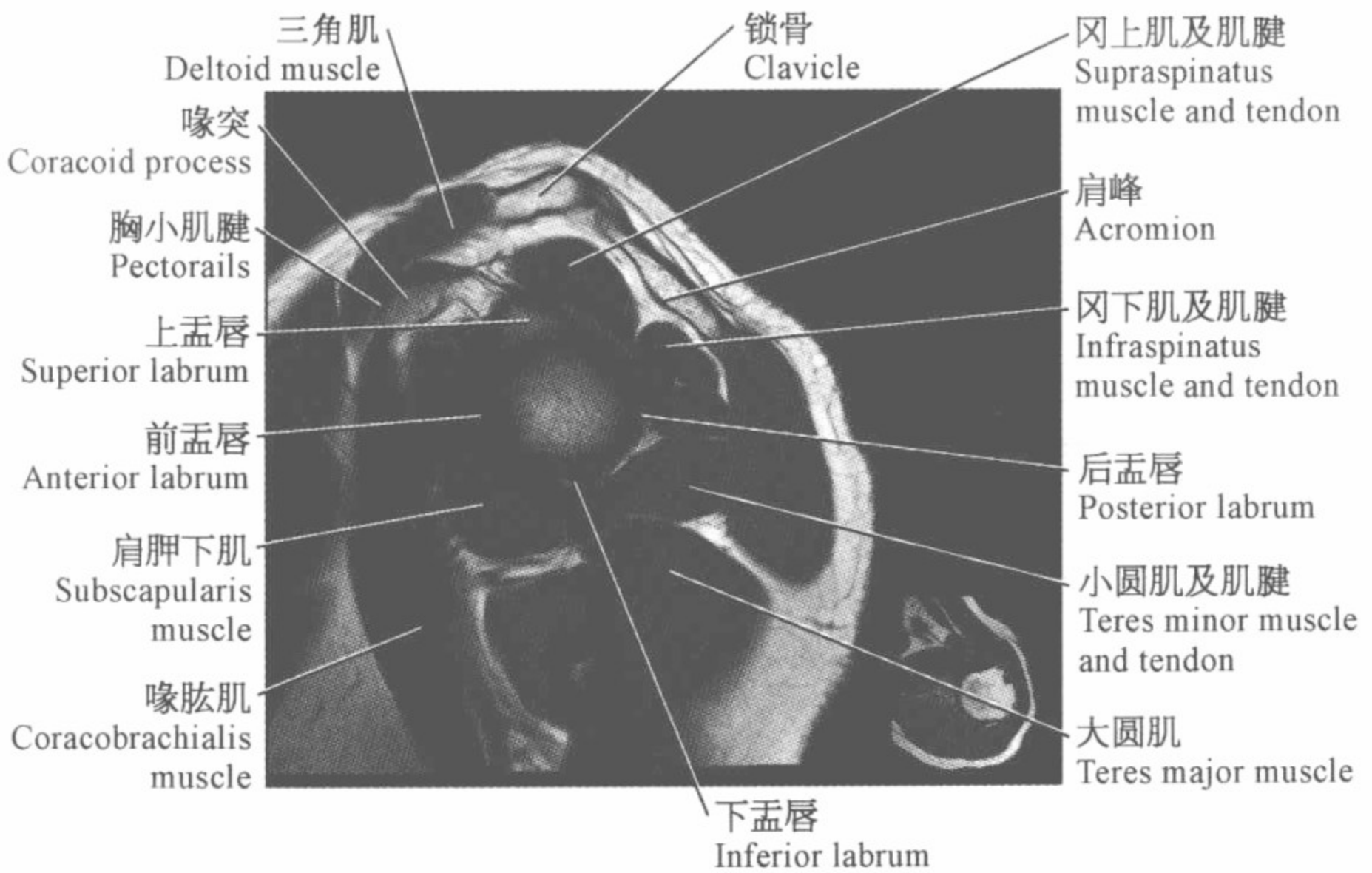
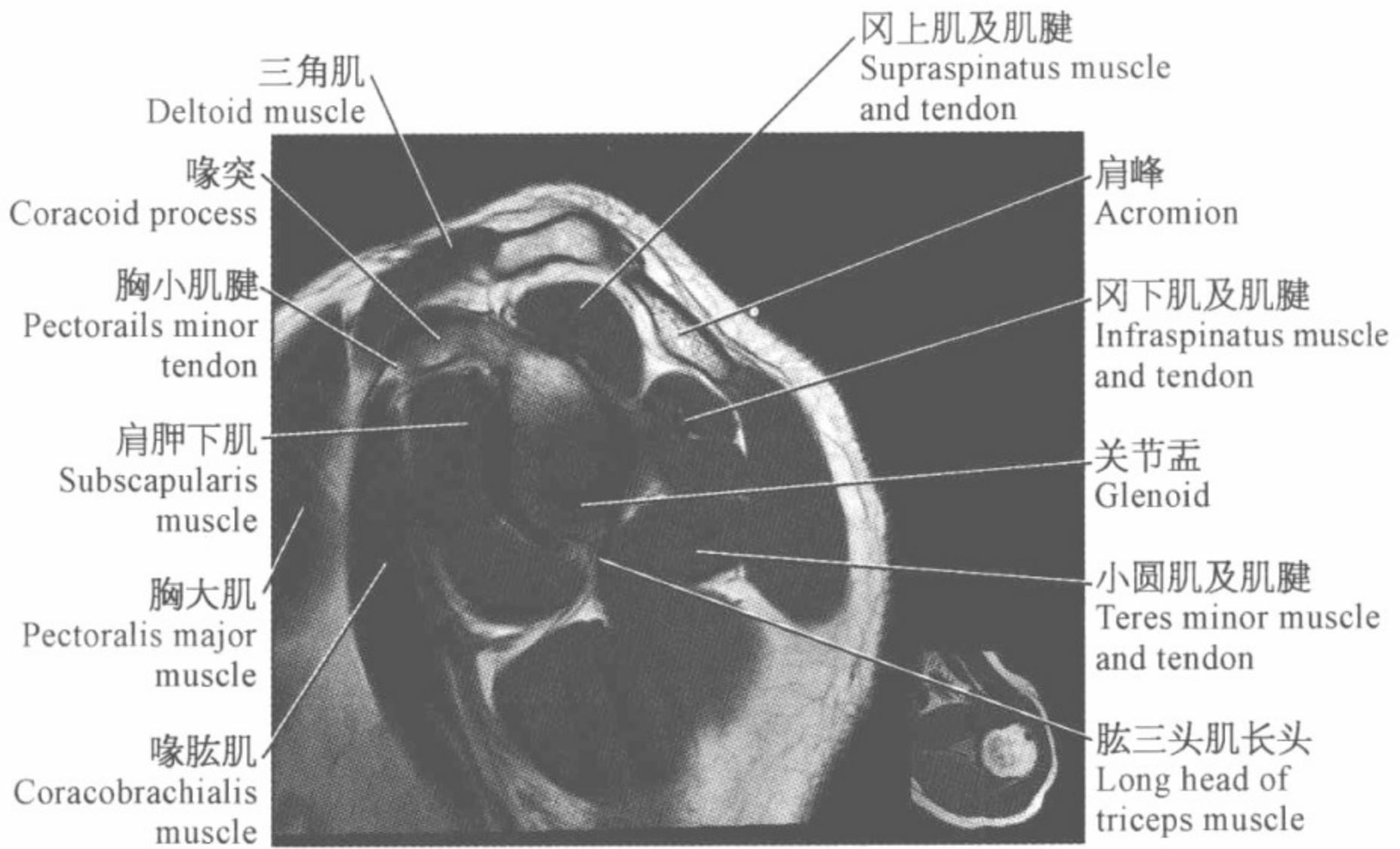


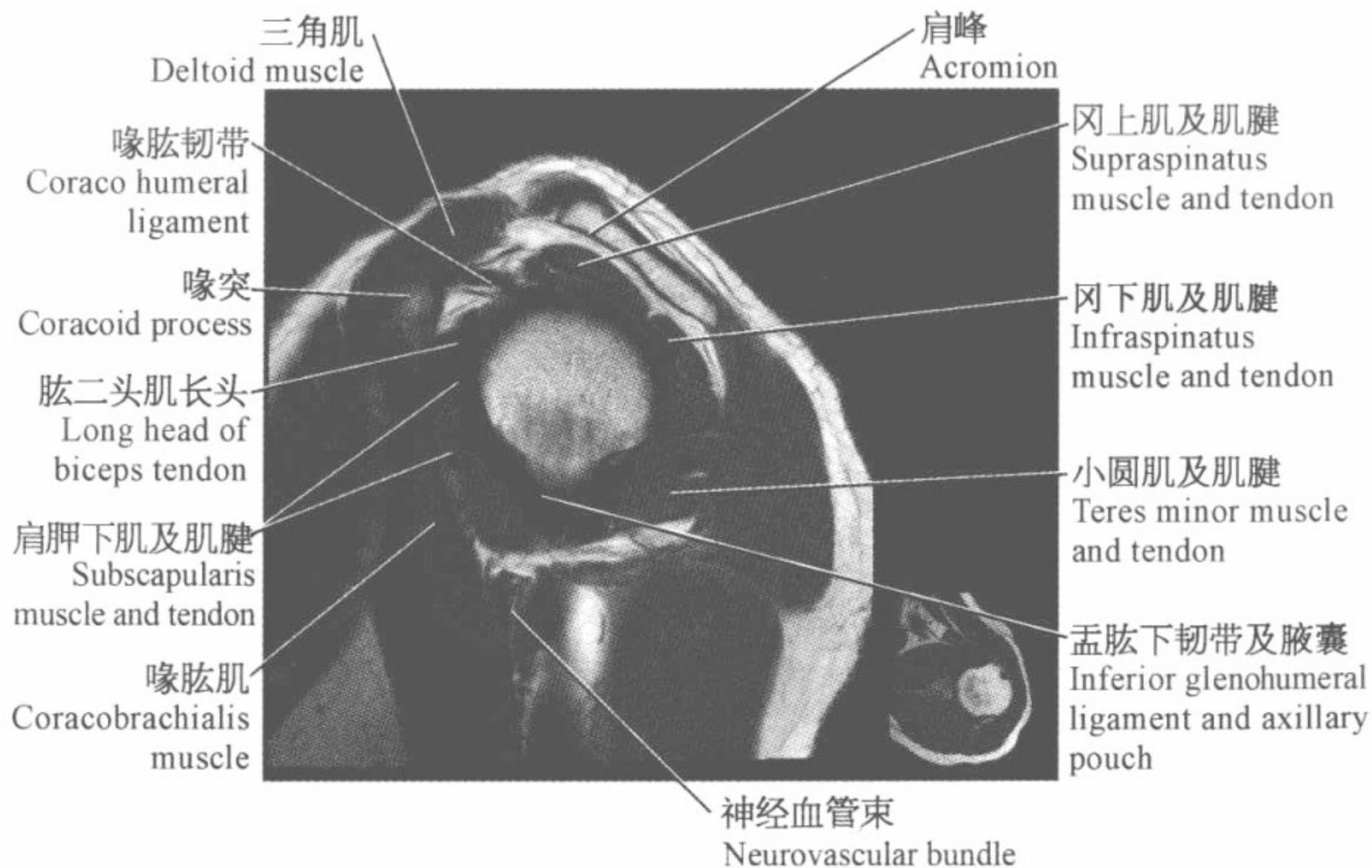
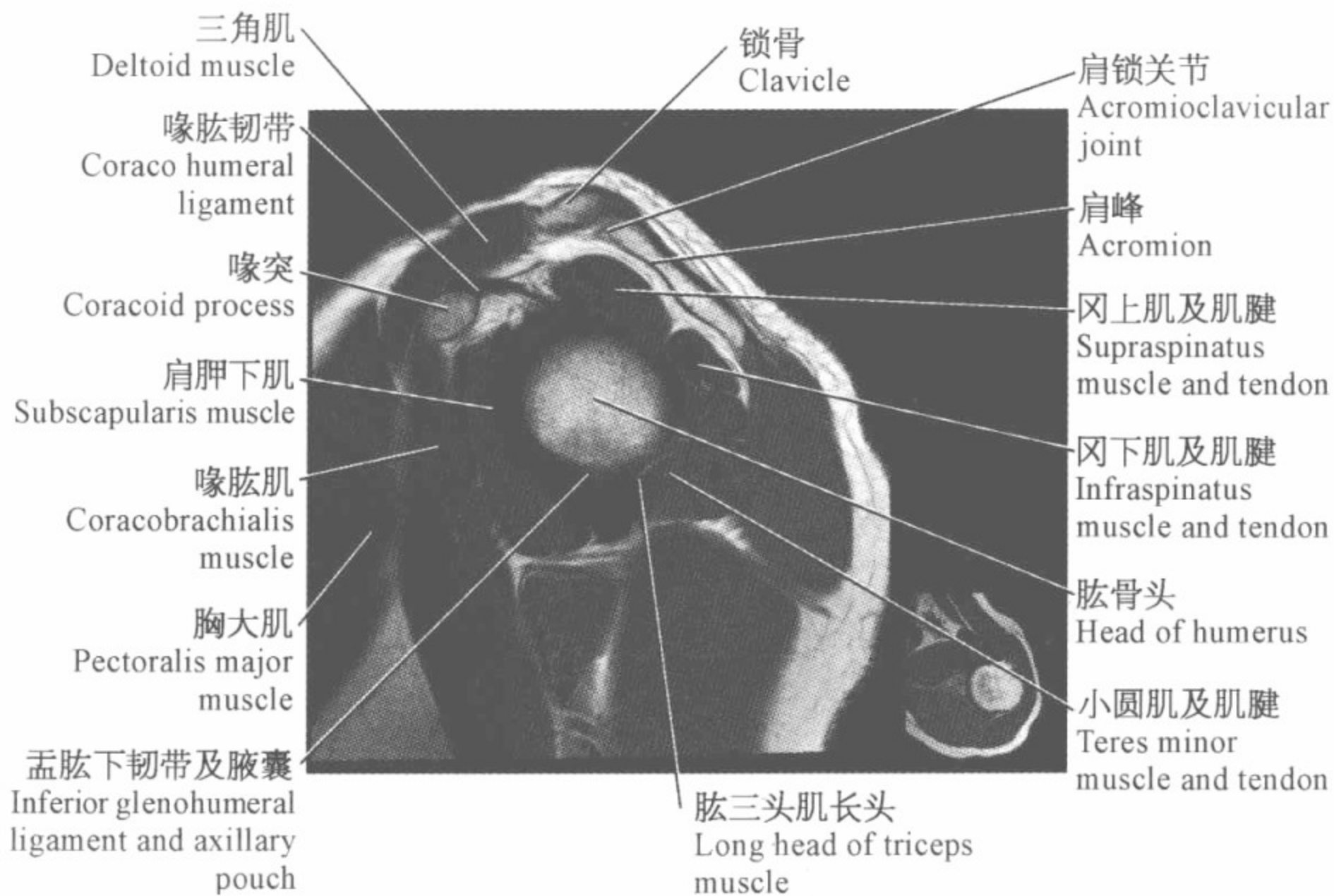
肩关节磁共振图谱

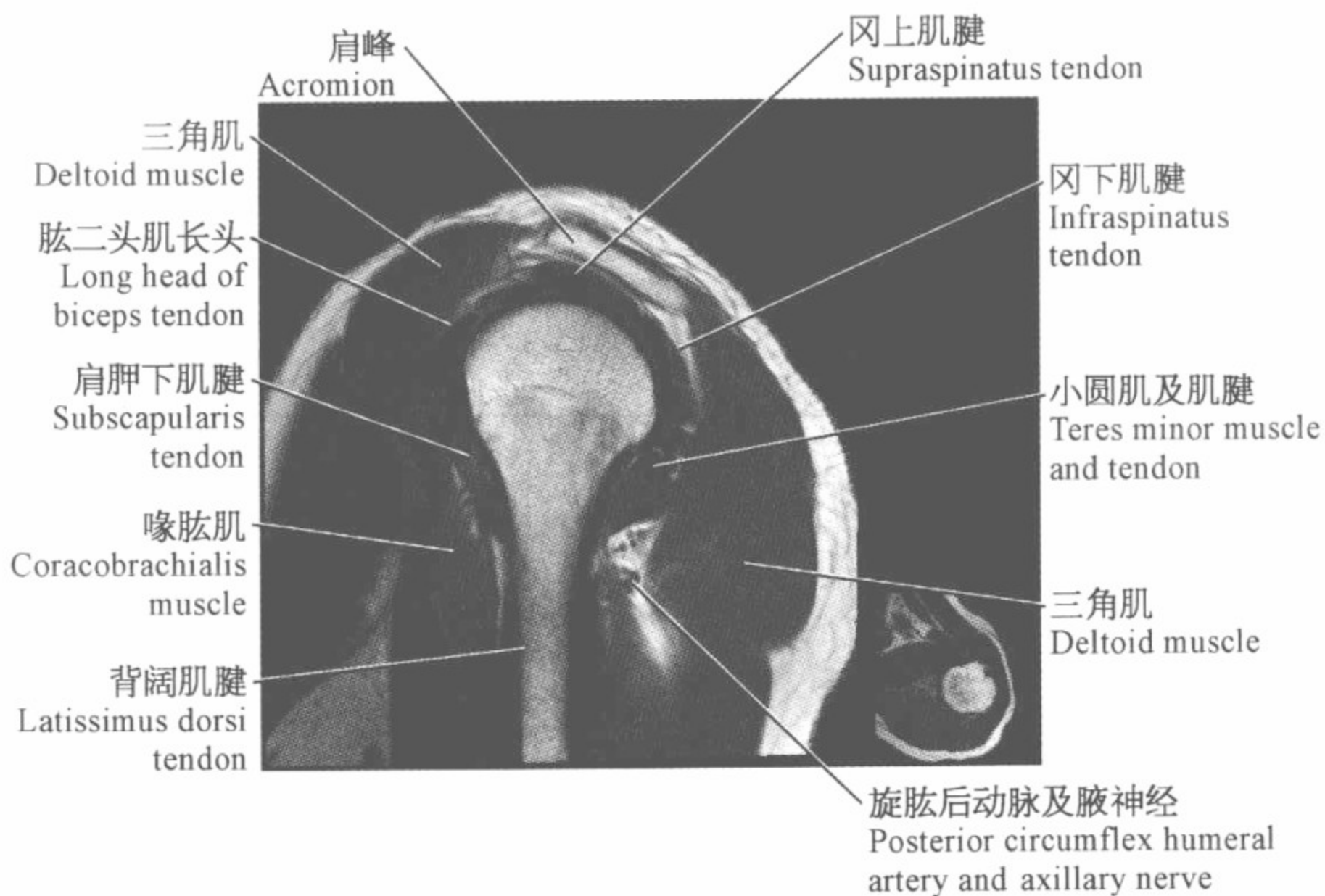
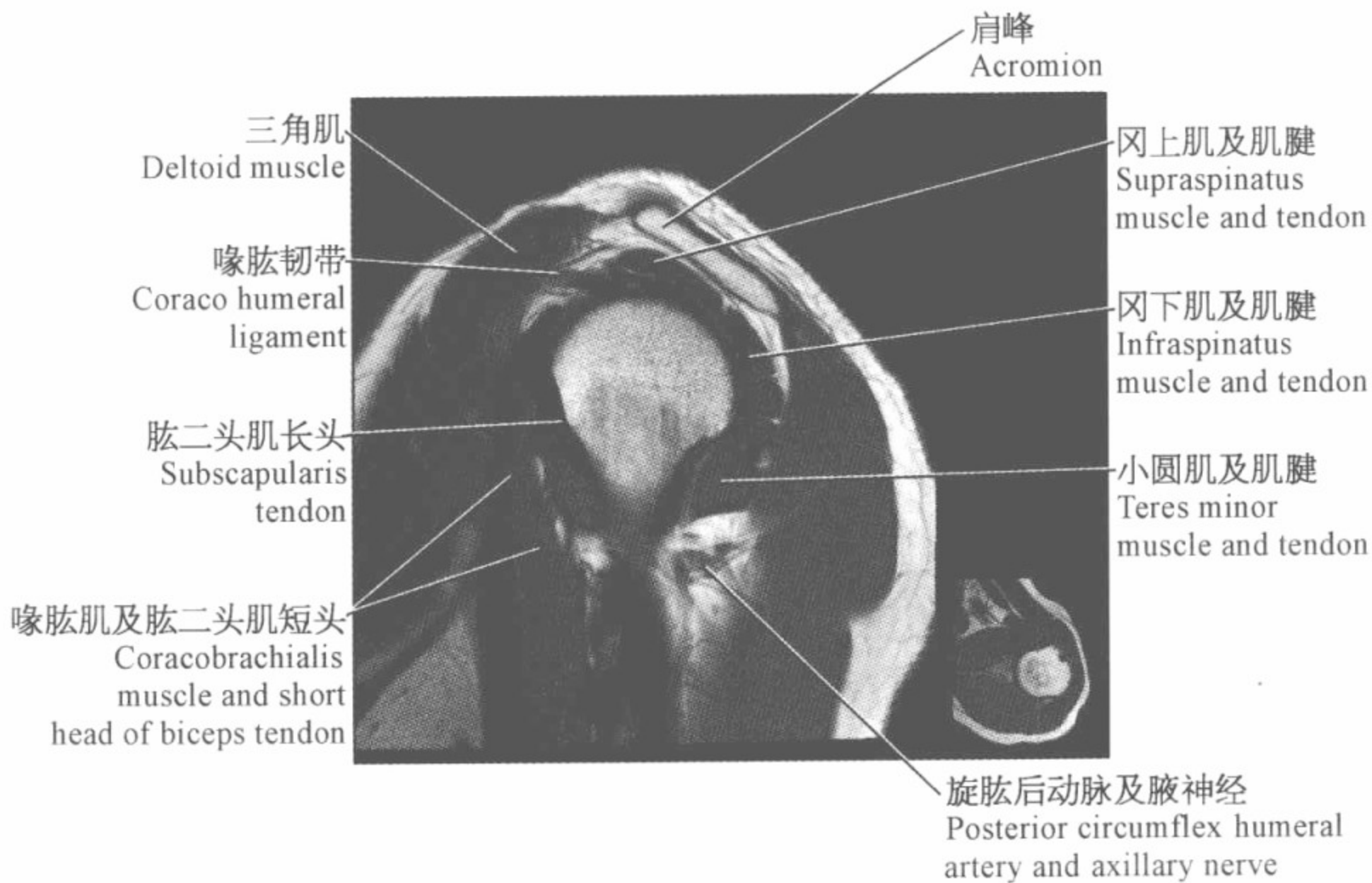
(矢状位)

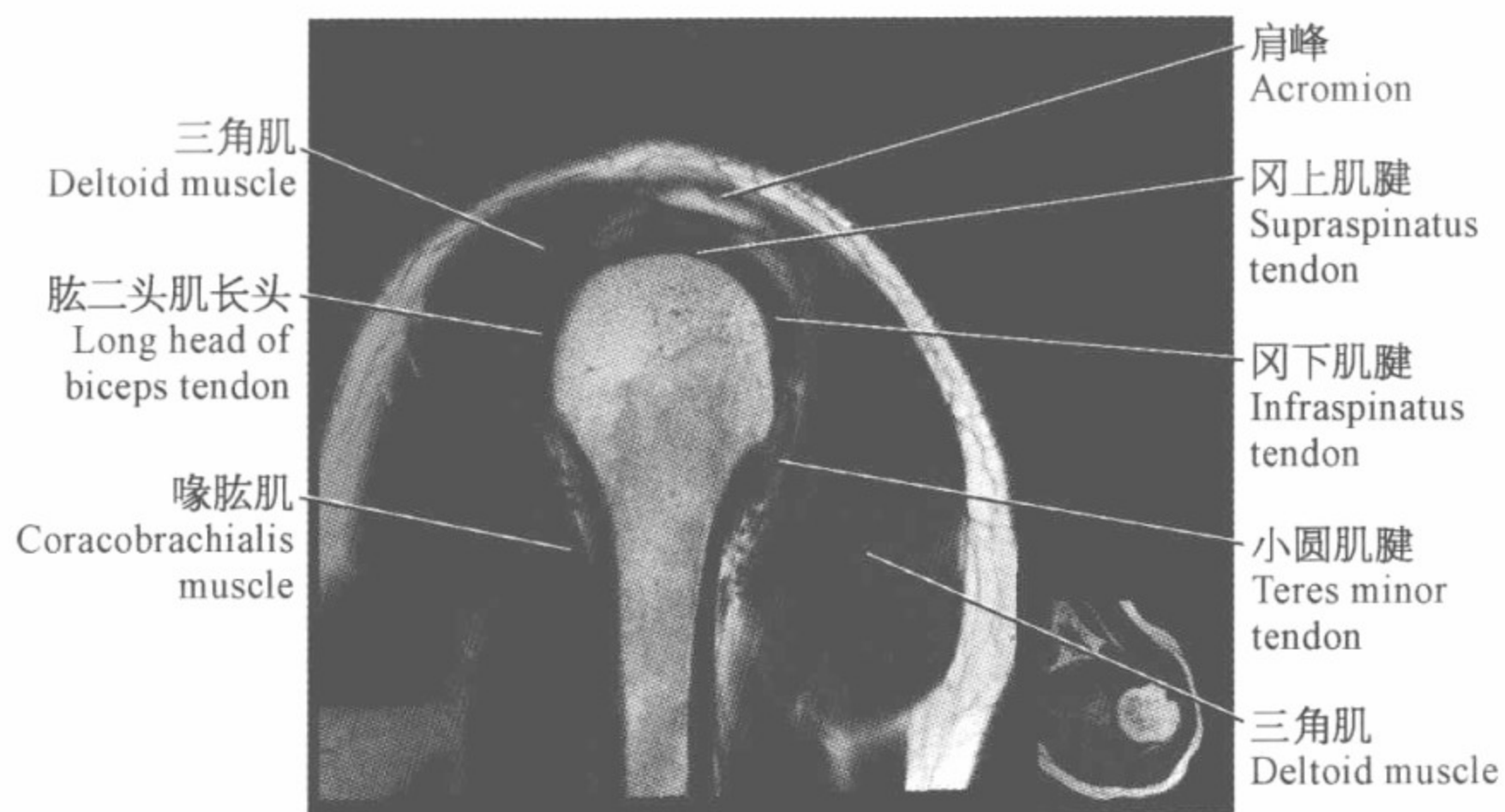
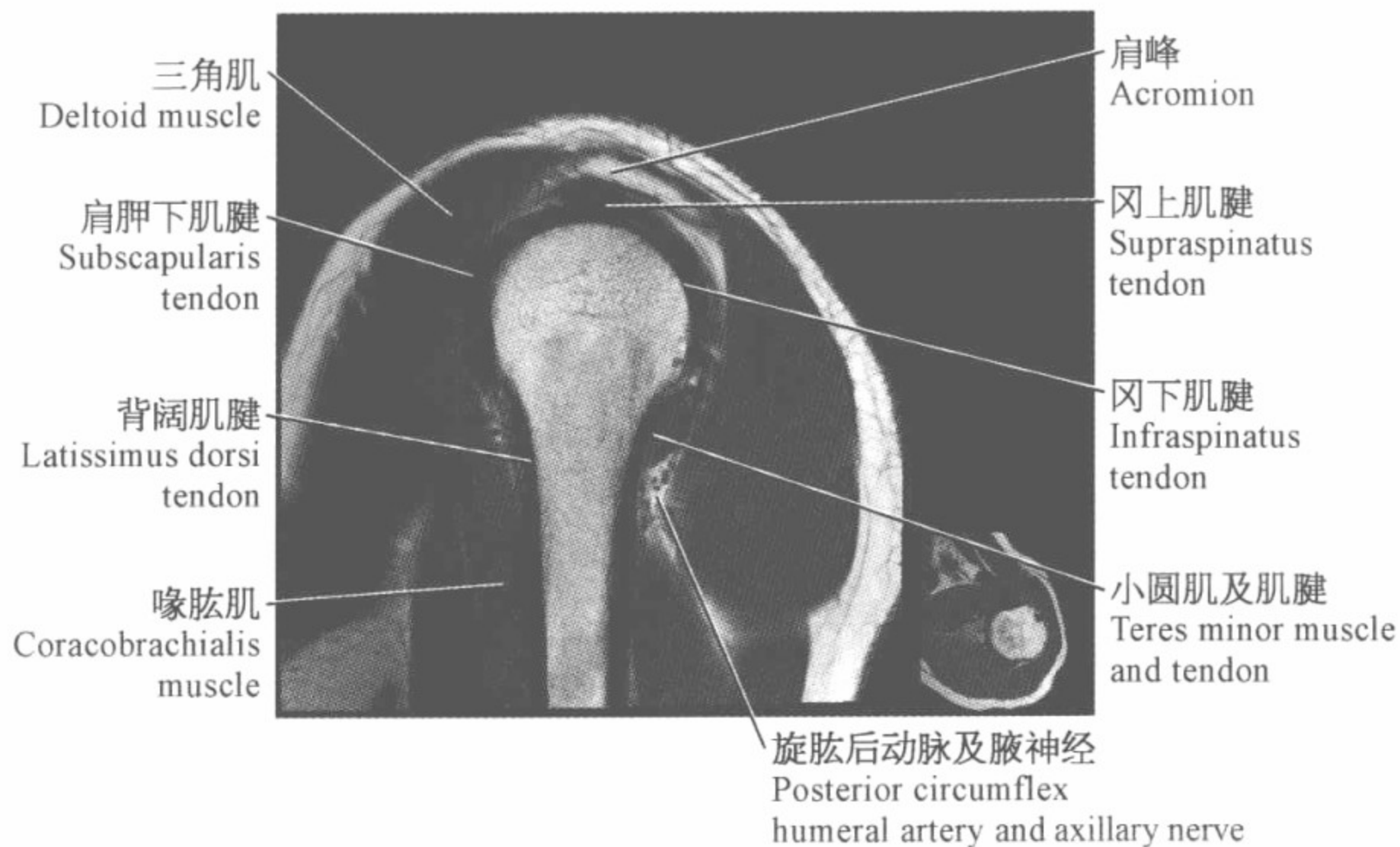


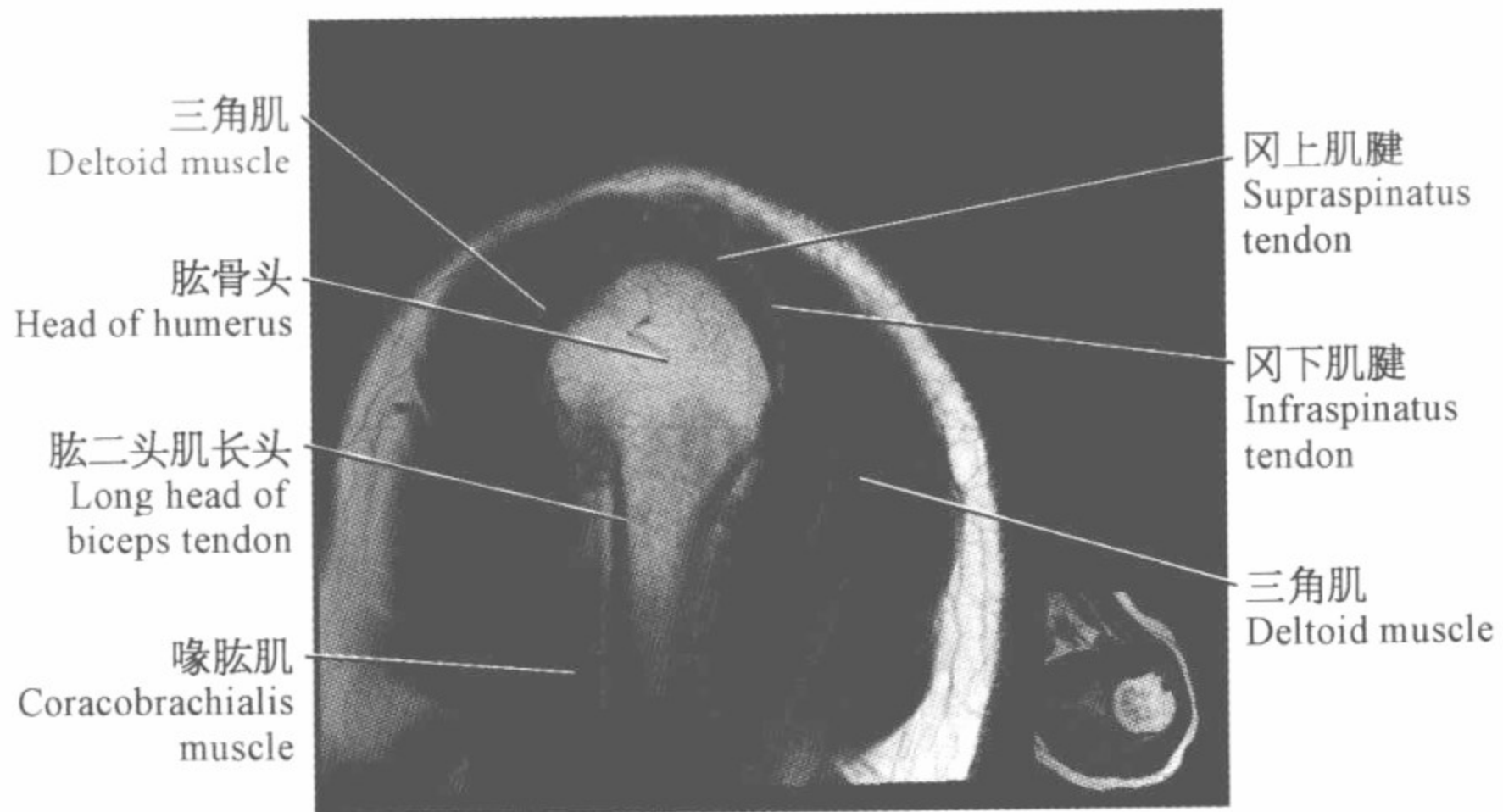
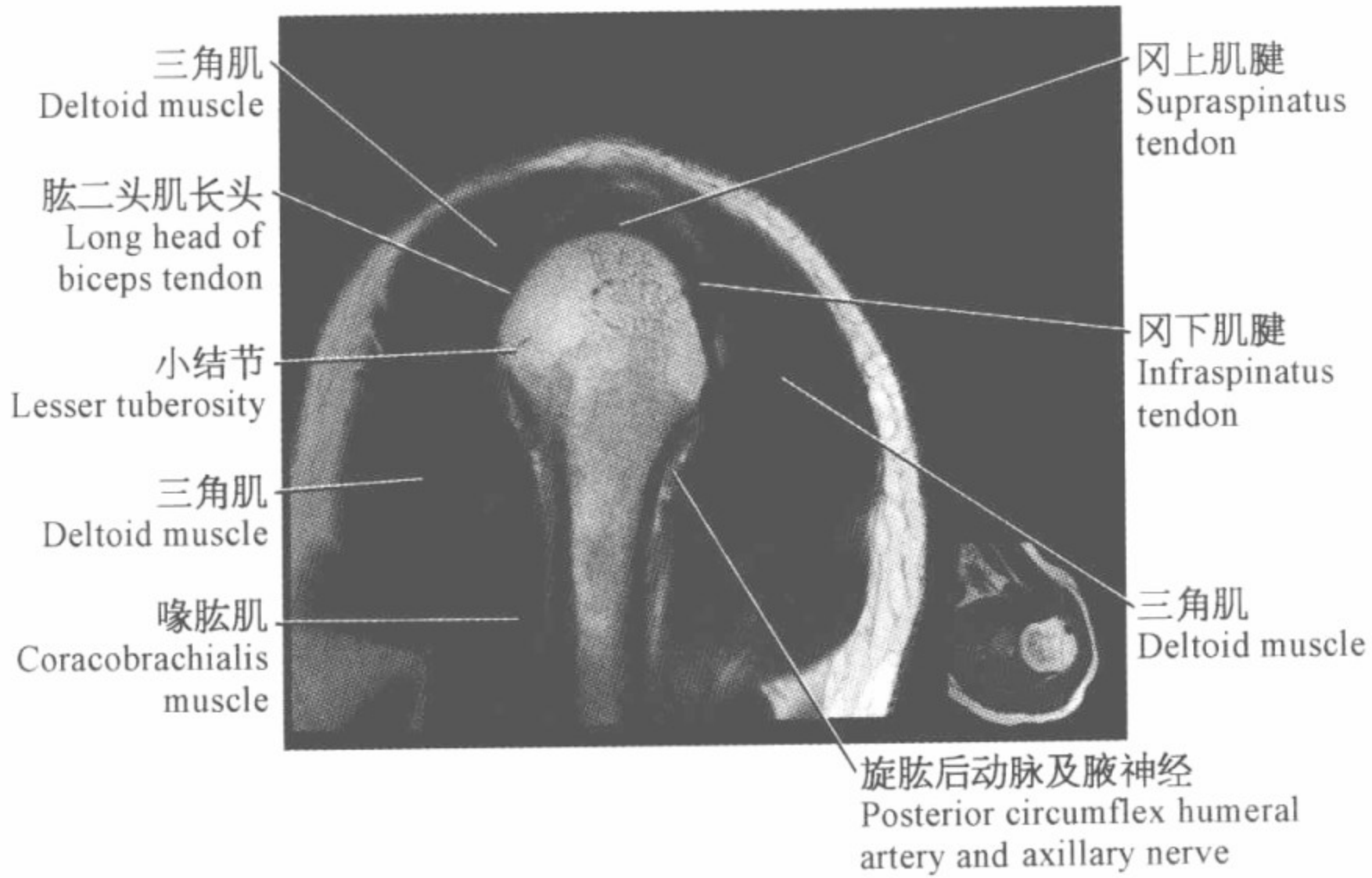


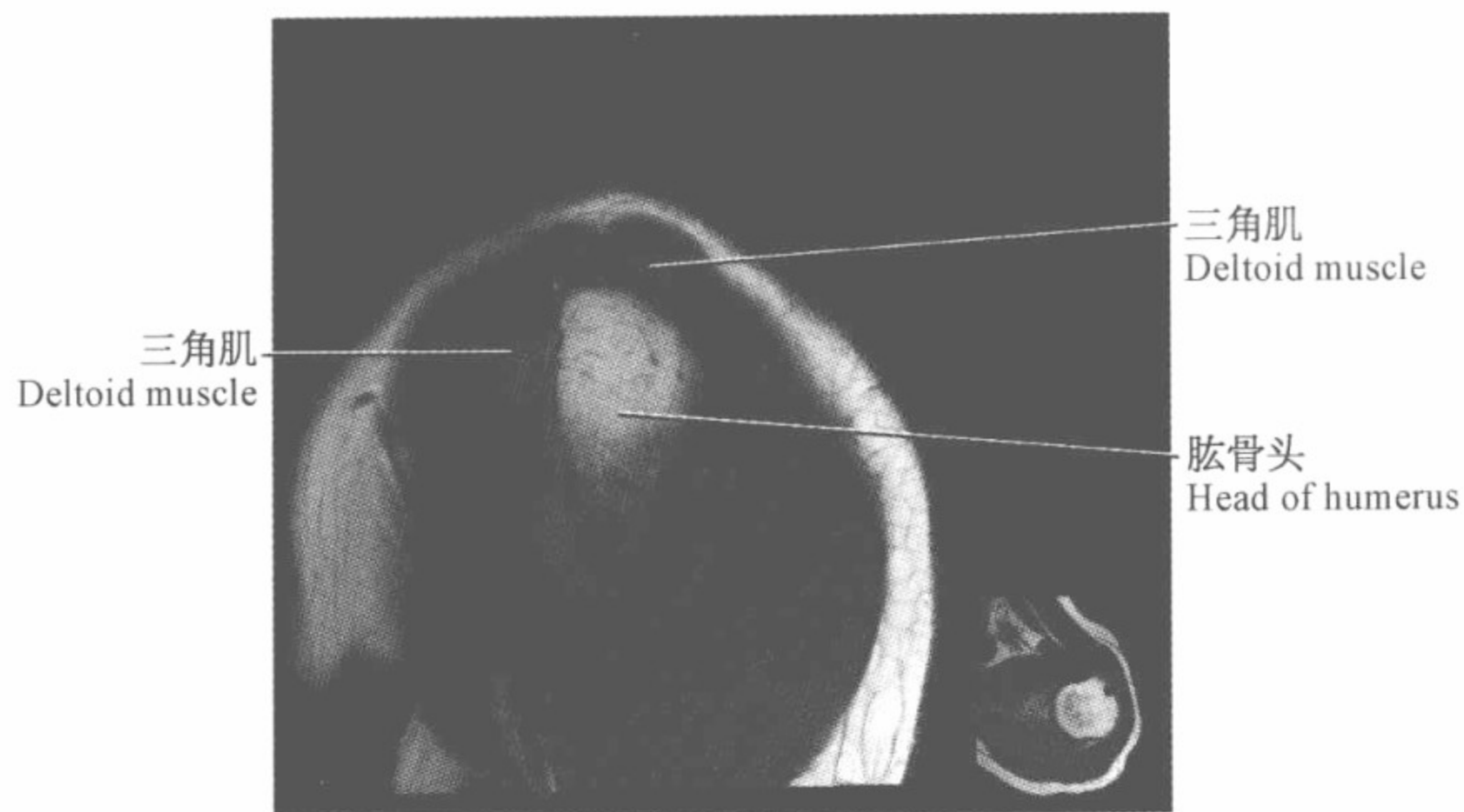
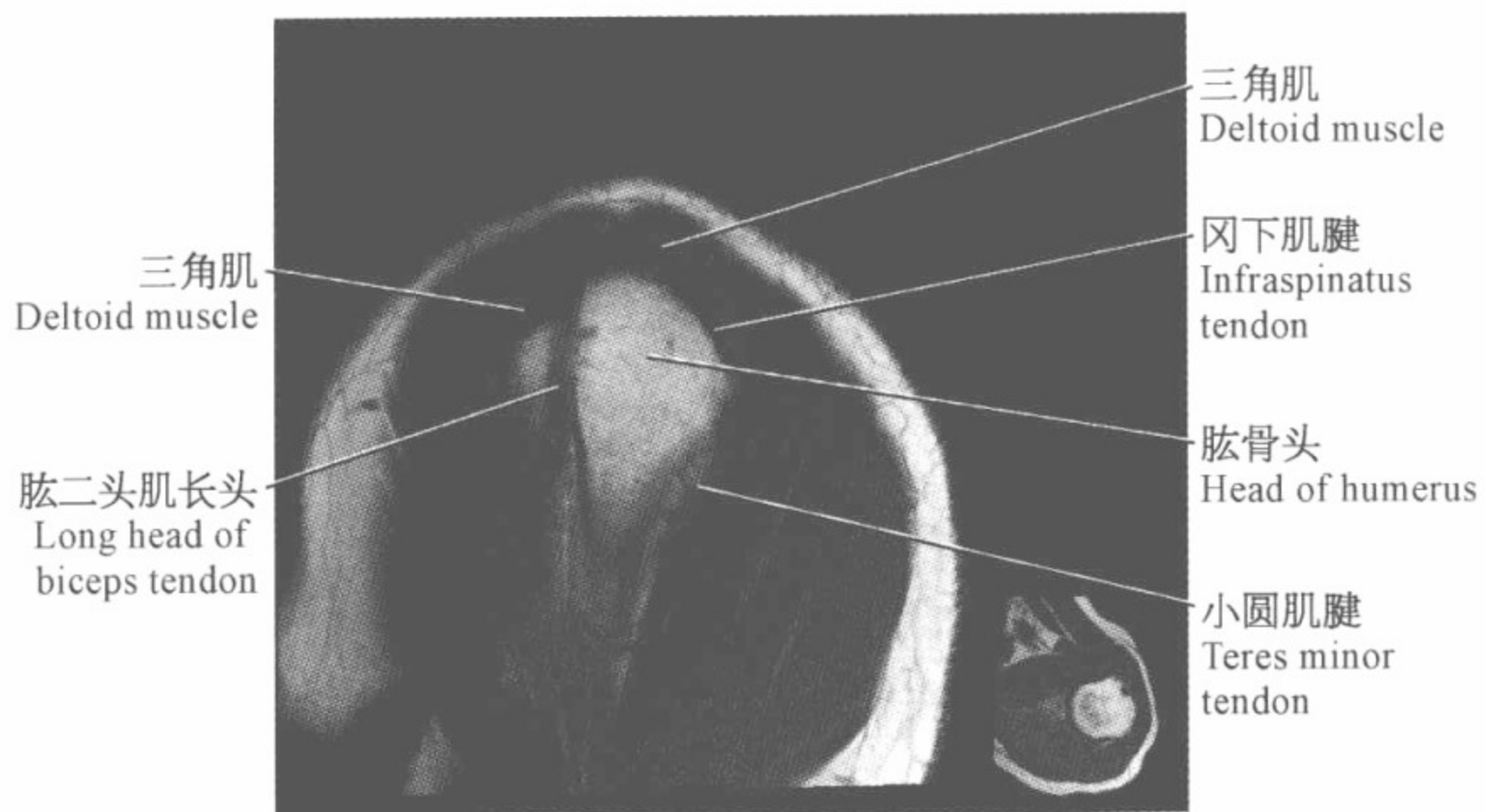


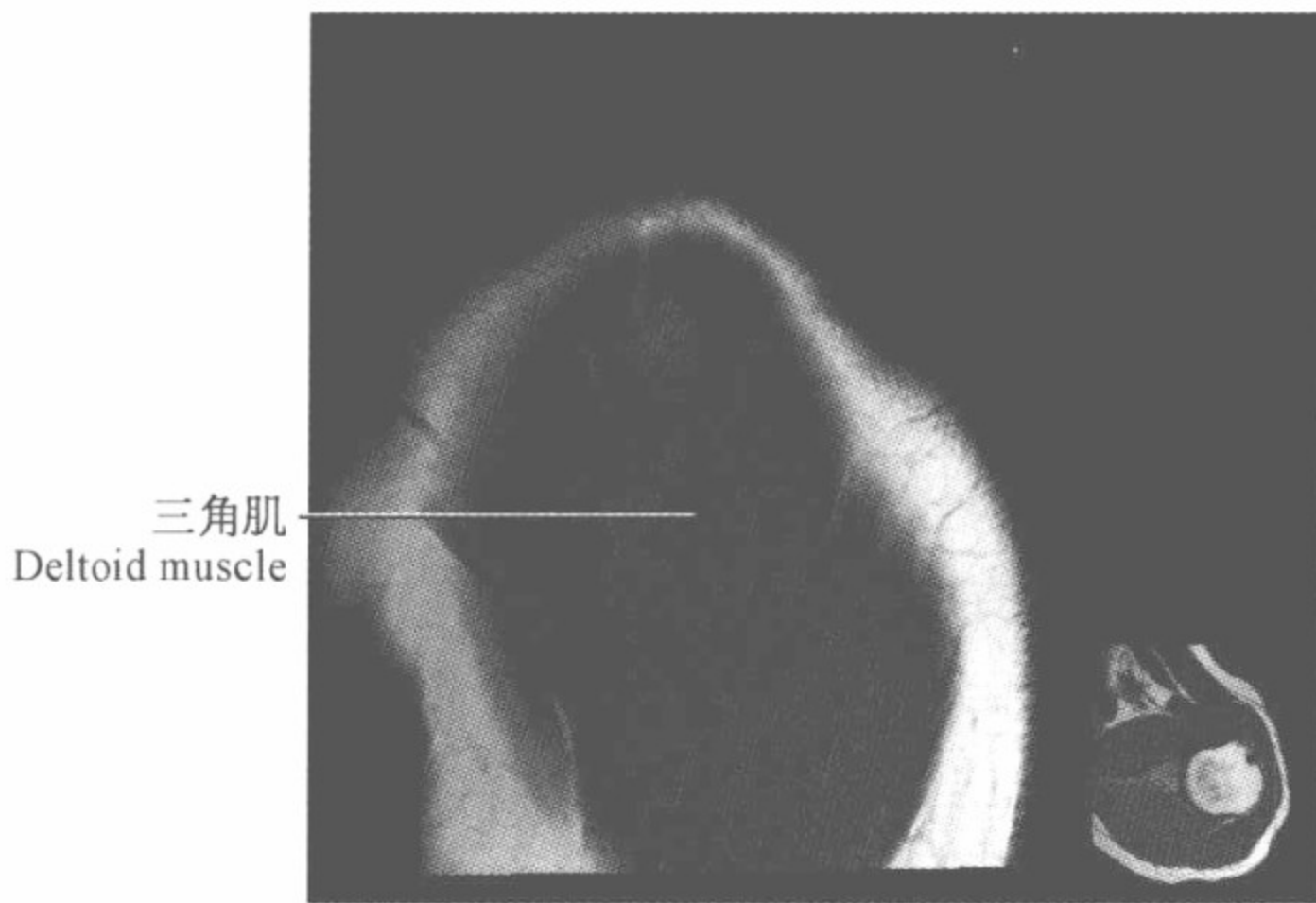
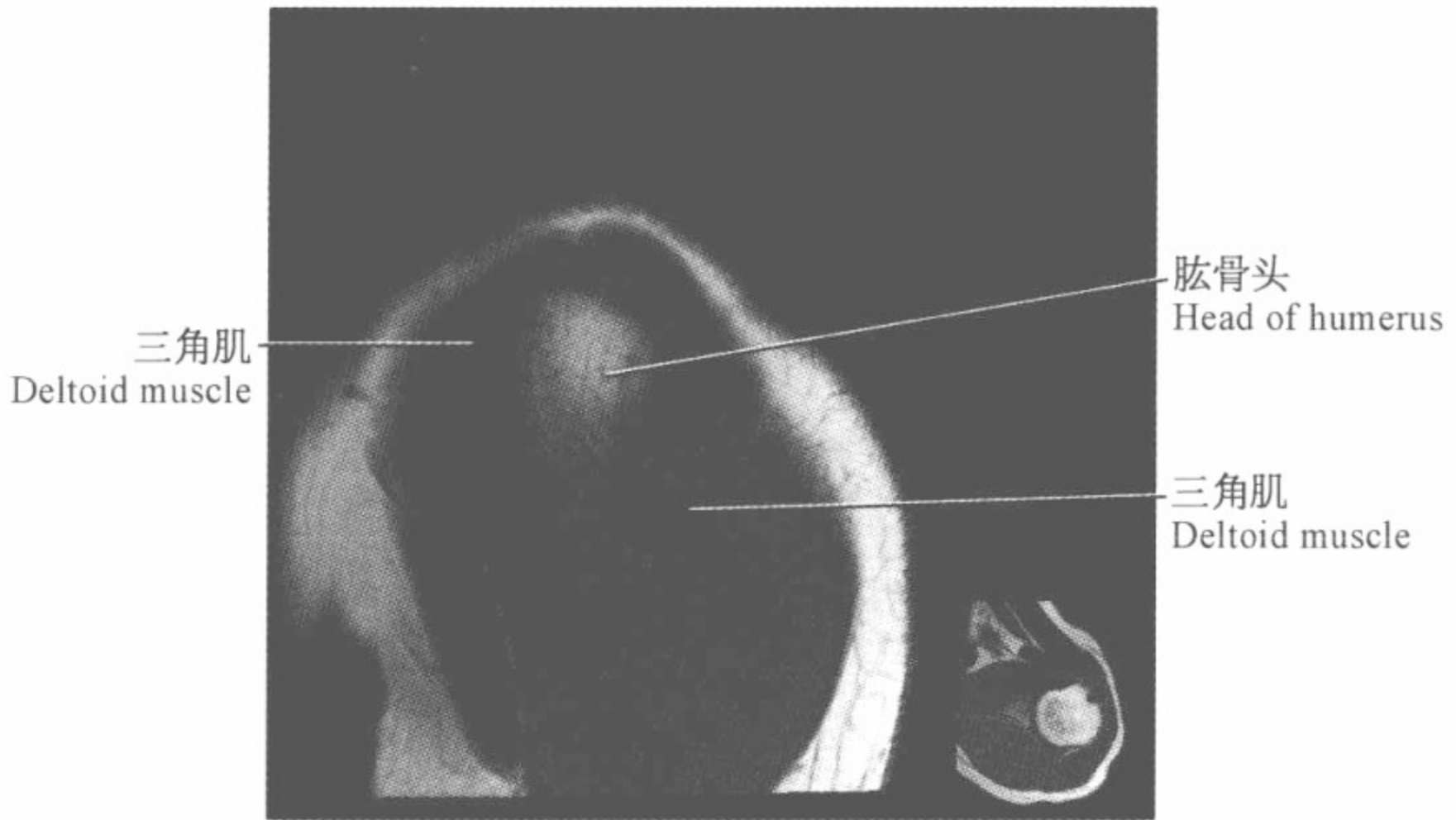










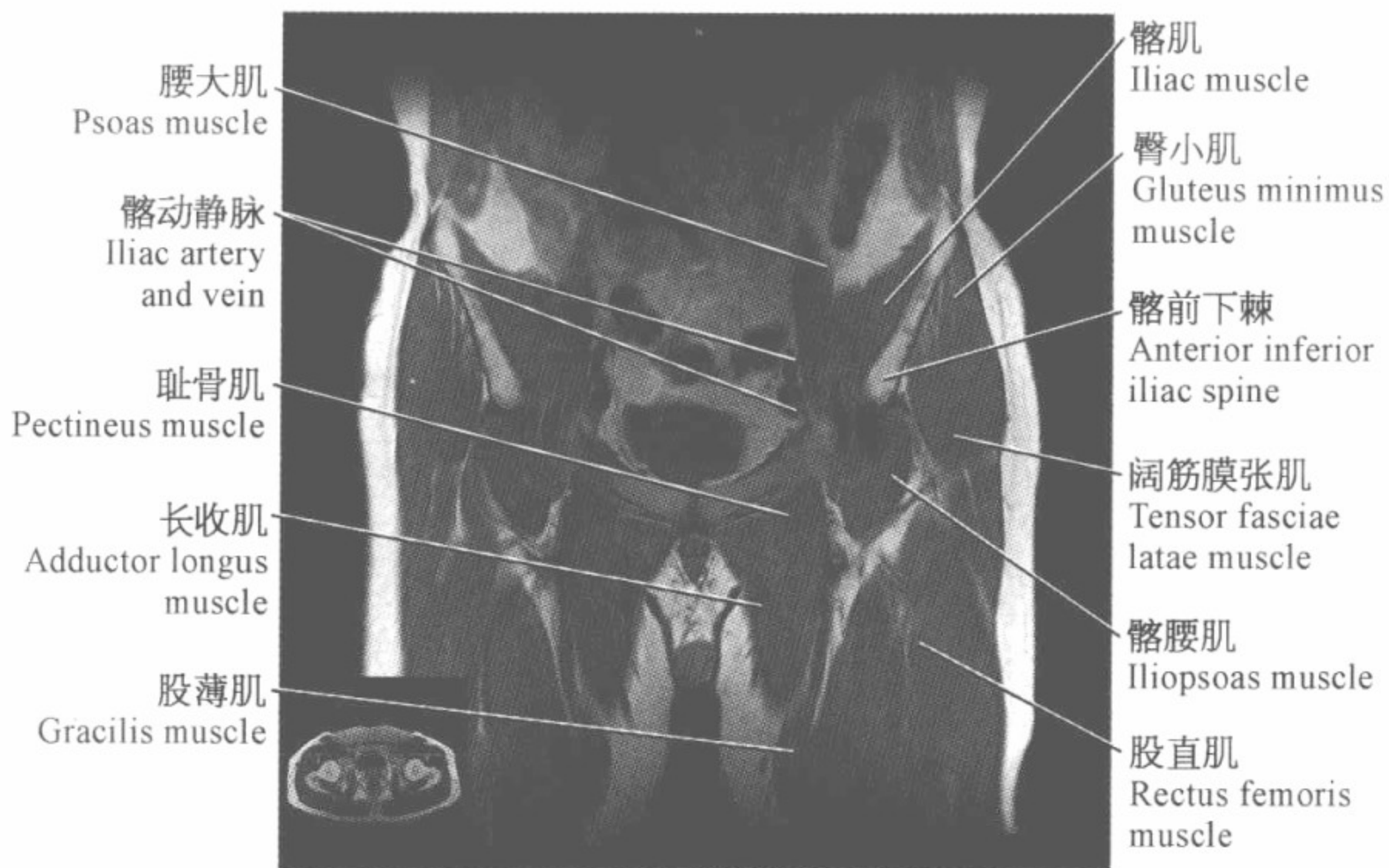
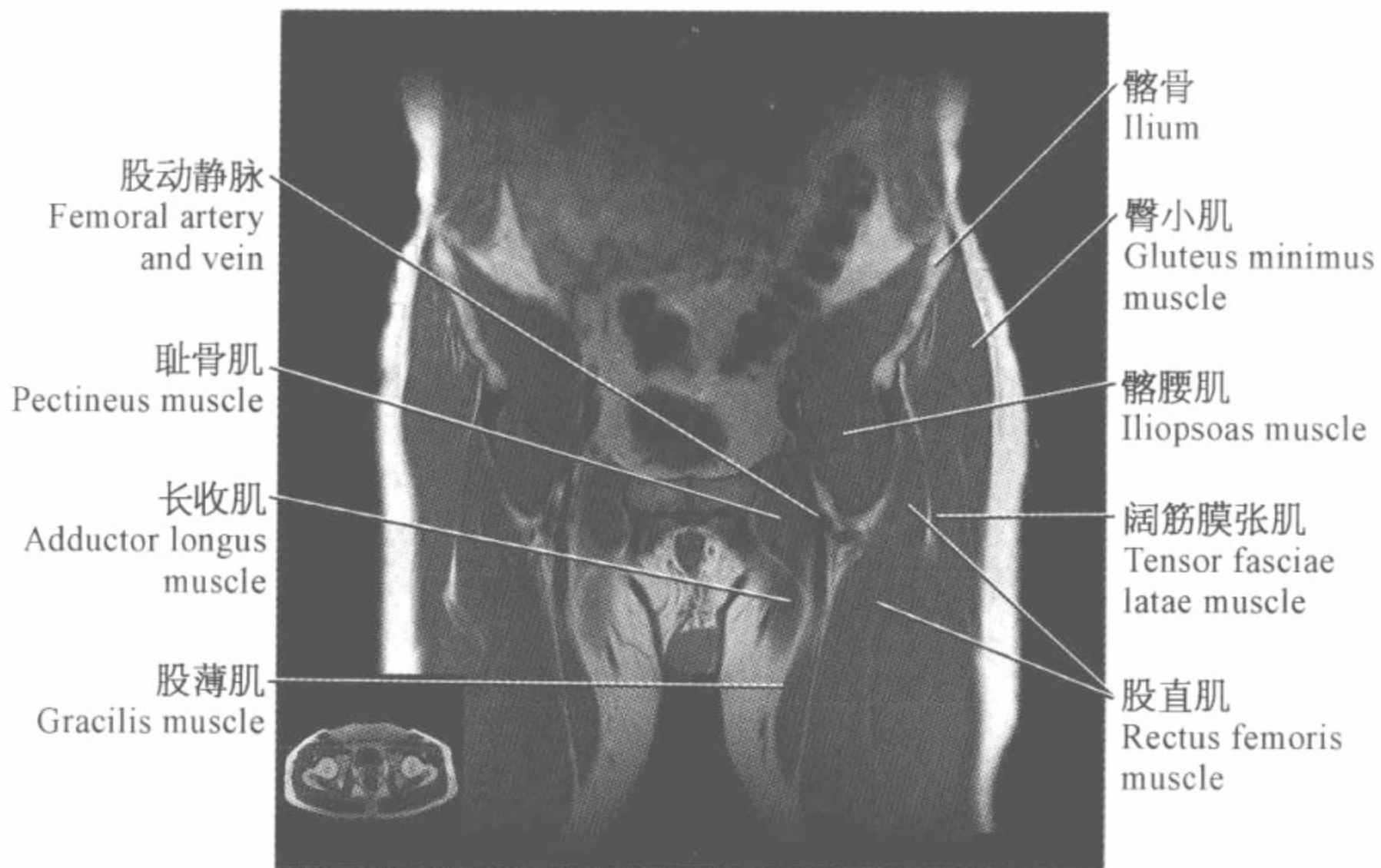


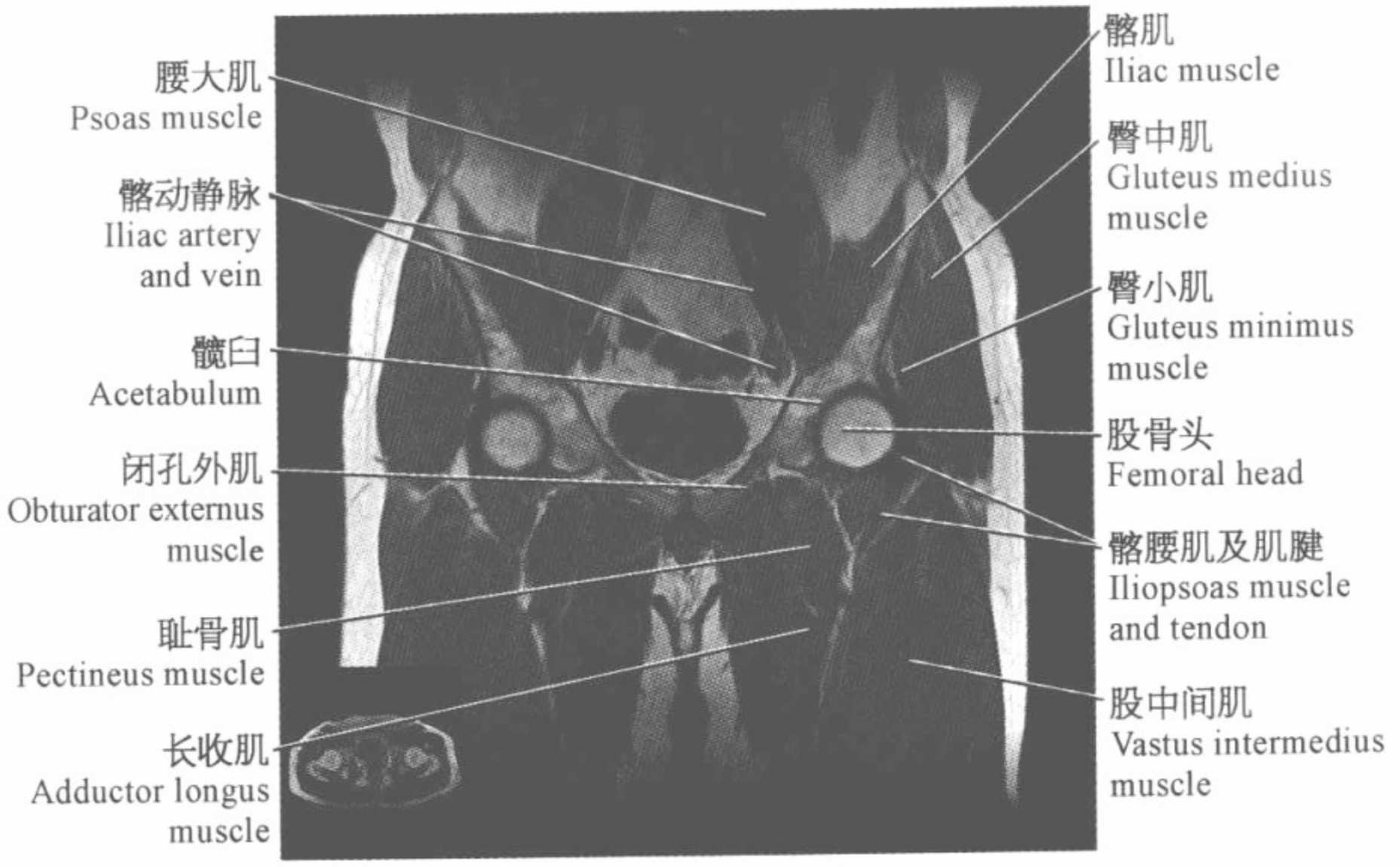
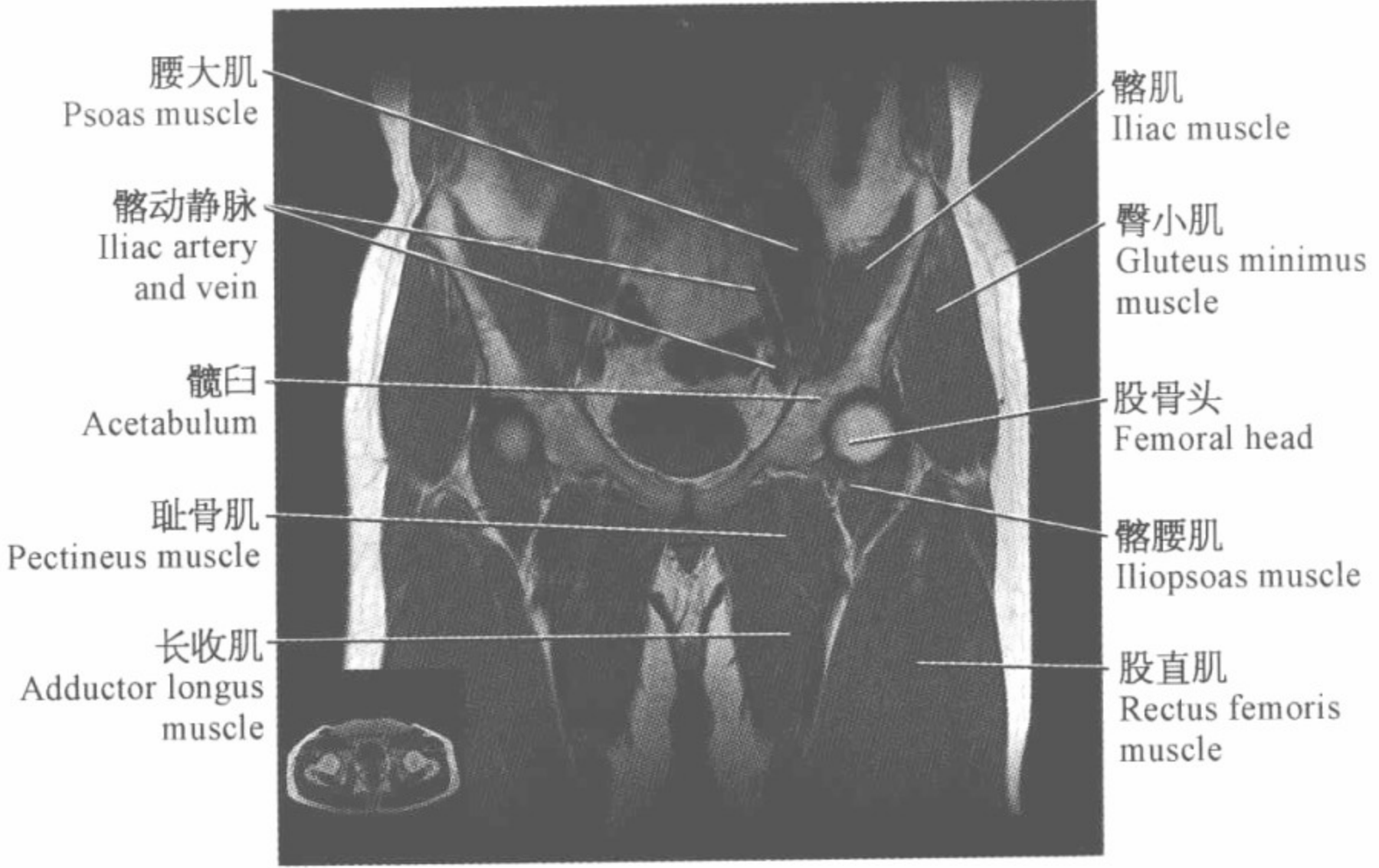


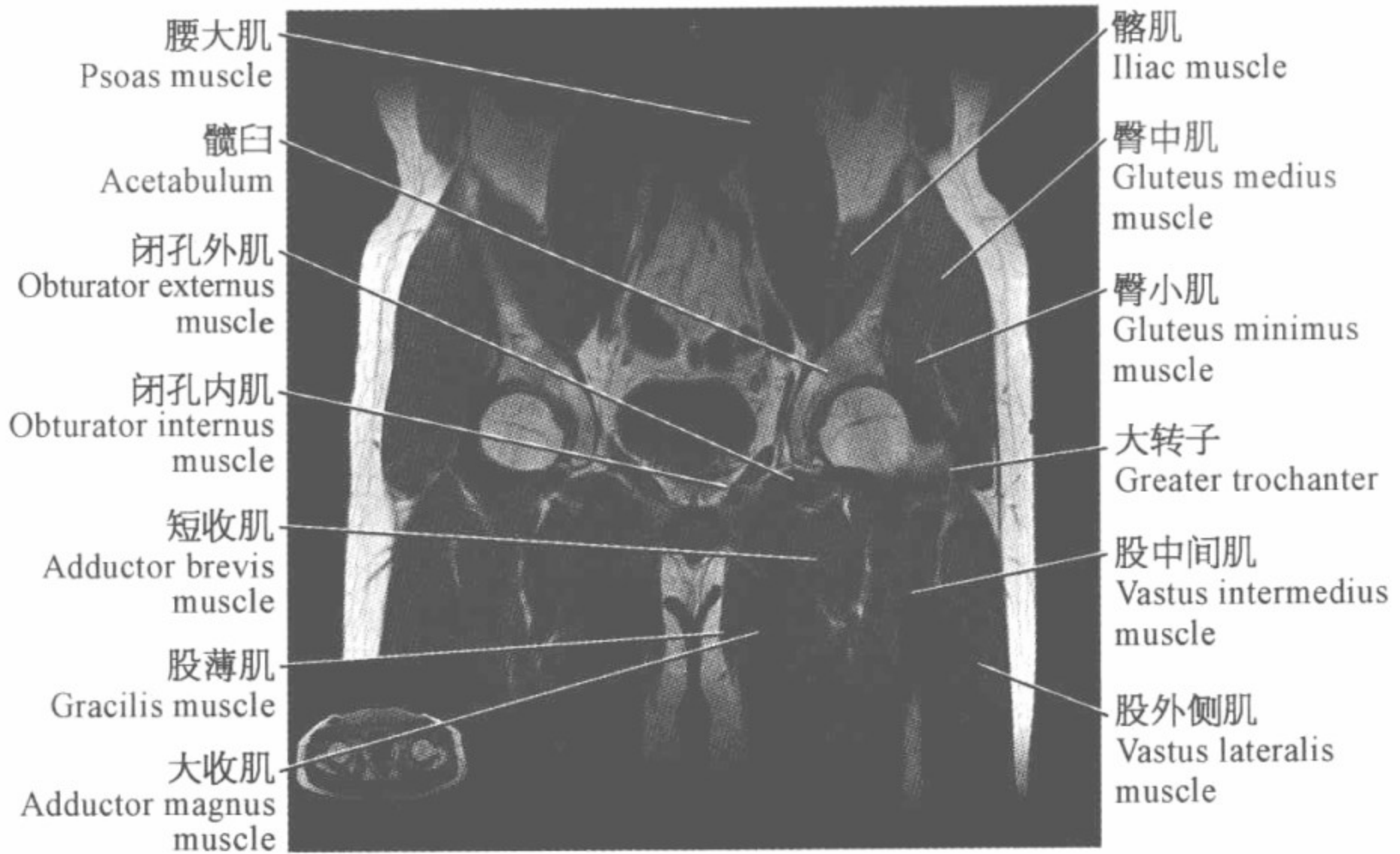
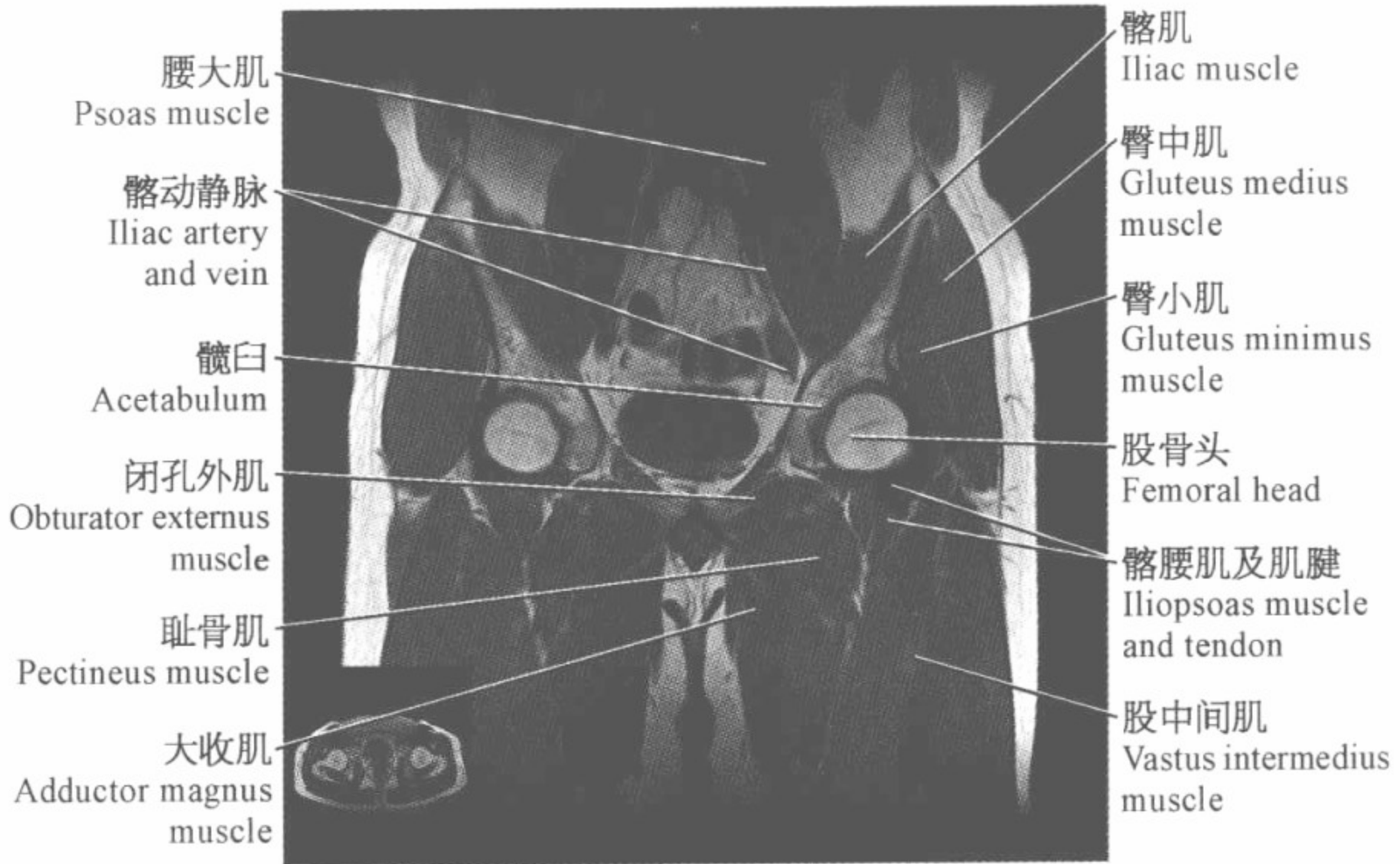腕关节磁共振图谱

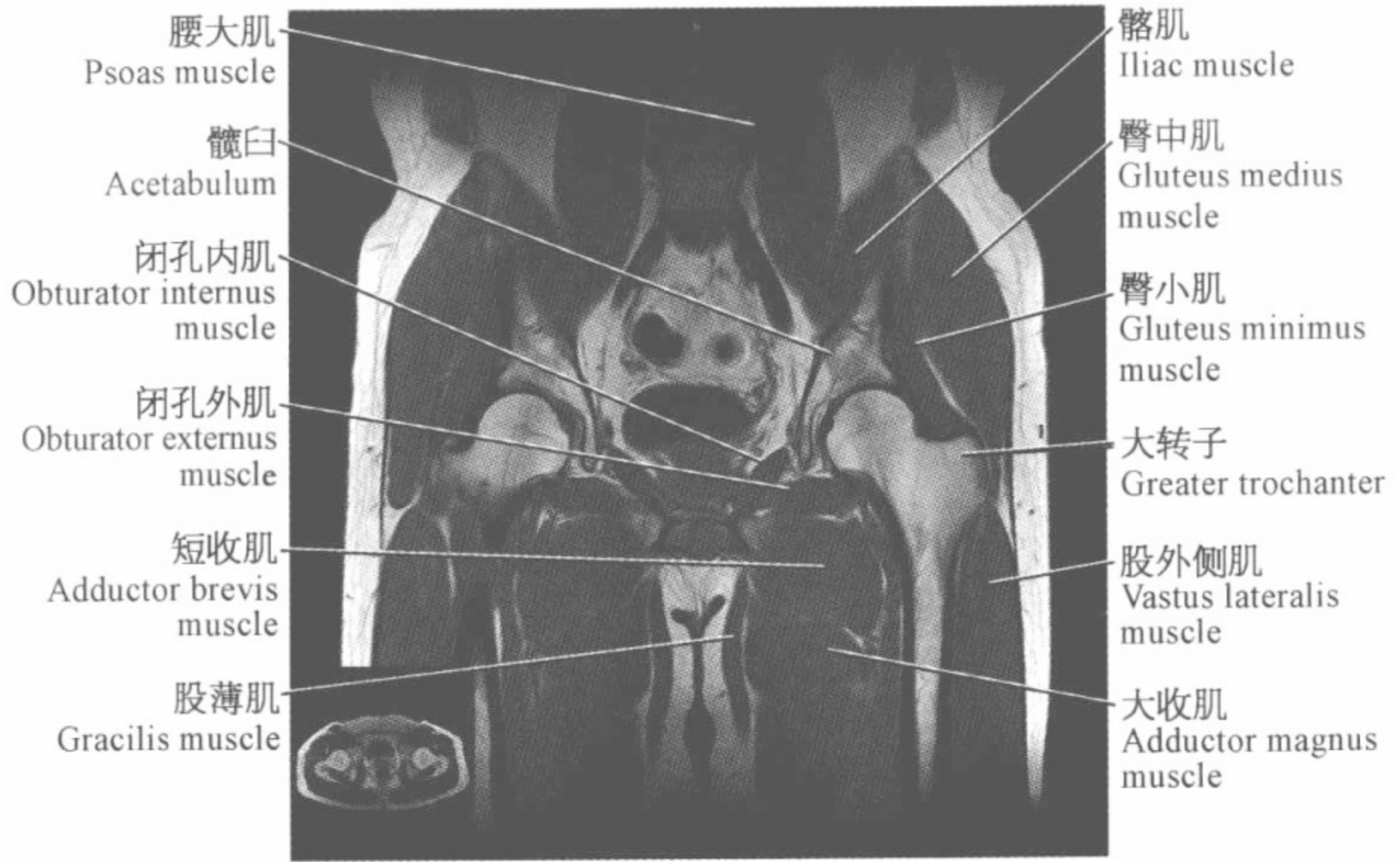
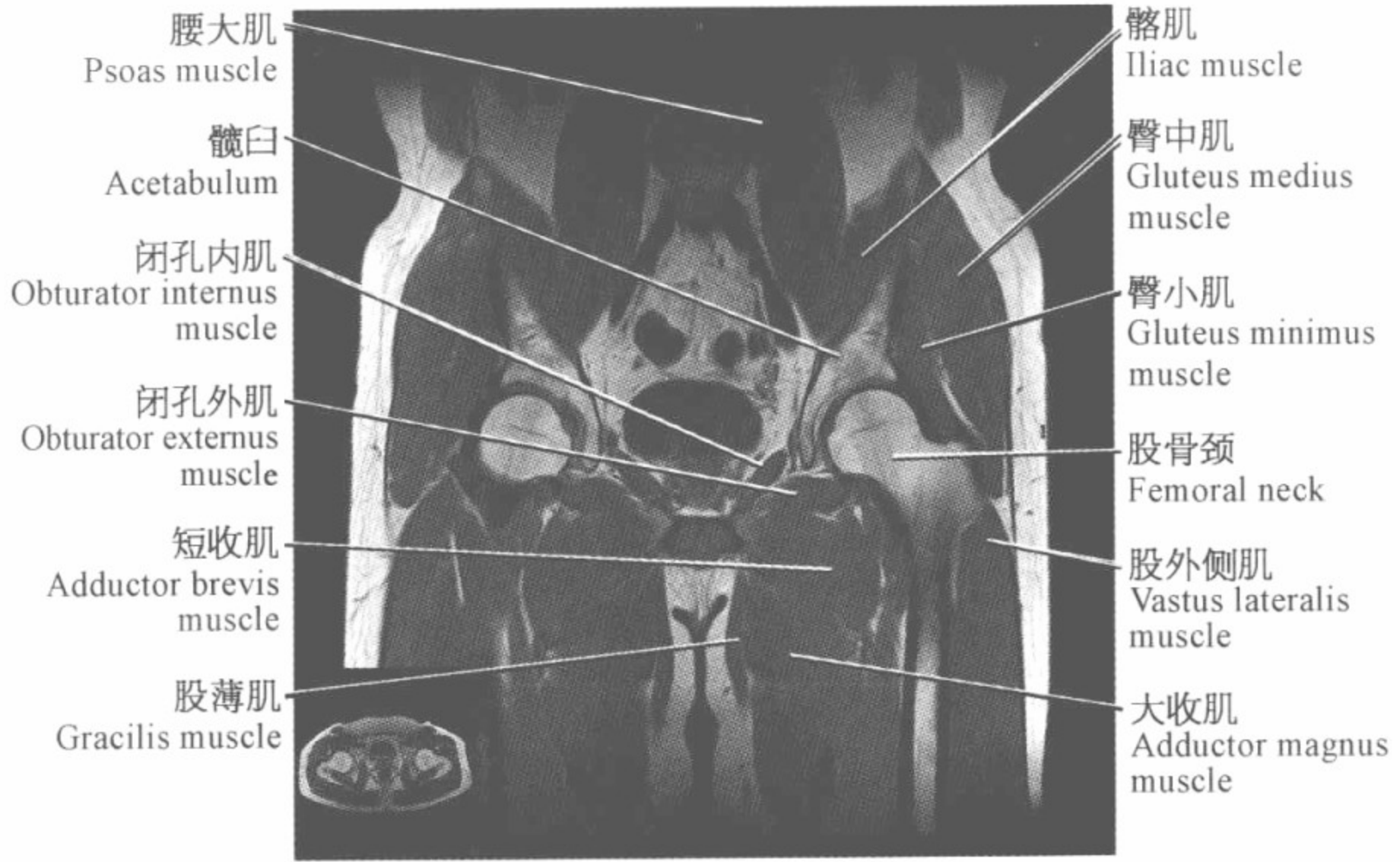
(冠状位)

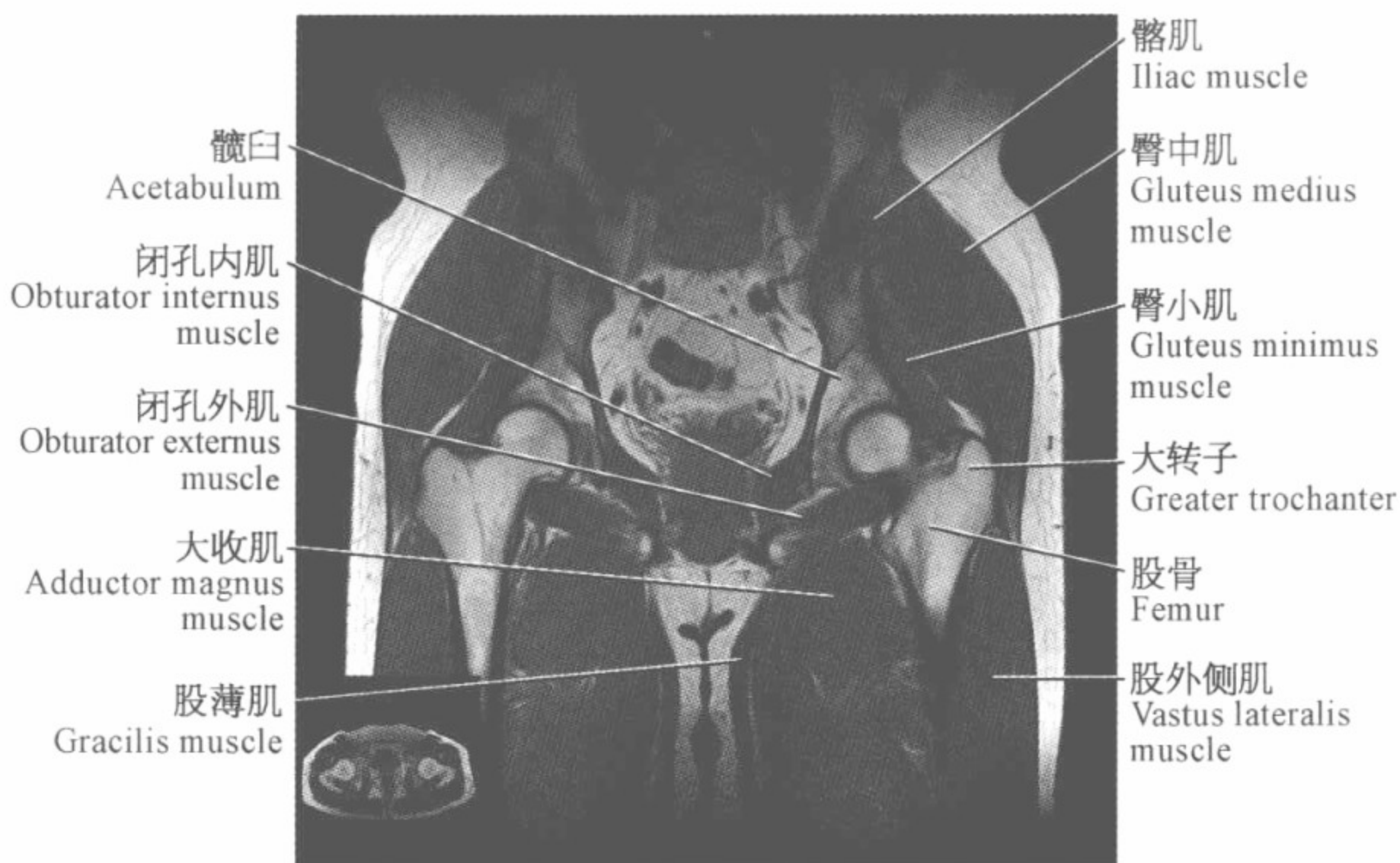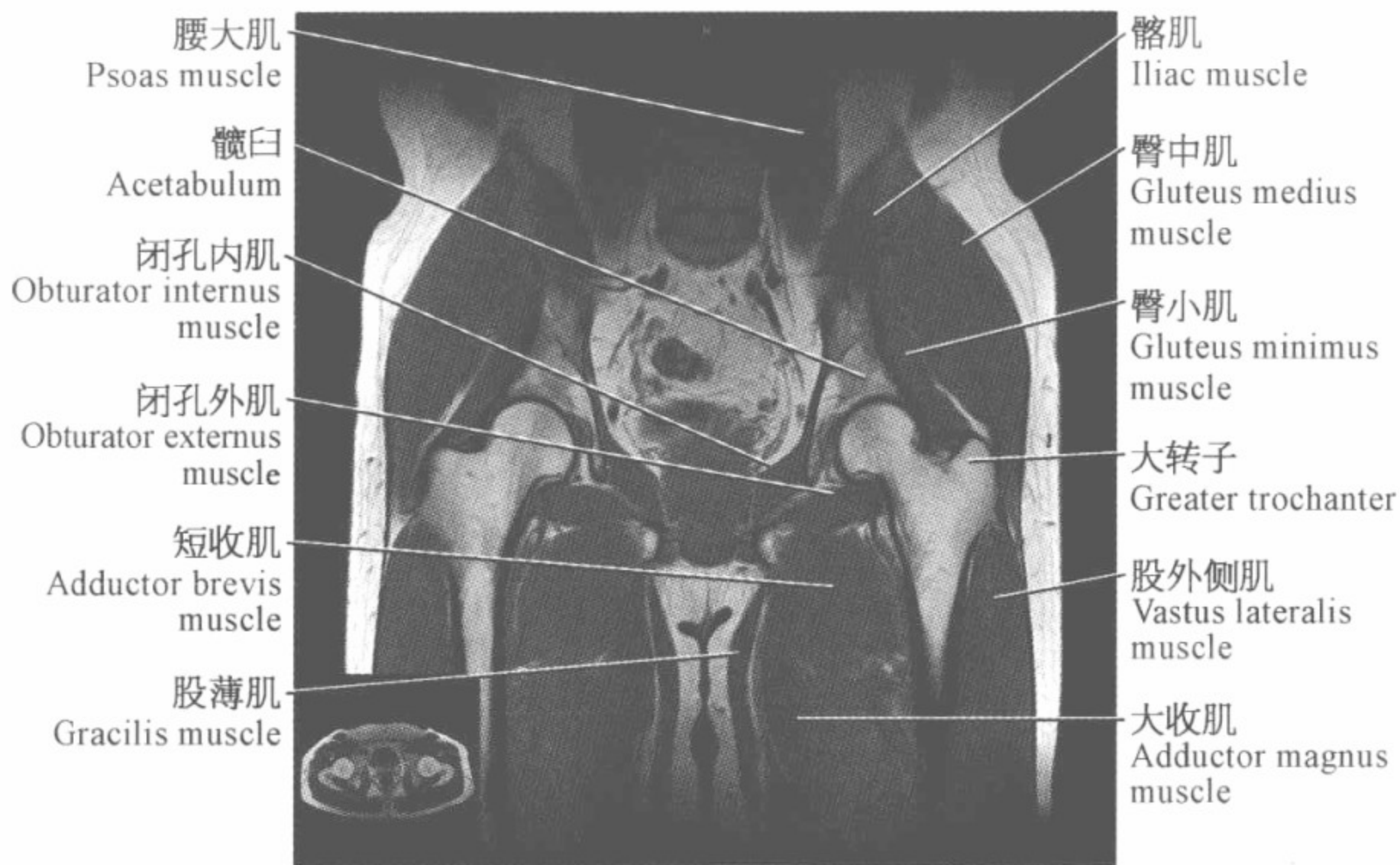


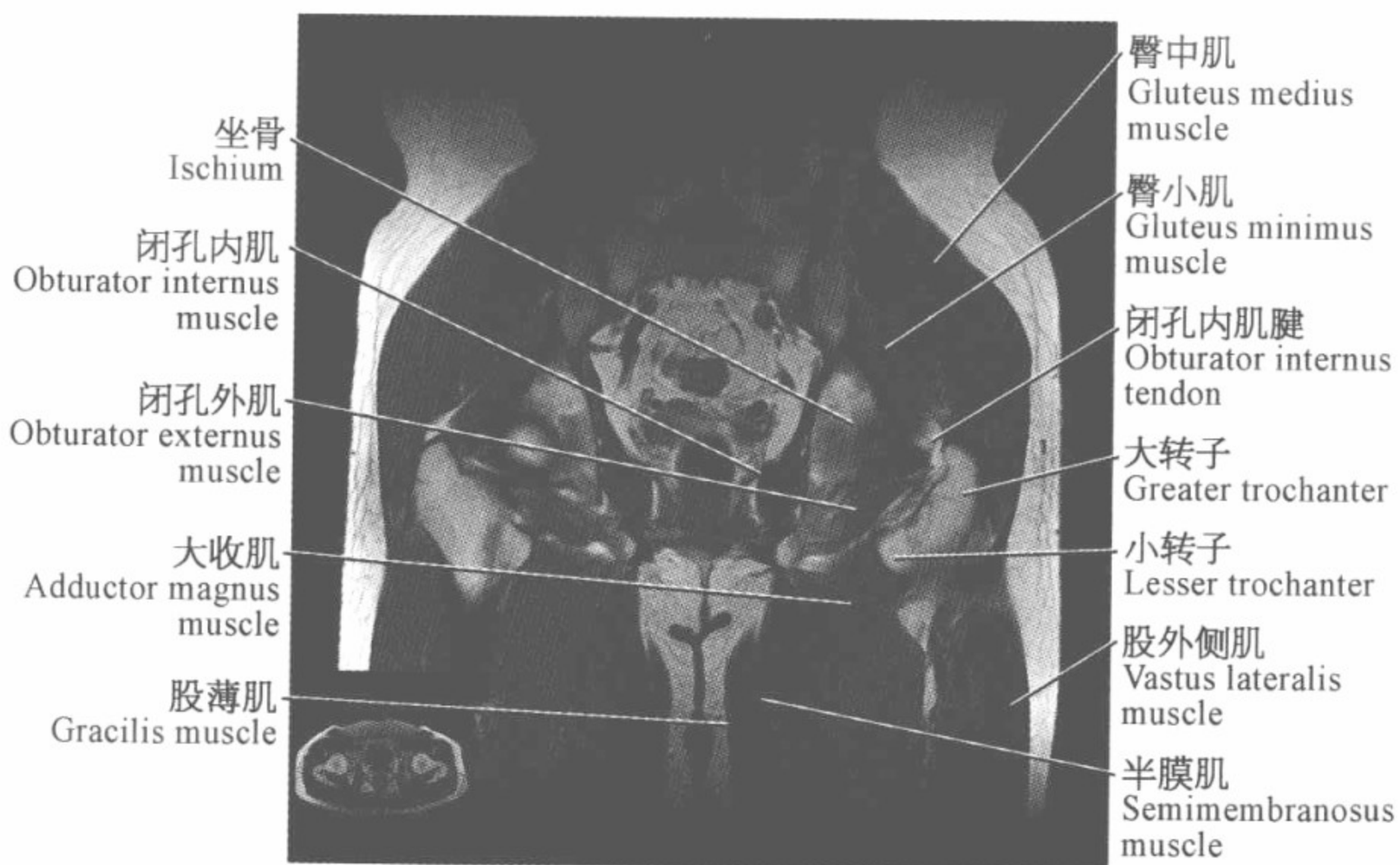

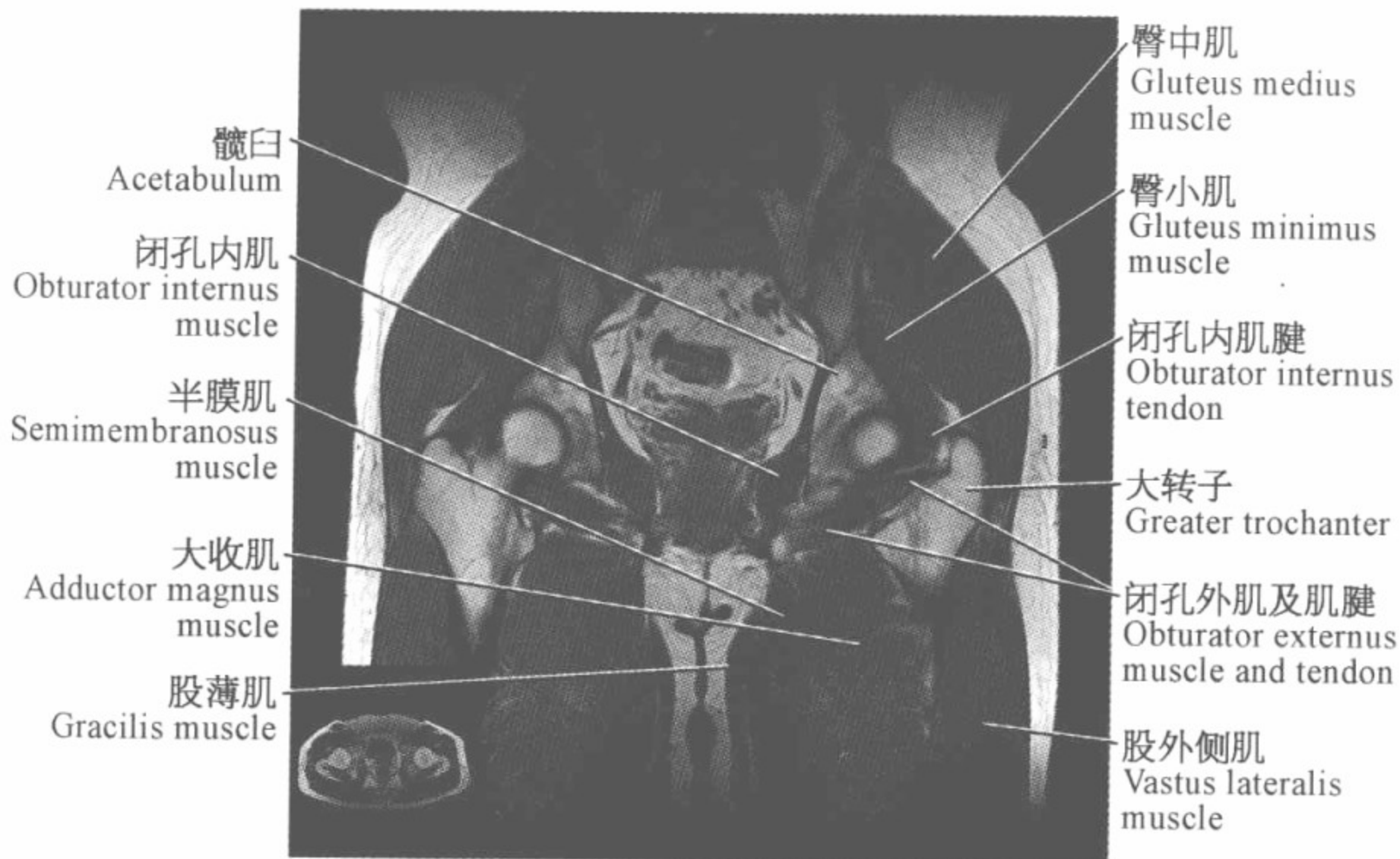

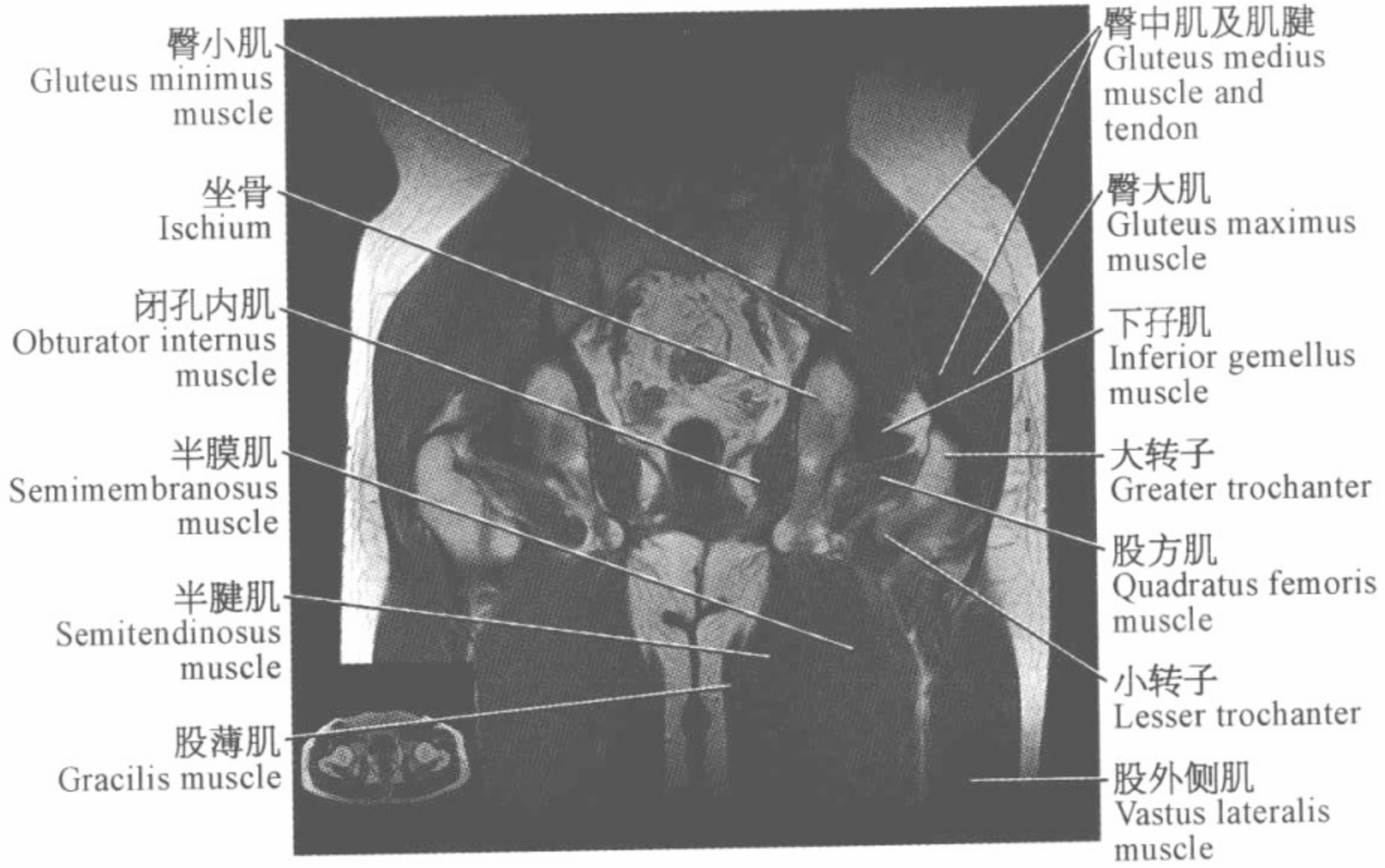












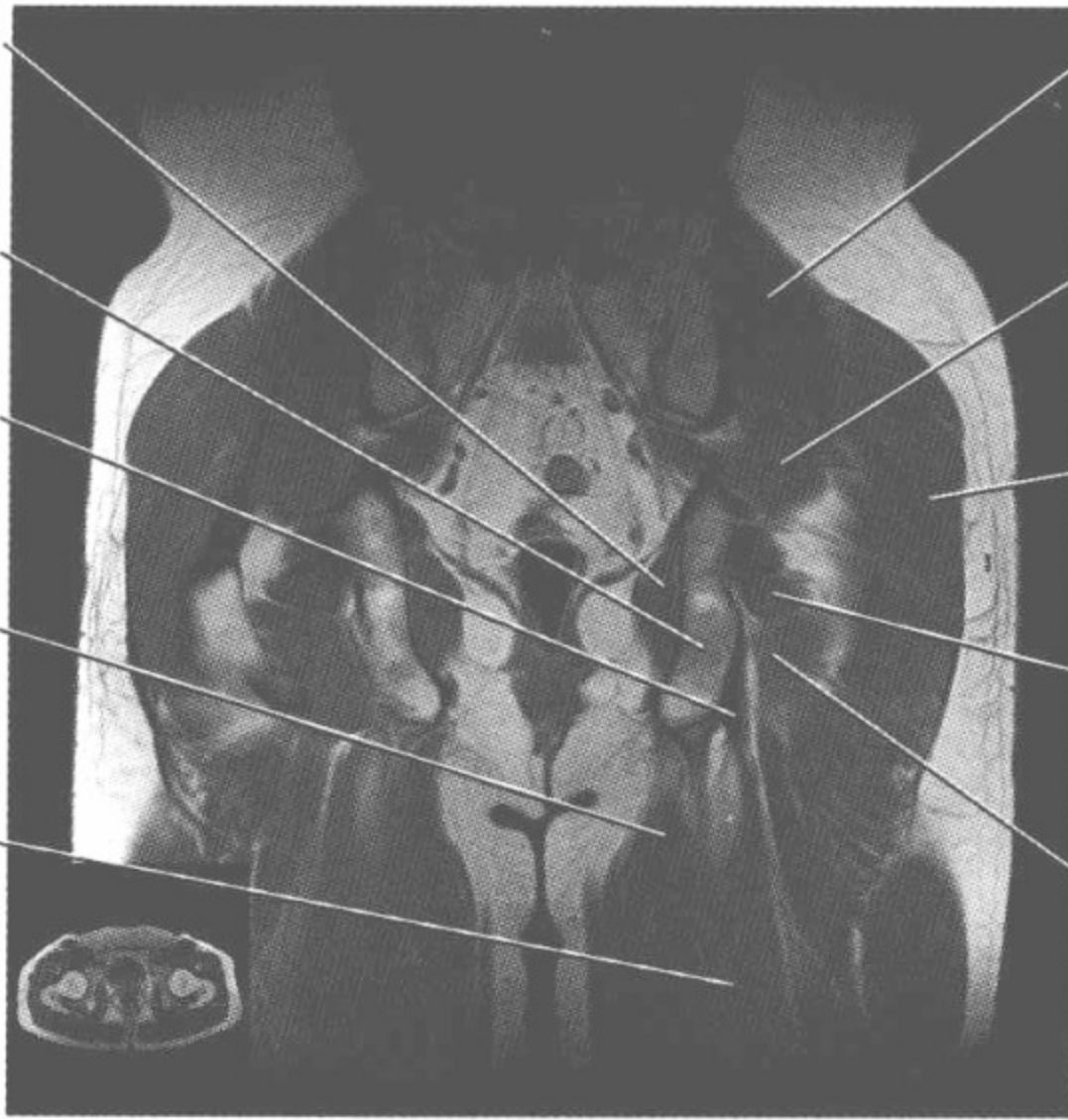
闭孔内肌
Obturator internus
muscle

坐骨结节
Ischial tuberosity

半膜肌腱
Semimembranosus
tendon

半腱肌
Semitendinosus
muscle

半膜肌
Semimembranosus
muscle



臀中肌
Gluteus medius
muscle

上孖肌
Superior gemellus
muscle

臀大肌
Gluteus maximus
muscle

下孖肌
Inferior gemellus
muscle

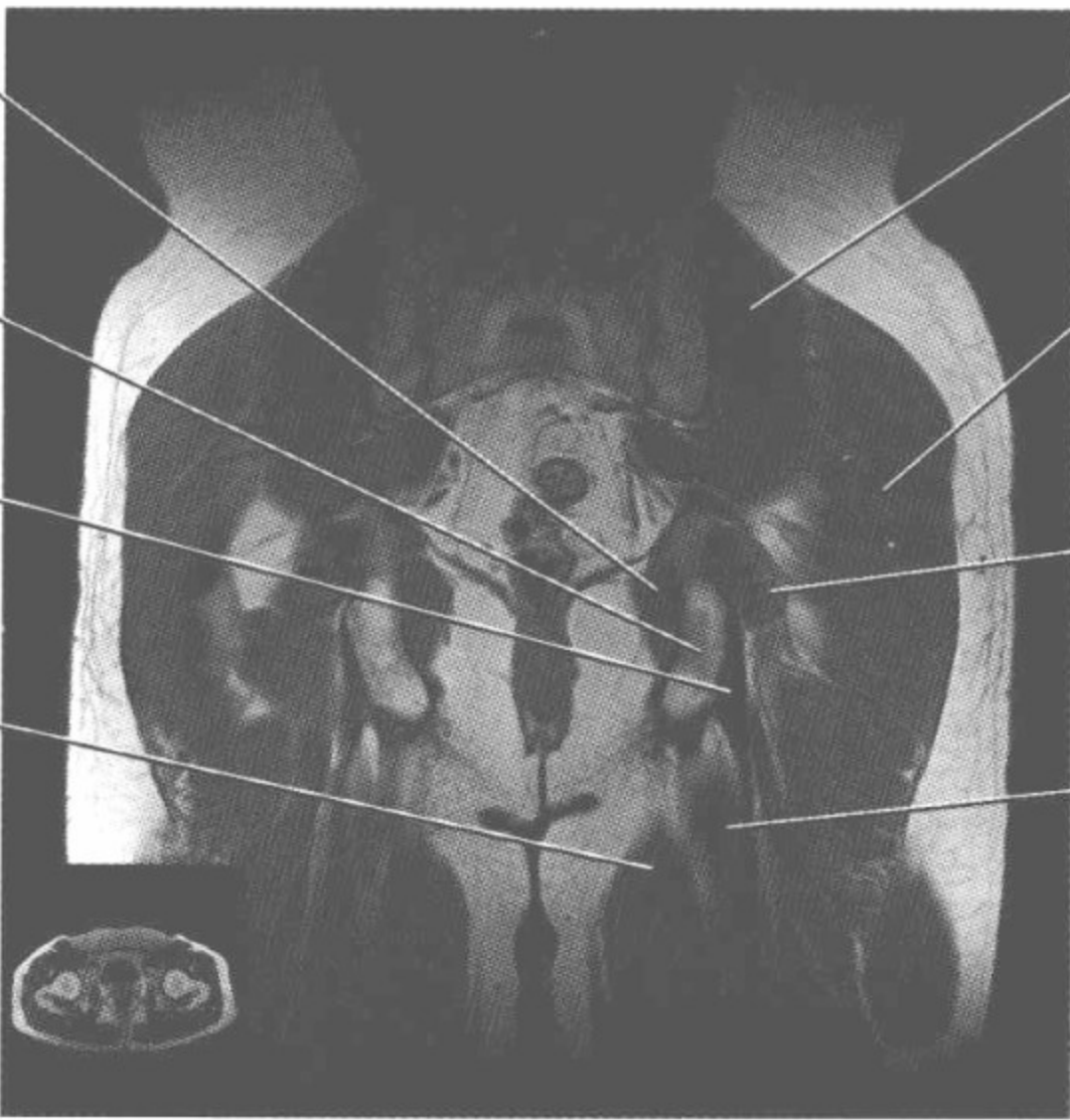
股方肌
Quadratus femoris
muscle

闭孔内肌
Obturator internus
muscle

坐骨结节
Ischial tuberosity

半膜肌腱
Semimembranosus
tendon

半腱肌
Semitendinosus
muscle



臀中肌
Gluteus medius
muscle

臀大肌
Gluteus maximus
muscle


下孖肌
Inferior gemellus
muscle

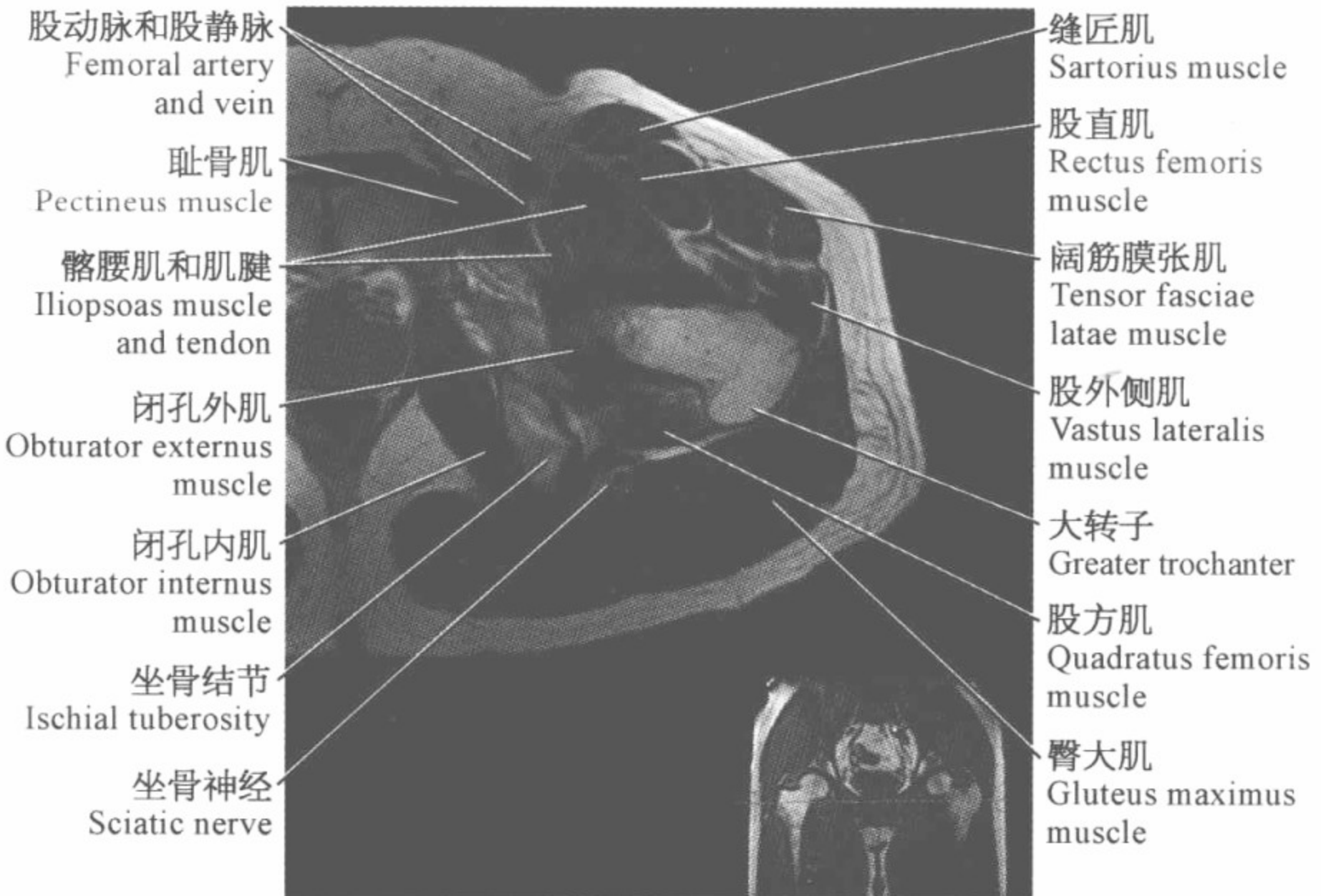
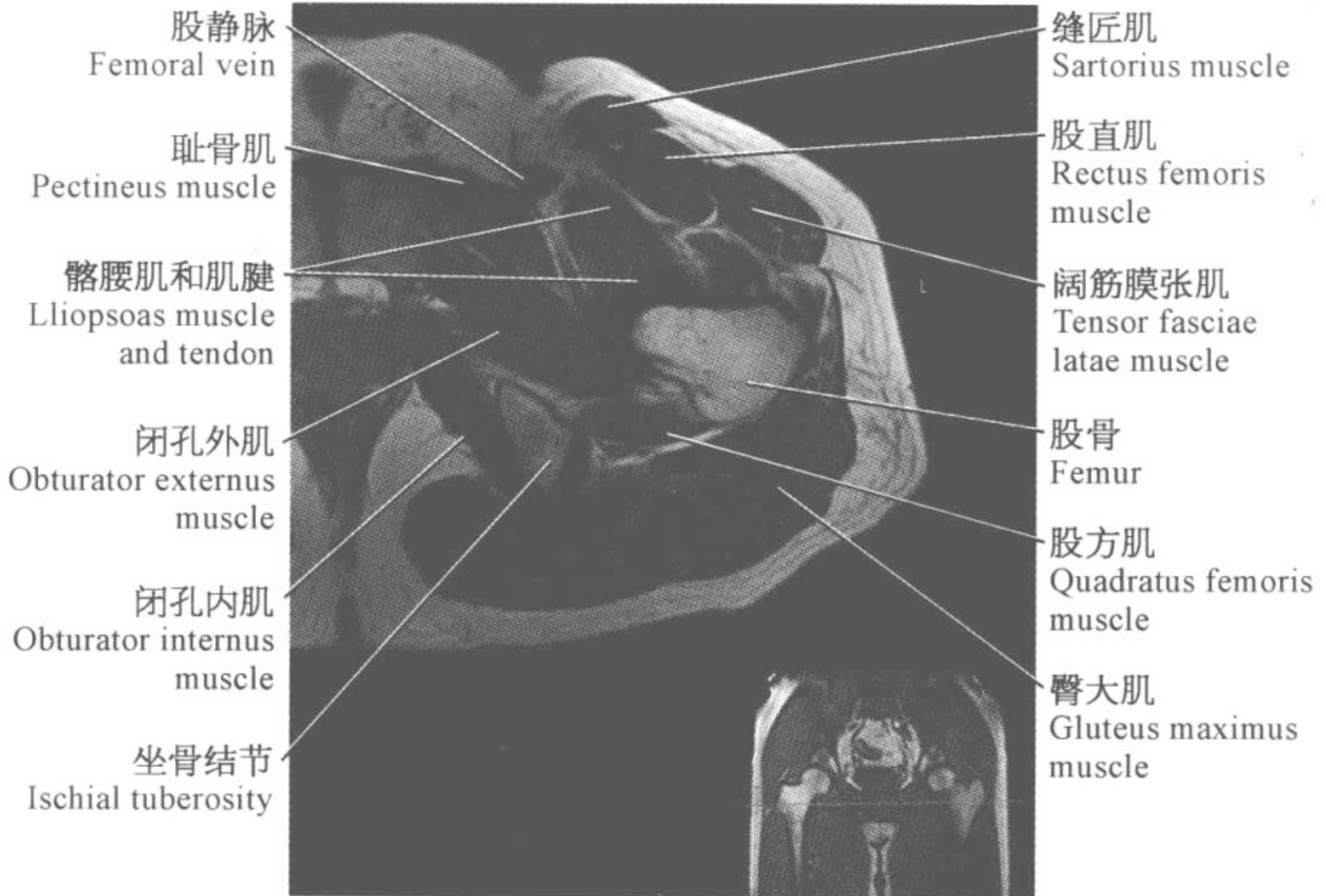
半膜肌
Semimembranosus
muscle



腕关节磁共振图谱

(横断位)





股静脉
Femoral vein


耻骨肌
Pectineus muscle

髂腰肌和肌腱
Iliopsoas muscle
and tendon

股骨头
Femoral head

闭孔内肌
Obturator internus
muscle

坐骨结节
Ischial tuberosity



缝匠肌
Sartorius muscle

股直肌
Rectus femoris
muscle

阔筋膜张肌
Tensor fasciae
latae muscle

股外侧肌
Vastus lateralis
muscle

大转子
Greater trochanter

股方肌
Quadratus femoris
muscle

臀大肌
Gluteus maximus
muscle

髂腰肌
Iliopsoas muscle

股动脉和静脉
Femoral artery
and vein

耻骨肌
Pectineus muscle

髂股韧带
Iliofemoral ligament

髋臼横韧带
Transverse acetabular
ligament

闭孔内肌
Obturator internus
muscle

坐骨
Ischial



缝匠肌
Sartorius muscle

股直肌
Rectus femoris
muscle

阔筋膜张肌
Tensor fasciae
latae muscle

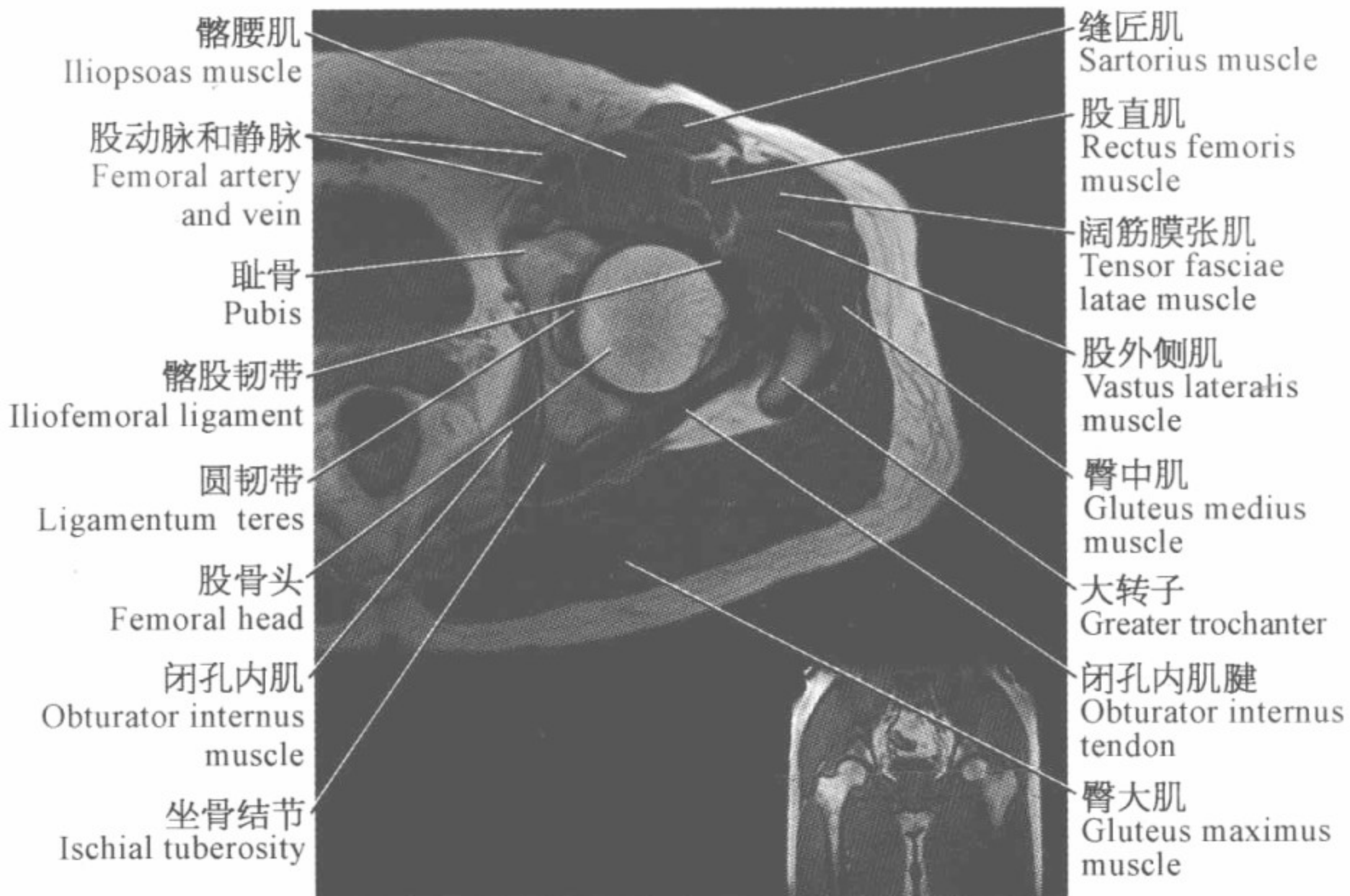
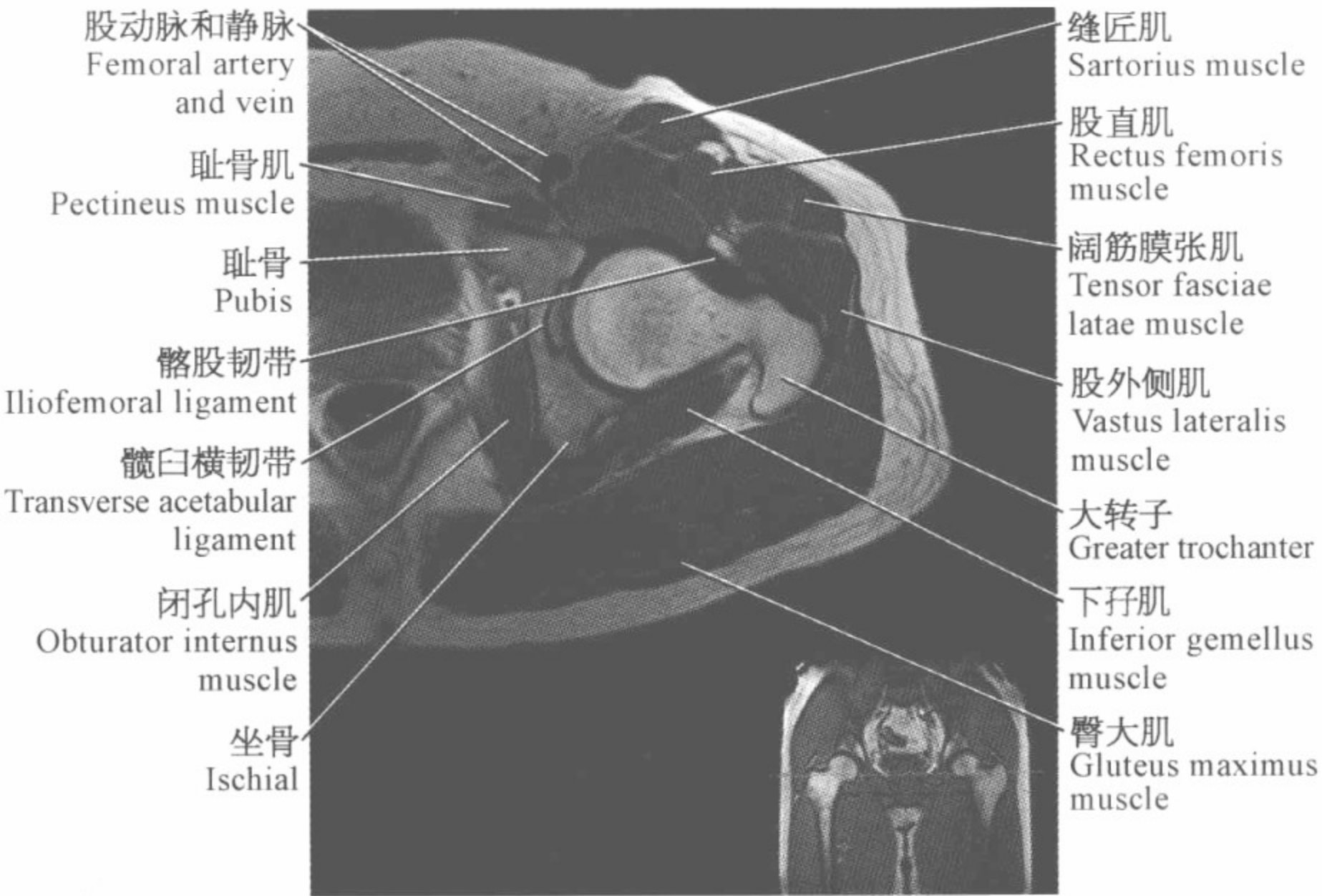
股外侧肌
Vastus lateralis
muscle

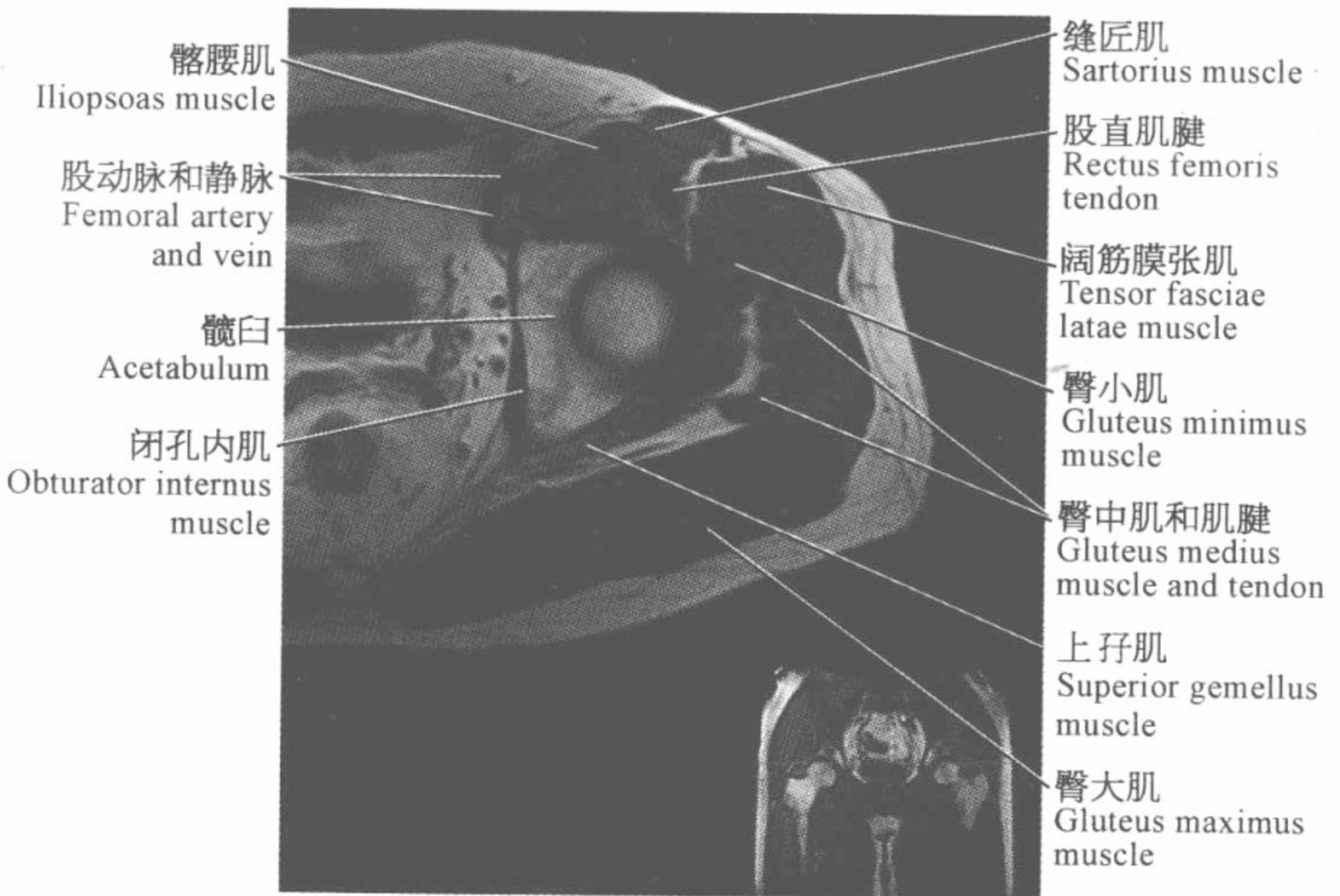
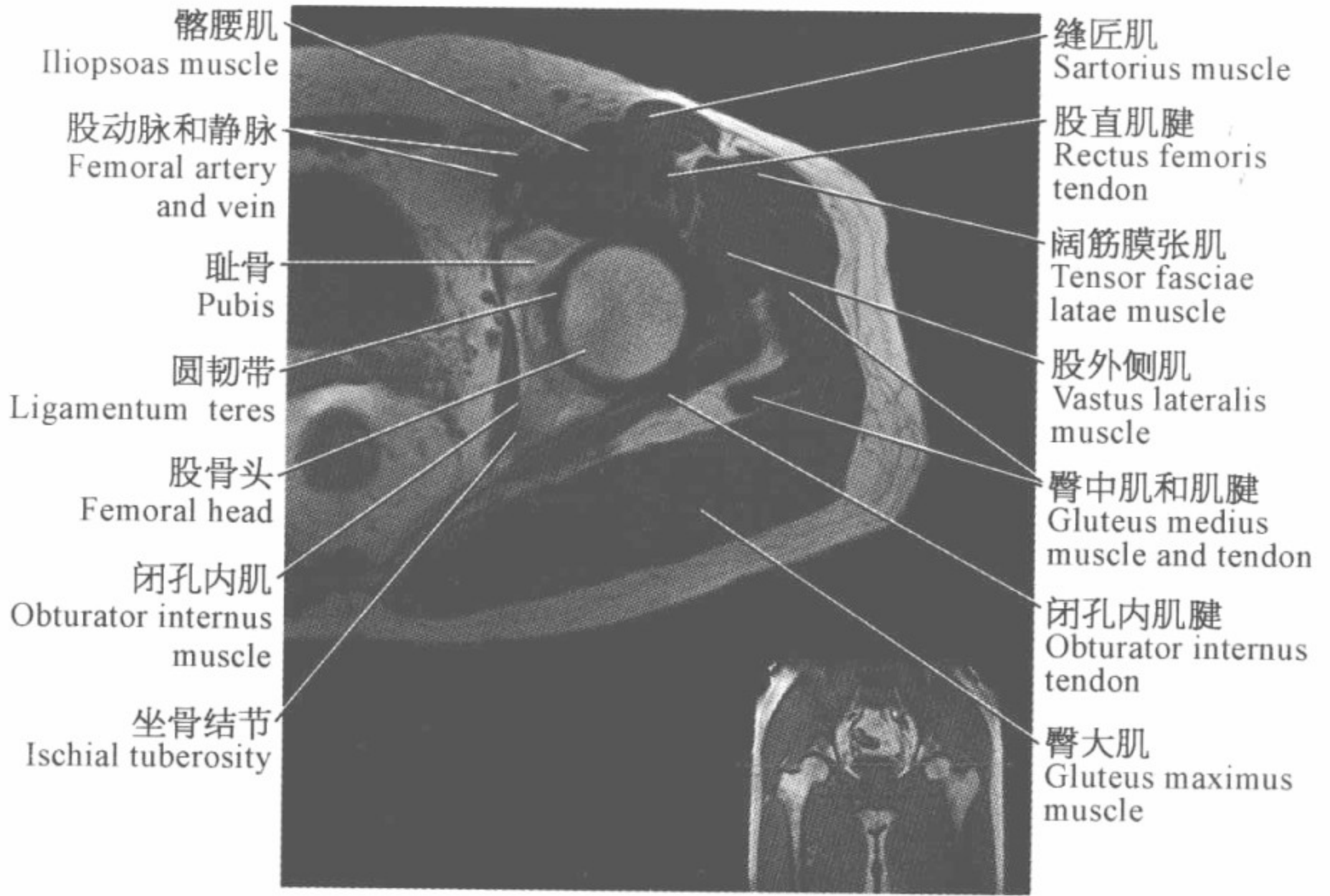
大转子
Greater trochanter

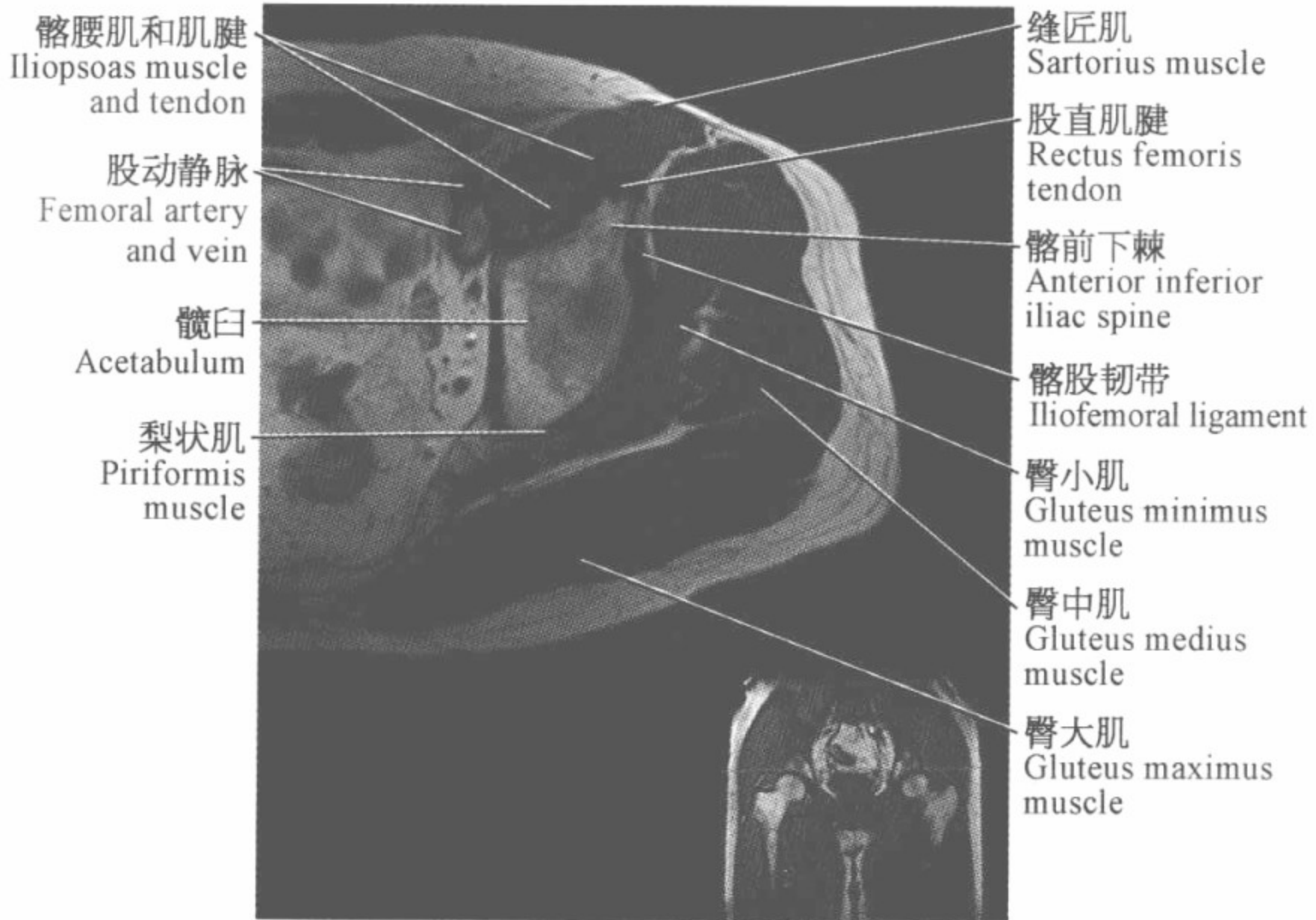
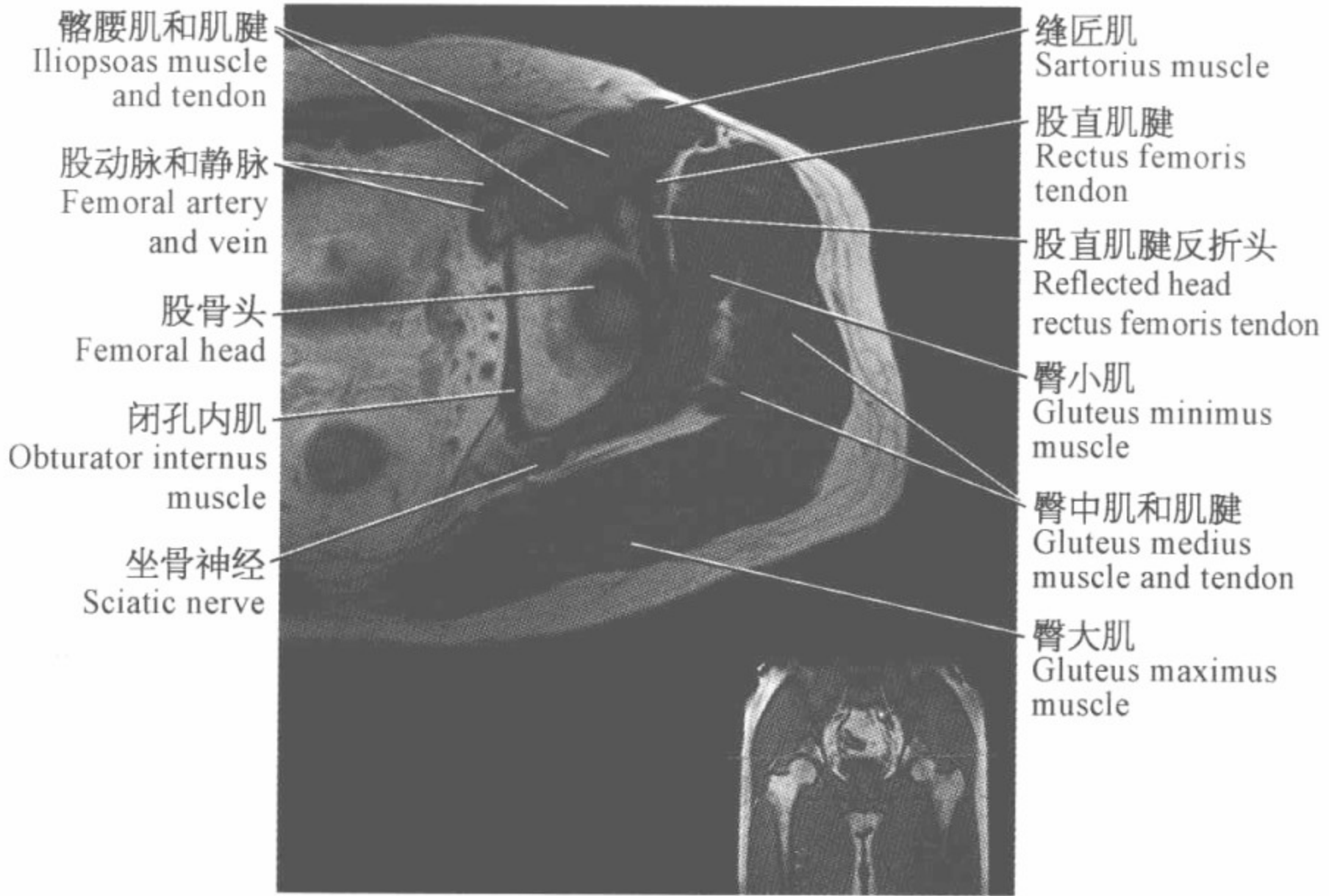
闭孔外肌腱
Obturator externus
tendon

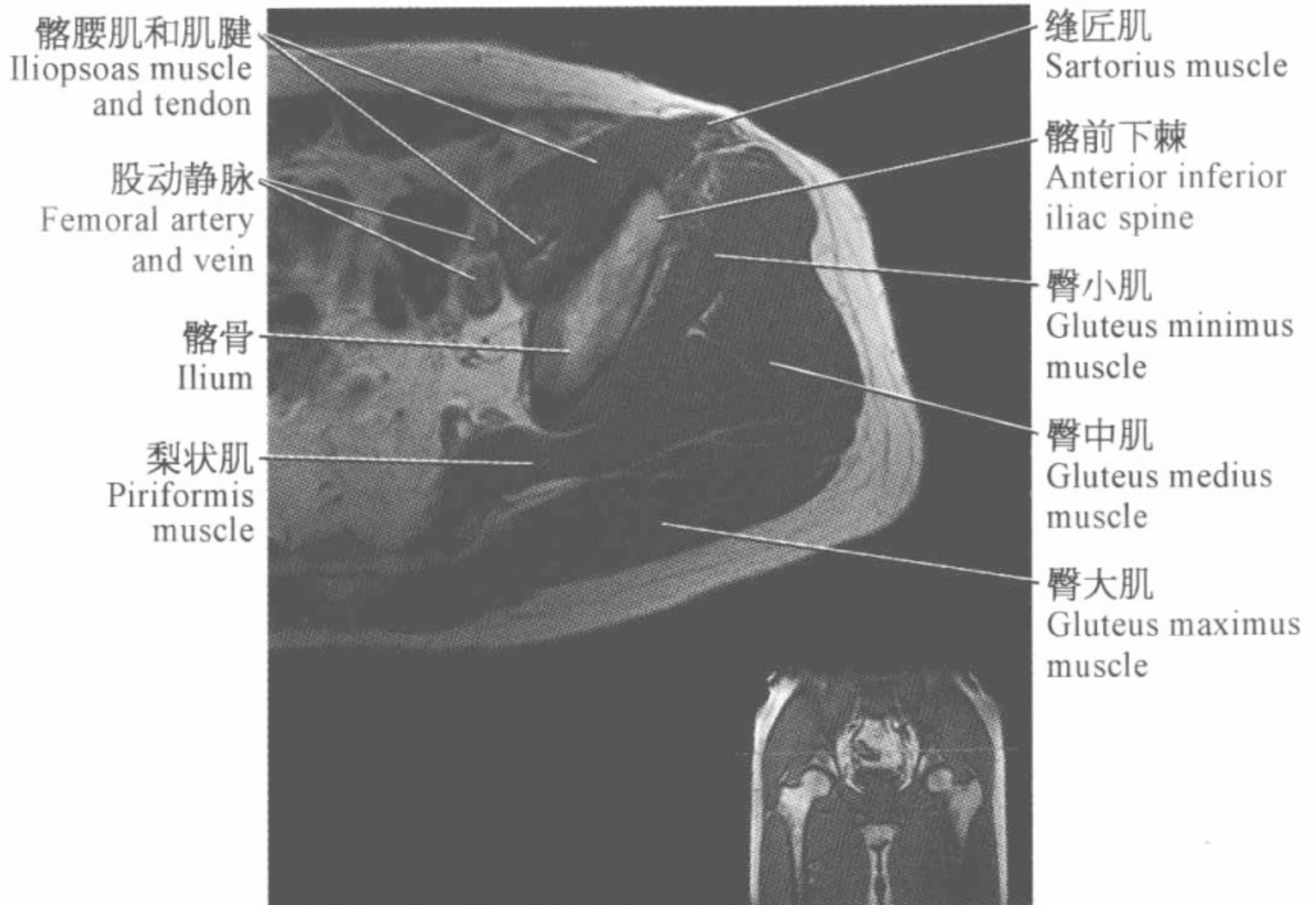
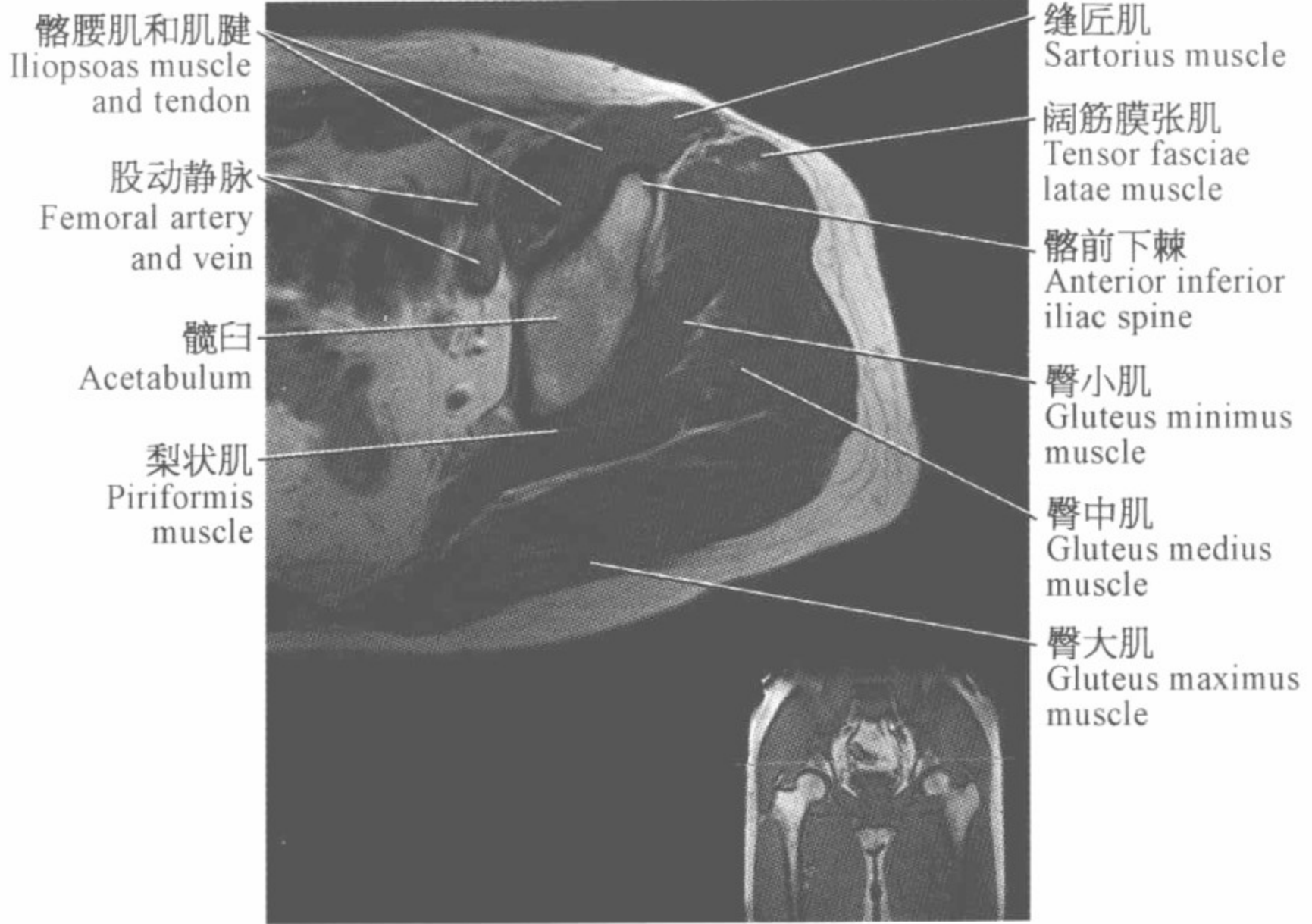
下孖肌
Inferior gemellus
muscle

臀大肌
Gluteus maximus
muscle








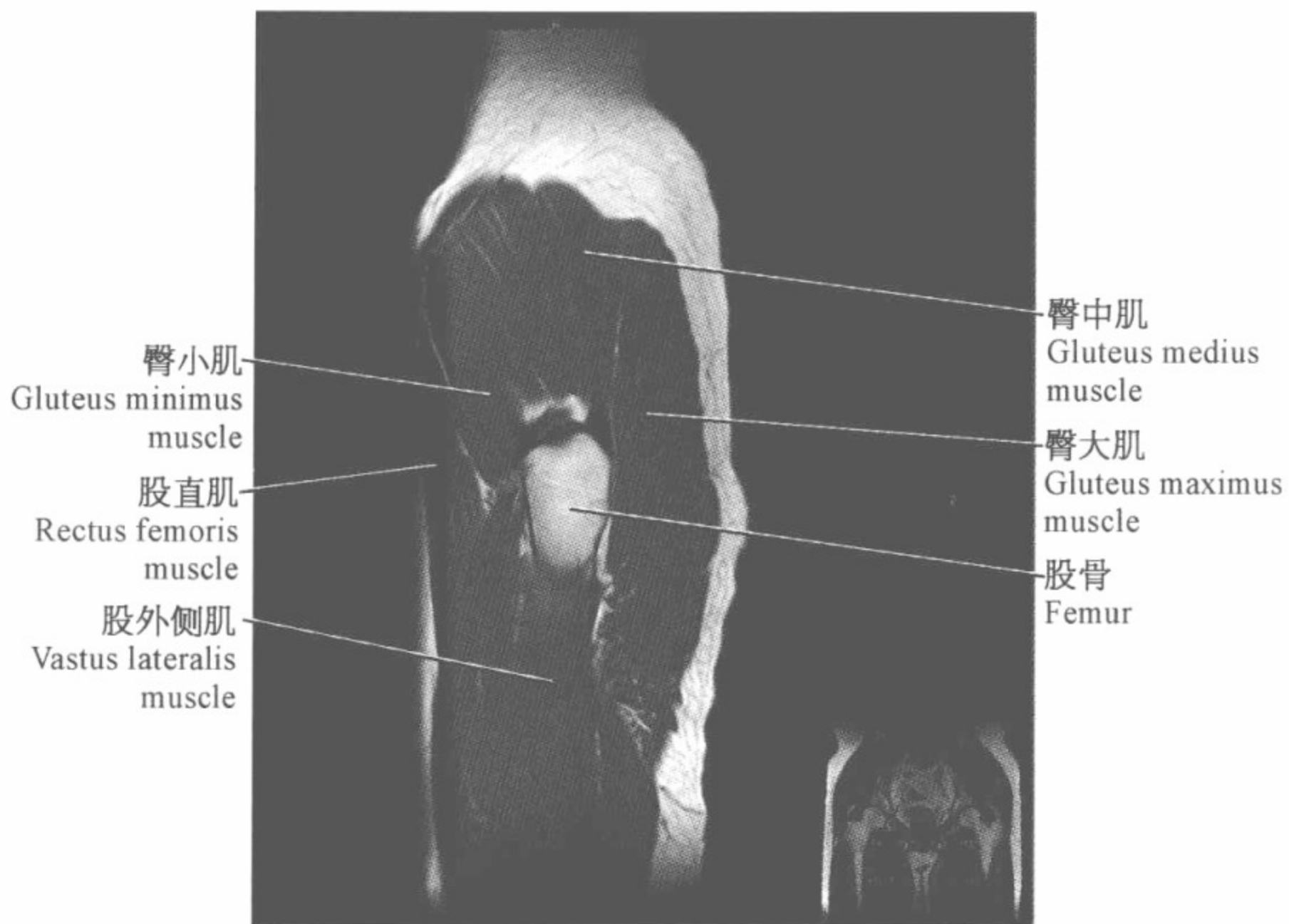
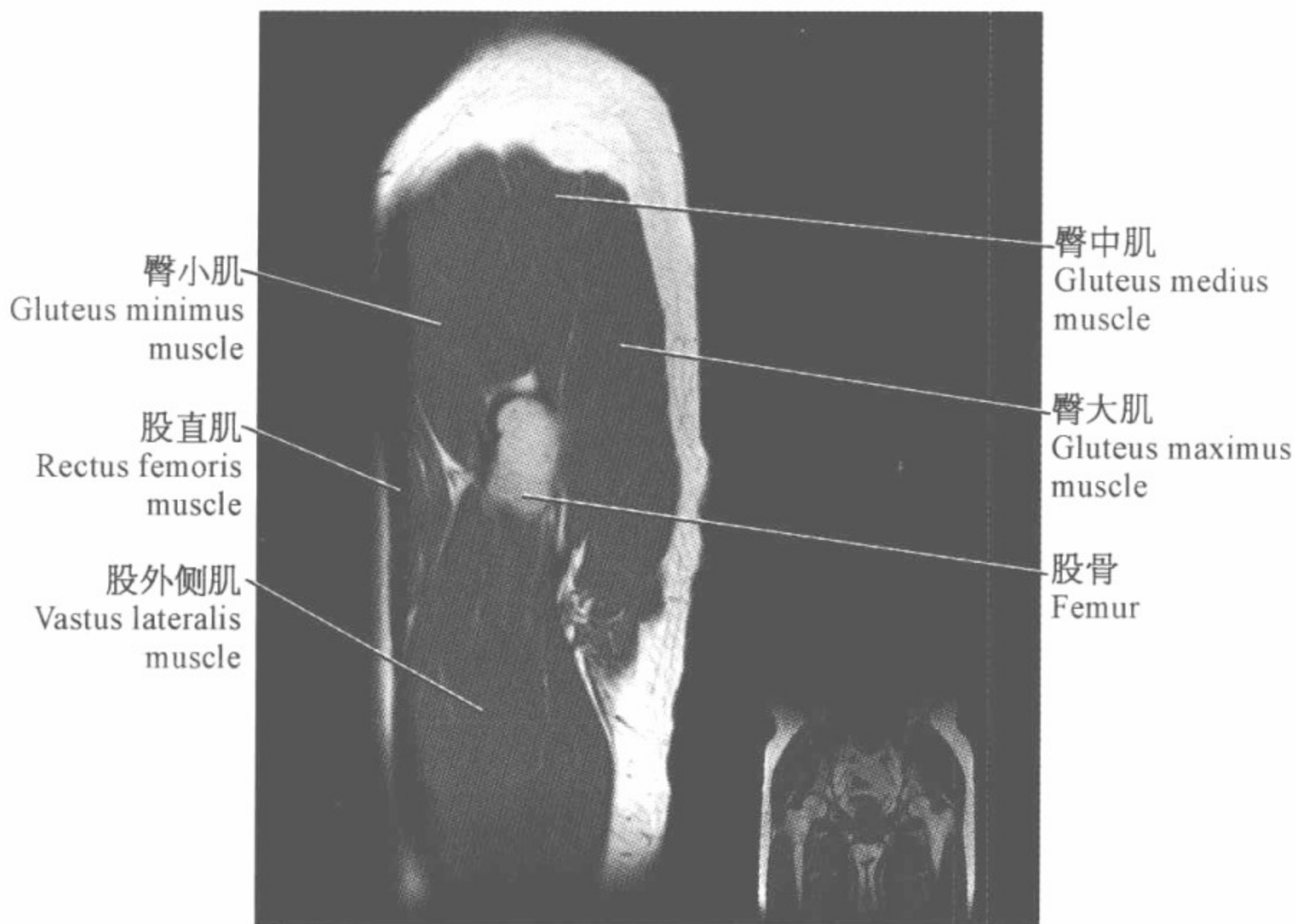




腕关节磁共振图谱

(矢状位)



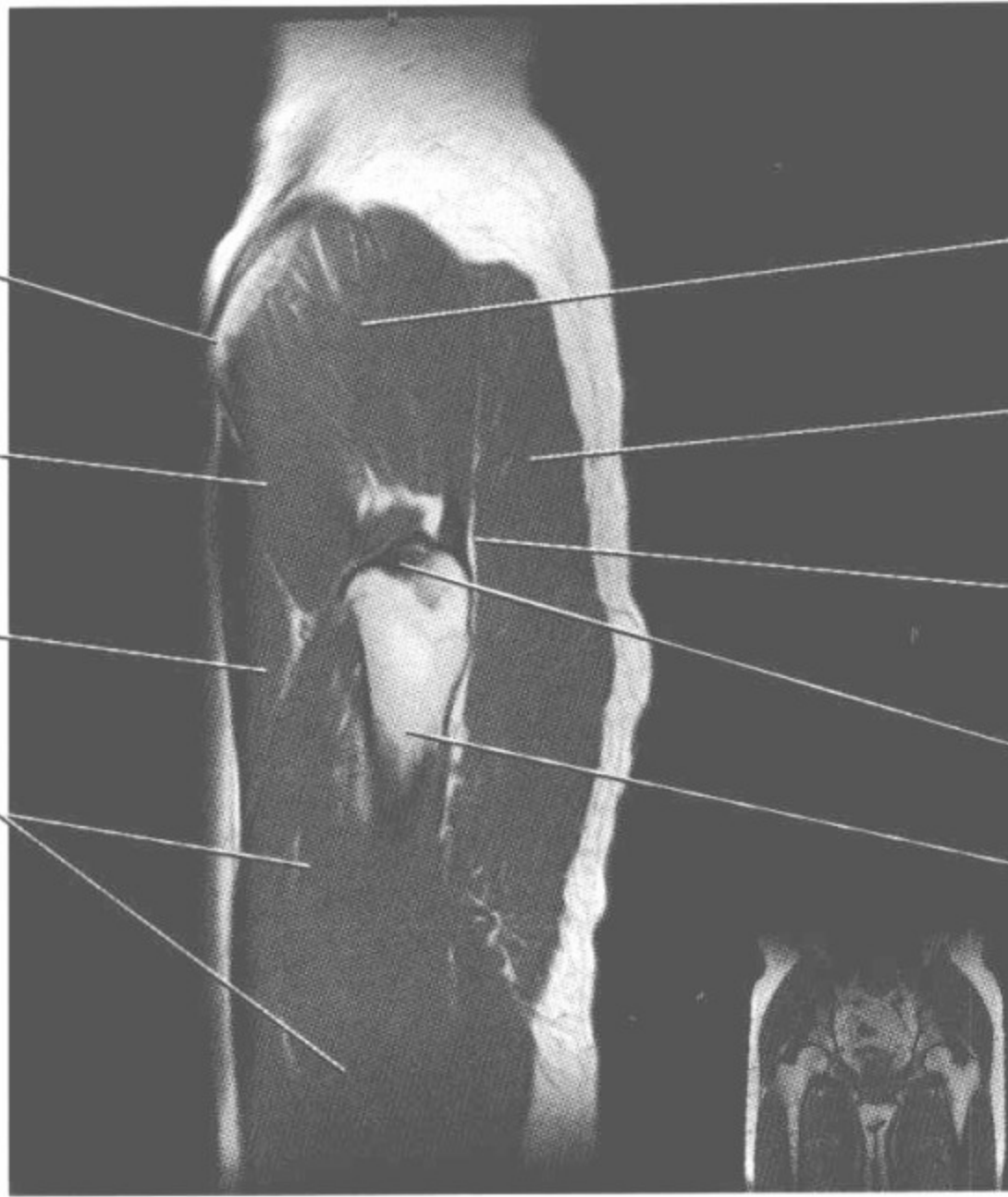


髂前下棘
Anterior inferior
iliac spine

臀小肌
Gluteus minimus
muscle

股直肌
Rectus femoris
muscle

股外侧肌
Vastus lateralis
muscle



臀中肌
Gluteus medius
muscle

臀大肌
Gluteus maximus
muscle

臀中肌肌腱
Gluteus medius
tendon

大转子
Greater trochanter

股骨
Femur

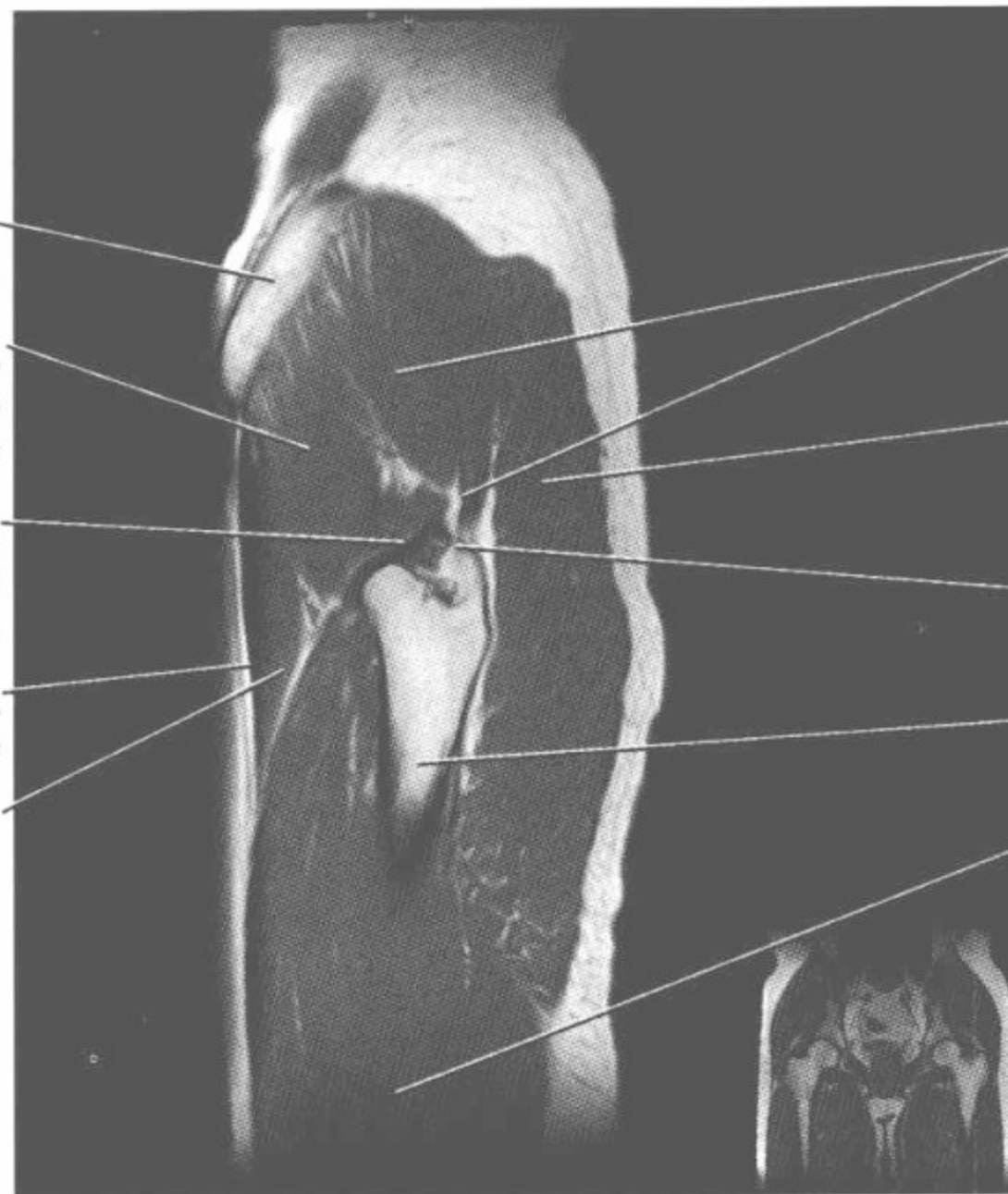
髌骨
Ilium

臀小肌
Gluteus minimus
muscle

闭孔内肌腱
Obturator internus
tendon

缝匠肌
Sartorius muscle

股直肌
Rectus femoris
muscle



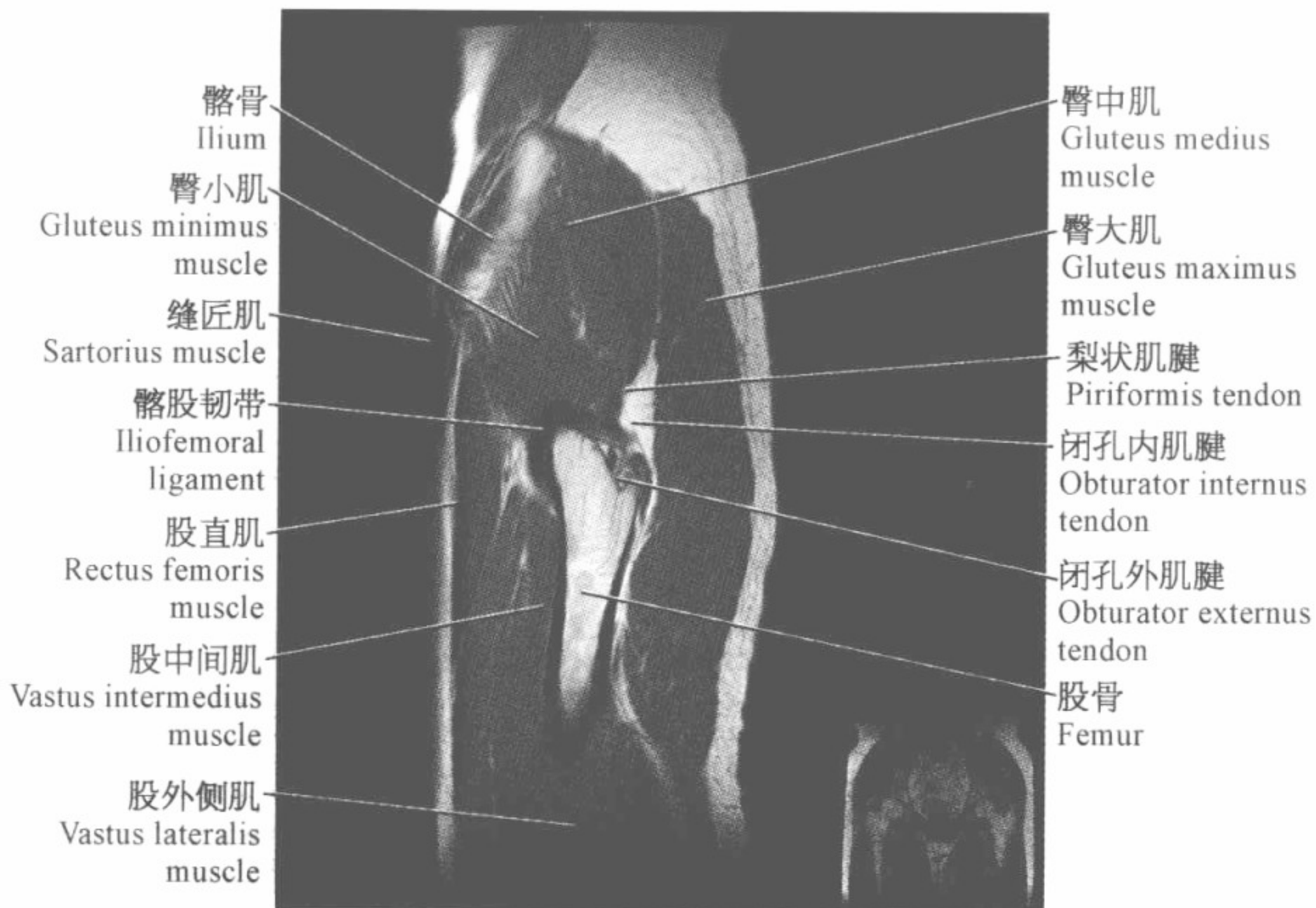
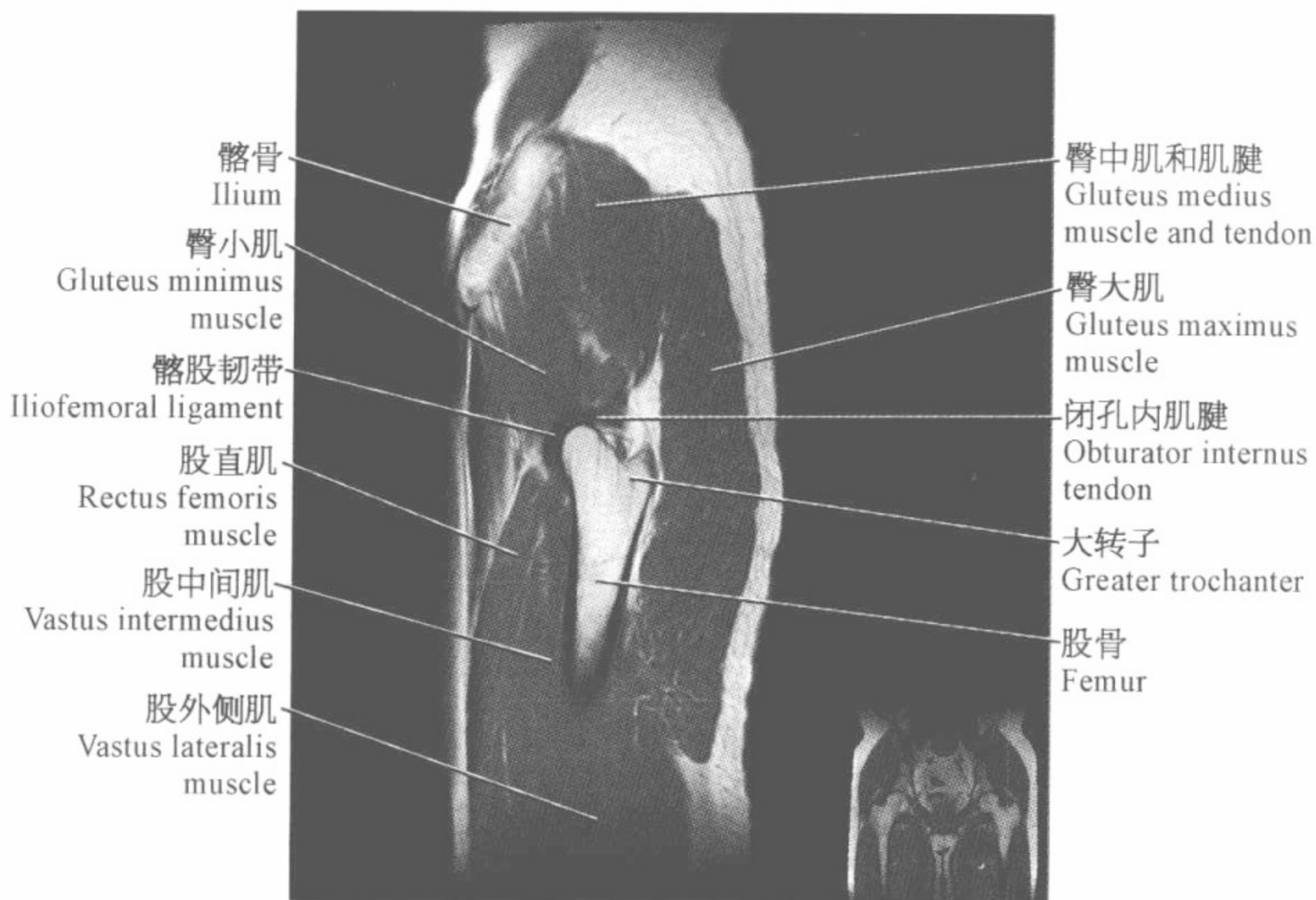
臀中肌和肌腱
Gluteus medius
muscle and tendon

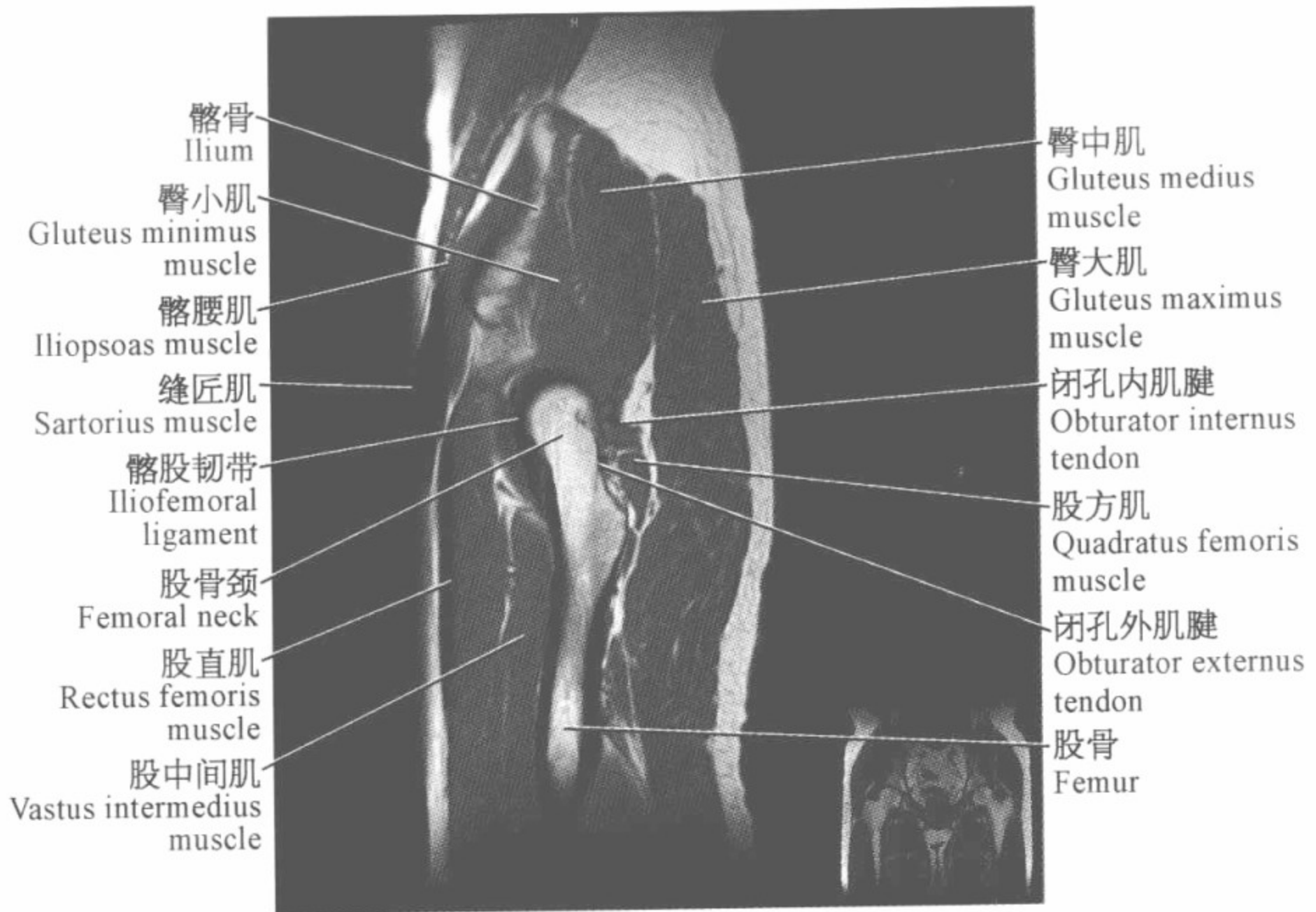
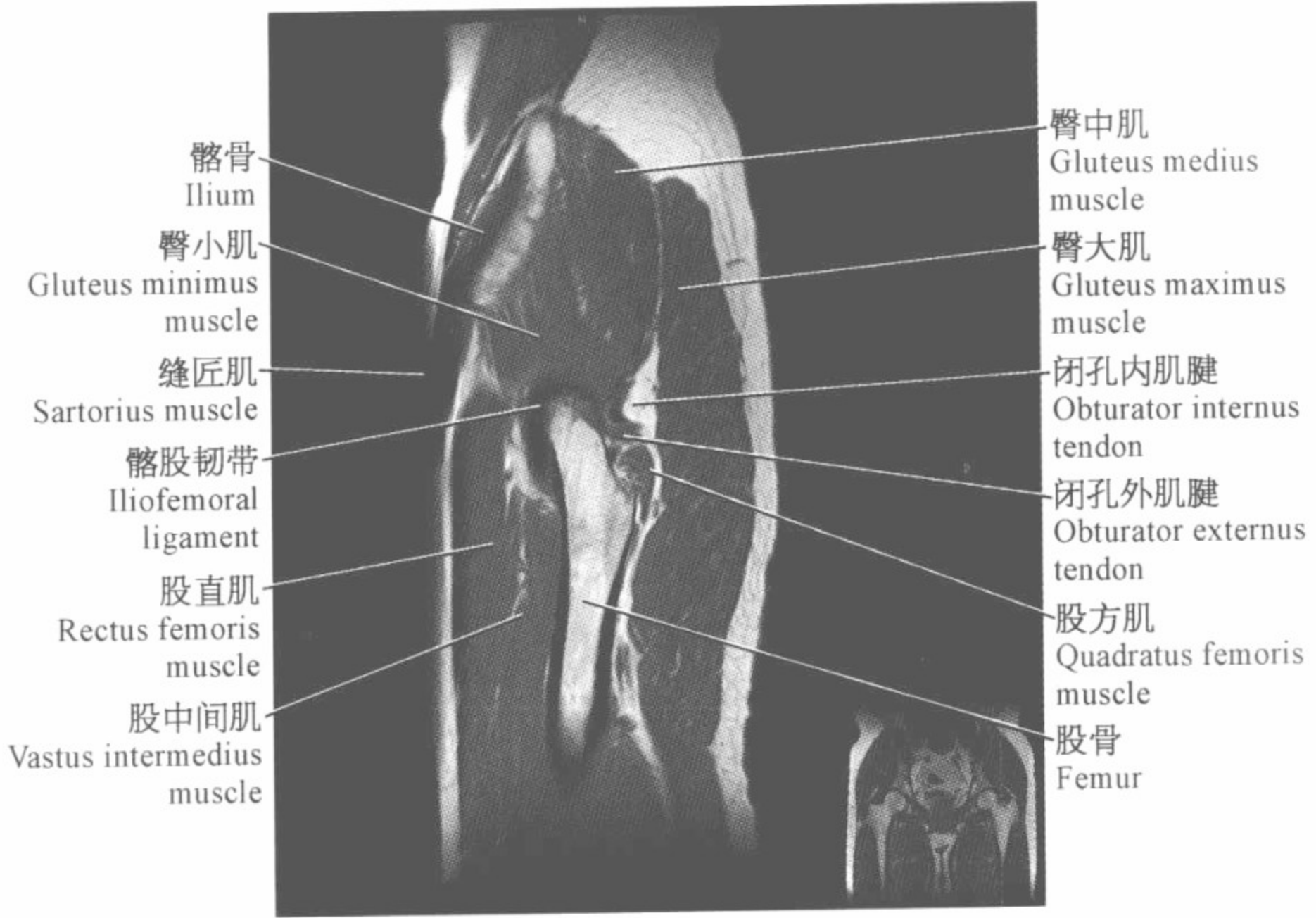
臀大肌
Gluteus maximus
muscle

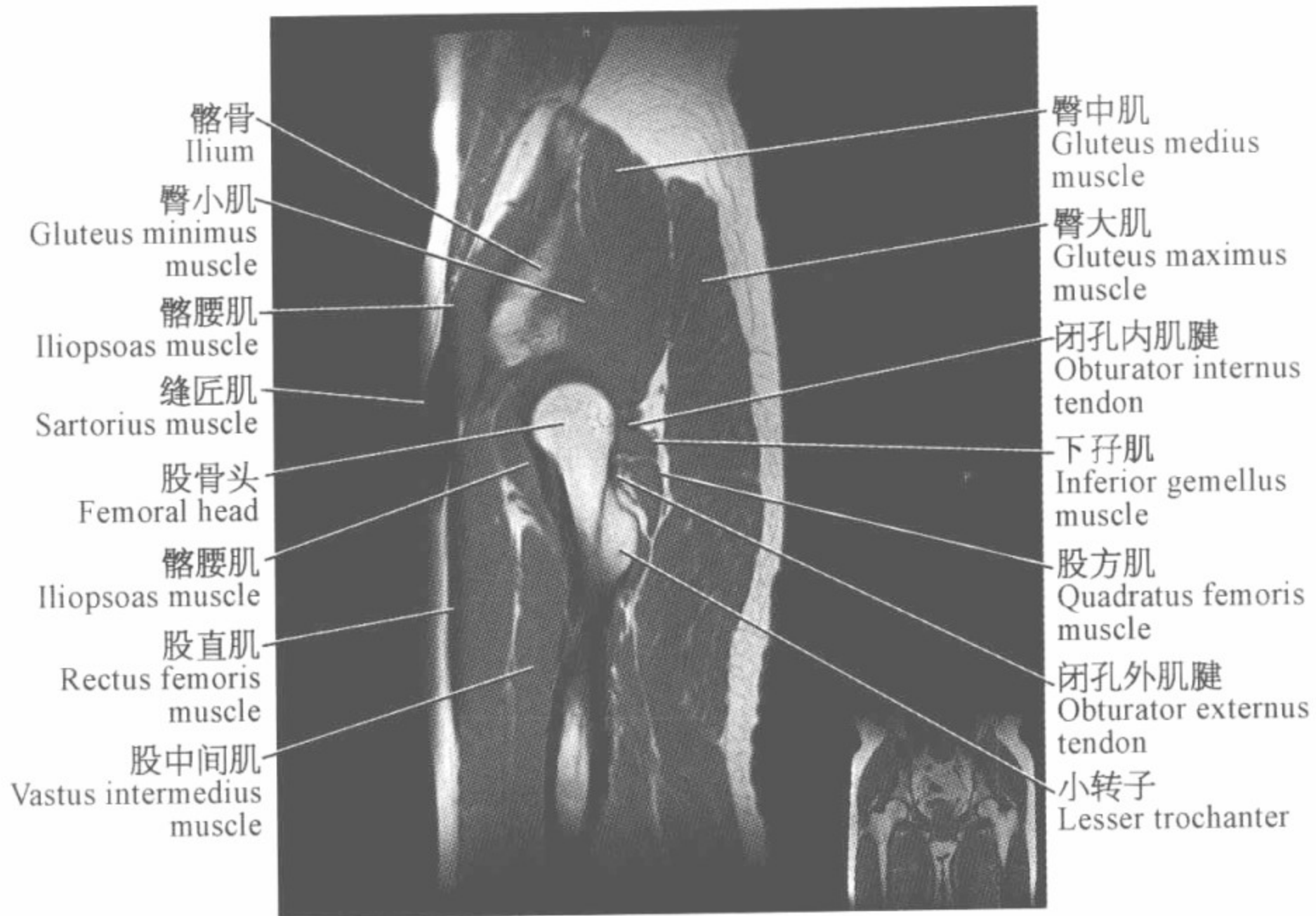
大转子
Greater trochanter

股骨
Femur

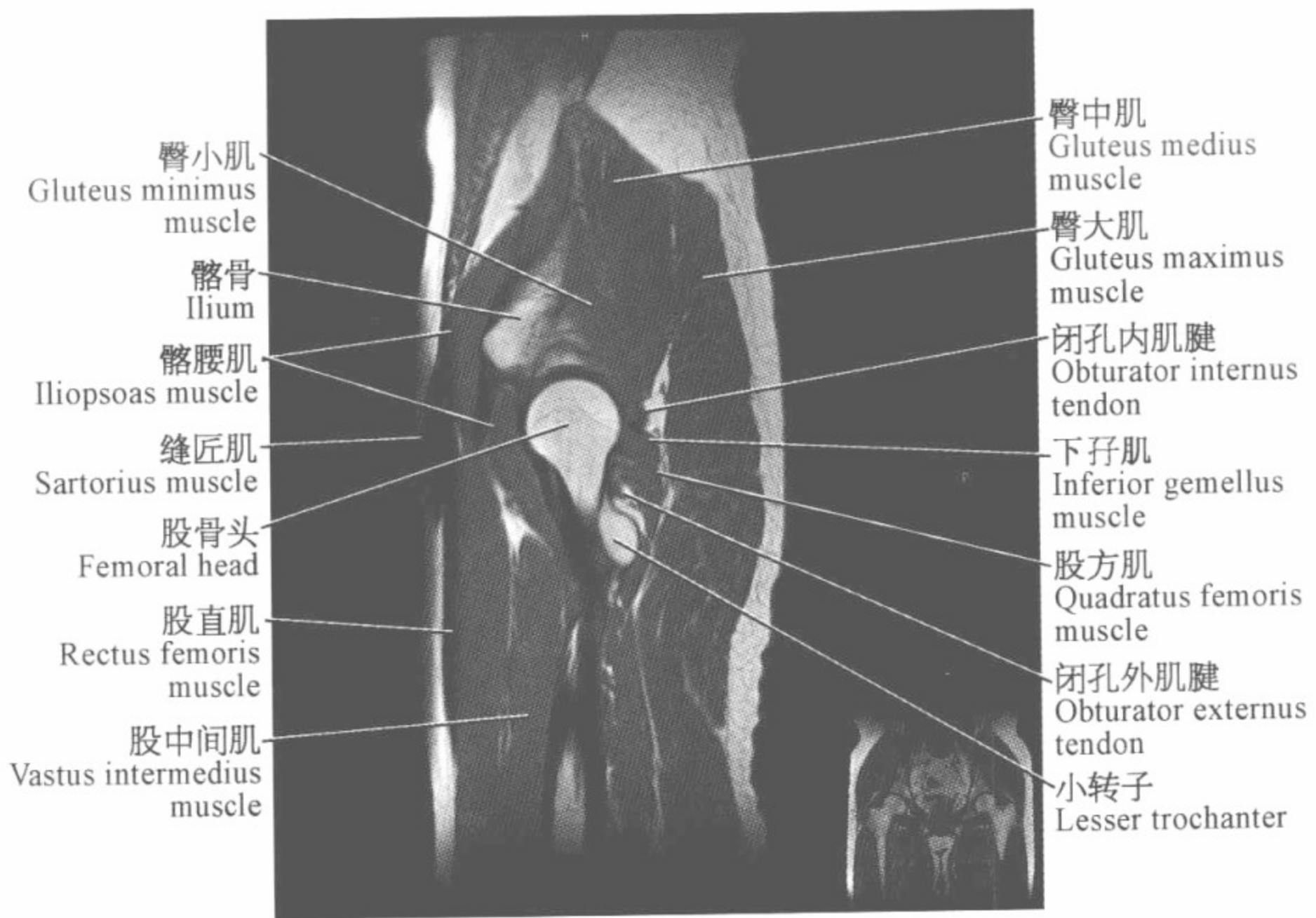
股外侧肌
Vastus lateralis
muscle



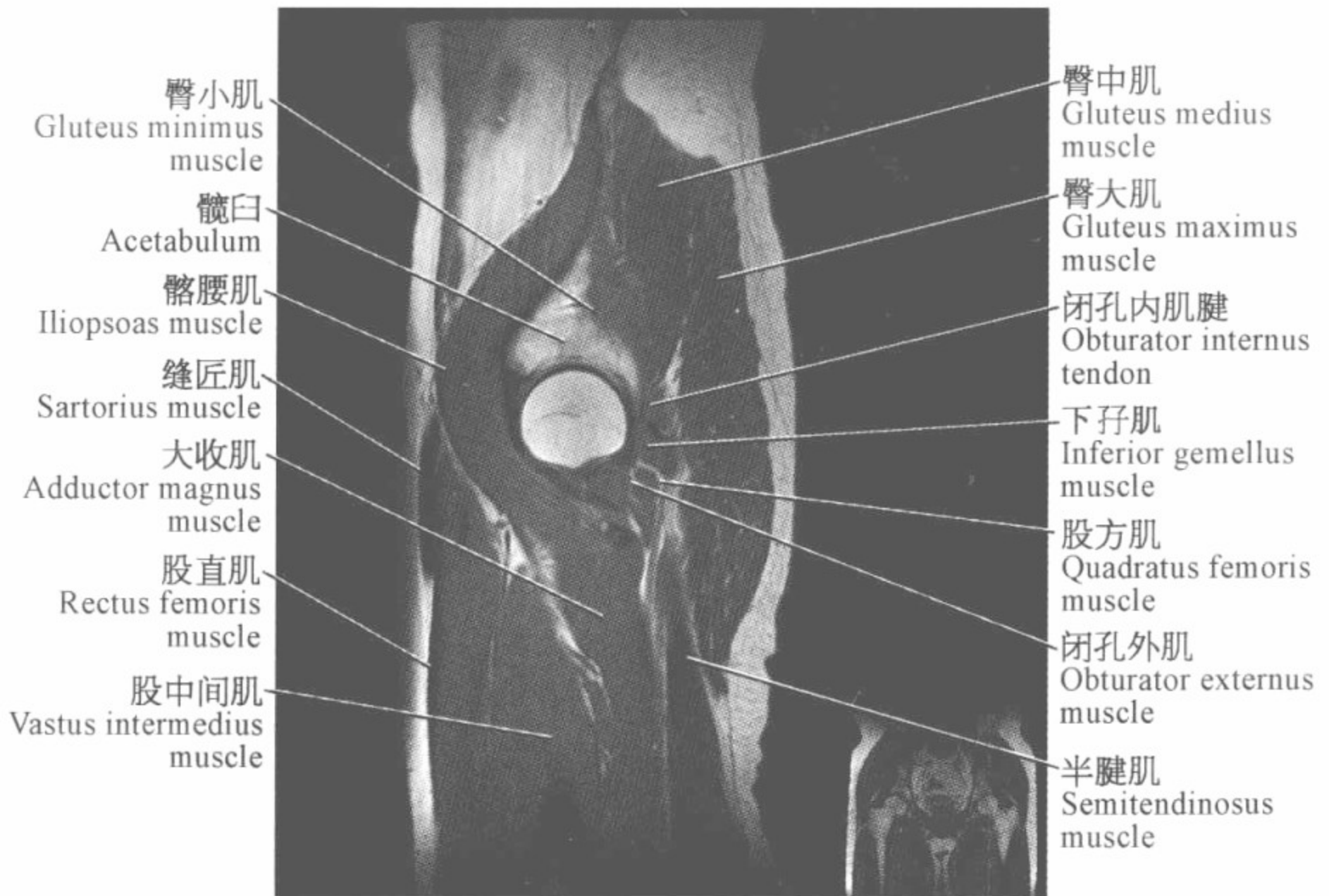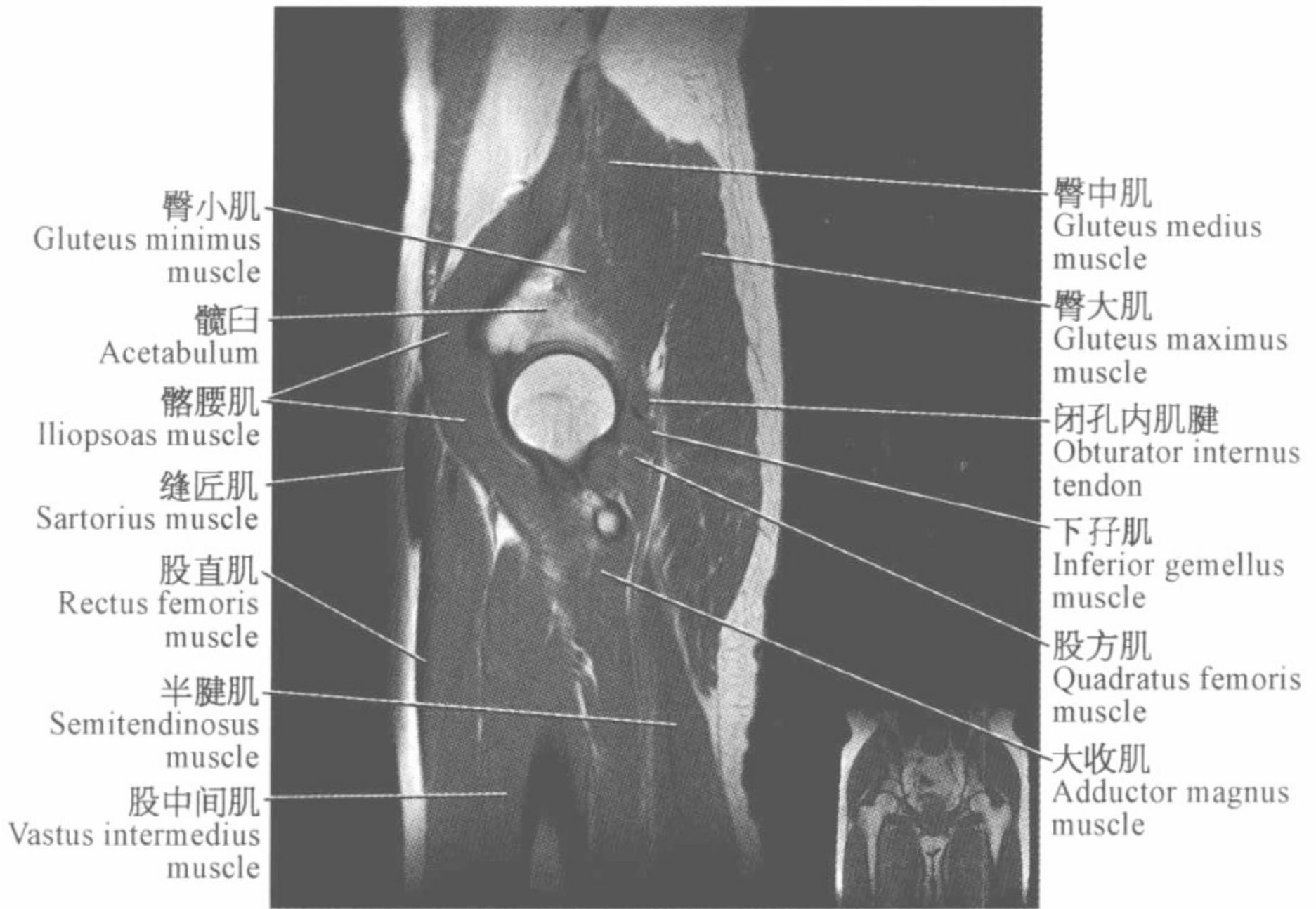



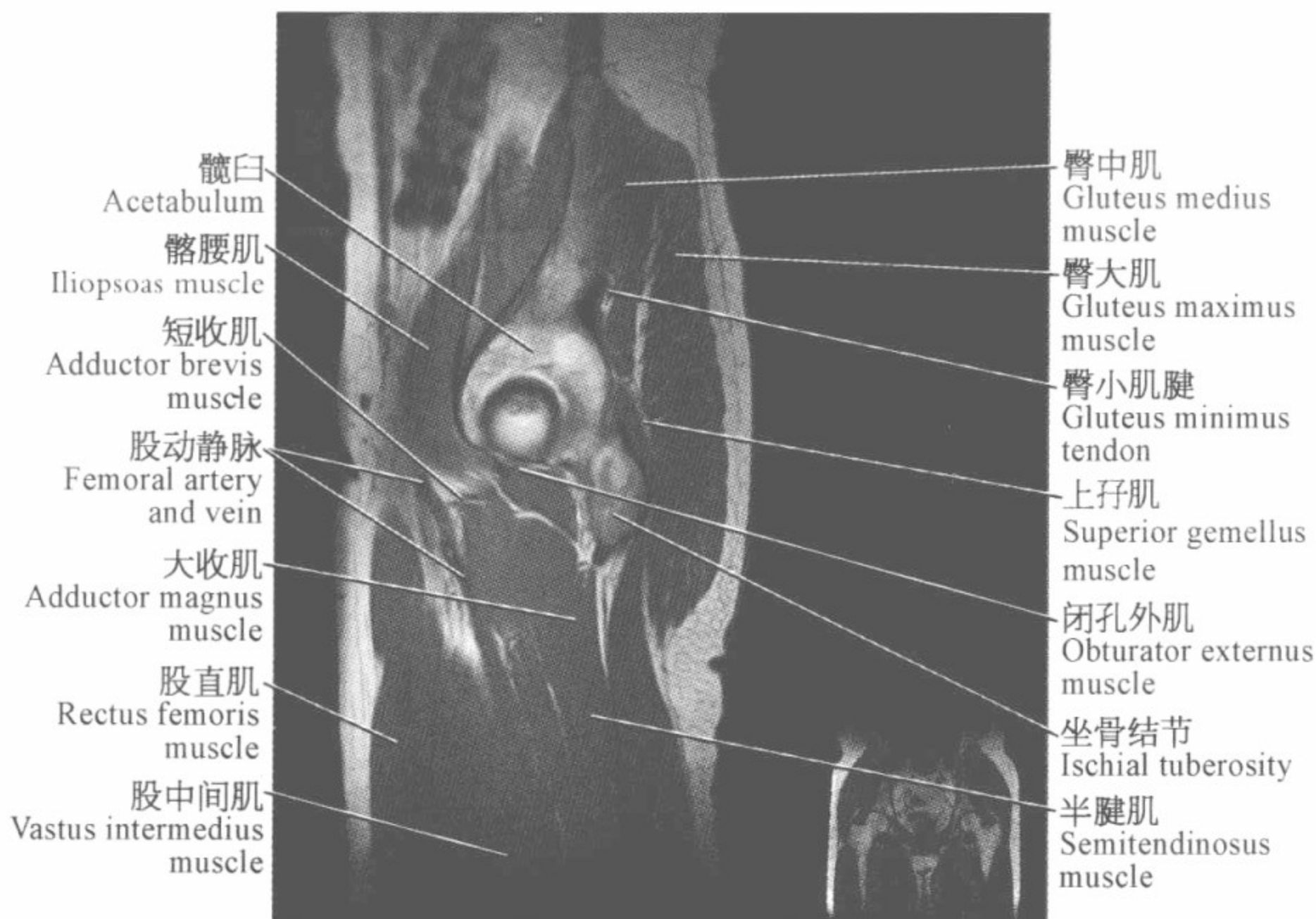
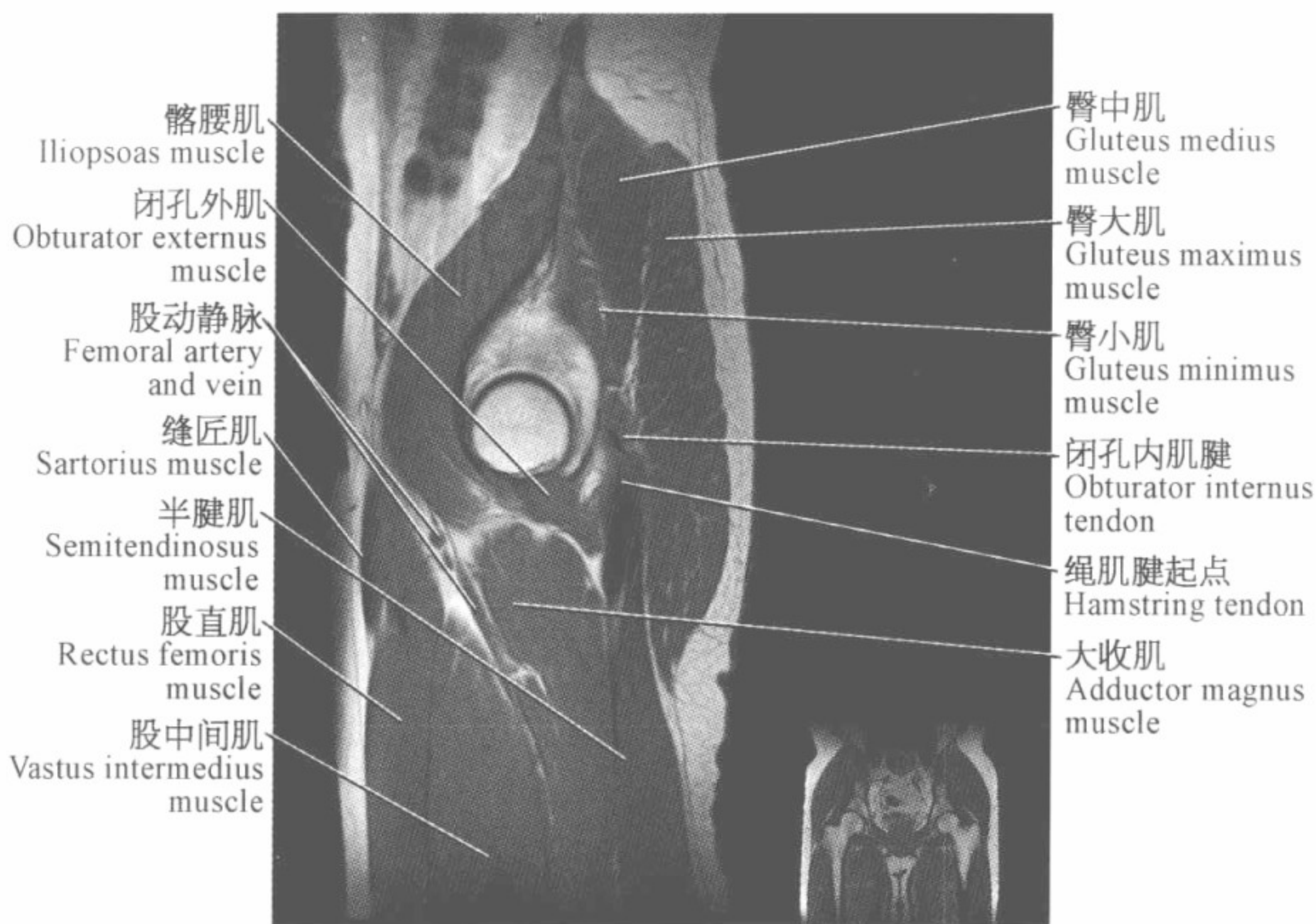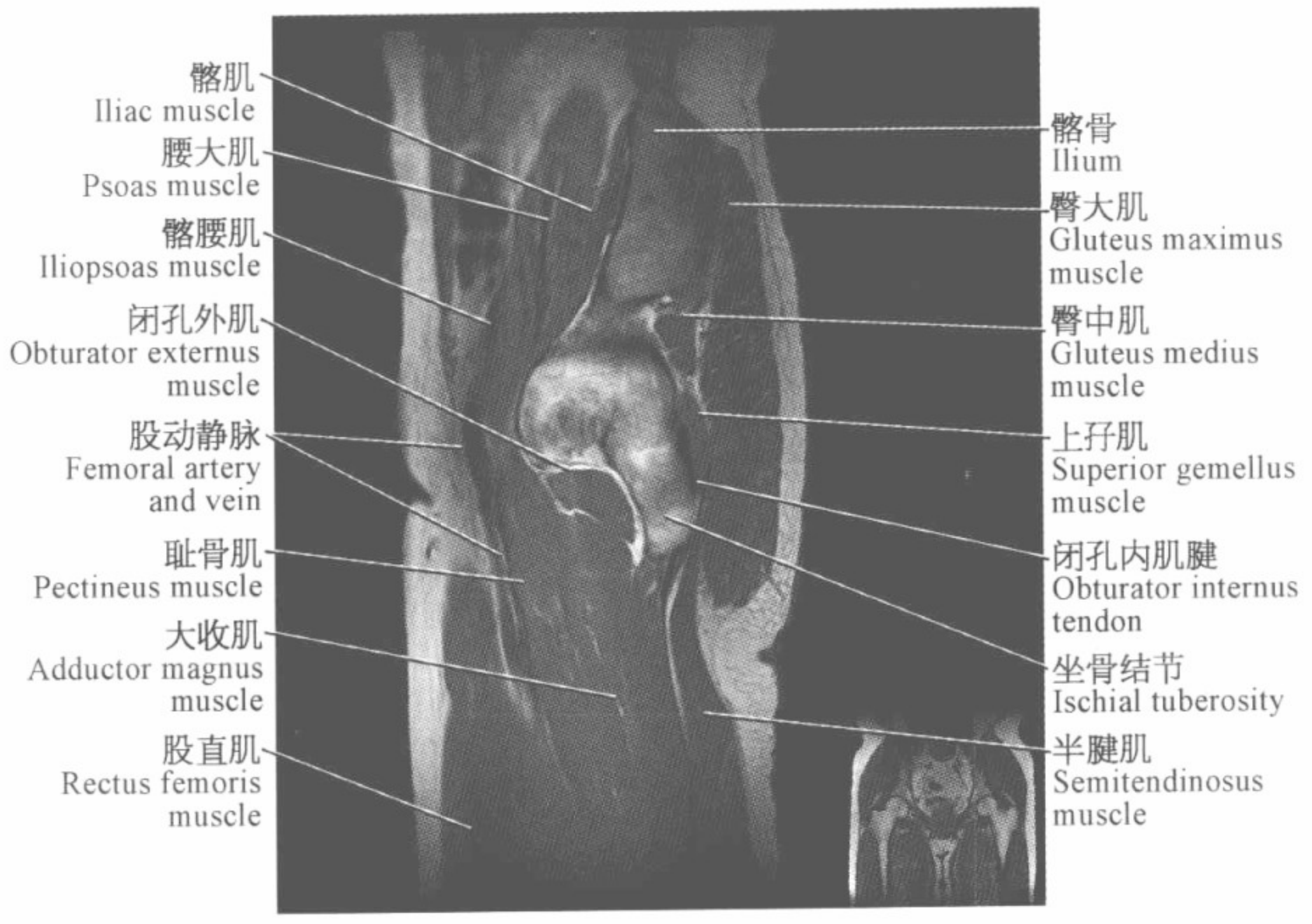
臀中肌 Gluteus medius muscle
 臀大肌 Gluteus maximus muscle
 闭孔内肌腱 Obturator internus tendon
 下孖肌 Inferior gemellus muscle
 股方肌 Quadratus femoris muscle
 闭孔外肌腱 Obturator externus tendon
 小转子 Lesser trochanter



臀中肌 Gluteus medius muscle
 臀大肌 Gluteus maximus muscle
 闭孔内肌腱 Obturator internus tendon
 下孖肌 Inferior gemellus muscle
 股方肌 Quadratus femoris muscle
 闭孔外肌腱 Obturator externus tendon
 小转子 Lesser trochanter

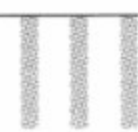


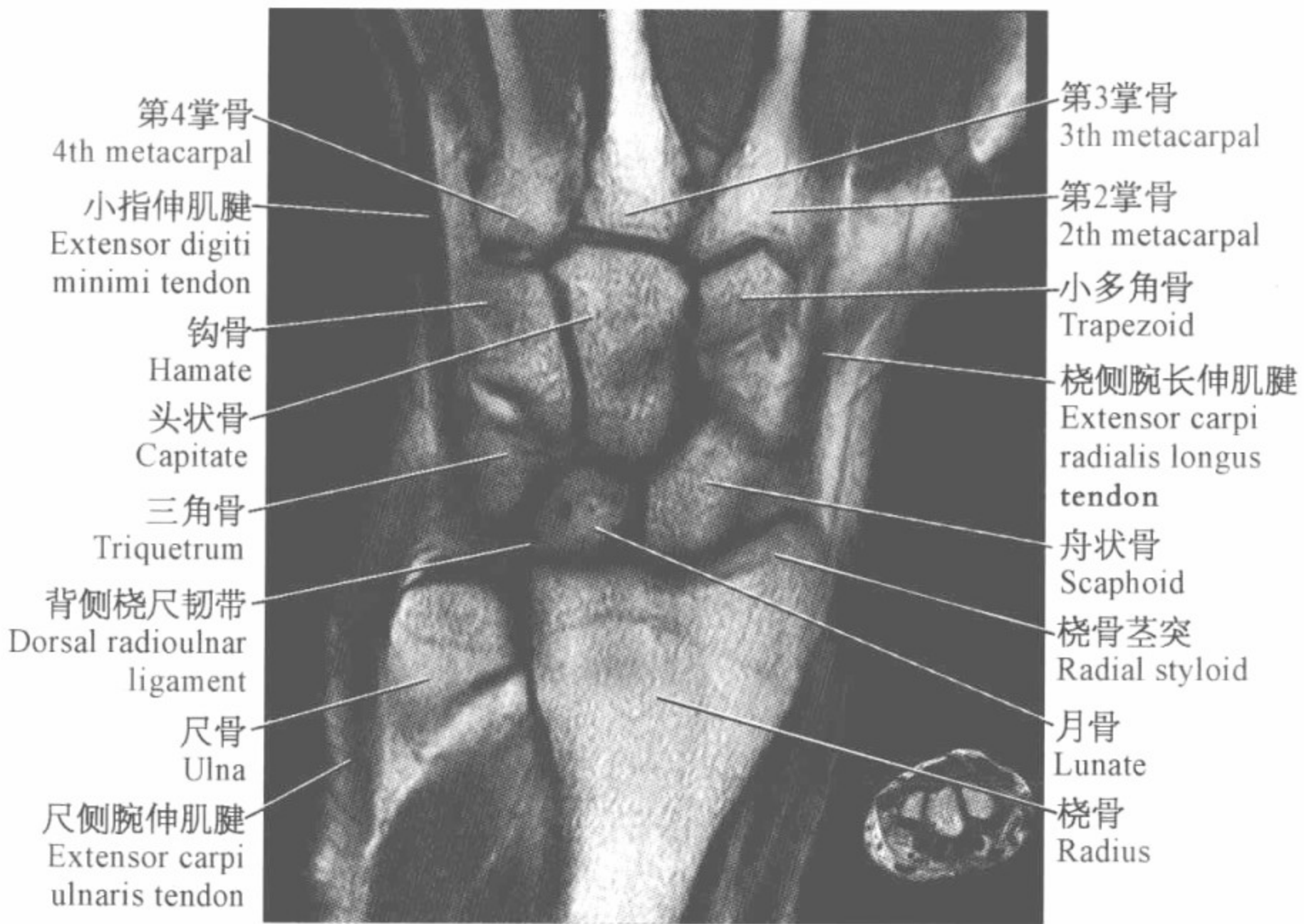
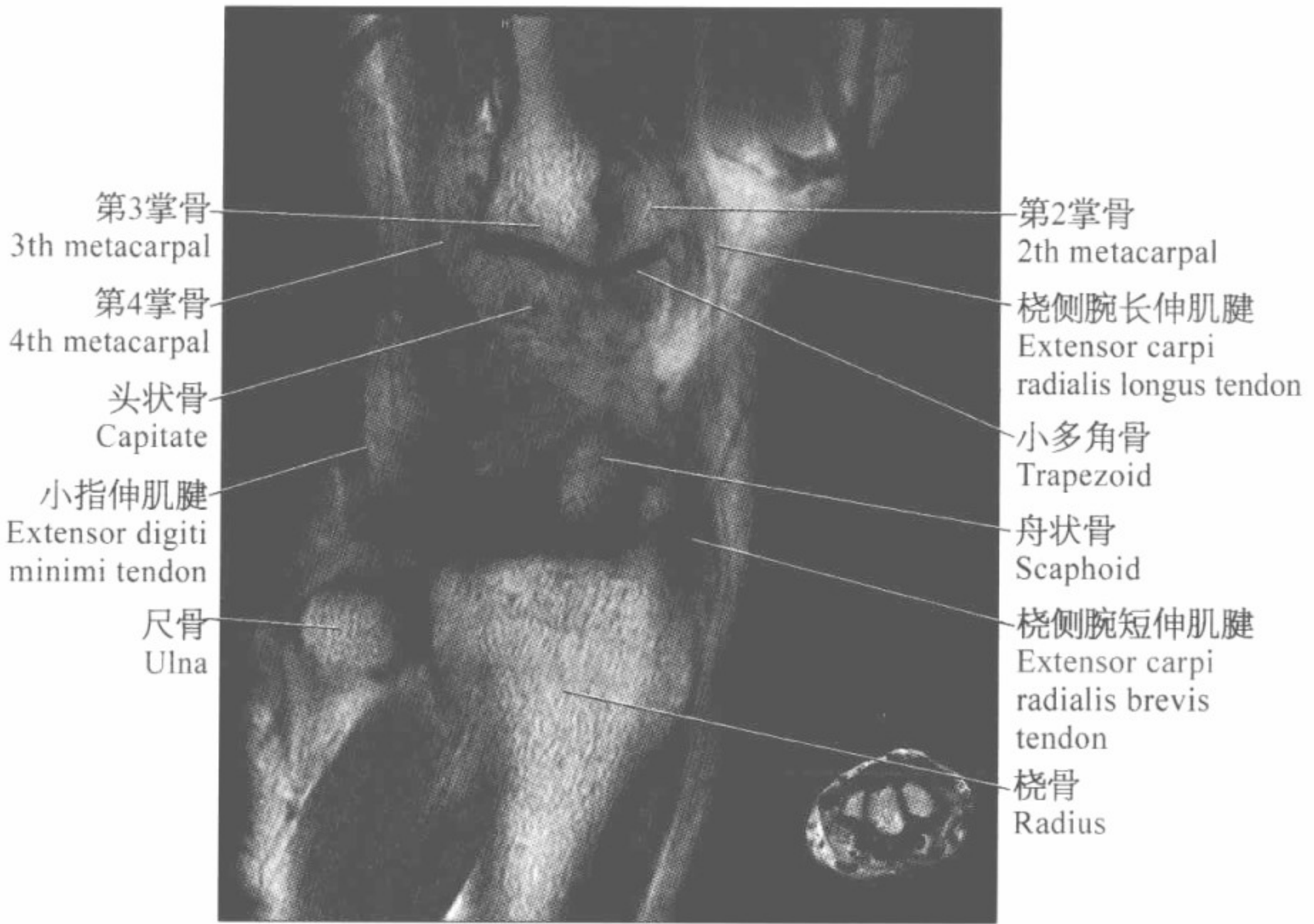

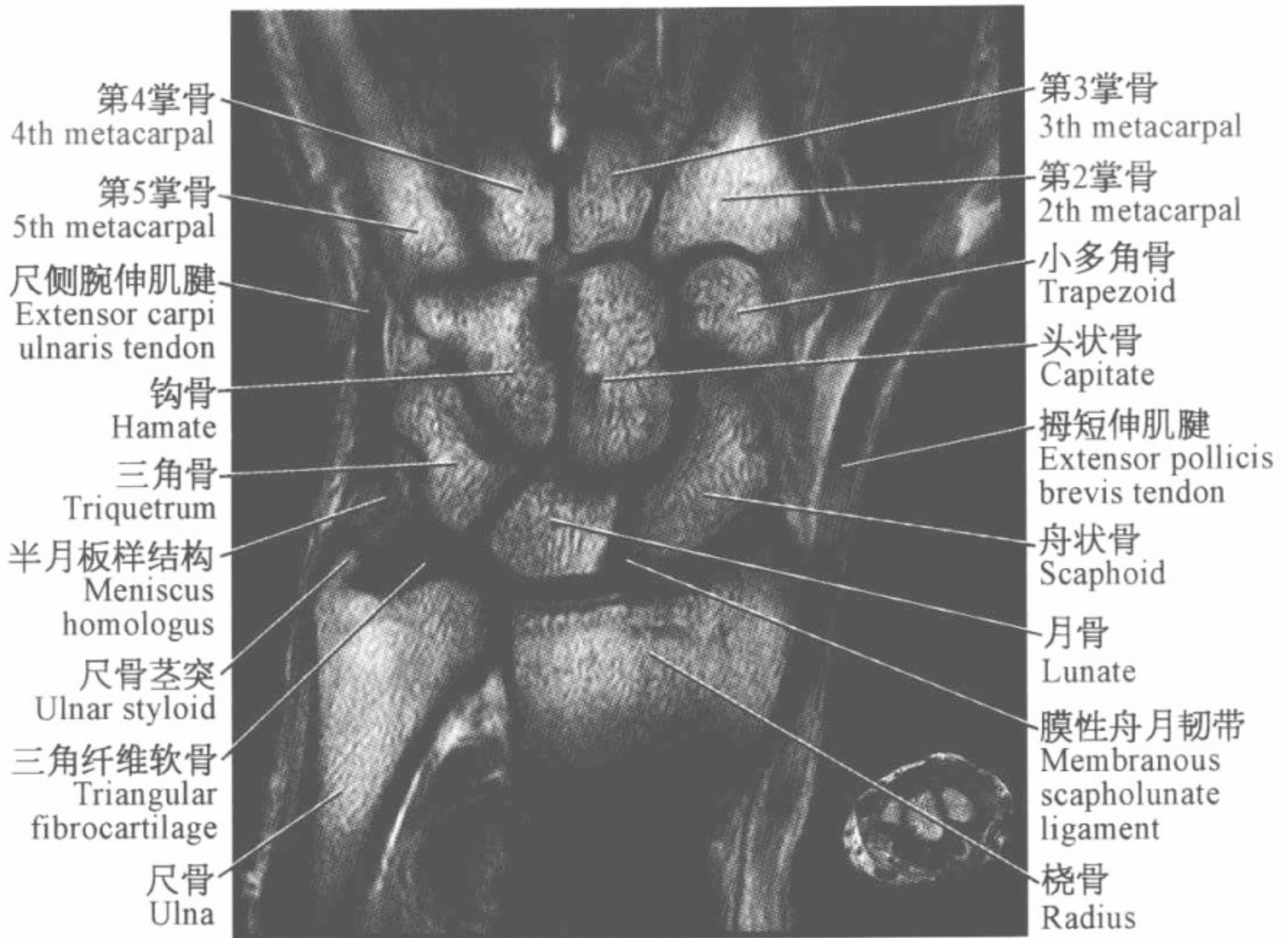
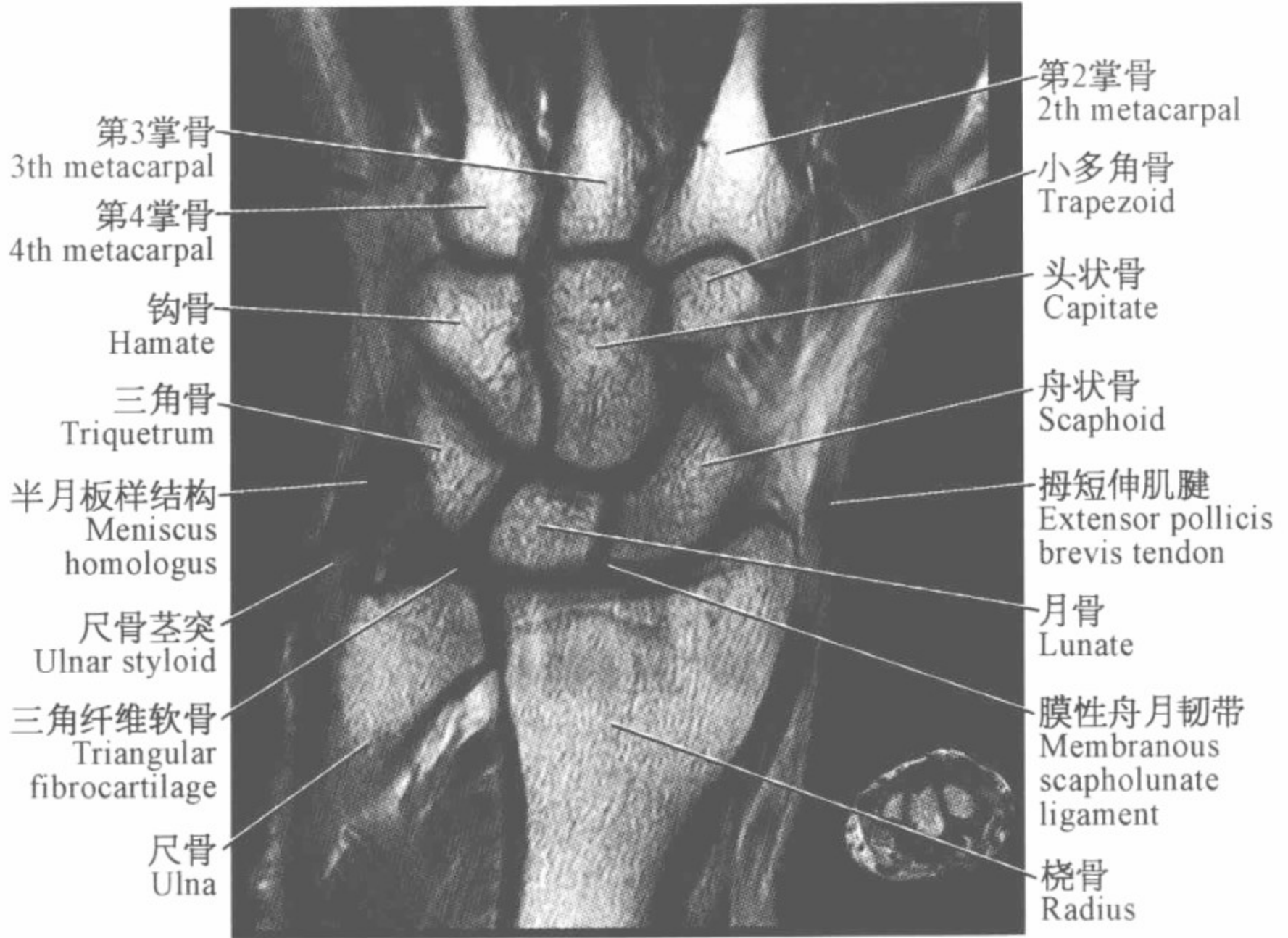


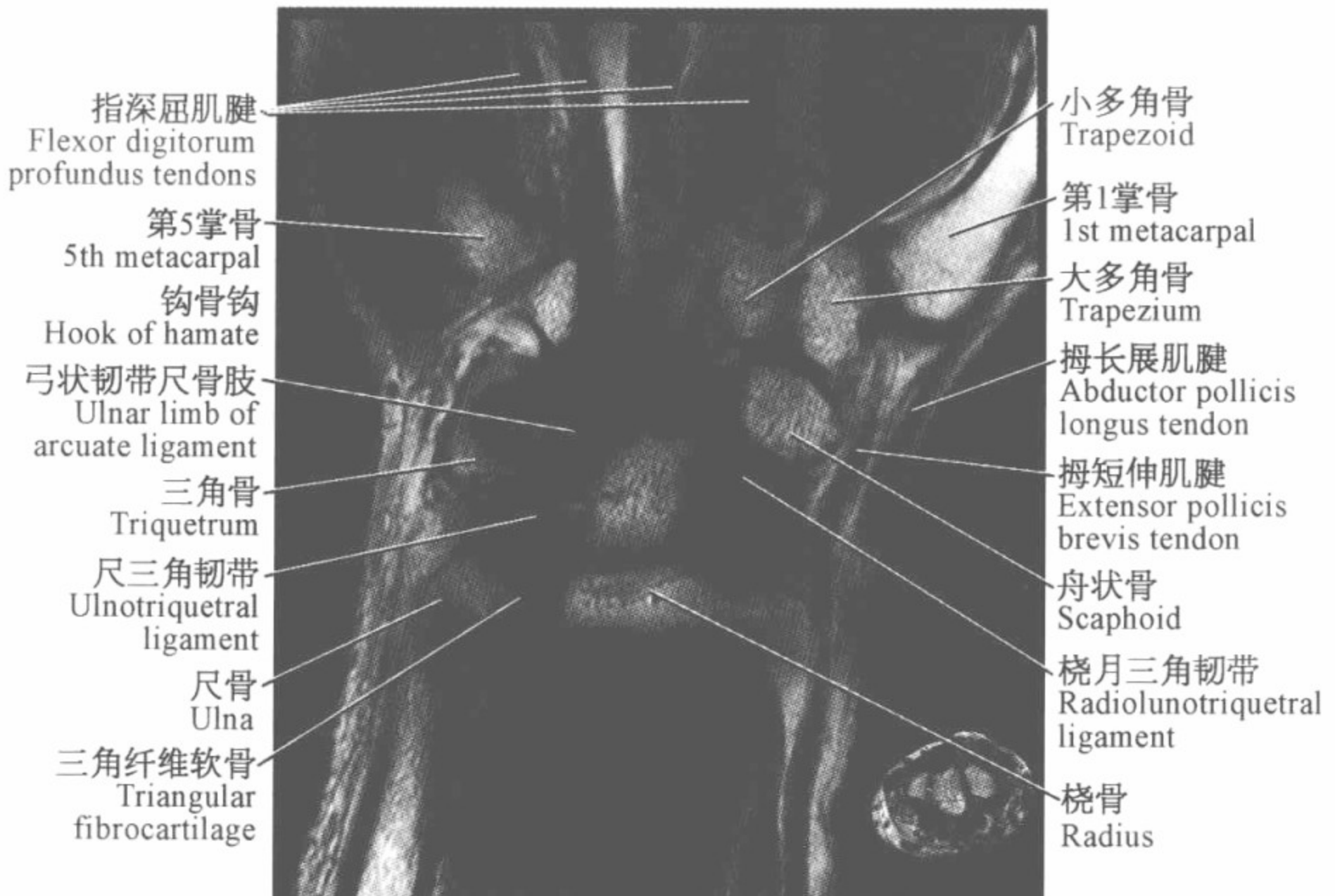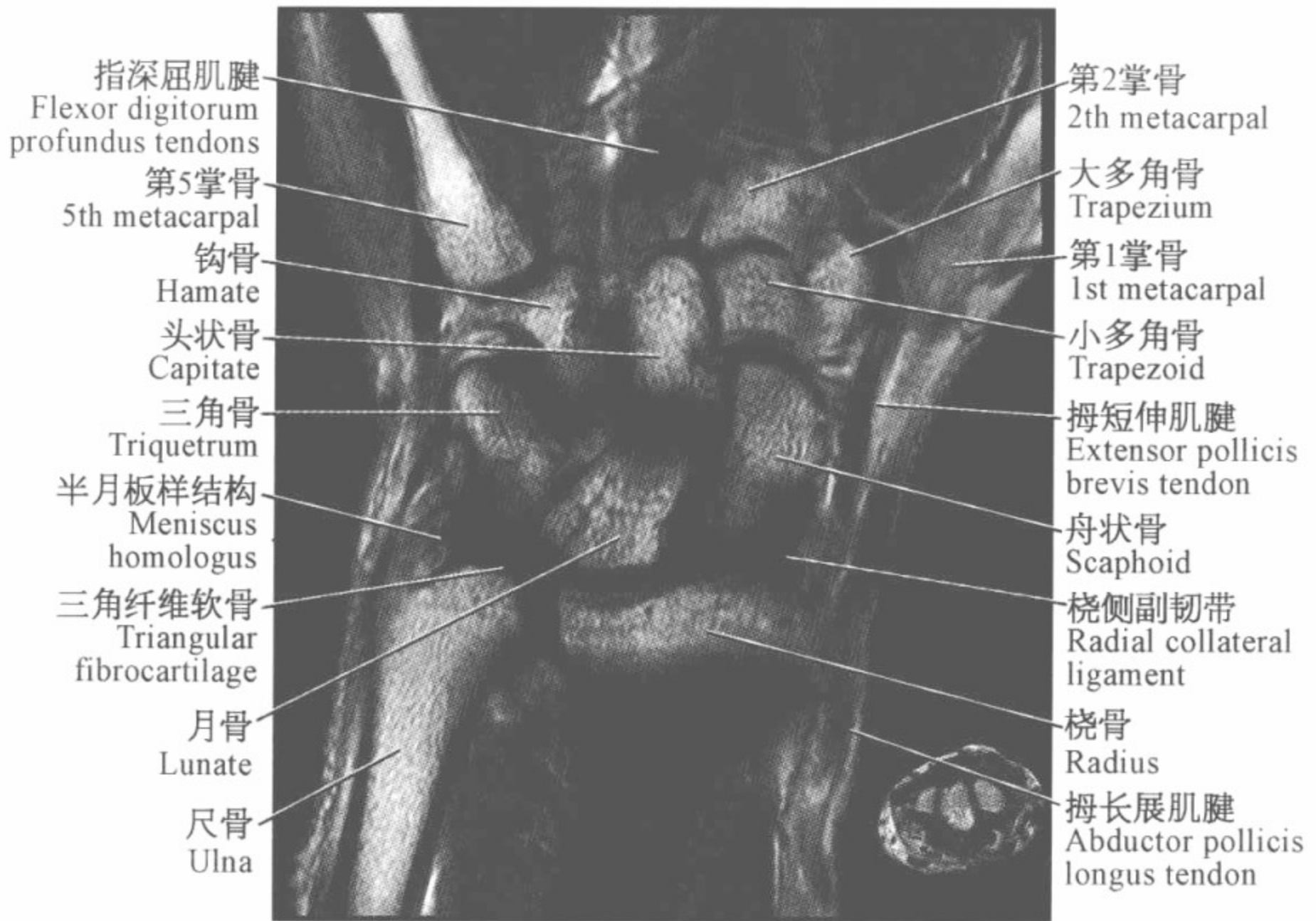||| 腕关节磁共振图谱

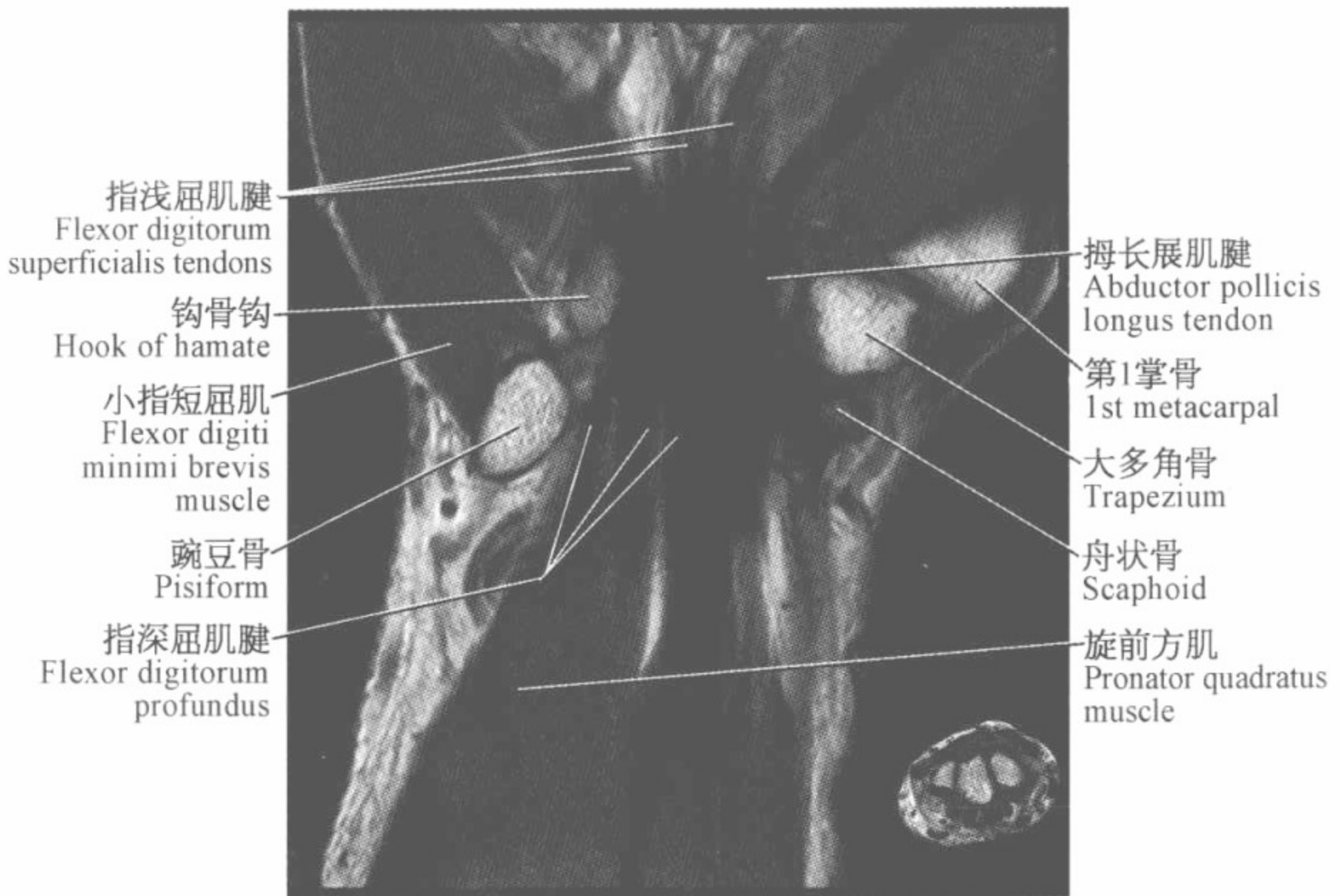
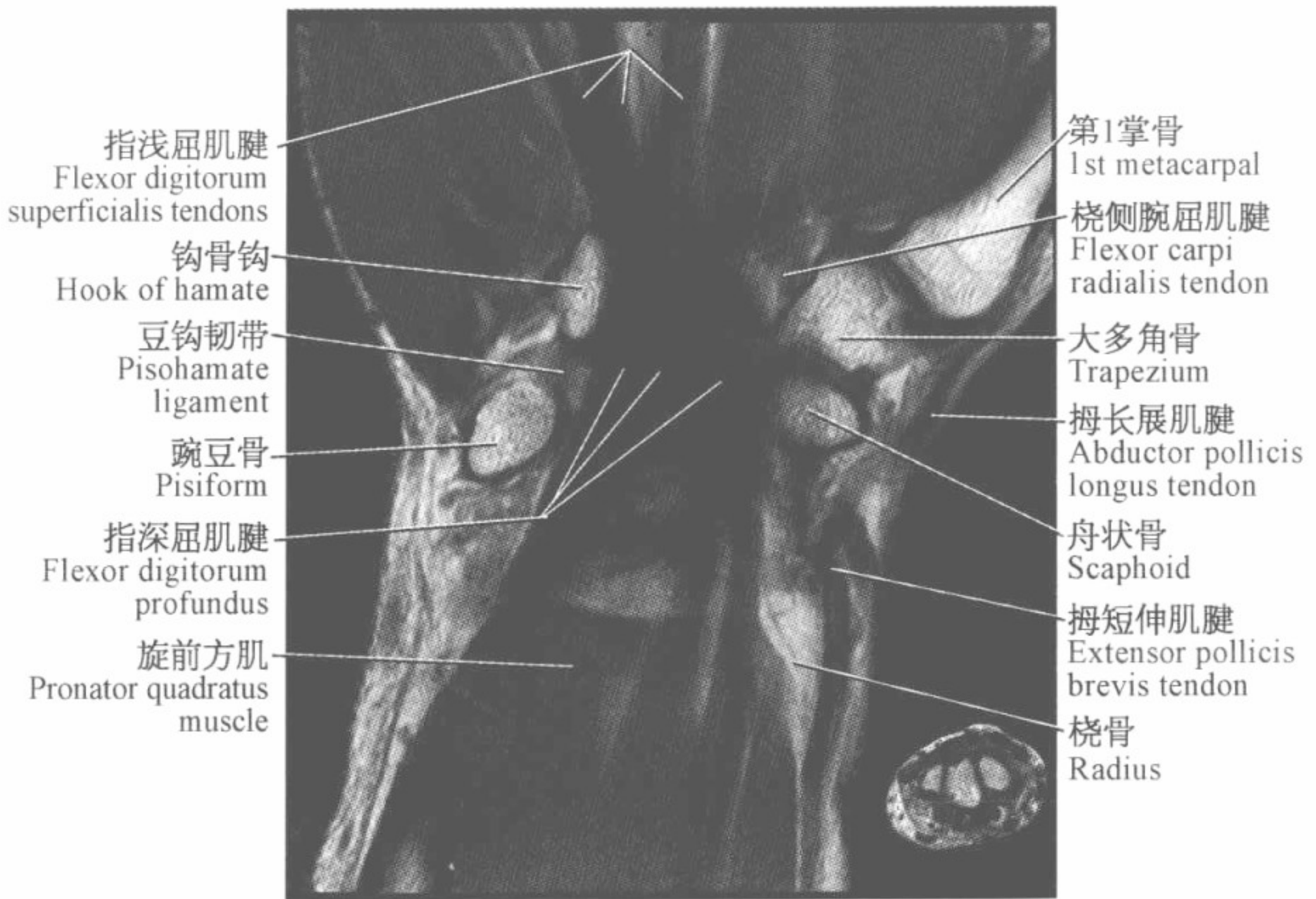
(冠状位)

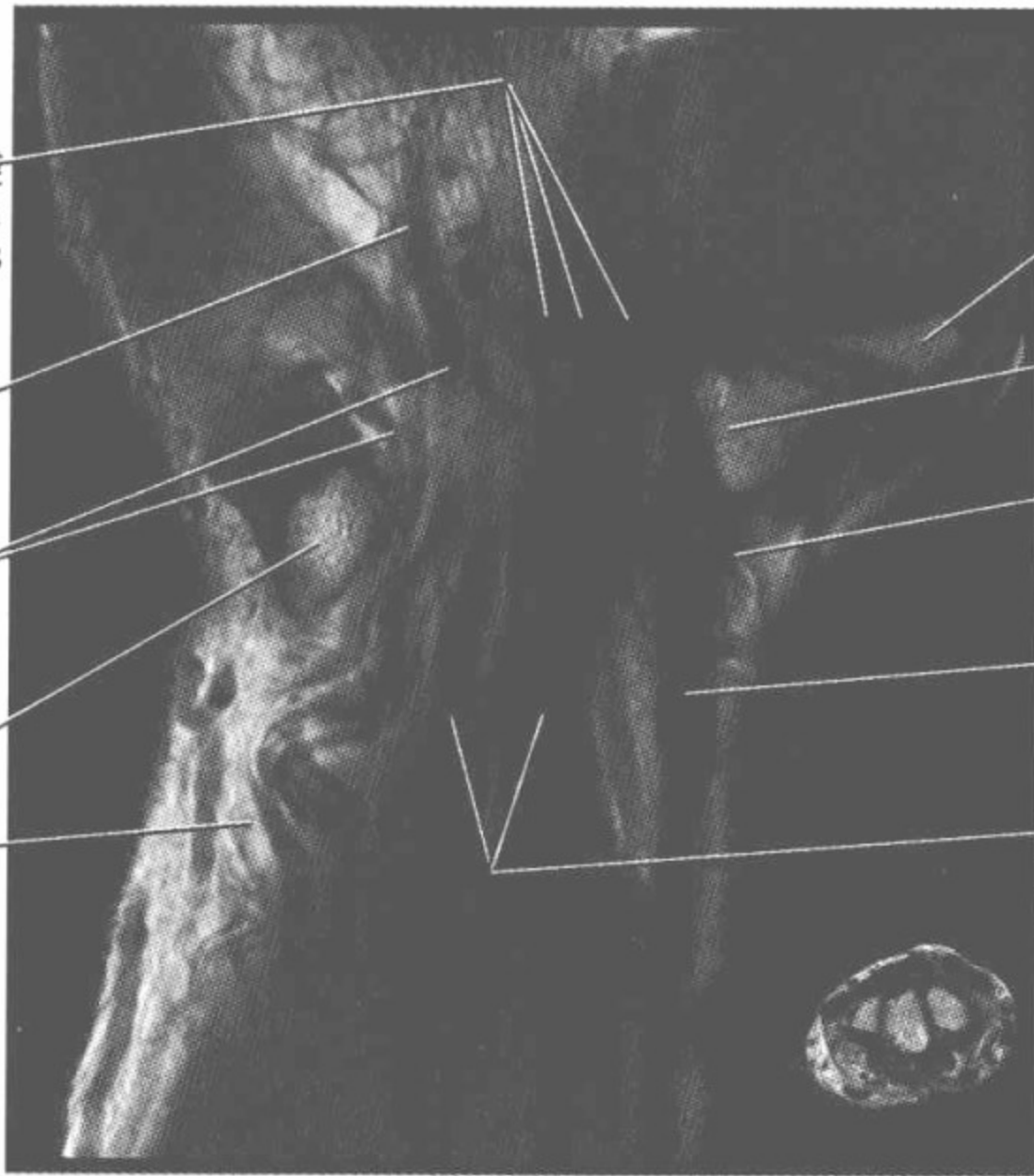












指浅屈肌腱
Flexor digitorum
superficialis tendons

尺神经深支
Deep branch
ulnar nerve

尺神经分支
Ulnar nerve
branches

豌豆骨
Pisiform

尺侧腕屈肌腱
Flexor carpi
ulnaris tendon

第1掌骨
1st metacarpal

大多角骨
Trapezium

桡侧腕屈肌腱
Flexor carpi
radialis tendon

拇长屈肌腱
Flexor pollicis
longus tendon

指深屈肌腱
Flexor digitorum
profundus tendons

尺神经深支
Deep branch
ulnar nerve

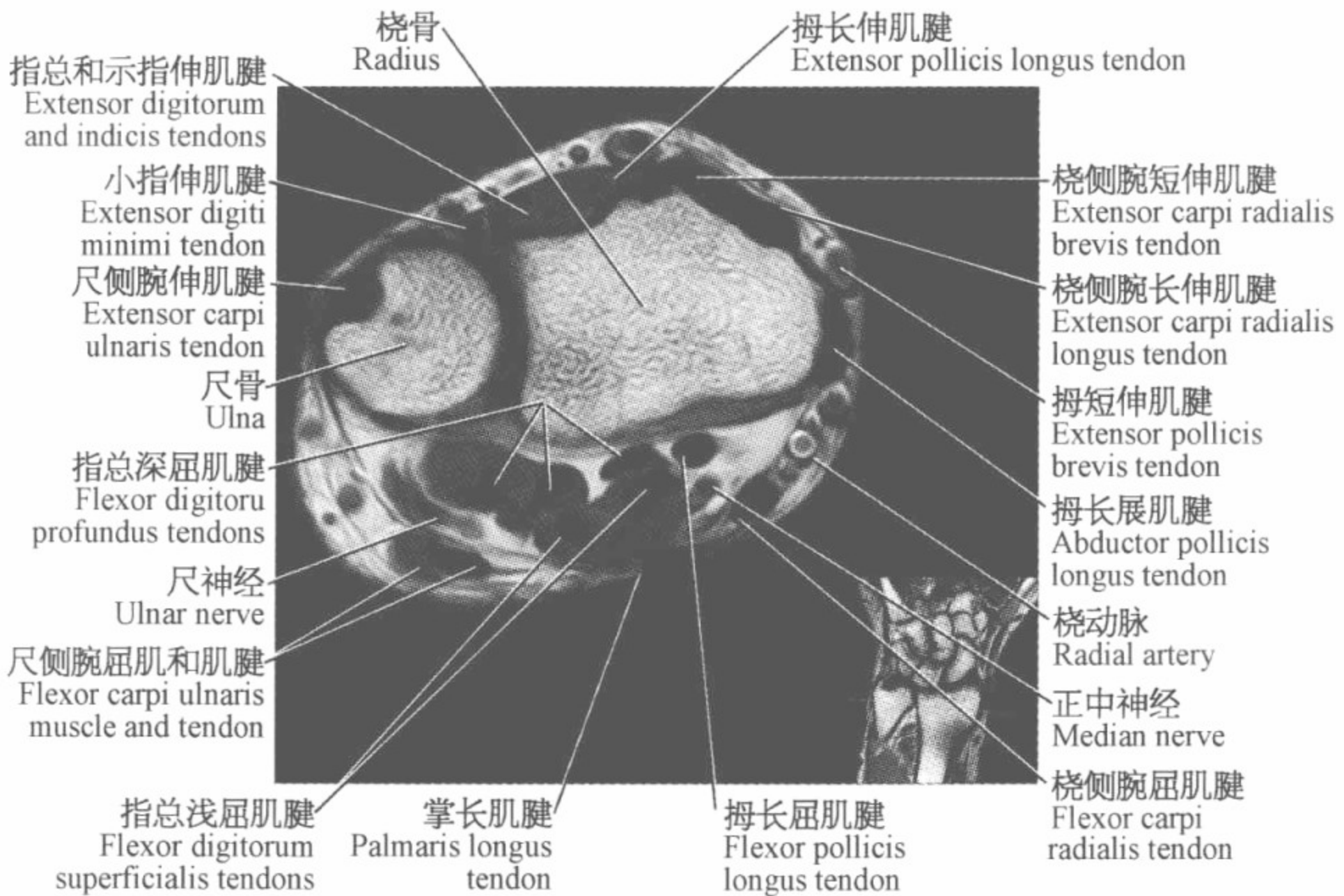
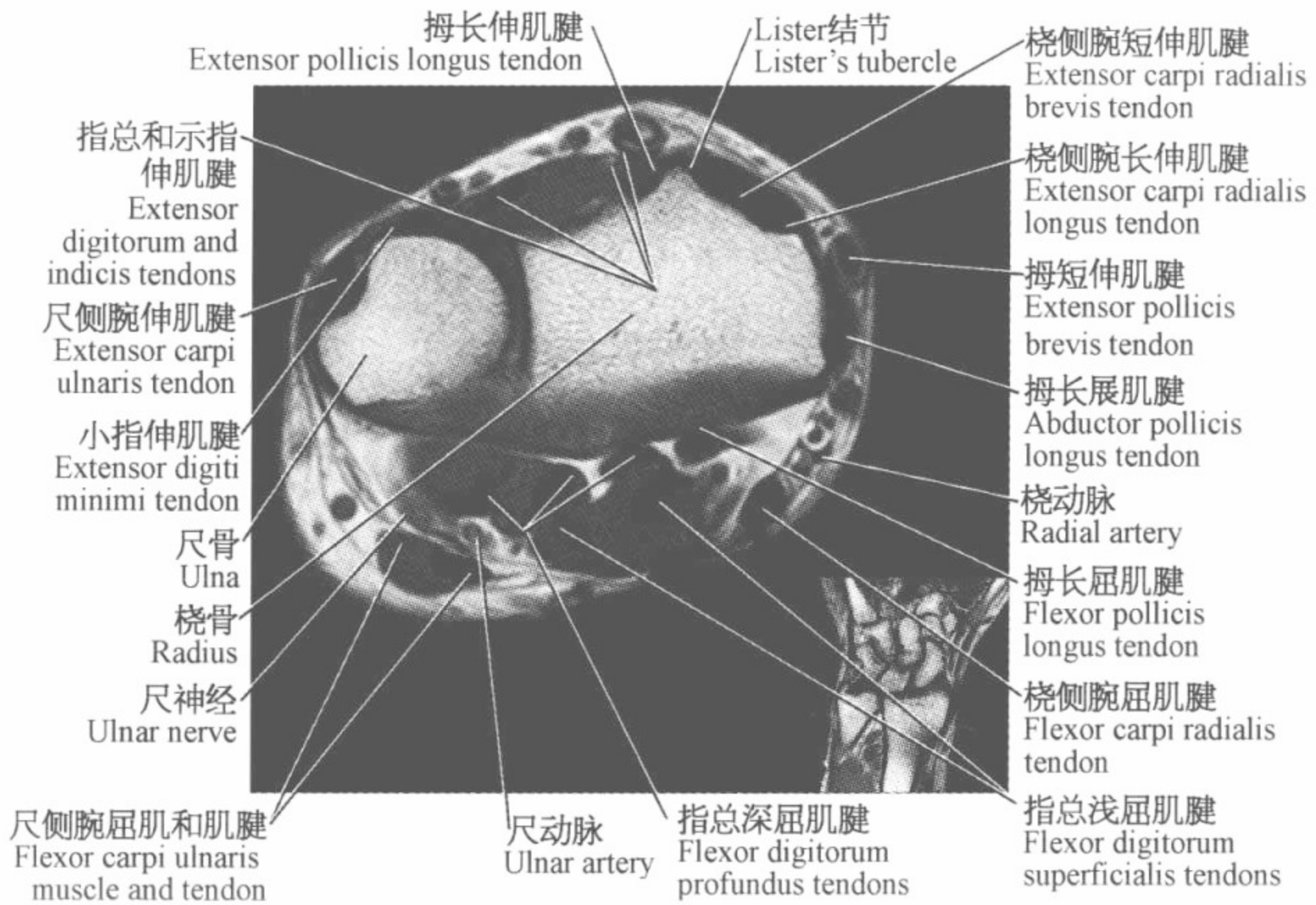
豌豆骨
Pisiform

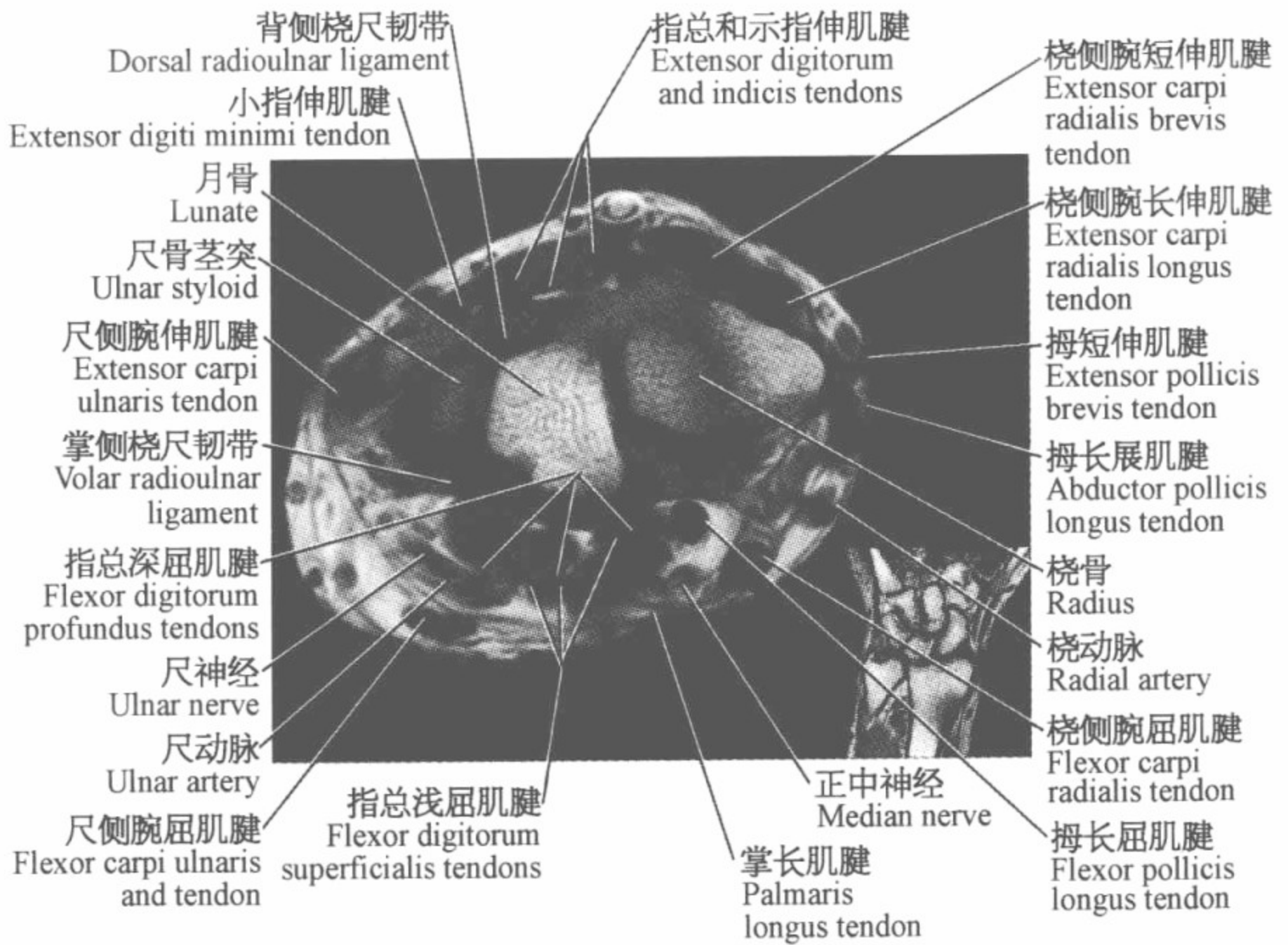
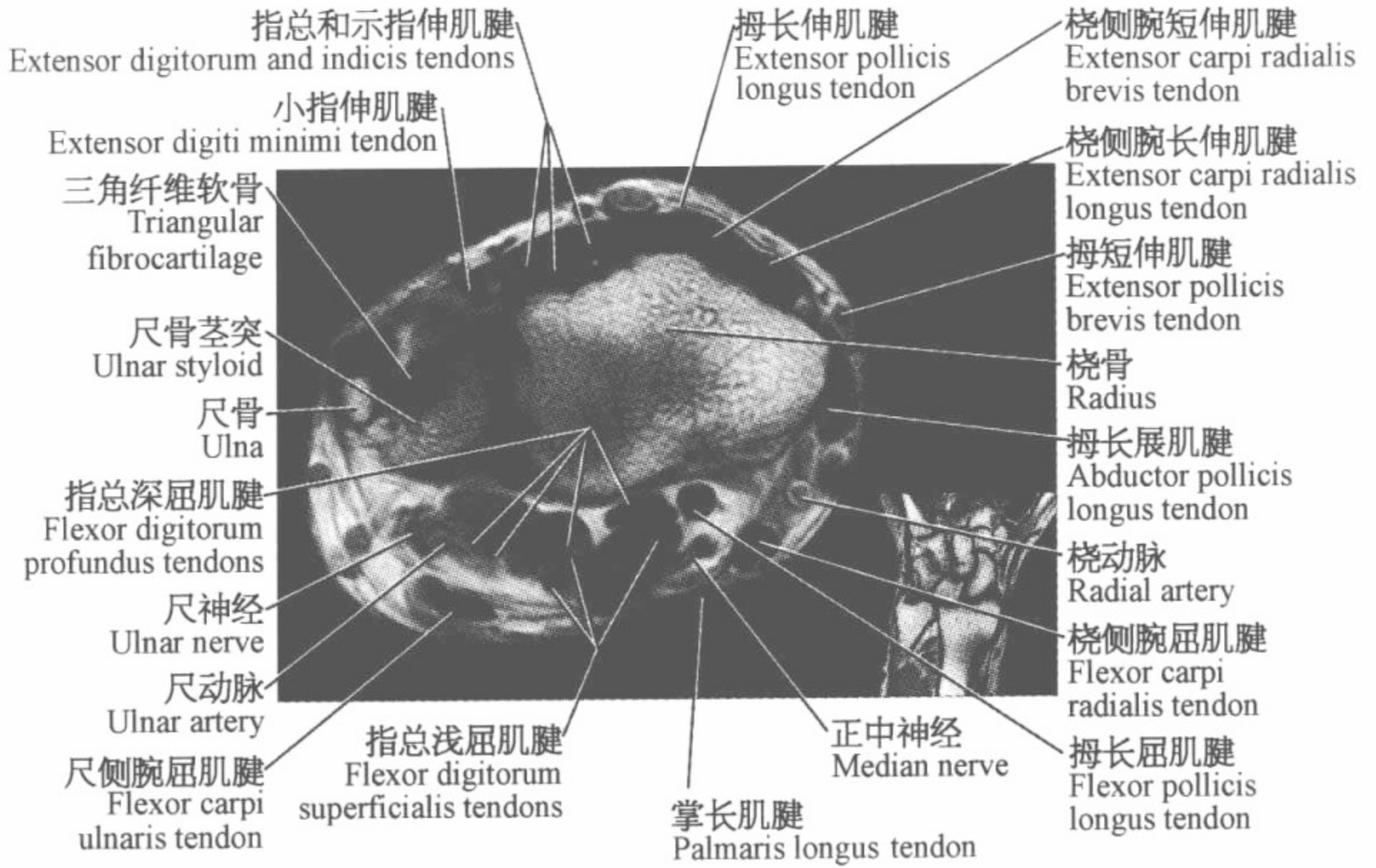
尺侧腕屈肌腱
Flexor carpi
ulnaris tendon

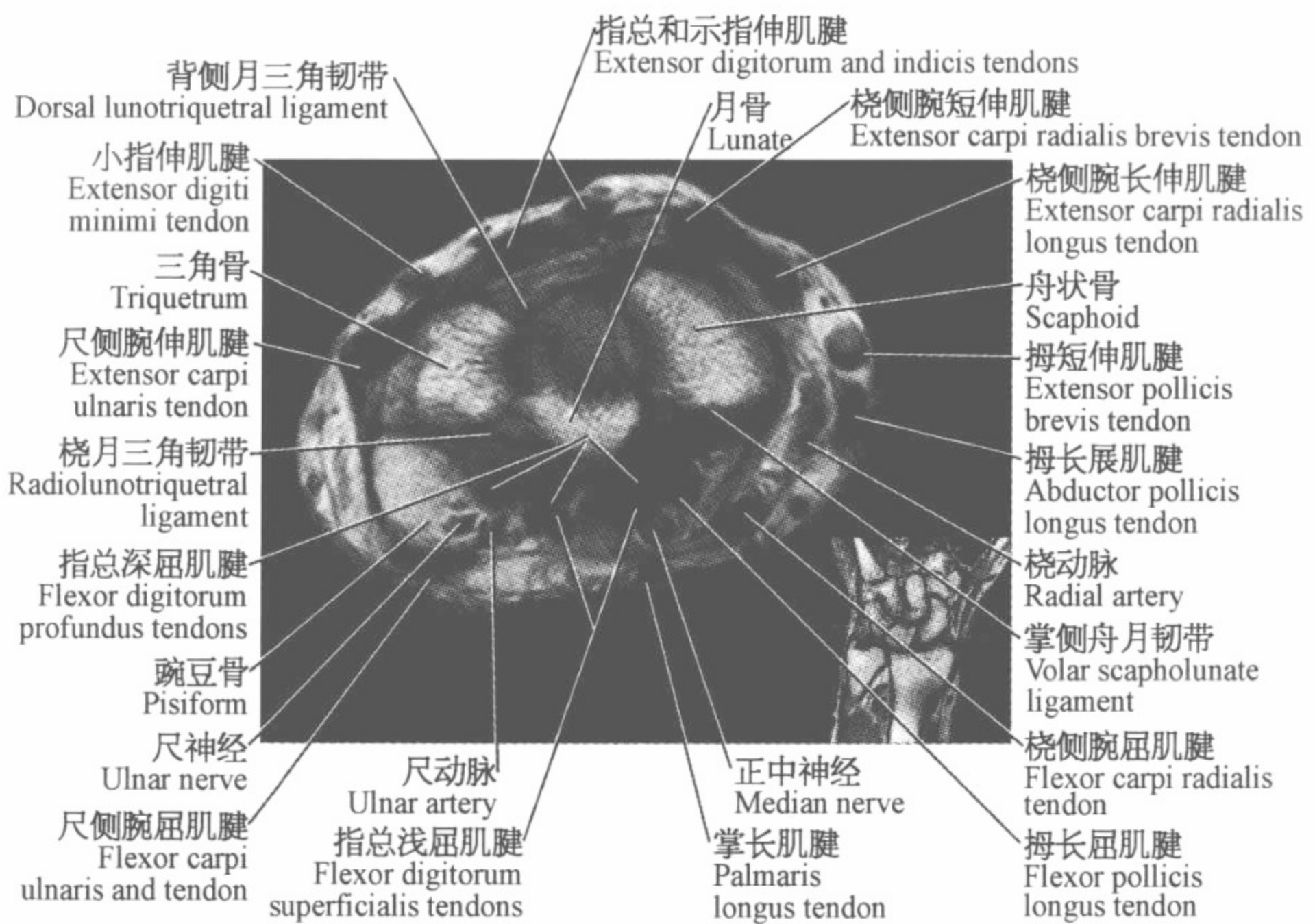
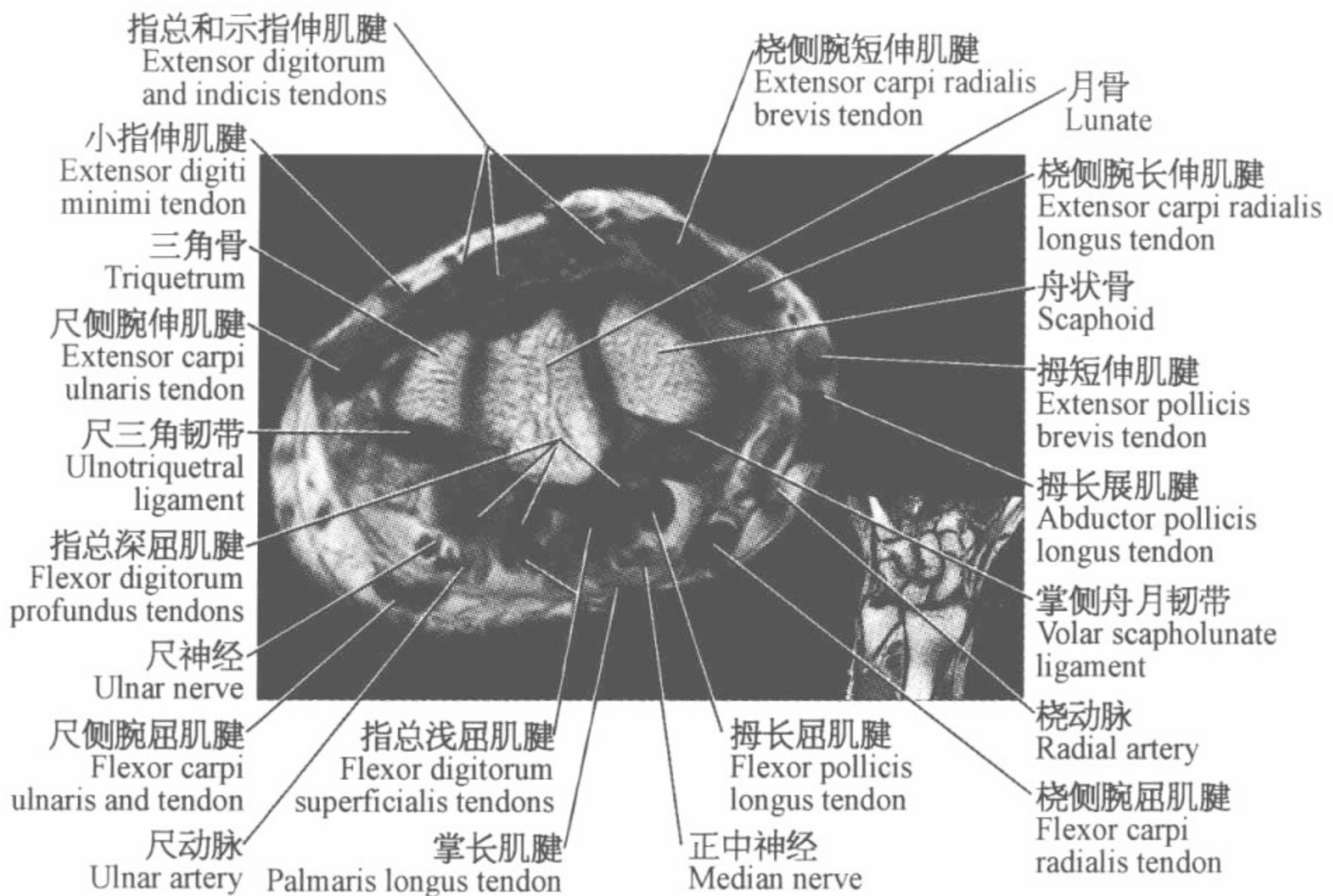
指浅屈肌腱
Flexor digitorum
superficialis tendons

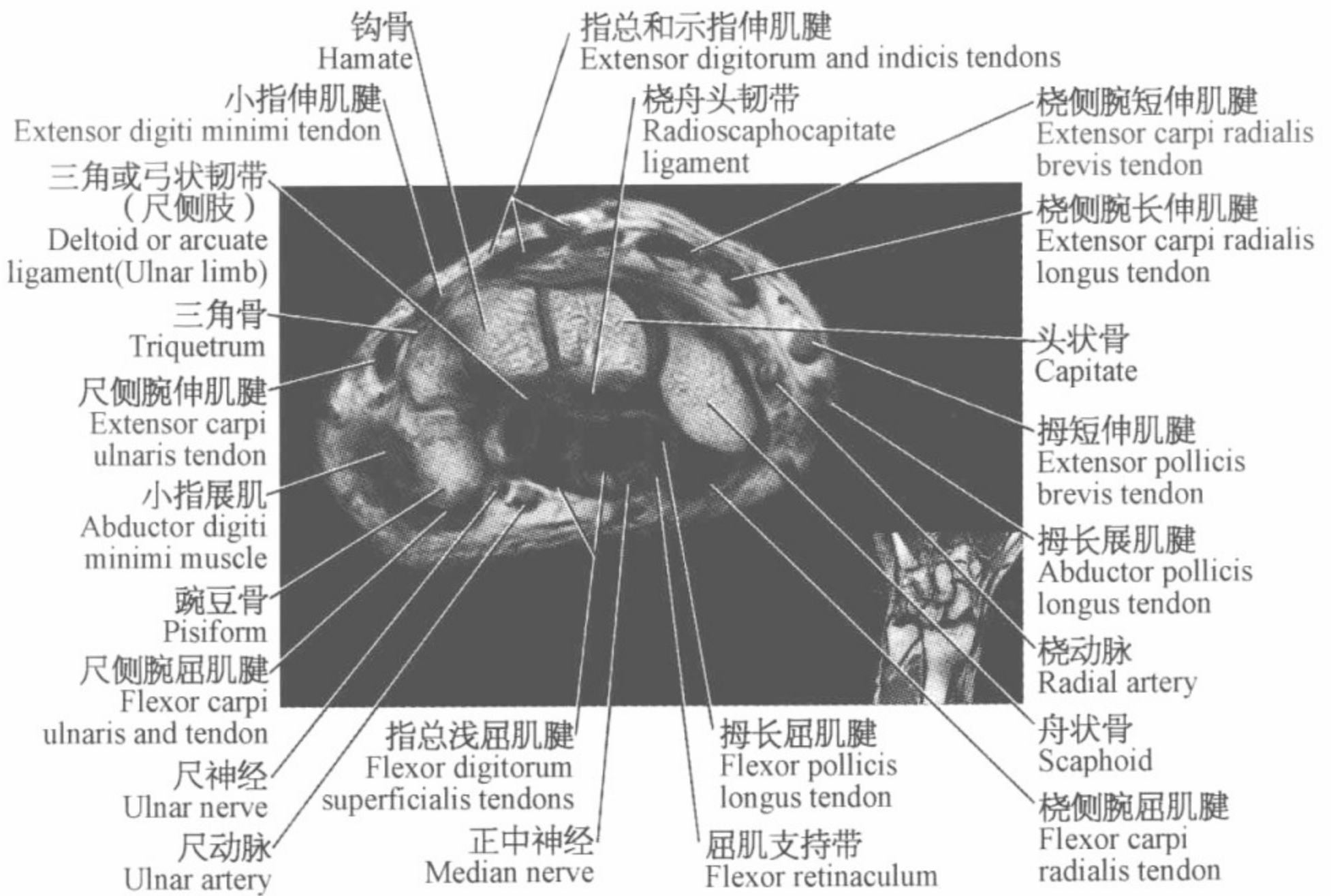
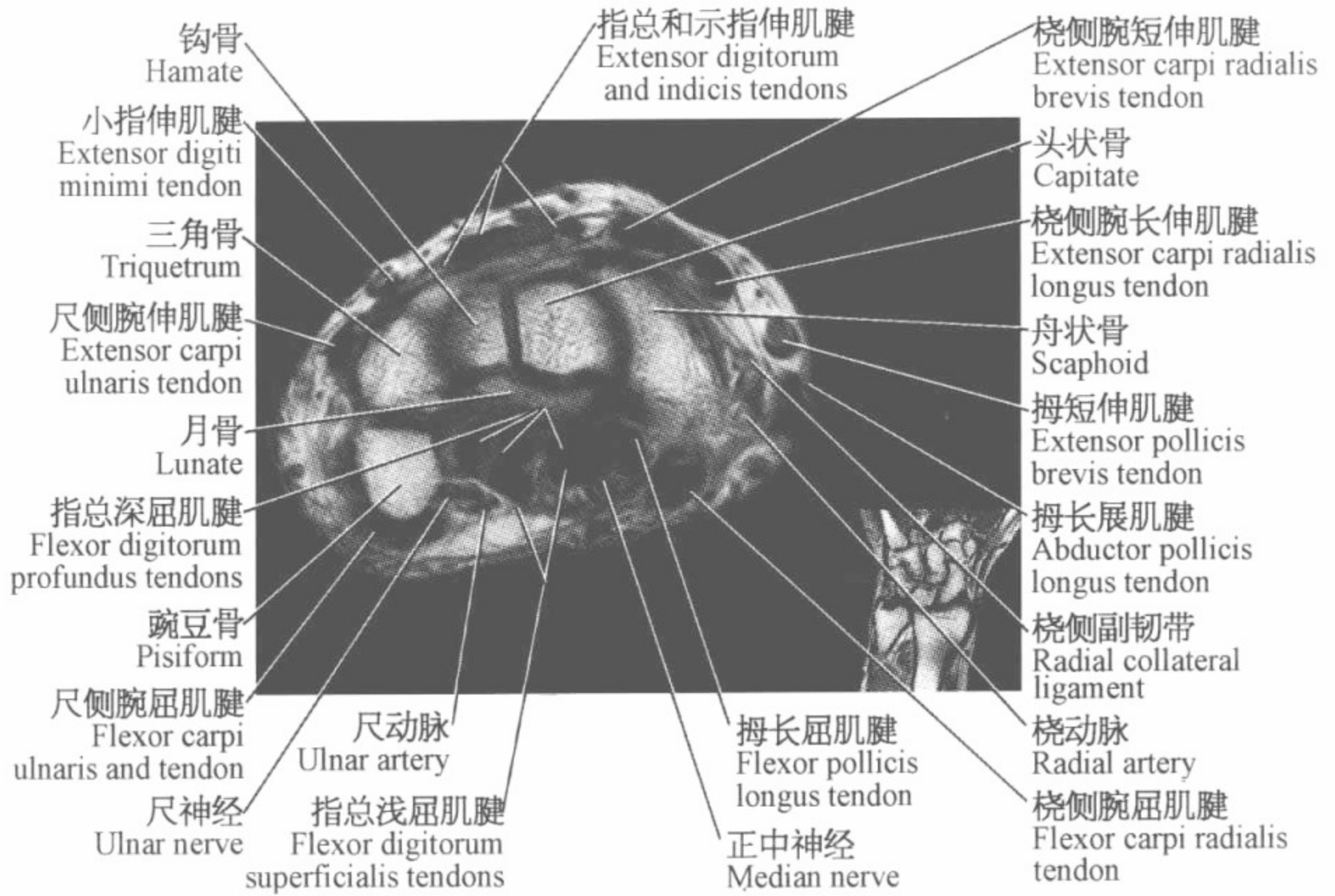
指浅屈肌腱
Flexor digitorum
superficialis tendons

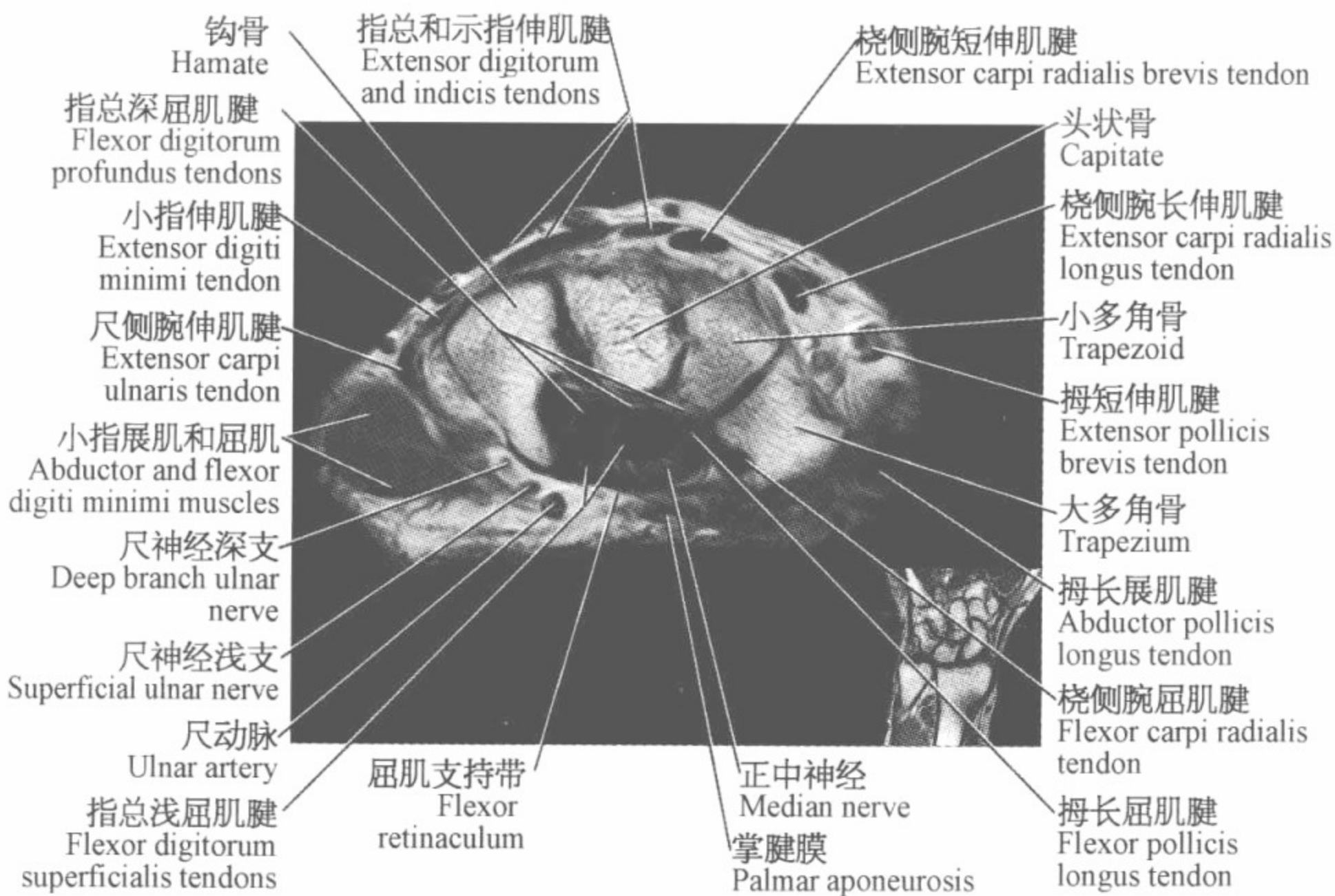
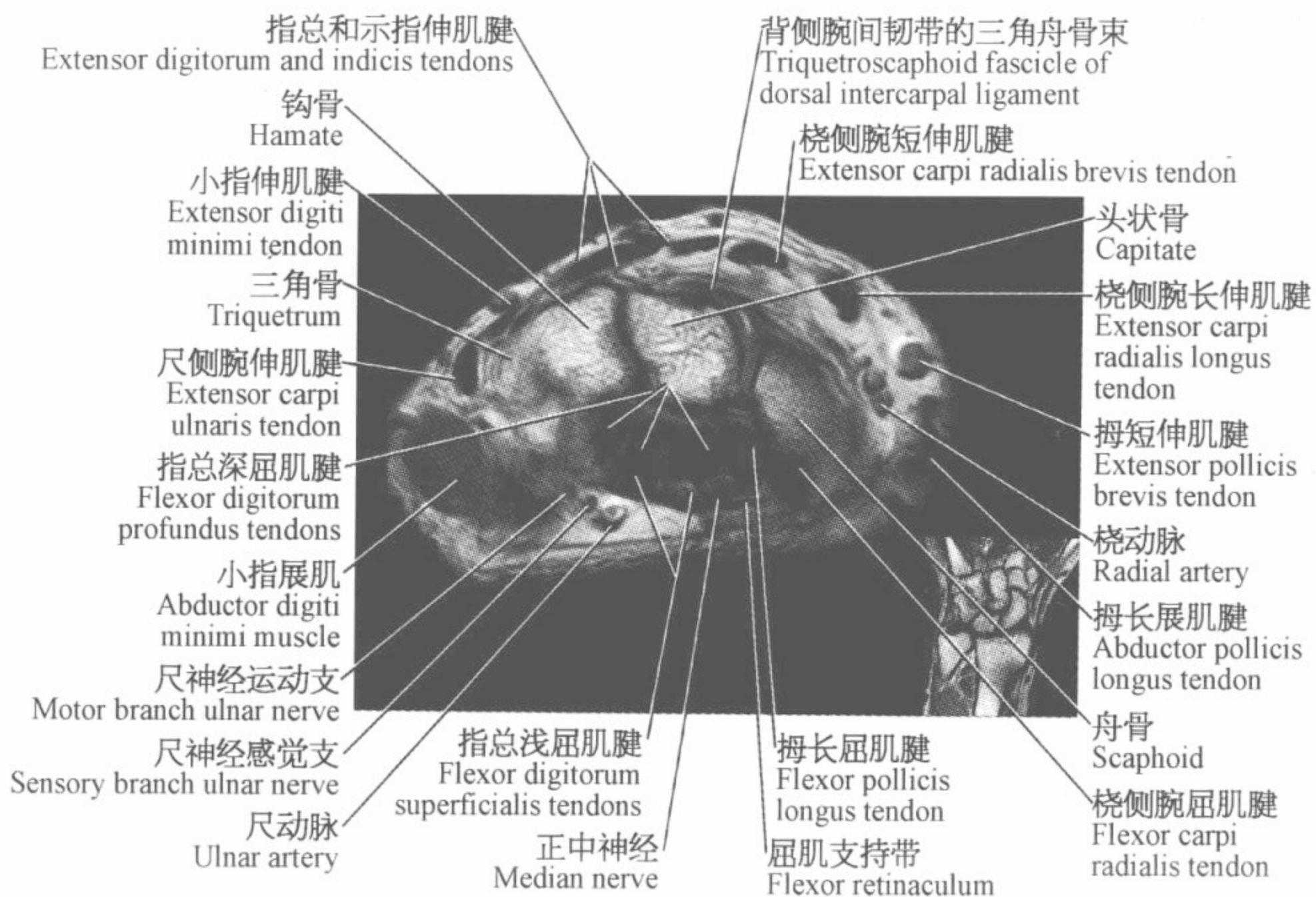
||| 腕关节磁共振图谱
—————
(横断位) |||

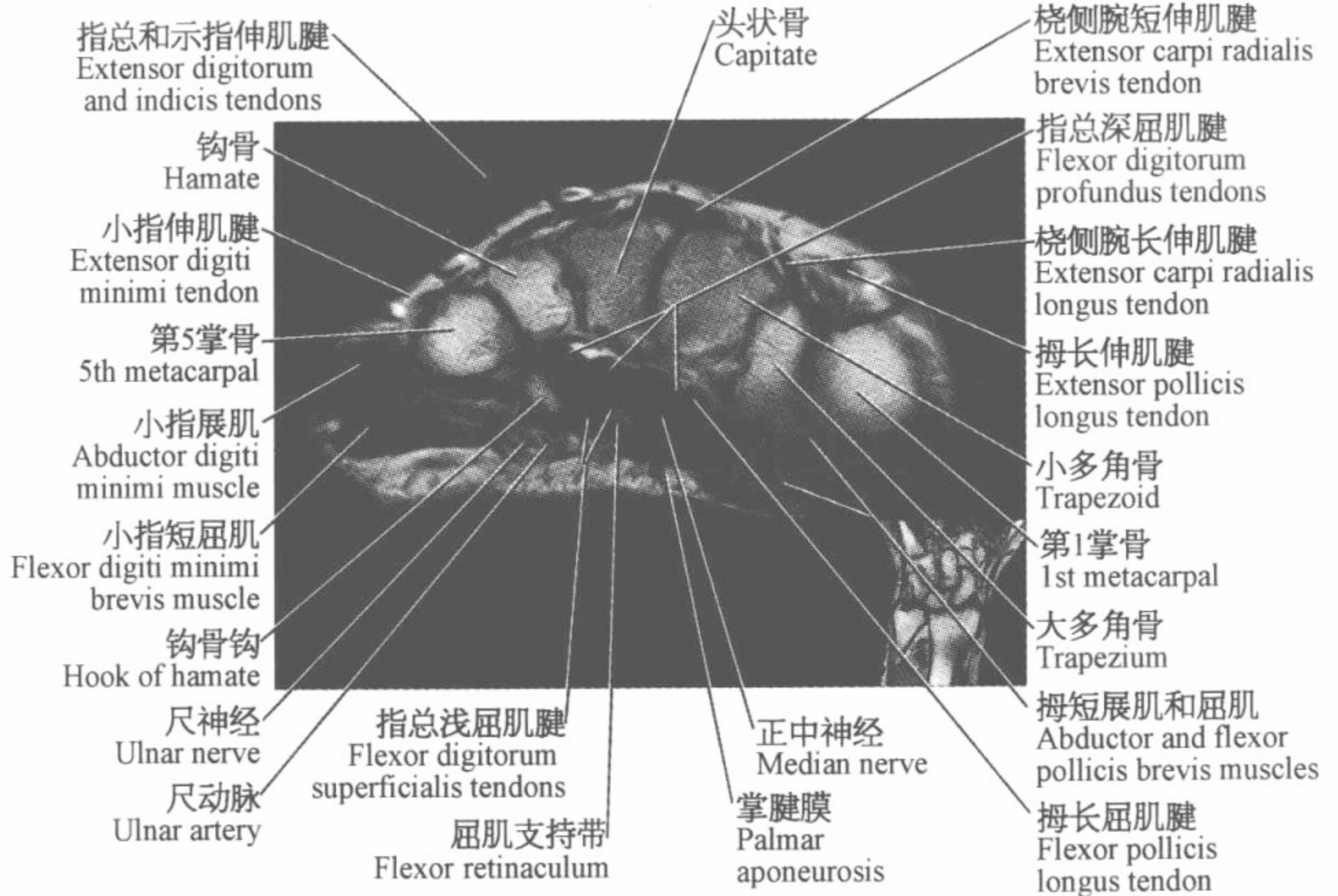
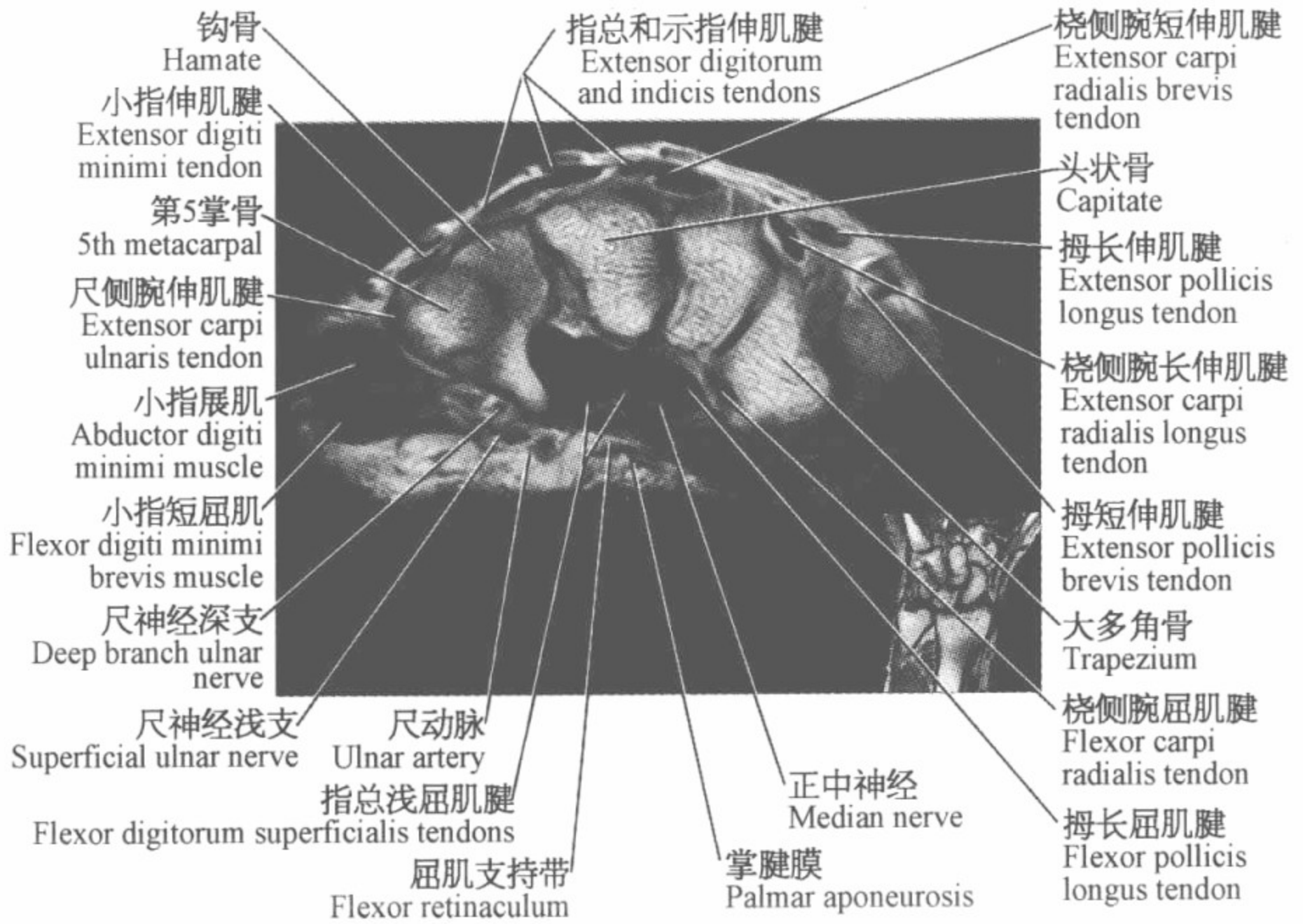








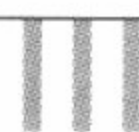


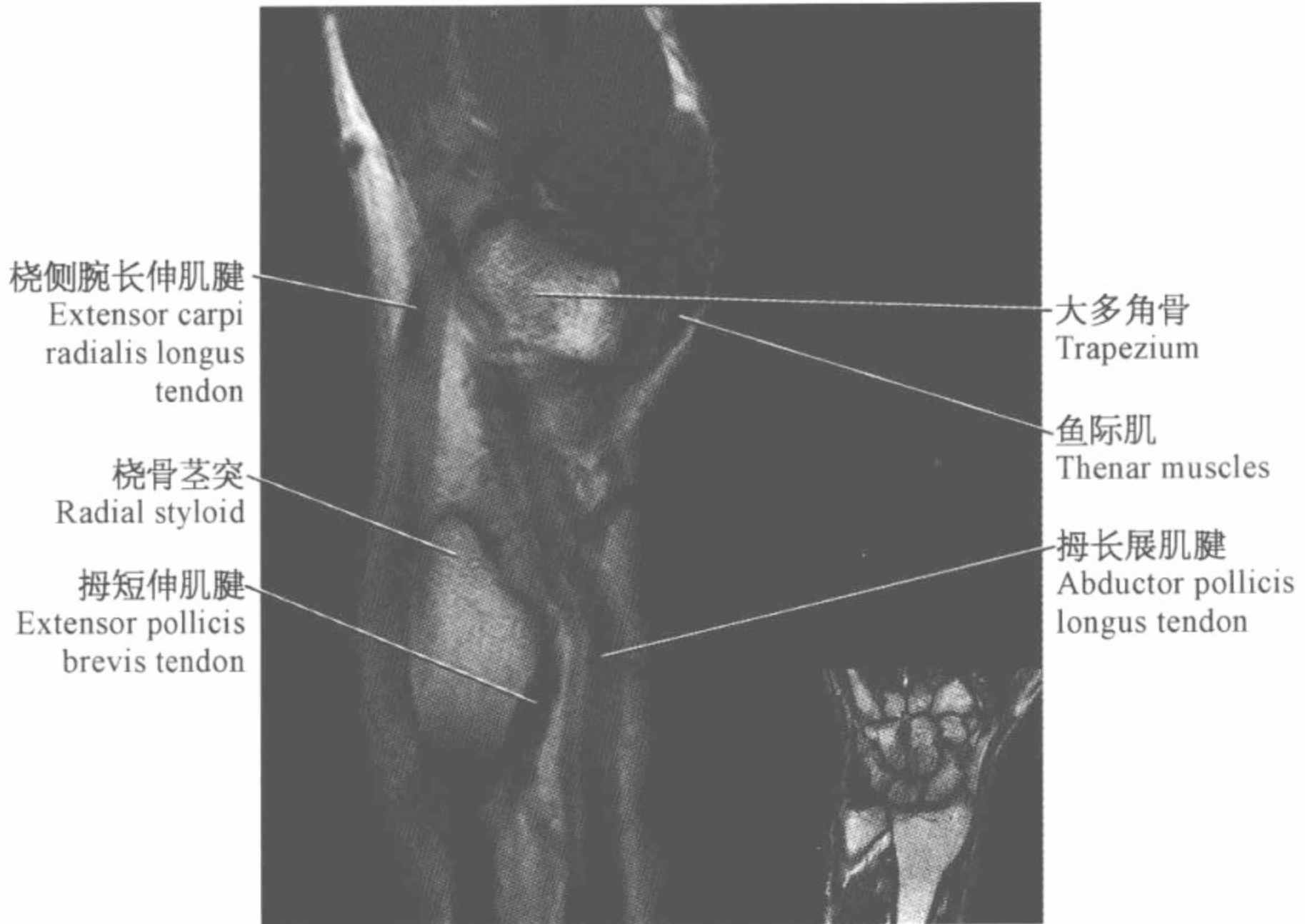
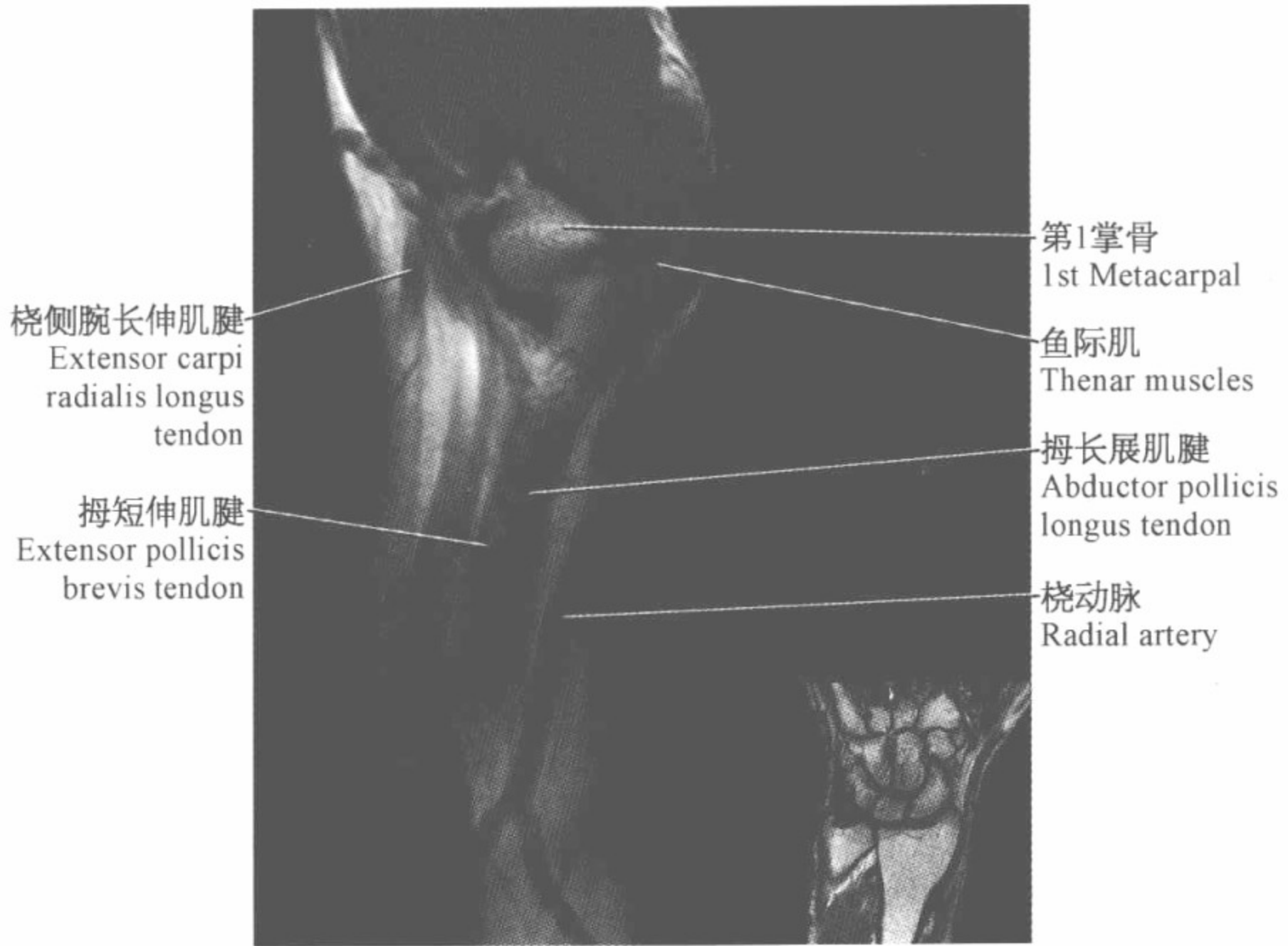


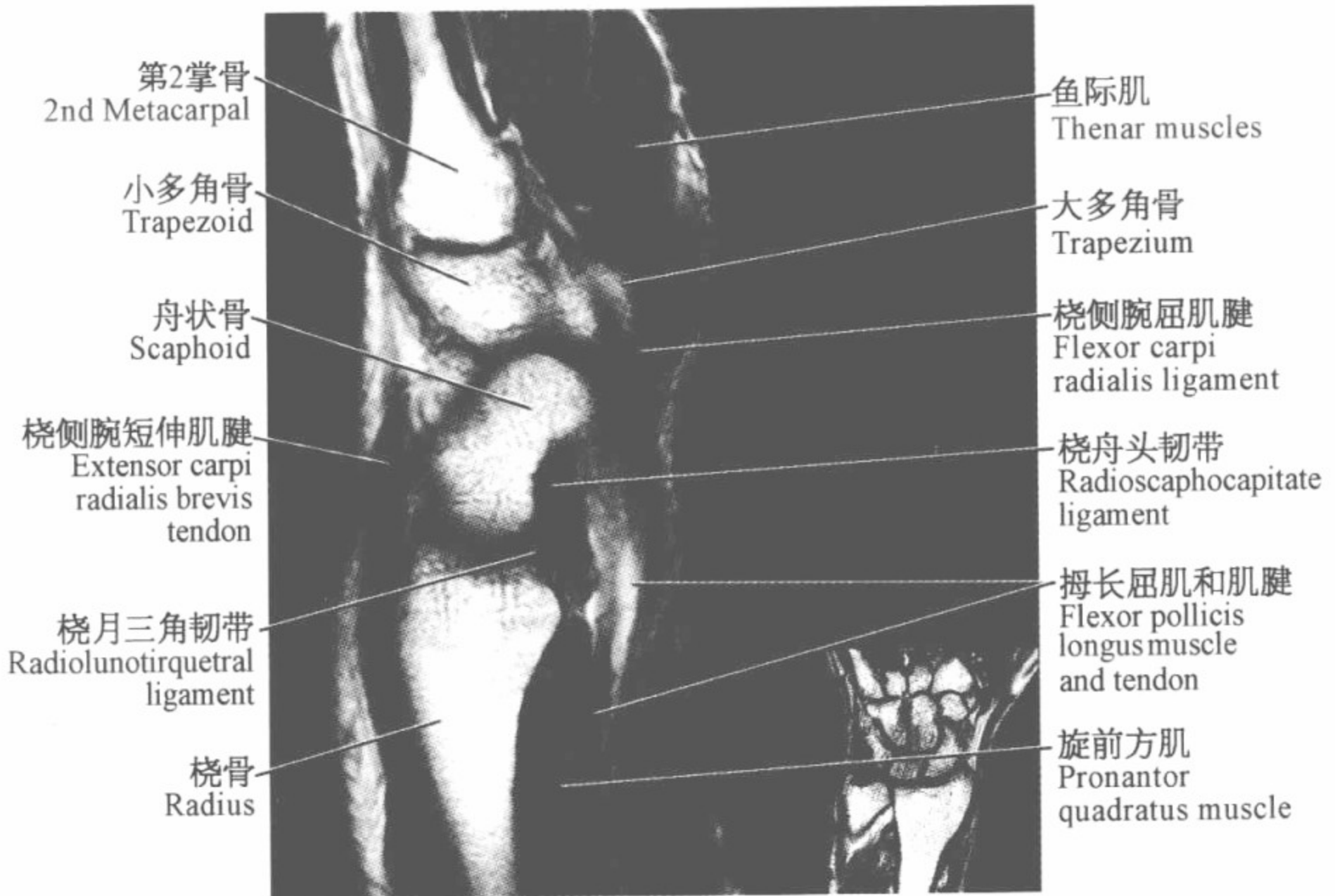
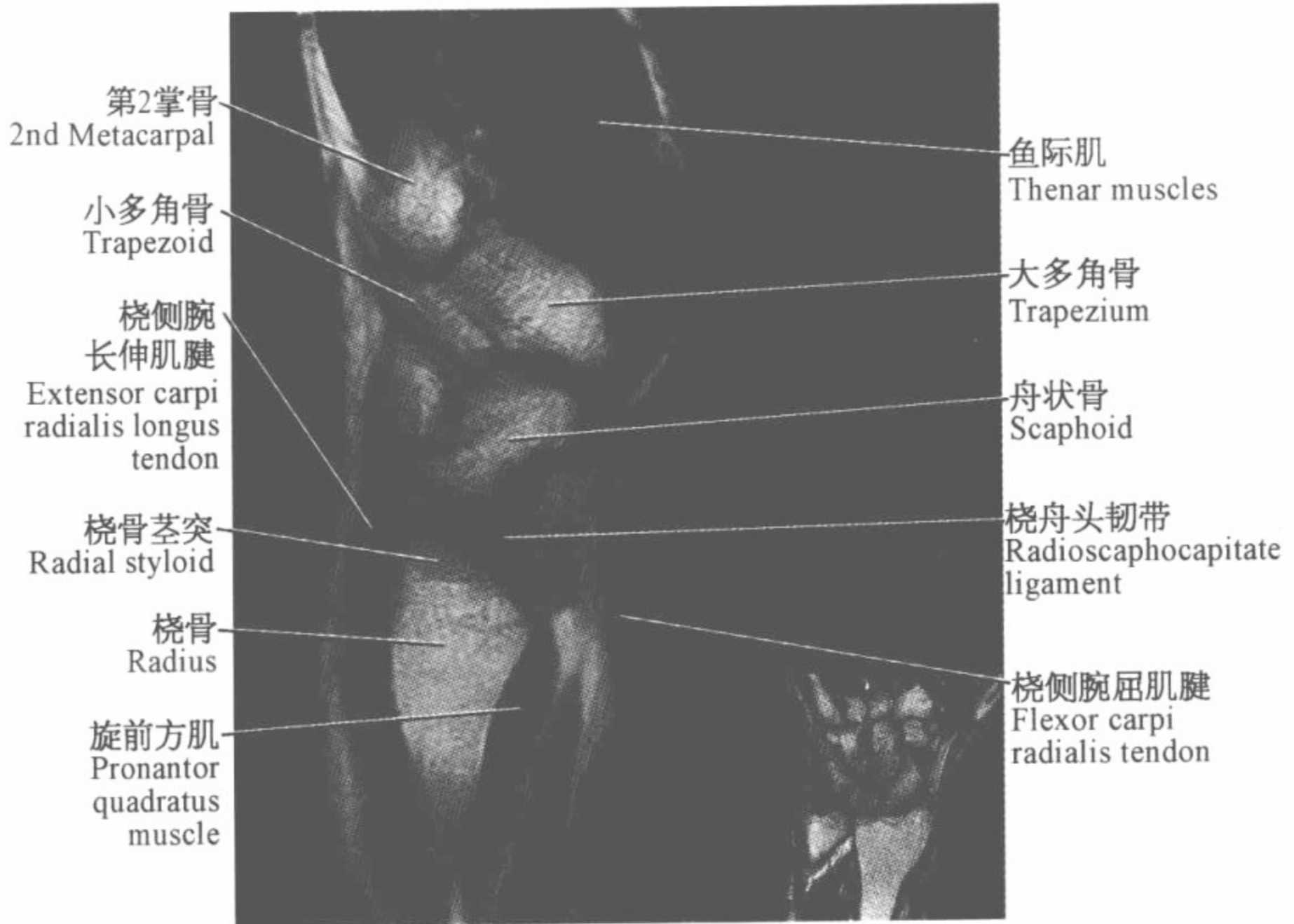


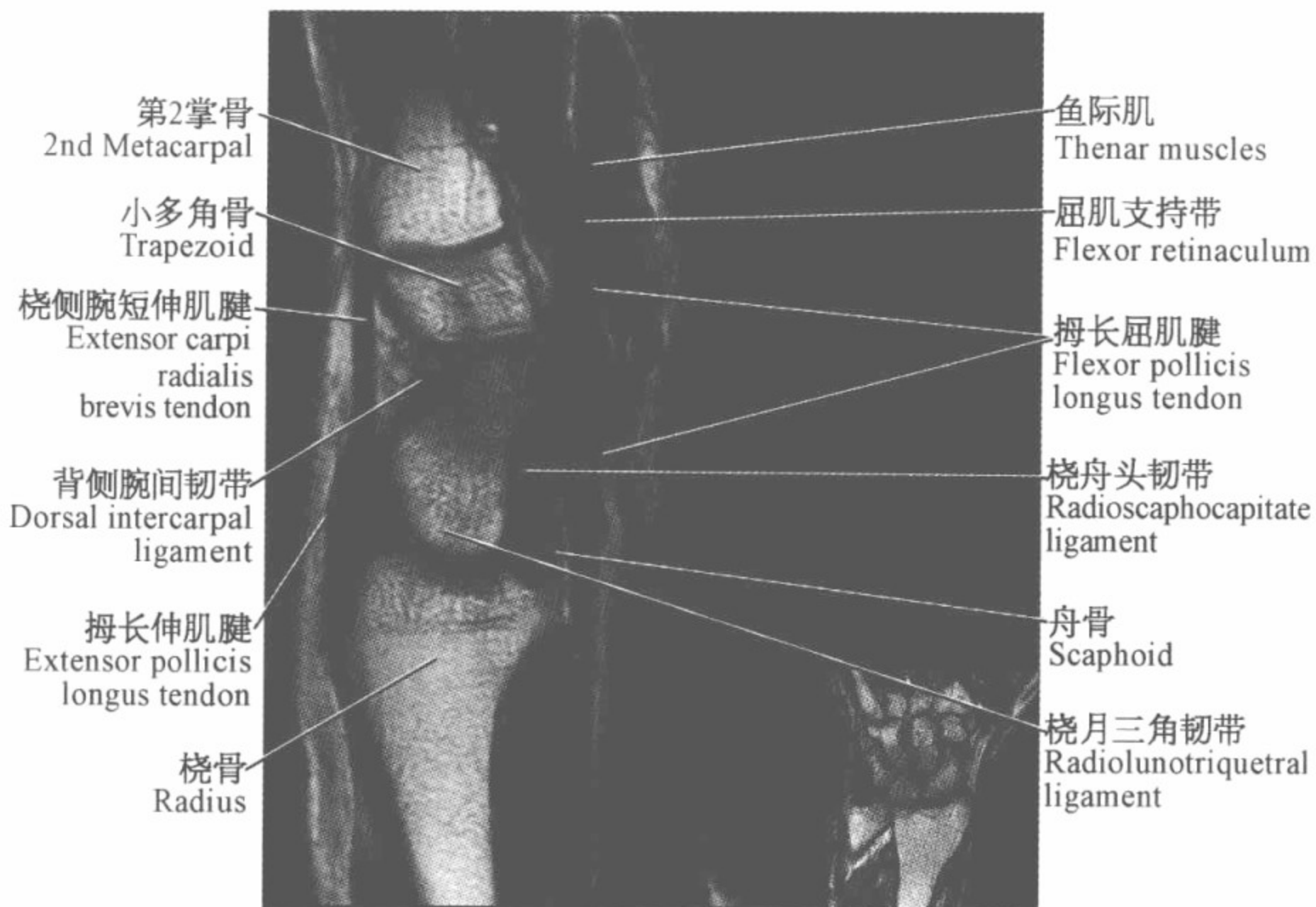
腕关节磁共振图谱

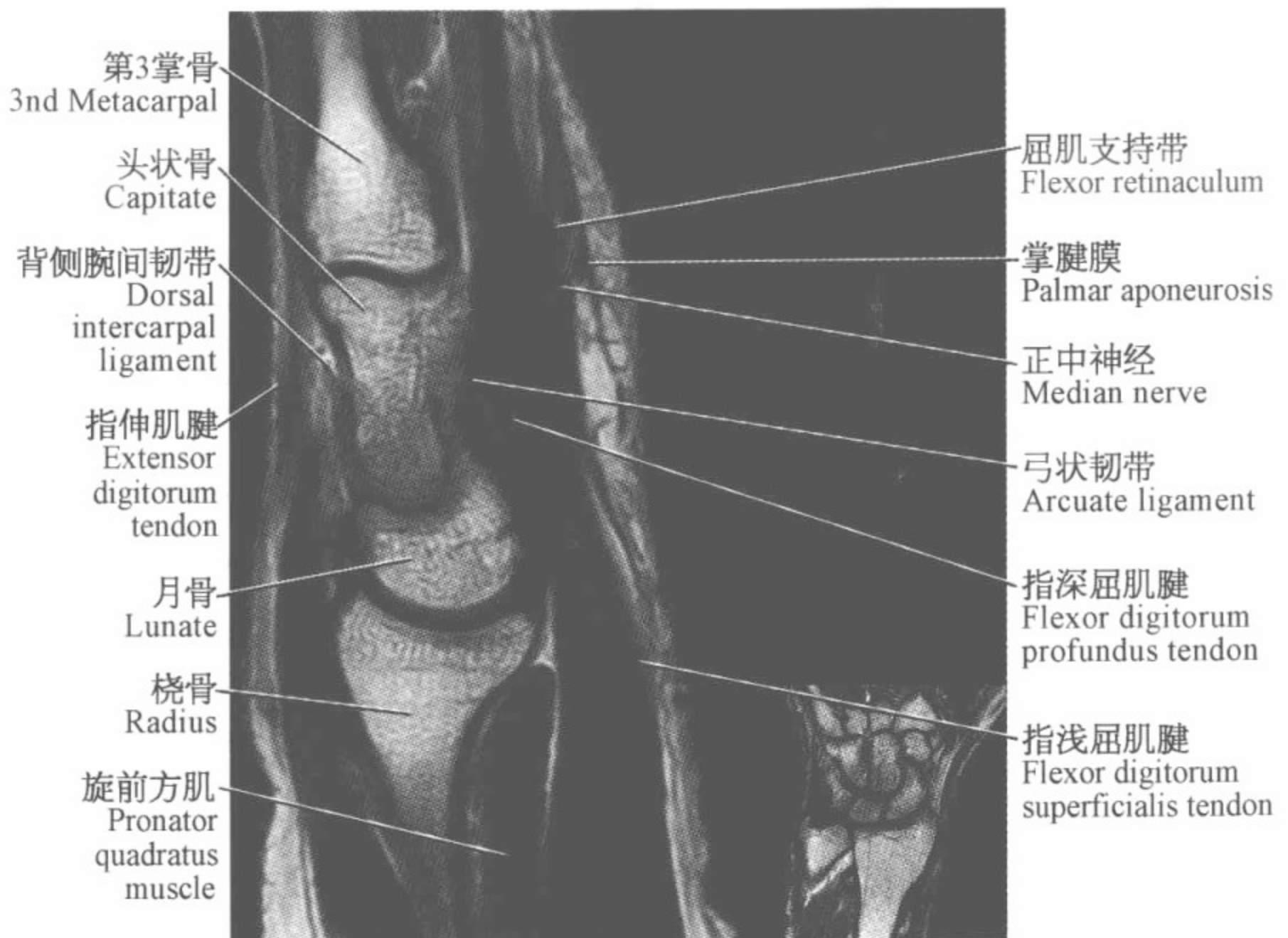
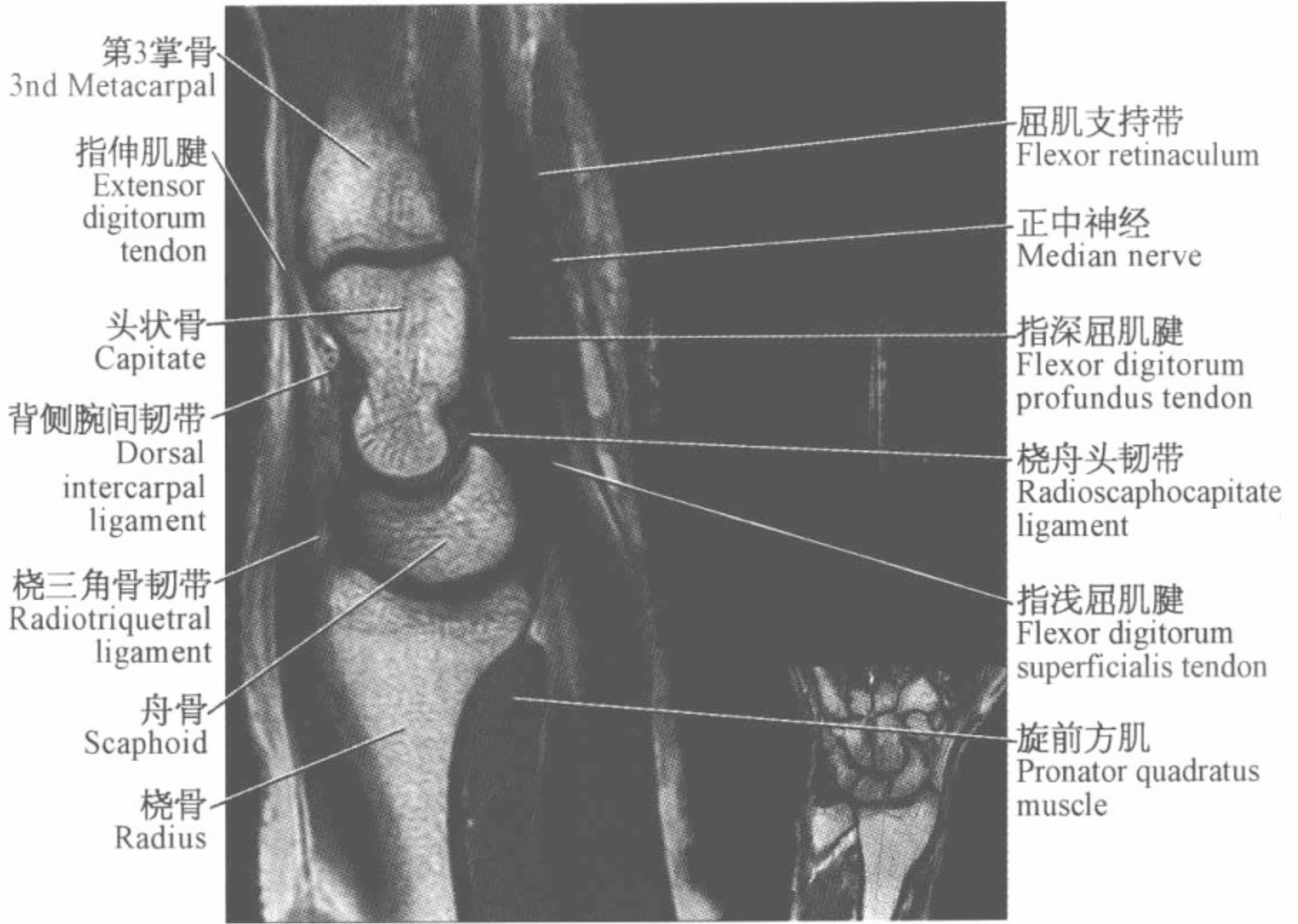
(矢状位)

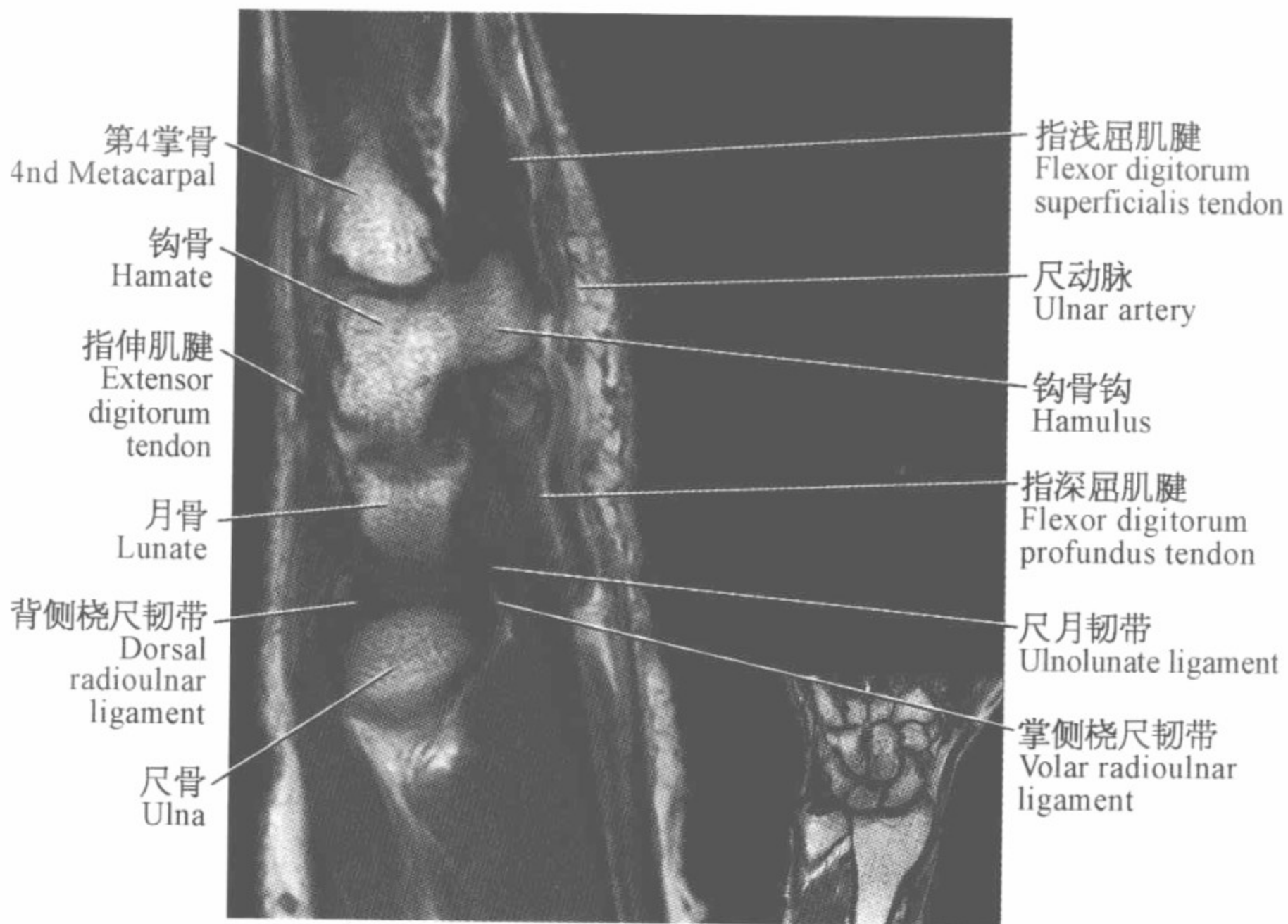
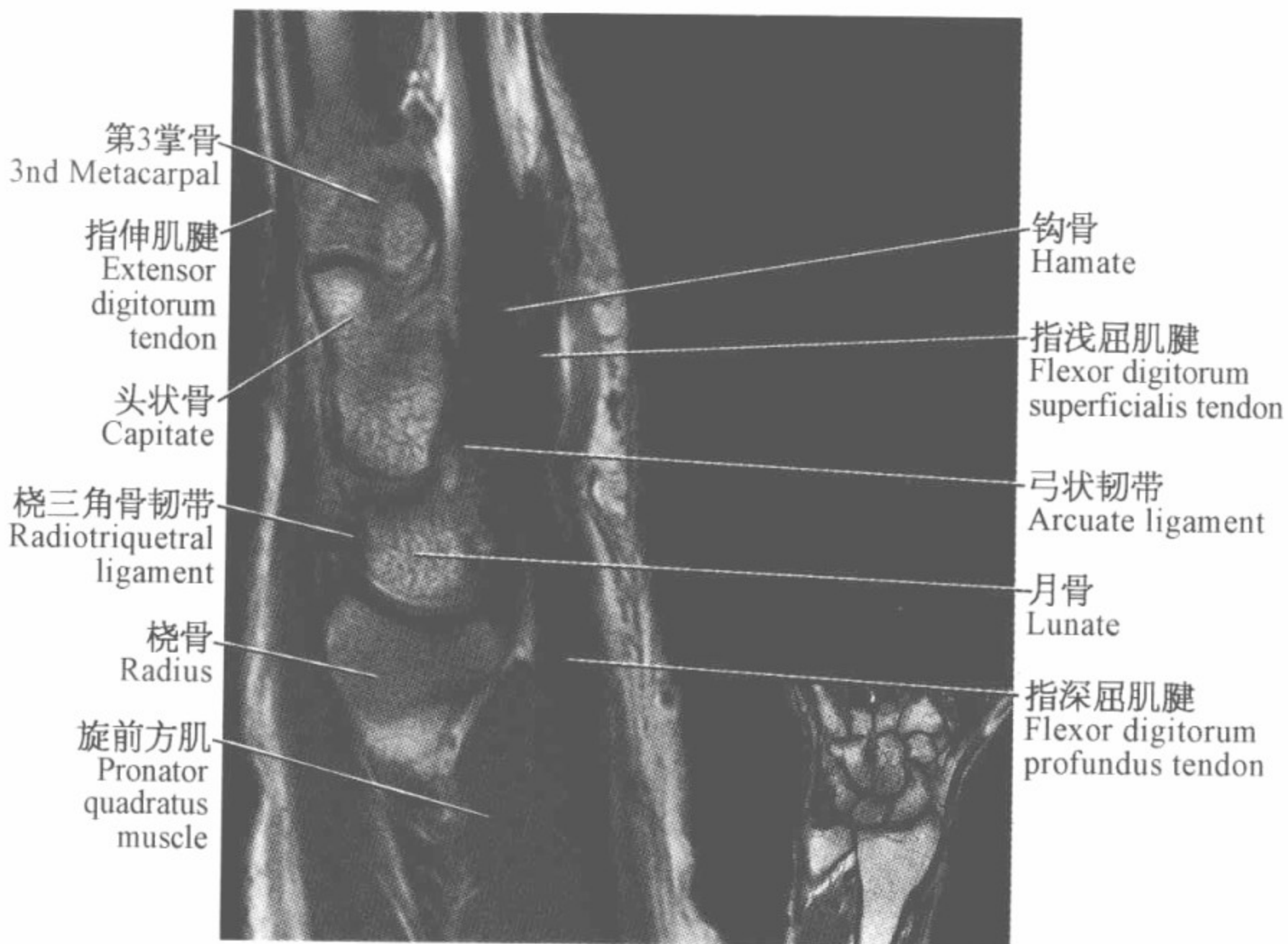


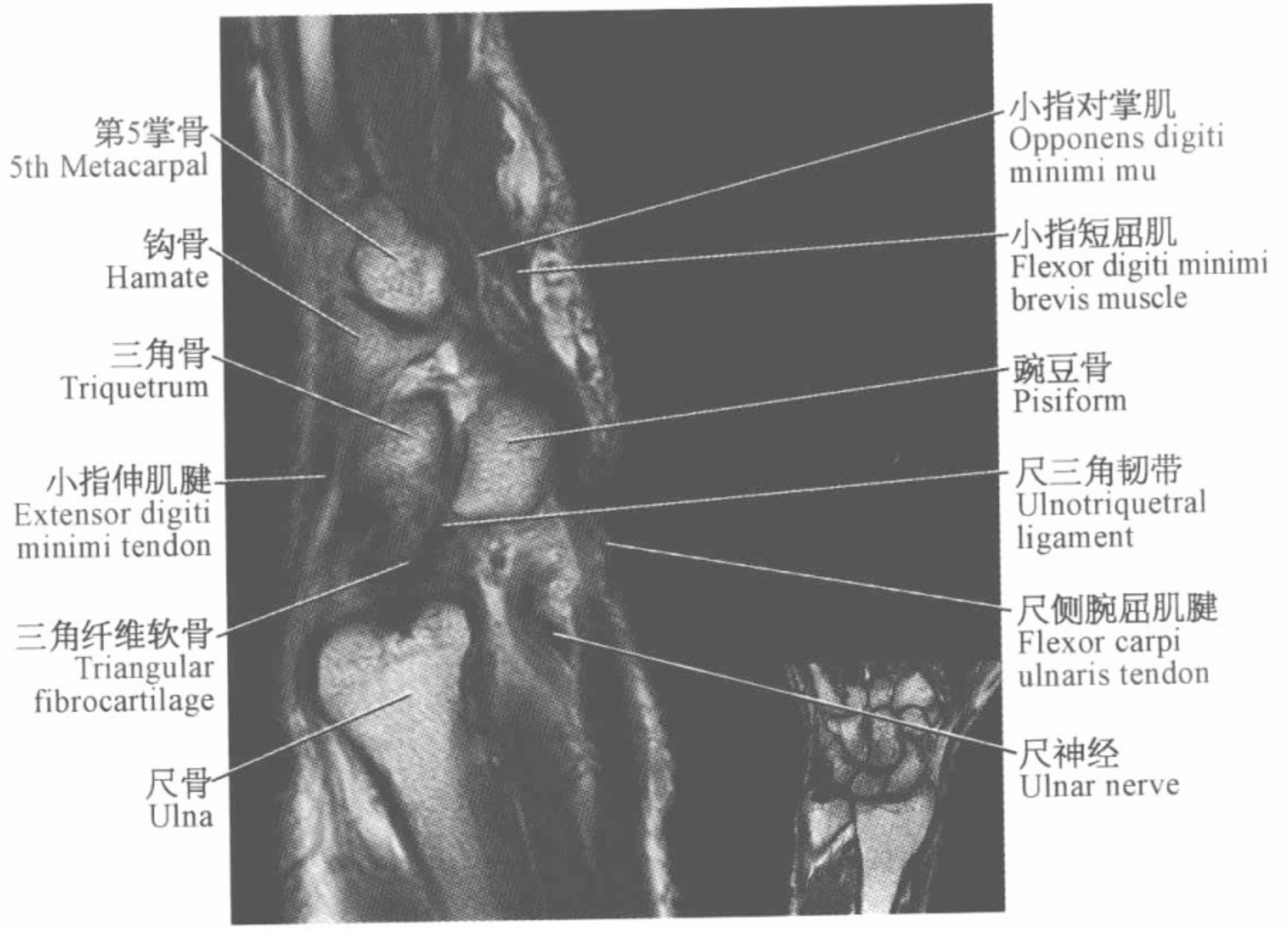
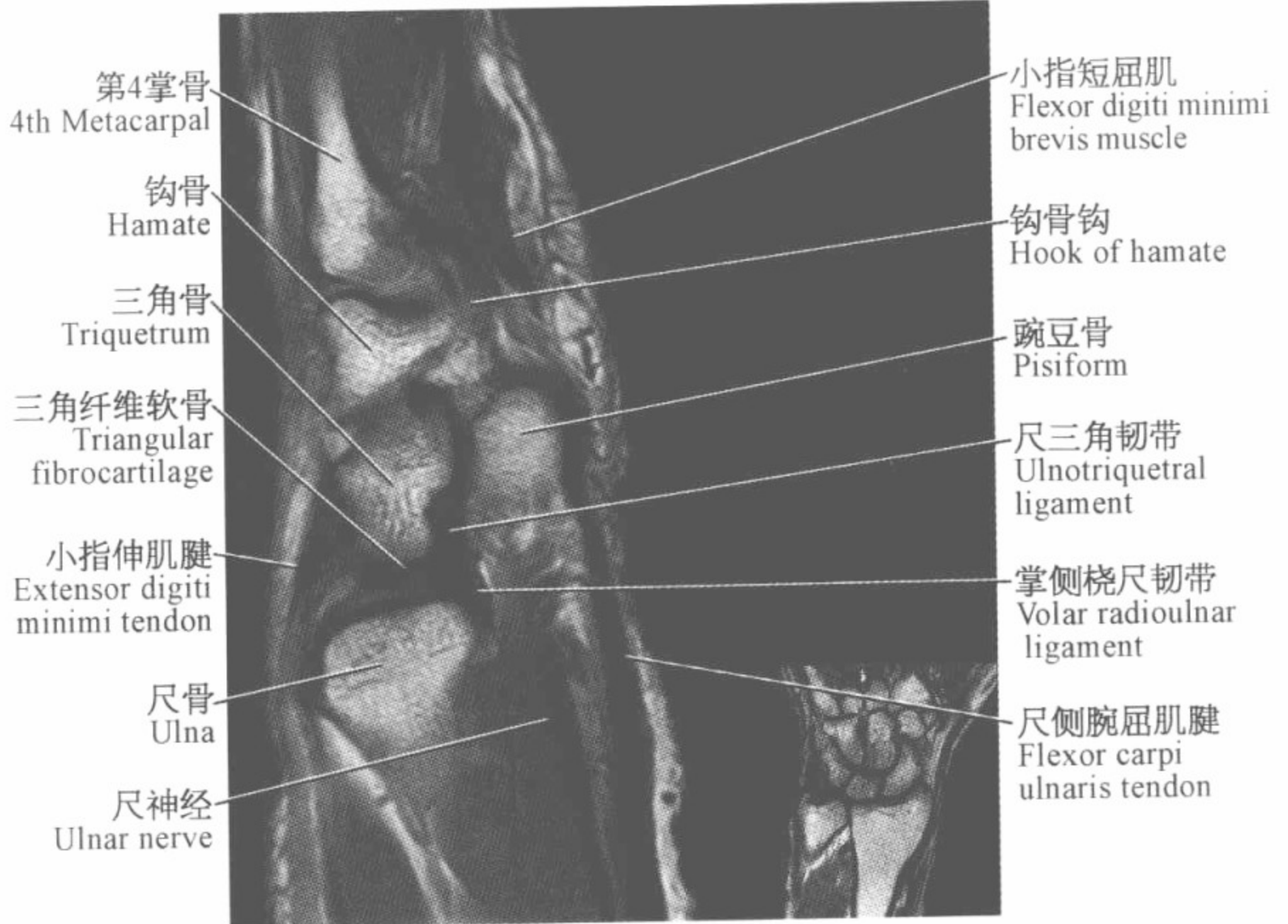


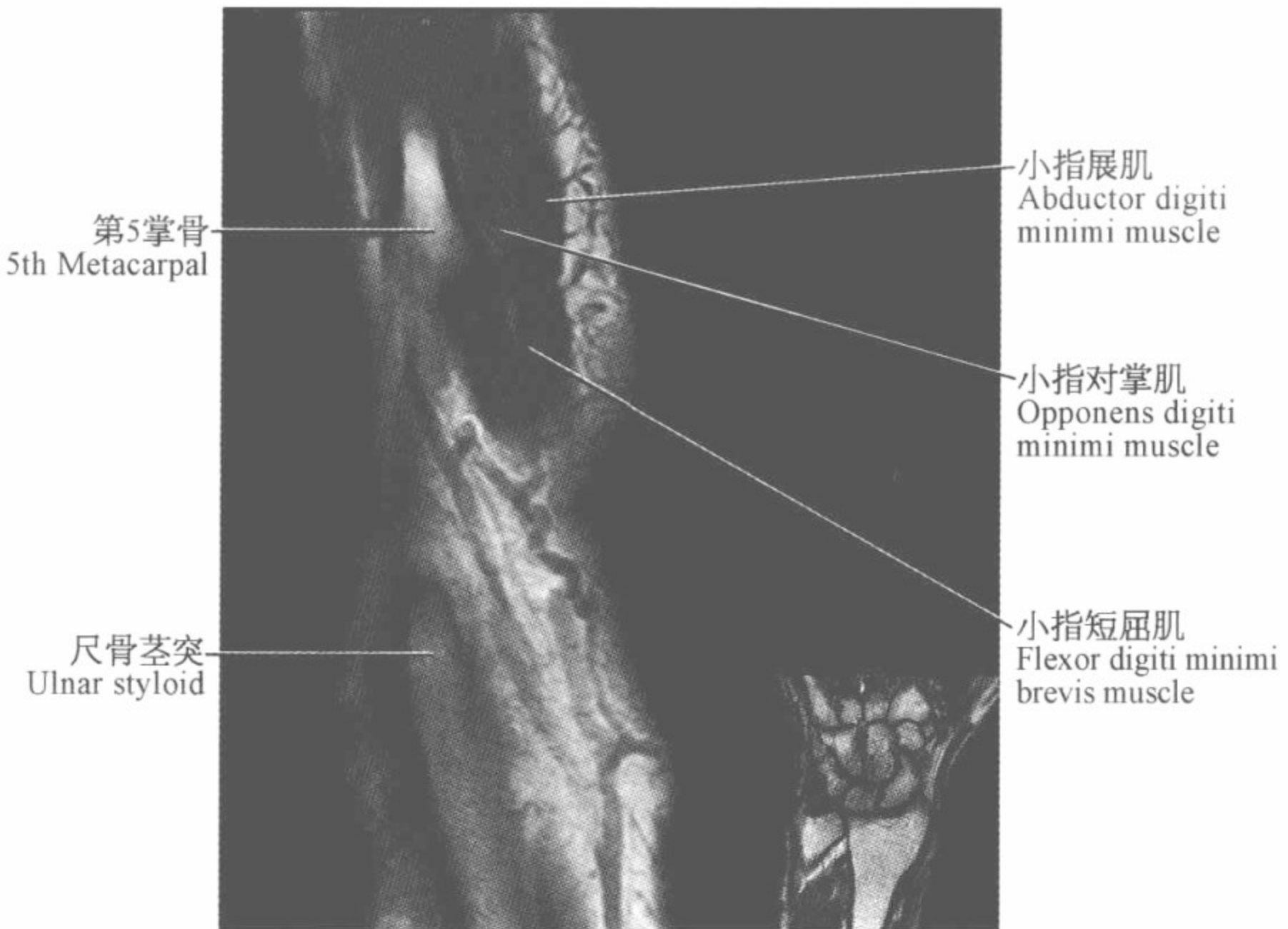
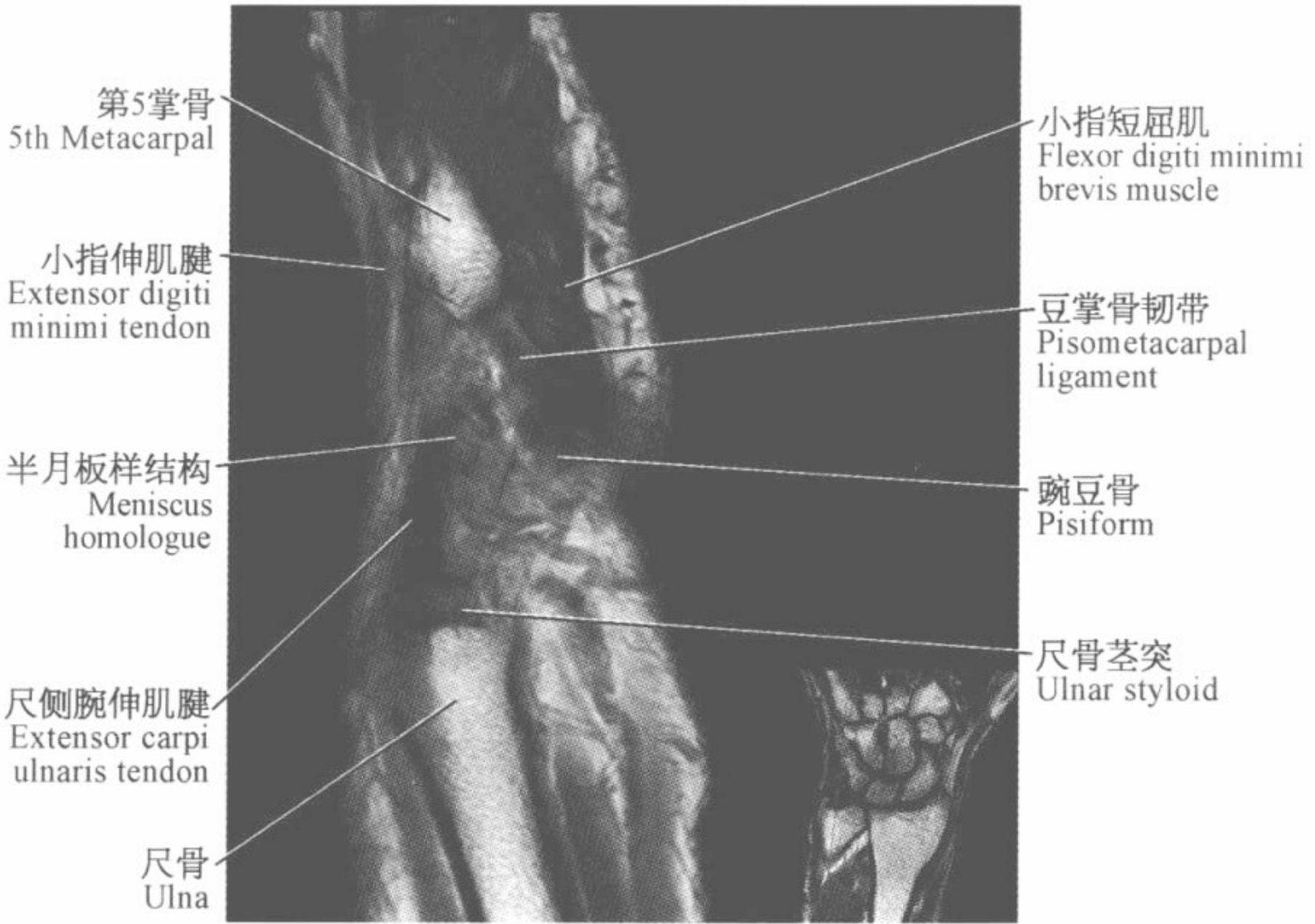




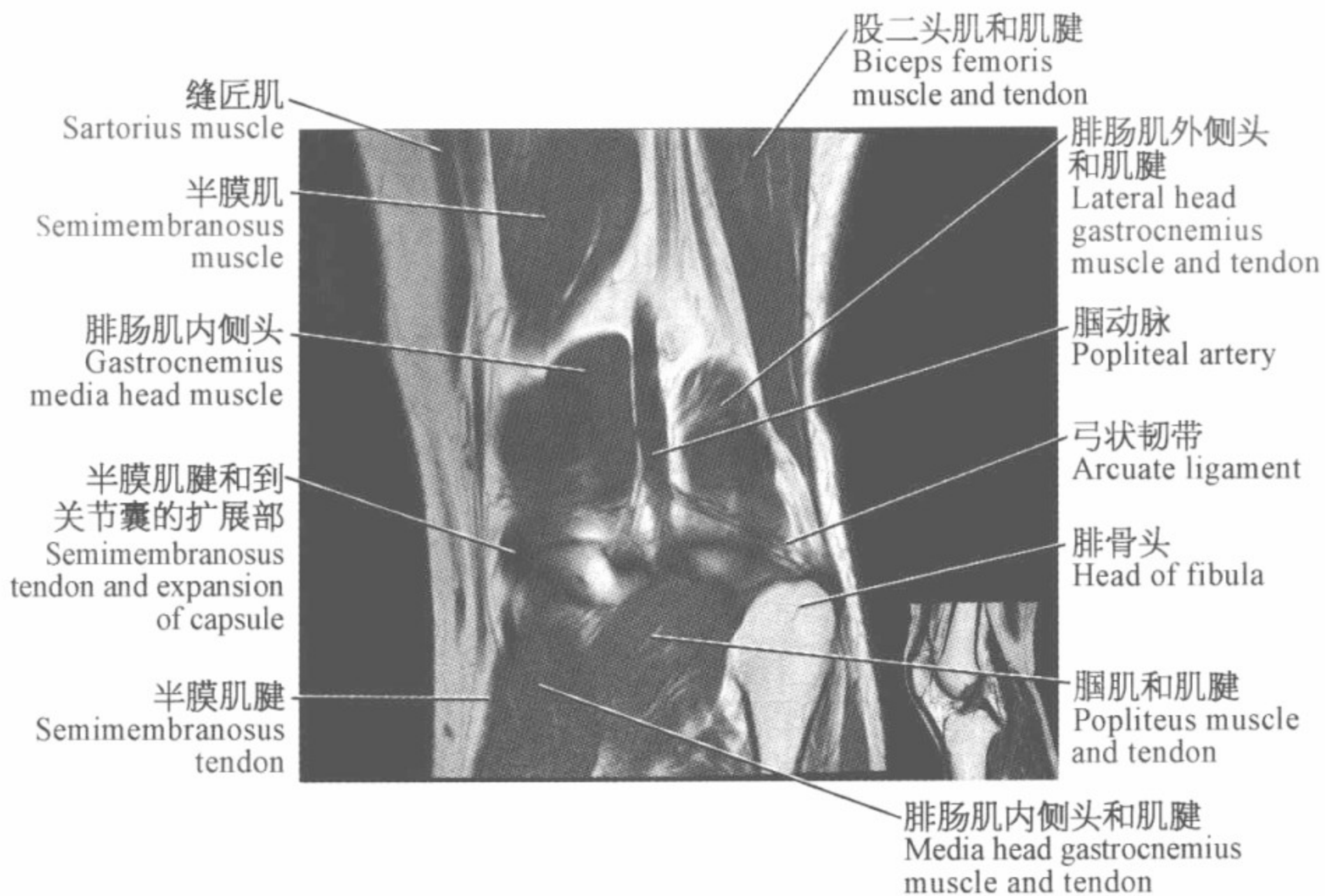
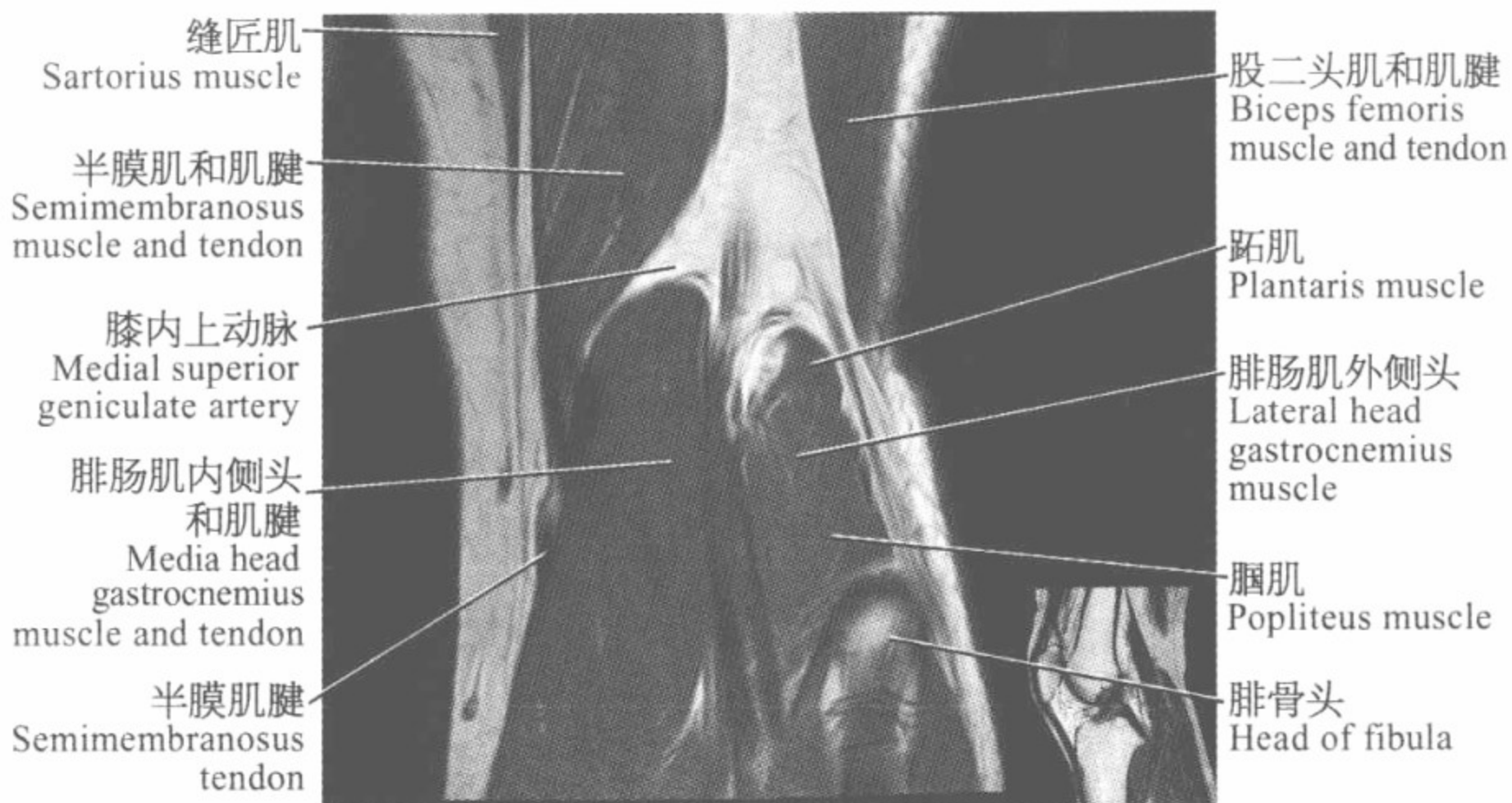


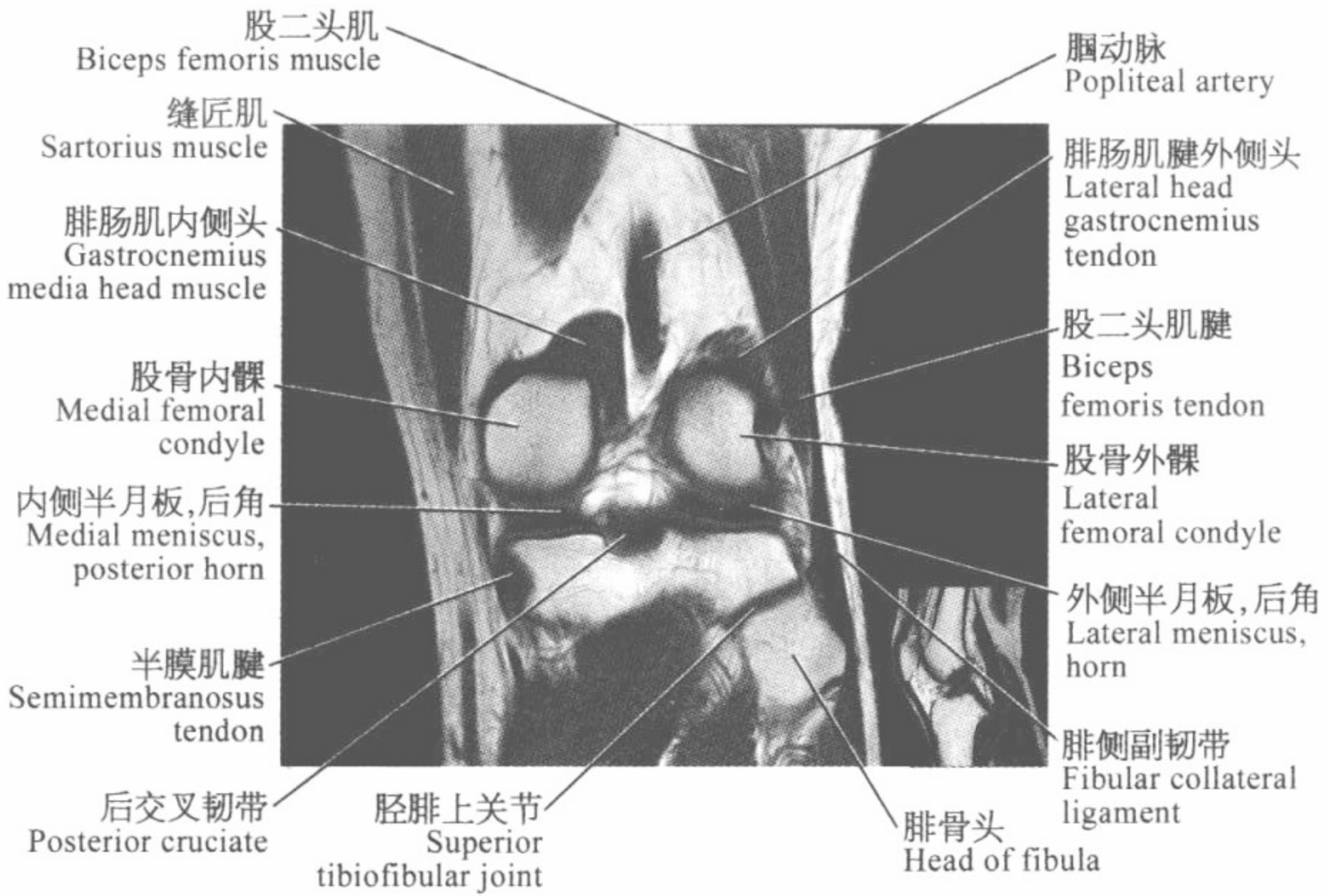
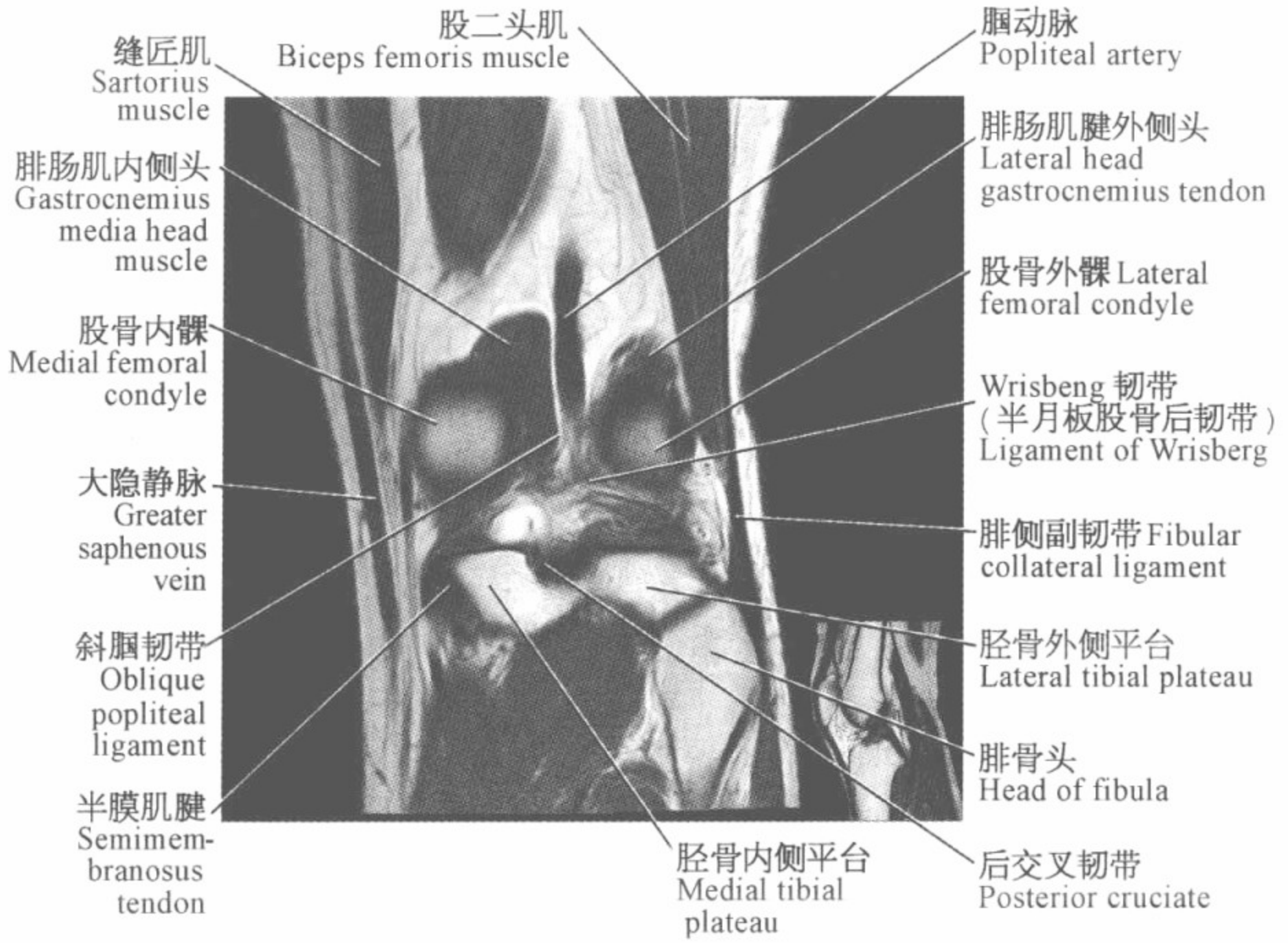


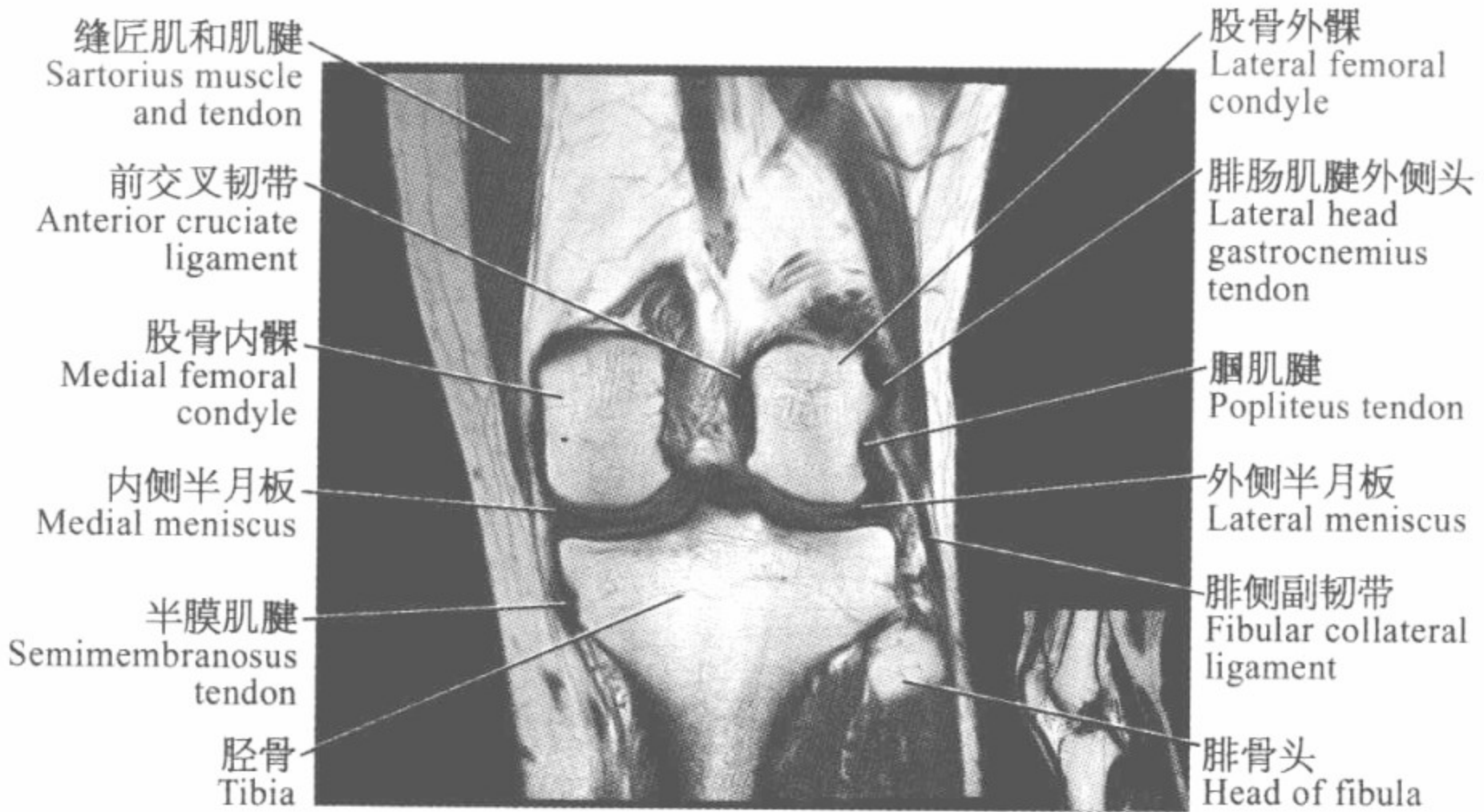
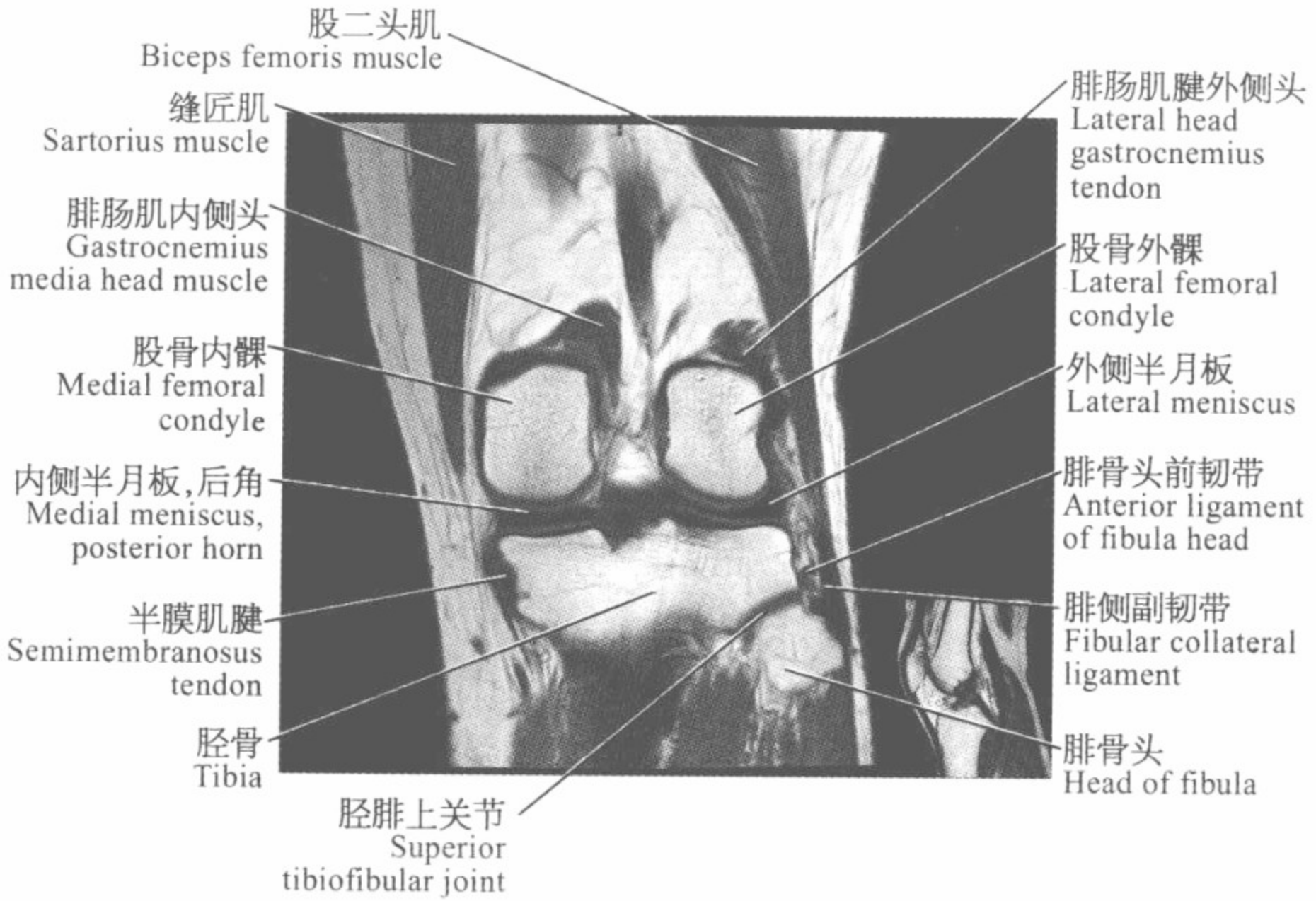


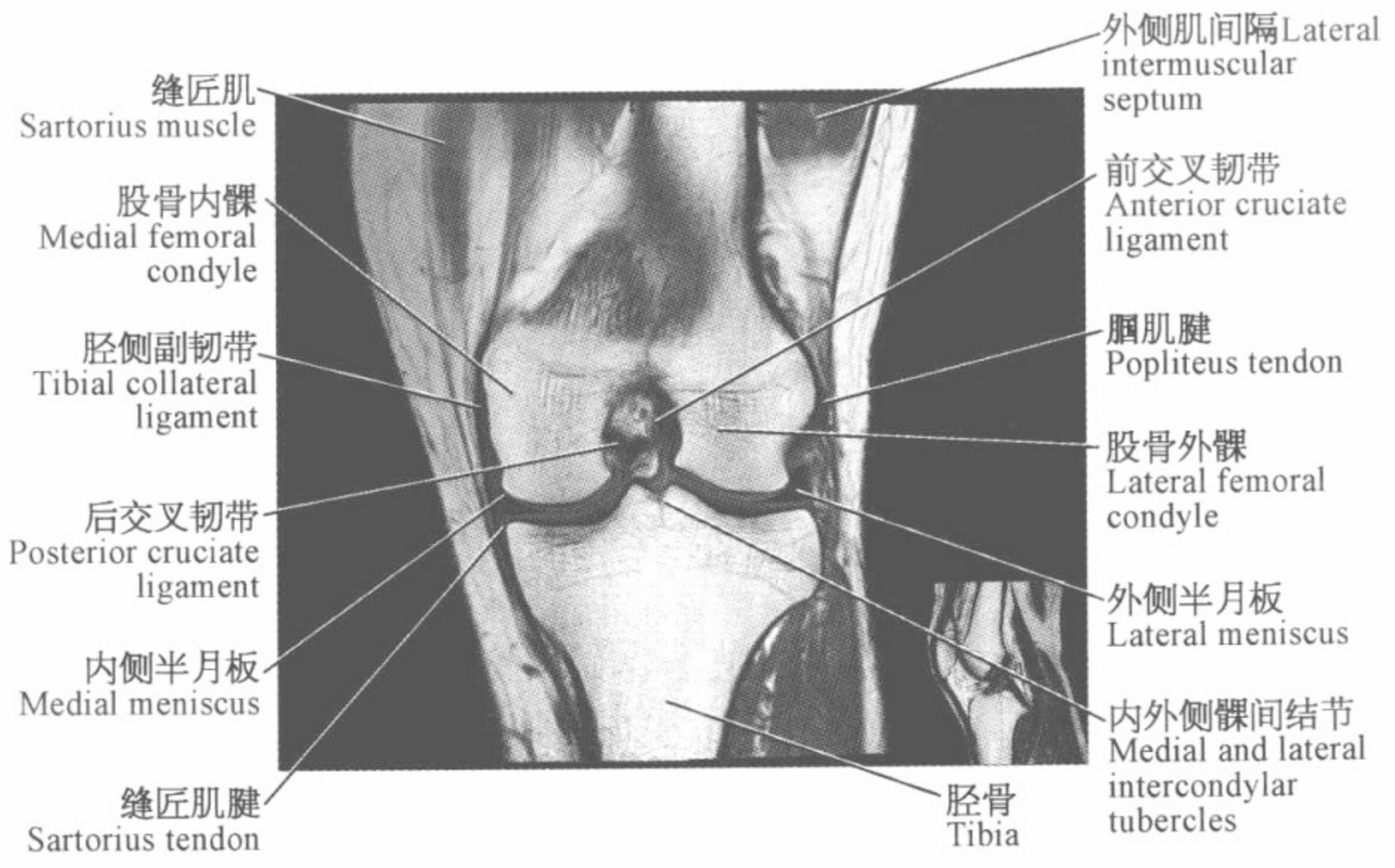
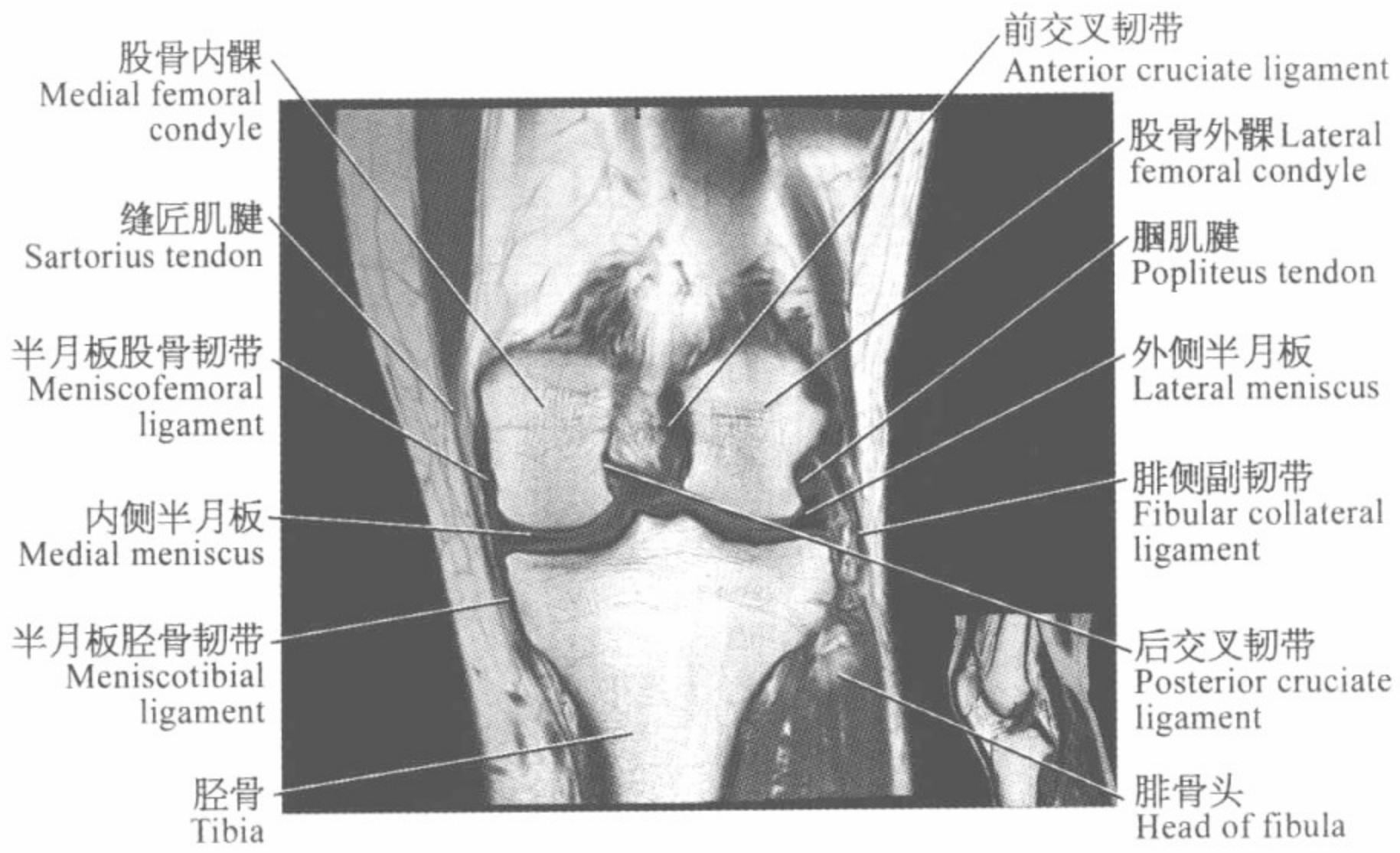


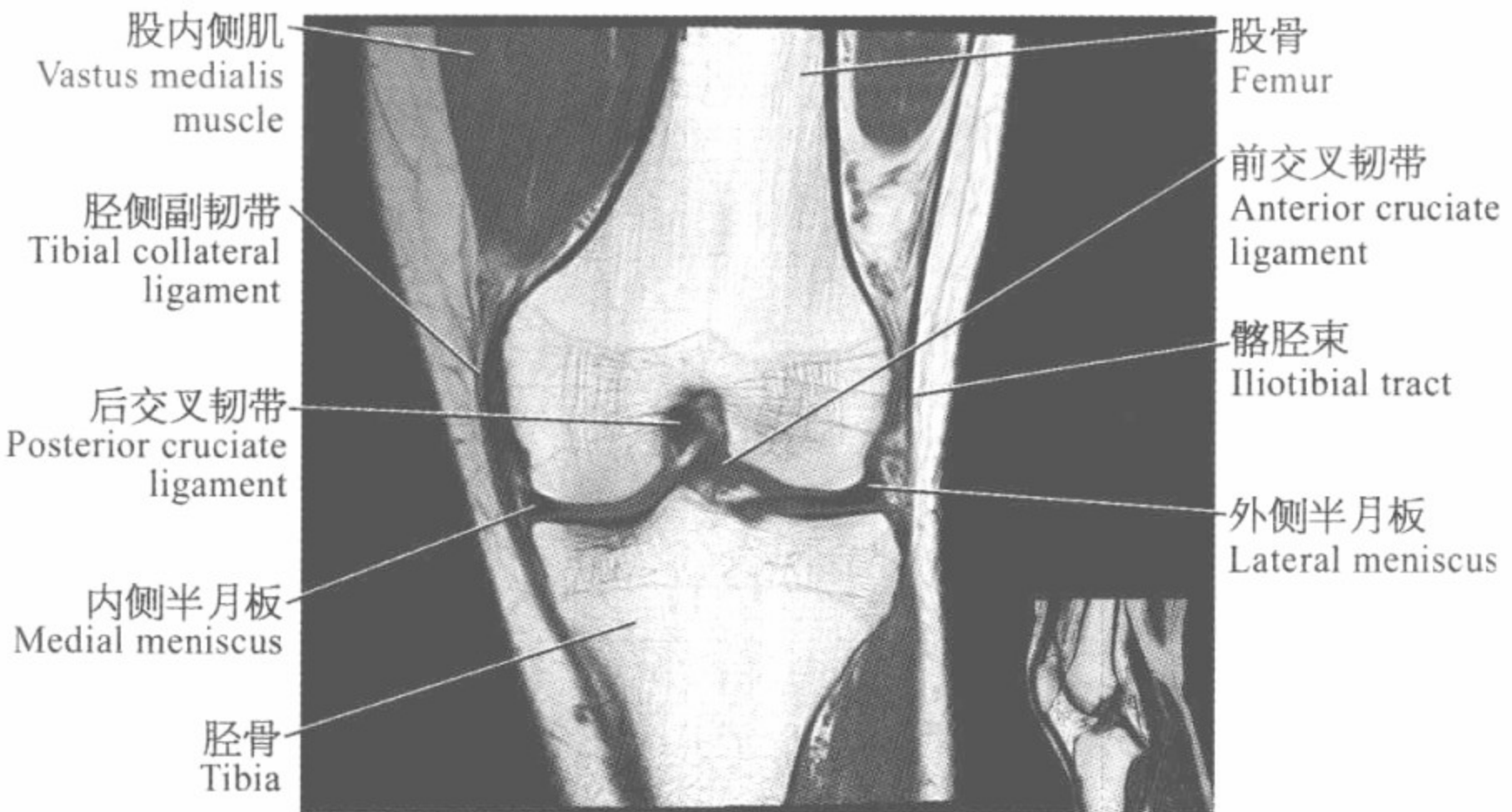
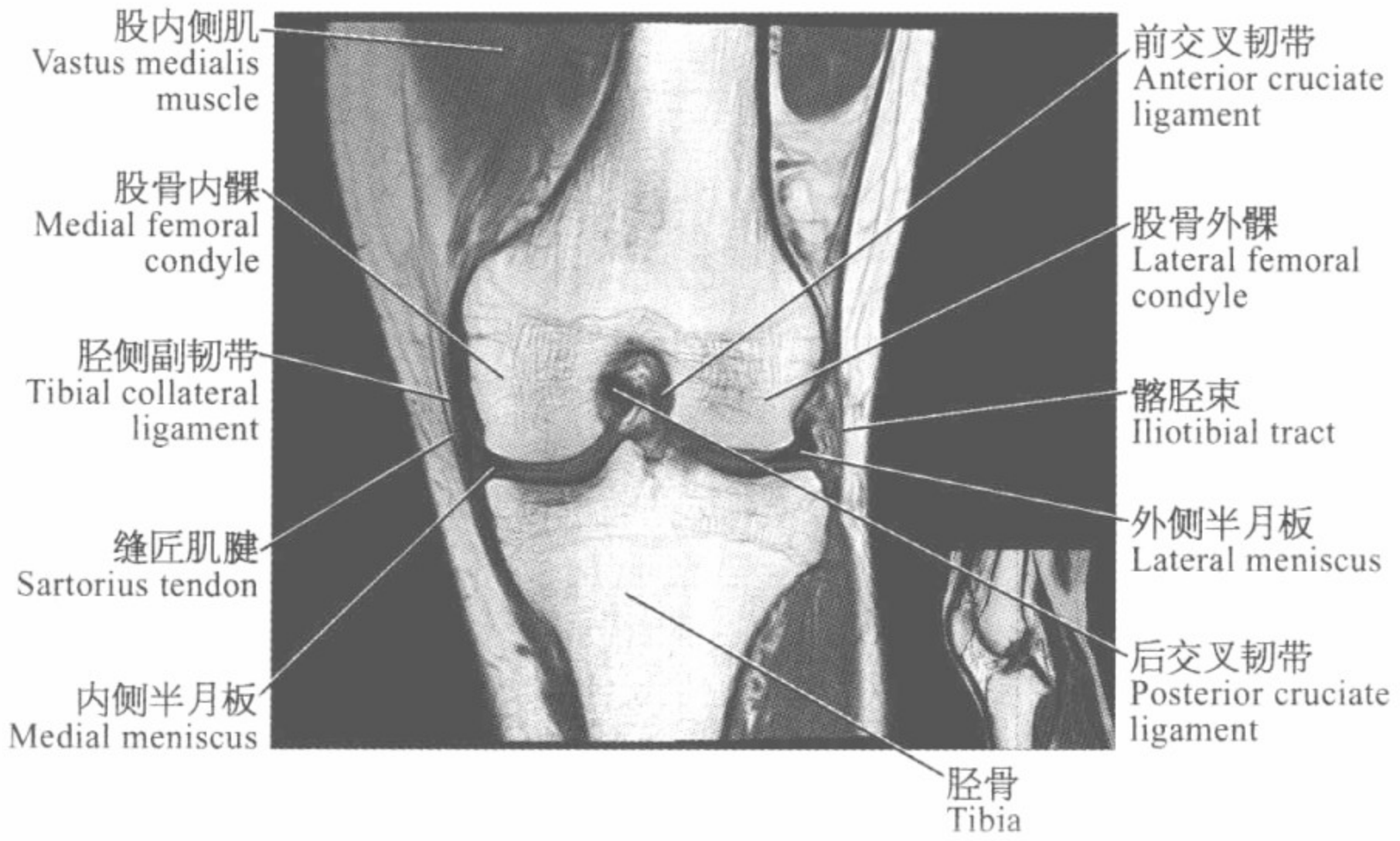
||| 膝关节磁共振图谱
—————
(冠状位) |||

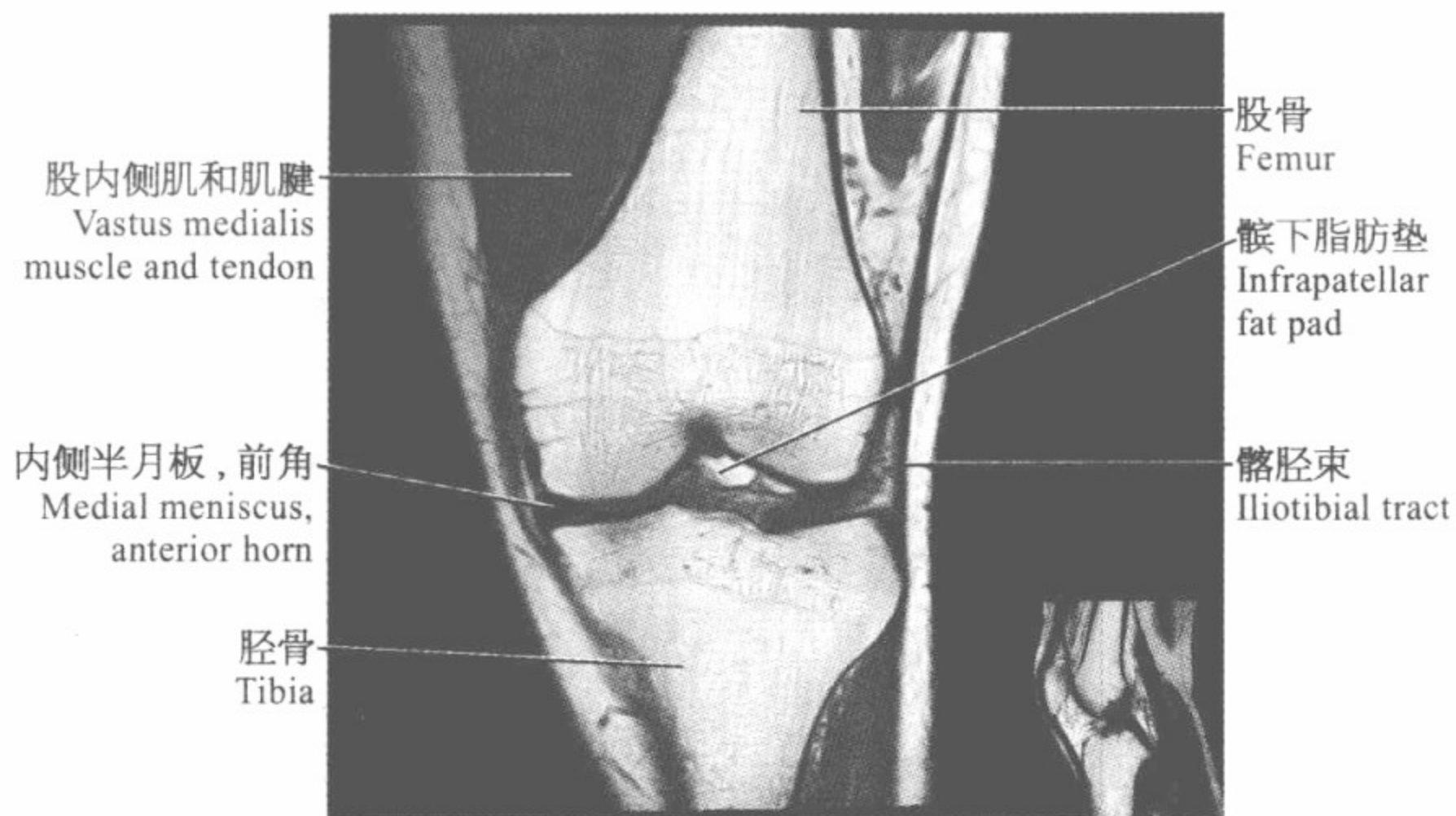
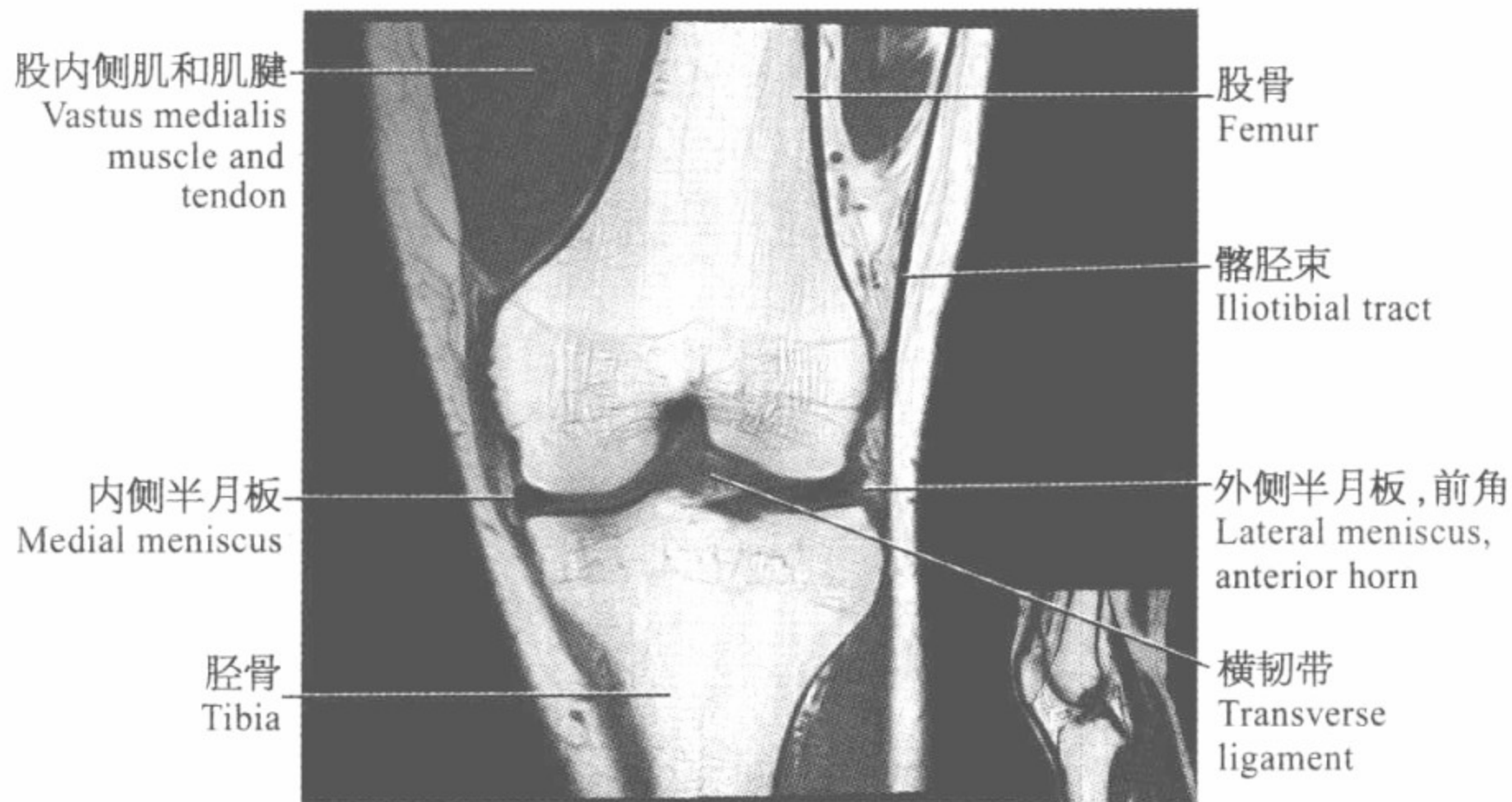


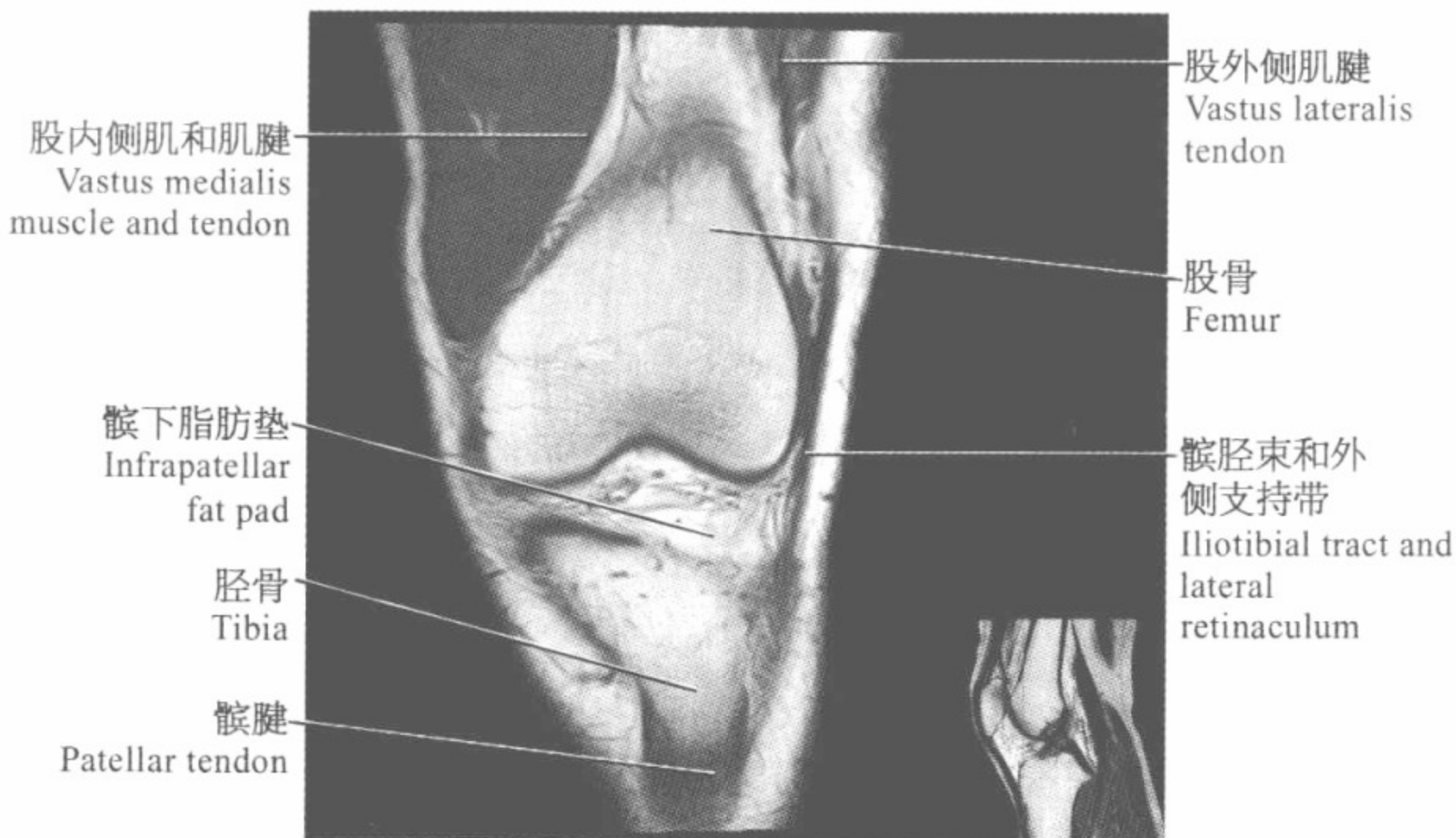
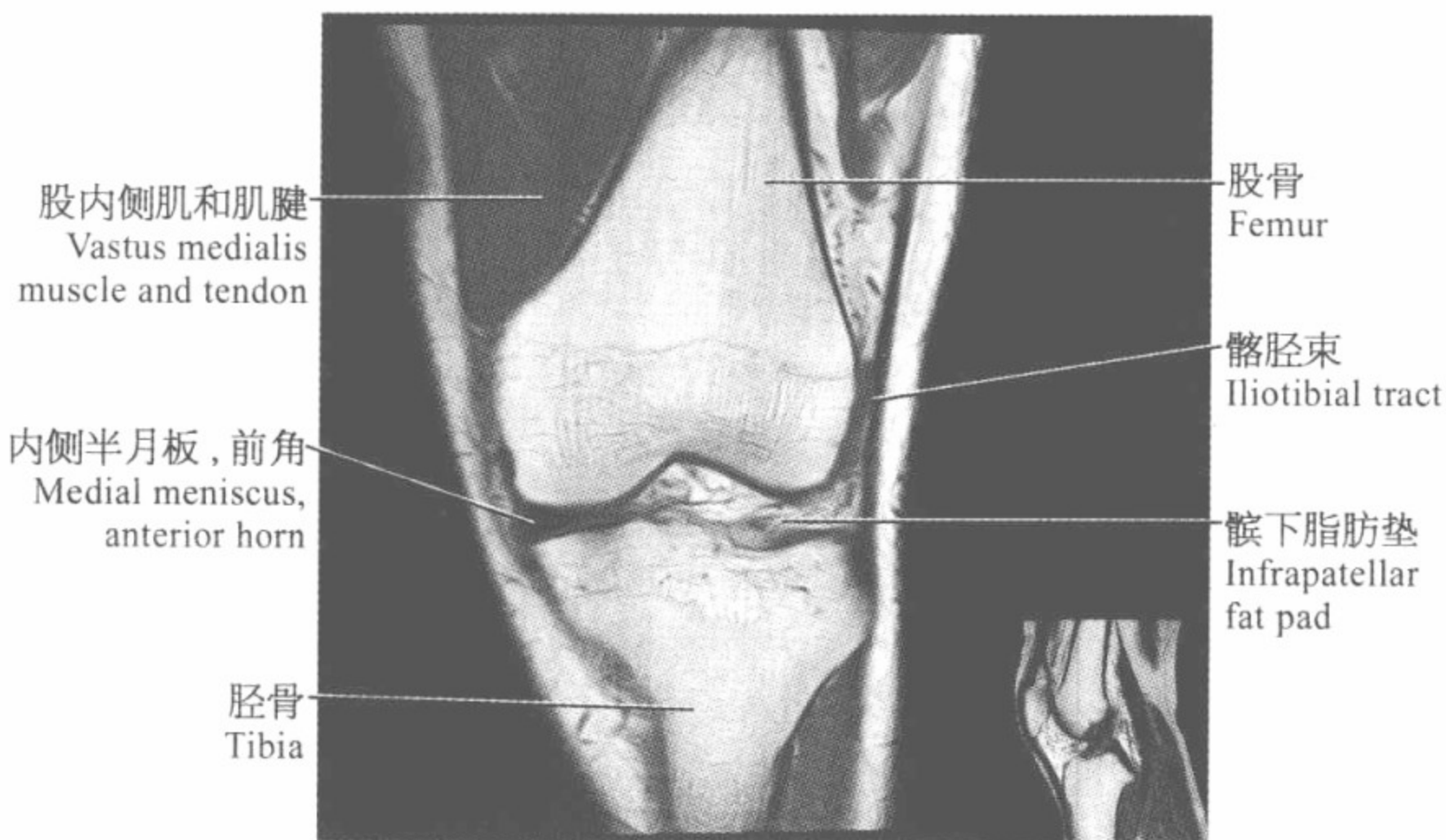












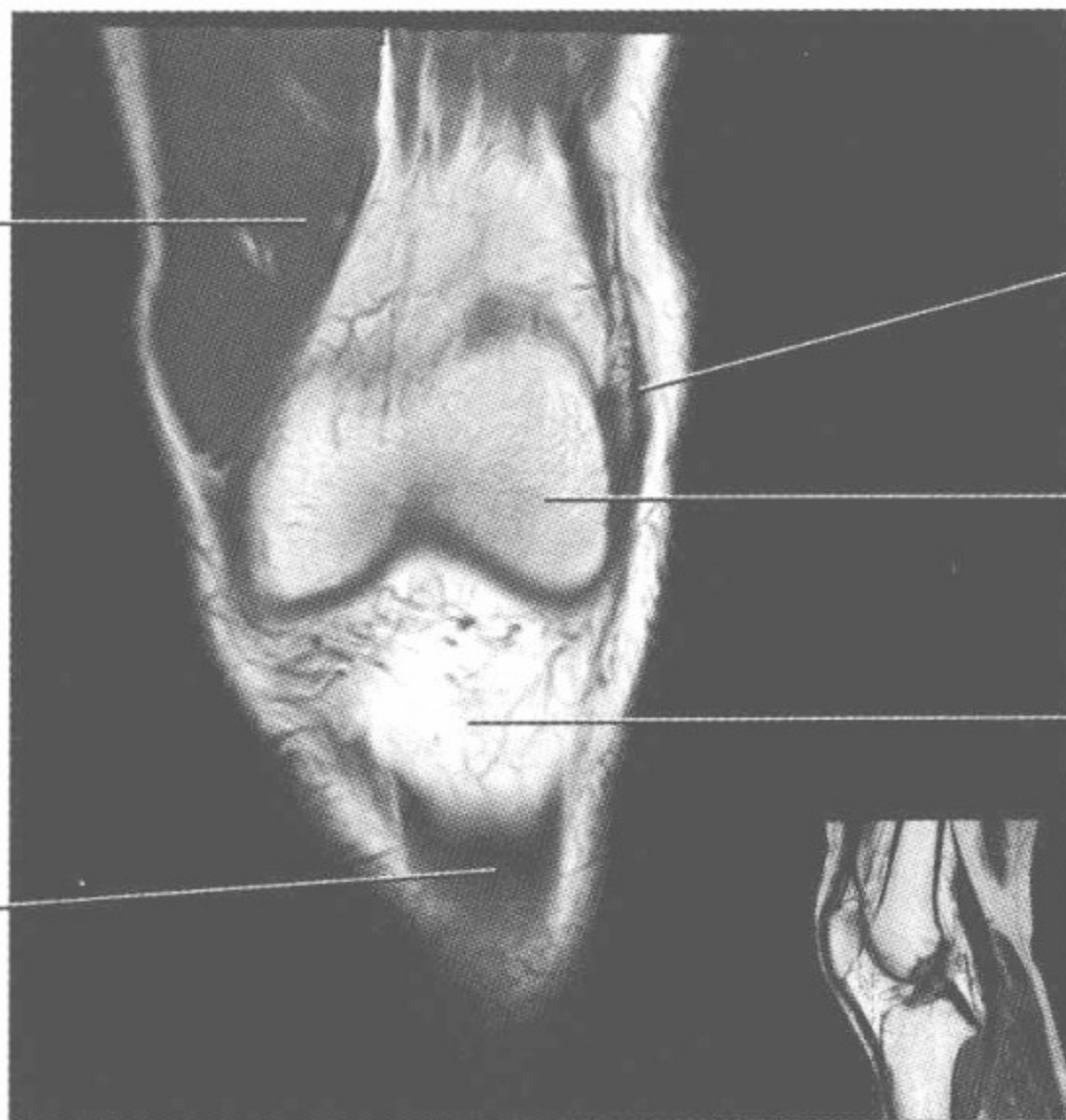
股内侧肌和肌腱
Vastus medialis
muscle and tendon

外侧支持带
Lateral retinaculum

股骨
Femur

髌下脂肪垫
Infrapatellar
fat pad

髌腱
Patellar tendon



股内侧肌和肌腱
Vastus medialis
muscle and tendon

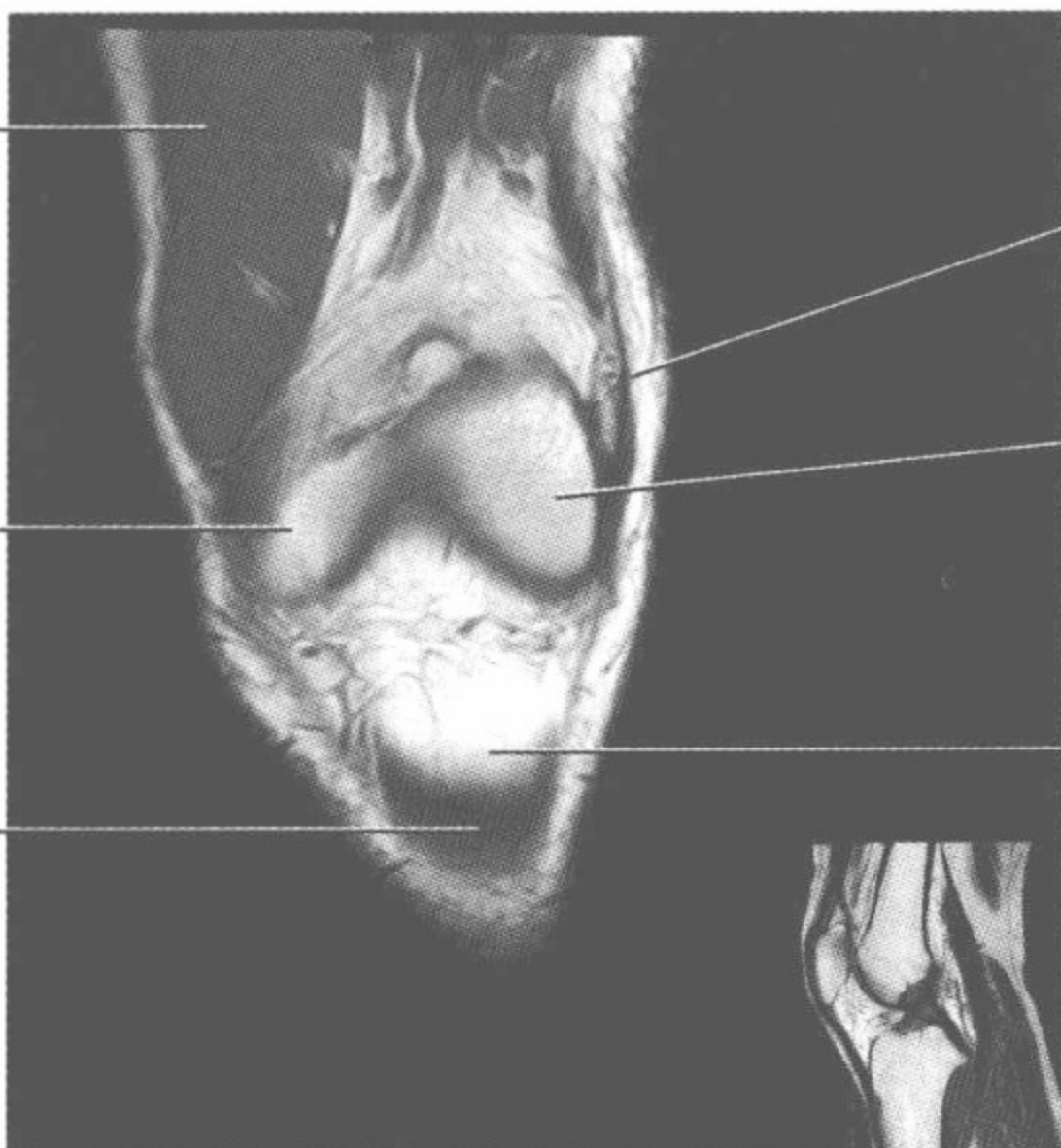
外侧支持带
Lateral retinaculum

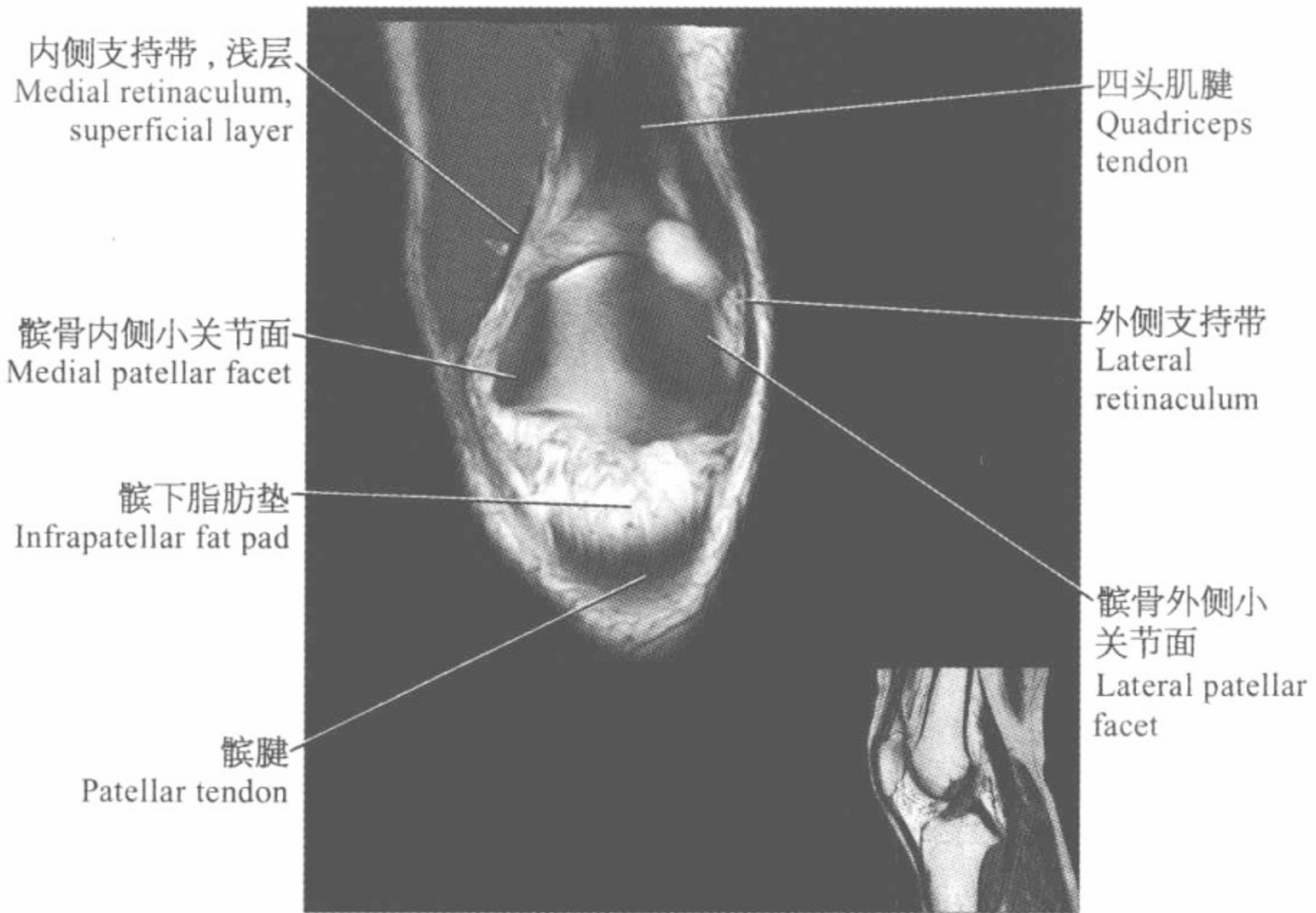
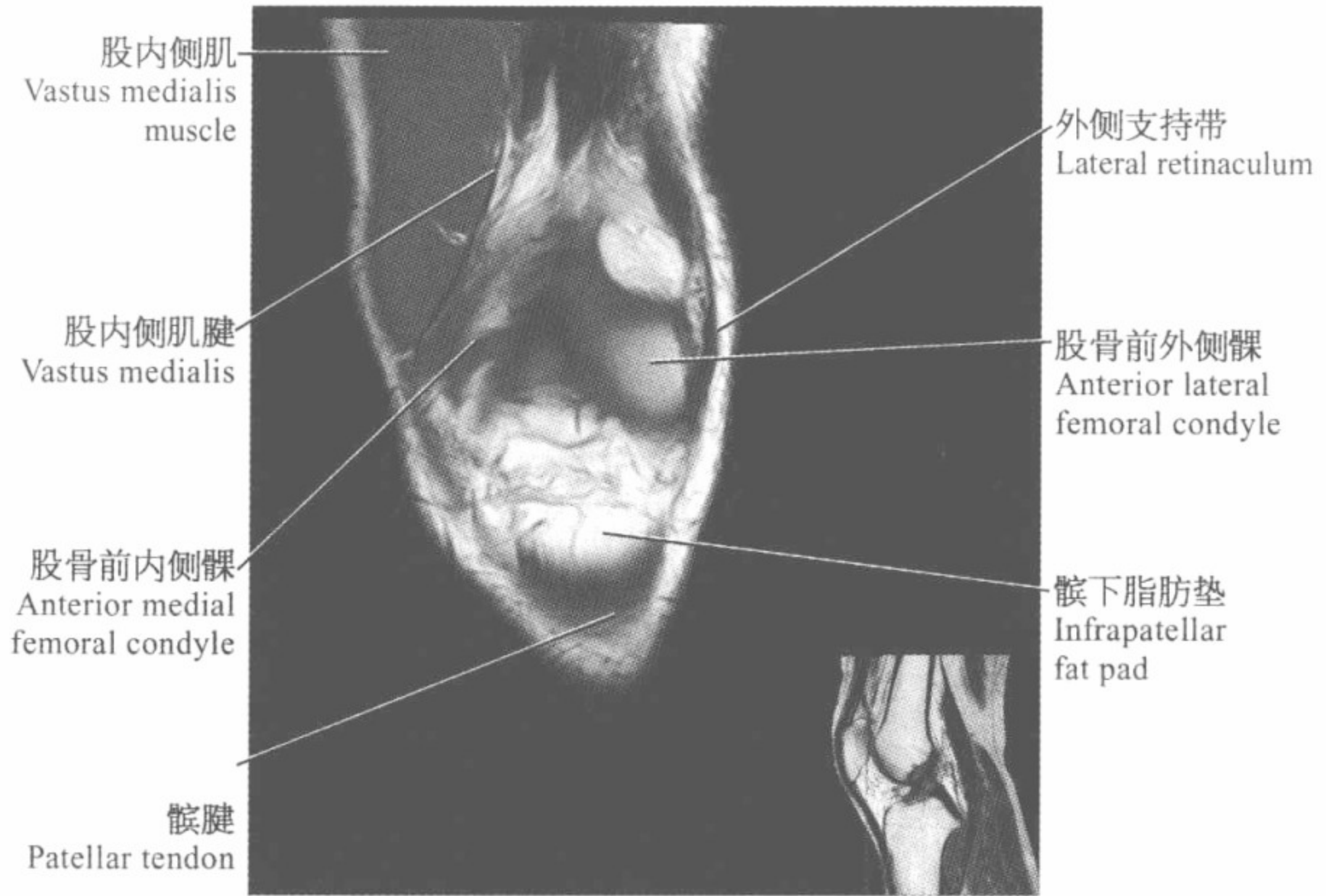
股骨前外侧髁
Anterior lateral
femoral condyle

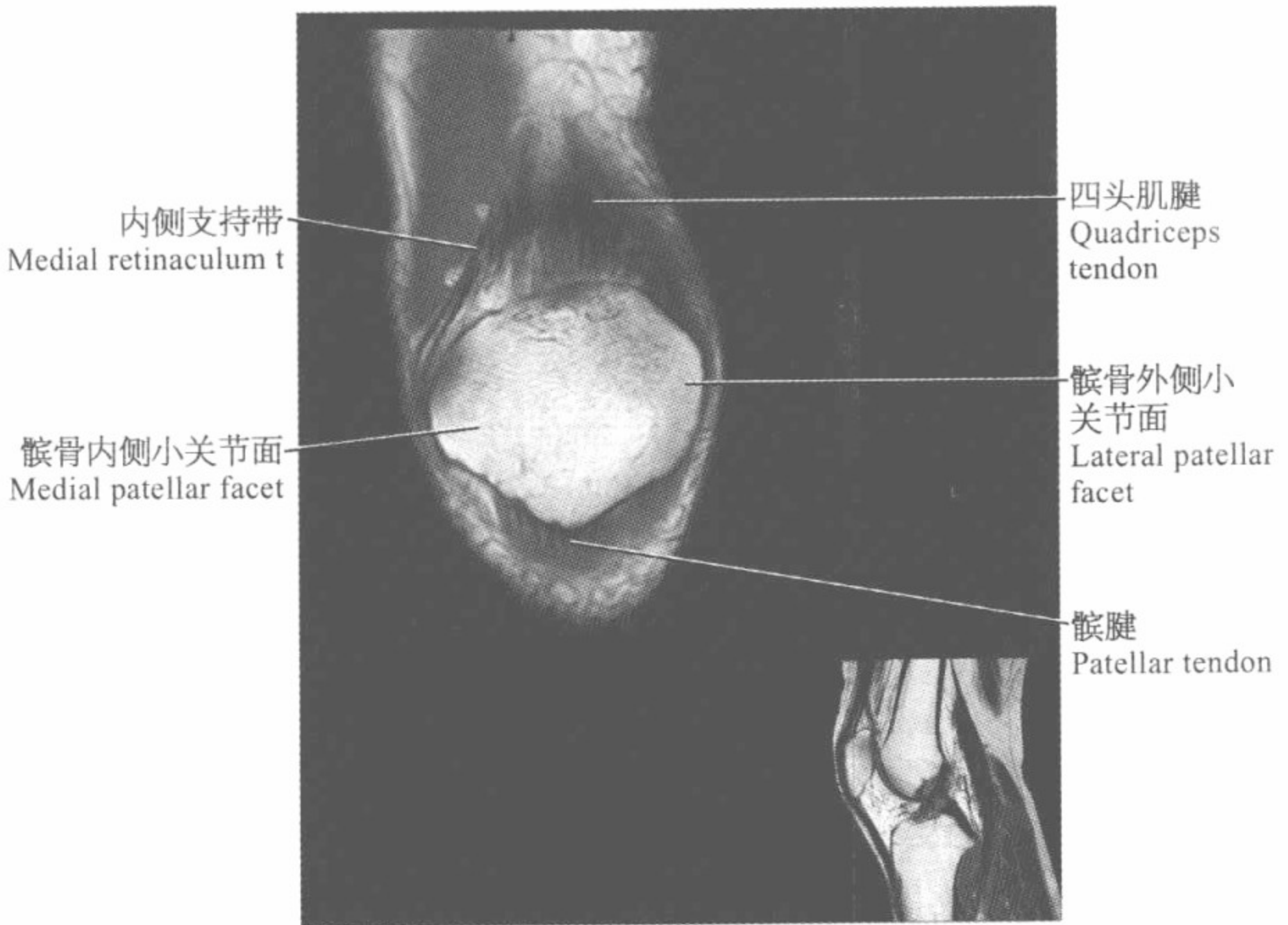
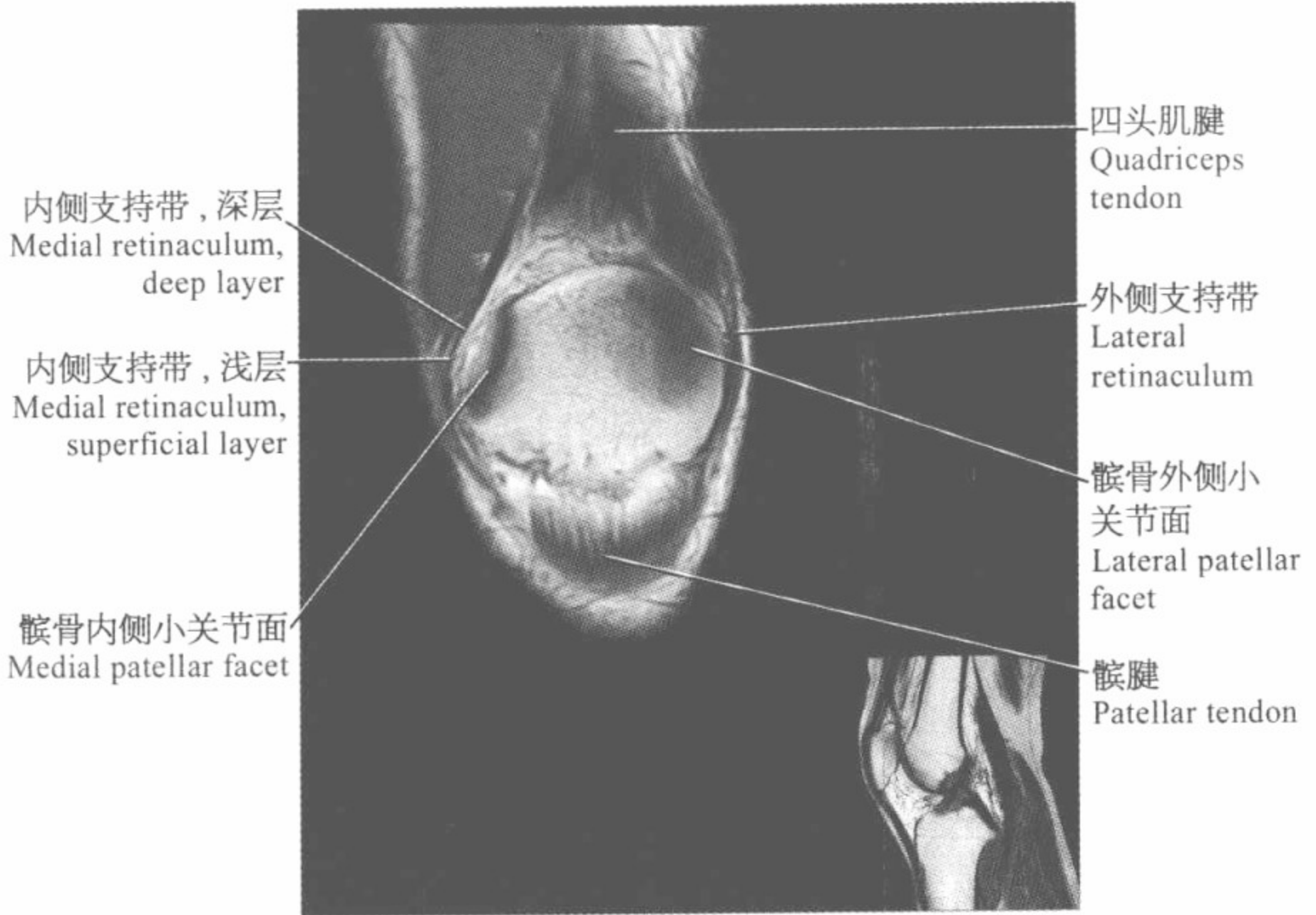
股骨前内侧髁
Anterior medial
femoral condyle

髌下脂肪垫
Infrapatellar
fat pad

髌腱
Patellar tendon





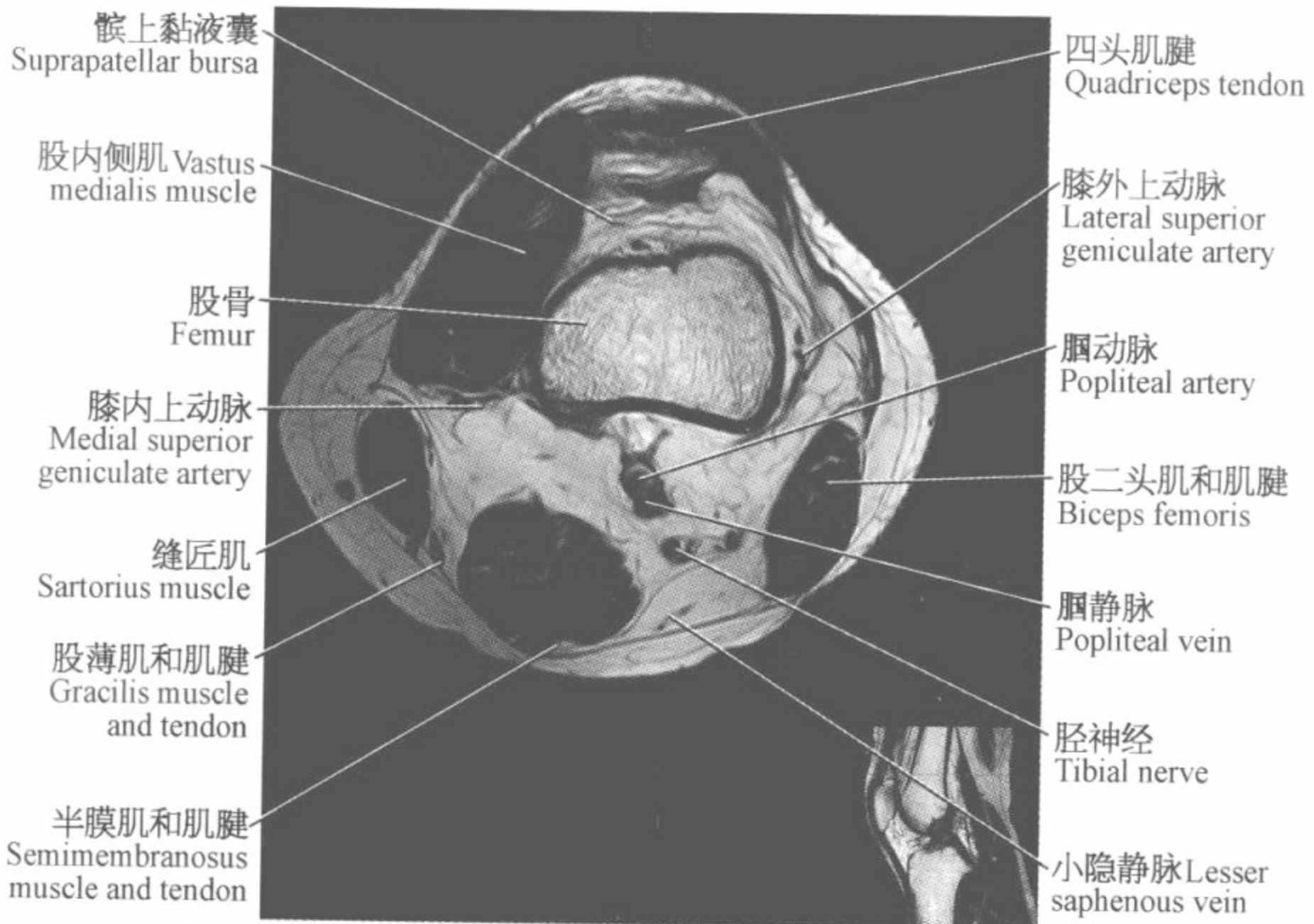
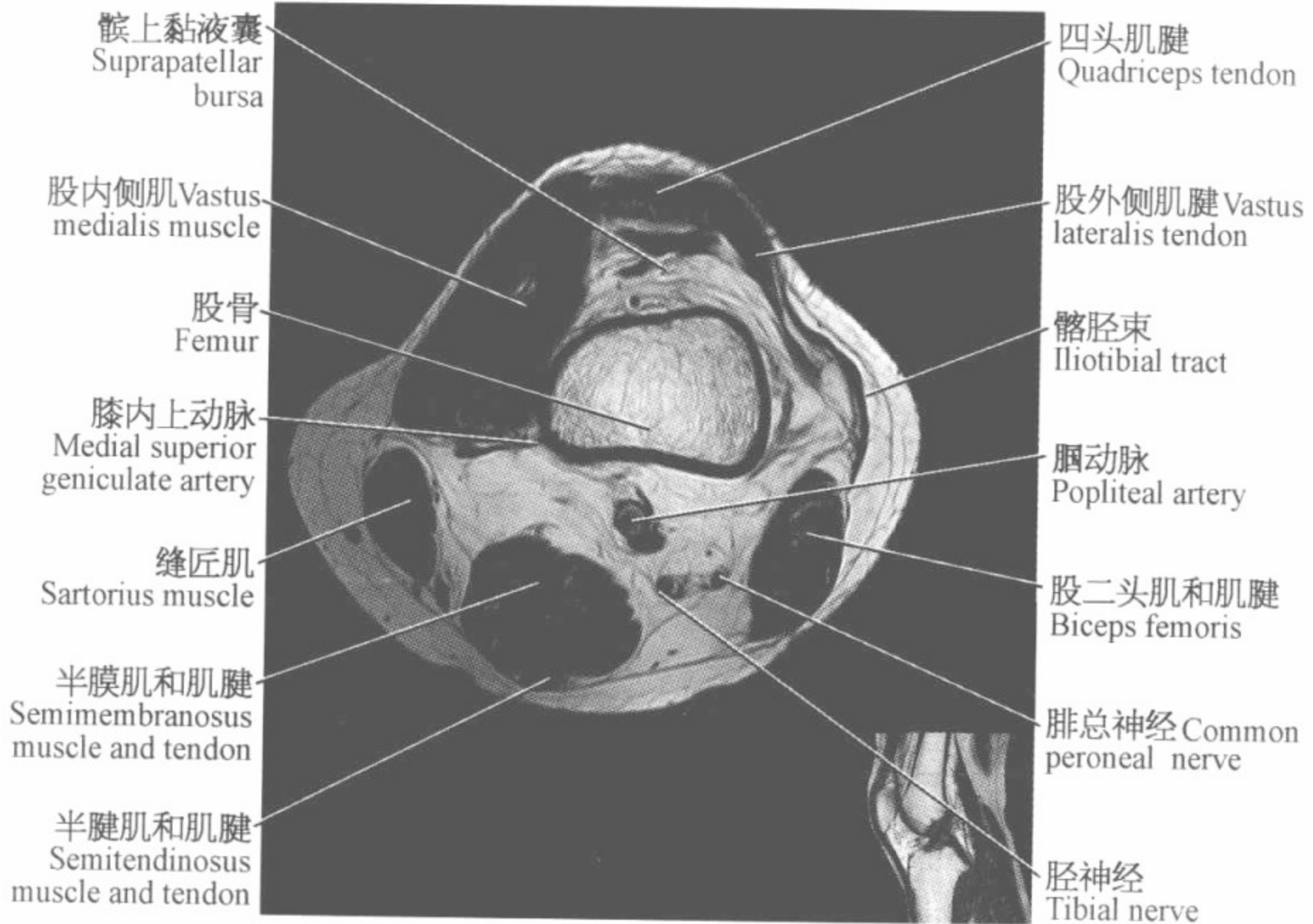


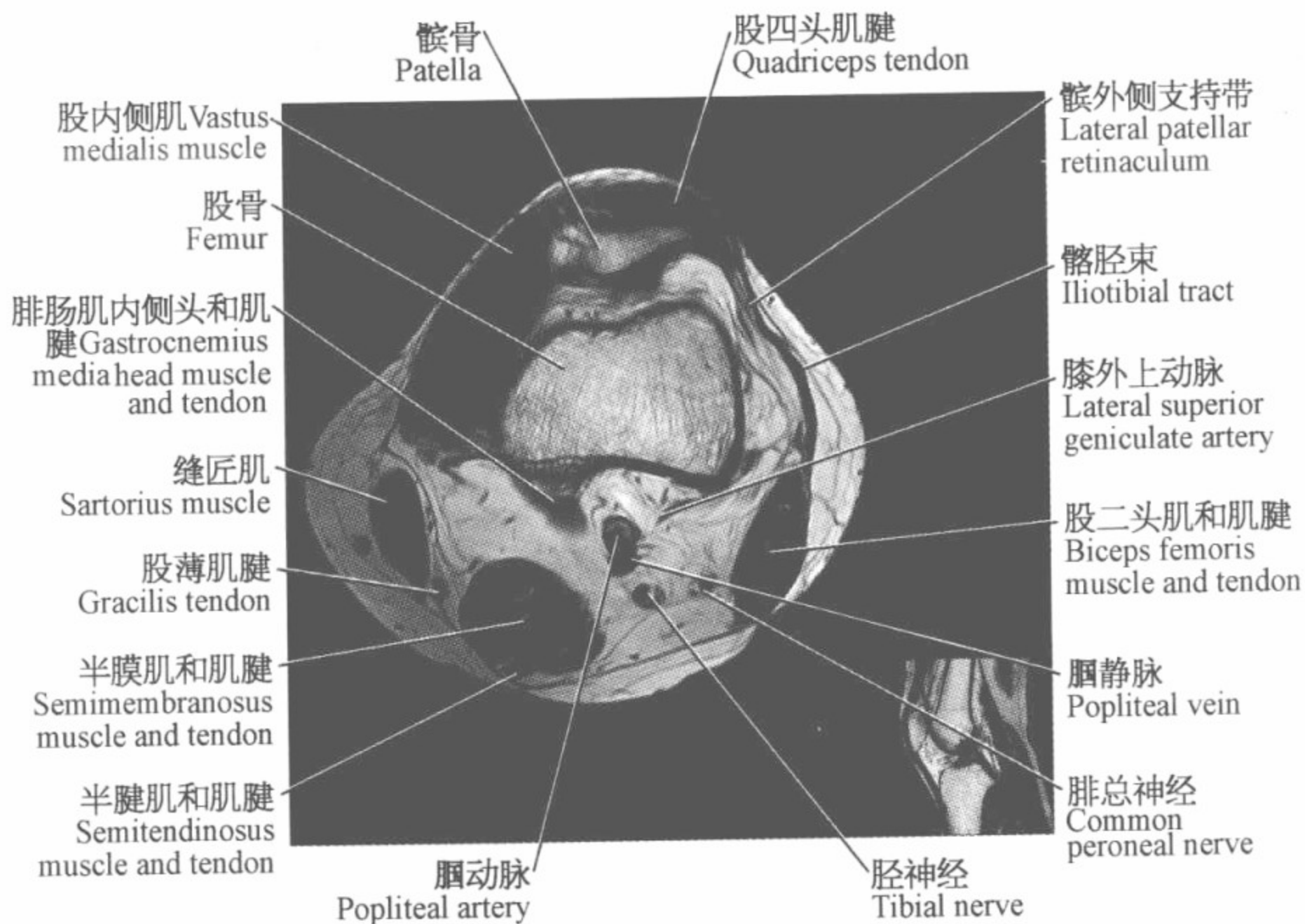
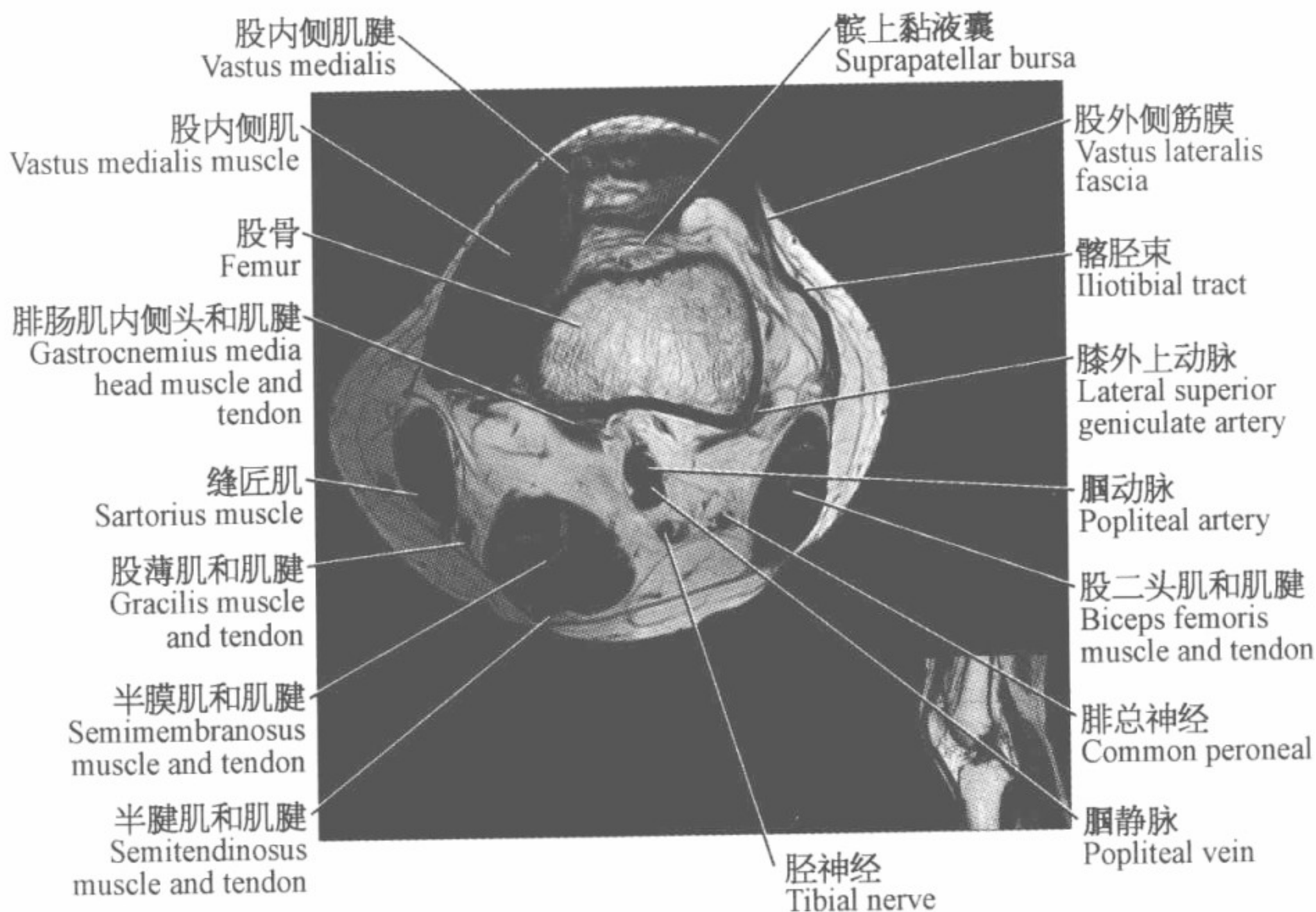


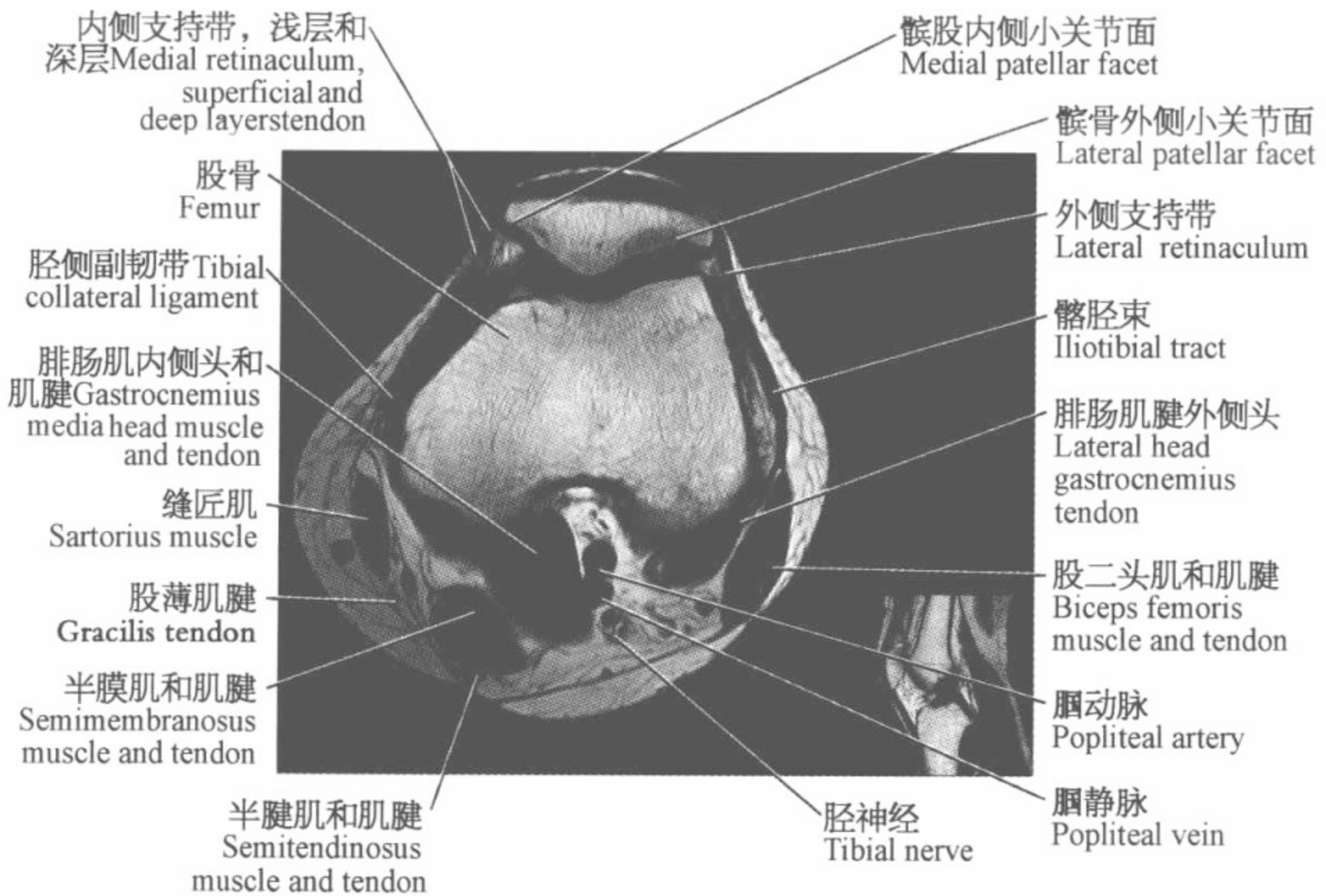
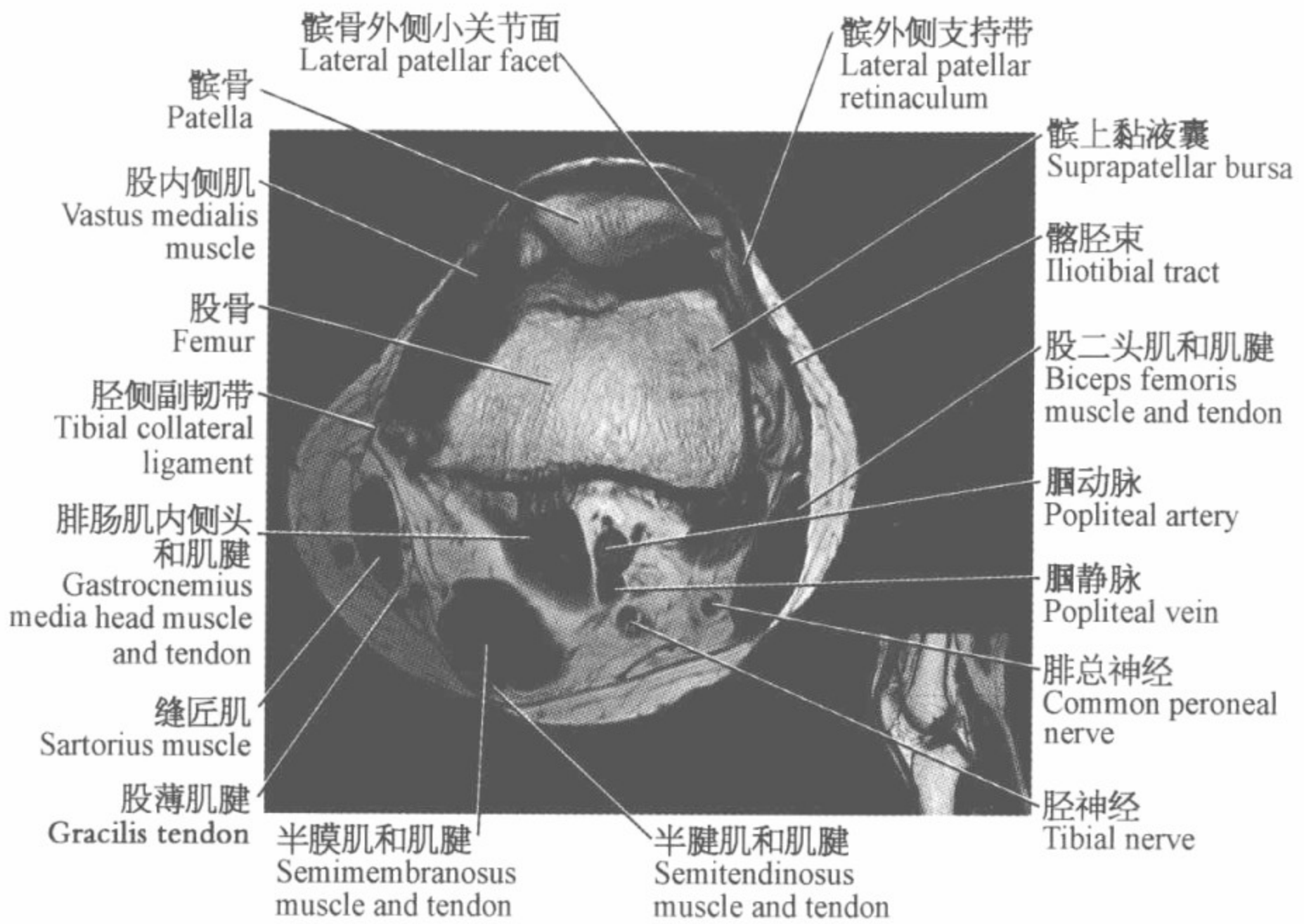
膝关节磁共振图谱

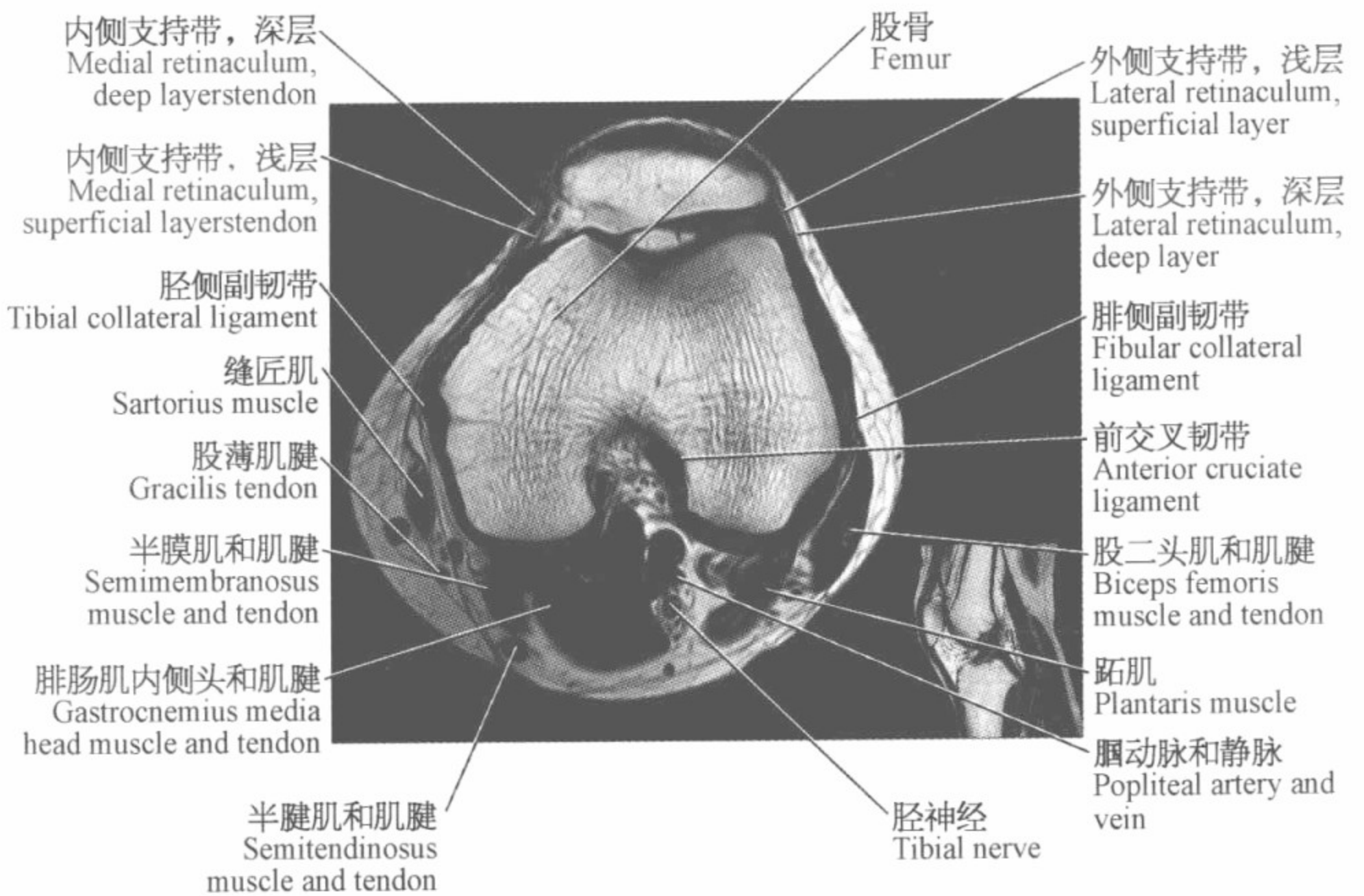
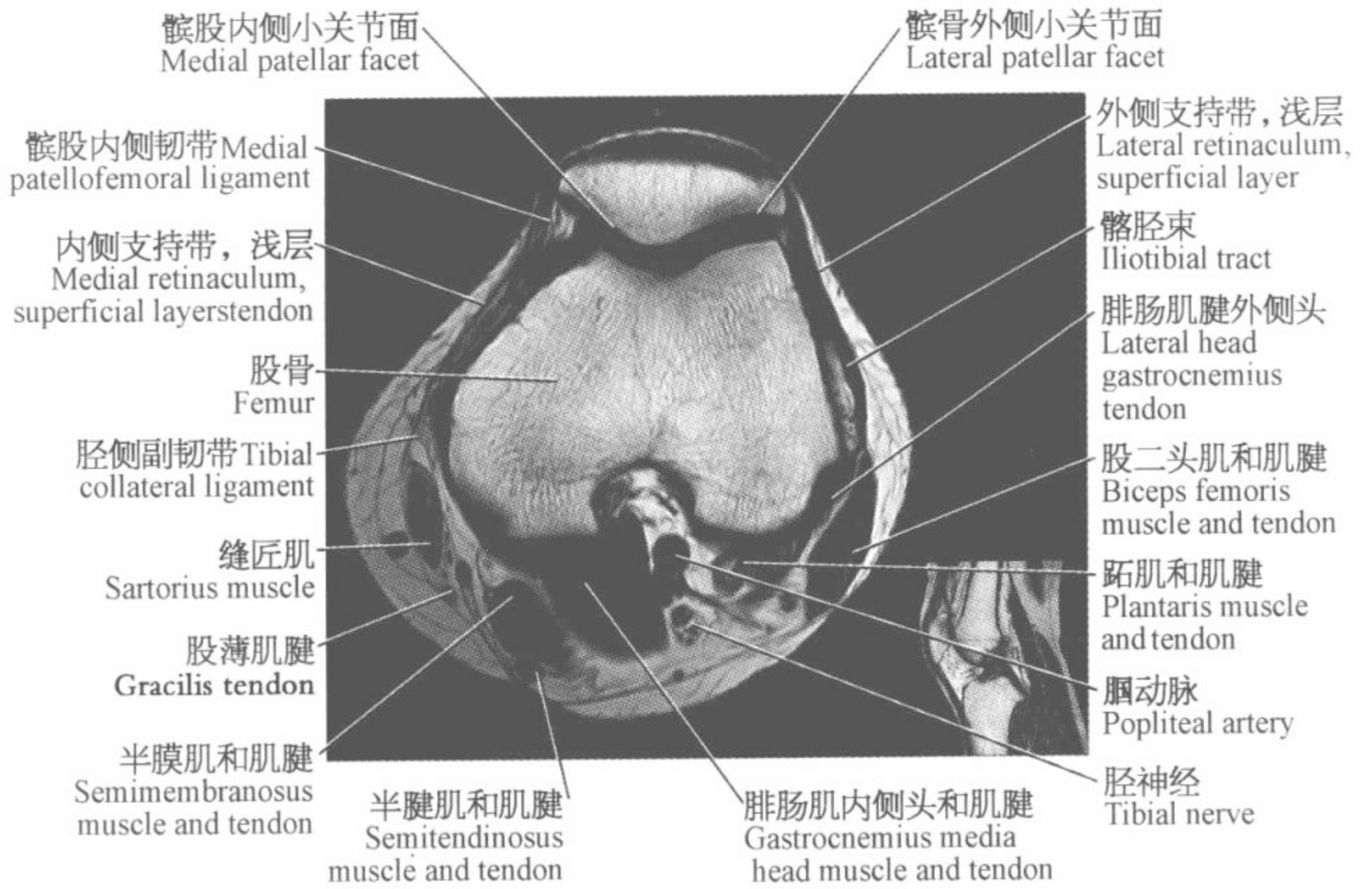
(横断位)

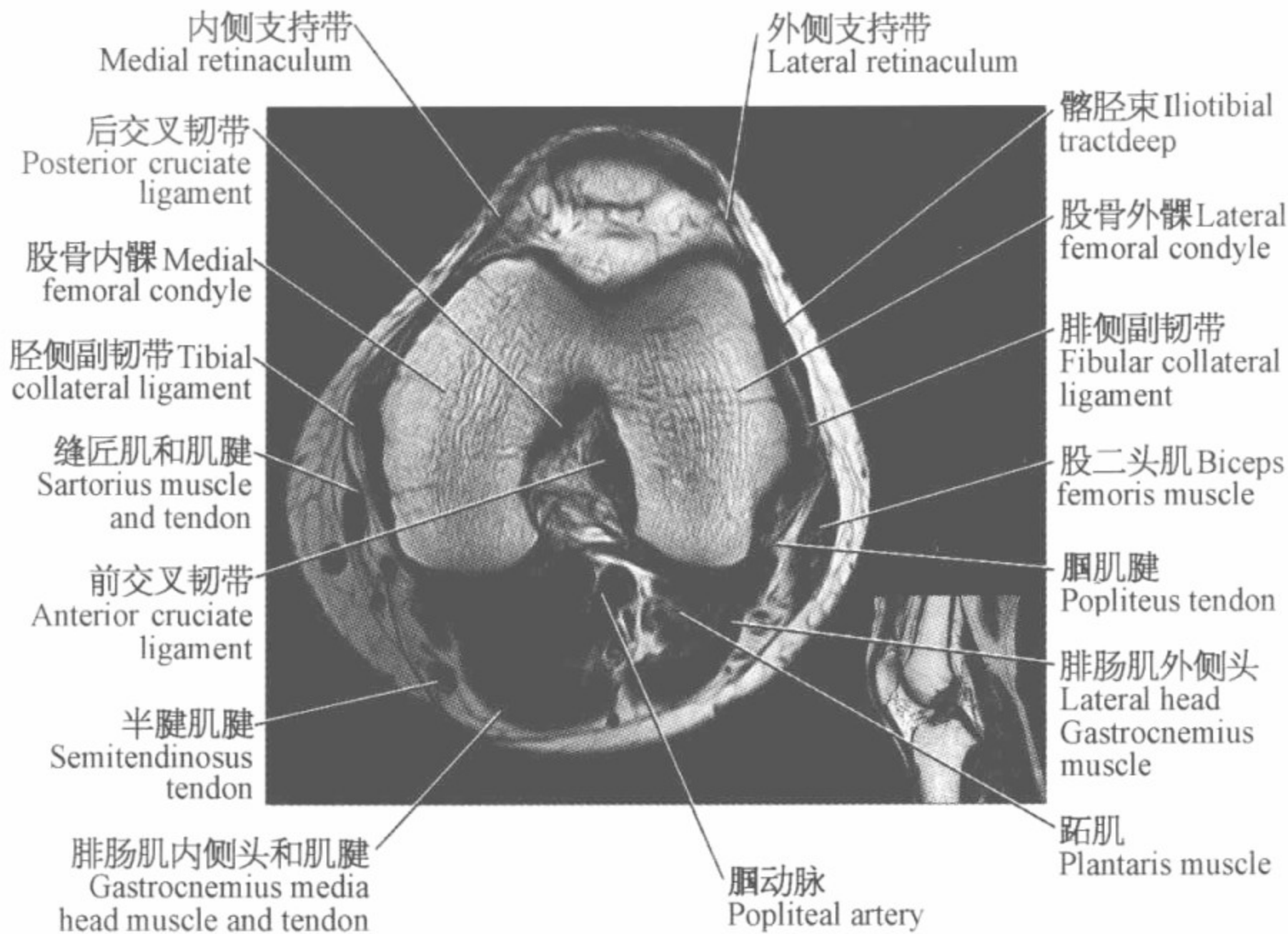
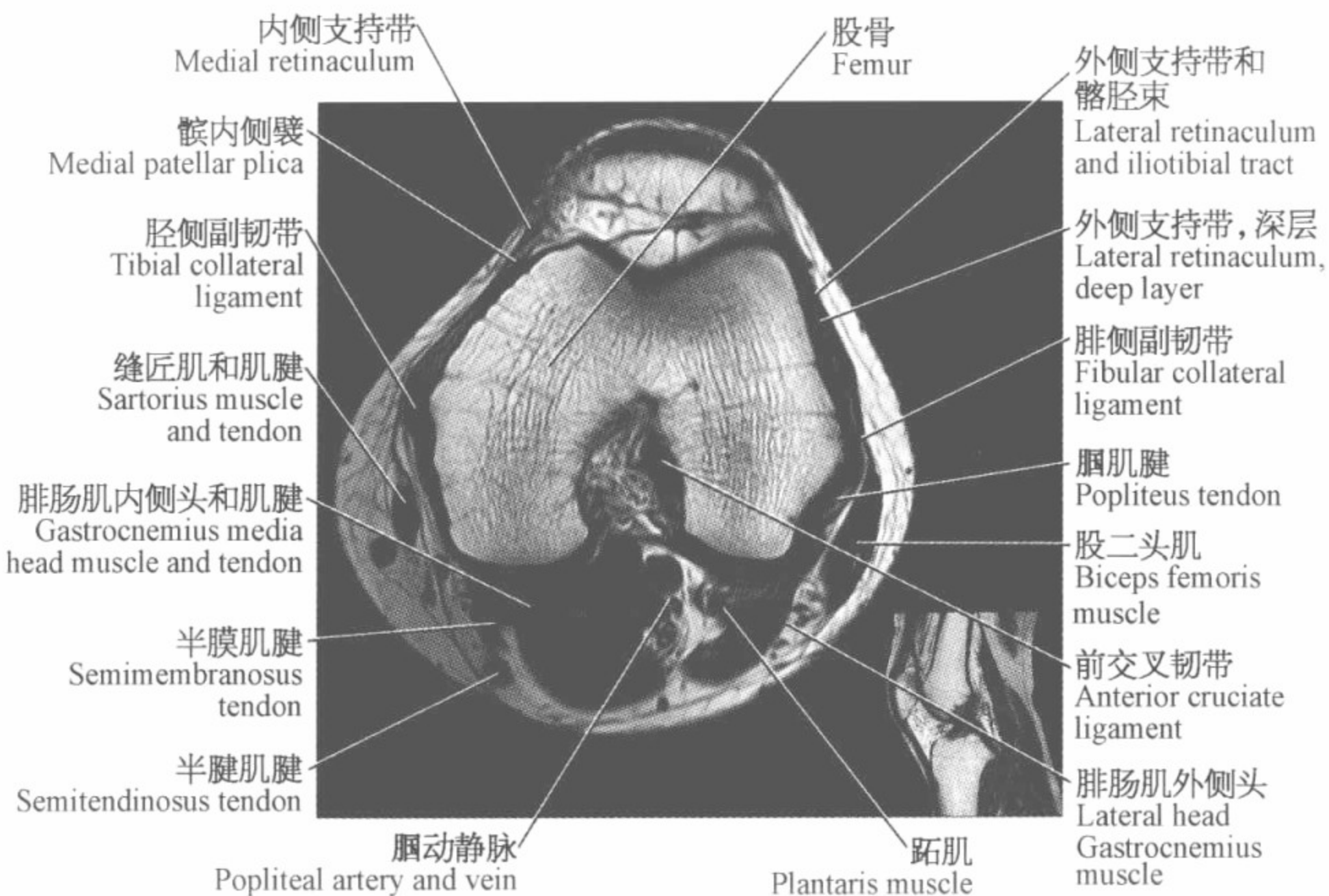


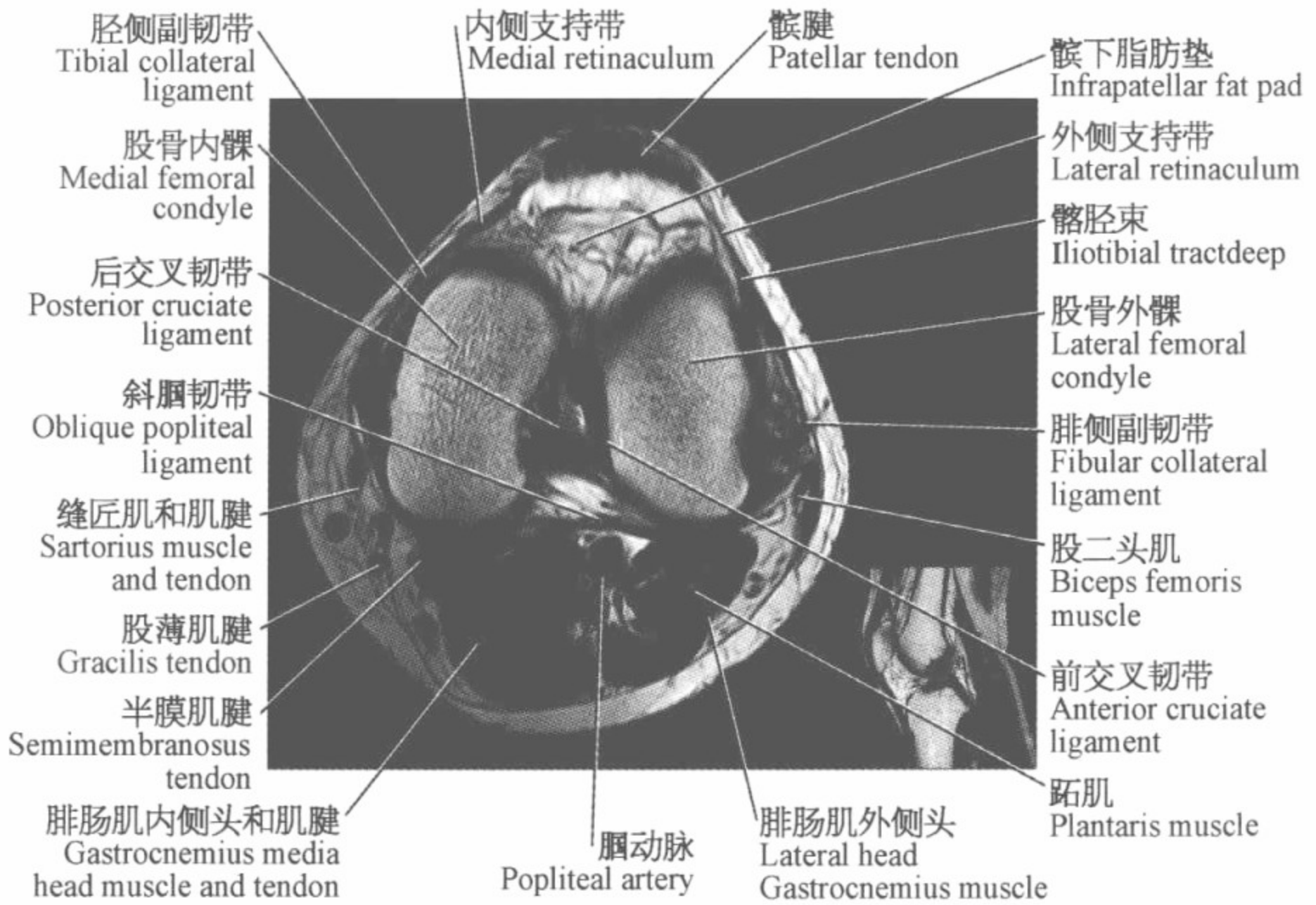
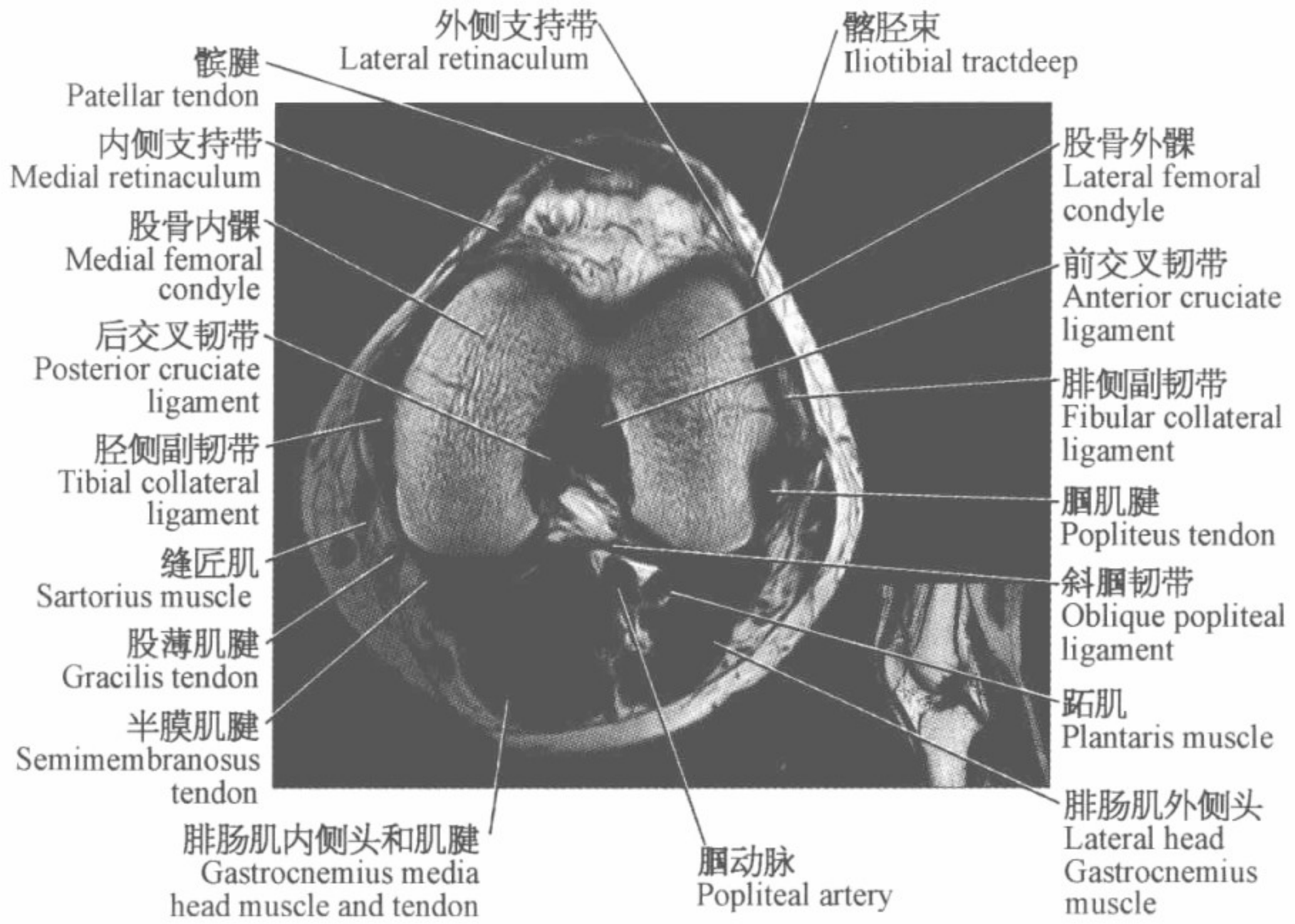


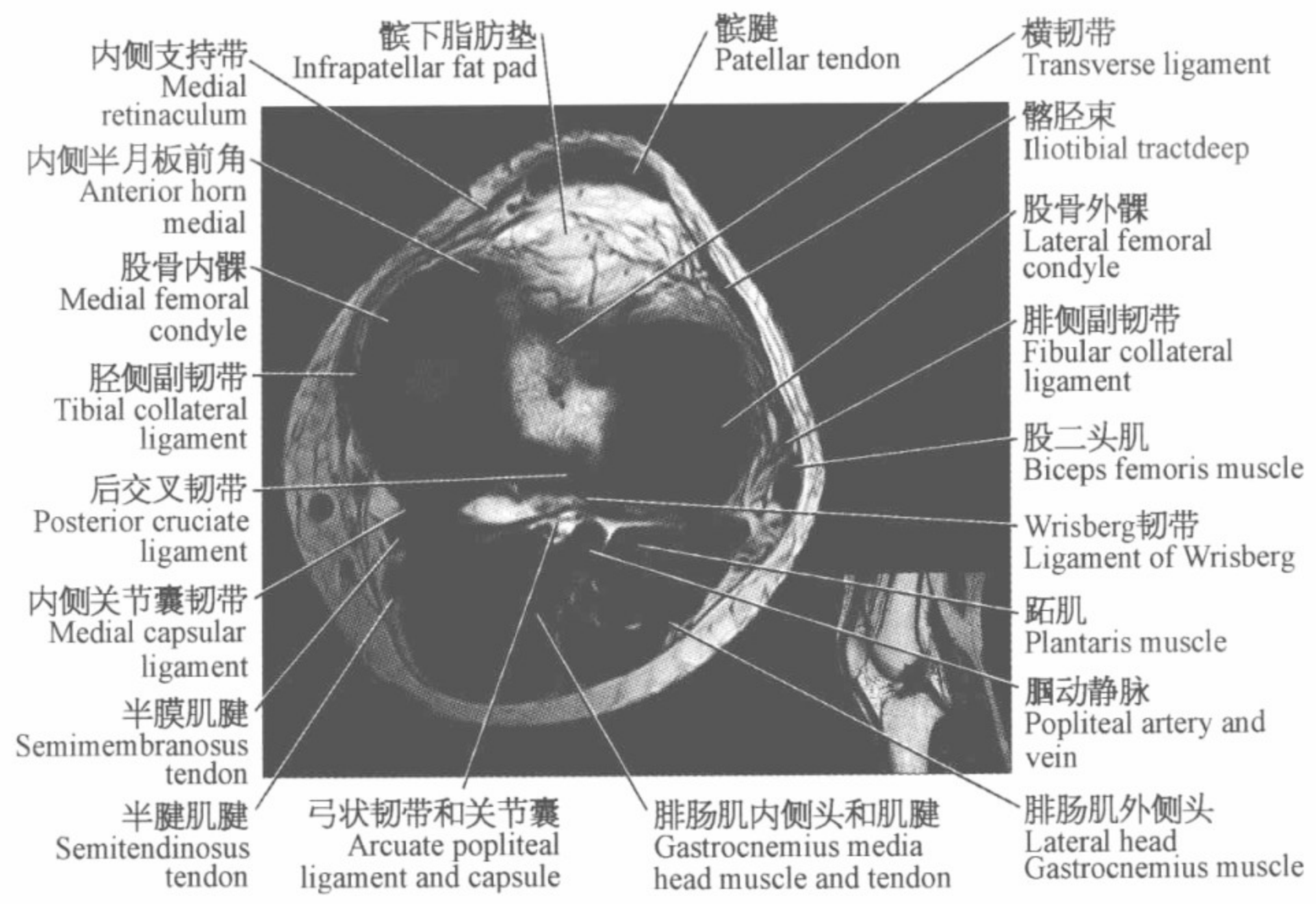
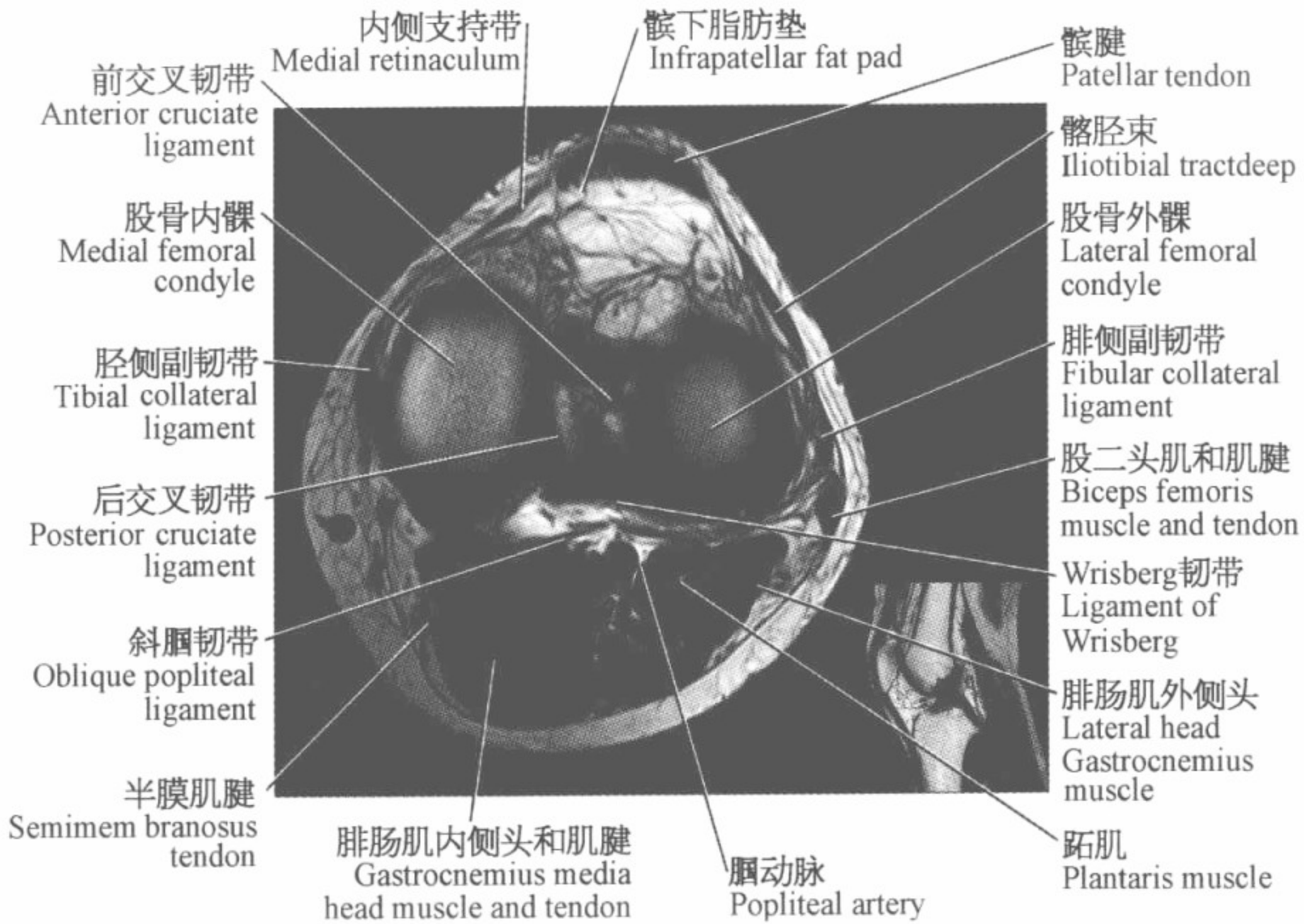


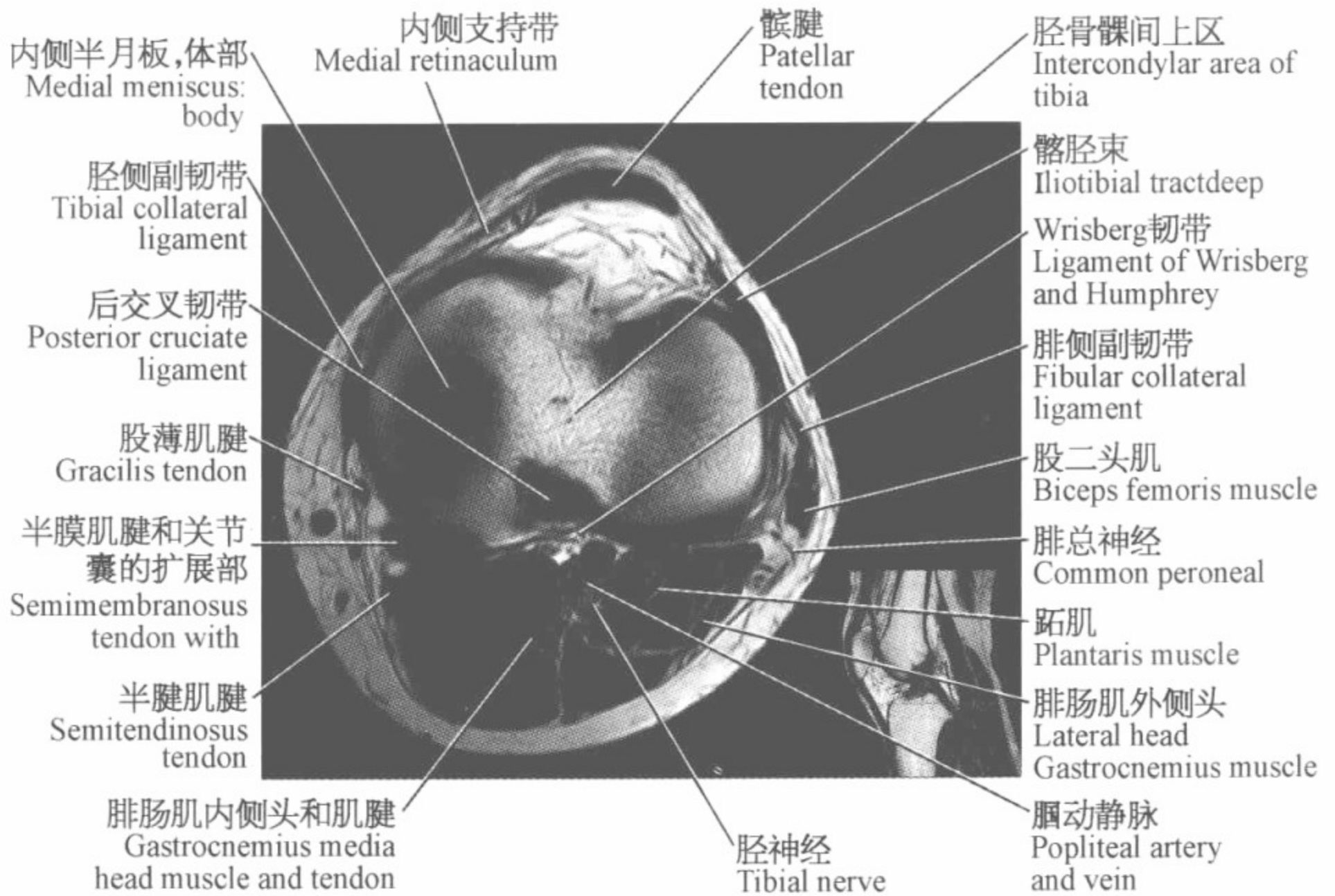
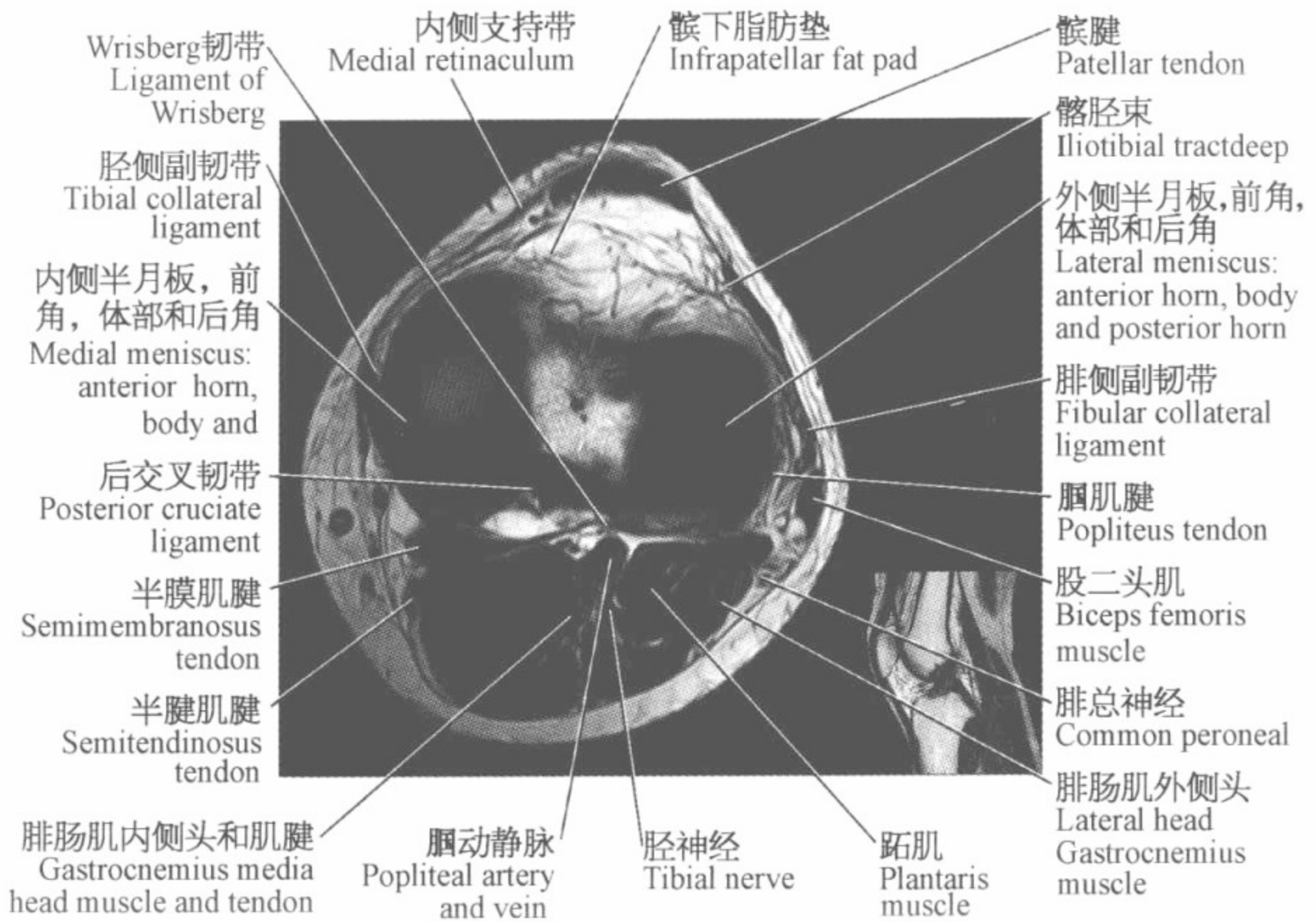


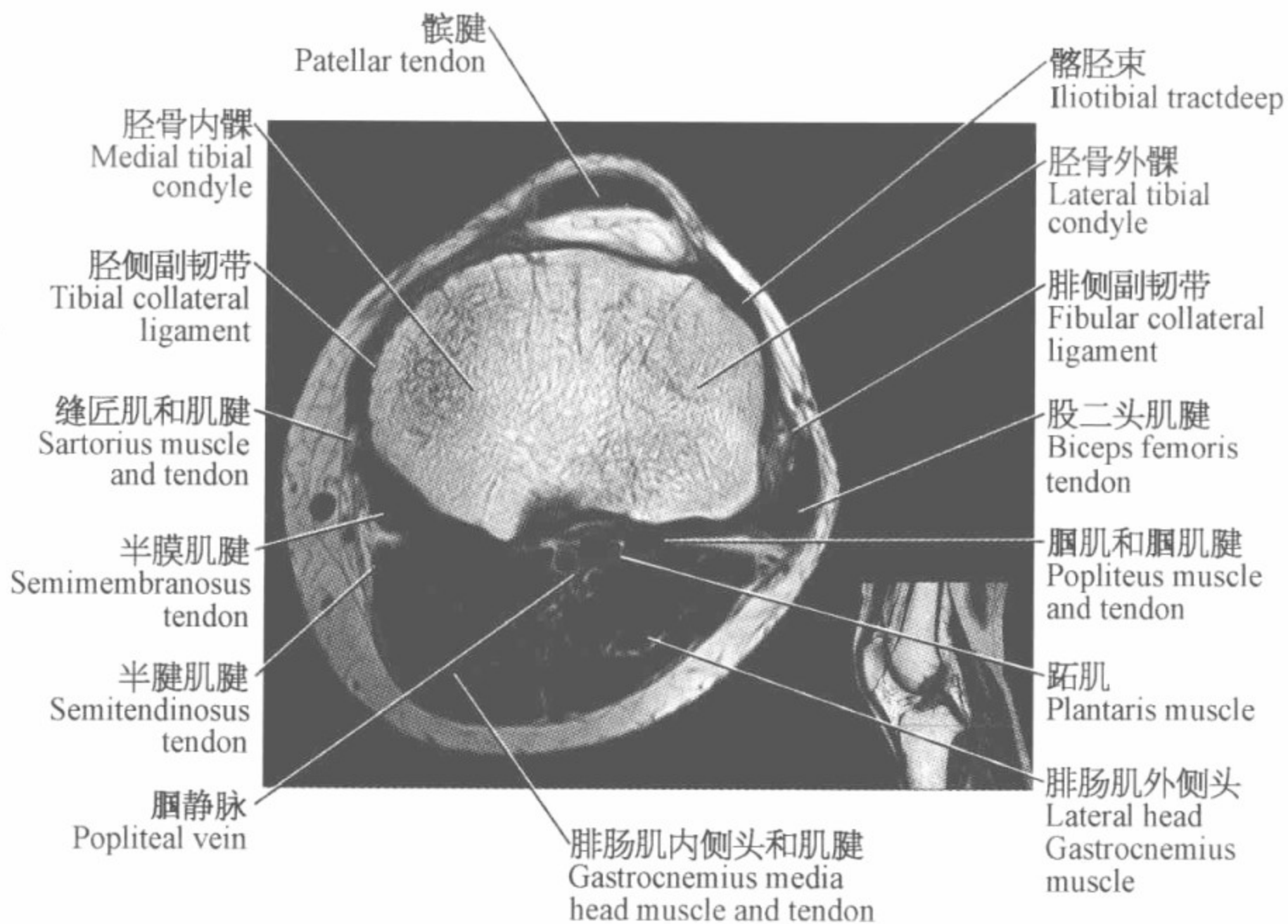
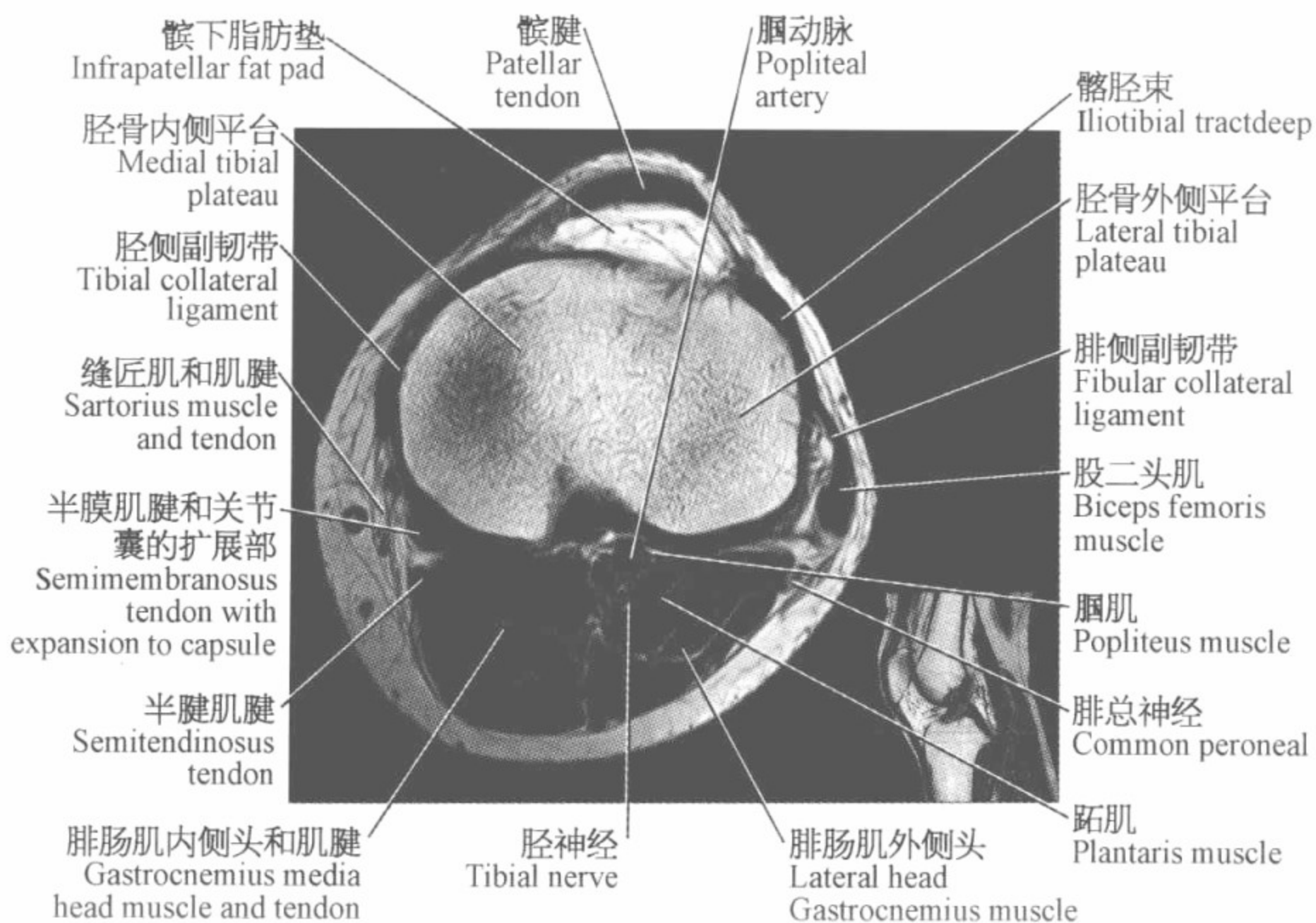


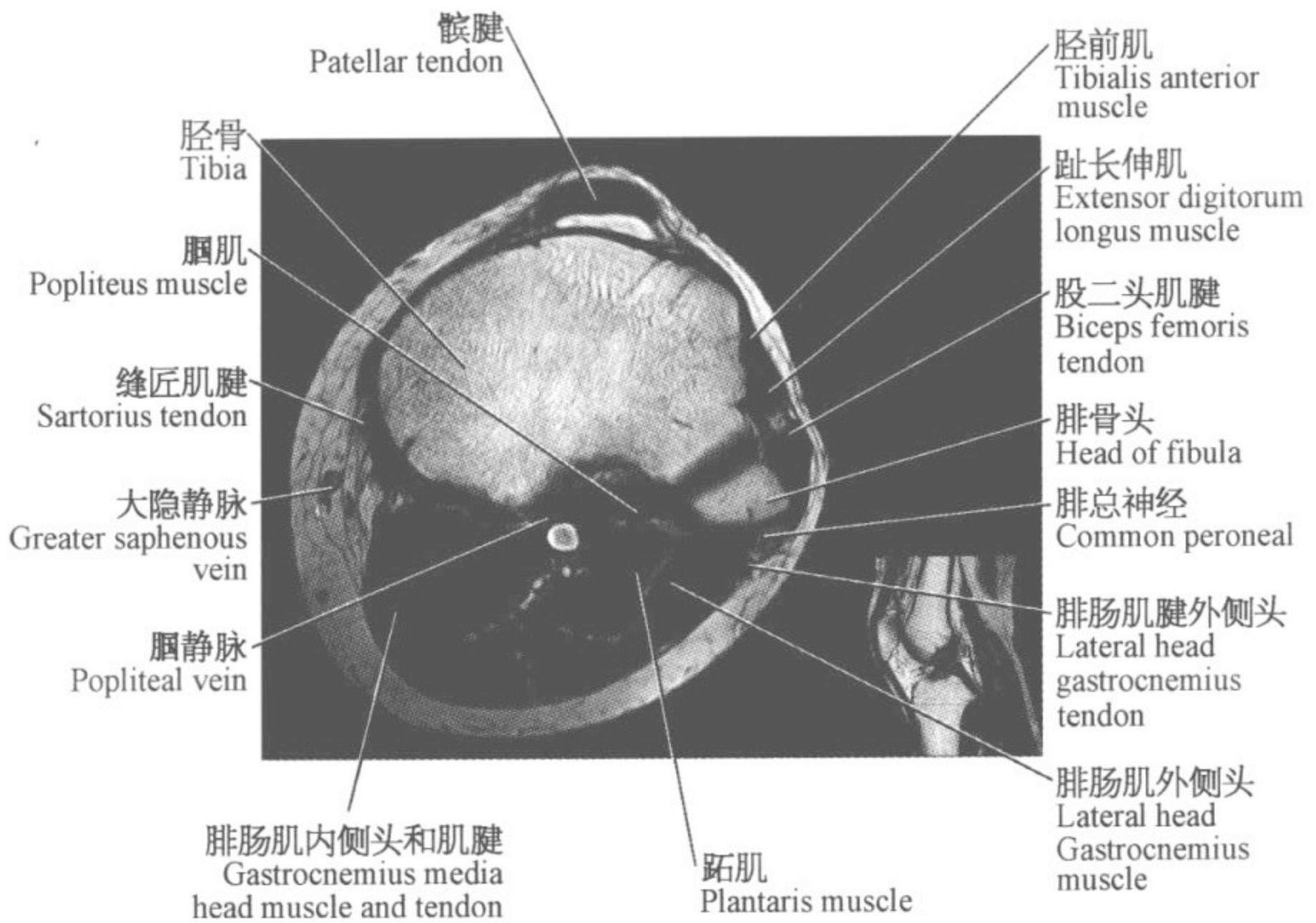
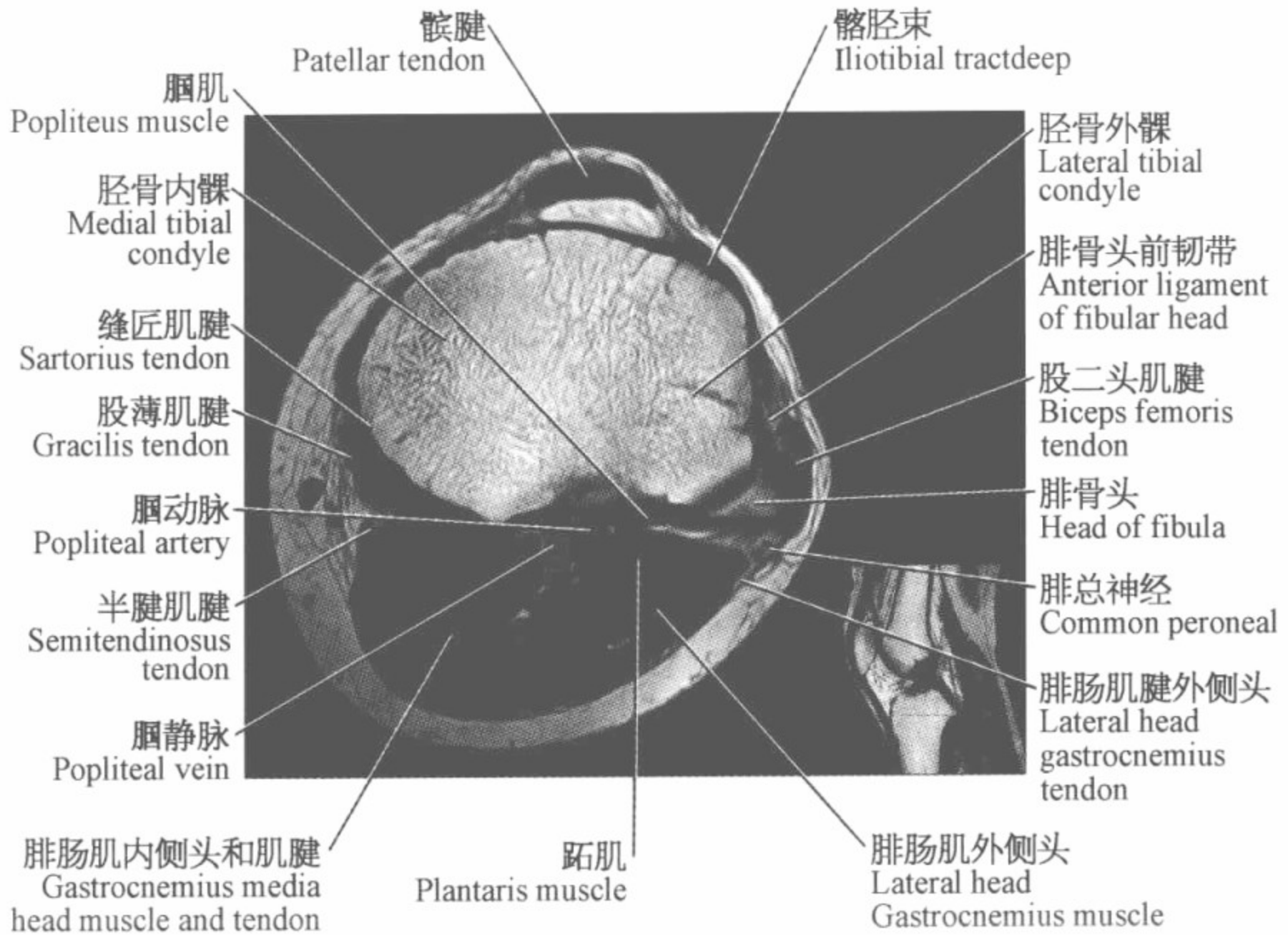








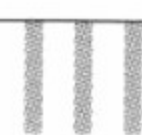




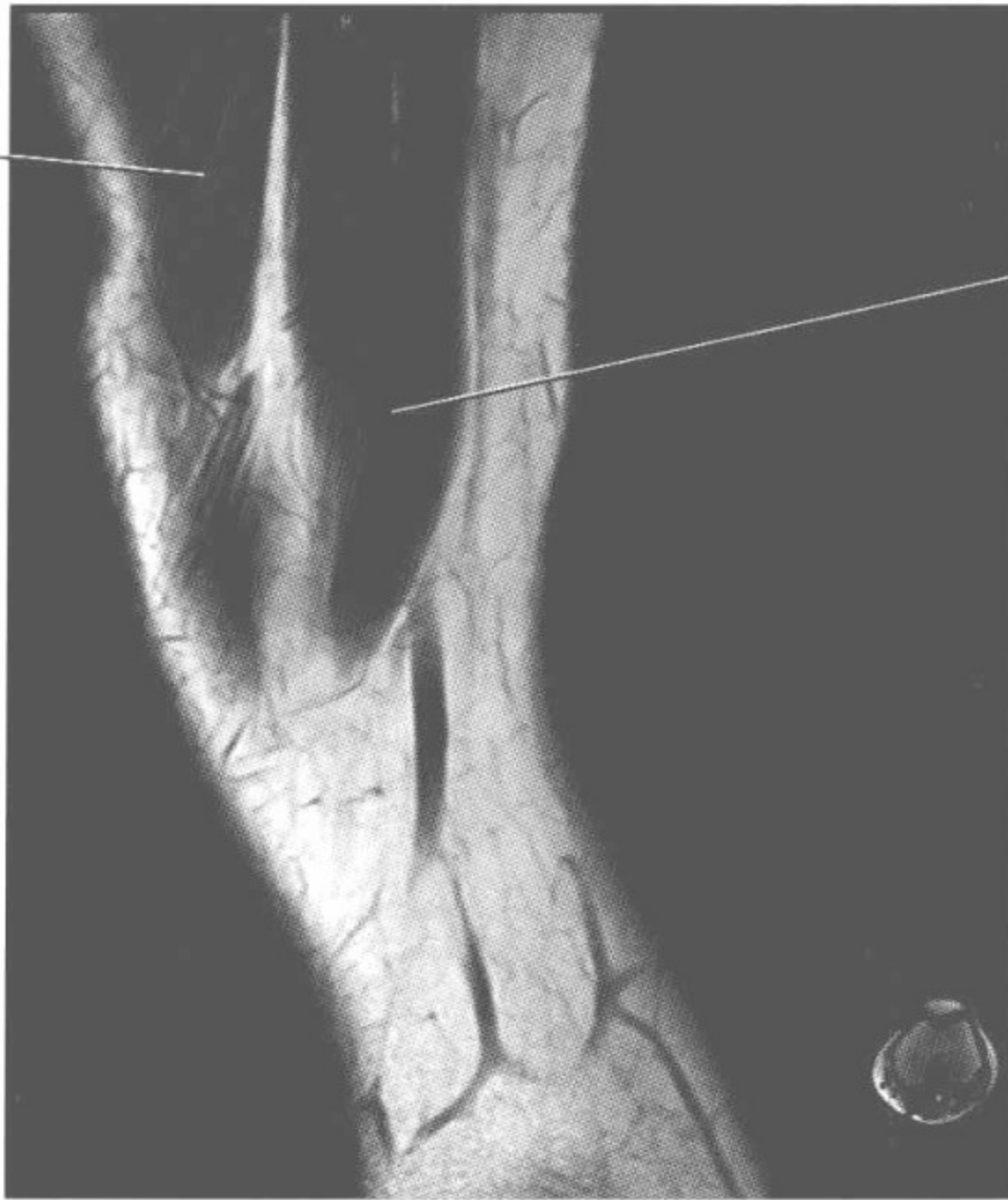
膝关节磁共振图谱

(矢状位)



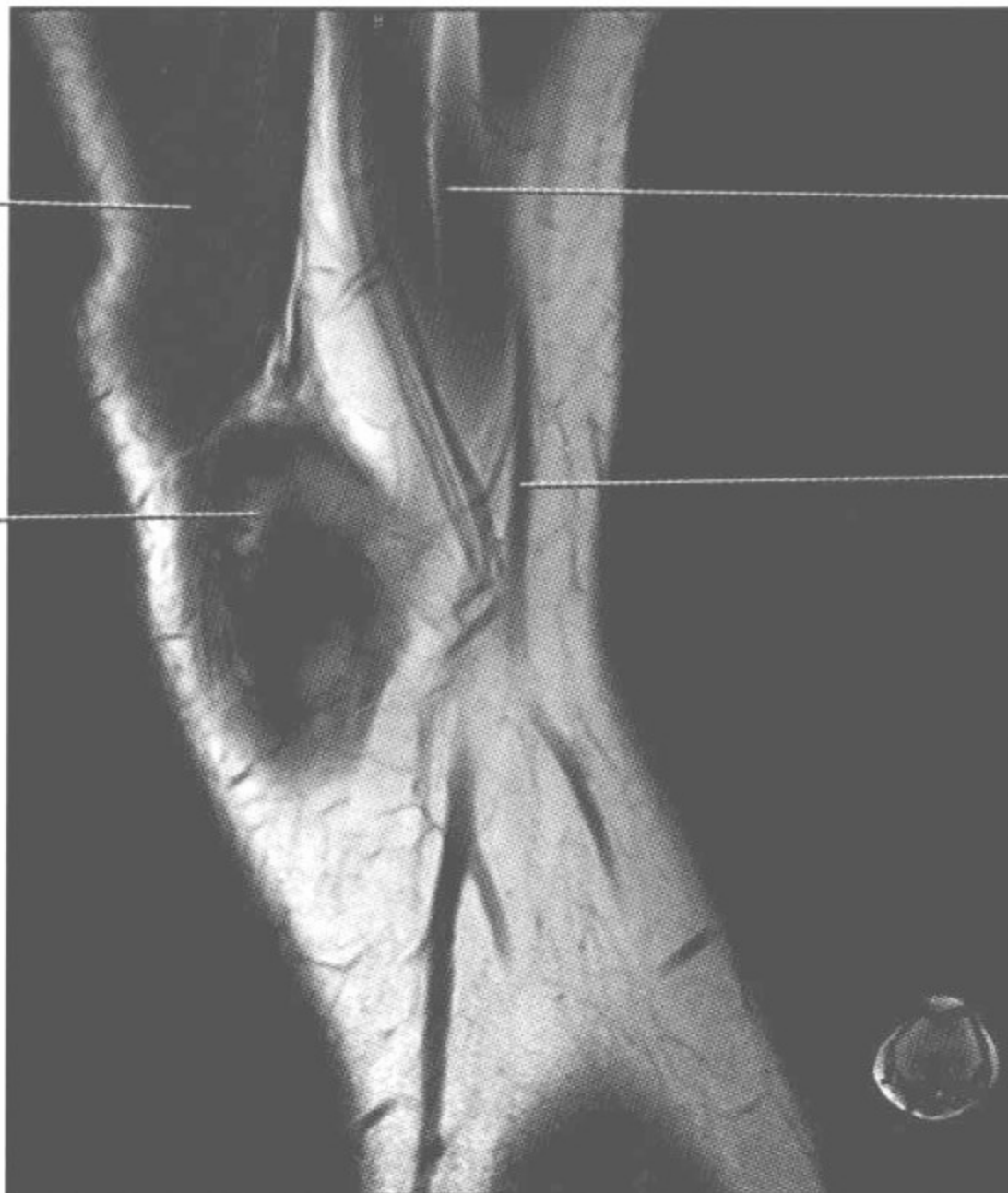股内侧肌
Vastus medialis
muscle



缝匠肌
Sartorius muscle

股内侧肌
Vastus medialis
muscle

股骨内髁
Medial femoral
condyle



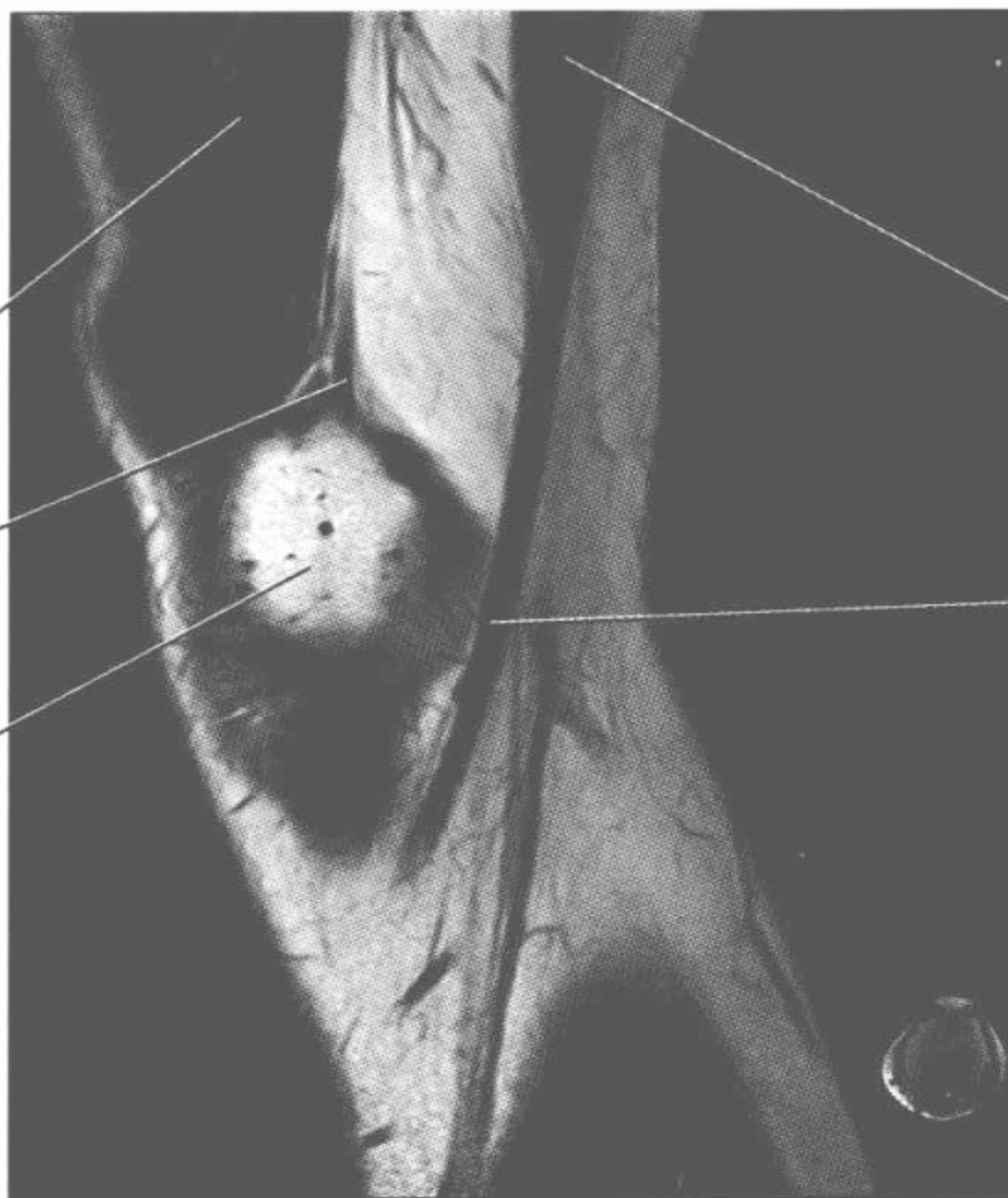缝匠肌
Sartorius muscle

大隐静脉
Great saphenous
vein

股内侧肌
Vastus medialis
muscle

大收肌腱
Adductor magnus
tendon

股骨内髁
Medial femoral
condyle



缝匠肌
Sartorius muscle

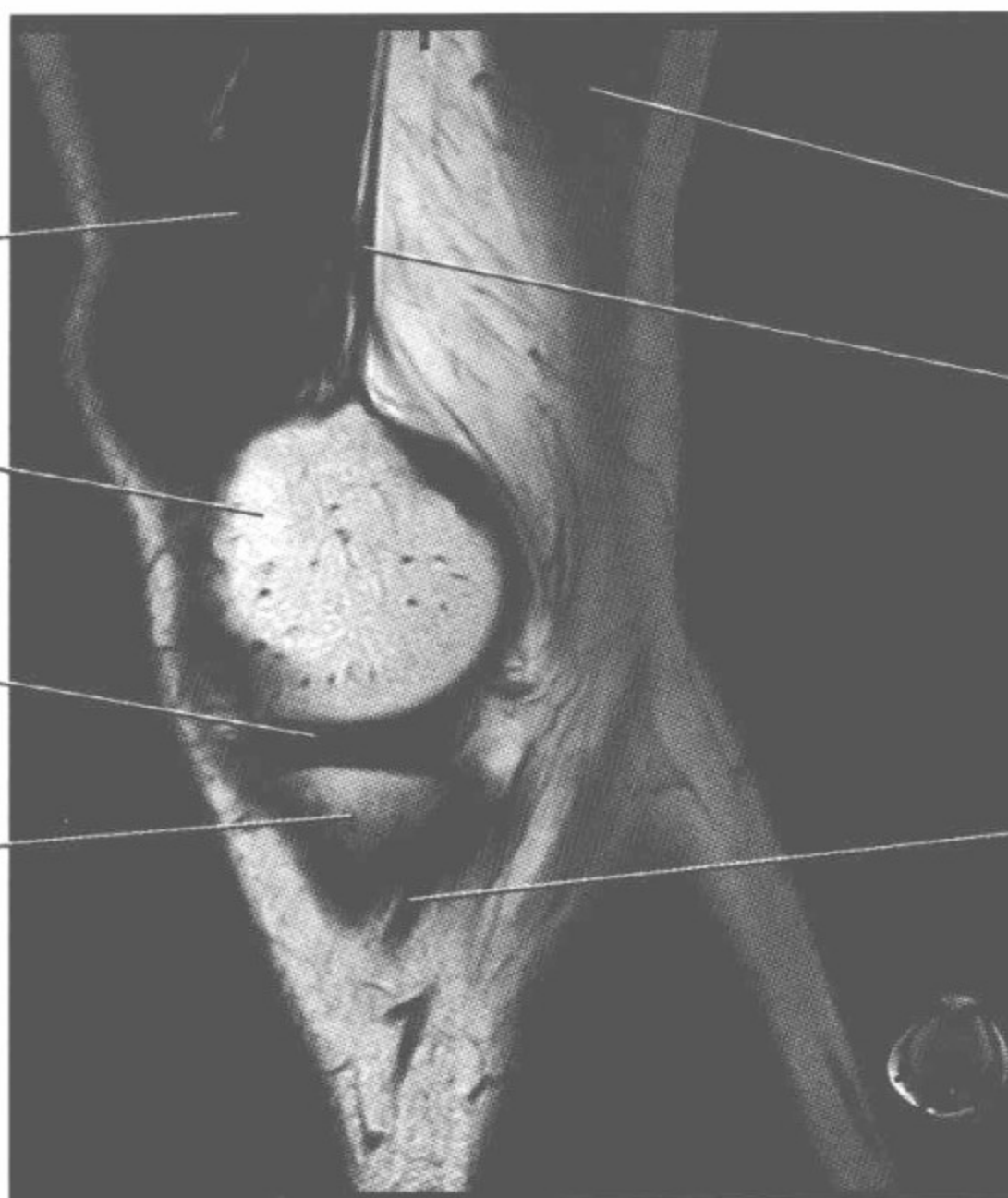
缝匠肌腱
Sartorius tendon

股内侧肌
Vastus medialis
muscle

股骨内髁
Medial femoral
condyle

内侧半月板
Medial meniscus

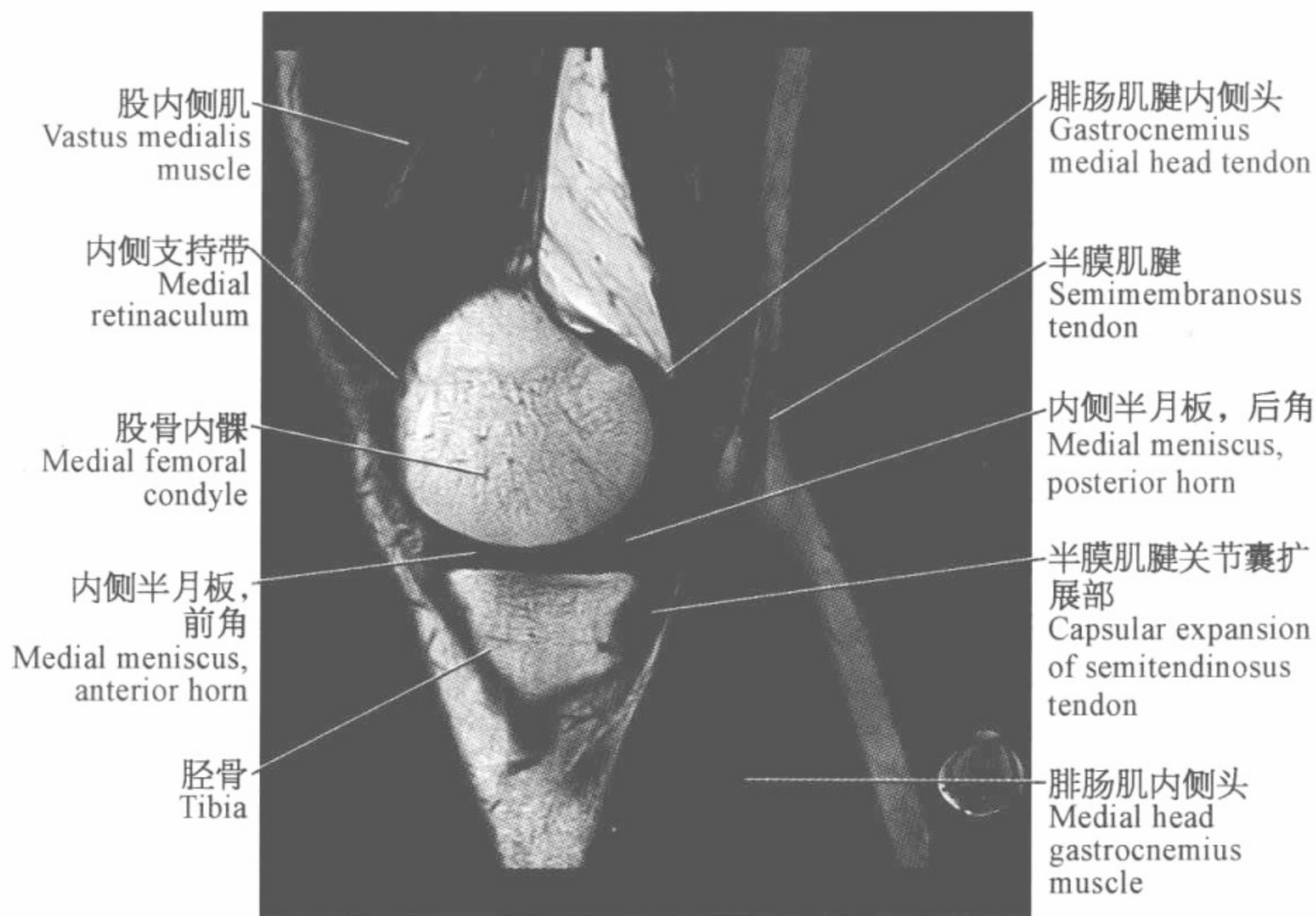
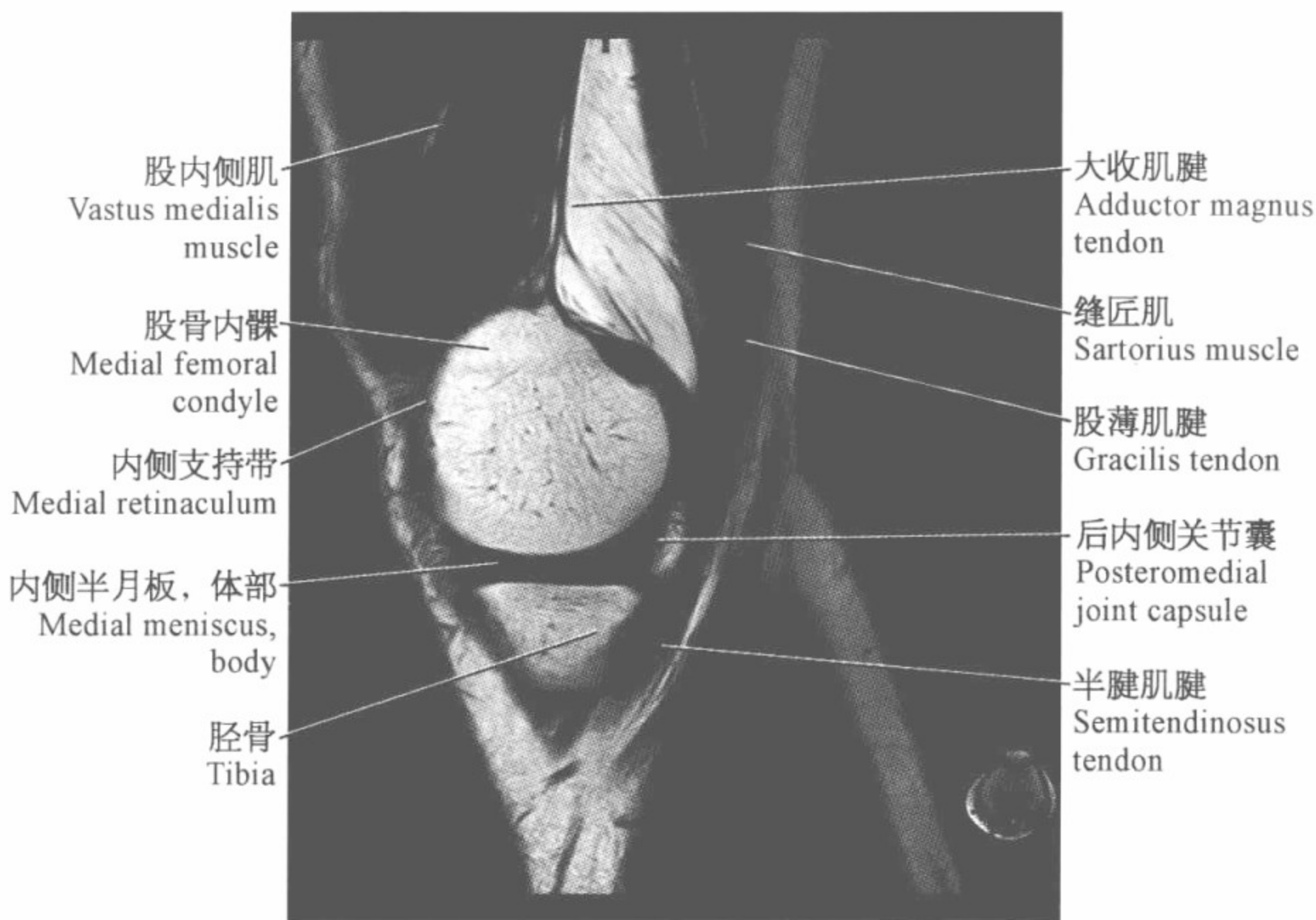
胫骨
Tibia

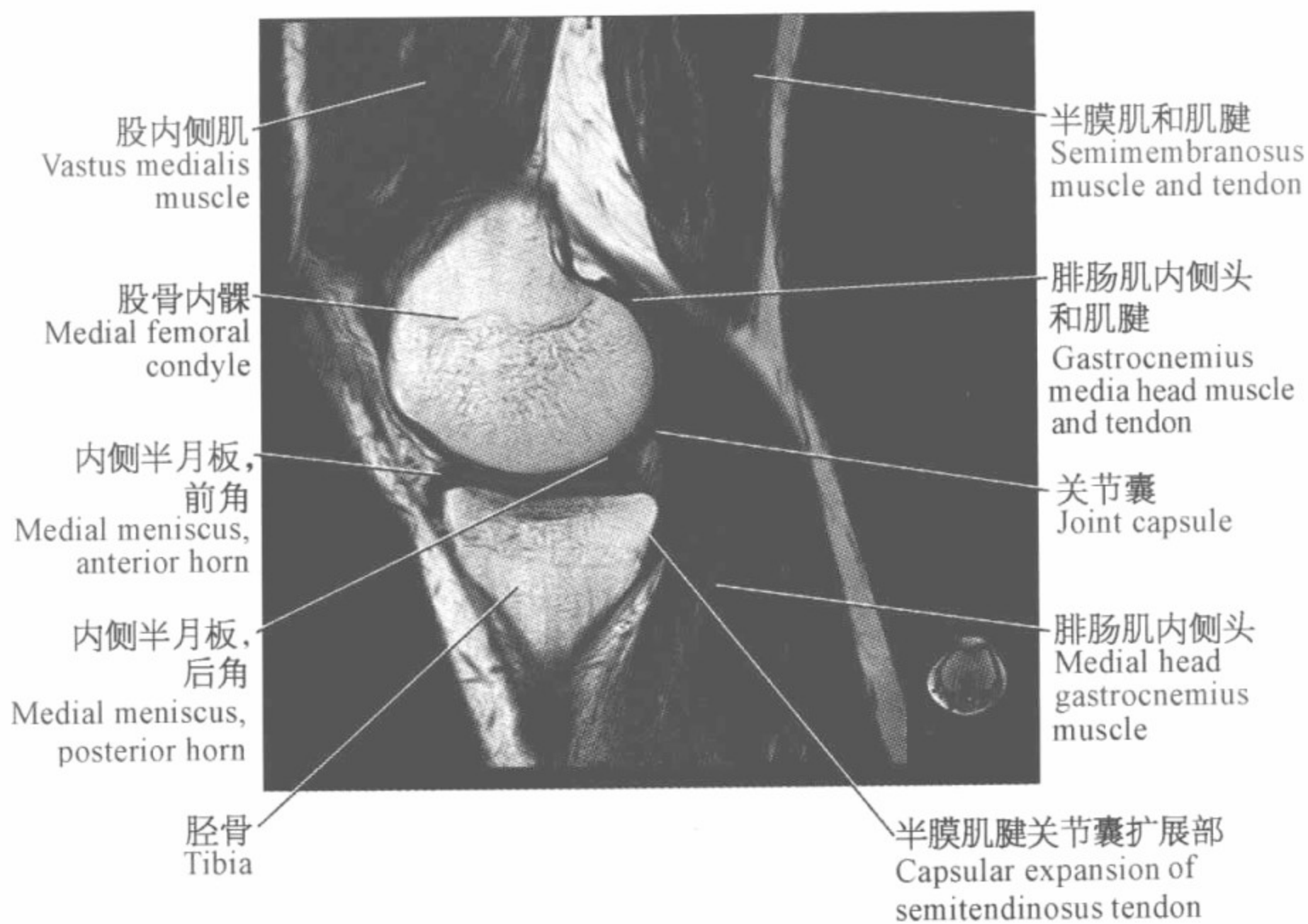
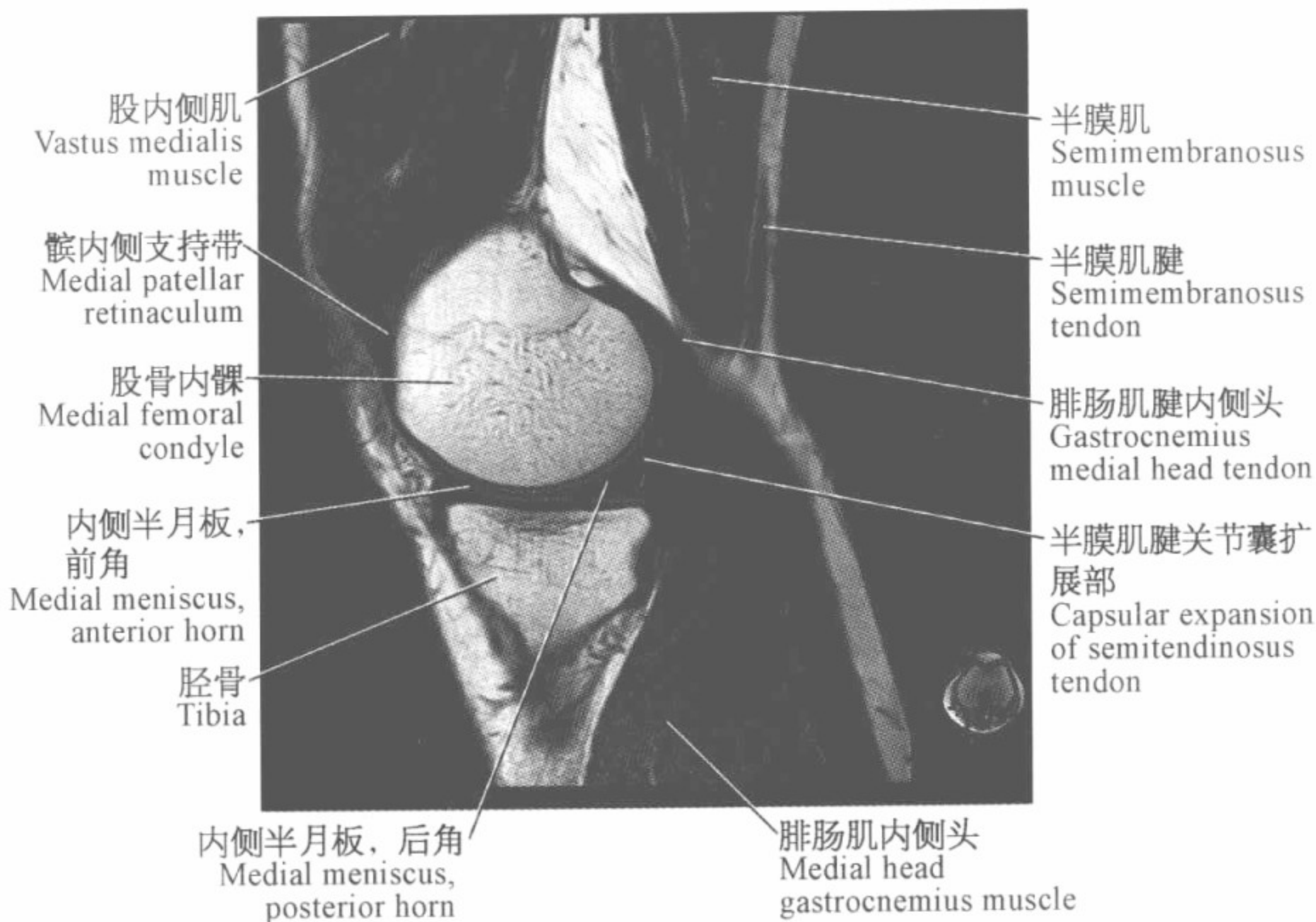


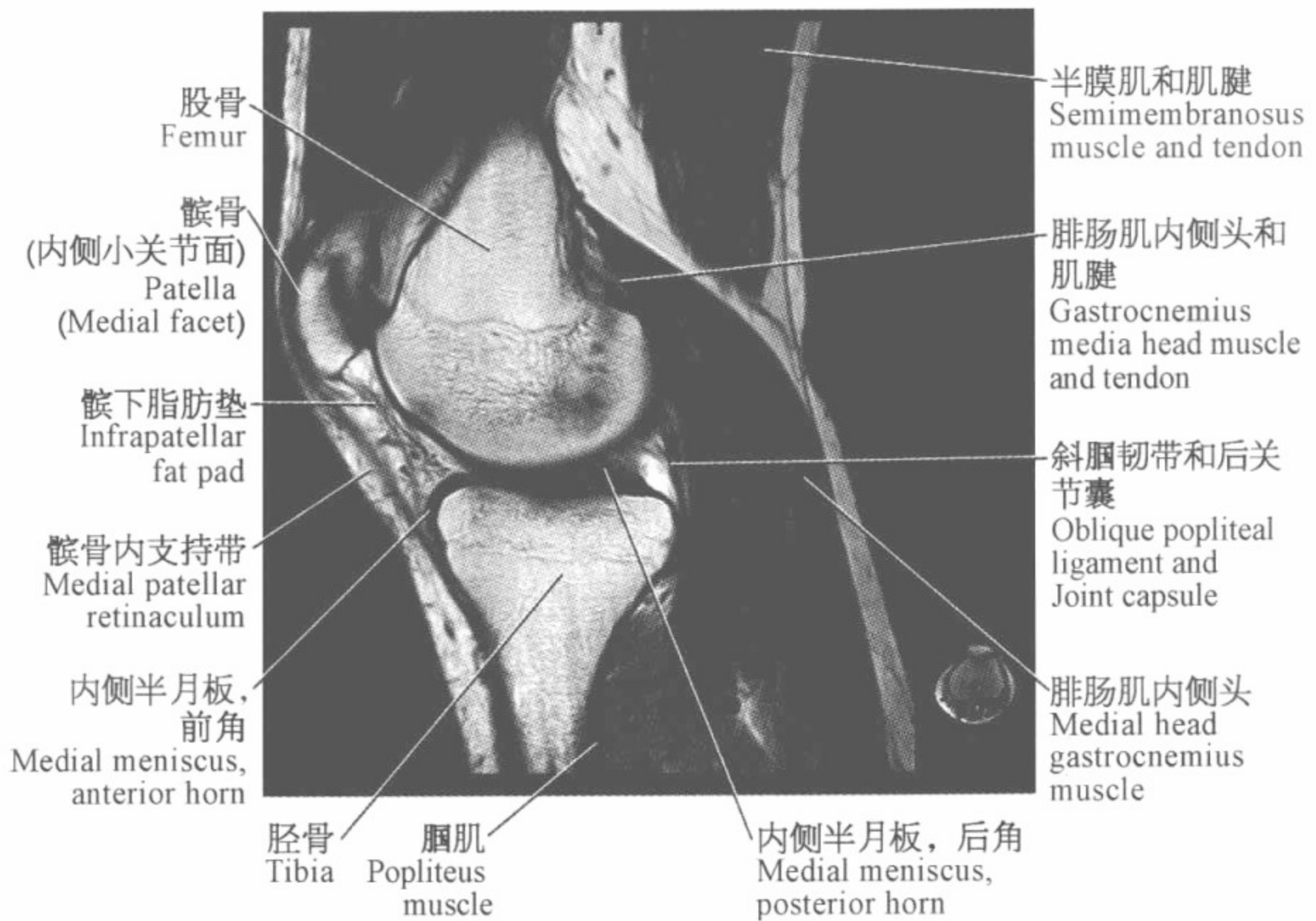
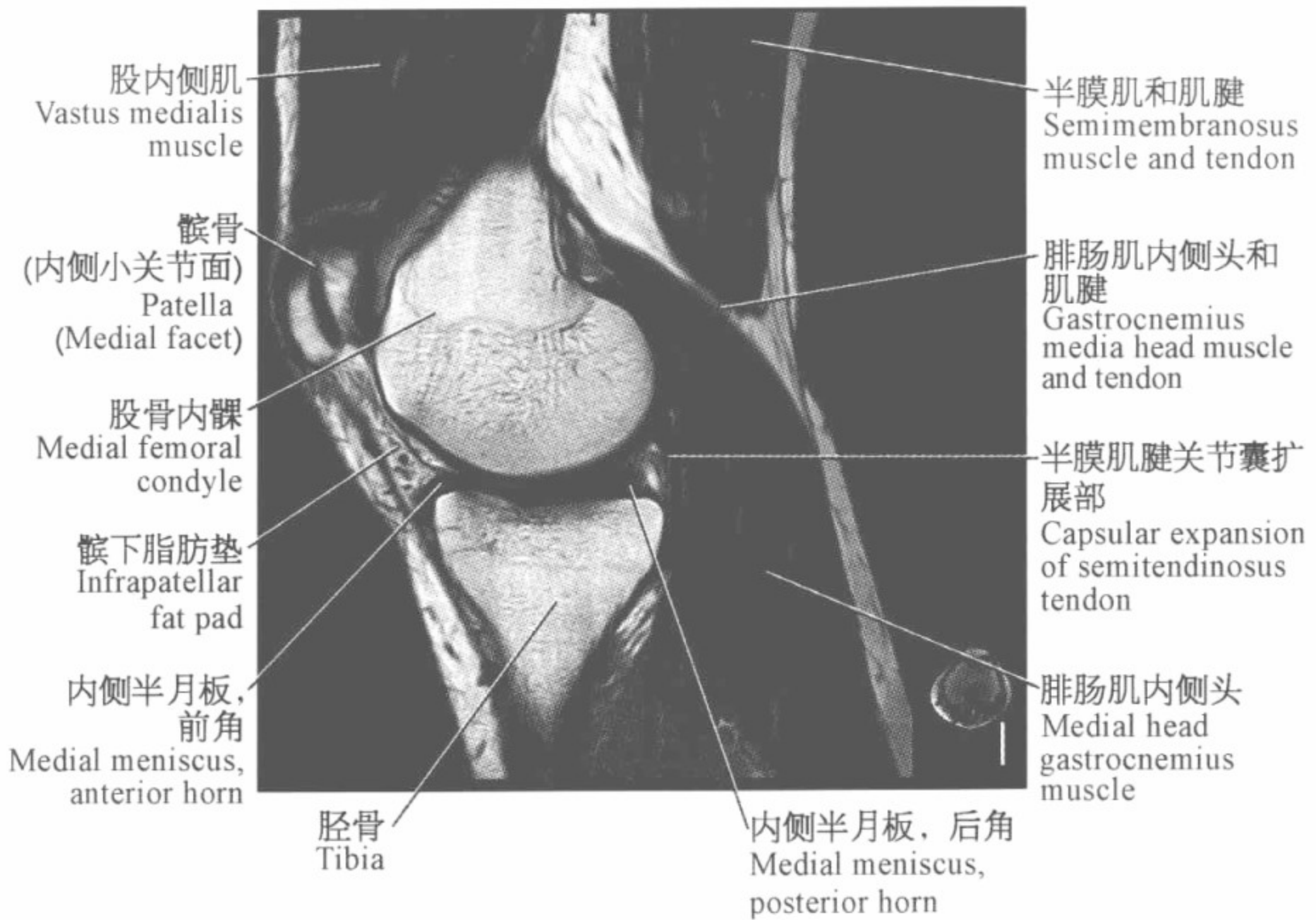
缝匠肌
Sartorius muscle

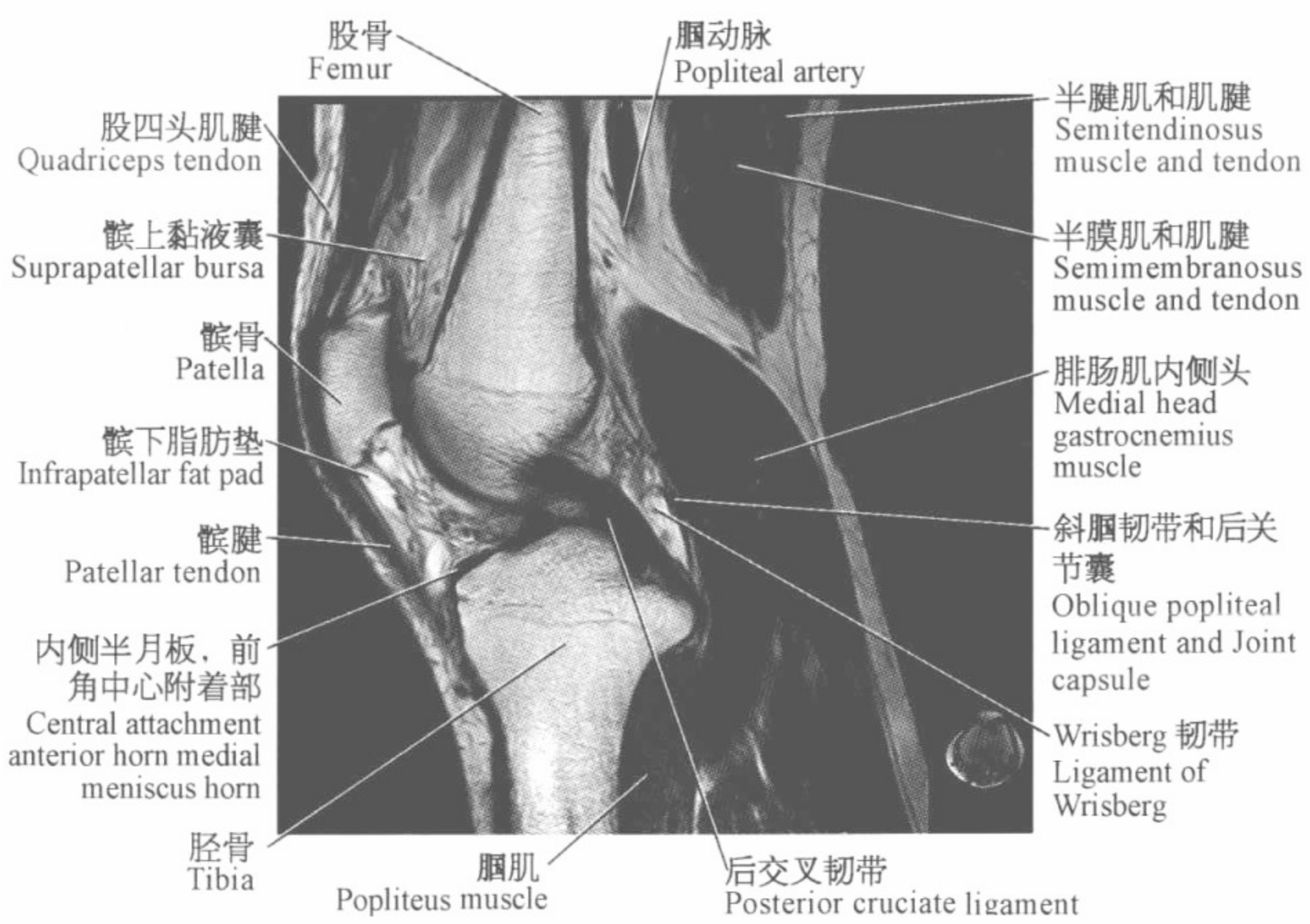
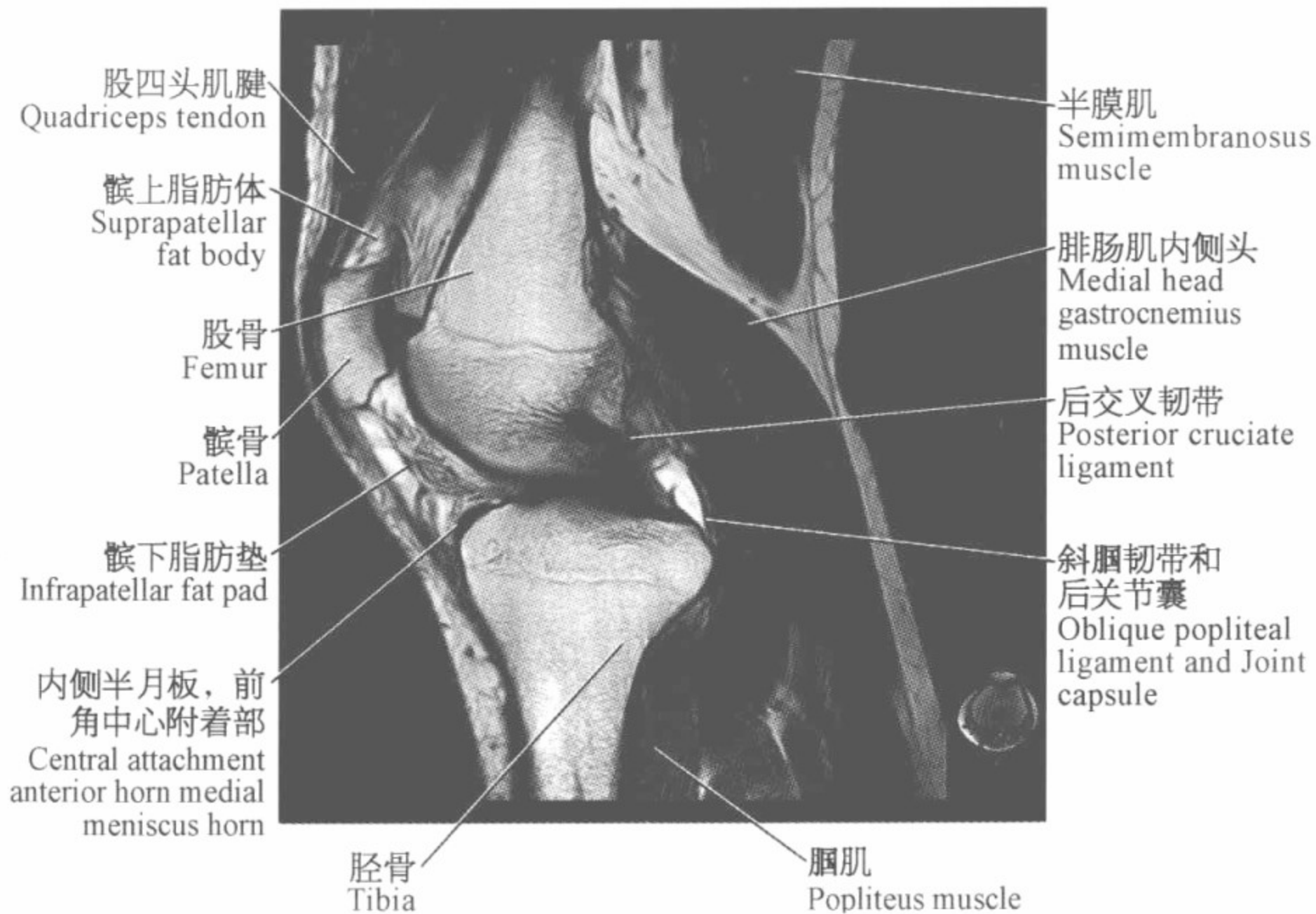
大收肌腱
Adductor magnus
tendon

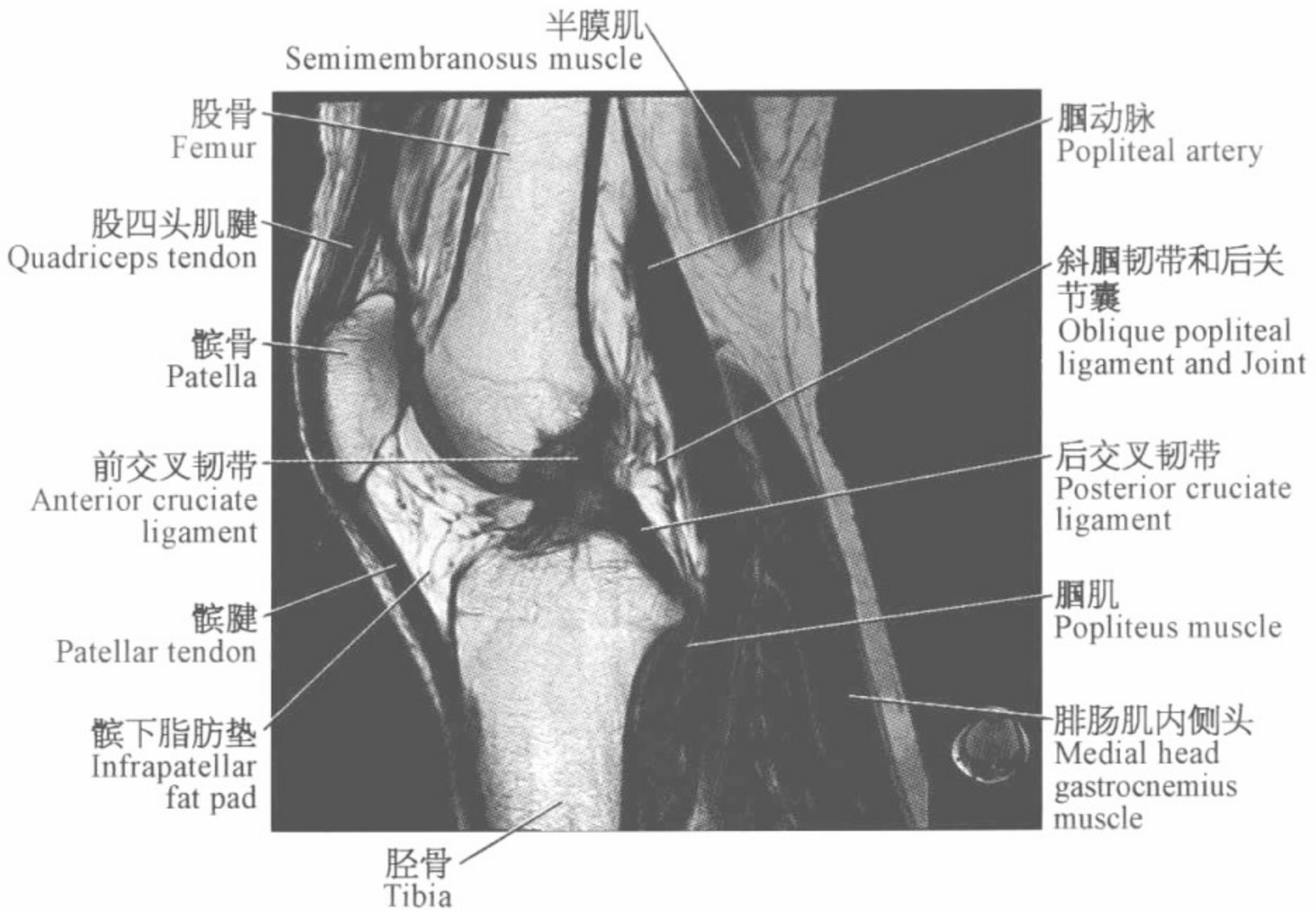
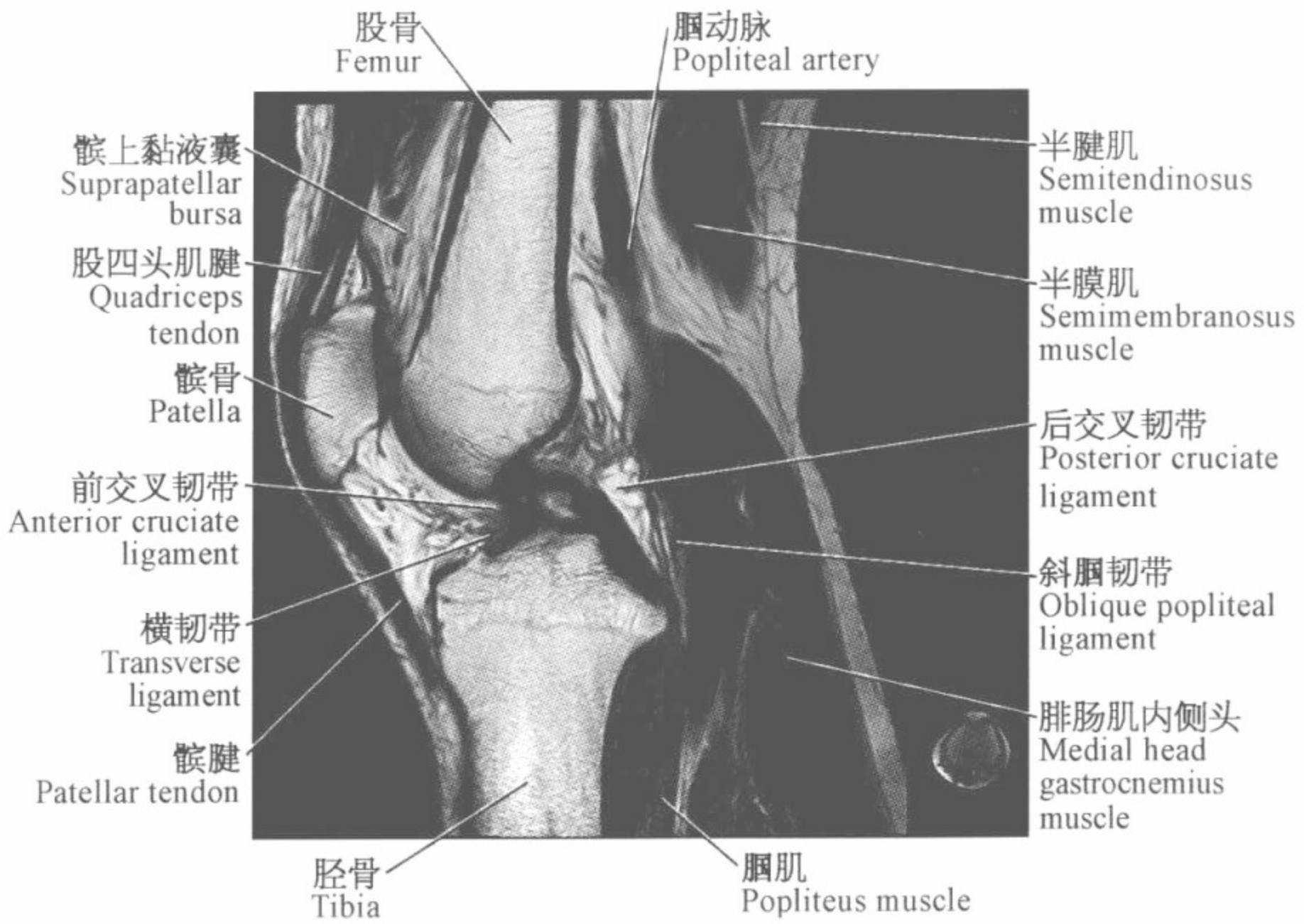
半腱肌腱
Semitendinosus
tendon

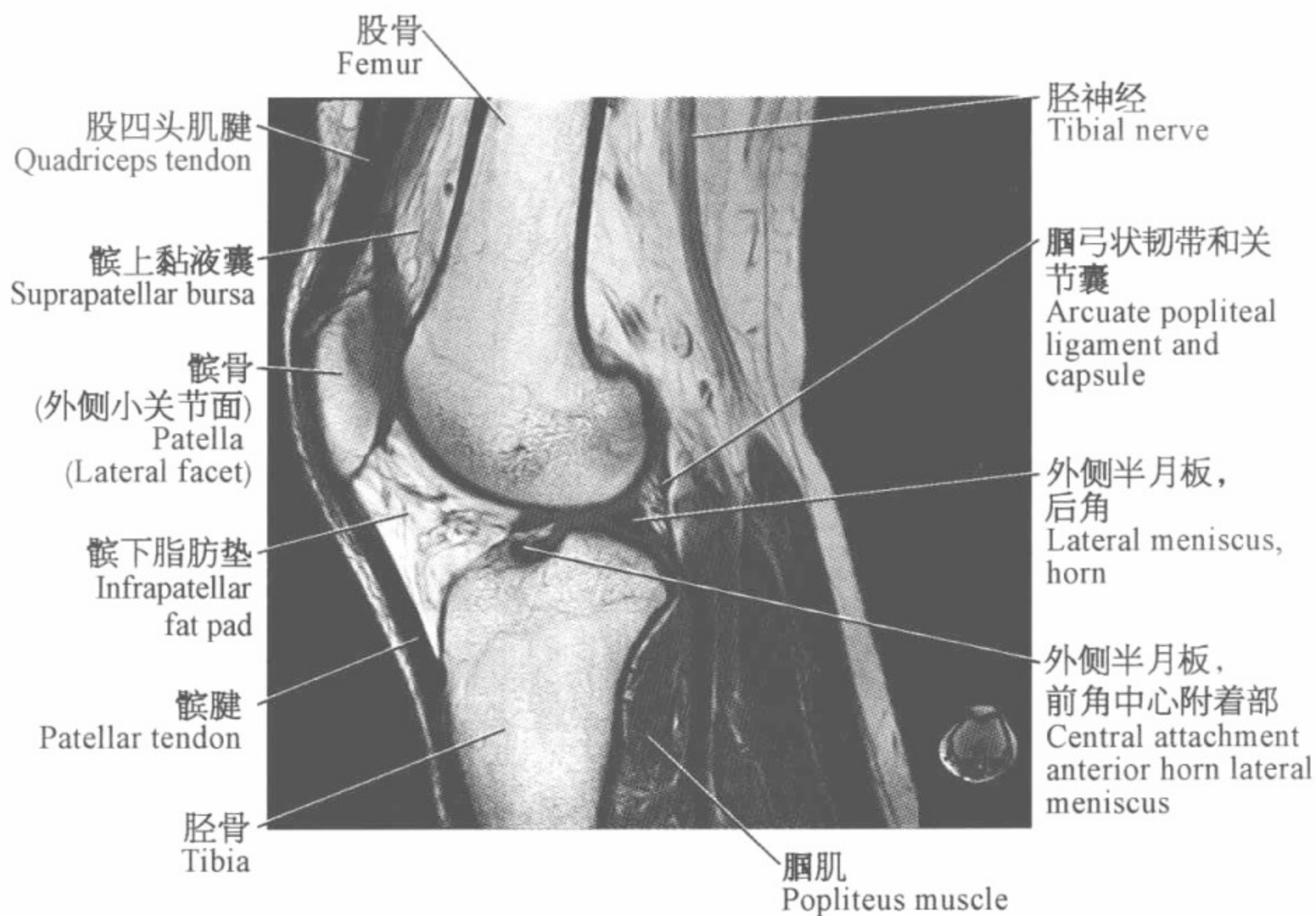
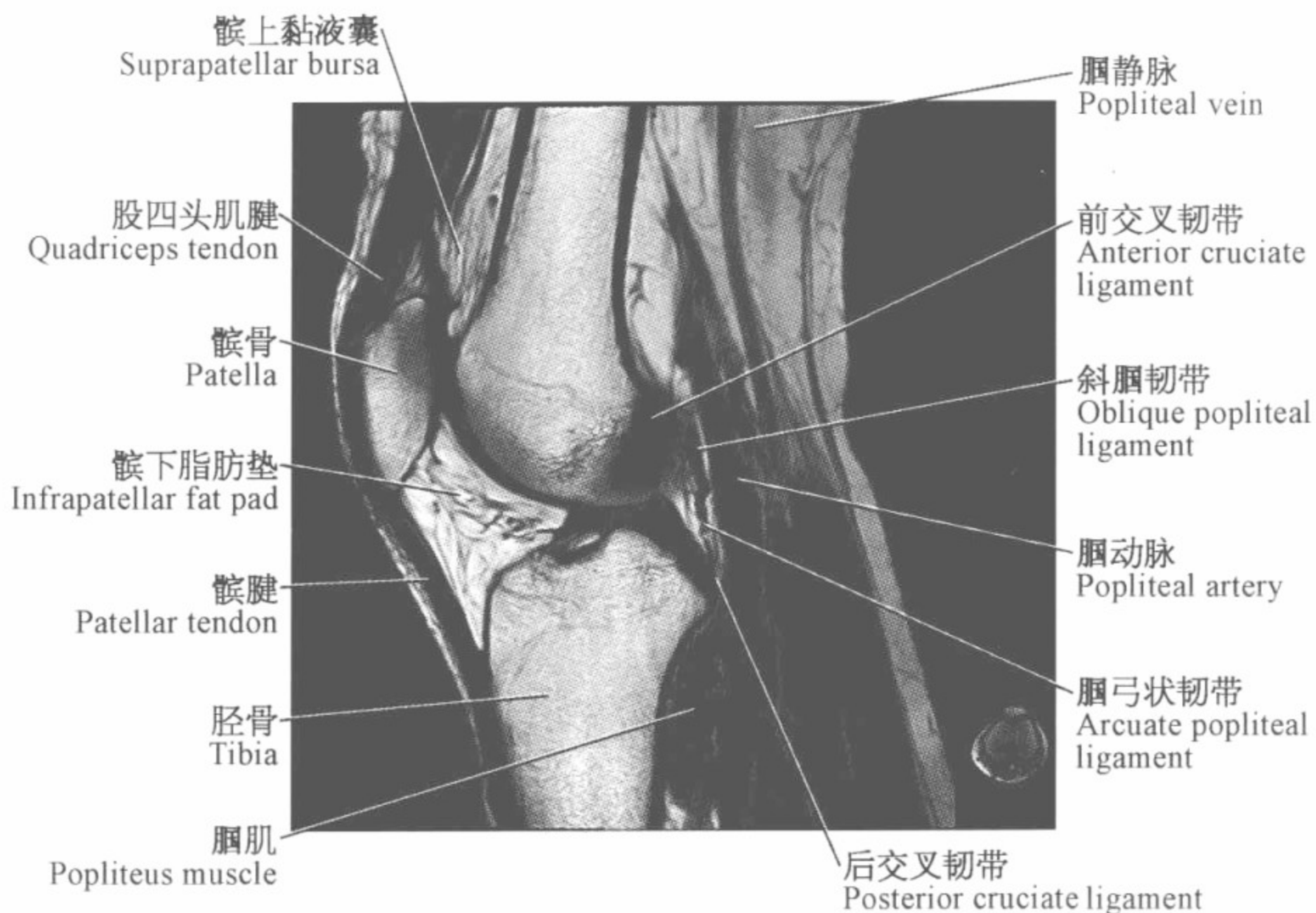


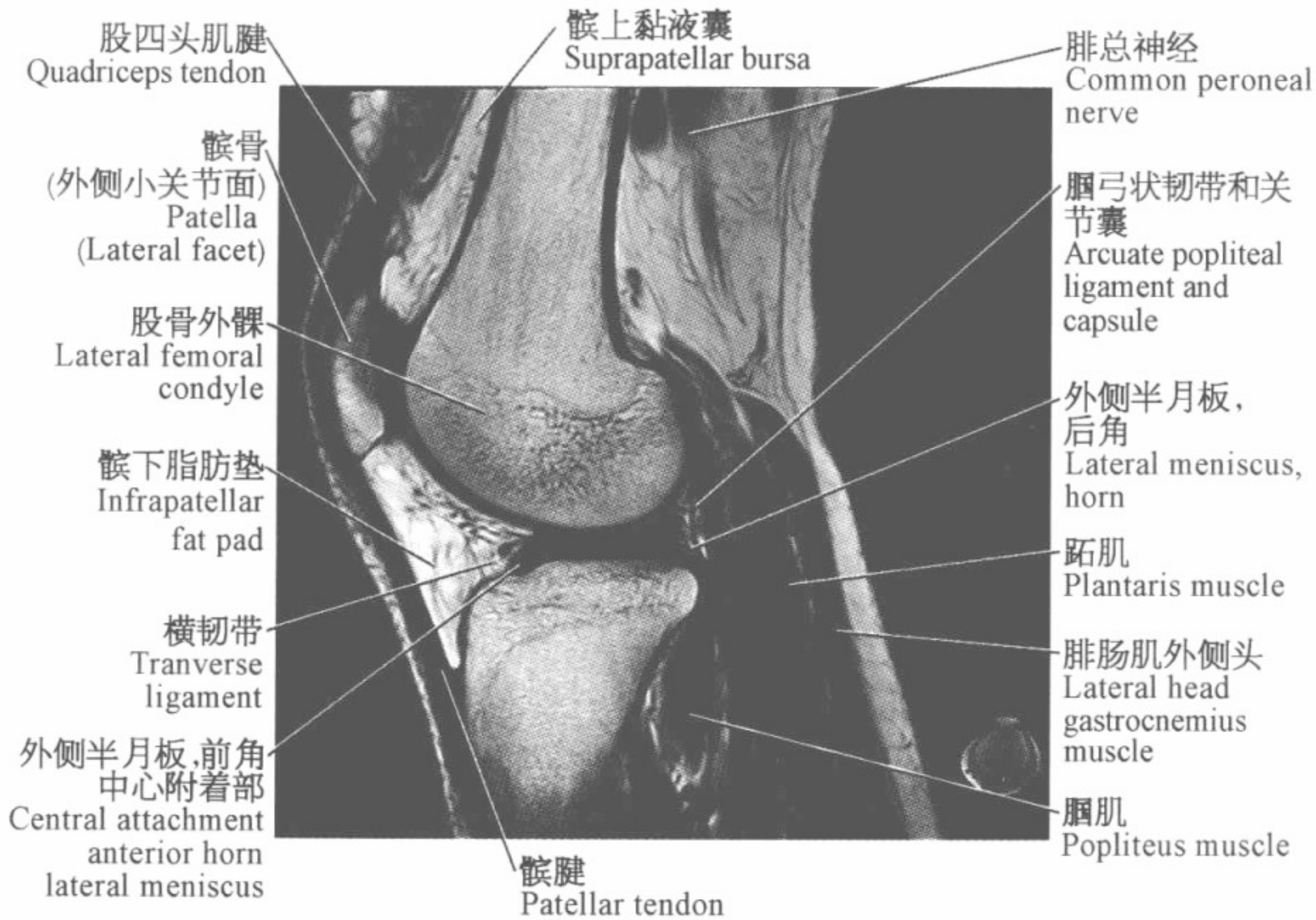
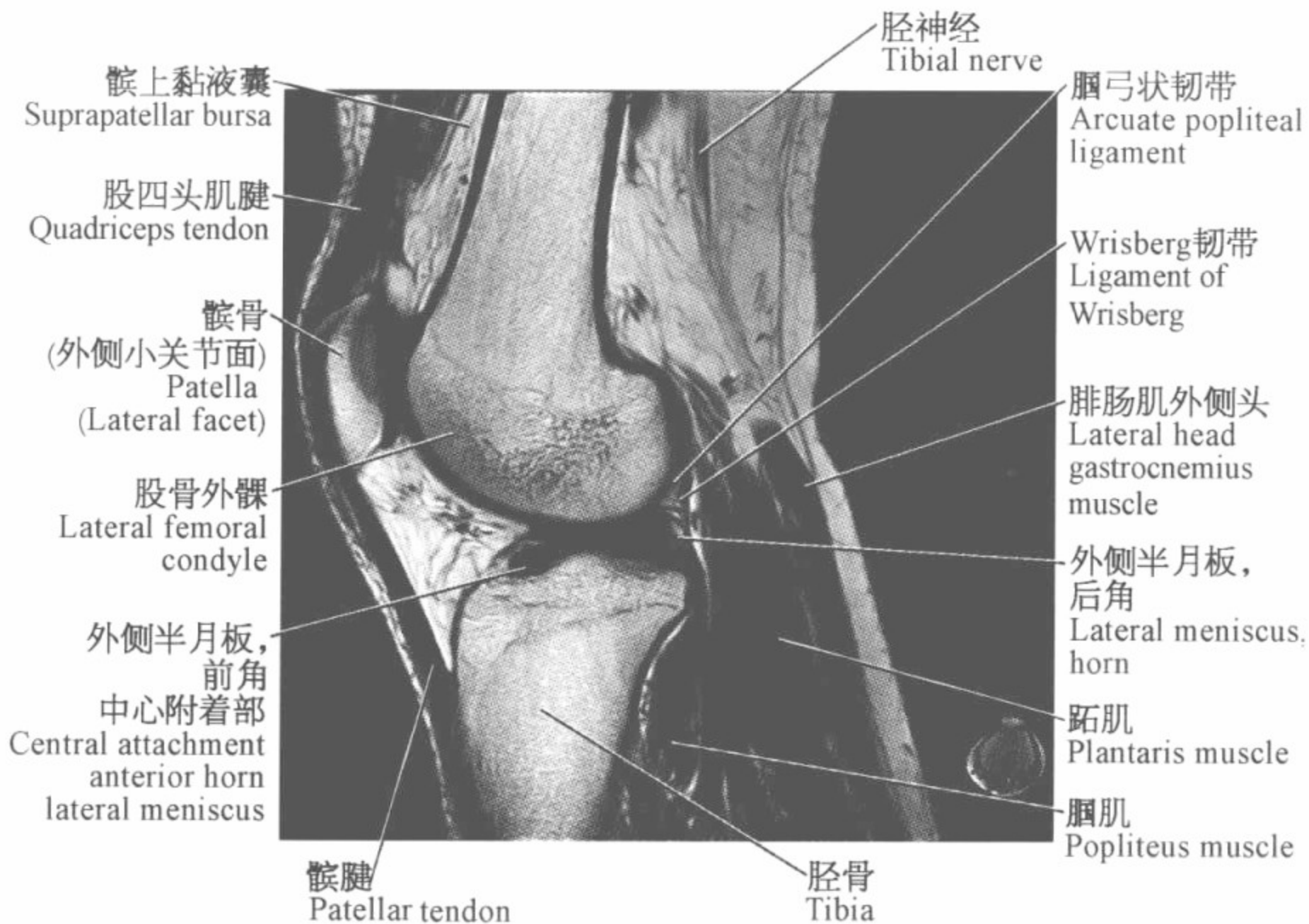


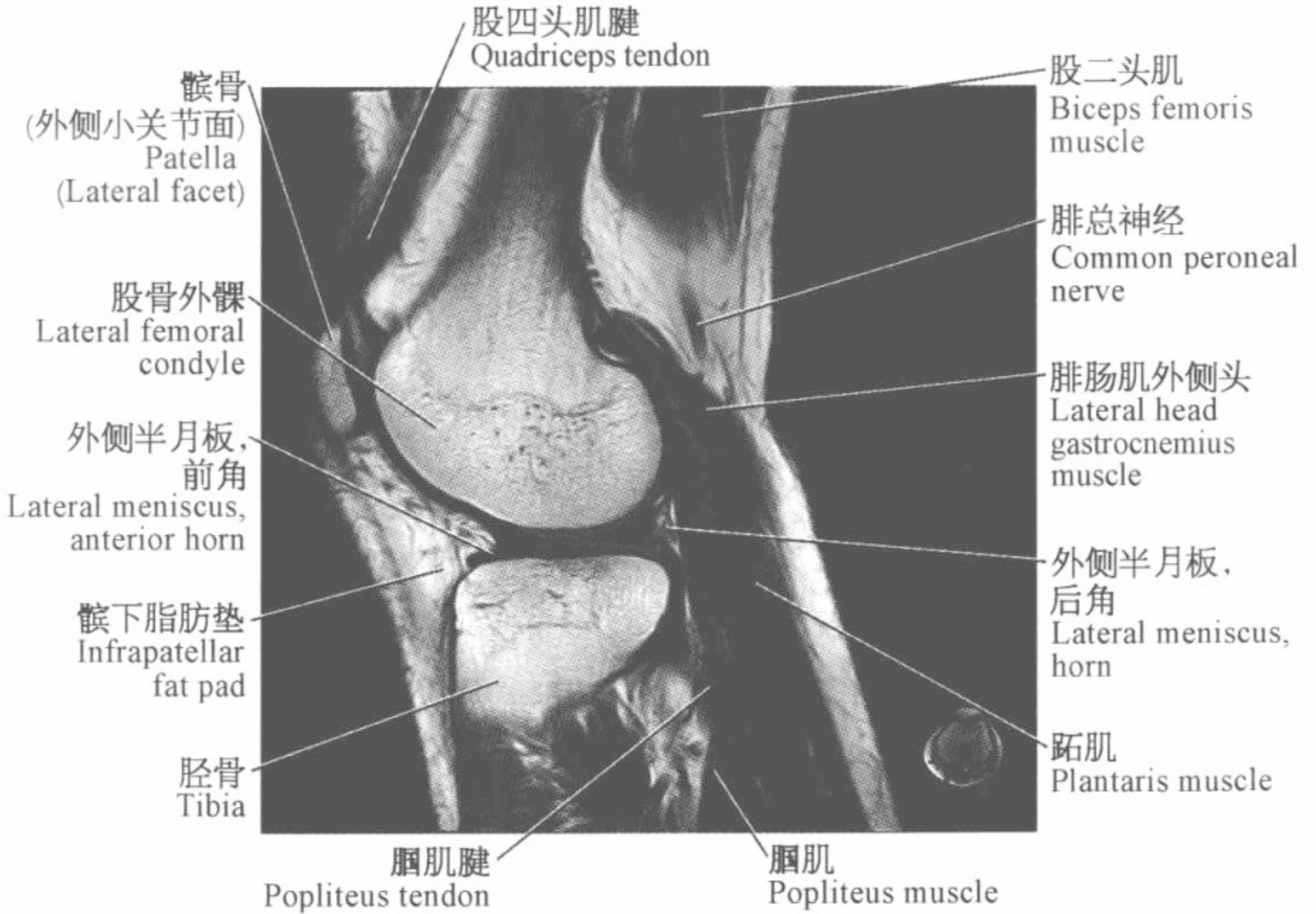
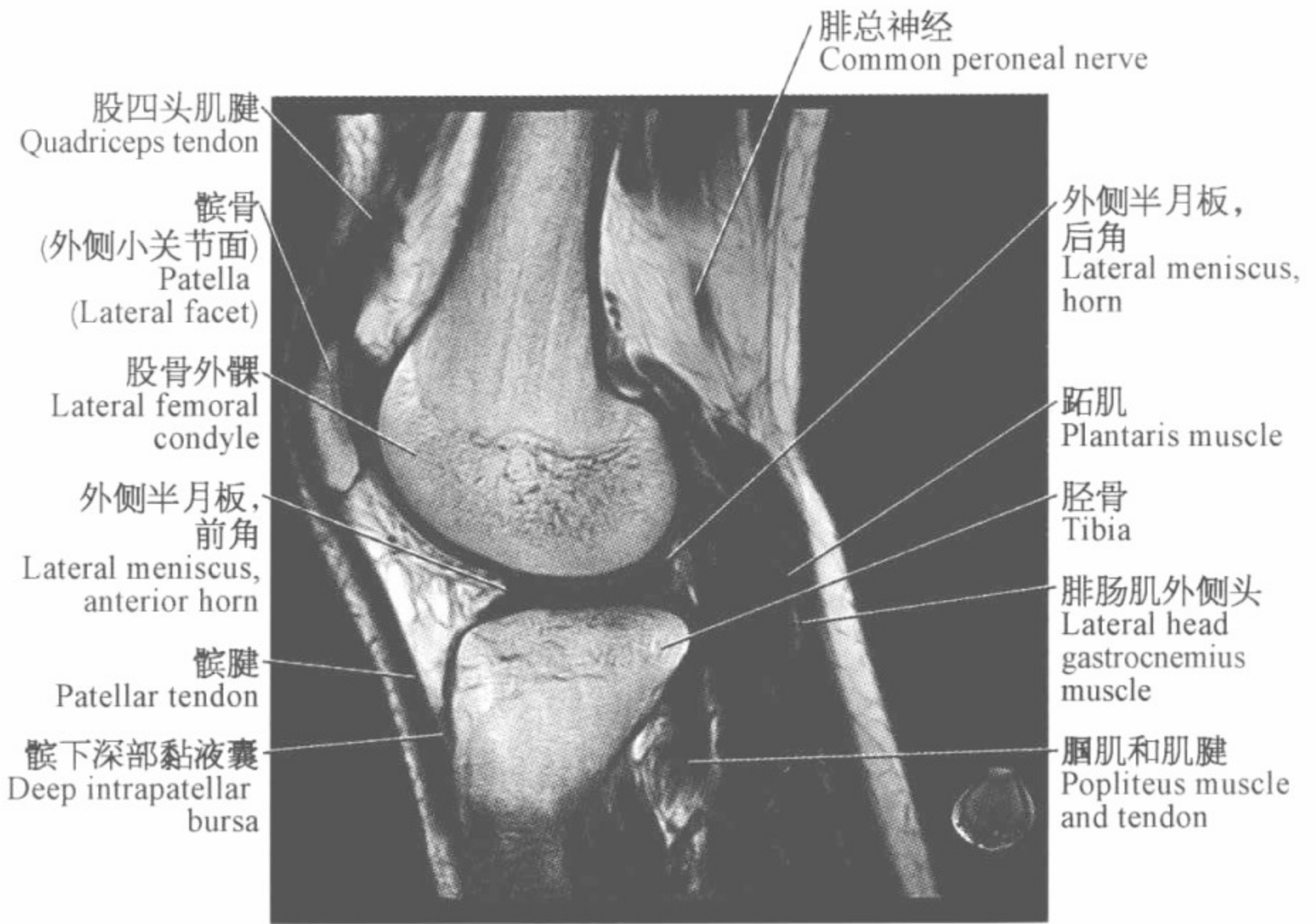


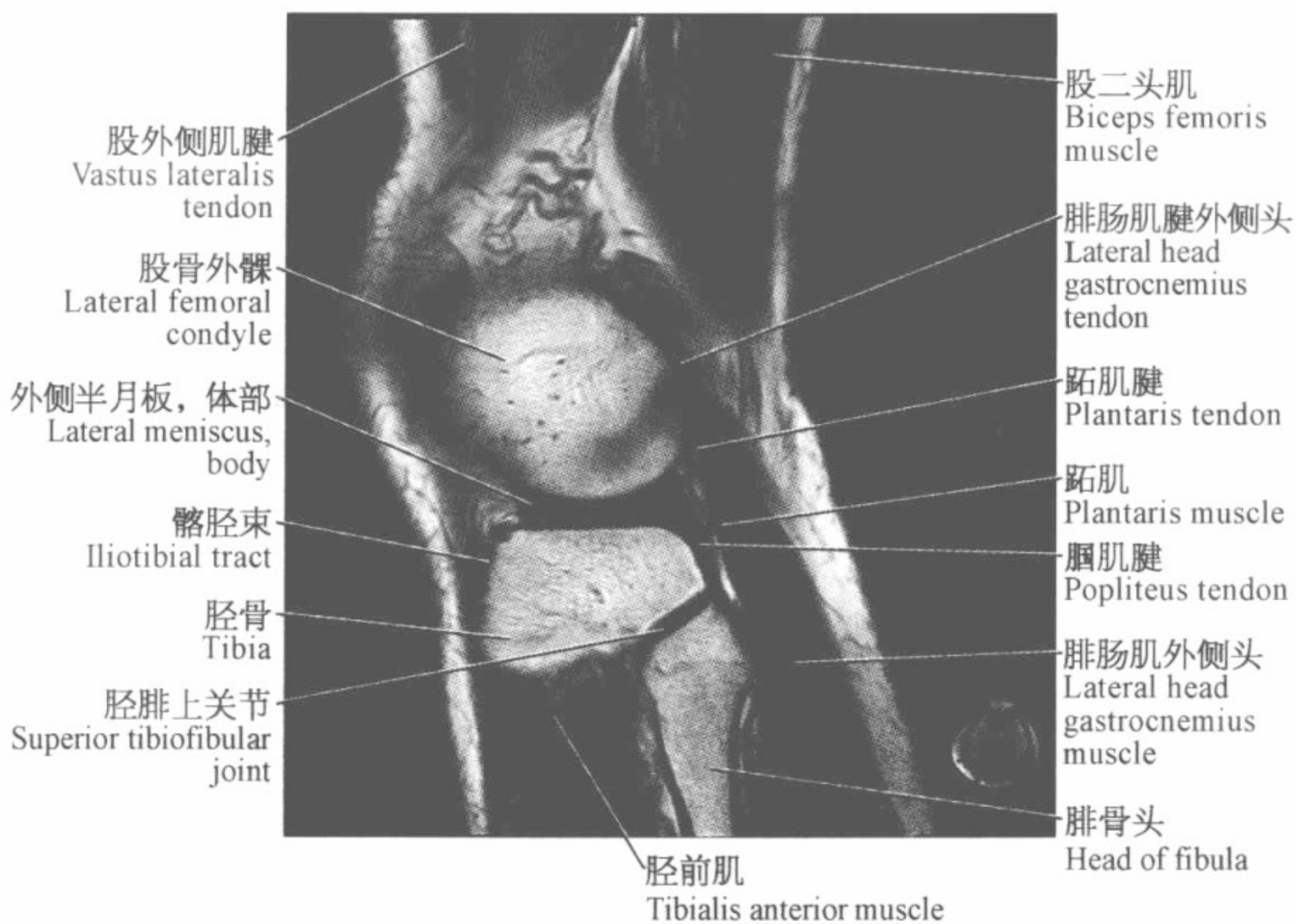
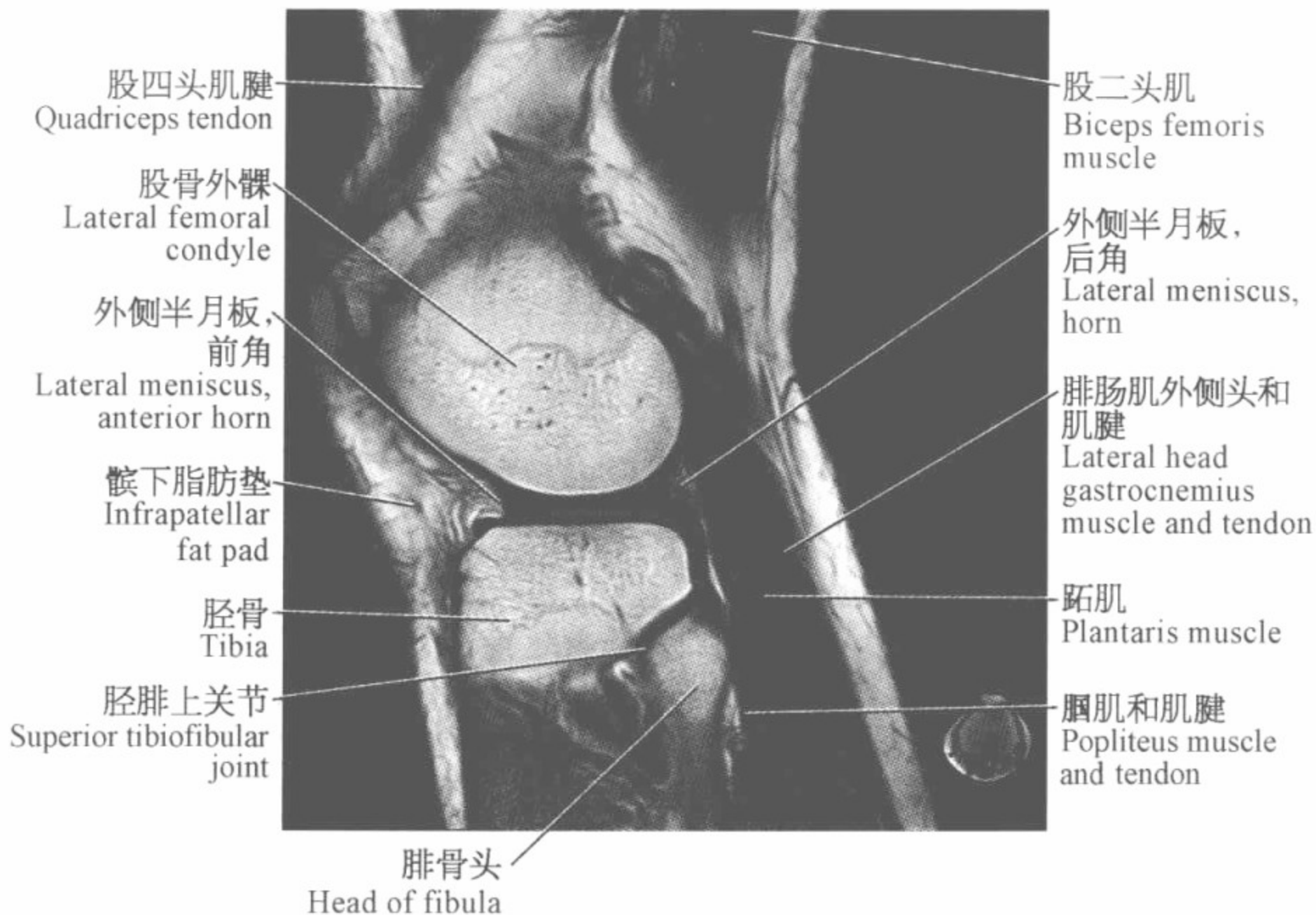


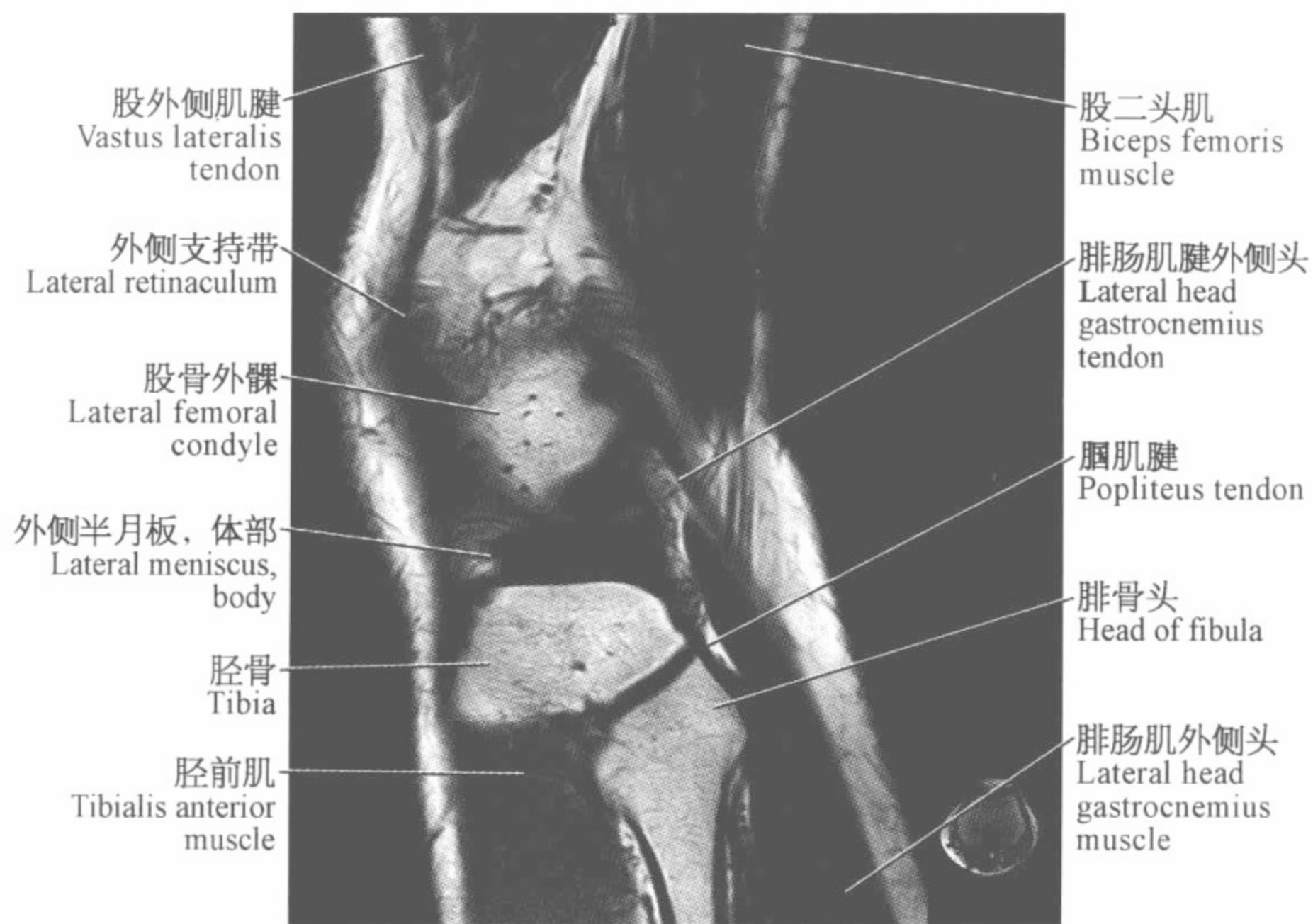




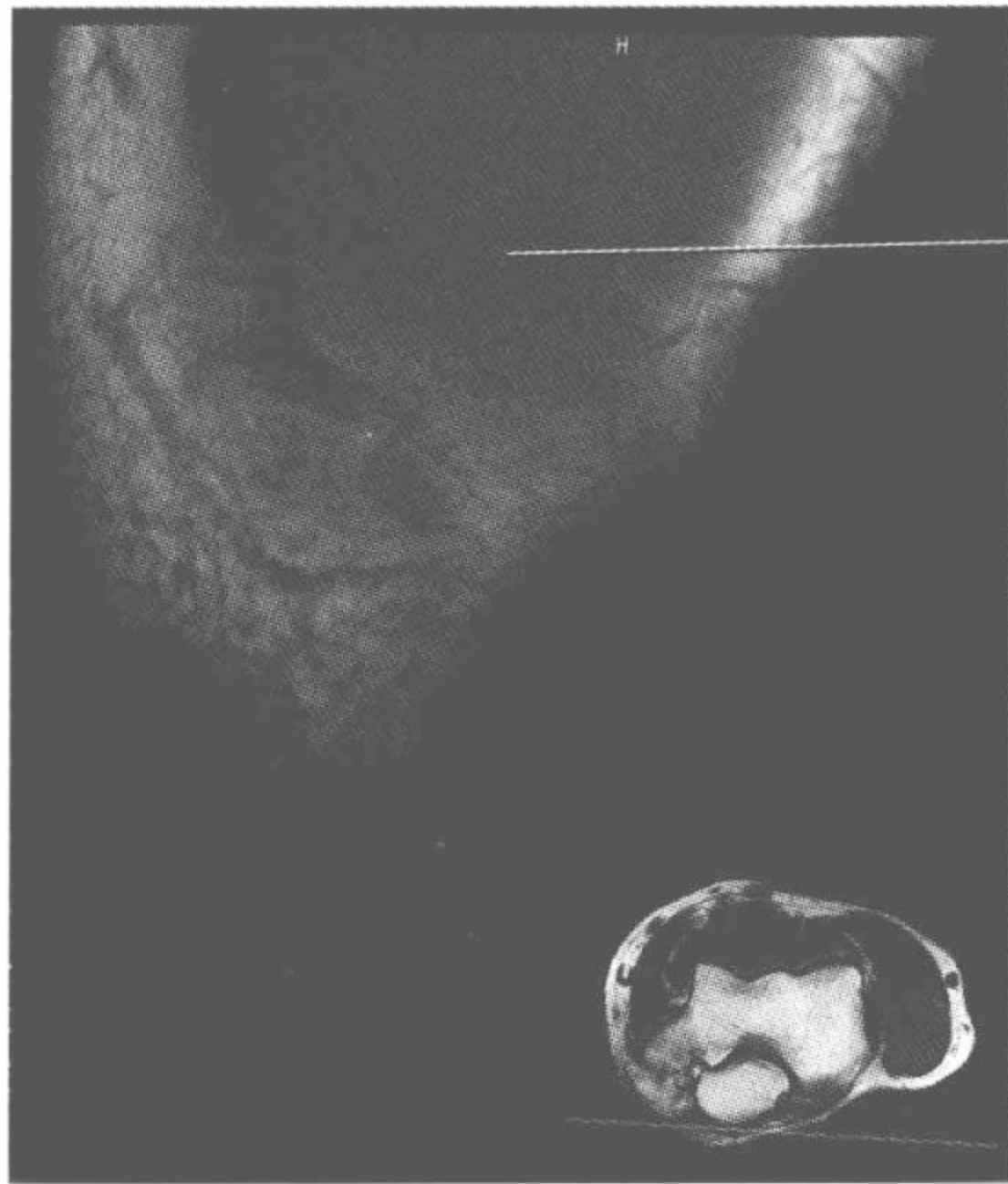








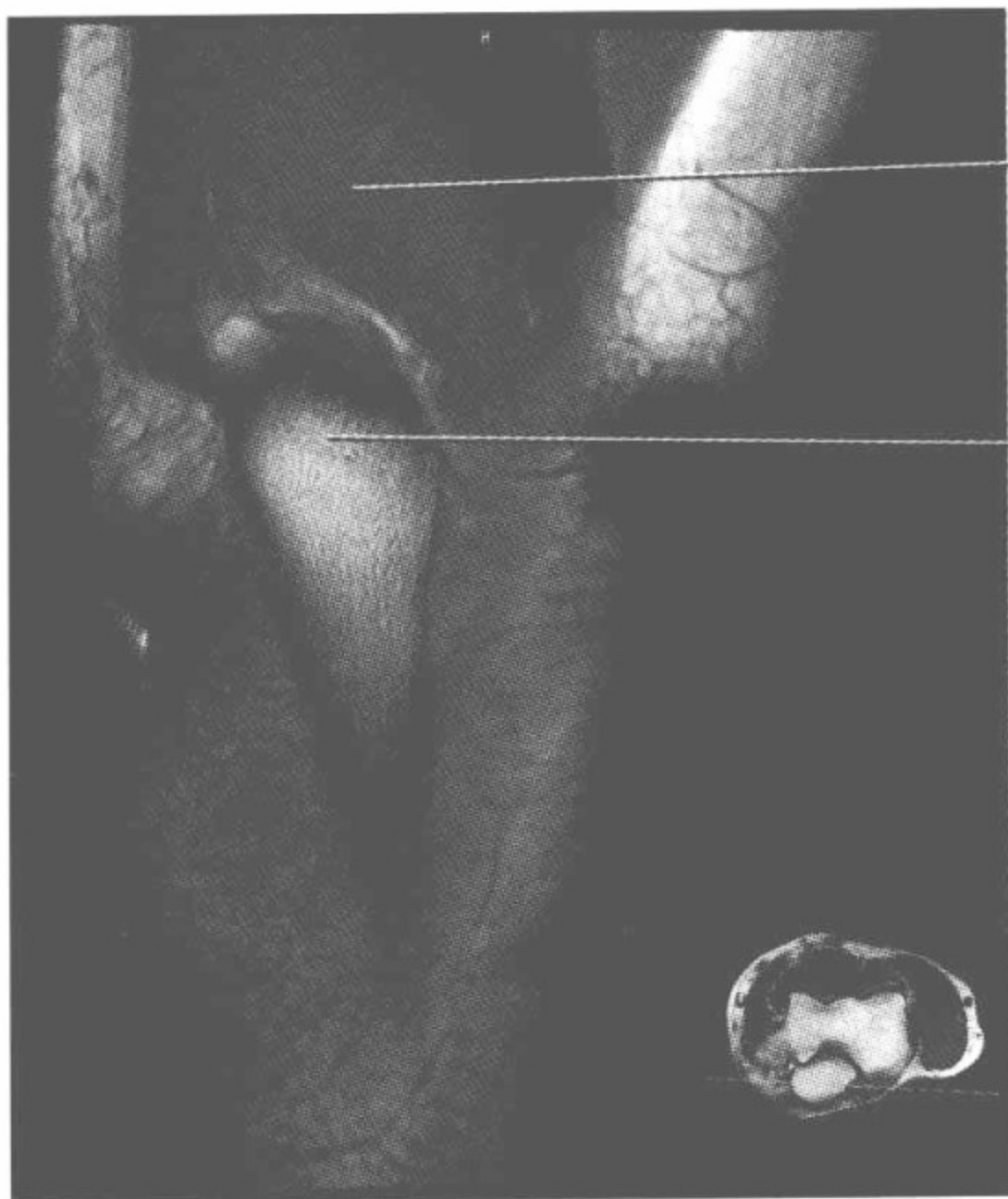
肘关节磁共振图谱
(冠状位)



肱三头肌
Triceps muscle

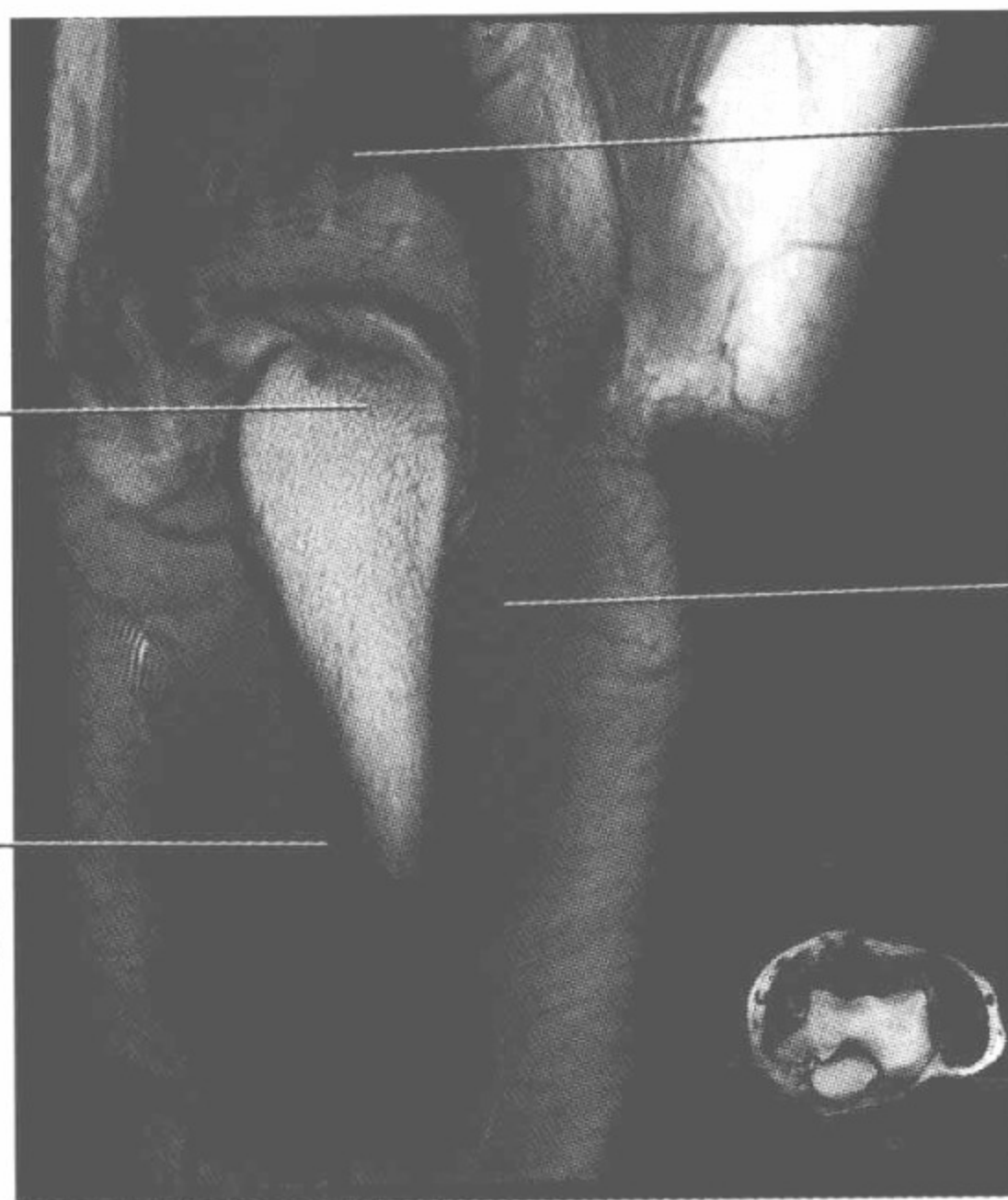

肱三头肌和肌腱
Triceps muscle
and tendon



肱三头肌和肌腱
Triceps muscle
and tendon

鹰嘴
Olecranon

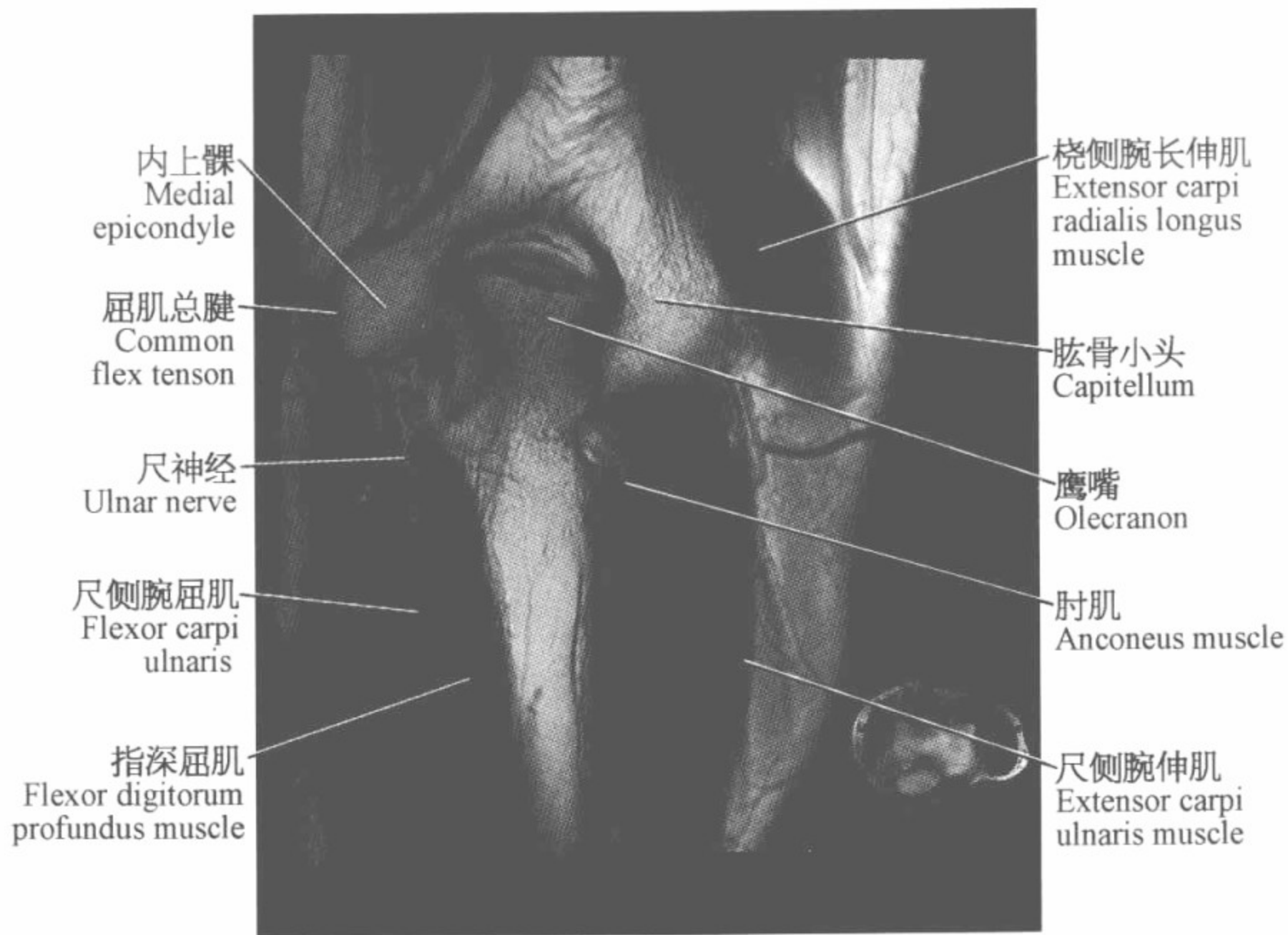
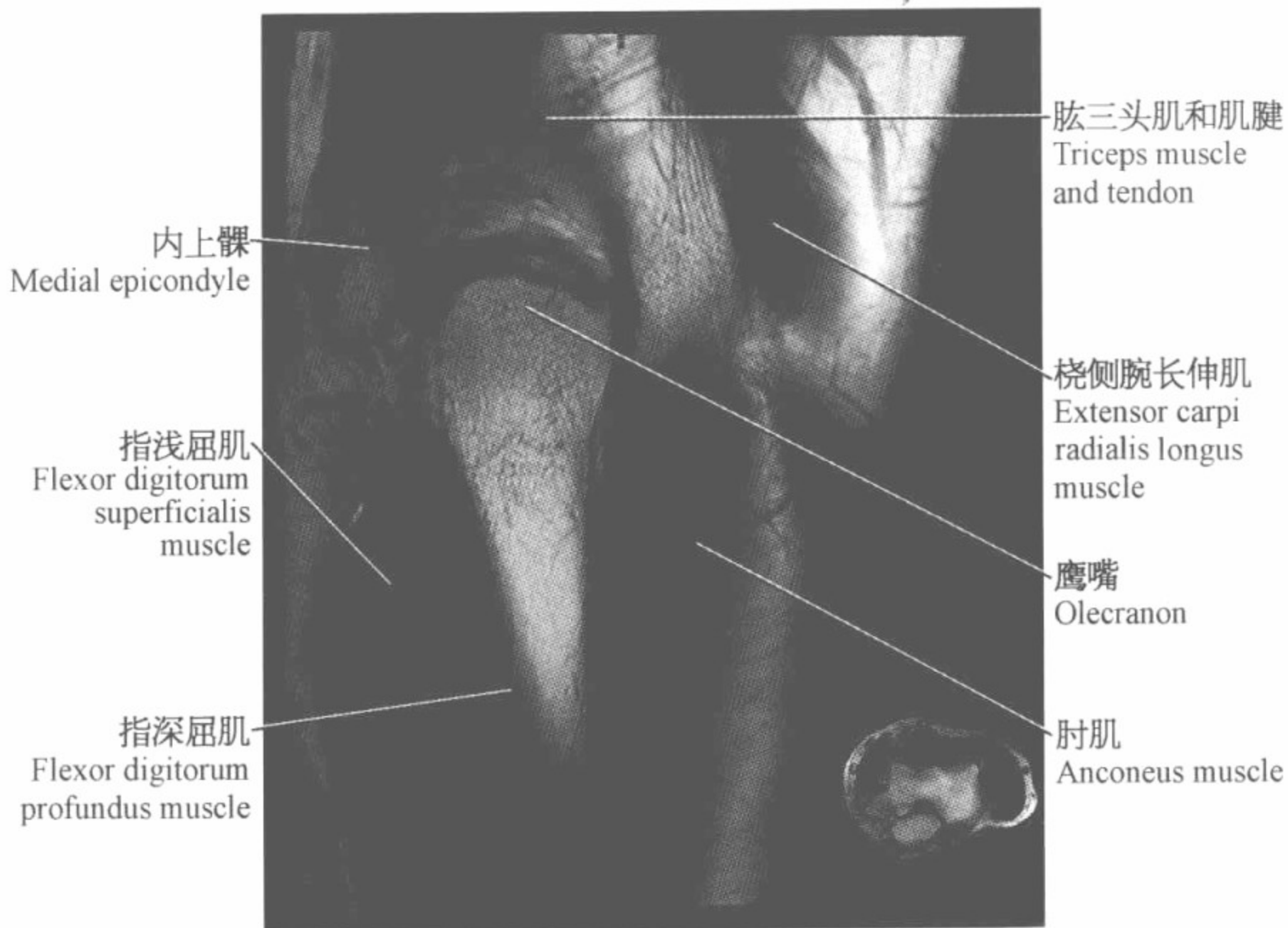


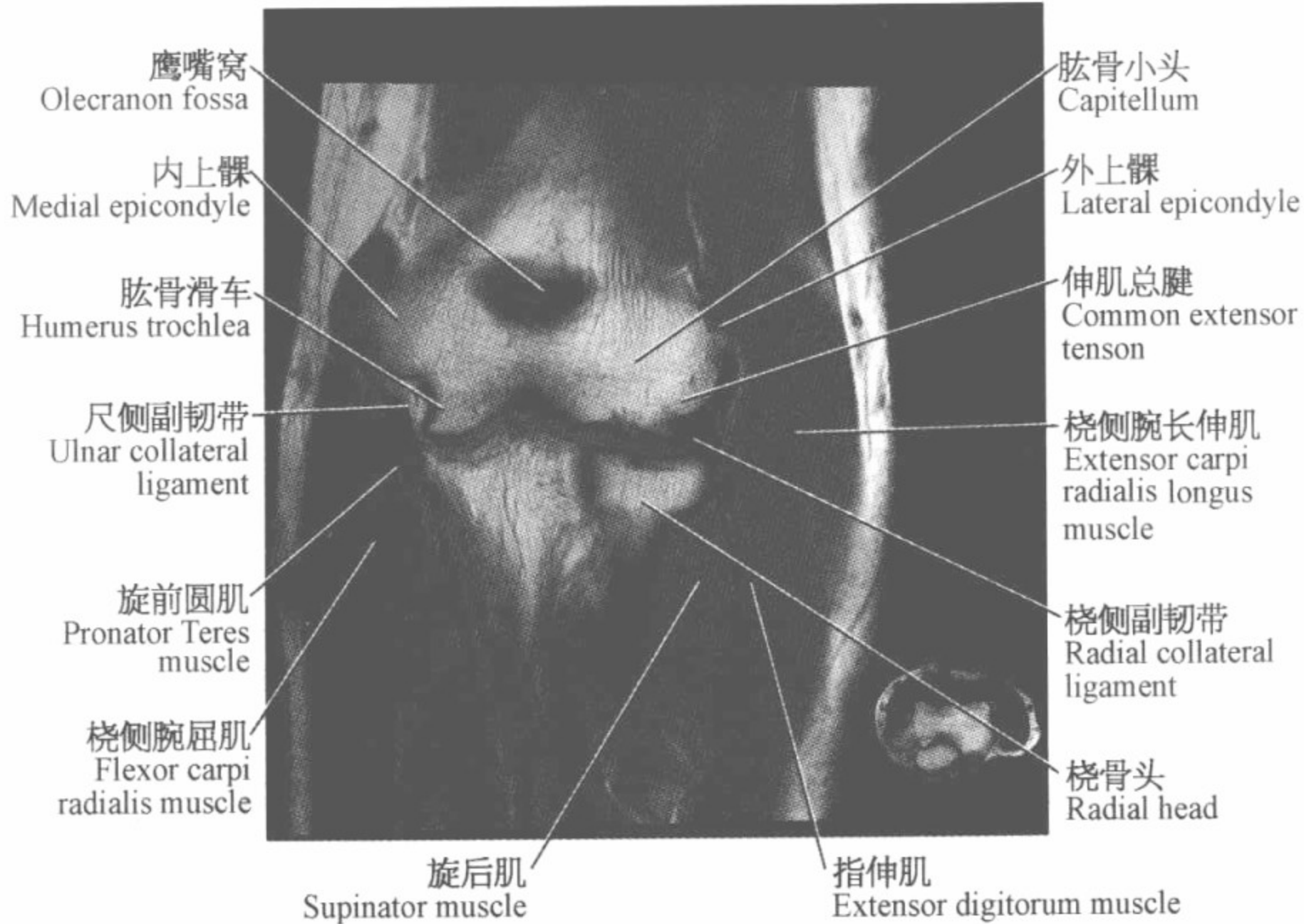
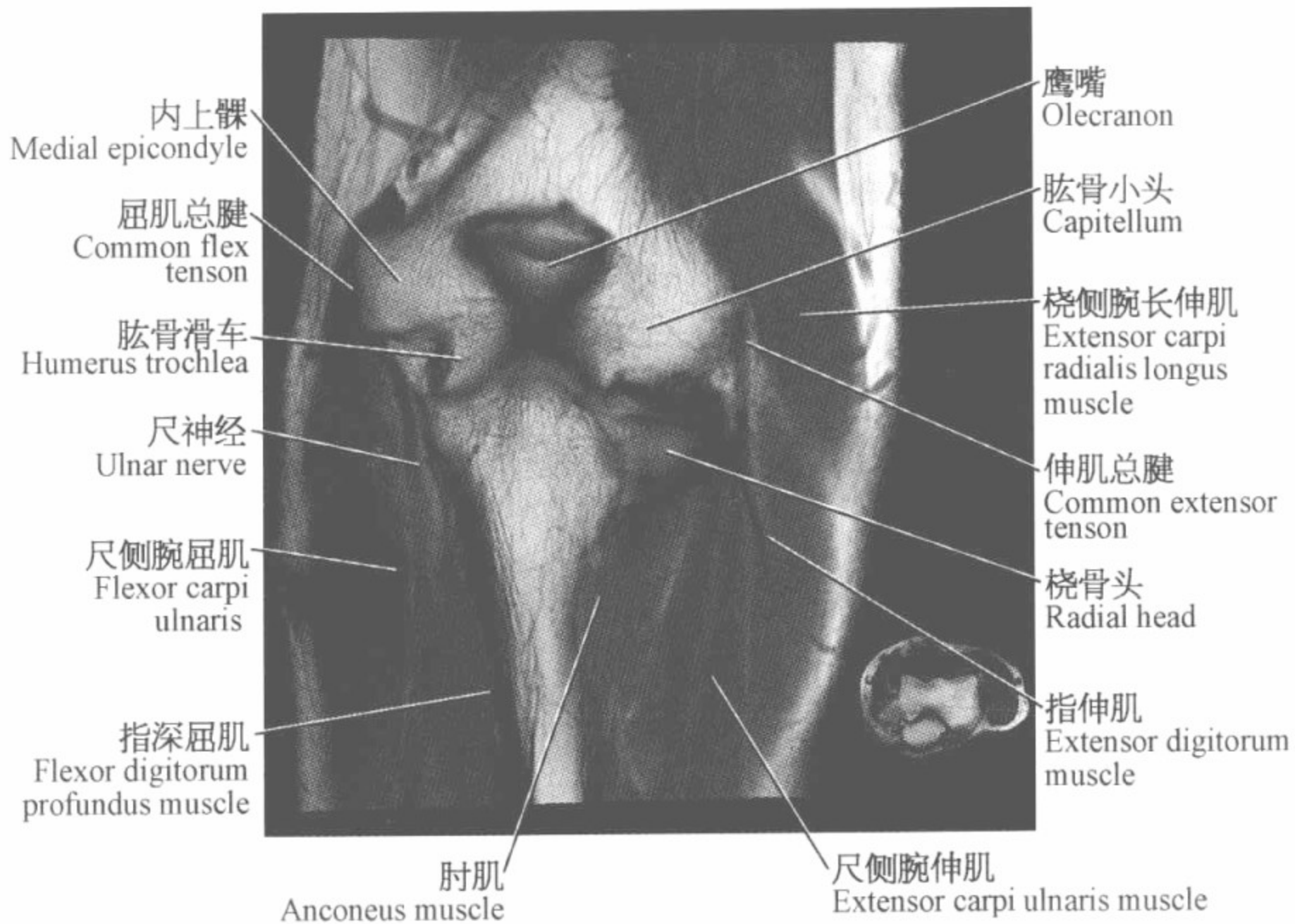
肱三头肌和肌腱
Triceps muscle
and tendon

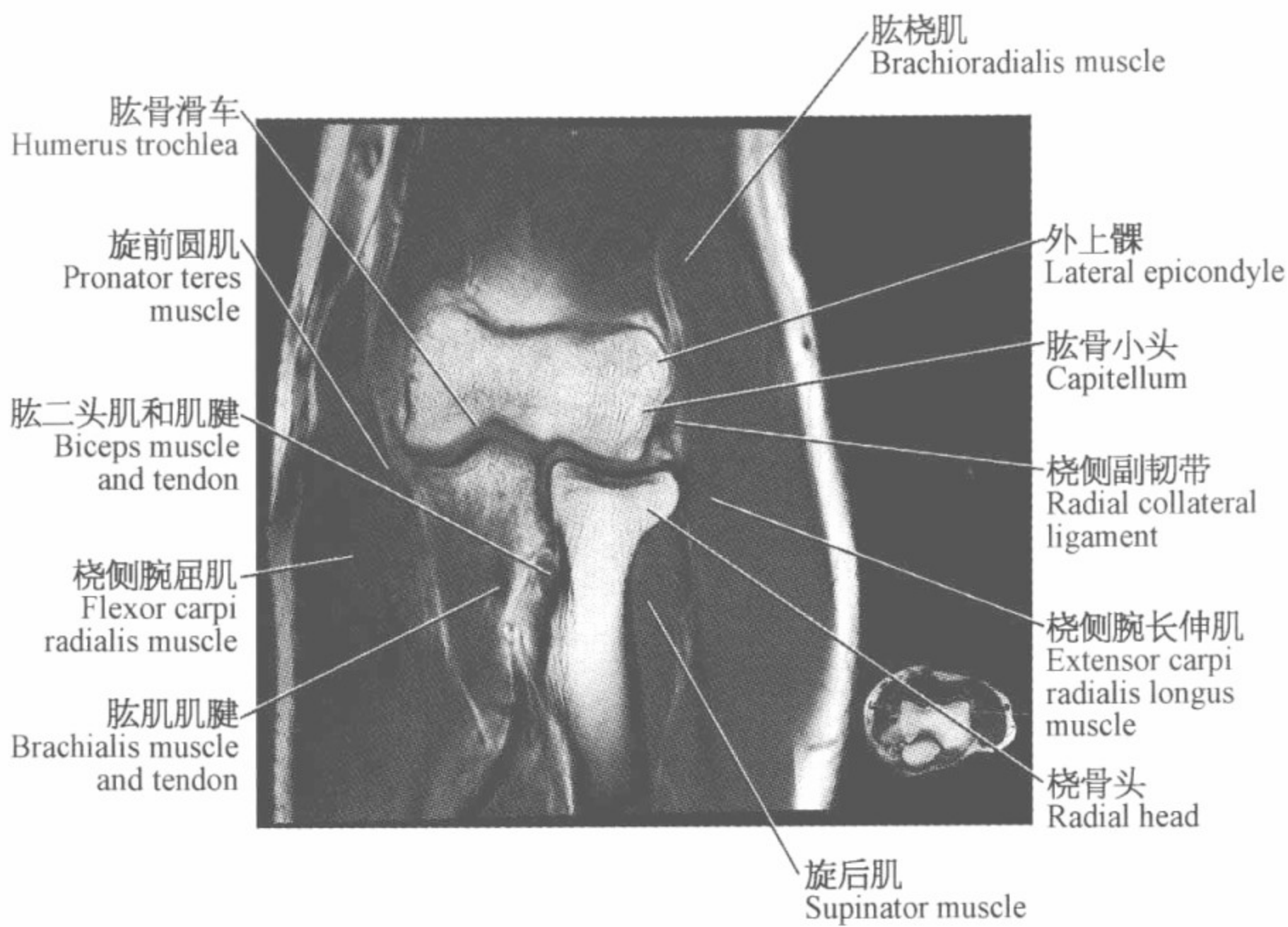
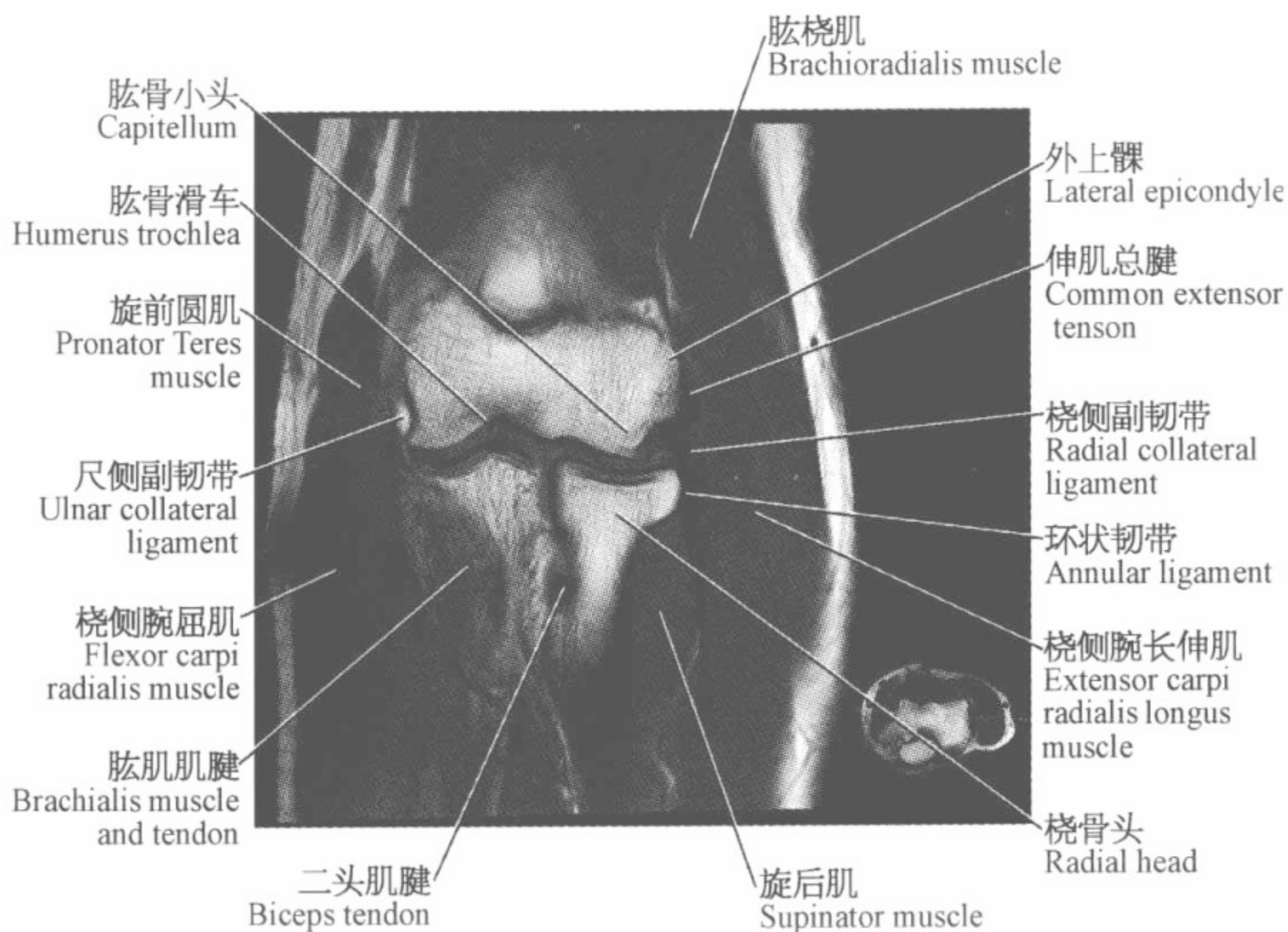
鹰嘴
Olecranon

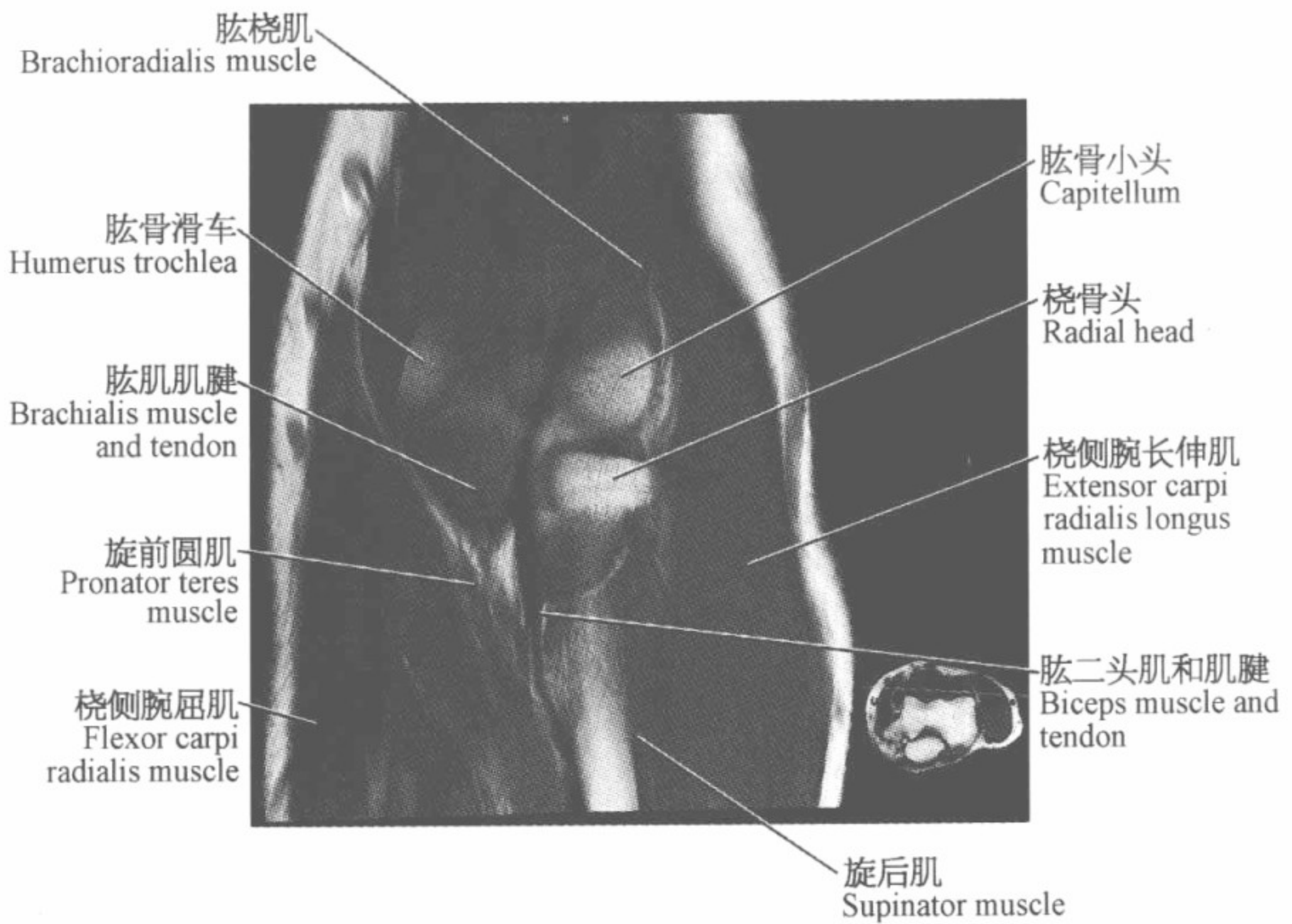
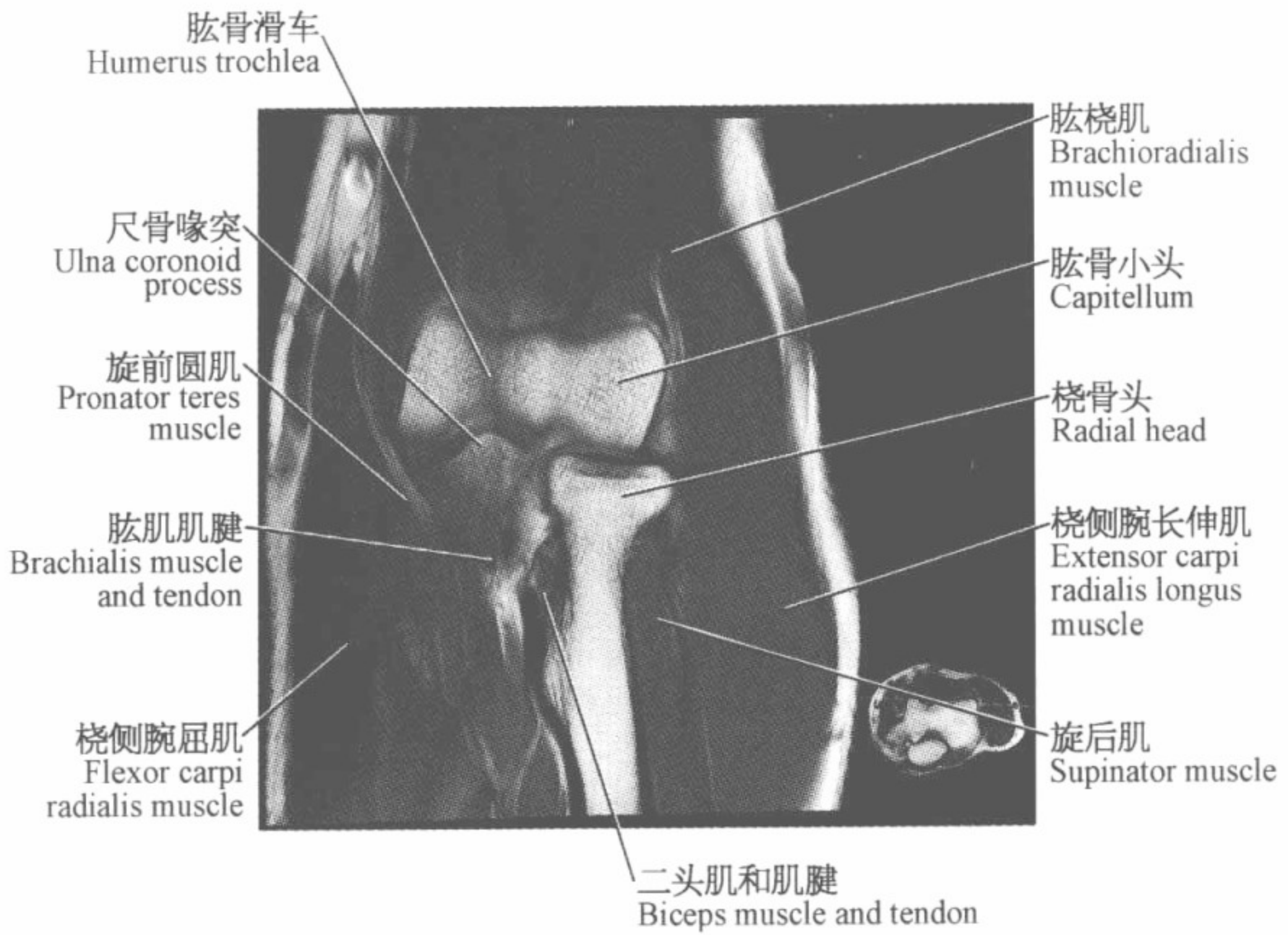
肘肌
Anconeus muscle

指深屈肌
Flexor digitorum
profundus muscle








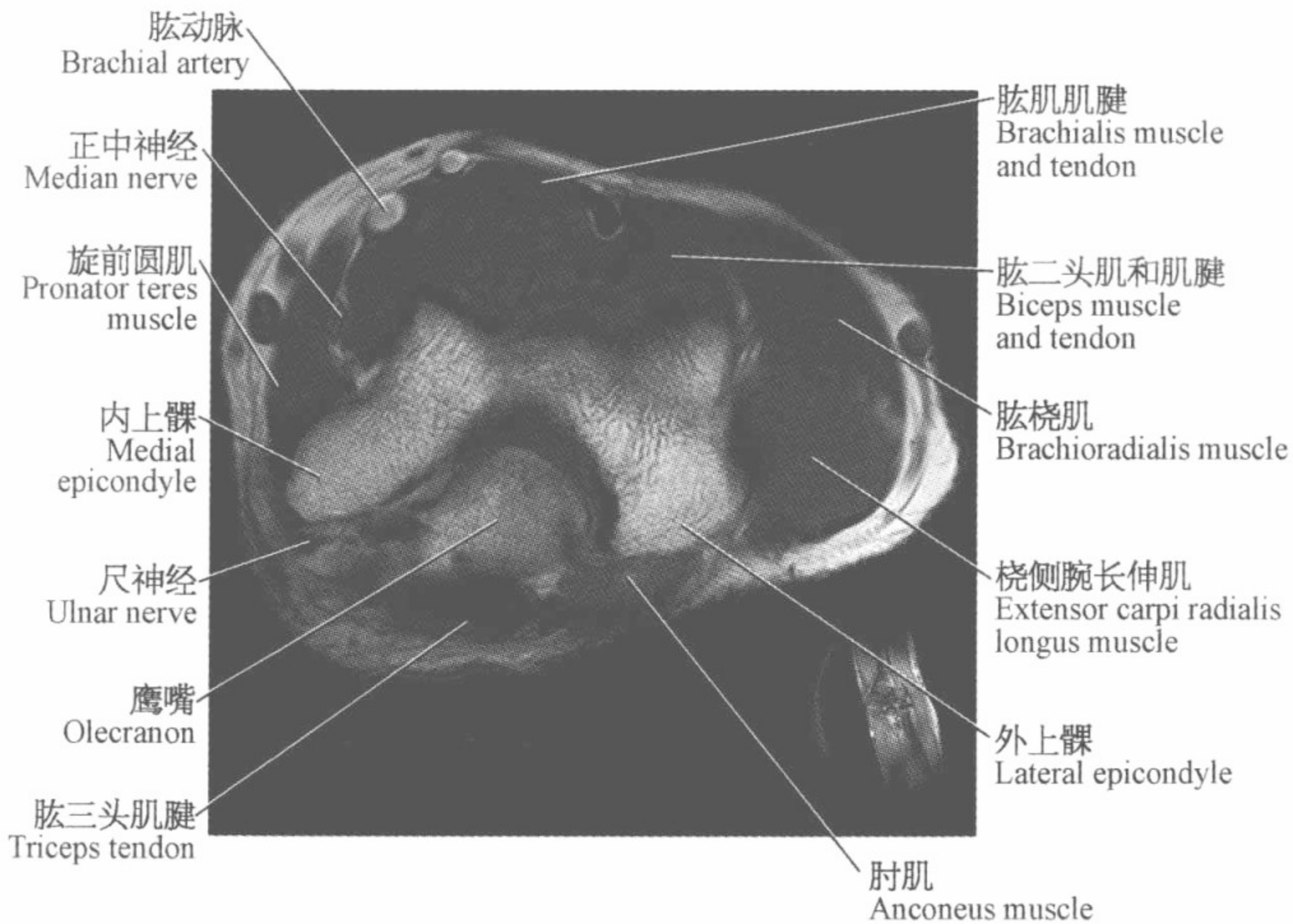
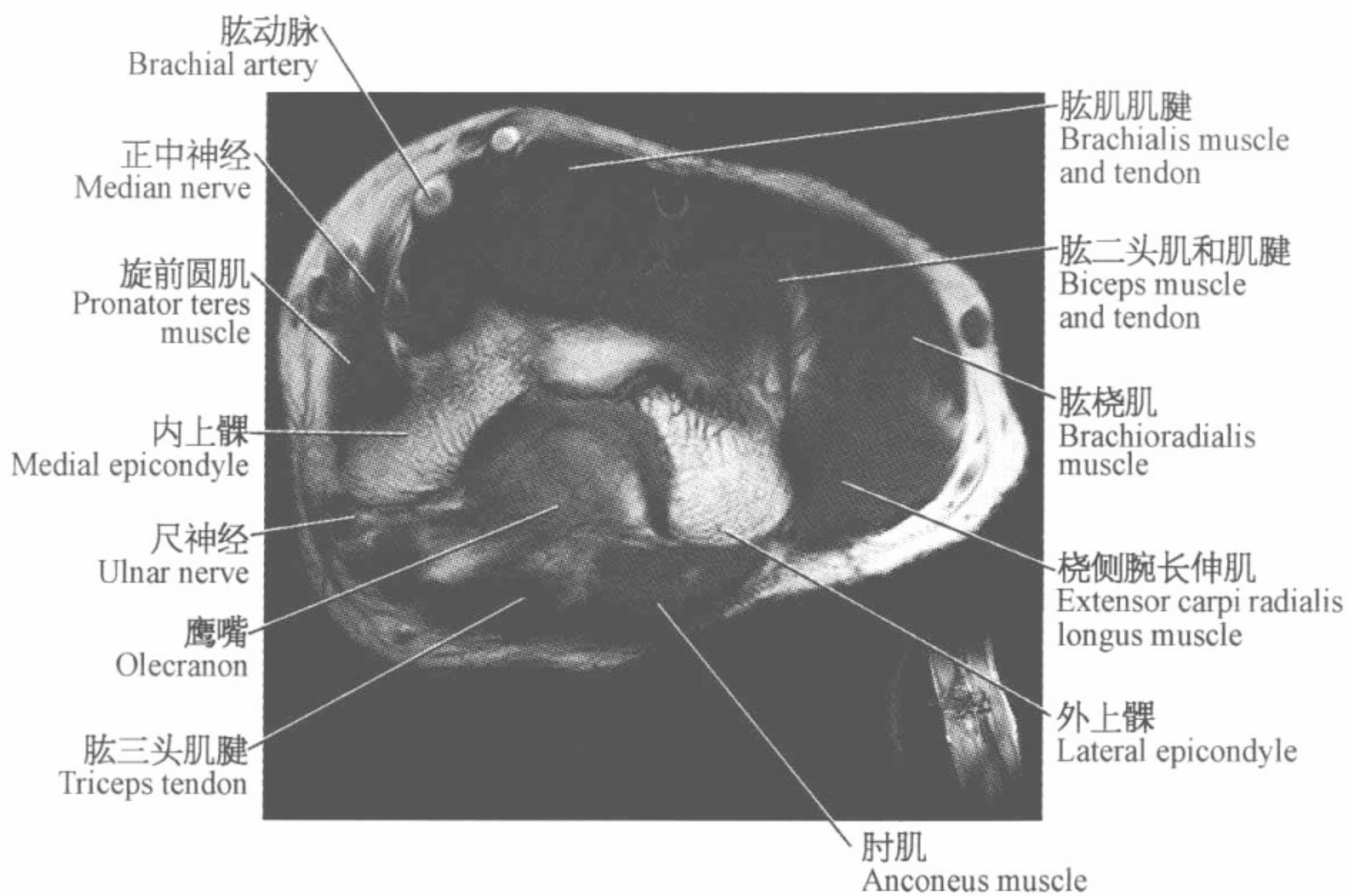


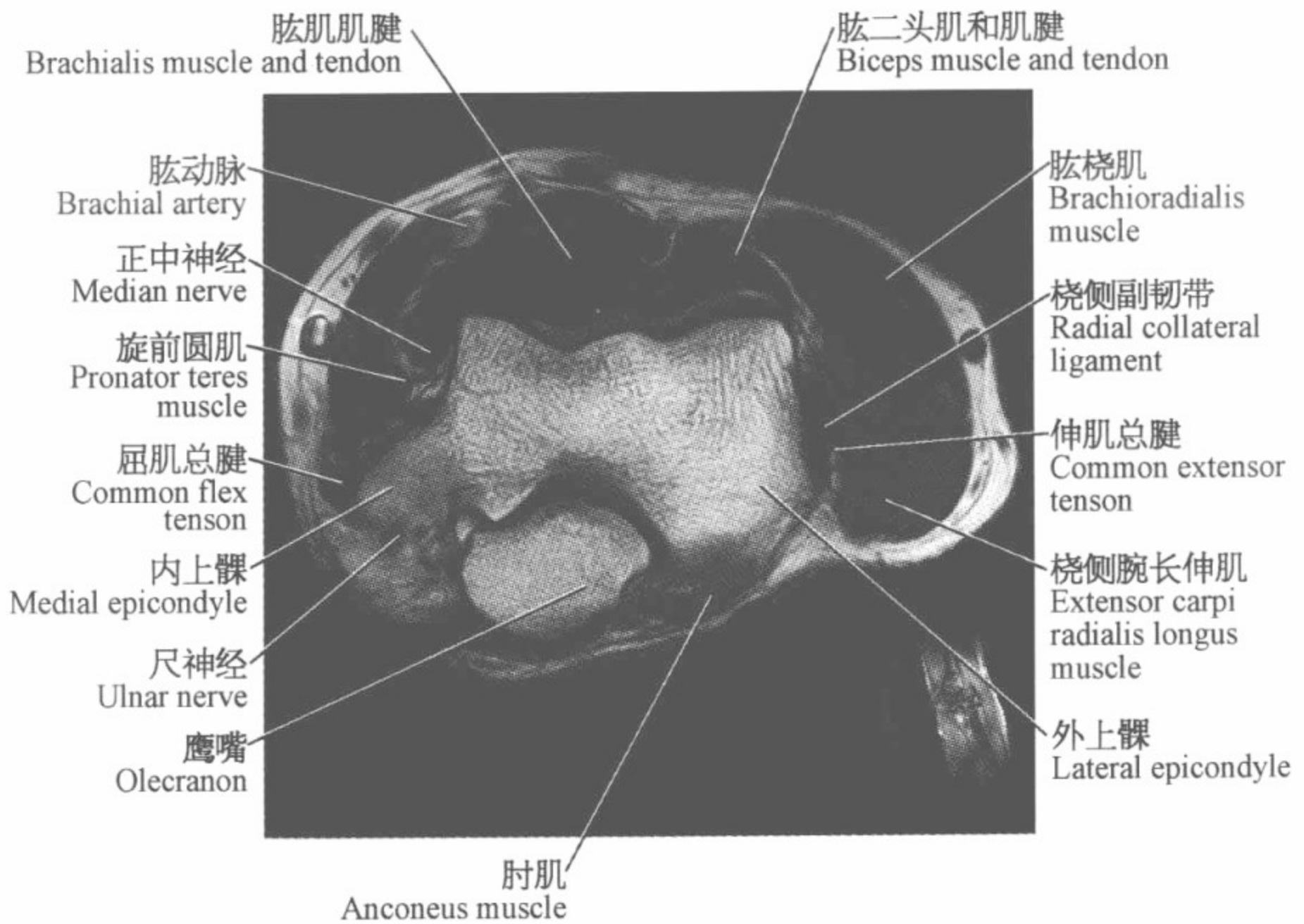
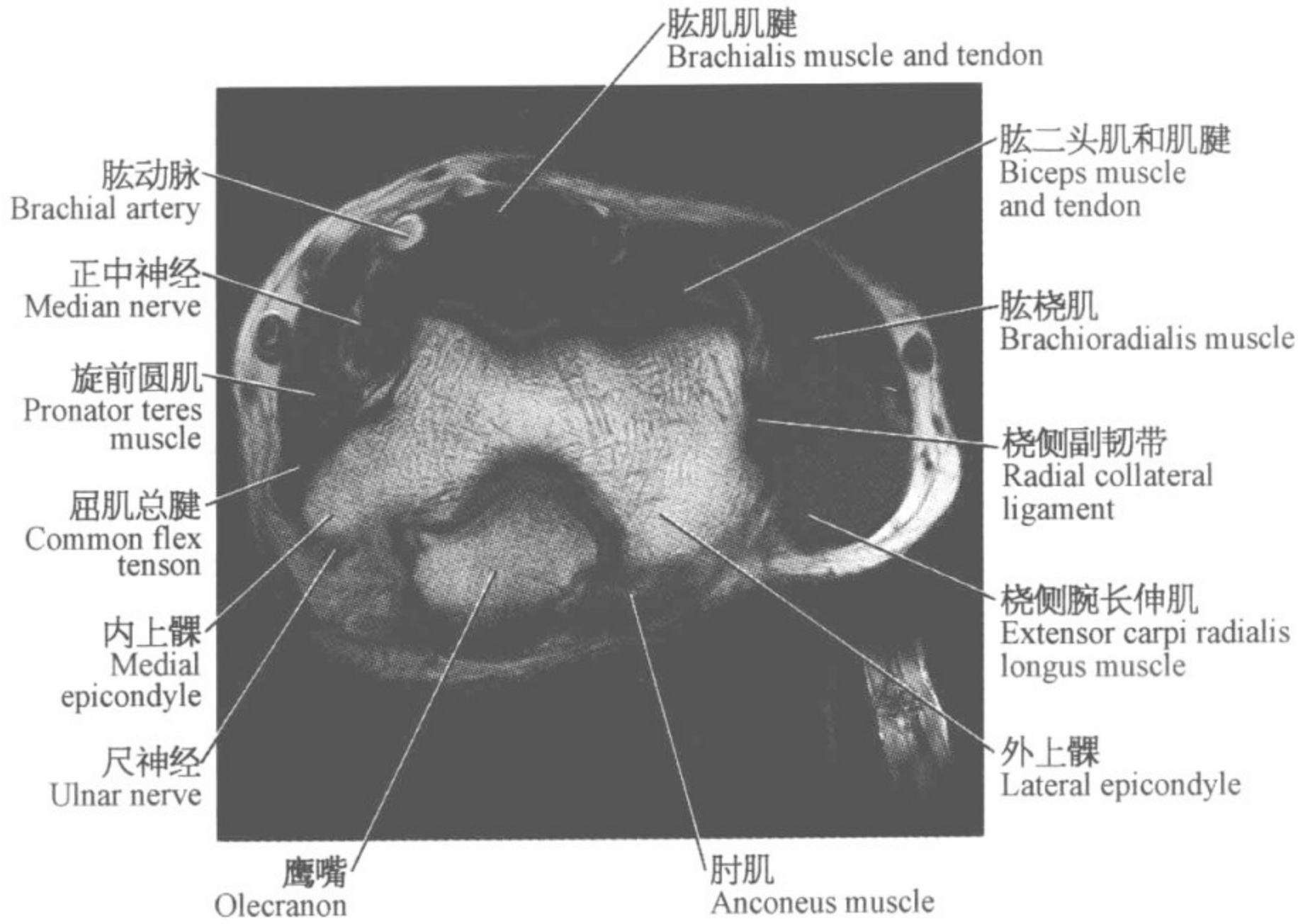


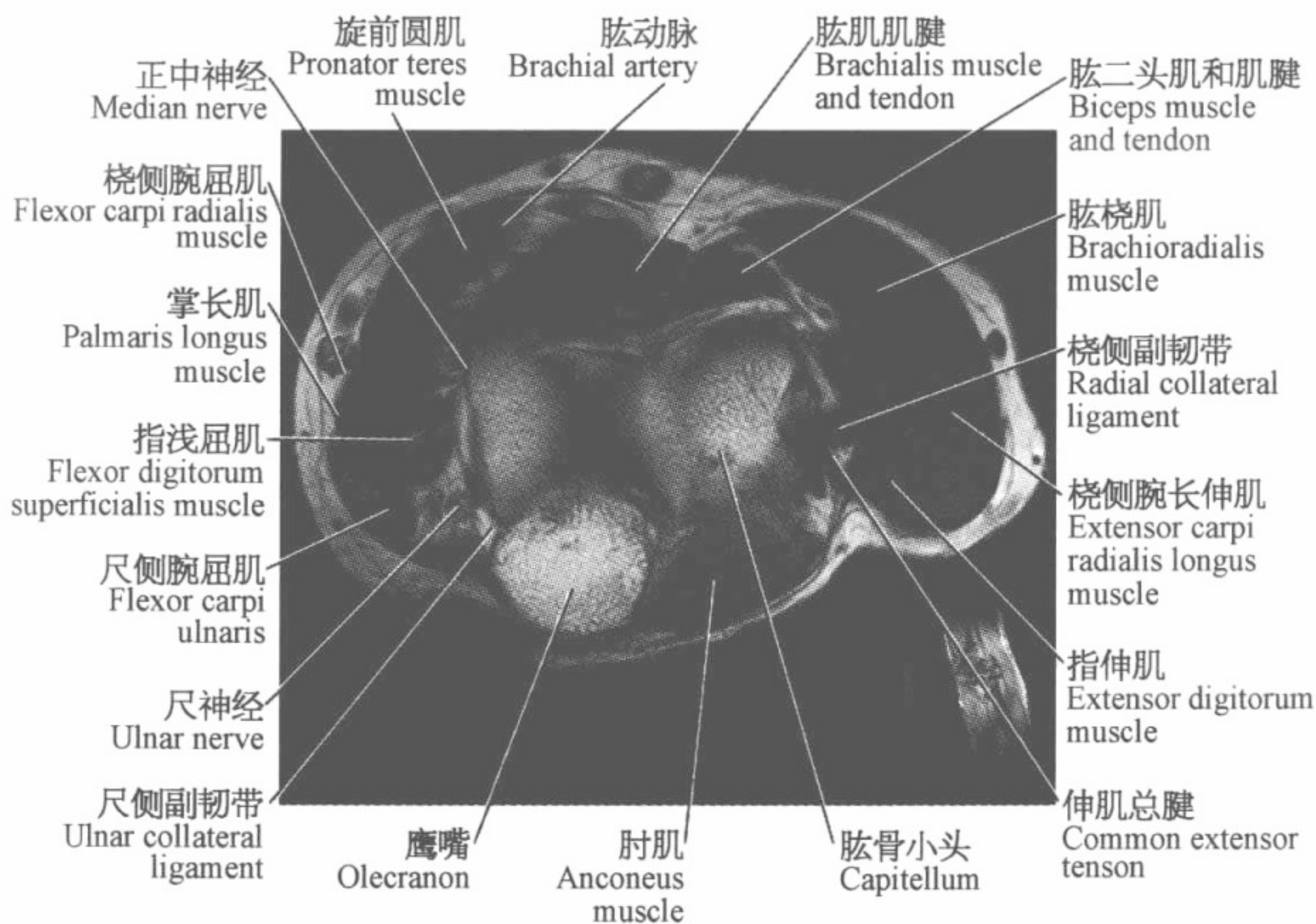
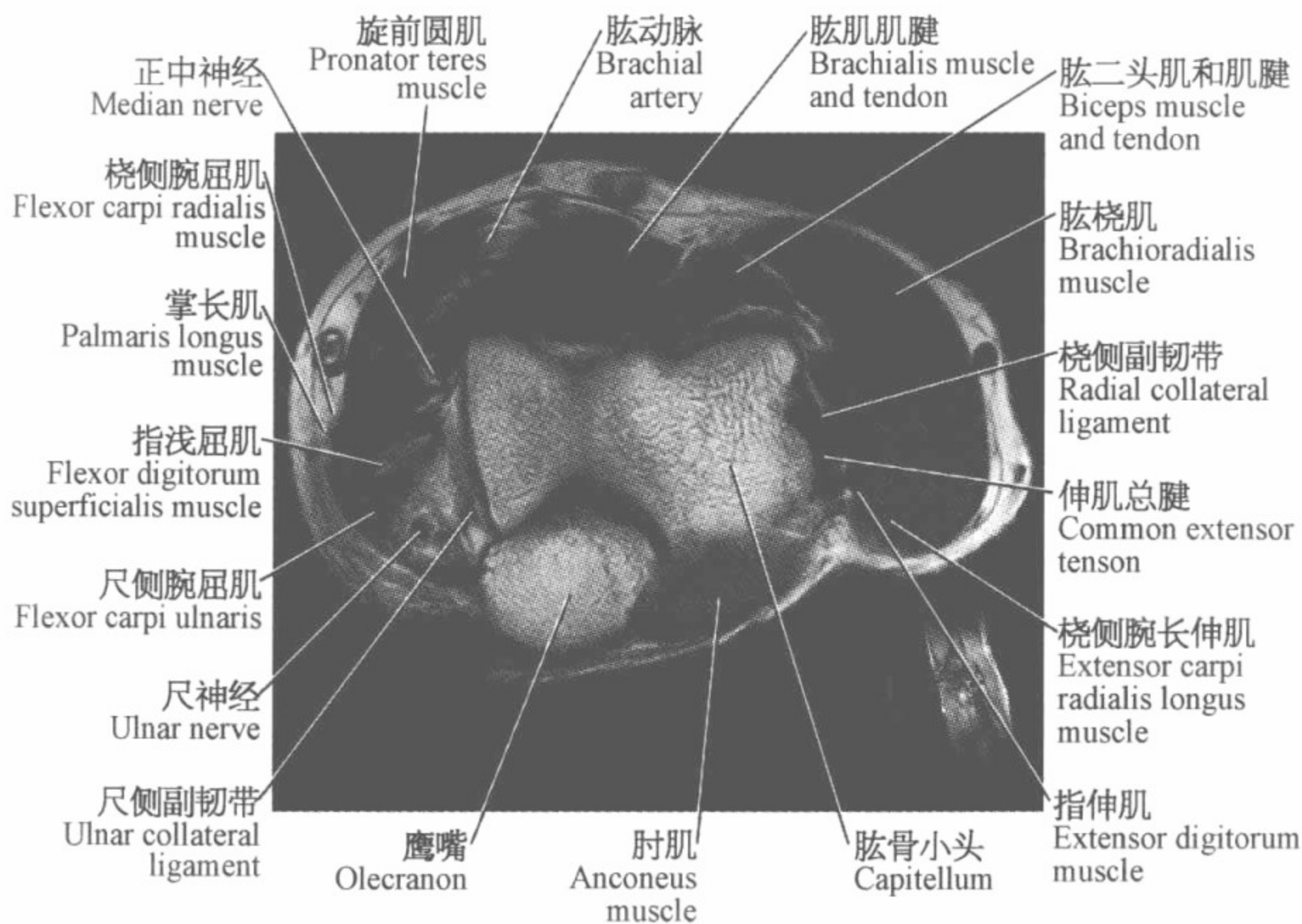
肘关节磁共振图谱

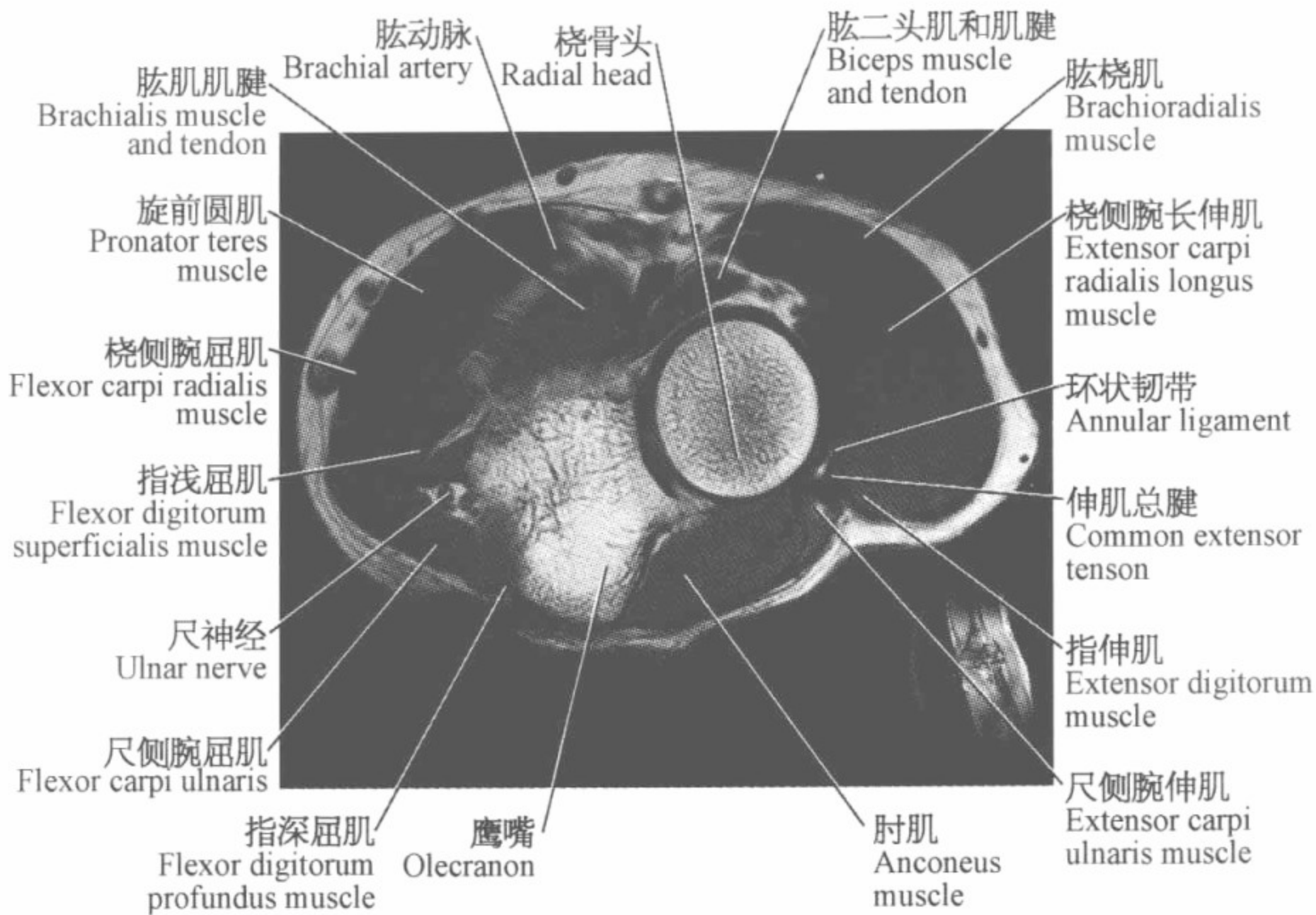
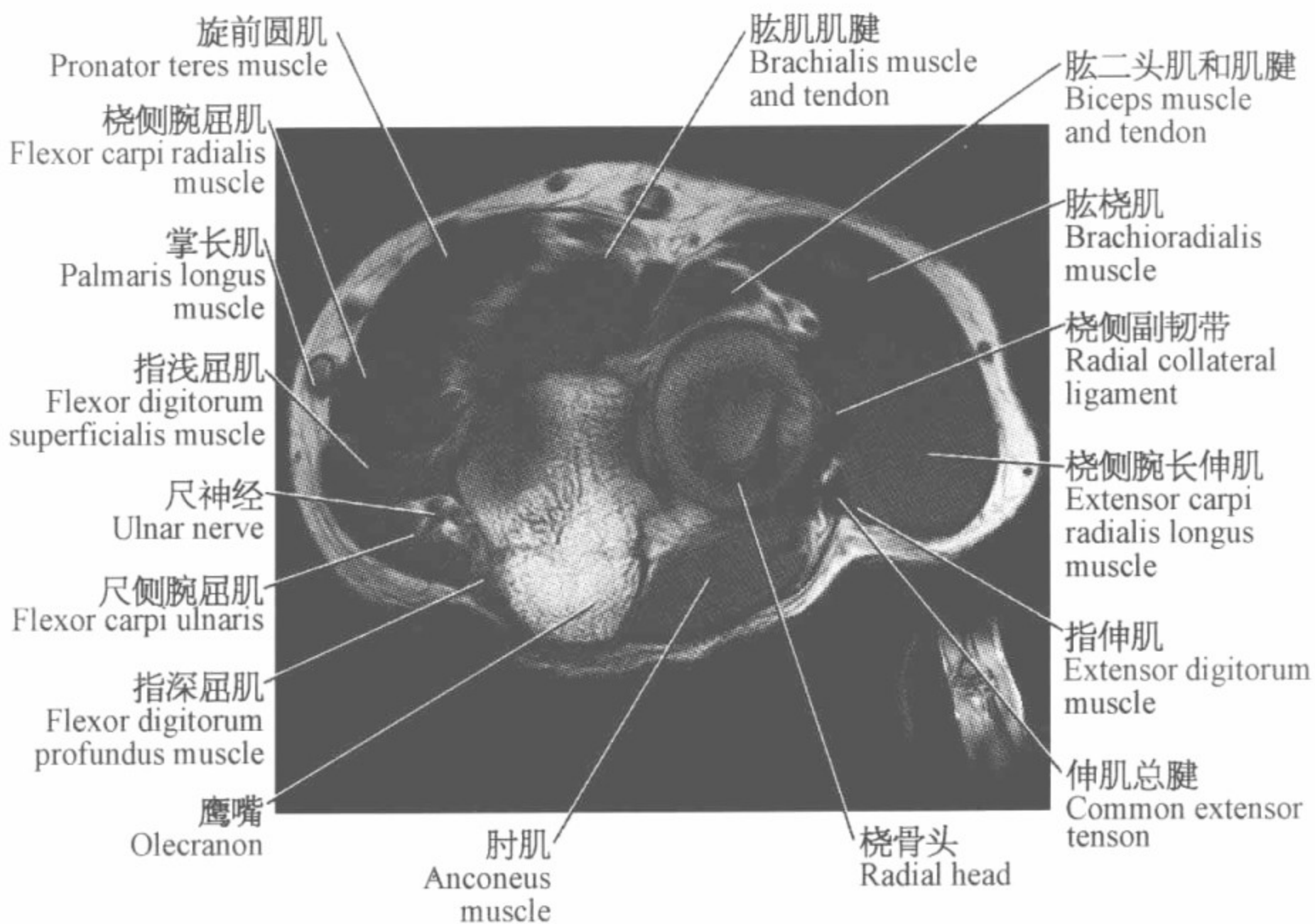
(横断位)

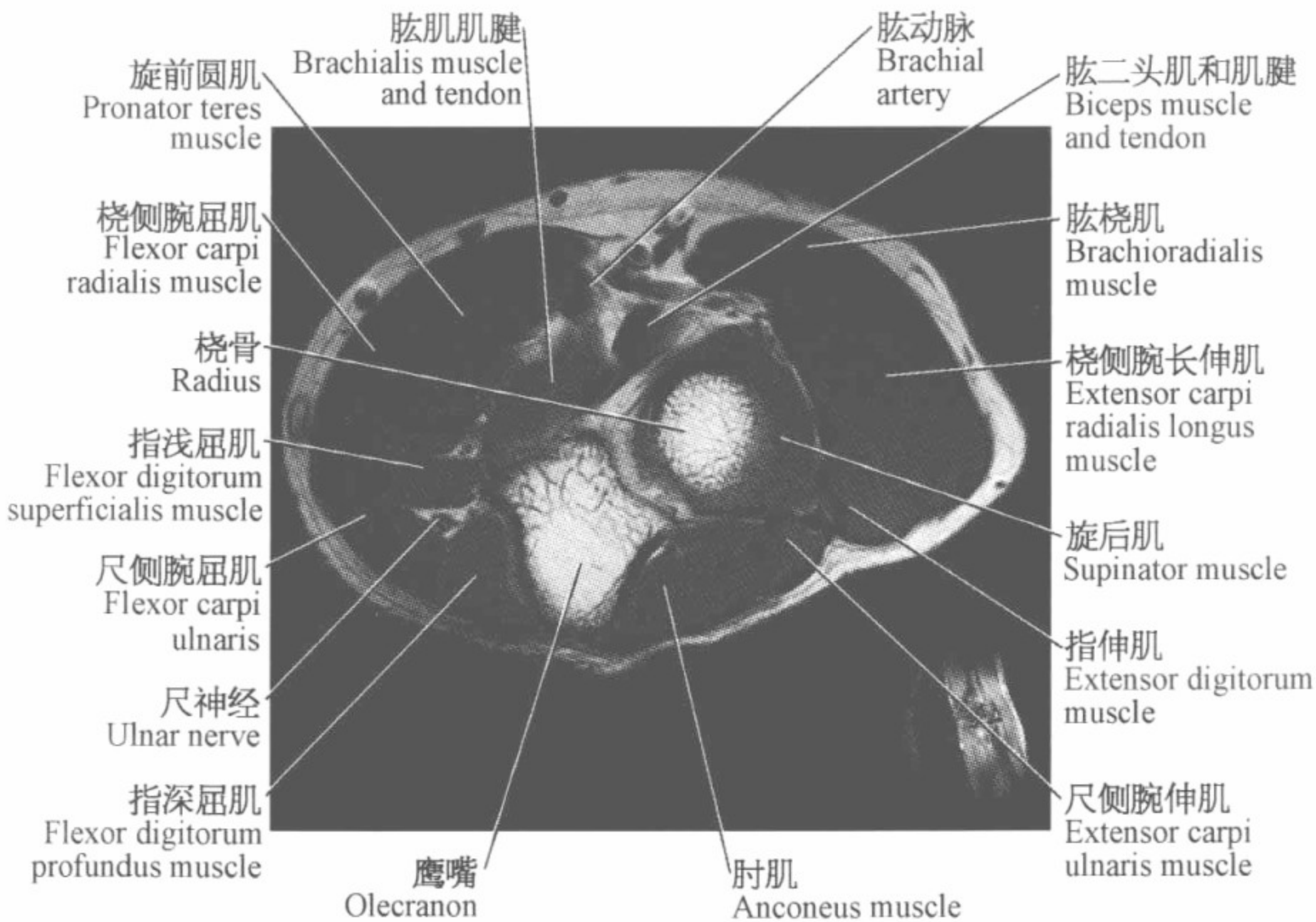
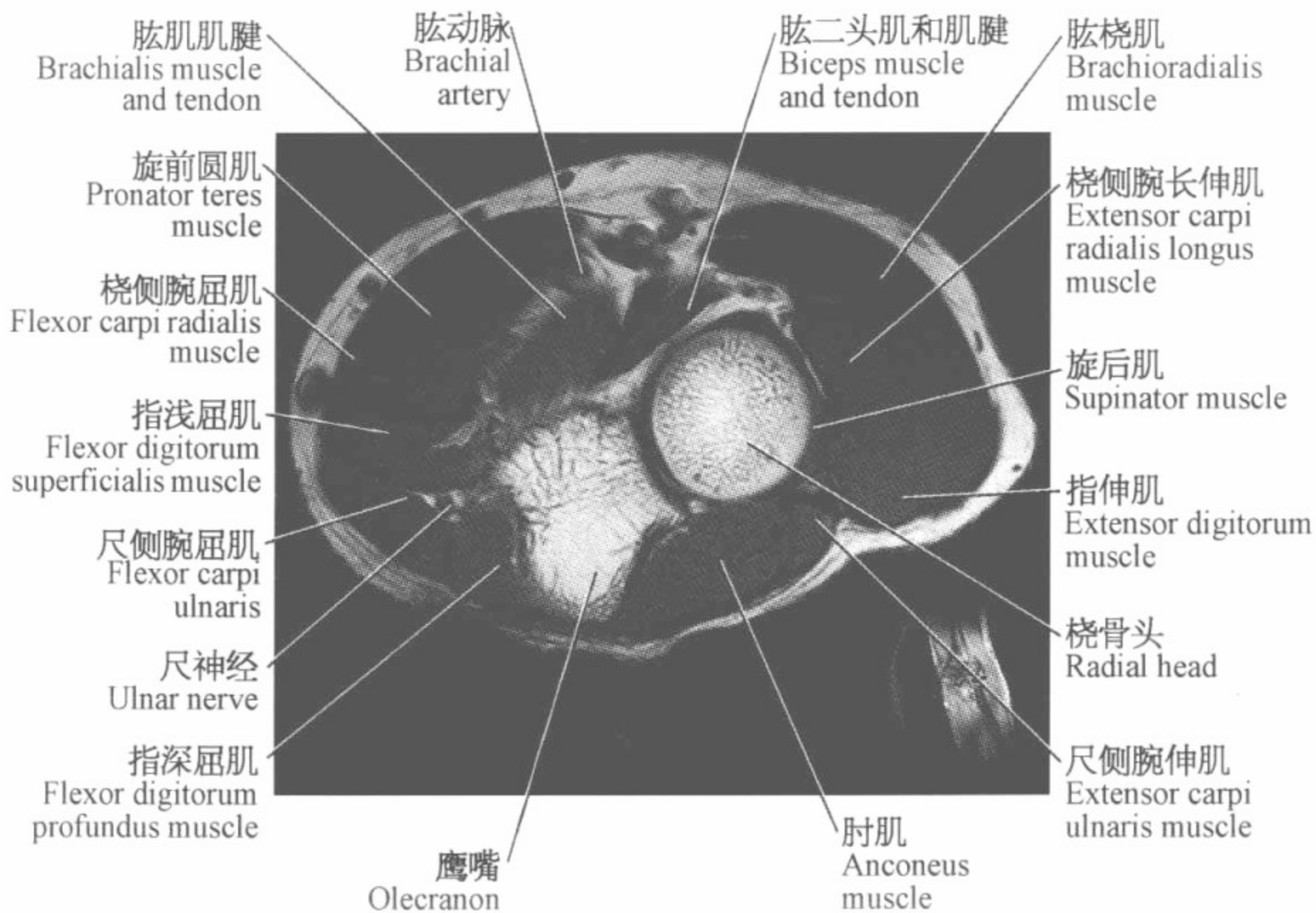


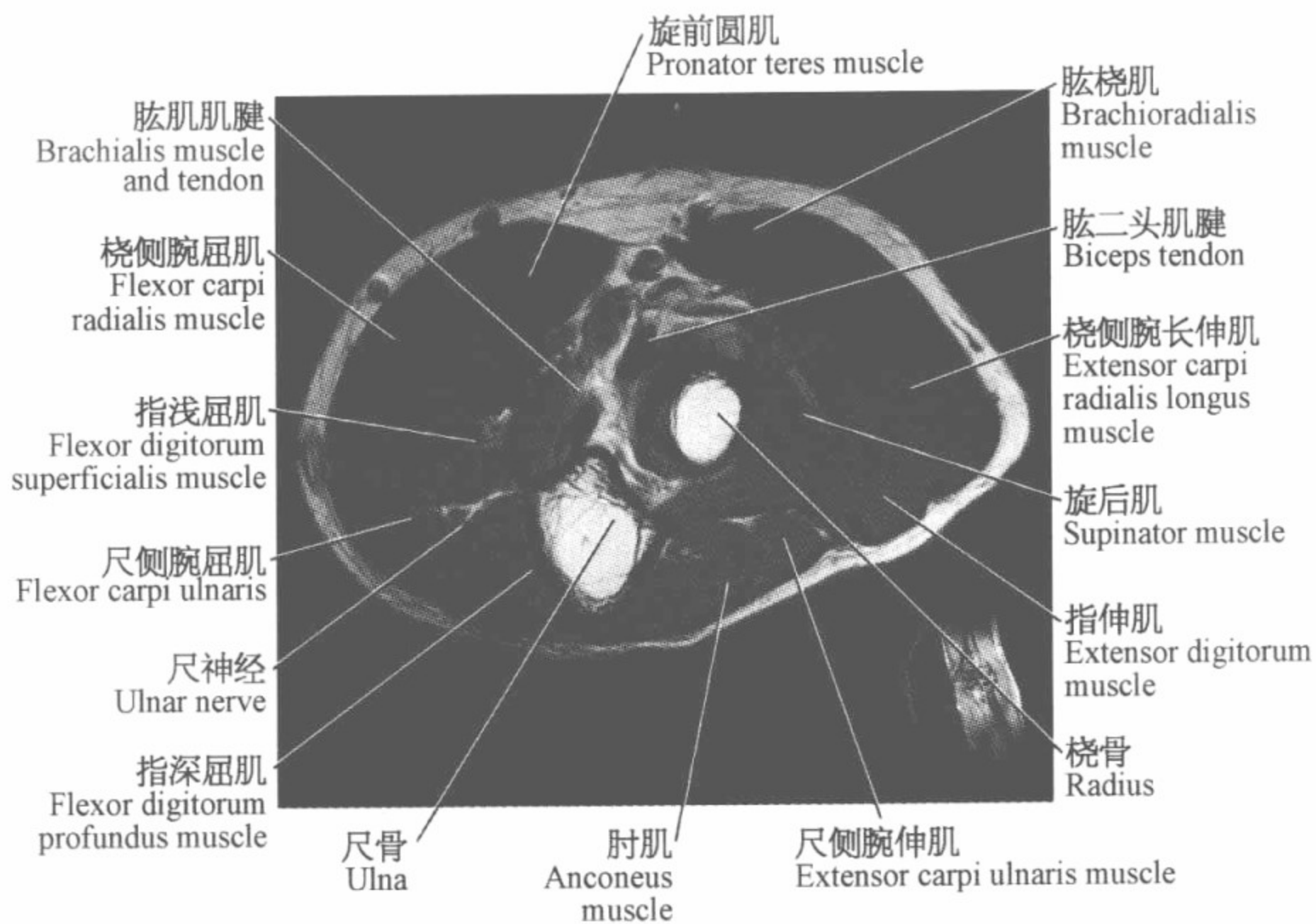
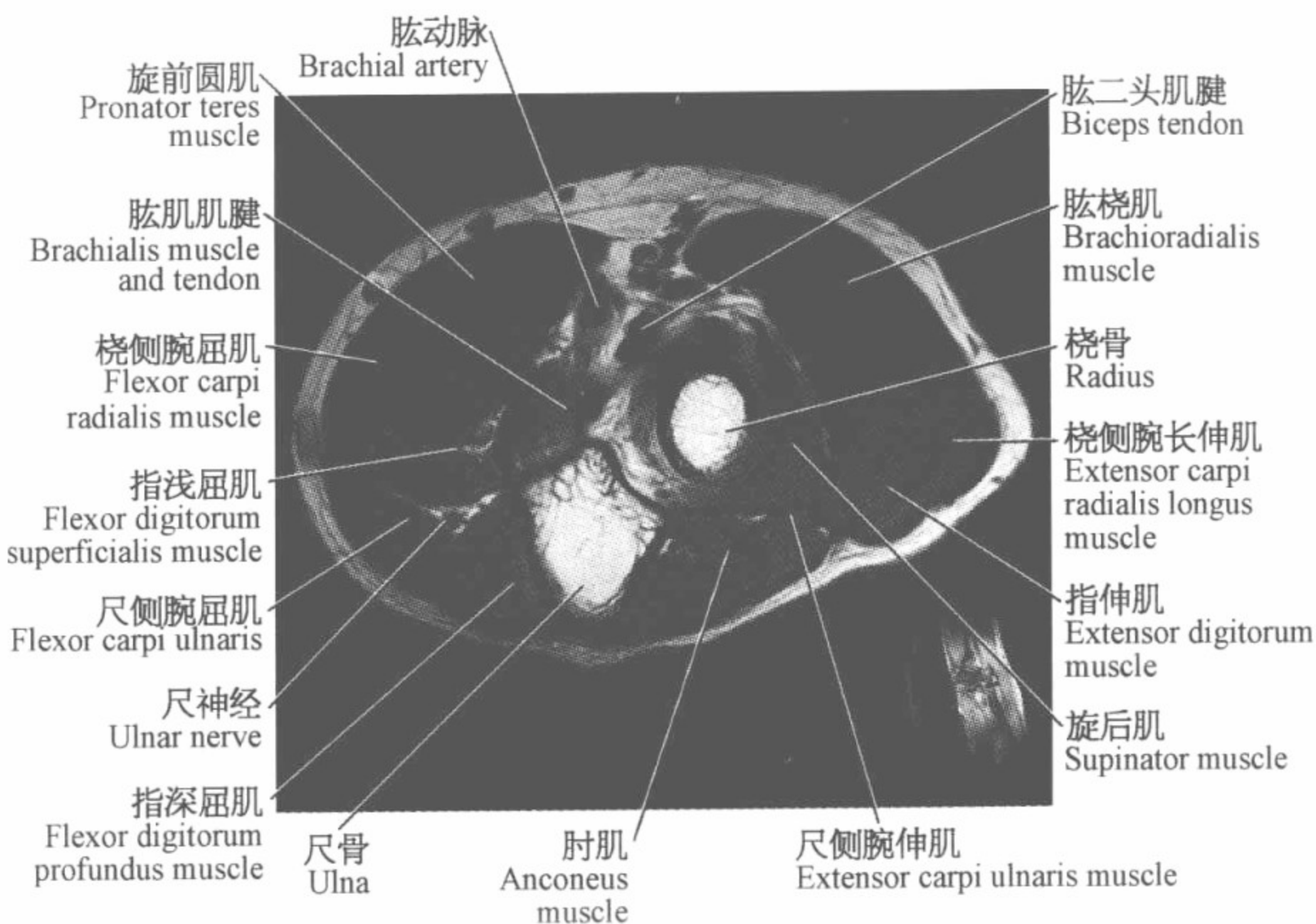








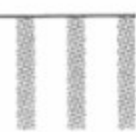


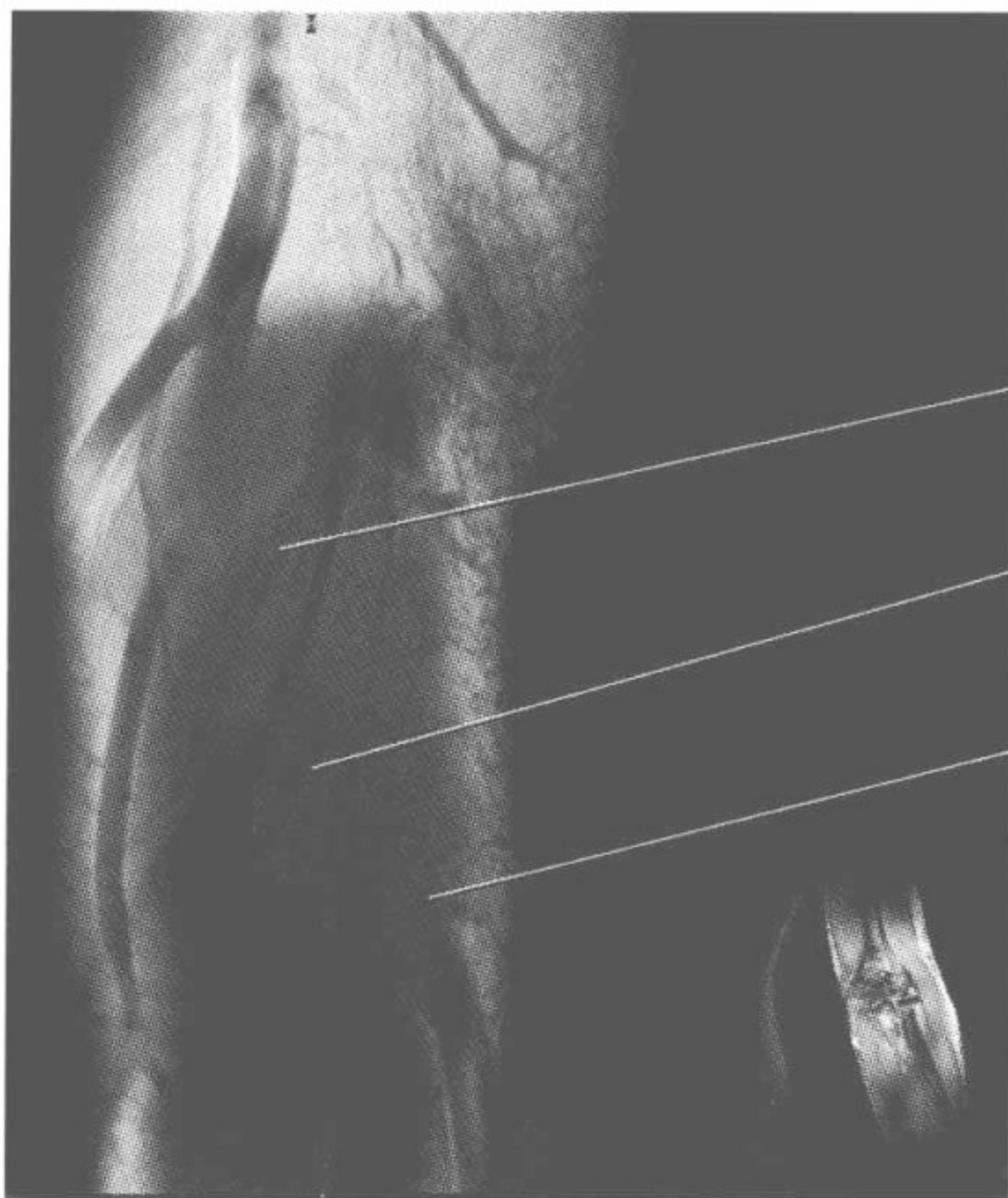




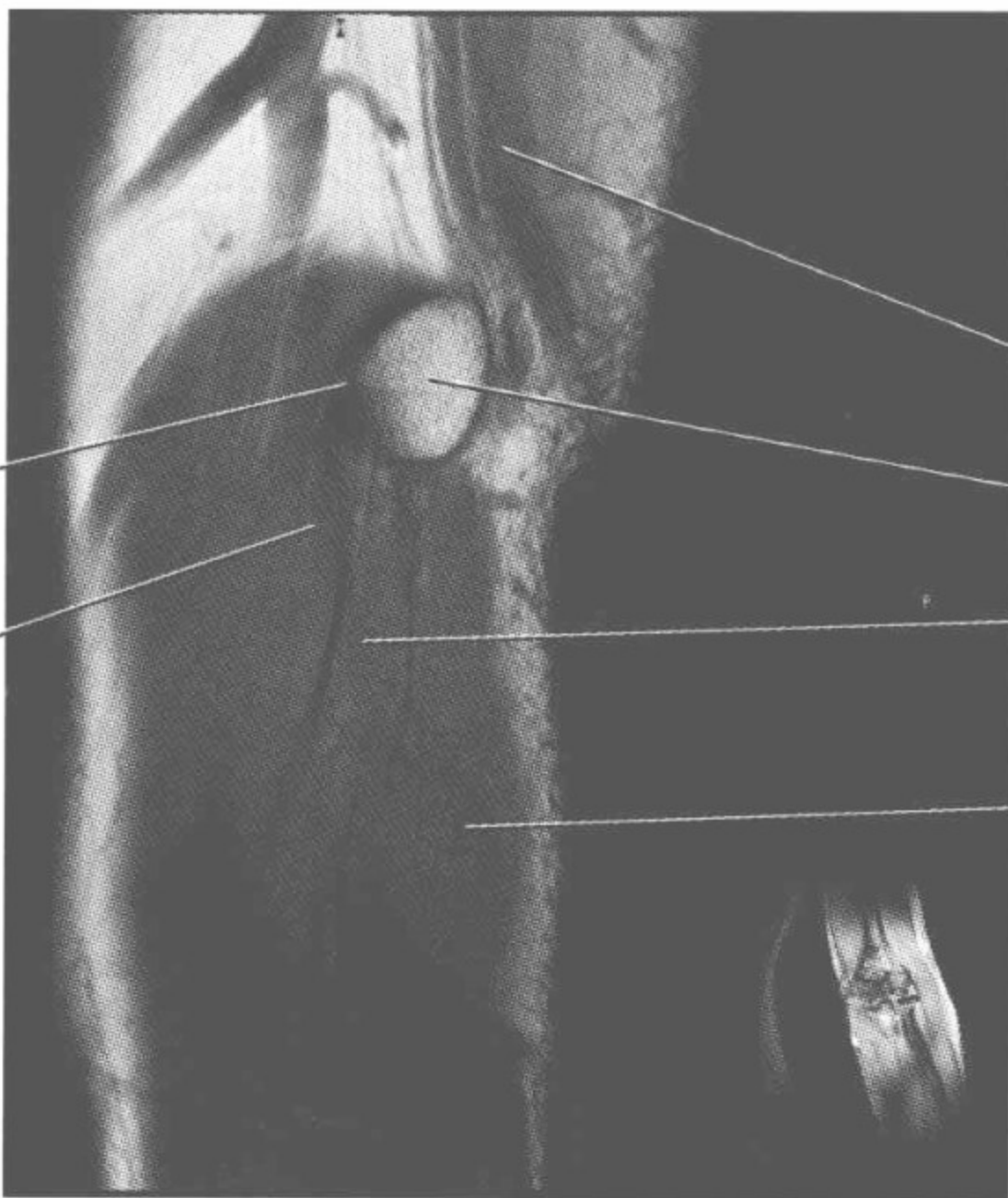
肘关节磁共振图谱

(矢状位)





桡侧腕屈肌
Flexor carpi
radialis muscle
指浅屈肌
Flexor digitorum
superficialis muscle
尺侧腕屈肌
Flexor carpi ulnaris



旋前圆肌
Pronator teres
muscle
桡侧腕屈肌
Flexor carpi
radialis muscle

肱三头肌
Triceps muscle
内上髁
Medial epicondyle
指浅屈肌
Flexor digitorum
superficialis muscle
尺侧腕伸肌
Extensor carpi
ulnaris muscle

