

冠脉CTA成像及诊断

复旦大学附属中山医院 杨姗 曾蒙苏 张志勇



冠脉成像技术

- 检查设备
- 检查流程及注意事项
- 重建技术
- 伪影识别

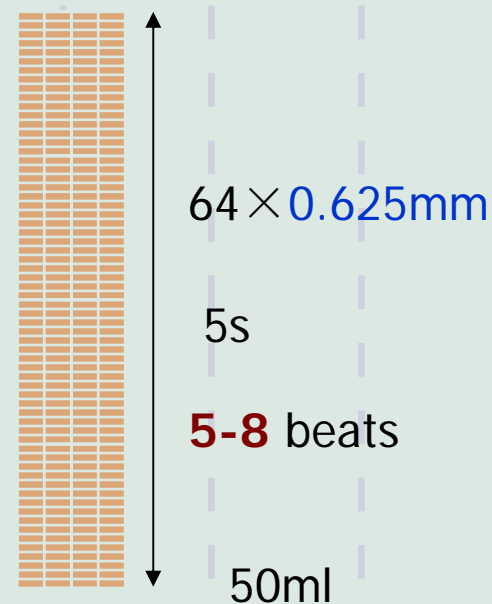
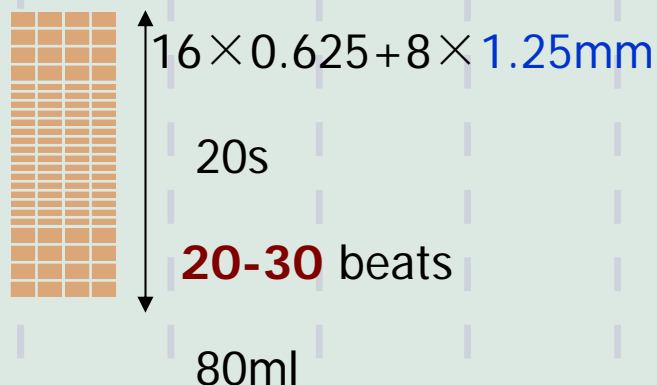
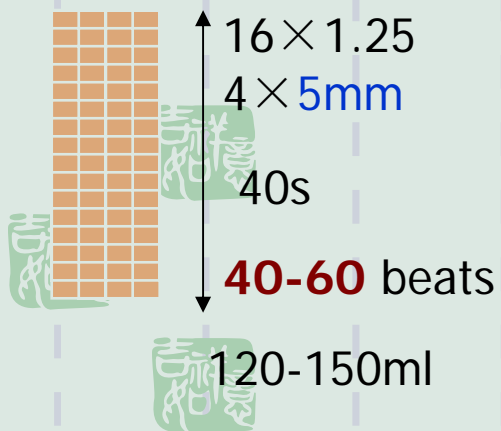


探测器（硬件）分布示意图

4排螺旋CT
20mm

16排螺旋CT
20mm

64排螺旋CT
40mm



时间空间分辨率不足
病人配合明显困难

屏气差，心率不
齐影响仍然存在

真正各向同性，
屏气缩短

运动脏器（冠脉）成像

吉祥

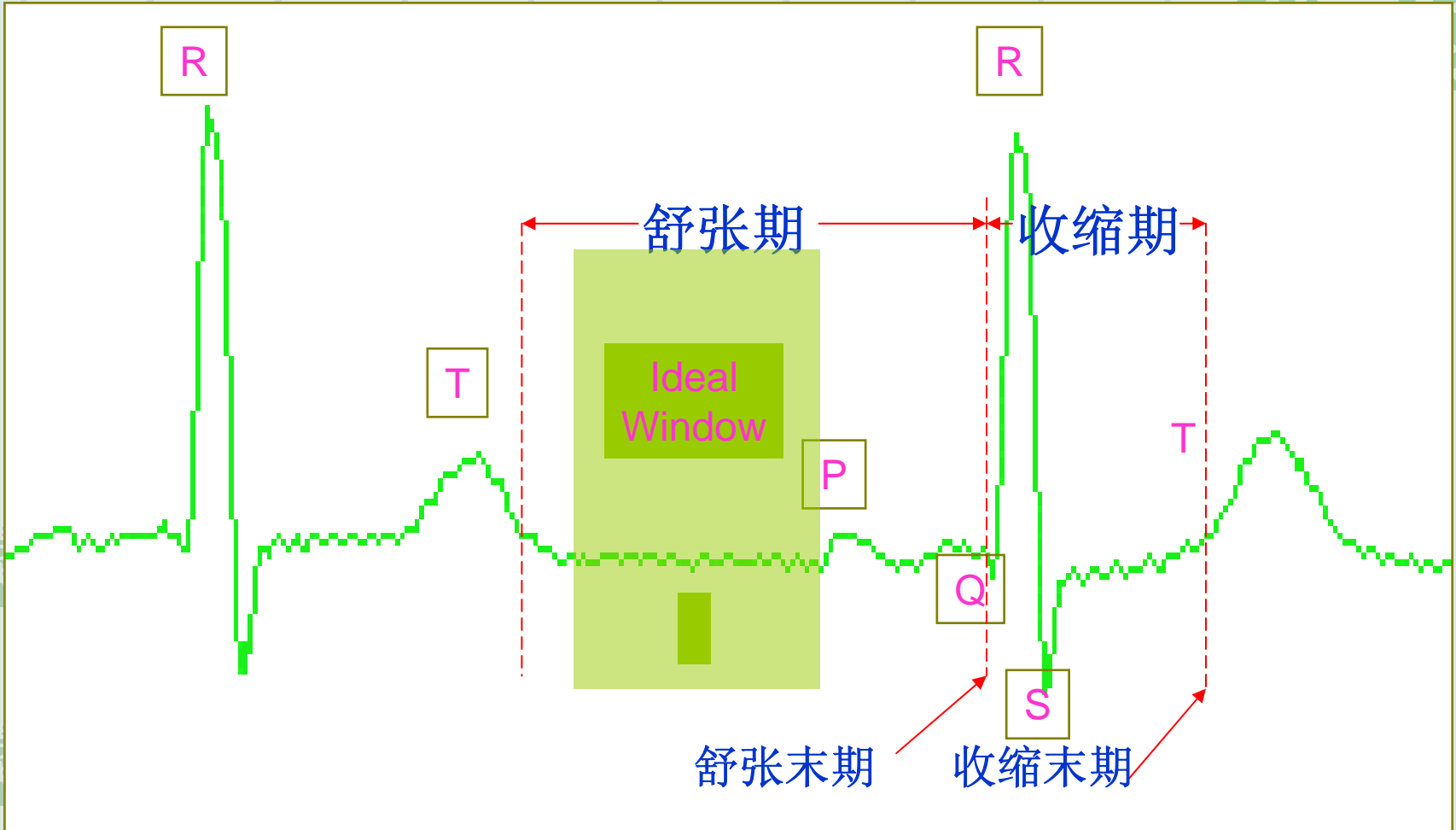
■ 呼吸运动 单次屏气 门控技术

■ 心脏波动 心电同步技术

前瞻性**ECG**触发

回顾性心电门控





前瞻性ECG触发

- 轴位扫描，并非3d容积扫描
- 剂量少
- 心率依赖
- 层厚大，Z轴分辨率不够

吉祥



回顾性ECG门控

- 慢速进床螺旋扫描
- 同步记录心电图—回顾分配数据
- 保证空间分辨率和扫描容积兼顾
- 射线剂量大，**ECG - modulated mA**
- 可行功能成像

吉祥



回顾性ECG门控

绝对门控

正向

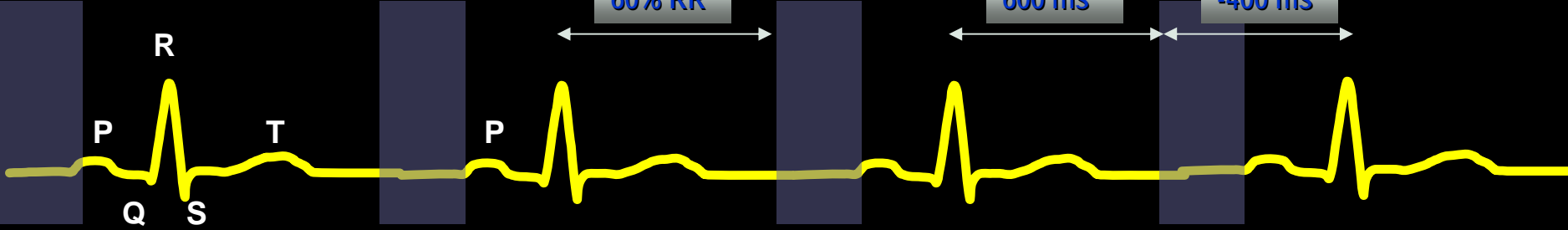
反向

相对门控

60% RR

600 ms

-400 ms



检查流程

■ 病人准备

- ▶ 提前1小时到达，静坐休息
- ▶ 心率较快患者 ($>65\text{bpm}$)

■ 排除禁忌症

- ▶ **BBB** 心功能不全 低血压 病窦综合症 慢阻肺和哮喘
- β -受体阻滞剂（倍他洛克）**25mg**，检查前**1h**
- 积极抢救，阿托平 **1 - 2mg** 异丙肾上腺素

■ 检查前硝酸甘油运用

- ▶ 目的：扩血管

检查流程

吉祥如意

■ 检查前硝酸甘油运用

➤ 目的：扩血管

➤ 舌下含服 **0.3-0.6mg** 2 - 30分钟

➤ 严格控制服用时间，不能过早过晚

➤ 禁用：

■ 严重低血压

■ 急性心肌梗死伴低充盈压

■ 肥厚梗阻型心肌病、缩窄性心包炎或心包填塞

■ 严重贫血

■ 青光眼；颅内压增高

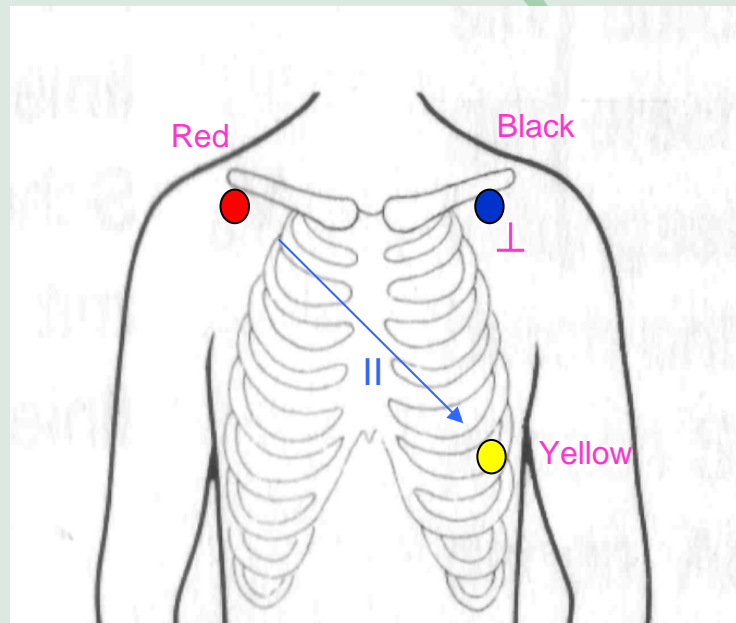
➤ 不良反应：头痛，低血压，**心率加快**



检查准备

■ 电极置放

- ▶ 两侧锁骨下和左侧肋弓下
- ▶ 避免脱落，注意皮肤清洁
- ▶ 观察基线平稳否



■ 呼吸培训

- ▶ 一般屏气时间**10**秒左右
- ▶ 注意观察*屏气效果*屏气后心率变化规律

扫描流程

- 定位片



- 非门控低剂量螺旋扫描或冠脉积分



- **Timing Bolus (主动脉根部)**



- 冠脉造影

吉祥



造影剂

- 碘浓度：370mg/ml

- 注射器：双桶 单桶

 - 20/90ml造影剂

 - 20/60ml生理盐水

- 速率：单相 5ml/s

- 剂量：检测/成像

 - 造影剂20/65ml，盐水20/30 - 40ml

 - 峰值时间过长或过短，相应增加或减少造影剂量

吉祥



冠脉造影

吉祥

- 心率 $< 70\text{bpm}$ ，**SSEG**单扇区采集模式
- $90 > \text{心率} \geq 70\text{bpm}$ ，**SSB**双扇区采集模式
- 心率 $> 90\text{bpm}$ ，**SSB**四扇区采集模式
- 重建扇区越多，要求心率越稳定
- 心率不稳，必要时可通过**override**尝试

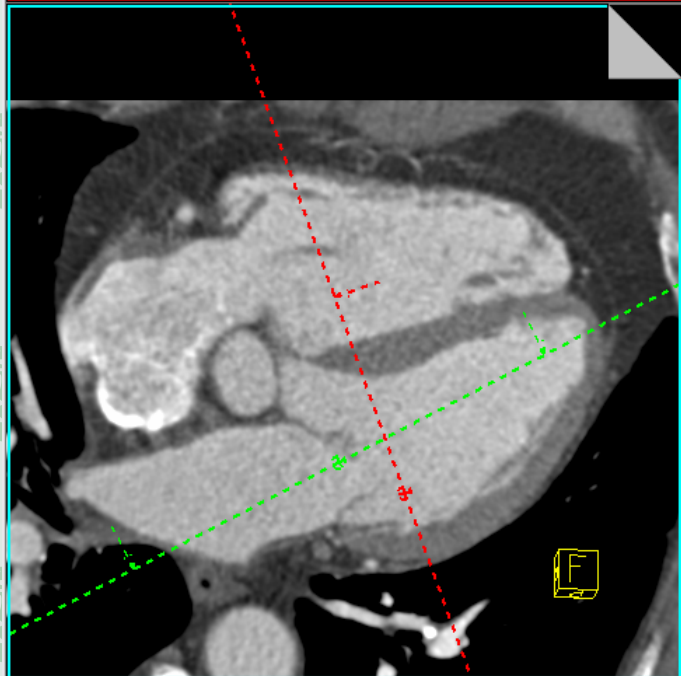
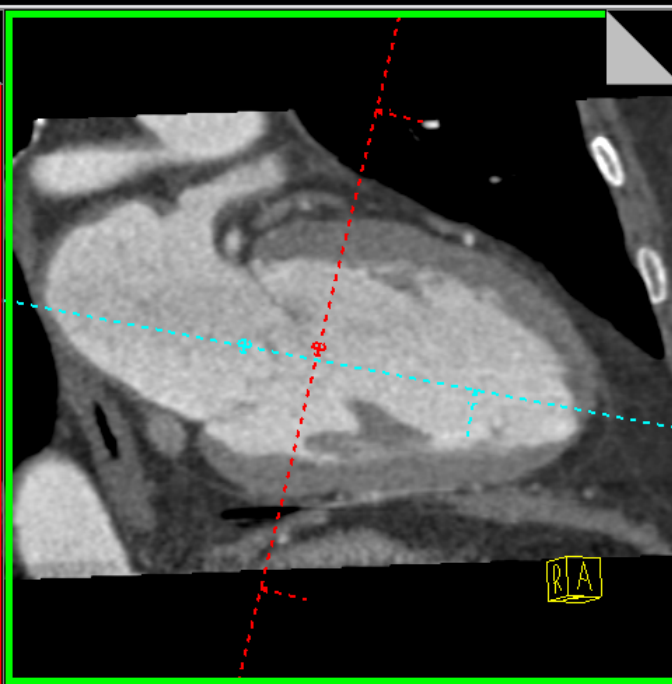
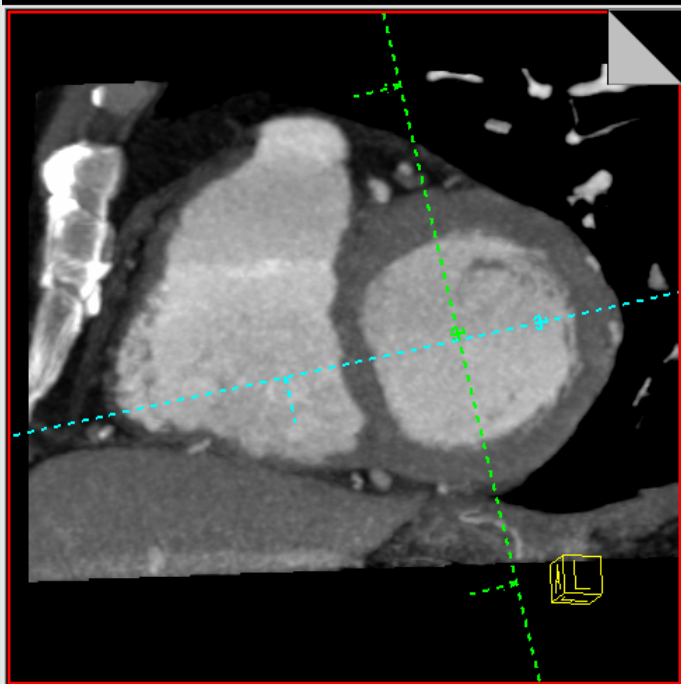
吉祥

吉祥

吉祥

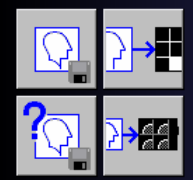
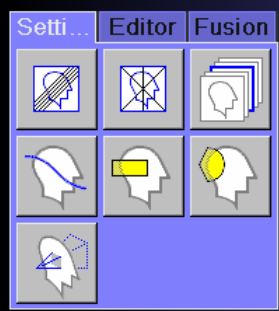
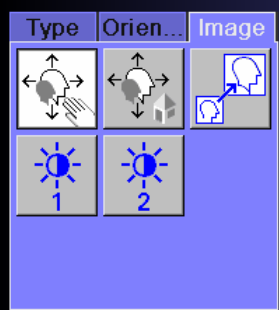
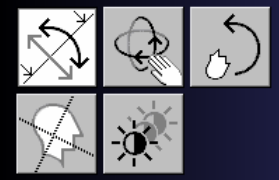
吉祥

吉祥



MPR parallel & orthogonal to the ventricular axis

HV VZ_Intermediat

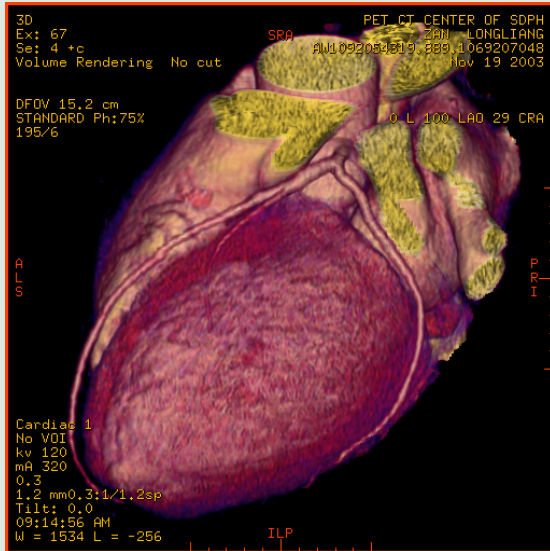
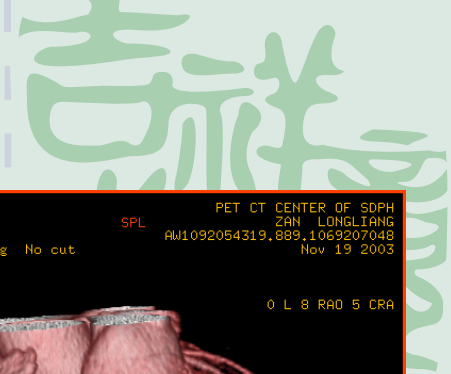


Viewing

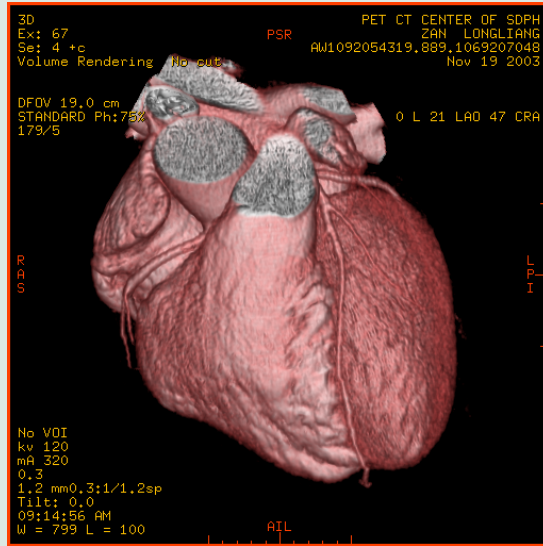
Filming

3D

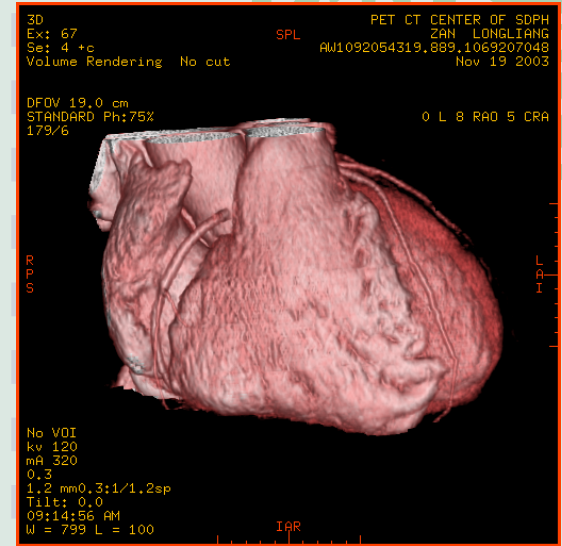
慢心率成像 (50~65次/分)



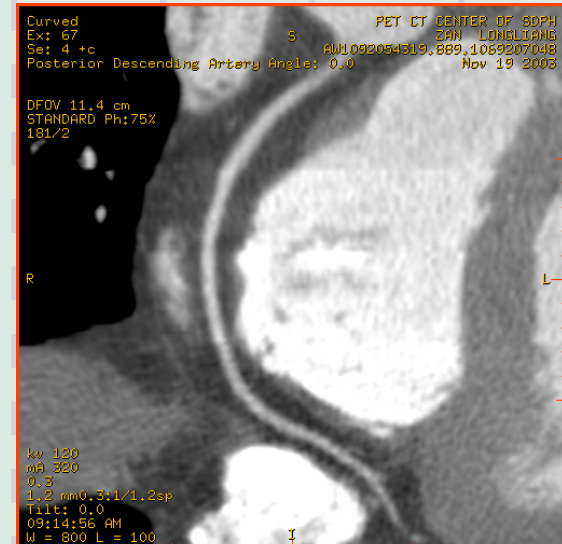
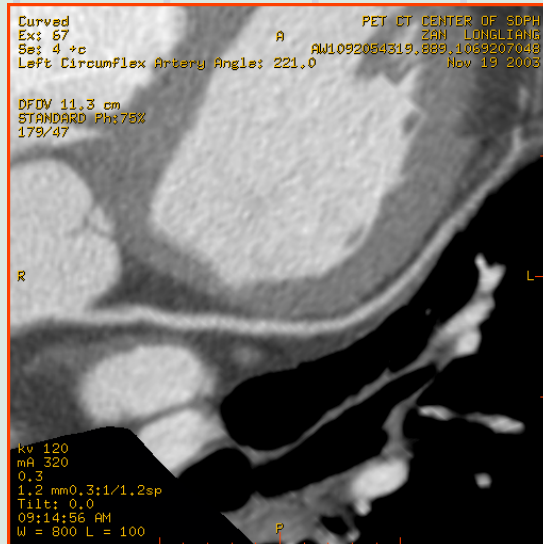
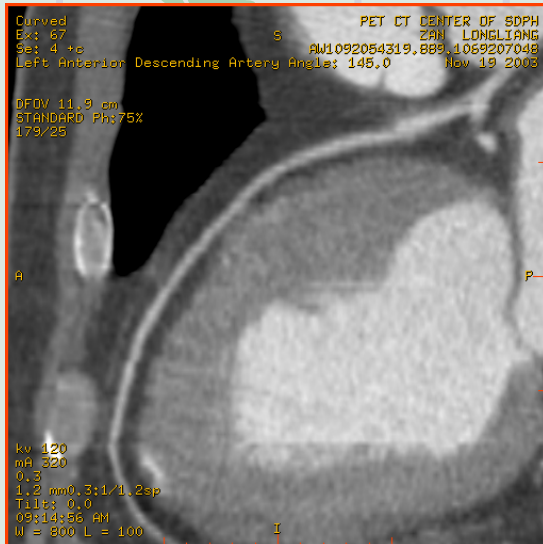
LAD

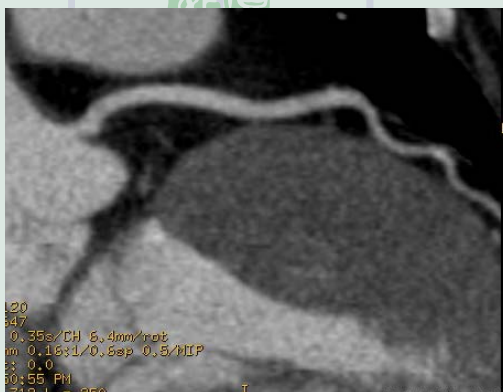
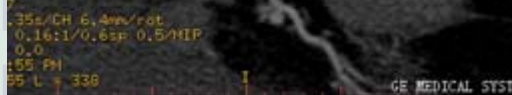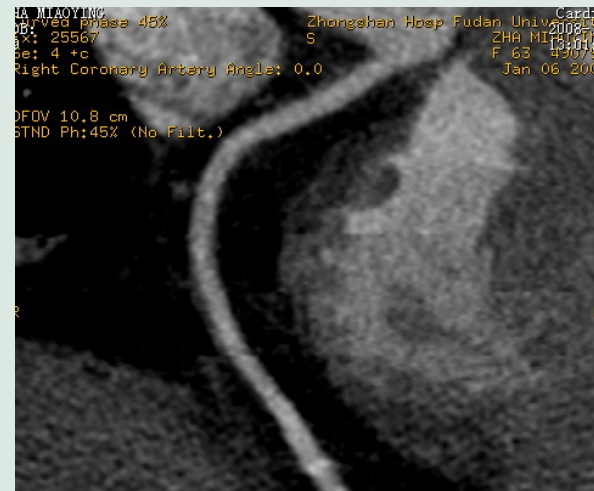
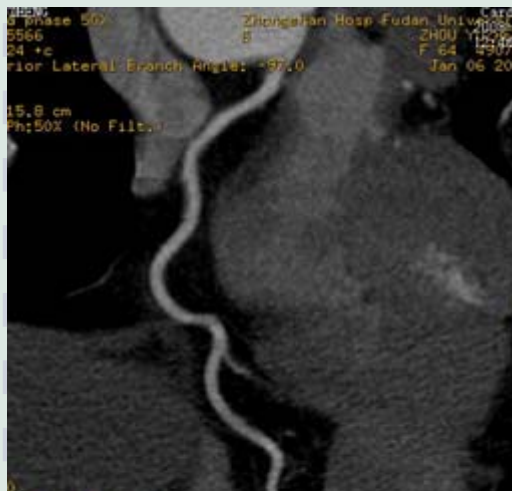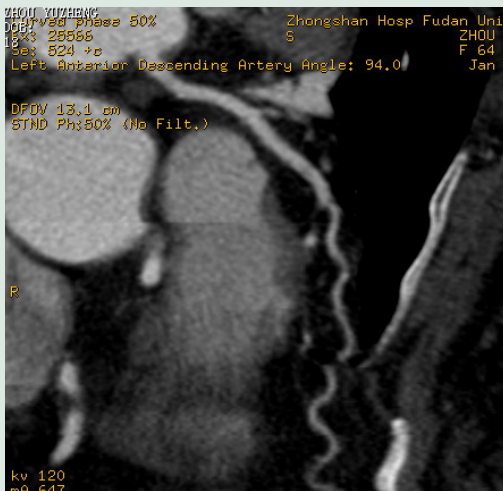
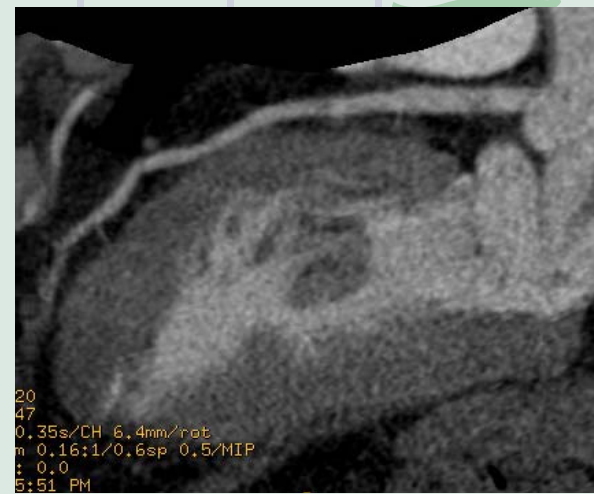
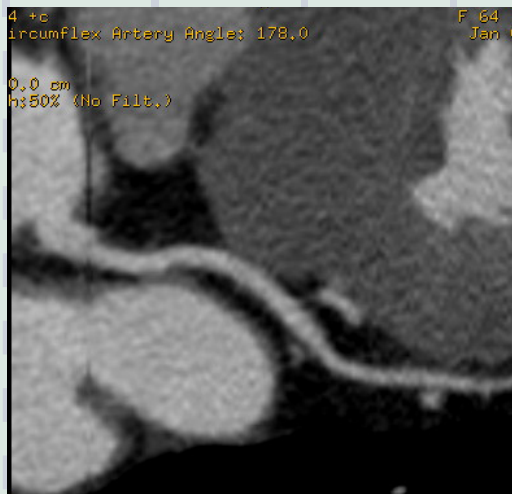
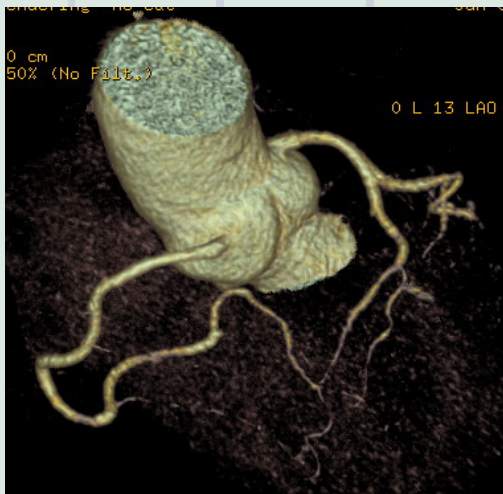


LCX



RCA





静

快
心
率
成
像

HR 105~114次/分

HR 100~102次/分

三维后处理技术

吉祥

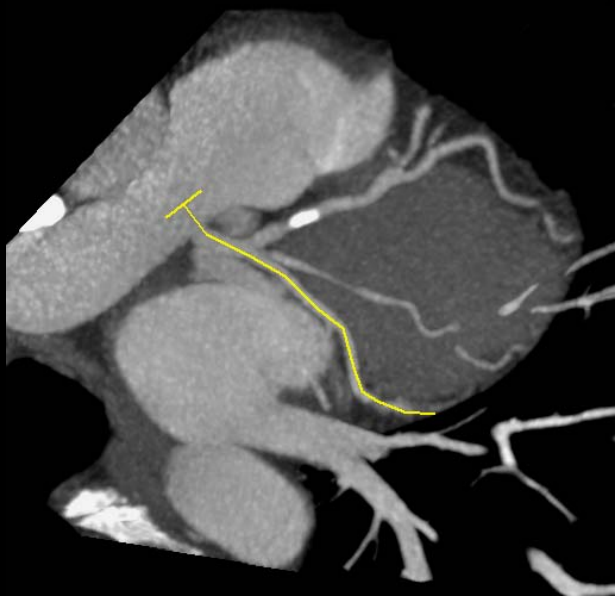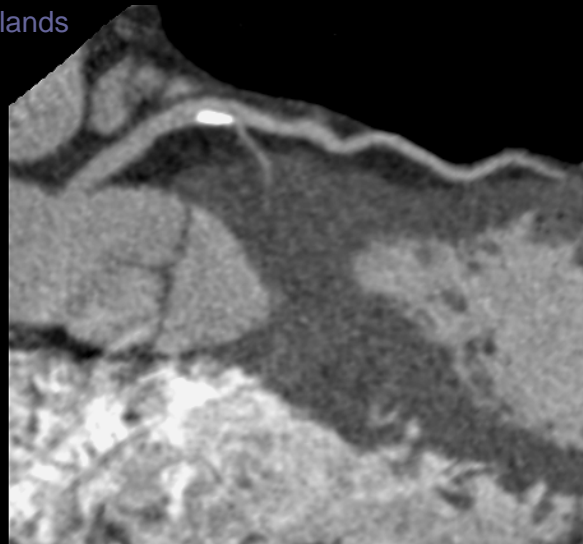
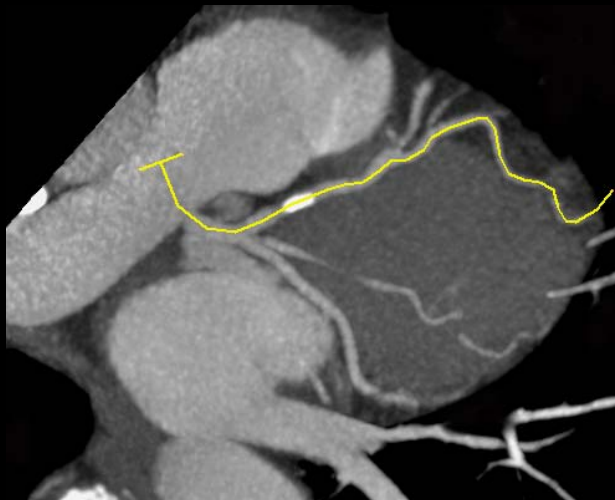- **MPR** **Multi-planar Reformats**
- **CPR** **Curved Planar Reformats**
- **ThinMIP** **Thin-slab Maximum Intensity Projection**
- **VRT** **InSpace - Volume Rendering Technique**
- **Vessel Tracking and Analysis Software**



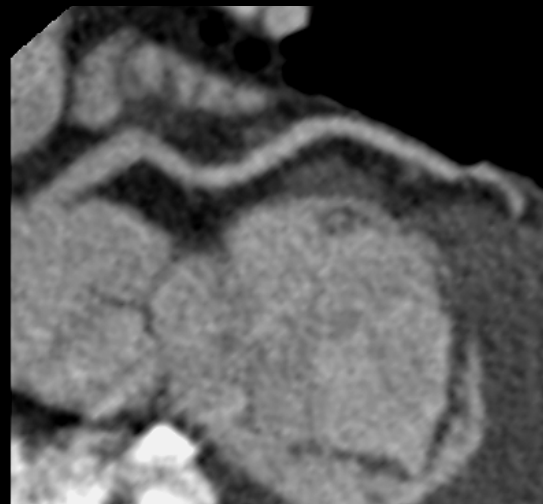
重建软件

CPR based on MIP Image - Lt. Anterior Descending Artery


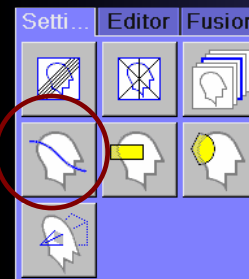
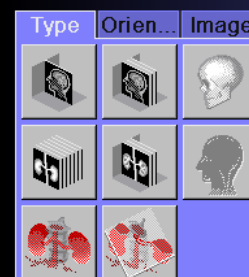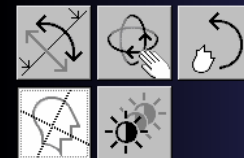
University Hospital Rotterdam, Dijkzigt, Netherlands



Lt. Circumflex Artery



HV VZ_Intermediat



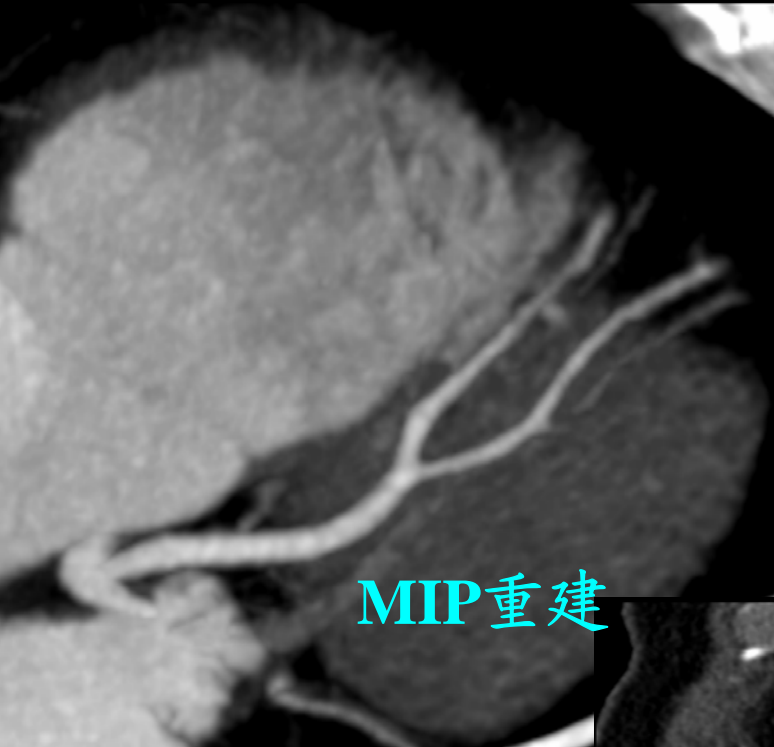
Viewing

Filming

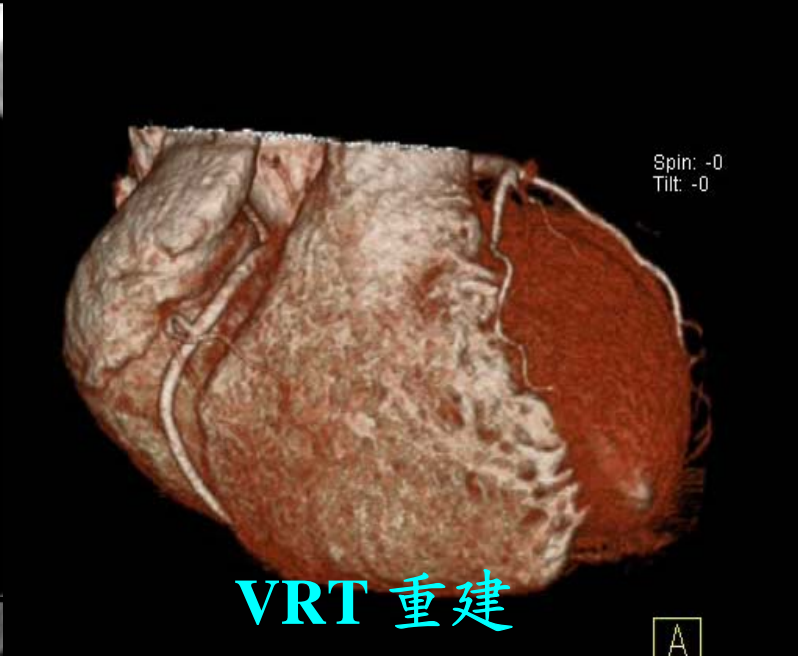
3D

影像


多种重建技术



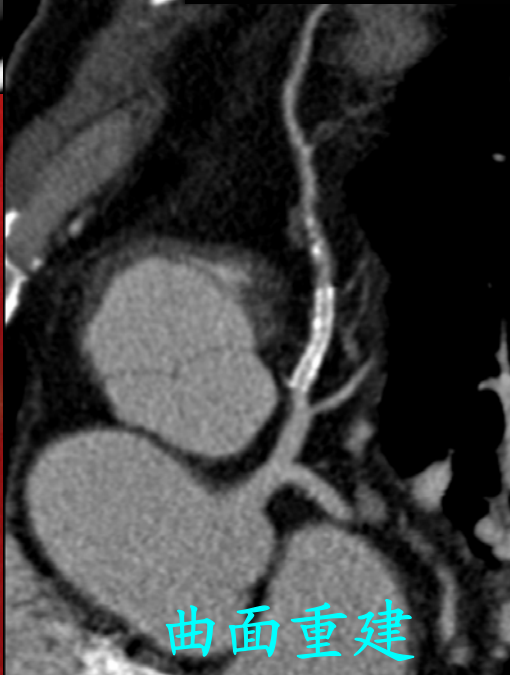MIP重建



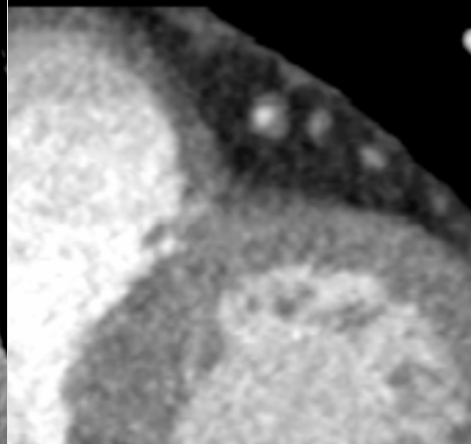
VRT重建



血管内窥镜



曲面重建



血管横断面

冠脉CTA成像中常见伪影

- 心脏搏动伪影、呼吸运动伪影
- 心律不稳
- 部分容积效应（高密度）
- 螺距选择
- 造影剂用法
- 被检者条件

冠脉CTA

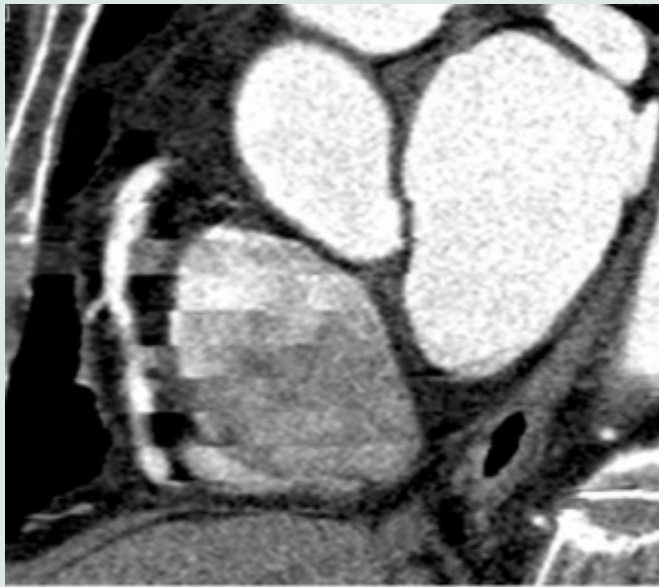

心脏搏动

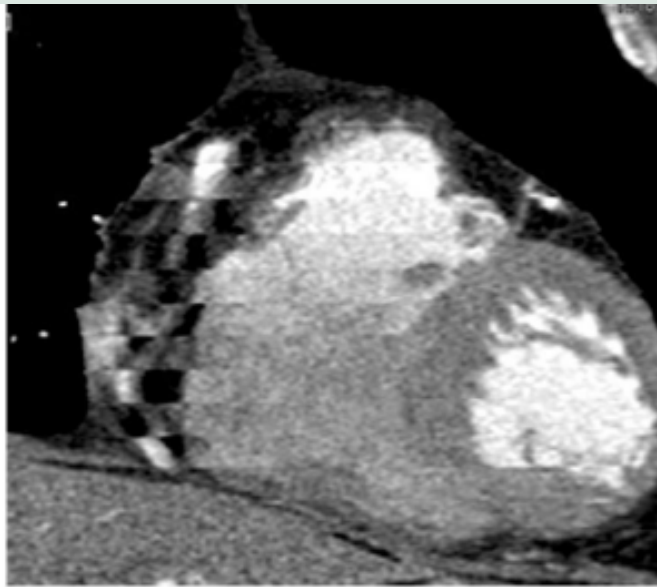
吉祥

- 最常见、最重要
- 心脏充盈期（舒张期）影响相对较小
- **RCA**靠近心房最易受影响，而**LAD**位于心室表面相对影响较小
- 中等/快心率对不同冠脉采用不同时相重建是必要的
- 慢心率（**50次/分**）往往单个时相即可满足三支冠脉的显示

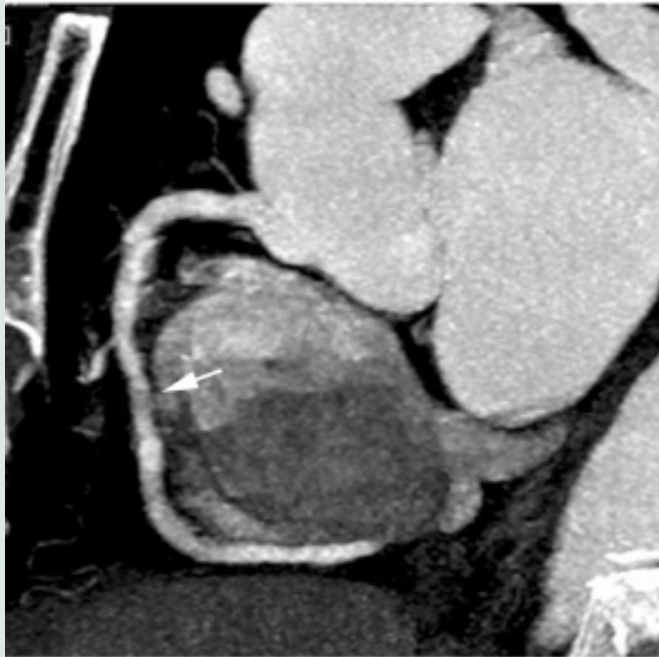




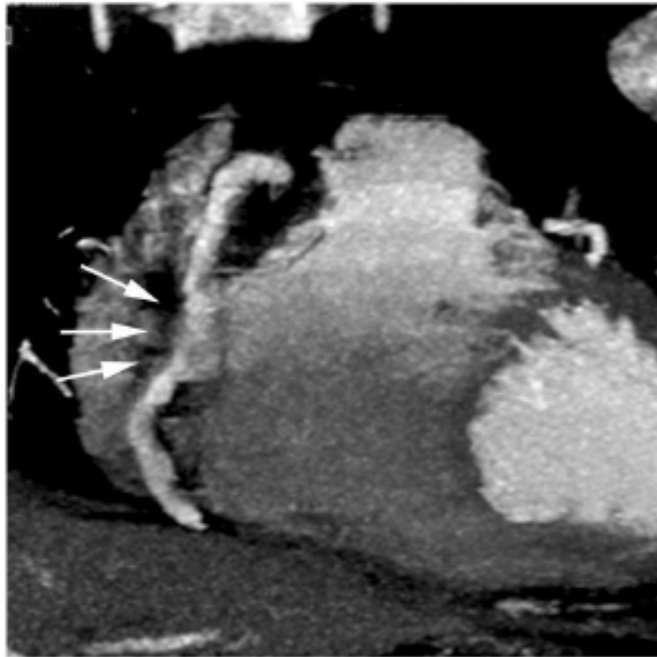
a.



b.

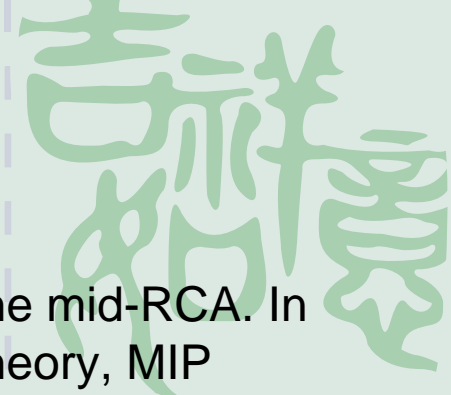


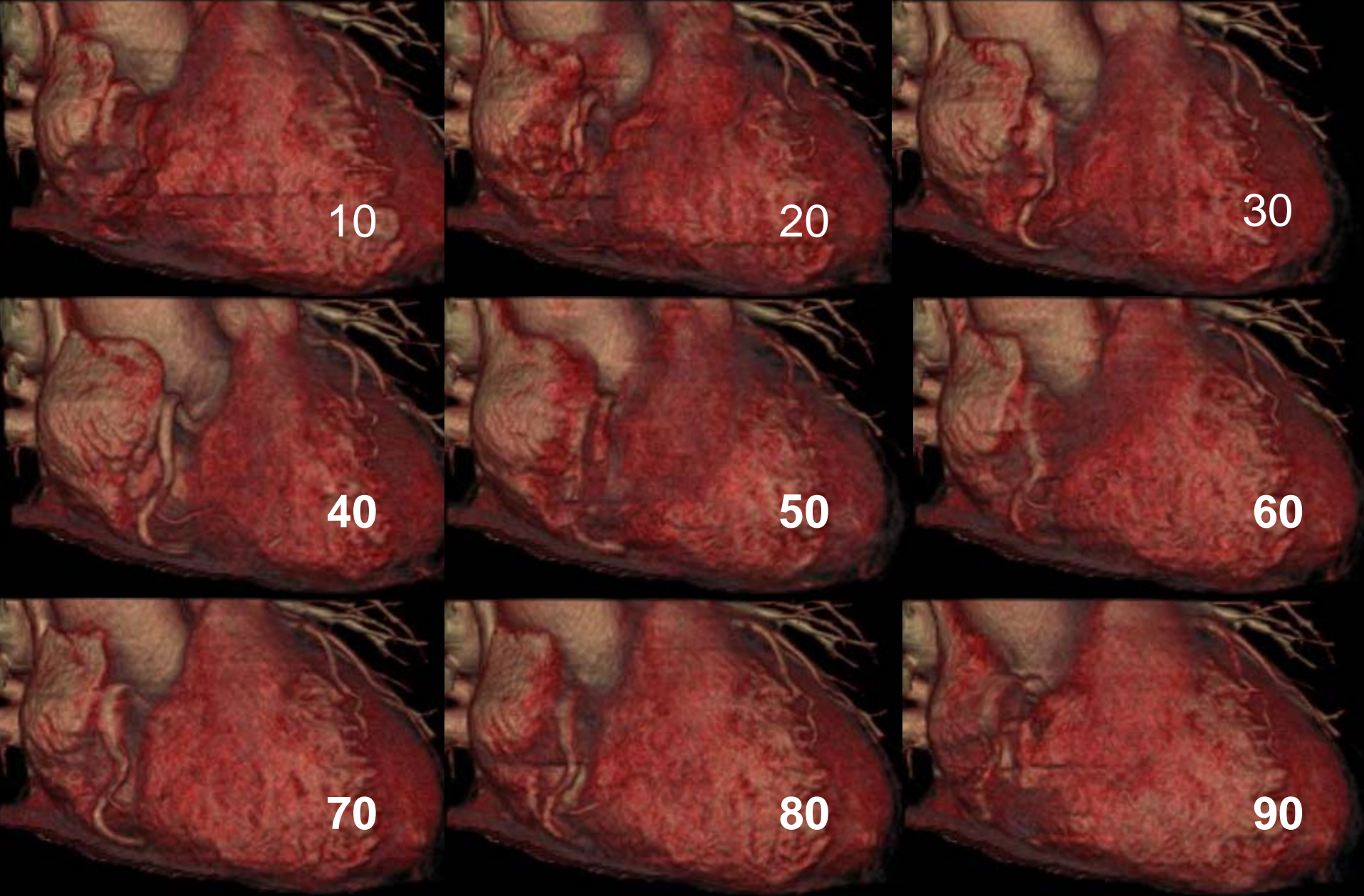
c.



d.

the mid-RCA. In theory, MIP obscures a kymographic gap perpendicular to the slab plane, since the appearances of thin-slab MIP images depend on slab thickness and the orientation of the vessel of interest relative to the slab plane.



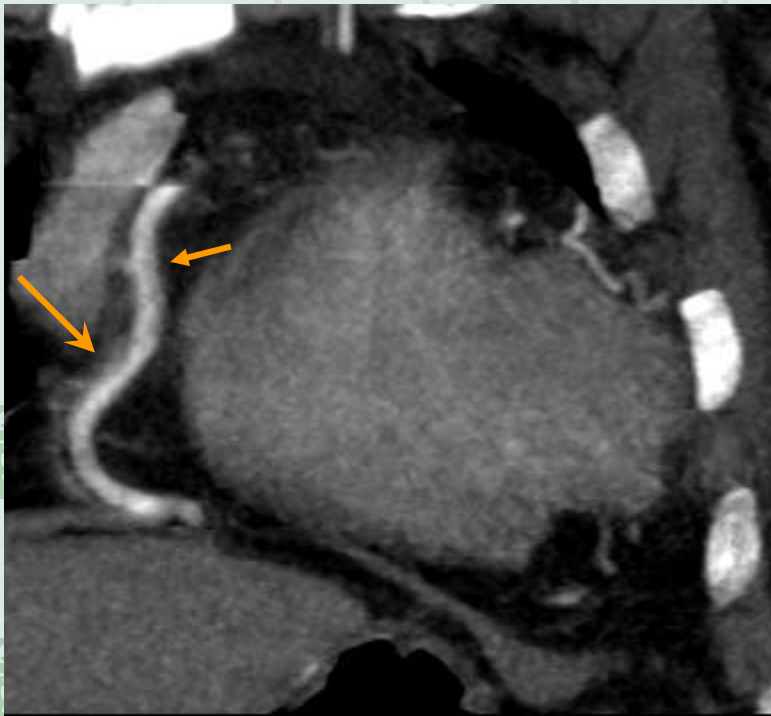

RCA为例，**R-R**间期（**10-90%**）不同**VR**图像

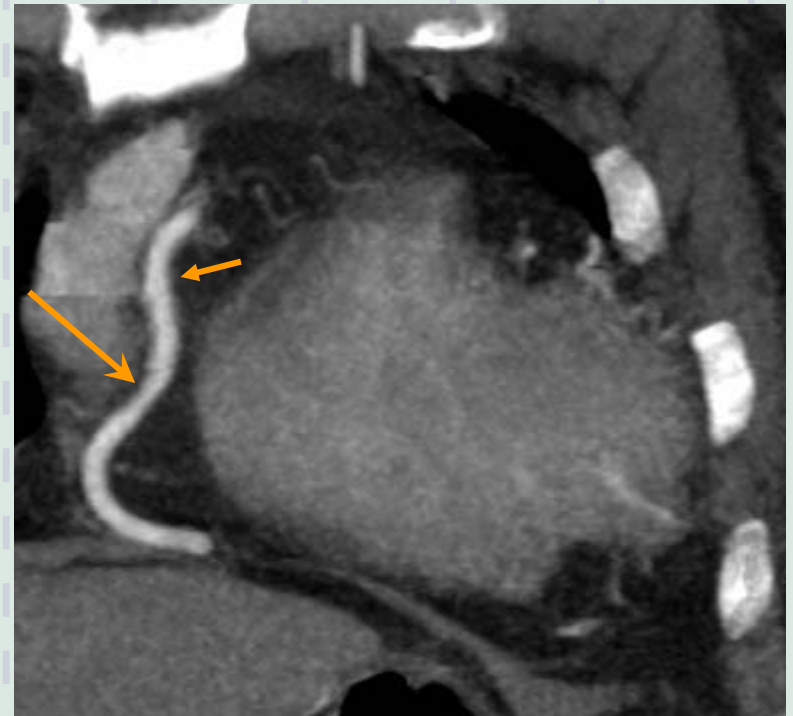


不同心脏周期对重建影响

吉祥



时相45%



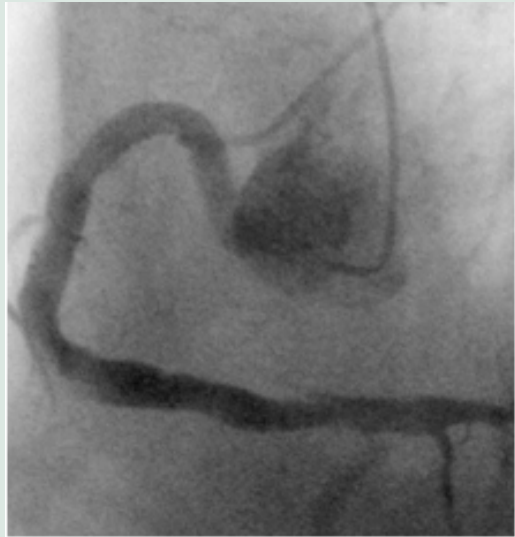
时相50%

吉祥

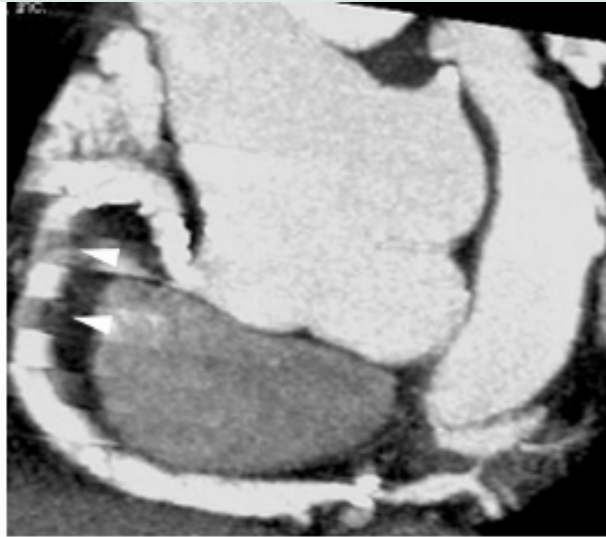
吉祥

吉祥

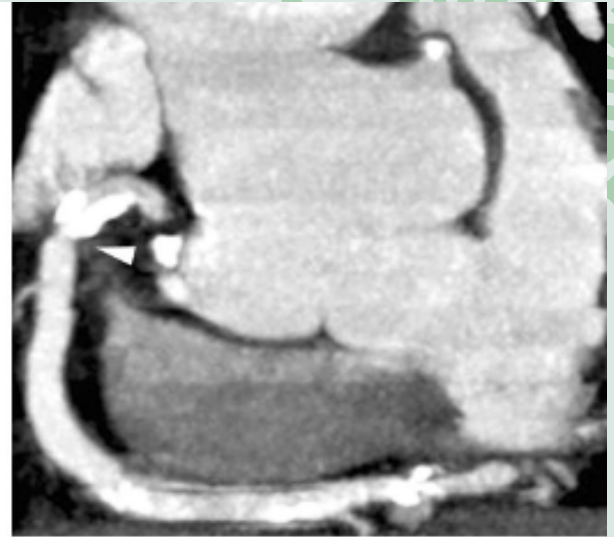
吉祥



a.



b.

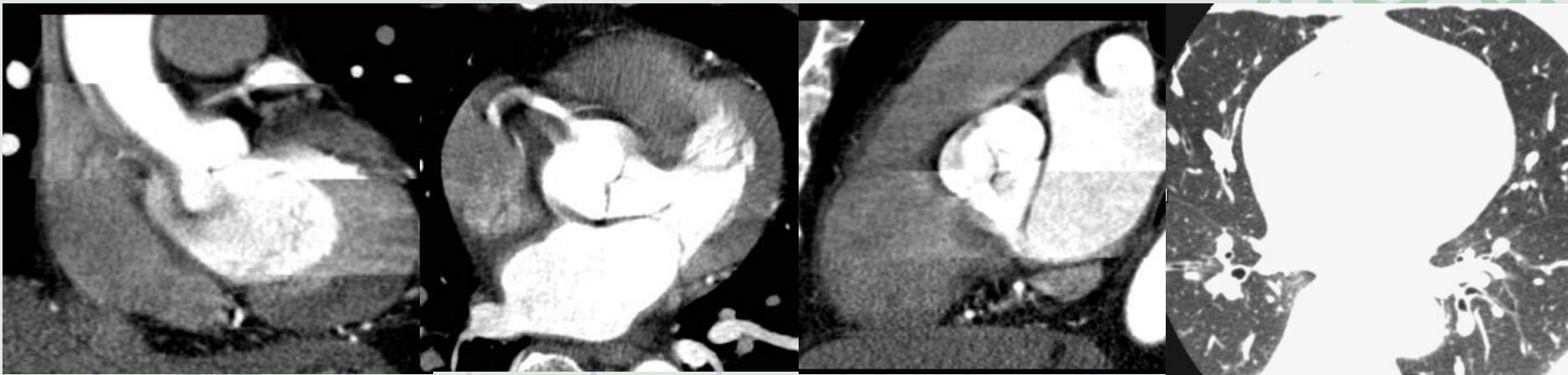


c.

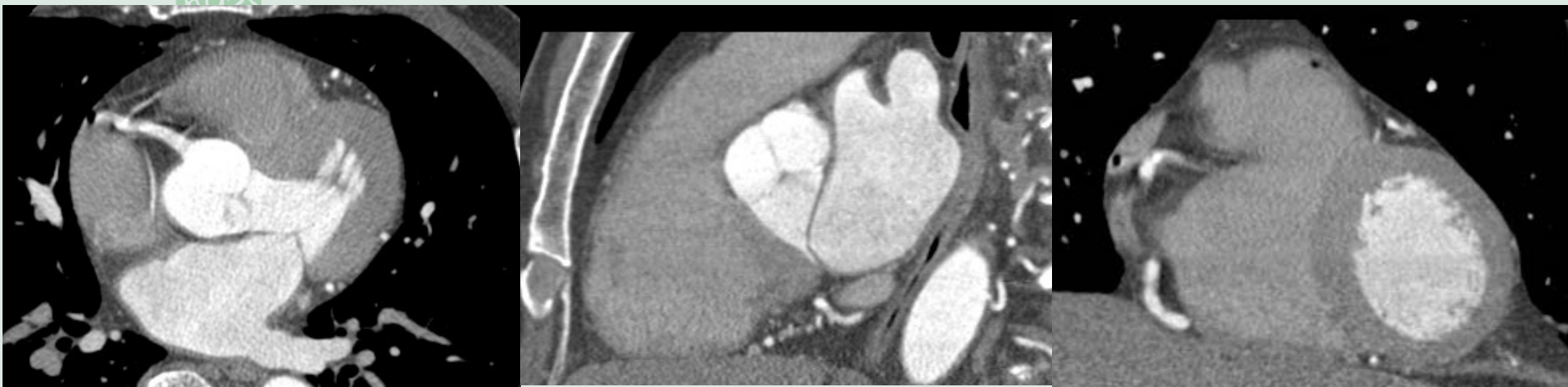Nonassessable segments are attributable to extensive motion artifacts and section gaps, whereas pseudostenosis is produced by minor motion artifacts and section gaps

心率变化

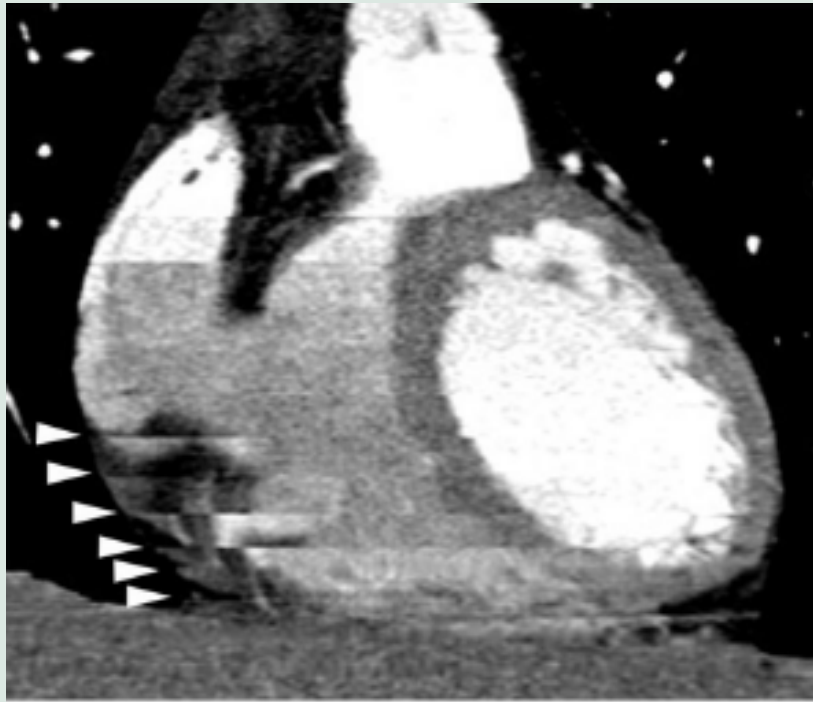
吉祥



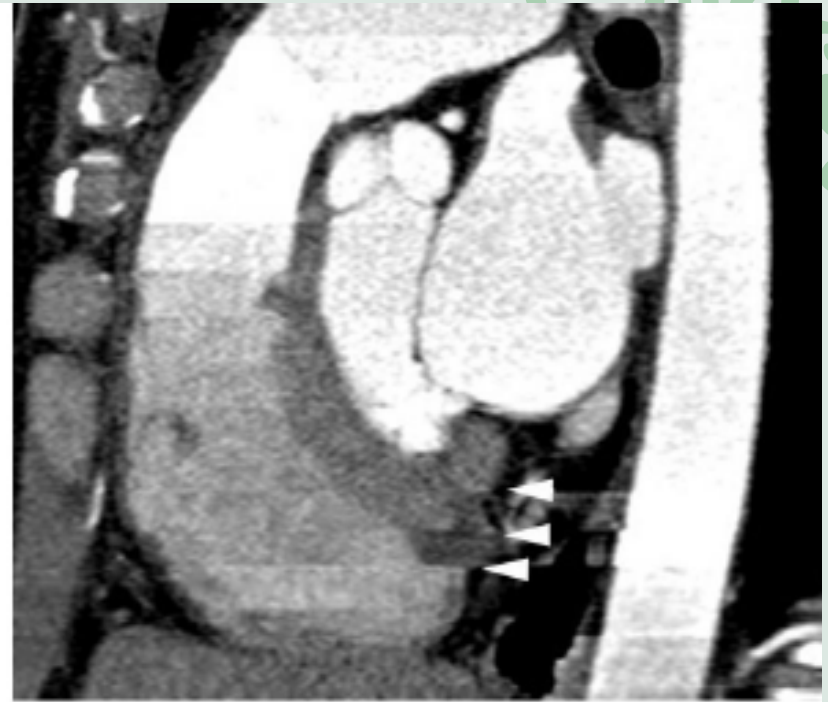
吉祥



吉祥



a.

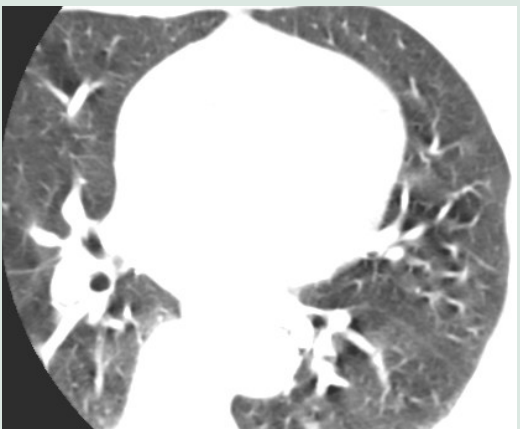
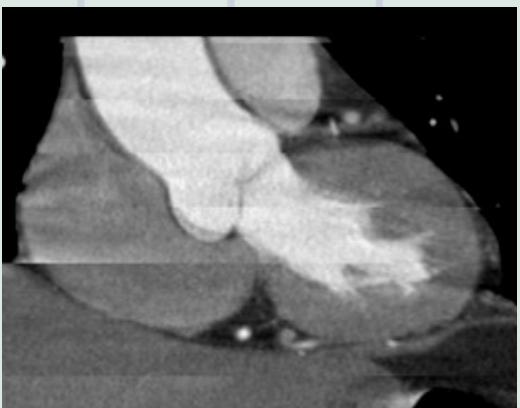
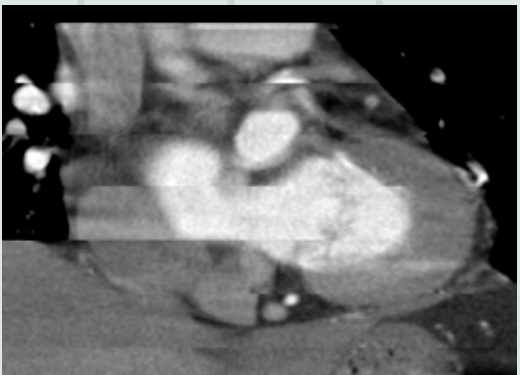
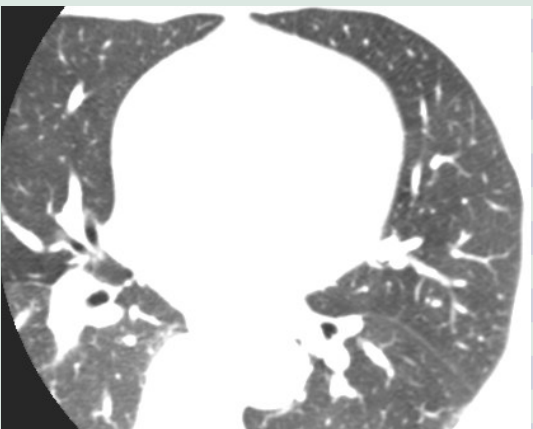
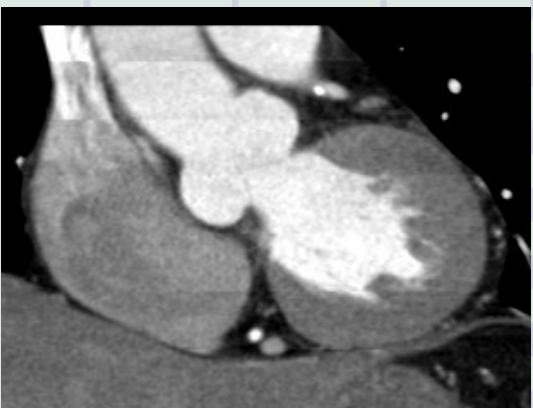
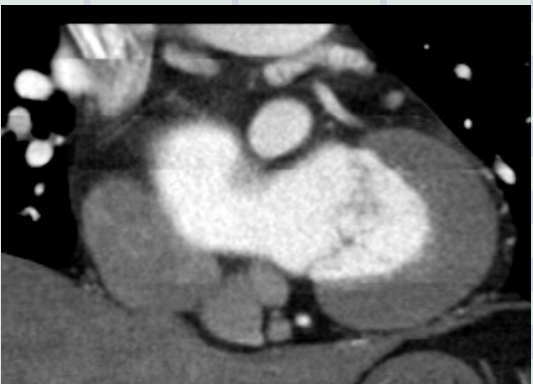
b.

Artifacts due to increased heart rate in a 46-year-old woman. The patient experienced alterations in heart rate in normal sinus rhythm during scanning, which was performed shortly after the sublingual administration of nitroglycerin. The patient's average heart rate was 51 bpm, increasing to 69 bpm in the last third of the acquisition. Coronal **(a)** and sagittal **(b)** reformatted images of the heart obtained from CT data demonstrate banding artifacts (arrowheads), which were observed only in the last third.

吉祥慶

呼吸伪影



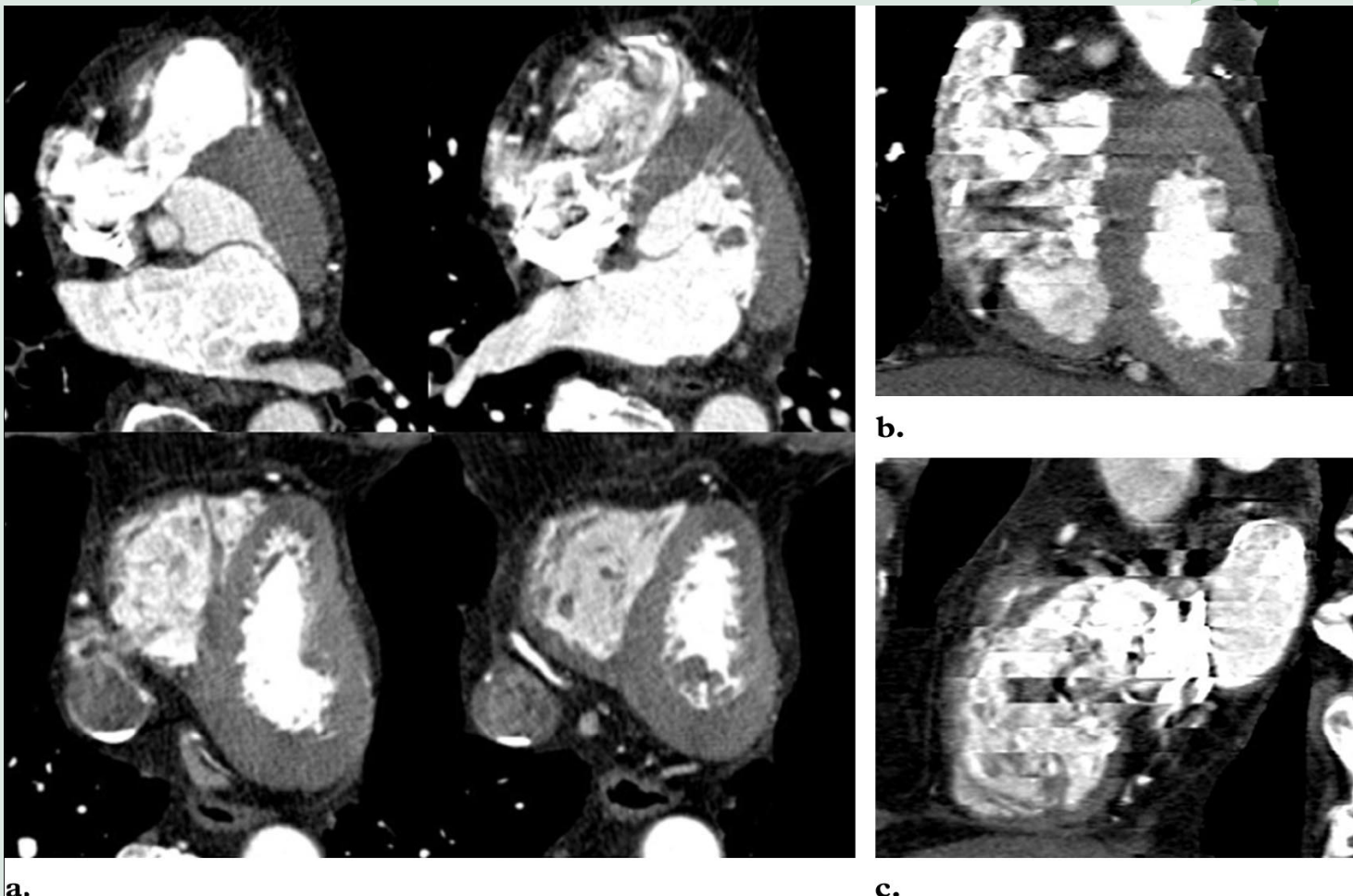
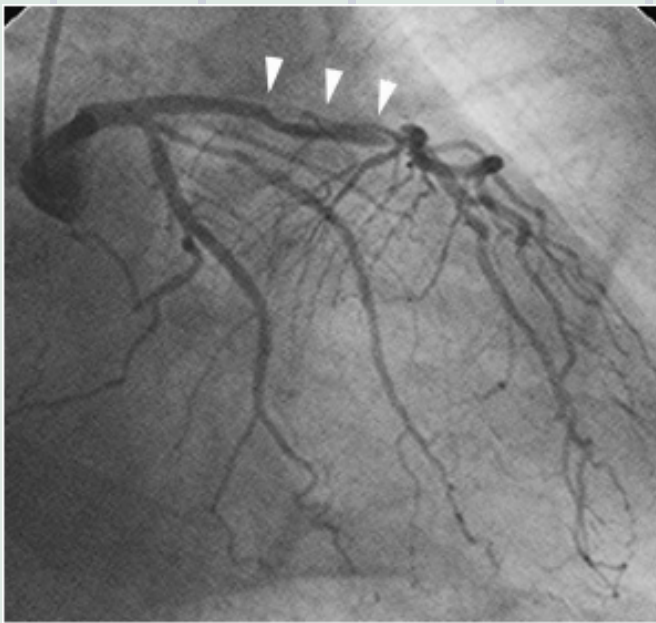
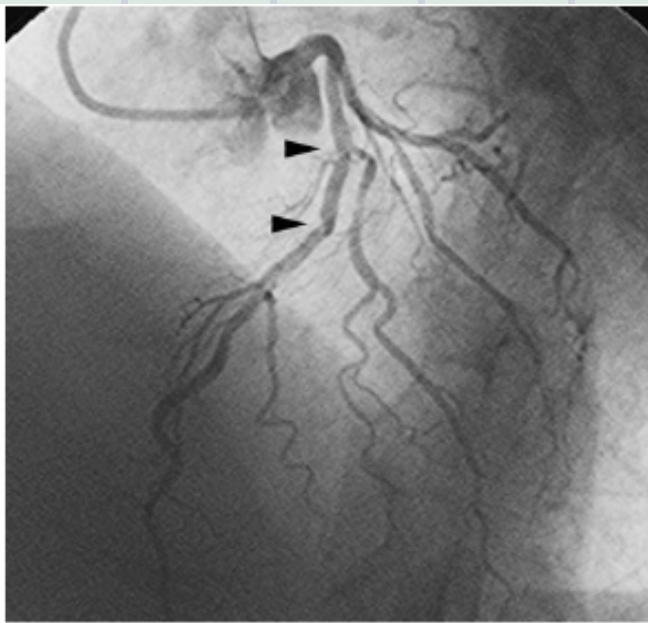


Figure 7. Artifacts due to incomplete breath holding. **(a)** Contiguous sections demonstrate almost no motion artifacts when each image is observed separately. **(b, c)** Coronal **(b)** and sagittal **(c)** reformatted images demonstrate banding artifacts with kymographic contours at the cardiac border. The patient had a heart rate of 58 bpm in normal sinus rhythm during scanning. Later, it was discovered that a microphone in the CT room was out of order and that breath-holding instructions had not been given to the patient.

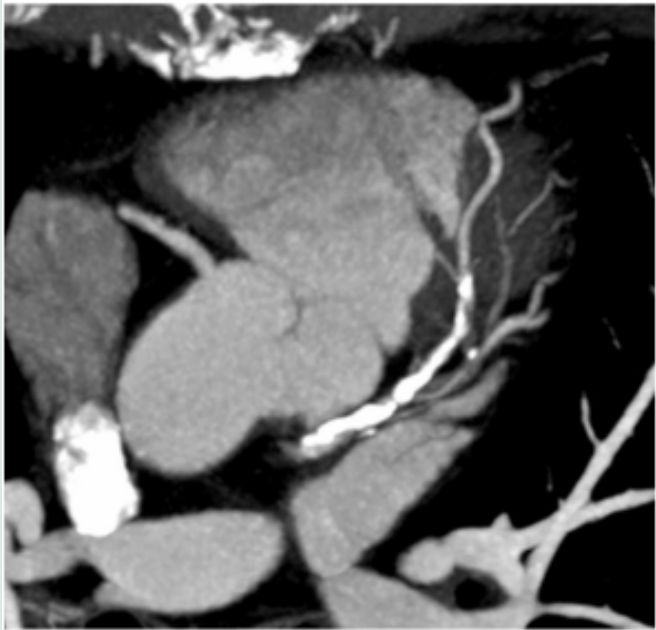
吉祥如意



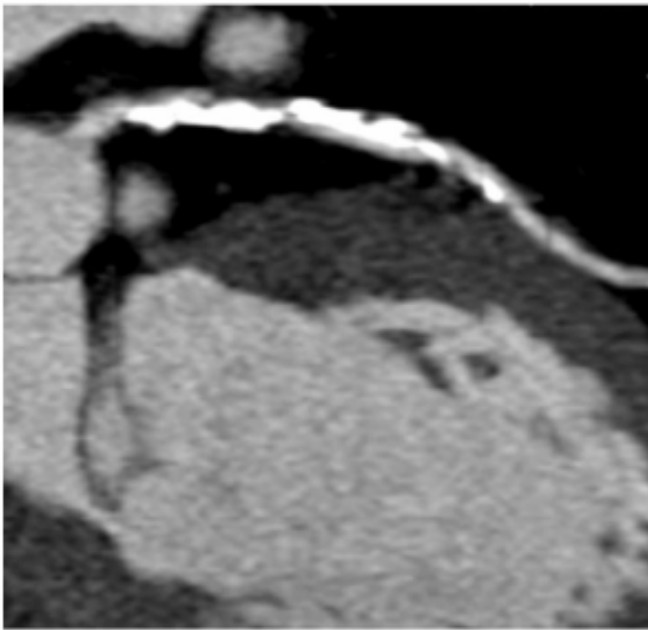
a.



b.



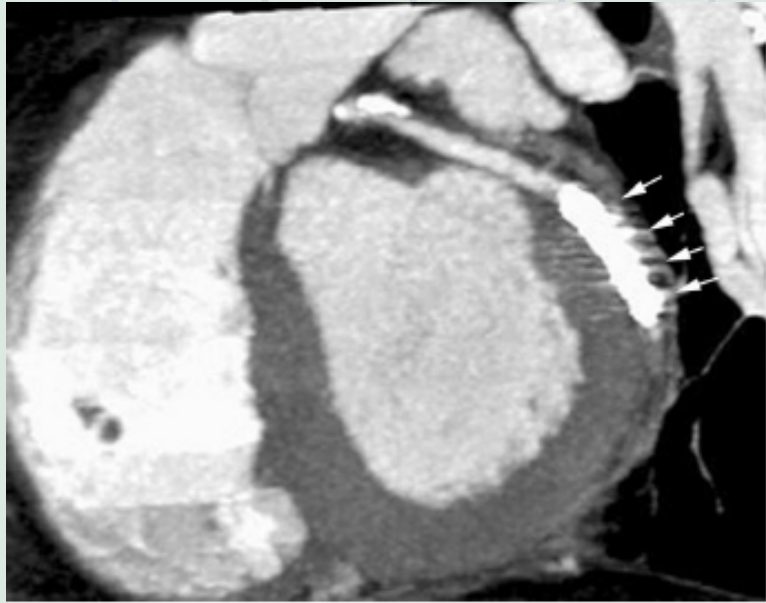
c.



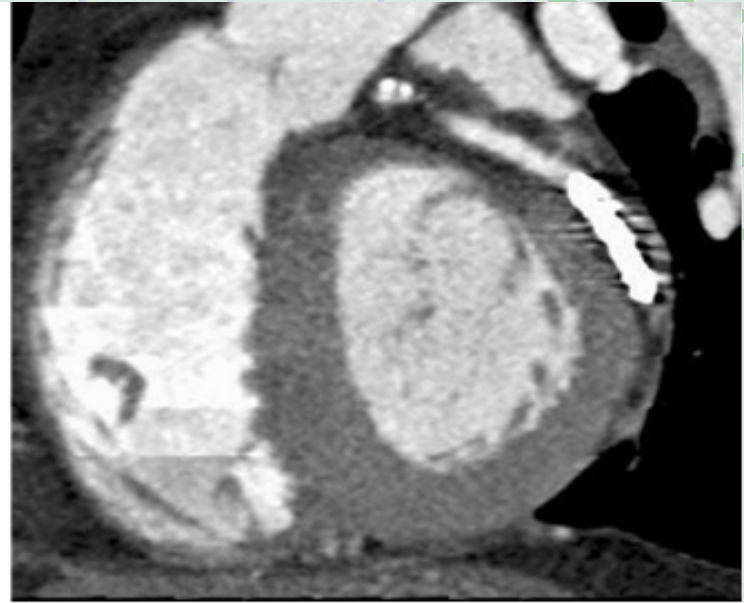
d.

部分容积效应 - 高密度
(钙化、金属支架)

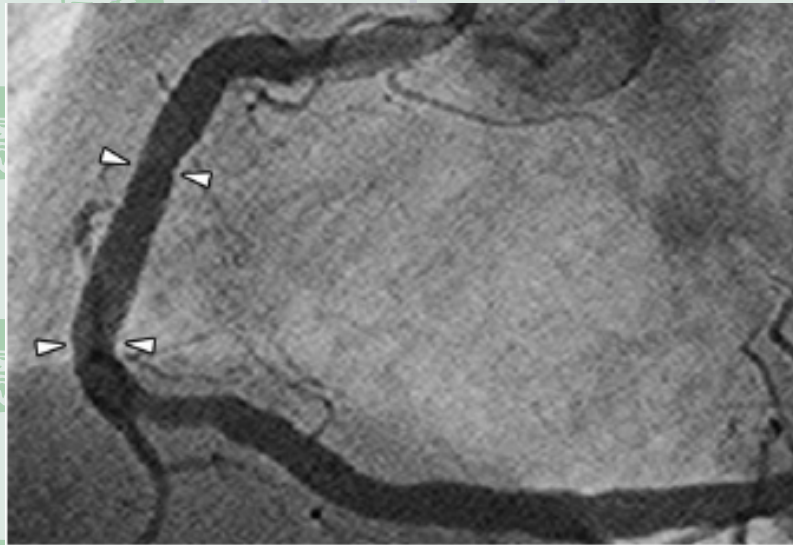
无法观察管腔内情况



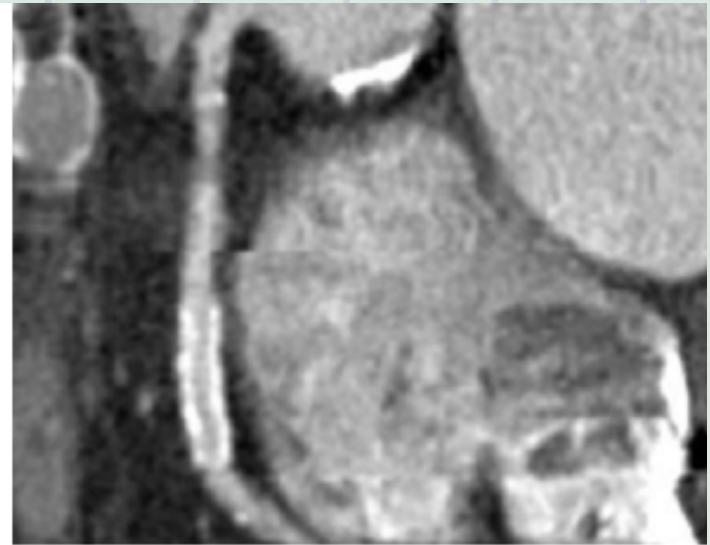
a.



b.



a.



c.

主
題

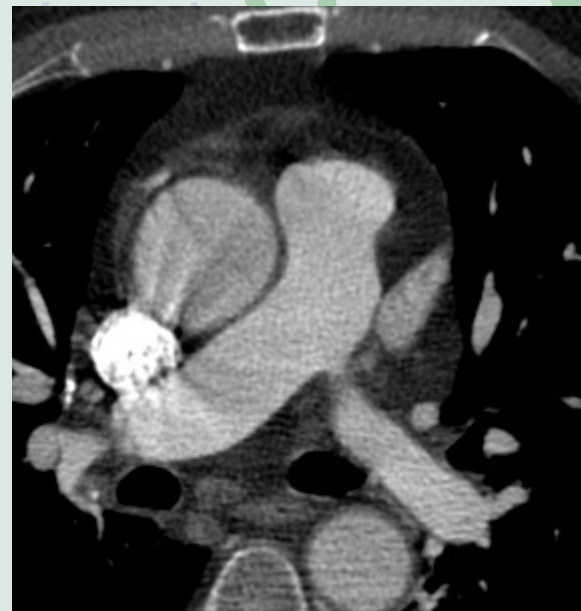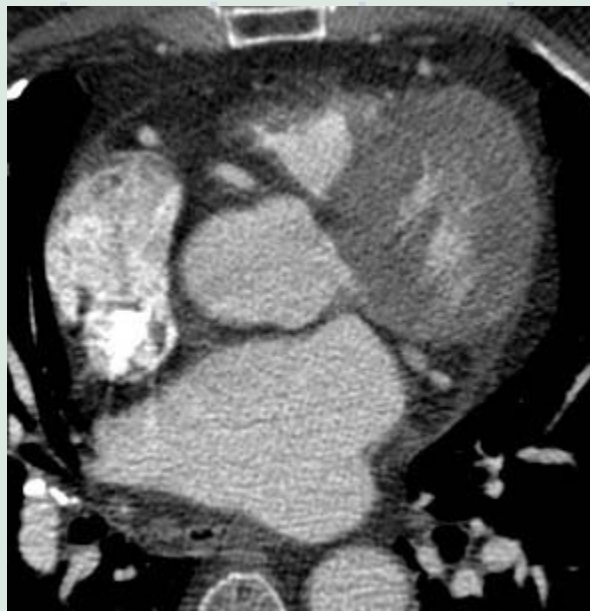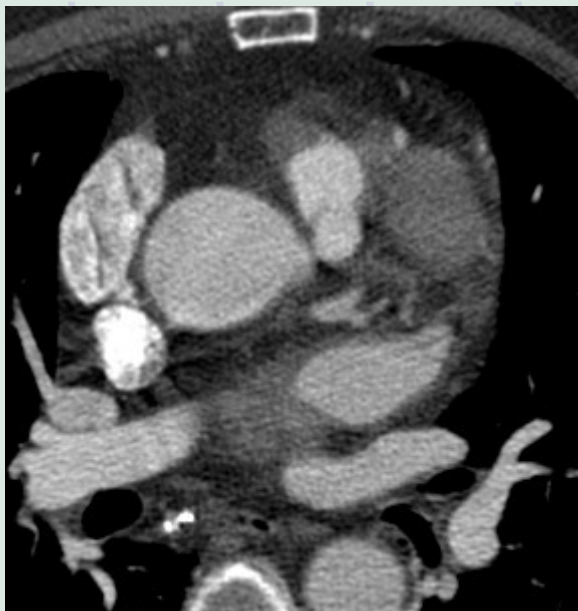吉
祥

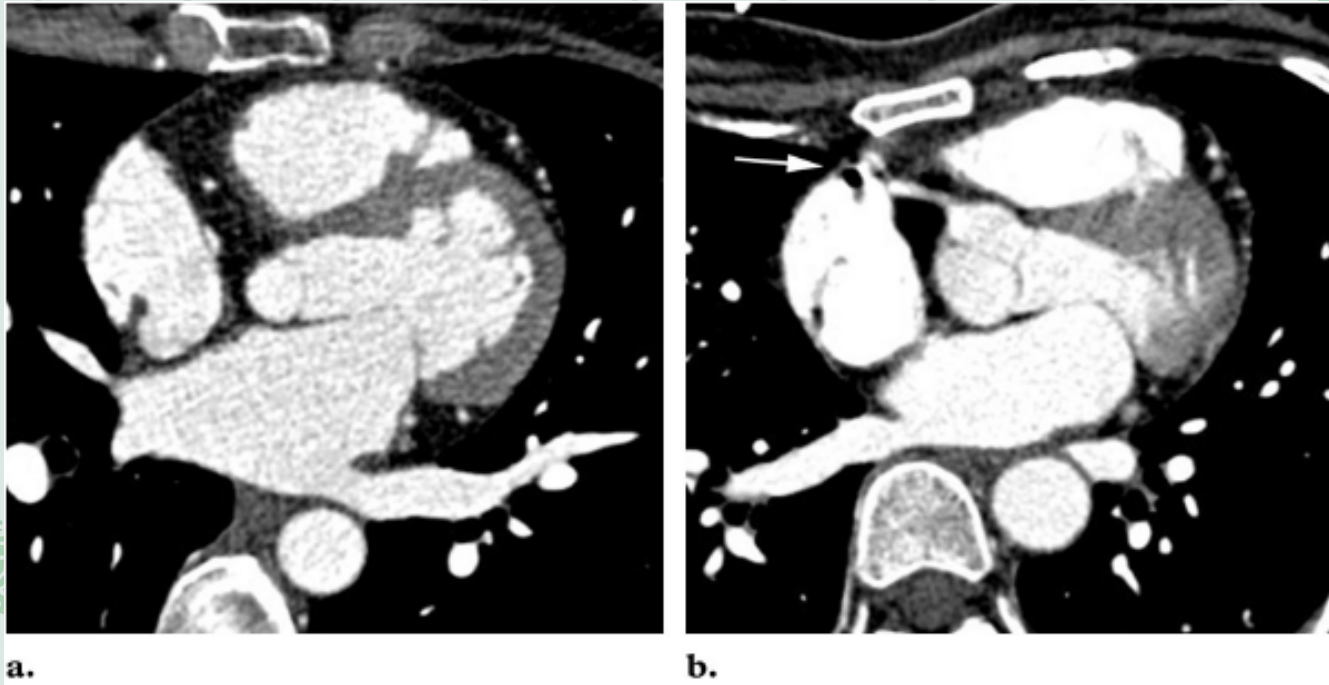
吉
祥

吉
祥

右房条形伪影

吉祥





Streak artifact

醫學

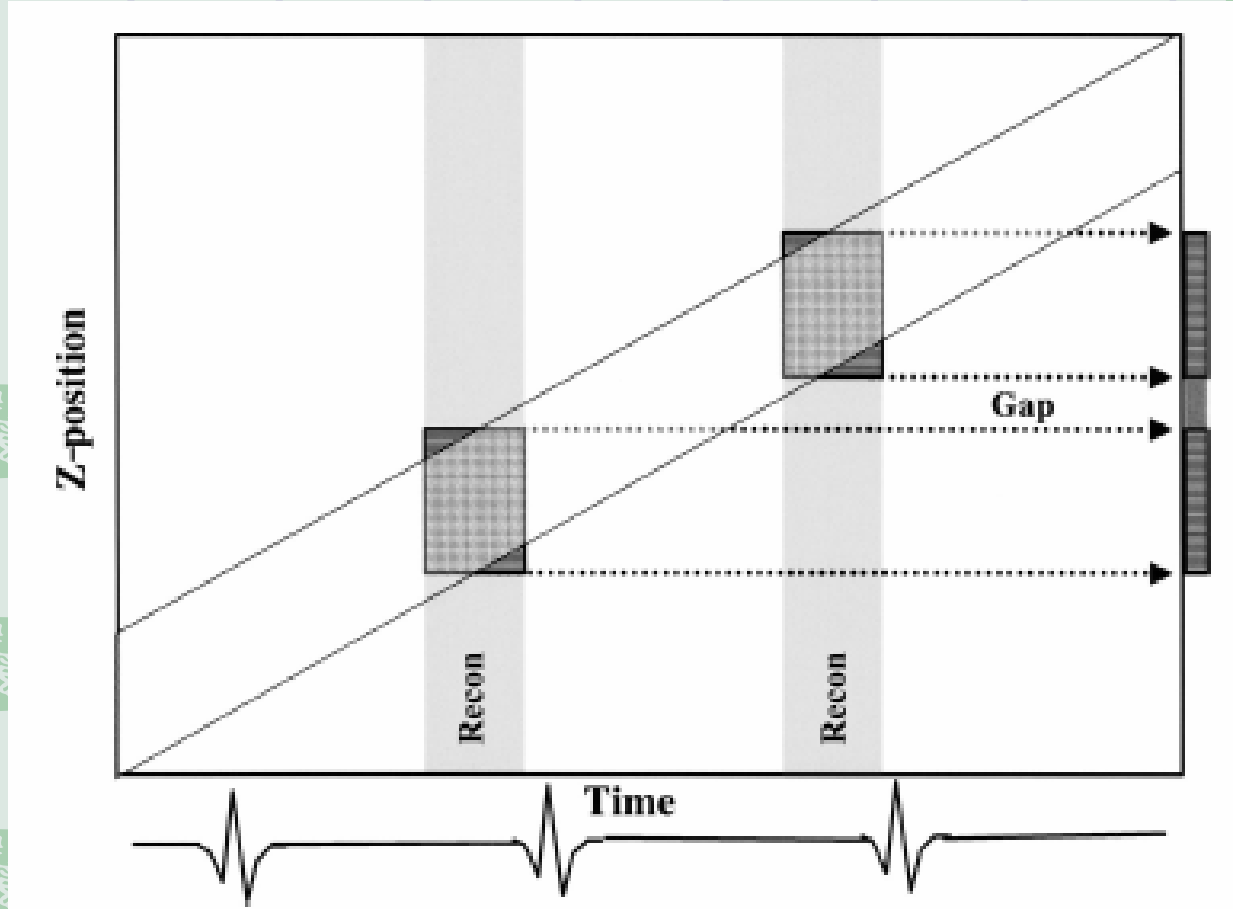
醫學

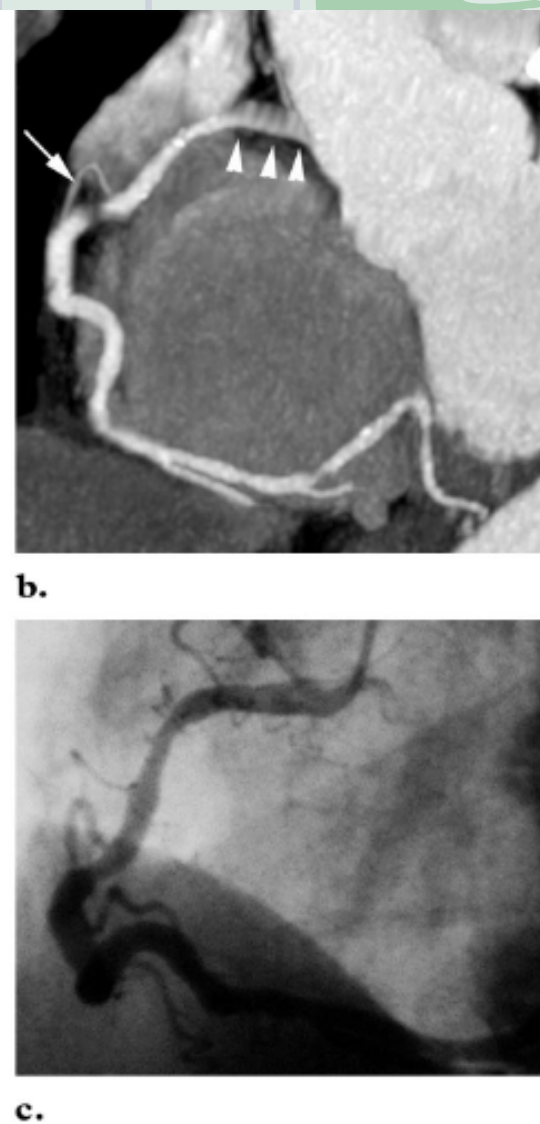
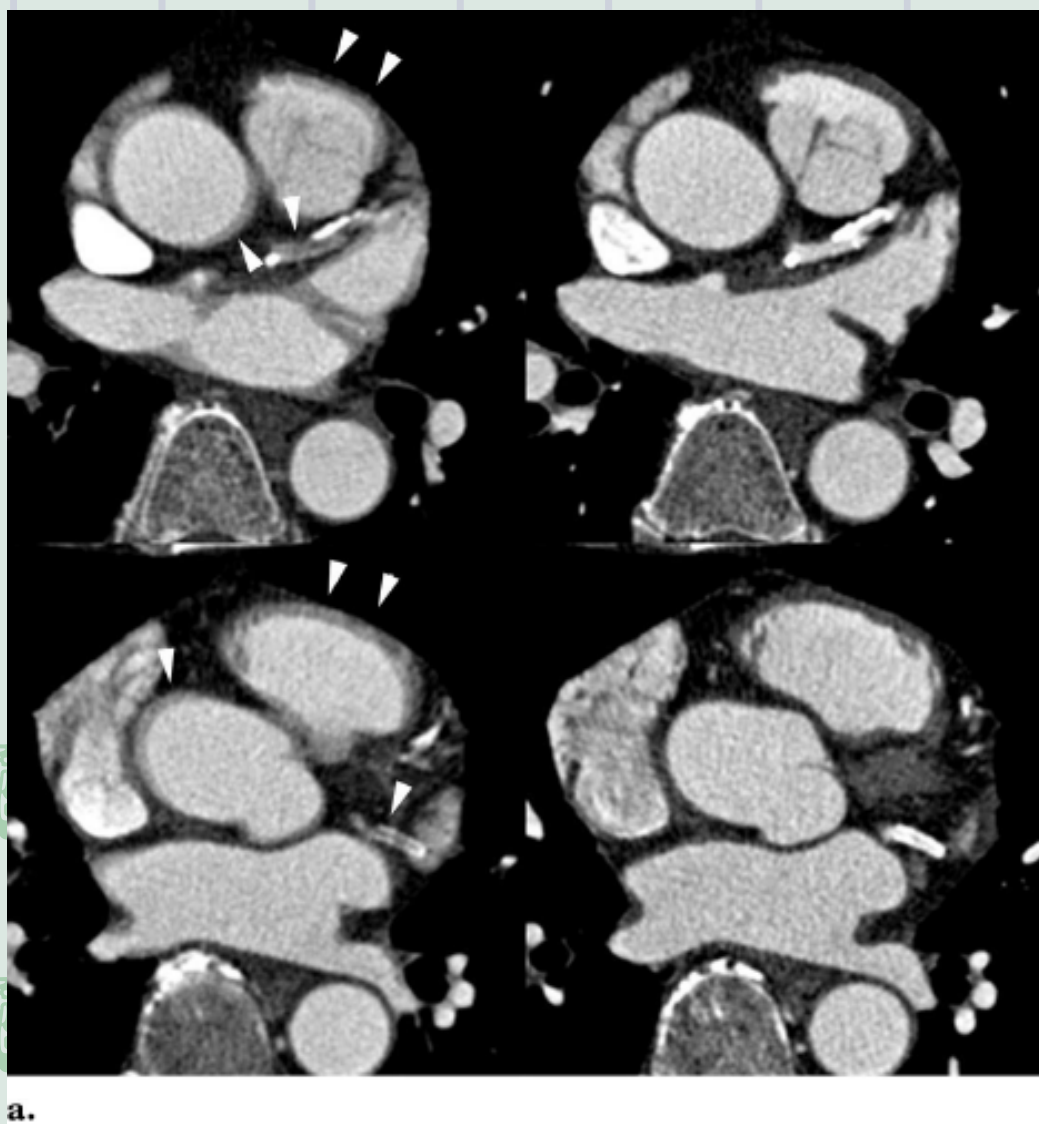
醫學

醫學

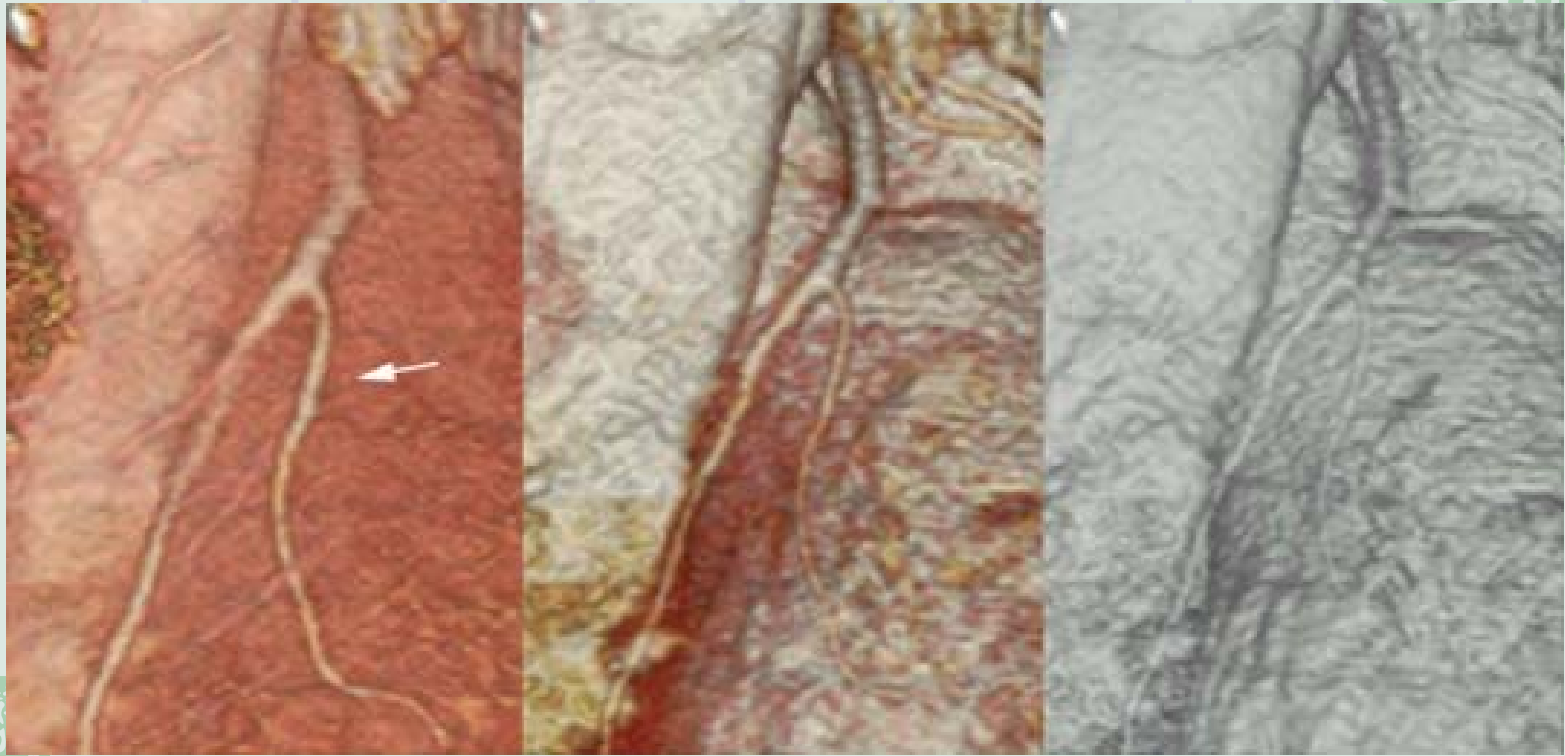
醫學

螺距的选择

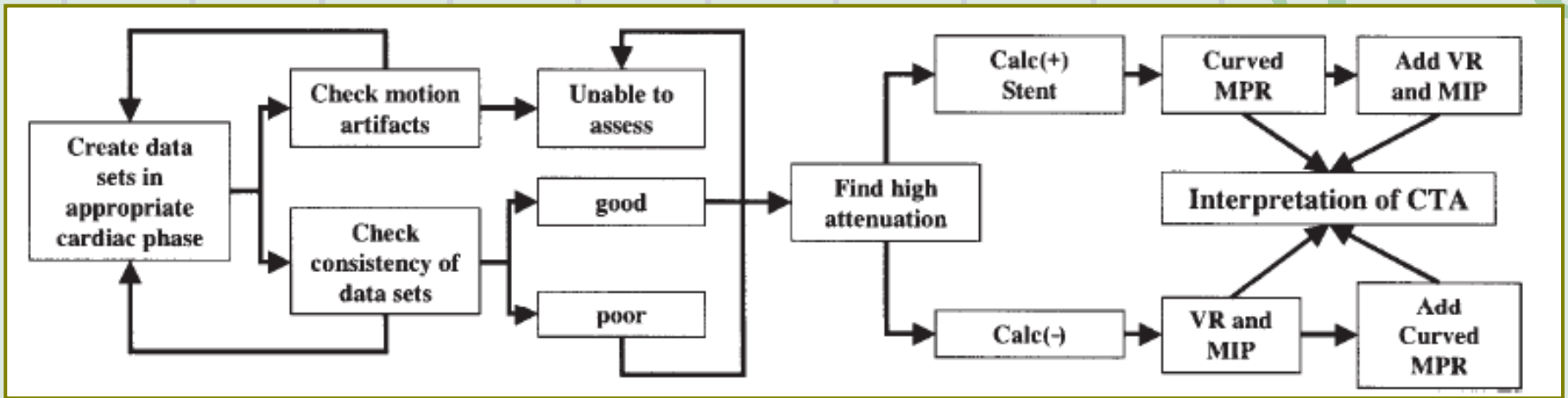




心率较慢，螺距较大，造成数据缺失，模糊伪影，假性狭窄



重建方法选择，VR的窗宽不同对管径的显示也不同，尤见于小血管



行名

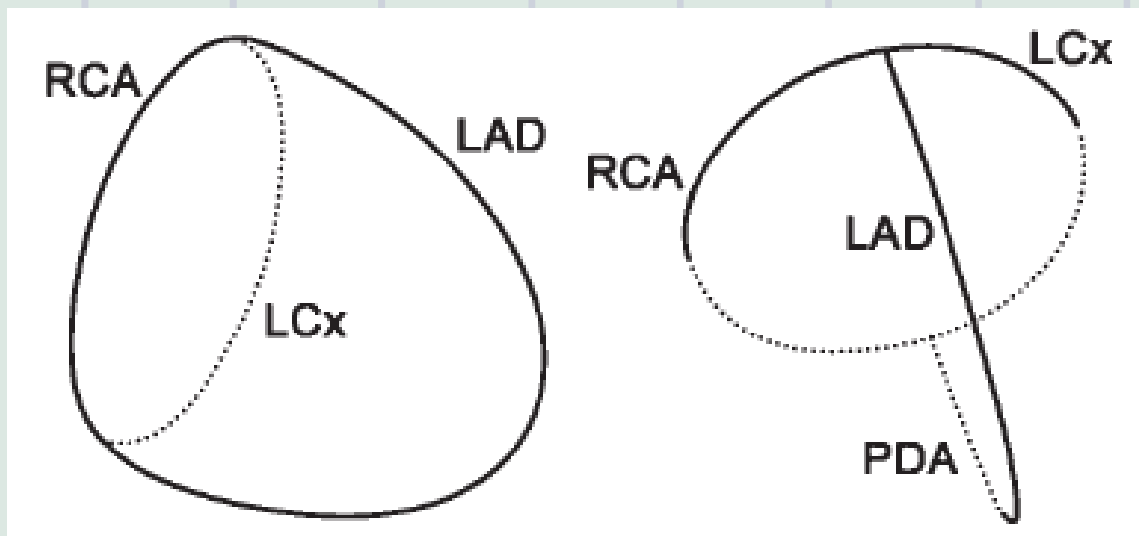
临床应用



冠状动脉临床应用

吉祥

■ 正常解剖



一个圆圈+半个弧形 (85%RCA 7~8%LCx 7-8%RCA+LCx)

吉祥

吉祥

吉祥

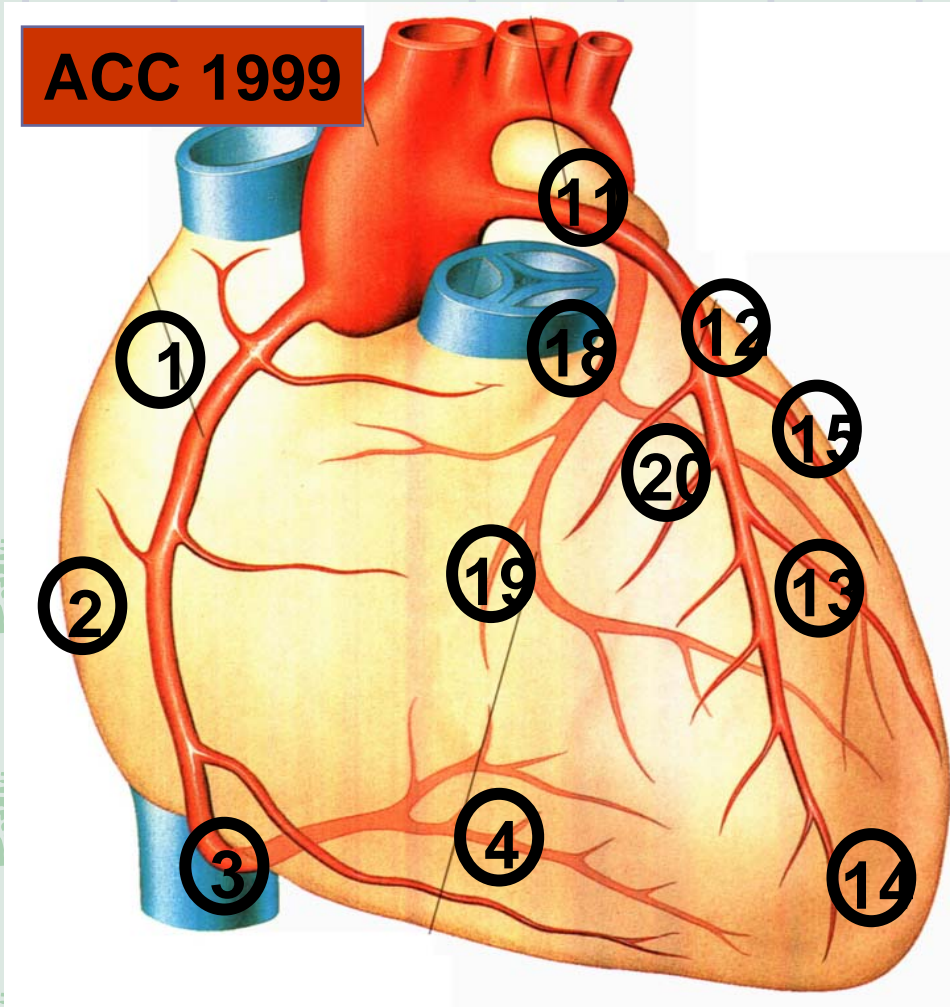
吉祥

吉祥

吉祥

冠脉解剖图

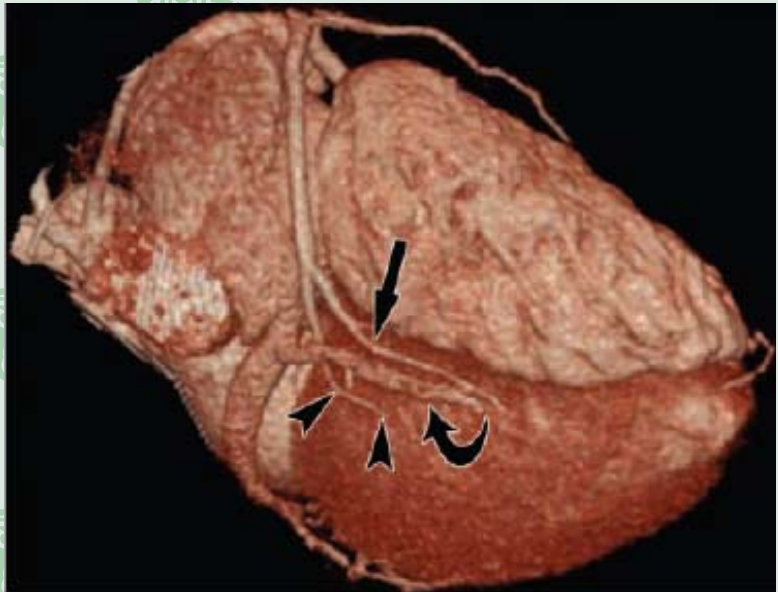
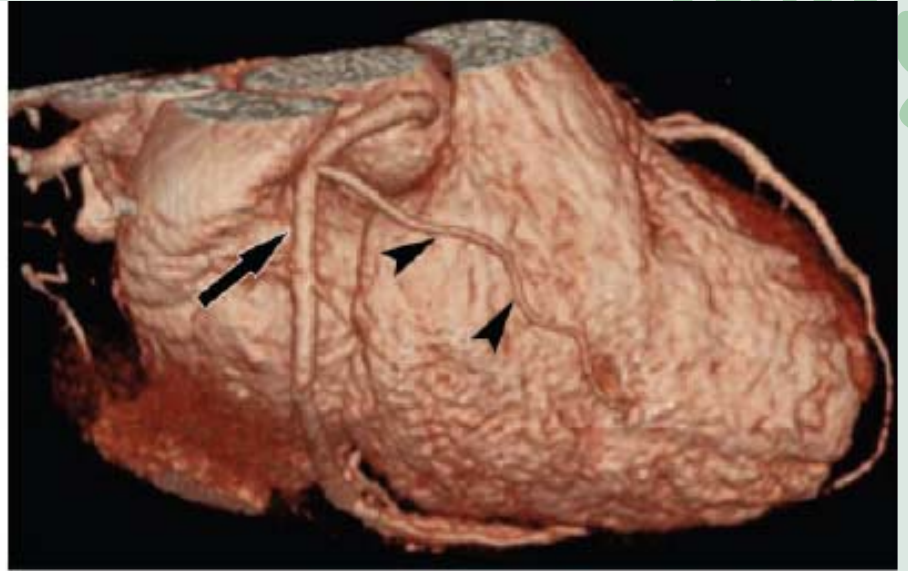
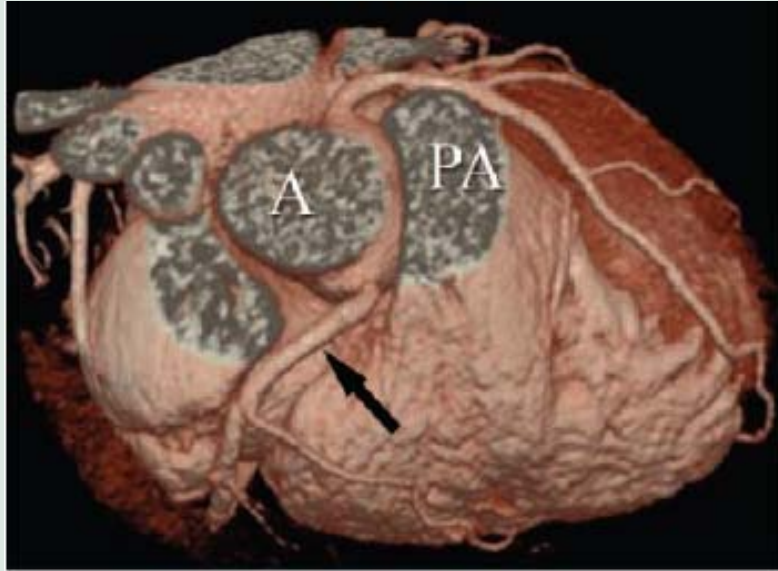
吉祥



RCA	proximal (1)	
	middle (2)	
	distal (3)	
LCA	main (11)	
LAD	proximal (12)	
	middle (13)	
	distal (14)	
	Diagonal 1	(15)
LCX	proximal (18)	
	distal (19)	
	Marginal 1	

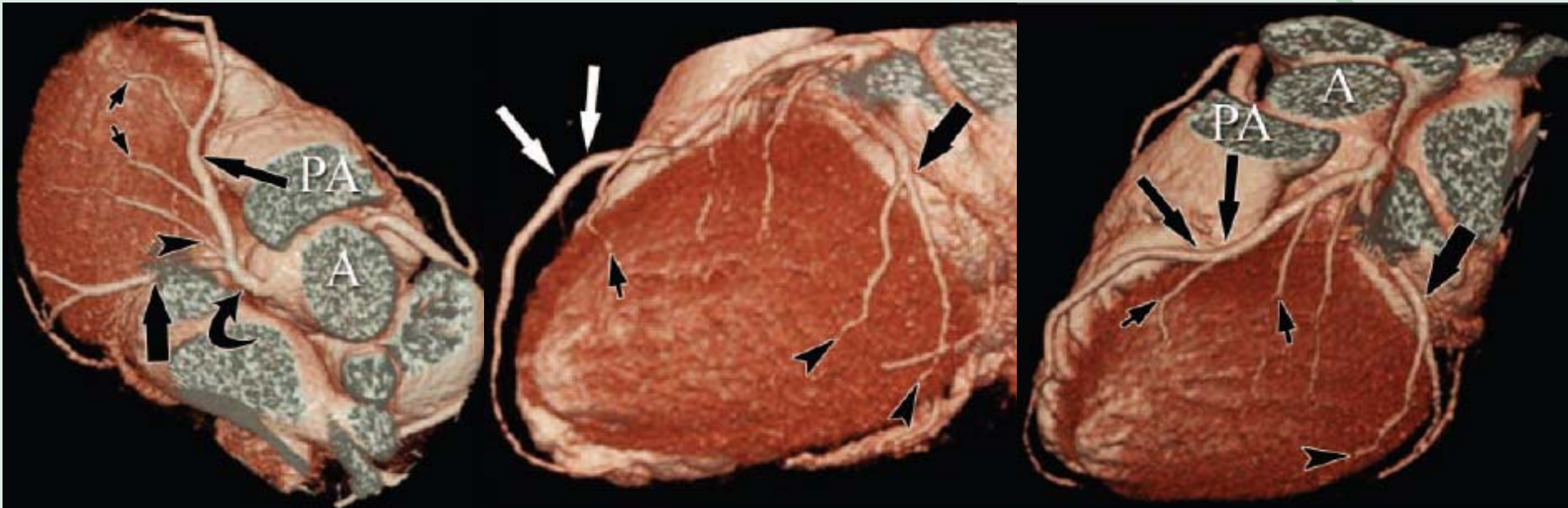
右冠解剖

吉祥



左冠解剖

吉
祥
名
醫



吉
祥
名
醫

吉
祥
名
醫

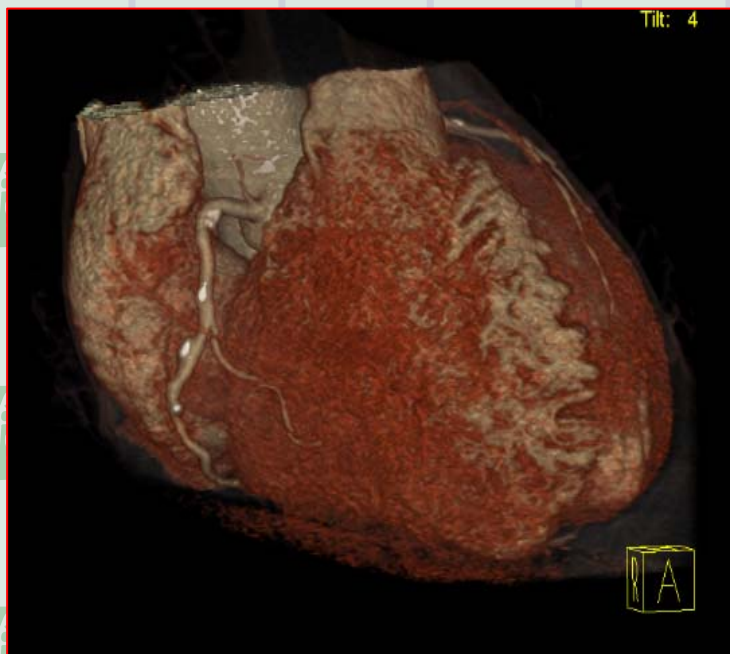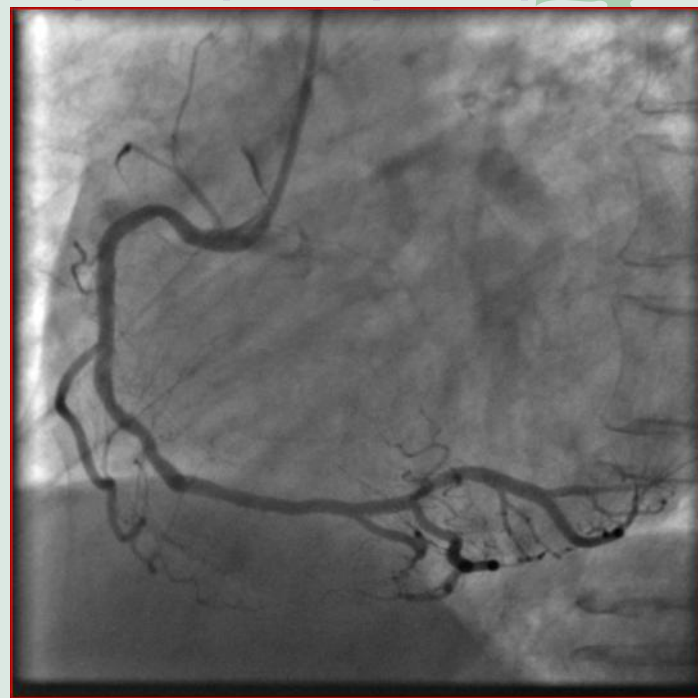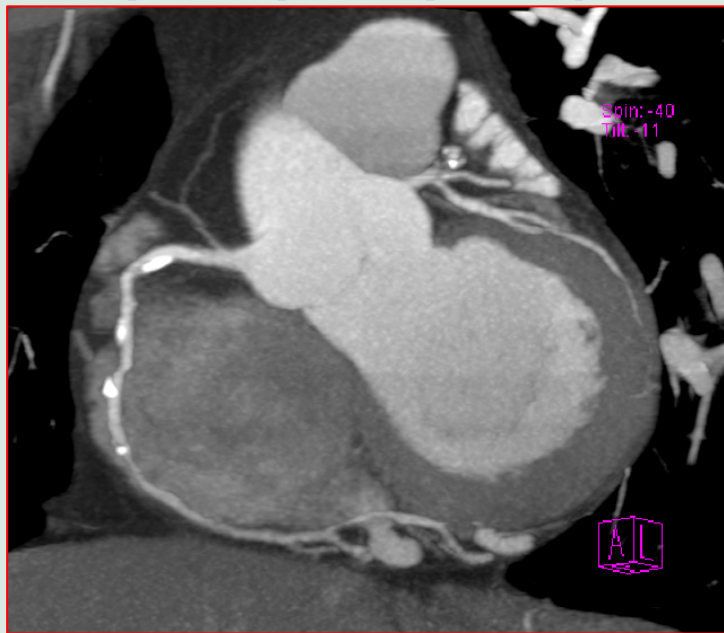吉
祥
名
醫

吉
祥
名
醫

CT冠脉成像

- 冠脉管腔开放度
- 斑块的非侵入性成像
- 支架，搭桥术后随访
- 冠脉先天异常

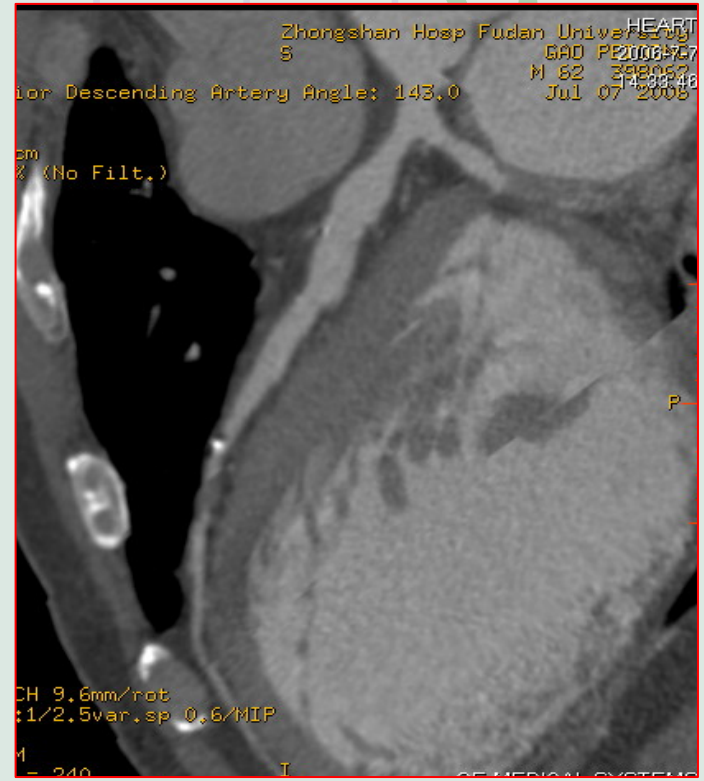
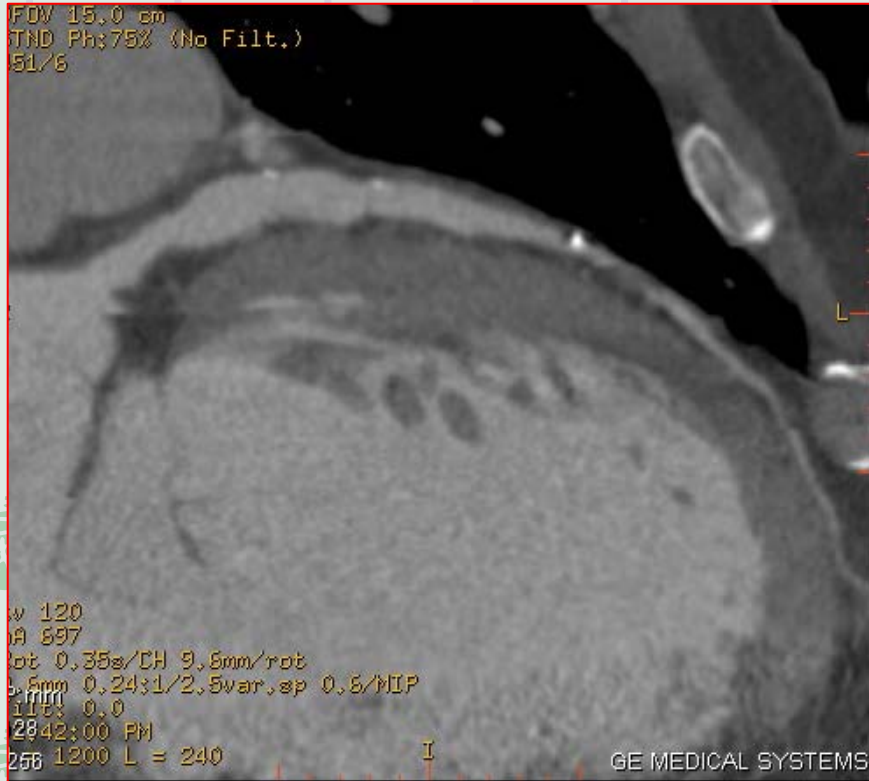



钙化斑块影响管腔
开放程度观察

冠脉动脉瘤

吉
祥
如
意



吉
祥
如
意

吉
祥
如
意

吉
祥
如
意

斑块成像

吉祥

- MI仅1/3直接源自冠脉狭窄
- 急性冠脉事件主要原因----易损斑块（多为富含脂质斑块），及继发破溃，形成血栓
- 钙化斑块多为稳定斑块
- 重塑（正性）----斑块逃脱检出（**DSA**）

吉祥

吉祥

吉祥

吉祥

吉祥

斑块成像

吉祥

- 根据密度差异
 - 富脂肪斑块 $50 \pm 12\text{HU}$
 - 纤维为主斑块 $89 \pm 31\text{HU}$
 - 钙化斑块 $> 120\text{HU}$
 - 混合斑块



和IVUS对照:

所有斑块检出敏感性82%，特异性88%，

钙化斑块敏感性94%，特异性94%，

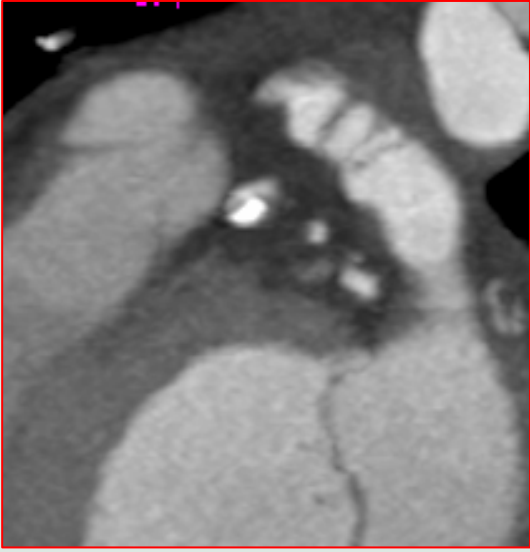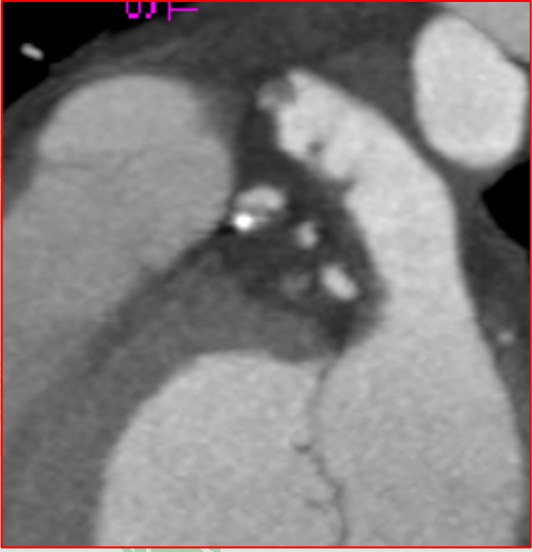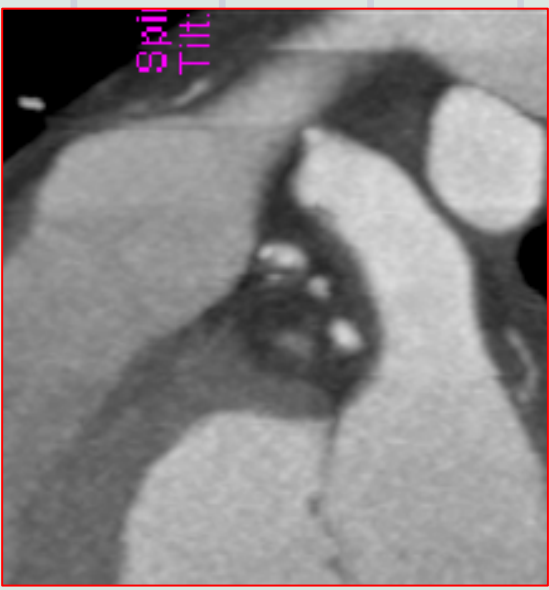
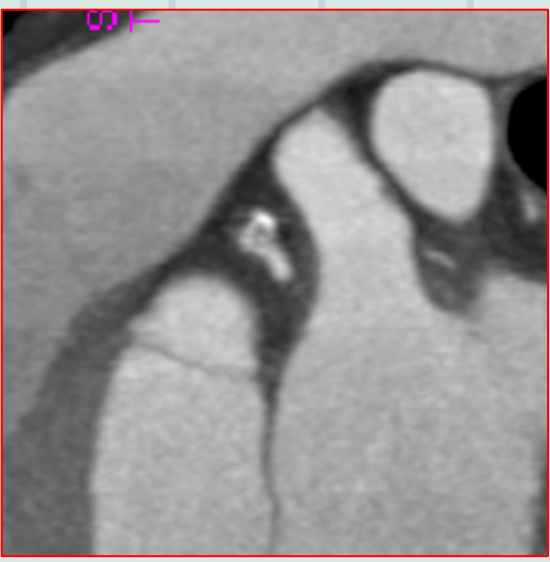含有非钙化斑块的敏感性78%，特异性87%

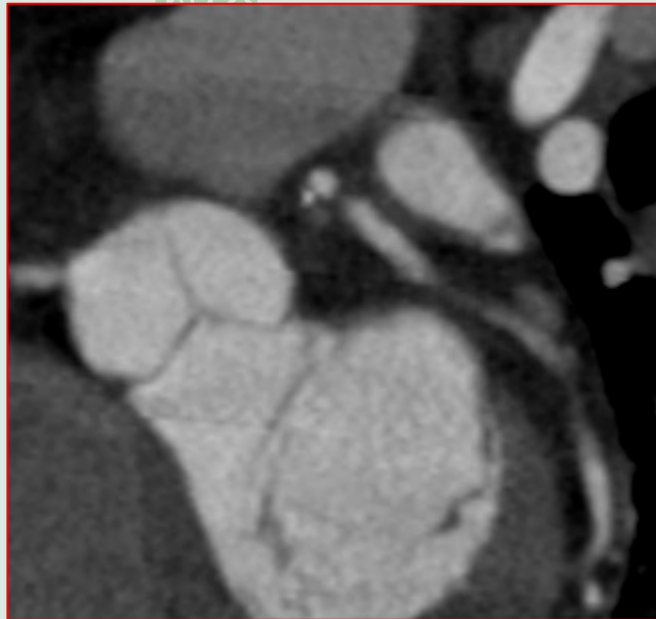
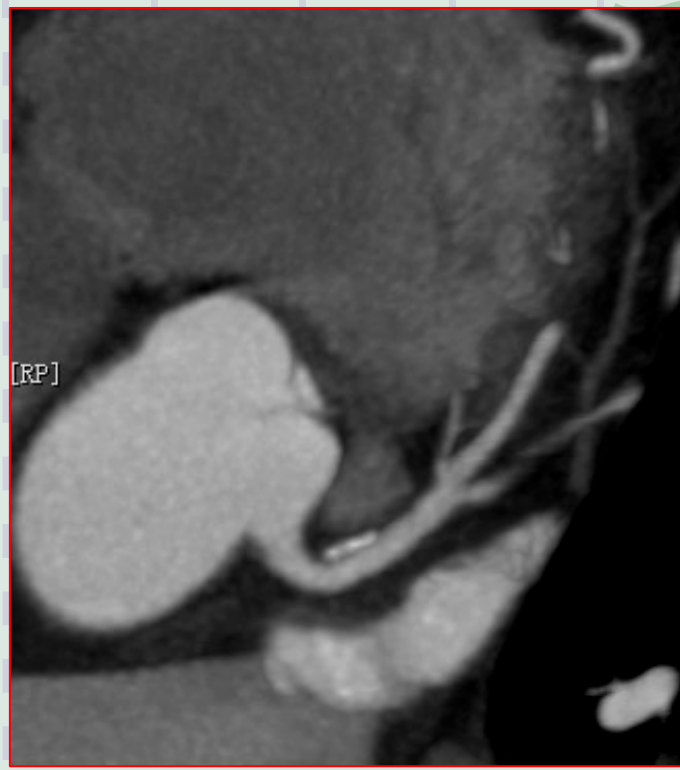
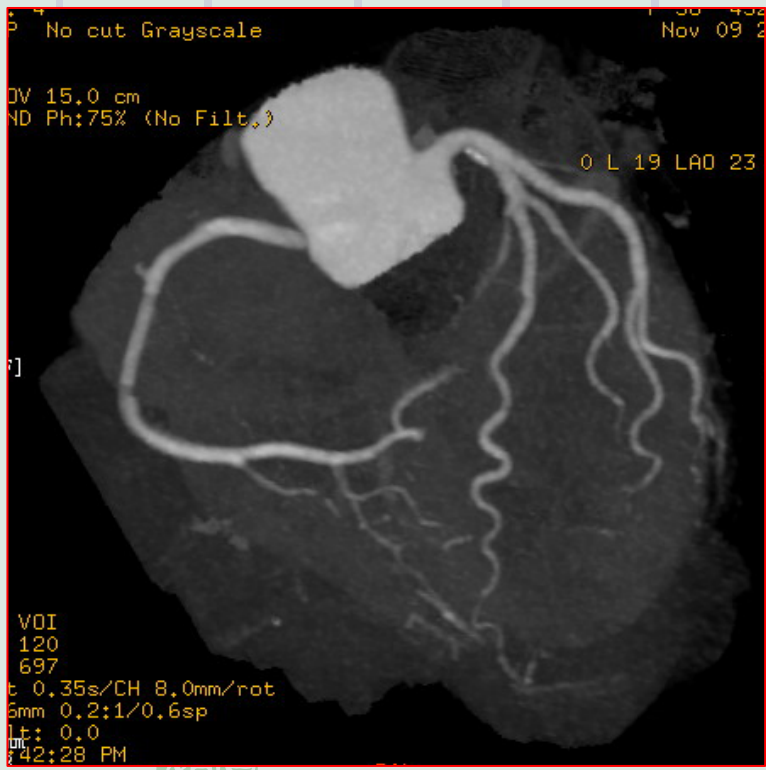
全部非钙化斑块的敏感性仅53%，

MDCT明显低估了斑块容积

— Achenbach S, Moselewski F, Ropers D, et al. Detection of calcified and noncalcified coronary atherosclerotic plaque by contrast-enhanced, submillimeter multidetector spiral computed tomography: a segment-based comparison with intravascular ultrasound. *Circulation* 2004;109: 14 – 17.

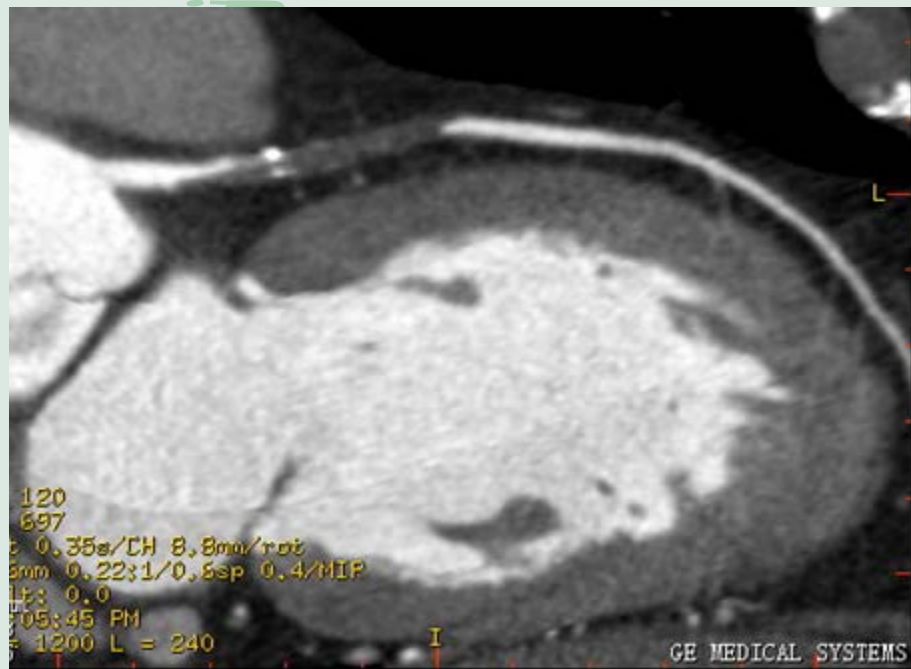
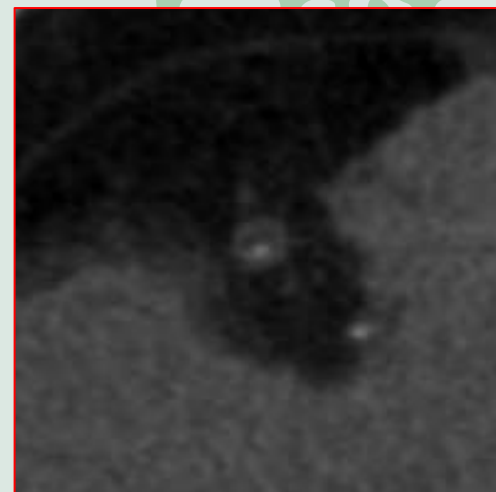
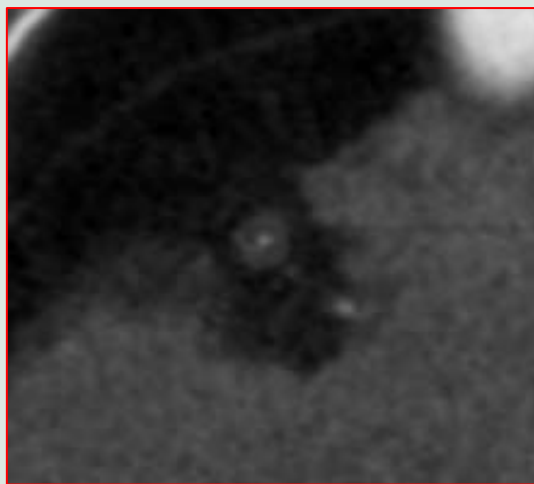
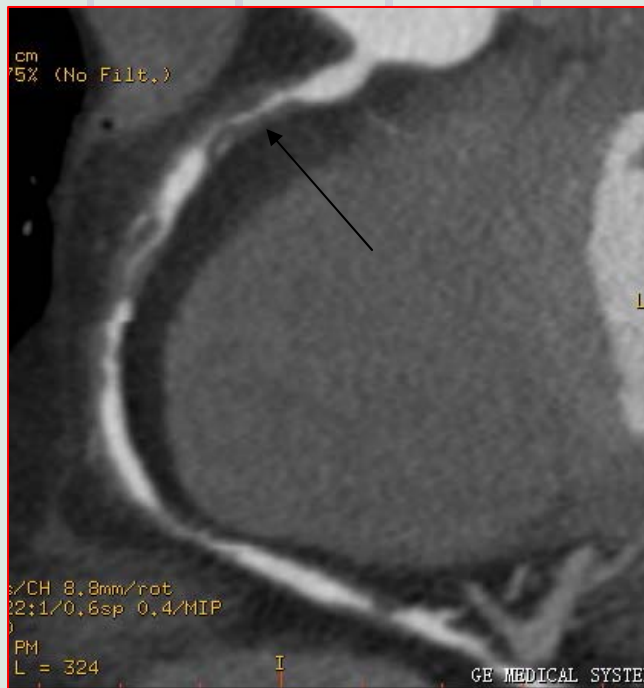
肺血管





冠
狀
動
脈
病
變



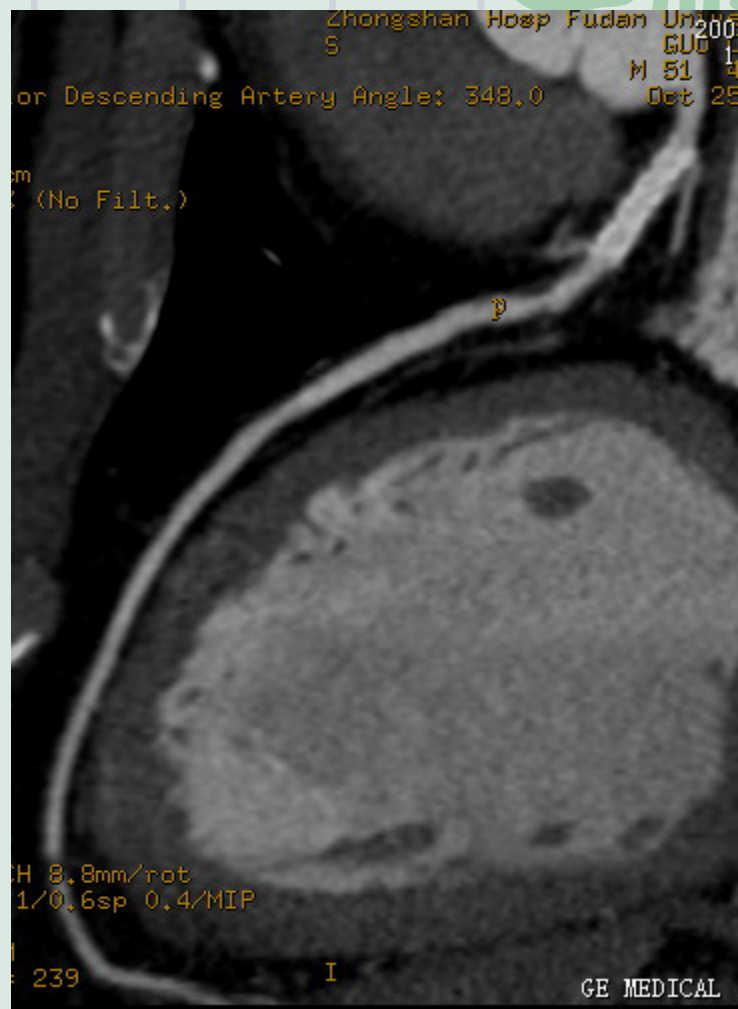
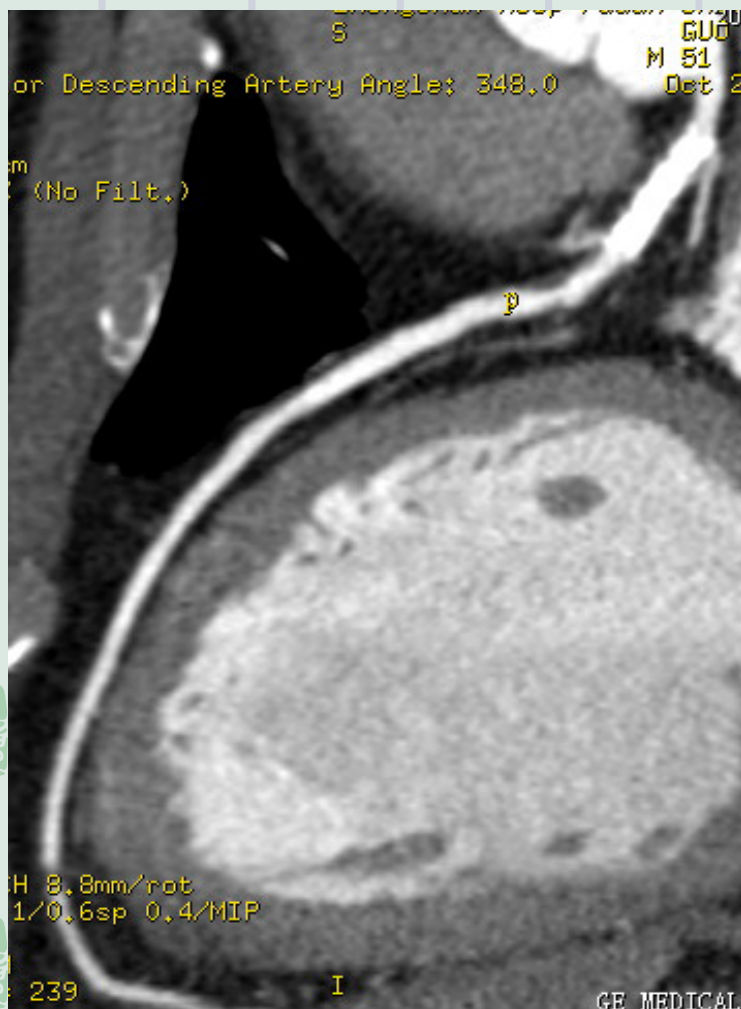


低密度斑块

支架术后评价

- 支架开放度，支架内再狭窄，
- 分辨率要求高，金属往往夸大狭窄程度
- 根据支架材质密度，涂膜用料，需考虑容积效应影响





普
安

普
安

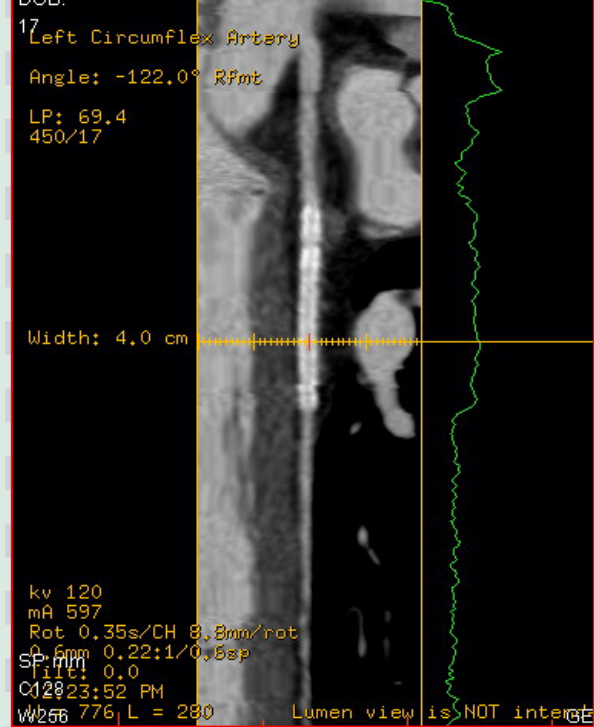
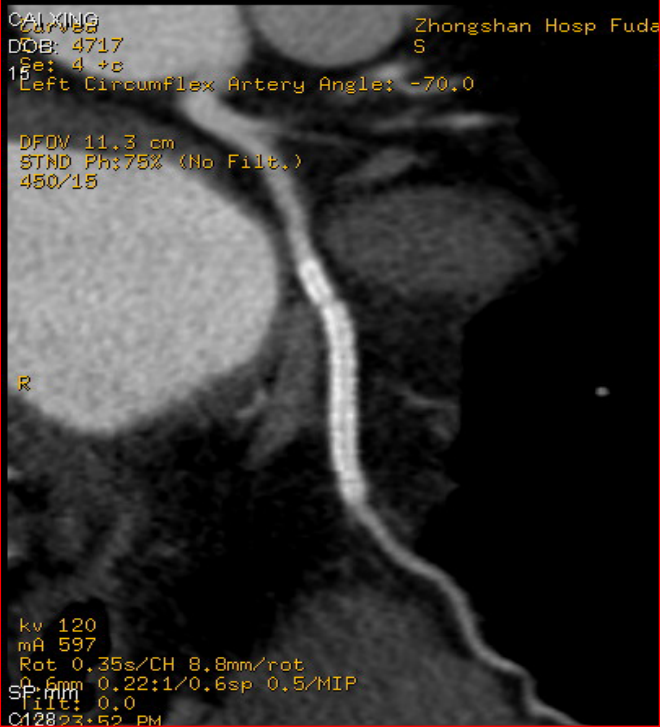
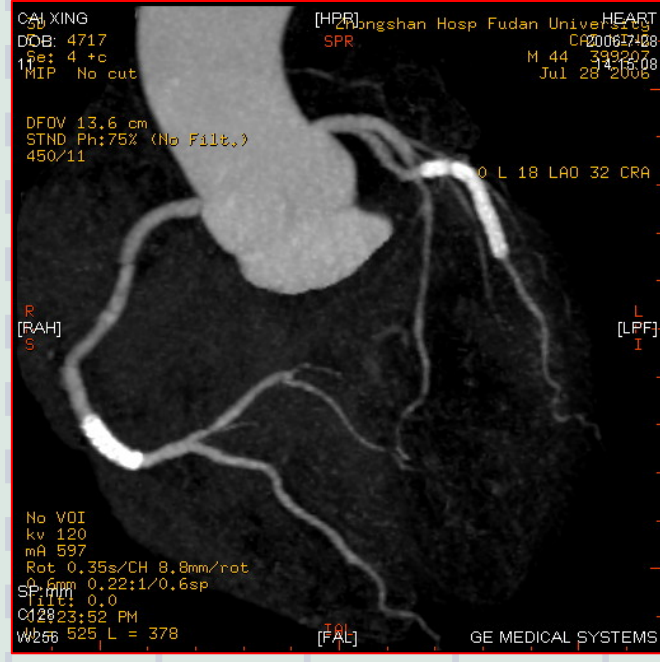
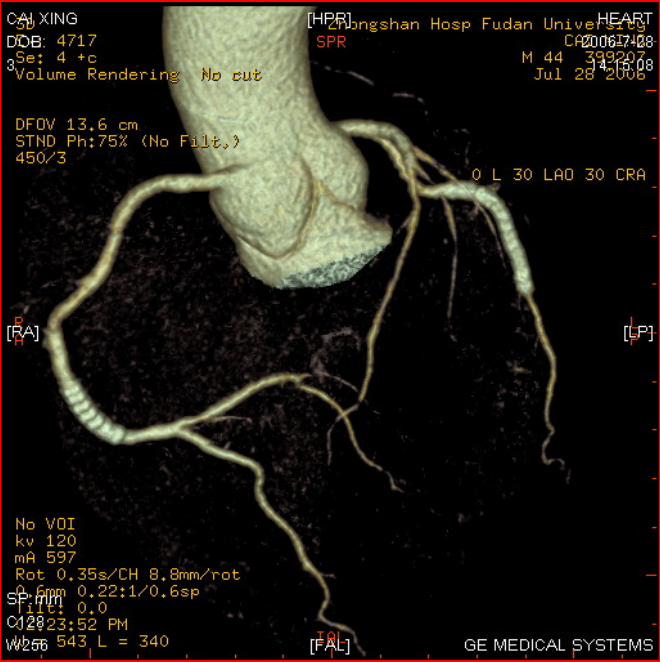
普
安

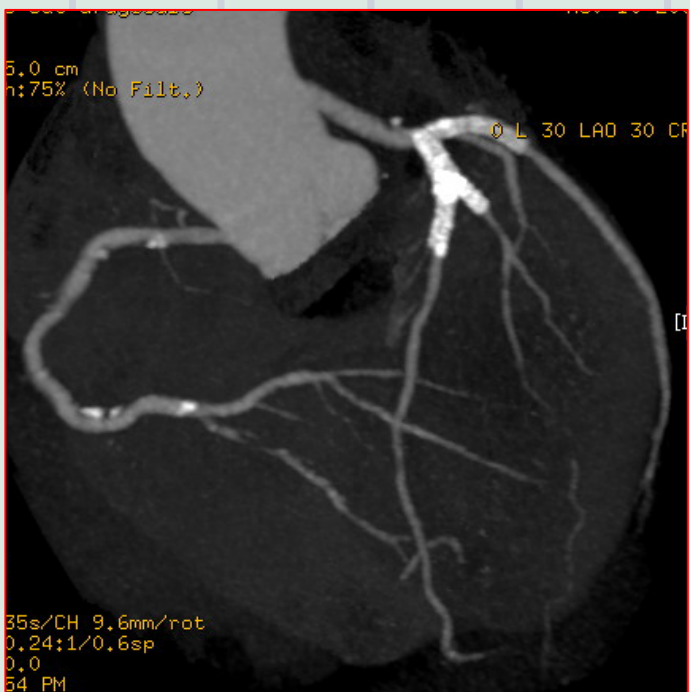
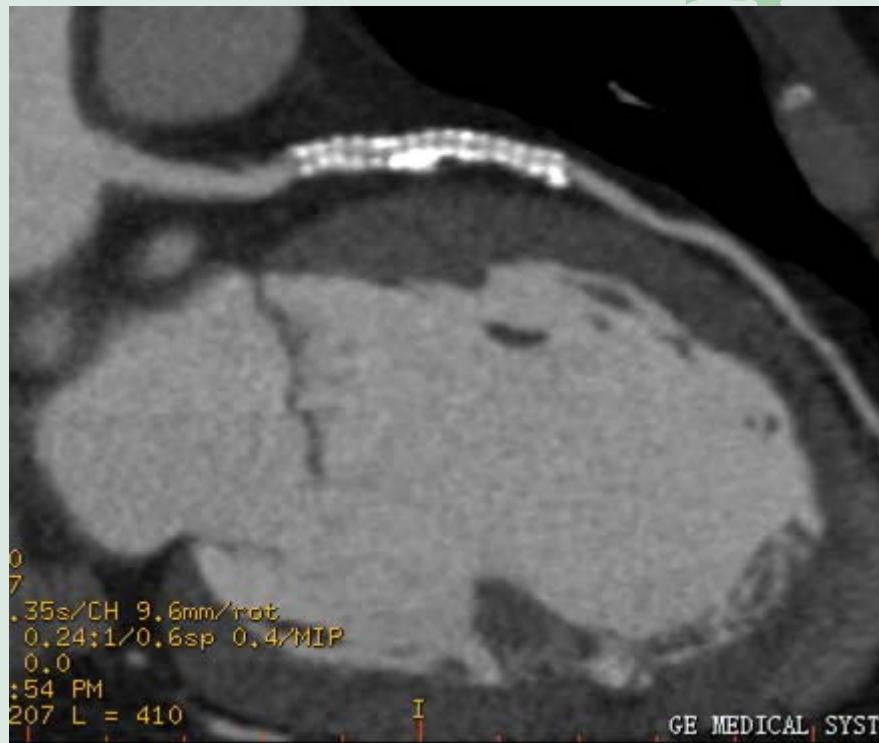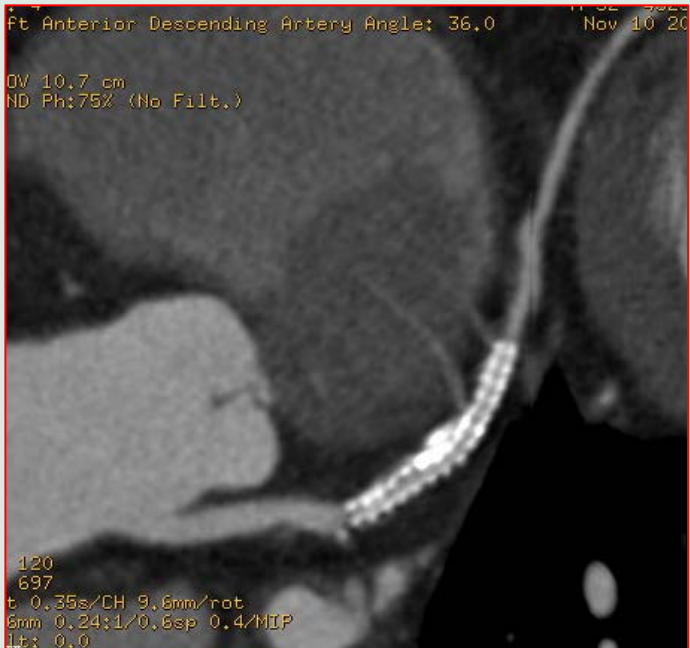普
安

普
安

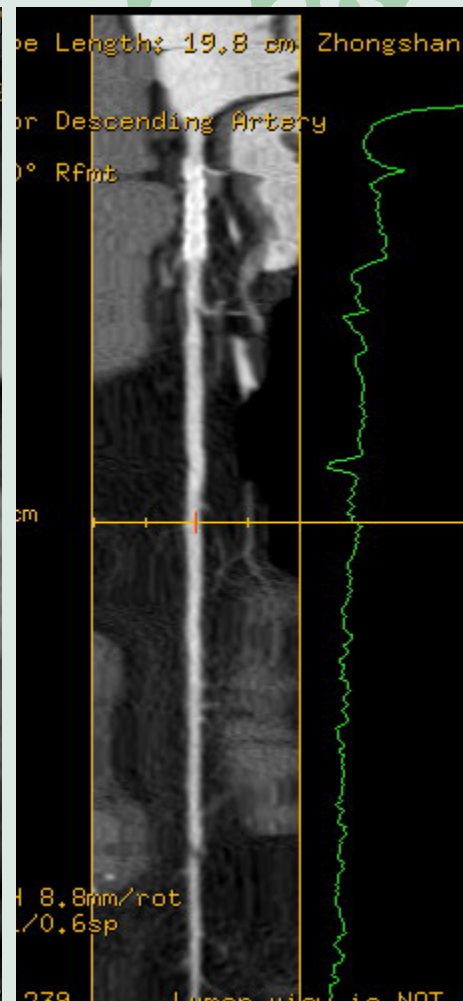
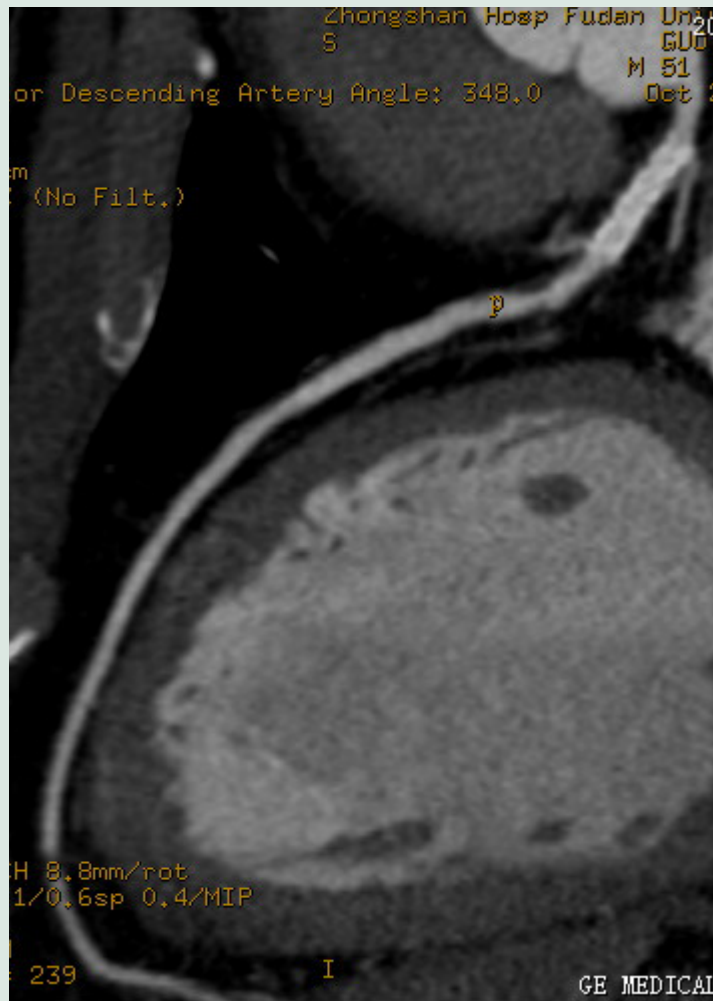
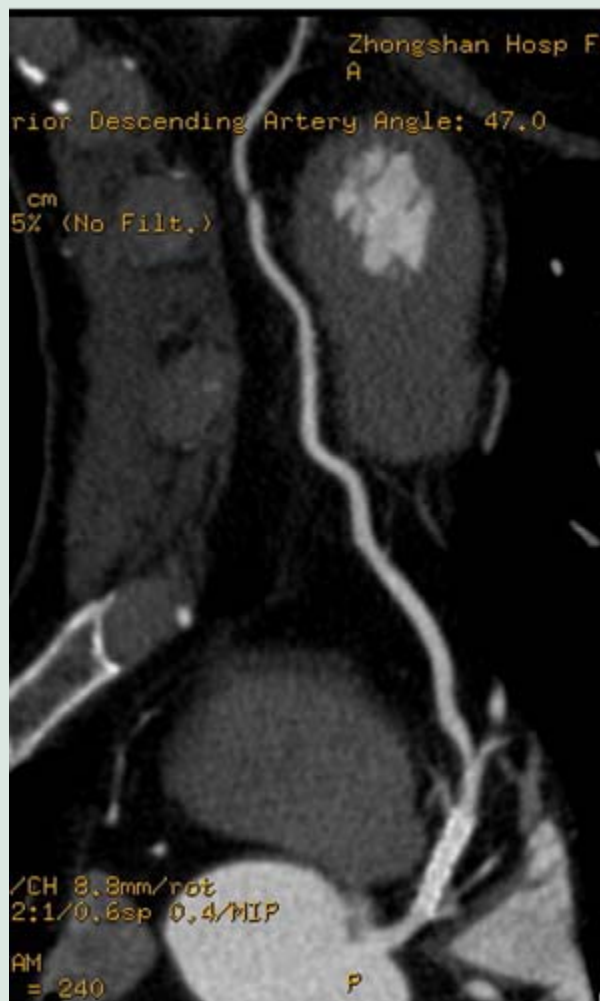吉祥如意

冠脉支架术后




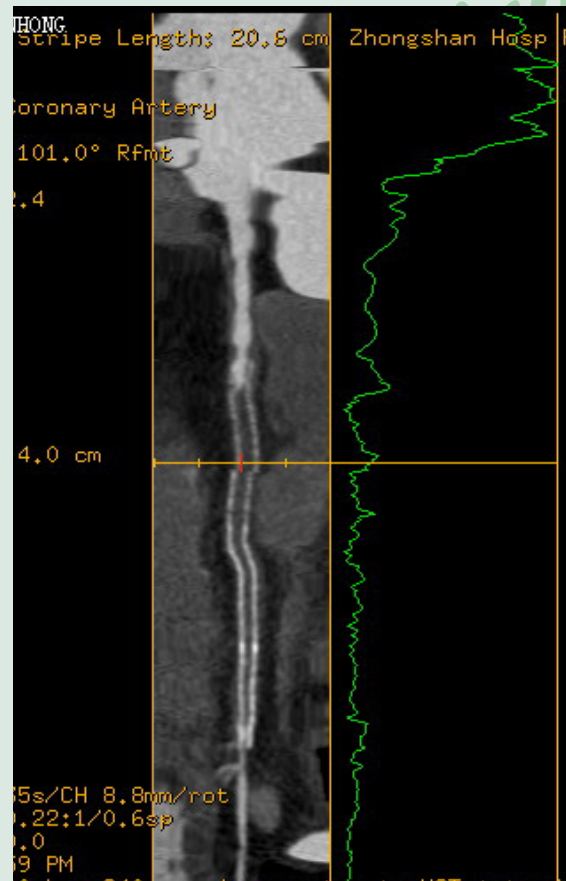
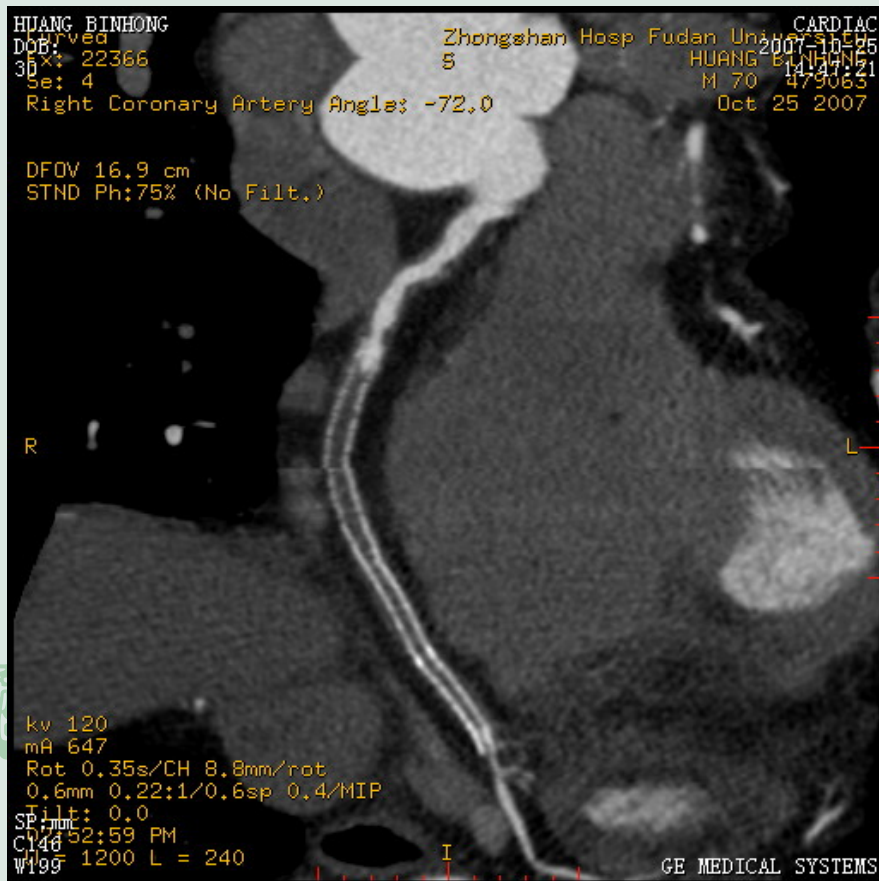


支架腔内情况



支架下方斑块形成





支架内血栓形成

冠状动脉变异

吉祥如意

- 分类
 - 起始点异常
 - 行程异常
 - 终点异常



Coronary Artery Anomalies

Anomalies of origin

- High takeoff
- Multiple ostia
- Single coronary artery
- Anomalous origin of coronary artery from pulmonary artery*
- Origin of coronary artery or branch from opposite or noncoronary sinus and an anomalous (retroaortic, interarterial,* prepulmonic, septal [subpulmonic]) course

Anomalies of course

- Myocardial bridging*
- Duplication of arteries

Anomalies of termination

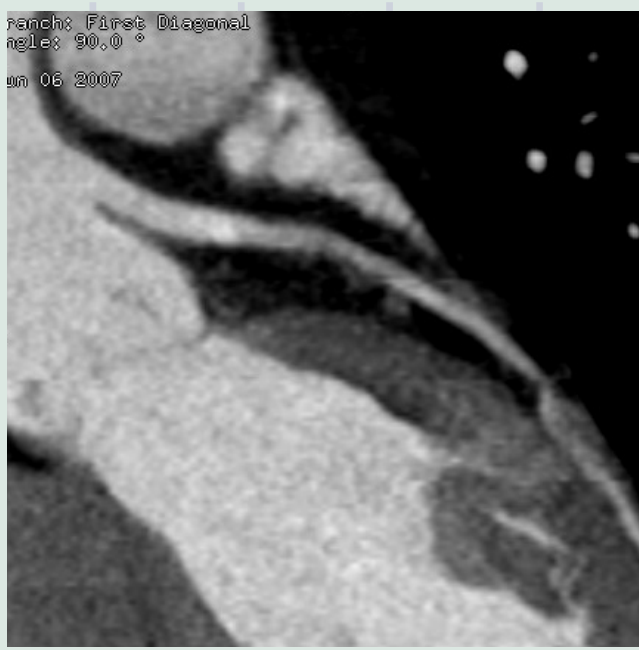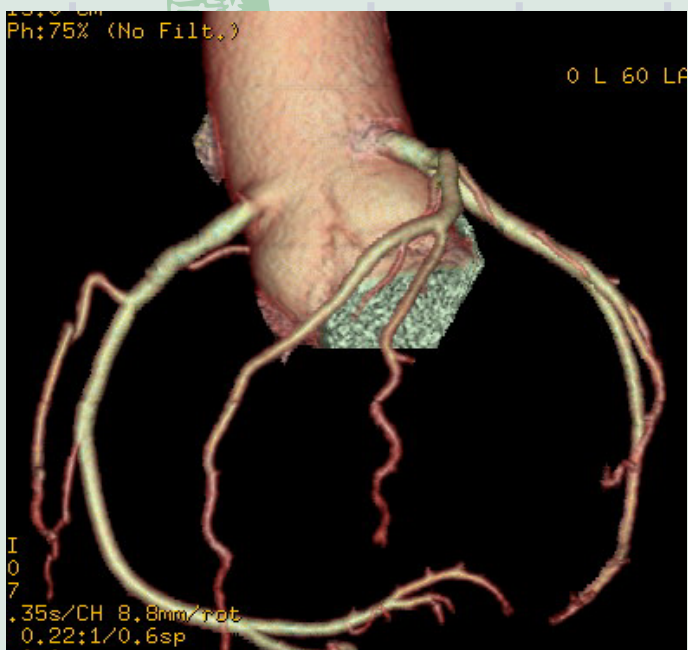
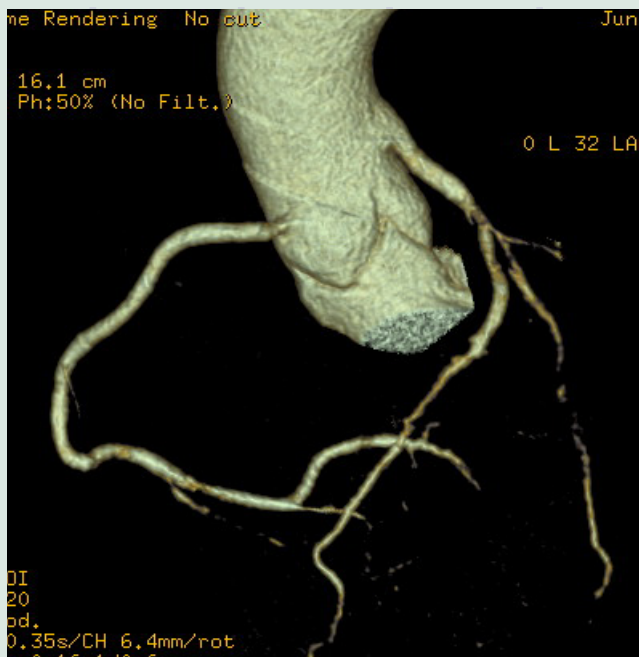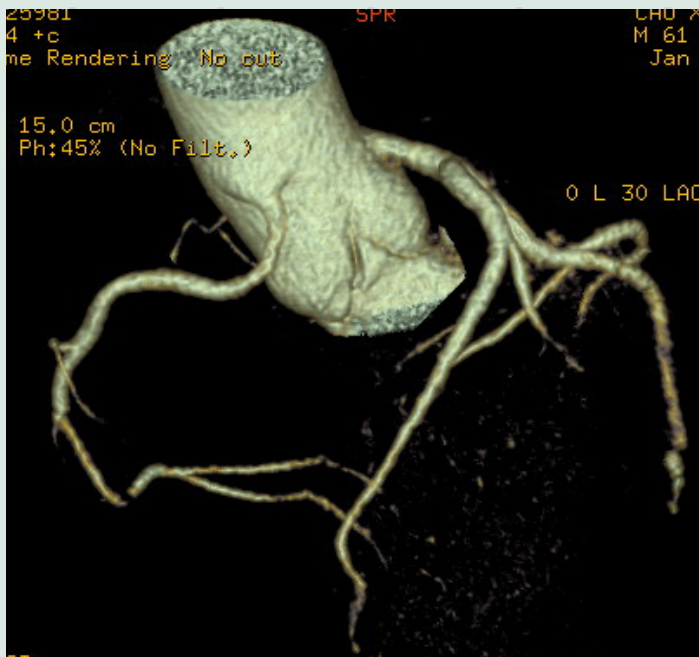
- Coronary artery fistula*
- Coronary arcade
- Extracardiac termination

Source.—Reference 13.

*Hemodynamically significant anomalies, which might be responsible for myocardial perfusion abnormalities.

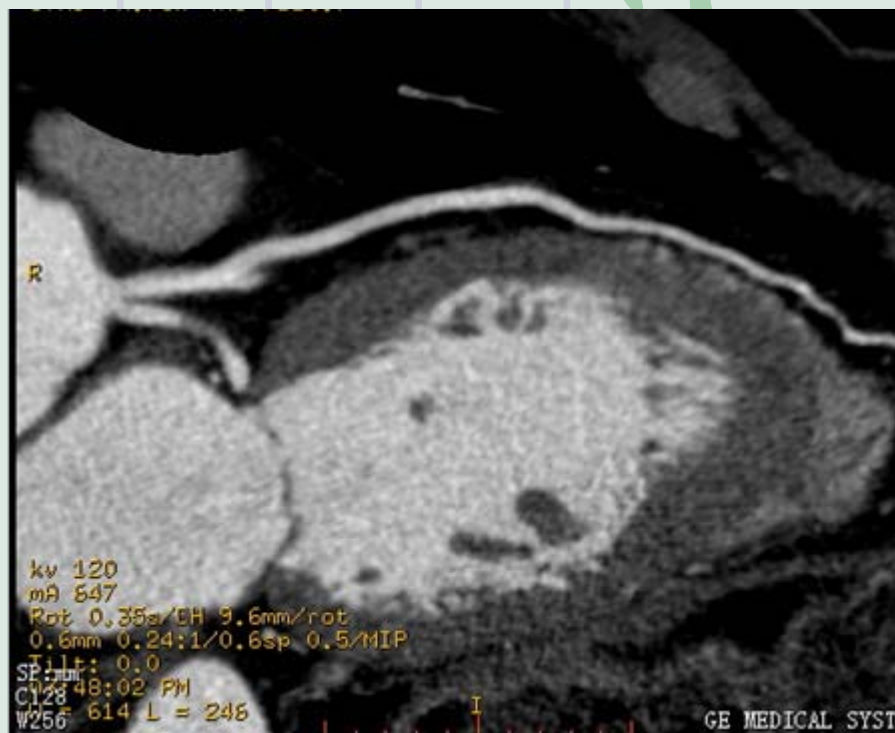
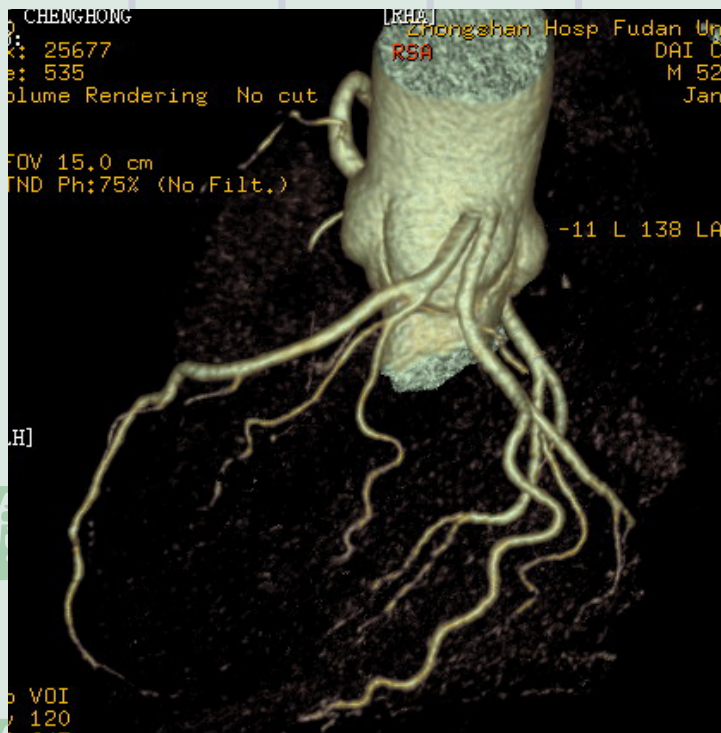
冠状动脉

起点高位



多起源

吉祥如意



吉祥如意

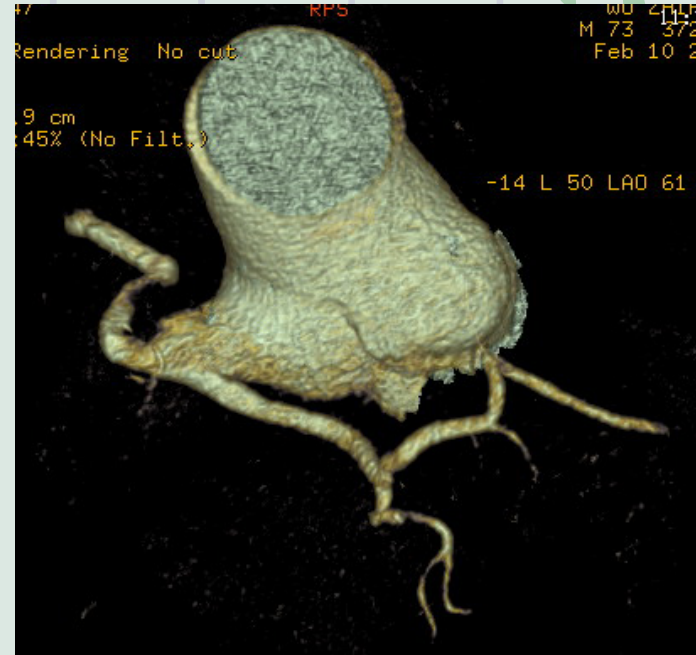
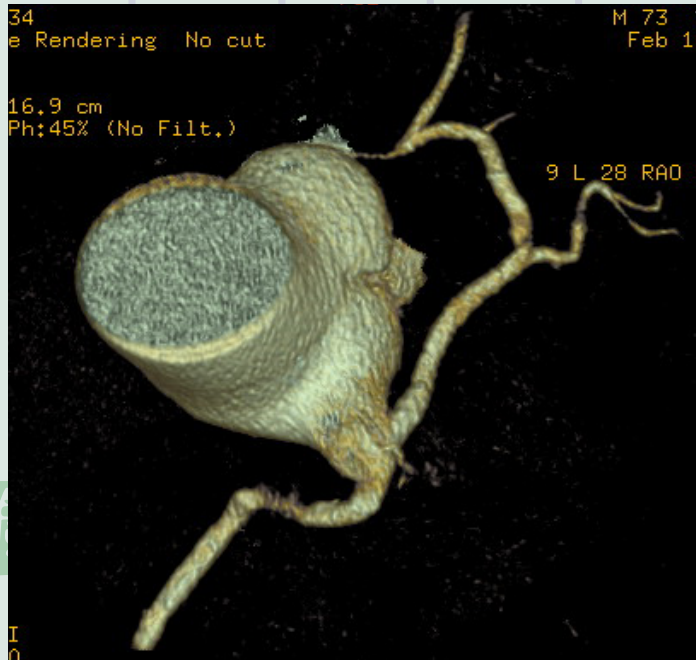
吉祥如意

吉祥如意

吉祥如意

单支冠脉

吉祥如意



吉祥

吉祥

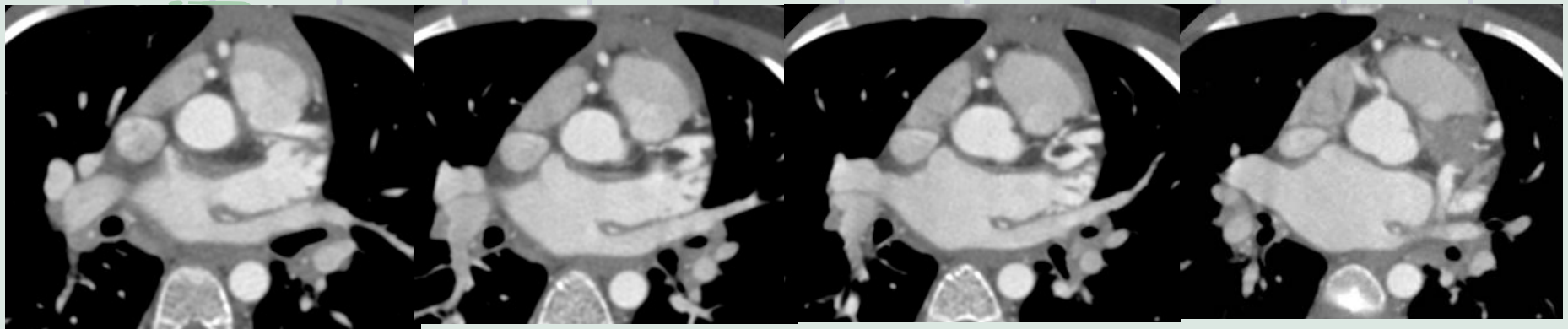
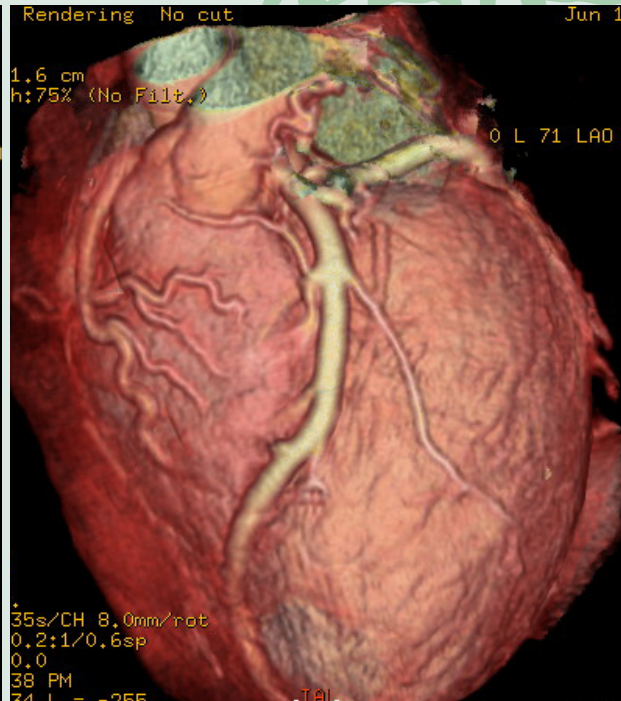
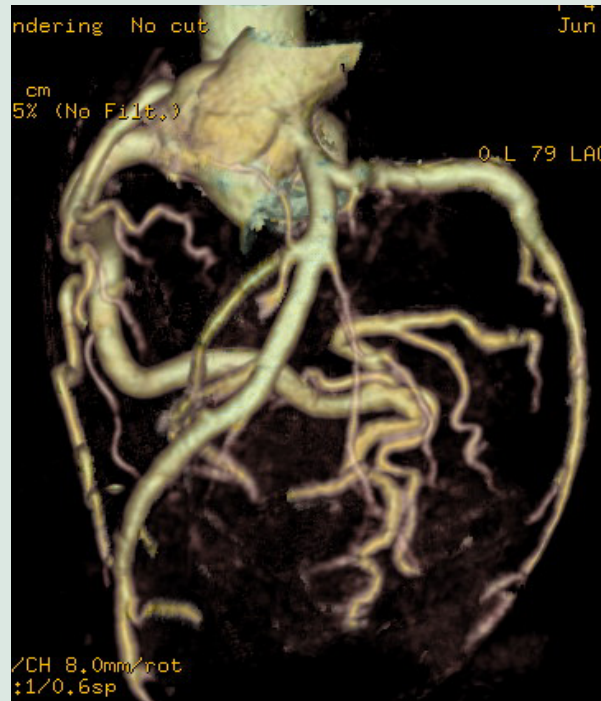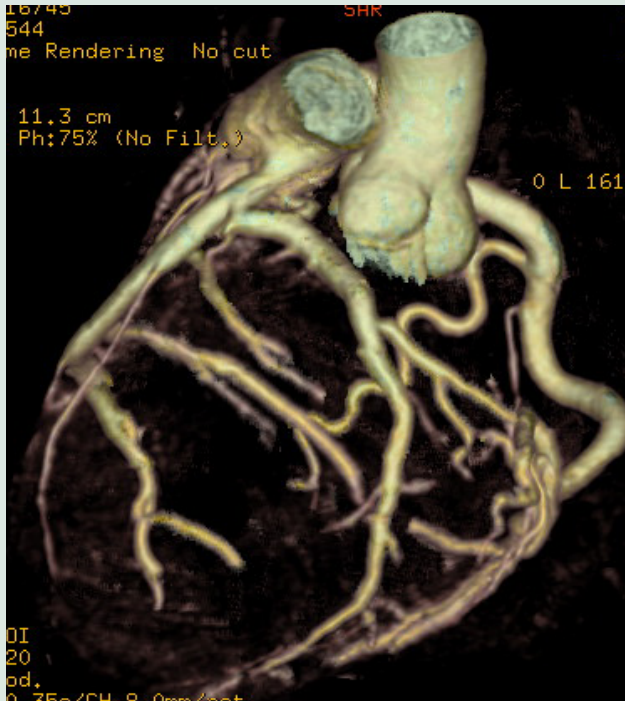吉祥

吉祥

吉祥

冠脉发自肺动脉

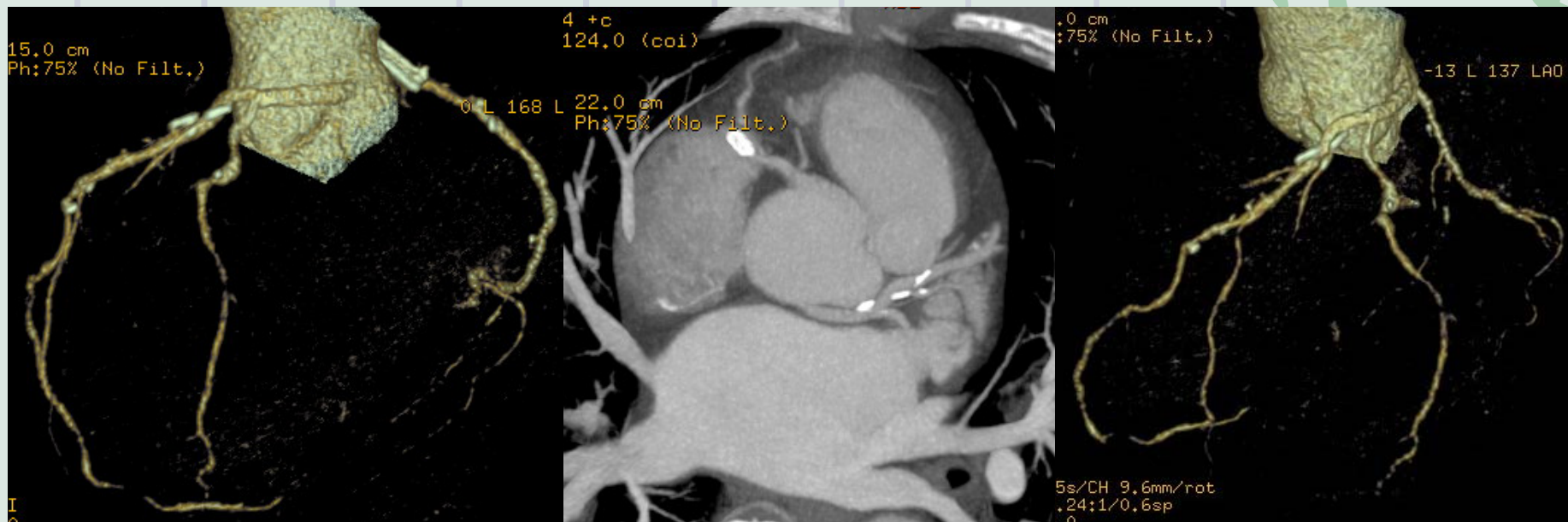
吉祥



Bland-White-Garland syndrome

起源异常冠状动脉

吉祥



吉祥

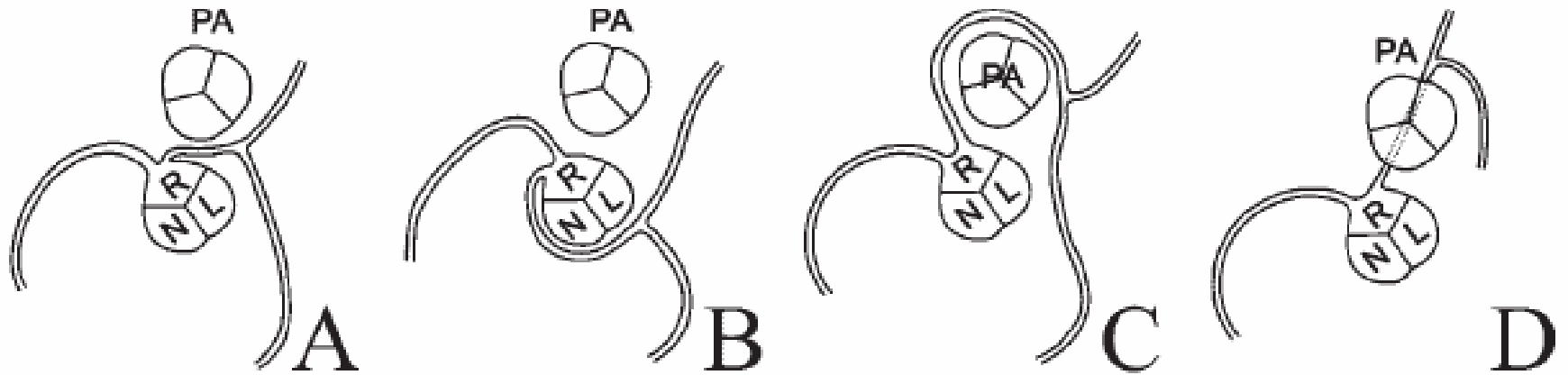
吉祥

吉祥

吉祥

冠脉异常起源伴走行异常

吉祥



吉祥

吉祥

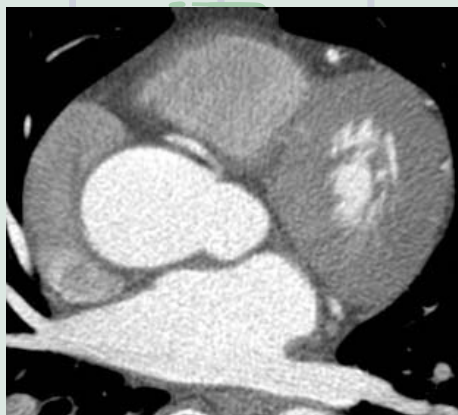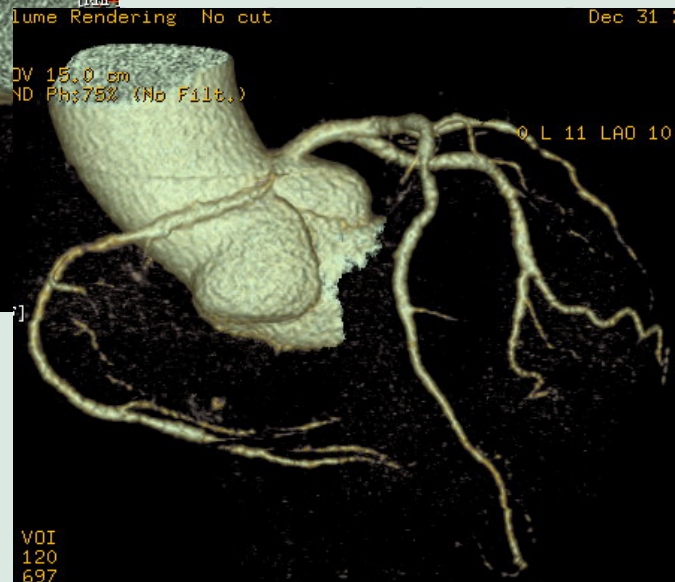
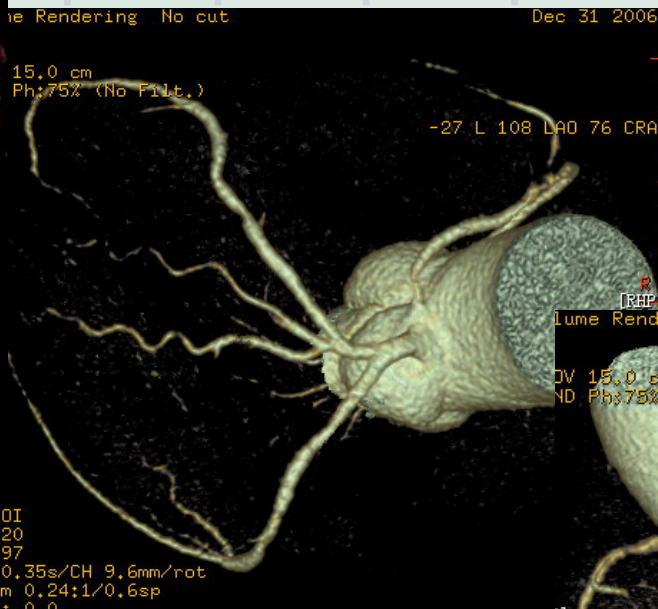
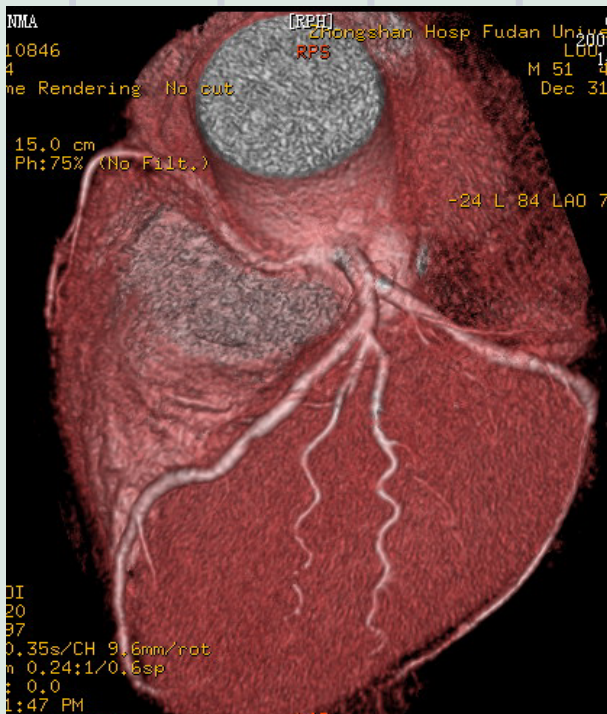
吉祥

吉祥

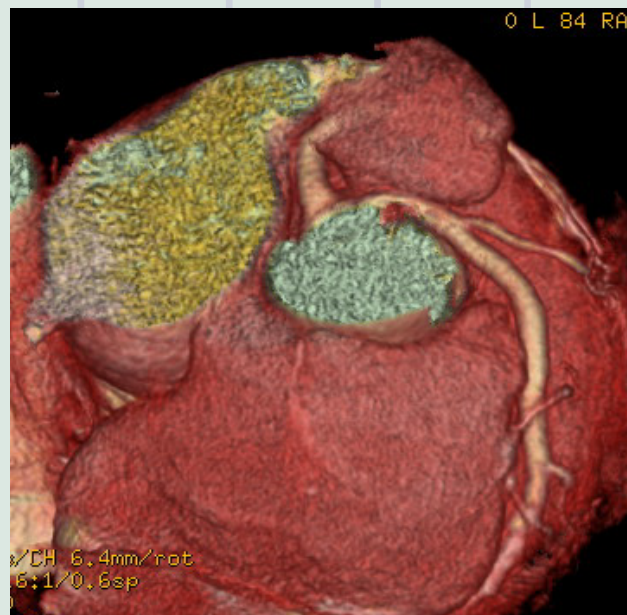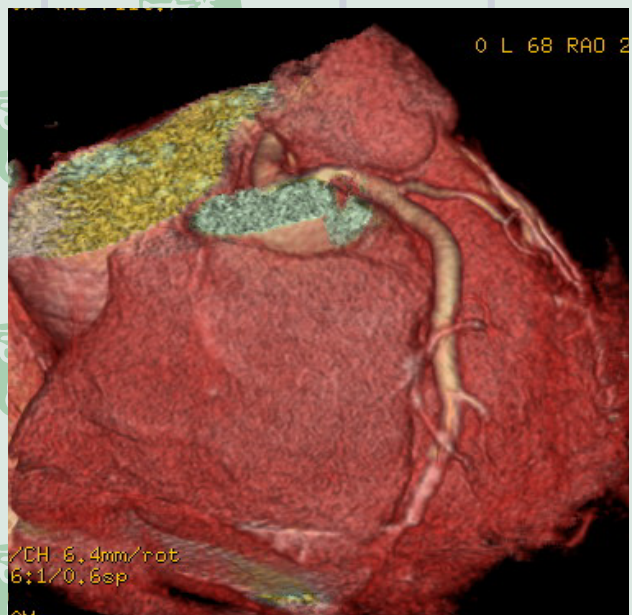
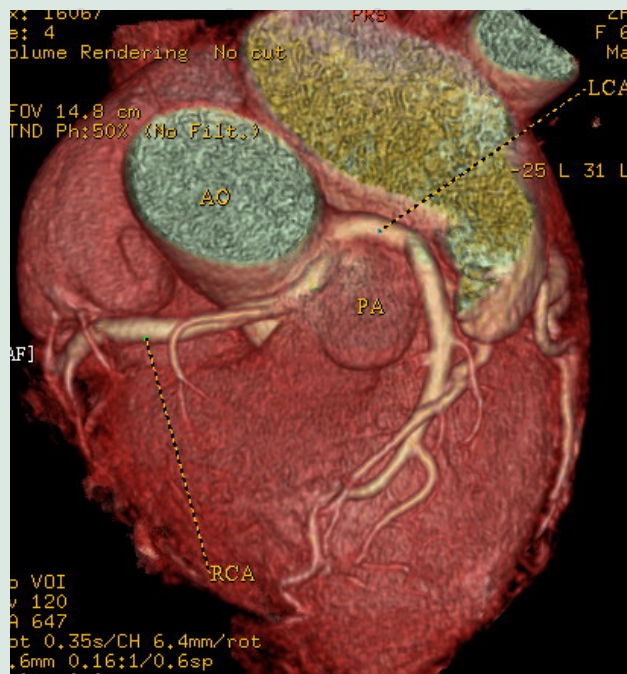
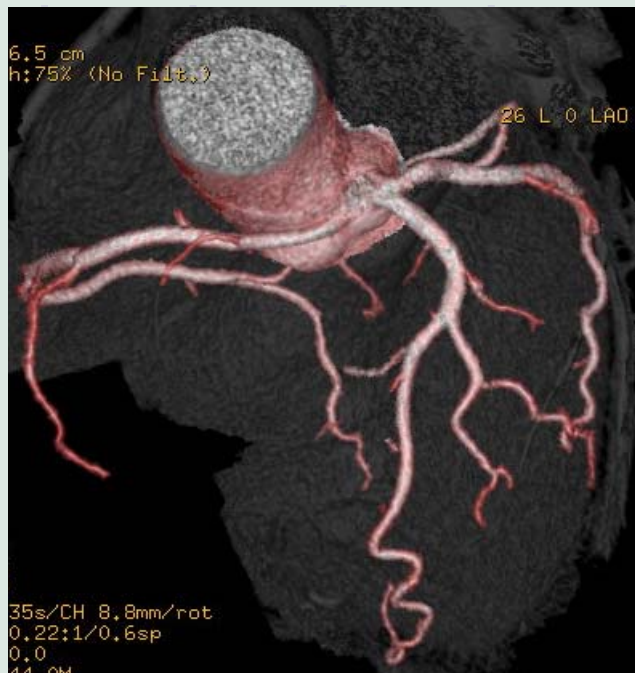
吉祥

冠脉异常起源伴走行异常

吉祥

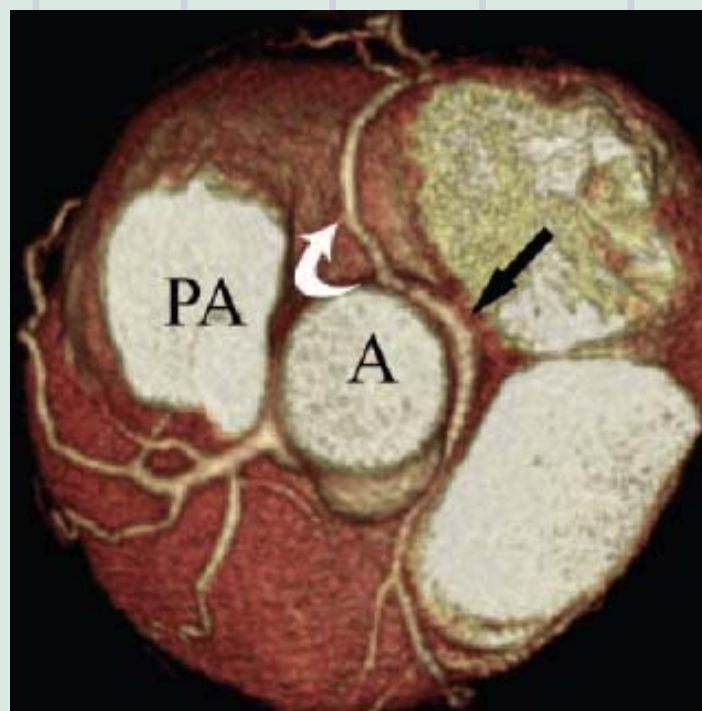
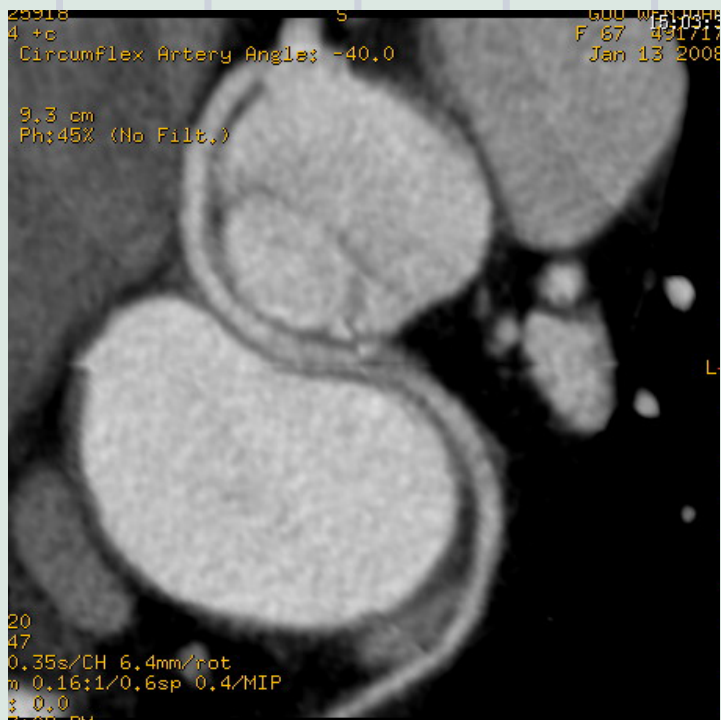
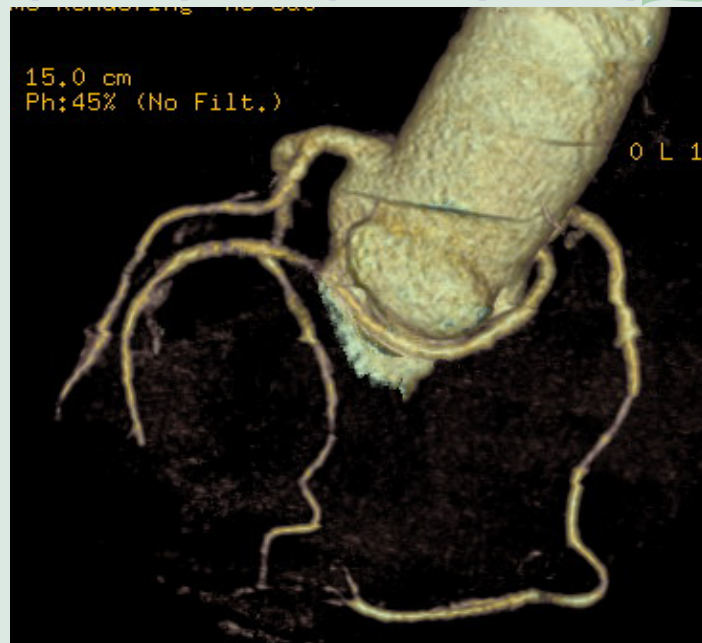
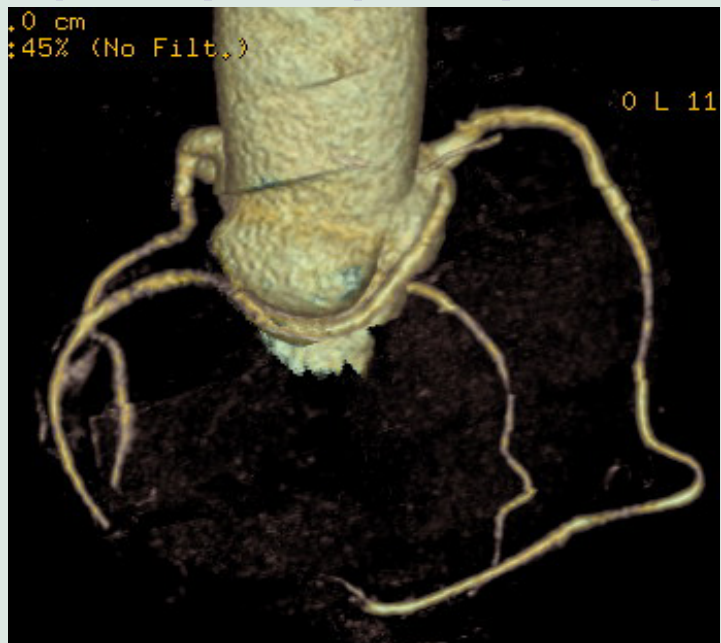

VOI
120
697



吉祥如意

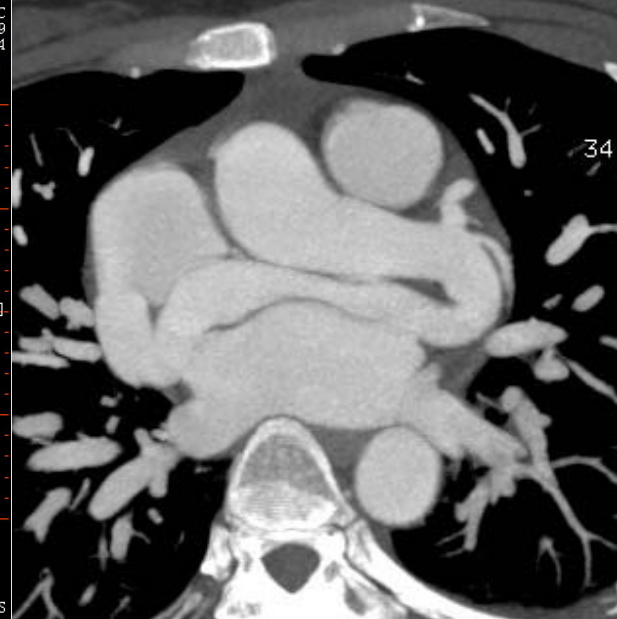
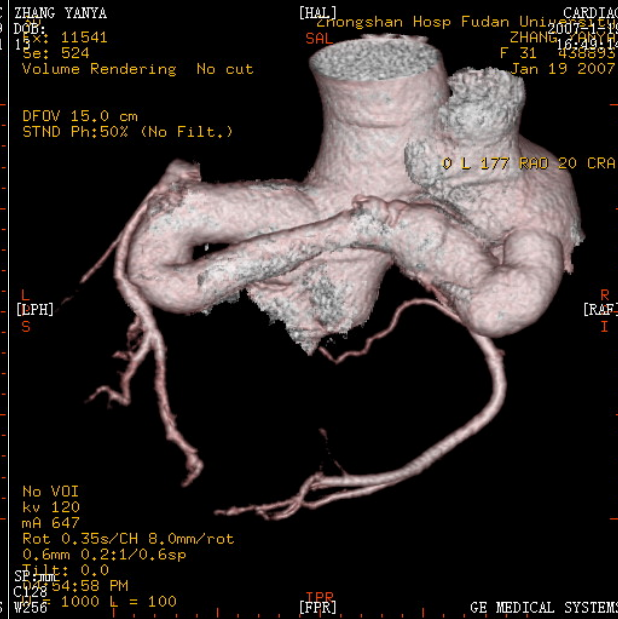
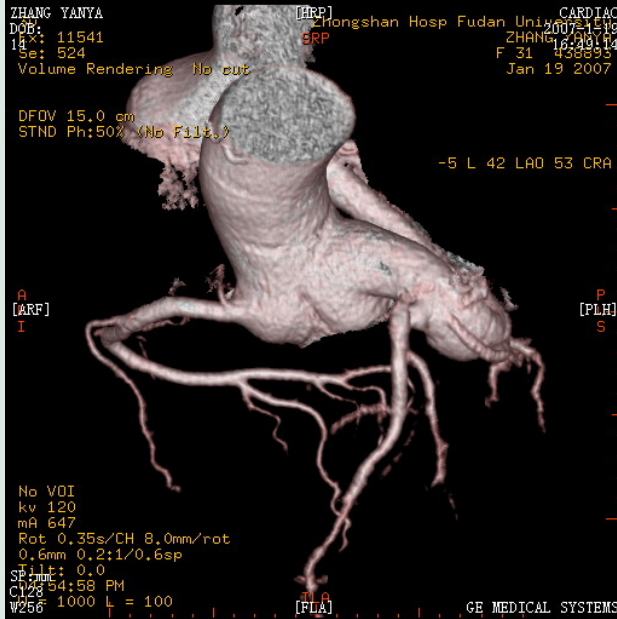
走行关系



醫學

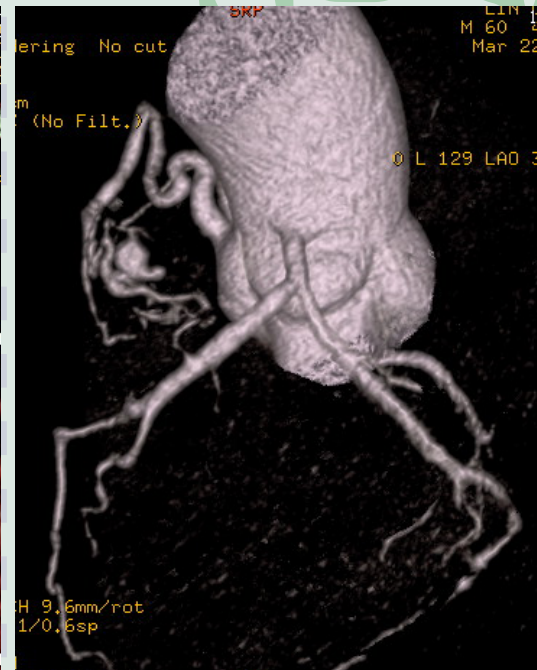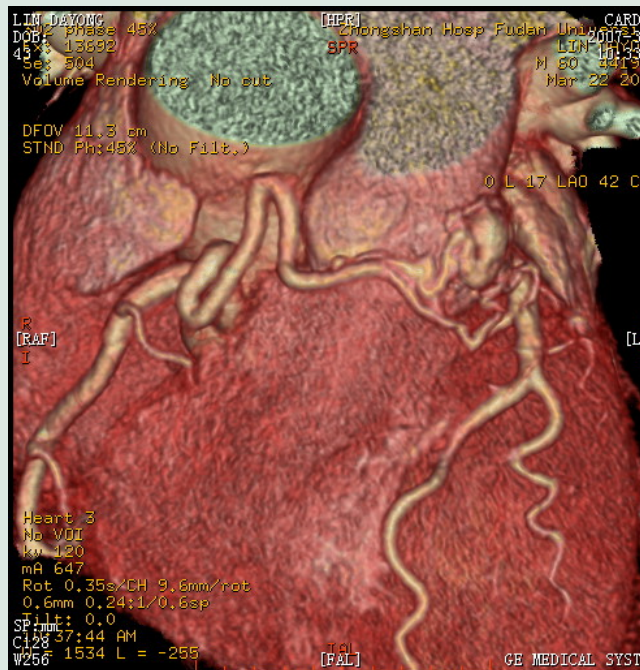
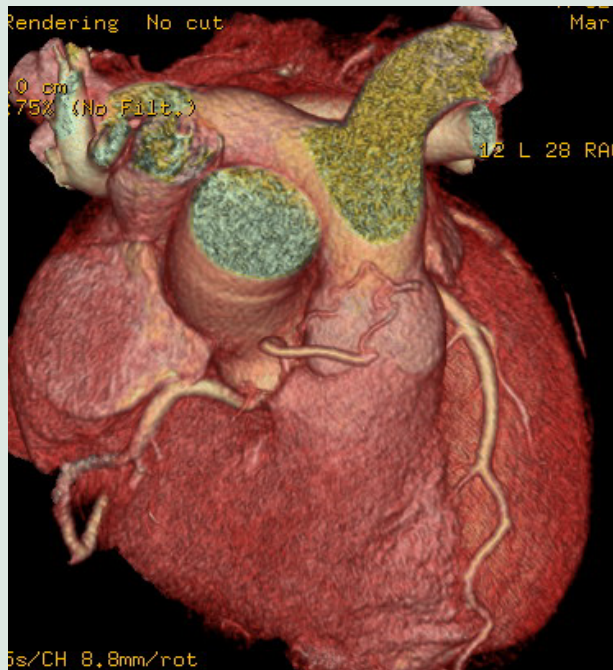
异常交通 (瘻)

吉祥如意



异常交通

吉祥



吉祥

吉祥

吉祥

吉祥

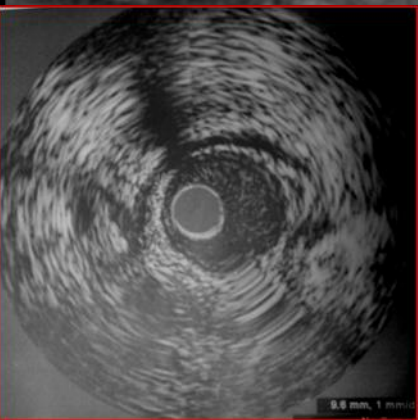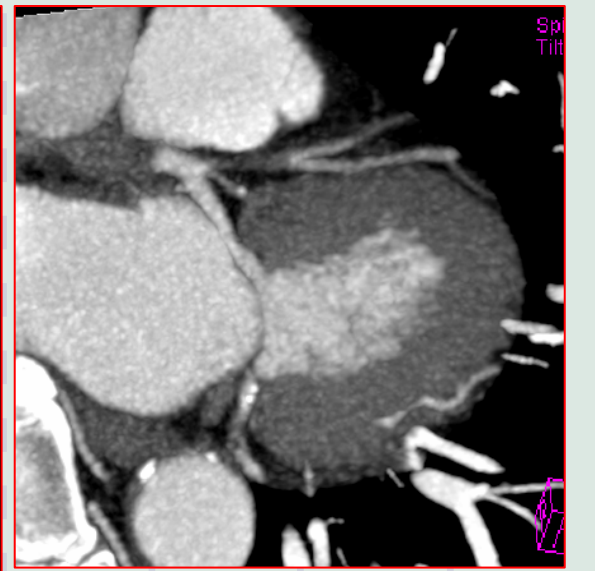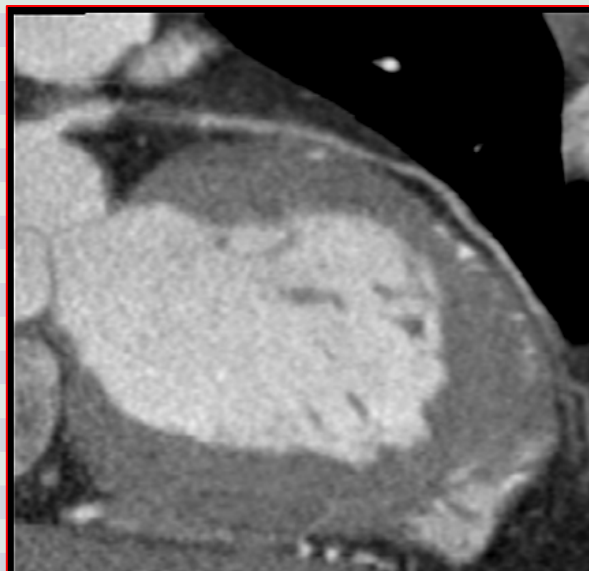
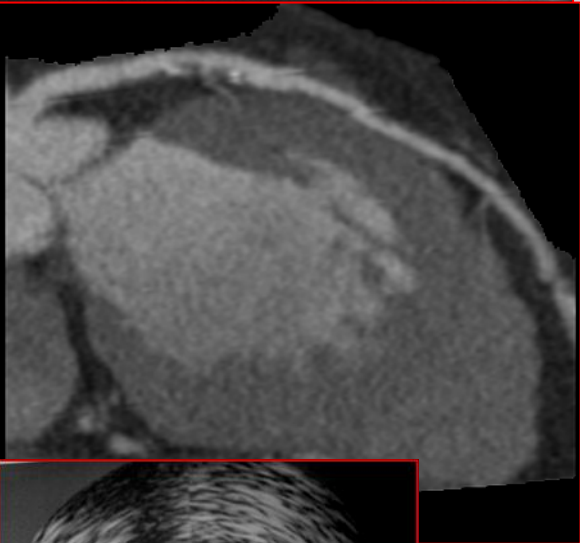
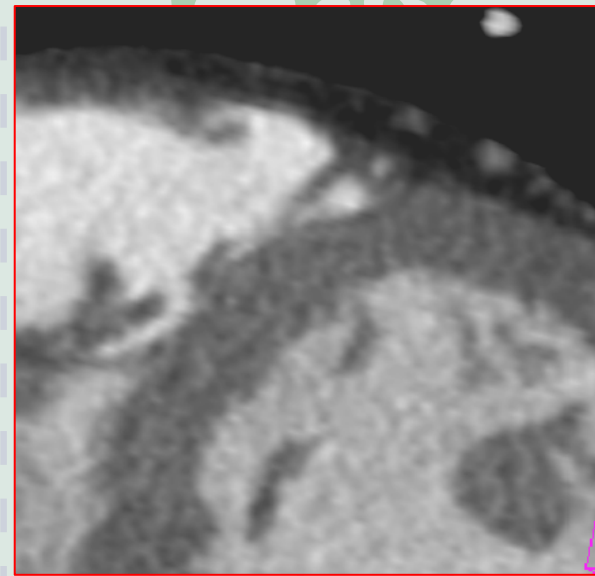
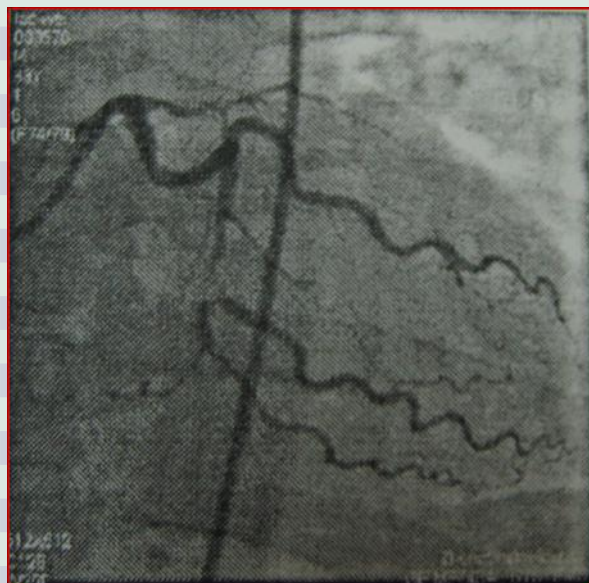
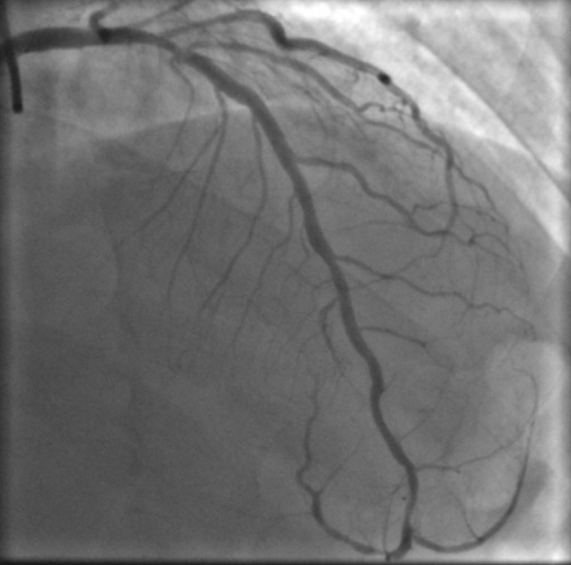心肌桥

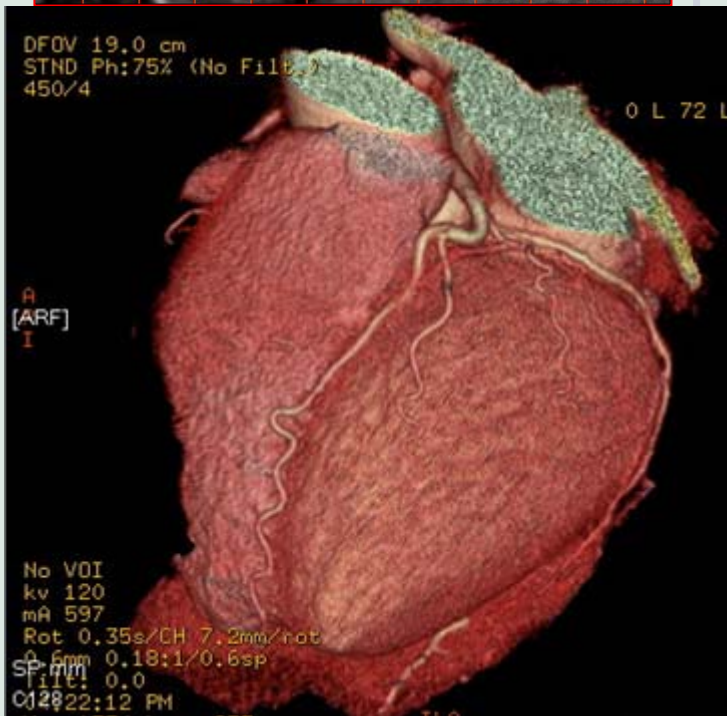
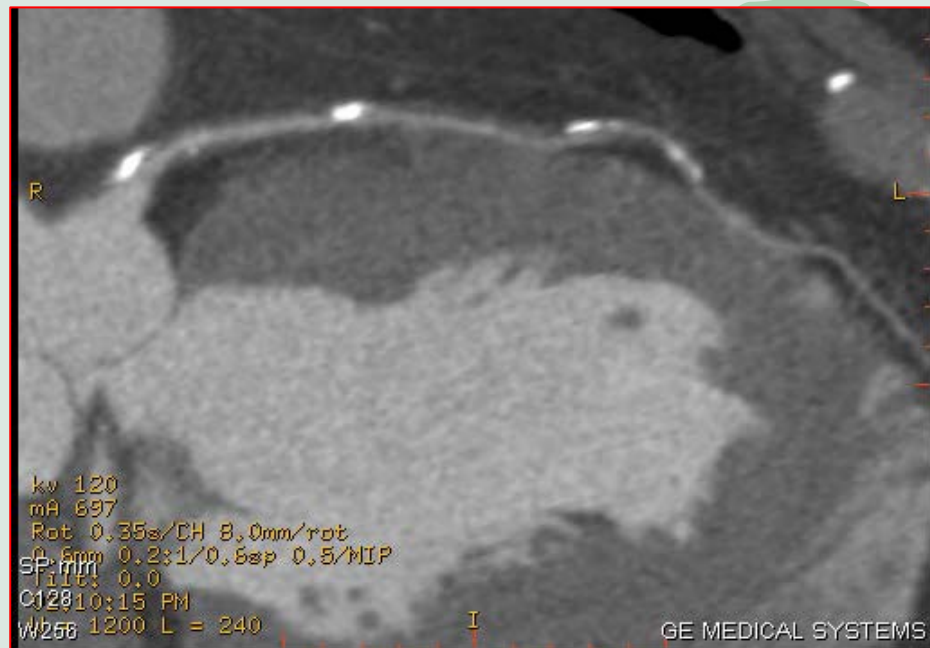
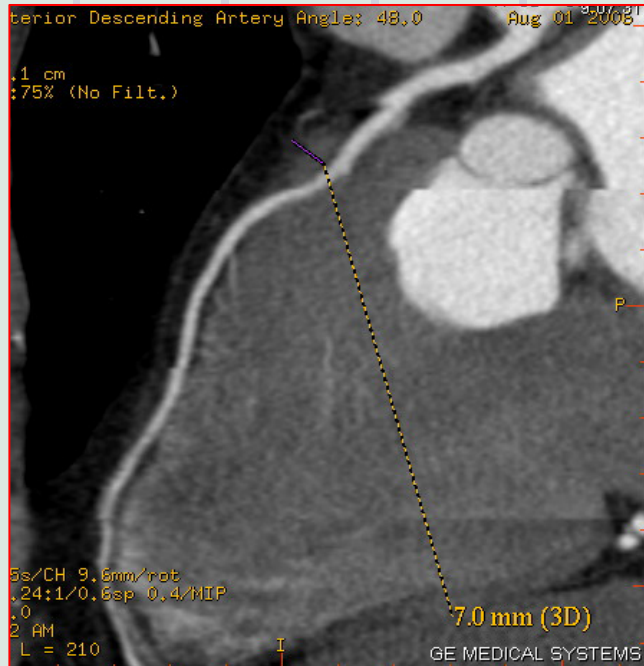- 左前降支中段，发生率约**30%**左右
- 桥血管段受保护，近端粥样硬化好发部位
- 造影和血管内超声：特征性表现

■ 无创性**CT**横断位成像，利于心肌桥检出







冠脉搭桥评价

吉祥

■ 检查方法

➤ 检查目的

- 评价桥血管
- 评价术后相关并发症

➤ 注意事项

- 扫描范围
- 重建方法
 - MRP
 - VR



冠脉搭桥

■ 手术方式

▶ 静脉桥

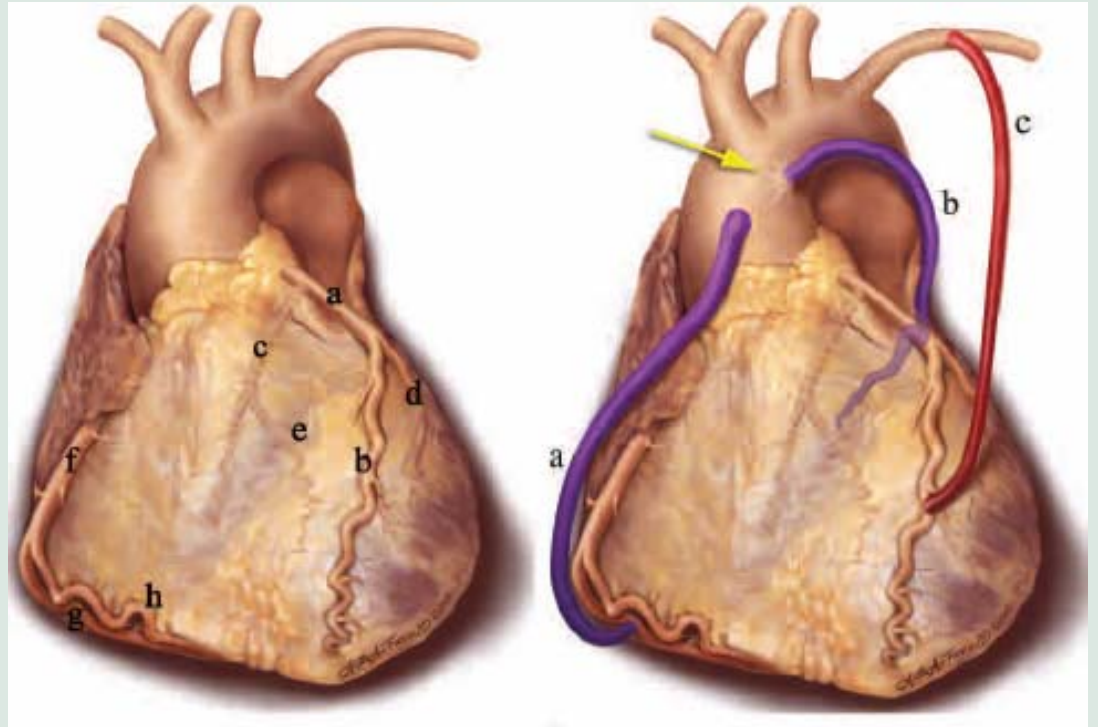
■ 选择的血管

■ 优缺点

▶ 动脉桥

■ 选择的血管

■ 优缺点



搭桥血管

吉祥

■ 常见的搭桥方式

- LIMA - LAD狭窄远端血管
- AO/LIMA - RA - D1/Rumas - OM1 - PDA
- AO - SVG - D1/Rumas - OM1 - PDA
- AO - SVG - RCA - PDA

■ 余搭桥血管

- RIMA - 游离血管/连接血管（类似RA）
- 胃网膜血管

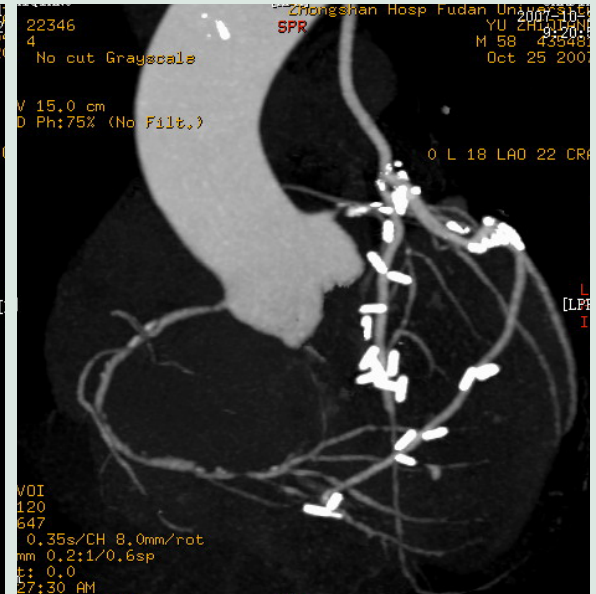
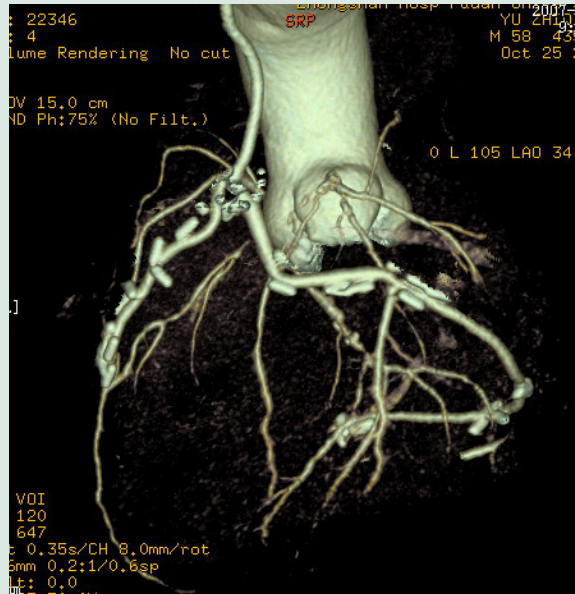
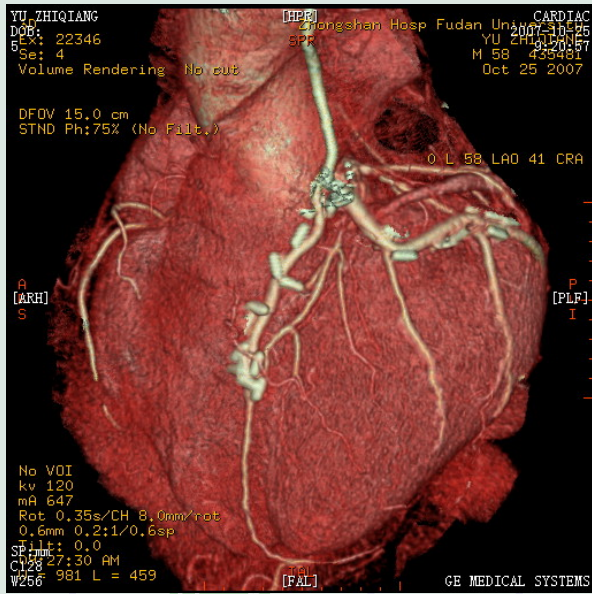
吉祥

吉祥

吉祥

吉祥如意

LIMA — RA — D1/Rumas — OM1 — PDA
LAD



吉祥如意

吉祥如意

吉祥如意

冠脉搭桥并发症

吉祥如意

■ 早期

- 血栓形成
- 桥血管位置异常或扭结
- 桥血管痉挛
- 医源性并发症
- 心包积液、胸腔积液
- 胸骨感染
- 肺栓塞

■ 晚期

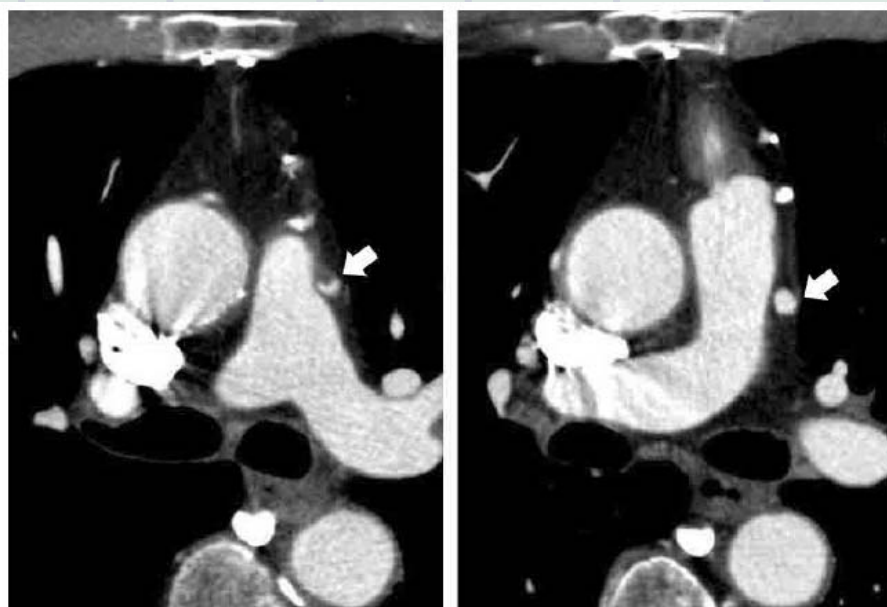
- 血管狭窄闭塞
- 桥血管动脉瘤



搭桥后血栓形成

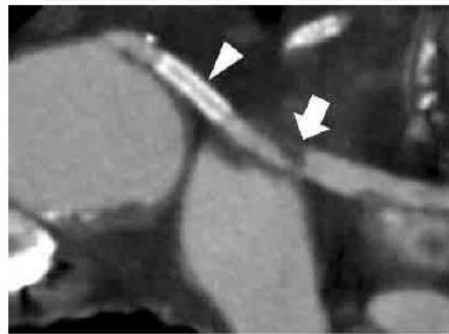
吉祥如意

- 发生时间
- 发生率
- 发生机制
- 表现



a.

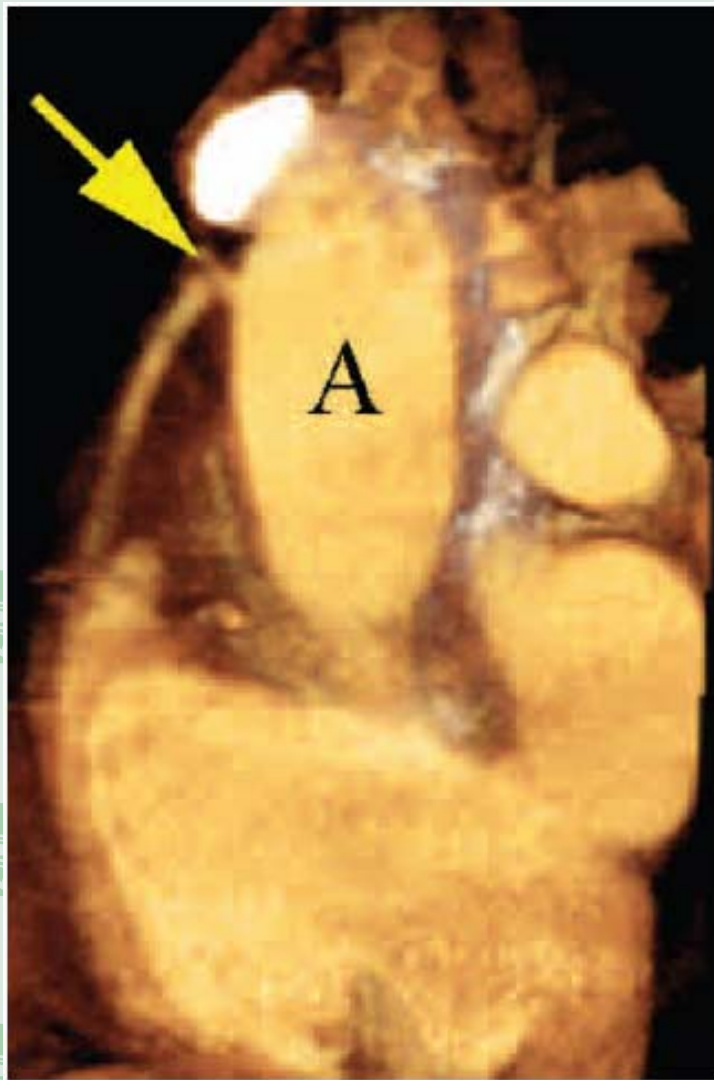
b.



c.

Figure 13. Thrombosis of an SVG.
(a) Axial multidetector CT image shows an SVG with an intraluminal thrombus (arrow) near its proximal anastomosis. (b) Axial multidetector CT image obtained slightly caudad shows that the graft is patent (arrow) with no evidence of thrombosis. (c) Curved axial multiplanar reformation image of the SVG shows a stent (arrowhead) and a thrombosed segment partly occluding the lumen (arrow).

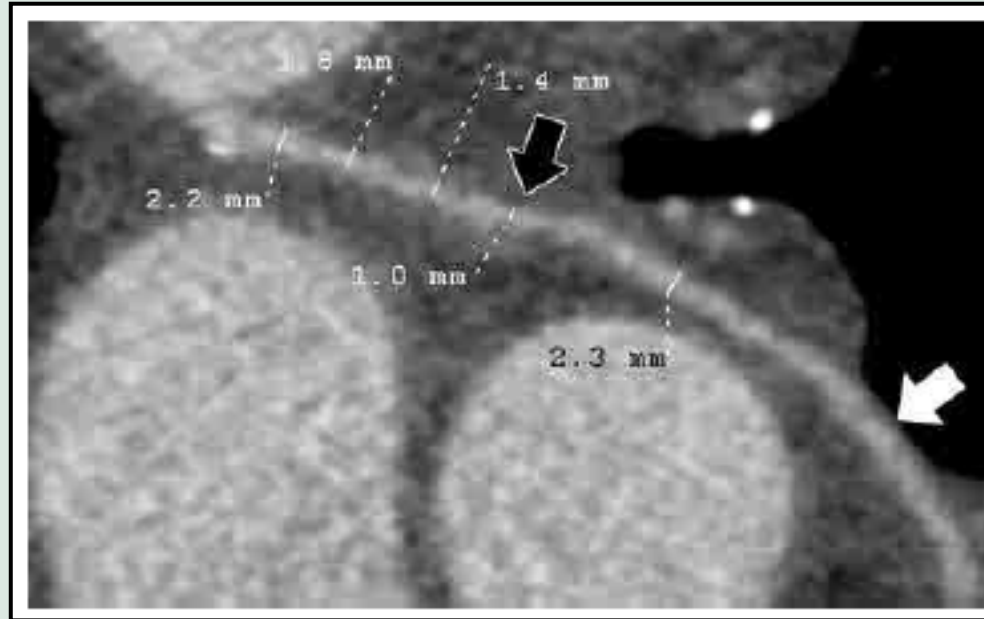
桥血管位置异常或扭结



- 选择适度的静脉桥血管
 - ▶ 过长
 - ▶ 过短
- 吻合口角度

桥血管痉挛

桥血管痉挛



- 桡动脉最易术后痉挛

吉祥

吉祥

吉祥

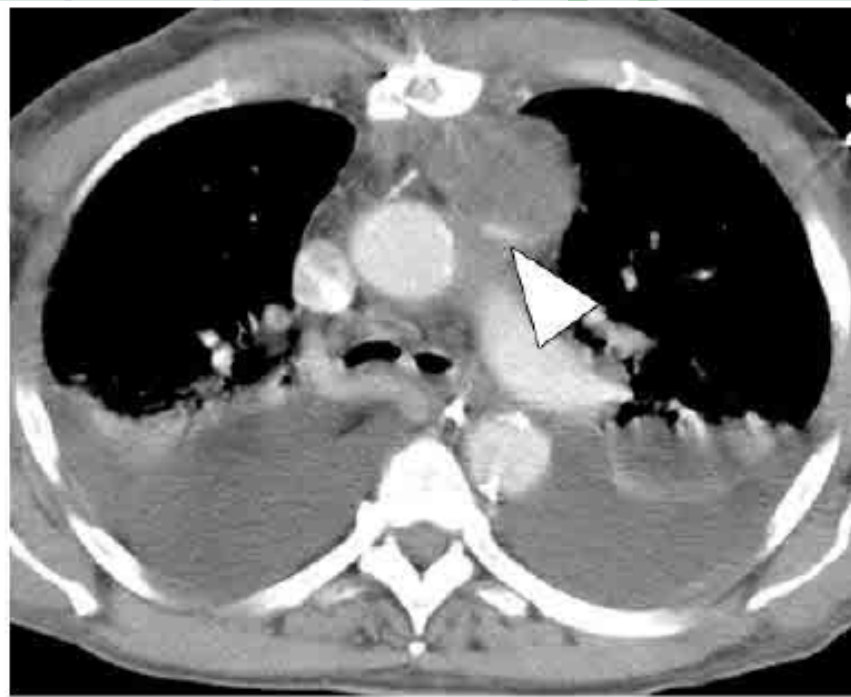
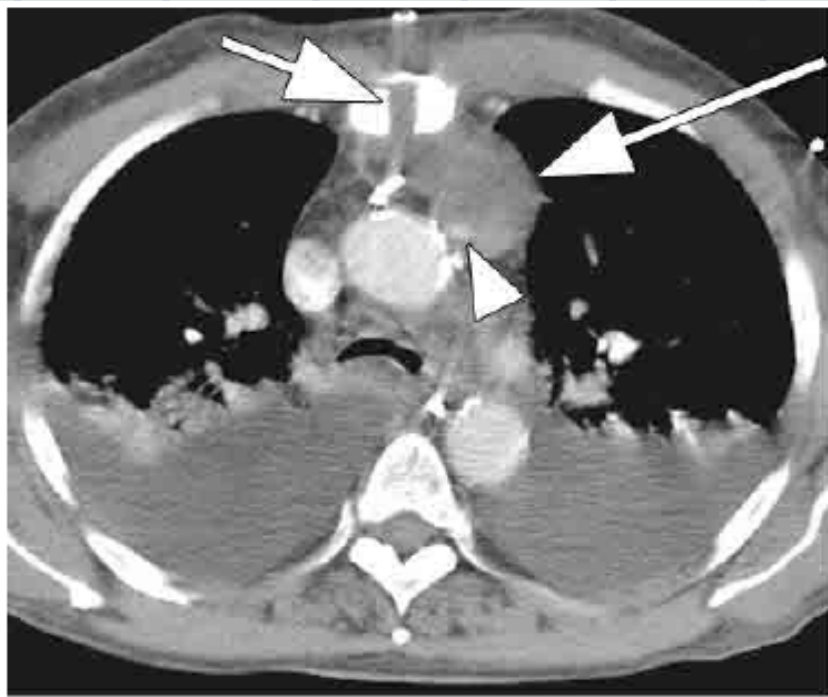
吉祥

吉祥

吉祥

胸骨感染

普
如
醫



普
如
醫

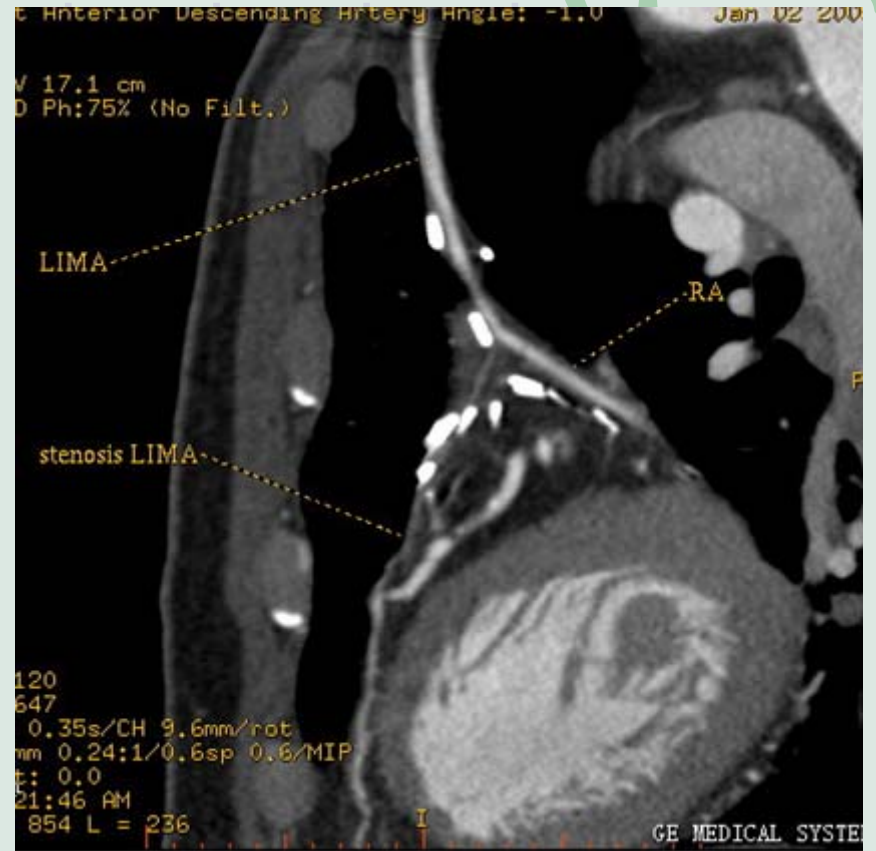
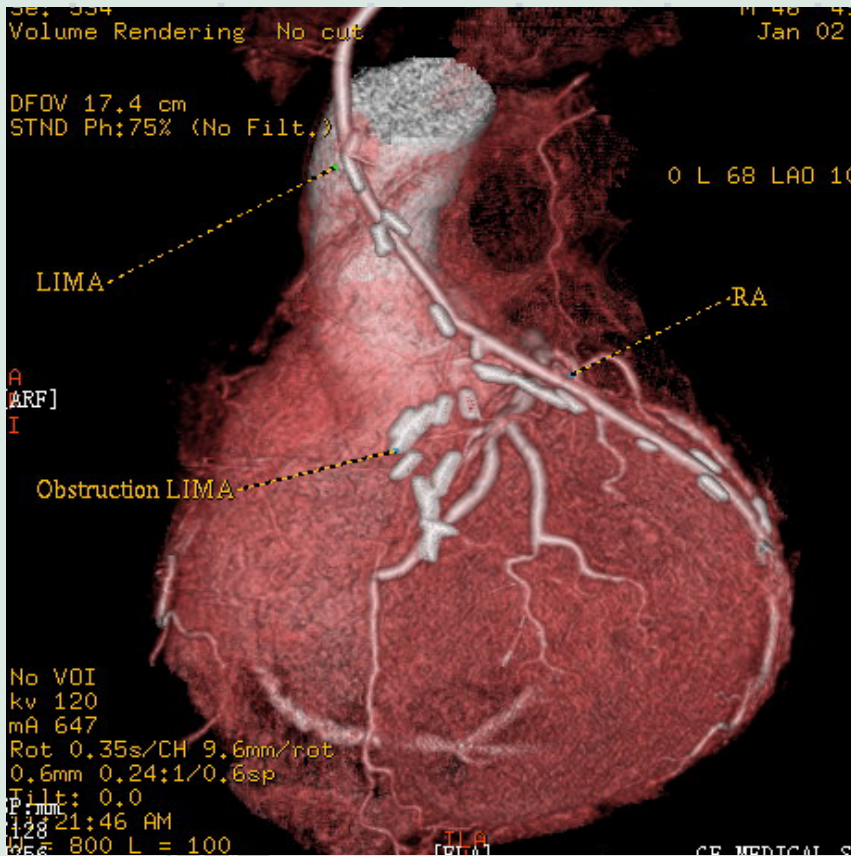
普
如
醫

普
如
醫

普
如
醫

桥血管狭窄

吉
祥
如
意

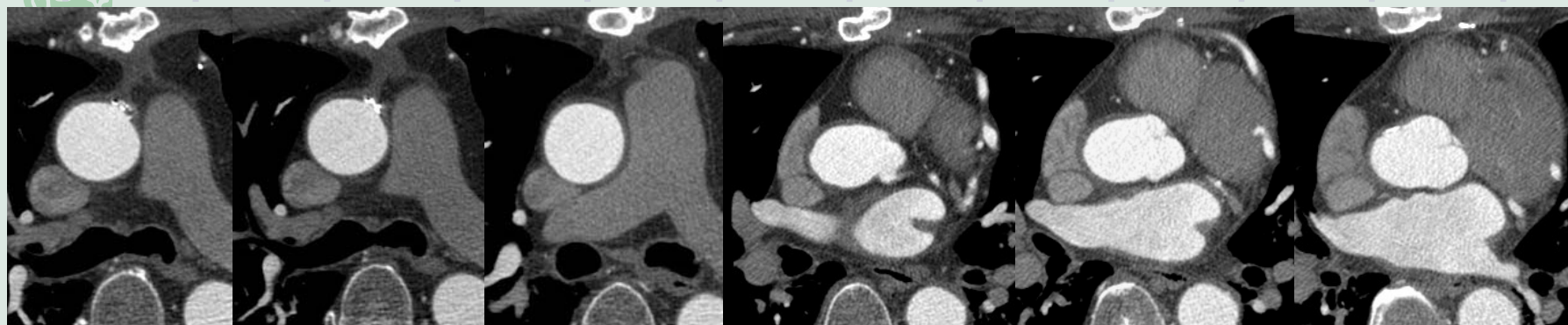
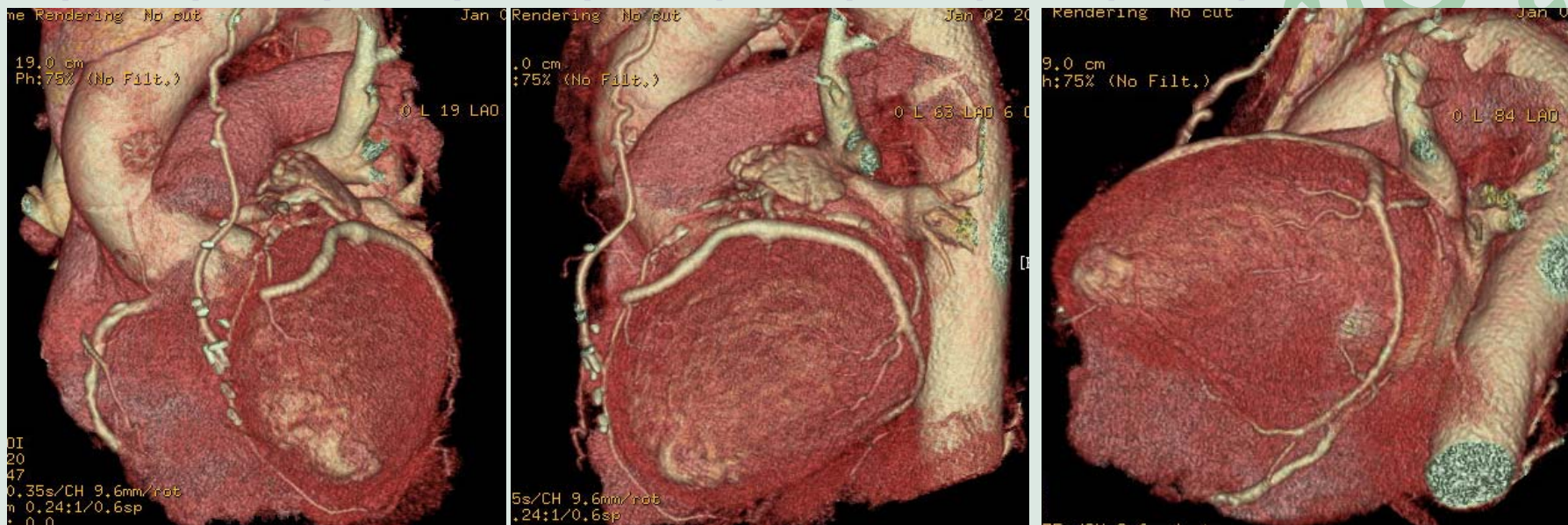


吉
祥
如
意

吉
祥
如
意

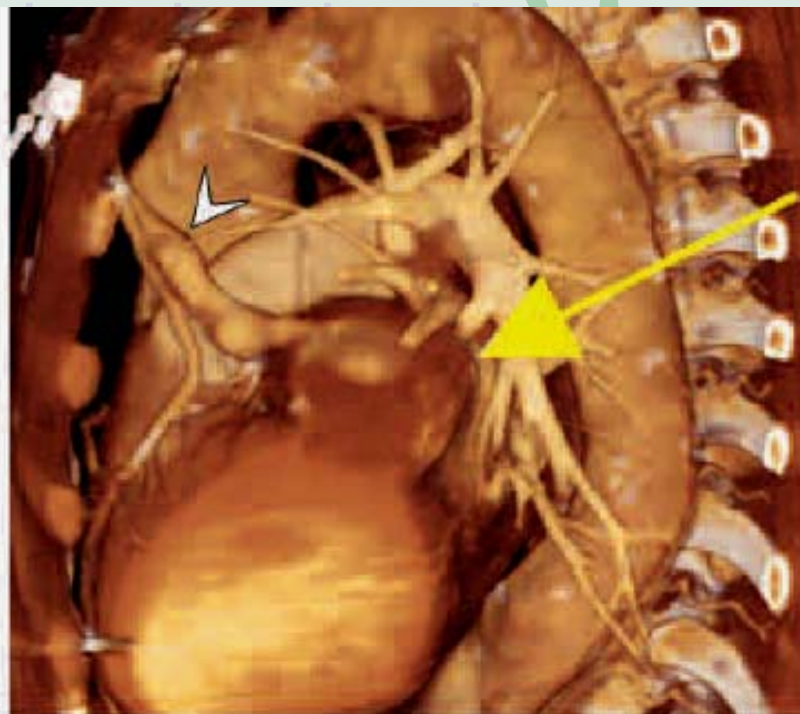
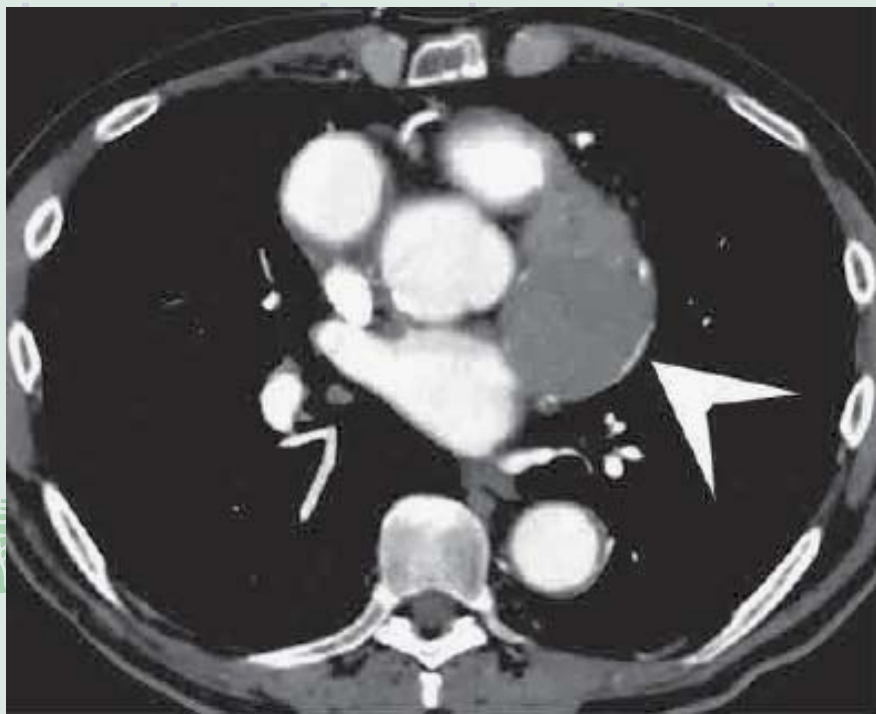
桥血管闭塞

吉祥



桥血管动脉瘤

普
慈



普
慈

普
慈

普
慈

普
慈

Thank for your attention