

应重视胃肠道造影检查

南京军区福州总医院医学影像科

吴纪瑞



福州总医院

FUZHOU GENERAL HOSPITAL



第一军医大学福州总医院
福建医科大学福州总医院

一、“问题”的提出：

- 胃肠道造影检查不被有些医学影像科所重视
- 从事胃肠道造影检查的研究人员逐渐减少。
- 许多年轻医生不会做胃肠道造影检查，这与老一辈教导的“胃肠道造影检查是放射科医生的看家本领”不相符。
- 这块阵地不能丢失。

二、胃肠造影检查的发展：

- 1895年Rontgen发现X线。
- 1903年“铋餐”造影（次硝酸铋）用了近20年。
- 1920年Bachem提出用硫酸钡代替，由铋剂到钡剂是重要转折。

造影方法：

- 20世纪60年代前单对比造影（铸型、剪影）
- 60年代中期在日本开始应用双对比造影：
DC—Double contrast radiography，（全景）日本学者白壁彦夫教授。

三、设备发展：

- 影像增强器与电视系统
- 焦点：小焦点 $0.3—0.6\text{m}^2$
- 摄片：连续摄片、录像、电影
- 遥控机：摇篮床
- 数字化成像
- 血管造影
- CT
- MRI

四、胃肠道疾病诊断进展

- 50—60年代：胃肠道造影占主导地位。
- 70年代：纤维内镜与胃肠造影二者互相补充。
- 80年代：对胃肠造影出现过贬，内镜检查为主，原因：**a**、消化内科医生掌握内镜不掌握胃肠造影；**b**、医学影像科医生致力于血管造影与CT者多，钻研胃肠造影少。

- 90年代：不少专家结论为二者作用应是互相补充，二者漏、误诊比例相仿。
- 应该看到我国主攻胃肠的专家较多，他们不懈努力为我们树立榜样。
- 对胃肠造影仍持无所作为观点的人应审视一下自己的工作，是否因自己水平差，经常误、漏诊。则应该投入胃肠造影实践，并与内镜检查相互补充。

五、需要澄清的几个问题：

- 双对比检查是否费时、费劲：
- 双对比检查与单对比检查关系：
- 是否需要大型摇控机：
- 胃肠检查与其他检查关系：



六、胃肠道疾患分类：

- 1、起源于粘膜病变：炎症、溃疡、肿瘤等。
- 2、起源于粘膜下病变。
- 3、器官形态结构改变的病变。
- 4、功能改变为主病变。
- 5、腔外病变压迫。

如何选择各种检查：

- 内镜：（1、2）；
- （3、4、5）以X线检查为主，X线可作出定位、定形、定质、定性“四定”。
- **Gelfond**说：“外科医师在手术时很需要在手术室的读片灯上有一张能反映病变全貌的X线片”

七、传统的“四相技术”：



- 1. 粘膜相
- 2. 充盈相
- 3. 加压相
- 4. 对比相

八、双对比造影：（高密度钡液与低密度气体在胃肠腔内形成双对比）

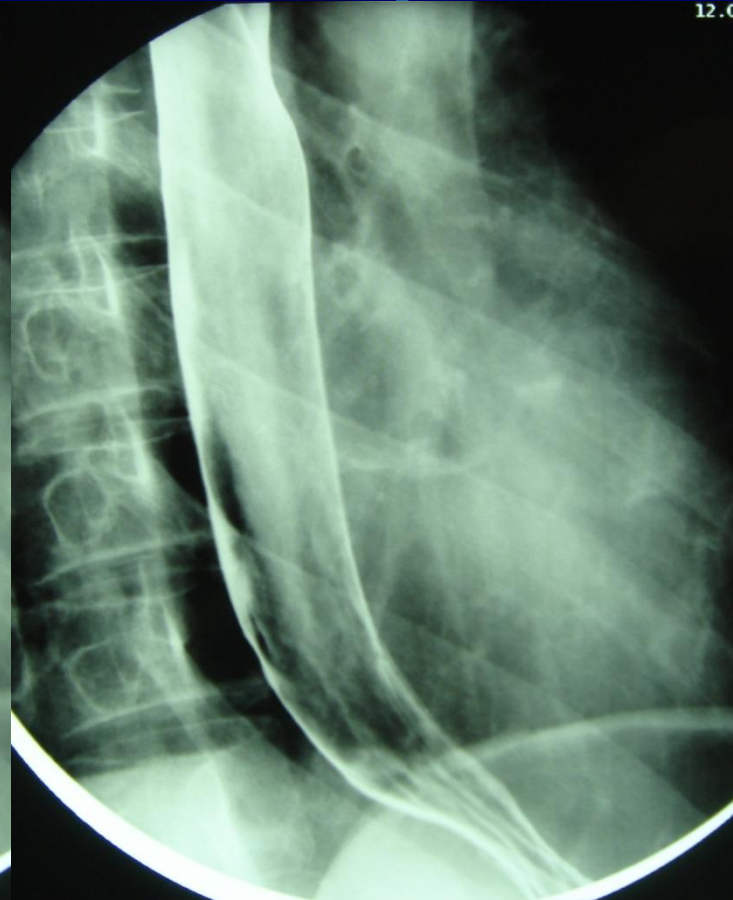
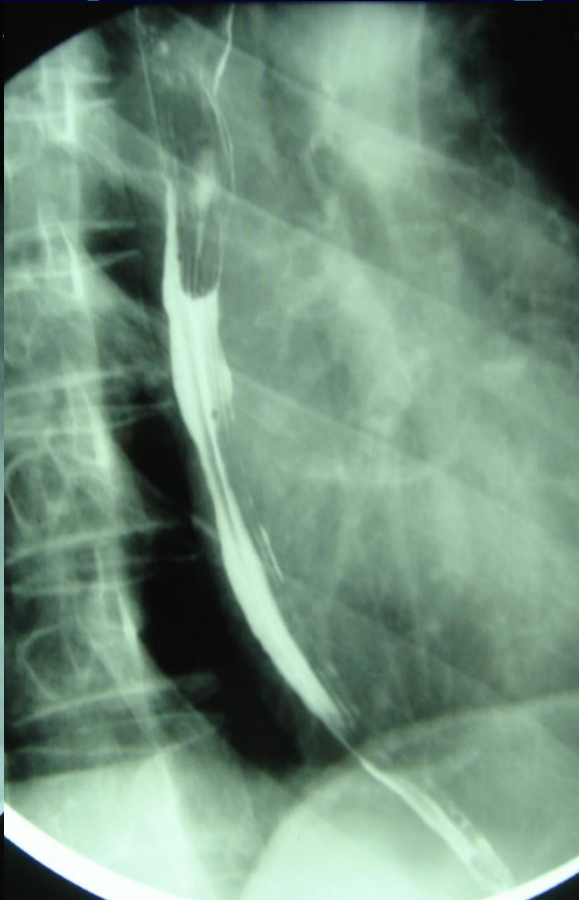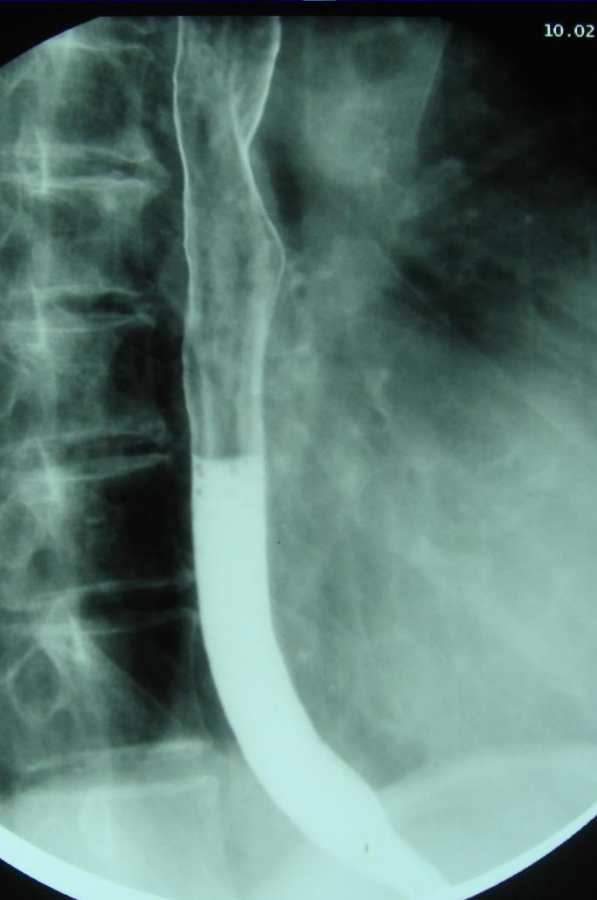
质量、技术要求：

- 1、双对比区:器官2/3
- 2、腔壁线:连续、均匀、清楚、纤细（<1mm）
- 3、囊腔扩张度:仰卧位胃角切迹至大弯之间横径7—10cm
- 4、微皱壁显示:胃小区、胃小沟、结肠无名沟
- 5、伪影:极少,无气泡凝聚。

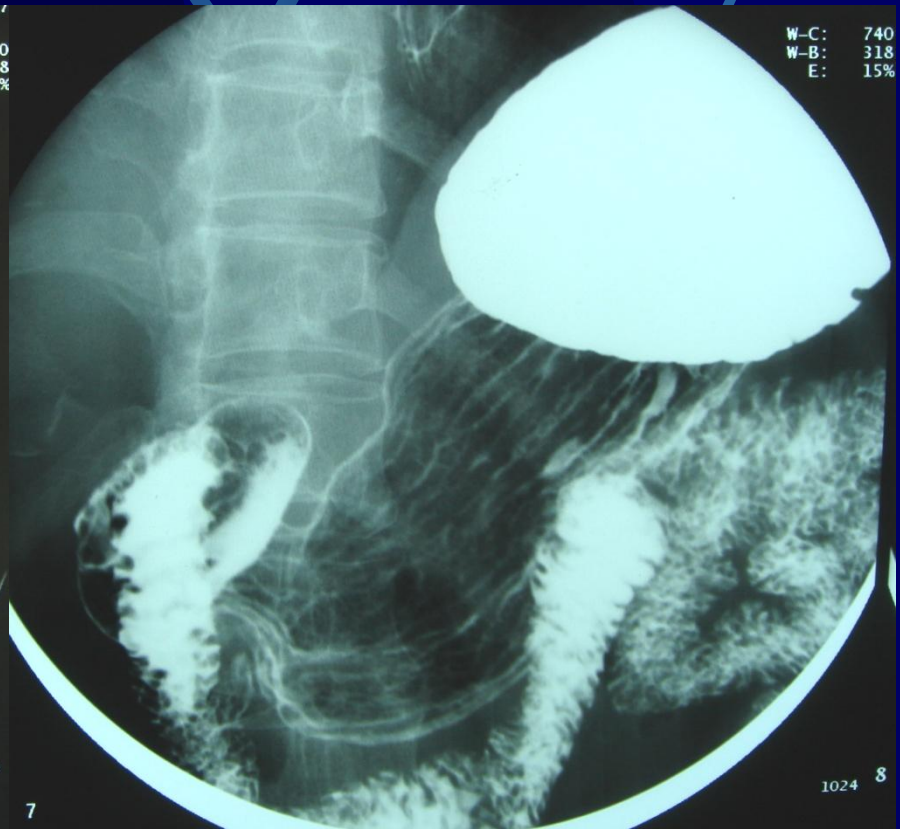
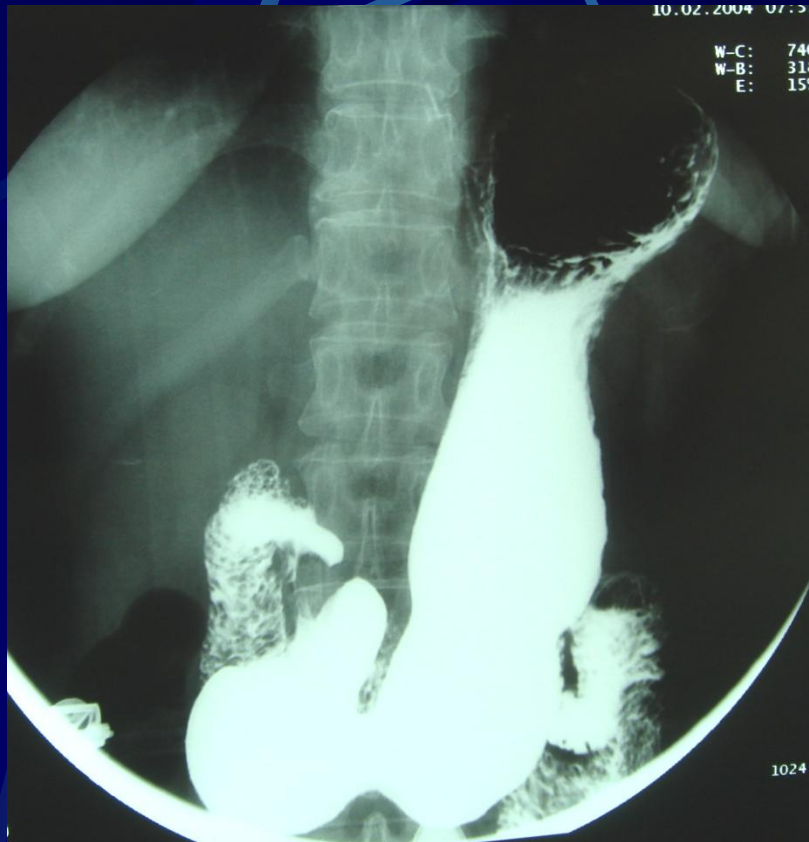
技术要求:

- 1、腔内空;
- 2、冲洗;
- 3、涂布;
- 4、流动显示;
- 5、分区显示;
- 6、检查时间。

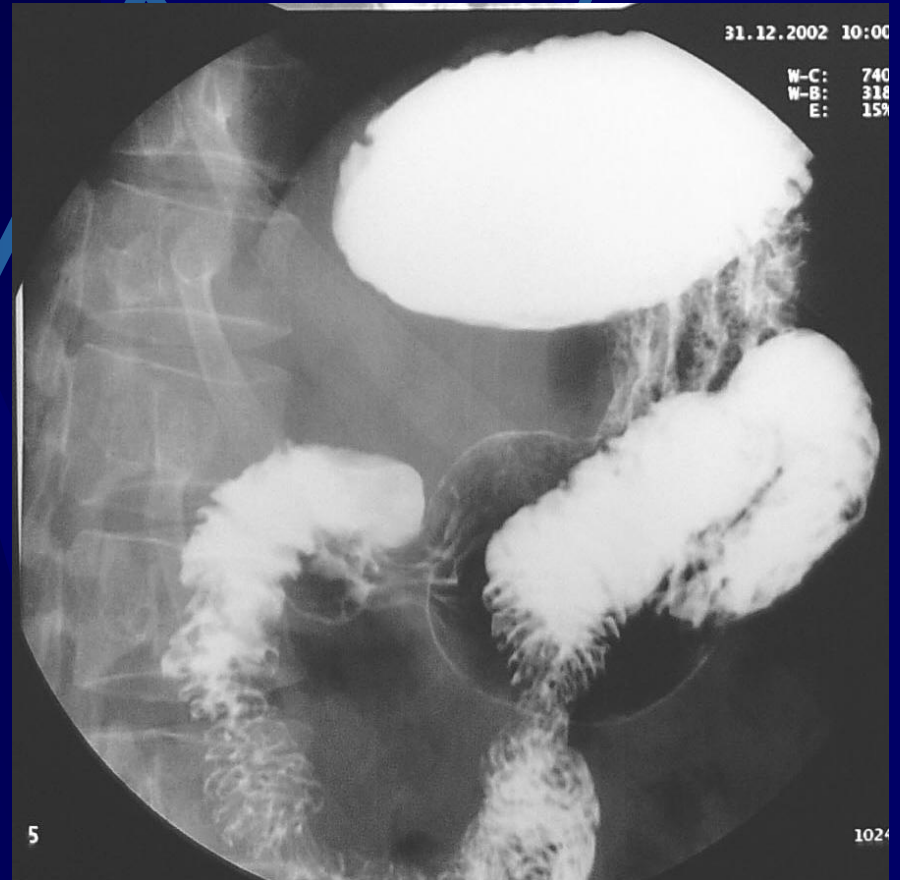
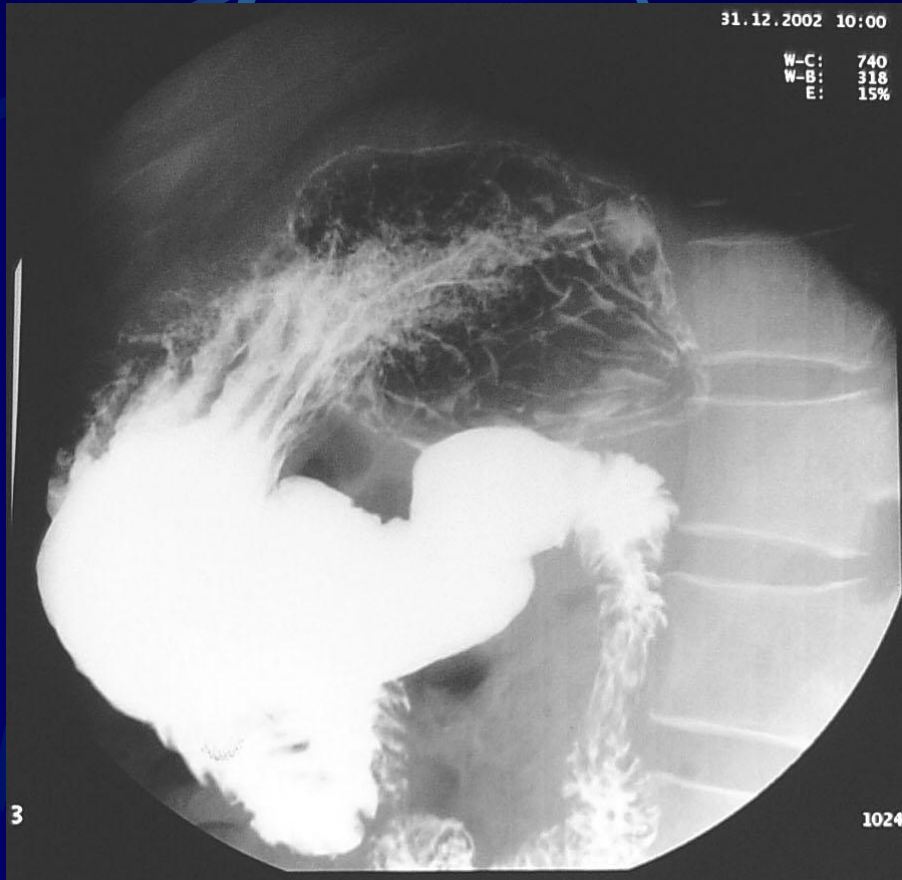正常消化道造影表现



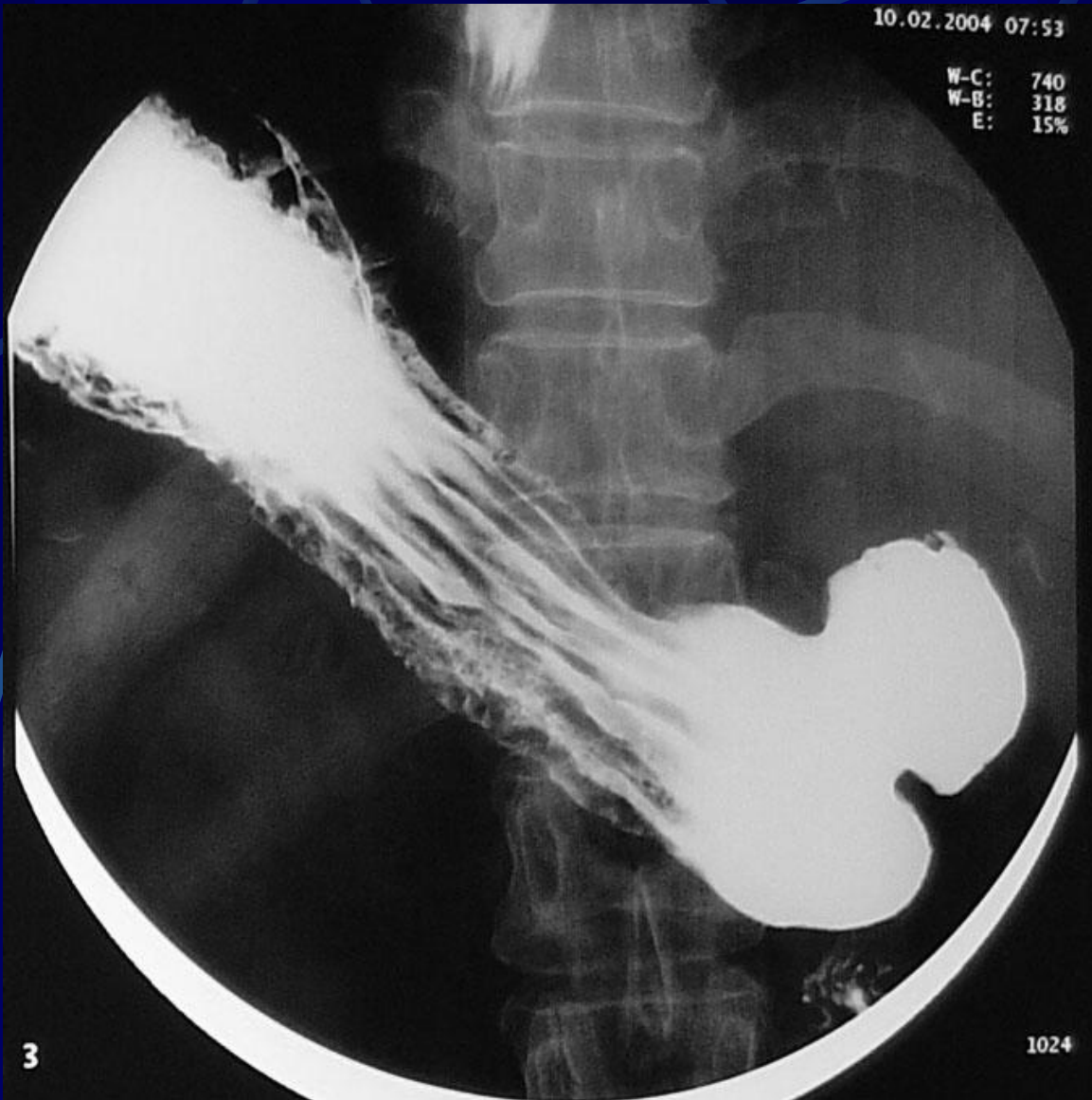正常消化道造影表现



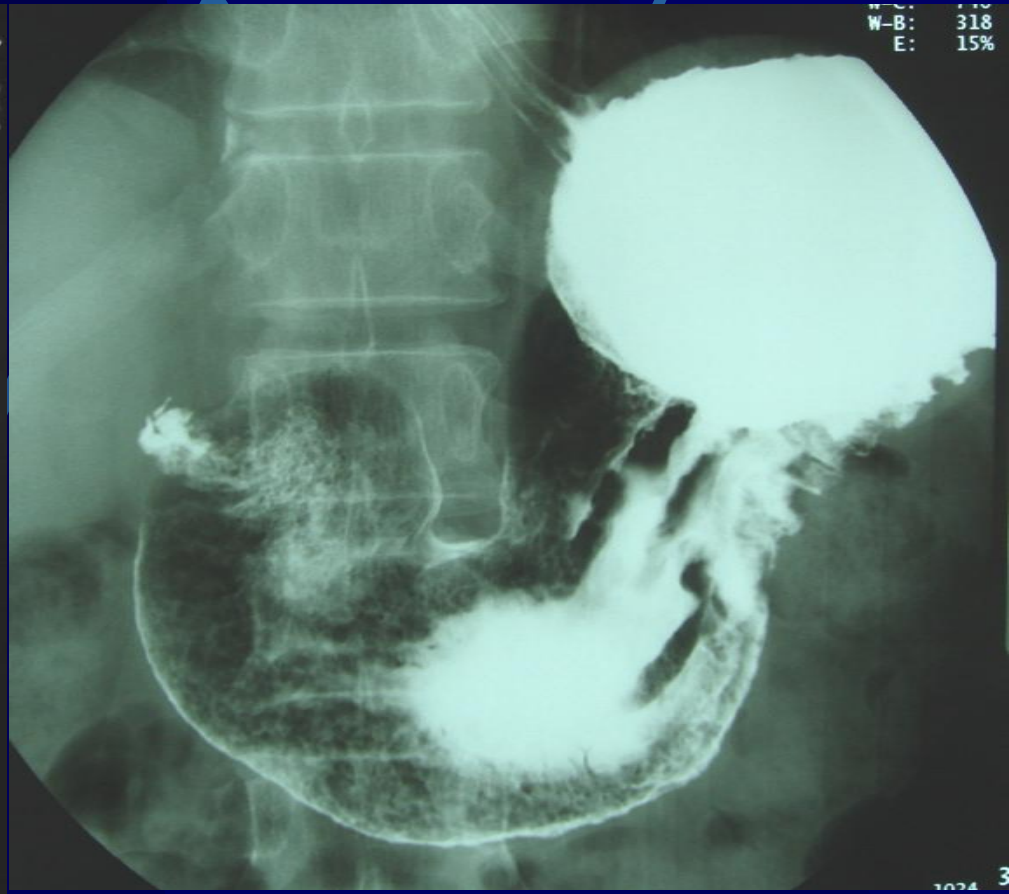
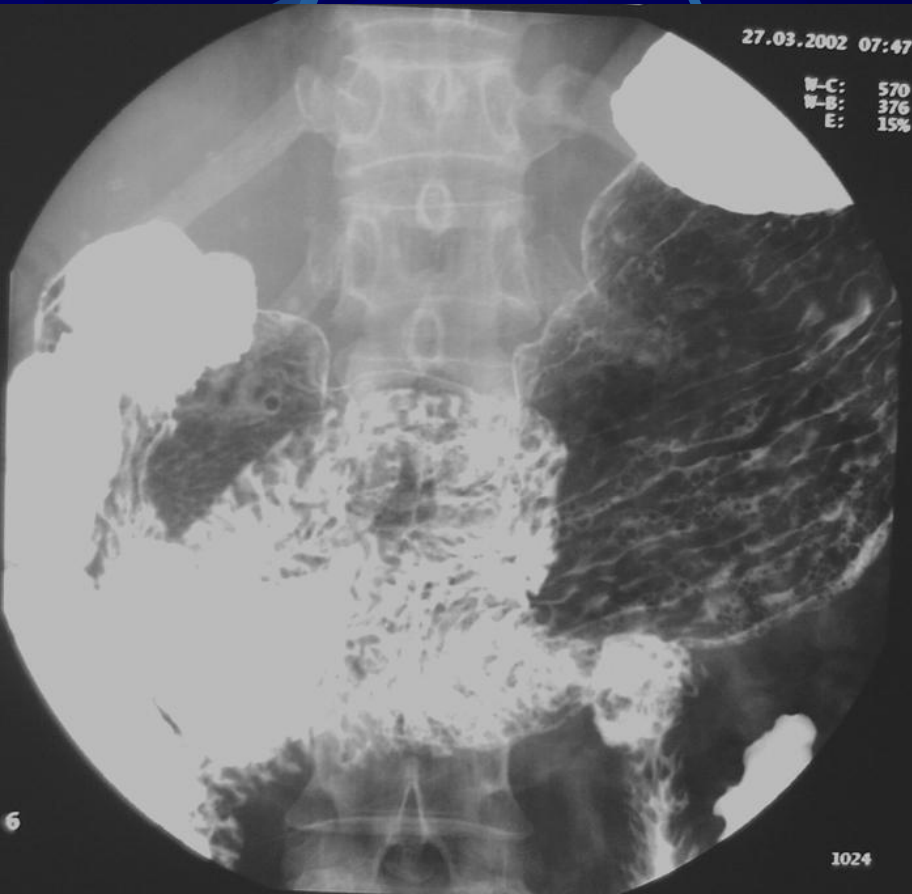正常消化道造影表现



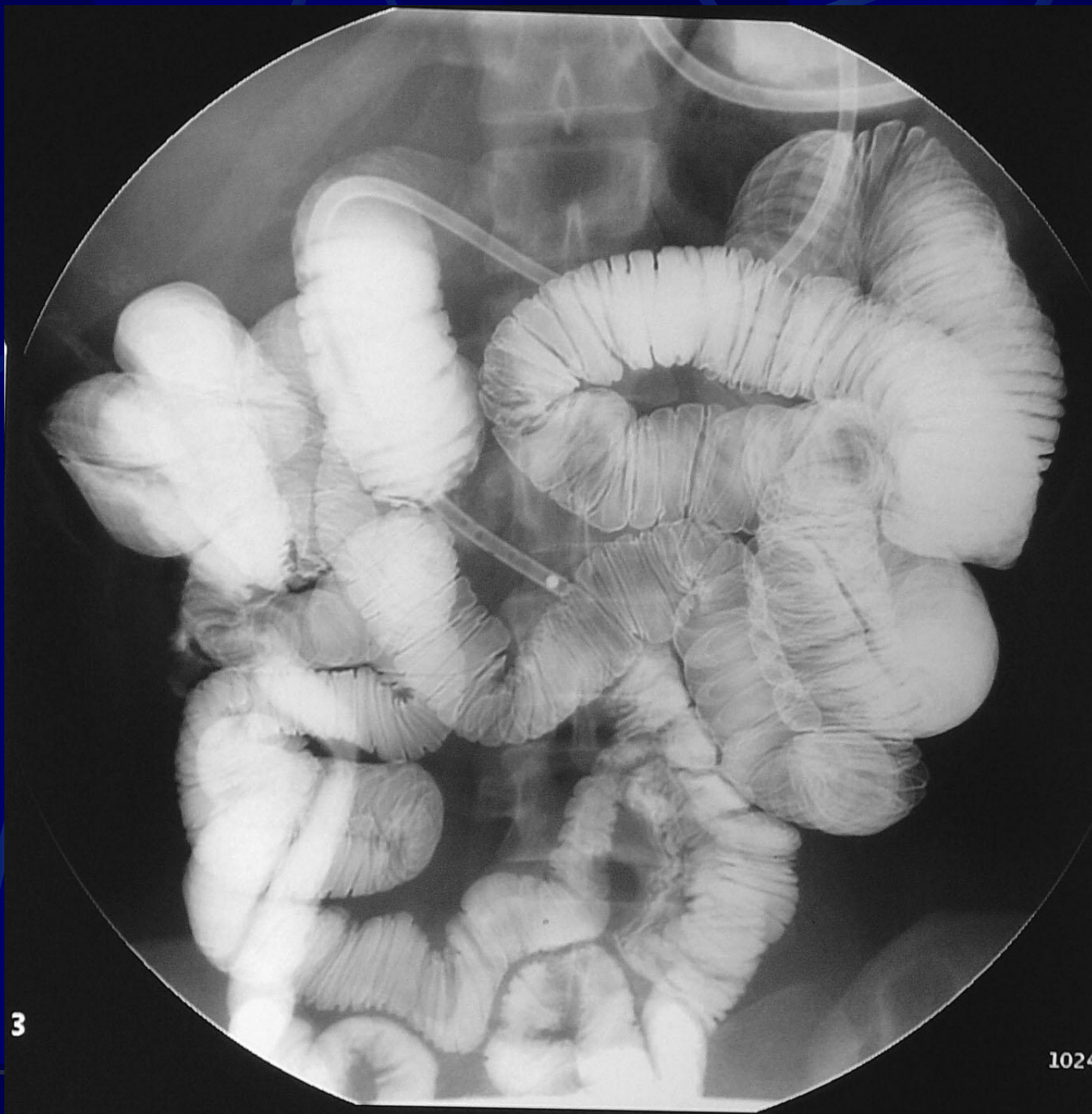正常消化道造影表现



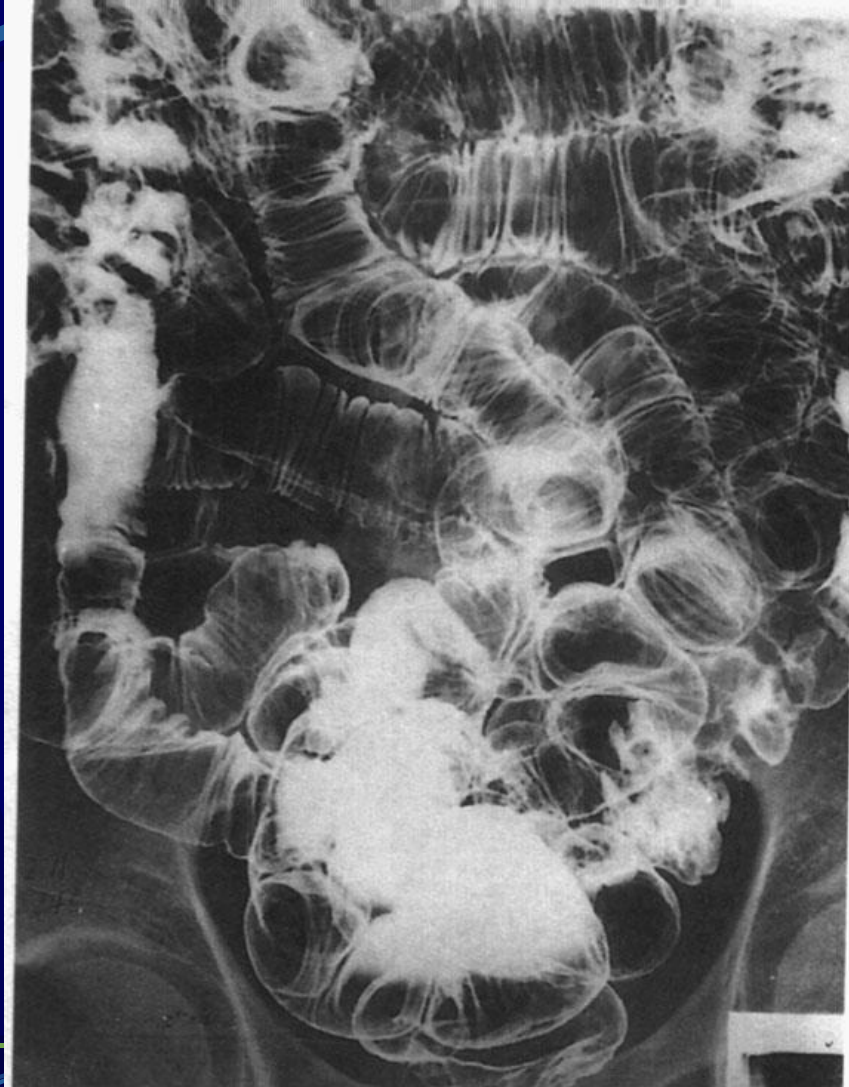
正常消化道造影表现



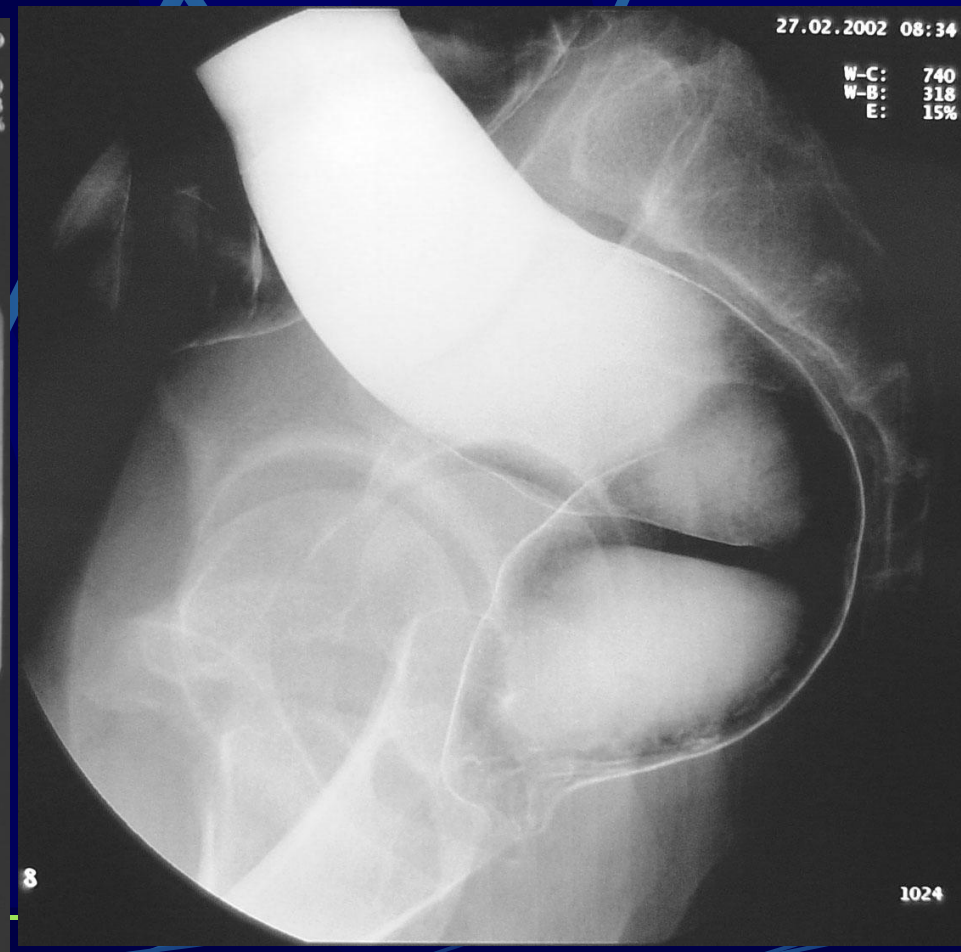
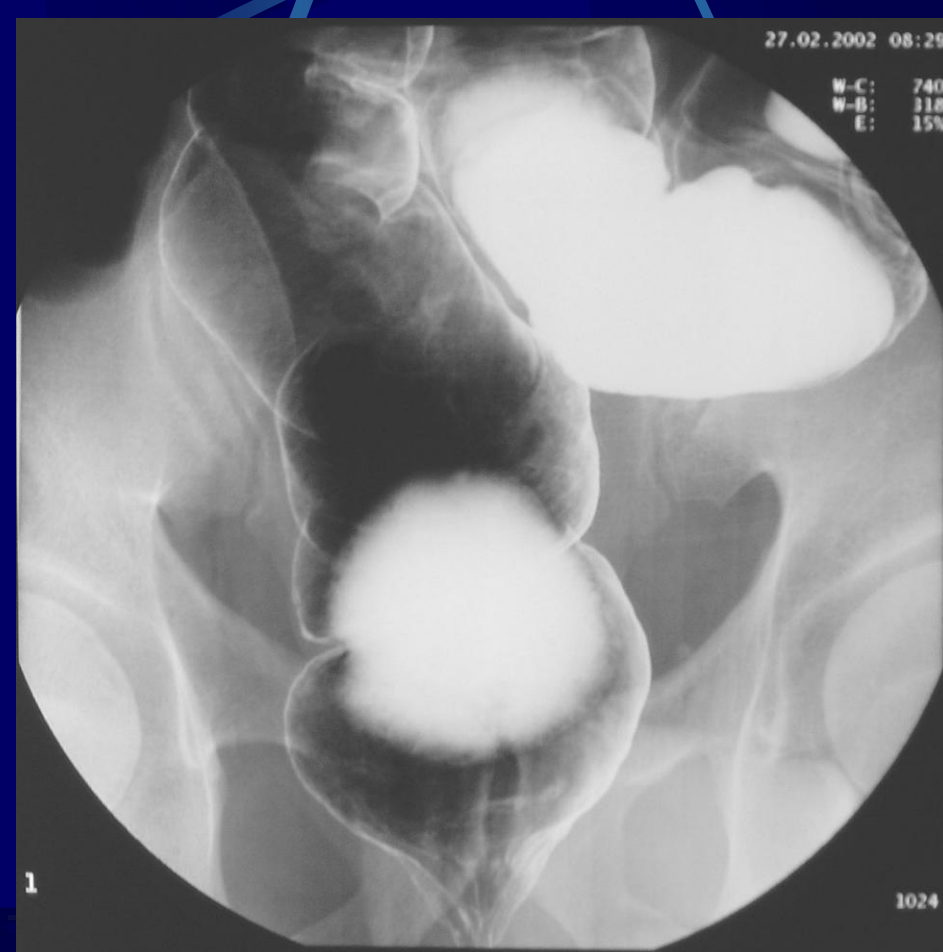正常消化道造影表现



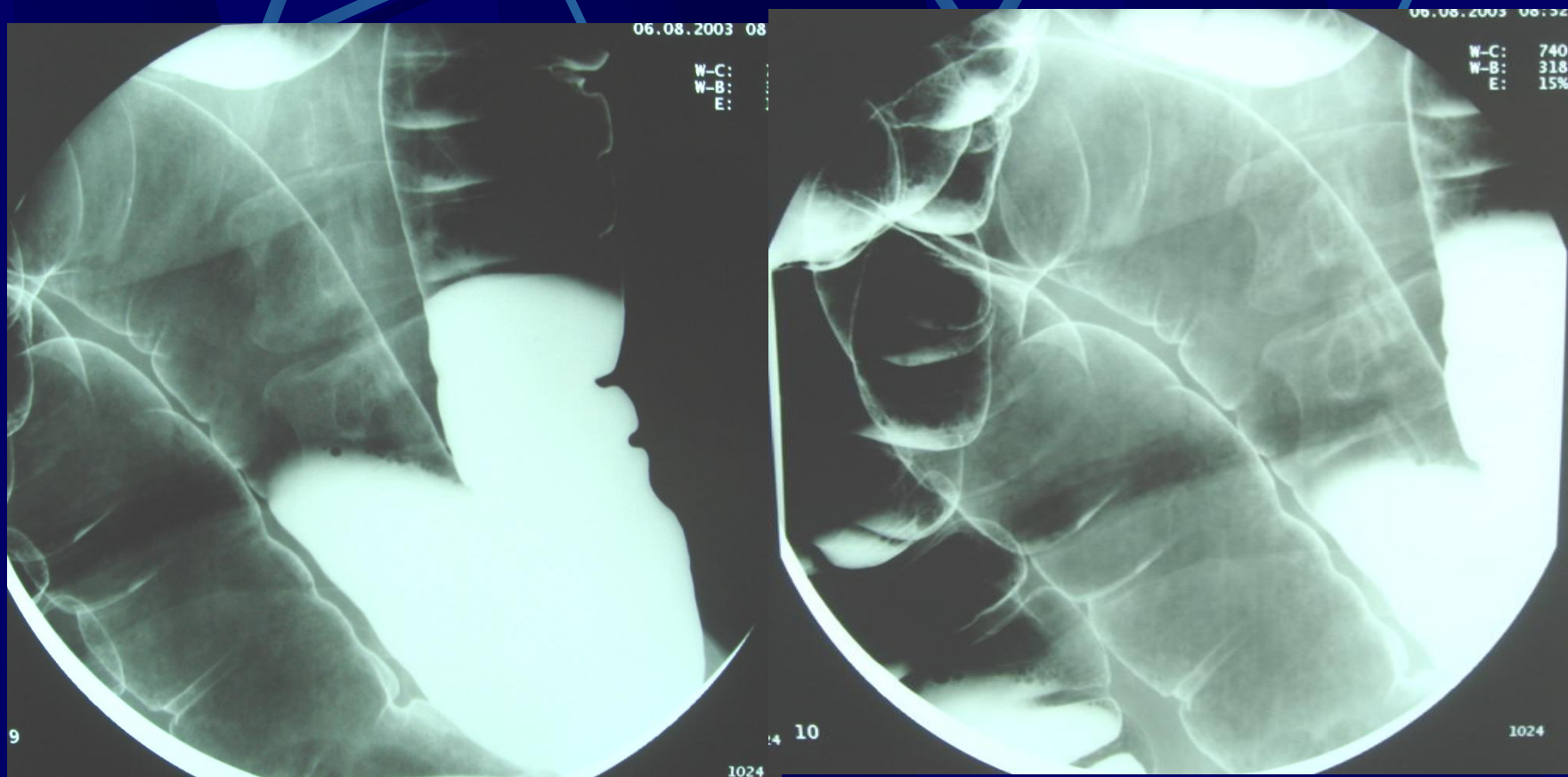
正常消化道造影表现



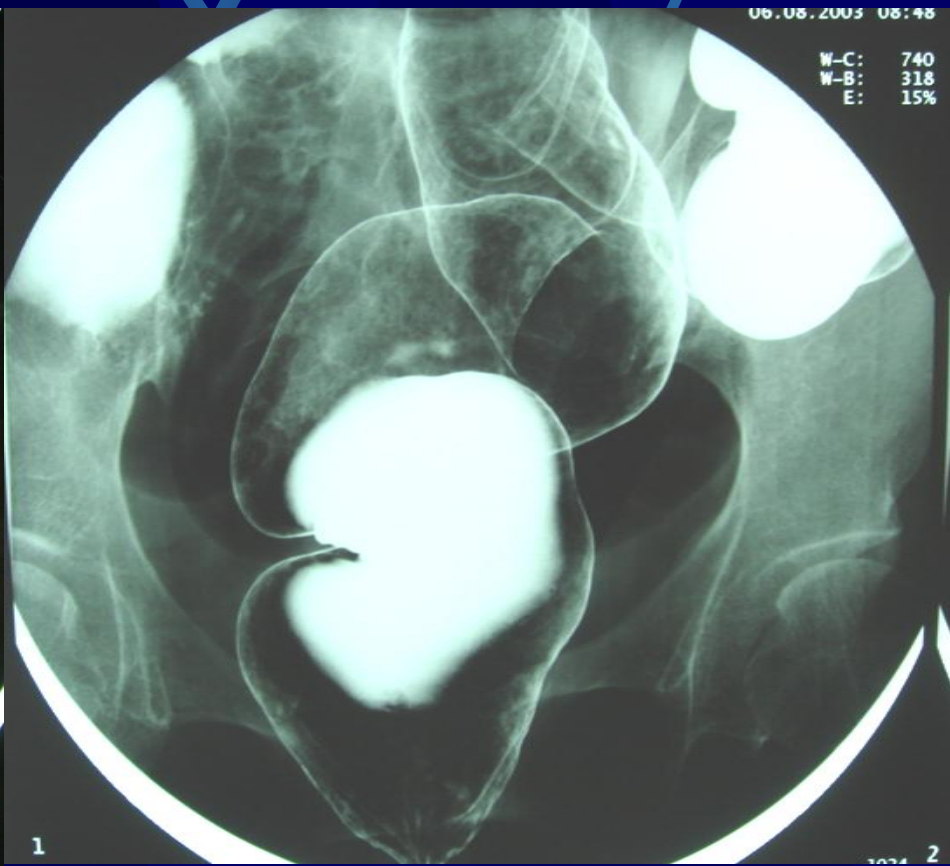
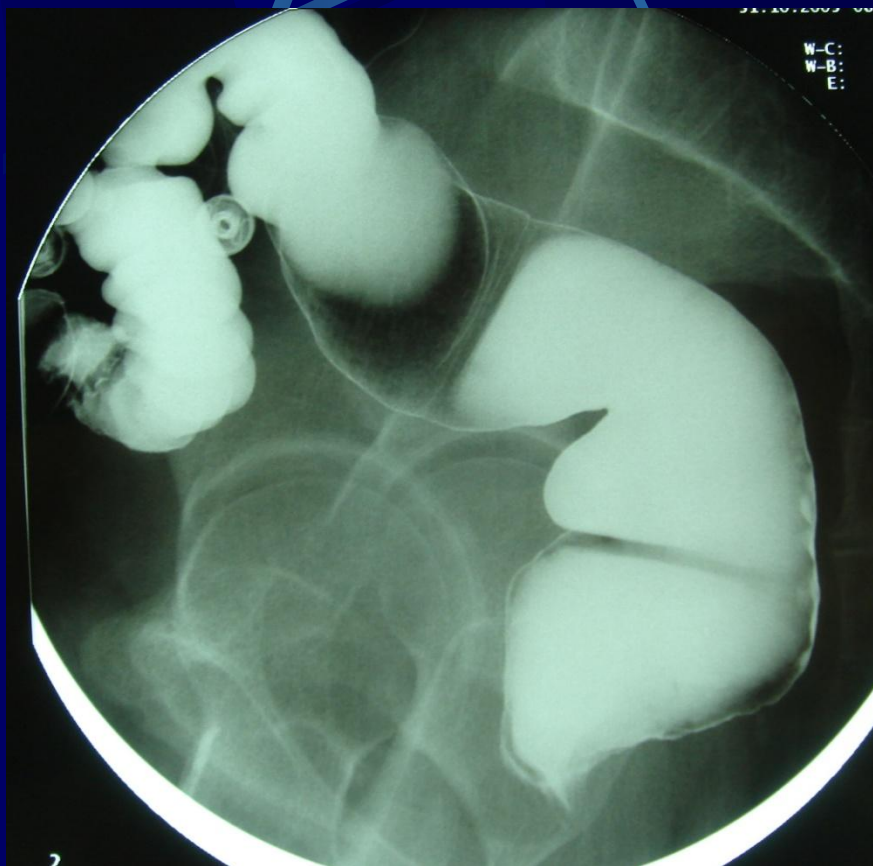
正常消化道造影表现

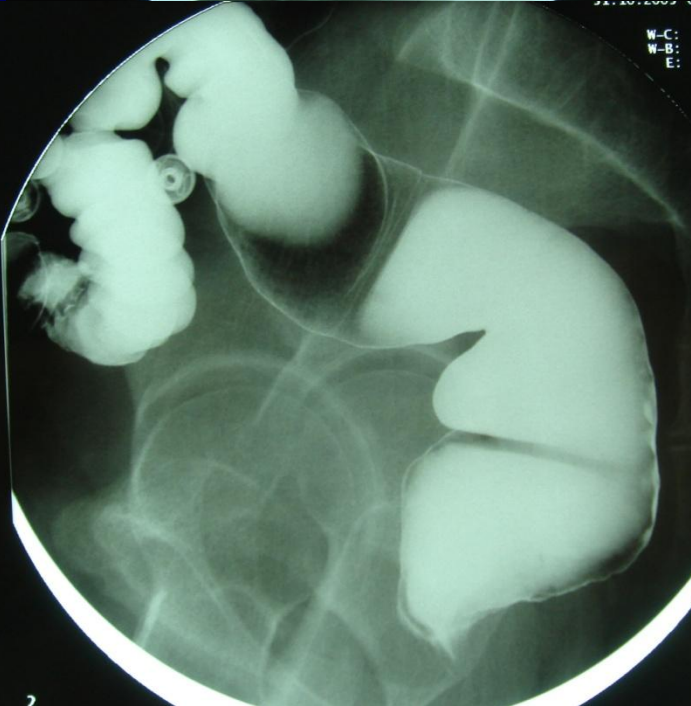
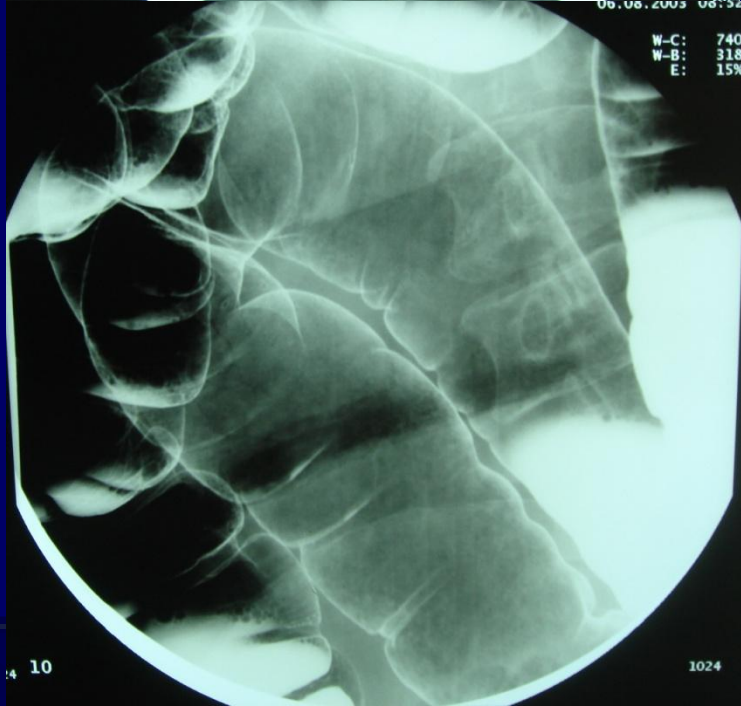
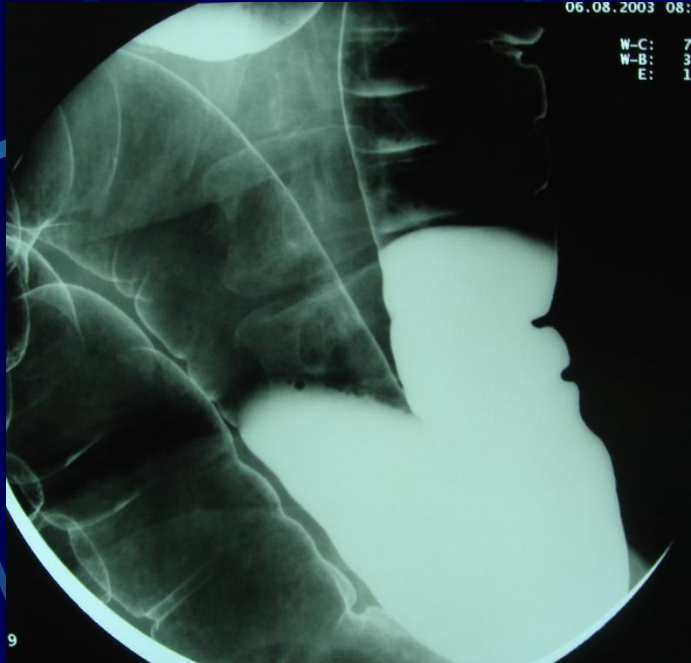
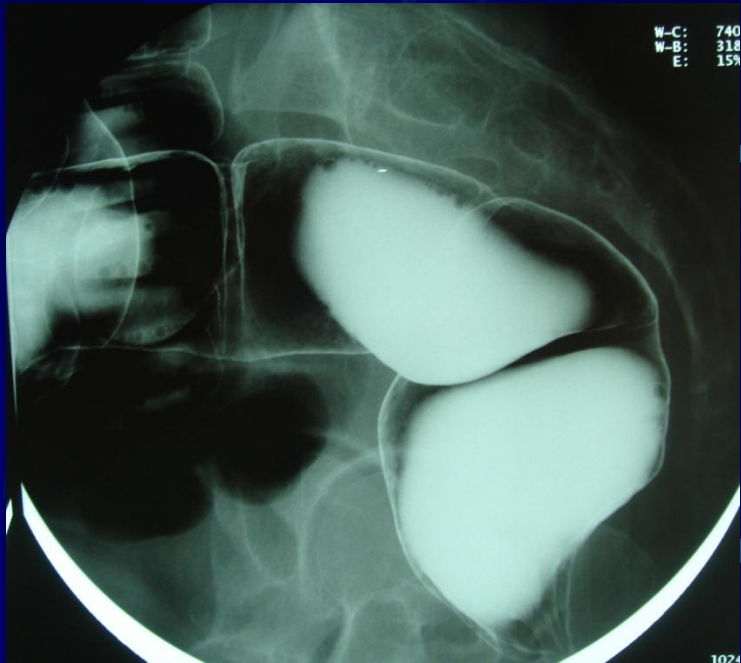


正常消化道造影表现

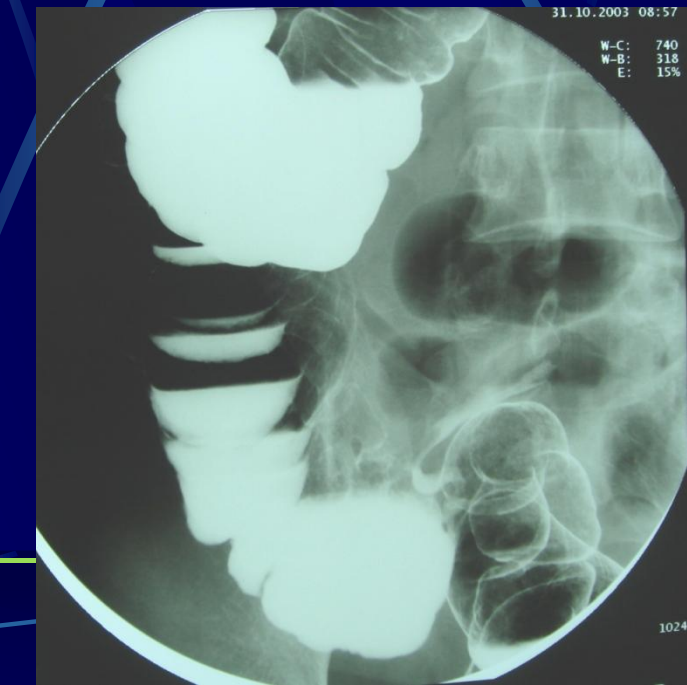
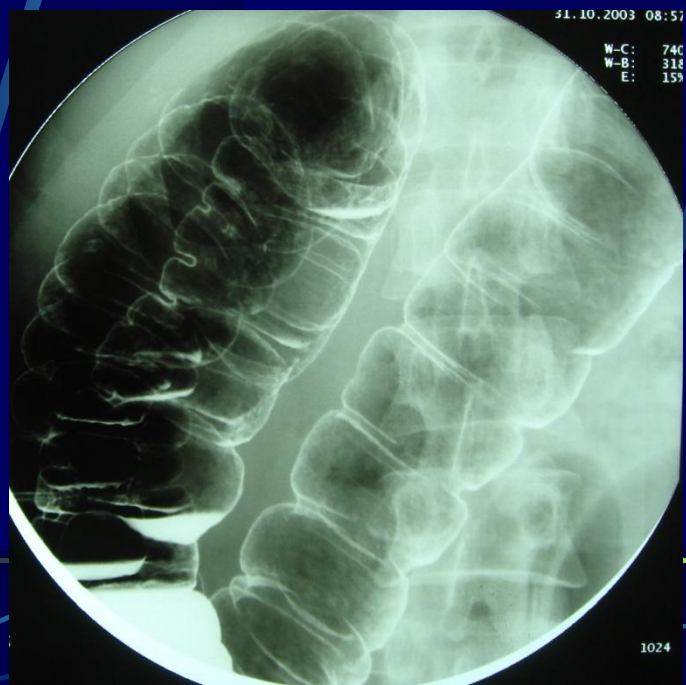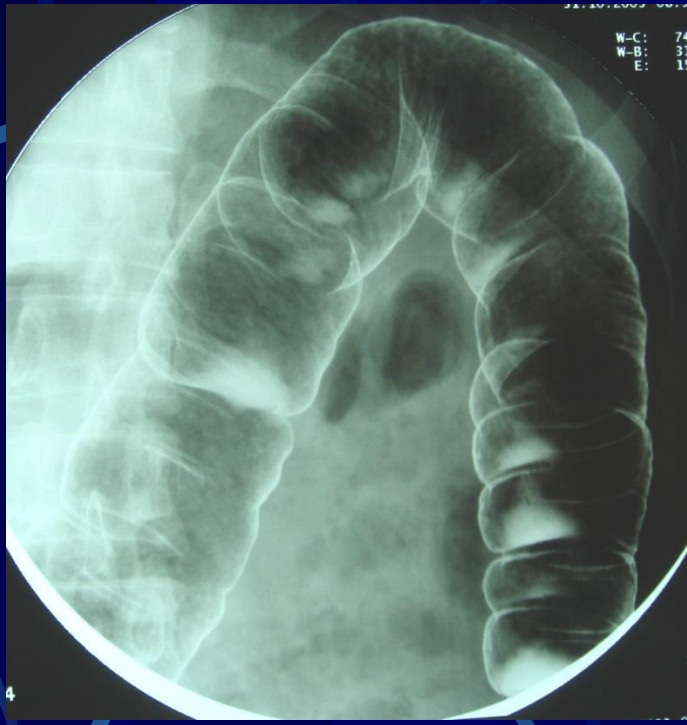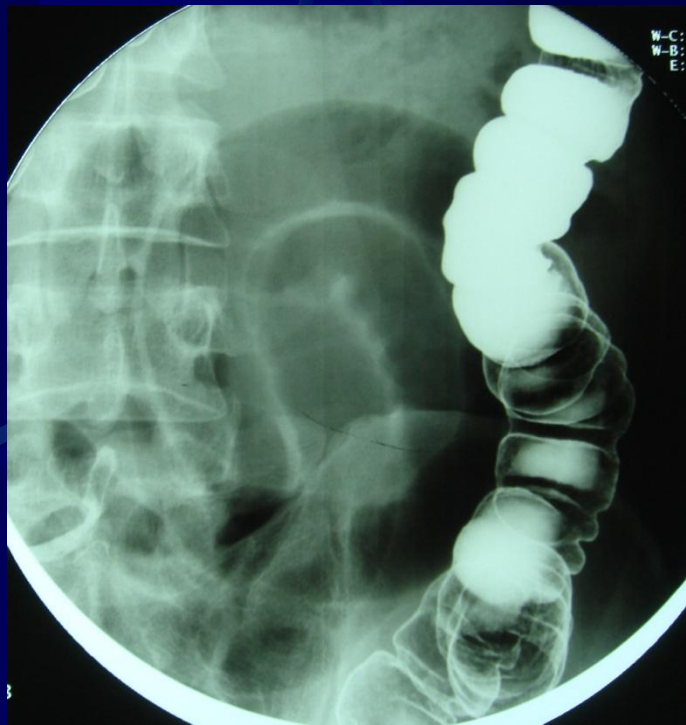


正常消化道造影表现





正常消化道造影表现



正常消化道造影表现

常见上消化道病变



食管静脉曲张

检查要点：

1.位置。

2.摄片时相。

3.深吸、呼后屏气

。



食管静脉曲张

轻度:

- 1.位于下段
- 2.粘膜稍增宽、迂曲
- 3.管腔边缘呈浅锯齿样
- 4.管腔可收缩

食管静脉曲张

中度：

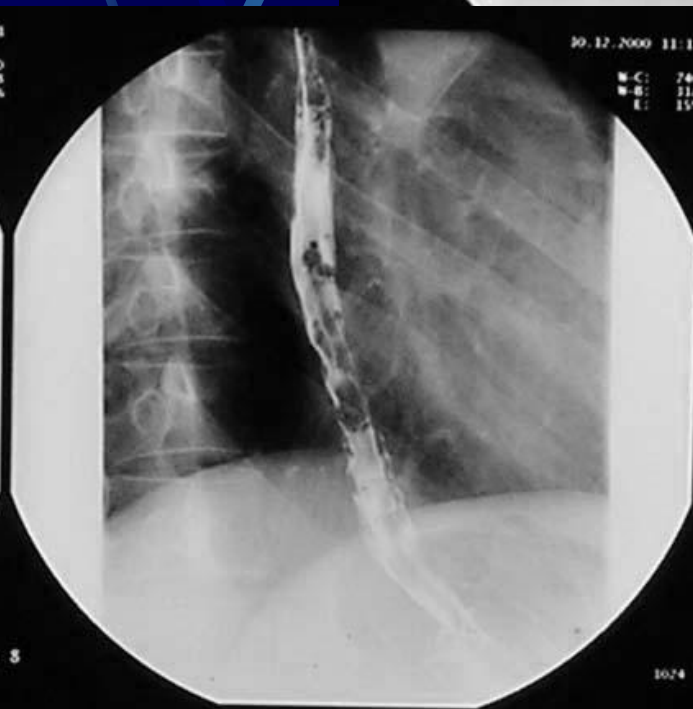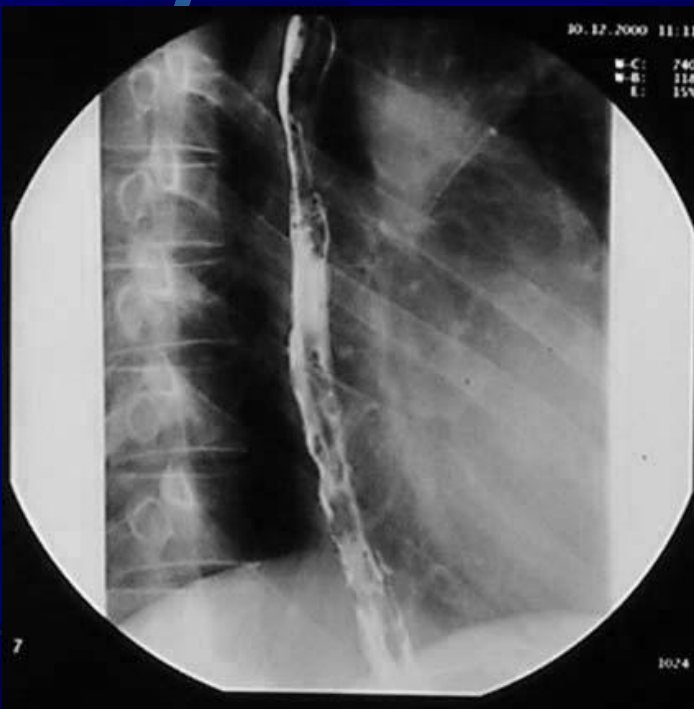
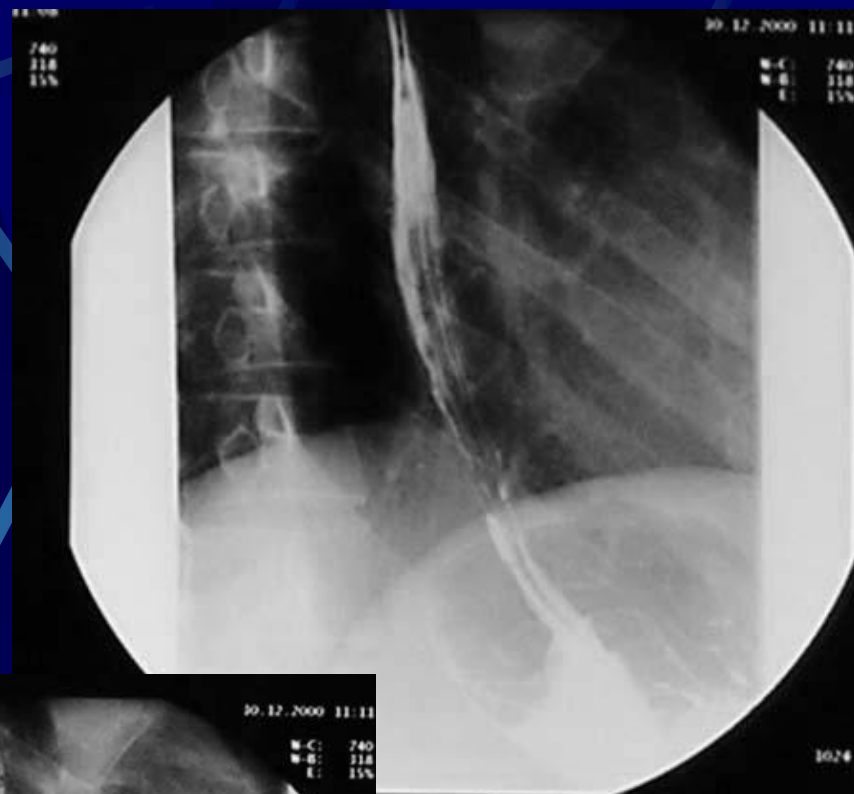- 1.位于中下段
- 2.粘膜增粗、迂曲，串珠样、蚯蚓样
- 3.管腔边缘凹凸不平
- 4.管腔收缩功能差

食管静脉曲张

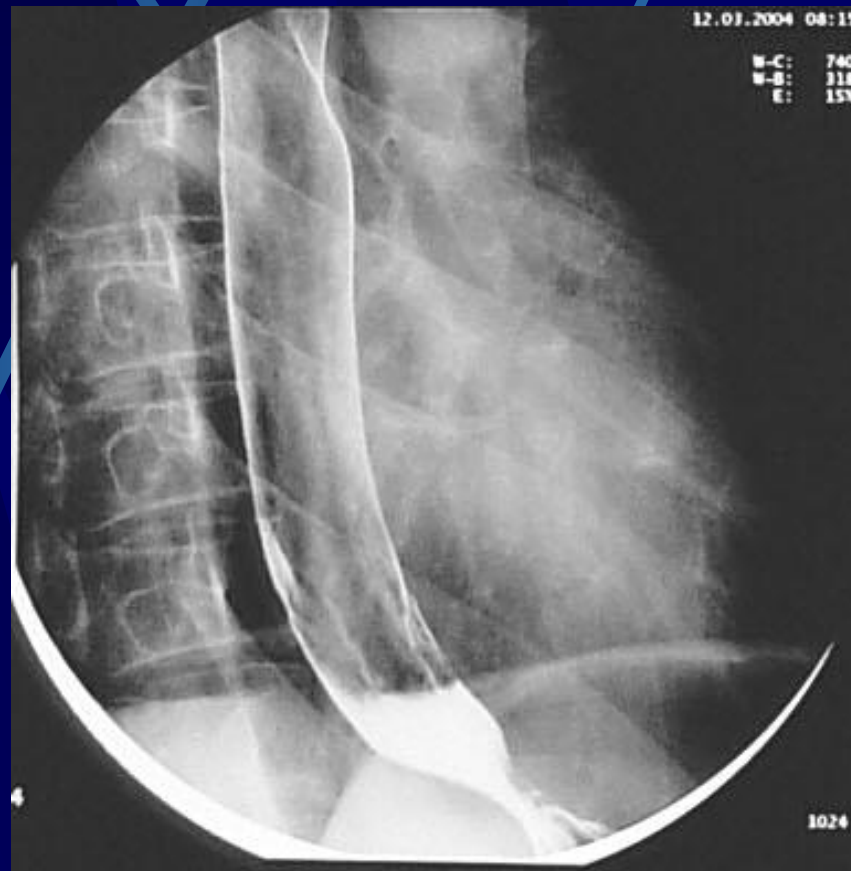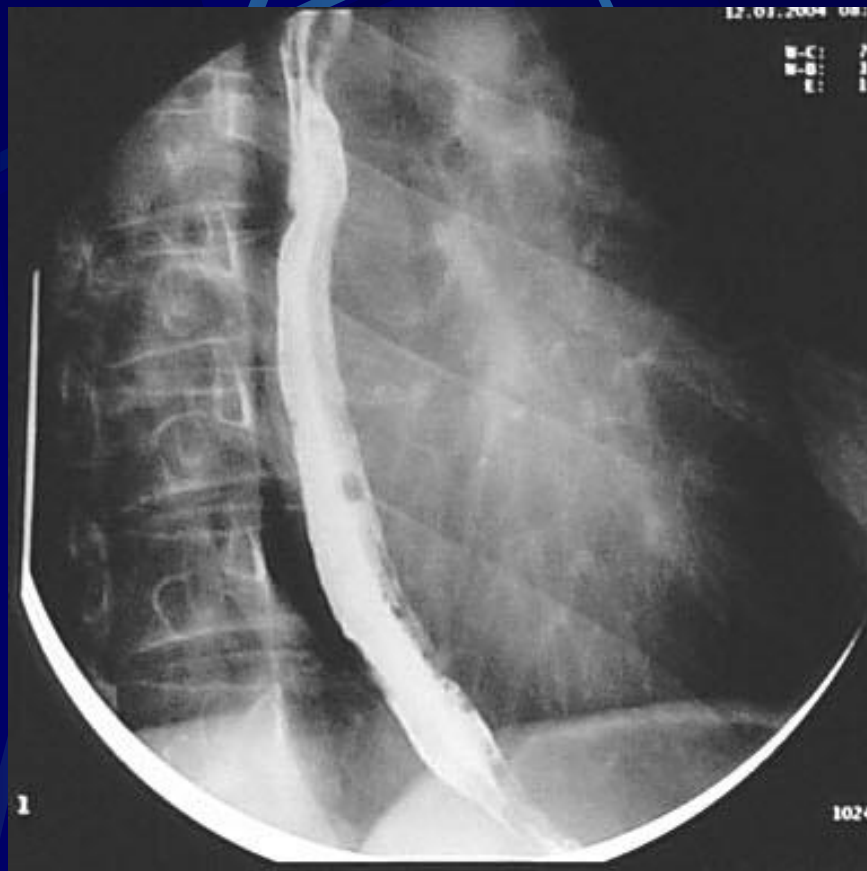重度：

- 1.位置扩展到中上段
- 2.腔内可见圆形、环状、串珠状充盈缺损
- 3.管壁呈虫蚀状、曲链状
- 4.管壁蠕动减弱，排空延迟

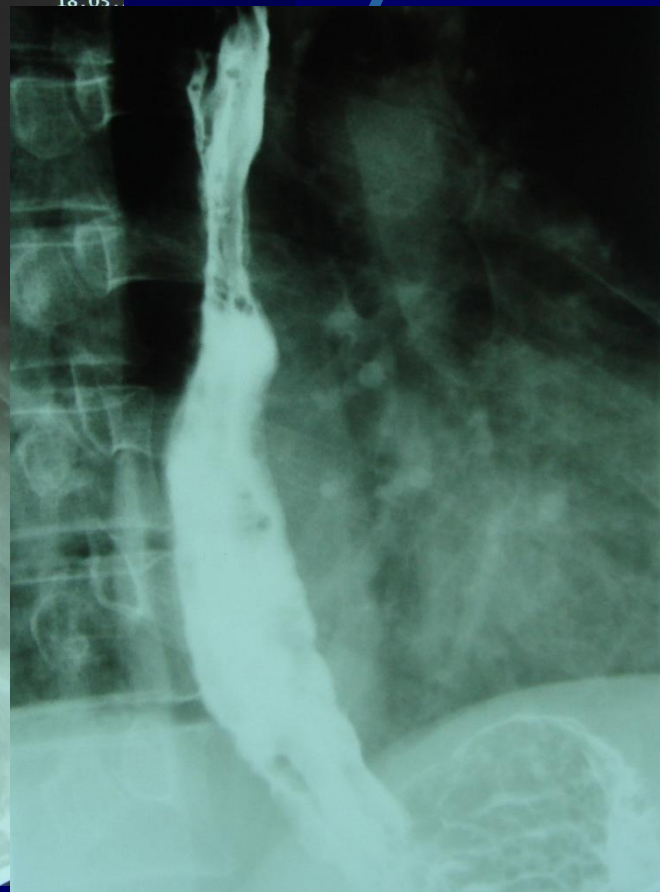
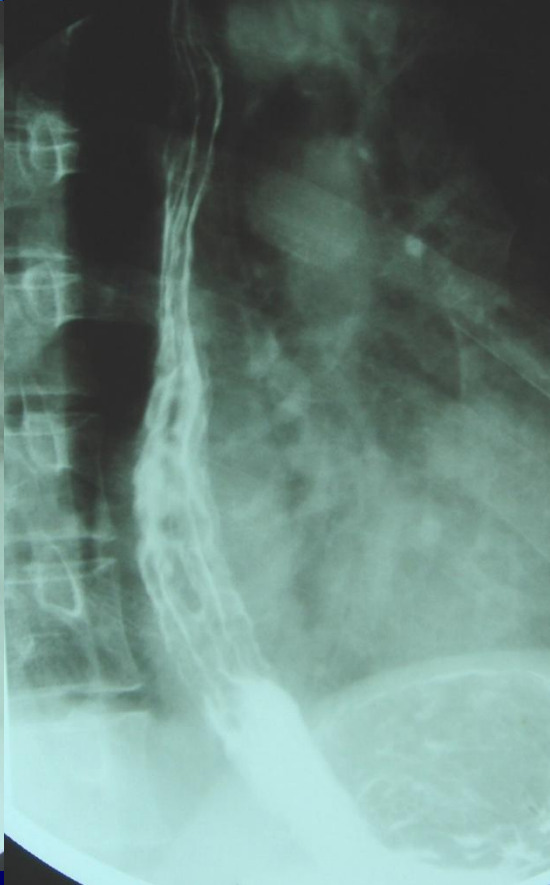
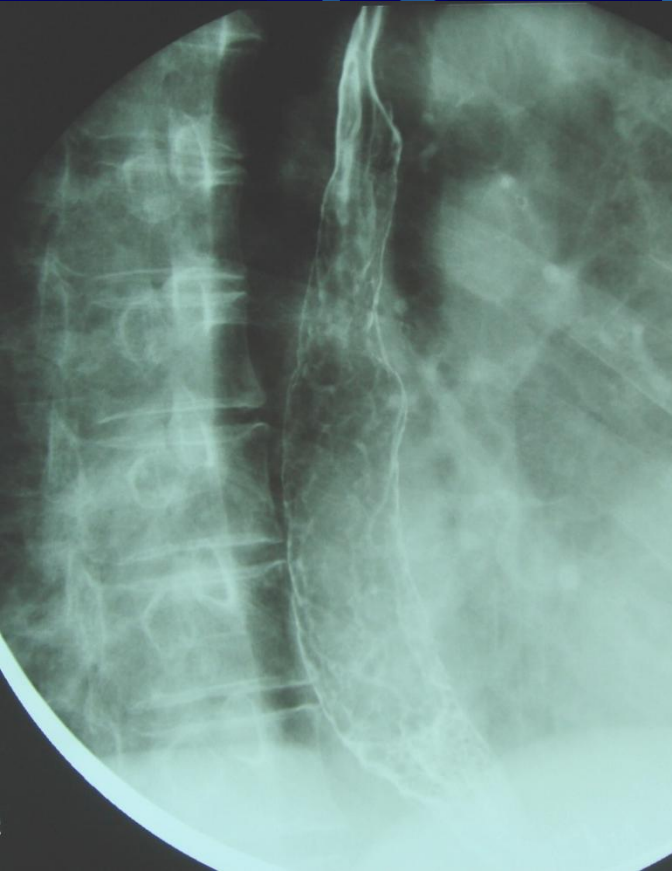
食管静脉曲张 (病例1)



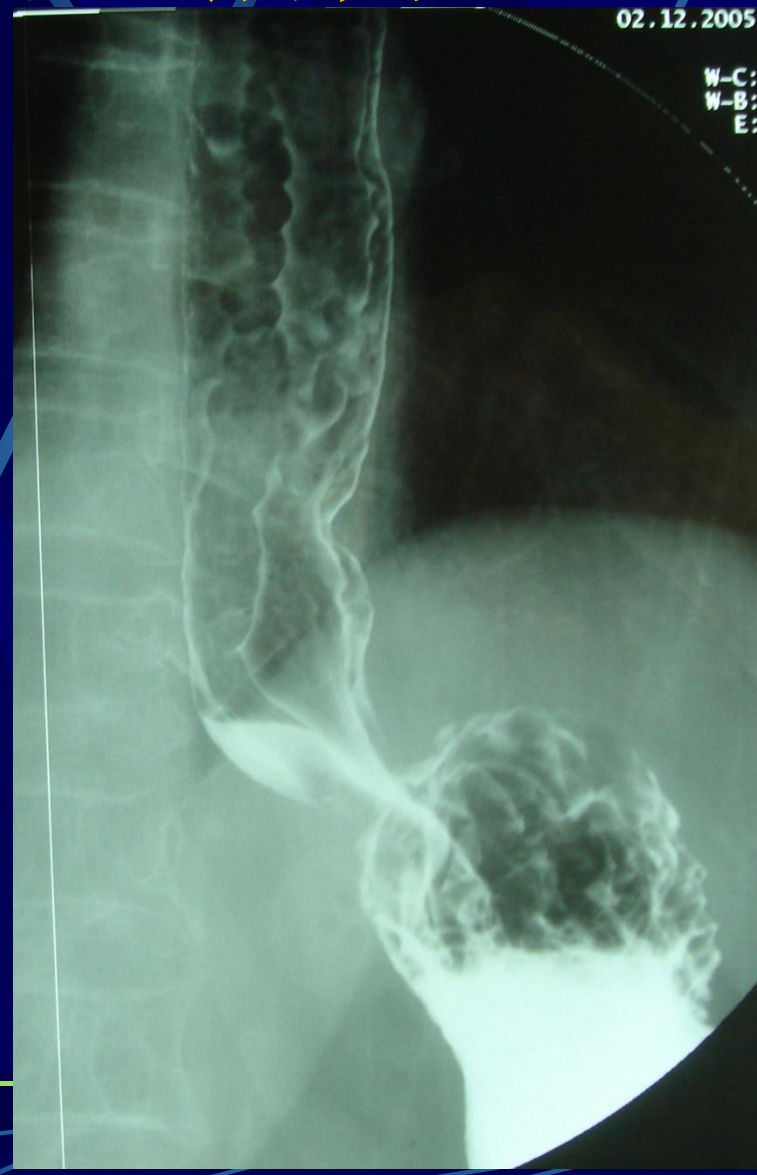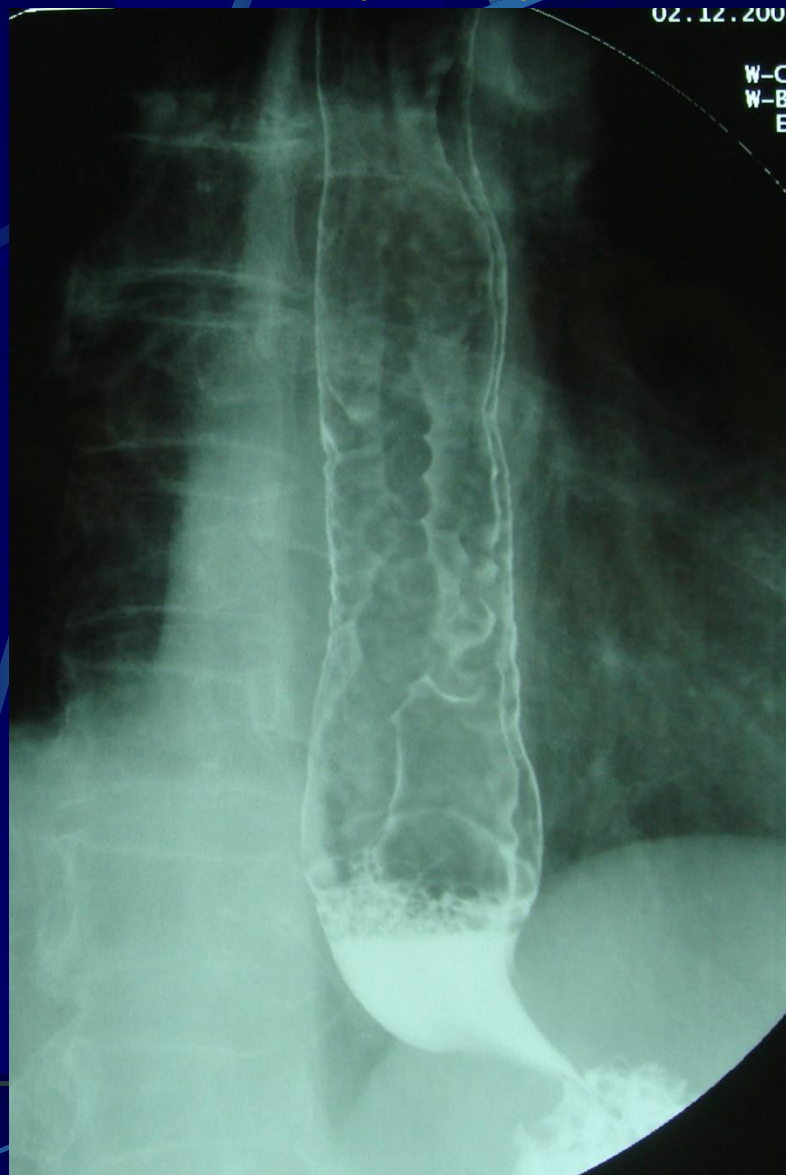
食管静脉曲张（病例2）



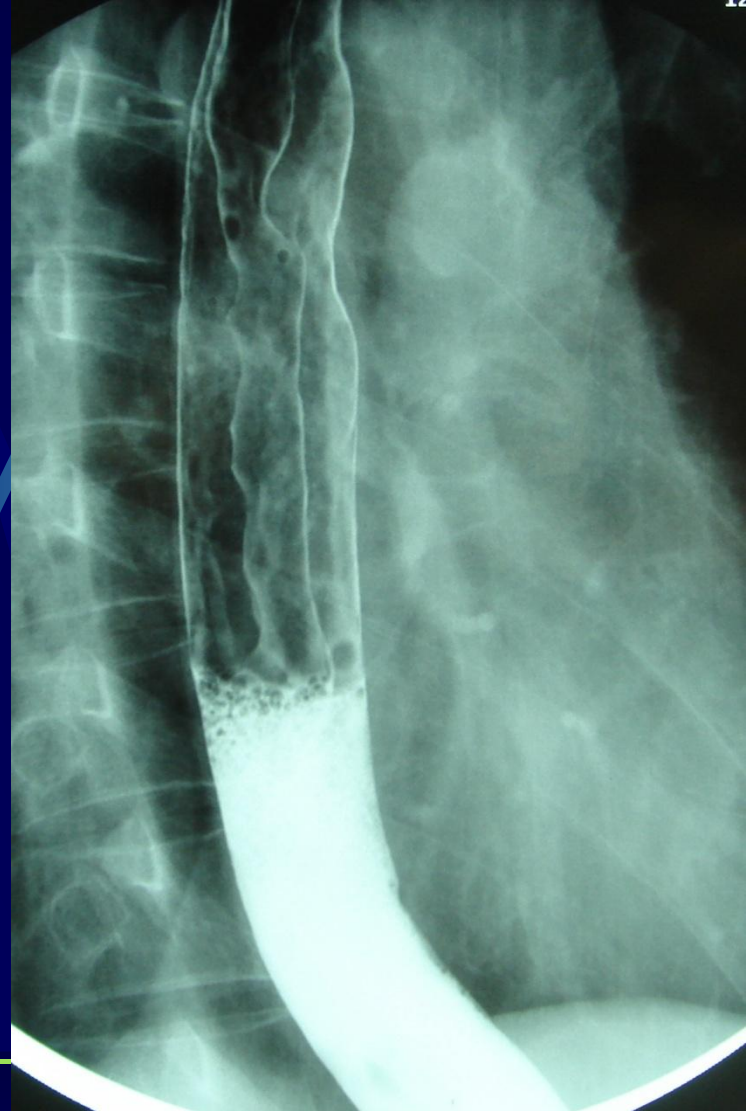
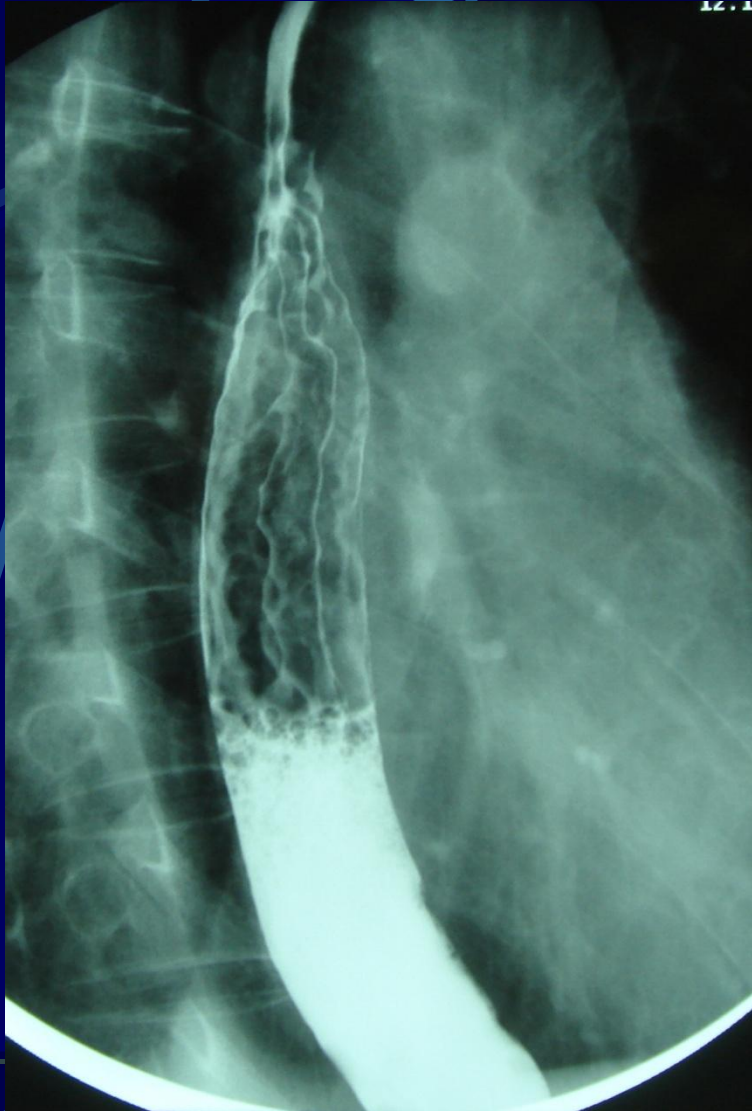
食管静脉曲张（病例3）



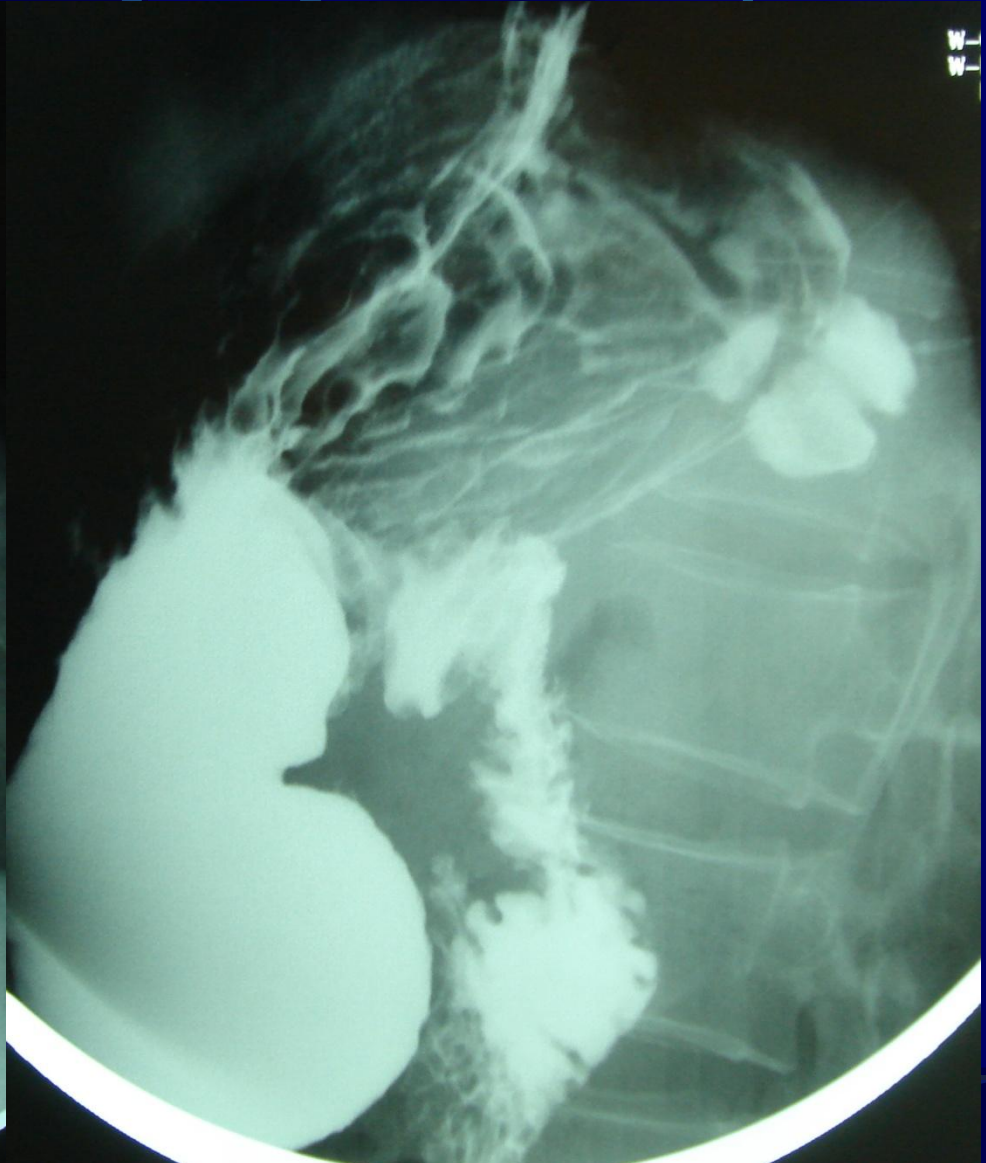
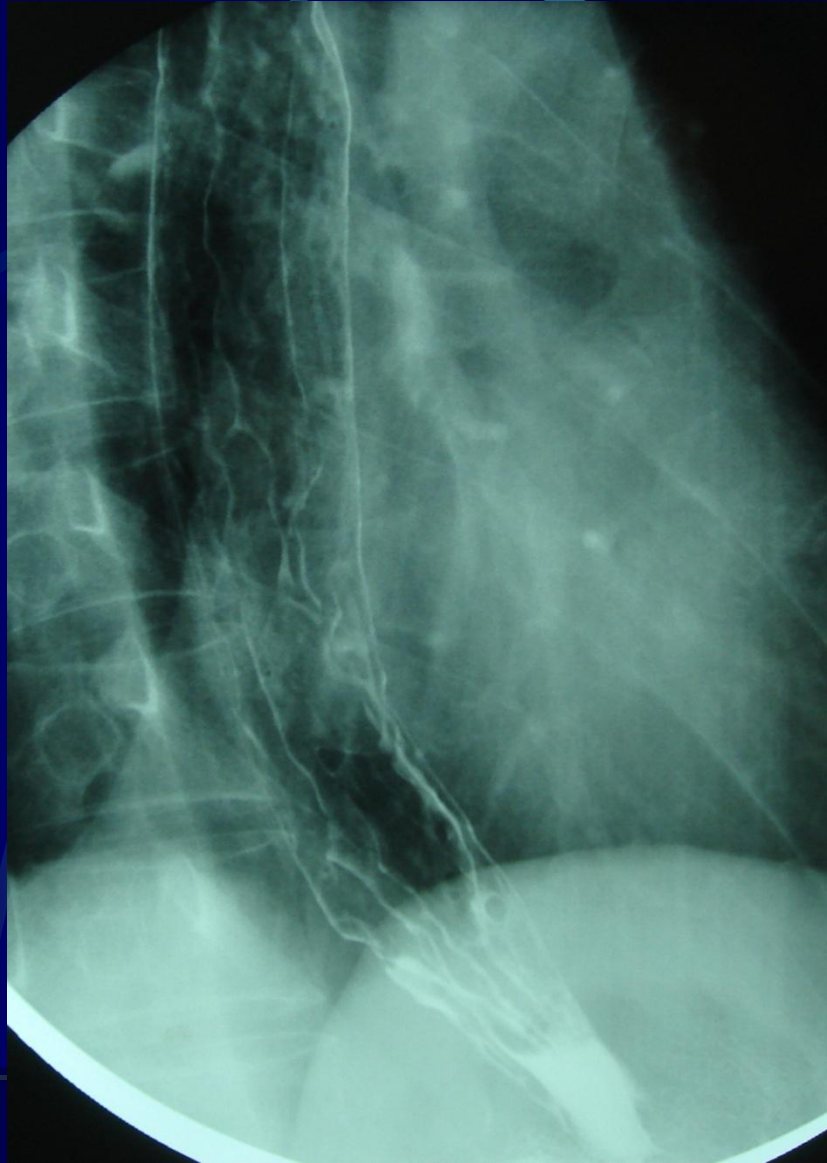
食管静脉曲张（病例4）



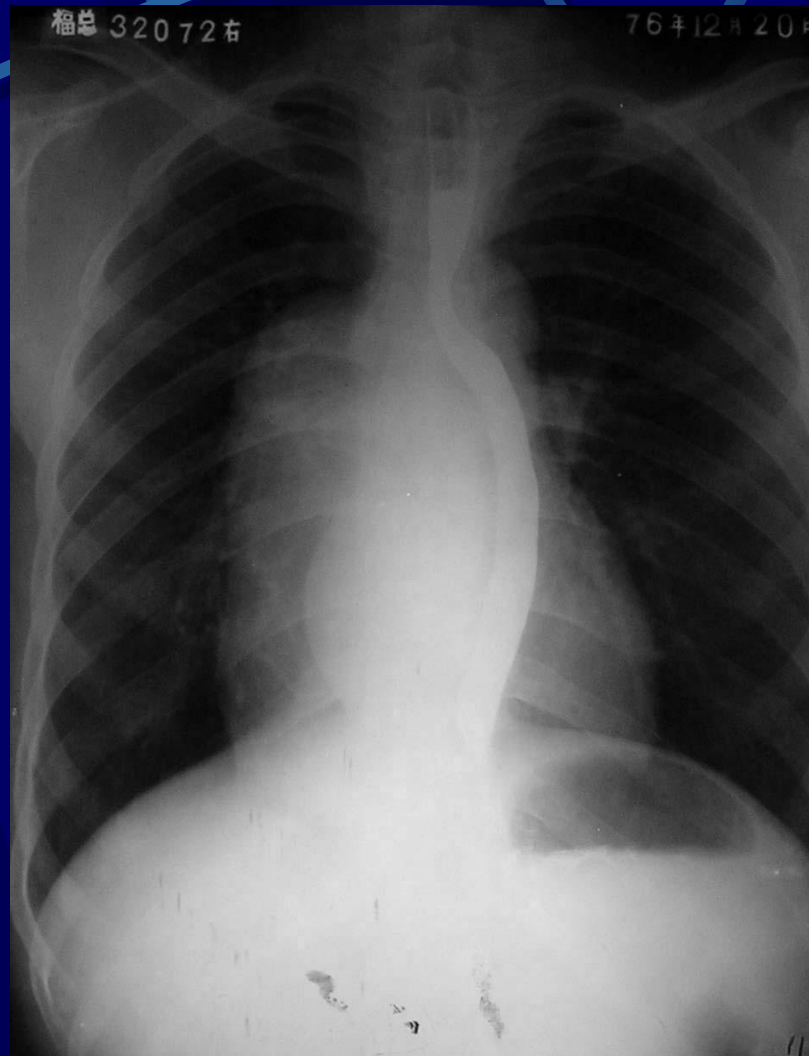食管静脉曲张（病例5）



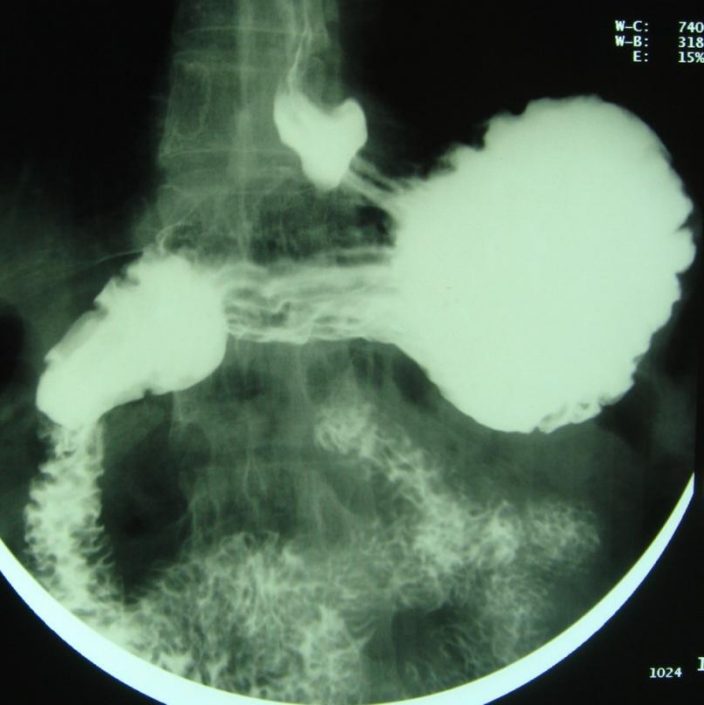
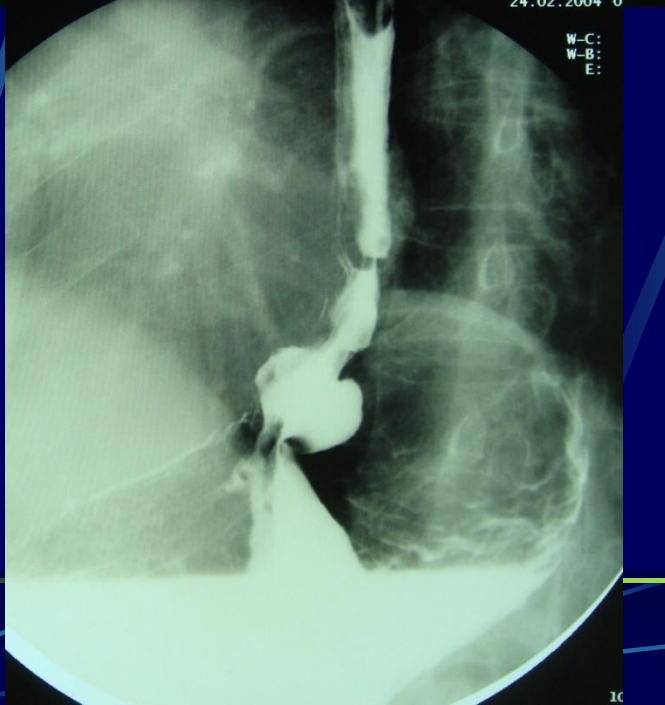
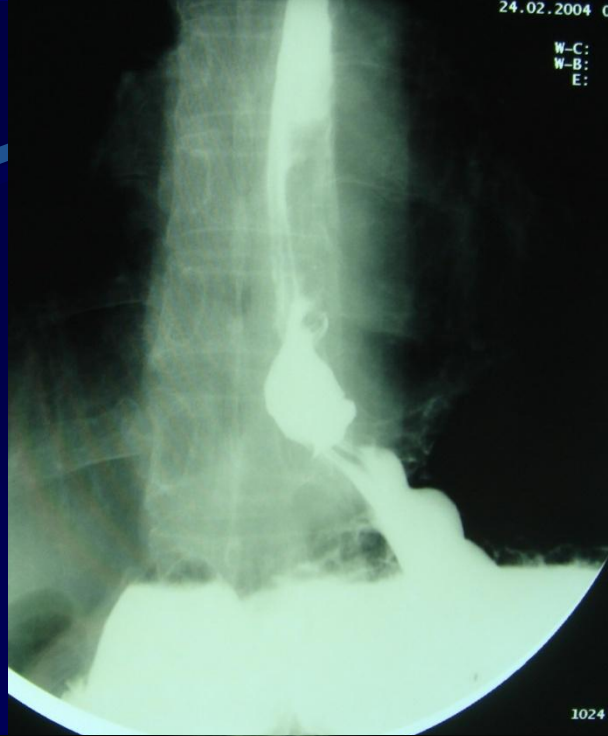
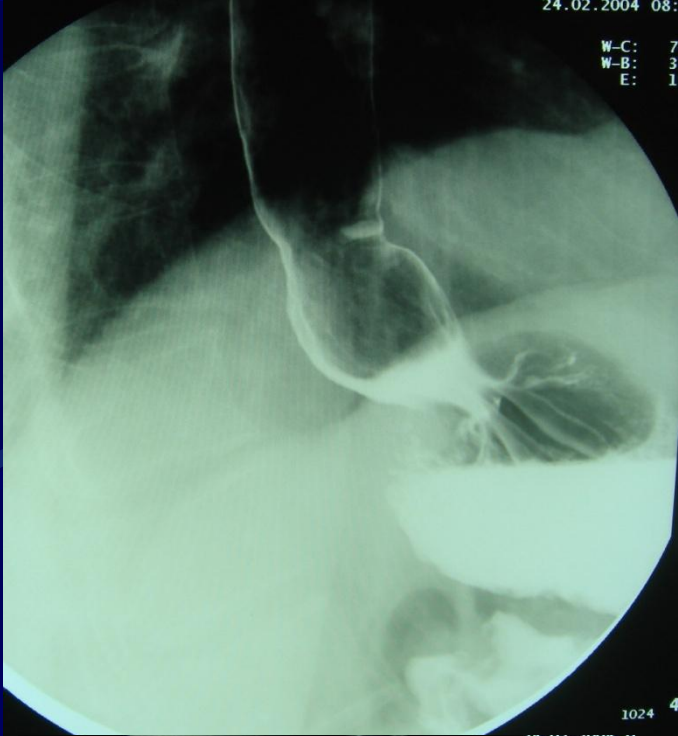
食管静脉曲张（病例5）



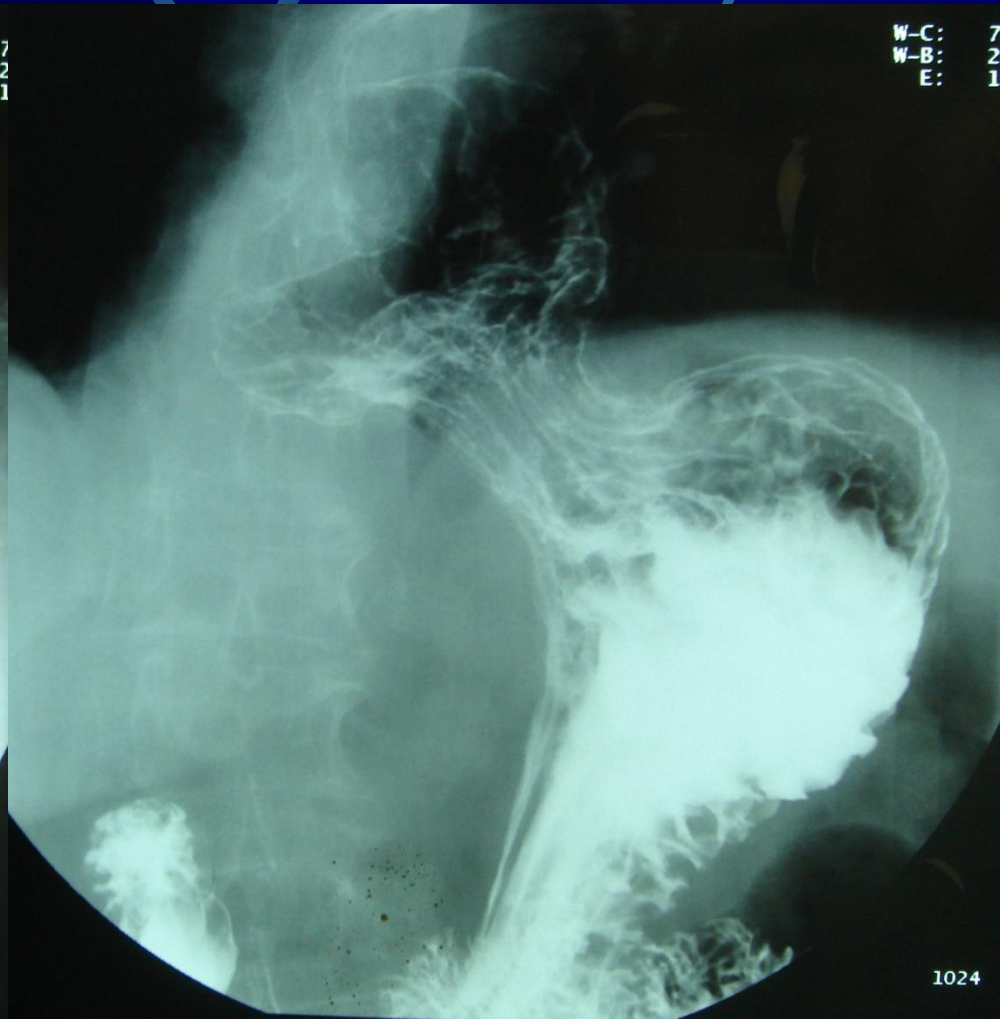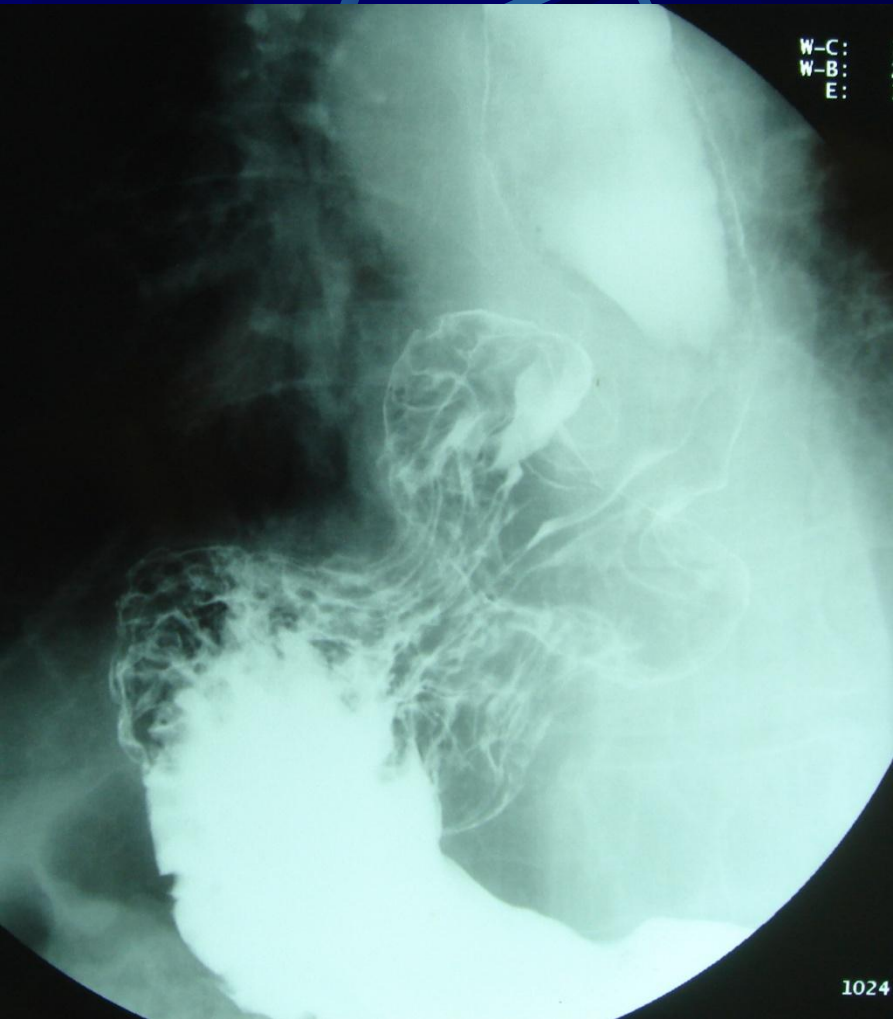食管囊肿



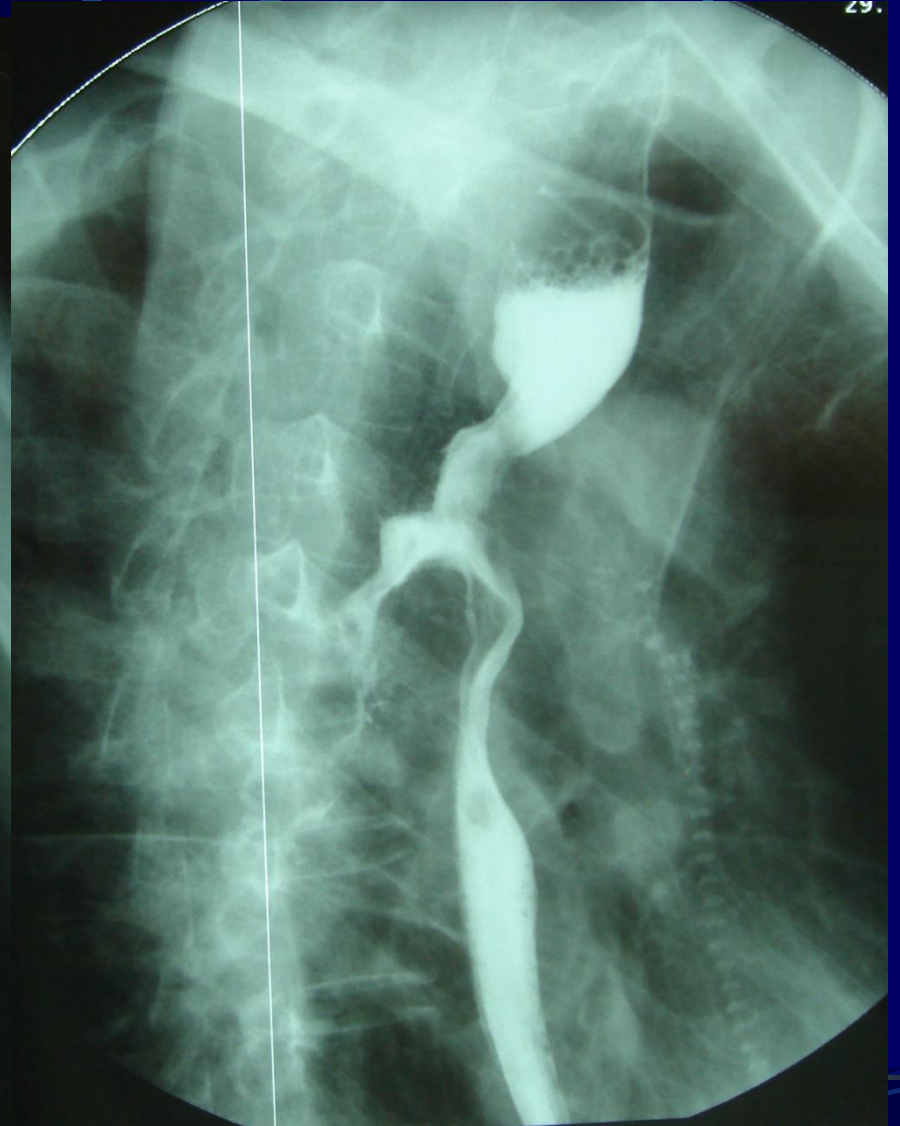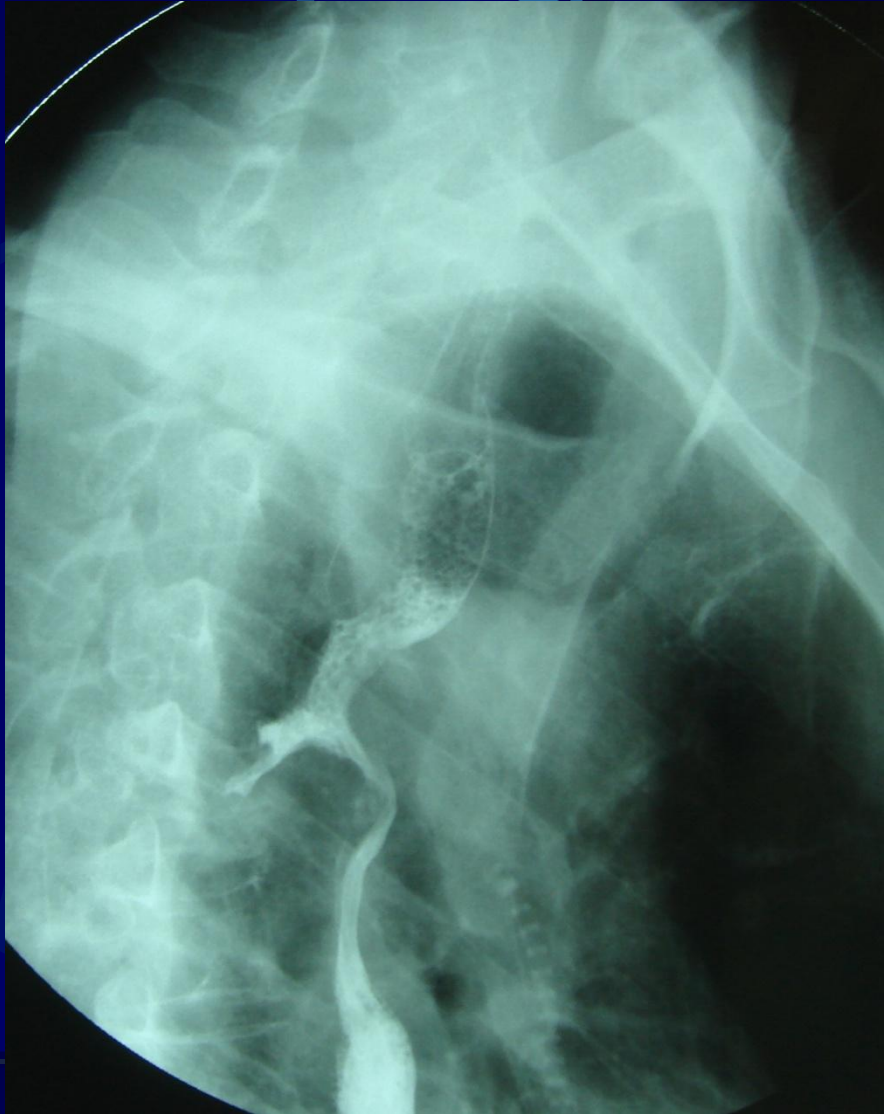返流性食道炎



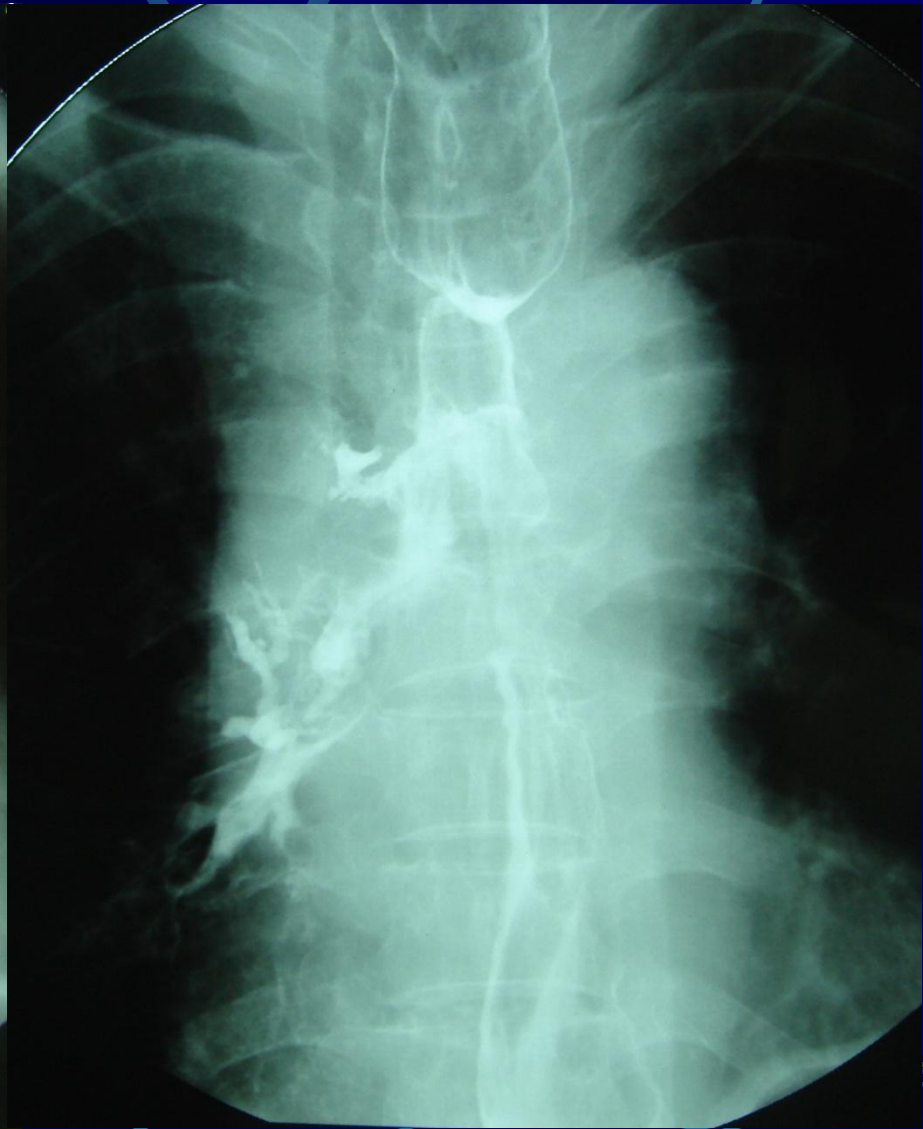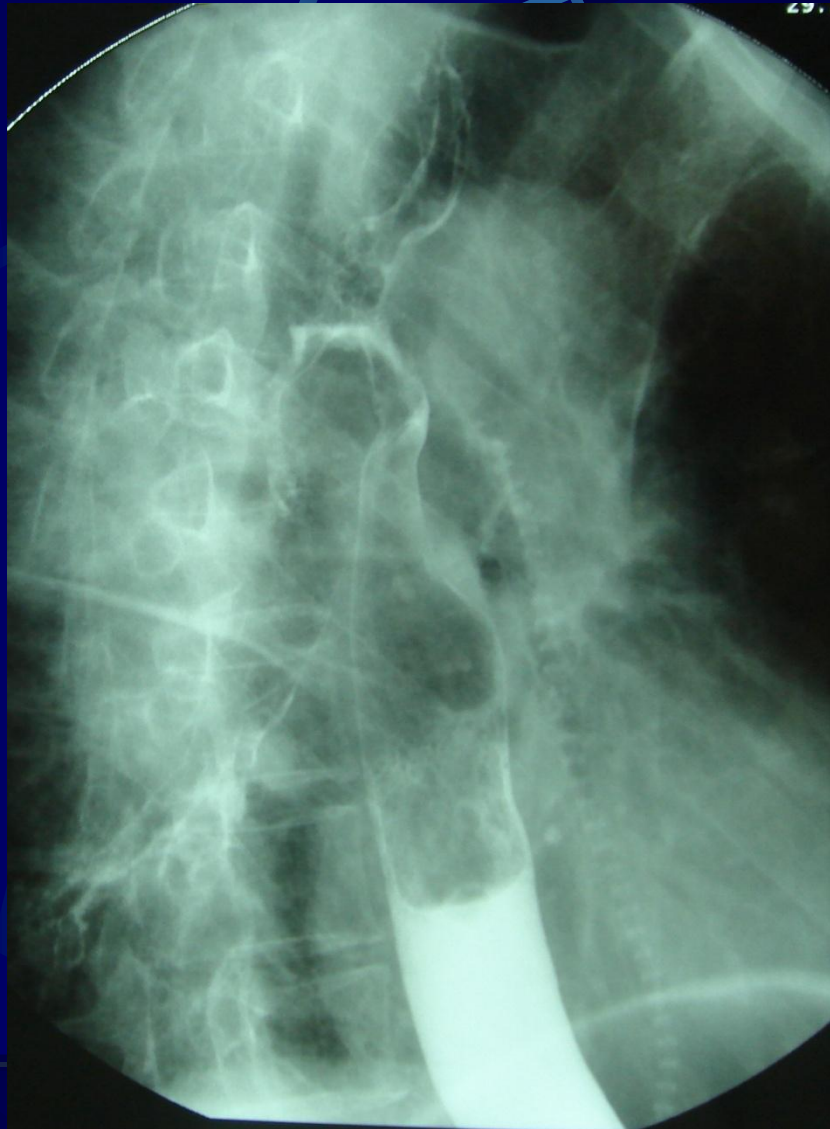
食管裂孔疝



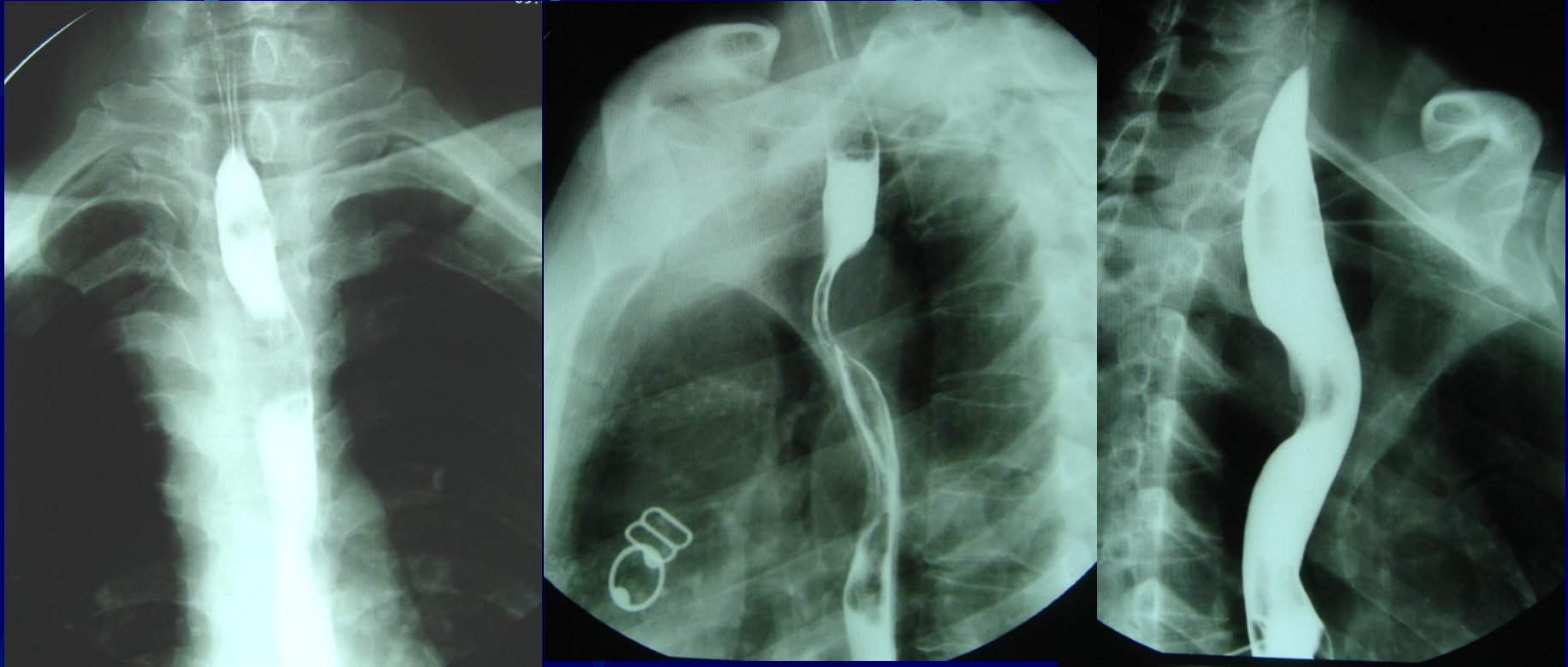
食管气管瘘



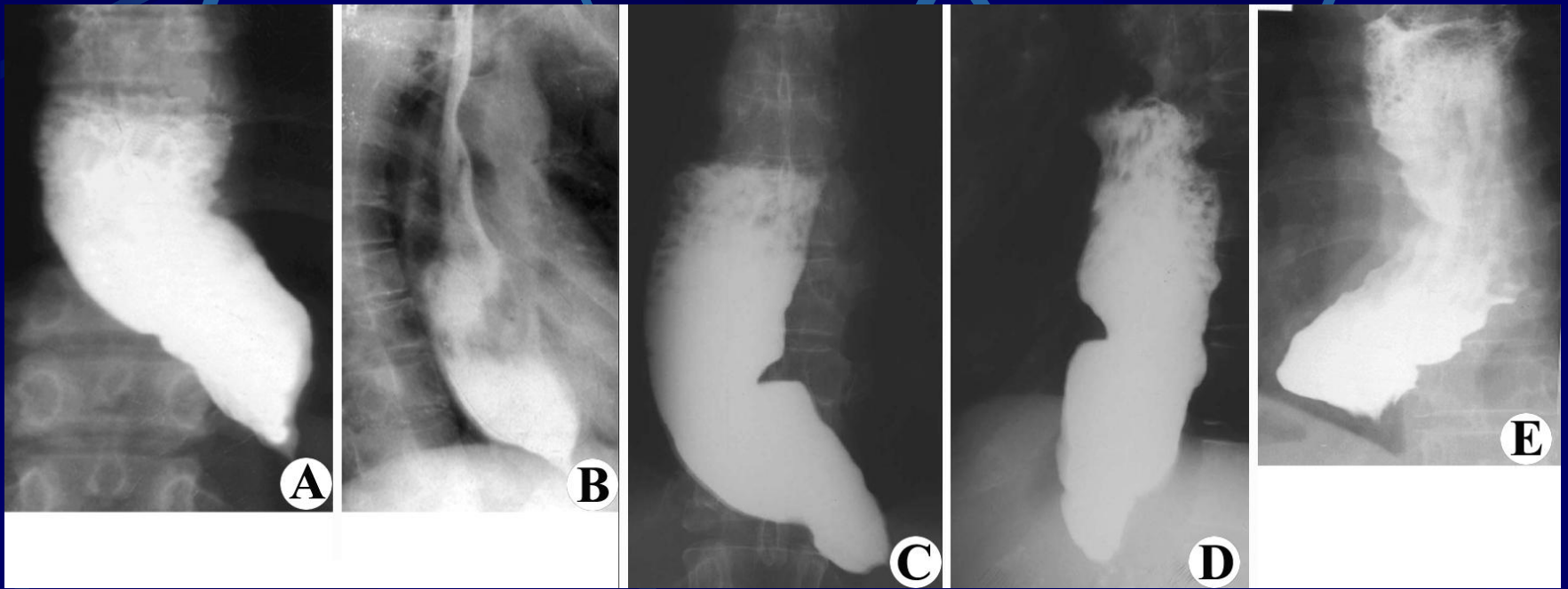
食管气管瘘

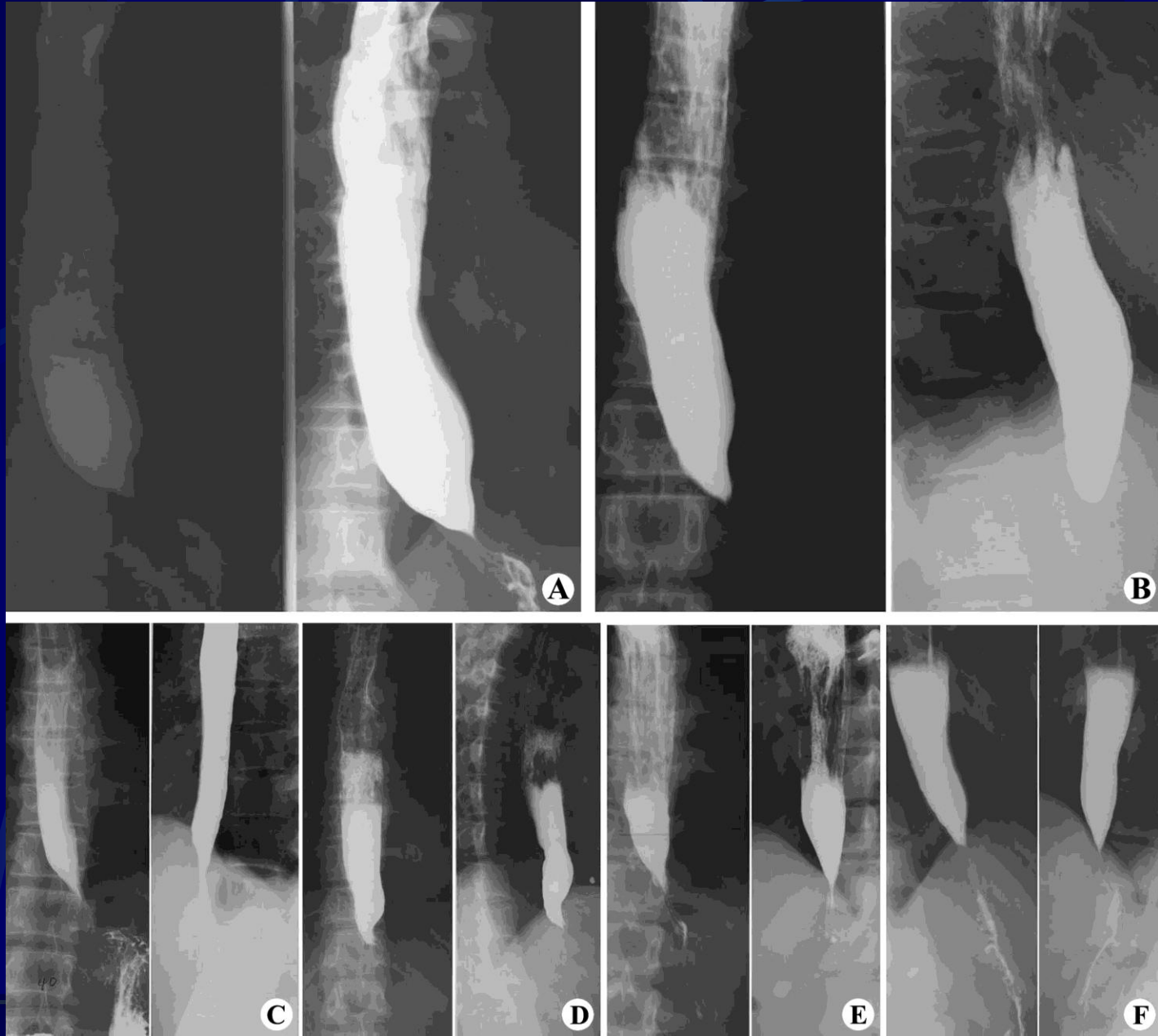


右位主动脉弓



食管贲门失弛缓症





食管贲门失弛缓症

食管平滑肌瘤

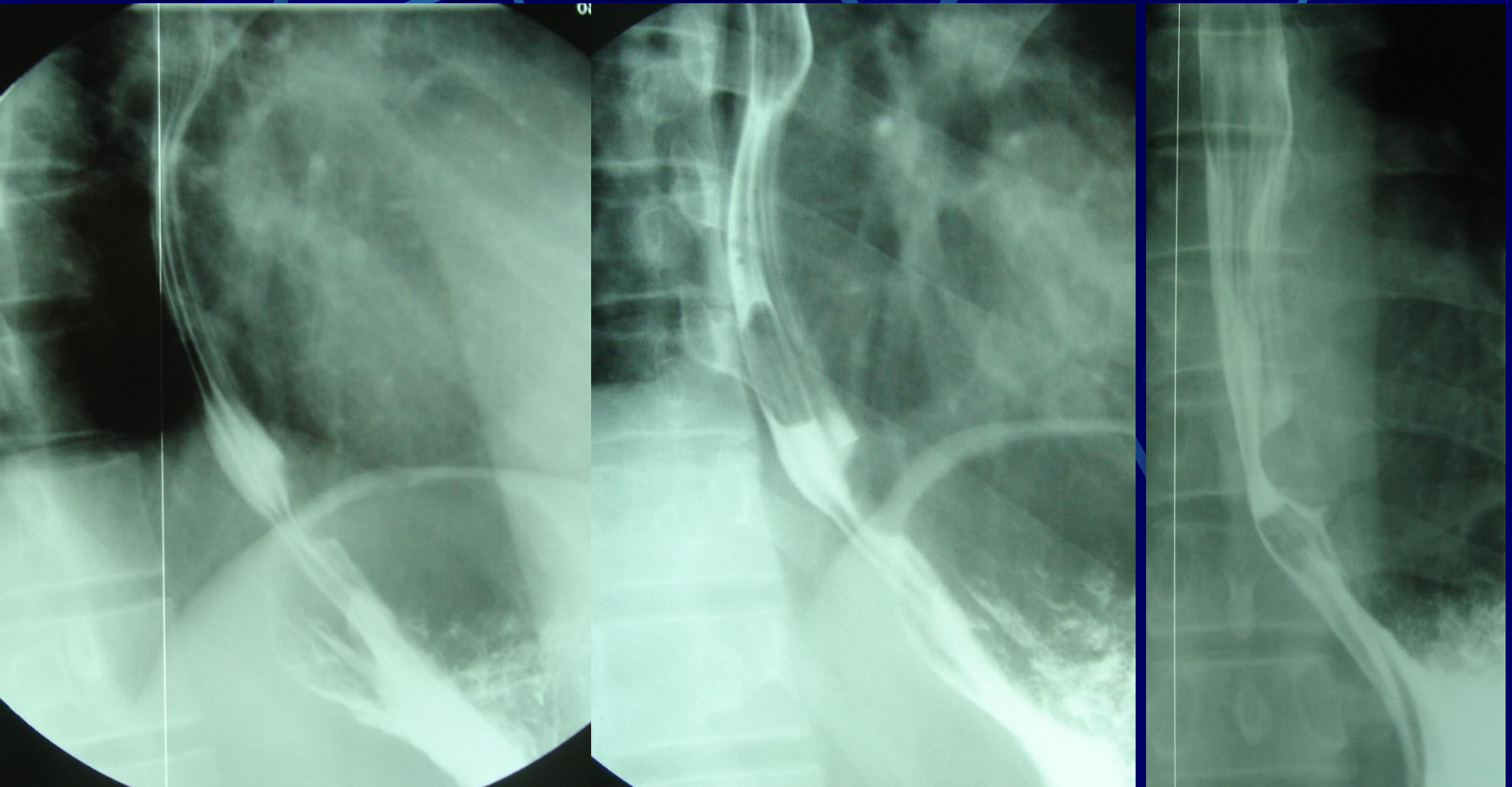
起于食管平滑肌或粘膜，血管平滑肌，位于下、中、上段。多数在壁内生长，单发多见。无明显症状。

食管平滑肌瘤

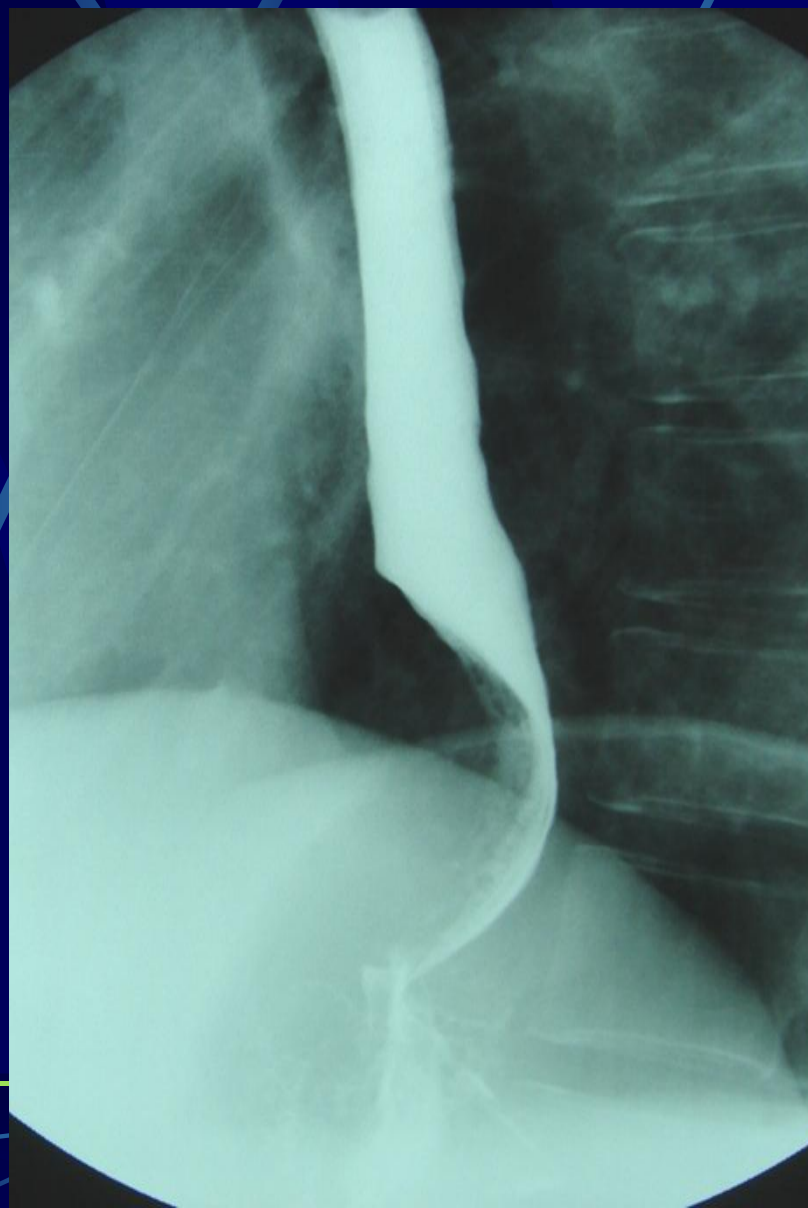
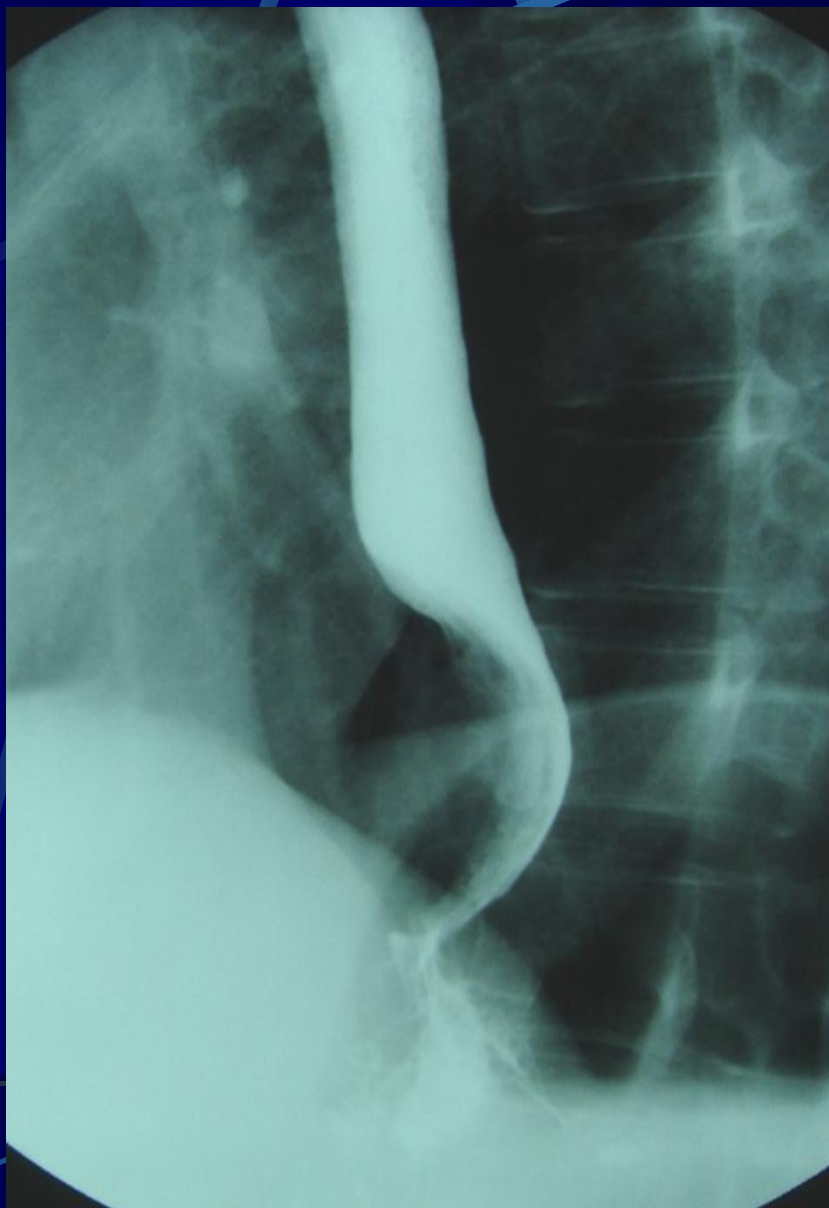
造影表现：

- 1.边缘锐利的充盈缺损，正面为圆形、类圆形充盈缺损
- 2.钡剂分流，管腔偏心狭窄
- 3.肿瘤区粘膜完整，展平，消失
- 4.长大可类似纵隔肿物
- 5.与外压区别

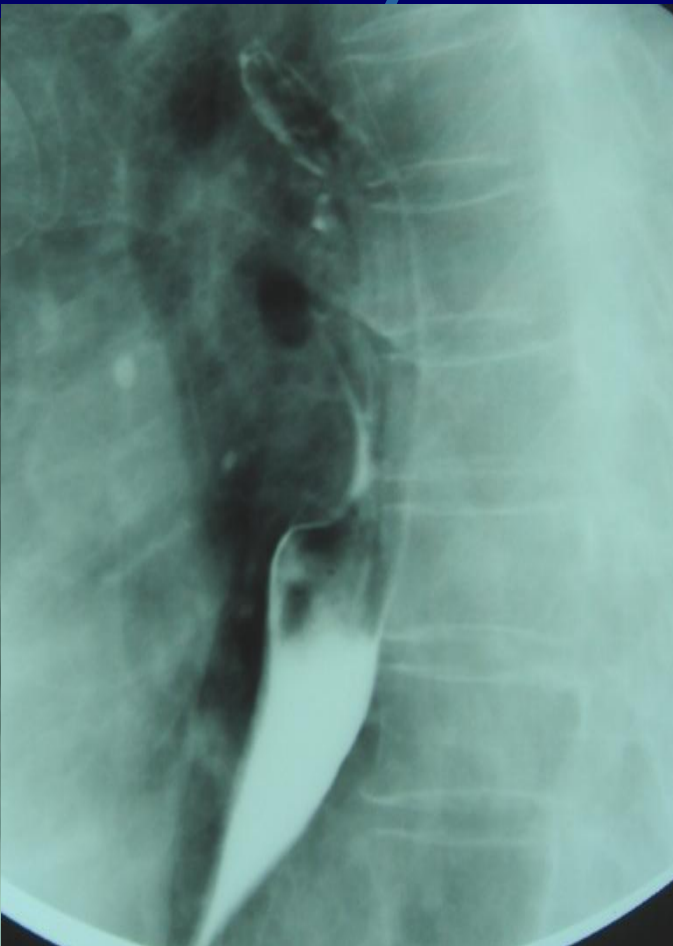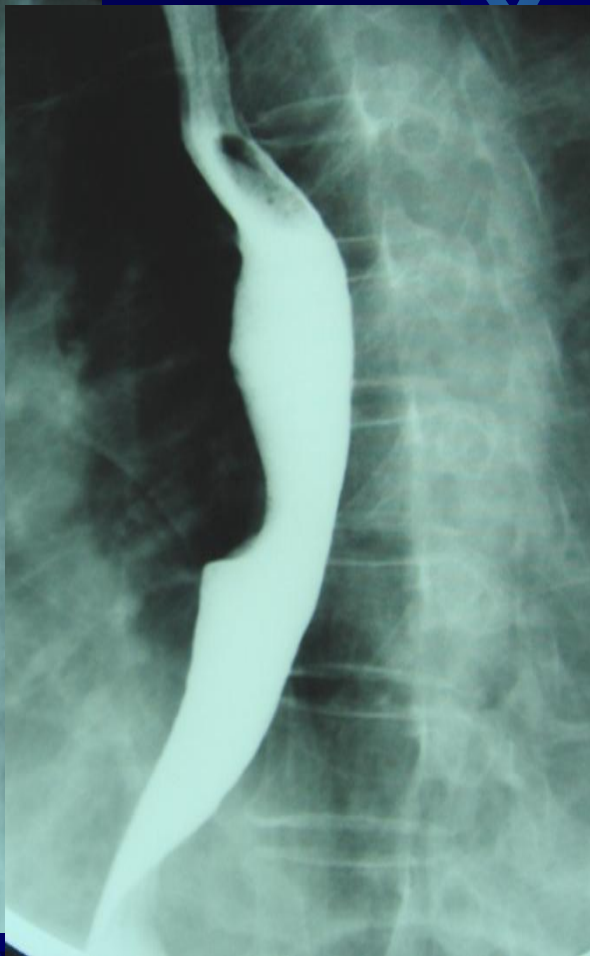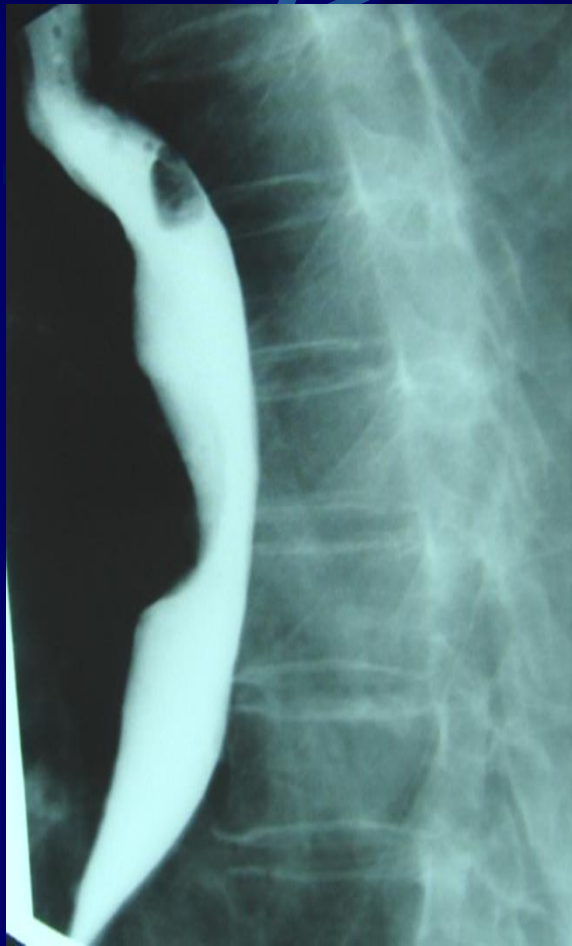
食管平滑肌瘤（病例1）

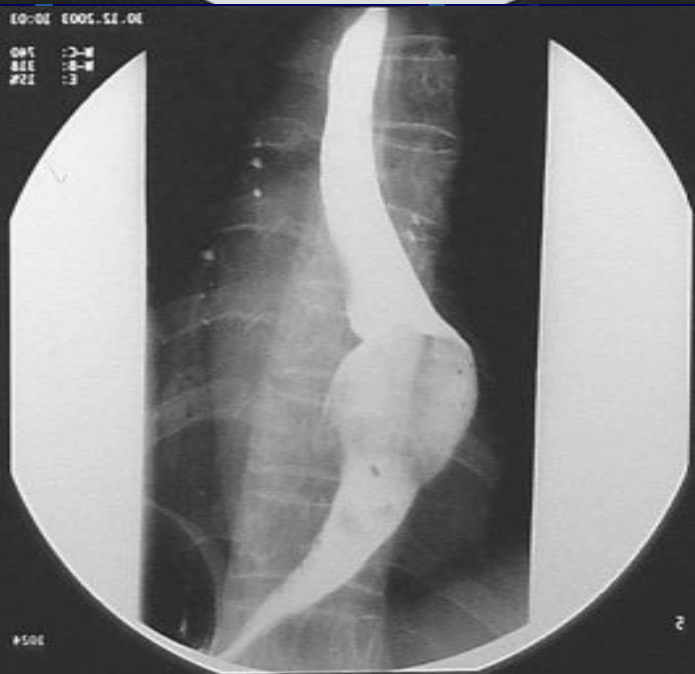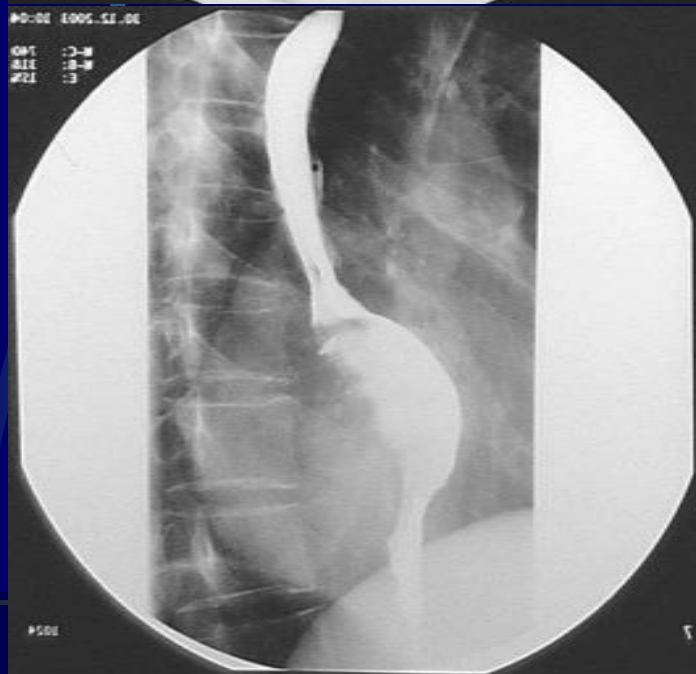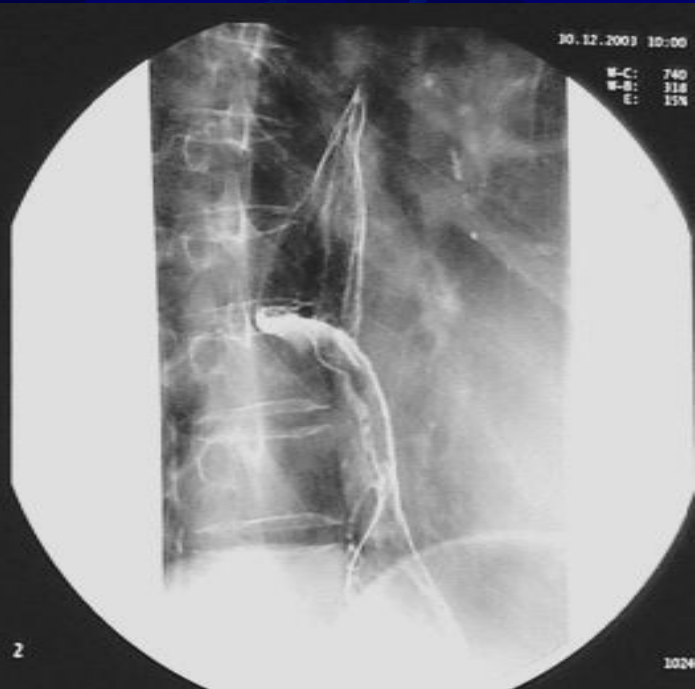


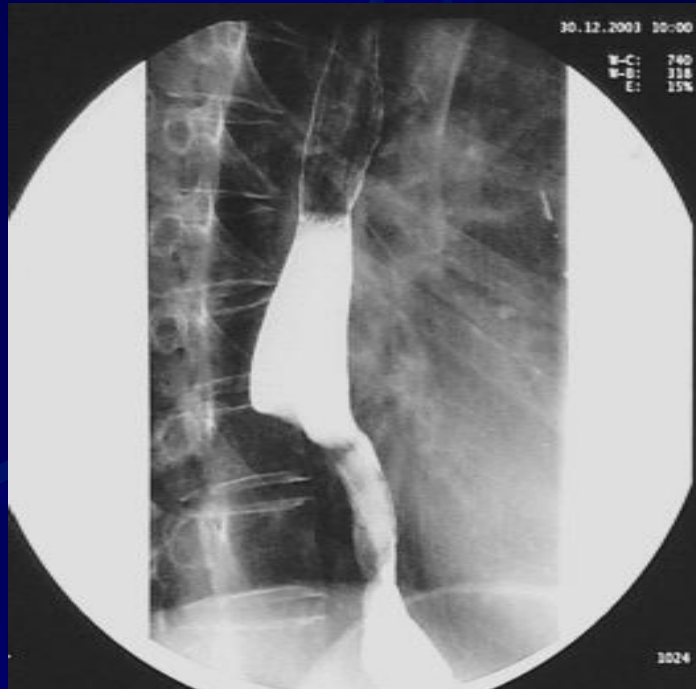食管平滑肌瘤（病例2）



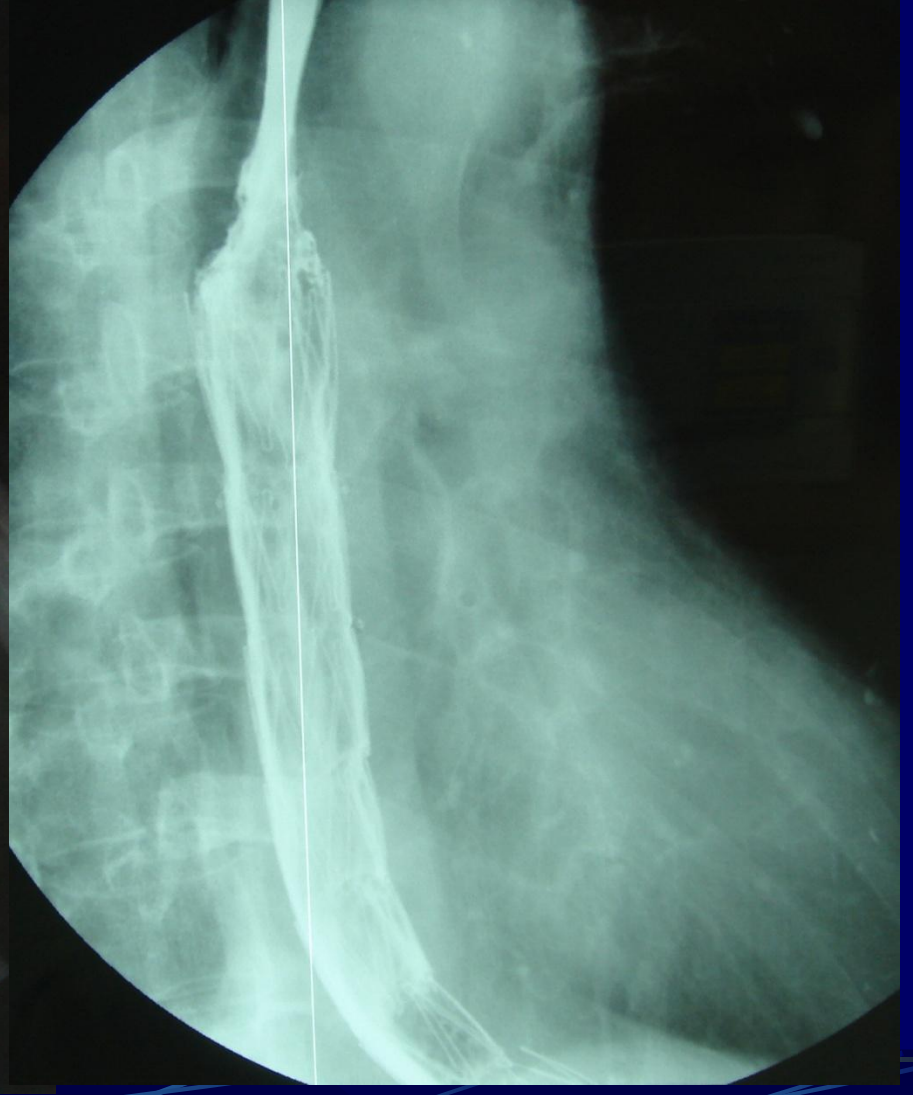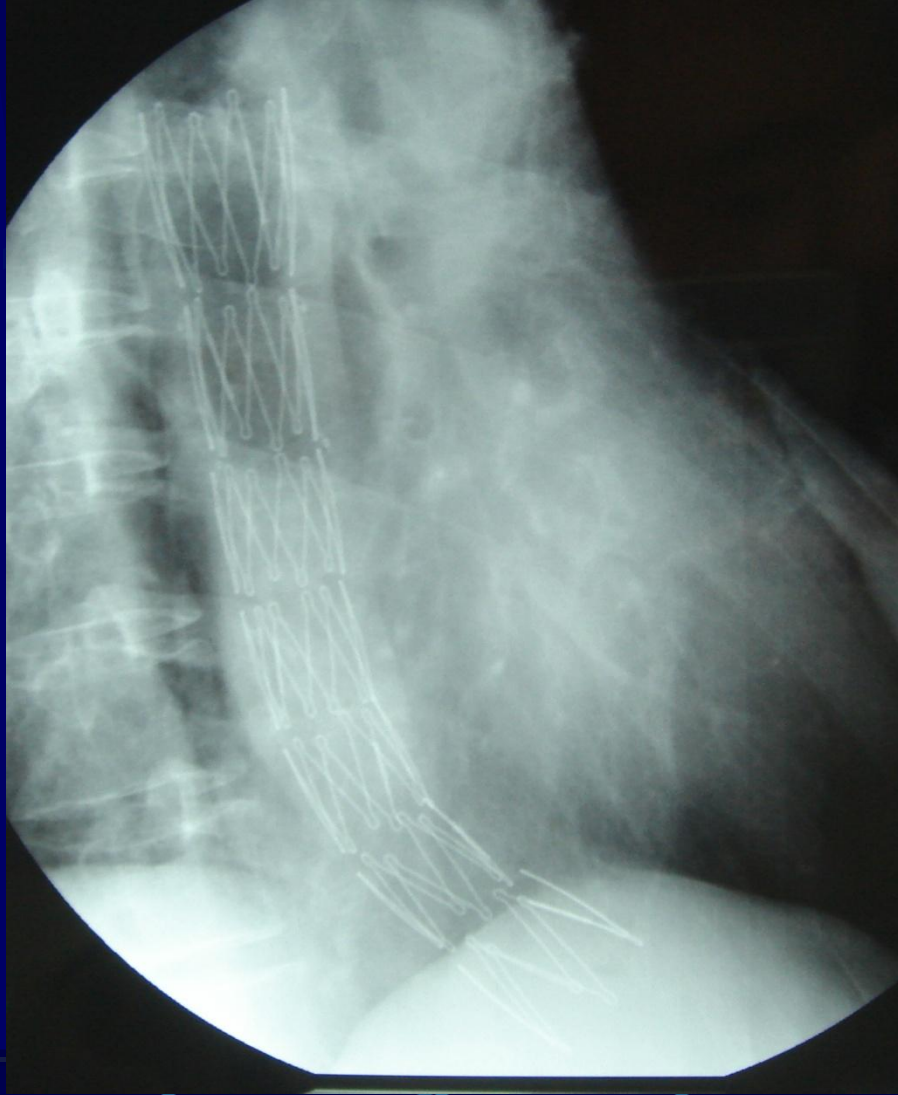食管平滑肌瘤（病例3）





食道平滑肌瘤 (病例 4)

食管内支架



食管癌

早期:

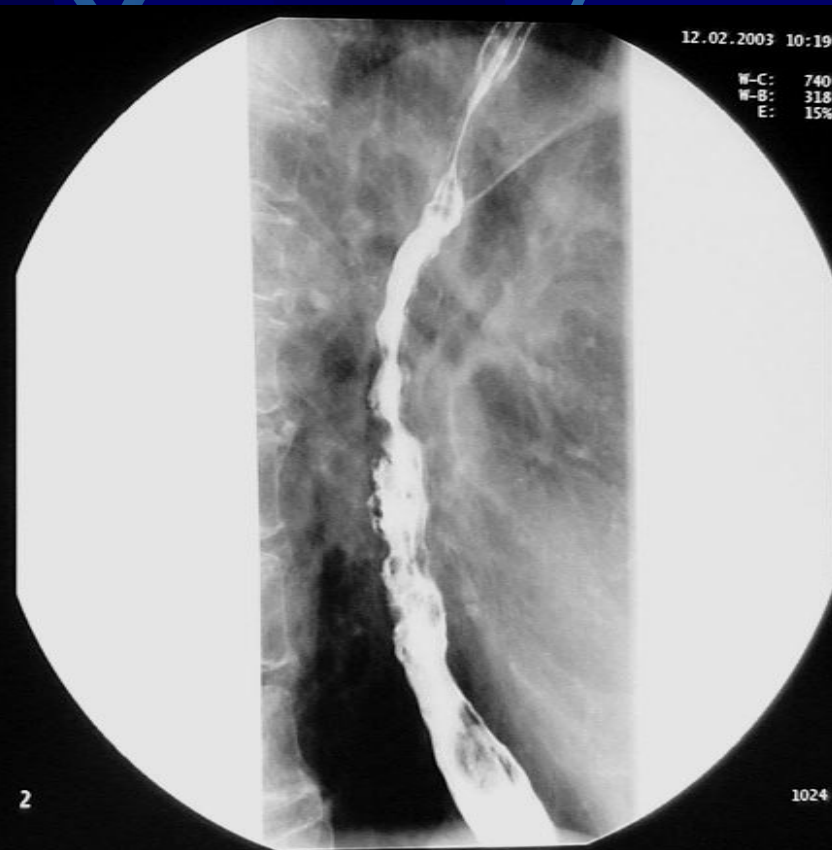
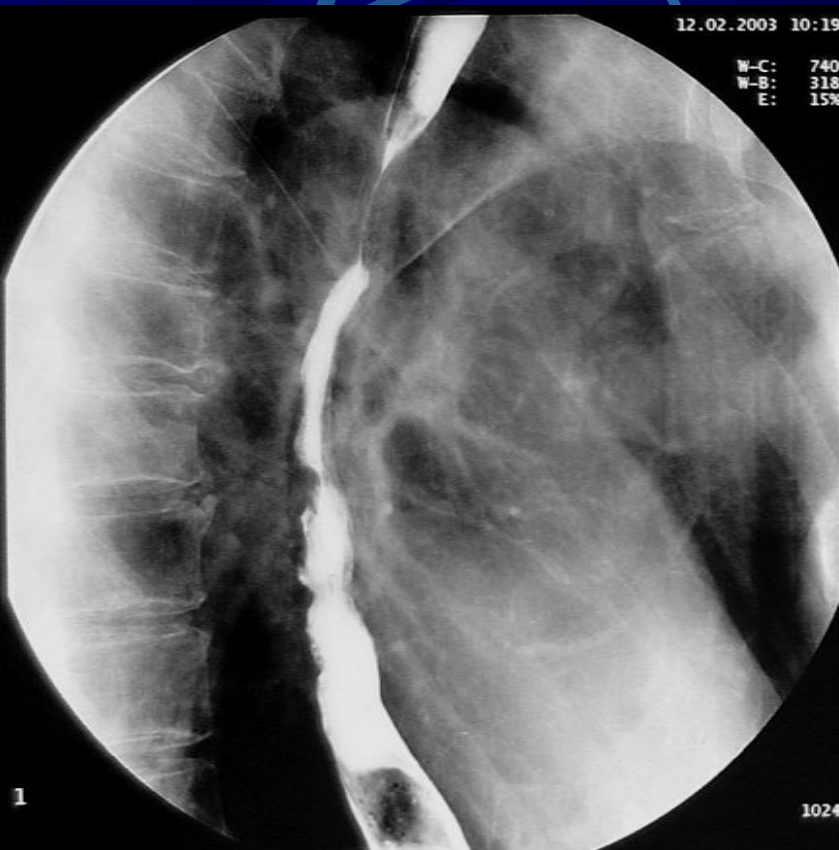
- 1、平坦型：粘膜局部血管充血，色泽较深。
- 2、微凹型：粘膜糜烂，浅表溃疡，周边粘膜微隆起。
- 3、微隆型：粘膜稍隆起，呈颗粒状，局部粘膜增粗、中断。

食管癌

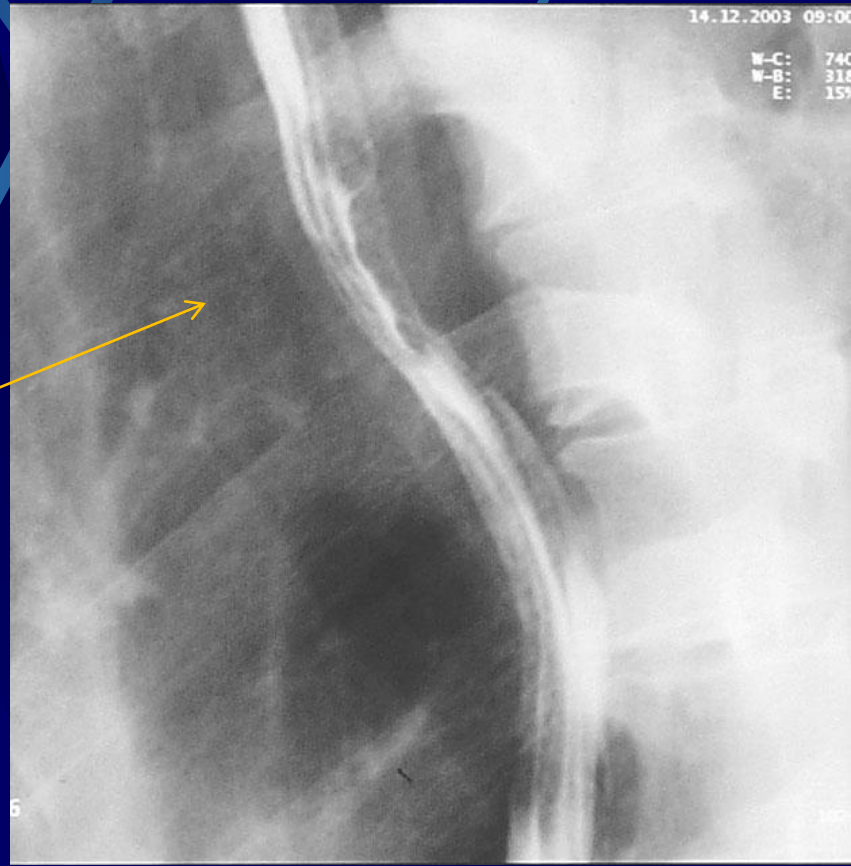
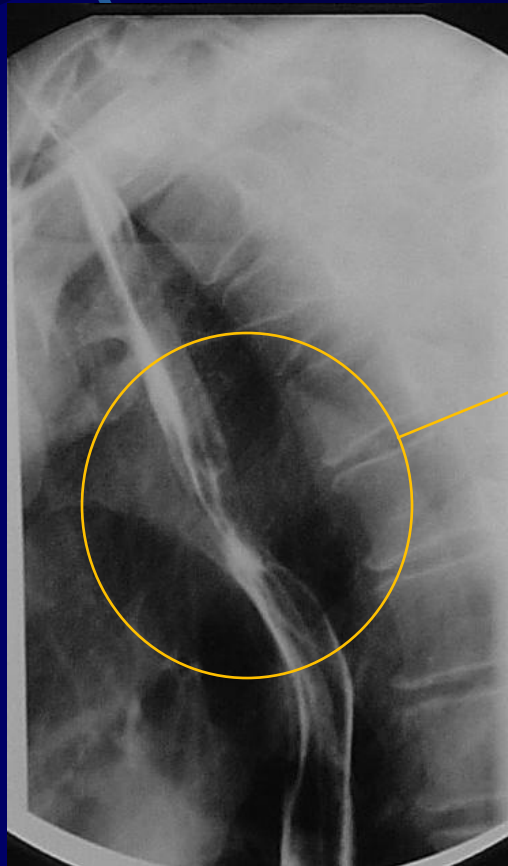
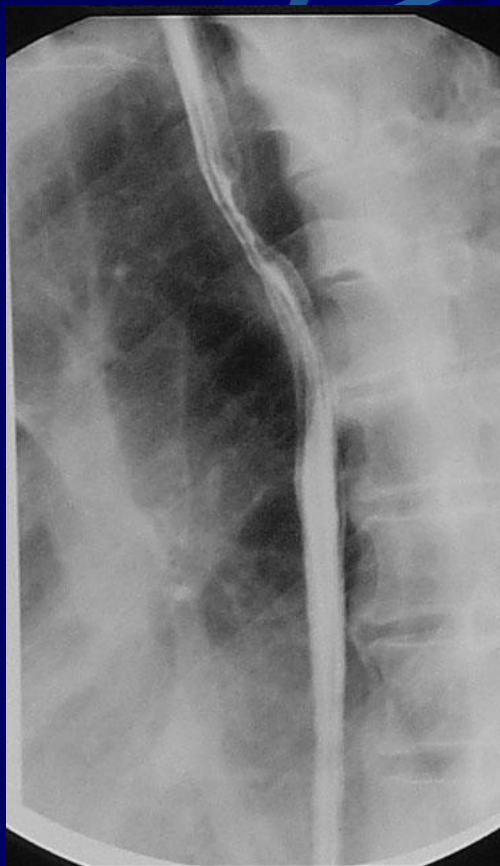
中晚期:

- 1.髓质型：管壁增厚，管腔变窄，粘膜不规则，溃疡形成。
- 2.蕈伞型：腔内肿物，粘膜破坏，溃疡形成，管腔改变。
- 3.溃疡型：腔内龛影，底部凹凸不平，深达肌层，周边受累，粘膜破坏。
- 4.缩窄型：环形狭窄，全周受累，粘膜破坏，近端扩张。
- 5.混合型：上述改变均可出现。

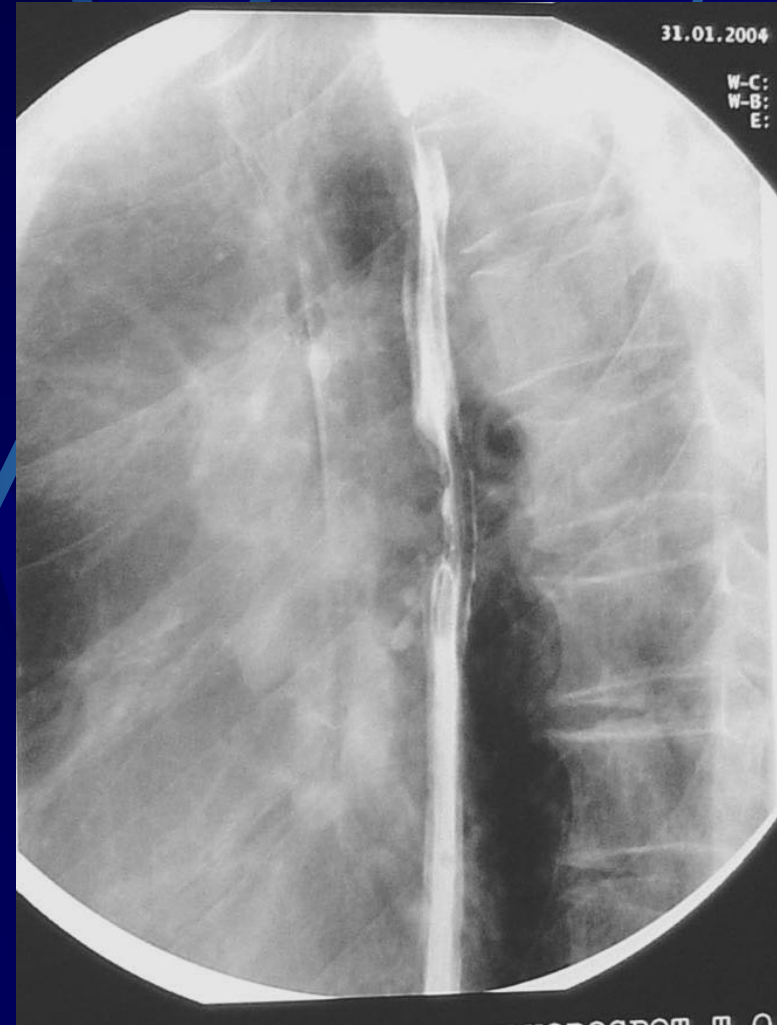
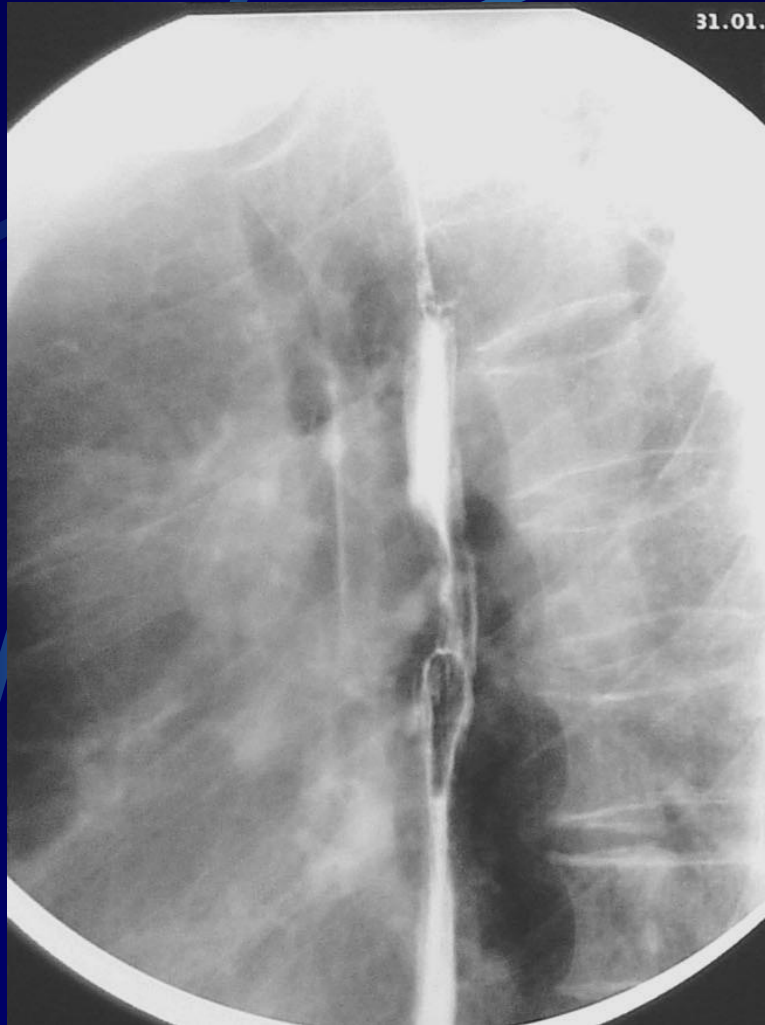
食管癌（病例1）



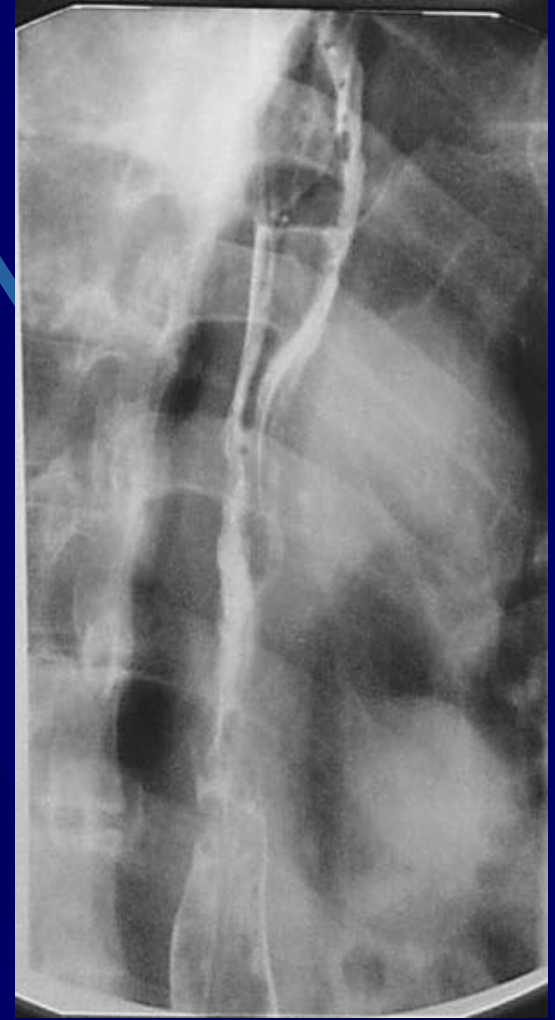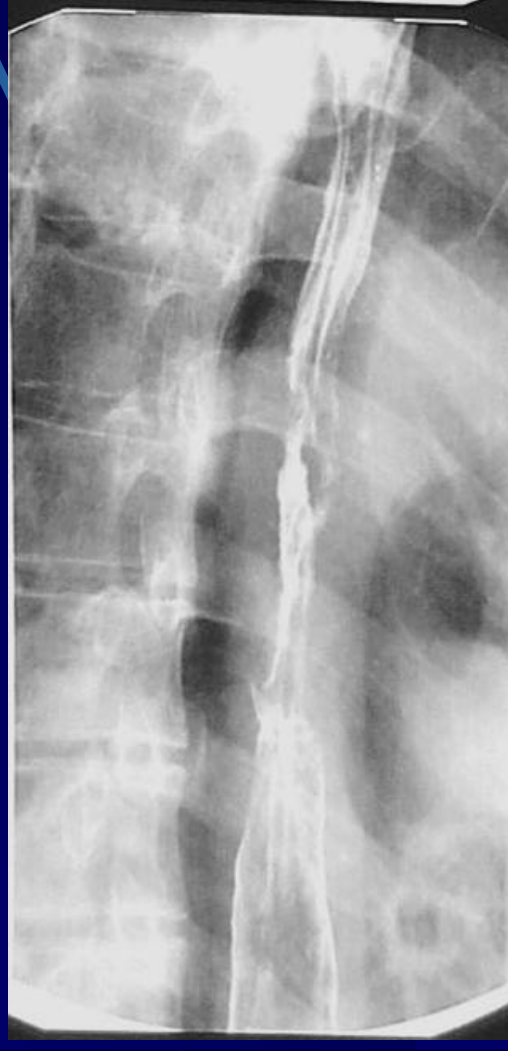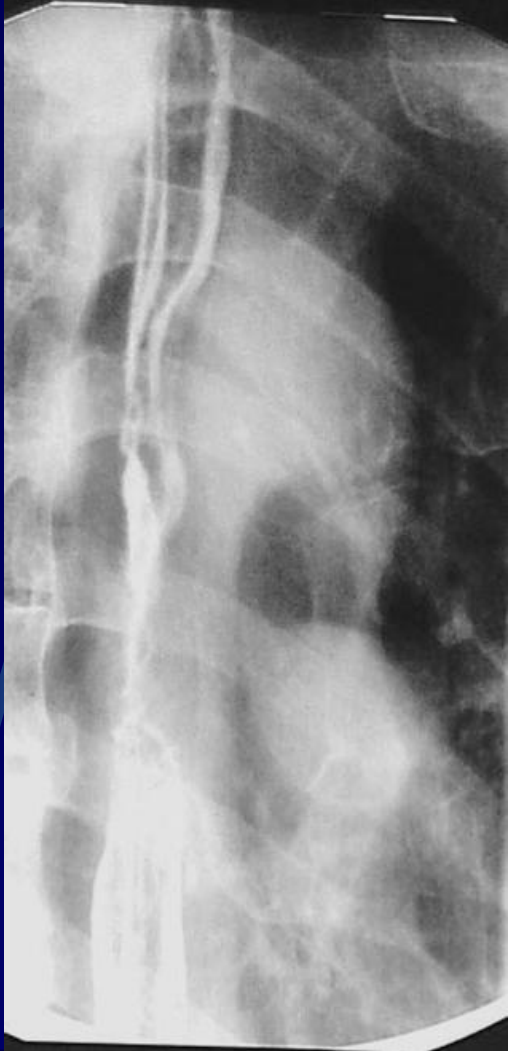食管癌（病例2）



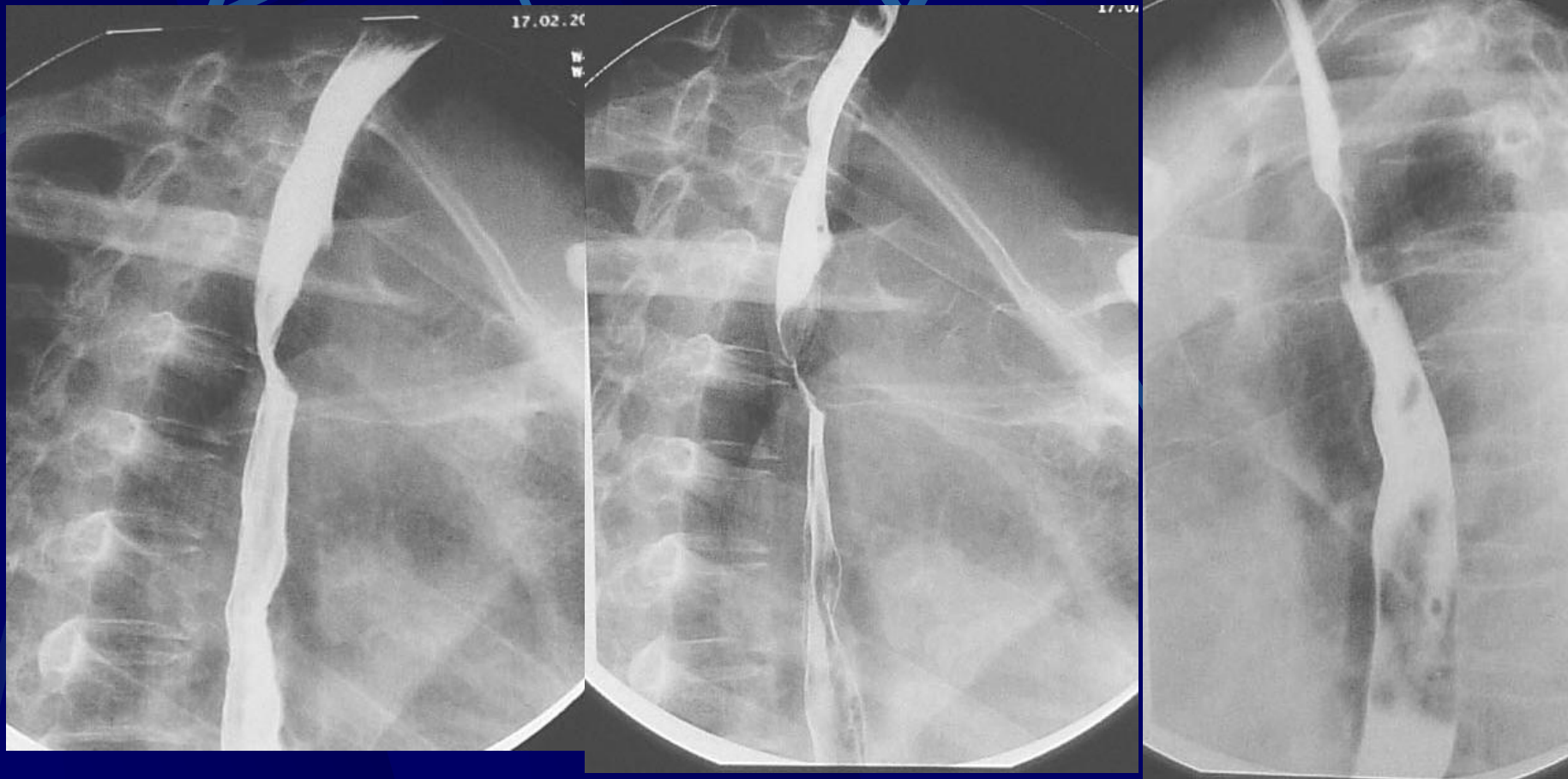
食管癌（病例3）



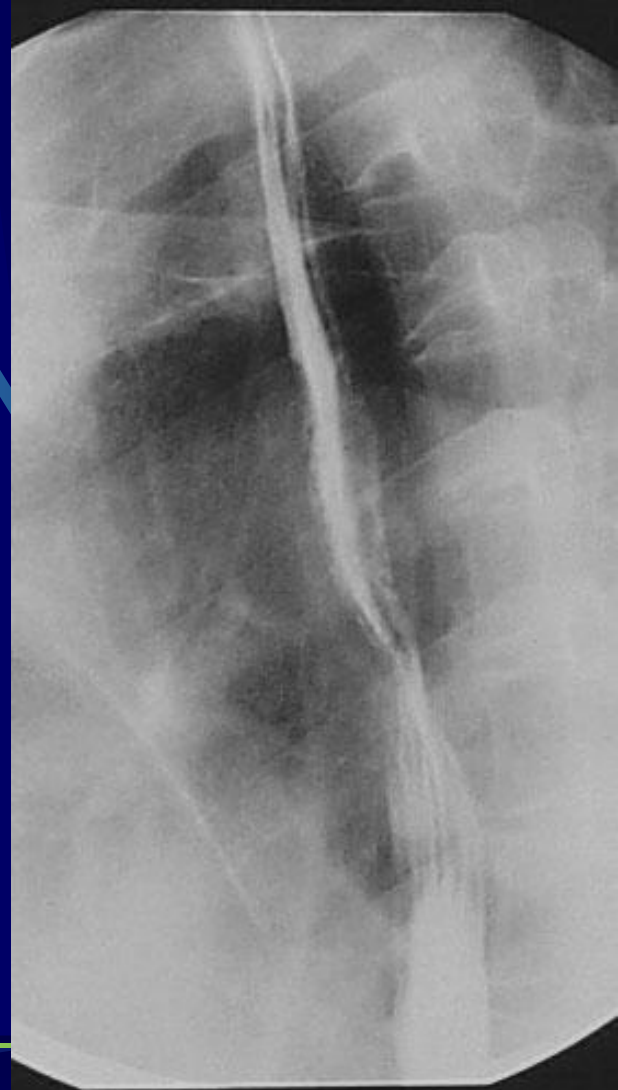
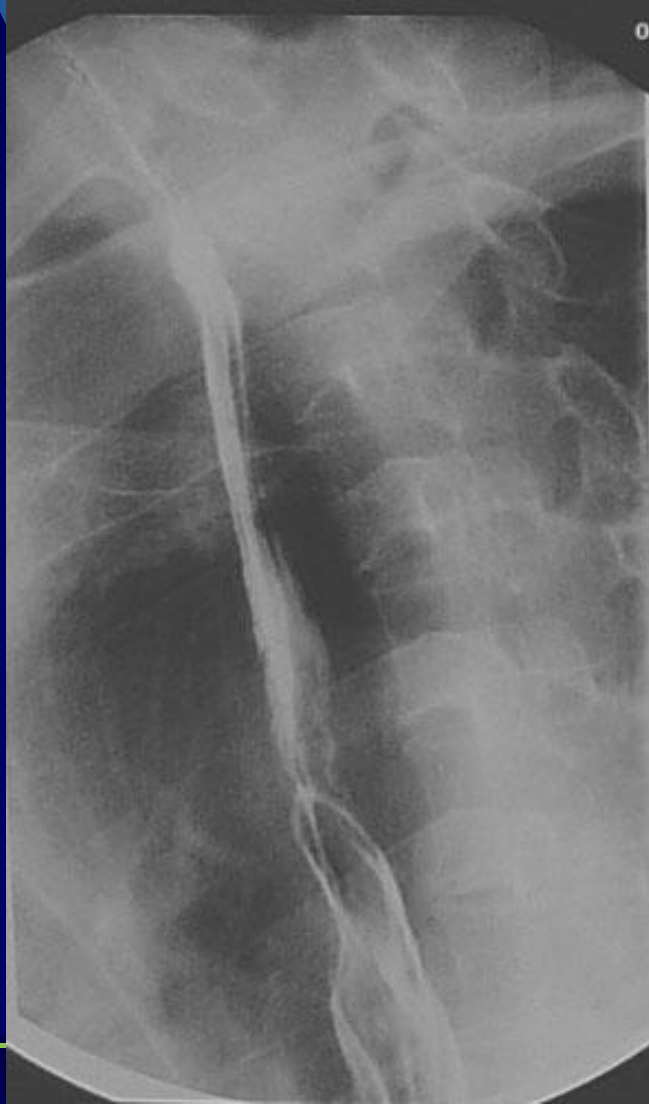
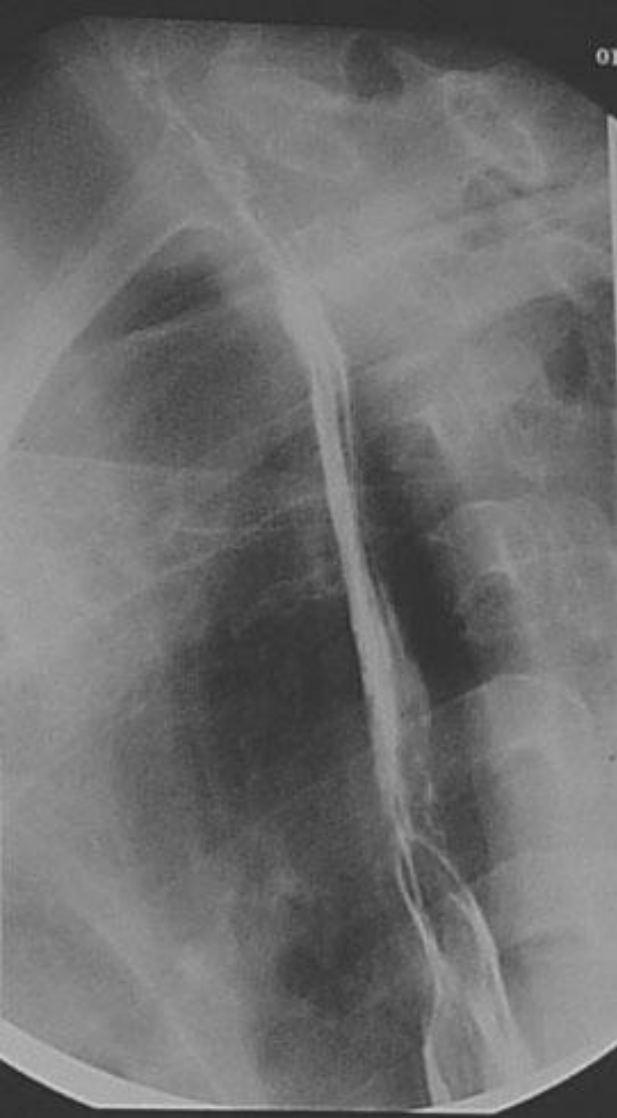
食管癌（病例4）



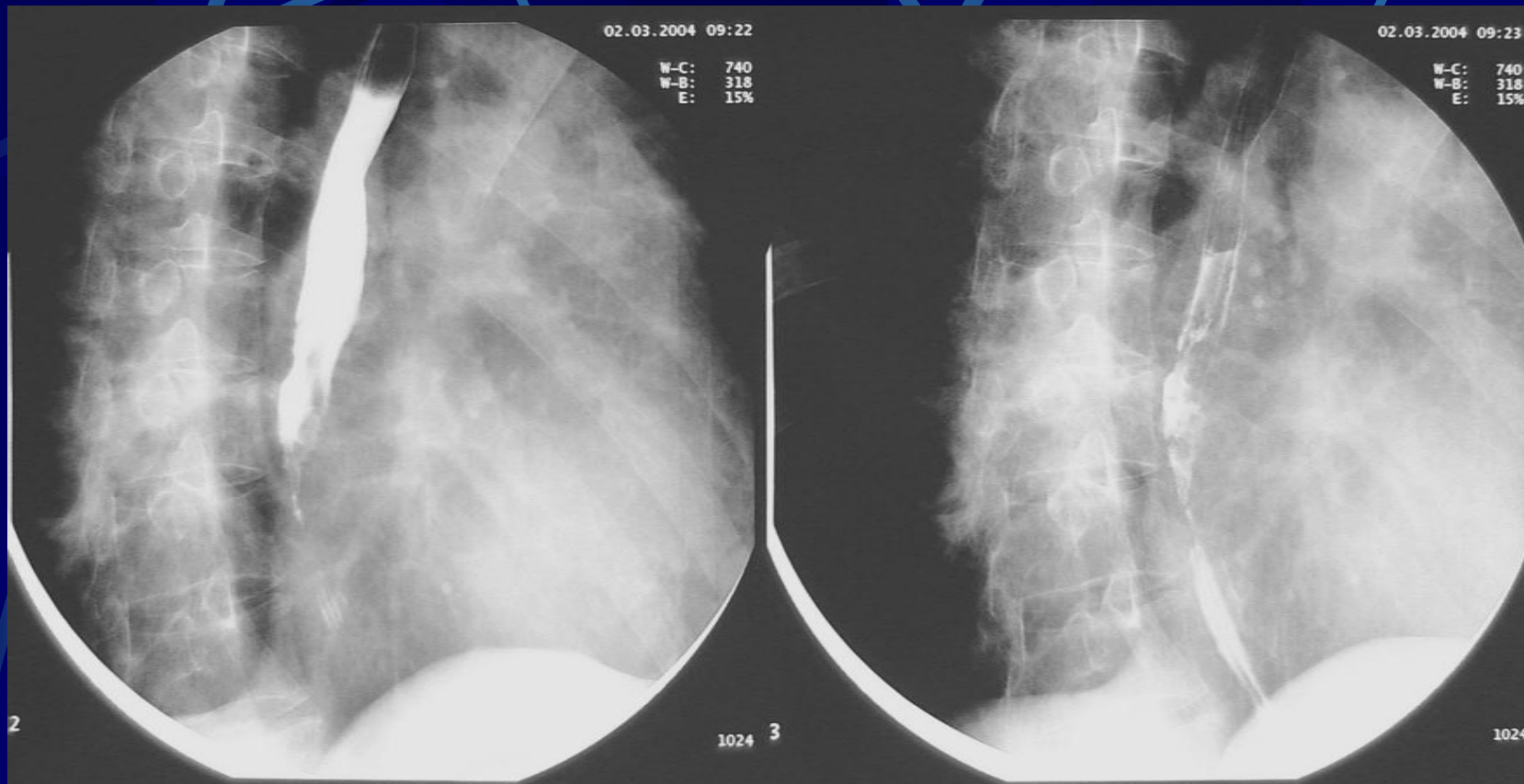
食管癌（病例5）



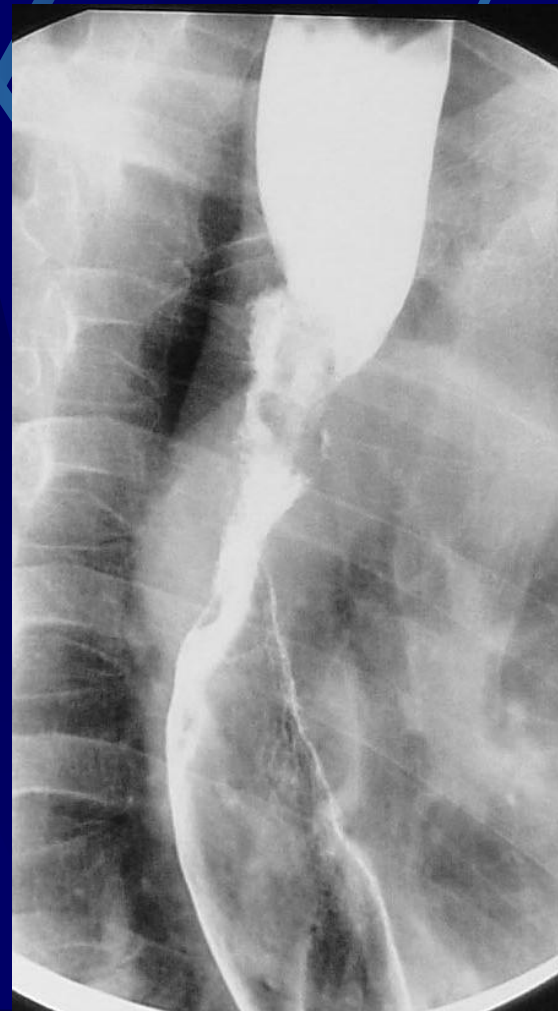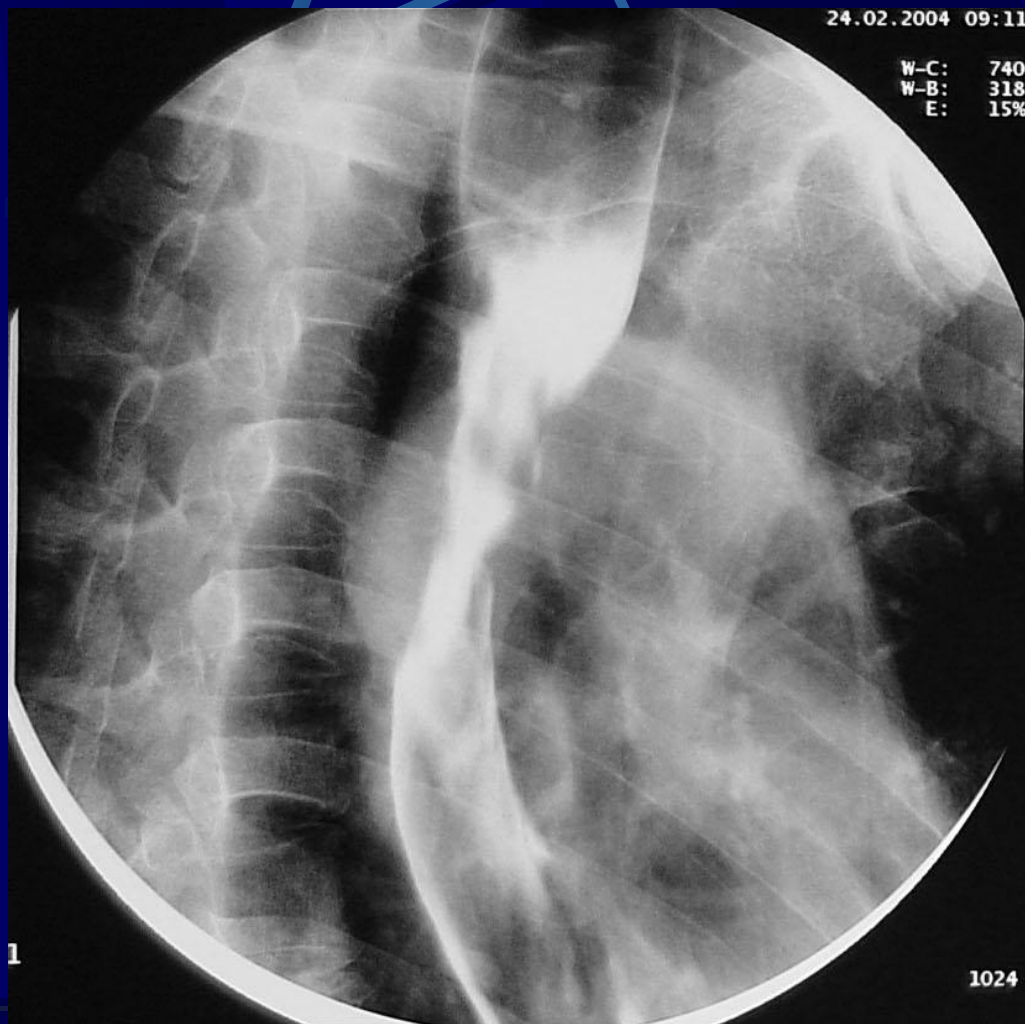
食管癌（病例6）



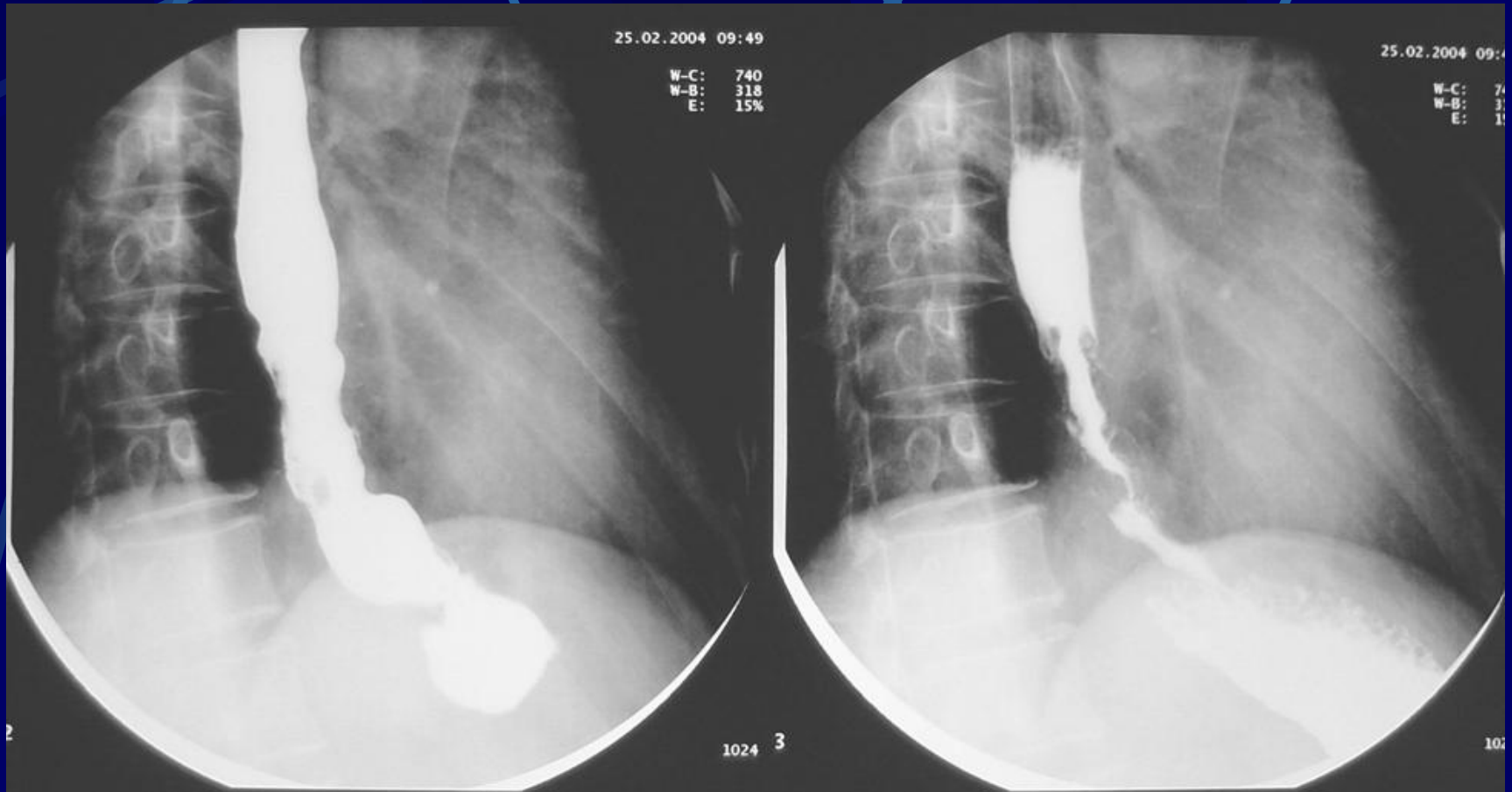食管癌（病例7）

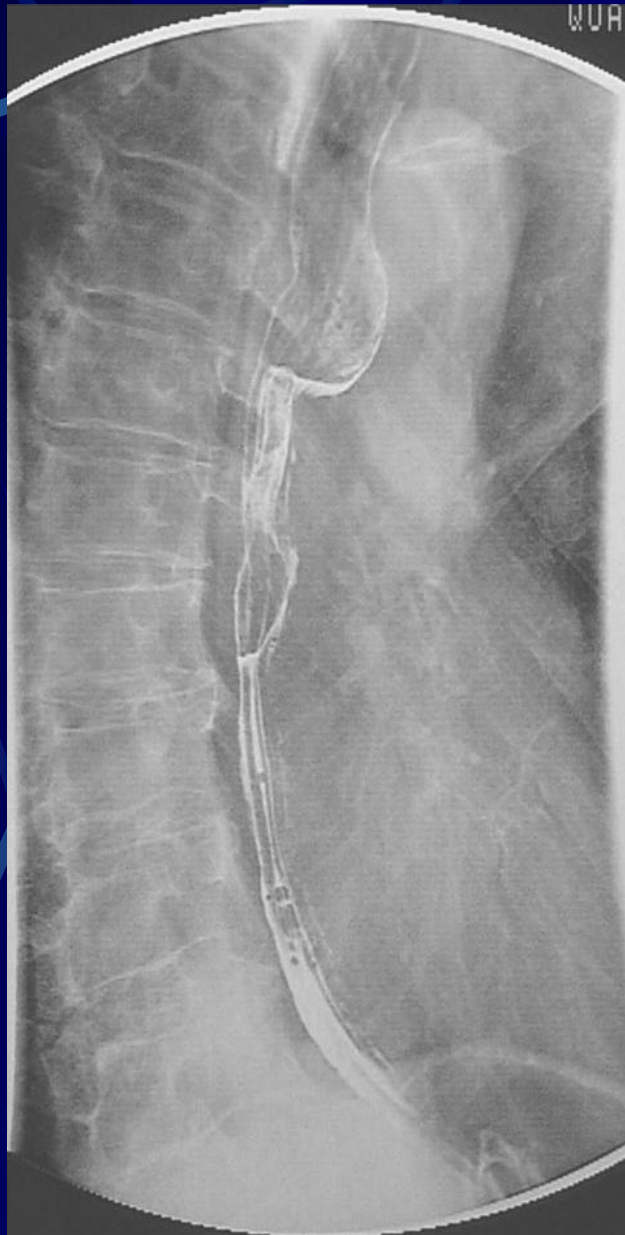
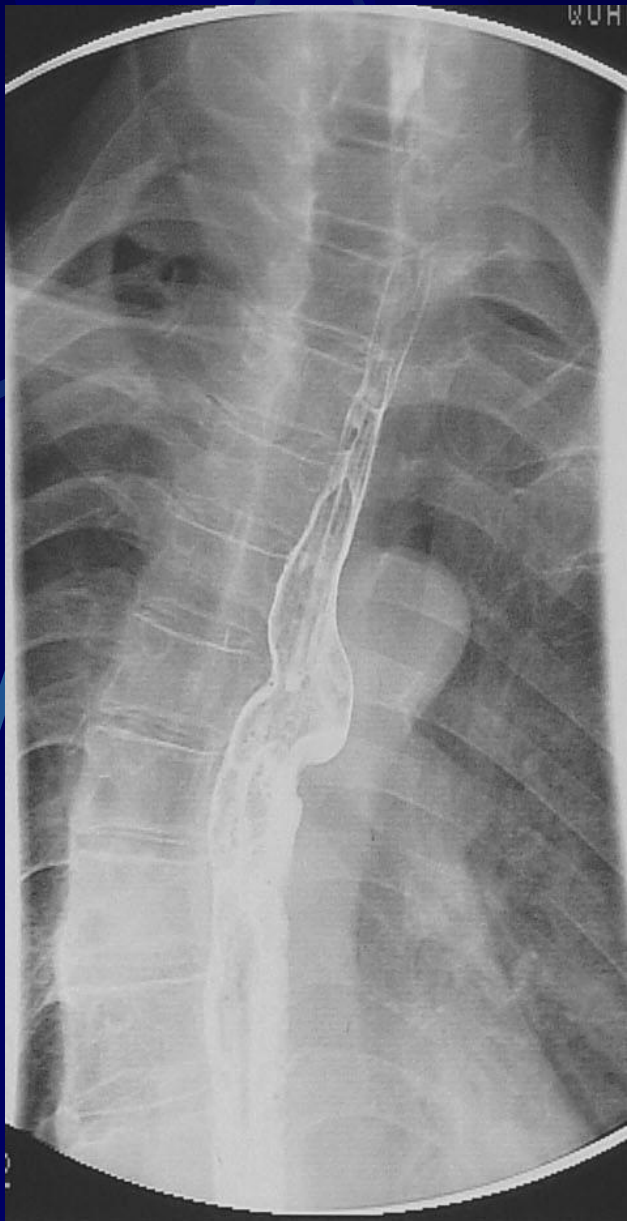
食管癌（病例8）



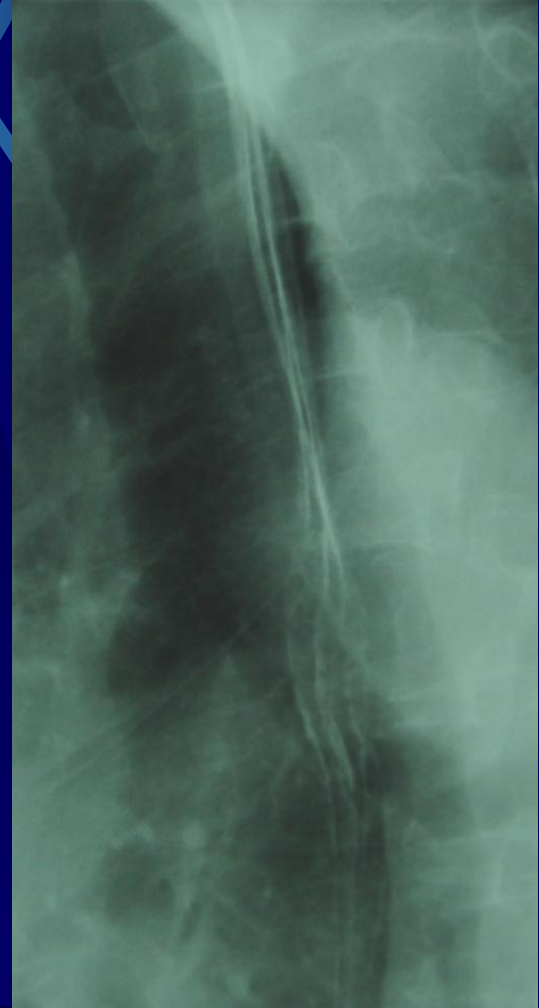
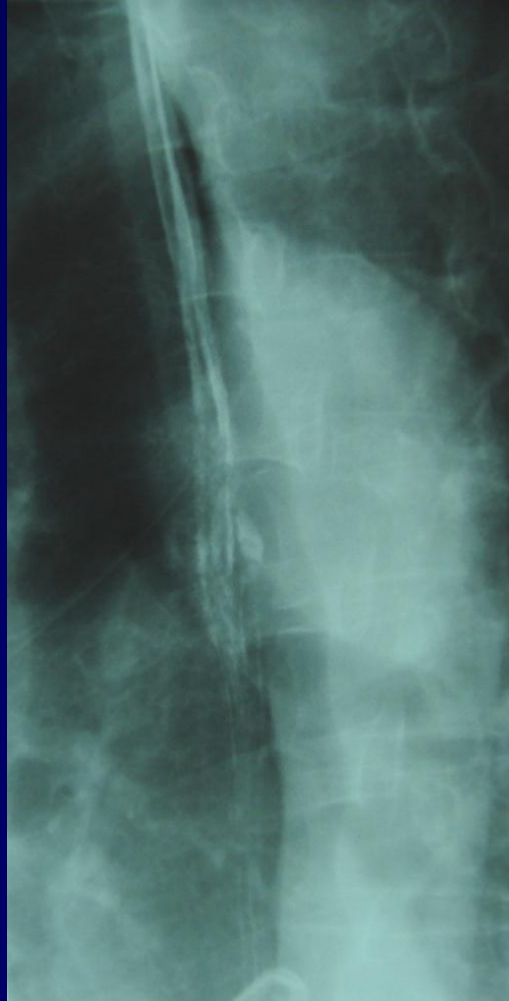
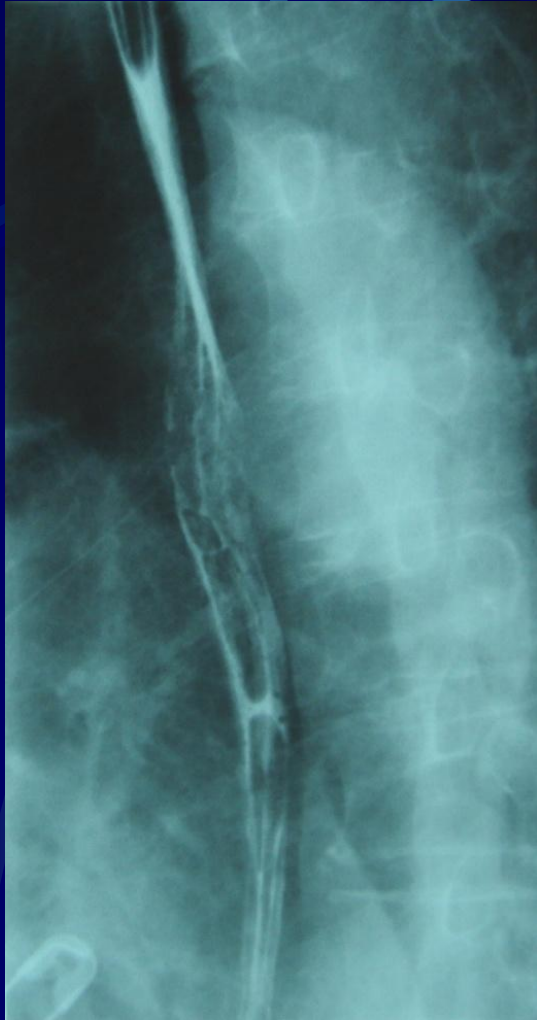
食管癌（病例9）



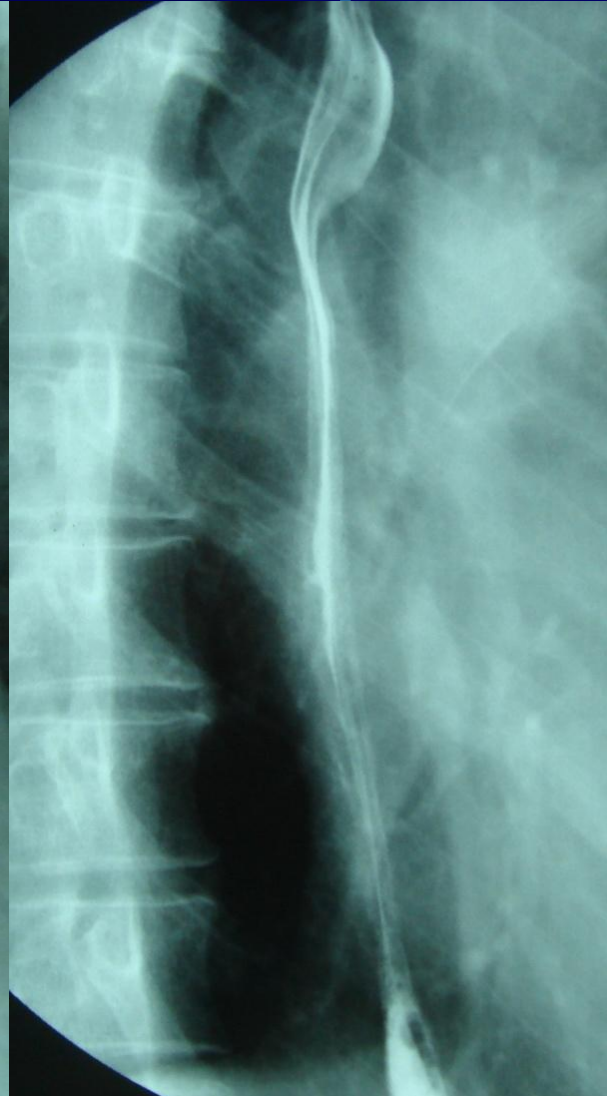
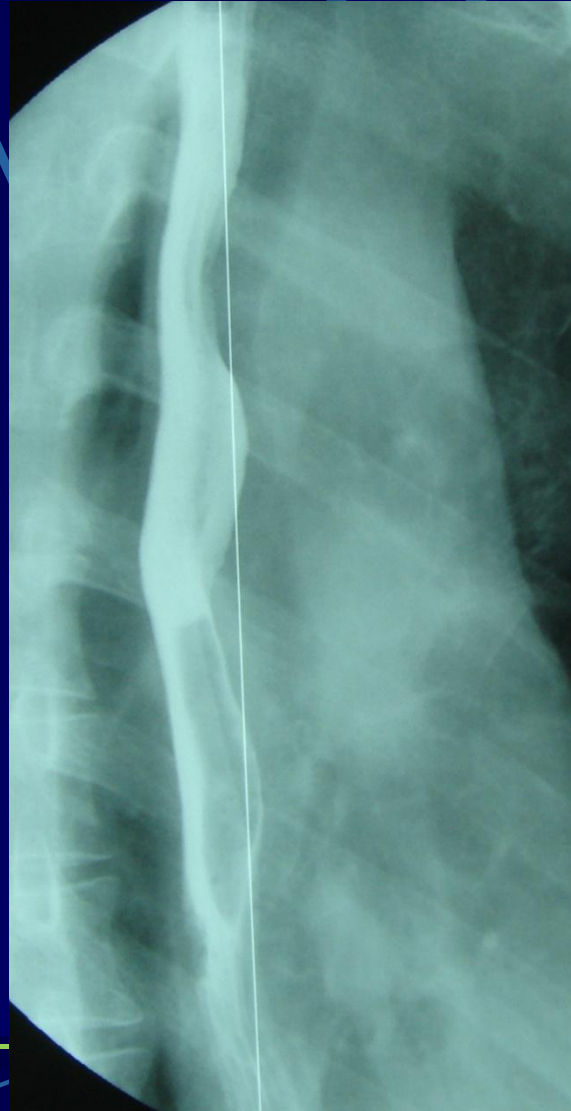
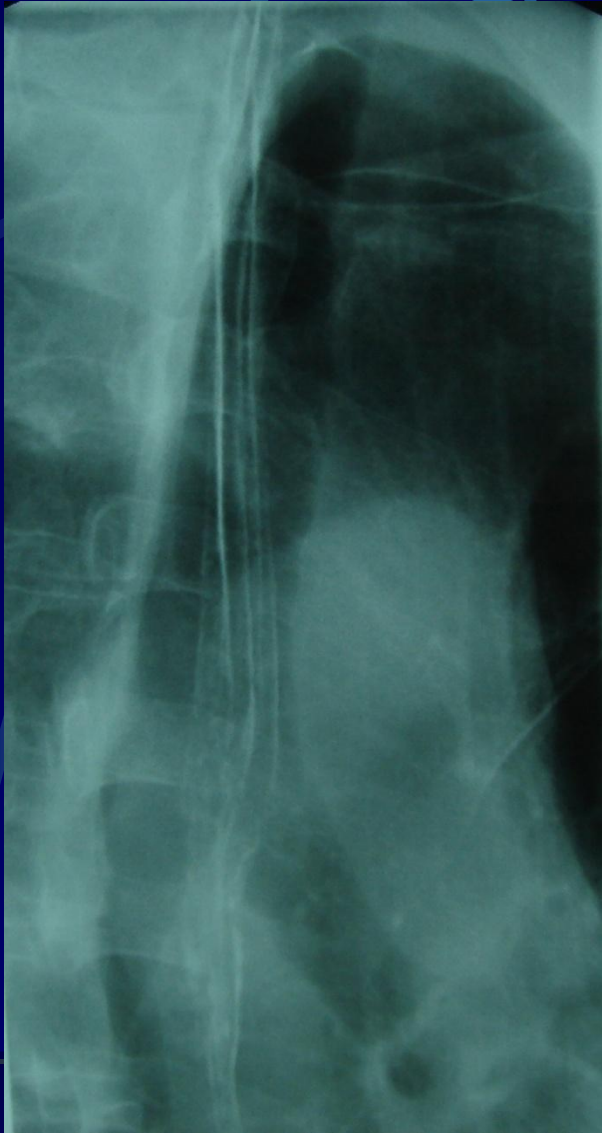


食管癌 (病例 10)

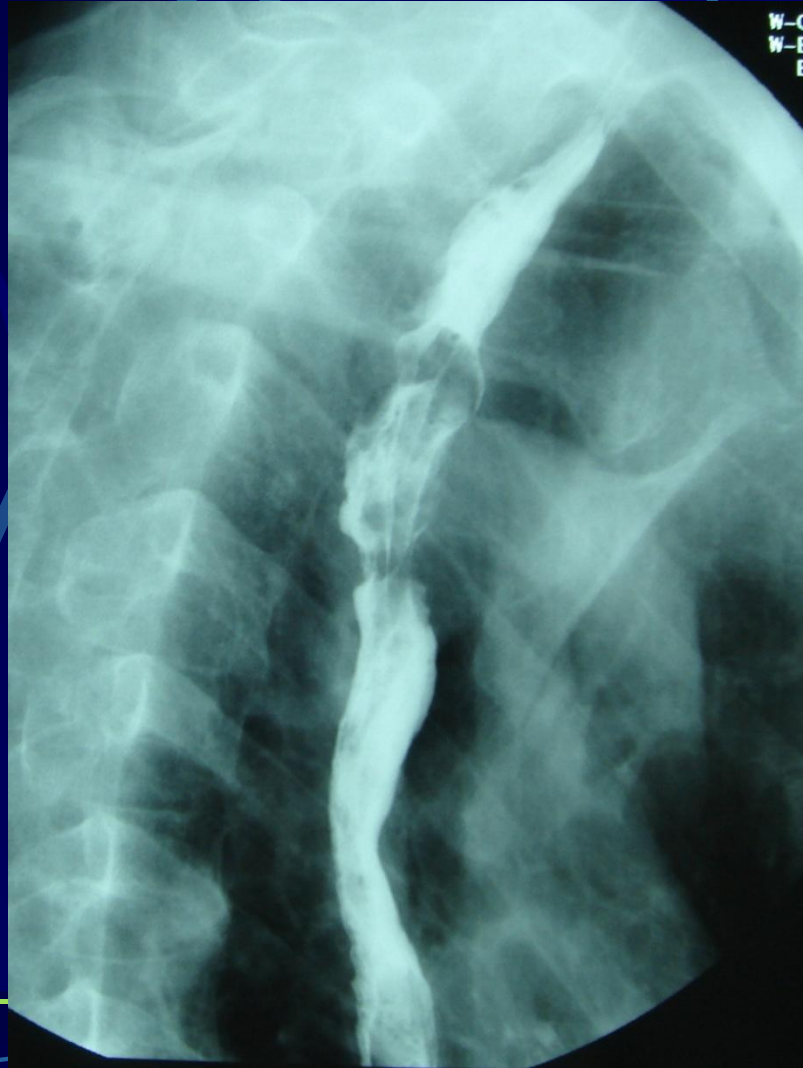
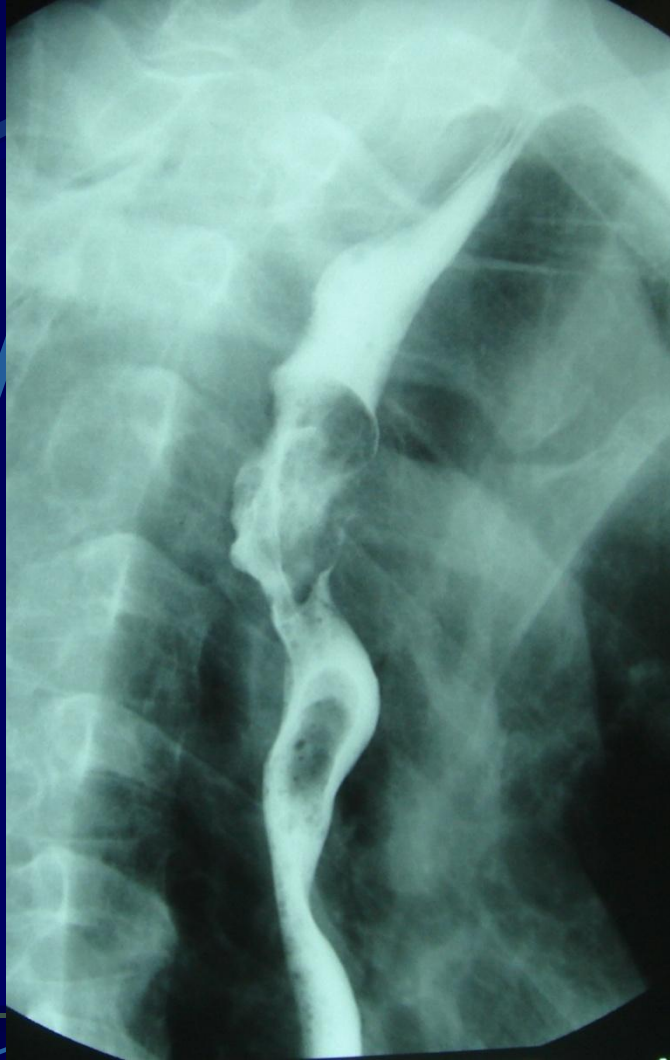食管癌（病例11）



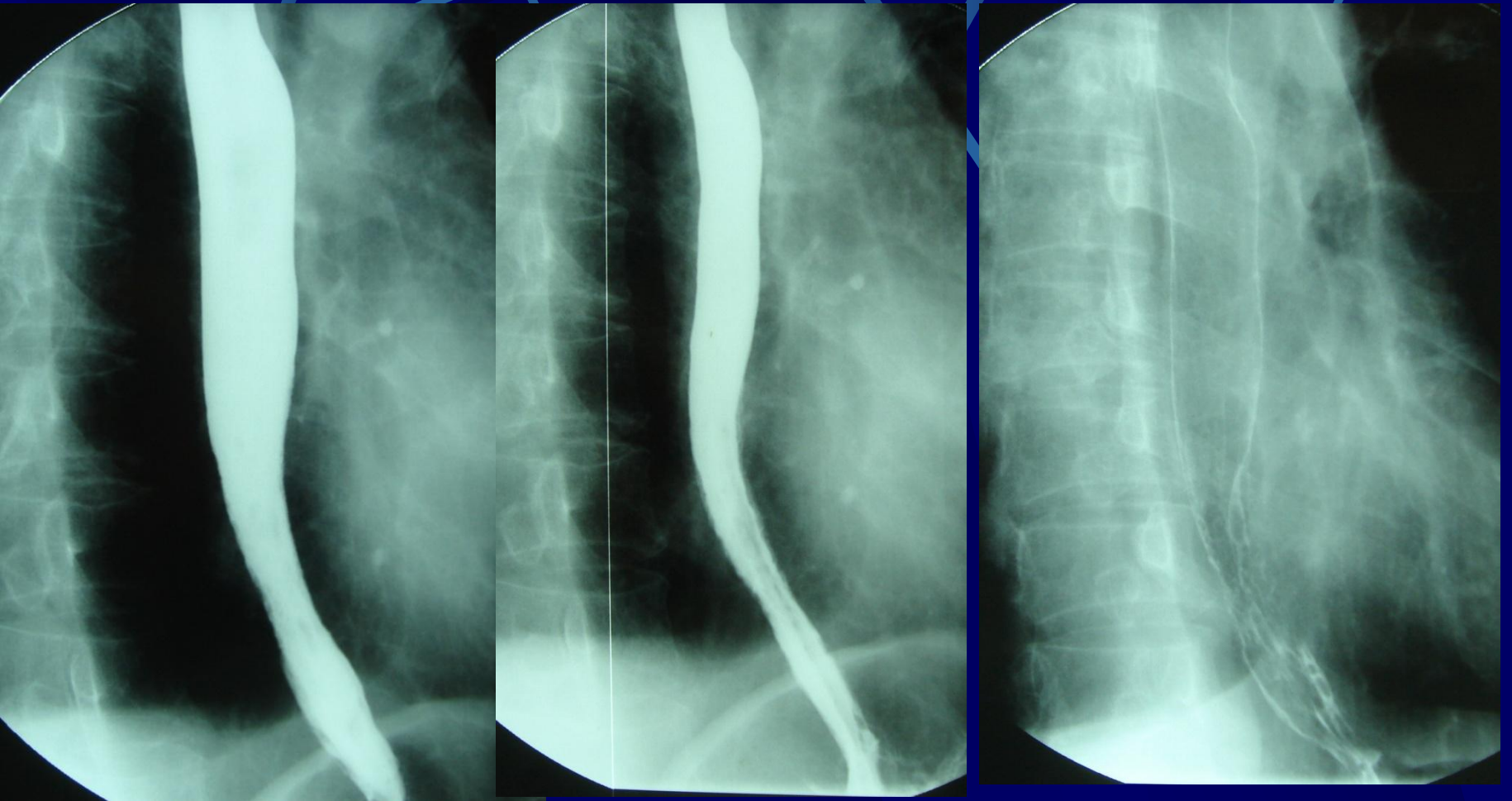
食管癌（病例12）



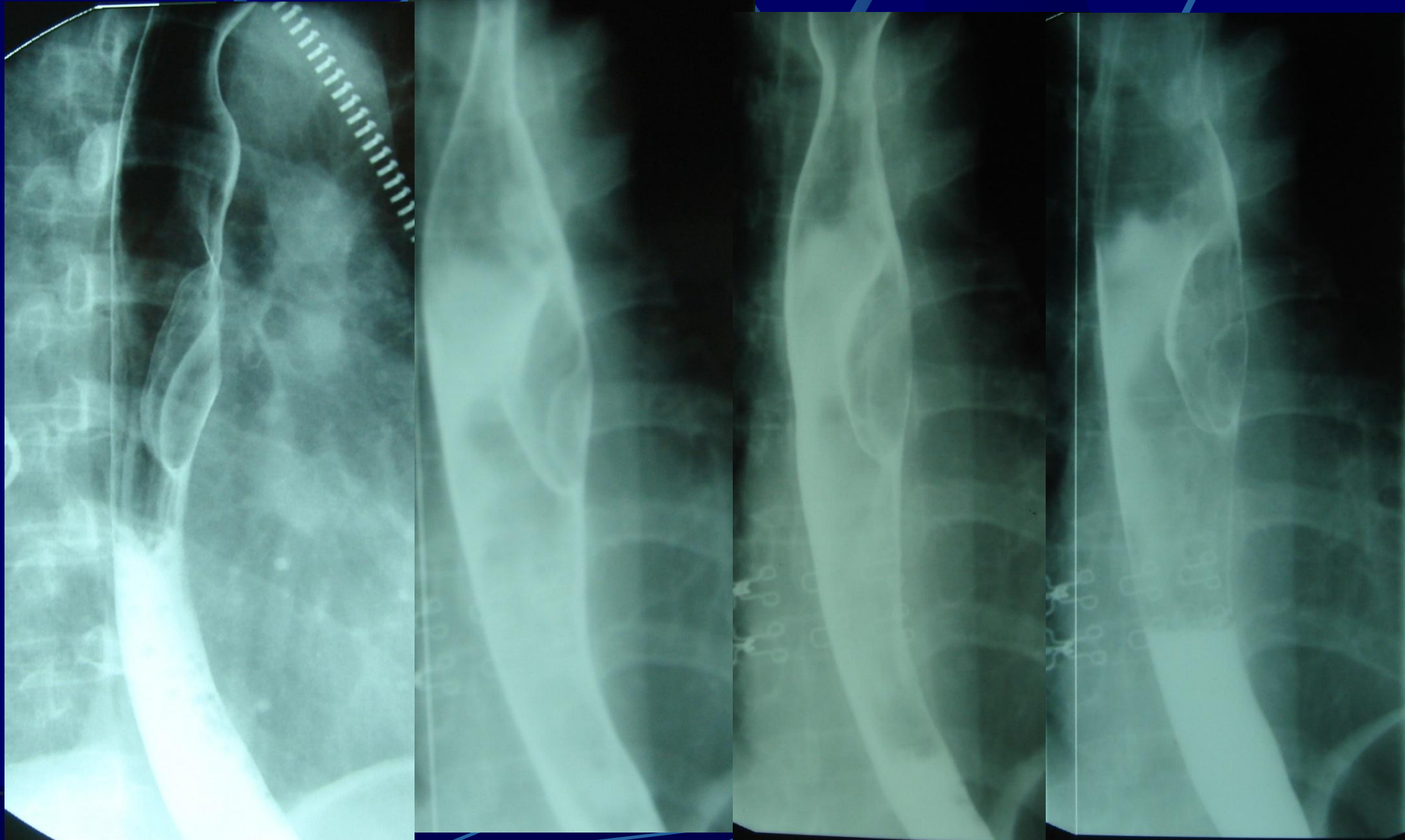
食管癌（病例13）

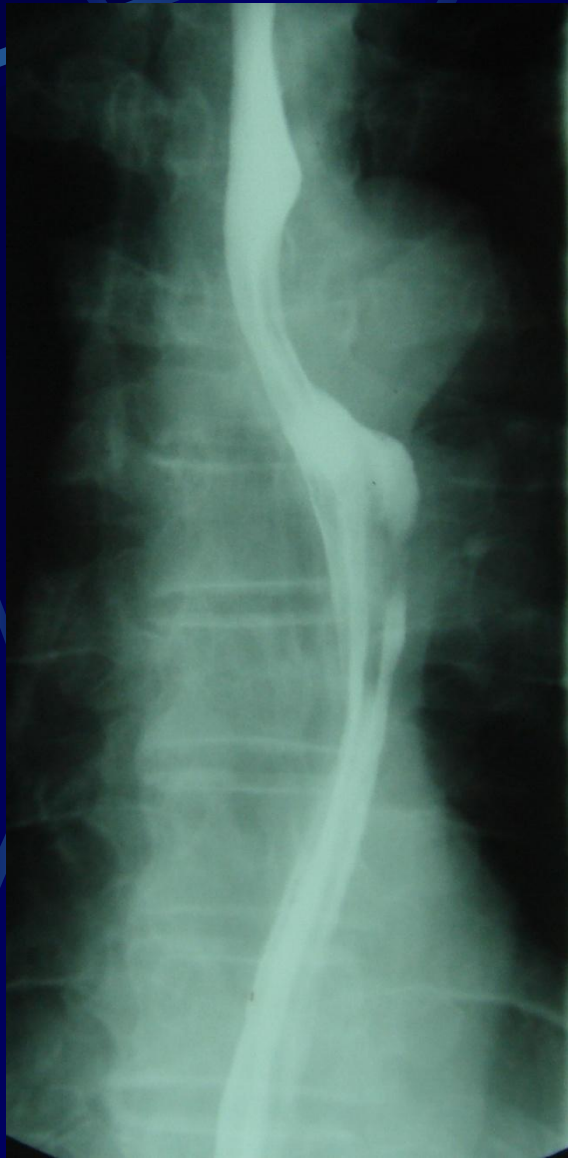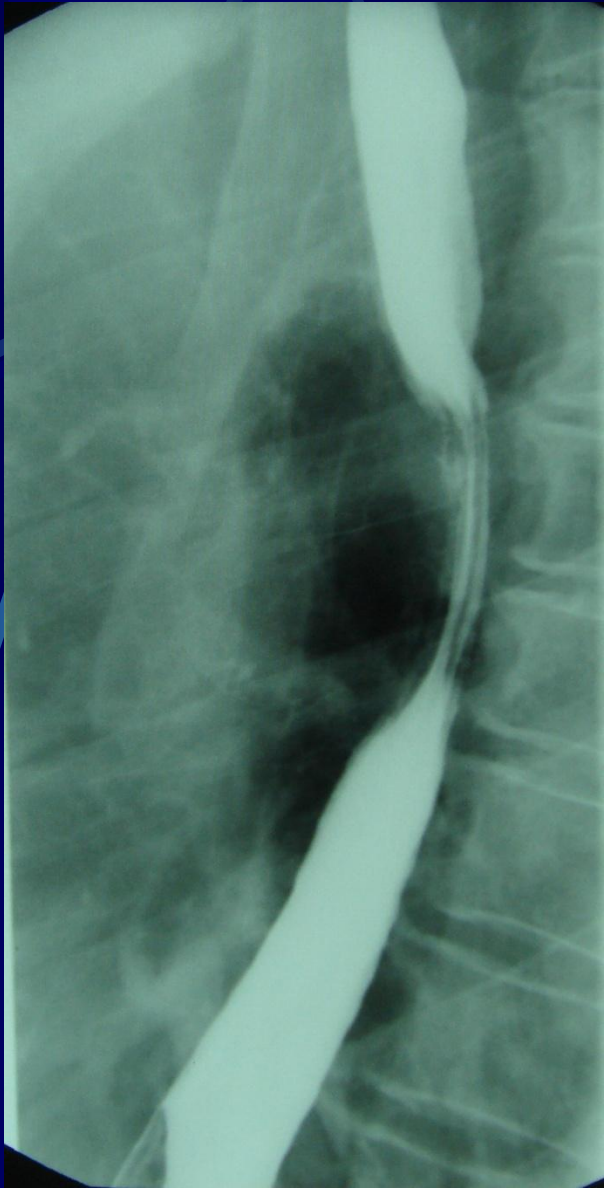


食管癌（病例14）



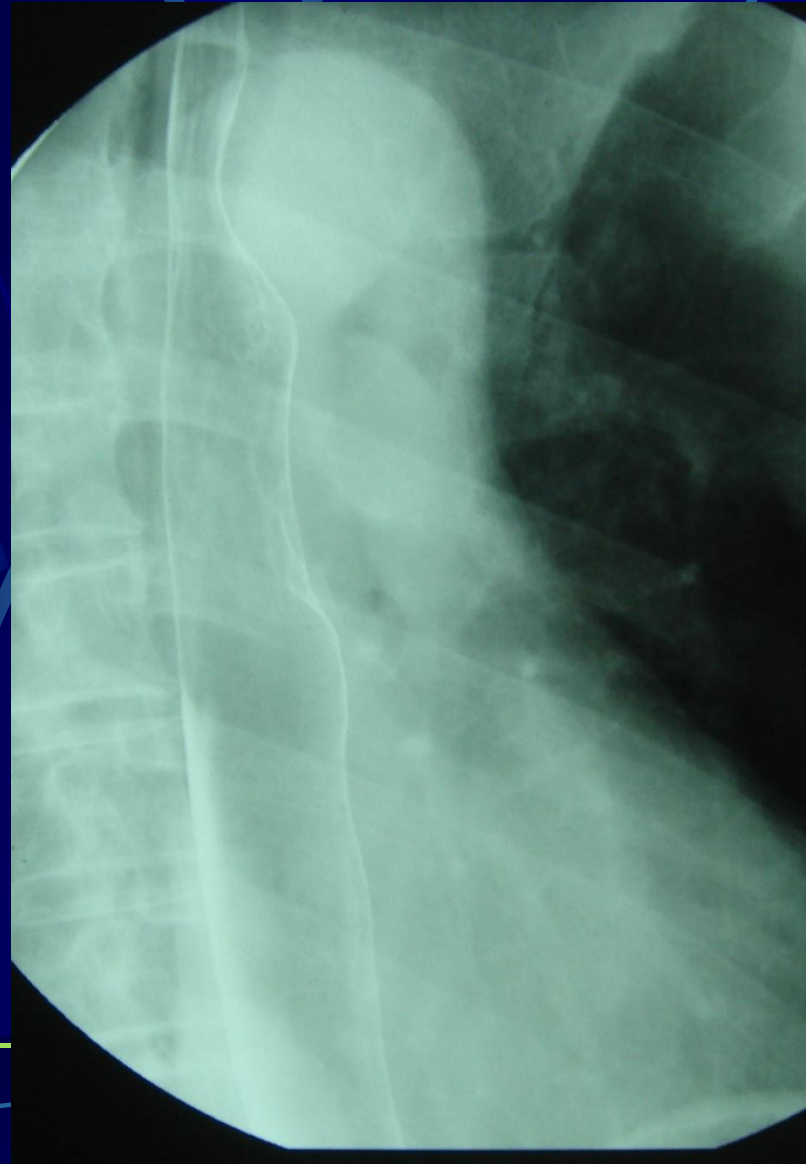
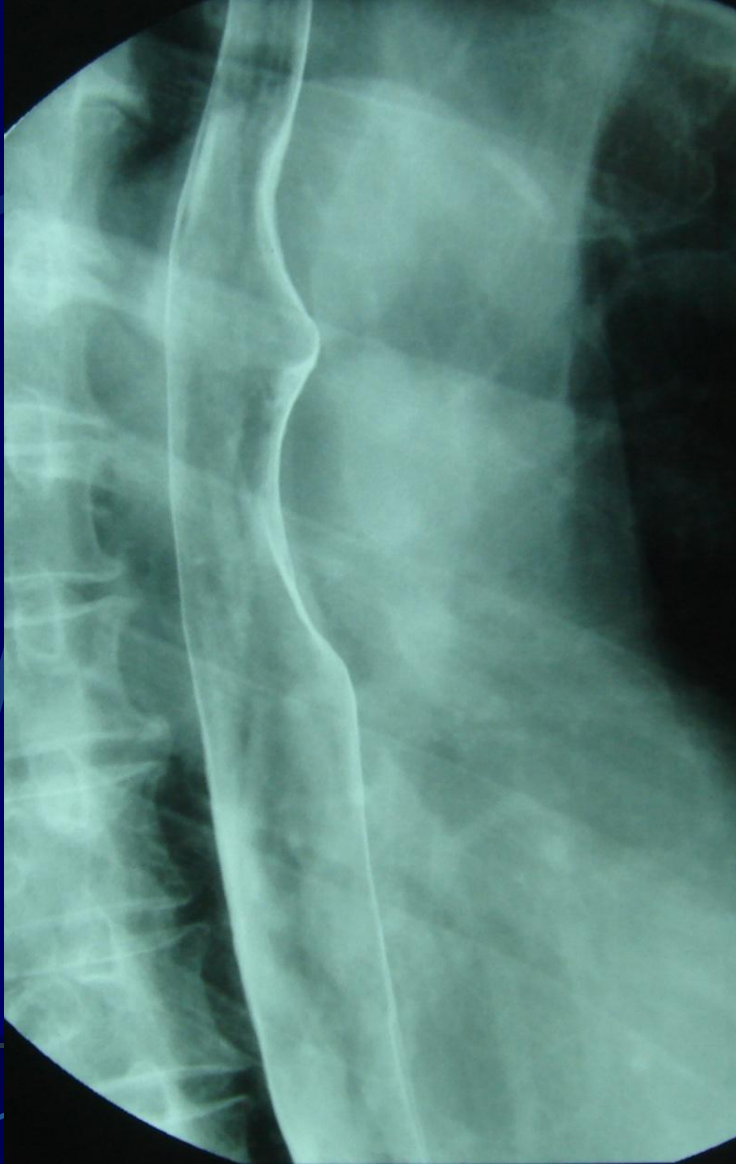
食管癌（病例15）



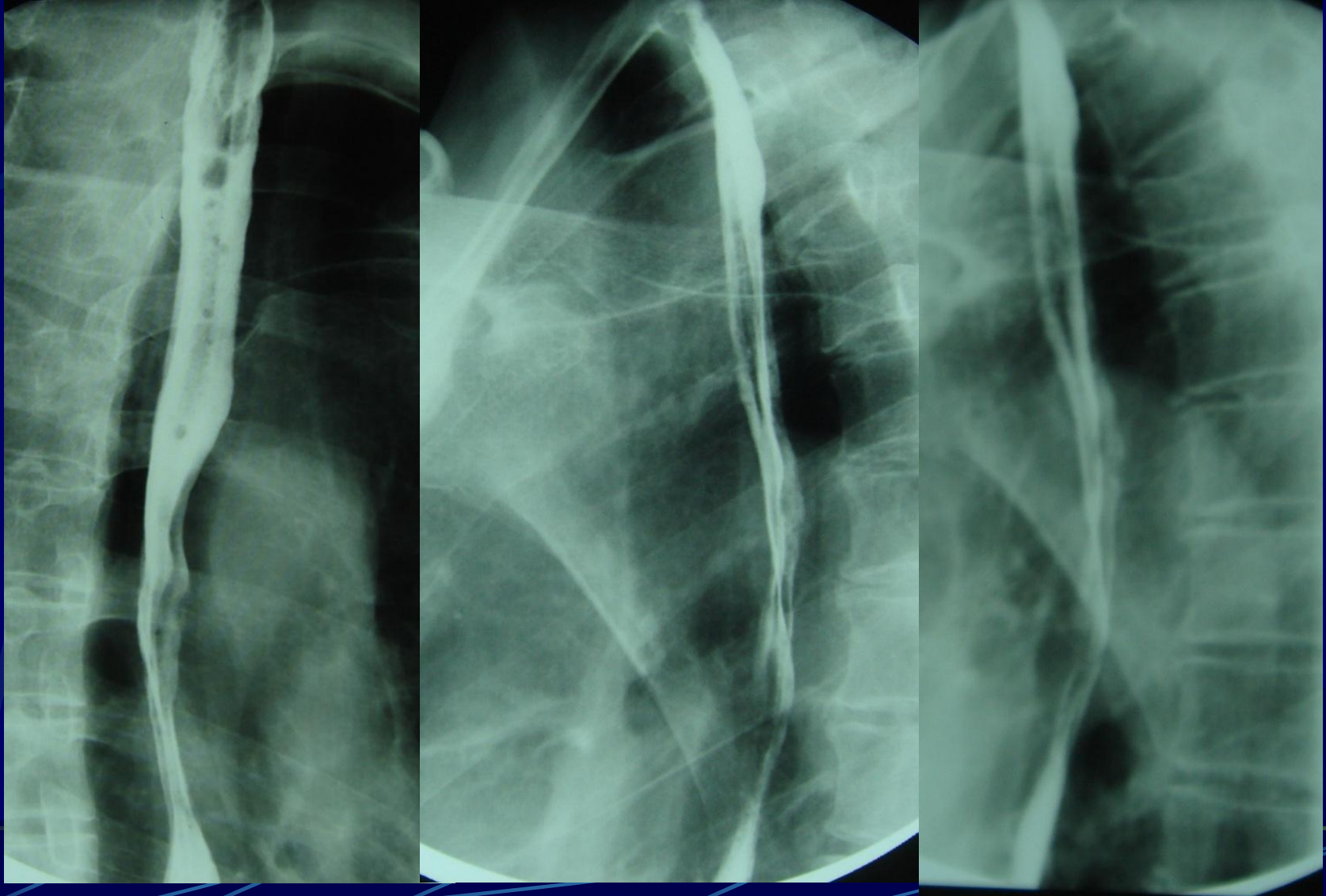


食管癌
(病例16)

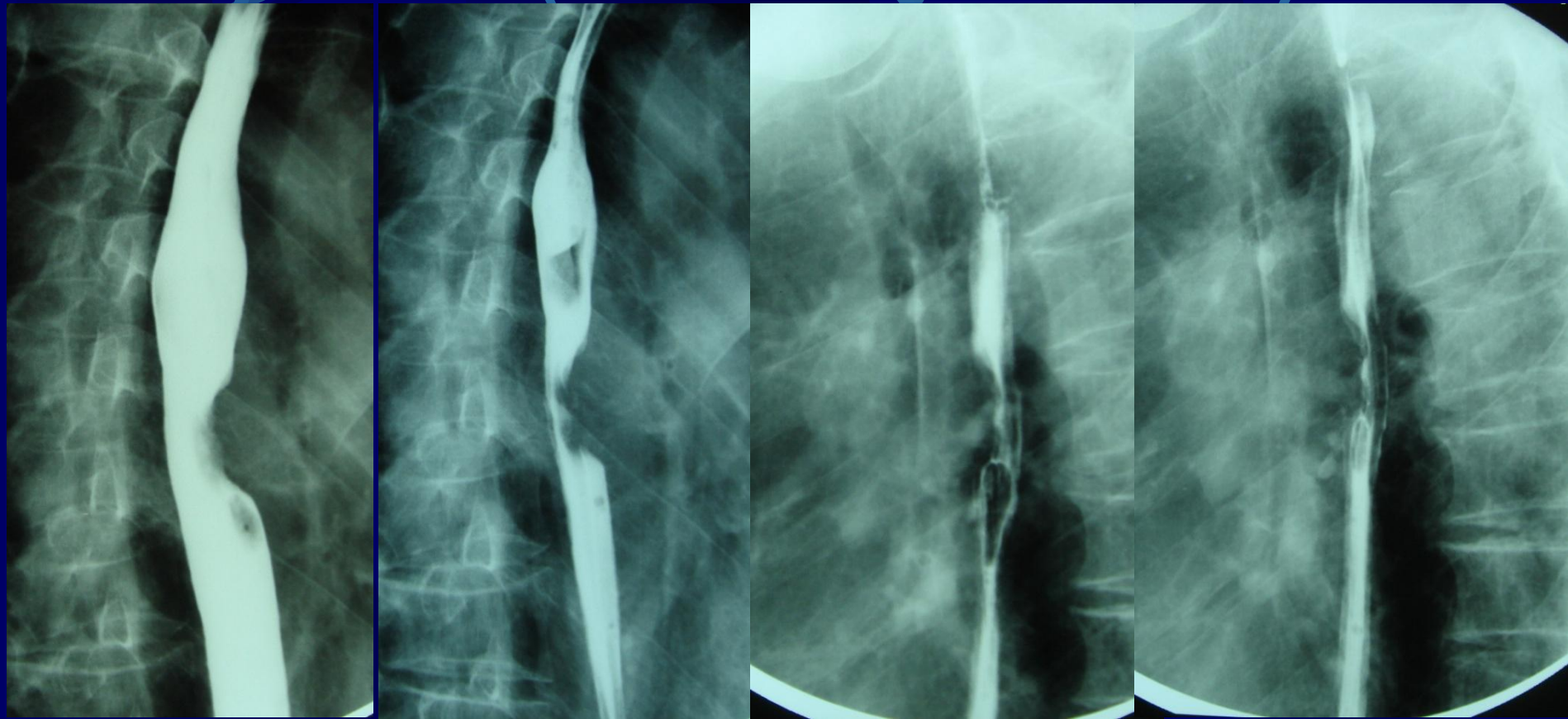
食管癌（病例16）



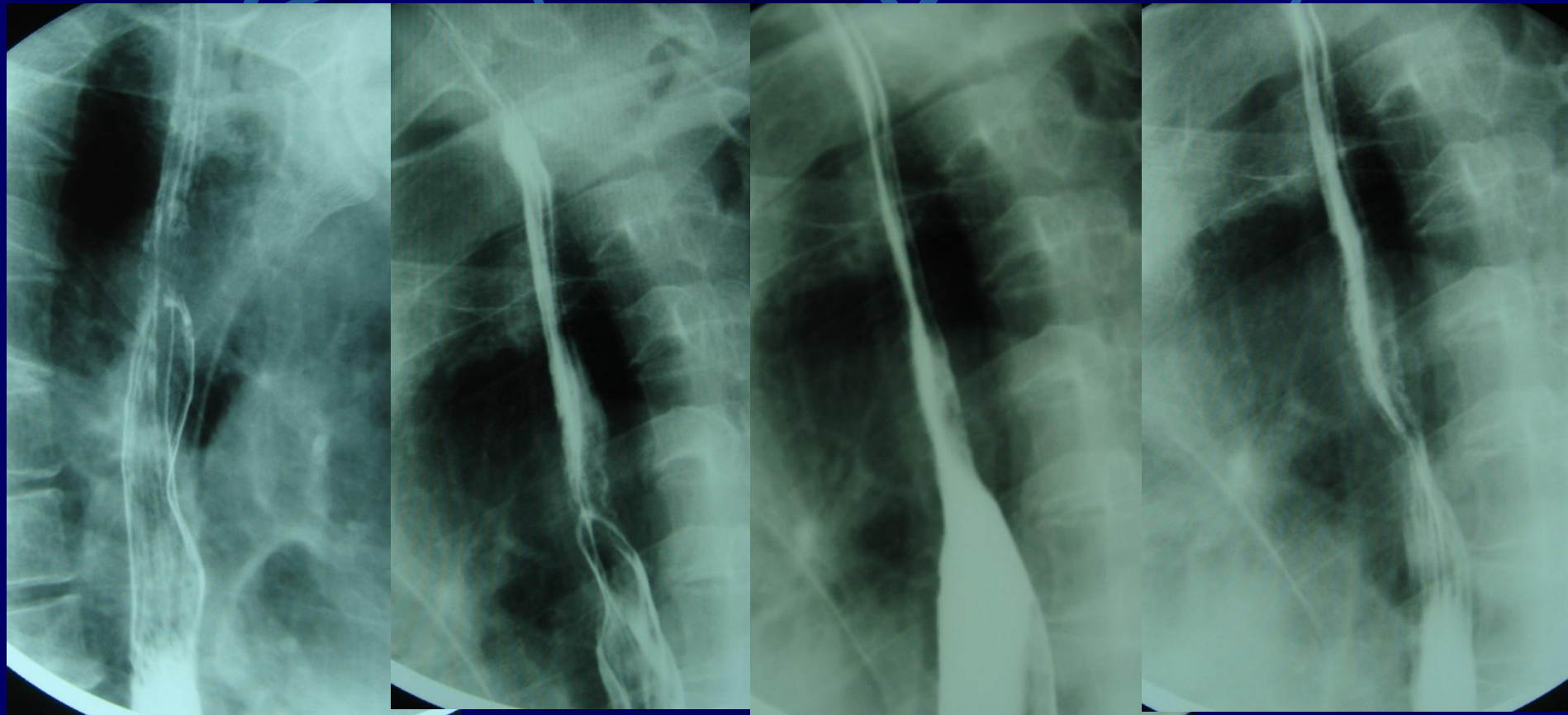
食管癌（病例17）



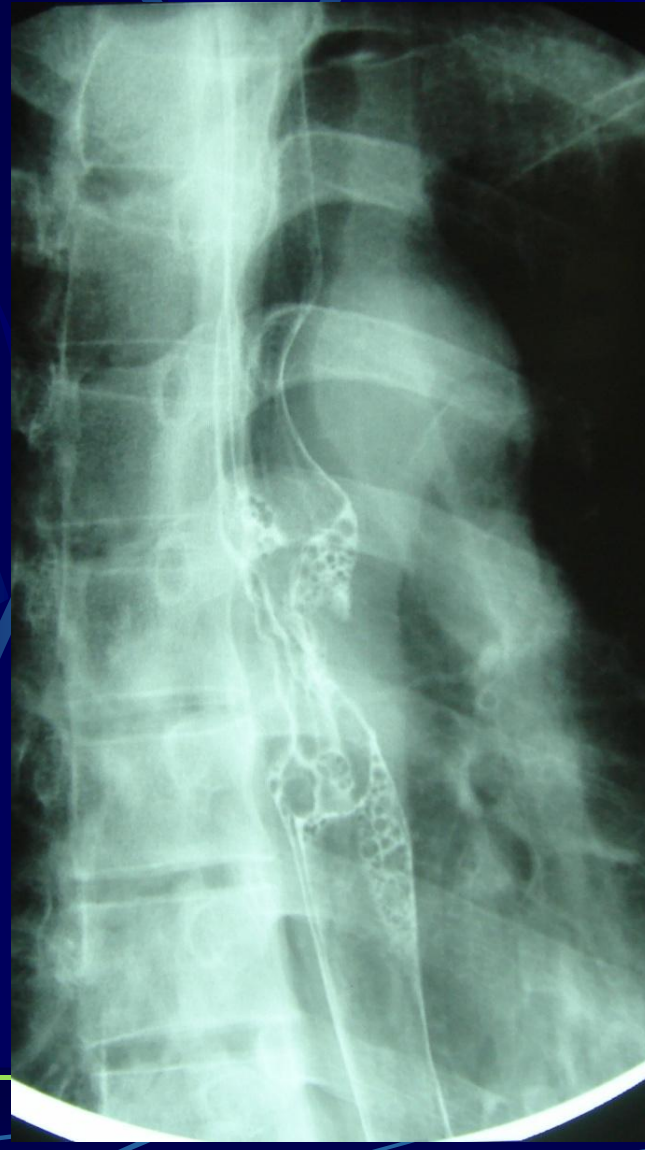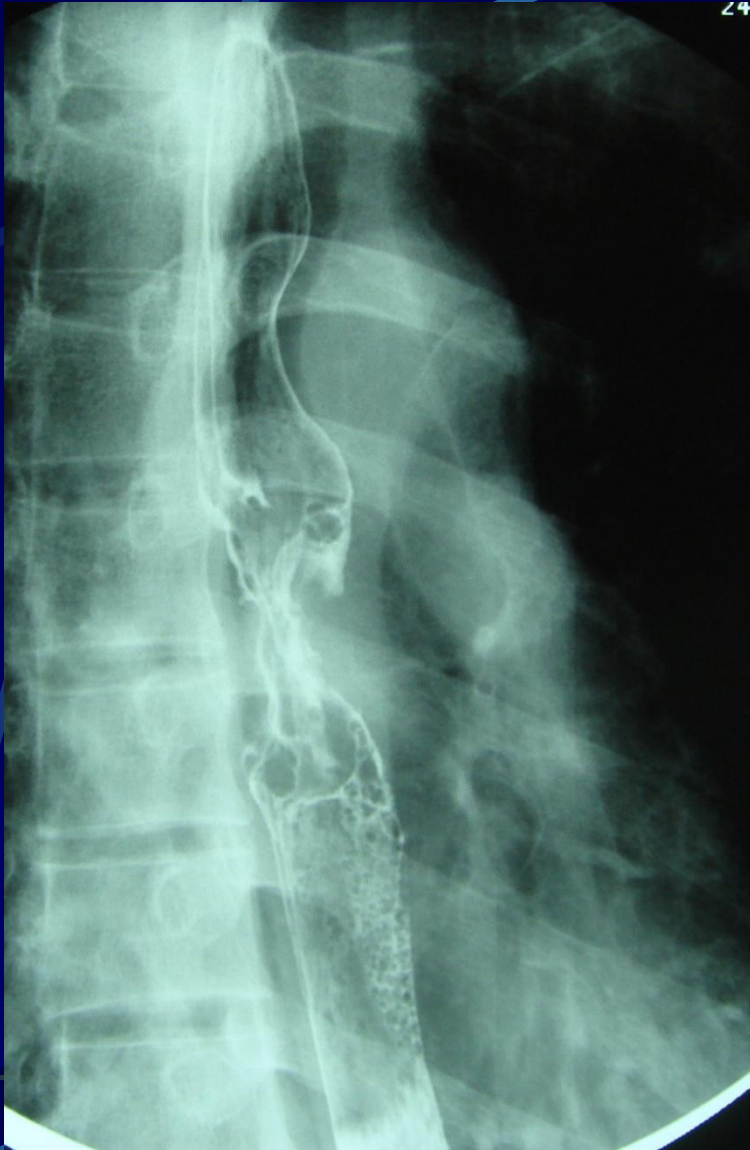食管癌（病例18）



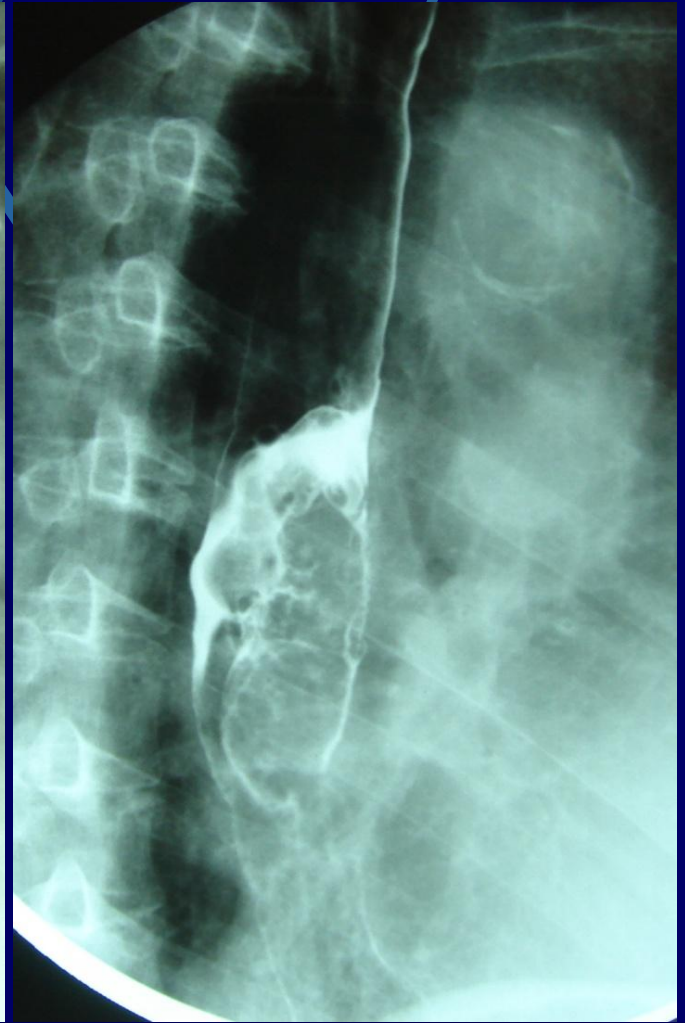
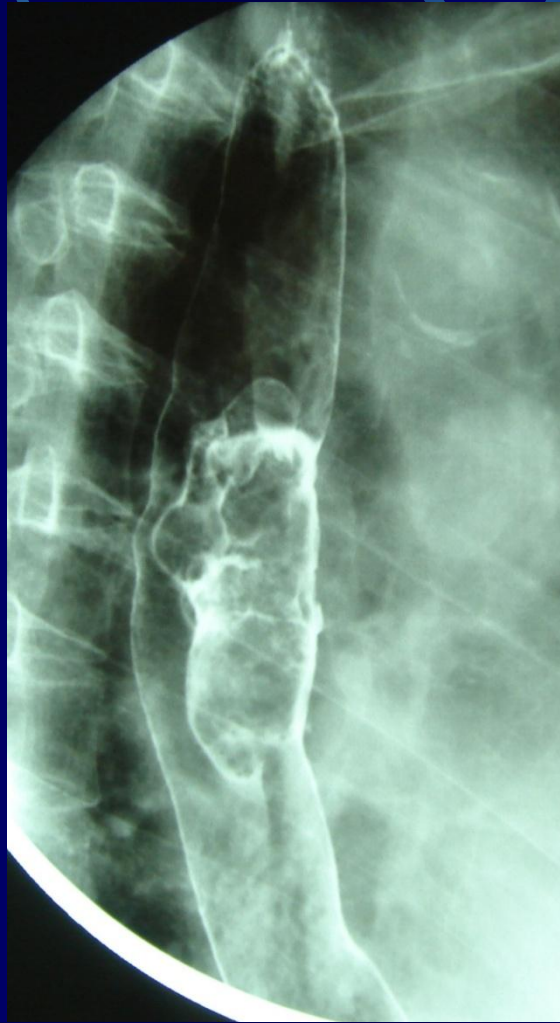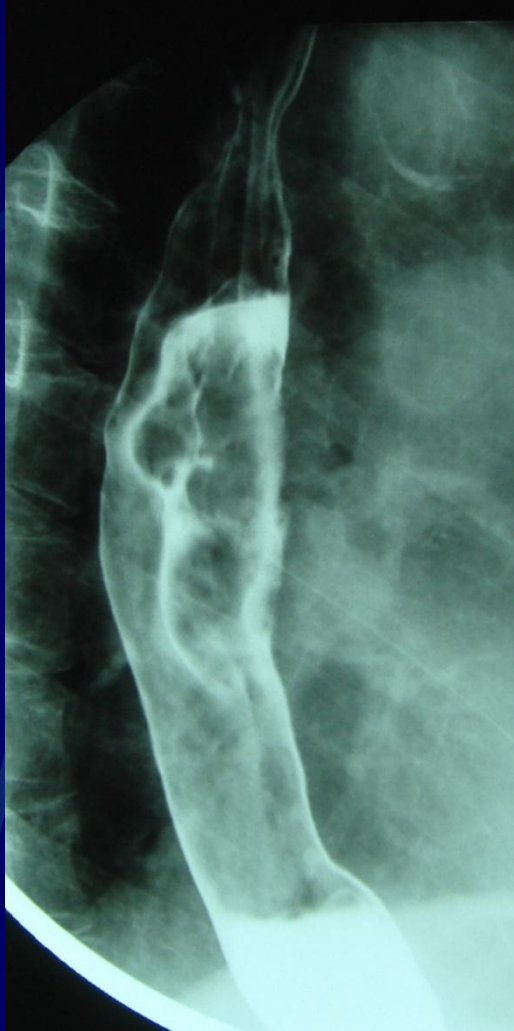
食管癌（病例19）



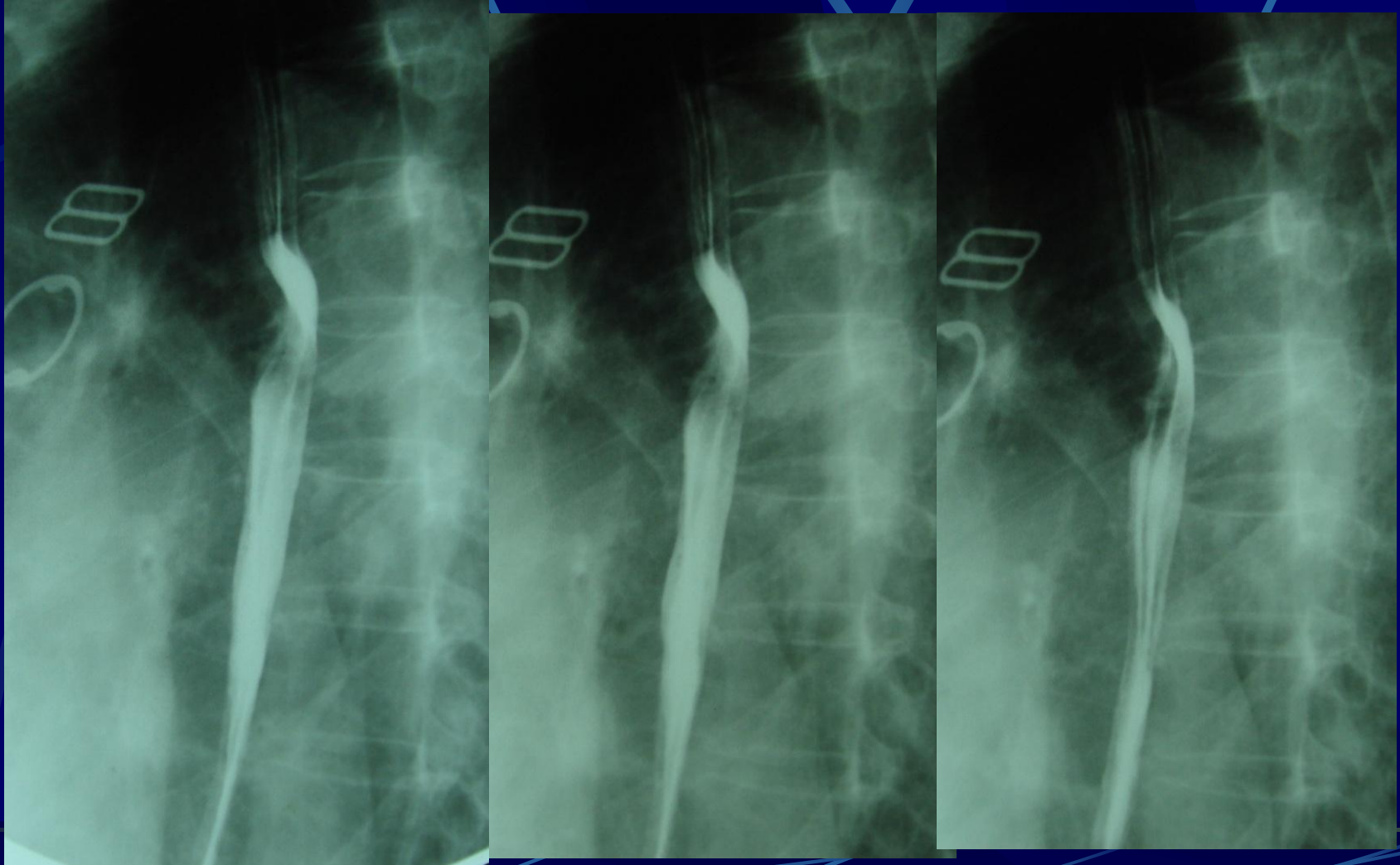
食管癌（病例20）



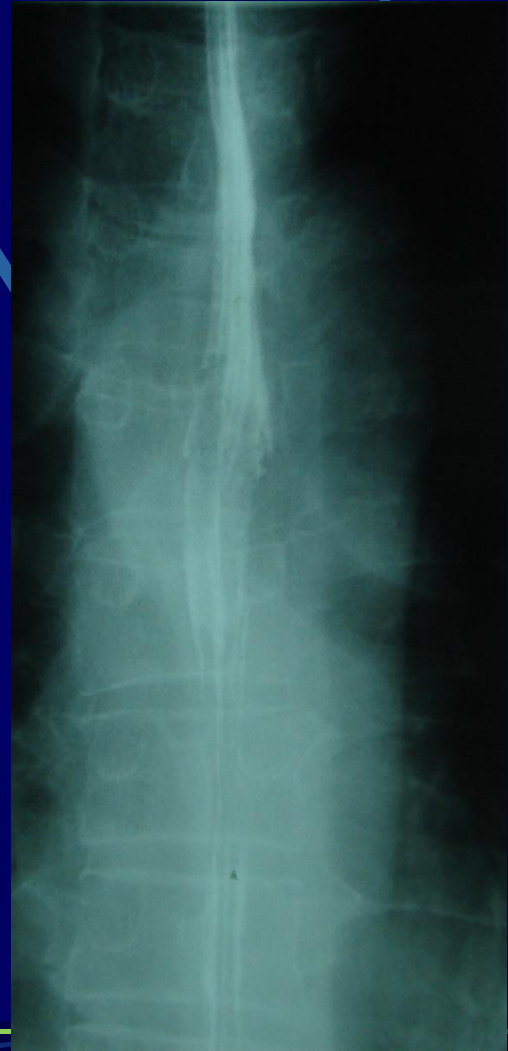
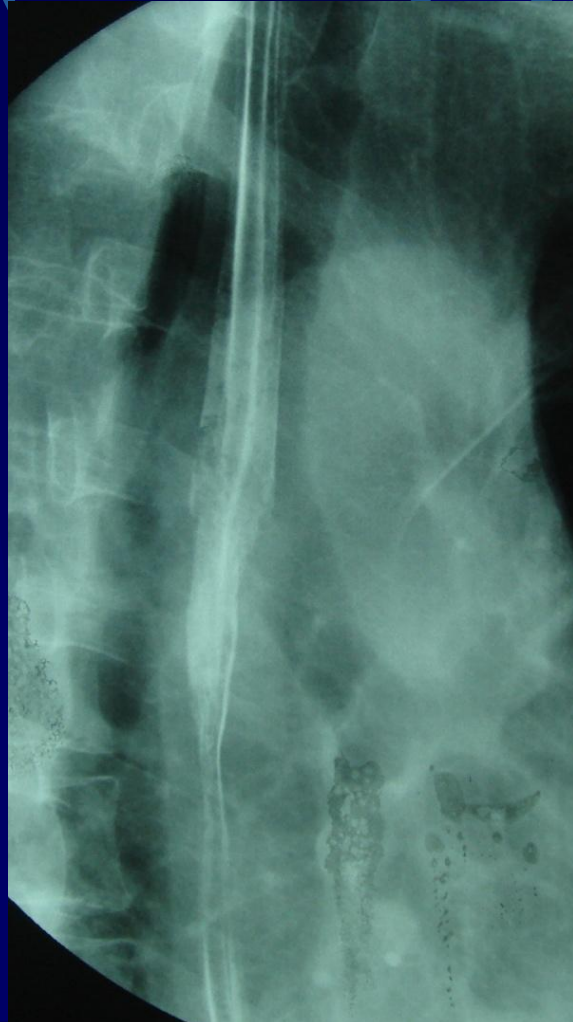
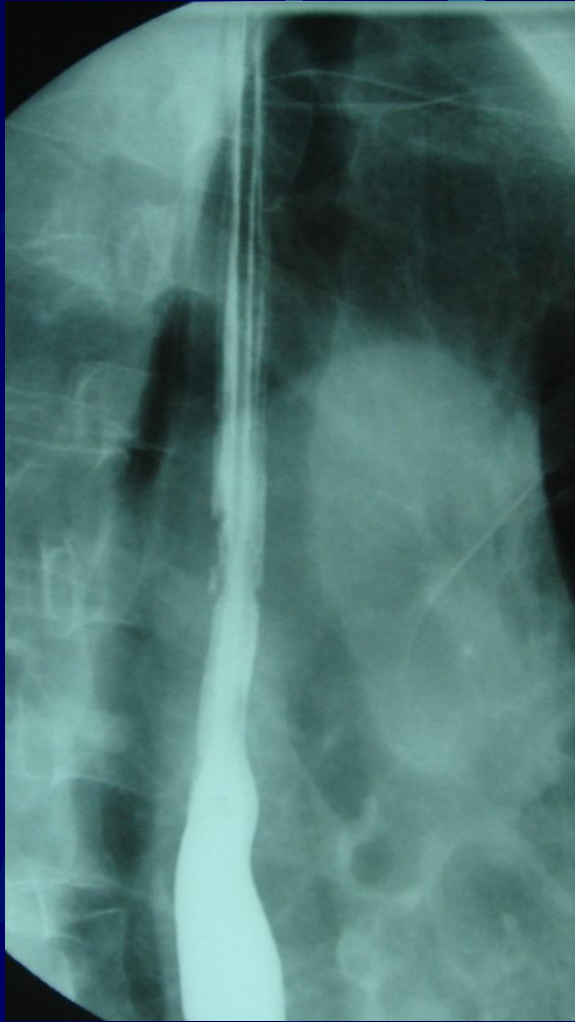
食管癌（病例20）



食管癌（病例21）

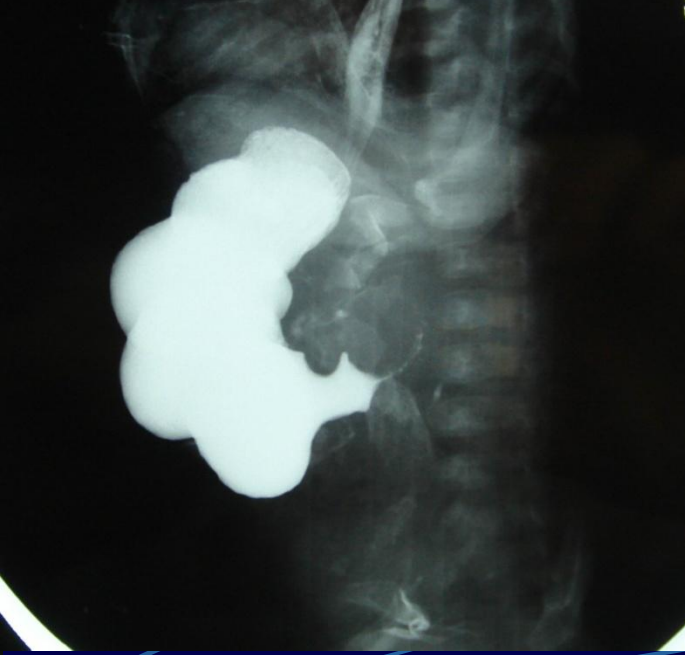
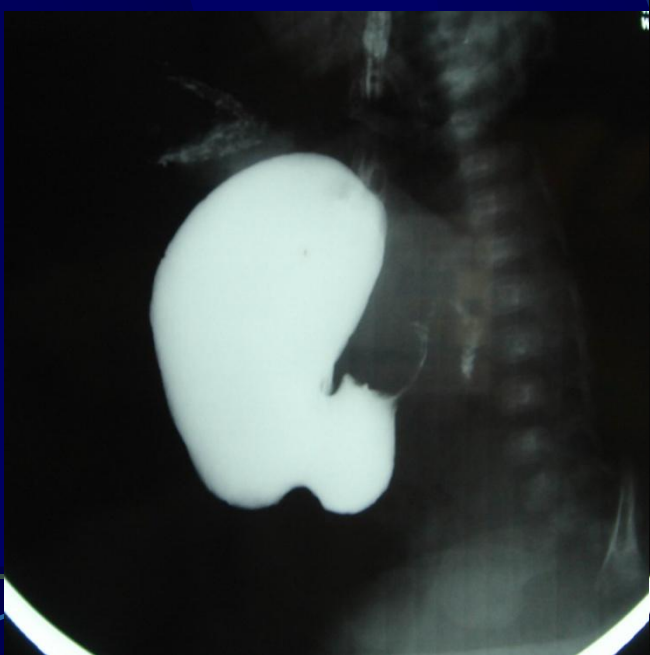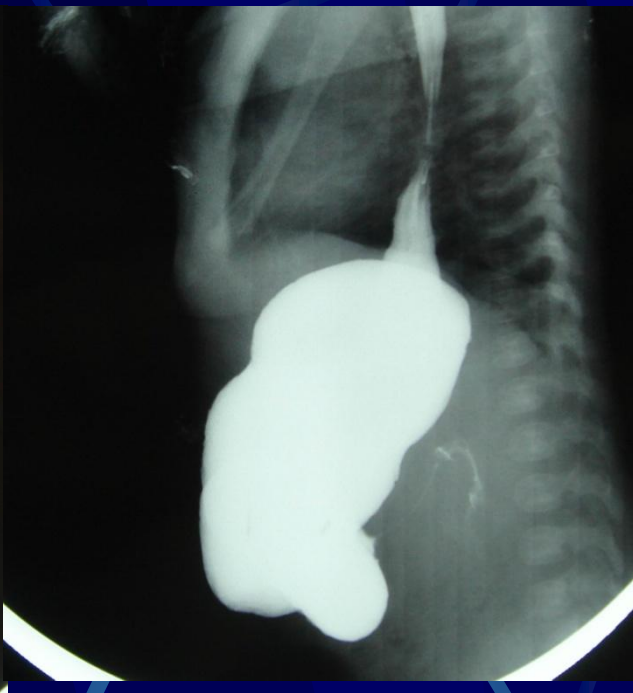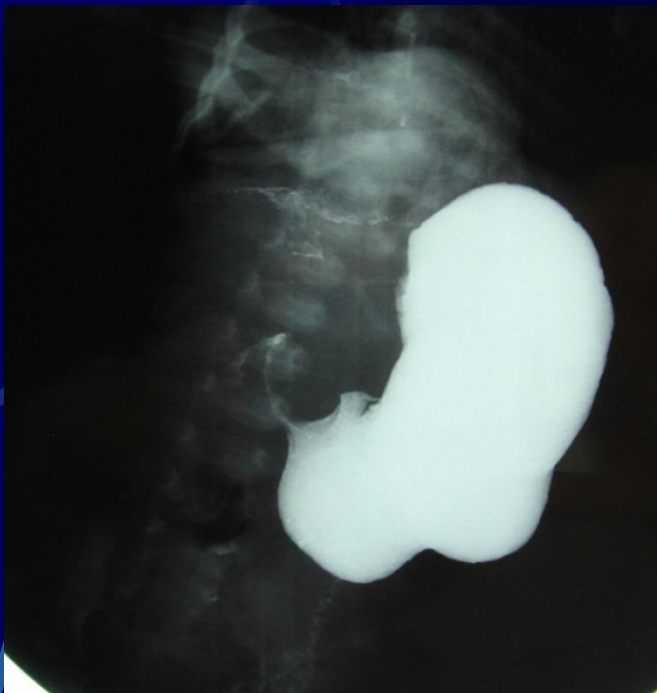


食管癌（病例22）

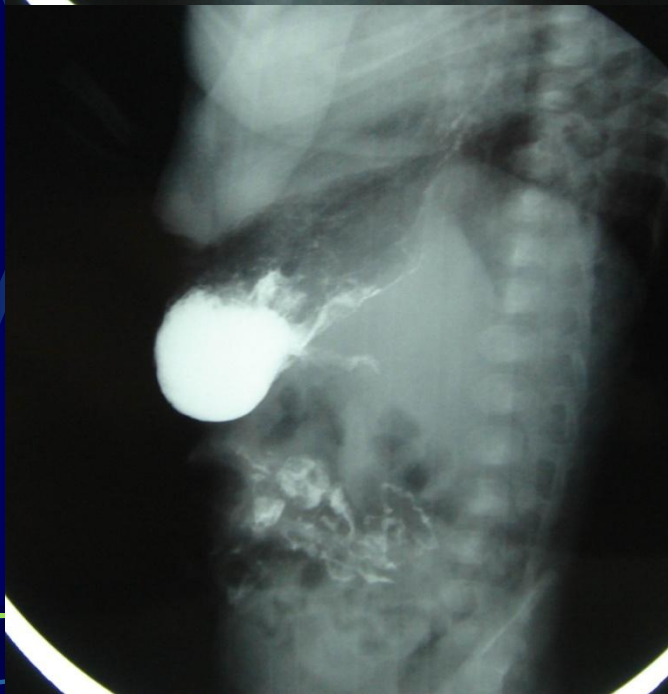
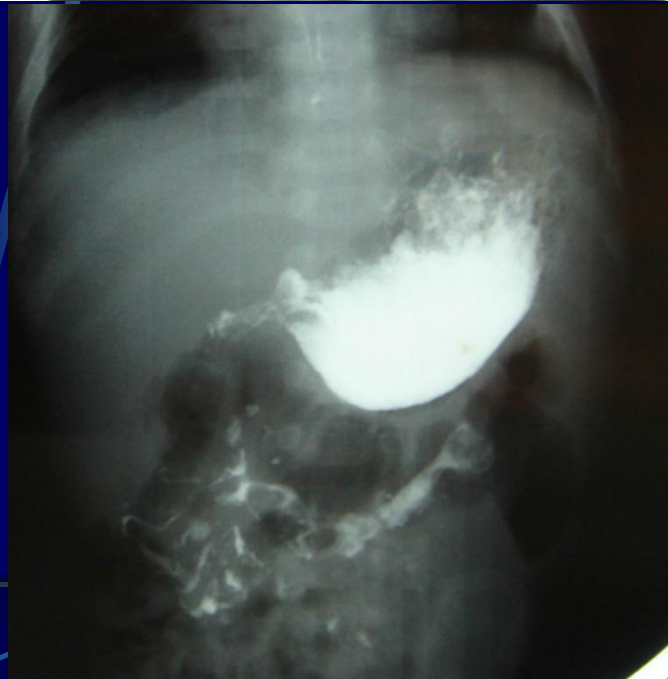
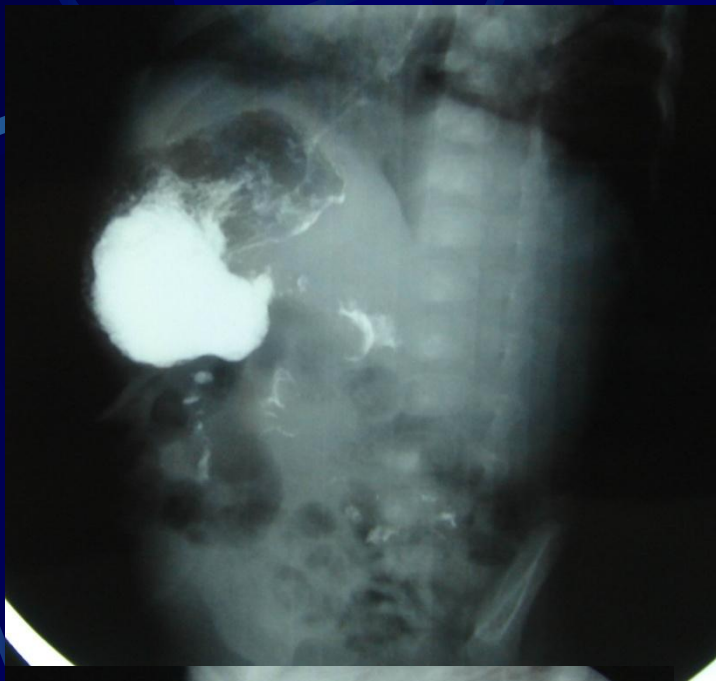
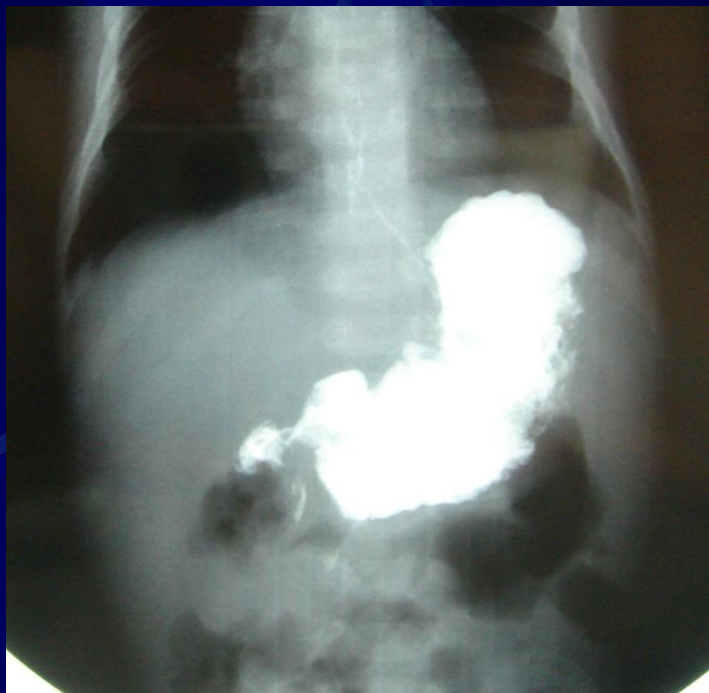
胃常见疾病

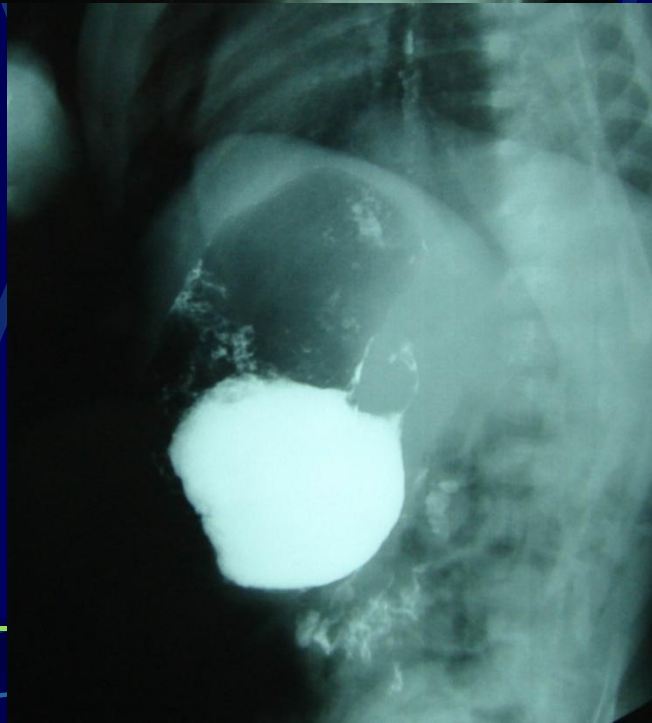
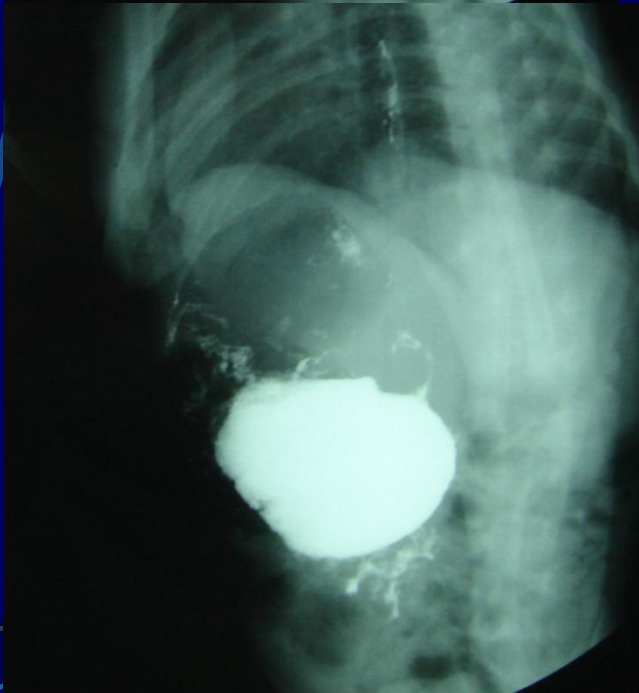
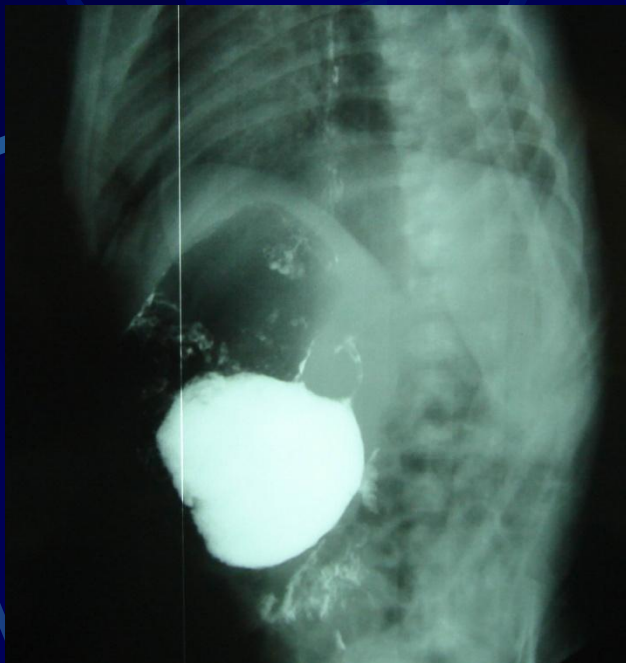
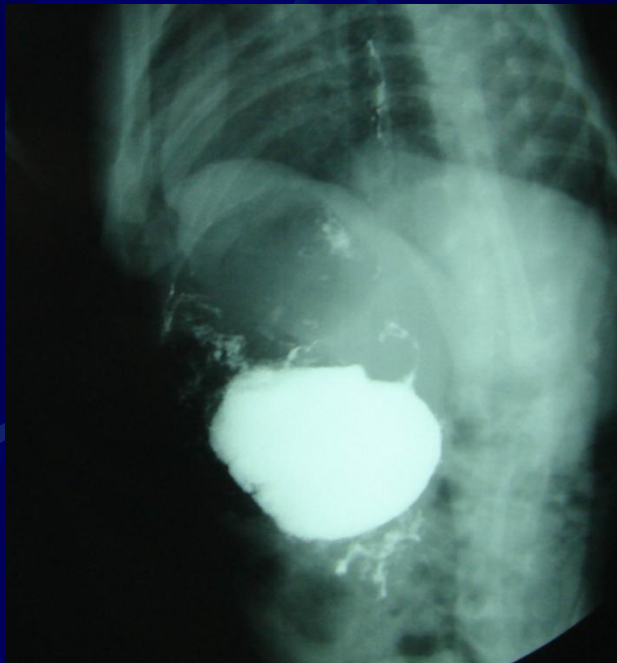
先天畸形



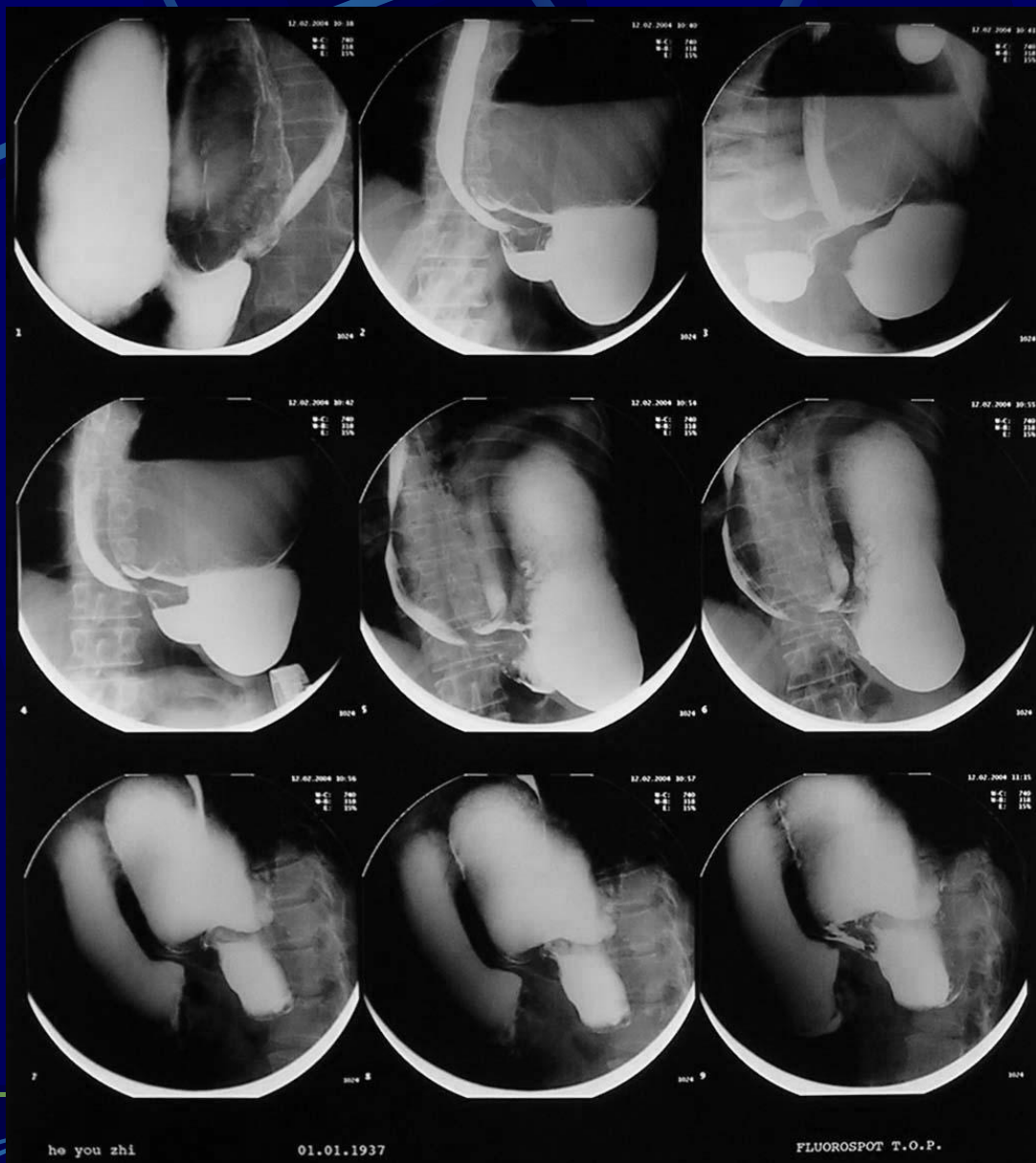先天畸形



先天畸形



胃扭转（器官轴型）伴幽门梗阻

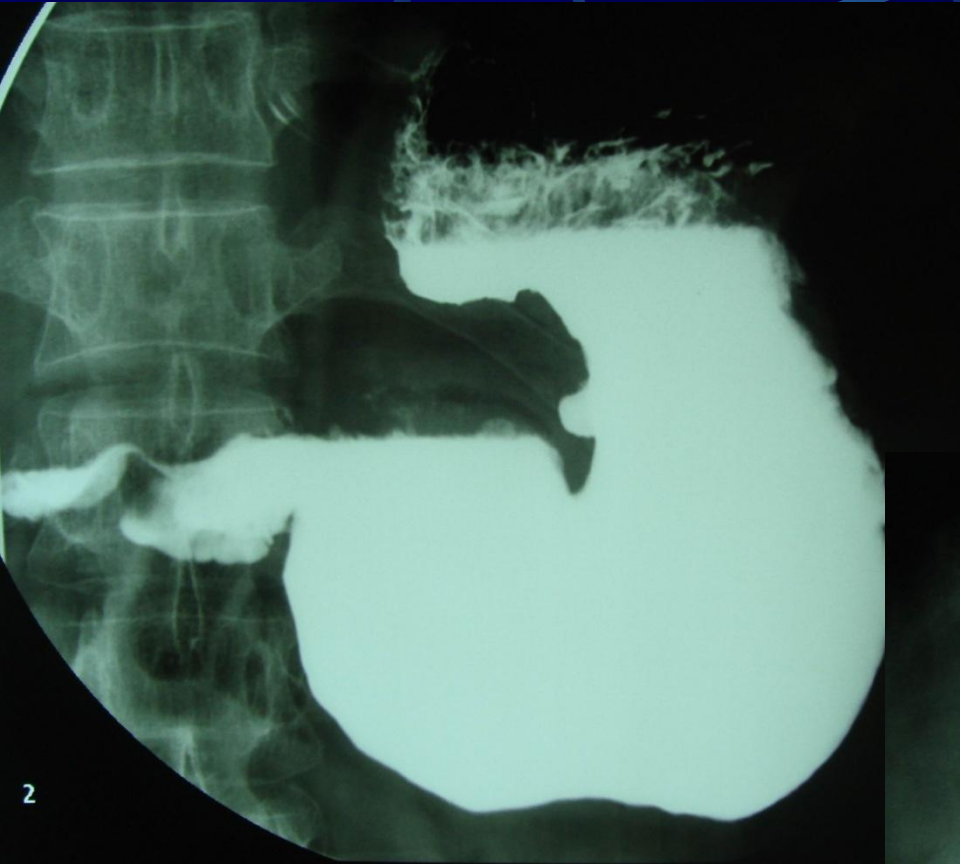


胃溃疡

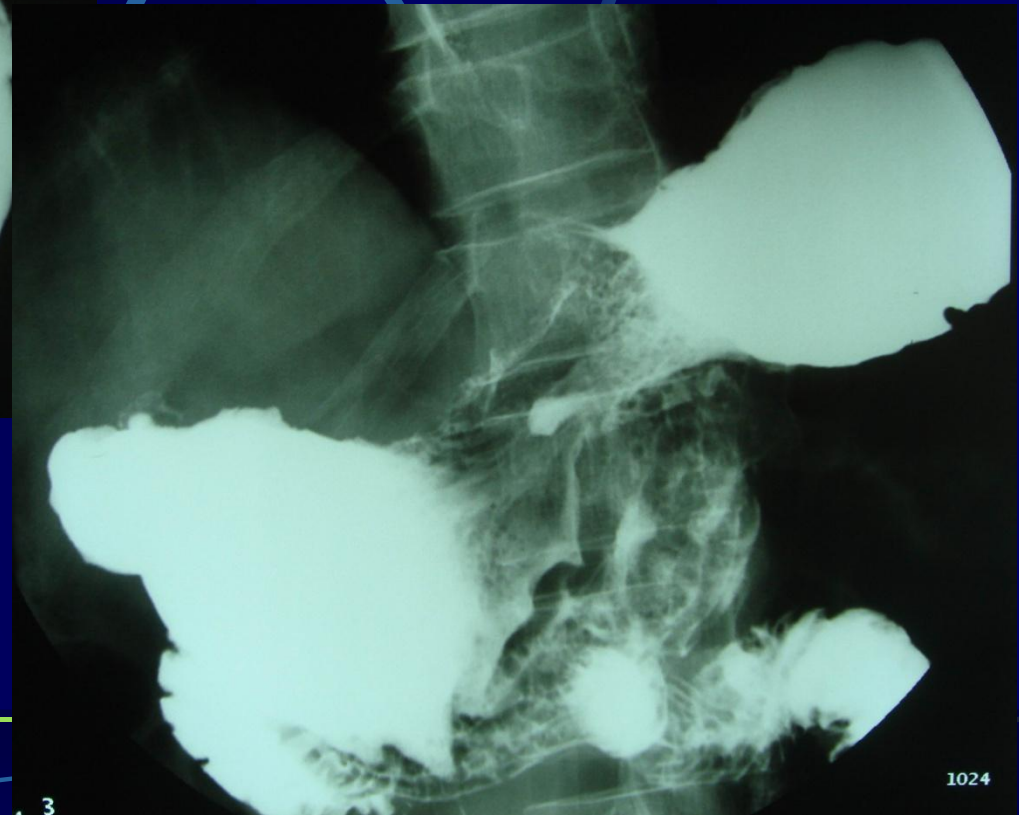
1. 钡斑
2. 环状影
3. 腔外龛影
4. 腔壁线局限性增厚
5. 线状龛影
6. 粘膜纠集
7. 胃小区、胃小沟改变
8. 其他继发改变



胃溃疡

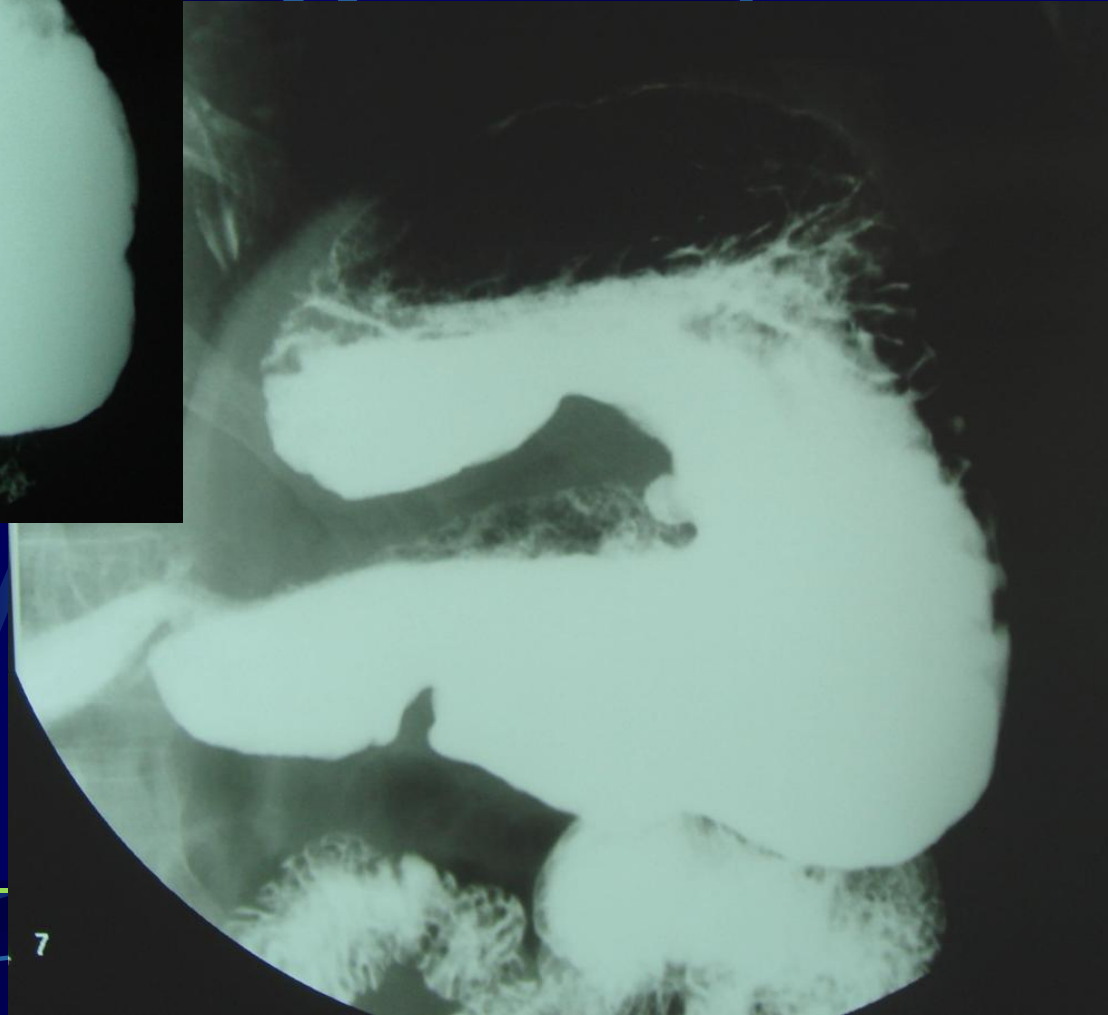
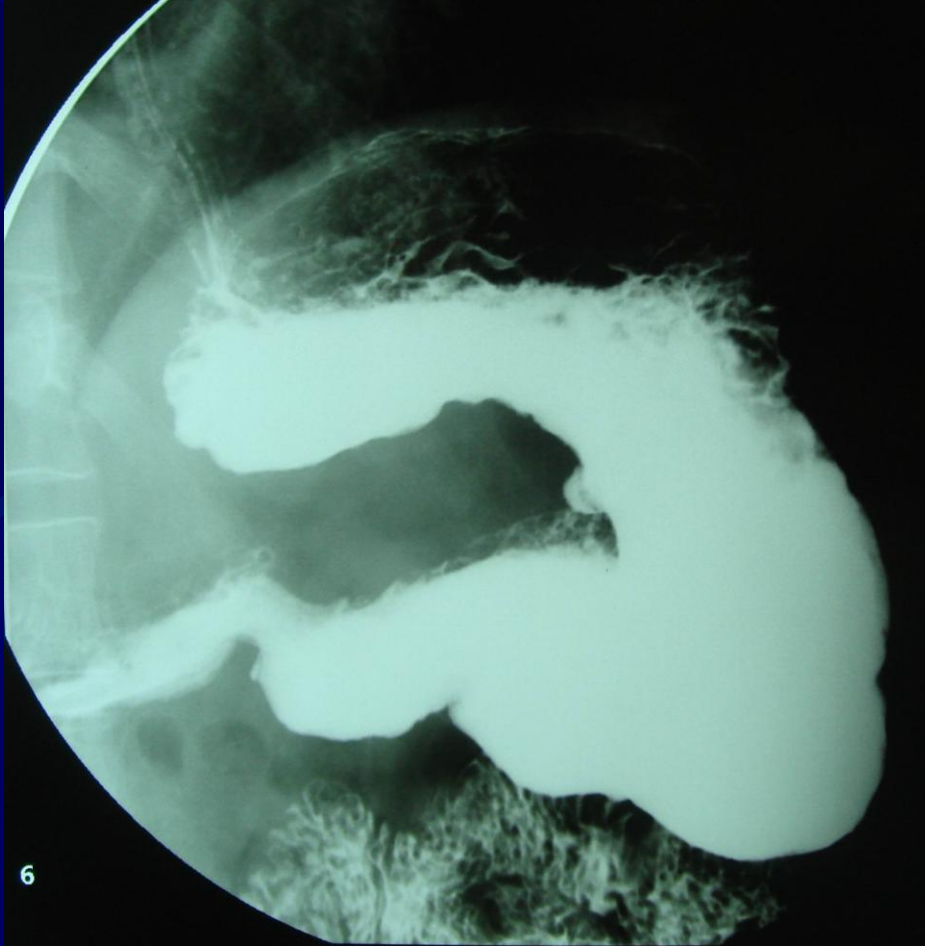


2

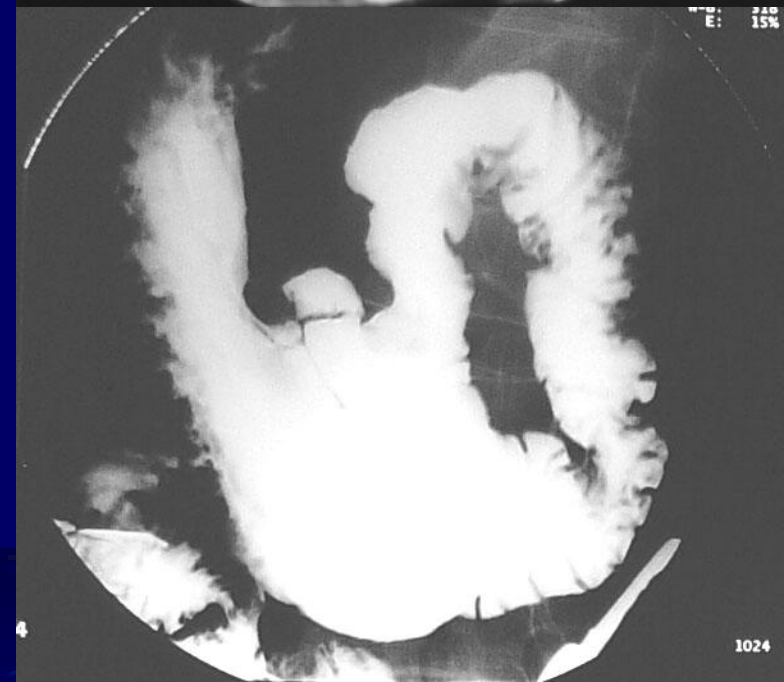
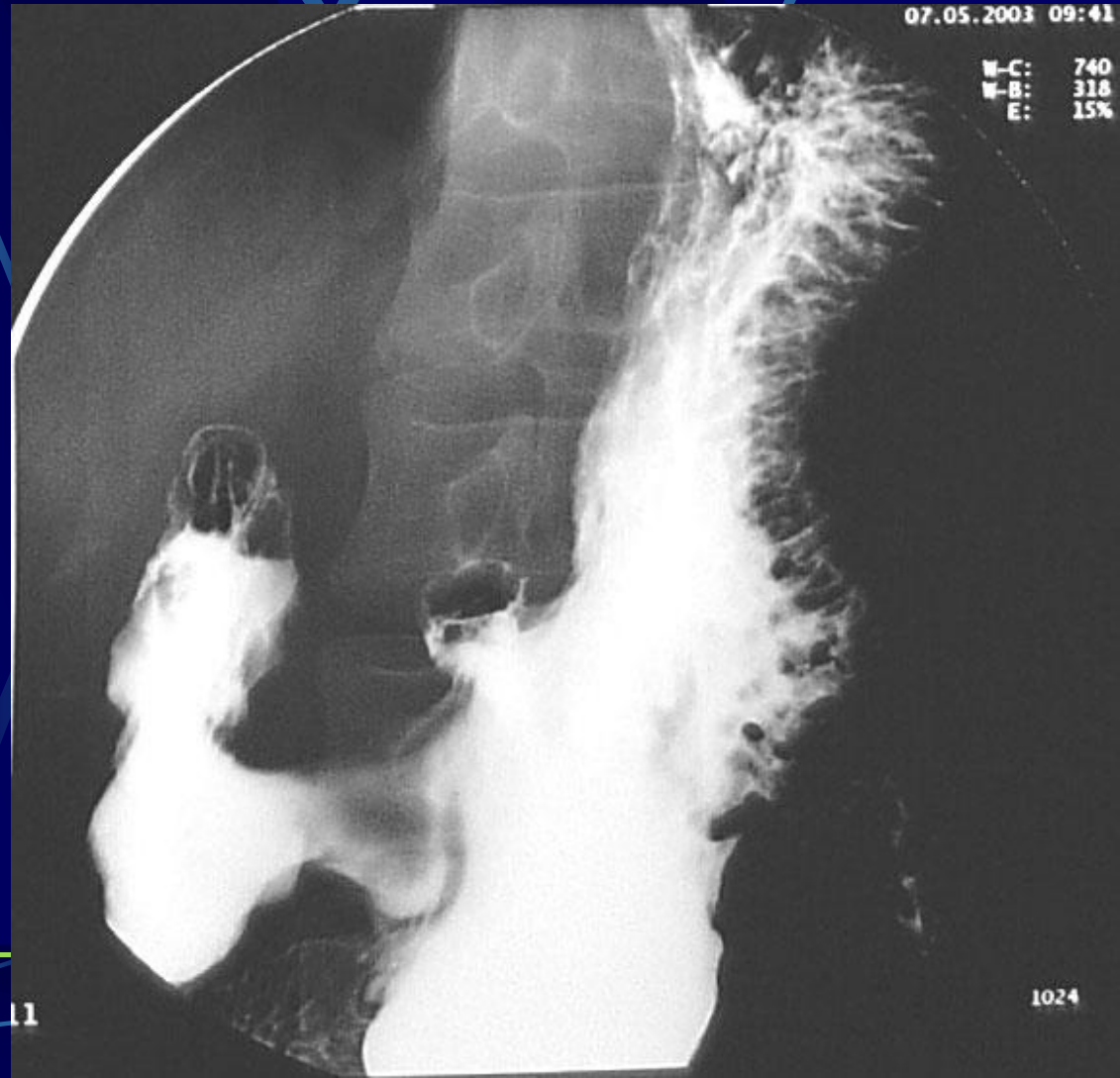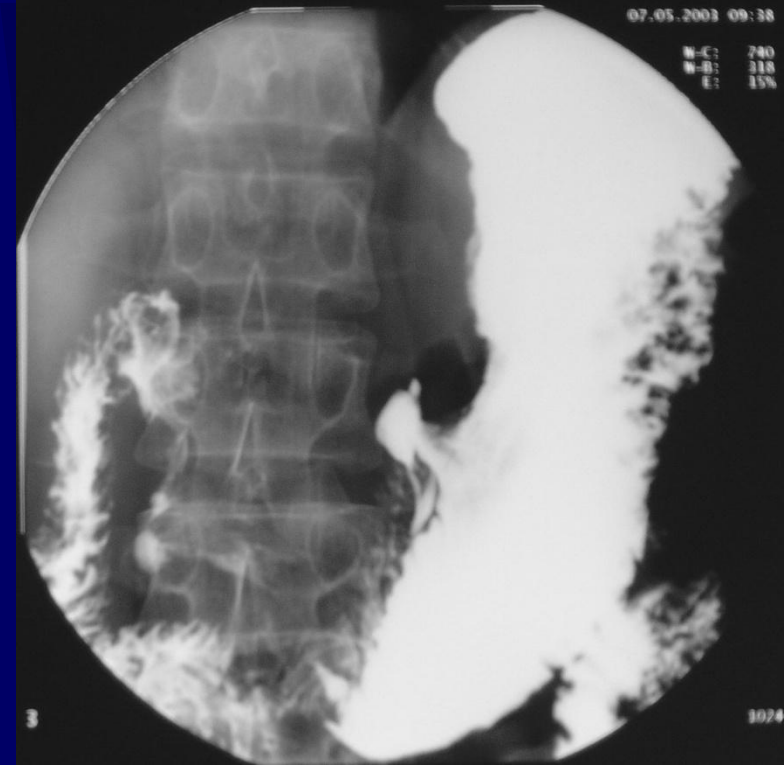


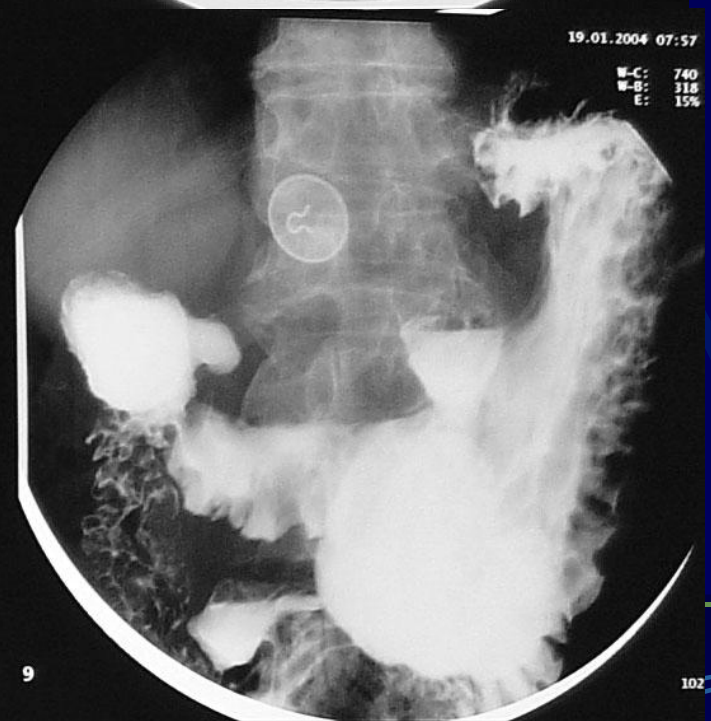
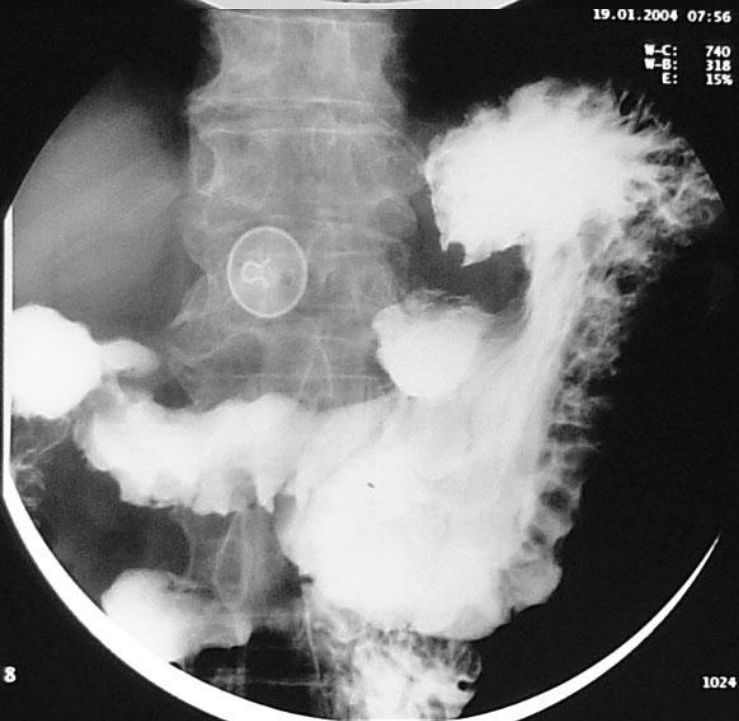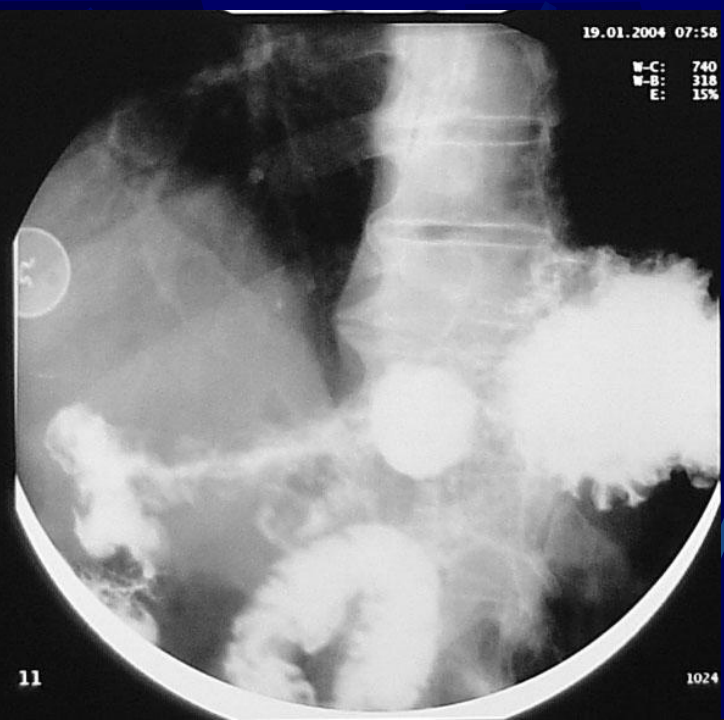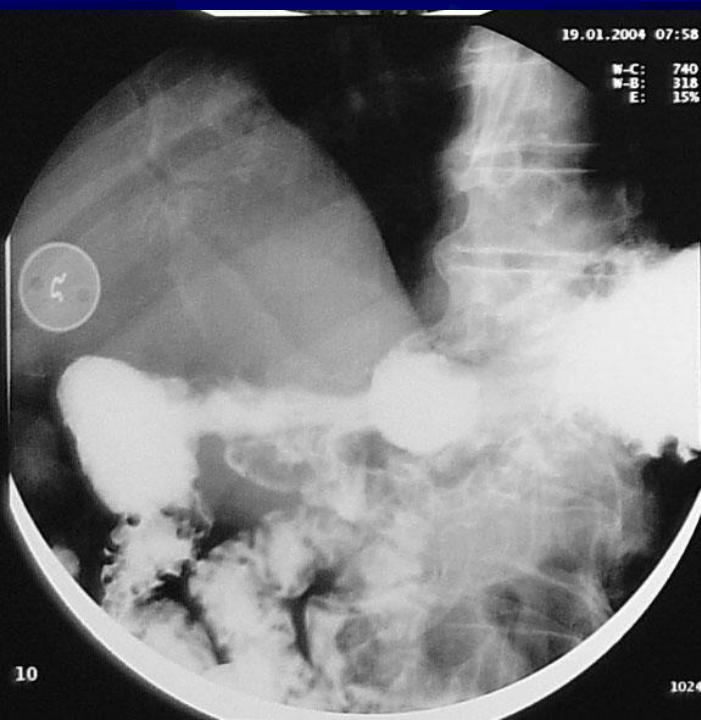
3

胃溃疡



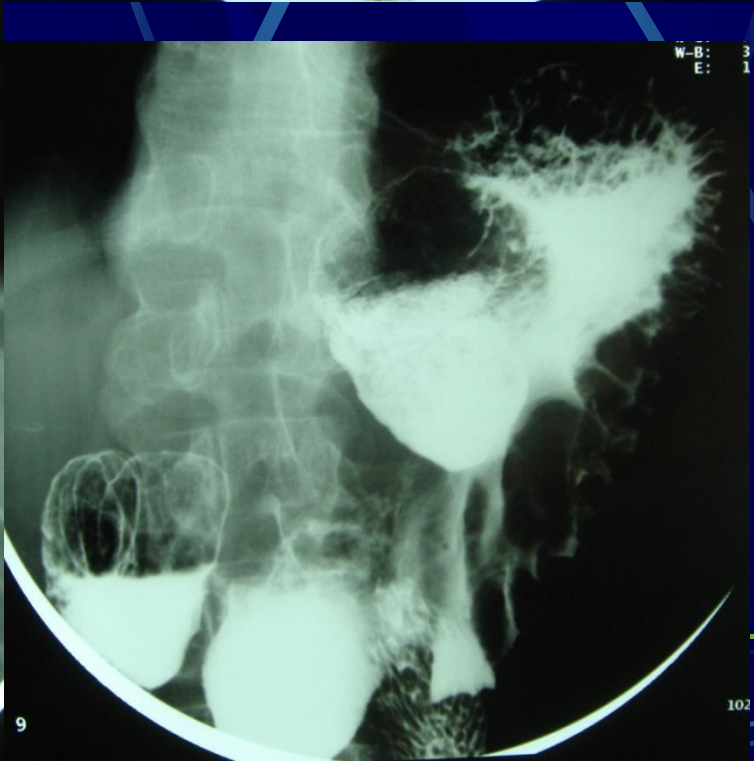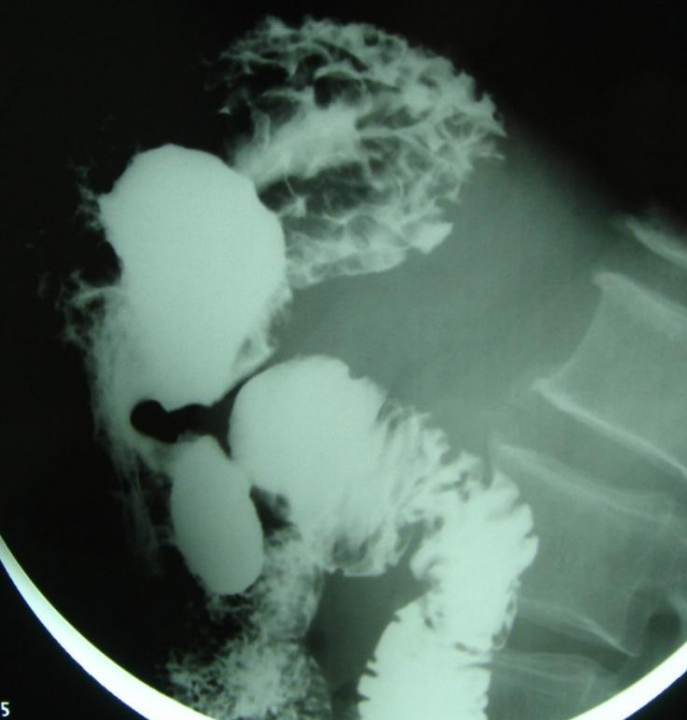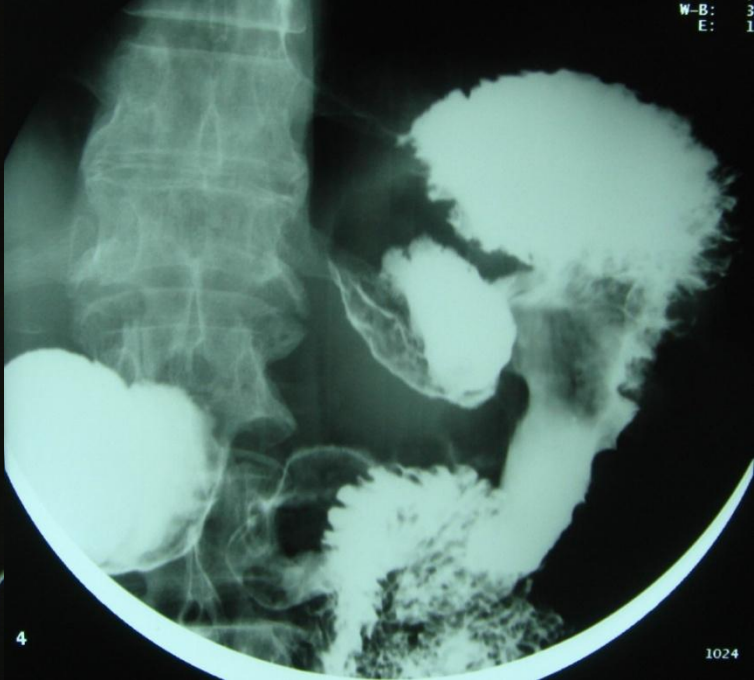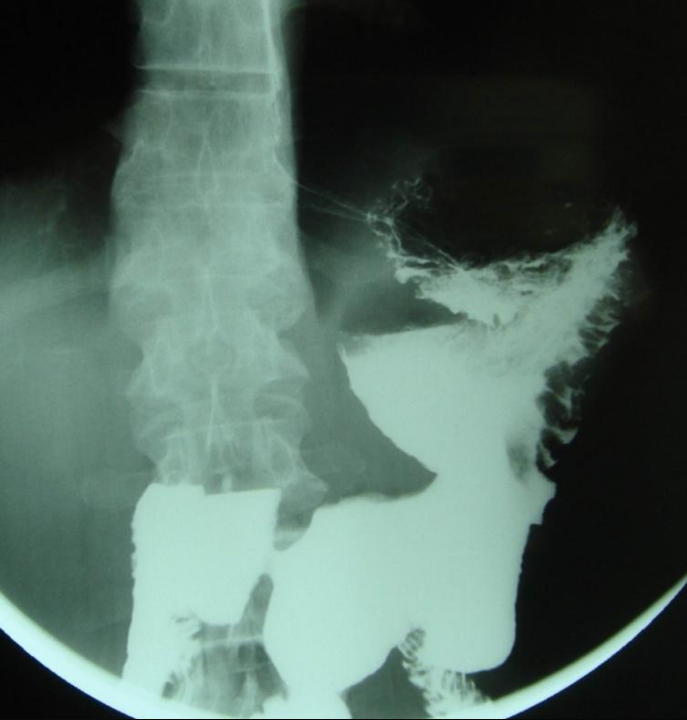胃小弯穿透性溃疡

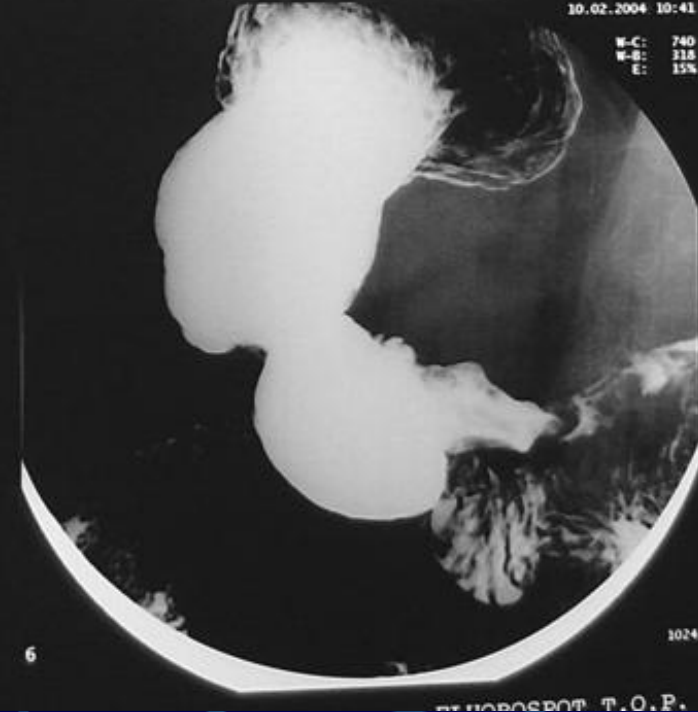
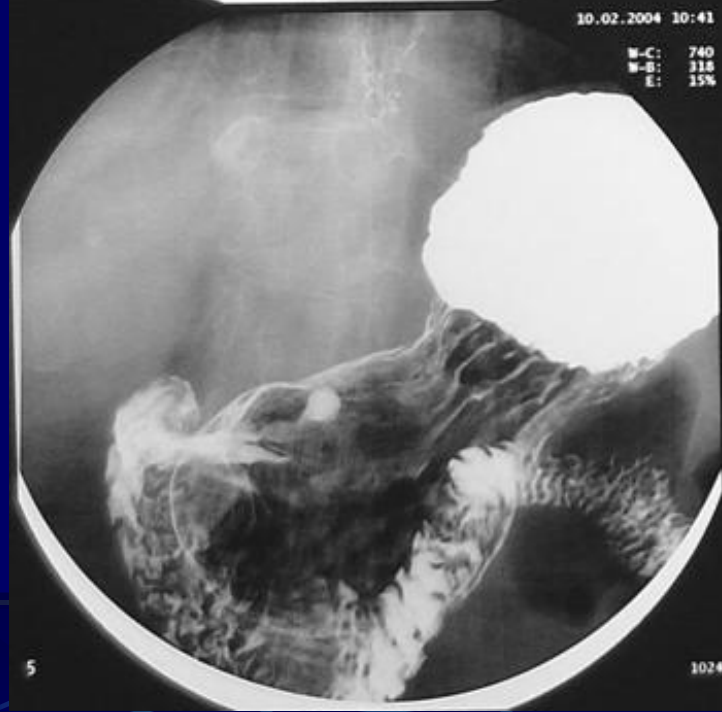
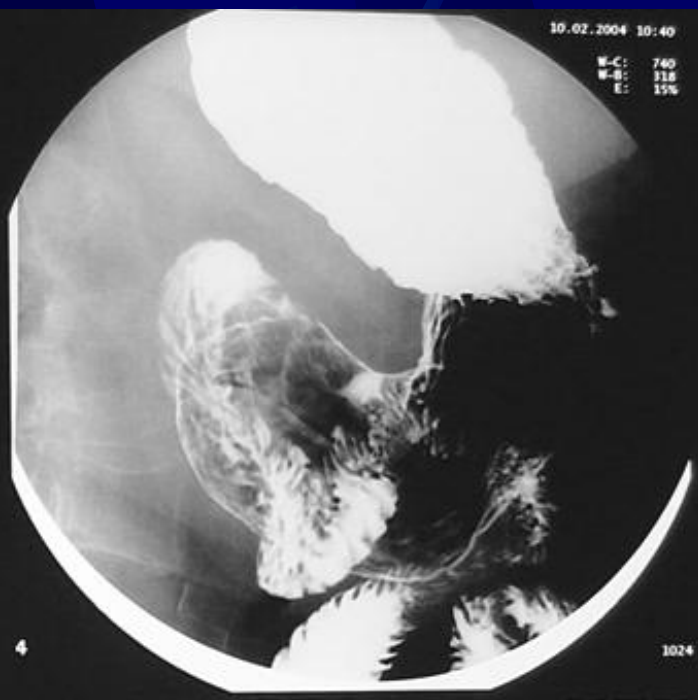
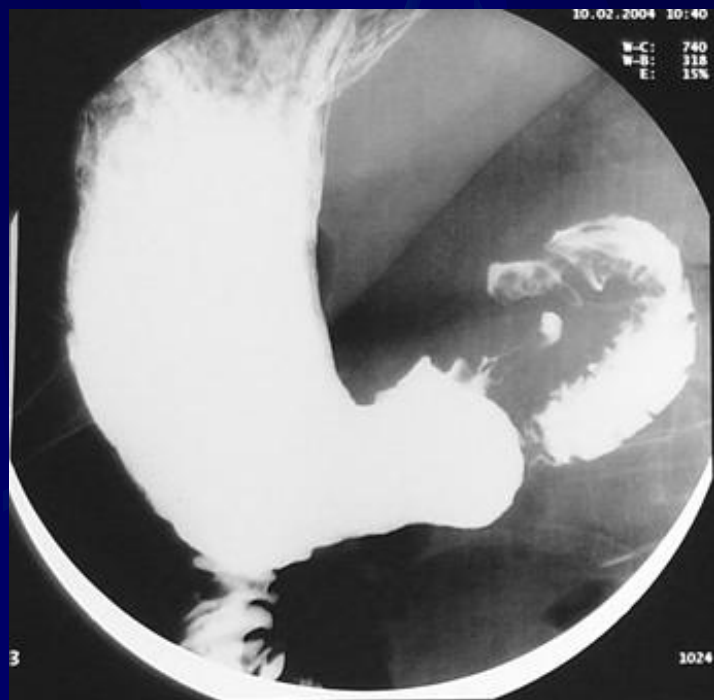
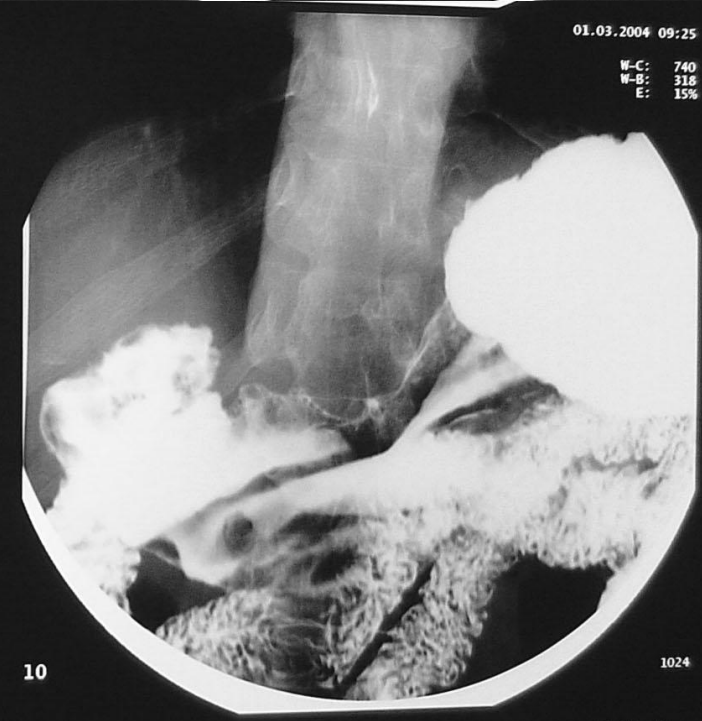
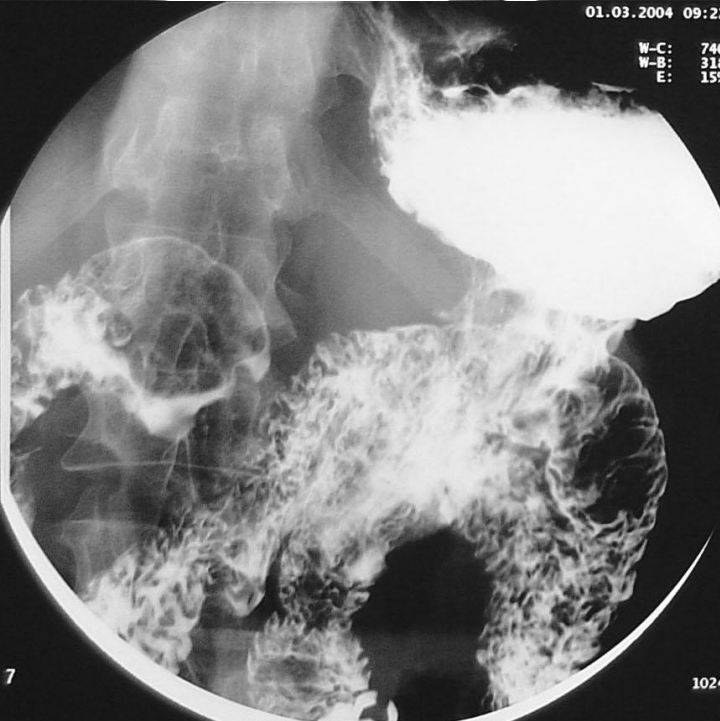
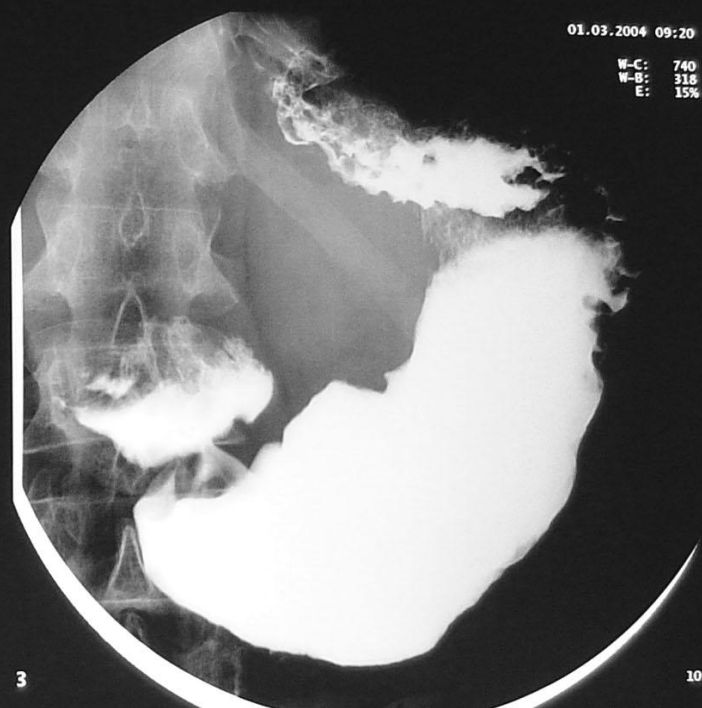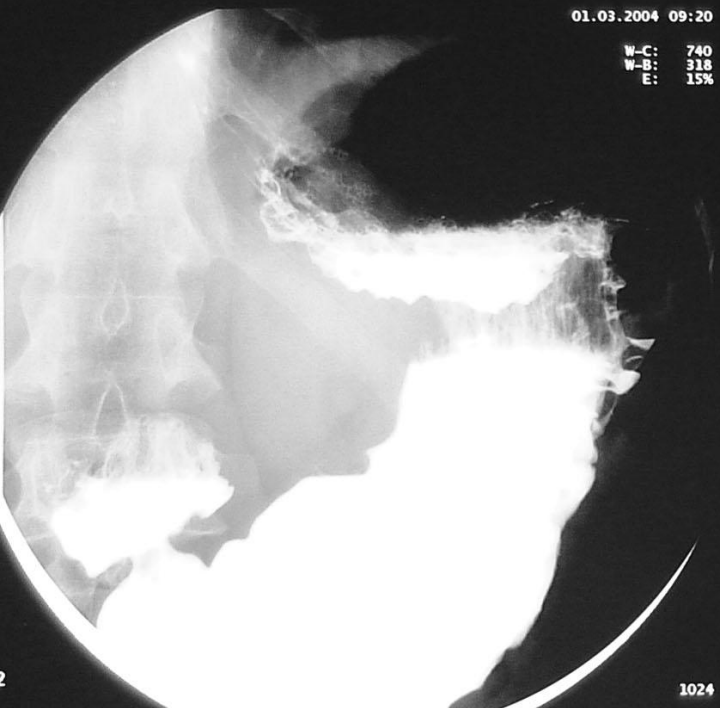胃小弯穿透性溃疡

胃穿透性溃疡





胃小弯溃疡



胃小弯溃疡

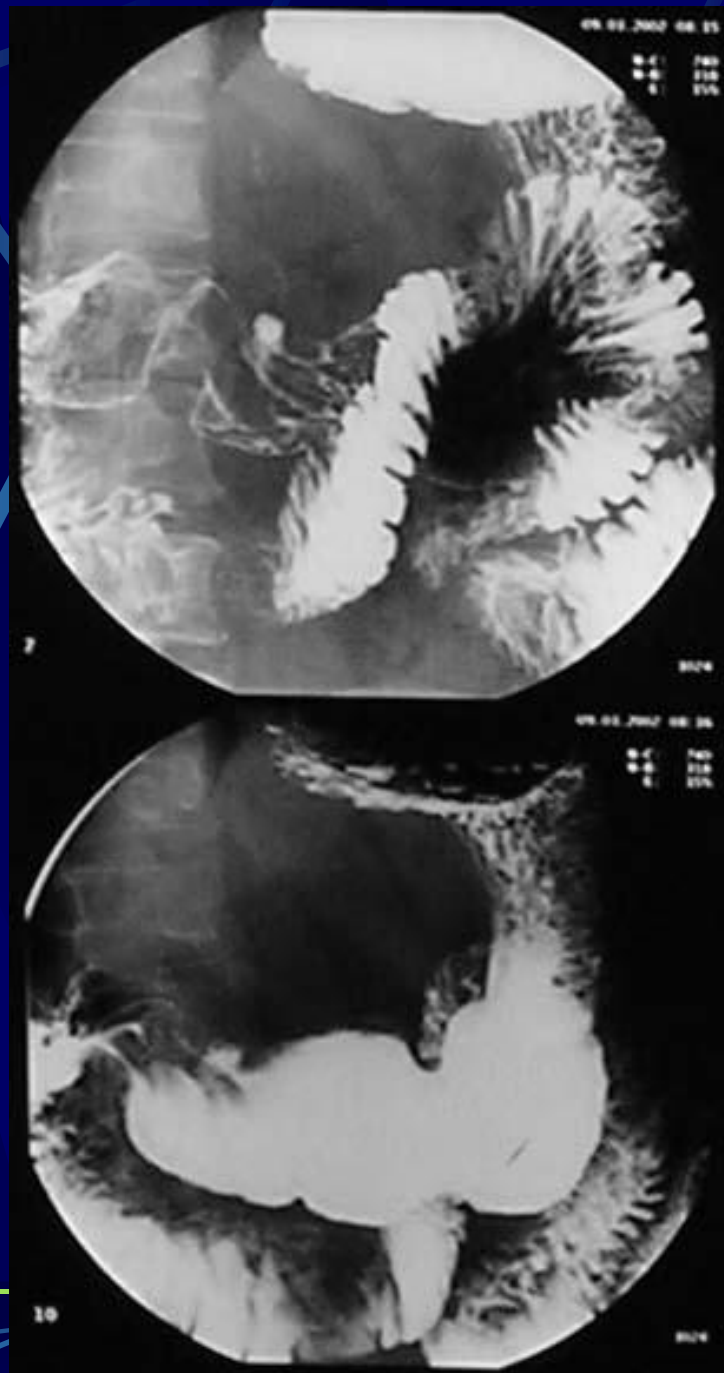
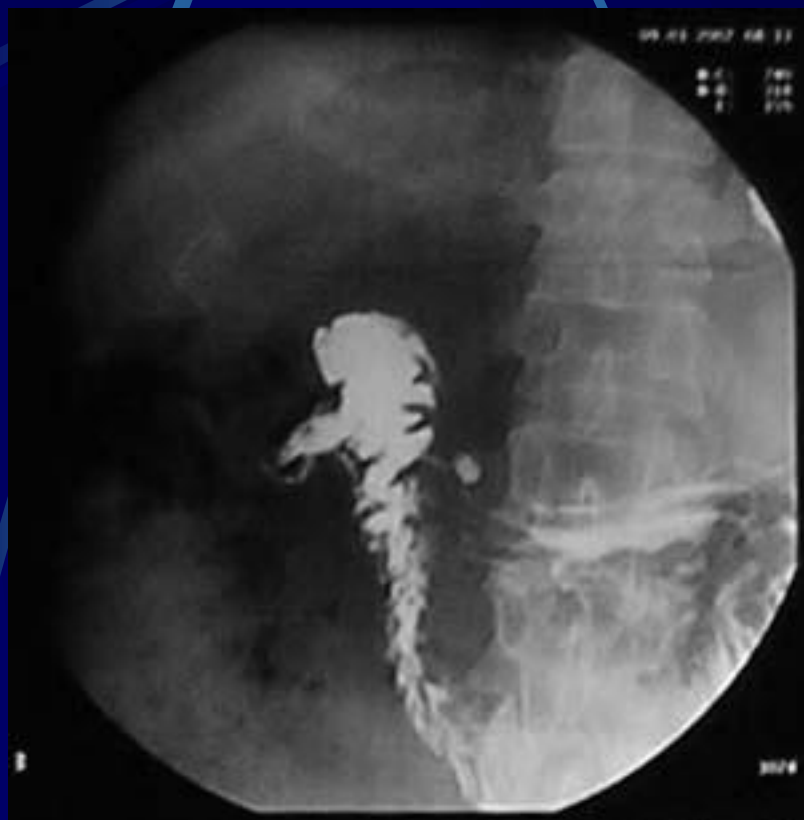7

1024

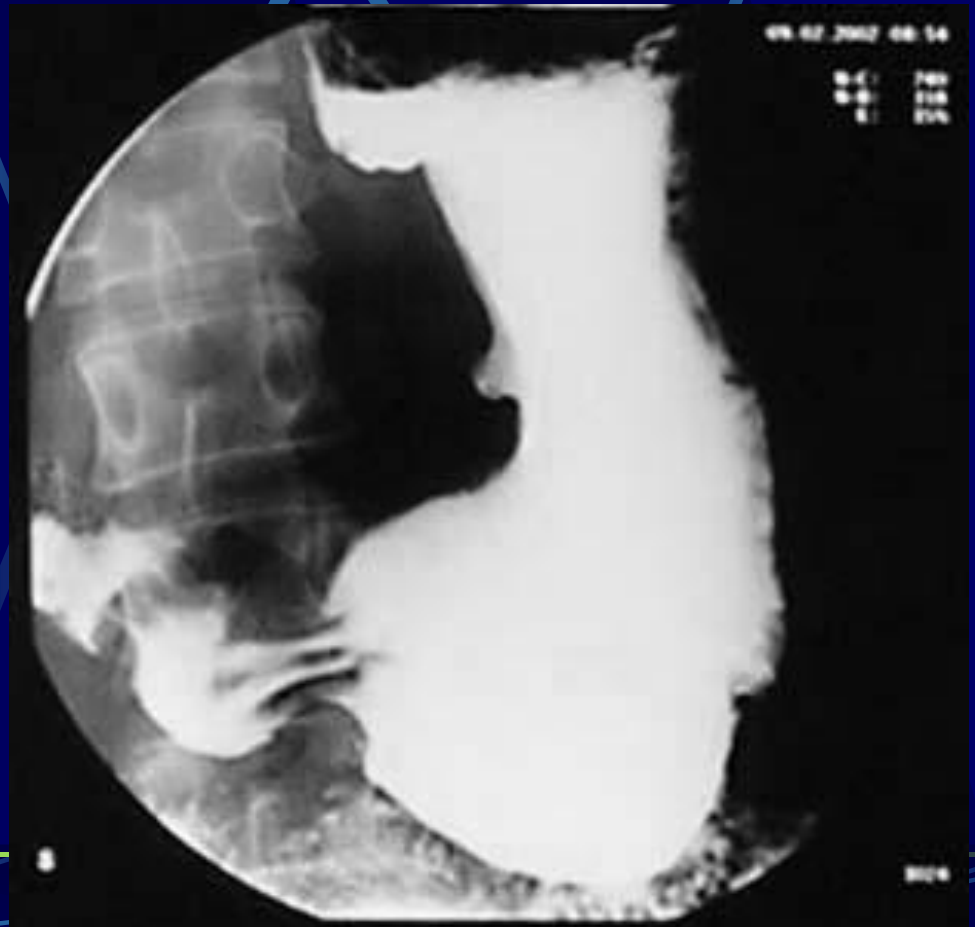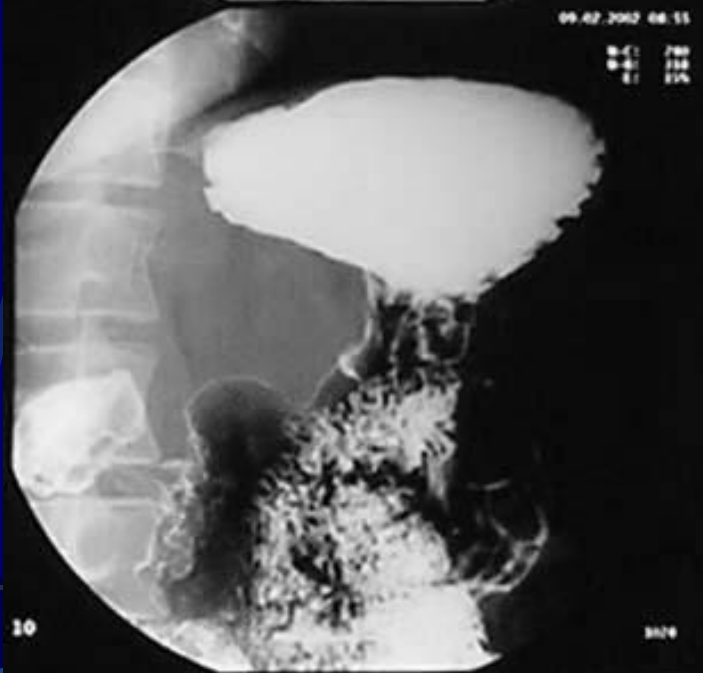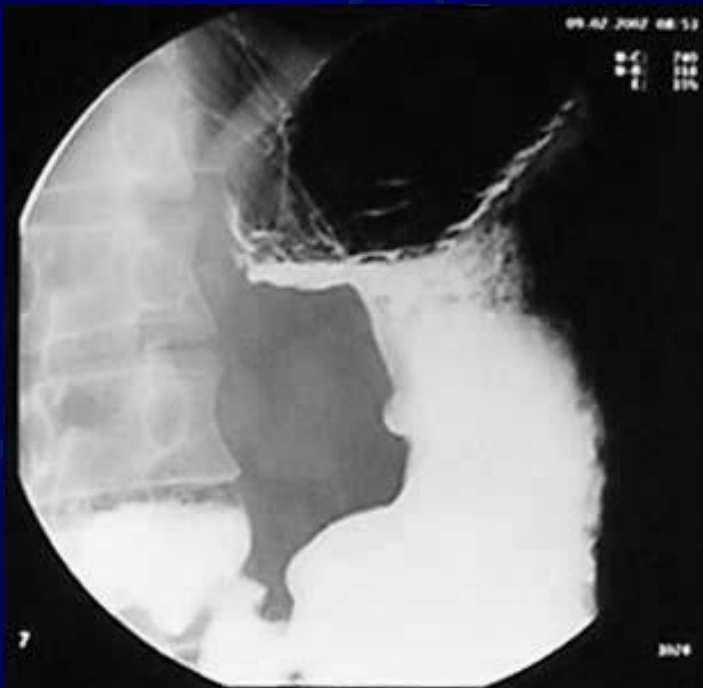10

1024

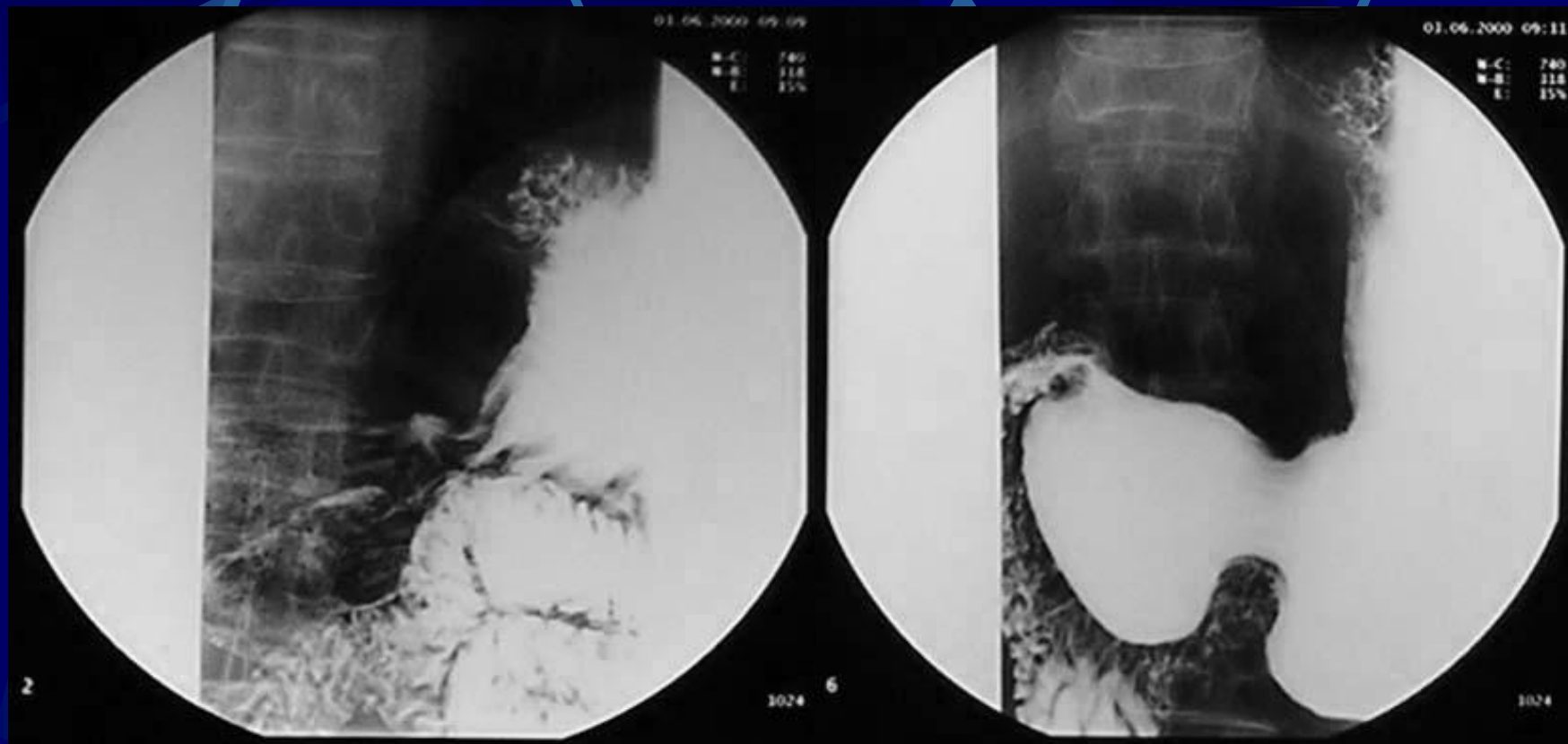
胃小弯侧溃疡



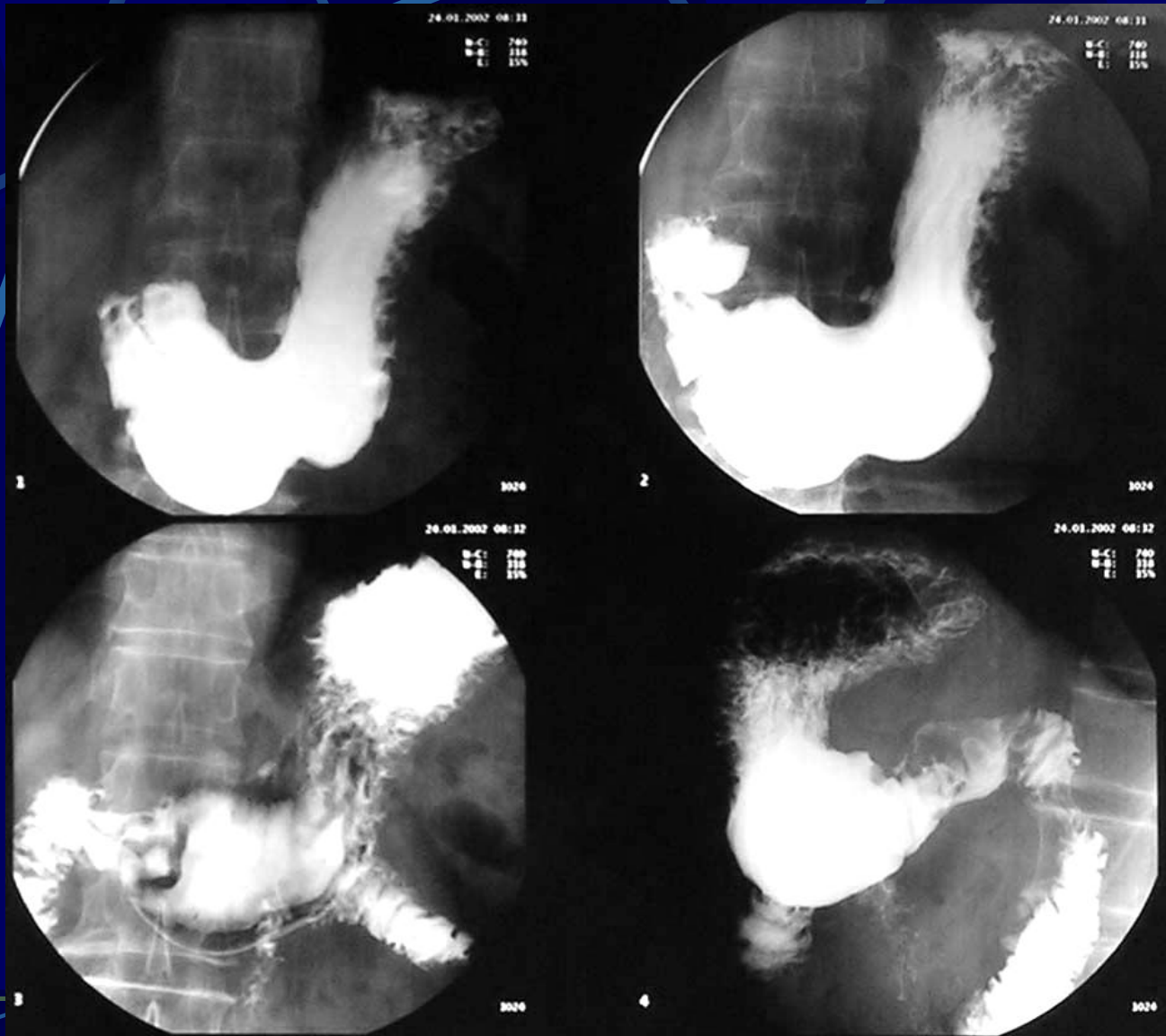
胃体小弯侧 垂直部溃疡



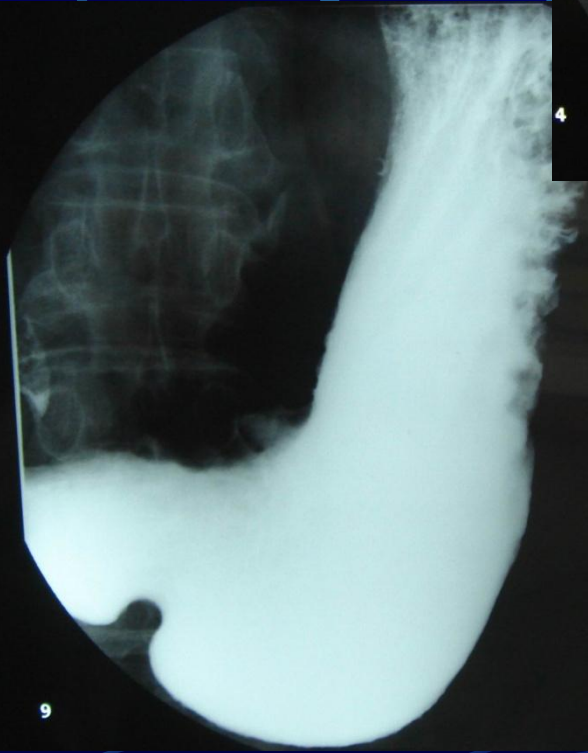
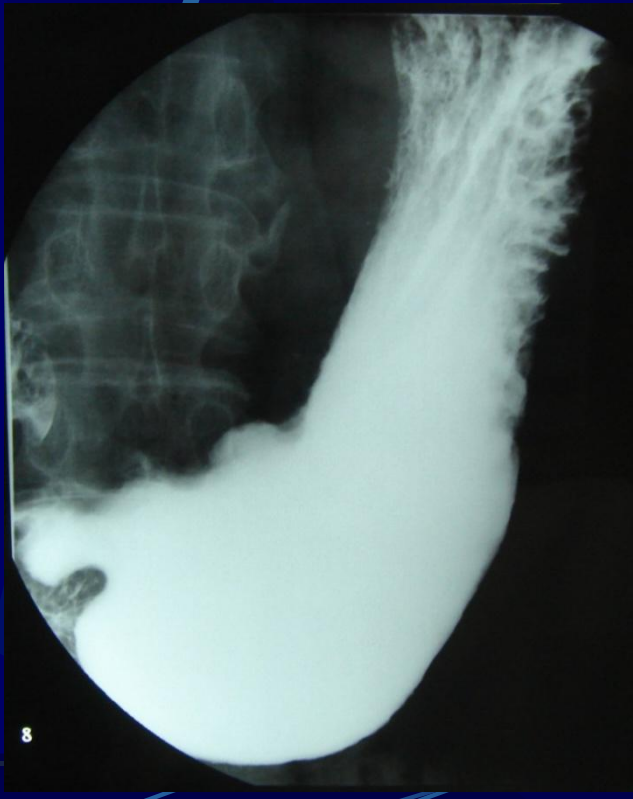
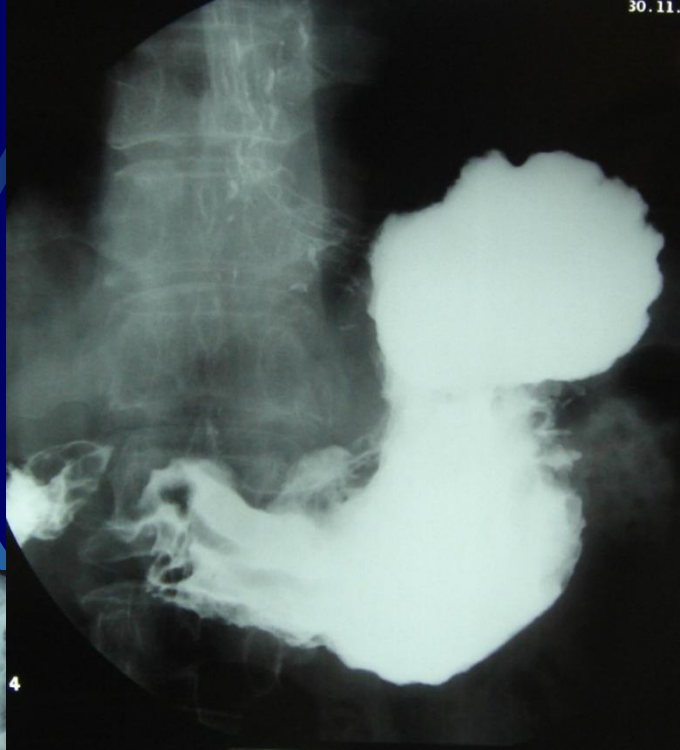胃角溃疡



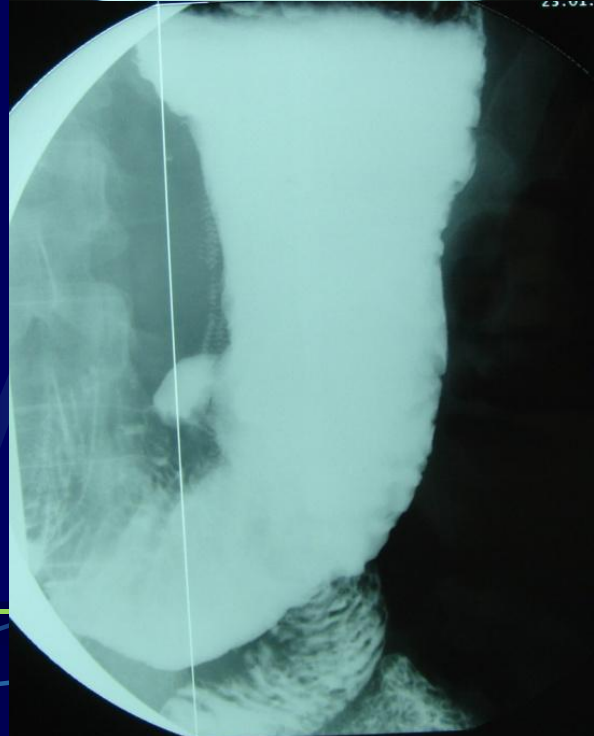
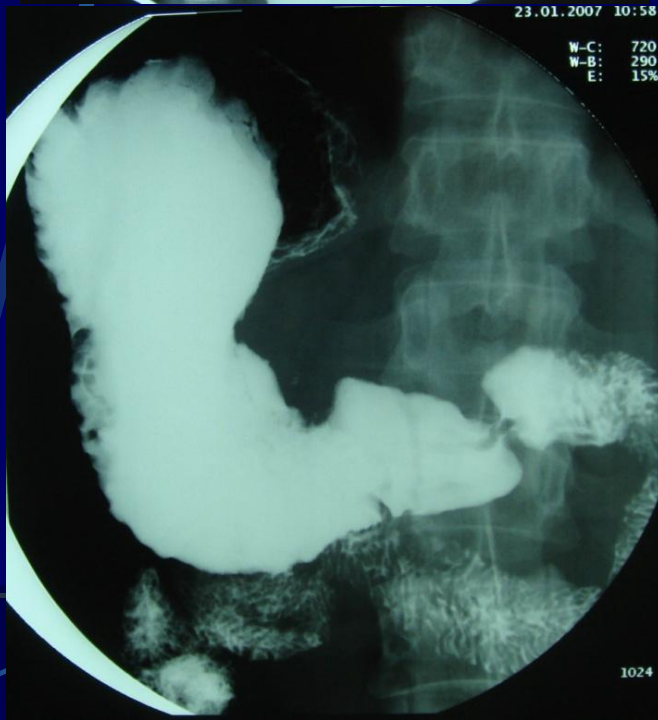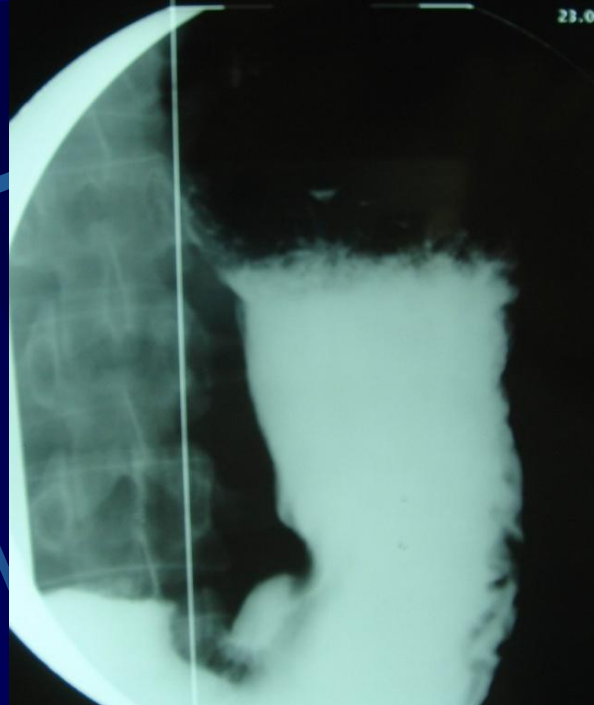
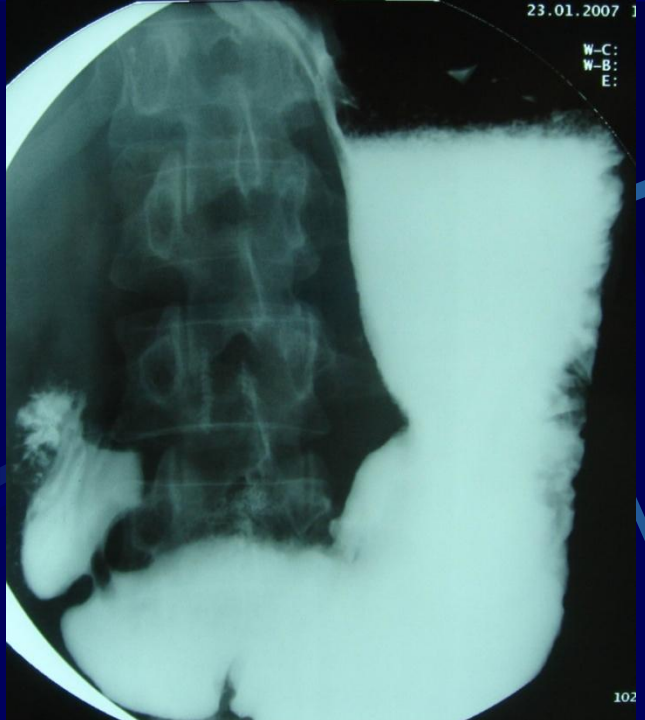胃角溃疡



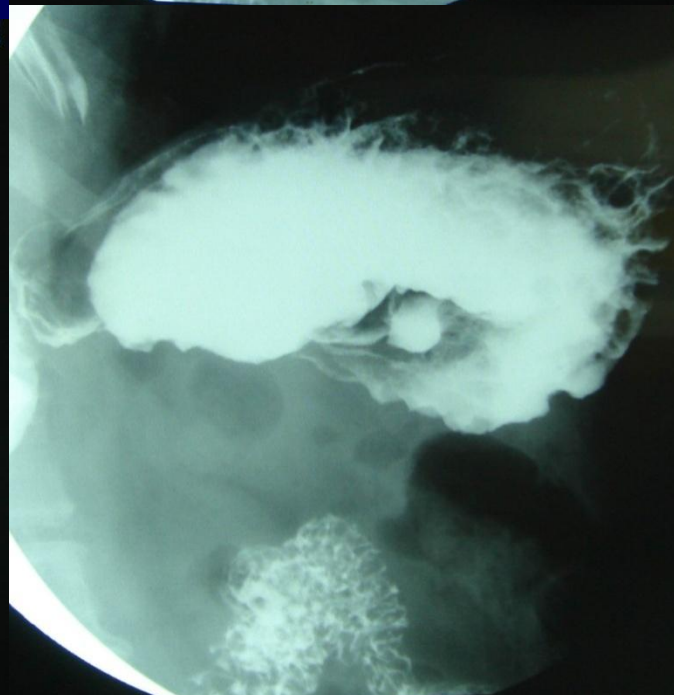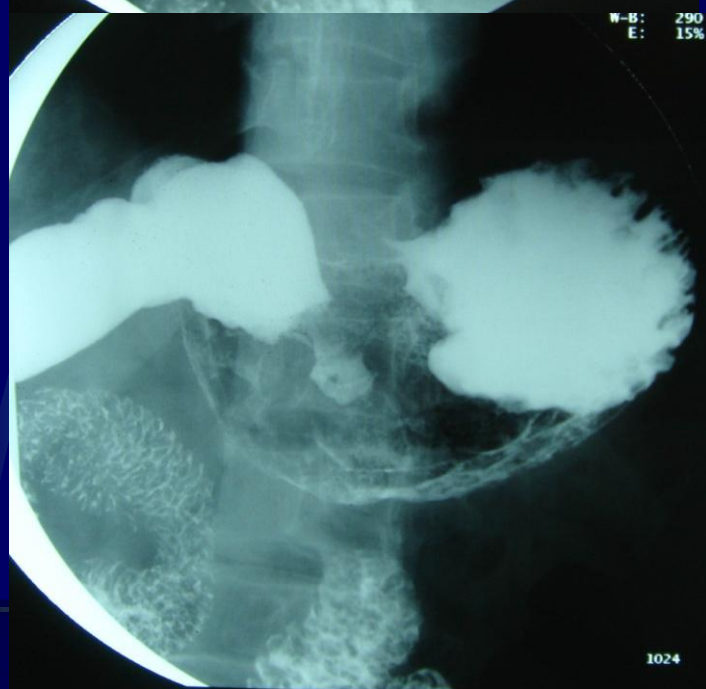
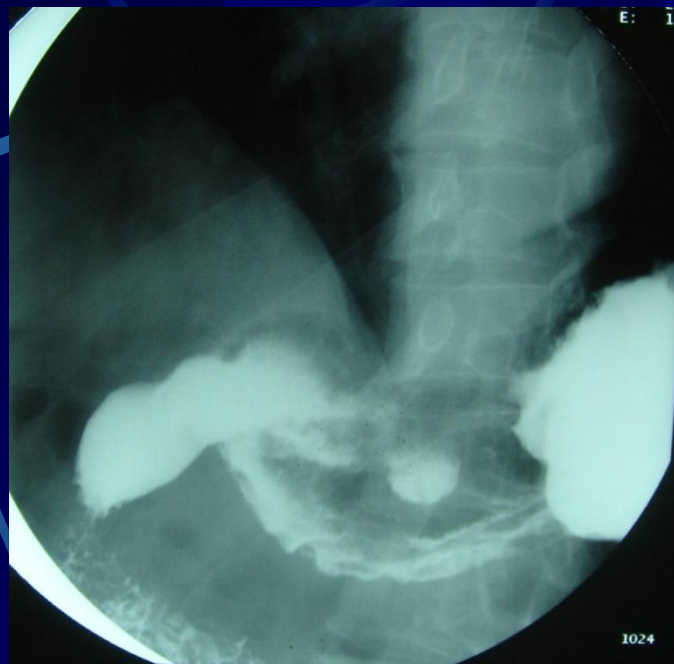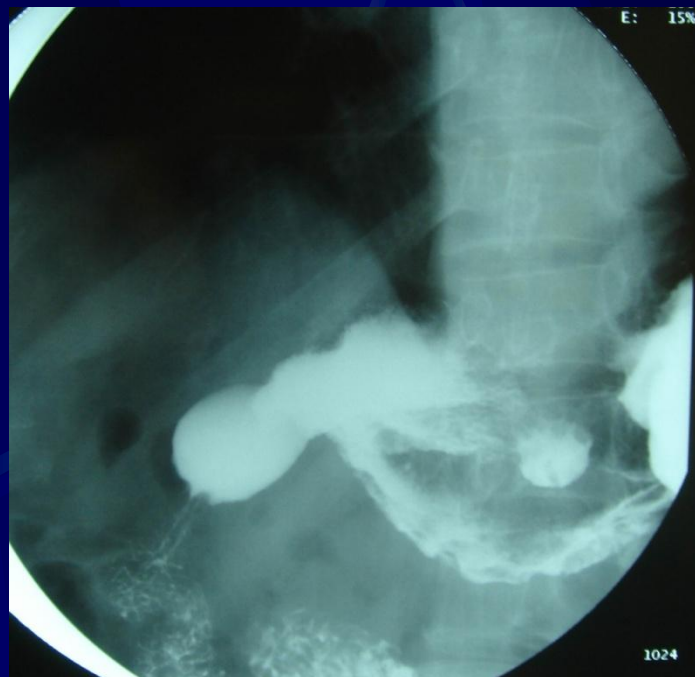胃溃疡



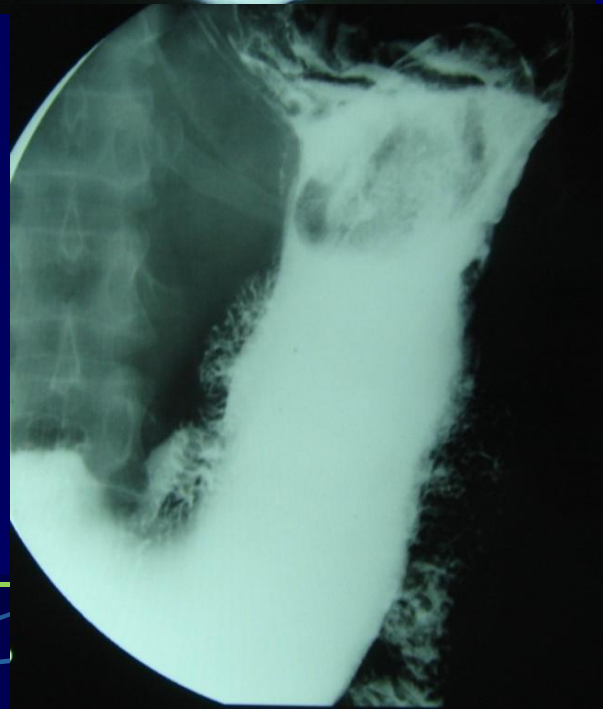
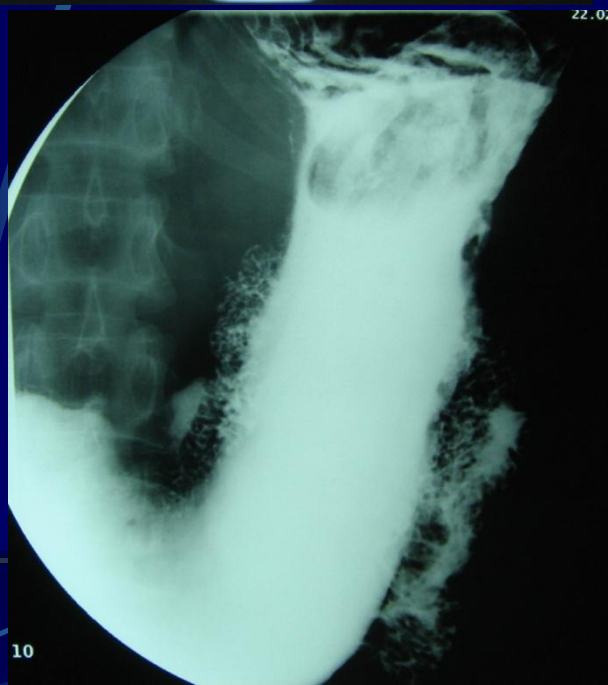
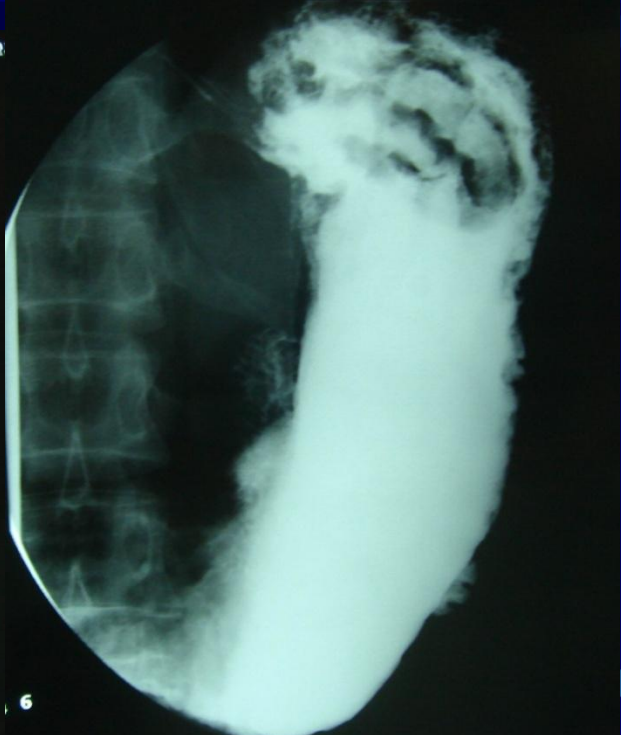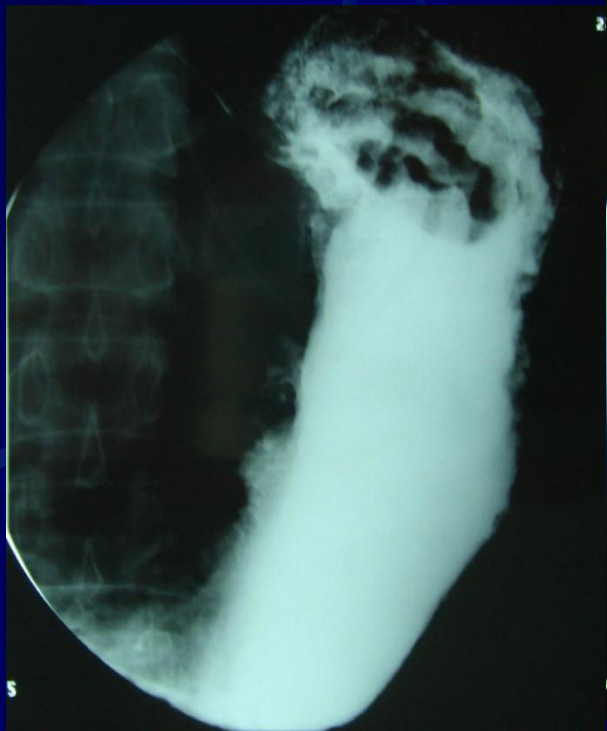
胃溃疡



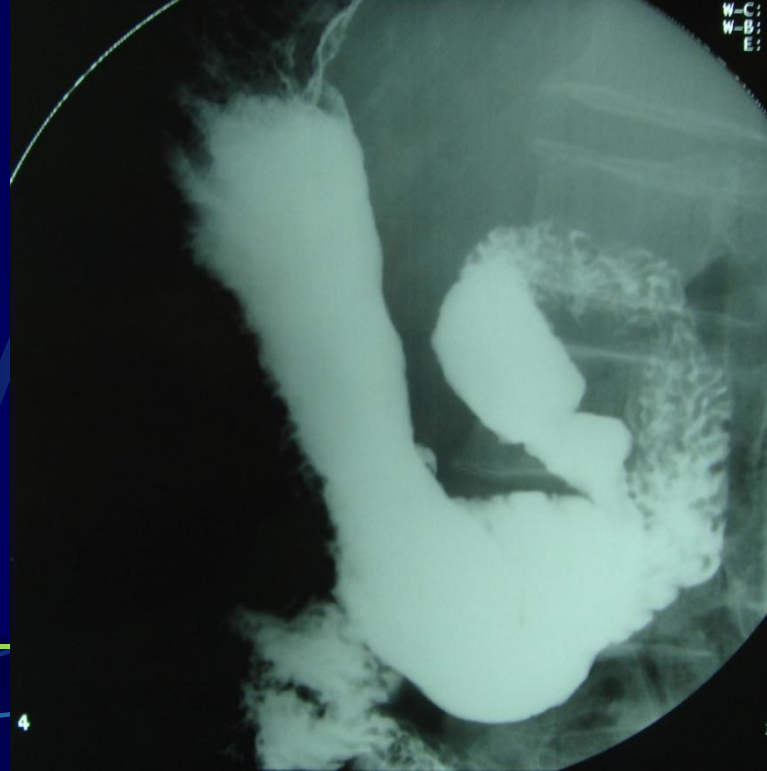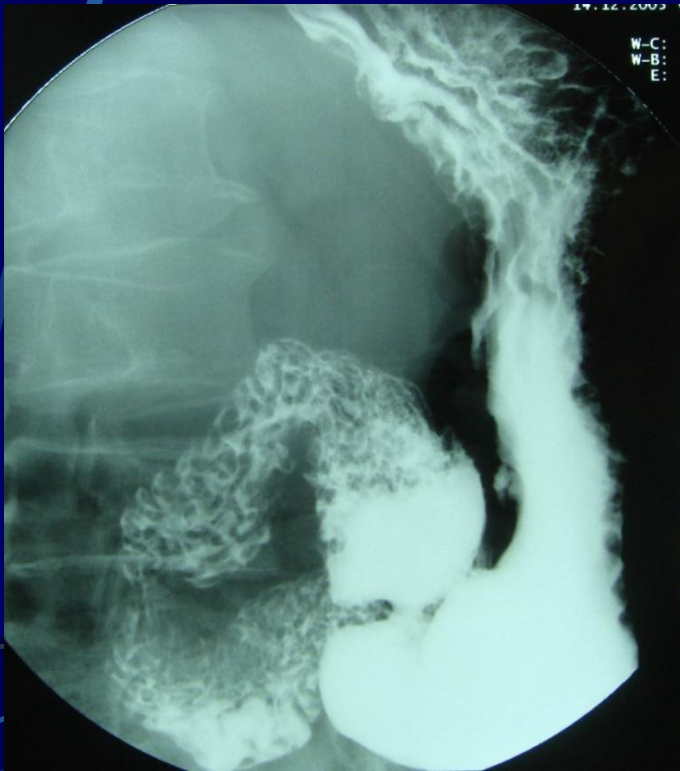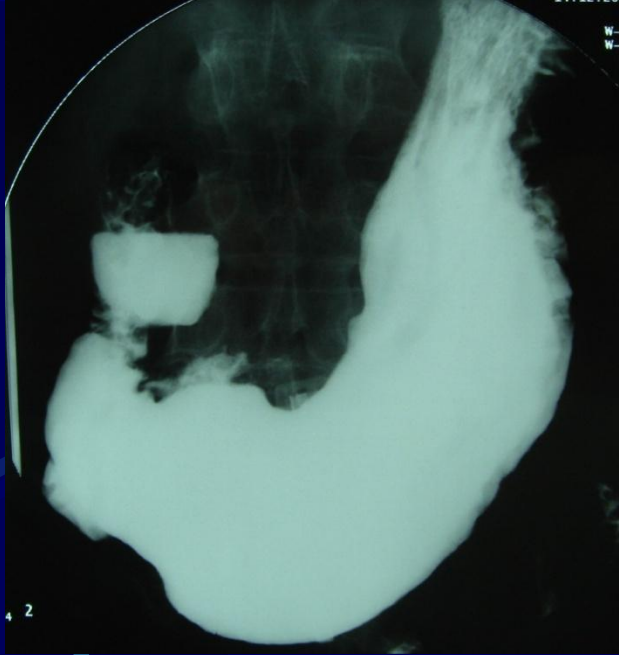
胃溃疡



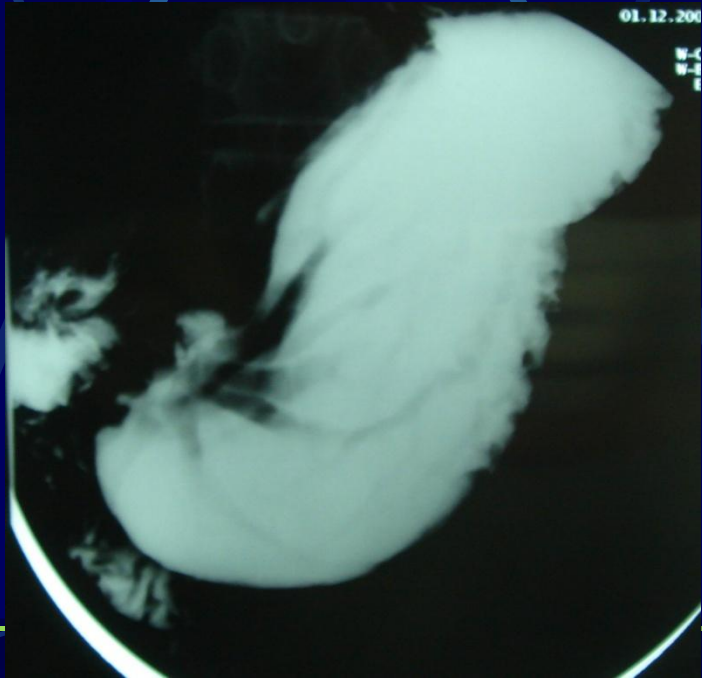
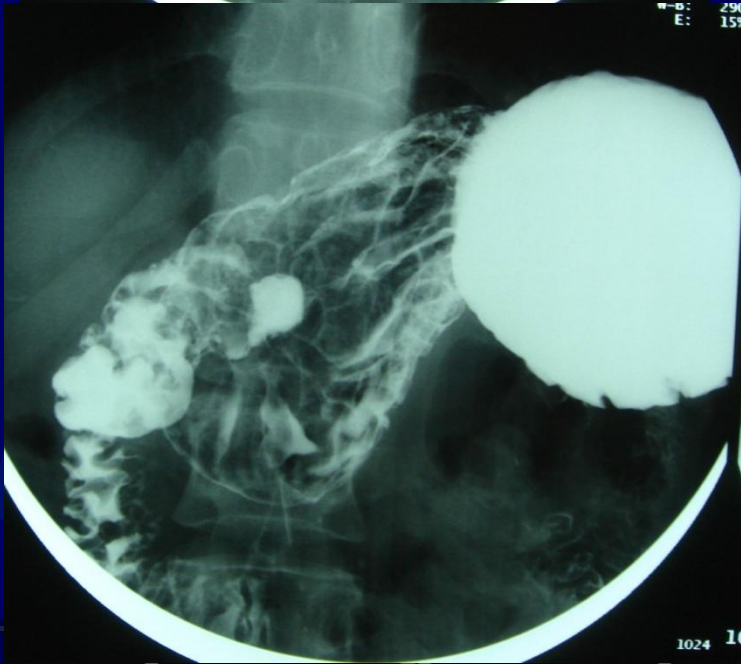
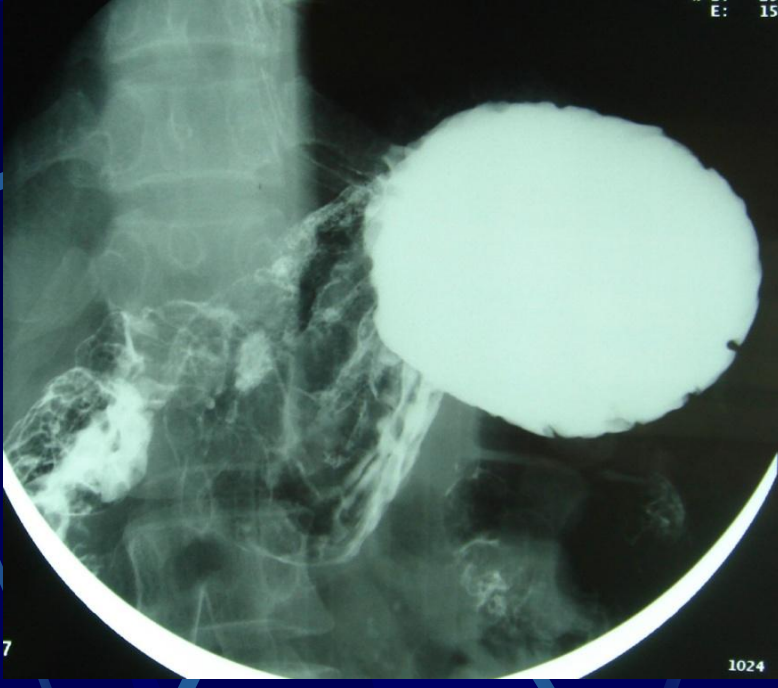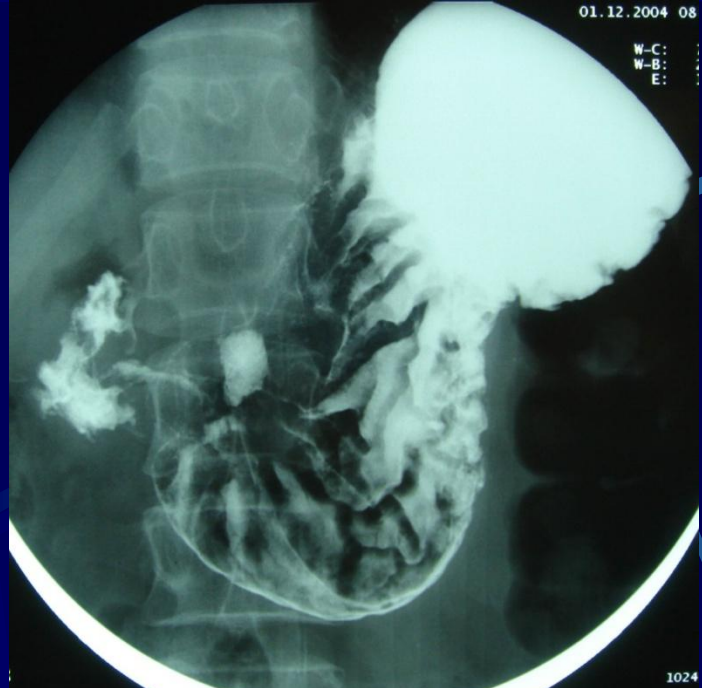胃溃疡



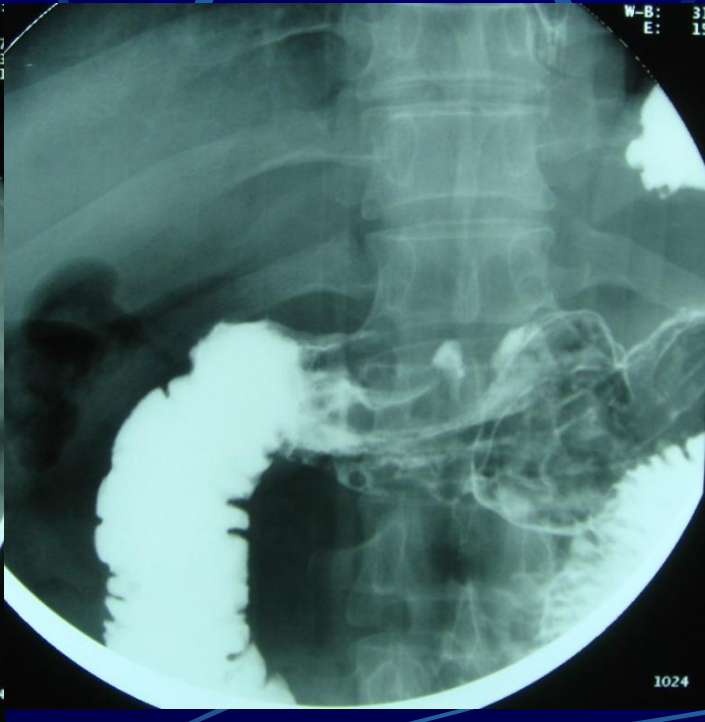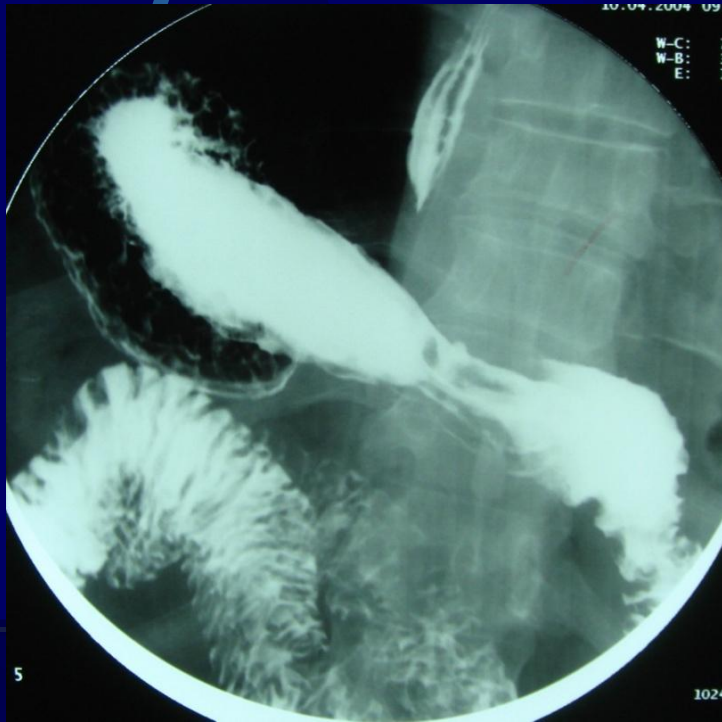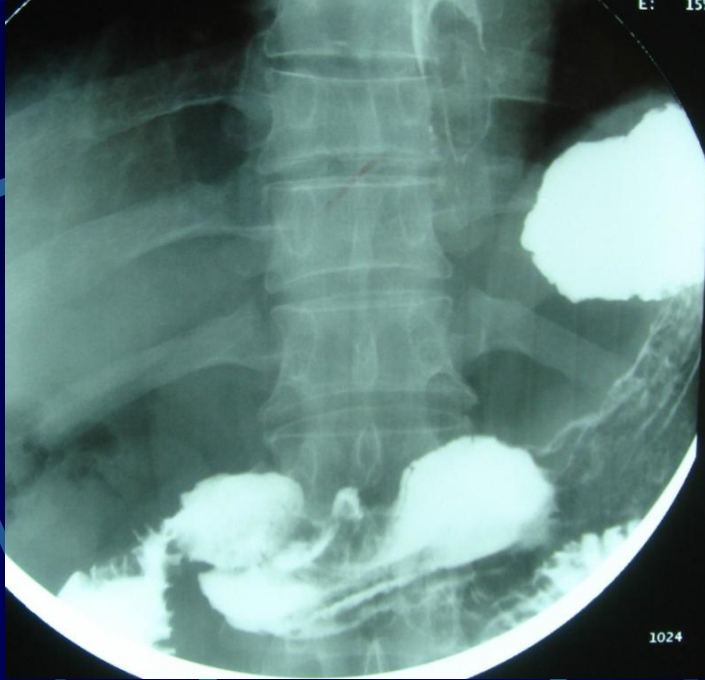
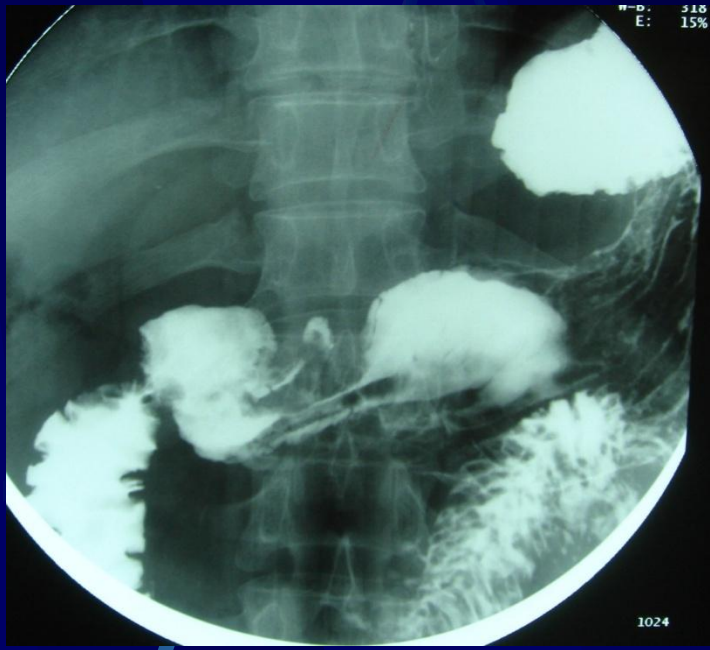
胃溃疡



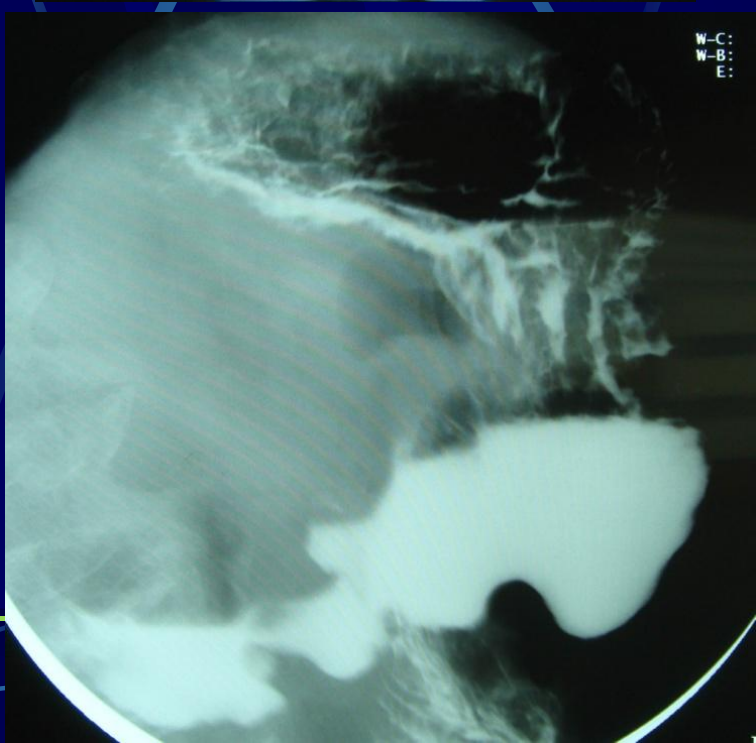
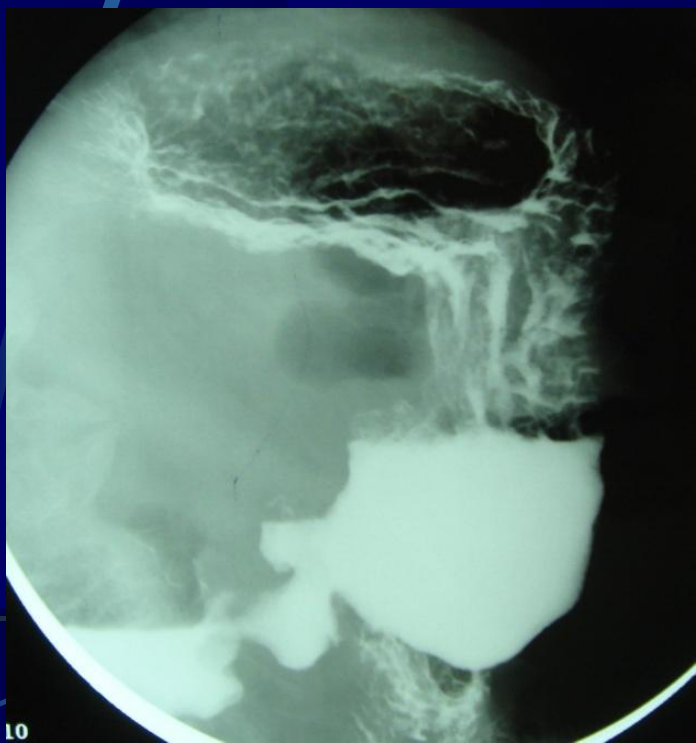
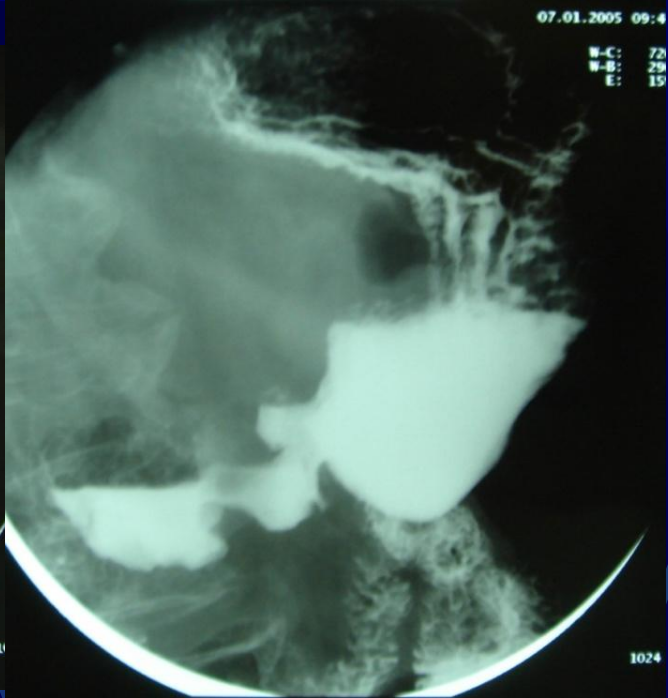
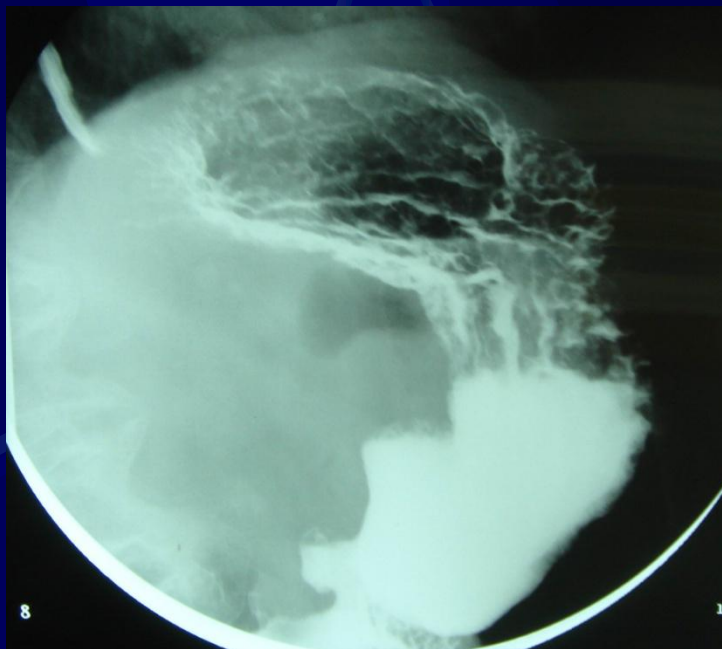
胃溃疡

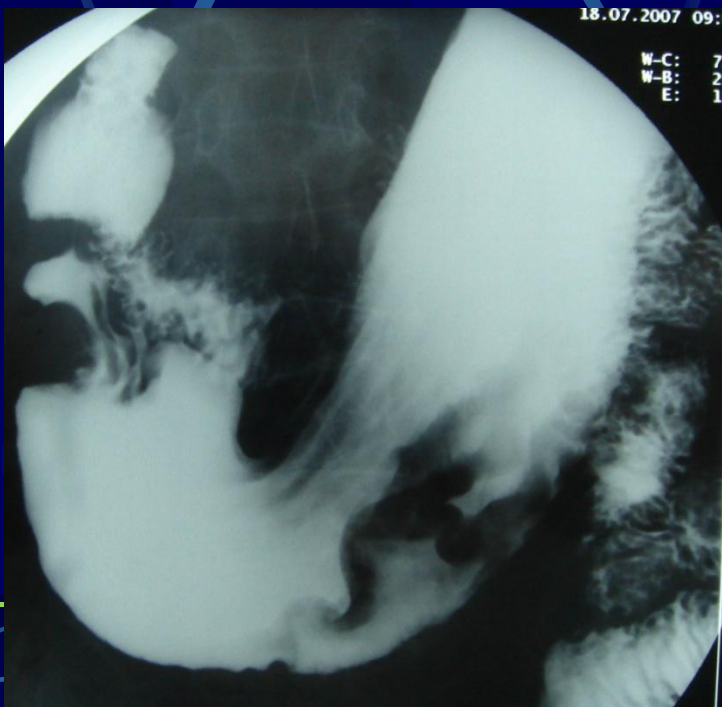
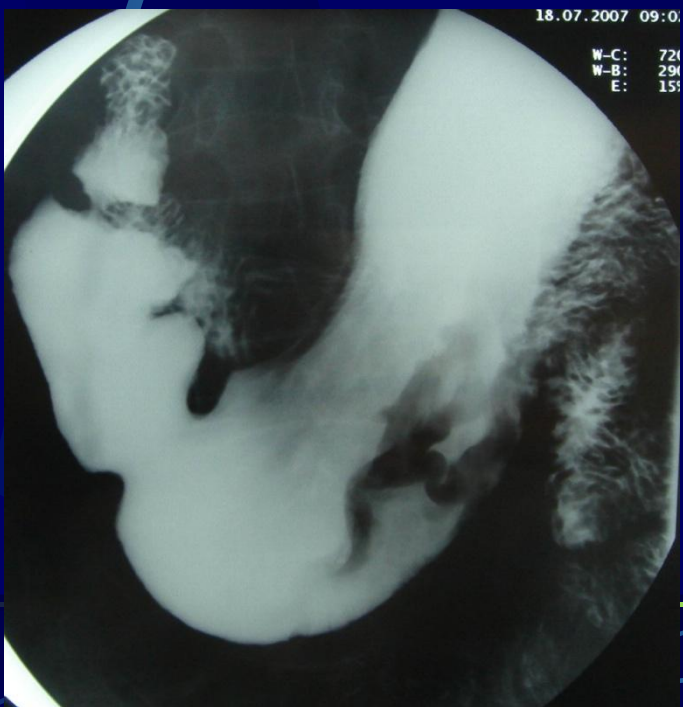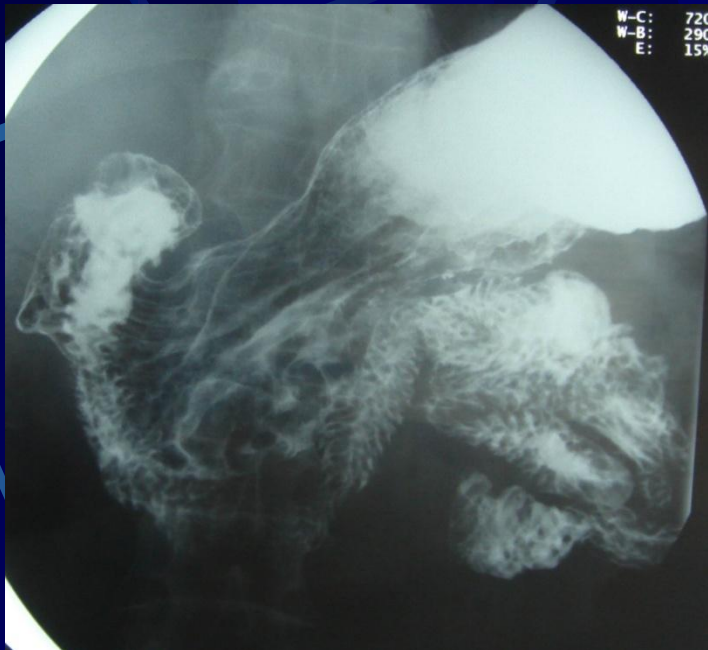

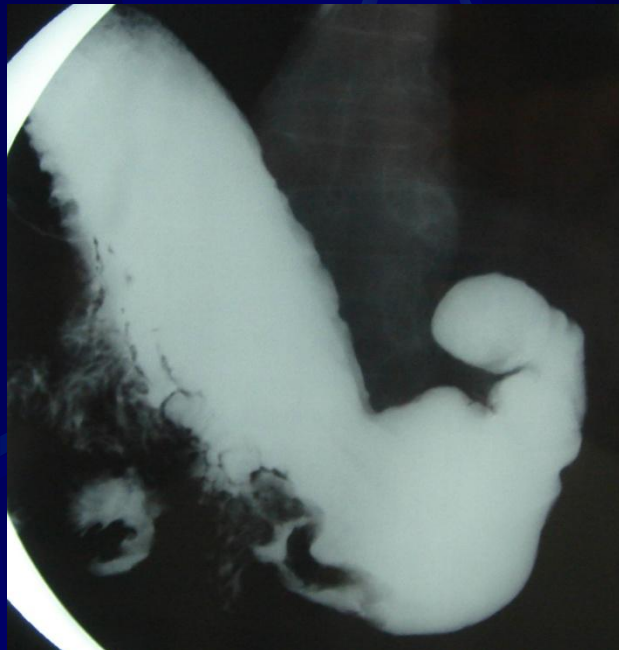
胃溃疡



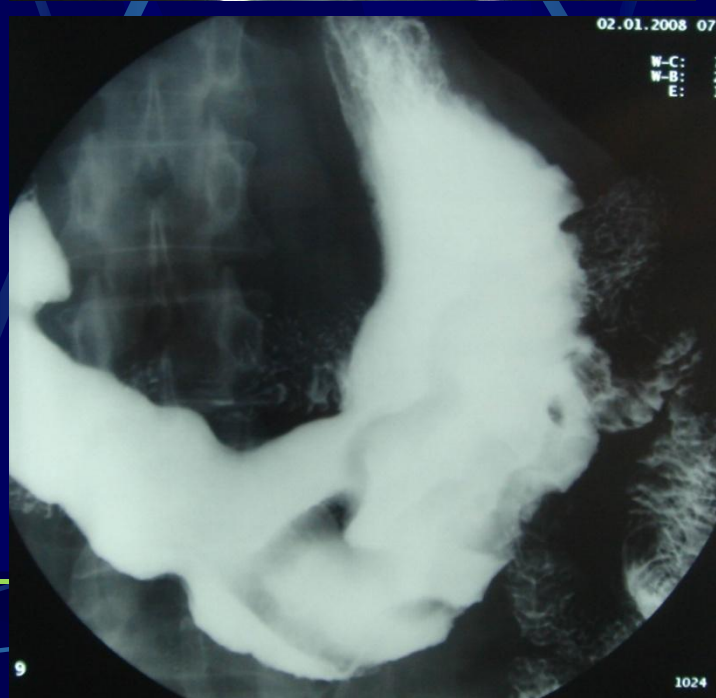
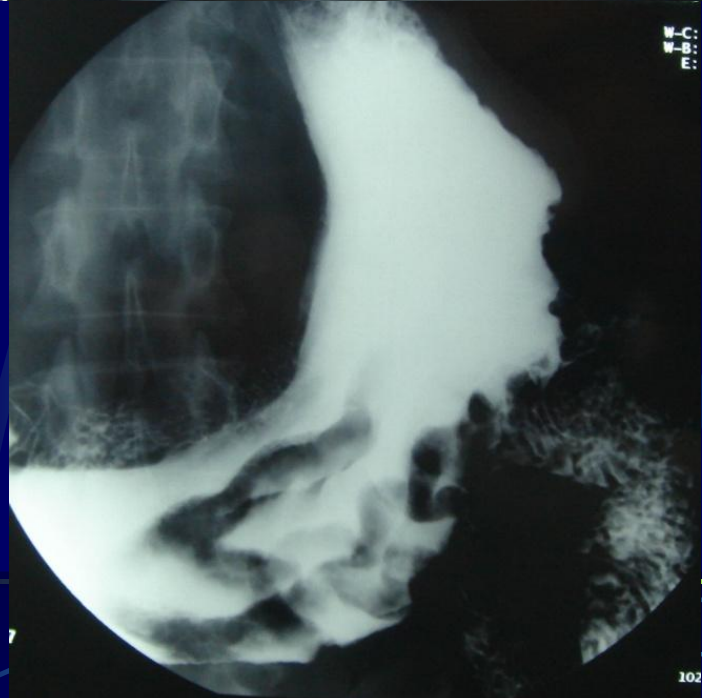
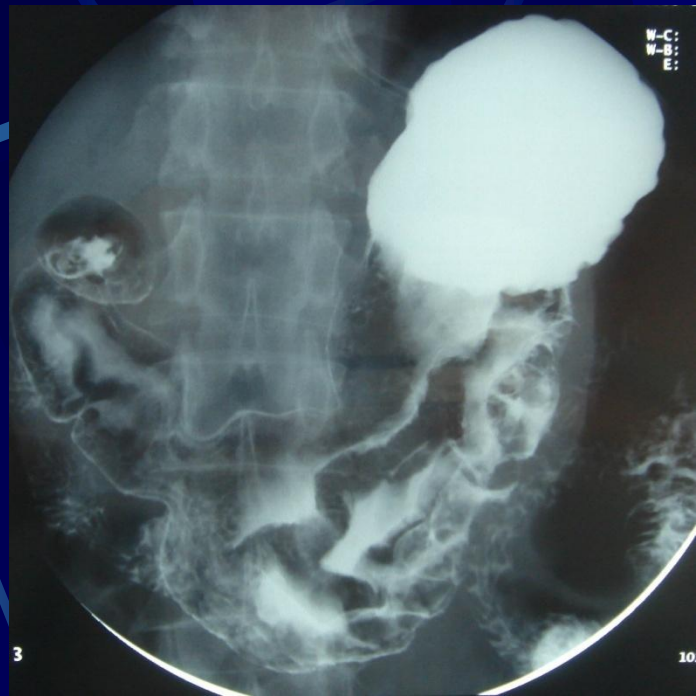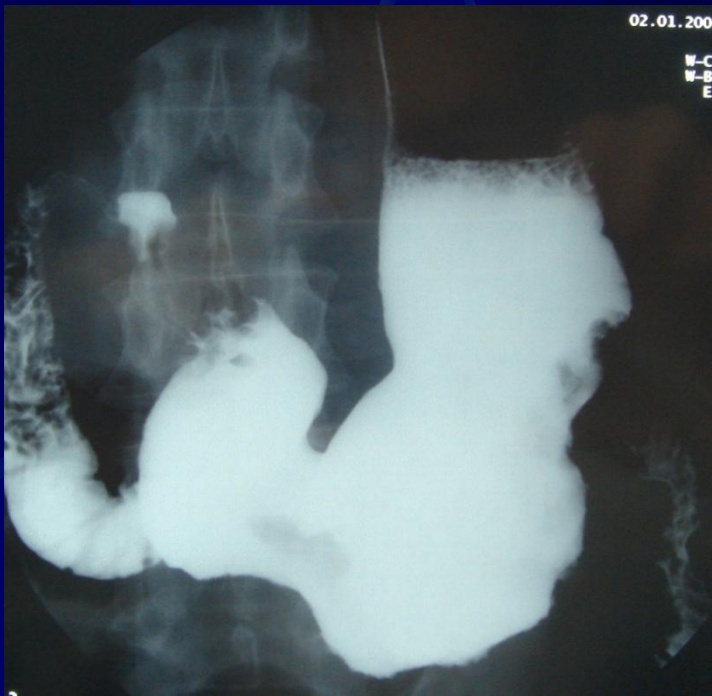胃穿透性溃疡



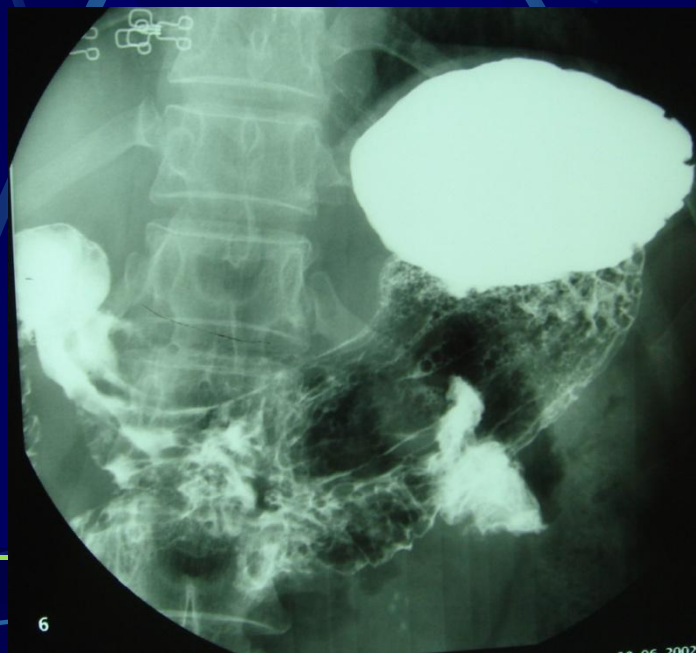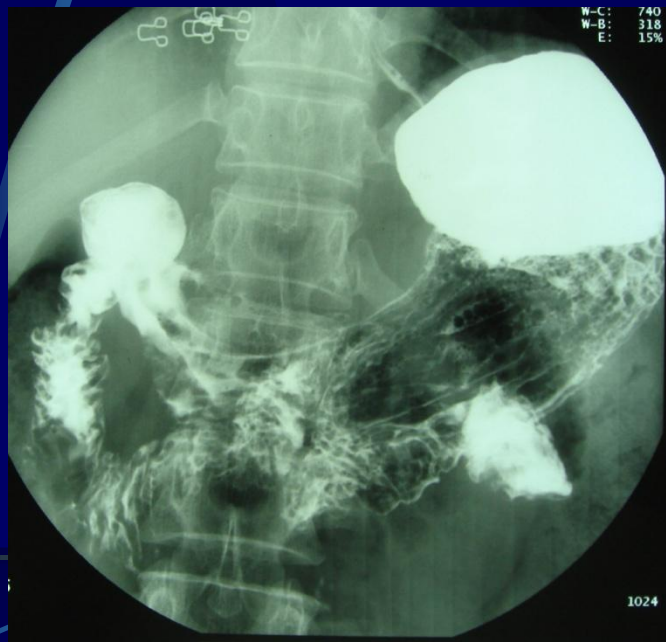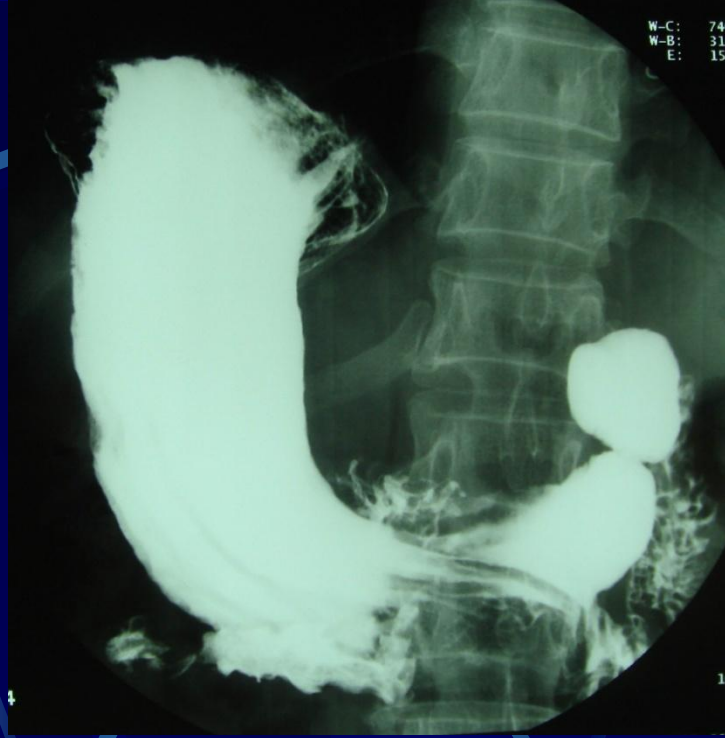


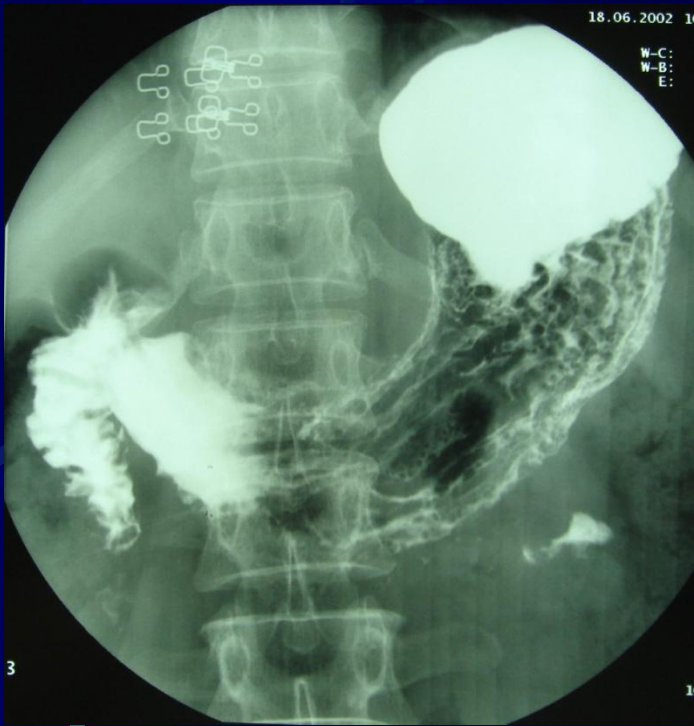局限性肥厚性胃炎

局限性肥厚性胃炎



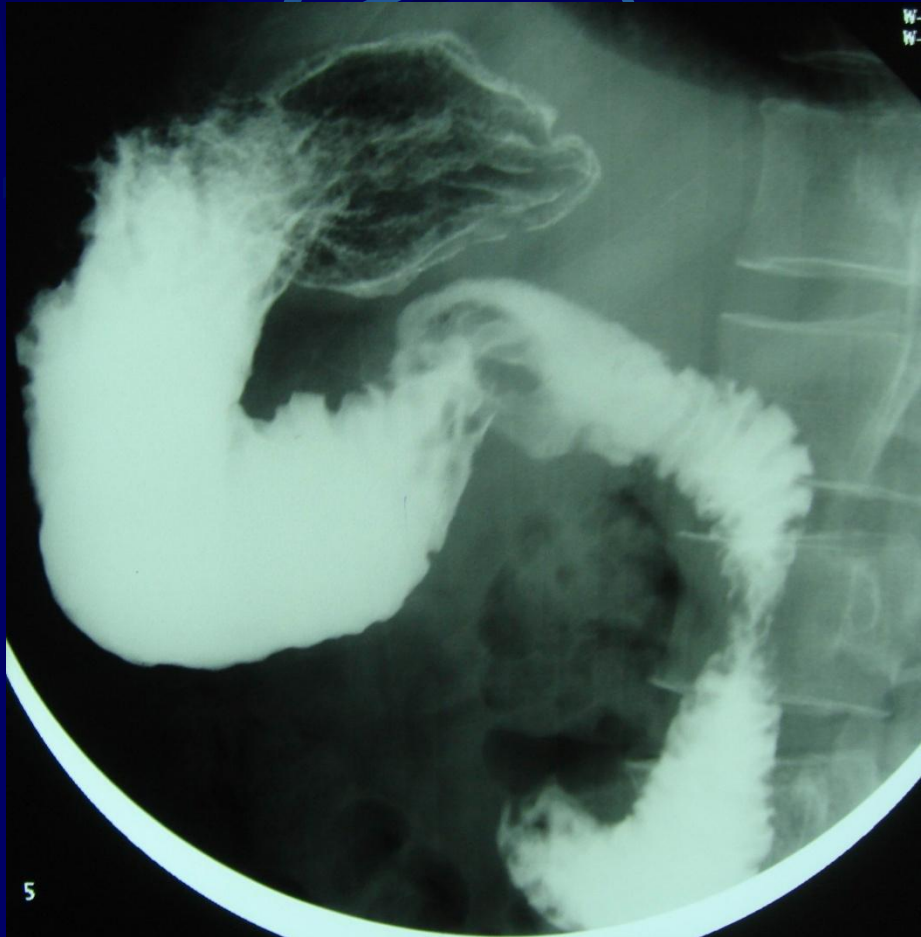
胃窦炎



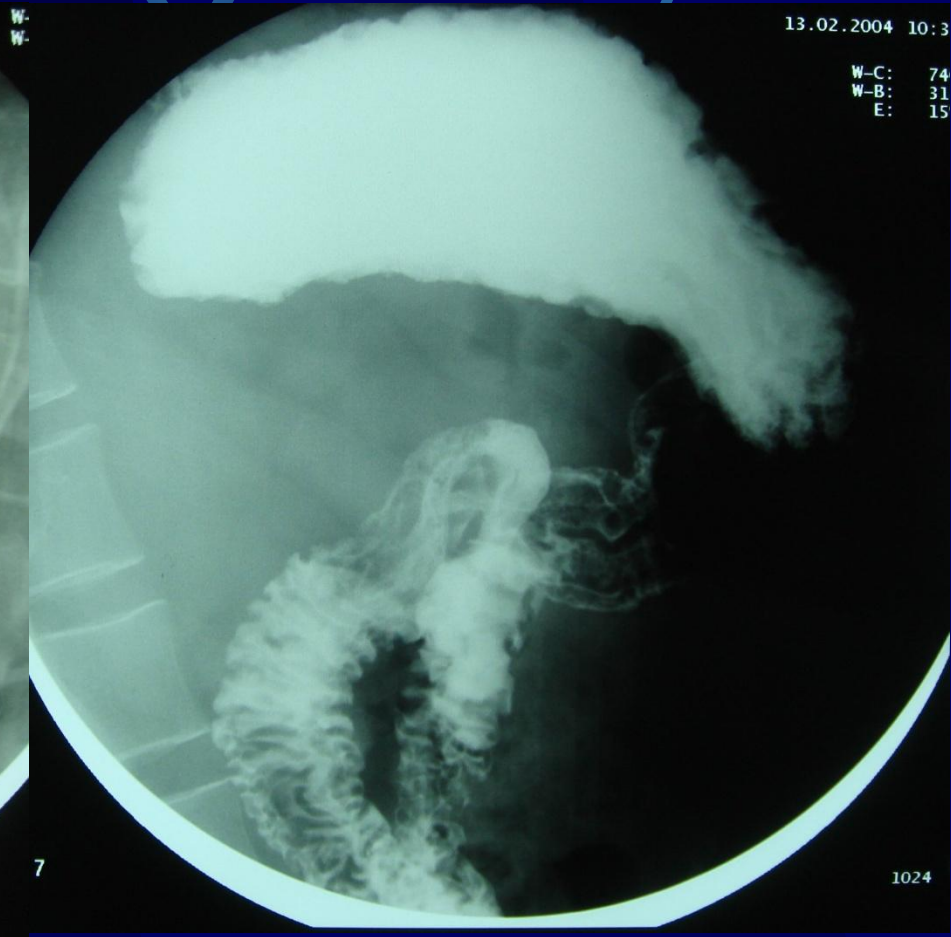
胃粘膜脱垂

1. 胃窦部炎症征像
2. 球底“蕈伞”样充盈缺损
3. 幽门管增宽





5



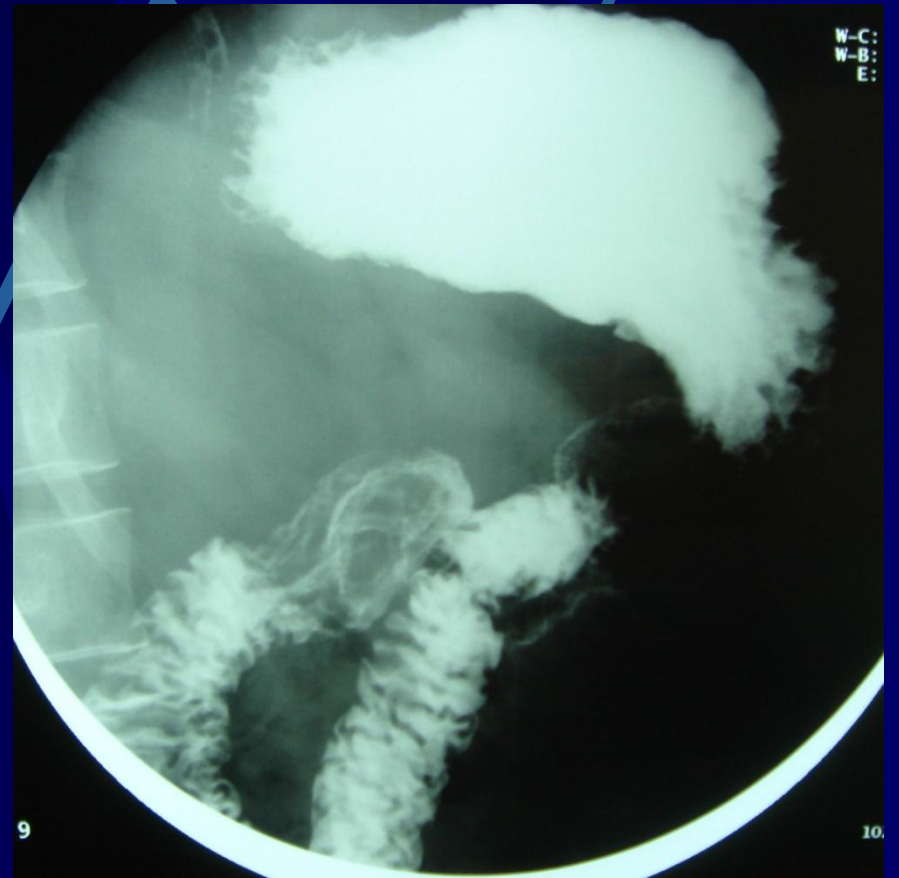
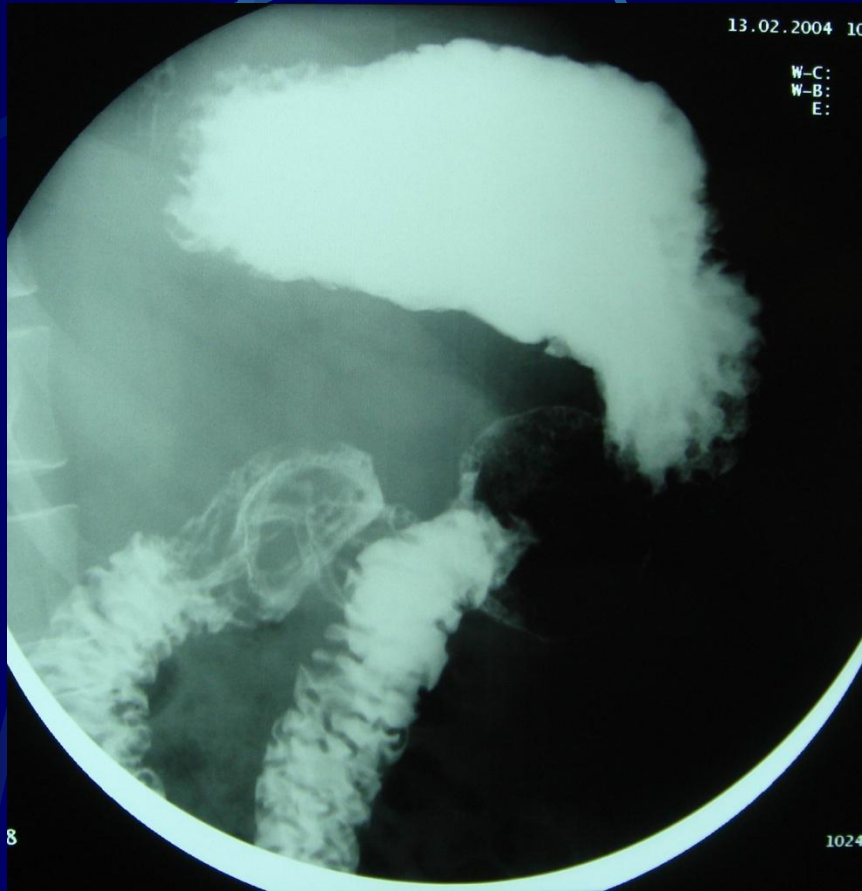
W-
W-

13.02.2004 10:3

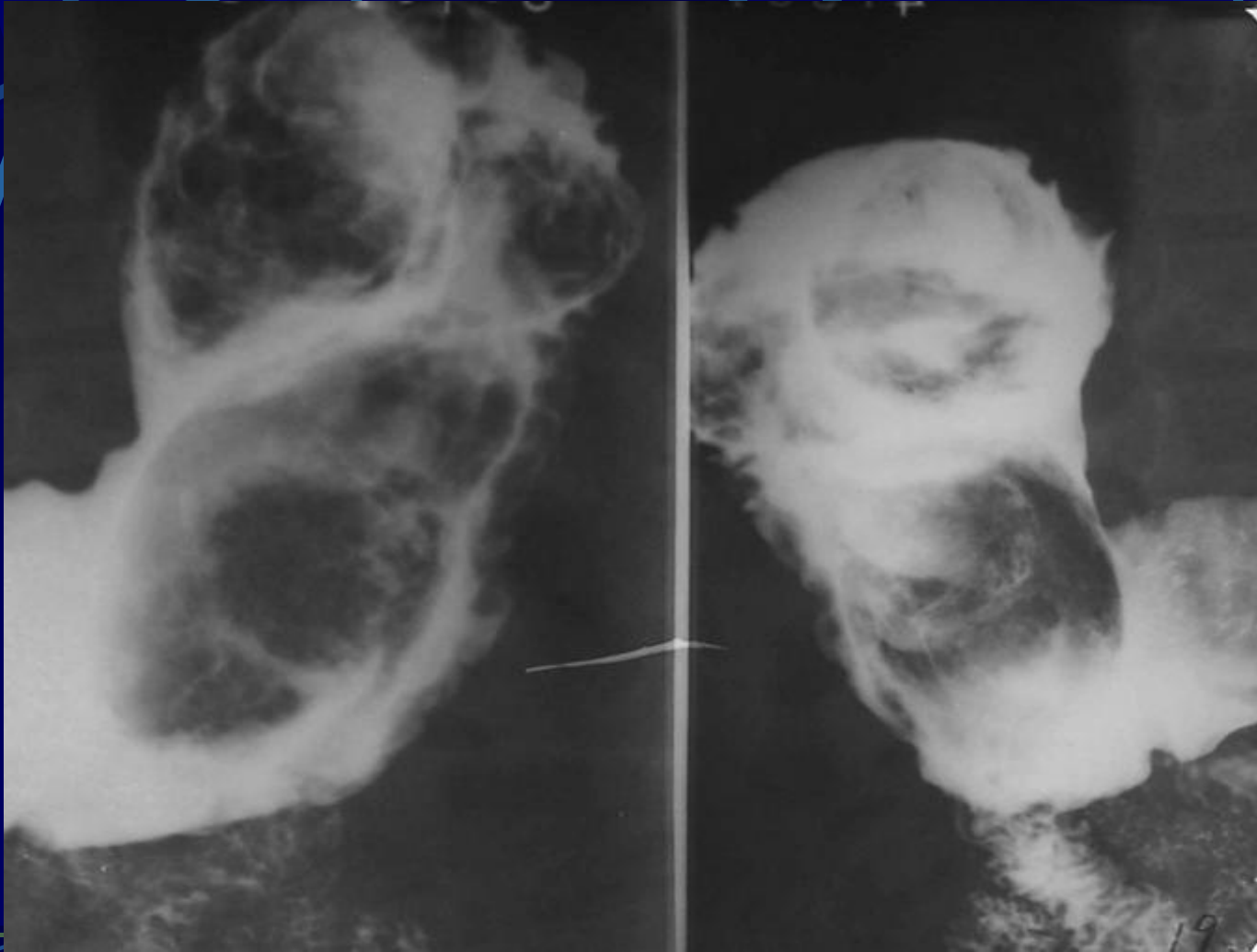
W-C: 74
W-B: 31
E: 15

7

1024



胃底、体部多发性胃石



食管胃连接的X线检查：

检查方法：

- 站立右前斜位（ 30° 左右）
- 1.半卧位、左前斜位、右侧位
- 2.俯卧或头低左后斜位
- 3.仰卧右前斜位
- 4.功能检查

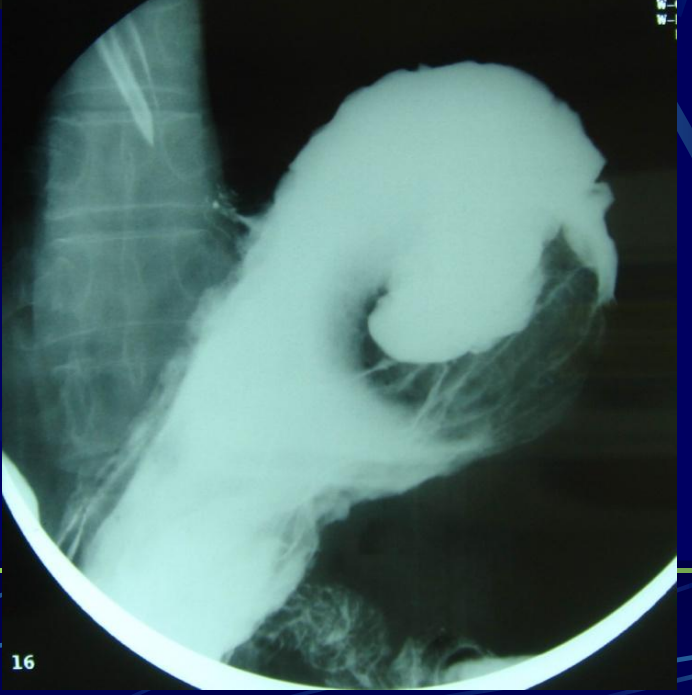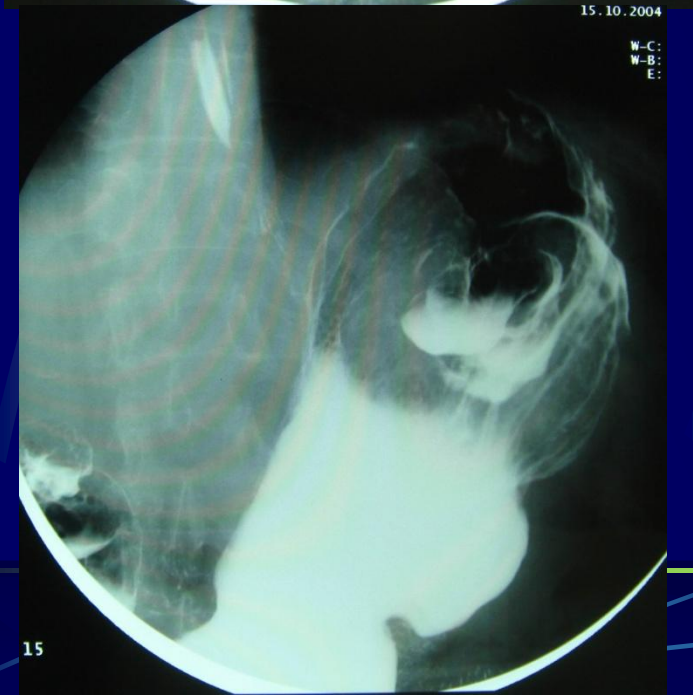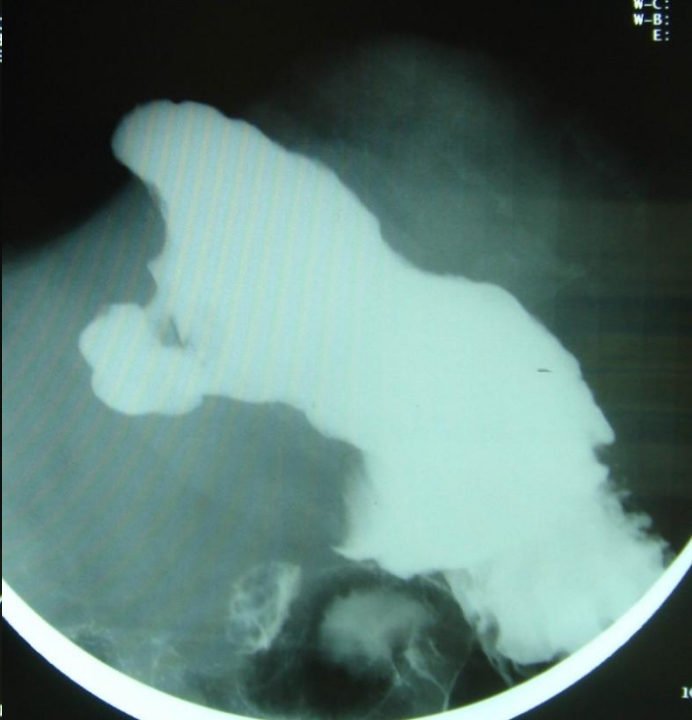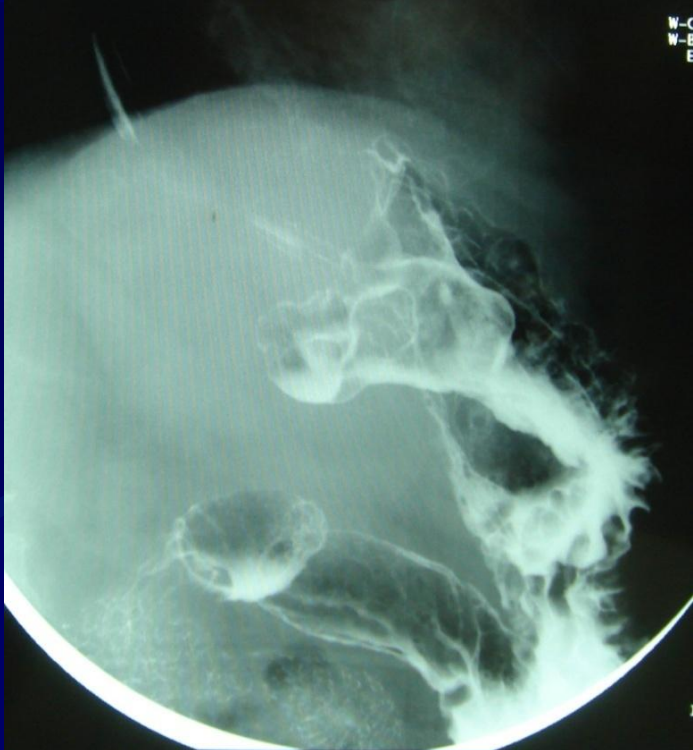贲门癌

X线表现:

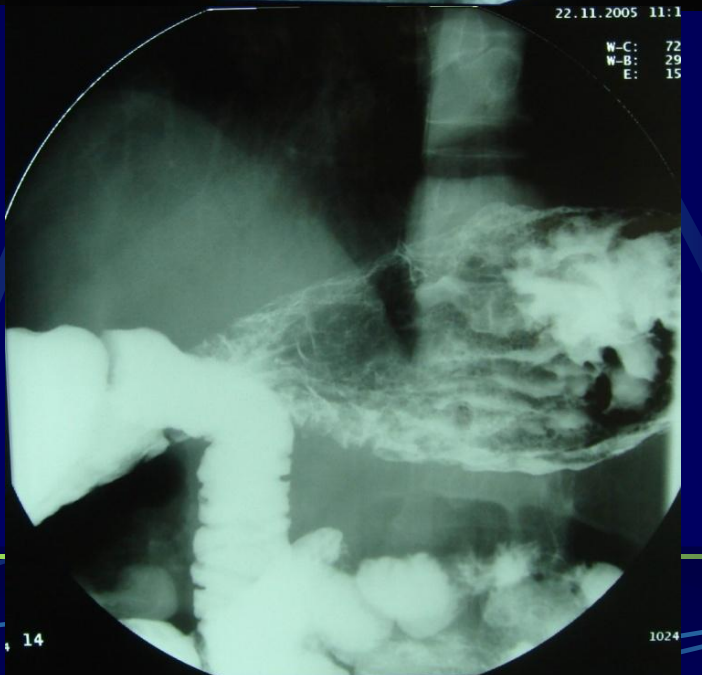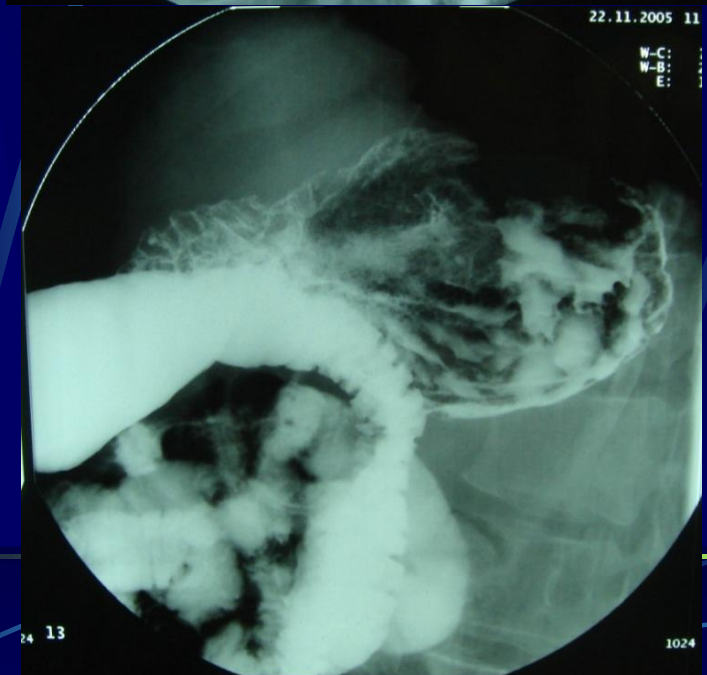
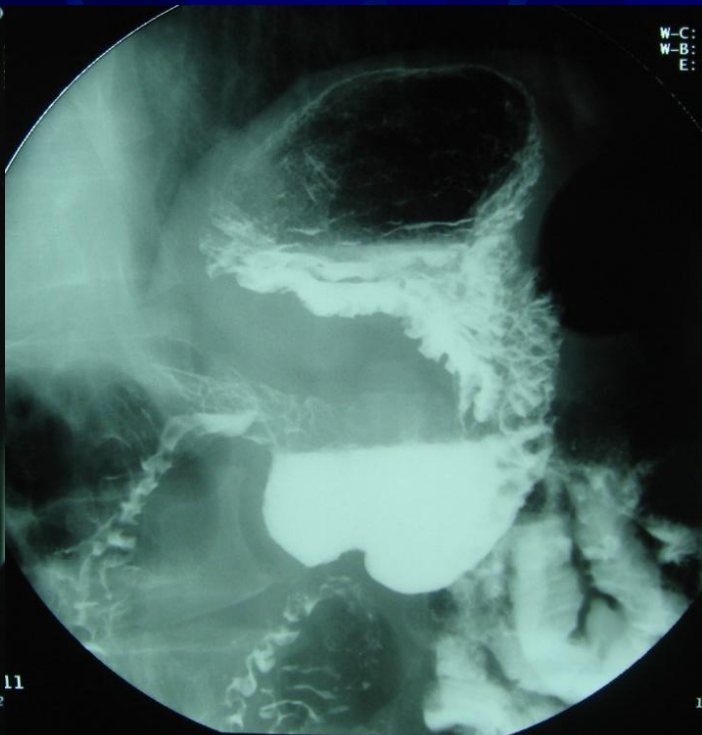
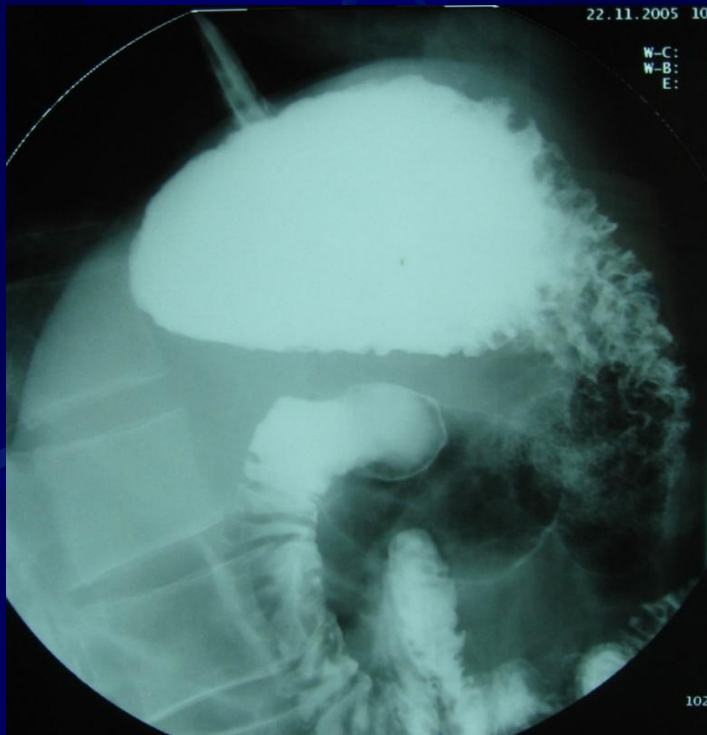
- 1.贲门区软组织块影
- 2.贲门区溃疡龛影
- 3.贲门区粘膜改变
- 4.食道下段改变
- 5.钡流通过情况
- 6.胃小弯后壁改变



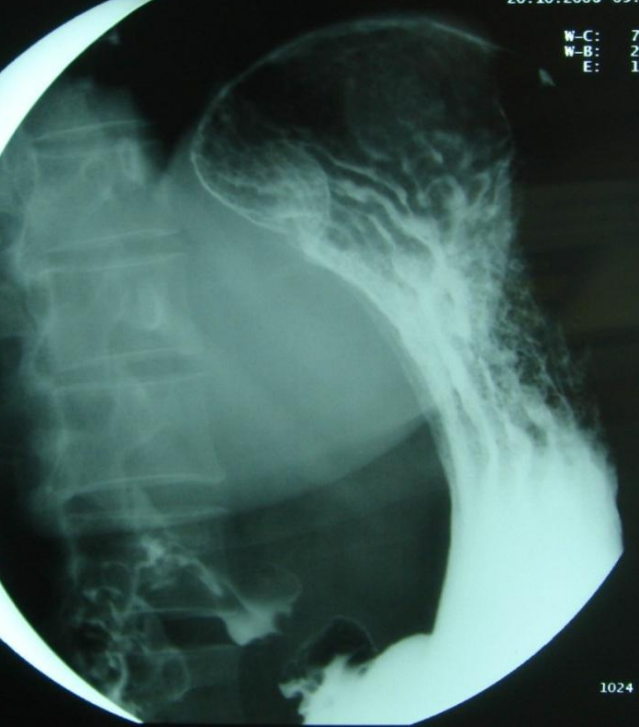
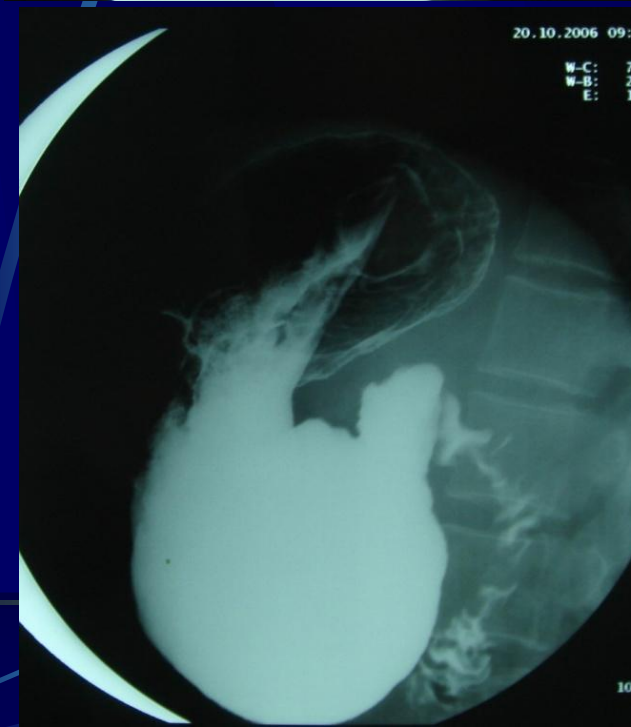
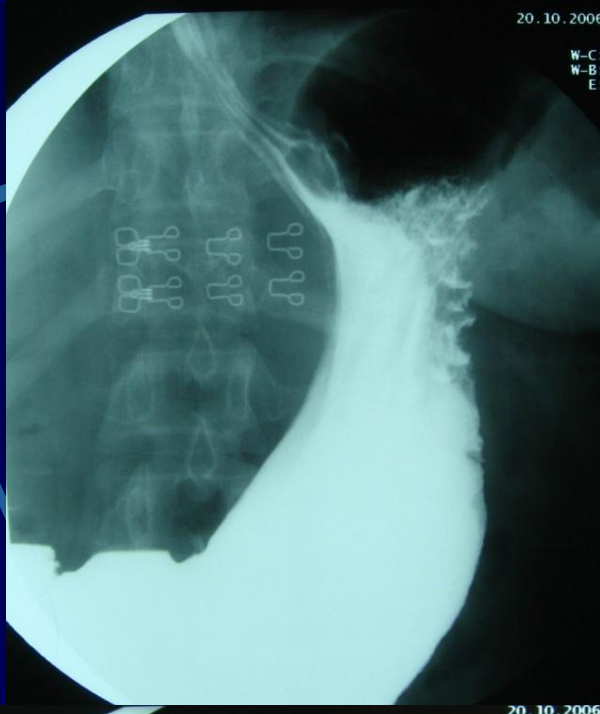
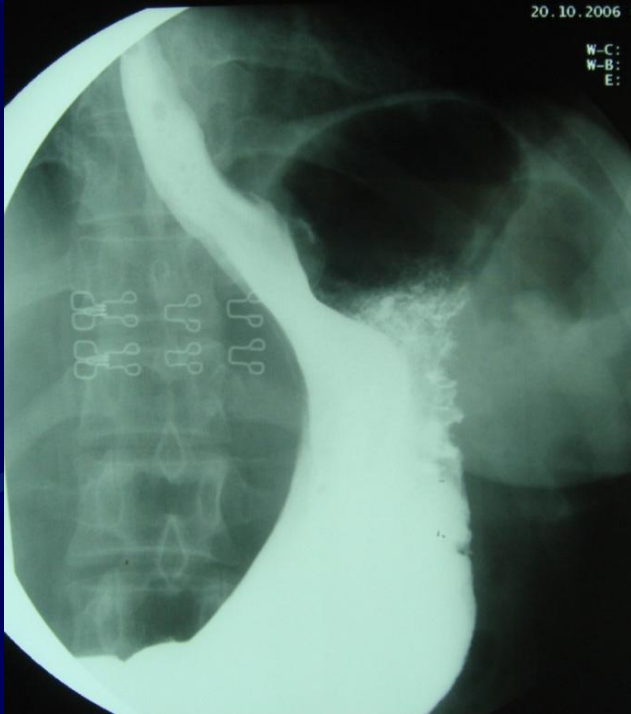
贲门癌



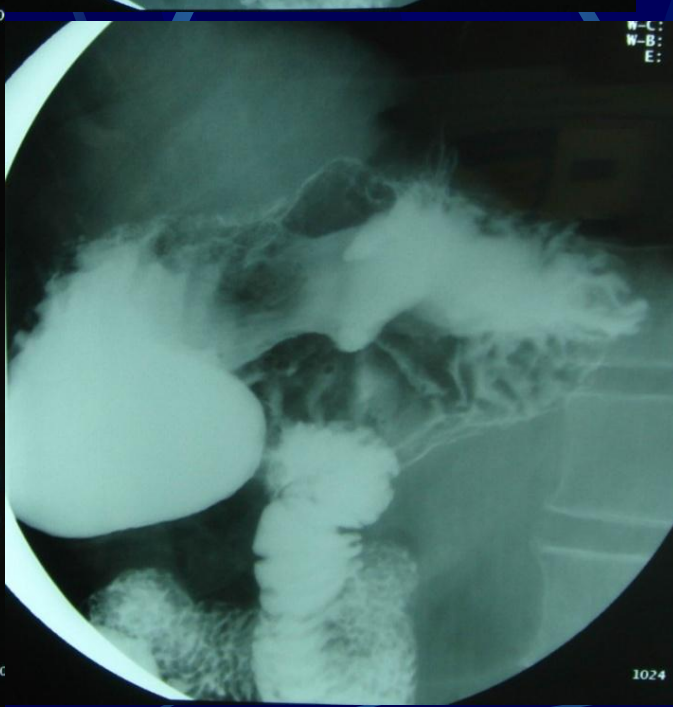
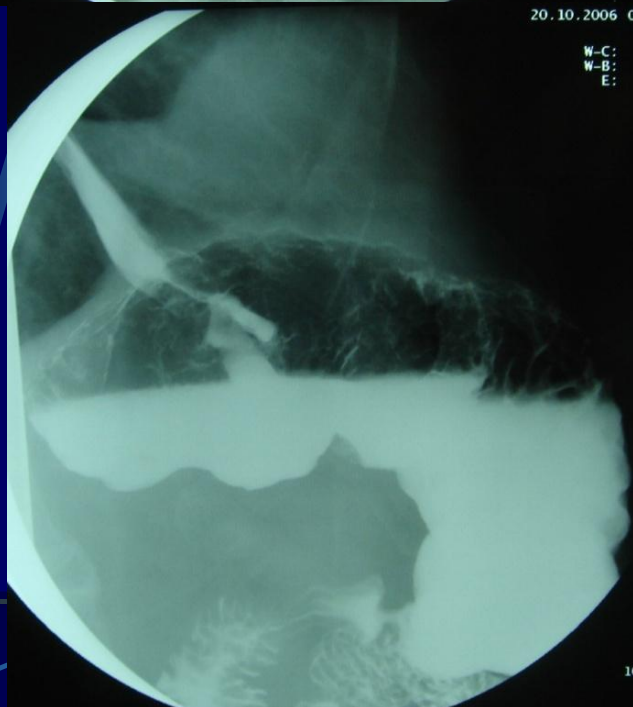
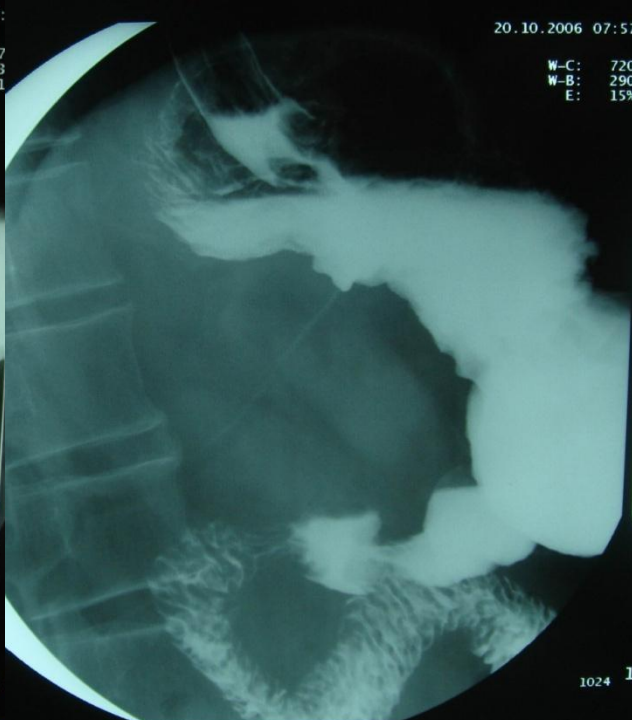
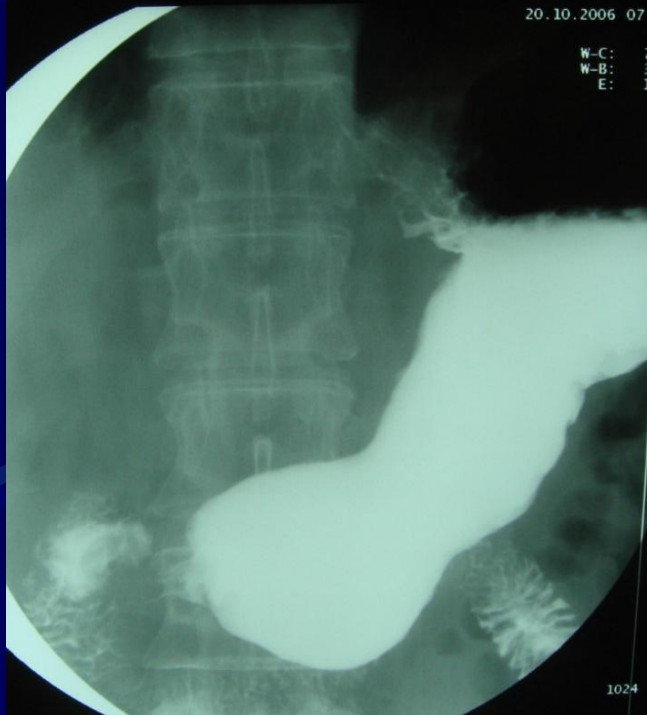贲门癌



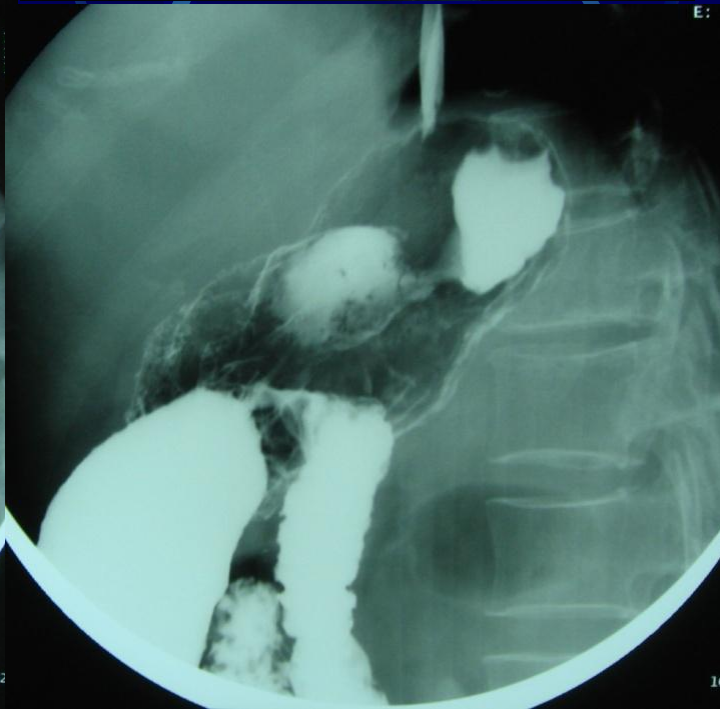
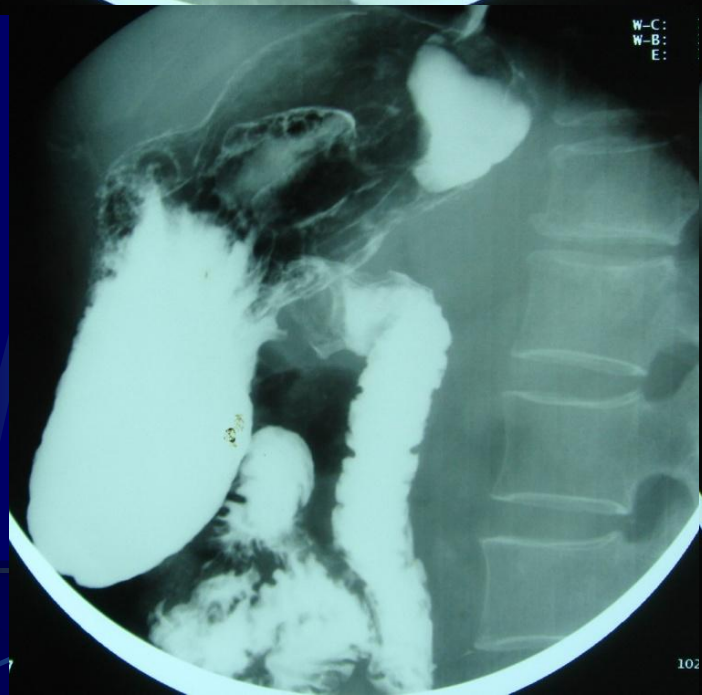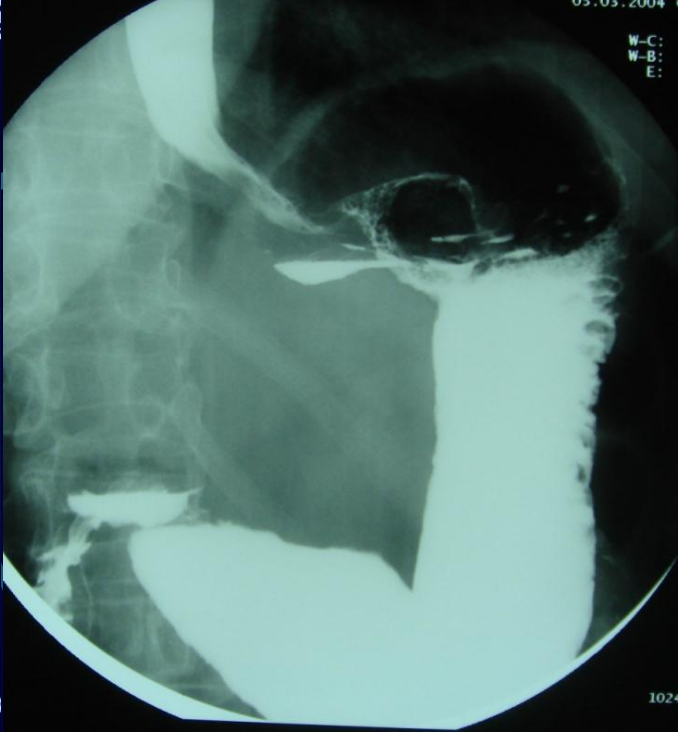
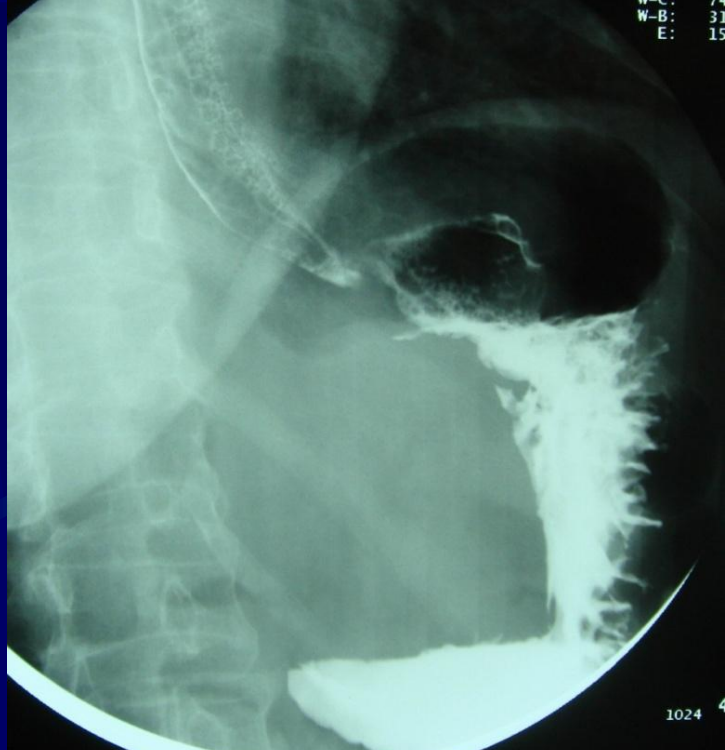贲门癌



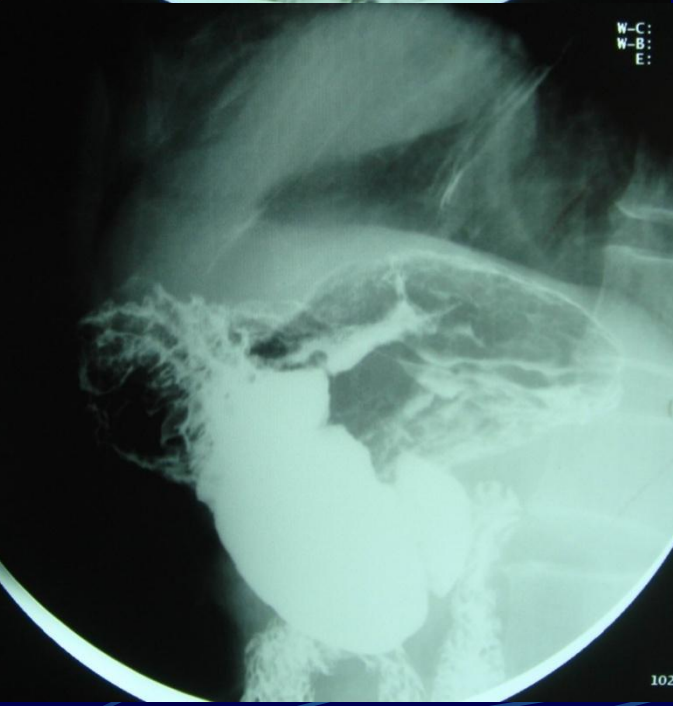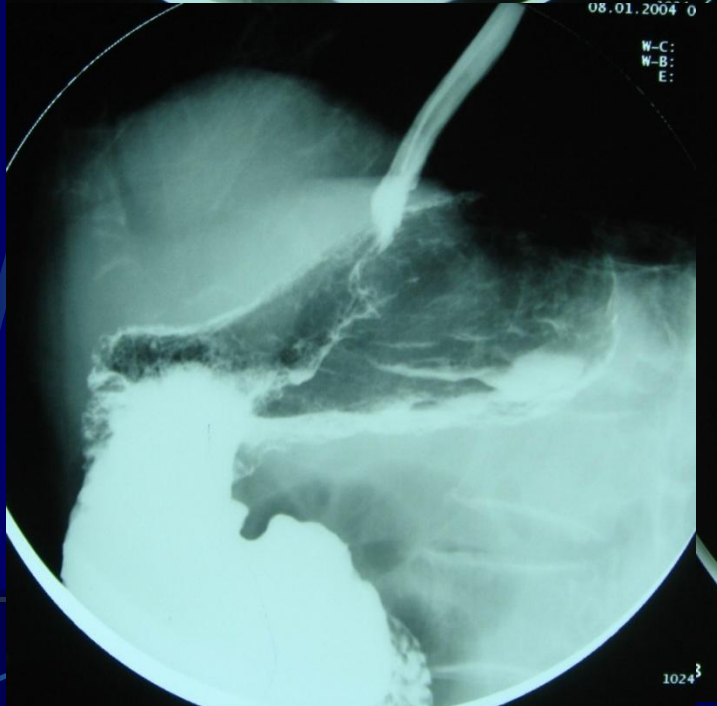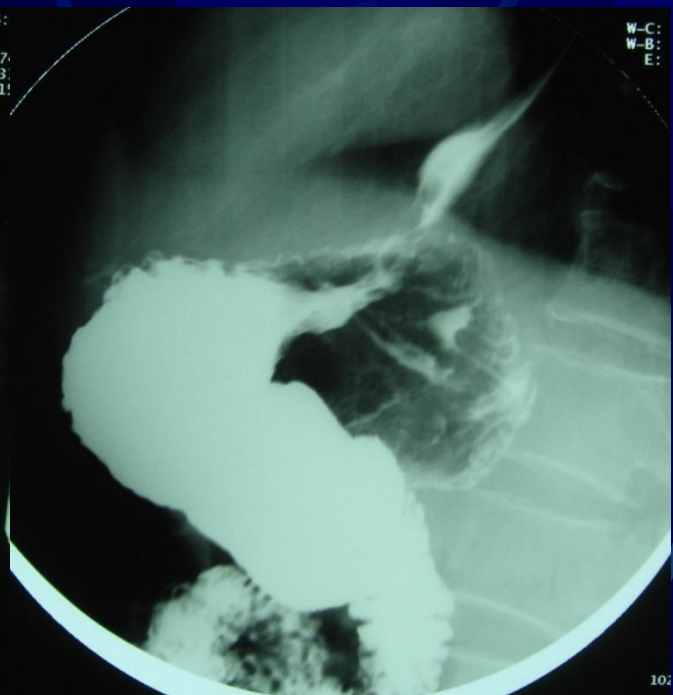
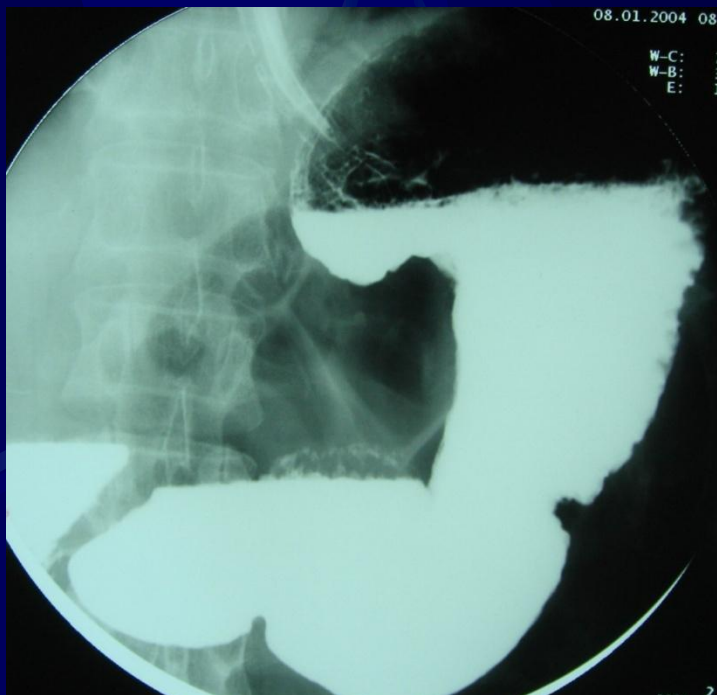
贲门癌



贲门癌



贲门癌



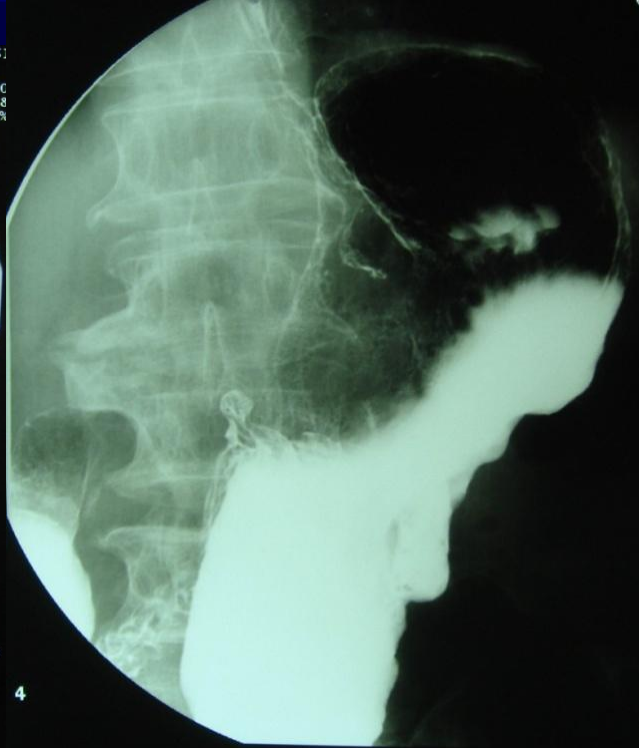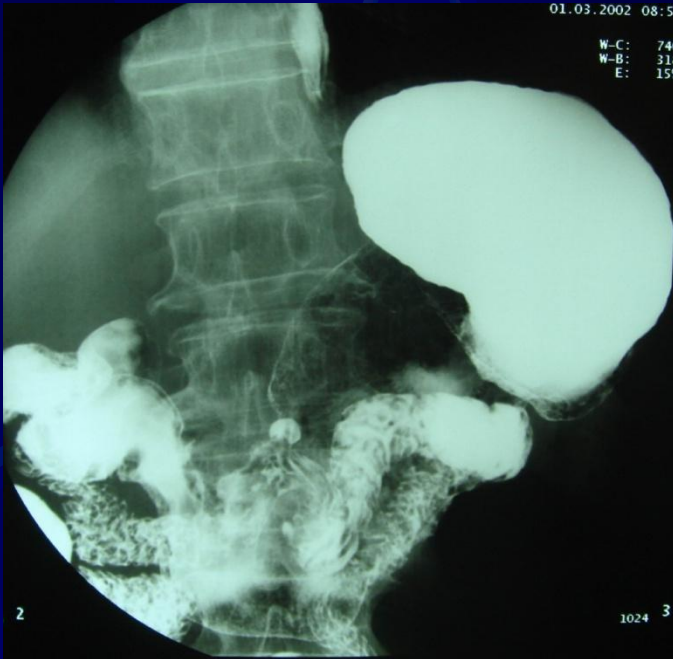1024

1024

贲门癌

01.03.2002 08:51

W-C: 740
W-B: 318
E: 15%

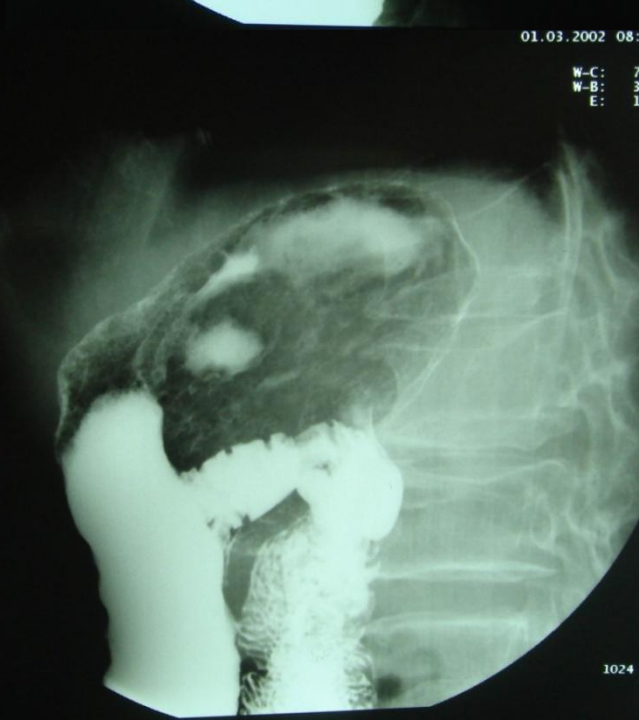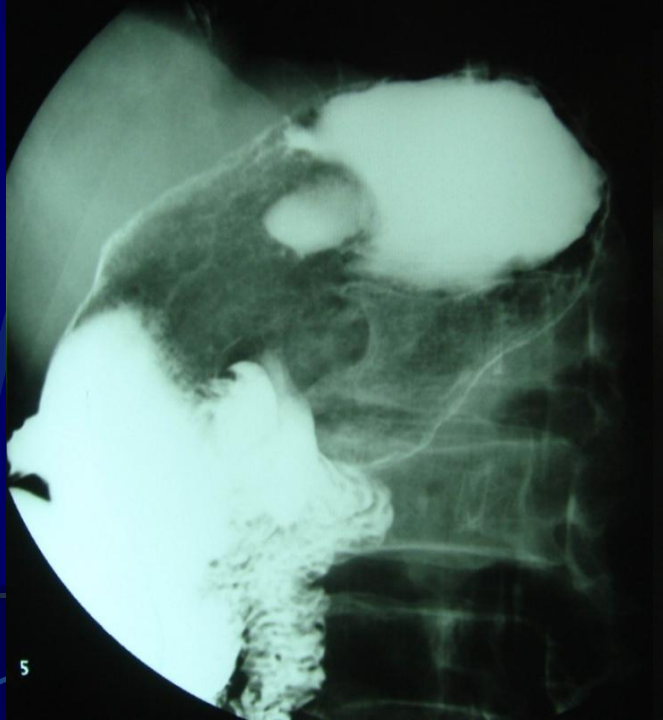


1024

4

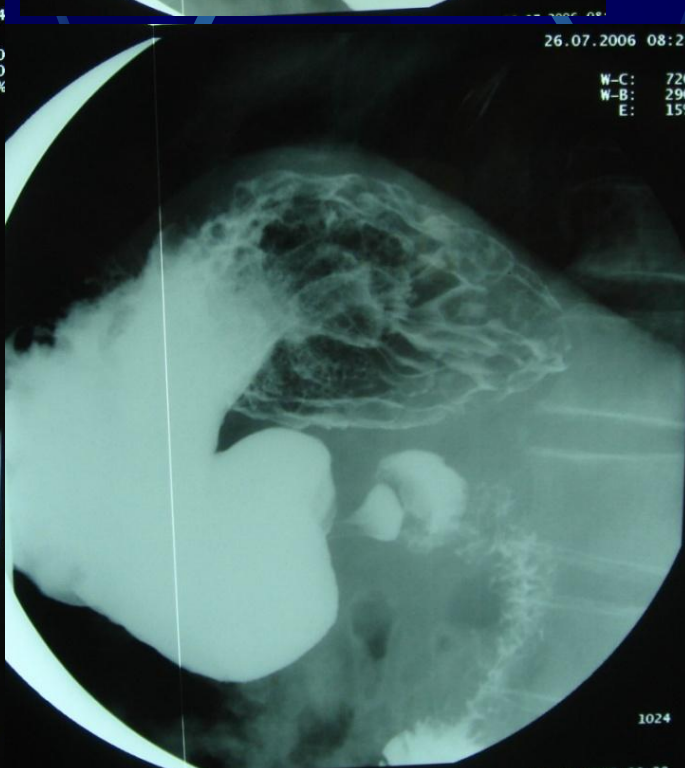
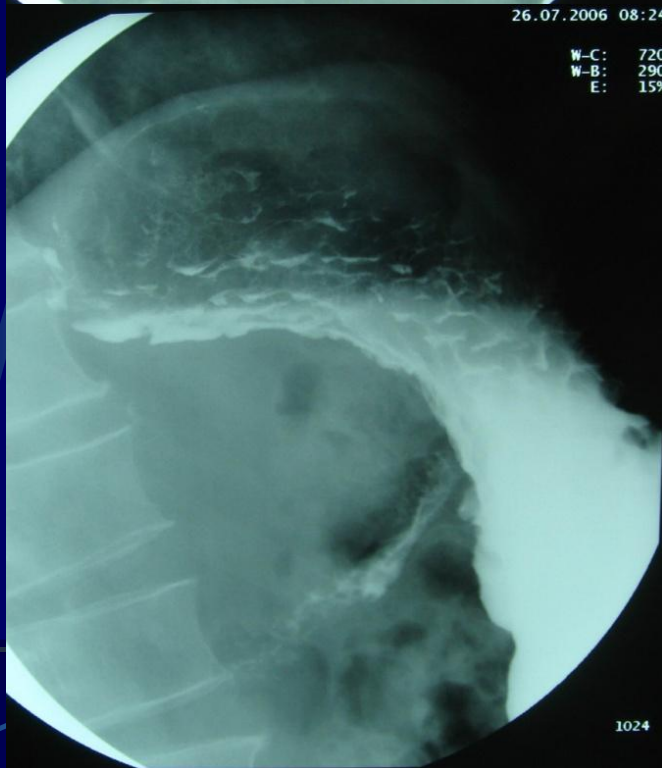
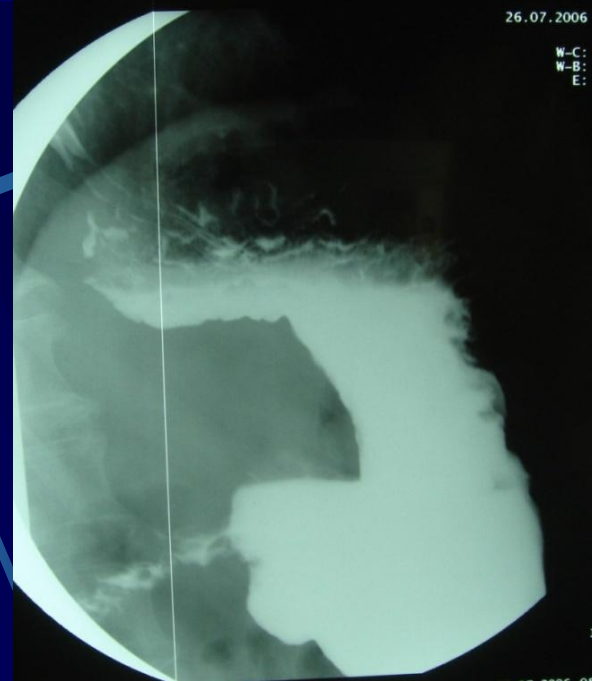
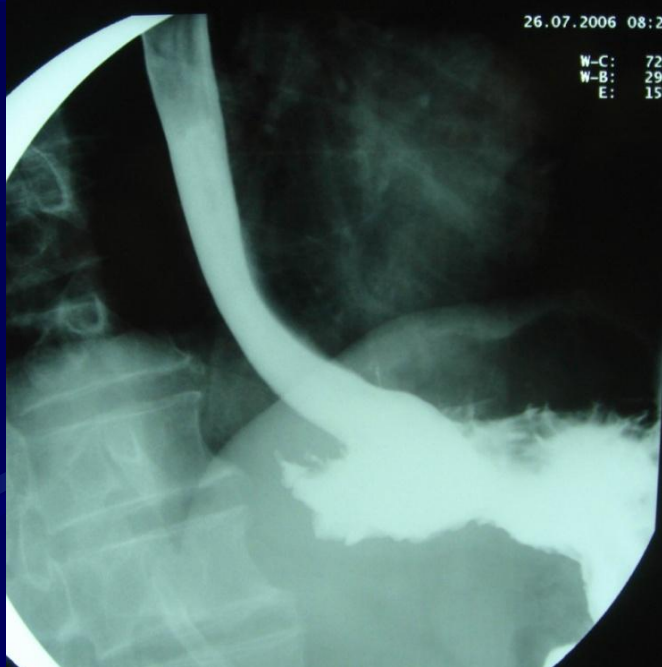
01.03.2002 08:55

W-C: 740
W-B: 318
E: 15%



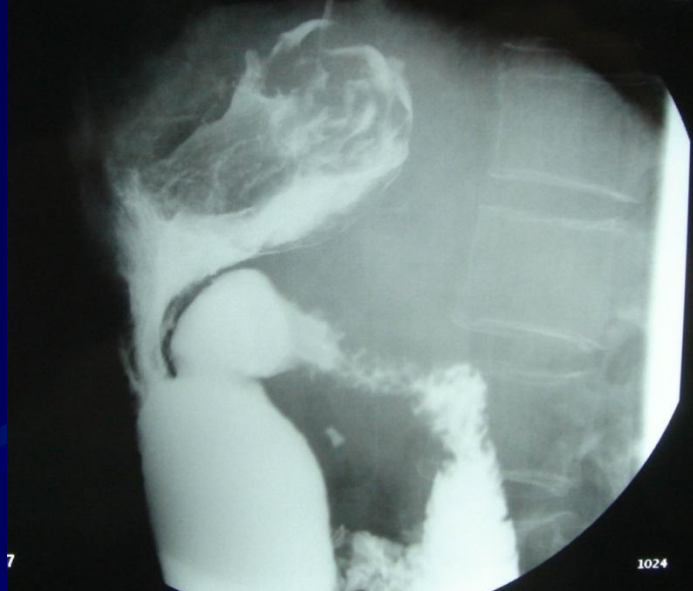1024

贲门癌

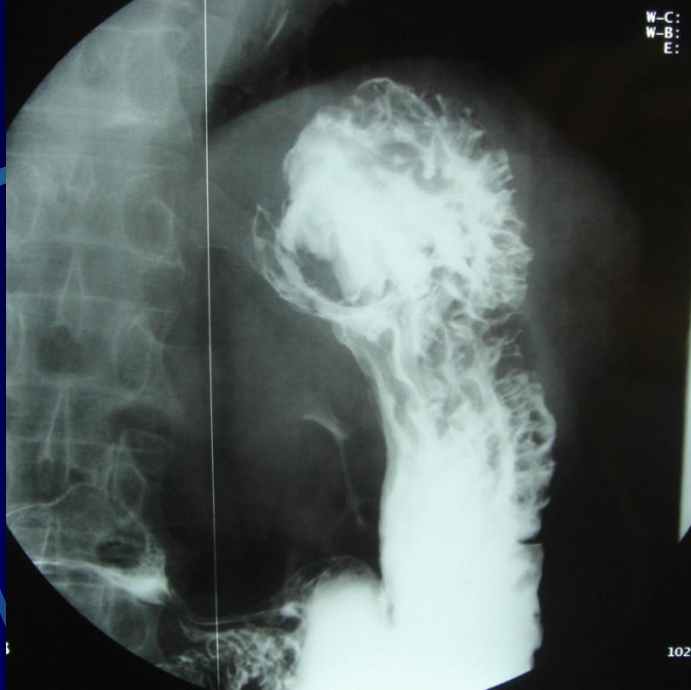


7

W-C: 720
W-B: 290
E: 15%



1024

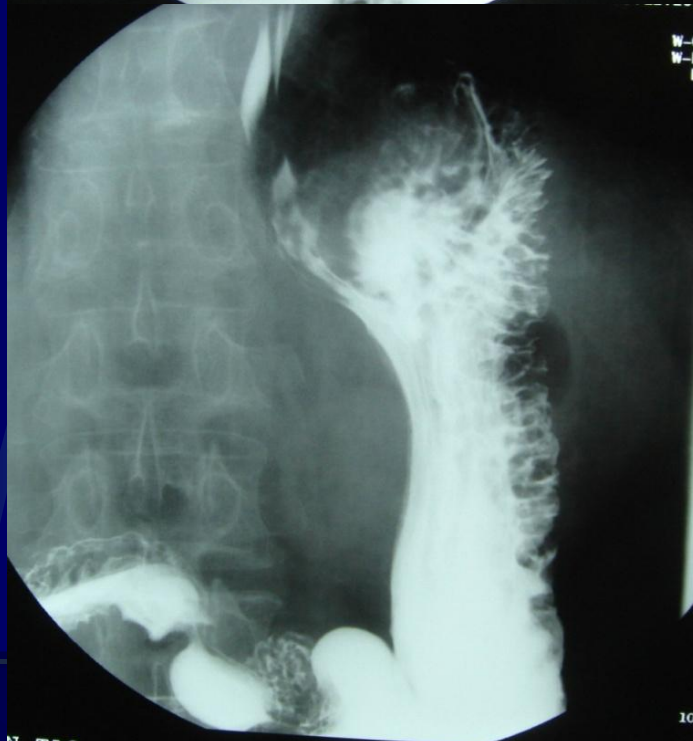

W-C:
W-B:
E:

1024

贲门癌

W-C:
W-B:
E:



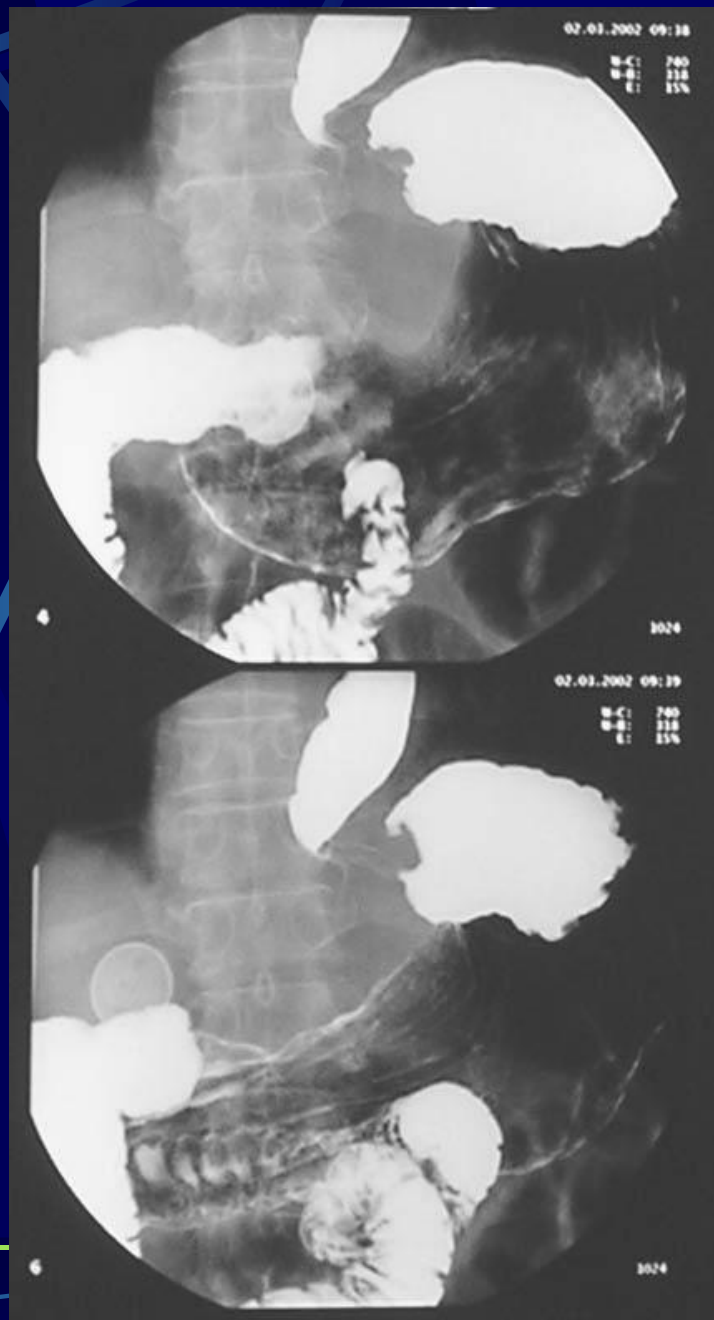
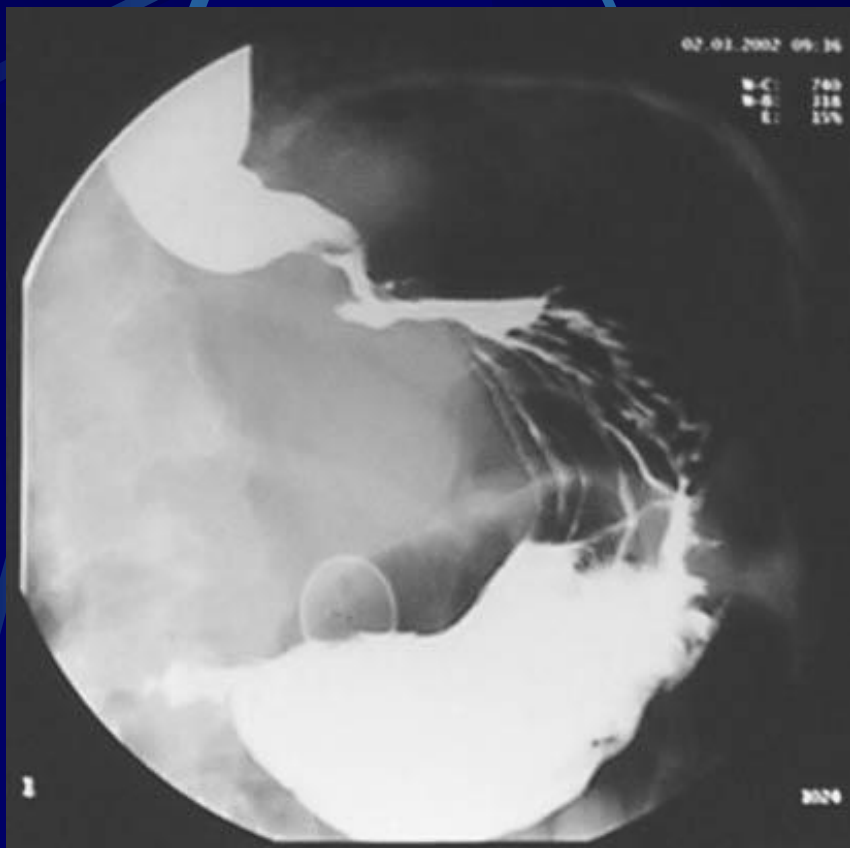
10
10.

W-C:
W-B:
E:

10.

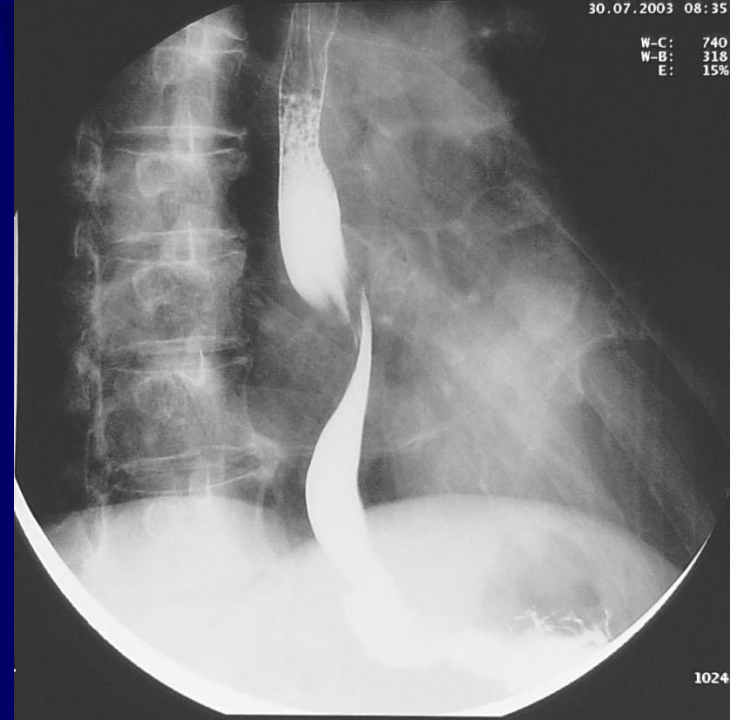
N 320

贲门癌



30.07.2003 08:35

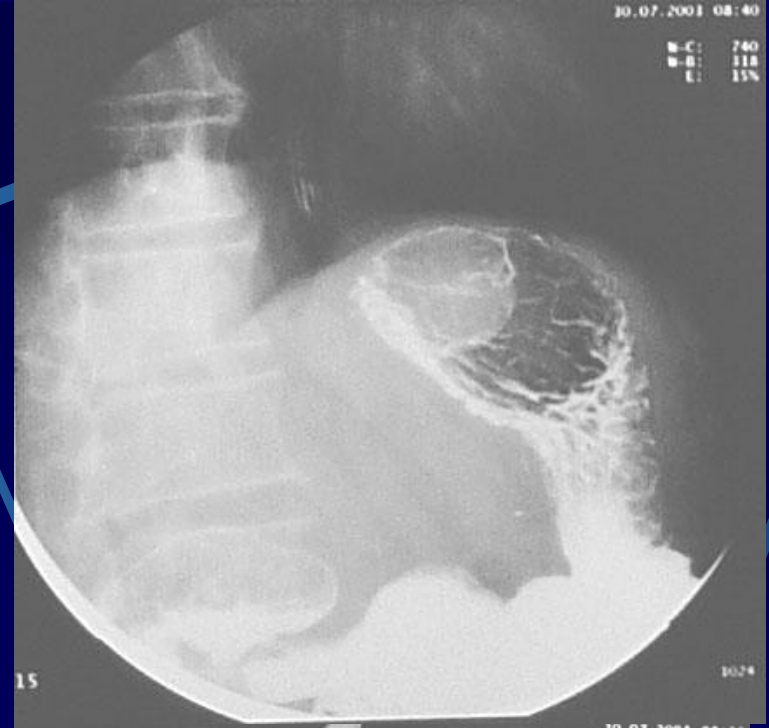
W-C: 740
W-B: 318
E: 15%



1024 15

30.07.2001 08:40

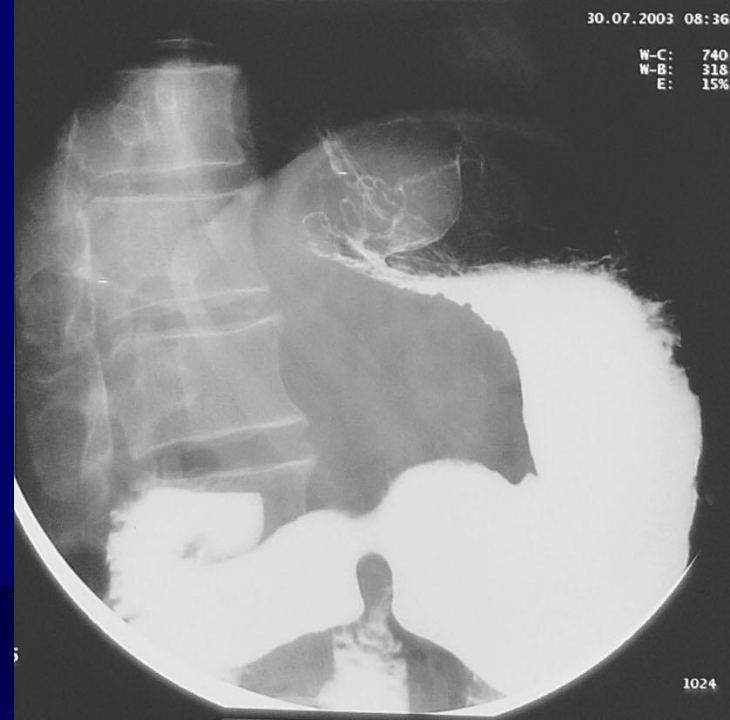
W-C: 740
W-B: 318
E: 15%



1024

30.07.2003 08:36

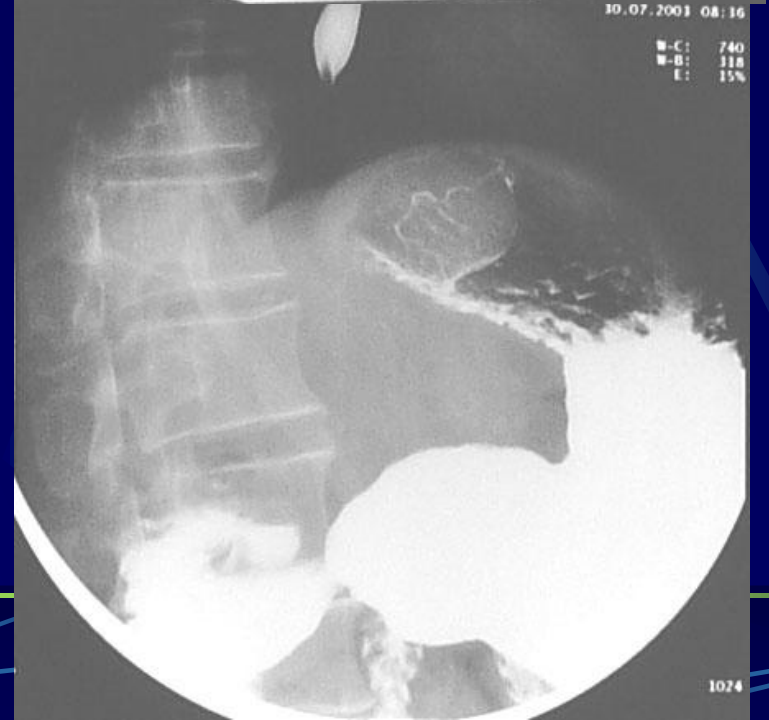
W-C: 740
W-B: 318
E: 15%



1024

30.07.2001 08:16

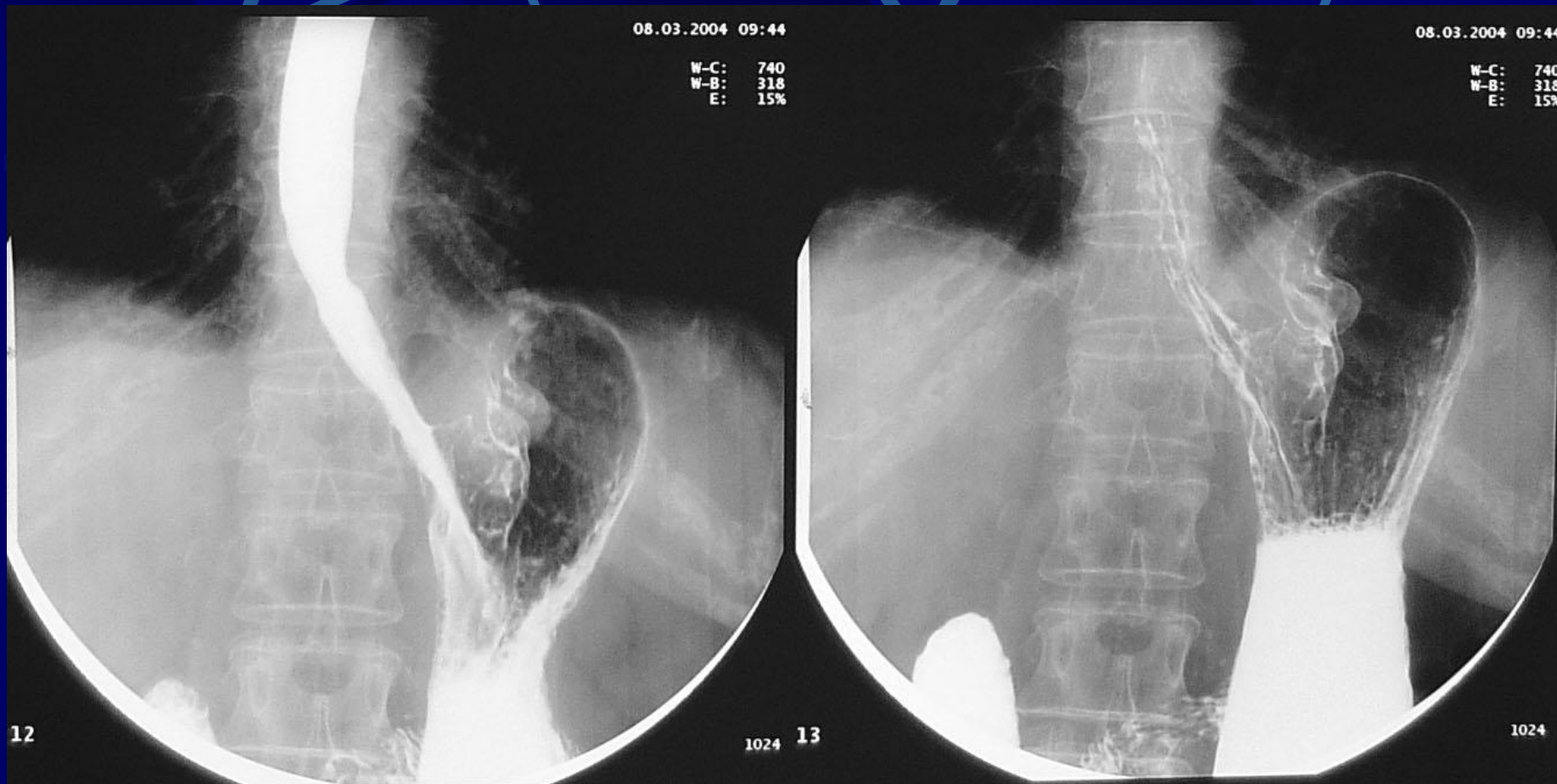
W-C: 740
W-B: 318
E: 15%

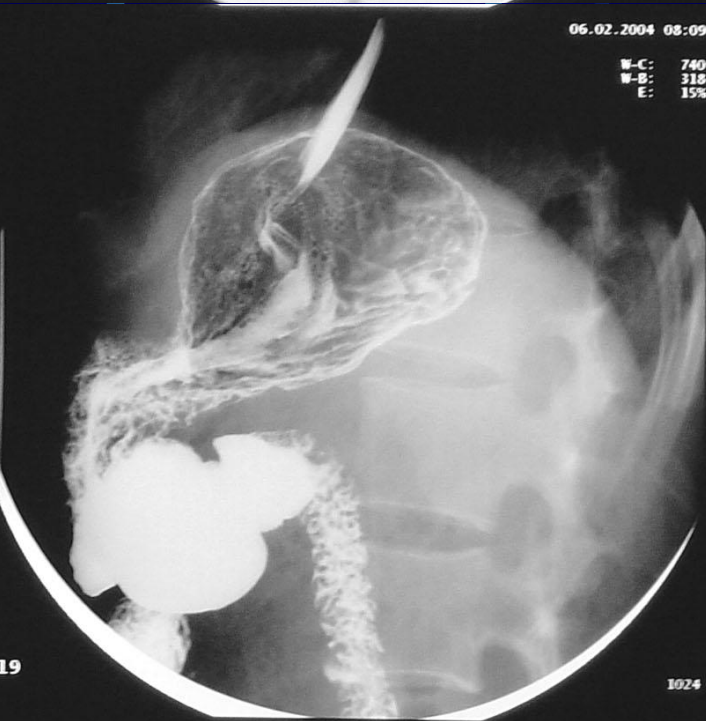
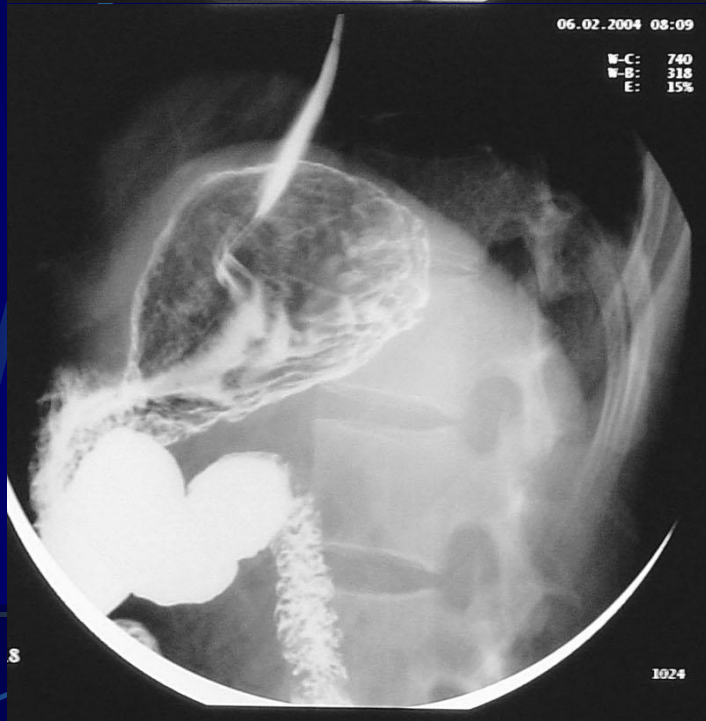
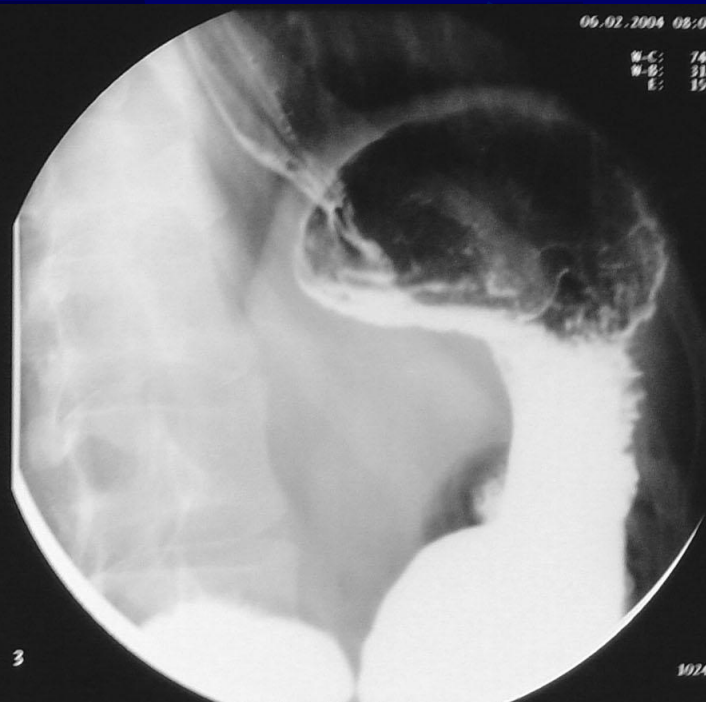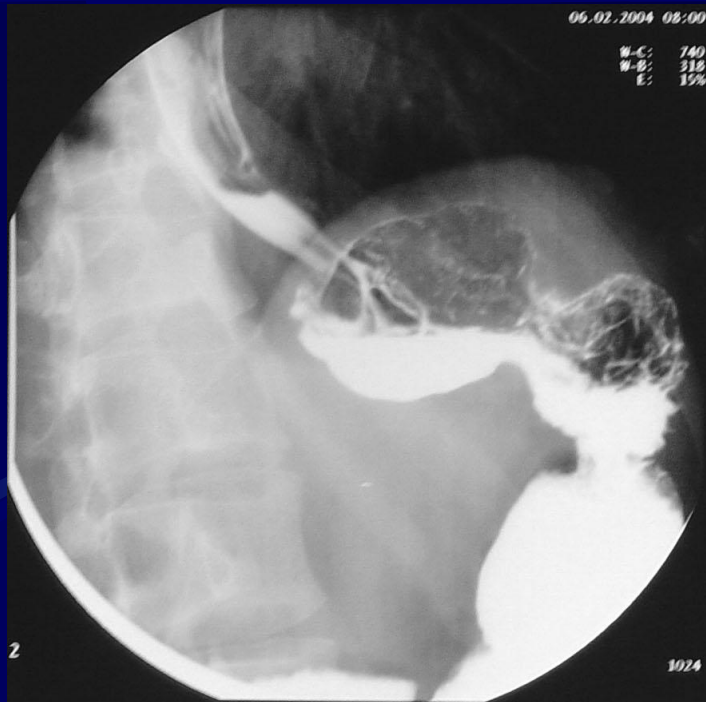1024

贲门癌

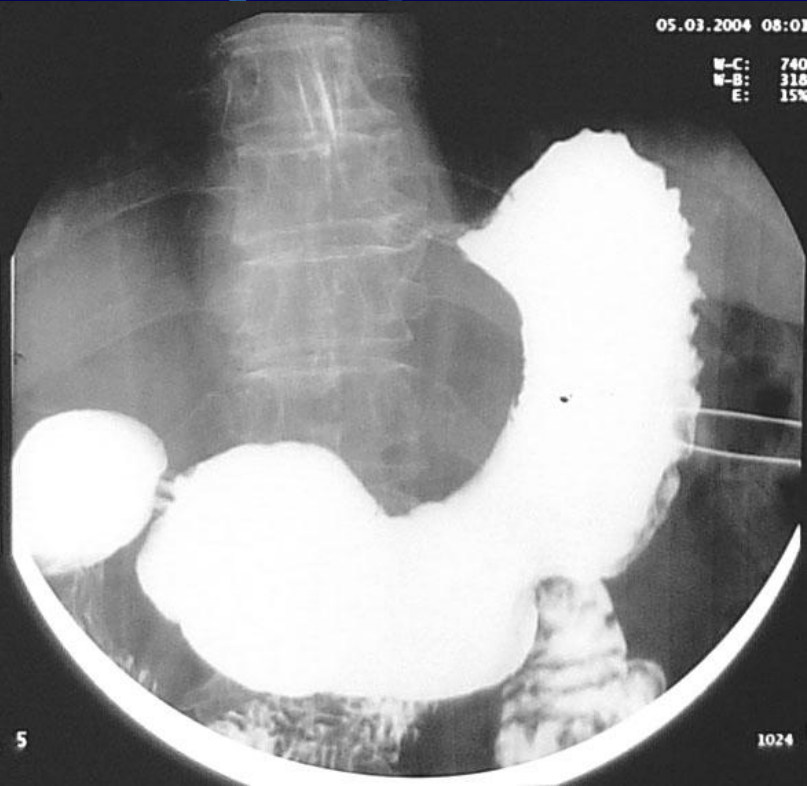
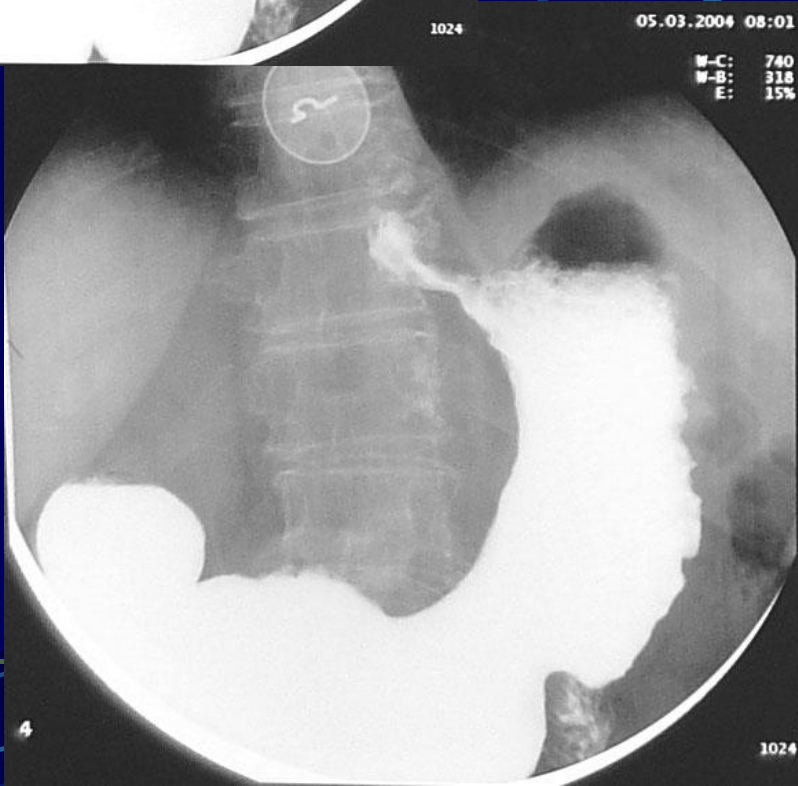
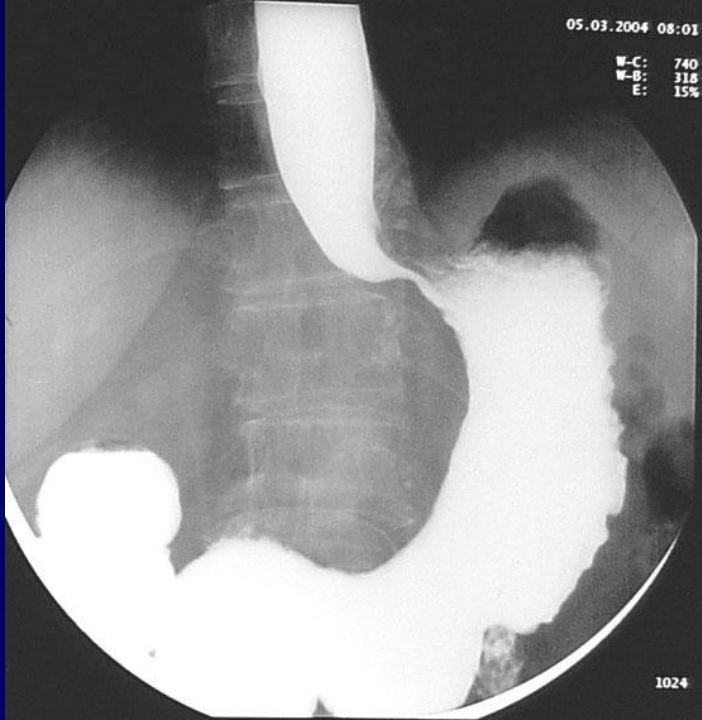
贲门癌



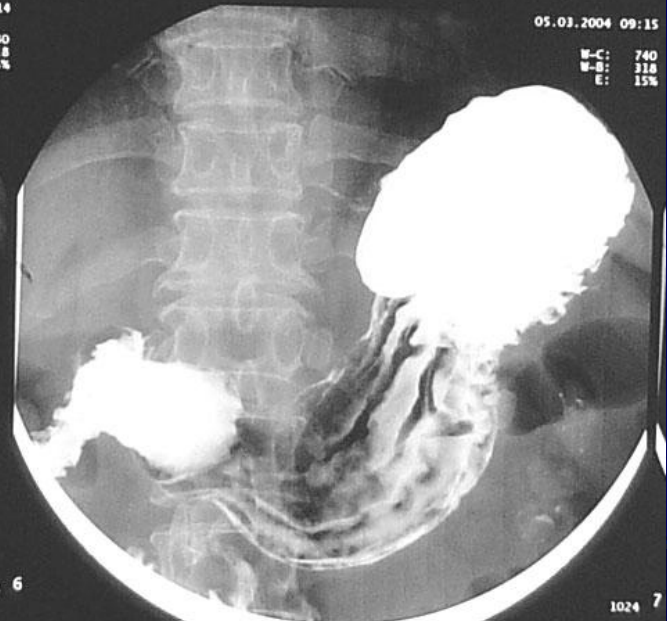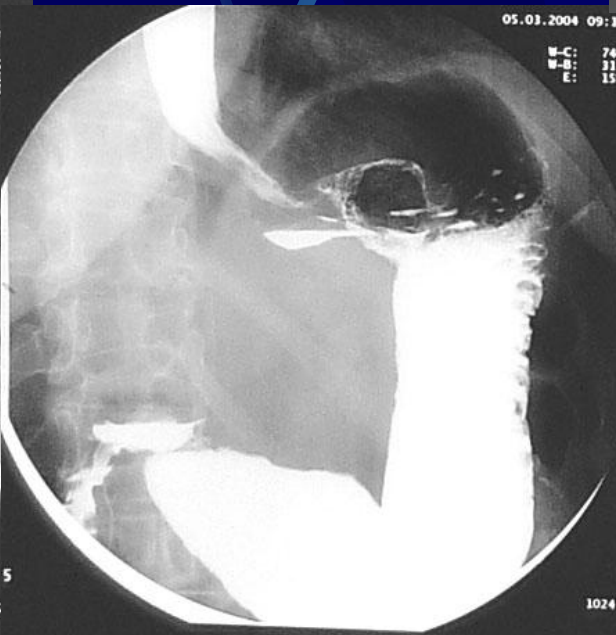
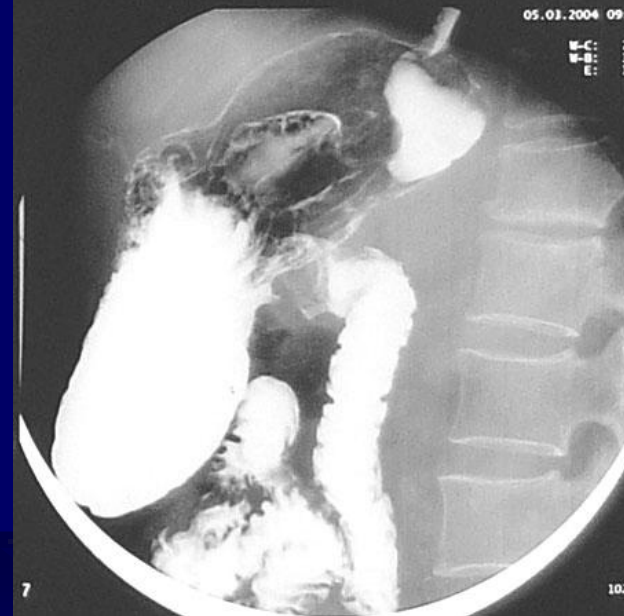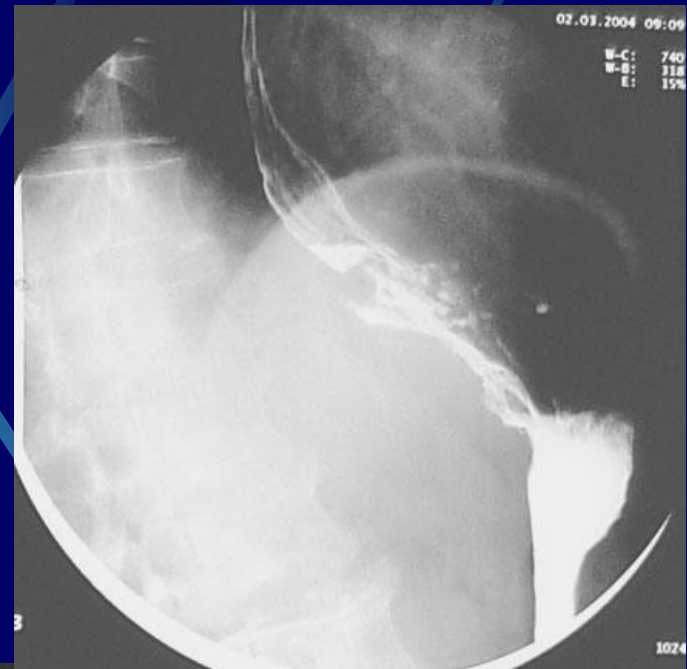


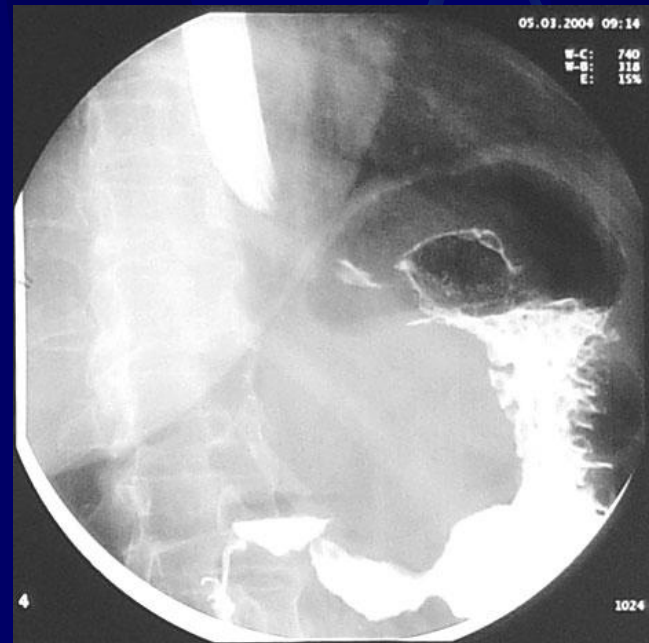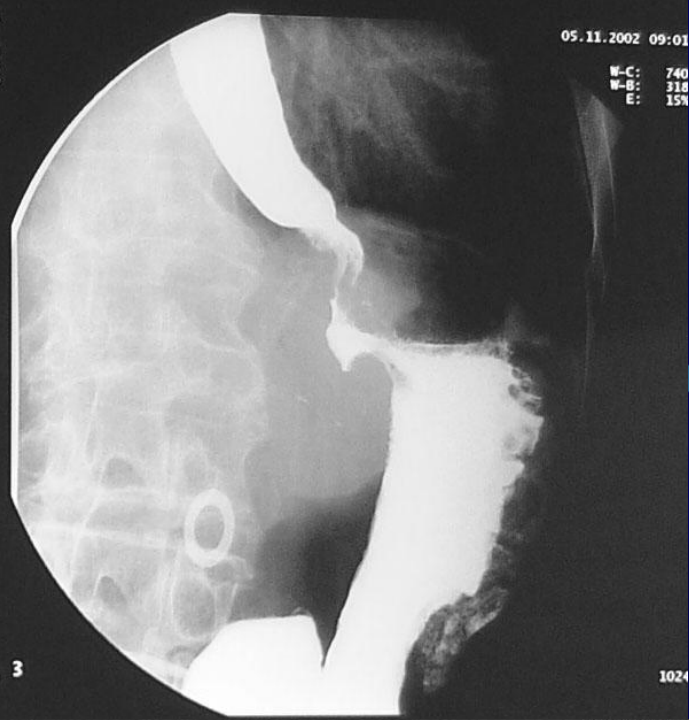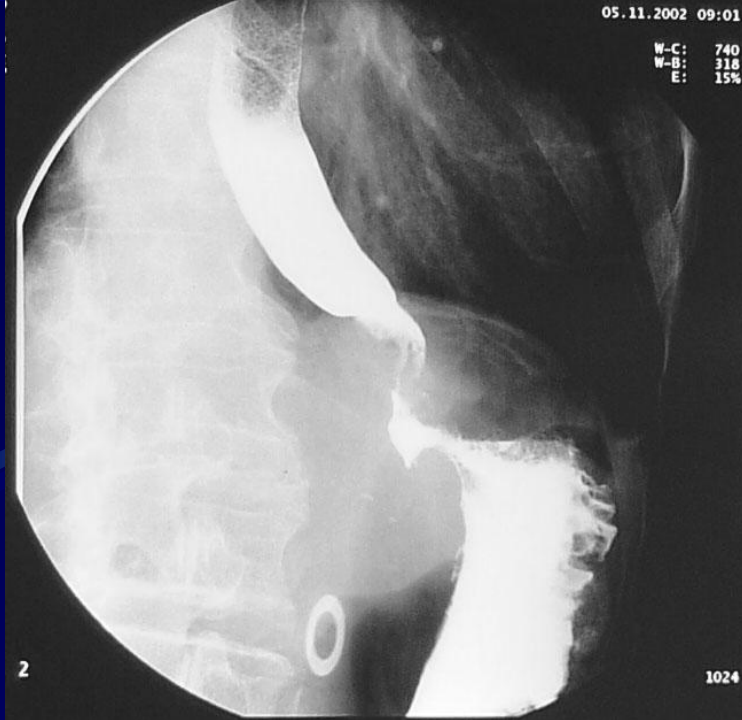贲门癌

贲门癌

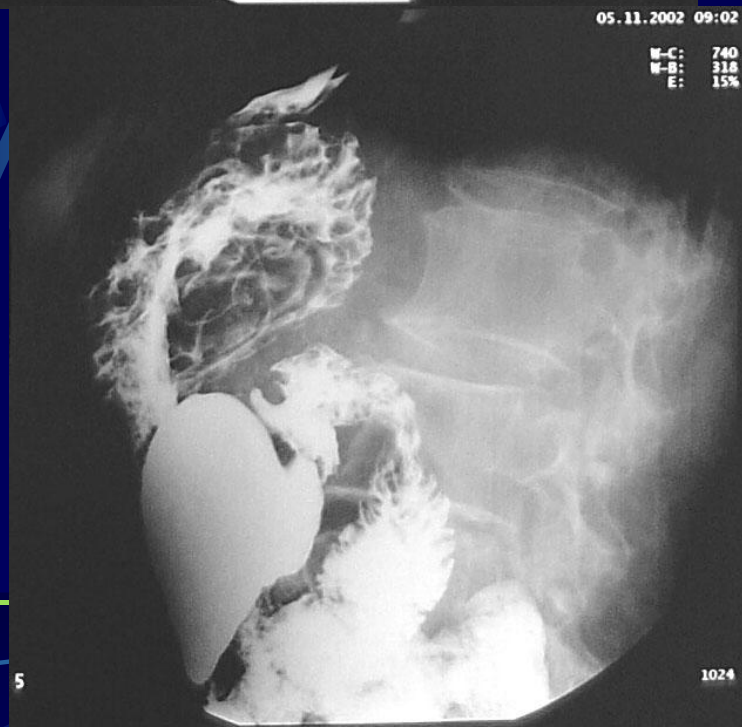


贲门癌





贲门癌



胃癌

1. 早期胃癌定义:

2. 早期胃癌分型:

a: 隆起型

b: 浅表型, 又分三亚型

c: 凹陷型

早期胃癌X线检查技术:

1. 注意观察粘膜细微改变
2. 局部胃壁改变（切线位，充盈相）
3. 不同部位检查方法：
 - a贲门部：右后斜位；
 - b幽门前区：充盈加压。

胃癌

早期胃癌间接X线征象:

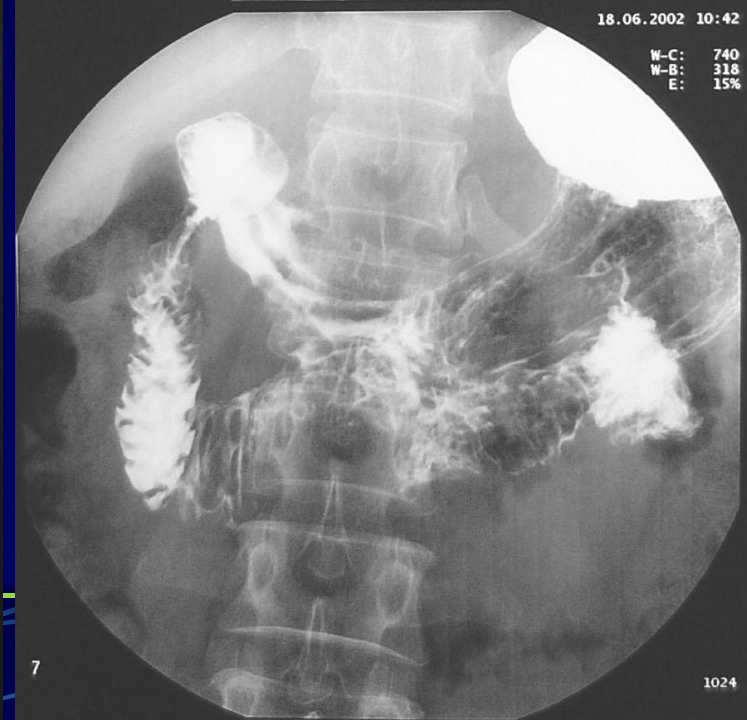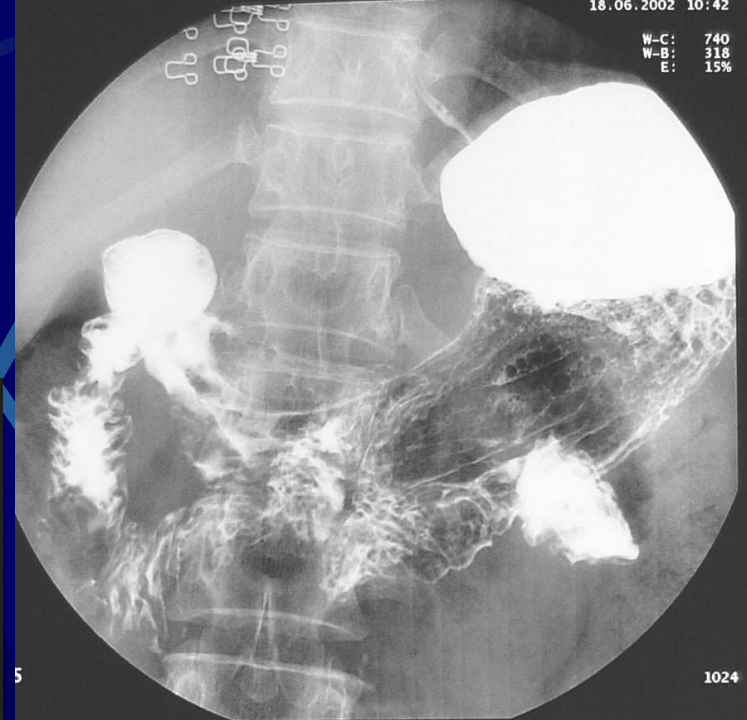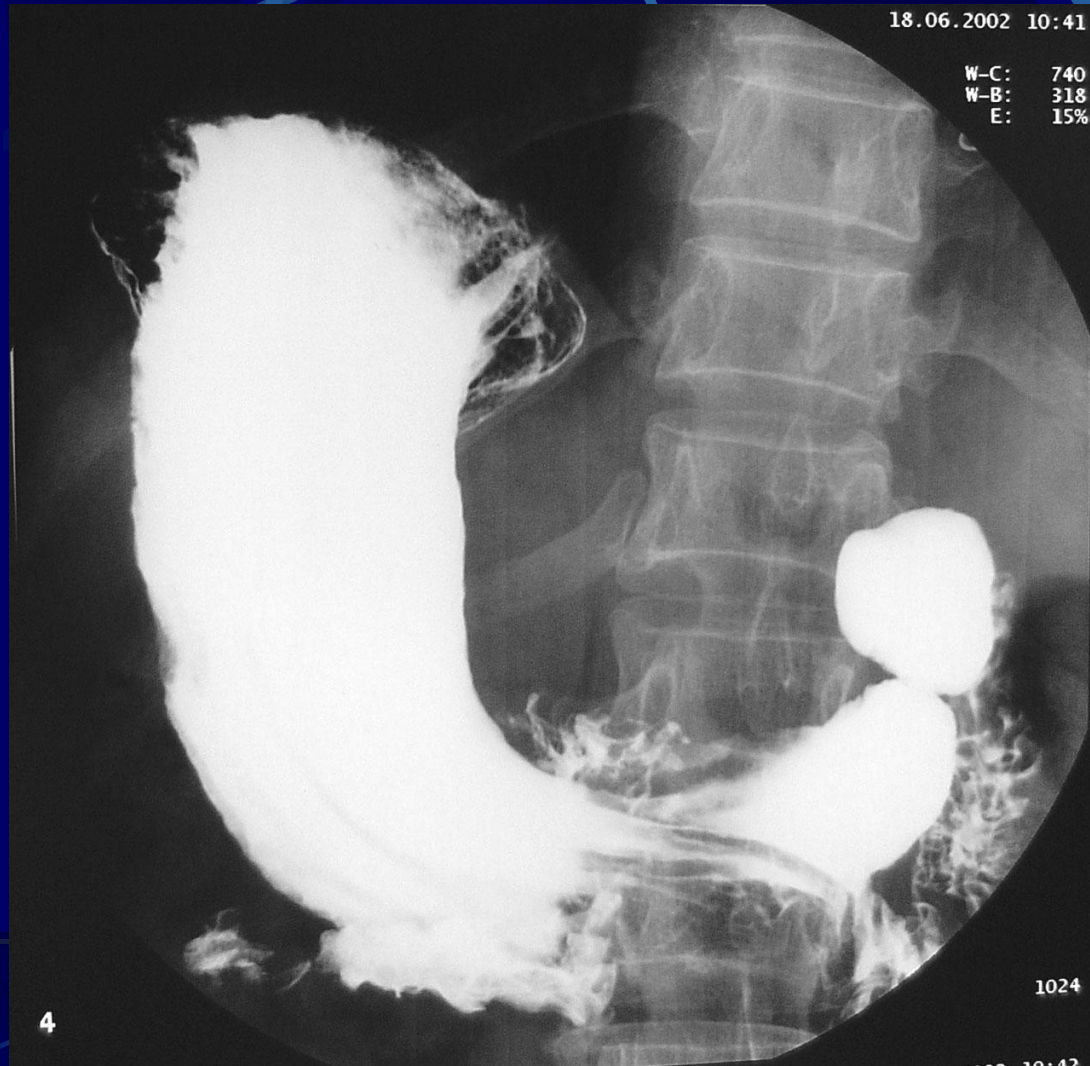1. 腔壁柔软度
2. 腔壁平直
3. 腔壁凹陷
4. 腔壁毛糙
5. 复线征

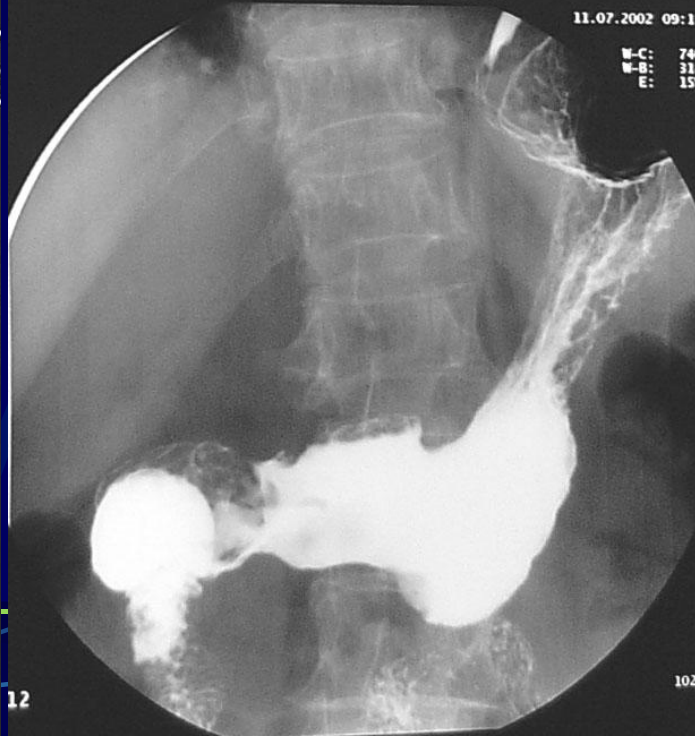
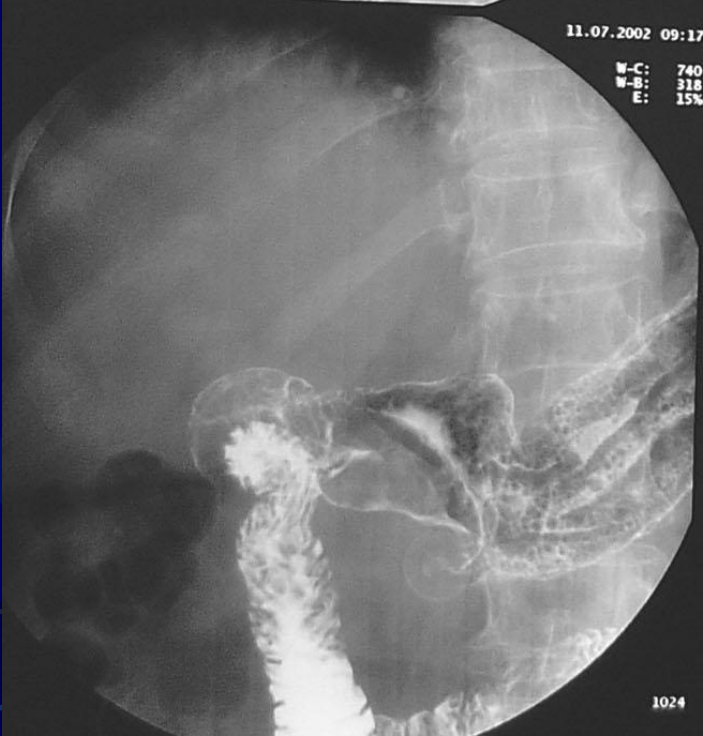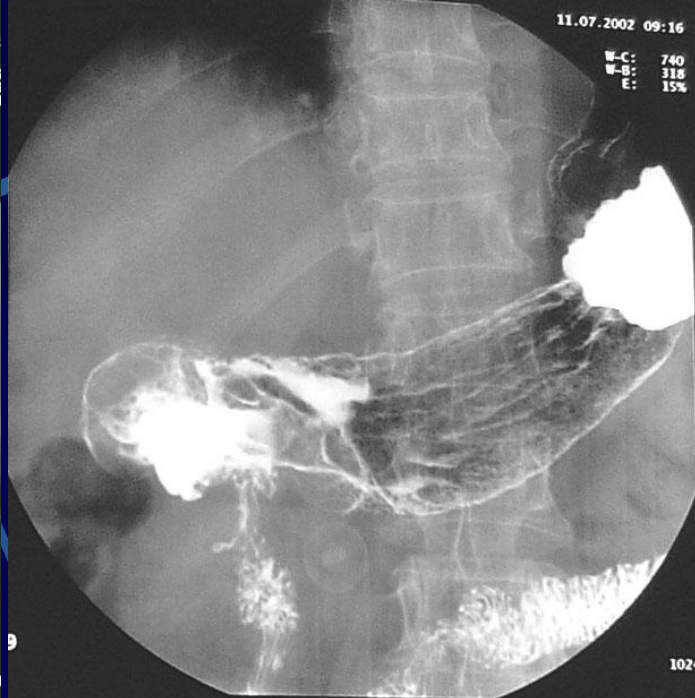
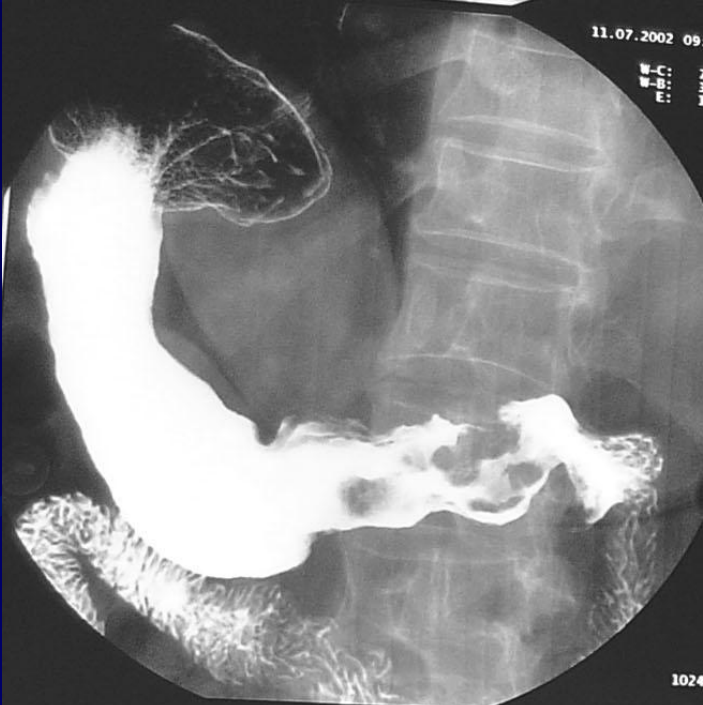进展期胃癌:

1. 蕈伞型
2. 溃疡型
3. 浸润型



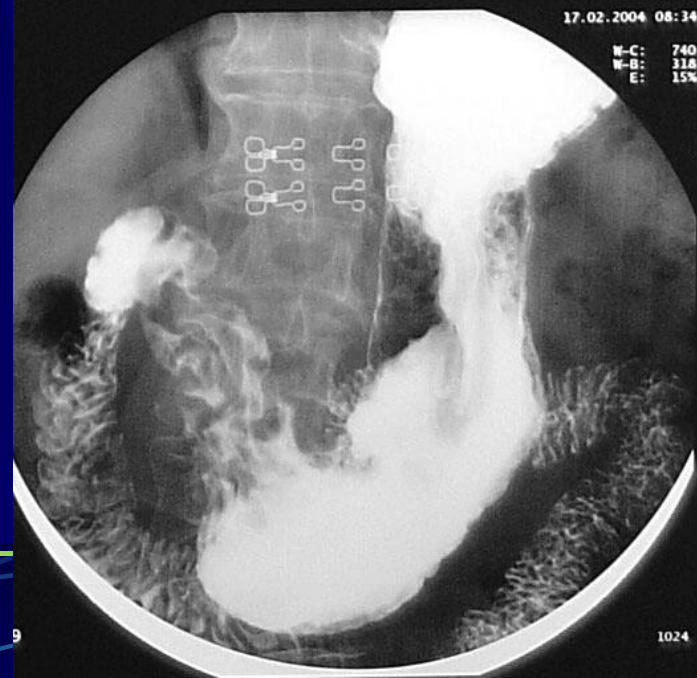
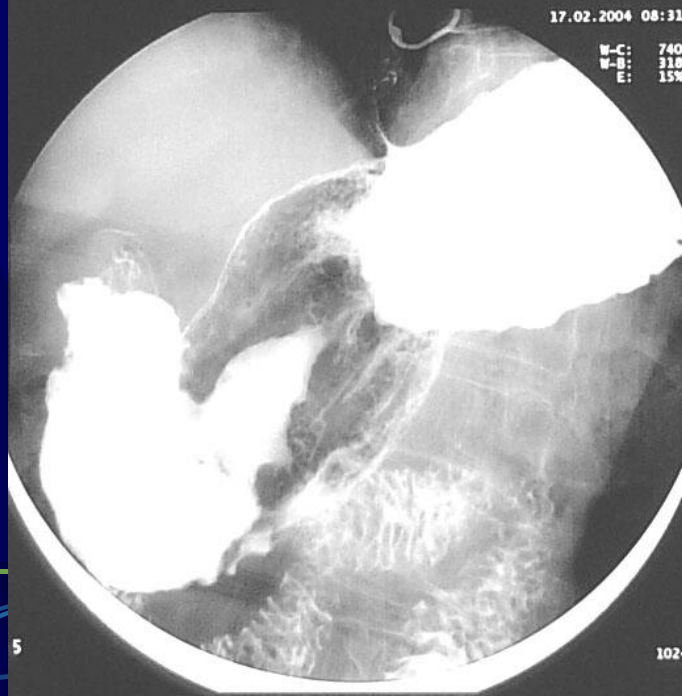
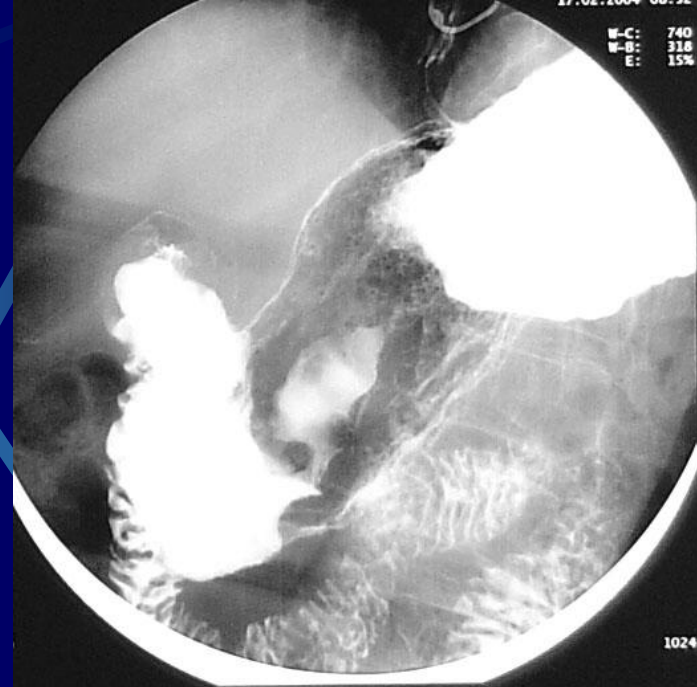
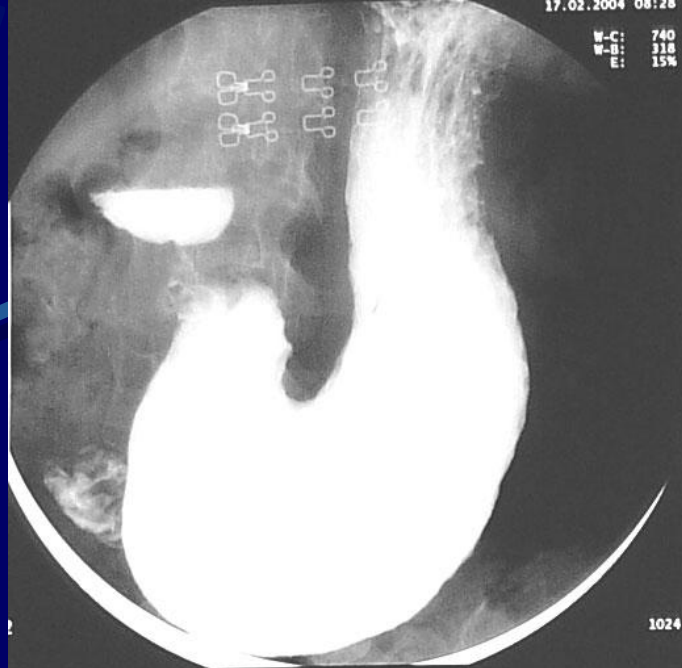胃窦癌





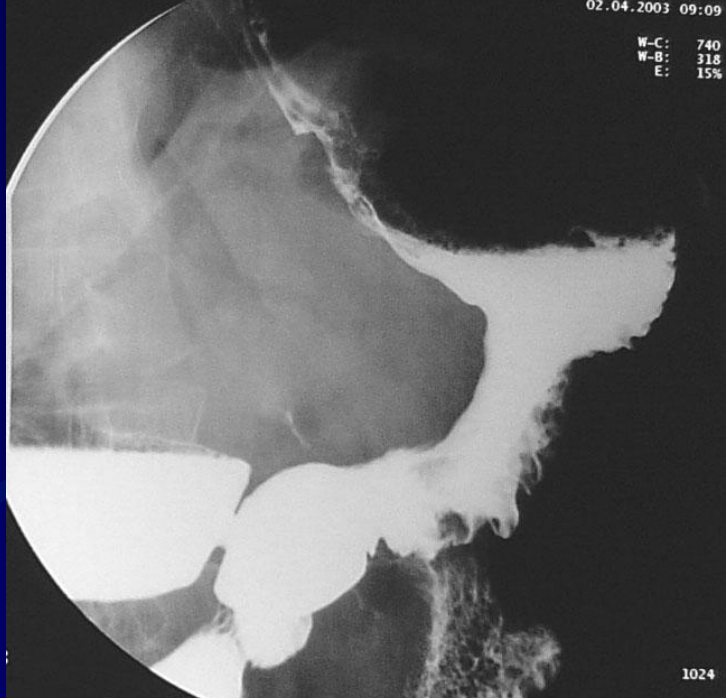胃窦癌

胃小弯溃疡型胃癌



02.04.2003 09:09

W-C: 740
W-B: 318
E: 15%

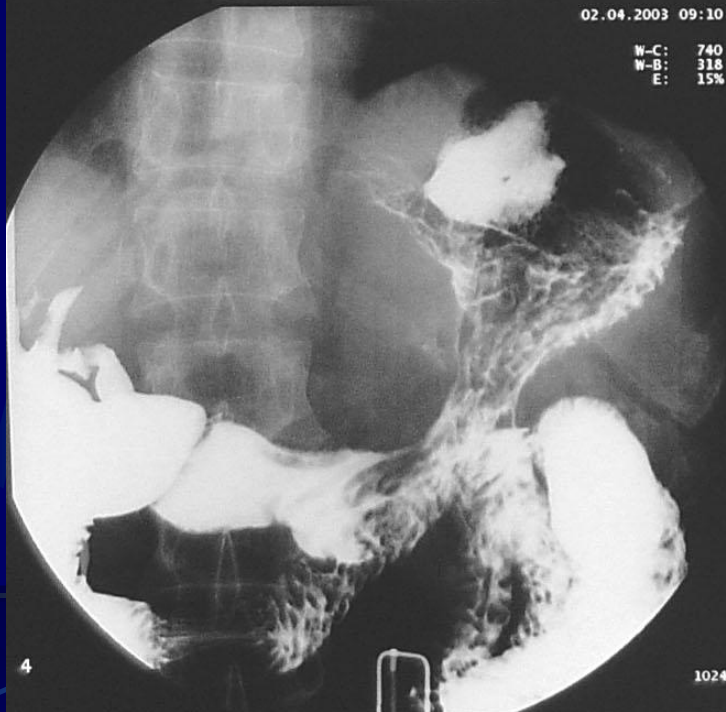


1024

浸润型胃癌伴十二指肠胆道瘘

02.04.2003 09:10

W-C: 740
W-B: 318
E: 15%

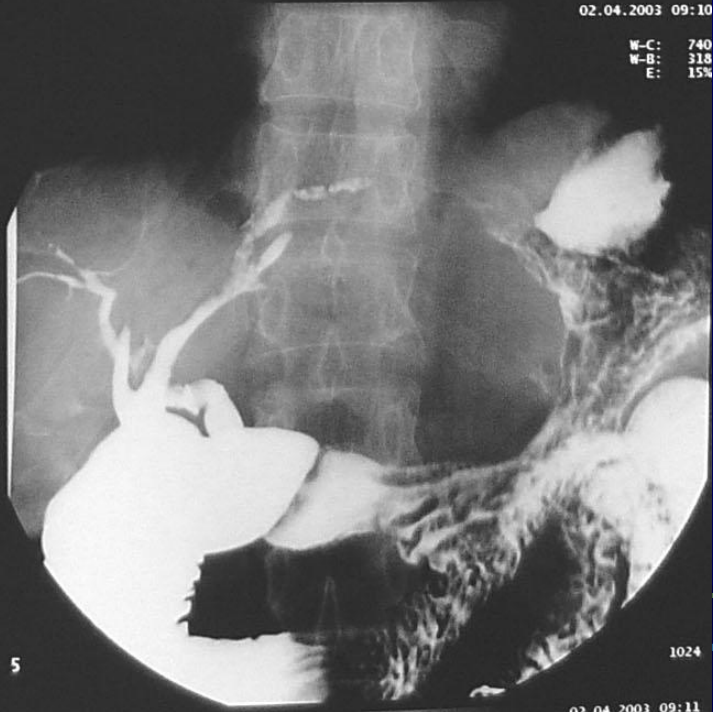


4

1024

02.04.2003 09:10

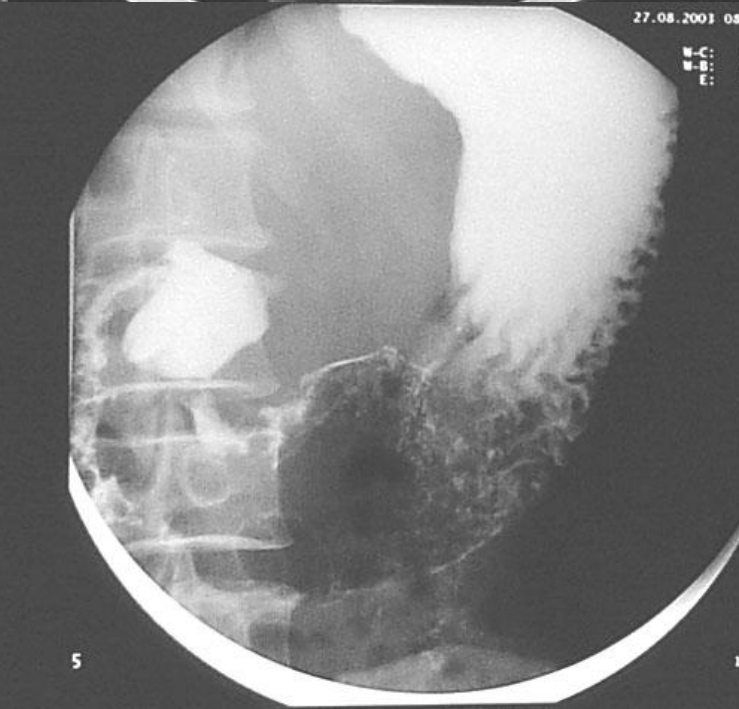
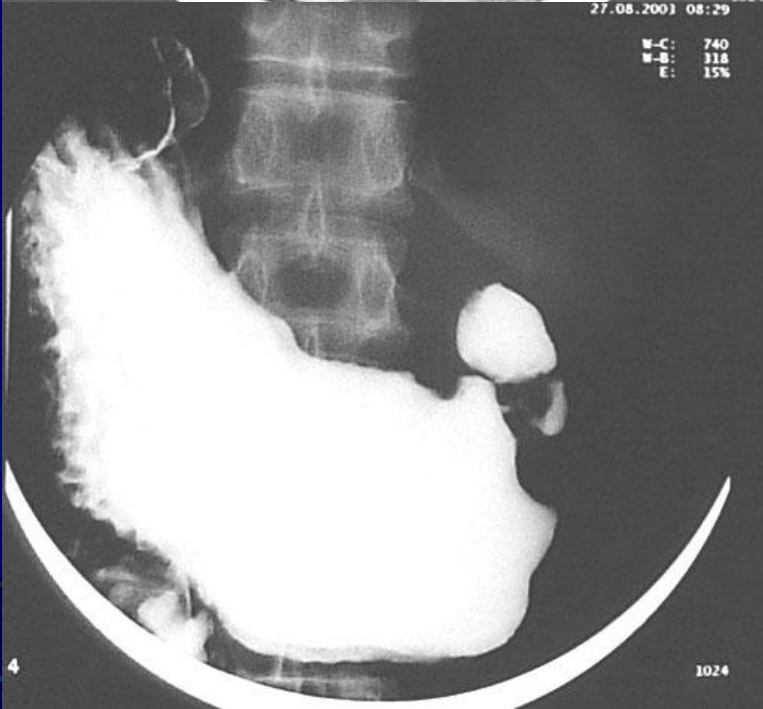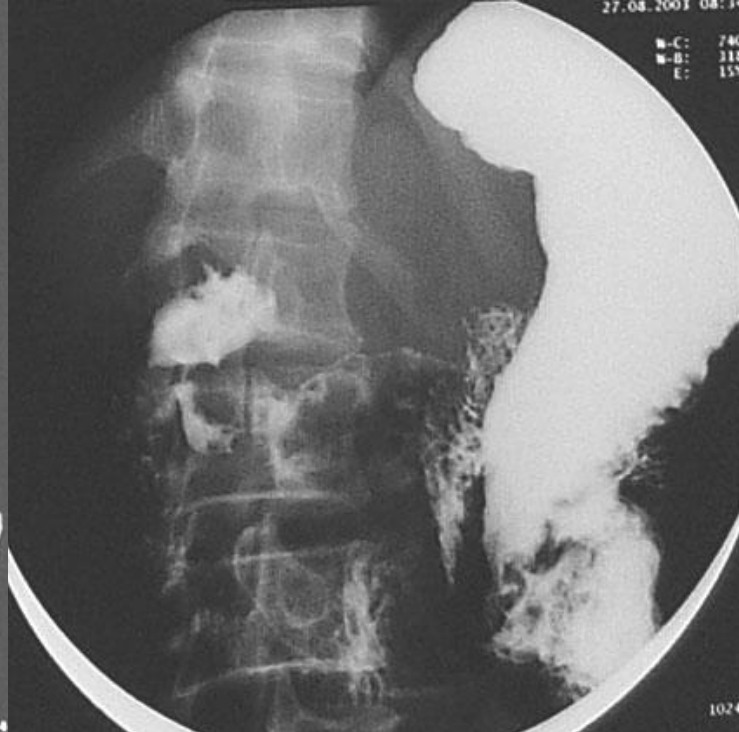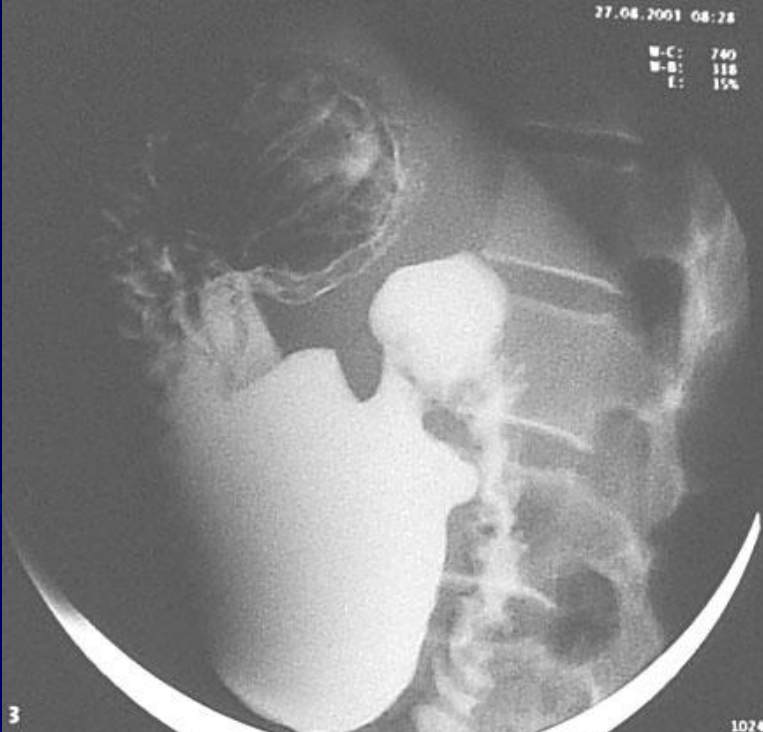W-C: 740
W-B: 318
E: 15%



5

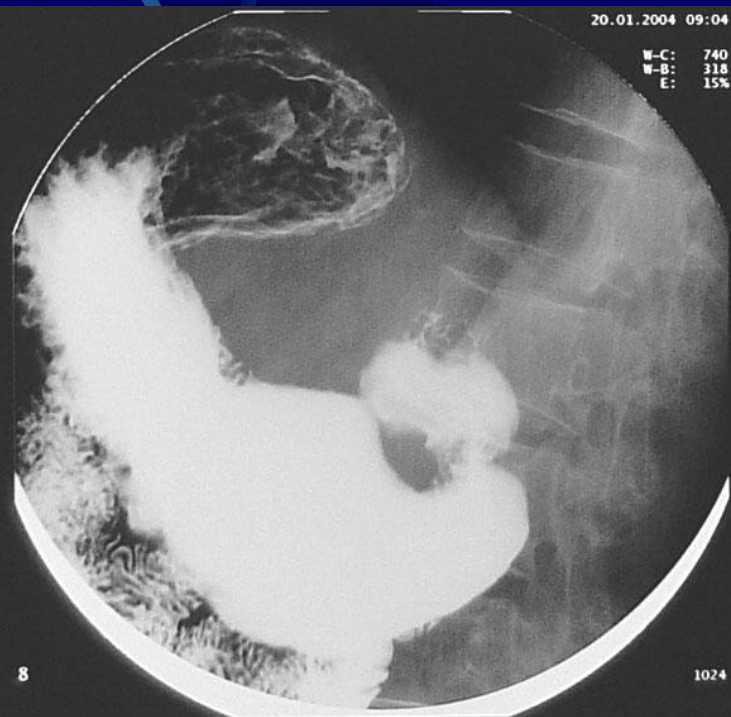
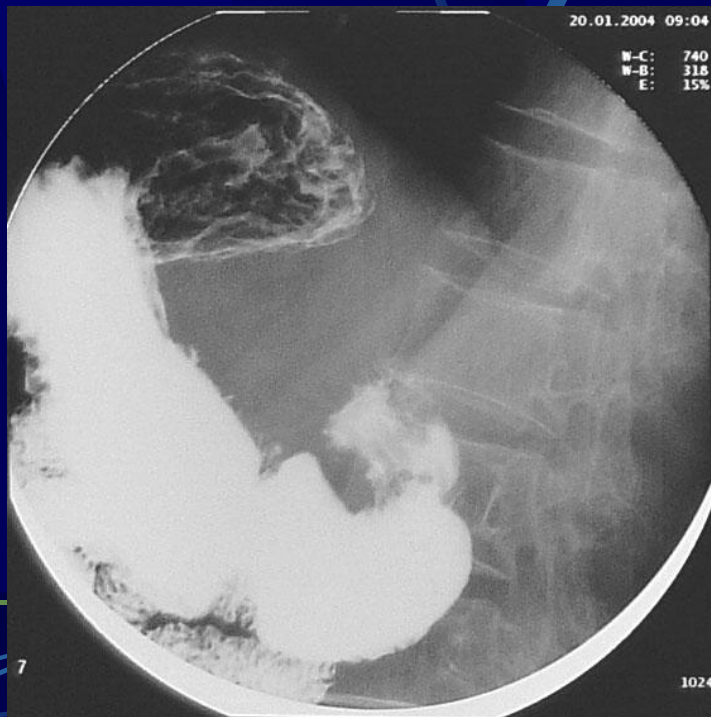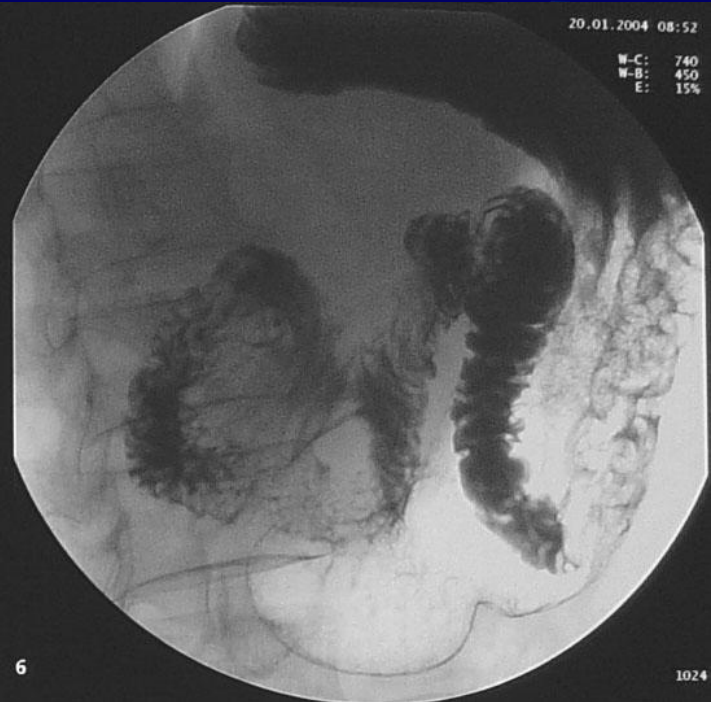
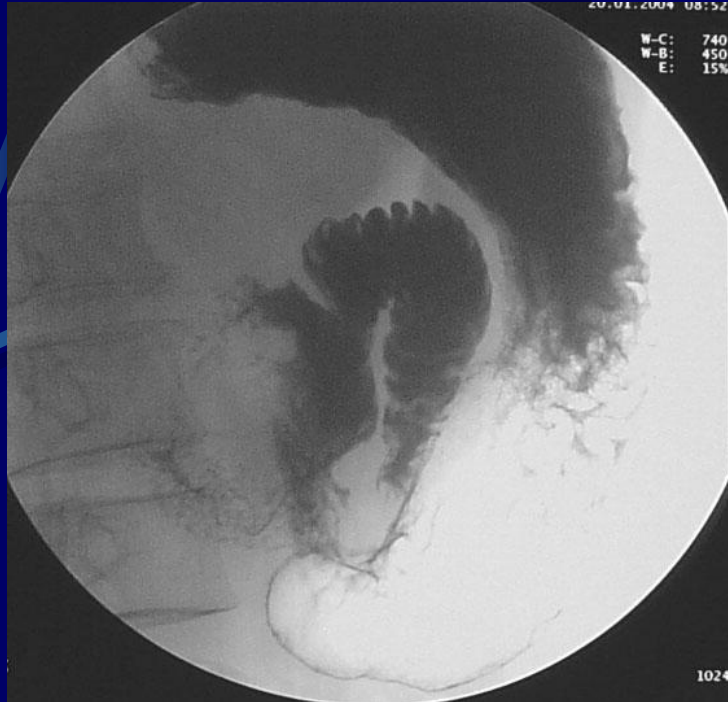1024

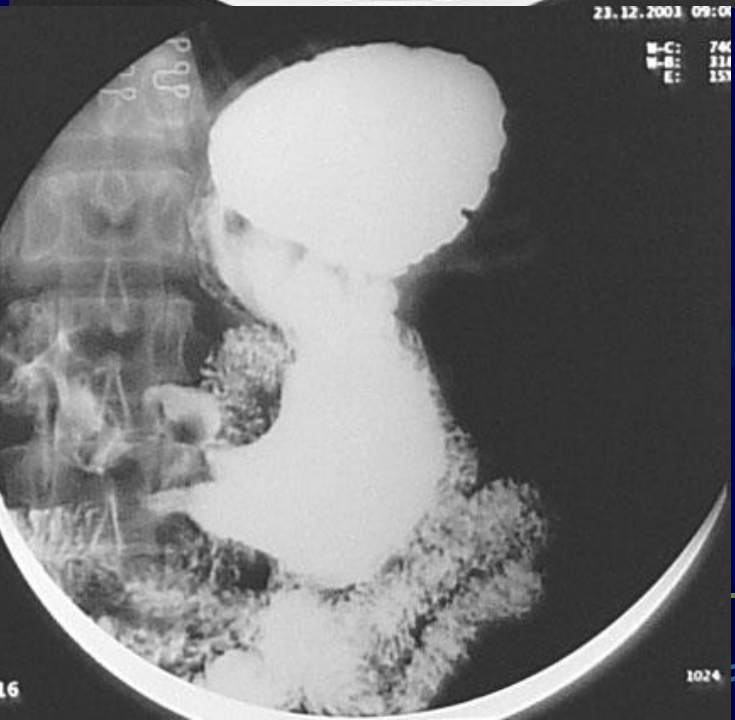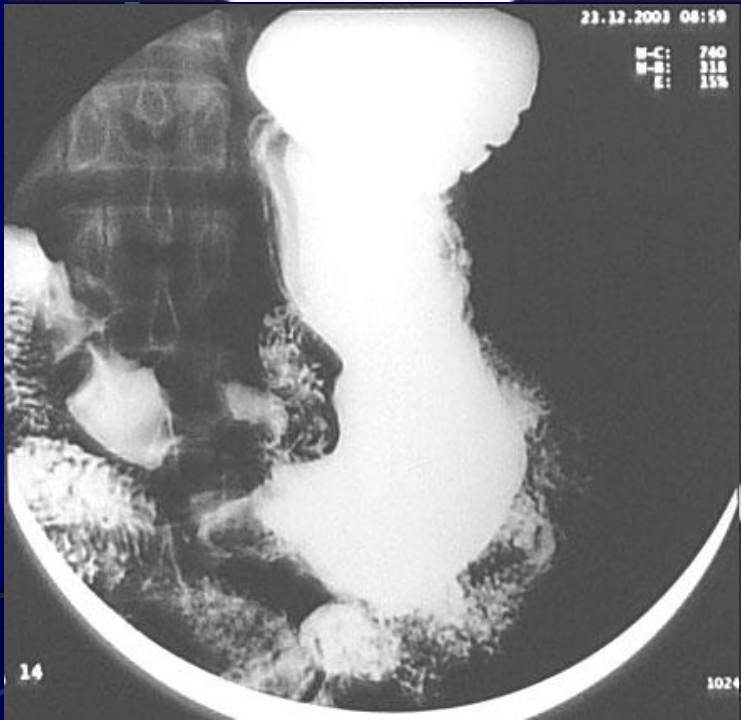
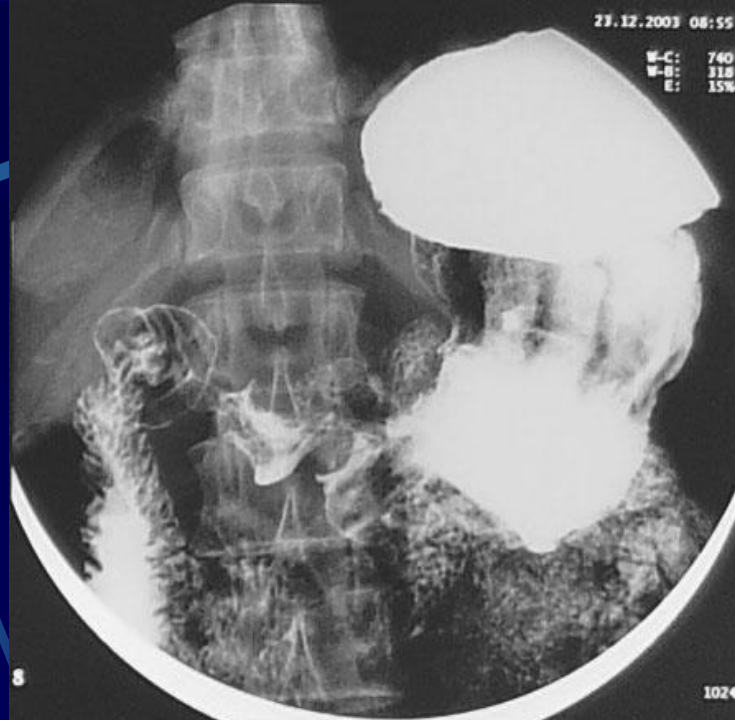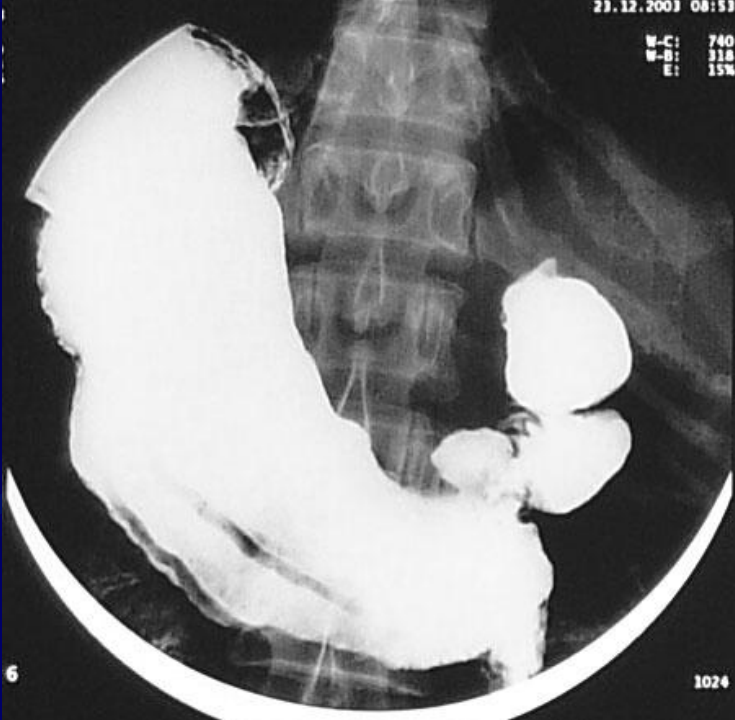
02.04.2003 09:11



胃窦癌

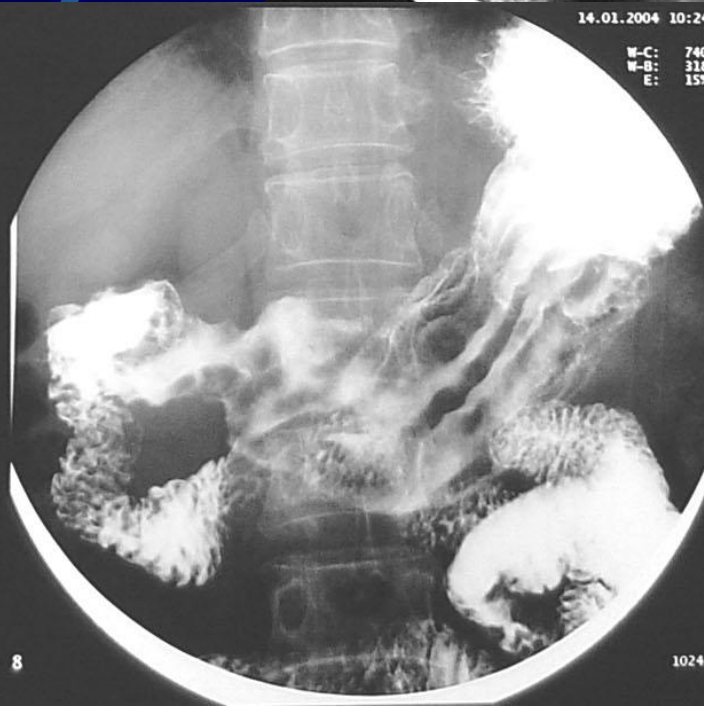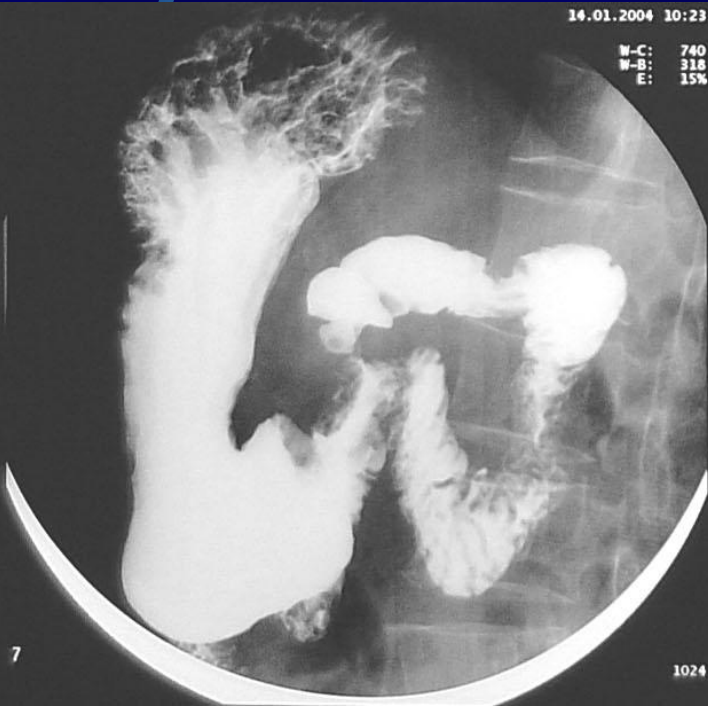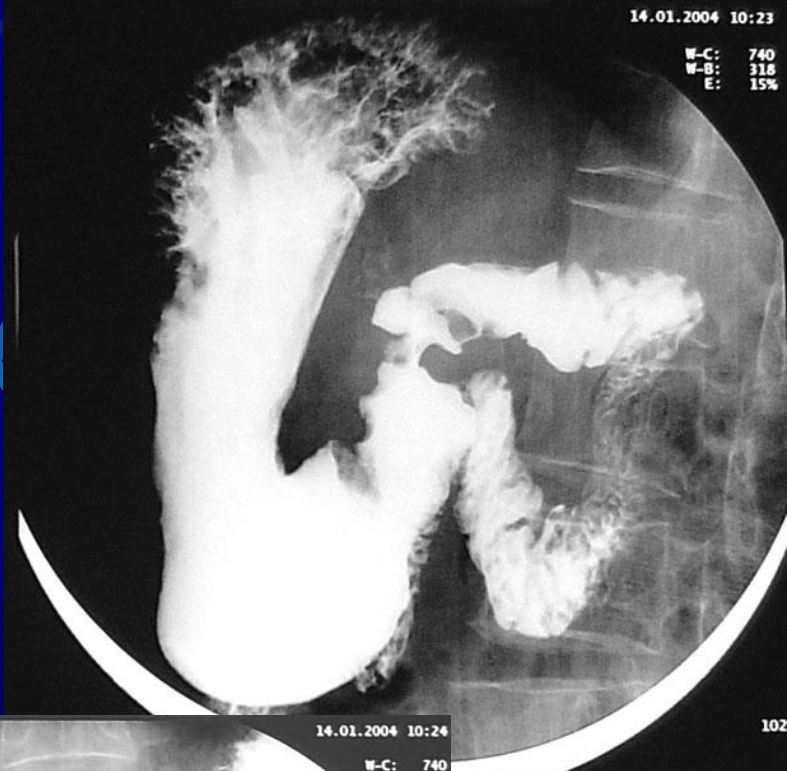胃幽门管癌



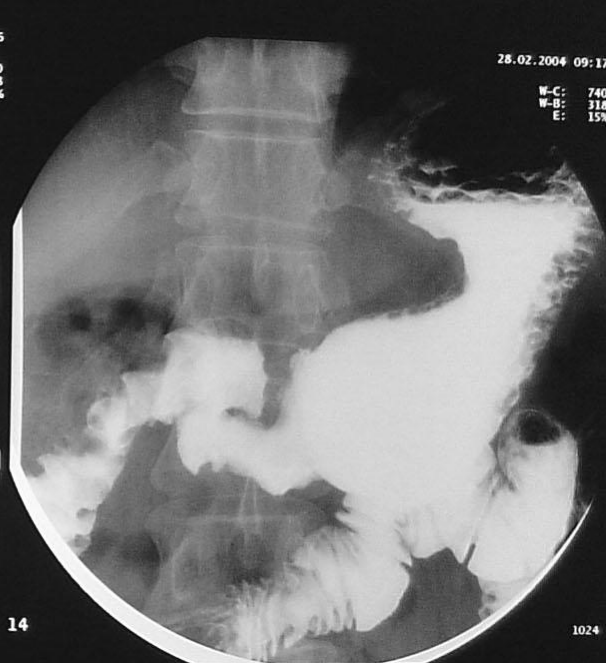
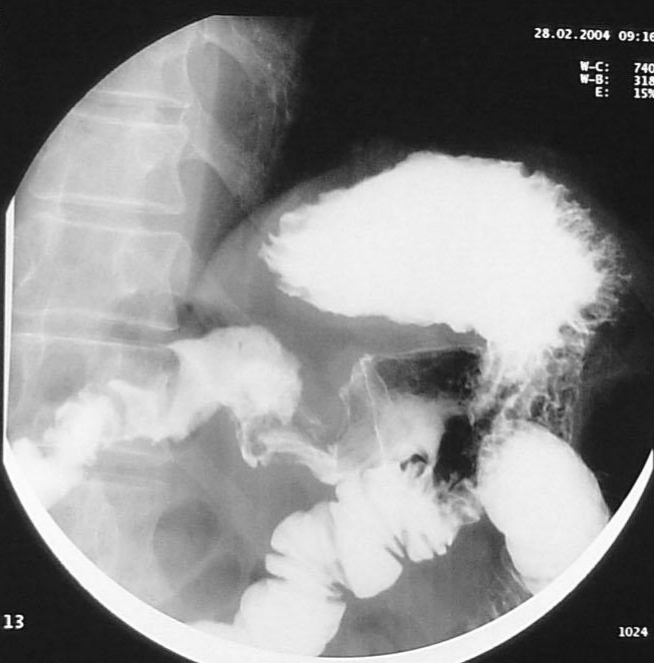
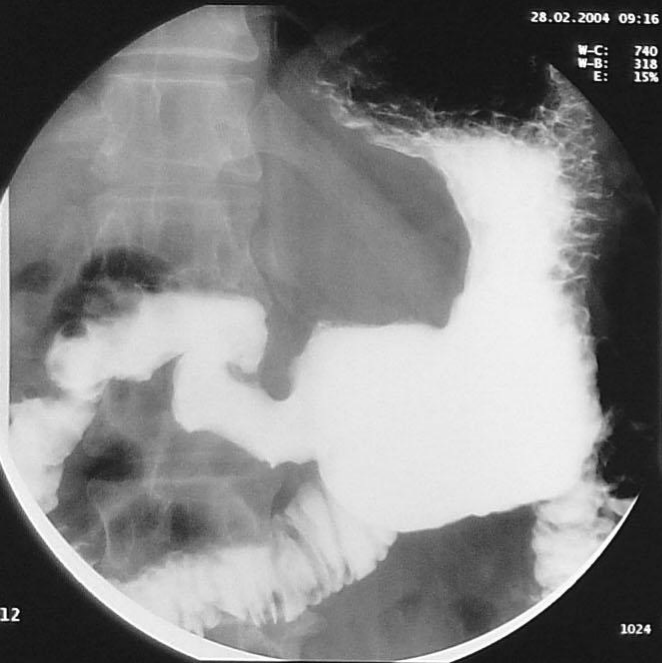胃窦癌

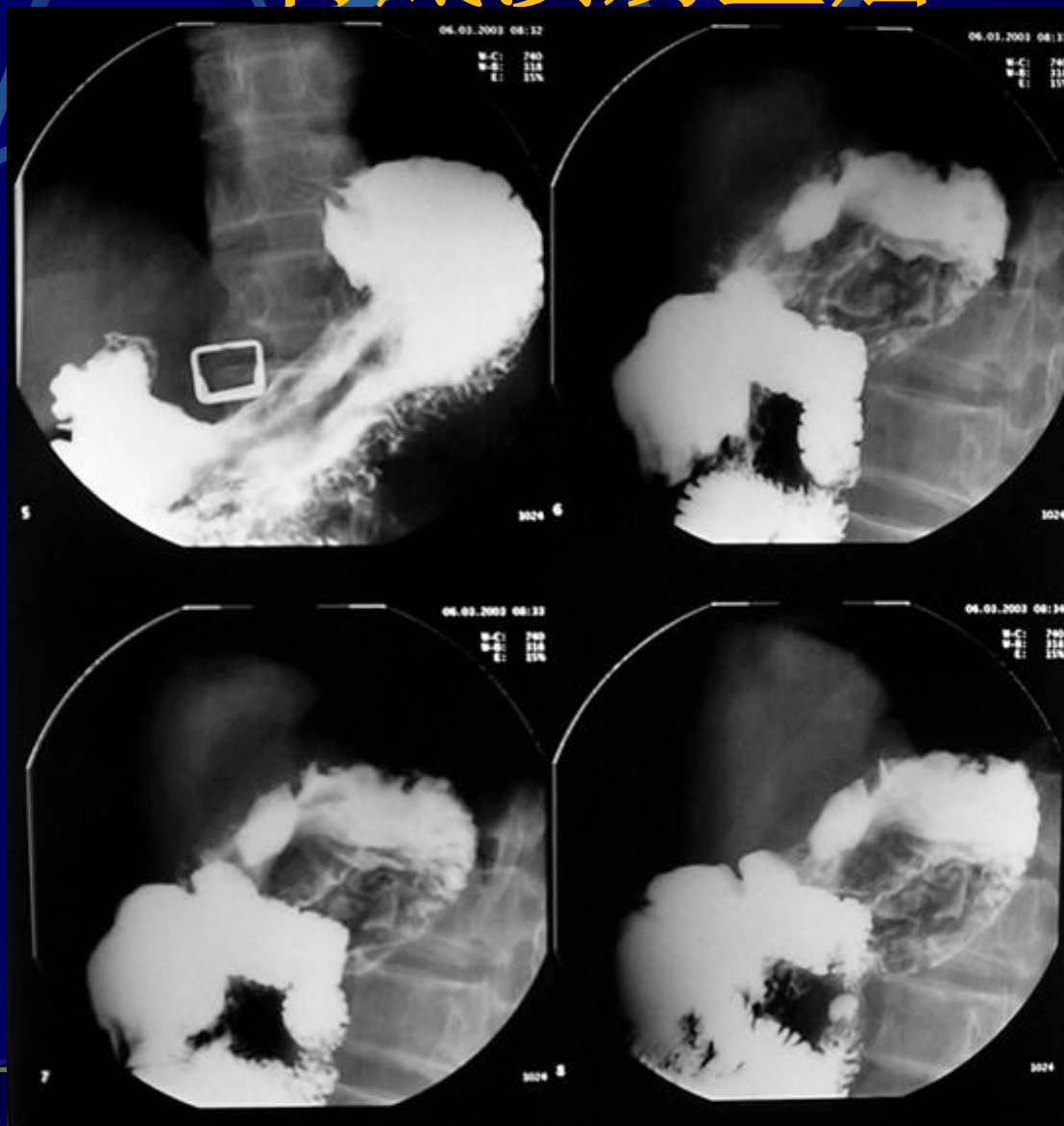胃窦癌侵犯 幽门管



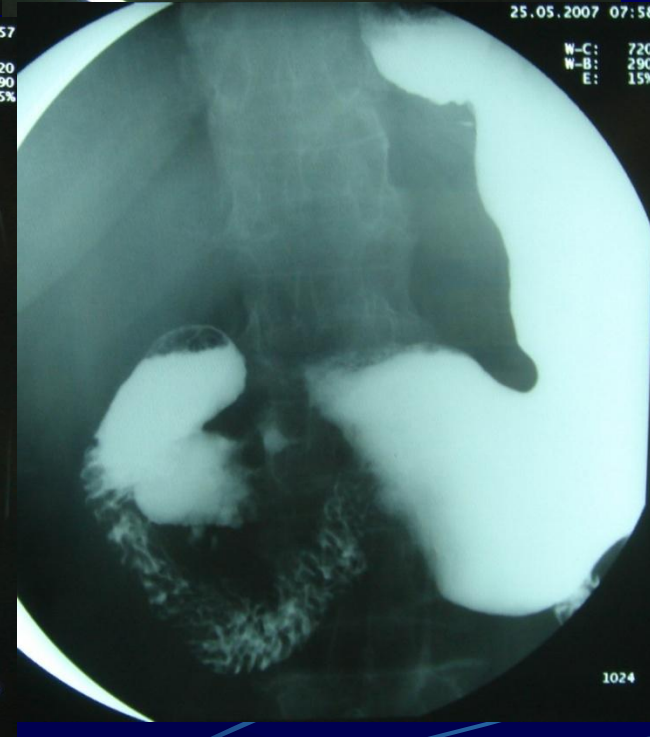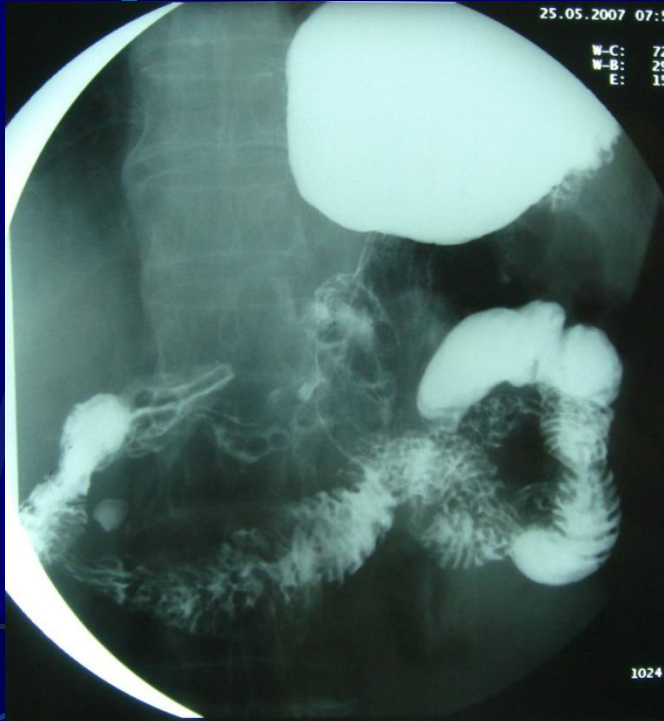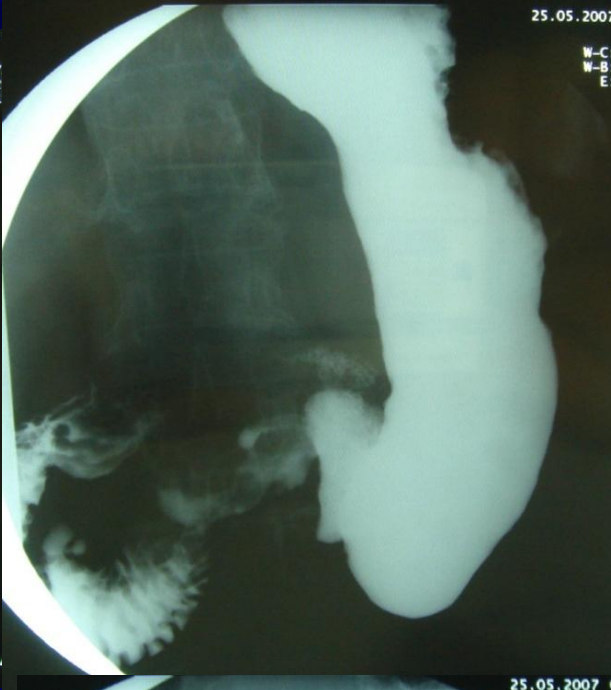
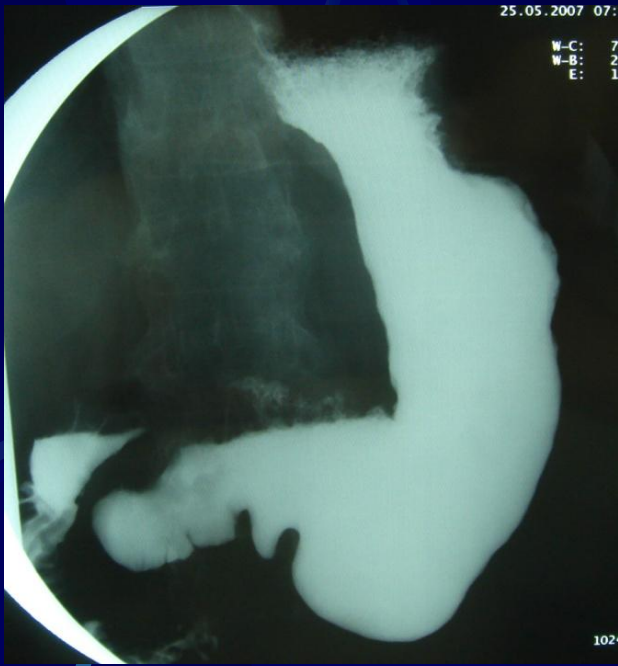
胃窦癌



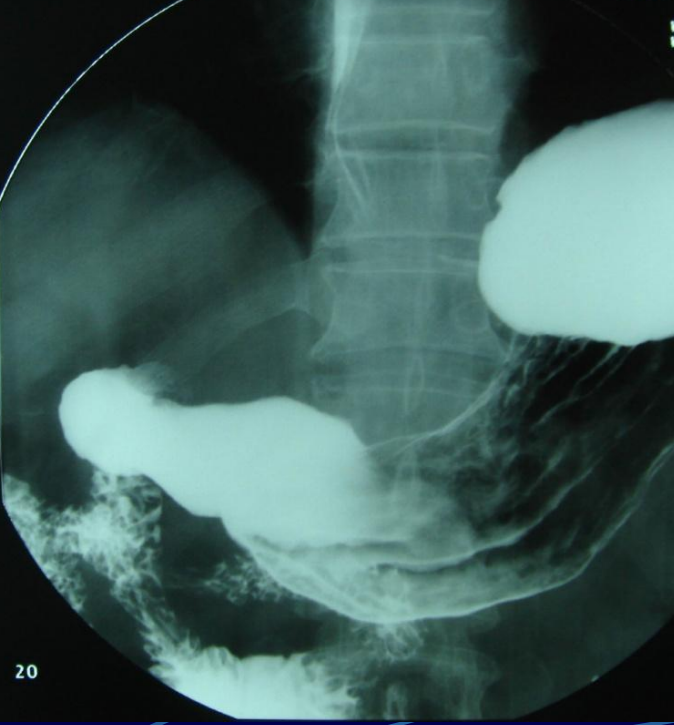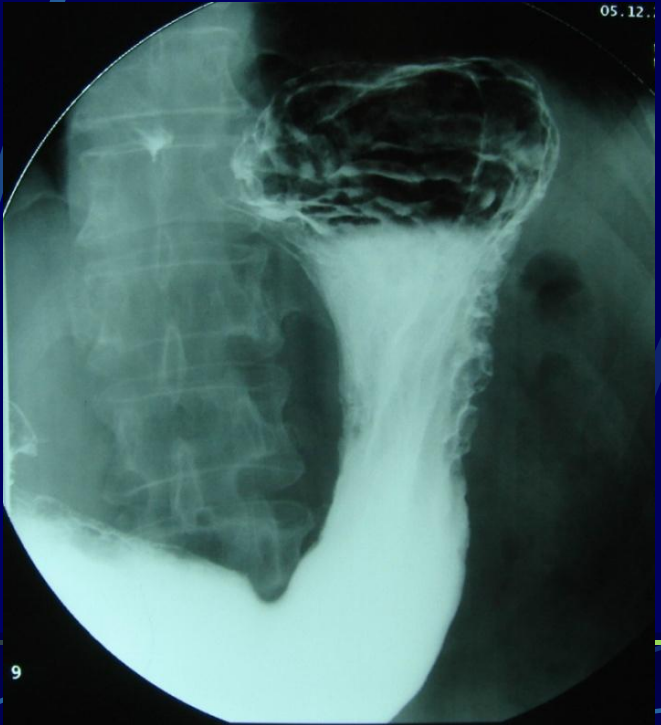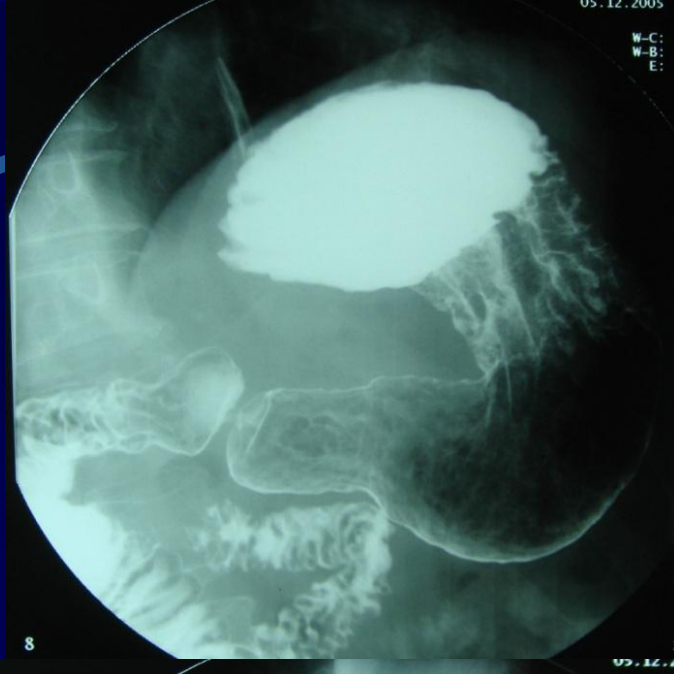
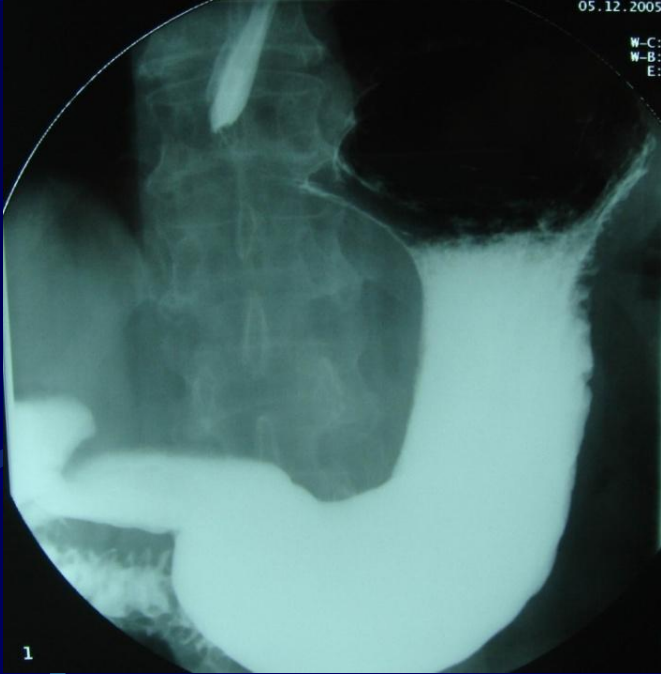
胃底溃疡型癌



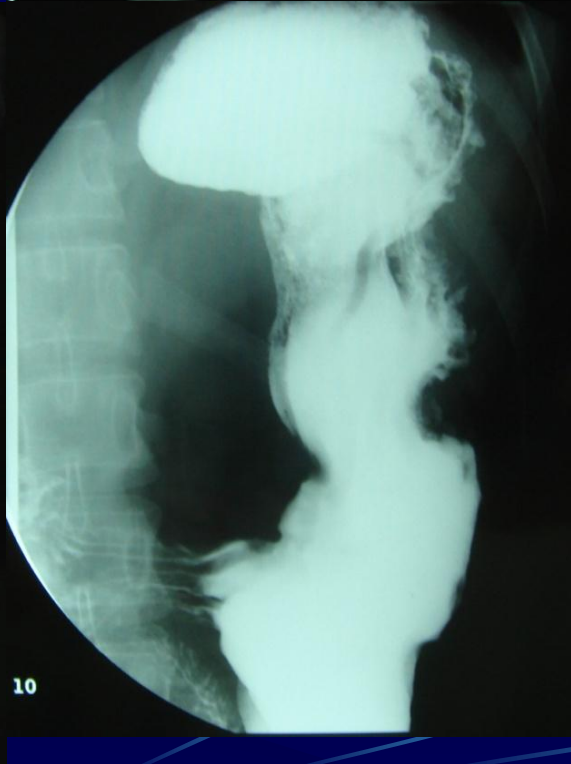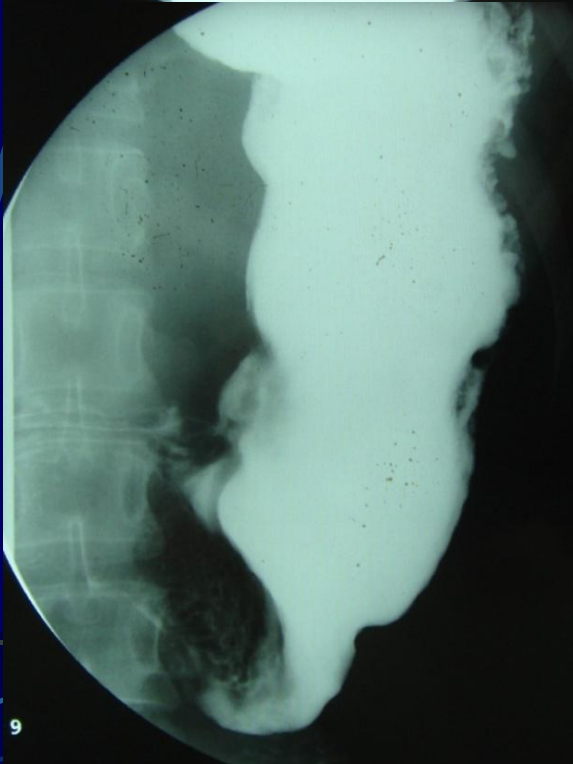
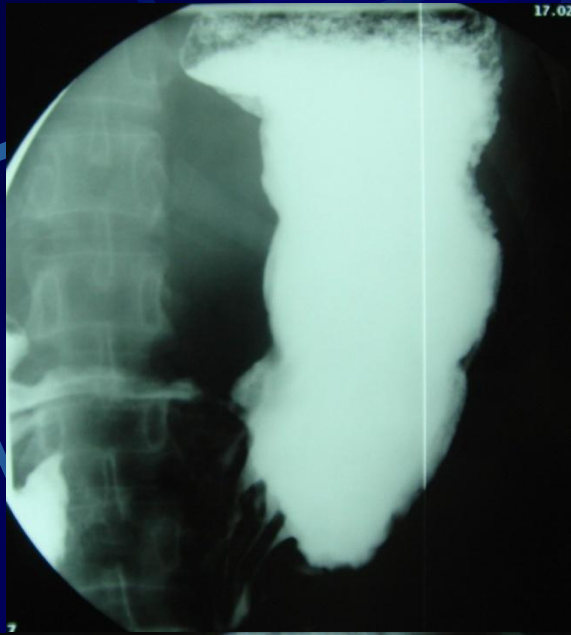
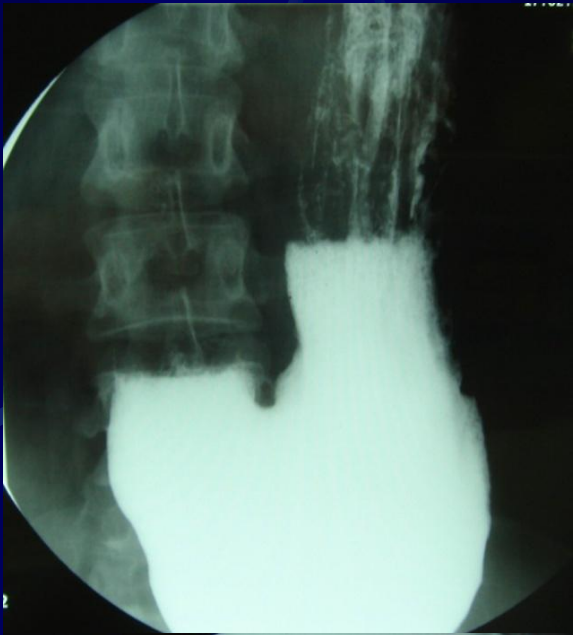胃窦癌

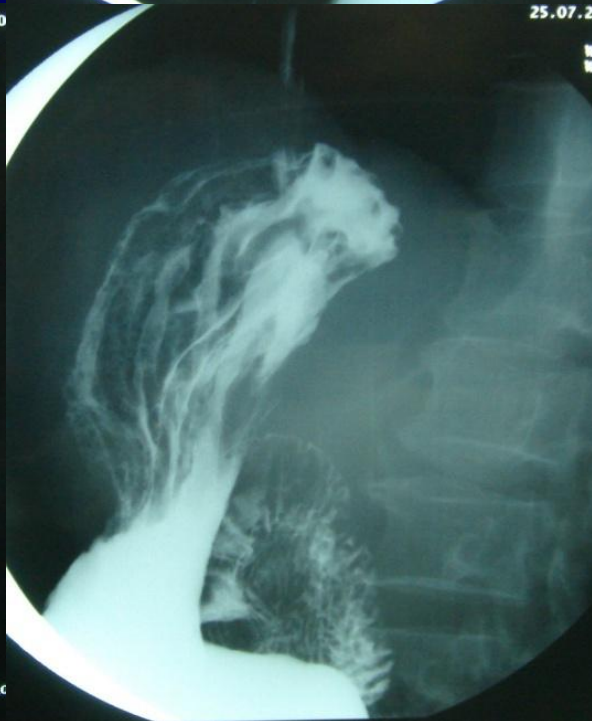
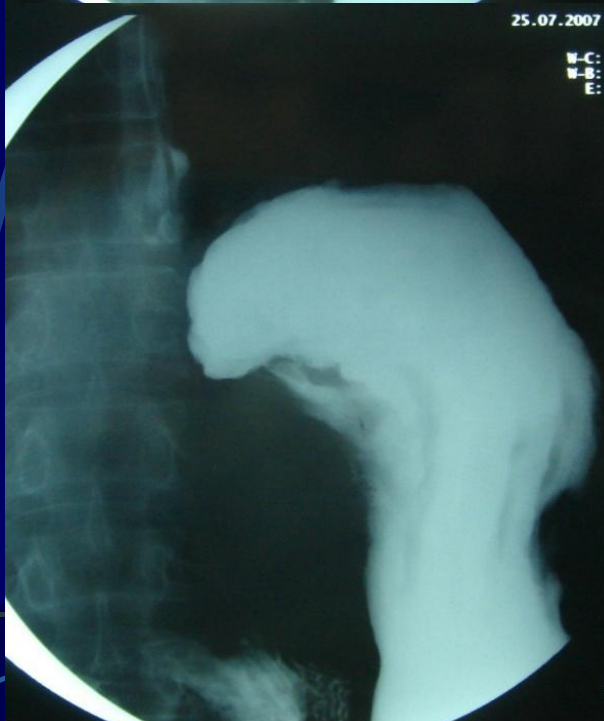
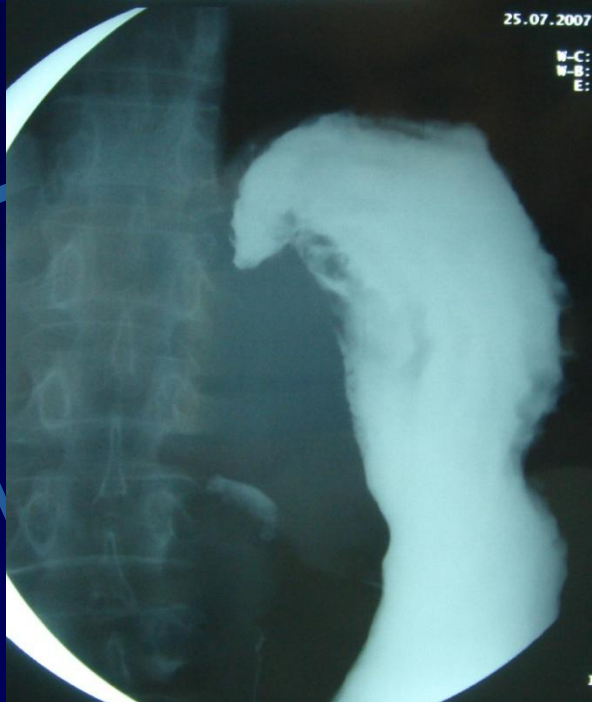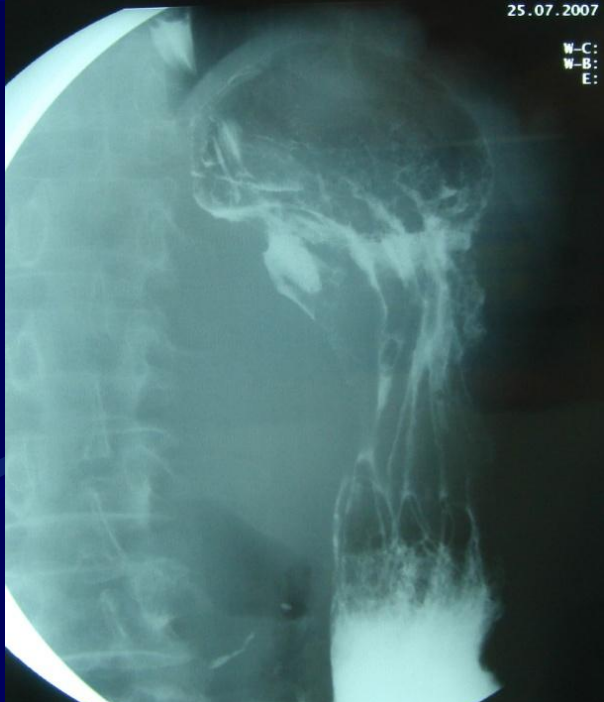胃小弯垂直部胃癌

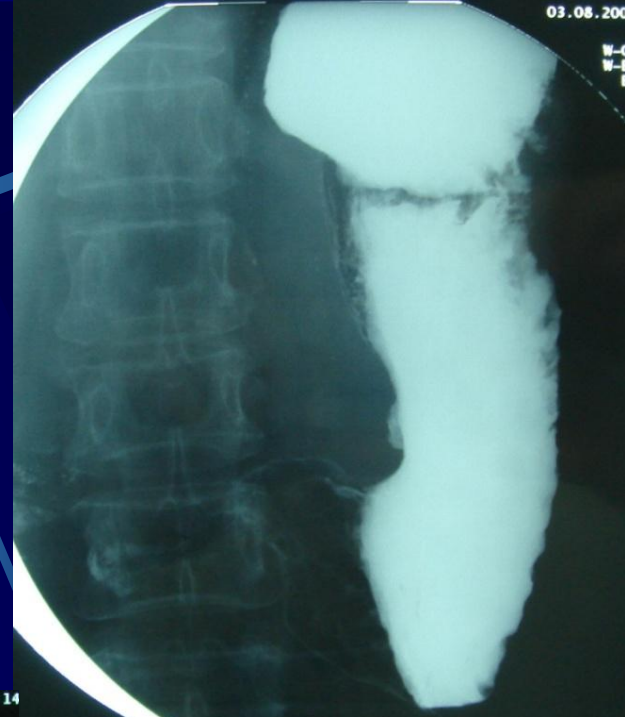
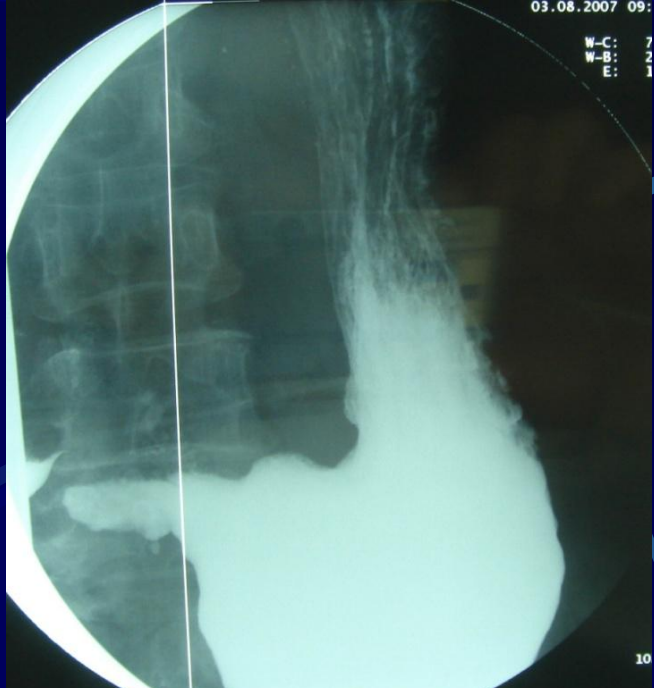


角切迹胃癌

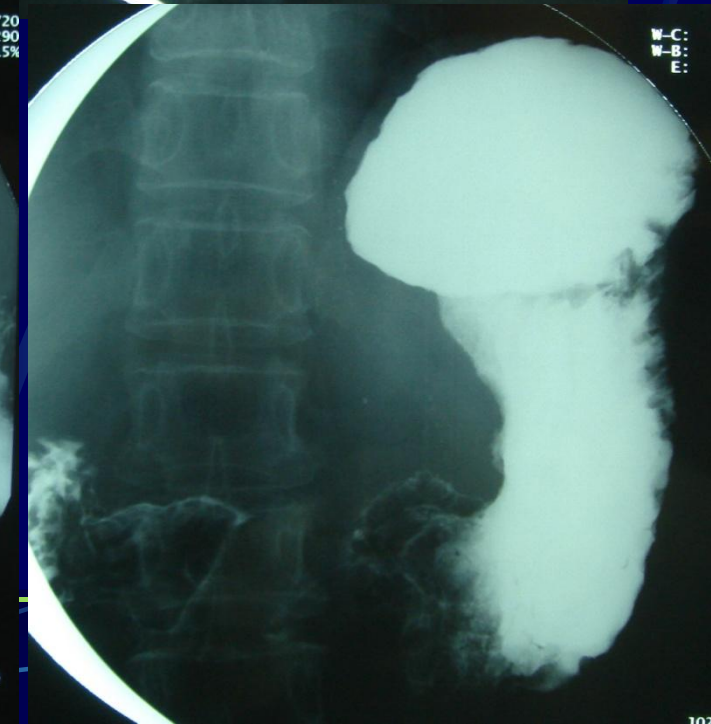



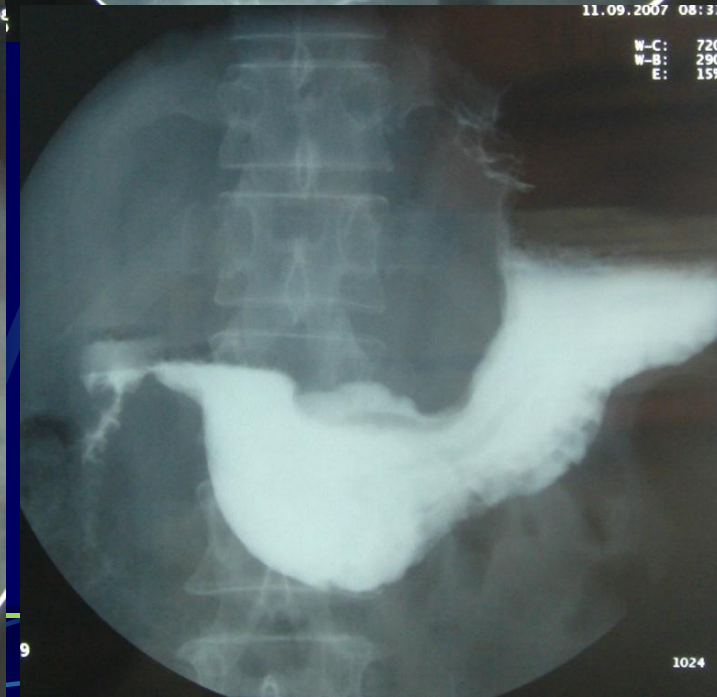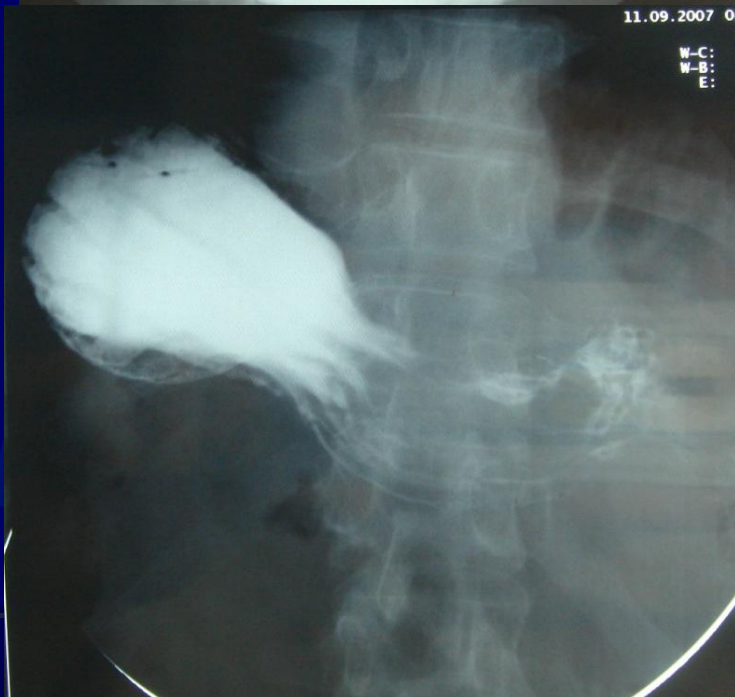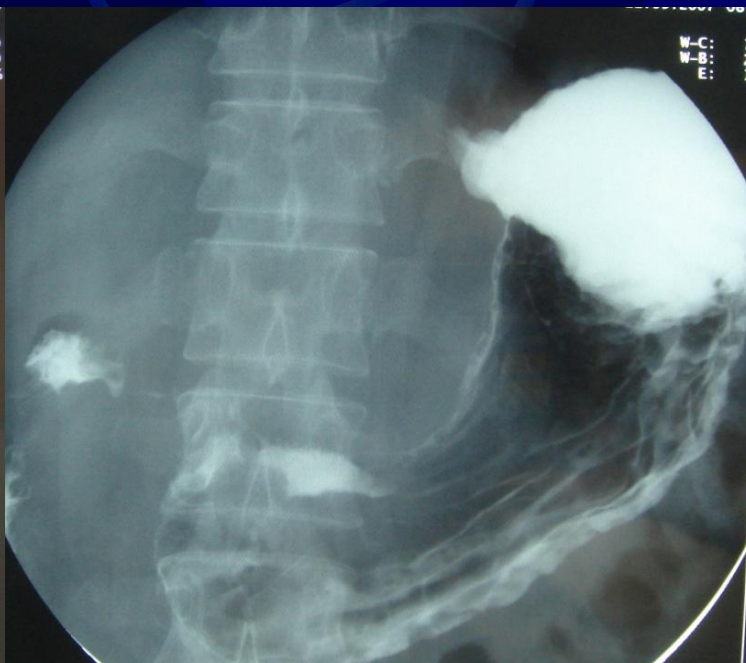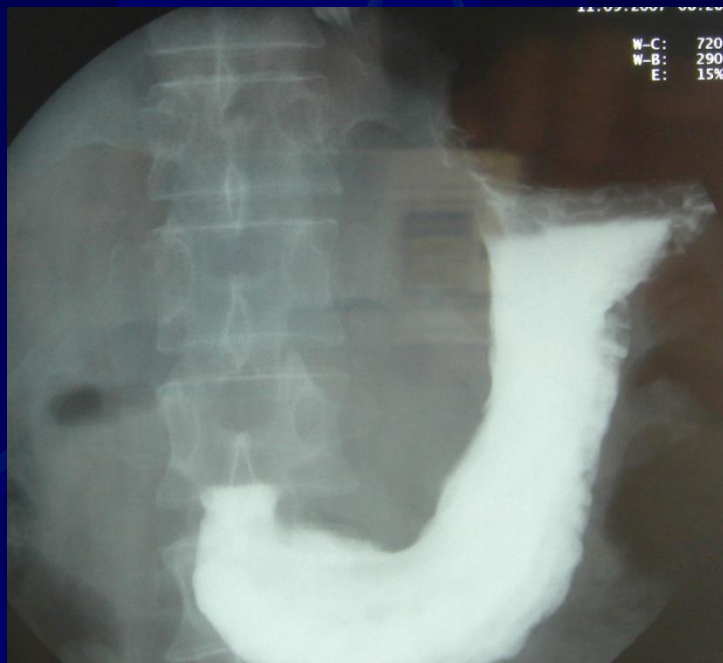小弯垂直部高位胃癌



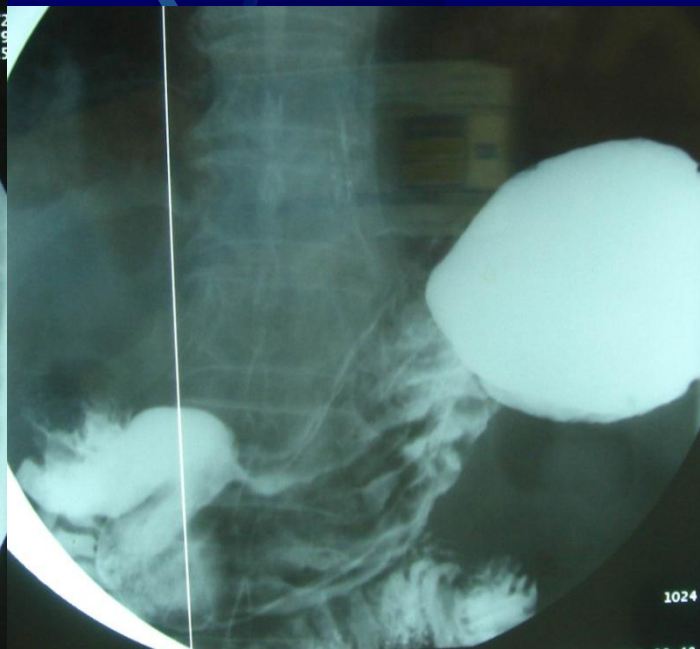
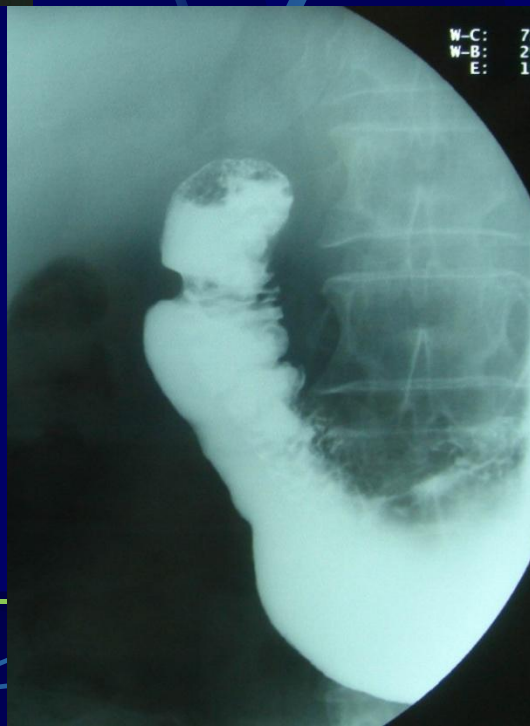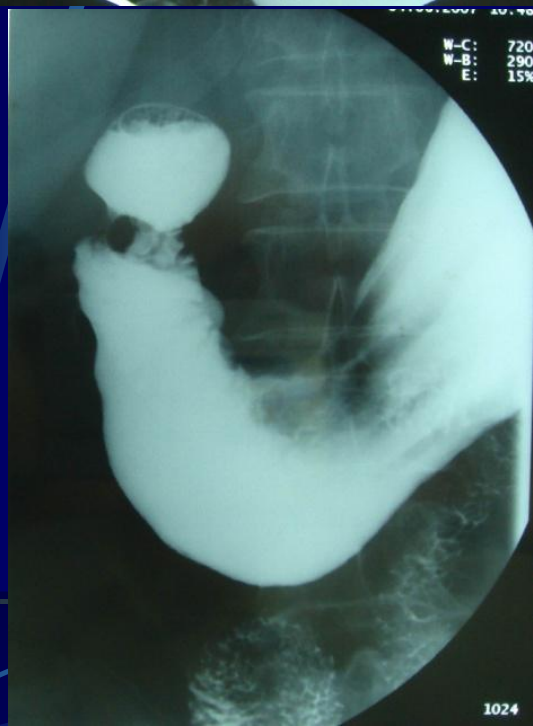
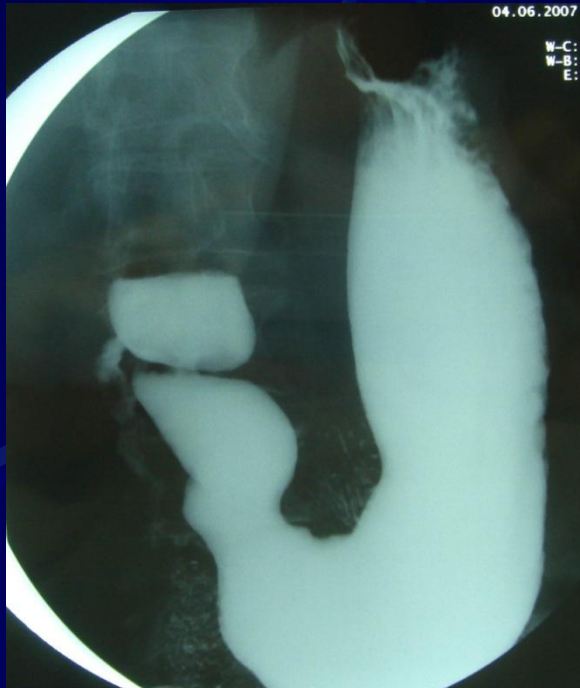
小弯垂直部 角切迹上方 胃癌



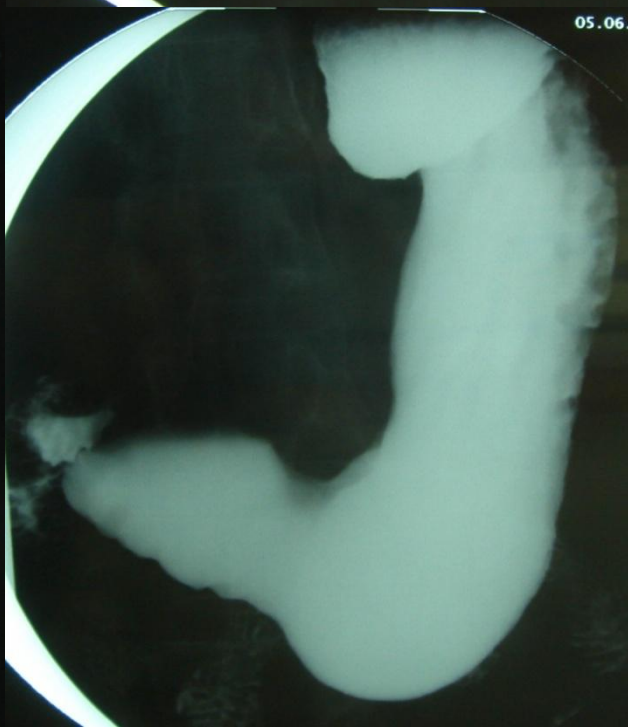
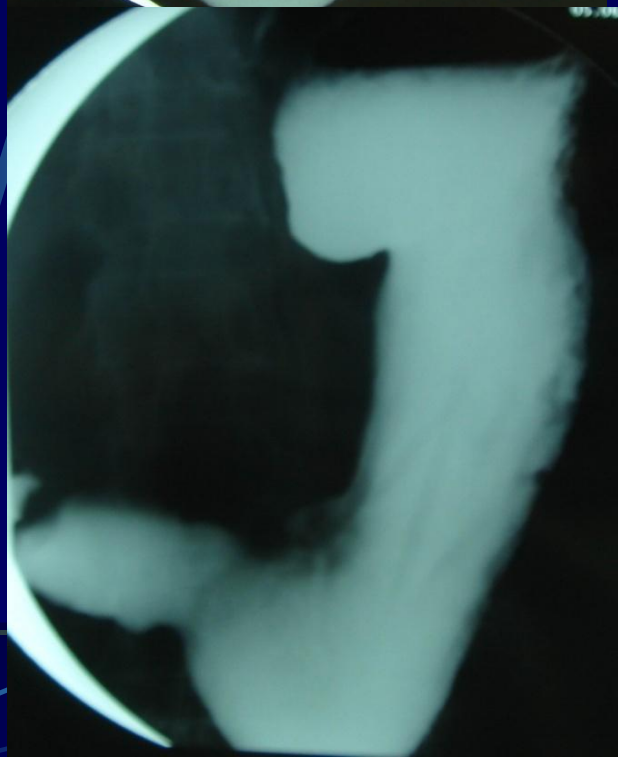
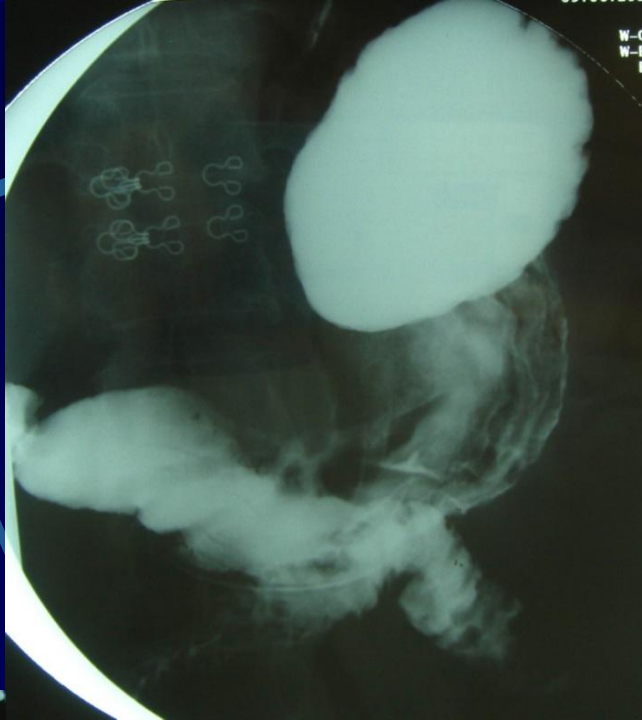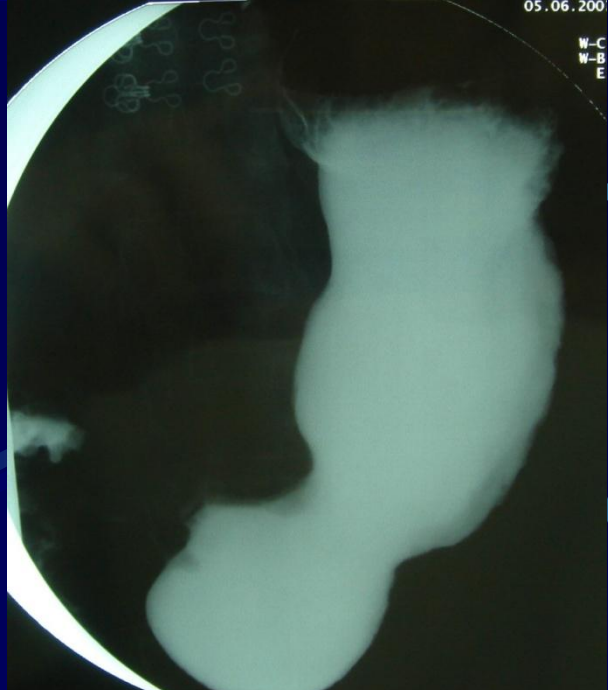
角切迹胃癌



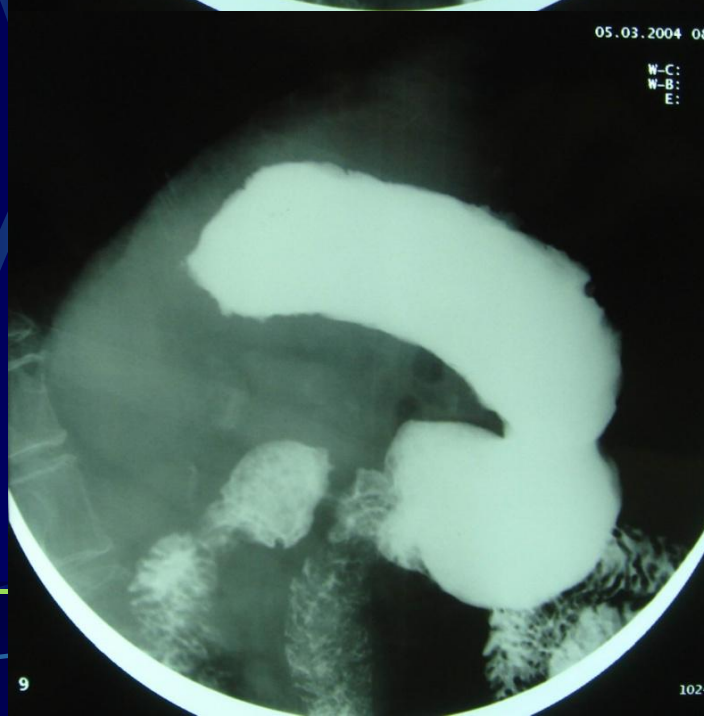
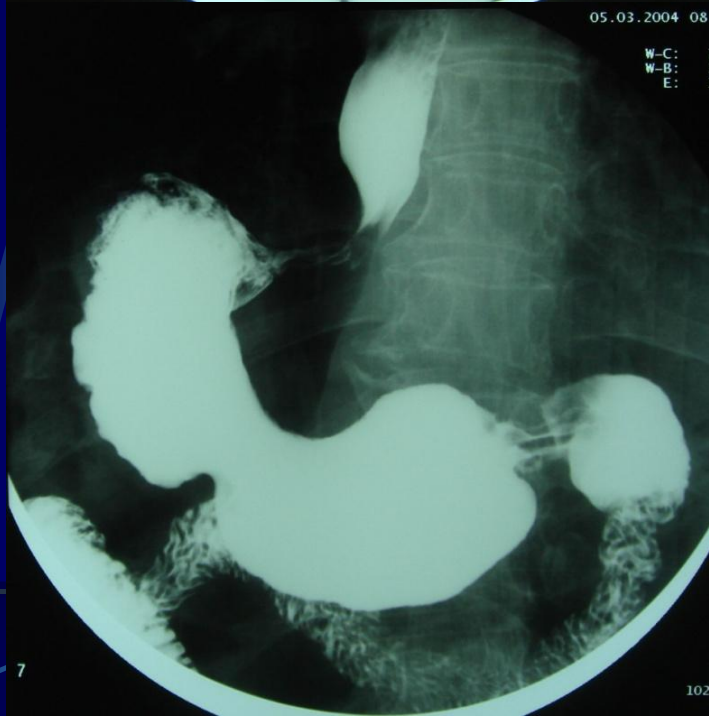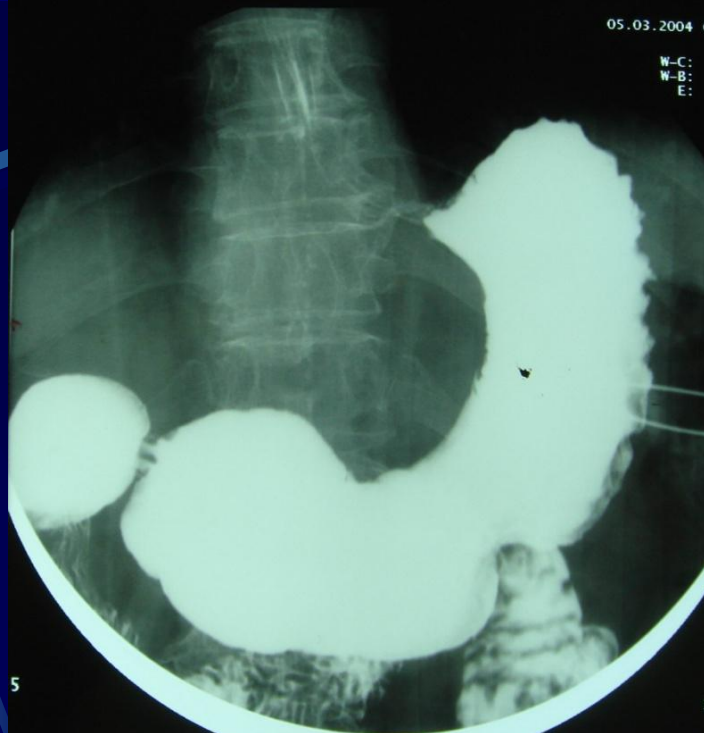
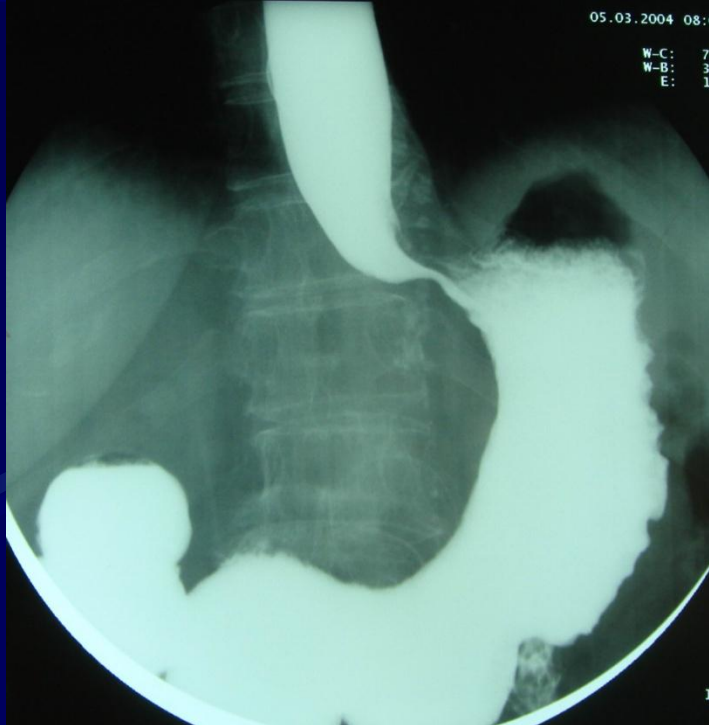角切迹胃癌



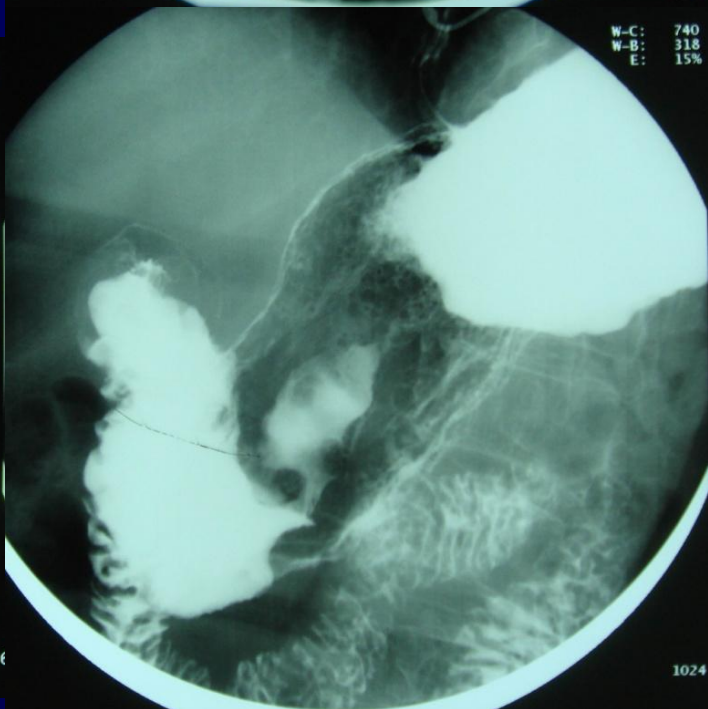
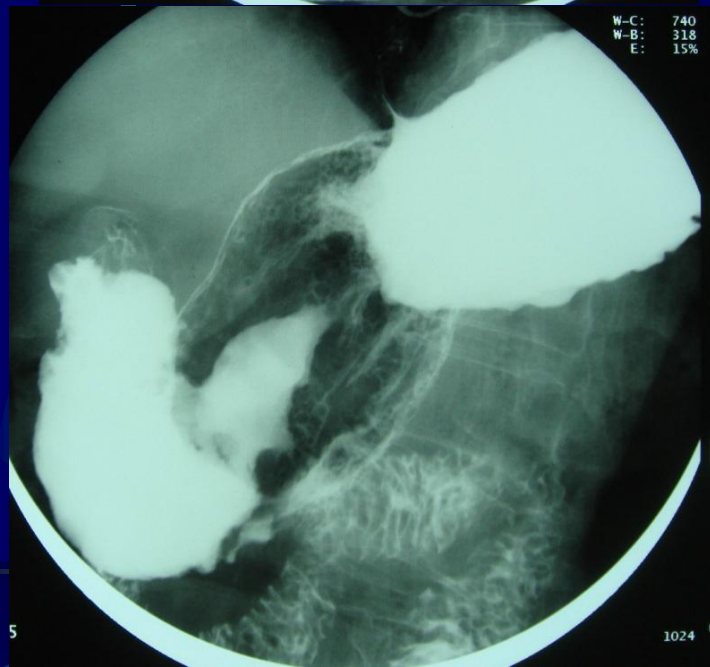
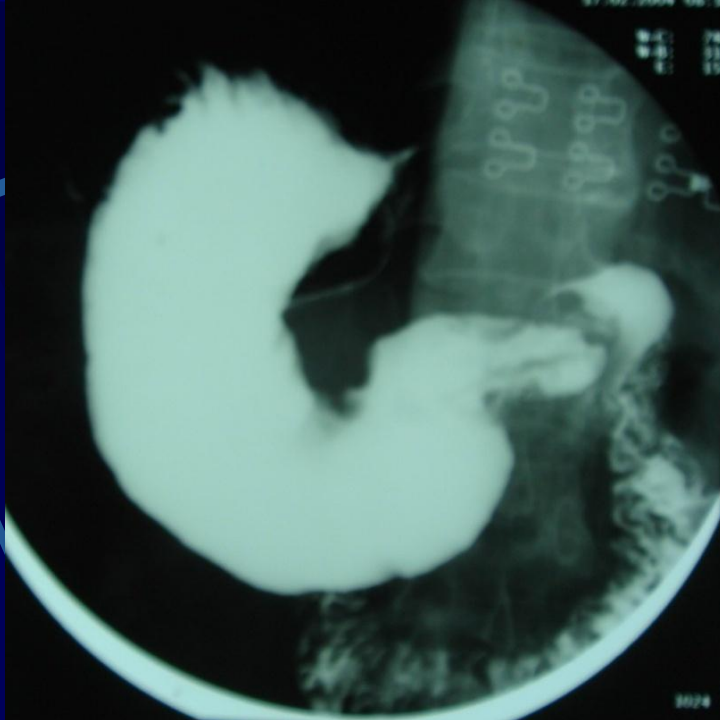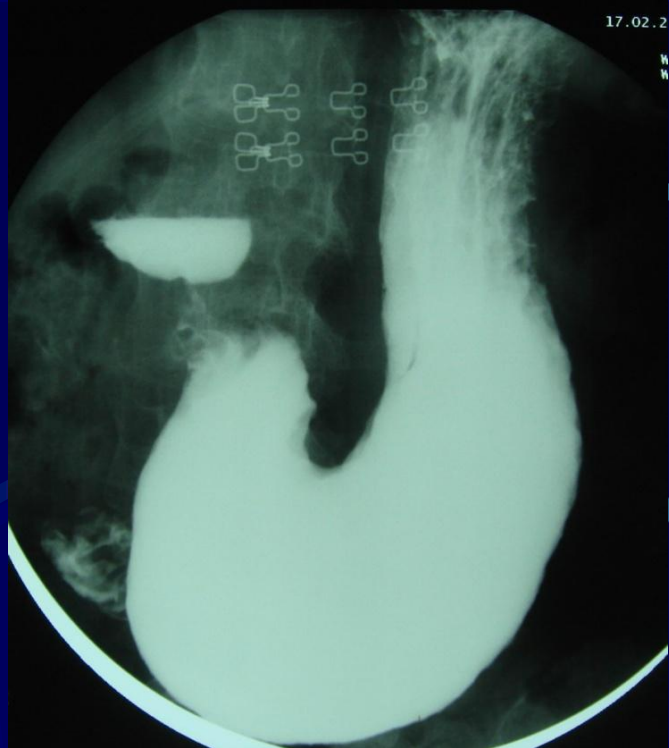角切迹胃癌



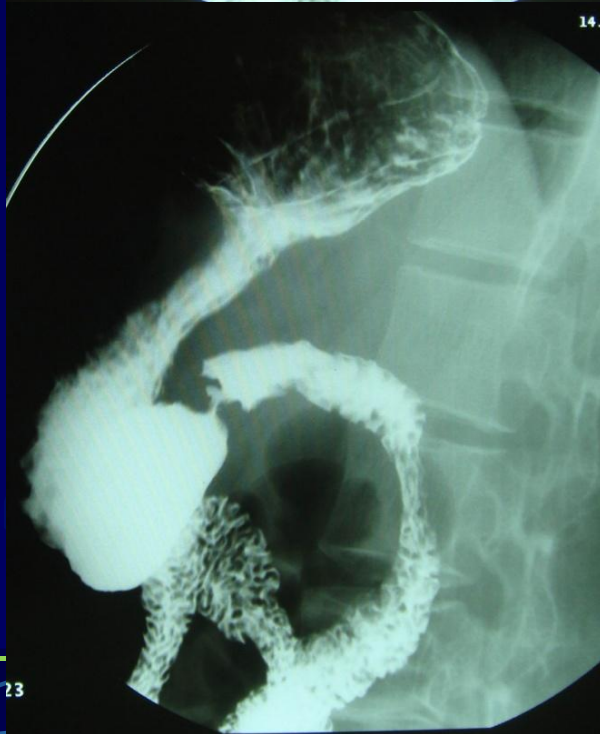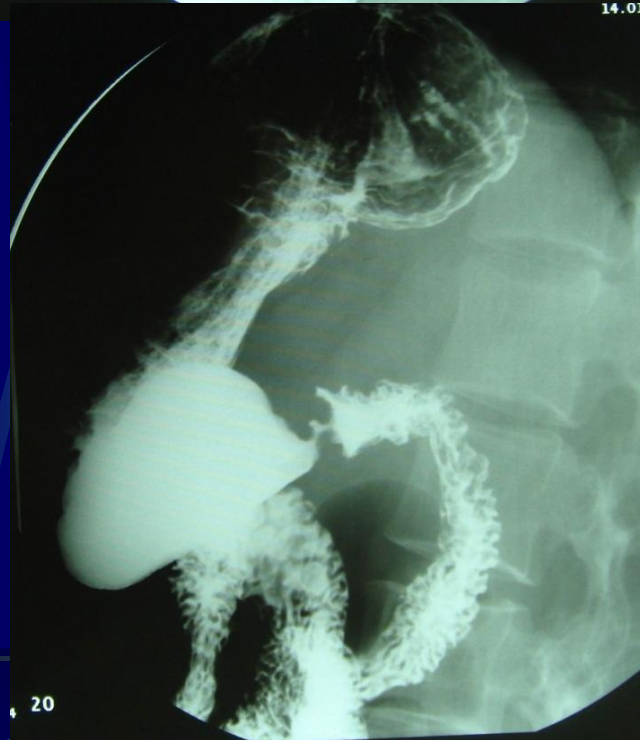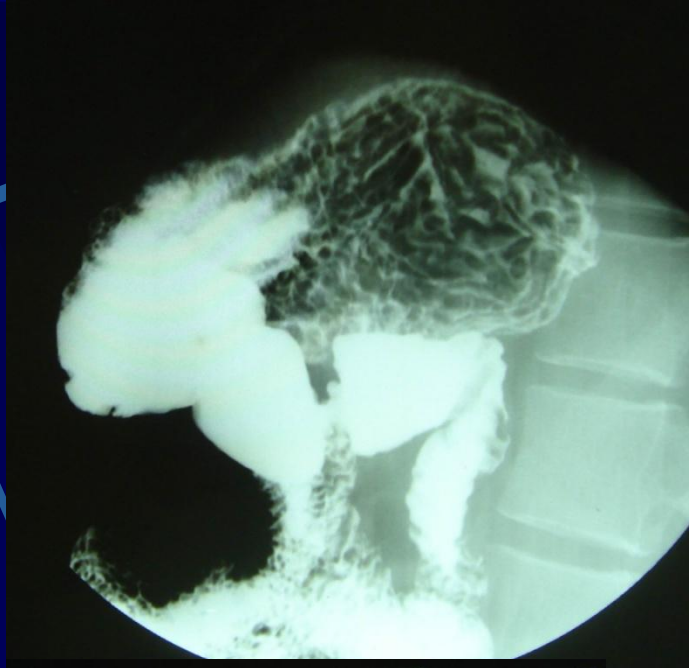
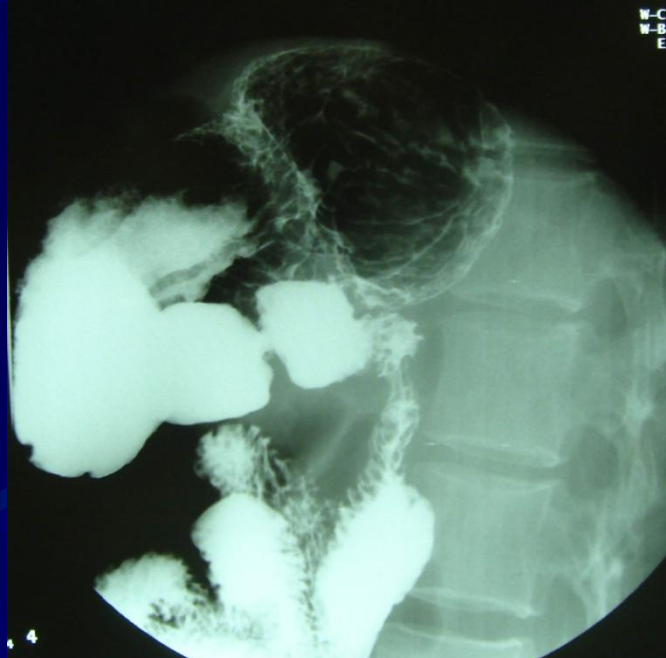浸润型胃癌



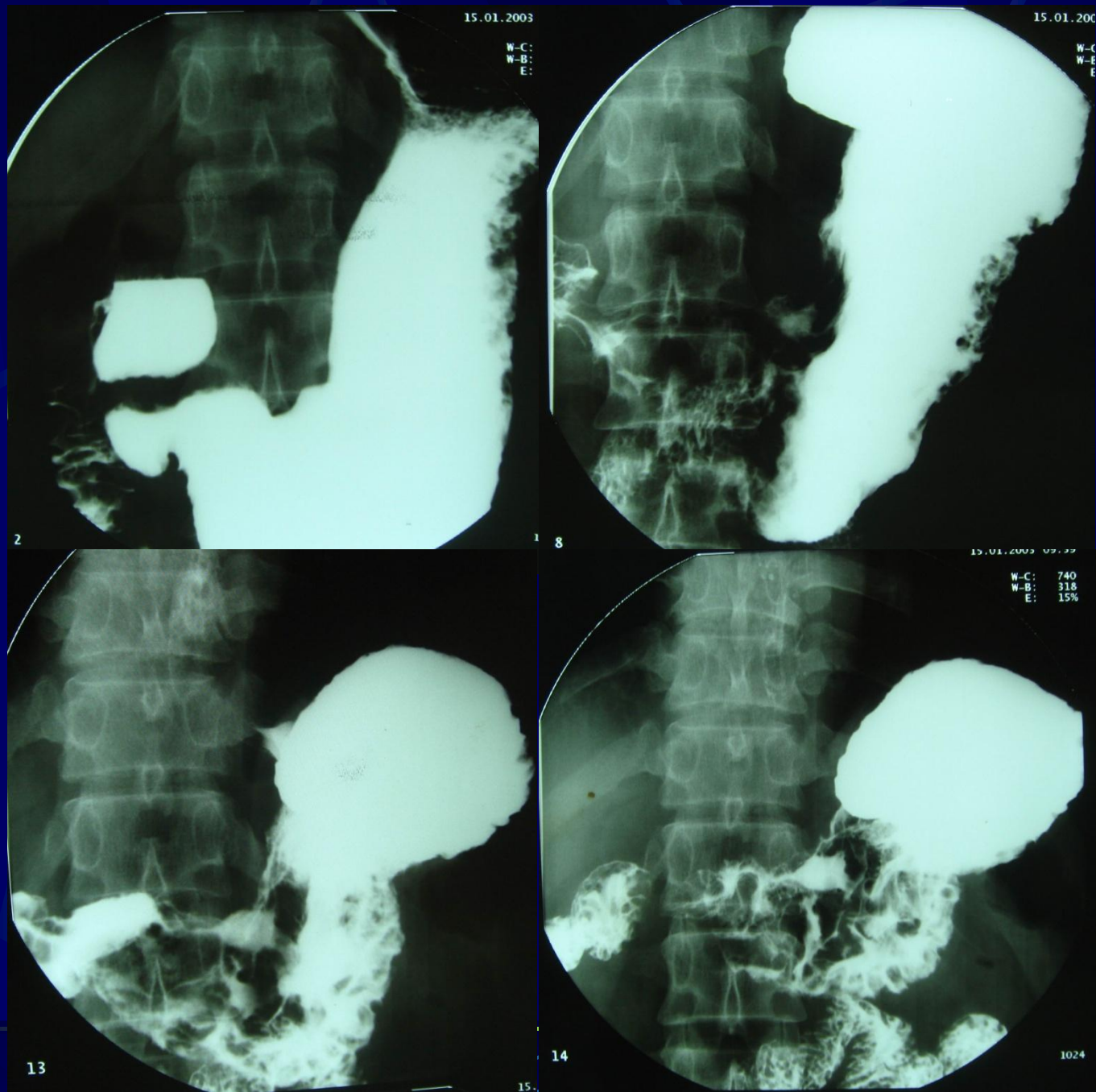
胃癌



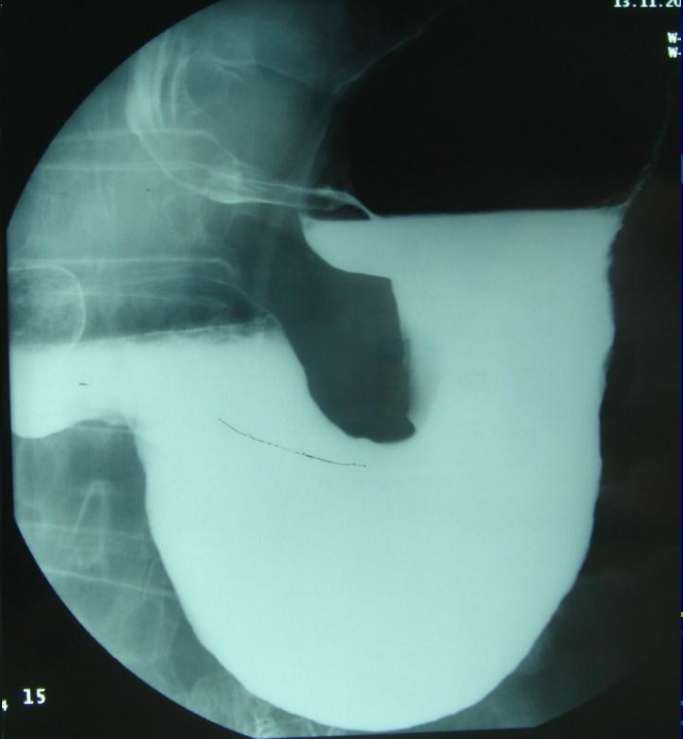
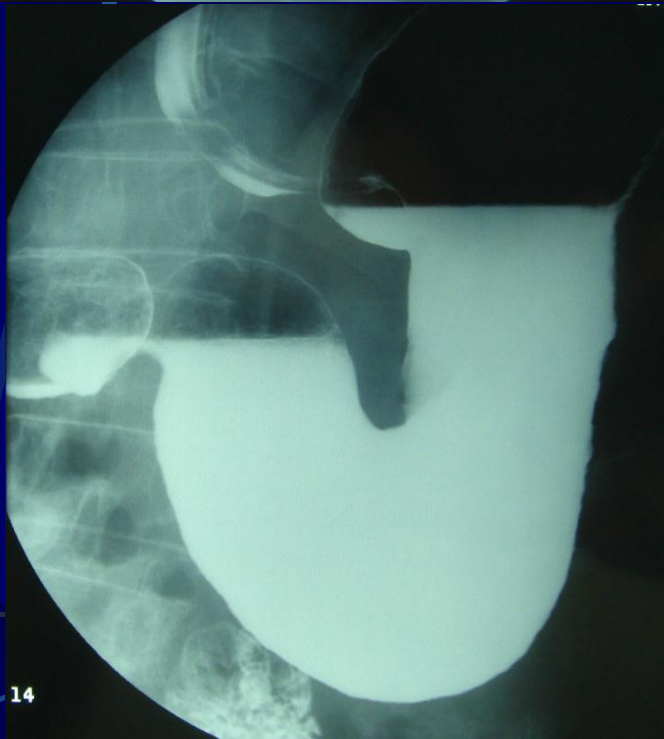
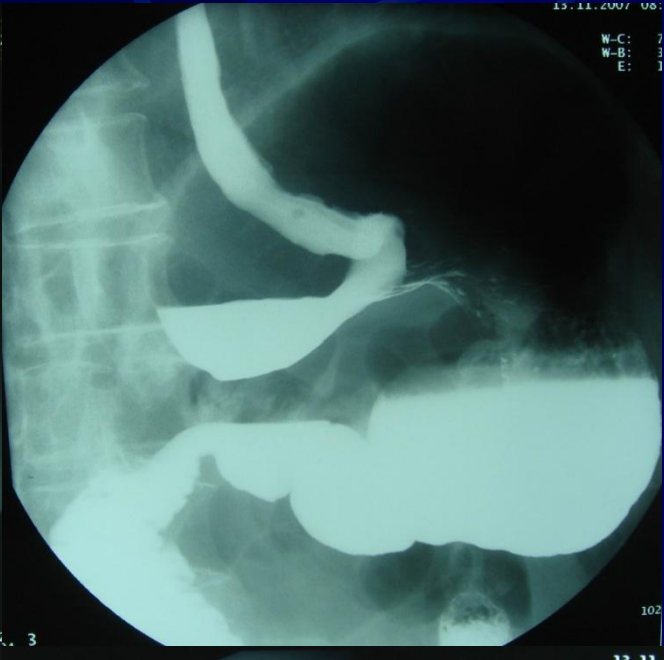
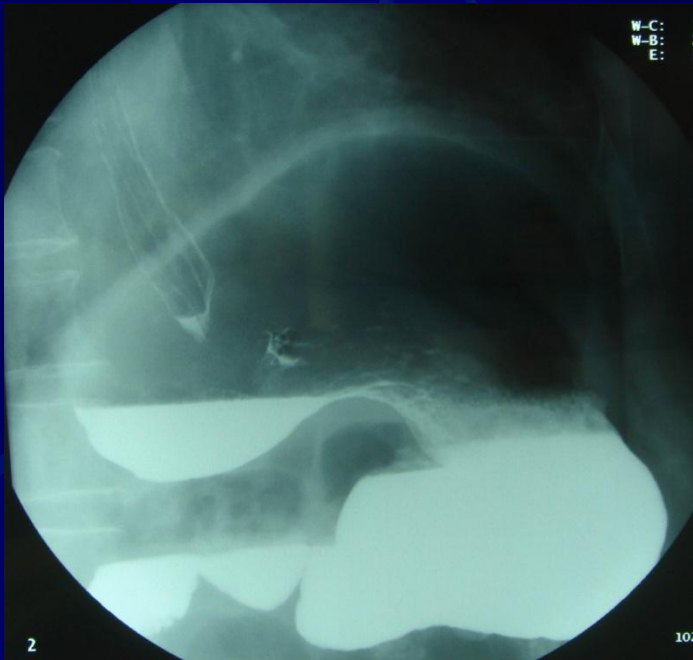
幽门管癌



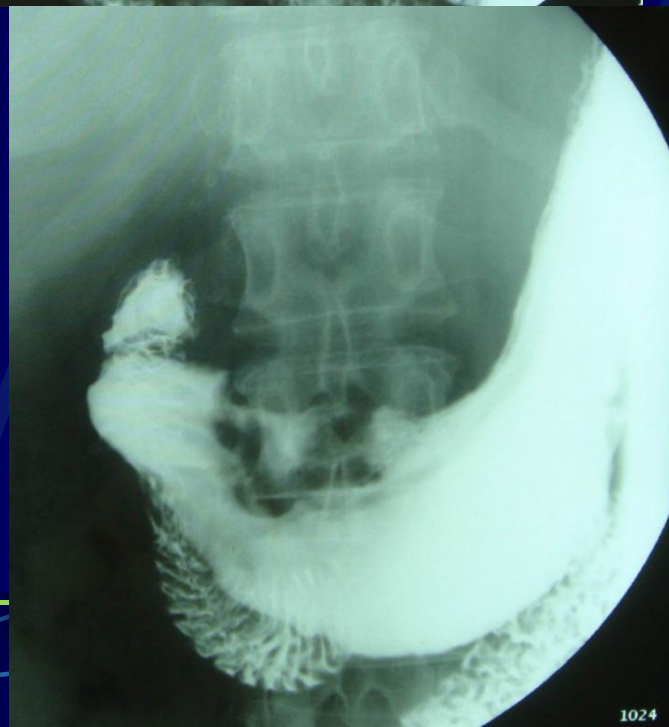
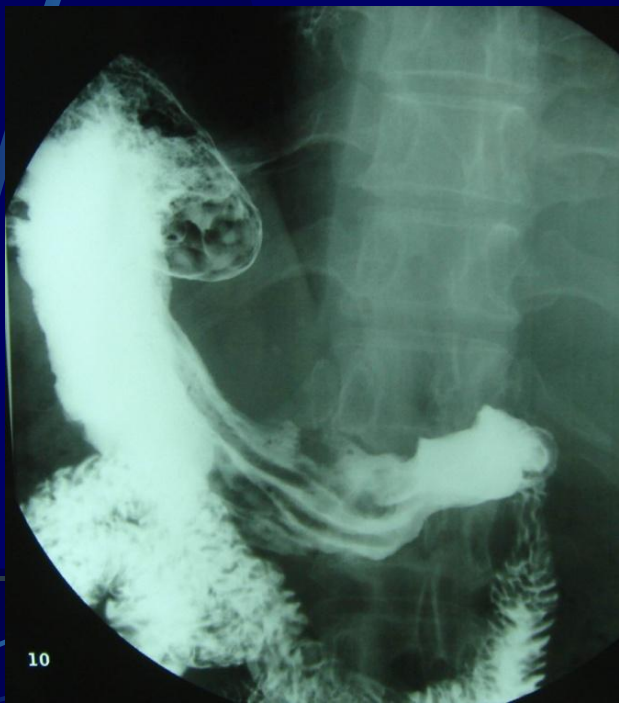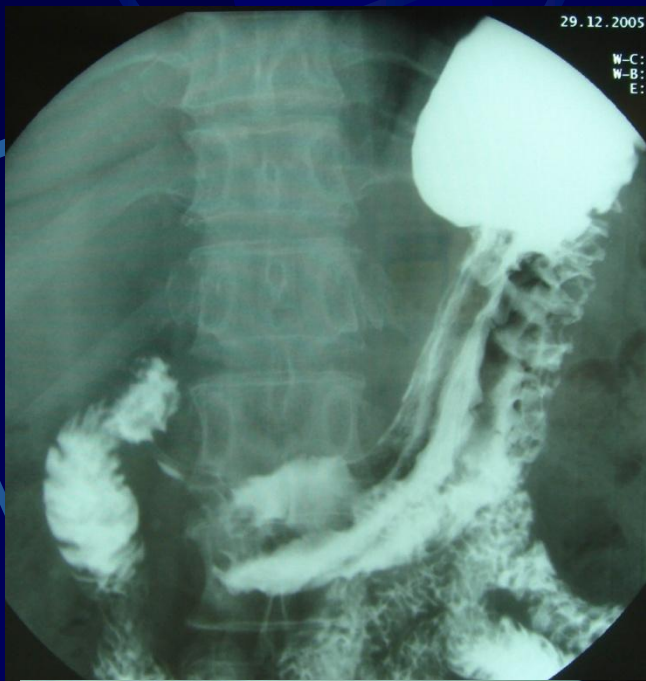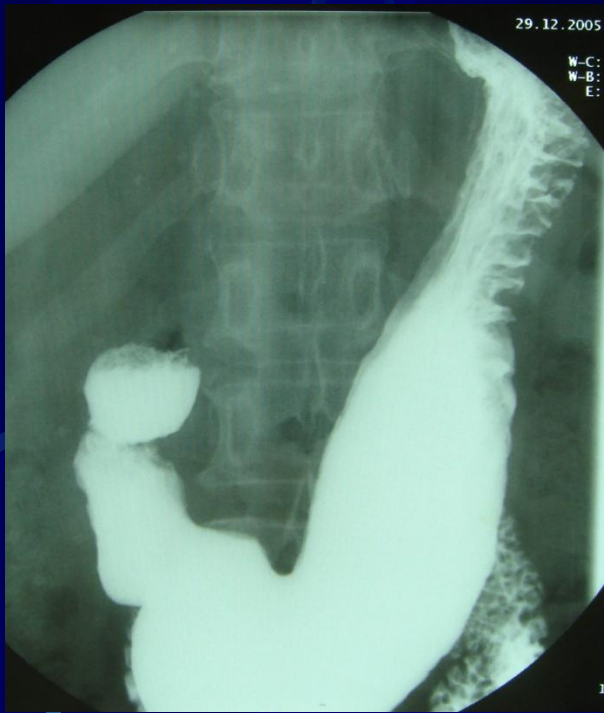
角切迹胃癌



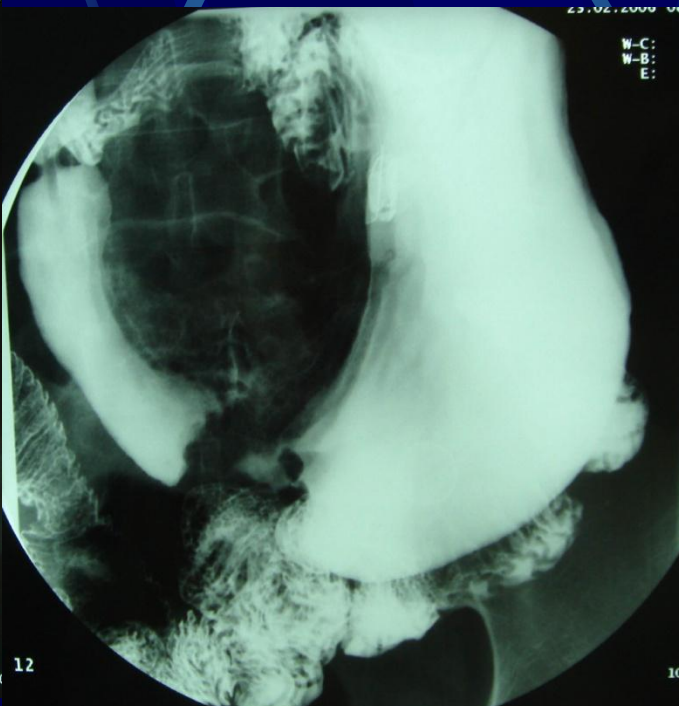
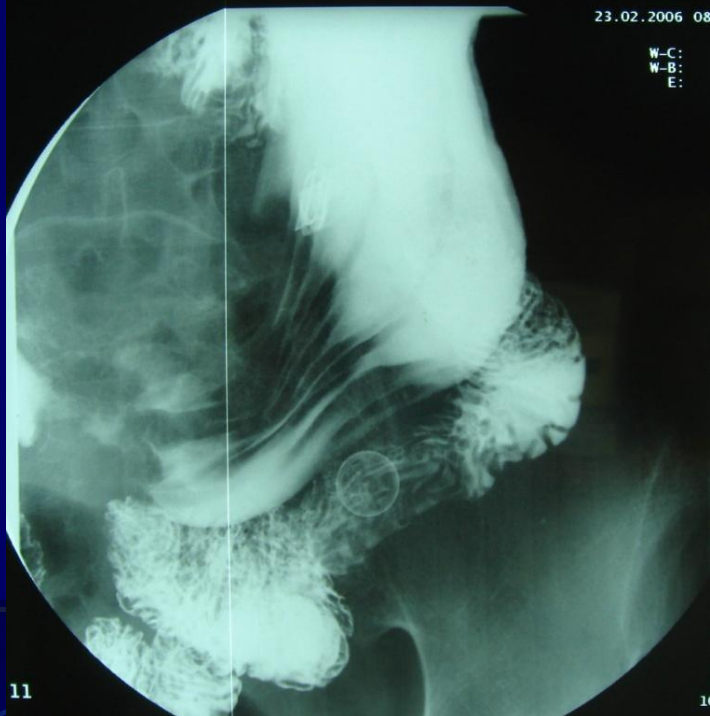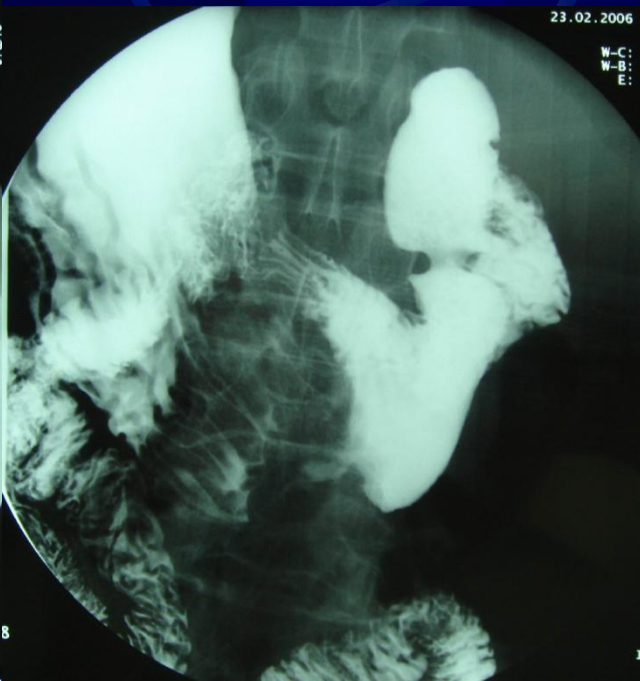
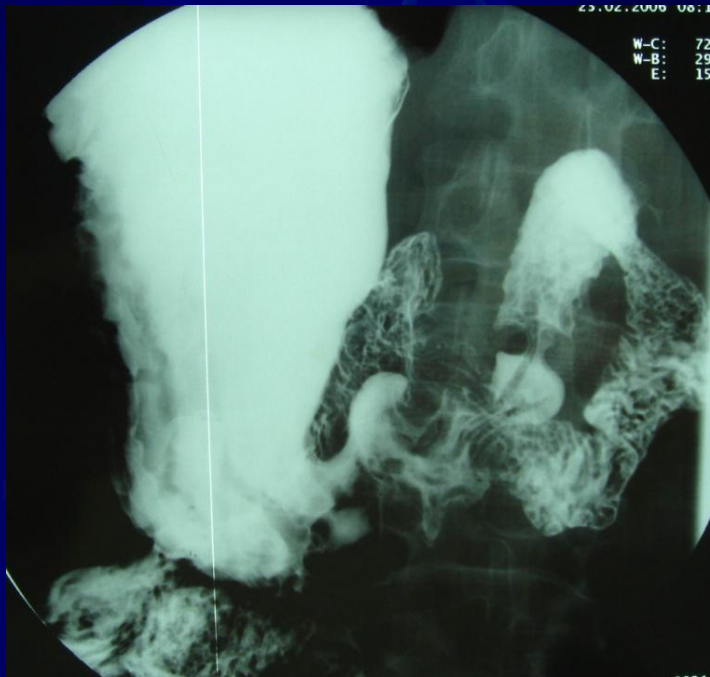
垂直部胃癌



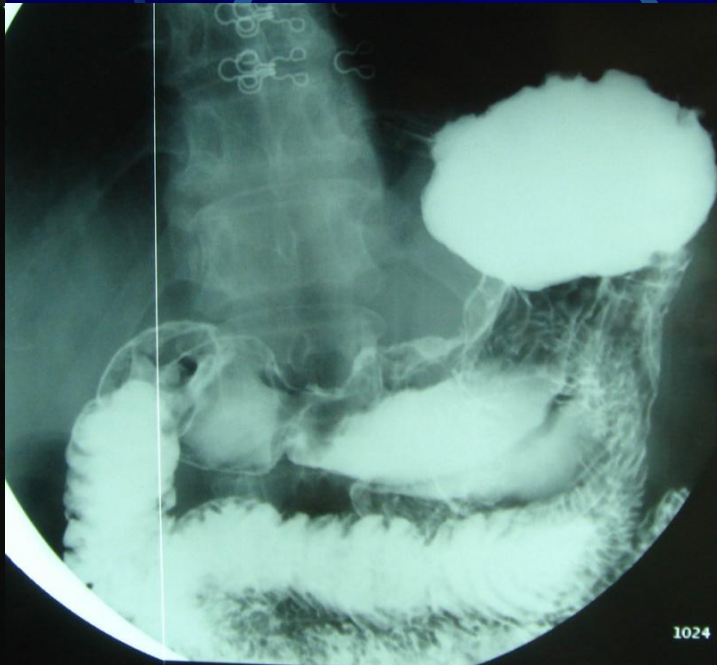
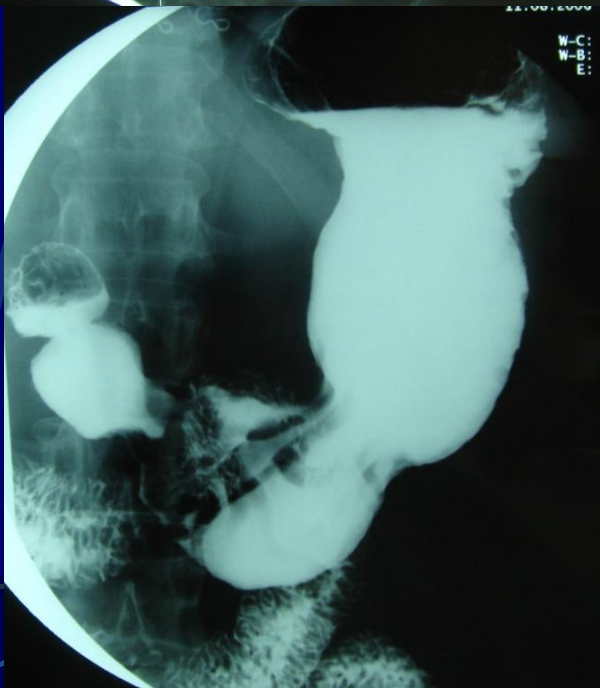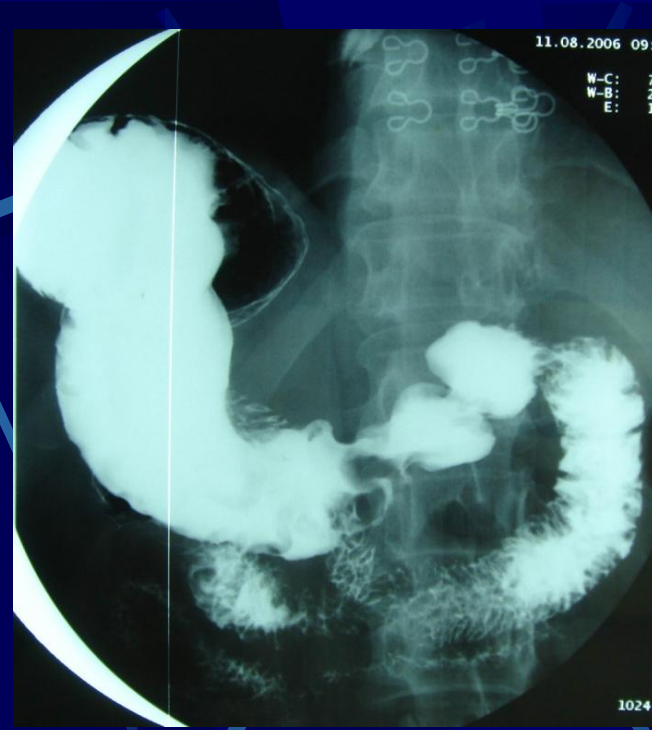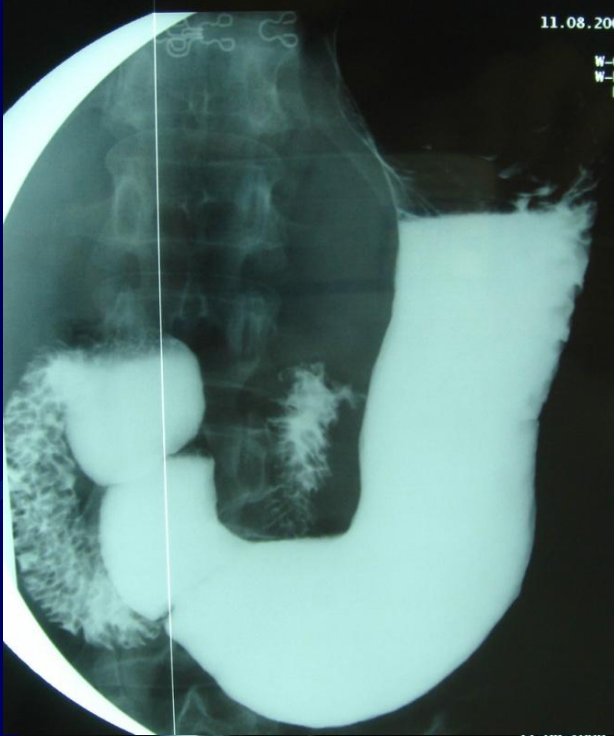
角切迹胃癌



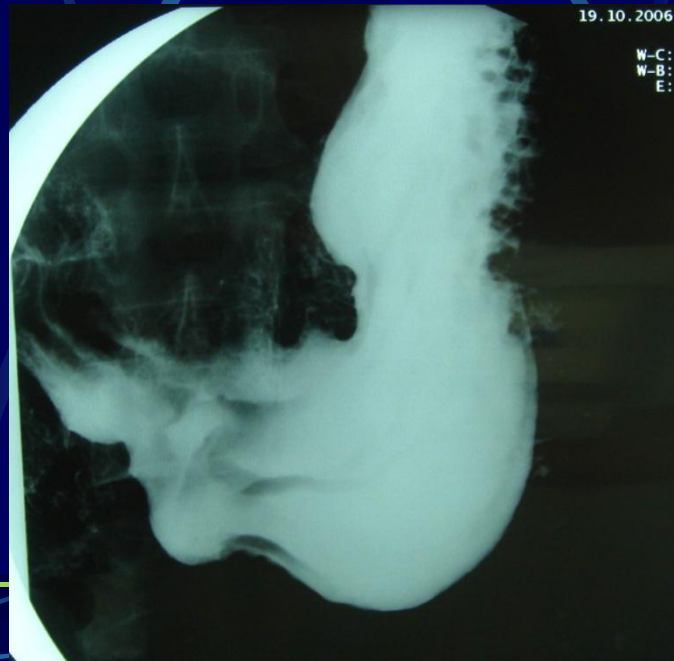
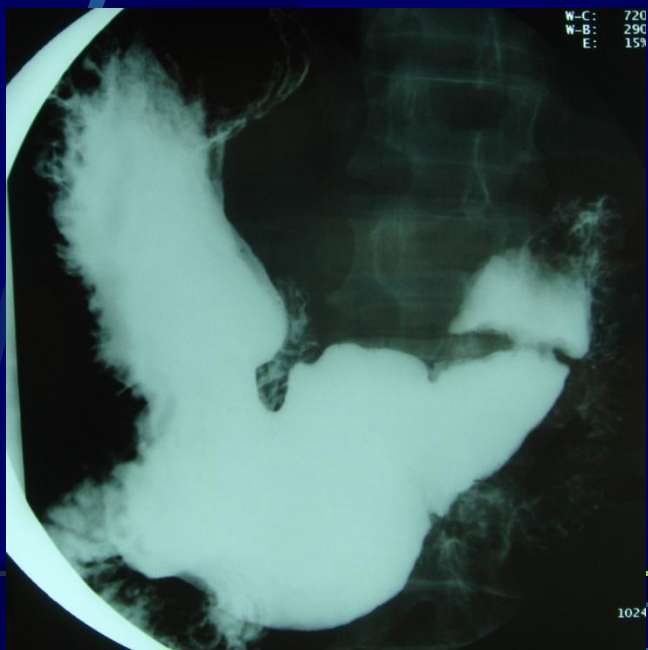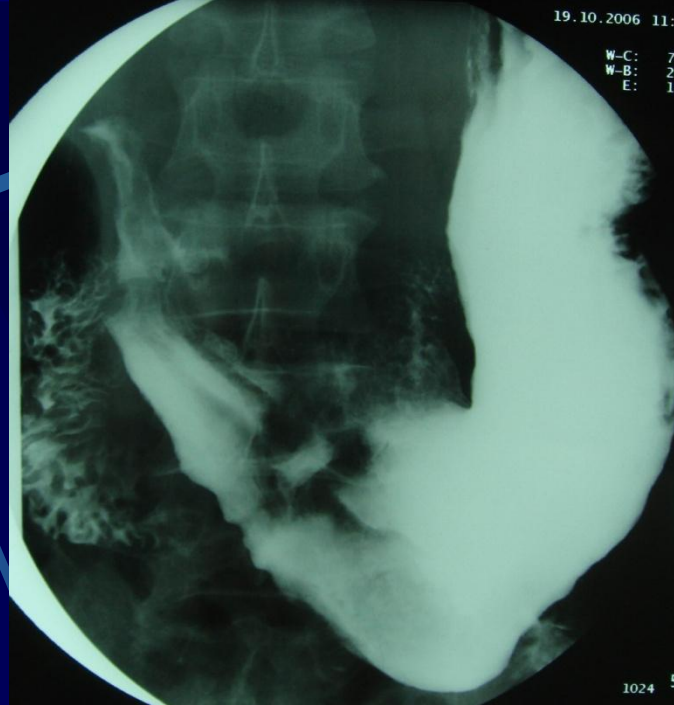
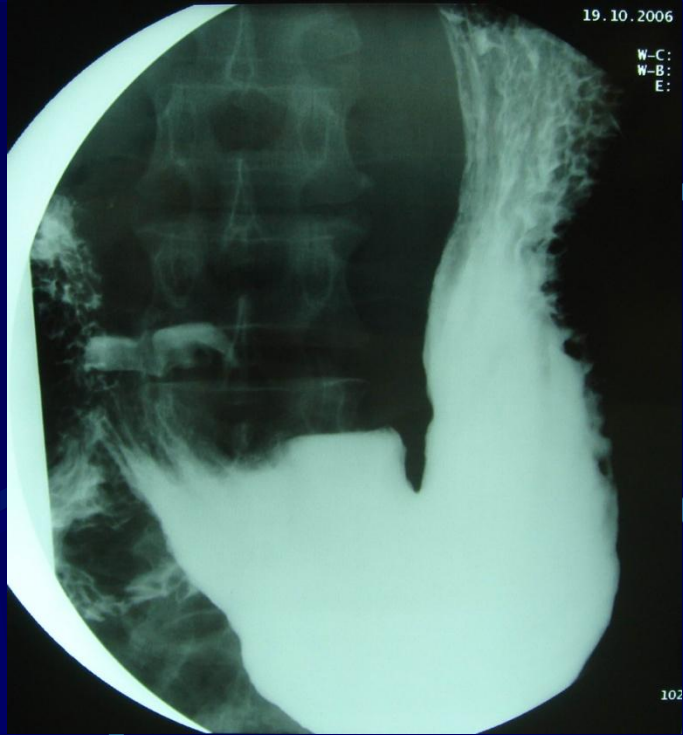
胃窦大弯侧胃癌



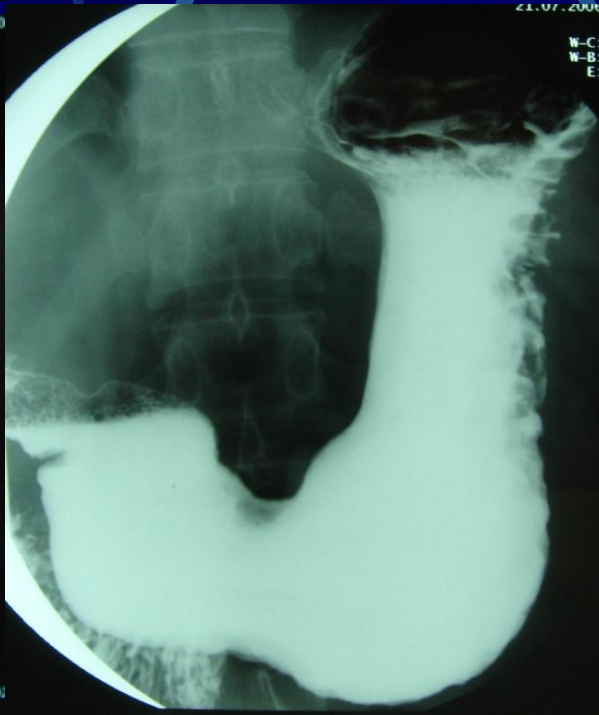
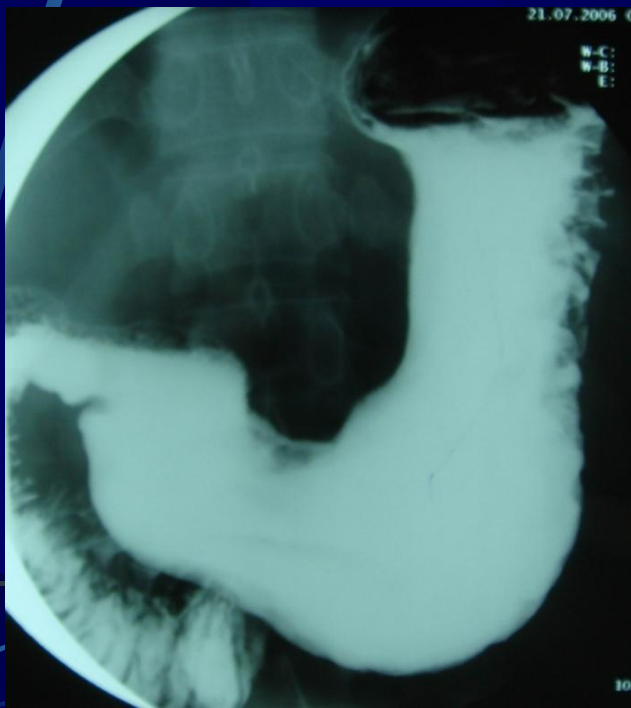
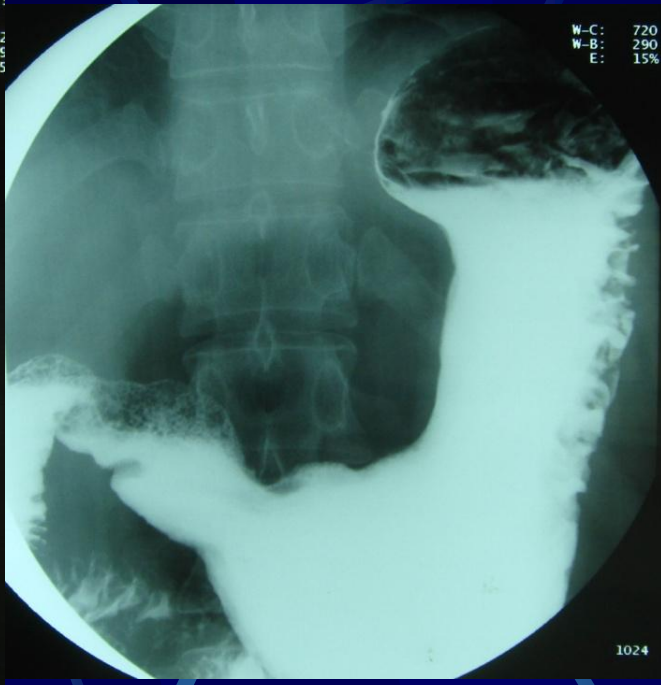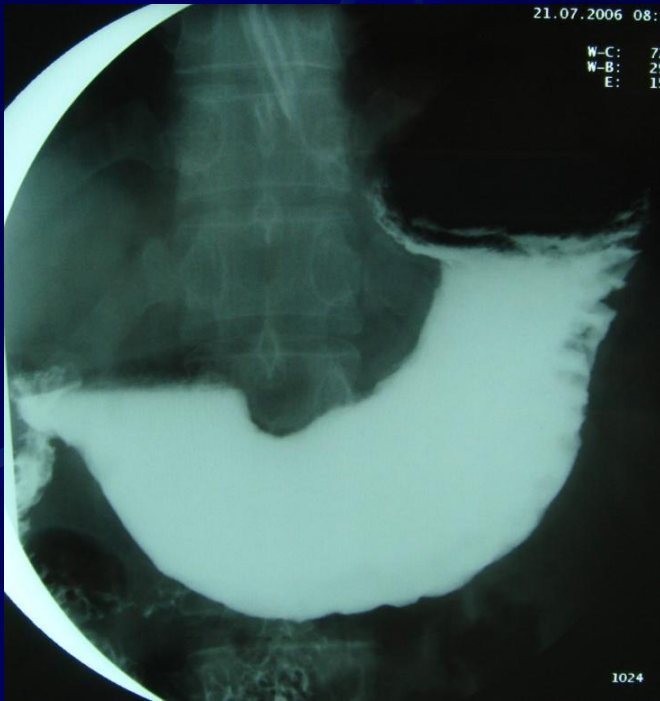
角切迹胃癌



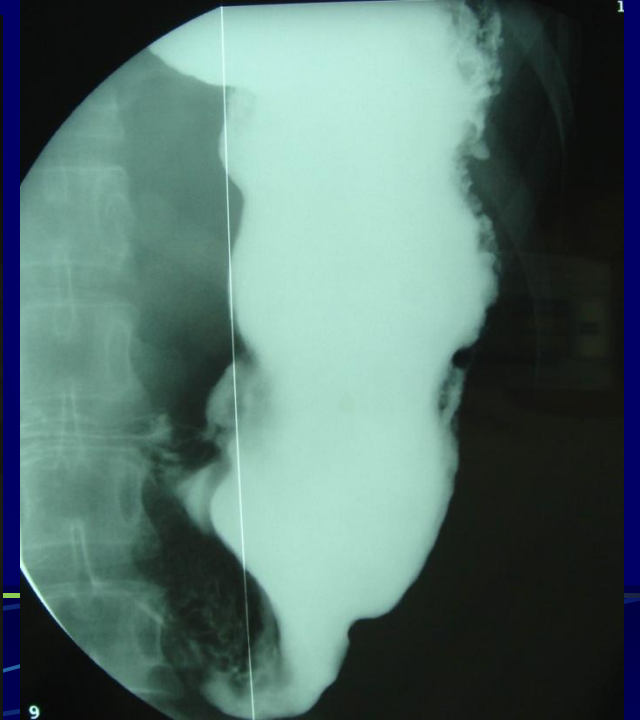
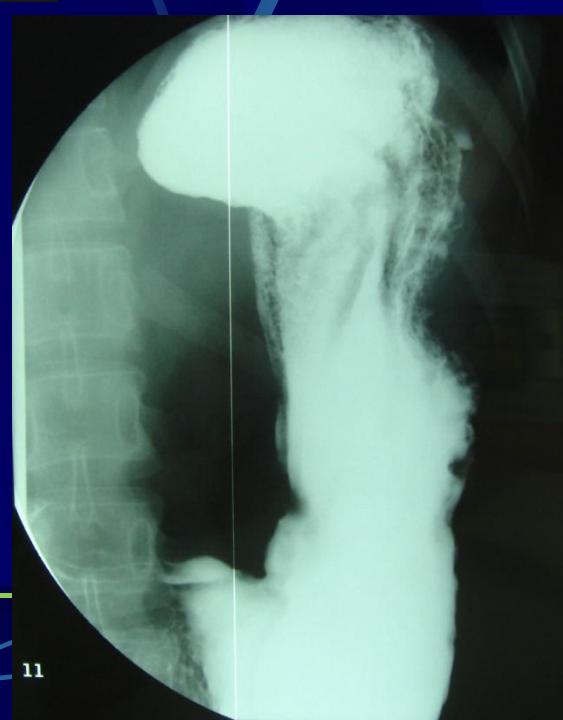
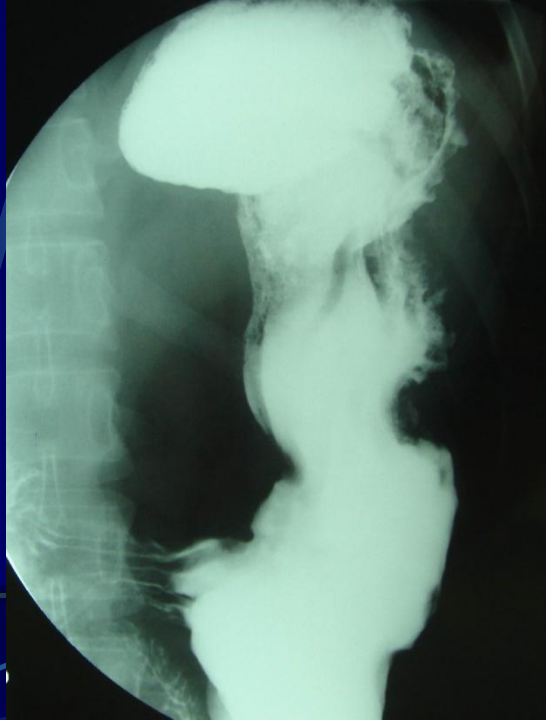
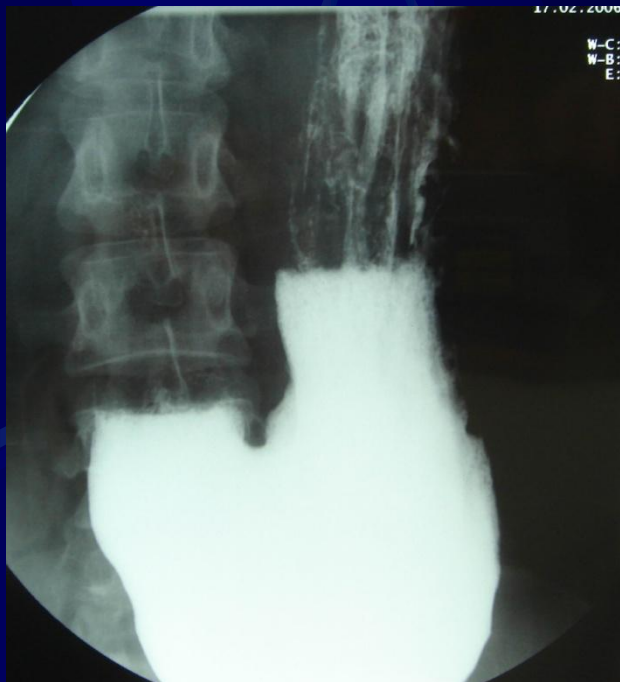胃窦癌

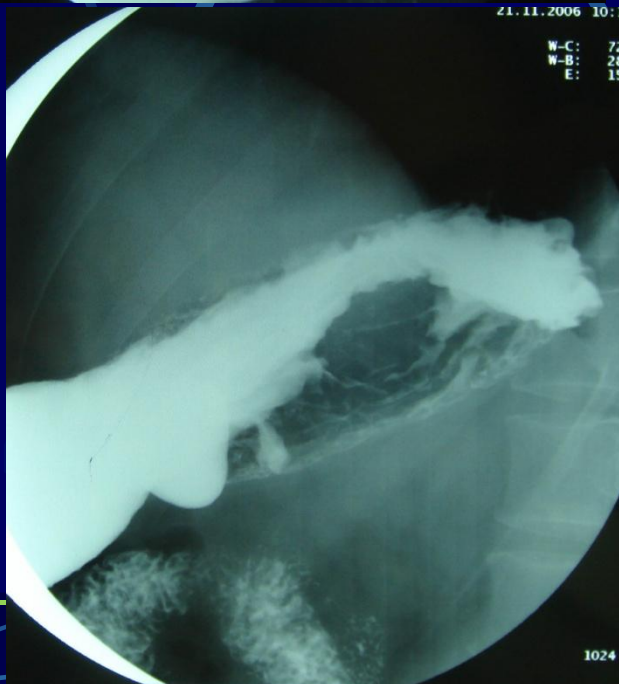
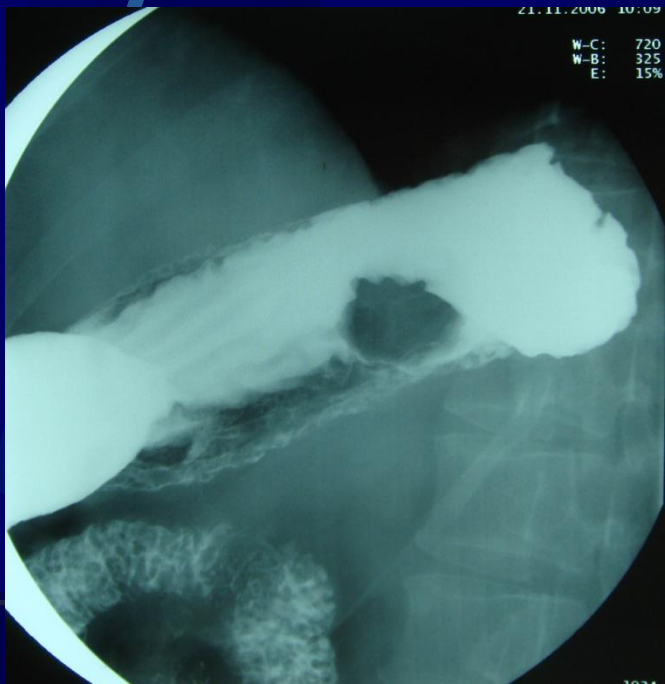
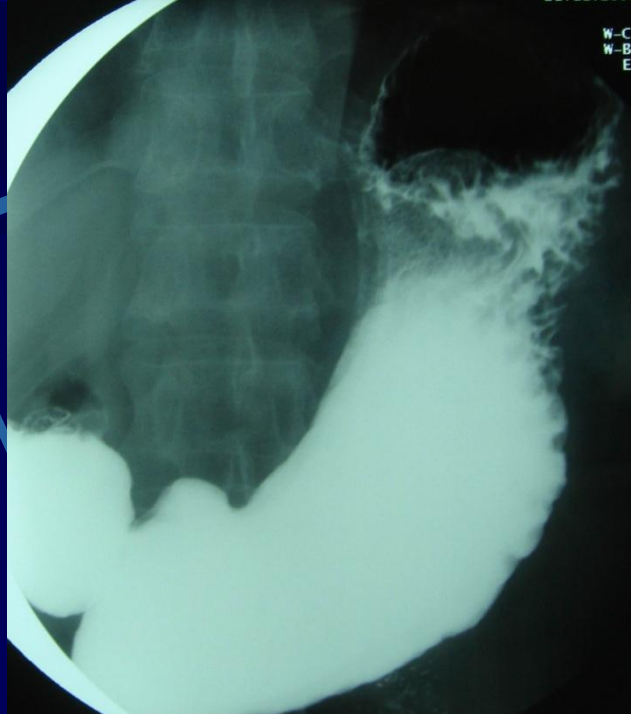
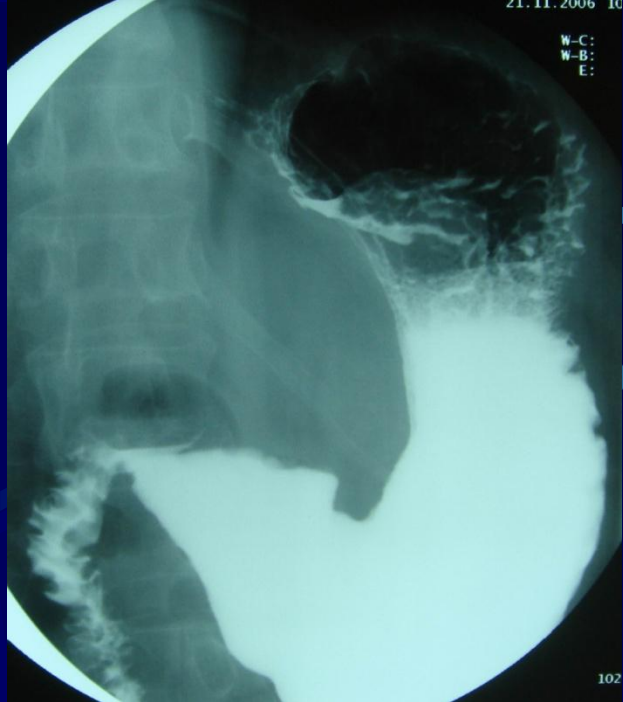


角切迹胃癌



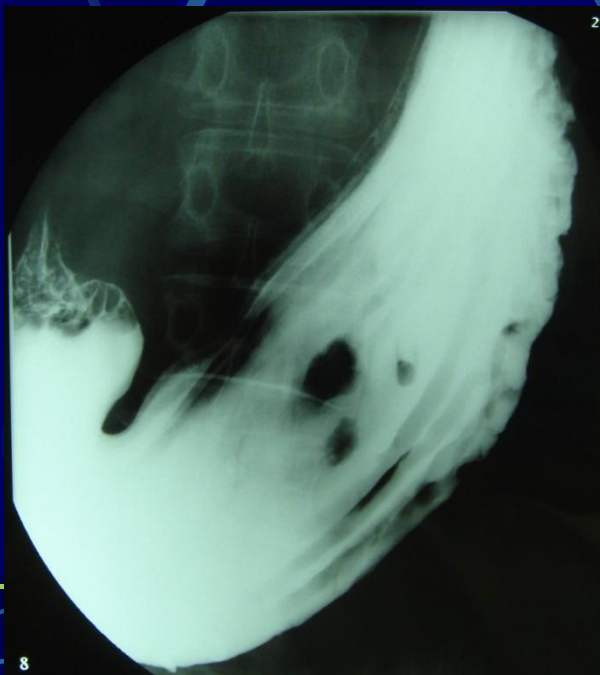
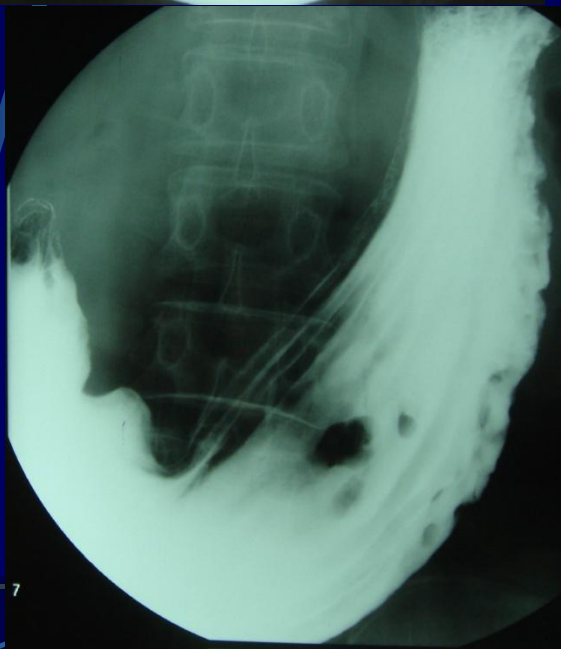
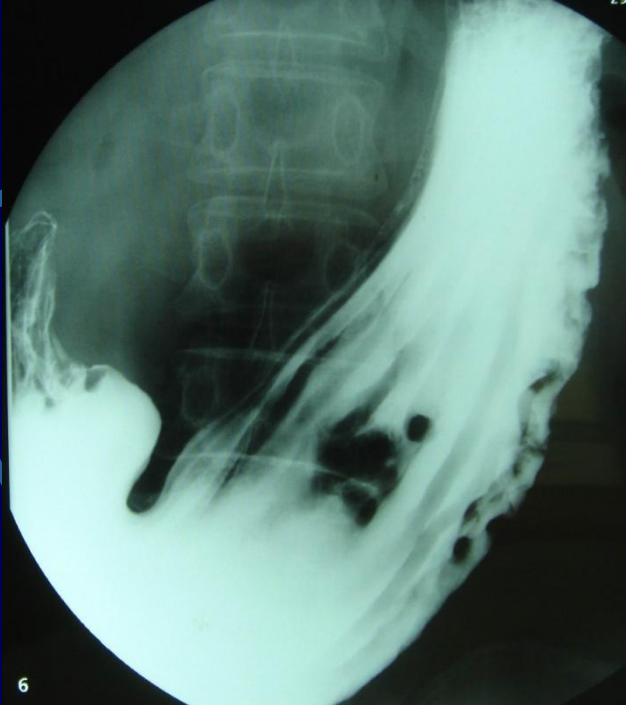
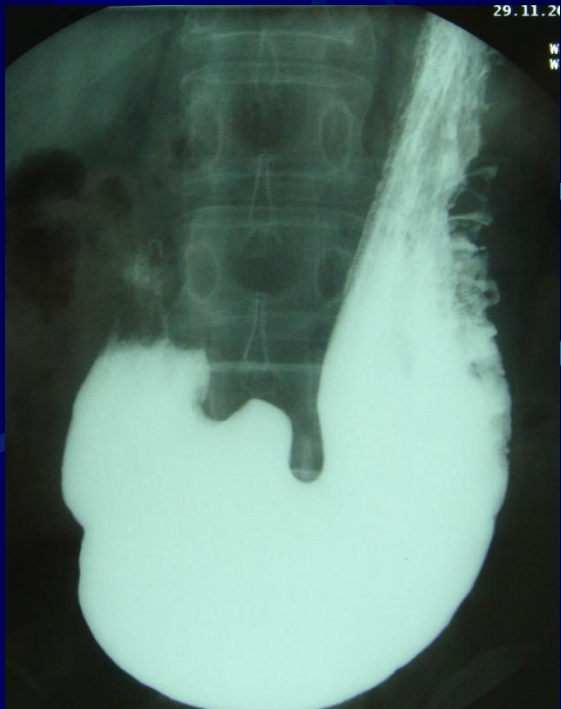垂直部胃癌



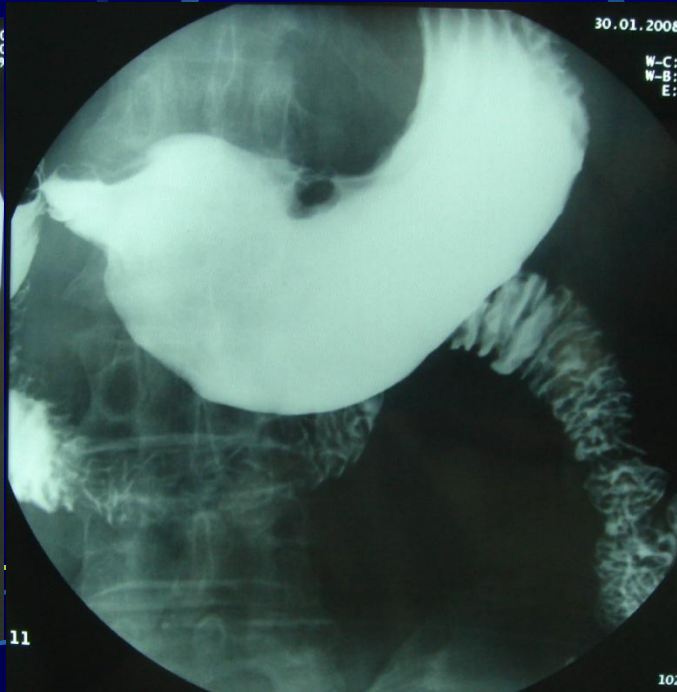
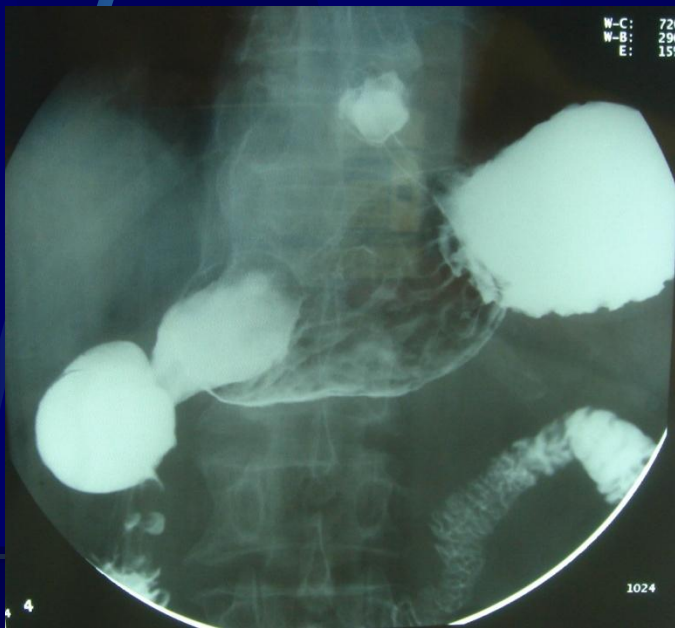
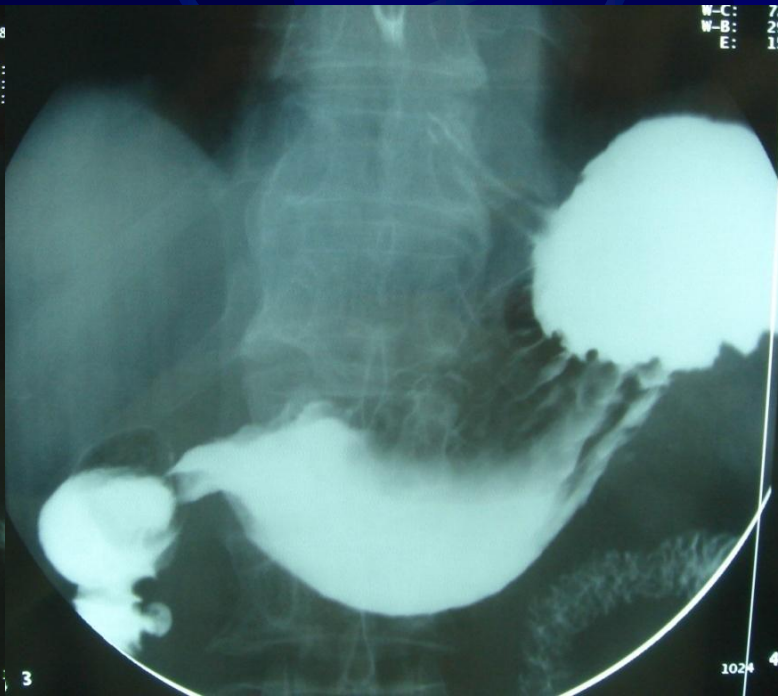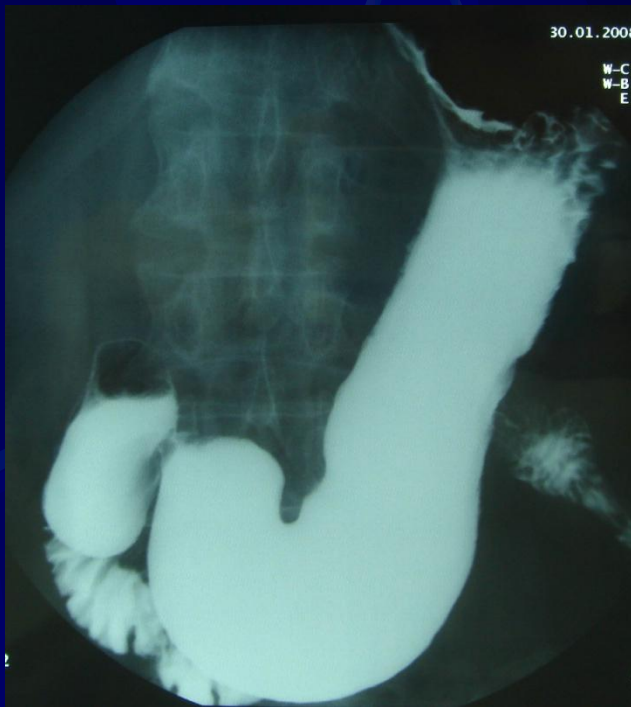胃底部胃癌

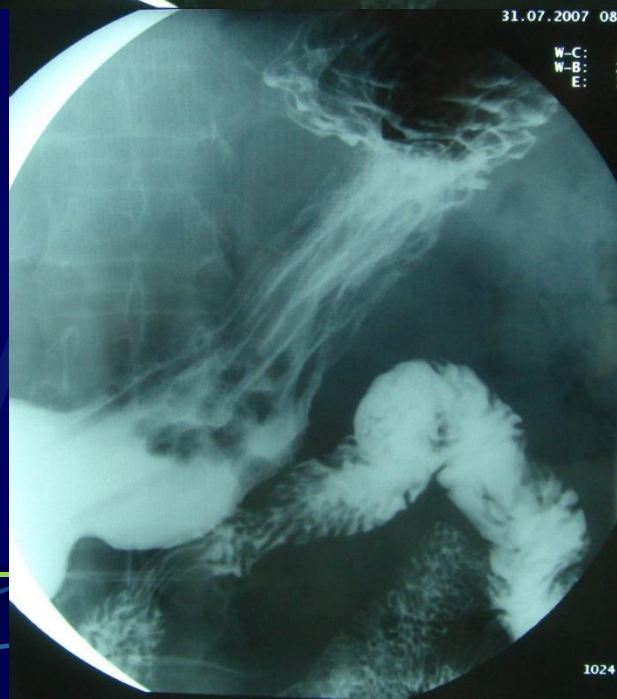
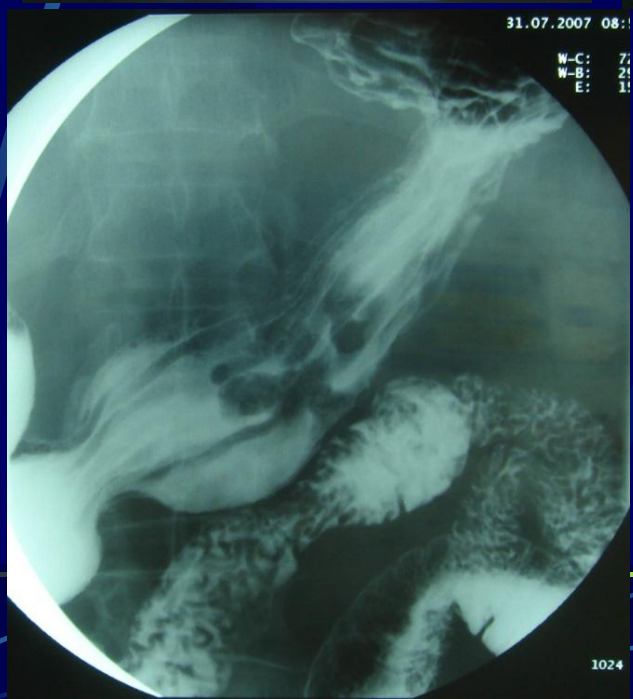
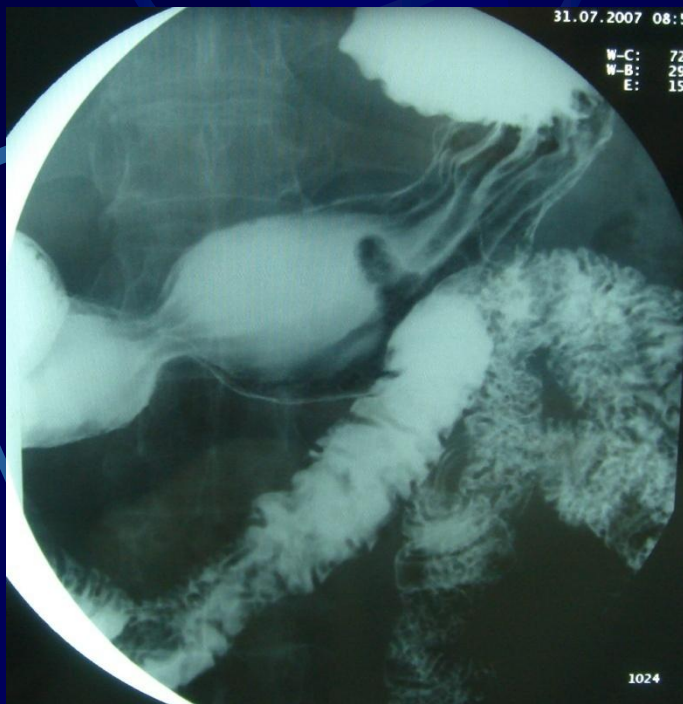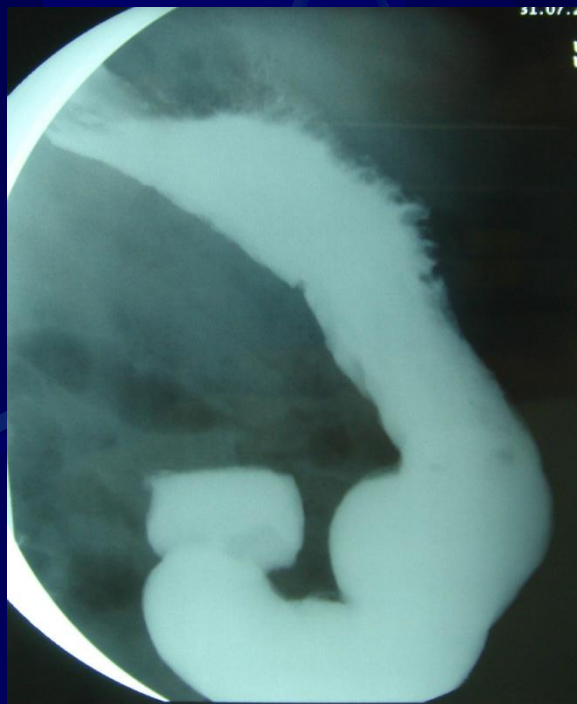胃体多发息肉



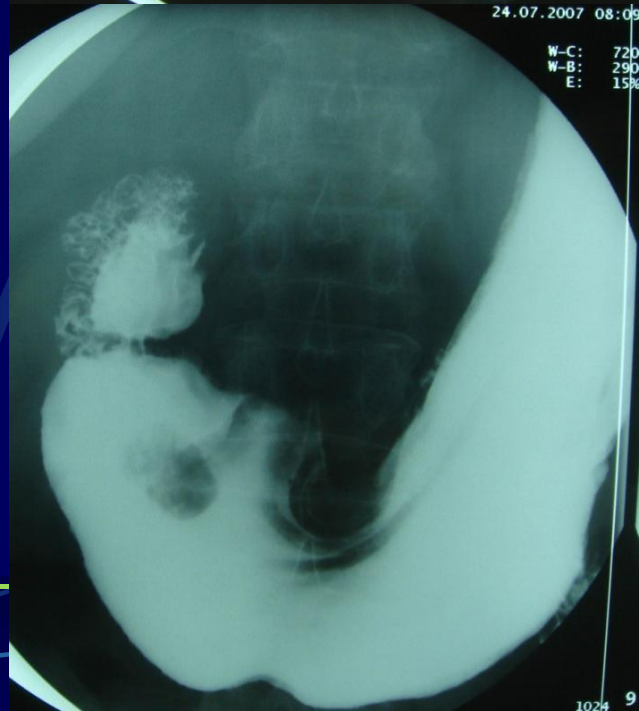
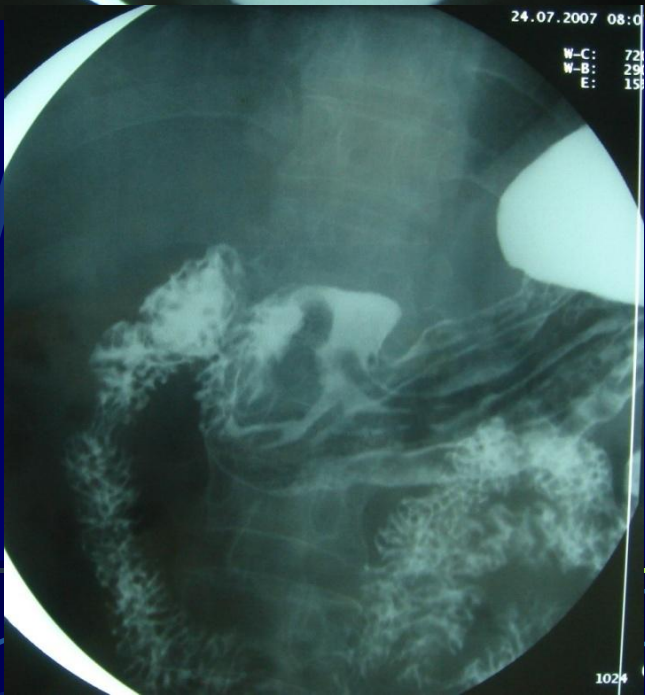
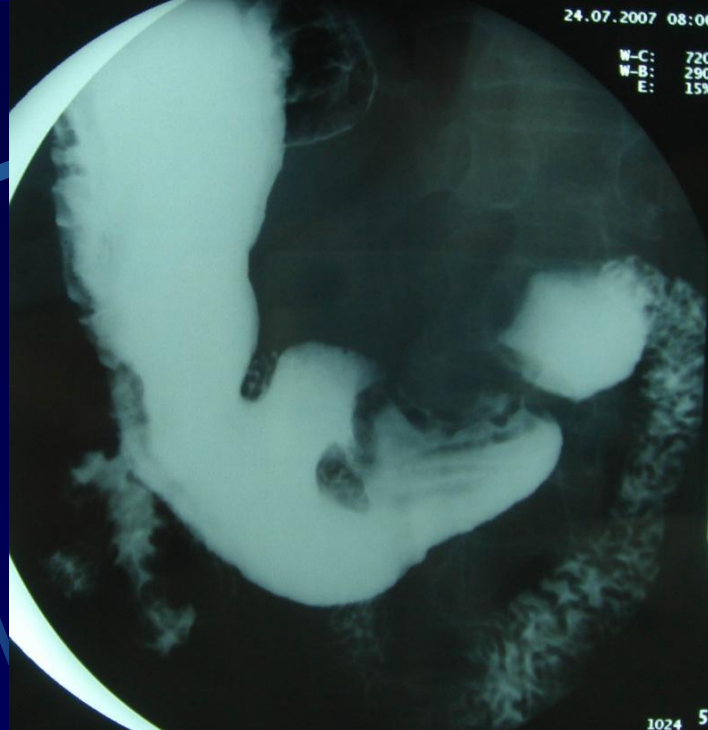
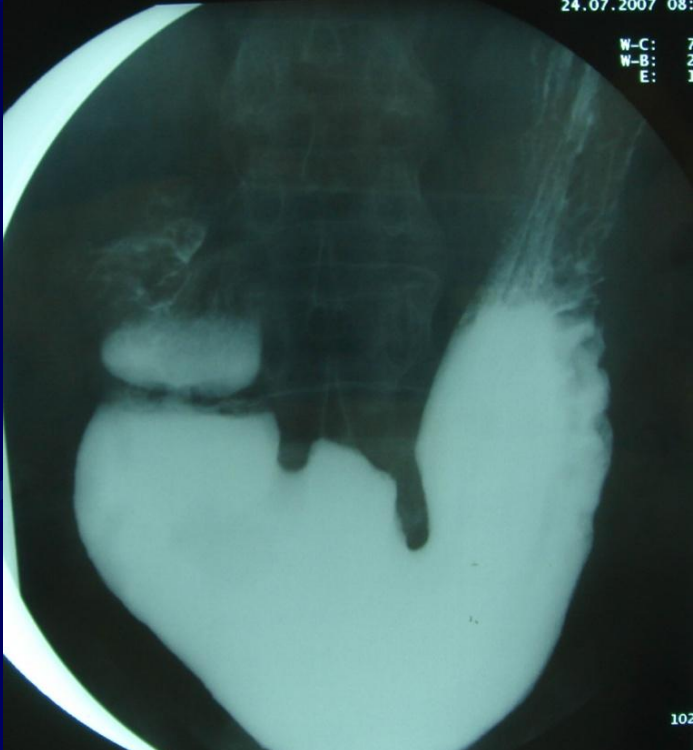角切迹息肉



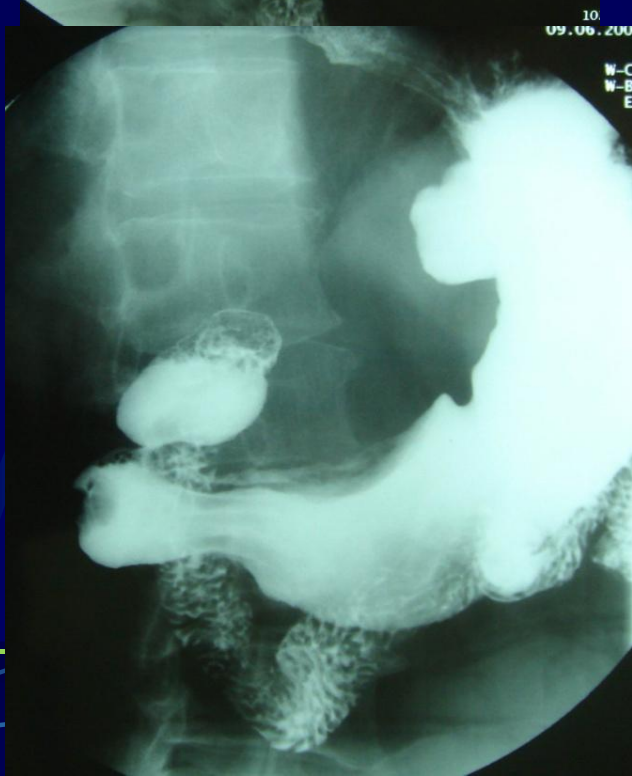
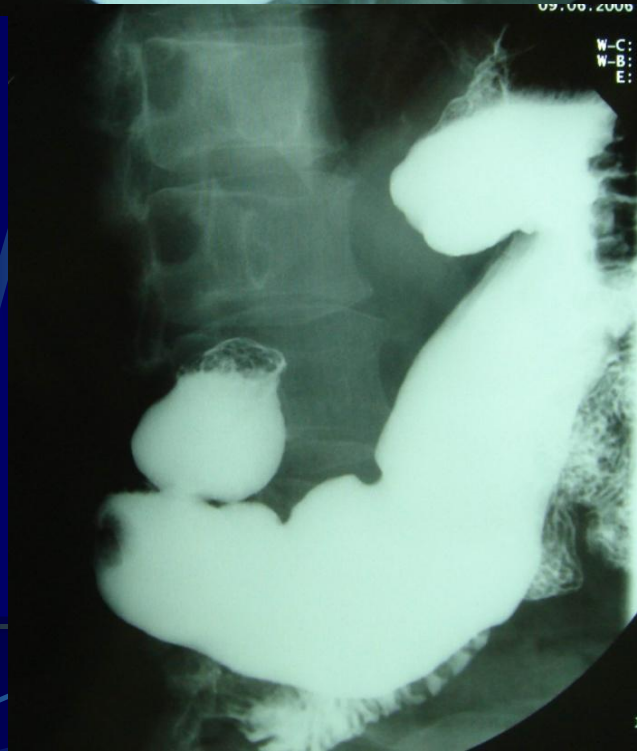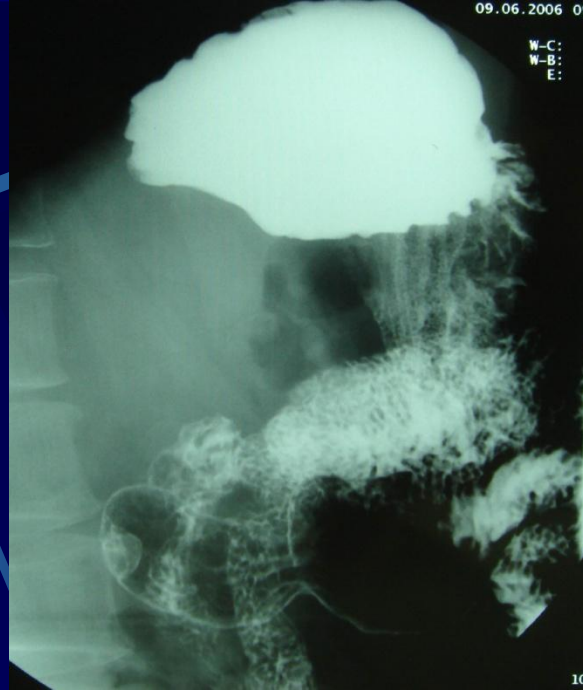
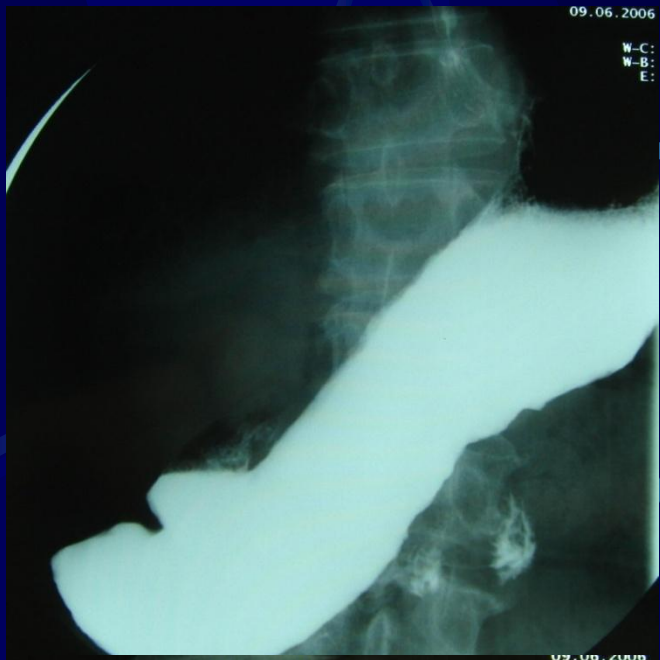胃体多发息肉

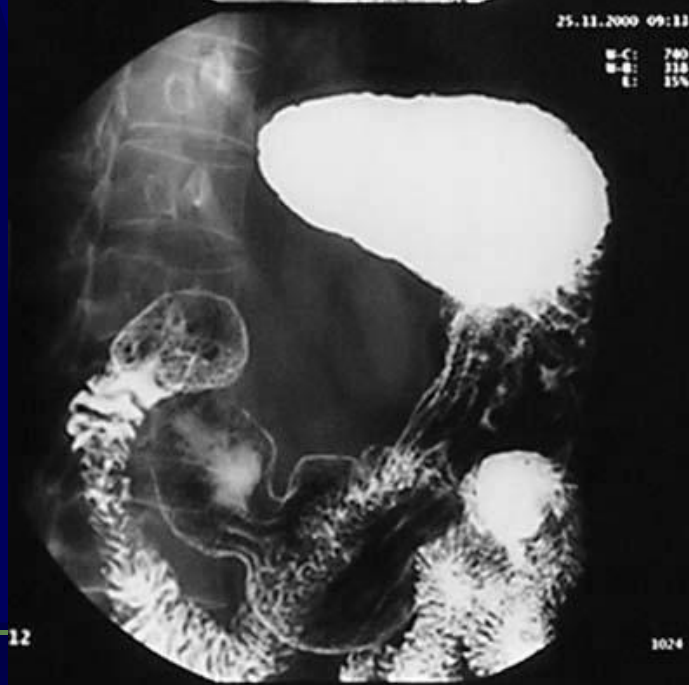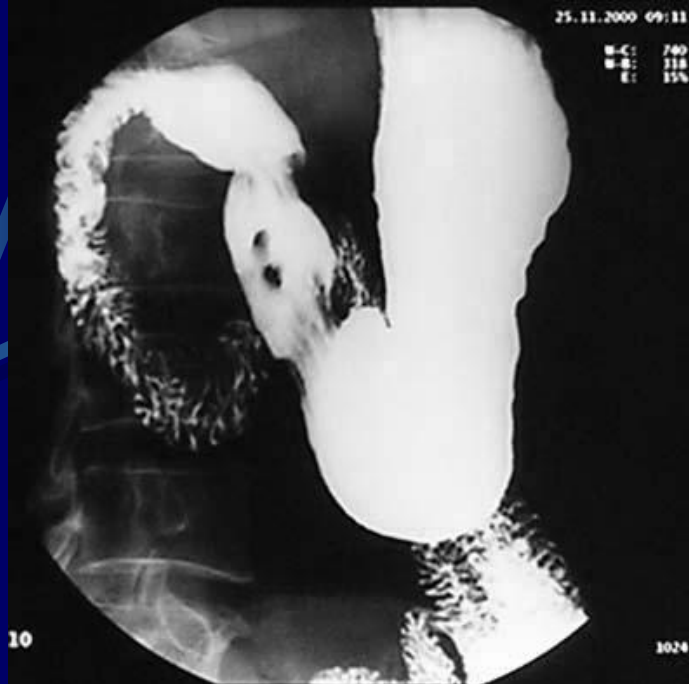


胃窦息肉



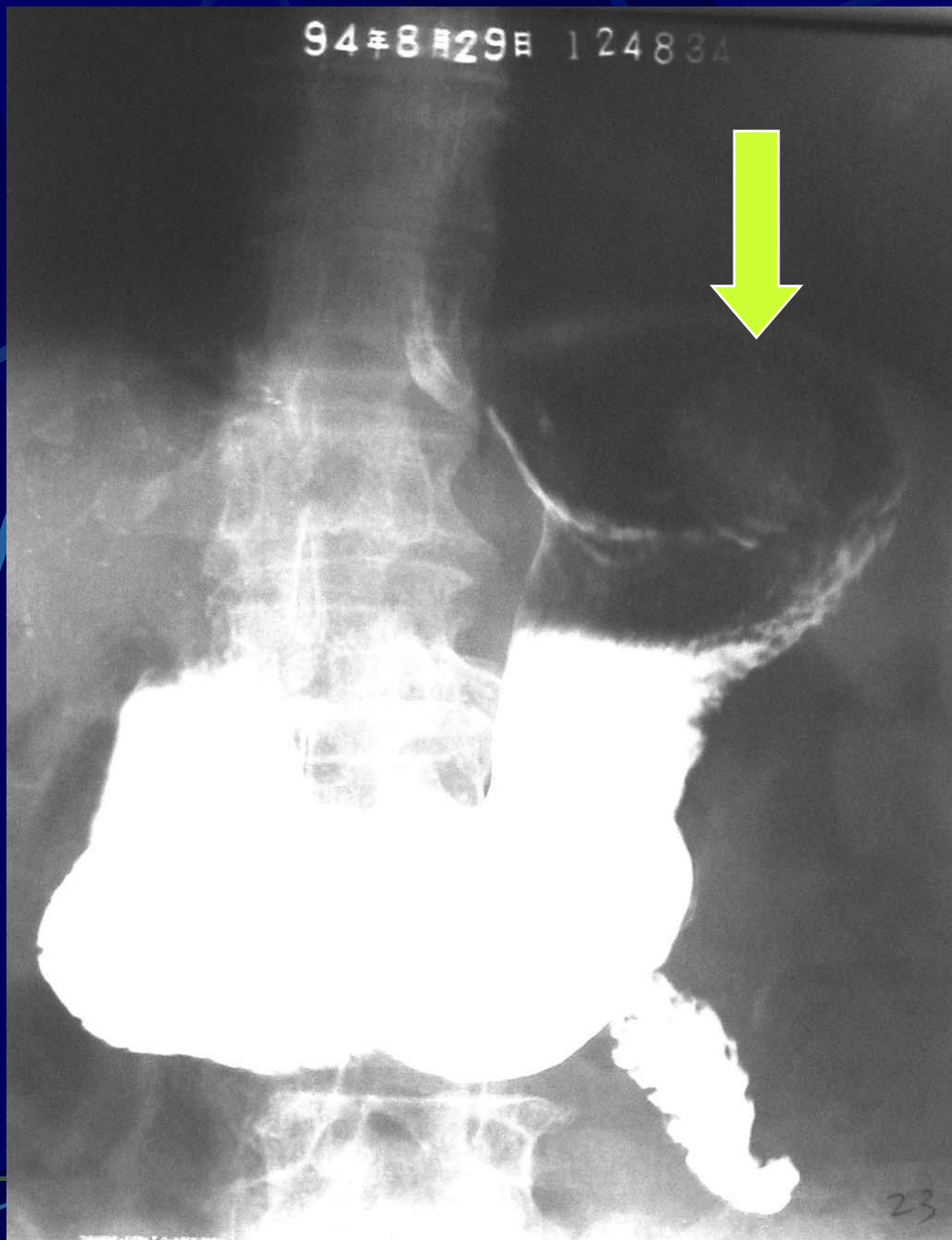
胃窦息肉





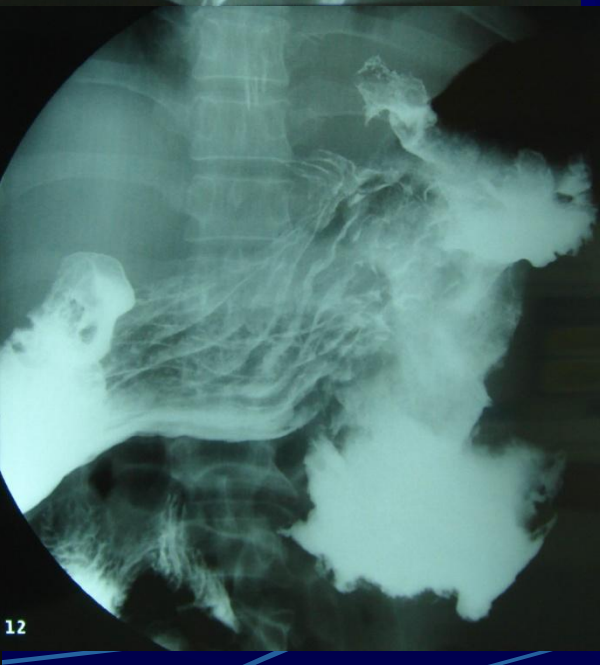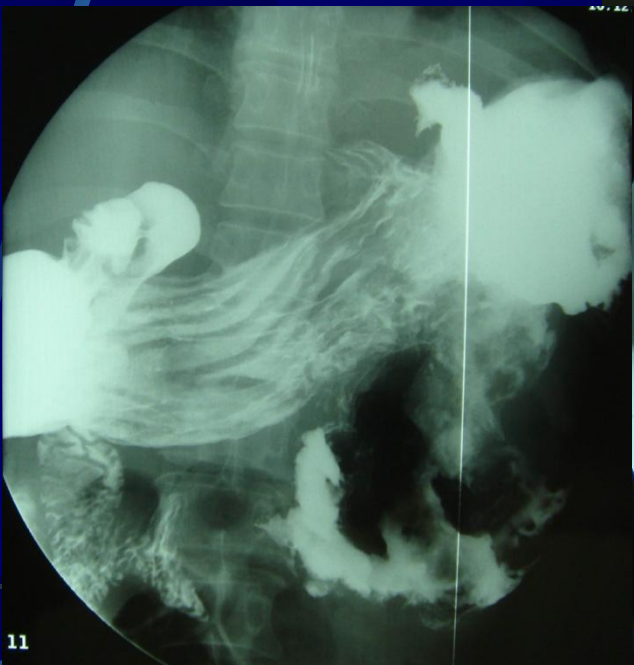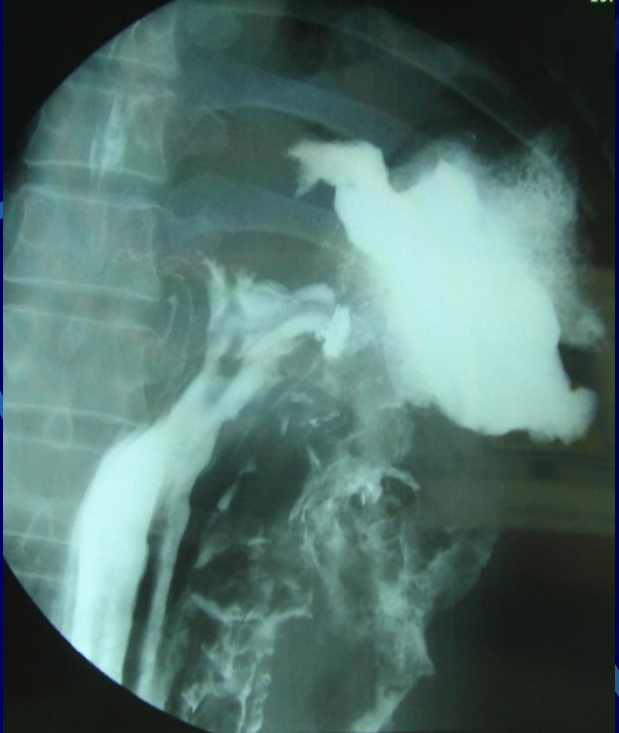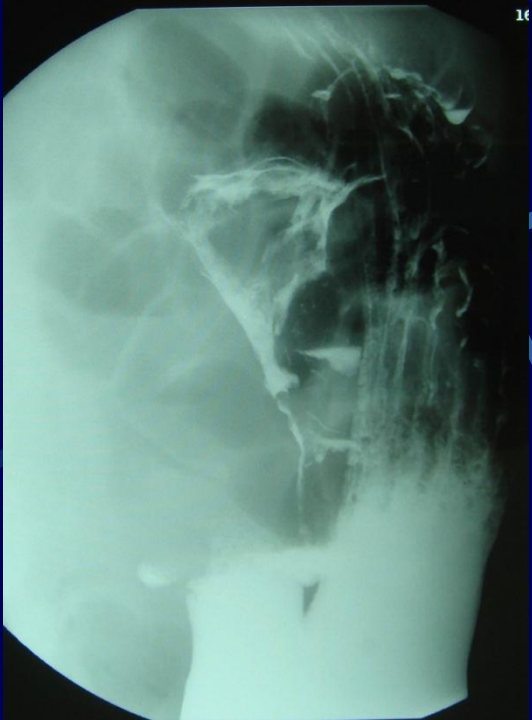
胃窦多发发性息肉

94年8月29日 124834

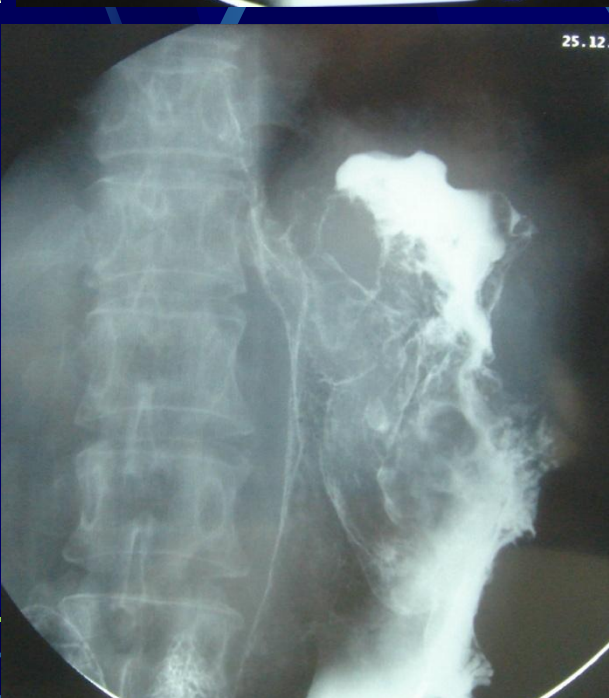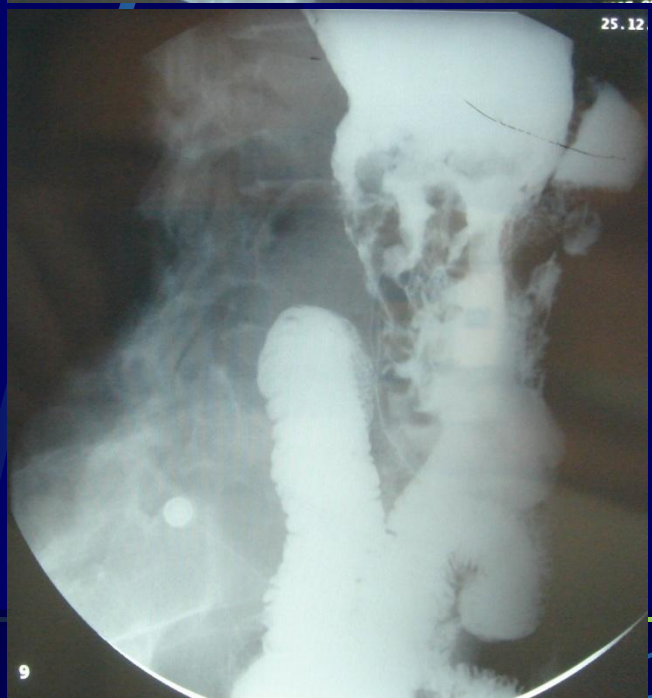

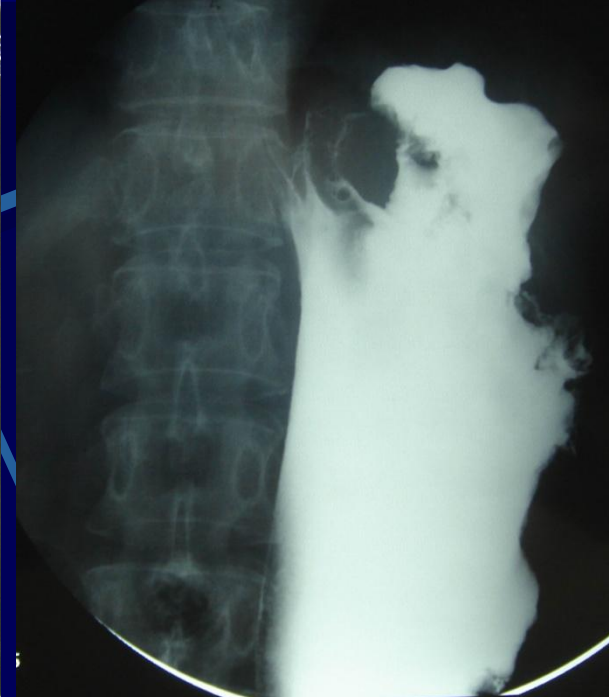
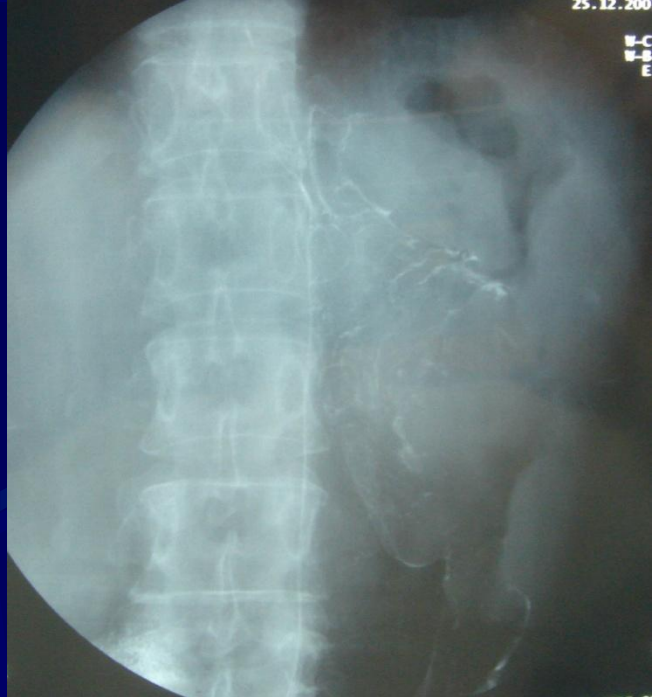胃底平滑肌瘤

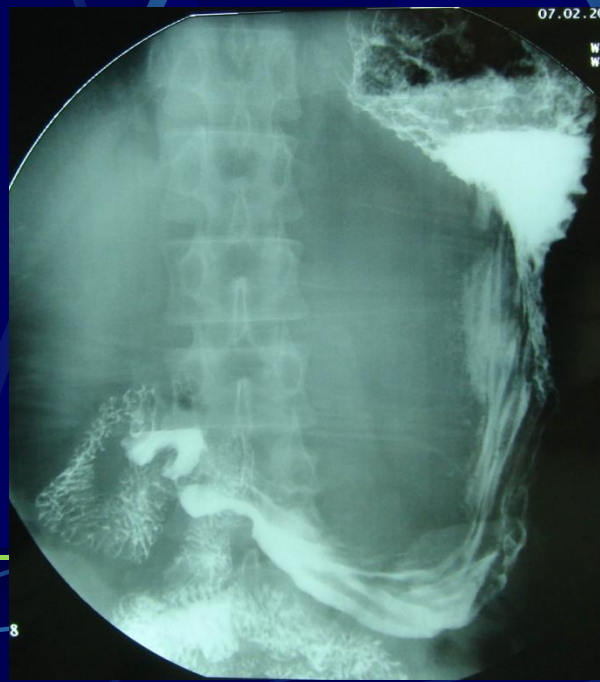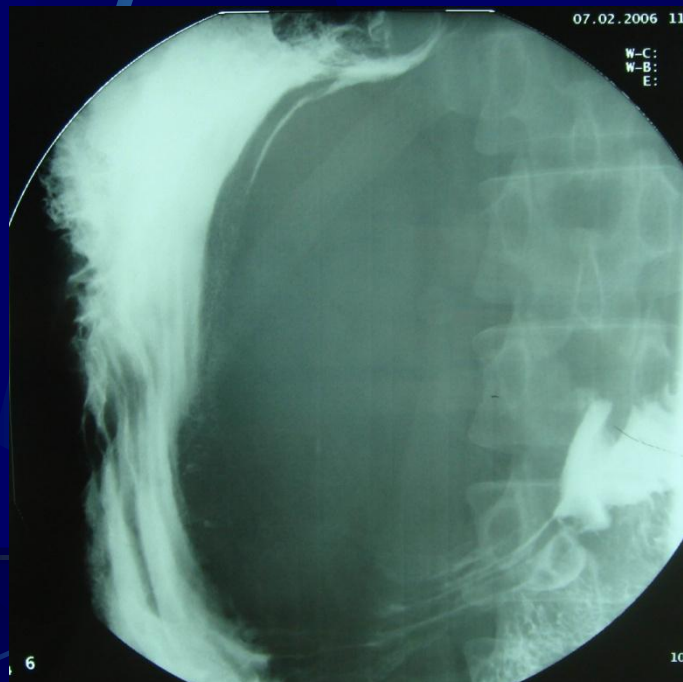
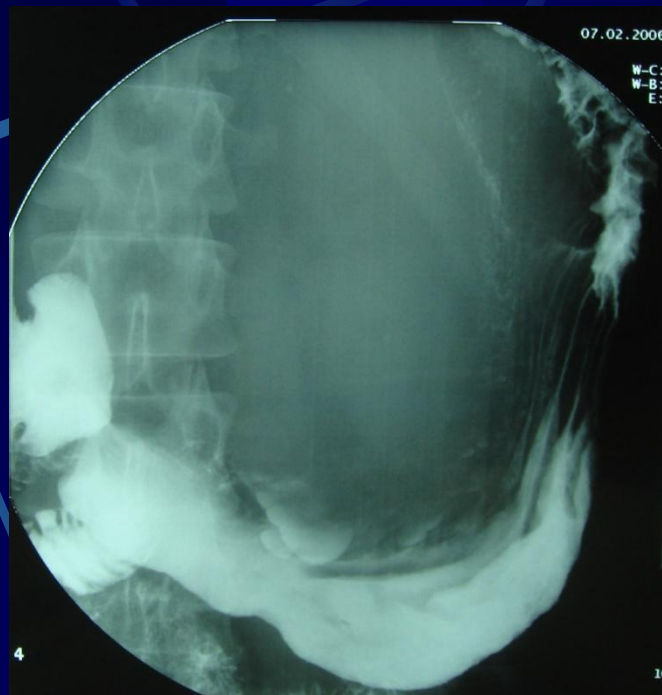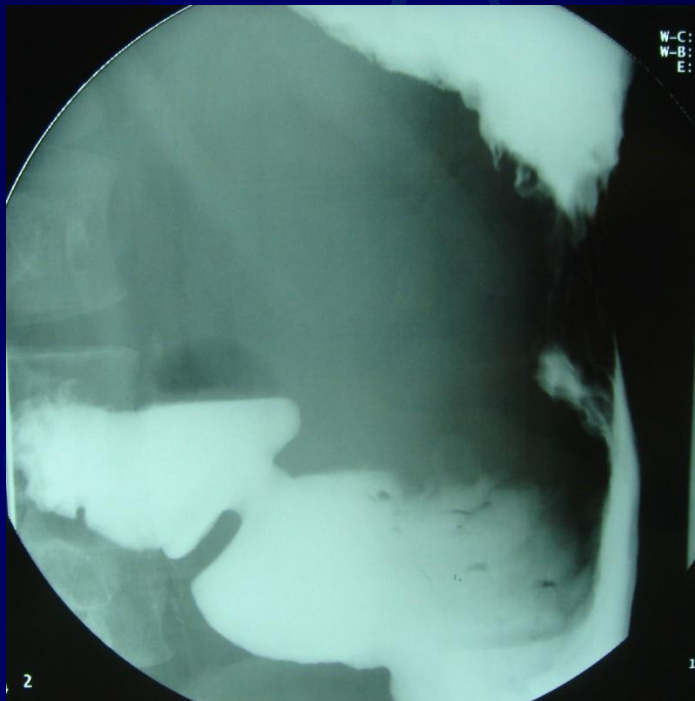
胃间质瘤



胃间质瘤

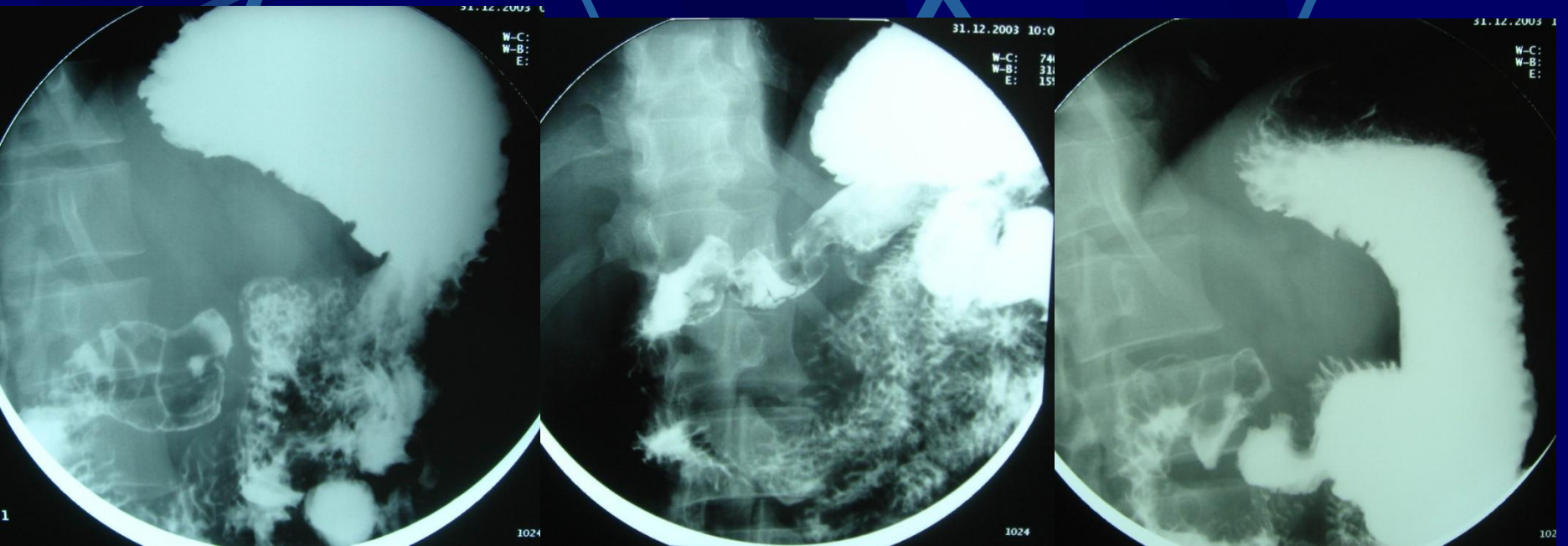

胃间质瘤

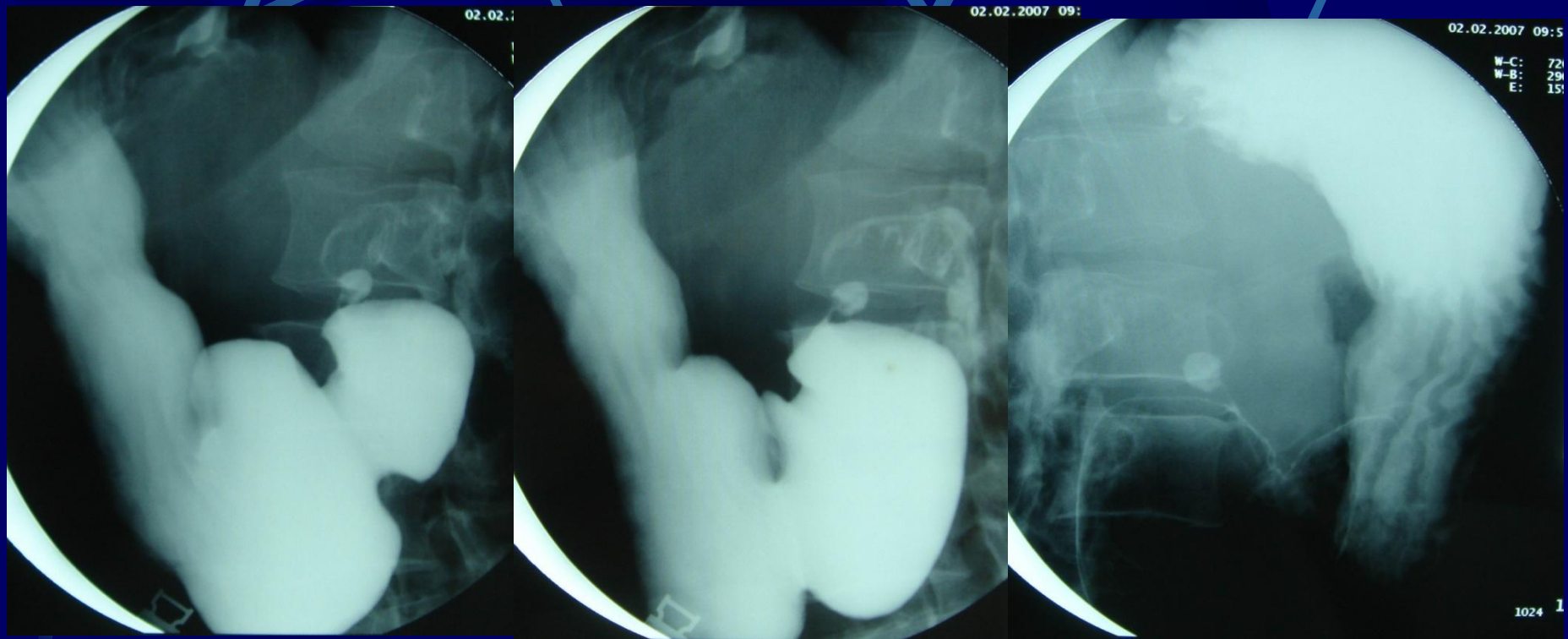


十二指肠、小肠病变

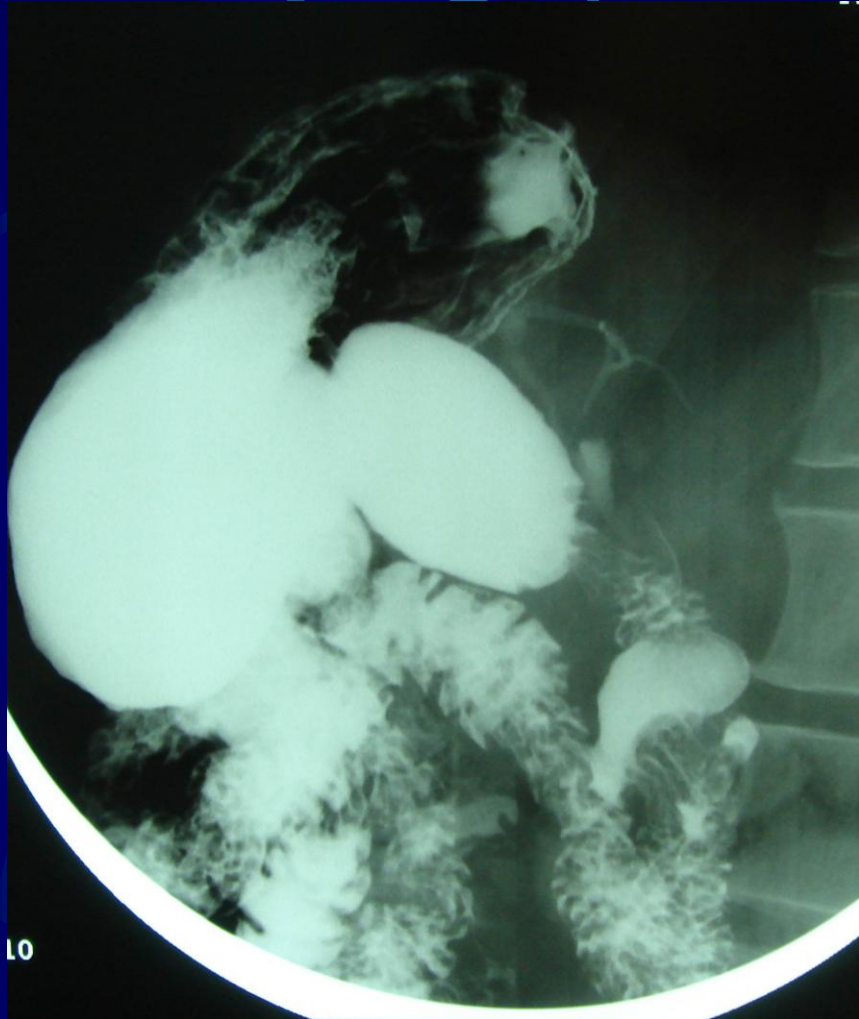十二指肠球部溃疡



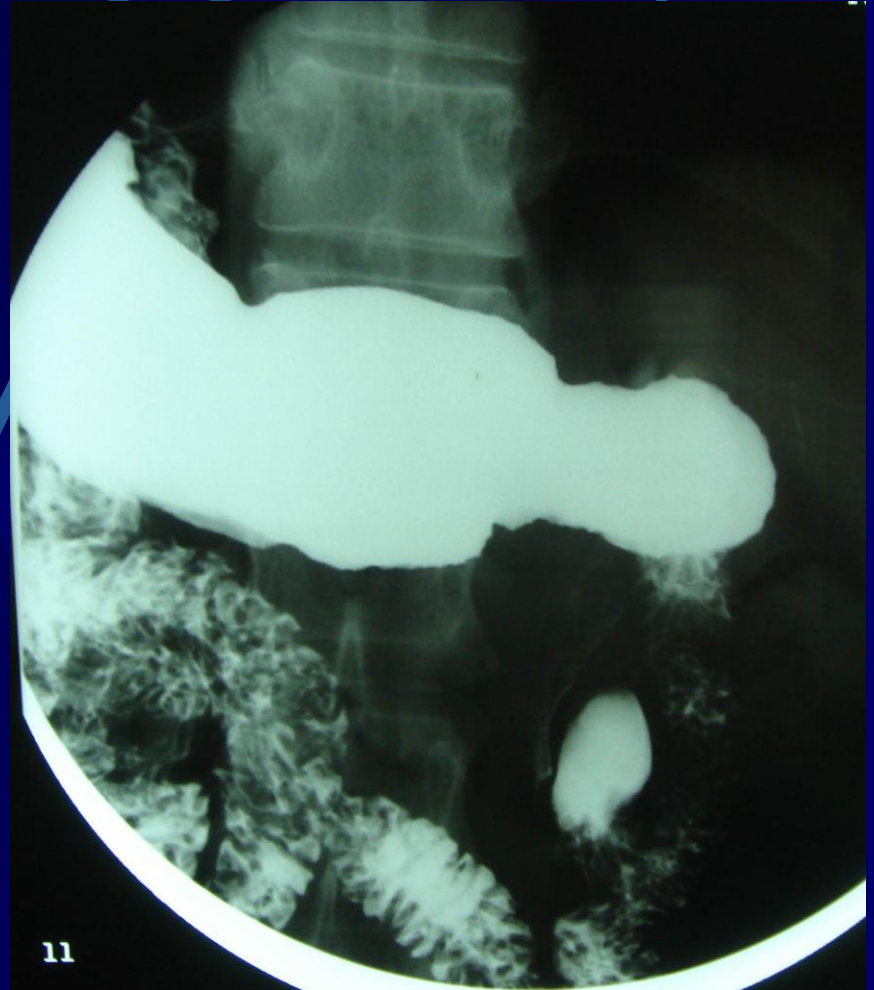十二指肠球部溃疡



十二指肠降部憩室

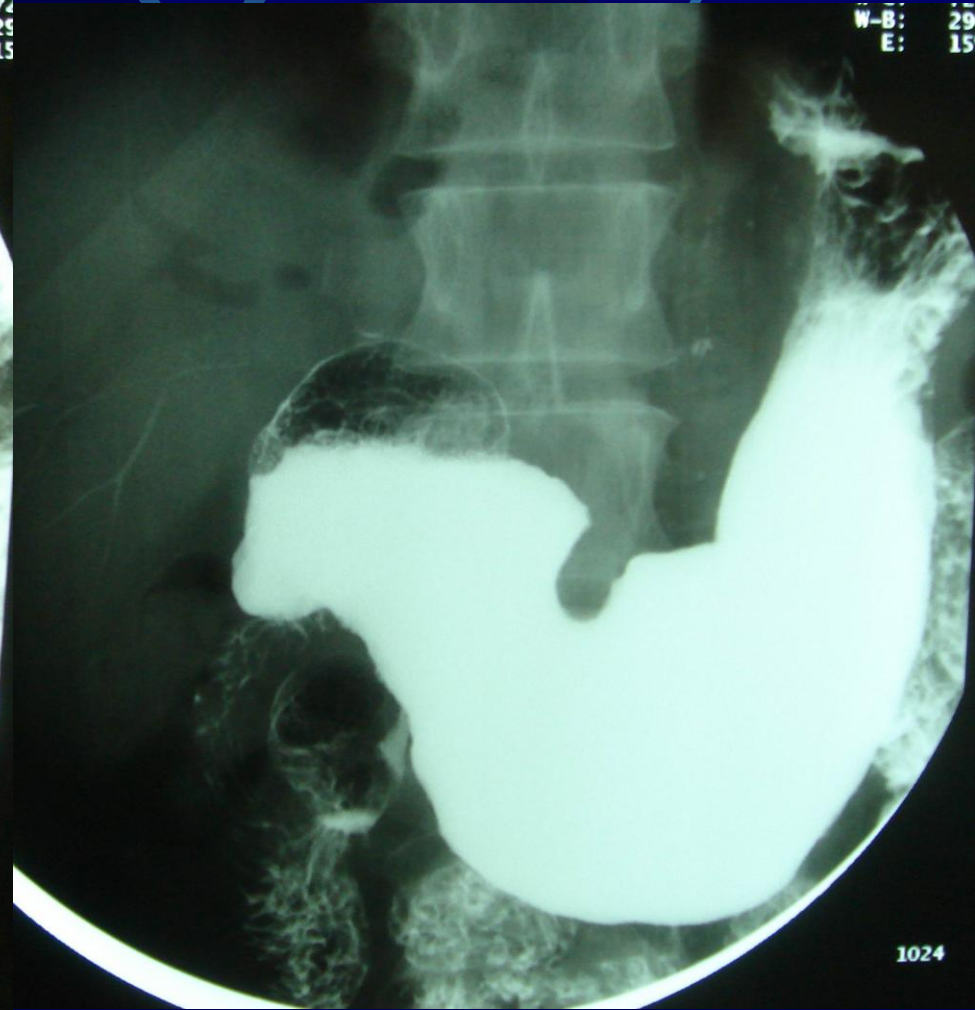
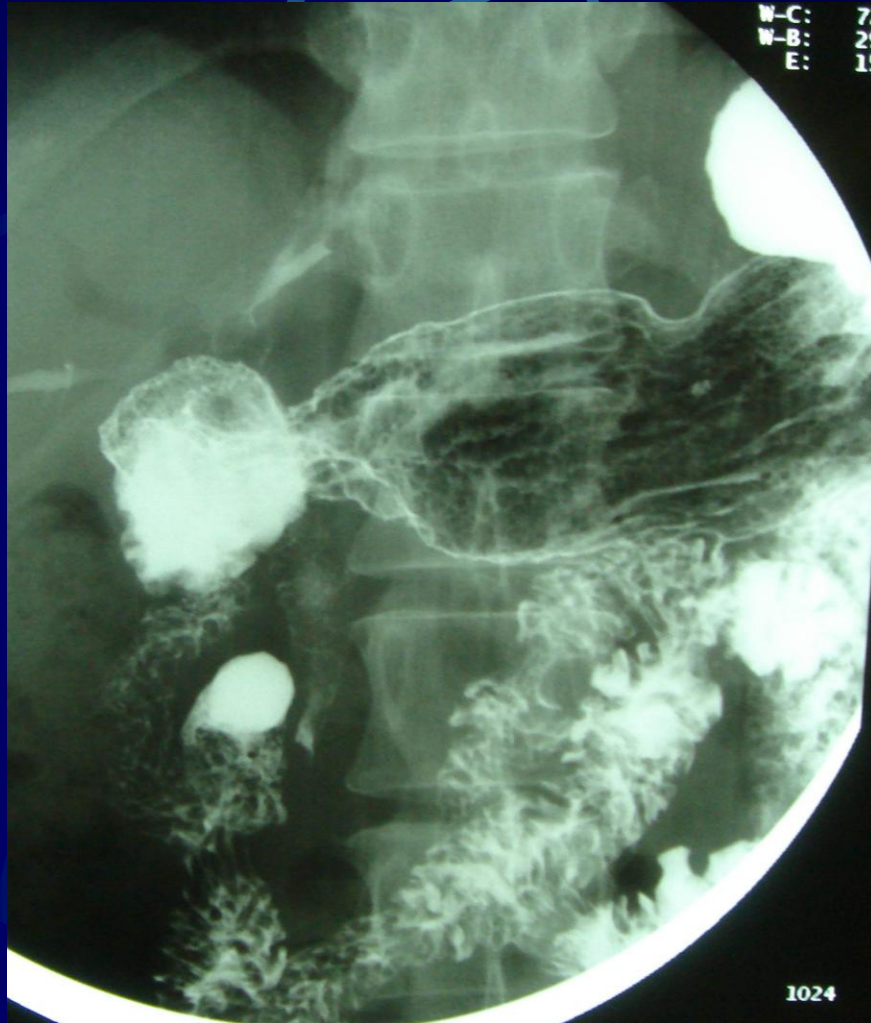
10

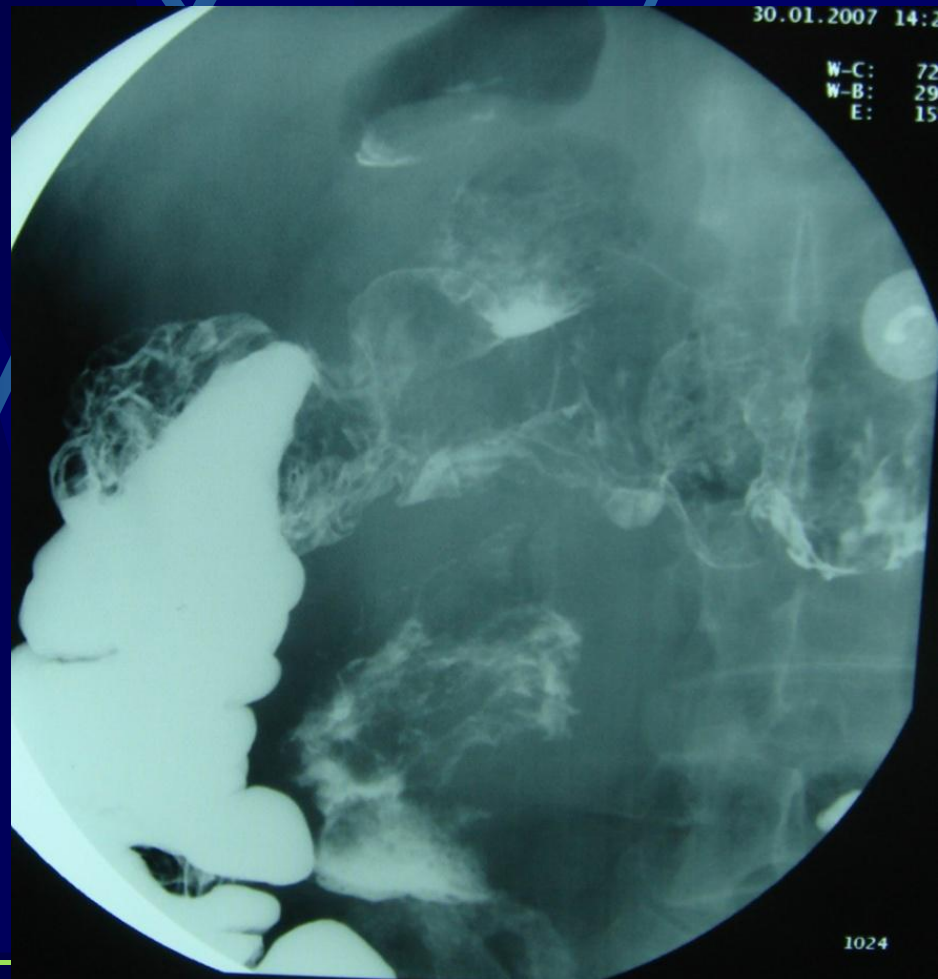
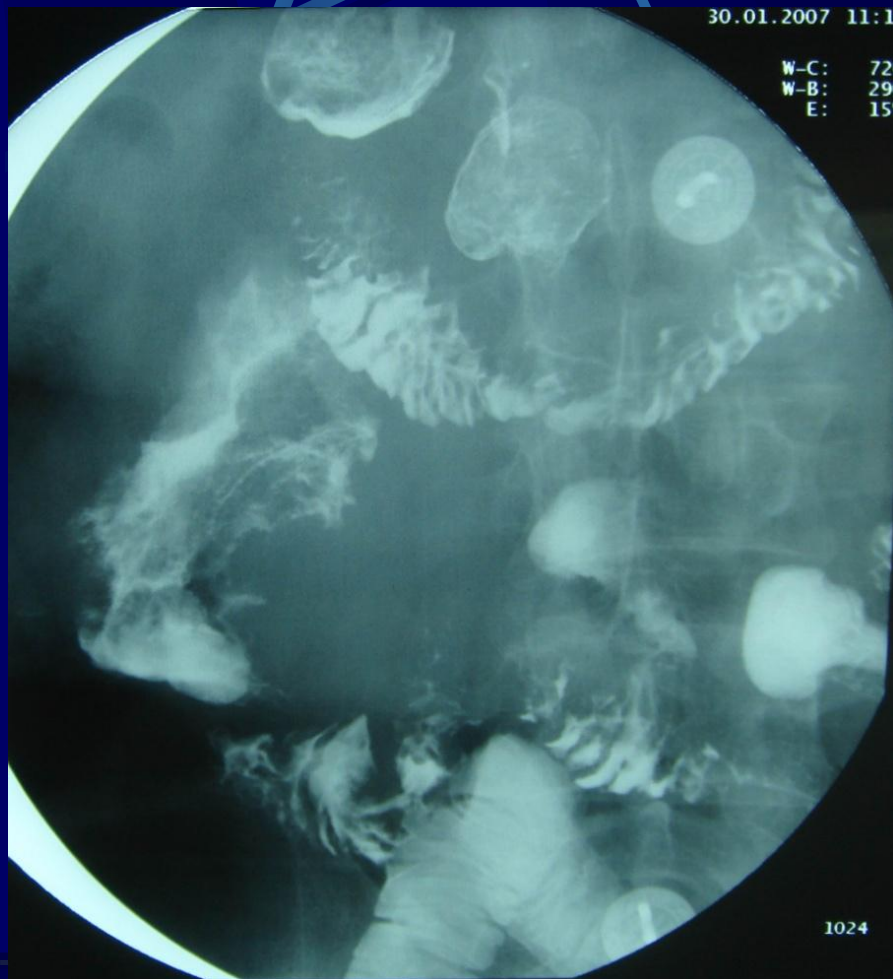


11

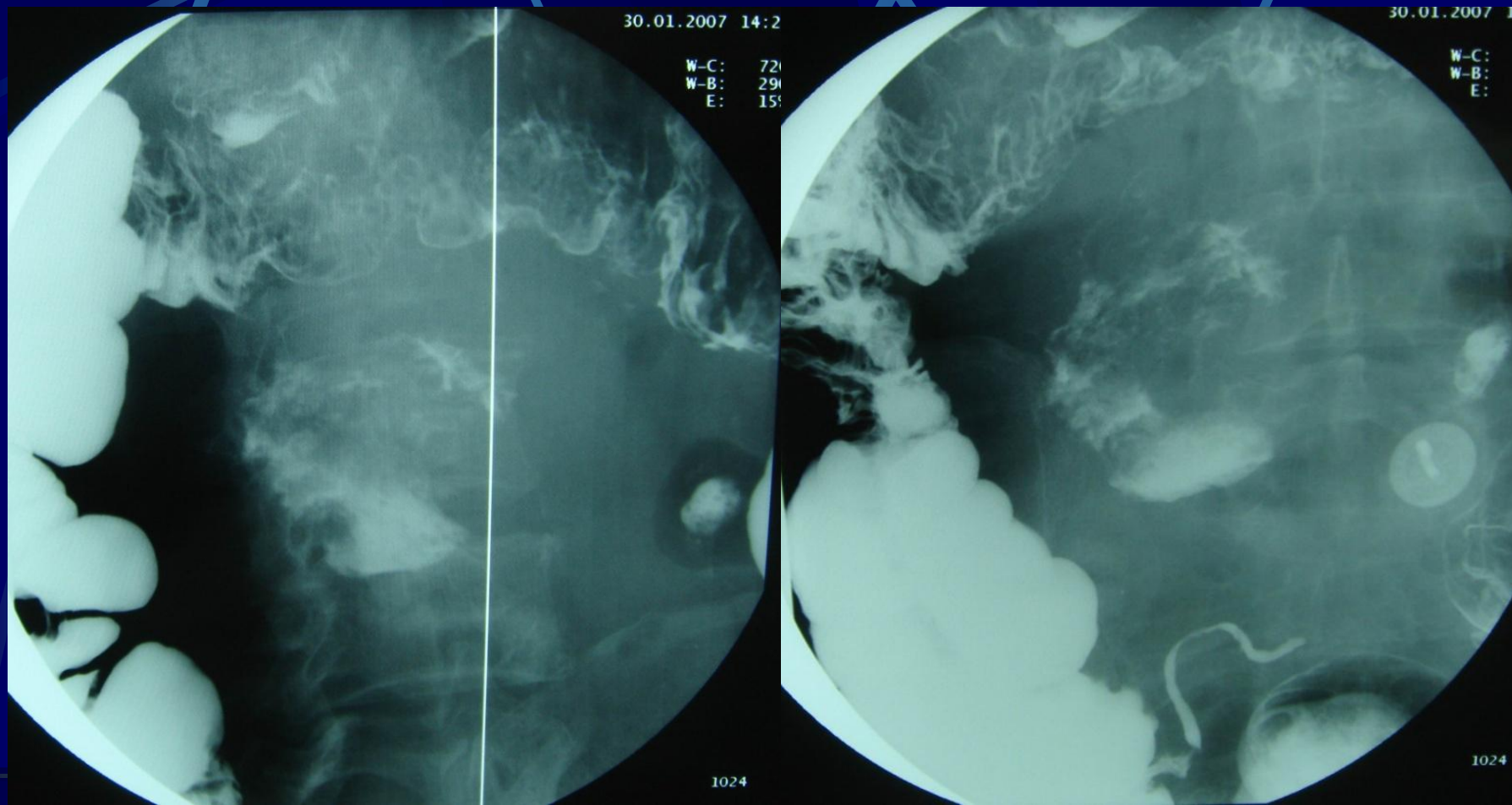
十二指肠降部憩室



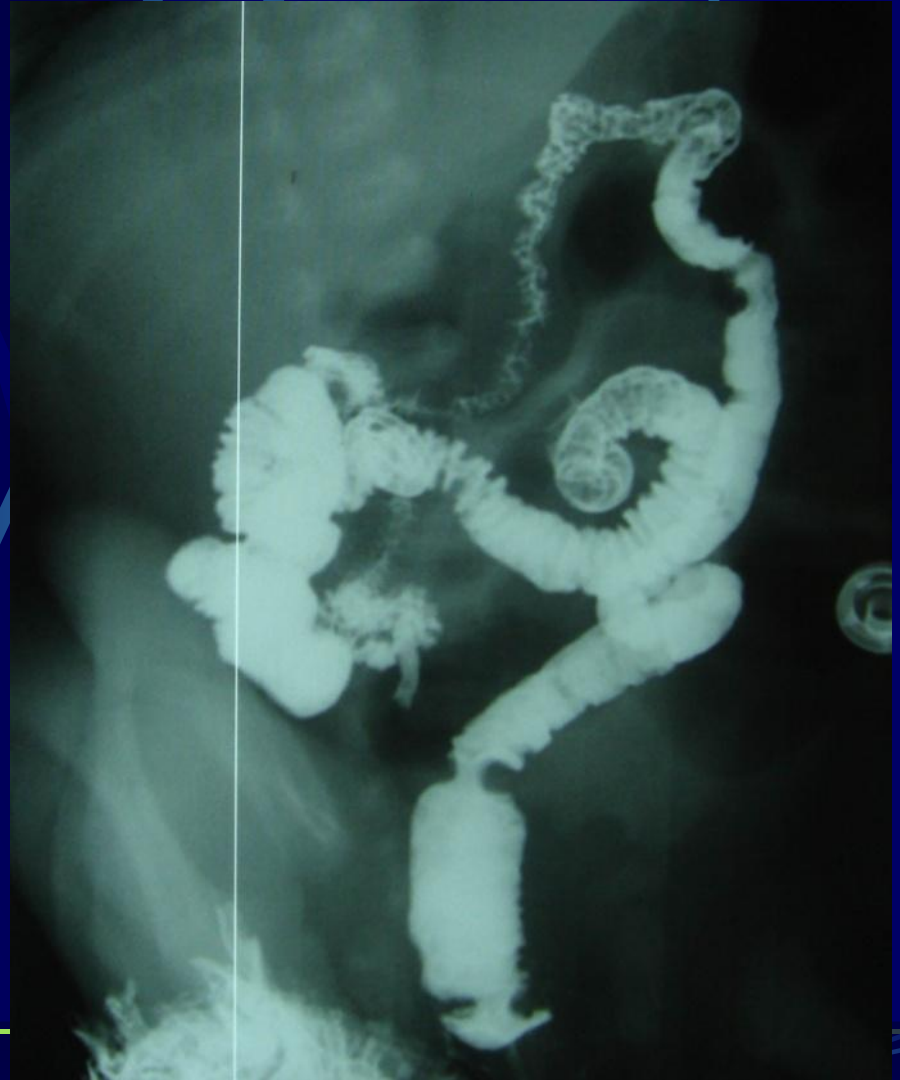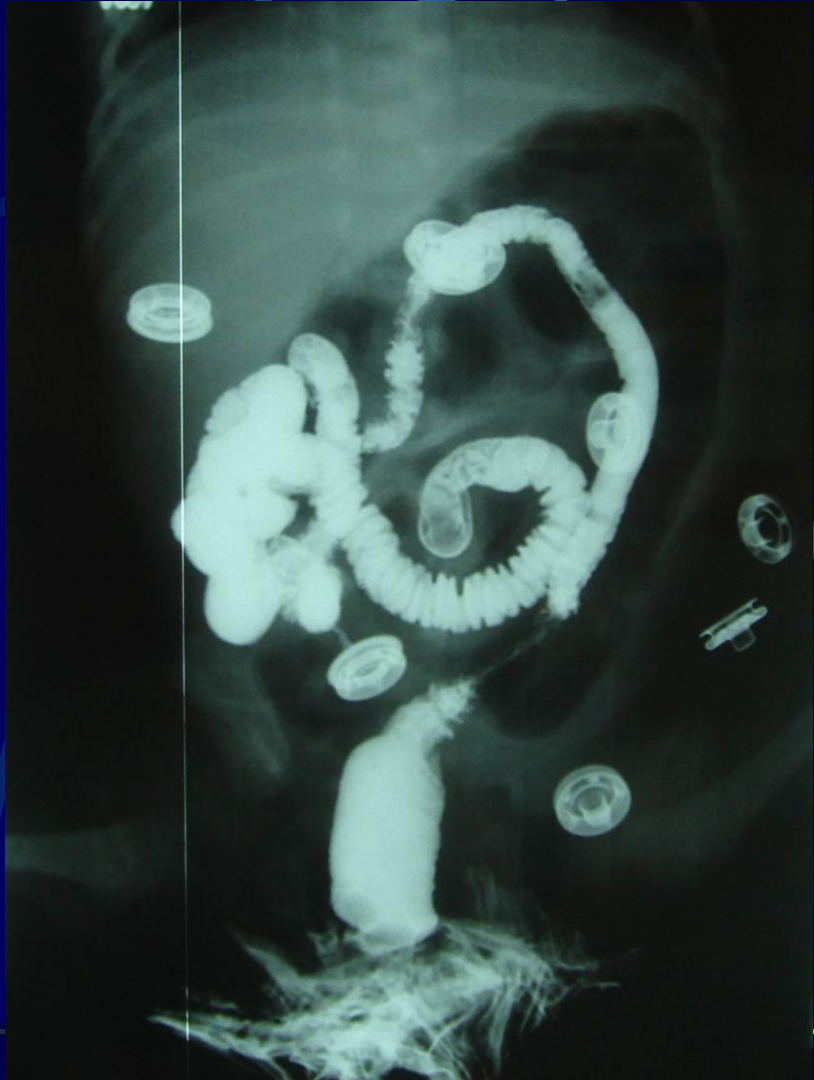克罗恩病（非特异性局限性肠炎）



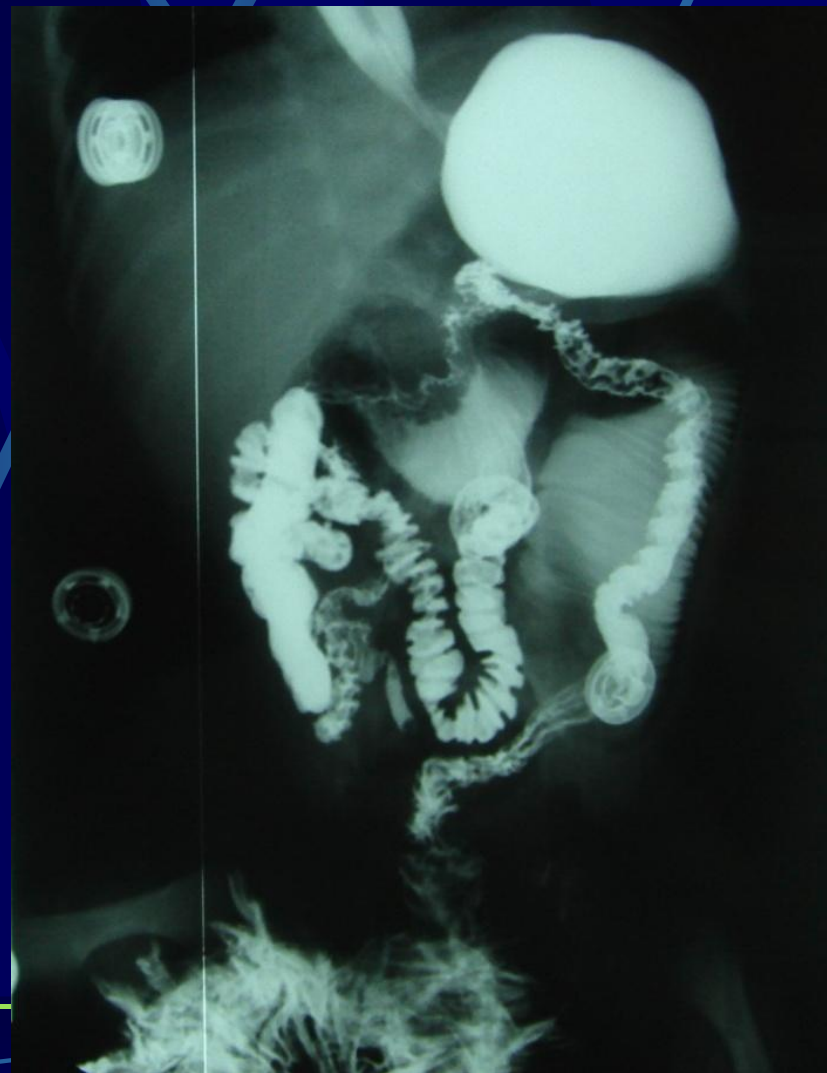
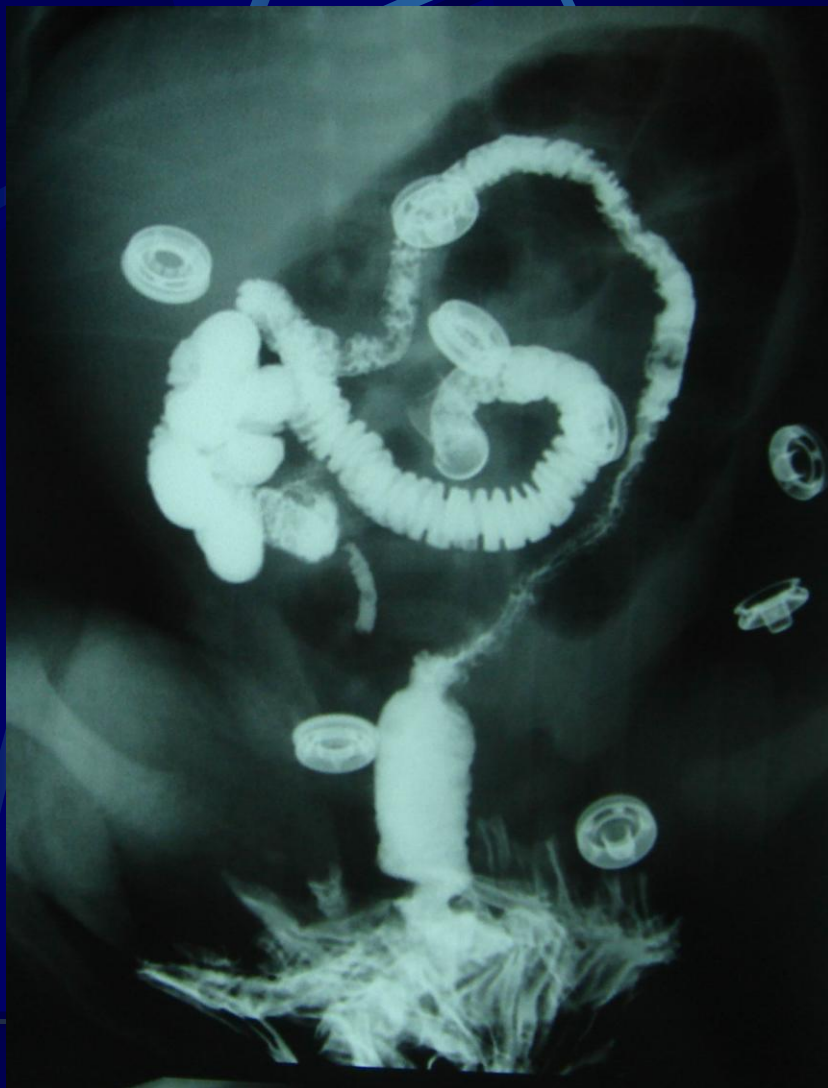
克罗恩病



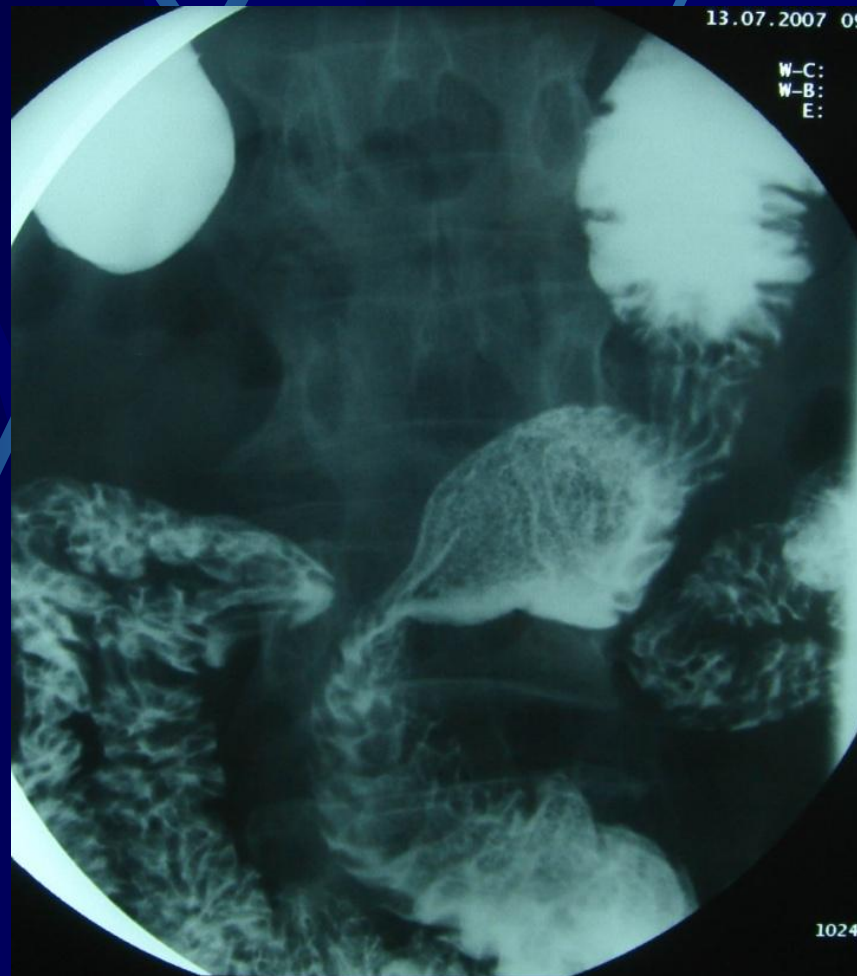
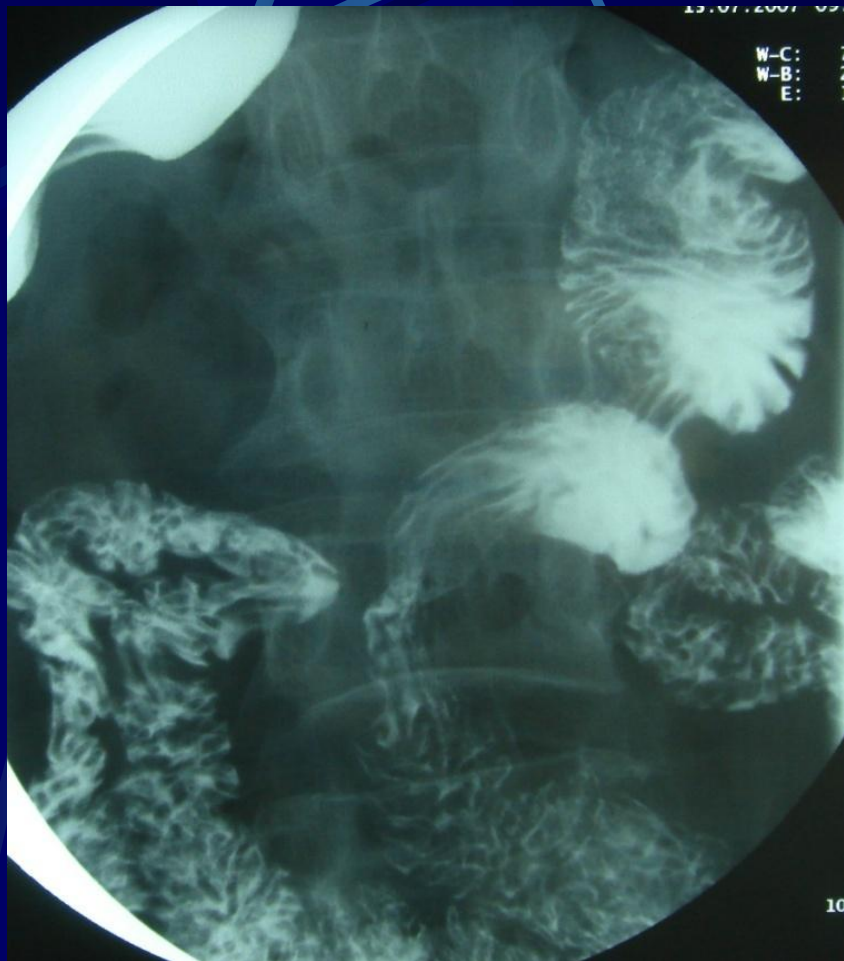
先天性小肠闭锁



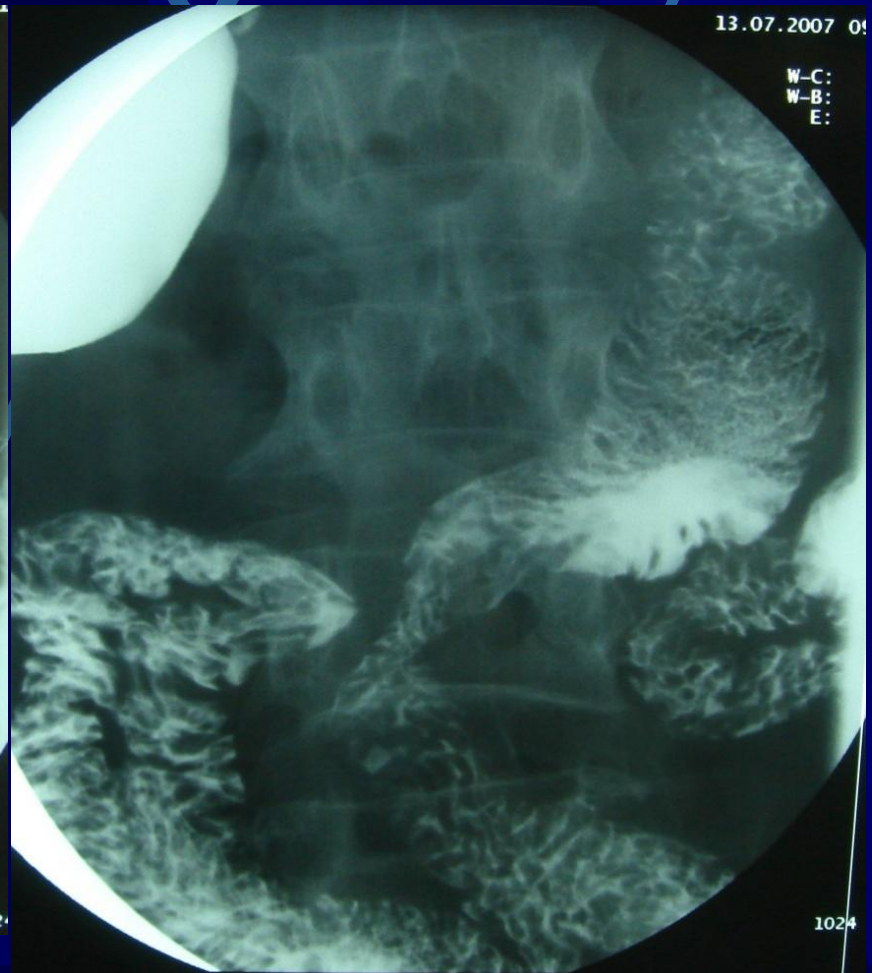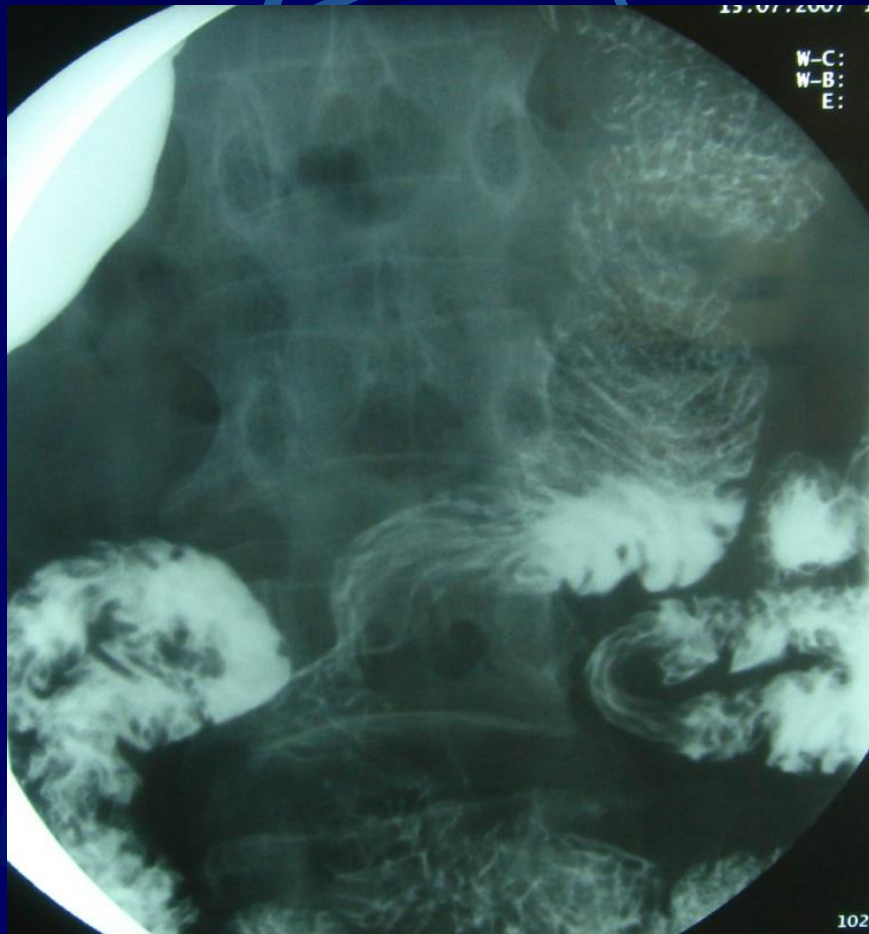先天性小肠闭锁



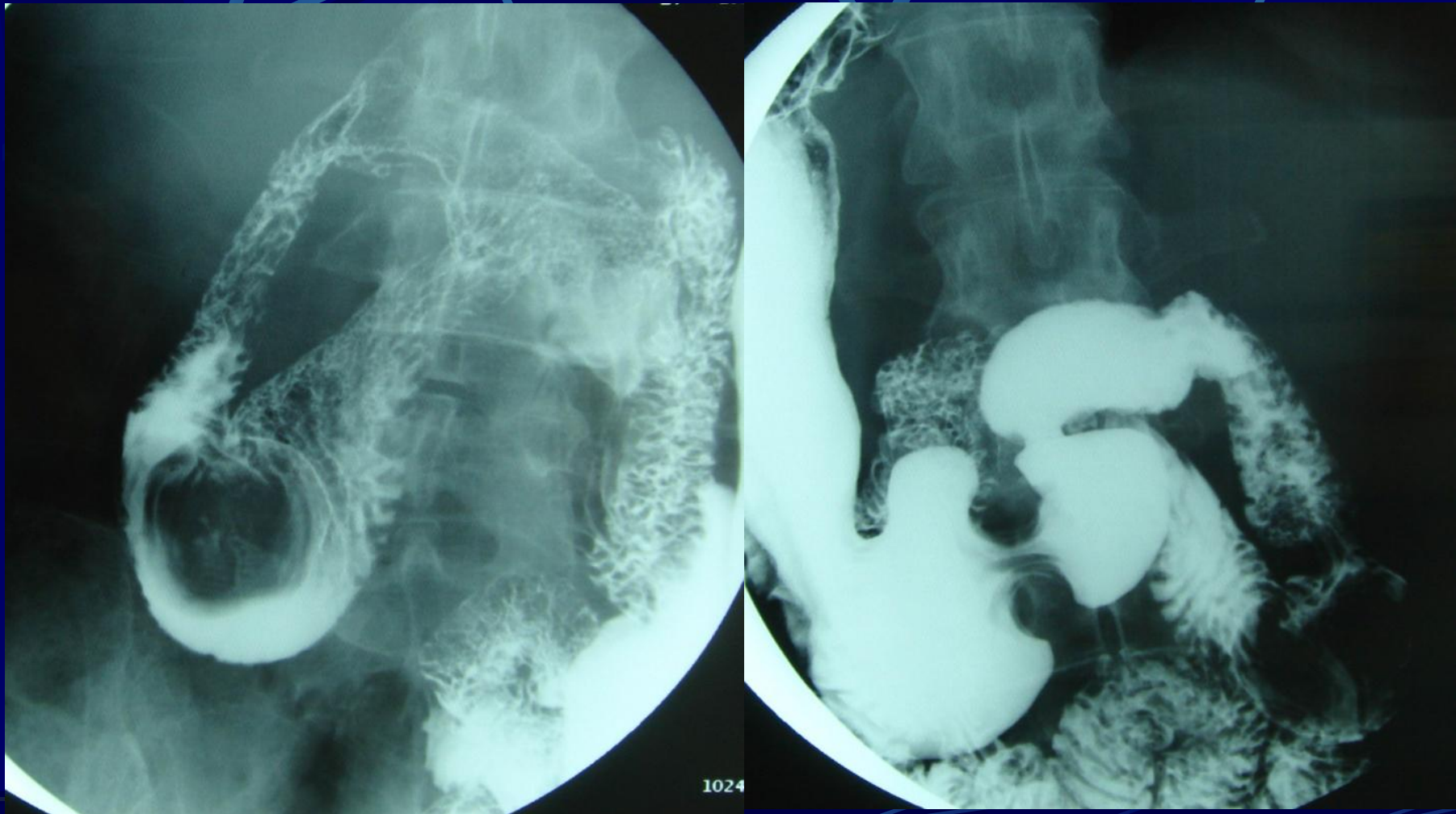小肠平滑肌瘤



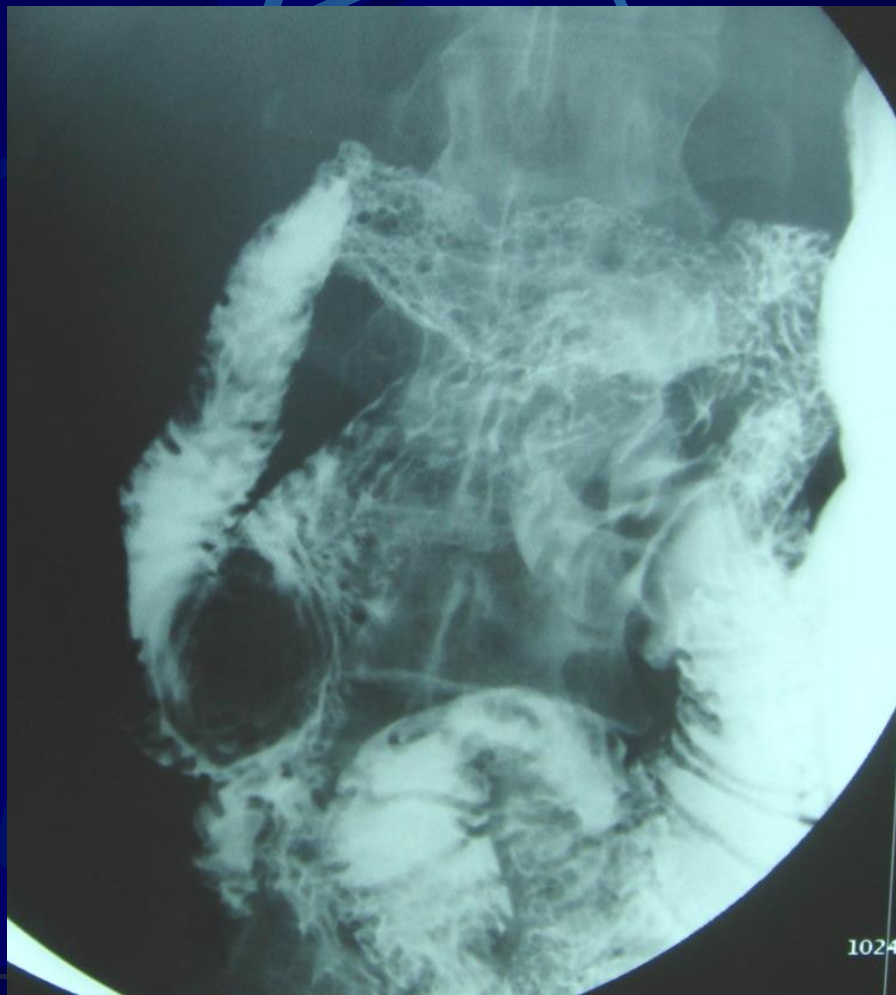小肠平滑肌瘤



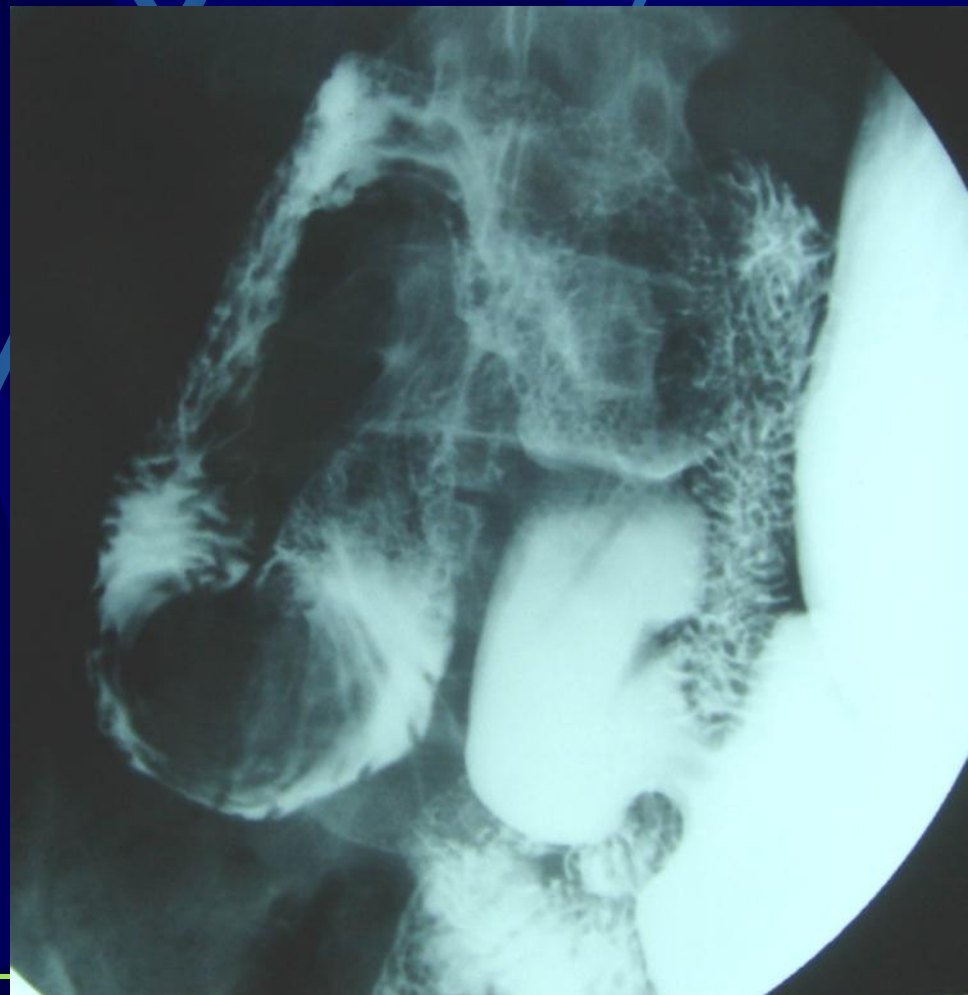
小肠平滑肌瘤



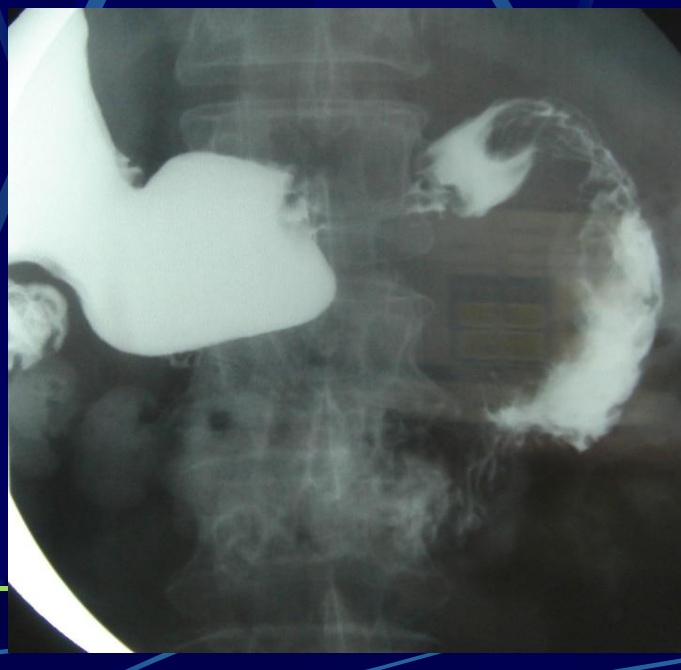
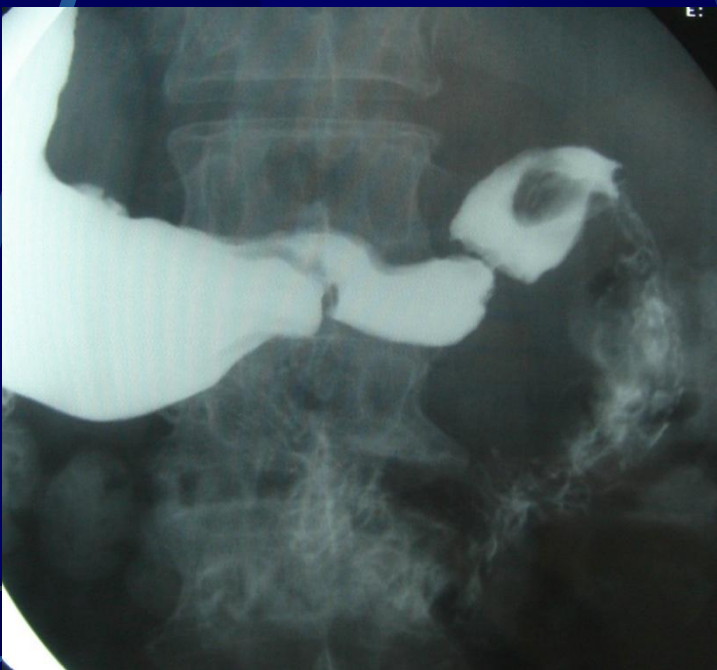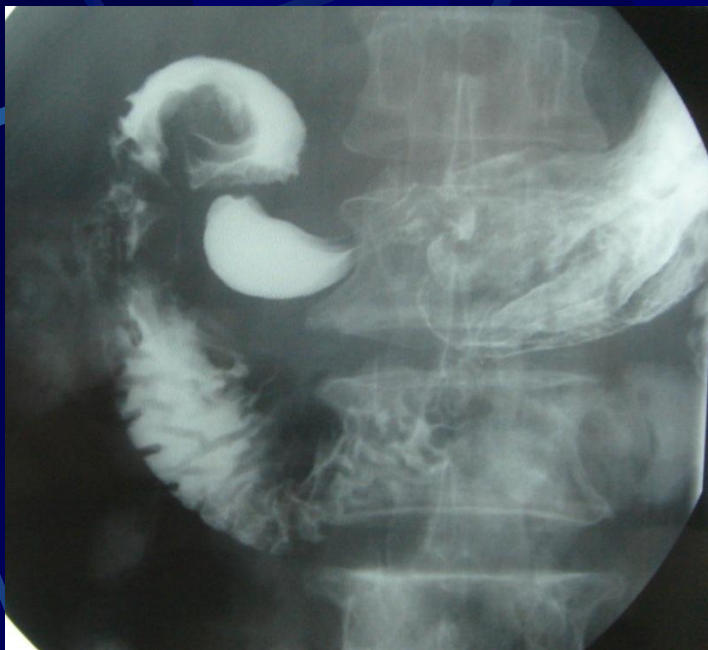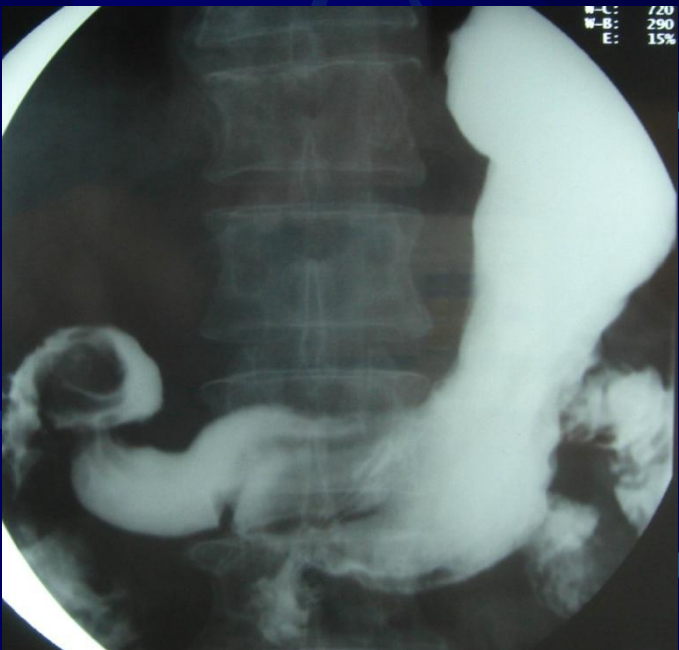小肠平滑肌瘤



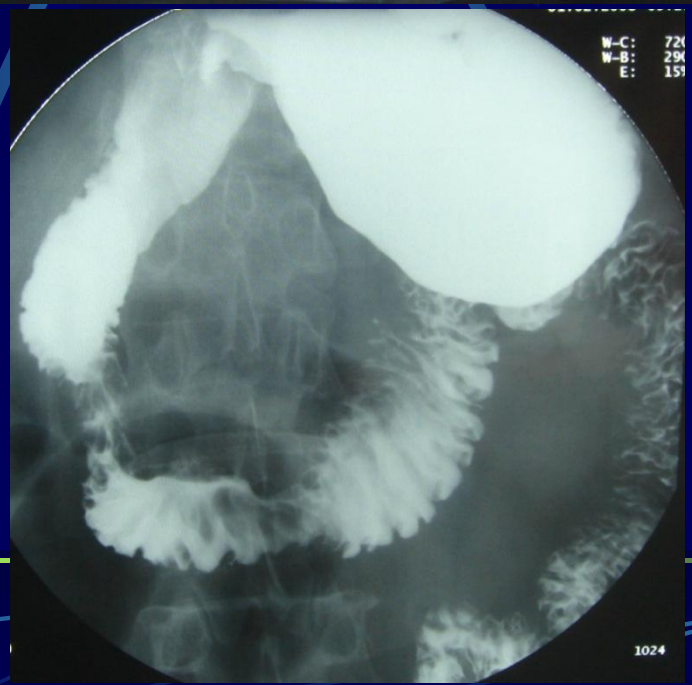
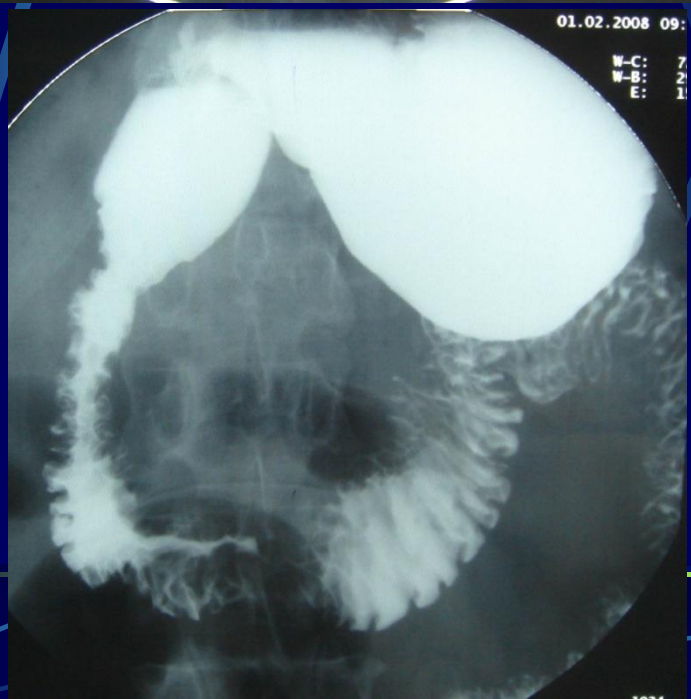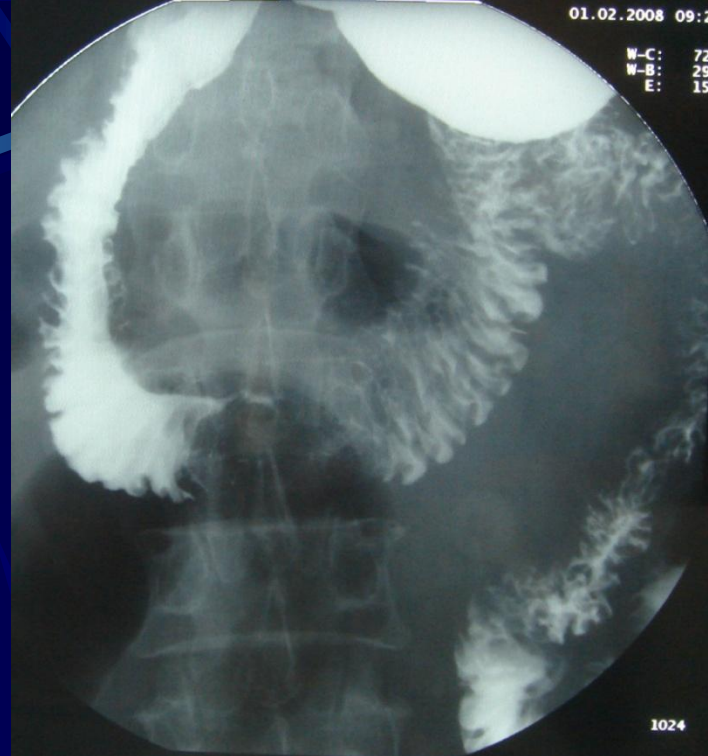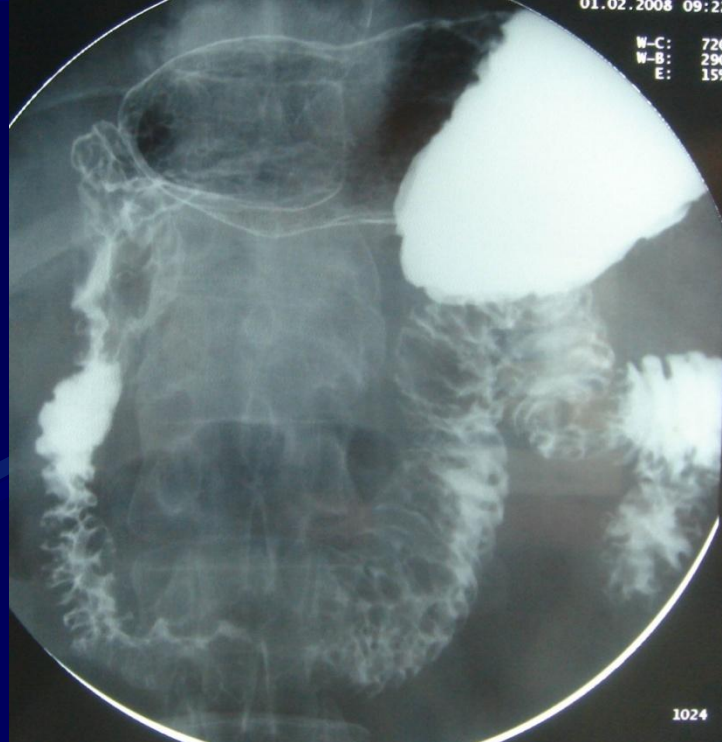1024

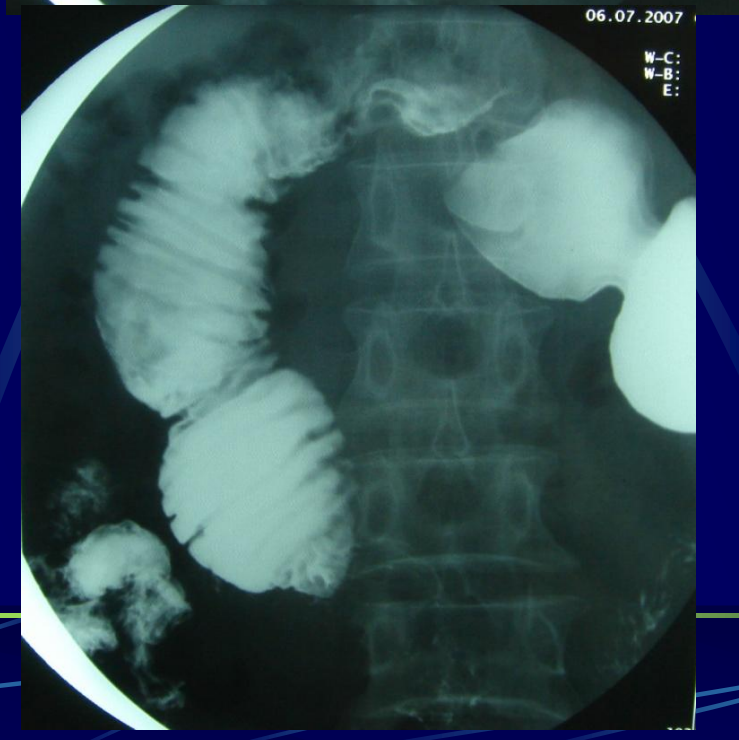
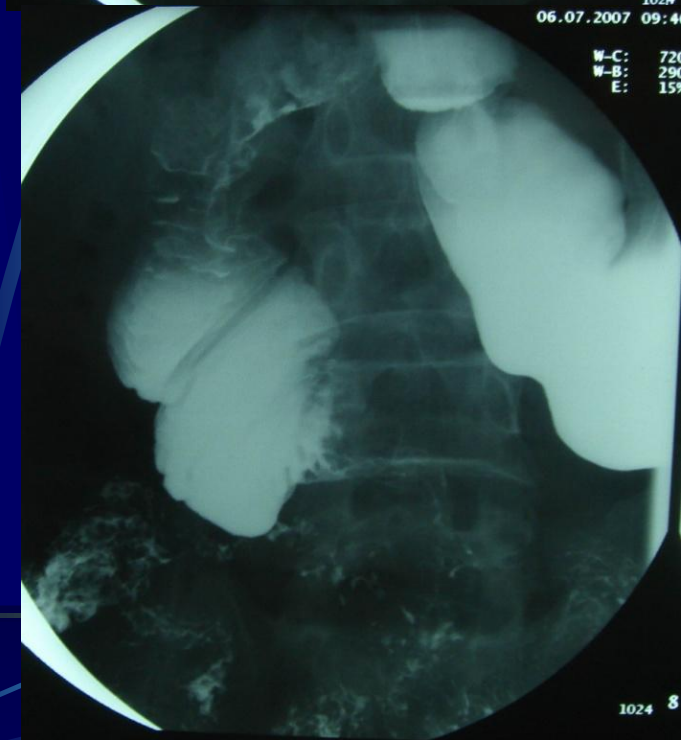
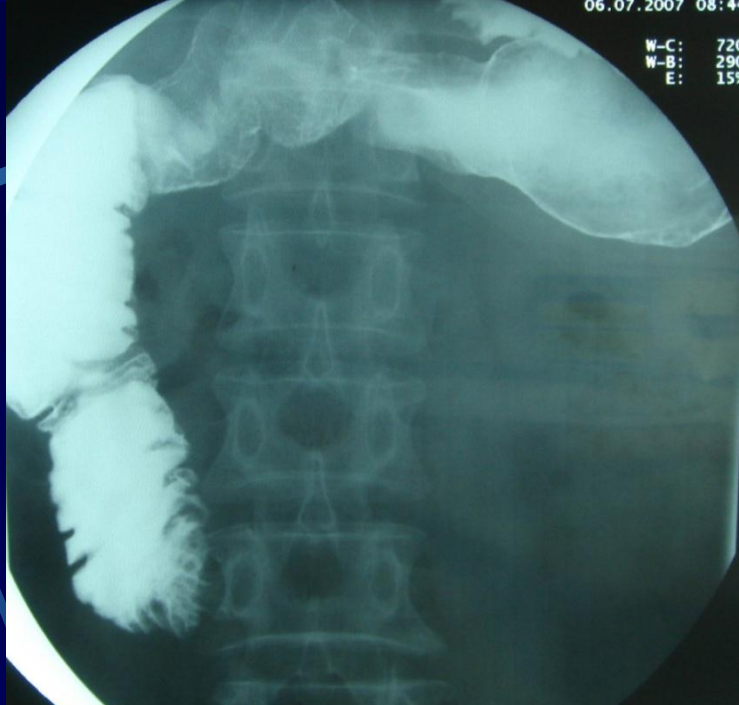
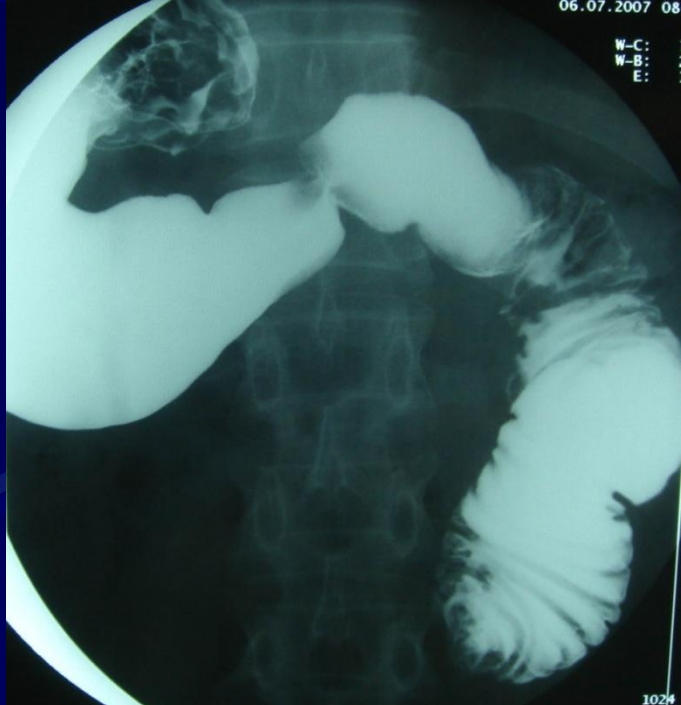
十二指肠肠球部良性肿瘤



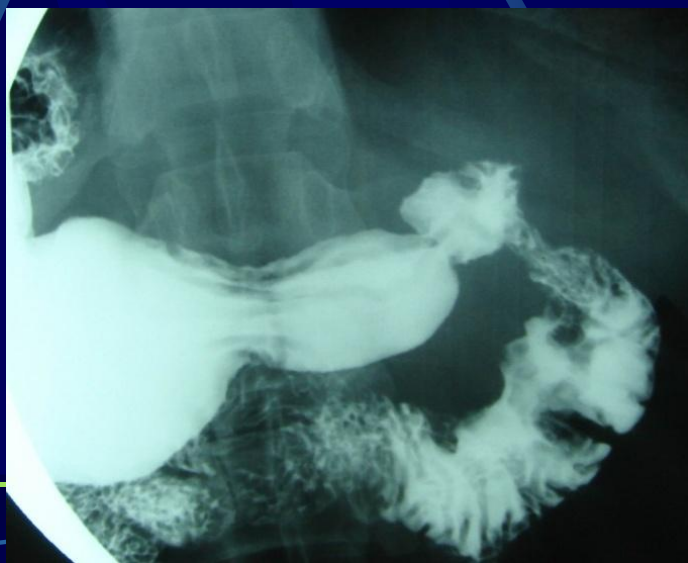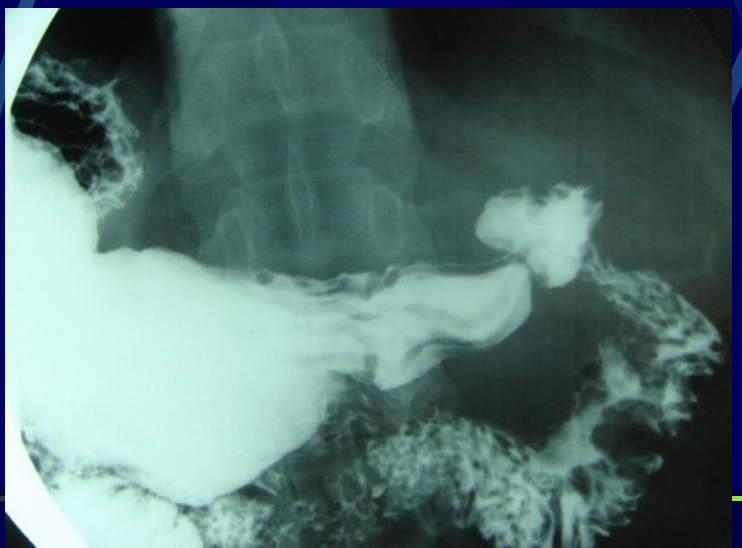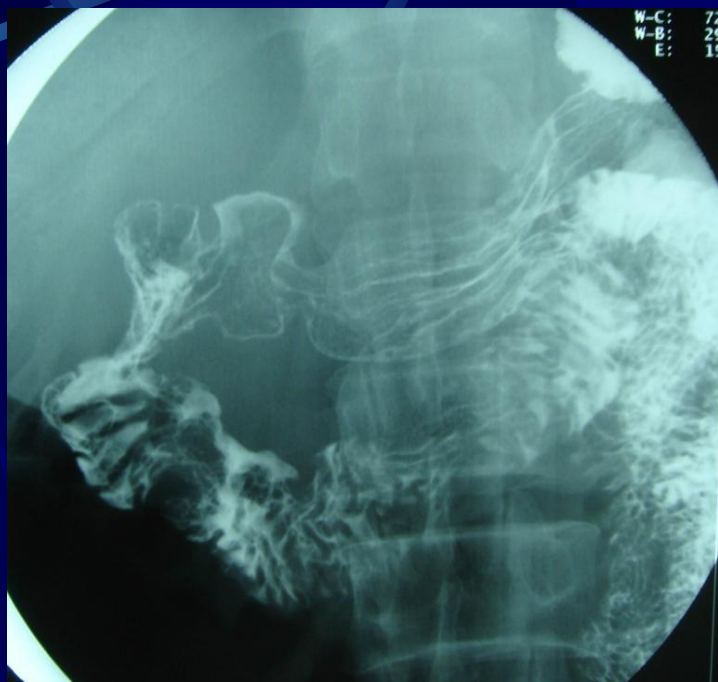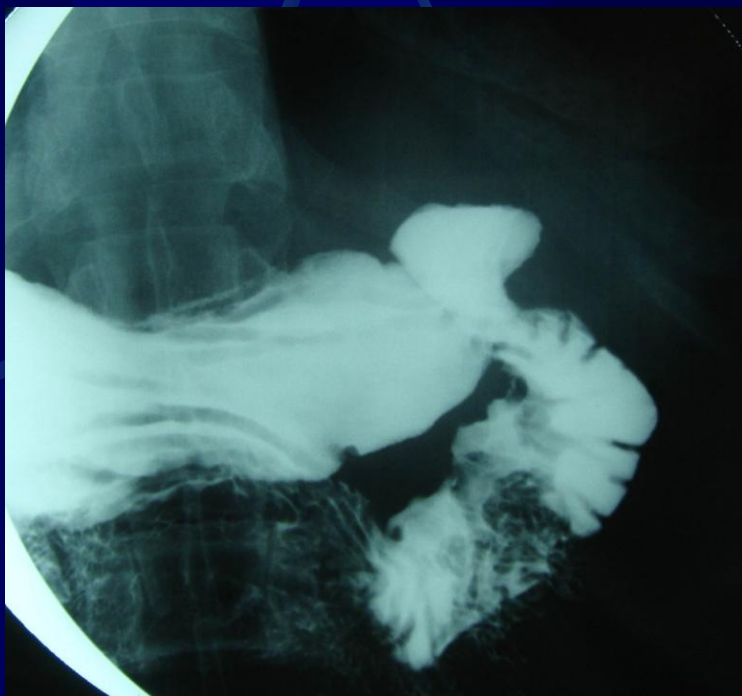十二指肠肠恶性肿瘤



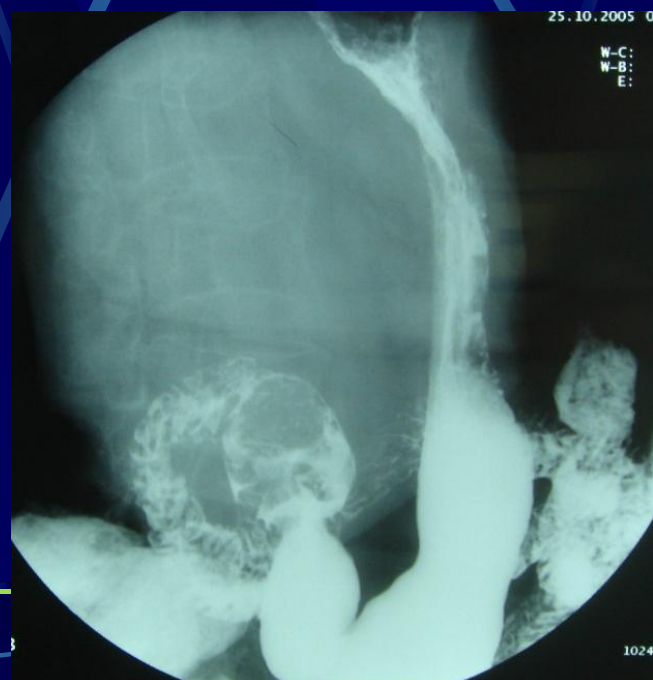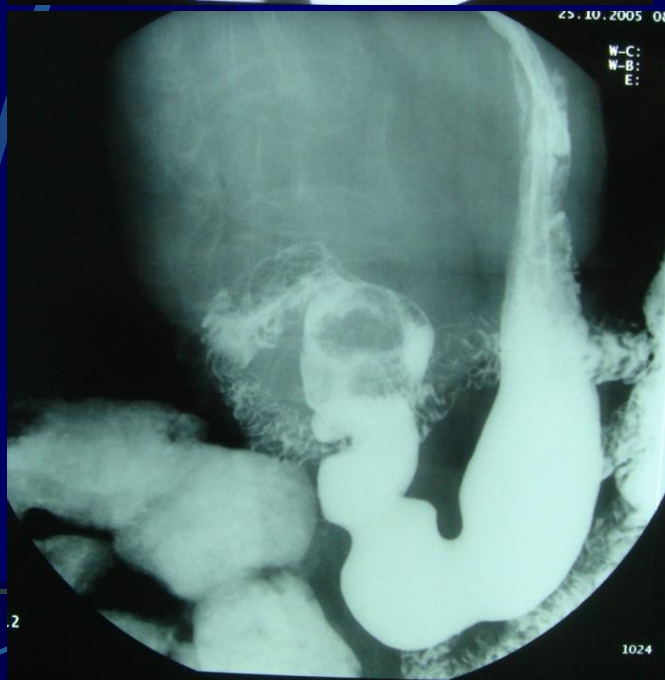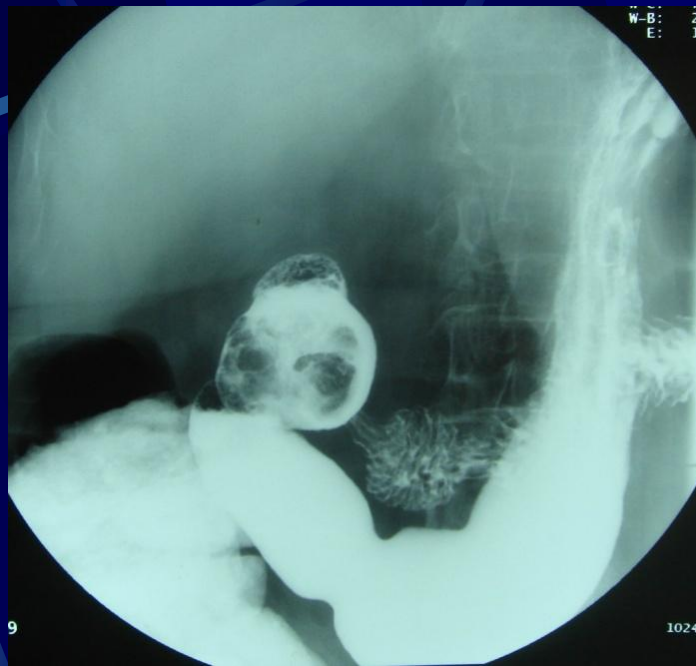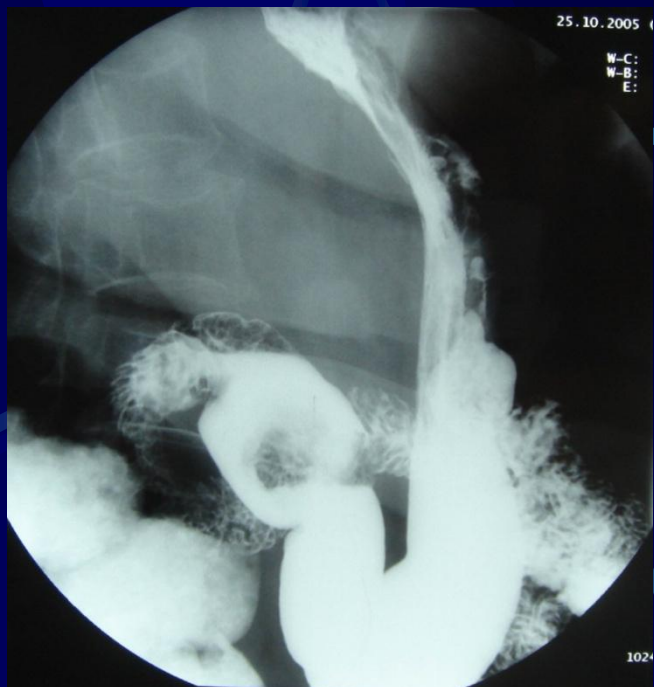


十二指肠肠恶性肿瘤

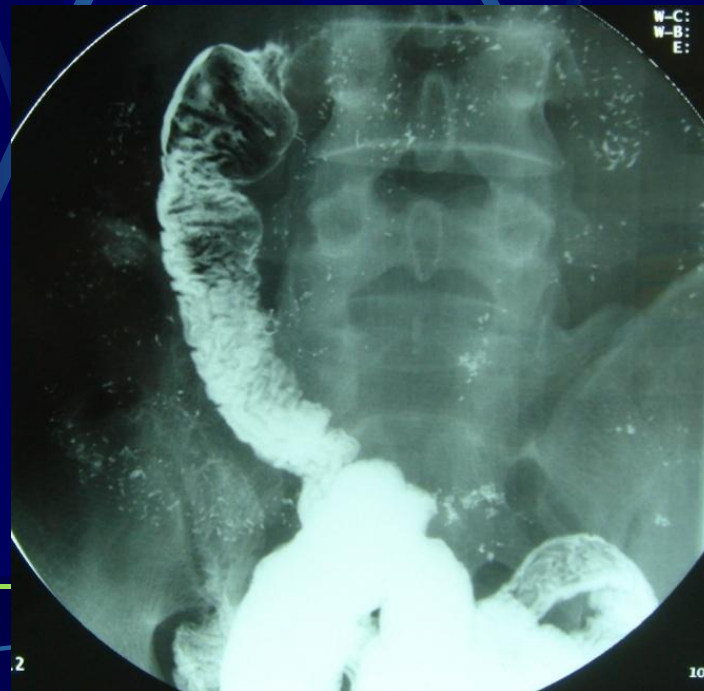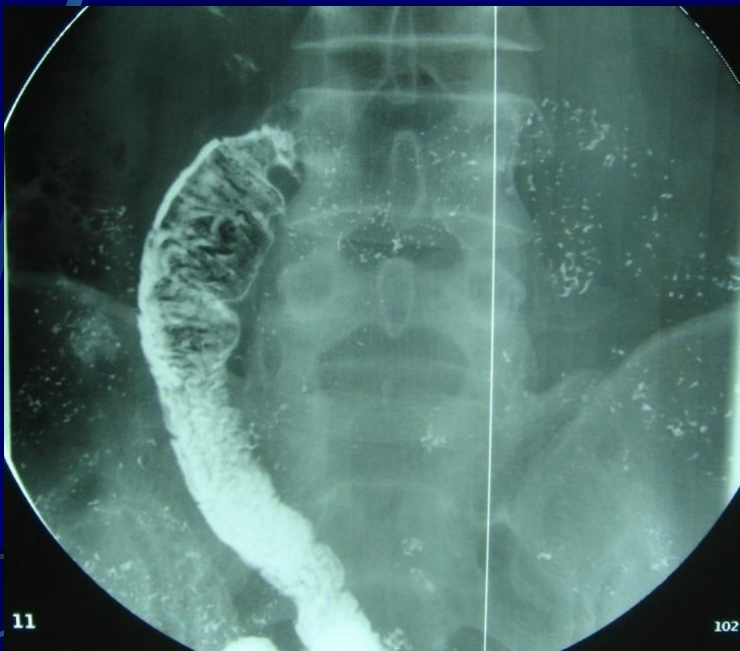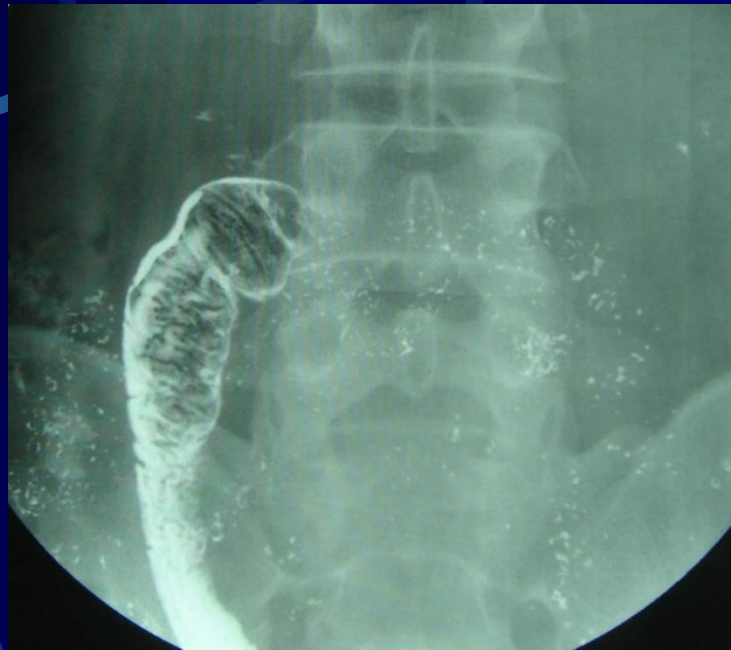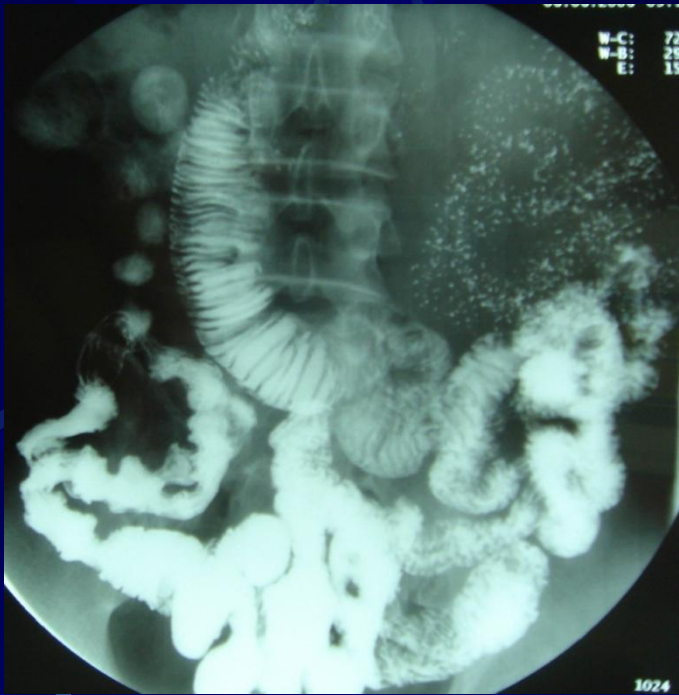
十二指肠恶性肿瘤



十二指肠肠球部恶性肿瘤

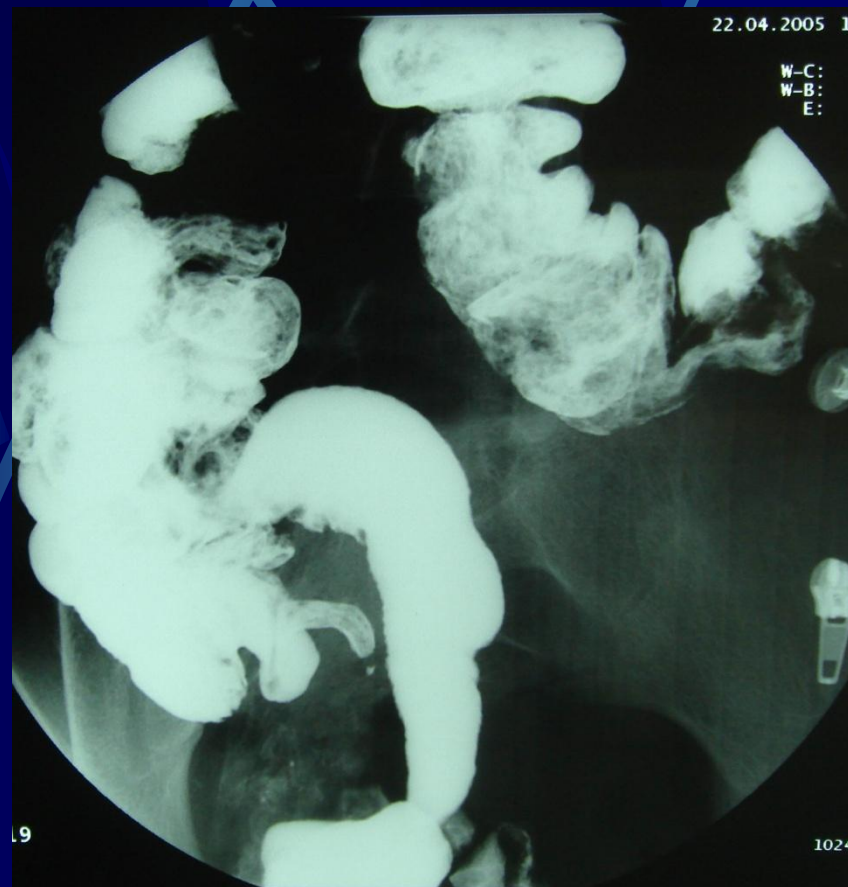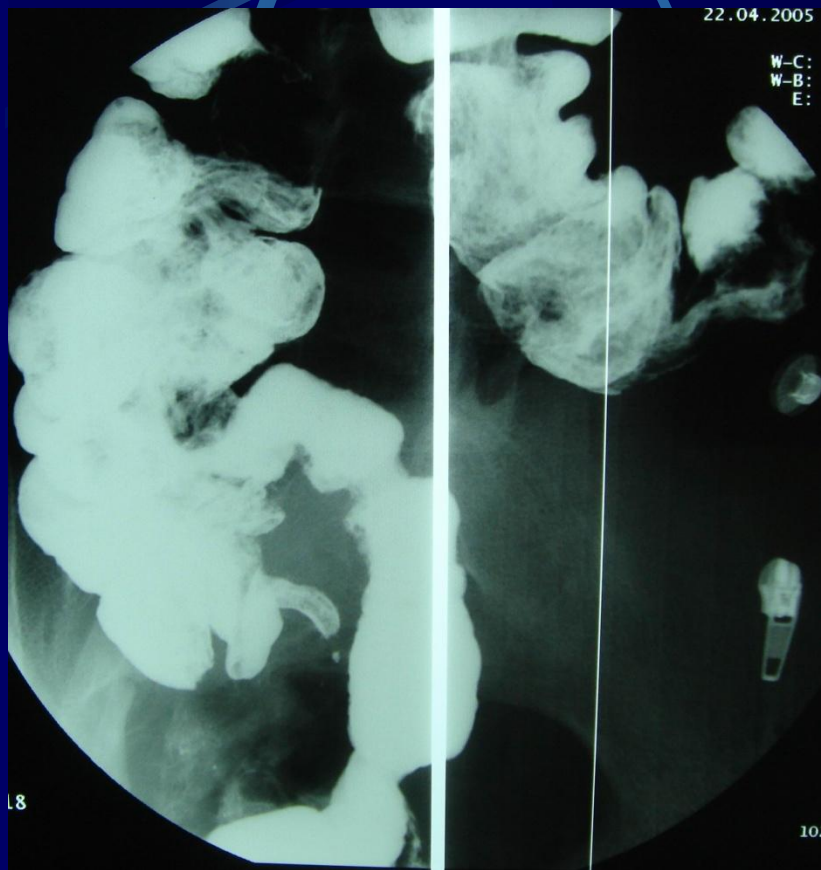


小肠恶性肿瘤

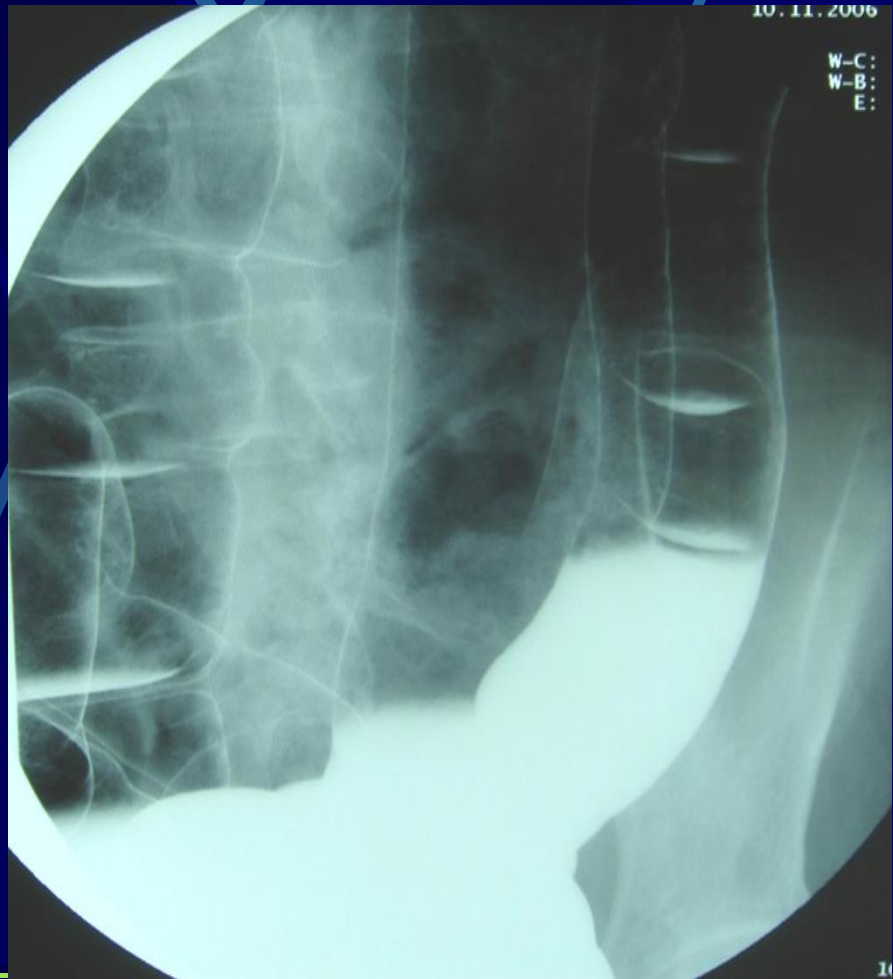
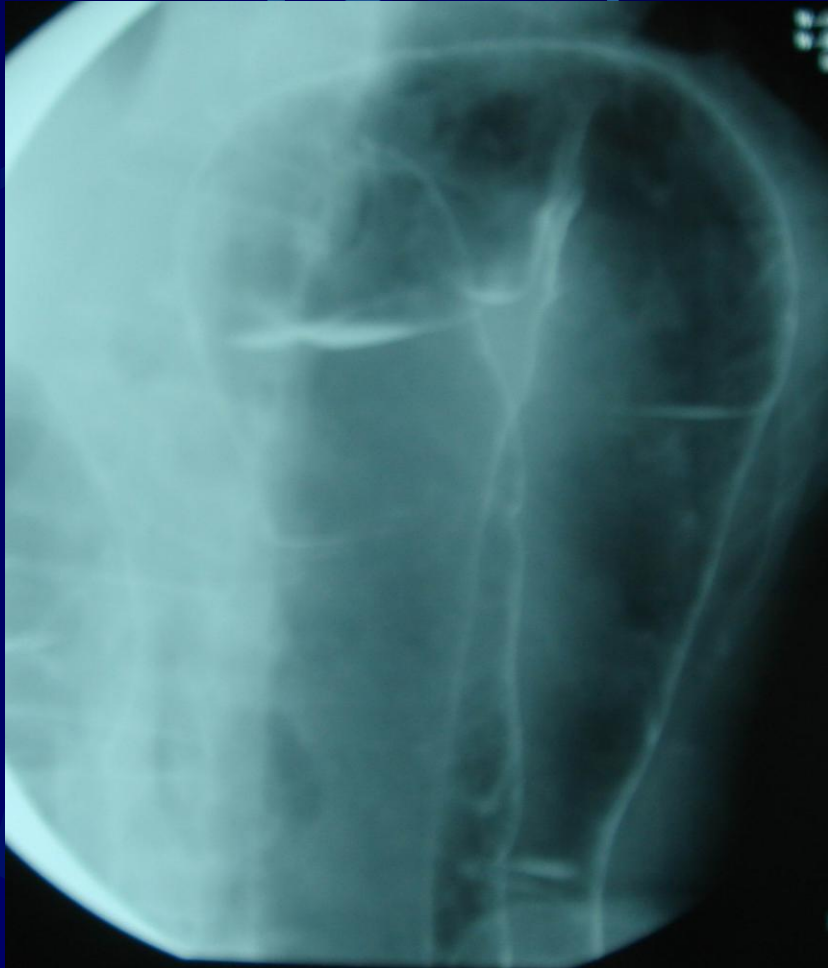

结肠常见疾病

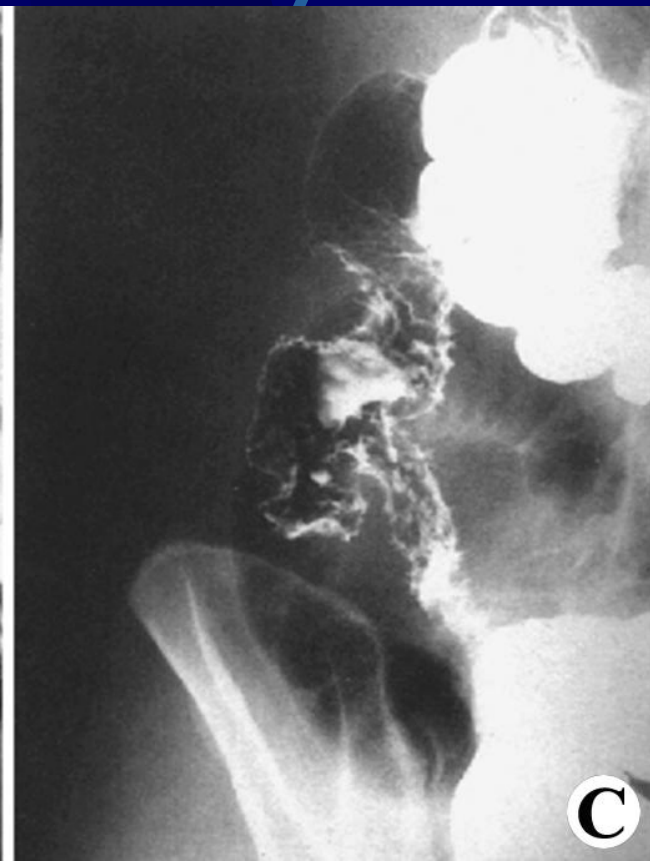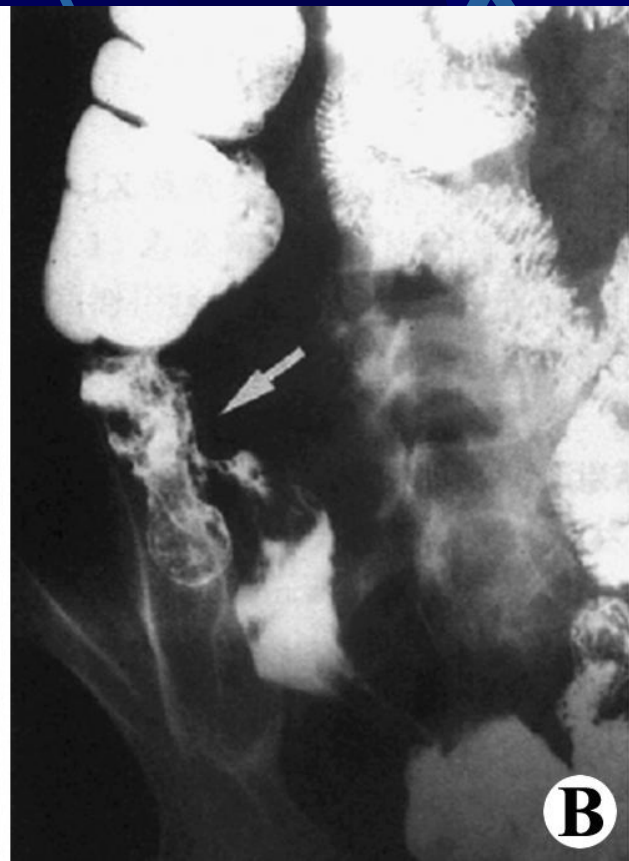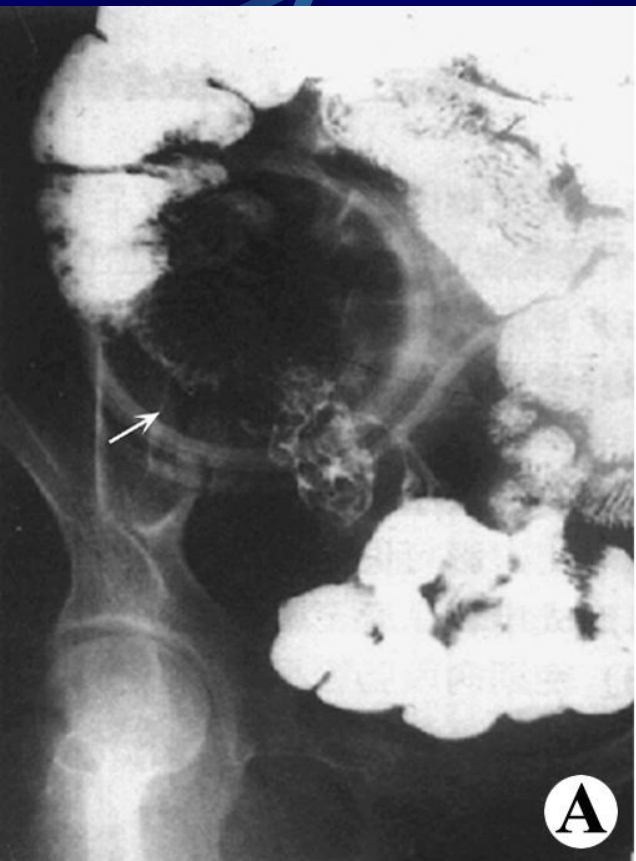
残株阑尾

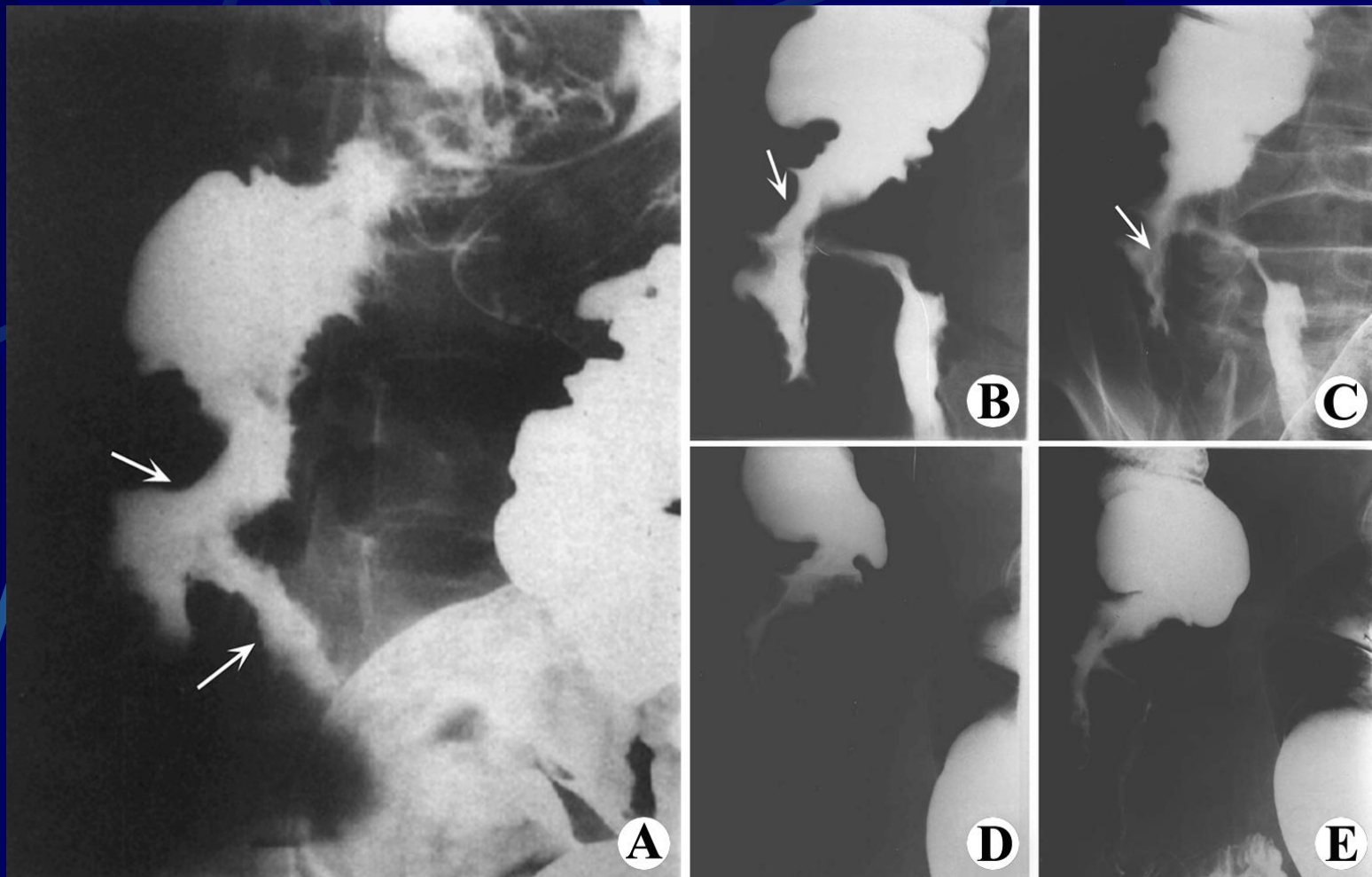


结肠炎



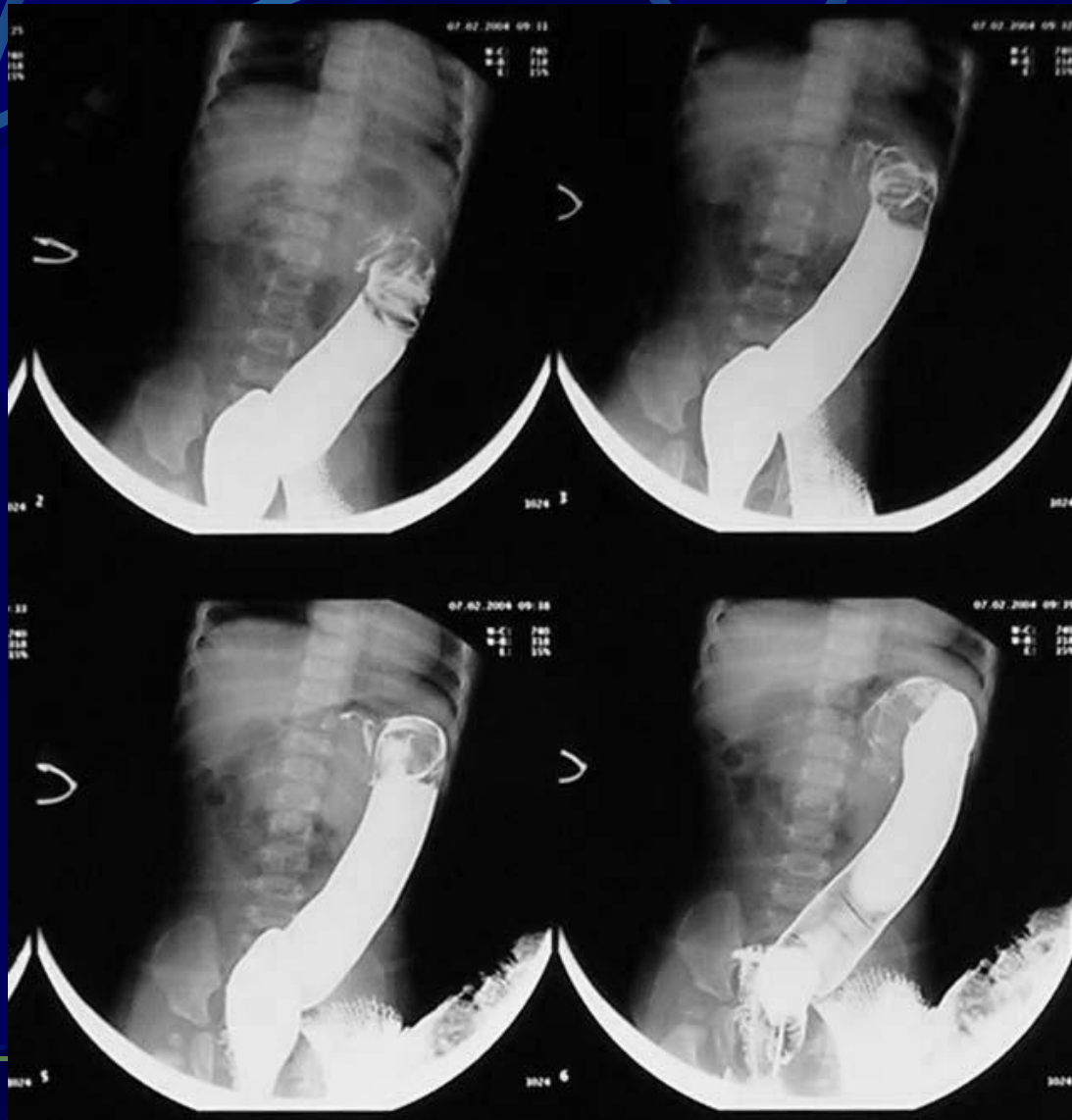肠结核（溃疡型）



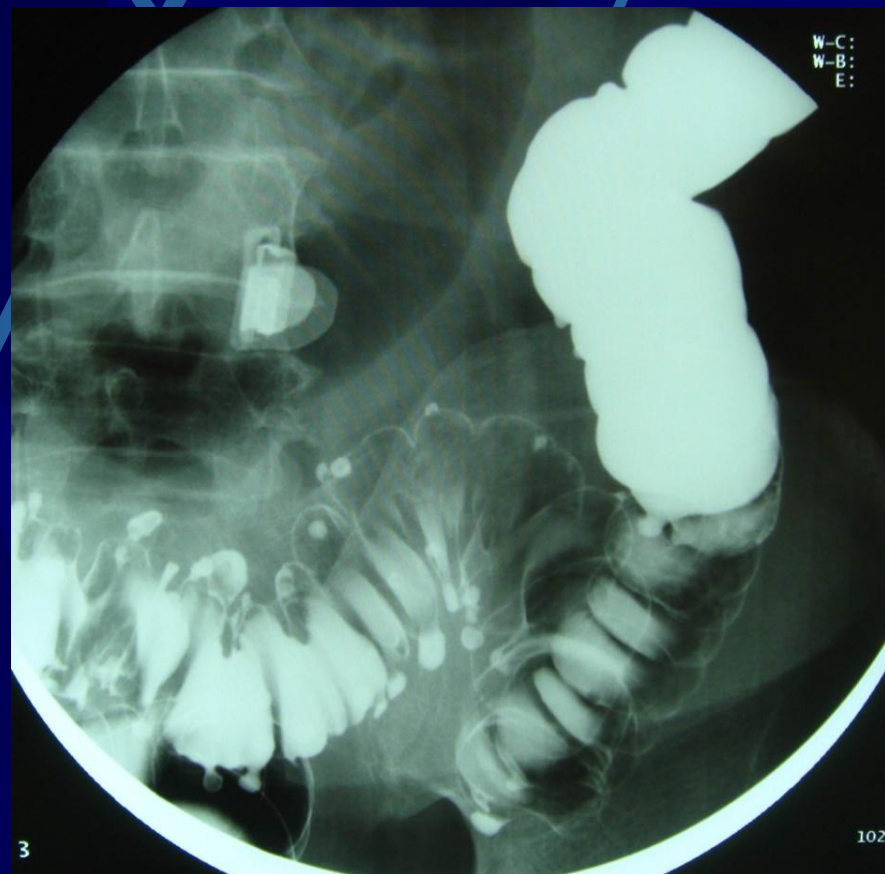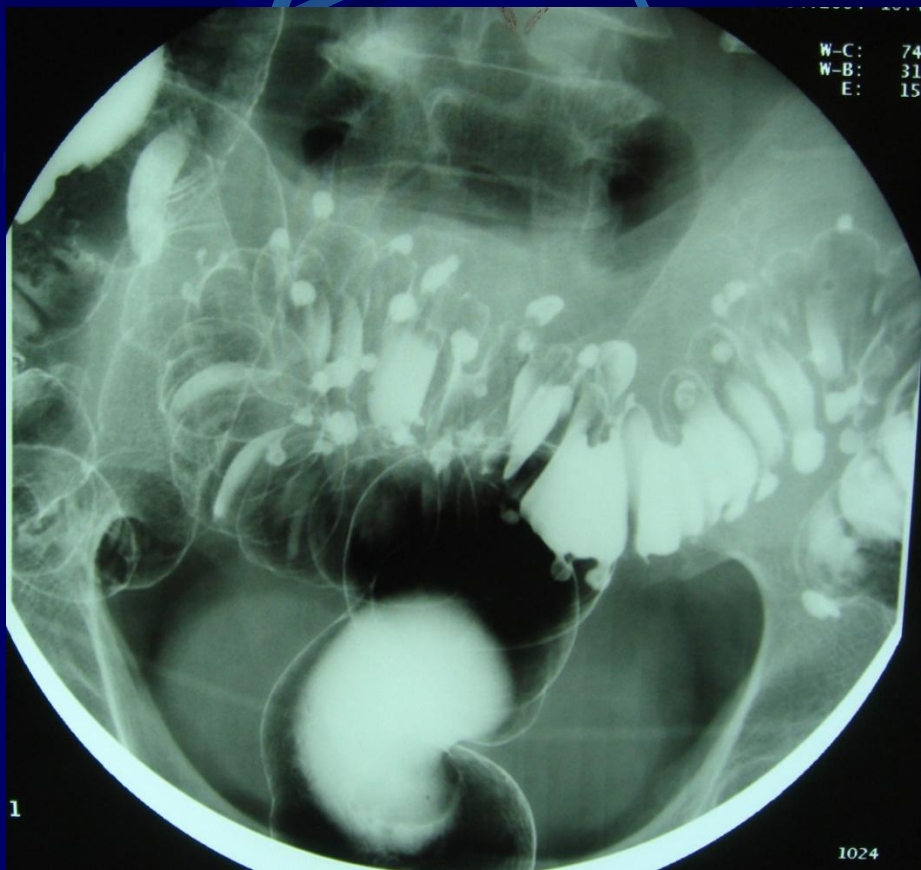


肠结核（增殖型）

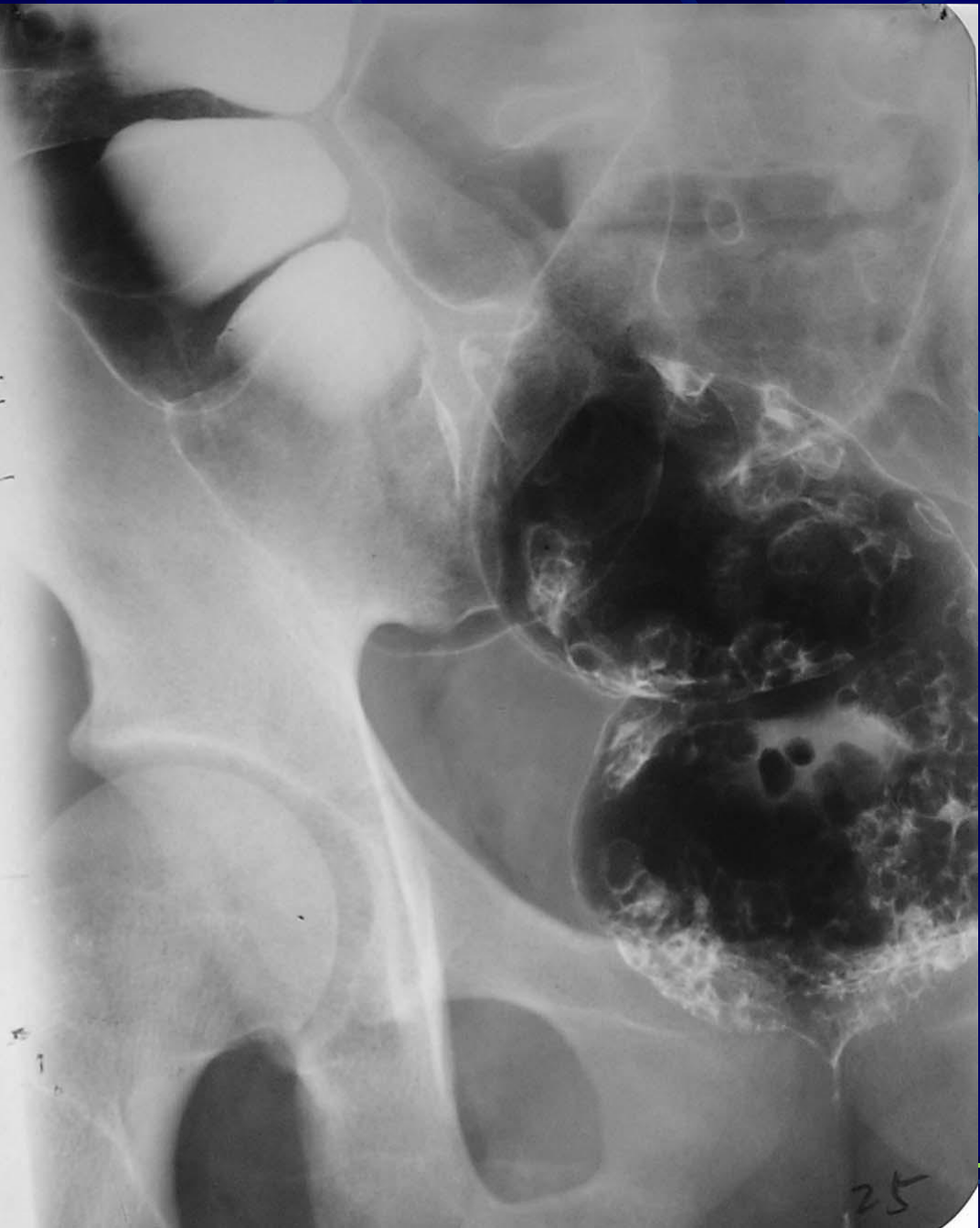肠套叠（结肠套结肠、阻塞端弹簧状）



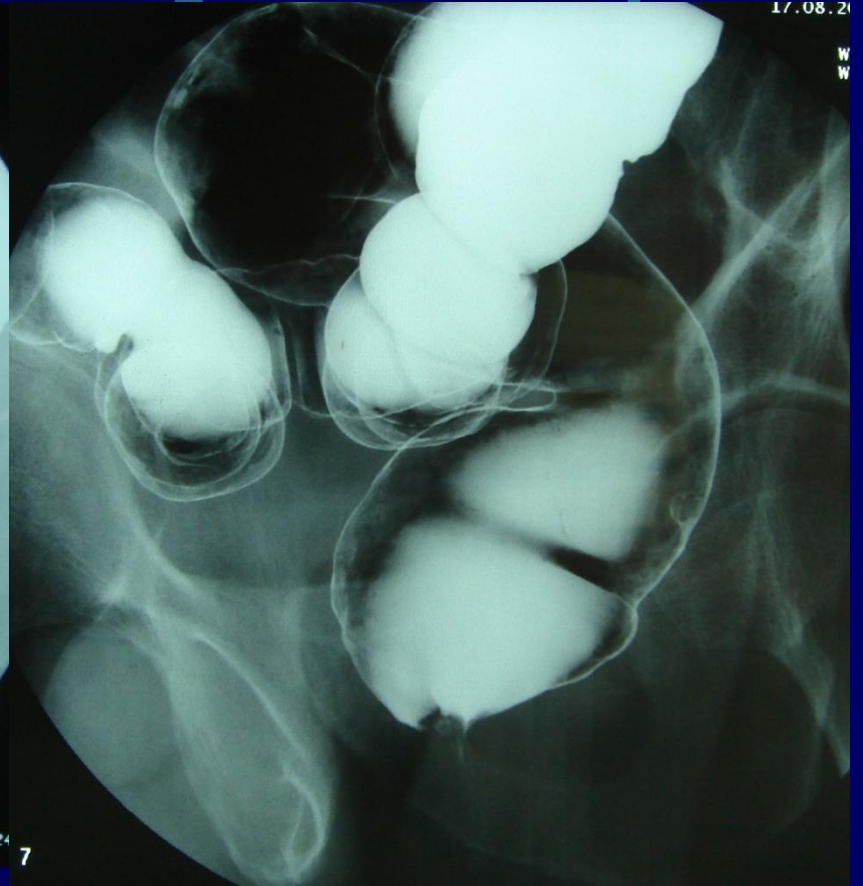
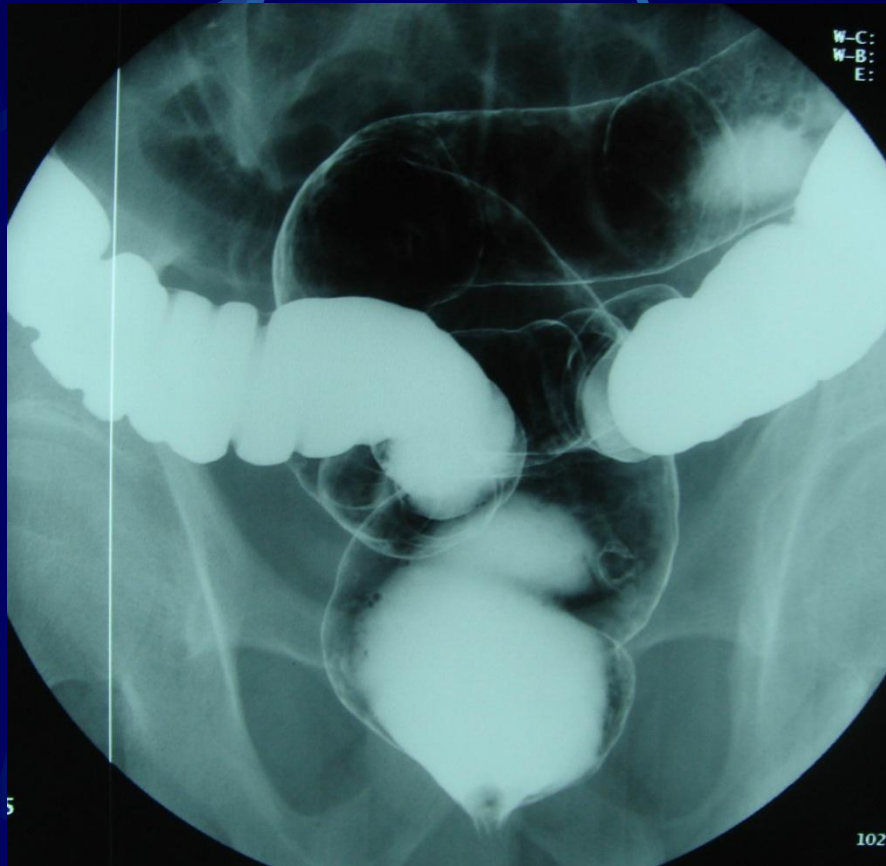
结肠多发憩室



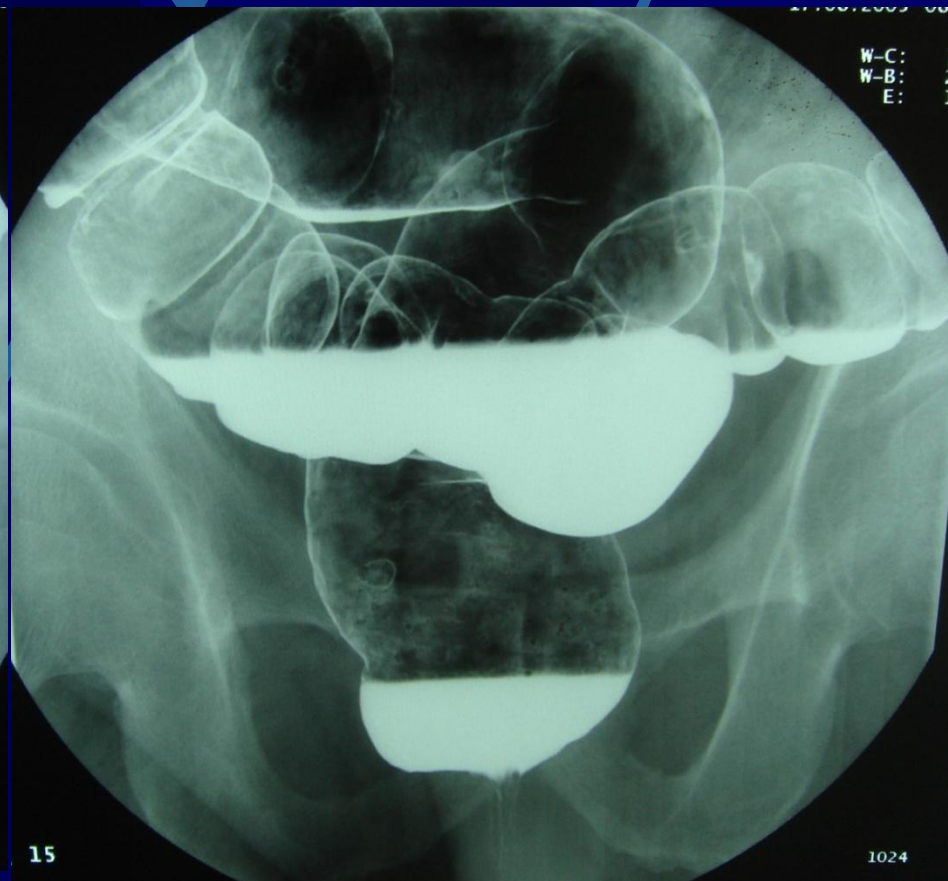
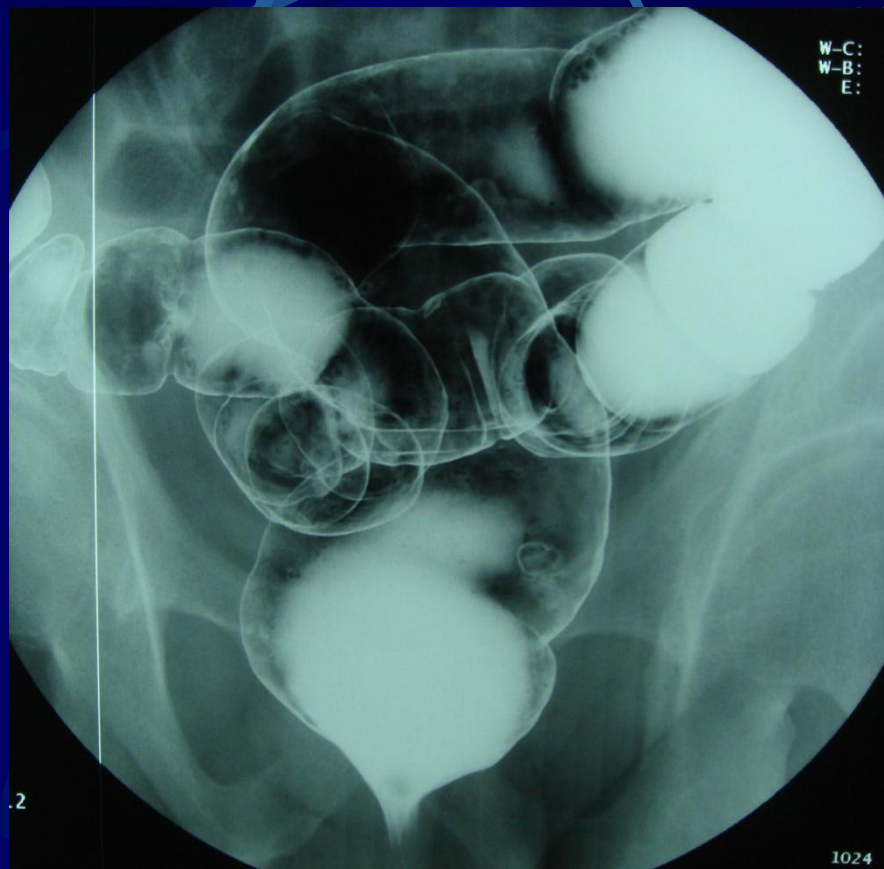
直肠多发发性息肉



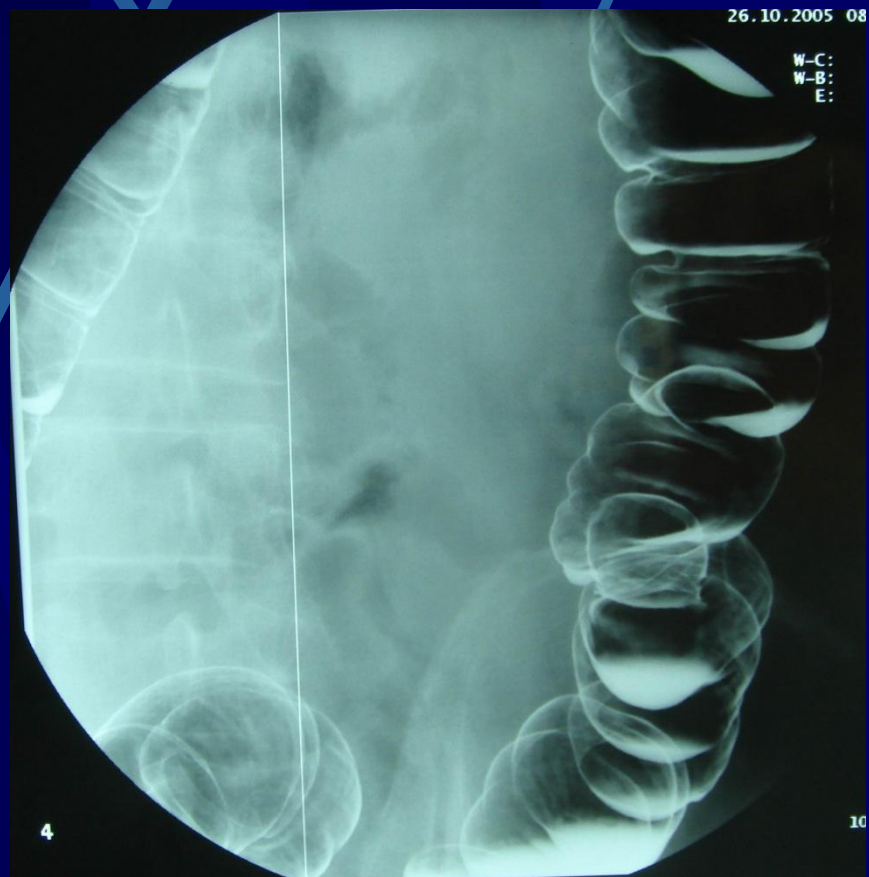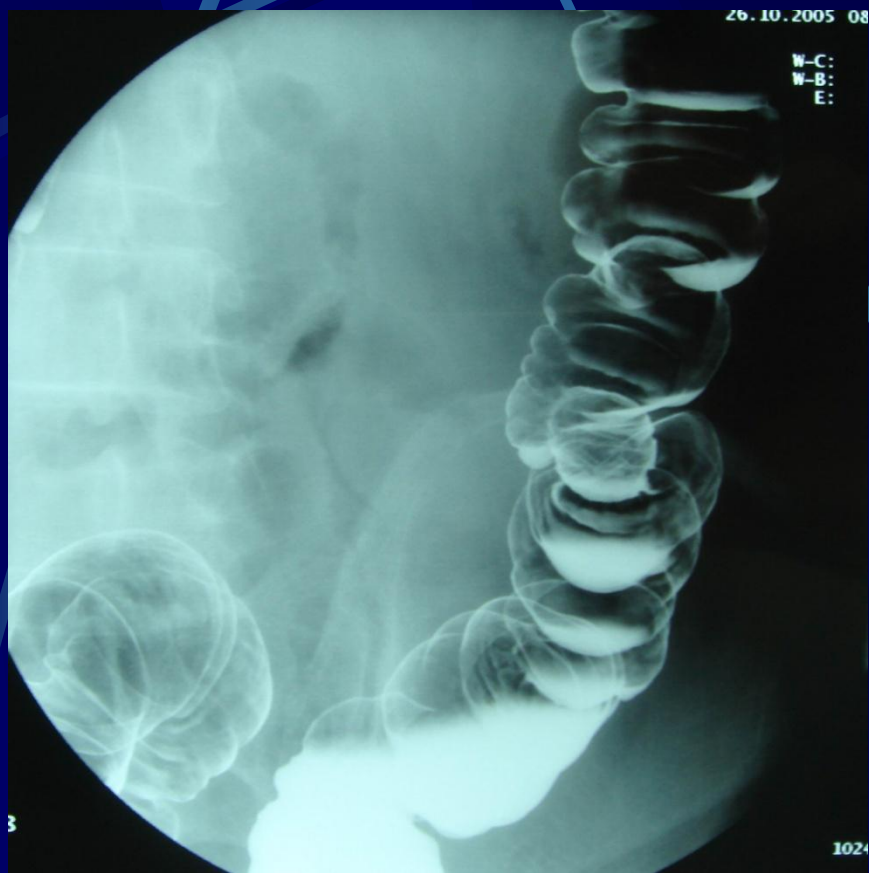直肠息肉



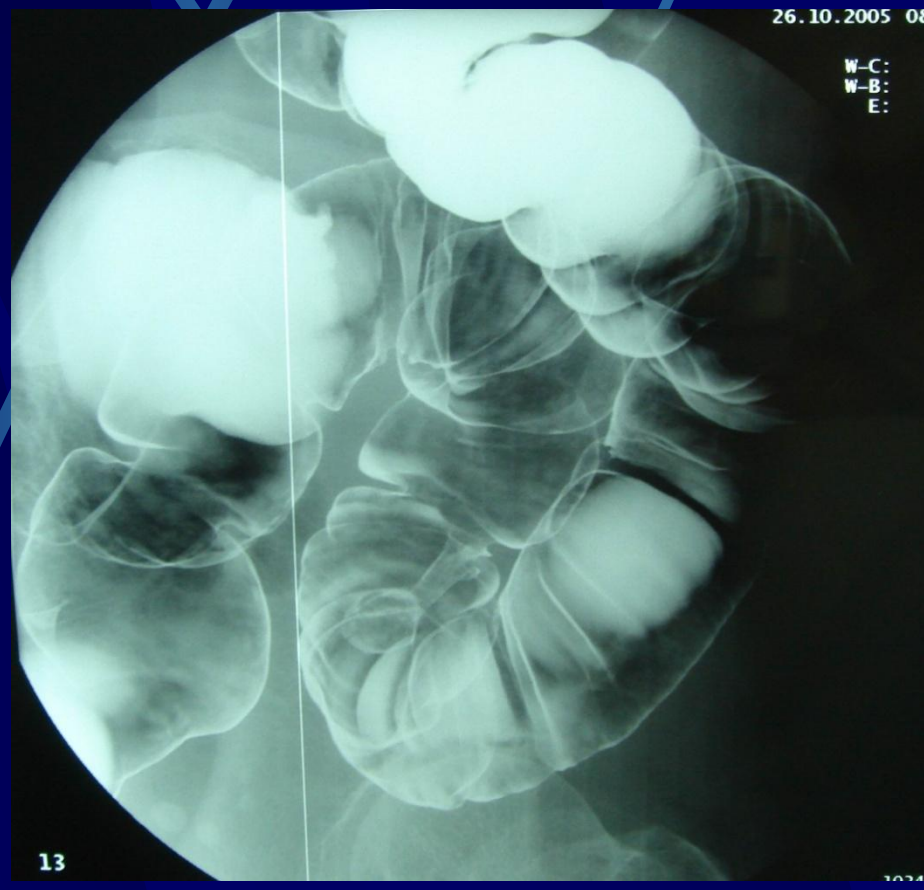
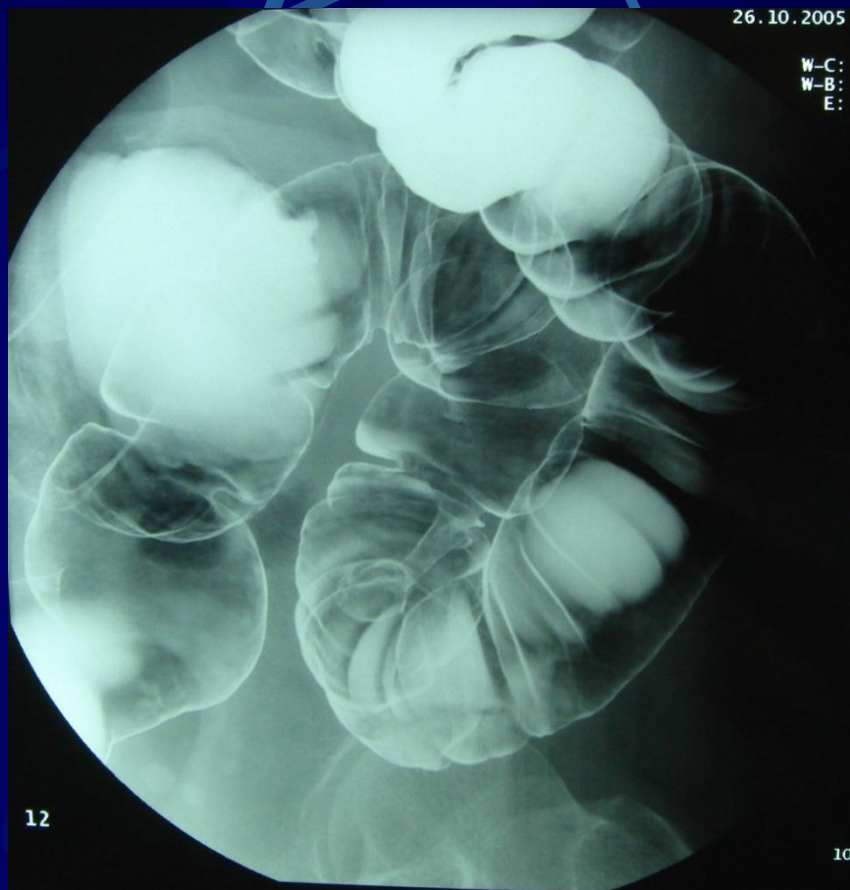
直肠息肉



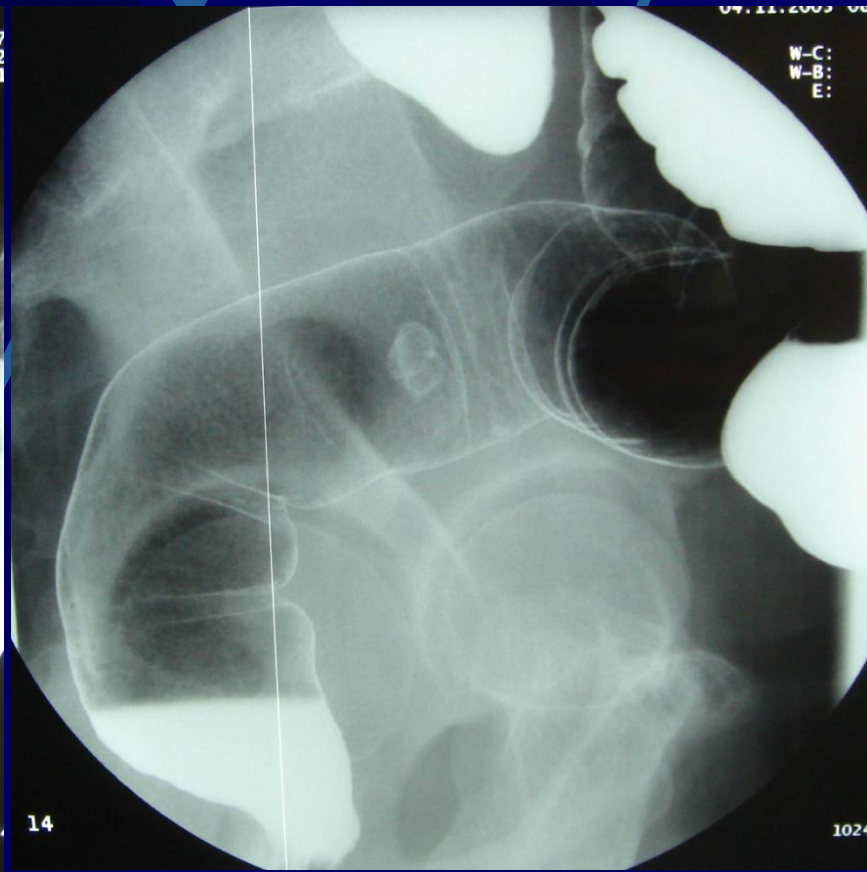
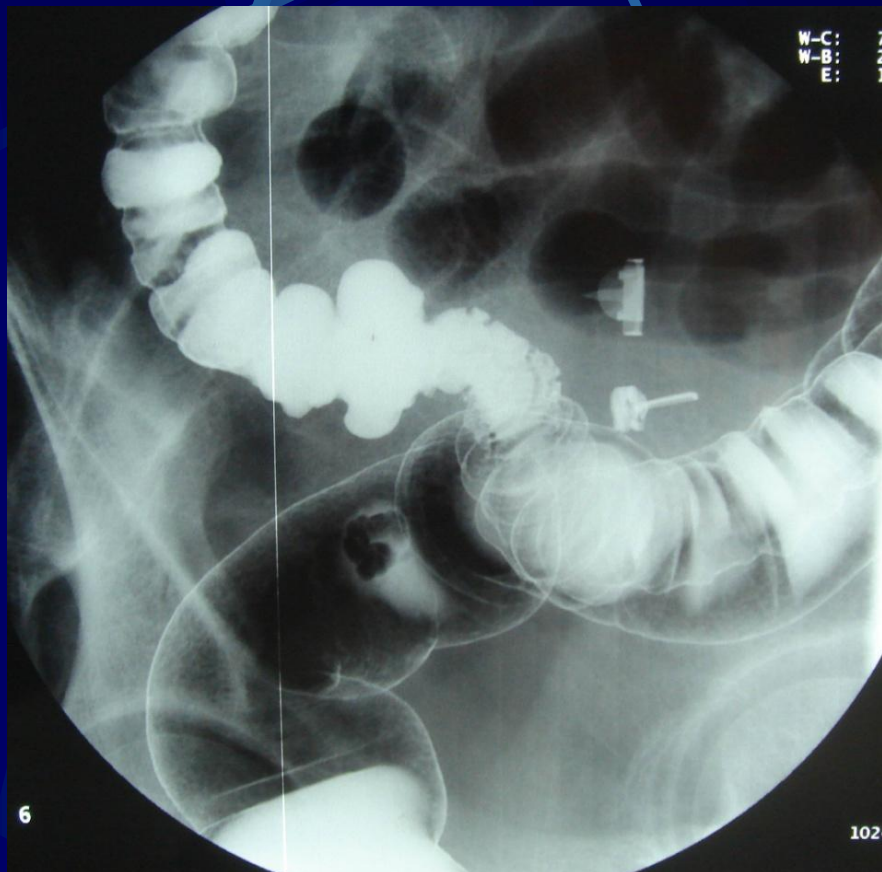结肠息肉



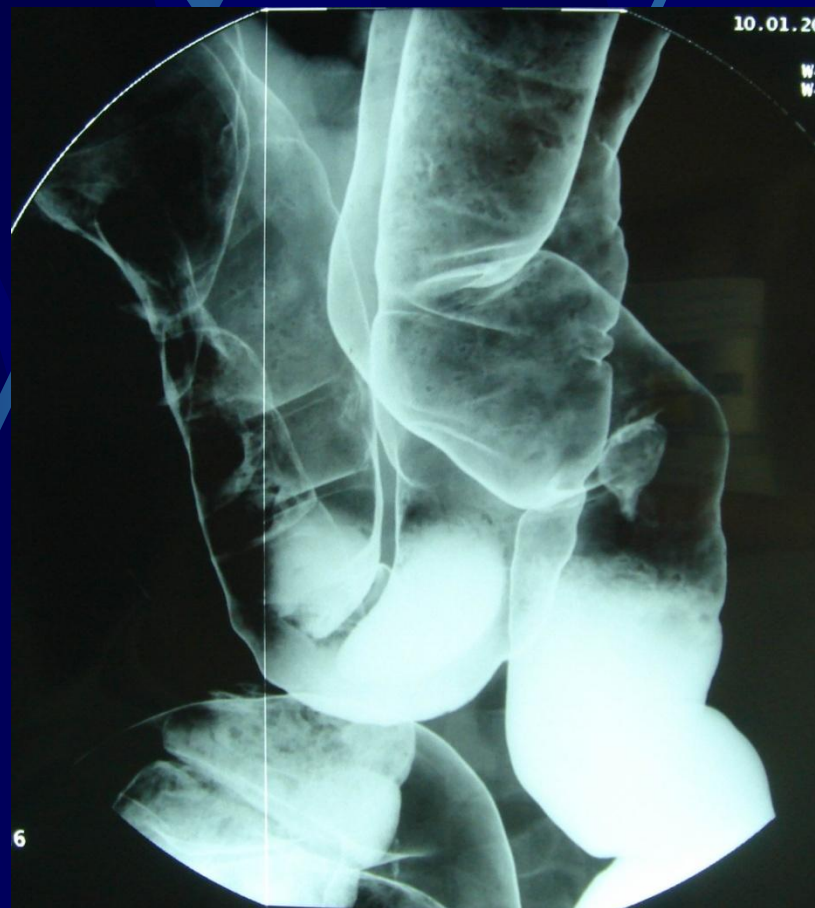
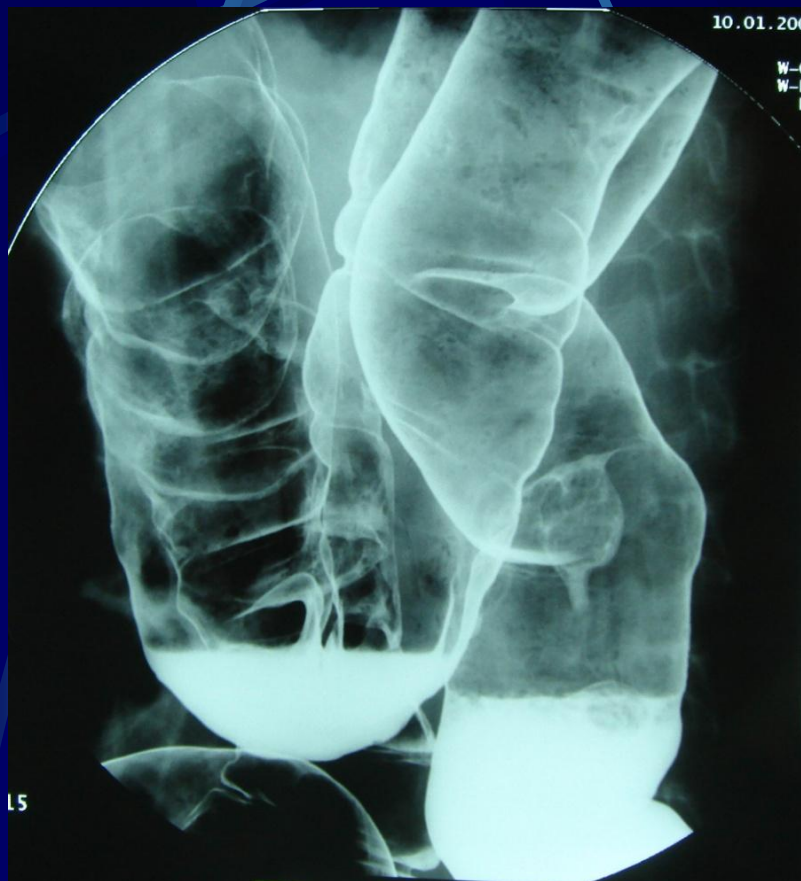
结肠息肉



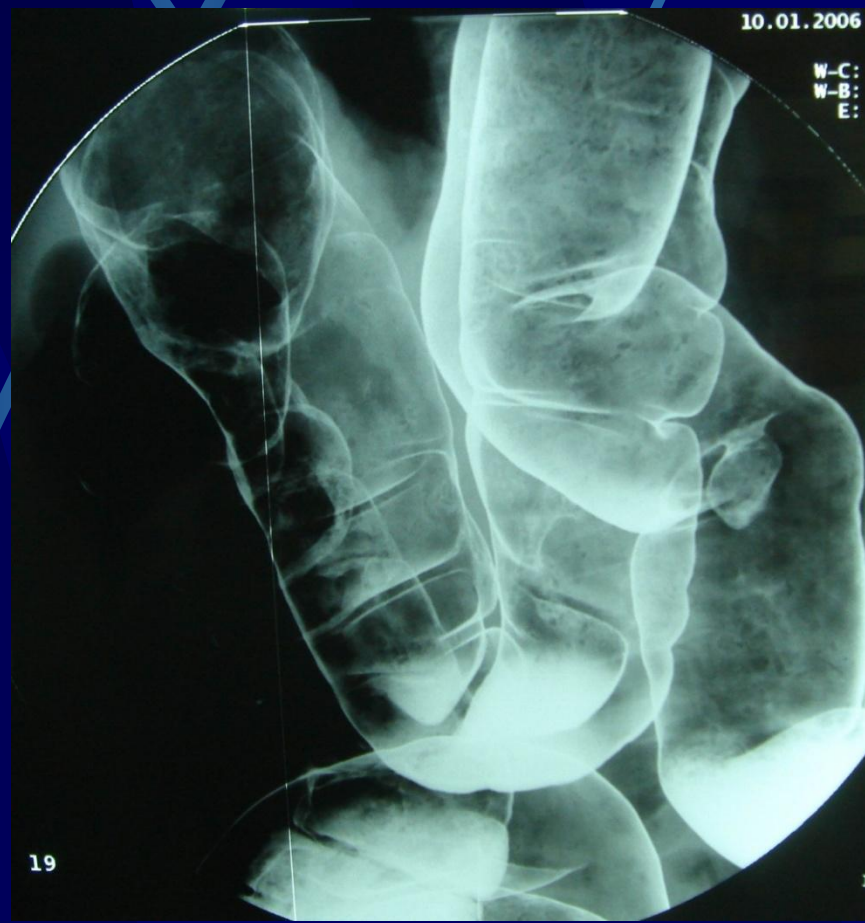
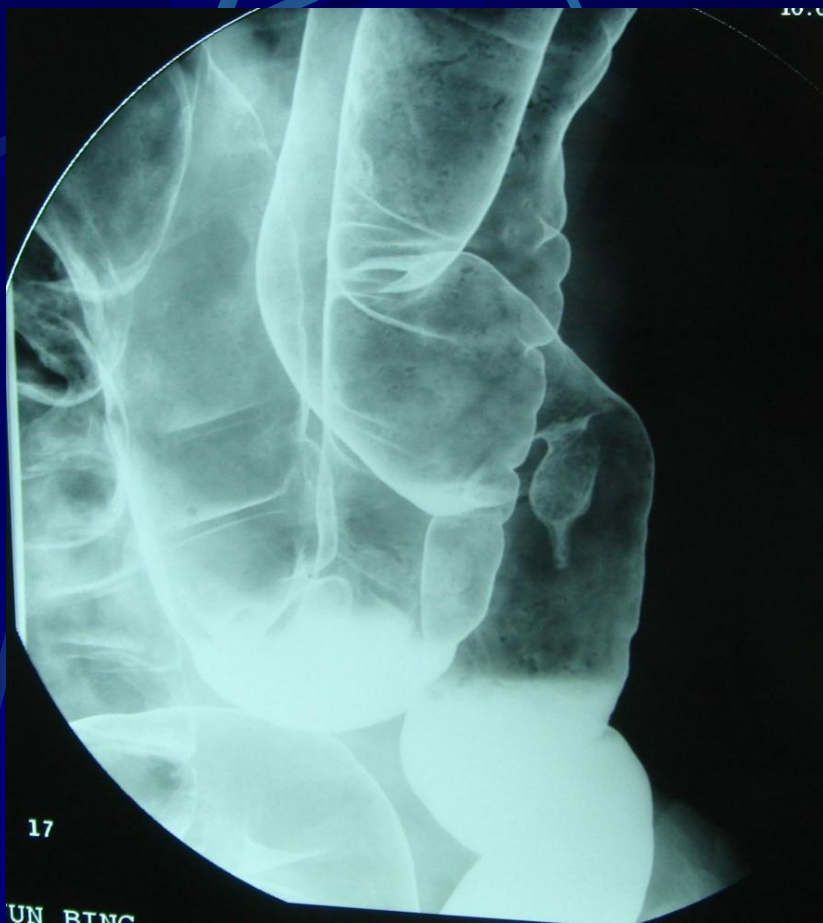结肠息肉



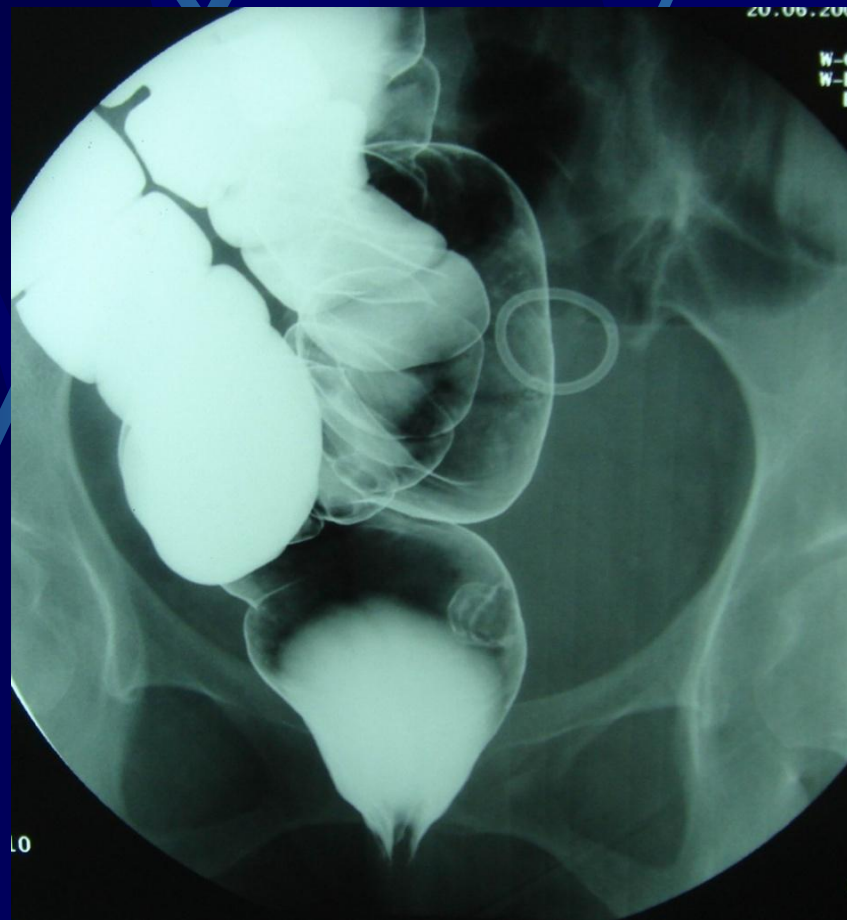
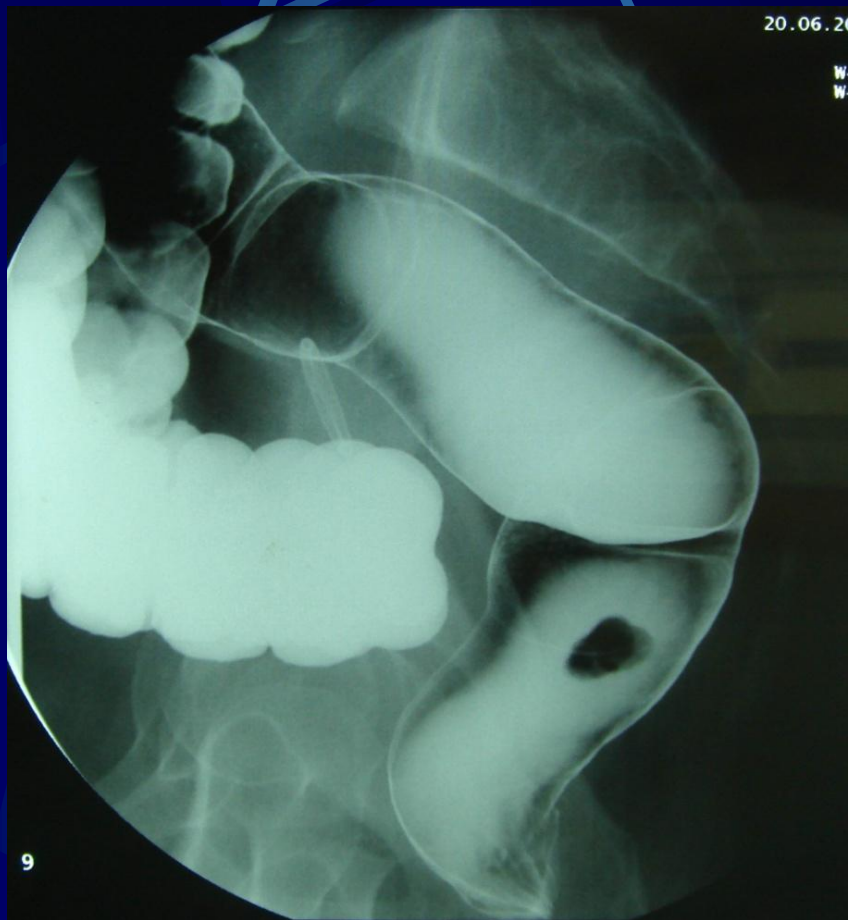结肠息肉



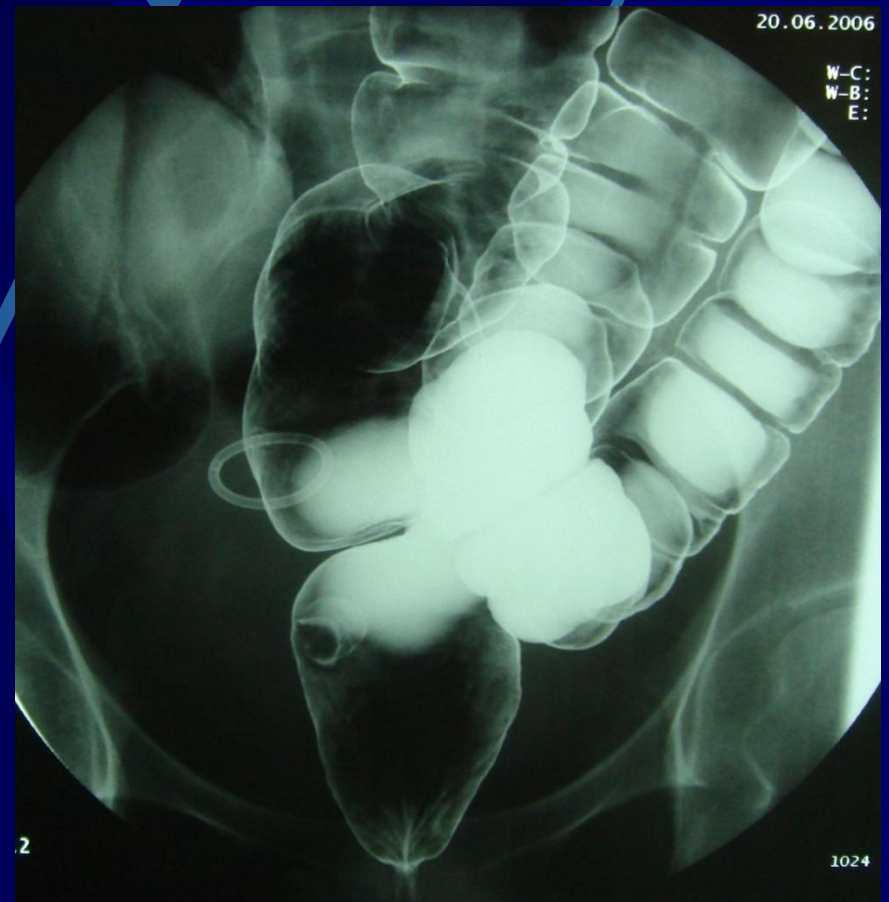
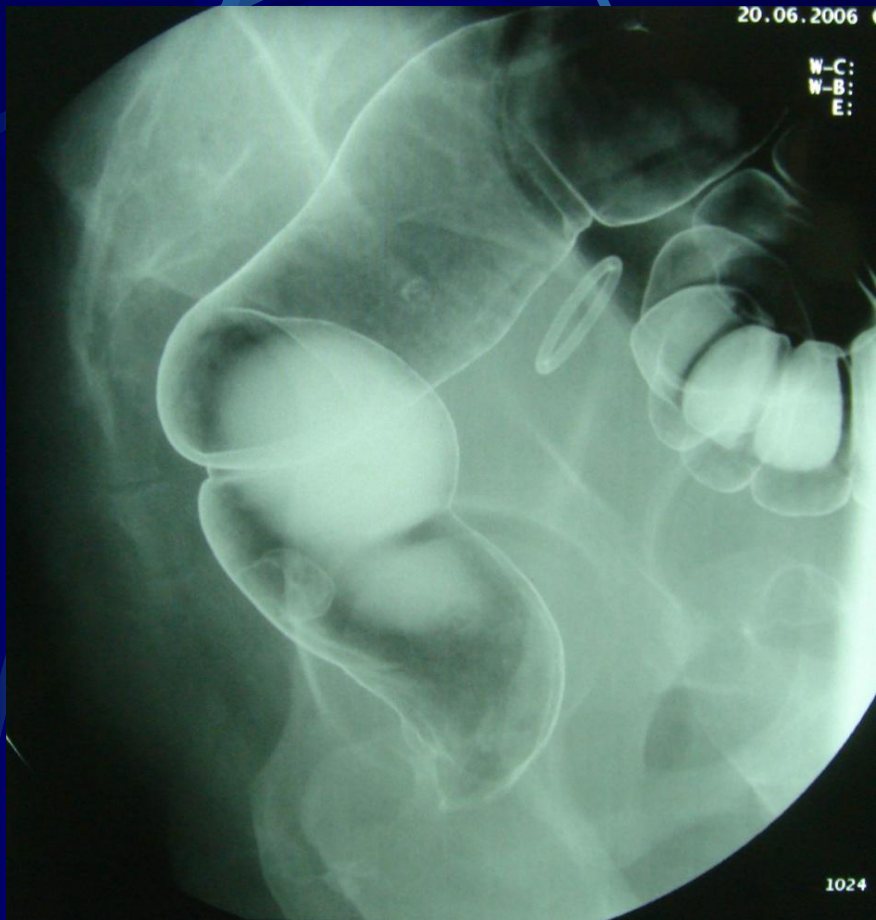结肠息肉



直肠息肉



直肠息肉



结肠癌

1. 早期结肠癌:

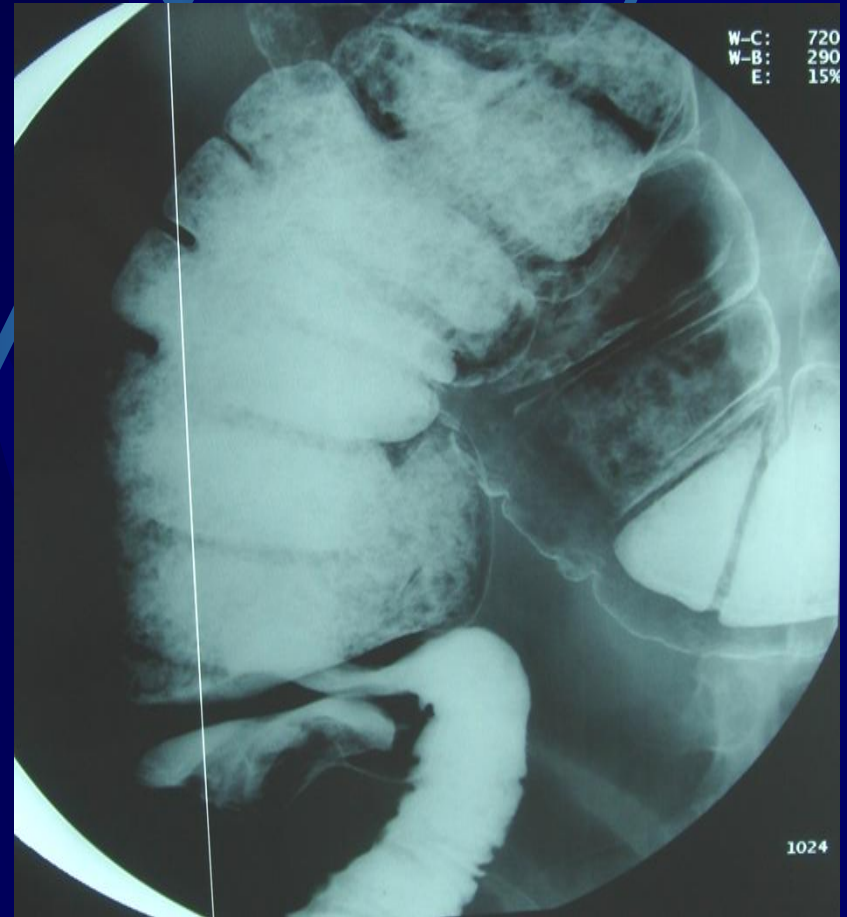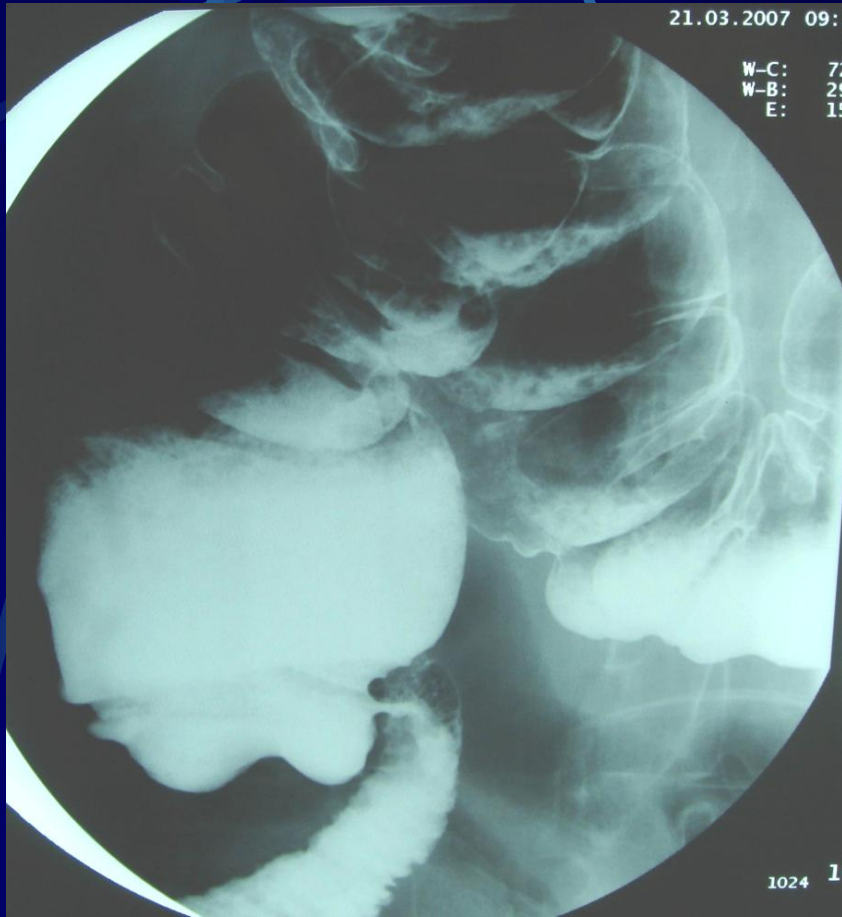a: 隆起型; **b:** 表浅型; **c:** 凹陷型。

多见隆起型, 典型表现为扁平, 无蒂类圆形隆起性病灶, 基底宽, 与结肠腔壁线形成不规则线样征, 短蒂息肉要注意癌变。

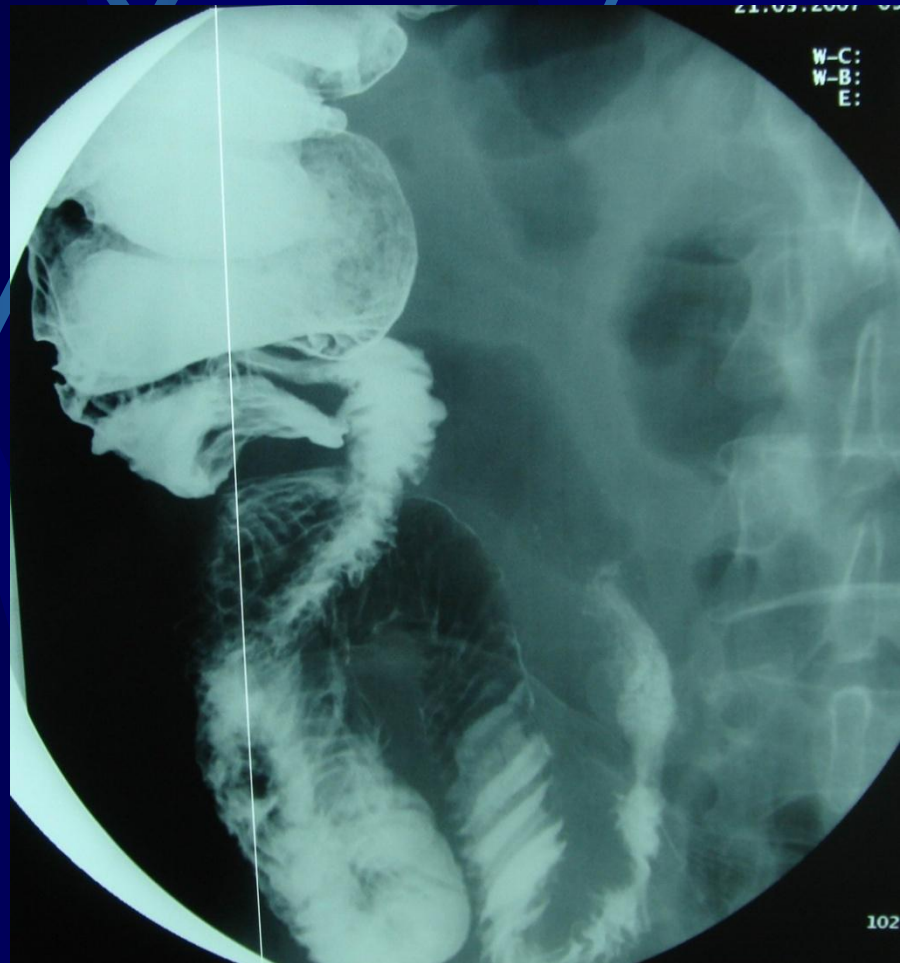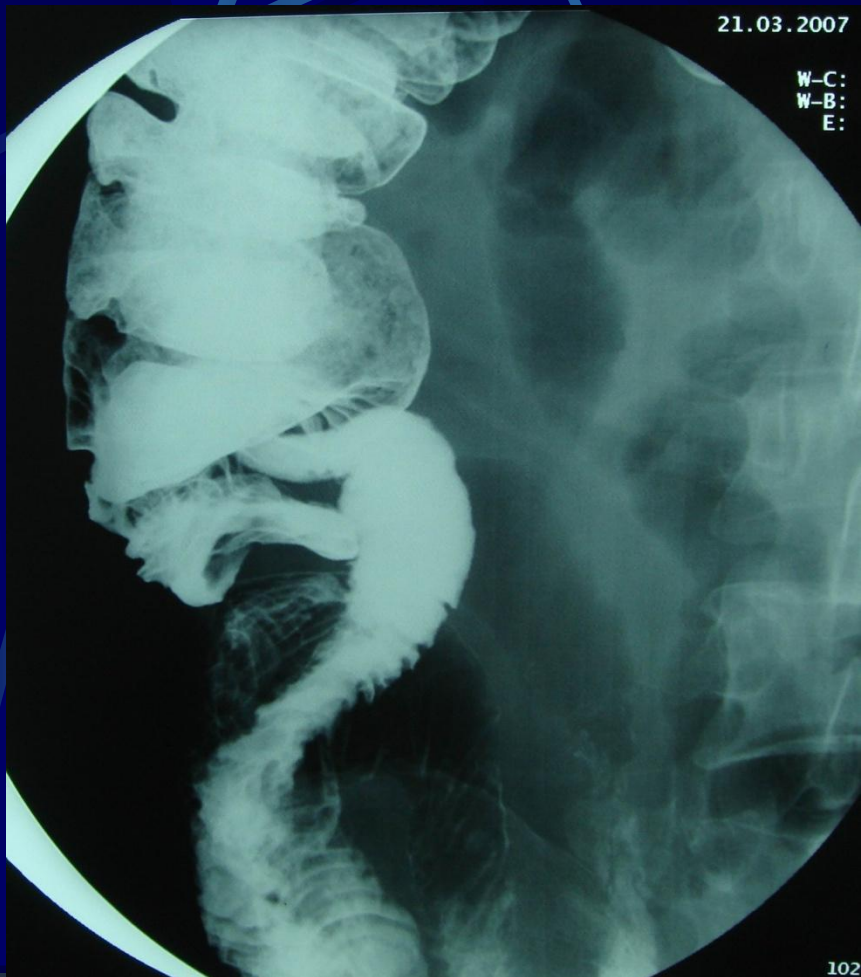2. 进展期结肠癌:

a.隆起型; **b.**浸润型; **c.**溃疡型。

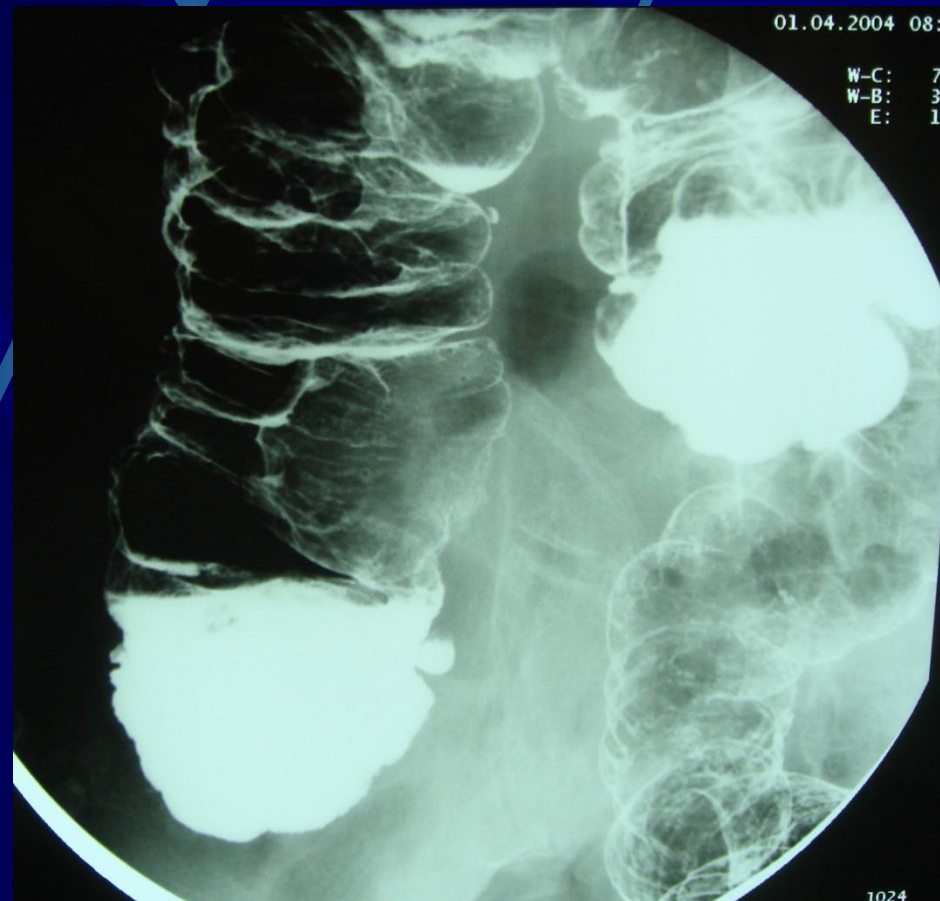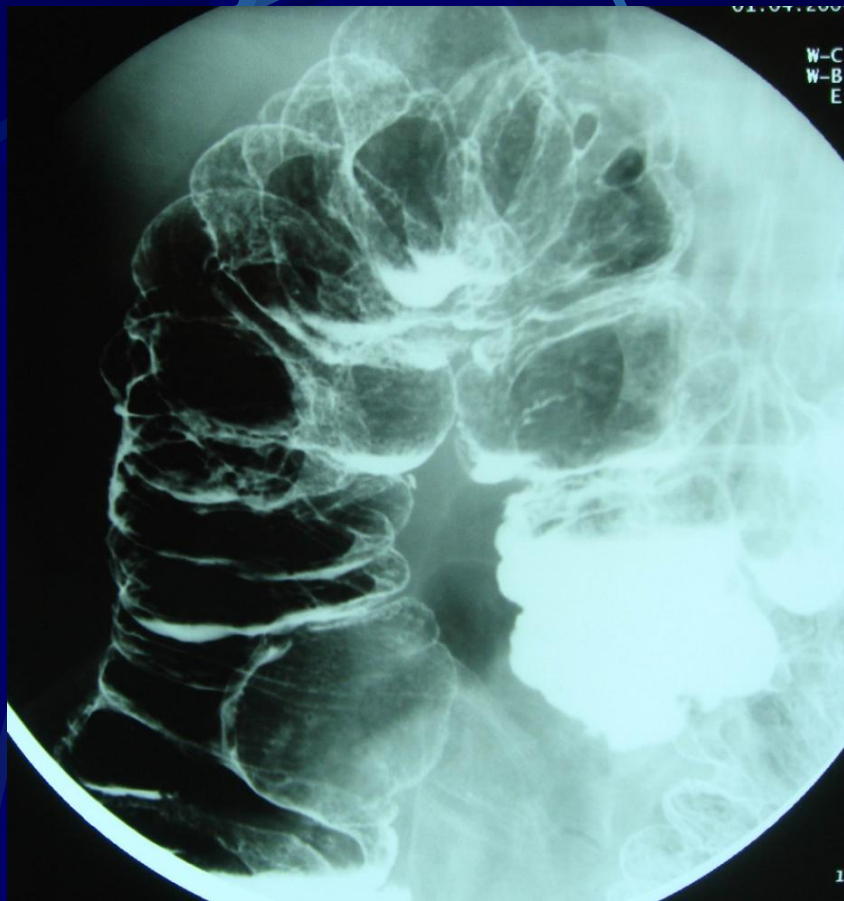病例1



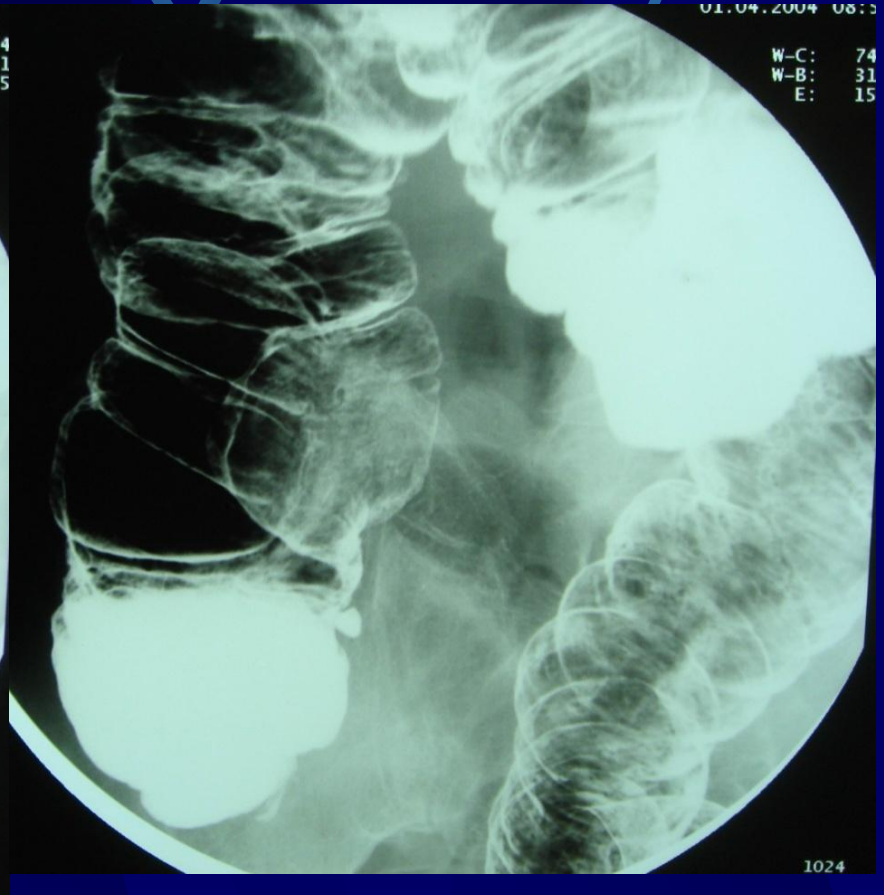
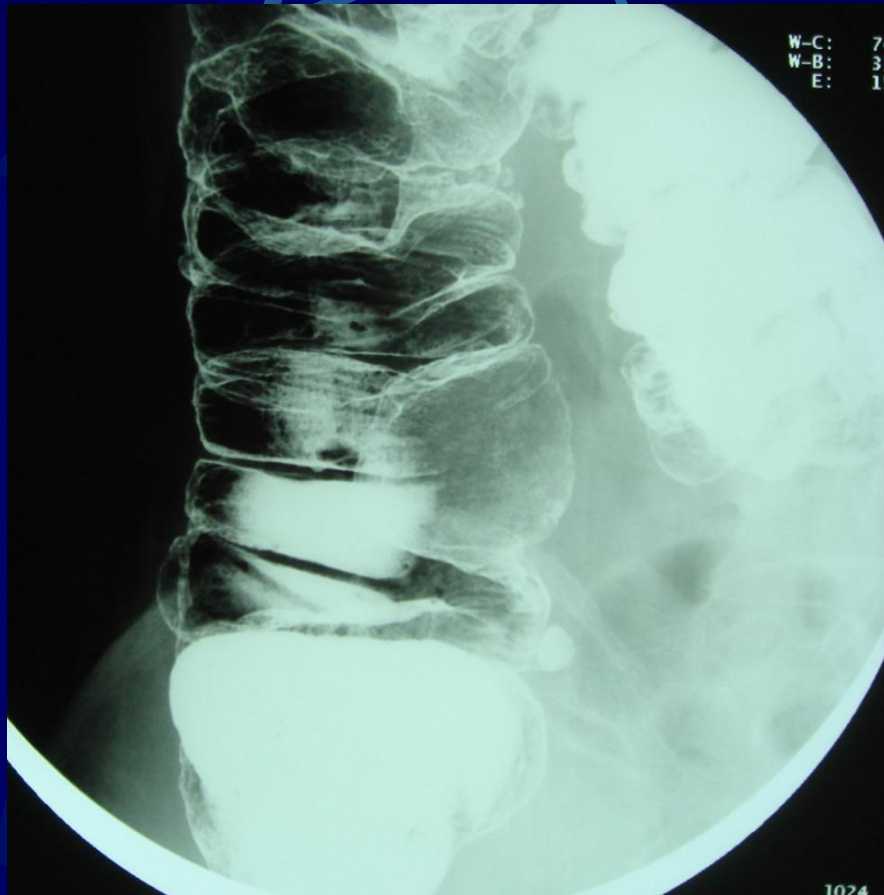
病例1



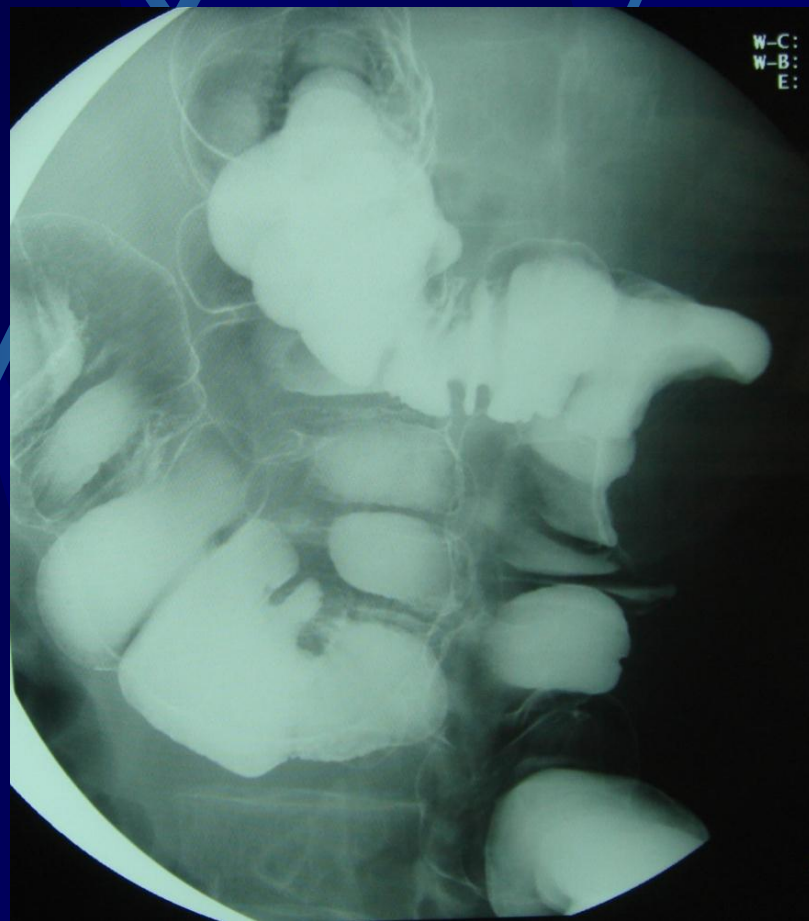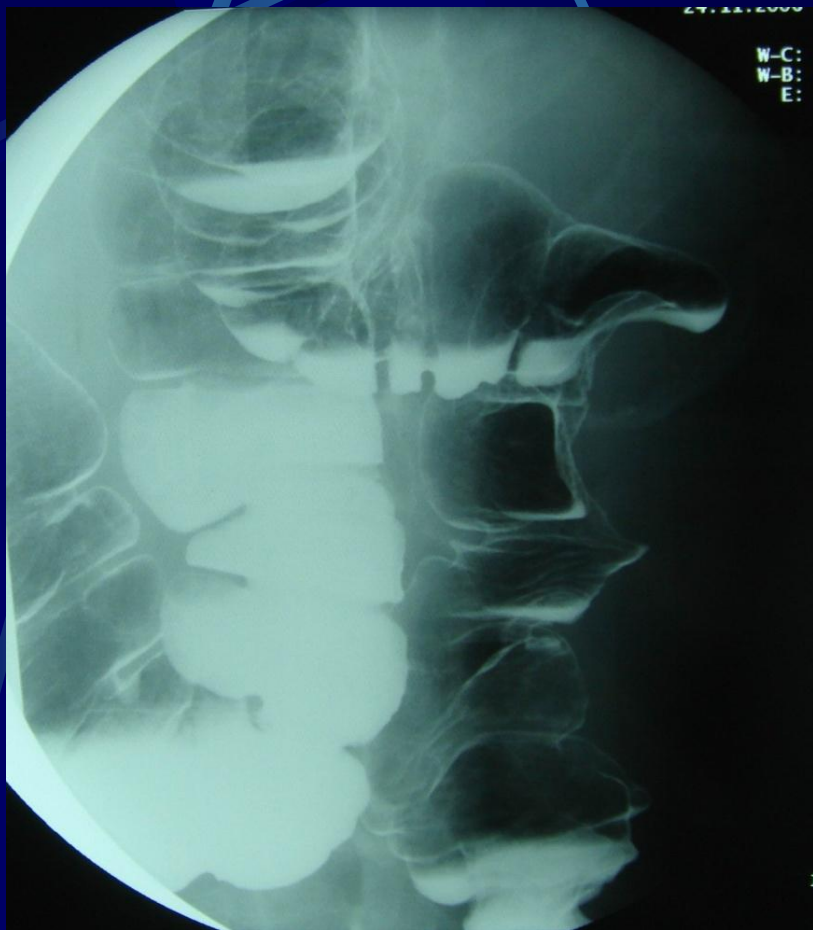
病例2



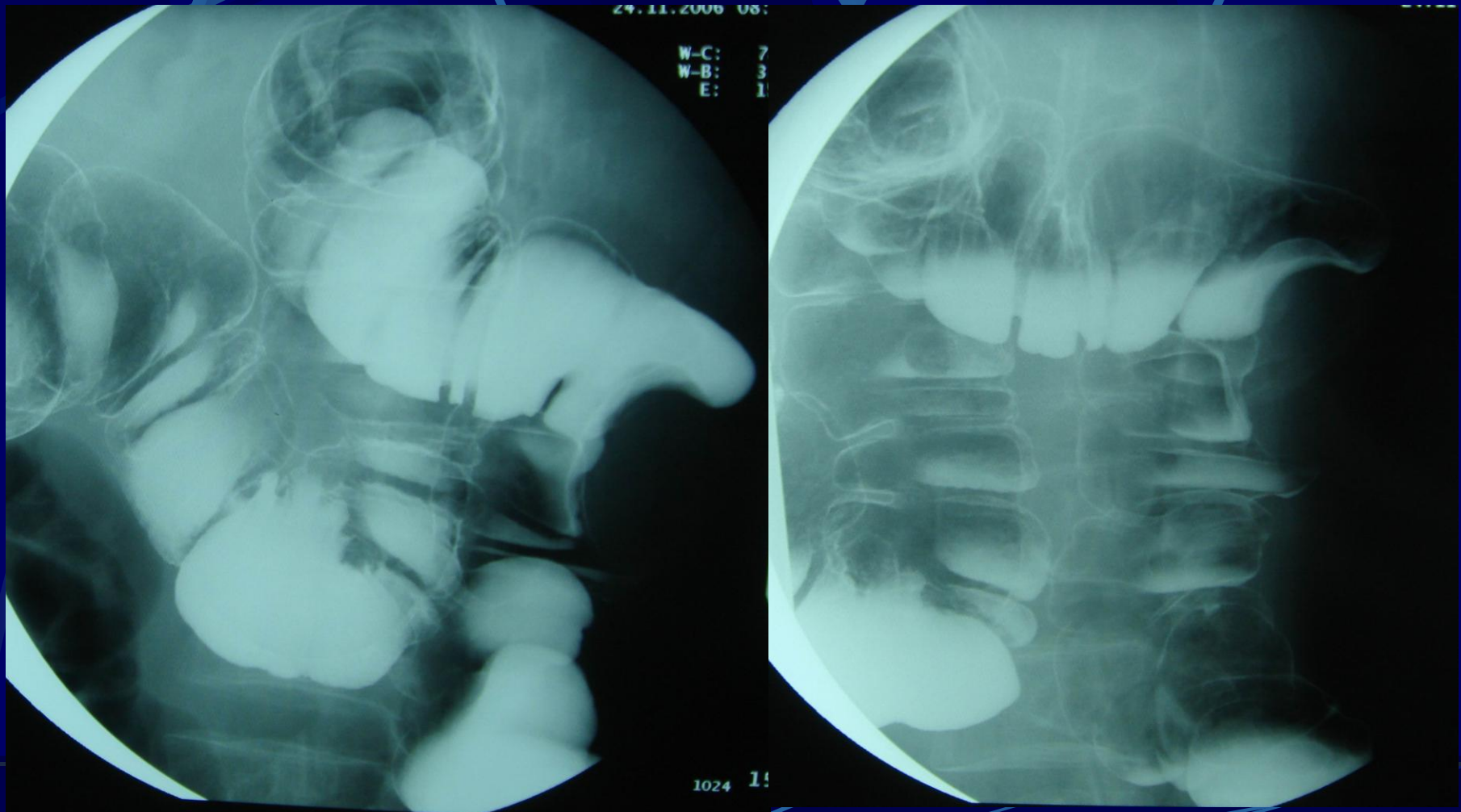
病例2



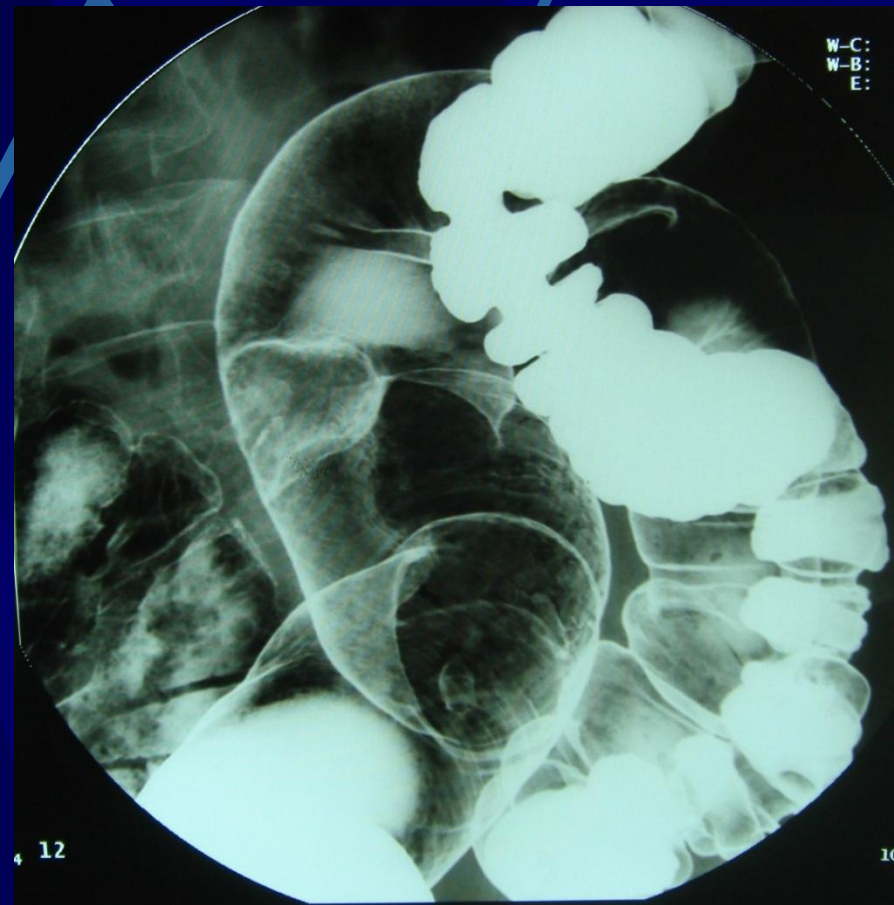
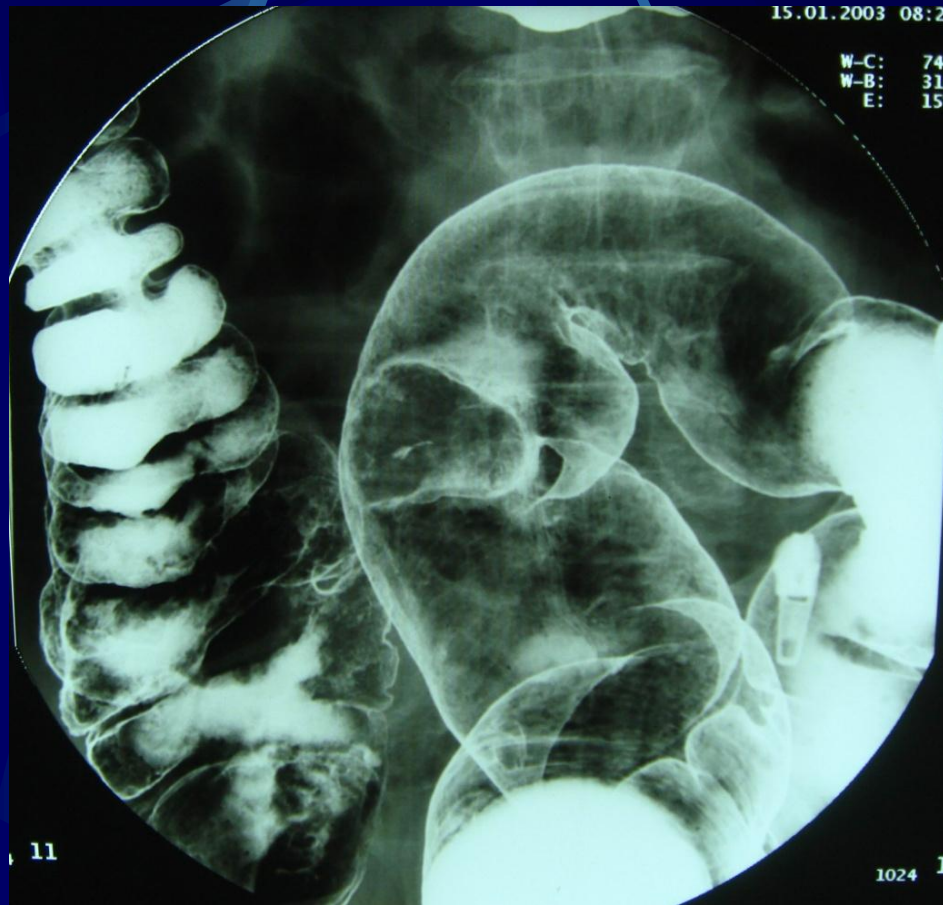
病例3



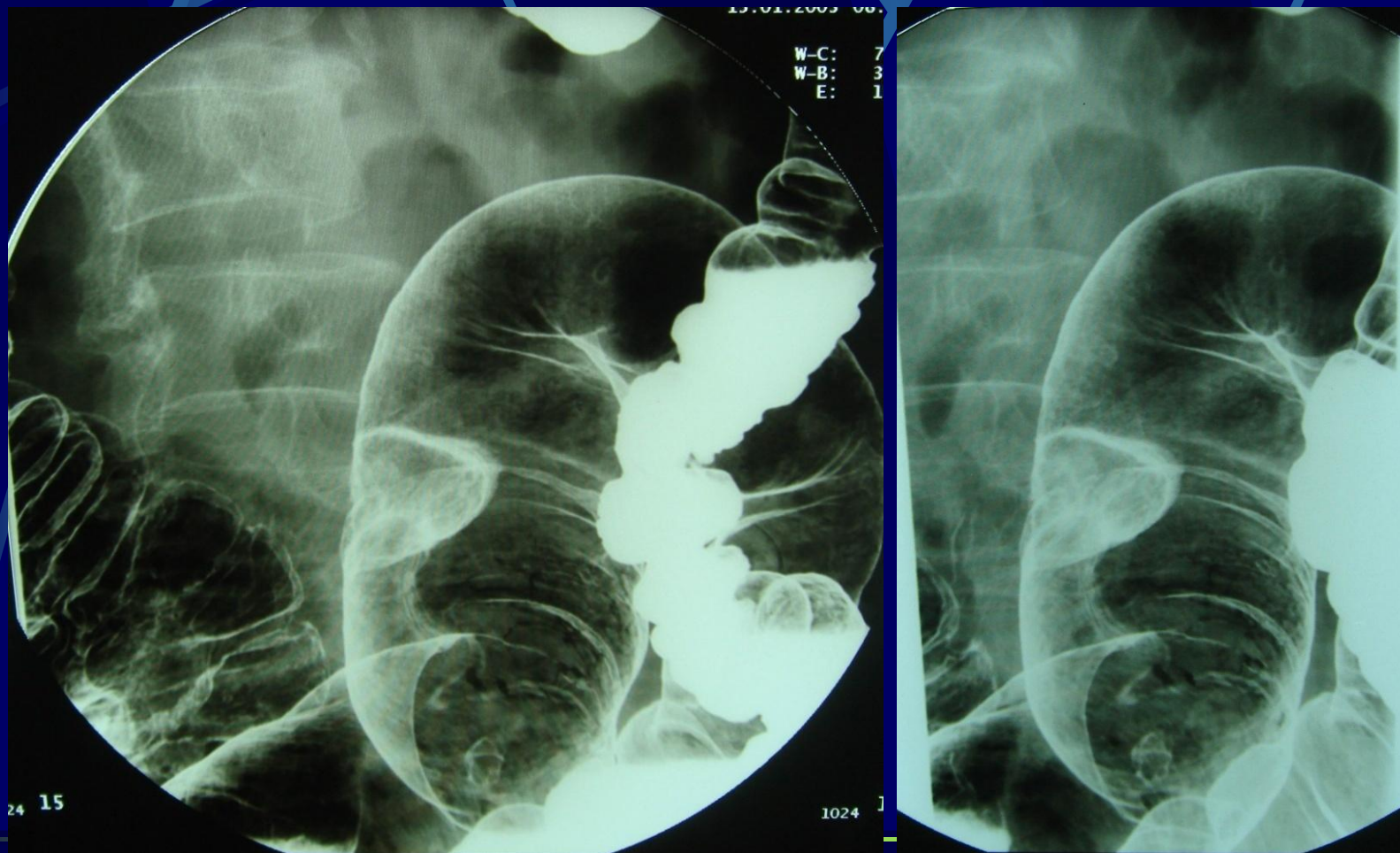
病例3



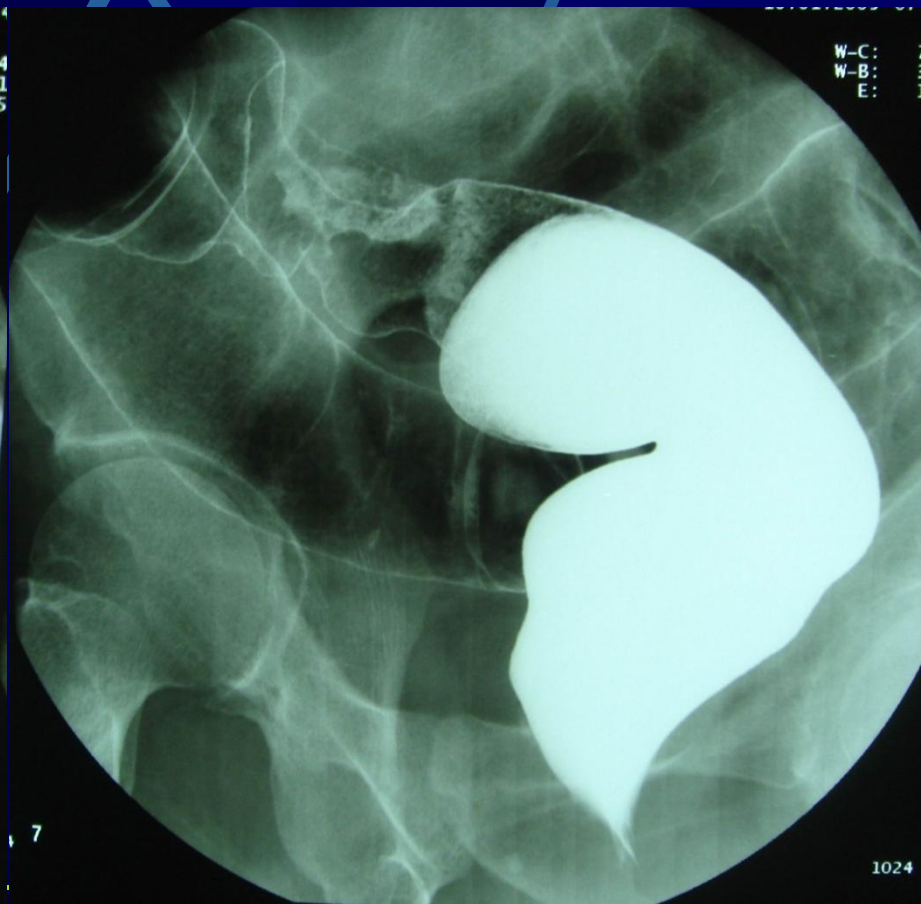
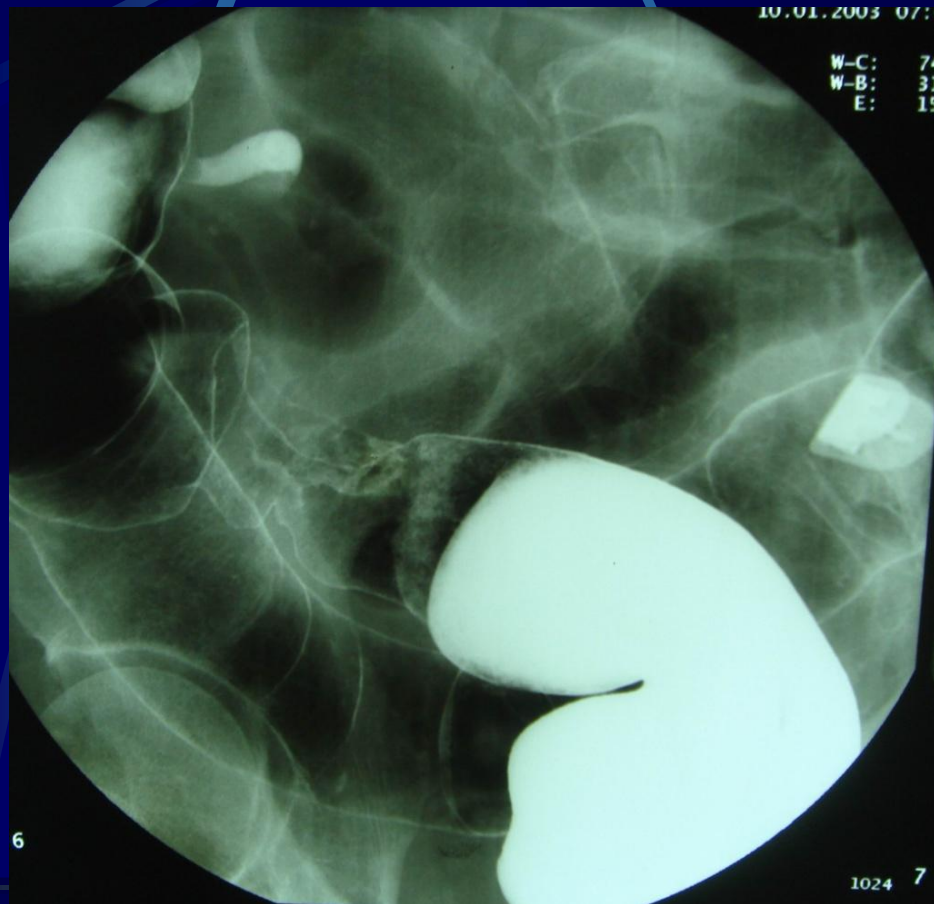病例4



病例4



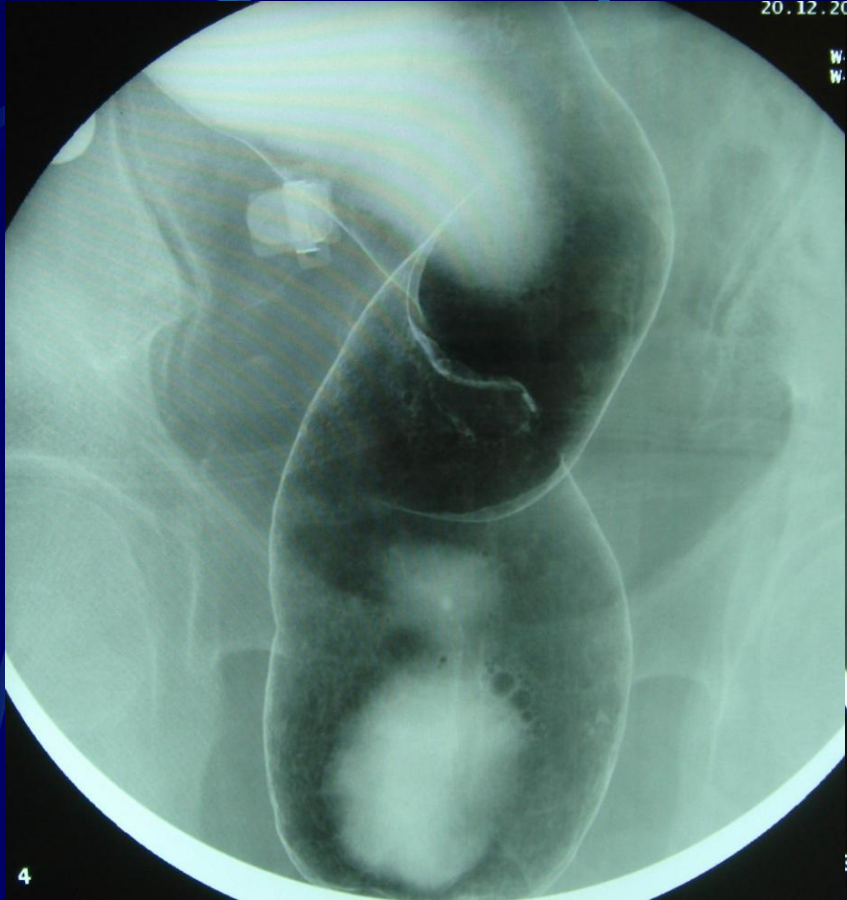病例5



病例6

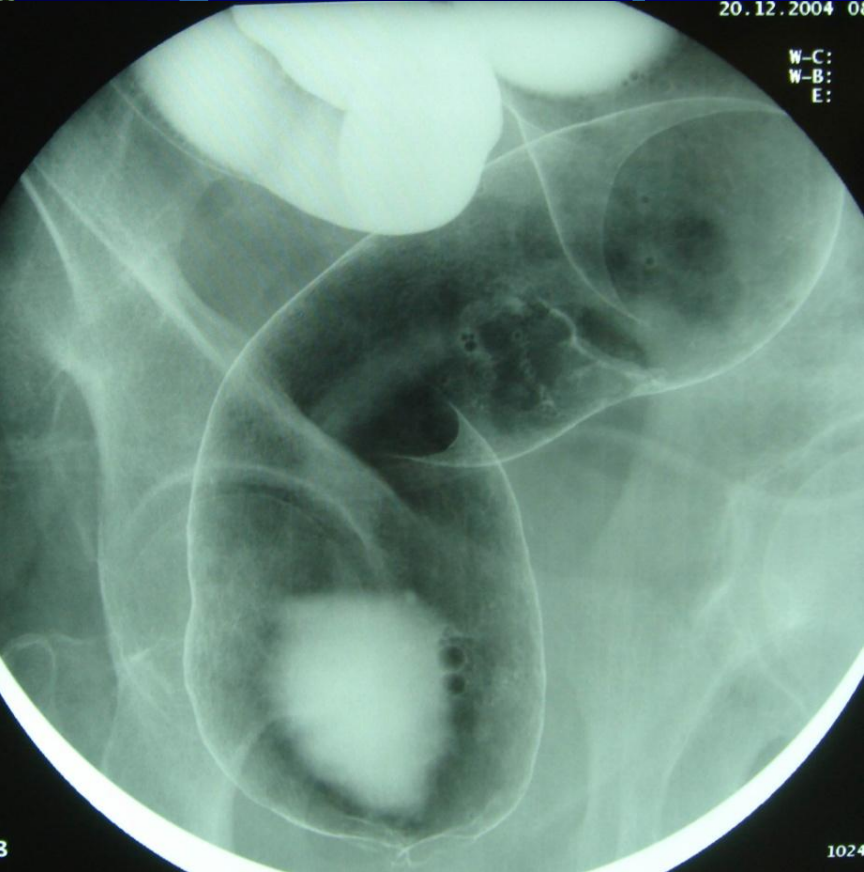20.12.200

W:
W:

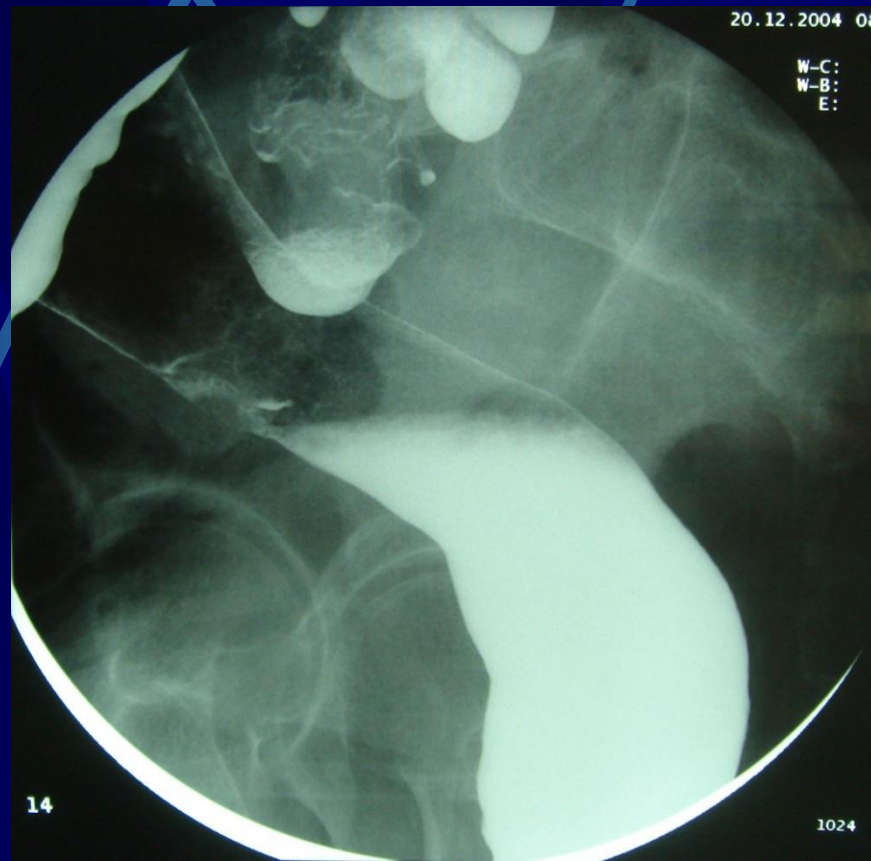
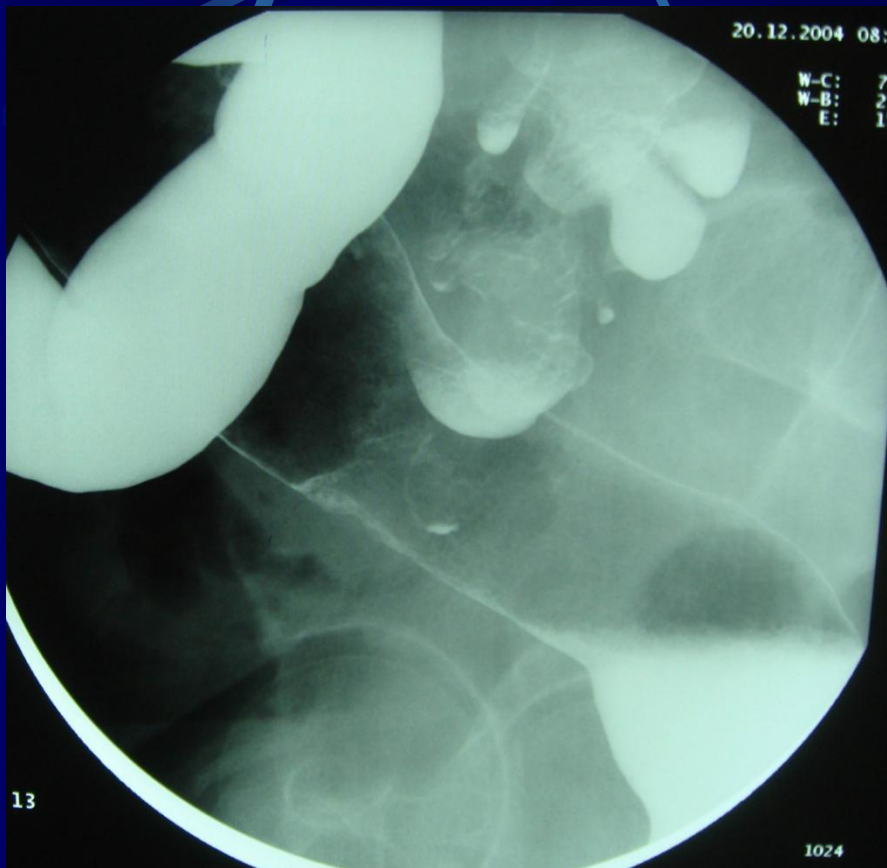
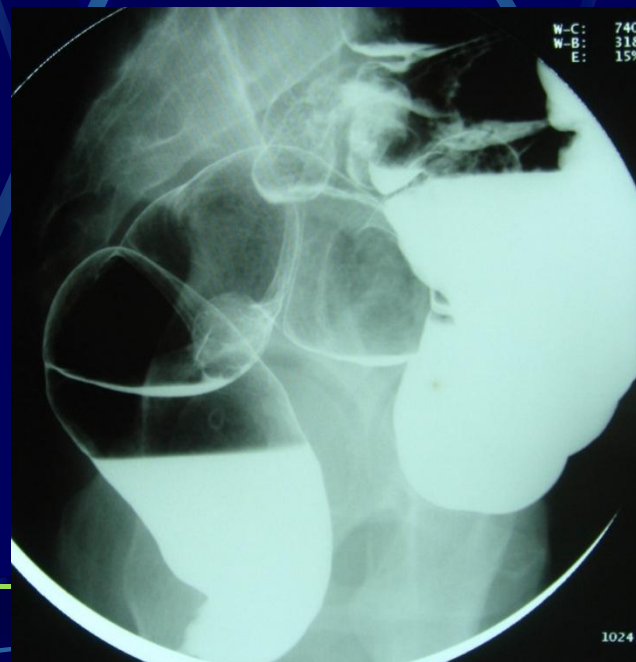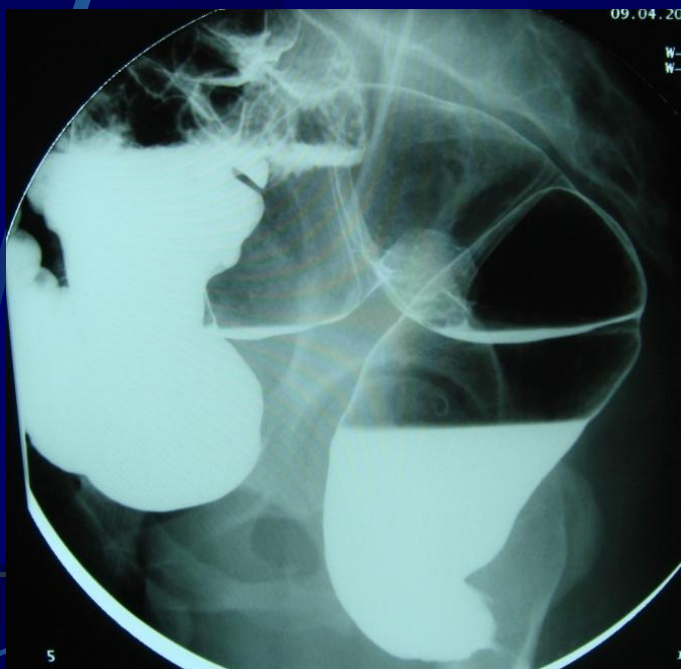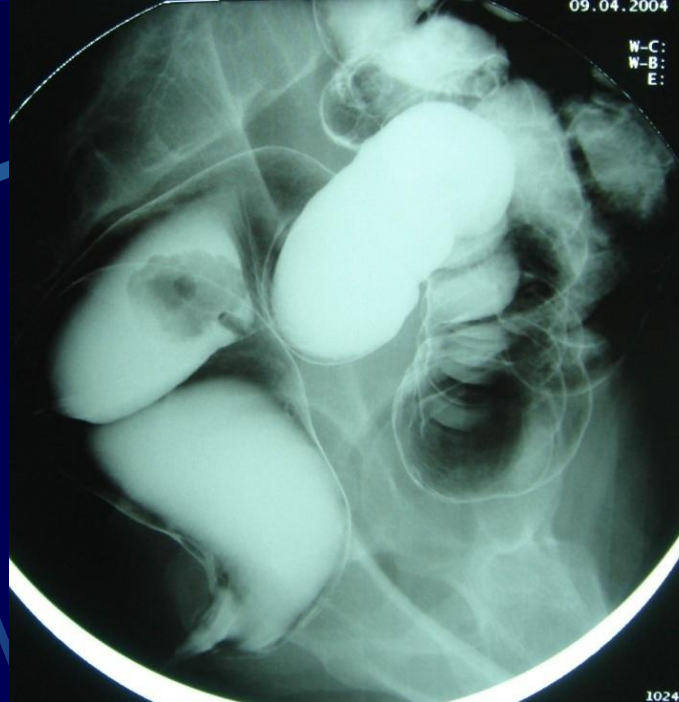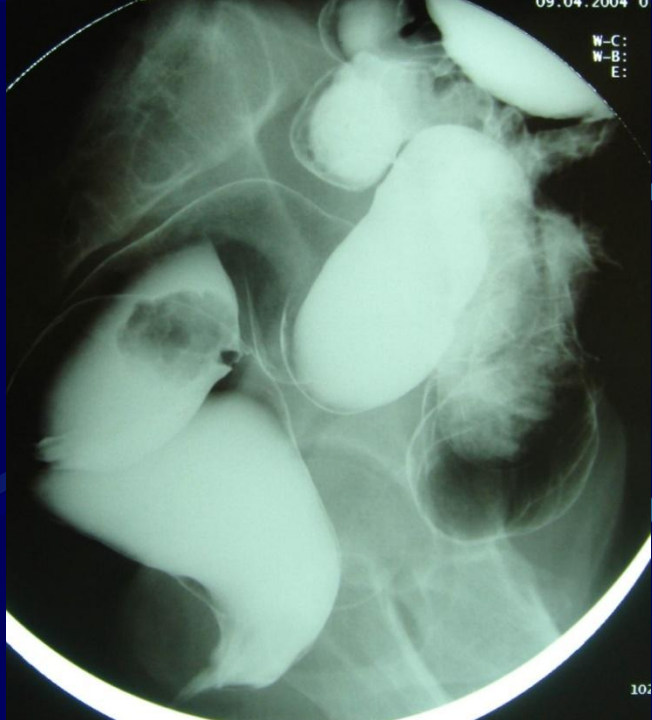20.12.2004 01

W-C:
W-B:
E:

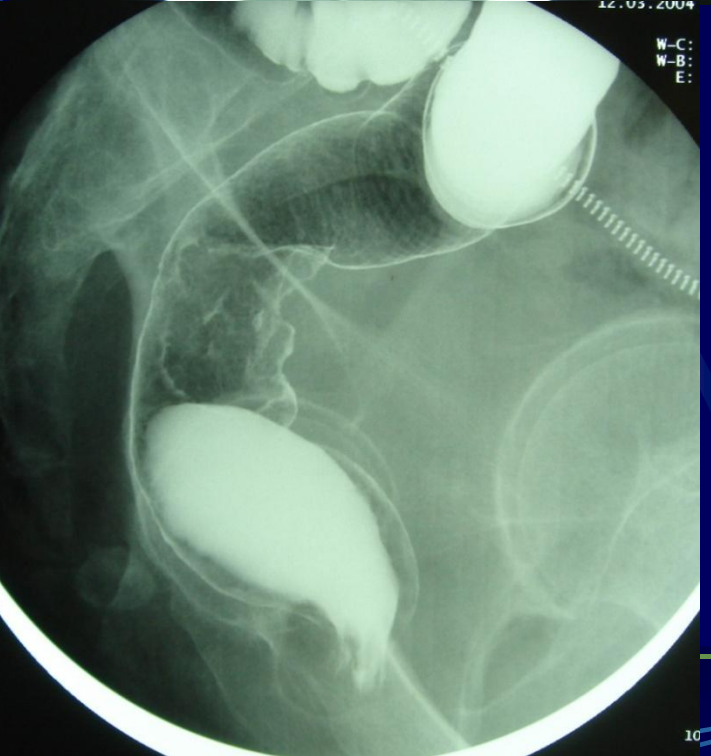
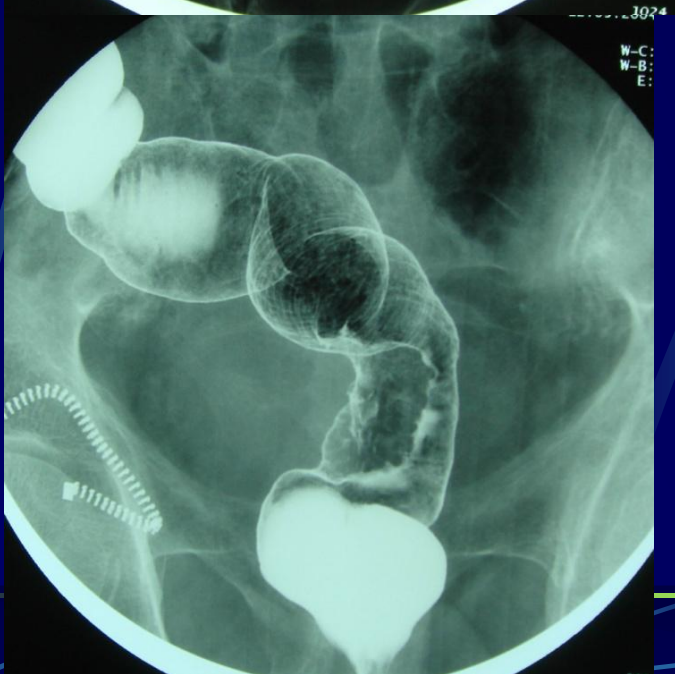
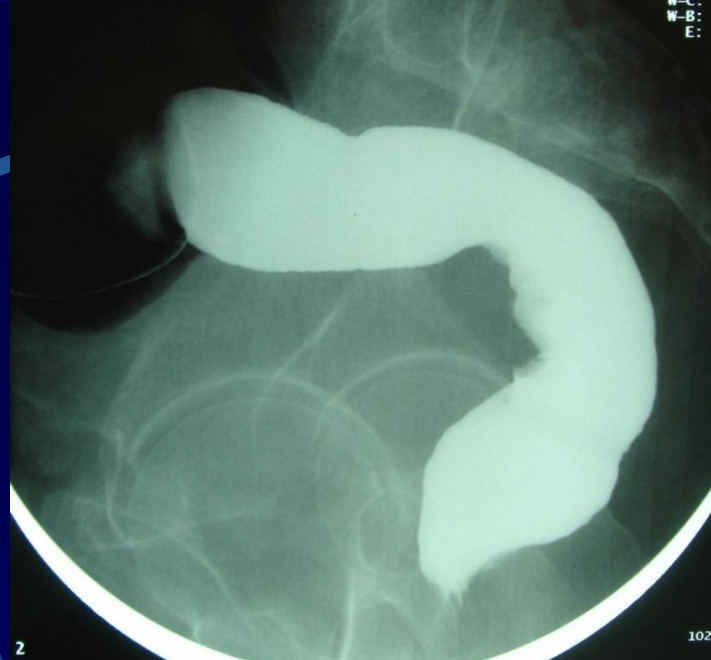
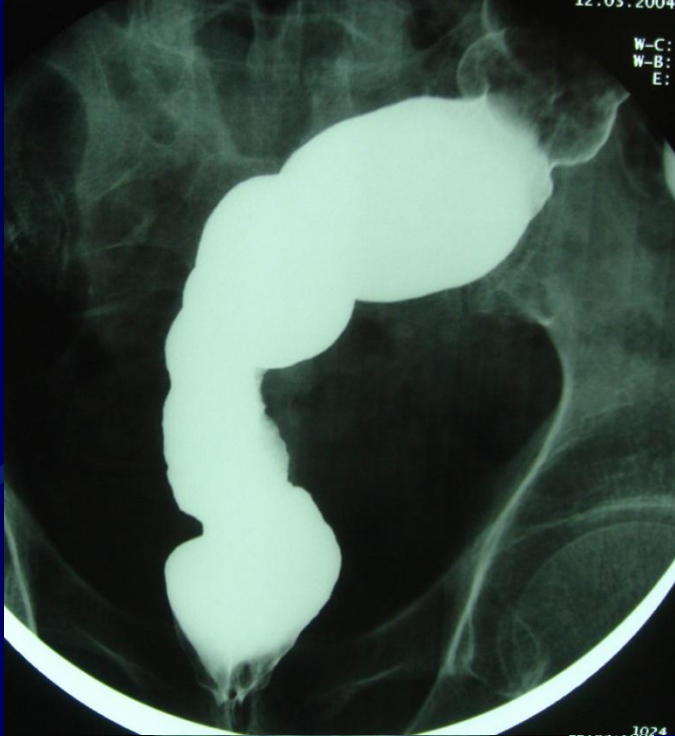
病例6

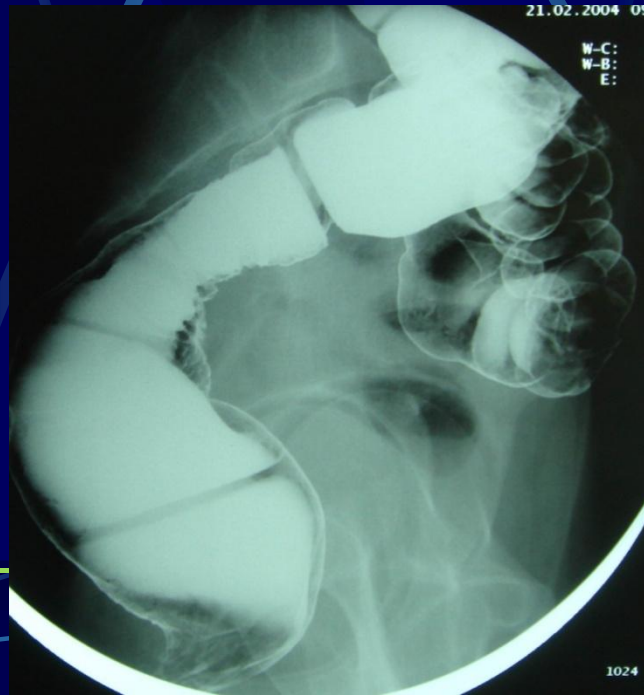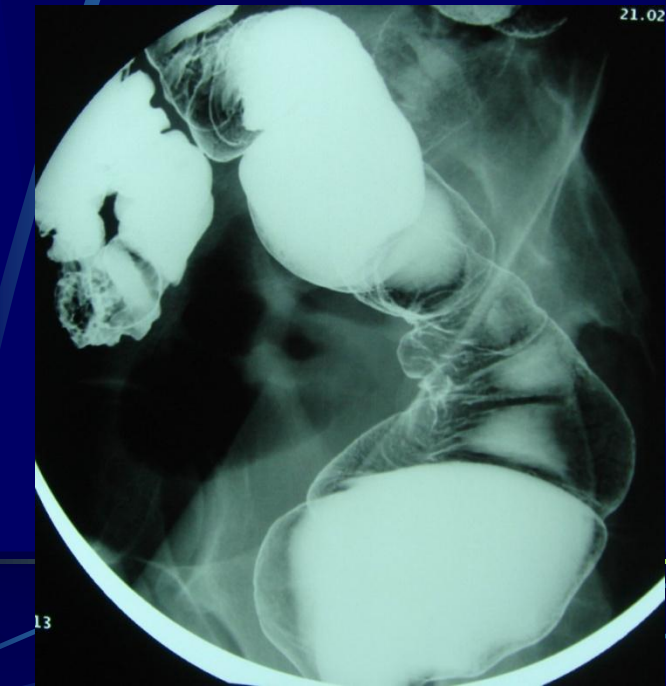
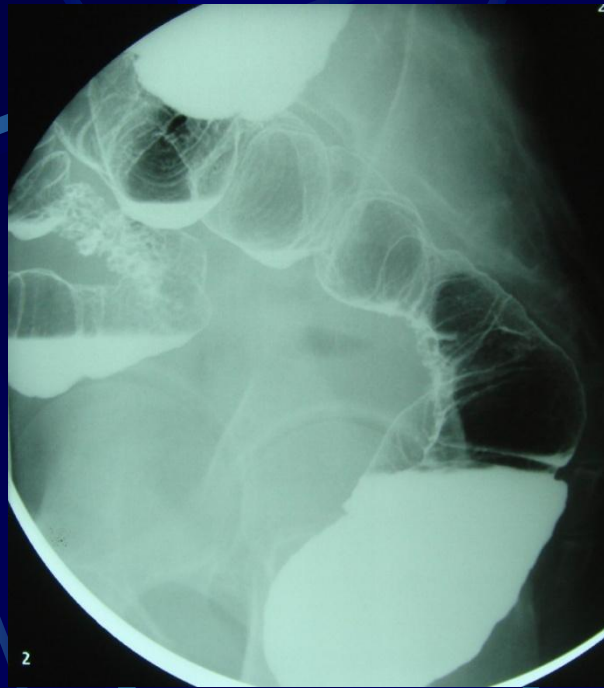

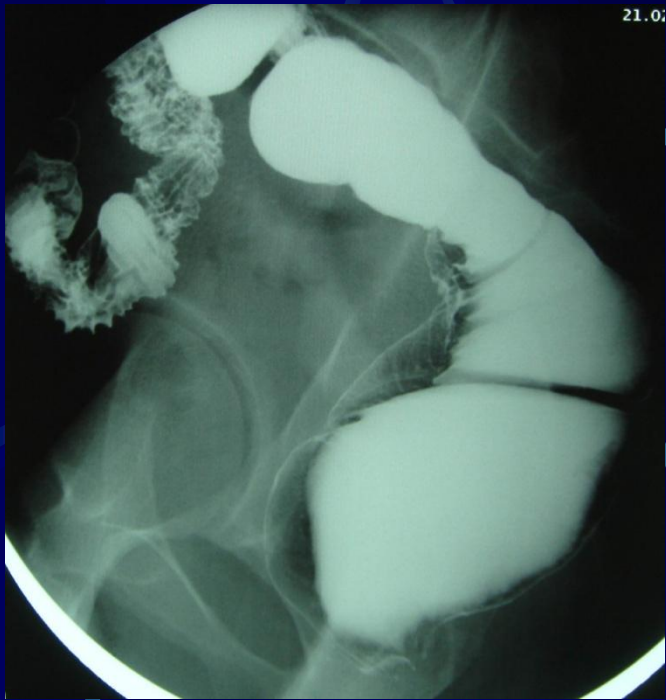


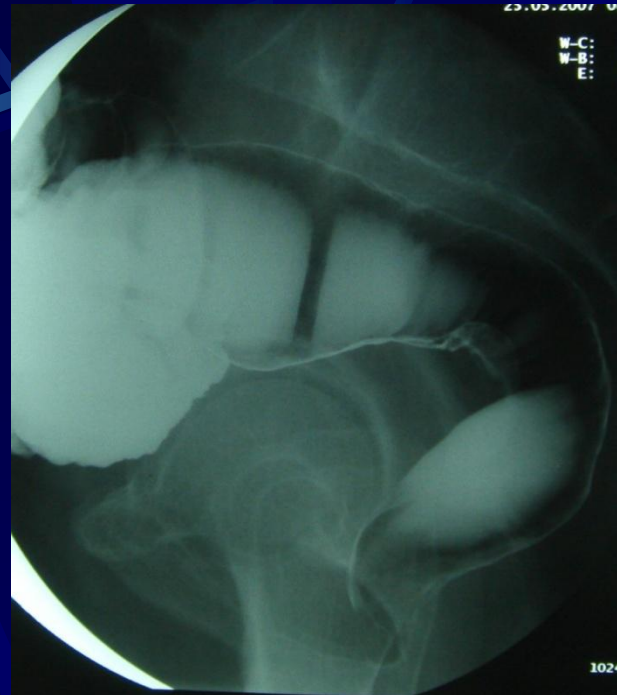
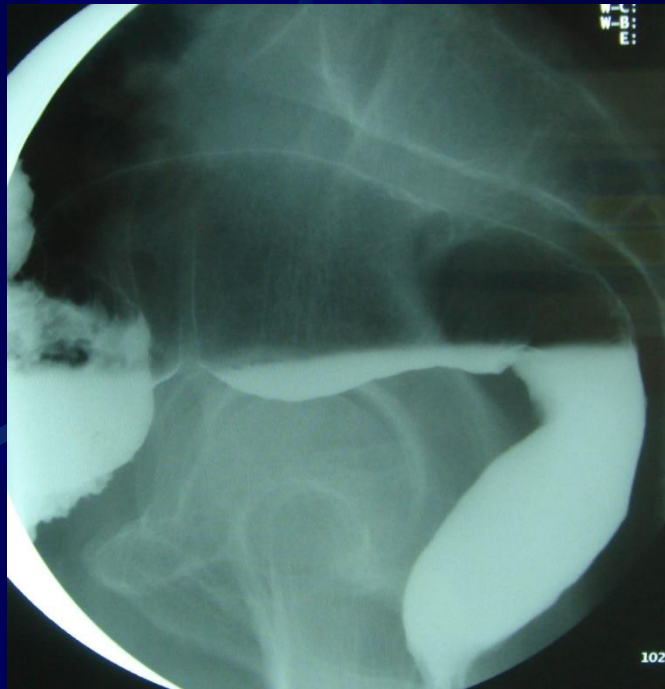病例 7



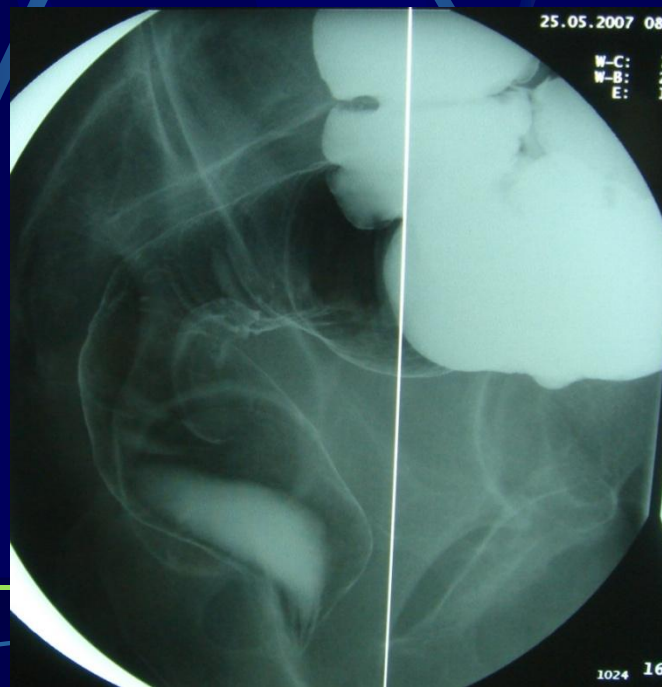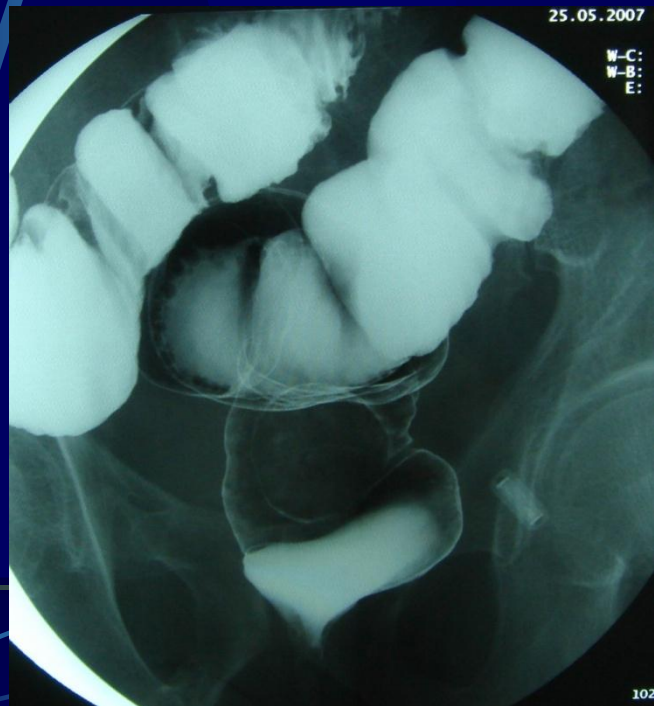
病例 8



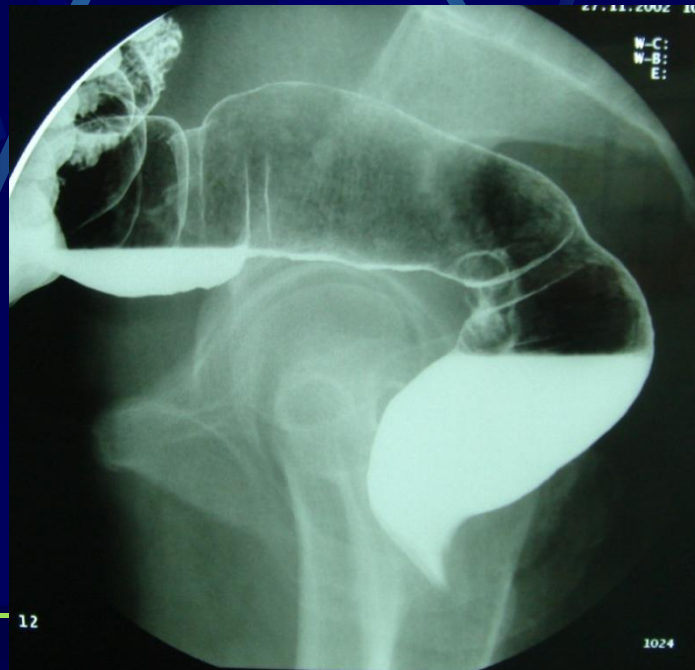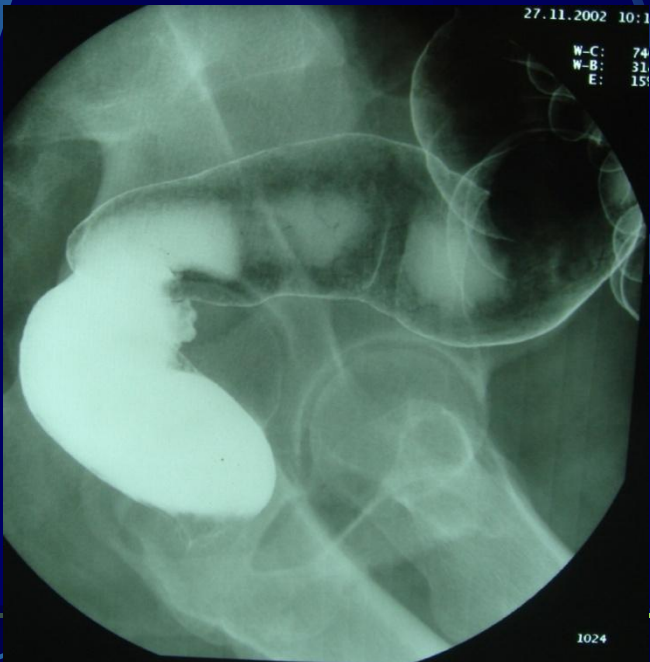
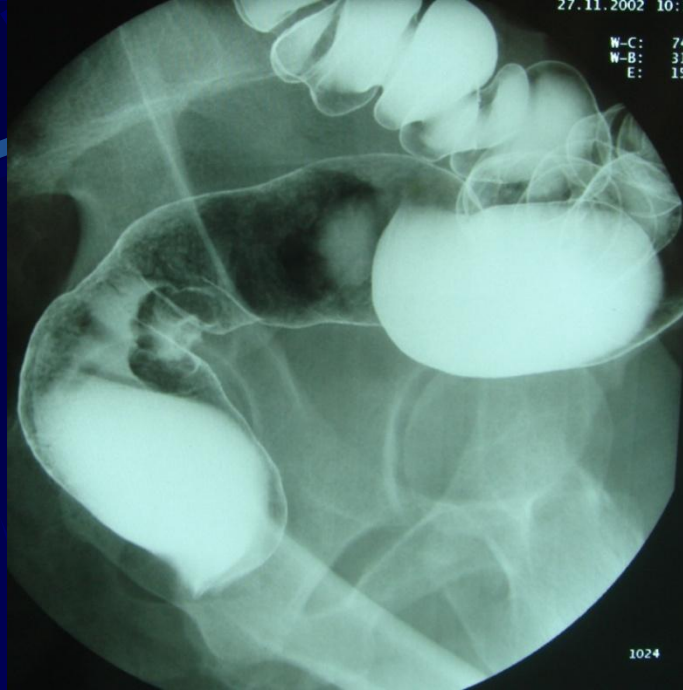
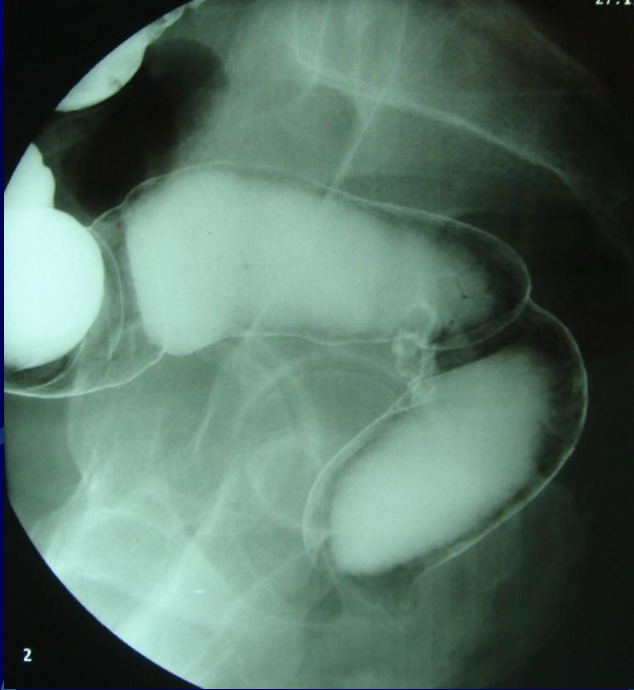
病例 9



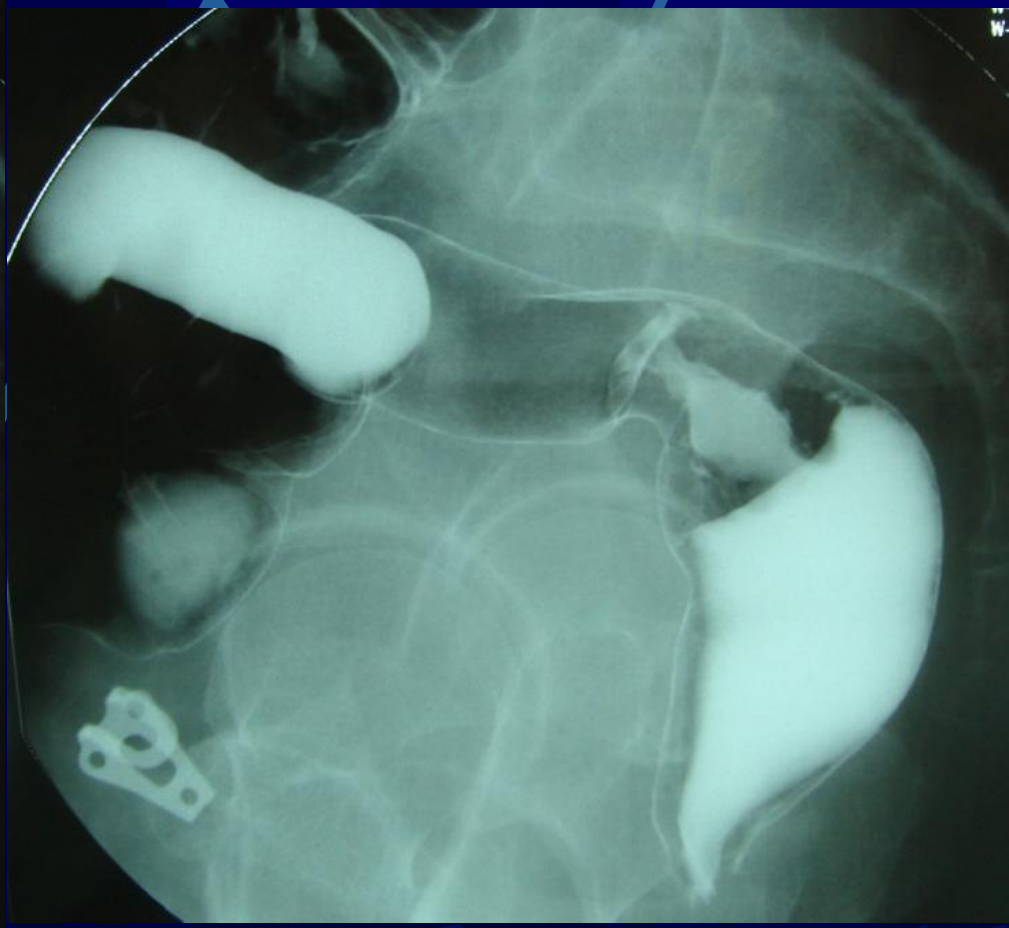
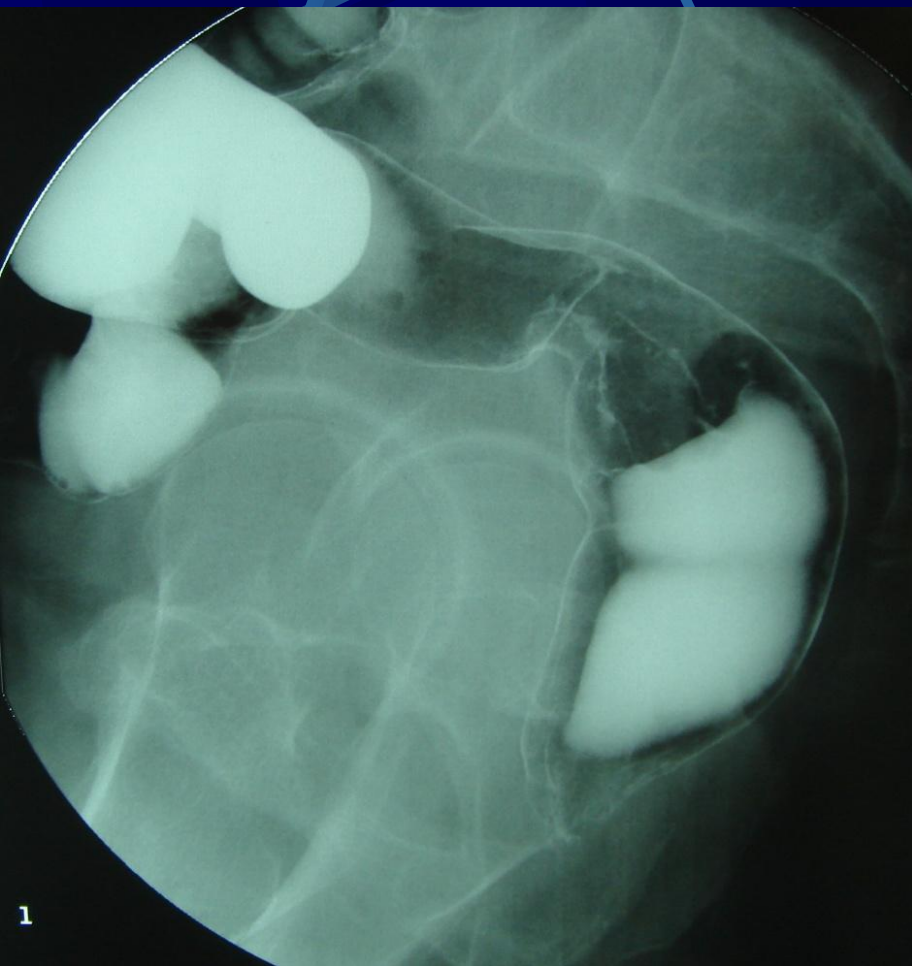
病例 10



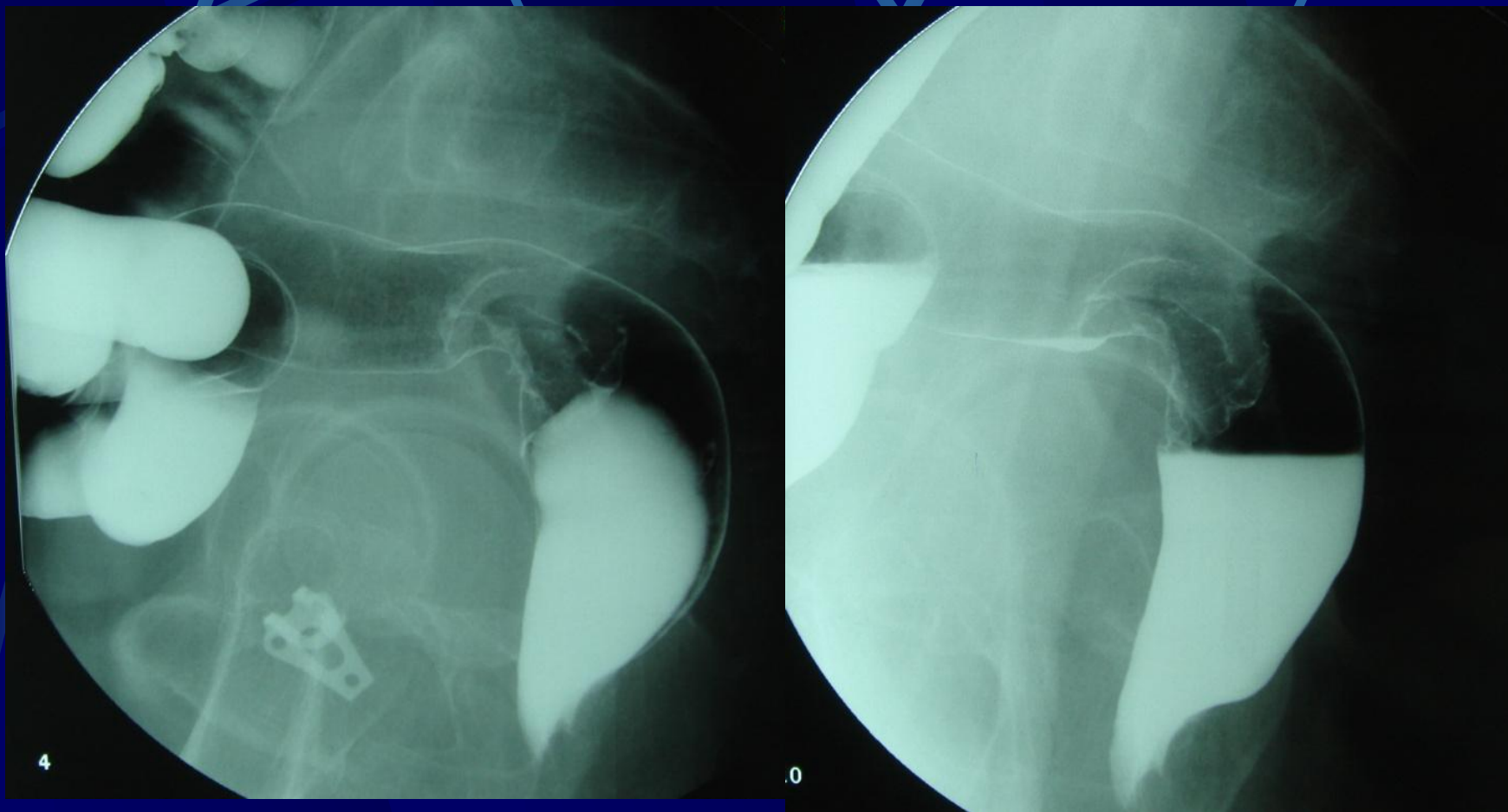
病例 11



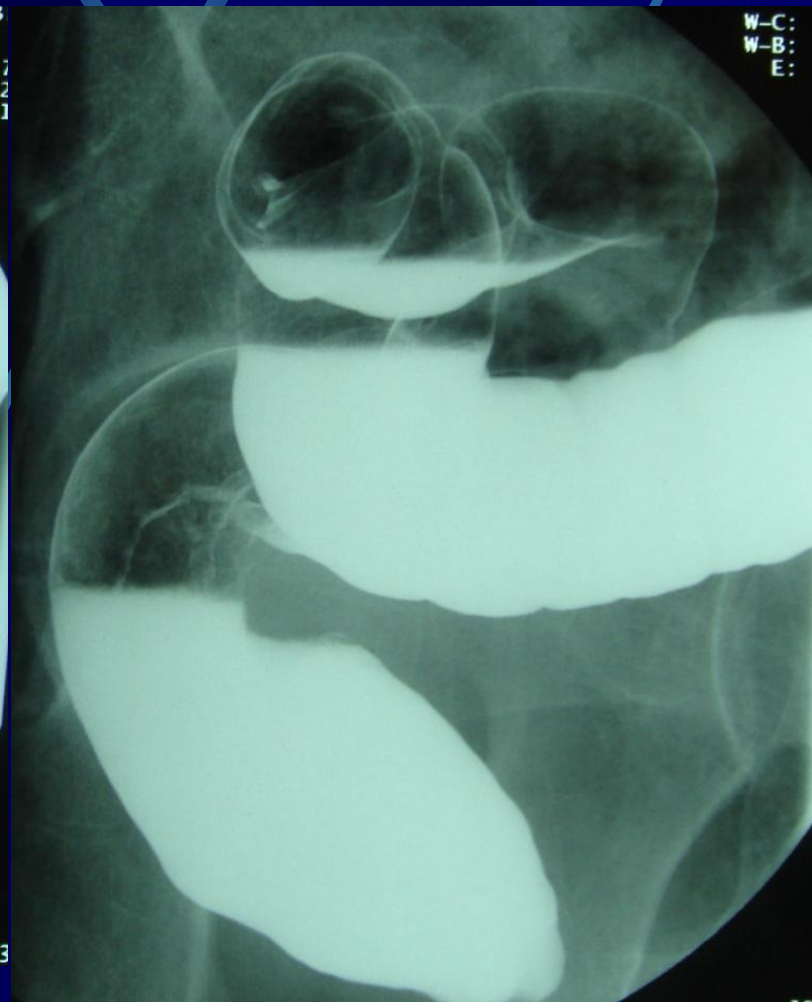
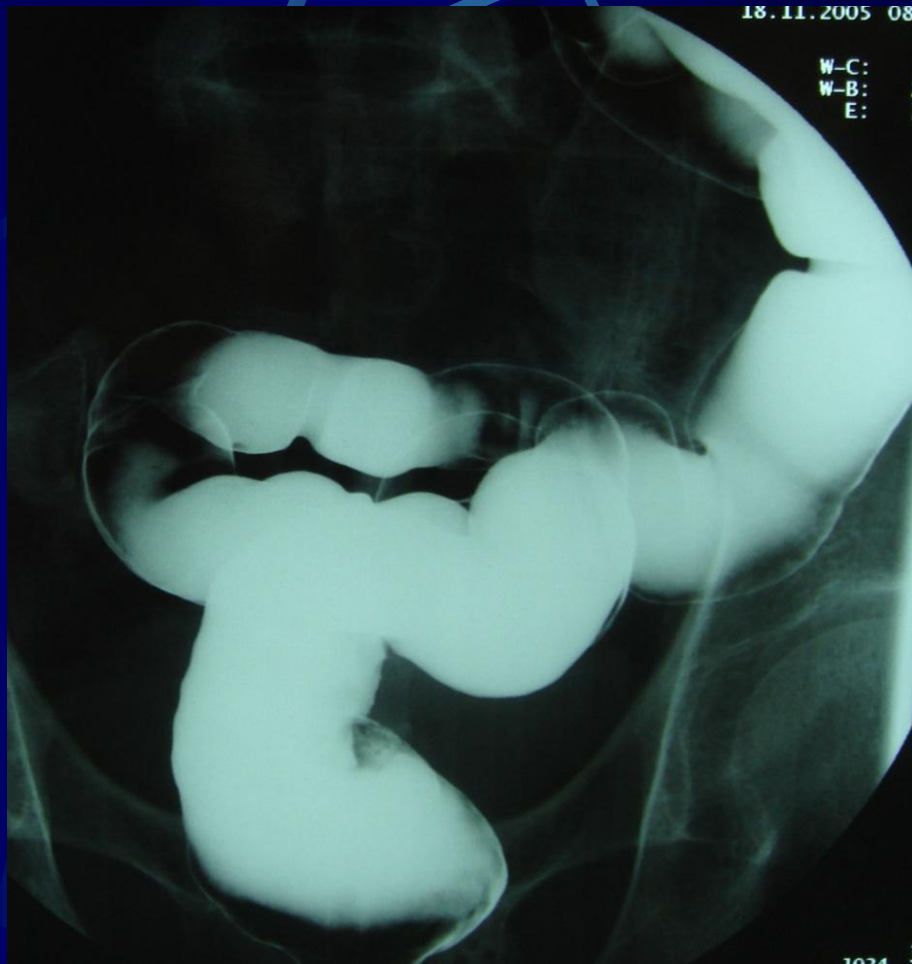病例12



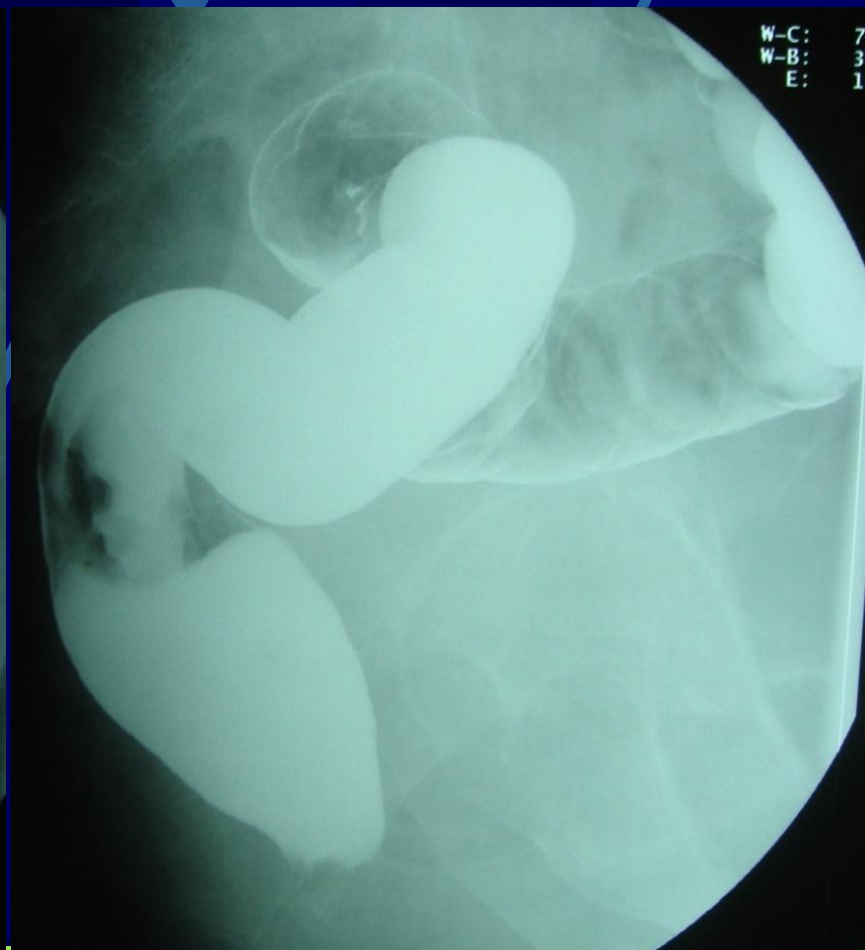
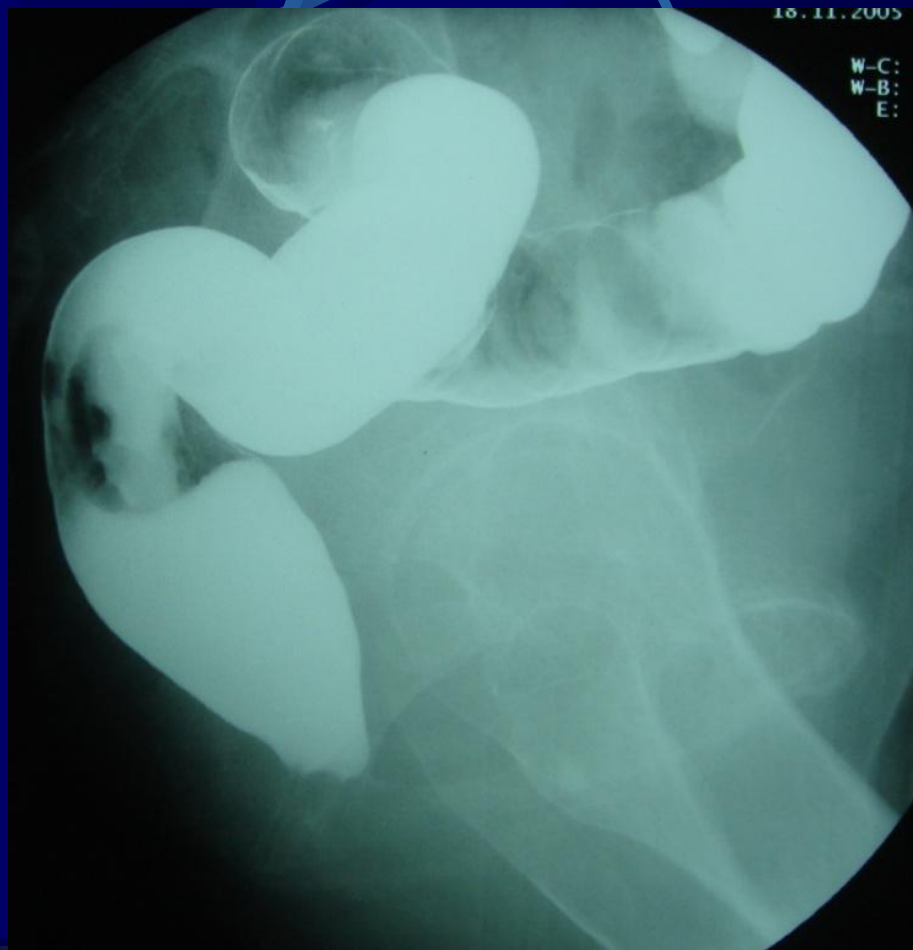病例12

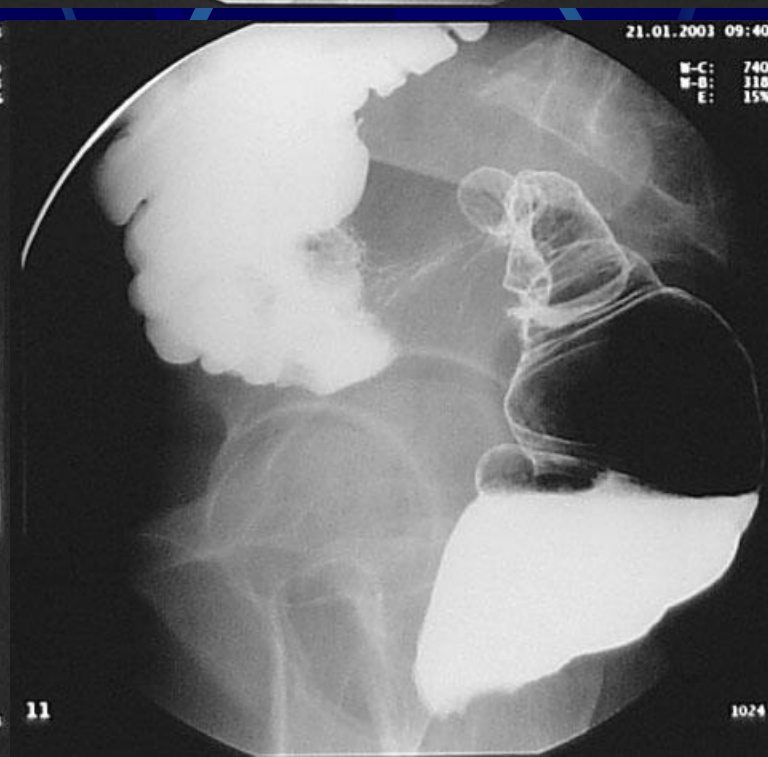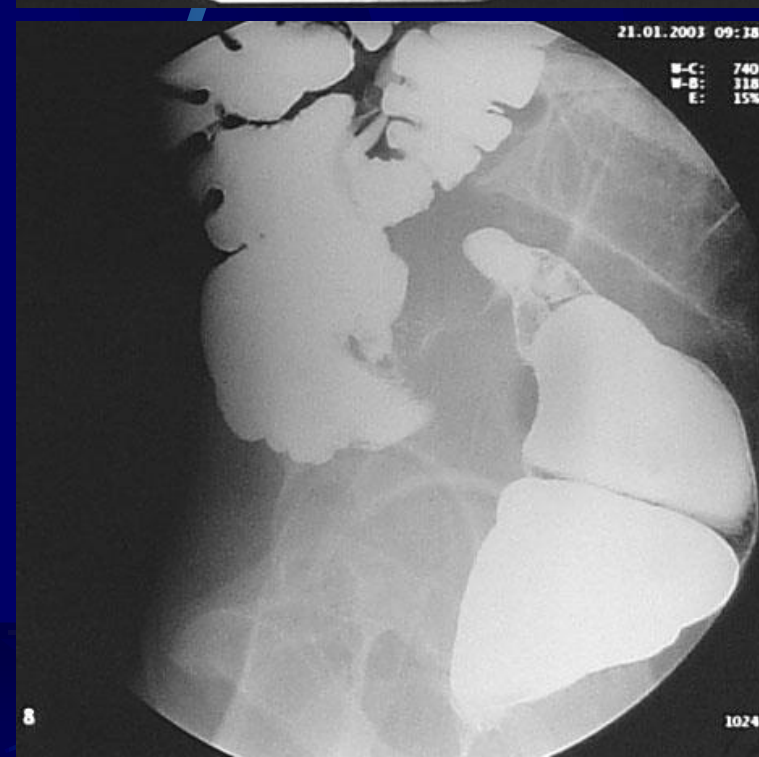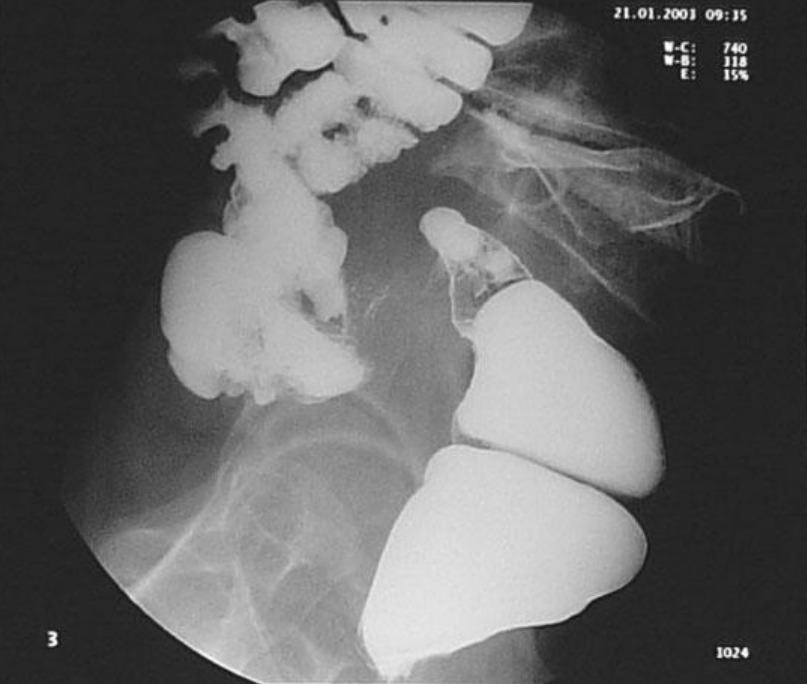


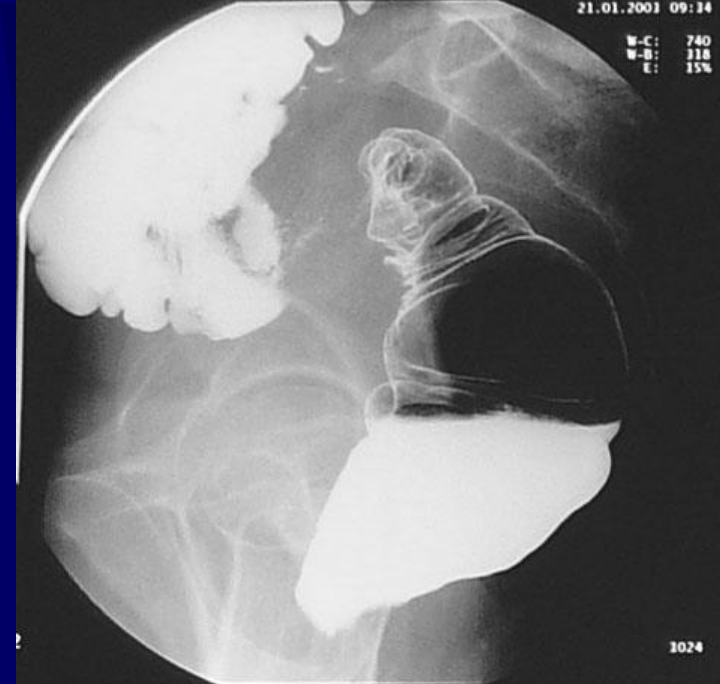病例13



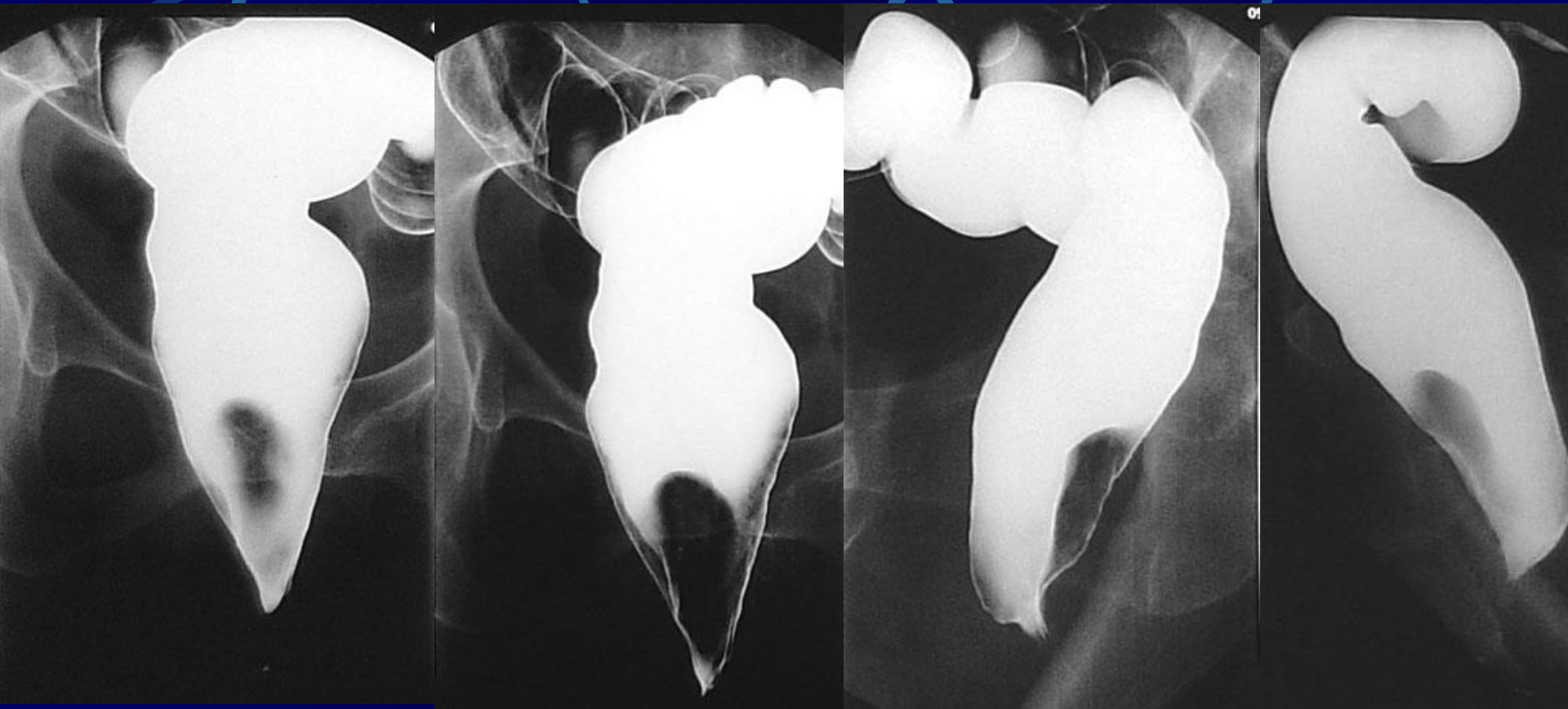
病例13



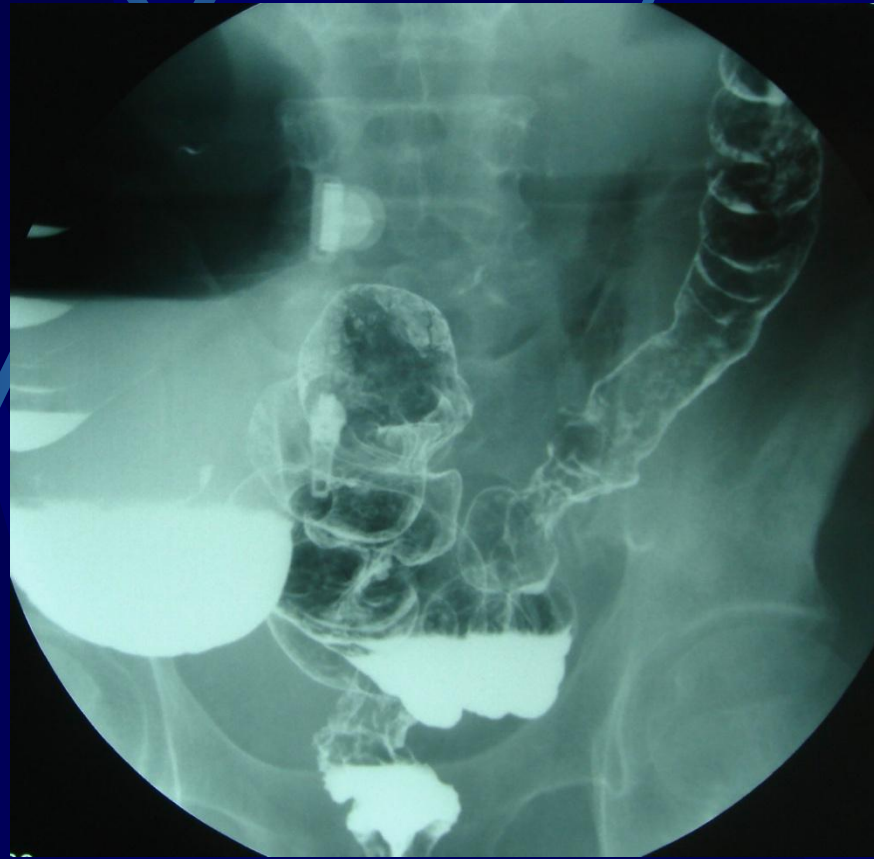
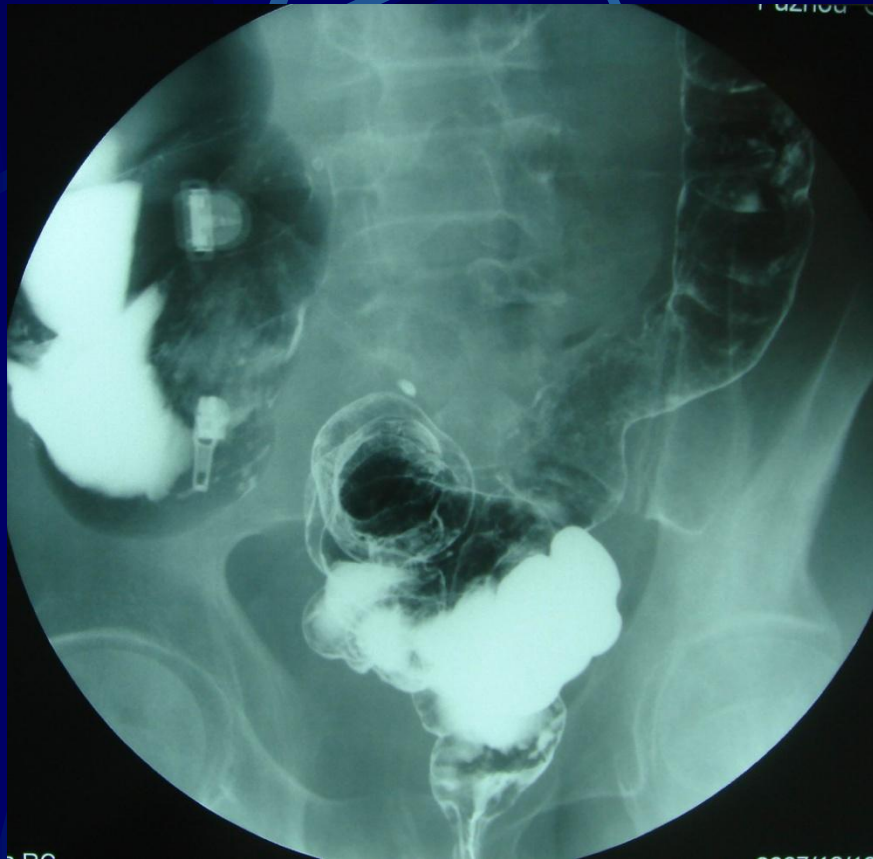

病例 14

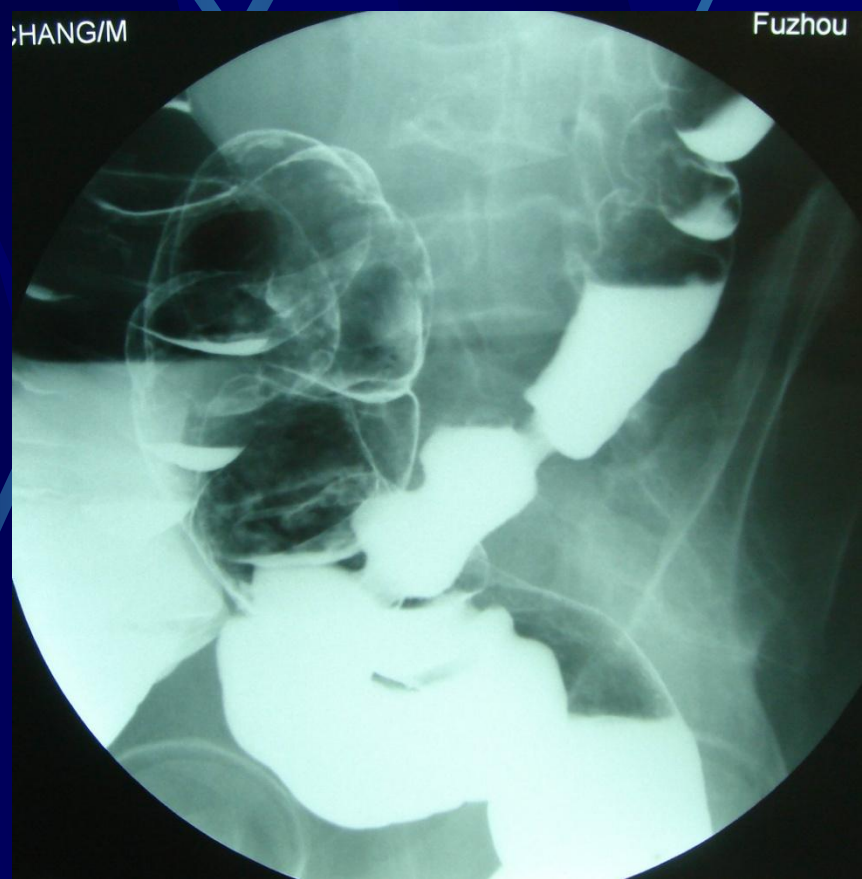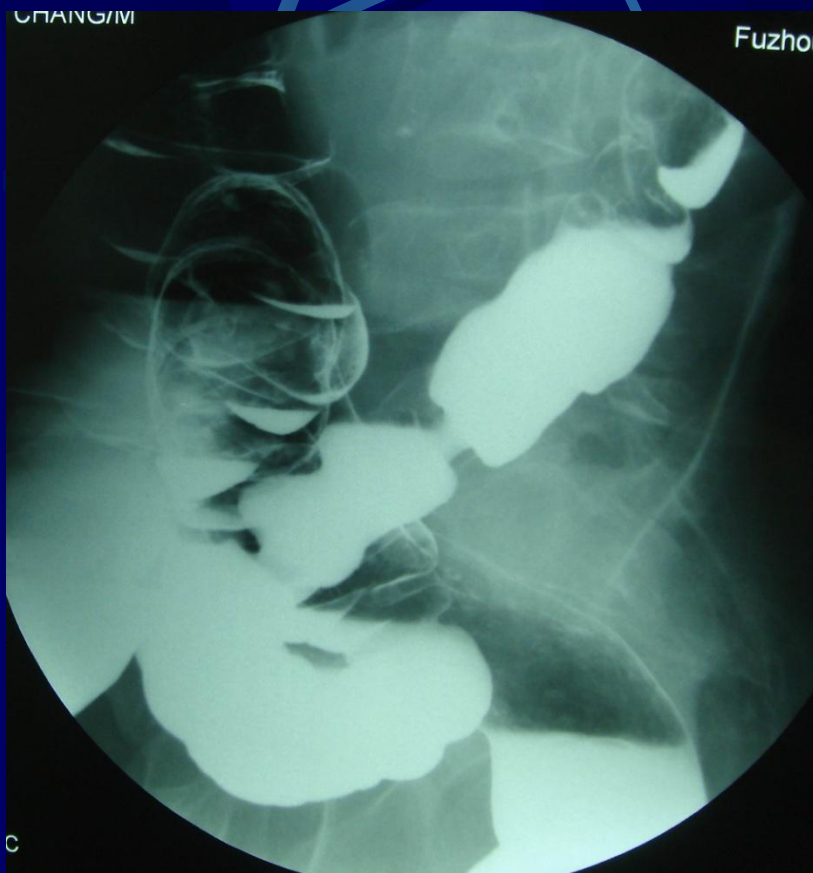
病例15

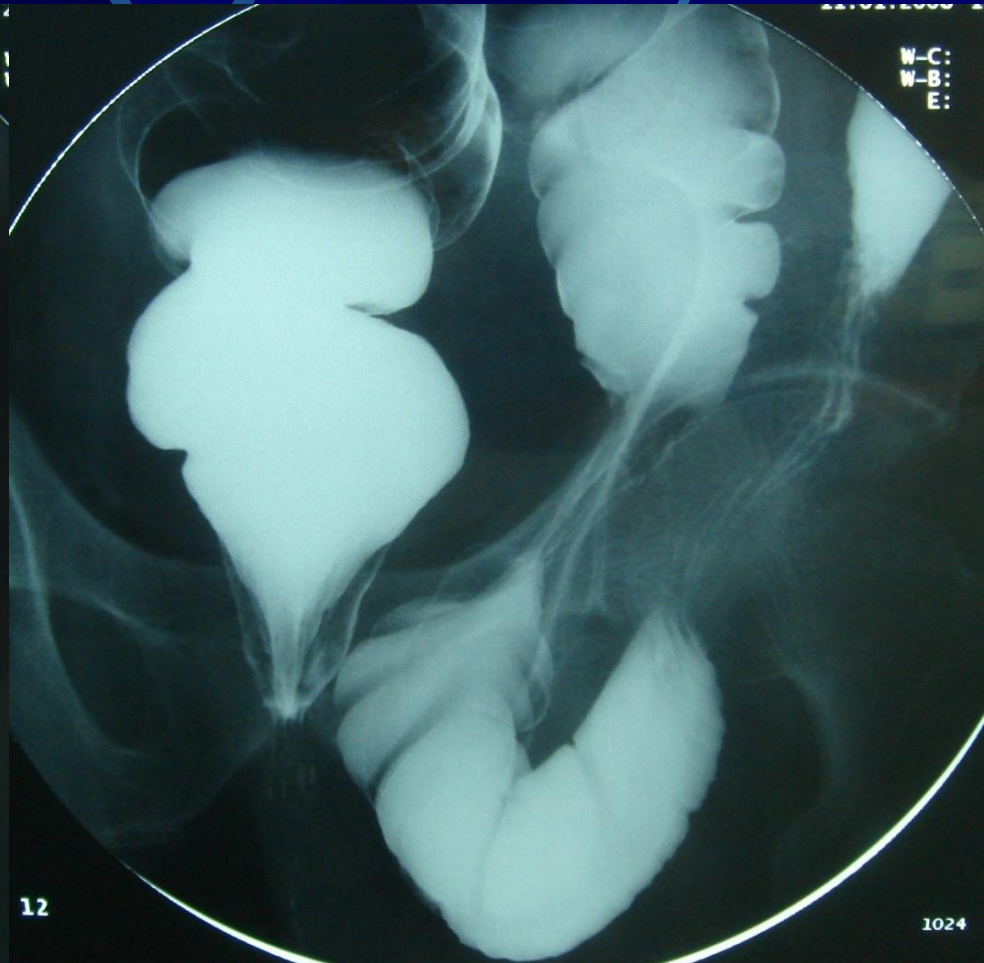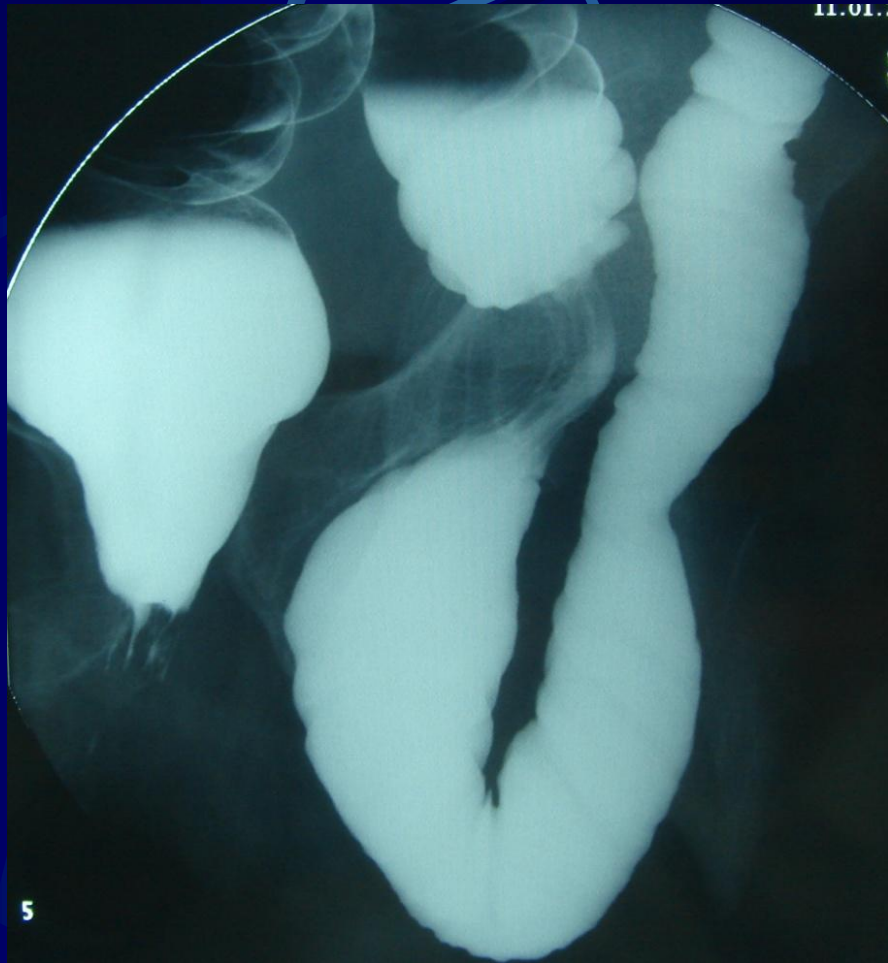


结肠炎？ 结肠癌？

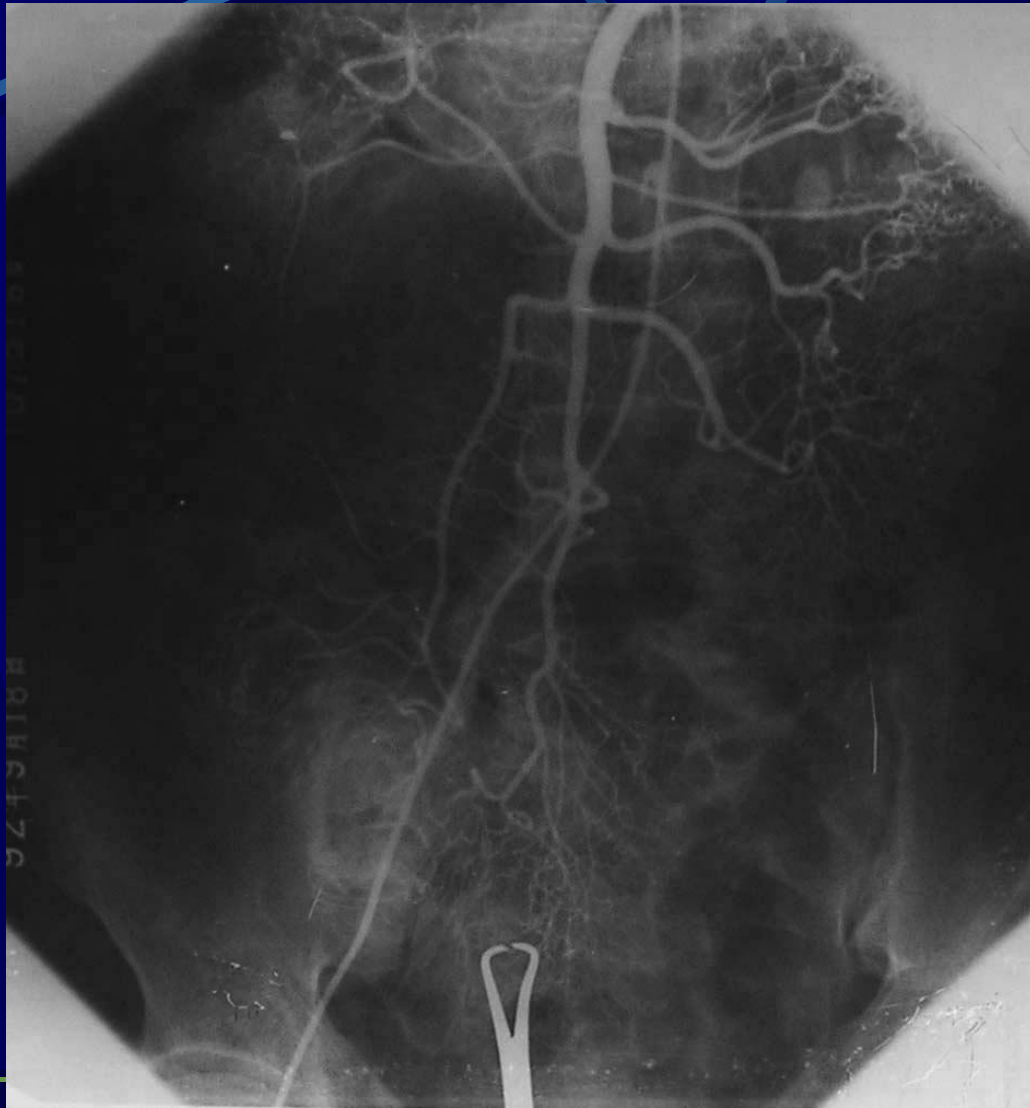


结肠炎？ 结肠癌？

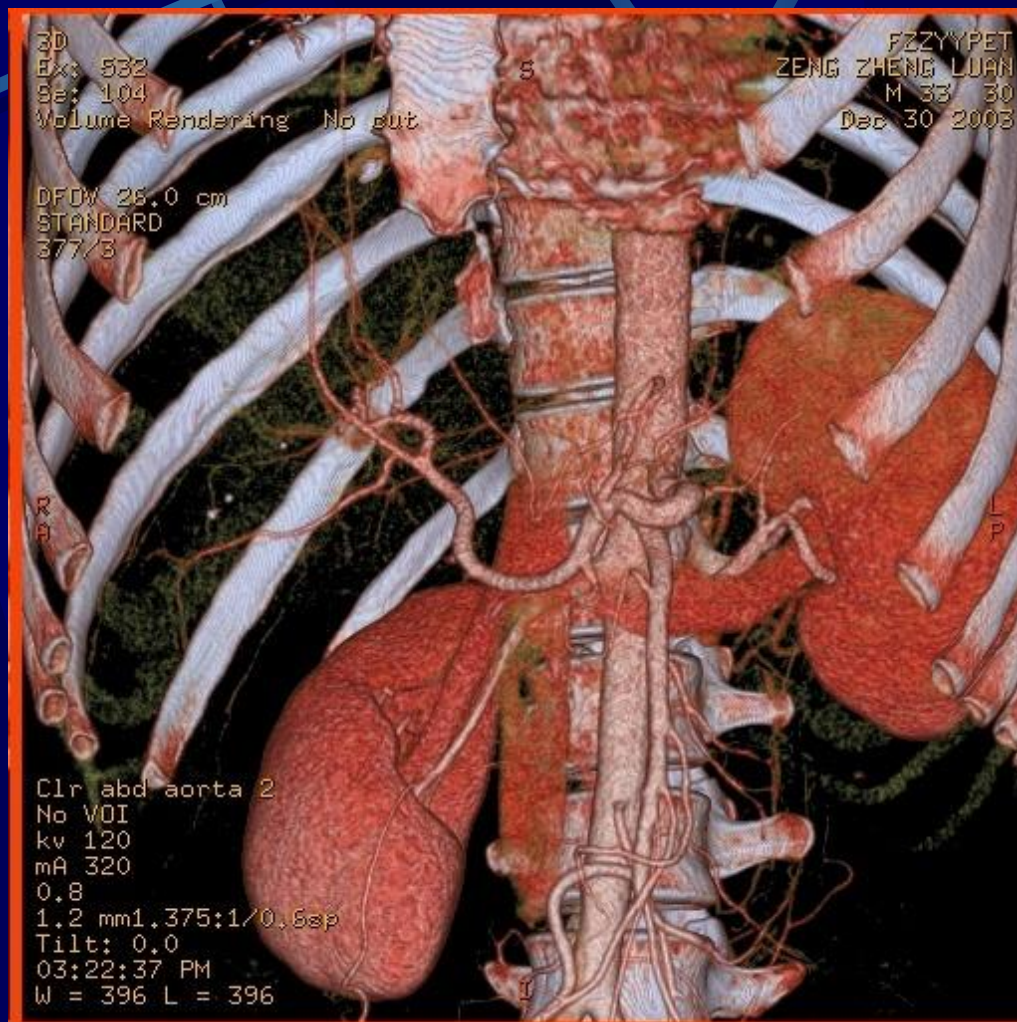




回盲部腺癌（肠系膜上动脉造影）



腹腔血管CTA三维重建



谢谢!

