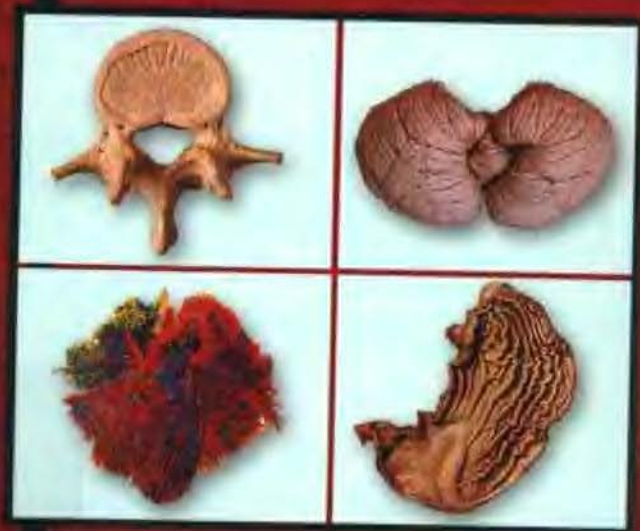


# 精编 人体解剖彩色图谱

CONCISE COLOUR ATLAS OF HUMAN ANATOMY

主 编 刘执玉 田 铎



科学出版社

www.sciencep.com

(R-1585.0101)

## 精编人体解剖彩色图谱

- 按照教育部教学大纲编写
- 按运动、内脏、消化、呼吸、泌尿、心血管、淋巴、感觉、内分泌、神经、局部解剖顺序编排
- 380余幅图片精心制作
- 图像立体感、层次感强
- 增加CT、MRI对照

医学院校本科生、高职高专学生、中专学生的必备书

ISBN 7-03-015099-6



9 787030 150998 >

科学出版社医学出版分社  
E-mail: med\_sp@sohu.com

ISBN 7-03-015099-6

定价: 29.80 元

R322  
LZ/a

128807

# 精编人体解剖彩色图谱

CONCISE COLOUR ATLAS OF HUMAN ANATOMY

主 编 刘执玉 田 铎



R322/6/05

\*C0252483\*



解放军医学院图书馆[书]

科学出版社

北京

## 内 容 简 介

《精编人体解剖彩色图谱》是按教育部规划教材内容要求,以精心设计、加工制作的新鲜标本拍照集成。标本制作精良,图像清晰、直观性强,便于记忆。本图谱共收录图片380余幅,按运动系统、内脏学概论、消化系统、呼吸系统、泌尿生殖系统、心脏、淋巴系统、视器与位听器、内分泌系统、神经系统和局部解剖学顺序编排。在本图谱各部分中精选部分有代表性和重要的断面解剖、X线、CT及MRI等图像。名词以全国自然科学名词审定委员会公布的《人体解剖学名词》为准。

本图谱适合医学本科生、高职高专学生、中专学生学习解剖学之用,也适用临床医生作为参考书。

### 图书在版编目(CIP数据)

精编人体解剖彩色图谱 / 刘执玉, 田铎主编. —北京: 科学出版社, 2005.3

ISBN 7-03-015099-6

I. 精… II. ①刘…②田… III. 人体解剖学—图谱  
IV. R322-64

中国版本图书馆CIP数据核字(2005)第016138号

责任编辑: 吴茵杰 / 责任校对: 刘小梅

责任印制: 刘士平 / 封面设计: 卢秋红

科学出版社 出版

北京东黄城根北街16号  
邮政编码: 100717  
<http://www.sciencep.com>

北京天对彩色印刷有限公司 印刷

科学出版社发行 各地新华书店经销

\*

2005年3月第 版 开本: 890 × 1240 1/32

2005年3月第一次印刷 印张: 8 1/2

印数: 1~10 000 字数: 245 000

定价: 29.80元

(如有印装质量问题, 我社负责调换<双青>)

# 前 言

《人体解剖彩色图谱》出版两年来，得到了读者充分的肯定和认可，许多读者纷纷来信，提出了许多很好的建议和意见。著名外科教授、器官移植专家夏穗生教授来信称赞图谱“色彩漂亮、清晰悦目、逼真动人，出版质量极高，令人钦佩和赞扬。”为满足不同读者的要求，我们在《人体解剖彩色图谱》的基础上，精选了学习人体解剖学必须掌握的基本内容，编著了这本《精编人体解剖彩色图谱》。本图谱不仅适合医学院校本科生、高职高专学生、中专学生使用，也适合临床各科医生作为参考工具书。

本图谱大部分标本是按教育部规划教材内容要求，以精心设计、加工制作的新鲜标本拍照集成，绝大部分标本制作精良。为使图像清晰，直观性强，便于记忆，有些神经、血管、淋巴管加了颜色，使图像立体感和层次感更强。

本图谱共收图 380 余幅，按运动系统、内脏学概论、消化系统、呼吸系统、泌尿生殖系统、心脏、淋巴系统、视器与位听器、内分泌系统、神经系统和局部解剖学顺序编排。图谱包括系统解剖学和局部解剖学两部分内容。但系统解剖学中的有关血管、神经部分可在局部解剖学部分中查阅。在本图谱各部分中精选有代表性的断面解剖、X 线、CT 及 MRI 等图像。图像解剖学名词以全国自然科学名词审定委员会 1991 年公布的《人体解剖学名词》为准，中英文对照。

由于我们水平有限，难免存在缺点和不足之处，恳请广大读者和同道给予指正。

编 者

2005 年 2 月

# 目 录

## 第 1 章 运动系统——骨 Locomotor System —— Bone

图 1	全身骨骼前面观 The skeleton (anterior aspect).....	2
图 2	骨的构造 Structure of the bone.....	3
图 3	胫骨上端冠状剖面 Coronal section of upper end of the tibia.....	3
图 4	颅盖板障 Diploic of the calvaria.....	4
图 5	椎骨剖面 Section of the vertebra.....	4
图 6	颅盖剖面 Section of the calvaria.....	4
图 7	脊柱(前面观、后面观) The vertebral column (anterior and posterior aspect).....	5
图 8	脊柱(外侧面观) The vertebral column (lateral aspect).....	5
图 9	寰椎(上面观) The atlas (superior aspect).....	6
图 10	枢椎(后面观) The axis (posterior aspect).....	6
图 11	颈椎(上面观) The cervical vertebra (superior aspect).....	7
图 12	隆椎(右侧面观) The vertebra prominens (right aspect).....	7
图 13	胸椎(上面观) The thoracic vertebra (superior aspect).....	8
图 14	胸椎(外侧面观) The thoracic vertebra (lateral aspect).....	8
图 15	腰椎(上面观) The lumbar vertebra (superior aspect).....	9
图 16	腰椎(外侧面观) The lumbar vertebra (lateral aspect).....	9
图 17	骶骨(前面观) The sacrum (anterior aspect).....	10
图 18	骶骨(后面观) The sacrum (posterior aspect).....	10
图 19	尾骨(前面观) The coccyx (anterior aspect).....	11
图 20	尾骨(后面观) The coccyx (posterior aspect).....	11
图 21	肋 The ribs.....	12
图 22	胸骨(前面观) The sternum (anterior aspect).....	13
图 23	胸骨(外侧面观) The sternum (lateral aspect).....	13

图 24	新生儿颅(上面观) The skull of the infant (superior aspect).....	14
图 25	新生儿颅(侧面观) The skull of the infant (lateral aspect).....	14
图 26	颅(前面观) The skull (anterior aspect).....	15
图 27	颅底内面观 The internal surface of base of the skull.....	16
图 28	颅底外面观 The external surface of base of the skull.....	17
图 29	下颌骨(外侧面观) The mandible (lateral aspect).....	18
图 30	下颌骨(后面观) The mandible (posterior aspect).....	18
图 31	下颌骨(内侧面观) The mandible (medial aspect).....	19
图 32	蝶骨(前面观) The sphenoid bone (anterior aspect).....	20
图 33	蝶骨(上面观) The sphenoid bone (superior aspect).....	21
图 34	蝶骨(后面观) The sphenoid bone (posterior aspect).....	21
图 35	泪骨(前面观) The lacrimal bone (anterior aspect).....	22
图 36	腭骨(内侧面观) The palatine bone (medial aspect).....	23
图 37	腭骨(后面观) The palatine bone (posterior aspect).....	23
图 38	舌骨(上面观) The hyoid bone (superior aspect).....	23
图 39a	锁骨(上面观) The clavicle (superior aspect).....	24
图 39b	锁骨(下面观) The clavicle (inferior aspect).....	24
图 40	肩胛骨(前面观) The scapula (anterior aspect).....	25
图 41	肩胛骨(后面观) The scapula (posterior aspect).....	25
图 42	肱骨(前面观) The humerus (anterior aspect).....	26
图 43	肱骨(后面观) The humerus (posterior aspect).....	26
图 44	肩 X 线图像(正位) Radiograph of the shoulder (anterior aspect).....	26
图 45	桡骨和尺骨(前面观) The radius and ulna (anterior aspect).....	27
图 46	桡骨和尺骨(后面观) The radius and ulna (posterior aspect).....	27
图 47	手骨(掌侧面) Bones of the hand (palmar aspect).....	28
图 48	手骨(背面观) Bones of the hand (dorsal aspect).....	28
图 49	髌骨(外面观) The hip bone (external aspect).....	29
图 50	髌骨(内面观) The hip bone (internal aspect).....	30
图 51	髌骨(前面观) The patella (anterior aspect).....	31
图 52	髌骨(后面观) The patella (posterior aspect).....	31
图 53	股骨(前面观) The femur (anterior aspect).....	32

图 54	股骨(后面观) The femur (posterior aspect).....	32
图 55	胫骨和腓骨(前面观) The tibia and fibula (anterior aspect).....	33
图 56	胫骨和腓骨(后面观) The tibia and fibula (posterior aspect).....	33
图 57	足骨(上面观) Bones of the foot (superior aspect).....	34
图 58	足骨(下面观) Bones of the foot (inferior aspect).....	34

## 第 2 章 运动系统——骨连结

### Locomotor System —— Joint

图 59	椎骨间的连结(前面观) The intervertebral joints (anterior aspect).....	36
图 60	椎骨间的连结(矢状面) The intervertebral joints (sagittal plane).....	37
图 61	椎间盘(下面观) The intervertebral disc (inferior aspect).....	38
图 62	颞下颌关节(外侧观) The temporomandibular joint (lateral aspect).....	38
图 63	胸廓(前面观) The thorax (anterior aspect).....	39
图 64	颈椎 X 线图像(正位) Radiograph of the cervical vertebrae (anterior aspect).....	40
图 65	颈椎 X 线图像(侧位) Radiograph of the cervical vertebrae (lateral aspect) .....	41
图 66	腰椎 X 线图像(正位) Radiograph of the lumbar vertebrae (anterior aspect) .....	41
图 67	腰椎 X 线图像(侧位) Radiograph of the lumbar vertebrae (lateral aspect).....	42
图 68	腰椎 MRI 图像(侧位) MRI of the lumbar vertebrae (lateral aspect).....	42
图 69	肩关节(前面观) The shoulder joint (anterior aspect) .....	43
图 70	肩关节(冠状切面) The shoulder joint (coronal section) .....	43
图 71	肩关节(内面观) The shoulder joint (medial aspect) .....	44
图 72	肘关节(前面观) The elbow joint (anterior aspect) .....	44
图 73	肘关节(后面观) The elbow joint (posterior aspect) .....	45
图 74	手关节(前面观) Joints of the hand (anterior aspect) .....	45
图 75	肘关节 X 线图像(正位) Radiograph of the elbow joint (anterior aspect) .....	46
图 76	肘关节 X 线图像(侧位) Radiograph of the elbow joint (lateral aspect) .....	46



图 77	手关节 X 线图像(正位) Radiograph of the hand joint (anterior aspect).....	47
图 78	手关节 X 线图像(正位) Radiograph of the hand joint (anterior aspect).....	47
图 79	骨盆的连结(前面观) Articulations of the pelvis (anterior aspect) .....	48
图 80	骨盆的连结(后面观) Articulations of the pelvis (posterior aspect).....	48
图 81	骨盆(女性) The pelvis (female) .....	49
图 82	骨盆(男性) The pelvis (male) .....	49
图 83	髋关节(打开关节腔) The hip joint (opened cavity) .....	50
图 84	骨盆 X 线图像(正位) Radiograph of the pelvis (anterior aspect).....	50
图 85	膝关节(前面观) The knee joint (anterior aspect).....	51
图 86	膝关节(后面观) The knee joint (posterior aspect).....	51
图 87	膝关节(打开关节腔) The knee joint (opened cavity) .....	52
图 88	膝关节(前面观, 打开关节腔) The knee joint (anterior aspect, opened cavity).....	52
图 89	膝关节(MRI) The knee joint (MRI) .....	53
图 90	膝关节(MRI) The knee joint (MRI) .....	53
图 91	膝关节 X 线图像(正位) Radiograph of the knee joint (anterior aspect).....	54
图 92	膝关节 X 线图像(侧位) Radiograph of the knee joint (lateral aspect).....	54
图 93	足的连结(内侧面观)Articulations of the foot (medial aspect).....	55
图 94	足的连结(外侧面观) Articulations of the foot (lateral aspect).....	55
图 95	足关节 X 线图像(正位) Radiograph of the foot joint (anterior aspect).....	56
图 96	足关节 X 线图像(侧位) Radiograph of the foot joint (lateral aspect).....	56

### 第 3 章 运动系统——肌

#### Locomotor System —— Muscle

图 97	全身体表及肌肉(前面观) Surface anatomy and muscles of the body (anterior aspect).....	58
图 98	全身体表及肌肉(后面观) Surface anatomy and muscles of the body (posterior aspect).....	59

图 99	躯干肌体表标志(侧面观) Surface markings of the muscles of the trunk (lateral aspect).....	60
图 100	躯干肌体表标志(后面观) Surface markings of the muscles of the trunk (posterior aspect).....	60
图 101	背部肌 Muscles of the back.....	61
图 102	背部肌 Muscles of the back.....	62
图 103	躯干肌 Muscles of the trunk.....	63
图 104	胸肌(前面观) Muscles of the thorax (anterior aspect) .....	64
图 105	肋间肌 The intercostales.....	64
图 106	腹前外侧壁肌层 Muscular layer of the anterolateral abdominal wall.....	65
图 107	膈(上面观) The diaphragm (superior aspect).....	65
图 108	膈(下面观) The diaphragm (inferior aspect).....	66
图 109	面部表情肌 Muscles of the facial expression.....	66
图 110	头部的肌 Muscles of the head.....	67
图 111	翼肌 The pterygoid.....	67
图 112	颈阔肌 The platysma.....	68
图 113	颈肌(侧面观) Muscles of the neck (lateral aspect).....	68
图 114	颈肌(侧面观) Muscles of the neck (lateral aspect).....	69
图 115	肩及臂部的肌肉(前面观 1) Muscles of the shoulder and arm (anterior aspect 1).....	70
图 116	肩及臂部的肌肉(前面观 2) Muscles of the shoulder and arm (anterior aspect 2).....	70
图 117	肩及臂部的肌肉(后面观 1) Muscles of the shoulder and arm (posterior aspect 1).....	71
图 118	肩及臂部的肌肉(后面观 2) Muscles of the shoulder and arm (posterior aspect 2).....	71
图 119	前臂肌(前面观 1) Muscles of the forearm (anterior aspect 1).....	72
图 120	前臂肌(前面观 2) Muscles of the forearm (anterior aspect 2).....	72
图 121	前臂肌(前面观 3) Muscles of the forearm (anterior aspect 3).....	73
图 122	前臂肌(前面观) Muscles of the forearm (posterior aspect).....	73

图 123	手体表标志(掌面观) Surface markings of the hand (palmar aspect).....	74
图 124	手肌(前面观 1) Muscles of the hand (anterior aspect 1).....	75
图 125	手肌(前面观 2) Muscles of the hand (anterior aspect 2).....	76
图 126	大腿肌(前面观 1) Muscles of the thigh (anterior aspect 1).....	77
图 127	大腿肌(前面观 2) Muscles of the thigh (anterior aspect 2).....	78
图 128	髋肌和大腿肌(后面观) Muscles of the hip and thigh (posterior aspect).....	78
图 129	髋肌(后面观) Muscles of the hip (posterior aspect) .....	79
图 130	大腿肌(后面观) Muscles of the thigh (posterior aspect).....	79
图 131	小腿肌(前面观) Muscles of the leg (anterior aspect).....	80
图 132	小腿肌(后面观 1) Muscles of the leg (posterior aspect 1).....	80
图 133	小腿肌(后面观 2) Muscles of the leg (posterior aspect 2).....	81
图 134	小腿肌(后面观 3) Muscles of the leg (posterior aspect 3).....	81
图 135	足背的体表标志 Surface markings of dorsum of the foot .....	82
图 136	足背肌 Muscles of dorsum of the foot .....	82
图 137	足底肌(1) Muscles of sole of the foot (1).....	83
图 138	足底肌(2) Muscles of sole of the foot (2).....	83

## 第 4 章 内脏学概论

### Splanchnology General Arrangement

图 139	人体器官的位置(正面观) Position of the human organs(anterior aspect).....	85
图 140	人体器官的位置(右侧面观) Position of the human organs (right lateral aspect).....	86
图 141	胸部标志线 Reference lines of the thorax.....	87
图 142	腹部分区 Regions of the abdomen.....	87
图 143	腹前壁体表标志 Surface markings of the anterior abdominal wall.....	87

## 第 5 章 消化系统

### Digestive System

图 144	消化系统概观 General arrangement of the digestive system.....	89
-------	---	----

图 145	口腔和咽峡 The oral cavity and isthmus of the fauces.....	90
图 146	口腔 The oral cavity .....	90
图 147	舌 The tongue.....	91
图 148	舌肌(纵切面) Muscles of the tongue.....	91
图 149	恒牙(1) The permanent teeth (1).....	92
图 150	恒牙(2) The permanent teeth (2).....	93
图 151	大唾液腺 The large salivary glands .....	93
图 152	头颈部(正中矢状切面) The head and neck (median sagittal section).....	94
图 153	咽腔(后面观) The pharyngeal cavity (posterior aspect).....	95
图 154	食管(前面观) The esophagus (anterior aspect).....	96
图 155	咽和食管(后面观) The pharynx and esophagus (posterior aspect).....	96
图 156	胃 The stomach.....	97
图 157	胃黏膜 The mucous membrane of the stomach.....	97
图 158	腹部脏器和网膜(前面观) The viscera of the abdomen and greater omentum (anterior aspect).....	98
图 159	小网膜 The lesser omentum.....	99
图 160	横结肠系膜 The transverse mesocolon.....	99
图 161	肠与阑尾系膜 The mesentery and mesoappendix.....	100
图 162	乙状结肠系膜 The sigmoid mesocolon.....	101
图 163	食管钡餐 X 线图像 Barium meal radiograph of the esophagus.....	102
图 164	胃钡餐 X 线图像 Barium meal radiograph of the stomach.....	102
图 165	小肠钡餐 X 线片 Barium meal radiograph of the small intestine.....	103
图 166	结肠钡餐 X 线图像 Barium meal radiograph of the colon.....	103
图 167	结肠(外面观) The colon (external aspect).....	104
图 168	盲肠与阑尾(The cecum and vermiform appendix).....	105
图 169	直肠与肛管(内面观) The rectum and anal canal (internal aspect).....	105
图 170	肝(上面观) The liver (superior aspect).....	106
图 171	肝(下面观) The liver (inferior aspect).....	106
图 172	胆道、十二指肠和胰腺(前面观) The bile ducts, duodenum and pancreas (anterior aspect).....	107
图 173	肝脏管道铸型(1) The cast of the hepatic ducts (1).....	108

图 174 肝脏管道铸型(2) The cast of the hepatic ducts (2).....108

## 第 6 章 呼吸系统

### Respiratory System

- 图 175 呼吸系统体表标志 Surface markings of the respiratory system.....110
- 图 176 鼻中隔 The nasal septum.....111
- 图 177 鼻腔外侧壁(1) The lateral wall of the nasal cavity (1).....112
- 图 178 鼻腔外侧壁(2) The lateral wall of the nasal cavity (2).....113
- 图 179 甲状软骨(前面观) The thyroid cartilage (anterior aspect).....114
- 图 180 甲状软骨(后面观) The thyroid cartilage (posterior aspect).....114
- 图 181 环状软骨、杓状软骨和小角软骨(前面观) The cricoid, arytenoid and corniculate cartilages(anterior aspect).....114
- 图 182 环状软骨、杓状软骨和小角软骨(后面观) The cricoid, arytenoid and corniculate cartilages (posterior aspect).....114
- 图 183 会厌软骨(后面观) The epiglottic cartilage (posterior aspect).....115
- 图 184 喉软骨的连结(前面观) Joints of the laryngeal cartilages (anterior aspect).....115
- 图 185 喉软骨的连结(后面观) Joints of the laryngeal cartilages (posterior aspect).....115
- 图 186 弹性圆锥和方形膜(侧面观) The conus elasticus and quadrangular membrane (lateral aspect).....116
- 图 187 弹性圆锥 The conus elasticus.....116
- 图 188 喉腔 The laryngeal cavity.....117
- 图 189 喉口(上面观) The aperture of the larynx (superior aspect) .....118
- 图 190 喉腔内镜图像 Endoscope image of the laryngeal cavity .....118
- 图 191 气管与支气管(前面观) The trachea and bronchi (anterior aspect) .....119
- 图 192 气管与支气管(切除前壁) The trachea and bronchi (part of anterior wall removed) .....119
- 图 193 气管与支气管(后面观) The trachea and bronchi (posterior aspect) .....119

图 194	右肺(前面观) The right lung (anterior aspect) .....	120
图 195	左肺(前面观) The left lung (anterior aspect) .....	120
图 196	右肺(内侧面观) The right lung (medial aspect) .....	121
图 197	左肺(内侧面观) The left lung (medial aspect) .....	121
图 198	胸膜(前面观) The pleura (anterior aspect) .....	122
图 199	胸膜(后面观) The pleura (posterior aspect) .....	122
图 200	胸膜腔(前面观) The pleural cavity (anterior aspect) .....	123
图 201	肺铸型 The cast of the lung .....	124
图 202	胸部 X 线图像(正位) Radiograph of the thorax (anterior aspect) .....	124

## 第 7 章 泌尿生殖系统

### Urogenital System

图 203	男性泌尿生殖系统概观 General arrangement of the male urogenital system.....	126
图 204	女性泌尿生殖系统概观 General arrangement of the female urogenital system .....	127
图 205	肾和输尿管的位置 Locations of the kidney and ureter .....	128
图 206	肾后面毗邻 Posterior relationship of the kidney .....	129
图 207	肾的体表标志 Surface markings of the kidney .....	129
图 208	右肾(前面观) The right kidney (anterior aspect) .....	130
图 209	左肾(前面观) The left kidney (anterior aspect) .....	130
图 210	肾铸型 The cast of the kidney .....	130
图 211	肾(冠状切面) The kidney (coronal section) .....	131
图 212	男性生殖系统概观(后面观) General arrangement of the male genital system (posterior aspect) .....	132
图 213	男性盆部(正中矢状切面) The pelvis of the male (median sagittal section) .....	133
图 214	膀胱和前列腺(前面观) The urinary bladder and prostate gland (anterior aspect) .....	134

图 215	膀胱、前列腺、精囊和输精管(后面观) The urinary bladder, prostate gland, seminal vesicle and ductus deferens (posterior aspect) .....	134
图 216	睾丸和附睾 The testis and epididymis .....	135
图 217	睾丸和精索被膜 Coverings of the testis and spermatic cord .....	135
图 218	阴茎 The penis .....	136
图 219	阴茎(横断面) The penis (transverse section) .....	136
图 220	阴茎(正中矢状切面) The penis (median sagittal section) .....	136
图 221	女性生殖系统概观 General arrangement of the female genital system.....	137
图 222	女性盆部(正中矢状切面) The pelvis of the female (median sagittal section) .....	138
图 223	女性外生殖器 External genital organs of the female .....	138
图 224	乳房(1) The mamma (1) .....	139
图 225	乳房(2) The mamma (2) .....	139

## 第 8 章 心脏

### Heart

图 226	心脏的位置 Position of the heart .....	141
图 227	心包(心脏已切除) The pericardium (heart removed) .....	142
图 228	心脏的体表标志 Surface markings of the heart .....	142
图 229	心脏的外形(前面观) External features of the heart (anterior aspect).....	143
图 230	心脏的外形(后面观) External features of the heart (posterior aspect).....	144
图 231	右心房(内面观) The right atrium (internal aspect) .....	145
图 232	右心室(内面观) The right ventricle (internal aspect) .....	146
图 233	左心房(内面观) The left atrium (internal aspect) .....	147
图 234	左心室(内面观) The left ventricle (internal aspect) .....	148
图 235	心脏内腔 The internal cavities of the heart .....	149
图 236	心瓣膜 The valves of the heart .....	149

图 237	心脏的血管(前面观) Blood vessels of the heart (anterior aspect).....	150
图 238	心脏的血管(后面观) Blood vessels of the heart (posterior aspect) .....	150
图 239	心血管铸型标本(1) The cast specimen of the cardiac blood vessels (1).....	151
图 240	心血管铸型标本(2) The cast specimen of the cardiac blood vessels(2) .....	151

## 第 9 章 淋巴系统

### Lymphatic System

图 241	淋巴系统模式图 Diagram of the lymphatic system.....	153
图 242	胸导管及淋巴干 The thoracic ducts and lymph trunks.....	154
图 243	头颈部浅淋巴管及淋巴结 Superficial lymphatic vessels and lymph nodes of the head and neck .....	155
图 244	头颈部深淋巴管及淋巴结 Deep lymphatic vessels and lymph nodes of the head and neck .....	155
图 245	颈前部淋巴管及淋巴结 Lymphatic vessels and lymph nodes of the neck.....	156
图 246	上肢淋巴管和淋巴结 Lymphatic vessels and lymph nodes of the upper limb.....	156
图 247	腋窝、乳房的淋巴管和淋巴结 Lymphatic vessels and lymph nodes of the axillary fossa and mamma.....	157
图 248	气管、支气管的淋巴管和淋巴结 Lymphatic vessels and lymph nodes of the trachea and bronchi .....	158
图 249	肺的淋巴引流 Lymph drainage of the lung.....	158
图 250	胃的淋巴管和淋巴结 Lymphatic vessels and lymph nodes of the stomach.....	159
图 251	腹部器官淋巴结 Lymph nodes of the abdominal viscera .....	159
图 252	盆部淋巴管和淋巴结(女性) Lymphatic vessels and lymph nodes of the pelvis (Female) .....	160



图 253	直肠的淋巴引流 Lymph drainage of the rectum .....	160
图 254	下肢浅淋巴管和淋巴结 Superficial lymphatic vessels and lymph nodes of the lower limb .....	161
图 255	腹股沟浅淋巴结 The superficial inguinal lymph nodes .....	161
图 256	腹股沟深淋巴结 The deep inguinal lymph nodes .....	161
图 257	脾(膈面观) The spleen (diaphragmatic aspect) .....	162
图 258	脾(脏面观) The spleen (visceral aspect) .....	162

## 第 10 章 视器与位听器

### Visual Organ and Vestibulocochlear Organ

图 259	右侧眼球模式图(水平断面) Diagram of the right eyeball (horizontal section) .....	164
图 260	眼球前部断面图 Diagram of the section through the anterior part of the eyeball .....	164
图 261	眼球壁结构模式图 Diagram of the wall of the eyeball.....	165
图 262	眼底图(右侧) Fundus of the eyeball (right side) .....	166
图 263	左眼(前面观) The left eye (anterior aspect) .....	166
图 264	泪器模式图 Diagram of the lacrimal apparatus.....	167
图 265	眼球外肌(上面观) The extraocular muscles (superior aspect).....	167
图 266	眼球外肌(外侧面观) The extraocular muscles (lateral aspect).....	168
图 267	眼球外肌(内侧面观) The extraocular muscles (medial aspect).....	168
图 268	眼的血管、神经 Blood vessels and nerves of the eye .....	169
图 269	眼的肌肉、血管、神经 Muscles, blood vessels and nerves of the eye .....	169
图 270	耳郭(外侧面观) The auricle (lateral aspect) .....	170
图 271	前庭蜗器概观(前外侧面观) General arrangement of the vestibulocochlear organ (anterolateral aspect).....	170
图 272	前庭蜗器概观(上面观) General arrangement of the vestibulocochlear organ (superior aspect) .....	171

图 273	鼓室内侧壁(1) Medial wall of the tympanic cavity (1).....	171
图 274	鼓室内侧壁(2) Medial wall of the tympanic cavity (2) .....	172
图 275	鼓膜模式图(外侧观) Diagram of the tympanic membrane (outer view) .....	172
图 276	听小骨链 The chain of the auditory ossicles.....	173
图 277	听小骨 The auditory ossicles.....	173
图 278	右耳骨迷路(1) The bony labyrinth of the right ear (1).....	174
图 279	右耳骨迷路(2) The bony labyrinth of the right ear (2).....	174
图 280	内耳道底 The fundus of the internal acoustic meatus.....	174
图 281	骨迷路模式图 Diagram of the bony labyrinth.....	175
图 282	骨迷路与膜迷路模式图 Diagram of the bony and membranous labyrinth.....	175
图 283	螺旋器模式图(横断面) Diagram of the spiral organ (transverse section).....	176
图 284	耳蜗模式图 Diagram of the cochlea.....	176

## 第 11 章 内分泌系统

### Endocrine System

图 285	内分泌腺 The endocrine glands .....	178
图 286	胸腺和甲状腺 Thymus and thyroid gland.....	179
图 287	甲状腺(前面观) The thyroid gland (anterior aspect).....	179
图 288	甲状腺(后面观) The thyroid gland (posterior aspect).....	179

## 第 12 章 神经系统——中枢神经

### Nervous System —— Central Nerve

图 289	婴儿脊髓和脊神经(后面观) Spinal cord and nerves in the fetus (posterior aspect).....	181
图 290	脊髓和脊神经 The spinal cord and nerves.....	182

图 291	颈段脊髓(横切面) Spinal cord of the cervical region (transverse section).....	183
图 292	胸段脊髓(横切面) Spinal cord of the thoracic region (transverse section).....	183
图 293	腰段脊髓(横切面) Spinal cord of the lumbar region (transverse section).....	183
图 294	脑干(腹面观) The brain stem (ventral aspect).....	184
图 295	脑干(背面观) The brain stem (dorsal aspect).....	185
图 296	延髓横切面(经丘系交叉) Transverse section of the medulla oblongata through the decussation of medial lemniscus.....	186
图 297	脑桥横切面(面神经丘水平) Transverse section of the pons at the level of the facial colliculus.....	187
图 298	中脑横切面(上丘水平) Transverse section of the midbrain at the level of the superior colliculus.....	188
图 299	小脑(上面观) The cerebellum (superior aspect).....	189
图 300	小脑(下后面观) The cerebellum (posteroinferior aspect).....	189
图 301	小脑(下前面观) The cerebellum (anteroinferior aspect).....	190
图 302	间脑(背面观) The diencephalon (dorsal aspect).....	191
图 303	丘脑核团模式图 Diagram of the thalamic nuclei.....	192
图 304	下丘脑核团模式图 Diagram of the hypothalamic nuclei.....	192
图 305	脑(底面观) The brain (basal aspect).....	193
图 306	脑(外侧观) The brain (lateral aspect).....	194
图 307	脑(正中矢状切面) The brain (median sagittal section).....	195
图 308	大脑半球(上外侧观) The cerebral hemisphere (superolateral aspect).....	196
图 309	岛叶 The insular lobe.....	196
图 310	大脑半球(内侧观) The cerebral hemisphere (medial aspect).....	197
图 311	内囊及基底核 The internal capsule and basal nuclei.....	197
图 312	内囊模式图 Diagram of the internal capsule .....	198
图 313	锥体束 The pyramidal tract.....	199

图 314	视束及视辐射 The optic tract and optic radiation .....	199
图 315	侧脑室(上面观) The lateral ventricle (superior aspect).....	200
图 316	脑冠状切面 Coronal section of the brain .....	201
图 317	头 MRI(T <sub>1</sub> ) MRI of the head (T <sub>1</sub> ).....	201
图 318	脑横断面 Transverse section of the brain.....	202
图 319	脑 CT X-ray CT of the brain .....	202
图 320	脑 MRI(T <sub>1</sub> WI) MRI of the brain (T <sub>1</sub> WI).....	203
图 321	脑 MRI(T <sub>2</sub> WI) MRI of the brain (T <sub>2</sub> WI).....	203
图 322	脑横断面 Transverse section of the brain .....	204
图 323	脑 CT X-ray CT of the brain .....	204
图 324	脑 MRI(T <sub>1</sub> WI) MRI of the brain (T <sub>1</sub> WI).....	205
图 325	脑 MRI(T <sub>2</sub> WI) MRI of the brain (T <sub>2</sub> WI).....	205
图 326	脑 CT X-ray CT of the brain .....	206
图 327	脑 MRI(T <sub>1</sub> WI) MRI of the brain (T <sub>1</sub> WI).....	207
图 328	脑 MRI(T <sub>2</sub> WI) MRI of the brain (T <sub>2</sub> WI).....	207
图 329	脑横断面 Transverse section of the brain.....	208
图 330	脑 CT X-ray CT of the brain .....	208
图 331	脑 MRI(T <sub>1</sub> WI) MRI of the brain (T <sub>1</sub> WI).....	209
图 332	脑 MRI(T <sub>2</sub> WI) MRI of the brain (T <sub>2</sub> WI).....	209
图 333	脑横断面 Transverse section of the brain.....	210
图 334	脑 CT X-ray CT of the brain .....	210
图 335	脑 MRI(T <sub>1</sub> WI) MRI of the brain (T <sub>1</sub> WI).....	211
图 336	脑 MRI(T <sub>2</sub> WI) MRI of the brain (T <sub>2</sub> WI).....	211
图 337	脑底动脉 Arteries at the base of the brain.....	212
图 338	脑底动脉 (MRI) Arteries at the base of the brain (MRI).....	212
图 339	蛛网膜粒 The arachnoid granulations.....	213
图 340	颅底硬脑膜 Dura mater of the base of the cranial cavity.....	214
图 341	硬脑膜 Cerebral dura mater.....	215
图 342	海绵窦冠状切面 Coronal section of the cavernous sinus .....	215
图 343	脑脊液循环模式图 Diagram of cerebrospinal fluid circulation.....	216

## 第 13 章 神经系统——内脏神经 Nervous System —— Visceral Nerve

- 图 344 内脏神经全貌 General arrangement of the visceral nerves.....218
- 图 345 交感神经干 The sympathetic trunks.....219
- 图 346 内脏神经(前面观) The visceral nerve (anterior aspect).....220
- 图 347 内脏神经(侧面观) The visceral nerve (lateral aspect).....221
- 图 348 颈部的迷走神经(前面观) The vagus nerves of the neck  
(anterior aspect).....222

## 第 14 章 局部解剖学 Regional Anatomy

- 图 349 头颈部的肌肉、血管和神经(侧面观 1) Muscles, blood vessels  
and nerves of the head and neck (lateral aspect 1).....224
- 图 350 颈部的血管和神经(侧面观 2) Blood vessels and nerves of the  
neck (lateral aspect 2).....225
- 图 351 头颈部的肌肉、血管和神经(侧面观 3) Muscles, blood  
vessels and nerves of the head and neck (lateral aspect 3).....226
- 图 352 头颈部的肌肉、血管和神经(侧面观 4) Muscles, blood  
vessels and nerves of the head and neck (lateral aspect 4).....227
- 图 353 胸腹壁浅层的肌肉、血管和神经(1) Muscles, blood vessels  
and nerves of the superficial thoracoepigastric wall (1).....228
- 图 354 胸腹壁的肌肉、血管和神经(2) Muscles, blood vessels and  
nerves of thoracoepigastric wall (2).....229
- 图 355 纵隔(右侧面观) The mediastinum (right aspect).....230
- 图 356 纵隔(左侧面观) The mediastinum (left aspect).....231
- 图 357 腹后壁(前面观) Posterior wall of the abdomen  
(anterior aspect).....232
- 图 358 腋窝的血管和神经(1) Blood vessels and nerves of the axillary  
fossa(1).....233

图 359	腋窝的血管和神经(2) Blood vessels and nerves of the axillary fossa(2).....	234
图 360	臂部的肌肉、血管和神经(前面观 1) Muscles, blood vessels and nerves of the arm (anterior aspect 1).....	235
图 361	臂部的肌肉、血管和神经(前面观 2) Muscles, blood vessels and nerves of the arm (anterior aspect 2).....	235
图 362	肩、臂部的肌肉、血管和神经(后面观 1) Muscles, blood vessels and nerves of the shoulder and arm (posterior aspect 1).....	236
图 363	肩、臂部的肌肉、血管和神经(后面观 2) Muscles, blood vessels and nerves of the shoulder and arm (posterior aspect 2).....	236
图 364	前臂的肌肉、血管和神经(前面观) Muscles, blood vessels and nerves of the forearm (anterior aspect).....	237
图 365	手的肌肉、血管和神经(掌侧面观) Muscles, blood vessels and nerves of the hand (palmar aspect).....	237
图 366	下肢的浅静脉 Superficial veins of the lower limb.....	238
图 367	小腿的浅静脉 Superficial veins of the leg.....	238
图 368	股前区皮神经和浅静脉 Cutaneous nerves and superficial veins of anterior region of the thigh.....	239
图 369	小腿的皮神经和浅静脉(前面观) Cutaneous nerves and superficial veins of the leg (anterior aspect).....	239
图 370	小腿的皮神经和浅静脉(后面观) Cutaneous nerves and superficial veins of the leg (posterior aspect).....	240
图 371	足背的神经和浅静脉 Nerves and superficial veins of dorsum of the foot.....	241
图 372	股前区的肌肉、血管和神经 Muscles, blood vessels and nerves of anterior region of the thigh.....	242
图 373	股前区的肌肉、血管和神经 Muscles, blood vessels and nerves of anterior region of the thigh.....	243
图 374	臀区和股后区的肌肉、血管和神经 Muscles, blood vessels and nerves of gluteal region and posterior region of the thigh.....	244
图 375	腘窝的肌肉、血管和神经 Muscles, blood vessels and nerves of the popliteal fossa.....	245

- 图 376 小腿的肌肉、血管和神经(后面观 1) Muscles, blood vessels  
and nerves of the leg (posterior aspect 1).....246
- 图 377 小腿的肌肉、血管和神经(后面观 2) Muscles, blood vessels  
and nerves of the leg (posterior aspect 2).....246
- 图 378 足底的肌肉、血管和神经(1) Muscles, blood vessels and nerves  
of sole of the foot (1).....247
- 图 379 足底的肌肉、血管和神经(2) Muscles, blood vessels and nerves  
of sole of the foot (2).....247

# 运动系统——骨

LOCOMOTOR SYSTEM——BONE

Chapter

1



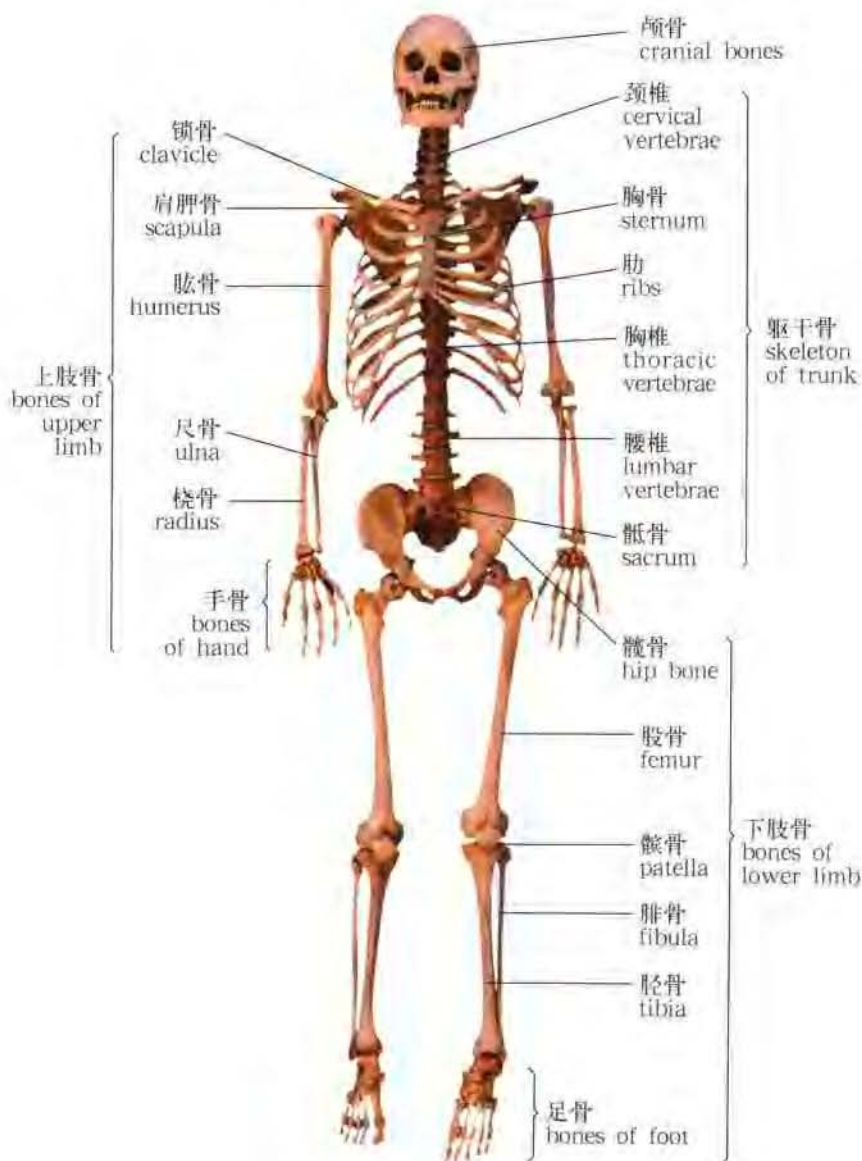


图1 全身骨骼前面观  
The skeleton (anterior aspect)

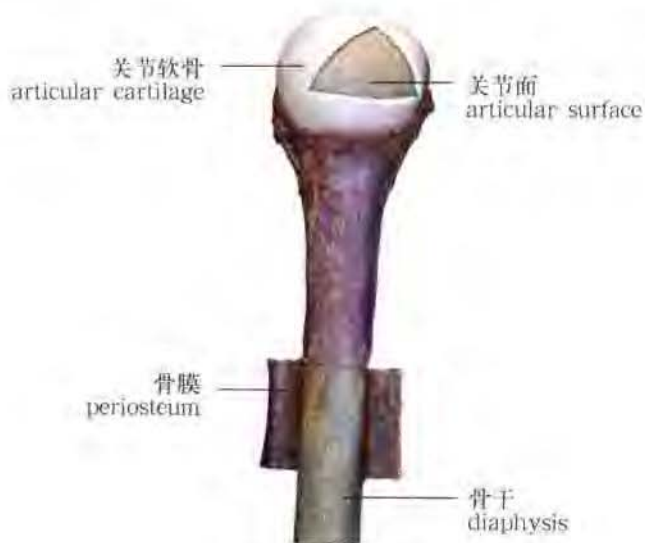

图2 骨的构造  
Structure of the bone

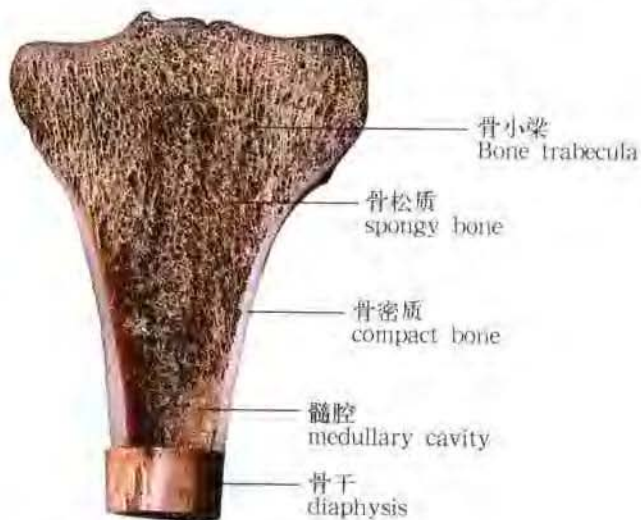

图3 胫骨上端冠状剖面  
Coronal section of upper end of the tibia

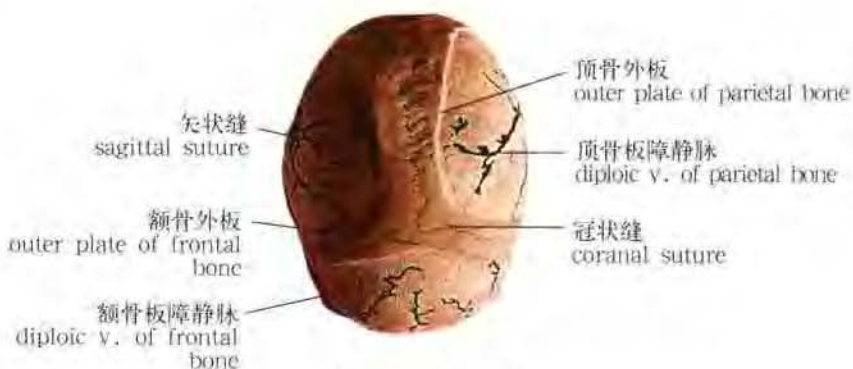


图4 颅盖板障  
Diploic of the calvaria



图5 椎骨剖面  
Section of the vertebra

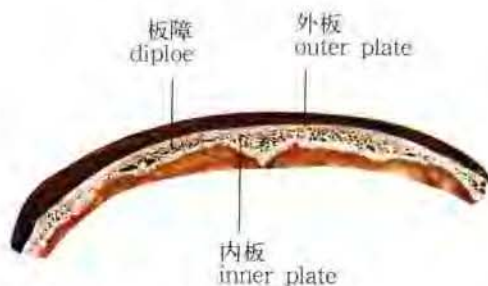


图6 颅盖剖面  
Section of the calvaria

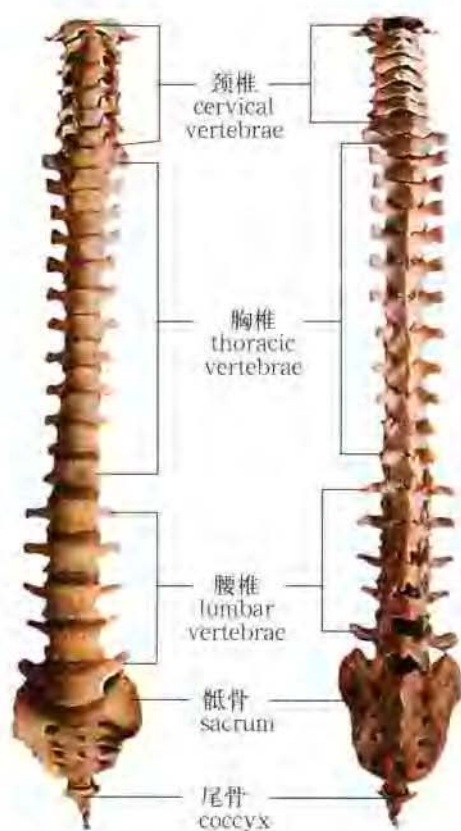


图7 脊柱 (前面观、后面观)  
The vertebral column  
(anterior and posterior aspect)

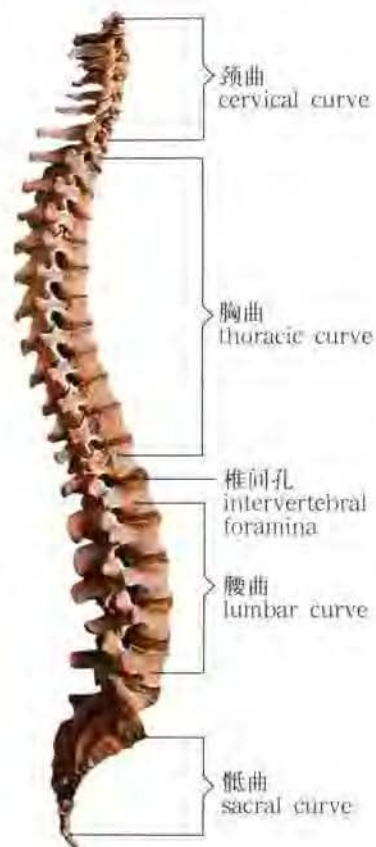


图8 脊柱 (外侧面观)  
The vertebral column  
(lateral aspect)

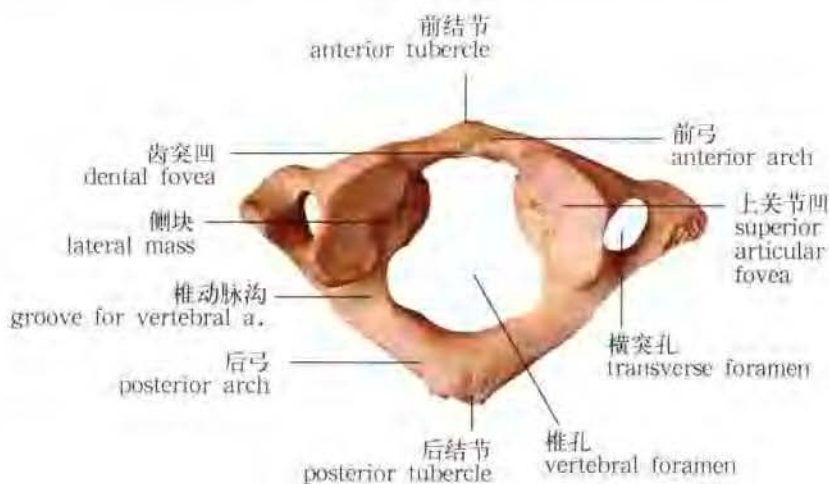


图9 寰椎 (上面观)  
The atlas (superior aspect)

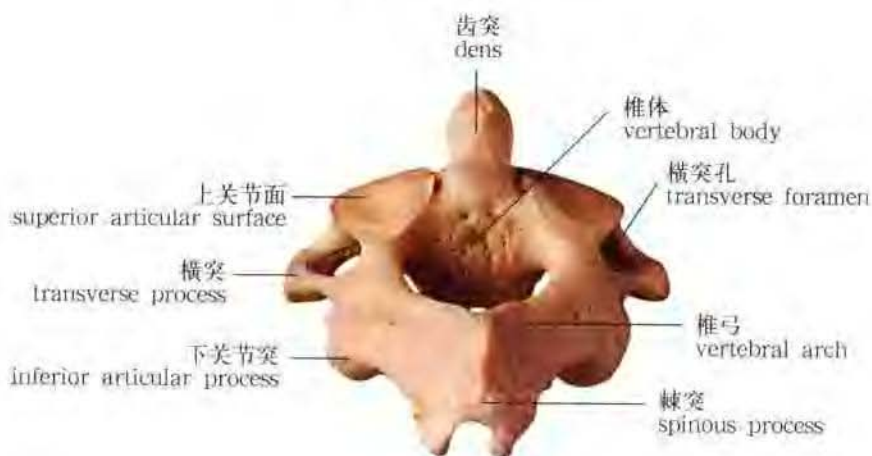

图10 枢椎 (后面观)  
The axis (posterior aspect)

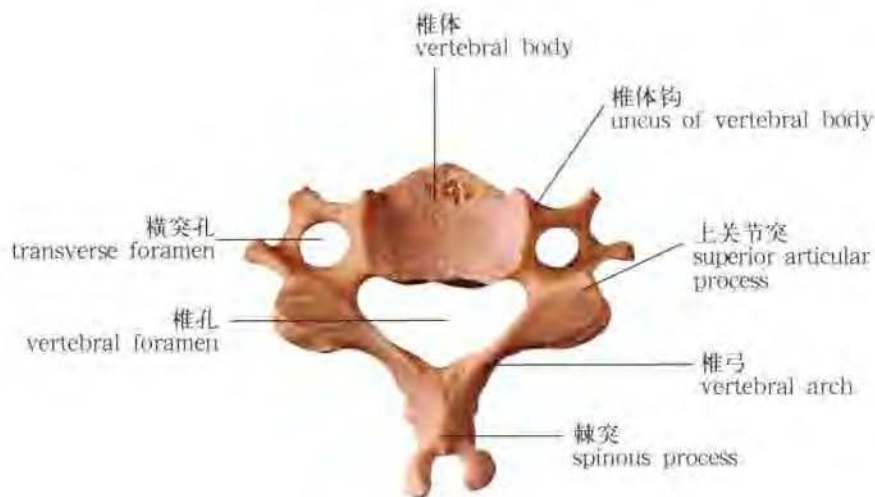


图 11 颈椎 (上面观)  
The cervical vertebra (superior aspect)

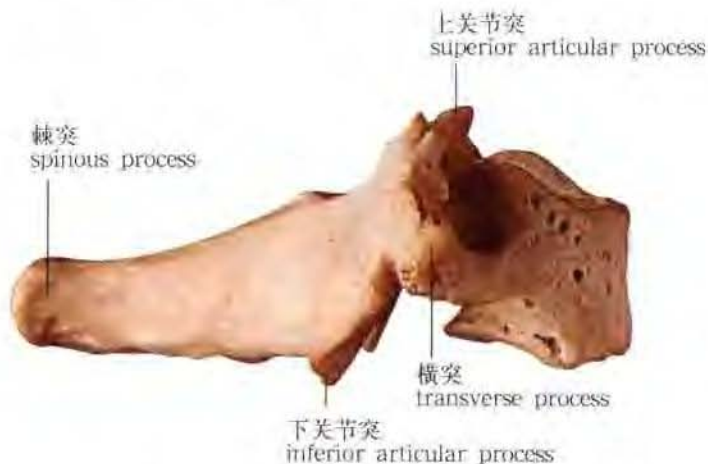

图 12 隆椎 (右侧面观)  
The vertebra prominens (right aspect)

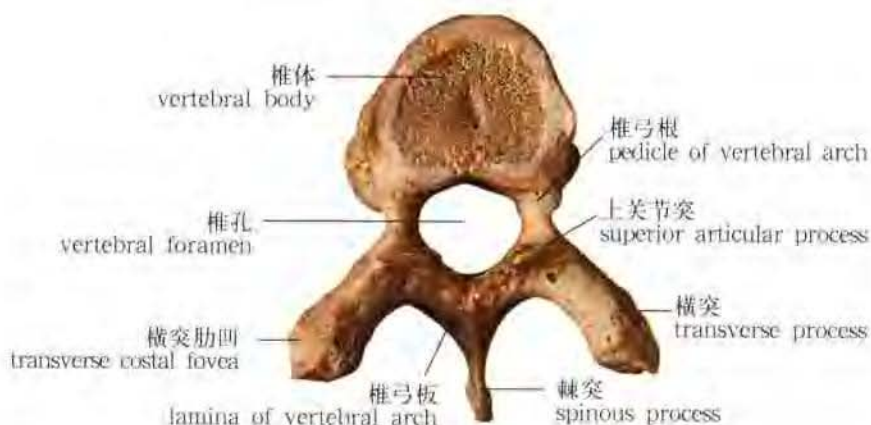

图 13 胸椎(上面观)  
The thoracic vertebra (superior aspect)

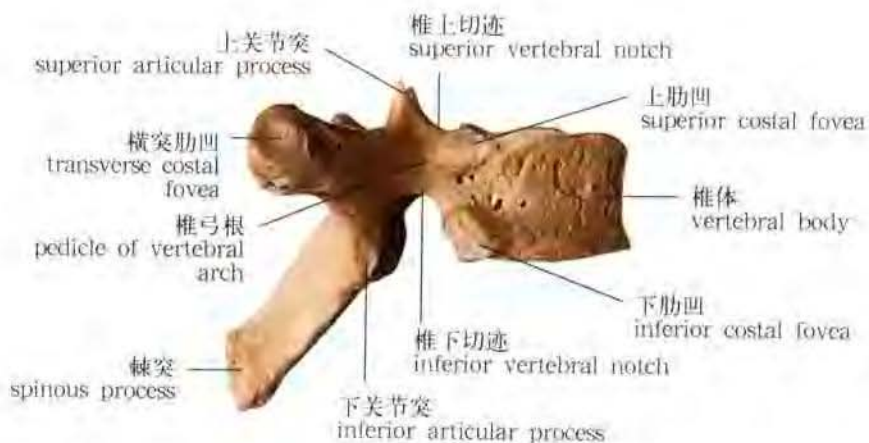

图 14 胸椎(外侧面观)  
The thoracic vertebra (lateral aspect)

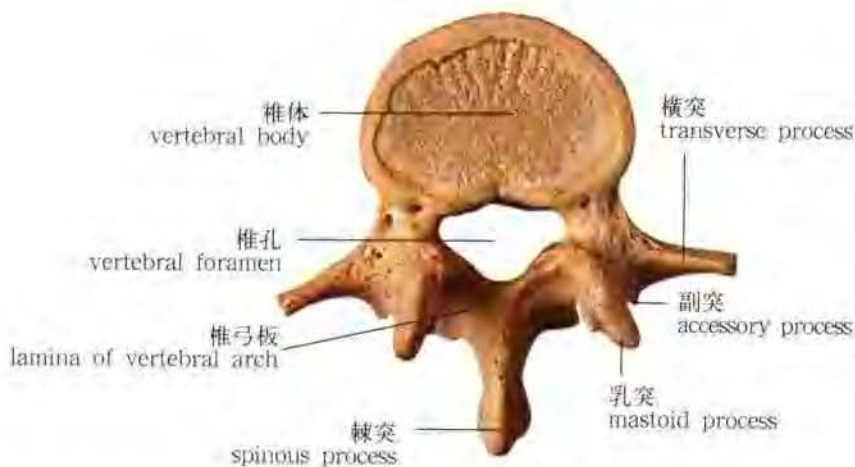


图 15 腰椎(上面观)  
The lumbar vertebra (superior aspect)

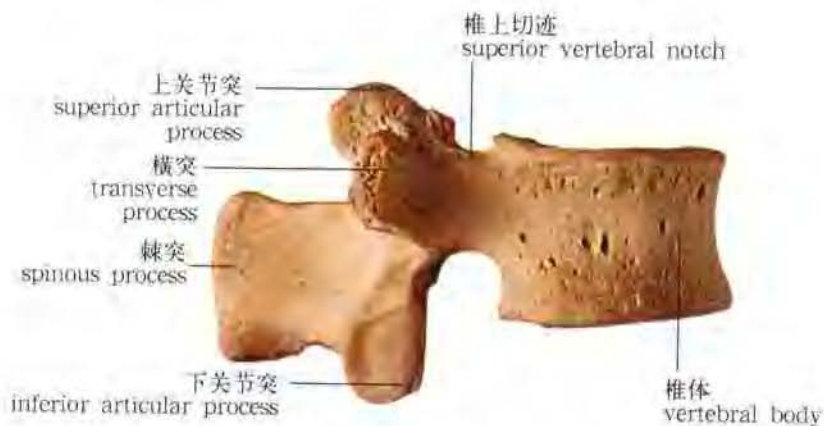


图 16 腰椎(外侧面观)  
The lumbar vertebra (lateral aspect)



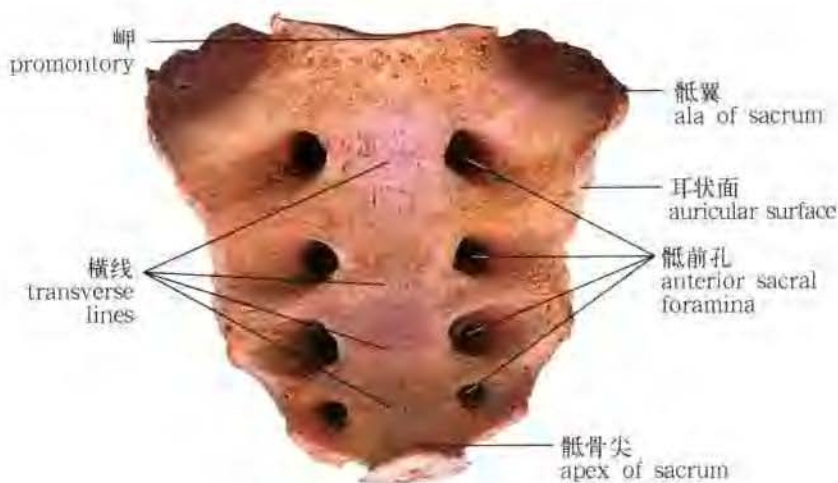


图 17 骶骨 (前面观)  
 The sacrum (anterior aspect)

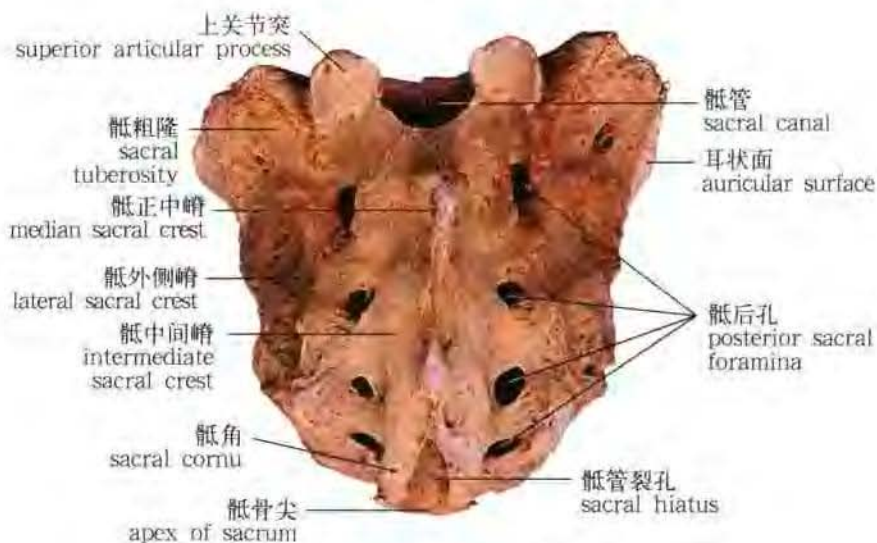


图 18 骶骨 (后面观)  
 The sacrum (posterior aspect)

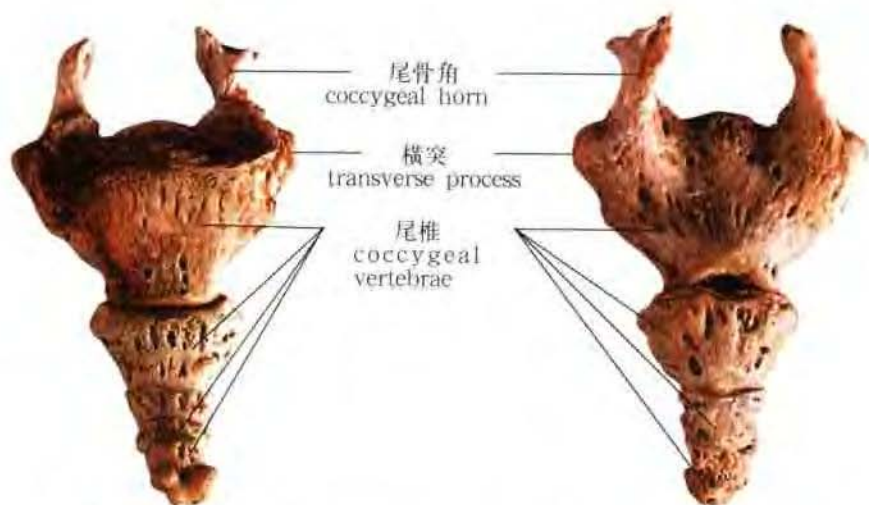


图19 尾骨 (前面观)  
The coccyx (anterior aspect)

图20 尾骨 (后面观)  
The coccyx (posterior aspect)

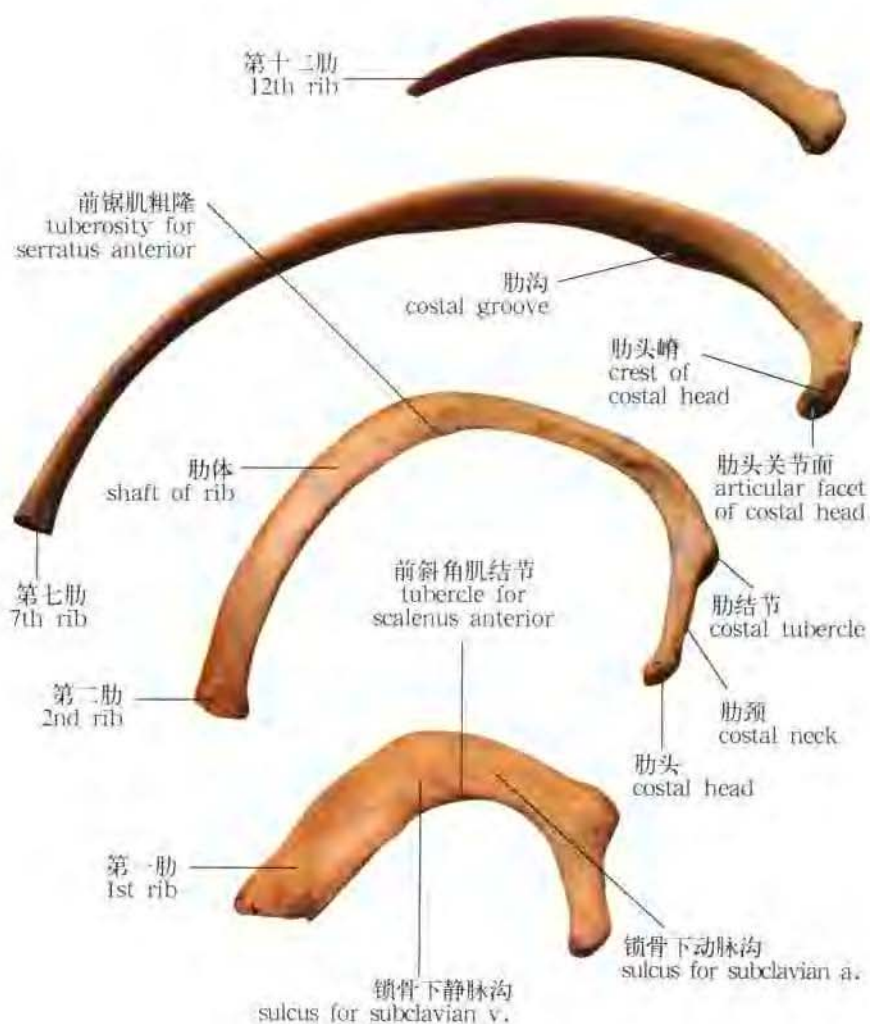


图 21 肋  
The ribs

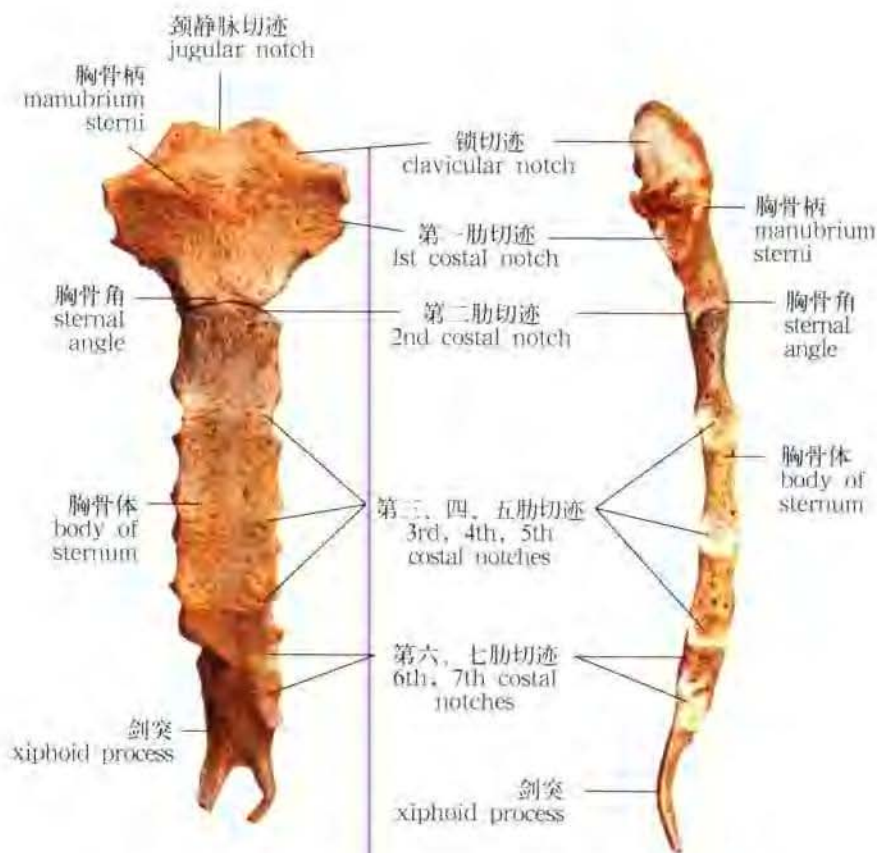

图 22 胸骨 (前面观)  
The sternum (anterior aspect)

图 23 胸骨 (外侧面观)  
The sternum (lateral aspect)

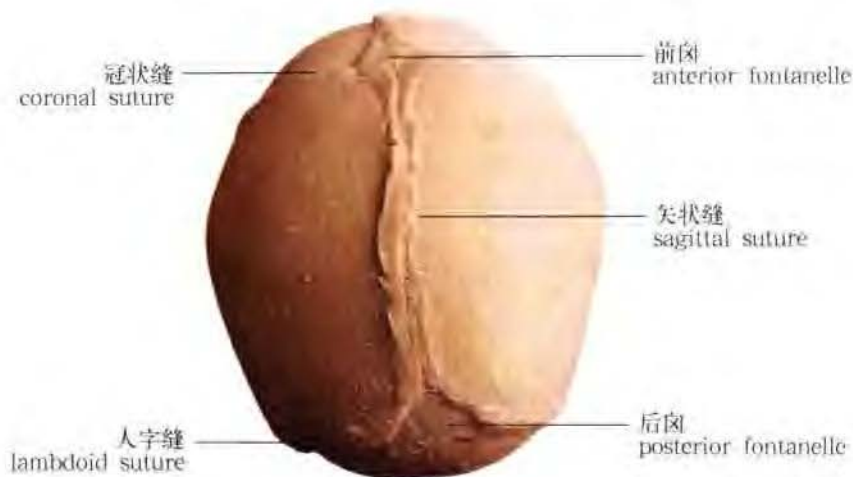


图 24 新生儿颅 (上面观)  
The skull of the infant (superior aspect)

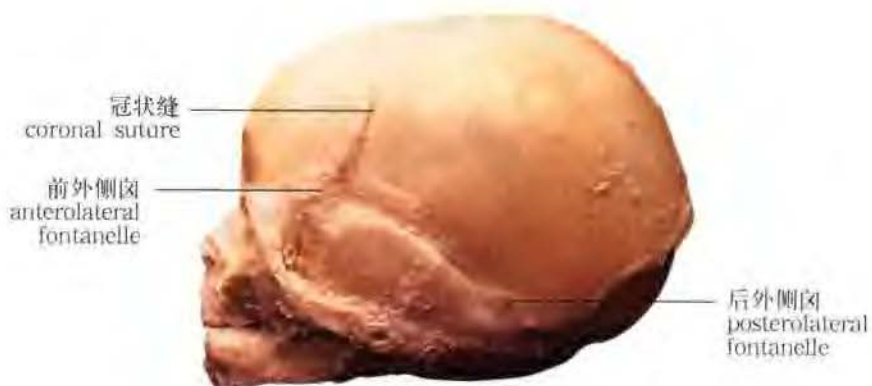


图 25 新生儿颅 (侧面观)  
The skull of the infant (lateral aspect)

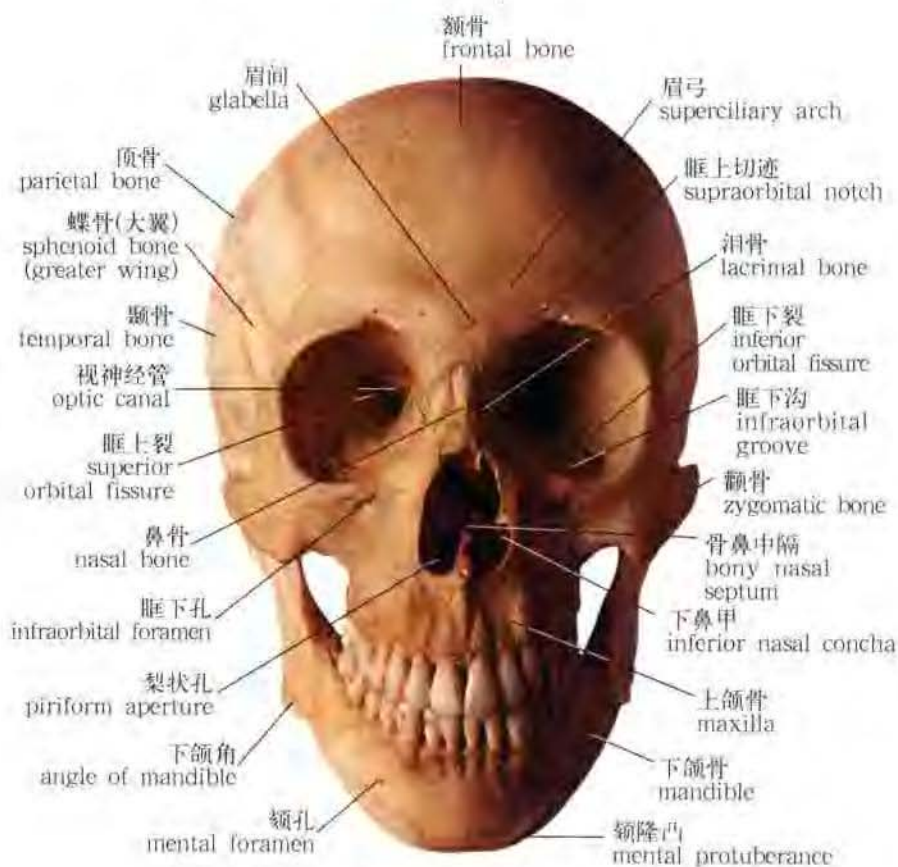


图 26 颅 (前面观)  
The skull (anterior aspect)

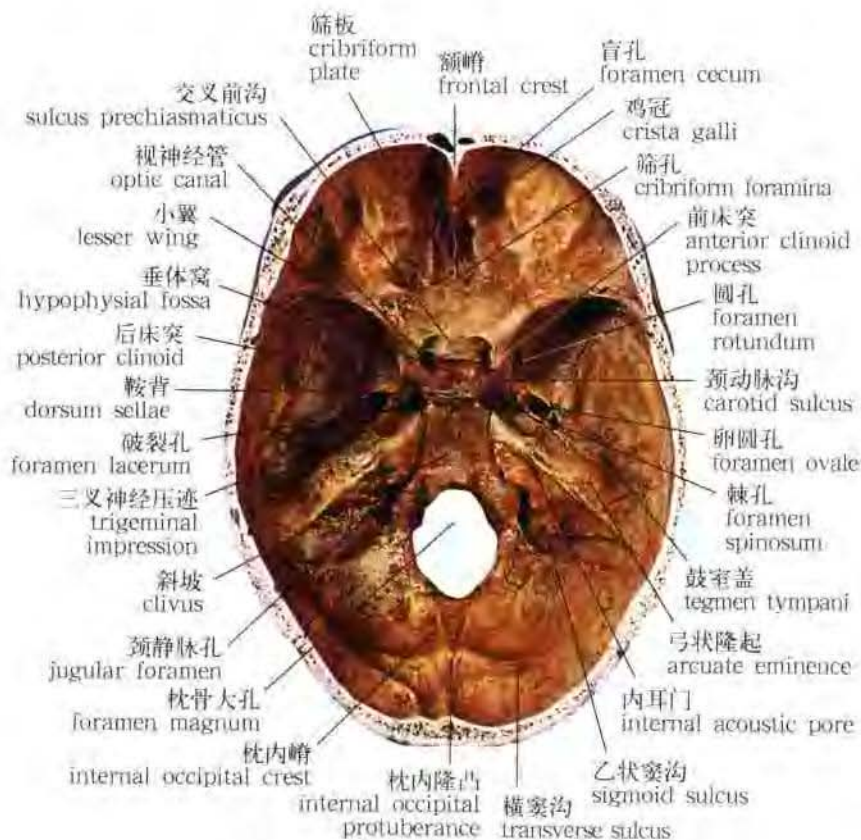

图 27 颅底内面观

The internal surface of base of the skull

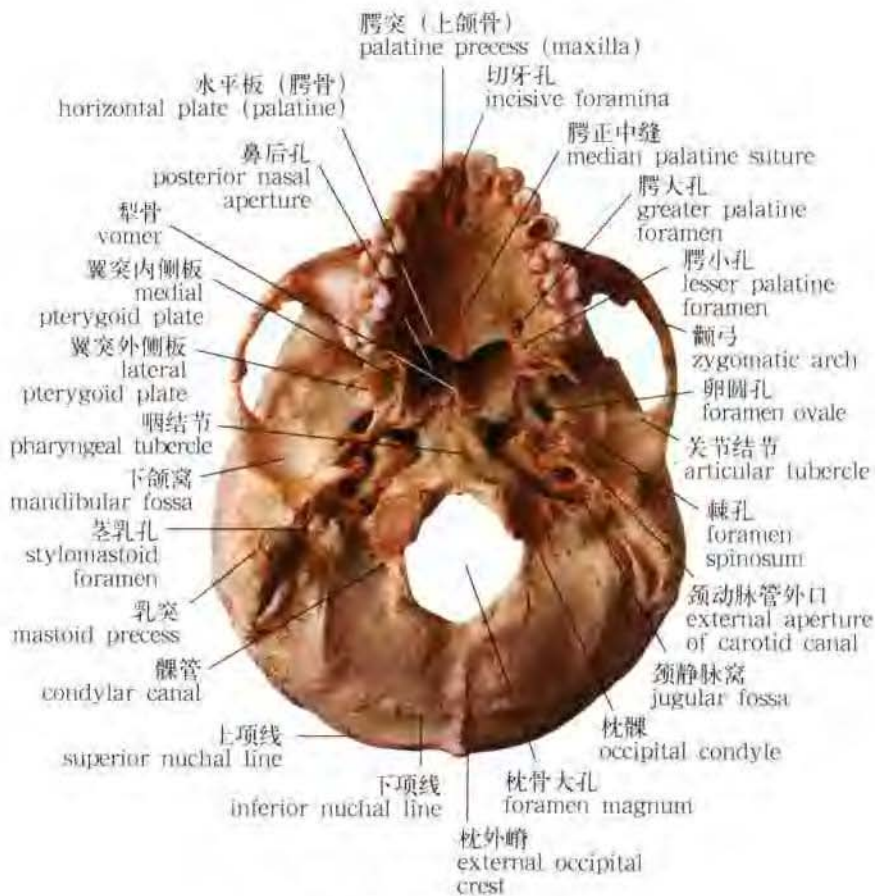

图 28 颅底外面观  
 The external surface of base of the skull



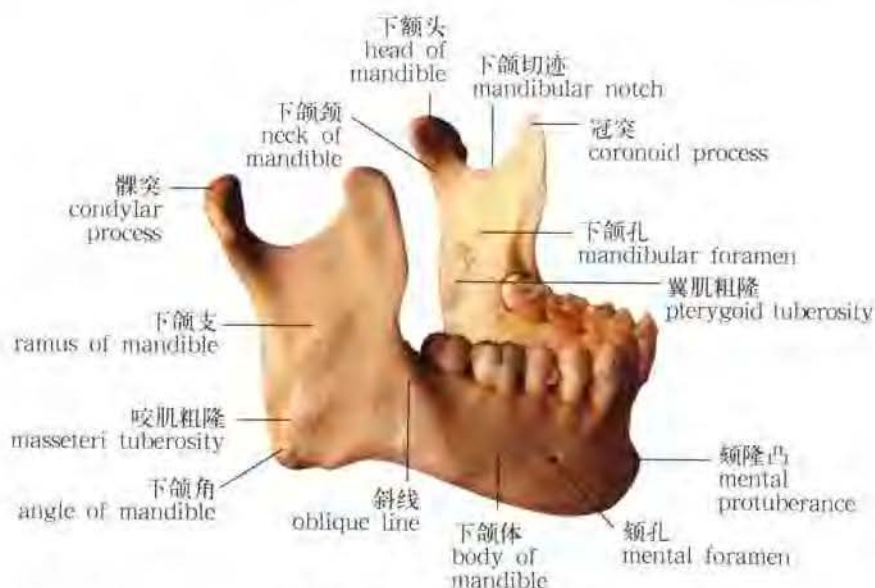

图 29 下颌骨 (外侧面观)  
The mandible (lateral aspect)

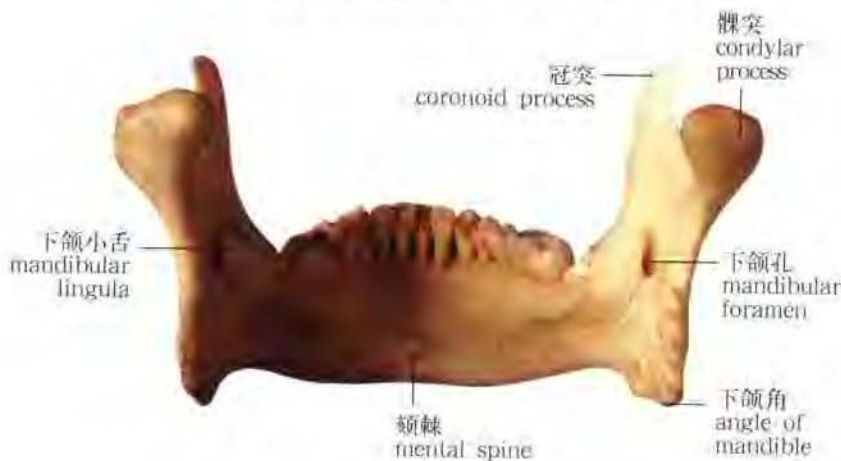


图 30 下颌骨 (后面观)  
The mandible (posterior aspect)

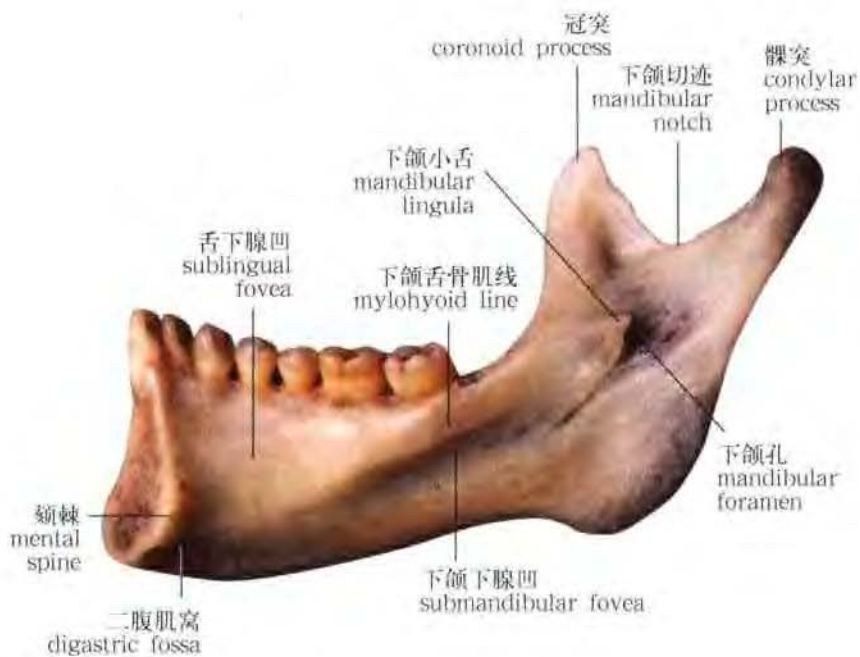

图 31 下颌骨 (内侧面观)  
The mandible (medial aspect)



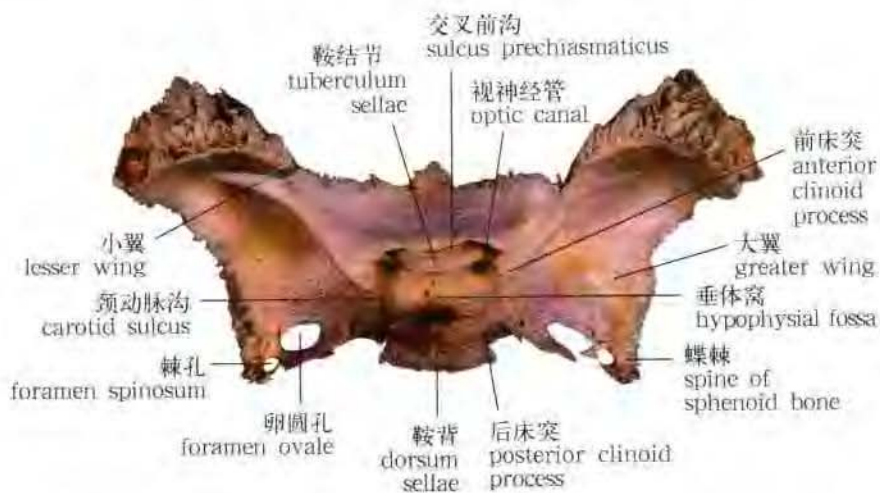


图 33 蝶骨 (上面观)  
The sphenoid bone (superior aspect)

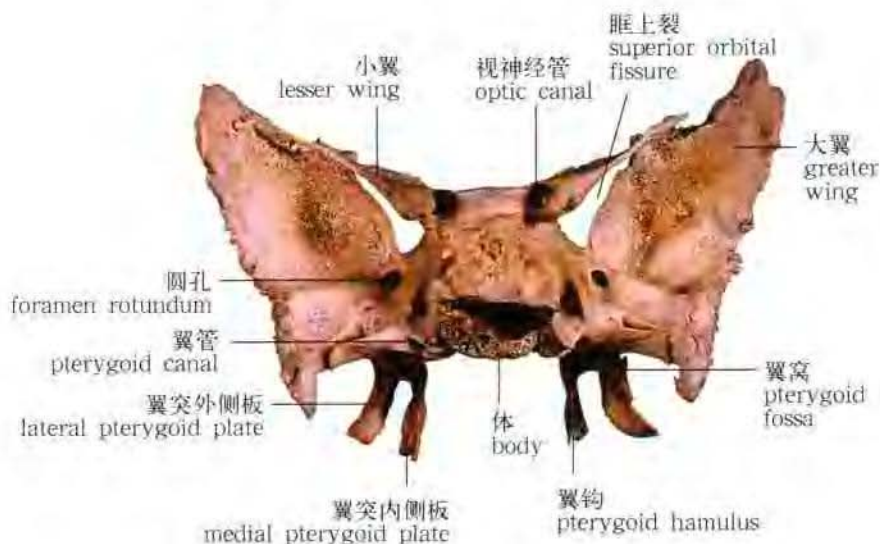


图 34 蝶骨 (后面观)  
The sphenoid bone (posterior aspect)

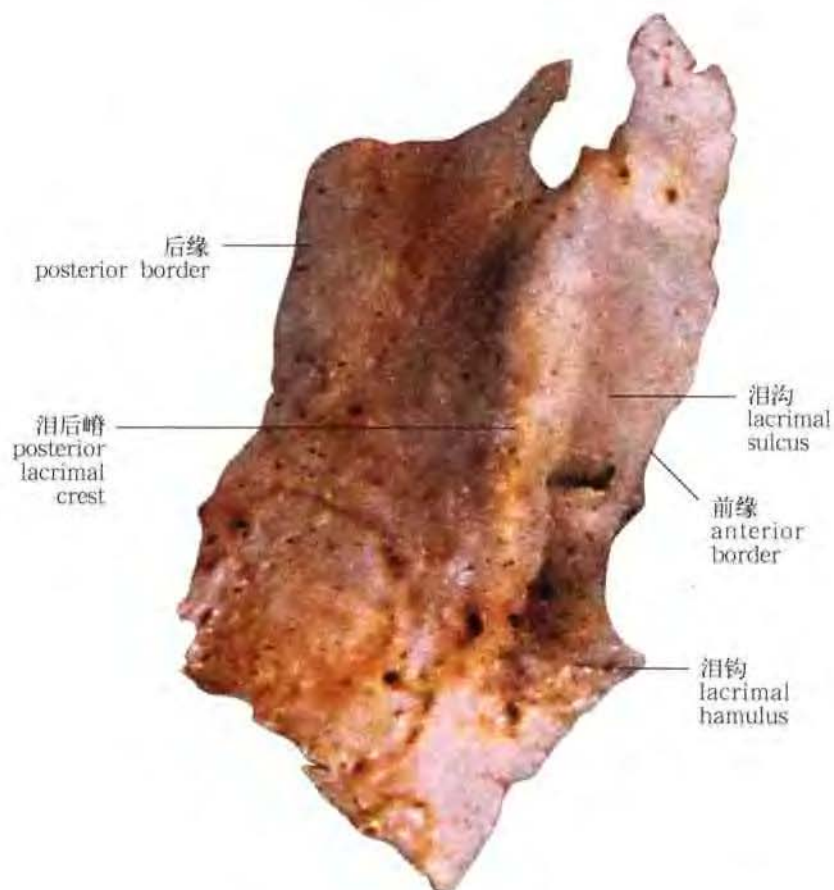


图 35 泪骨 (前面观)  
The lacrimal bone (anterior aspect)

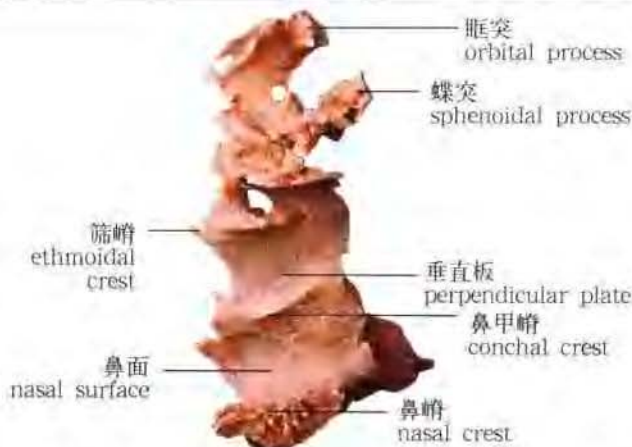

图 36 腭骨 (内侧面观)  
The palatine bone (medial aspect)

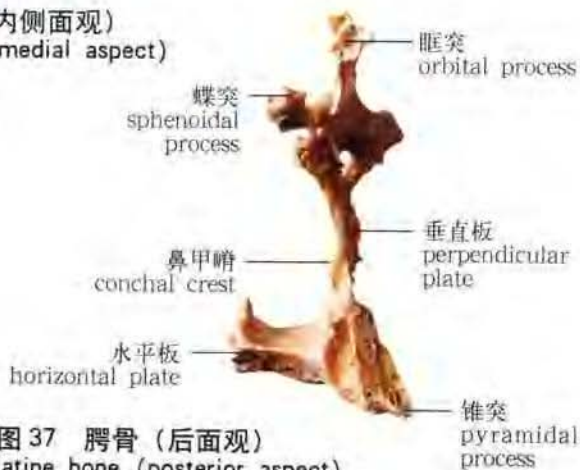

图 37 腭骨 (后面观)  
The palatine bone (posterior aspect)

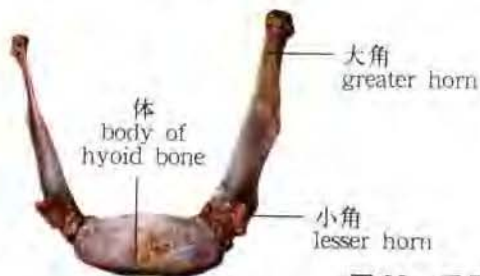

图 38 舌骨 (上面观)  
The hyoid bone (superior aspect)

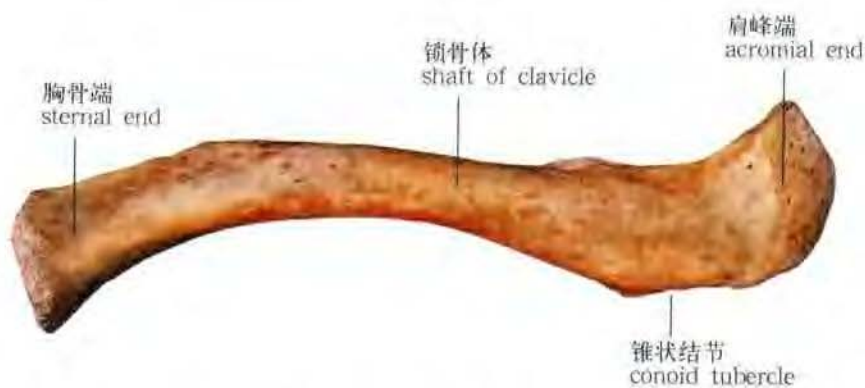


图 39a 锁骨 (上面观)  
The clavicle (superior aspect)

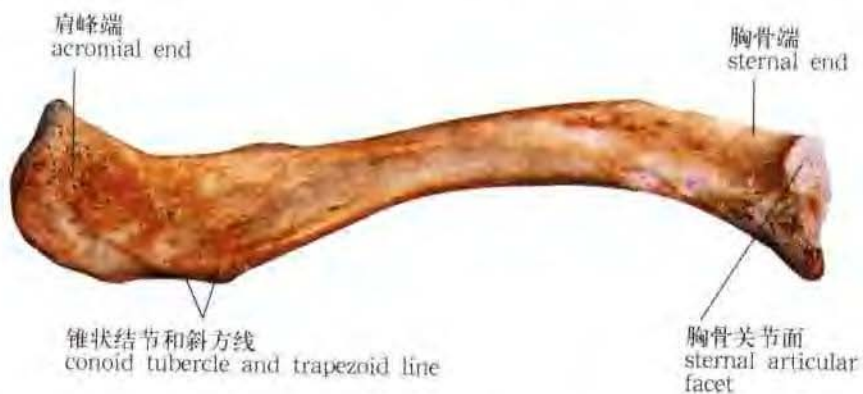


图 39b 锁骨 (下面观)  
The clavicle (inferior aspect)

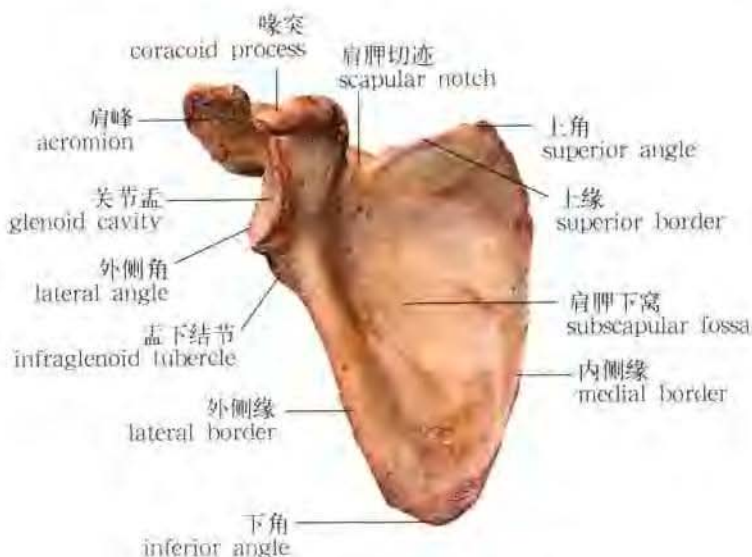

图 40 肩胛骨 (前面观)  
The scapula (anterior aspect)

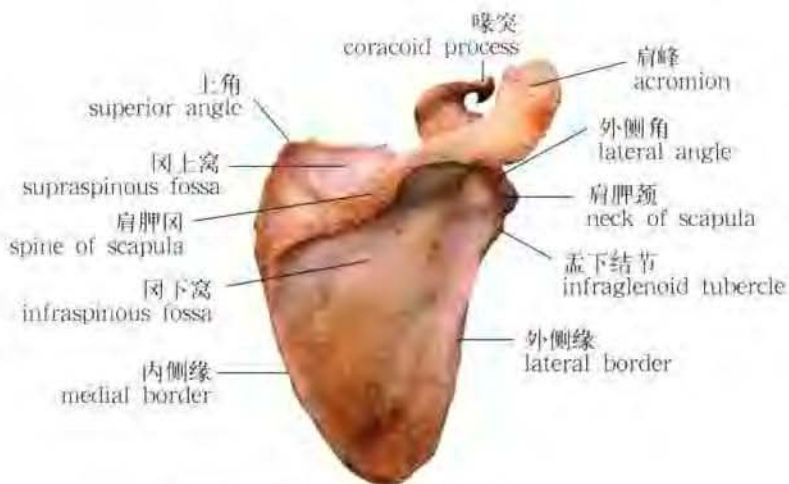


图 41 肩胛骨 (后面观)  
The scapula (posterior aspect)



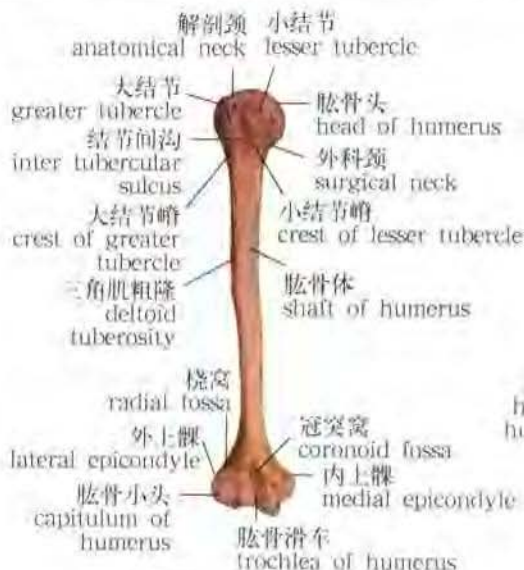

图 42 肱骨 (前面观)  
The humerus (anterior aspect)

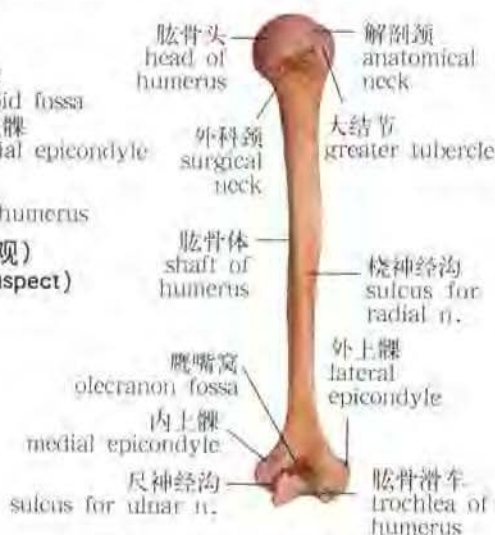


图 43 肱骨 (后面观)  
The humerus (posterior aspect)

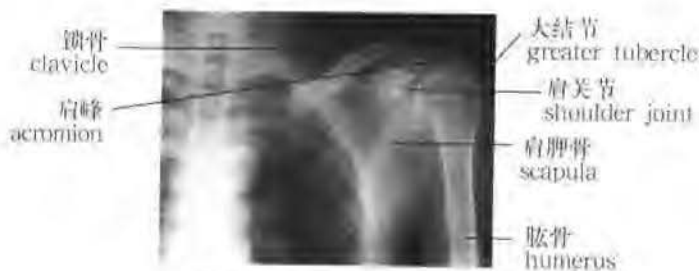

图 44 肩 X 线图像 (正位)  
Radiograph of the shoulder (anterior aspect)

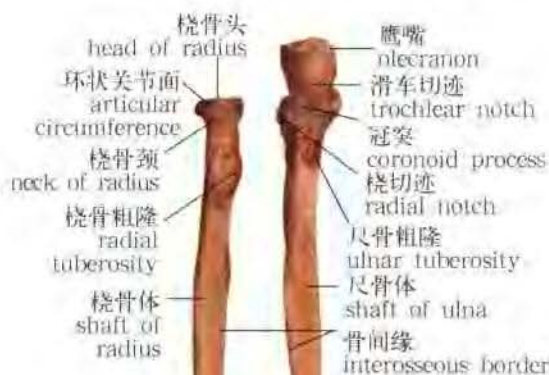

图 45 桡骨和尺骨 (前面观)  
The radius and ulna  
(anterior aspect)

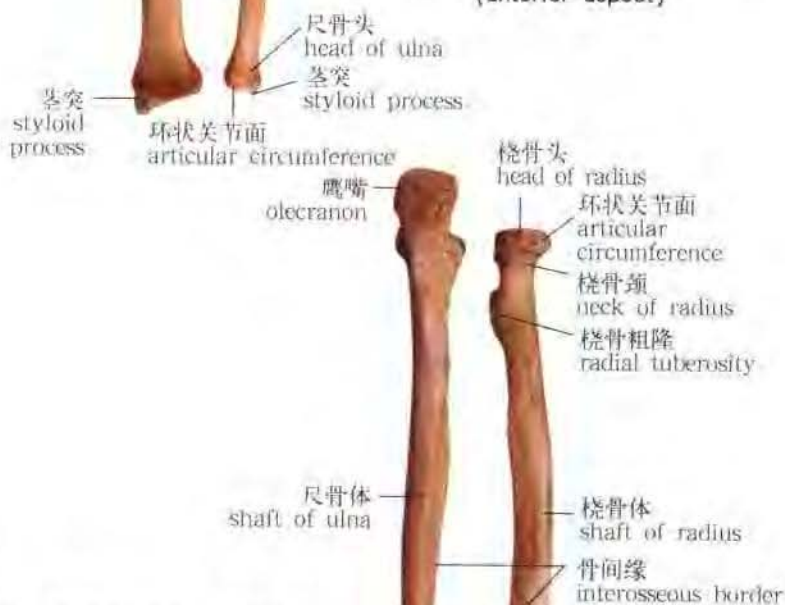
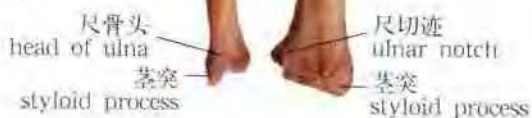
图 46 桡骨和尺骨 (后面观)  
The radius and ulna  
(posterior aspect)



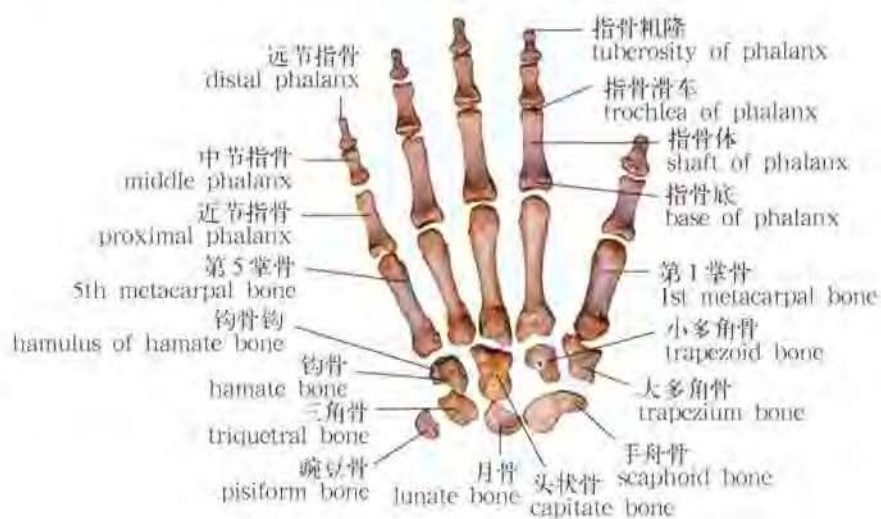

图 47 手骨 (掌侧面)  
Bones of the hand (palmar aspect)

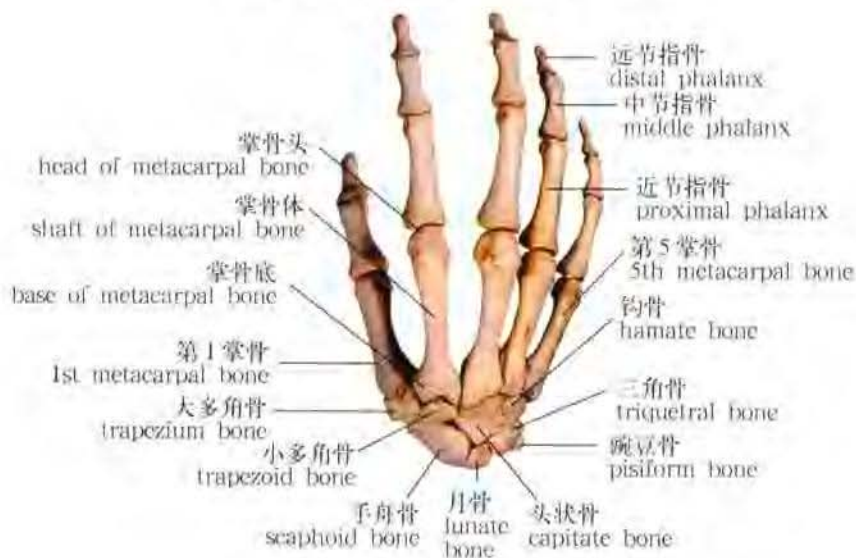

图 48 手骨 (背面观)  
Bones of the hand (dorsal aspect)



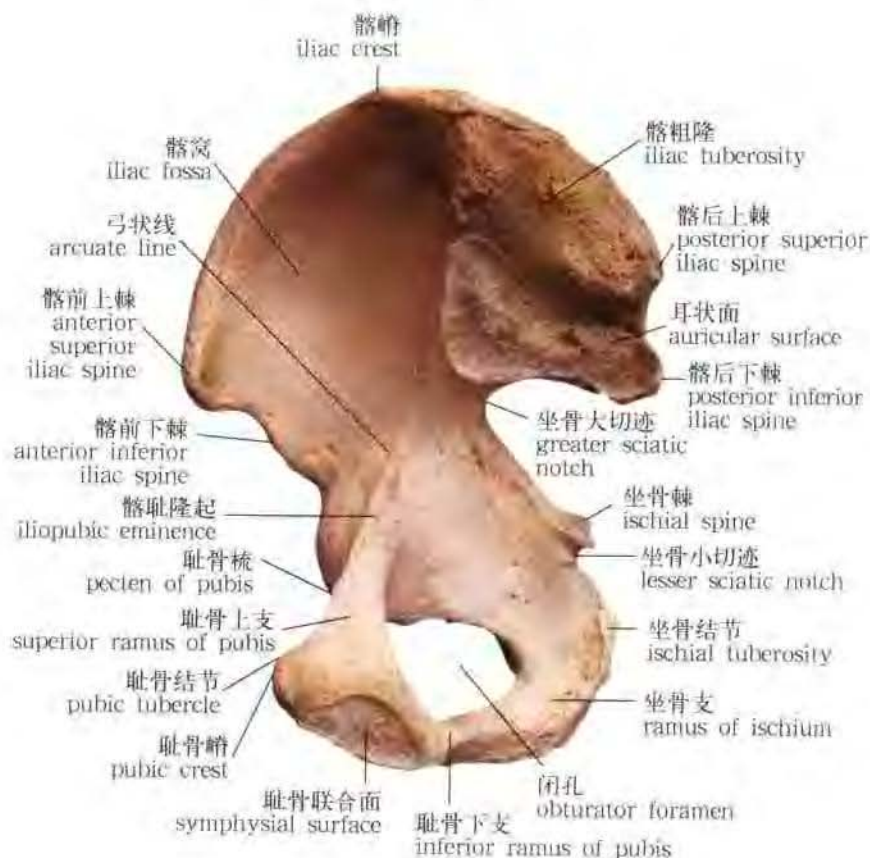

图 50 髋骨 (内面观)  
The hip bone (internal aspect)



图 51 髌骨 (前面观)  
The patella (anterior aspect)

图 52 髌骨 (后面观)  
The patella (posterior aspect)

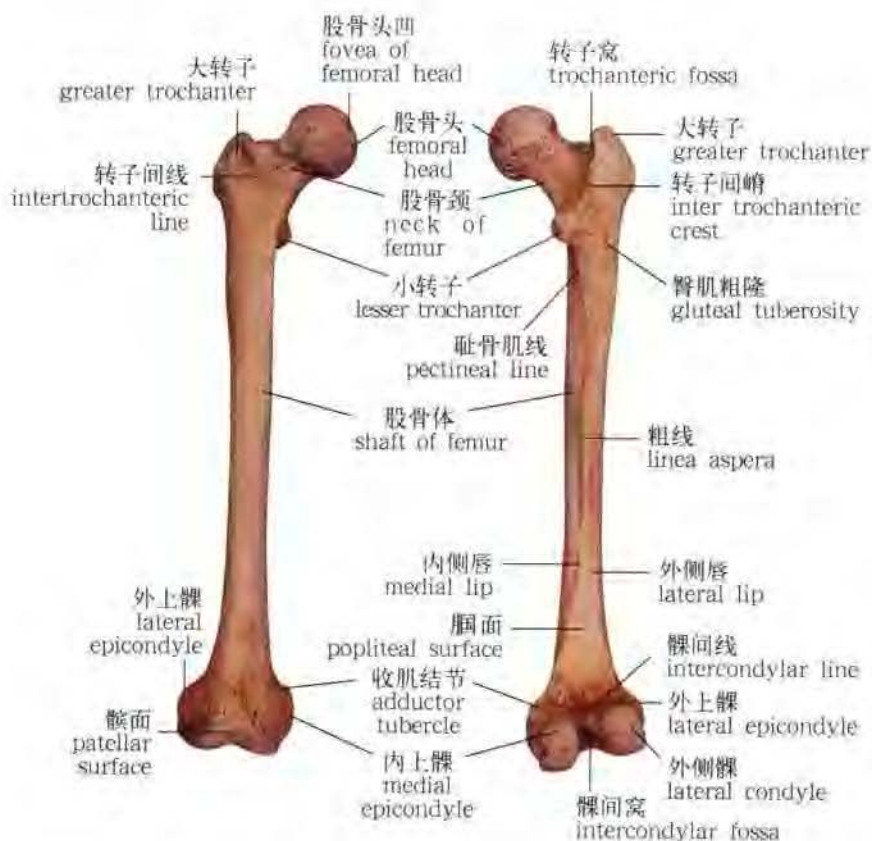


图 53 股骨 (前面观)  
The femur (anterior aspect)

图 54 股骨 (后面观)  
The femur (posterior aspect)

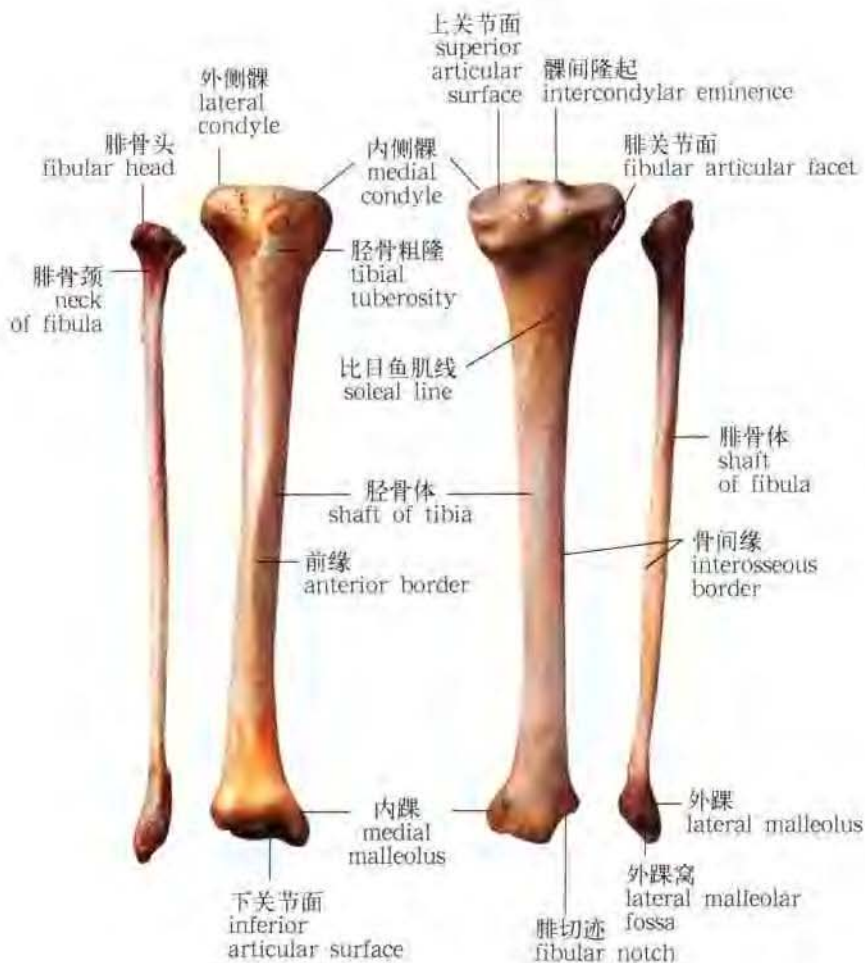

图 55 胫骨和腓骨 (前面观)  
The tibia and fibula  
(anterior aspect)

图 56 胫骨和腓骨 (后面观)  
The tibia and fibula  
(posterior aspect)



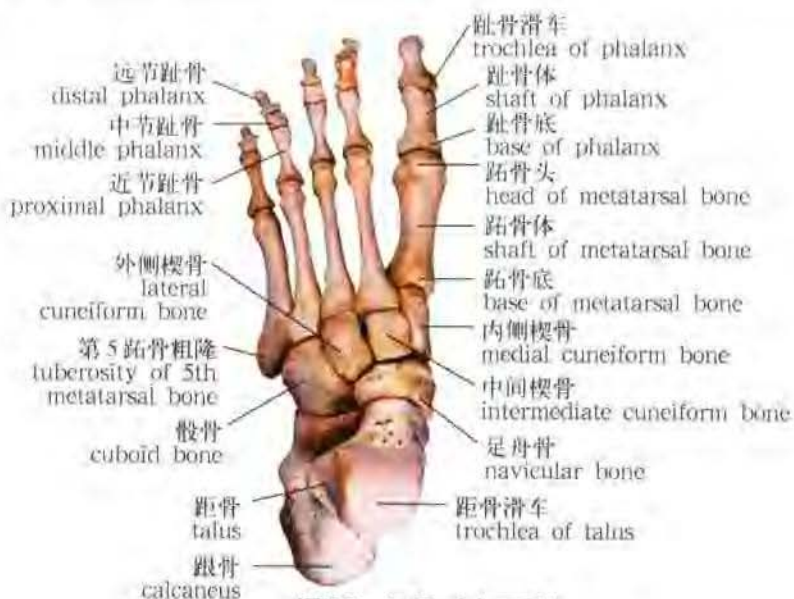

图 57 足骨 (上面观)  
Bones of the foot (superior aspect)

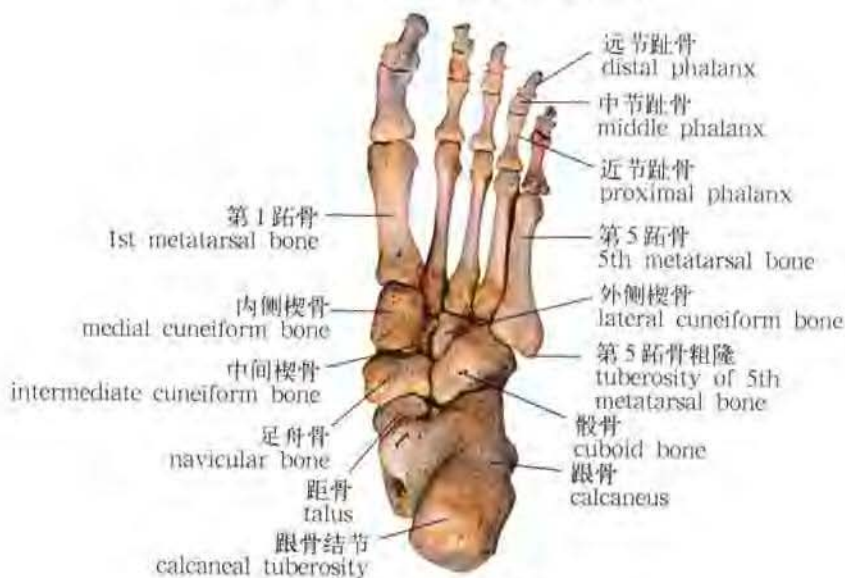

图 58 足骨 (下面观)  
Bones of the foot (inferior aspect)

# 运动系统——骨连结

LOCOMOTOR SYSTEM —— JOINT

# Chapter 2



图 59 椎骨间的连结 (前面观)  
The intervertebral joints (anterior aspect)

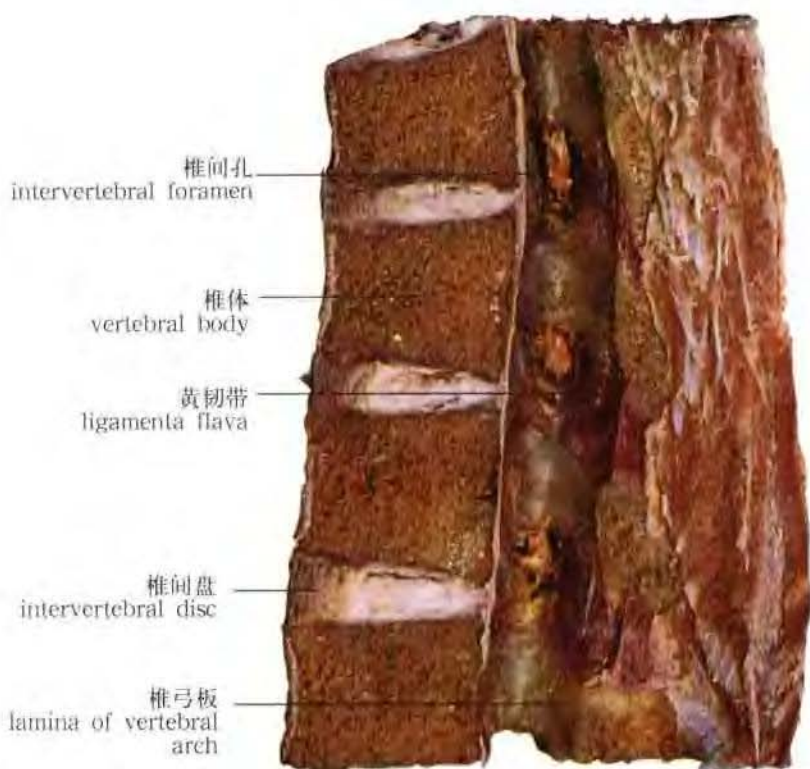


图 60 椎骨间的连结 (矢状面)  
The intervertebral joints (sagittal plane)

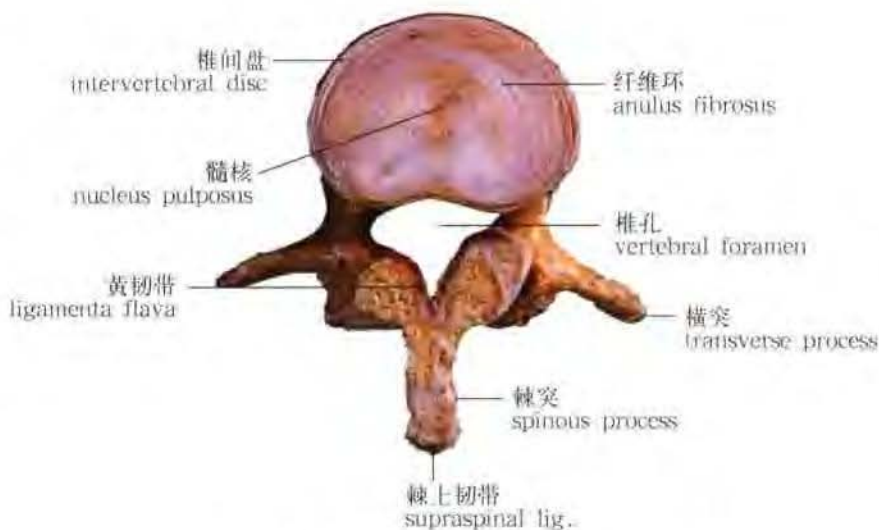

图 61 椎间盘 (下面观)  
The intervertebral disc (inferior aspect)

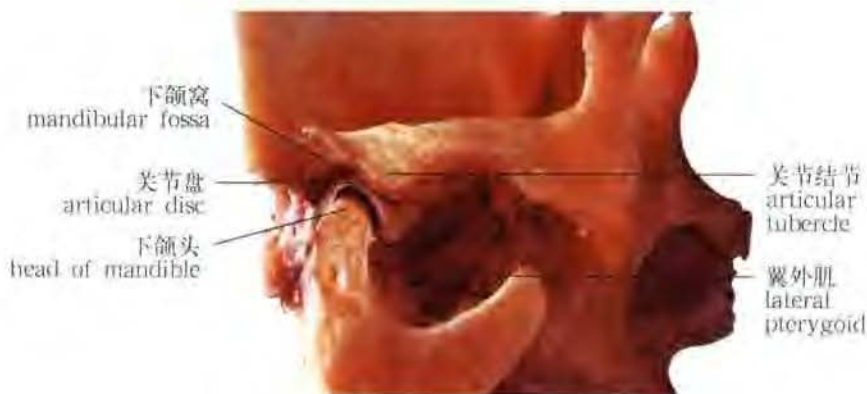

图 62 颞下颌关节 (外侧面观)  
The temporomandibular joint (lateral aspect)

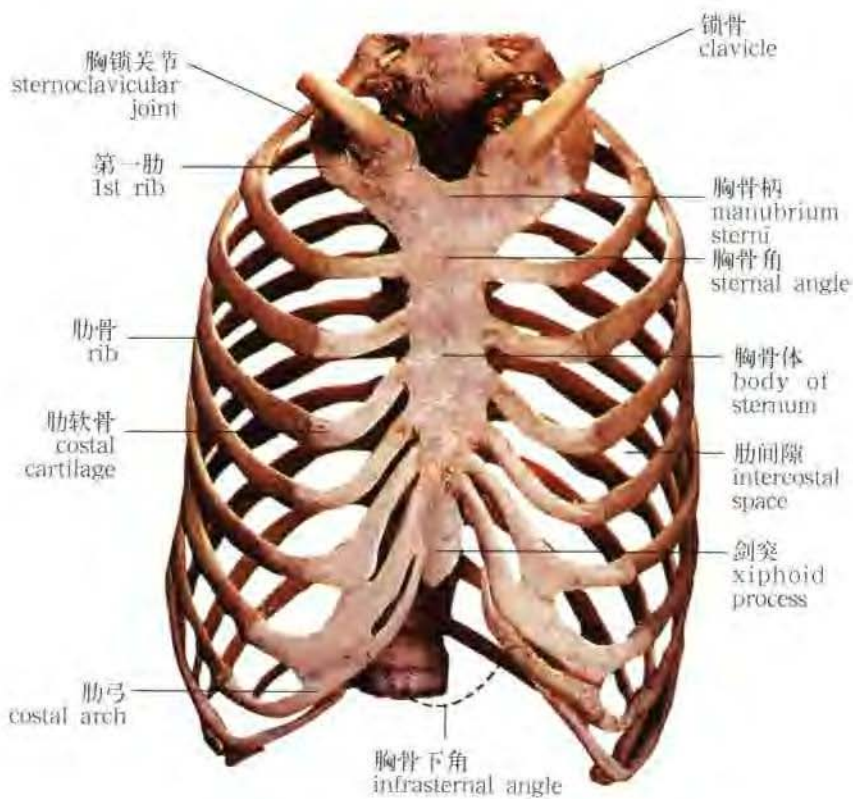


图 63 胸廓 (前面观)  
The thorax (anterior aspect)

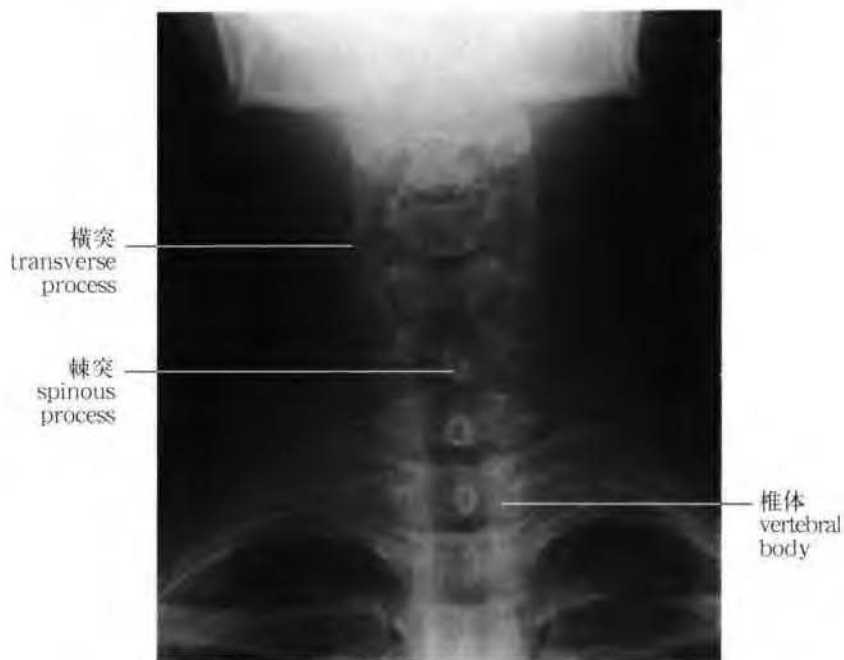

图 64 颈椎 X 线图像 (正位)  
Radiograph of the cervical vertebrae (anterior aspect)

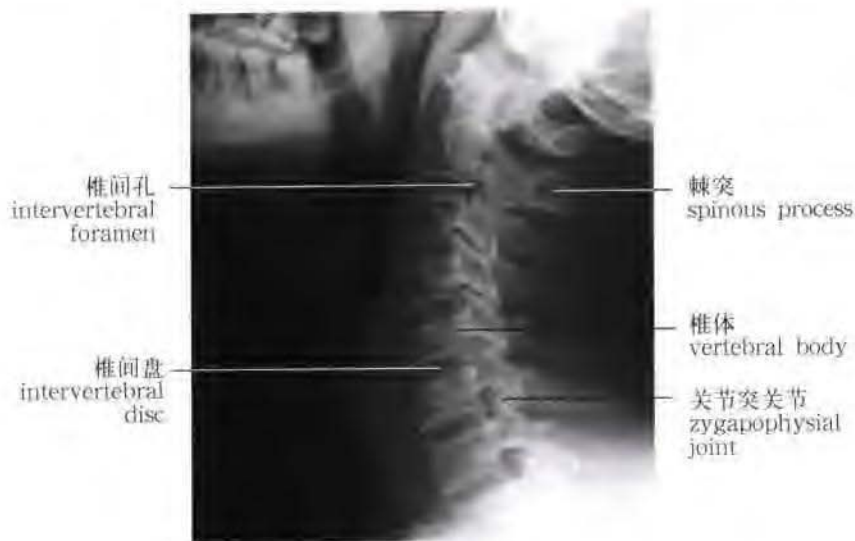

图 65 颈椎 X 线图像 (侧位)  
Radiograph of the cervical vertebrae (lateral aspect)

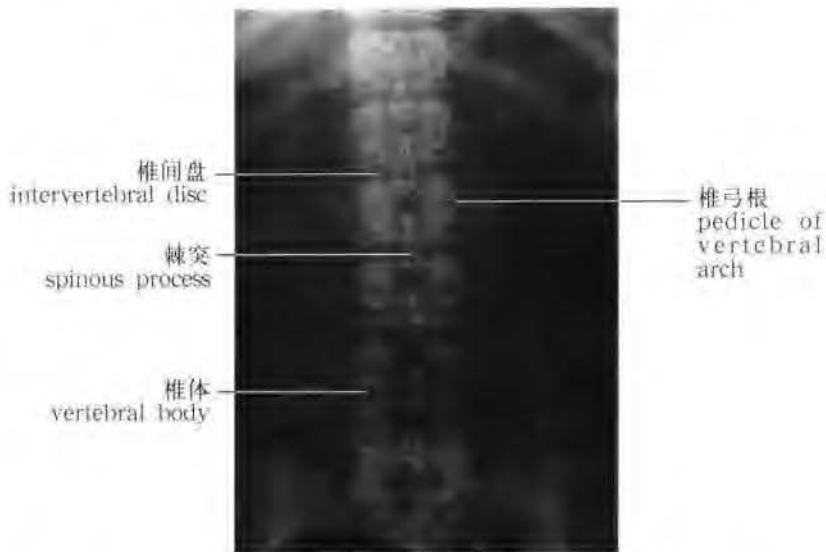

图 66 腰椎 X 线图像 (正位)  
Radiograph of the lumbar vertebrae (anterior aspect)



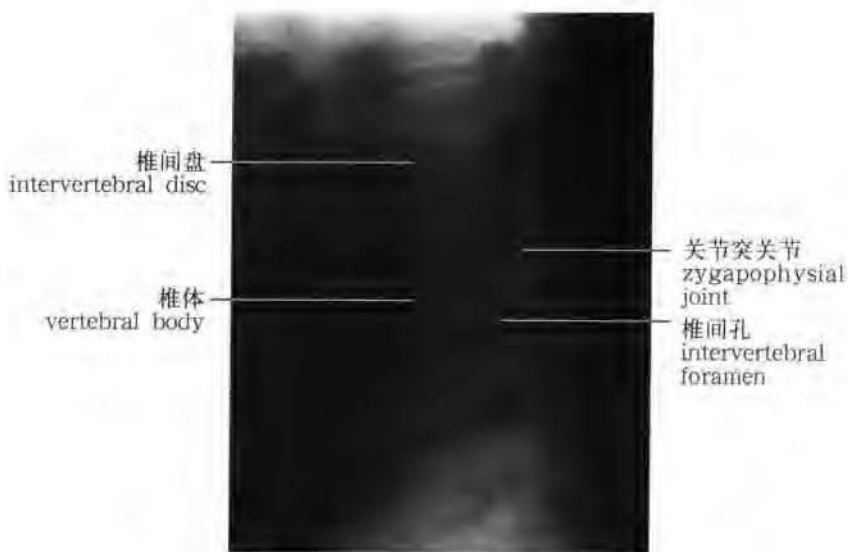


图 67 腰椎 X 线图像 (侧位)  
Radiograph of the lumbar vertebrae (lateral aspect)

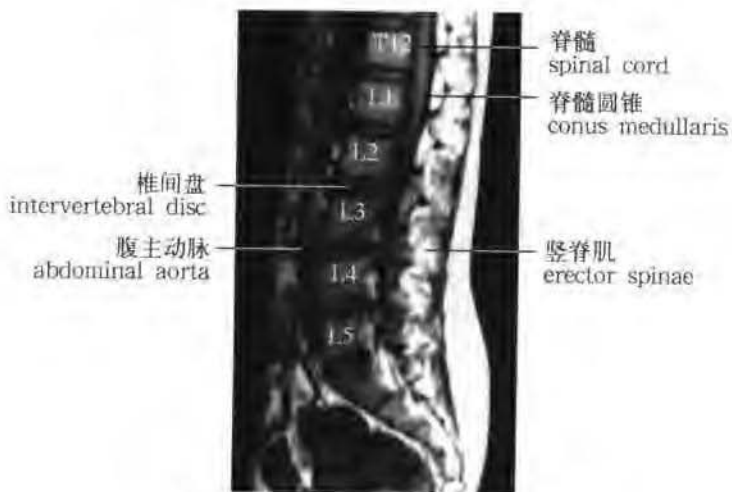


图 68 腰椎 MRI 图像 (侧位)  
MRI of the lumbar vertebrae (lateral aspect)

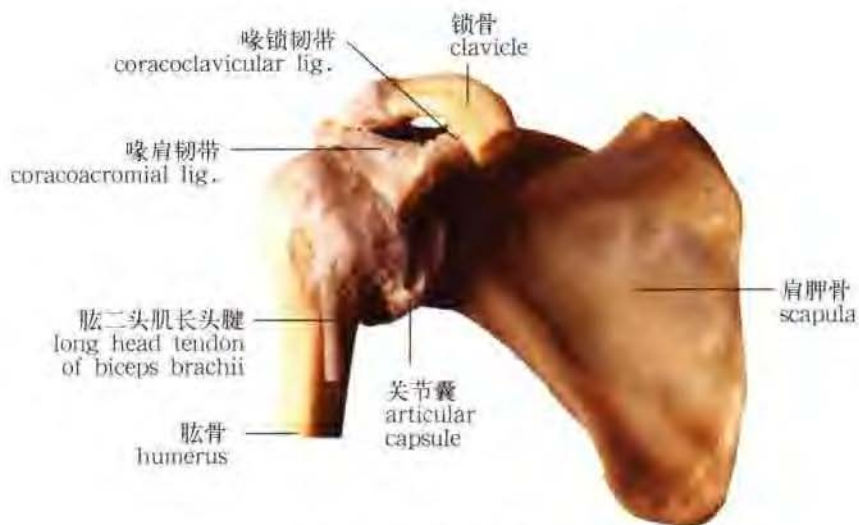


图 69 肩关节 (前面观)  
The shoulder joint (anterior aspect)

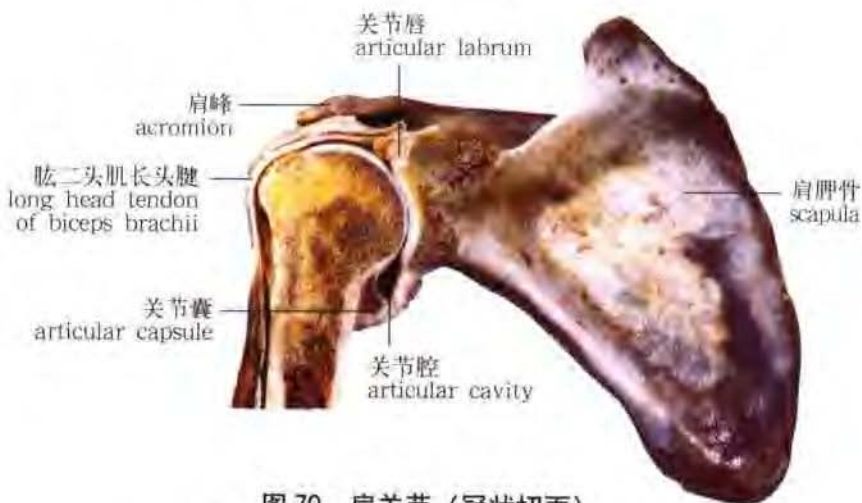

图 70 肩关节 (冠状切面)  
The shoulder joint (coronal section)

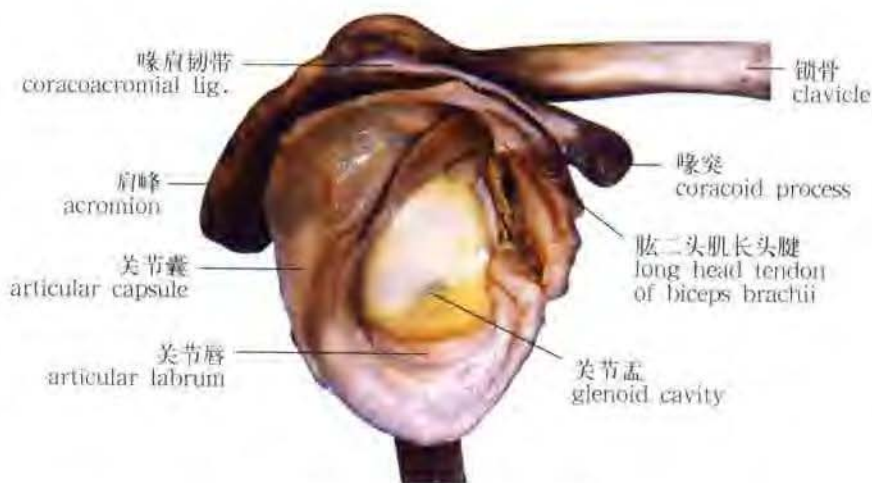


图 71 肩关节 (内面观)  
The shoulder joint (medial aspect)

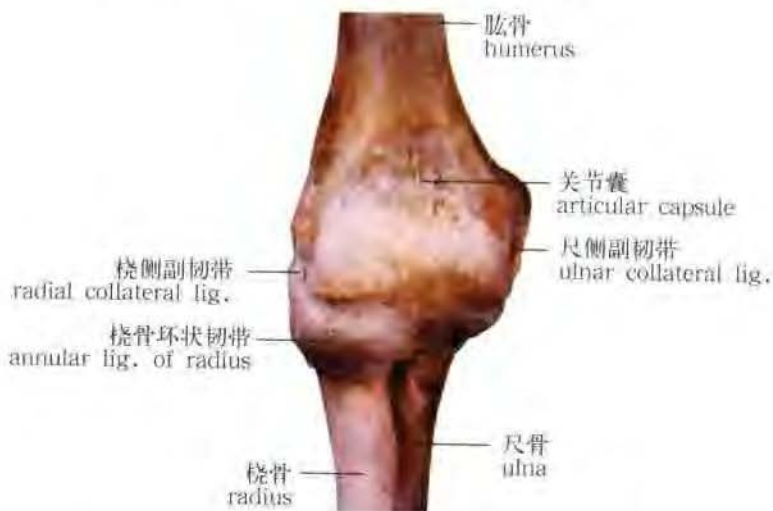

图 72 肘关节 (前面观)  
The elbow joint (anterior aspect)

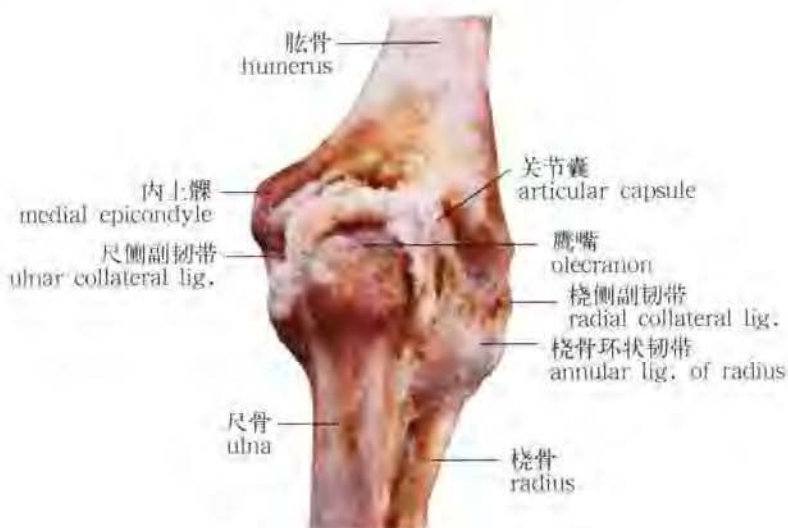

图 73 肘关节 (后面观)  
The elbow joint (posterior aspect)

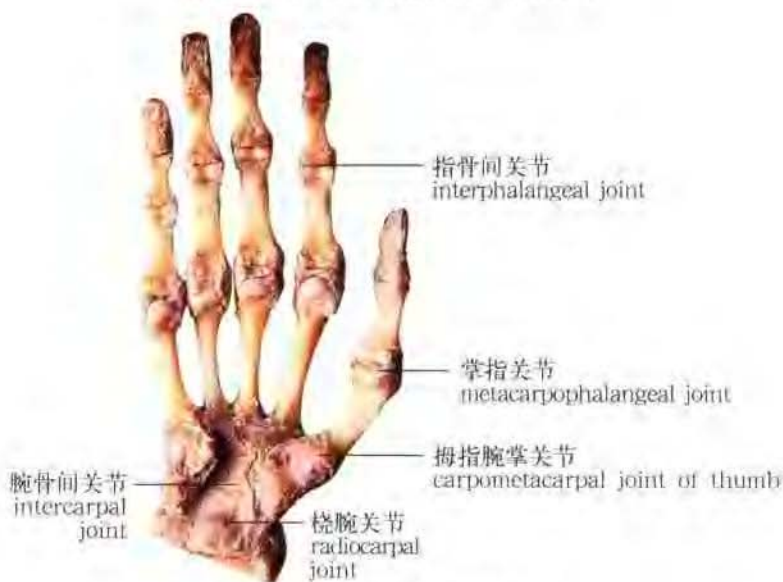

图 74 手关节 (前面观)  
Joints of the hand (anterior aspect)

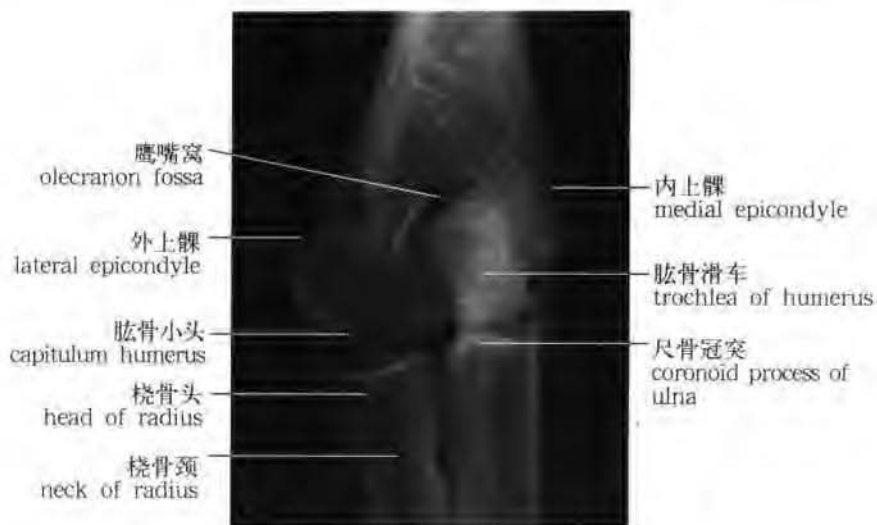

图 75 肘关节 X 线图像 (正位)  
Radiograph of the elbow joint (anterior aspect)

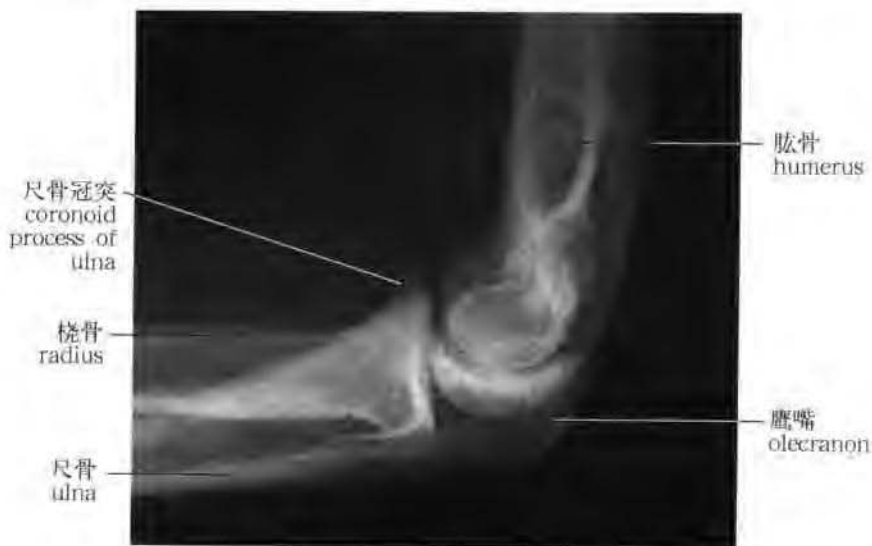

图 76 肘关节 X 线图像 (侧位)  
Radiograph of the elbow joint (lateral aspect)

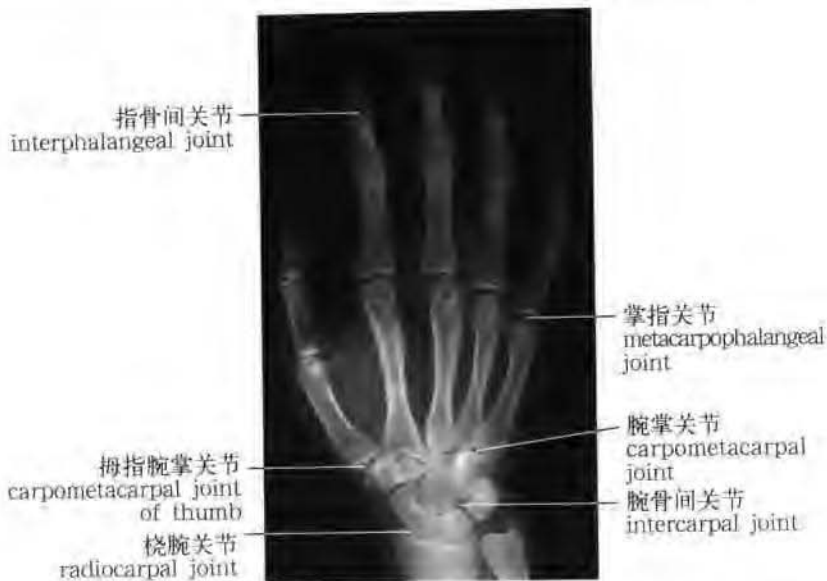

图 77 手关节 X 线图像 (正位)  
Radiograph of the hand joint (anterior aspect)

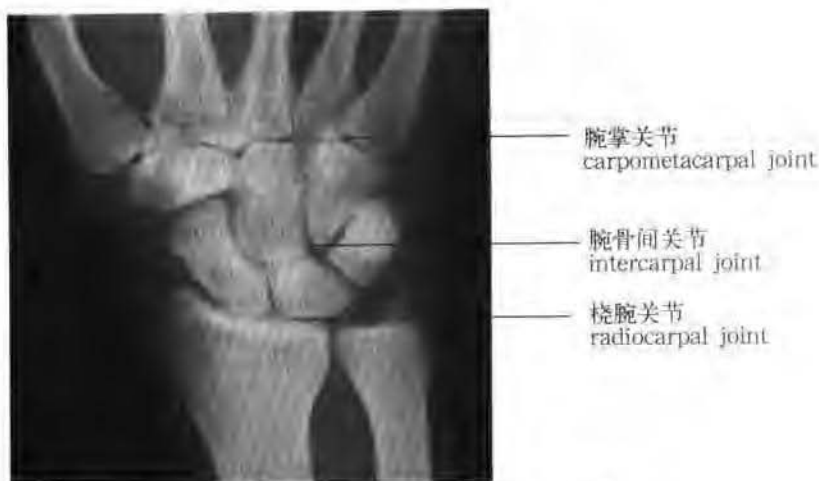

图 78 手关节 X 线图像 (正位)  
Radiograph of the hand joint (anterior aspect)

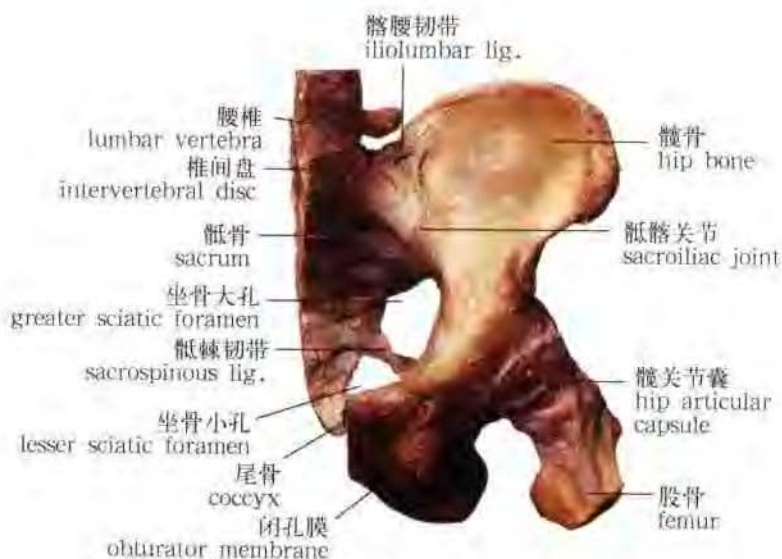

图 79 骨盆的连结 (前面观)  
Articulations of the pelvis (anterior aspect)

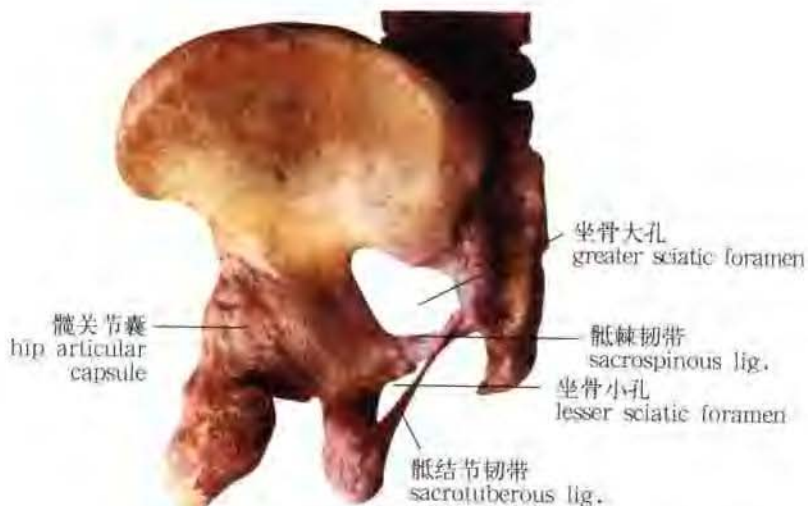

图 80 骨盆的连结 (后面观)  
Articulations of the pelvis (posterior aspect)

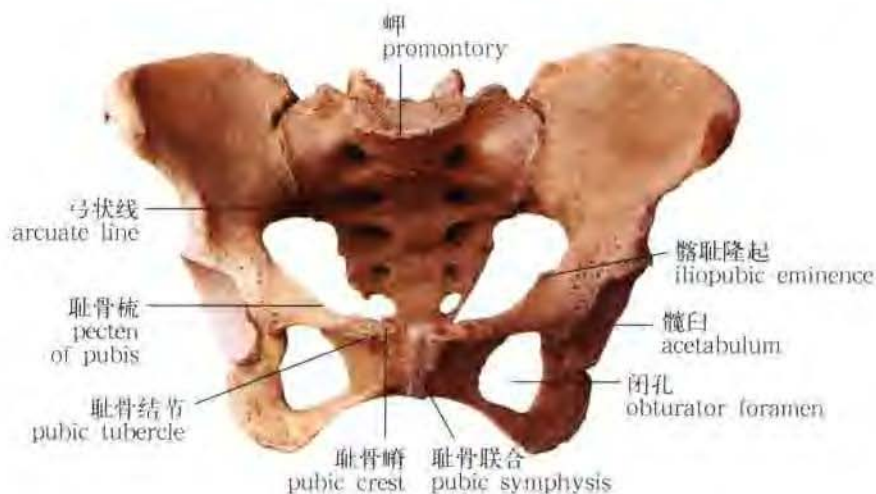

图81 骨盆(女性)  
The pelvis (female)

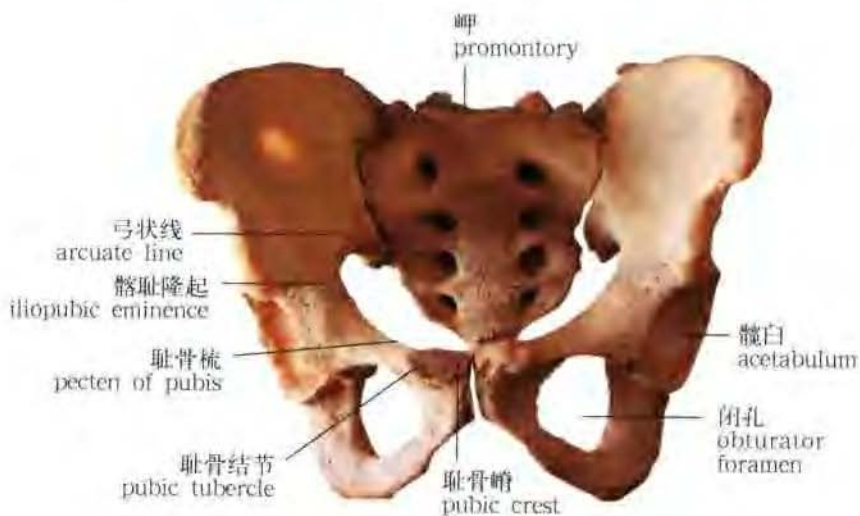


图82 骨盆(男性)  
The pelvis (male)



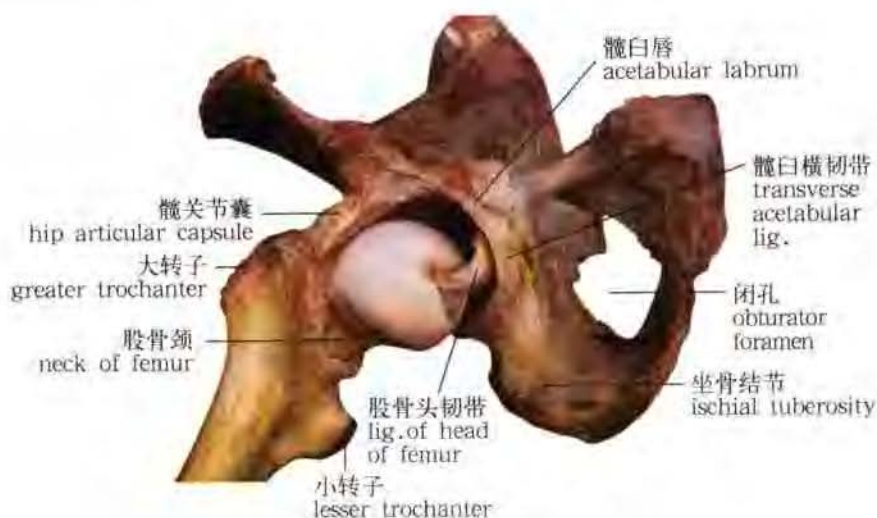

图 83 髋关节 (打开关节腔)  
The hip joint (opened cavity)

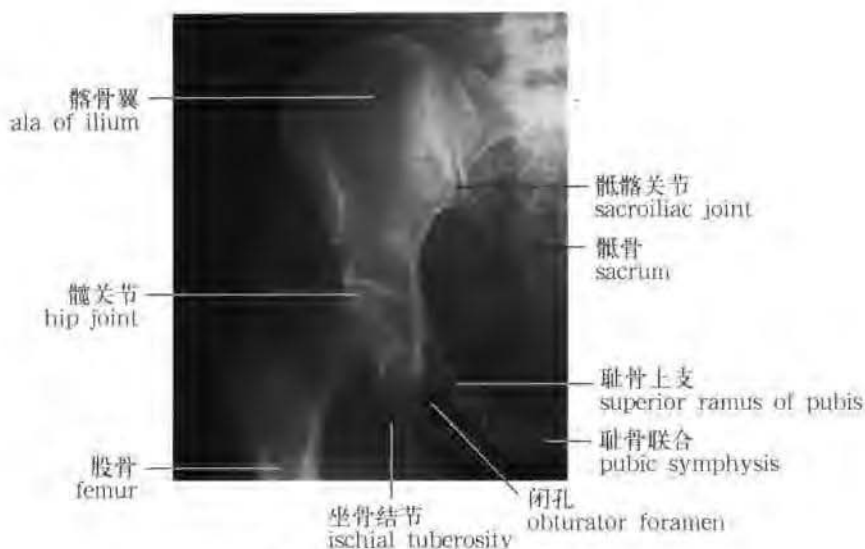

图 84 骨盆 X 线图像 (正位)  
Radiograph of the pelvis (anterior aspect)

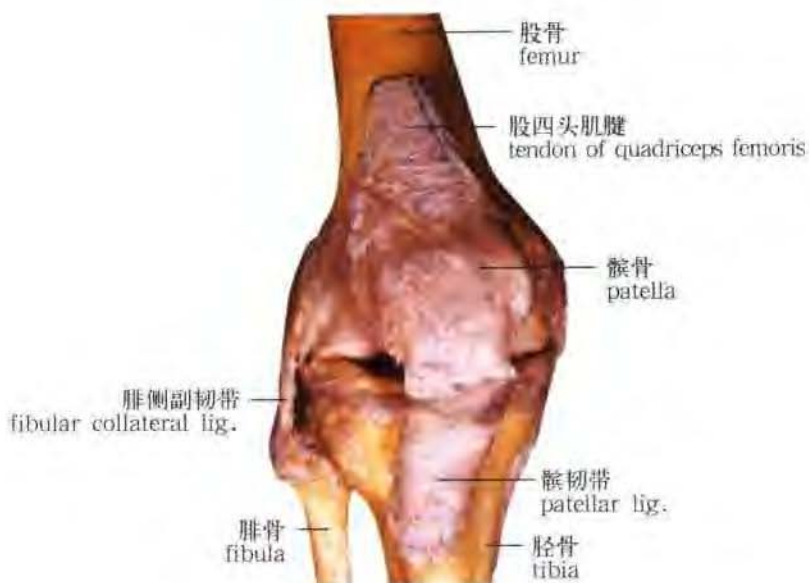

图 85 膝关节 (前面观)  
The knee joint (anterior aspect)

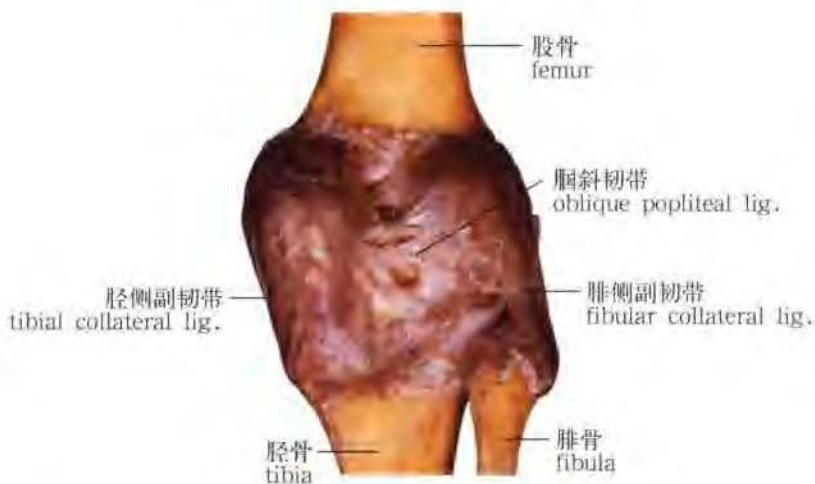

图 86 膝关节 (后面观)  
The knee joint (posterior aspect)

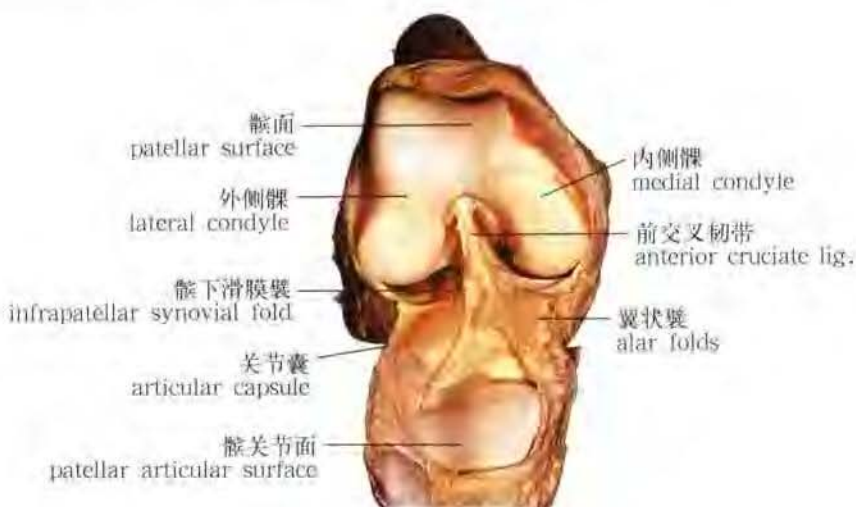

图 87 膝关节 (打开关节腔)  
The knee joint (opened cavity)

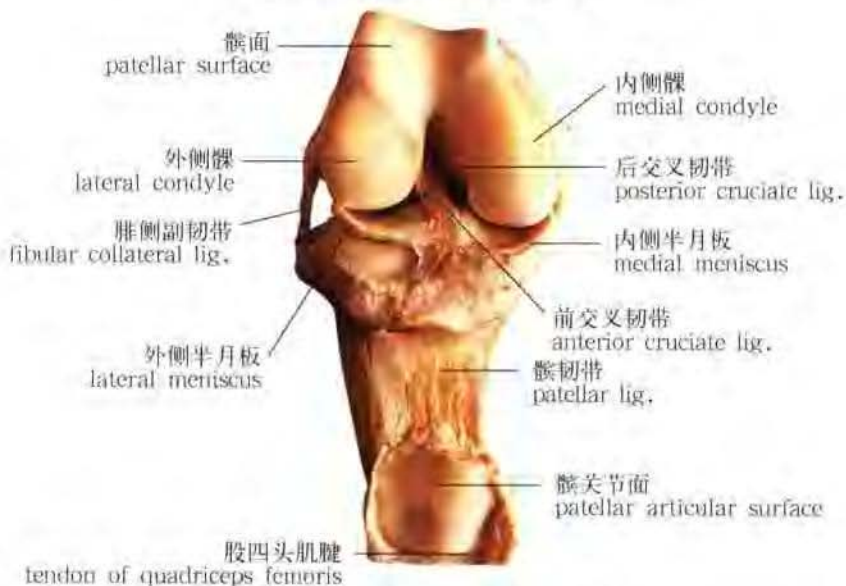

图 88 膝关节 (前面观, 打开关节腔)  
The knee joint (anterior aspect, opened cavity)

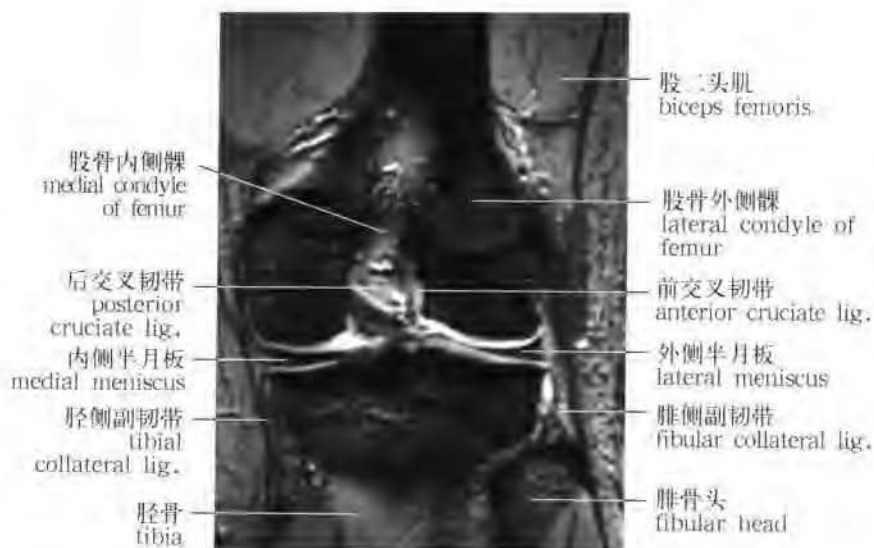

图 89 膝关节 (MRI)  
The knee joint (MRI)

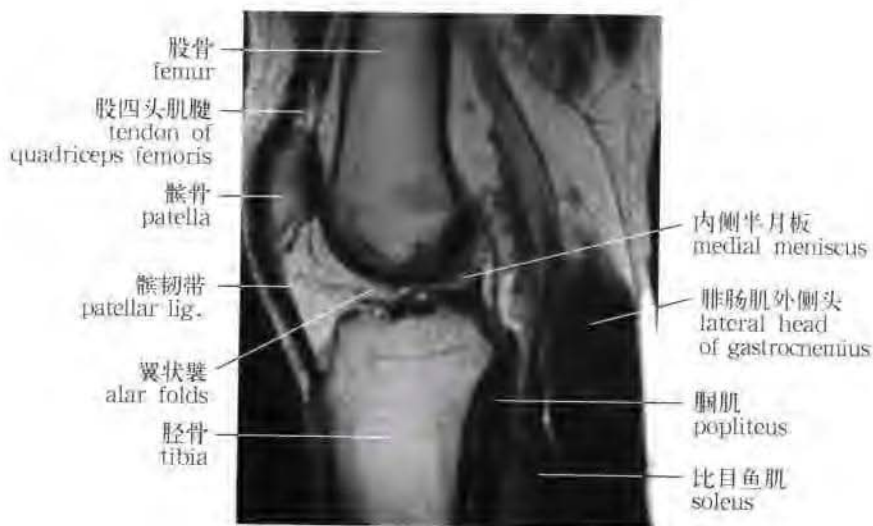


图 90 膝关节 (MRI)  
The knee joint (MRI)

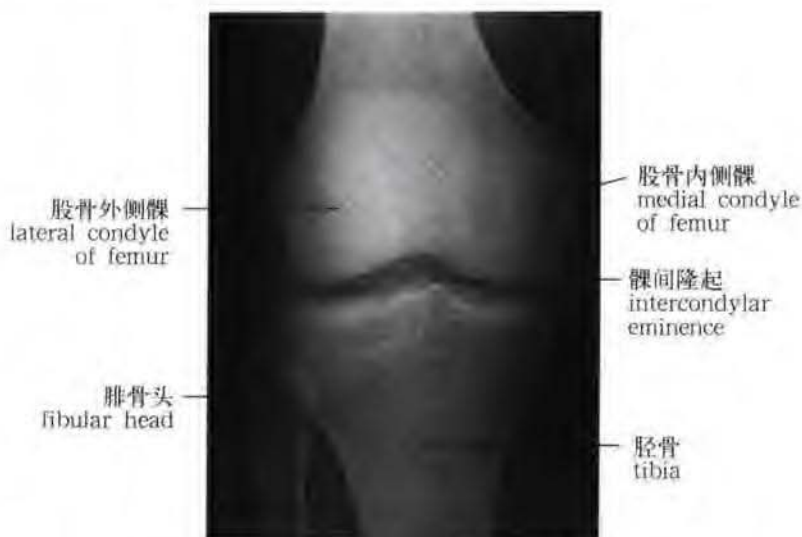

图 91 膝关节 X 线图像 (正位)  
Radiograph of the knee joint (anterior aspect)

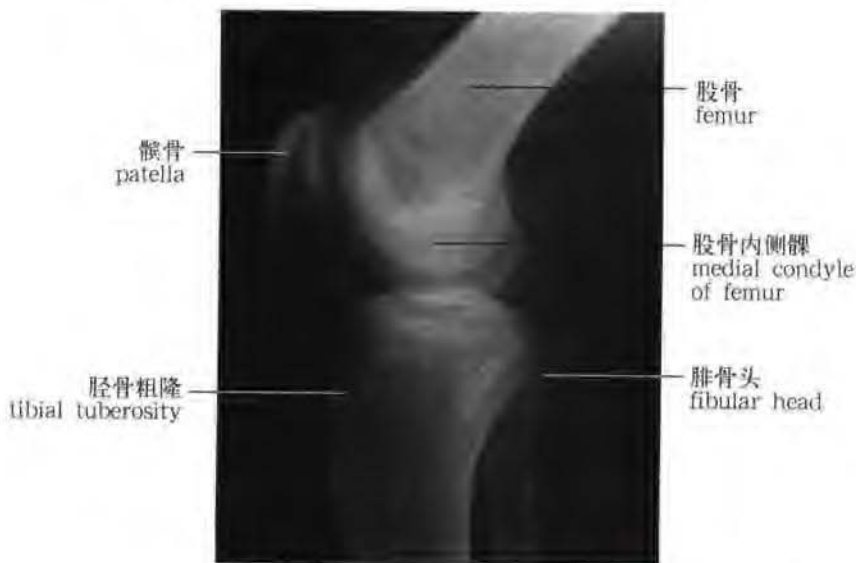


图 92 膝关节 X 线图像 (侧位)  
Radiograph of the knee joint (lateral aspect)

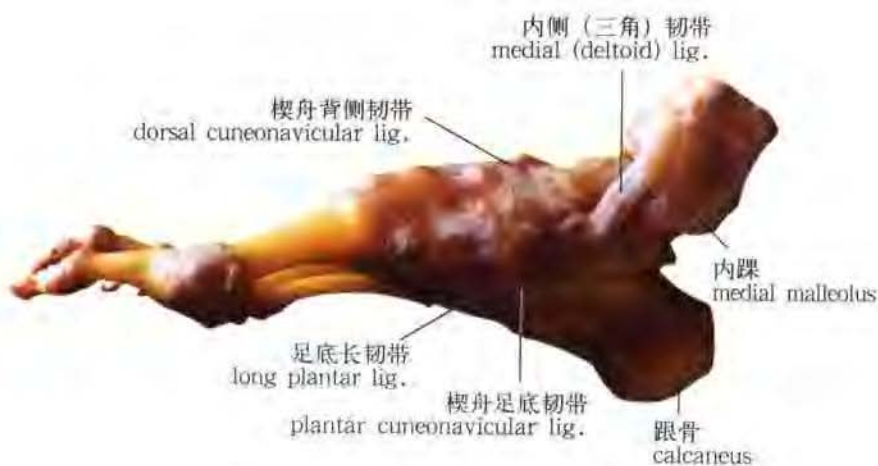


图 93 足的连结 (内侧面观)  
Articulations of the foot (medial aspect)

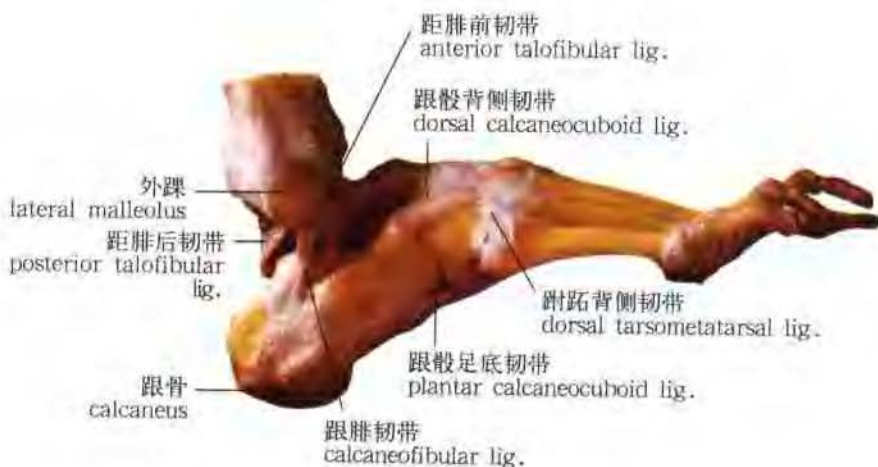

图 94 足的连结 (外侧面观)  
Articulations of the foot (lateral aspect)

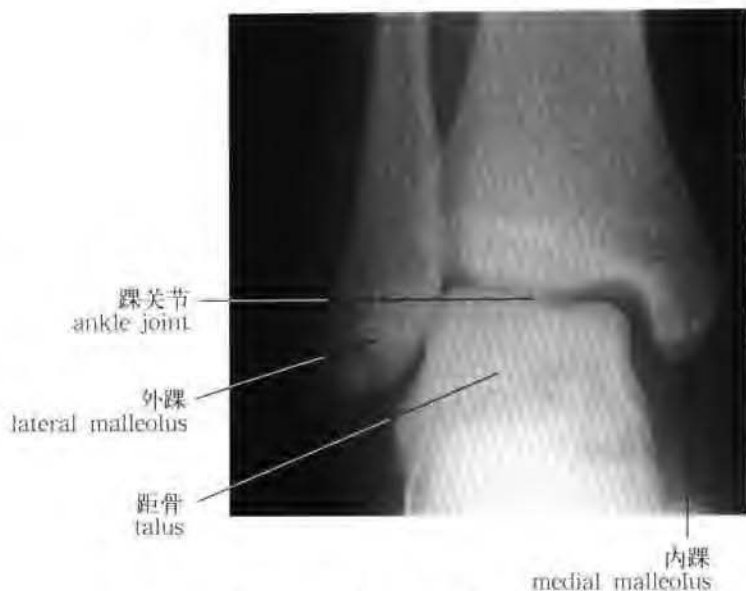

图 95 足关节 X 线图像 (正位)  
Radiograph of the foot joint (anterior aspect)

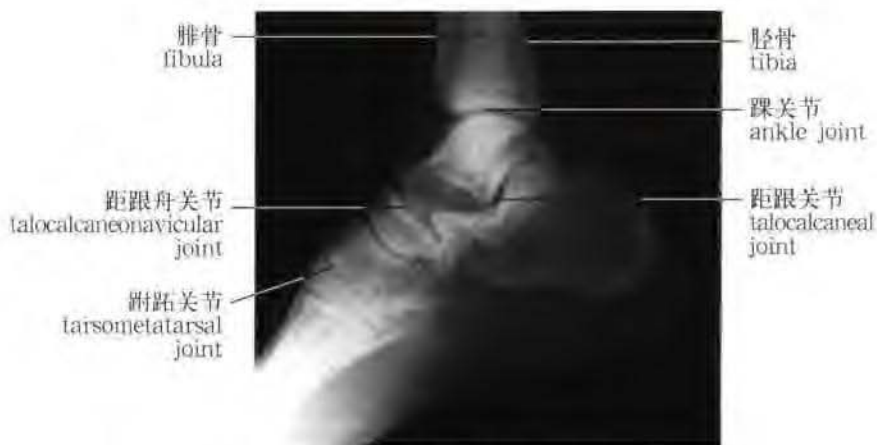


图 96 足关节 X 线图像 (侧位)  
Radiograph of the foot joint (lateral aspect)

# 运动系统——肌

LOCOMOTOR SYSTEM——MUSCLE

Chapter

3





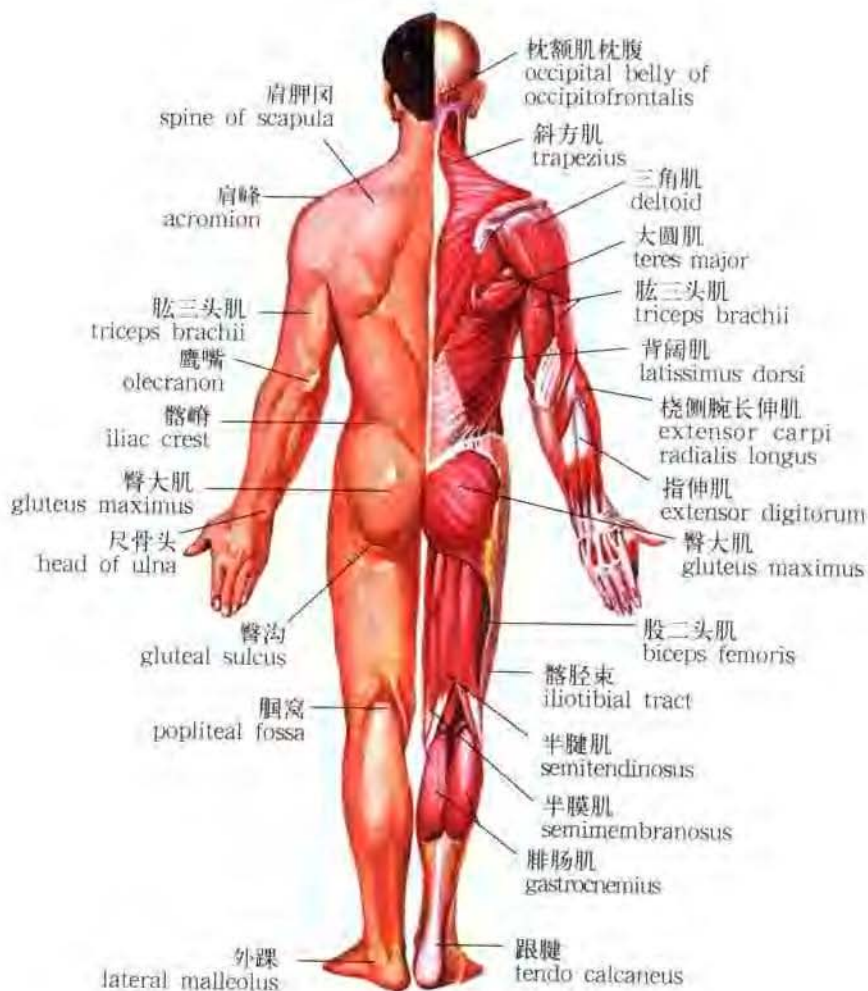

图 98 全身体表及肌肉 (后面观)  
Surface anatomy and muscles of the body (posterior aspect)

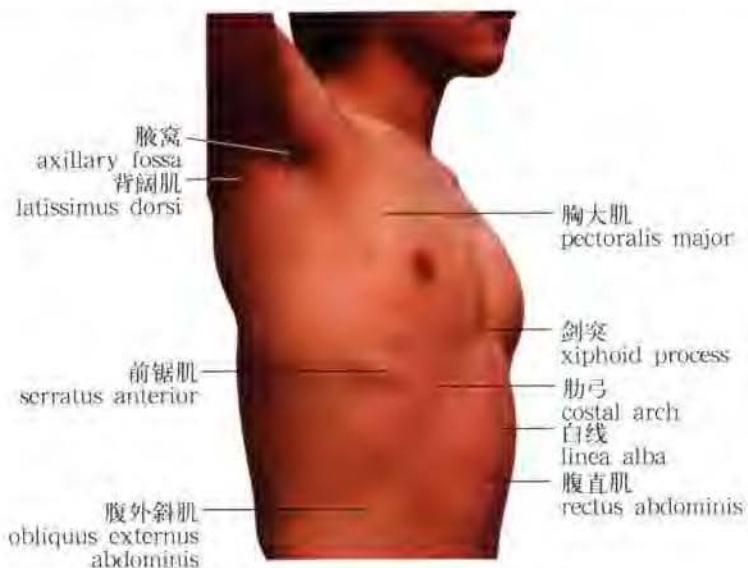


图 99 躯干肌体表标志 (侧面观)  
Surface markings of the muscles of the trunk (lateral aspect)

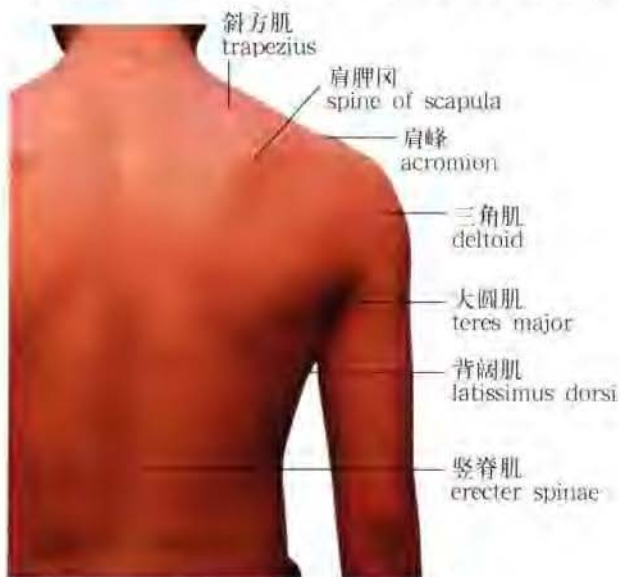

图 100 躯干肌体表标志 (后面观)  
Surface markings of the muscles of the trunk (posterior aspect)

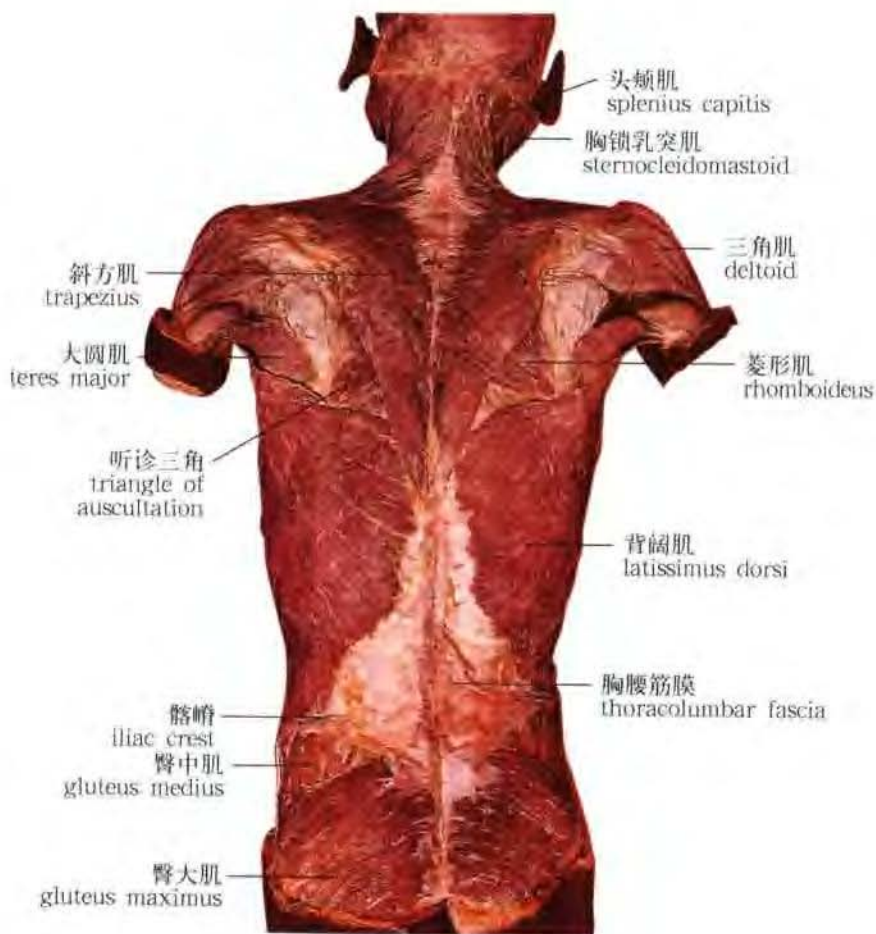


图 101 背部肌  
Muscles of the back

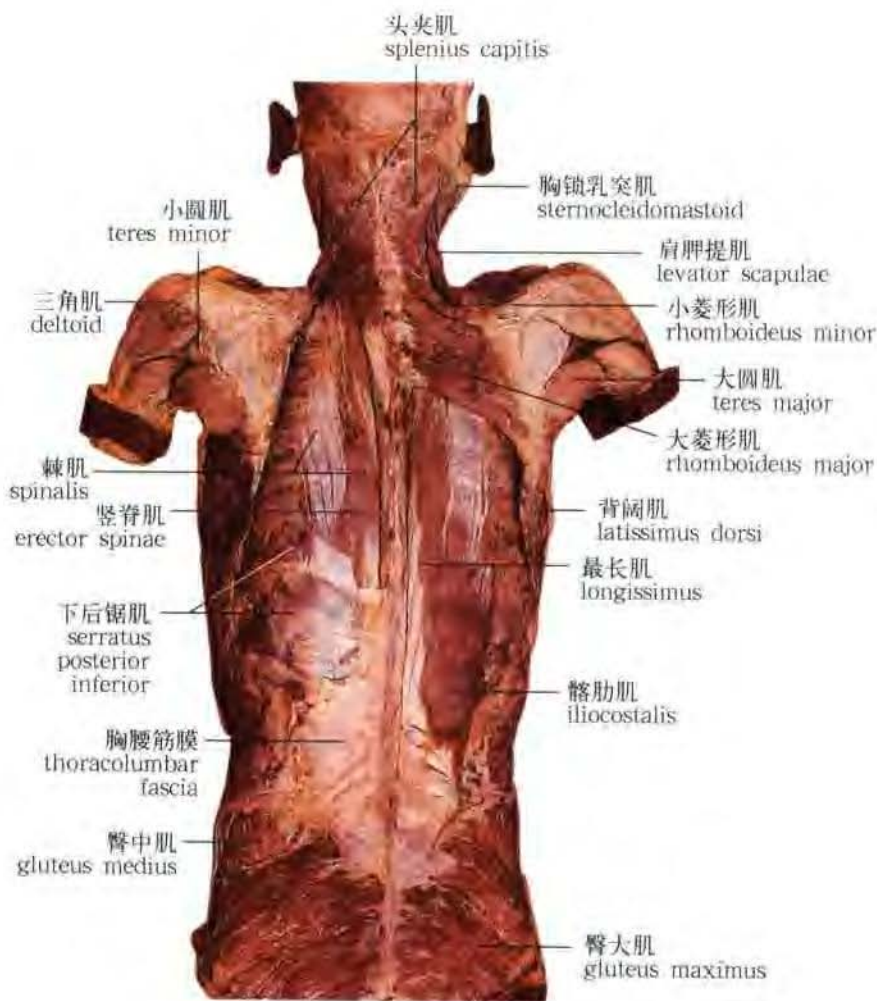


图 102 背部肌  
Muscles of the back

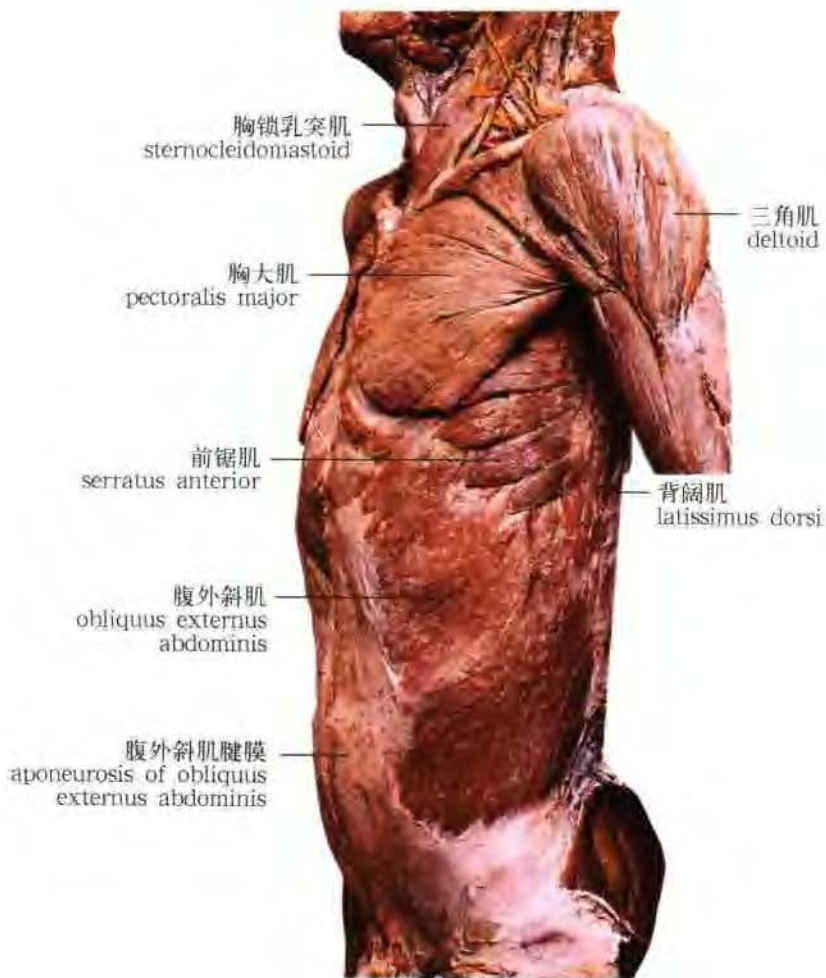

图 103 躯干肌  
Muscles of the trunk

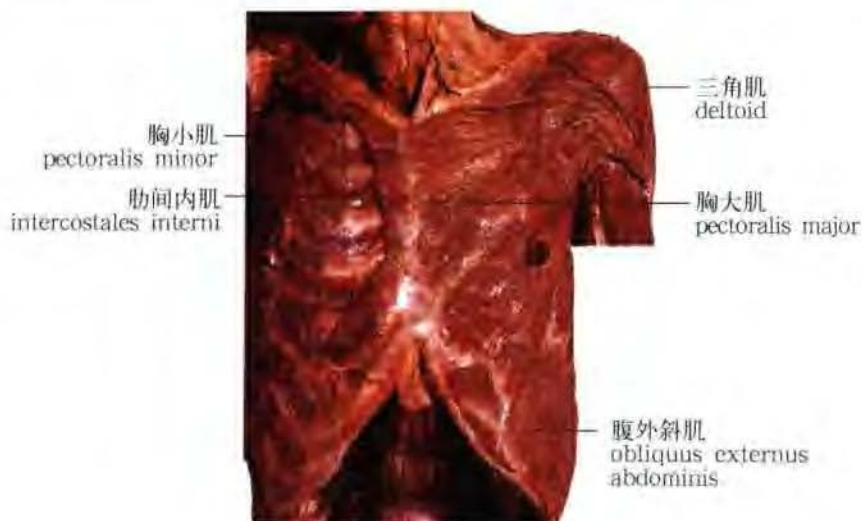


图 104 胸肌 (前面观)  
Muscles of the thorax (anterior aspect)

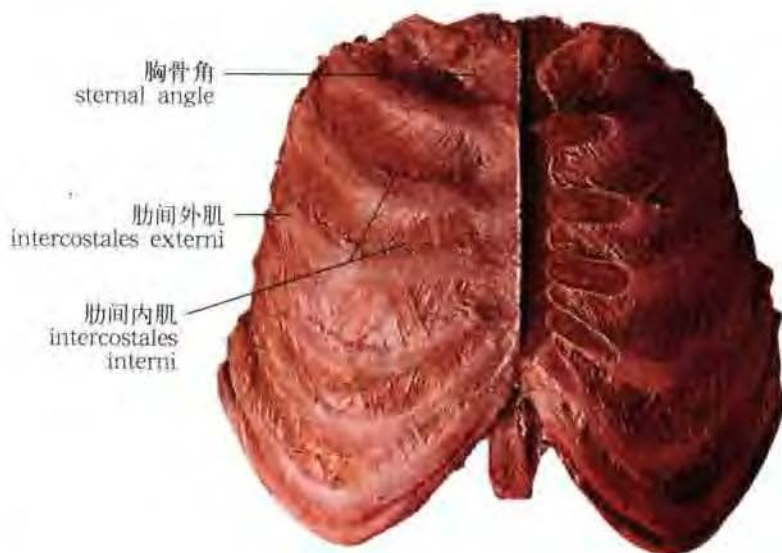


图 105 肋间肌  
The intercostales



图 106 腹前外侧壁肌层  
Muscular layer of the anterolateral abdominal wall

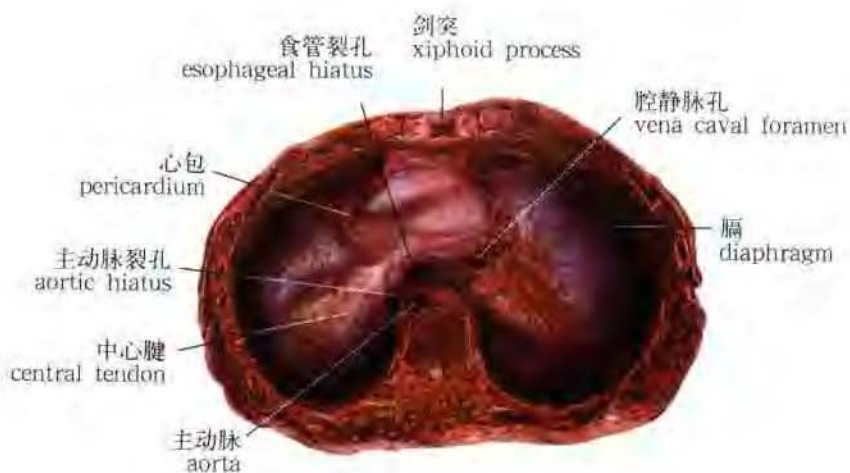


图 107 膈 (上面观)  
The diaphragm (superior aspect)



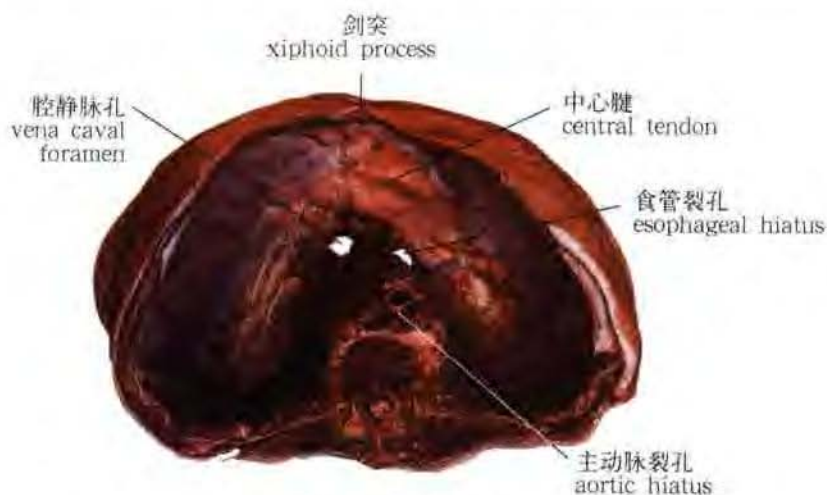


图 108 膈 (下面观)  
The diaphragm (inferior aspect)

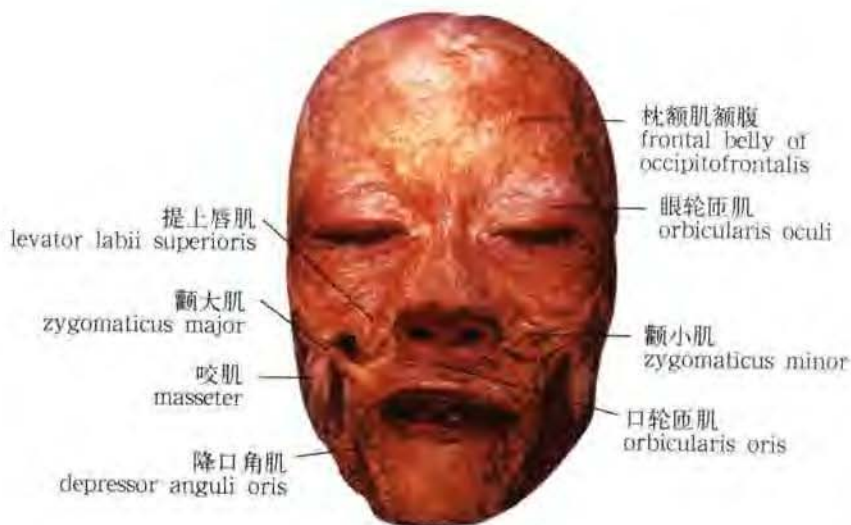

图 109 面部表情肌  
Muscles of the facial expression

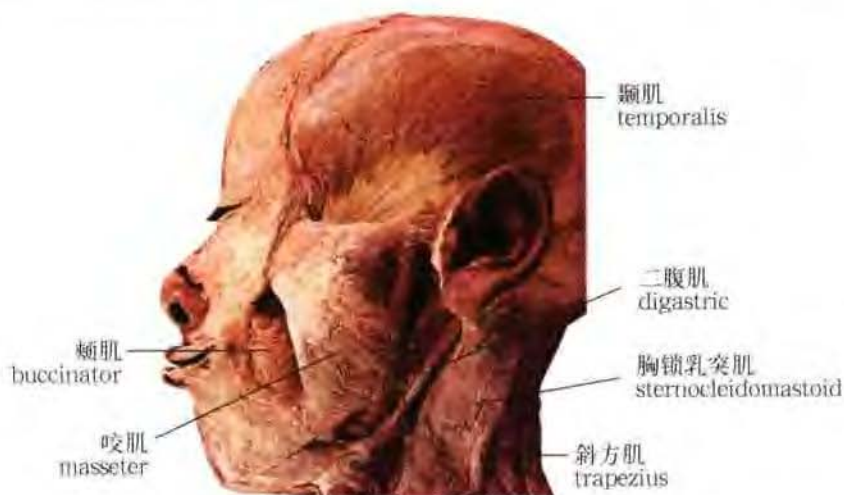


图 110 头部的肌  
Muscles of the head

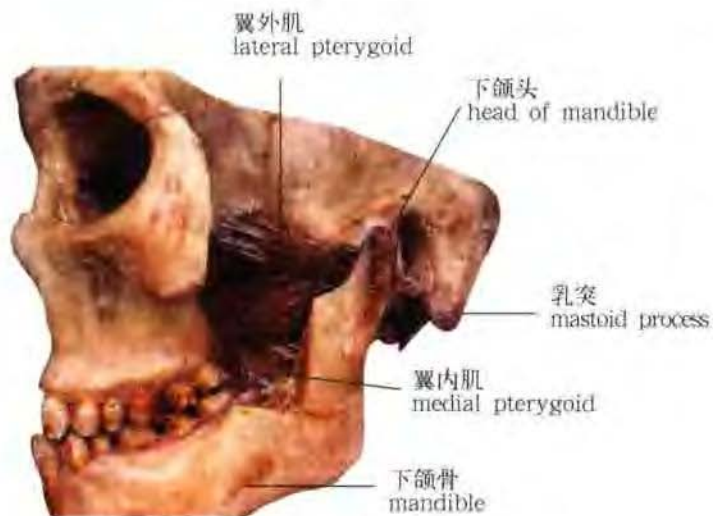

图 111 翼肌  
The pterygoid

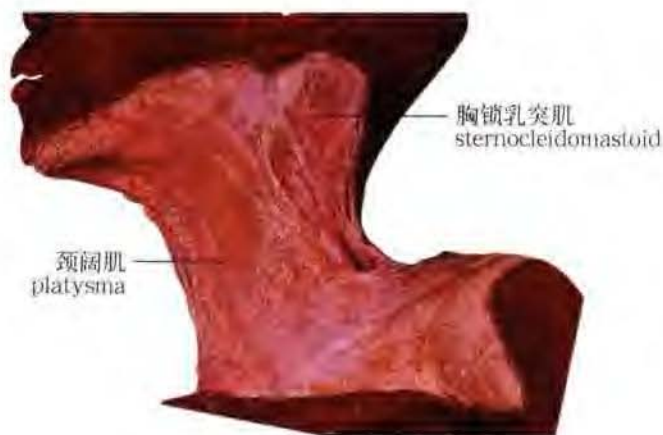


图 112 颈阔肌  
The platysma

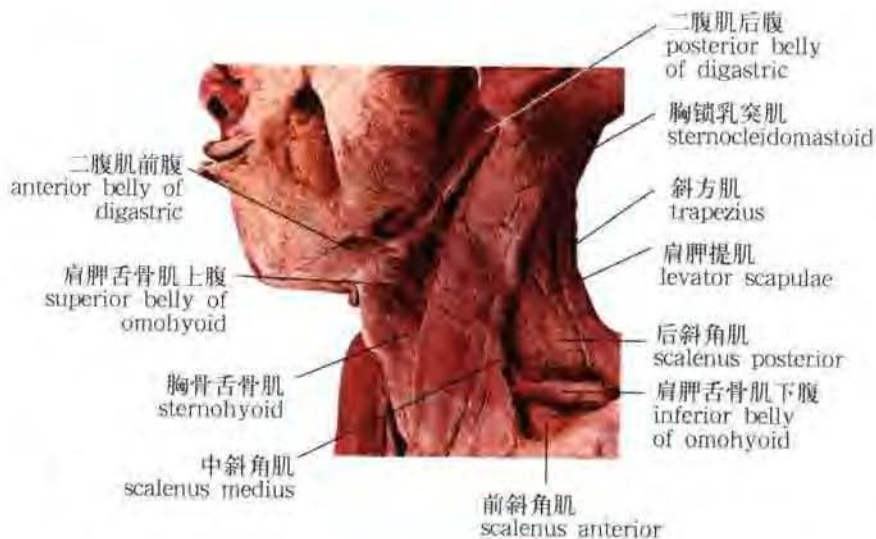


图 113 颈肌 (侧面观)  
Muscles of the neck (lateral aspect)

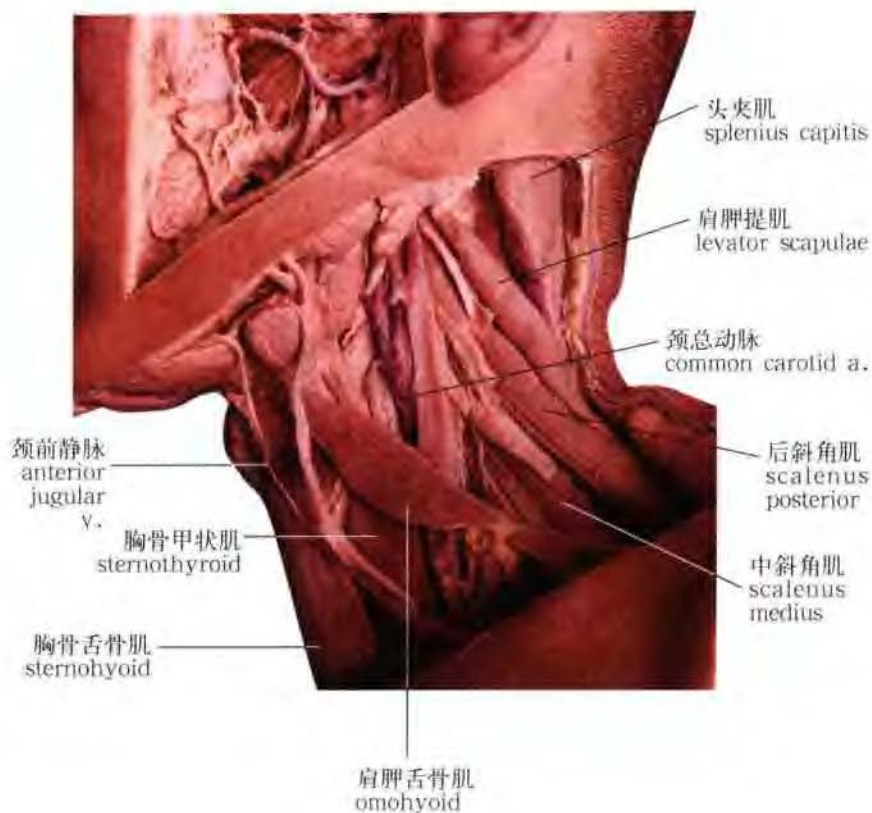


图 114 颈肌 (侧面观)  
 Muscles of the neck (lateral aspect)

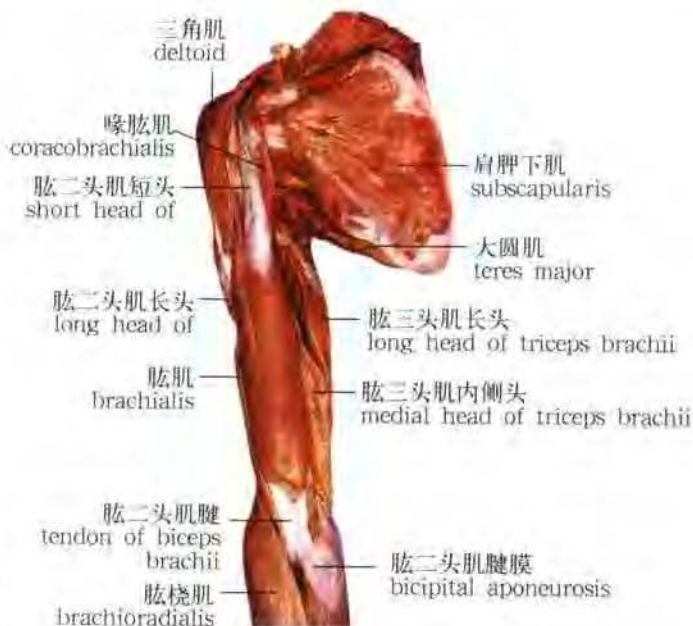

图 115 肩及臂部的肌肉 (前面观 1)  
Muscles of the shoulder and arm  
(anterior aspect 1)

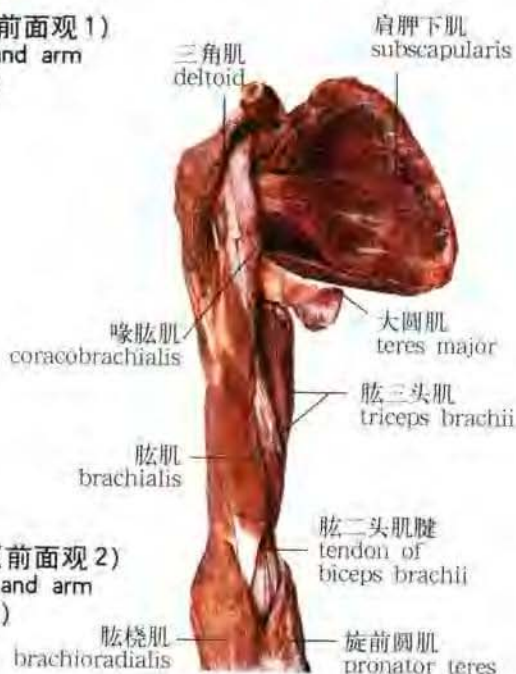

图 116 肩及臂部的肌肉 (前面观 2)  
Muscles of the shoulder and arm  
(anterior aspect 2)

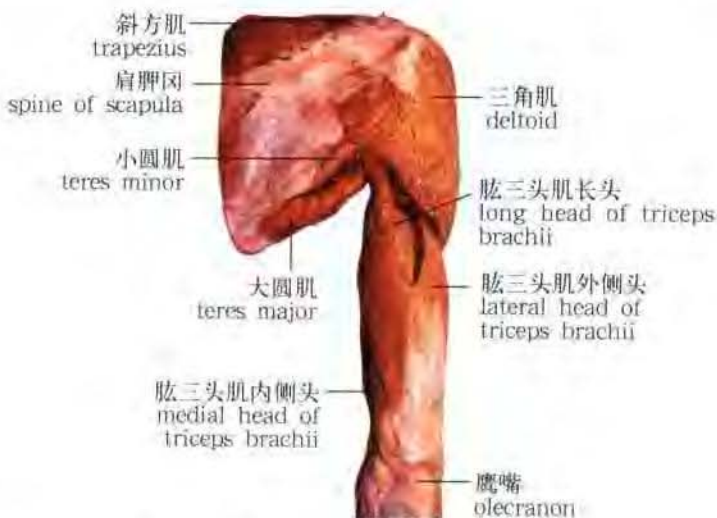

图 117 肩及臂部的肌肉 (后面观 1)  
Muscles of the shoulder and arm (posterior aspect 1)

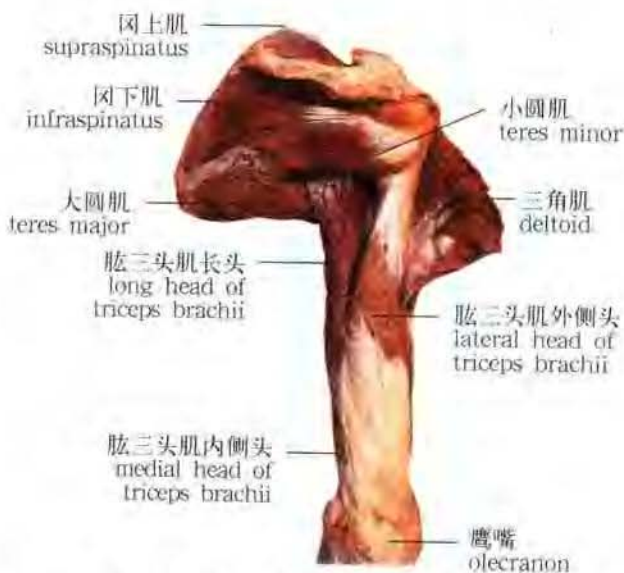

图 118 肩及臂部的肌肉 (后面观 2)  
Muscles of the shoulder and arm (posterior aspect 2)

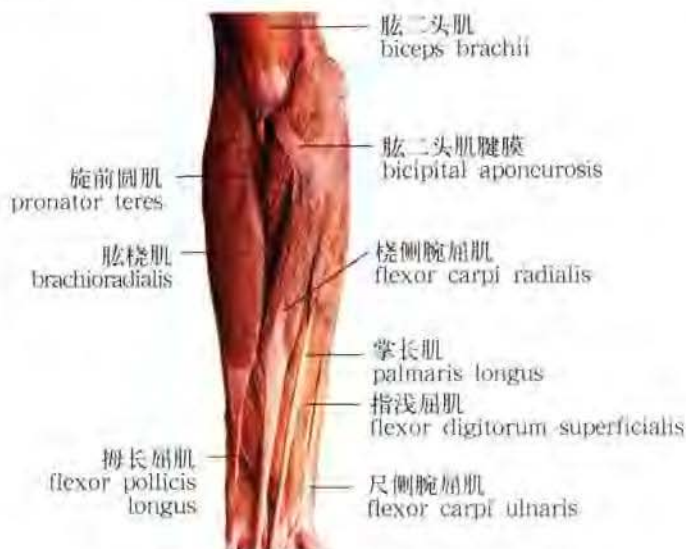

图 119 前臂肌 (前面观 1)  
 Muscles of the forearm (anterior aspect 1)

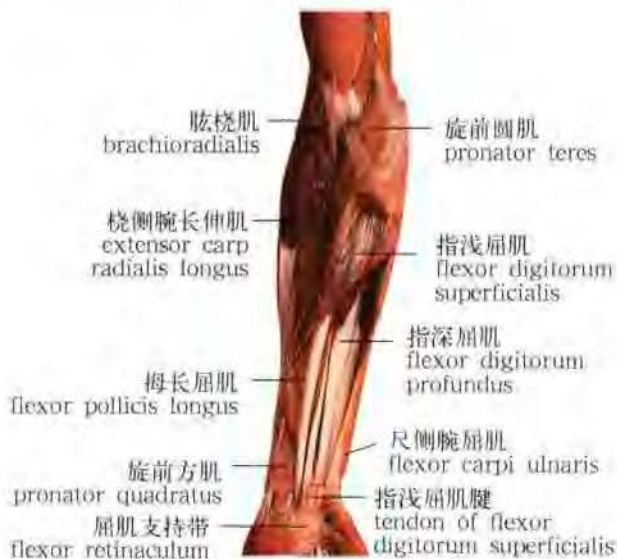

图 120 前臂肌 (前面观 2)  
 Muscles of the forearm (anterior aspect 2)

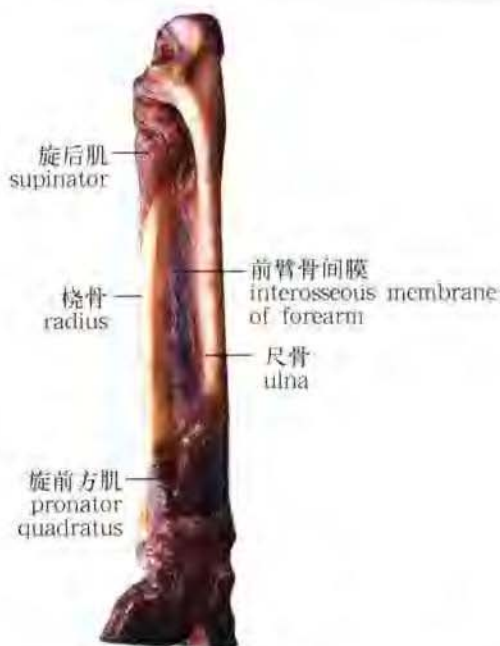

图 121 前臂肌  
(前面观 3)  
Muscles of the forearm  
(anterior aspect 3)

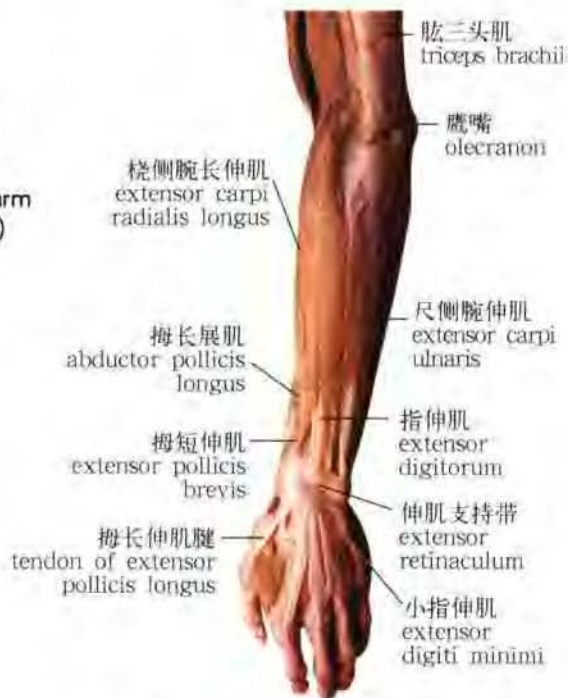

图 122 前臂肌 (后面观)  
Muscles of the forearm (posterior aspect)



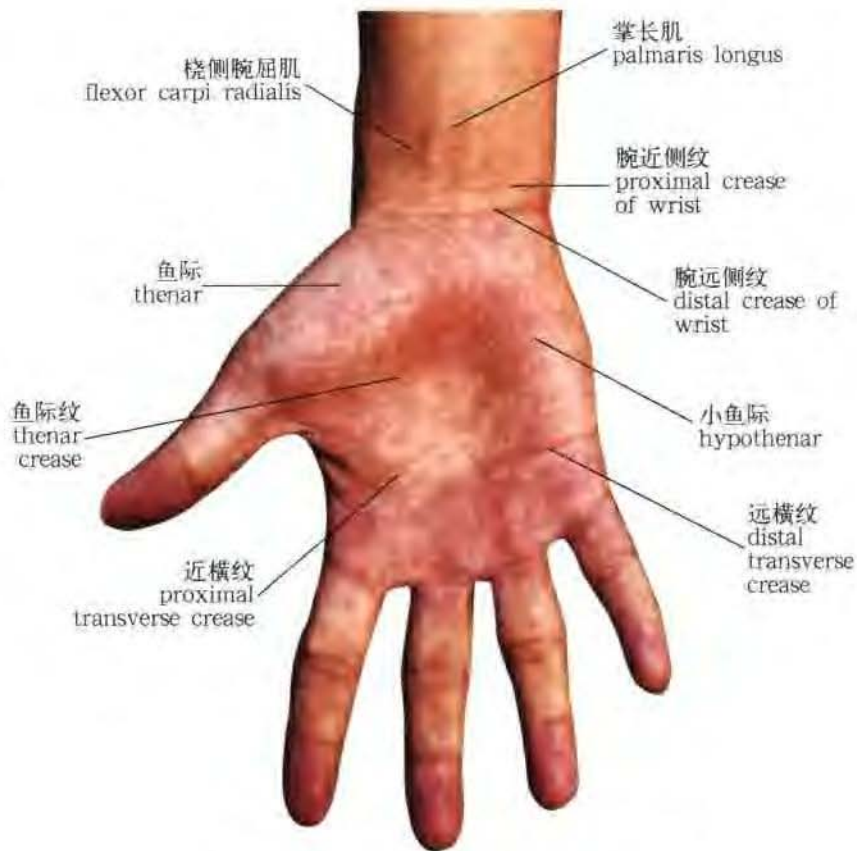

图 123 手体表标志 (掌面观)  
Surface markings of the hand  
(palmar aspect)

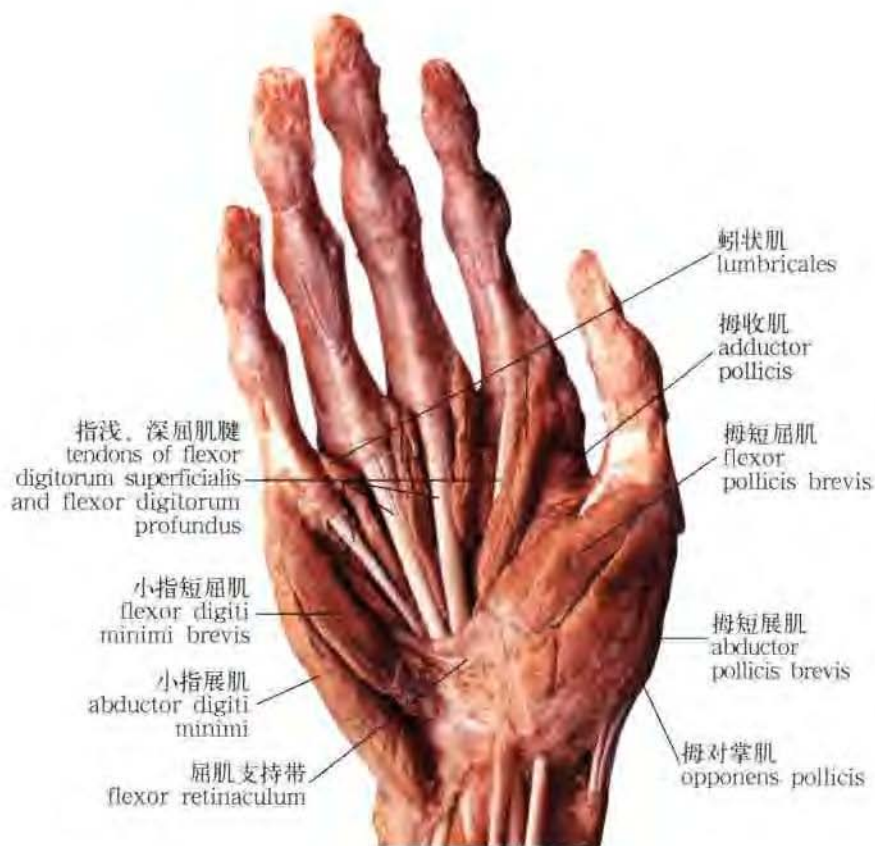

图 124 手肌 (前面观 1)  
Muscles of the hand  
(anterior aspect 1)

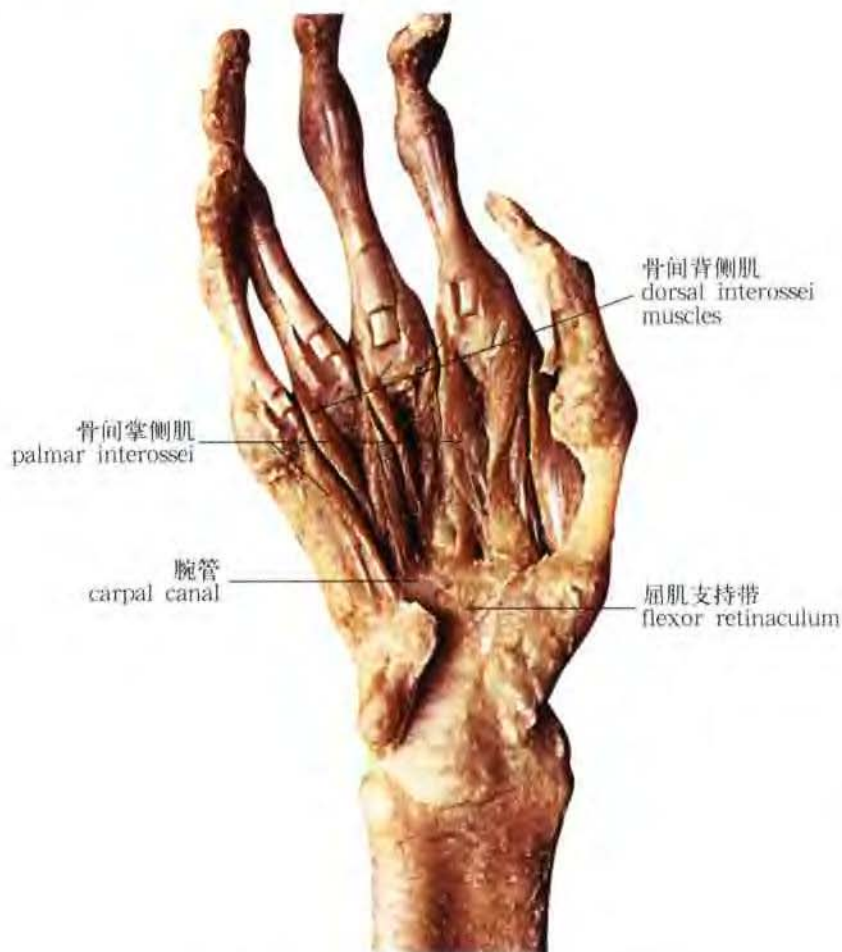

图 125 手肌 (前面观 2)  
Muscles of the hand (anterior aspect 2)

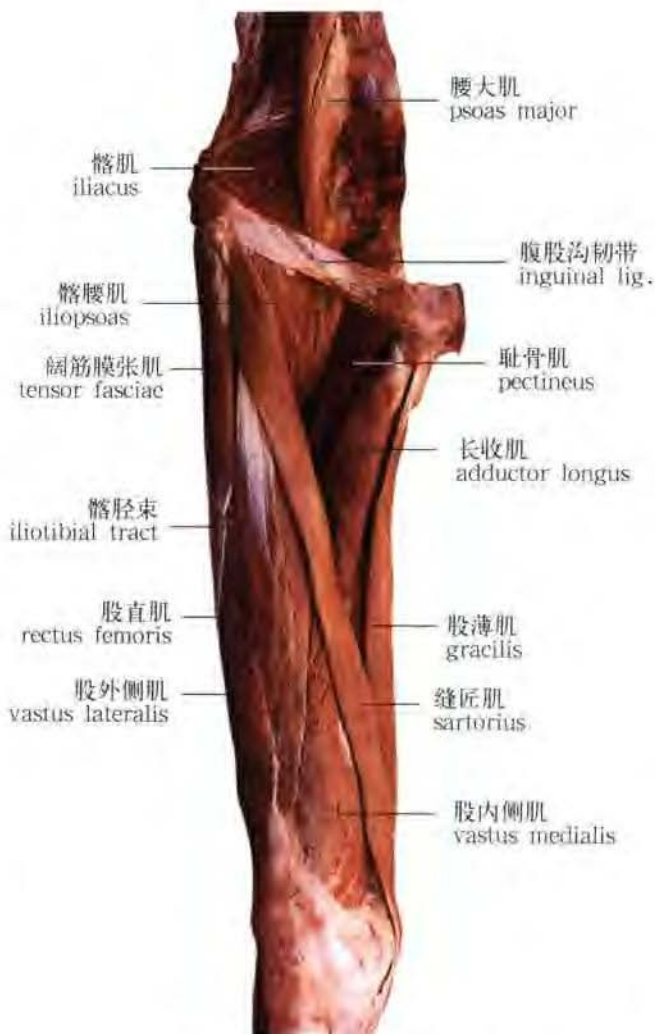

图 126 大腿肌 (前面观 1)  
Muscles of the thigh  
(anterior aspect 1)

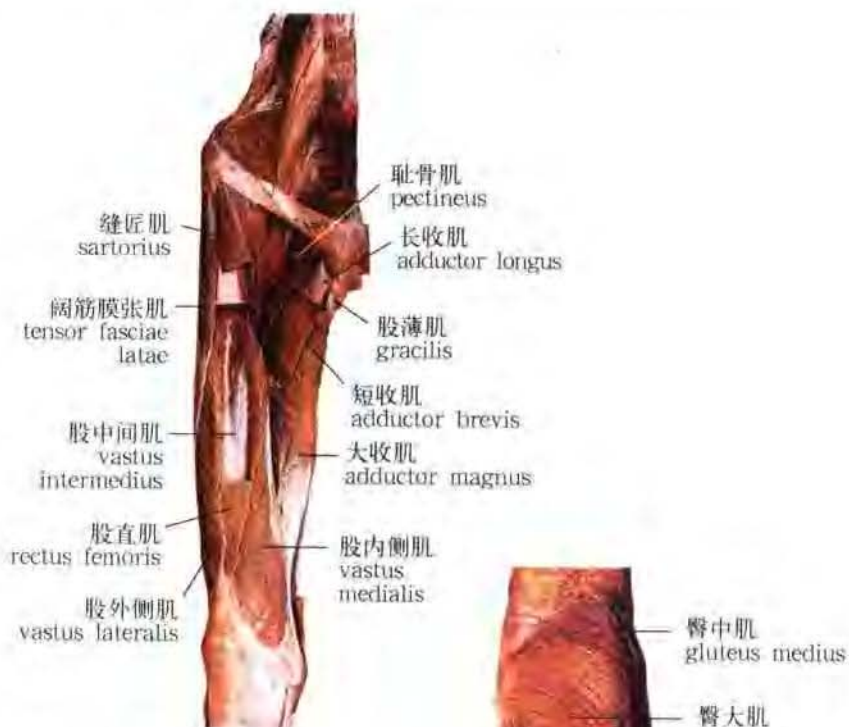

图 127 大腿肌 (前面观 2)  
Muscles of the thigh (anterior aspect 2)

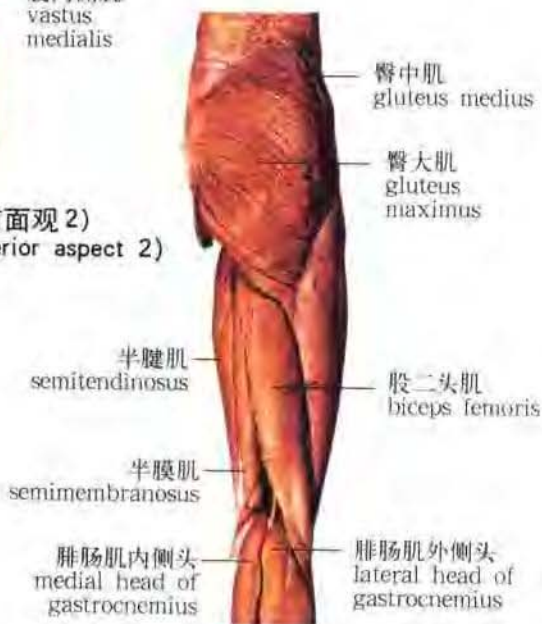


图 128 髋肌和大腿肌 (后面观)  
Muscles of the hip and thigh  
(posterior aspect)

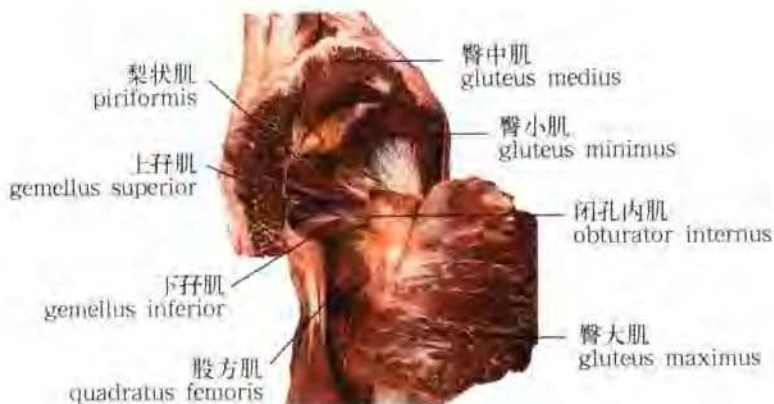

图 129 髋肌 (后面观)  
Muscles of the hip (posterior aspect)

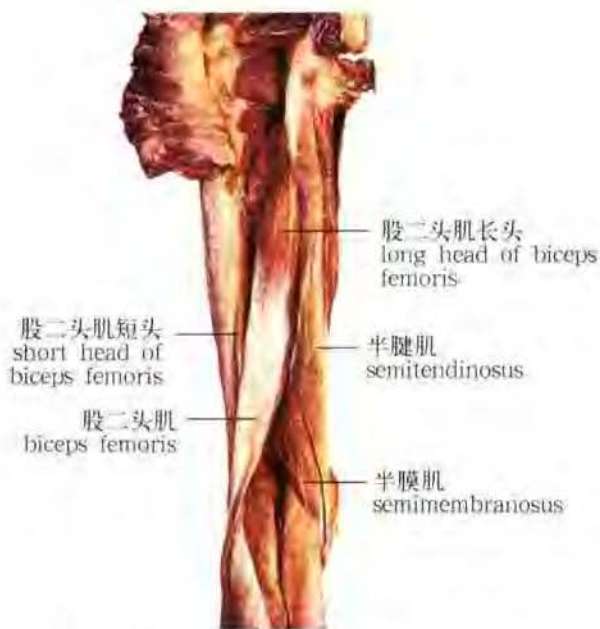

图 130 大腿肌 (后面观)  
Muscles of the thigh (posterior aspect)

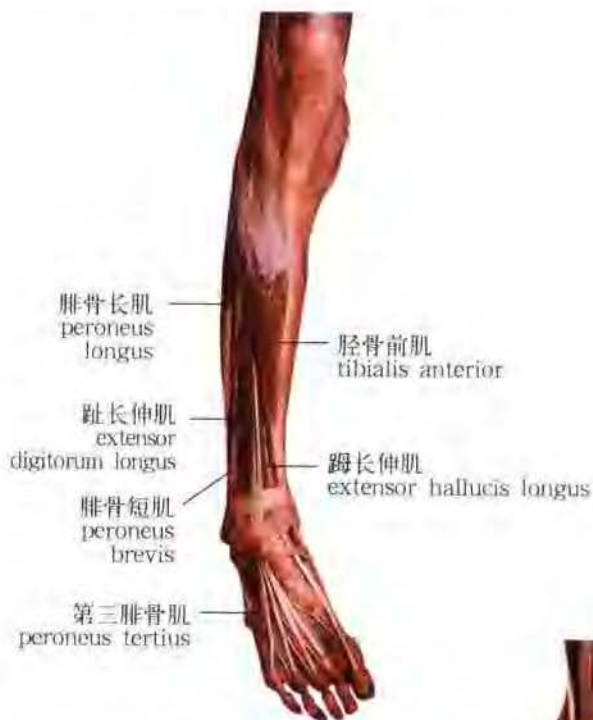

图 131 小腿肌 (前面观)  
Muscles of the leg (anterior aspect)

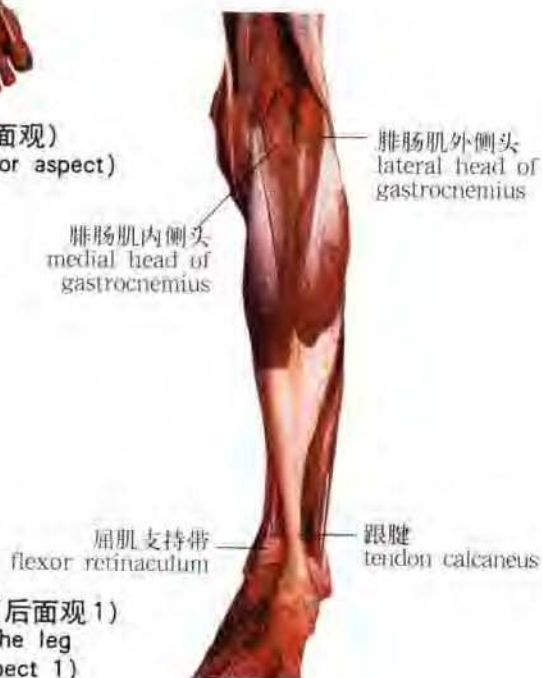

图 132 小腿肌 (后面观 1)  
Muscles of the leg  
(posterior aspect 1)

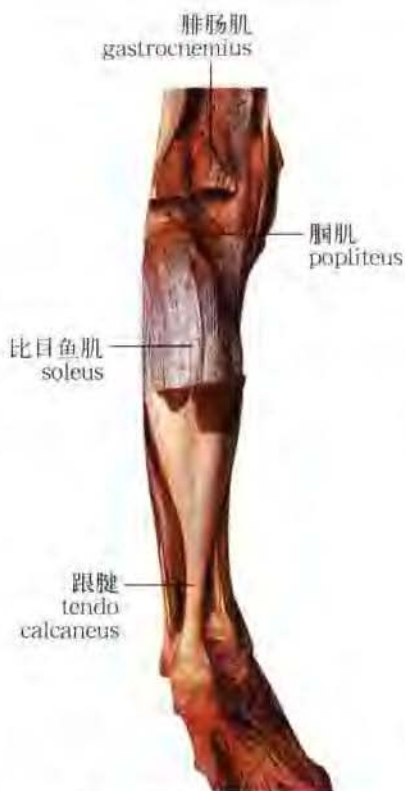

图 133 小腿肌 (后面观 2)  
Muscles of the leg  
(posterior aspect 2)

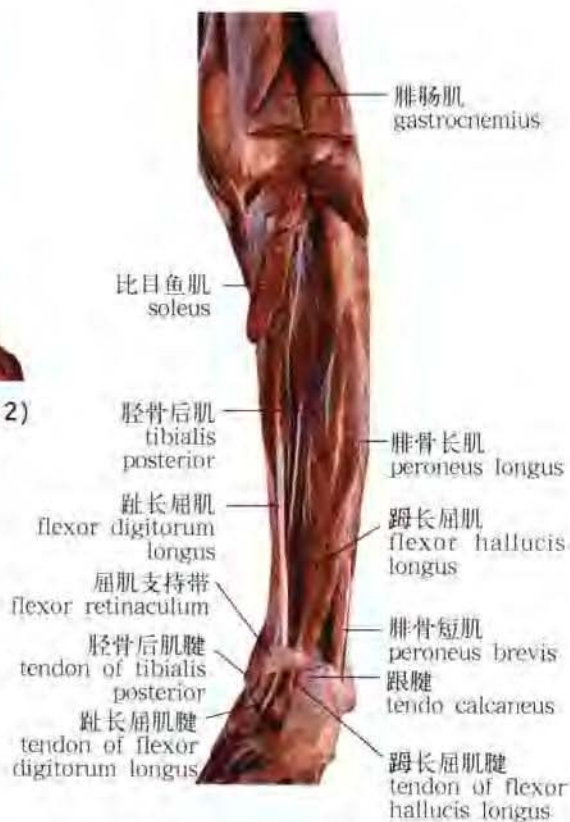

图 134 小腿肌 (后面观 3)  
Muscles of the leg (posterior aspect 3)



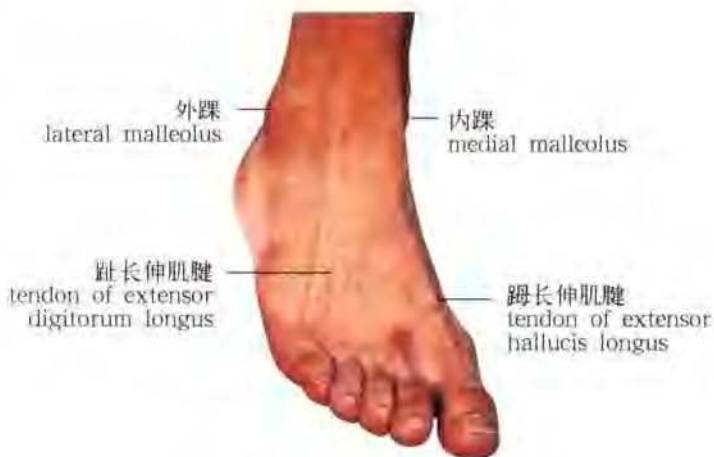

图 135 足背的体表标志  
Surface markings of dorsum of the foot

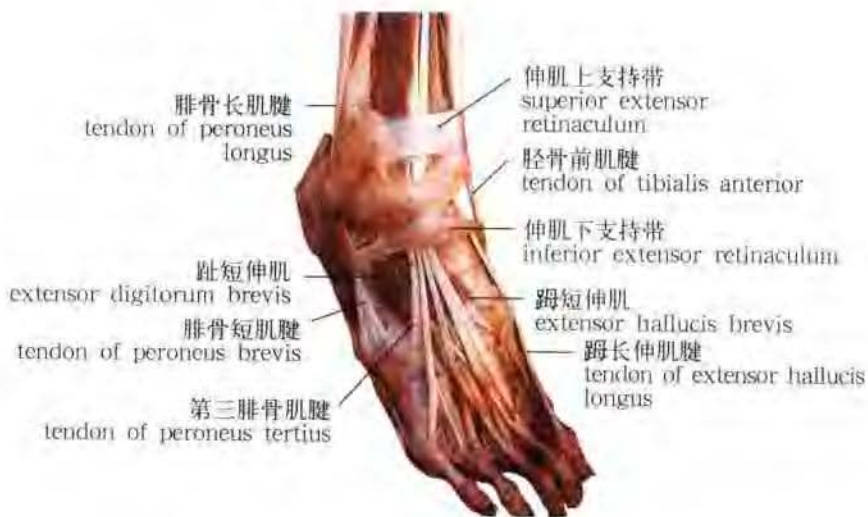

图 136 足背肌  
Muscles of dorsum of the foot

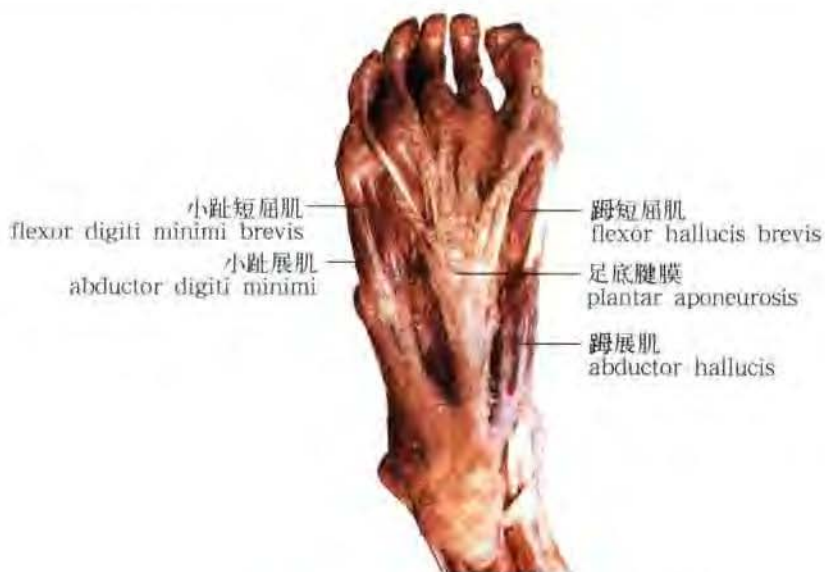

图 137 足底肌 (1)  
Muscles of sole of the foot (1)

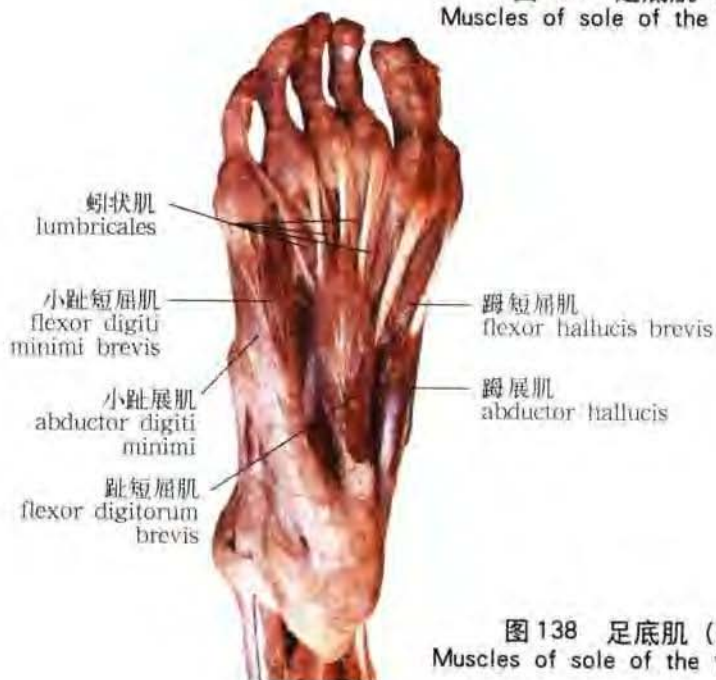

图 138 足底肌 (2)  
Muscles of sole of the foot (2)



# 内 脏 学 概 论

SPLANCHNOLOGY

GENERAL ARRANGEMENT

---

Chapter

4

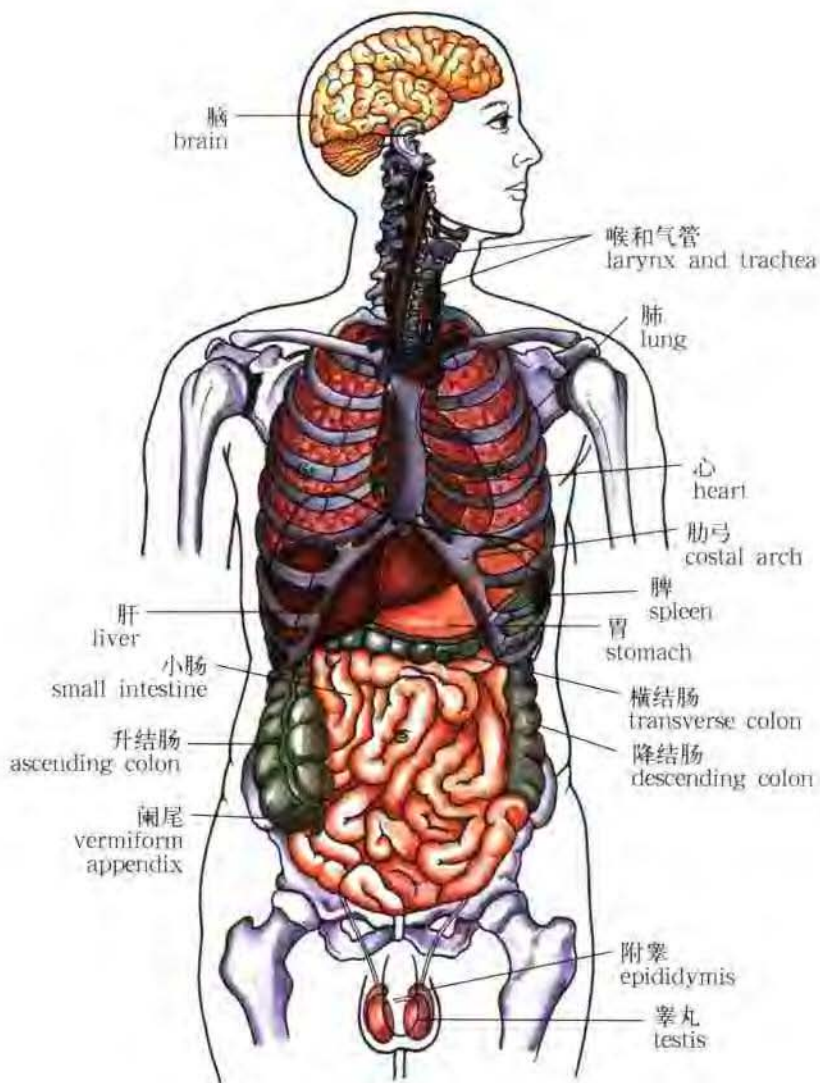


图 139 人体器官的位置 (正面观)  
Position of the human organs (anterior aspect)

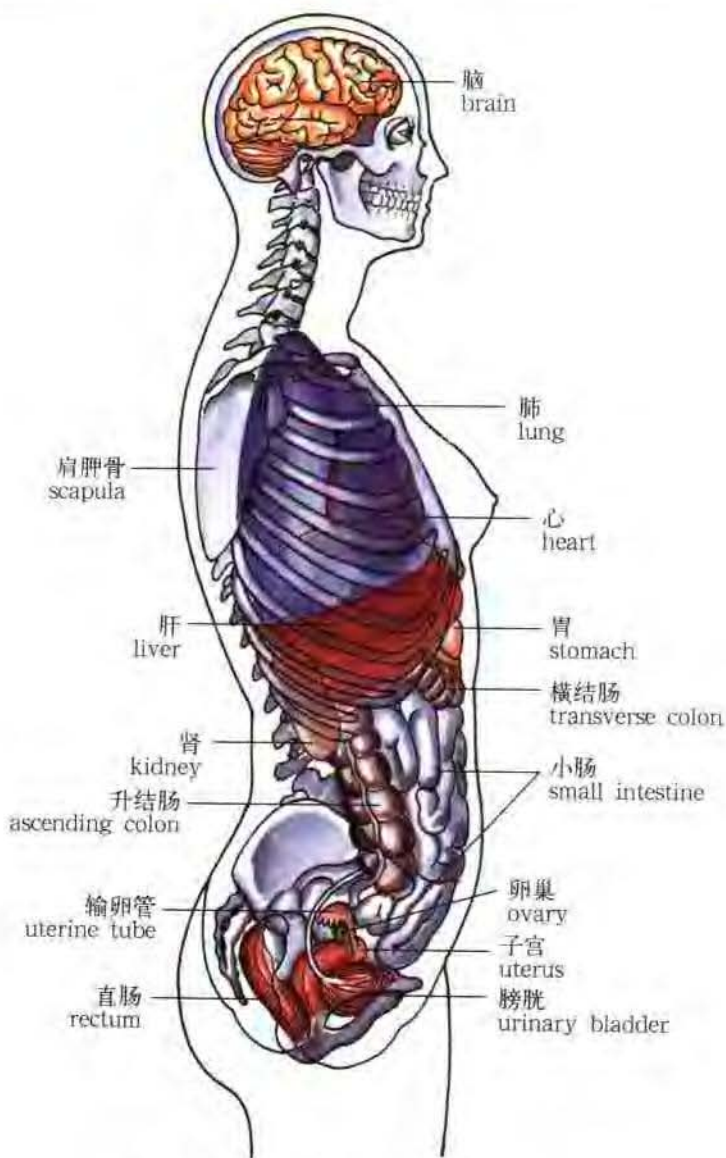


图 140 人体器官的位置 (右侧面观)  
Position of the human organs (right lateral aspect)

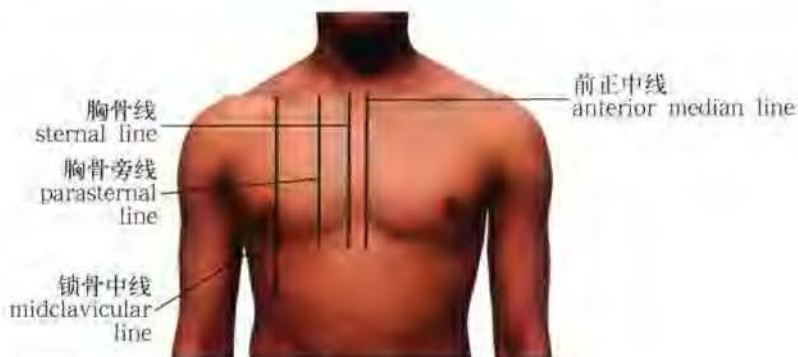


图 141 胸部标志线  
Reference lines of the thorax

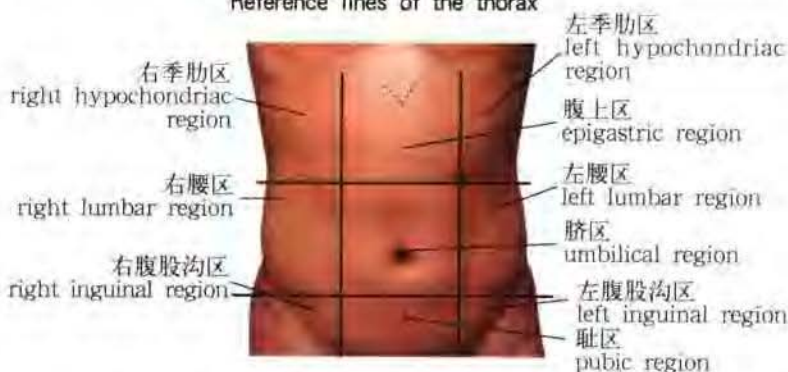


图 142 腹部分区  
Regions of the abdomen

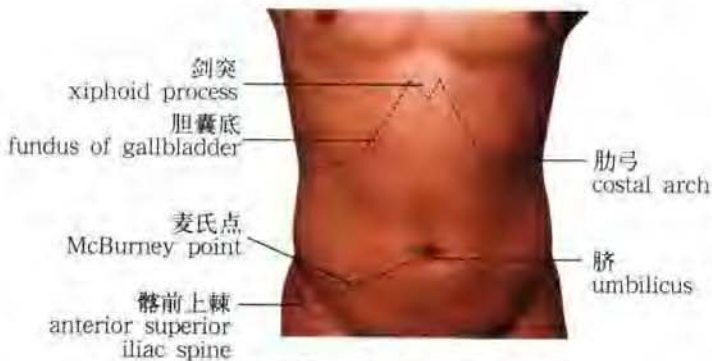


图 143 腹前壁体表标志  
Surface markings of the anterior abdominal wall



# 消化系统

DIGESTIVE SYSTEM

---

Chapter

5

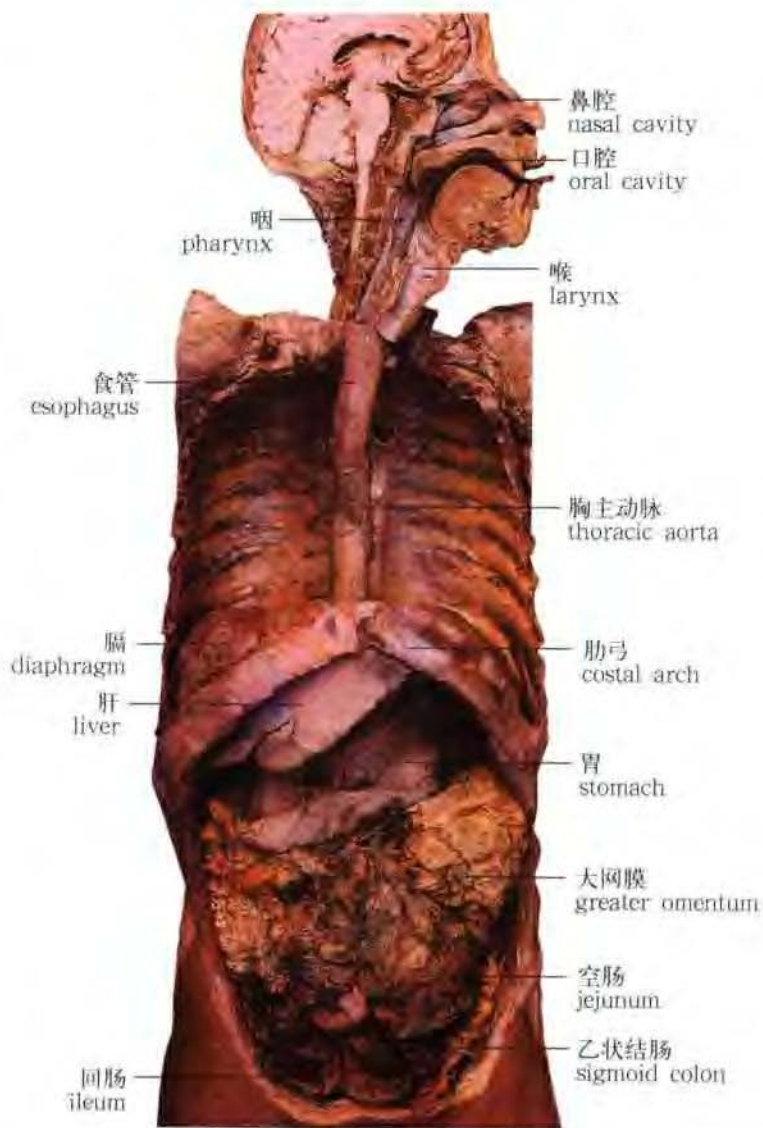


图 144 消化系统概观  
 General arrangement of the digestive system



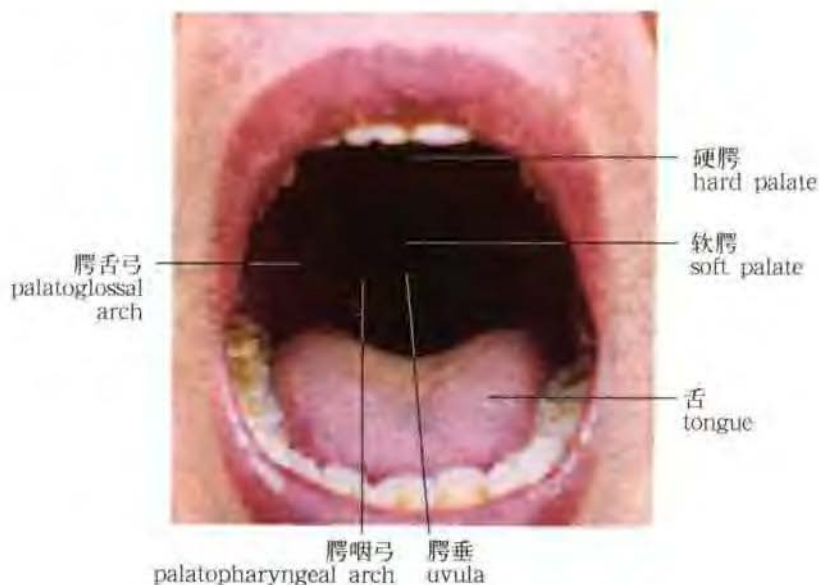


图 145 口腔和咽峡  
The oral cavity and isthmus of the fauces

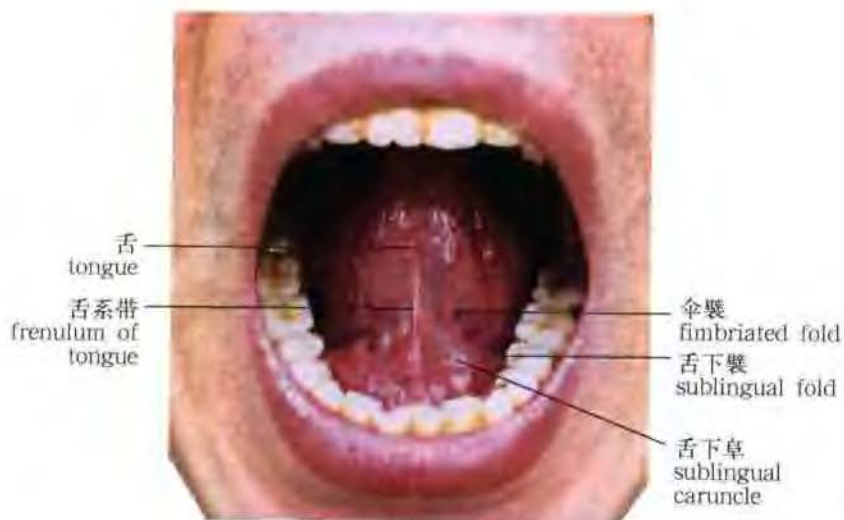

图 146 口腔  
The oral cavity

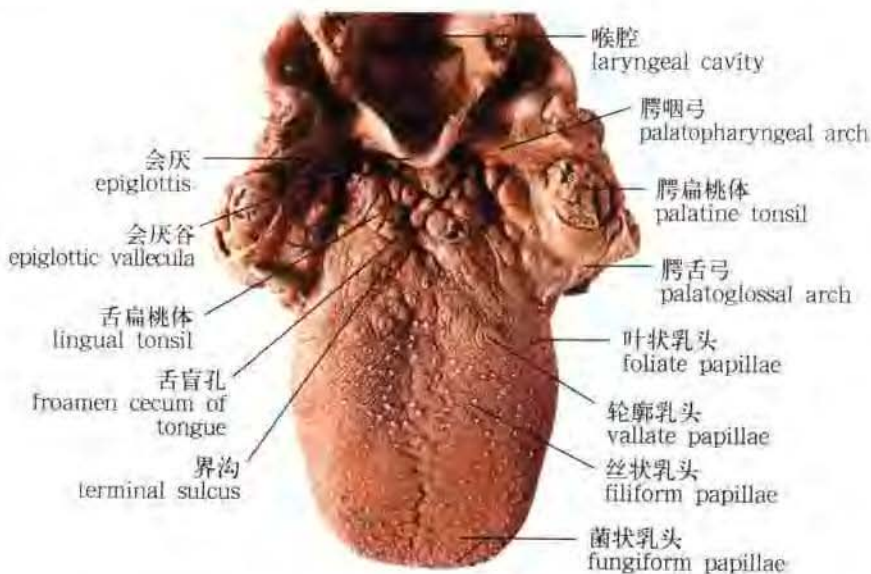


图 147 舌  
The tongue

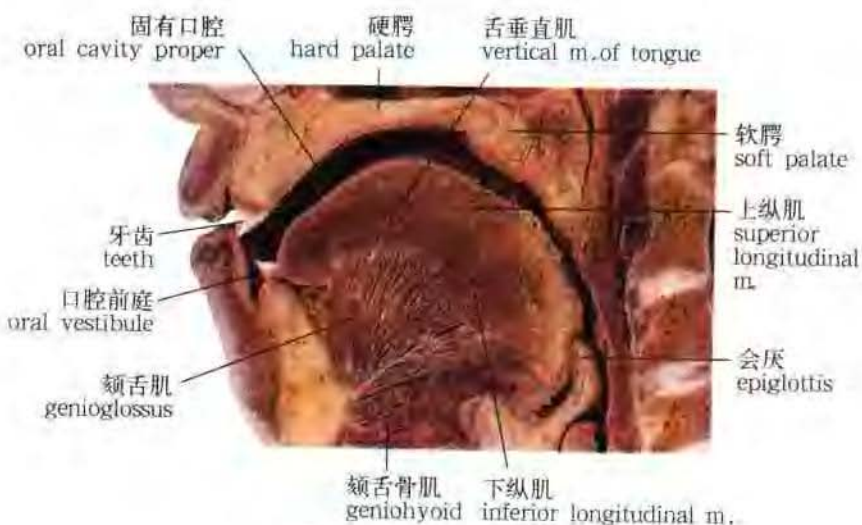


图 148 舌肌 (纵切面)  
Muscles of the tongue

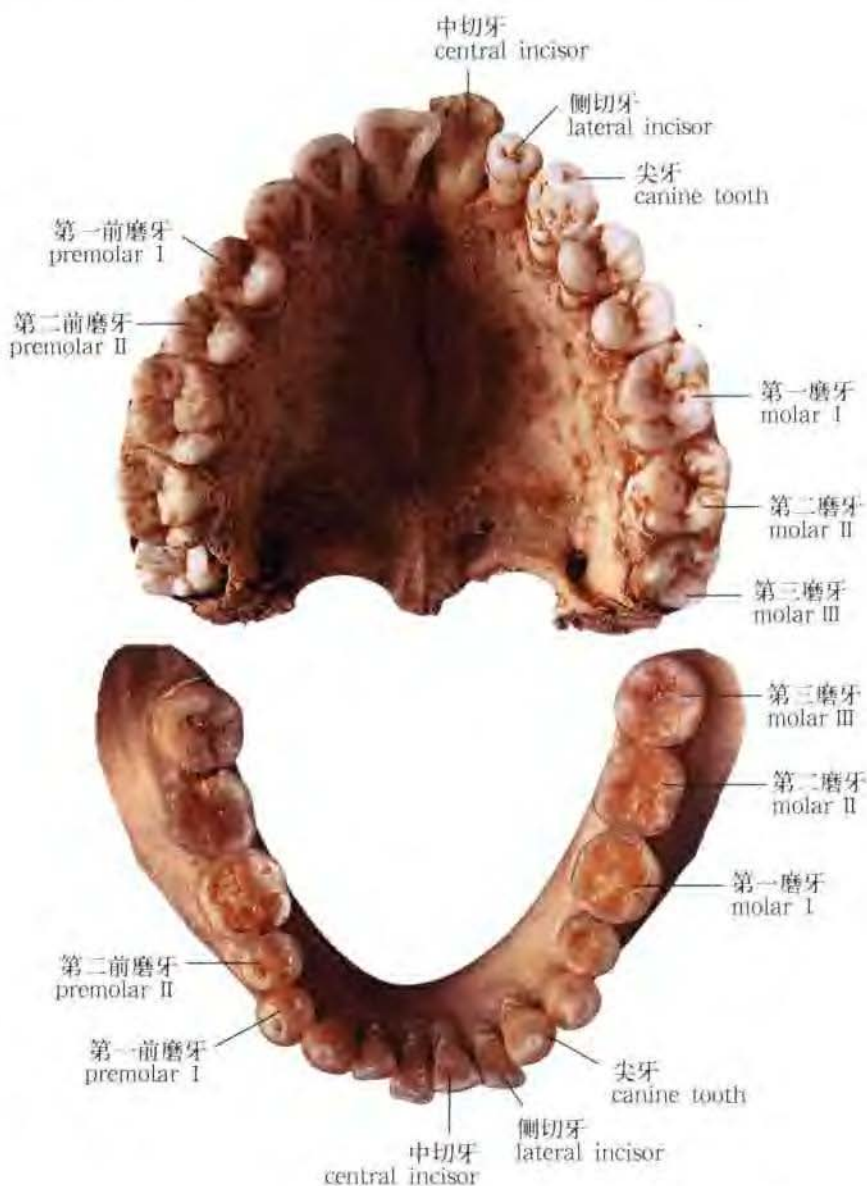

图 149 恒牙 (1)  
The permanent teeth (1)

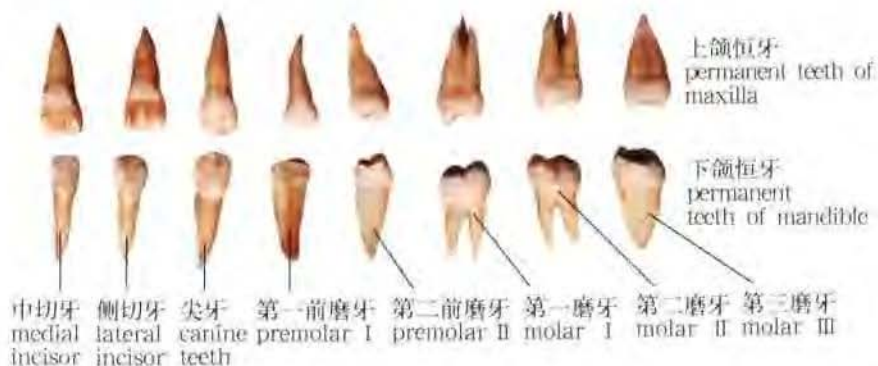

图 150 恒牙(2)  
The permanent teeth(2)

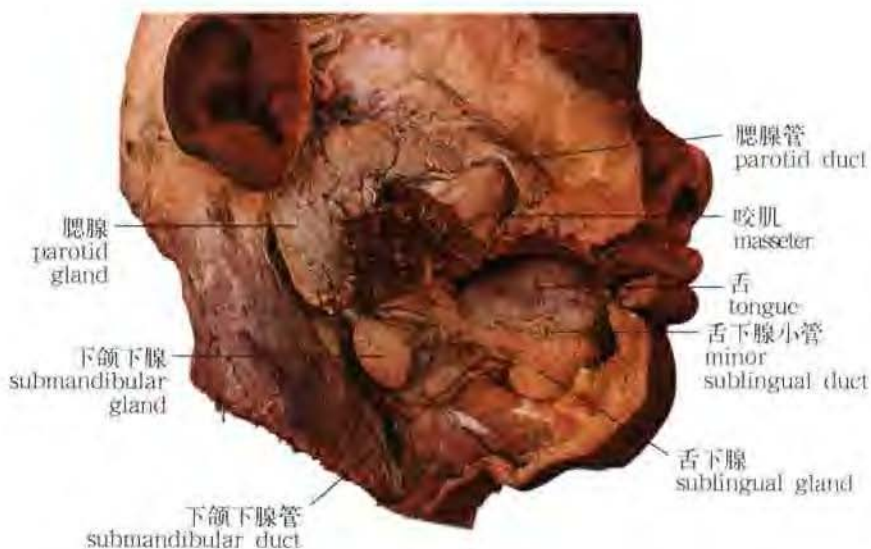


图 151 大唾液腺  
The large salivary glands

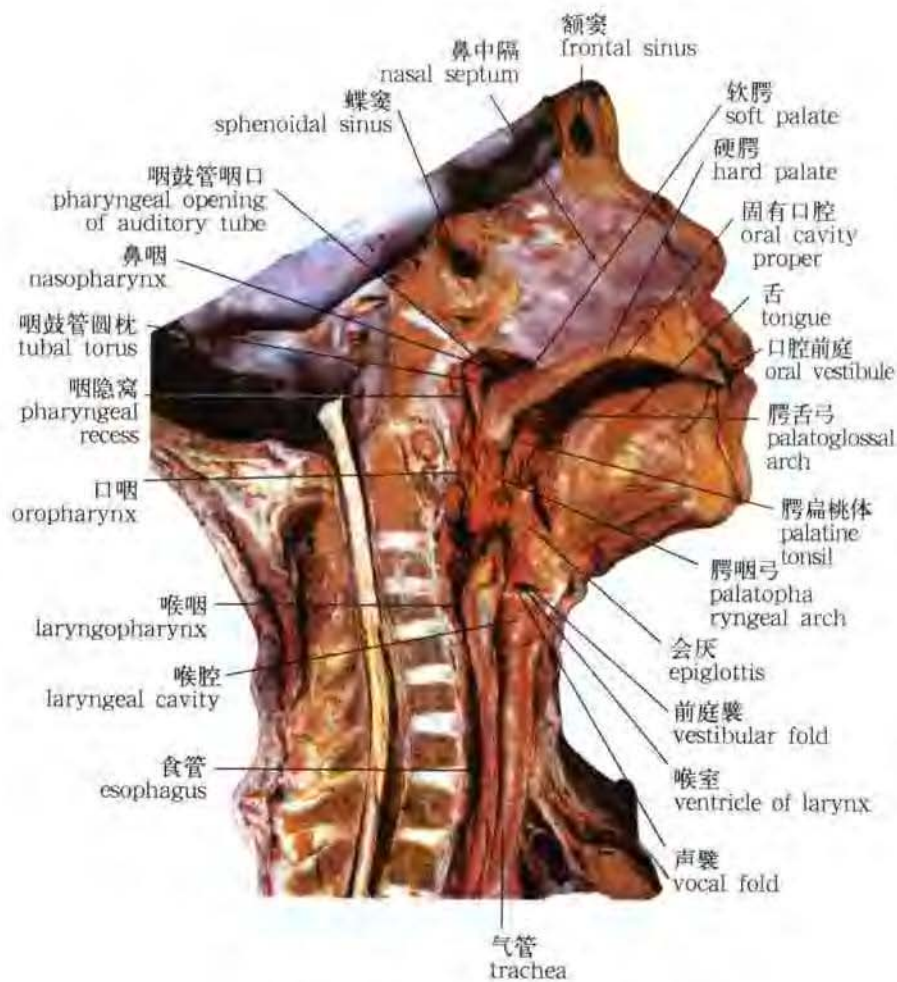

图 152 头颈部 (正中矢状切面)  
The head and neck (median sagittal section)

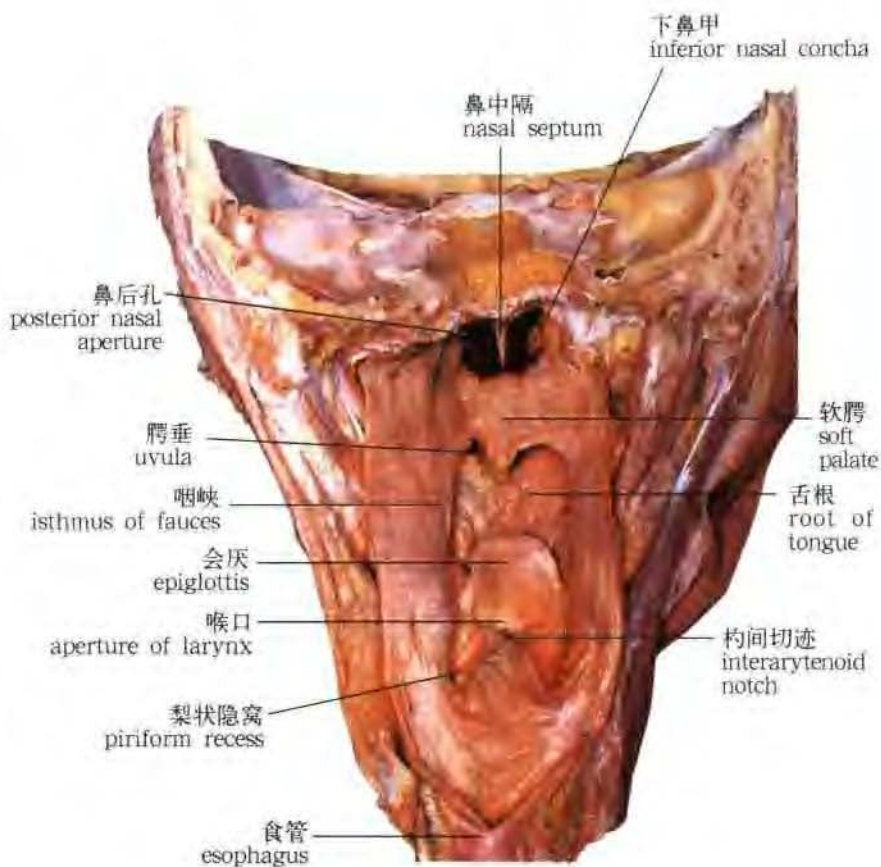


图 153 咽腔 (后面观)  
The pharyngeal cavity (posterior aspect)

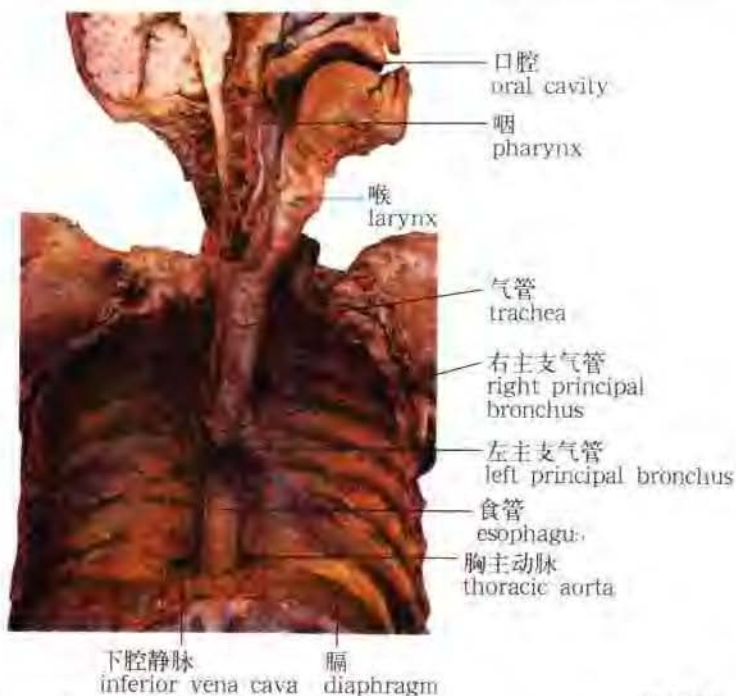

图 154 食管 (前面观)  
The esophagus (anterior aspect)

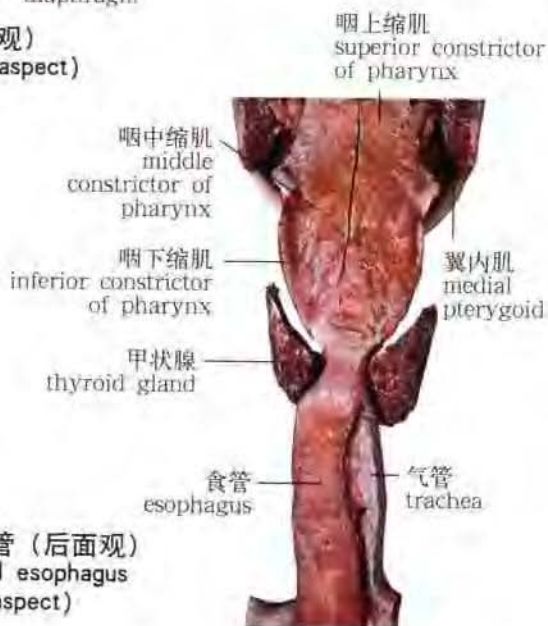

图 155 咽和食管 (后面观)  
The pharynx and esophagus  
(posterior aspect)

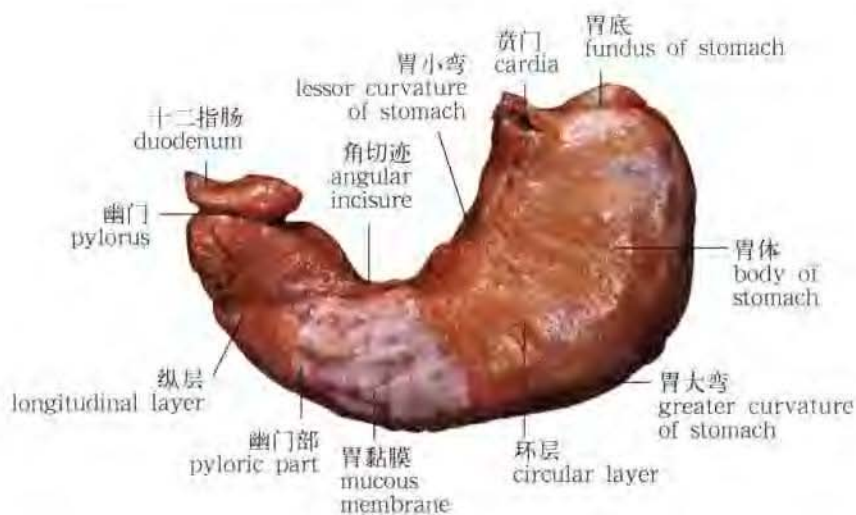


图 156 胃  
The stomach

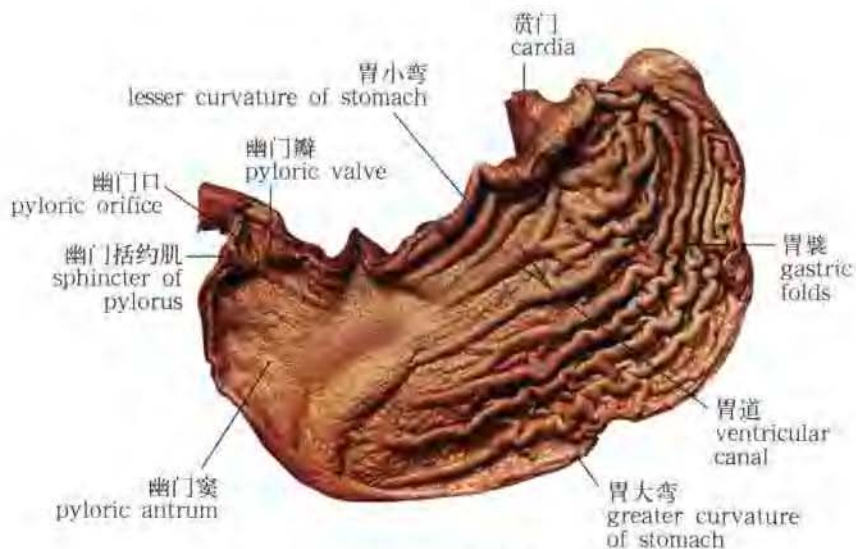


图 157 胃黏膜  
The mucous membrane of the stomach



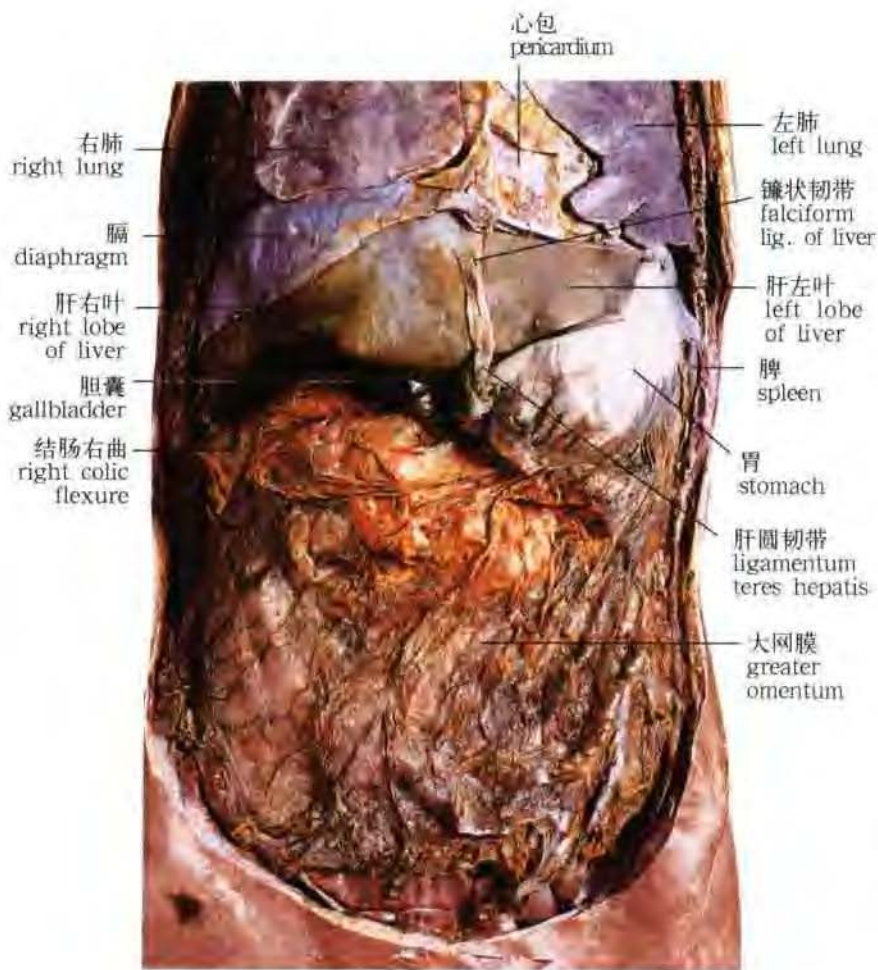


图 158 腹部脏器和大网膜 (前面观)

The viscera of the abdomen and greater omentum (anterior aspect)

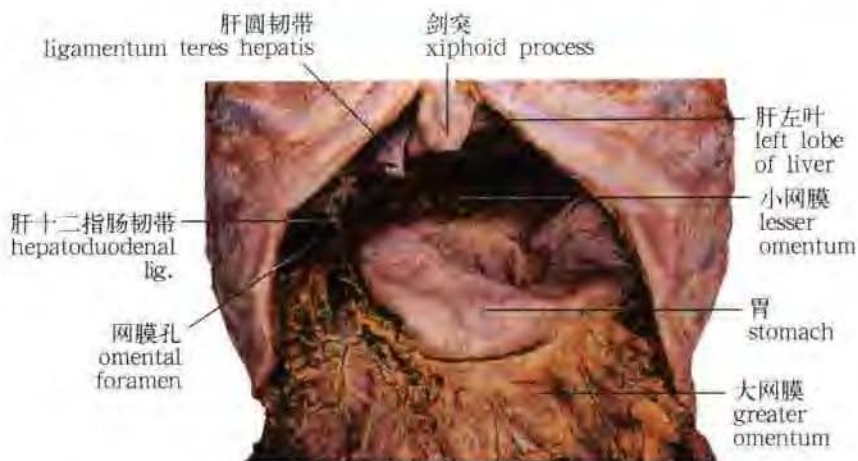


图 159 小网膜  
The lesser omentum

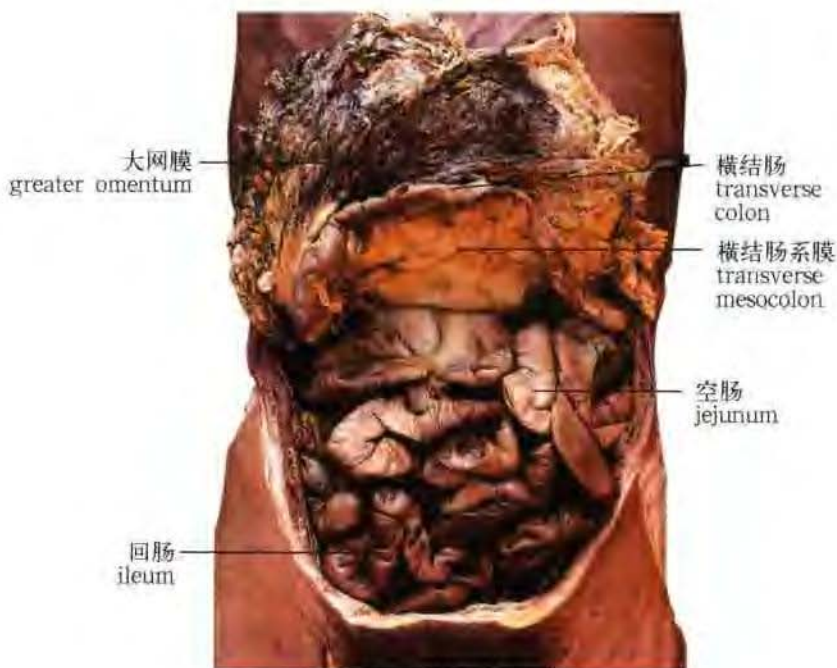


图 160 横结肠系膜  
The transverse mesocolon

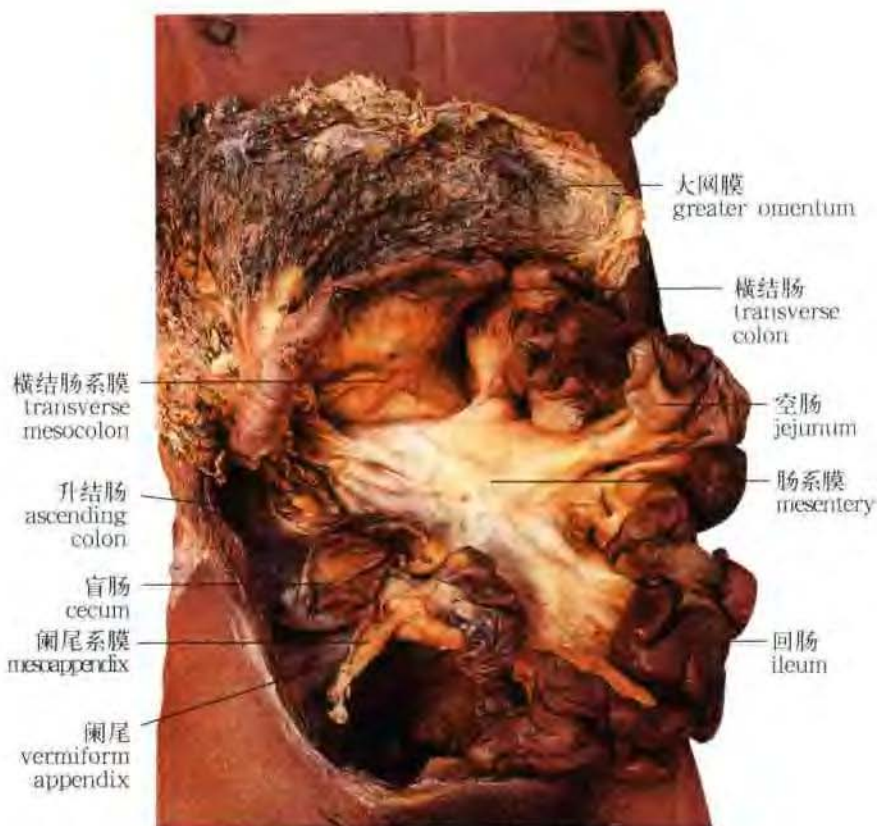

图 161 肠与阑尾系膜  
The mesentery and mesoappendix

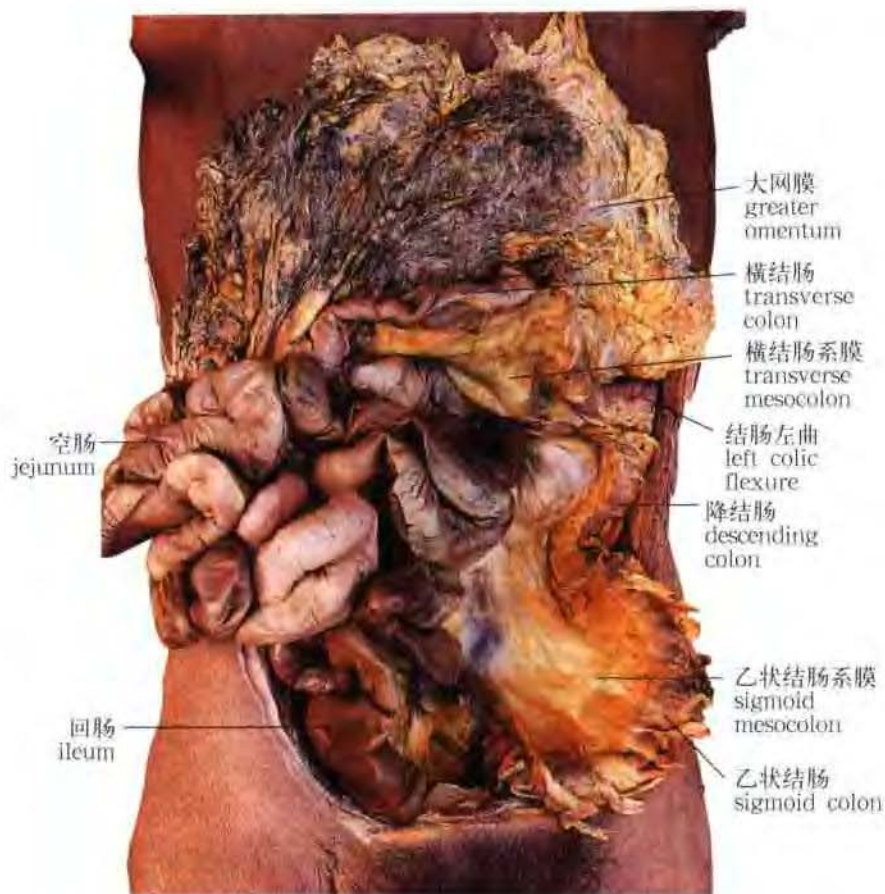

图 162 乙状结肠系膜  
The sigmoid mesocolon

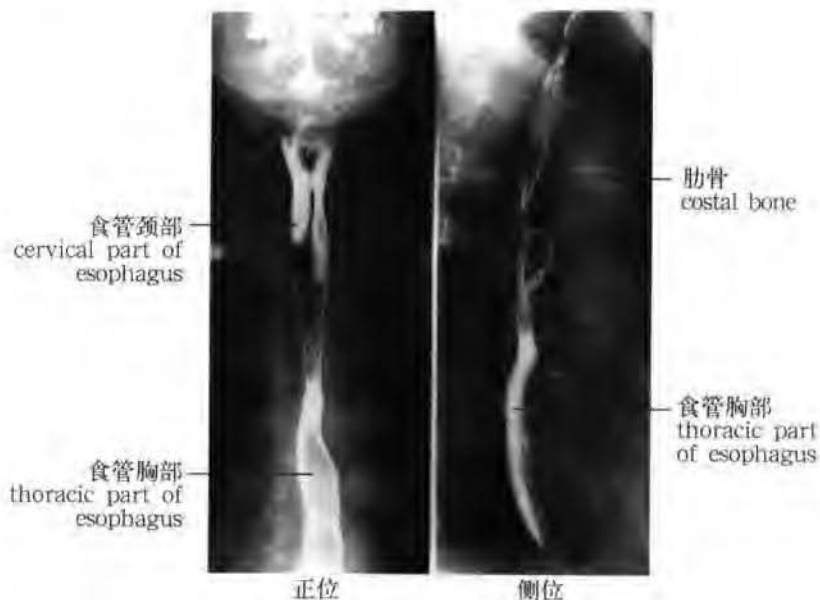


图 163 食管钡餐 X 线图像  
Barium meal radiograph of the esophagus

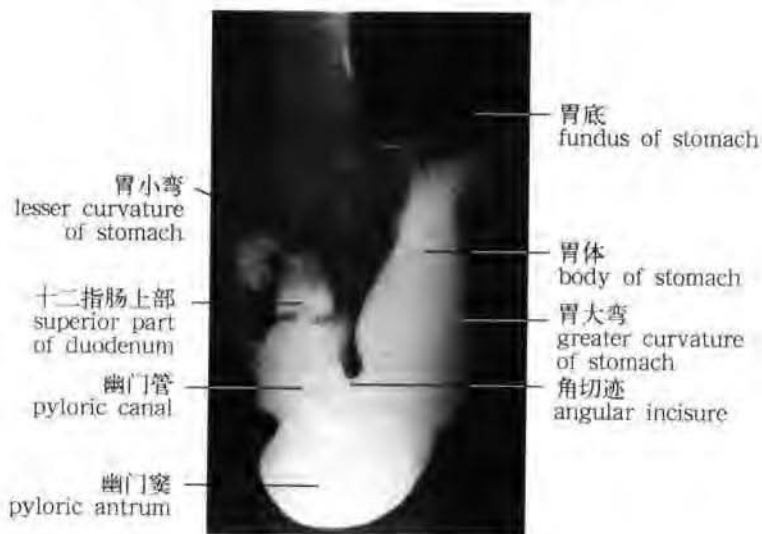


图 164 胃钡餐 X 线图像  
Barium meal radiograph of the stomach

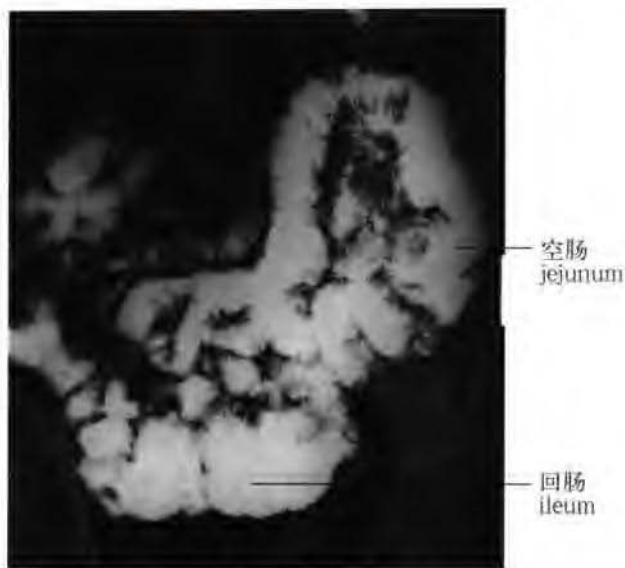

图 165 小肠钡餐 X 线片  
Barium meal radiograph of the small intestine

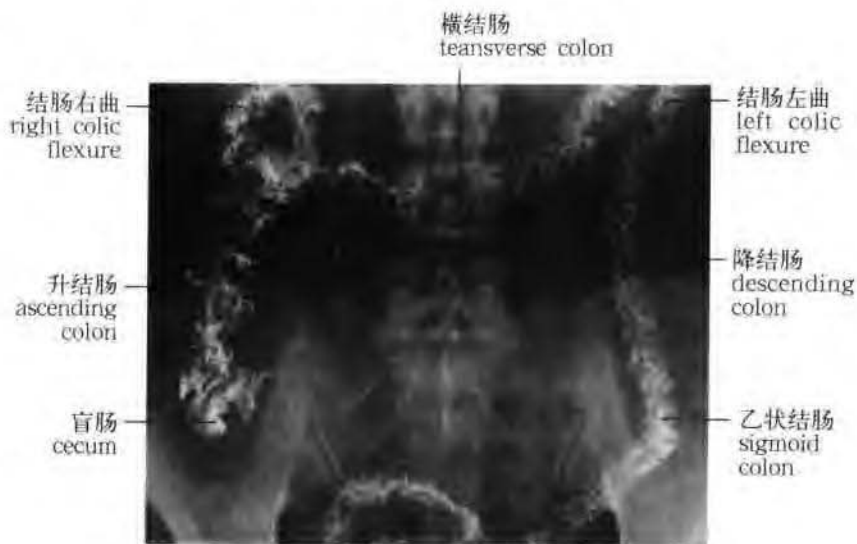

图 166 结肠钡餐 X 线图像  
Barium meal radiograph of the colon

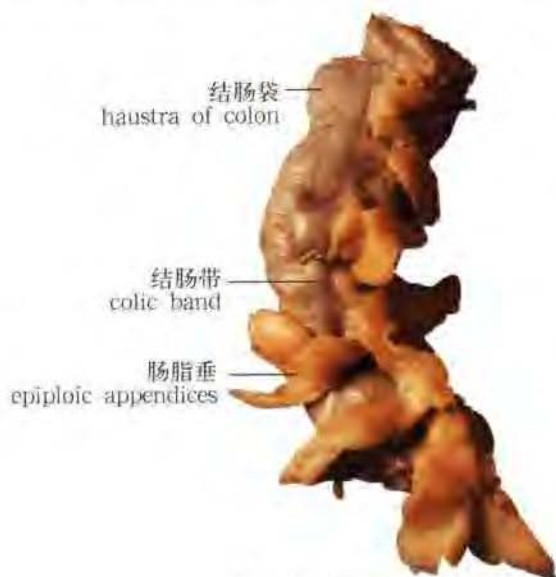

图 167 结肠 (外面观)  
The colon (external aspect)

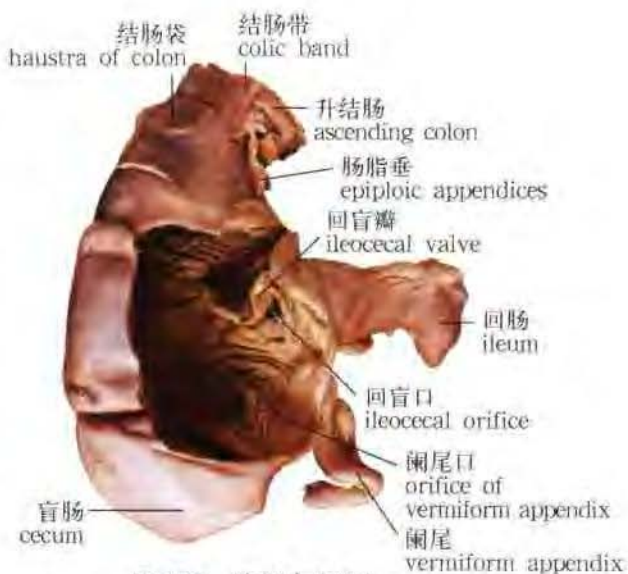

图 168 盲肠与阑尾  
The cecum and vermiform appendix

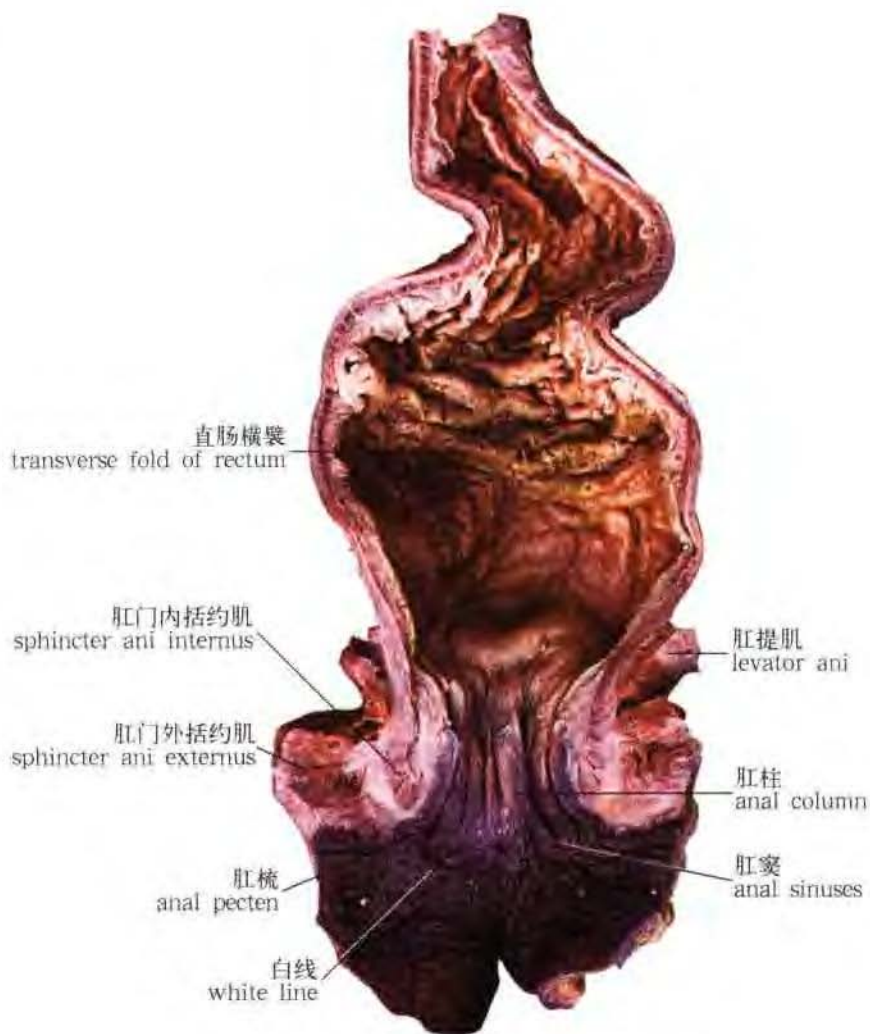

图 169 直肠与肛管 (内面观)  
The rectum and anal canal (internal aspect)



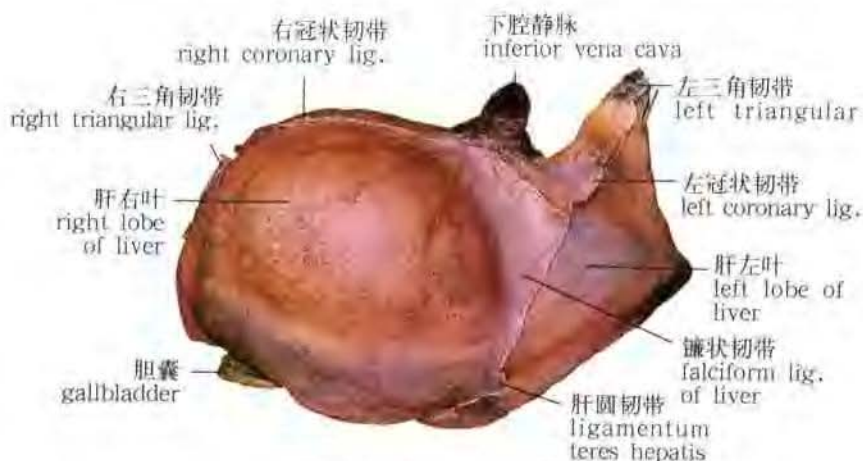


图 170 肝 (上面观)  
The liver (superior aspect)

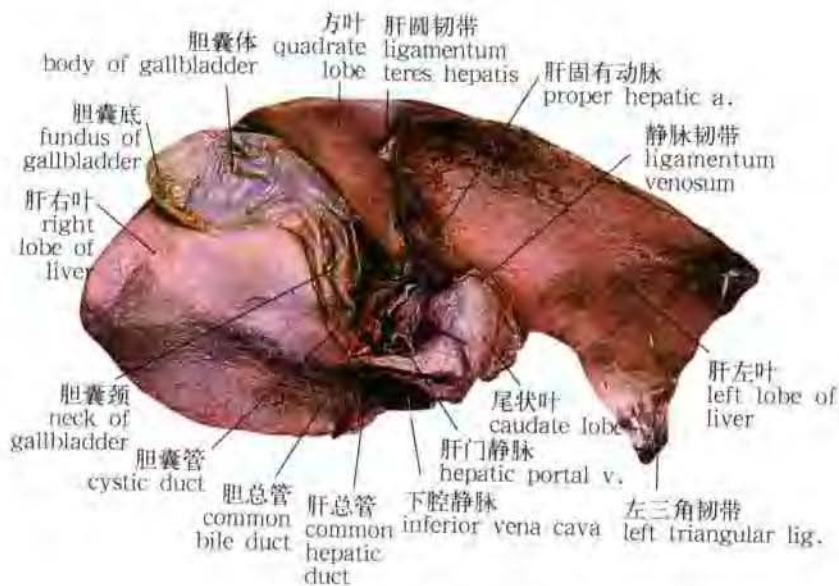

图 171 肝 (下面观)  
The liver (inferior aspect)

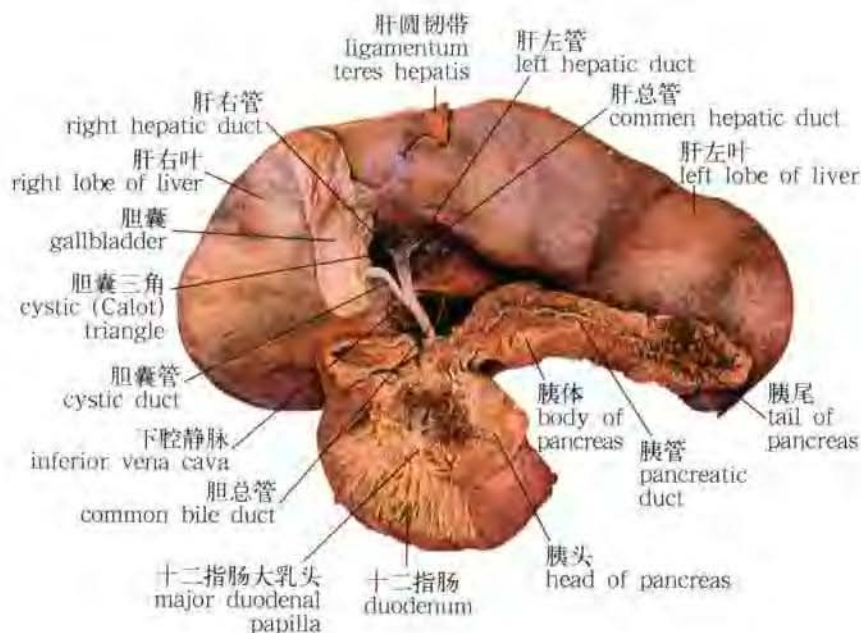
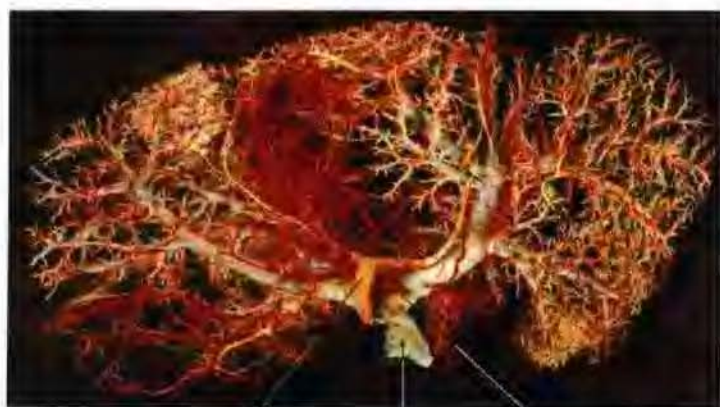

图 172 胆道、十二指肠和胰腺 (前面观)  
The bile ducts, duodenum and pancreas (anterior aspect)



肝总管 common hepatic duct      肝门静脉 hepatic portal v.      肝固有动脉 proper hepatic a.

图 173 肝脏管道铸型 (1)  
The cast of the hepatic ducts (1)



胆囊 gallbladder      胆囊动脉 cystic a.      肝总管 common hepatic duct  
胆囊管 cystic duct      胆总管 common bile duct      下腔静脉 inferior vena cava      肝门静脉 hepatic portal v.      肝固有动脉 proper hepatic a.

图 174 肝脏管道铸型 (2)  
The cast of the hepatic ducts (2)

# 呼 吸 系 统

RESPIRATORY SYSTEM

Chapter

6

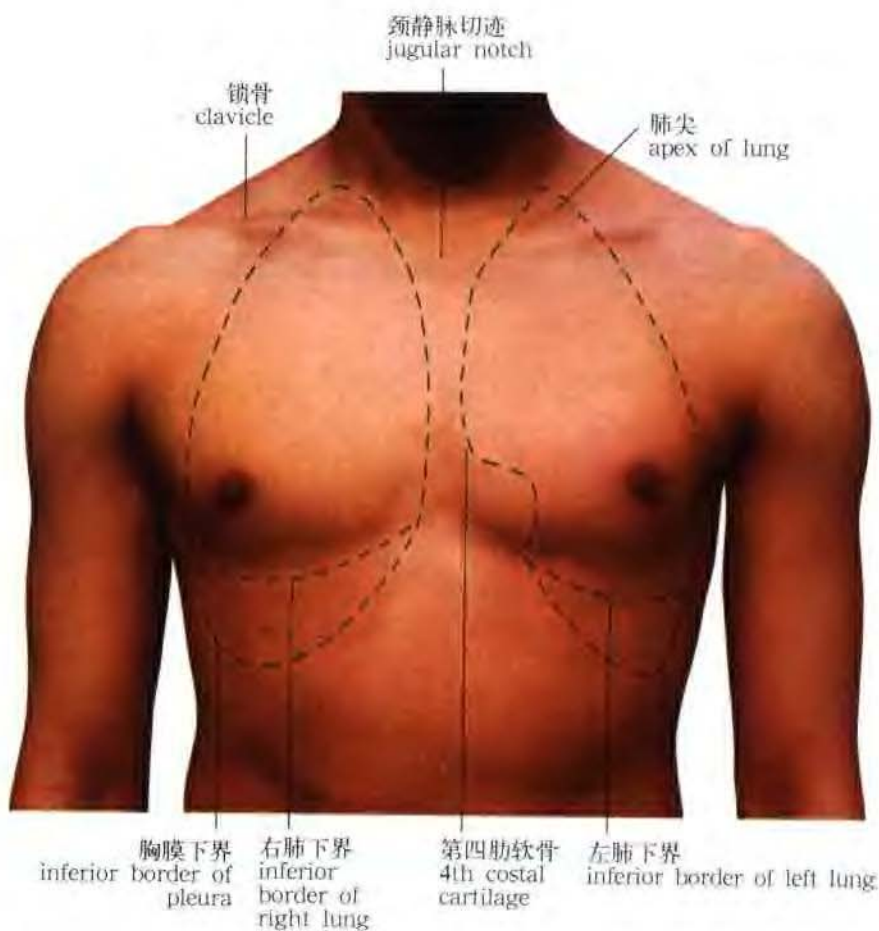


图 175 呼吸系统体表标志  
Surface markings of the respiratory system

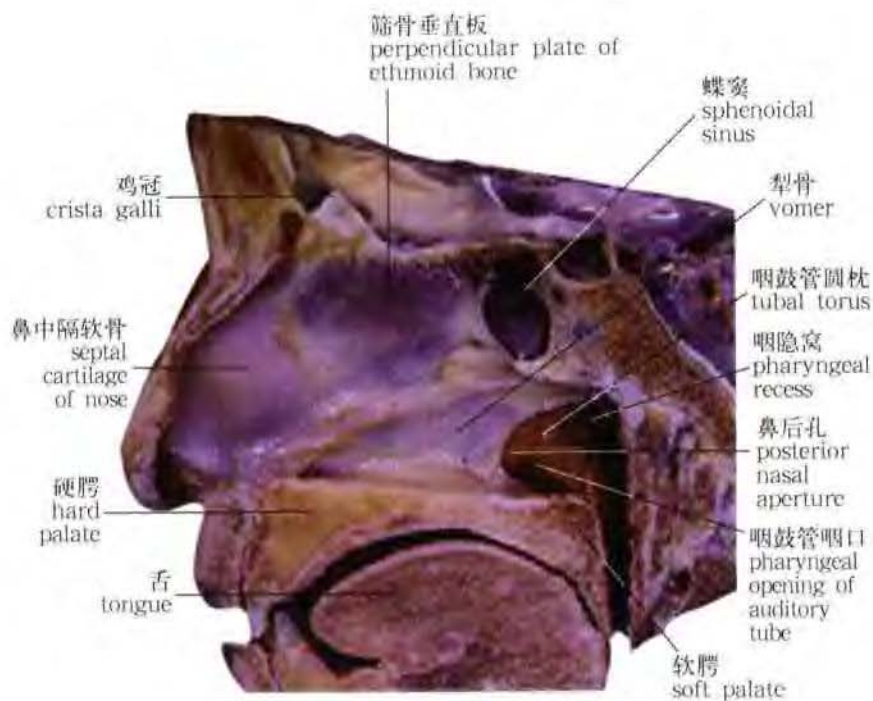


图 176 鼻中隔  
The nasal septum

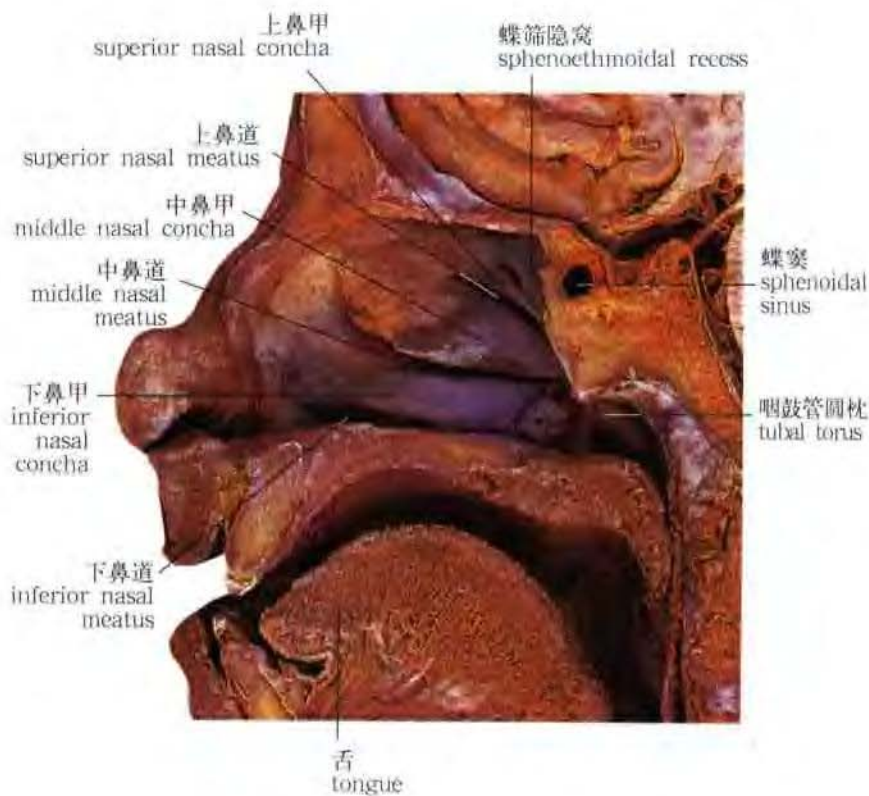


图 177 鼻腔外侧壁 (1)  
The lateral wall of the nasal cavity (1)

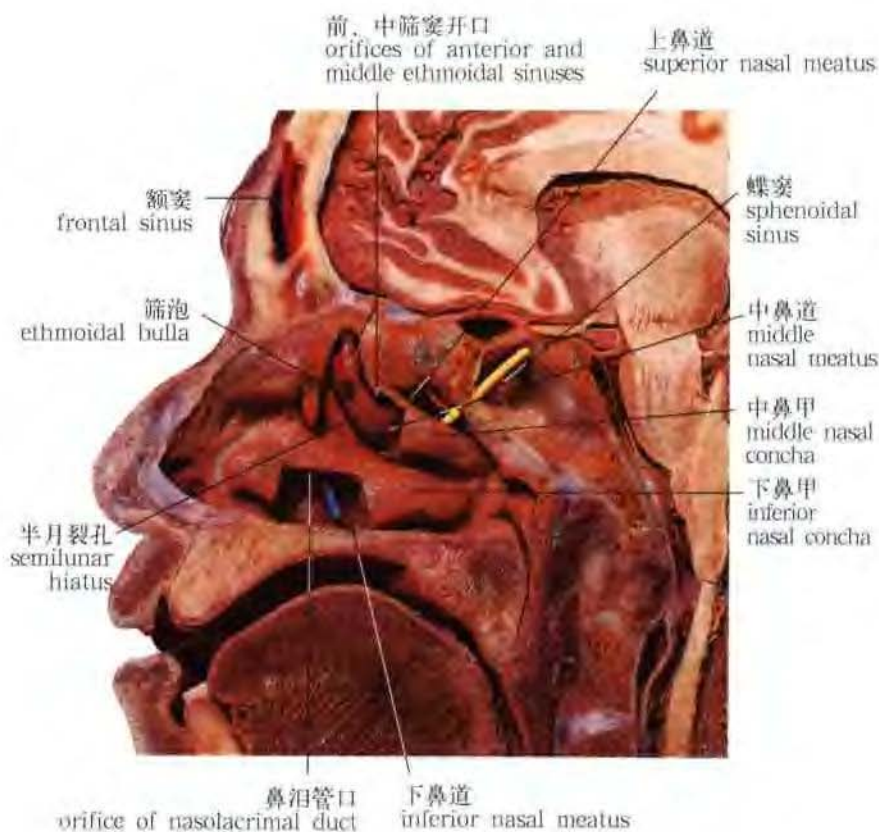


图 178 鼻腔外侧壁 (2)  
The lateral wall of the nasal cavity (2)



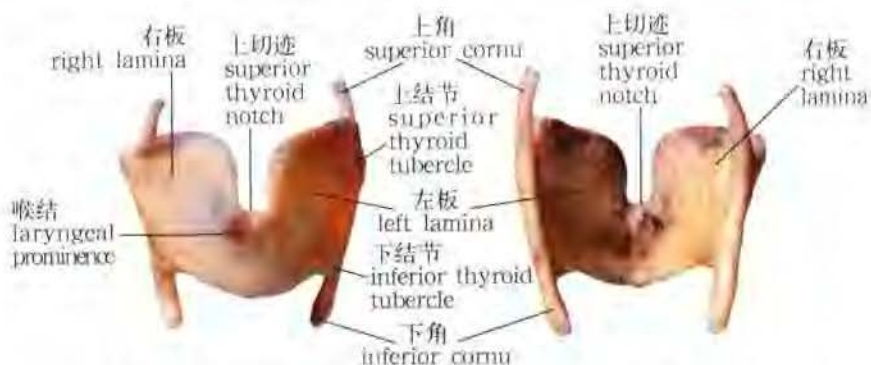


图 179 甲状软骨 (前面观)  
The thyroid cartilage  
(anterior aspect)

图 180 甲状软骨 (后面观)  
The thyroid cartilage  
(posterior aspect)

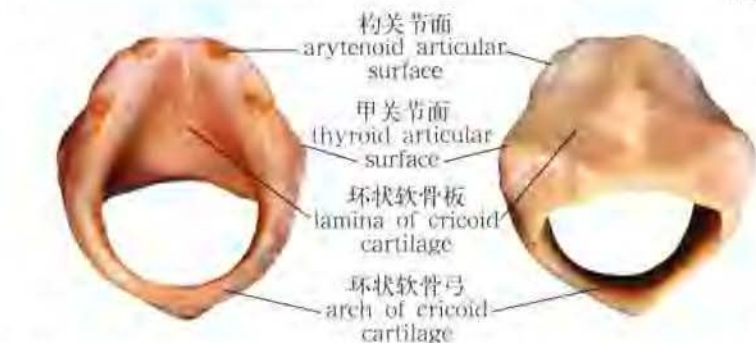
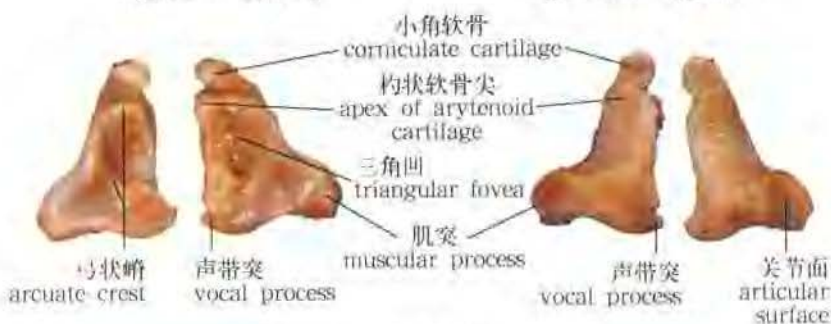
图 181 环状软骨、杓状软骨和小角软骨 (前面观)  
The cricoid, arytenoid and corniculate cartilages (anterior aspect)

图 182 环状软骨、杓状软骨和小角软骨 (后面观)  
The cricoid, arytenoid and corniculate cartilages (posterior aspect)



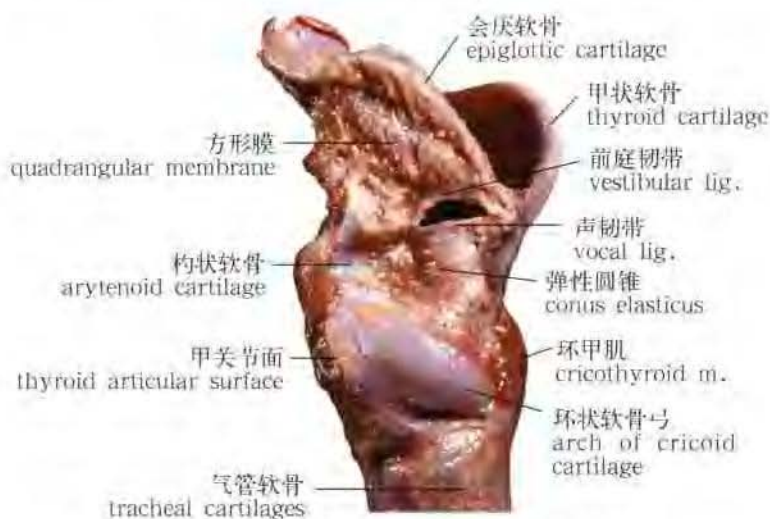

图 186 弹性圆锥和方形膜 (侧面观)  
The conus elasticus and quadrangular membrane (lateral aspect)

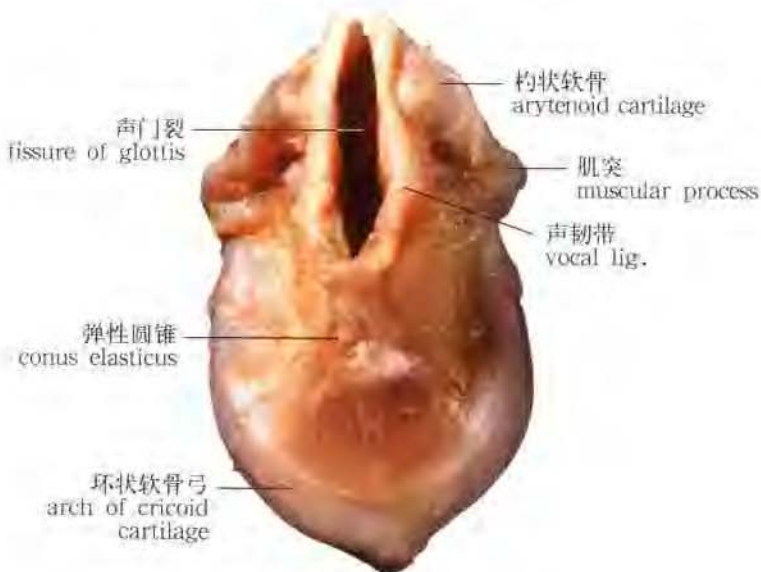

图 187 弹性圆锥  
The conus elasticus

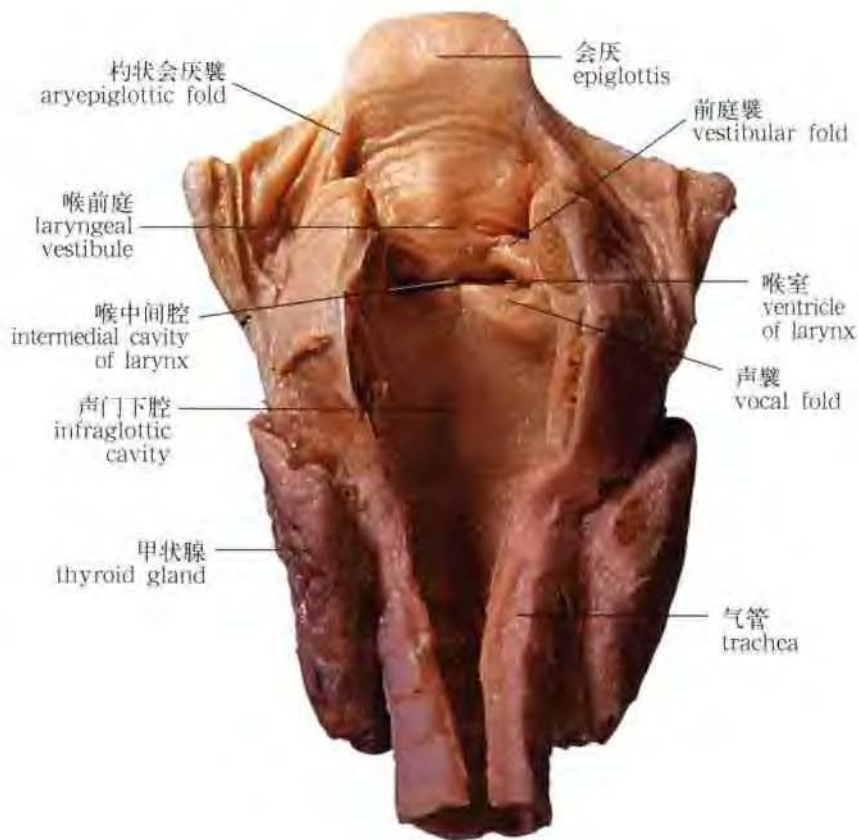


图 188 喉腔  
The laryngeal cavity

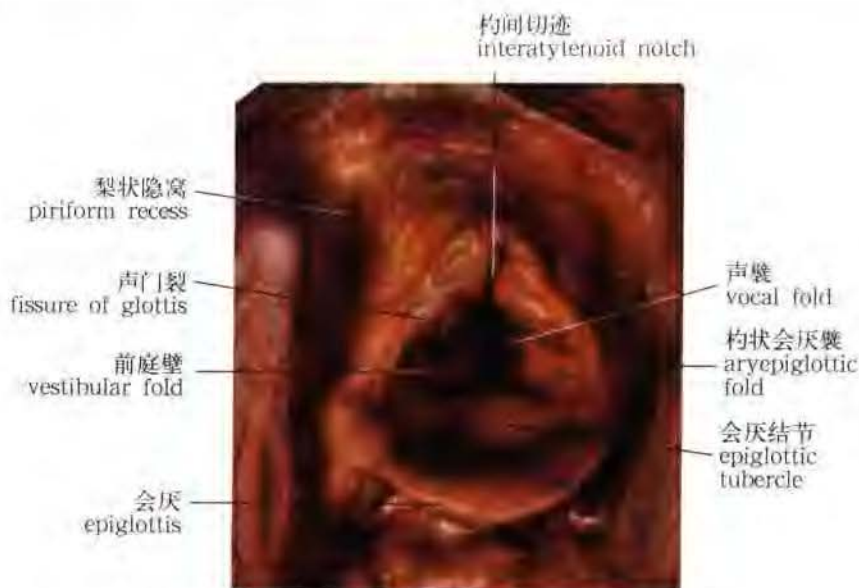


图 189 喉口 (上面观)  
The aperture of the larynx (superior aspect)

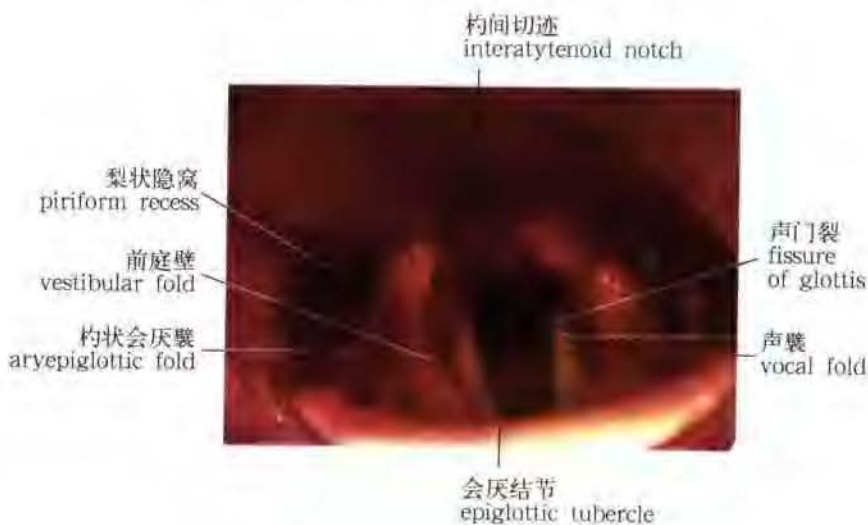


图 190 喉腔内镜图像  
Endoscope image of the laryngeal cavity

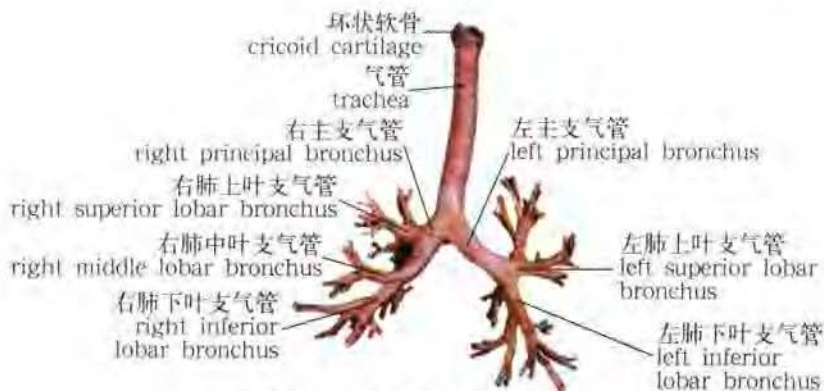

图 191 气管与支气管 (前面观)  
The trachea and bronchi (anterior aspect)

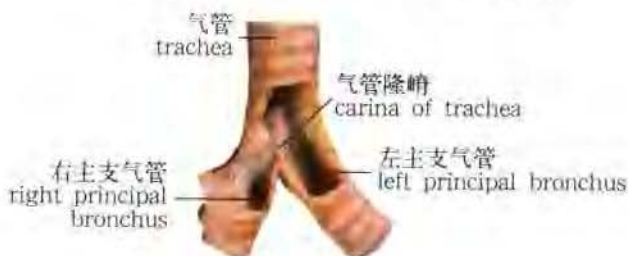

图 192 气管与支气管 (切除前壁)  
The trachea and bronchi (part of anterior wall removed)

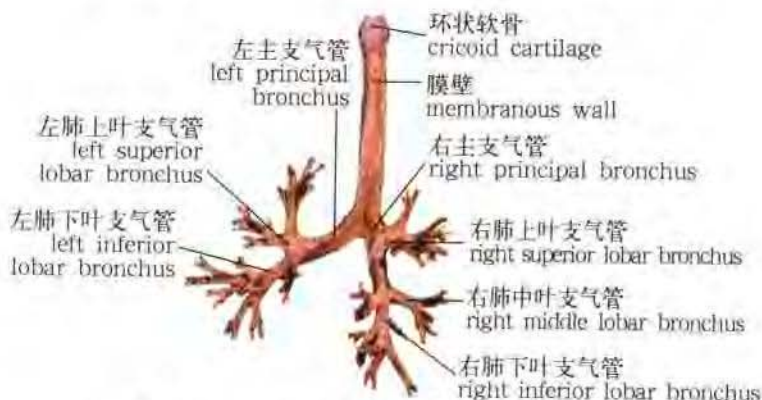


图 193 气管与支气管 (后面观)  
The trachea and bronchi (posterior aspect)

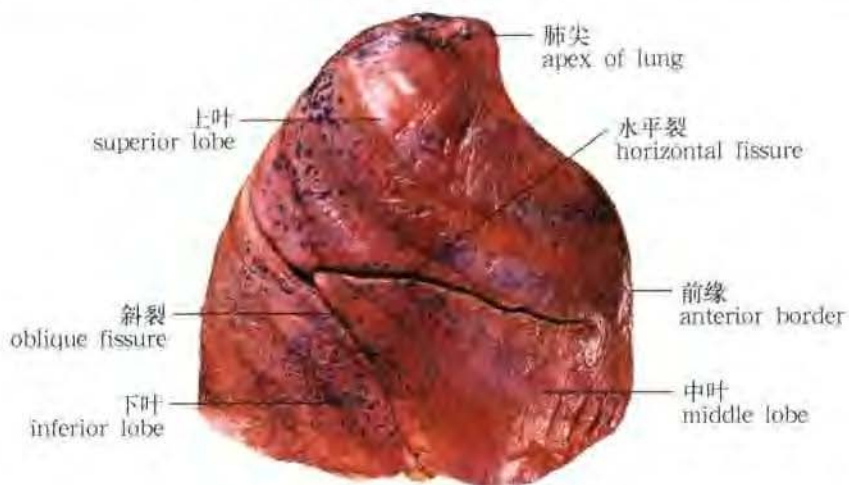


图 194 右肺 (前面观)  
The right lung (anterior aspect)

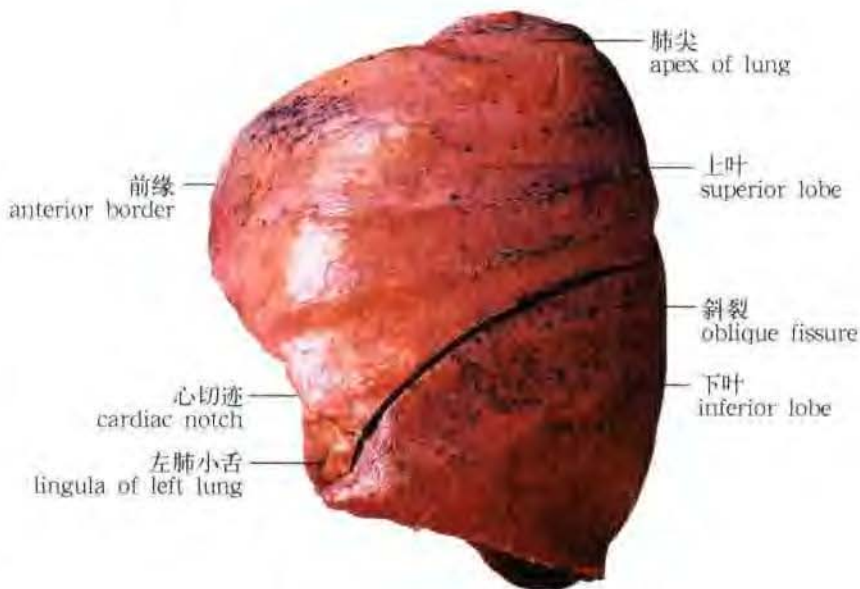


图 195 左肺 (前面观)  
The left lung (anterior aspect)

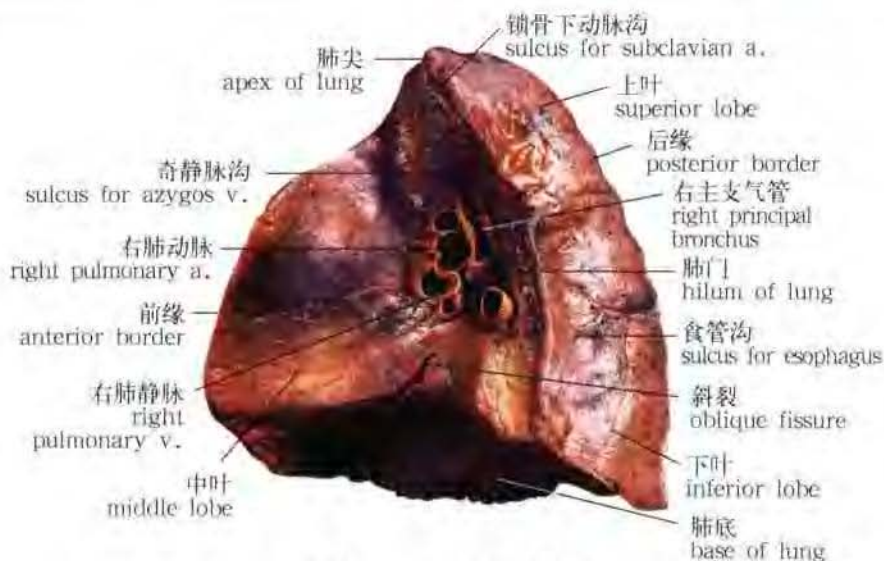


图 196 右肺 (内侧面观)  
The right lung (medial aspect)

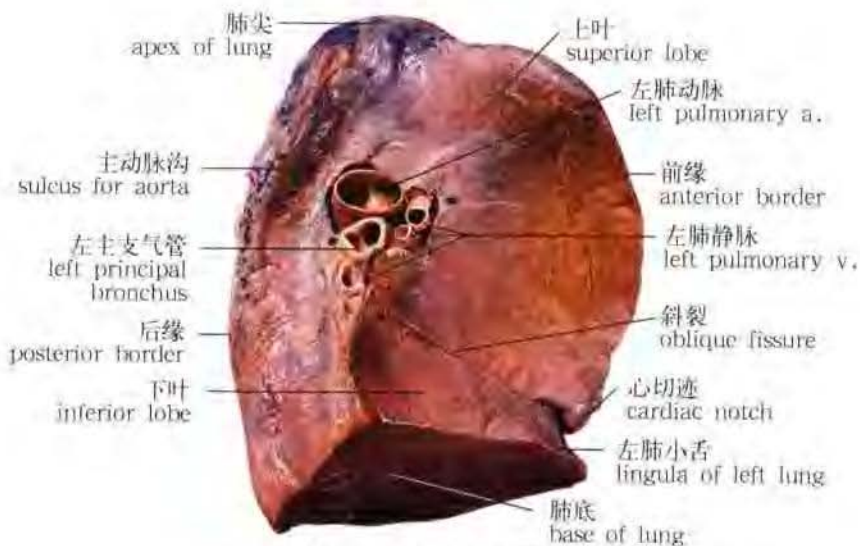


图 197 左肺 (内侧面观)  
The left lung (medial aspect)



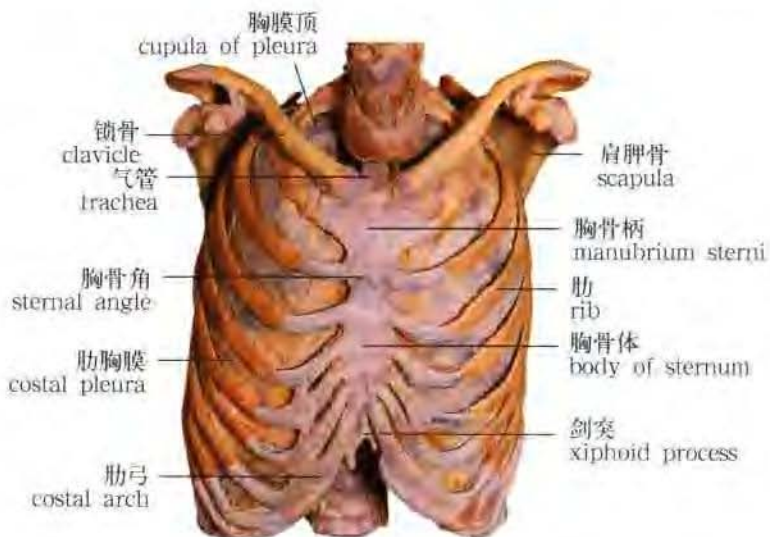


图 198 胸膜 (前面观)  
The pleura (anterior aspect)

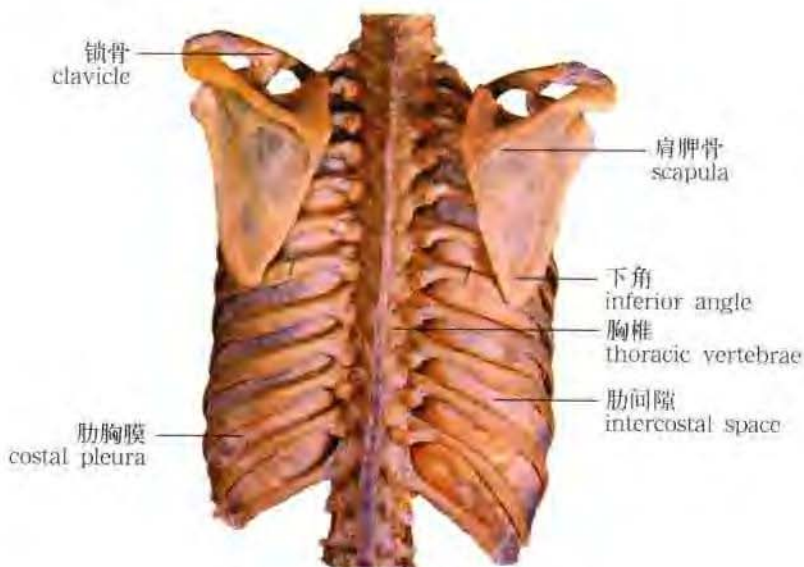


图 199 胸膜 (后面观)  
The pleura (posterior aspect)

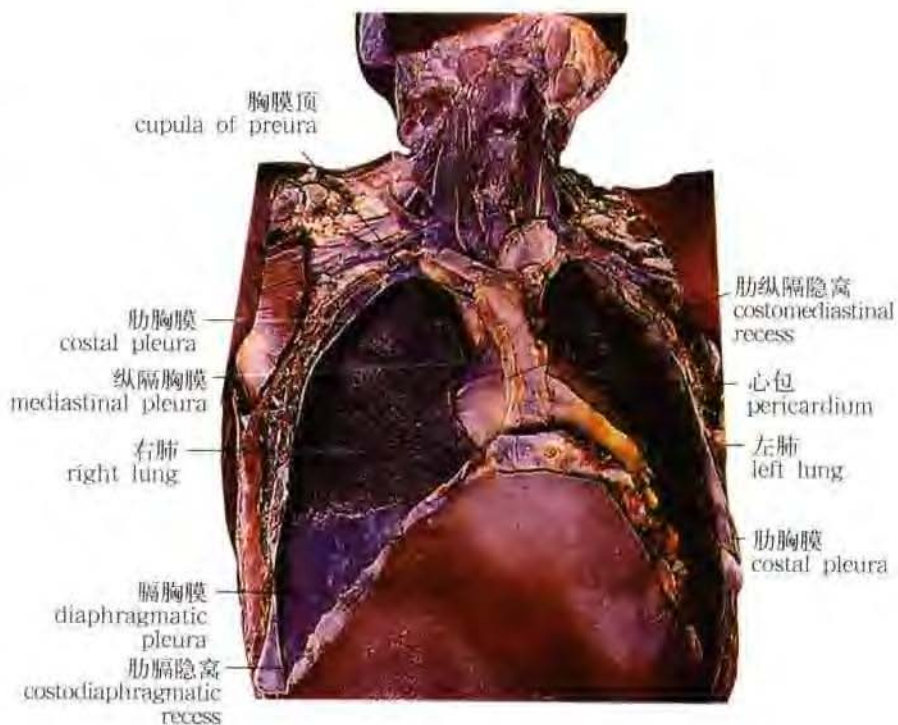


图 200 胸膜腔 (前面观)  
The pleural cavity (anterior aspect)

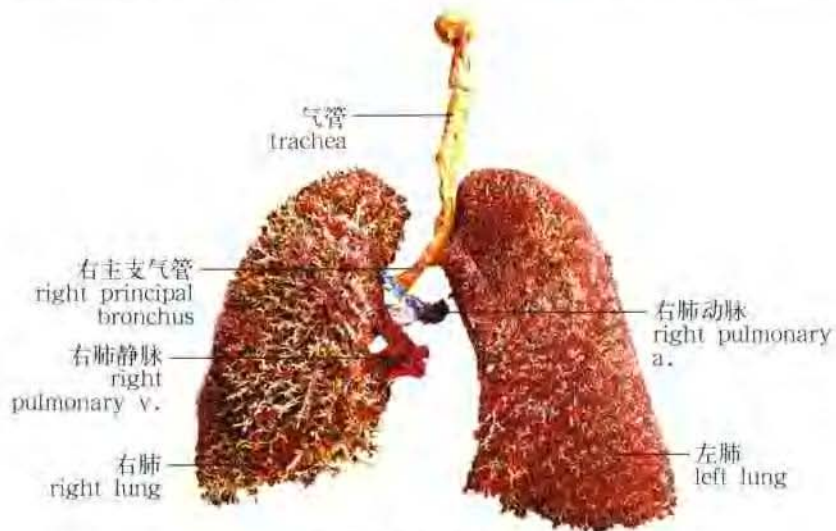


图 201 肺铸型  
The cast of the lung

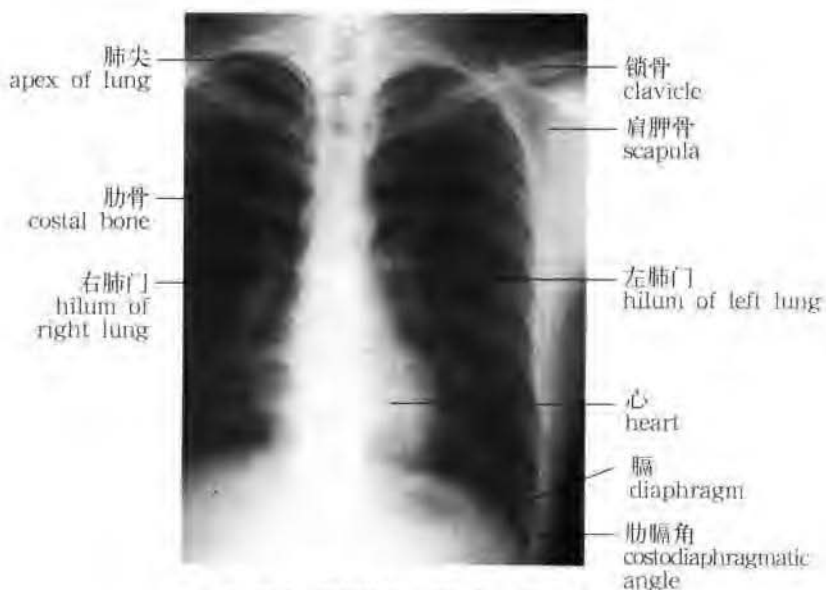

图 202 胸部 X 线图像 (正位)  
Radiograph of the thorax (anterior aspect)

# 泌尿生殖系统

UROGENITAL SYSTEM

Chapter

7

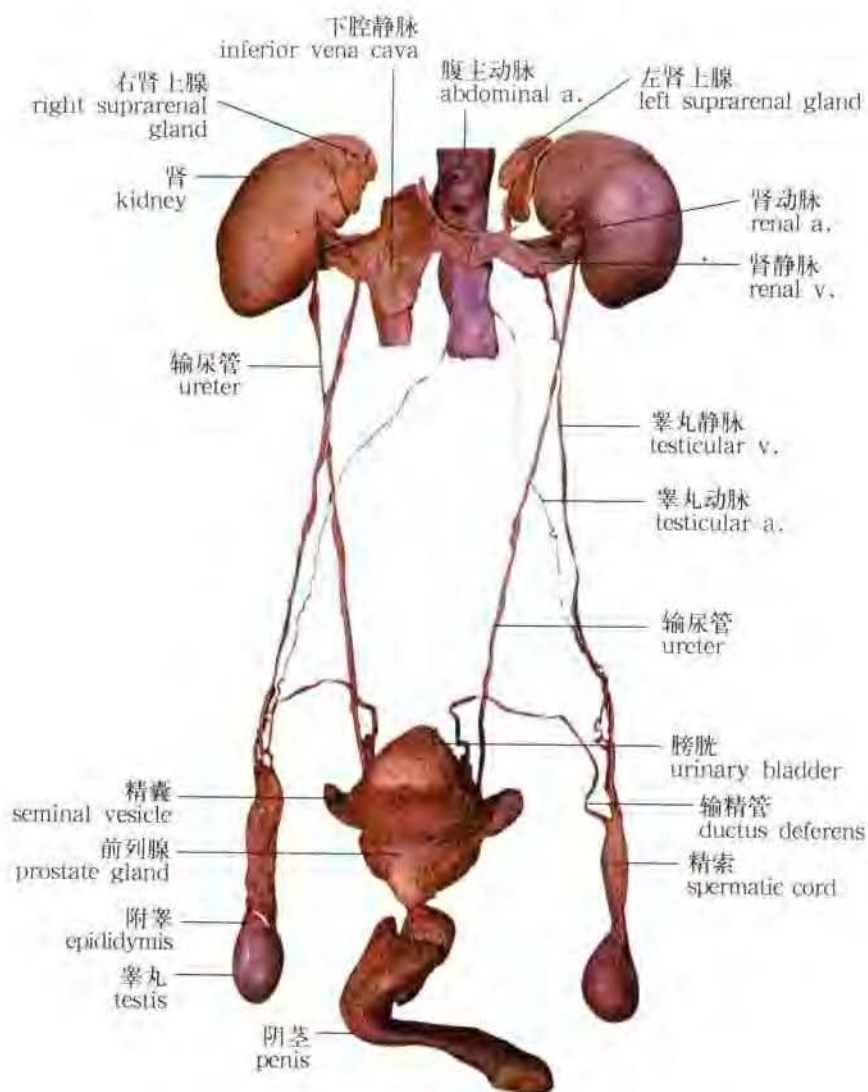


图 203 男性泌尿生殖系统概观  
General arrangement of the male urogenital system

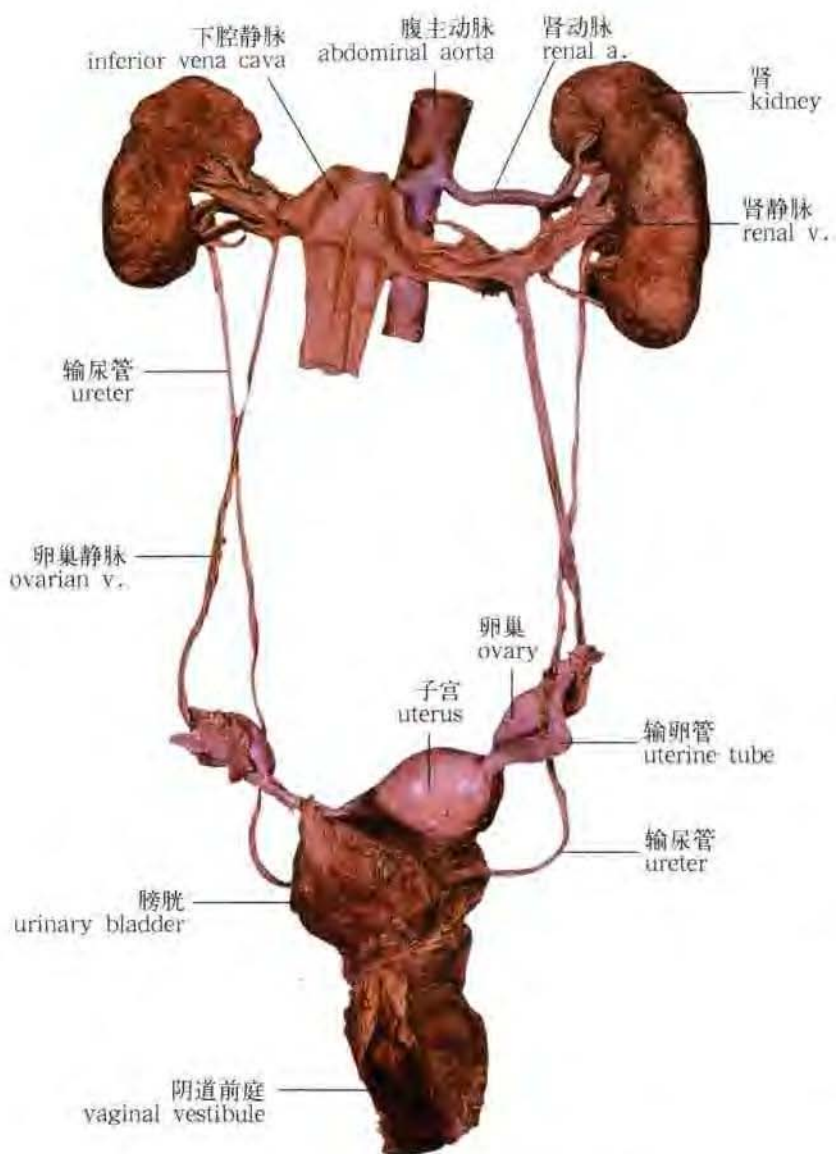


图 204 女性泌尿生殖系统概观  
General arrangement of the female urogenital system

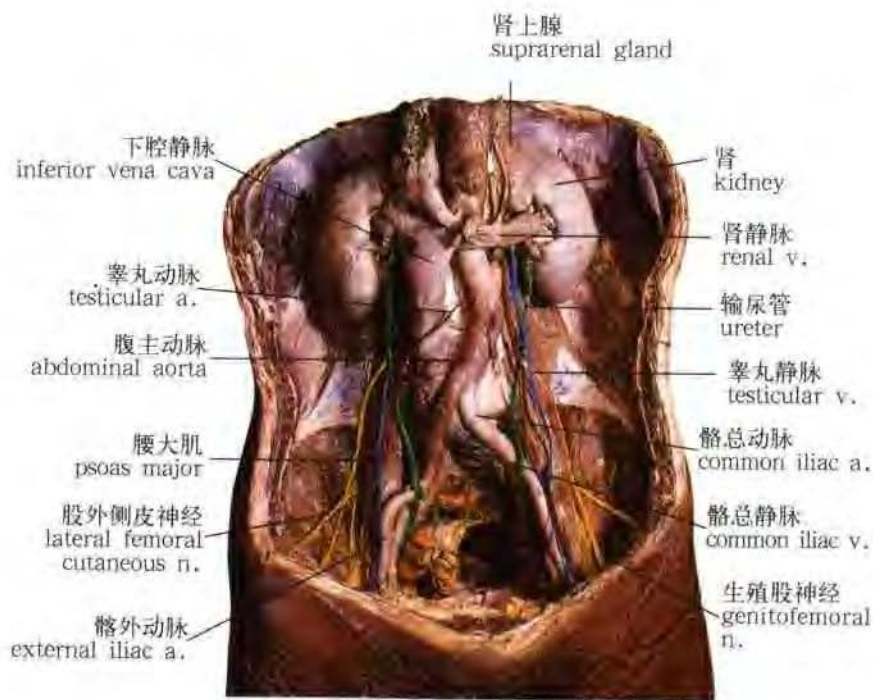


图 205 肾和输尿管的位置  
Locations of the kidney and ureter

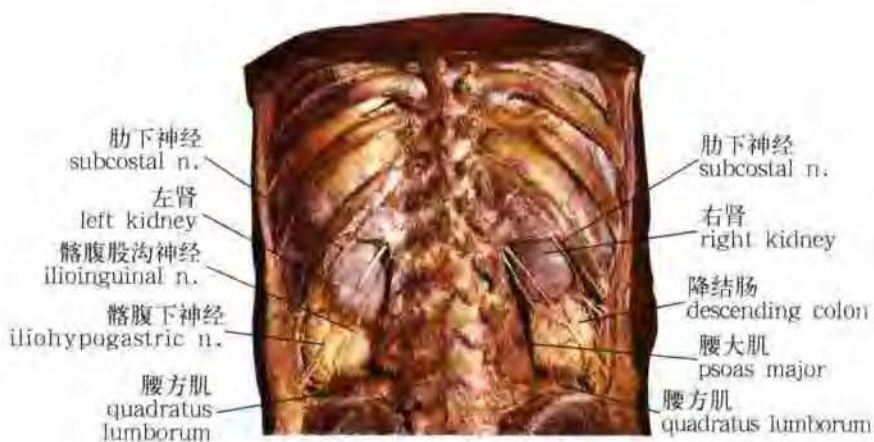


图 206 肾后面毗邻  
Posterior relationship of the kidney

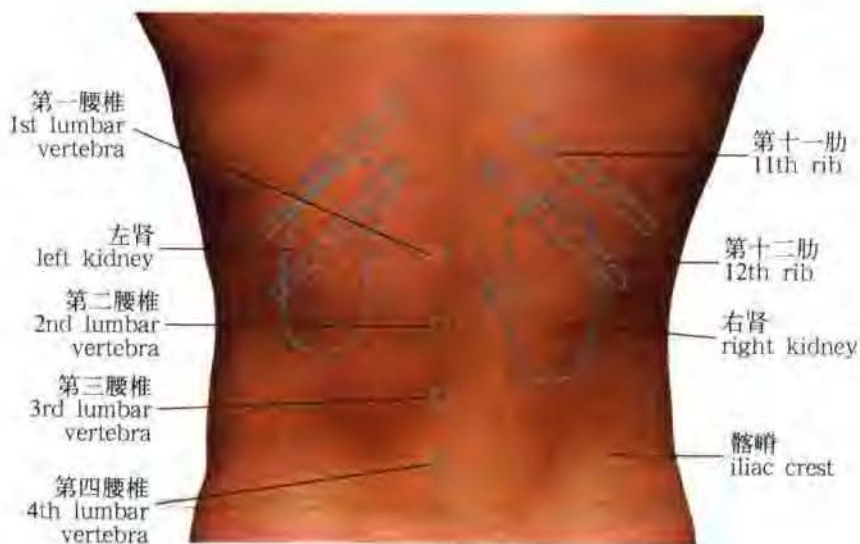

图 207 肾的体表标志  
Surface markings of the kidney



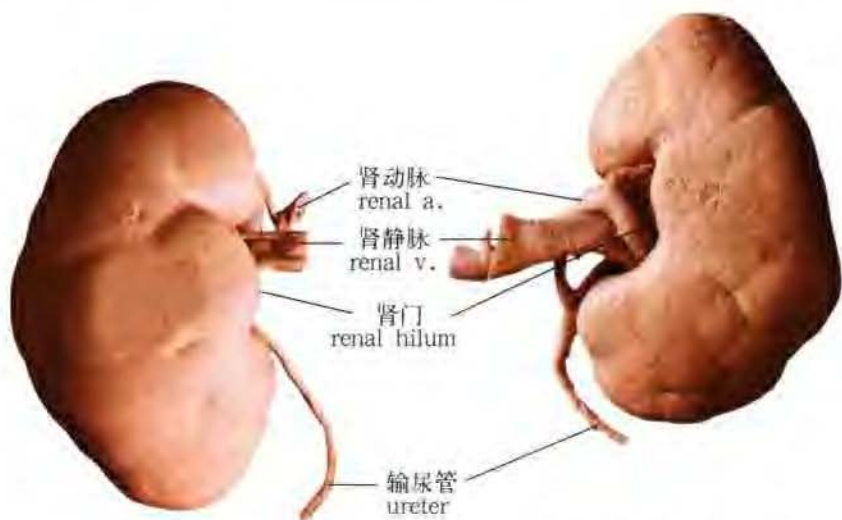


图 208 右肾 (前面观)  
The right kidney (anterior aspect)

图 209 左肾 (前面观)  
The left kidney (anterior aspect)

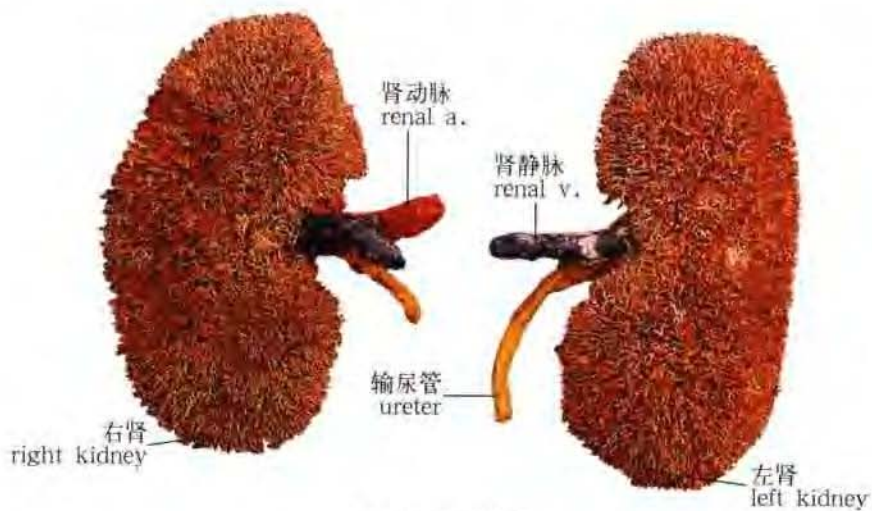

图 210 肾铸型  
The cast of the kidney

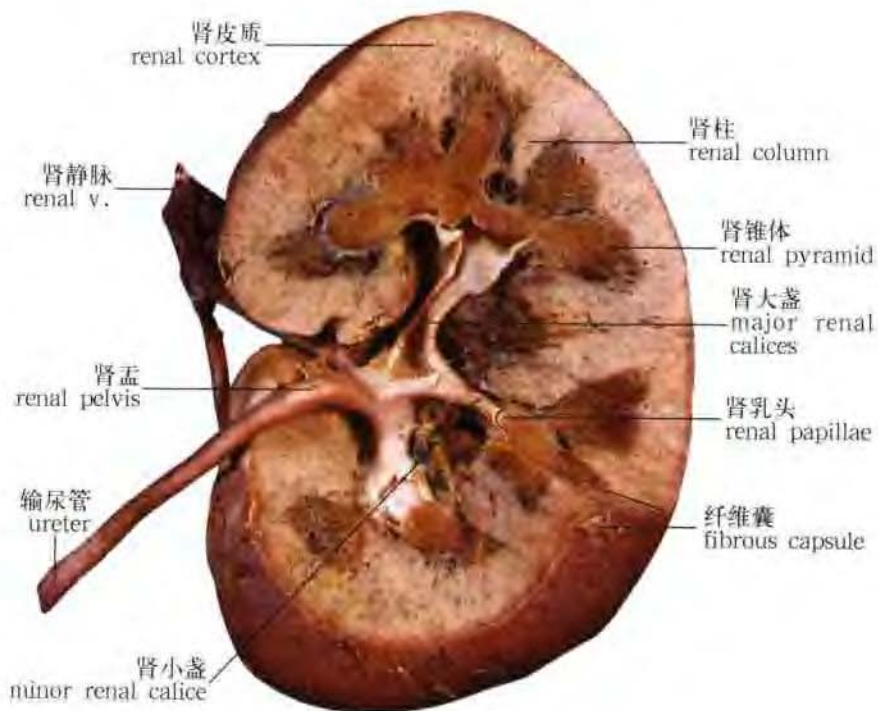


图 211 肾 (冠状切面)  
The kidney (coronal section)

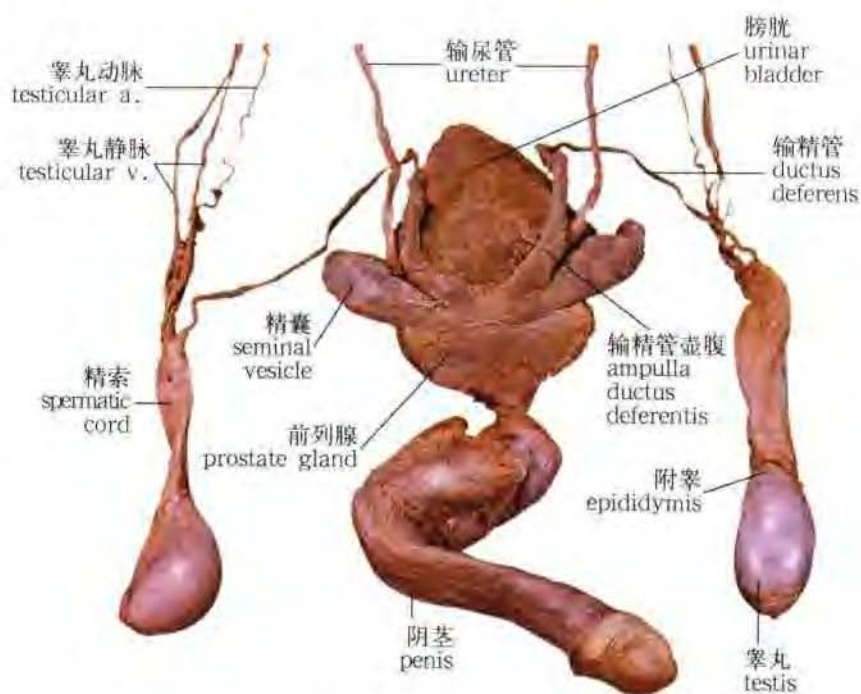


图 212 男性生殖系统概观 (后面观)  
 General arrangement of the male genital system (posterior aspect)

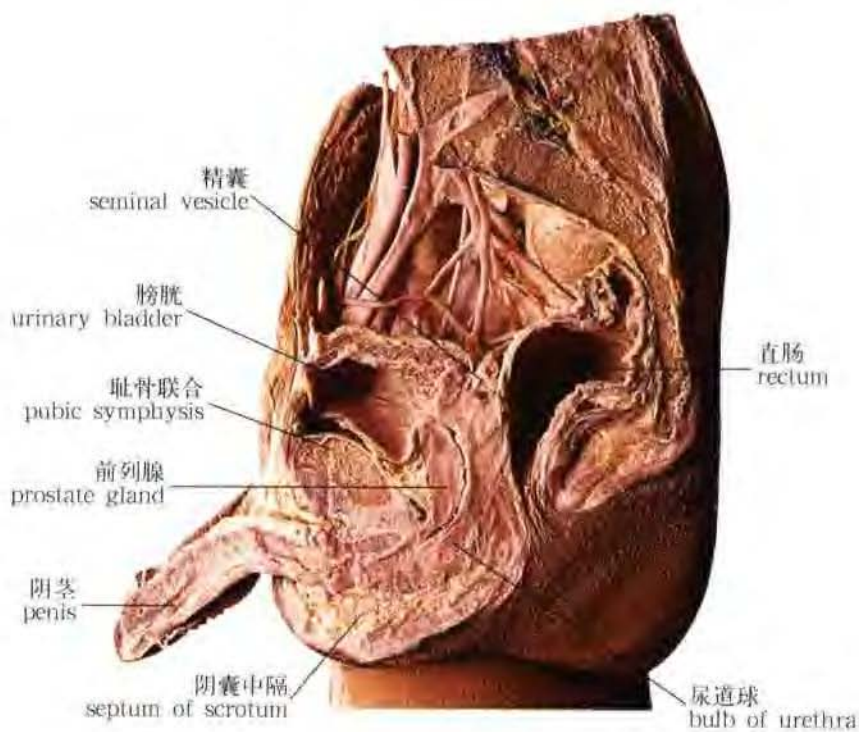


图 213 男性盆部 (正中矢状切面)  
The pelvis of the male (median sagittal section)

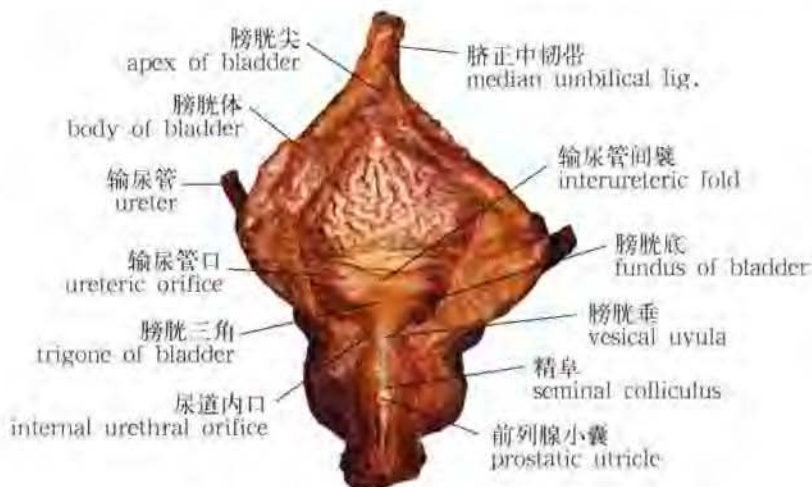

图 214 膀胱和前列腺 (前面观)  
The urinary bladder and prostate gland (anterior aspect)

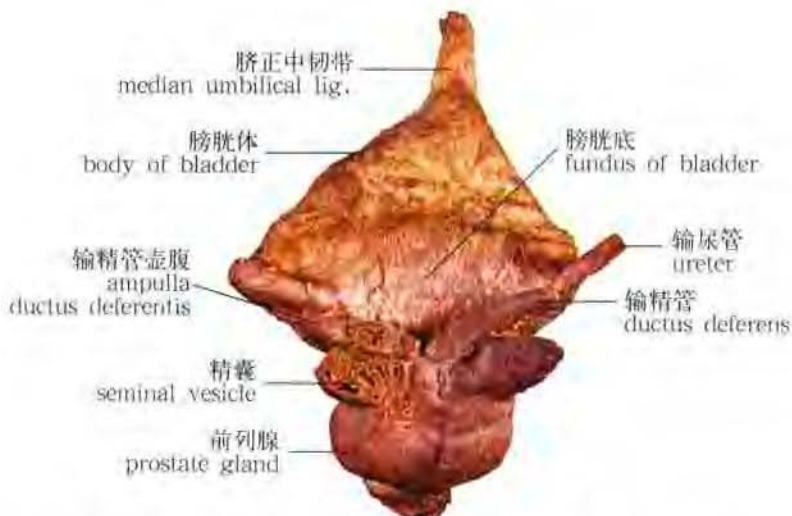


图 215 膀胱、前列腺、精囊和输精管 (后面观)  
The urinary bladder, prostate gland, seminal vesicle and ductus deferens  
(posterior aspect)

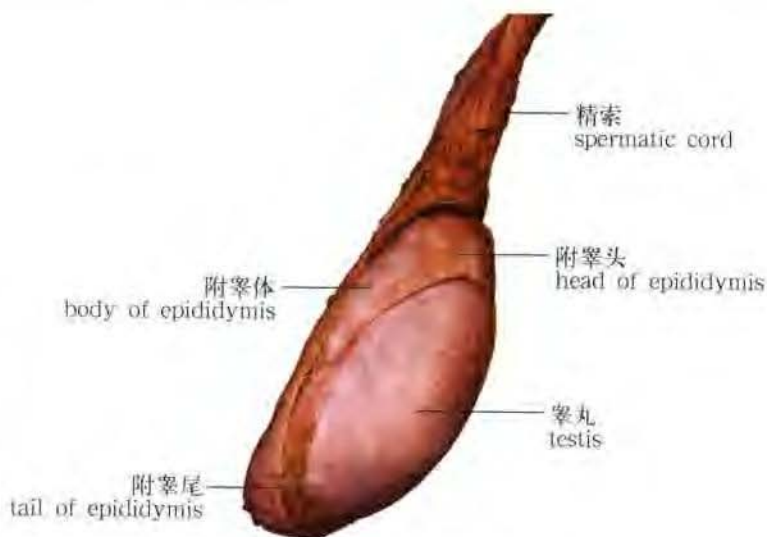


图 216 睾丸和附睾  
The testis and epididymis

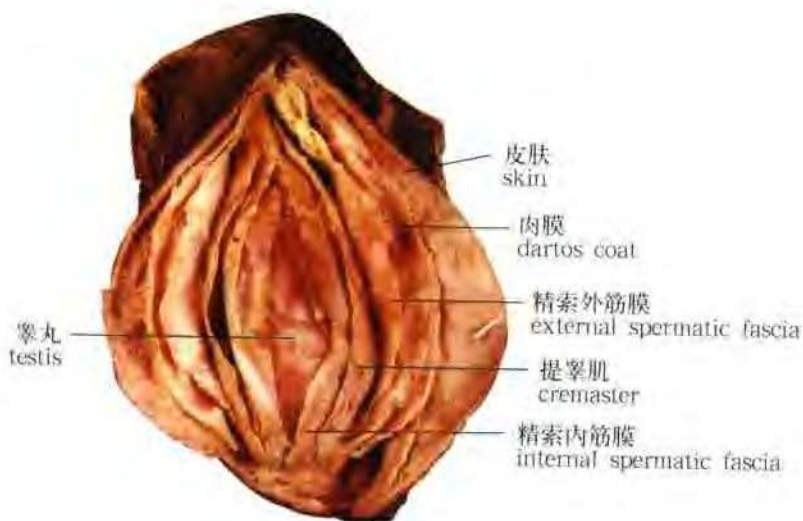

图 217 睾丸和精索被膜  
Coverings of the testis and spermatic cord

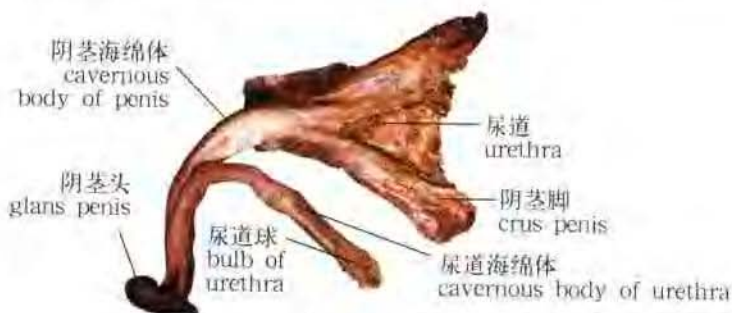

图 218 阴茎  
The penis

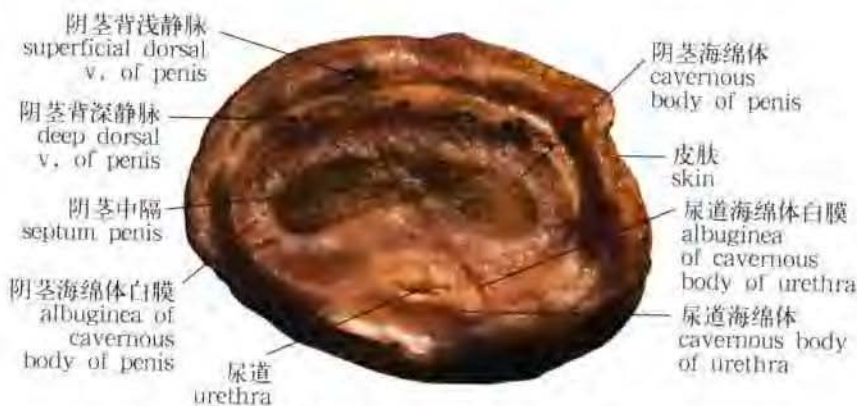

图 219 阴茎 (横断面)  
The penis (transverse section)

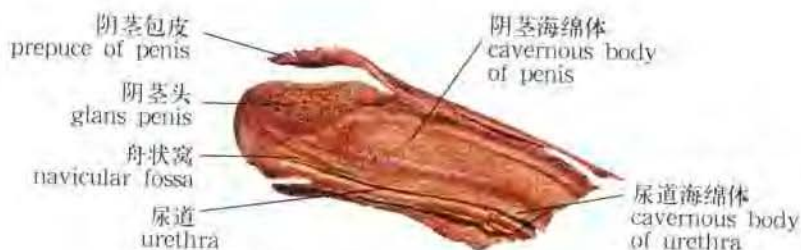

图 220 阴茎 (正中矢状切面)  
The penis (median sagittal section)

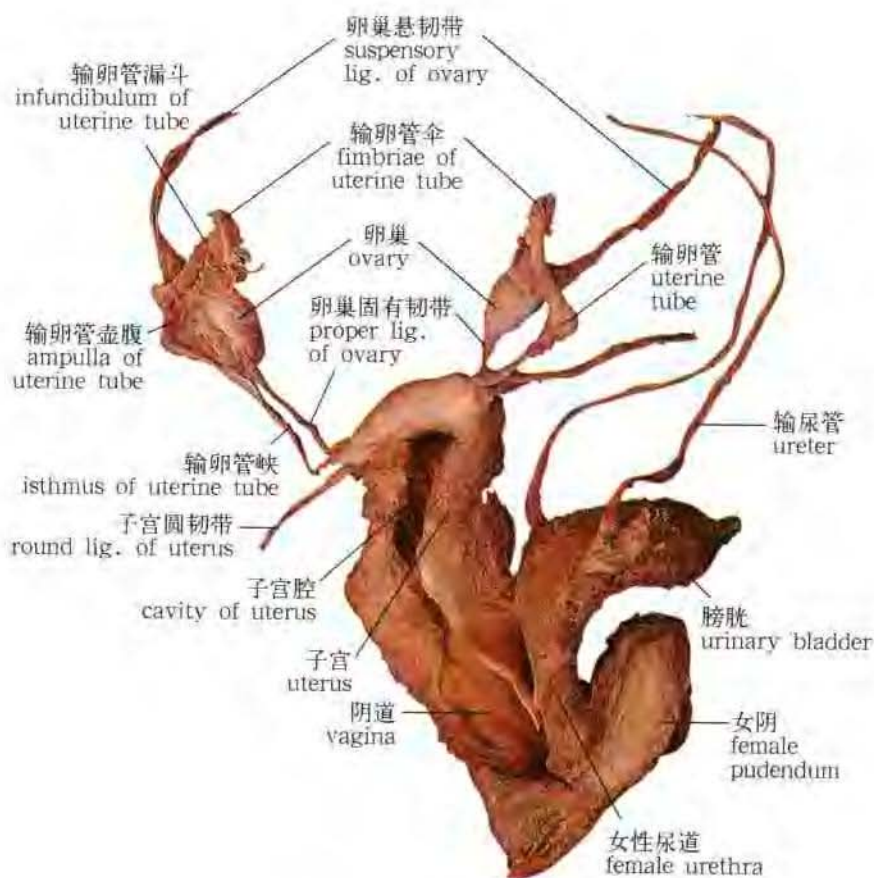


图 221 女性生殖系统概观  
General arrangement of the female genital system



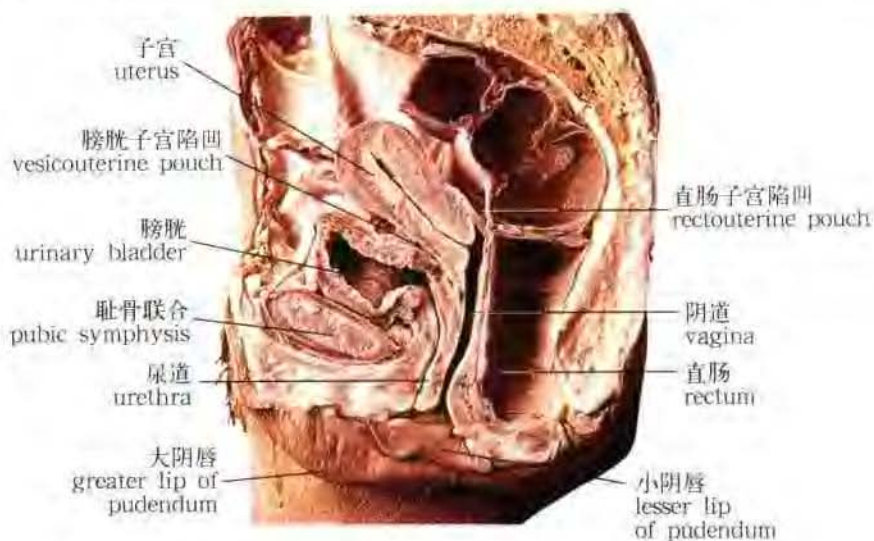


图 222 女性盆部 (正中矢状切面)  
The pelvis of the female (median sagittal section)

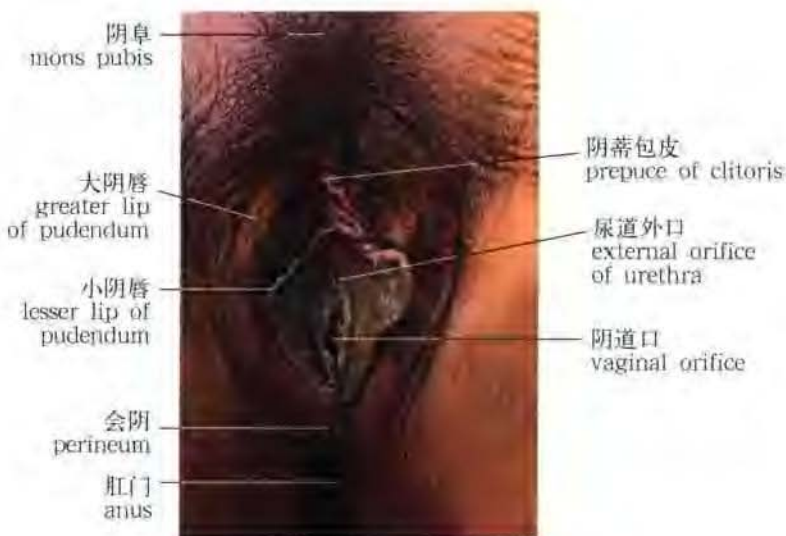


图 223 女性外生殖器  
External genital organs of the female

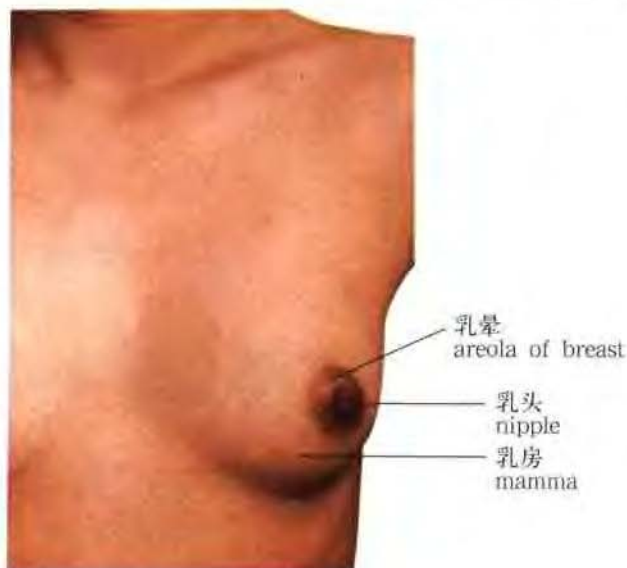


图 224 乳房 (1)  
The mamma (1)

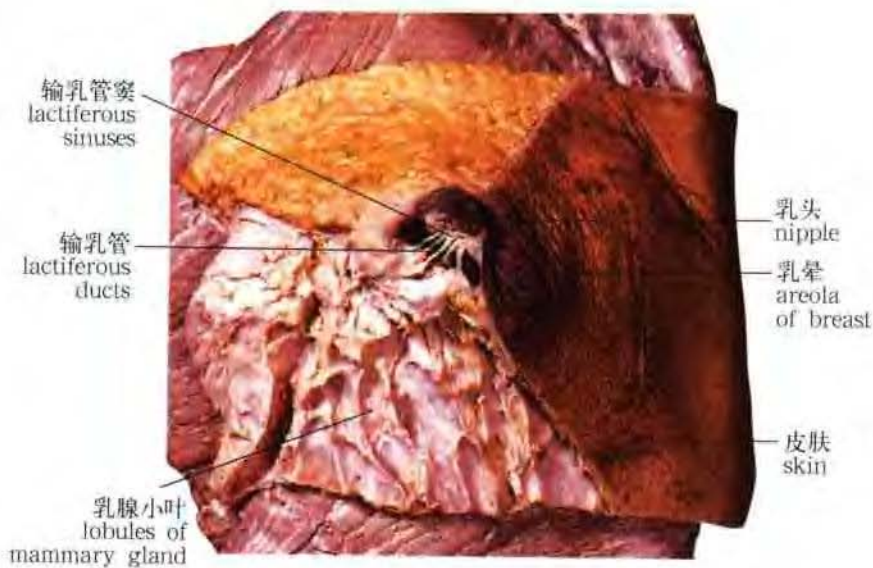


图 225 乳房 (2)  
The mamma (2)



心脏

HEART

---

Chapter

8

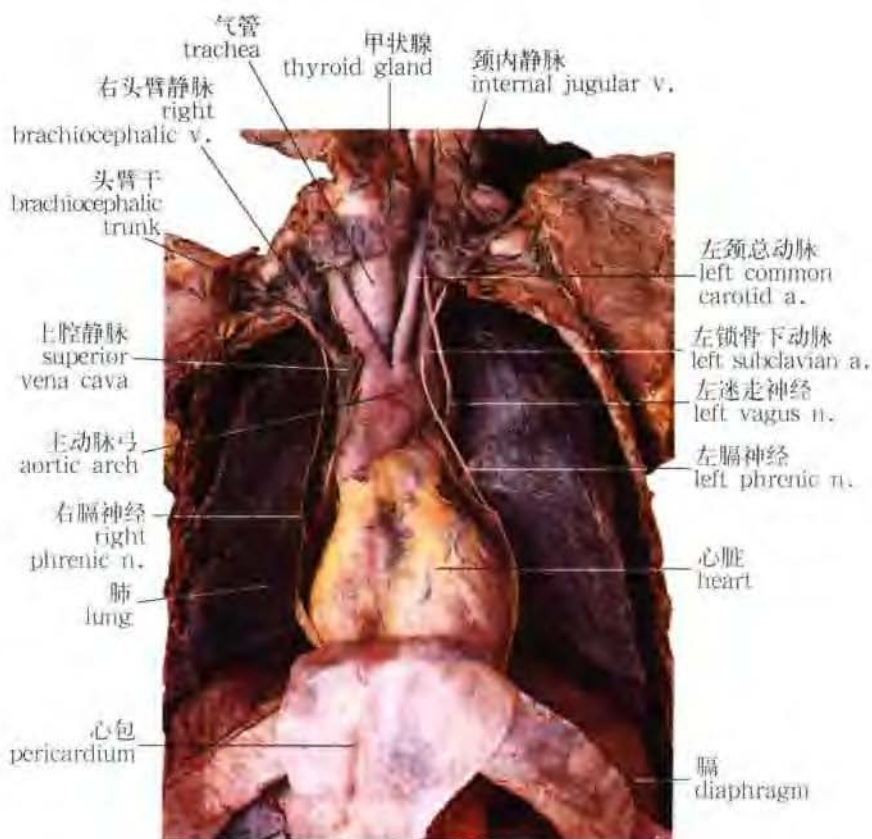


图 226 心脏的位置  
Position of the heart

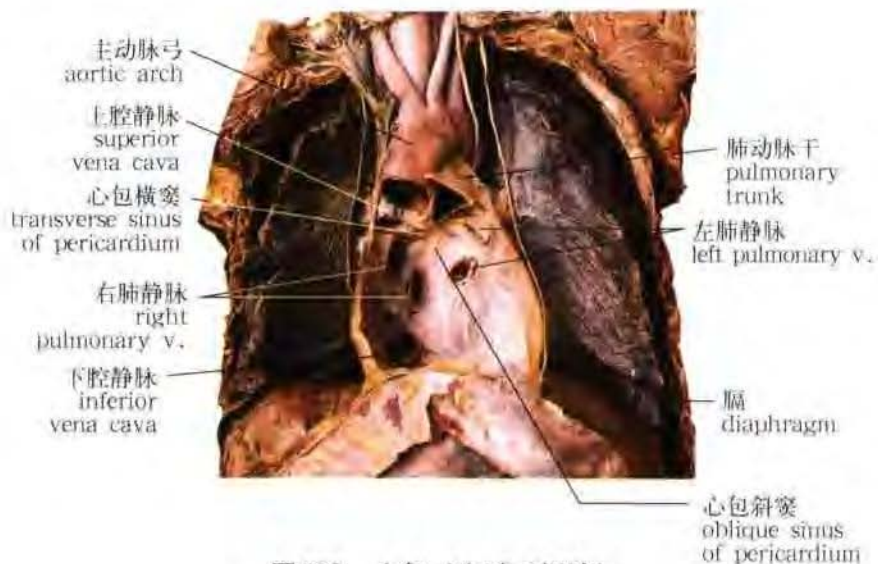


图 227 心包 (心脏已切除)  
The pericardium (heart removed)

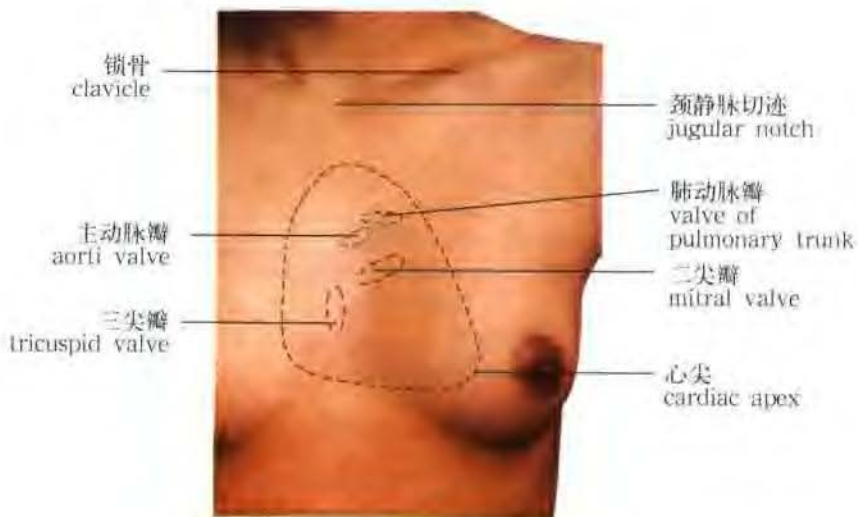


图 228 心脏的体表标志  
Surface markings of the heart

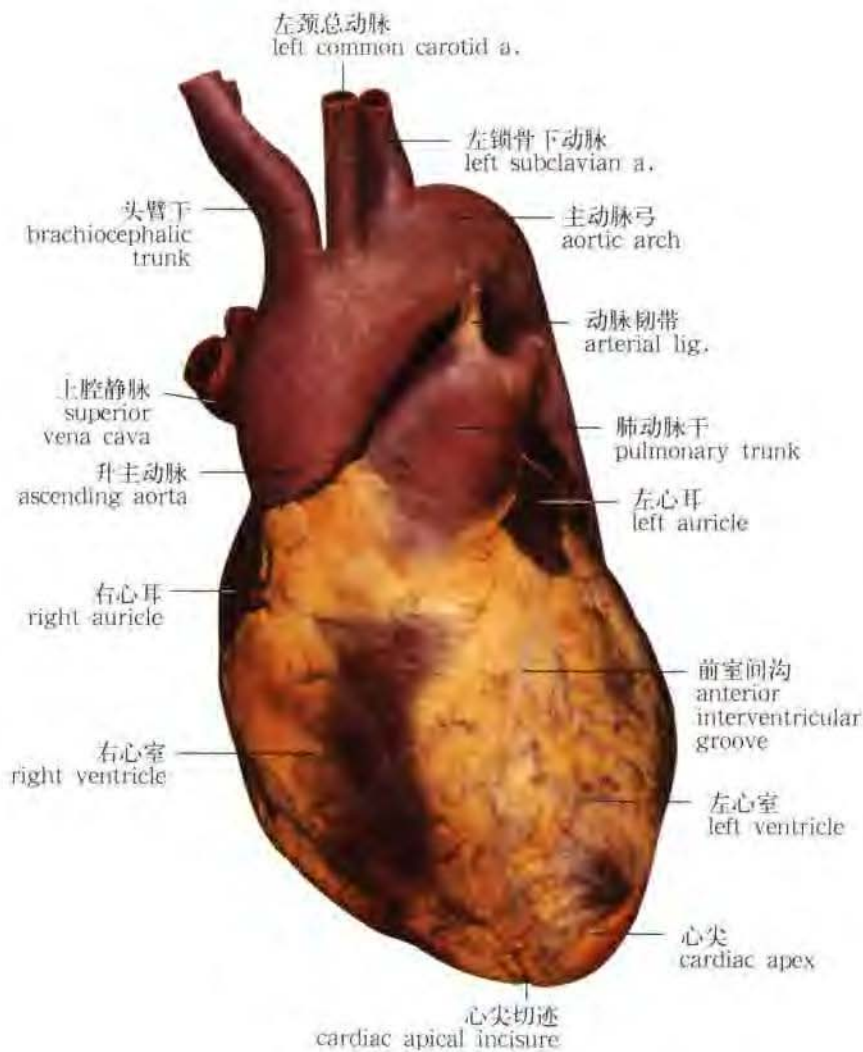


图 229 心脏的外形 (前面观)  
 External features of the heart (anterior aspect)

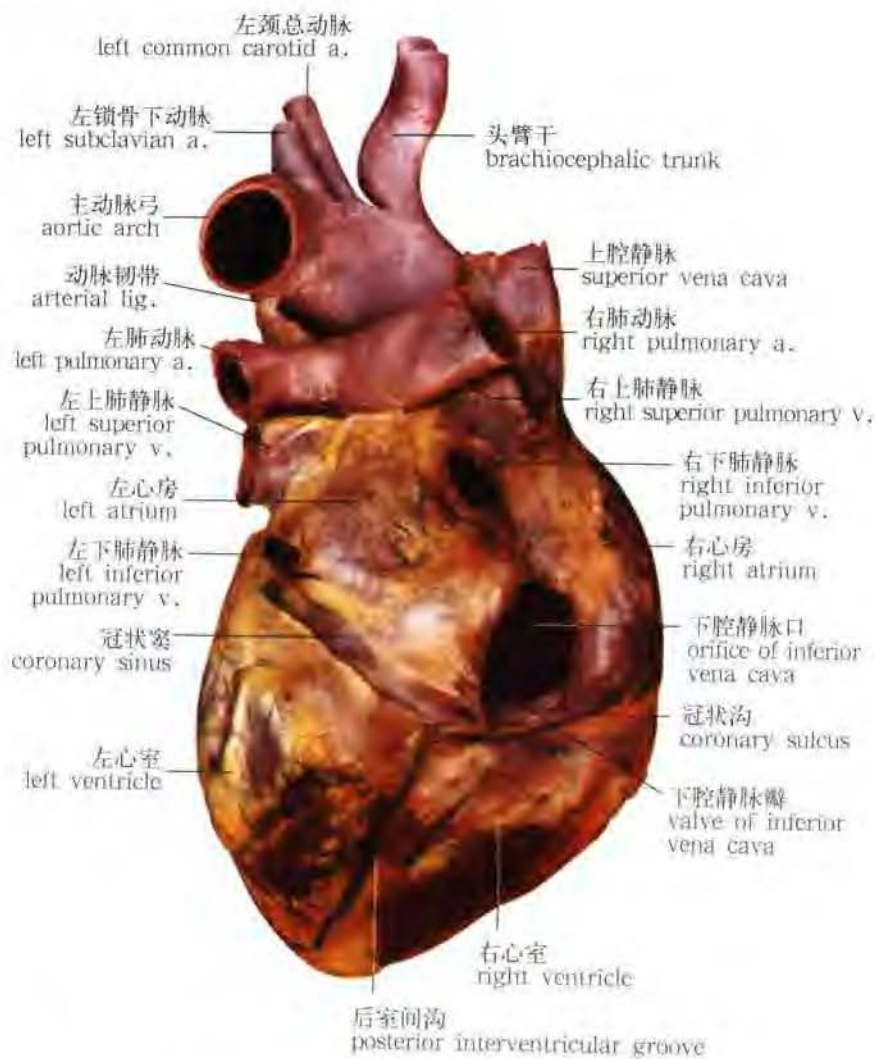


图 230 心脏的外形 (后面观)  
 External features of the heart (posterior aspect)

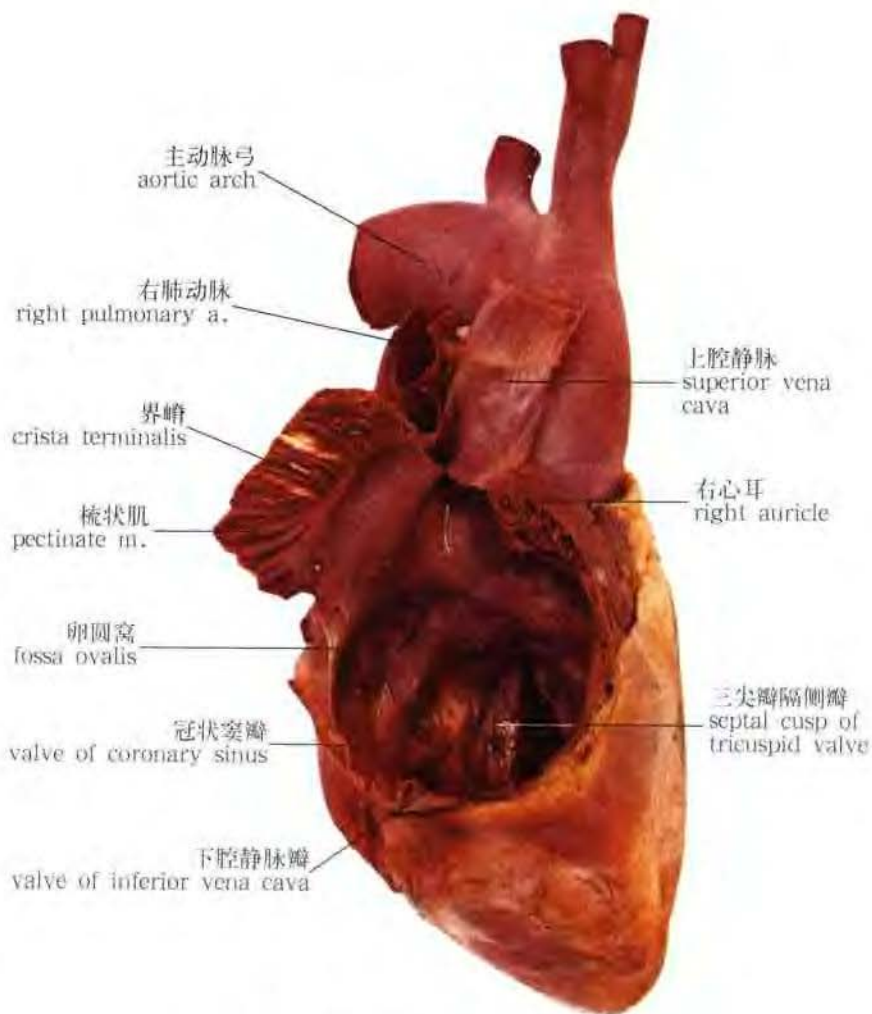


图 231 右心房 (内面观)  
The right atrium (internal aspect)



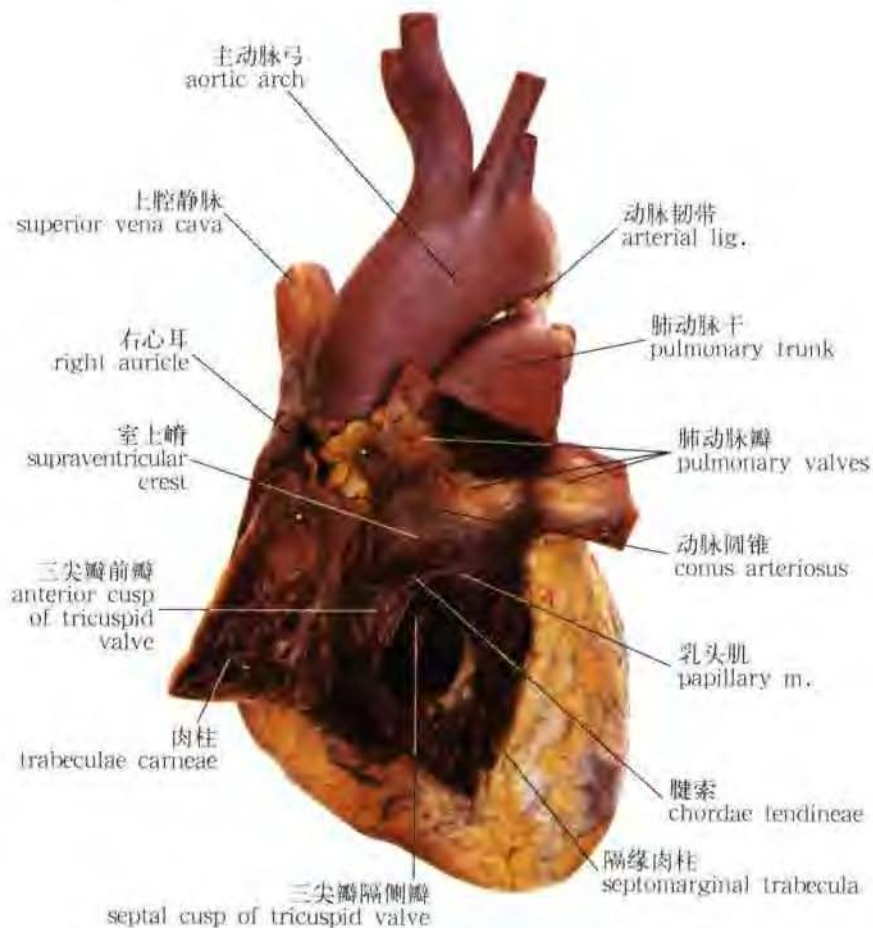


图 232 右心室 (内面观)  
The right ventricle (internal aspect)

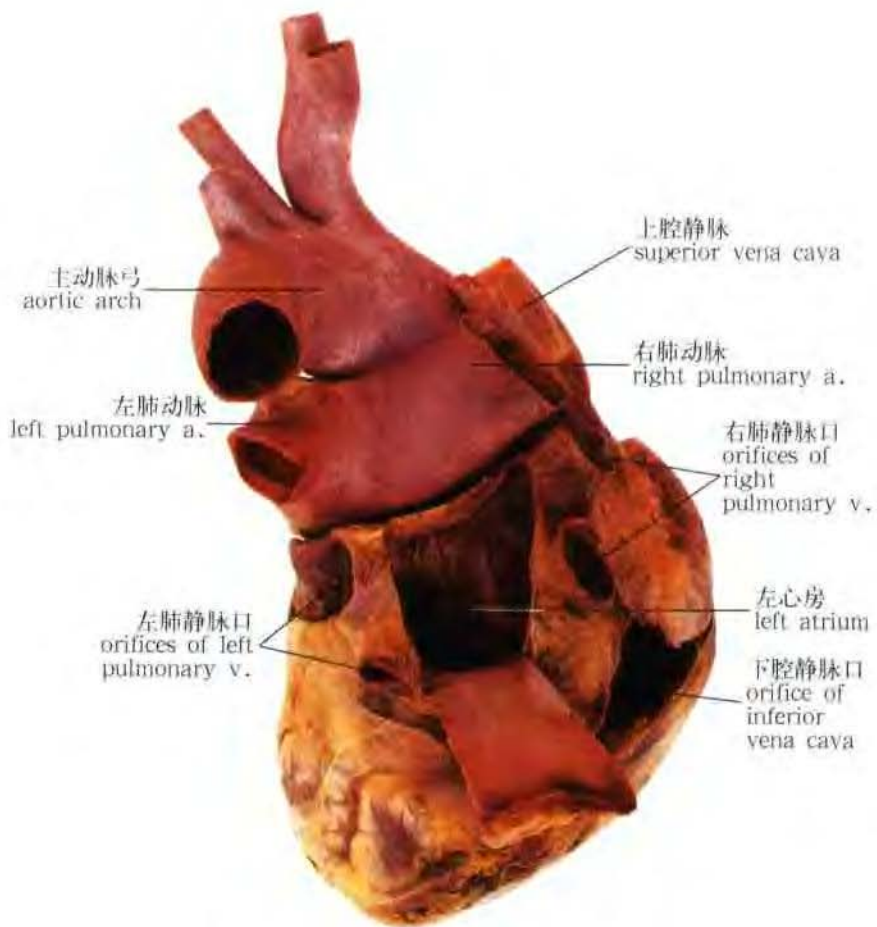


图 233 左心房 (内面观)  
The left atrium (internal aspect)

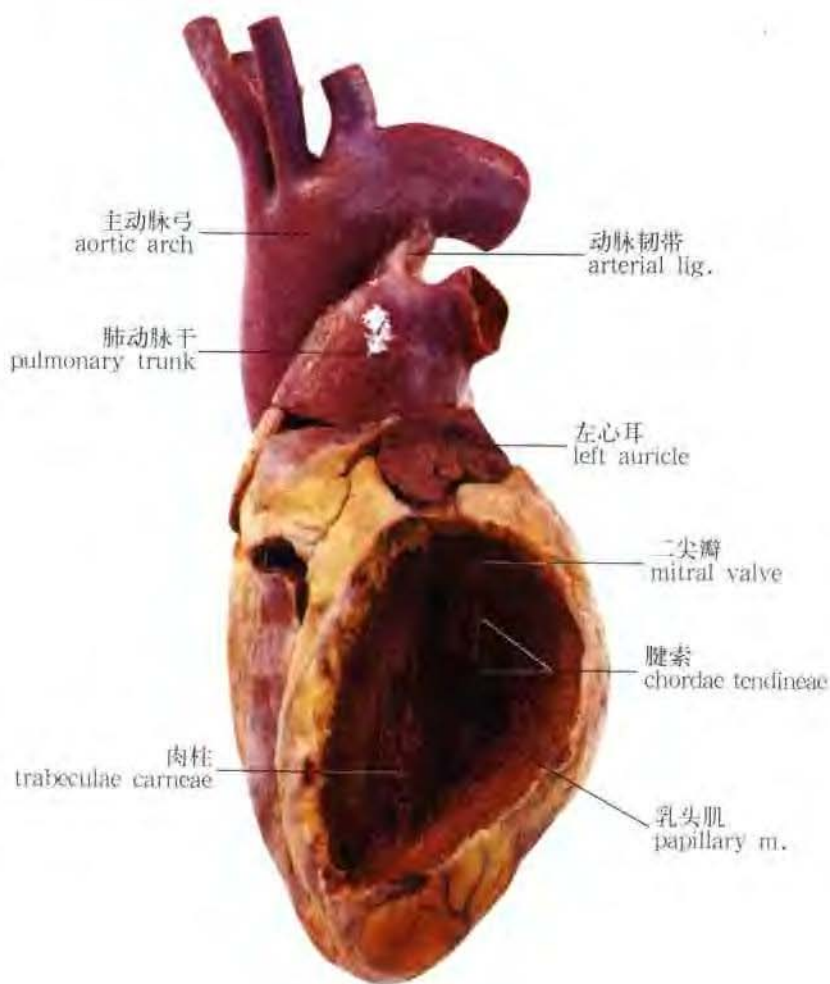


图 234 左心室 (内面观)  
The left ventricle (internal aspect)

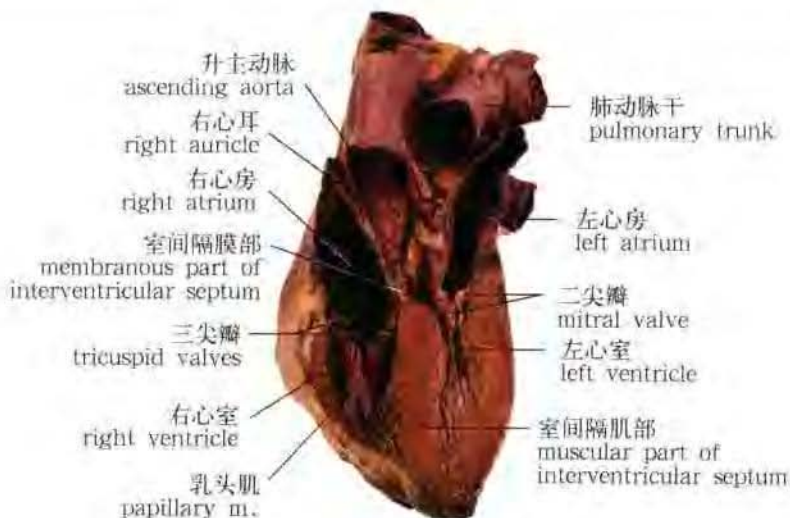


图 235 心脏内腔  
The internal cavities of the heart

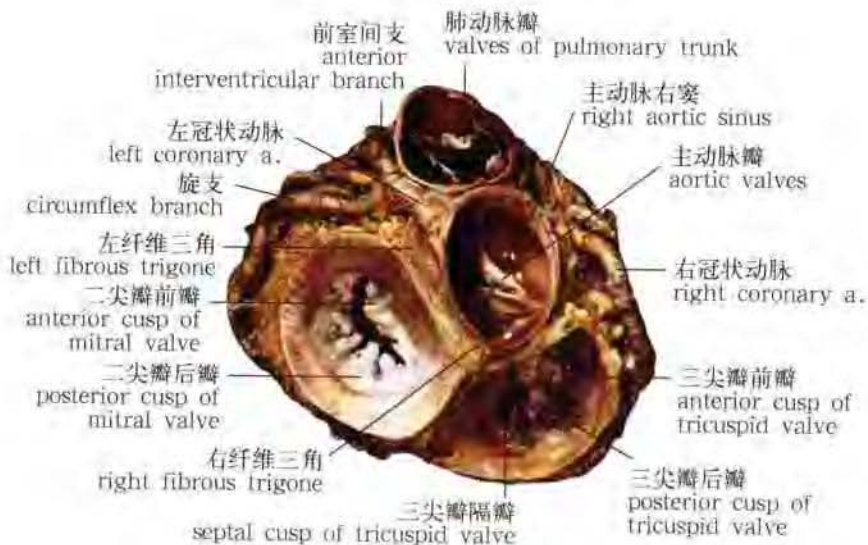


图 236 心瓣膜  
The valves of the heart

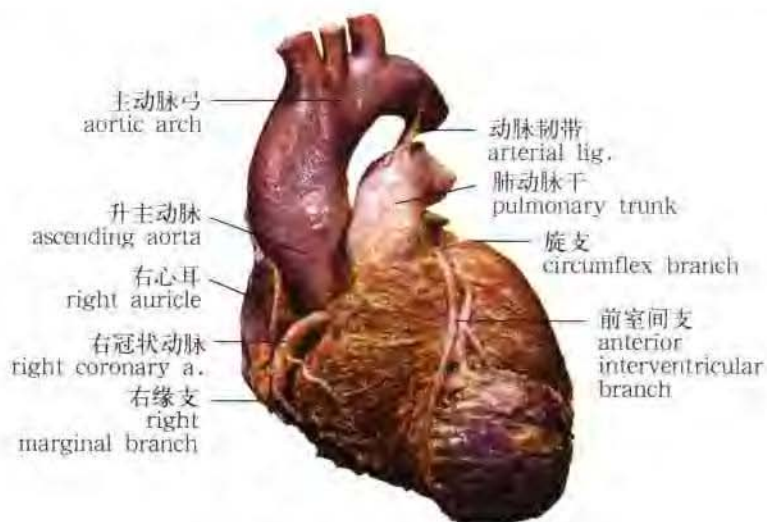

图 237 心脏的血管 (前面观)  
Blood vessels of the heart (anterior aspect)

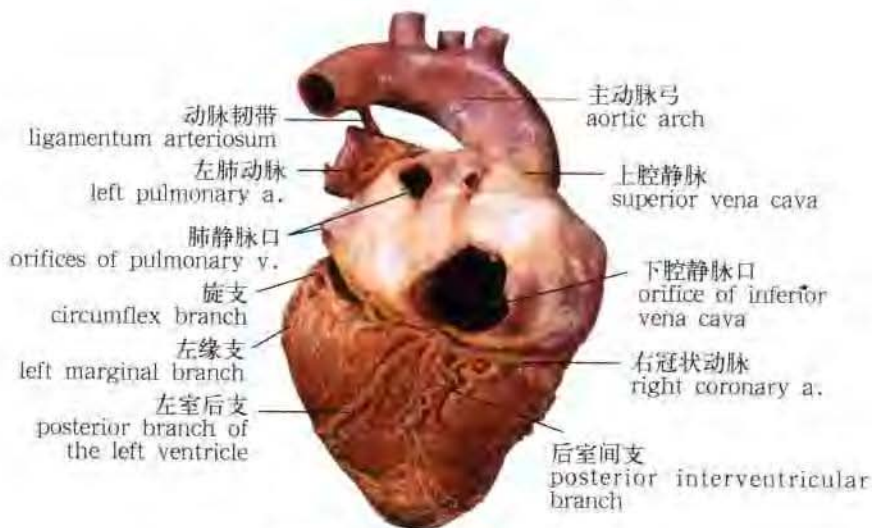


图 238 心脏的血管 (后面观)  
Blood vessels of the heart (posterior aspect)

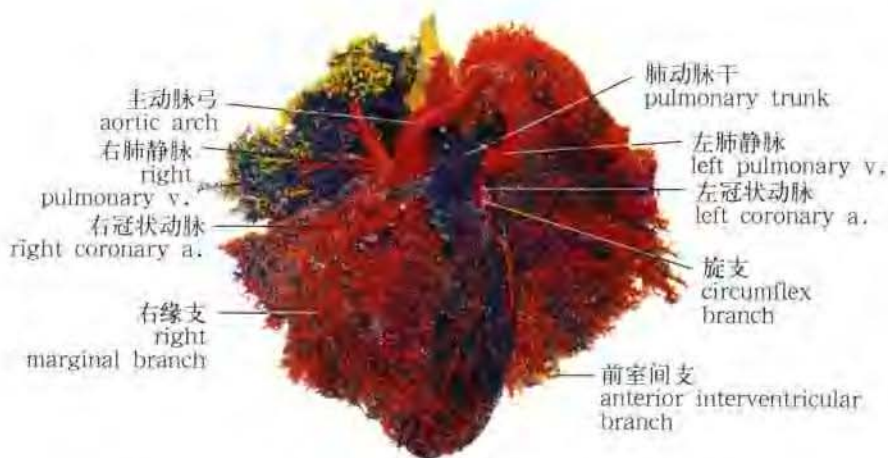


图 239 心血管铸型标本 (1)  
The cast specimen of the cardiac blood vessels (1)

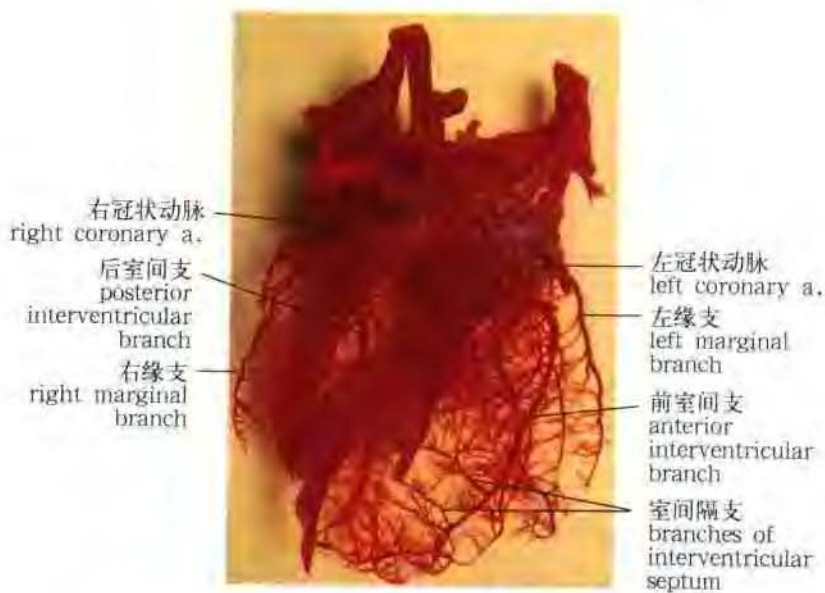


图 240 心血管铸型标本 (2)  
The cast specimen of the cardiac blood vessels (2)



# 淋巴系统

LYMPHATIC SYSTEM

---

# Chapter 9

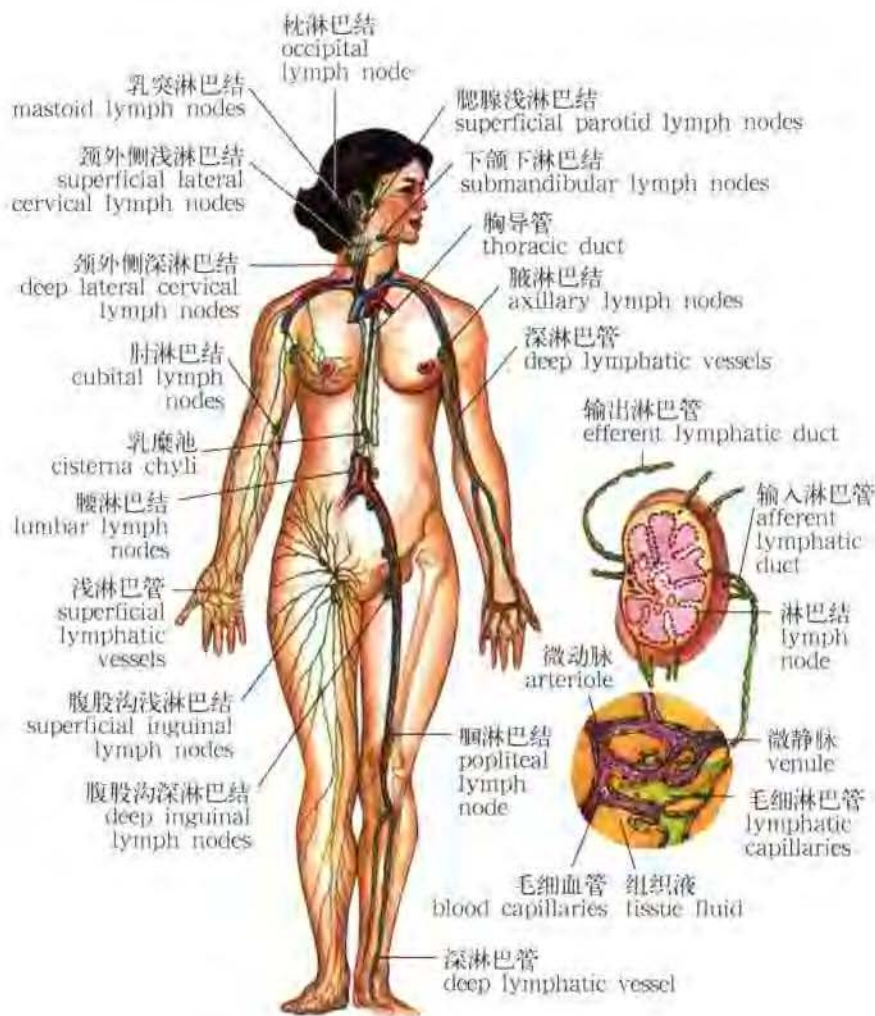

图 241 淋巴系统模式图  
Diagram of the lymphatic system



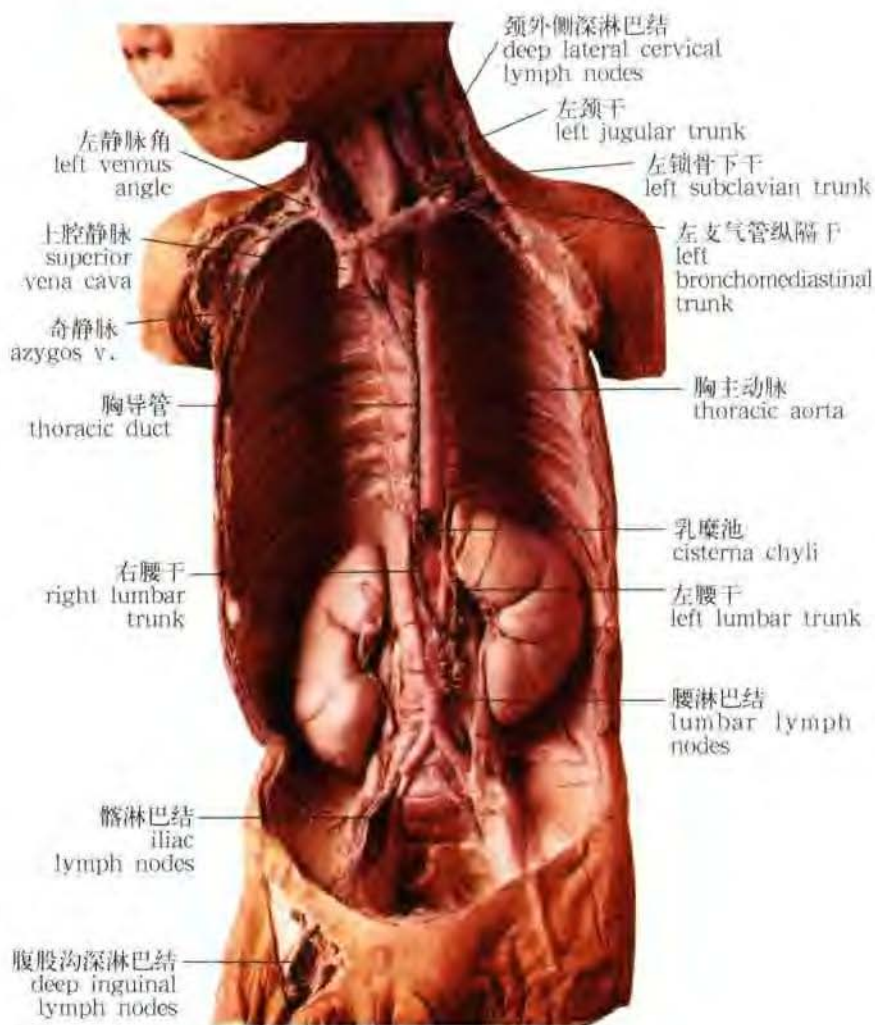

图 242 胸导管及淋巴干  
 The thoracic ducts and lymph trunks

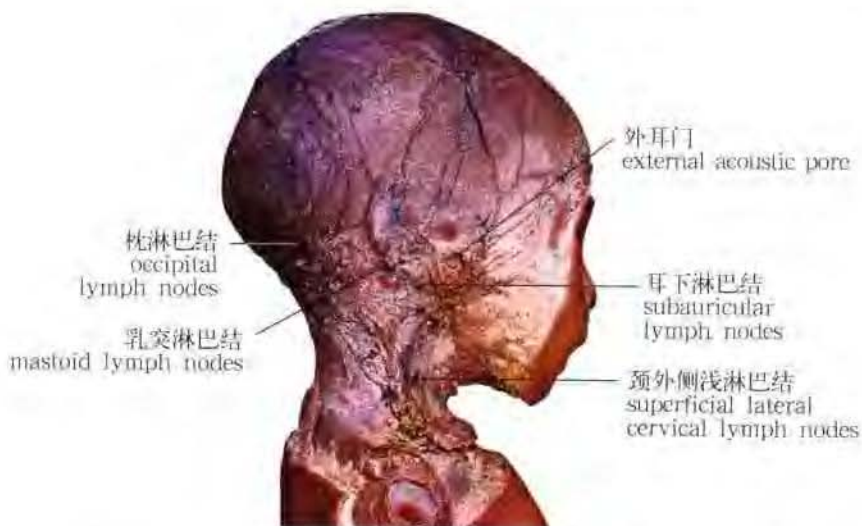


图 243 头颈部浅淋巴管及淋巴结  
Superficial lymphatic vessels and lymph nodes of the head and neck

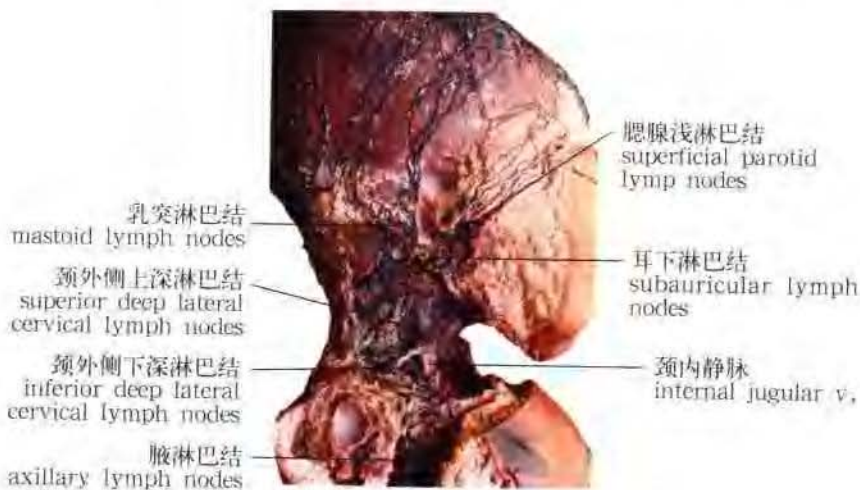


图 244 头颈部深淋巴管及淋巴结  
Deep lymphatic vessels and lymph nodes of the head and neck

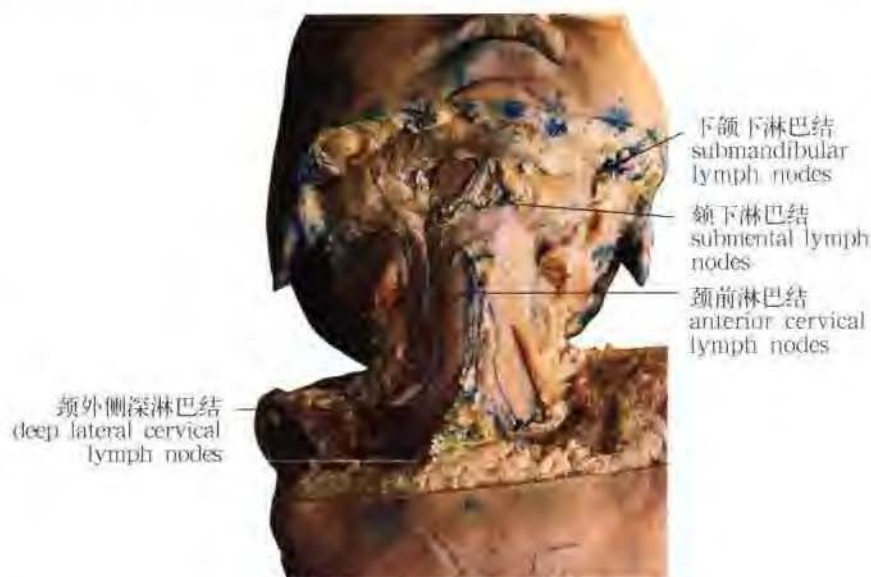

图 245 颈前部淋巴管及淋巴结  
Lymphatic vessels and lymph nodes of the neck

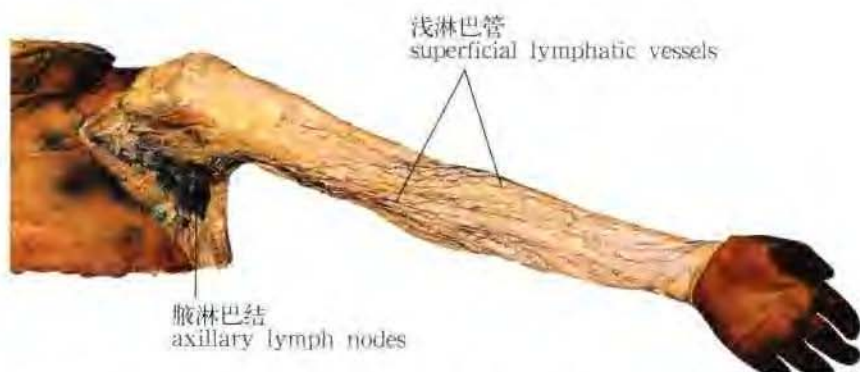


图 246 上肢淋巴管和淋巴结  
Lymphatic vessels and lymph nodes of the upper limb

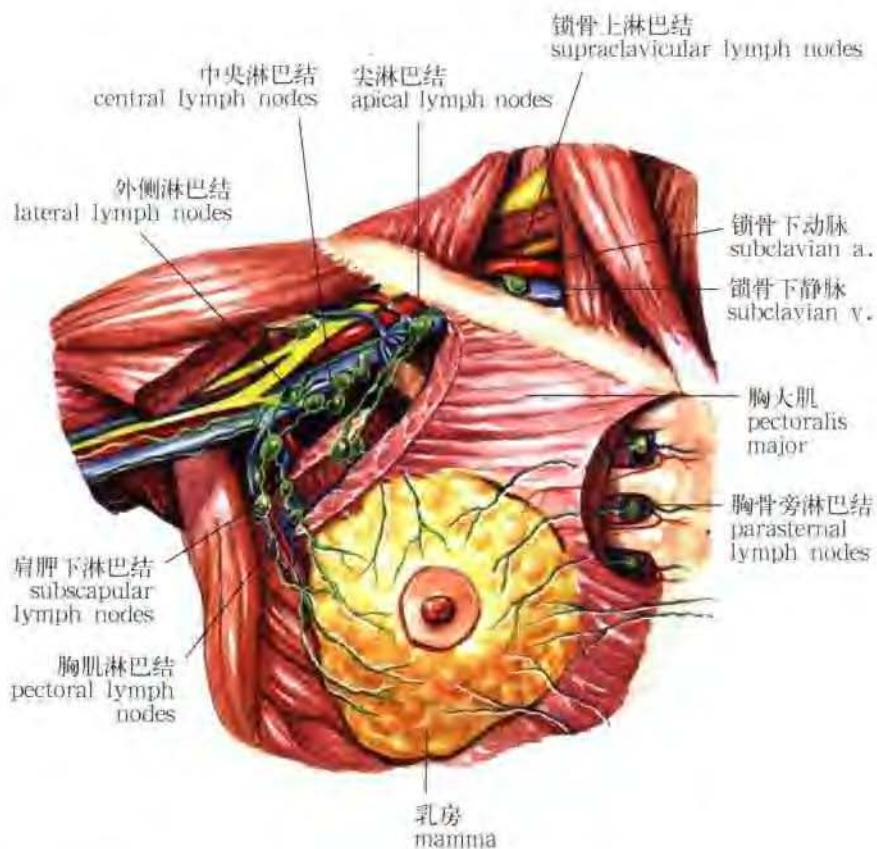


图 247 腋窝、乳房的淋巴管和淋巴结  
Lymphatic vessels and lymph nodes of the axillary fossa and mamma

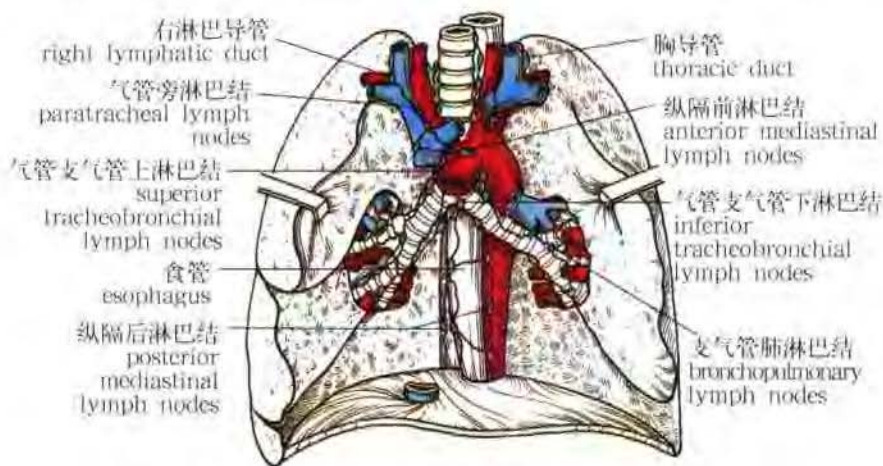


图 248 气管、支气管的淋巴管和淋巴结  
Lymphatic vessels and lymph nodes of the trachea and bronchi

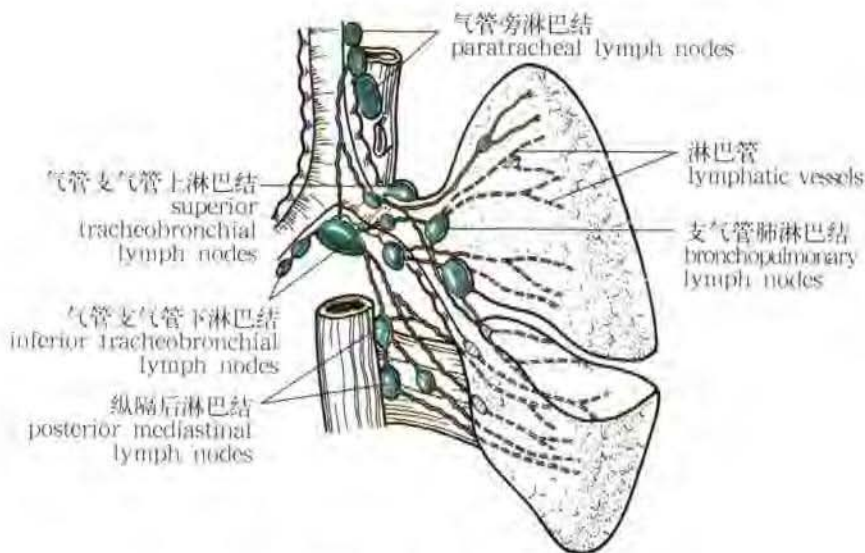


图 249 肺的淋巴引流  
Lymph drainage of the lung

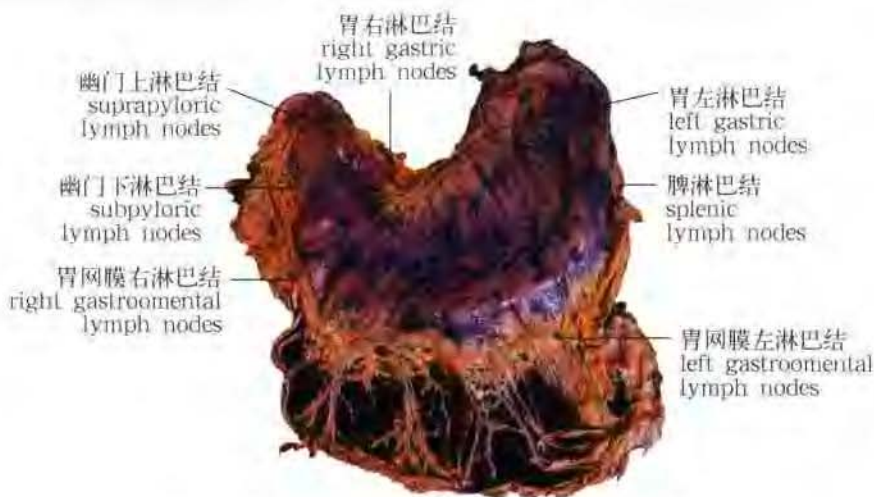


图 250 胃的淋巴管和淋巴结  
Lymphatic vessels and lymph nodes of the stomach

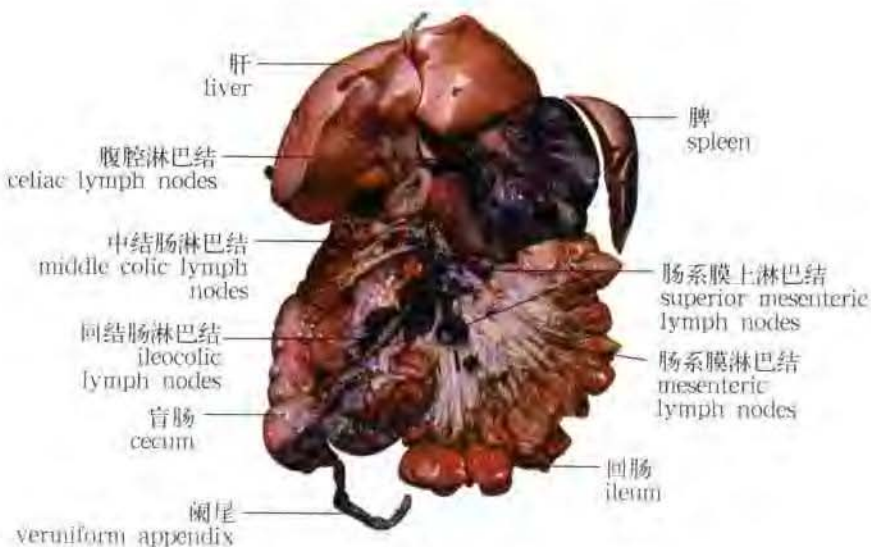


图 251 腹部器官淋巴结  
Lymph nodes of the abdominal viscera

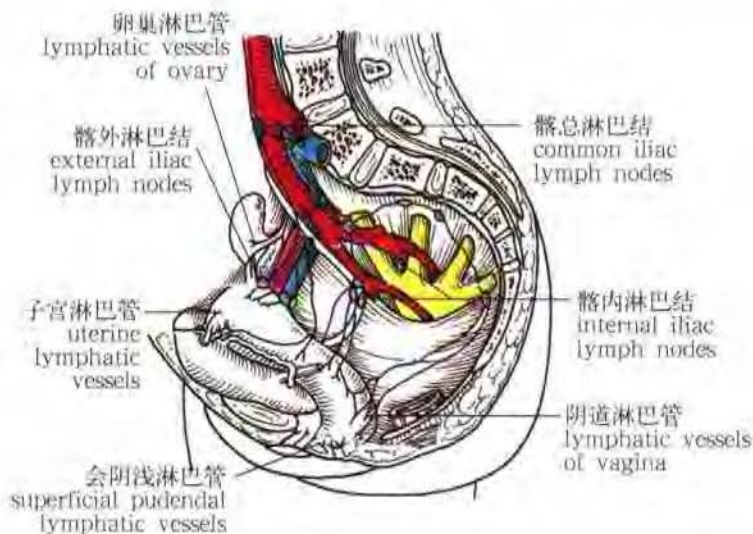


图 252 盆部淋巴管和淋巴结 (女性)  
Lymphatic vessels and lymph nodes of the pelvis (Female)

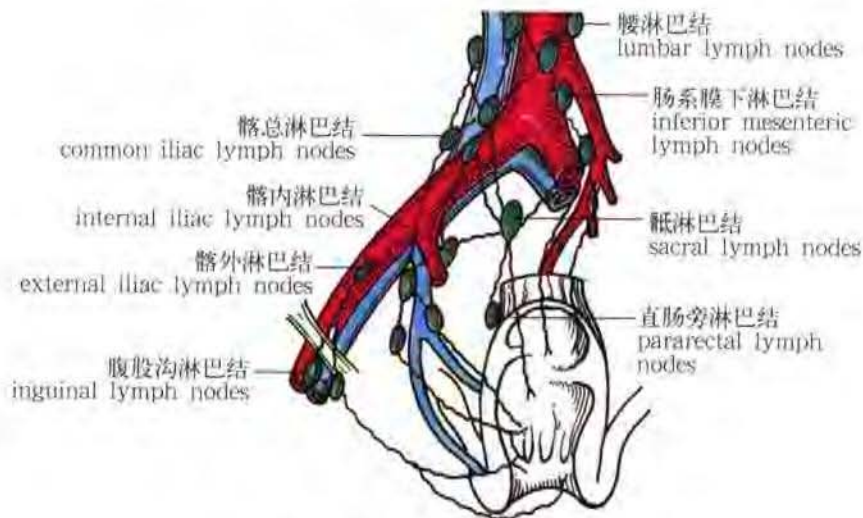


图 253 直肠的淋巴引流  
Lymph drainage of the rectum

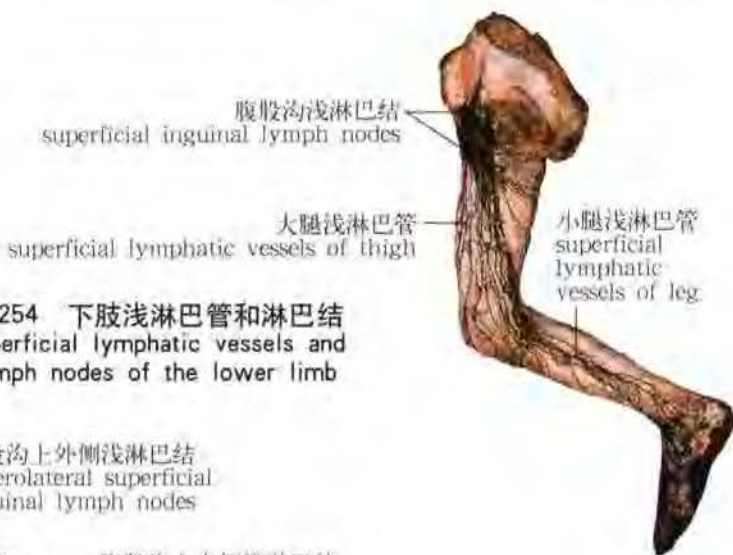

图 254 下肢浅淋巴管和淋巴结  
Superficial lymphatic vessels and lymph nodes of the lower limb

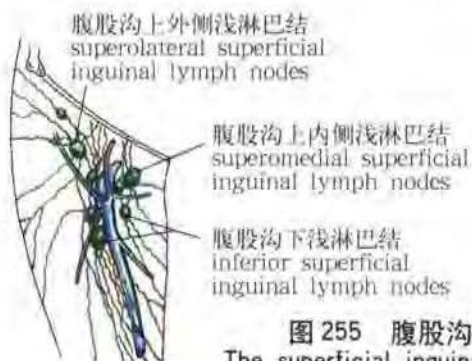


图 255 腹股沟浅淋巴结  
The superficial inguinal lymph nodes

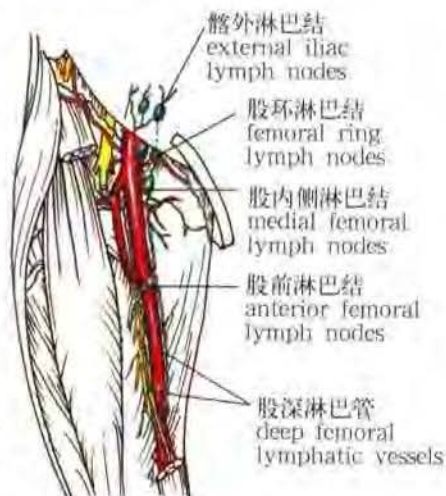


图 256 腹股沟深淋巴结  
The deep inguinal lymph nodes



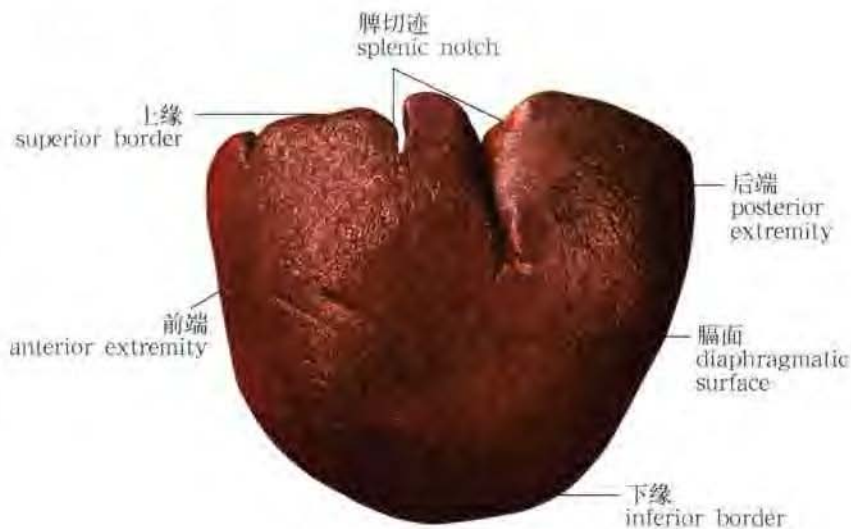


图 257 脾 (膈面观)  
The spleen (diaphragmatic aspect)

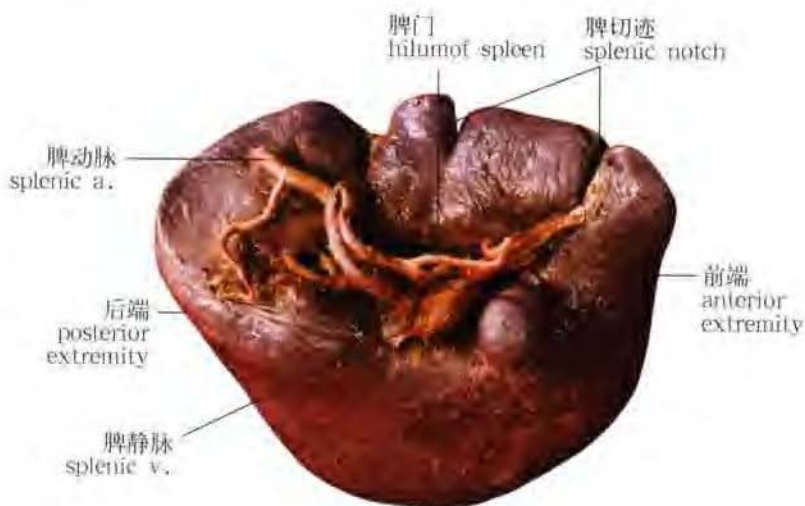


图 258 脾 (脏面观)  
The spleen (visceral aspect)

# 视器与位听器

VISUAL ORGAN AND

VESTIBULOCOCHLEAR ORGAN

# Chapter 10

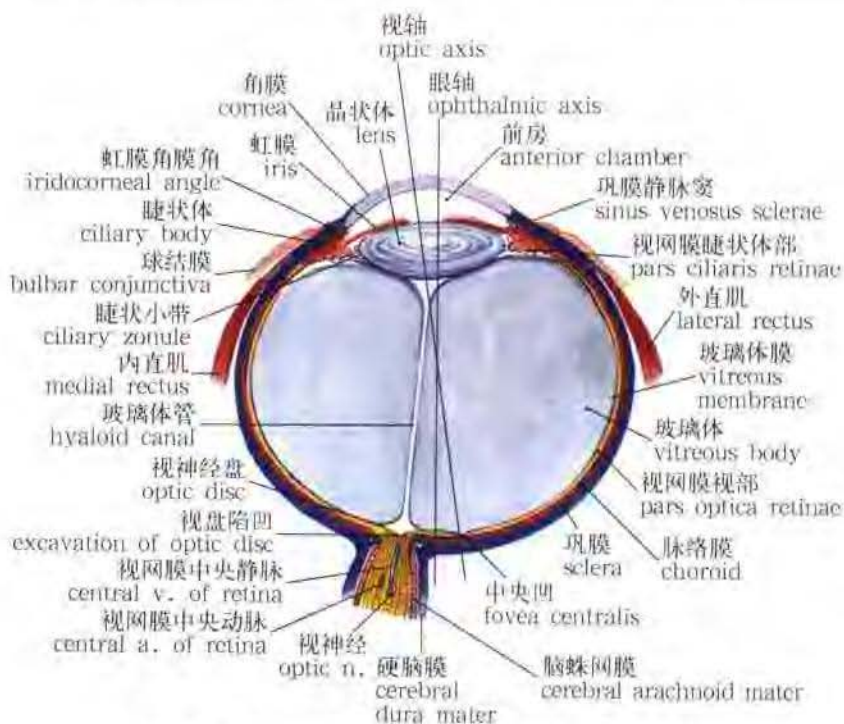


图 259 右侧眼球模式图 (水平断面)  
Diagram of the right eyeball (horizontal section)

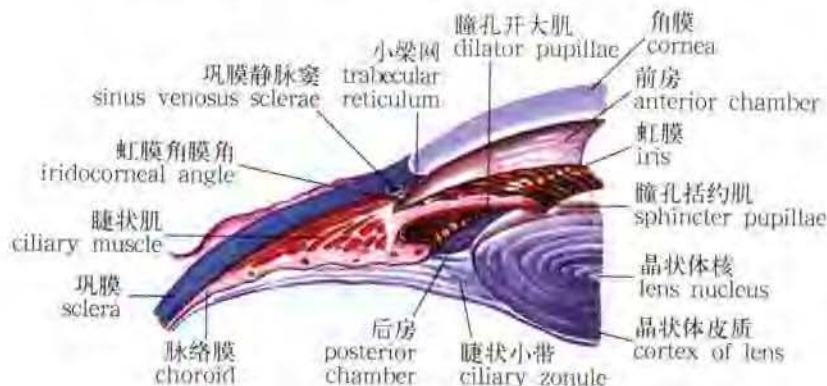


图 260 眼球前部断面图  
Diagram of the section through the anterior part of the eyeball

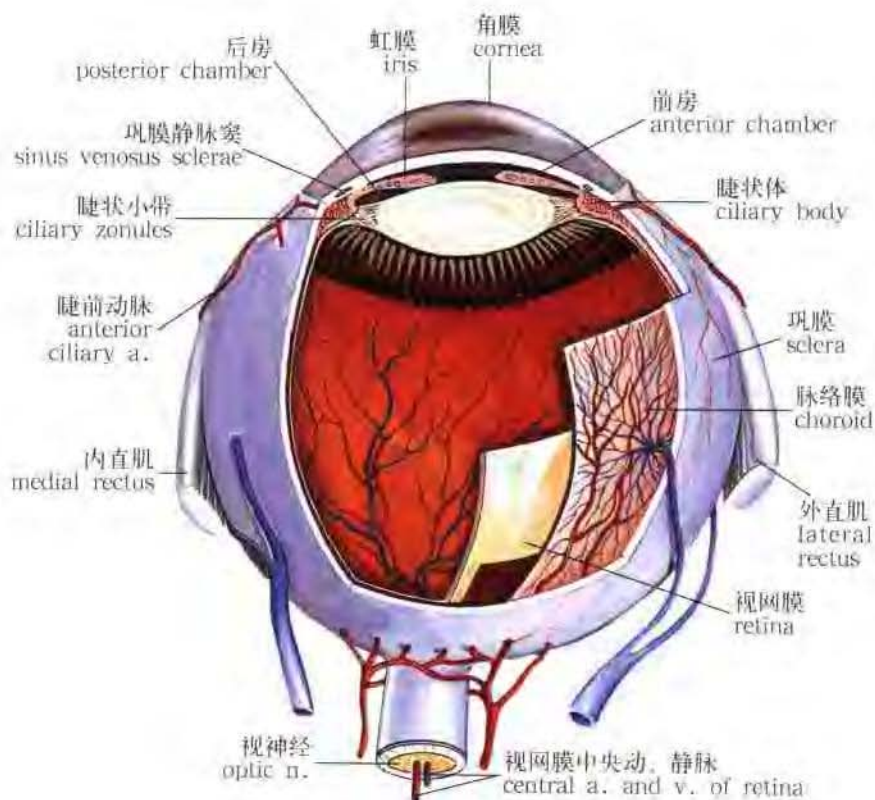


图 261 眼球壁结构模式图  
Diagram of the wall of the eyeball

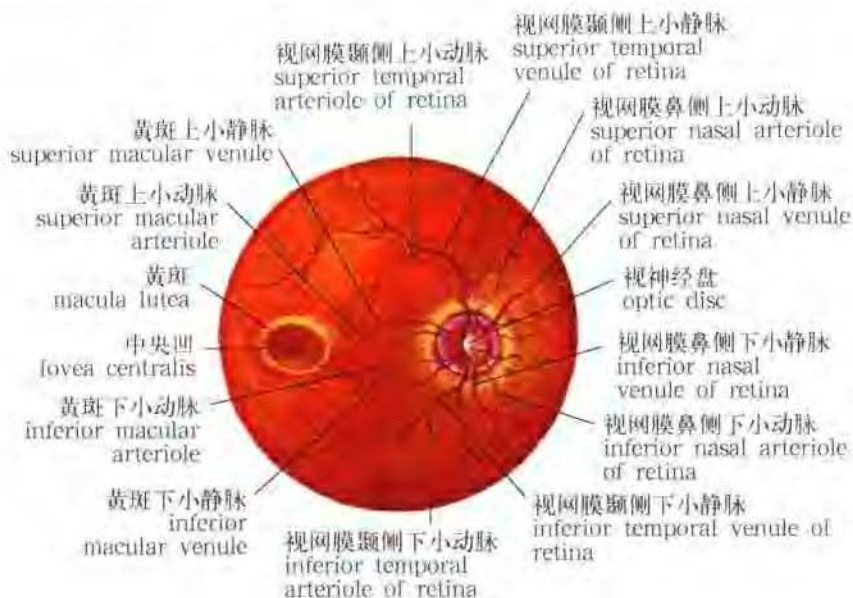


图 262 眼底图 (右侧)  
Fundus of the eyeball (right side)

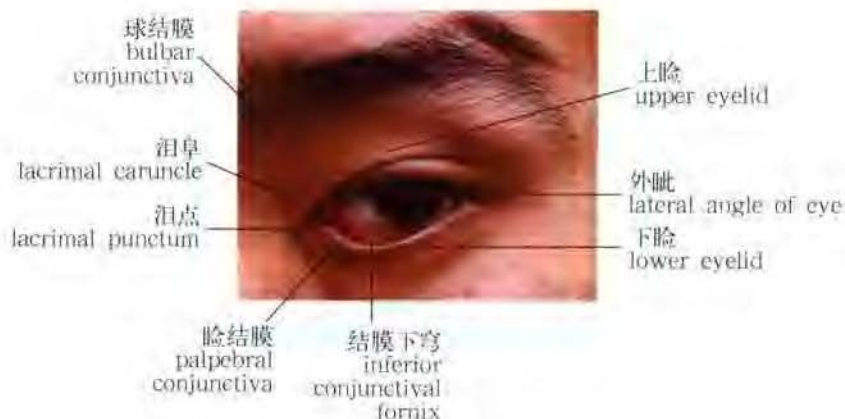

图 263 左眼 (前面观)  
The left eye (anterior aspect)

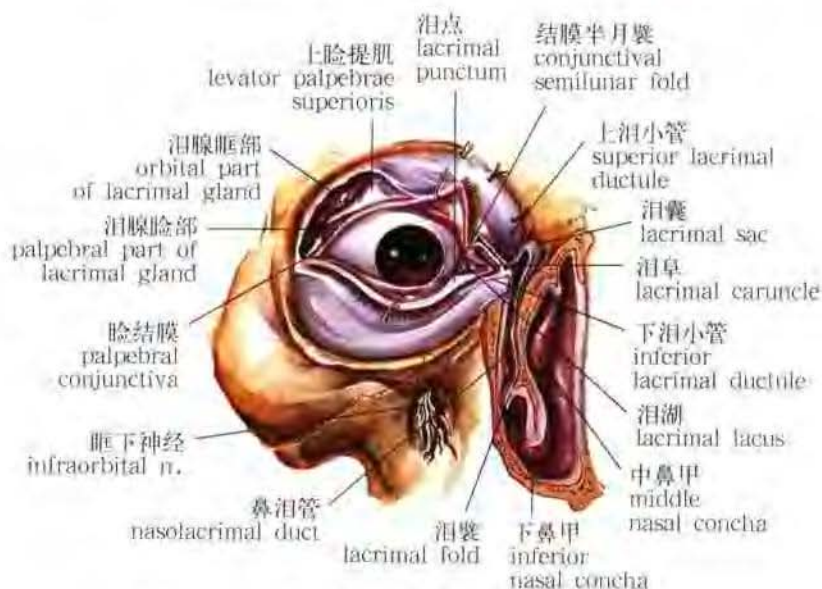


图 264 泪器模式图  
Diagram of the lacrimal apparatus

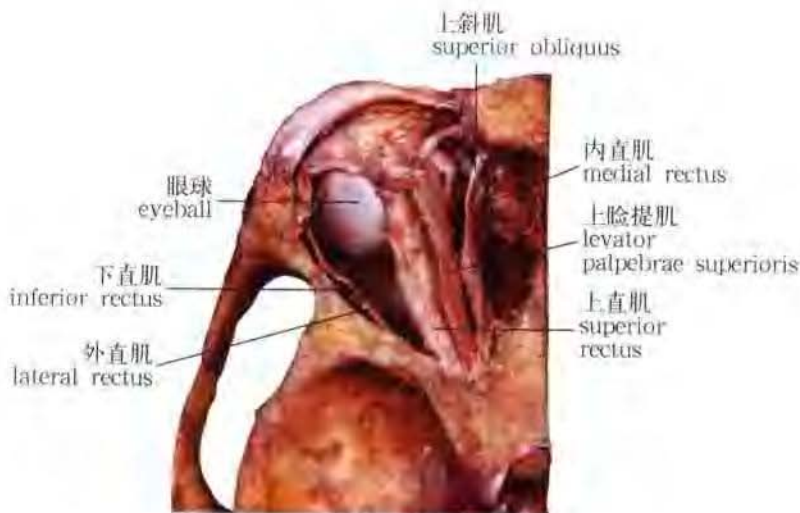


图 265 眼球外肌 (上面观)  
The extraocular muscles (superior aspect)

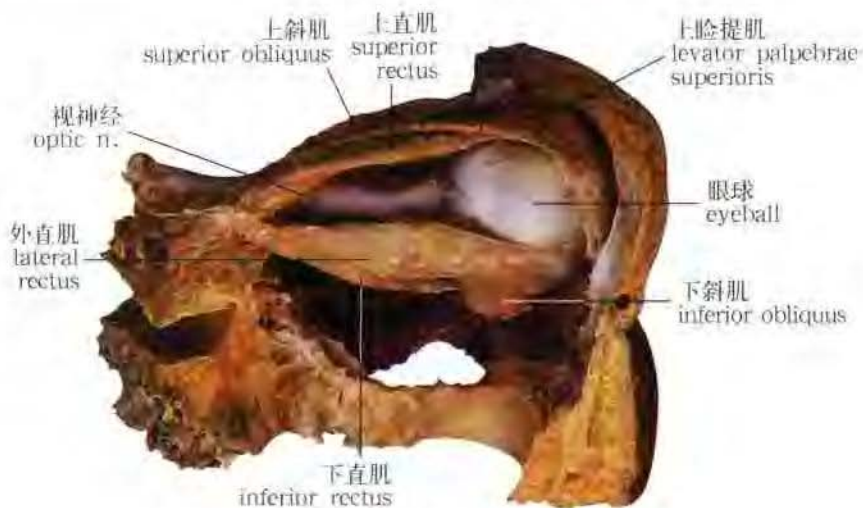


图 266 眼球外肌 (外侧面观)  
The extraocular muscles (lateral aspect)

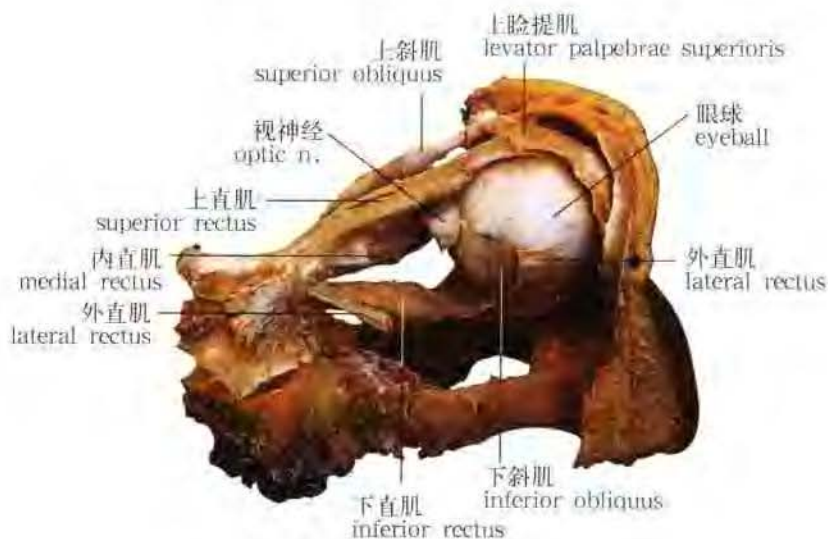

图 267 眼球外肌 (内侧面观)  
The extraocular muscles (medial aspect)

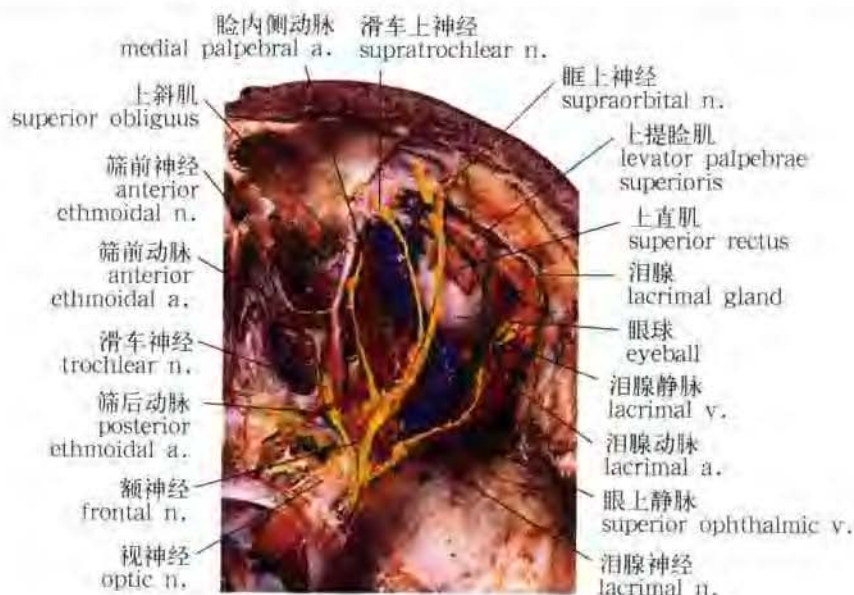


图 268 眼的血管、神经  
Blood vessels and nerves of the eye

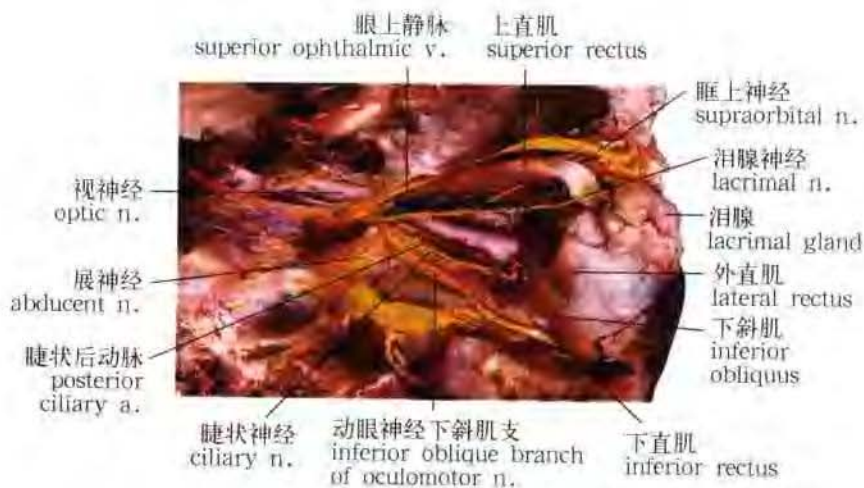

图 269 眼的肌肉、血管、神经  
Muscles, blood vessels and nerves of the eye



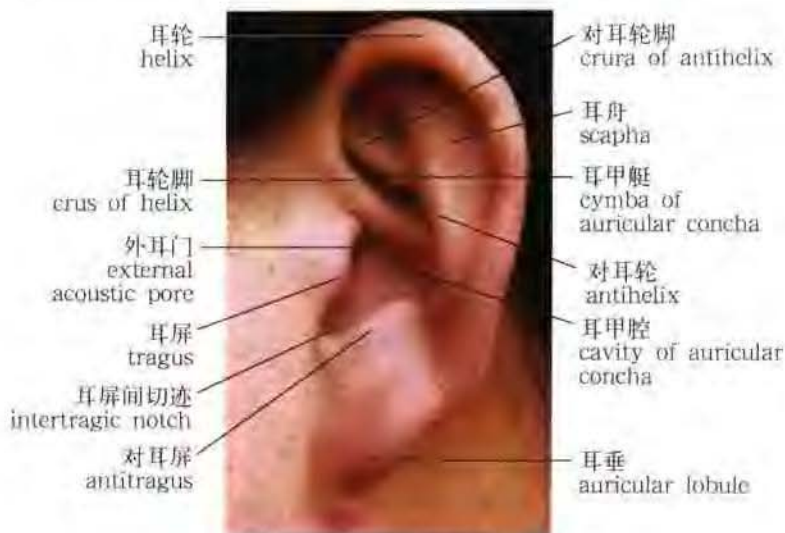

图 270 耳郭 (外侧面观)  
The auricle (lateral aspect)

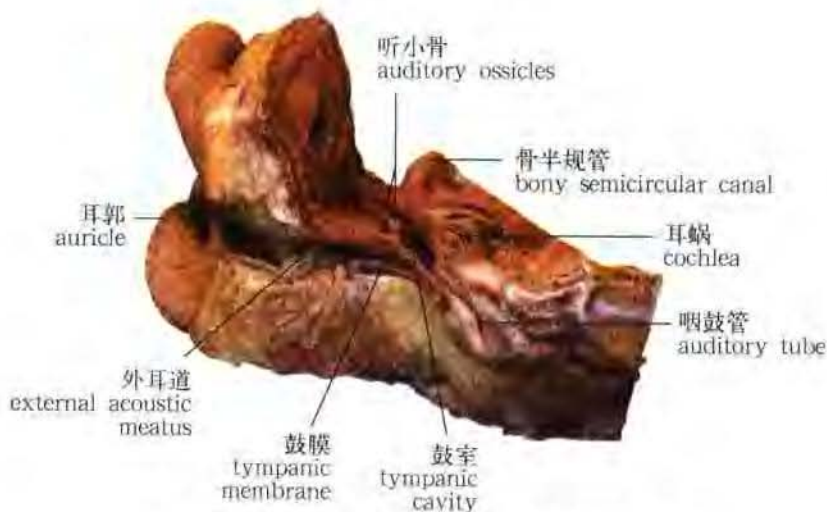


图 271 前庭蜗器概观 (前外侧面观)  
General arrangement of the vestibulocochlear organ  
(anterolateral aspect)

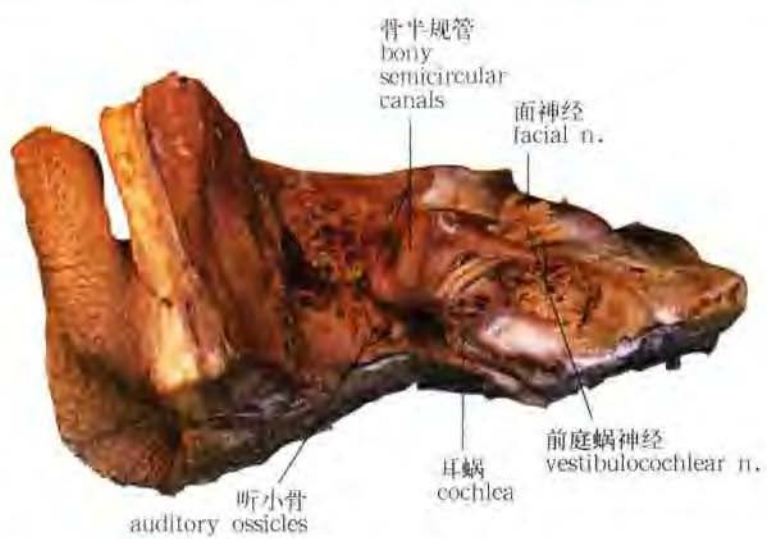


图 272 前庭蜗器概观 (上面观)  
General arrangement of the vestibulocochlear organ (superior aspect)

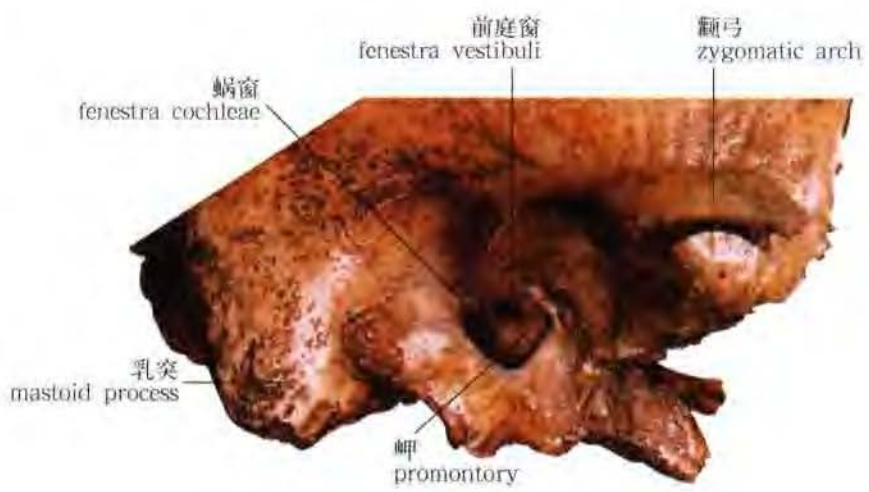

图 273 鼓室内侧壁 (1)  
Medial wall of the tympanic cavity (1)

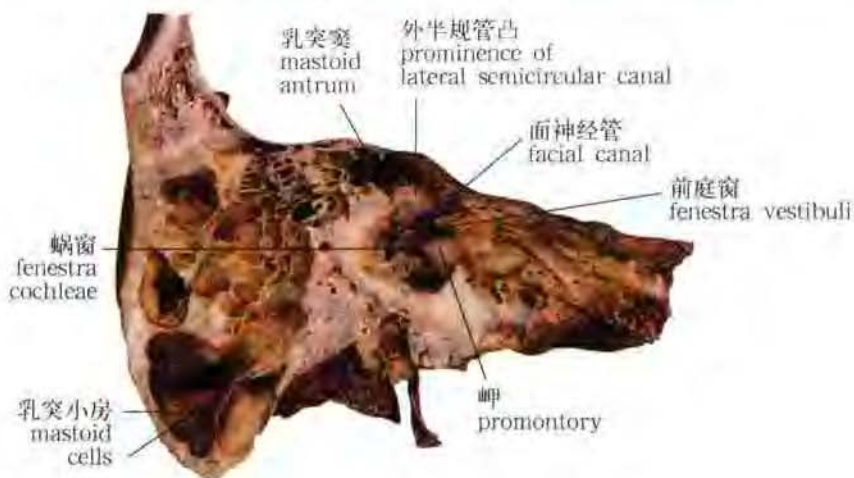


图 274 鼓室内侧壁 (2)  
Medial wall of the tympanic cavity (2)

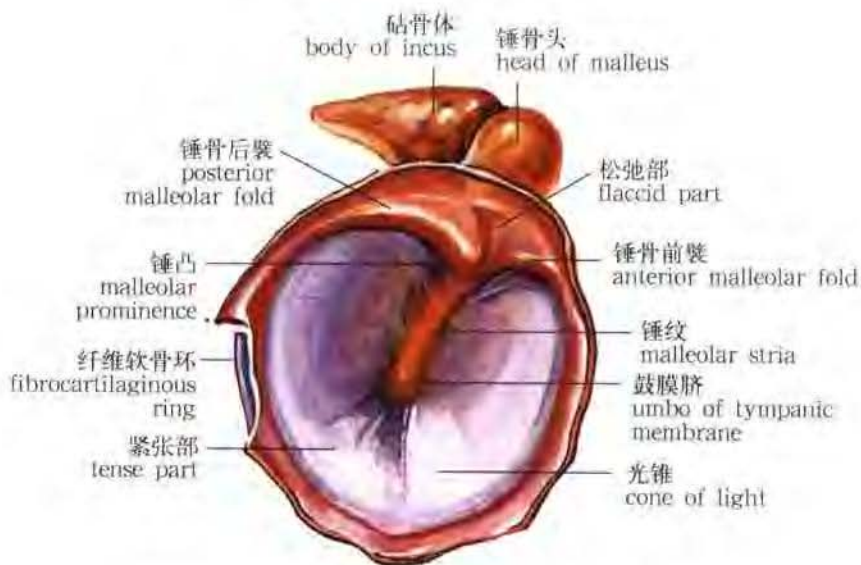


图 275 鼓膜模式图 (外侧观)  
Diagram of the tympanic membrane (outer view)

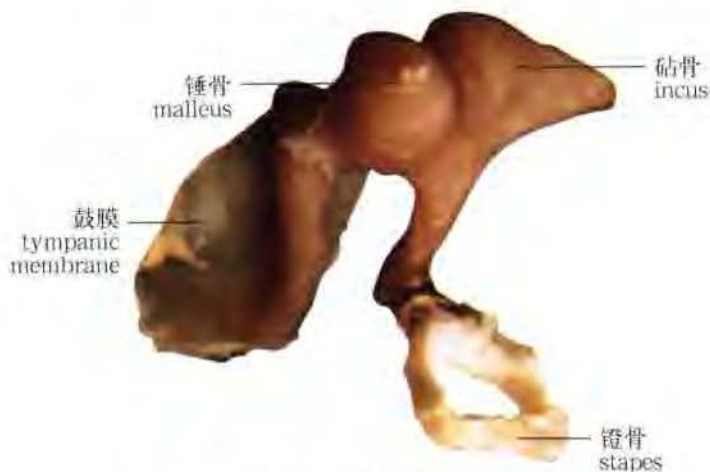

图 276 听小骨链  
The chain of the auditory ossicles

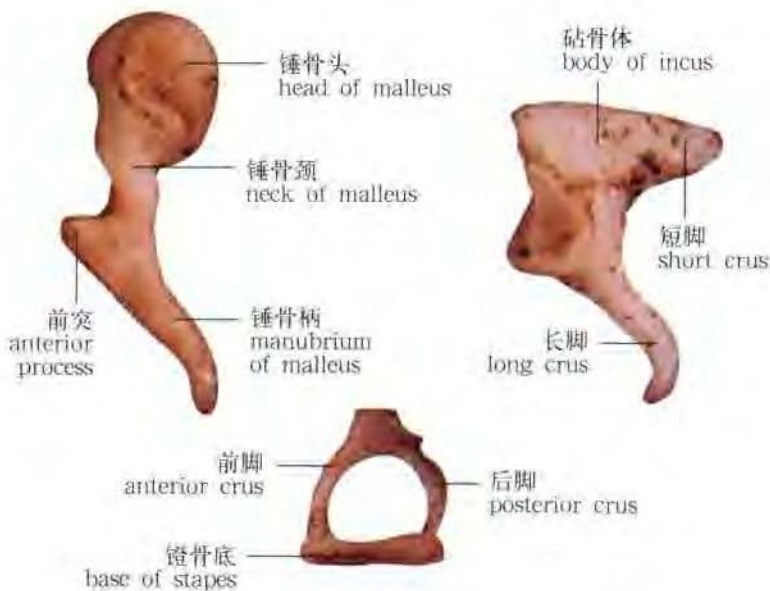

图 277 听小骨  
The auditory ossicles

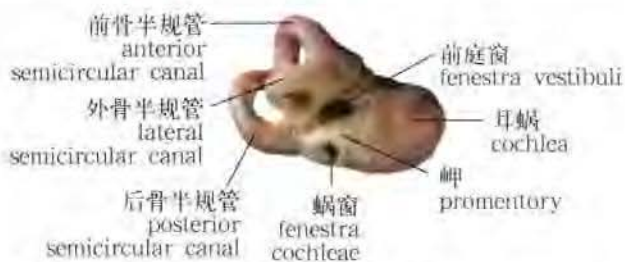


图 278 右耳骨迷路 (1)  
The bony labyrinth of the right ear (1)

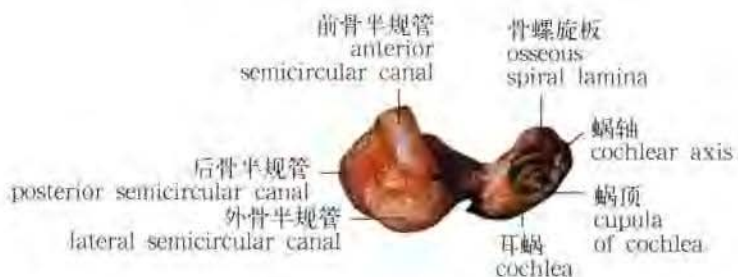

图 279 右耳骨迷路 (2)  
The bony labyrinth of the right ear (2)

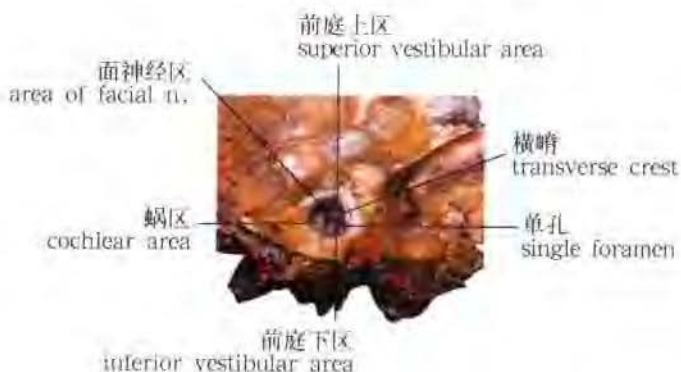

图 280 内耳道底  
The fundus of the internal acoustic meatus

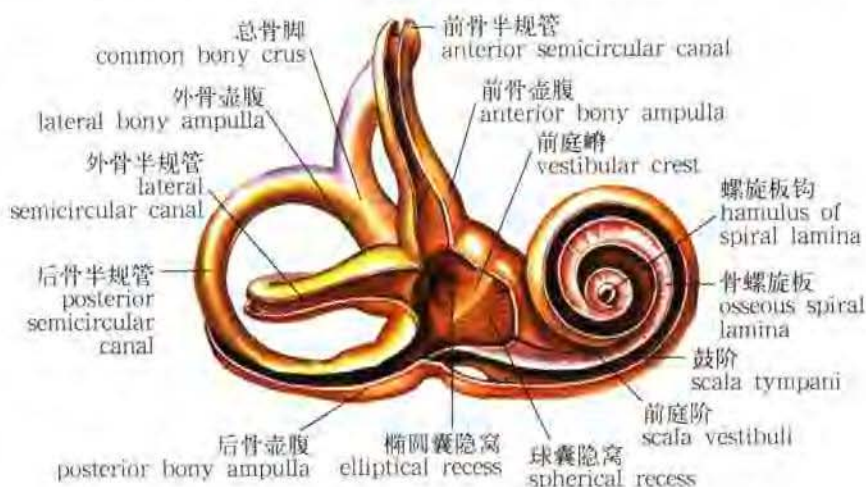

图 281 骨迷路模式图  
Diagram of the bony labyrinth

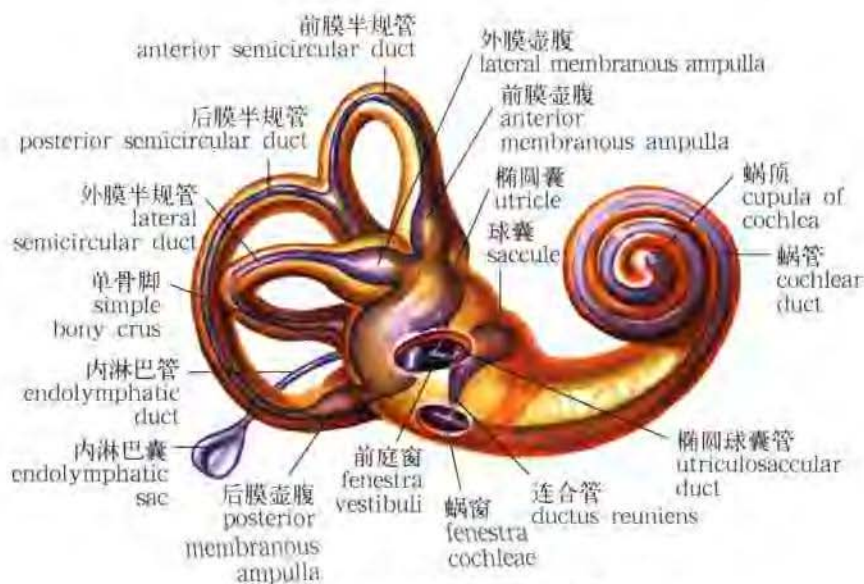


图 282 骨迷路与膜迷路模式图  
Diagram of the bony and membranous labyrinth

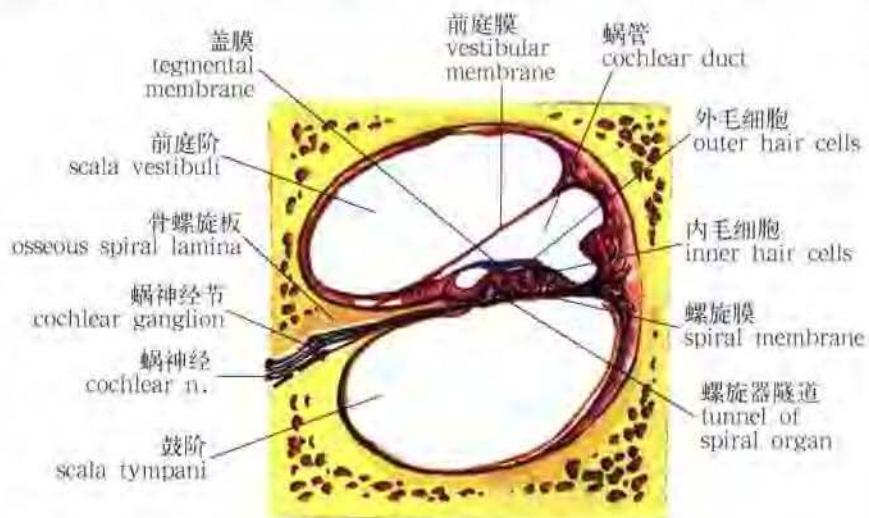


图 283 螺旋器模式图 (横断面)  
Diagram of the spiral organ (transverse section)

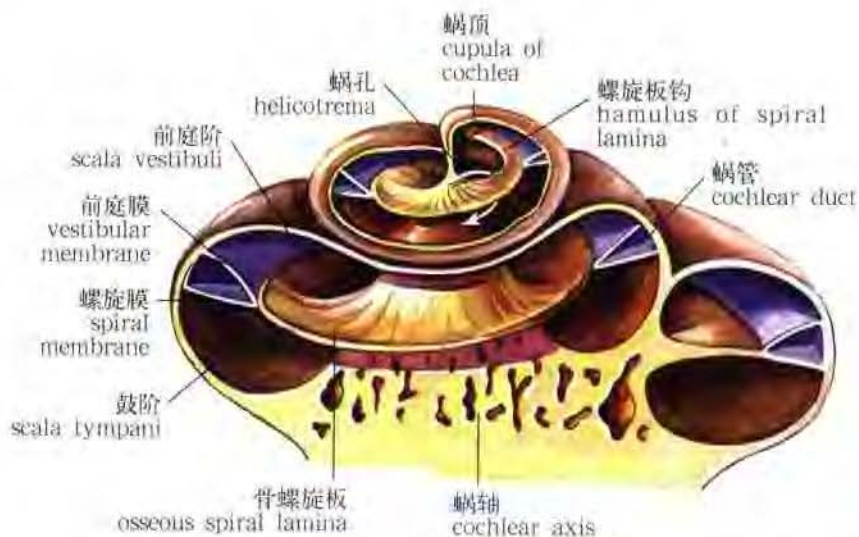

图 284 耳蜗模式图  
Diagram of the cochlea

# 内分泌系统

ENDOCRINE SYSTEM

# Chapter 11



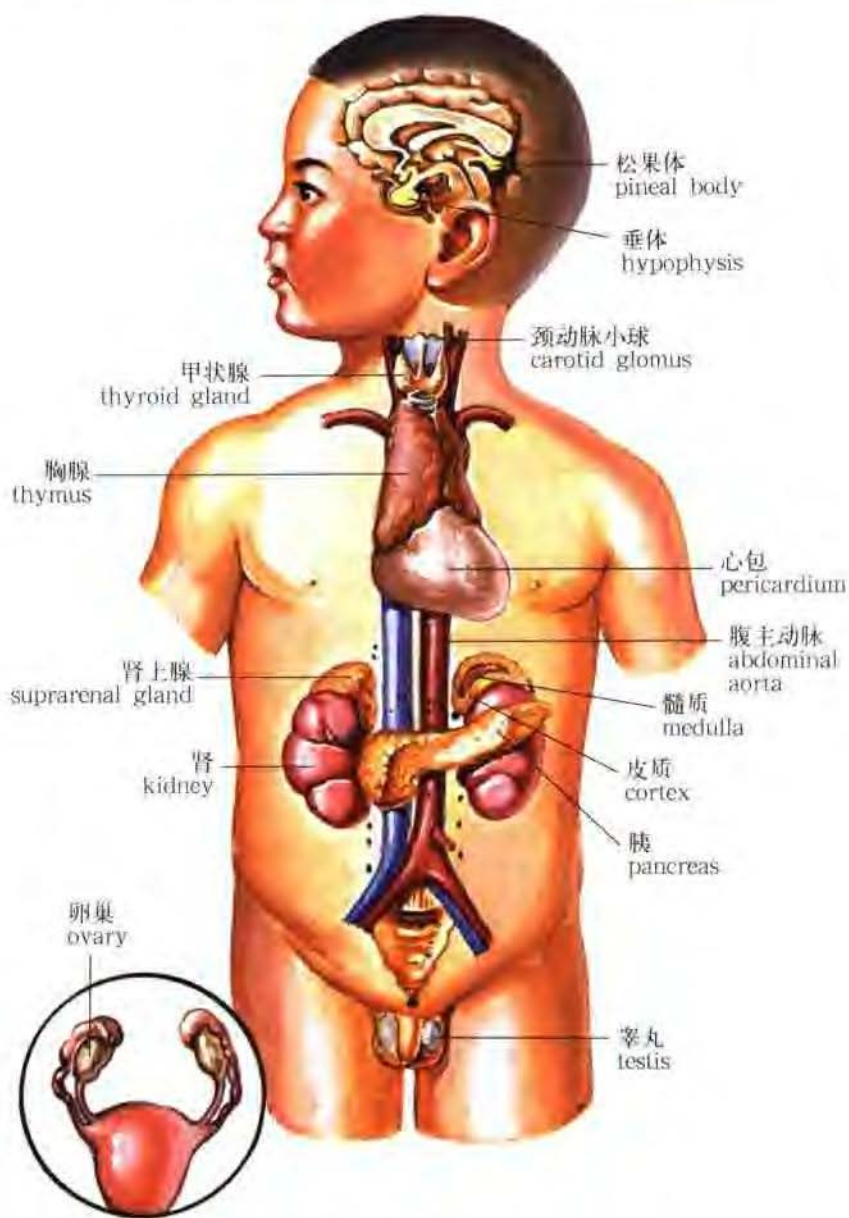


图 285 内分泌腺  
The endocrine glands

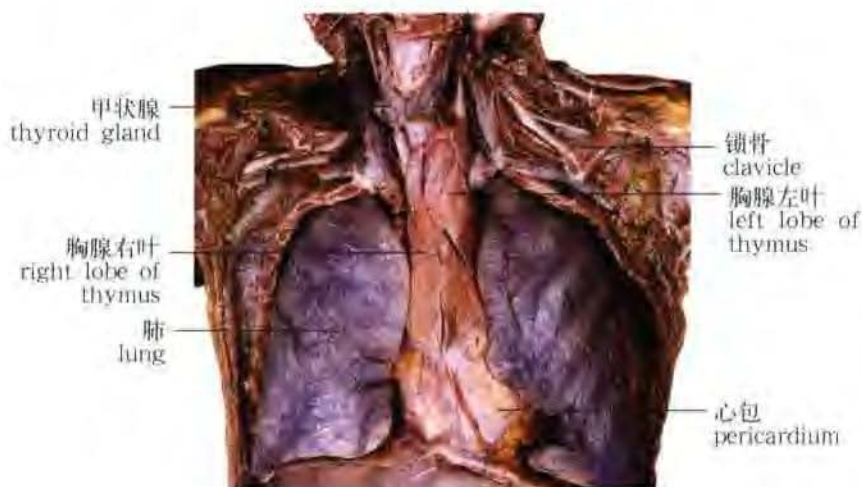

图 286 胸腺和甲状腺  
Thymus and thyroid gland

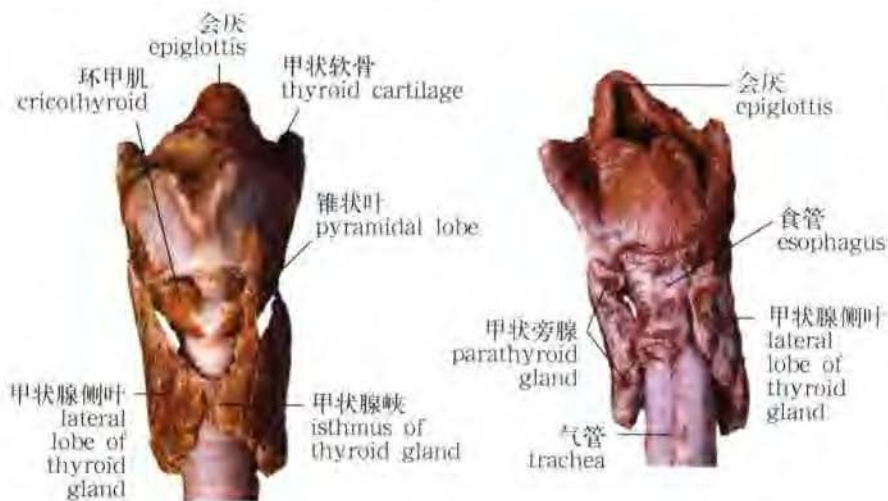

图 287 甲状腺 (前面观)  
The thyroid gland  
(anterior aspect)

图 288 甲状腺 (后面观)  
The thyroid gland  
(posterior aspect)



# 神经系统——中枢神经

NERVOUS SYSTEM——CENTRAL NERVE

# Chapter 12

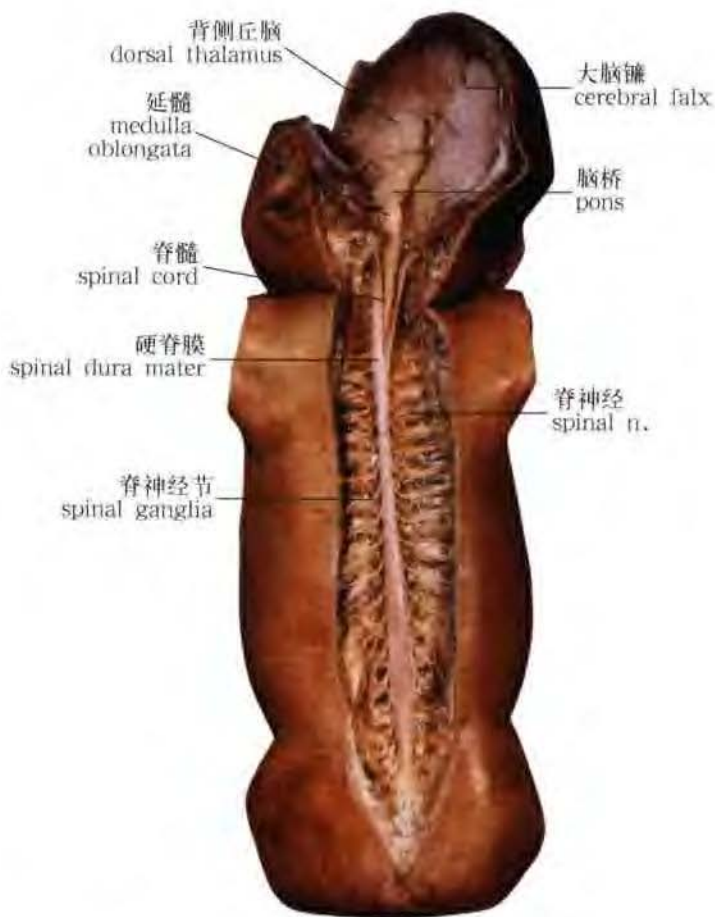

图 289 婴儿脊髓和脊神经 (后面观)  
Spinal cord and nerves in the fetus (posterior aspect)

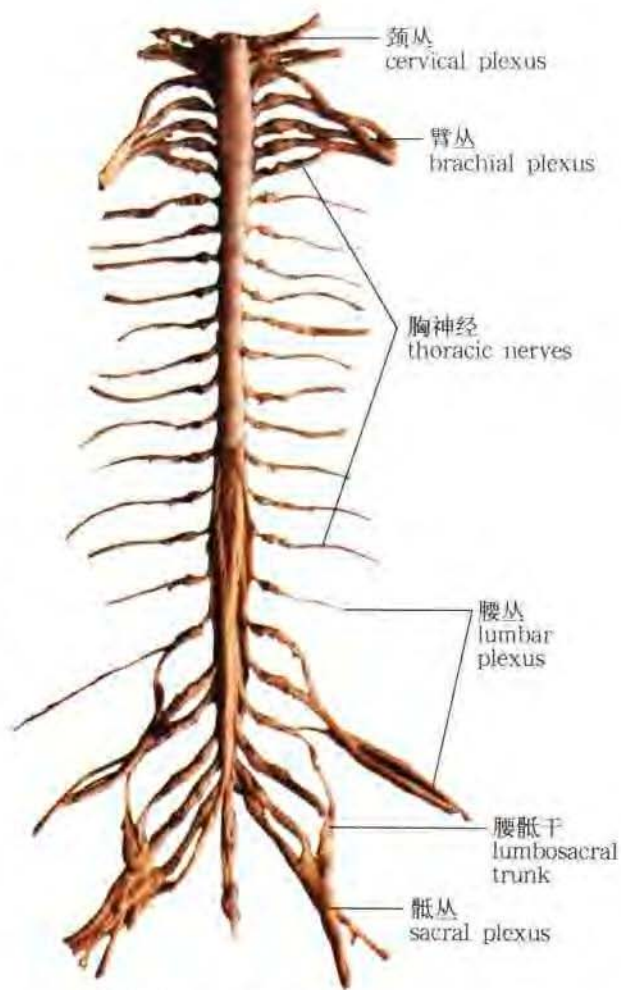


图 290 脊髓和脊神经  
The spinal cord and nerves

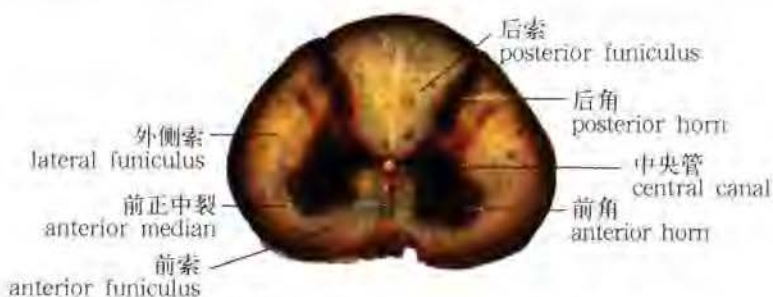


图 291 颈段脊髓 (横切面)  
Spinal cord of the cervical region (transverse section)

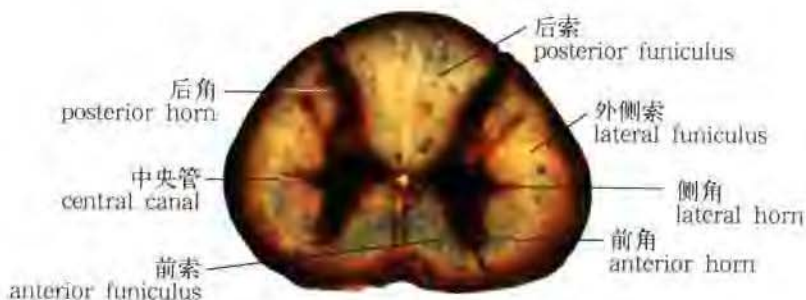


图 292 胸段脊髓 (横切面)  
Spinal cord of the thoracic region (transverse section)

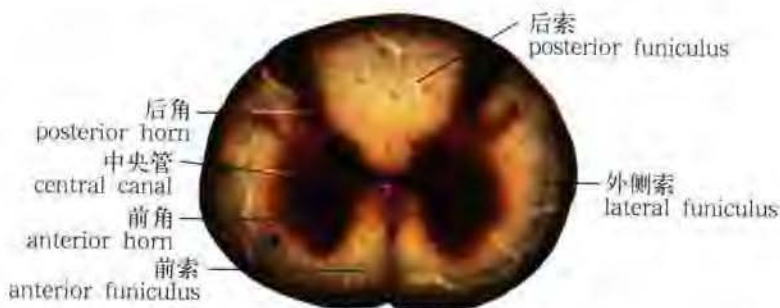


图 293 腰段脊髓 (横切面)  
Spinal cord of the lumbar region (transverse section)

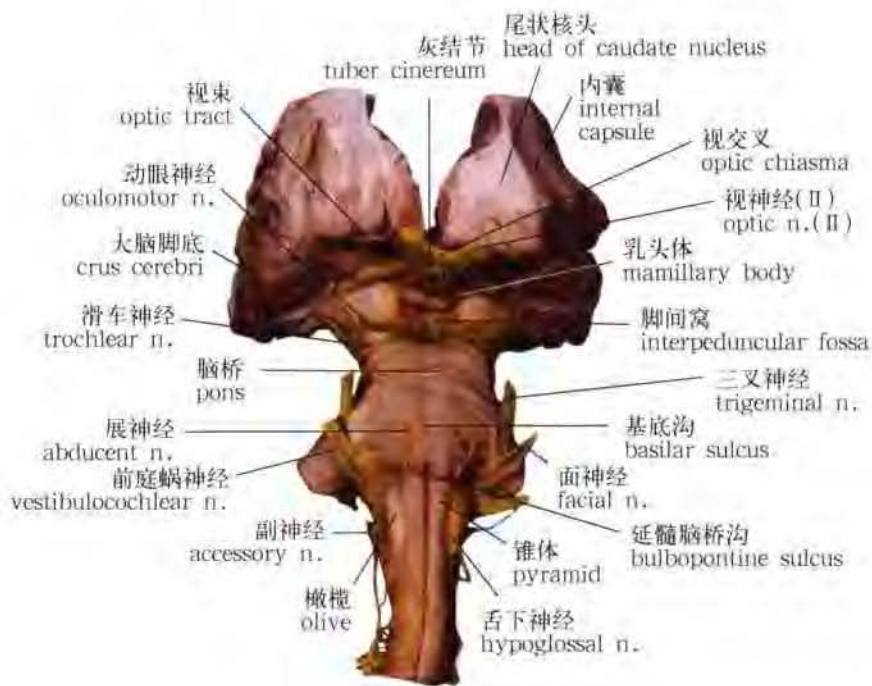


图 294 脑干(腹面观)  
The brain stem(ventral aspect)

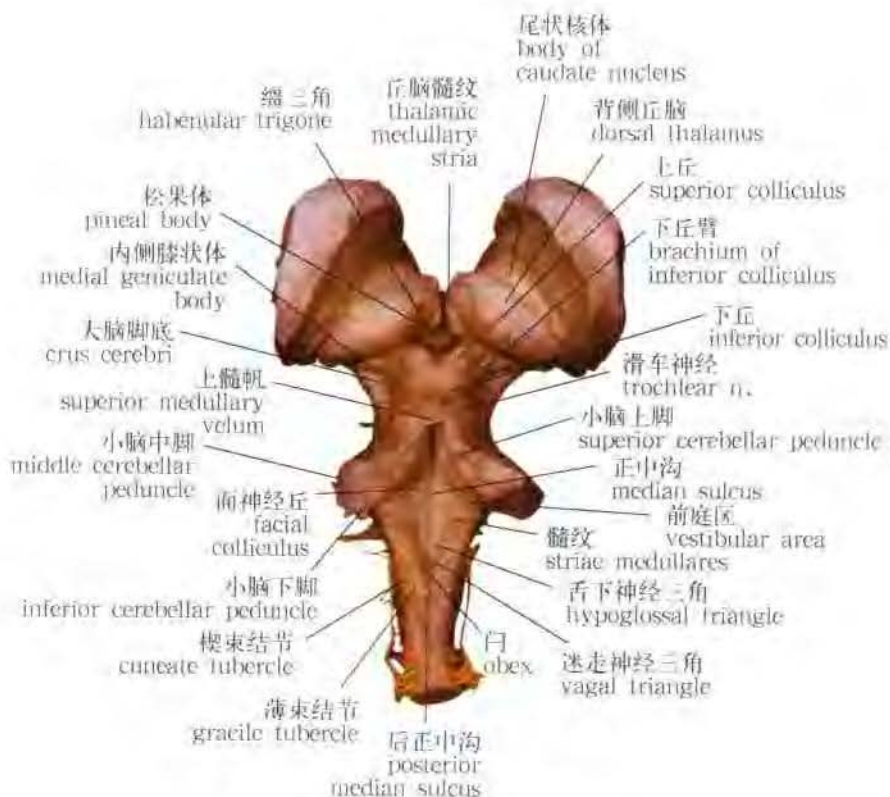

图 295 脑干(背面观)  
The brain stem (dorsal aspect)



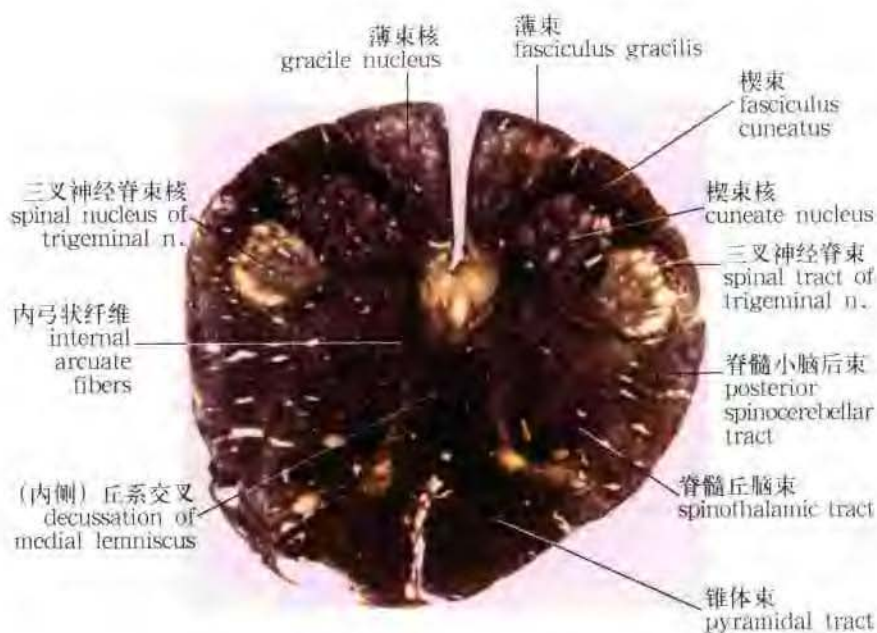

图 296 延髓横切面 (经丘系交叉)  
Transverse section of the medulla oblongata  
through the decussation of medial lemniscus

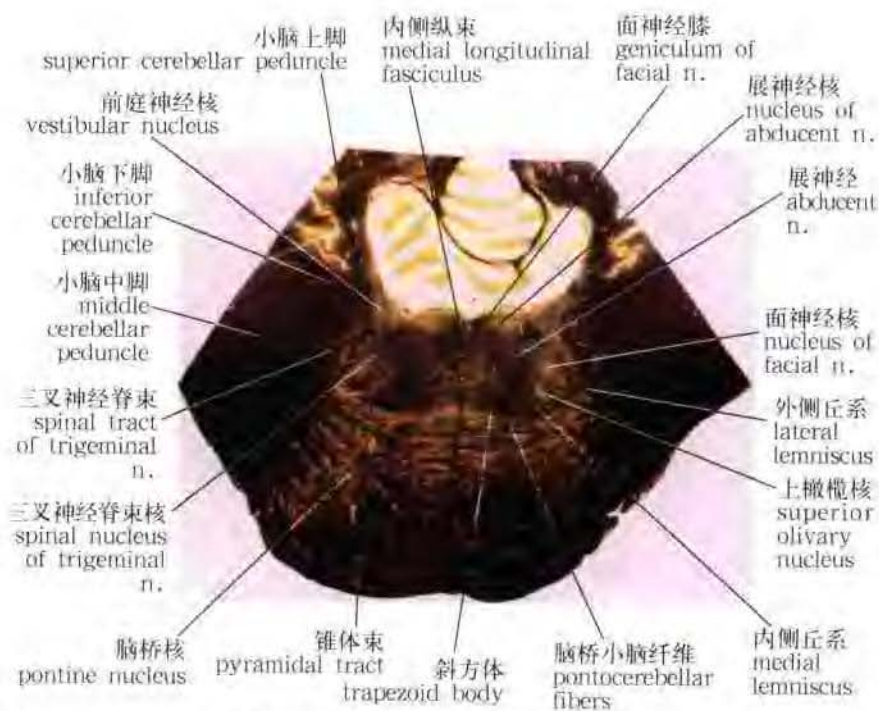


图 297 脑桥横切面 (面神经丘水平)  
Transverse section of the pons at the level of the facial colliculus

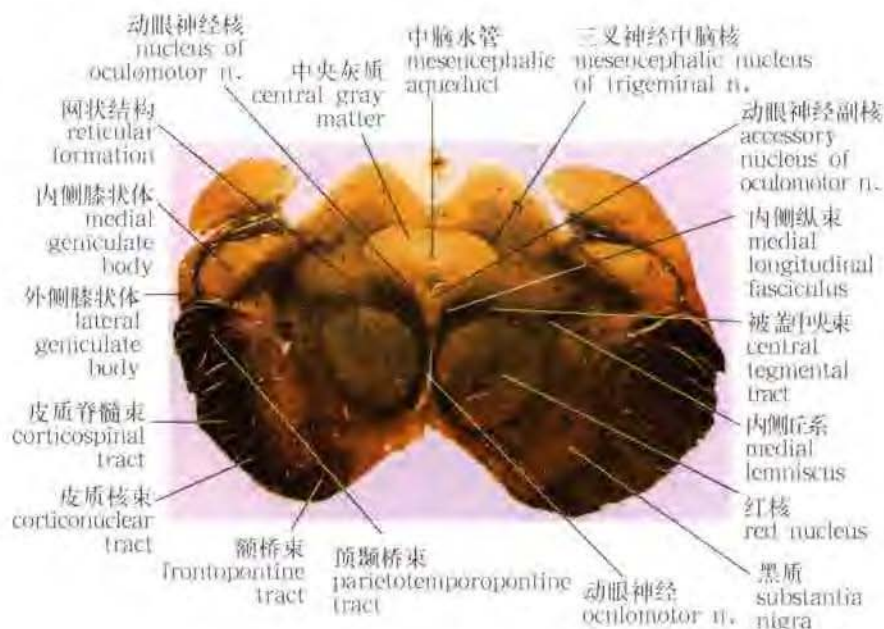


图 298 中脑横切面 (上丘水平)  
 Transverse section of the midbrain at the level of the superior colliculus

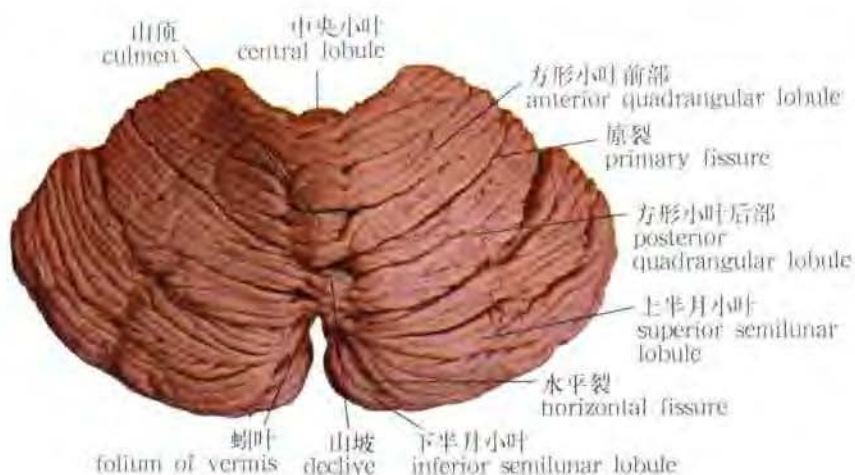


图 299 小脑(上面观)  
The cerebellum (superior aspect)

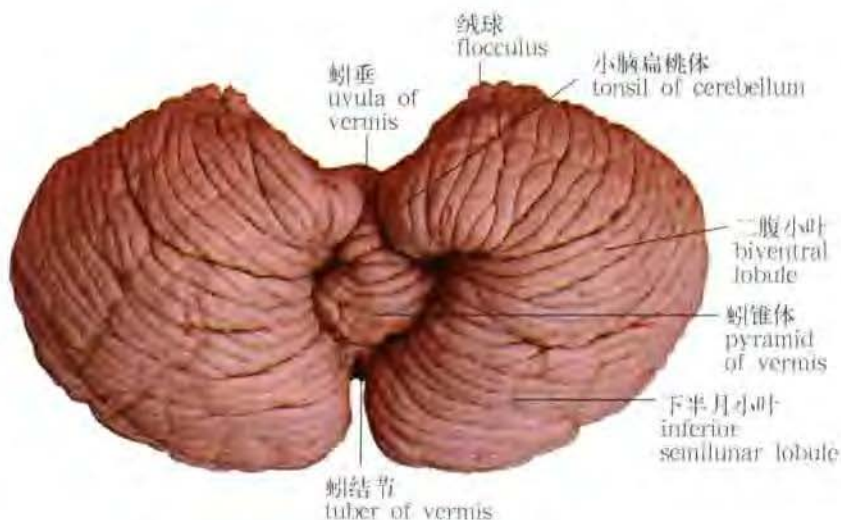


图 300 小脑(下后面观)  
The cerebellum (postero-inferior aspect)

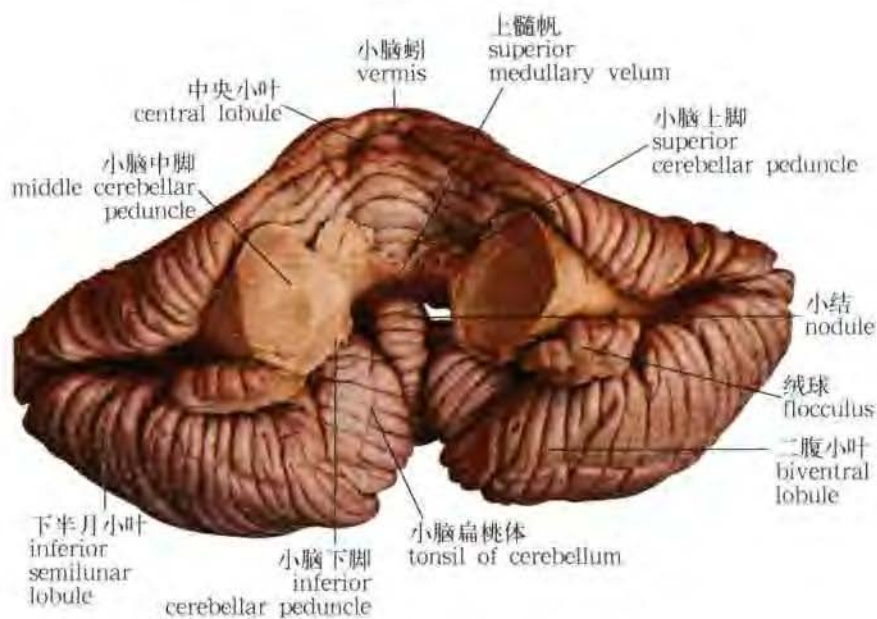


图 301 小脑 (下前面观)  
The cerebellum (anteroinferior aspect)

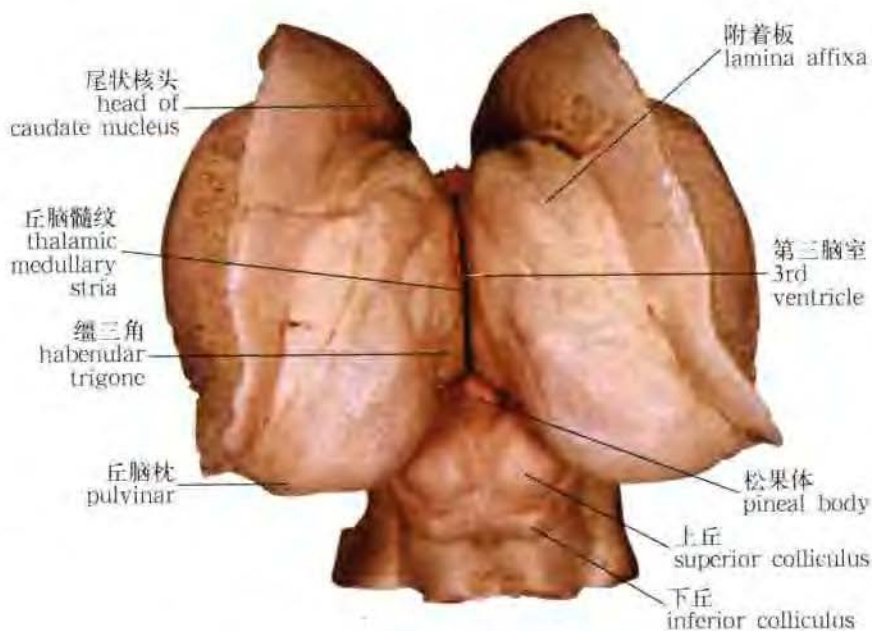


图 302 间脑 (背面观)  
The diencephalon (dorsal aspect)

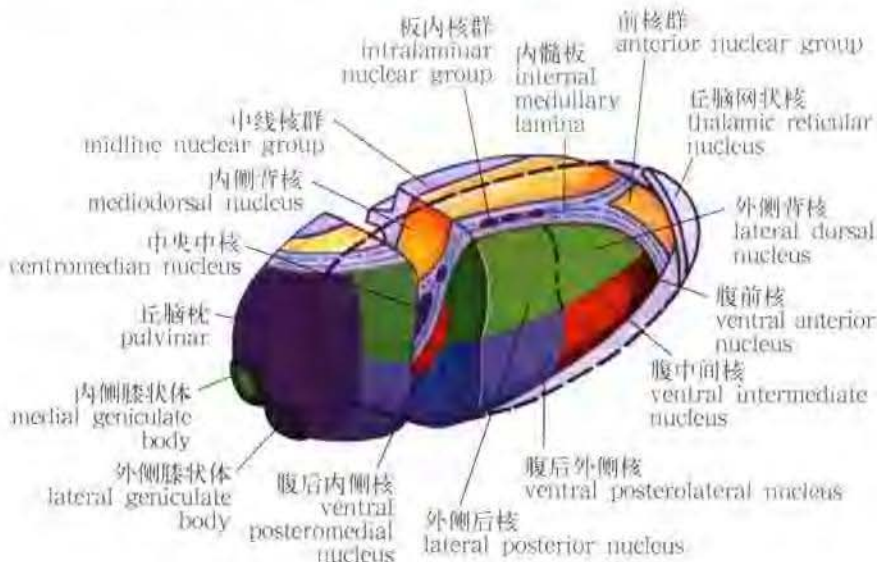


图 303 丘脑核团模式图  
Diagram of the thalamic nuclei

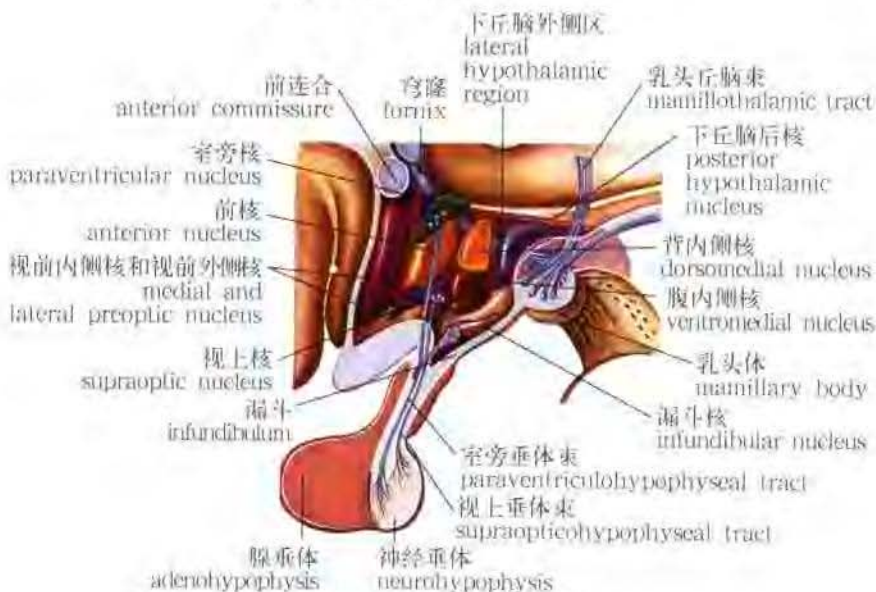


图 304 下丘脑核团模式图  
Diagram of the hypothalamic nuclei

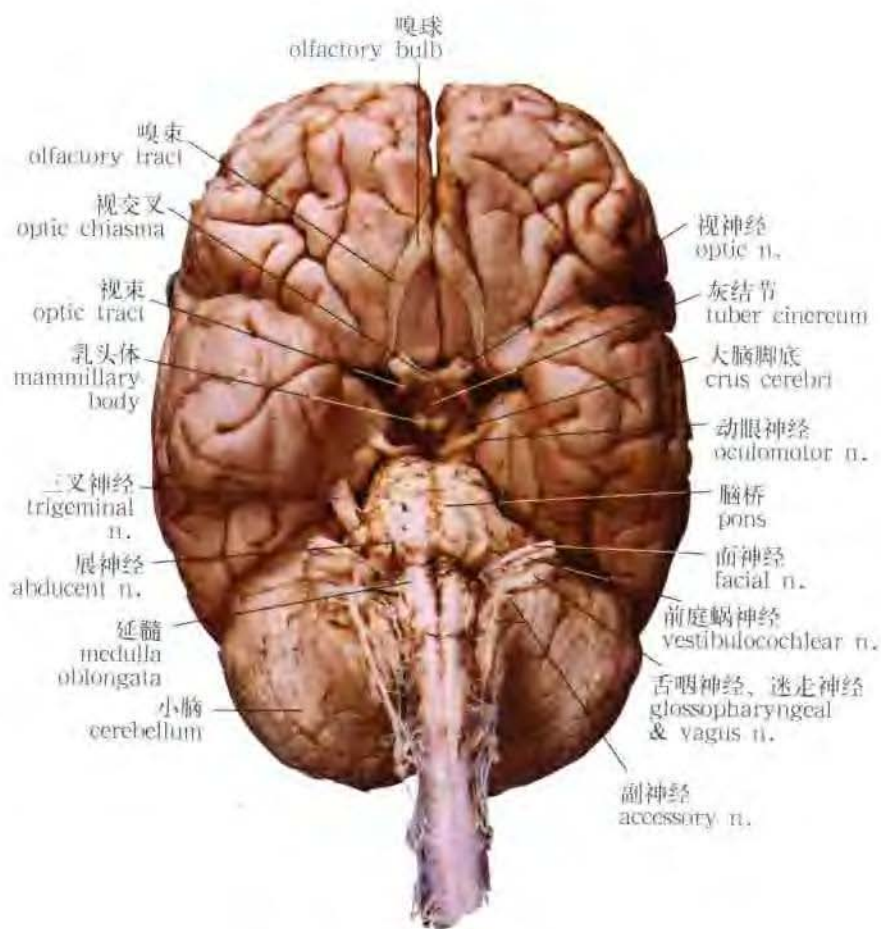


图 305 脑 (底面观)  
The brain (basal aspect)



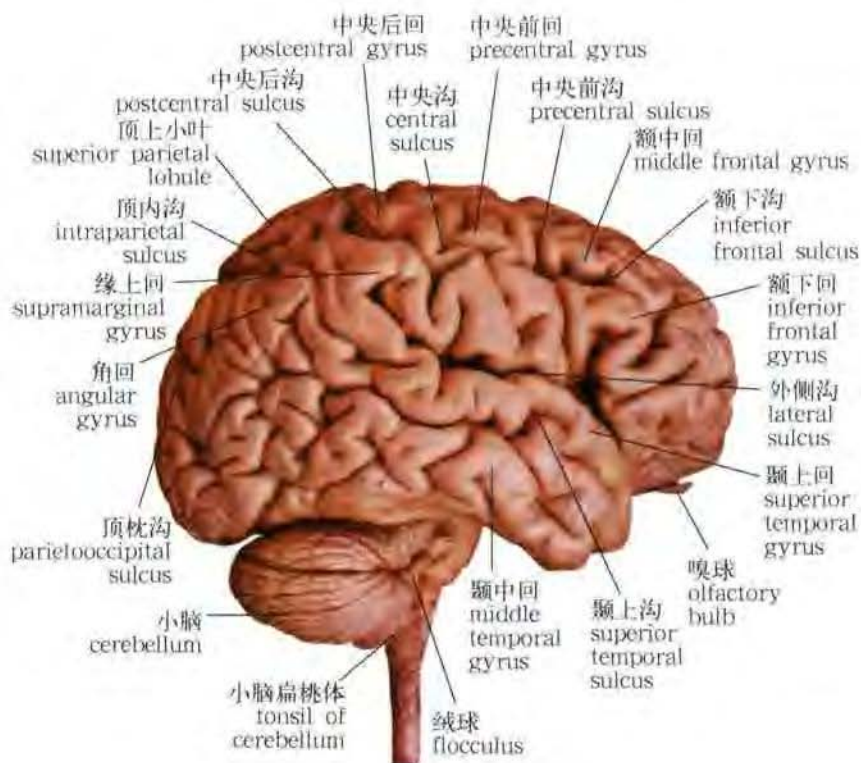

图 306 脑 (外侧面观)  
The brain (lateral aspect)

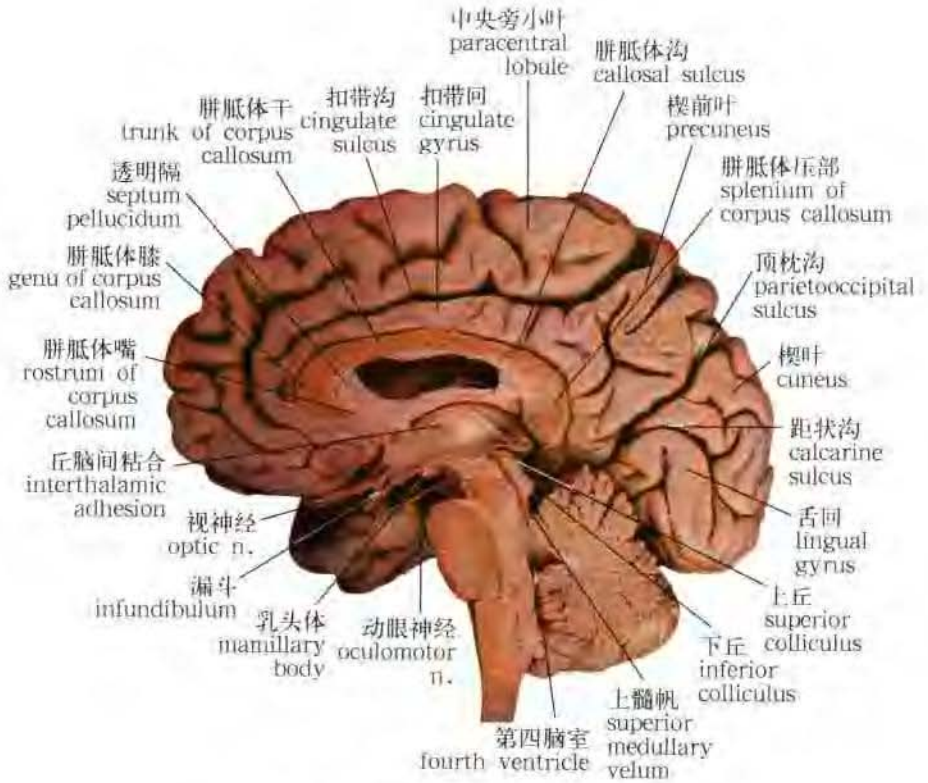

图 307 脑 (正中矢状切面)  
The brain (median sagittal section)

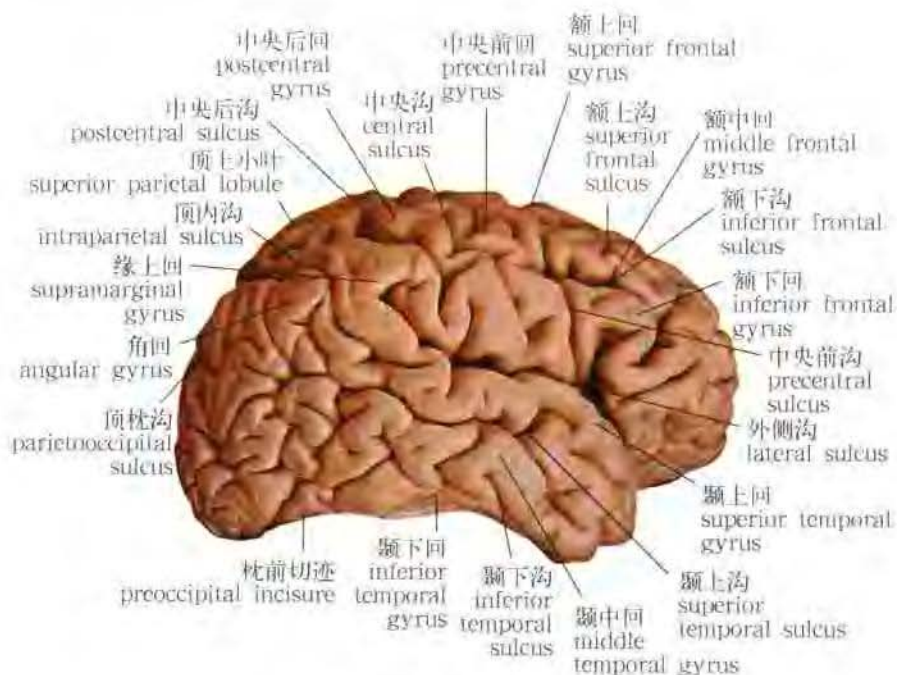


图 308 大脑半球 (上外侧面观)  
The cerebral hemisphere (superolateral aspect)

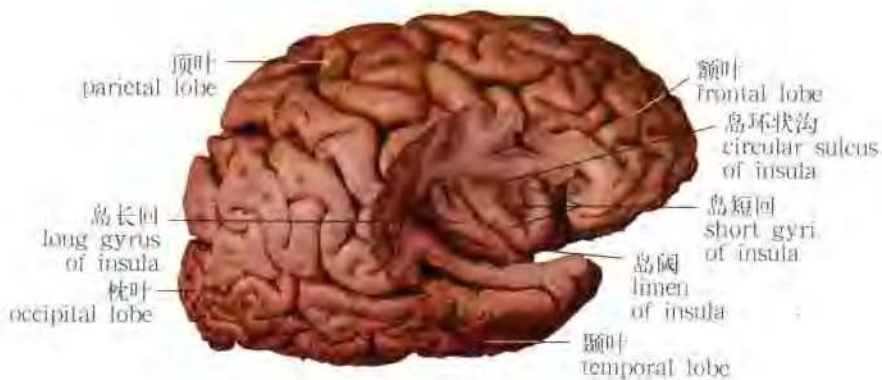

图 309 岛叶  
The insular lobe

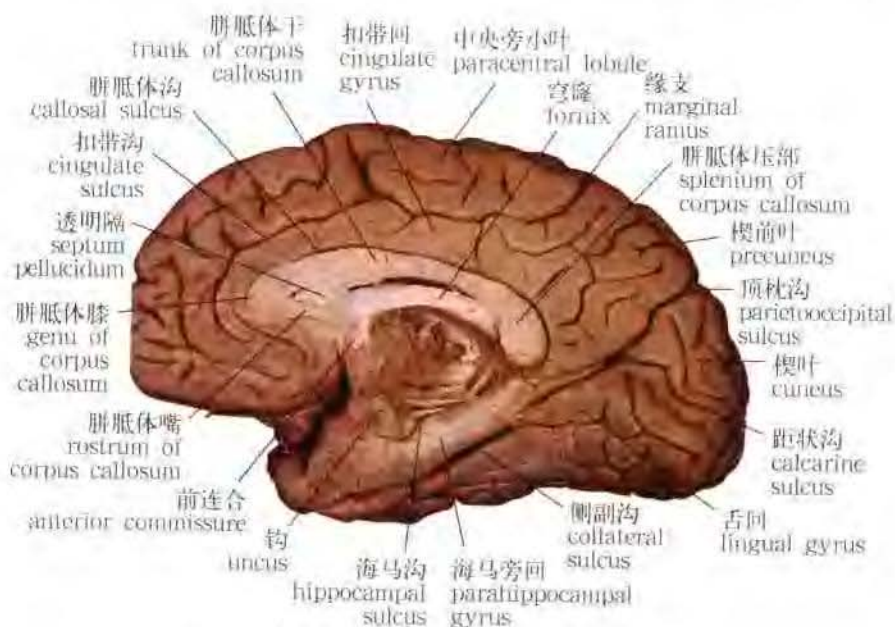


图 310 大脑半球 (内侧面观)  
The cerebral hemisphere (medial aspect)

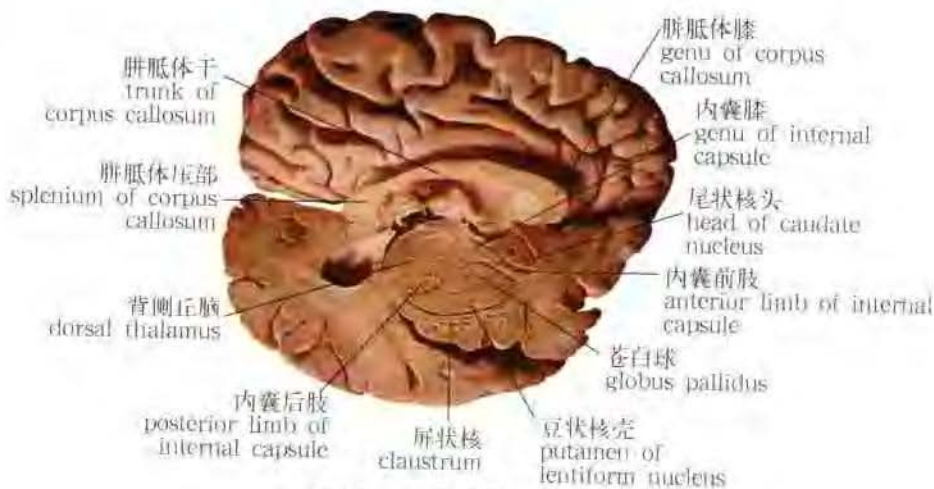


图 311 内囊及基底核  
The internal capsule and basal nuclei

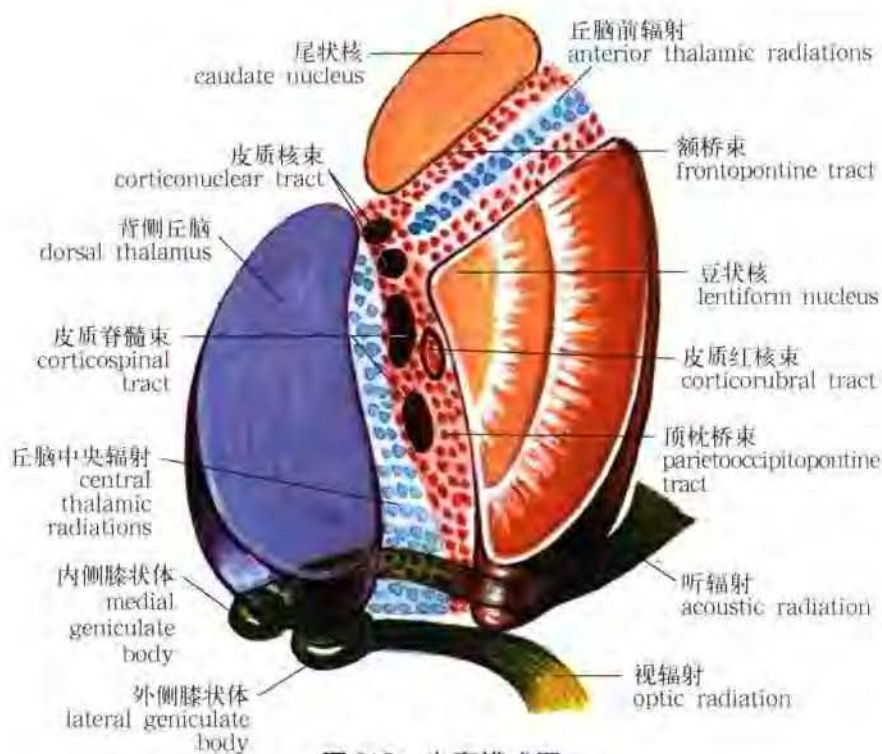


图 312 内囊模式图  
Diagram of the internal capsule

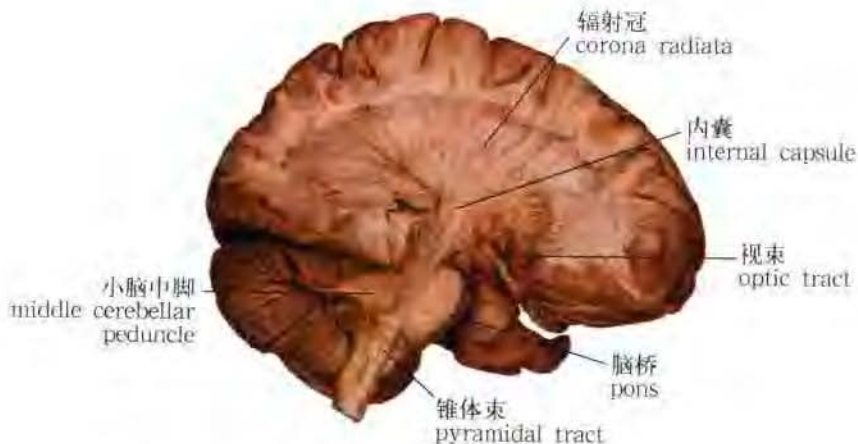

图 313 锥体束  
The pyramidal tract

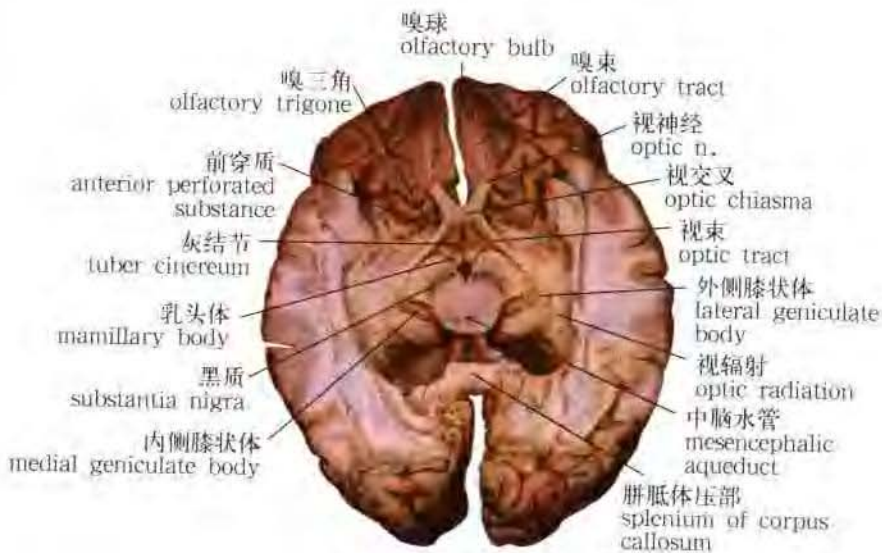


图 314 视束及视辐射  
The optic tract and optic radiation

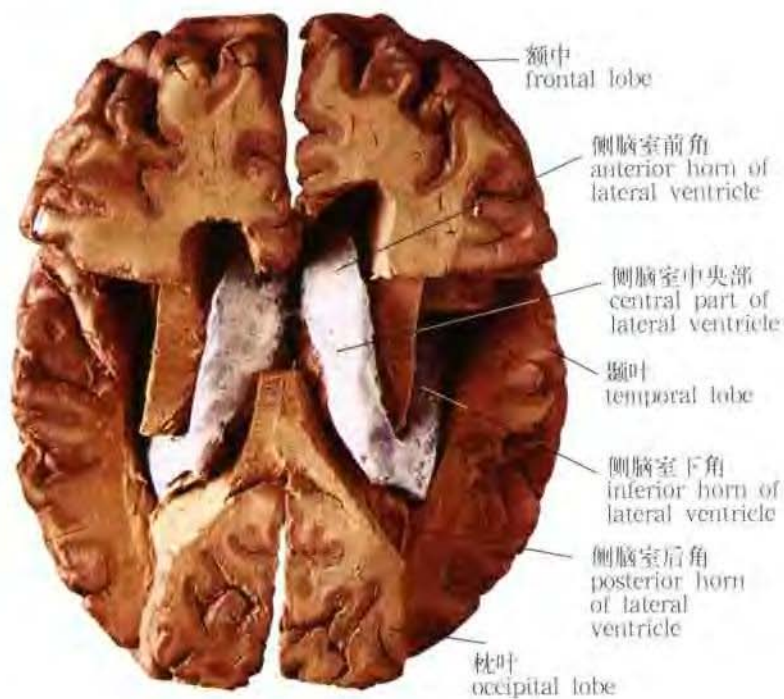


图 315 侧脑室 (上面观)  
The lateral ventricle (superior aspect)

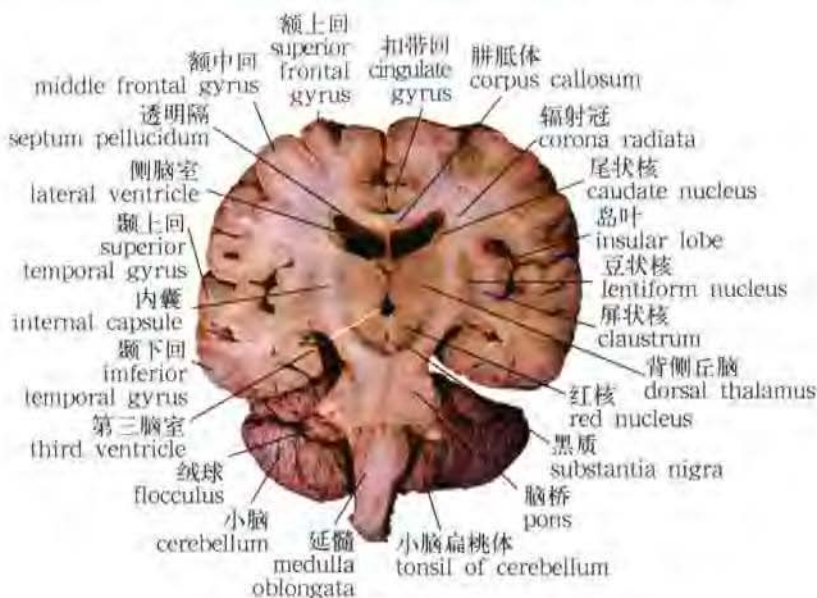


图 316 脑冠状切面  
Coronal section of the brain

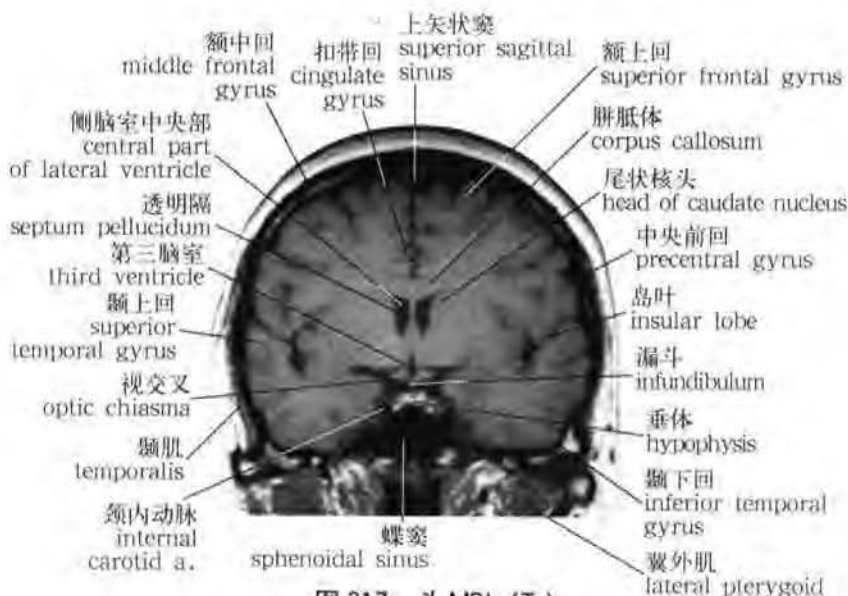

图 317 头 MRI (T<sub>1</sub>)  
MRI of the head (T<sub>1</sub>)



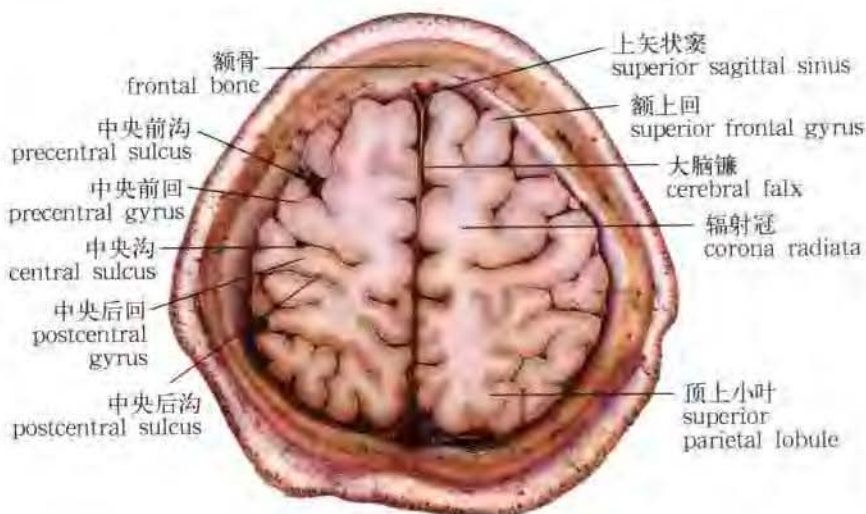


图 318 脑横断面  
Transverse section of the brain

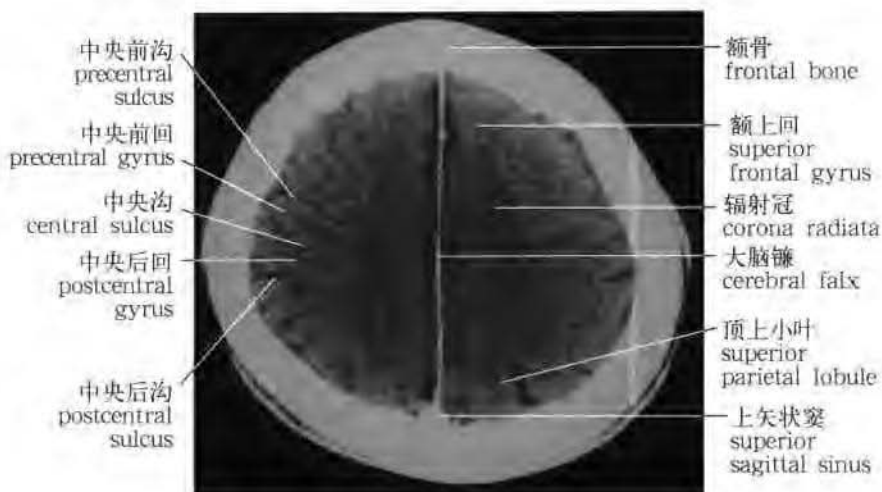


图 319 脑 CT  
X-ray CT of the brain

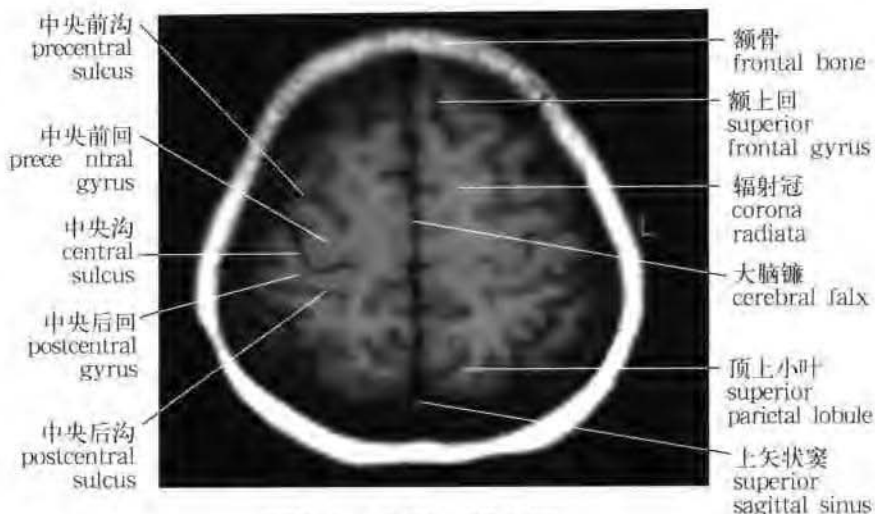


图 320 脑 MRI (T<sub>1</sub>WI)  
MRI of the brain (T<sub>1</sub>WI)

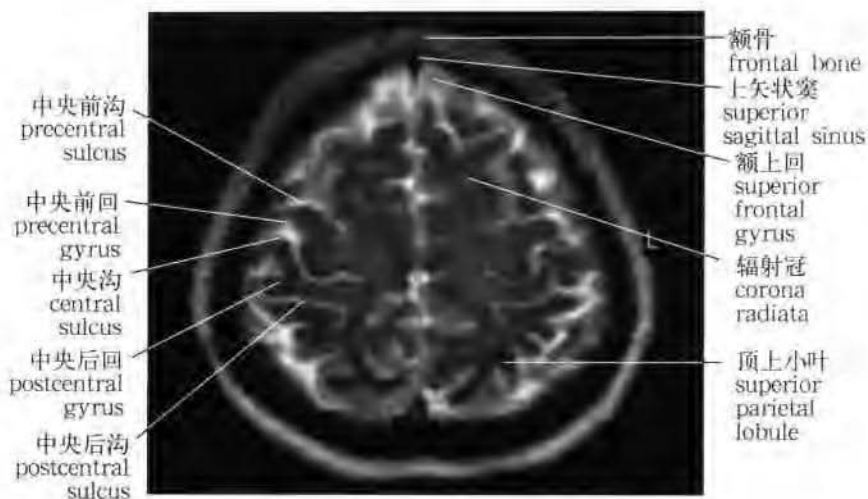


图 321 脑 MRI (T<sub>2</sub>WI)  
MRI of the brain (T<sub>2</sub>WI)

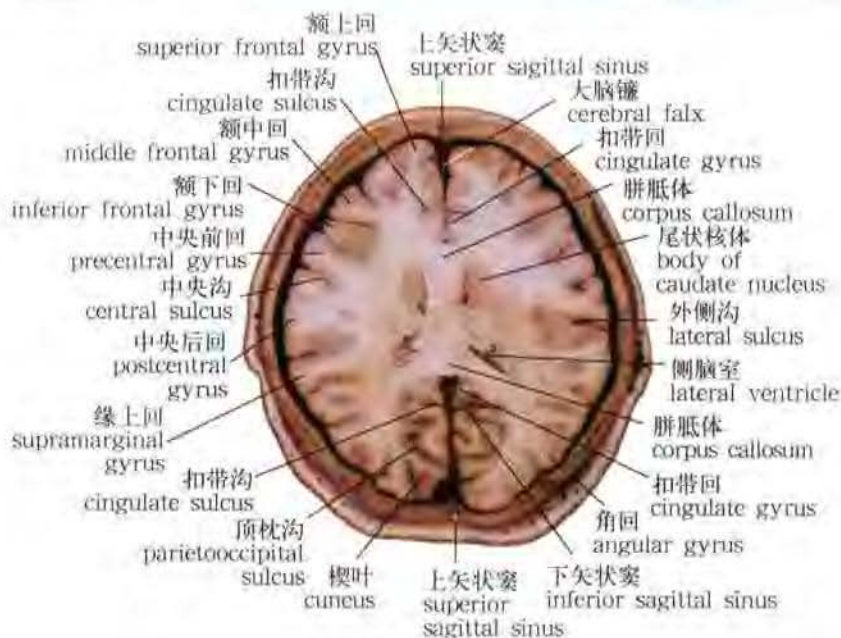


图 322 脑横断面  
Transverse section of the brain

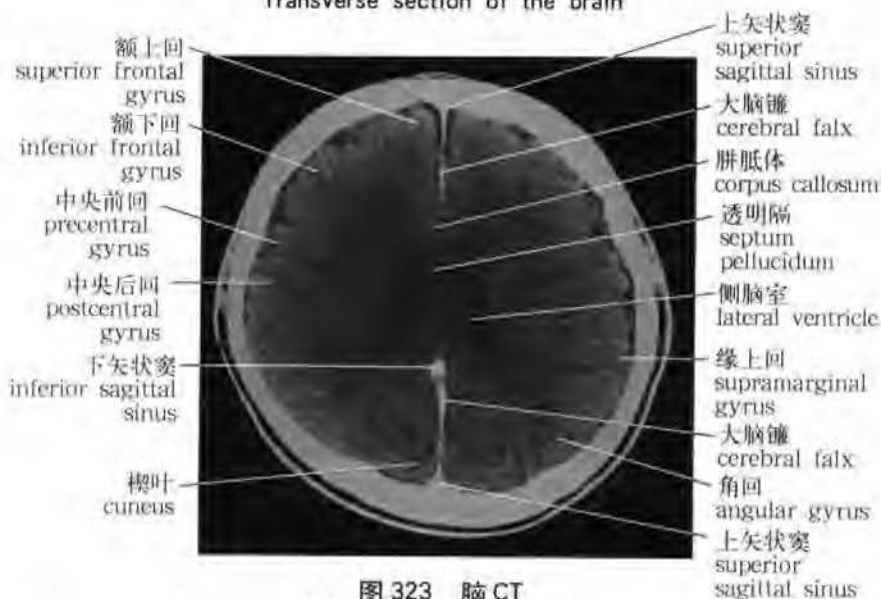


图 323 脑 CT  
X-ray CT of the brain

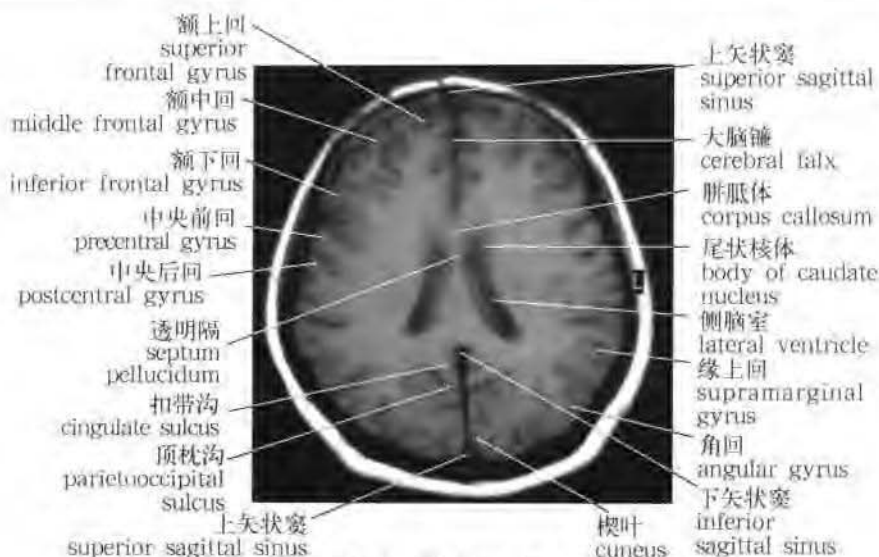

图 324 脑 MRI (T<sub>1</sub>WI)  
MRI of the brain (T<sub>1</sub>WI)

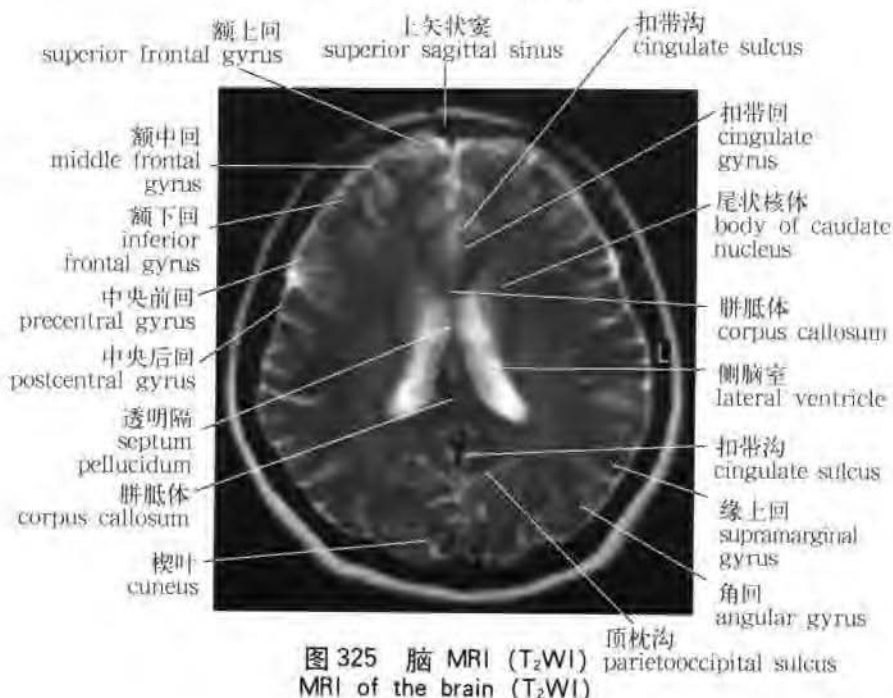

图 325 脑 MRI (T<sub>2</sub>WI)  
MRI of the brain (T<sub>2</sub>WI)

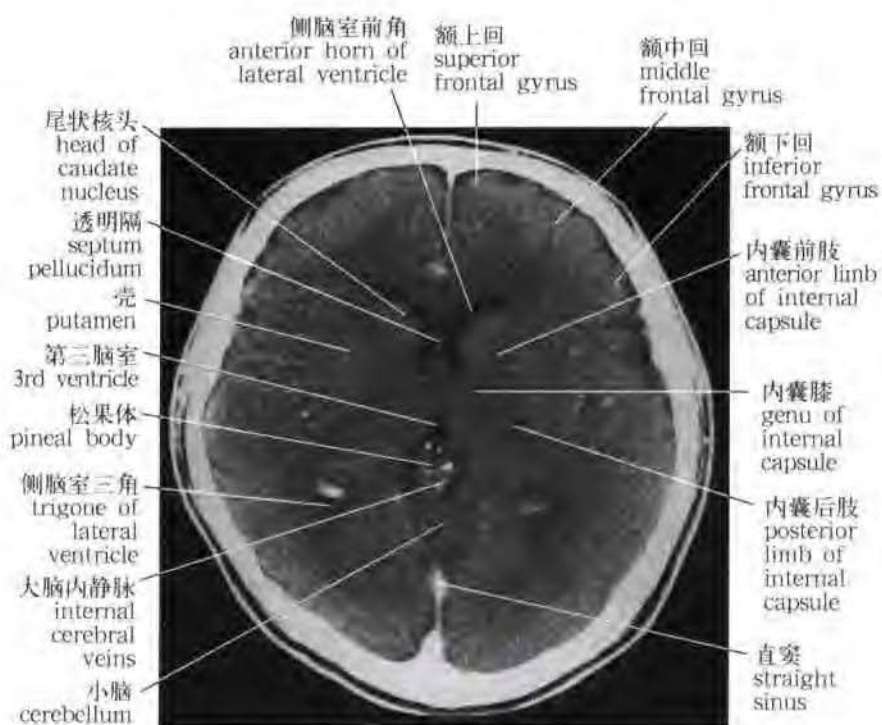


图 326 脑 CT  
X-ray CT of the brain

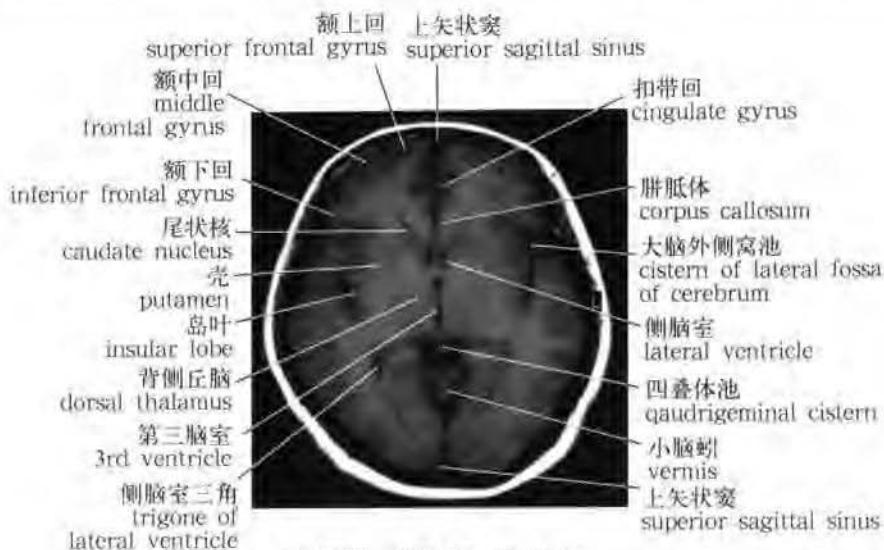


图 327 脑 MRI (T<sub>1</sub>WI)  
MRI of the brain (T<sub>1</sub>WI)

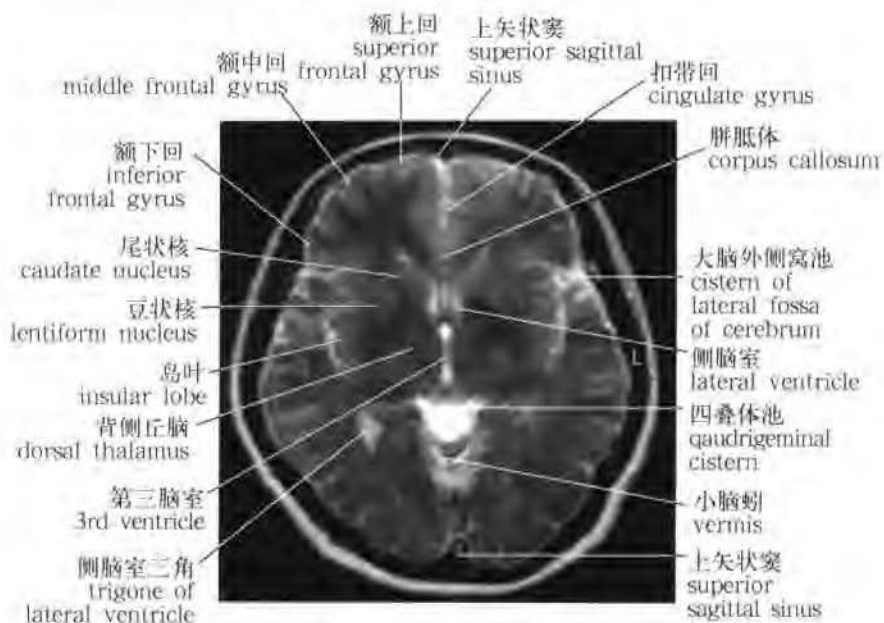

图 328 脑 MRI (T<sub>2</sub>WI)  
MRI of the brain (T<sub>2</sub>WI)

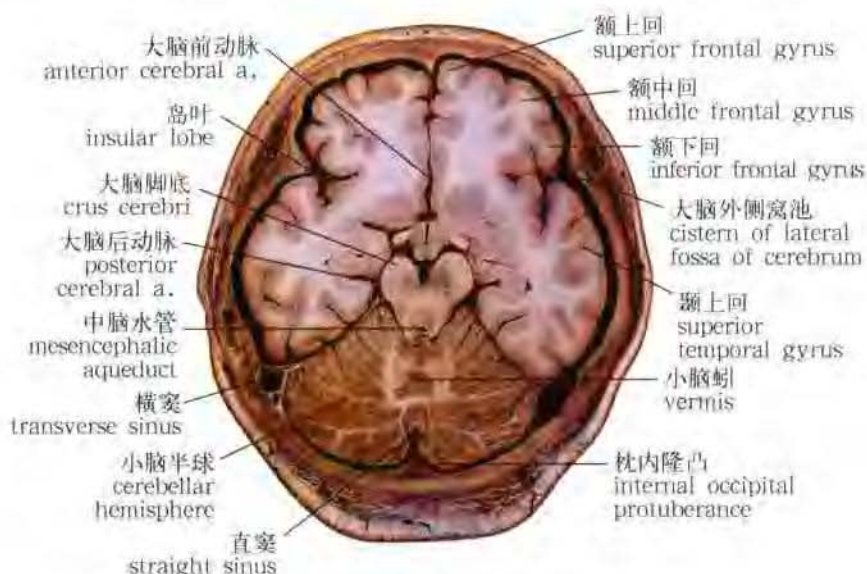


图 329 脑横断面  
Transverse section of the brain

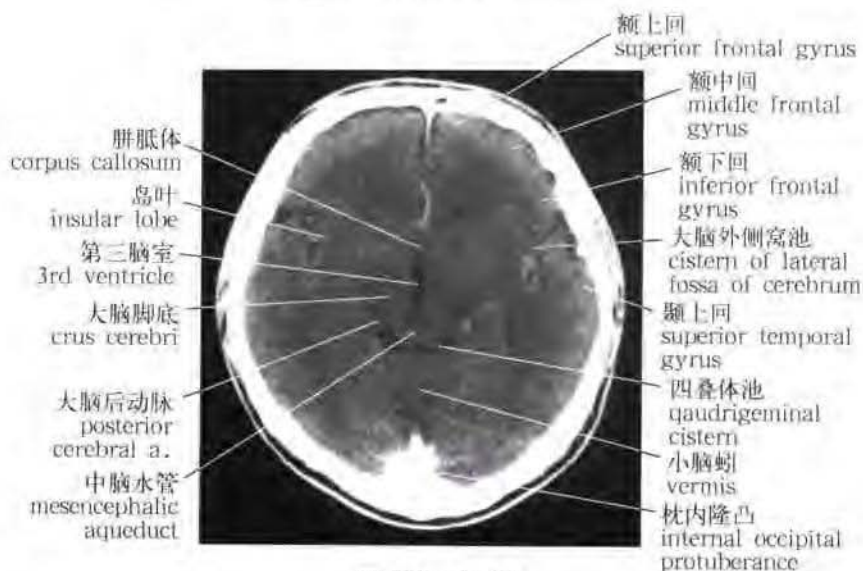


图 330 脑 CT  
X-ray CT of the brain

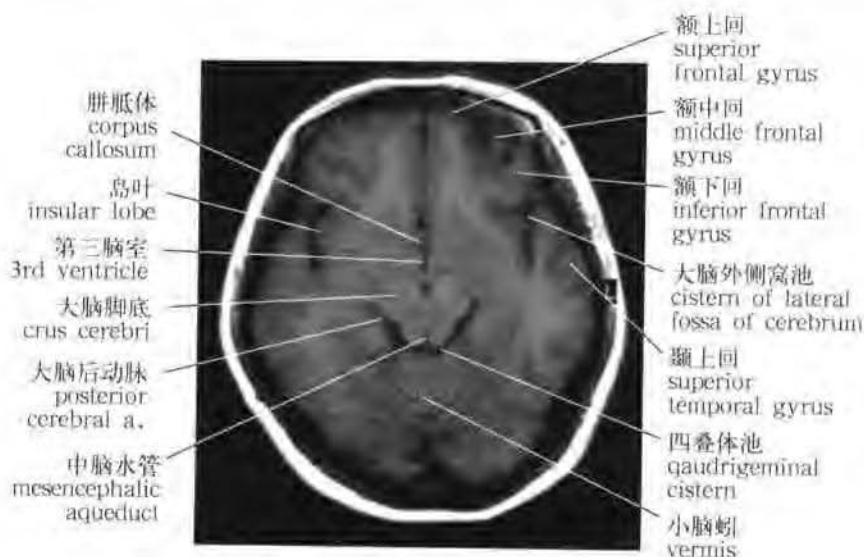


图 331 脑 MRI (T<sub>1</sub>WI)  
MRI of the brain (T<sub>1</sub>WI)

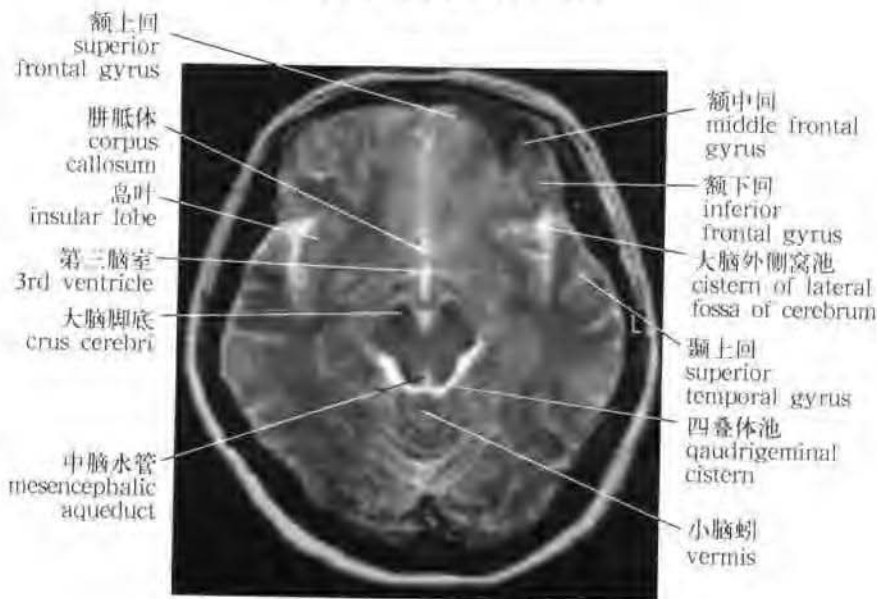


图 332 脑 MRI (T<sub>2</sub>WI)  
MRI of the brain (T<sub>2</sub>WI)



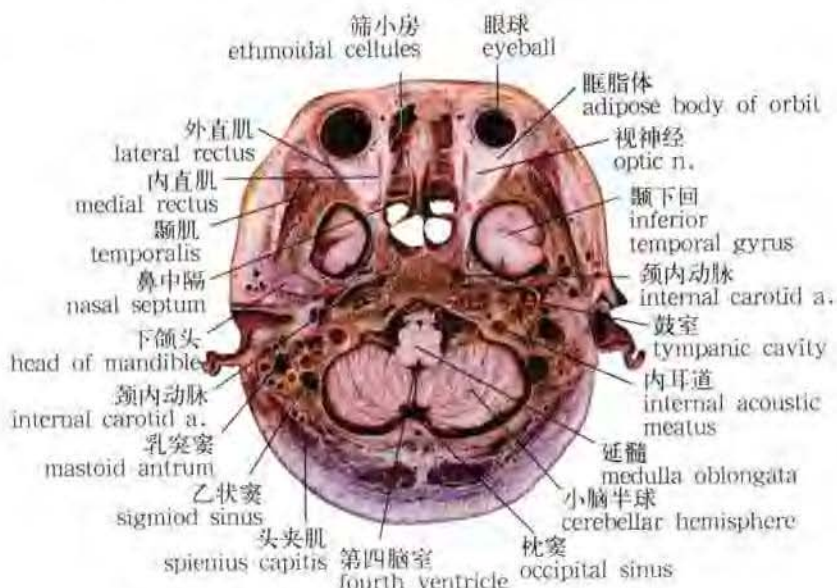


图 333 脑横断面  
Transverse section of the brain

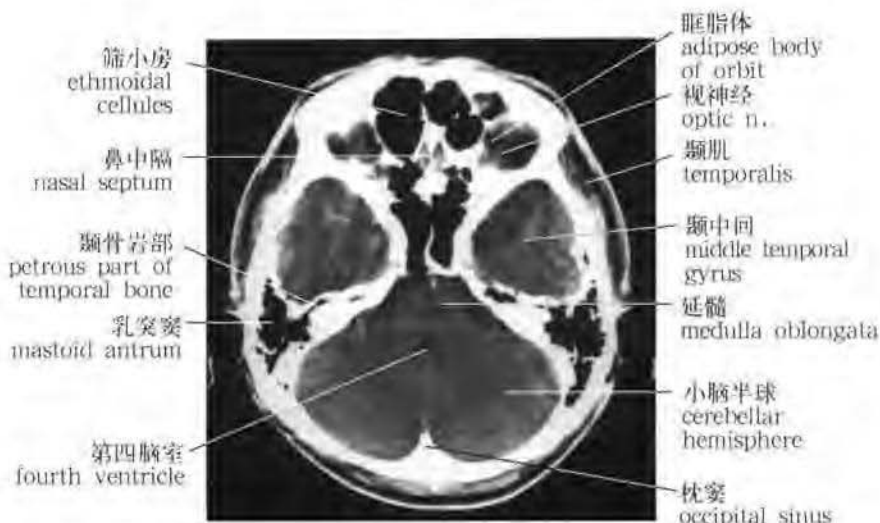


图 334 脑 CT  
X-ray CT of the brain

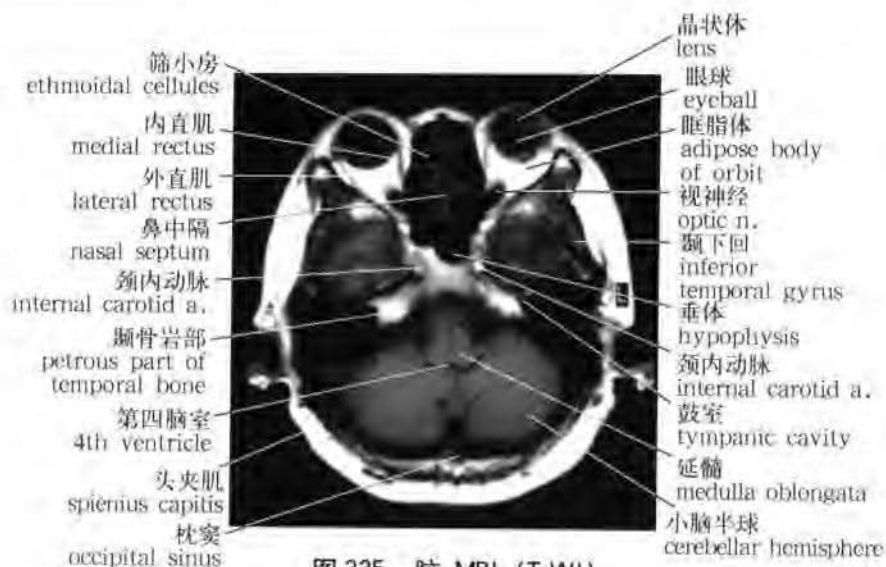

图 335 脑 MRI (T<sub>1</sub>WI)  
MRI of the brain (T<sub>1</sub>WI)

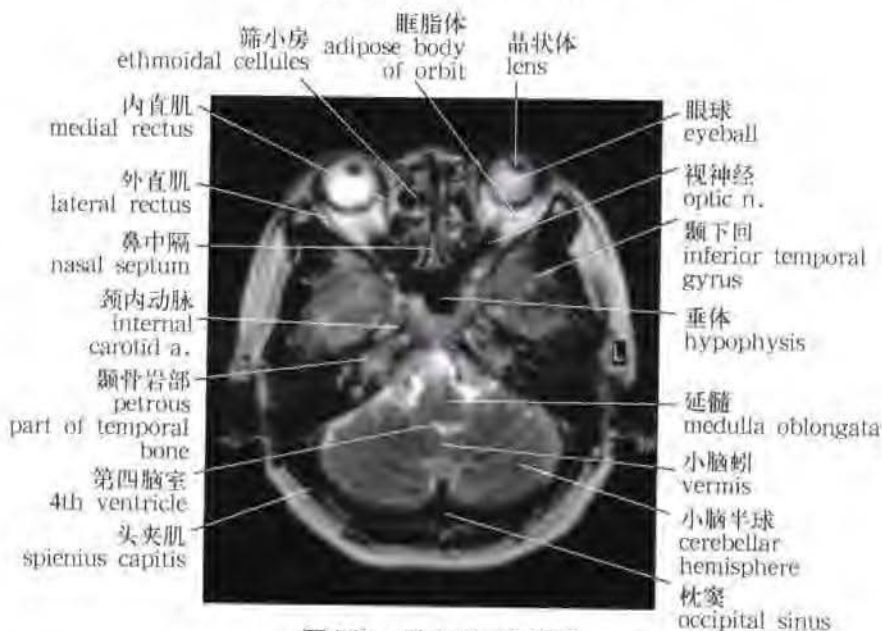


图 336 脑 MRI (T<sub>2</sub>WI)  
MRI of the brain (T<sub>2</sub>WI)

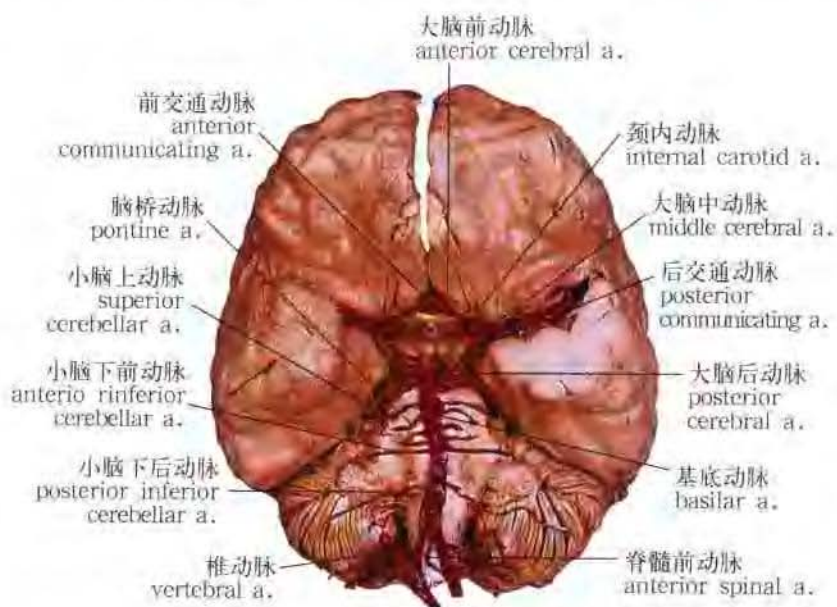


图 337 脑底动脉  
Arteries at the base of the brain

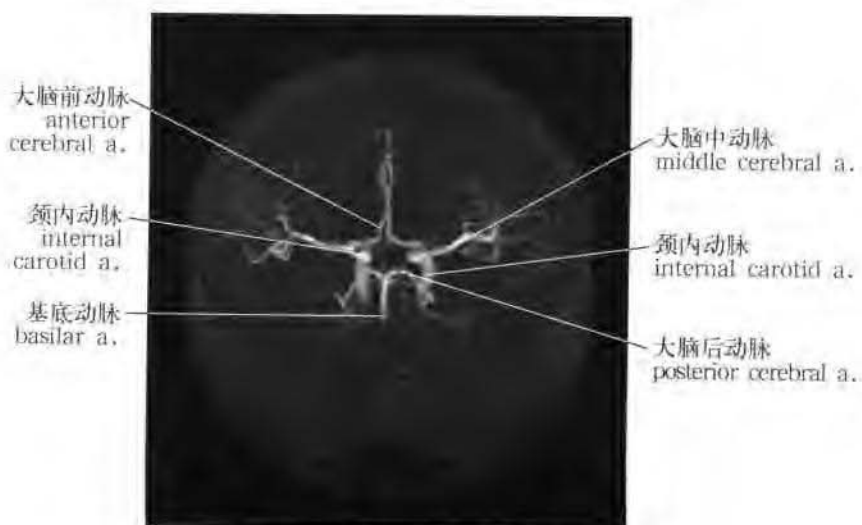


图 338 脑底动脉(MRI)  
Arteries at the base of the brain (MRI)

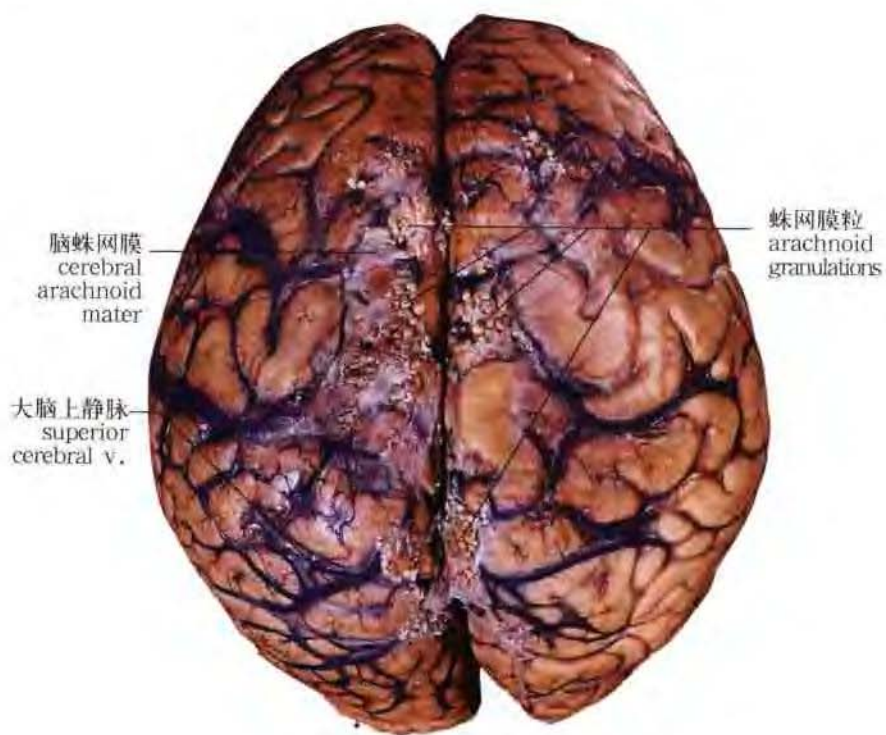


图 339 蛛网膜粒  
The arachnoid granulations

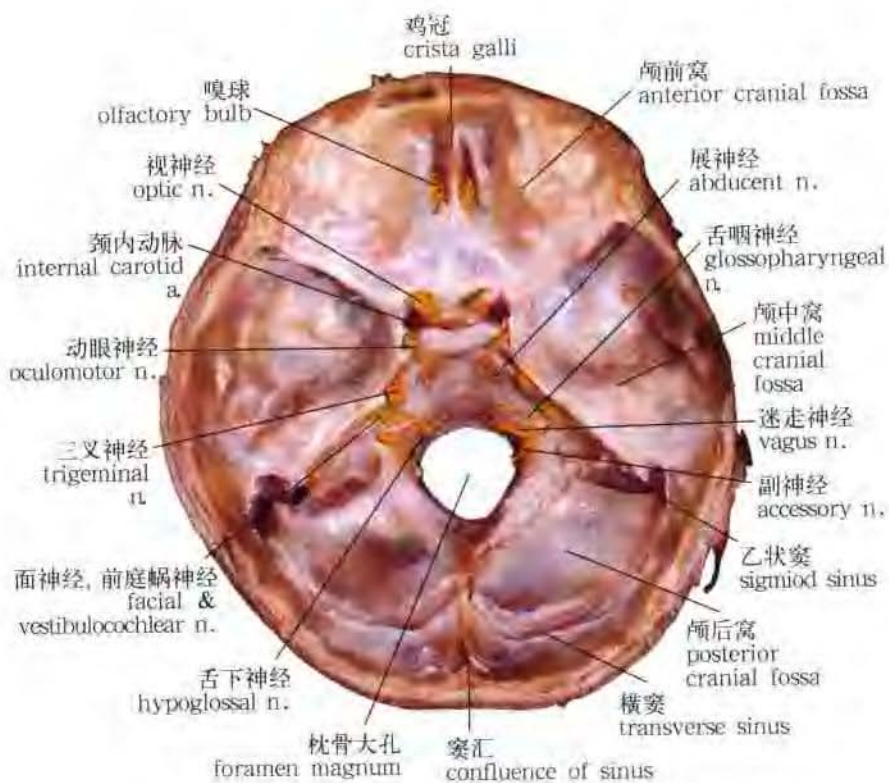


图 340 颅底硬脑膜  
Dura mater of the base of the cranial cavity

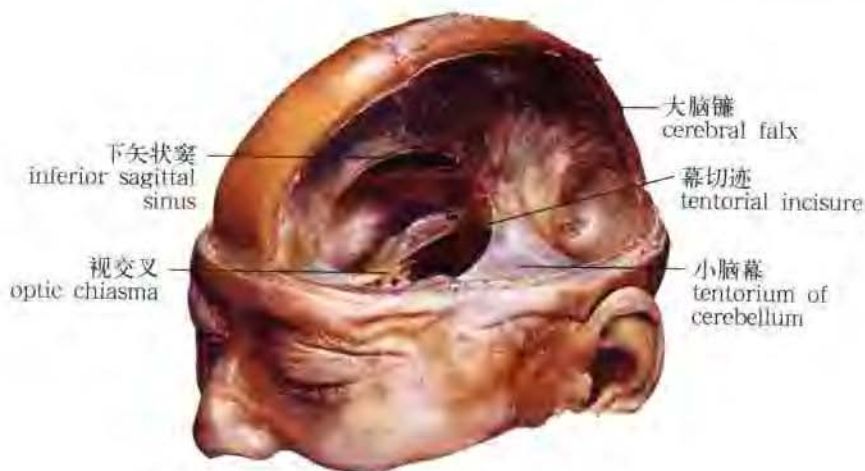

图 341 硬脑膜  
Cerebral dura mater

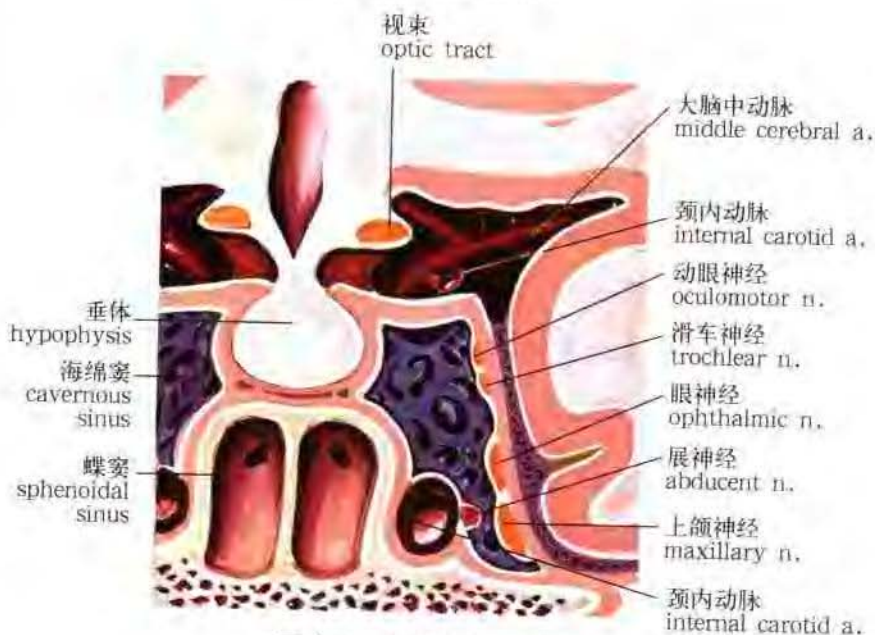


图 342 海绵窦冠状切面  
Coronal section of the cavernous sinus

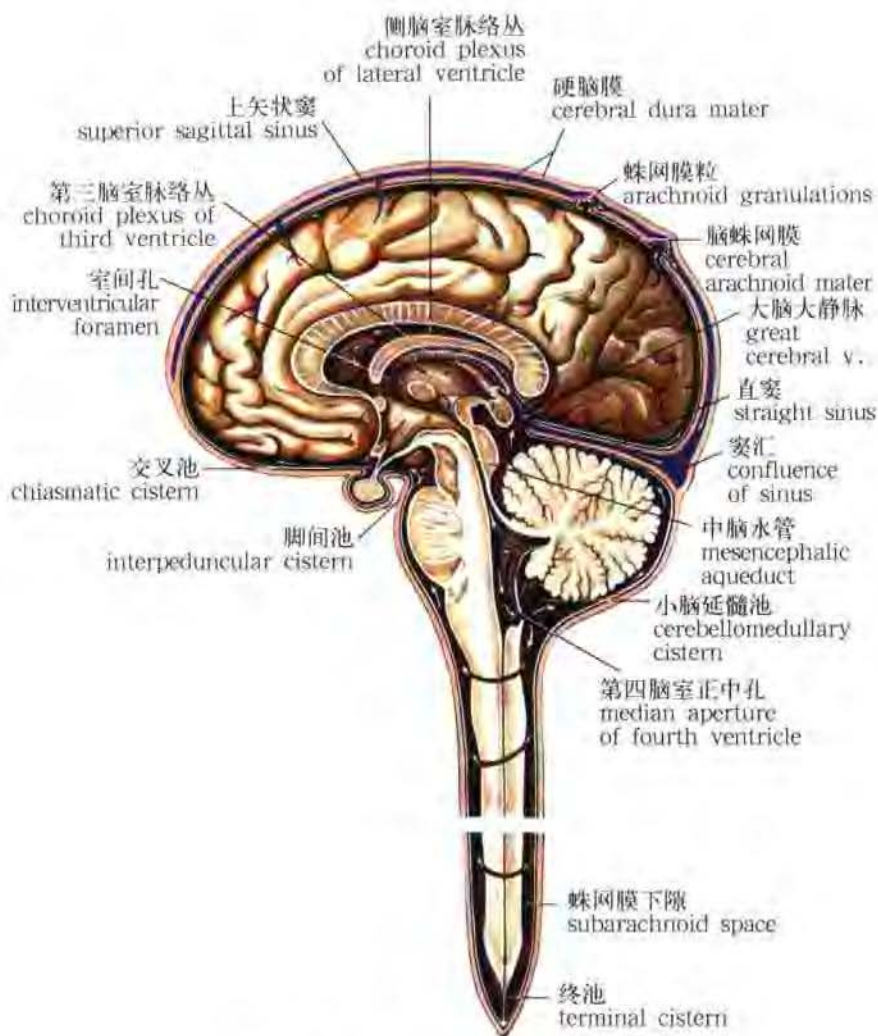


图 343 脑脊液循环模式图  
Diagram of cerebrospinal fluid circulation

# 神经系统——内脏神经

NERVOUS SYSTEM——VISCERAL NERVE

# Chapter 13



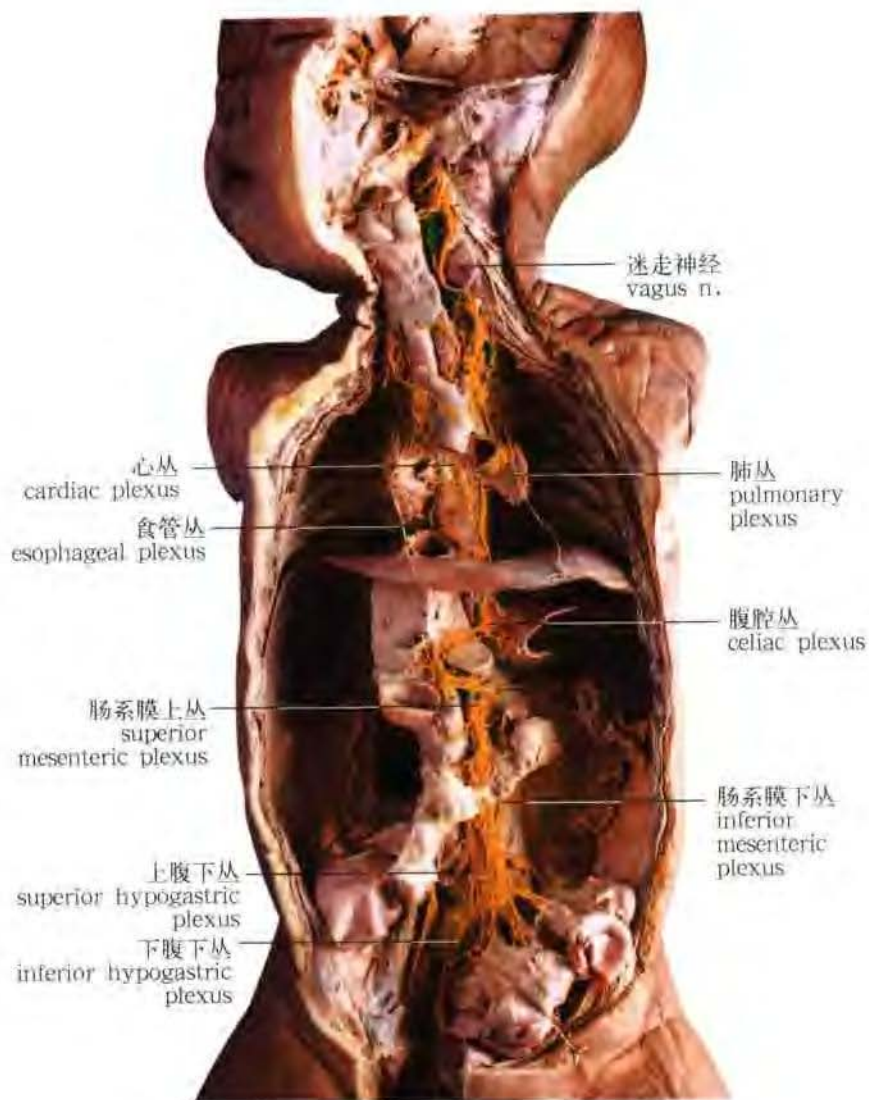


图 344 内脏神经全貌  
General arrangement of the visceral nerves

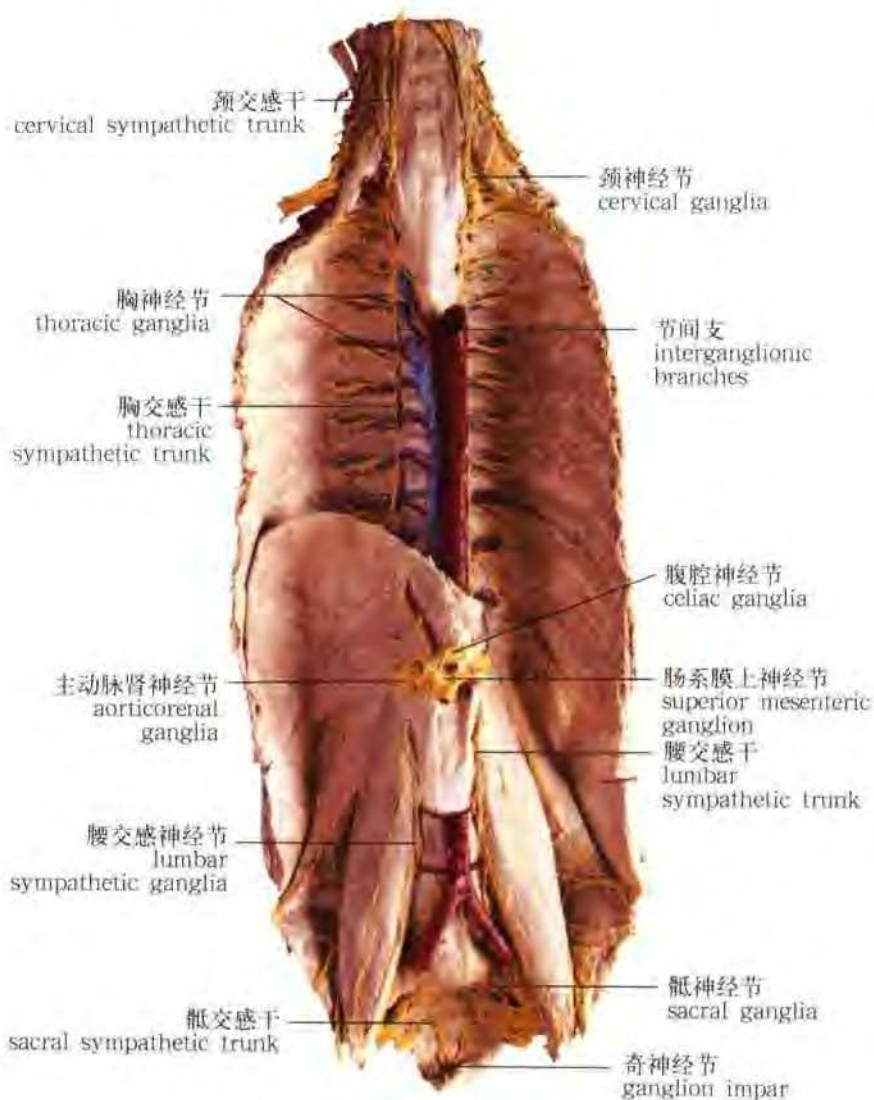


图 345 交感神经干  
The sympathetic trunks

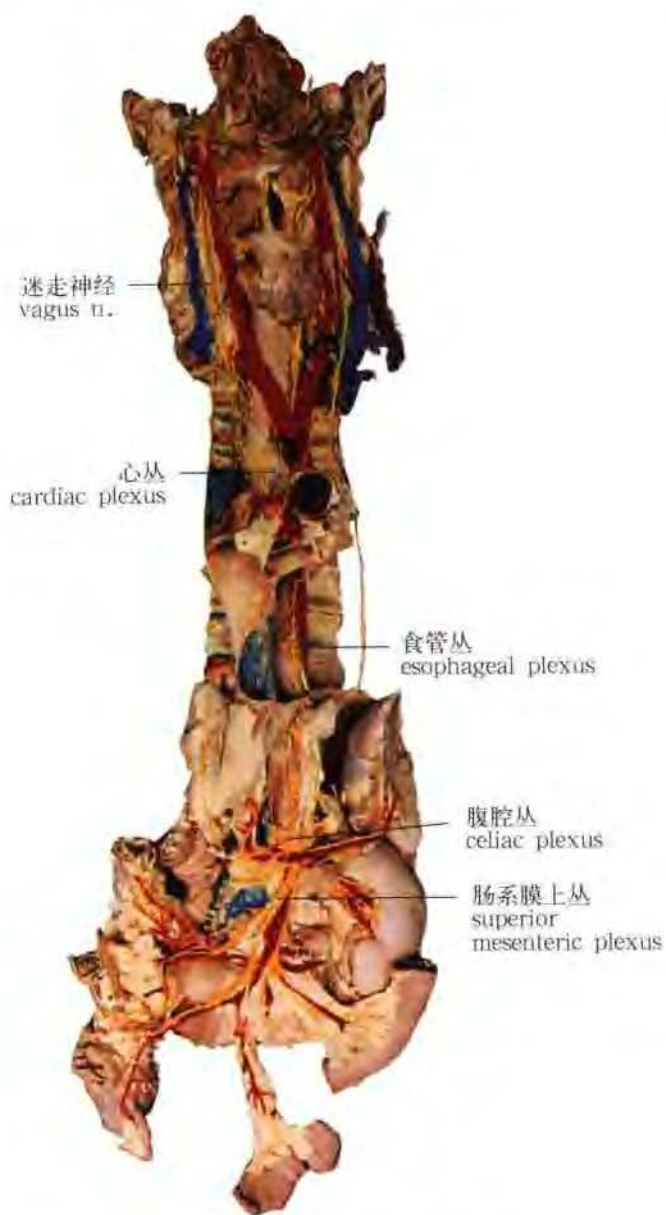


图 346 内脏神经 (前面观)  
The visceral nerve (anterior aspect)

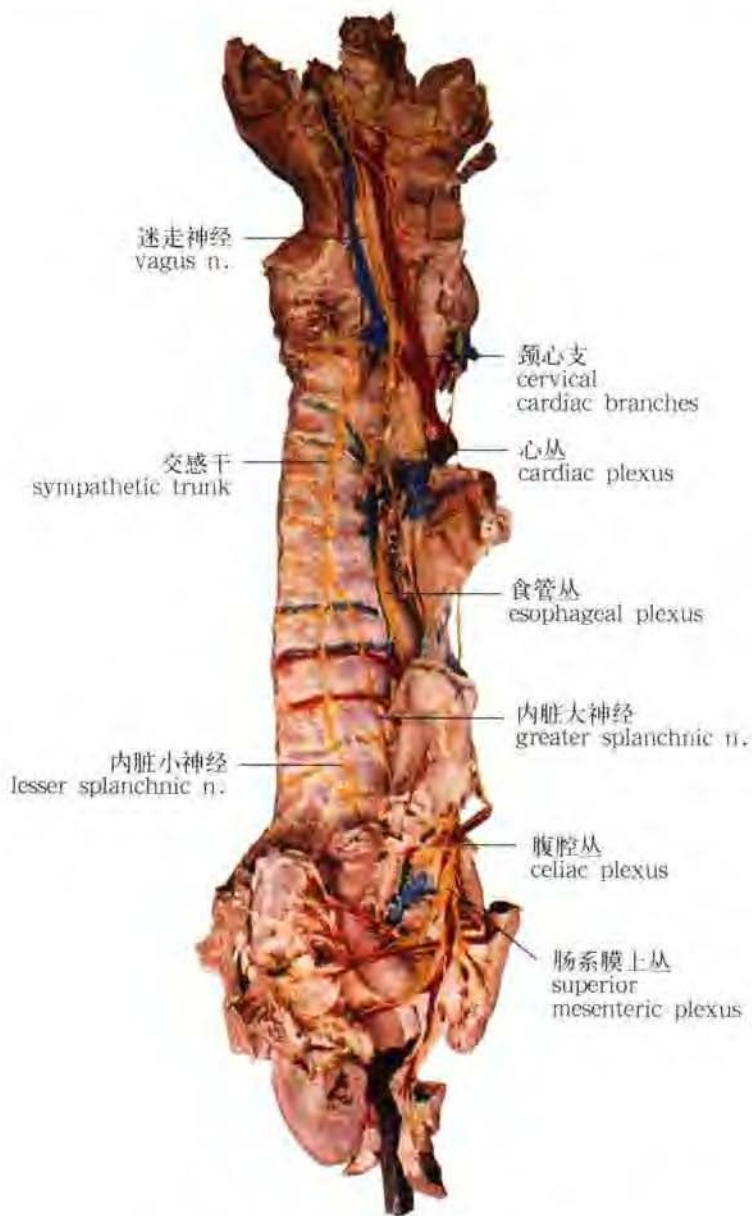


图 347 内脏神经 (侧面观)  
The visceral nerve (lateral aspect)

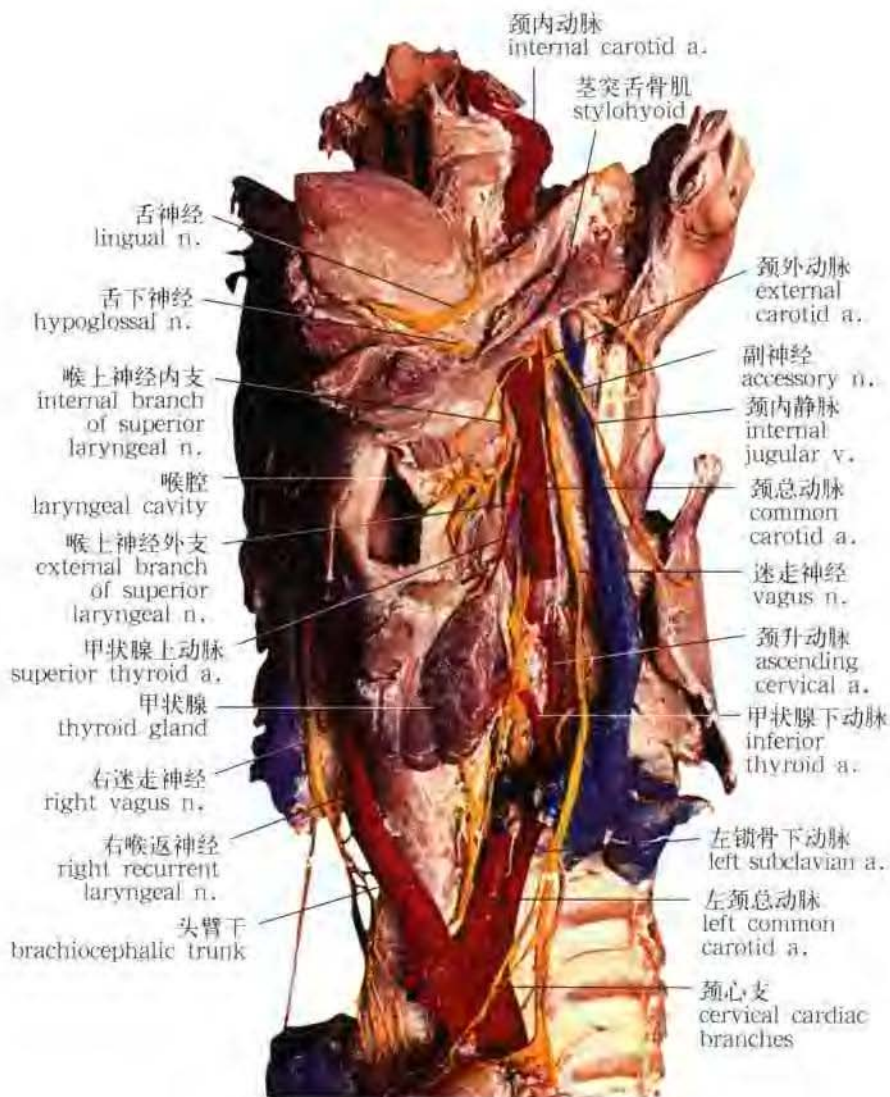

图 348 颈部的迷走神经 (前面观)  
The vagus nerves of the neck (anterior aspect)

# 局部解剖学

REGIONAL ANATOMY

# Chapter 14

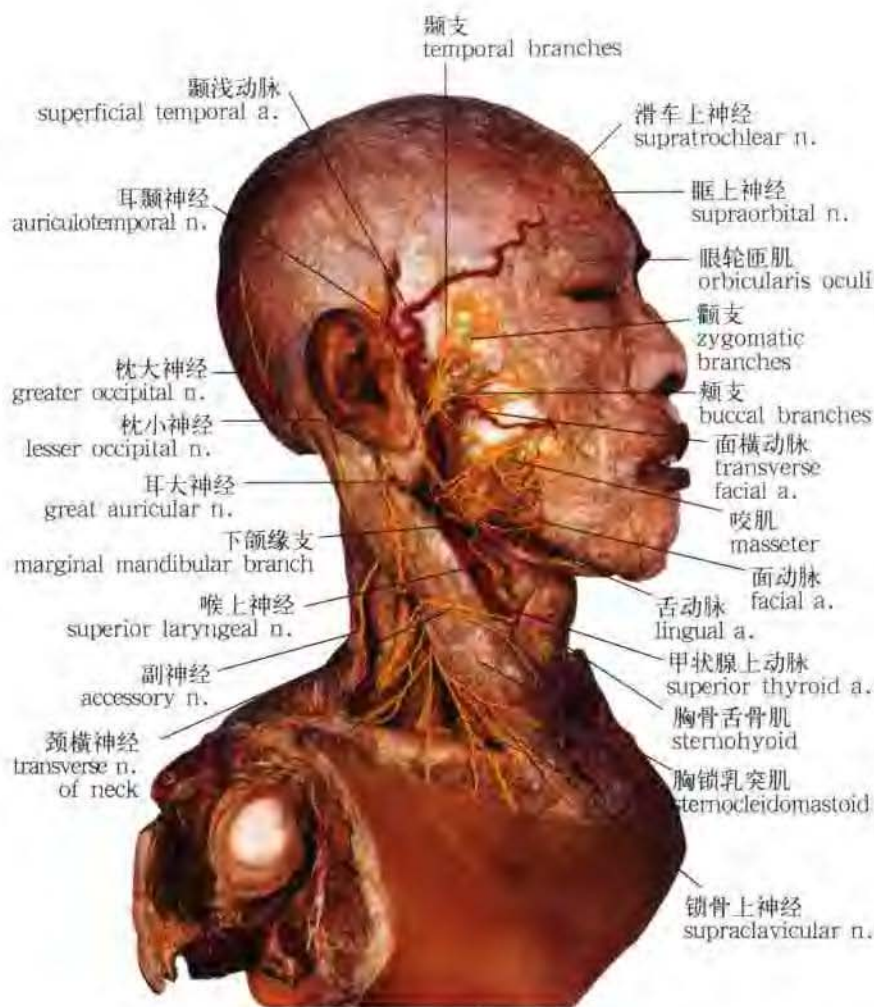

图 349 头颈部的肌肉、血管和神经 (侧面观 1)  
Muscles, blood vessels and nerves of the head and neck  
(lateral aspect 1)

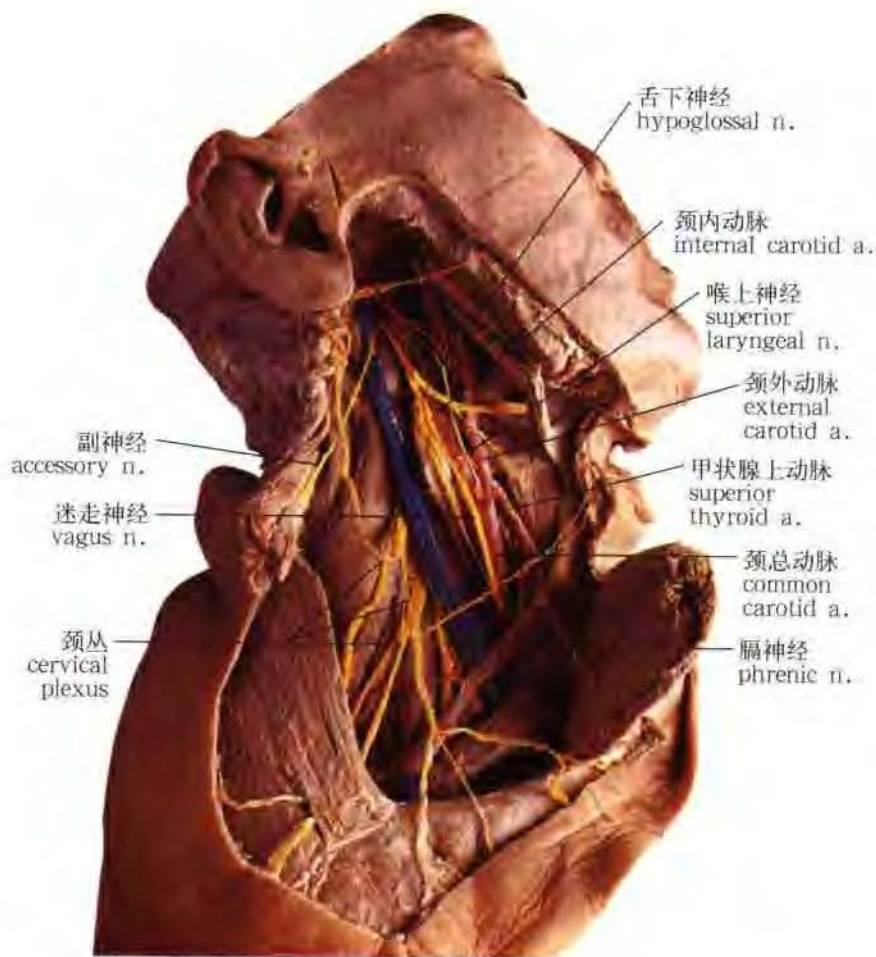


图 350 颈部的血管和神经 (侧面观 2)  
Blood vessels and nerves of the neck (lateral aspect 2)



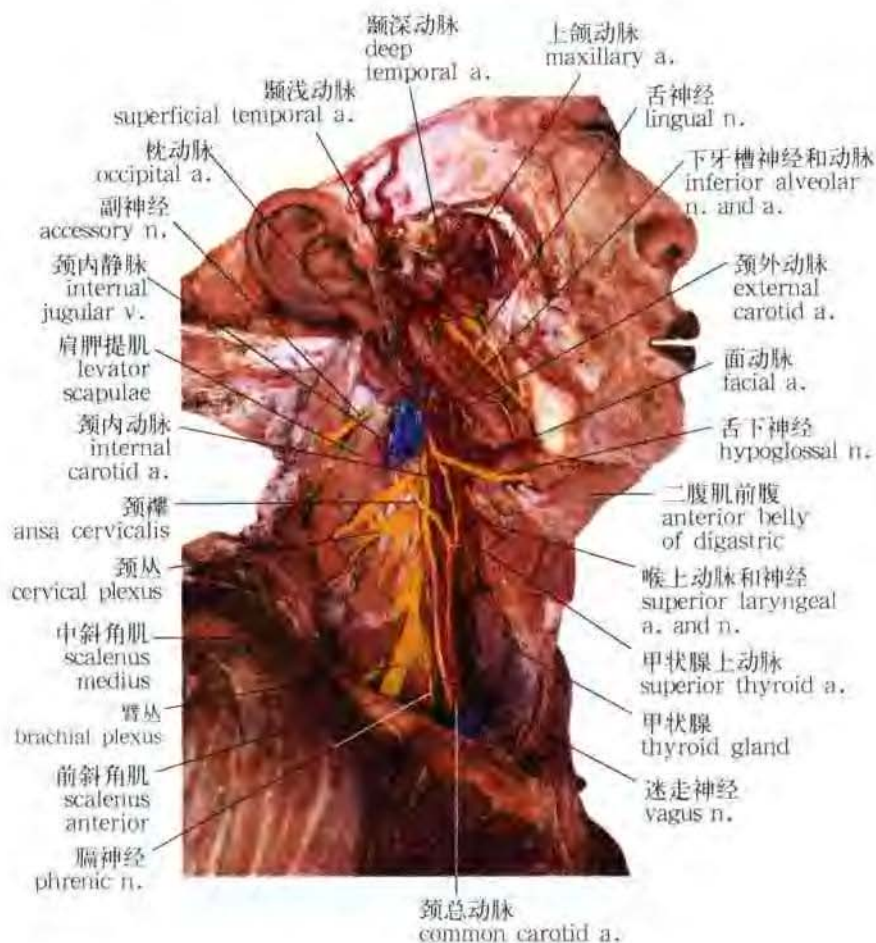

图 351 头颈部的肌肉、血管和神经 (侧面观 3)  
 Muscles, blood vessels and nerves  
 of the head and neck (lateral aspect 3)

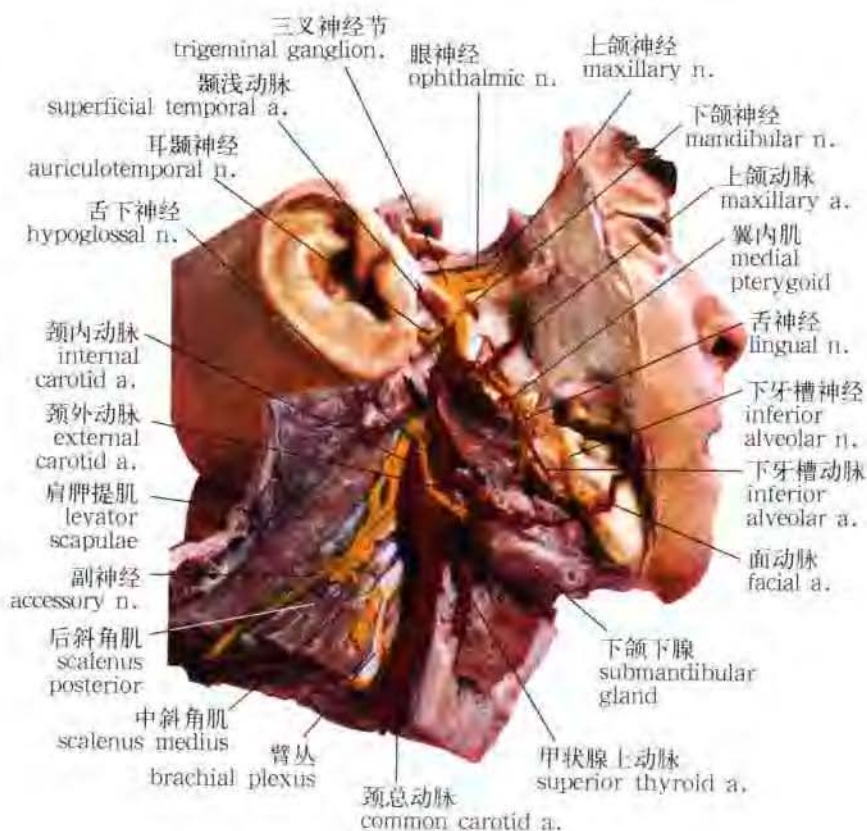


图 352 头颈部的肌肉、血管和神经 (侧面观 4)  
Muscles, blood vessels and nerves of the head and neck  
(lateral aspect 4)

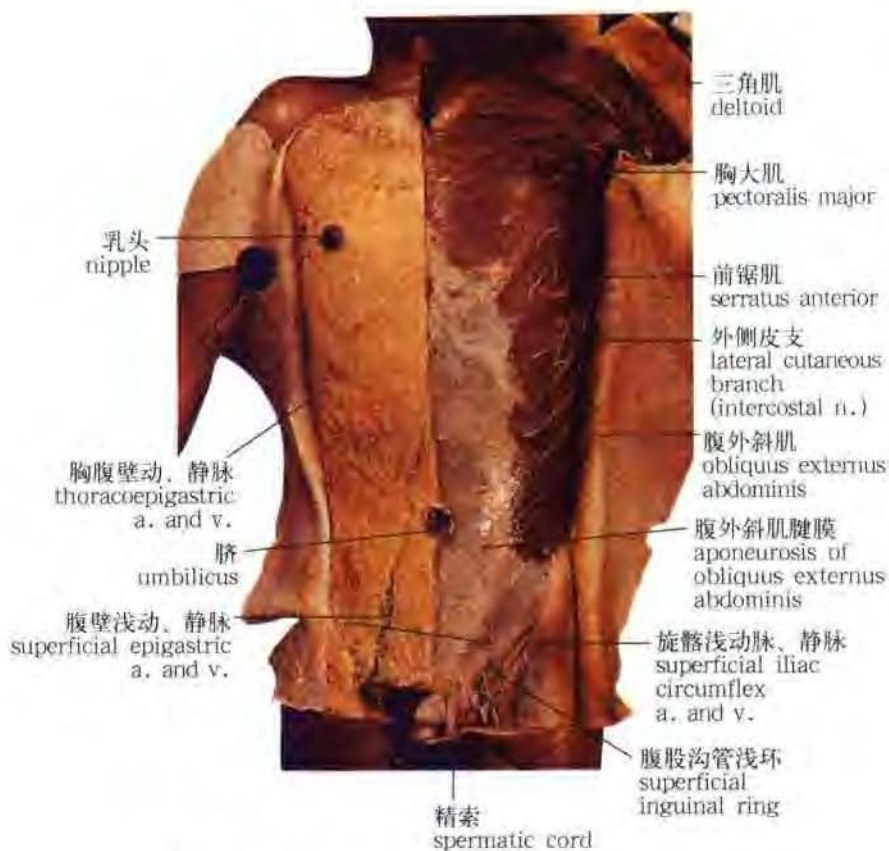

图 353 胸腹壁浅层的肌肉、血管和神经 (1)  
Muscles, blood vessels and nerves  
of the superficial thoracoepigastric wall (1)

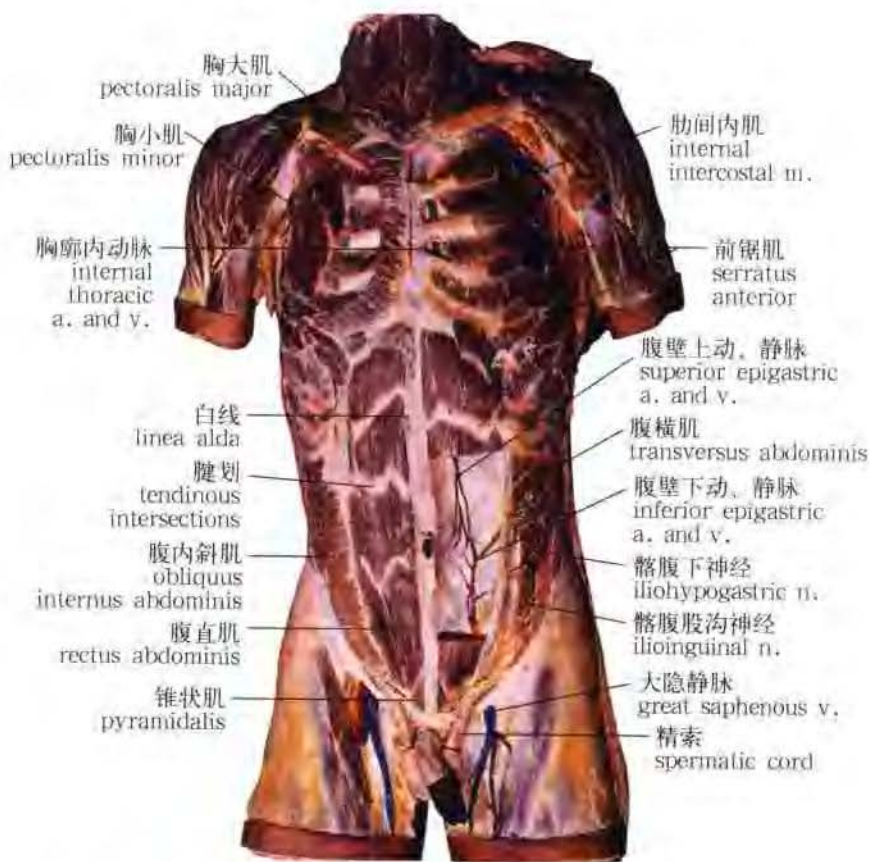

图 354 胸腹壁的肌肉、血管和神经 (2)  
Muscles, blood vessels and nerves of thoracoepigastric wall (2)

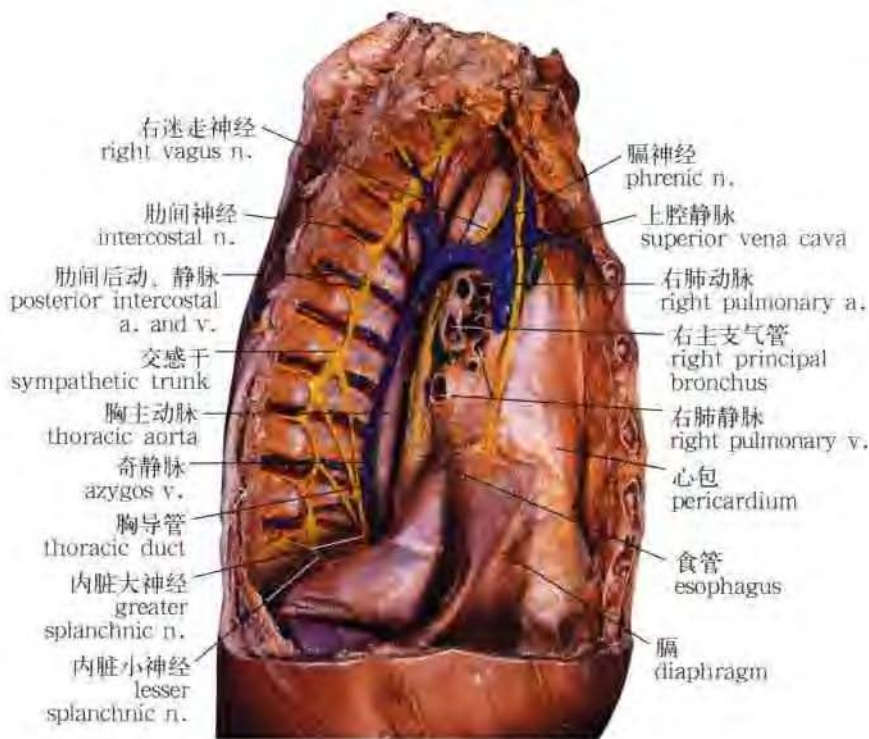

图 355 纵隔 (右侧面观)  
The mediastinum (right aspect)

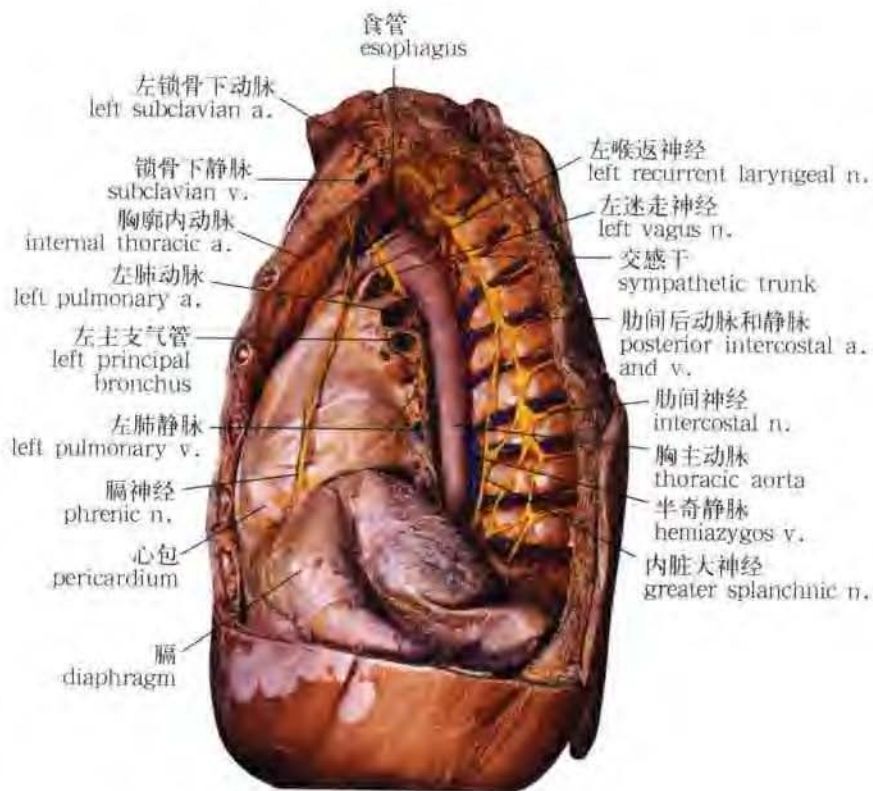


图 356 纵隔(左侧面观)  
The mediastinum(left aspect)

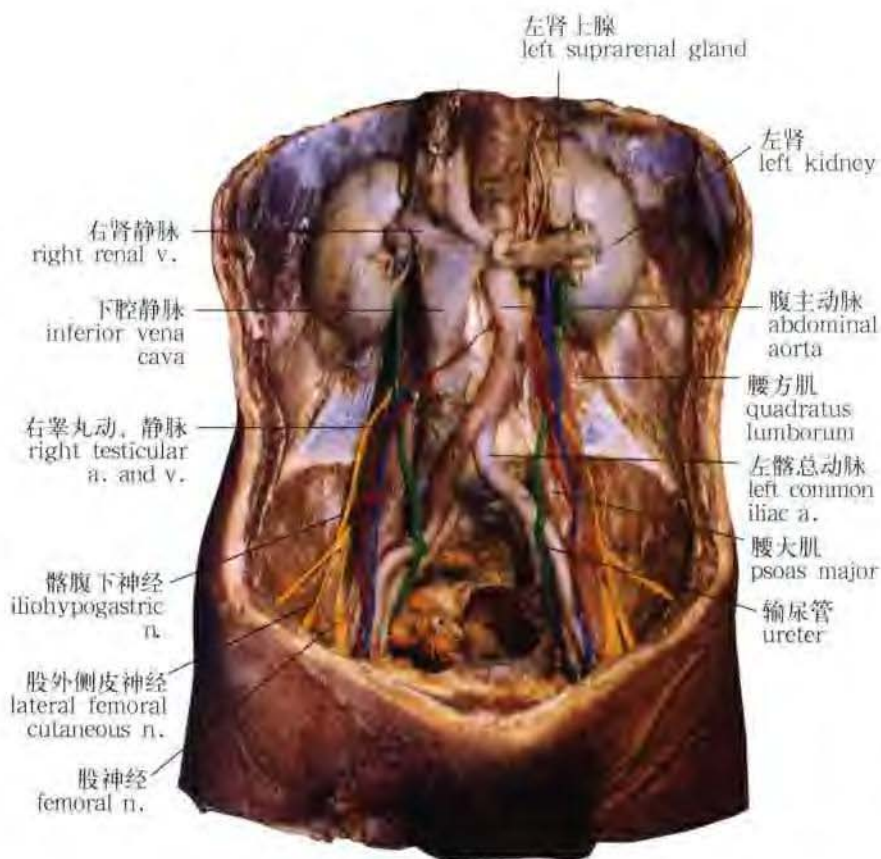


图 357 腹后壁 (前面观)  
 Posterior wall of the abdomen (anterior aspect)

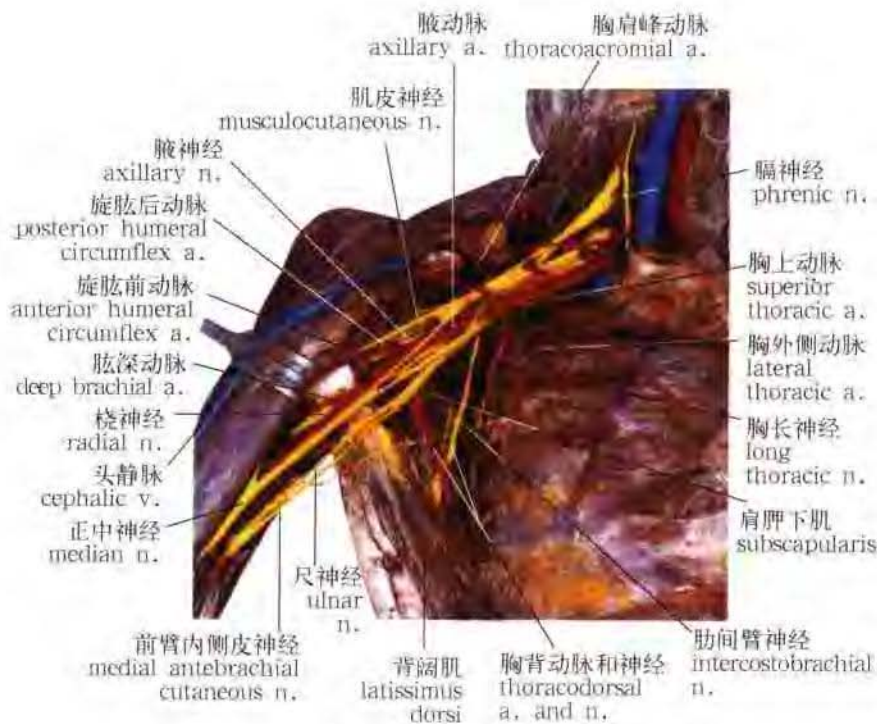


图 358 腋窝的血管和神经 (1)  
 Blood vessels and nerves of the axillary fossa (1)



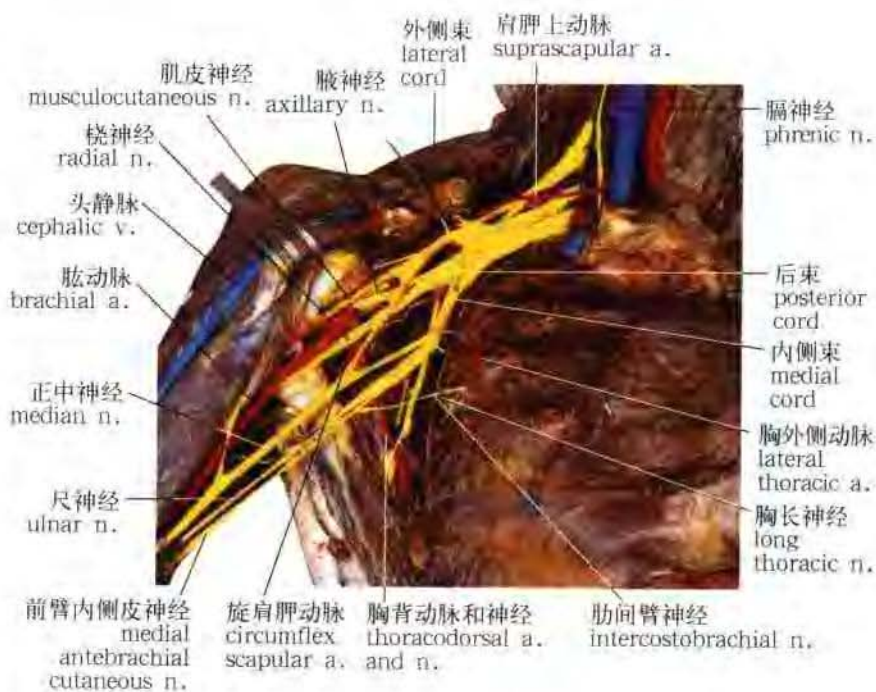


图 359 腋窝的血管和神经 (2)  
 Blood vessels and nerves of the axillary fossa (2)

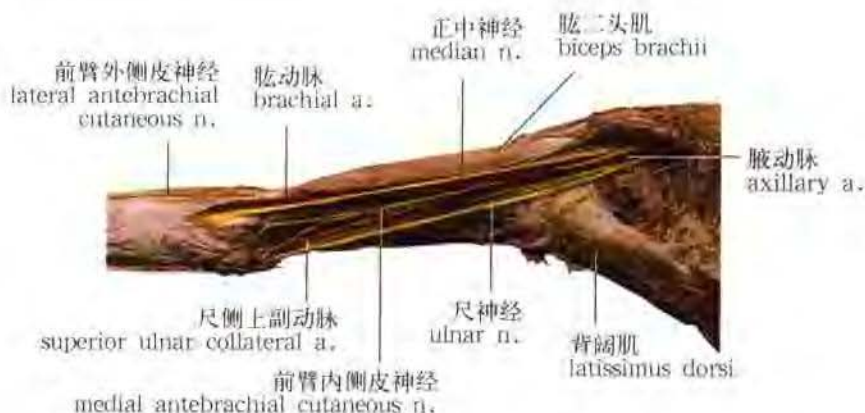

图 360 臂部的肌肉、血管和神经 (前面观 1)  
Muscles, blood vessels and nerves of the arm (anterior aspect 1)

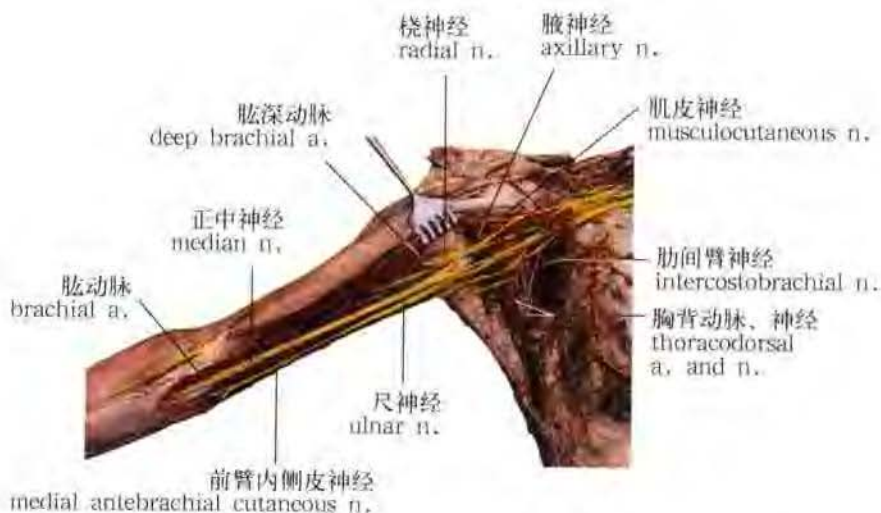

图 361 臂部的肌肉、血管和神经 (前面观 2)  
Muscles, blood vessels and nerves of the arm (anterior aspect 2)

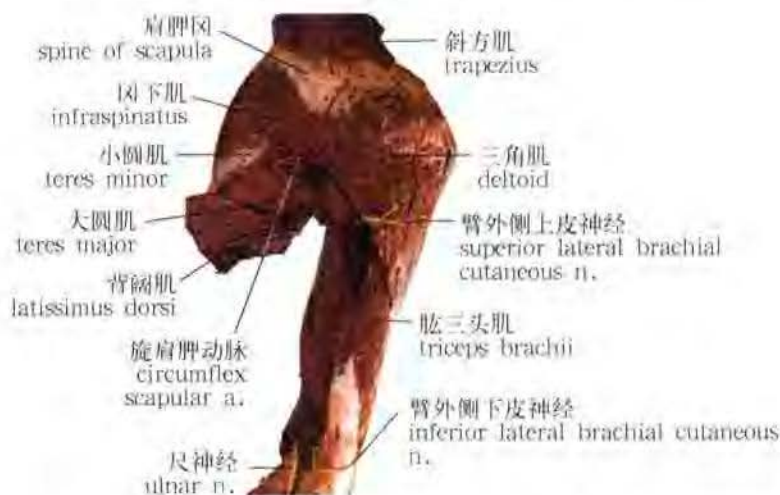

图 362 肩、臂部的肌肉、血管和神经 (后面观 1)  
 Muscles, blood vessels and nerves of the shoulder and arm (posterior aspect 1)

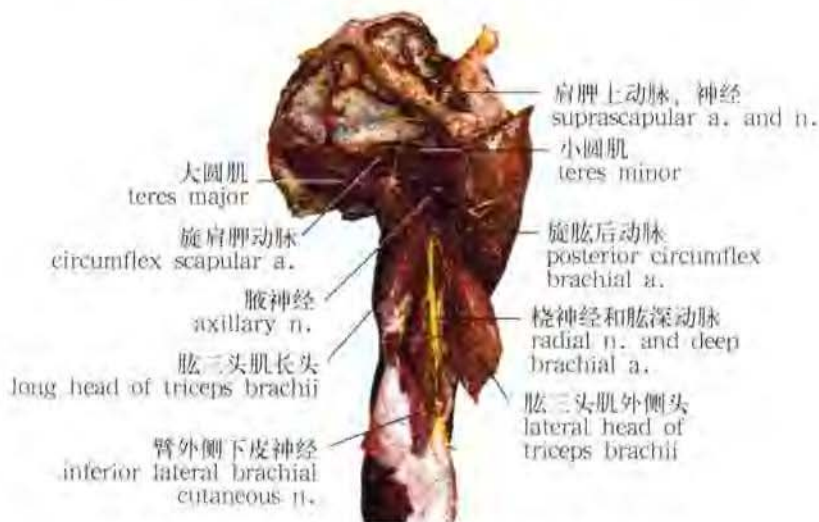

图 363 肩、臂部的肌肉、血管和神经 (后面观 2)  
 Muscles, blood vessels and nerves of the shoulder and arm (posterior aspect 2)

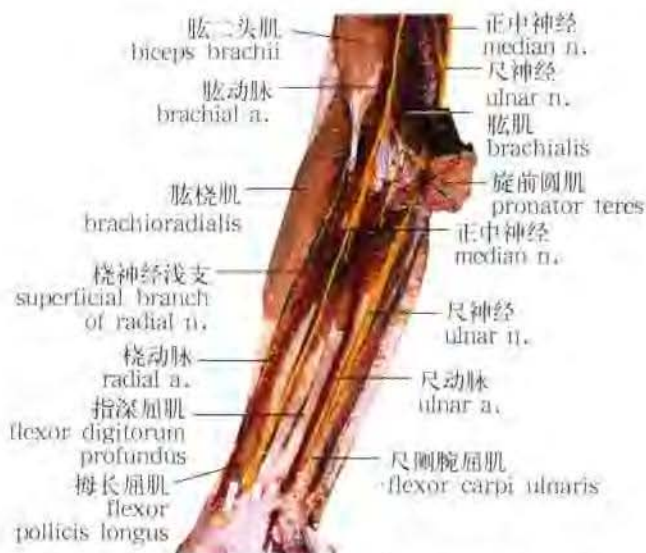

图 364 前臂的肌肉、血管和神经 (前面观)  
Muscles, blood vessels and nerves of the forearm (anterior aspect)

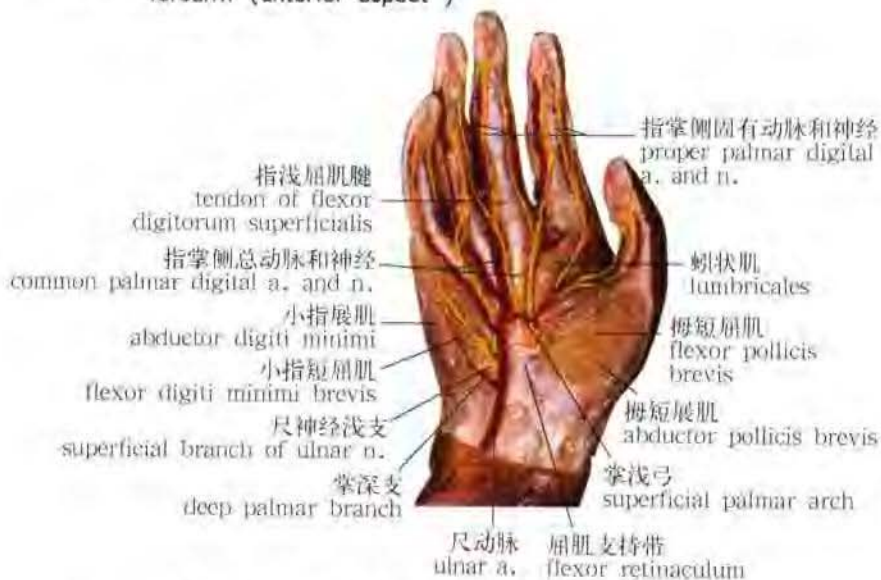

图 365 手的肌肉、血管和神经 (掌侧面观)  
Muscles, blood vessels and nerves of the hand (palmar aspect)

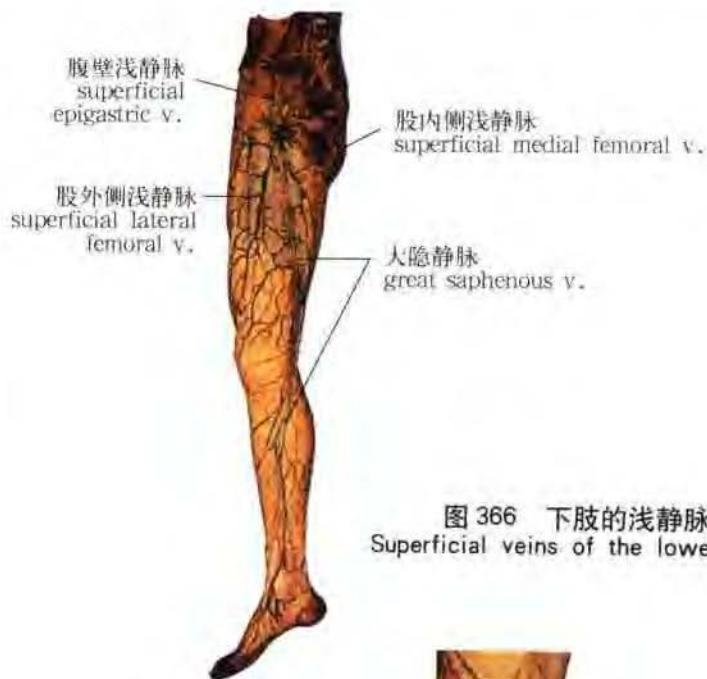

图 366 下肢的浅静脉  
Superficial veins of the lower limb

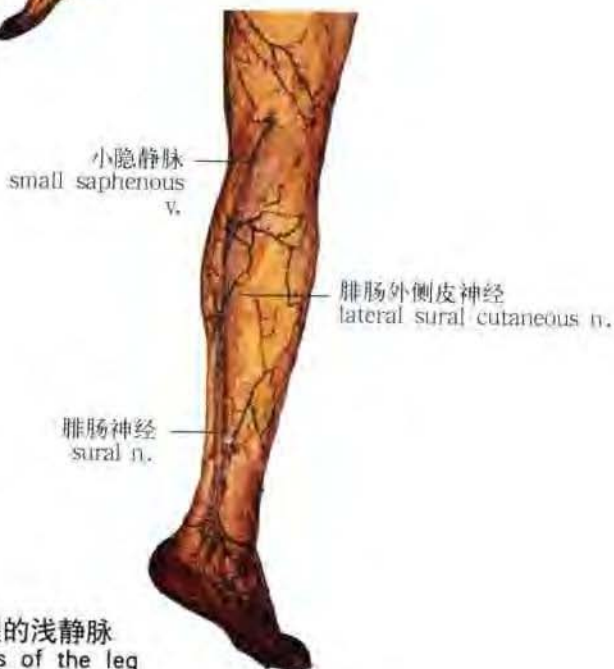

图 367 小腿的浅静脉  
Superficial veins of the leg

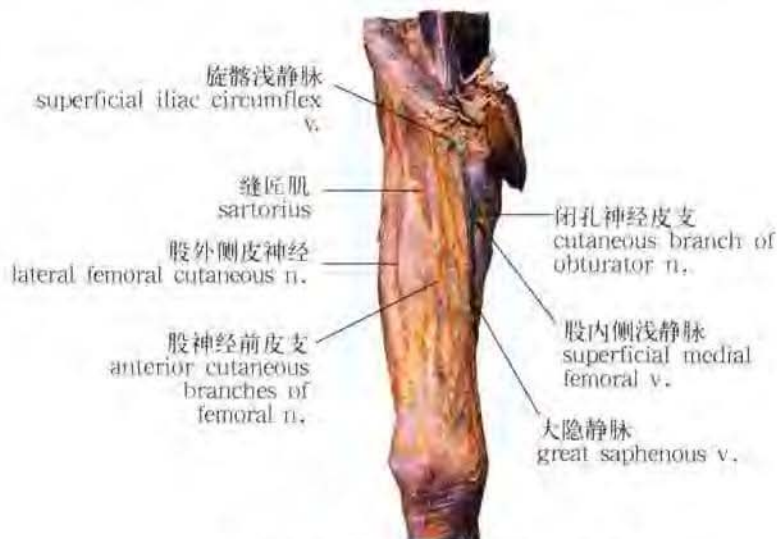


图 368 股前区皮神经和浅静脉  
 Cutaneous nerves and superficial veins of anterior region of the thigh

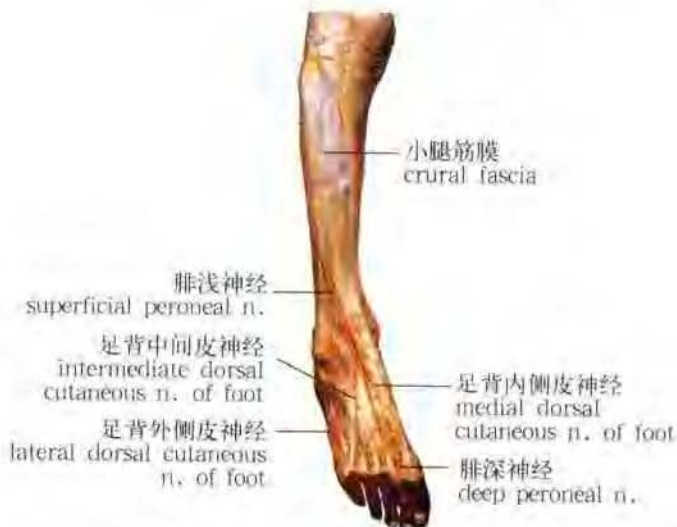

图 369 小腿的皮神经和浅静脉(前面观)  
 Cutaneous nerves and superficial veins of the leg (anterior aspect)

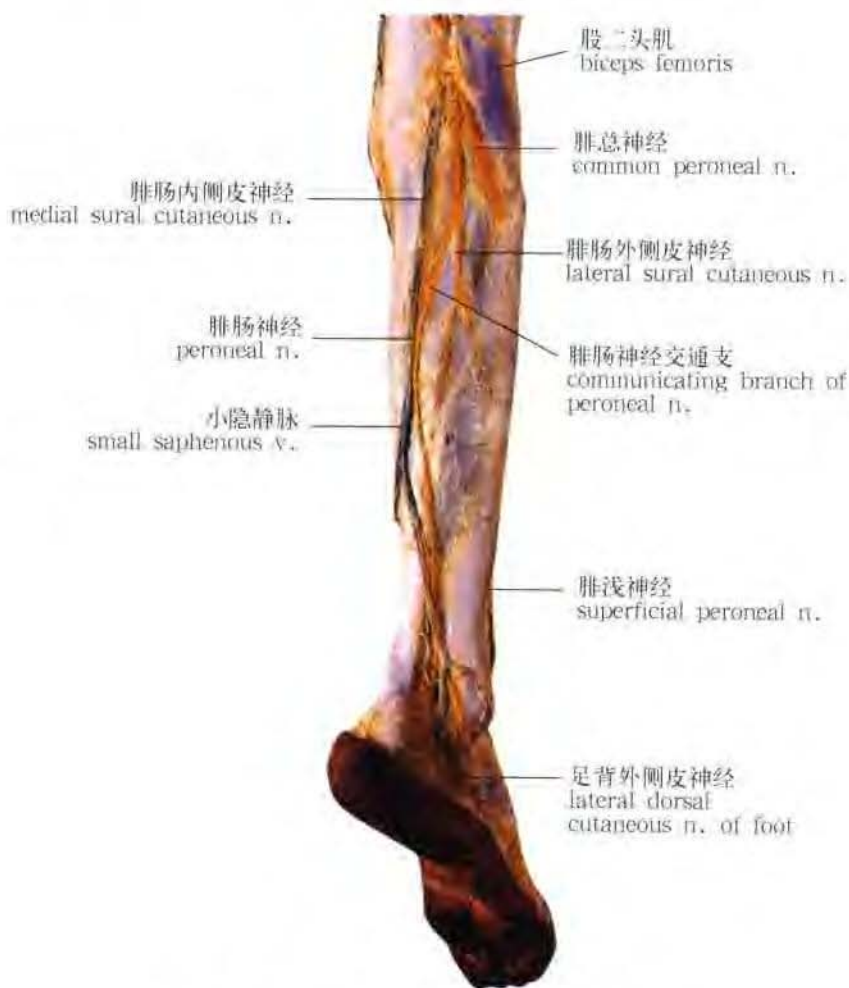

图 370 小腿的皮神经和浅静脉(后面观)  
Cutaneous nerves and superficial veins of the leg  
(posterior aspect)

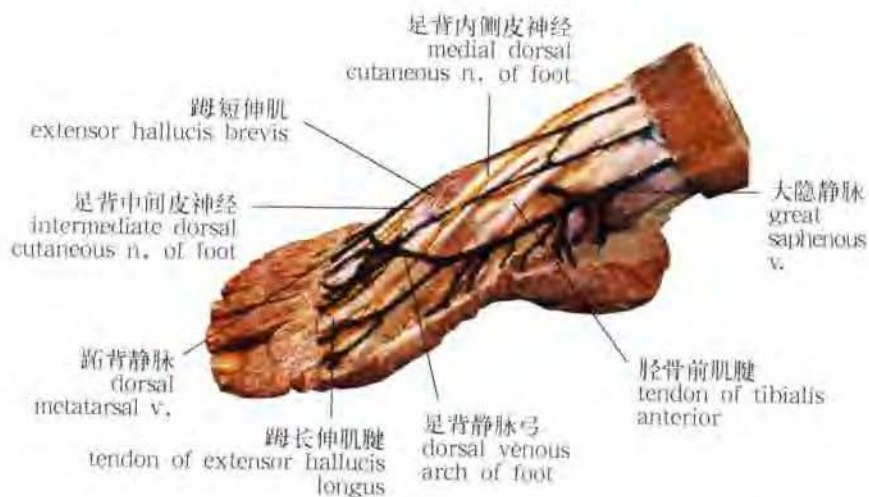

图 371 足背的神经和浅静脉  
 Nerves and superficial veins of dorsum of the foot



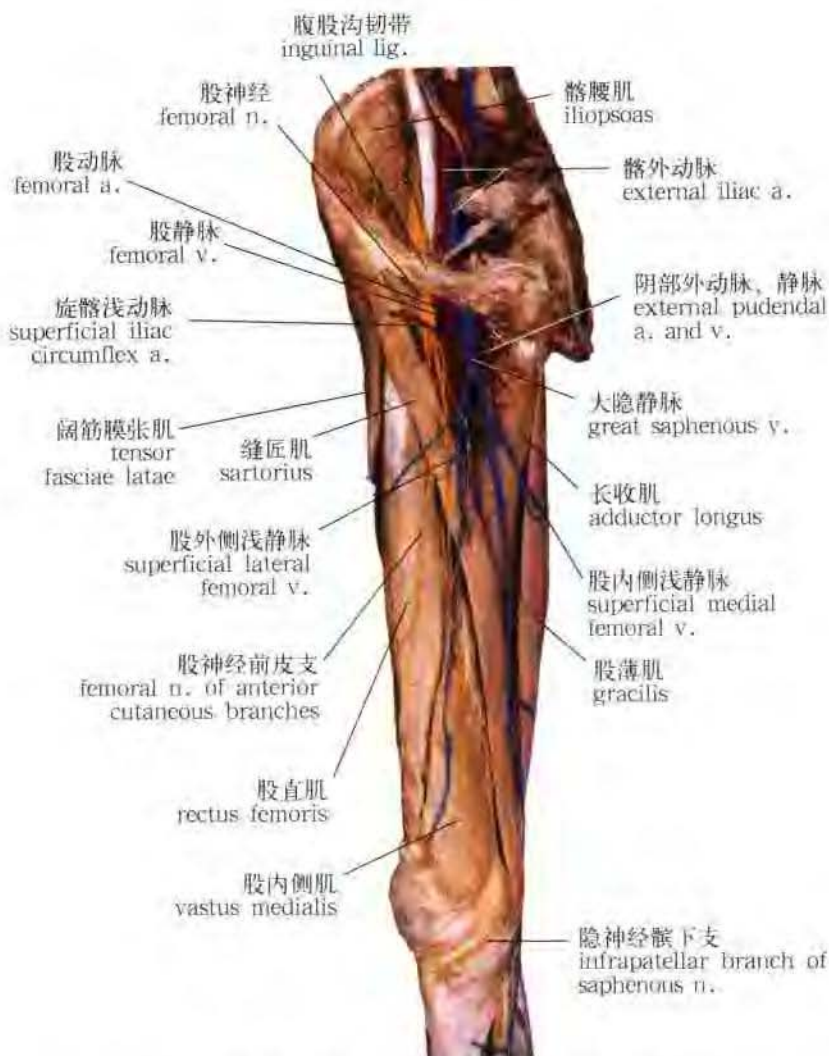

图 372 股前区的肌肉、血管和神经  
Muscles, blood vessels and nerves of anterior region of the thigh

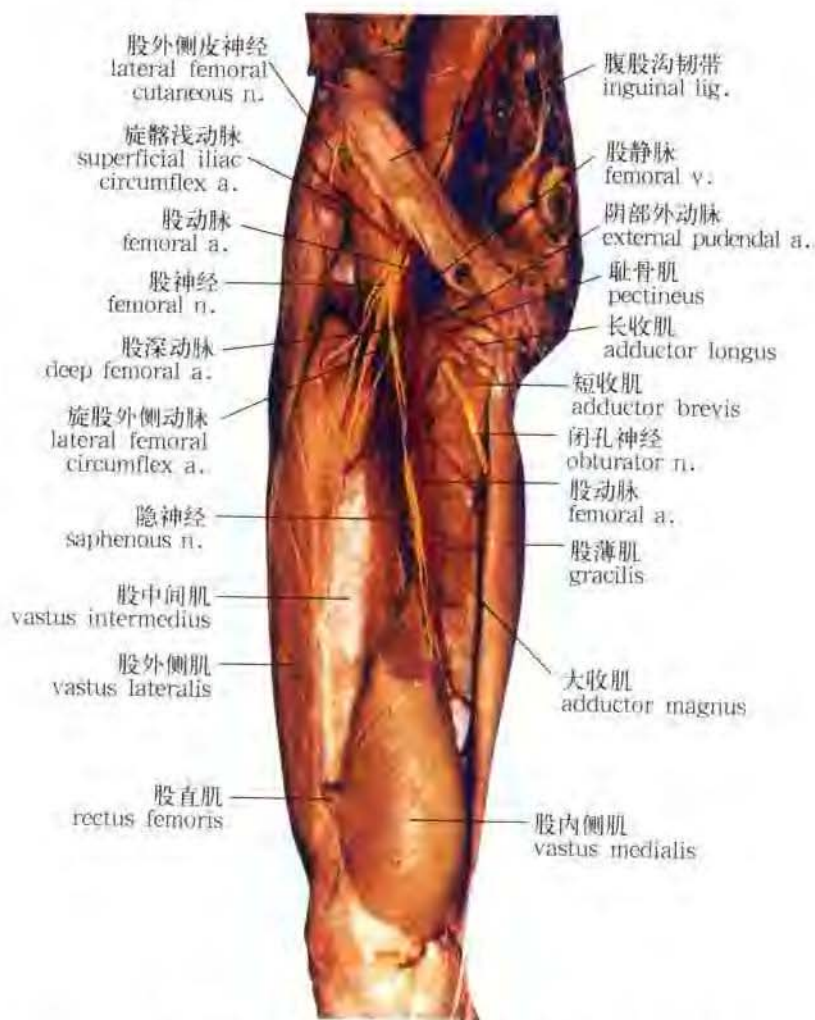

图 373 股前区的肌肉、血管和神经  
Muscles, blood vessels and nerves of anterior region of the thigh

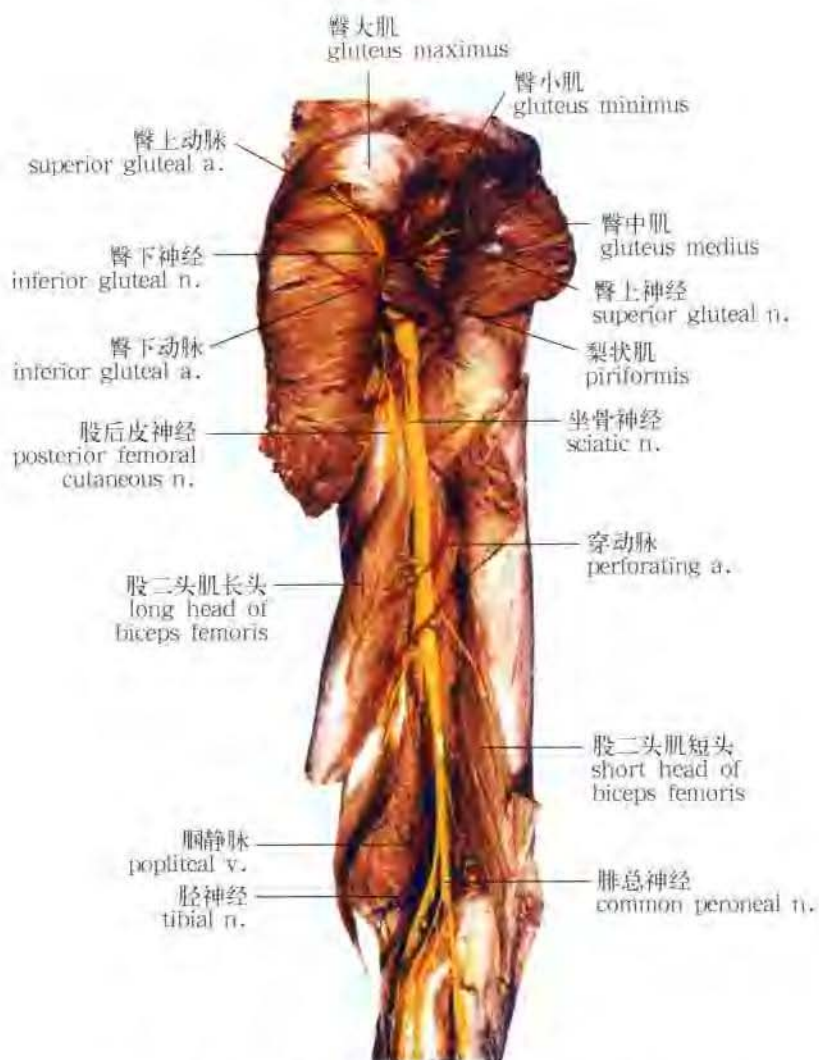

图 374 臀区和股后区的肌肉、血管和神经  
Muscles, blood vessels and nerves of gluteal region  
and posterior region of the thigh

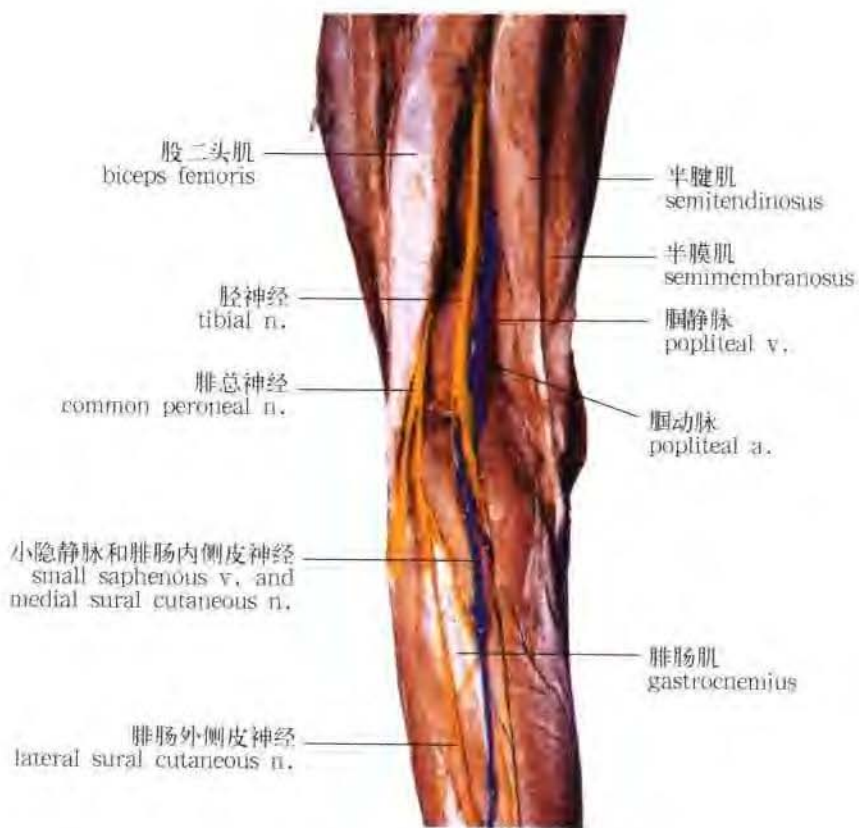

图 375 腘窝的肌肉、血管和神经  
 Muscles, blood vessels and nerves of the popliteal fossa

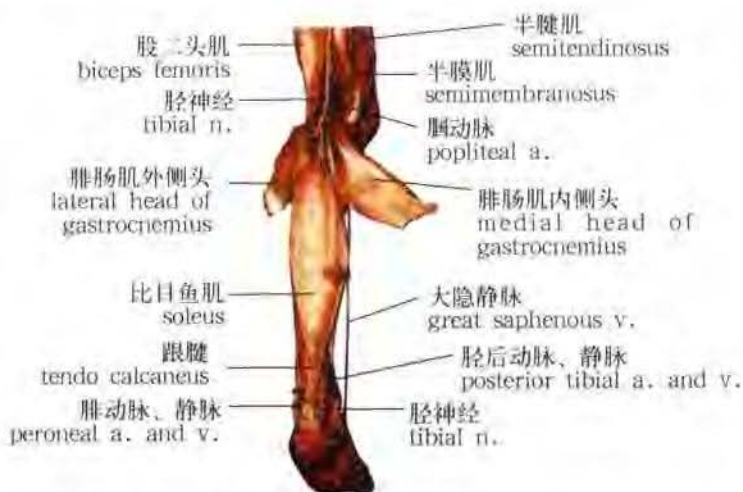

图 376 小腿的肌肉、血管和神经 (后面观 1)  
Muscles, blood vessels and nerves of the leg (posterior aspect 1)

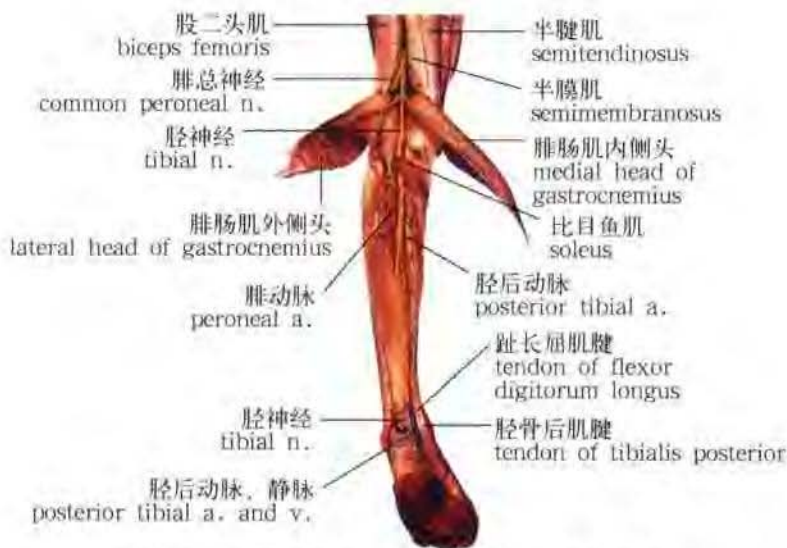

图 377 小腿的肌肉、血管和神经 (后面观 2)  
Muscles, blood vessels and nerves of the leg (posterior aspect 2)

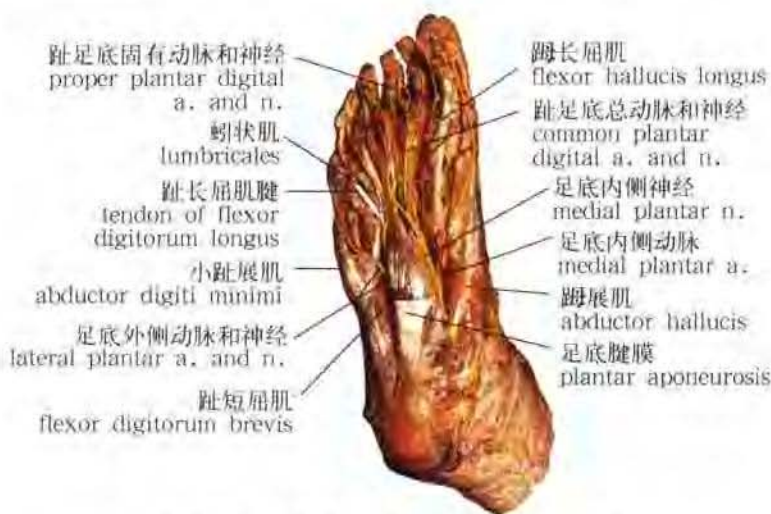

图 378 足底的肌肉、血管和神经 (1)  
Muscles, blood vessels and nerves of sole of the foot(1)

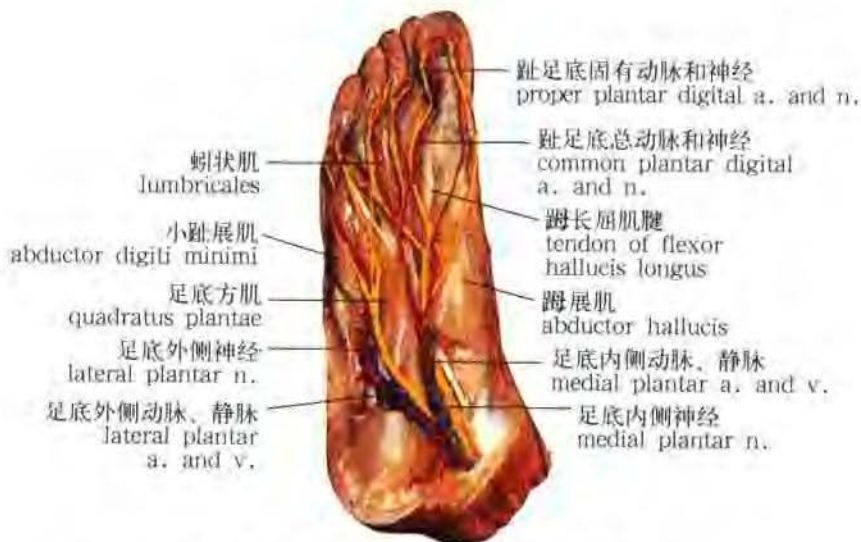

图 379 足底的肌肉、血管和神经 (2)  
Muscles, blood vessels and nerves of sole of the foot(2)