

主编

刘树伟



编者

刘树伟 (山东大学医学院解剖学教研室)
李振平 (山东大学医学院解剖学教研室)
李传福 (山东大学齐鲁医院放射科)
赵 斌 (山东省医学影像学研究所)
柳 澄 (山东省医学影像学研究所)
马祥兴 (山东大学齐鲁医院放射科)
高 波 (山东大学医学院解剖学教研室)
郑金勇 (山东大学齐鲁医院放射科)
于台飞 (山东省医学影像学研究所)
林祥涛 (山东大学医学院影像诊断学教研室)
丁 娟 (山东大学医学院解剖学教研室)
曹建书 (山东大学医学院解剖学教研室)

标本制作

刘树伟 王 政 尹群生 王宏宇 高 波 宋 涛 李贵宝
田广平 刘书涛 (山东大学医学院解剖学教研室)

摄影

刘树伟 高 波

前 言

人体断层解剖学是用断层方法研究和表达人体正常形态结构和基本功能的科学,是分析和识别现代医学图像的形态学基础。1970年以来,由于超声成像(US)、X线计算机断层成像(CT)、磁共振成像(MRI)、单光子发射计算机断层显像(SPECT)和正电子发射计算机断层显像(PET)等断层影像技术的出现,人体断层解剖学得到了空前发展,其研究范围扩展为解剖断层和影像断层两个方面,前者主要研究人体断层标本,后者主要研究正常人体的US、CT和MRI等断层图像。目前,US、CT和MRI等技术已被广泛应用于疾病的诊断和介入治疗,每一位临床医师均有必要学会正确地阅读和解释CT、MRI图像。因此,人体断层解剖学已成为高等医学院校学生的必修课程,并被卫生部纳入临床医师继续医学教育的内容。

我校自1989年便开设了人体断层解剖学课程,并自1993年始连续举办了10届全国断层解剖学学习班(为国家级继续医学教育项目),所取得的教学成果于1997年获国家级教学成果二等奖。在教学过程中,师生们均感到如能有一本与教材相匹配的断层解剖学图谱在手,必能有利于教师的备课和学生的自学,从而大大提高教学效果。然而,目前尚无这样的图谱出版。为此,我们从多年积累的科研资料中精选图片,编著了这部《人体断层解剖学图谱》,供高等医学院校的教师和学生在学习中使用时,亦可供临床各科医师在分析疾病的US、CT和MRI图像时参考。

图谱是表达断层解剖学的最好形式。一部好的断层解剖图谱,不仅具有持久的艺术魅力,而且还能锻炼读者的观察能力和空间思维能力。为实现编写目的,我们力求做到以下几点:①与教材相匹配,内容的选择以刘树伟主编的高等医学院校教材《断层解剖学》为主要依据;②除脊柱区和四肢外,选用连续断层,以有益于对某一结构的连续追踪观察,建立空间思维;③强调解剖断层与影像断层的融合,每一断层均包括断层标本彩色照片与CT、MRI图像;④标注细致,采用中、英文对照形式,解剖学名词以国家自然科学名词审定委员会公布的《人体解剖学名词》(科学出版社,1991)为准。

全书共有成人断层标本彩色照片120幅、CT和MRI图像270幅。人体断层标本由山东大学医学院解剖学教研室采用冰冻切片技术制作,头部和四肢断层标本的层厚为8mm,躯干部断层标本的层厚为10mm。头部横断层标本的制作以眦耳线为基线,头部矢状断层标本的制作基线平行于正中矢状面,头部冠状断层标本的制作基线垂直于

眦耳线。CT和MRI图像取自活体，由山东大学齐鲁医院放射科和山东省医学影像学研究所制作，CT扫描机为螺旋CT和多层螺旋CT，MRI扫描机的场强为1.5 T。需要指出的是：高波、林祥涛和刘学静医师，不顾X线对组织的损害，提供了自己身体的CT和MRI图像。这种忘我的牺牲精神，令人钦佩。栾铭箴教授和华伯坝教授多年来一直给予悉心指导，山东大学医学院解剖学教研室的老师们给予了许多帮助，在此一并表示衷心感谢。

尽管我们反复校阅，书中一定还有许多不足之处，望不吝赐教。

中国解剖学会断层影像解剖学专业委员会主任委员 刘树伟

Preface

Human sectional anatomy is the science which studies and demonstrates normal structure and basic function of the human body with the sectioning methods. It has become morphological fundament for analyzing and recognizing modern medical imaging. Since 1970, human sectional anatomy has gotten an unprecedented development and expanded its research area to the cadaver section and imaging section with the booming of sectional imaging modalities, such as ultrasound (US), X-ray computed tomography (CT), magnetic resonance imaging (MRI), single photon emission computed tomography (SPECT), and positron emission computed tomography (PET). At present, as US, CT, and MRI have been widely used in the diagnoses and interventional treatment of the diseases, it is urgent that every clinician understand and interpret CT and MRI images competently. Therefore, human sectional anatomy has become a required course for the students of higher medical school and has been put into the contents of continuing medical education under the sponsorship of national health ministry of China.

In 1989, our university began to offer the course of sectional anatomy for medical students. Since 1993, we have sponsored 10 national study classes of sectional anatomy (the national project of continuing medical education). In 1997, we got the second prize of national achievement in teaching for our course of sectional anatomy. During the teaching activity, both the teachers and students feel that an atlas of sectional anatomy matching with textbook is necessary. This atlas would contribute to the preparing the lessons for the teachers and the teaching themselves for the students. Therefore, we carefully chose the pictures accumulated in our research works over ten years and compiled this book-*Atlas of Human Sectional Anatomy*. We hope this atlas will be used in the sectional anatomic teaching by the teachers and students of the higher medical school and provide the reference for the physicians of the hospitals when they are interpreting US, CT, and MRI images of the diseases.

Atlas is the best modality for showing the sectional anatomy. A good atlas of the sectional anatomy can not only endure its art charm, but also train the reader's ability of observation and the ability of three-dimensional thinking. In order to realize the purpose of compiling, we try hard to reach the following: ① matching this atlas with textbook of the sectional anatomy

edited by Liu Shuwei; ② choosing and using the serial sections except the vertebral region and limbs, which is beneficial of tracing some structures on serial sections and helping the students to establish the space thinking; ③ enhancing matching the cadaver sections with imaging sections; ④ giving a detailed legends both in Chinese and English. The anatomic terms are used according to *the Human Anatomic Terms* published in 1991 by the National Examination and Approval Committee on Natural Scientific Terminology.

This atlas comprises 120 color pictures of sectional specimen of adult and 270 CT and MRI images. The sectional specimens of the human body are prepared by the freezing section technique in department of anatomy of College of Medicine, Shandong University. The thickness of sections is 8mm for head and limbs and 10mm for trunk. The plane of reference for horizontal sections of the head is the plane through the canthomeatal line. The plane of reference for sagittal sections of the head is the median plane. The plane of reference for coronal sections of the head is perpendicular to the canthomeatal line. CT and MRI images are scanned by spiral or multislice spiral CT machine and 1.5 Tesla MR scanner in department of radiology of Cheeloo Hospital, Shandong University and Shandong Institute for Medical Imaging respectively.

I would like to express my gratitude to Prof. Luan Mingzhen and Prof. Hua Boxun who have given me a lot of directors for this book. I also want to give my thanks to Dr. Gao Bo, Dr. Lin Xiangtao, and Dr. Liu Xuejing who had their bodies X-rayed for obtaining CT and MRI images.

Chairman of Committee for Sectional
and Imaging Anatomy of Chinese Society
for Anatomical Sciences

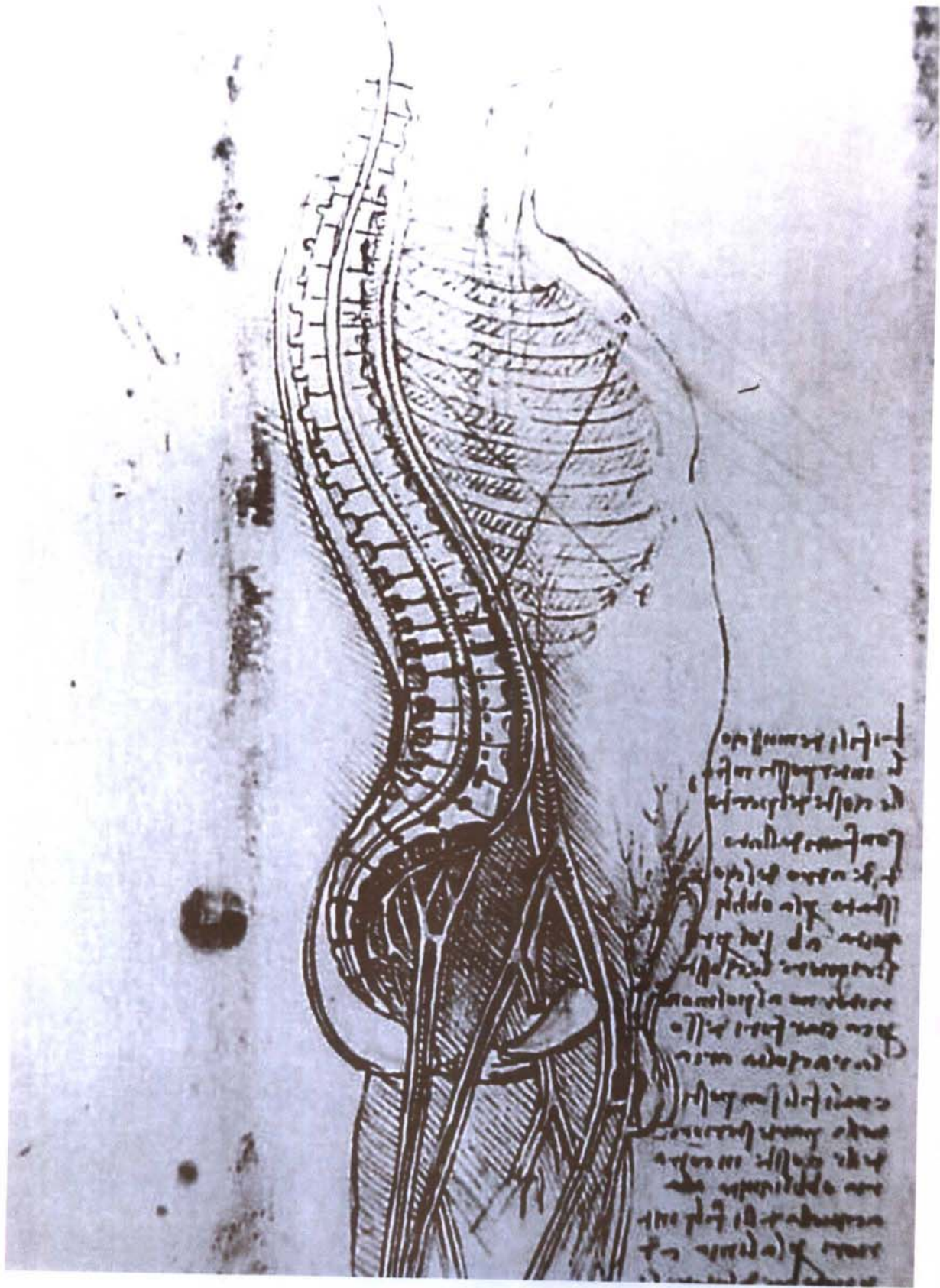
Liu Shuwei

目 录

第一章 头部连续横断层	2
第二章 颈部连续横断层	30
第三章 头颈部连续矢状断层	42
第四章 头颈部连续冠状断层	54
第五章 胸部连续横断层	84
第六章 腹部连续横断层	118
第七章 男性盆部连续横断层	152
第八章 女性盆部连续横断层	164
第九章 脊柱区横、矢、冠状断层	194
第十章 上肢横断层	206
第十一章 下肢横、矢、冠状断层	220
参考文献	242
中文索引	243
英文索引	252

Contents

Preface	
Chapter 1 Serial Transverse Sections of Head	2
Chapter 2 Serial Transverse Sections of Neck	30
Chapter 3 Serial Sagittal Sections of Head and Neck	42
Chapter 4 Serial Coronal Sections of Head and Neck	54
Chapter 5 Serial Transverse Sections of Thorax	84
Chapter 6 Serial Transverse Sections of Abdomen	118
Chapter 7 Serial Transverse Sections of Male Pelvis	152
Chapter 8 Serial Transverse Sections of Female Pelvis	164
Chapter 9 Transverse, Sagittal, and Coronal Sections of Vertebral Region	194
Chapter 10 Transverse Sections of Upper Limb	206
Chapter 11 Transverse, Sagittal, and Coronal Sections of Lower Limb	220
References	242
Index (Chinese)	243
Index (English)	252



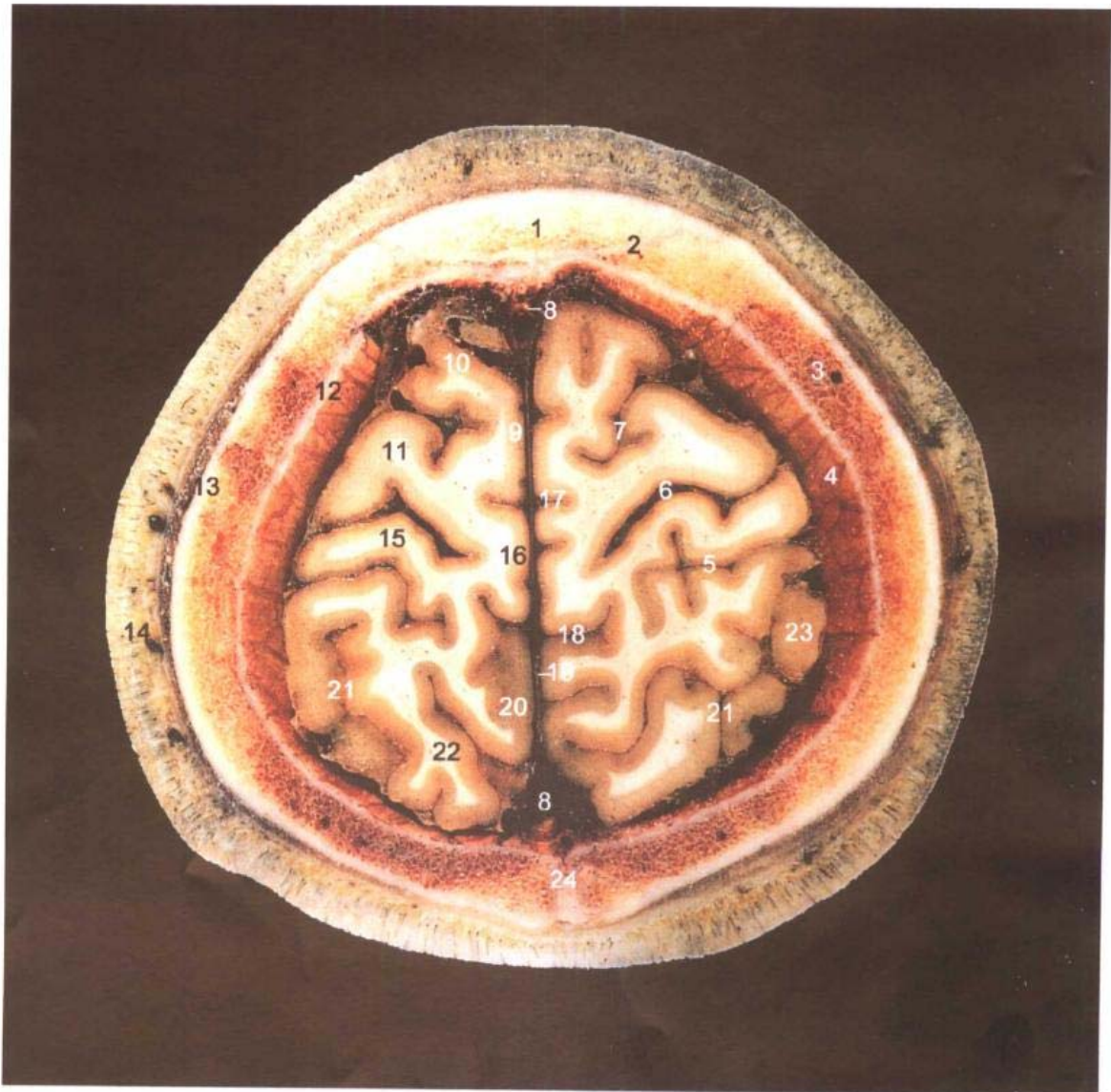
意大利画家达·芬奇于16世纪初绘制的男性躯干部正中矢状断面图。
Median sagittal section of the male trunk pictured by Leonardo da Vinci,
in the early part of the 16th century.

第一章 头部连续横断层

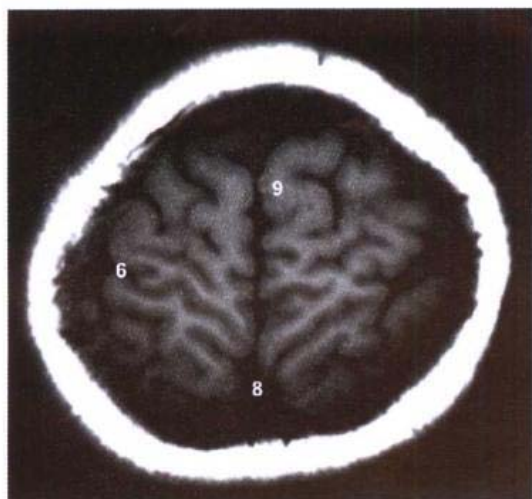
Chapter 1 Serial Transverse Sections of Head

图 1-1 经中央旁小叶上份的横断层

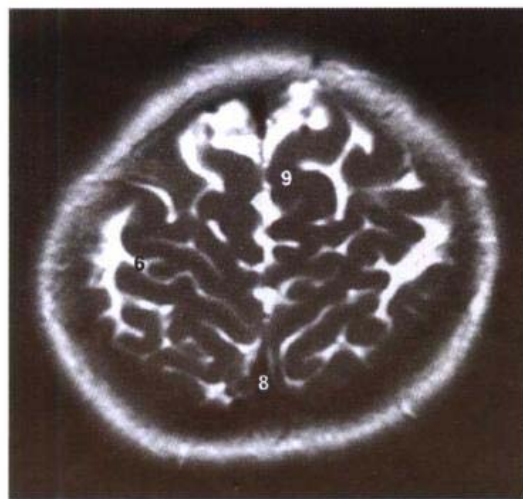
Fig. 1-1 Transverse section through upper part of paracentral lobule



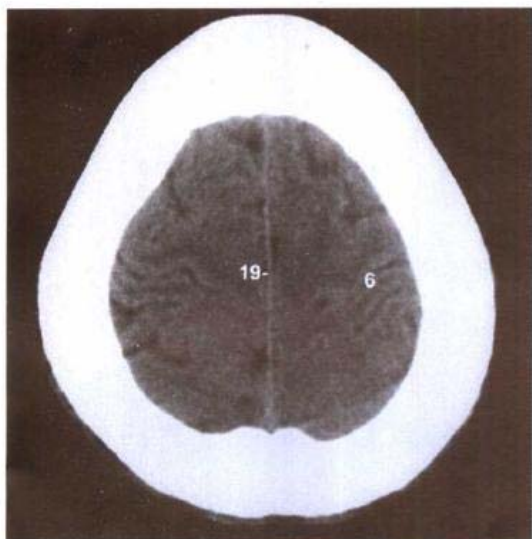A. 断层标本(sectional specimen)



B. MRI T₁ WI

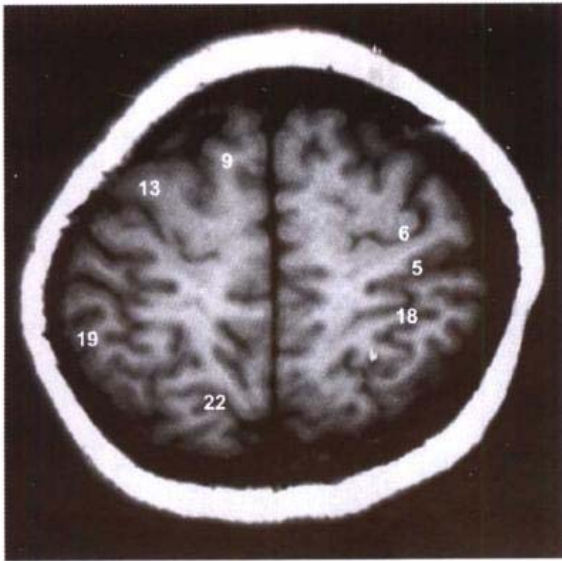

C. MRI T₂ WI

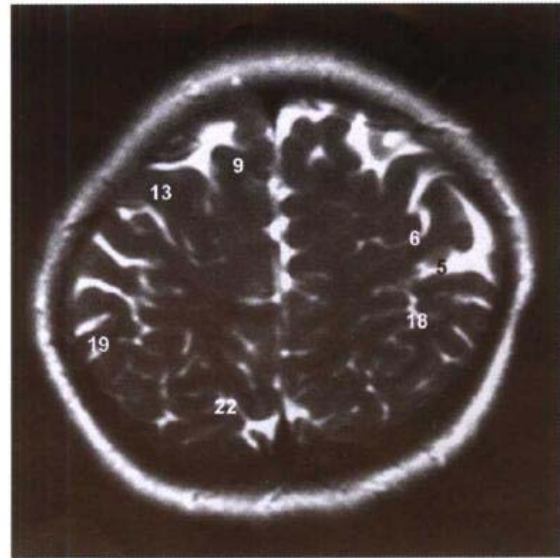


D. CT

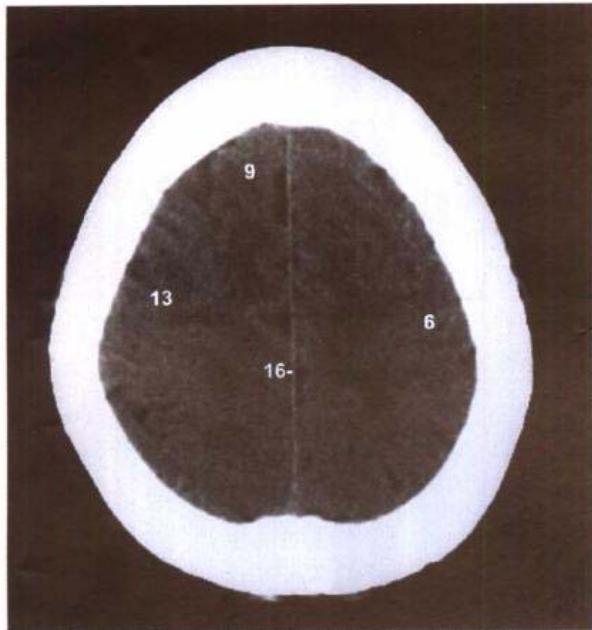
1. 额骨 frontal bone
2. 冠状缝 coronal suture
3. 板障 diploë
4. 硬脑膜 cerebral dura mater
5. 中央后沟 postcentral sulcus
6. 中央沟 central sulcus
7. 中央前沟 precentral sulcus
8. 上矢状窦 superior sagittal sinus
9. 额内侧回 medial frontal gyrus
10. 额上回 superior frontal gyrus
11. 中央前回 precentral gyrus
12. 内板 inner plate
13. 外板 outer plate
14. 头皮 scalp
15. 中央后回 postcentral gyrus
16. 中央旁小叶 paracentral lobule
17. 中央旁沟 paracentral sulcus
18. 扣带沟缘支 marginal ramus of cingulate sulcus
19. 大脑镰 cerebral falx
20. 楔前叶 precuneus
21. 顶内沟 intraparietal sulcus
22. 顶上小叶 superior parietal lobule
23. 顶下小叶 inferior parietal lobule
24. 矢状缝 sagittal suture



B. MRI T₁ WI



C. MRI T₂ WI

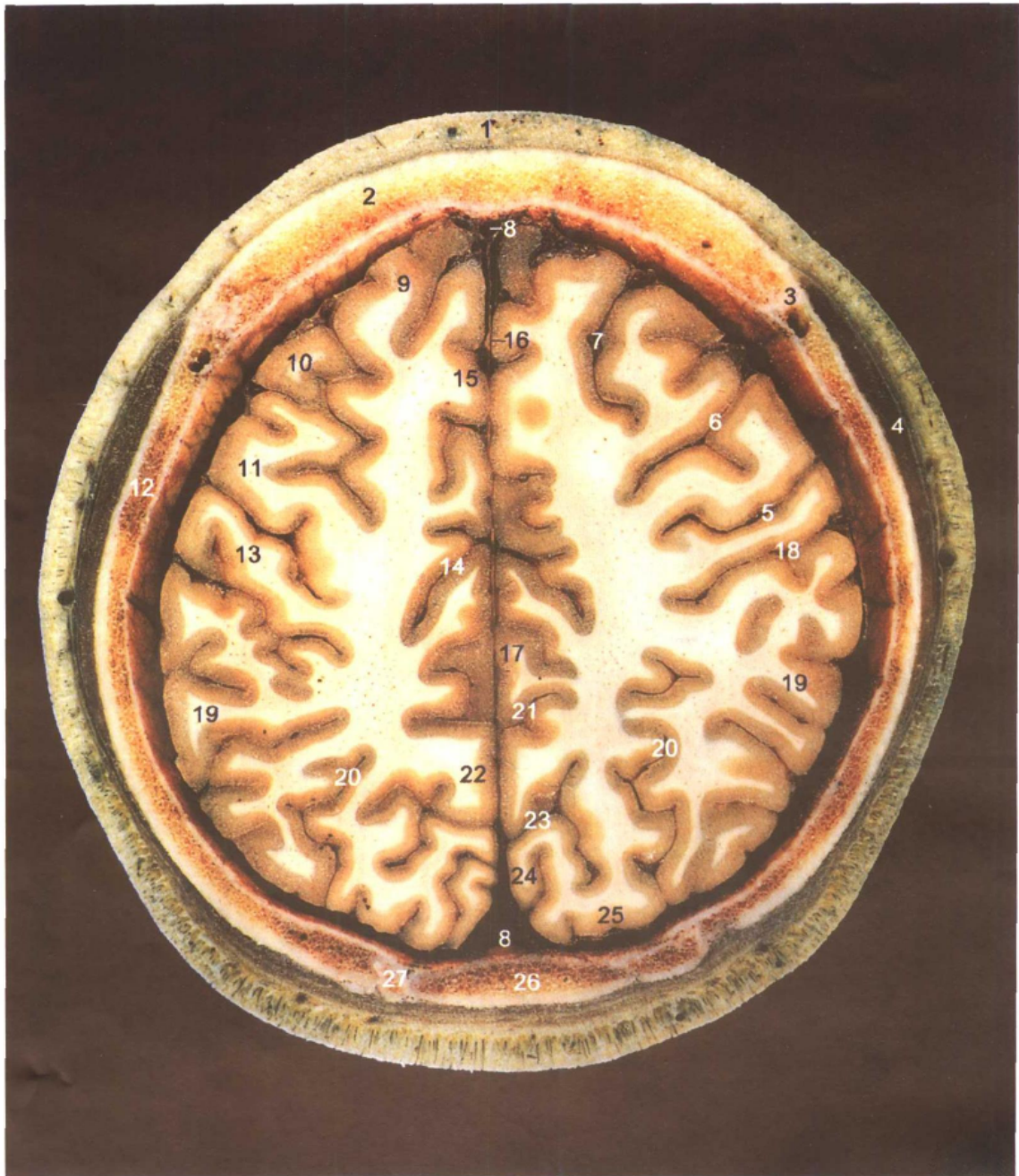


D. CT

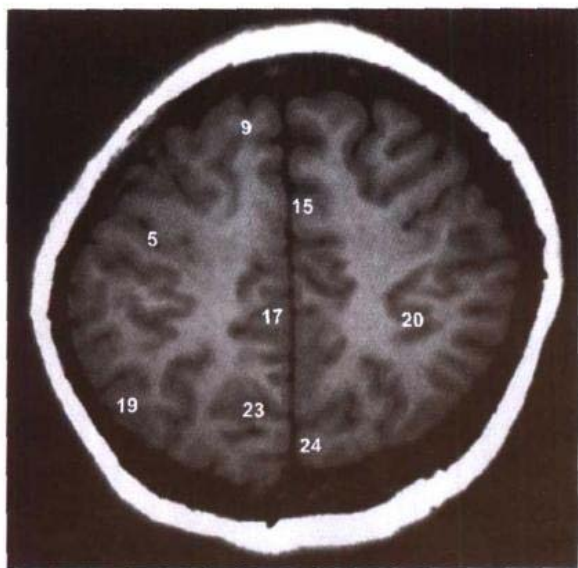
1. 头皮 scalp
2. 额骨 frontal bone
3. 冠状缝 coronal suture
4. 颞肌 temporalis
5. 中央后沟 postcentral sulcus
6. 中央沟 central sulcus
7. 额上沟 superior frontal sulcus
8. 上矢状窦 superior sagittal sinus
9. 额上回 superior frontal gyrus
10. 额中回 middle frontal gyrus
11. 顶骨 parietal bone
12. 中央前沟 precentral sulcus
13. 中央前回 precentral gyrus
14. 额内侧回 medial frontal gyrus
15. 中央旁小叶 paracentral lobule
16. 大脑镰 cerebral falx
17. 扣带沟缘支 marginal ramus of cingulate sulcus
18. 顶内沟 intraparietal sulcus
19. 顶下小叶 inferior parietal lobule
20. 枕叶 occipital lobe
21. 楔前叶 precuneus
22. 顶枕沟 parietooccipital sulcus
23. 中央后回 postcentral gyrus
24. 顶上小叶 superior parietal lobule
25. 人字缝 lambdoid suture
26. 枕骨 occipital bone

图 1-3 经顶枕沟上份的横断层

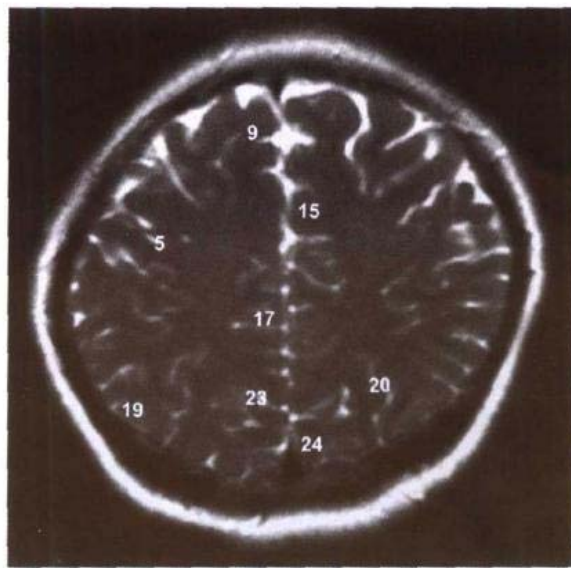
Fig.1-3 Transverse section through upper part of parietooccipital sulcus



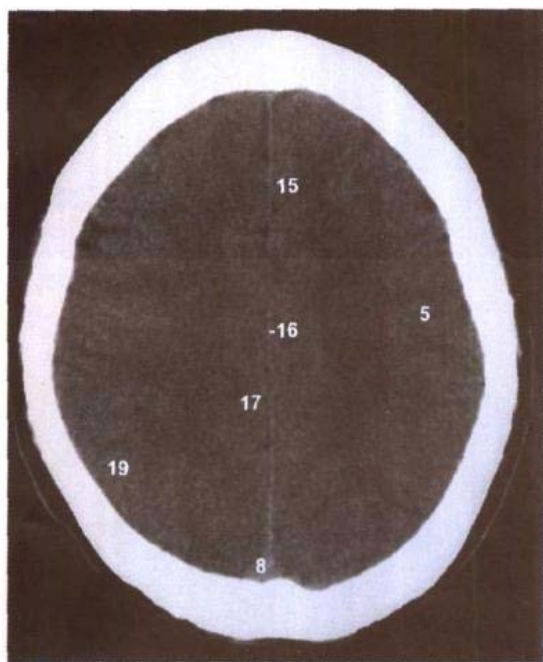
A. 断层标本(sectional specimen)



B. MRI T₁ WI



C. MRI T₂ WI

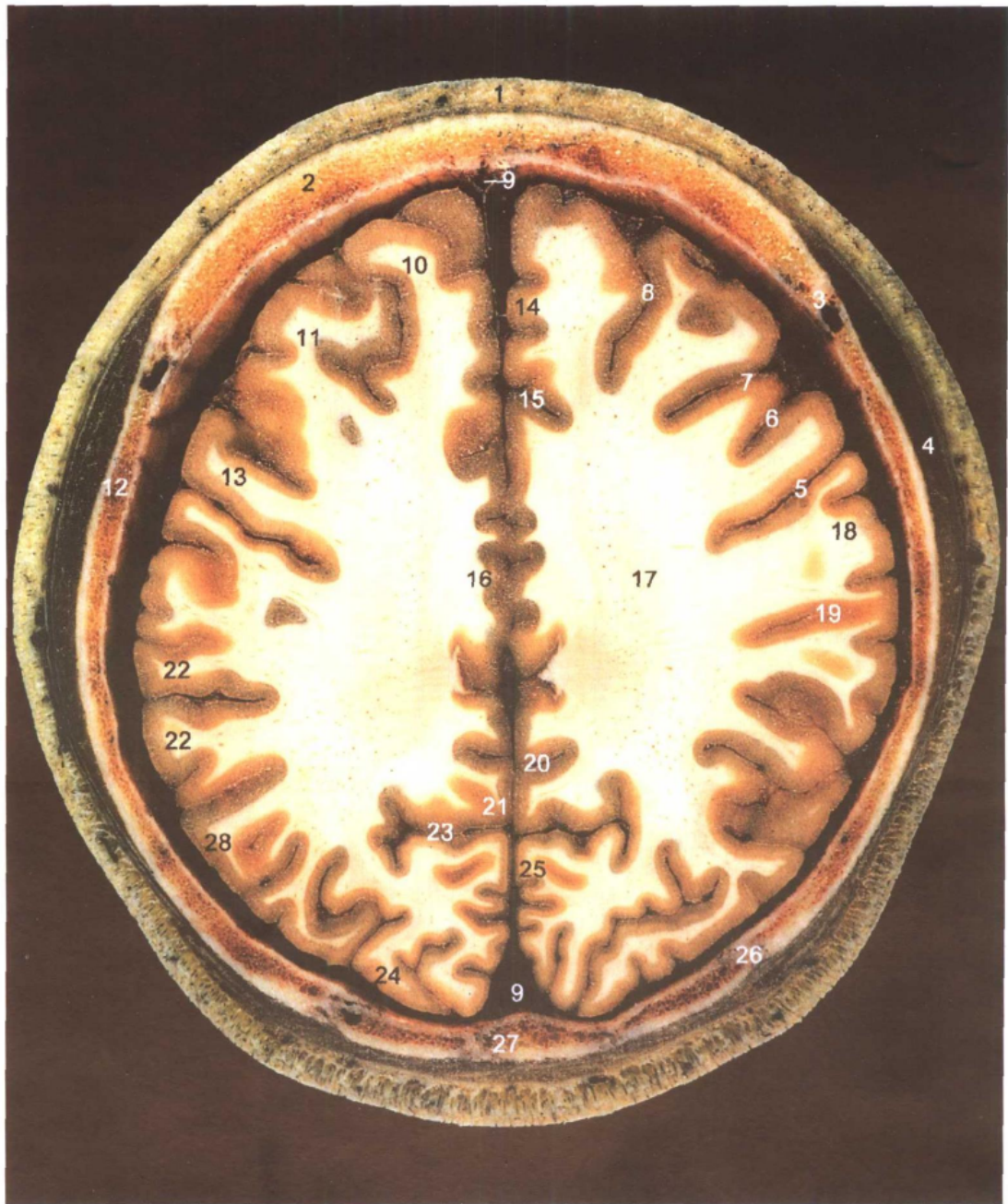


D. CT

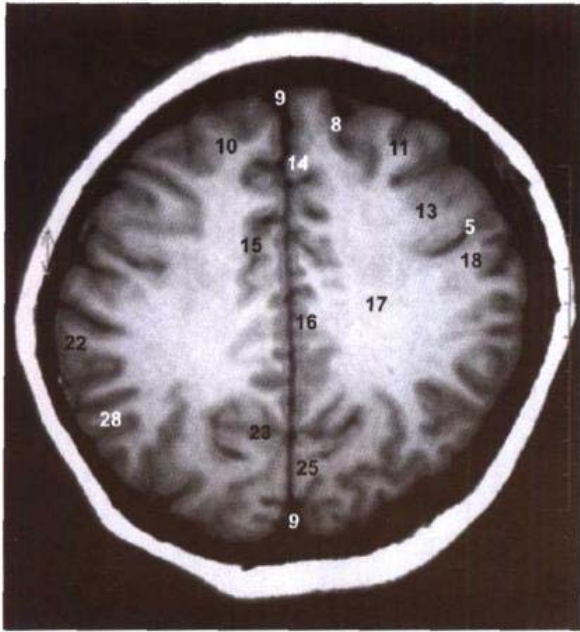
1. 头皮 scalp
2. 额骨 frontal bone
3. 冠状缝 coronal suture
4. 颞肌 temporalis
5. 中央沟 central sulcus
6. 中央前沟 precentral sulcus
7. 额上沟 superior frontal sulcus
8. 上矢状窦 superior sagittal sinus
9. 额上回 superior frontal gyrus
10. 额中回 middle frontal gyrus
11. 中央前回 precentral gyrus
12. 顶骨 parietal bone
13. 中央后回 postcentral gyrus
14. 扣带沟 cingulate sulcus
15. 额内侧回 medial frontal gyrus
16. 大脑镰 cerebral falx
17. 扣带回 cingulate gyrus
18. 中央后沟 postcentral sulcus
19. 顶下小叶 inferior parietal lobule
20. 顶内沟 intraparietal sulcus
21. 顶下沟 subparietal sulcus
22. 楔前叶 precuneus
23. 顶枕沟 parietooccipital sulcus
24. 楔叶 cuneus
25. 枕外侧回 lateral occipital gyrus
26. 枕骨 occipital bone
27. 人字缝 lambdoid suture

图 1-4 经半卵圆中心的横断层

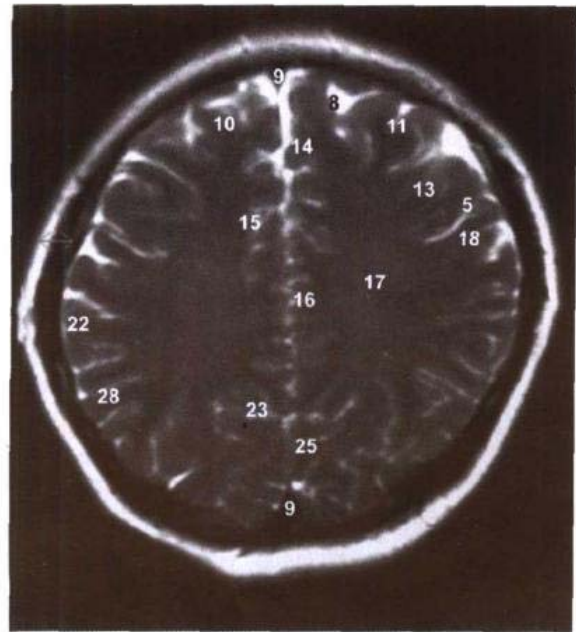
Fig.1-4 Transverse section through centrum semiovale



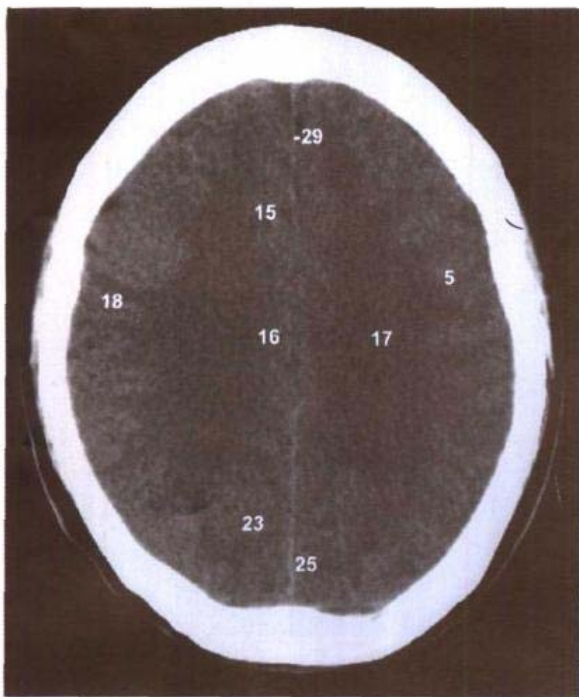
A. 断层标本(sectional specimen)



B. MRI T₁ WI



C. MRI T₂ WI



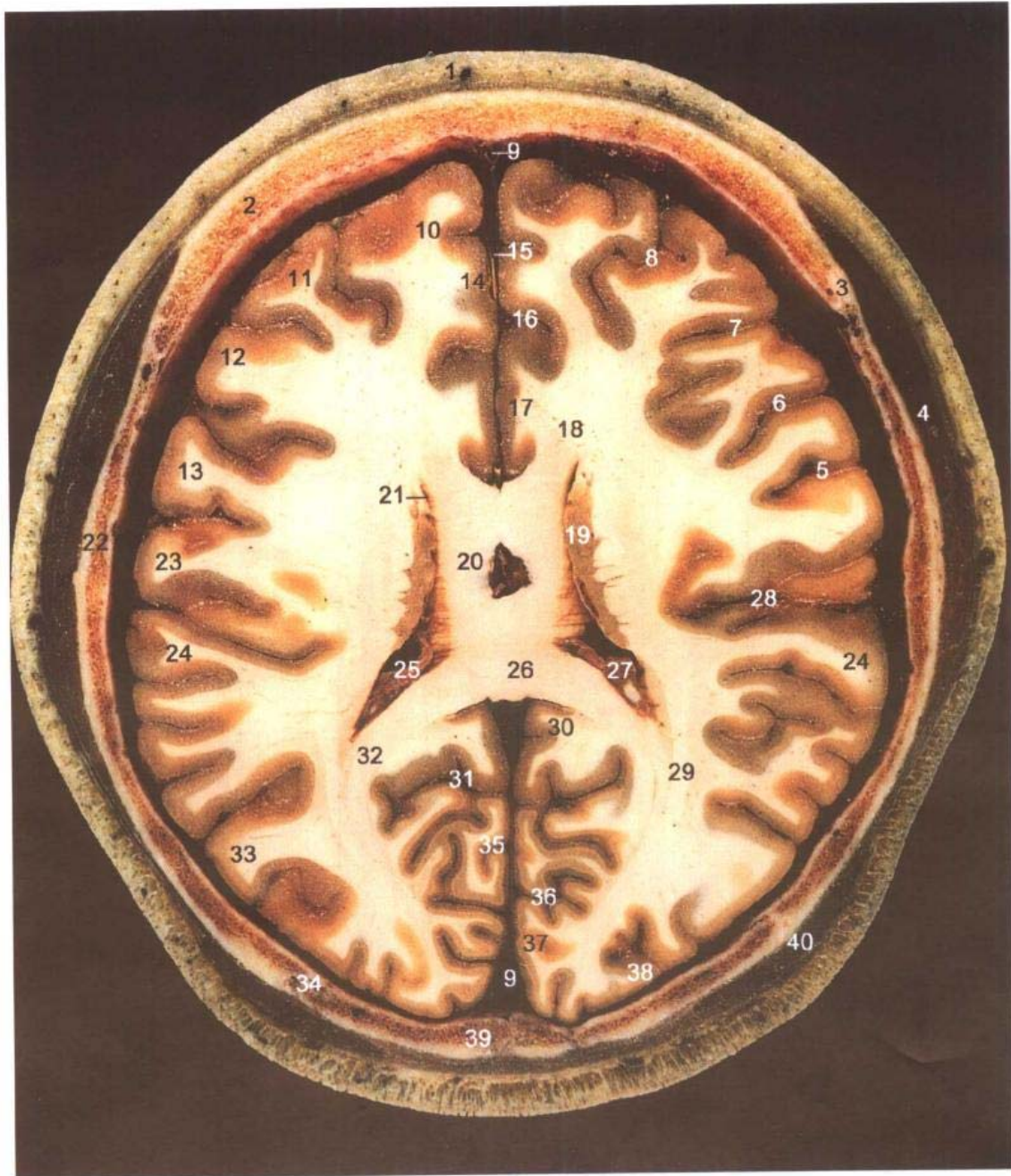
D. CT

1. 头皮 scalp
2. 额骨 frontal bone
3. 冠状缝 coronal suture
4. 颞肌 temporalis

5. 中央沟 central sulcus
6. 中央前沟 precentral sulcus
7. 额下沟 inferior frontal sulcus
8. 额上沟 superior frontal sulcus
9. 上矢状窦 superior sagittal sinus
10. 额上回 superior frontal gyrus
11. 额中回 middle frontal gyrus
12. 顶骨 parietal bone
13. 中央前回 precentral gyrus
14. 额内侧回 medial frontal gyrus
15. 扣带沟 cingulate sulcus
16. 扣带回 cingulate gyrus
17. 半卵圆中心 centrum semiovale
18. 中央后回 postcentral gyrus
19. 中央后沟 postcentral sulcus
20. 顶下沟 subparietal sulcus
21. 楔前叶 precuneus
22. 缘上回 supramarginal gyrus
23. 顶枕沟 parietooccipital sulcus
24. 枕外侧回 lateral occipital gyrus
25. 楔叶 cuneus
26. 人字缝 lambdoid suture
27. 枕骨 occipital bone
28. 角回 angular gyrus
29. 大脑镰 cerebral falx

图 1-5 经胼胝体干的横断层

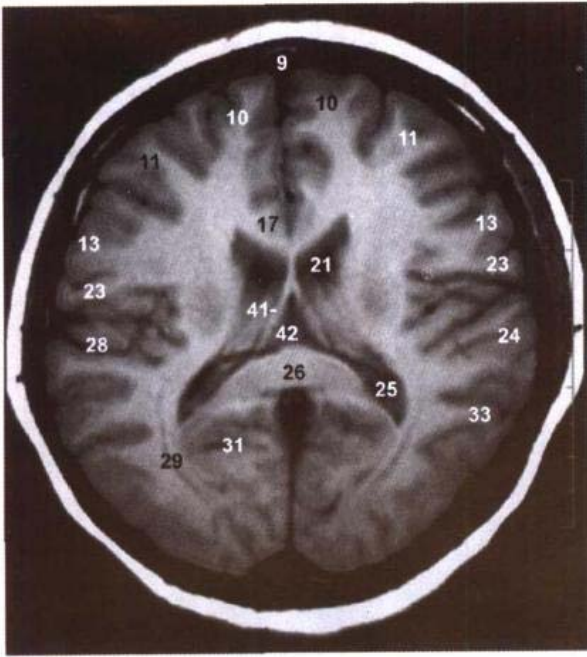
Fig.1-5 Transverse section through trunk of corpus callosum



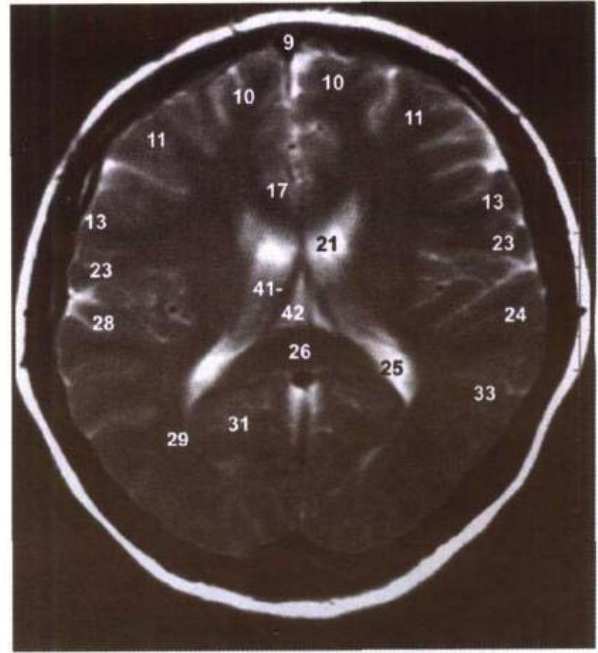
A. 断层标本(sectional specimen)

- 1. 头皮 scalp
- 2. 额骨 frontal bone
- 3. 冠状缝 coronal suture
- 4. 颞肌 temporalis
- 5. 中央沟 central sulcus
- 6. 中央前沟 precentral sulcus

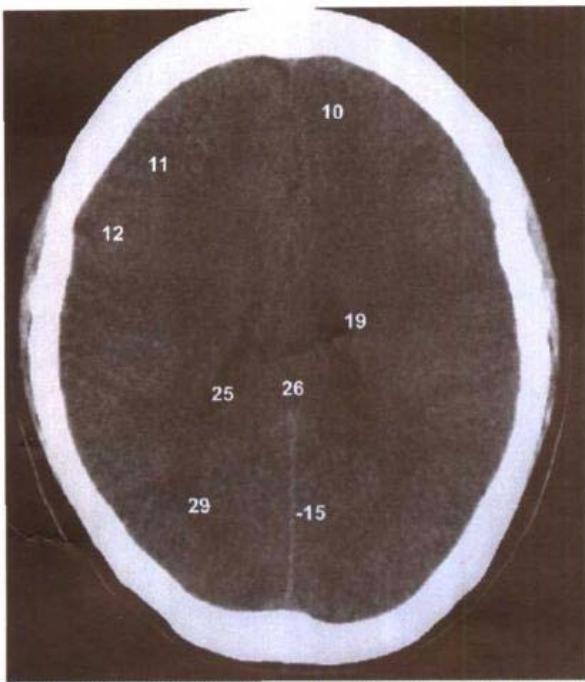
- 7. 额下沟 inferior frontal sulcus
- 8. 额上沟 superior frontal sulcus
- 9. 上矢状窦 superior sagittal sinus
- 10. 额上回 superior frontal gyrus
- 11. 额中回 middle frontal gyrus
- 12. 额下回 inferior frontal gyrus



B. MRI T₁ WI



C. MRI T₂ WI



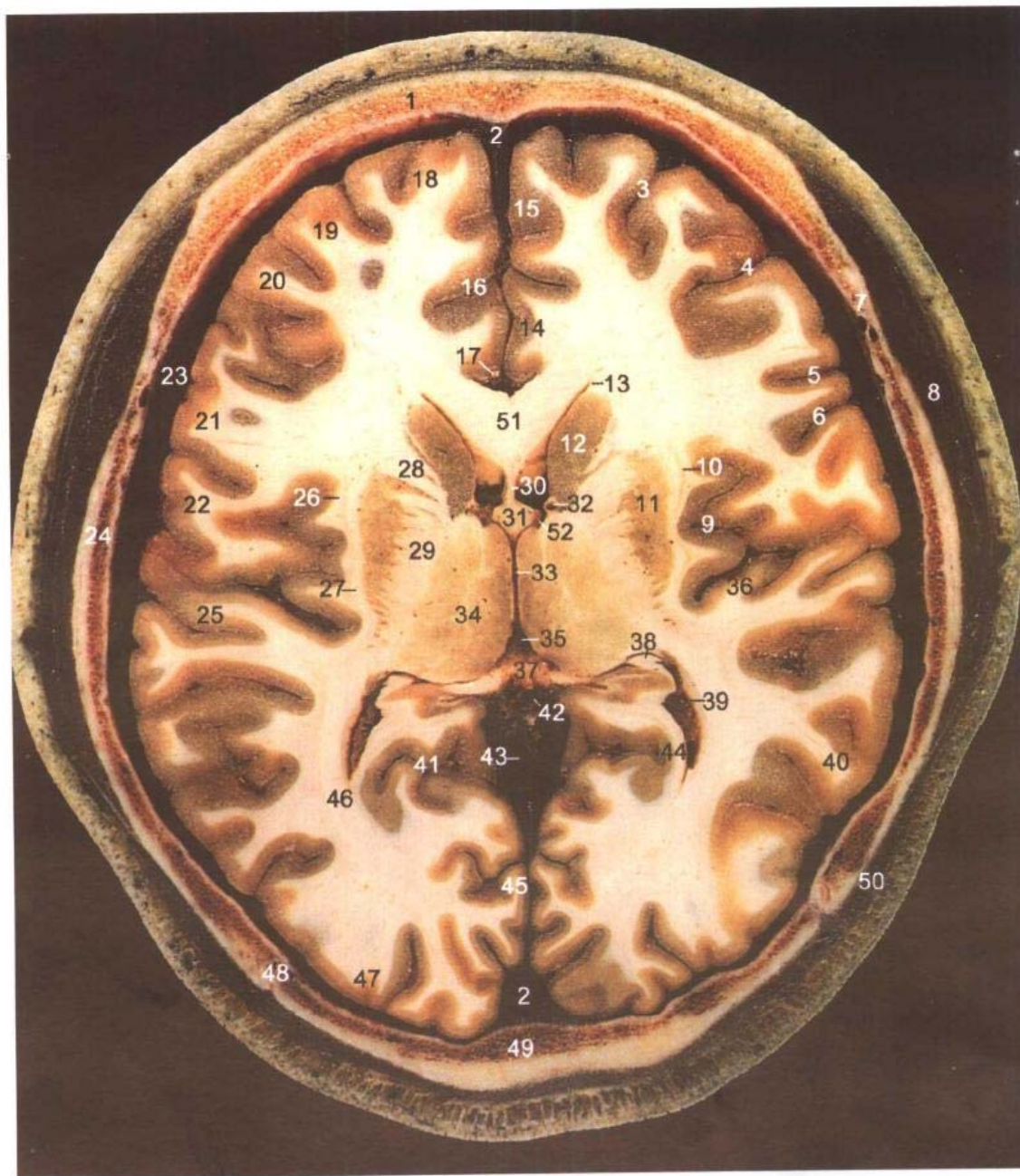
D. CT

- 13. 中央前回 precentral gyrus
- 14. 额内侧回 medial frontal gyrus
- 15. 大脑镰 cerebral falx
- 16. 扣带沟 cingulate sulcus
- 17. 扣带回 cingulate gyrus
- 18. 额钳 frontal forceps

- 19. 尾状核 caudate nucleus
- 20. 胼胝体干 trunk of corpus callosum
- 21. 侧脑室前角 anterior horn of lateral ventricle
- 22. 顶骨 parietal bone
- 23. 中央后回 postcentral gyrus
- 24. 缘上回 supramarginal gyrus
- 25. 侧脑室后角 posterior horn of lateral ventricle
- 26. 胼胝体压部 splenium of corpus callosum
- 27. 脉络丛 choroid plexus
- 28. 外侧沟 lateral sulcus
- 29. 视辐射 optic radiation
- 30. 扣带回峡 isthmus of cingulate gyrus
- 31. 距状沟前部 anterior part of calcarine sulcus
- 32. 枕钳 occipital forceps
- 33. 角回 angular gyrus
- 34. 人字缝 lambdoid suture
- 35. 舌回 lingual gyrus
- 36. 距状沟后部 posterior part of calcarine sulcus
- 37. 楔叶 cuneus
- 38. 枕外侧回 lateral occipital gyrus
- 39. 枕骨 occipital bone
- 40. 枕额肌枕腹 occipital belly of occipitofrontalis
- 41. 穹窿 fornix
- 42. 帆间池 cistern of velum interpositum

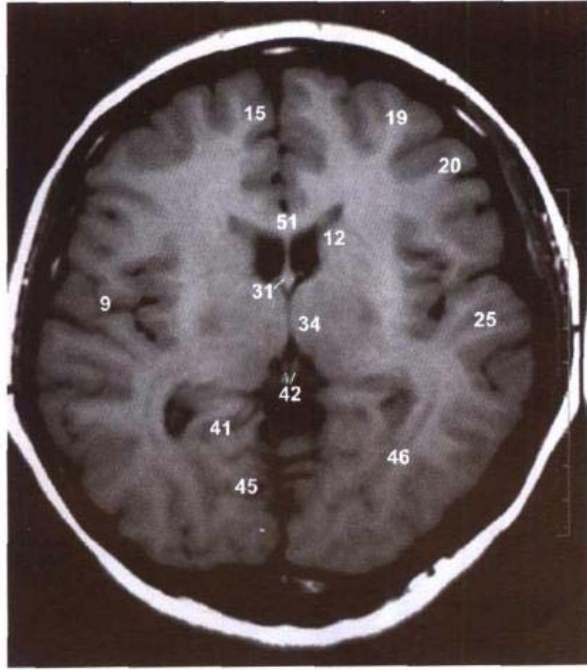
图 1-6 经胼胝体压部的横断层

Fig.1-6 Transverse section through splenium of corpus callosum

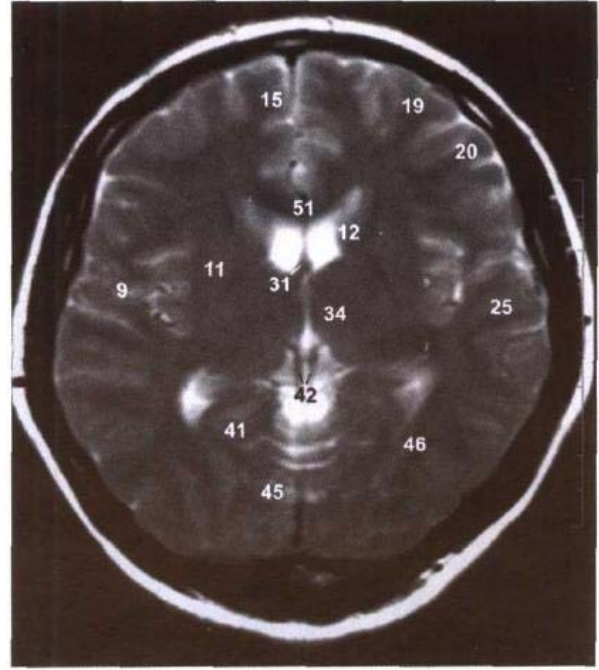


A. 断层标本(sectional specimen)

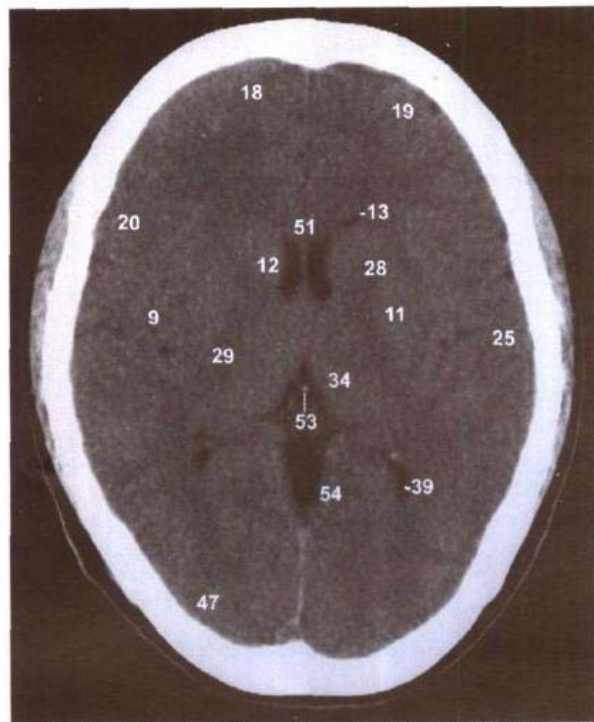
- | | |
|---------------------------------|--|
| 1. 额骨 frontal bone | 10. 屏状核 claustrum |
| 2. 上矢状窦 superior sagittal sinus | 11. 壳 putamen |
| 3. 额上沟 superior frontal sulcus | 12. 尾状核 caudate nucleus |
| 4. 额下沟 inferior frontal sulcus | 13. 侧脑室前角 anterior horn of lateral ventricle |
| 5. 中央前沟 precentral sulcus | 14. 扣带回 cingulate gyrus |
| 6. 中央沟 central sulcus | 15. 额内侧回 medial frontal gyrus |
| 7. 冠状缝 coronal suture | 16. 扣带沟 cingulate sulcus |
| 8. 颞肌 temporalis | 17. 大脑前动脉 anterior cerebral artery |
| 9. 外侧沟 lateral sulcus | 18. 额上回 superior frontal gyrus |



B. MRI T₁ WI



C. MRI T₂ WI



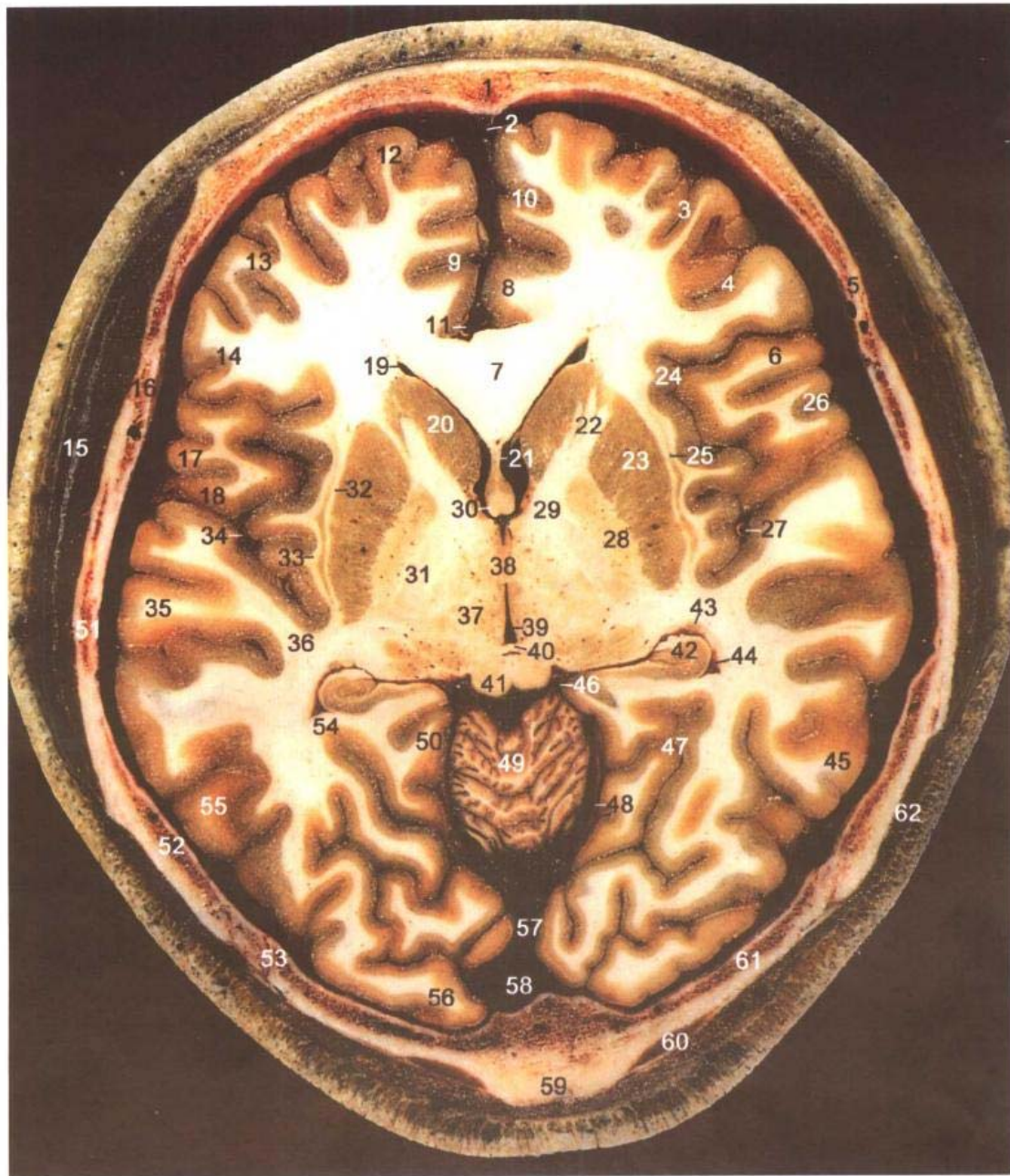
D. CT

- 19. 额中回 middle frontal gyrus
- 20. 额下回 inferior frontal gyrus
- 21. 中央前回 precentral gyrus
- 22. 中央后回 postcentral gyrus
- 23. 蛛网膜下隙 subarachnoid space
- 24. 顶骨 parietal bone
- 25. 颞上回 superior temporal gyrus

- 26. 最外囊 extreme capsule
- 27. 外囊 external capsule
- 28. 内囊前肢 anterior limb of internal capsule
- 29. 内囊后肢 posterior limb of internal capsule
- 30. 透明隔 septum pellucidum
- 31. 穹窿 fornix
- 32. 丘纹静脉 thalamostriate vein
- 33. 第三脑室 third ventricle
- 34. 背侧丘脑 dorsal thalamus
- 35. 帆间池 cistern of velum interpositum
- 36. 颞横回 transverse temporal gyrus
- 37. 胼胝体压部 splenium of corpus callosum
- 38. 海马伞 fimbria of hippocampus
- 39. 侧脑室后角 posterior horn of lateral ventricle
- 40. 颞中回 middle temporal gyrus
- 41. 距状沟 calcarine sulcus
- 42. 大脑内静脉 internal cerebral vein
- 43. 大脑大静脉 greater cerebral vein
- 44. 禽距 calcar avis
- 45. 舌回 lingual gyrus
- 46. 视辐射 optic radiation
- 47. 枕外侧回 lateral occipital gyrus
- 48. 人字缝 lambdoid suture
- 49. 枕骨 occipital bone
- 50. 枕额肌枕腹 occipital belly of occipitofrontalis
- 51. 胼胝体膝 genu of corpus callosum
- 52. 室间孔 interventricular foramen
- 53. 松果体 pineal body
- 54. 小脑幕 tentorium of cerebellum

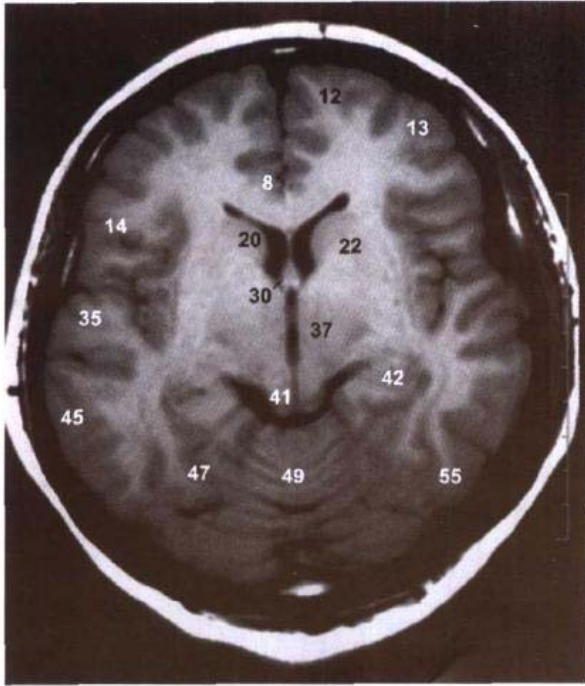
图 1-7 经上丘和后连合的横断层

Fig.1-7 Transverse section through superior colliculus and posterior commissure

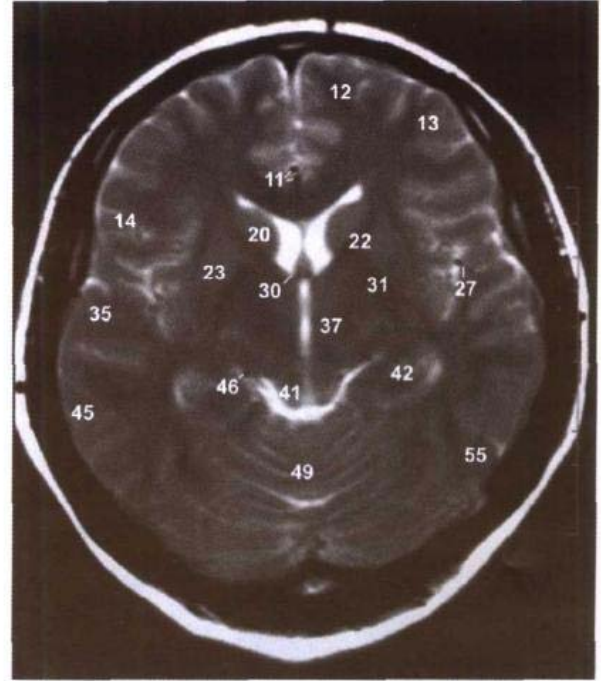


A. 断层标本(sectional specimen)

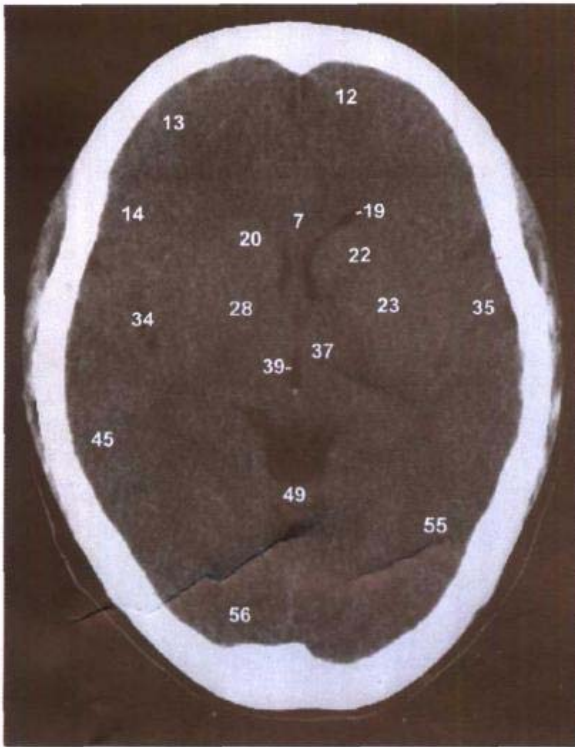
- | | | |
|--|--|--|
| 1. 额骨 frontal bone | 9. 扣带沟 cingulate sulcus | 16. 蝶骨大翼 greater wing of sphenoid bone |
| 2. 上矢状窦 superior sagittal sinus | 10. 额内侧回 medial frontal gyrus | 17. 中央前回 precentral gyrus |
| 3. 额上沟 superior frontal sulcus | 11. 大脑前动脉 anterior cerebral artery | 18. 中央后回 postcentral gyrus |
| 4. 额下沟 inferior frontal sulcus | 12. 额上回 superior frontal gyrus | 19. 侧脑室前角 anterior horn of lateral ventricle |
| 5. 翼点 pterion | 13. 额中回 middle frontal gyrus | 20. 尾状核 caudate nucleus |
| 6. 额下回岛盖部 opercular part of inferior frontal gyrus | 14. 额下回三角部 triangular part of inferior frontal gyrus | 21. 透明隔 septum pellucidum |
| 7. 胼胝体膝 genu of corpus callosum | 15. 颞肌 temporalis | 22. 内囊前肢 anterior limb of |
| 8. 扣带回 cingulate gyrus | | |



B. MRI T₁ WI



C. MRI T₂ WI



D. CT

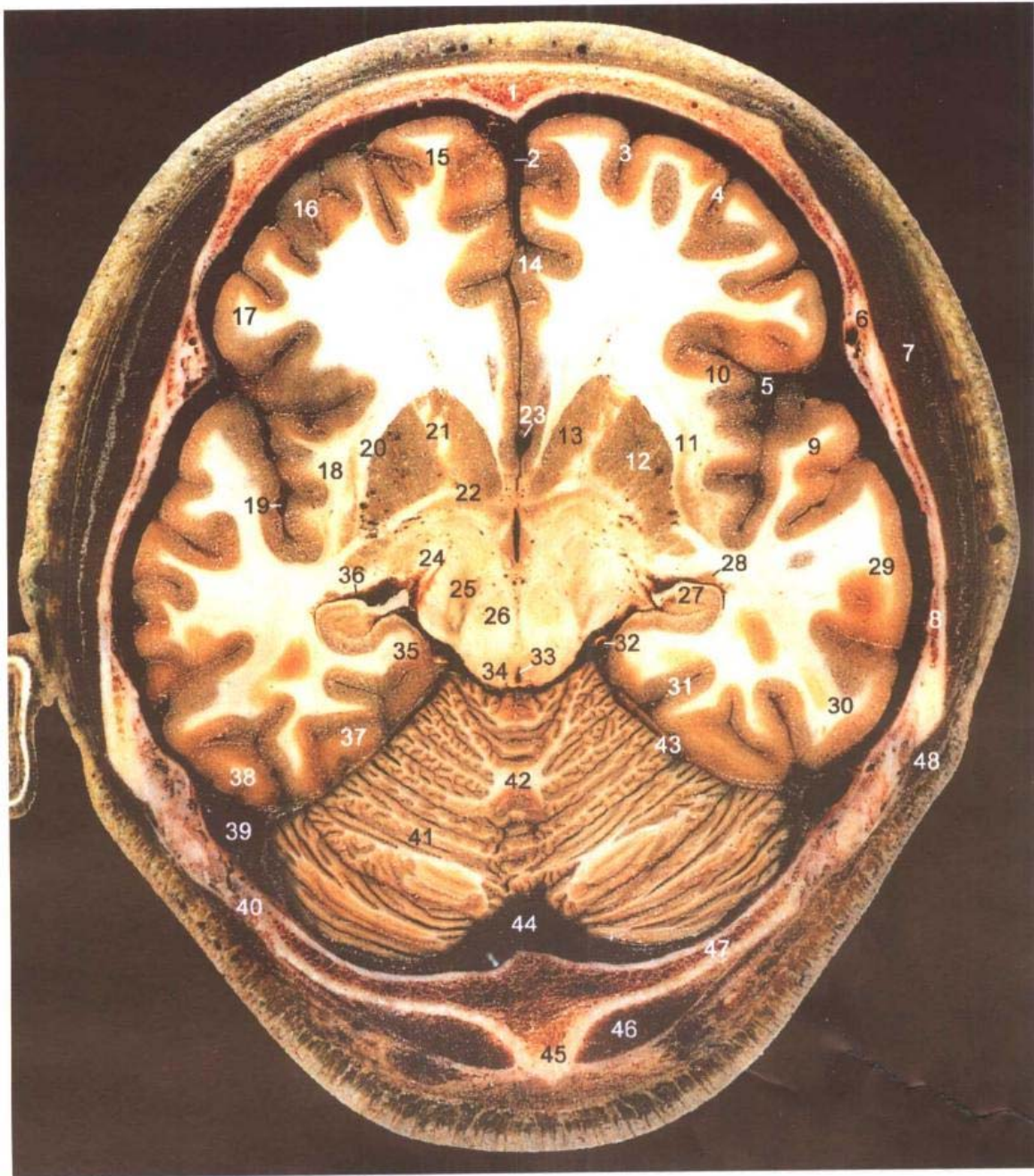- internal capsule
- 23. 壳 putamen
- 24. 岛叶 insula
- 25. 屏状核 claustrum
- 26. 中央沟 central sulcus
- 27. 大脑中动脉 middle cerebral artery

- 28. 苍白球 globus pallidus
- 29. 内囊膝 genu of internal capsule
- 30. 穹窿 fornix
- 31. 内囊后肢 posterior limb of internal capsule
- 32. 外囊 external capsule
- 33. 最外囊 extreme capsule
- 34. 外侧沟 lateral sulcus
- 35. 颞上回 superior temporal gyrus
- 36. 听辐射 acoustic radiation
- 37. 背侧丘脑 dorsal thalamus
- 38. 丘脑间粘合 interthalamic adhesion
- 39. 第三脑室 third ventricle
- 40. 后连合 posterior commissure
- 41. 上丘 superior colliculus
- 42. 海马 hippocampus
- 43. 尾状核尾 tail of caudate nucleus
- 44. 侧脑室下角 inferior horn of lateral ventricle

- 45. 颞中回 middle temporal gyrus
- 46. 大脑后动脉 posterior cerebral artery
- 47. 侧副沟 collateral sulcus
- 48. 小脑幕 tentorium of cerebellum
- 49. 小脑蚓 vermis of cerebellum
- 50. 海马旁回 parahippocampal gyrus
- 51. 颞骨鳞部 squamous part of temporal bone
- 52. 顶骨 parietal bone
- 53. 人字缝 lambdoid suture
- 54. 侧副隆起 collateral eminence
- 55. 颞下回 inferior temporal gyrus
- 56. 枕叶 occipital lobe
- 57. 直窦 straight sinus
- 58. 窦汇 confluence of sinus
- 59. 枕外隆凸 lateral occipital protuberance
- 60. 头半棘肌 semispinalis capitis
- 61. 枕骨 occipital bone
- 62. 枕额肌枕腹 occipital belly of occipitofrontalis

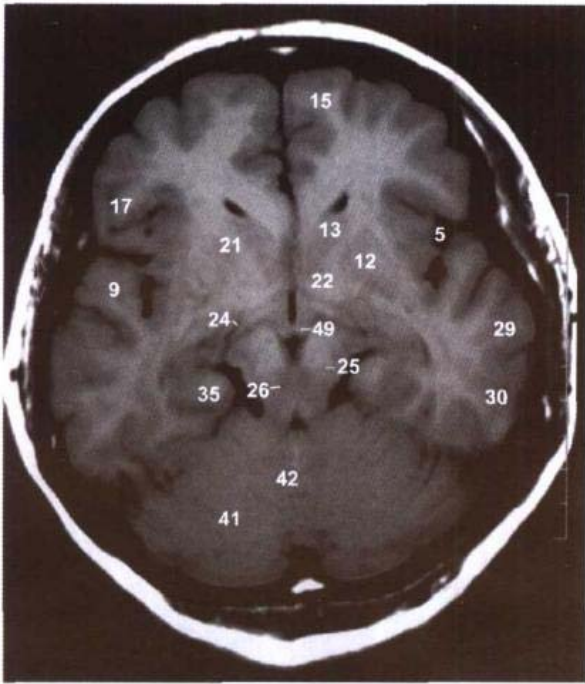
图 1-8 经下丘和前连合的横断层

Fig.1-8 Transverse section through inferior colliculus and anterior commissure

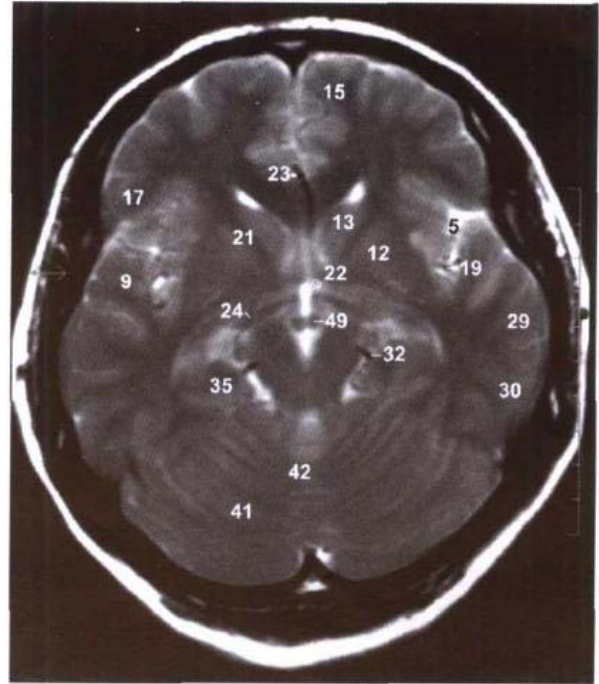


A. 断层标本(sectional specimen)

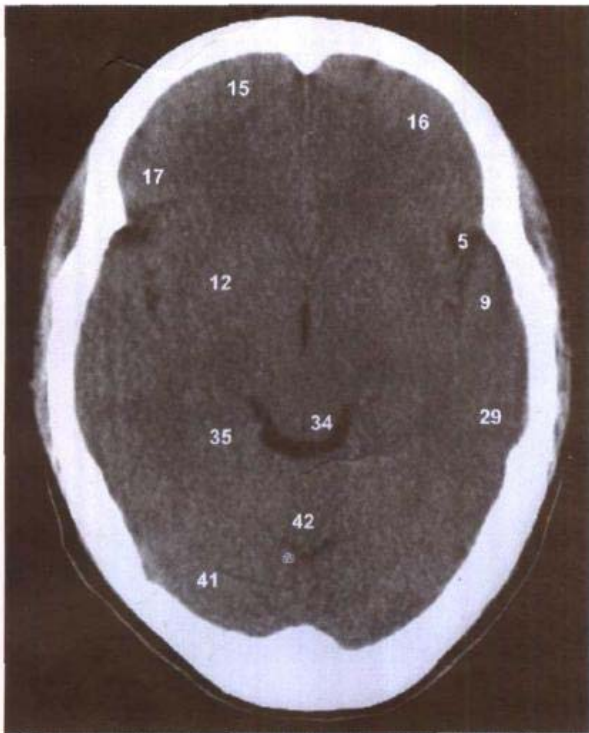
- | | |
|--|--------------------------------|
| 1. 额骨 frontal bone | 9. 颞上回 superior temporal gyrus |
| 2. 大脑镰 cerebral falx | 10. 岛叶 insula |
| 3. 额上沟 superior frontal sulcus | 11. 屏状核 claustrum |
| 4. 额下沟 inferior frontal sulcus | 12. 壳 putamen |
| 5. 外侧沟 lateral sulcus | 13. 尾状核 caudate nucleus |
| 6. 蝶骨大翼 greater wing of sphenoid bone | 14. 额内侧回 medial frontal gyrus |
| 7. 颞肌 temporalis | 15. 额上回 superior frontal gyrus |
| 8. 颞骨鳞部 squamous part of temporal bone | 16. 额中回 middle frontal gyrus |



B. MRI T₁ WI



C. MRI T₂ WI



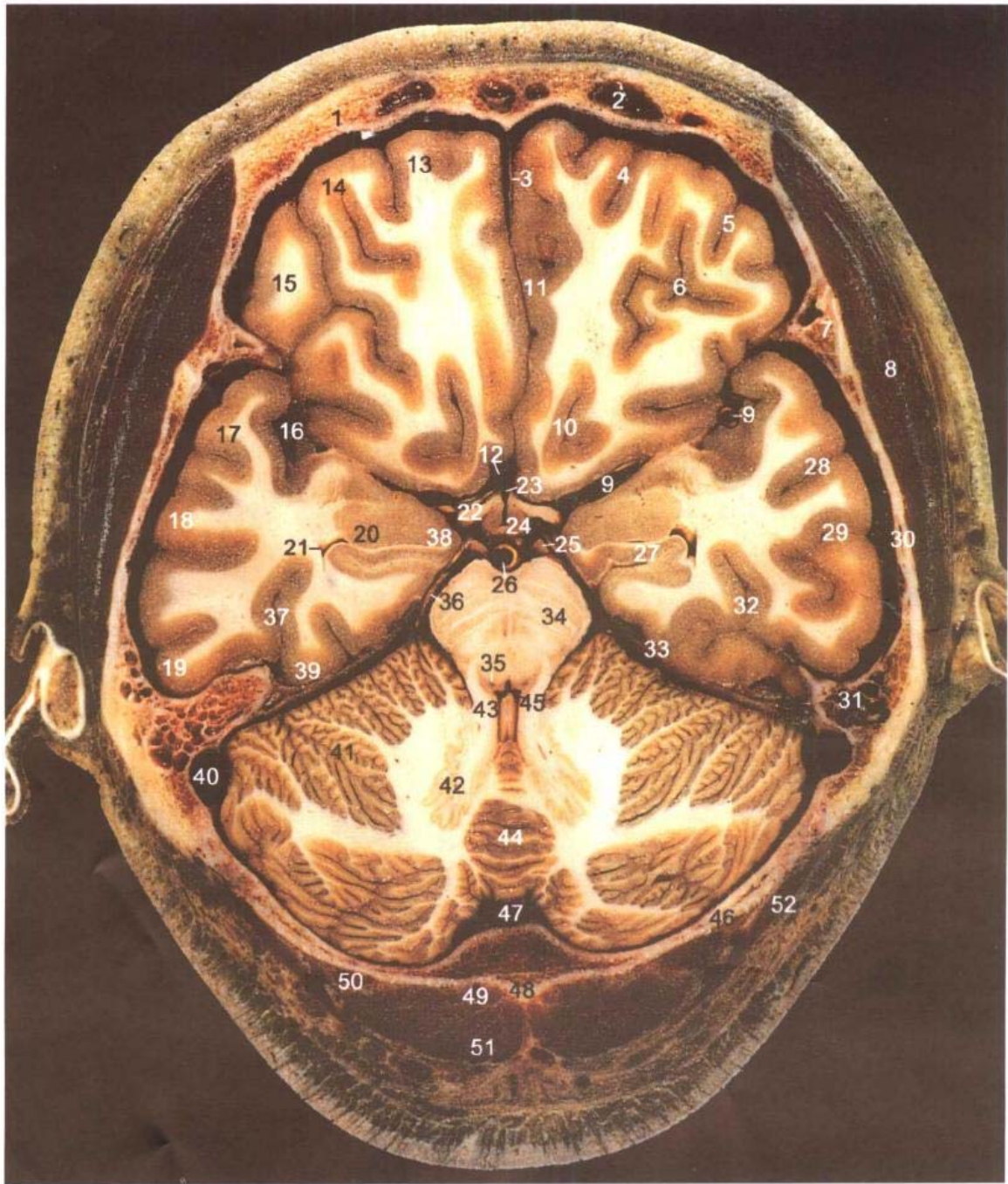
D. CT

- 17. 额下回 inferior frontal gyrus
- 18. 最外囊 extreme capsule
- 19. 大脑中动脉 middle cerebral artery
- 20. 外囊 external capsule
- 21. 内囊前肢 anterior limb of internal capsule

- 22. 前连合 anterior commissure
- 23. 大脑前动脉 anterior cerebral artery
- 24. 视束 optic tract
- 25. 黑质 substantia nigra
- 26. 红核 red nucleus
- 27. 海马 hippocampus
- 28. 尾状核尾 tail of caudate nucleus
- 29. 颞中回 middle temporal gyrus
- 30. 颞下回 inferior temporal gyrus
- 31. 侧副沟 collateral sulcus
- 32. 大脑后动脉 posterior cerebral artery
- 33. 中脑水管 mesencephalic aqueduct
- 34. 下丘 inferior colliculus
- 35. 海马旁回 parahippocampal gyrus
- 36. 侧脑室下角 inferior horn of lateral ventricle
- 37. 枕颞内侧回 medial occipitotemporal gyrus
- 38. 枕颞外侧回 lateral occipitotemporal gyrus
- 39. 横窦 transverse sinus
- 40. 人字缝 lambdoid suture
- 41. 小脑半球 cerebellar hemisphere
- 42. 小脑蚓 vermis of cerebellum
- 43. 小脑幕 tentorium of cerebellum
- 44. 窦汇 confluence of sinus
- 45. 枕外隆凸 lateral occipital protuberance
- 46. 头半棘肌 semispinalis capitis
- 47. 枕骨 occipital bone
- 48. 枕额肌枕腹 occipital belly of occipitofrontalis
- 49. 乳头体 mamillary body

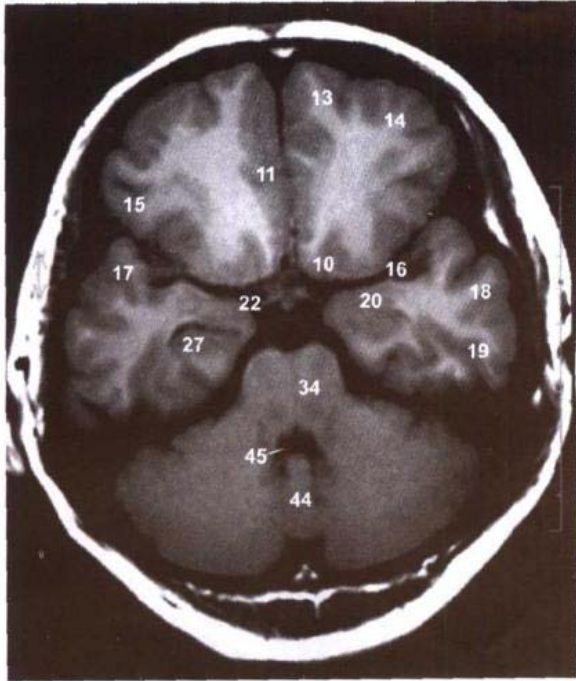
图 1-9 经小脑上脚的横断层

Fig.1-9 Transverse section through superior cerebellar peduncle

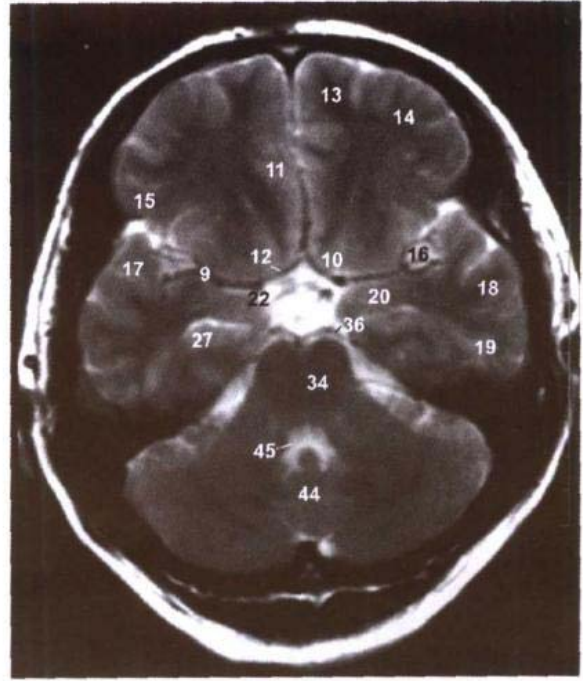


A. 断层标本(sectional specimen)

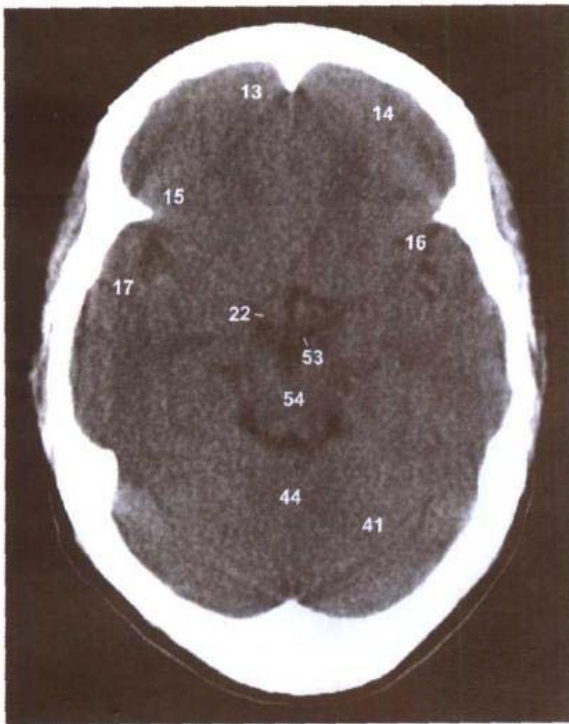
- | | |
|---------------------------------------|---|
| 1. 额骨 frontal bone | 12. 大脑前动脉 anterior cerebral artery |
| 2. 额窦 frontal sinus | 13. 额上回 superior frontal gyrus |
| 3. 大脑镰 cerebral falx | 14. 额中回 middle frontal gyrus |
| 4. 额上沟 superior frontal sulcus | 15. 额下回 inferior frontal gyrus |
| 5. 额下沟 inferior frontal sulcus | 16. 外侧沟 lateral sulcus |
| 6. 眶沟 orbital sulci | 17. 颞上回 superior temporal |
| 7. 蝶骨大翼 greater wing of sphenoid bone | 18. 颞中回 middle temporal gyrus |
| 8. 颞肌 temporalis | 19. 颞下回 inferior temporal gyrus |
| 9. 大脑中动脉 middle cerebral artery | 20. 嗅束 olfactory tract |
| 10. 嗅束沟 olfactory sulcus | 21. 嗅沟 olfactory sulcus |
| 11. 额内侧回 medial frontal gyrus | 22. 嗅球 olfactory bulb |
| | 23. 嗅神经 olfactory nerve |
| | 24. 视交叉 optic chiasm |
| | 25. 视束 optic tract |
| | 26. 视交叉前缘 anterior margin of optic chiasm |
| | 27. 视交叉后缘 posterior margin of optic chiasm |
| | 28. 视交叉侧缘 lateral margin of optic chiasm |
| | 29. 视交叉前缘前部 anterior part of anterior margin of optic chiasm |
| | 30. 视交叉前缘中部 middle part of anterior margin of optic chiasm |
| | 31. 视交叉前缘后部 posterior part of anterior margin of optic chiasm |
| | 32. 视交叉后缘前部 anterior part of posterior margin of optic chiasm |
| | 33. 视交叉后缘中部 middle part of posterior margin of optic chiasm |
| | 34. 视交叉后缘后部 posterior part of posterior margin of optic chiasm |
| | 35. 视交叉侧缘前部 anterior part of lateral margin of optic chiasm |
| | 36. 视交叉侧缘中部 middle part of lateral margin of optic chiasm |
| | 37. 视交叉侧缘后部 posterior part of lateral margin of optic chiasm |
| | 38. 视交叉前缘前部前部 anterior part of anterior part of anterior margin of optic chiasm |
| | 39. 视交叉前缘前部中部 middle part of anterior part of anterior margin of optic chiasm |
| | 40. 视交叉前缘前部后部 posterior part of anterior part of anterior margin of optic chiasm |
| | 41. 视交叉前缘中部前部 anterior part of middle part of anterior margin of optic chiasm |
| | 42. 视交叉前缘中部中部 middle part of middle part of anterior margin of optic chiasm |
| | 43. 视交叉前缘中部后部 posterior part of middle part of anterior margin of optic chiasm |
| | 44. 视交叉前缘后部前部 anterior part of posterior part of anterior margin of optic chiasm |
| | 45. 视交叉前缘后部中部 middle part of posterior part of anterior margin of optic chiasm |
| | 46. 视交叉前缘后部后部 posterior part of posterior part of anterior margin of optic chiasm |
| | 47. 视交叉侧缘前部前部 anterior part of anterior part of lateral margin of optic chiasm |
| | 48. 视交叉侧缘前部中部 middle part of anterior part of lateral margin of optic chiasm |
| | 49. 视交叉侧缘前部后部 posterior part of anterior part of lateral margin of optic chiasm |
| | 50. 视交叉侧缘中部前部 anterior part of middle part of lateral margin of optic chiasm |
| | 51. 视交叉侧缘中部中部 middle part of middle part of lateral margin of optic chiasm |
| | 52. 视交叉侧缘中部后部 posterior part of middle part of lateral margin of optic chiasm |



B. MRI T₁ WI



C. MRI T₂ WI



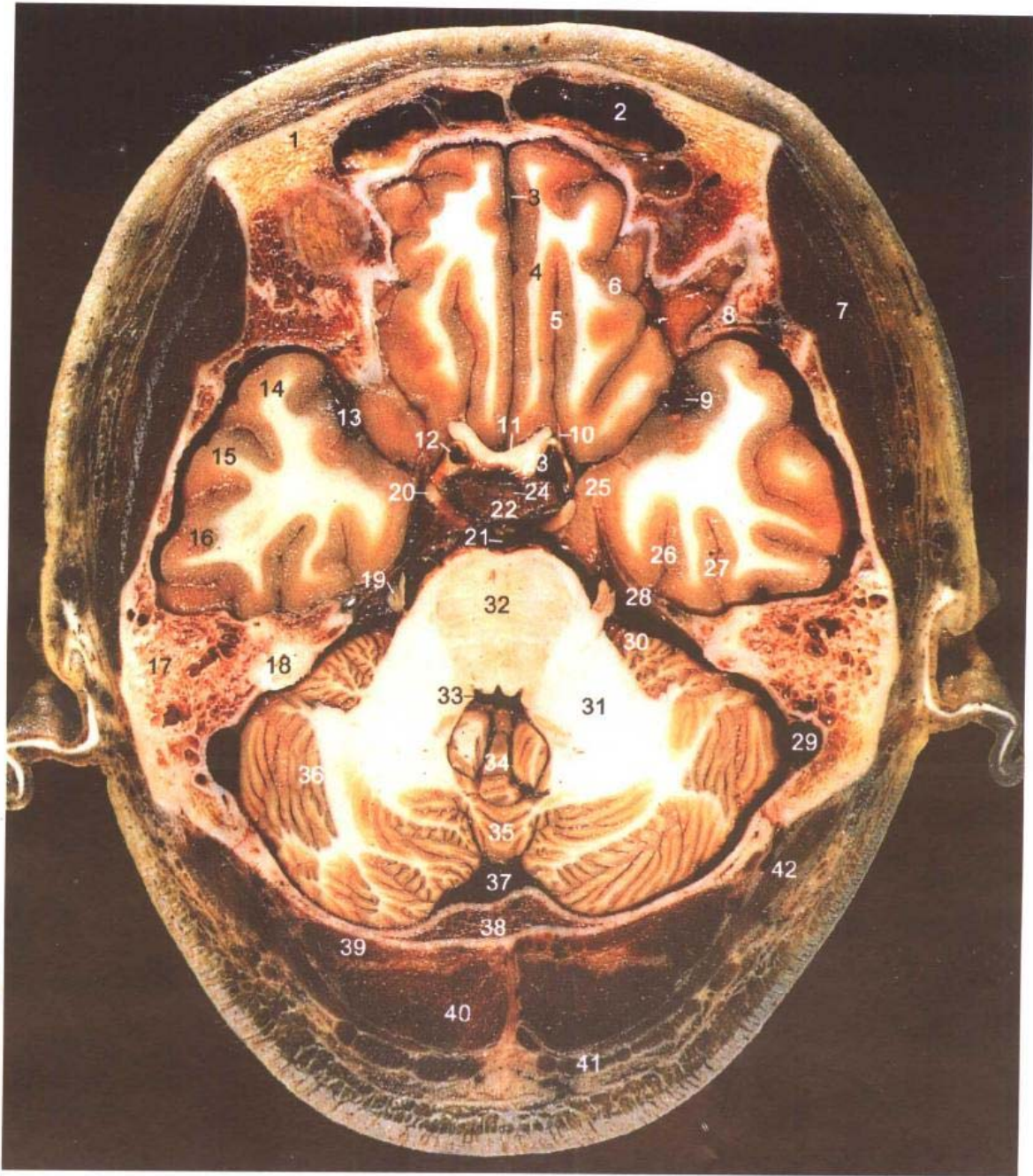
D. CT

- gyrus
- 18. 颞中回 middle temporal gyrus
- 19. 颞下回 inferior temporal gyrus
- 20. 杏仁体 amygdaloid body

- 21. 侧脑室下角 inferior horn of lateral ventricle
- 22. 视束 optic tract
- 23. 第三脑室漏斗隐窝 infundibular recess of third ventricle
- 24. 下丘脑 hypothalamus
- 25. 动眼神经 oculomotor nerve
- 26. 基底动脉 basilar artery
- 27. 海马 hippocampus
- 28. 颞上沟 superior temporal sulcus
- 29. 颞下沟 inferior temporal sulcus
- 30. 颞骨鳞部 squamous part of temporal bone
- 31. 颞骨岩部 petrous part of temporal bone
- 32. 侧副沟 collateral sulcus
- 33. 小脑幕 tentorium of cerebellum
- 34. 脑桥 pons
- 35. 蓝斑 locus ceruleus
- 36. 大脑后动脉 posterior cerebral artery
- 37. 枕颞沟 occipitotemporal sulcus
- 38. 钩 uncus
- 39. 枕颞内侧回 medial occipitotemporal gyrus
- 40. 乙状窦 sigmoid sinus
- 41. 小脑半球 cerebellar hemisphere
- 42. 齿状核 dentate nucleus
- 43. 小脑上脚 superior cerebellar peduncle
- 44. 小脑蚓 vermis of cerebellum
- 45. 第四脑室 fourth ventricle
- 46. 枕骨 occipital bone
- 47. 枕窦 occipital sinus
- 48. 枕外隆凸 lateral occipital protuberance
- 49. 头后小直肌 rectus capitis posterior minor
- 50. 头上斜肌 obliquus capitis superior
- 51. 头半棘肌 semispinalis capitis
- 52. 头夹肌 splenius capitis
- 53. 乳头体 mamillary body
- 54. 中脑 midbrain

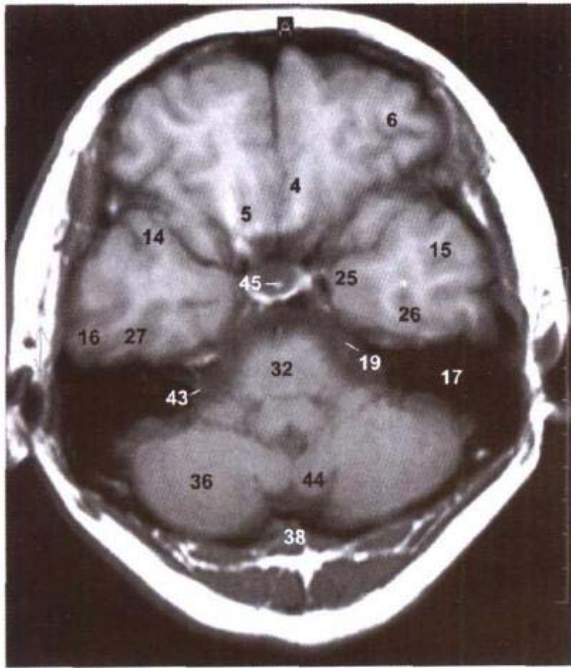
图 1-10 经垂体的横断层

Fig.1-10 Transverse section through hypophysis

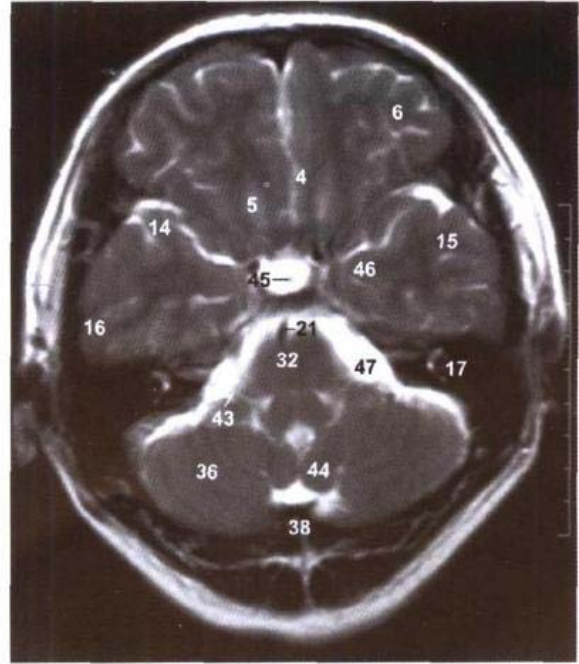


A. 断层标本(sectional specimen)

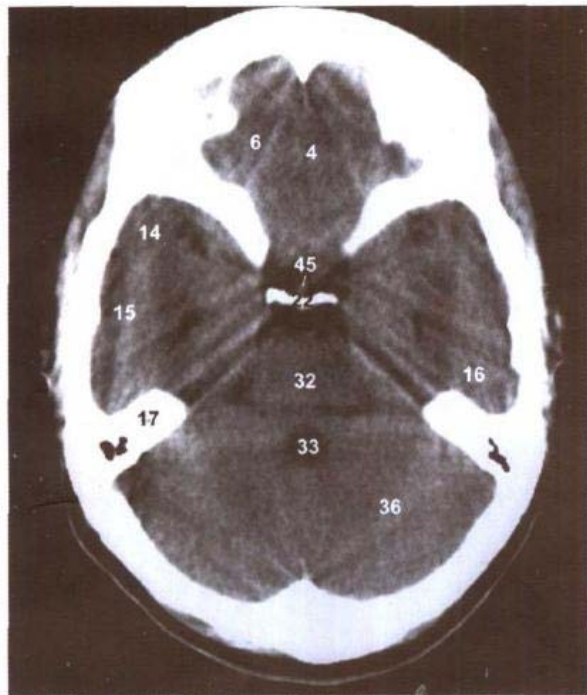- | | |
|-------------------------|--------------------------------------|
| 1. 额骨 frontal bone | 8. 蝶骨小翼 lesser wing of sphenoid bone |
| 2. 额窦 frontal sinus | 9. 大脑中动脉 middle cerebral artery |
| 3. 大脑镰 cerebral falx | 10. 嗅束 olfactory tract |
| 4. 直回 gyrus rectus | 11. 视交叉 optic chiasma |
| 5. 嗅束沟 olfactory sulcus | 12. 颈内动脉 internal carotid artery |
| 6. 眶回 orbital gyri | 13. 外侧沟 lateral sulcus |
| 7. 颞肌 temporalis | 14. 颞上回 superior temporal gyrus |



B. MRI T₁ WI



C. MRI T₂ WI



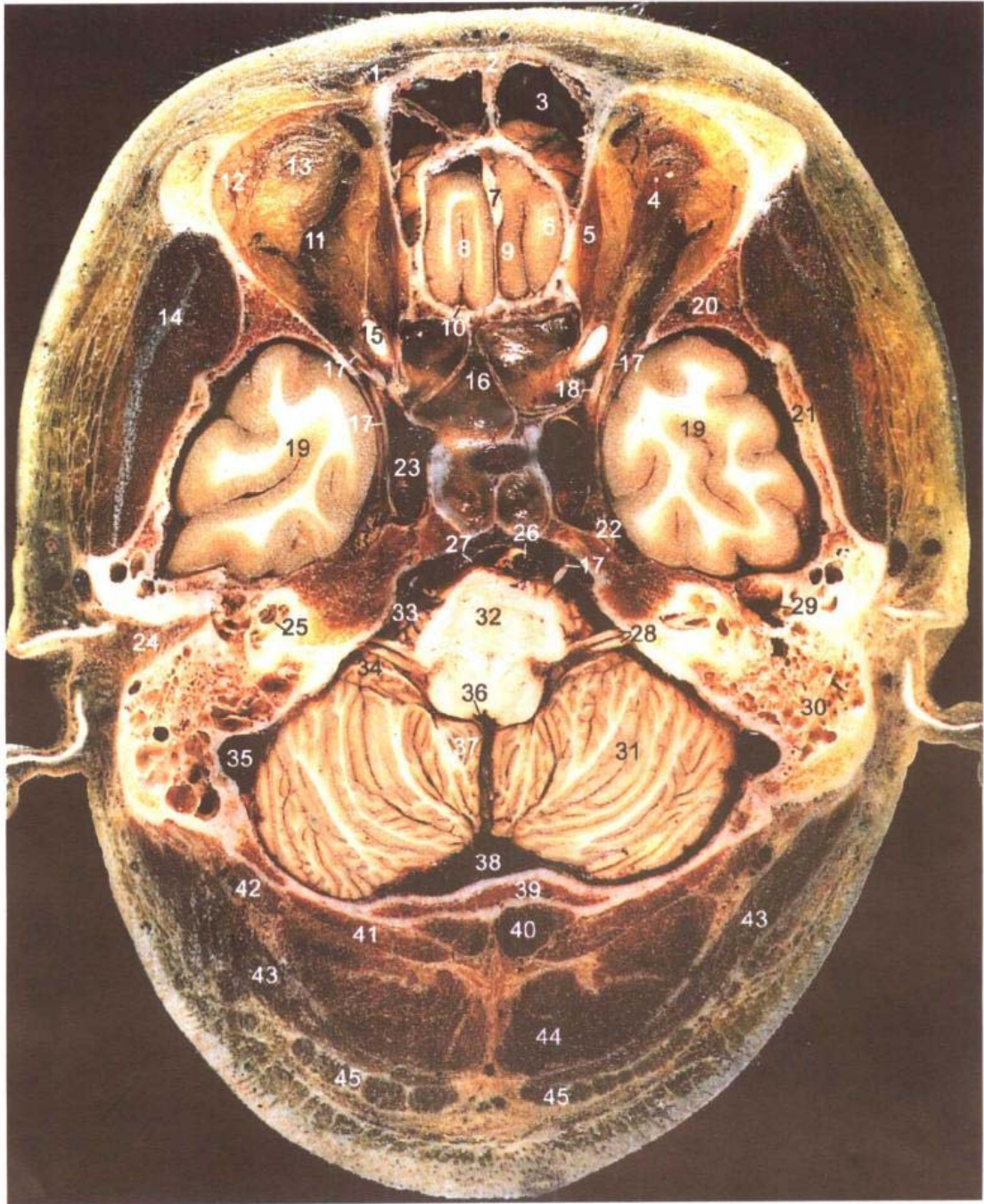
D. CT

- 15. 颞中回 middle temporal gyrus
- 16. 颞下回 inferior temporal gyrus
- 17. 颞骨岩部 petrous part of temporal bone
- 18. 骨半规管 bony semicircular canal
- 19. 三叉神经 trigeminal nerve
- 20. 动眼神经 oculomotor nerve
- 21. 基底动脉 basilar artery

- 22. 鞍背 dorsum sellae
- 23. 漏斗 infundibulum
- 24. 垂体 hypophysis
- 25. 钩 uncus
- 26. 侧副沟 collateral sulcus
- 27. 枕颞沟 occipitotemporal sulcus
- 28. 小脑幕 tentorium of cerebellum
- 29. 乙状窦 sigmoid sinus
- 30. 绒球 flocculus
- 31. 小脑中脚 middle cerebellar peduncle
- 32. 脑桥 pons
- 33. 第四脑室 fourth ventricle
- 34. 小结 nodule
- 35. 蚓锥体 pyramid of vermis
- 36. 小脑半球 cerebellar hemisphere
- 37. 枕窦 occipital sinus
- 38. 枕骨 occipital bone
- 39. 头后大直肌 rectus capitis posterior major
- 40. 头半棘肌 semispinalis capitis
- 41. 斜方肌 trapezius
- 42. 头夹肌 splenius capitis
- 43. 面神经和前庭蜗神经 facial and vestibulocochlear nerves
- 44. 小脑扁桃体 tonsil of cerebellum
- 45. 垂体柄 stalk of hypophysis
- 46. 杏仁体 amygdaloid body
- 47. 脑桥小脑角池 cistern of pontocerebellar trigone

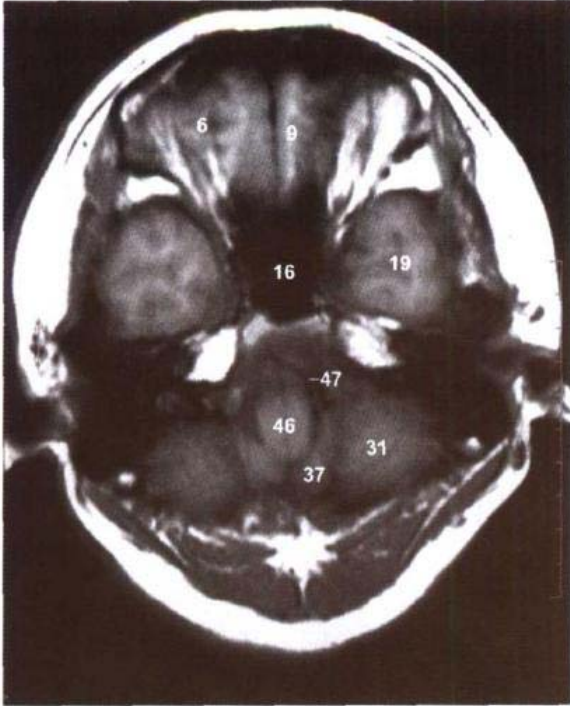
图 1-11 经海绵窦的横断层

Fig.1-11 Transverse section through cavernous sinus

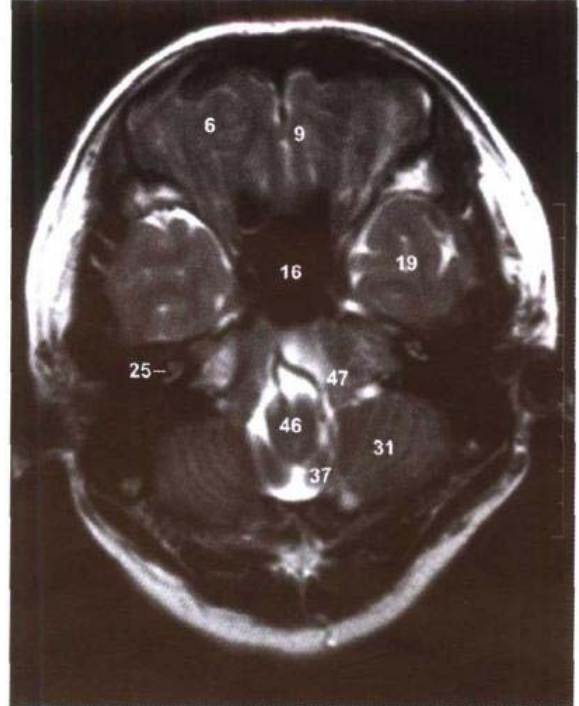


A. 断层标本(sectional specimen)

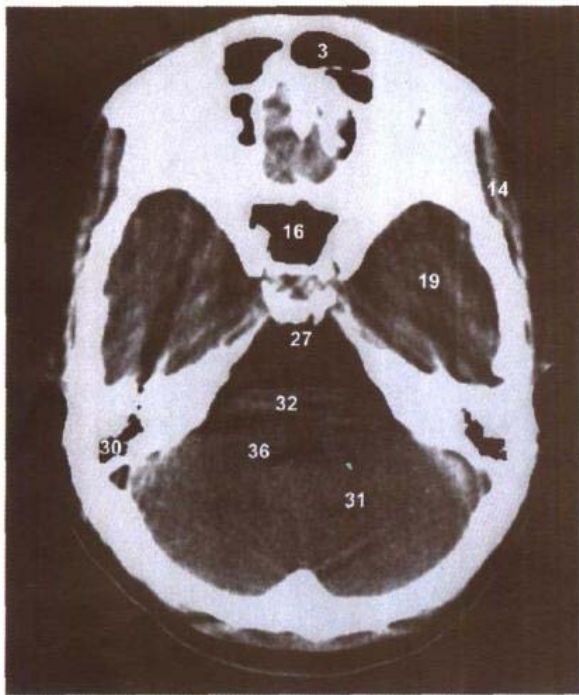
- | | |
|---|-----------------------------------|
| 1. 枕额肌额腹 frontal belly of occipitofrontalis | 8. 嗅束沟 olfactory sulcus |
| 2. 额骨 frontal bone | 9. 直回 gyrus rectus |
| 3. 额窦 frontal sinus | 10. 嗅束 olfactory tract |
| 4. 上直肌 superior rectus | 11. 眼上静脉 superior ophthalmic vein |
| 5. 上斜肌 superior obliquus | 12. 泪腺 lacrimal gland |
| 6. 眶回 orbital gyri | 13. 眶脂体 adipose body of orbit |
| 7. 鸡冠 crista galli | 14. 颞肌 temporalis |



B. MRI T₁ WI



C. MRI T₂ WI



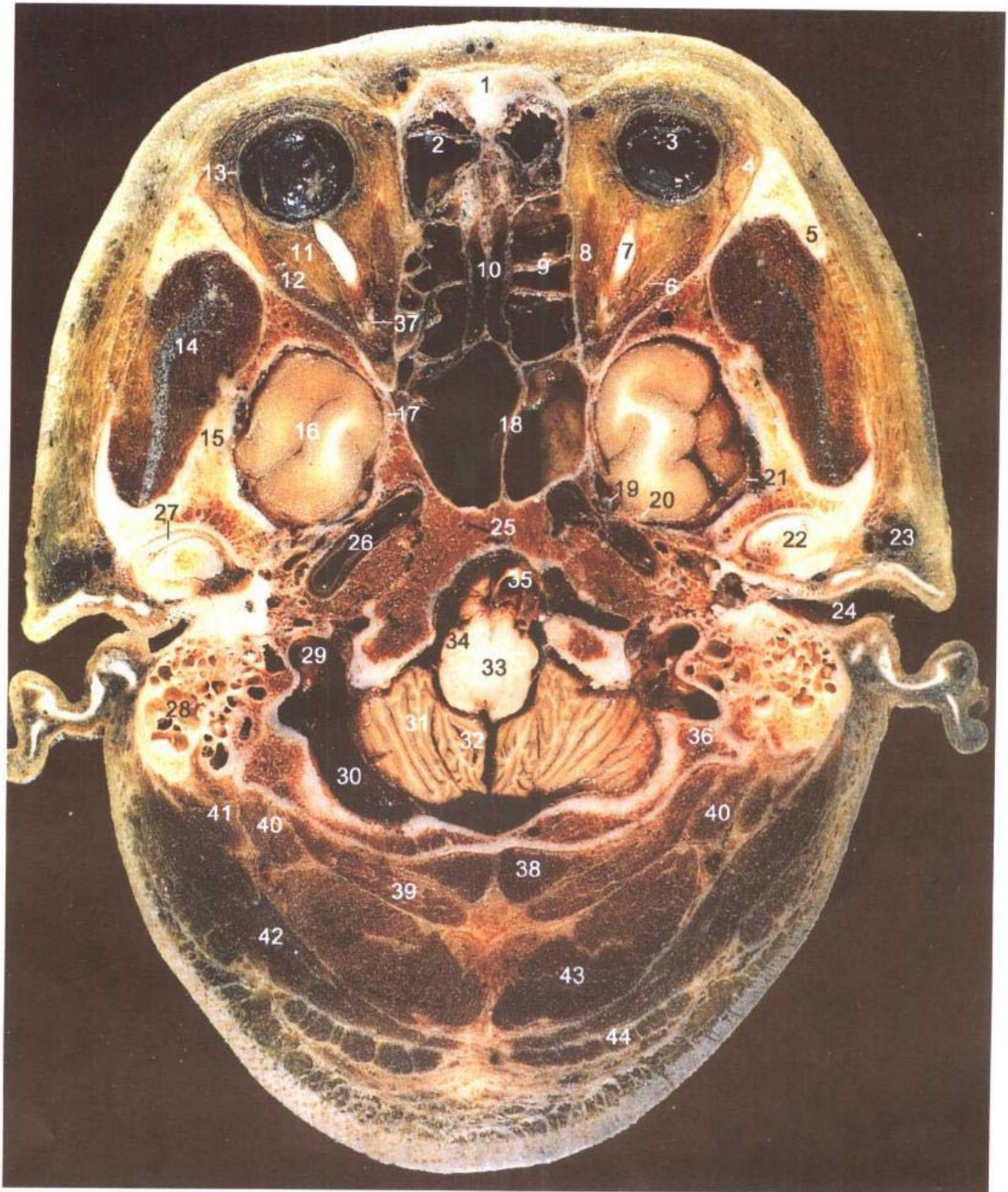
D. CT

- 15. 视神经 optic nerve
- 16. 蝶窦 sphenoidal sinus
- 17. 展神经 abducent nerve
- 18. 眼神经 ophthalmic nerve
- 19. 颞叶 temporal lobe
- 20. 蝶骨 sphenoid bone
- 21. 颞骨鳞部 squamous part of temporal bone

- 22. 三叉神经节 trigeminal ganglion
- 23. 颈内动脉和海绵窦 internal carotid artery and cavernous sinus
- 24. 外耳道 external acoustic meatus
- 25. 耳蜗 cochlea
- 26. 基底动脉 basilar artery
- 27. 桥池 pontine cistern
- 28. 面神经和前庭蜗神经 facial and vestibulocochlear nerves
- 29. 鼓室 tympanic cavity
- 30. 乳突小房 mastoid cells
- 31. 小脑半球 cerebellar hemisphere
- 32. 脑桥基底部 basilar part of pons
- 33. 脑桥小脑角池 cistern of pontocerebellar trigone
- 34. 绒球 flocculus
- 35. 乙状窦 sigmoid sinus
- 36. 第四脑室 fourth ventricle
- 37. 小脑扁桃体 tonsil of cerebellum
- 38. 枕窦 occipital sinus
- 39. 枕骨 occipital bone
- 40. 头后小直肌 rectus capitis posterior minor
- 41. 头后大直肌 rectus capitis posterior major
- 42. 头最长肌 longissimus capitis
- 43. 头夹肌 splenius capitis
- 44. 头半棘肌 semispinalis capitis
- 45. 斜方肌 trapezius
- 46. 延髓 medulla oblongata
- 47. 椎动脉 vertebral artery

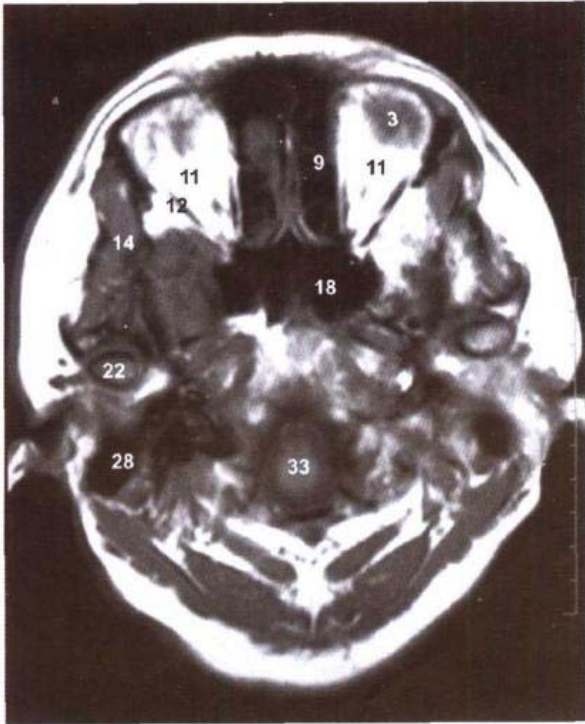
图 1-12 经颞下颌关节的横断层

Fig.1-12 Transverse section through temporomandibular joint

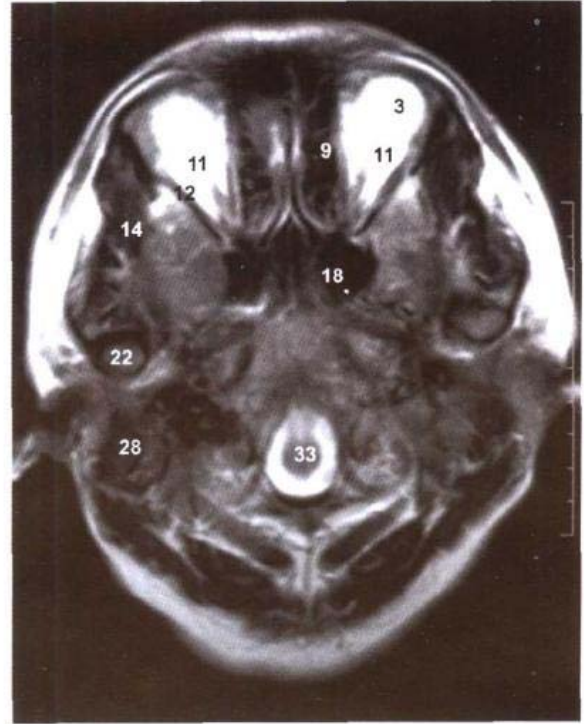


A. 断层标本(sectional specimen)

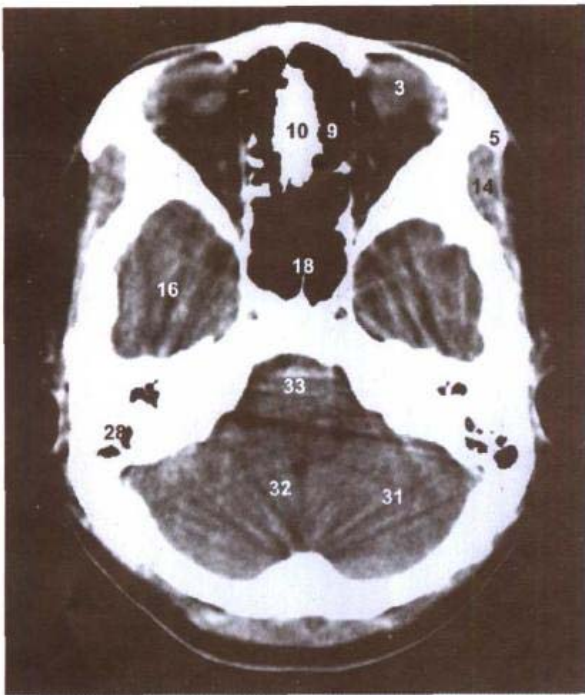
- | | |
|-----------------------|-------------------------------|
| 1. 额骨 frontal bone | 7. 视神经 optic nerve |
| 2. 额窦 frontal sinus | 8. 内直肌 medial rectus |
| 3. 视网膜 retina | 9. 筛窦 ethmoidal cells |
| 4. 泪腺 lacrimal gland | 10. 鼻中隔 nasal septum |
| 5. 颧弓 zygomatic arch | 11. 眶脂体 adipose body of orbit |
| 6. 展神经 abducent nerve | 12. 外直肌 lateral rectus |



B. MRI T₁ WI



C. MRI T₂ WI



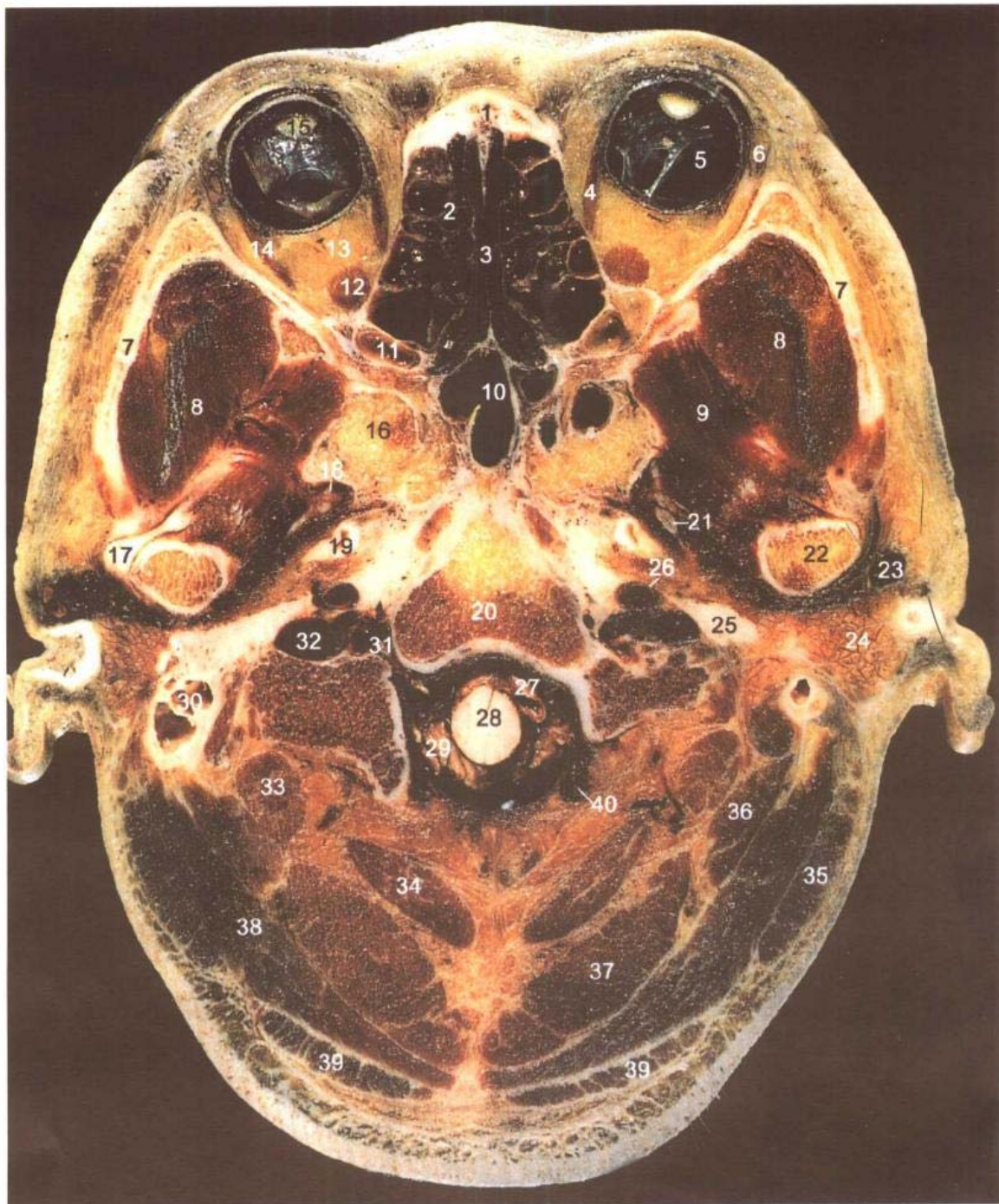
D. CT

- 13. 巩膜 sclera
- 14. 颞肌 temporalis
- 15. 颞骨鳞部 squamous part of temporal bone
- 16. 颞叶 temporal lobe
- 17. 眼神经 ophthalmic nerve
- 18. 蝶窦 sphenoidal sinus
- 19. 上颌神经 maxillary nerve

- 20. 下颌神经 mandibular nerve
- 21. 硬脑膜 cerebral dura mater
- 22. 下颌骨髁突 condylar process of mandible
- 23. 颞浅静脉 superficial temporal vein
- 24. 外耳道 external acoustic meatus
- 25. 枕骨基底部 basilar part of occipital bone
- 26. 颈动脉管和颈内动脉 carotid canal and internal carotid artery
- 27. 关节盘 articular disc
- 28. 乳突小房 mastoid cells
- 29. 颈静脉孔 jugular foramen
- 30. 乙状窦 sigmoid sinus
- 31. 小脑半球 cerebellar hemisphere
- 32. 小脑扁桃体 tonsil of cerebellum
- 33. 延髓 medulla oblongata
- 34. 下橄榄核 inferior olivary nucleus
- 35. 椎动脉 vertebral artery
- 36. 枕骨 occipital bone
- 37. 动眼神经 oculomotor nerve
- 38. 头后小直肌 rectus capitis posterior minor
- 39. 头后大直肌 rectus capitis posterior major
- 40. 头上斜肌 obliquus capitis superior
- 41. 头最长肌 longissimus capitis
- 42. 头夹肌 splenius capitis
- 43. 头半棘肌 semispinalis capitis
- 44. 斜方肌 trapezius

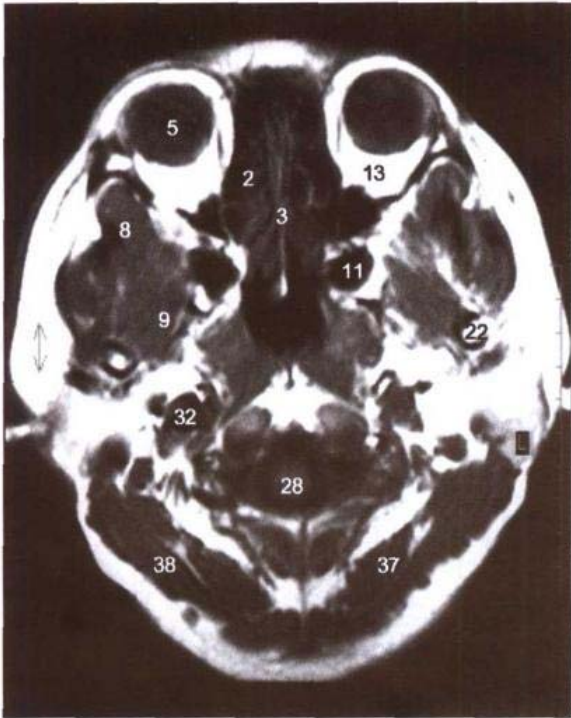图 1-13 经枕骨大孔的横断层

Fig.1-13 Transverse section through foramen magnum of occipital bone

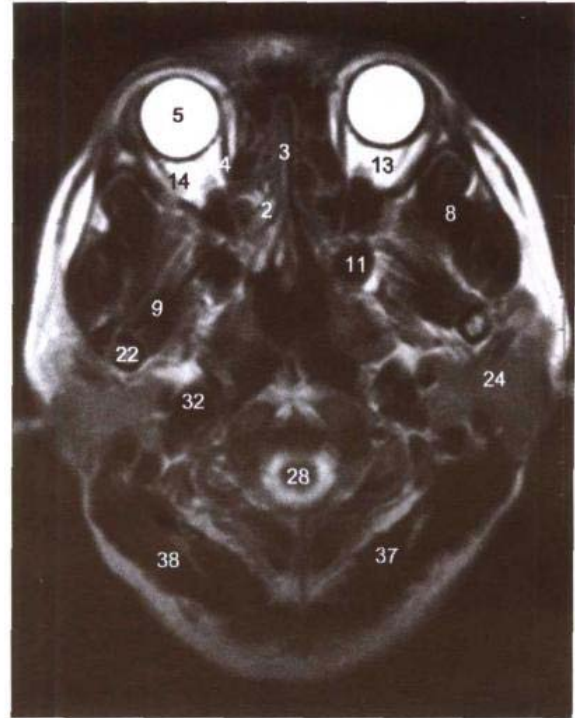


A. 断层标本(sectional specimen)

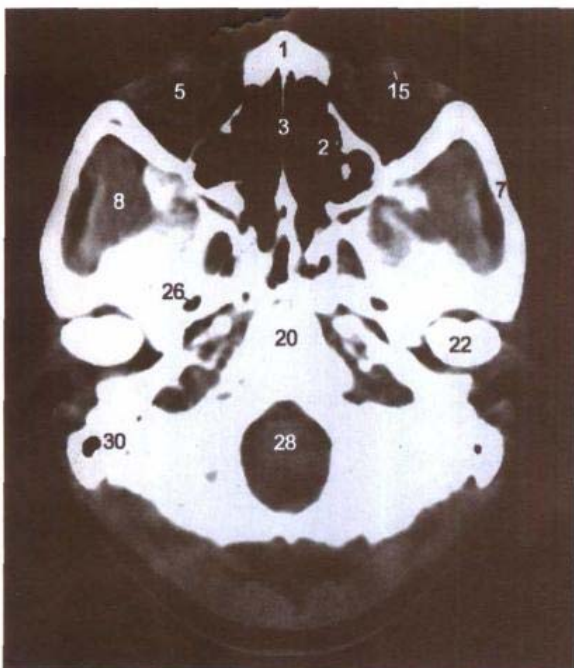
- | | |
|--------------------------|--------------------------|
| 1. 鼻骨 nasal bone | 6. 泪腺 lacrimal gland |
| 2. 筛窦 ethmoidal cellules | 7. 颧弓 zygomatic arch |
| 3. 鼻中隔 nasal septum | 8. 颞肌 temporalis |
| 4. 内直肌 medial rectus | 9. 翼外肌 lateral pterygoid |
| 5. 视网膜 retina | 10. 蝶窦 sphenoidal sinus |



B. MRI T₁ WI



C. MRI T₂ WI



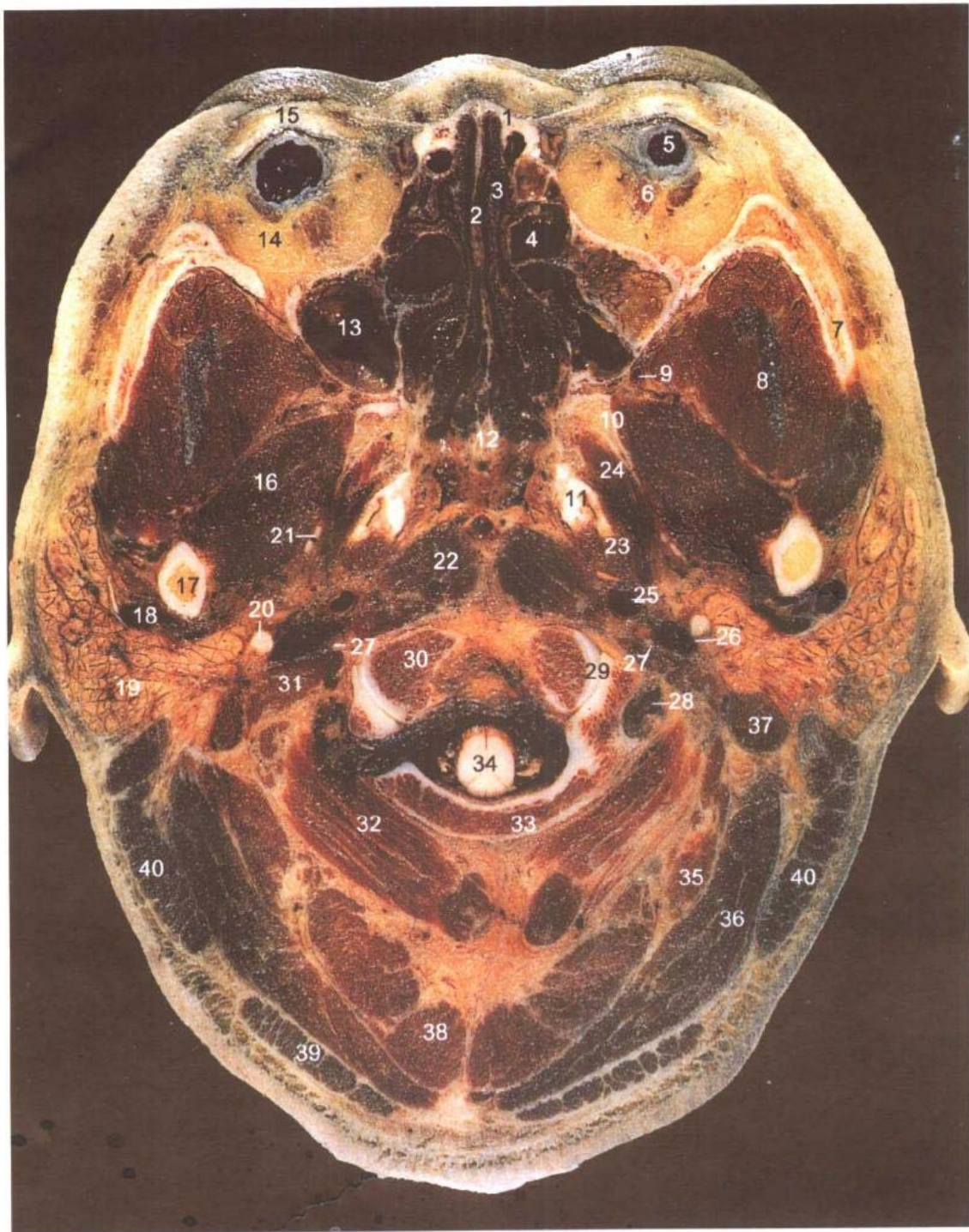
D. CT

- 11. 上颌窦 maxillary sinus
- 12. 下直肌 inferior rectus
- 13. 眶脂体 adipose body of orbit
- 14. 外直肌 lateral rectus
- 15. 晶状体 lens
- 16. 蝶骨大翼 greater wing of sphenoid bone

- 17. 关节盘 articular disc
- 18. 上颌神经 maxillary nerve
- 19. 咽鼓管软骨 cartilage of auditory tube
- 20. 枕骨底部 basilar part of occipital bone
- 21. 下颌神经 mandibular nerve
- 22. 下颌骨髁突 condylar process of mandible
- 23. 颞浅静脉 superficial temporal vein
- 24. 腮腺 parotid gland
- 25. 茎突 styloid process
- 26. 颈内动脉 internal carotid artery
- 27. 椎动脉 vertebral artery
- 28. 延髓 medulla oblongata
- 29. 小脑扁桃体 tonsil of cerebellum
- 30. 乳突 mastoid process
- 31. 舌下神经管和舌下神经 hypoglossal canal and nerve
- 32. 颈内静脉 internal jugular vein
- 33. 头上斜肌 obliquus capitis superior
- 34. 头后大直肌 rectus capitis posterior major
- 35. 胸锁乳突肌 sternocleidomastoid
- 36. 头最长肌 longissimus capitis
- 37. 头半棘肌 semispinalis capitis
- 38. 头夹肌 splenius capitis
- 39. 斜方肌 trapezius
- 40. 基底静脉丛 basal venous plexus

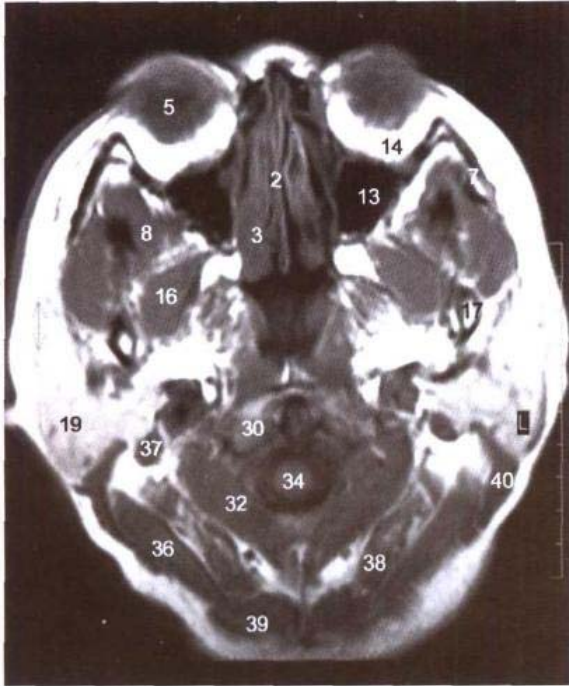
图 1-14 经寰枕关节的横断层

Fig.1-14 Transverse section through atlantooccipital joint

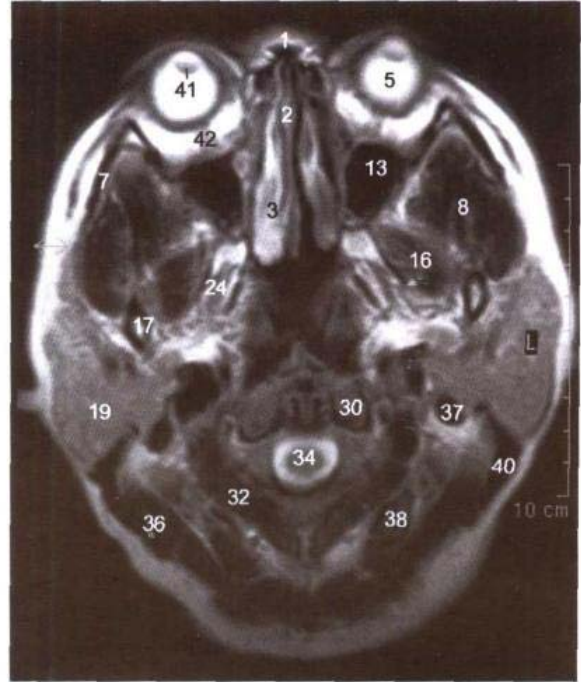


A. 断层标本(sectional specimen)

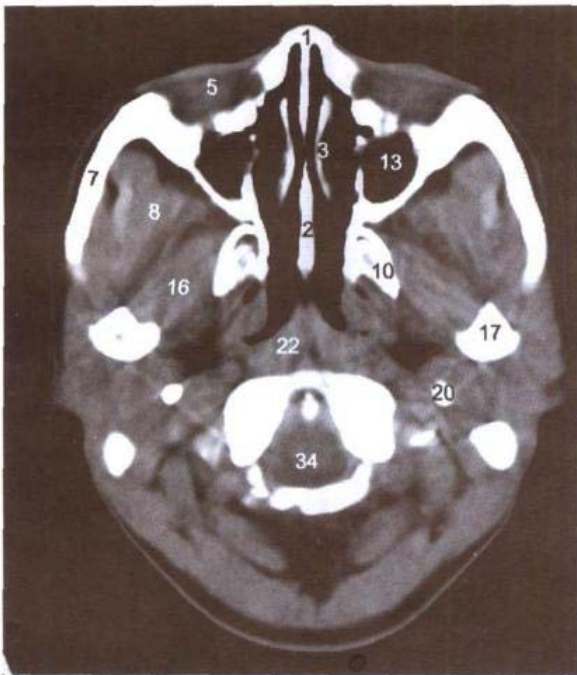- | | |
|----------------------------|-----------------------------------|
| 1. 鼻骨 nasal bone | 6. 下直肌 inferior rectus |
| 2. 鼻中隔 nasal septum | 7. 颧弓 zygomatic arch |
| 3. 中鼻甲 middle nasal concha | 8. 颞肌 temporalis |
| 4. 筛窦 ethmoidal cellules | 9. 蝶腭动脉 sphenopalatine artery |
| 5. 眼球 eyeball | 10. 翼突外侧板 lateral pterygoid plate |



B. MRI T₁ WI



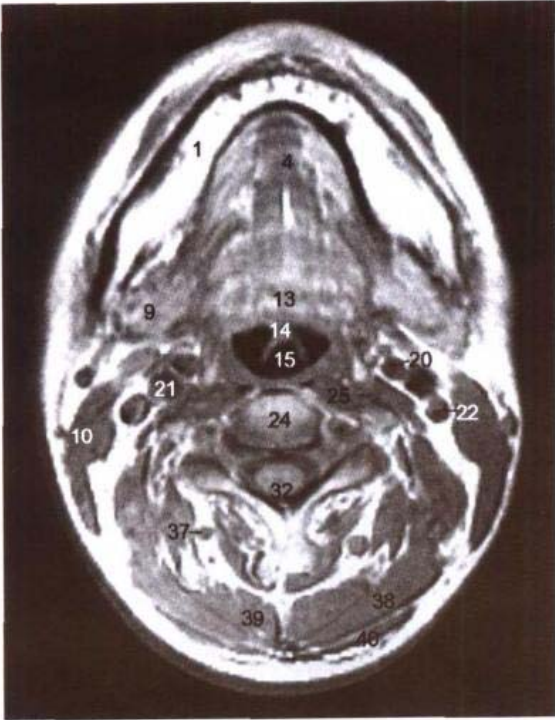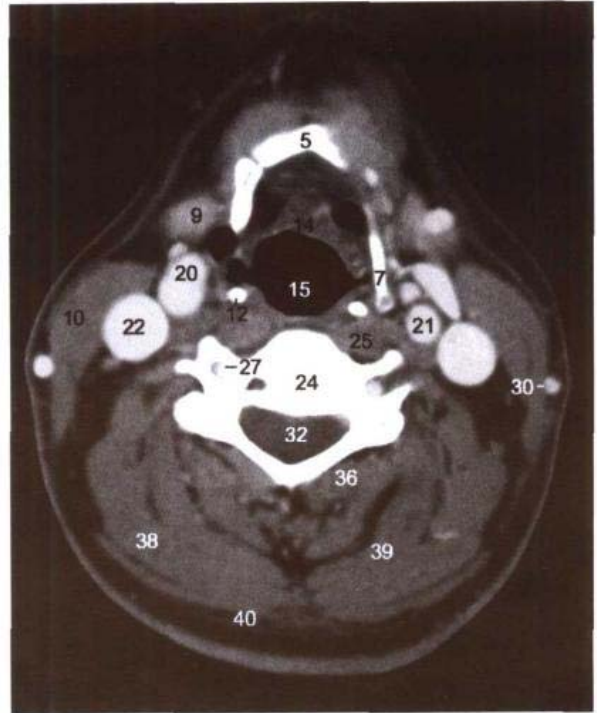
C. MRI T₂ WI



D. CT

- 11. 咽鼓管软骨 cartilage of auditory tube
- 12. 犁骨 vomer
- 13. 上颌窦 maxillary sinus
- 14. 眶脂体 adipose body of orbit
- 15. 下睑 lower eyelid
- 16. 翼外肌 lateral pterygoid
- 17. 下颌颈 neck of mandible

- 18. 颈外动脉和下颌后静脉 external carotid artery and retromandibular vein
- 19. 腮腺 parotid gland
- 20. 茎突 styloid process
- 21. 下颌神经 mandibular nerve
- 22. 头长肌和颈长肌 longus capitis and colli
- 23. 腭帆张肌 tensor veli palatini
- 24. 翼内肌 medial pterygoid
- 25. 颈内动脉 internal carotid artery
- 26. 颈内静脉 internal jugular vein
- 27. 迷走神经 vagus nerve
- 28. 椎动脉 vertebral artery
- 29. 寰枕关节 atlantooccipital joint
- 30. 枕髁 occipital condyle
- 31. 中、后斜角肌 scalenus medius and posterior
- 32. 头后大直肌 rectus capitis posterior major
- 33. 寰椎后弓 posterior arch of atlas
- 34. 脊髓 spinal cord
- 35. 头最长肌 longissimus capitis
- 36. 头夹肌 splenius captitis
- 37. 二腹肌后腹 posterior belly of digastric
- 38. 头半棘肌 semispinalis capitis
- 39. 斜方肌 trapezius
- 40. 胸锁乳突肌 sternocleidomastoid
- 41. 晶状体 lens
- 42. 视神经 optic nerve

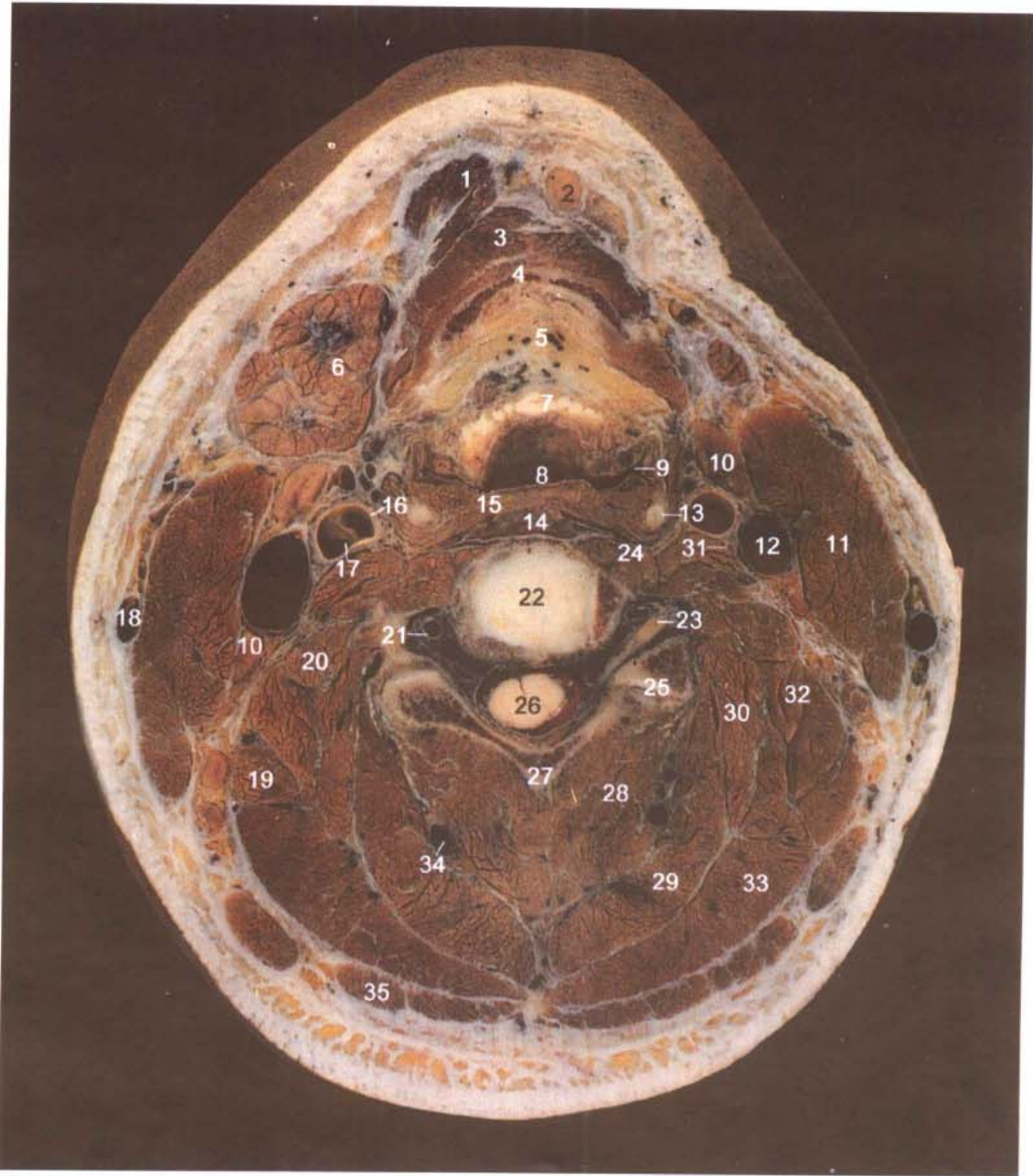
B. MRI T₁ WI

C. CT

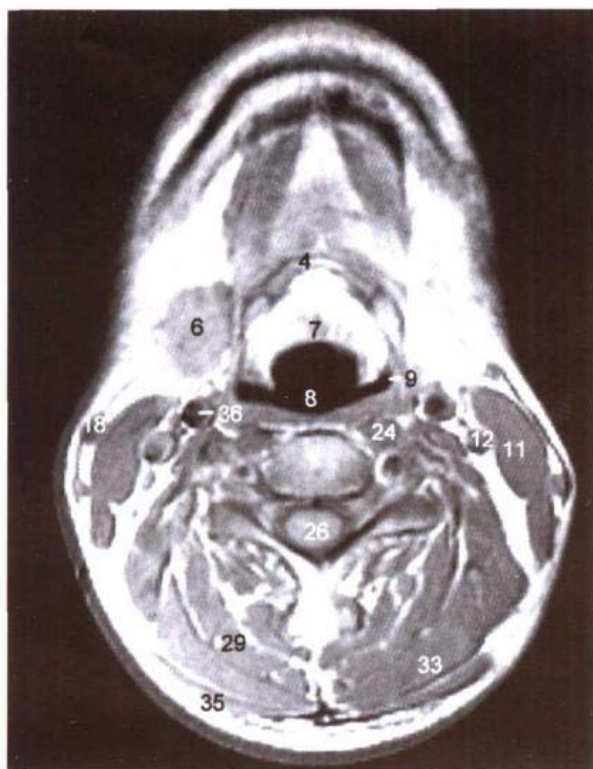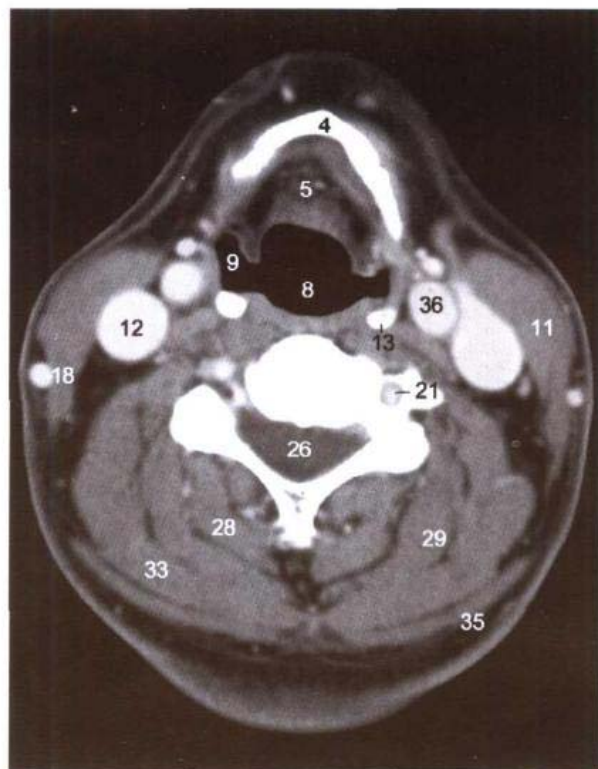- | | |
|--|--------------------------------------|
| 1. 下颌骨 mandible | and superior thyroid artery |
| 2. 二腹肌前腹 anterior belly of digastric | 21. 颈内动脉 internal carotid artery |
| 3. 下颌舌骨肌 mylohyoid | 22. 颈内静脉 internal jugular vein |
| 4. 颏舌肌 genioglossus | 23. 前斜角肌 scalenus anterior |
| 5. 舌骨体 body of hyoid bone | 24. 第4颈椎 4th cervical vertebrae |
| 6. 二腹肌中间腱 intermediate tendon of digastric | 25. 头长肌和颈长肌 longus capitis and colli |
| 7. 舌骨大角 greater horn of hyoid bone | 26. 迷走神经 vagus nerve |
| 8. 舌骨舌肌 hyoglossus | 27. 椎动脉 vertebral artery |
| 9. 下颌下腺 submandibular gland | 28. 中斜角肌 scalenus medius |
| 10. 胸锁乳突肌 sternocleidomastoid | 29. 最长肌 longissimus |
| 11. 颈总动脉 common carotid artery | 30. 颈外静脉 external jugular vein |
| 12. 甲状软骨上角 superior cornu of thyroid cartilage | 31. 蛛网膜下隙 subarachnoid space |
| 13. 舌扁桃体 lingual tonsil | 32. 脊髓 spinal cord |
| 14. 会厌 epiglottis | 33. 第4颈神经 4th cervical nerve |
| 15. 喉咽 laryngopharynx | 34. 肩胛提肌 levator scapulae |
| 16. 口腔 oral cavity | 35. 颈夹肌 splenius cervicis |
| 17. 下颌下淋巴结 submandibular lymph nodes | 36. 多裂肌 multifidi |
| 18. 面动、静脉 facial artery and vein | 37. 颈深静脉 deep cervical vein |
| 19. 颈外侧深淋巴结 deep lateral cervical lymph nodes | 38. 头夹肌 splenius capitis |
| 20. 颈外动脉和甲状腺上动脉 external carotid artery | 39. 头半棘肌 semispinalis capitis |
| | 40. 斜方肌 trapezius |

图 2-2 经舌骨体的横断层

Fig.2-2 Transverse section through body of hyoid bone



A. 断层标本(sectional specimen)

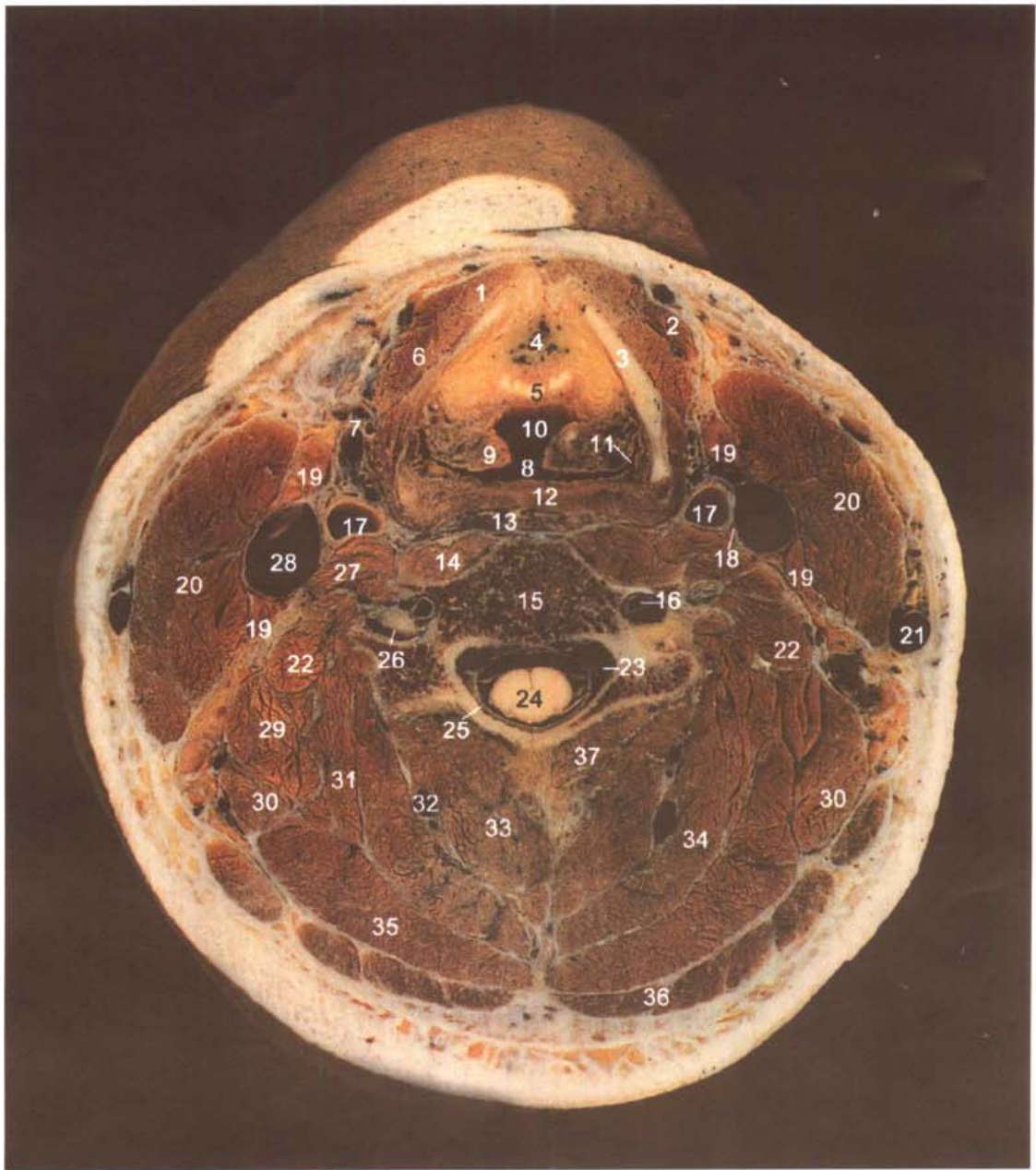
B. MRI T₁ WI

C. CT

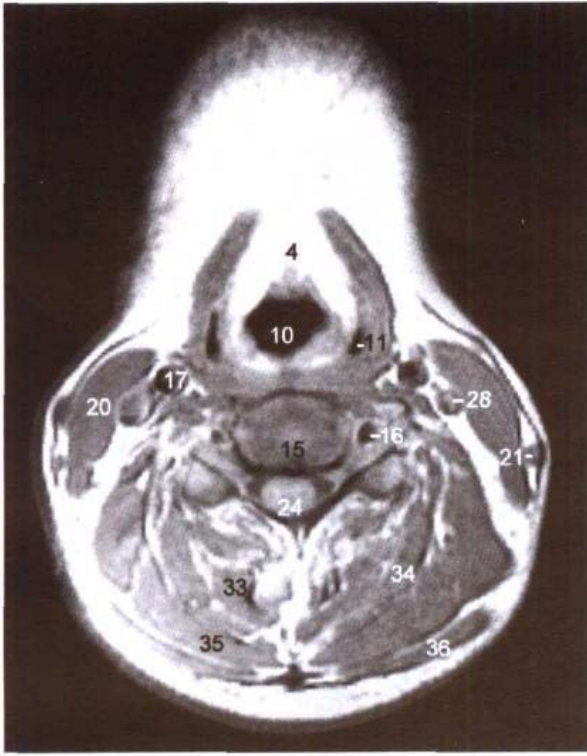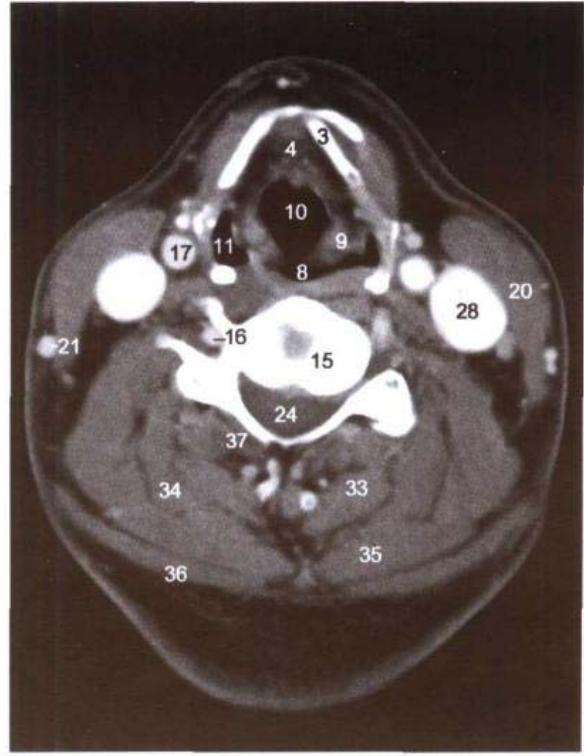
- | | |
|---|---|
| 1. 二腹肌前腹 anterior belly of digastric | 18. 颈外静脉 external jugular vein |
| 2. 下颌下淋巴结 submandibular lymph nodes | 19. 肩胛提肌 levator scapulae |
| 3. 胸骨舌骨肌和肩胛舌骨肌上腹 sternohyoid and superior belly of omohyoid | 20. 中斜角肌 scalenus medius |
| 4. 舌骨体 body of hyoid bone | 21. 椎动脉 vertebral artery |
| 5. 会厌前间隙 preepiglottic space | 22. 第4颈椎间盘 4th cervical intervertebral disc |
| 6. 下颌下腺 submandibular gland | 23. 第4颈神经 4th cervical nerve |
| 7. 会厌软骨 epiglottic cartilage | 24. 头长肌和颈长肌 longus capitis and colli |
| 8. 喉咽 laryngopharynx | 25. 关节突关节 zygapophysial joint |
| 9. 梨状隐窝 piriform recess | 26. 脊髓 spinal cord |
| 10. 颈外侧深淋巴结 deep lateral cervical lymph nodes | 27. 棘突 spinous process |
| 11. 胸锁乳突肌 sternocleidomastoid | 28. 颈半棘肌 semispinalis cervicis |
| 12. 颈内静脉 internal jugular vein | 29. 头半棘肌 semispinalis capitis |
| 13. 甲状软骨上角 superior cornu of thyroid cartilage | 30. 最长肌 longissimus |
| 14. 咽后间隙 retropharyngeal space | 31. 迷走神经 vagus nerve |
| 15. 咽下缩肌 inferior constrictor of pharynx | 32. 后斜角肌 scalenus posterior |
| 16. 颈外动脉 external carotid artery | 33. 头夹肌 splenius capitis |
| 17. 颈内动脉 internal carotid artery | 34. 颈深静脉 deep cervical vein |
| | 35. 斜方肌 trapezius |
| | 36. 颈总动脉 common carotid artery |

图 2-3 经甲状软骨上份的横断层

Fig.2-3 Transverse section through upper part of thyroid cartilage

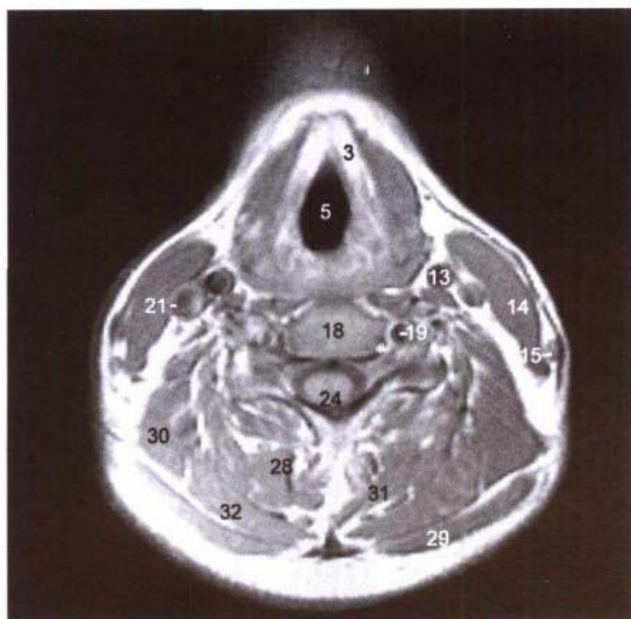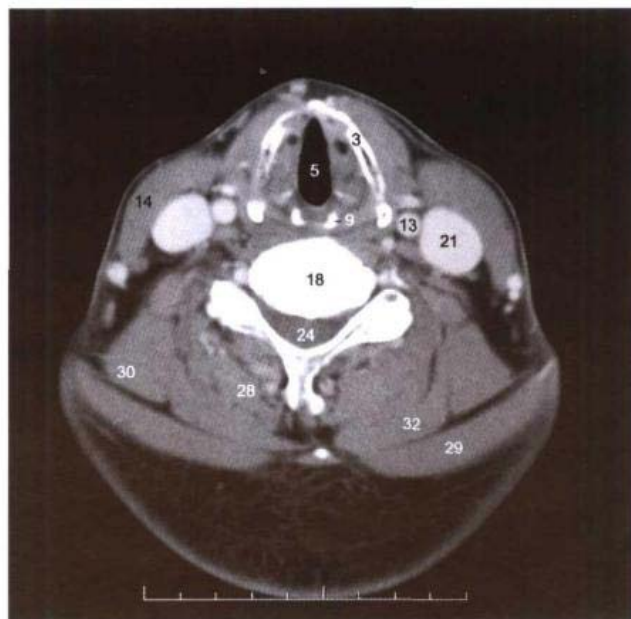


A. 断层标本(sectional specimen)

B. MRI T₁ WI

C. CT

- | | |
|--|--|
| 1. 胸骨舌骨肌 sternohyoid | nodes |
| 2. 肩胛舌骨肌上腹 superior belly of omohyoid | 20. 胸锁乳突肌 sternocleidomastoid |
| 3. 甲状软骨 thyroid cartilage | 21. 颈外静脉 external jugular vein |
| 4. 会厌前间隙 preepiglottic space | 22. 中斜角肌 scalenus medius |
| 5. 会厌软骨 epiglottic cartilage | 23. 椎内静脉丛 internal vertebral venous plexus |
| 6. 甲状舌骨肌 thyrohyoid | 24. 脊髓 spinal cord |
| 7. 甲状腺上动、静脉 superior thyroid artery and vein | 25. 硬脊膜 spinal dura mater |
| 8. 喉咽 laryngopharynx | 26. 第5颈神经 5th cervical nerve |
| 9. 杓状会厌襞 aryepiglottic fold | 27. 前斜角肌 scalenus anterior |
| 10. 喉前庭 laryngeal vestibule | 28. 颈内静脉 internal jugular vein |
| 11. 梨状隐窝 piriform recess | 29. 后斜角肌 scalenus posterior |
| 12. 咽下缩肌 inferior constrictor of pharynx | 30. 肩胛提肌 levator scapulae |
| 13. 咽后间隙 retropharyngeal space | 31. 最长肌 longissimus |
| 14. 颈长肌 longus colli | 32. 颈深静脉 deep cervical vein |
| 15. 第5颈椎 5th cervical vertebrae | 33. 颈半棘肌 semispinalis cervicis |
| 16. 椎动脉 vertebral artery | 34. 头半棘肌 semispinalis capitis |
| 17. 颈总动脉 common carotid artery | 35. 头夹肌 splenius capitis |
| 18. 迷走神经 vagus nerve | 36. 斜方肌 trapezius |
| 19. 颈外侧深淋巴结 deep lateral cervical lymph | 37. 多裂肌 multifidi |

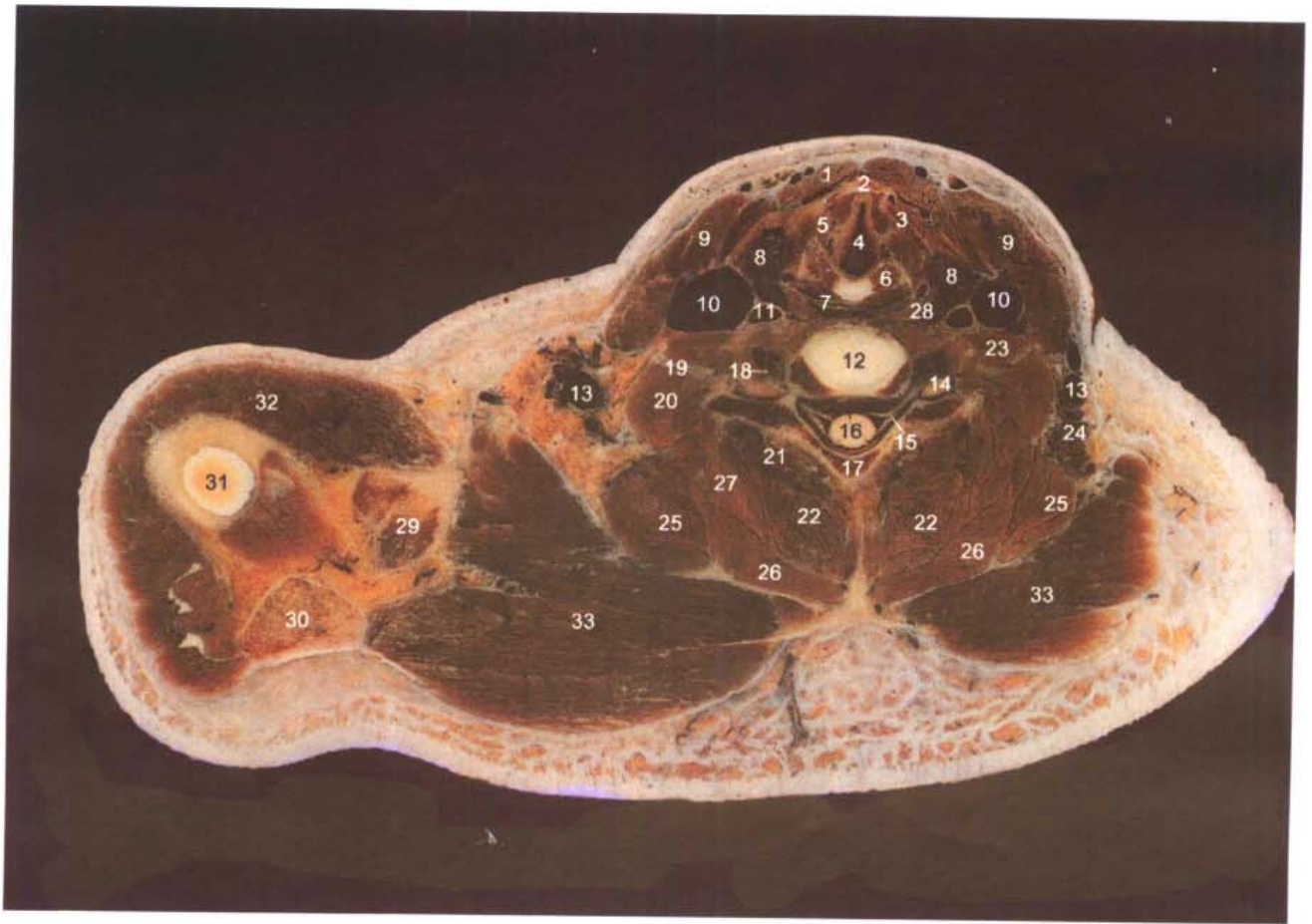
B. MRI T₁ WI

C. CT

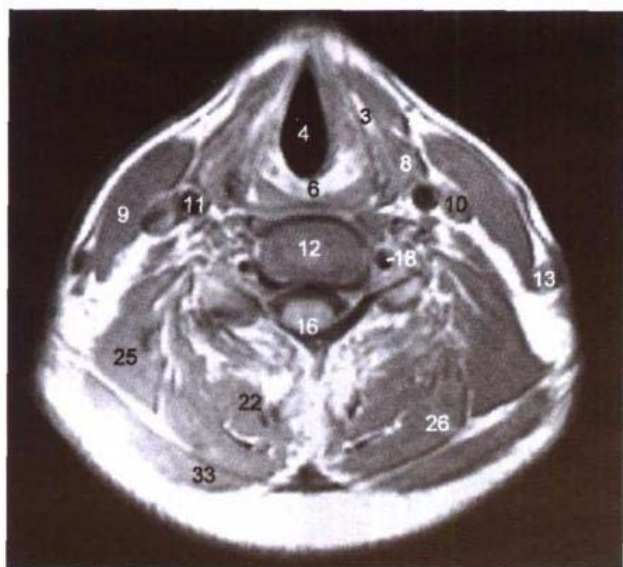
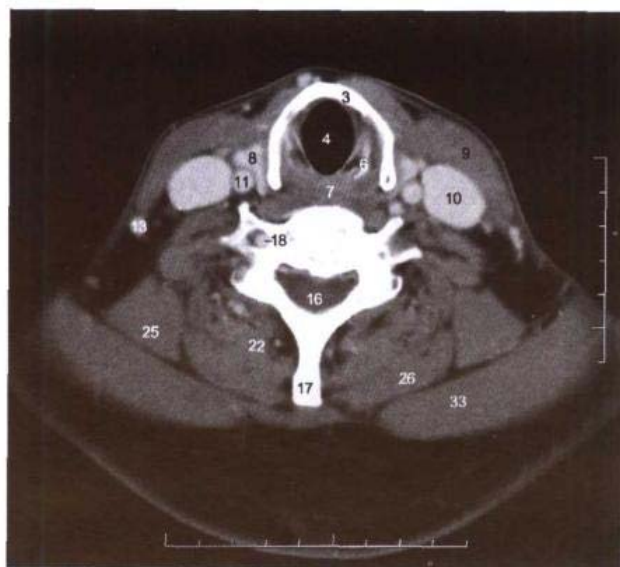
- | | |
|--|--|
| 1. 胸骨舌骨肌 sternohyoid | 19. 椎动脉 vertebral artery |
| 2. 肩胛舌骨肌上腹 superior belly of omohyoid | 20. 第6颈神经 6th cervical nerve |
| 3. 甲状软骨 thyroid cartilage | 21. 颈内静脉 internal jugular vein |
| 4. 喉旁间隙 paralaryngeal space | 22. 迷走神经 vagus nerve |
| 5. 喉中间腔 intermedial cavity of larynx | 23. 中、后斜角肌 scalenus medius and posterior |
| 6. 甲杓肌 thyroarytenoid | 24. 脊髓 spinal cord |
| 7. 甲状舌骨肌 thyrohyoid | 25. 颈外侧深淋巴结 deep lateral cervical lymph nodes |
| 8. 甲状腺 thyroid gland | 26. 多裂肌 multifidi |
| 9. 杓状软骨 arytenoid cartilage | 27. 横突后结节 posterior tubercle of transverse process |
| 10. 杓横肌 transverse arytenoid | 28. 颈半棘肌 semispinalis cervicis |
| 11. 喉咽 laryngopharynx | 29. 斜方肌 trapezius |
| 12. 咽下缩肌 inferior constrictor of pharynx | 30. 肩胛提肌 levator scapulae |
| 13. 颈总动脉 common carotid artery | 31. 头半棘肌 semispinalis capitis |
| 14. 胸锁乳突肌 sternocleidomastoid | 32. 头夹肌 splenius capitis |
| 15. 颈外静脉 external jugular vein | 33. 锁骨肩峰端 acromial end of clavicle |
| 16. 前斜角肌 scalenus anterior | 34. 肩峰 acromion |
| 17. 颈长肌 longus colli | |
| 18. 第6颈椎 6th cervical vertebrae | |

图 2-5 经声襞和环状软骨板的横断层

Fig.2-5 Transverse section through vocal fold and lamina of cricoid cartilage



A. 断层标本(sectional specimen)

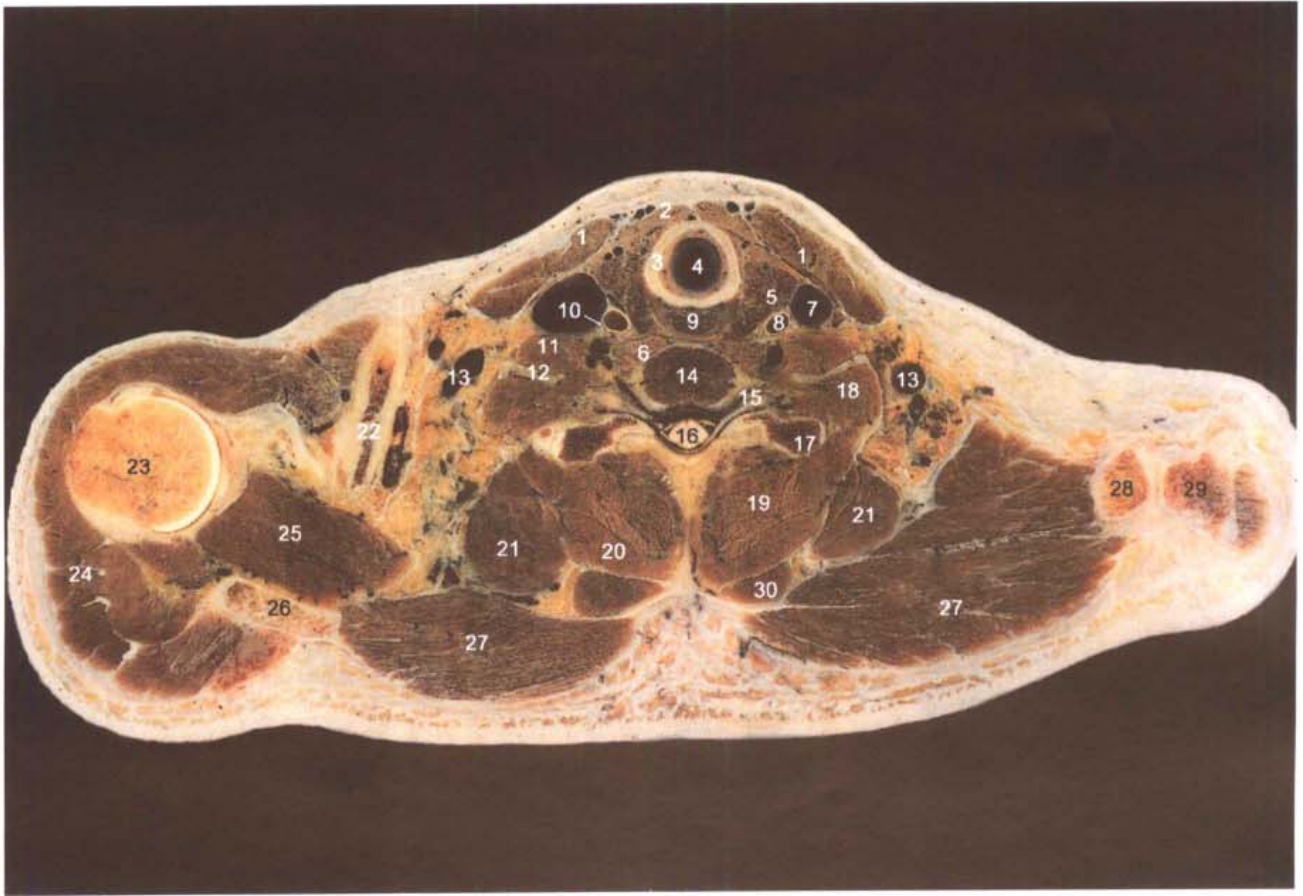
B. MRI T₁ WI

C. CT

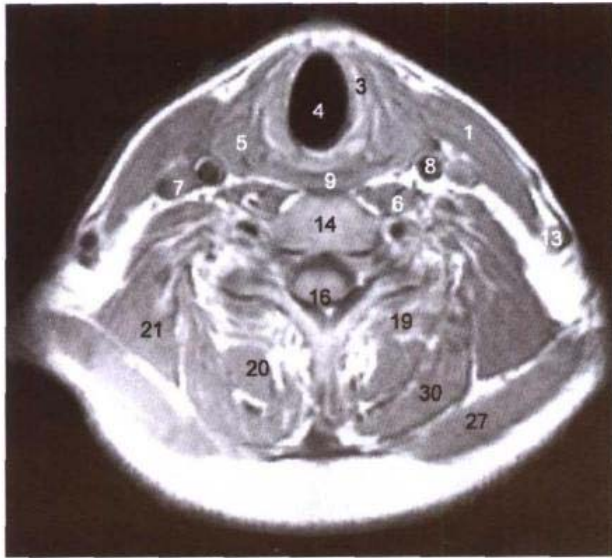
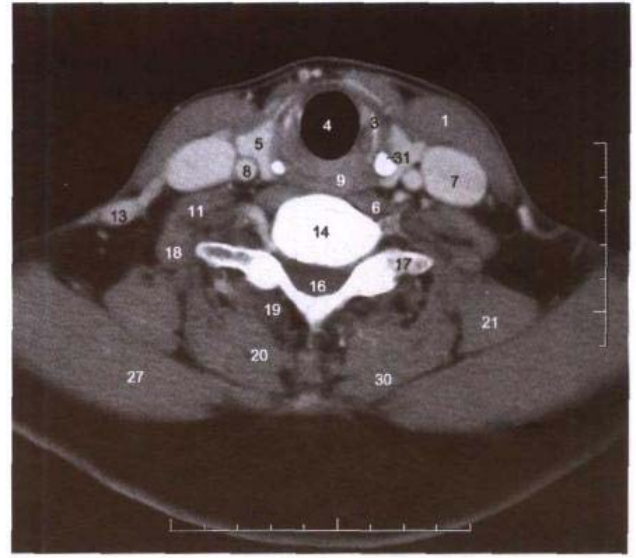
- | | |
|---|--|
| 1. 胸骨舌骨肌 sternohyoid | 19. 臂丛 brachial plexus |
| 2. 喉结 laryngeal prominence | 20. 中、后斜角肌 scalenus medius and posterior |
| 3. 甲状软骨 thyroid cartilage | 21. 多裂肌 multifidi |
| 4. 喉中间腔 intermedial cavity of larynx | 22. 颈半棘肌 semispinalis cervicis |
| 5. 环甲肌 cricothyroid | 23. 前斜角肌 scalenus anterior |
| 6. 环状软骨板 lamina of cricoid cartilage | 24. 颈外侧浅淋巴结 superficial lateral cervical lymph nodes |
| 7. 喉咽 laryngopharynx | 25. 肩胛提肌 levator scapulae |
| 8. 甲状腺 thyroid gland | 26. 夹肌 splenius |
| 9. 胸锁乳突肌 sternocleidomastoid | 27. 最长肌 longissimus |
| 10. 颈内静脉 internal jugular vein | 28. 甲状软骨下角 inferior cornu of thyroid cartilage |
| 11. 颈总动脉 common carotid artery | 29. 锁骨 clavicle |
| 12. 第6颈椎间盘 6th cervical intervertebral disc | 30. 肩峰 acromion |
| 13. 颈外静脉 external jugular vein | 31. 肱骨头 head of humerus |
| 14. 第6颈神经 6th cervical nerve | 32. 三角肌 deltoid |
| 15. 颈神经根 root of cervical nerve | 33. 斜方肌 trapezius |
| 16. 脊髓 spinal cord | |
| 17. 棘突 spinous process | |
| 18. 椎动脉 vertebral artery | |

图 2-6 经环状软骨和声门下腔的横断层

Fig.2-6 Transverse section through cricoid cartilage and infraglottic cavity



A. 断层标本(sectional specimen)

B. MRI T₁ WI

C. CT

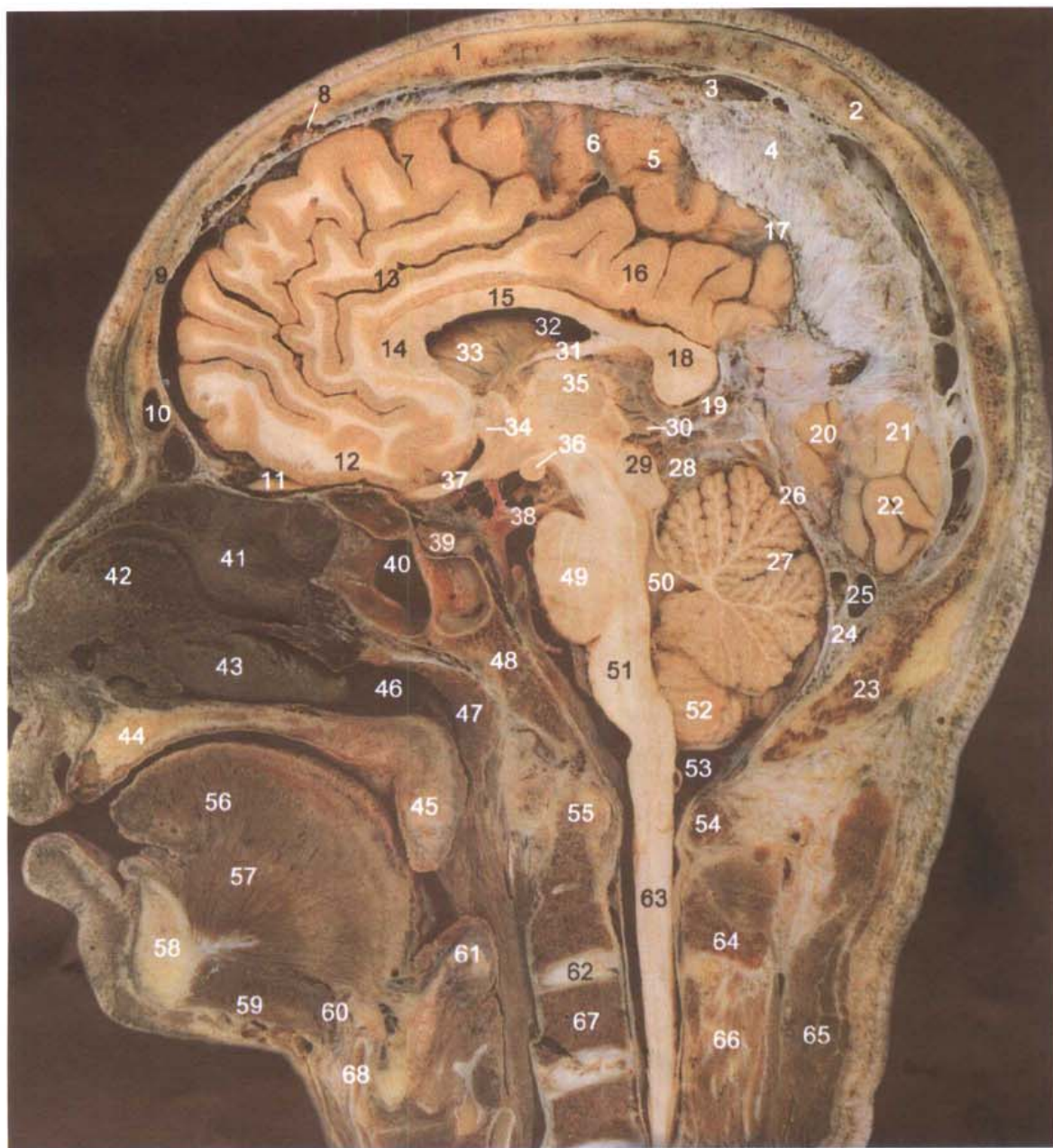
- | | |
|---------------------------------|--|
| 1. 胸锁乳突肌 sternocleidomastoid | 18. 中、后斜角肌 scalenus medius and posterior |
| 2. 胸骨舌骨肌 sternohyoid | 19. 多裂肌和颈半棘肌 multifidi and semispinalis cervicis |
| 3. 环状软骨 cricoid cartilage | 20. 头半棘肌 semispinalis capitis |
| 4. 声门下腔 infraglottic cavity | 21. 肩胛提肌 levator scapulae |
| 5. 甲状腺 thyroid gland | 22. 锁骨 clavicle |
| 6. 颈长肌 longus colli | 23. 肱骨头 head of humerus |
| 7. 颈内静脉 internal jugular vein | 24. 三角肌 deltoid |
| 8. 颈总动脉 common carotid artery | 25. 冈上肌 supraspinatus |
| 9. 食管 esophagus | 26. 肩胛冈 spine of scapula |
| 10. 迷走神经 vagus nerve | 27. 斜方肌 trapezius |
| 11. 前斜角肌 scalenus anterior | 28. 锁骨肩峰端 acromial end of clavicle |
| 12. 臂丛 brachial plexus | 29. 肩峰 acromion |
| 13. 颈外静脉 external jugular vein | 30. 夹肌 splenius |
| 14. 第7颈椎 7th cervical vertebrae | 31. 甲状软骨下角 inferior horn of thyroid cartilage |
| 15. 第7颈神经 7th cervical nerve | |
| 16. 脊髓 spinal cord | |
| 17. 横突 transverse process | |

第三章 头颈部连续矢状断层

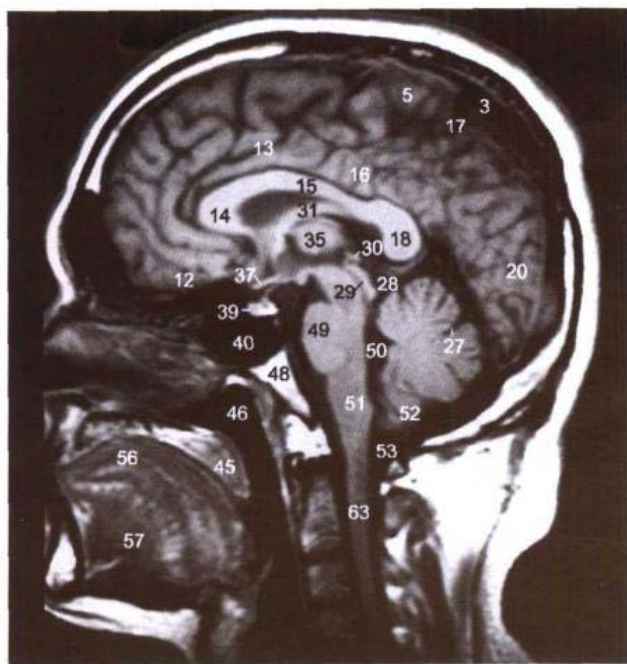
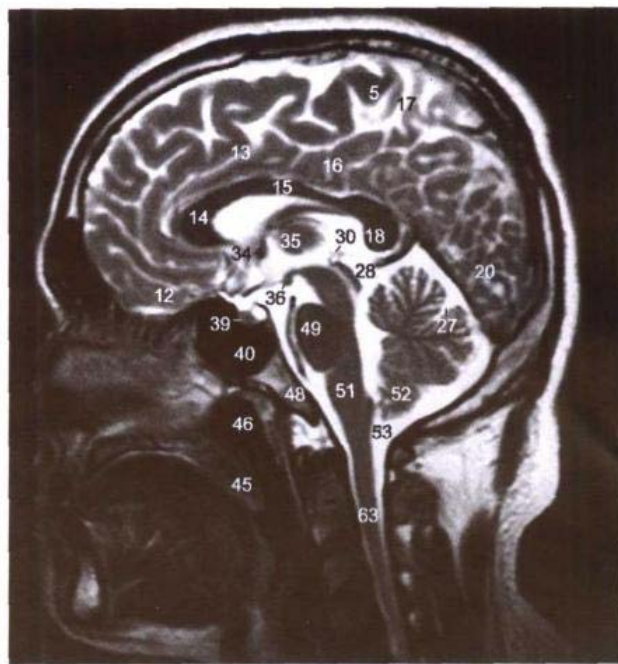
Chapter 3 Serial Sagittal Sections of Head and Neck

图 3-1 正中矢状面

Fig.3-1 Median sagittal plane



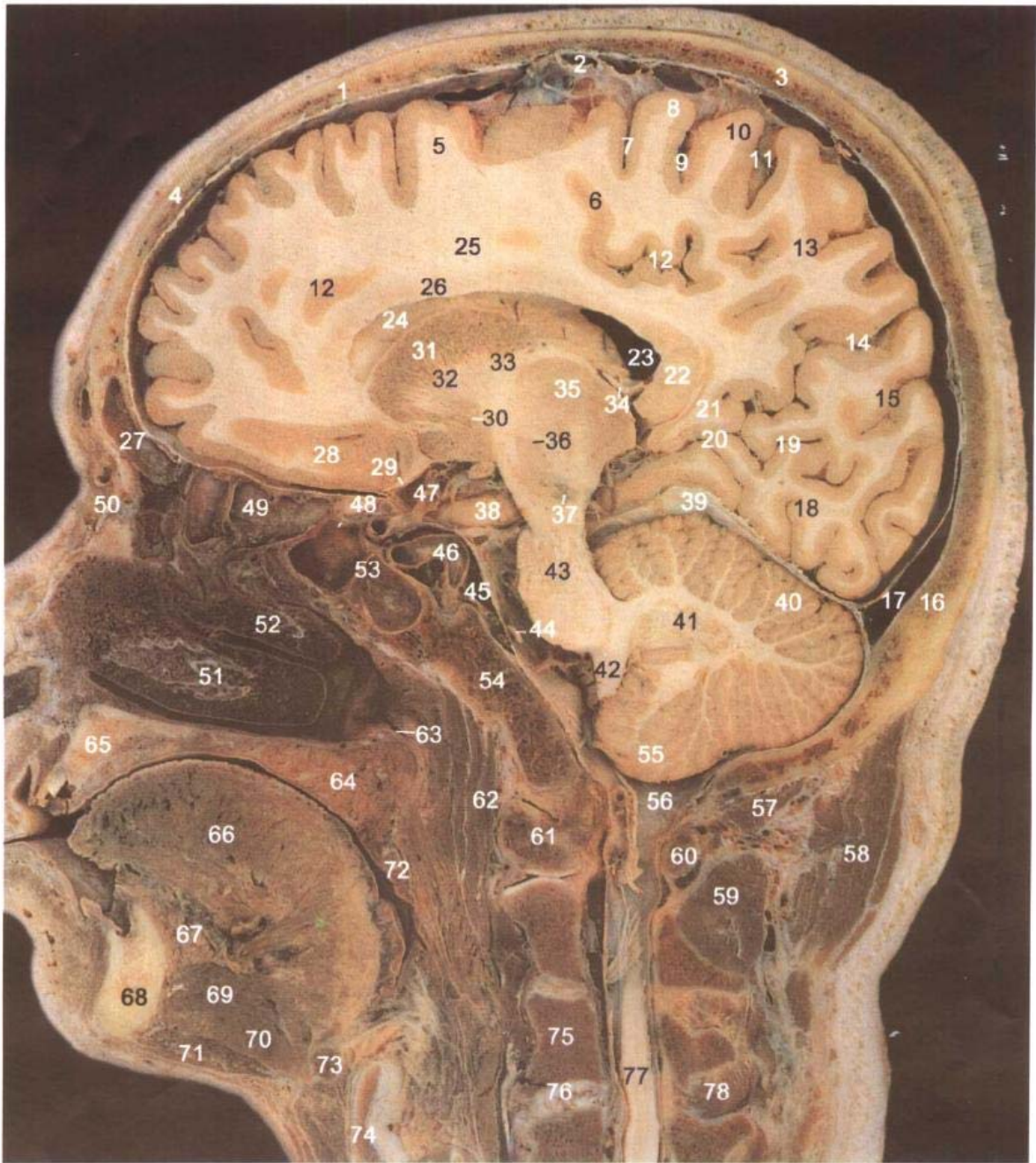
A. 断层标本(sectional specimen)

B. MRI T₁ WIC. MRI T₂ WI

- | | | |
|---|--|---|
| 1. 冠状缝 coronal suture | 22. 左舌回 left lingual gyrus | 49. 脑桥基底部 basilar part of pons |
| 2. 矢状缝 sagittal suture | 23. 枕骨 occipital bone | 50. 第四脑室 4th ventricle |
| 3. 上矢状窦 superior sagittal sinus | 24. 小脑镰 cerebellar falx | 51. 延髓 medulla oblongata |
| 4. 大脑镰 cerebral falx | 25. 窦汇 confluence of sinus | 52. 小脑扁桃体 tonsil of cerebellum |
| 5. 中央旁小叶 paracentral lobule | 26. 直窦 straight sinus | 53. 小脑延髓池 cerebellomedullary cistern |
| 6. 中央旁沟和旁中央动脉 paracentral sulcus and paracentral artery | 27. 小脑原裂 primary fissure of cerebellum | 54. 寰椎后弓 posterior arch of atlas |
| 7. 额上回 superior frontal gyrus | 28. 四叠体池 quadrigeminal cistern | 55. 枢椎齿突 dens of axis |
| 8. 上矢状窦外侧陷窝 lateral lacuna of superior sagittal sinus | 29. 四叠体 quadrigeminal body | 56. 舌体 body of tongue |
| 9. 额骨 frontal bone | 30. 松果体 pineal body | 57. 颞舌肌 genioglossus |
| 10. 额窦 frontal sinus | 31. 穹窿体 body of fornix | 58. 下颌骨体 body of mandible |
| 11. 嗅球 olfactory bulb | 32. 侧脑室 lateral ventricle | 59. 下颌舌骨肌 mylohyoid |
| 12. 直回 gyrus rectus | 33. 尾状核 caudate nucleus | 60. 舌骨 hyoid bone |
| 13. 扣带沟 cingulate sulcus | 34. 前连合 anterior commissure | 61. 会厌 epiglottis |
| 14. 胼胝体膝 genu of corpus callosum | 35. 背侧丘脑 dorsal thalamus | 62. 第2颈椎间盘 2nd cervical intervertebral disc |
| 15. 胼胝体干 trunk of corpus callosum | 36. 乳头体 mamillary body | 63. 脊髓 spinal cord |
| 16. 扣带回 cingulate gyrus | 37. 视交叉 optic chiasma | 64. 枢椎棘突 spinous process of axis |
| 17. 扣带沟缘支 marginal ramus of cingulate sulcus | 38. 动眼神经 oculomotor nerve | 65. 头夹肌 splenius capitis |
| 18. 胼胝体压部 splenium of corpus callosum | 39. 垂体 hypophysis | 66. 棘间肌 interspinales |
| 19. 大脑大静脉 great cerebral vein | 40. 蝶窦 sphenoidal sinus | 67. 第3颈椎体 3rd cervical vertebral body |
| 20. 枕叶 occipital lobe | 41. 中鼻甲 middle nasal concha | 68. 甲状软骨 thyroid cartilage |
| 21. 左楔叶 left cuneus | 42. 鼻中隔 nasal septum | |
| | 43. 下鼻甲 inferior nasal concha | |
| | 44. 上颌骨 maxilla | |
| | 45. 软腭 soft palate | |
| | 46. 鼻咽 nasopharynx | |
| | 47. 咽壁 pharyngeal wall | |
| | 48. 斜坡 clivus | |

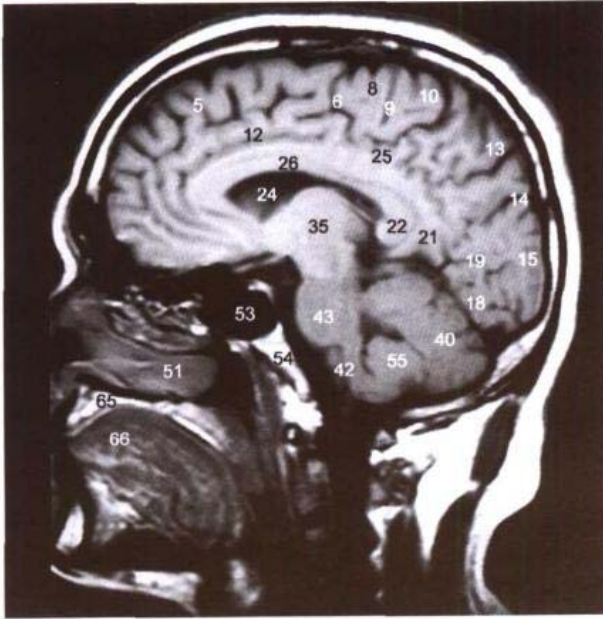
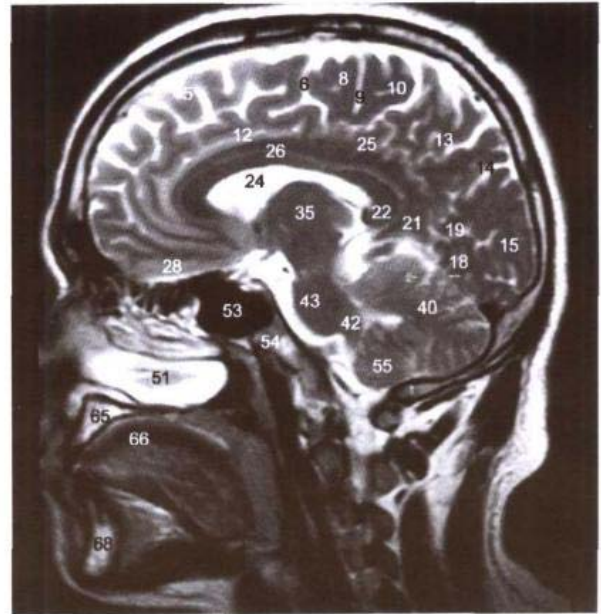
图 3-2 经右黑质和红核的矢状断层

Fig.3-2 The sagittal section through right substantia nigra and red nucleus



A. 断层标本(sectional specimen)

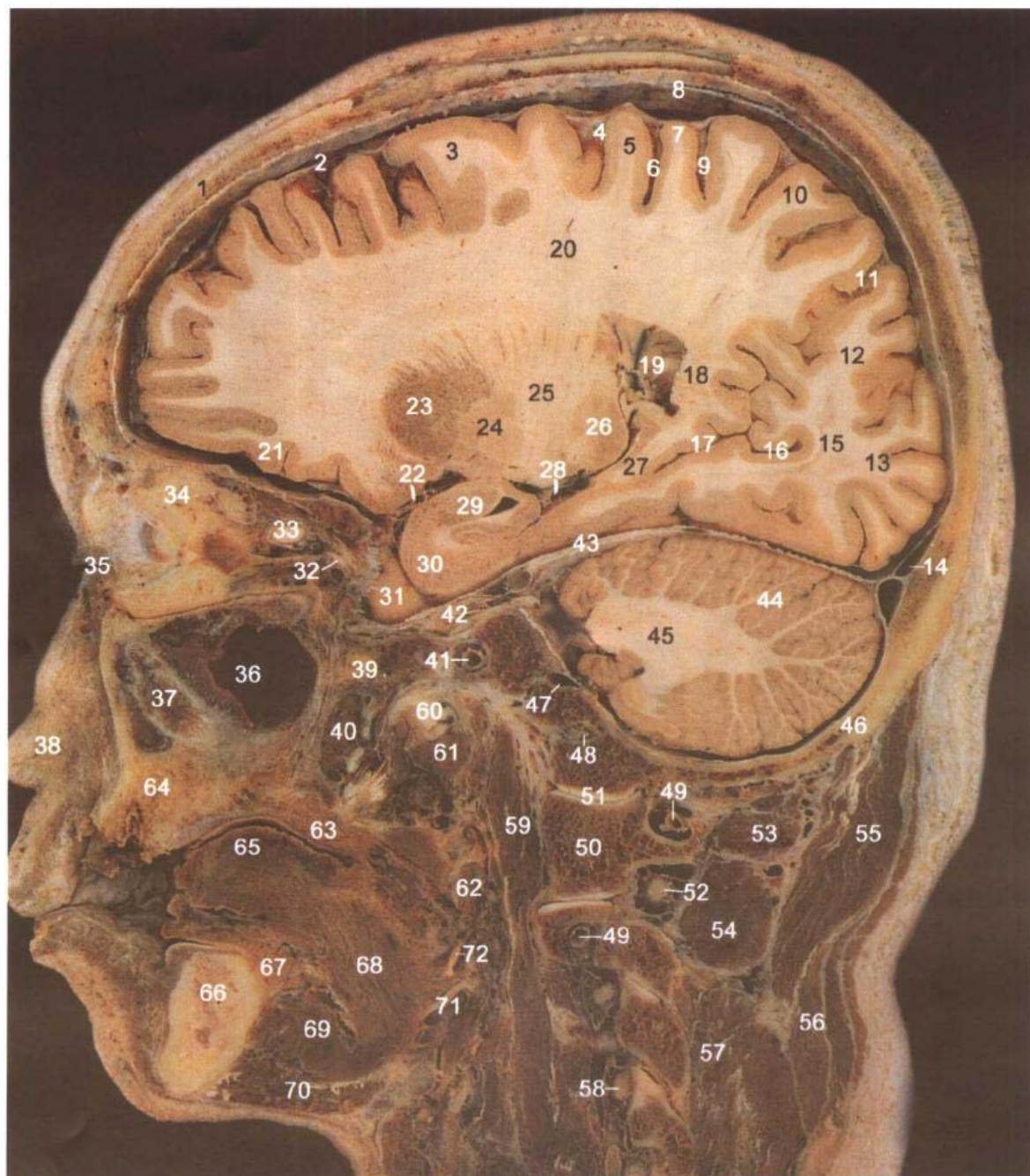
- | | |
|-------------------------------|----------------------------------|
| 1. 冠状缝 coronal suture | 10. 中央后回 postcentral gyrus |
| 2. 蛛网膜 arachnoid mater | 11. 中央后沟 postcentral sulcus |
| 3. 顶骨 parietal bone | 12. 扣带沟 cingulate sulcus |
| 4. 额骨 frontal bone | 13. 楔前叶 precuneus |
| 5. 额上回 superior frontal gyrus | 14. 顶枕沟 parietooccipital sulcus |
| 6. 中央旁沟 paracentral sulcus | 15. 楔叶 cuneus |
| 7. 中央前沟 precentral sulcus | 16. 枕骨 occipital bone |
| 8. 中央前回 precentral gyrus | 17. 上矢状窦 superior sagittal sinus |
| 9. 中央沟 central sulcus | 18. 舌回 lingual gyrus |

B. MRI T₁ WIC. MRI T₂ WI

- | | |
|---|---|
| 19. 距状沟后部 posterior part of calcarine sulcus | 48. 视神经 optic nerve |
| 20. 距状沟前部 anterior part of calcarine sulcus | 49. 筛窦 ethmoidal cellules |
| 21. 扣带回峡 isthmus of cingulate gyrus | 50. 内眦动、静脉 medial angular artery and vein |
| 22. 胼胝体压部 splenium of corpus callosum | 51. 下鼻甲 inferior nasal concha |
| 23. 侧脑室三角区 trigone of lateral ventricle | 52. 中鼻甲 middle nasal concha |
| 24. 侧脑室前角 anterior horn of lateral ventricle | 53. 蝶窦 sphenoidal sinus |
| 25. 扣带 cingulum | 54. 斜坡 clivus |
| 26. 胼胝体干 trunk of corpus callosum | 55. 小脑扁桃体 tonsil of cerebellum |
| 27. 额窦 frontal sinus | 56. 小脑延髓池 cerebellomedullary cistern |
| 28. 直回 gyrus rectus | 57. 头后小直肌 rectus capitis posterior minor |
| 29. 嗅束 olfactory tract | 58. 头夹肌 splenius capitis |
| 30. 苍白球和前连合 globus pallidus and anterior commissure | 59. 头后大直肌 rectus capitis posterior major |
| 31. 尾状核头 head of caudate nucleus | 60. 寰椎后弓 posterior arch of atlas |
| 32. 内囊前肢 anterior limb of internal capsule | 61. 寰椎前弓 anterior arch of atlas |
| 33. 内囊膝 genu of internal capsule | 62. 头长肌 longus capitis |
| 34. 海马伞 fimbria of hippocampus | 63. 咽鼓管咽口 pharyngeal opening of auditory tube |
| 35. 背侧丘脑 dorsal thalamus | 64. 腭腺 palatine glands |
| 36. 红核 red nucleus | 65. 上颌骨 maxilla |
| 37. 黑质 substantia nigra | 66. 舌体 body of tongue |
| 38. 钩 uncus | 67. 舌下腺 sublingual gland |
| 39. 小脑幕 tentorium of cerebellum | 68. 下颌骨体 body of mandible |
| 40. 小脑半球 cerebellar hemisphere | 69. 颞舌骨肌 geniohyoid |
| 41. 齿状核 dentate nucleus | 70. 下颌舌骨肌 mylohyoid |
| 42. 延髓 medulla oblongata | 71. 二腹肌前腹 anterior belly of digastric |
| 43. 脑桥 pons | 72. 腭扁桃体 palatine tonsil |
| 44. 展神经 abducent nerve | 73. 舌骨 hyoid bone |
| 45. 海绵窦 cavernous sinus | 74. 甲状软骨 thyroid cartilage |
| 46. 颈内动脉海绵窦段 cavernous segment of internal carotid artery | 75. 第3颈椎体 3rd cervical vertebral body |
| 47. 颈内动脉后膝段 posterior genu segment of internal carotid artery | 76. 第3椎间盘 3rd cervical intervertebral disc |
| | 77. 脊髓 spinal cord |
| | 78. 棘间肌 interspinales |

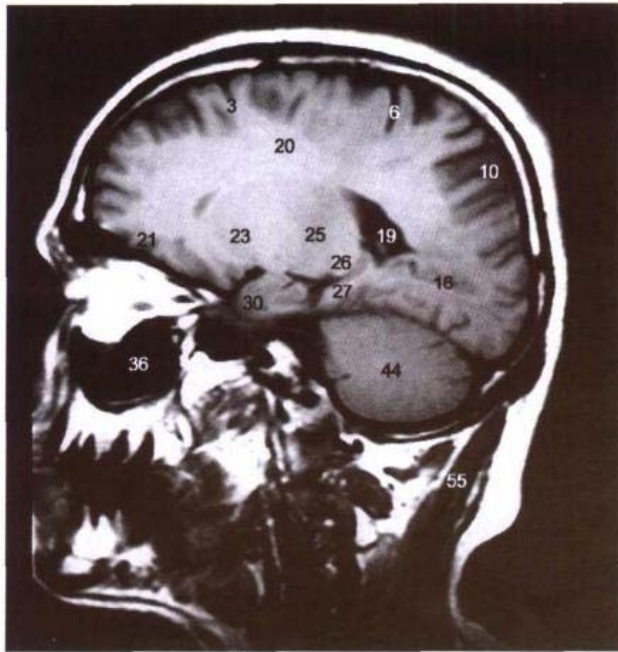
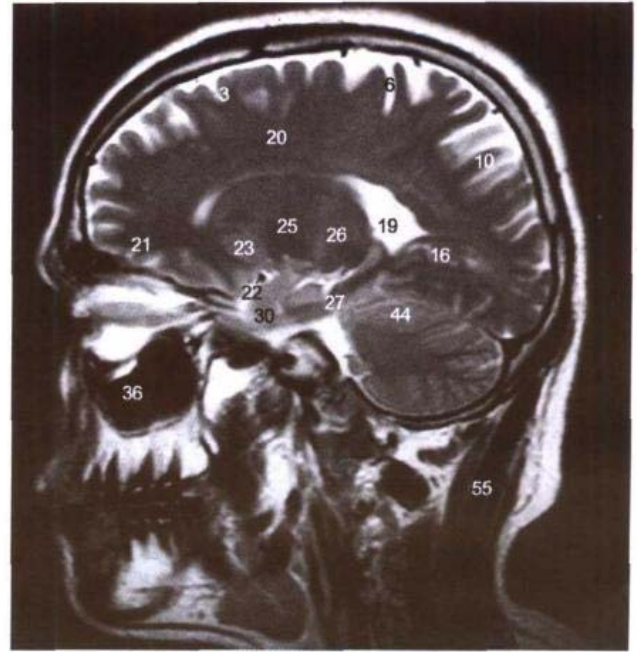
图 3-3 经右苍白球的矢状断层

Fig.3-3 The sagittal section through right globus pallidus



A. 断层标本(sectional specimen)

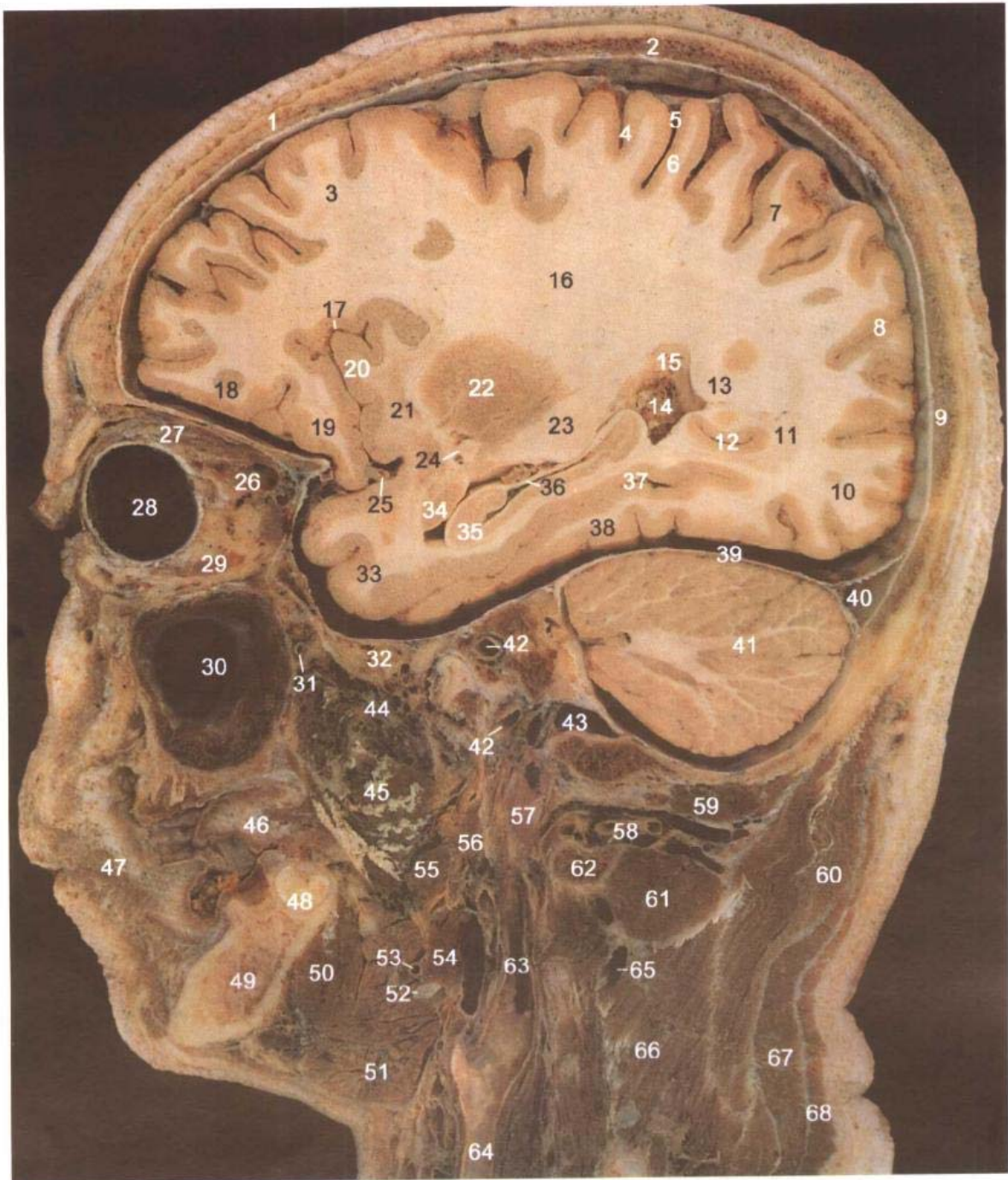
- | | |
|-------------------------------|--|
| 1. 额骨 frontal bone | 9. 中央后沟 postcentral sulcus |
| 2. 蛛网膜 arachnoid mater | 10. 顶上小叶 superior parietal lobule |
| 3. 额上回 superior frontal gyrus | 11. 顶枕沟 parietooccipital sulcus |
| 4. 中央前沟 precentral sulcus | 12. 楔叶 cuneus |
| 5. 中央前回 precentral gyrus | 13. 舌回 lingual gyrus |
| 6. 中央沟 central sulcus | 14. 上矢状窦 superior sagittal sinus |
| 7. 中央后回 postcentral gyrus | 15. 视辐射 optic radiation |
| 8. 硬脑膜 cerebral dura mater | 16. 距状沟后部 posterior part of calcarine sulcus |

B. MRI T₁ WIC. MRI T₂ WI

- | | |
|---|--|
| 17. 距状沟前部 anterior part of calcarine sulcus | 46. 枕骨 occipital bone |
| 18. 胼胝体压部 splenium of corpus callosum | 47. 岩下窦 inferior petrosal sinus |
| 19. 侧脑室三角区 trigone of lateral ventricle | 48. 舌下神经和舌下神经管 hypoglossal nerve and canal |
| 20. 放射冠 corona radiata | 49. 椎动脉 vertebral artery |
| 21. 眶回 orbital gyri | 50. 寰椎侧块 lateral mass of atlas |
| 22. 大脑中动脉 middle cerebral artery | 51. 寰枕关节 atlantooccipital joint |
| 23. 壳 putamen | 52. 第2颈神经 2nd cervical nerve |
| 24. 苍白球 globus pallidus | 53. 头后大直肌 rectus capitis posterior major |
| 25. 内囊后肢 posterior limb of internal capsule | 54. 头下斜肌 obliquus capitis inferior |
| 26. 背侧丘脑 dorsal thalamus | 55. 头半棘肌 semispinalis capitis |
| 27. 海马旁回 parahippocampal gyrus | 56. 颈半棘肌 semispinalis cervicis |
| 28. 大脑后动脉 posterior cerebral artery | 57. 横突棘肌 spinales transverse |
| 29. 杏仁体 amygdaloid body | 58. 第4颈神经 4th cervical nerve |
| 30. 钩 uncus | 59. 头长肌 longus capitis |
| 31. 颞叶 temporal lobe | 60. 咽鼓管软骨 cartilage of auditory tube |
| 32. 动眼神经 oculomotor nerve | 61. 腭帆提肌 levator veli palatini |
| 33. 视神经 optic nerve | 62. 茎突咽肌 stylopharyngeus |
| 34. 眶脂体 adipose body of orbit | 63. 腭腺 palatine glands |
| 35. 内眦 medial angle of eye | 64. 上颌骨牙槽突 alveolar process of maxilla |
| 36. 上颌窦 maxillary sinus | 65. 舌体 body of tongue |
| 37. 上颌骨 maxilla | 66. 下颌骨体 body of mandible |
| 38. 鼻翼 alae nasi | 67. 舌下腺 sublingual gland |
| 39. 翼突 pterygoid process | 68. 舌骨舌肌 hyoglossus |
| 40. 翼内肌 medial pterygoid | 69. 下颌舌骨肌 mylohyoid |
| 41. 颈内动脉 internal carotid artery | 70. 二腹肌前腹 anterior belly of digastric |
| 42. 三叉神经节 trigeminal ganglion | 71. 舌下神经和舌动、静脉 hypoglossal nerve and lingual artery and vein |
| 43. 小脑幕 tentorium of cerebellum | 72. 舌咽神经 glossopharyngeal nerve |
| 44. 小脑半球 cerebellar hemisphere | |
| 45. 小脑中脚 middle cerebellar peduncle | |

图 3-4 经右壳的矢状断层

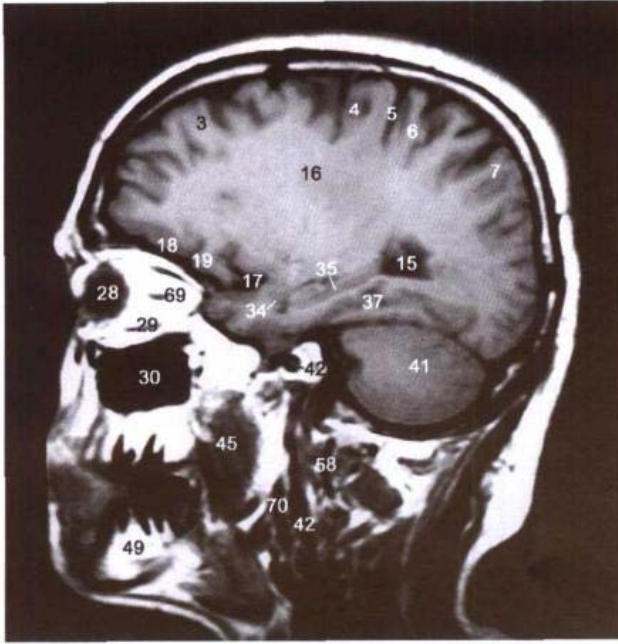
Fig.3-4 The sagittal section through right putamen



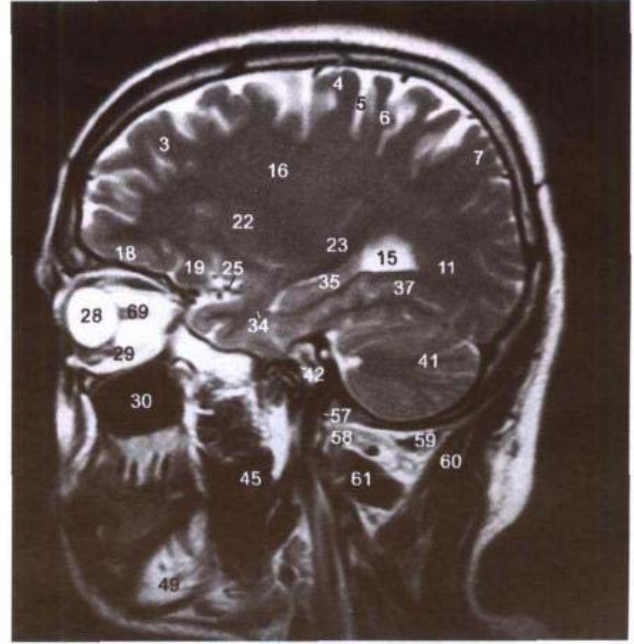
A. 断层标本(sectional specimen)

1. 额骨 frontal bone
2. 顶骨 parietal bone
3. 额上回 superior frontal gyrus
4. 中央前回 precentral gyrus
5. 中央沟 central sulcus
6. 中央后回 postcentral gyrus
7. 顶上小叶 superior parietal lobule

8. 顶枕沟 parietooccipital sulcus
9. 枕骨 occipital bone
10. 舌回 lingual gyrus
11. 视辐射 optic radiation
12. 距状沟 calcarine sulcus
13. 毯 tapetum
14. 侧脑室脉络丛 choroid plexus of lateral ven-



B. MRI T₁ WI



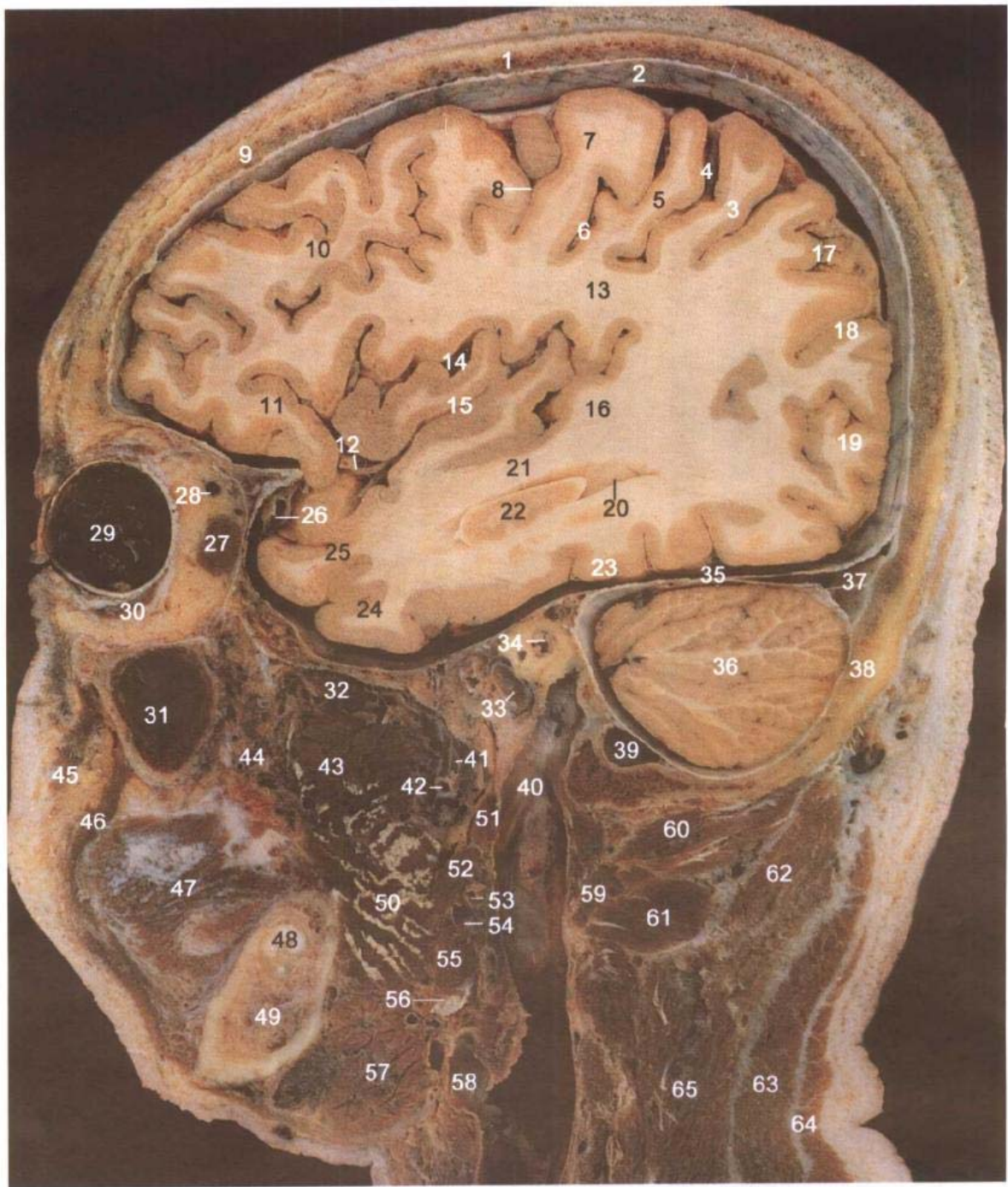
C. MRI T₂ WI

- tricle
15. 侧脑室三角区 trigone of lateral ventricle
 16. 辐射冠 corona radiata
 17. 外侧沟 lateral sulcus
 18. 眶回 orbital gyri
 19. 额下回 inferior frontal gyrus
 20. 岛叶 insula
 21. 屏状核 claustrum
 22. 壳 putamen
 23. 听辐射 acoustic radiation
 24. 前连合 anterior commissure
 25. 大脑中动脉 middle cerebral artery
 26. 眼上静脉 superior ophthalmic vein
 27. 提上睑肌、上斜肌和上直肌 levator palpebrae superioris, superior obliquus and superior rectus
 28. 眼球 eyeball
 29. 下直肌 inferior rectus
 30. 上颌窦 maxillary sinus
 31. 上颌动脉 maxillary artery
 32. 蝶骨大翼 greater wing of sphenoid bone
 33. 颞中回 middle temporal gyrus
 34. 杏仁体 amygdaloid body
 35. 海马 hippocampus
 36. 海马伞 fimbria hippocampus
 37. 侧副沟 collateral sulcus
 38. 枕颞内侧回(梭状回) medial occipitotemporal gyrus
 39. 小脑幕 tentorium of cerebellum
 40. 横窦 transverse sinus
 41. 小脑半球 cerebellar hemisphere

42. 颈内动脉 internal carotid artery
43. 颈静脉孔 jugular foramen
44. 翼静脉丛 pterygoid venous plexus
45. 翼内肌 medial pterygoid
46. 舌 tongue
47. 颊肌 buccinator
48. 第2磨牙 2nd molar
49. 下颌骨体 body of mandible
50. 下颌舌骨肌 mylohyoid
51. 下颌下腺 submandibular gland
52. 二腹肌中间腱 intermediate tendon of digastric
53. 舌动脉 lingual artery
54. 茎突舌骨肌 stylohyoid
55. 茎突舌肌 styloglossus
56. 茎突咽肌 stylopharyngeus
57. 颈内静脉 internal jugular vein
58. 椎动、静脉 vertebral artery and vein
59. 头后大直肌 rectus capitis posterior major
60. 头半棘肌 semispinalis capitis
61. 头下斜肌 obliquus capitis inferior
62. 寰椎横突 transverse process of atlas
63. 颈内动脉 internal carotid artery
64. 颈总动脉 common carotid artery
65. 颈深静脉 deep cervical vein
66. 横突棘肌 transversospinales
67. 头夹肌 splenius capitis
68. 斜方肌 trapezius
69. 视神经 optic nerve
70. 颈外动脉 external carotid artery

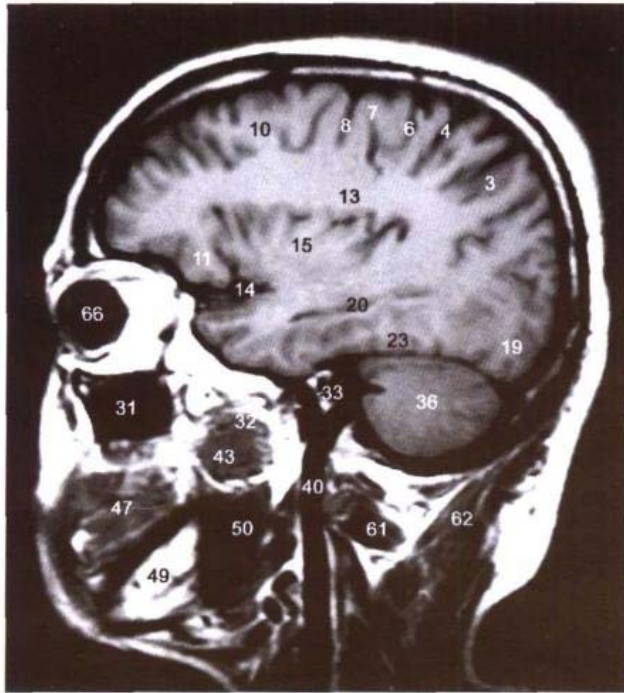
图 3-5 经右颈内静脉的矢状断层

Fig.3-5 The sagittal section through right internal jugular vein

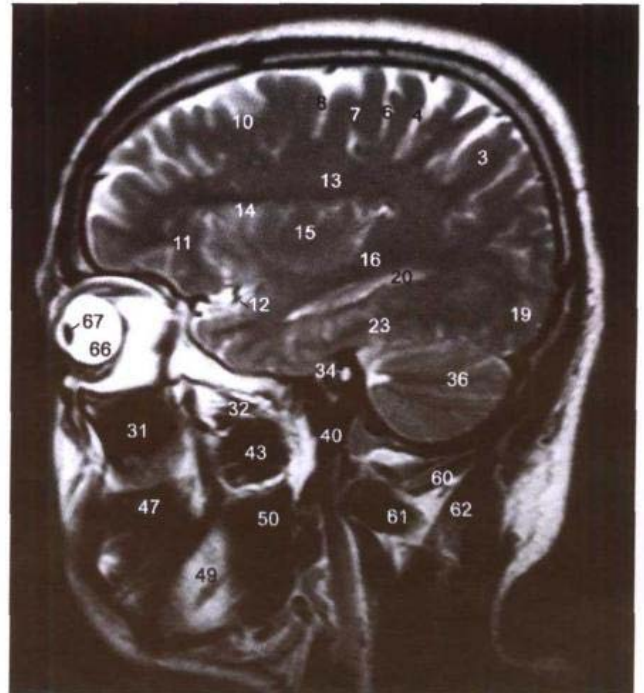


A. 断层标本(sectional specimen)

- | | |
|----------------------------------|----------------------------------|
| 1. 顶骨 parietal bone | 7. 中央前回 precentral gyrus |
| 2. 硬脑膜 cerebral dura mater | 8. 中央前沟 precentral sulcus |
| 3. 顶下小叶 inferior parietal lobule | 9. 额骨 frontal bone |
| 4. 中央后沟 postcentral sulcus | 10. 额中回 middle frontal gyrus |
| 5. 中央后回 postcentral gyrus | 11. 额下回 inferior frontal gyrus |
| 6. 中央沟 central sulcus | 12. 大脑中动脉 middle cerebral artery |



B. MRI T₁ WI

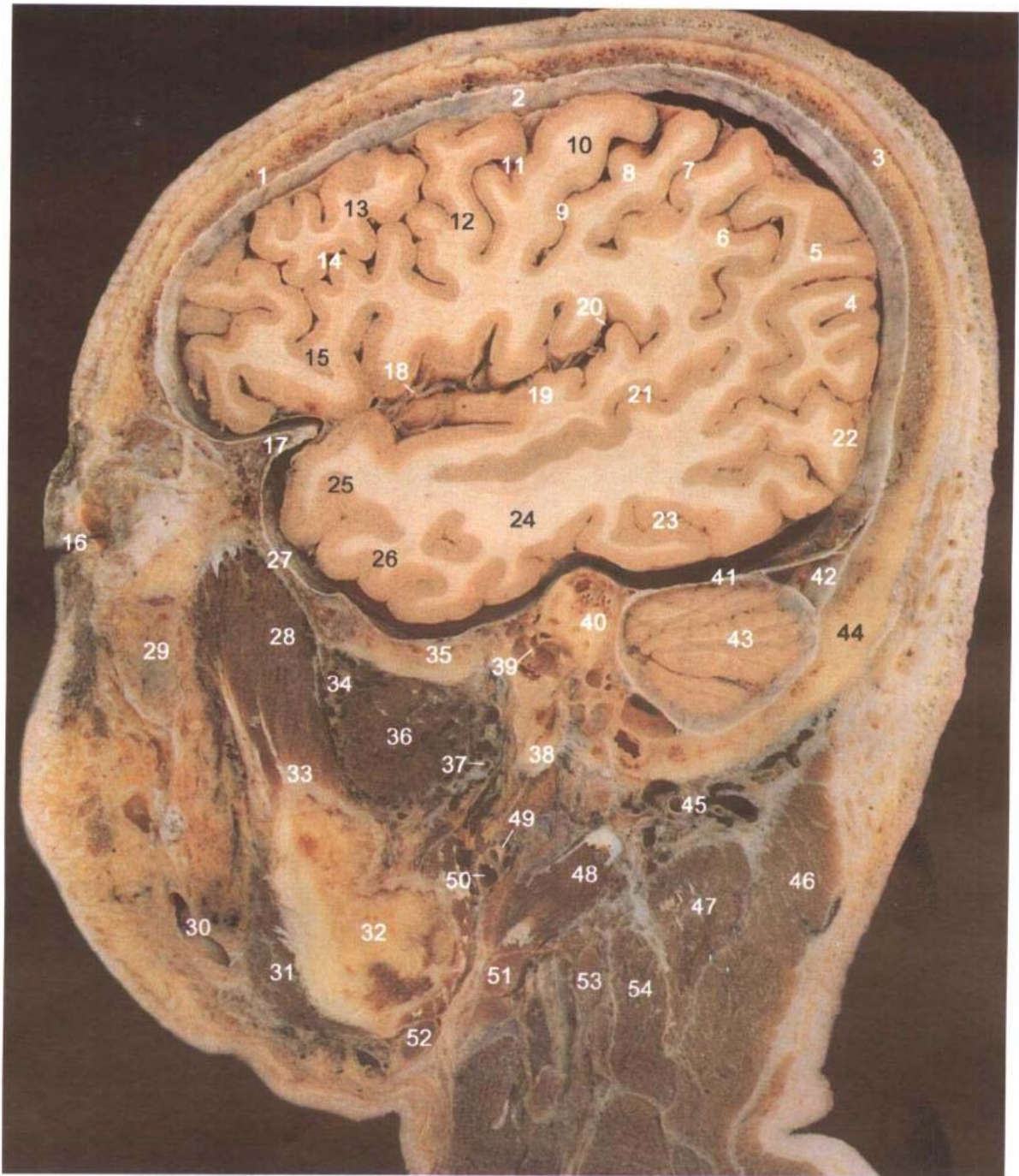


C. MRI T₂ WI

- | | |
|---|--|
| 13. 钩束 uncinat fasciculus | 40. 颈内静脉 internal jugular vein |
| 14. 外侧沟 lateral sulcus | 41. 脑膜中动脉 middle meningeal artery |
| 15. 岛叶 insula | 42. 上颌动脉 maxillary artery |
| 16. 听辐射 acoustic radiation | 43. 翼外肌下头 inferior head of lateral pterygoid |
| 17. 顶内沟 intraparietal sulcus | 44. 翼静脉丛 pterygoid venous plexus |
| 18. 顶下小叶 inferior parietal lobule | 45. 颧小肌 zygomaticus minor |
| 19. 枕叶 occipital lobe | 46. 提上唇肌 levator labii superior |
| 20. 侧脑室下角 inferior horn of lateral ventricle | 47. 颊肌 buccinator |
| 21. 颞上回 superior temporal gyrus | 48. 第3磨牙 3rd molar |
| 22. 海马 hippocampus | 49. 下颌体 body of mandible |
| 23. 枕颞外侧回 lateral occipitotemporal gyrus | 50. 翼内肌 medial pterygoid |
| 24. 颞下回 inferior temporal gyrus | 51. 茎突咽肌 stylopharyngeus |
| 25. 颞中回 middle temporal gyrus | 52. 茎突舌肌 styloglossus |
| 26. 大脑中浅静脉 superficial middle cerebral vein | 53. 颈外动脉 external carotid artery |
| 27. 外直肌 lateral rectus | 54. 下颌后静脉 retromandibular vein |
| 28. 眼上静脉 superior ophthalmic vein | 55. 茎突舌骨肌 stylohyoid |
| 29. 视网膜 retina | 56. 二腹肌中间腱 intermediate tendon of digastric |
| 30. 下斜肌 inferior obliquus | 57. 下颌下腺 submandibular gland |
| 31. 上颌窦 maxillary sinus | 58. 面静脉 facial vein |
| 32. 翼外肌上头 superior head of lateral pterygoid | 59. 寰椎横突 transverse process of atlas |
| 33. 颈内动脉 internal carotid artery | 60. 头后大直肌 rectus capitis posterior major |
| 34. 内耳道和面神经、前庭蜗神经 internal acoustic meatus, facial and vestibulocochlear nevers | 61. 头下斜肌 obliquus capitis inferior |
| 35. 小脑幕 tentorium of cerebellum | 62. 头半棘肌 semispinalis capitis |
| 36. 小脑半球 cerebellar hemisphere | 63. 头夹肌 splenius capitis |
| 37. 横窦 transverse sinus | 64. 斜方肌 trapezius |
| 38. 枕鳞 occipital squama | 65. 横突棘肌 transversospinales |
| 39. 乙状窦 sigmoid sinus | 66. 眼球 eye ball |
| | 67. 晶状体 lens |

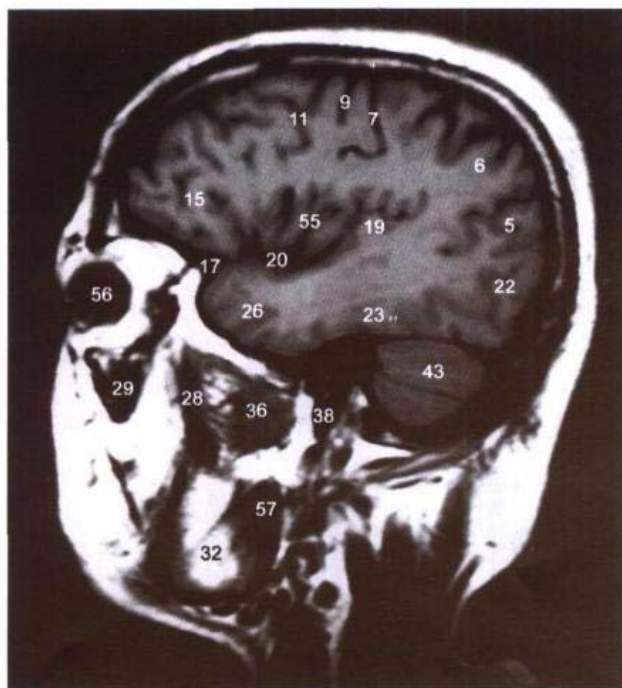
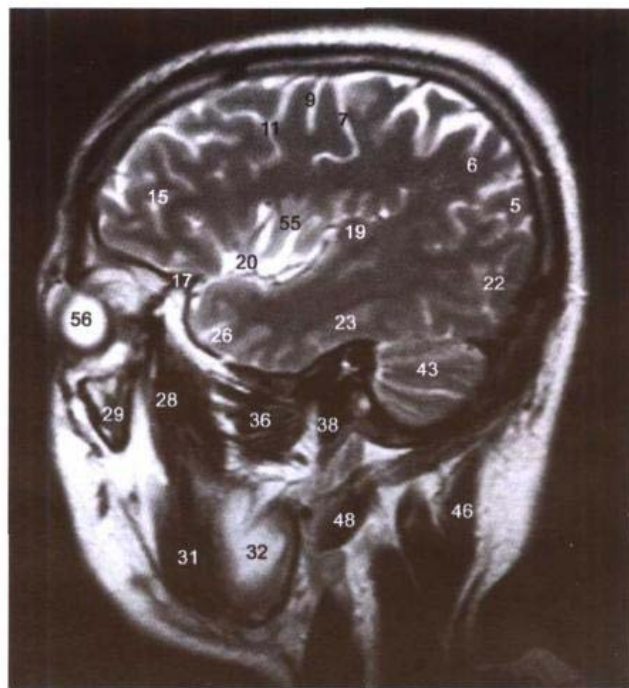
图 3-6 经右茎突的矢状断层

Fig.3-6 The sagittal section through right styloid process



A. 断层标本(sectional specimen)

- | | |
|----------------------------------|----------------------------|
| 1. 额骨 frontal bone | 7. 中央后沟 postcentral sulcus |
| 2. 硬脑膜 cerebral dura mater | 8. 中央后回 postcentral gyrus |
| 3. 顶骨 parietal bone | 9. 中央沟 central sulcus |
| 4. 顶下小叶 inferior parietal lobule | 10. 中央前回 precentral gyrus |
| 5. 角回 angular gyrus | 11. 中央前沟 precentral sulcus |
| 6. 缘上回 supramarginal gyrus | 12. 书写中枢 writing area |

B. MRI T₁ WIC. MRI T₂ WI

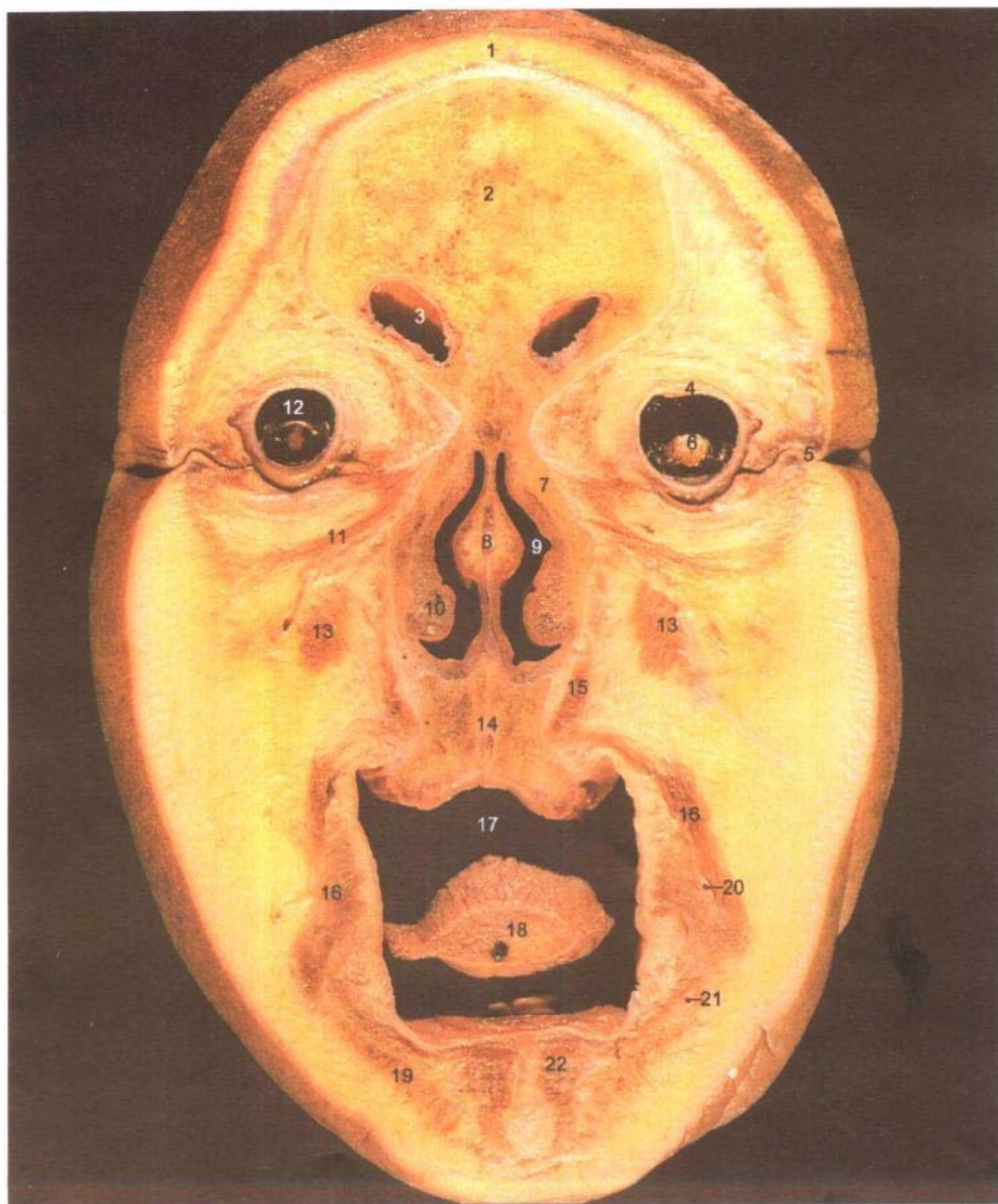
- | | |
|--|--|
| 13. 额中回 middle frontal gyrus | 37. 上颌动脉 maxillary artery |
| 14. 额下沟 inferior frontal sulcus | 38. 茎突 styloid process |
| 15. 额下回 inferior frontal gyrus | 39. 锤骨柄 manubrium of malleus |
| 16. 外眦 lateral angle of eye | 40. 骨半规管 bony semicircular canal |
| 17. 蝶嵴 sphenoid crest | 41. 小脑幕 tentorium of cerebellum |
| 18. 大脑中动脉 middle cerebral artery | 42. 横窦 transverse sinus |
| 19. 颞横回 transverse temporal gyri | 43. 小脑半球 cerebellar hemisphere |
| 20. 外侧沟 lateral sulcus | 44. 枕鳞 occipital squama |
| 21. 颞上沟 superior temporal sulcus | 45. 枕动、静脉 occipital artery and vein |
| 22. 枕叶 occipital lobe | 46. 头夹肌 splenius capitis |
| 23. 枕颞外侧回 lateral occipitotemporal gyrus | 47. 头最长肌 longissimus capitis |
| 24. 颞下回 inferior temporal gyrus | 48. 二腹肌后腹 posterior belly of digastric |
| 25. 颞上回 superior temporal gyrus | 49. 颈外动脉 external carotid artery |
| 26. 颞中回 middle temporal gyrus | 50. 下颌后静脉 retromandibular vein |
| 27. 蝶骨大翼 greater wing of sphenoid bone | 51. 颈外侧浅淋巴结 superficial lateral cervical lymph nodes |
| 28. 颞肌 temporalis | 52. 下颌下淋巴结 submandibular lymph nodes |
| 29. 颧弓 zygomatic arch | 53. 颈外侧深淋巴结 deep lateral cervical lymph nodes |
| 30. 面静脉 facial vein | 54. 胸锁乳突肌 sternocleidomastoid |
| 31. 咬肌 masseter | 55. 岛叶 insula |
| 32. 下颌角 angle of mandible | 56. 眼球 eye ball |
| 33. 下颌骨冠突 coronoid process of mandible | 57. 翼内肌 medial pterygoid |
| 34. 翼静脉丛 pterygoid venous plexus | |
| 35. 颞骨鳞部 squamous part of temporal bone | |
| 36. 翼外肌 lateral pterygoid | |

第四章 头颈部连续冠状断层

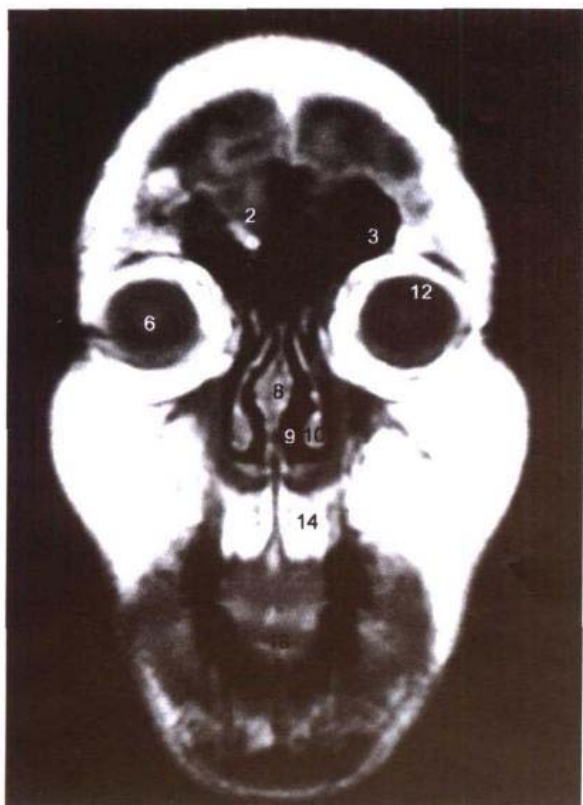Chapter 4 Serial Coronal Sections of Head and Neck

图 4-1 经额窦和晶状体的冠状断层

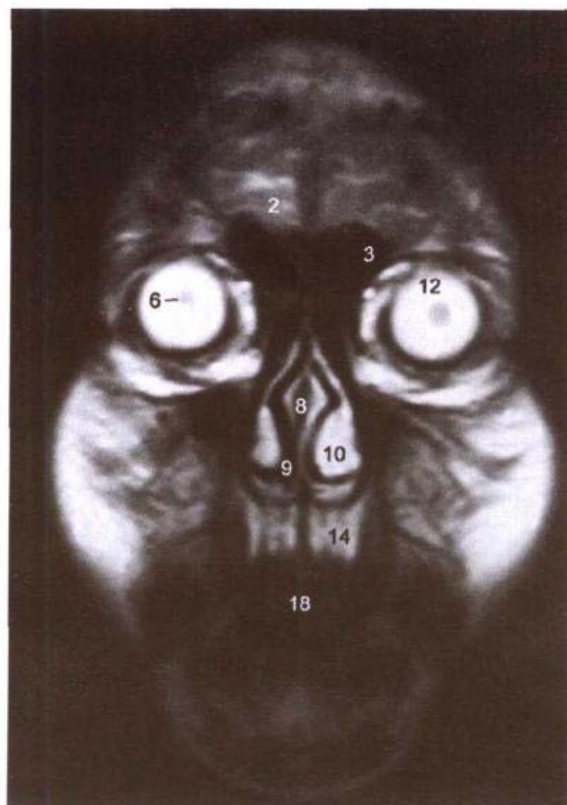
Fig.4-1 Coronal section through frontal sinus and lens



A. 断层标本(sectional specimen)



B. MRI T₁ WI



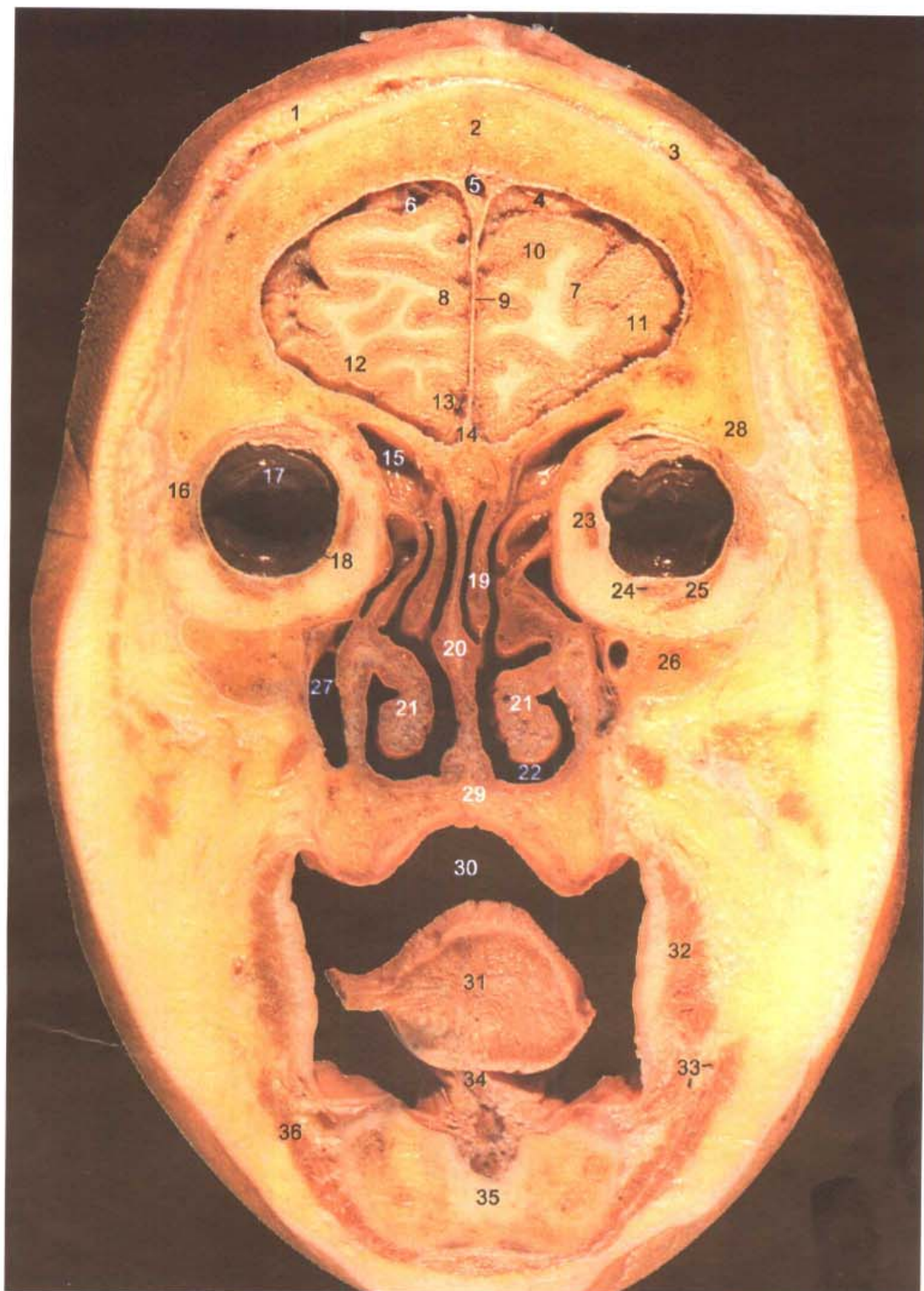C. MRI T₂ WI

1. 皮肤 skin
2. 额骨 frontal bone
3. 额窦 frontal sinus
4. 巩膜 sclera
5. 外眦 lateral angle of eye
6. 晶状体 lens
7. 上颌骨额突 frontal process of maxilla
8. 鼻中隔 nasal septum
9. 鼻腔 nasal cavity
10. 下鼻甲 inferior nasal concha
11. 眼轮匝肌 orbicularis oculi
12. 眼球 eyeball

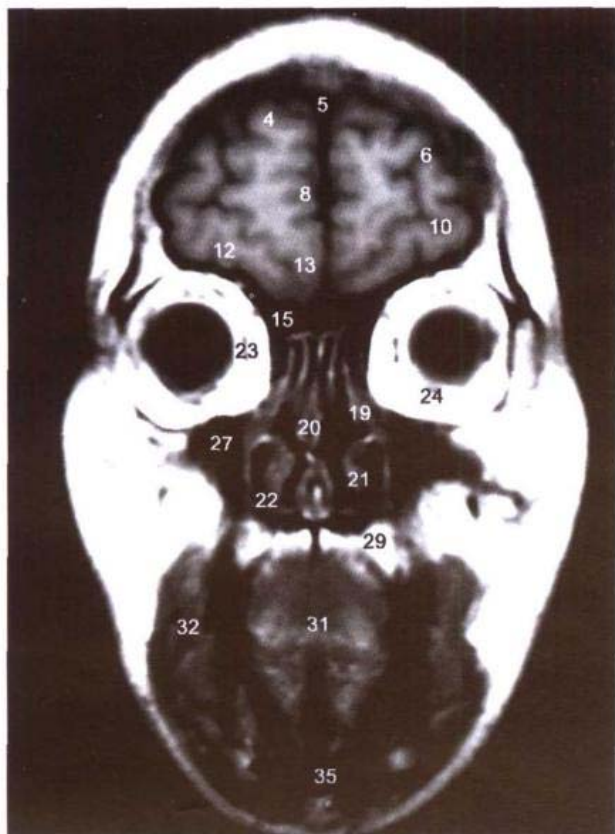
13. 提上唇肌 levator labii superior
14. 上颌骨 maxilla
15. 提上唇鼻翼肌 levator labii superioris alaeque nasi
16. 口轮匝肌 orbicularis oris
17. 口腔 oral cavity
18. 舌尖 apex of tongue
19. 降口角肌 depressor anguli oris
20. 上唇动脉 superior labial artery
21. 下唇动脉 inferior labial artery
22. 颏肌 mentalis

图 4-2 经额嵴的冠状断层

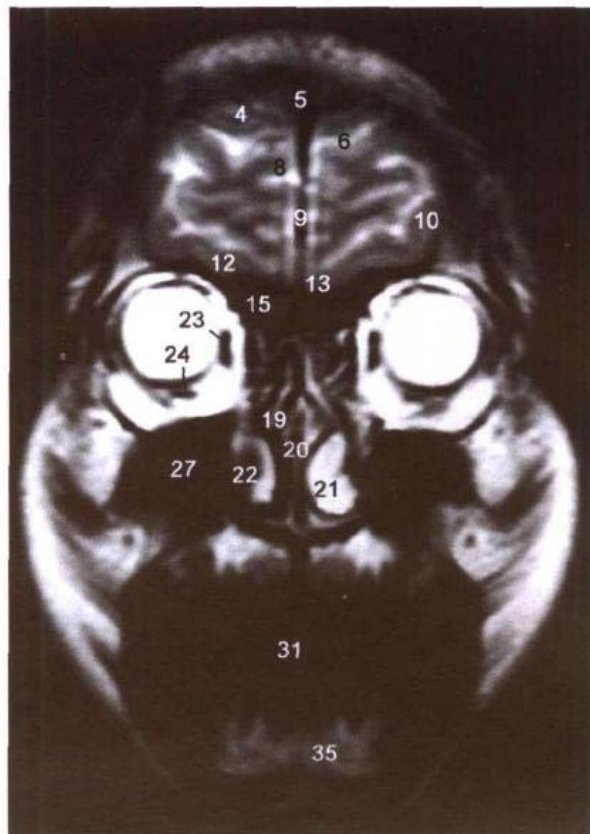
Fig.4-2 Coronal section through frontal crest



A. 断层标本(sectional specimen)



B. MRI T₁ WI



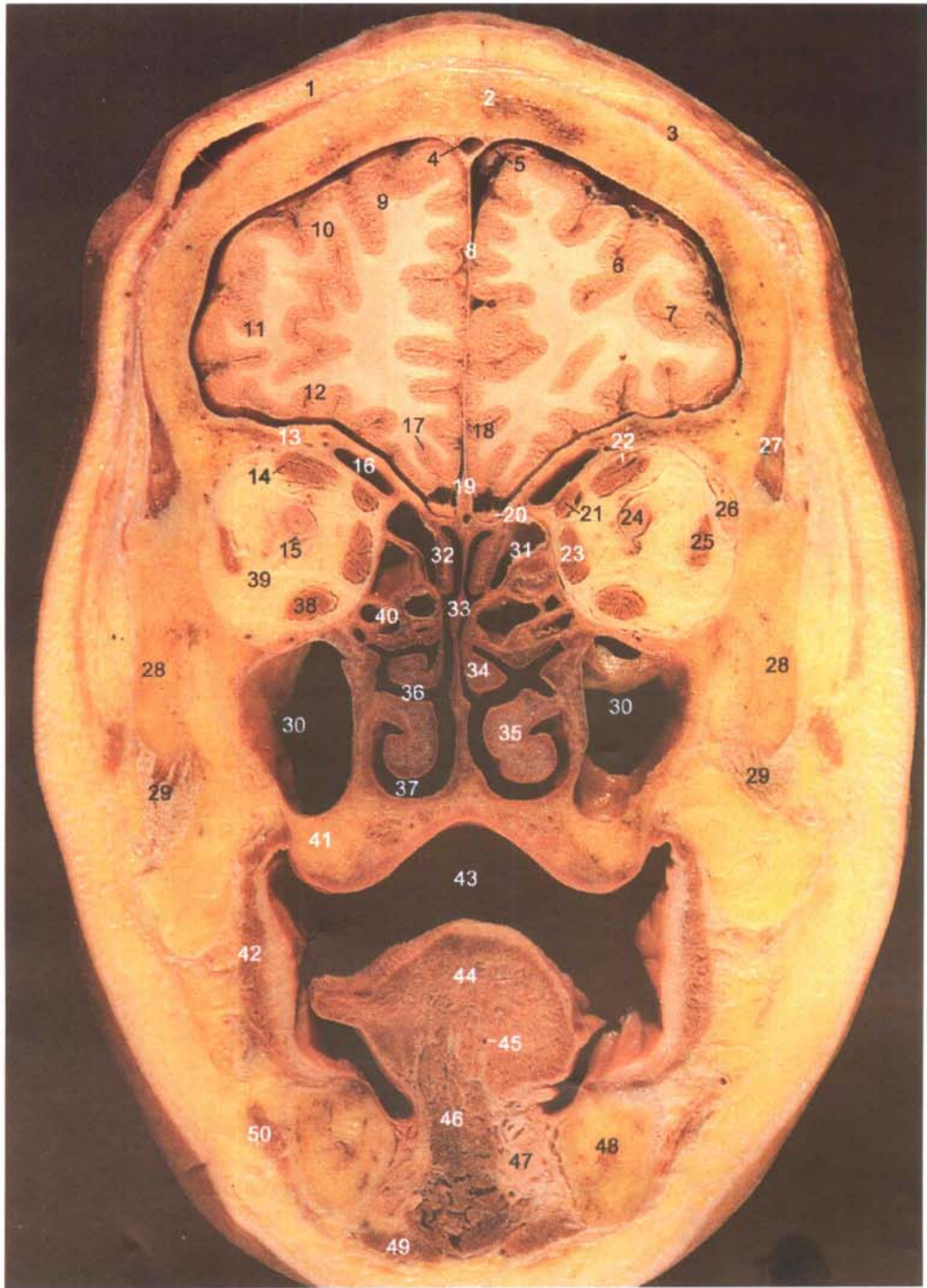
C. MRI T₂ WI

1. 头皮 scalp
2. 额骨 frontal bone
3. 枕额肌额腹 frontal belly of occipitofrontalis
4. 额上回 superior frontal gyrus
5. 上矢状窦 superior sagittal sinus
6. 额上沟 superior frontal sulcus
7. 额下沟 inferior frontal sulcus
8. 额内侧回 medial frontal gyrus
9. 大脑镰 cerebral falx
10. 额中回 middle frontal gyrus
11. 额下回 inferior frontal gyrus
12. 眶回 orbital gyri
13. 直回 gyrus rectus
14. 额嵴 frontal crest
15. 额窦 frontal sinus
16. 泪腺 lacrimal gland
17. 视网膜 retina
18. 巩膜 sclera

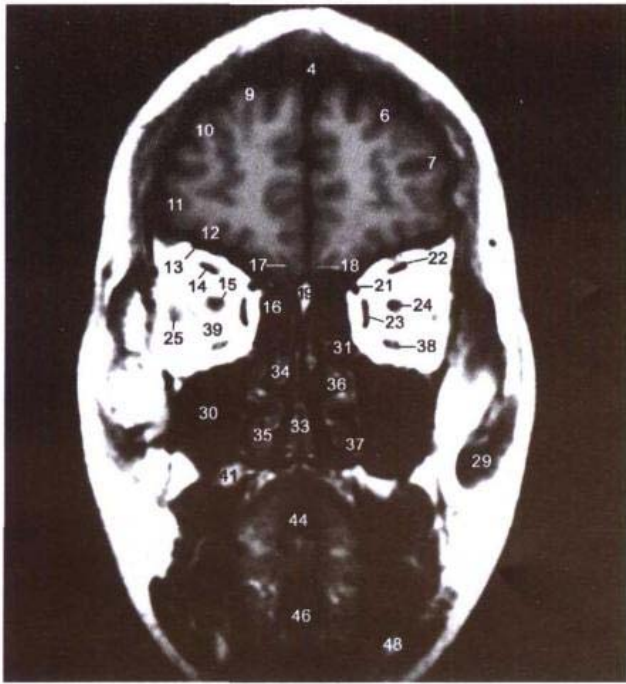
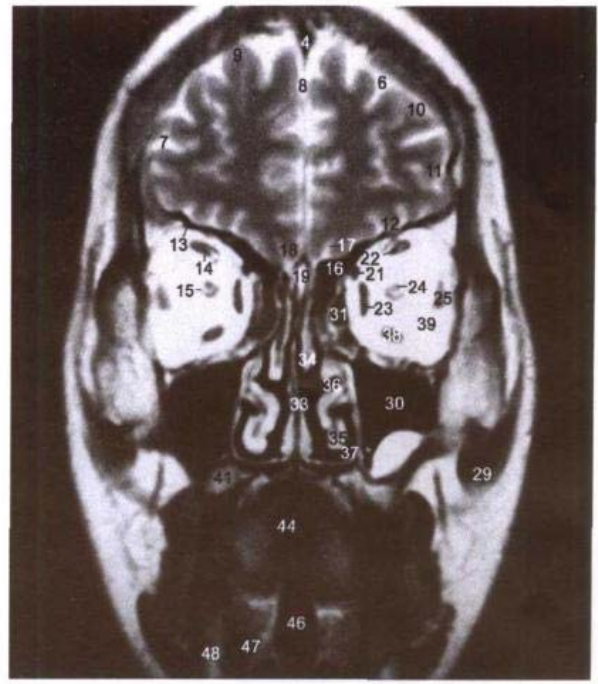
19. 中鼻甲 middle nasal concha
20. 鼻中隔 nasal septum
21. 下鼻甲 inferior nasal concha
22. 下鼻道 inferior nasal meatus
23. 内直肌 medial rectus
24. 下直肌 inferior rectus
25. 下斜肌 inferior obliquus
26. 颧骨 zygomatic bone
27. 上颌窦 maxillary sinus
28. 额骨颧突 zygomatic process of frontal bone
29. 上颌骨 maxilla
30. 口腔 oral cavity
31. 舌体 body of tongue
32. 颊肌 buccinator
33. 下唇动脉 inferior labial artery
34. 舌系带 frenulum of tongue
35. 下颌体 body of mandible
36. 降口角肌 depressor anguli oris

图 4-3 经筛骨鸡冠的冠状断层

Fig.4-3 Coronal section through crista galli of ethmoid bone



A. 断层标本(sectional specimen)

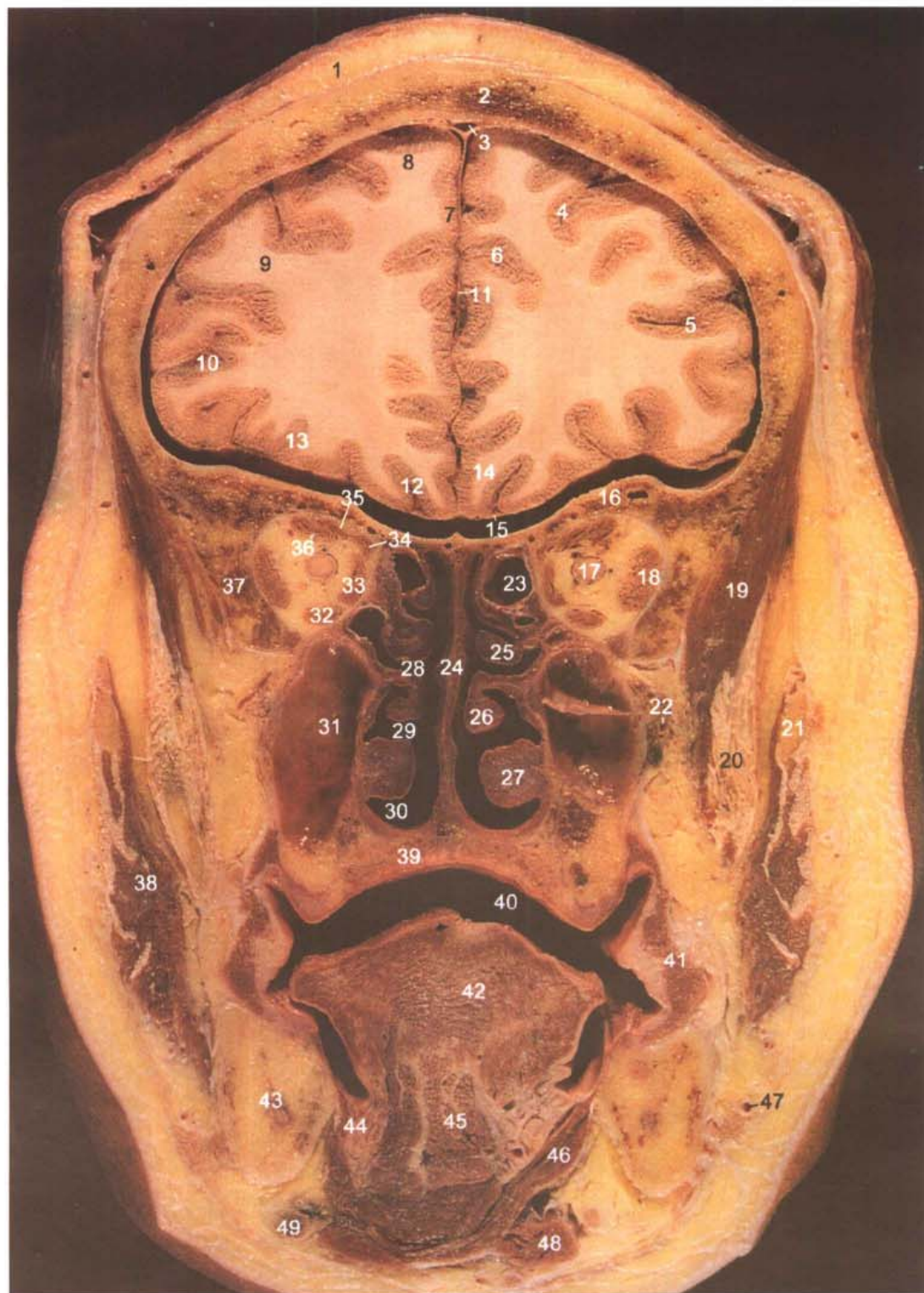
B. MRI T₁ WIC. MRI T₂ WI

1. 头皮 scalp
2. 额骨 frontal bone
3. 枕额肌额腹 frontal belly of occipitofrontalis
4. 上矢状窦 superior sagittal sinus
5. 大脑上静脉 superior cerebral veins
6. 额上沟 superior frontal sulcus
7. 额下沟 inferior frontal sulcus
8. 大脑镰 cerebral falx
9. 额上回 superior frontal gyrus
10. 额中回 middle frontal gyrus
11. 额下回 inferior frontal gyrus
12. 眶回 orbital gyri
13. 眶板 orbital plate
14. 上直肌 superior rectus
15. 视神经鞘 sheath of optic nerve
16. 额窦 frontal sinus
17. 嗅束沟 olfactory sulcus
18. 直回 gyrus rectus
19. 鸡冠 crista galli
20. 嗅球 olfactory bulb
21. 上斜肌 superior obliquus
22. 提上睑肌 levator palpebrae superior
23. 内直肌 medial rectus
24. 视神经 optic nerve
25. 外直肌 lateral rectus

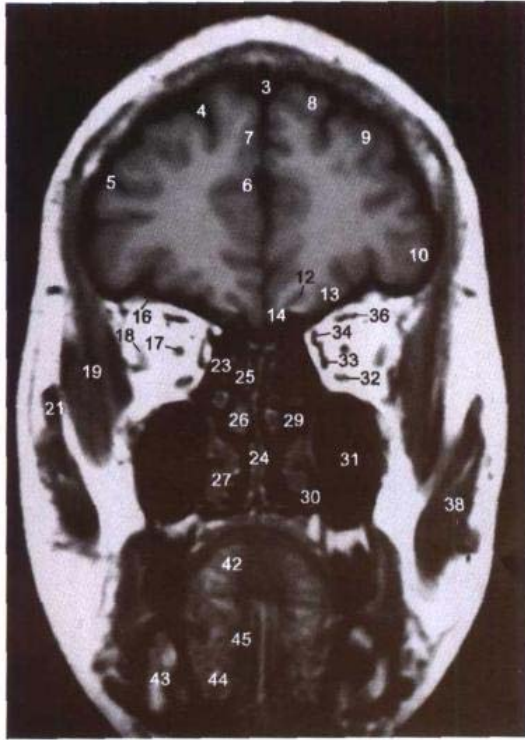
26. 泪腺 lacrimal gland
27. 颞肌 temporalis
28. 颧骨额突 frontal process of zygomatic bone
29. 咬肌腱 tendon of masseter
30. 上颌窦 maxillary sinus
31. 筛窦 ethmoidal cellules
32. 上鼻甲 superior nasal concha
33. 鼻中隔 nasal septum
34. 中鼻甲 middle nasal concha
35. 下鼻甲 inferior nasal concha
36. 中鼻道 middle nasal meatus
37. 下鼻道 inferior nasal meatus
38. 下直肌 inferior rectus
39. 眶脂体 adipose body of orbit
40. 筛骨 ethmoid bone
41. 上颌骨 maxilla
42. 颊肌 buccinator
43. 口腔 oral cavity
44. 舌体 body of tongue
45. 舌深动脉 deep lingual artery
46. 颏舌肌 genioglossus
47. 舌下腺 sublingual gland
48. 下颌体 body of mandible
49. 二腹肌前腹 anterior belly of digastric
50. 降下唇肌 depressor labii inferior

图 4-4 经上颌窦后份的冠状断层

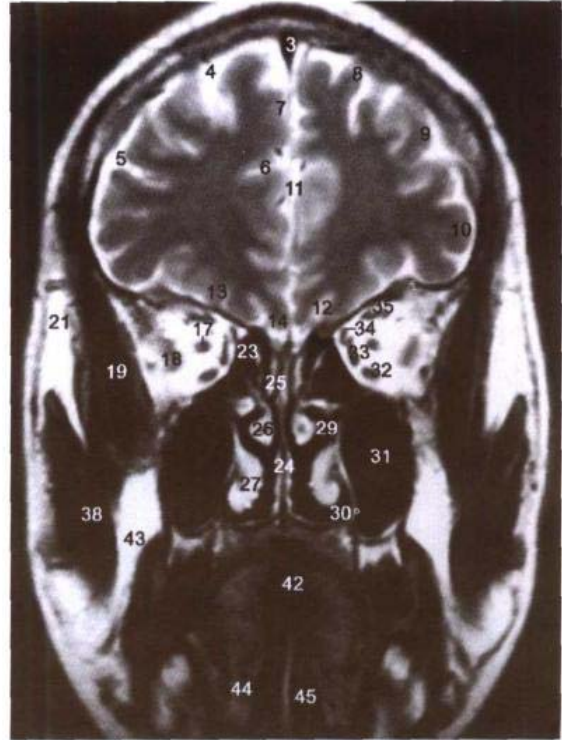
Fig.4-4 Coronal section through posterior part of maxillary sinus



A. 断层标本(sectional specimen)



B. MRI T₁ WI



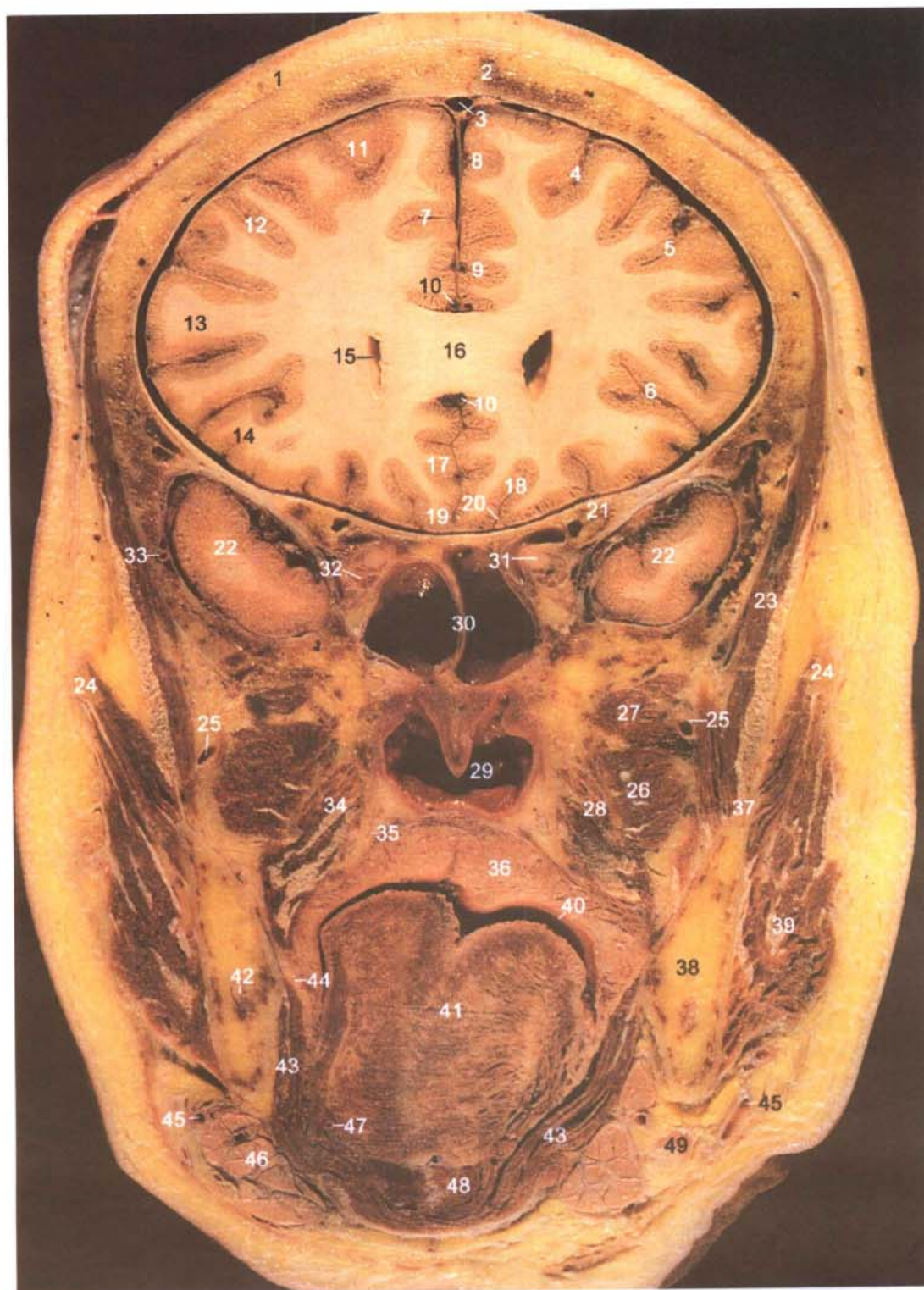
C. MRI T₂ WI

1. 头皮 scalp
2. 额骨 frontal bone
3. 上矢状窦 superior sagittal sinus
4. 额上沟 superior frontal sulcus
5. 额下沟 inferior frontal sulcus
6. 扣带沟 cingulate sulcus
7. 额内侧回 medial frontal gyrus
8. 额上回 superior frontal gyrus
9. 额中回 middle frontal gyrus
10. 额下回 inferior frontal gyrus
11. 大脑镰 cerebral falx
12. 嗅束沟 olfactory sulcus
13. 眶回 orbital gyri
14. 直回 gyrus rectus
15. 嗅束 olfactory tract
16. 眶板 orbital plate
17. 视神经 optic nerve
18. 外直肌 lateral rectus
19. 颞肌 temporalis
20. 颞肌腱 tendon of temporalis
21. 颞弓 zygomatic arch
22. 上颌动脉分支 branch of maxillary artery
23. 筛窦 ethmoidal cellules
24. 鼻中隔 nasal septum
25. 上鼻甲 superior nasal concha

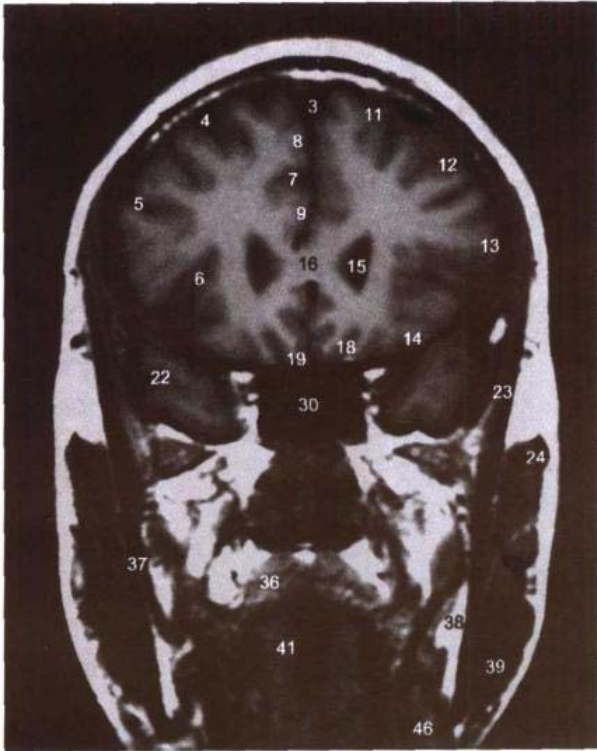
26. 中鼻甲 middle nasal concha
27. 下鼻甲 inferior nasal concha
28. 上鼻道 superior nasal meatus
29. 中鼻道 middle nasal meatus
30. 下鼻道 inferior nasal meatus
31. 上颌窦 maxillary sinus
32. 下直肌 inferior rectus
33. 内直肌 medial rectus
34. 上斜肌 superior obliquus
35. 提上睑肌 levator papebrae superior
36. 上直肌 superior rectus
37. 颧骨 zygomatic bone
38. 咬肌 masseter
39. 腭腺 palatine glands
40. 口腔 oral cavity
41. 颊肌 buccinator
42. 舌体 body of tongue
43. 下颌骨 mandible
44. 舌下腺 sublingual gland
45. 颞舌肌 genioglossus
46. 下颌舌骨肌 mylohyoid
47. 面动脉 facial artery
48. 二腹肌前腹 anterior belly of digastric
49. 下颌下淋巴结 submandibular lymph nodes

图 4-5 经颞极的冠状断层

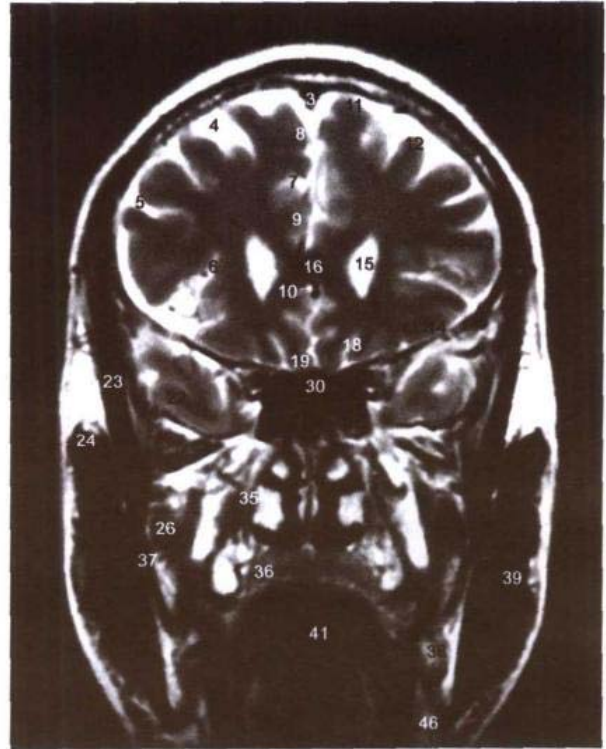
Fig.4-5 Coronal section through temporal pole



A. 断层标本(sectional specimen)

B. MRI T₁ WI

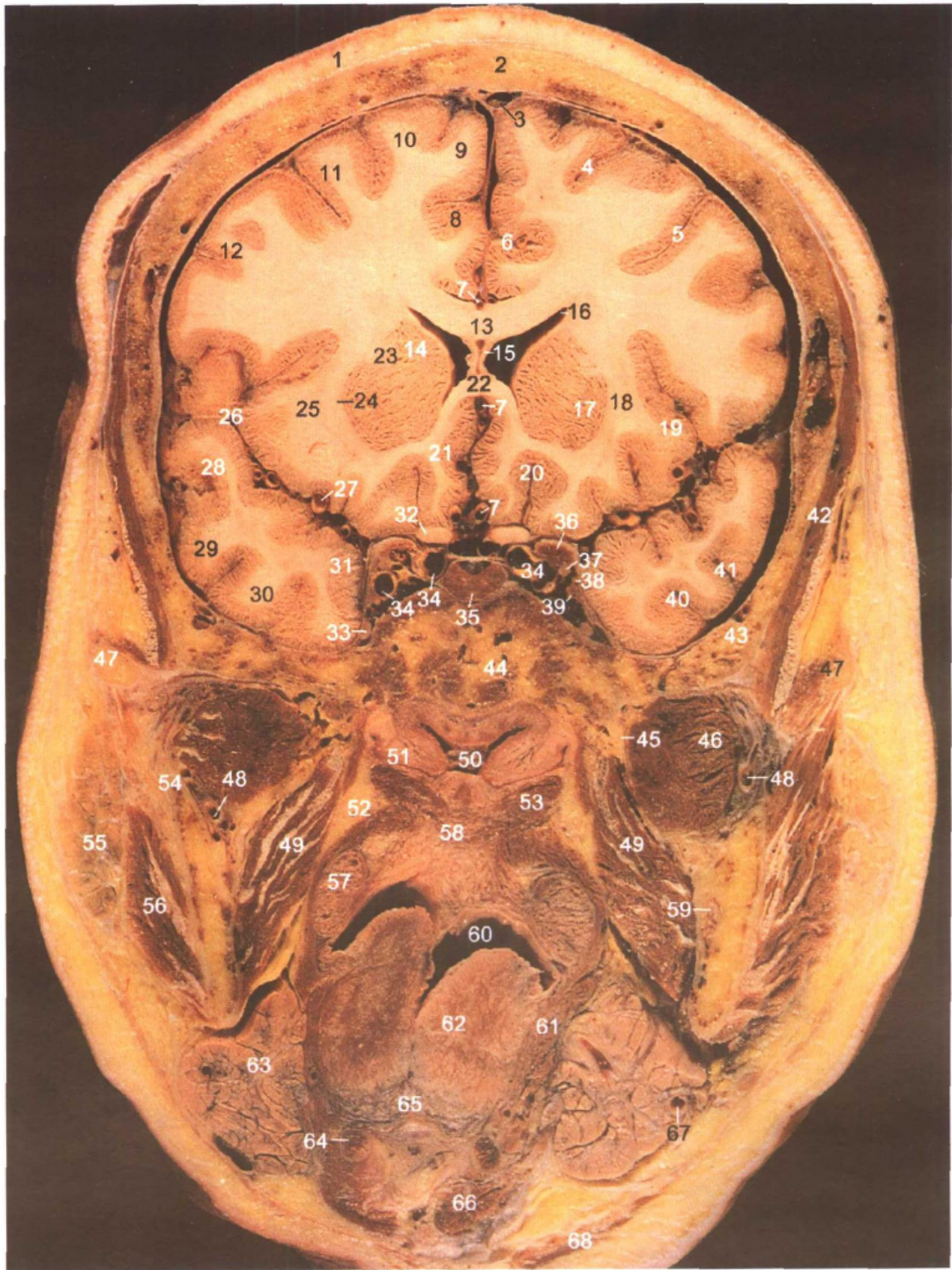1. 头皮 scalp
2. 额骨 frontal bone
3. 上矢状窦 superior sagittal sinus
4. 额上沟 superior frontal sulcus
5. 额下沟 inferior frontal sulcus
6. 外侧沟前支 anterior branch of lateral sulcus
7. 扣带沟 cingulate sulcus
8. 额内侧回 medial frontal gyrus
9. 扣带回 cingulate gyrus
10. 大脑前动脉 anterior cerebral artery
11. 额上回 superior frontal gyrus
12. 额中回 middle frontal gyrus
13. 额下回 inferior frontal gyrus
14. 眶回 orbital gyri
15. 侧脑室前角 anterior horn of lateral ventricle
16. 胼胝体膝 genu of corpus callosum
17. 胼胝体下区 subcallosal area
18. 嗅束沟 olfactory sulcus
19. 直回 gyrus rectus
20. 嗅束 olfactory tract
21. 蝶骨小翼 lesser wing of sphenoid bone
22. 颞叶 temporal lobe
23. 颞肌 temporalis
24. 颧弓 zygomatic arch
25. 上颌动脉 maxillary artery

C. MRI T₂ WI

26. 翼外肌下头 inferior head of lateral pterygoid
27. 翼外肌上头 superior head of lateral pterygoid
28. 翼突外侧板 lateral pterygoid plate
29. 鼻咽 nasopharynx
30. 蝶窦 sphenoidal sinus
31. 视神经 optic nerve
32. 下直肌 inferior rectus
33. 脑膜中动脉 middle meningeal artery
34. 翼内肌 medial pterygoid
35. 翼突内侧板 medial pterygoid plate
36. 腭腺 palatine glands
37. 下颌骨冠突 coronoid process of mandible
38. 下颌支 ramus of mandible
39. 咬肌 masseter
40. 口腔 oral cavity
41. 舌体 body of tongue
42. 下颌管和下牙槽神经 mandibular canal and inferior alveolar nerve
43. 下颌舌骨肌 mylohyoid
44. 舌神经 lingual nerve
45. 面动脉 facial artery
46. 下颌下腺 submandibular gland
47. 舌深动脉 deep lingual artery
48. 颏舌骨肌 geniohyoid
49. 下颌下淋巴结 submandibular lymph nodes

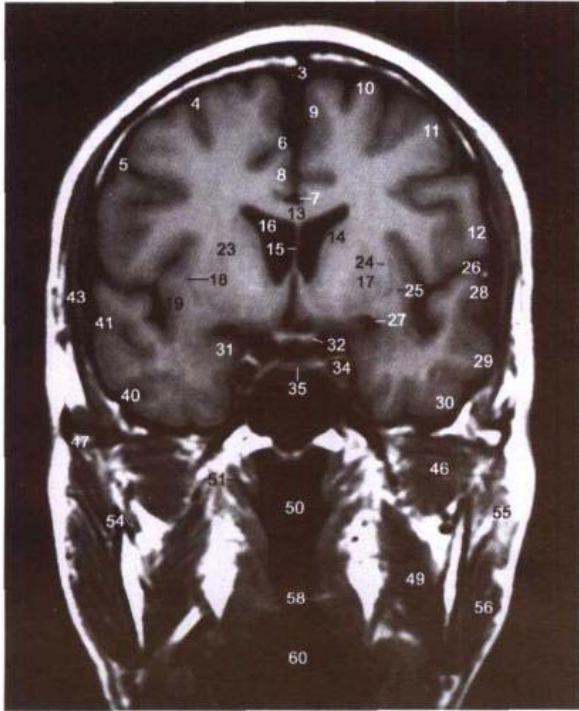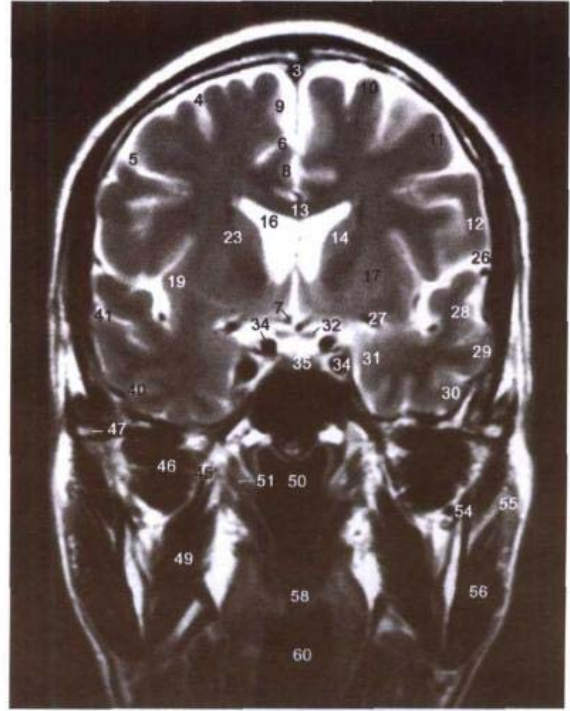
图 4-6 经胼胝体嘴的冠状断层

Fig.4-6 Coronal section through rostrum of corpus callosum



A. 断层标本(sectional specimen)

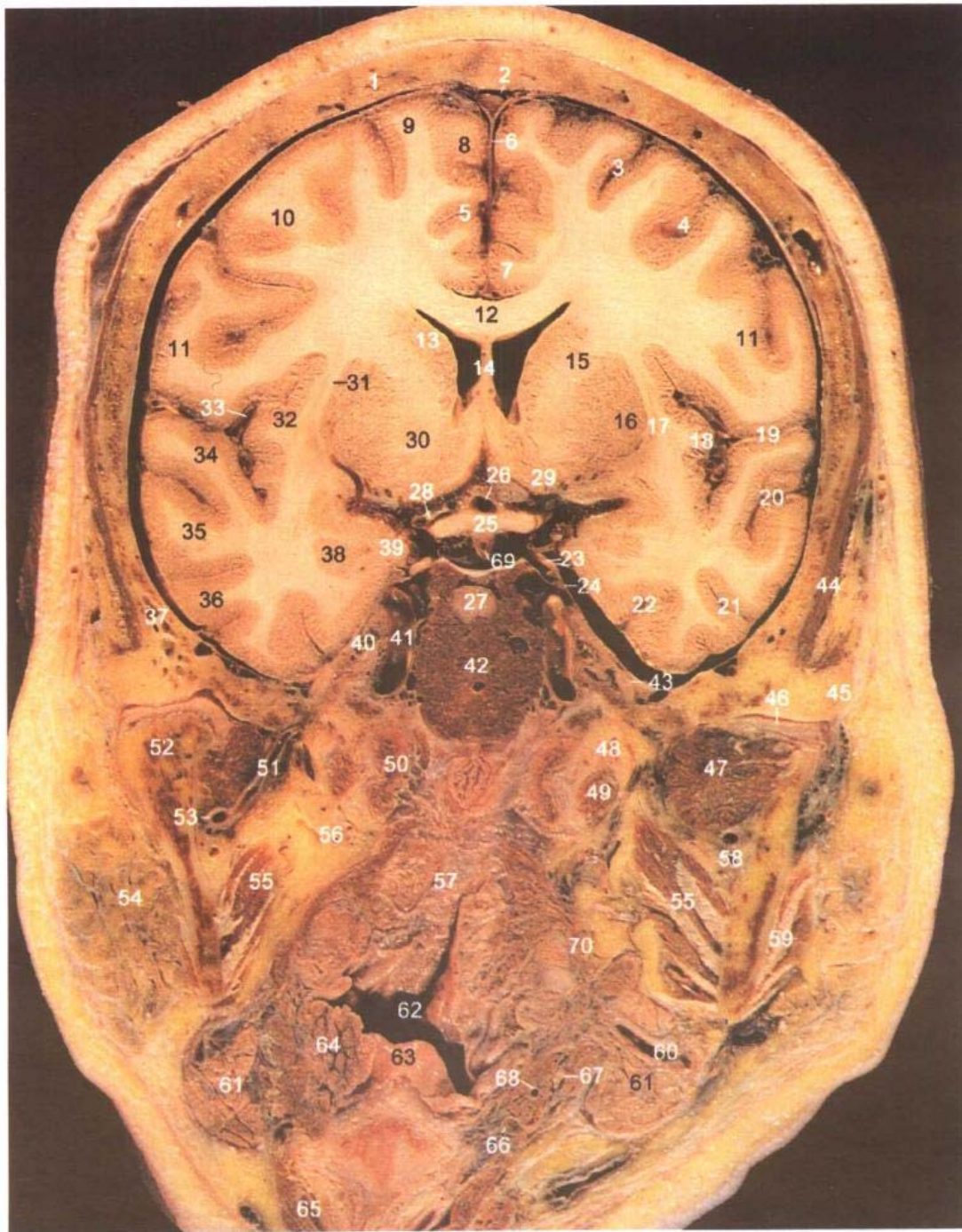
- | | | |
|---------------------------------|--------------------------------|-----------------------------------|
| 1. 头皮 scalp | nus | 6. 扣带沟 cingulate sulcus |
| 2. 额骨 frontal bone | 4. 额上沟 superior frontal sulcus | 7. 大脑前动脉 anterior cerebral artery |
| 3. 上矢状窦 superior sagittal sinus | 5. 额下沟 inferior frontal sulcus | |

B. MRI T₁ WIC. MRI T₂ WI

- | | | |
|--|---|--|
| 8. 扣带回 cingulate gyrus | 30. 颞下回 inferior temporal gyrus | 51. 咽隐窝 pharyngeal recess |
| 9. 额内侧回 medial frontal gyrus | 31. 钩 uncus | 52. 咽外侧间隙 lateropharyngeal space |
| 10. 额上回 superior frontal gyrus | 32. 视神经 optic nerve | 53. 腭帆提肌和腭帆张肌 levator veli palatini and tensor veli palatini |
| 11. 额中回 middle frontal gyrus | 33. 上颌神经 maxillary nerve | 54. 下颌骨冠突 coronoid process of mandible |
| 12. 额下回 inferior frontal gyrus | 34. 颈内动脉 internal carotid artery | 55. 腮腺 parotid gland |
| 13. 胼胝体干 trunk of corpus callosum | 35. 垂体前叶 anterior lobe of hypophysis | 56. 咬肌 masseter |
| 14. 尾状核 caudate nucleus | 36. 前床突 anterior clinoid process | 57. 腭扁桃体 palatine tonsil |
| 15. 透明隔 septum pellucidum | 37. 动眼神经 oculomotor nerve | 58. 软腭 soft palate |
| 16. 侧脑室前角 anterior horn of lateral ventricle | 38. 滑车神经 trochlear nerve | 59. 下颌管和下牙齿槽神经 mandibular canal and inferior alveolar nerve |
| 17. 壳 putamen | 39. 展神经 abducent nerve | 60. 口腔 oral cavity |
| 18. 屏状核 claustrum | 40. 颞下沟 inferior temporal sulcus | 61. 茎突舌肌 styloglossus |
| 19. 岛叶 insula | 41. 颞上沟 superior temporal sulcus | 62. 舌体 body of tongue |
| 20. 嗅束沟 olfactory sulcus | 42. 颞肌 temporalis | 63. 下颌下腺 submandibular gland |
| 21. 胼胝体下区 subcallosal area | 43. 颞骨鳞部 squamous part of temporal bone | 64. 舌骨大角 greater horn of hyoid bone |
| 22. 胼胝体嘴 rostrum of corpus callosum | 44. 蝶骨体 body of sphenoid | 65. 舌下腺 sublingual gland |
| 23. 内囊前肢 anterior limb of internal capsule | 45. 翼突外侧板 lateral pterygoid plate | 66. 二腹肌前腹 anterior belly of digastric |
| 24. 外囊 external capsule | 46. 翼外肌 lateral pterygoid | 67. 面动脉 facial artery |
| 25. 最外囊 extreme capsule | 47. 颧弓 zygomatic arch | 68. 颈阔肌 platysma |
| 26. 外侧沟 lateral sulcus | 48. 上颌动脉 maxillary artery | |
| 27. 大脑中动脉 middle cerebral artery | 49. 翼内肌 medial pterygoid | |
| 28. 颞上回 superior temporal gyrus | 50. 鼻咽 nasopharynx | |
| 29. 颞中回 middle temporal gyrus | | |

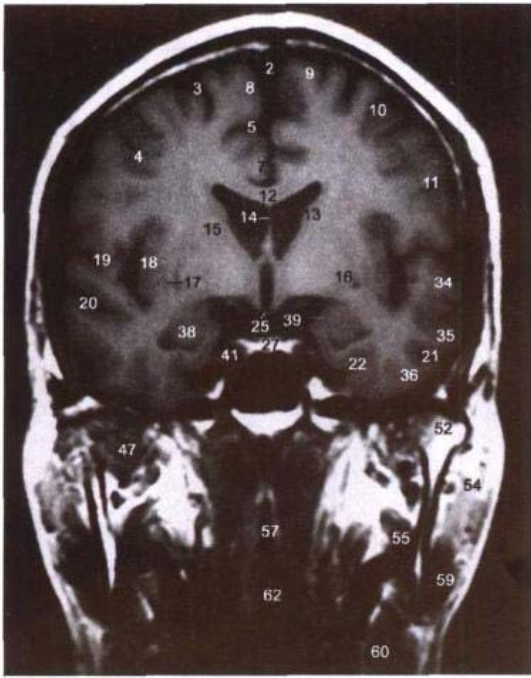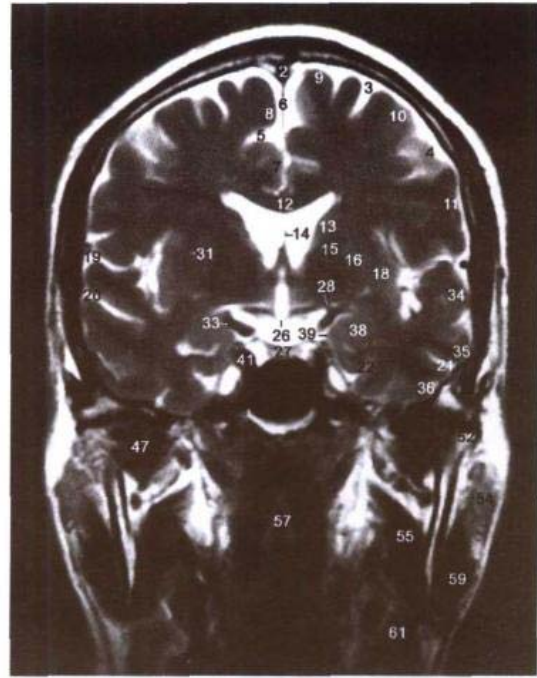
图 4-7 经三叉神经节的冠状断层

Fig.4-7 Coronal section through trigeminal ganglion



A. 断层标本(sectional specimen)

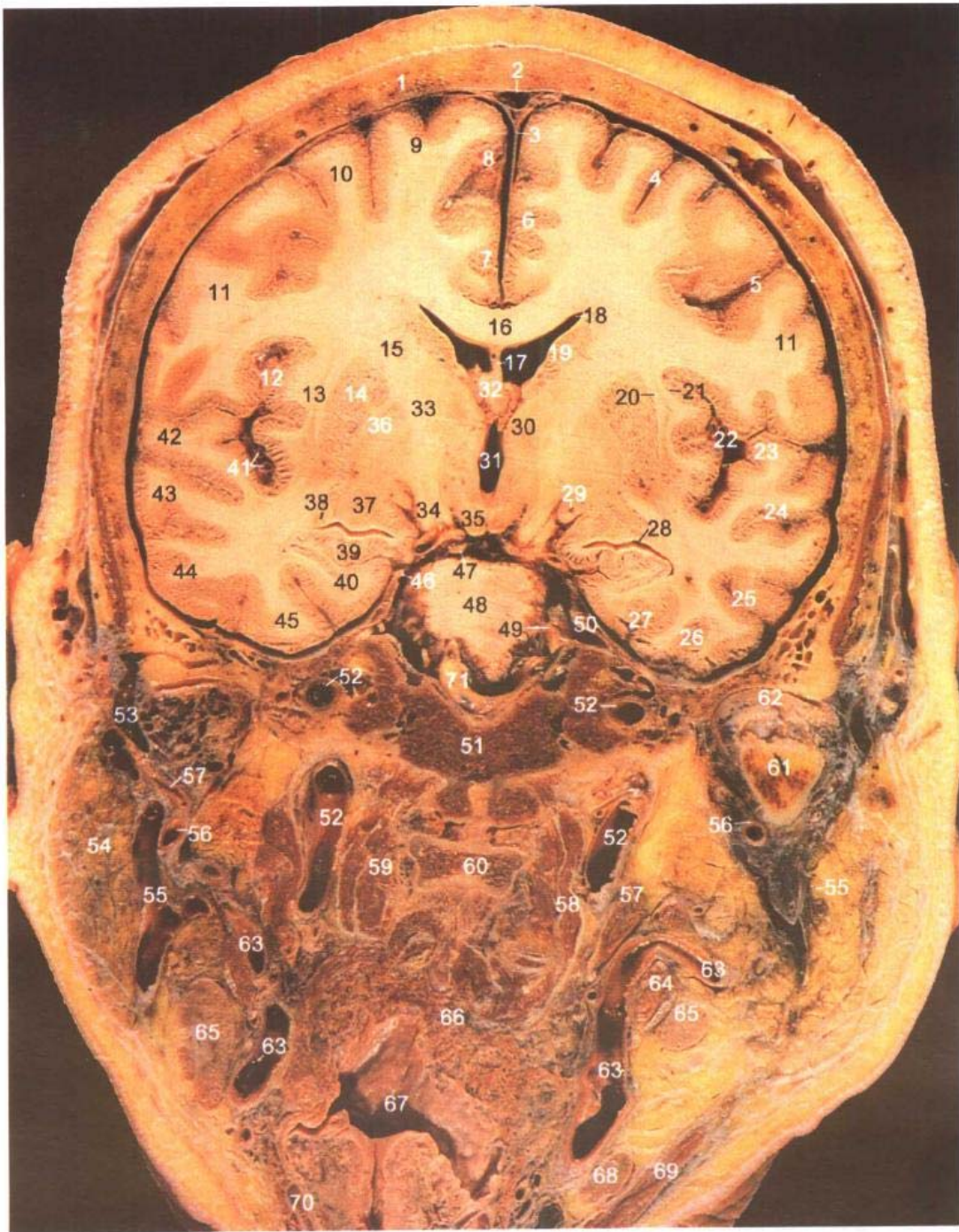
- | | |
|---------------------------------|-----------------------------------|
| 1. 额骨 frontal bone | 7. 扣带回 cingulate gyrus |
| 2. 上矢状窦 superior sagittal sinus | 8. 额内侧回 medial frontal gyrus |
| 3. 额上沟 superior frontal sulcus | 9. 额上回 superior frontal gyrus |
| 4. 中央前沟 precentral sulcus | 10. 额中回 middle frontal gyrus |
| 5. 扣带沟 cingulate sulcus | 11. 中央前回 precentral gyrus |
| 6. 大脑镰 cerebral falx | 12. 胼胝体干 trunk of corpus callosum |

B. MRI T₁ WIC. MRI T₂ WI

- | | |
|---|--|
| 13. 尾状核 caudate nucleus | 42. 蝶骨体 body of sphenoid bone |
| 14. 透明隔 septum pellucidum | 43. 下颌神经 mandibular nerve |
| 15. 内囊前肢 anterior limb of internal capsule | 44. 颞肌 temporalis |
| 16. 壳 putamen | 45. 关节结节 articular tubercle |
| 17. 屏状核 claustrum | 46. 关节盘 articular disc |
| 18. 岛叶 insula | 47. 翼外肌 lateral pterygoid |
| 19. 外侧沟 lateral sulcus | 48. 咽鼓管软骨 cartilage of auditory tube |
| 20. 颞上沟 superior temporal sulcus | 49. 腭帆张肌 tensor veli palatini |
| 21. 颞下沟 inferior temporal sulcus | 50. 颈长肌 longus colli |
| 22. 侧副沟 collateral sulcus | 51. 脑膜中动脉 middle meningeal artery |
| 23. 动眼神经 oculomotor nerve | 52. 下颌骨髁突 condylar process of mandible |
| 24. 滑车神经 trochlear nerve | 53. 上颌动脉 axillary artery |
| 25. 视交叉 optic chiasma | 54. 腮腺 parotid gland |
| 26. 第三脑室视隐窝 optic recess of third ventricle | 55. 翼内肌 medial pterygoid |
| 27. 垂体后叶 posterior lobe of hypophysis | 56. 咽外侧间隙 lateral pharyngeal space |
| 28. 大脑前动脉 anterior cerebral artery | 57. 鼻咽 nasopharynx |
| 29. 伏隔核 nucleus accumbens septi | 58. 下牙齿槽动脉 inferior alveolar artery |
| 30. 前连合 anterior commissure | 59. 咬肌 masseter |
| 31. 外囊 external capsule | 60. 面动脉 facial artery |
| 32. 最外囊 extreme capsule | 61. 下颌下腺 submandibular gland |
| 33. 大脑中动脉 middle cerebral artery | 62. 口咽 oropharynx |
| 34. 颞上回 superior temporal gyrus | 63. 会厌 epiglottic |
| 35. 颞中回 middle temporal gyrus | 64. 腭扁桃体 palatine tonsil |
| 36. 颞下回 inferior temporal gyrus | 65. 甲状软骨 thyroid cartilage |
| 37. 颞骨鳞部 squamous part of temporal bone | 66. 舌骨大角 greater horn of hyoid bone |
| 38. 杏仁体 amygdaloid body | 67. 舌下神经 hypoglossal nerve |
| 39. 钩 uncus | 68. 舌动脉 lingual artery |
| 40. 三叉神经节 trigeminal ganglion | 69. 垂体柄 pituitary stalk |
| 41. 颈内动脉 internal carotid artery | 70. 腭咽肌 palatopharyngeus |

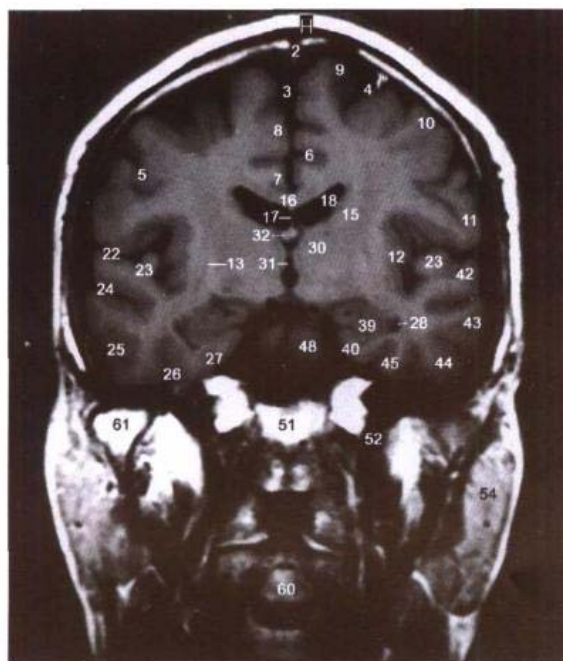
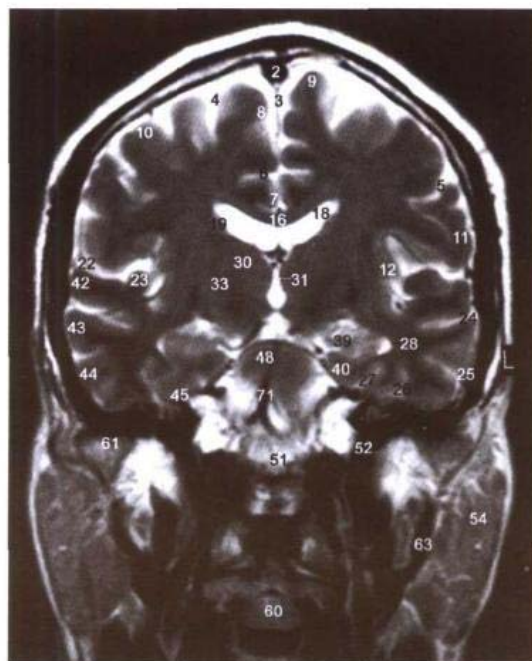图 4-8 经乳头体的冠状断层

Fig .4-8 Coronal section through mamillary body



A. 断层标本(sectional specimen)

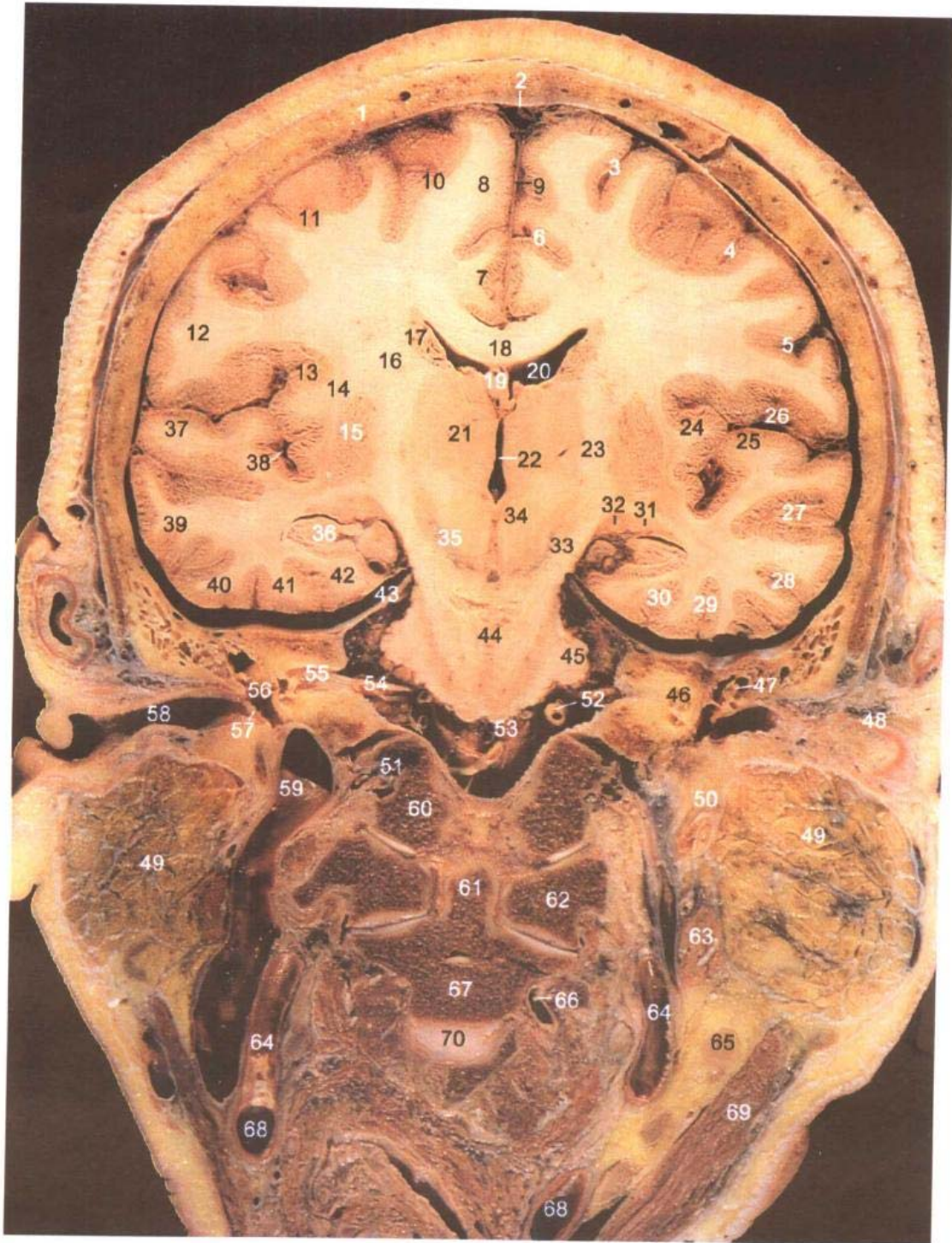
- | | |
|---------------------------------|-------------------------------|
| 1. 额骨 frontal bone | 7. 扣带回 cingulate gyrus |
| 2. 上矢状窦 superior sagittal sinus | 8. 额内侧回 medial frontal gyrus |
| 3. 大脑镰 cerebral falx | 9. 额上回 superior frontal gyrus |
| 4. 额上沟 superior frontal sulcus | 10. 额中回 middle frontal gyrus |
| 5. 中央前沟 precentral sulcus | 11. 中央前回 precentral gyrus |
| 6. 扣带沟 cingulate sulcus | 12. 岛叶 insula |

B. MRI T₁ WIC. MRI T₂ WI

- | | |
|--|---|
| 13. 屏状核 claustrum | 43. 颞中回 middle temporal gyrus |
| 14. 壳 putamen | 44. 颞下回 inferior temporal gyrus |
| 15. 内囊前肢 anterior limb of internal capsule | 45. 枕颞内侧回 medial occipitotemporal gyrus |
| 16. 胼胝体干 trunk of corpus callosum | 46. 滑车神经 trochlear nerve |
| 17. 透明隔 septum pellucidum | 47. 动眼神经 oculomotor nerve |
| 18. 侧脑室前角 anterior horn of lateral ventricle | 48. 脑桥 pons |
| 19. 尾状核 caudate nucleus | 49. 三叉神经 trigeminal nerve |
| 20. 外囊 external capsule | 50. 小脑幕 tentorium of cerebellum |
| 21. 最外囊 extreme capsule | 51. 枕骨基部 basilar part of occipital bone |
| 22. 外侧沟 lateral sulcus | 52. 颈内动脉 internal carotid artery |
| 23. 颞横回 transverse temporal gyri | 53. 颞浅静脉 superficial temporal vein |
| 24. 颞上沟 superior temporal sulcus | 54. 腮腺 parotid gland |
| 25. 颞下沟 inferior temporal sulcus | 55. 下颌后静脉 retromandible vein |
| 26. 枕颞沟 occipitotemporal sulcus | 56. 上颌动脉 maxillary artery |
| 27. 侧副沟 collateral sulcus | 57. 颞浅动脉 superficial temporal artery |
| 28. 侧脑室下角 inferior horn of lateral ventricle | 58. 头长肌 longus capitis |
| 29. 视束 optic tract | 59. 颈长肌 longus colli |
| 30. 背侧丘脑 dorsal thalamus | 60. 枢椎 axis |
| 31. 第三脑室 third ventricle | 61. 下颌骨髁突 condylar process of mandible |
| 32. 穹隆 fornix | 62. 关节盘 articular disc |
| 33. 内囊膝 genu of internal capsule | 63. 颈外动脉 external carotid artery |
| 34. 大脑脚底 crus cerebri | 64. 二腹肌后腹 posterior belly of digastric |
| 35. 乳头体 mamillary body | 65. 腮腺淋巴结 parotid lymph nodes |
| 36. 苍白球 globus pallidus | 66. 咽缩肌 constrictor of pharynx |
| 37. 杏仁体 amygdaloid body | 67. 口咽 oropharynx |
| 38. 尾状核尾 tail of caudate nucleus | 68. 颈外侧深淋巴结 deep lateral cervical lymph nodes |
| 39. 海马 hippocampus | 69. 胸锁乳突肌 sternocleidomastoid |
| 40. 海马旁回 parahippocampal gyrus | 70. 甲状软骨 thyroid cartilage |
| 41. 大脑中动脉 middle cerebral artery | 71. 基底动脉 basilar artery |
| 42. 颞上回 superior temporal gyrus | |

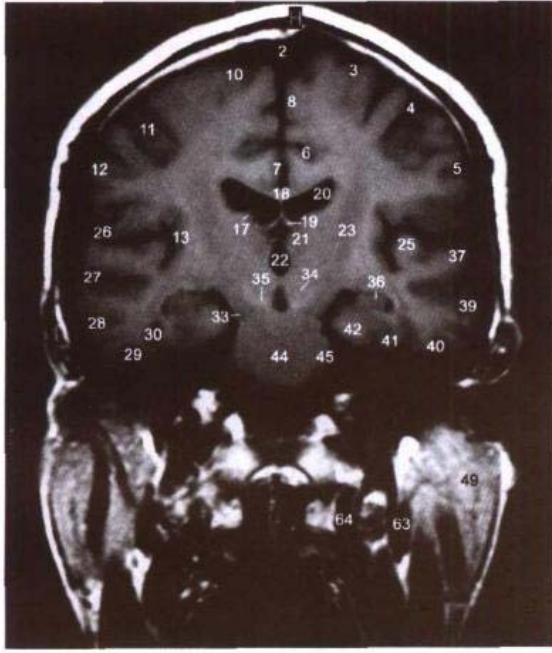
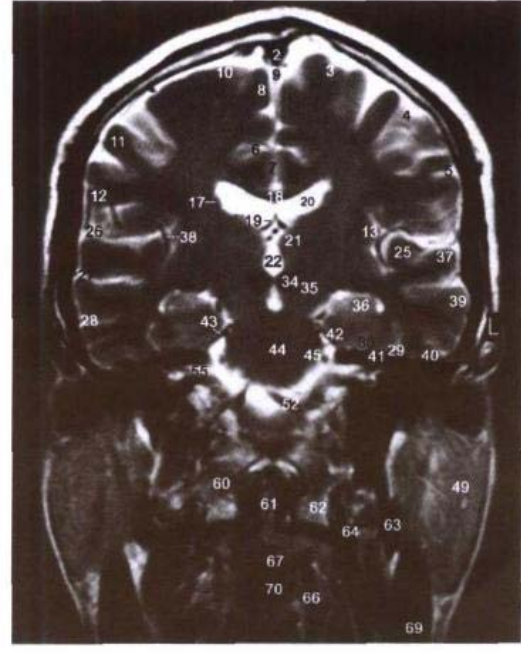
图 4-9 经红核和黑质的冠状断层

Fig.4-9 Coronal section through red nucleus and substantia nigra



A. 断层标本(sectional specimen)

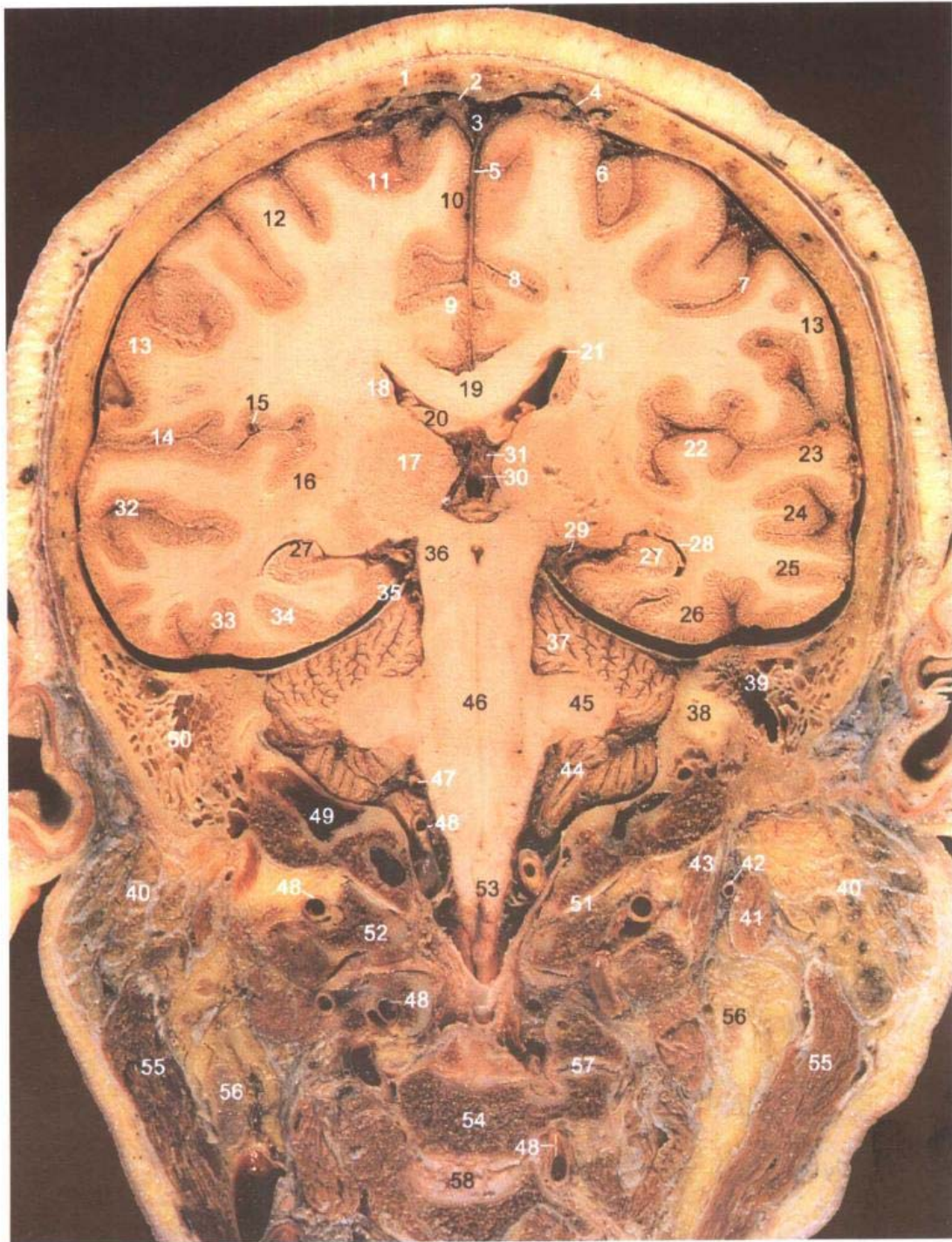
- | | |
|---------------------------------|--------------------------------|
| 1. 额骨 frontal bone | 6. 扣带沟 cingulate sulcus |
| 2. 上矢状窦 superior sagittal sinus | 7. 扣带回 cingulate gyrus |
| 3. 额上沟 superior frontal sulcus | 8. 额内侧回 medial frontal gyrus |
| 4. 中央前沟 precentral sulcus | 9. 大脑镰 cerebral falx |
| 5. 中央沟 central sulcus | 10. 额上回 superior frontal gyrus |

B. MRI T₁ WIC. MRI T₂ WI

- | | |
|--|---|
| 11. 中央前回 precentral gyrus | 42. 海马旁回 parahippocampal gyrus |
| 12. 中央后回 postcentral gyrus | 43. 小脑幕 tentorium of cerebellum |
| 13. 岛叶 insula | 44. 脑桥基底部 basilar part of pons |
| 14. 屏状核 claustrum | 45. 小脑中脚 middle cerebellar peduncle |
| 15. 壳 putamen | 46. 耳蜗 cochlea |
| 16. 内囊前肢 anterior limb of internal capsule | 47. 听小骨 auditory ossicles |
| 17. 尾状核 caudate nucleus | 48. 耳廓软骨 cartilage of auricle |
| 18. 胼胝体干 trunk of corpus callosum | 49. 腮腺 parotid gland |
| 19. 穹窿体 body of corpus callosum | 50. 茎突 styloid process |
| 20. 侧脑室前角 anterior horn of lateral ventricle | 51. 舌下神经和舌下神经管 hypoglossal nerve and canal |
| 21. 背侧丘脑 dorsal thalamus | 52. 椎动脉 vertebral artery |
| 22. 第三脑室 third ventricle | 53. 延髓 medulla oblongata |
| 23. 内囊后肢 posterior limb of internal capsule | 54. 面神经和前庭蜗神经 facial and vestibulocochlear nerves |
| 24. 最外囊 extreme capsule | 55. 内耳道 internal acoustic meatus |
| 25. 颞横回 transverse temporal gyrus | 56. 鼓室 tympanic cavity |
| 26. 外侧沟 lateral sulcus | 57. 鼓膜 tympanic membrane |
| 27. 颞上沟 superior temporal sulcus | 58. 外耳道 external acoustic meatus |
| 28. 颞下沟 inferior temporal sulcus | 59. 颈内静脉 internal jugular vein |
| 29. 枕颞沟 occipitotemporal sulcus | 60. 枕髁 occipital condyle |
| 30. 侧副沟 collateral sulcus | 61. 枢椎齿突 dens of axis |
| 31. 尾状核尾 tail of caudate nucleus | 62. 寰椎侧块 lateral mass of atlas |
| 32. 外侧膝状体 medial geniculate body | 63. 二腹肌后腹 posterior belly of digastric |
| 33. 大脑脚底 crus cerebri | 64. 颈内动脉 interneal carotid artery |
| 34. 红核 red nucleus | 65. 颈外侧深淋巴结 deep lateral cervical lymph nodes |
| 35. 黑质 substantia nigra | 66. 椎动脉 vertebral artery |
| 36. 海马 hippocampus | 67. 枢椎体 body of axis |
| 37. 颞上回 superior temporal gyrus | 68. 颈总动脉 common carotid artery |
| 38. 大脑中动脉 middle cerebral artery | 69. 胸锁乳突肌 sternocleidomastoid |
| 39. 颞中回 middle temporal gyrus | |
| 40. 枕颞外侧回 lateral occipitotemporal gyrus | |
| 41. 枕颞内侧回 medial occipitotemporal gyrus | |

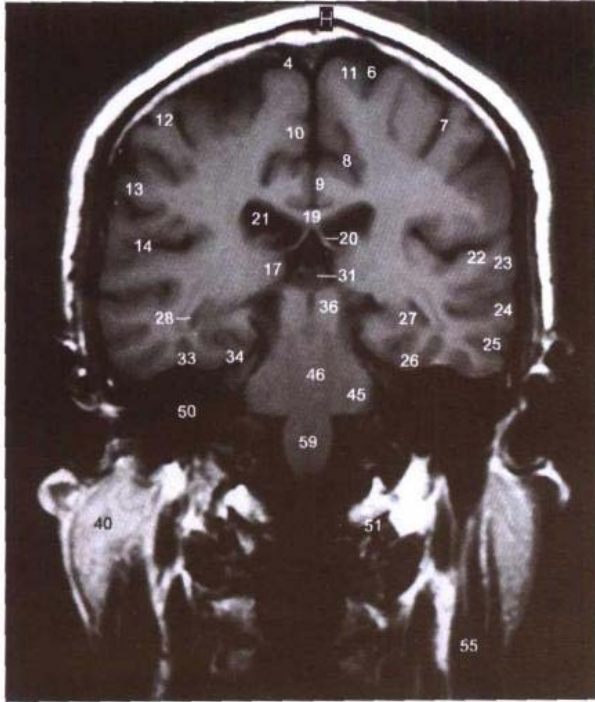
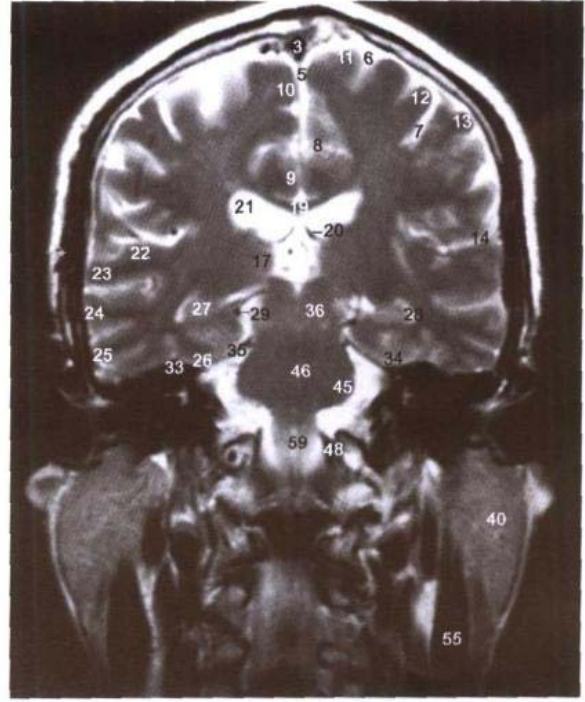
图 4-10 经小脑中脚的冠状断层

Fig.4-10 Coronal section through cerebellar hemisphere



A. 断层标本(sectional specimen)

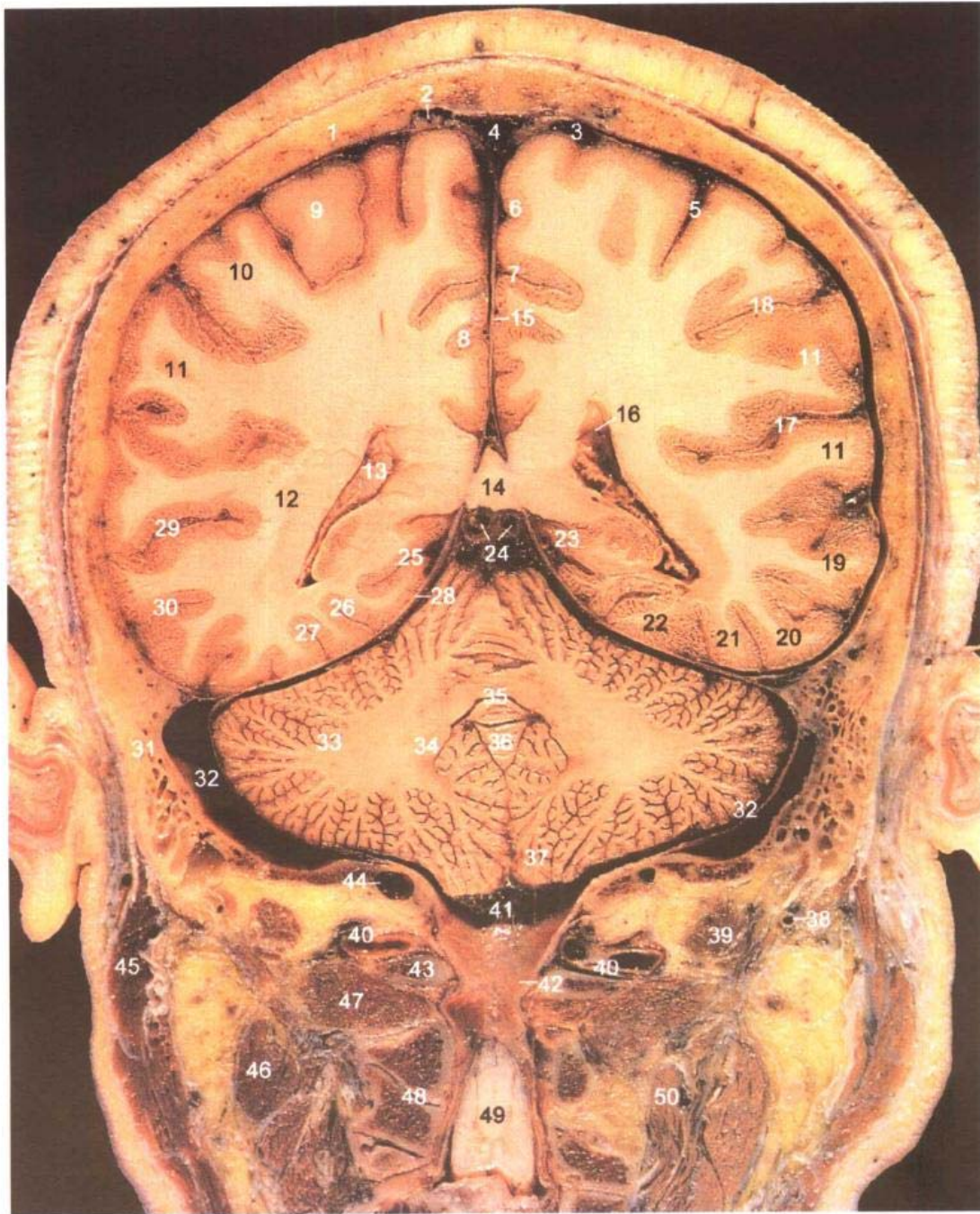
- | | |
|--|--------------------------------|
| 1. 额骨 frontal bone | 5. 大脑镰 cerebral falx |
| 2. 蛛网膜粒 arachnoid granulations | 6. 额上沟 superior frontal sulcus |
| 3. 上矢状窦 superior sagittal sinus | 7. 中央沟 central sulcus |
| 4. 上矢状窦外侧陷窝 lateral lacunae of superior sagittal sinus | 8. 扣带沟 cingulate sulcus |
| | 9. 扣带回 cingulate gyrus |

B. MRI T₁ WIC. MRI T₂ WI

- | | |
|--|--|
| 10. 额内侧回 medial frontal gyrus | 35. 小脑幕 tentorium of cerebellum |
| 11. 额上回 superior frontal gyrus | 36. 中脑被盖部 tegmental part of midbrain |
| 12. 中央前回 precentral gyrus | 37. 小脑半球 cerebellar hemisphere |
| 13. 中央后回 postcentral gyrus | 38. 骨半规管 bony semicircular canals |
| 14. 外侧沟 lateral sulcus | 39. 乳突窝 mastoid antrum |
| 15. 大脑中动脉 middle cerebral artery | 40. 腮腺 parotid gland |
| 16. 视辐射 optic radiation | 41. 二腹肌后腹 posterior belly of digastric |
| 17. 背侧丘脑 dorsal thalamus | 42. 枕动脉 occipital artery |
| 18. 尾状核 caudate nucleus | 43. 茎突咽肌 stylopharyngeus |
| 19. 胼胝体干 trunk of corpus callosum | 44. 小脑扁桃体 tonsil of cerebellum |
| 20. 穹窿 fornix | 45. 小脑中脚 middle cerebellar peduncle |
| 21. 侧脑室 lateral ventricle | 46. 脑桥 pons |
| 22. 颞横回 transverse temporal gyri | 47. 小脑下前动脉 anterior inferior cerebellar artery |
| 23. 颞上回 superior temporal gyrus | 48. 椎动脉 vertebral artery |
| 24. 颞中回 middle temporal gyrus | 49. 颈静脉孔 jugular foramen |
| 25. 颞下回 inferior temporal gyrus | 50. 乳突小房 mastoid cells |
| 26. 枕颞内侧回 medial occipitotemporal gyrus | 51. 寰枕关节 atlantooccipital joint |
| 27. 海马 hippocampus | 52. 寰椎侧块 lateral mass of atlas |
| 28. 侧脑室下角 inferior horn of lateral ventricle | 53. 脊髓 spinal cord |
| 29. 大脑后动脉 posterior cerebral artery | 54. 第3颈椎 3rd cervical vertebrae |
| 30. 第三脑室松果体隐窝 pineal recess of third ventricle | 55. 胸锁乳突肌 sternocleidomastoid |
| 31. 大脑内静脉 internal cerebral veins | 56. 颈外侧深淋巴结 deep lateral cervical lymph nodes |
| 32. 颞上沟 superior temporal sulcus | 57. 关节突关节 zygapophysial joint |
| 33. 枕颞沟 occipitotemporal sulcus | 58. 第3颈椎间盘 3rd cervical vertebral disc |
| 34. 侧副沟 collateral sulcus | 59. 延髓 medulla oblongata |

图 4-11 经胼胝体压部的冠状断层

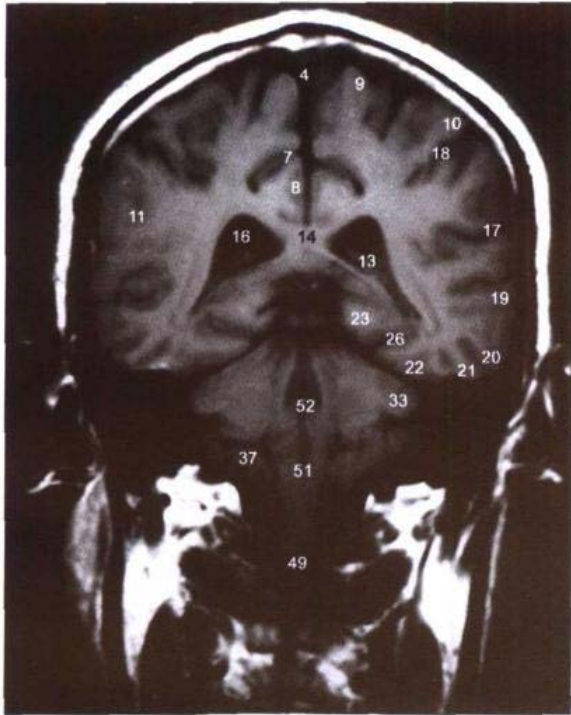
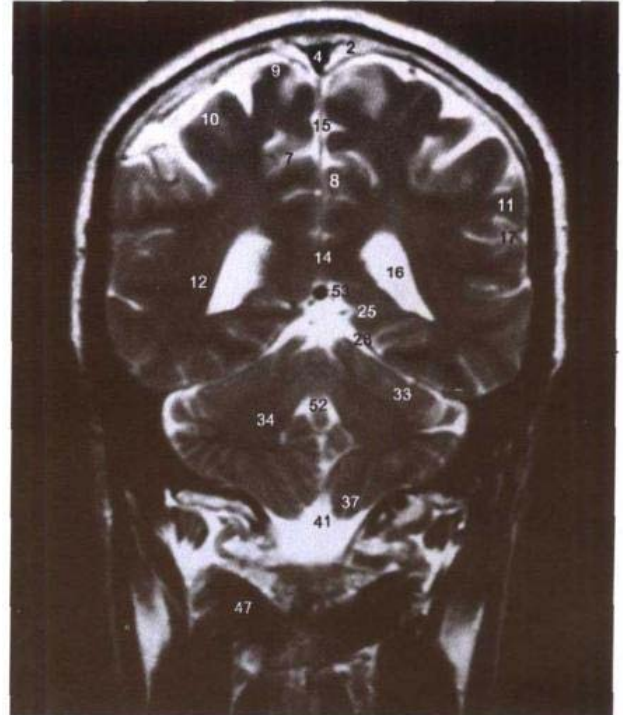
Fig.4-11 Coronal section through splenium of corpus callosum



A. 断层标本(sectional specimen)

1. 顶骨 perietal bone
2. 蛛网膜粒 arachnoid granulations
3. 大脑上静脉 superior cerebral veins
4. 上矢状窦 superior sagittal sinus
5. 中央沟 central sulcus

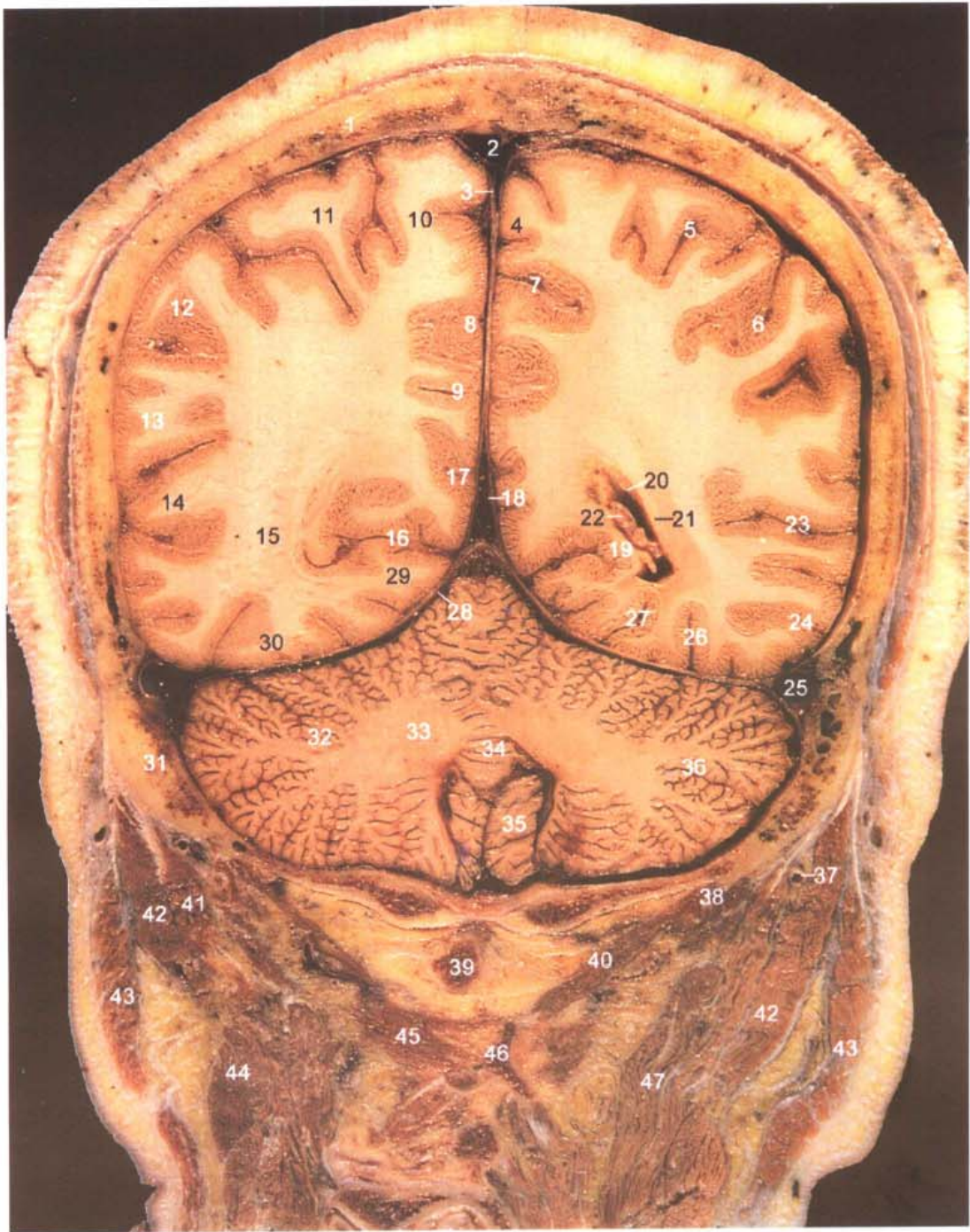
6. 额内侧回 medial frontal gyrus
7. 扣带沟 cingulate sulcus
8. 扣带回 cingulate gyrus
9. 中央前回 precentral gyrus
10. 中央后回 postcentral gyrus

B. MRI T₁ WIC. MRI T₂ WI

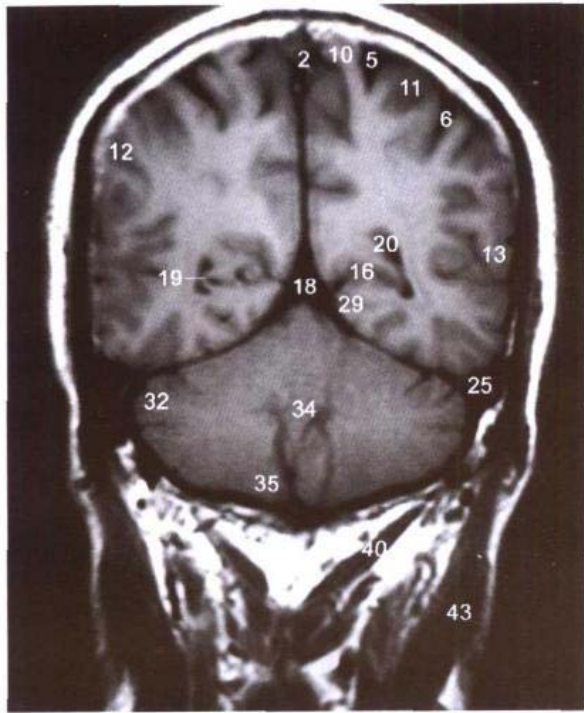
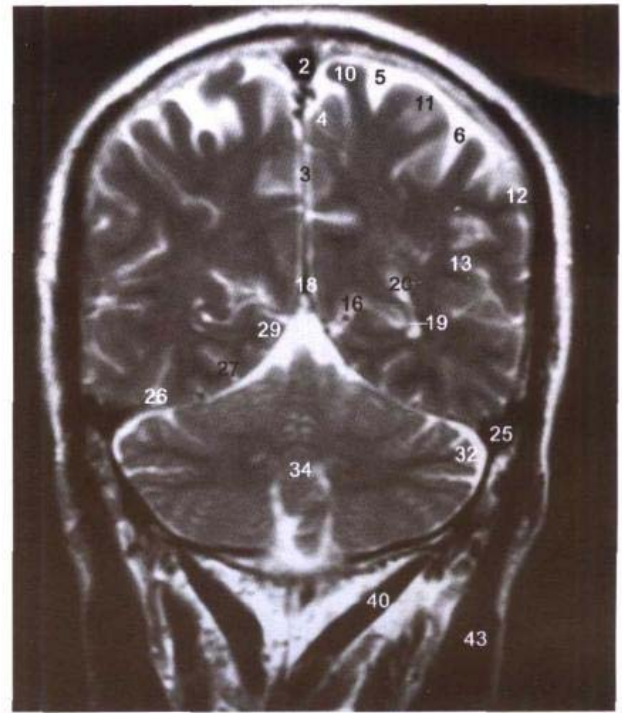
- | | |
|---|--------------------------------------|
| 11. 缘上回 supramarginal gyrus | 33. 小脑半球 cerebellar hemisphere |
| 12. 视辐射 optic radiation | 34. 齿状核 dentate nucleus |
| 13. 脉络丛 choroid plexus | 35. 蚓垂 uvula vermis |
| 14. 胼胝体压部 splenium of corpus callosum | 36. 小结 nodule |
| 15. 大脑镰 cerebral falx | 37. 小脑扁桃体 tonsil of cerebellum |
| 16. 侧脑室三角区 trigone of lateral ventricle | 38. 枕动脉 occipital artery |
| 17. 外侧沟 lateral sulcus | 39. 头上斜肌 obliquus capitis superior |
| 18. 中央后沟 postcentral sulcus | 40. 椎动脉 vertebral artery |
| 19. 颞中回 middle temporal gyrus | 41. 小脑延髓池 cerebellomedullary cistern |
| 20. 颞下回 inferior temporal gyrus | 42. 硬脊膜 spinal dura mater |
| 21. 枕颞外侧回 lateral occipitotemporal gyrus | 43. 寰椎横突 transverse process of atlas |
| 22. 枕颞内侧回 medial occipitotemporal gyrus | 44. 髁导静脉 condylar emissary veins |
| 23. 海马旁回 parahippocampal gyrus | 45. 胸锁乳突肌 sternocleidomastoid |
| 24. 大脑内静脉 internal cerebral veins | 46. 肩胛提肌 levator scapulae |
| 25. 距状沟前部 anterior part of calcarine sulcus | 47. 头下斜肌 obliquus capitis inferior |
| 26. 侧副沟 collateral sulcus | 48. 关节突关节 zygapophysial joint |
| 27. 枕颞沟 occipitotemporal sulcus | 49. 脊髓 spinal cord |
| 28. 小脑幕 tentorium of cerebellum | 50. 颈长肌 longus colli |
| 29. 颞上沟 superior temporal sulcus | 51. 延髓 medulla oblongata |
| 30. 颞下沟 inferior temporal sulcus | 52. 第四脑室 fourth ventricle |
| 31. 枕骨 occipital bone | 53. 大脑大静脉 great cerebral vein |
| 32. 乙状窦 sigmoid sinus | |

图 4-12 经侧脑室后角的冠状断层

Fig.4-12 Coronal section through posterior horn of lateral ventricle



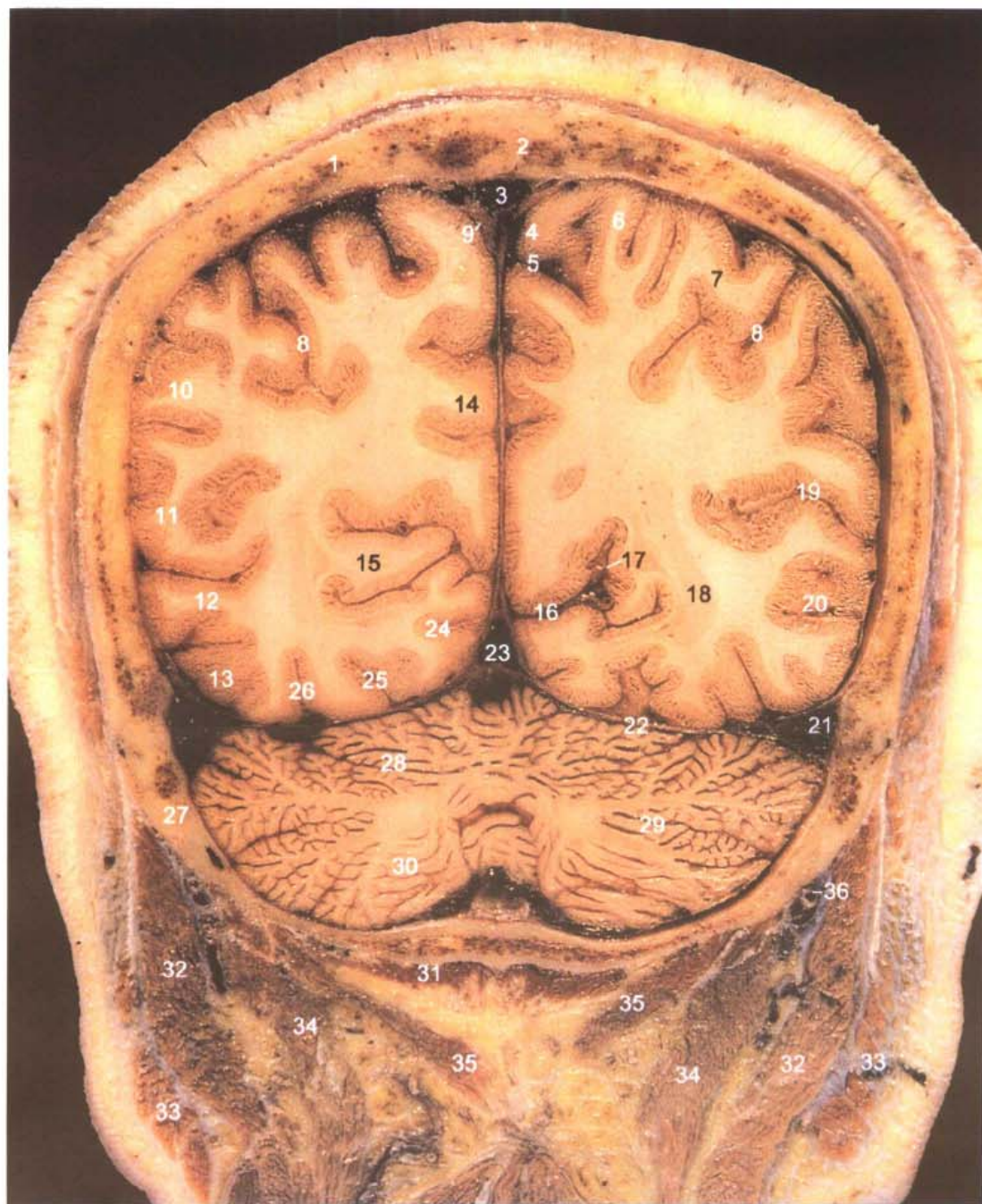
A. 断层标本(sectional specimen)

B. MRI T₁ WIC. MRI T₂ WI

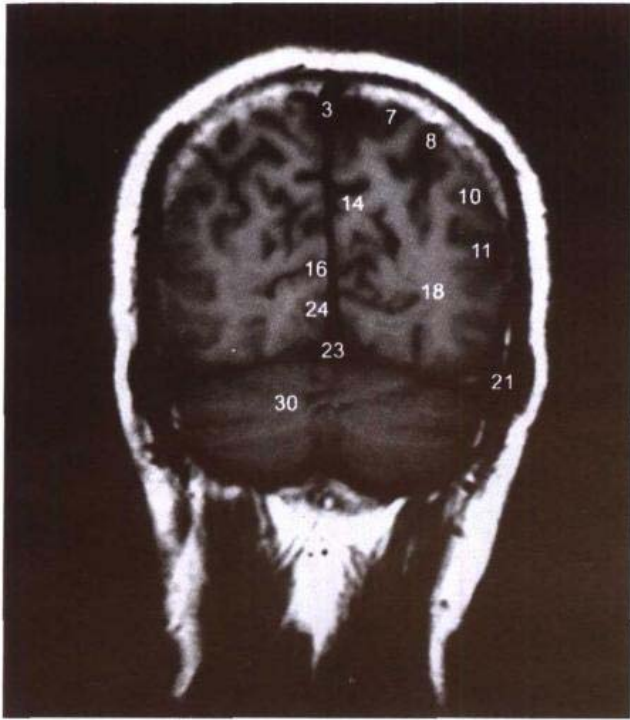
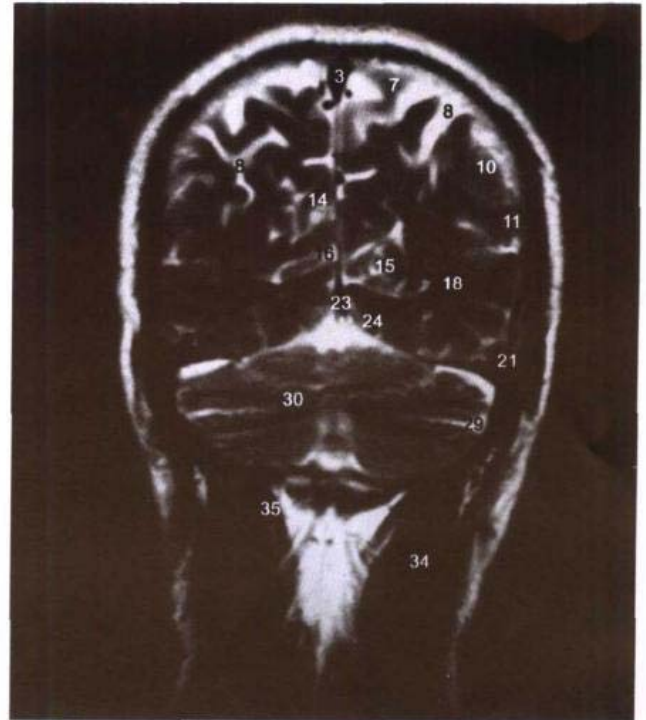
- | | |
|---|--|
| 1. 顶骨 parietal bone | 24. 颞下沟 inferior temporal sulcus |
| 2. 上矢状窦 superior sagittal sinus | 25. 横窦 transverse sinus |
| 3. 大脑镰 cerebral falx | 26. 枕颞沟 occipitotemporal sulcus |
| 4. 中央旁小叶后部 posterior part of paracentral lobule | 27. 侧副沟 collateral sulcus |
| 5. 中央后沟 postcentral sulcus | 28. 小脑幕 tentorium of cerebellum |
| 6. 顶内沟 intraparietal sulcus | 29. 舌回 lingual gyrus |
| 7. 扣带沟 cingulate sulcus | 30. 枕颞外侧回 lateral occipitotemporal gyrus |
| 8. 楔前叶 precuneus | 31. 枕骨 occipital bone |
| 9. 顶下沟 subparietal sulcus | 32. 小脑半球 cerebellar hemisphere |
| 10. 中央后回 postcentral gyrus | 33. 齿状核 dentate nucleus |
| 11. 顶上小叶 superior parietal lobule | 34. 蚓垂 uvula vermis |
| 12. 顶下小叶 inferior parietal lobule | 35. 小脑扁桃体 tonsil of cerebellum |
| 13. 角回 angular gyrus | 36. 水平裂 horizontal fissure |
| 14. 颞中回 middle temporal gyrus | 37. 枕动脉 occipital artery |
| 15. 视辐射 optic radiation | 38. 头上斜肌 obliquus capitis superior |
| 16. 距状沟前部 anterior part of calcarine sulcus | 39. 寰椎后弓 posterior arch of atlas |
| 17. 扣带回峡 isthmus of cingulate gyrus | 40. 头后大直肌 rectus capitis posterior major |
| 18. 直窦 straight sinus | 41. 头最长肌 longissimus capitis |
| 19. 禽距 calcar avis | 42. 头夹肌 splenius capitis |
| 20. 侧脑室后角 posterior horn of lateral ventricle | 43. 胸锁乳突肌 sternocleidomastoid |
| 21. 毯 tapetum | 44. 肩胛提肌 levator scapulae |
| 22. 脉络丛 choroid plexus | 45. 头下斜肌 obliquus capitis inferior |
| 23. 颞上沟 superior temporal sulcus | 46. 枢椎椎弓 vertebral arch of axis |
| | 47. 头半棘肌 semispinalis capitis |

图 4-13 经距状隐回的冠状断层

Fig.4-13 Coronal section through calcarine gyri



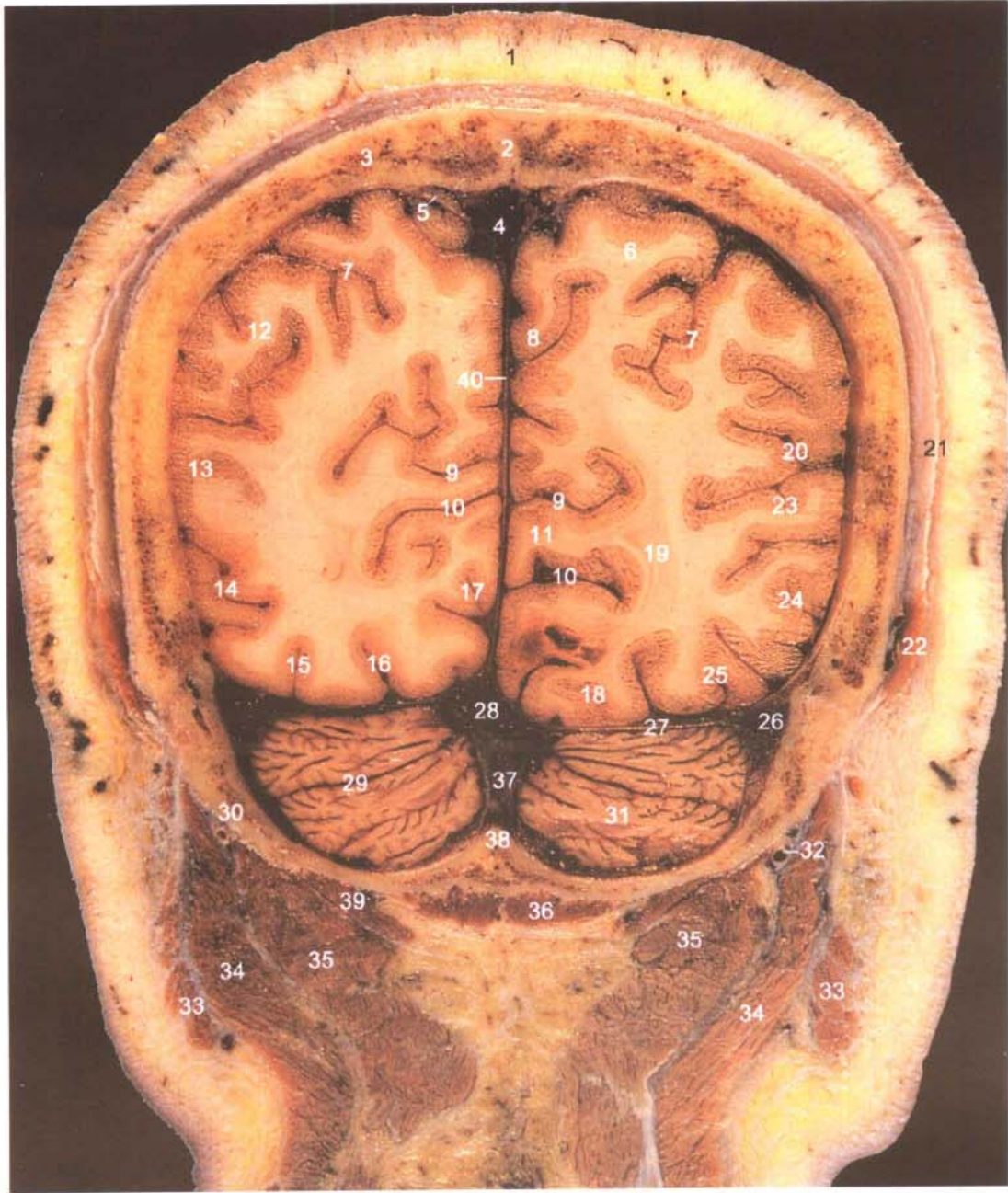
A. 断层标本(sectional specimen)

B. MRI T₁ WIC. MRI T₂ WI

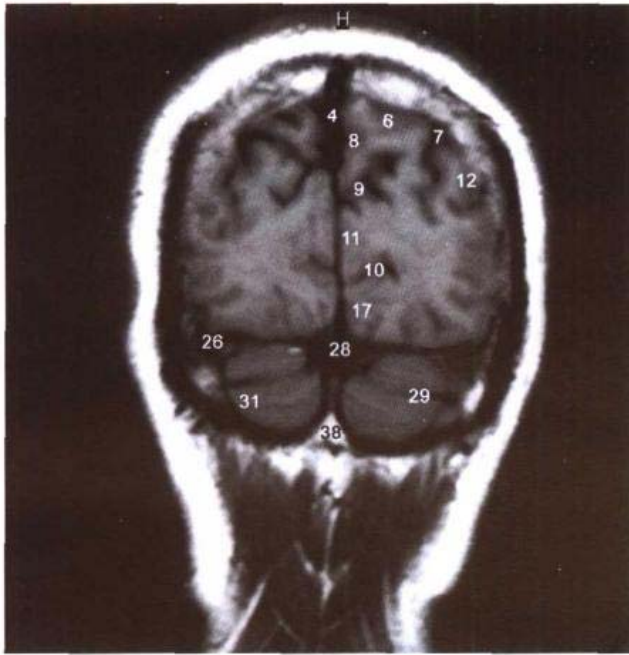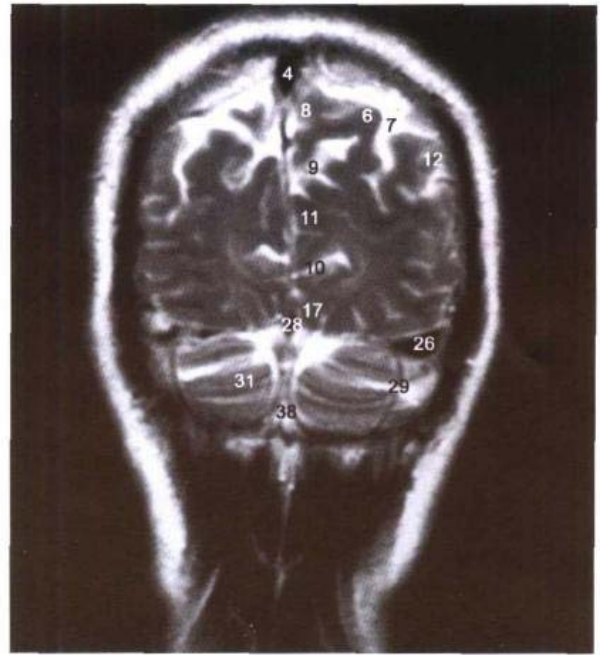
- | | |
|---|--|
| 1. 顶骨 parietal bone | 19. 颞上沟 superior temporal sulcus |
| 2. 矢状缝 sagittal suture | 20. 颞下沟 inferior temporal sulcus |
| 3. 上矢状窦 superior sagittal sinus | 21. 横窦 transverse sinus |
| 4. 中央旁小叶后部 posterior part of paracentral lobule | 22. 小脑幕 tentorium of cerebellum |
| 5. 扣带沟缘支 marginal ramus of cingulate sulcus | 23. 直窦 straight sinus |
| 6. 中央后回 postcentral gyrus | 24. 舌回 lingual gyrus |
| 7. 顶上小叶 superior parietal lobule | 25. 侧副沟 collateral sulcus |
| 8. 顶内沟 intraparietal sulcus | 26. 枕颞沟 occipitotemporal sulcus |
| 9. 蛛网膜粒 arachnoid granulations | 27. 枕骨 occipital bone |
| 10. 顶下小叶 inferior parietal lobule | 28. 后半月裂 postlunate fissure |
| 11. 角回 angular gyrus | 29. 水平裂 horizontal fissure |
| 12. 颞中回 middle temporal gyrus | 30. 小脑半球 cerebellar hemisphere |
| 13. 颞下回 inferior temporal gyrus | 31. 头后小直肌 rectus capitis posterior minor |
| 14. 楔前叶 precuneus | 32. 头夹肌 splenius capitis |
| 15. 距状隐回 cryptocalcarine gyri | 33. 胸锁乳突肌 sternocleidomastoid |
| 16. 距状沟 calcarine sulcus | 34. 头半棘肌 semispinalis capitis |
| 17. 距状沟动脉 calcarine artery | 35. 头后大直肌 rectus capitis posterior major |
| 18. 视辐射 optic radiation | 36. 枕动脉 occipital artery |

图 4-14 经窦汇的冠状断层

Fig.4-14 Coronal section through confluence of sinus



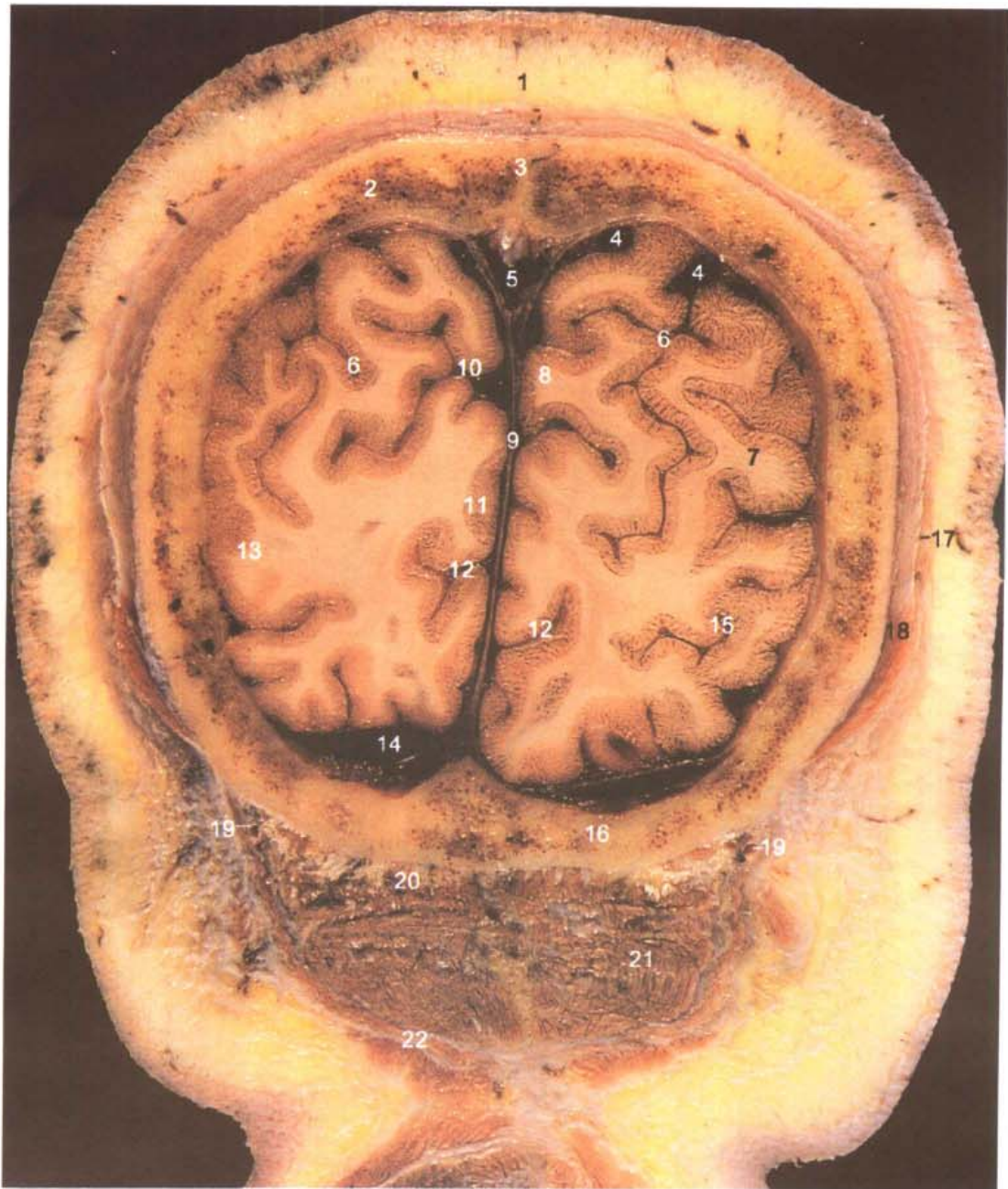A. 断层标本(sectional specimen)

B. MRI T₁ WIC. MRI T₂ WI

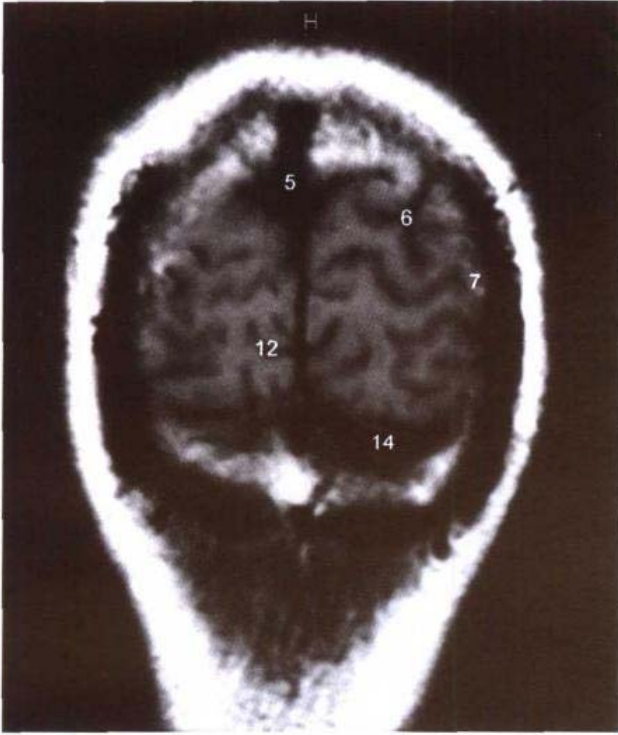
- | | |
|---|--|
| 1. 头皮 scalp | 21. 帽状腱膜 epicranial aponeurosis |
| 2. 矢状缝 sagittal suture | 22. 枕额肌枕腹 occipital belly of occipitofrontalis |
| 3. 顶骨 parietal bone | 23. 颞中回 middle temporal gyrus |
| 4. 上矢状窦 superior sagittal sinus | 24. 颞下回 inferior temporal gyrus |
| 5. 蛛网膜粒 arachnoid granulations | 25. 枕颞外侧回 lateral occipitotemporal gyrus |
| 6. 顶上小叶 superior parietal lobule | 26. 横窦 transverse sinus |
| 7. 顶内沟 intraparietal sulcus | 27. 小脑幕 tentorium of cerebellum |
| 8. 楔前叶 precuneus | 28. 窦汇 confluence of sinus |
| 9. 顶枕沟 parietooccipital sulcus | 29. 水平裂 horizontal fissure |
| 10. 距状沟 calcarine sulcus | 30. 枕骨 occipital bone |
| 11. 楔叶 cuneus | 31. 小脑半球 cerebellar hemisphere |
| 12. 顶下小叶 inferior parietal lobule | 32. 枕动脉 occipital artery |
| 13. 角回 angular gyrus | 33. 胸锁乳突肌 sternocleidomastoid |
| 14. 颞下沟 inferior temporal sulcus | 34. 头夹肌 splenius capitis |
| 15. 枕颞沟 occipitotemporal sulcus | 35. 头半棘肌 semispinalis capitis |
| 16. 侧副沟 collateral sulcus | 36. 头后小直肌 rectus capitis posterior minor |
| 17. 舌回 lingual gyrus | 37. 枕窦 occipital sinus |
| 18. 枕颞内侧回 medial occipitotemporal gyrus | 38. 枕内嵴 internal occipital crest |
| 19. 视辐射 optic radiation | 39. 头后大直肌 rectus capitis posterior major |
| 20. 颞上沟 superior temporal sulcus | 40. 大脑镰 cerebral falx |

图 4-15 经顶叶和枕叶的冠状断层

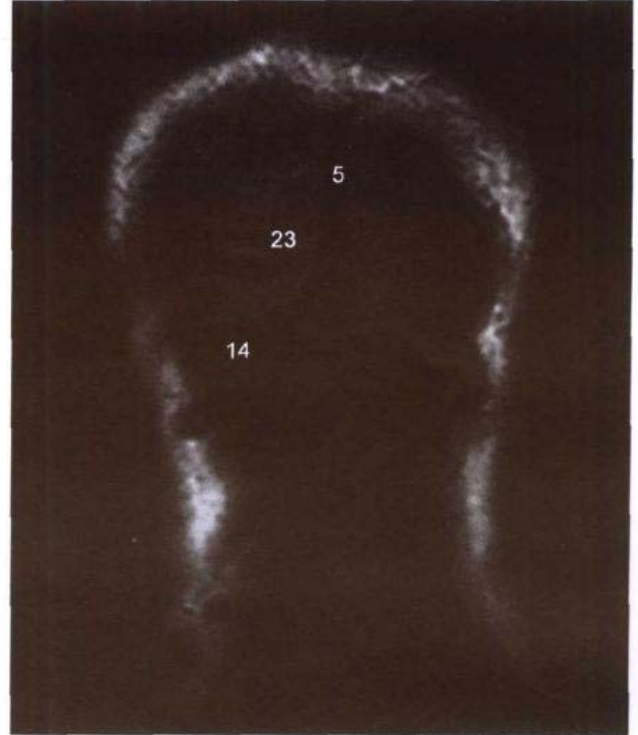
Fig.4-15 Coronal section through parietal and occipital lobes



A. 断层标本(sectional specimen)



B. MRI T₁ WI



C. MRI T₂ WI

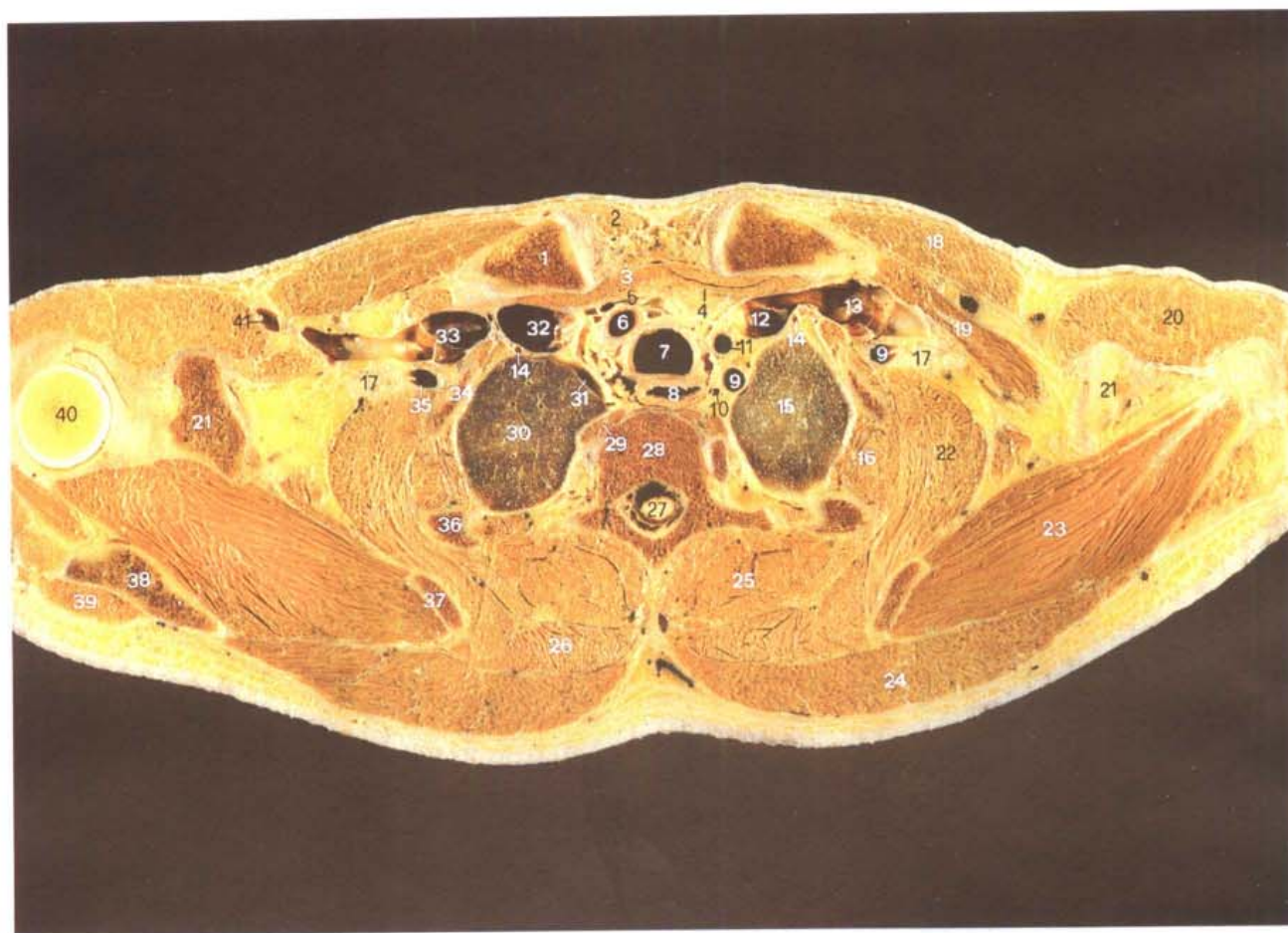
- | | |
|--|---|
| <ol style="list-style-type: none"> 1. 头皮 scalp 2. 顶骨 parietal bone 3. 矢状缝 sagittal suture 4. 大脑上静脉 superior cerebral veins 5. 上矢状窦 superior sagittal sinus 6. 顶内沟 intraparietal sulcus 7. 顶下小叶 inferior parietal lobule 8. 楔前叶 precuneus 9. 大脑镰 cerebral falx 10. 顶枕沟 parietooccipital sulcus 11. 楔叶 cuneus 12. 距状沟 calcarine sulcus | <ol style="list-style-type: none"> 13. 颞中回 middle temporal gyrus 14. 横窦 transverse sinus 15. 颞下回 inferior temporal gyrus 16. 枕骨 occipital bone 17. 帽状腱膜 epicranial aponeurosis 18. 枕额肌枕腹 occipital belly of occipitofrontalis 19. 枕动脉 occipital artery 20. 头后大直肌 rectus capitis posterior major 21. 头半棘肌 semispinalis capitis 22. 头夹肌 splenius capitis 23. 枕叶 occipital lobe |
|--|---|

第五章 胸部连续横断层

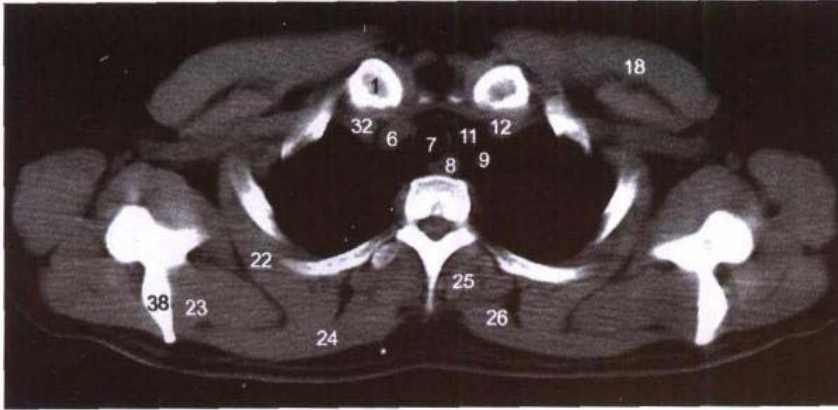
Chapter 5 Serial Transverse Sections Of Thorax

图 5-1 经左、右静脉角的横断层

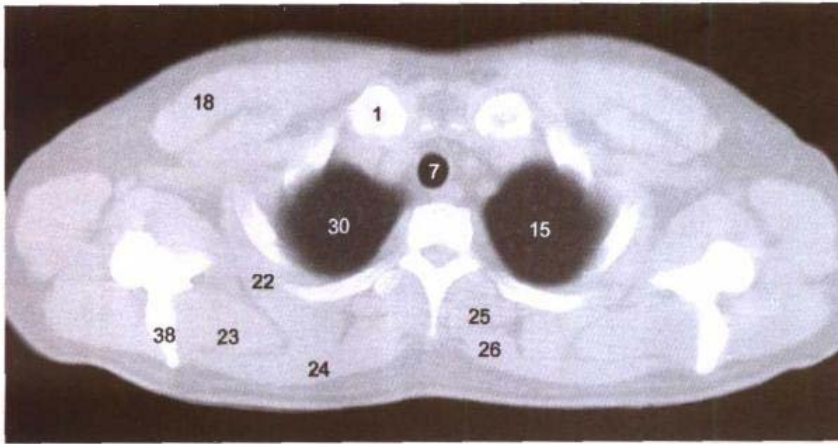
Fig.5-1 Transverse section through left and right venous angles



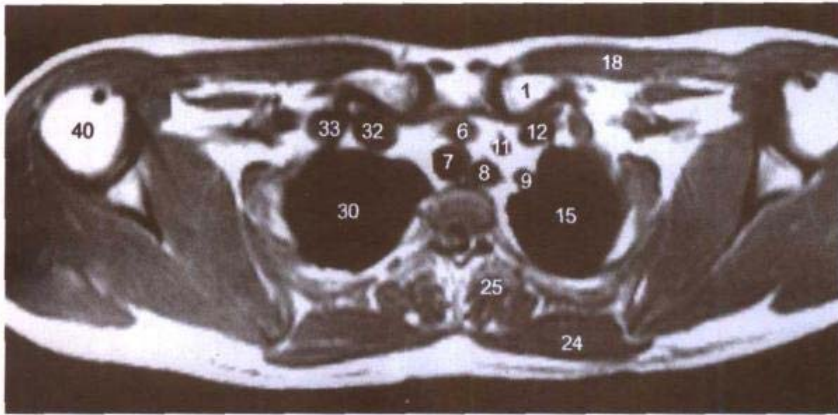
A. 断层标本(sectional specimen)



B. CT (纵隔窗 mediastinal window)



C. CT (肺窗 lung window)



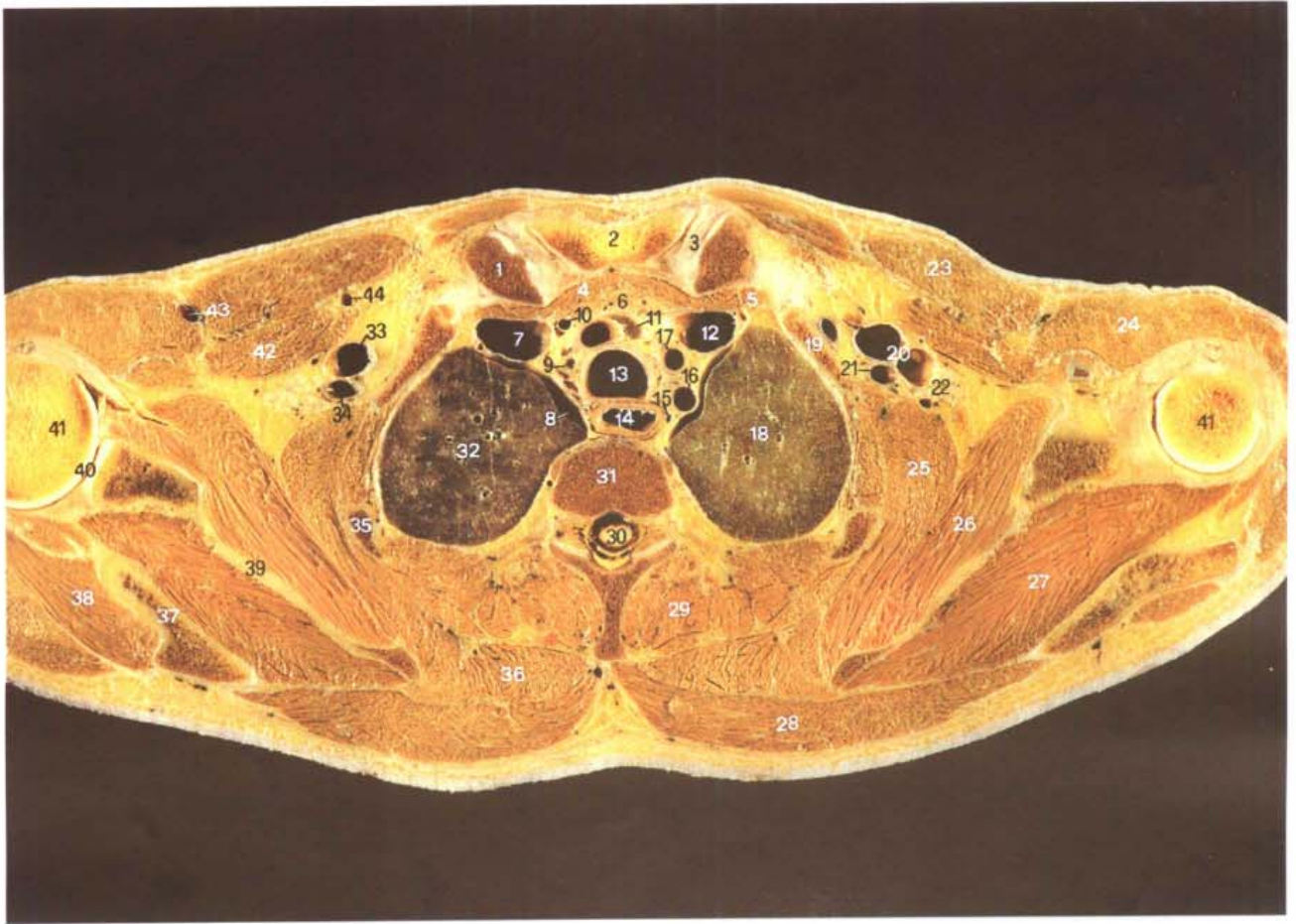
D. MRI T₁WI

- | | | |
|-----------|-------------------------|-----------|
| 1. 锁骨胸骨端 | sternal end of clavicle | vein |
| 2. 胸锁乳突肌 | sternocleidomastoid | 6. 头臂干 |
| 3. 胸骨舌骨肌 | sternohyoid | 7. 气管 |
| 4. 胸骨甲状肌 | sternothyroid | 8. 食管 |
| 5. 甲状腺下静脉 | inferior thyroid vein | 9. 左锁骨下动脉 |
| | | 10. 胸导管 |

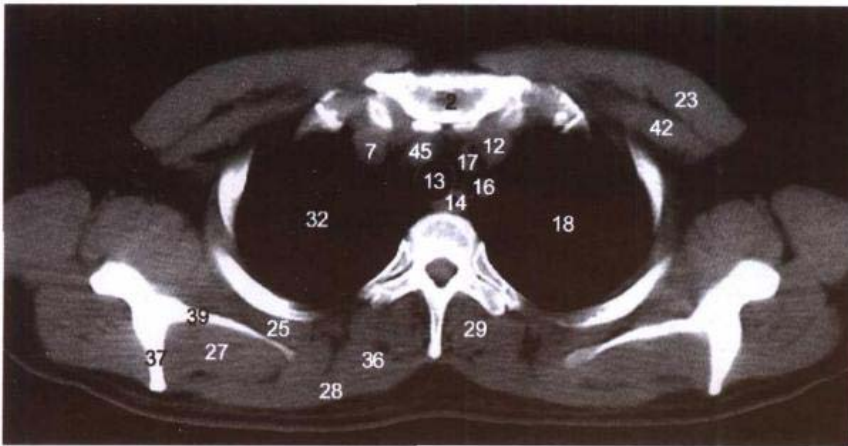
- | | |
|------------|-----------------------------------|
| 11. 左颈总动脉 | left common carotid artery |
| 12. 左头臂静脉 | left brachiocephalic vein |
| 13. 左锁骨下静脉 | left subclavian vein |
| 14. 胸廓内动脉 | internal thoracic artery |
| 15. 左肺尖 | apex of left lung |
| 16. 肋间内、外肌 | intercostales interni and externi |
| 17. 臂丛 | brachial plexus |
| 18. 胸大肌 | pectoralis major |
| 19. 锁骨下肌 | subclavius |
| 20. 三角肌 | deltoid |
| 21. 肩胛骨喙突 | coracoid process of scapula |
| 22. 前锯肌 | serratus anterior |
| 23. 冈上肌 | supraspinatus |
| 24. 斜方肌 | trapezius |
| 25. 竖脊肌 | erector spinae |
| 26. 大菱形肌 | rhomboides major |
| 27. 脊髓 | spinal cord |
| 28. 第2胸椎体 | body of 2nd thoracic vertebrae |
| 29. 颈长肌 | longus colli |
| 30. 右肺尖 | apex of right lung |
| 31. 胸膜腔 | pleural cavity |
| 32. 右头臂静脉 | right brachiocephalic vein |
| 33. 右锁骨下静脉 | right subclavian vein |
| 34. 第1肋 | 1st rib |
| 35. 右锁骨下动脉 | right subclavian artery |
| 36. 第2肋 | 2nd rib |
| 37. 肩胛骨上角 | superior angle of scapula |
| 38. 肩胛冈 | spine of scapula |
| 39. 冈下肌 | infraspinatus |
| 40. 肱骨头 | head of humerus |
| 41. 头静脉 | cephalic vein |

图 5-2 经胸锁关节的横断层

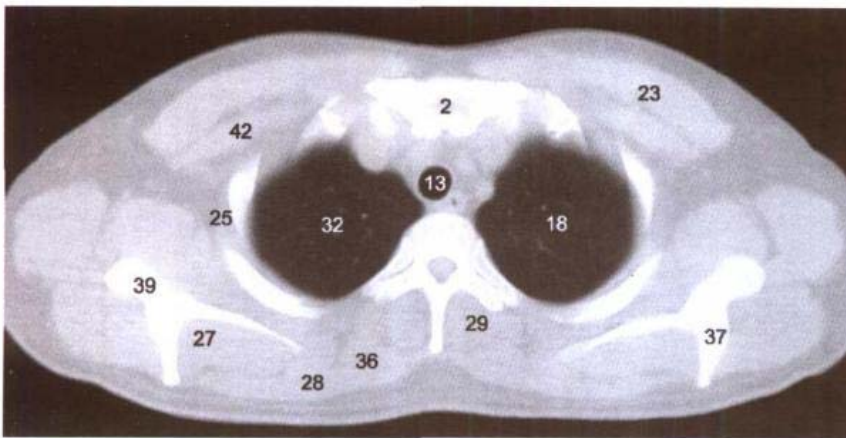
Fig.5-2 Transverse section through sternoclavicular joint



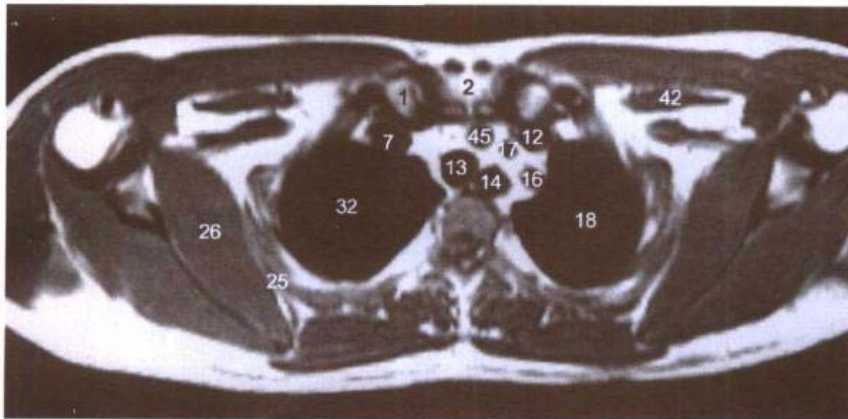
A. 断层标本 (sectional specimen)



B. CT (纵隔窗 mediastinal window)



C. CT (肺窗 lung window)



D. MRI T₁WI

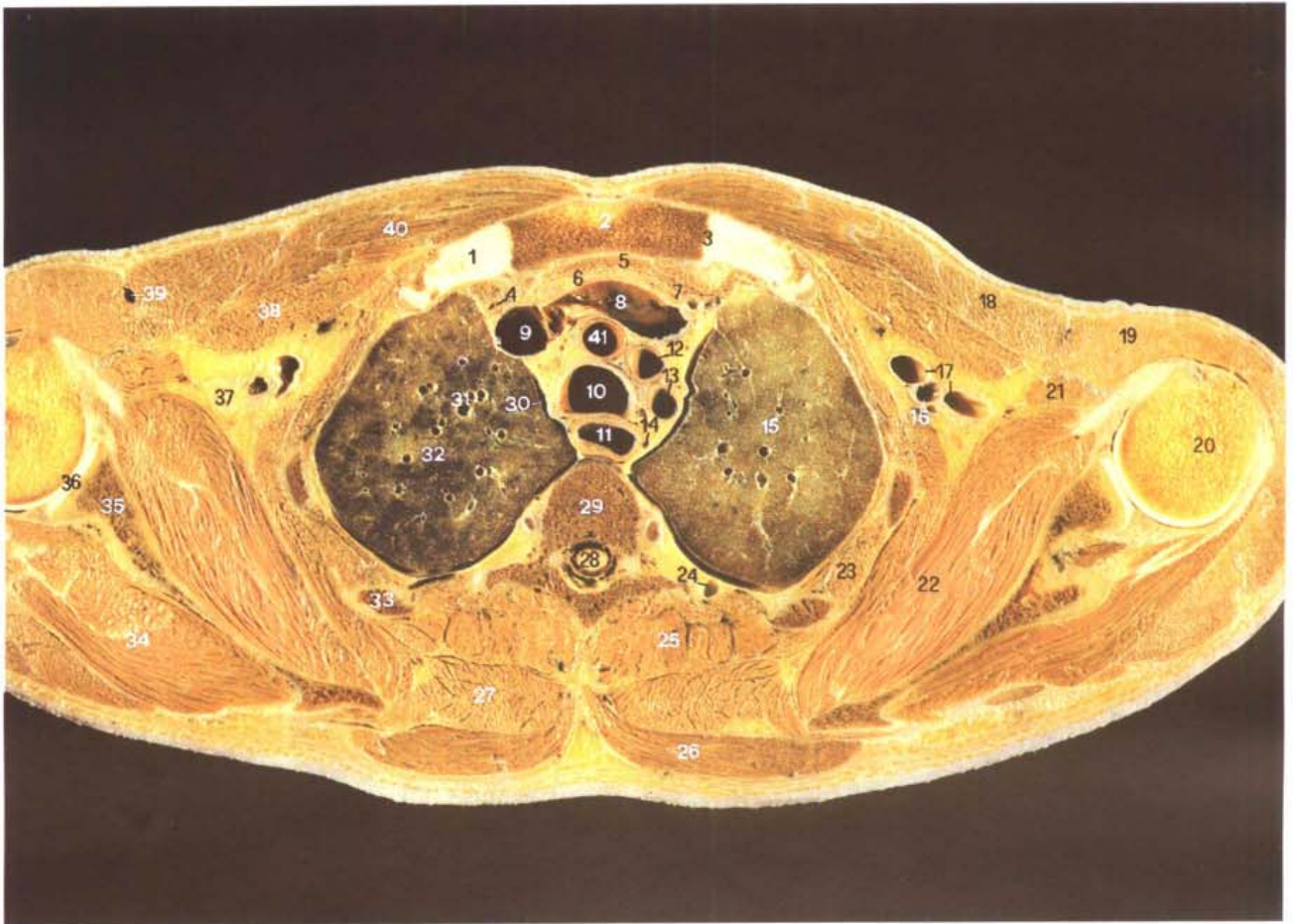
1. 锁骨胸骨端 sternal end of clavicle
2. 胸骨柄 manubrium sterni
3. 关节盘 articular disc
4. 胸骨舌骨肌 sternohyoid
5. 胸骨甲状肌 sternothyroid
6. 胸腺 thymus

7. 右头臂静脉 right brachiocephalic vein
8. 胸膜腔 pleural cavity
9. 右上气管旁淋巴结 right upper paratracheal lymph nodes
10. 甲状腺下静脉 inferior thyroid vein

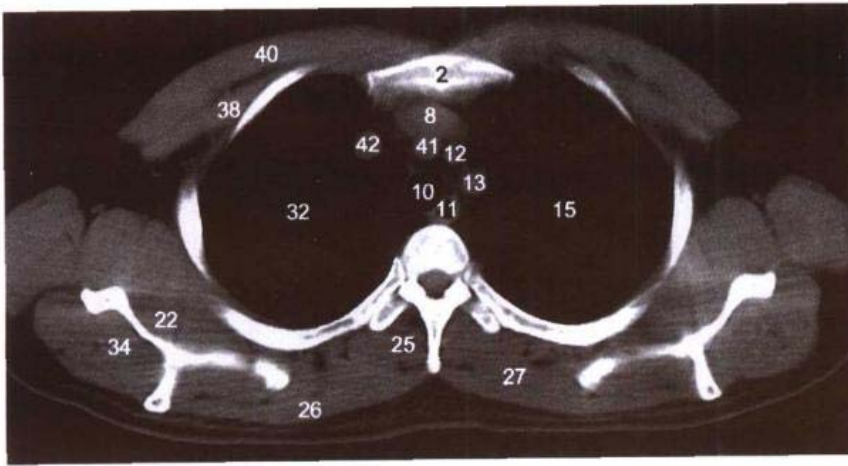
11. 前纵隔淋巴结 anterior mediastinal lymph nodes
12. 左头臂静脉 left brachiocephalic vein
13. 气管 trachea
14. 食管 esophagus
15. 胸导管 thoracic duct
16. 左锁骨下动脉 left subclavian artery
17. 左颈总动脉 left common carotid artery
18. 左肺上叶 superior lobe of left lung
19. 第1肋 1st rib
20. 左腋静脉 left axillary vein
21. 左腋动脉 left axillary artery
22. 臂丛 brachial plexus
23. 胸大肌 pectoralis major
24. 三角肌 deltoid
25. 前锯肌 serratus anterior
26. 肩胛下肌 subscapularis
27. 冈上肌 supraspinatus
28. 斜方肌 trapezius
29. 竖脊肌 erector spinae
30. 脊髓 spinal cord
31. 第2胸椎体 body of 2nd thoracic vertebrae
32. 右肺上叶 superior lobe of right lung
33. 右腋静脉 right axillary vein
34. 右腋动脉 right axillary artery
35. 第2肋 2nd rib
36. 大菱形肌 rhomboideus major
37. 肩胛冈 spine of scapula
38. 冈下肌 infraspinatus
39. 肩胛骨 scapula
40. 肩关节 shoulder joint
41. 肱骨头 head of humerus
42. 胸小肌 pectoralis minor
43. 头静脉 cephalic vein
44. 胸外侧动、静脉 lateral thoracic artery and vein
45. 头臂干 cephalic trunk

图 5-3 经第 1 肋胸肋结合的横断层

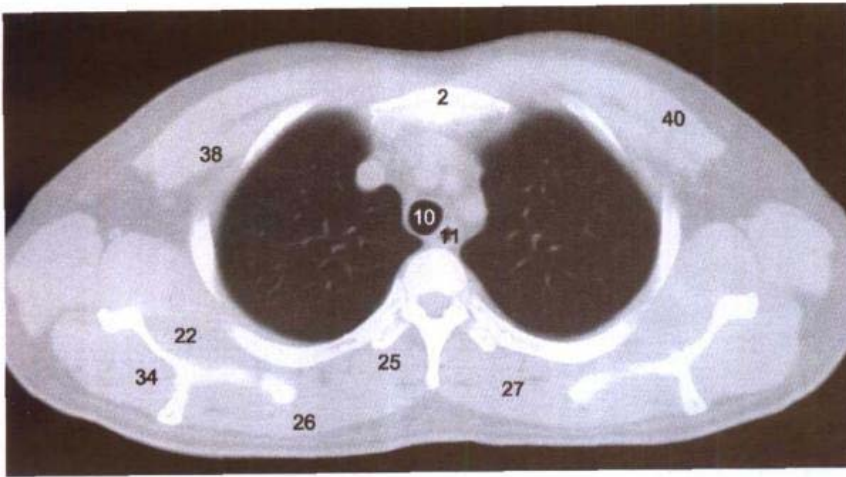
Fig.5-3 Transverse section through sternocostal synchondrosis of first rib



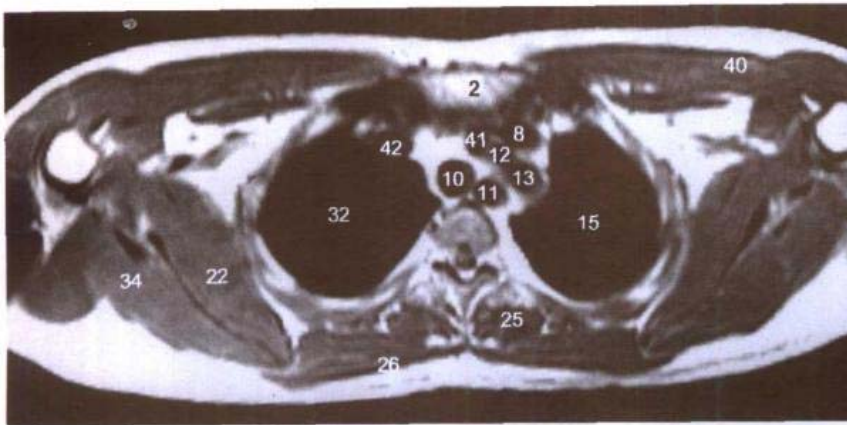
A. 断层标本 (sectional specimen)



B. CT (纵隔窗 mediastinal window)



C. CT (肺窗 lung window)



D. MRI T1WI

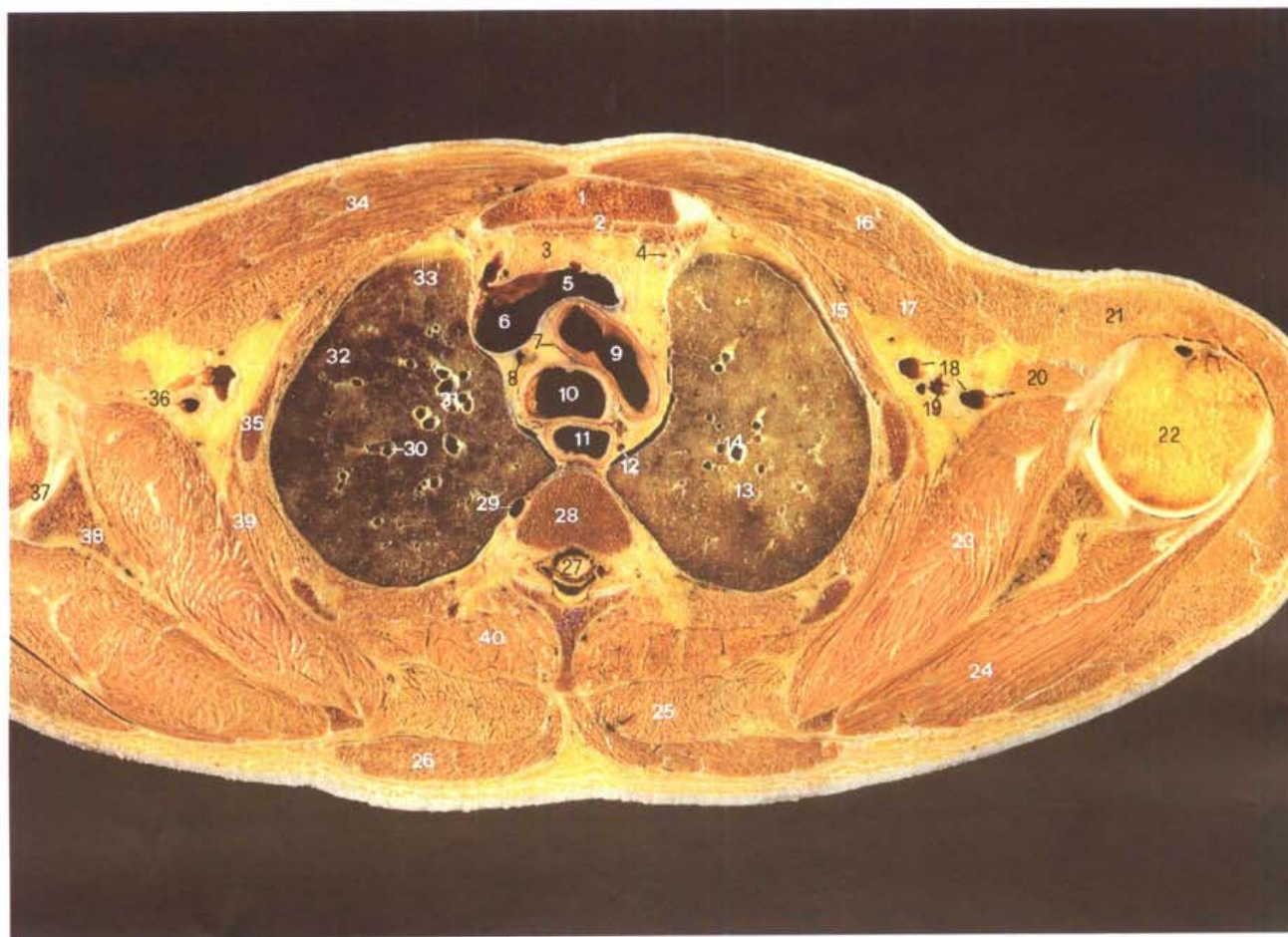1. 第1肋软骨 1st costal cartilage
2. 胸骨柄 manubrium sterni
3. 第1肋胸肋结合 sternocostal synchondrosis of first rib
4. 胸廓内动、静脉 internal thoracic artery and vein

5. 胸骨舌骨肌 sternohyoid
6. 胸腺 thymus
7. 胸骨甲状肌 sternothyroid
8. 左头臂静脉 left brachiocephalic vein
9. 上腔静脉 superior vena cava

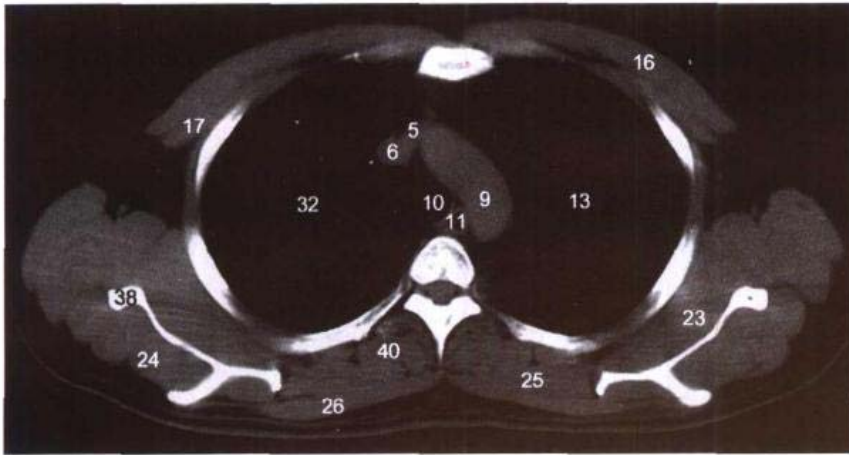
10. 气管 trachea
11. 食管 esophagus
12. 左颈总动脉 left common carotid artery
13. 左锁骨下动脉 left subclavian artery
14. 胸导管 thoracic duct
15. 左肺上叶 superior lobe of left lung
16. 腋动脉 axillary artery
17. 腋静脉 axillary vein
18. 胸大肌 pectoralis major
19. 三角肌 deltoid
20. 肱骨头 head of humerus
21. 喙肱肌和肱二头肌短头 coracobrachialis and short head of biceps brachii
22. 肩胛下肌 subscapularis
23. 肋间内、外肌 intercostales interni and externi
24. 肋间后静脉 posterior intercostal vein
25. 竖脊肌 erector spinae
26. 斜方肌 trapezius
27. 大菱形肌 rhomboideus major
28. 脊髓 spinal cord
29. 第3胸椎体 body of 3rd thoracic vertebrae
30. 胸膜腔 pleural cavity
31. 尖段支气管(B1)和动脉(A1) apical segmental bronchus and artery
32. 右肺上叶 superior lobe of right lung
33. 第3肋 3rd rib
34. 冈下肌 infraspinatus
35. 肩胛骨 scapula
36. 肩关节 shoulder joint
37. 臂丛 brachial plexus
38. 胸小肌 pectoralis minor
39. 头静脉 cephalic vein
40. 胸大肌 pectoralis major
41. 头臂干 cephalic trunk
42. 右头臂静脉 right brachiocephalic vein

图 5-4 经主动脉弓上份的横断层

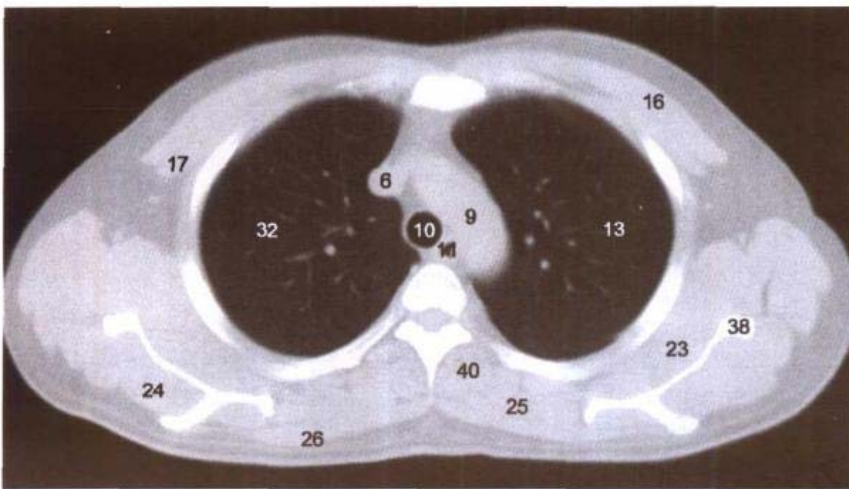
Fig.5-4 Transverse section through upper part of aortic arch



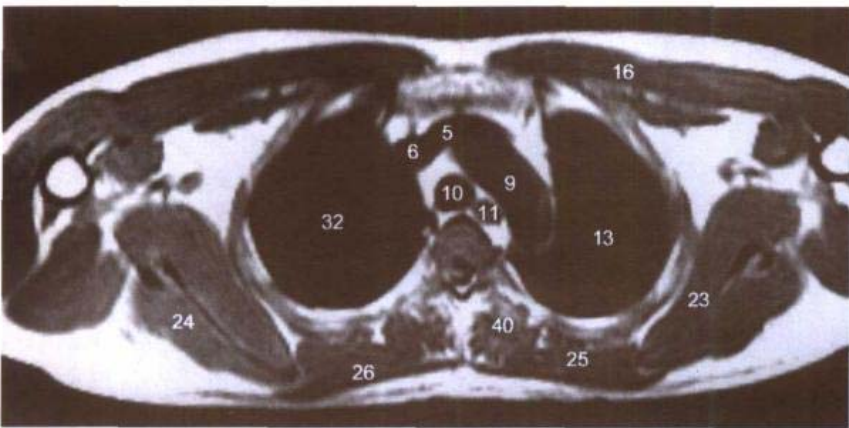
A. 断层标本 (sectional specimen)



B. CT (纵隔窗 mediastinal window)



C. CT (肺窗 lung window)

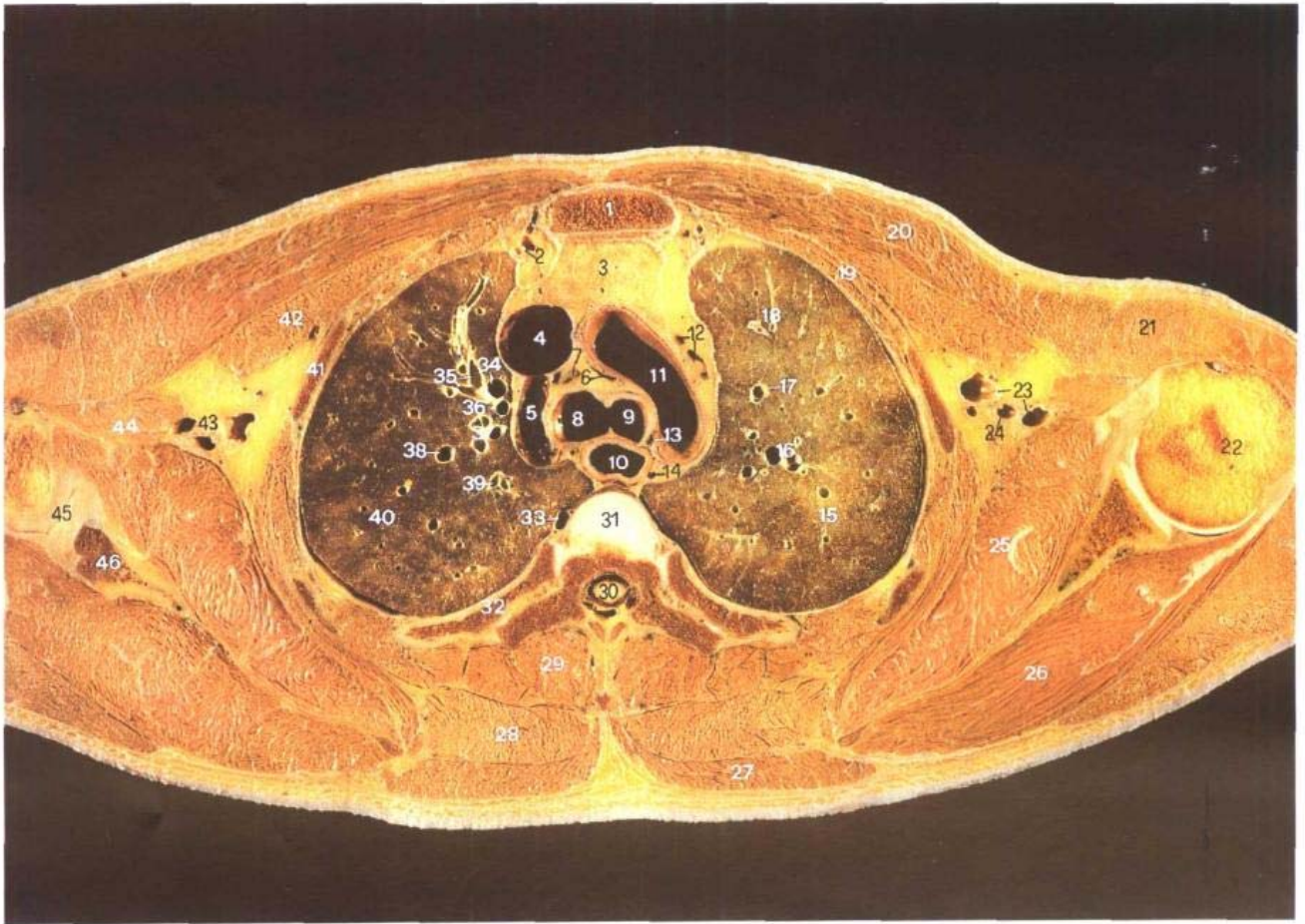
D. MRI T₁WI

- | | |
|--|---|
| 1. 胸骨柄 manubrium sterni | 5. 左头臂静脉 left brachiocephalic vein |
| 2. 胸骨舌骨肌 sternohyoid | 6. 上腔静脉 superior vena cava |
| 3. 胸腺 thymus | 7. 心包上隐窝 superior recess of pericardium |
| 4. 胸廓内动、静脉 internal thoracic artery and vein | |

- | |
|--|
| 8. 右下气管旁淋巴结 right lower paratracheal lymph nodes |
| 9. 主动脉弓 aortic arch |
| 10. 气管 trachea |
| 11. 食管 esophagus |
| 12. 胸导管 thoracic duct |
| 13. 左肺上叶 superior lobe of left lung |
| 14. 尖后段支气管(B1+2)和动脉(A1+2) apicoposterior segmental bronchus and artery |
| 15. 肋间内、外肌 intercostales interni and externi |
| 16. 胸大肌 pectoralis major |
| 17. 胸小肌 pectoralis minor |
| 18. 腋静脉 axillary vein |
| 19. 腋动脉 axillary artery |
| 20. 喙肱肌与肱二头肌短头 coracobrachialis and short head of biceps brachii |
| 21. 三角肌 deltoid |
| 22. 肱骨头 head of humerus |
| 23. 肩胛下肌 subscapularis |
| 24. 冈下肌 infraspinatus |
| 25. 大菱形肌 rhomboideus major |
| 26. 斜方肌 trapezius |
| 27. 脊髓 spinal cord |
| 28. 第3胸椎体 body of 3rd thoracic vertebrae |
| 29. 肋间后静脉 posterior intercostal vein |
| 30. 后段静脉(V2) posterior segmental vein |
| 31. 尖段支气管(B1)和动脉(A1) apical segmental bronchus and artery |
| 32. 右肺上叶 superior lobe of right lung |
| 33. 胸膜腔 pleural cavity |
| 34. 胸大肌 pectoralis major |
| 35. 第2肋 2nd rib |
| 36. 臂丛 brachial plexus |
| 37. 肩关节 shoulder joint |
| 38. 肩胛骨 scapula |
| 39. 前锯肌 serratus anterior |
| 40. 竖脊肌 erector spinae |

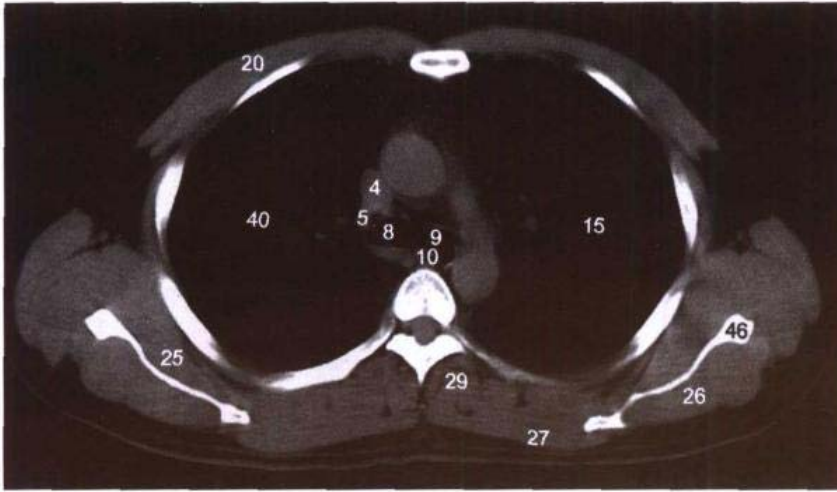
图 5-5 经主动脉弓下份的横断层

Fig.5-5 Transverse section through lower part of aortic arch

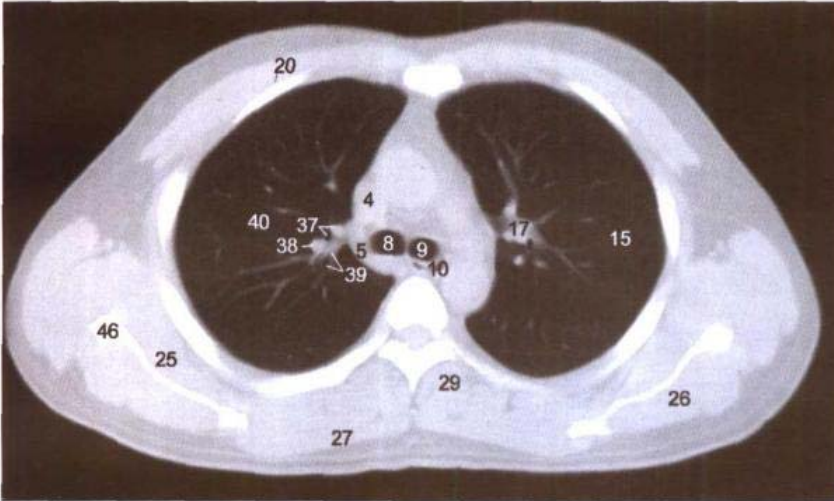


A. 断层标本 (sectional specimen)

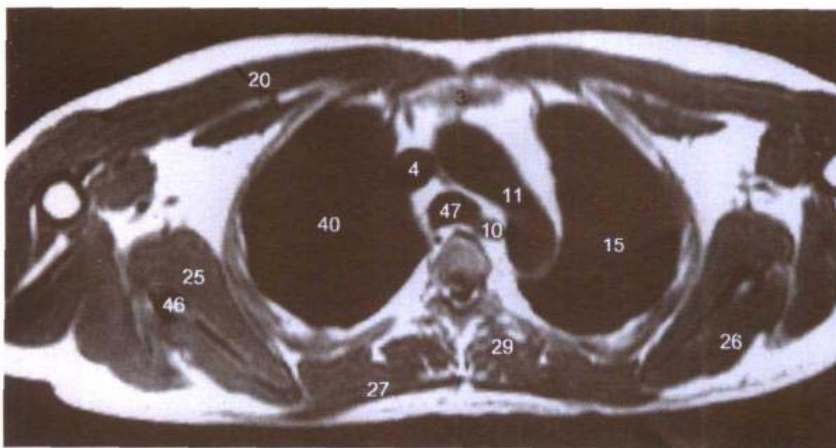
- | | | |
|---|--|---|
| 1. 胸骨柄 manubrium sterni | 7. 右气管支气管淋巴结 right tra-
cheobronchial lymph nodes | 12. 主动脉肺淋巴结 aorticpul-
monary lymph nodes |
| 2. 胸廓内动、静脉 internal tho-
racic artery and vein | 8. 右主支气管 right principal
bronchus | 13. 左下气管旁淋巴结 left lower
paratracheal lymph nodes |
| 3. 胸腺 thymus | 9. 左主支气管 left principal bro-
nchus | 14. 胸导管 thoracic duct |
| 4. 上腔静脉 superior vena cava | 10. 食管 esophagus | 15. 左肺上叶 superior lobe of
left lung |
| 5. 奇静脉弓 arch of azygos vein | 11. 主动脉弓 aortic arch | 16. 尖后段支气管(B1+2)和动脉 |
| 6. 心包上隐窝 superior recess of
pericardium | | |



B. CT (纵隔窗 mediastinal window)



C. CT (肺窗 lung window)



D. MRI T1WI

and artery

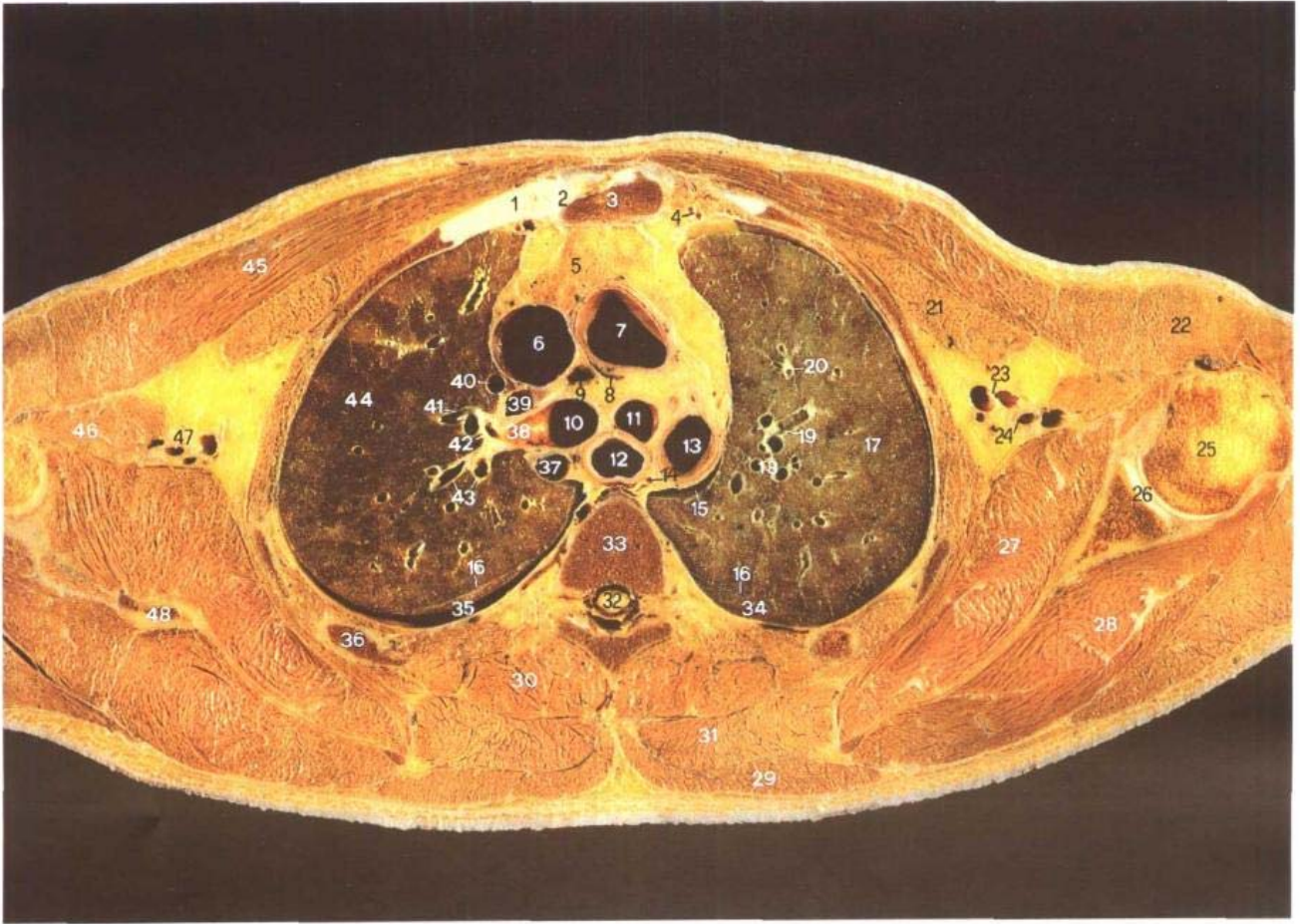
19. 肋间内、外肌 intercostales interni and externi
20. 胸大肌 pectoralis major
21. 三角肌 deltoid
22. 肱骨头 head of humerus
23. 腋静脉 axillary vein
24. 腋动脉 axillary artery
25. 肩胛下肌 subscapularis
26. 冈下肌 infraspinatus
27. 斜方肌 trapezius
28. 大菱形肌 rhomboideus major
29. 竖脊肌 erector spinae
30. 脊髓 spinal cord
31. 第3胸椎间盘 3rd thoracic intervertebral disc
32. 第4肋 4th rib
33. 肋间后静脉 posterior intercostal vein
34. 尖段静脉(V1) apical segmental vein
35. 前段动脉(A3) anterior segmental artery
36. 尖段动脉(A1) apical segmental artery
37. 尖段支气管(B1)和动脉(A1) apical segmental bronchus and artery
38. 后段静脉(V2) posterior segmental vein
39. 后段支气管(B2)和动脉(A2) posterior segmental bronchus and artery
40. 右肺上叶 superior lobe of right lung
41. 第2肋 2nd rib
42. 胸小肌 pectoralis minor
43. 臂丛 brachial plexus
44. 喙肱肌和肱二头肌短头 coracobrachialis and short head of biceps brachii
45. 肩关节 shoulder joint
46. 肩胛骨 scapula
47. 气管 trachea

(A1+2) apicoposterior segmental bronchus and artery
17. 尖后段静脉(V1+2) apicoposterior segmental vein

sterior segmental vein
18. 前段支气管(B3)和动脉(A3) anterior segmental bronchus and artery

图 5-6 经主动脉肺动脉窗的横断层

Fig.5-6 Transverse section through aorticopulmonary window

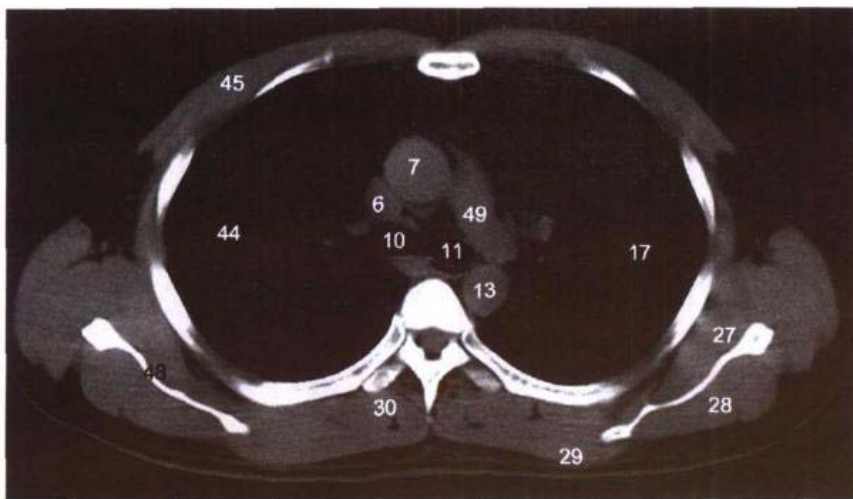


A. 断层标本 (sectional specimen)

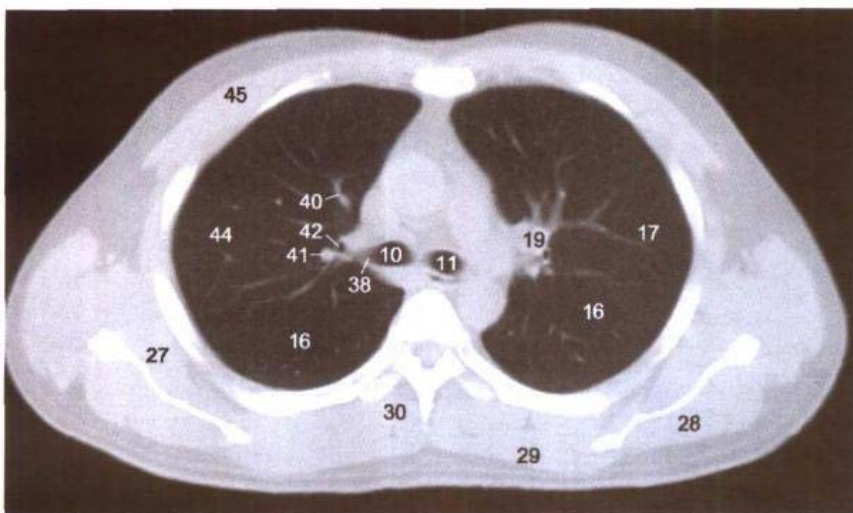
1. 第2肋软骨 2nd costal cartilage
2. 第2胸肋关节 2nd sternocostal joint
3. 胸骨角 sternal angle
4. 胸廓内动、静脉 internal thoracic artery and vein
5. 胸腺 thymus
6. 上腔静脉 superior vena cava
7. 升主动脉 ascending aorta
8. 心包上隐窝 superior recess

9. 右气管支气管淋巴结 right tracheobronchial lymph nodes
10. 右主支气管 right principal bronchus
11. 左主支气管 left principal bronchus
12. 食管 esophagus
13. 胸主动脉 thoracic aorta
14. 胸导管 thoracic duct

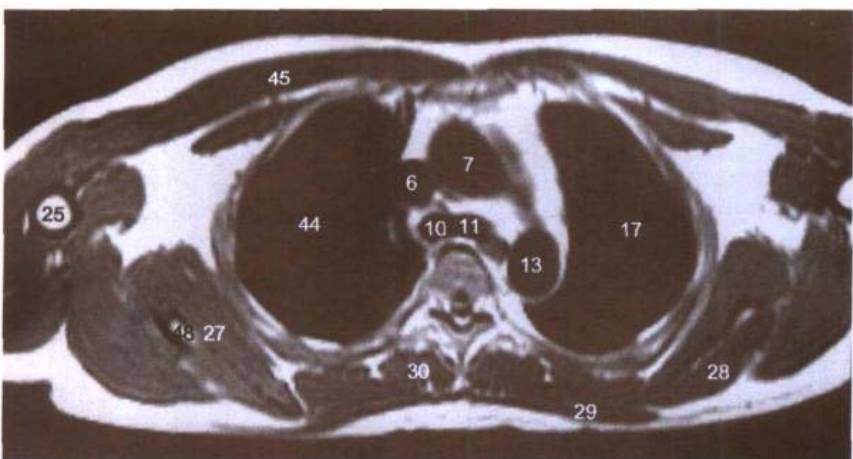
15. 胸膜腔 pleural cavity
16. 斜裂 oblique fissure
17. 左肺上叶 superior lobe of left lung
18. 尖后段支气管(B1+2)和动脉(A1+2) apicoposterior segmental bronchus and artery
19. 尖后段静脉(V1+2) apicoposterior segmental vein
20. 前段支气管(B3)和动脉(A3)



B. CT (纵隔窗 mediastinal window)



C. CT (肺窗 lung window)



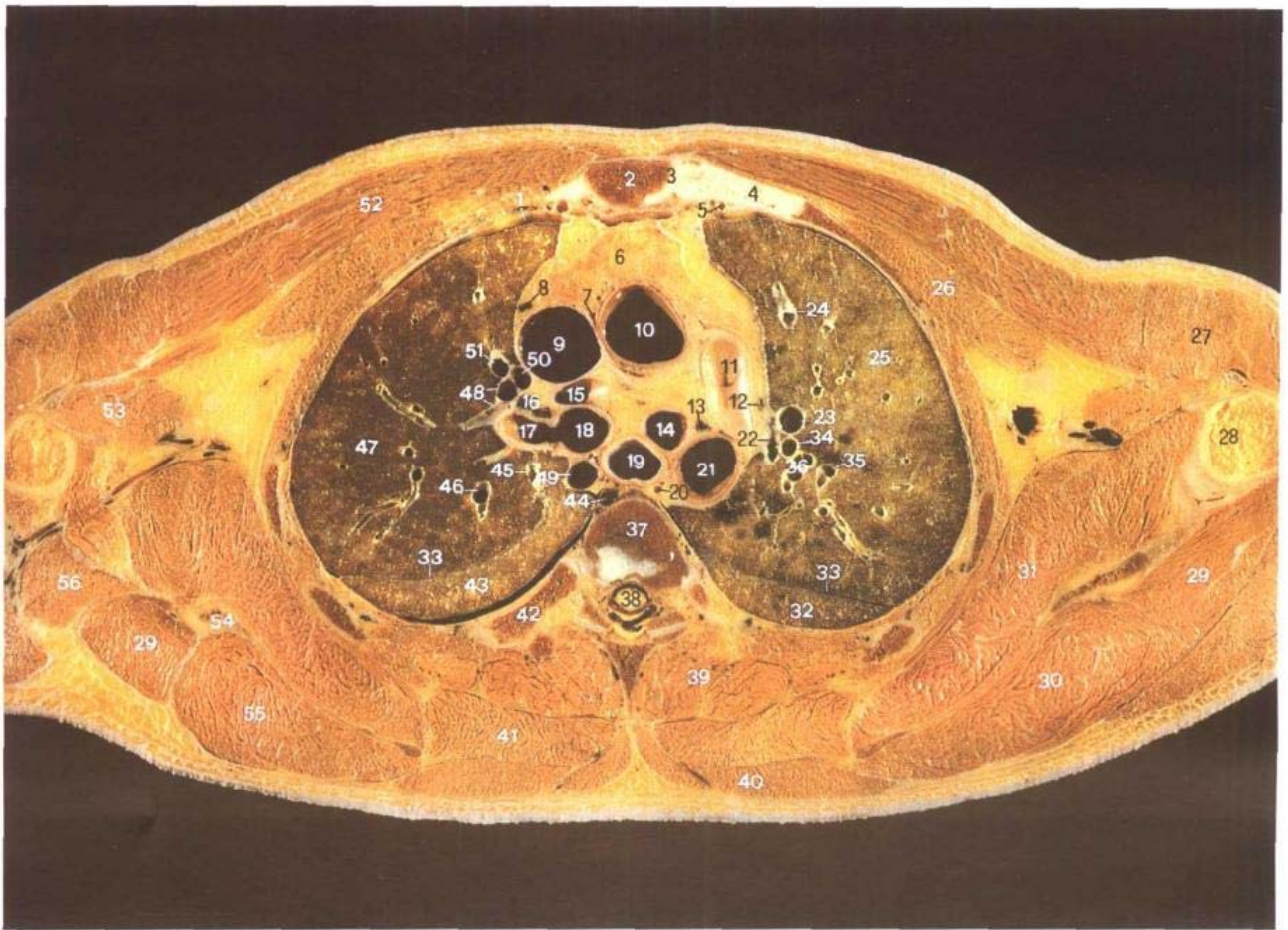
D. MRI T1WI

anterior segmental bronchus
and artery

21. 胸小肌 pectoralis minor
22. 三角肌 deltoid
23. 腋静脉 axillary vein
24. 腋动脉 axillary artery
25. 肱骨头 head of humerus
26. 肩关节 shoulder joint
27. 肩胛下肌 subscapularis
28. 冈下肌 infraspinatus
29. 斜方肌 trapezius
30. 竖脊肌 erector spinae
31. 大菱形肌 rhomboideus major
32. 脊髓 spinal cord
33. 第4胸椎体 body of 4th thoracic vertebrae
34. 左肺下叶 inferior lobe of left lung
35. 右肺下叶 inferior lobe of right lung
36. 第4肋 4th rib
37. 奇静脉 azygos vein
38. 右肺上叶支气管 right superior lobar bronchus
39. 右肺上叶动脉 right superior lobar artery
40. 尖段静脉(V1) apical segmental vein
41. 后段静脉(V2) posterior segmental vein
42. 尖段支气管(B1) apical segmental bronchus
43. 后段支气管(B2)和动脉(A2) posterior segmental bronchus and artery
44. 右肺上叶 superior lobe of right lung
45. 胸大肌 pectoralis major
46. 喙肱肌和肱二头肌短头 coracobrachialis and short head of biceps brachii
47. 臂丛 brachial plexus
48. 肩胛骨 scapula
49. 左肺动脉 left pulmonary artery

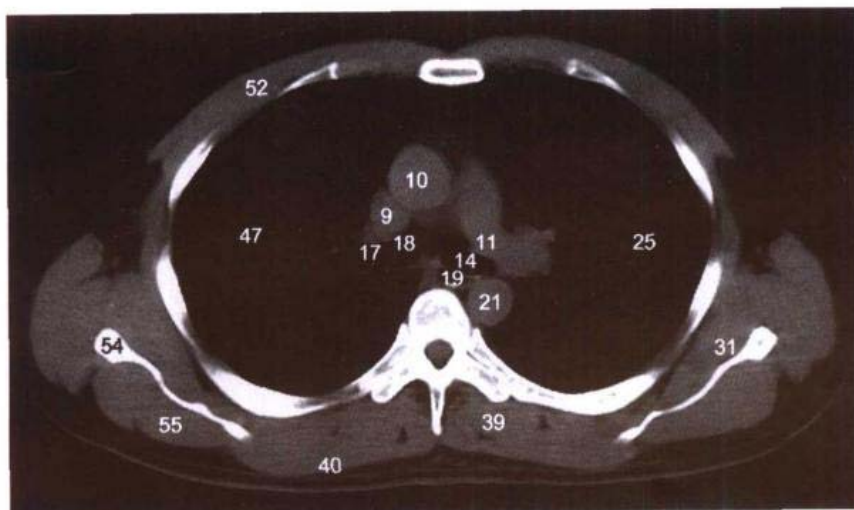
图 5-7 经左肺动脉的横断层

Fig.5-7 Transverse section through left pulmonary artery

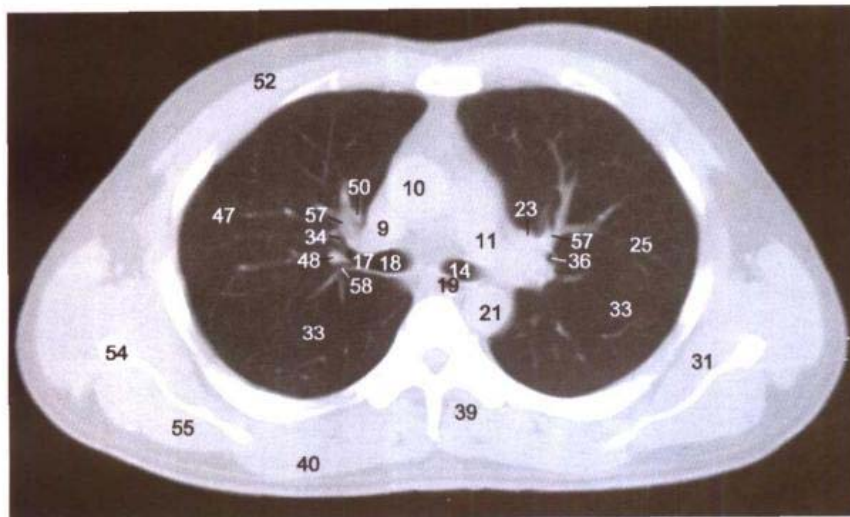


A. 断层标本 (sectional specimen)

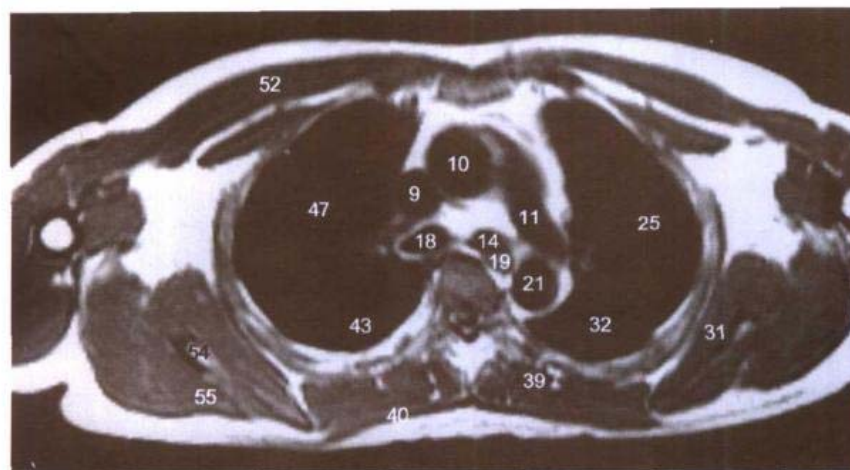
- | | | |
|--|--|---|
| 1. 胸膜腔 pleural cavity | 12. 主动脉肺淋巴结 aorticopulmonary lymph nodes | 22. 尖后段动脉(A1+2) apicoposterior segmental artery |
| 2. 胸骨角 sternal angle | 13. 左支气管旁淋巴结 left paratracheal lymph nodes | 23. 尖后段静脉(V1+2)段间支 intersegmental branch of apicoposterior segmental vein |
| 3. 第2胸肋关节 2nd sternocostal joint | 14. 左主支气管 left principal bronchus | 24. 前段静脉(V3)上支 superior branch of anterior segmental vein |
| 4. 第2肋软骨 2nd costal cartilage | 15. 右肺上叶动脉 right superior lobar artery | 25. 左肺上叶 superior lobe of left lung |
| 5. 胸廓内动脉 internal thoracic artery | 16. 右肺门淋巴结 right pulmonary hilar lymph nodes | 26. 胸小肌 pectoralis minor |
| 6. 胸腺 thymus | 17. 右肺上叶支气管 right superior lobar bronchus | 27. 三角肌 deltoid |
| 7. 心包上隐窝 superior recess of pericardium | 18. 右主支气管 right principal bronchus | 28. 肱骨 humerus |
| 8. 前纵隔淋巴结 anterior mediastinal lymph nodes | 19. 食管 esophagus | 29. 小圆肌 teres minor |
| 9. 上腔静脉 superior vena cava | 20. 胸导管 thoracic duct | 30. 冈下肌 infraspinatus |
| 10. 升主动脉 ascending aorta | 21. 胸主动脉 thoracic aorta | 31. 肩胛下肌 subscapularis |
| 11. 左肺动脉 left pulmonary artery | | 32. 左肺下叶 inferior lobe of left lung |



B. CT (纵隔窗 mediastinal window)



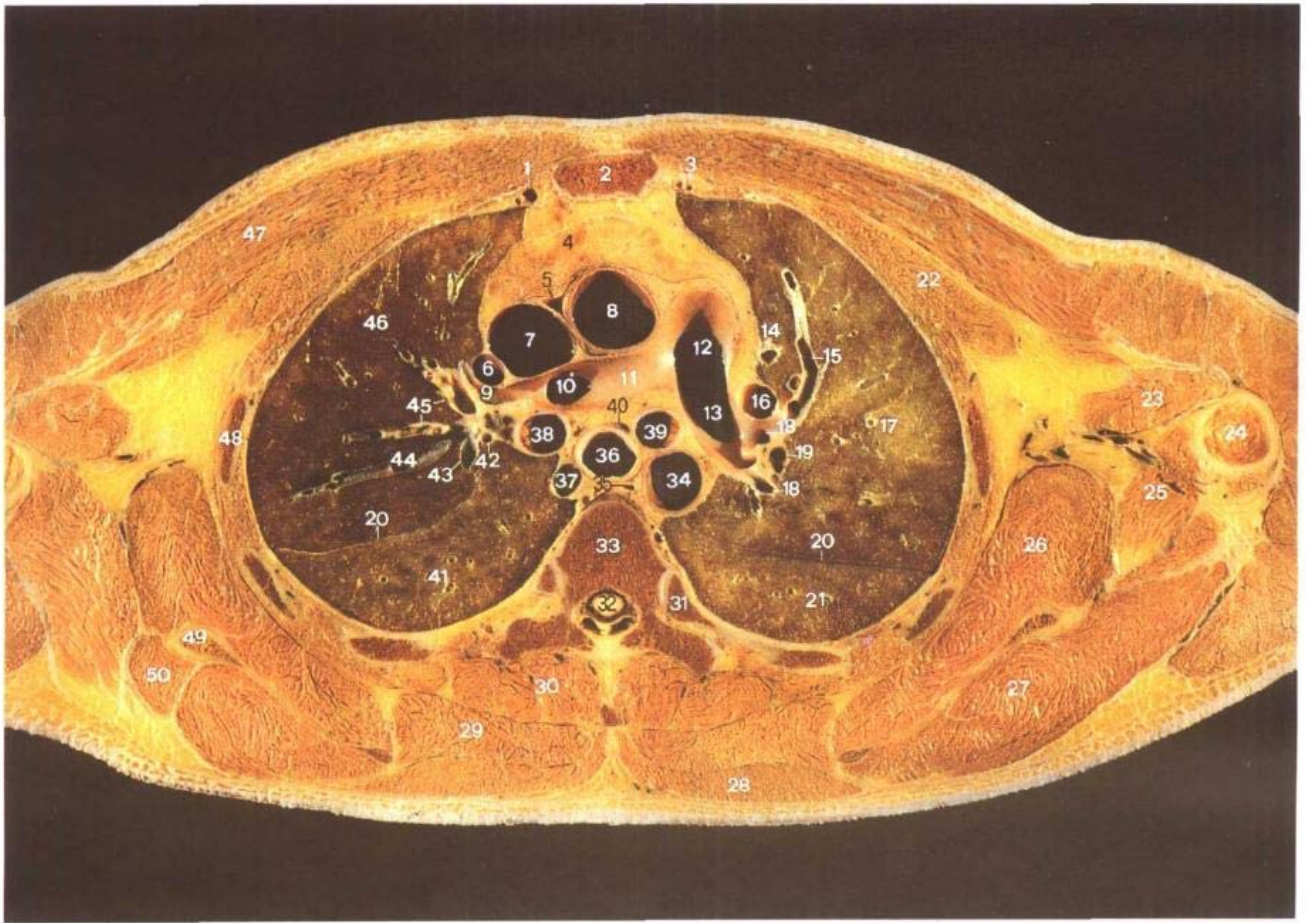
C. CT (肺窗 lung window)

D. MRI T₁WI

- lung
33. 斜裂 oblique fissure
 34. 前段支气管(B₃) anterior segmental bronchus
 35. 尖后段静脉(V₃)段内支 intrasegmental branch of apicoposterior segmental vein
 36. 尖后段支气管(B₁₊₂) apicoposterior segmental bronchus
 37. 第4胸椎体 body of 4th thoracic vertebrae
 38. 脊髓 spinal cord
 39. 竖脊肌 erector spinae
 40. 斜方肌 trapezius
 41. 大菱形肌 rhomboideus major
 42. 第5肋 5th rib
 43. 右肺下叶 inferior lobe of right lung
 44. 肋间后静脉 posterior intercostal vein
 45. 后段静脉(V₂)叶间支 interlobar branch of posterior segmental vein
 46. 后段静脉(V₂)段内支 intrasegmental branch of posterior segmental vein
 47. 右肺上叶 superior lobe of right lung
 48. 后段静脉(V₂)段间支 intersegmental branch of posterior segmental vein
 49. 奇静脉 azygos vein
 50. 尖段静脉(V₁) apical segmental vein
 51. 前段静脉(V₃) anterior segmental vein
 52. 胸大肌 pectoralis major
 53. 喙肱肌和肱二头肌短头 coracobrachialis and short head of biceps brachii
 54. 肩胛骨 scapula
 55. 冈下肌 infraspinatus
 56. 肱三头肌长头 long head of biceps brachii
 57. 前段动脉(A₃) anterior segmental artery
 58. 后段支气管(B₂) posterior segmental bronchus

图 5-8 经肺动脉杈的横断层

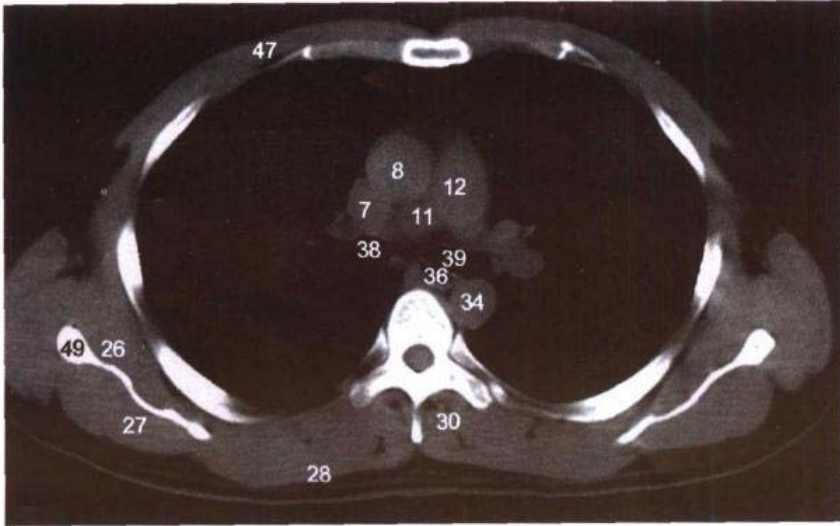
Fig.5-8 Transverse section through pulmonary bifurcation



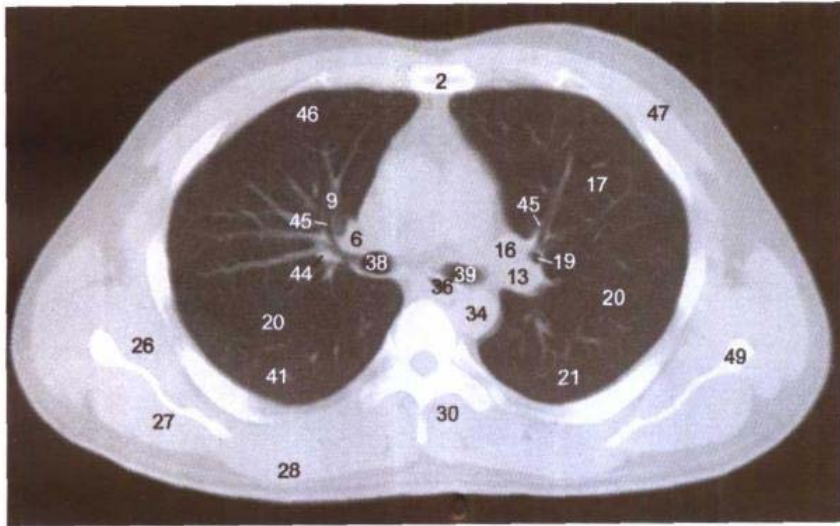
A. 断层标本 (sectional specimen)

- | | | |
|---|--|--|
| 1. 胸廓内静脉 internal thoracic vein | 9. 前段动脉(A3) anterior segmental artery | 15. 前段动脉(A3) anterior segmental artery |
| 2. 胸骨体 body of sternum | 10. 右肺上叶动脉 right superior lobar artery | 16. 左上肺静脉 left superior pulmonary vein |
| 3. 胸廓内动脉 internal thoracic artery | 11. 右肺动脉 right pulmonary artery | 17. 左肺上叶 superior lobe of left lung |
| 4. 胸腺 thymus | 12. 肺动脉干 pulmonary trunk | 18. 尖后段动脉(A1+2) apicoposterior segmental artery |
| 5. 心包上隐窝 superior recess of pericardium | 13. 左肺动脉 left pulmonary artery | 19. 左肺上叶支气管上干 superior trunk of left superior lobar bronchus |
| 6. 右上肺静脉 right superior pulmonary vein | 14. 前段静脉(V3) 上支 superior branch of anterior segmental vein | 20. 斜裂 oblique fissure |
| 7. 上腔静脉 superior vena cava | | |
| 8. 升主动脉 ascending aorta | | |

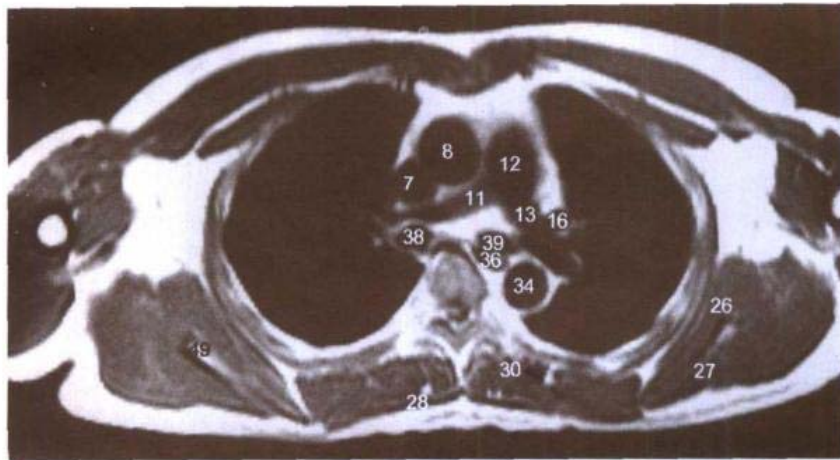
华西医科大学图书馆



B. CT (纵隔窗 mediastinal window)



C. CT (肺窗 lung window)

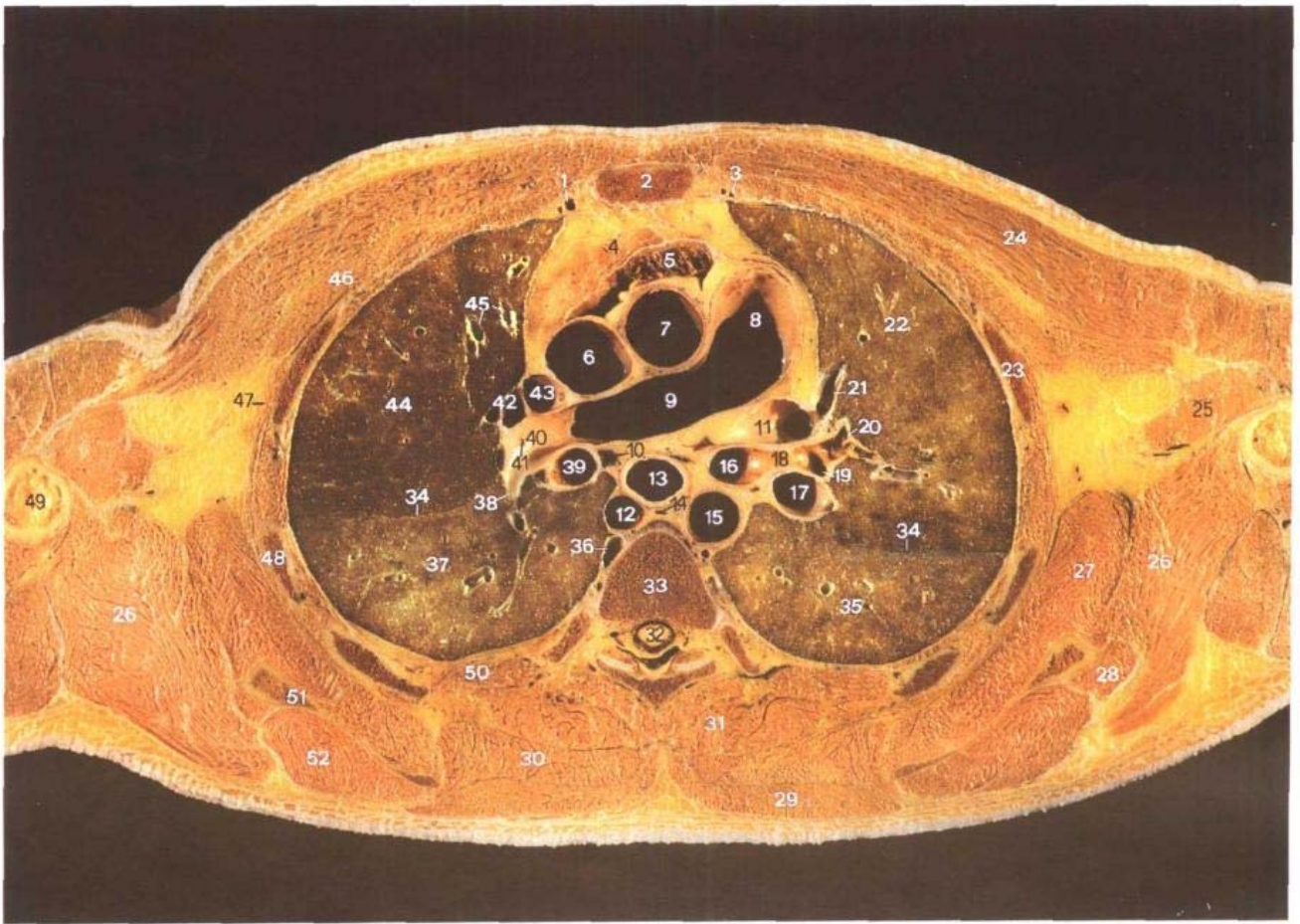


D. MRI T₁WI

21. 左肺下叶 inferior lobe of left lung
22. 胸小肌 pectoralis minor
23. 喙肱肌和肱二头肌短头 coracobrachialis and short head of biceps brachii
24. 肱骨 humerus
25. 大圆肌 teres major
26. 肩胛下肌 subscapularis
27. 冈下肌 infraspinatus
28. 斜方肌 trapezius
29. 大菱形肌 rhomboideus major
30. 竖脊肌 erector spinae
31. 第5肋 5th rib
32. 脊髓 spinal cord
33. 第5胸椎体 body of 5th thoracic vertebrae
34. 胸主动脉 thoracic aorta
35. 胸导管 thoracic duct
36. 食管 esophagus
37. 奇静脉 azygos vein
38. 中间支气管 intermediate bronchus
39. 左主支气管 left principal bronchus
40. 隆嵴下淋巴结 subcarina lymph nodes
41. 右肺下叶 inferior lobe of right lung
42. 后升动脉(A2) posterior ascending aorta
43. 后段静脉(V2)叶间支 interlobar branch of posterior segmental vein
44. 后段静脉(V2)段间支 intersegment branch of posterior segmental vein
45. 前段支气管(B3) anterior segmental bronchus
46. 右肺上叶 superior lobe of right lung
47. 胸大肌 pectoralis major
48. 第3肋 3rd rib
49. 肩胛骨 scapula
50. 小圆肌 teres minor

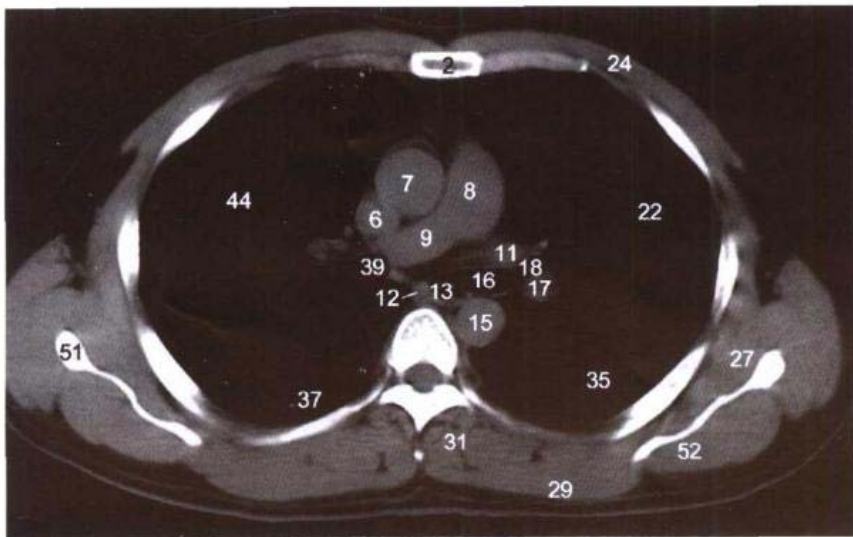
图 5-9 经右肺动脉的横断层

Fig.5-9 Transverse section through right pulmonary artery

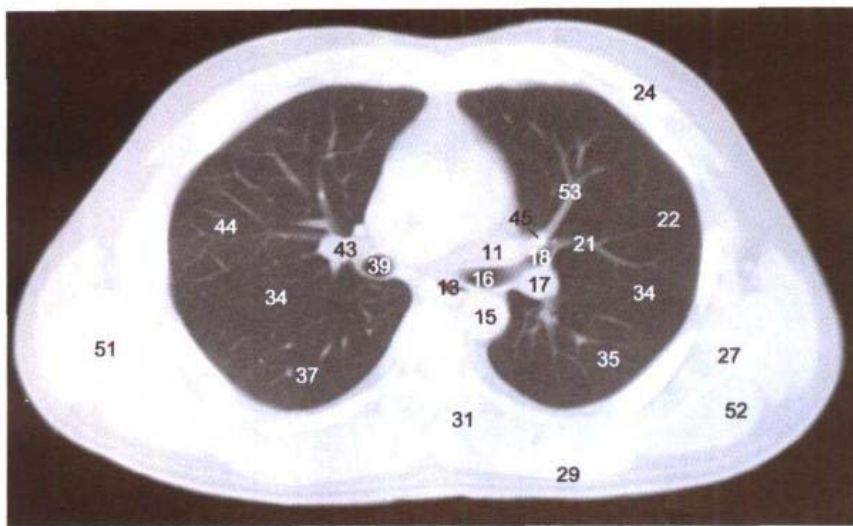


A. 断层标本 (sectional specimen)

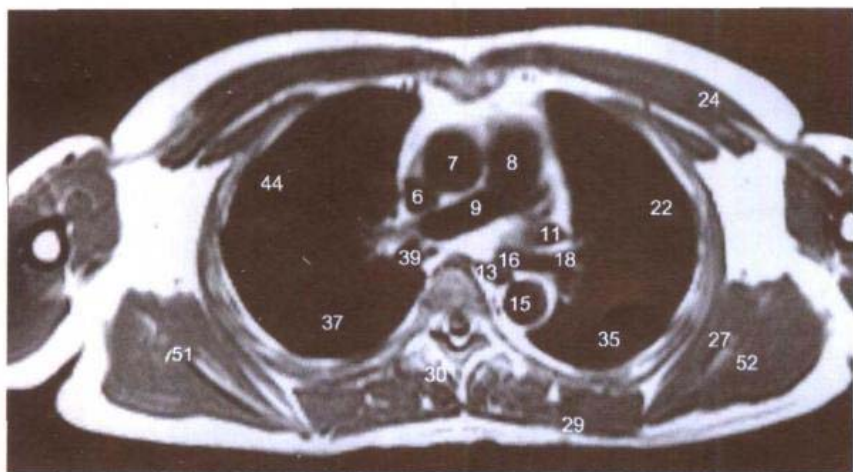
- | | | |
|-----------------------------------|---|--|
| 1. 胸廓内静脉 internal thoracic vein | 11. 左上肺静脉 left superior pulmonary vein | lobar bronchus |
| 2. 胸骨体 body of sternum | 12. 奇静脉 azygos vein | 20. 上舌段支气管 superior lingular bronchus |
| 3. 胸廓内动脉 internal thoracic artery | 13. 食管 esophagus | 21. 前段静脉(V3)下支 inferior branch of anterior segmental vein |
| 4. 胸腺 thymus | 14. 胸导管 thoracic duct | 22. 左肺上叶 superior lobe of left lung |
| 5. 右心耳 right auricle | 15. 胸主动脉 thoracic aorta | 23. 第3肋 3rd rib |
| 6. 上腔静脉 superior vena cava | 16. 左主支气管 left principal bronchus | 24. 胸大肌 pectoralis major |
| 7. 升主动脉 ascending aorta | 17. 左肺下叶动脉 left inferior lobar artery | 25. 喙肱肌和肱二头肌短头 coracobrachialis and short head of biceps brachii |
| 8. 肺动脉干 pulmonary trunk | 18. 左肺上叶支气管 left superior lobar bronchus | 26. 大圆肌 teres major |
| 9. 右肺动脉 right pulmonary artery | 19. 左肺上叶支气管主干 superior trunk of left superior | |
| 10. 隆嵴下淋巴结 subcarina lymph nodes | | |



B. CT (纵隔窗 mediastinal window)



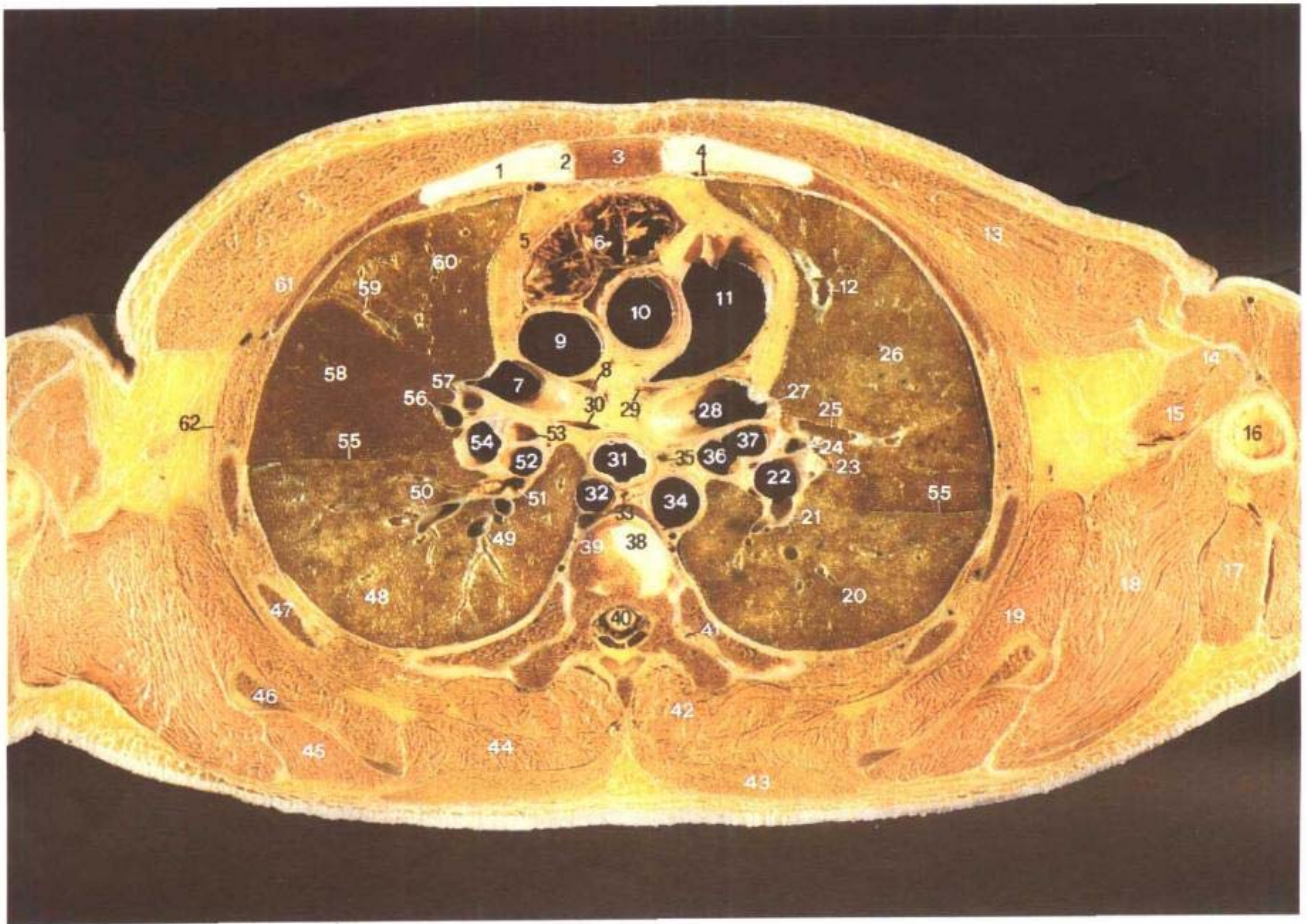
C. CT(肺窗 lung window)

D. MRI T₁WI

27. 肩胛下肌 subscapularis
28. 小圆肌 teres minor
29. 斜方肌 trapezius
30. 大菱形肌 rhomboideus major
31. 竖脊肌 erector spinae
32. 脊髓 spinal cord
33. 第5胸椎体 body of 5th thoracic vertebrae
34. 斜裂 oblique fissure
35. 左肺下叶 inferior lobe of left lung
36. 肋间后静脉 posterior intercostal vein
37. 右肺下叶 inferior lobe of right lung
38. 上段动脉(A6) superior segmental artery
39. 中间支气管 intermediate bronchus
40. 叶间动脉 interlobar artery
41. 后升动脉口 orifice of posterior ascending artery
42. 后段静脉(V2) posterior segmental vein
43. 右上肺静脉 right superior pulmonary vein
44. 右肺上叶 superior lobe of right lung
45. 前段静脉(V3) anterior segmental vein
46. 胸小肌 pectoralis minor
47. 前锯肌 serratus anterior
48. 第4肋 4th rib
49. 肱骨 humerus
50. 肋间内、外肌 intercostales interni and externi
51. 肩胛骨 scapula
52. 冈下肌 infraspinatus
53. 前段静脉上支 superior branch of anterior segmental vein

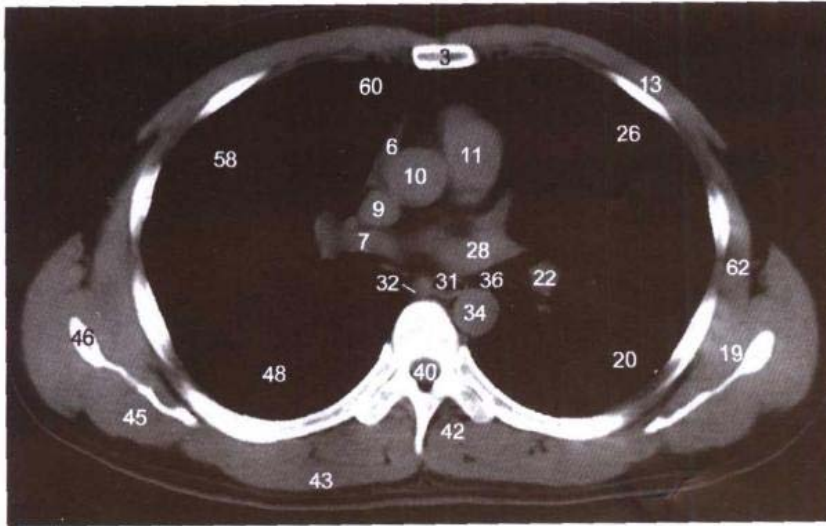
图 5-10 经左上肺静脉的横断层

Fig.5-10 Transverse section through left superior pulmonary vein

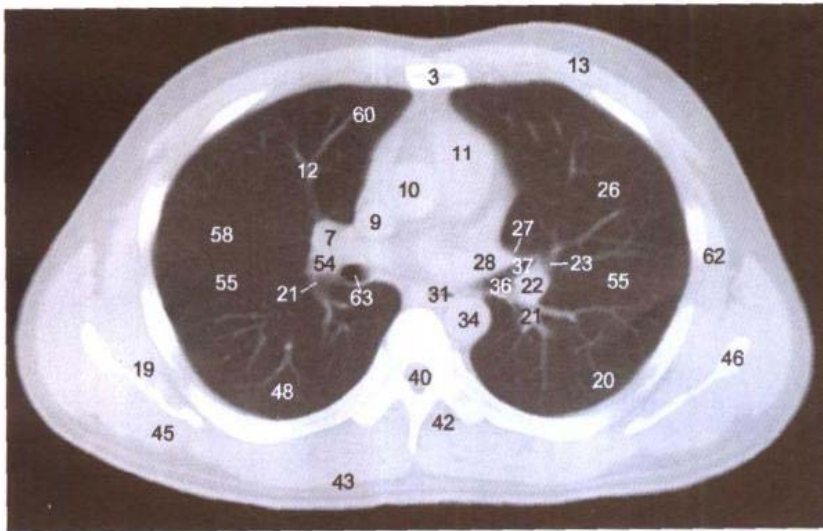


A. 断层标本 (sectional specimen)

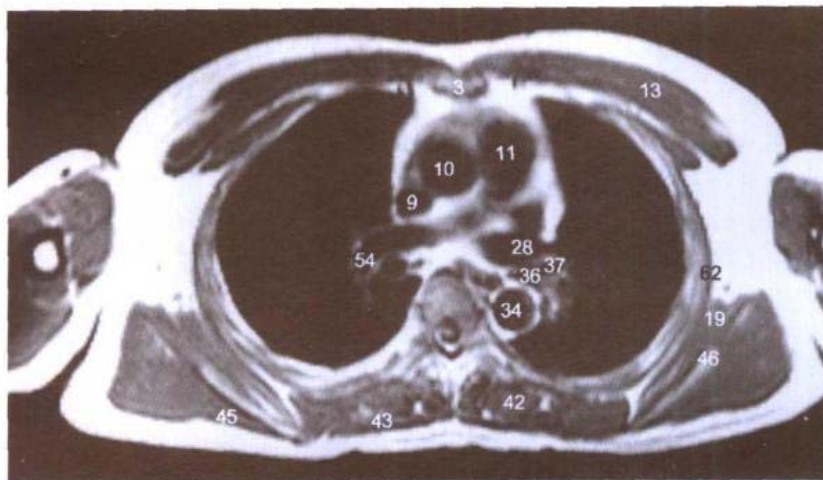
- | | | |
|--|---|--|
| 1. 第3肋软骨 3rd costal cartilage | 13. 胸大肌 pectoralis major | hilum lymph nodes |
| 2. 第3胸肋关节 3rd sternocostal joint | 14. 肱二头肌 biceps brachii | 25. 上舌段静脉(V4) superior lingular vein |
| 3. 胸骨体 body of sternum | 15. 喙肱肌 coracobrachialis | 26. 左肺上叶 superior lobe of left lung |
| 4. 胸廓内动脉 internal thoracic artery | 16. 肱骨 humerus | 27. 舌静脉干(V4+5) lingular venous trunk |
| 5. 胸腺 thymus | 17. 肱三头肌长头 long head of triceps brachii | 28. 左上肺静脉 left superior pulmonary vein |
| 6. 右心耳 right auricle | 18. 大圆肌 teres major | 29. 心包横窦 transverse sinus of pericardium |
| 7. 右上肺静脉 right superior pulmonary vein | 19. 肩胛下肌 subscapularis | 30. 心包斜窦 oblique sinus of pericardium |
| 8. 腔静脉后隐窝 retrocaval recess | 20. 左肺下叶 inferior lobe of left lung | 31. 食管 esophagus |
| 9. 上腔静脉 superior vena cava | 21. 上段动脉(A6) superior segmental artery | 32. 奇静脉 azygos vein |
| 10. 升主动脉 ascending aorta | 22. 左肺下叶动脉 left inferior lobar artery | 33. 胸导管 thoracic duct |
| 11. 肺动脉干 pulmonary trunk | 23. 上舌段动脉(A4) superior lingular artery | 34. 胸主动脉 thoracic aorta |
| 12. 前段静脉(V3)下支 inferior branch of anterior segmental | 24. 左肺门淋巴结 left pulmonary | 35. 左食管旁淋巴结 left parae- |



B. CT (纵隔窗 mediastinal window)



C. CT (肺窗 lung window)

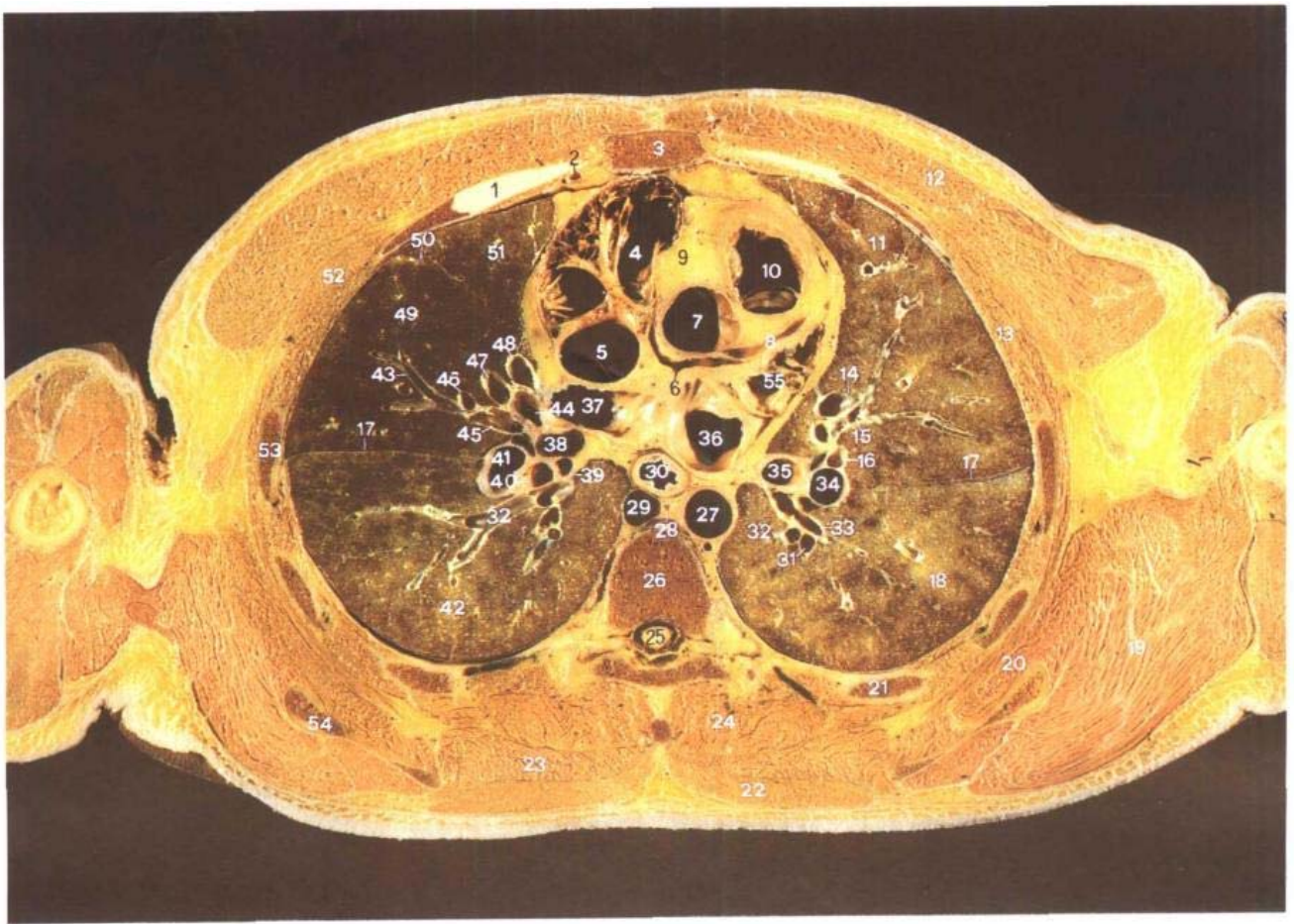


D. MRI T₁-WI

- sophagus lymph nodes
- 36. 左肺下叶支气管 left inferior lobar bronchus
- 37. 左肺上叶支气管 left superior lobar bronchus
- 38. 第5胸椎间盘 5th thoracic intervertebral disc
- 39. 肋间后静脉 posterior intercostal vein
- 40. 脊髓 spinal cord
- 41. 第6肋 6th rib
- 42. 竖脊肌 erector spinae
- 43. 斜方肌 trapezius
- 44. 大菱形肌 rhomboideus major
- 45. 冈下肌 infraspinatus
- 46. 肩胛骨 scapula
- 47. 第5肋 5th rib
- 48. 右肺下叶 inferior lobe of right lung
- 49. 上段静脉(V6) superior segmental vein
- 50. 上段动脉(A6) superior segmental artery
- 51. 上段支气管(B6) superior segmental bronchus
- 52. 右肺下叶支气管 right inferior lobar bronchus
- 53. 右肺中叶支气管 right middle lobar bronchus
- 54. 右肺下叶动脉 right inferior lobar artery
- 55. 斜裂 oblique fissure
- 56. 外侧段动脉(A4) lateral segmental artery
- 57. 内侧段动脉(A5) medial segmental artery
- 58. 右肺中叶 middle lobe of right lung
- 59. 水平裂 horizontal fissure
- 60. 右肺上叶 superior lobe of right lung
- 61. 胸小肌 pectoralis minor
- 62. 前锯肌 serratus anterior
- 63. 中间支气管 intermediate bronchus

图 5-11 经右上肺静脉的横断层

Fig.5-11 Transverse section through right superior pulmonary vein

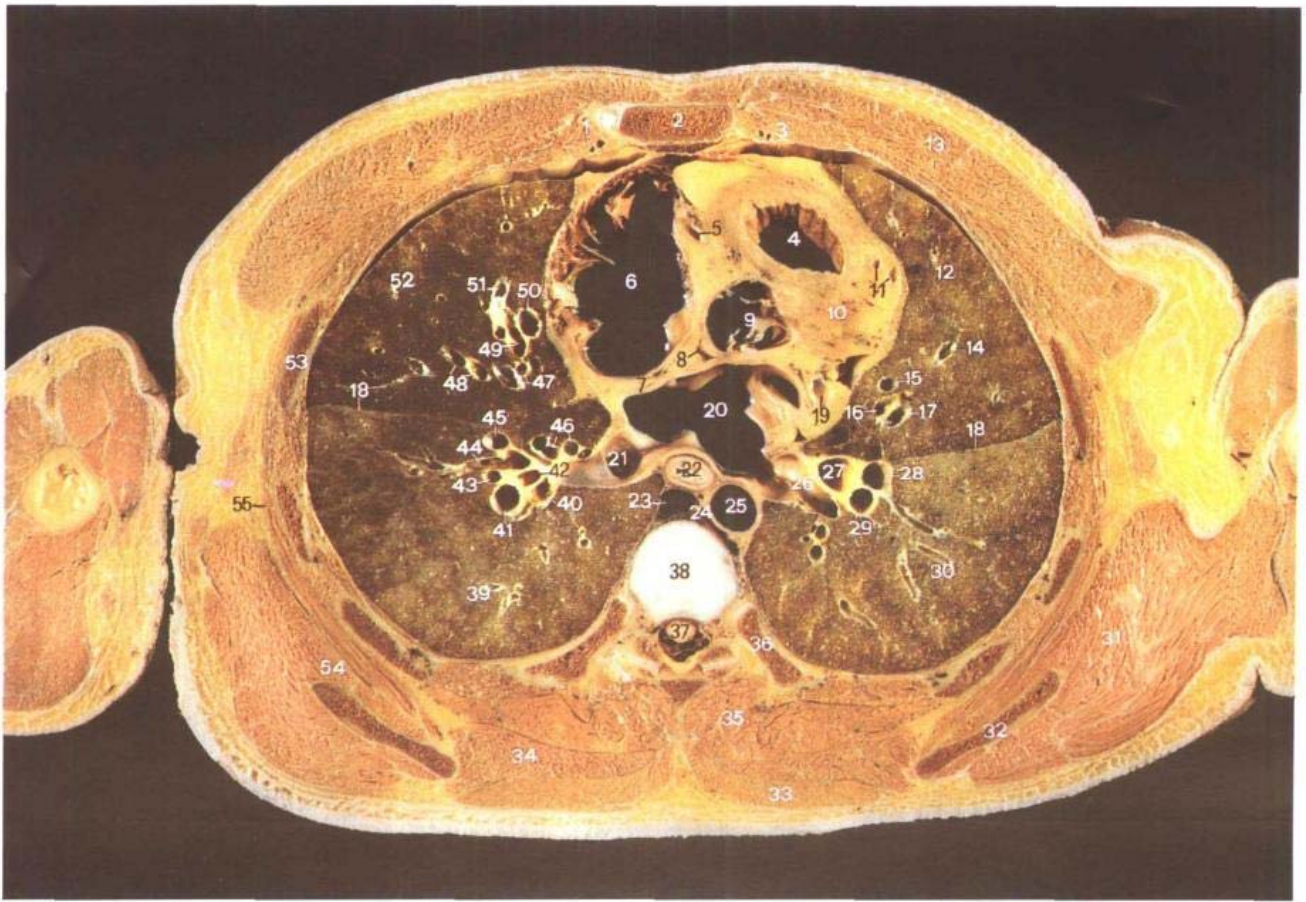


A. 断层标本 (sectional specimen)

- | | | |
|-------------------------------------|---|--|
| 1. 第3肋软骨 3rd costal cartilage | 11. 左肺上叶 superior lobe of left lung | 21. 第6肋 6th rib |
| 2. 胸廓内静脉 internal thoracic vein | 12. 胸大肌 pectoralis major | 22. 斜方肌 trapezius |
| 3. 胸骨体 body of sternum | 13. 肋间内、外肌 intercostales interni and externi | 23. 大菱形肌 rhomboideus major |
| 4. 右心房 right atrium | 14. 舌静脉干(V4+5) lingular venous trunk | 24. 竖脊肌 erector spinae |
| 5. 上腔静脉 superior vena cava | 15. 下舌段支气管(B5) inferior lingular segmental bronchus | 25. 脊髓 spinal cord |
| 6. 主动脉下隐窝 infraaortic recess | 16. 下舌段动脉(A5) inferior lingular segmental artery | 26. 第6胸椎体 body of 6th thoracic vertebrae |
| 7. 升主动脉 ascending aorta | 17. 斜裂 oblique fissure | 27. 胸主动脉 thoracic aorta |
| 8. 左冠状动脉 left coronary artery | 18. 左肺下叶 inferior lobe of left lung | 28. 胸导管 thoracic duct |
| 9. 升主动脉囊 ascending aortic fold | 19. 大圆肌 teres major | 29. 奇静脉 azygos vein |
| 10. 肺动脉口 orifice of pulmonary trunk | 20. 肩胛下肌 subscapularis | 30. 食管 esophagus |
| | | 31. 上段动脉(A6) superior segmental artery |
| | | 32. 上段静脉(V6) superior segmental vein |
| | | 33. 上段支气管(B6) superior se- |

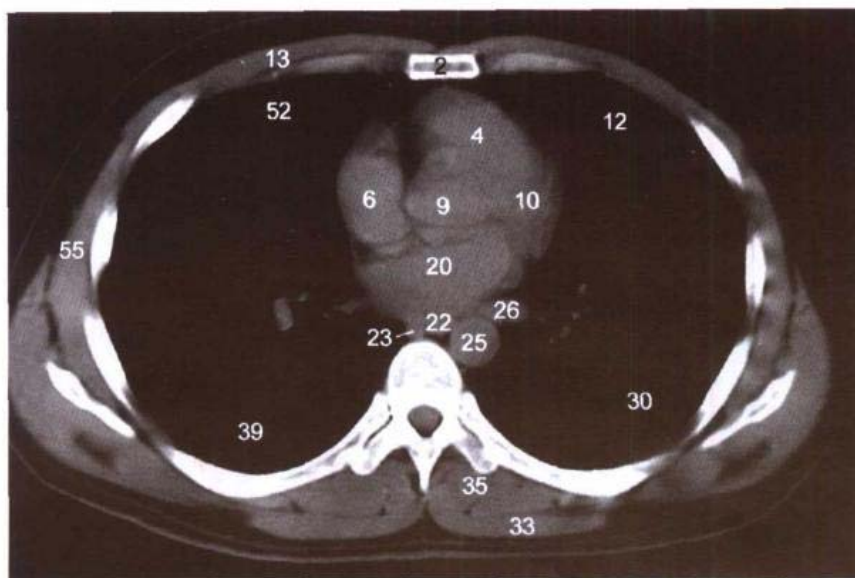
图 5-12 经左、右下肺静脉的横断层

Fig.5-12 Transverse section through left and right inferior pulmonary veins

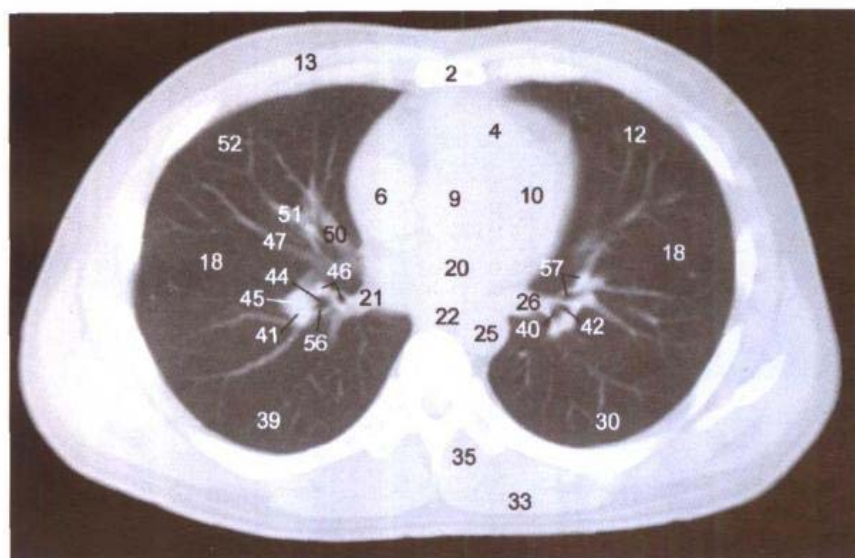


A. 断层标本 (sectional specimen)

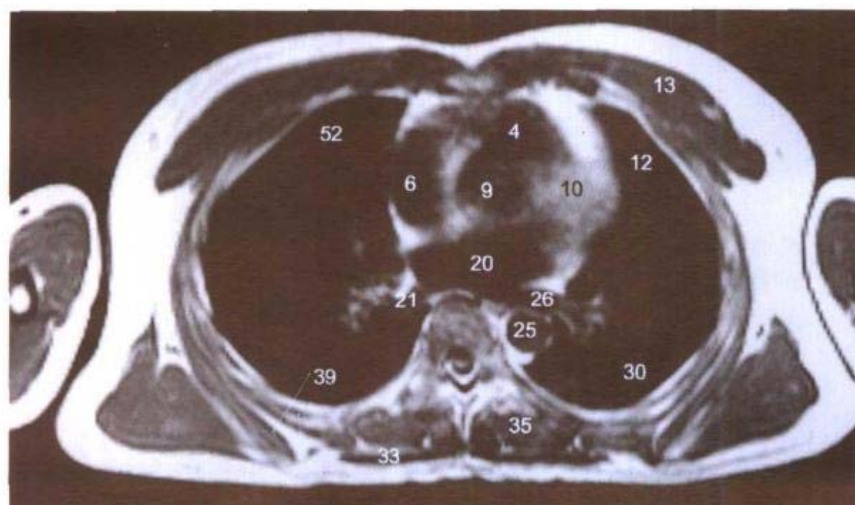
- | | | |
|--|---|---|
| 1. 胸廓内动脉 internal thoracic artery | 12. 左肺上叶 superior lobe of left lung | 23. 奇静脉 azygos vein |
| 2. 胸骨体 body of sternum | 13. 胸大肌 pectoralis major | 24. 胸导管 thoracic duct |
| 3. 肋纵隔隐窝 costomediastinal recess | 14. 上舌段静脉(V4) superior lingular vein | 25. 胸主动脉 thoracic aorta |
| 4. 右心室流出道 outflow tract of right ventricle | 15. 下舌段静脉(V5) inferior lingular vein | 26. 左下肺静脉 left inferior pulmonary vein |
| 5. 右冠状动脉 right coronary artery | 16. 下舌段支气管(B5) inferior lingular bronchus | 27. 左肺下叶支气管 left inferior lobar bronchus |
| 6. 右心房 right atrium | 17. 下舌段动脉(A5) inferior lingular artery | 28. 内前底段动脉(A7+8) medio-anterior basal segmental artery |
| 7. 房间隔 interatrial septum | 18. 斜裂 oblique fissure | 29. 外后底段动脉(A9+10) latero-posterior basal segmental artery |
| 8. 主动脉下隐窝 infraaortic recess | 19. 心大静脉 great cardiac vein | 30. 左肺下叶 inferior lobe of left lung |
| 9. 主动脉口 aortic orifice | 20. 左心房 left atrium | 31. 大圆肌 teres major |
| 10. 左心室 left ventricle | 21. 右下肺静脉 right inferior pulmonary vein | 32. 肩胛骨 scapula |
| 11. 左冠状动脉前室间支和心大静脉 anterior interventricular branch of left coronary artery and great cardiac vein | 22. 食管 esophagus | 33. 斜方肌 trapezius |



B. CT(纵隔窗 mediastinal window)



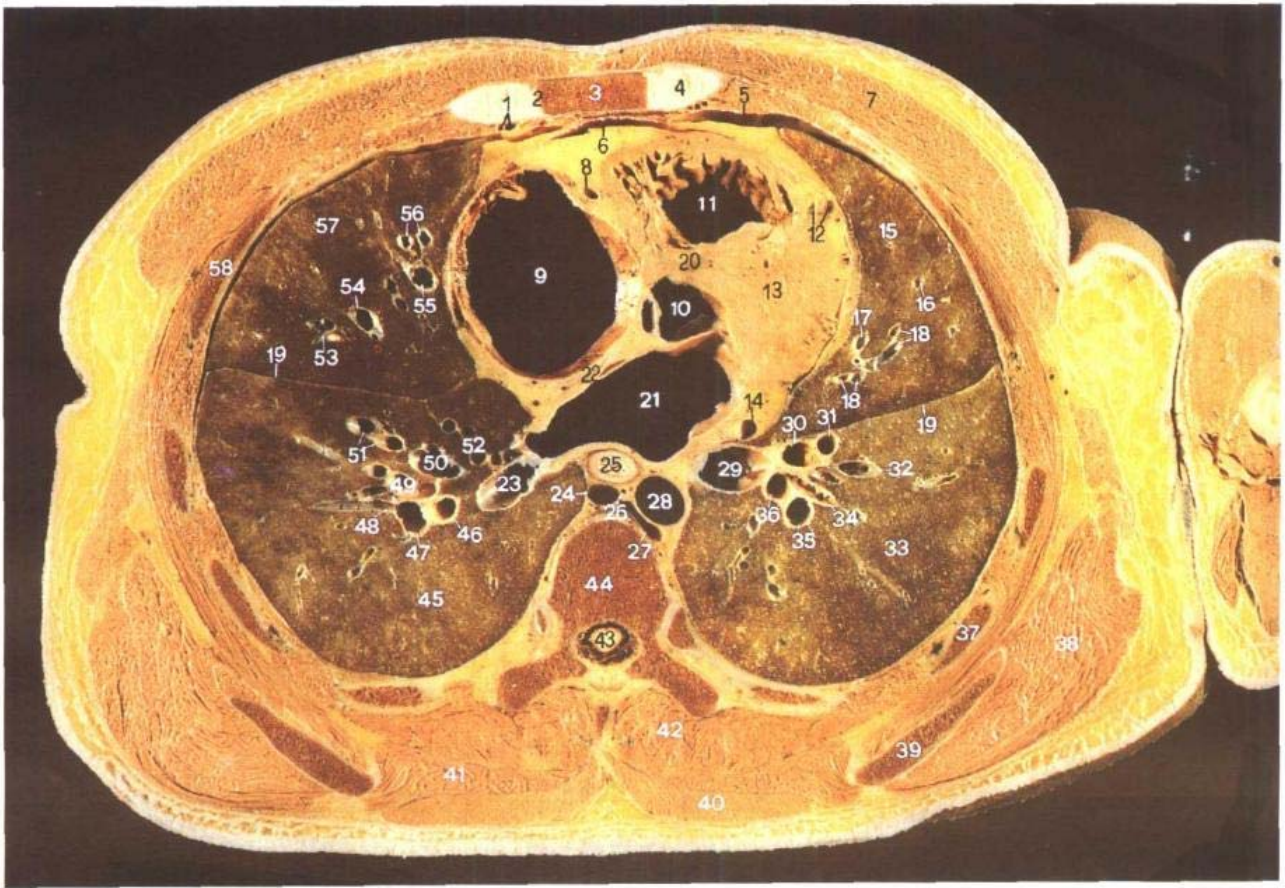
C. CT(肺窗 lung window)

D. MRI T₁WI

34. 大菱形肌 rhomboideus major
35. 竖脊肌 erector spinae
36. 第7肋 7th rib
37. 脊髓 spinal cord
38. 第6胸椎间盘 6th thoracic intervertebral disc
39. 右肺下叶 inferior lobe of right lung
40. 后底段支气管(B10) posterior basal segmental bronchus
41. 外后底段动脉(A9+10) latero-posterior basal segmental artery
42. 外侧底段支气管(B9) lateral basal segmental bronchus
43. 外侧底段动脉(A9) lateral basal segmental artery
44. 前底段支气管(B8) anterior basal segmental bronchus
45. 前底段动脉(A8) anterior basal segmental artery
46. 内侧底段支气管(B7)和动脉(A7) medial basal segmental bronchus and artery
47. 外侧段静脉(V4) lateral segmental vein
48. 外侧段支气管(B4)和动脉(A4) lateral segmental bronchus and artery
49. 内侧段支气管(B5) medial segmental bronchus
50. 内侧段静脉(V5) medial segmental vein
51. 内侧段动脉(A5) medial segmental artery
52. 右肺中叶 middle lobe of right lung
53. 第4肋 4th rib
54. 肩胛下肌 subscapularis
55. 前锯肌 serratus anterior
56. 外后底段支气管 lateroposterior basal segmental bronchus
57. 内前底段支气管(B7+8)和动脉(A7+8) medioanterior basal segmental bronchus and artery

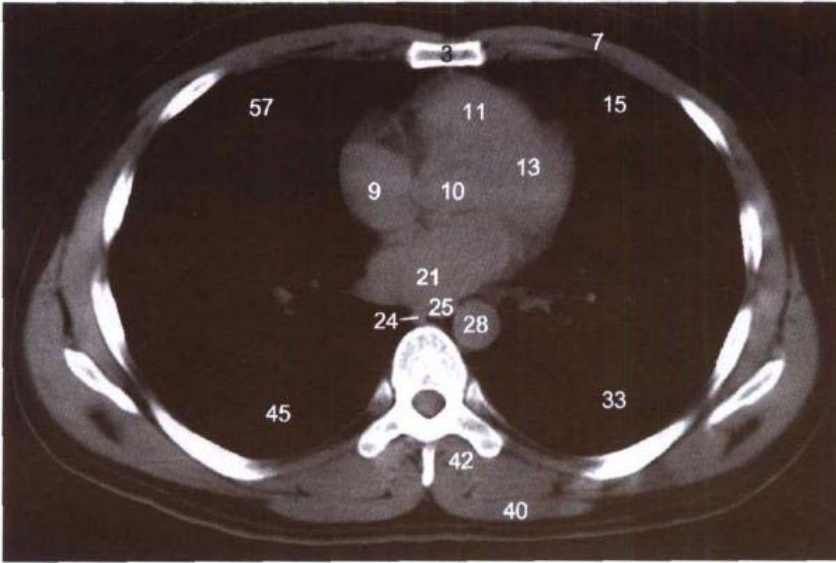
图 5-13 经主动脉口的横断层

Fig.5-13 Transverse section through aortic orifice

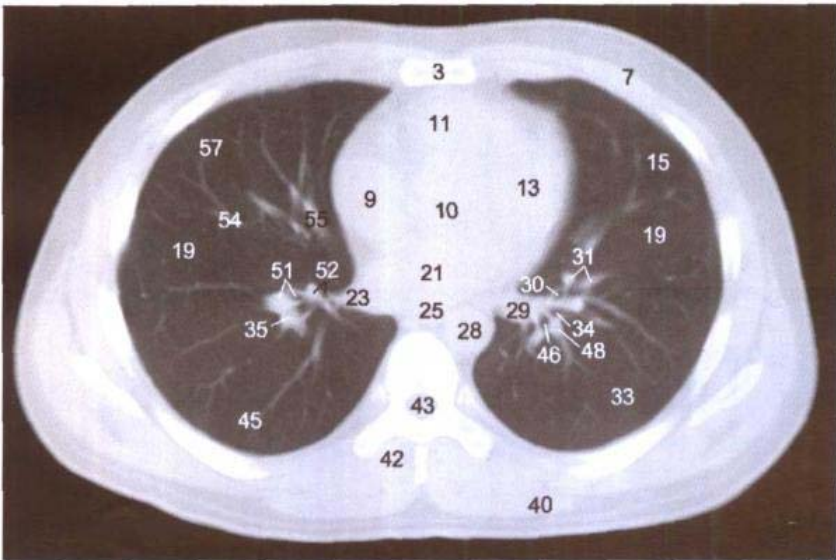


A. 断层标本 (sectional specimen)

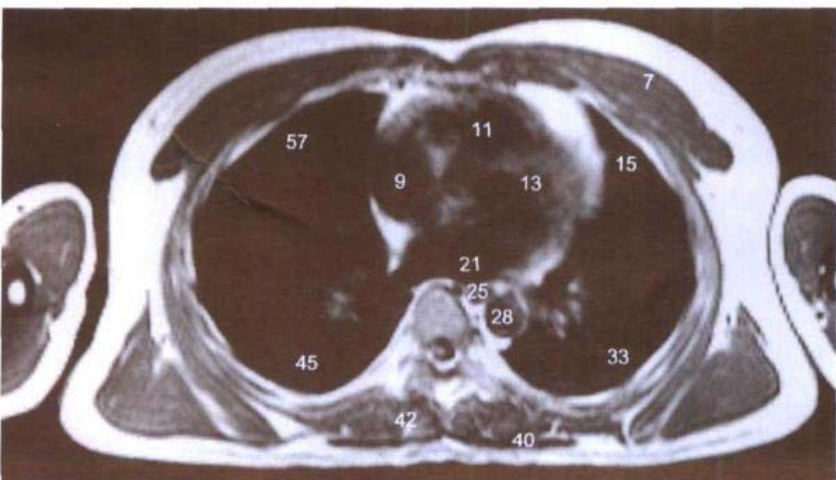
- | | | |
|--|---|---|
| 1. 胸廓内动、静脉 internal thoracic artery and vein | 13. 左心室 left ventricle | 25. 食管 esophagus |
| 2. 第4胸肋关节 4th sternocostal joint | 14. 心大静脉 great cardiac vein | 26. 胸导管 thoracic duct |
| 3. 胸骨体 body of sternum | 15. 左肺上叶 superior lobe of left lung | 27. 半奇静脉 hemiazygos vein |
| 4. 第4肋软骨 4th costal cartilage | 16. 上舌段静脉(V4) superior lingular vein | 28. 胸主动脉 thoracic aorta |
| 5. 肋纵隔隐窝 costomediastinal recess | 17. 下舌段静脉(V5) inferior lingular vein | 29. 底段总静脉 common basal vein |
| 6. 心包腔 pericardial cavity | 18. 下舌段支气管(B5)和动脉(A5) inferior lingular bronchus and artery | 30. 内前底段支气管(B7+8) medioanterior basal segmental bronchus |
| 7. 胸大肌 pectoralis major | 19. 斜裂 oblique fissure | 31. 内前底段动脉(A7+8) medioanterior basal artery |
| 8. 右冠状动脉 right coronary artery | 20. 室间隔 interventricular septum | 32. 内前底段静脉(V7+8)的属支 tributary of medioanterior basal vein |
| 9. 右心房 right atrium | 21. 左心房 left atrium | 33. 左肺下叶 inferior lobe of left lung |
| 10. 主动脉前庭 aortic vestibule | 22. 房间隔 interatrial septum | 34. 外侧底段支气管 lateral basal segmental bronchus |
| 11. 右心室 right ventricle | 23. 底段下静脉 inferior basal vein | 35. 外后底段动脉(A9+10) later- |
| 12. 左冠状动脉前室间支和心大静脉 anterior interventricular branch of left coronary artery and great cardiac vein | 24. 奇静脉 azygos vein | |



B. CT (纵隔窗 mediastinal window)



C. CT (肺窗 lung window)

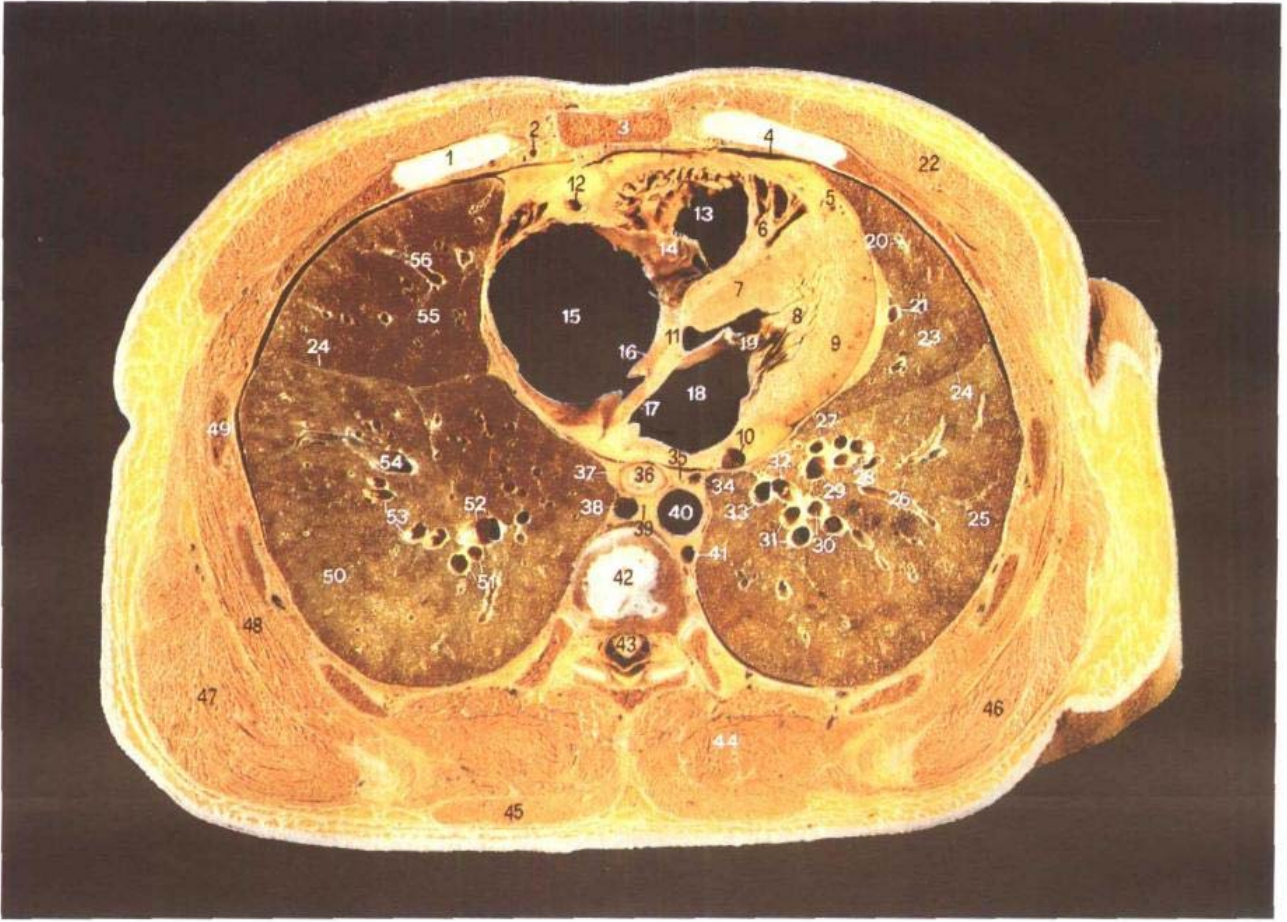


D. MRI T₁WI

- oposterior basal artery
- 36. 后底段支气管(B10) posterior basal segmental bronchus
- 37. 第7肋 7th rib
- 38. 大圆肌 teres major
- 39. 肩胛骨下角 inferior angle of scapula
- 40. 斜方肌 trapezius
- 41. 大菱形肌 rhomboideus major
- 42. 竖脊肌 erector spinae
- 43. 脊髓 spinal cord
- 44. 第7胸椎体 body of 7th thoracic vertebrae
- 45. 右肺下叶 inferior lobe of right lung
- 46. 后底段支气管(B10) posterior basal segmental bronchus
- 47. 后底段动脉(A10) posterior basal segmental artery
- 48. 外侧底段动脉(A9) lateral basal segmental artery
- 49. 外侧底段支气管(B9)和动脉(A9) lateral basal segmental bronchus and artery
- 50. 底段上静脉 superior basal vein
- 51. 前底段支气管(B8)和动脉(A8) anterior basal segmental bronchus and artery
- 52. 内侧底段支气管(B7)和动脉(A7) medial basal bronchus and artery
- 53. 外侧段支气管(B4)和动脉(A4) lateral segmental bronchus and artery
- 54. 外侧段静脉(V4) lateral segmental vein
- 55. 内侧段静脉(V5) medial segmental vein
- 56. 内侧段支气管(B5)和动脉(A5) medial segmental bronchus and artery
- 57. 右肺中叶 middle lobe of right lung
- 58. 第5肋 5th rib

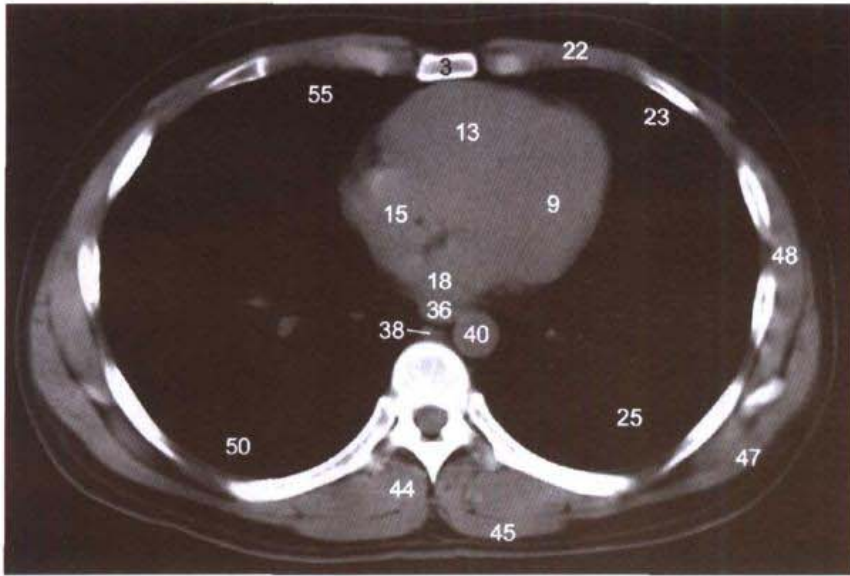
图 5-14 经卵圆窝的横断层

Fig.5-14 Transverse section through fossa ovalis

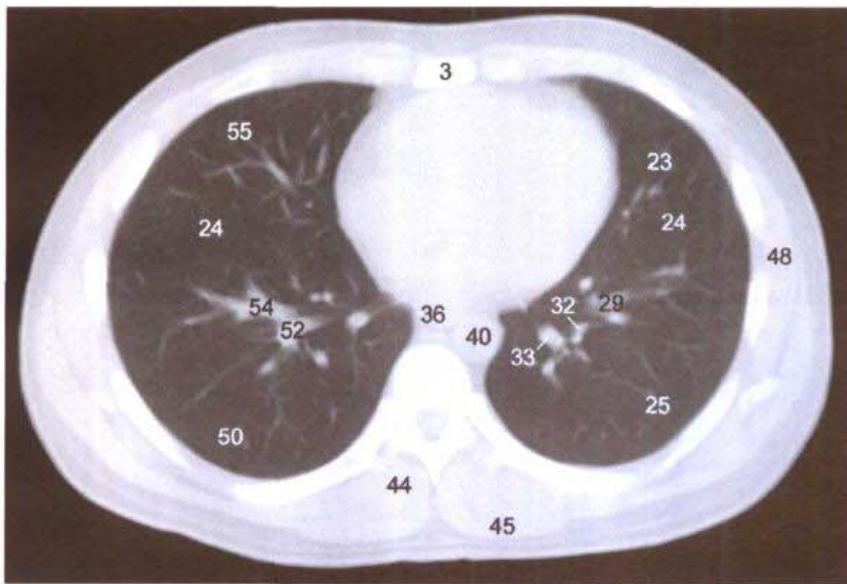


A. 断层标本 (sectional specimen)

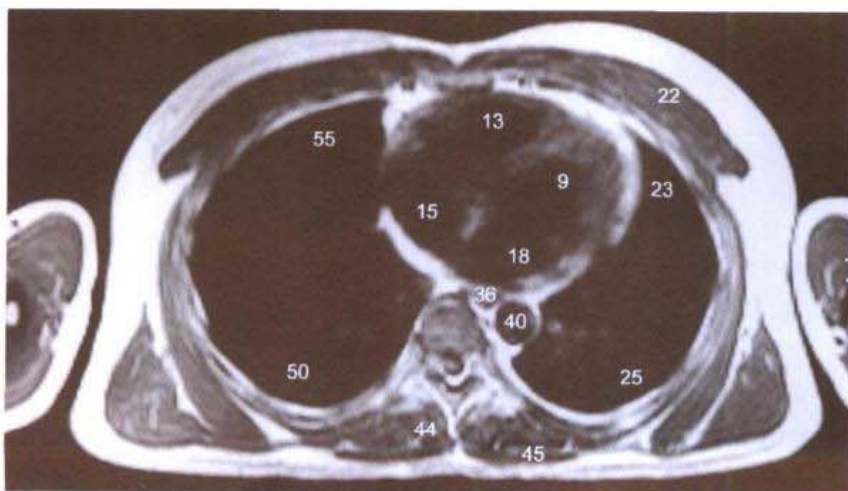
- | | | |
|---|--|---|
| 1. 第4肋软骨 4th costal cartilage | 10. 心大静脉 great cardiac vein | 23. 左肺上叶 superior lobe of left lung |
| 2. 胸廓内静脉 internal thoracic vein | 11. 室间隔膜部 membranous part of interventricular septum | 24. 斜裂 oblique fissure |
| 3. 胸骨体 body of sternum | 12. 右冠状动脉 right coronary artery | 25. 左肺下叶 inferior lobe of left lung |
| 4. 肋纵隔隐窝 costomediastinal recess | 13. 右心室 right ventricle | 26. 内前底段静脉(V7+8)的属支 tributary of medioanterior basal segmental vein |
| 5. 左冠状动脉前室间支和心大静脉 anterior interventricular branch of left coronary artery and great cardiac vein | 14. 三尖瓣 tricuspid valve | 27. 内侧底段支气管(B7)和动脉(A7) medial basal segmental bronchus and artery |
| 6. 隔缘肉柱 septomarginal trabecula | 15. 右心房 right atrium | 28. 前底段支气管(B8)和动脉(A8) anterior basal segmental bronchus and artery |
| 7. 室间隔肌部 muscular part of interventricular septum | 16. 房间隔 interatrial septum | 29. 内前底段静脉(V7+8) medioanterior basal segmental vein |
| 8. 乳头肌 papillary muscles | 17. 卵圆窝 fossa ovalis | 30. 外侧底段支气管(B9)和动脉 |
| 9. 左心室 left ventricle | 18. 左心房 left atrium | |
| | 19. 二尖瓣 mitral valve | |
| | 20. 上舌段静脉(V4) superior lingular vein | |
| | 21. 下舌段静脉(V5) inferior lingular vein | |
| | 22. 胸大肌 pectoralis major | |



B. CT (纵隔窗 mediastinal window)



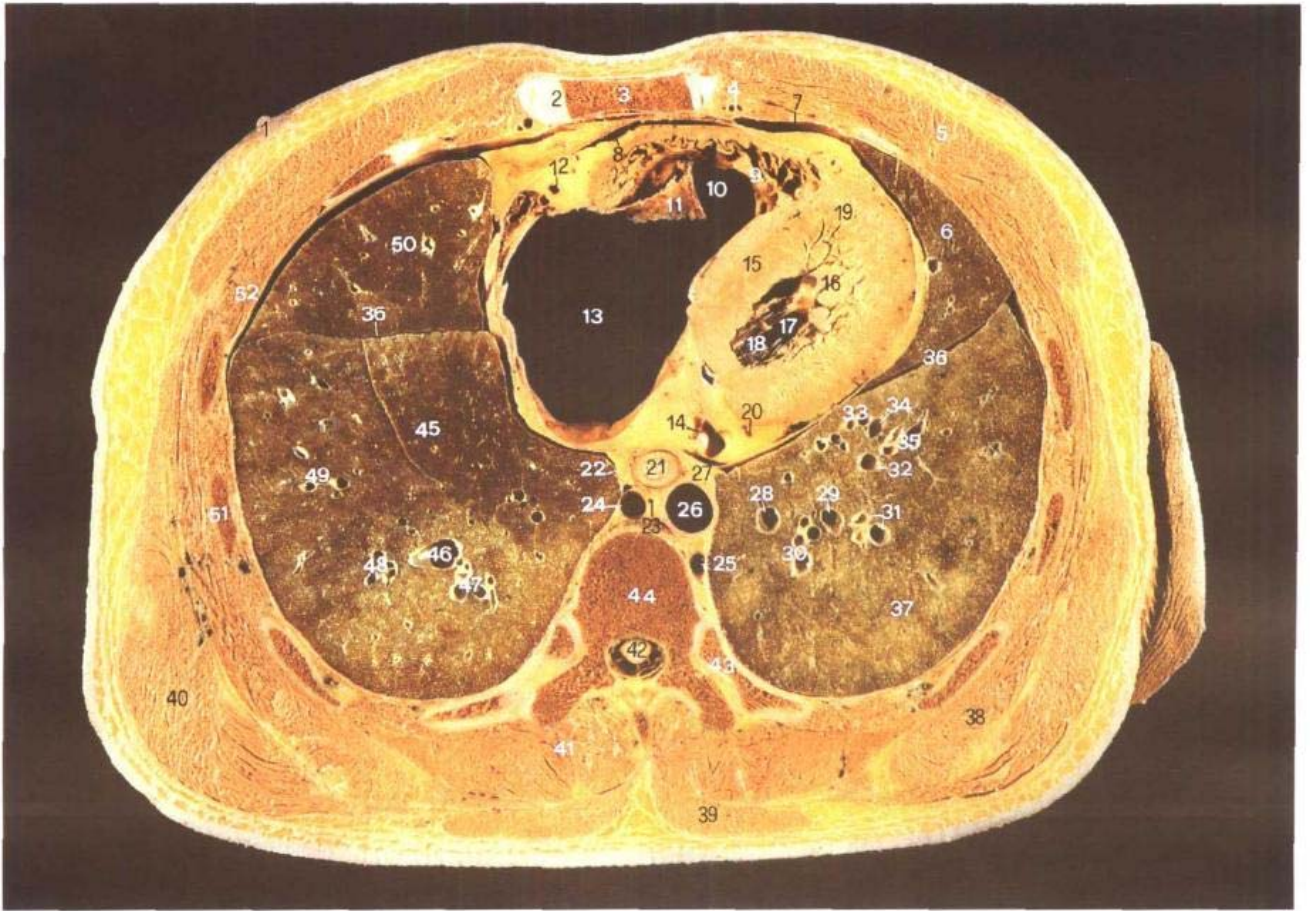
C. CT (肺窗 lung window)

D. MRI T₁WI

- (A9) lateral basal segmental bronchus and artery
31. 后底段支气管(B10)和动脉
(A10) posterior basal segmental bronchus and artery
32. 外侧底段静脉(V9) lateral basal segmental vein
33. 后底段静脉(V10) posterior basal segmental vein
34. 左肺韧带淋巴结 left pulmonary ligament lymph nodes
35. 左肺韧带 left pulmonary ligament
36. 食管 esophagus
37. 右肺韧带 right pulmonary ligament
38. 奇静脉 azygos vein
39. 胸导管 thoracic duct
40. 胸主动脉 thoracic aorta
41. 半奇静脉 hemiazygos vein
42. 第7胸椎间盘 7th thoracic intervertebral disc
43. 脊髓 spinal cord
44. 竖脊肌 erector spinae
45. 斜方肌 trapezius
46. 大圆肌 teres major
47. 背阔肌 latissimus dorsi
48. 前锯肌 serratus anterior
49. 第5肋 5th rib
50. 右肺下叶 inferior lobe of right lung
51. 后底段支气管(B10)和动脉
(A10) posterior basal segmental bronchus and artery
52. 底段下静脉(V9+10) inferior basal vein
53. 外侧底段支气管(B9)和动脉
(A9) lateral basal segmental bronchus and artery
54. 底段上静脉(V8) superior basal vein
55. 右肺中叶 middle lobe of right lung
56. 内侧段静脉(V5) medial segmental vein

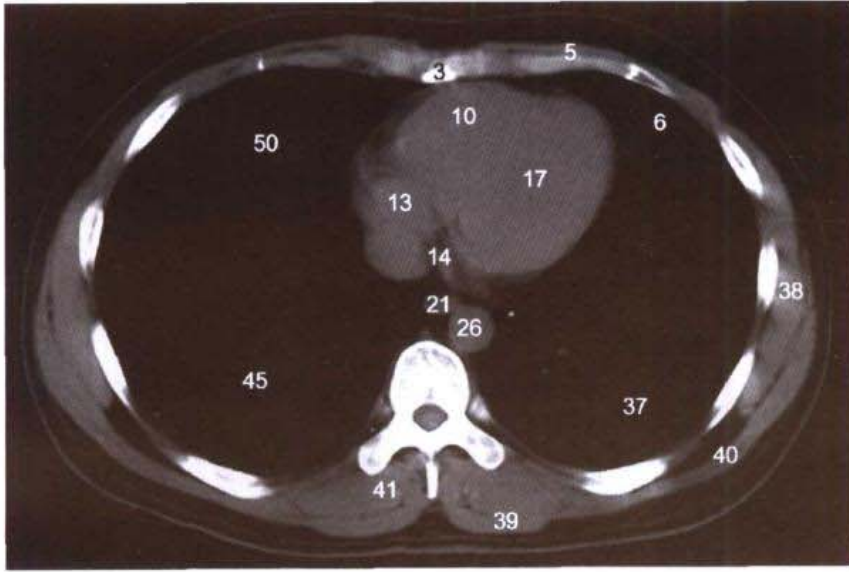
图 5-15 经第 8 胸椎体的横断层

Fig.5-15 Transverse section through body of 8th thoracic vertebrae

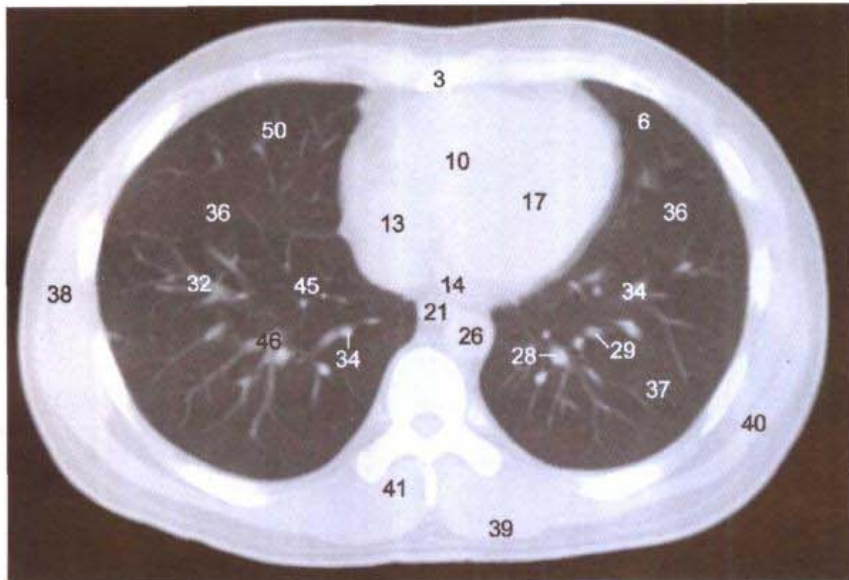


A. 断层标本 (sectional specimen)

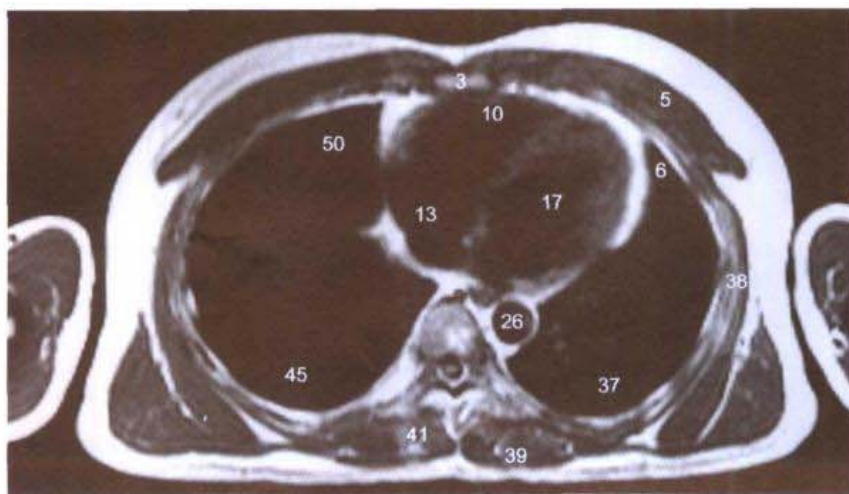
- | | | |
|--|---|---|
| 1. 乳头 mammary papilla | 12. 右冠状动脉 right coronary artery | 22. 右肺韧带 right pulmonary ligament |
| 2. 第 5 胸肋关节 5th sternocostal joint | 13. 右心房 right atrium | 23. 胸导管 thoracic duct |
| 3. 胸骨体 body of sternum | 14. 冠状窦 coronary sinus | 24. 奇静脉 azygos vein |
| 4. 胸廓内动、静脉 internal thoracic artery and vein | 15. 室间隔 interventricular septum | 25. 半奇静脉 hemiazygos vein |
| 5. 胸大肌 pectoralis major | 16. 乳头肌 papillary muscles | 26. 胸主动脉 thoracic aorta |
| 6. 左肺上叶 superior lobe of left lung | 17. 左心室腔 cavity of left ventricle | 27. 左肺韧带 left pulmonary ligament |
| 7. 肋纵隔隐窝 costomediastinal recess | 18. 腱索 chordae tendineae | 28. 后底段静脉(V10) posterior basal segmental vein |
| 8. 心包腔 pericardial cavity | 19. 左心室壁 wall of left ventricle | 29. 外侧底段静脉(V9) lateral basal segmental vein |
| 9. 隔缘肉柱 septomarginal trabecula | 20. 左冠状动脉旋支 circumflex branch of left coronary artery | 30. 后底段支气管(B10)和动脉(A10) posterior basal segmental bronchus and artery |
| 10. 右心室 right ventricle | 21. 食管 esophagus | 31. 外侧底段支气管(B9)和动脉 |
| 11. 三尖瓣 tricuspid valve | | |



B. CT (纵隔窗 mediastinal window)



C. CT (肺窗 lung window)

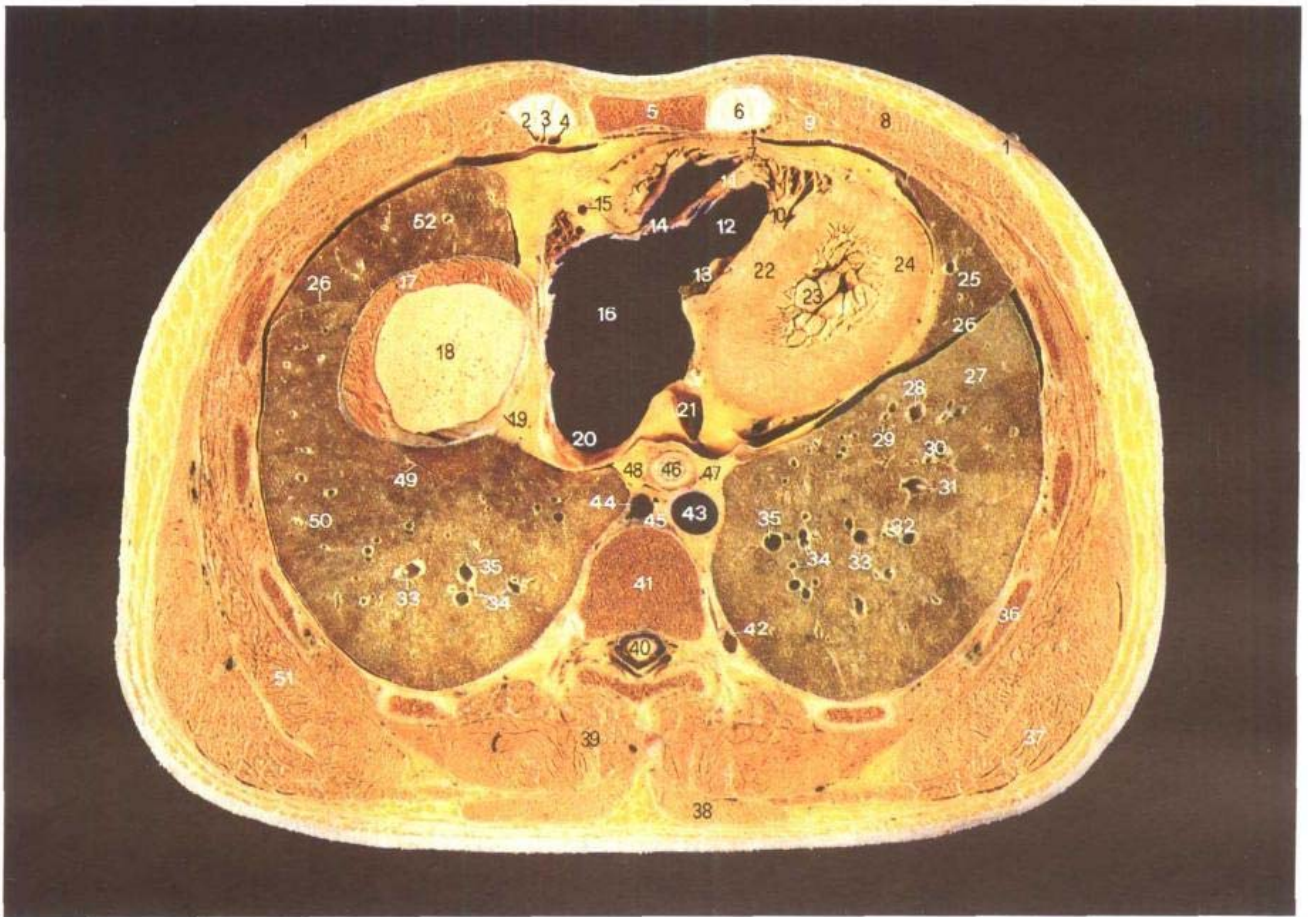


D. MRI T₁WI

- (A9) lateral basal segmental bronchus and artery
- 32. 前底段静脉(V8) anterior basal segmental vein
- 33. 内侧底段支气管(B7)和动脉(A7) medial basal segmental bronchus and artery
- 34. 内侧底段静脉(V7) medial basal segmental vein
- 35. 前底段支气管(B8)和动脉(A8) anterior basal segmental bronchus and artery
- 36. 斜裂 oblique fissure
- 37. 左肺下叶 inferior lobe of left lung
- 38. 前锯肌 serratus anterior
- 39. 斜方肌 trapezius
- 40. 背阔肌 latissimus dorsi
- 41. 竖脊肌 erector spinae
- 42. 脊髓 spinal cord
- 43. 第9肋 9th rib
- 44. 第8胸椎体 body of 8th thoracic vertebrae
- 45. 右肺下叶 inferior lobe of right lung
- 46. 底段下静脉 (V9+10) inferior basal vein
- 47. 后底段支气管(B10)和动脉

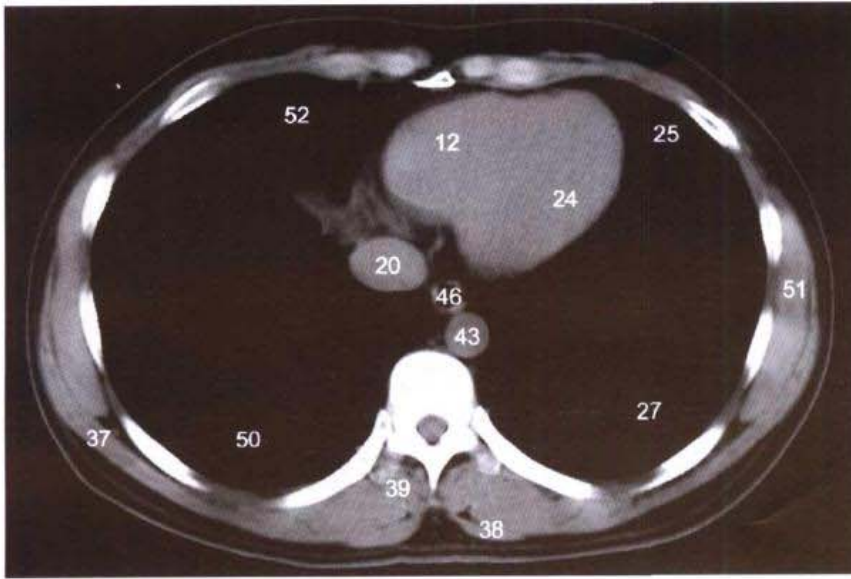
图 5-16 经冠状窦的横断层

Fig.5-16 Transverse section through coronary sinus

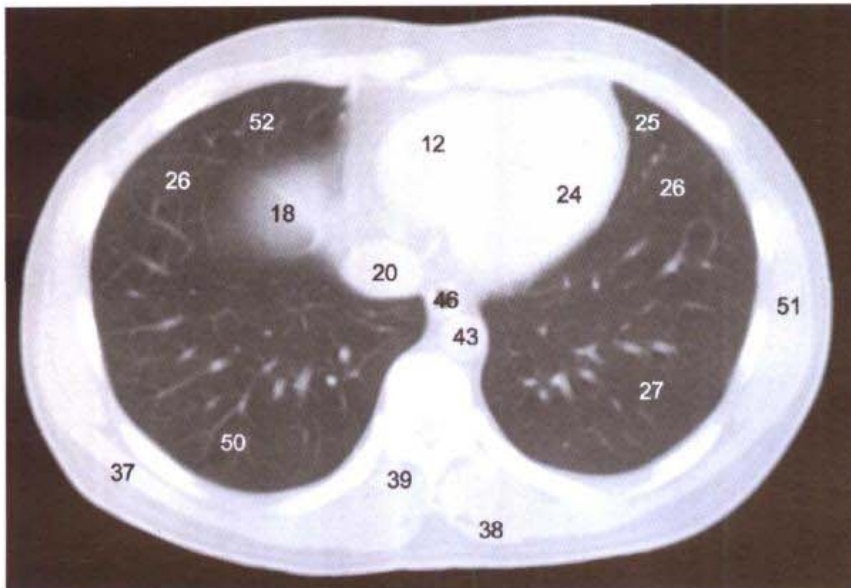


A. 断层标本 (sectional specimen)

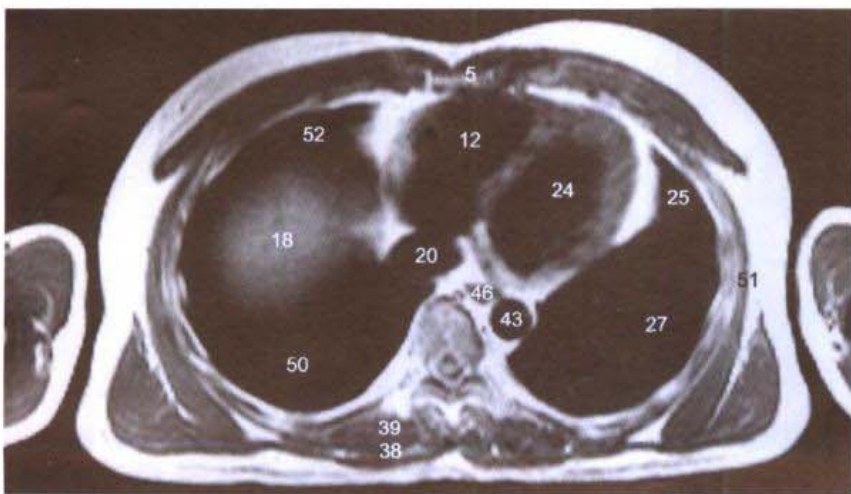
- | | | |
|--|--|---|
| 1. 乳头 mammary papilla | 10. 隔缘肉柱 septomarginal tra-
becula | diaphragm |
| 2. 肌膈动脉 musculophrenic
artery | 11. 前乳头肌 anterior papillary
muscles | 20. 下腔静脉口 orifice of inferior
vena cava |
| 3. 腹壁上动脉 superior epigastric
artery | 12. 右心室 right ventricle | 21. 冠状窦 coronary sinus |
| 4. 胸廓内静脉 internal thoracic
vein | 13. 三尖瓣后尖 posterior cusp
of tricuspid valve | 22. 室间隔 interventricular sep-
tum |
| 5. 胸骨体 body of sternum | 14. 三尖瓣前尖 anterior cusp of
tricuspid valve | 23. 乳头肌 papillary muscles |
| 6. 第5肋软骨 5th costal carti-
lage | 15. 右冠状动脉 right coronary
artery | 24. 左心室 left ventricle |
| 7. 腹壁上静脉 superior epigastric
vein | 16. 右心房 right atrium | 25. 左肺上叶 superior lobe of
left lung |
| 8. 胸大肌 pectoralis major | 17. 膈 diaphragm | 26. 斜裂 oblique fissure |
| 9. 肋纵隔隐窝 costomediastinal
recess | 18. 肝右叶 right lobe of liver | 27. 左肺下叶 inferior lobe of
left lung |
| | 19. 膈中心腱 central tendon of | 28. 内侧底段静脉(V7) medial
basal segmental vein |



B. CT (纵隔窗 mediastinal window)



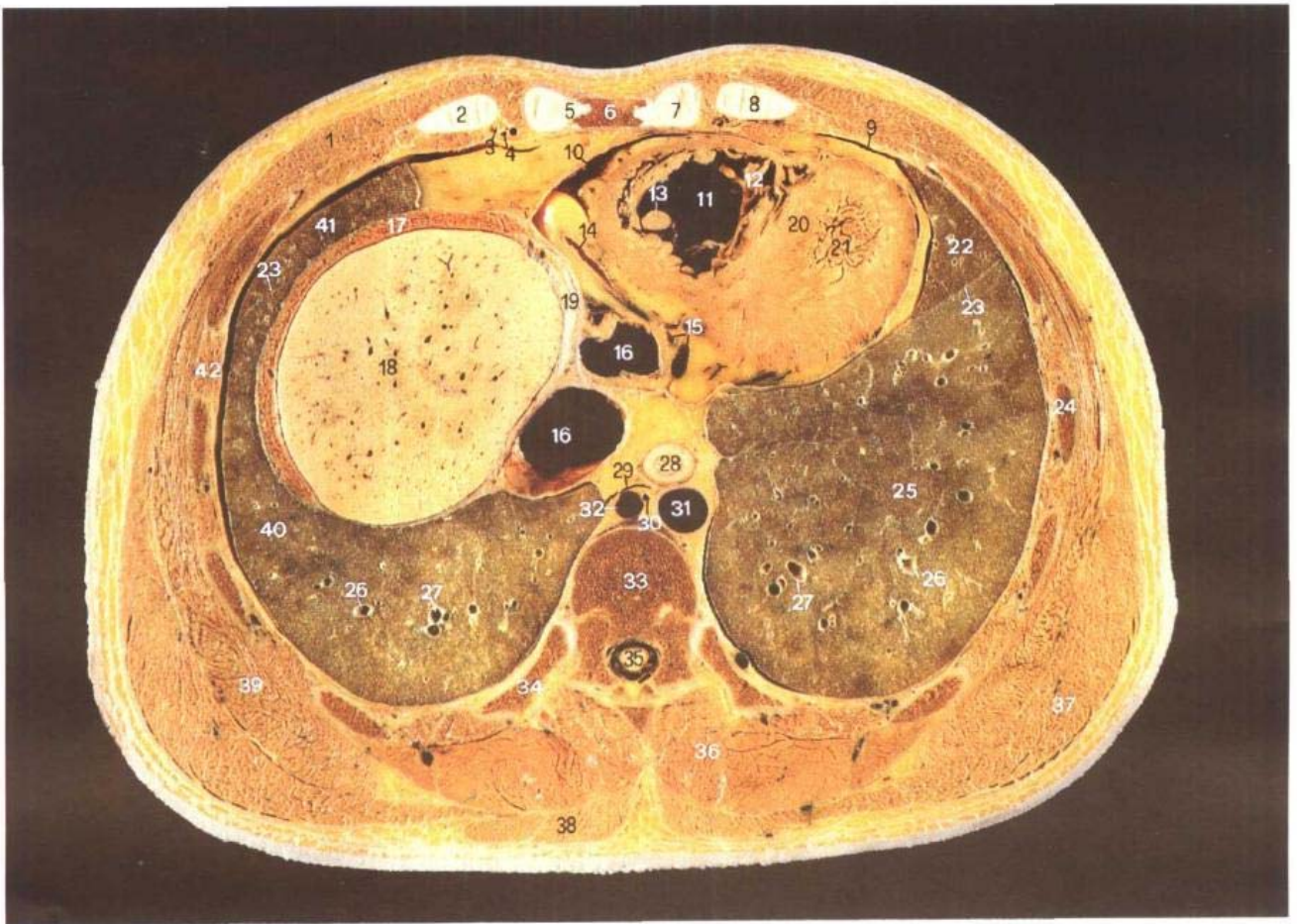
C. CT (肺窗 lung window)

D. MRI T₁WI

29. 内侧底段支气管(B7)和动脉(A7) medial basal segmental bronchus and artery
30. 前底段支气管(B8)和动脉(A8) anterior basal segmental bronchus and artery
31. 前底段静脉(V8) anterior basal segmental vein
32. 外侧底段支气管(B5)和动脉(A9) lateral basal segmental bronchus and artery
33. 外侧底段静脉(V9) lateral basal segmental vein
34. 后底段支气管(B10)和动脉(A10) posterior basal segmental bronchus and artery
35. 后底段静脉(V10) posterior basal segmental vein
36. 第7肋 7th rib
37. 背阔肌 latissimus dorsi
38. 斜方肌 trapezius
39. 竖脊肌 erector spinae
40. 脊髓 spinal cord
41. 第8胸椎体 body of 8th thoracic vertebrae
42. 肋间后静脉 posterior intercostal vein
43. 胸主动脉 thoracic aorta
44. 奇静脉 azygos vein
45. 胸导管 thoracic duct
46. 食管 esophagus
47. 左肺韧带 left pulmonary ligament
48. 右肺韧带 right pulmonary ligament
49. 额外裂 extra fissure
50. 右肺下叶 inferior lobe of right lung
51. 前锯肌 serratus anterior
52. 右肺中叶 middle lobe of right lung

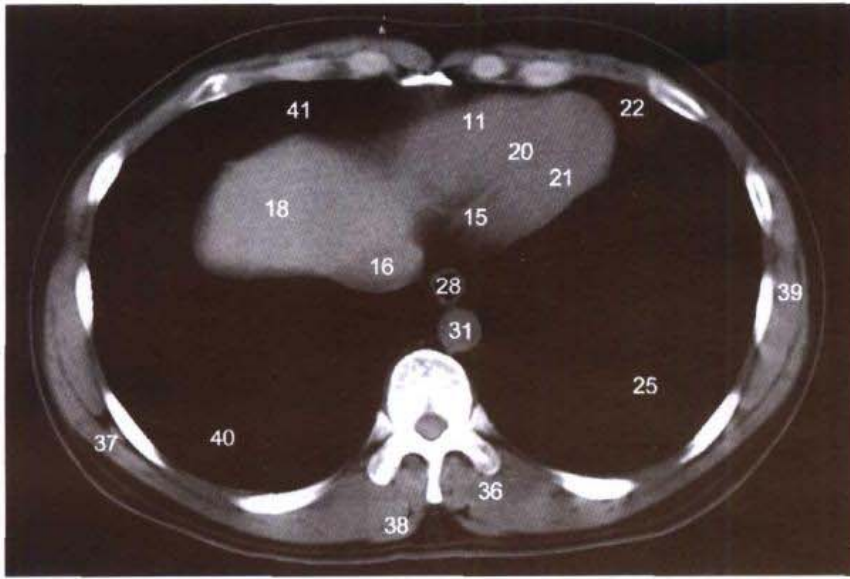
图 5-17 经第 9 胸椎体上份的横断层

Fig.5-17 Transverse section through upper part of 9th thoracic vertebrae

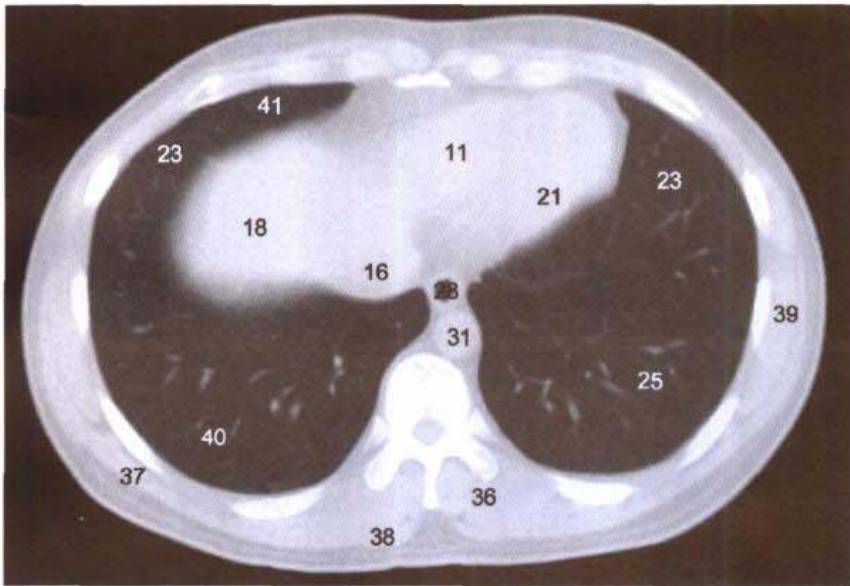


A. 断层标本 (sectional specimen)

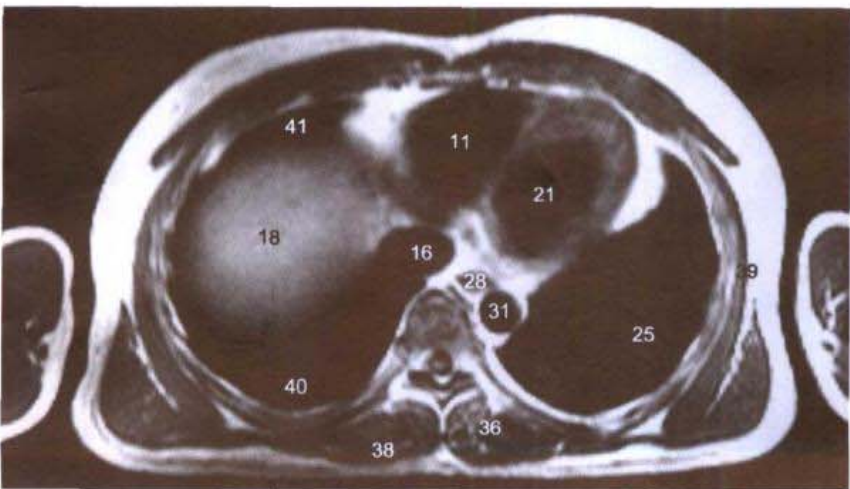
- | | | |
|--|---------------------------------------|---|
| 1. 胸大肌 pectoralis major | 8. 左第 5 肋软骨 5th left costal cartilage | 15. 右冠状动脉后室间支和心中静脉 posterior interventricular branch of right coronary artery and middle cardiac vein |
| 2. 右第 5 肋软骨 5th right costal cartilage | 9. 肋纵隔隐窝 costomediastinal recess | 16. 下腔静脉 inferior vena cava |
| 3. 肌膈动、静脉 musculophrenic artery and vein | 10. 心包腔 pericardial cavity | 17. 膈 diaphragm |
| 4. 腹壁上动脉 superior epigastric artery | 11. 右心室 right ventricle | 18. 肝右叶 right lobe of liver |
| 5. 第 6 胸肋关节 6th sternocostal joint | 12. 肉柱 trabeculae carneae | 19. 膈中心腱 central tendon of diaphragm |
| 6. 胸骨体 body of sternum | 13. 前乳头肌 anterior papillary muscle | 20. 室间隔 interventricular septum |
| 7. 第 6 肋软骨 6th costal cartilage | 14. 右冠状动脉 right coronary artery | |



B. CT (纵隔窗 mediastinal window)



C. CT (肺窗 lung window)



D. MRI T₁WI

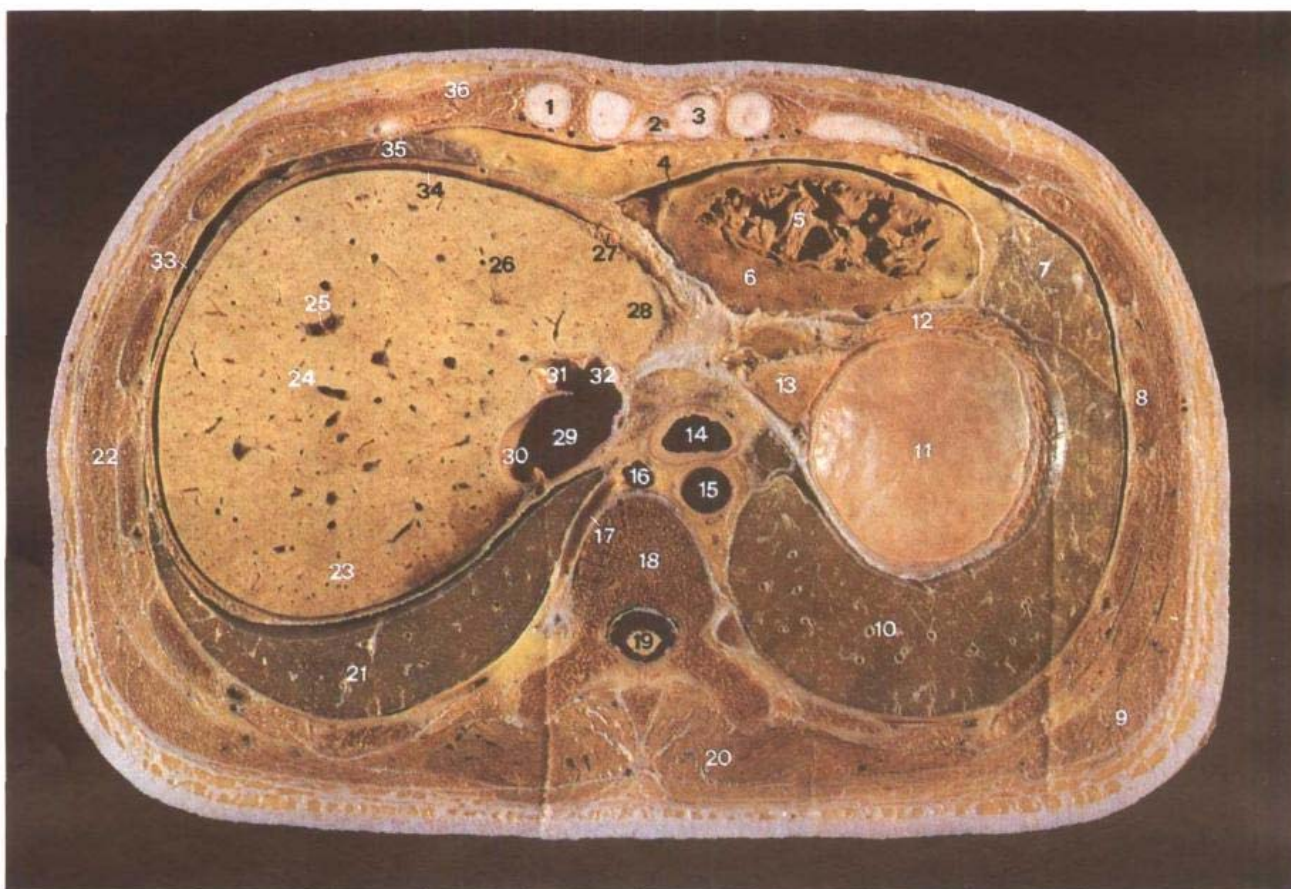
21. 左心室 left ventricle
22. 左肺上叶 superior lobe of left lung
23. 斜裂 oblique fissure
24. 第6肋 6th rib
25. 左肺下叶 inferior lobe of left lung
26. 外侧底段静脉(V9) lateral basal segmental vein
27. 后底段静脉(V10) posterior basal segmental vein
28. 食管 esophagus
29. 奇静脉食管隐窝 azygoesophageal recess
30. 胸导管 thoracic duct
31. 胸主动脉 thoracic aorta
32. 奇静脉 azygos vein
33. 第9胸椎体 body of 9th thoracic vertebrae
34. 第9肋 9th rib
35. 脊髓 spinal cord
36. 竖脊肌 erector spinae
37. 背阔肌 latissimus dorsi
38. 斜方肌 trapezius
39. 前锯肌 serratus anterior
40. 右肺下叶 inferior lobe of right lung
41. 右肺中叶 middle lobe of right lung
42. 肋间内、外肌 intercostales interni and externi

第六章 腹部连续横断层

Chapter 6 Serial Transverse Sections of Abdomen

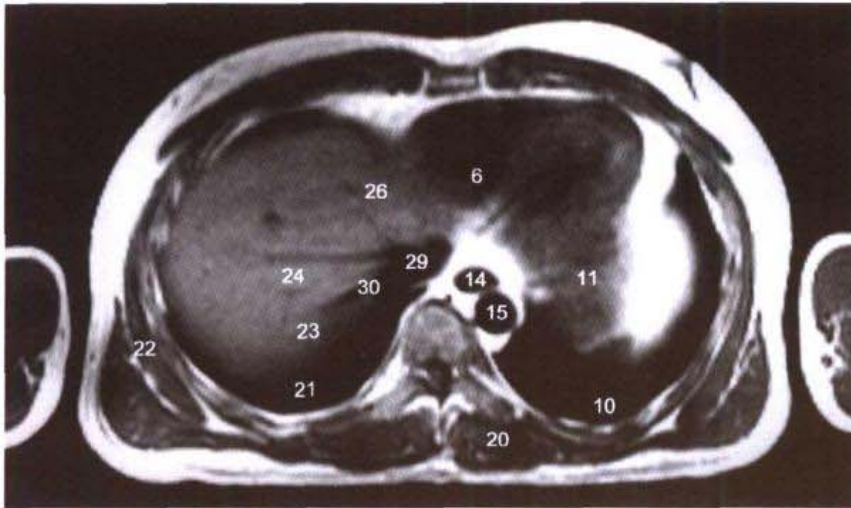
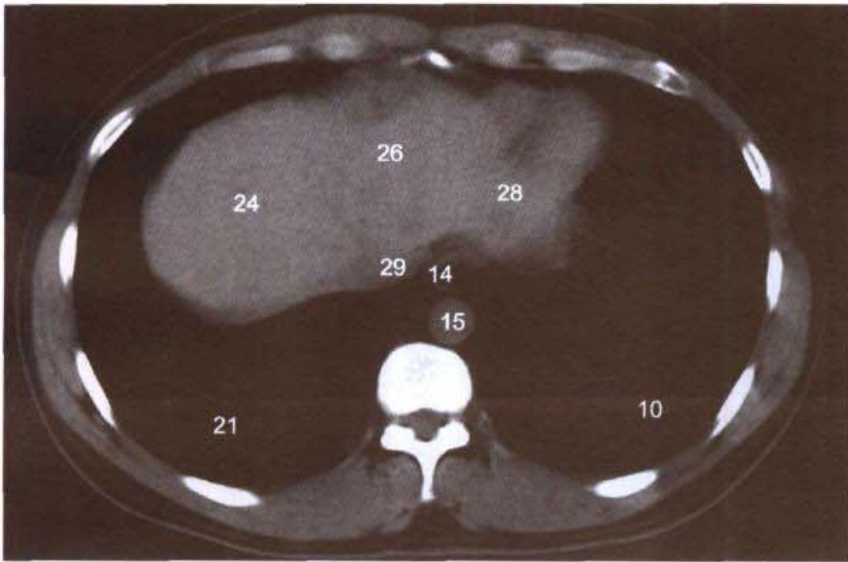
图 6-1 经第二肝门的横断层

Fig.6-1 Transverse section through second porta hepatis

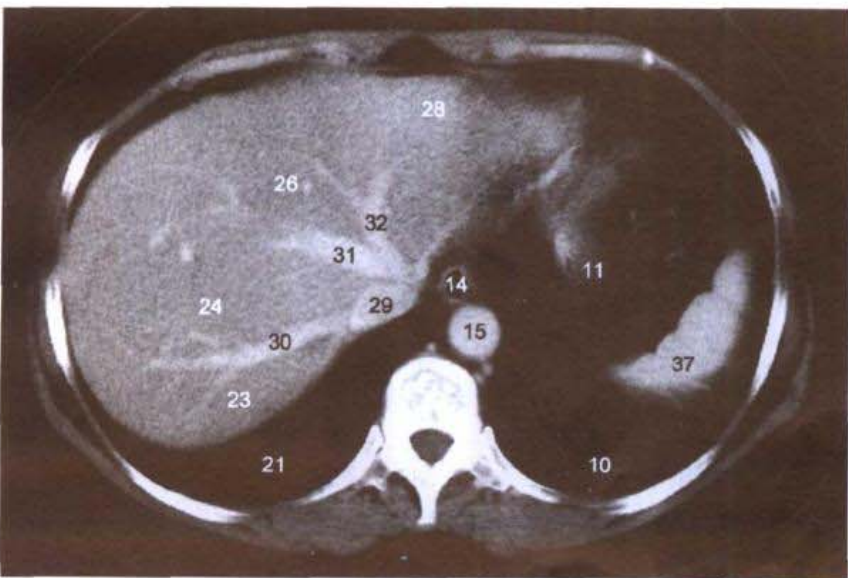


A. 断层标本 (sectional specimen)

- | | | |
|------------------------------------|------------------------------------|-------------------------------------|
| 1. 第 6 肋软骨 6th costal cartilage | 4. 心包腔 pericardial cavity | 9. 背阔肌 latissimus |
| 2. 胸骨剑突 xiphoid process of sternum | 5. 肉柱 trabeculae carneae | 10. 左肺下叶 inferior lobe of left lung |
| 3. 第 7 肋软骨 7th costal cartilage | 6. 右心室 right ventricle | 11. 胃底 fundus of stomach |
| | 7. 左肺上叶 superior lobe of left lung | 12. 膈 diaphragm |
| | 8. 第 7 肋 7th rib | 13. 肝左外叶上段 superior seg- |

B. MRI T₁WI

C. CT



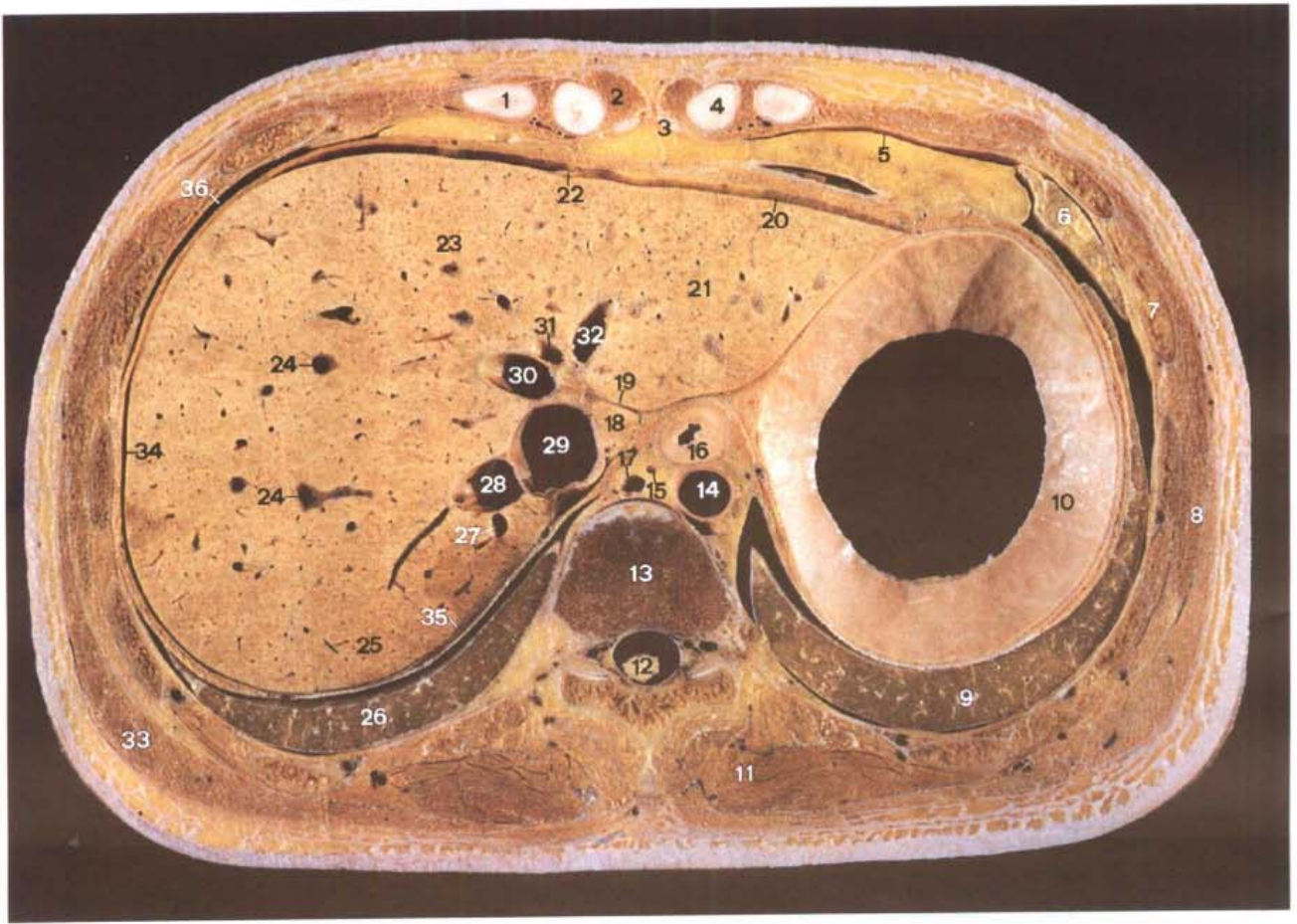
D. CT

ment of left lateral lobe
of liver

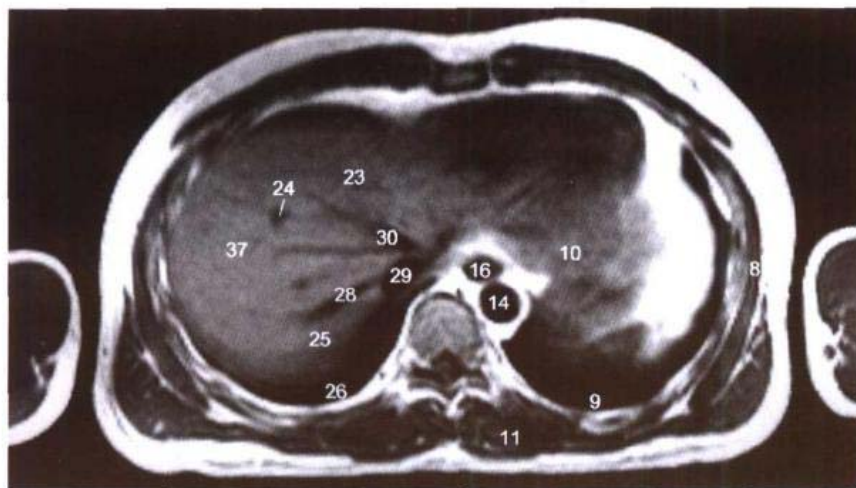
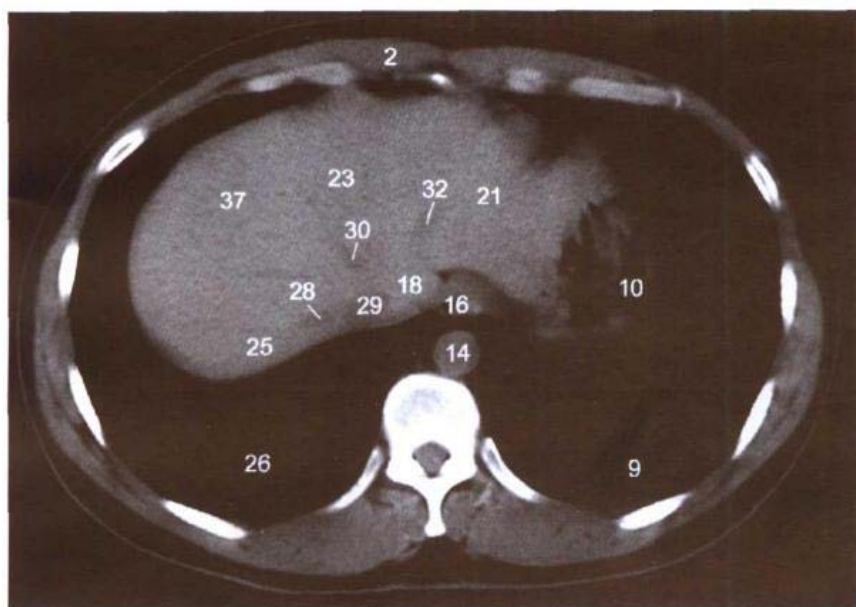
14. 食管 esophagus
15. 胸主动脉 thoracic aorta
16. 奇静脉 azygos vein
17. 肋间后静脉 posterior intercostal veins
18. 第10胸椎体 body of 10th thoracic vertebrae
19. 脊髓 spinal cord
20. 竖脊肌 erector spinae
21. 右肺下叶 inferior lobe of right lung
22. 前锯肌 serratus anterior
23. 肝右后叶 right posterior lobe of liver
24. 肝右前叶 right anterior lobe of liver
25. 肝门静脉右前上支 right anteriosuperior branch of hepatic portal vein
26. 肝左内叶 left medial lobe of liver
27. 肝镰状韧带 falciform ligament of liver
28. 肝左外叶 left lateral lobe of liver
29. 下腔静脉 inferior vena cava
30. 肝右静脉 right hepatic vein
31. 肝中静脉 middle hepatic vein
32. 肝左静脉 left hepatic vein
33. 肋膈隐窝 costodiaphragmatic recess
34. 右肝上间隙 right suprahepatic space
35. 右肺中叶 middle lobe of right lung
36. 胸大肌 pectoralis major
37. 脾 spleen

图 6-2 经食管裂孔的横断层

Fig.6-2 Transverse section through esophageal hiatus



A. 断层标本 (sectional specimen)

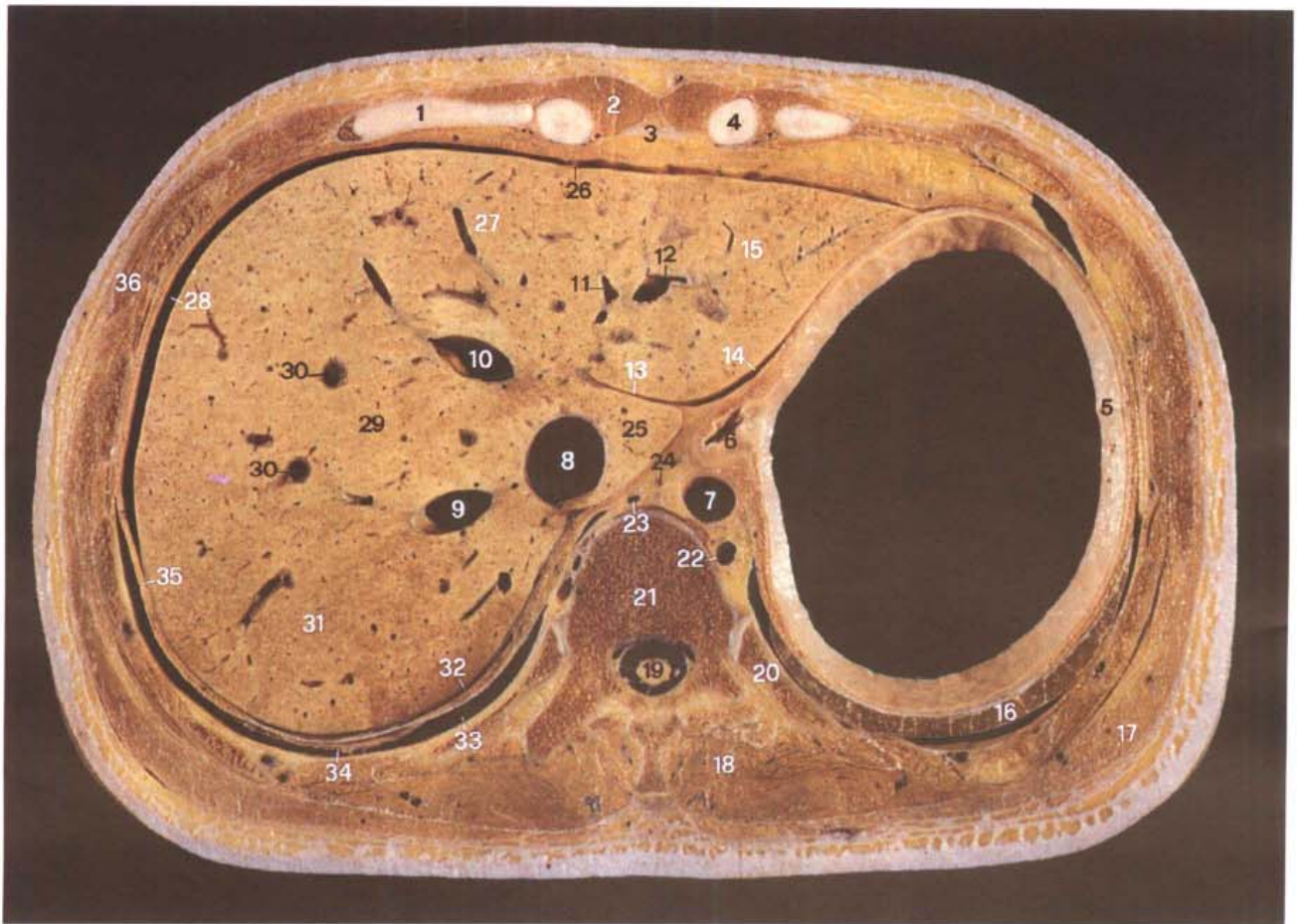B. MRI T₁-WI

C. CT

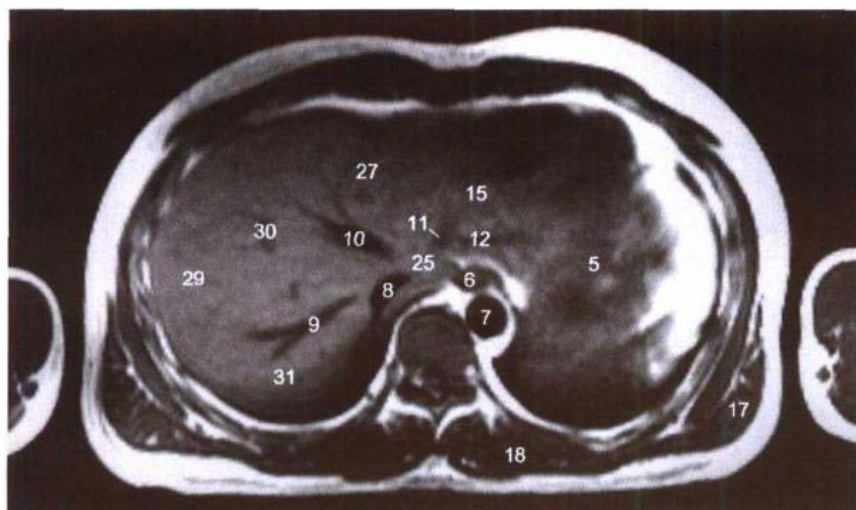
- | | | |
|------------------------------------|--|--|
| 1. 第6肋软骨 6th costal cartilage | 9. 左肺下叶 inferior lobe of left lung | 19. 静脉韧带裂 fissur for ligamentum venosum |
| 2. 腹直肌 rectus abdominis | 10. 胃底 fundus of stomach | 20. 左肝上前间隙 anterior left suprahepatic space |
| 3. 胸骨剑突 xiphoid process of sternum | 11. 竖脊肌 erector spinae | 21. 肝左外叶 left lateral lobe of liver |
| 4. 第7肋软骨 7th costal cartilage | 12. 脊髓 spinal cord | 22. 肝镰状韧带 falciform ligament of liver |
| 5. 肋纵隔隐窝 costamediastinal recess | 13. 第10胸椎体 body of 10th thoracic vertebrae | 23. 肝左内叶 left medial lobe of liver |
| 6. 左肺上叶 superior lobe of left lung | 14. 胸主动脉 thoracic aorta | 24. 肝门静脉右前上支 right anteriosuperior branch of hepatic portal vein |
| 7. 第7肋 7th rib | 15. 胸导管 thoracic duct | 25. 肝右后叶 right posterior lobe of liver |
| 8. 前锯肌 serratus anterior | 16. 食管 esophagus | 26. 右肺下叶 inferior lobe of right lung |
| | 17. 奇静脉 azygos vein | 27. 肝右后上缘静脉 right posterior supramarginal hepatic vein |
| | 18. 肝尾状叶 caudate lobe of liver | 28. 肝右静脉 right hepatic vein |
| | | 29. 下腔静脉 inferior vena cava |
| | | 30. 肝中静脉 middle hepatic vein |
| | | 31. 左叶间静脉 left interlobar vein |
| | | 32. 肝左静脉 left hepatic vein |
| | | 33. 背阔肌 latissimus dorsi |
| | | 34. 右肝上间隙 right suprahepatic space |
| | | 35. 肝裸区 bare area of liver |
| | | 36. 肋膈隐窝 costodiaphragmatic recess |
| | | 37. 肝右前叶 right anterior lobe of liver |

图 6-3 经食管腹部的横断层

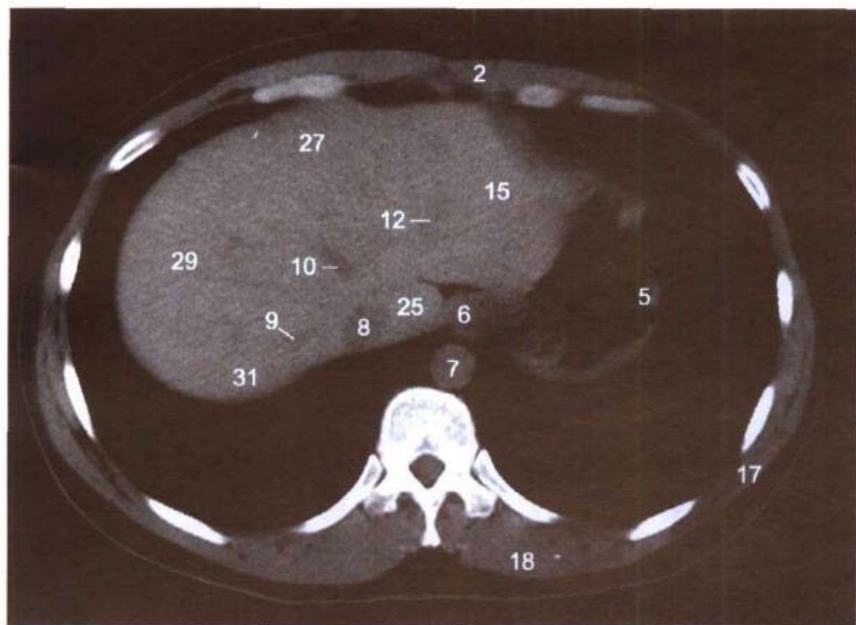Fig.6-3 Transverse section through abdominal part of esophagus



A. 断层标本 (sectional specimen)



B. MRI T1WI



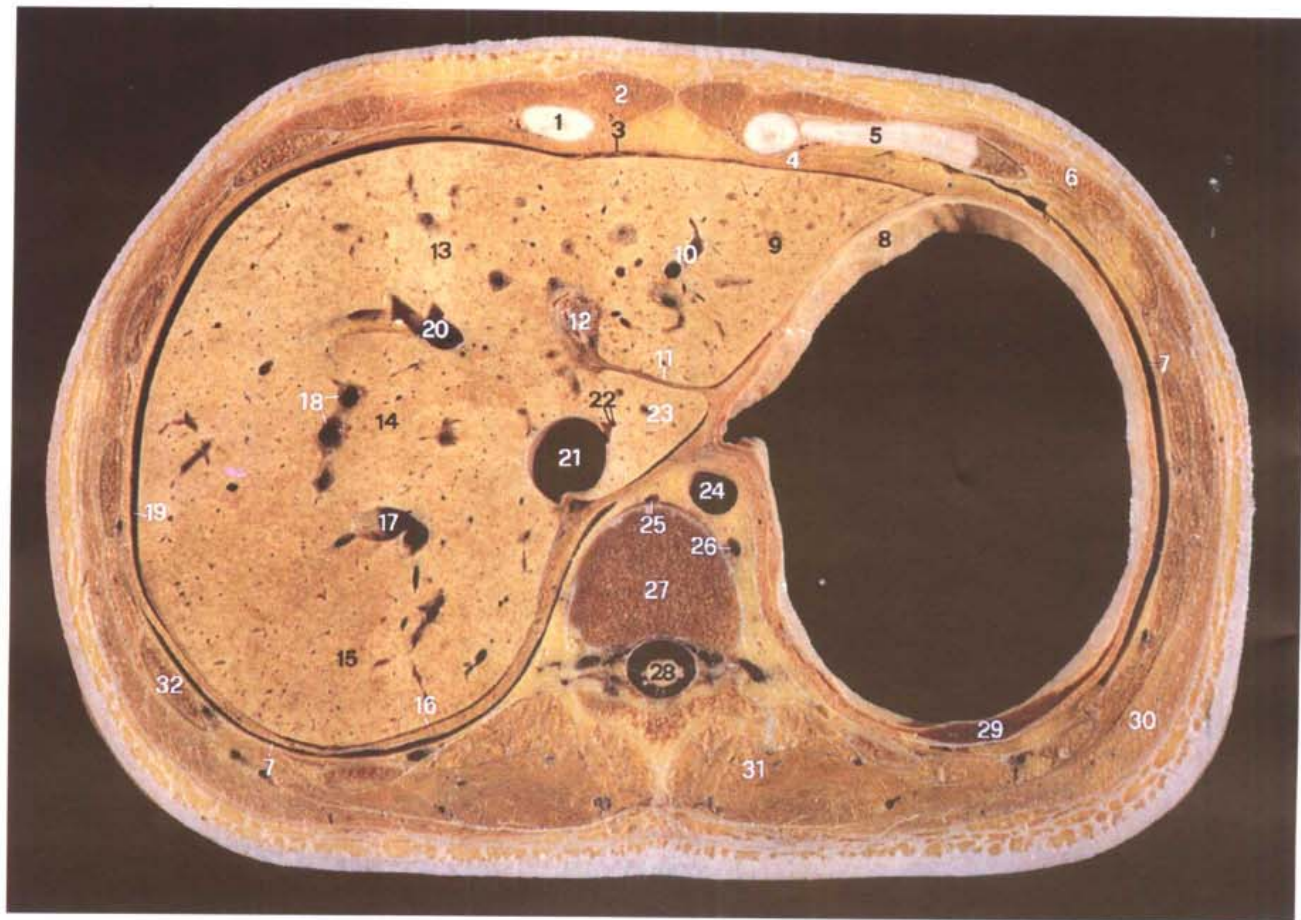
C. CT

- | | |
|-------------------------------------|--|
| 1. 第6肋软骨 6th costal cartilage | 9. 肝右静脉 right hepatic vein |
| 2. 腹直肌 rectus abdominis | 10. 肝中静脉 middle hepatic vein |
| 3. 胸骨剑突 xiphoid process of sternum | 11. 肝左静脉内侧支 medial branch of left hepatic vein |
| 4. 第7肋软骨 7th costal cartilage | 12. 肝左静脉 left hepatic vein |
| 5. 胃底 fundus of stomach | 13. 静脉韧带裂 fissure for ligamentum venosum |
| 6. 食管腹部 abdominal part of esophagus | 14. 胃肝隐窝 gastrohepatic recess |
| 7. 胸主动脉 thoracic aorta | 15. 肝左外叶 left lateral lobe of liver |
| 8. 下腔静脉 inferior vena cava | |

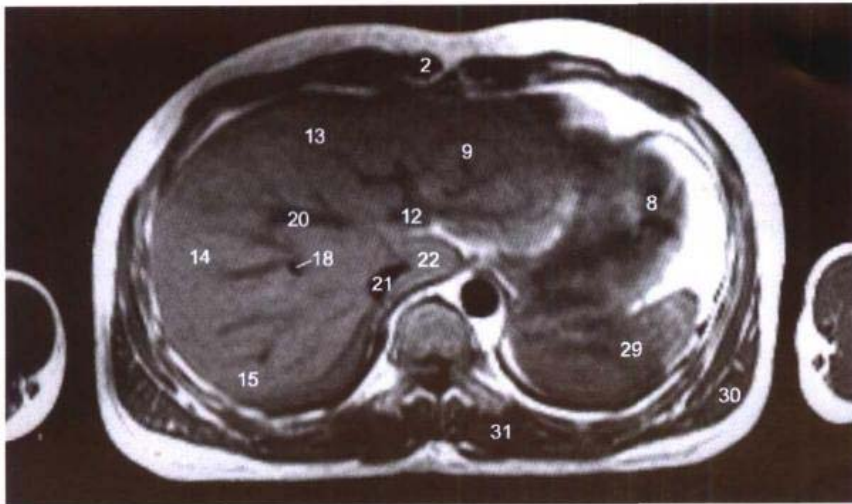
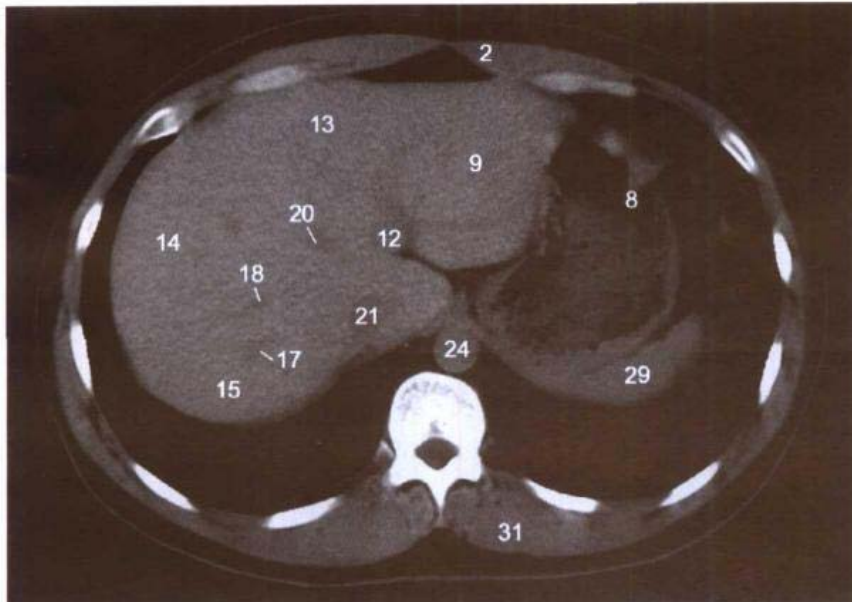
- | |
|---|
| 16. 左肺下叶 inferior lobe of left lung |
| 17. 背阔肌 latissimus dorsi |
| 18. 竖脊肌 erector spinae |
| 19. 脊髓 spinal cord |
| 20. 第11肋 11th rib |
| 21. 第11胸椎体 body of 11th thoracic vertebrae |
| 22. 半奇静脉 hemiazygos vein |
| 23. 奇静脉 azygos vein |
| 24. 胸导管 thoracic duct |
| 25. 肝尾状叶 caudate lobe of liver |
| 26. 肝镰状韧带 falciform ligament of liver |
| 27. 肝左内叶 left medial lobe of liver |
| 28. 右肝上间隙 right suprahepatic space |
| 29. 肝右前叶 right anterior lobe of liver |
| 30. 肝门静脉右前上支 right anterosuperior branch of hepatic portal vein |
| 31. 肝右后叶 right posterior lobe of liver |
| 32. 肝裸区 bare area of liver |
| 33. 肋膈隐窝 costodiaphragmatic recess |
| 34. 右肺下叶 inferior lobe of right lung |
| 35. 膈 diaphragm |
| 36. 腹外斜肌 obliquus externus abdominis |

图 6-4 经肝门静脉左支角部的横断层

Fig.6-4 Transverse section through angular part of left hepatic portal vein



A. 断层标本 (sectional specimen)

B. MRI T₁WI

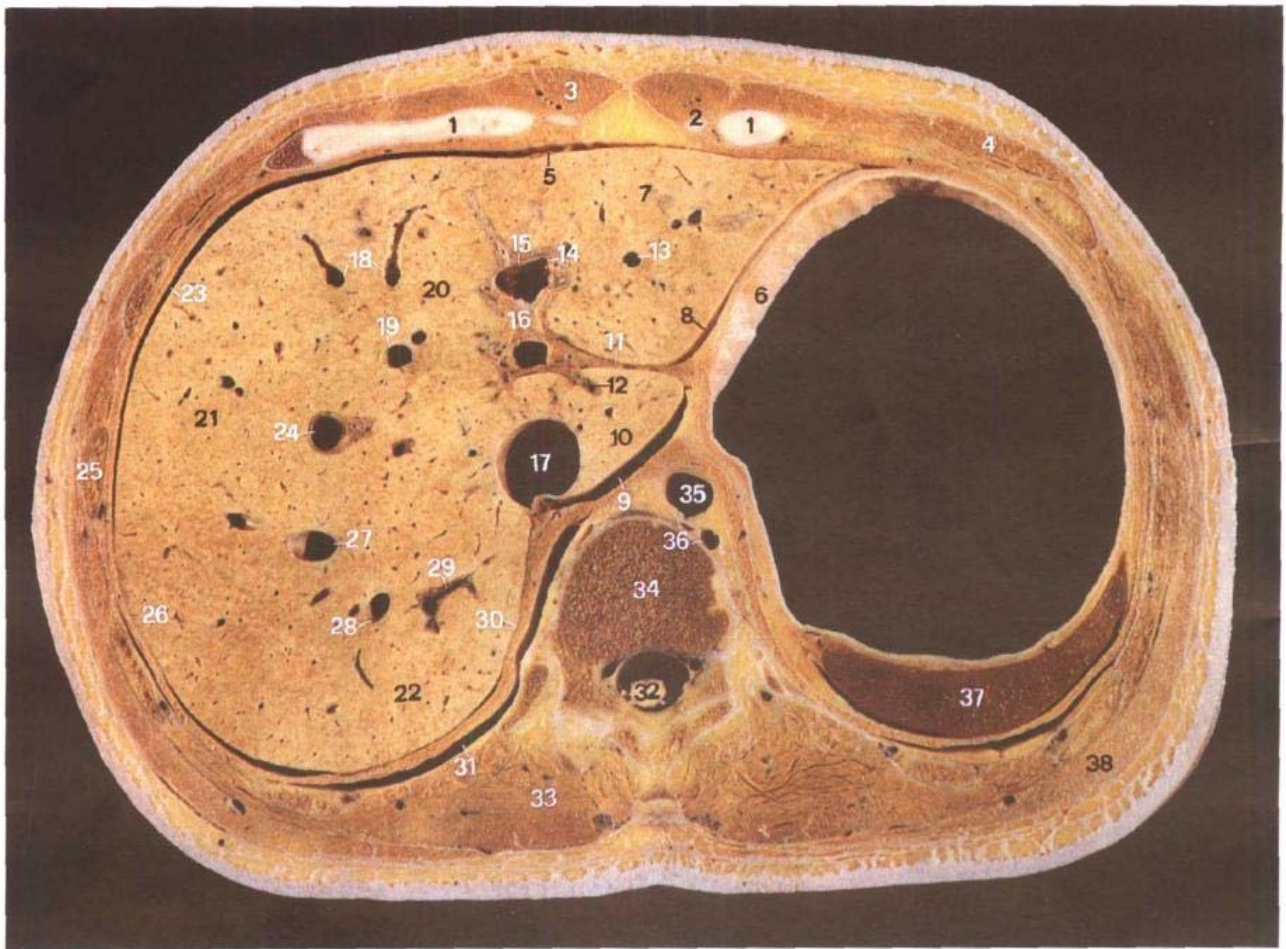
C. CT

- | | |
|--------------------------------------|---|
| 1. 第7肋软骨 7th costal cartilage | 9. 肝左外叶 left lateral lobe of liver |
| 2. 腹直肌 rectus abdominis | 10. 肝左静脉 left hepatic vein |
| 3. 肝镰状韧带 falciform ligament of liver | 11. 静脉韧带裂 fissure for ligamentum venosum |
| 4. 膈 diaphragm | 12. 肝门静脉左支角部 angular part of left hepatic portal vein |
| 5. 第6肋软骨 6th costal cartilage | 13. 肝左内叶 left medial lobe of liver |
| 6. 腹外斜肌 obliquus externus abdominis | 14. 肝右前叶 right anterior lobe of liver |
| 7. 肋膈隐窝 costodiaphragmatic recess | 15. 肝右后叶 right posterior |
| 8. 胃底 fundus of stomach | |

- | | |
|---|---------------|
| | lobe of liver |
| 16. 肝裸区 bare area of liver | |
| 17. 肝右静脉 right hepatic vein | |
| 18. 肝门静脉右前上支 right anterosuperior branch of hepatic portal vein | |
| 19. 右肝上间隙 right suprahepatic space | |
| 20. 肝中静脉 middle hepatic vein | |
| 21. 下腔静脉 inferior vena cava | |
| 22. 尾状叶静脉 caudate hepatic vein | |
| 23. 肝尾状叶 caudate lobe of liver | |
| 24. 胸主动脉 thoracic aorta | |
| 25. 奇静脉 azygos vein | |
| 26. 半奇静脉 hemiazygos vein | |
| 27. 第11胸椎体 body of 11th thoracic vertebrae | |
| 28. 脊髓 spinal cord | |
| 29. 脾 spleen | |
| 30. 背阔肌 latissimus dorsi | |
| 31. 竖脊肌 erector spinae | |
| 32. 第10肋 10th rib | |

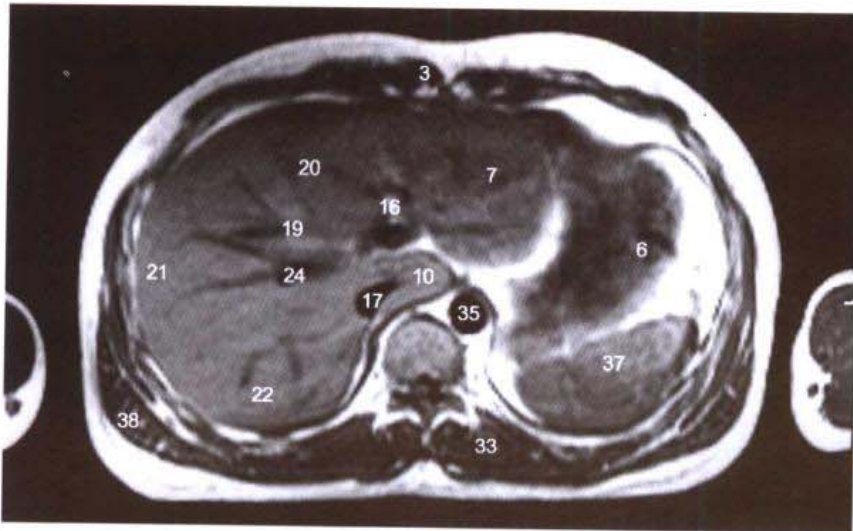
图 6-5 经肝门静脉左支矢状部的横断层

Fig.6-5 Transverse section through sagittal part of left hepatic portal vein

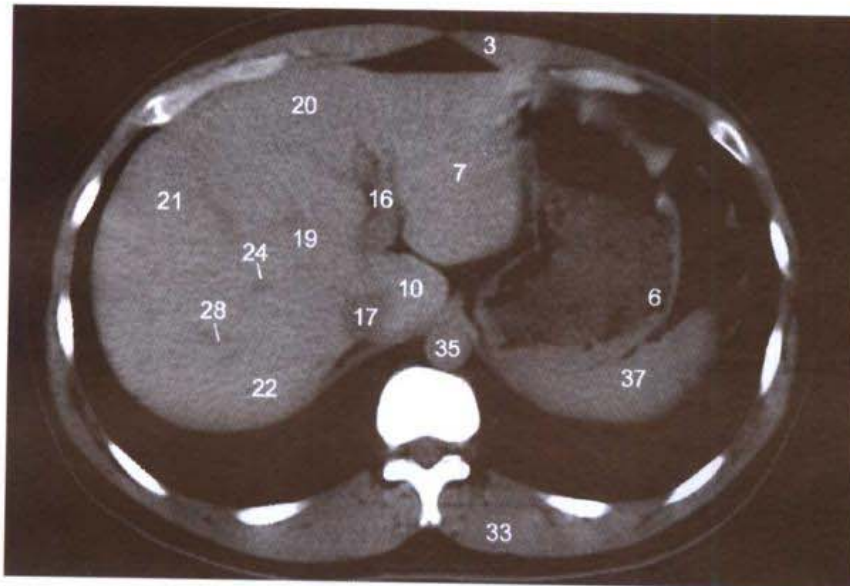


A. 断层标本 (sectional specimen)

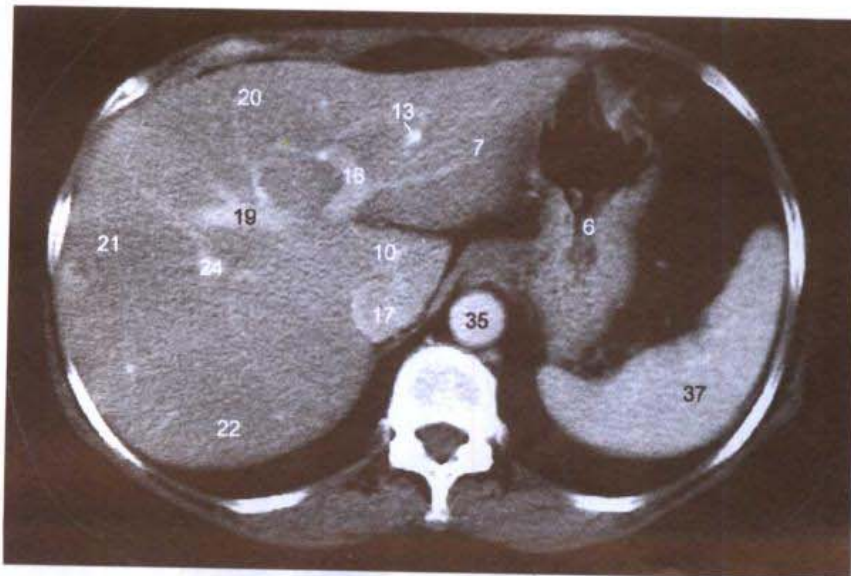
- | | | |
|--|--|---|
| 1. 第7肋软骨 7th costal cartilage | 10. 肝尾状叶 caudate lobe of liver | part of left hepatic portal vein |
| 2. 第8肋软骨 8th costal cartilage | 11. 肝胃韧带 hepatogastric ligament | 17. 下腔静脉 inferior vena cava |
| 3. 腹直肌 rectus abdominis | 12. 肝门静脉尾状叶支 caudate branch of hepatic portal vein | 18. 肝中静脉属支 tributary of middle hepatic vein |
| 4. 腹外斜肌 obliquus externus abdominis | 13. 肝左静脉 left hepatic vein | 19. 肝中静脉 middle hepatic vein |
| 5. 肝镰状韧带 falciform ligament of liver | 14. 肝门静脉左外下支 left lateroinferior branch of hepatic portal vein | 20. 肝左内叶 left medial lobe of liver |
| 6. 胃底 fundus of stomach | 15. 肝门静脉左支囊部 capsule part of left hepatic portal vein | 21. 肝右前叶 right anterior lobe of liver |
| 7. 肝左外叶 left lateral lobe of liver | 16. 肝门静脉左支矢状部 sagittal | 22. 肝右后叶 right posterior lobe of liver |
| 8. 胃肝隐窝 gastrohepatic recess | | 23. 右肝上间隙 right suprahe- |
| 9. 网膜囊上隐窝 superior recess of omental bursa | | |



B. MRI T₁WI



C. CT

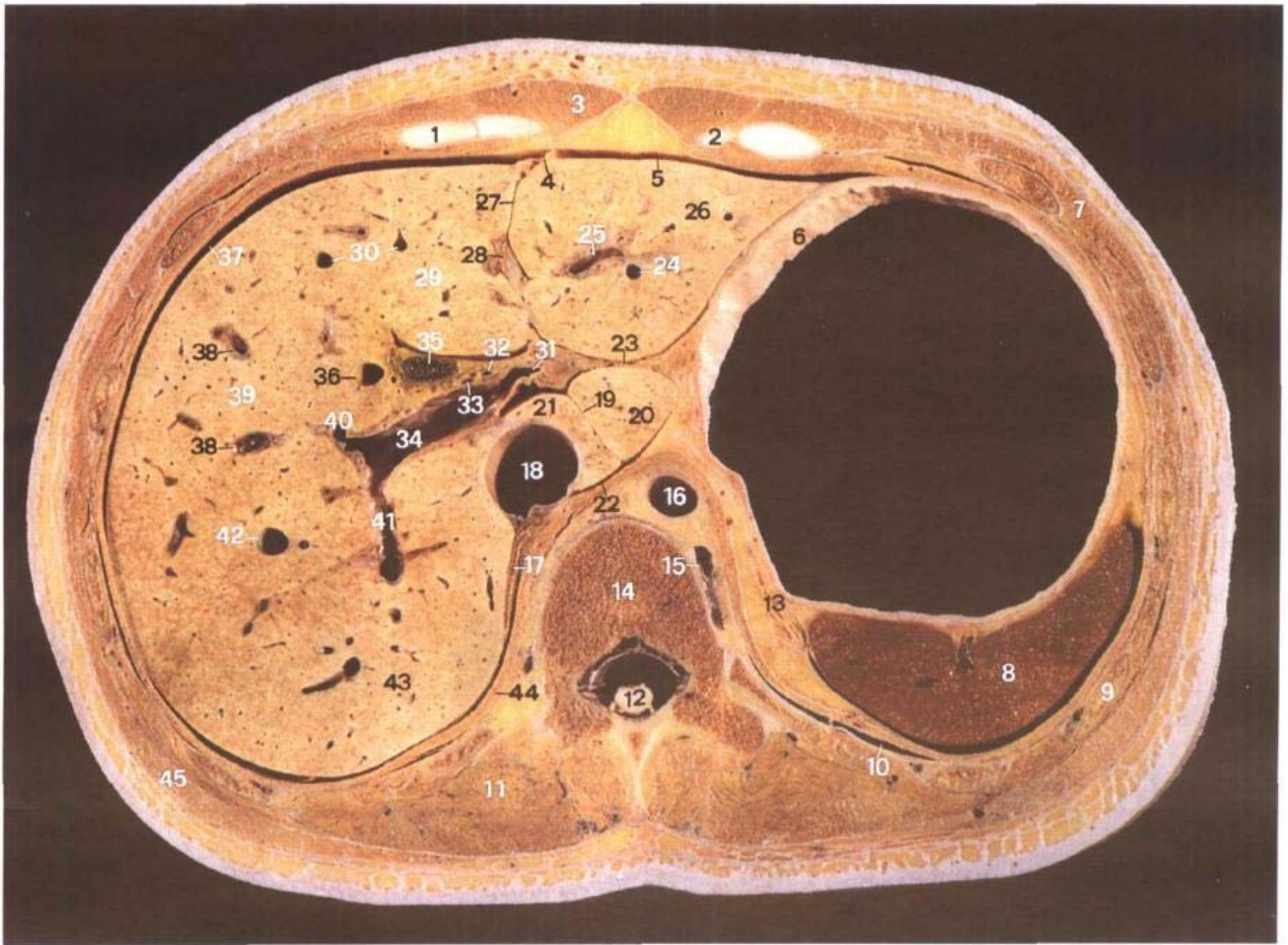


D. CT

- 24. 肝门静脉右前上支 right anterosuperior branch of hepatic portal vein
- 25. 第9肋 9th rib
- 26. 膈 diaphragm
- 27. 肝右静脉 right hepatic vein
- 28. 肝右静脉属支 tributary of right hepatic vein
- 29. 肝门静脉右后上支 right posteriosuperior branch of hepatic portal vein
- 30. 肝裸区 bare area of liver
- 31. 肋膈隐窝 costodiaphragmatic recess
- 32. 脊髓 spinal cord
- 33. 竖脊肌 erector spinae
- 34. 第12胸椎 12th thoracic vertebrae
- 35. 胸主动脉 thoracic aorta
- 36. 半奇静脉 hemiazygos vein
- 37. 脾 spleen
- 38. 背阔肌 latissimus dorsi

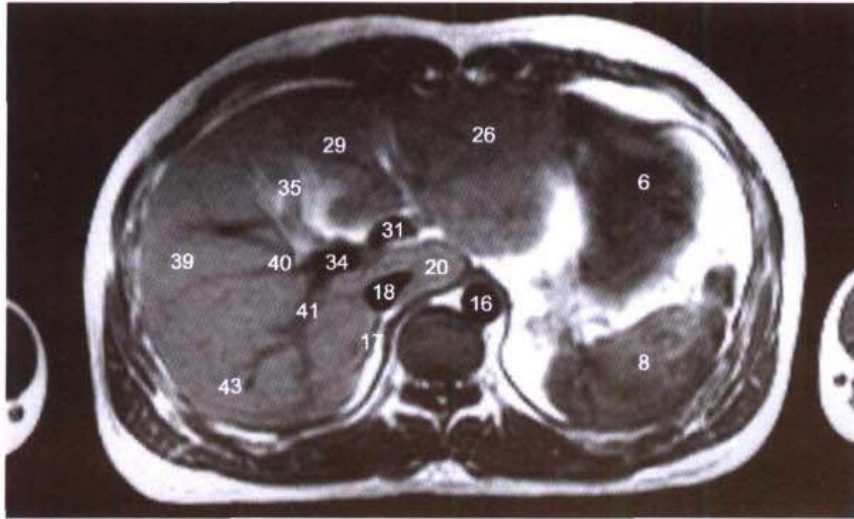
图 6-6 经肝门静脉右支的横断层

Fig.6-6 Transverse section through right hepatic portal vein

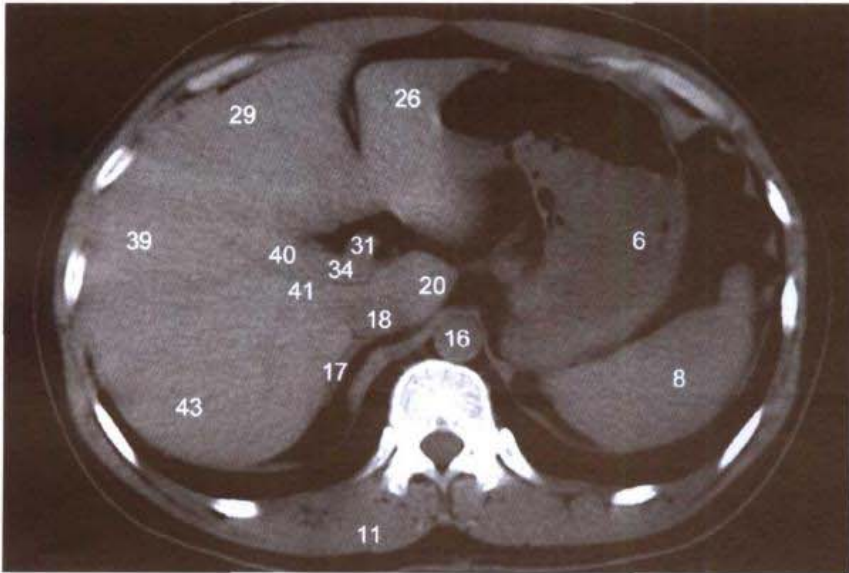


A. 断层标本 (sectional specimen)

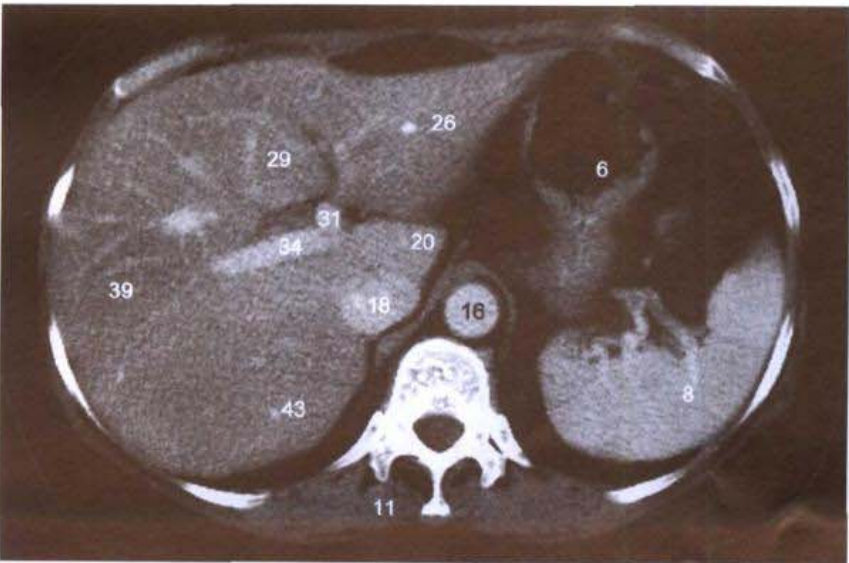- | | | |
|--|--|--|
| 1. 第7肋 7th rib | 10. 肋膈隐窝 costodiaphragmatic recess | gland |
| 2. 第8肋 8th rib | 11. 竖脊肌 erector spinae | 18. 下腔静脉 inferior vena cava |
| 3. 腹直肌 rectus abdominis | 12. 脊髓 spinal cord | 19. 弓状切迹 arcuate notch |
| 4. 肝镰状韧带 falciform ligament of liver | 13. 左肾上腺 left suprarenal gland | 20. 乳头突 papillary process |
| 5. 左肝上前间隙 anterior left suprahepatic space | 14. 第12胸椎体 body of 12th thoracic vertebrae | 21. 尾状突 caudate process |
| 6. 胃底 fundus of stomach | 15. 肋间后静脉 posterior intercostal vein | 22. 网膜囊上隐窝 superior recess of omental bursa |
| 7. 腹外斜肌 obliquus externus abdominis | 16. 胸主动脉 thoracic aorta | 23. 肝胃韧带 hepatogastric ligament |
| 8. 脾 spleen | 17. 右肾上腺 right suprarenal gland | 24. 肝左静脉 left hepatic vein |
| 9. 第10肋 10th rib | | 25. 肝门静脉左外下支 left lateroinferior branch of hepatic |



B. MRI T₁WI



C. CT

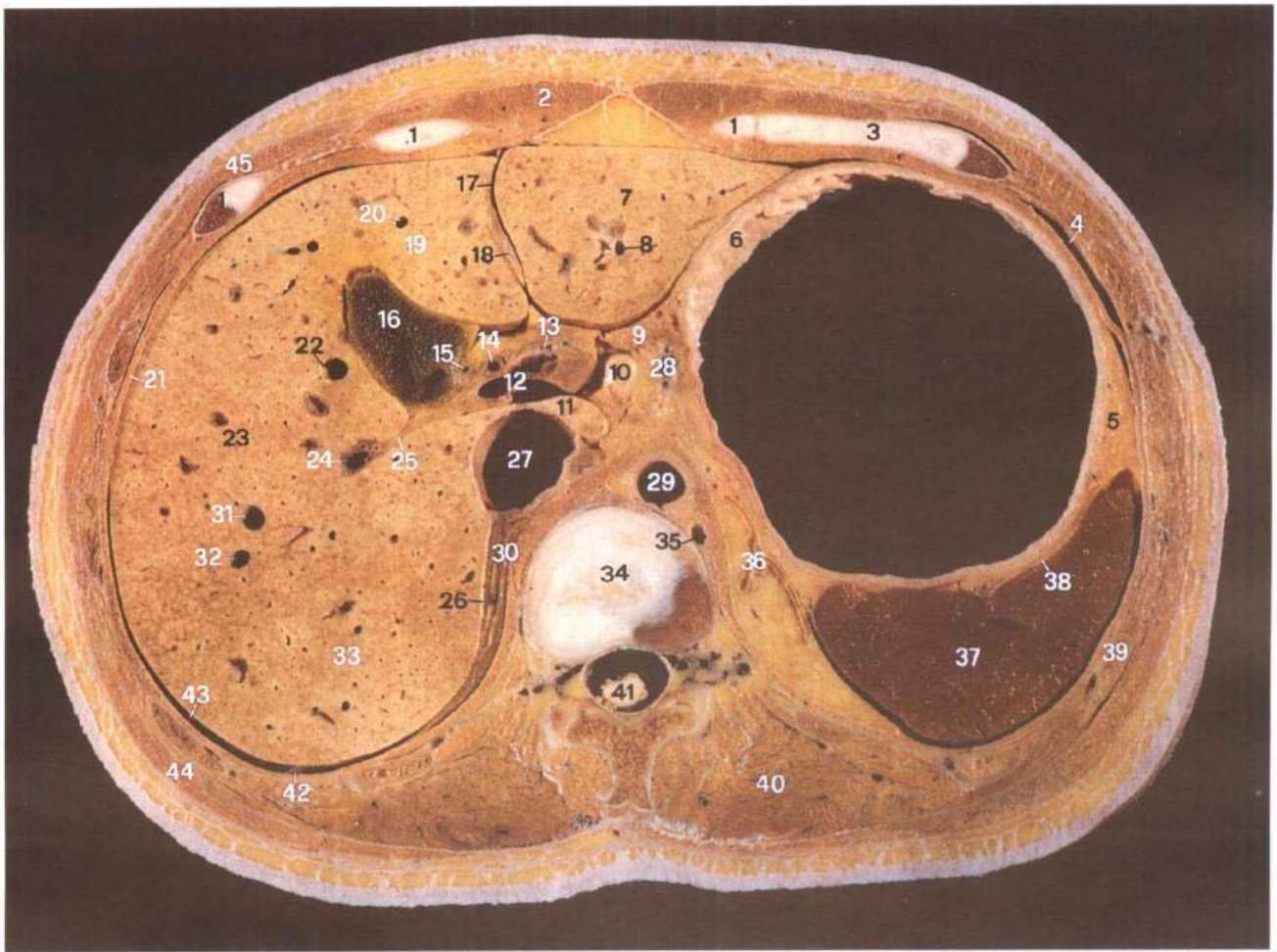


D. CT

- portal vein
- 26. 肝左外叶 left lateral lobe of liver
- 27. 肝圆韧带裂 fissure for ligamentum teres hepatis
- 28. 肝圆韧带 ligamentum teres hepatis
- 29. 肝左内叶 left medial lobe of liver
- 30. 肝中静脉属支 tributary of middle hepatic vein
- 31. 肝门静脉左支横部 transverse part of left hepatic portal vein
- 32. 肝固有动脉 proper hepatic artery
- 33. 肝左管 left hepatic duct
- 34. 肝门静脉右支 right hepatic portal vein
- 35. 胆囊 gallbladder
- 36. 肝中静脉 middle hepatic vein
- 37. 右肝上间隙 right suprahepatic space
- 38. 肝门静脉右前上支 right anteriosuperior branch of hepatic portal vein
- 39. 肝右前叶 right anterior lobe of liver
- 40. 肝门静脉右前支 anterior branch of right hepatic portal vein
- 41. 肝门静脉右后支 posterior branch of right hepatic portal vein
- 42. 肝右静脉 right hepatic vein
- 43. 肝右后叶 right posterior lobe of liver
- 44. 膈 diaphragm
- 45. 背阔肌 latissimus dorsi

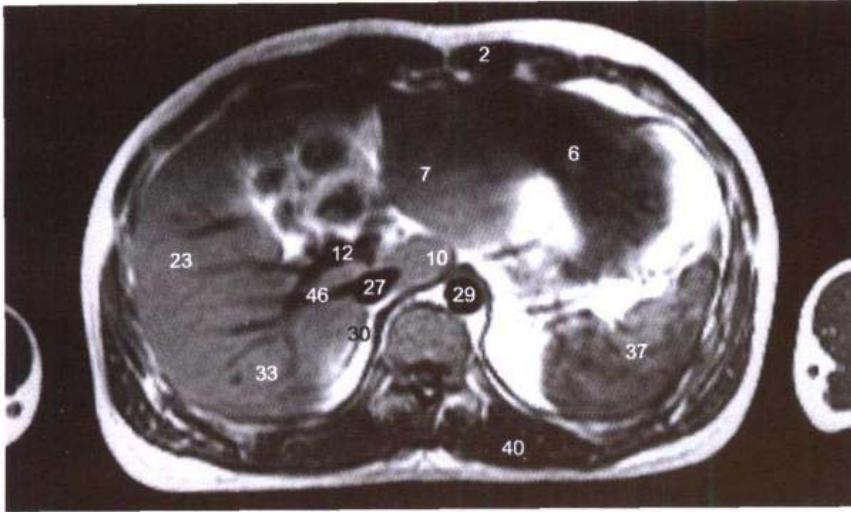
图 6-7 经胆囊窝上份的横断层

Fig.6-7 Transverse section through upper part of fossa for gallbladder

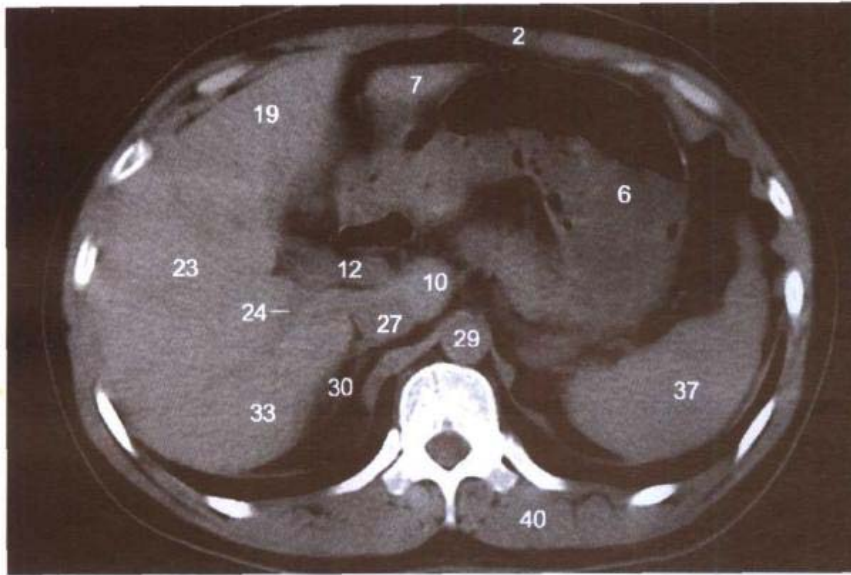


A. 断层标本 (sectional specimen)

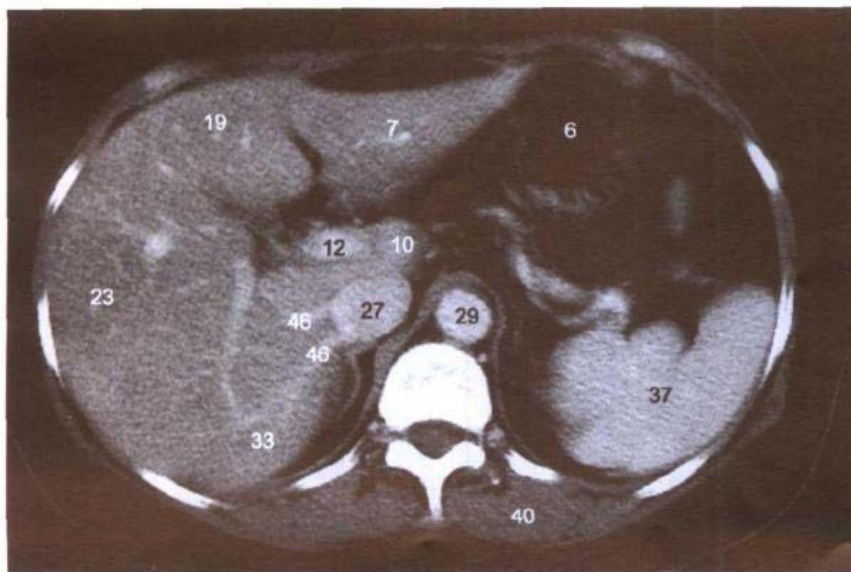
- | | | |
|------------------------------------|--|--|
| 1. 第 8 肋软骨 8th costal cartilage | 8. 肝左静脉下根 inferior root of left hepatic vein | 17. 肝圆韧带裂 fissure for ligamentum teres hepatis |
| 2. 腹直肌 rectus abdominis | 9. 小网膜 lesser omentum | 18. 肝圆韧带 ligamentum teres hepatis |
| 3. 第 7 肋软骨 7th costal cartilage | 10. 乳头突 papillary process | 19. 肝左内叶 left medial lobe of liver |
| 4. 肋膈隐窝 costodiaphragmatic recess | 11. 尾状突 caudate process | 20. 肝中静脉左根 left root of middle hepatic vein |
| 5. 大网膜 greater omentum | 12. 肝门静脉 hepatic portal vein | 21. 膈 diaphragm |
| 6. 胃体 body of stomach | 13. 肝固有动脉 proper hepatic artery | 22. 肝中静脉右根 right root of middle hepatic vein |
| 7. 肝左外叶 left lateral lobe of liver | 14. 肝总管 common hepatic duct | |
| | 15. 胆囊管 cystic duct | |
| | 16. 胆囊体 body of gallbladder | |



B. MRI T₁WI



C. CT

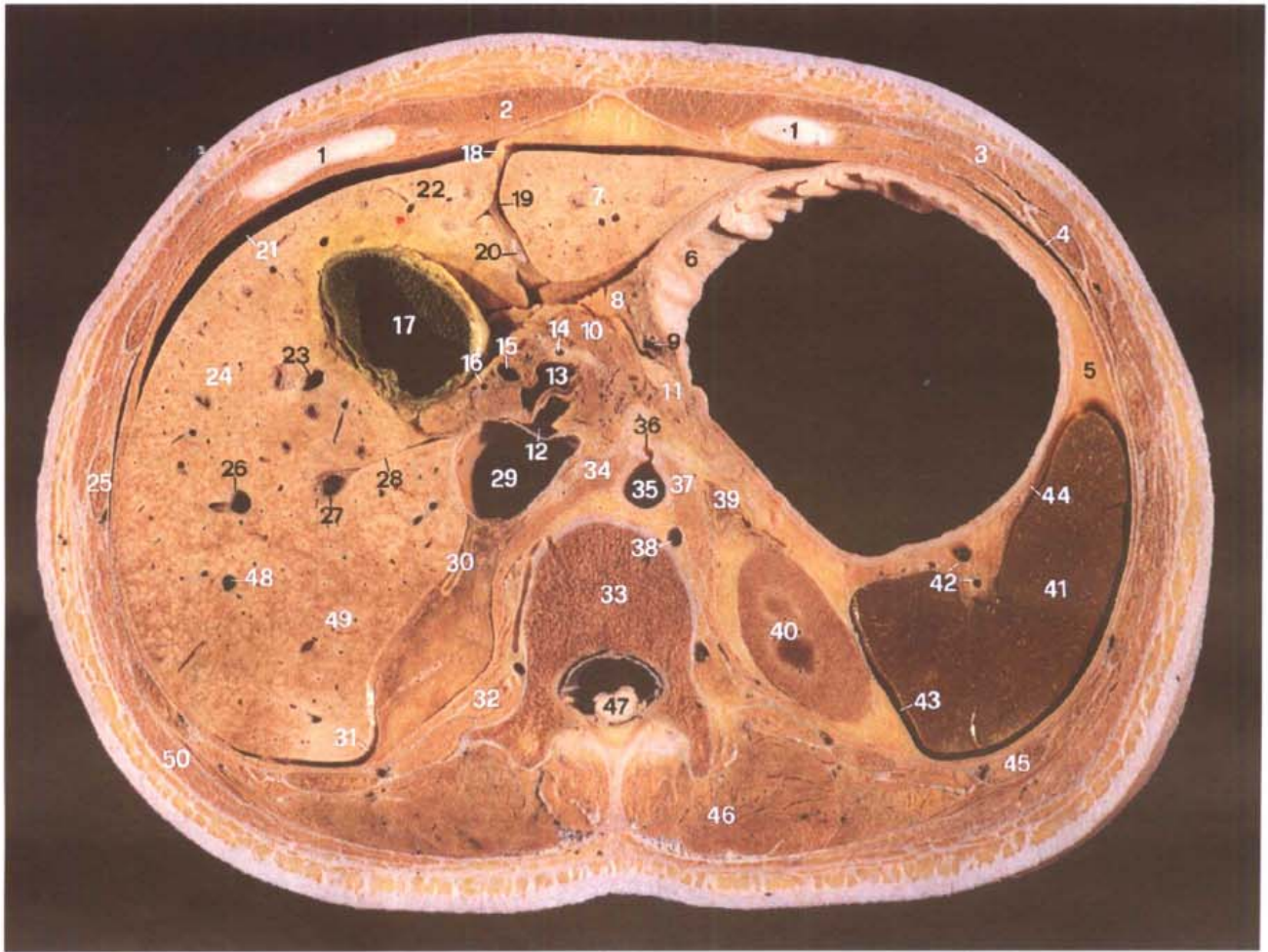


D. CT

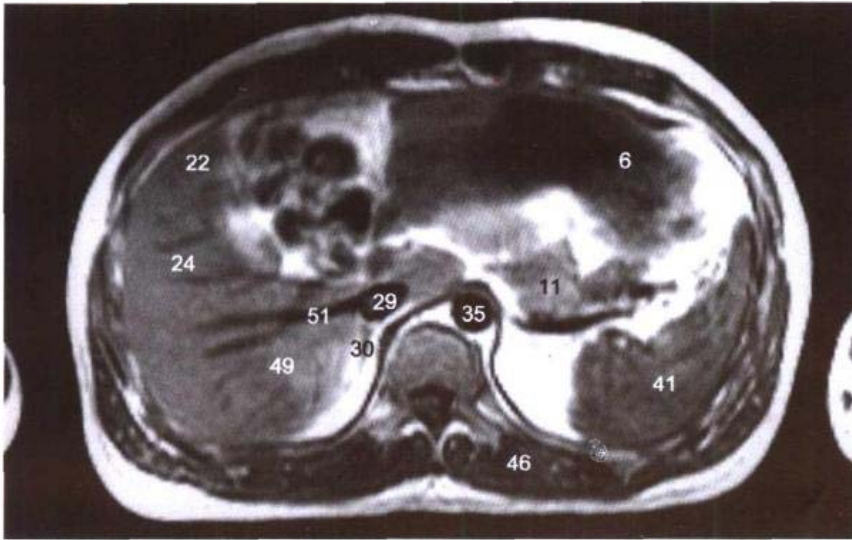
23. 肝右前叶 right anterior lobe of liver
24. 肝门静脉右后下支 right posteroinferior branch of hepatic portal vein
25. 肝门右切迹 right notch of portal hepatis
26. 肝裸区 bare area of liver
27. 下腔静脉 inferior vena cava
28. 胃左血管 left gastric vessels
29. 胸主动脉 thoracic aorta
30. 右肾上腺 right suprarenal gland
31. 肝右静脉前根 anterior root of right hepatic vein
32. 肝右静脉后根 posterior root of right hepatic vein
33. 肝右后叶 right posterior lobe of liver
34. 第12胸椎间盘 12th thoracic intervertebral disc
35. 半奇静脉 hemiazygos vein
36. 左肾上腺 left suprarenal gland
37. 脾 spleen
38. 胃脾韧带 gastrosplenic ligament
39. 第10肋 10th rib
40. 竖脊肌 erector spinae
41. 脊髓 spinal cord
42. 肝右三角韧带 right triangular ligament of liver
43. 右肝上间隙 right suprahepatic space
44. 背阔肌 latissimus dorsi
45. 腹外斜肌 obliquus externus abdominis
46. 肝右后下静脉 inferior right posterior hepatic veins

图 6-8 经腹腔干的横断层

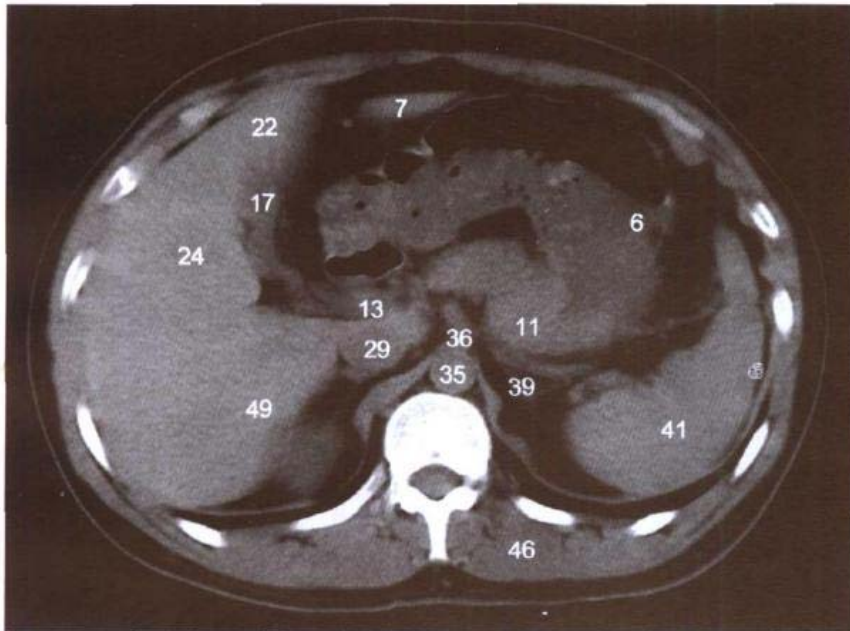
Fig.6-8 Transverse section through celiac trunk



A. 断层标本 (sectional specimen)



B. MRI T1WI



C. CT

1. 第8肋软骨 8th costal cartilage
2. 腹直肌 rectus abdominis
3. 腹外斜肌 obliquus externus abdominis
4. 肋膈隐窝 costodiaphragmatic recess
5. 大网膜 greater omentum
6. 胃体 body of stomach
7. 肝左外叶 left lateral lobe of liver
8. 小网膜 lesser omentum
9. 胃左血管 left gastric vessels
10. 肝淋巴结 hepatic lymph

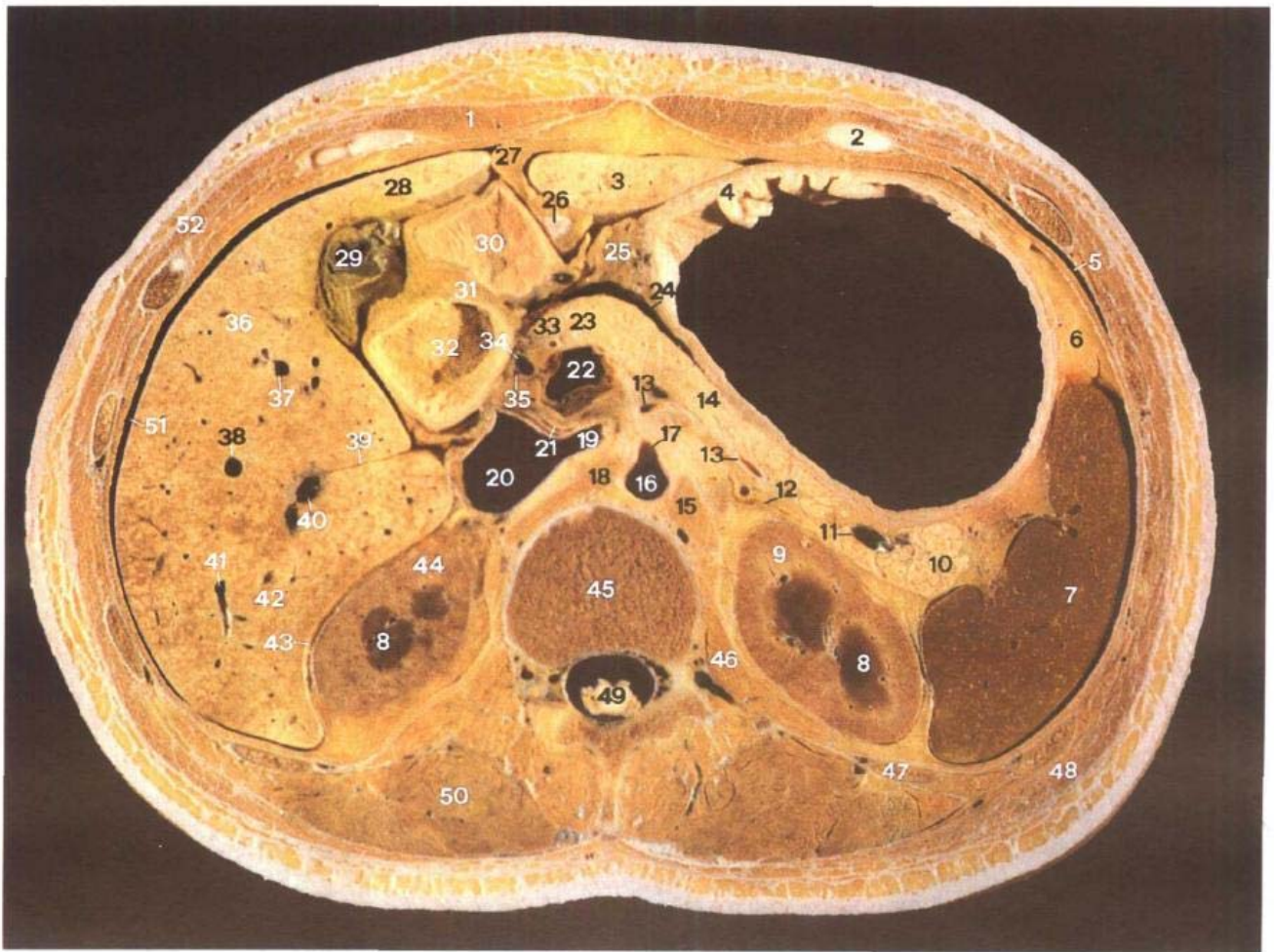
- nodes
11. 胰体 body of pancreas
12. 网膜孔 omental foramen
13. 肝门静脉 hepatic portal vein
14. 肝固有动脉 proper hepatic artery
15. 肝总管 common hepatic duct
16. 胆囊管 cystic duct
17. 胆囊体 body of gallbladder
18. 肝镰状韧带 falciform ligament of liver
19. 肝圆韧带裂 fissure for ligamentum teres hepatis
20. 肝圆韧带 ligamentum teres

hepatis

21. 右肝上间隙 right suprahepatic space
22. 肝左内叶 left medial lobe of liver
23. 肝中静脉右根 right root of middle hepatic vein
24. 肝右前叶 right anterior lobe of liver
25. 第10肋 10th rib
26. 肝右静脉前根 anterior root of right hepatic vein
27. 肝门静脉右后下支 right posteroinferior branch of hepatic portal vein
28. 肝门右切迹 right notch of porta hepatis
29. 下腔静脉 inferior vena cava
30. 右肾上腺 right suprarenal gland
31. 肝肾隐窝 hepatorenal recess
32. 腰大肌 psoas major
33. 第1腰椎体 body of 1st lumbar vertebrae
34. 右膈脚 right crus of diaphragm
35. 腹主动脉 abdominal aorta
36. 腹腔干 celiac trunk
37. 左膈脚 left crus of diaphragm
38. 半奇静脉 hemiazygos vein
39. 左肾上腺 left suprarenal gland
40. 左肾 left kidney
41. 脾 spleen
42. 脾动、静脉 splenic artery and vein
43. 脾肾隐窝 splenorenal recess
44. 胃脾韧带 gastrosplenic ligament
45. 第11肋 11th rib
46. 竖脊肌 erector spinae
47. 脊髓 spinal cord
48. 肝右静脉后根 posterior root of right hepatic vein
49. 肝右后叶 right posterior lobe of liver
50. 背阔肌 latissimus dorsi
51. 肝右后下静脉 inferior right posterior hepatic veins

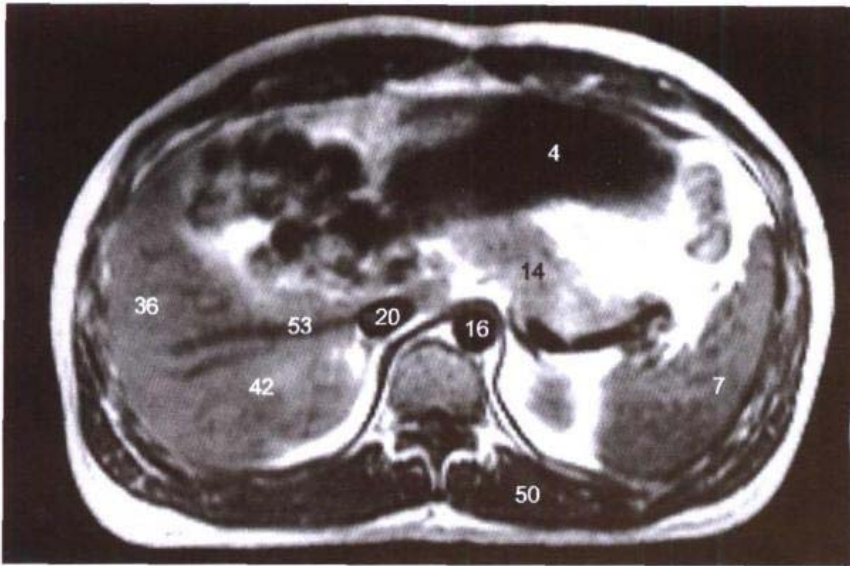
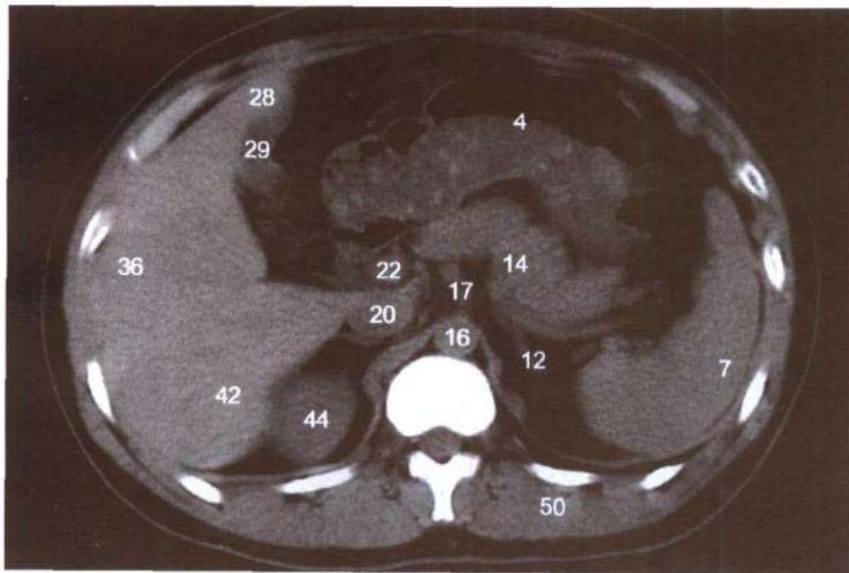
图 6-9 经幽门的横断层

Fig.6-9 Transverse section through pylorus



A. 断层标本 (sectional specimen)

- | | | |
|------------------------------------|--------------------------------|---------------------------------------|
| 1. 腹直肌 rectus abdominis | 8. 肾锥体 renal pyramids | 17. 肠系膜上动脉 superior mesenteric artery |
| 2. 第8肋软骨 8th costal cartilage | 9. 左肾 left kidney | 18. 右膈脚 right crus of diaphragm |
| 3. 肝左外叶 left lateral lobe of liver | 10. 胰尾 tail of pancreas | 19. 左肾静脉 left renal vein |
| 4. 胃体 body of stomach | 11. 脾静脉 splenic vein | 20. 下腔静脉 inferior vena cava |
| 5. 肋膈隐窝 costodiaphragmatic recess | 12. 左肾上腺 left suprarenal gland | 21. 门腔淋巴结 portocaval lymph nodes |
| 6. 大网膜 greater omentum | 13. 脾动脉 splenic artery | 22. 肝门静脉 hepatic portal vein |
| 7. 脾 spleen | 14. 胰体 body of pancreas | 23. 胰颈 neck of pancreas |
| | 15. 左膈脚 left crus of diaphragm | |
| | 16. 腹主动脉 abdominal aorta | |

B. MRI T₁WI

C. CT

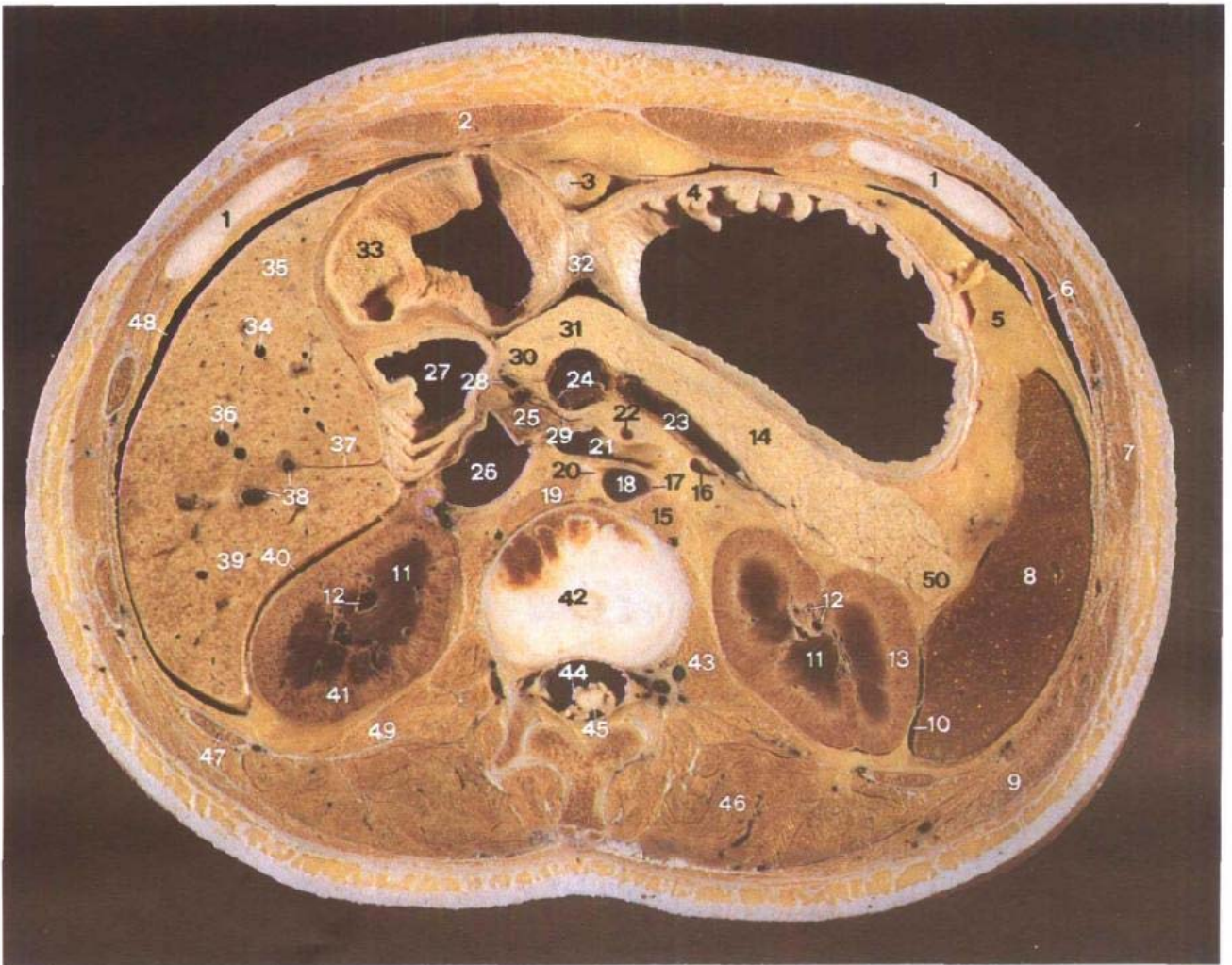
- | | |
|---|--|
| 24. 网膜囊下隐窝 inferior recess of omental bursa | 32. 十二指肠上部 superior part of duodenum |
| 25. 小网膜 lesser omentum | 33. 胃十二指肠动脉 gastroduodenal artery |
| 26. 肝圆韧带 ligamentum teres hepatis | 34. 肝总管 common hepatic duct |
| 27. 肝镰状韧带 falciform ligament of liver | 35. 胆囊管 cystic duct |
| 28. 肝左内叶 left medial lobe of liver | 36. 肝右前叶 right anterior lobe of liver |
| 29. 胆囊底 fundus of gallbladder | 37. 肝中静脉右根 right root of middle hepatic vein |
| 30. 胃幽门部 pyloric part of stomach | 38. 肝右静脉前根 anterior root of right hepatic vein |
| 31. 幽门括约肌 pyloric sphincter | 39. 肝门右切迹 right notch of |

porta hepatis

- | |
|--|
| 40. 肝门静脉右后下支 right posteroinferior branch of hepatic portal vein |
| 41. 肝右静脉后根 posterior root of right hepatic vein |
| 42. 肝右后叶 right posterior lobe of liver |
| 43. 肝肾隐窝 hepatorenal recess |
| 44. 右肾 right kidney |
| 45. 第1腰椎体 body of 1st lumbar vertebrae |
| 46. 腰大肌 psoas major |
| 47. 第12肋 12th rib |
| 48. 背阔肌 latissimus dorsi |
| 49. 脊髓 spinal cord |
| 50. 竖脊肌 erector spinae |
| 51. 右肝上前间隙 anterior right suprahepatic space |
| 52. 腹外斜肌 obliquus externus abdominis |
| 53. 肝右后下静脉 inferior right posterior hepatic veins |

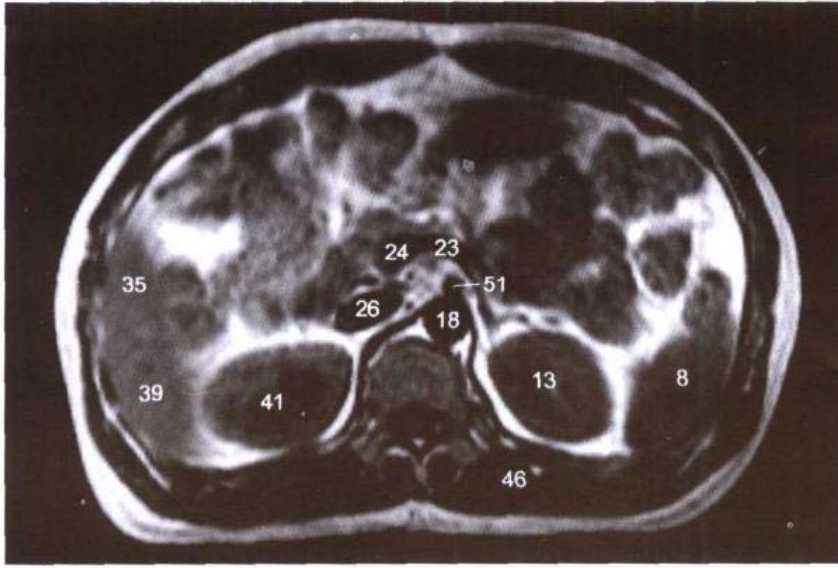
图 6-10 经肝门静脉起始部的横断层

Fig.6-10 Transverse section through origin of hepatic portal vein

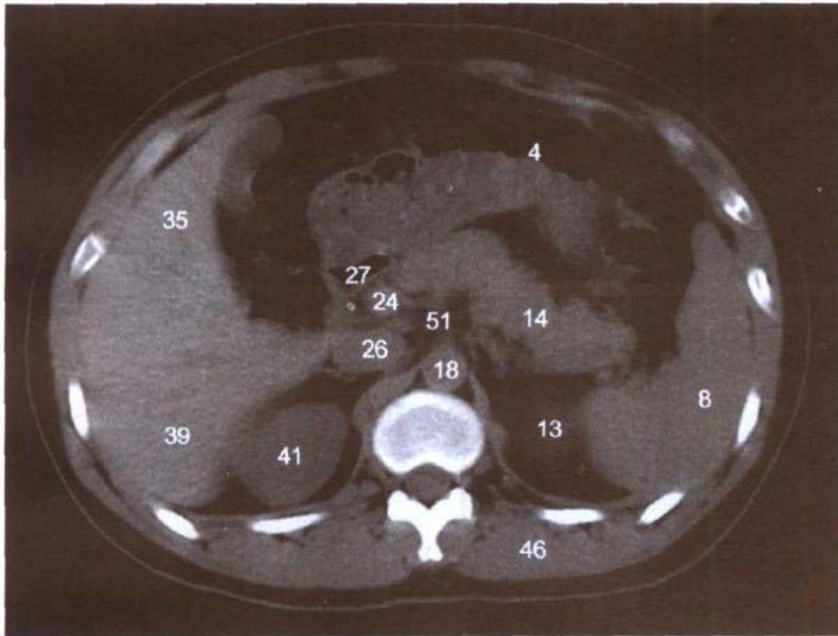


A. 断层标本 (sectional specimen)

- | | | |
|-------------------------------------|---------------------------------|---------------------------------------|
| 1. 第9肋软骨 9th costal cartilage | 8. 脾 spleen | 18. 腹主动脉 abdominal aorta |
| 2. 腹直肌 rectus abdominis | 9. 背阔肌 latissimus dorsi | 19. 右膈脚 right crus of diaphragm |
| 3. 肝圆韧带 ligamentum teres hepatis | 10. 脾肾隐窝 splenorenal recess | 20. 右肾动脉 right renal artery |
| 4. 胃体 body of stomach | 11. 肾锥体 renal pyramid | 21. 左肾静脉 left renal vein |
| 5. 大网膜 greater omentum | 12. 肾动、静脉 renal artery and vein | 22. 肠系膜上动脉 superior mesenteric artery |
| 6. 肋膈隐窝 costodiaphragmatic recess | 13. 左肾 left kidney | 23. 脾静脉 splenic vein |
| 7. 腹外斜肌 obliquus externus abdominis | 14. 胰体 body of pancreas | 24. 肠系膜上静脉 superior mesenteric vein |
| | 15. 左膈脚 left crus of diaphragm | 25. 门腔淋巴结 portocaval lymph |
| | 16. 脾动脉 splenic artery | |
| | 17. 左肾动脉 left renal artery | |



B. MRI T₁WI



C. CT

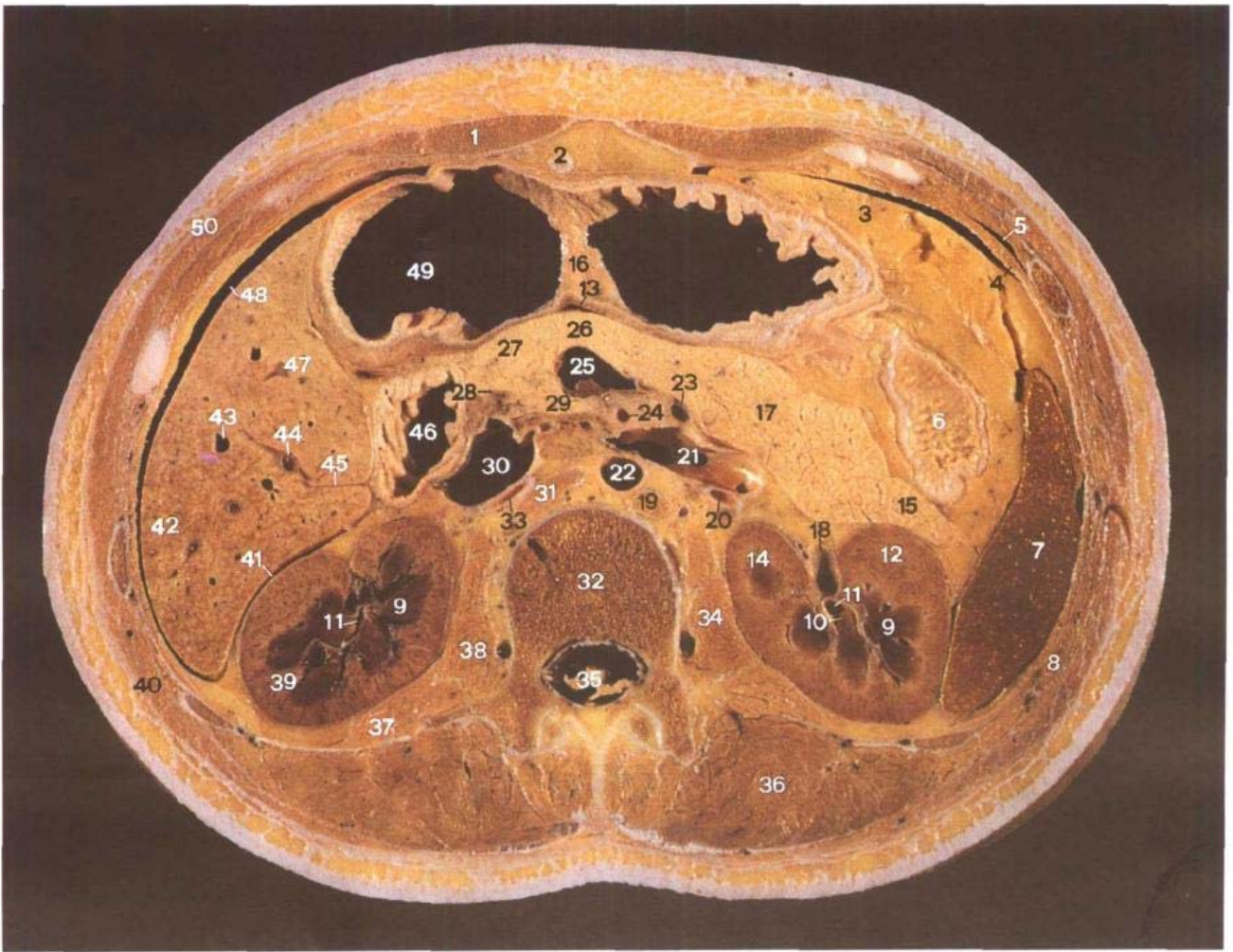
steroinferior branch of hepatic portal vein

- 39. 肝右后叶 right posterior lobe of liver
- 40. 肝肾隐窝 hepatorenal recess
- 41. 右肾 right kidney
- 42. 第1腰椎间盘 1st lumbar intervertebral disc
- 43. 腰大肌 psoas major
- 44. 马尾 cauda equina
- 45. 脊髓圆锥 conus medullaris
- 46. 竖脊肌 erector spinae
- 47. 第12肋 12th rib
- 48. 右肝上间隙 right suprahepatic space
- 49. 腰方肌 quadratus lumborum
- 50. 胰尾 tail of pancreas
- 51. 腹腔干 celiac artery

- nodes
- 26. 下腔静脉 inferior vena cava
- 27. 十二指肠降部 descending part of duodenum
- 28. 胆总管 common bile duct
- 29. 胰钩突 uncinat process of pancreas
- 30. 胰头 head of pancreas
- 31. 胰颈 neck of pancreas
- 32. 网膜囊下隐窝 inferior recess of omental bursa
- 33. 胃幽门部 pyloric part of stomach
- 34. 肝中静脉右根 right root of middle hepatic vein
- 35. 肝右前叶 right anterior lobe of liver
- 36. 肝右静脉前根 anterior root of right hepatic vein
- 37. 肝门右切迹 right notch of porta hepatis
- 38. 肝门静脉右后下支 right po-

图 6-11 经第 2 腰椎体上份的横断层

Fig.6-11 Transverse section through upper part of second lumbar vertebrae

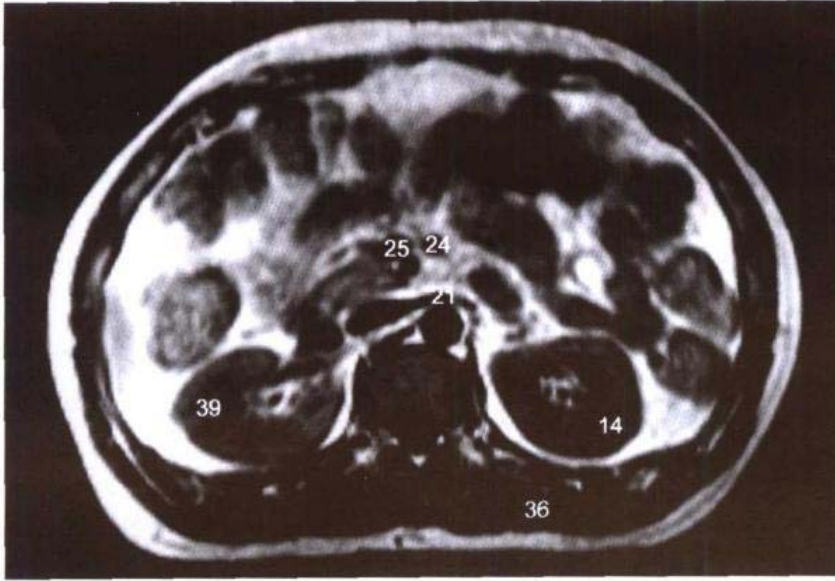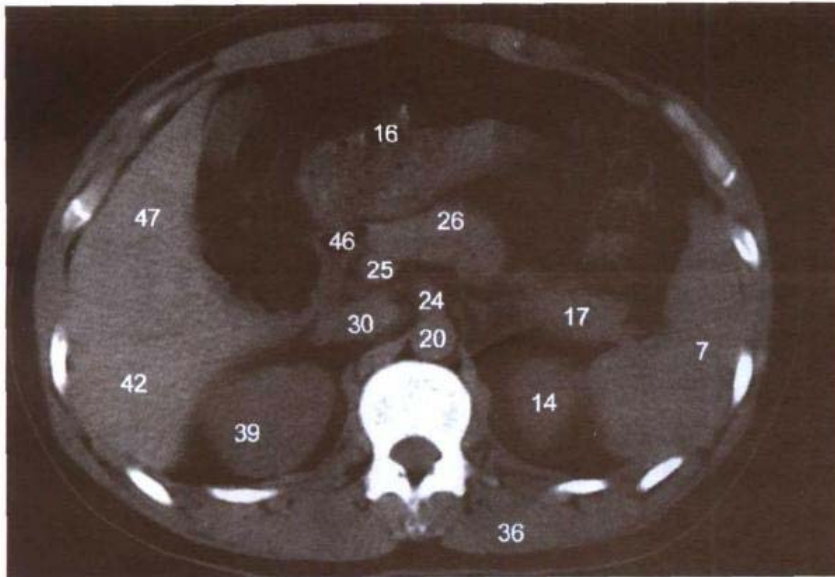


A. 断层标本 (sectional Specimen)

- 1. 腹直肌 rectus abdominis
- 2. 肝圆韧带 ligamentum teres hepatis
- 3. 大网膜 greater omentum
- 4. 膈 diaphragm
- 5. 肋膈隐窝 costodiaphragmatic recess
- 6. 结肠左曲 left colic flexure
- 7. 脾 spleen

- 8. 第 11 肋 11th rib
- 9. 肾锥体 renal pyramid
- 10. 肾乳头 renal papillae
- 11. 肾小盏 minor renal calices
- 12. 肾皮质 renal cortex
- 13. 网膜囊下隐窝 inferior recess of omental bursa
- 14. 左肾 left kidney
- 15. 胰尾 tail of pancreas

- 16. 胃体 body of stomach
- 17. 胰体 body of pancreas
- 18. 左肾静脉 left renal vein
- 19. 左膈脚 left crus of diaphragm
- 20. 左肾动脉 left renal artery
- 21. 左肾静脉 left renal vein
- 22. 腹主动脉 abdominal aorta
- 23. 肠系膜下静脉 inferior me-

B. MRI T₁WI

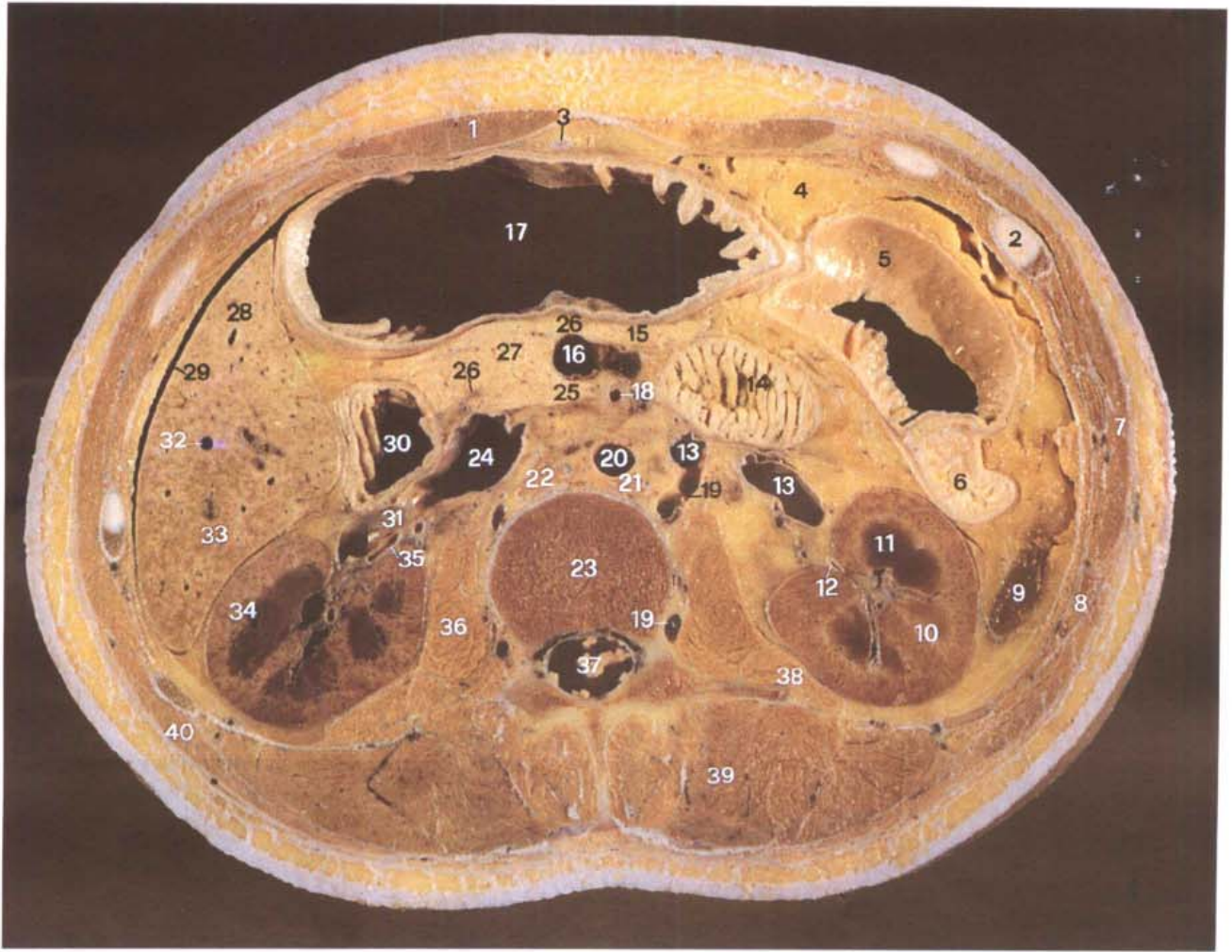
C. CT

42. 肝右后叶 right posterior lobe of liver
43. 肝右静脉前根 anterior root of right hepatic vein
44. 肝门静脉右后下支 right posteroinferior branch of hepatic portal vein
45. 肝门右切迹 right notch of porta hepatis
46. 十二指肠降部 descending part of duodenum
47. 肝右前叶 right anterior lobe of liver
48. 右肝上间隙 right suprahepatic space
49. 胃幽门部 pyloric part of stomach
50. 腹外斜肌 obliquus externus abdominis

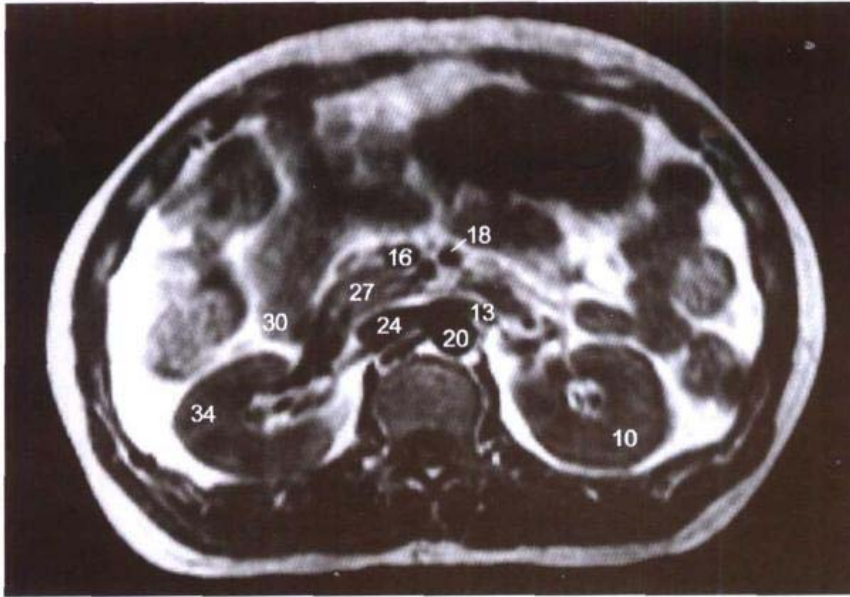
- | | |
|---------------------------------------|--|
| 24. 肠系膜上动脉 superior mesenteric artery | 32. 第2腰椎体 body of 2nd lumbar vertebrae |
| 25. 肠系膜上静脉 superior mesenteric vein | 33. 右肾动脉 right renal artery |
| 26. 胰颈 neck of pancreas | 34. 腰大肌 psoas major |
| 27. 胰头 head of pancreas | 35. 马尾 cauda equina |
| 28. 胆总管 common bile duct | 36. 竖脊肌 erector spinae |
| 29. 胰钩突 uncinat process of pancreas | 37. 腰方肌 quadratus lumborum |
| 30. 下腔静脉 inferior vena cava | 38. 腰静脉 lumbar vein |
| 31. 右膈脚 right crus of diaphragm | 39. 右肾 right kidney |
| | 40. 背阔肌 latissimus dorsi |
| | 41. 肝肾隐窝 hepatorenal recess |

图 6-12 经十二指肠空肠曲的横断层

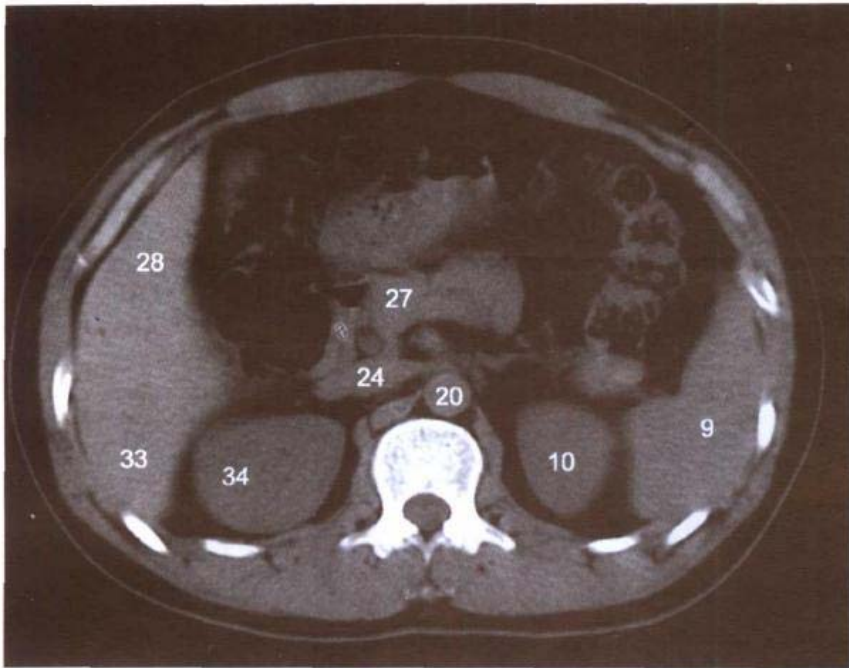
Fig.6-12 Transverse section through duodenojejunal flexure



A. 断层标本 (sectional specimen)



B. MRI T1WI



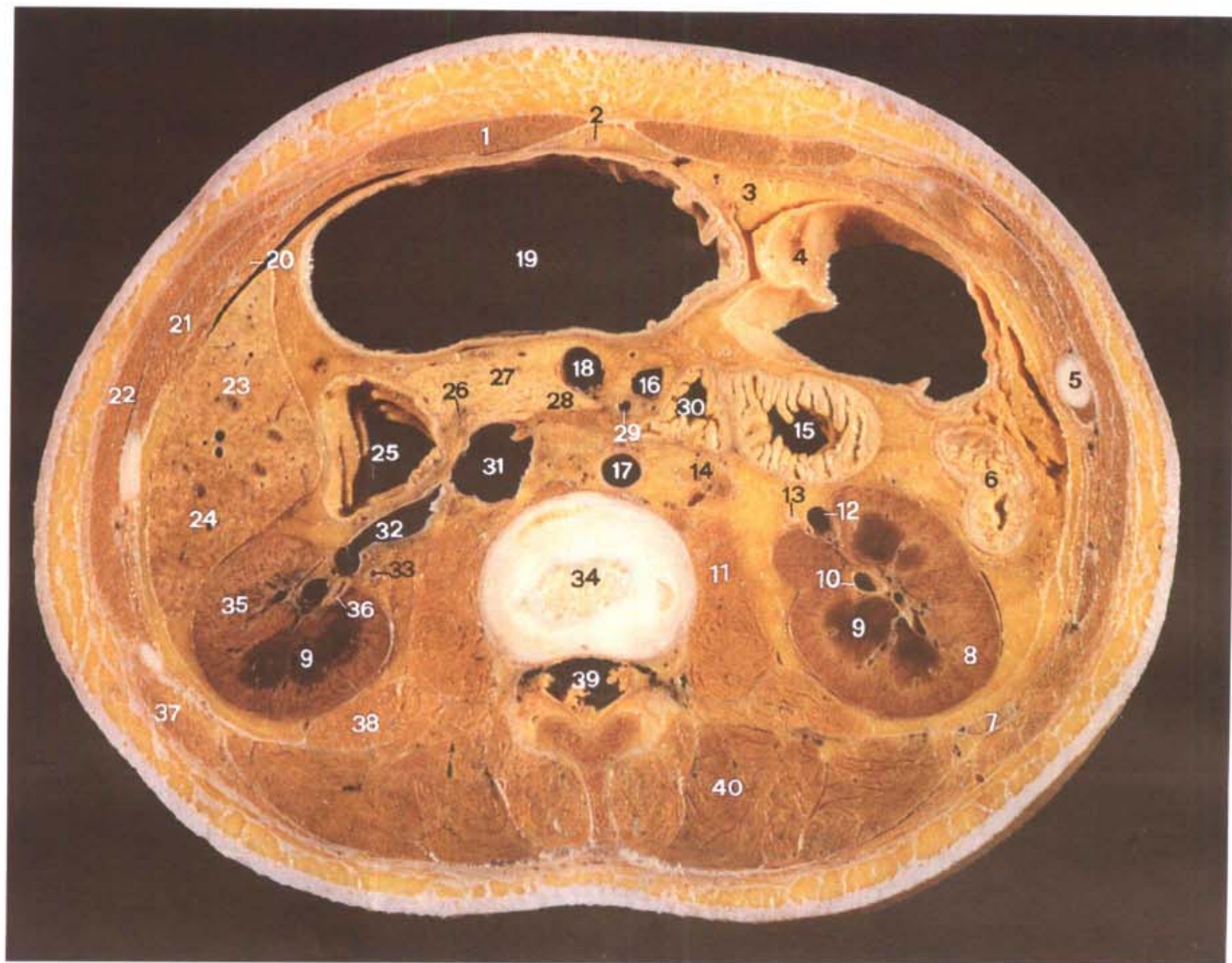
C. CT

- | | |
|---------------------------------|------------------------------------|
| 1. 腹直肌 rectus abdominis | 8. 第11肋 11th rib |
| 2. 第9肋软骨 9th costal cartilage | 9. 脾 spleen |
| 3. 肝圆韧带 ligamentum tereshepatis | 10. 左肾 left kidney |
| 4. 大网膜 greater omentum | 11. 肾锥体 renal pyramid |
| 5. 横结肠 transverse colon | 12. 左肾盂 left renal pelvis |
| 6. 降结肠 descending colon | 13. 左肾静脉 left renal vein |
| 7. 腹外斜肌 obliquus externus | 14. 十二指肠空肠曲 duodenojejunal flexure |

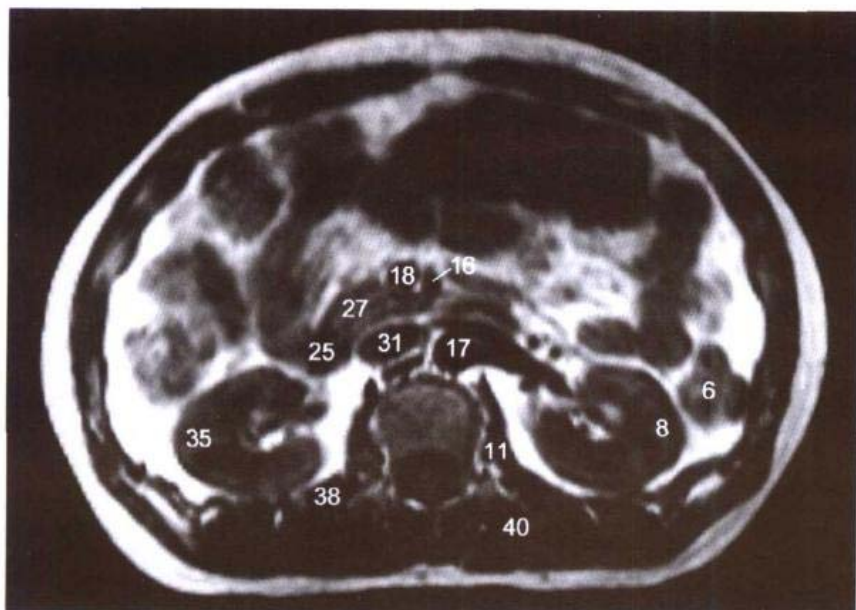
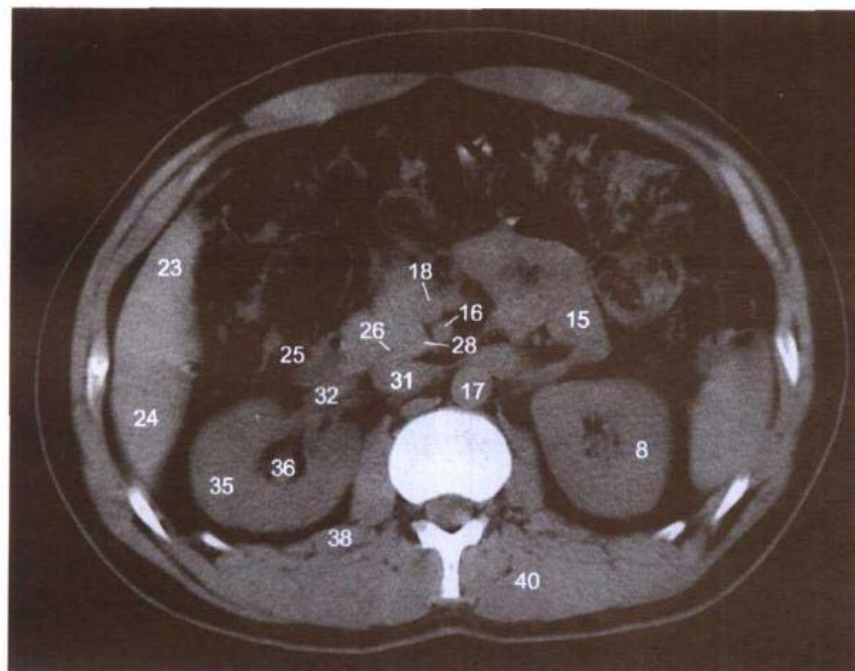
- | |
|---|
| 15. 胰体 body of pancreas |
| 16. 肠系膜上静脉 superior mesenteric vein |
| 17. 胃体 body of stomach |
| 18. 肠系膜上动脉 superior mesenteric artery |
| 19. 腰静脉 lumbar vein |
| 20. 腹主动脉 abdominal aorta |
| 21. 左膈脚 left crus of diaphragm |
| 22. 右膈脚 right crus of diaphragm |
| 23. 第2腰椎体 body of 2nd lumbar vertebrae |
| 24. 下腔静脉 inferior vena cava |
| 25. 胰钩突 uncinat process of pancreas |
| 26. 胰及胆总管 neck of pancreas and common bile duct |
| 27. 胰头 head of pancreas |
| 28. 肝右前叶 right anterior lobe of liver |
| 29. 右肝上间隙 right suprahepatic space |
| 30. 十二指肠降部 descending part of duodenum |
| 31. 右肾静脉 right renal vein |
| 32. 肝右静脉前根 anterior root of right hepatic vein |
| 33. 肝右后叶 right posterior lobe of liver |
| 34. 右肾 right kidney |
| 35. 右肾动脉 right renal artery |
| 36. 腰大肌 psoas major |
| 37. 马尾 cauda equina |
| 38. 腰方肌 quadratus lumborum |
| 39. 竖脊肌 erector spinae |
| 40. 背阔肌 latissimus dorsi |

图 6-13 经第 2 腰椎间盘的横断层

Fig.6-13 Transverse section through second lumbar intervertebral disc



A. 断层标本 (sectional specimen)

B. MRI T₁WI

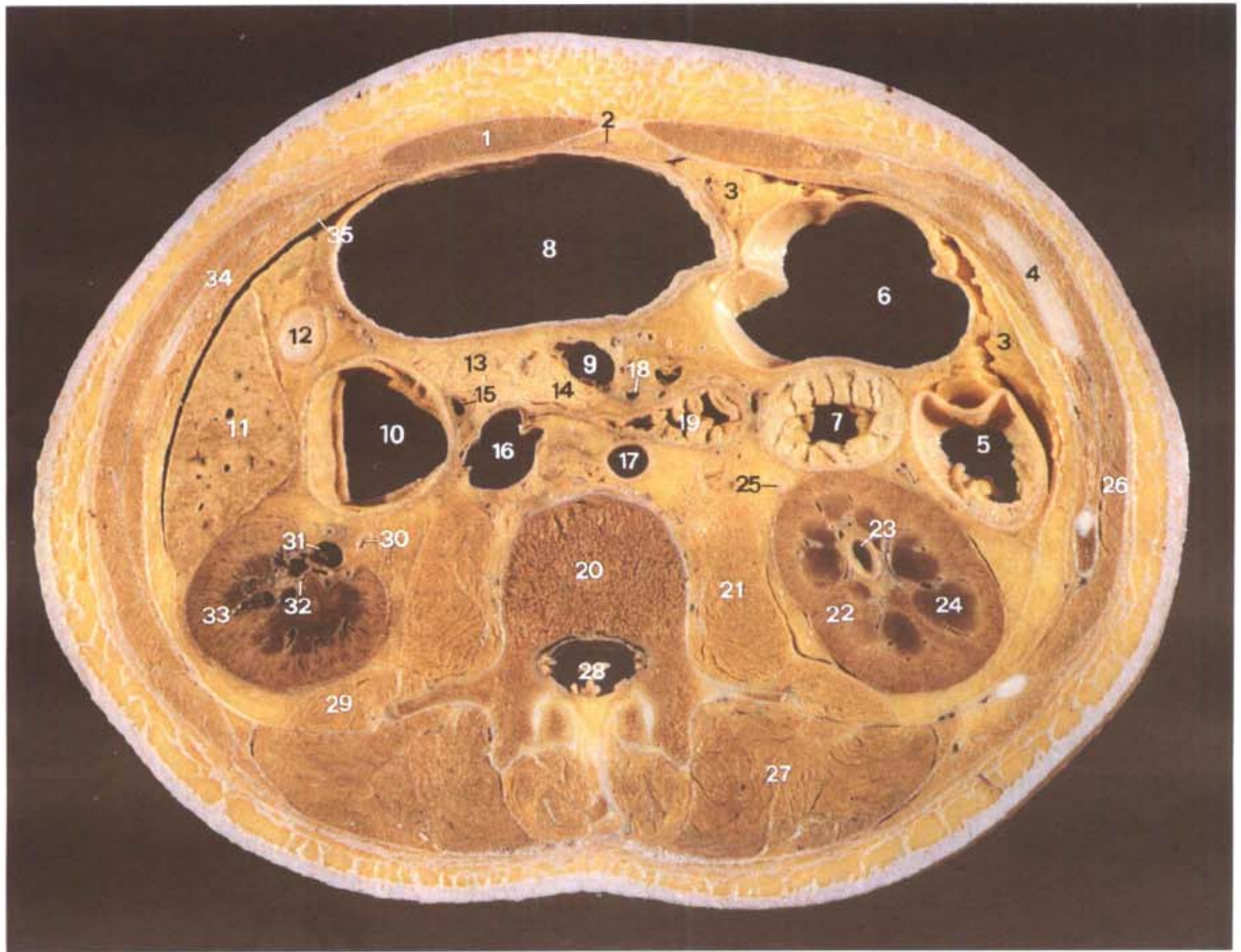
C. CT

- | | |
|----------------------------------|-------------------------------------|
| 1. 腹直肌 rectus abdominis | 9. 肾锥体 renal pyramid |
| 2. 肝圆韧带 ligamentum teres hepatis | 10. 左肾盂 left renal pelvis |
| 3. 大网膜 greater omentum | 11. 腰大肌 psoas major |
| 4. 横结肠 transverse colon | 12. 左肾静脉 left renal vein |
| 5. 第10肋软骨 10th costal cartilage | 13. 左输尿管 left ureter |
| 6. 降结肠 descending colon | 14. 腰淋巴结 lumbar lymph nodes |
| 7. 第12肋 12th rib | 15. 空肠 jejunum |
| 8. 左肾 left kidney | 16. 空肠静脉 jejunal vein |
| | 17. 腹主动脉 abdominal aorta |
| | 18. 肠系膜上静脉 superior mesenteric vein |

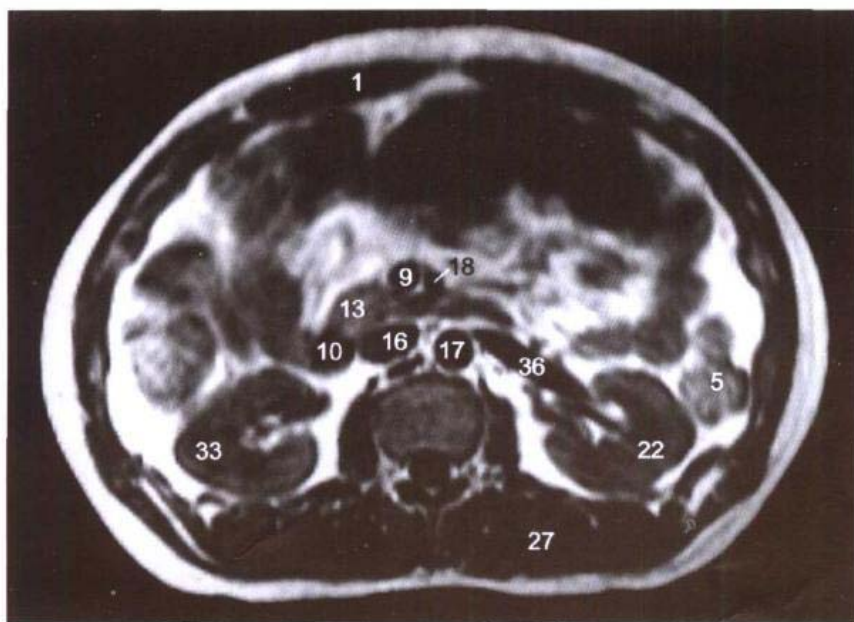
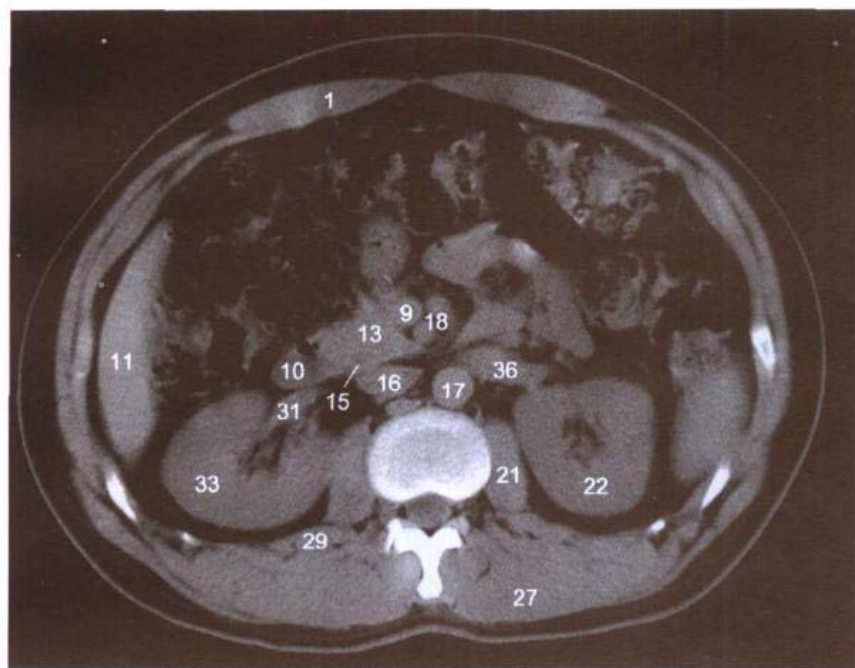
- | |
|---|
| 19. 胃体 body of stomach |
| 20. 腹横肌 transversus abdominis |
| 21. 腹内斜肌 obliquus internus abdominis |
| 22. 腹外斜肌 obliquus externus abdominis |
| 23. 肝右前叶 right anterior lobe of liver |
| 24. 肝右后叶 right posterior lobe of liver |
| 25. 十二指肠降部 descending part of duodenum |
| 26. 胆总管 common bile duct |
| 27. 胰头 head of pancreas |
| 28. 胰钩突 uncinus process of pancreas |
| 29. 肠系膜上动脉 superior mesenteric artery |
| 30. 十二指肠升部 ascending part of duodenum |
| 31. 下腔静脉 inferior vena cava |
| 32. 右肾静脉 right renal vein |
| 33. 右肾动脉 right renal artery |
| 34. 第2腰椎间盘 2nd lumbar intervertebral disc |
| 35. 右肾 right kidney |
| 36. 右肾盂 right renal pelvis |
| 37. 背阔肌 latissimus dorsi |
| 38. 腰方肌 quadratus lumborum |
| 39. 马尾 cauda equina |
| 40. 竖脊肌 erector spinae |

图 6-14 经第 3 腰椎体上份的横断层

Fig.6-14 Transverse section through upper part of body of third lumbar vertebrae



A. 断层标本 (sectional specimen)

B. MRI T₁WI

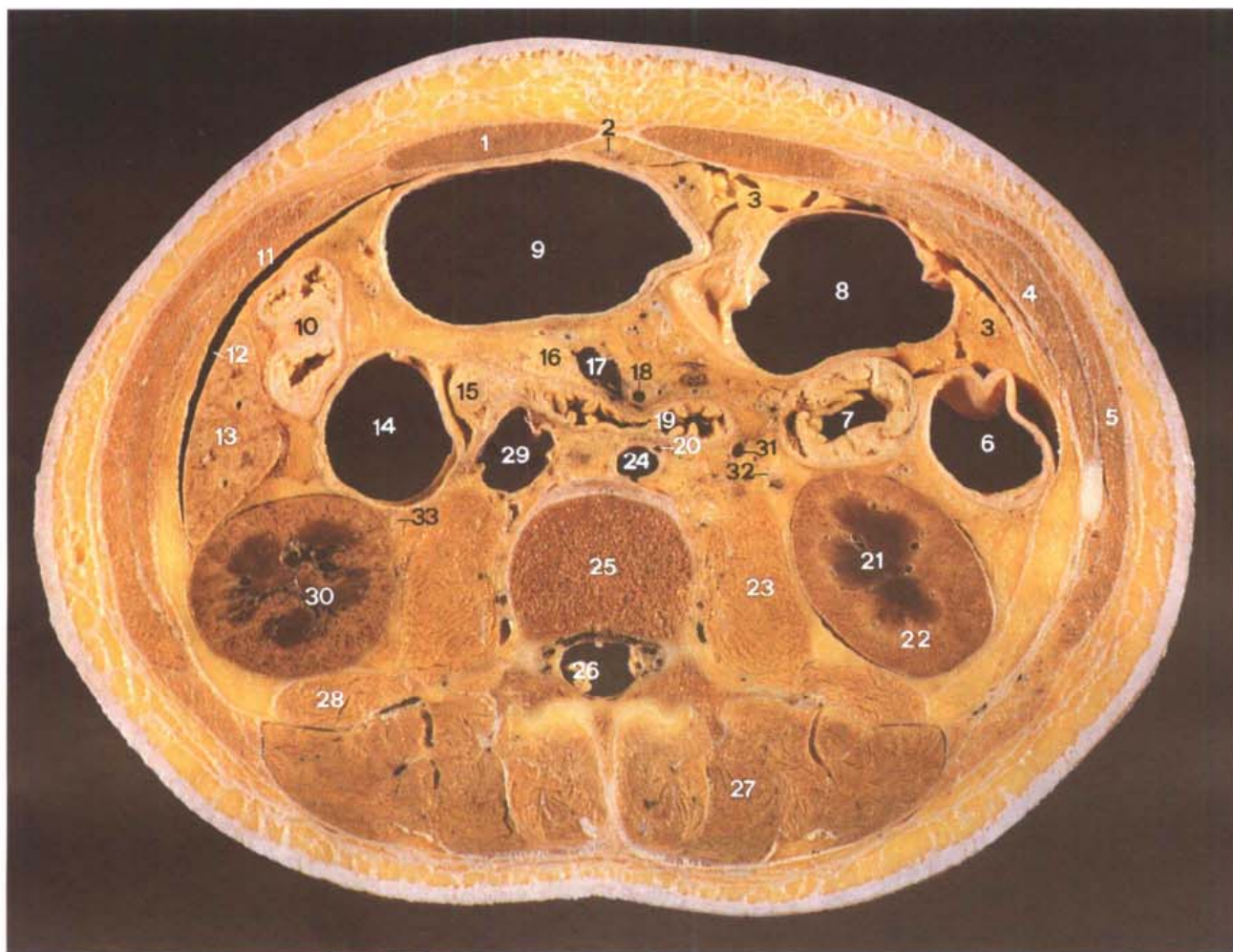
C. CT

- | | |
|----------------------------------|--|
| 1. 腹直肌 rectus abdominis | 8. 胃体 body of stomach |
| 2. 肝圆韧带 ligamentum teres hepatis | 9. 肠系膜上静脉 superior mesenteric vein |
| 3. 大网膜 greater omentum | 10. 十二指肠降部 descending part of duodenum |
| 4. 第10肋软骨 10th costal cartilage | 11. 肝右叶 right lobe of liver |
| 5. 降结肠 descending colon | 12. 结肠右曲 right colic flexure |
| 6. 横结肠 transverse colon | 13. 胰头 head of pancreas |
| 7. 空肠 jejunum | 14. 胰钩突 uncinat process of |

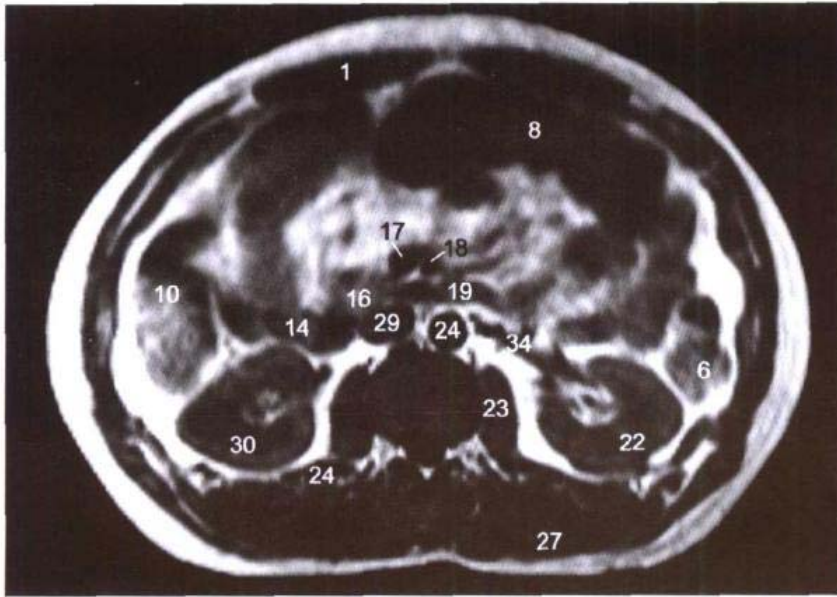
- | |
|--|
| pancreas |
| 15. 胆总管 common bile duct |
| 16. 下腔静脉 inferior vena cava |
| 17. 腹主动脉 abdominal aorta |
| 18. 肠系膜上动脉 superior mesenteric artery |
| 19. 十二指肠升部 ascending part of duodenum |
| 20. 第3腰椎体 body of 3rd lumbar vertebrae |
| 21. 腰大肌 psoas major |
| 22. 左肾 left kidney |
| 23. 左肾盂 left renal pelvis |
| 24. 肾锥体 renal pyramid |
| 25. 左输尿管 left ureter |
| 26. 腹外斜肌 obliquus externus abdominis |
| 27. 竖脊肌 erector spinae |
| 28. 马尾 cauda equina |
| 29. 腰方肌 quadratus lumborum |
| 30. 右肾盂 right renal pelvis |
| 31. 右肾静脉 right renal vein |
| 32. 肾小盏 minor renal calices |
| 33. 右肾 right kidney |
| 34. 腹内斜肌 obliquus internus abdominis |
| 35. 腹横肌 transversus abdominis |
| 36. 左肾静脉 left renal vein |

图 6-15 经十二指肠大乳头的横断层

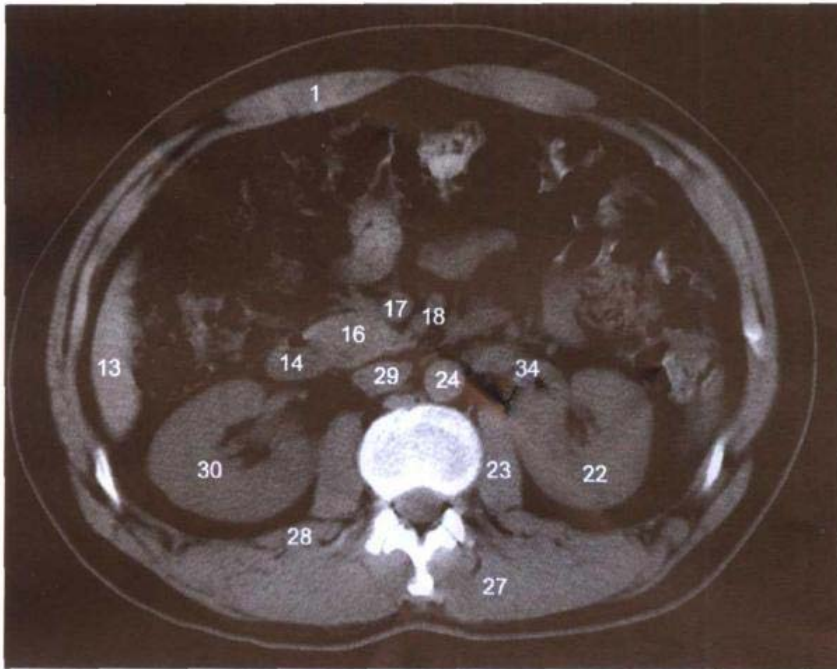
Fig.6-15 Transverse section through major duodenal papilla



A.断层标本 (sectional specimen)



B. MRI T1WI



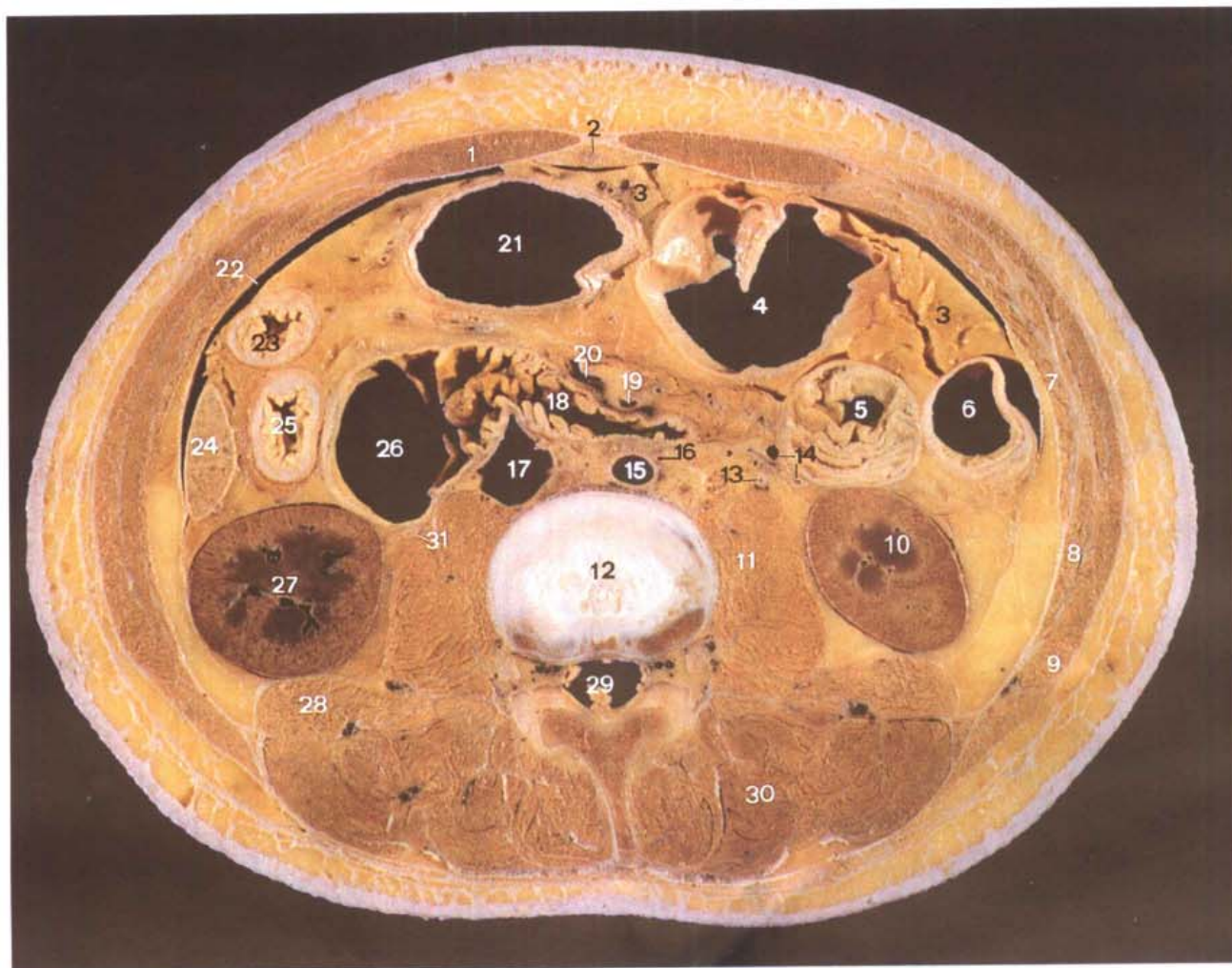
C. CT

15. 十二指肠大乳头 major duodenal papilla
16. 胰头 head of pancreas
17. 肠系膜上静脉 superior mesenteric vein
18. 肠系膜上动脉 superior mesenteric artery
19. 十二指肠水平部 horizontal part of duodenum
20. 肠系膜下动脉 inferior mesenteric artery
21. 肾锥体 renal pyramid
22. 左肾 left kidney
23. 腰大肌 psoas major
24. 腹主动脉 abdominal aorta
25. 第3腰椎体 body of 3rd lumbar vertebrae
26. 马尾 cauda equina
27. 竖脊肌 erector spinae
28. 腰方肌 quadratus lumborum
29. 下腔静脉 inferior vena cava
30. 右肾 right kidney
31. 左睾丸静脉 left testicular vein
32. 左输尿管 left ureter
33. 右输尿管 right ureter
34. 左肾静脉 left renal vein

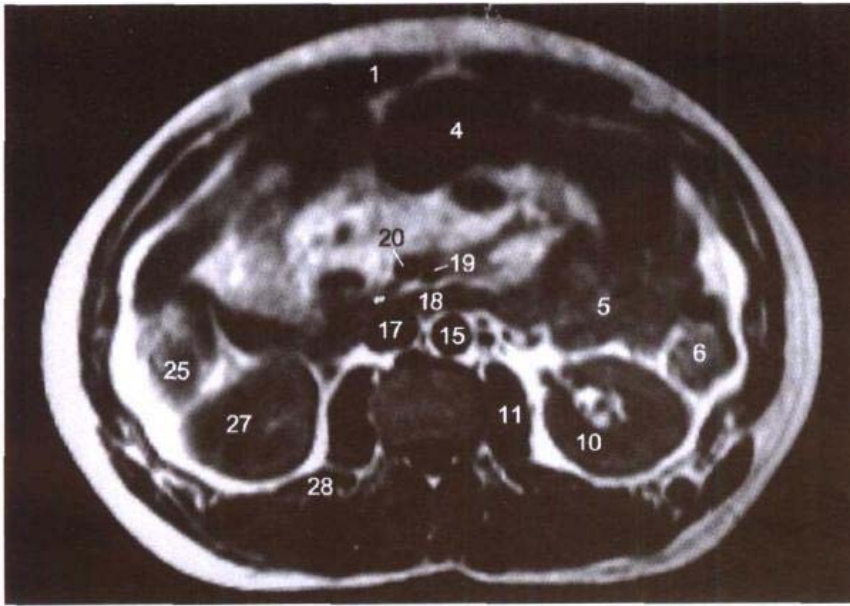
1. 腹直肌 rectus abdominis
2. 肝圆韧带 ligamentum teres hepatis
3. 大网膜 greater omentum
4. 腹内斜肌 obliquus internus abdominis
5. 腹外斜肌 obliquus externus abdominis
6. 降结肠 descending colon
7. 空肠 jejunum
8. 横结肠 transverse colon
9. 胃体 body of stomach
10. 结肠右曲 right colic flexure
11. 腹横肌 transversus abdominis
12. 腹膜腔 peritoneal cavity
13. 肝右叶 right lobe of liver
14. 十二指肠降部 descending part of duodenum

图 6-16 经第 3 腰椎间盘的横断层

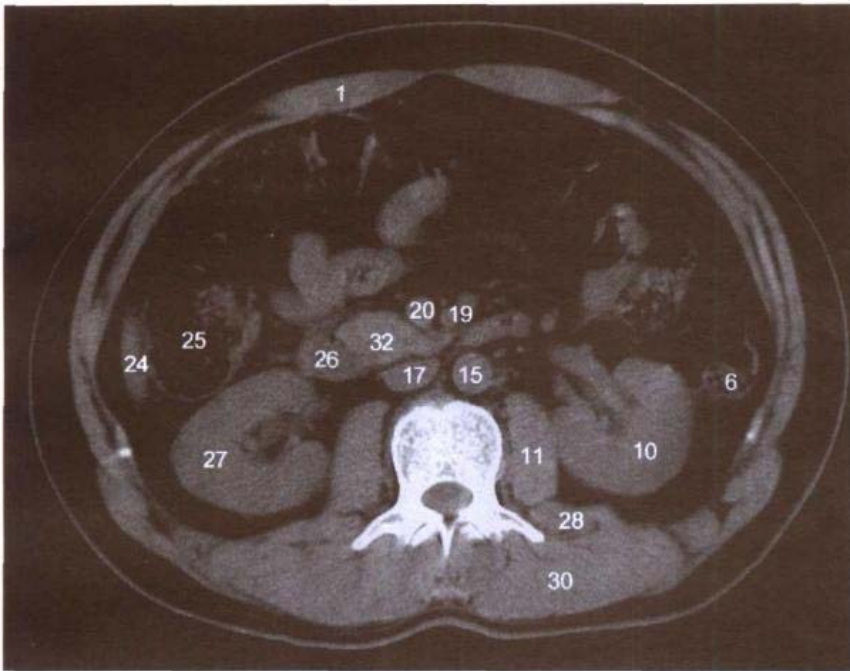
Fig.6-16 Transverse section through third lumbar intervertebral disc



A.断层标本 (sectional specimen)



B. MRI T1WI



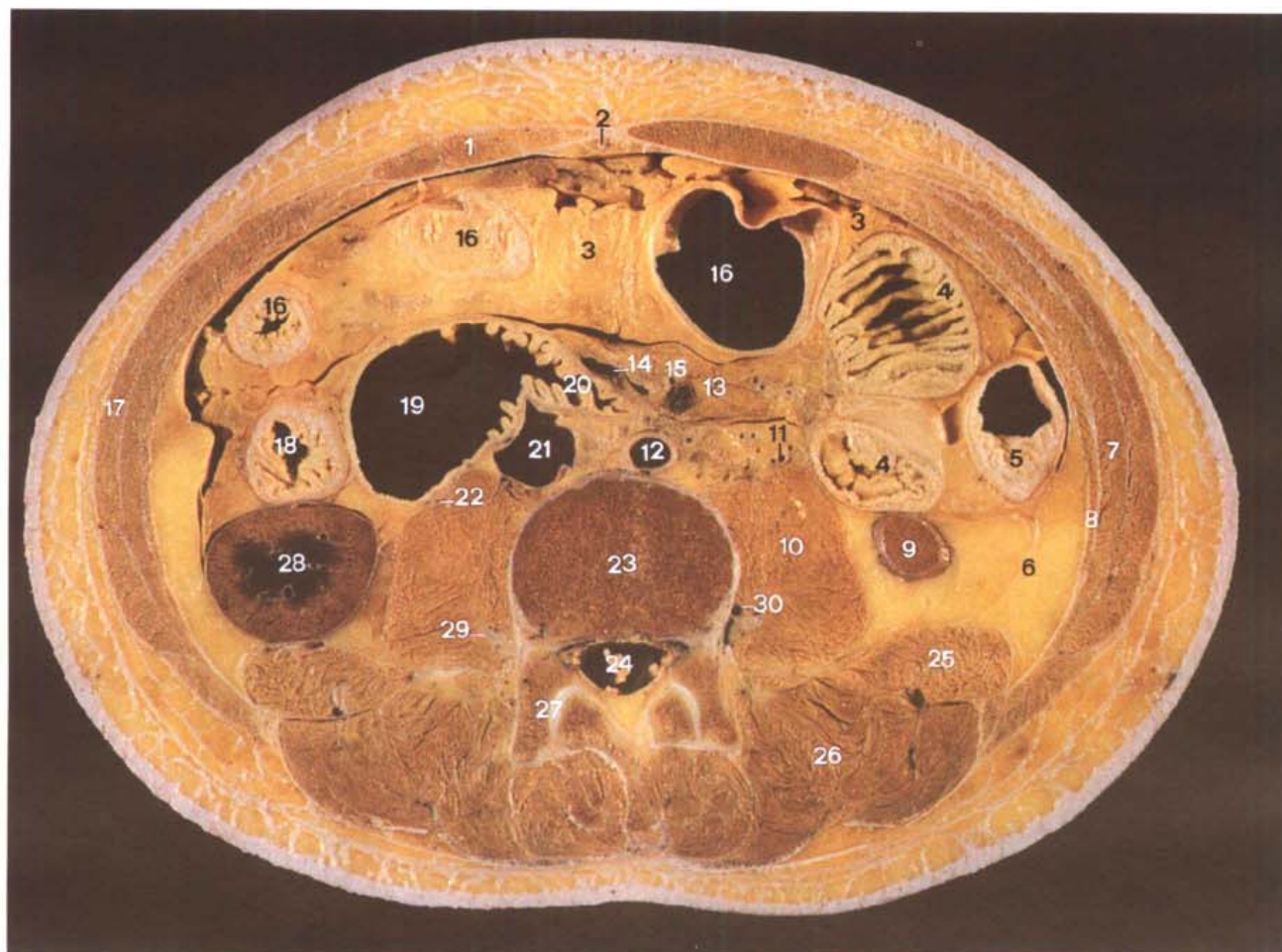
C. CT

- lar artery and vein
 15. 腹主动脉 abdominal aorta
 16. 肠系膜下动脉 inferior mesenteric artery
 17. 下腔静脉 inferior vena cava
 18. 十二指肠水平部 horizontal part of duodenum
 19. 肠系膜上动脉 superior mesenteric artery
 20. 肠系膜上静脉 superior mesenteric vein
 21. 胃体 body of stomach
 22. 腹膜腔 peritoneal cavity
 23. 横结肠 transverse colon
 24. 肝右叶 right lobe of liver
 25. 升结肠 ascending colon
 26. 十二指肠降部 descending part of duodenum
 27. 右肾 right kidney
 28. 腰方肌 quadratus lumborum
 29. 马尾 cauda equina
 30. 竖脊肌 erector spinae
 31. 右输尿管 right ureter
 32. 胰头 head of pancreas

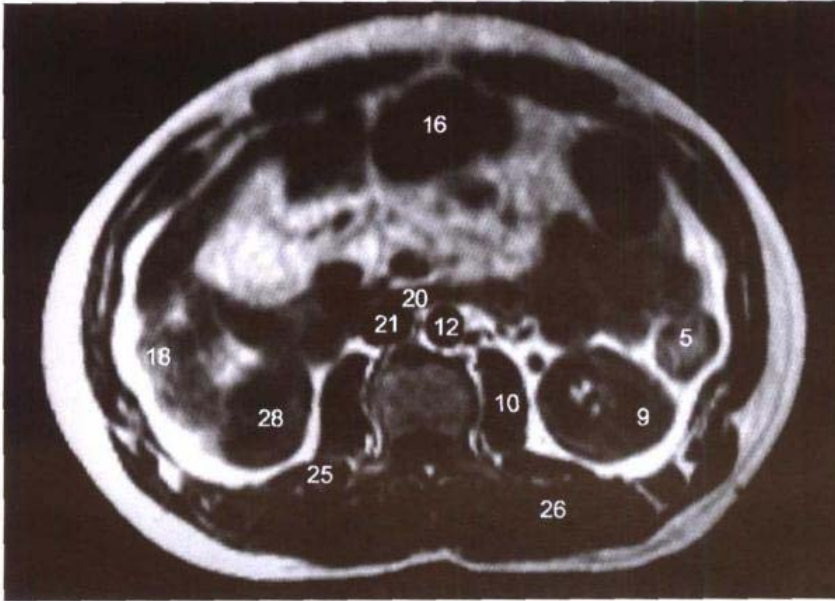
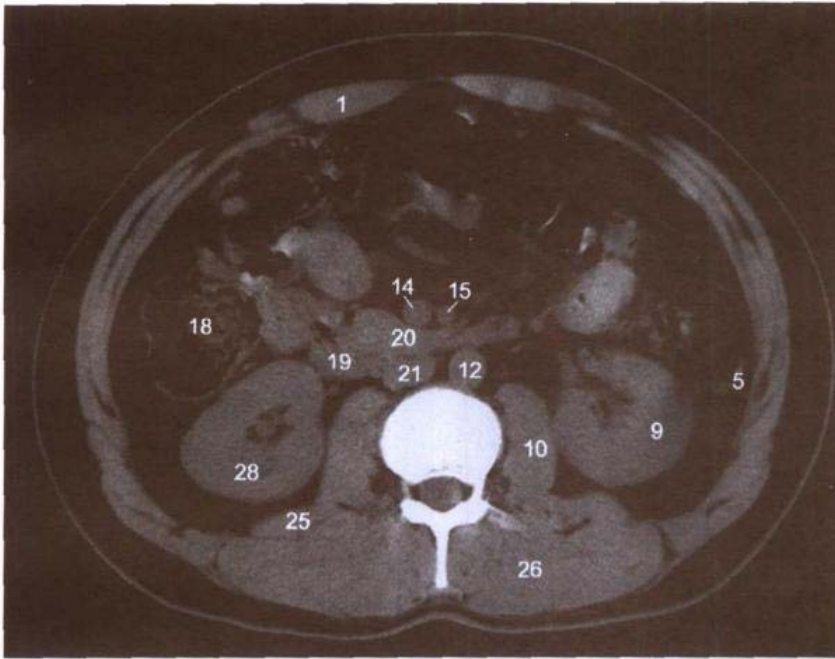
- | | |
|----------------------------------|---|
| 1. 腹直肌 rectus abdominis | abdominis |
| 2. 肝圆韧带 ligamentum teres hepatis | 9. 腹外斜肌 obliquus externus abdominis |
| 3. 大网膜 greater omentum | 10. 左肾 left kidney |
| 4. 横结肠 transverse colon | 11. 腰大肌 psoas major |
| 5. 空肠 jejunum | 12. 第3腰椎间盘 3rd lumbar intervertebral disc |
| 6. 降结肠 descending colon | 13. 左输尿管 left ureter |
| 7. 腹横肌 transversus abdominis | 14. 左睾丸动、静脉 left testicu |
| 8. 腹内斜肌 obliquus internus | |

图 6-17 经左肾下极的横断层

Fig.6-17 Transverse section through lower pole of left kidney



A. 断层标本 (sectional specimen)

B. MRI T₁WI

C. CT

15. 肠系膜上动脉 superior mesenteric artery
16. 横结肠 transverse colon
17. 腹外斜肌 obliquus externus abdominis
18. 升结肠 ascending colon
19. 十二指肠降部 descending part of duodenum
20. 十二指肠水平部 horizontal part of duodenum
21. 下腔静脉 inferior vena cava
22. 右输尿管 right ureter
23. 第4腰椎体 body of 4th lumbar vertebrae
24. 马尾 cauda equina
25. 腰方肌 quadratus lumborum
26. 竖脊肌 erector spinae
27. 关节突关节 zygapophysial joint
28. 右肾 right kidney
29. 第2、3腰椎神经 2nd and 3rd lumbar nerves
30. 腰静脉 lumbar vein

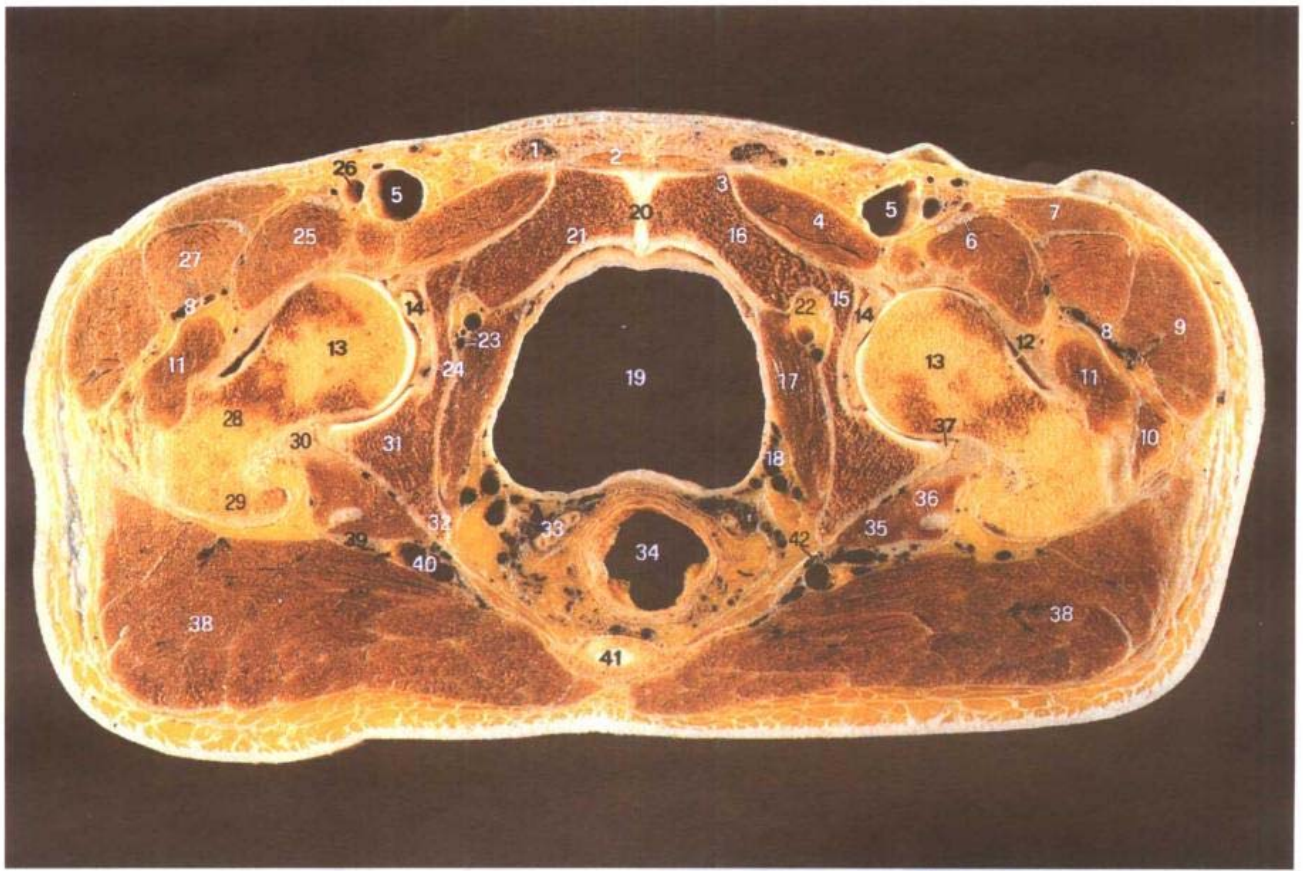
- | | |
|-------------------------------------|-----------|
| 1. 腹直肌 rectus abdominis | abdominis |
| 2. 肝圆韧带 ligamentum teres hepatis | |
| 3. 大网膜 greater omentum | |
| 4. 空肠 jejunum | |
| 5. 降结肠 descending colon | |
| 6. 腹膜外脂肪 extraperitoneal fat | |
| 7. 腹内斜肌 obliquus internus | |
| 8. 腹横肌 transversus abdominis | |
| 9. 左肾 left kidney | |
| 10. 腰大肌 psoas major | |
| 11. 左输尿管 left ureter | |
| 12. 腹主动脉 abdominal aorta | |
| 13. 肠系膜 mesentery | |
| 14. 肠系膜上静脉 superior mesenteric vein | |

第七章 男性盆部连续横断层

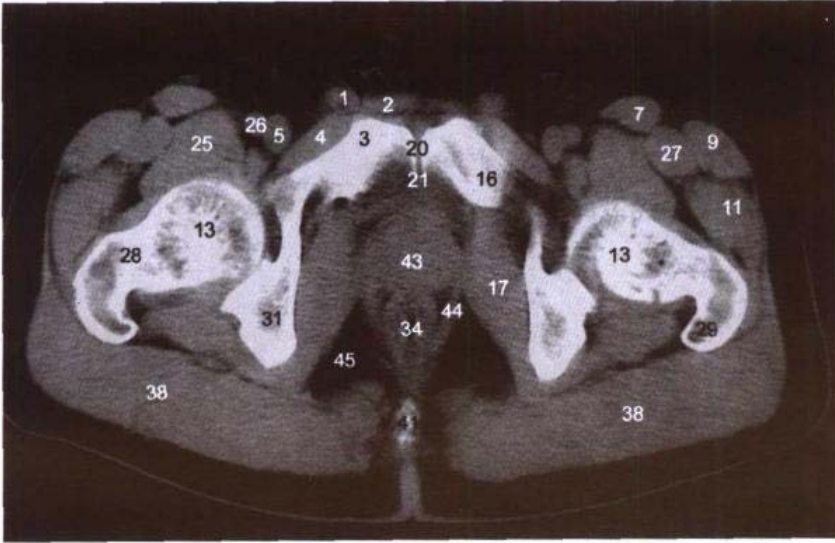
Chapter 7 Serial Transverse Sections of Male Pelvis

图 7-1 经耻骨联合上份的横断层

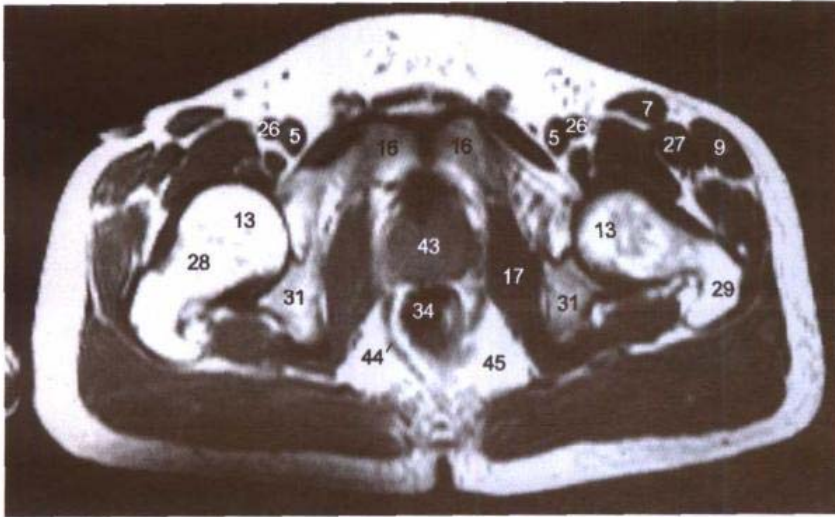
Fig.7-1 Transverse section through upper part of pubic symphysis



A. 断层标本 (sectional specimen)



B. CT

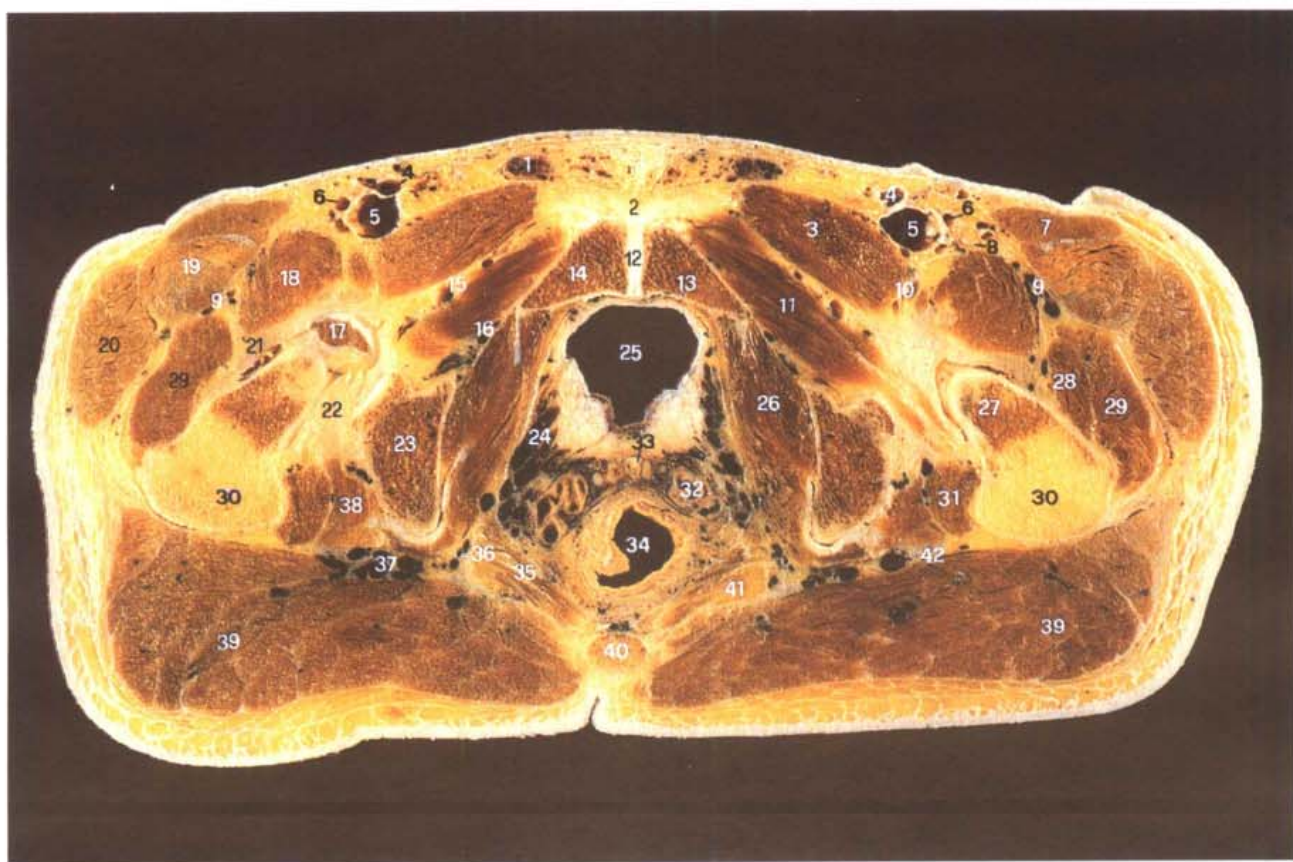


C. MRI T₁WI

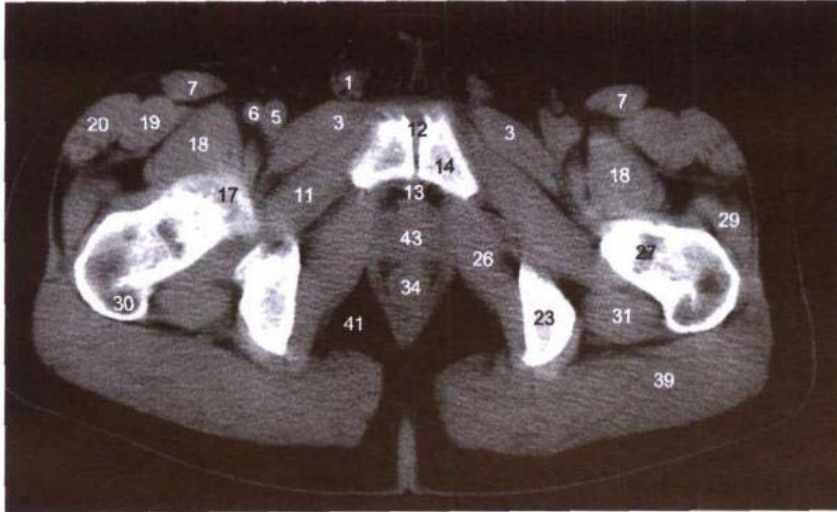
- | | |
|--|---|
| 1. 精索 spermatic cord | 13. 股骨头 femoral head |
| 2. 腹直肌 rectus abdominis | 14. 股骨头韧带 ligament of head of femur |
| 3. 耻骨结节 pubic tubercle | 15. 闭孔神经 obturator nerve |
| 4. 耻骨肌 pectineus | 16. 耻骨上支 superior ramus of pubis |
| 5. 股静脉 femoral vein | 17. 闭孔内肌 obturator internus |
| 6. 股神经 femoral nerve | 18. 膀胱静脉丛 vesical venous plexus |
| 7. 缝匠肌 sartorius | 19. 膀胱 urinary bladder |
| 8. 旋股外侧动、静脉 lateral femoral circumflex artery and vein | 20. 耻骨联合 pubic symphysis |
| 9. 阔筋膜张肌 tensor fasciae latae | 21. 耻骨后间隙 retropubic space |
| 10. 臀中肌 gluteus medius | 22. 闭膜管 obturator canal |
| 11. 股外侧肌 vastus lateralis | 23. 闭孔动、静脉 obturator art-ery and vein |
| 12. 髂股韧带 iliofemoral ligament | 24. 髋臼窝 acetabular fossa |
| | 25. 髂腰肌 iliopsoas |
| | 26. 股动脉 femoral artery |
| | 27. 股直肌 rectus femoris |
| | 28. 股骨颈 neck of femur |
| | 29. 大转子 greater trochanter |
| | 30. 坐股韧带 ischiofemoral ligament |
| | 31. 坐骨体 body of ischium |
| | 32. 坐骨棘 ischial spine |
| | 33. 输精管壶腹 ampulla ductus deferentis |
| | 34. 直肠 rectum |
| | 35. 下孖肌 gemellus inferior |
| | 36. 闭孔内肌腱 tendon of obturator internus |
| | 37. 髋臼唇 acetabular labrum |
| | 38. 臀大肌 gluteus maximus |
| | 39. 坐骨神经 sciatic nerve |
| | 40. 臀下动、静脉 inferior gluteal artery and vein |
| | 41. 第5骶椎间盘 5th sacral intervertebral disc |
| | 42. 阴部内动、静脉 internal pudendal artery and vein |
| | 43. 前列腺 prostate gland |
| | 44. 肛提肌 levator ani |
| | 45. 坐骨肛门窝 ischioanal fossa |

图 7-2 经耻骨联合中份的横断层

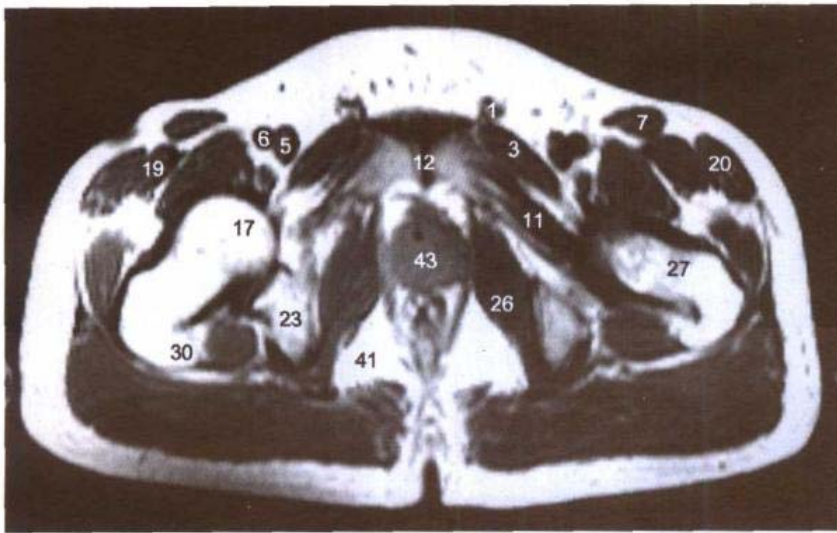
Fig.7-2 Transverse section through middle part of pubic symphysis



A. 断层标本 (sectional specimen)



B. CT



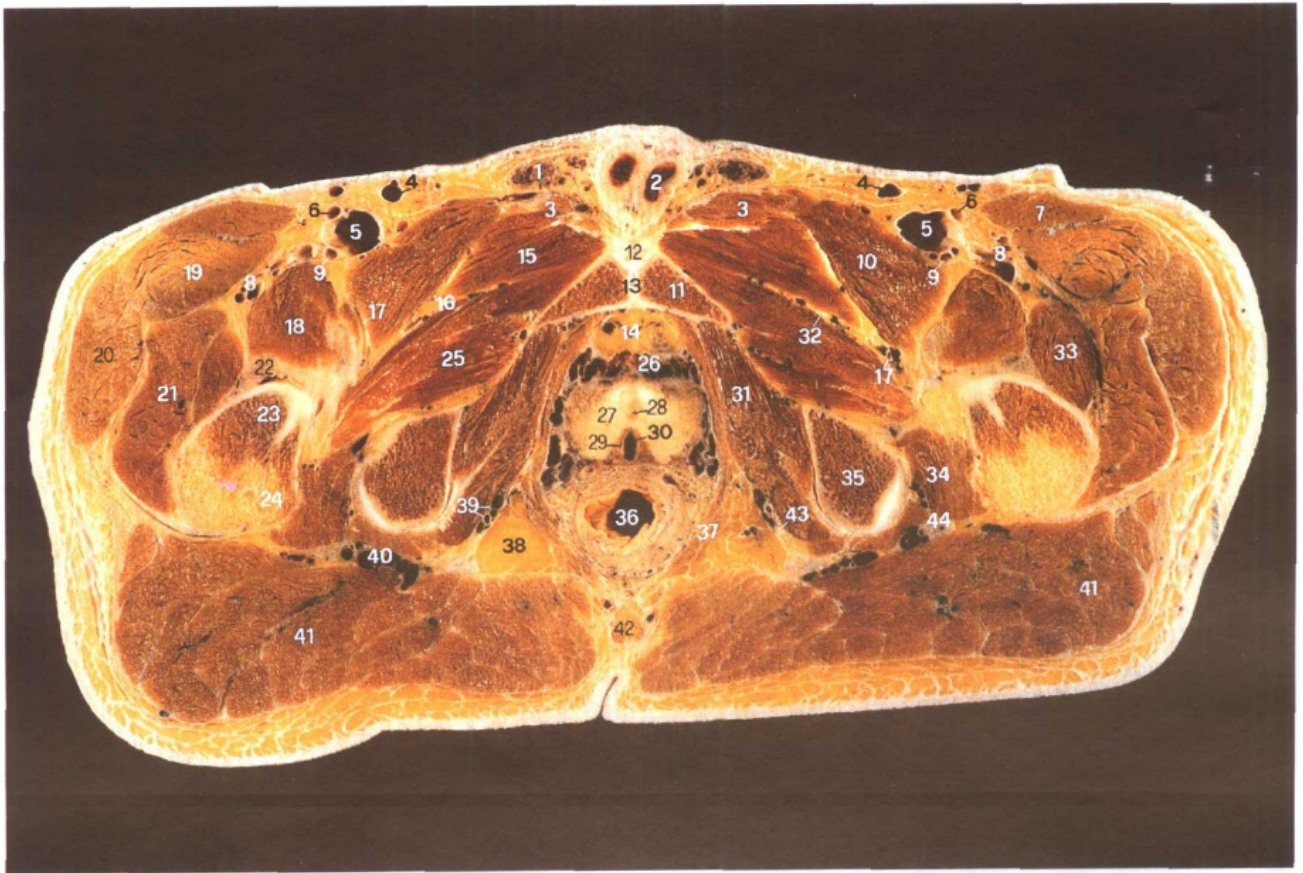
C. MRI T1WI

- latae
- 21. 髂股韧带 iliofemoral ligament
- 22. 坐股韧带 ischiofemoral ligament
- 23. 坐骨结节 ischial tuberosity
- 24. 膀胱静脉丛 vesical venous plexus
- 25. 膀胱 urinary bladder
- 26. 闭孔内肌 obturator internus
- 27. 股骨颈 neck of femur
- 28. 股中间肌 vastus intermedius
- 29. 股外侧肌 vastus lateralis
- 30. 大转子 greater trochanter
- 31. 股方肌 quadratus femoris
- 32. 精囊 seminal vesicle
- 33. 输精管壶腹 ampulla ductus deferentis
- 34. 直肠 rectum
- 35. 尾骨肌 coccygeus
- 36. 阴部内动、静脉 internal pudendal artery and vein
- 37. 臀下动、静脉 inferior gluteal artery and vein
- 38. 下孖肌 gemellus inferior
- 39. 臀大肌 gluteus maximus
- 40. 尾骨 coccyx
- 41. 坐骨肛门窝 ischioanal fossa
- 42. 坐骨神经 sciatic nerve
- 43. 前列腺 prostate gland

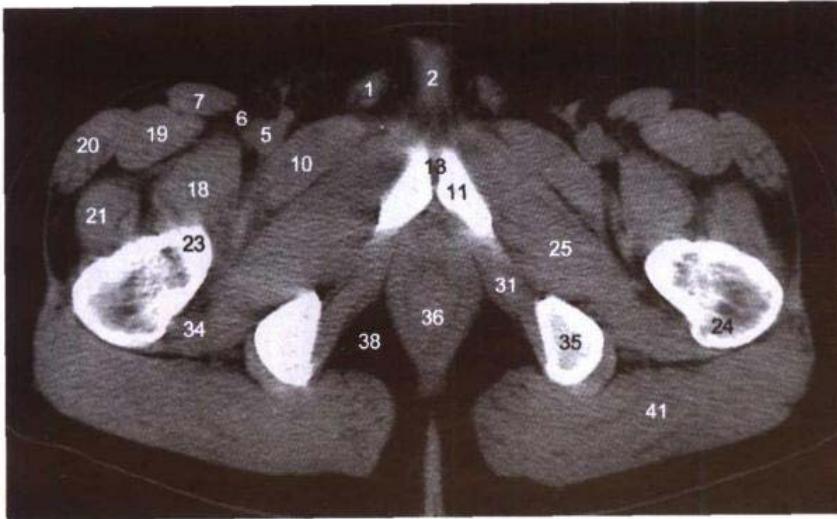
- 1. 精索 spermatic cord
- 2. 耻骨前韧带 anterior pubic ligament
- 3. 耻骨肌 pectineus
- 4. 大隐静脉 great saphenous vein
- 5. 股静脉 femoral vein
- 6. 股动脉 femoral artery
- 7. 缝匠肌 sartorius
- 8. 股神经 femoral nerve
- 9. 旋股外侧动、静脉 lateral femoral circumflex artery and vein
- 10. 旋股内侧动、静脉 medial femoral circumflex artery and vein
- 11. 闭孔外肌 obturator externus
- 12. 耻骨间盘 interpubic disc
- 13. 耻骨后间隙 retropubic space
- 14. 耻骨下支 inferior ramus of pubis
- 15. 闭孔血管前支 anterior branch of obturator artery and vein
- 16. 闭孔血管后支 posterior branch of obturator artery and vein
- 17. 股骨头 femoral head
- 18. 髂腰肌 iliopsoas
- 19. 股直肌 rectus femoris
- 20. 阔筋膜张肌 tensor fasciae

图 7-3 经耻骨联合下份的横断层

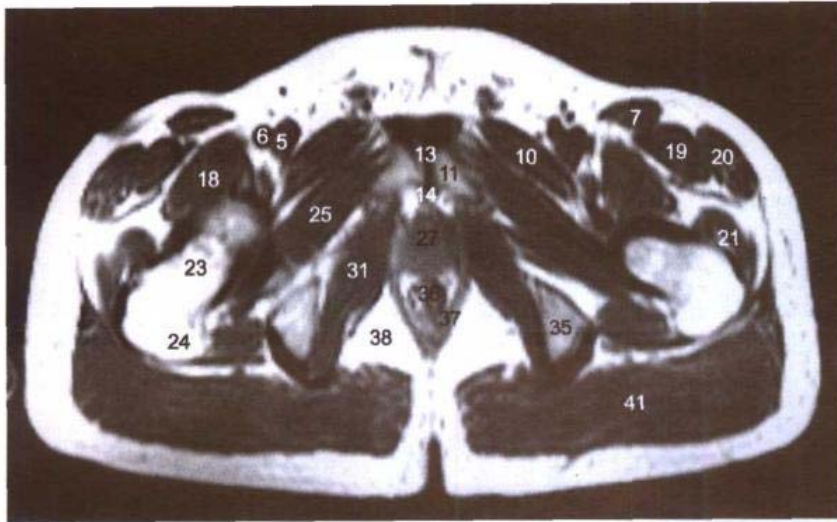
Fig.7-3 Transverse section through lower part of pubic symphysis



A. 断层标本 (sectional specimen)



B. CT



C. MRI T:WI

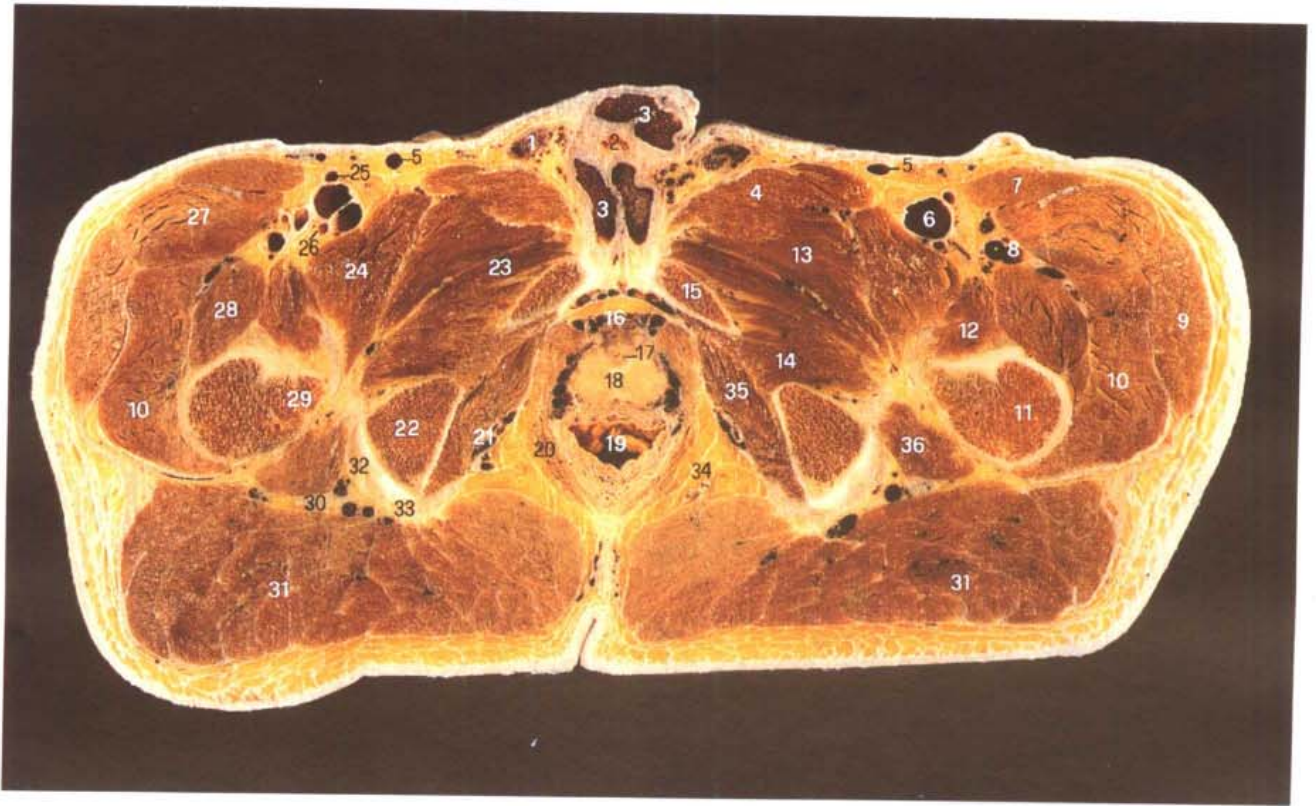
1. 精索 spermatic cord
2. 阴茎海绵体 cavernous body of penis
3. 长收肌 adductor longus
4. 大隐静脉 great saphenous vein
5. 股静脉 femoral vein
6. 股动脉 femoral artery
7. 缝匠肌 sartorius
8. 旋股外侧动、静脉 lateral femoral circumflex artery and vein
9. 股深动脉 deep femoral artery
10. 耻骨肌 pectineus

11. 耻骨下支 inferior ramus of pubis
12. 耻骨前韧带 anterior pubic ligament
13. 耻骨联合 pubic symphysis
14. 耻骨后间隙 retropubic space
15. 短收肌 adductor brevis
16. 闭孔动、静脉前支 anterior branch of obturator artery and vein
17. 旋股内侧动、静脉 medial femoral circumflex artery and vein
18. 髂腰肌 iliopsoas

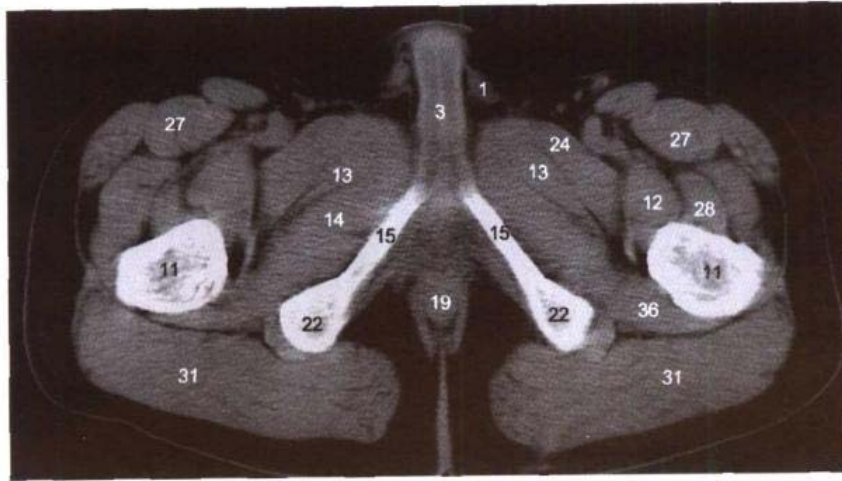
19. 股直肌 rectus femoris
20. 阔筋膜张肌 tensor fasciae latae
21. 股外侧肌 vastus lateralis
22. 髂股韧带 iliofemoral ligament
23. 股颈 neck of femur
24. 大转子 greater trochanter
25. 闭孔外肌 obturator externus
26. 前列腺静脉丛 prostatic venous plexus
27. 前列腺 prostate
28. 尿道前列腺部 prostatic part of urethra
29. 射精管 ejaculatory duct
30. 前列腺小囊 prostatic utricle
31. 闭孔内肌 obturator internus
32. 闭孔神经前支 anterior branch of obturator nerve
33. 股中间肌 vastus intermedius
34. 股方肌 quadratus femoris
35. 坐骨结节 ischial tuberosity
36. 直肠 rectum
37. 肛提肌 levator ani
38. 坐骨肛门窝 ischioanal fossa
39. 阴部内动、静脉 internal pudendal artery and vein
40. 臀下动、静脉 inferior gluteal artery and vein
41. 臀大肌 gluteus maximus
42. 尾骨 coccyx
43. 阴部神经 pudendal nerve
44. 坐骨神经 sciatic nerve

图 7-4 经耻骨下支和坐骨结节的横断层

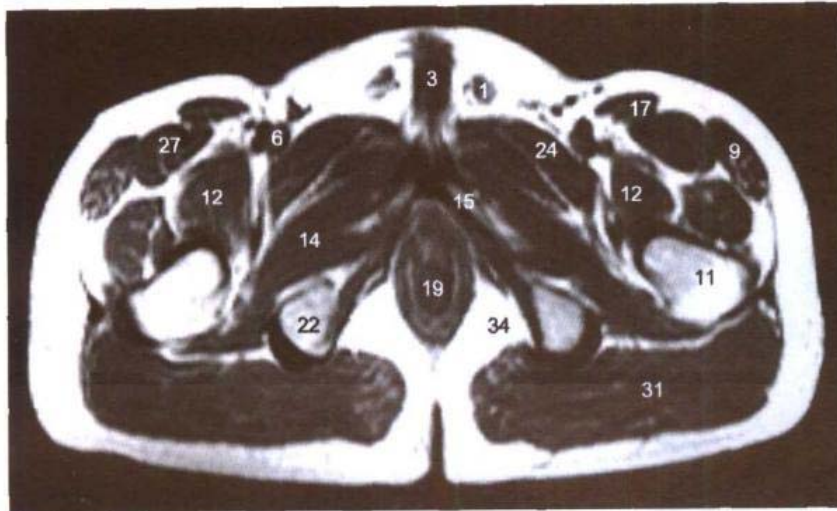
Fig.7-4 Transverse section through inferior ramus of pubis and ischial tuberosity



A. 断层标本 (sectional specimen)



B. CT



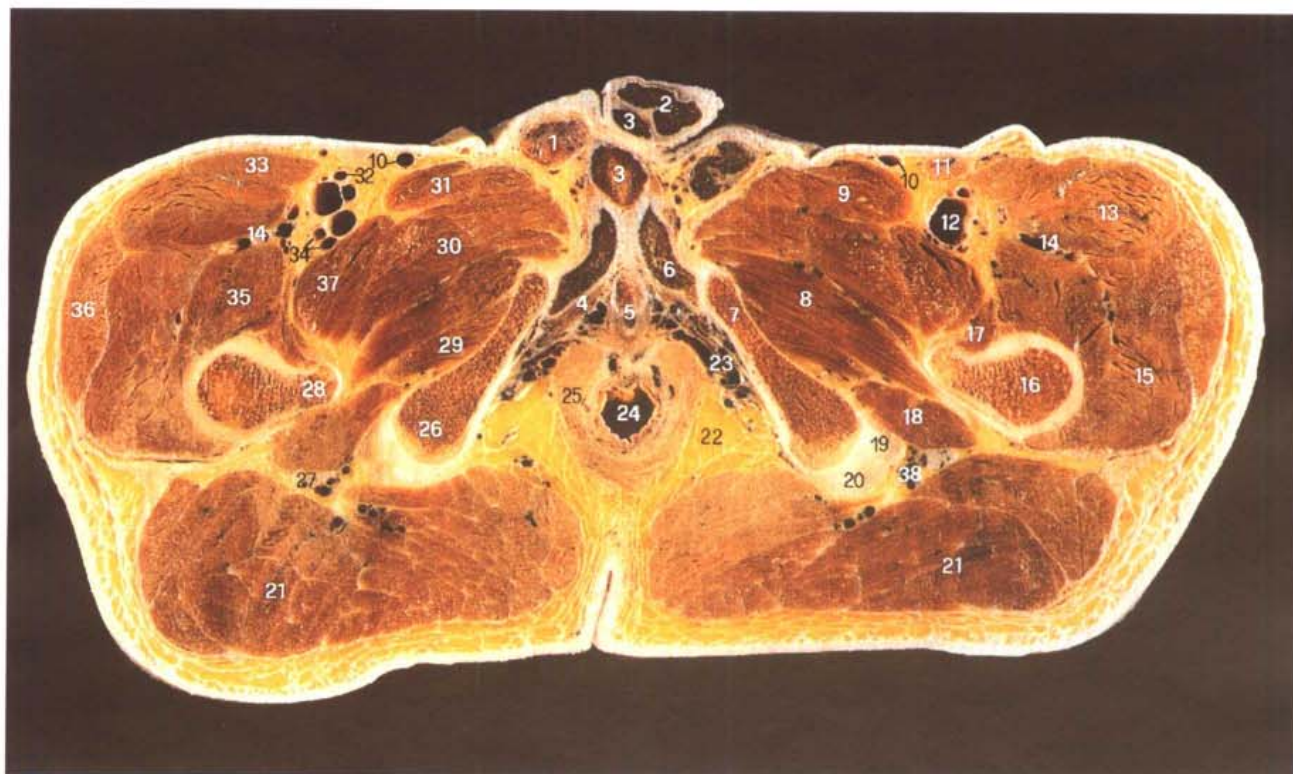
C. MRI T₁WI

- 23. 大收肌 adductor magnus
- 24. 耻骨肌 pectineus
- 25. 股动脉 femoral artery
- 26. 股深动脉 deep femoral artery
- 27. 股直肌 rectus femoris
- 28. 股中间肌 vastus intermedius
- 29. 小转子 lesser trochanter
- 30. 坐骨神经 sciatic nerve
- 31. 臀大肌 gluteus maximus
- 32. 半膜肌腱 tendon of semi-membranosus
- 33. 股二头肌长头与半腱肌总腱 common tendon of long head of biceps femoris and semi-tendinosus
- 34. 坐骨肛门窝 ischioanal fossa
- 35. 闭孔内肌 obturator internus
- 36. 股方肌 quadratus femoris

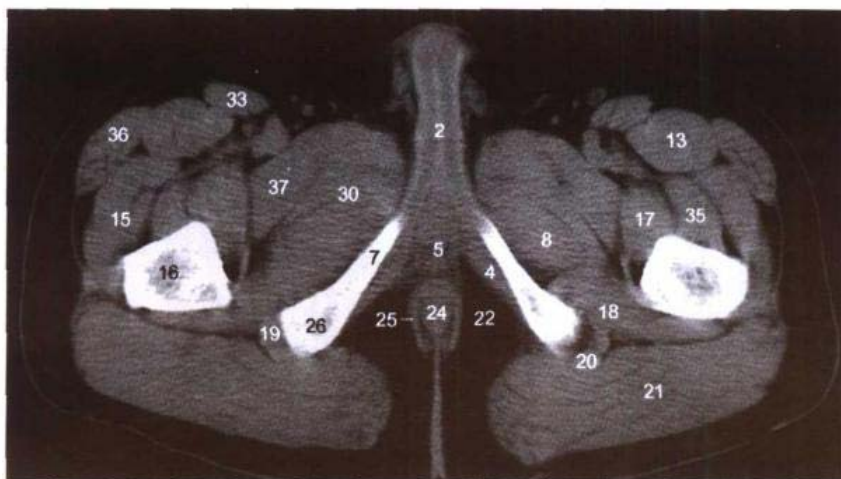
- 1. 精索 spermatic cord
- 2. 尿道海绵体 cavernous body of urethra
- 3. 阴茎海绵体 cavernous body of penis
- 4. 长收肌 adductor longus
- 5. 大隐静脉 great saphenous vein
- 6. 股静脉 femoral vein
- 7. 缝匠肌 sartorius
- 8. 旋股外侧动、静脉 lateral femoral circumflex artery and vein
- 9. 阔筋膜张肌 tensor fasciae latae
- 10. 股外侧肌 vastus lateralis
- 11. 股骨 femur
- 12. 髂腰肌 iliopsoas
- 13. 短收肌 adductor brevis
- 14. 闭孔外肌 obturator externus
- 15. 耻骨下支 inferior ramus of pubis
- 16. 前列腺静脉丛 prostatic venous plexus
- 17. 尿道前列腺部 prostatic part of urethra
- 18. 前列腺 prostate
- 19. 直肠 rectum
- 20. 肛提肌 levator ani
- 21. 阴部内动、静脉 internal pudendal artery and vein
- 22. 坐骨结节 ischial tuberosity

图 7-5 经坐骨支和坐骨结节的横断层

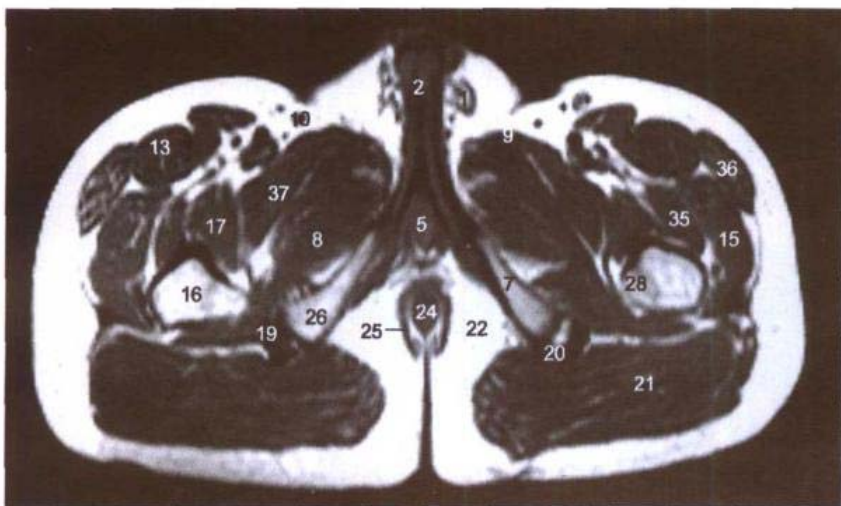
Fig.7-5 Transverse section through ramus and tuberosity of ischium



A. 断层标本 (sectional specimen)



B. CT



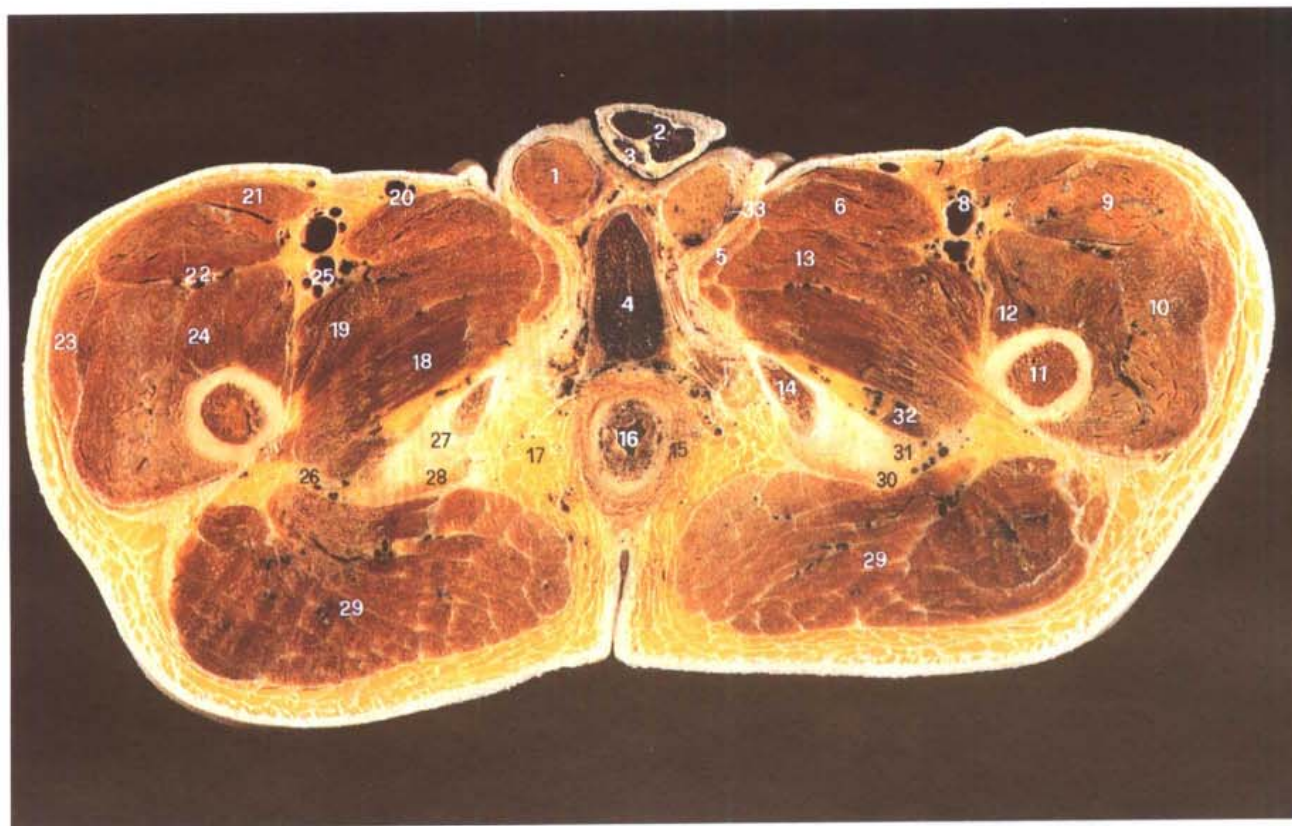
C. MRI T1WI

- common tendon of long head of biceps femoris and semitendinosus
- 21. 臀大肌 gluteus maximus
- 22. 坐骨肛门窝 ischioanal fossa
- 23. 肛动、静脉 anal artery and vein
- 24. 肛管 anal canal
- 25. 肛门外括约肌 sphincter ani externus
- 26. 坐骨结节 ischial tuberosity
- 27. 坐骨神经 sciatic nerve
- 28. 小转子 lesser trochanter
- 29. 闭孔外肌 obturator externus
- 30. 短收肌 adductor brevis
- 31. 长收肌 adductor longus
- 32. 股动脉 femoral artery
- 33. 缝匠肌 sartorius
- 34. 股深动、静脉 deep femoral artery and vein
- 35. 股中间肌 vastus intermedius
- 36. 阔筋膜张肌 tensor fasciae latae
- 37. 耻骨肌 pectineus
- 38. 臀下动、静脉 inferior gluteal artery and vein

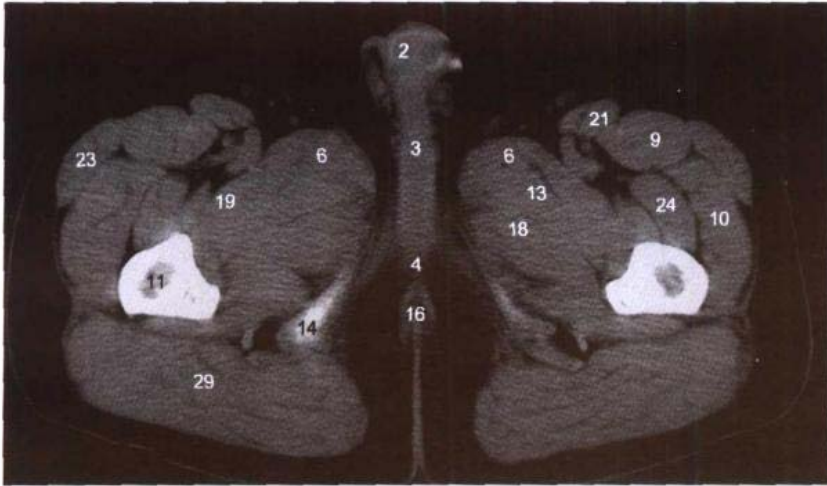
- 1. 精索 spermatic cord
- 2. 阴茎海绵体 cavernous body of penis
- 3. 尿道海绵体 cavernous body of urethra
- 4. 坐骨海绵体肌 ischiocavernosus
- 5. 尿道球 bulb of urethra
- 6. 阴茎脚 crus of penis
- 7. 坐骨支 ramus of ischium
- 8. 大收肌 adductor magnus
- 9. 长收肌 adductor longus
- 10. 大隐静脉 great saphenous vein
- 11. 腹股沟浅淋巴结 superficial inguinal lymph nodes
- 12. 股静脉 femoral vein
- 13. 股直肌 rectus femoris
- 14. 旋股外侧动、静脉 lateral femoral circumflex artery and vein
- 15. 股外侧肌 vastus lateralis
- 16. 股骨 femur
- 17. 髂腰肌 iliopsoas
- 18. 股方肌 quadratus femoris
- 19. 半膜肌腱 tendon of semimembranosus
- 20. 股二头肌长头和半腱肌总腱

图 7-6 经尿道球上份的横断层

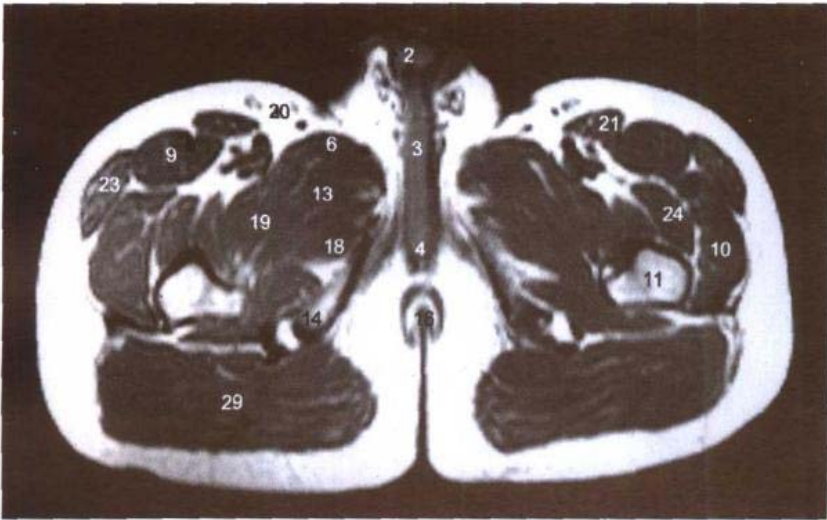
Fig.7-6 Transverse section through upper part of bulb of urethra



A. 断层标本 (sectional specime)



B. CT



C. MRI T₁WI

- 21. 缝匠肌 sartorius
- 22. 旋股外侧动、静脉 lateral femoral circumflex artery and vein
- 23. 阔筋膜张肌 tensor fasciae latae
- 24. 股中间肌 vastus intermedius
- 25. 股深动、静脉 deep femoral artery and vein
- 26. 坐骨神经 sciatic nerve
- 27. 大收肌腱 tendon of adductor magnus
- 28. 半腱肌 semitendinosus
- 29. 臀大肌 gluteus maximus
- 30. 股二头肌长头腱 tendon of long head of biceps femoris
- 31. 半膜肌腱 tendon of semi-membranosus
- 32. 股方肌 quadratus femoris
- 33. 附睾 epididymis

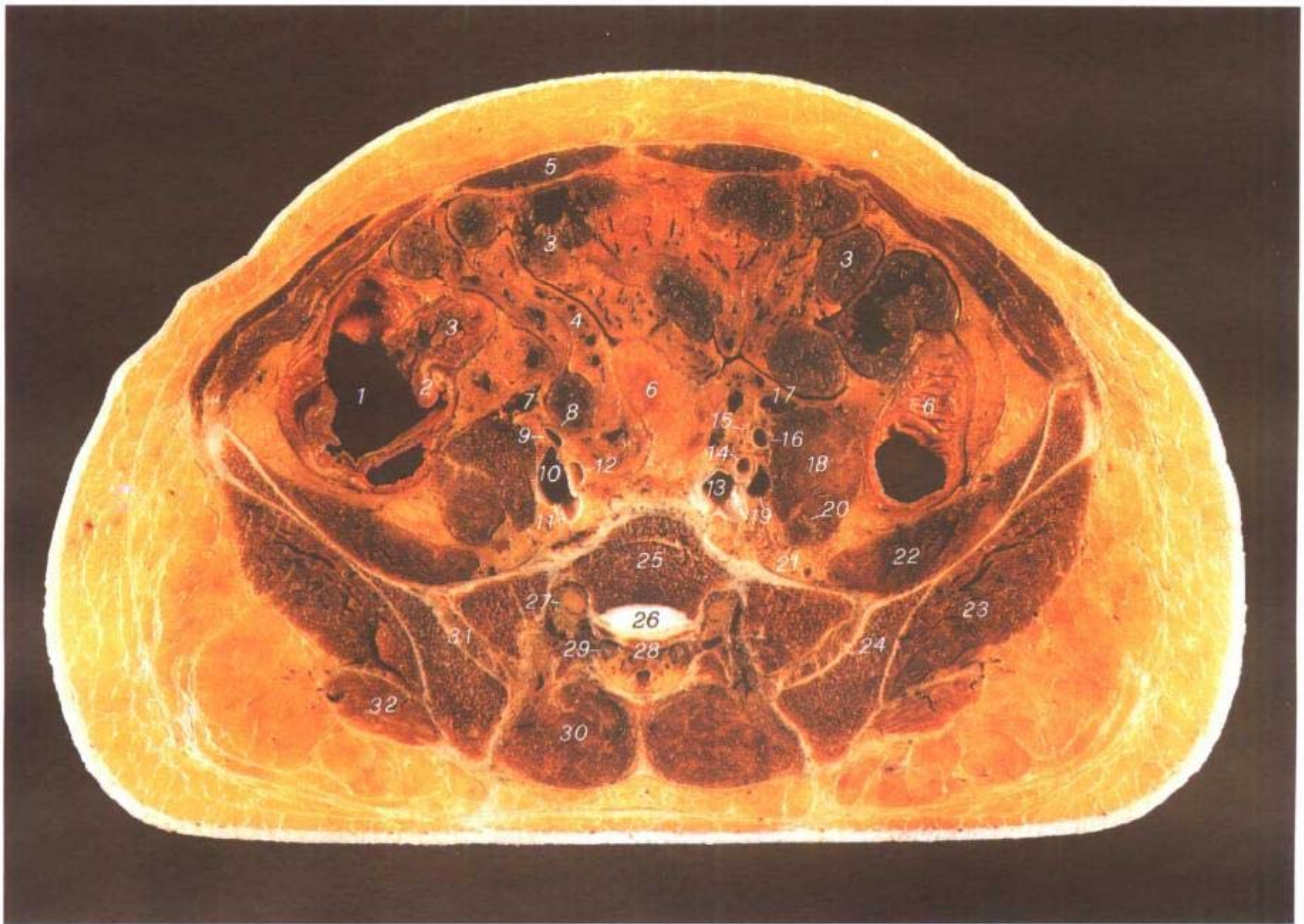
- 1. 睾丸 testis
- 2. 阴茎海绵体 cavernous body of penis
- 3. 尿道海绵体 cavernous body of urethra
- 4. 尿道球 bulb of urethra
- 5. 股薄肌 gracilis
- 6. 长收肌 adductor longus
- 7. 腹股沟浅淋巴结 superficial inguinal lymph nodes
- 8. 股动、静脉 femoral artery and vein
- 9. 股直肌 rectus femoris
- 10. 股外侧肌 vastus lateralis
- 11. 股骨 femur
- 12. 股内侧肌 vastus medialis
- 13. 短收肌 adductor brevis
- 14. 坐骨结节 ischial tuberosity
- 15. 肛门外括约肌 sphincter ani externus
- 16. 肛管 anal canal
- 17. 坐骨肛门窝 ischioanal fossa
- 18. 大收肌 adductor magnus
- 19. 耻骨肌 pectineus
- 20. 大隐静脉 great saphenous vein

第八章 女性盆部连续横断层

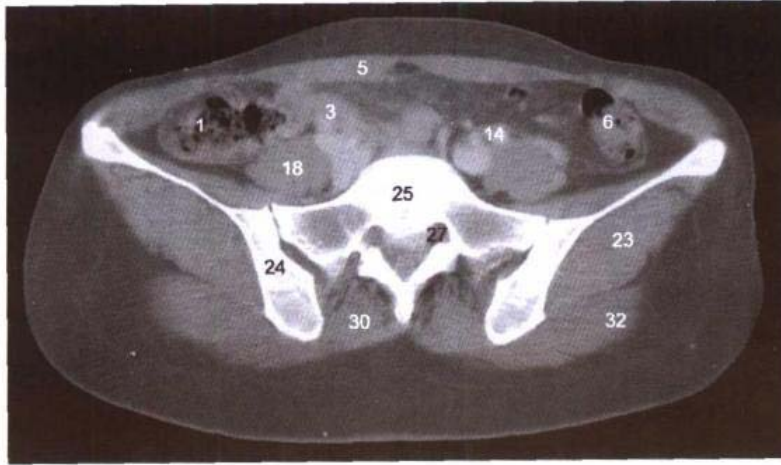
Chapter 8 Serial Transverse Sections of Female Pelvis

图 8-1 经第 1 骶椎的横断层

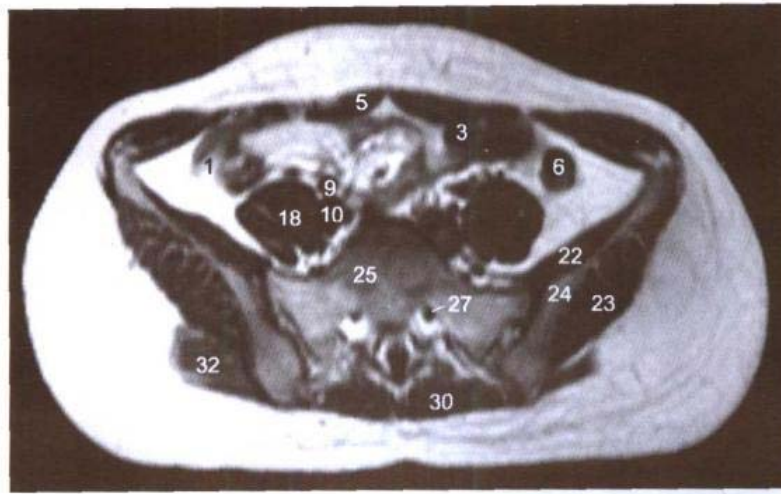
Fig.8-1 Transverse section through 1st sacral vertebrae



A. 断层标本 (sectional specimen)

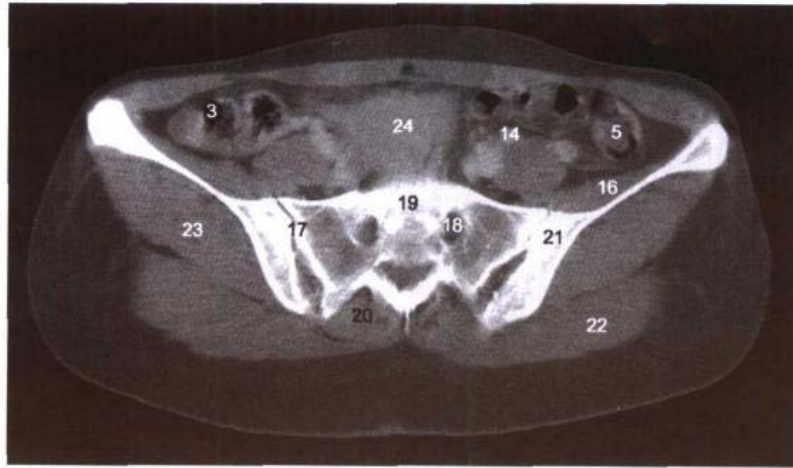


B. CT

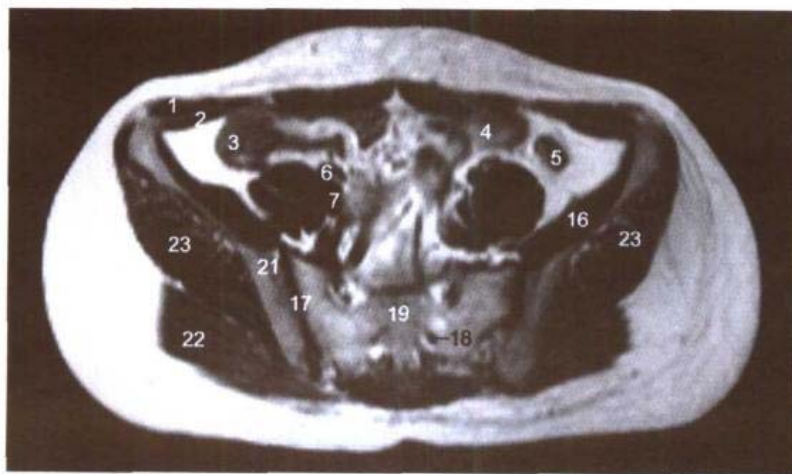


C. MRI T1WI

- | | |
|--|--|
| 1. 盲肠 cecum | 17. 左卵巢动、静脉 left ovarian artery and vein |
| 2. 回盲瓣 ileocecal valve | 18. 腰大肌 psoas major |
| 3. 回肠 ileum | 19. 左髂外静脉 left external iliac vein |
| 4. 肠系膜 mesentery | 20. 股神经 femoral nerve |
| 5. 腹直肌 rectus abdominis | 21. 腰骶干 lumbosacral trunk |
| 6. 乙状结肠 sigmoid colon | 22. 髂肌 iliacus |
| 7. 右卵巢动、静脉 right ovarian artery and vein | 23. 臀中肌 gluteus medius |
| 8. 右输尿管 right ureter | 24. 髂骨翼 ala of ilium |
| 9. 右髂外动脉 right external iliac artery | 25. 第1骶椎 1st sacral vertebrae |
| 10. 右髂外静脉 right external iliac vein | 26. 第1骶椎间盘 1st sacral intervertebral disc |
| 11. 右髂内静脉 right internal iliac vein | 27. 第1骶神经 1st sacral nerve |
| 12. 右髂内动脉 right internal iliac artery | 28. 第2骶椎 2nd sacral vertebrae |
| 13. 左髂内静脉 left internal iliac vein | 29. 第2骶神经 2nd sacral nerve |
| 14. 左髂内动脉 left internal iliac artery | 30. 竖脊肌 erector spinae |
| 15. 左输尿管 left ureter | 31. 骶髂骨间韧带 interosseous sacroiliac ligaments |
| 16. 左髂外动脉 left external iliac artery | 32. 臀大肌 gluteus maximus |



B. CT

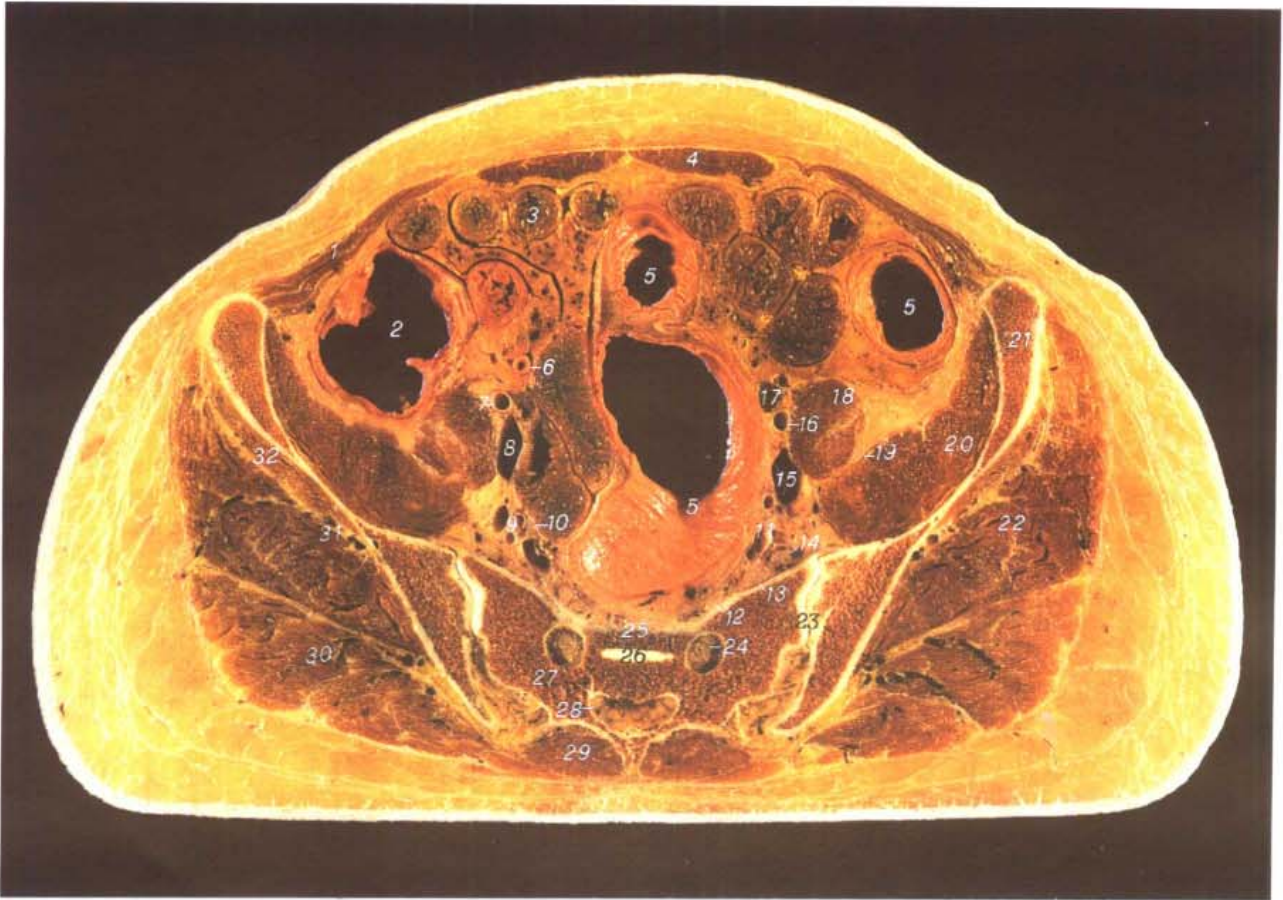

C. MRI T1WI

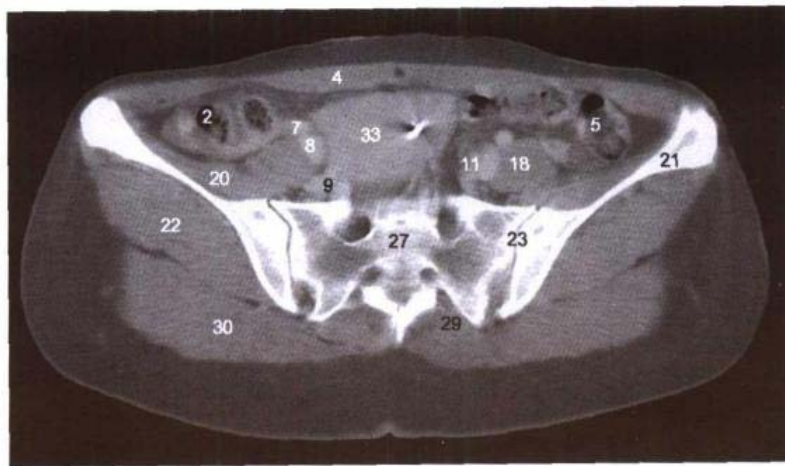
- | | |
|--------------------------------------|--------------------------------------|
| 1. 腹外斜肌 obliquus externus abdominis | 13. 左输尿管 left ureter |
| 2. 腹内斜肌 obliquus internus abdominis | 14. 左髂外动脉 left external iliac artery |
| 3. 盲肠 cecum | 15. 股神经 femoral nerve |
| 4. 回肠 ileum | 16. 髂肌 iliacus |
| 5. 乙状结肠 sigmoid colon | 17. 骶髂关节 sacroiliac joint |
| 6. 右髂外动脉 right external iliac artery | 18. 第2骶神经 2nd sacral nerve |
| 7. 右髂外静脉 right external iliac vein | 19. 第2骶椎 2nd sacral vertebrae |
| 8. 右输尿管 right ureter | 20. 竖脊肌 erector spinae |
| 9. 右髂内动脉 right internal iliac artery | 21. 髂骨翼 ala of ilium |
| 10. 右髂内静脉 right internal iliac vein | 22. 臀大肌 gluteus maximus |
| 11. 第1骶神经 1st sacral nerve | 23. 臀中肌 gluteus medius |
| 12. 腰骶干 lumbosacral trunk | 24. 子宫 uterus |

图 8-3 经第 2 骶椎间盘的横断层

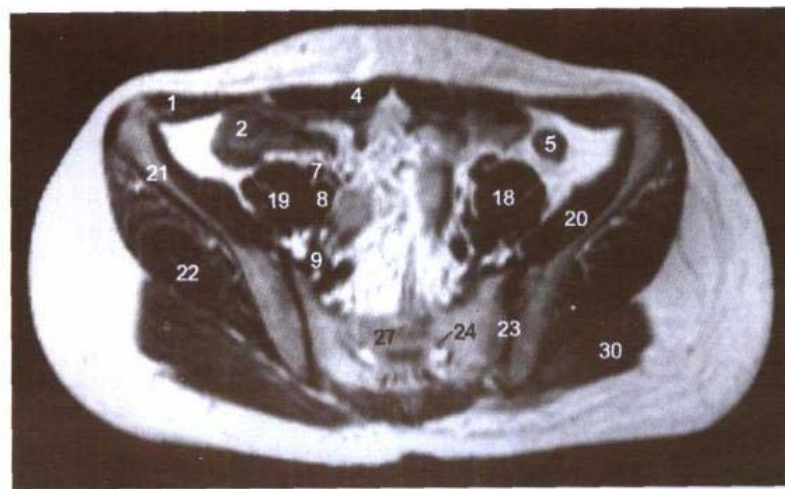
Fig.8-3 Transverse section through 2nd sacral intervertebral disc



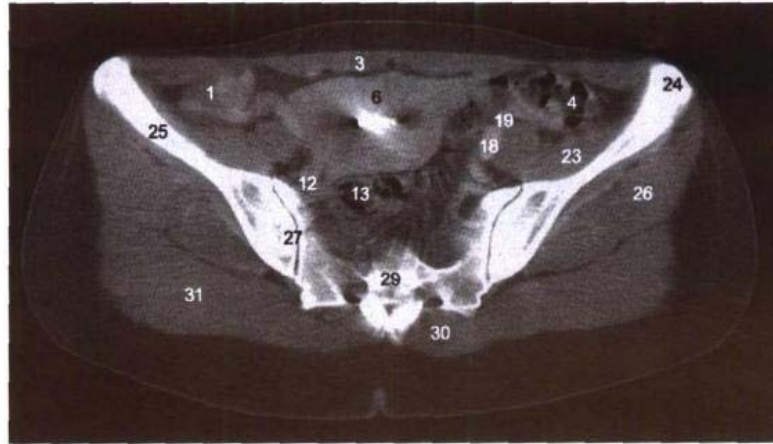
A. 断层标本 (sectional specimen)



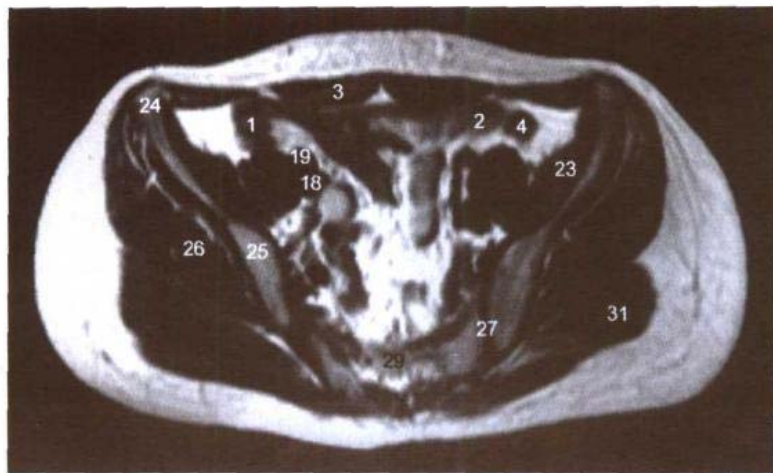
B. CT

C. MRI T₁WI

- | | |
|---|---|
| 1. 腹内斜肌 obliquus internus abdominis | 17. 左卵巢动、静脉 left ovarian artery and vein |
| 2. 盲肠 cecum | 18. 腰大肌 psoas major |
| 3. 回肠 ileum | 19. 股神经 femoral nerve |
| 4. 腹直肌 rectus abdominis | 20. 髂肌 iliacus |
| 5. 乙状结肠 sigmoid colon | 21. 髂骨翼 ala of ilium |
| 6. 阑尾 vermiform appendix | 22. 臀中肌 gluteus medius |
| 7. 右髂外动脉 right external iliac artery | 23. 骶髂关节 sacroiliac joint |
| 8. 右髂外静脉 right external iliac vein | 24. 第3骶神经 3rd sacral nerve |
| 9. 右髂内动、静脉 right internal iliac artery and vein | 25. 第2骶椎 2nd sacral vertebrae |
| 10. 右输尿管 right ureter | 26. 第2骶椎间盘 2nd sacral intervertebral disc |
| 11. 左髂内动、静脉 left internal iliac artery and vein | 27. 第3骶椎 3rd sacral vertebrae |
| 12. 第2骶神经 2nd sacral nerve | 28. 第4骶神经 4th sacral nerve |
| 13. 第1骶神经 1st sacral nerve | 29. 竖脊肌 erector spinae |
| 14. 腰骶干 lumbosacral trunk | 30. 臀大肌 gluteus maximus |
| 15. 左髂外静脉 left external iliac vein | 31. 臀上动、静脉 superior gluteal artery and vein |
| 16. 左髂外动脉 left external iliac artery | 32. 臀小肌 gluteus minimus |
| | 33. 子宫 uterus |



B. CT

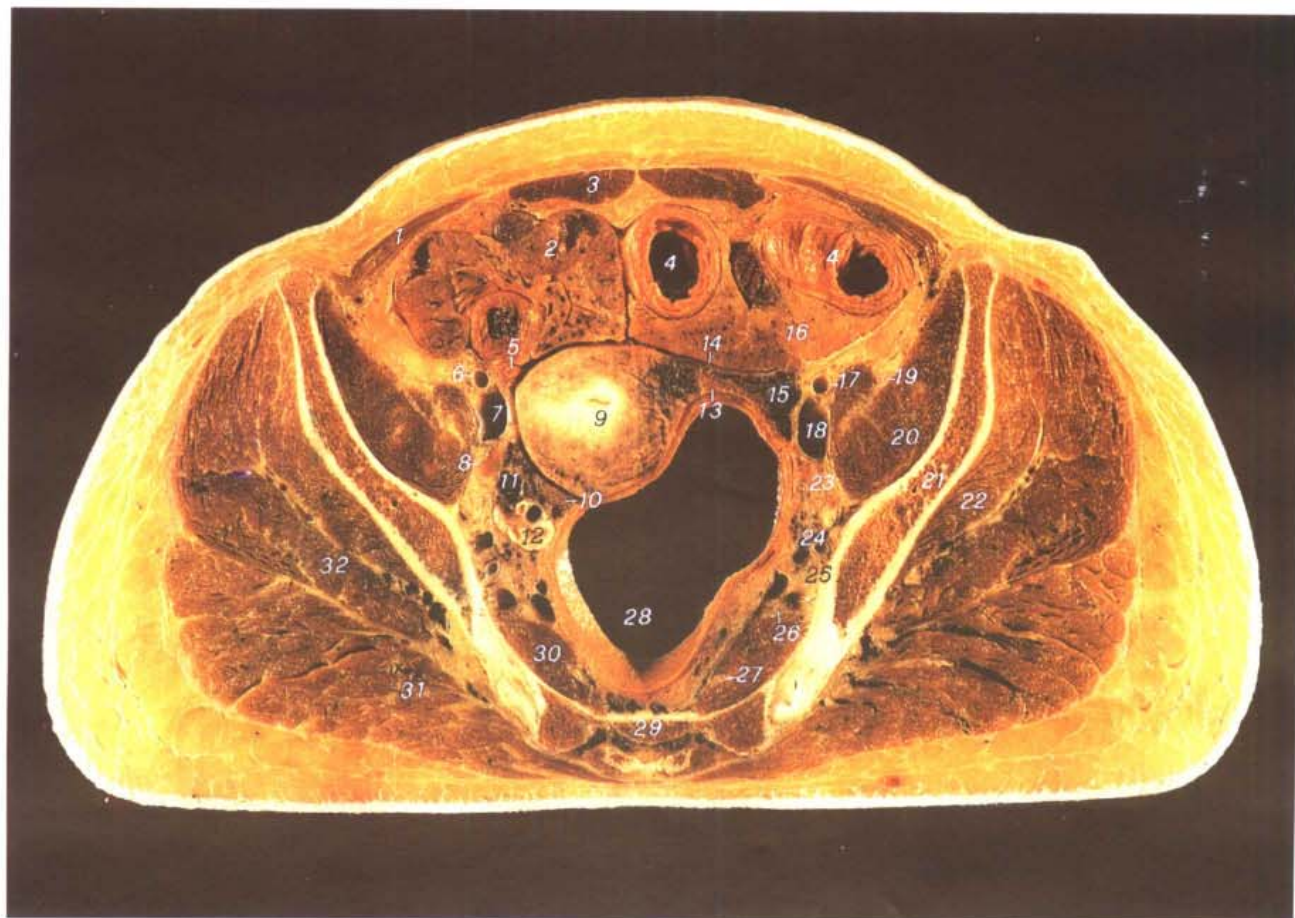

C. MRI T1WI

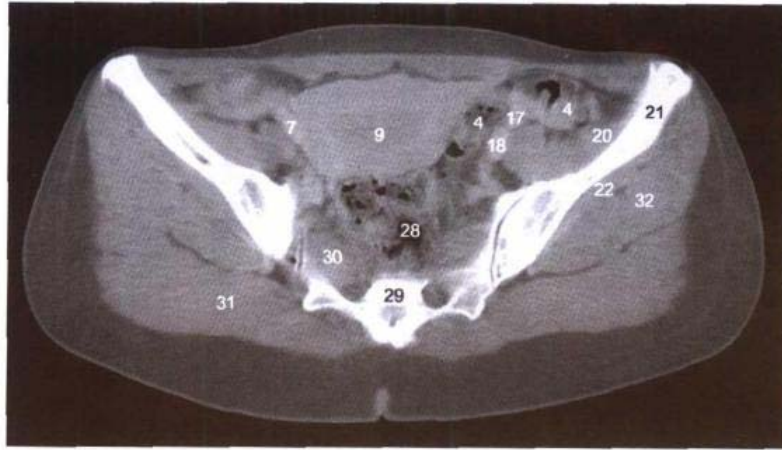
- | | |
|--|--|
| 1. 盲肠 cecum | 17. 腰骶干 lumbosacral trunk |
| 2. 回肠 ileum | 18. 左髂外静脉 left external iliac vein |
| 3. 腹直肌 rectus abdominis | 19. 左髂外动脉 left external iliac artery |
| 4. 乙状结肠 sigmoid colon | 20. 左卵巢动、静脉 left ovarian artery and vein |
| 5. 阑尾 vermiform appendix | 21. 左髂外淋巴结 left external iliac lymph nodes |
| 6. 子宫底 fundus of uterus | 22. 股神经 femoral nerve |
| 7. 右卵巢动、静脉 right ovarian artery and vein | 23. 髂肌 iliacus |
| 8. 右卵巢 right ovary | 24. 髂前上棘 anterior superior iliac spine |
| 9. 右髂外淋巴结 right external iliac lymph nodes | 25. 髂骨翼 ala of ilium |
| 10. 右髂外动脉 right external iliac artery | 26. 臀中肌 gluteus medius |
| 11. 右髂外静脉 right external iliac vein | 27. 骶髂关节 sacroiliac joint |
| 12. 右髂内动、静脉 right internal iliac artery and vein | 28. 第4骶神经 4th sacral nerve |
| 13. 直肠 rectum | 29. 第3骶椎 3rd sacral vertebrae |
| 14. 梨状肌 piriformis | 30. 竖脊肌 erector spinae |
| 15. 第3骶神经 3rd sacral nerve | 31. 臀大肌 gluteus maximus |
| 16. 第1、2骶神经 1st and 2nd sacral nerves | 32. 臀小肌 gluteus minimus |

图 8-5 经第 4 骶椎的横断层

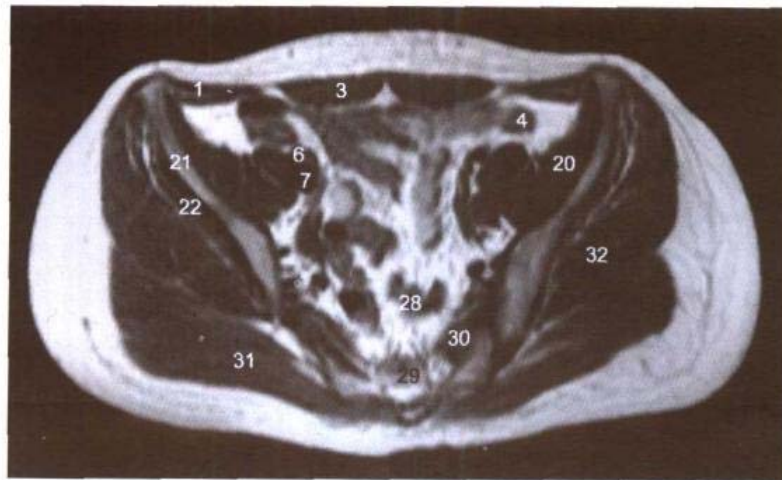
Fig.8-5 Transverse section through 4th sacral vertebrae



A. 断层标本 (sectional specimen)



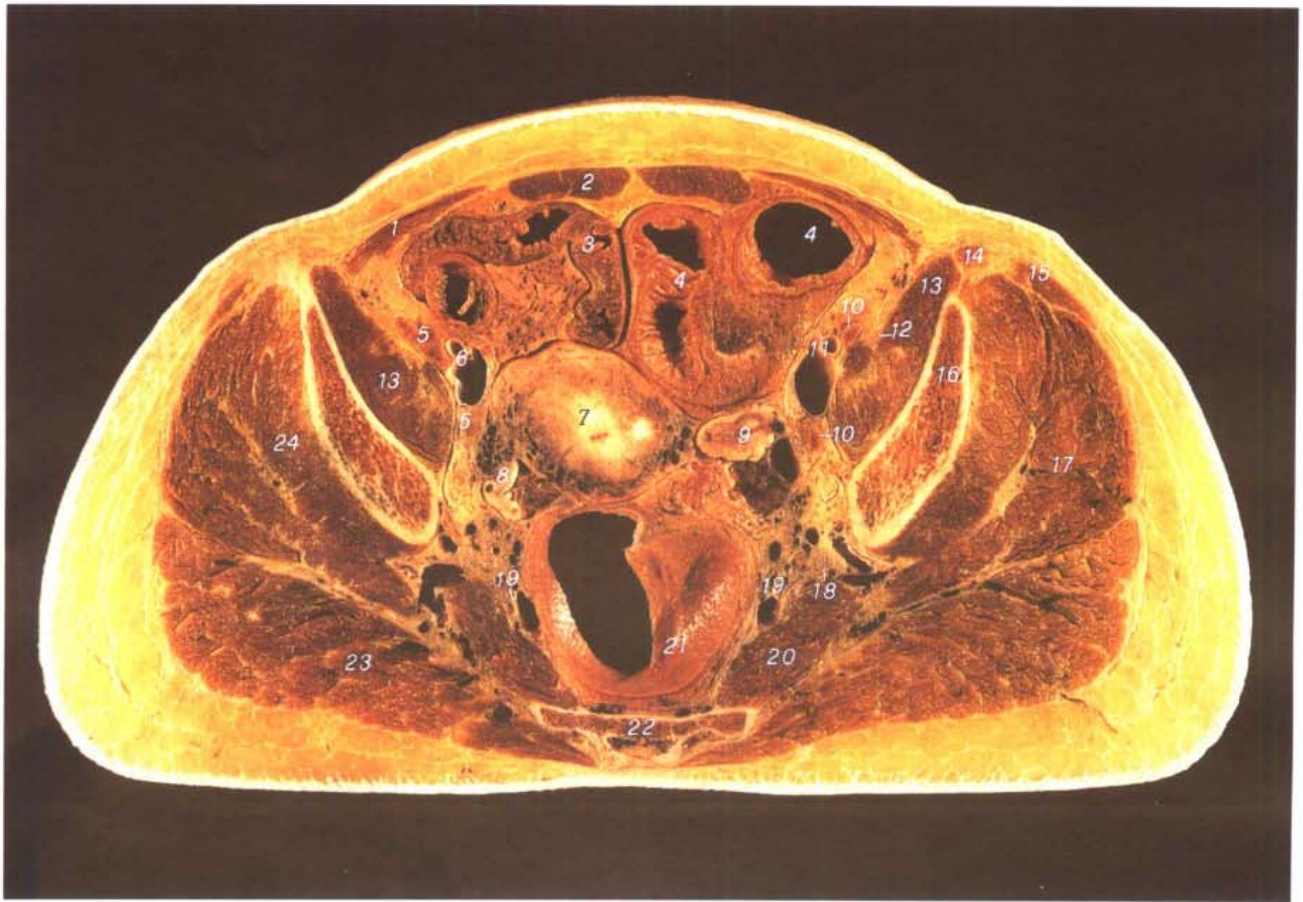
B. CT

C. MRI T₁WI

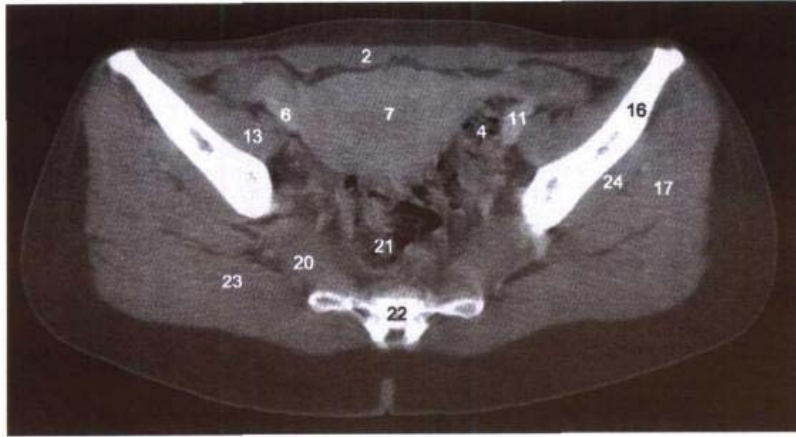- | | |
|--|---|
| 1. 腹内斜肌 obliquus internus abdominis | 17. 左髂外动脉 left external iliac artery |
| 2. 回肠 ileum | 18. 左髂外静脉 left external iliac vein |
| 3. 腹直肌 rectus abdominis | 19. 股神经 femoral nerve |
| 4. 乙状结肠 sigmoid colon | 20. 髂肌 iliacus |
| 5. 阑尾 vermiform appendix | 21. 髂骨翼 ala of ilium |
| 6. 右髂外动脉 right external iliac artery | 22. 臀小肌 gluteus minimus |
| 7. 右髂外静脉 right external iliac vein | 23. 左髂外淋巴结 left external iliac lymph nodes |
| 8. 右髂外淋巴结 right external iliac lymph nodes | 24. 左髂内动、静脉 left internal iliac artery and vein |
| 9. 子宫体 body of uterus | 25. 坐骨神经 sciatic nerve |
| 10. 右输卵管 right uterine tube | 26. 第3骶神经 3rd sacral nerve |
| 11. 右卵巢动、静脉 right ovarian artery and vein | 27. 第4骶神经 4th sacral nerve |
| 12. 右卵巢 right ovary | 28. 直肠 rectum |
| 13. 左输卵管 left uterine tube | 29. 第4骶椎 4th sacral vertebrae |
| 14. 左子宫阔韧带 left broad ligament of uterus | 30. 梨状肌 piriformis |
| 15. 左卵巢动、静脉 left ovarian artery and vein | 31. 臀大肌 gluteus maximus |
| 16. 乙状结肠系膜 sigmoid mesocolon | 32. 臀中肌 gluteus medius |

图 8-6 经坐骨大孔和子宫体的横断层

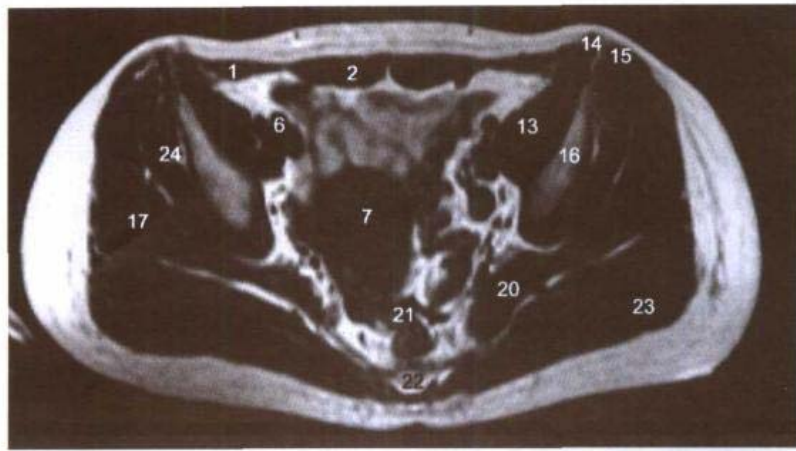
Fig.8-6 Transverse section through greater sciatic foramen and body of uterus



A. 断层标本 (sectional specimen)



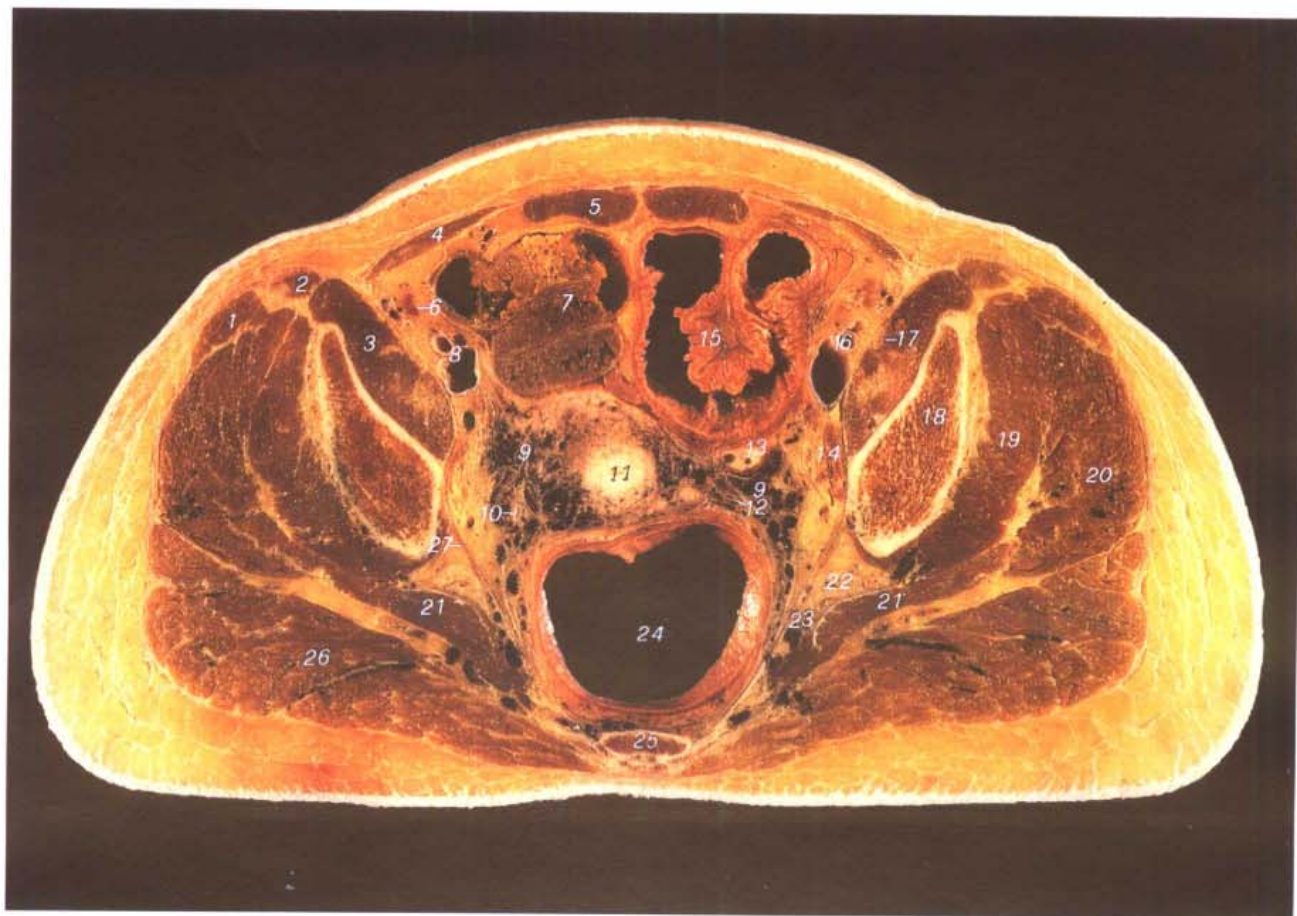
B. CT

C. MRI T₁WI

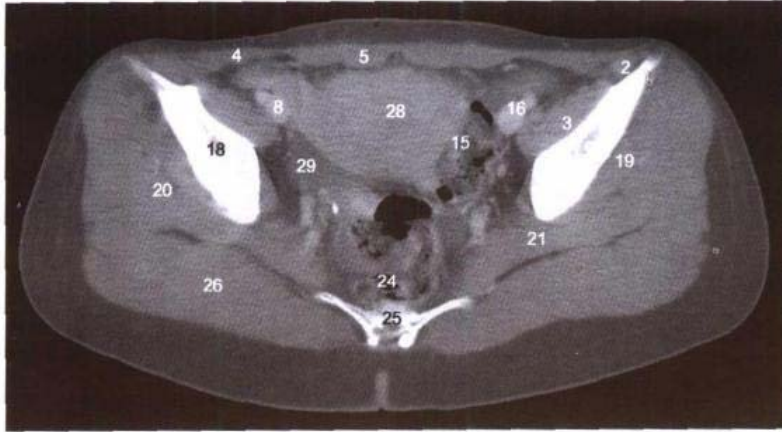
- | | |
|---|---|
| 1. 腹内斜肌 obliquus internus abdominis | 13. 髂腰肌 iliopsoas |
| 2. 腹直肌 rectus abdominis | 14. 缝匠肌 sartorius |
| 3. 回肠 ileum | 15. 阔筋膜张肌 tensor fasciae latae |
| 4. 乙状结肠 sigmoid colon | 16. 髂骨翼 ala of ilium |
| 5. 右髂外淋巴结 right external iliac lymph nodes | 17. 臀中肌 gluteus medius |
| 6. 右髂外动、静脉 right external iliac artery and vein | 18. 坐骨神经 sciatic nerve |
| 7. 子宫体 body of uterus | 19. 臀下动、静脉 inferior gluteal artery and vein |
| 8. 右卵巢 right ovary | 20. 梨状肌 piriformis |
| 9. 左卵巢 left ovary | 21. 直肠 rectum |
| 10. 左髂外淋巴结 left external iliac lymph nodes | 22. 第4骶椎 4th sacral vertebrae |
| 11. 左髂外动、静脉 left external iliac artery and vein | 23. 臀大肌 gluteus maximus |
| 12. 股神经 femoral nerve | 24. 臀小肌 gluteus minimus |

图 8-7 经第 5 骶椎和子宫颈的横断层

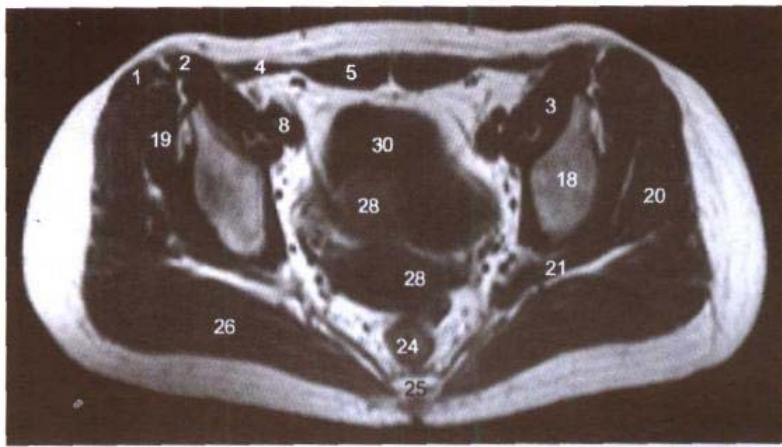
Fig.8-7 Transverse section through 5th sacral vertebrae and neck of uterus



A. 断层标本 (sectional specimen)



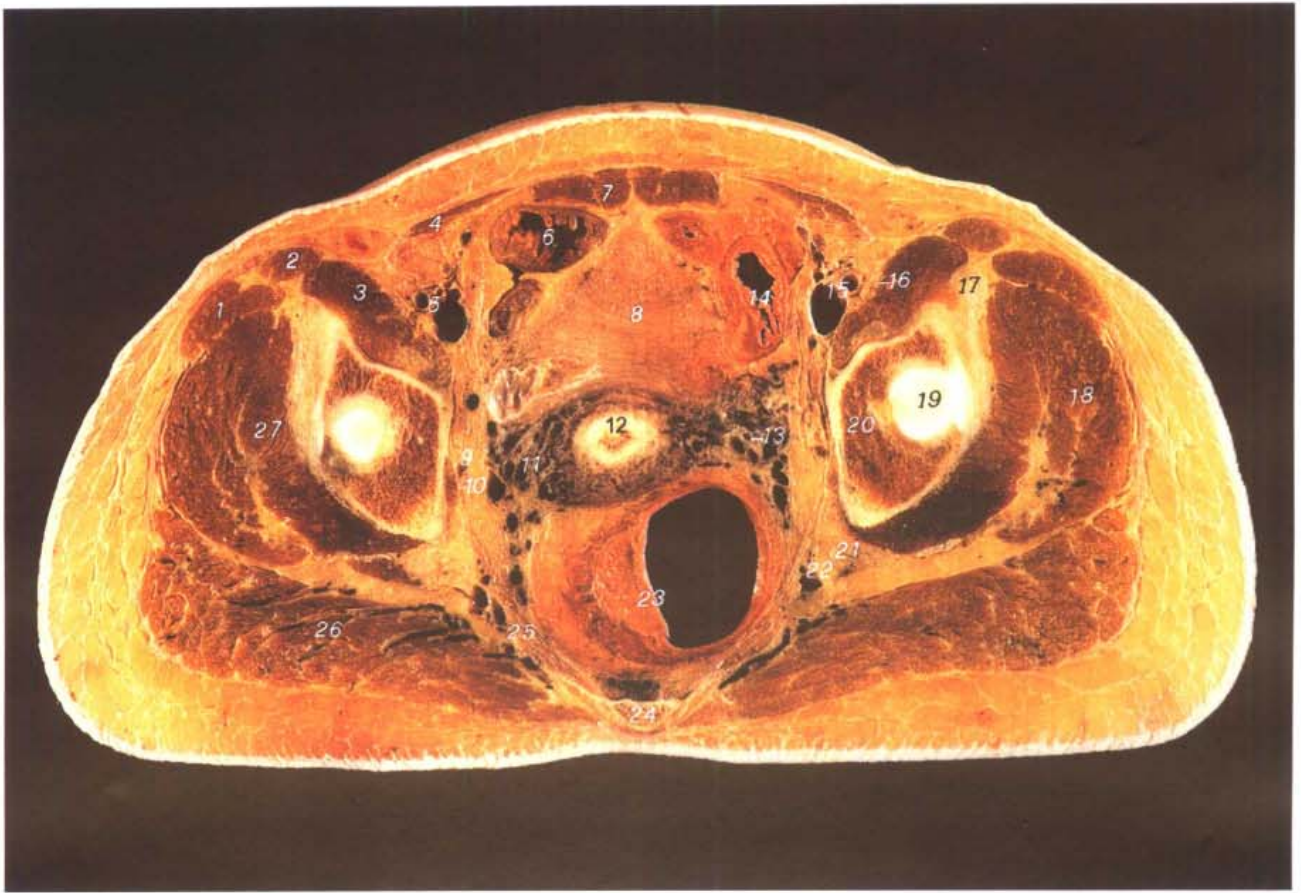
B. CT

C. MRI T₁WI

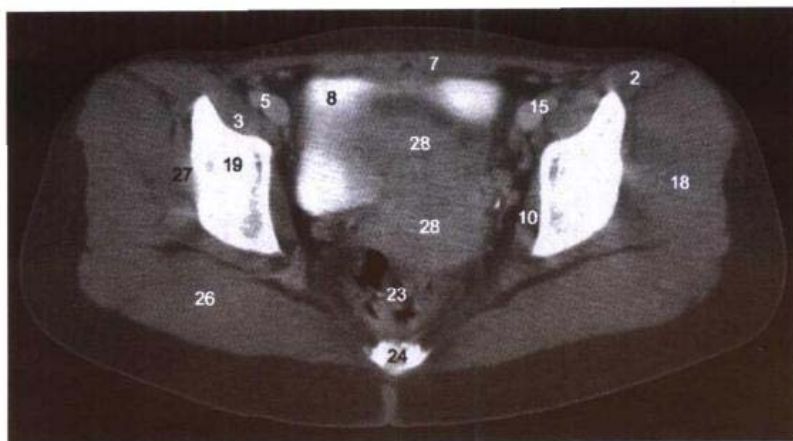
- | | |
|---|---|
| 1. 阔筋膜张肌 tensor fasciae latae | 16. 左髂外动、静脉 left external iliac artery and vein |
| 2. 缝匠肌 sartorius | 17. 股神经 femoral nerve |
| 3. 髂腰肌 iliopsoas | 18. 髌骨体 body of ilium |
| 4. 腹内斜肌 obliquus internus abdominis | 19. 臀小肌 gluteus minimus |
| 5. 腹直肌 rectus abdominis | 20. 臀中肌 gluteus medius |
| 6. 右髂外淋巴结 right external iliac lymph nodes | 21. 梨状肌 piriformis |
| 7. 回肠 ileum | 22. 坐骨神经 sciatic nerve |
| 8. 右髂外动、静脉 right external iliac artery and vein | 23. 臀下动、静脉 inferior gluteal artery and vein |
| 9. 子宫主韧带 cardinal ligament of uterus | 24. 直肠 rectum |
| 10. 右输尿管 right ureter | 25. 第5骶椎 5th sacral vertebrae |
| 11. 子宫颈 neck of uterus | 26. 臀大肌 gluteus maximus |
| 12. 左输尿管 left ureter | 27. 尾骨肌 coccygeus |
| 13. 左卵巢 left ovary | 28. 子宫体 body of uterus |
| 14. 左髂外淋巴结 left external iliac lymph nodes | 29. 右卵巢 right ovary |
| 15. 乙状结肠 sigmoid colon | 30. 膀胱 urinary bladder |

图 8-8 经尾骨和子宫颈的横断层

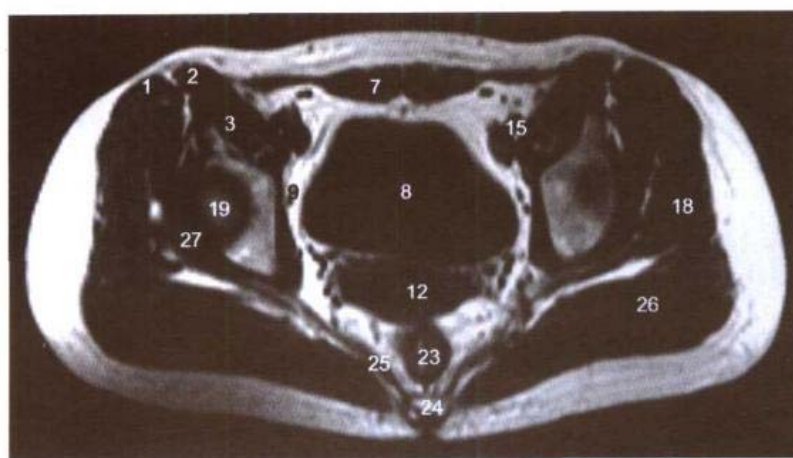
Fig.8-8 Transverse section through coccyx and neck of uterus



A. 断层标本 (sectional specimen)



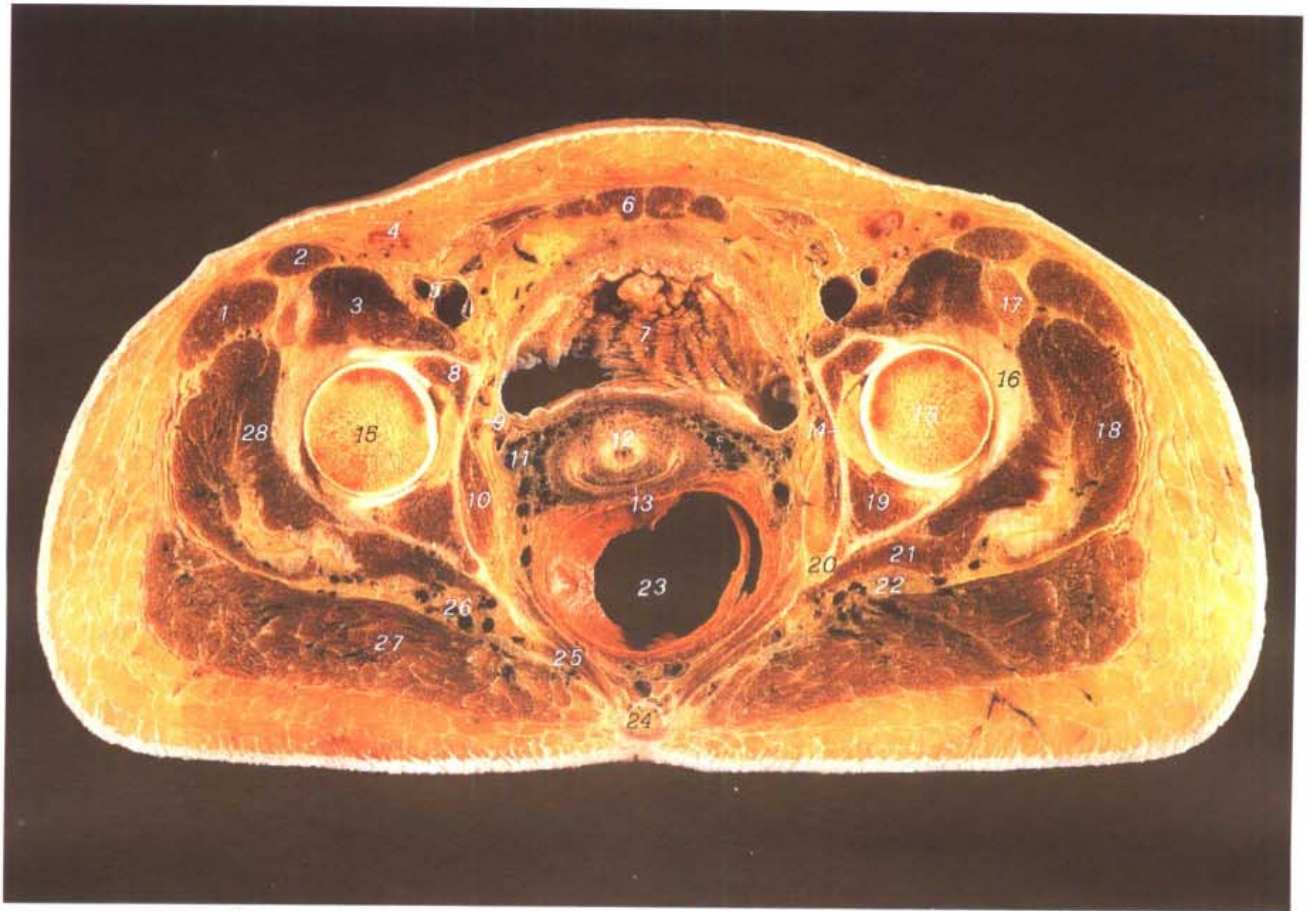
B. CT

C. MRI T₁WI

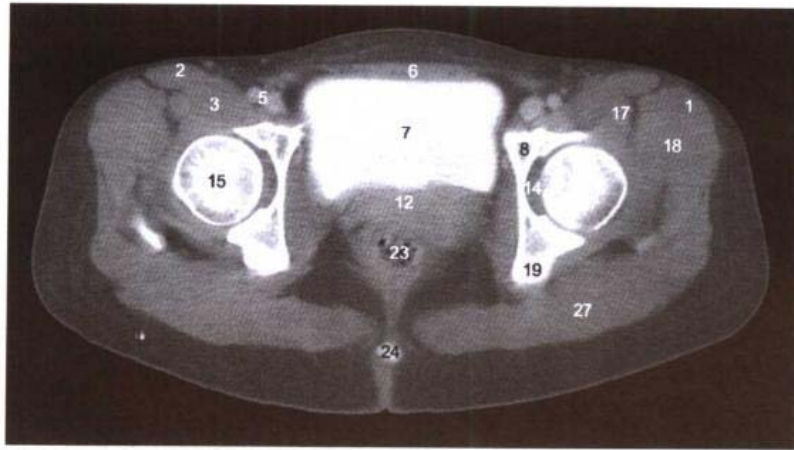
- | | |
|---|---|
| 1. 阔筋膜张肌 tensor fasciae latae | 15. 左髂外动、静脉 left external iliac artery and vein |
| 2. 缝匠肌 sartorius | 16. 股神经 femoral nerve |
| 3. 髂腰肌 iliopsoas | 17. 髂股韧带 iliofemoral ligament |
| 4. 腹内斜肌 obliquus internus abdominis | 18. 臀中肌 gluteus medius |
| 5. 右髂外动、静脉 right external iliac artery and vein | 19. 髋臼 acetabulum |
| 6. 回肠 ileum | 20. 坐骨体 body of ischium |
| 7. 腹直肌 rectus abdominis | 21. 坐骨神经 sciatic nerve |
| 8. 膀胱 urinary bladder | 22. 臀下动、静脉 inferior gluteal artery and vein |
| 9. 闭孔动脉 obturator artery | 23. 直肠 rectum |
| 10. 闭孔内肌 obturator internus | 24. 尾骨 coccyx |
| 11. 子宫主韧带 cardinal ligament of uterus | 25. 尾骨肌 coccygeus |
| 12. 子宫颈 neck of uterus | 26. 臀大肌 gluteus maximus |
| 13. 左输尿管 left ureter | 27. 臀小肌 gluteus minimus |
| 14. 乙状结肠 sigmoid colon | 28. 子宫体 body of uterus |

图 8-9 经尾骨和股骨头的横断层

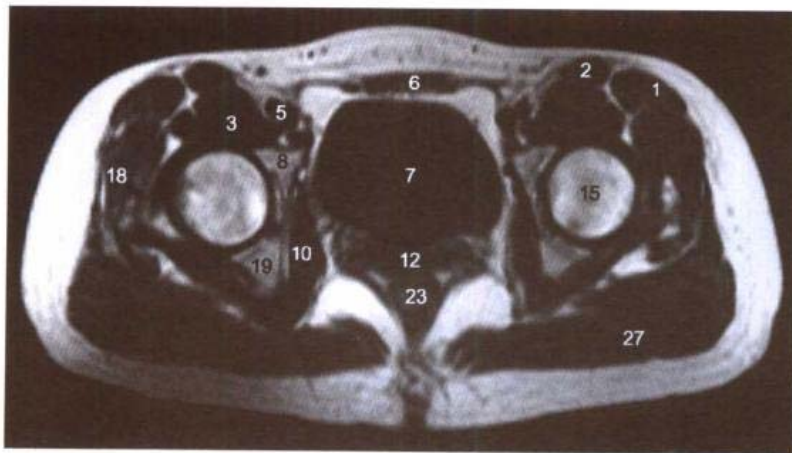
Fig.8-9 Transverse section through coccyx and femoral head



A. 断层标本 (sectional specimen)



B. CT

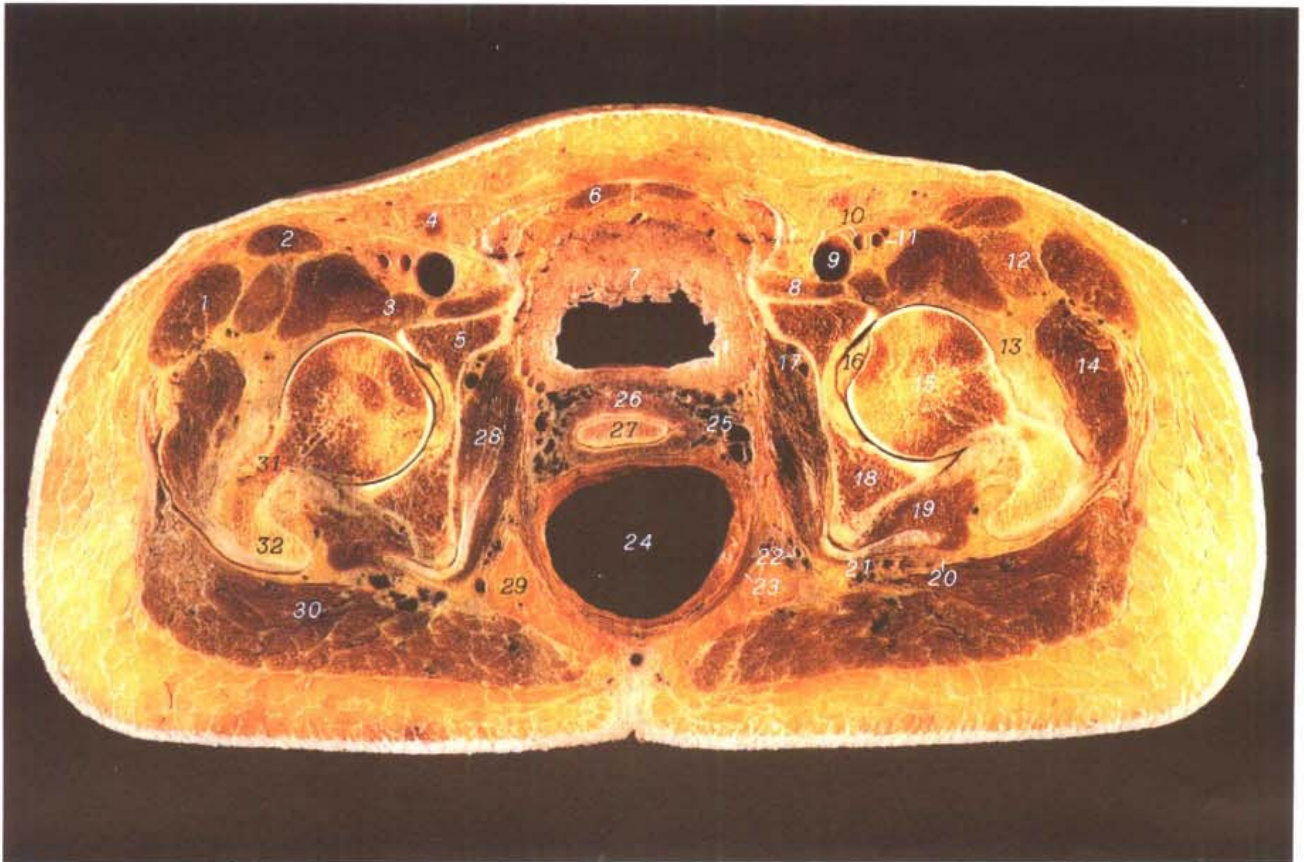


C. MRI T1WI

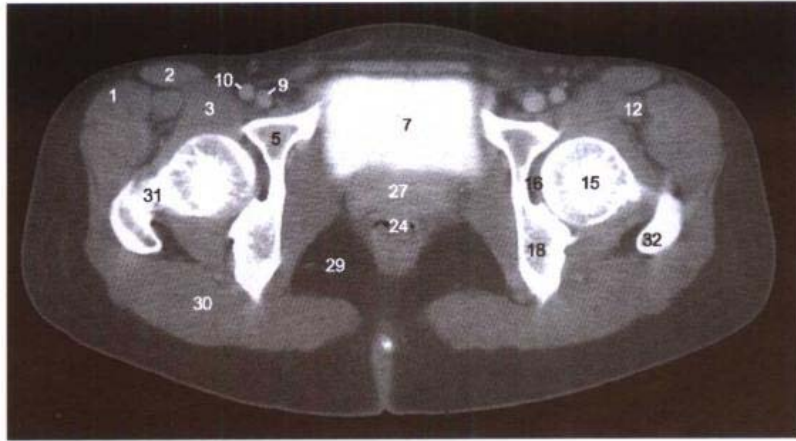
- | | |
|---|---|
| 1. 阔筋膜张肌 tensor fasciae latae | 15. 股骨头 head of femur |
| 2. 缝匠肌 sartorius | 16. 髂股韧带 iliofemoral ligament |
| 3. 髂腰肌 iliopsoas | 17. 股直肌 rectus femoris |
| 4. 腹股沟浅淋巴结 superficial inguinal lymph nodes | 18. 臀中肌 gluteus medius |
| 5. 股动、静脉 femoral artery and vein | 19. 坐骨体 body of ischium |
| 6. 腹直肌 rectus abdominis | 20. 坐骨棘 ischial spine |
| 7. 膀胱 urinary bladder | 21. 上孖肌 gemellus superior |
| 8. 耻骨体 body of pubis | 22. 坐骨神经 sciatic nerve |
| 9. 闭孔动脉 obturator artery | 23. 直肠 rectum |
| 10. 闭孔内肌 obturator internus | 24. 尾骨 coccyx |
| 11. 子宫阴道静脉丛 uterovaginal venous plexus | 25. 肛提肌 levator ani |
| 12. 子宫颈 neck of uterus | 26. 臀下动、静脉 inferior gluteal artery and vein |
| 13. 阴道穹 fornix of vagina | 27. 臀大肌 gluteus maximus |
| 14. 髋臼窝 acetabular fossa | 28. 臀小肌 gluteus minimus |

图 8-10 经股骨头韧带的横断层

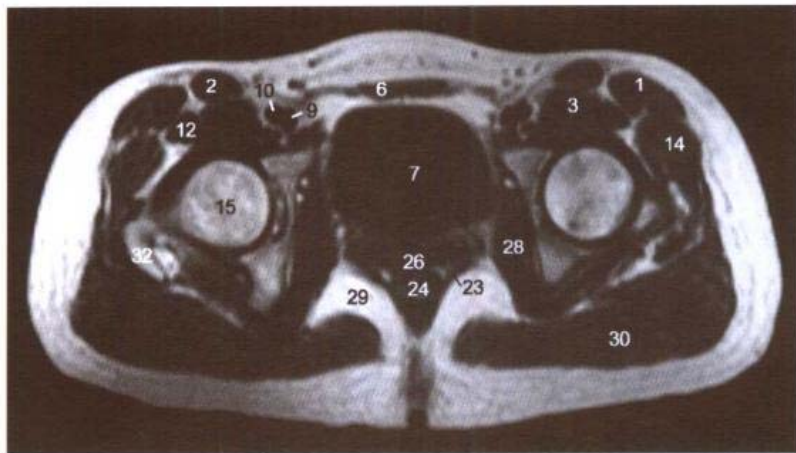
Fig.8-10 Transverse section through ligament of femoral head



A. 断层标本 (sectional specimen)



B. CT

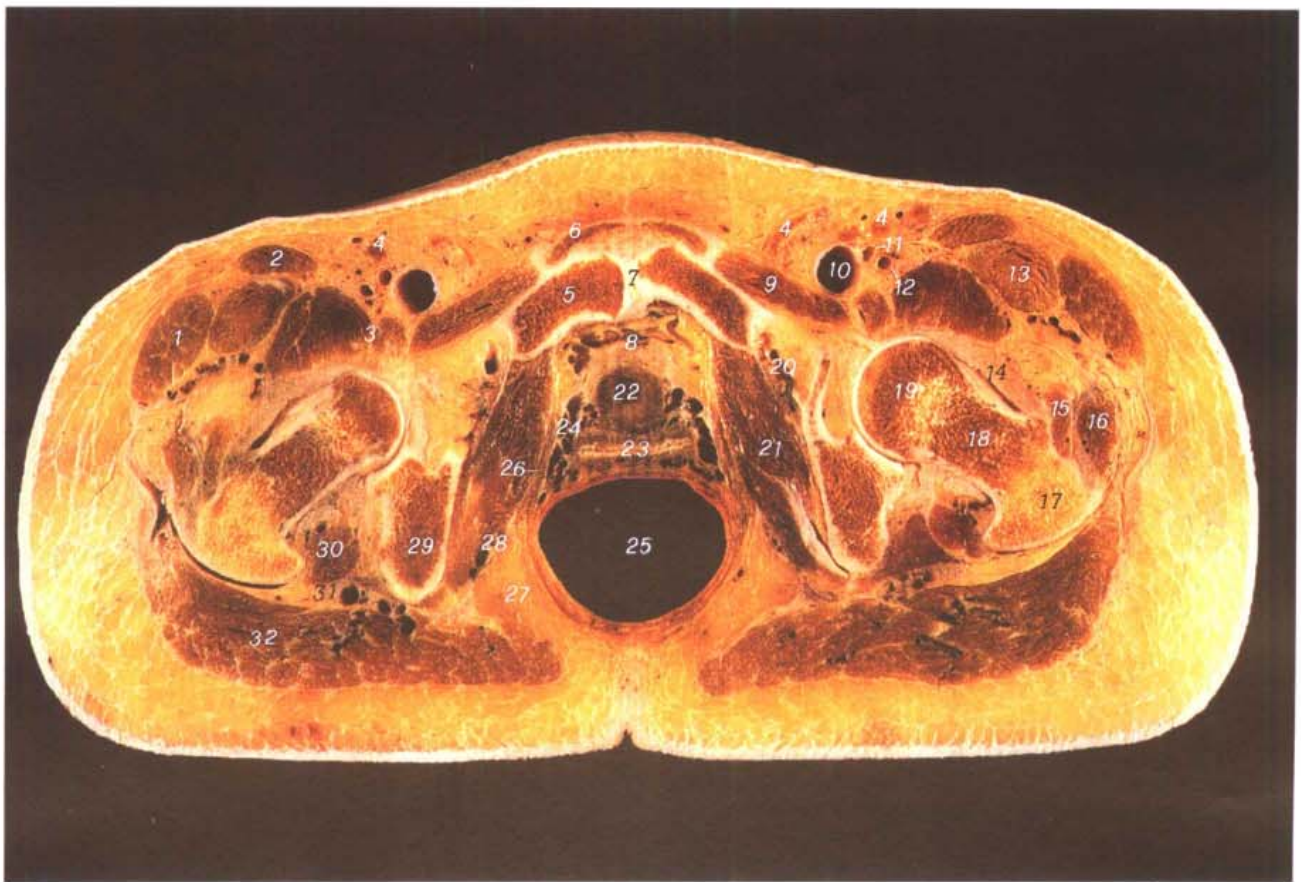


C. MRI T1WI

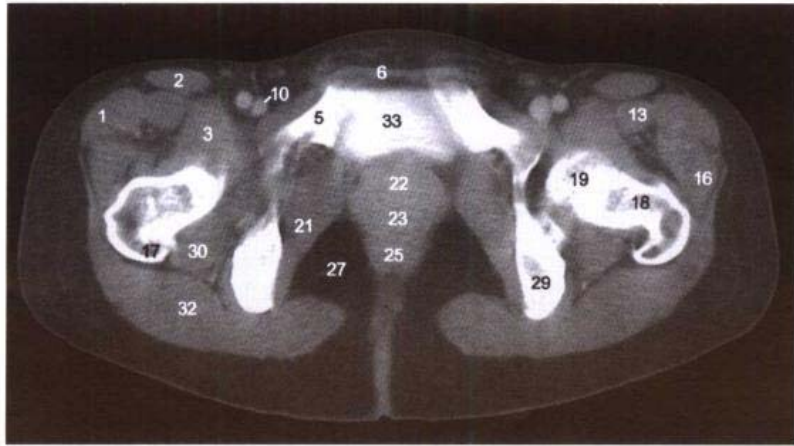
- | | |
|---|---|
| 1. 阔筋膜张肌 tensor fasciae latae | 17. 闭孔血管、神经 obturator vessels and nerve |
| 2. 缝匠肌 sartorius | 18. 坐骨体 body of ischium |
| 3. 髂腰肌 iliopsoas | 19. 下孖肌 gemellus inferior |
| 4. 腹股沟浅淋巴结 superficial inguinal lymph nodes | 20. 坐骨神经 sciatic nerve |
| 5. 耻骨体 body of pubis | 21. 臀下动、静脉 inferior gluteal artery and vein |
| 6. 腹直肌 rectus abdominis | 22. 阴部内动脉 internal pudendal artery |
| 7. 膀胱 urinary bladder | 23. 肛提肌 levator ani |
| 8. 耻骨肌 pectineus | 24. 直肠 rectum |
| 9. 股静脉 femoral vein | 25. 阴道静脉丛 vaginal venous plexus |
| 10. 股动脉 femoral artery | 26. 阴道 vagina |
| 11. 股深动脉 deep femoral artery | 27. 子宫颈 neck of uterus |
| 12. 股直肌 rectus femoris | 28. 闭孔内肌 obturator internus |
| 13. 髂股韧带 iliofemoral ligament | 29. 坐骨肛门窝 ischioanal fossa |
| 14. 臀中肌 gluteus medius | 30. 臀大肌 gluteus maximus |
| 15. 股骨头 femoral head | 31. 股骨颈 neck of femur |
| 16. 股骨头韧带 ligament of femoral head | 32. 大转子 greater trochanter |

图 8-11 经耻骨联合上份的横断层

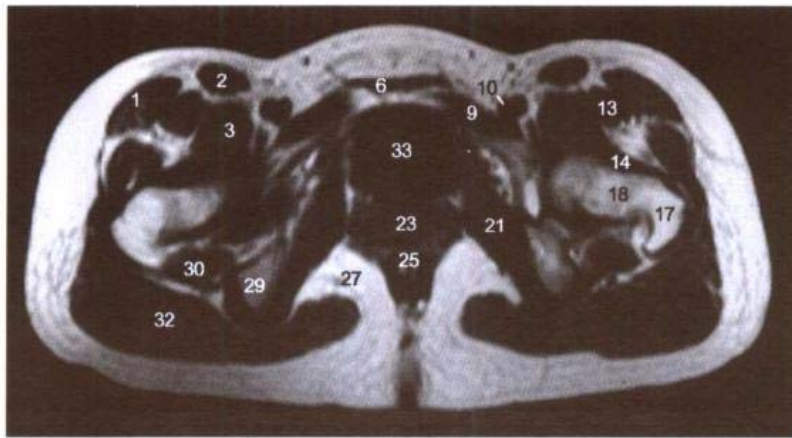
Fig.8-11 Transverse section through upper part of pubic symphysis



A. 断层标本 (sectional specimen)



B. CT

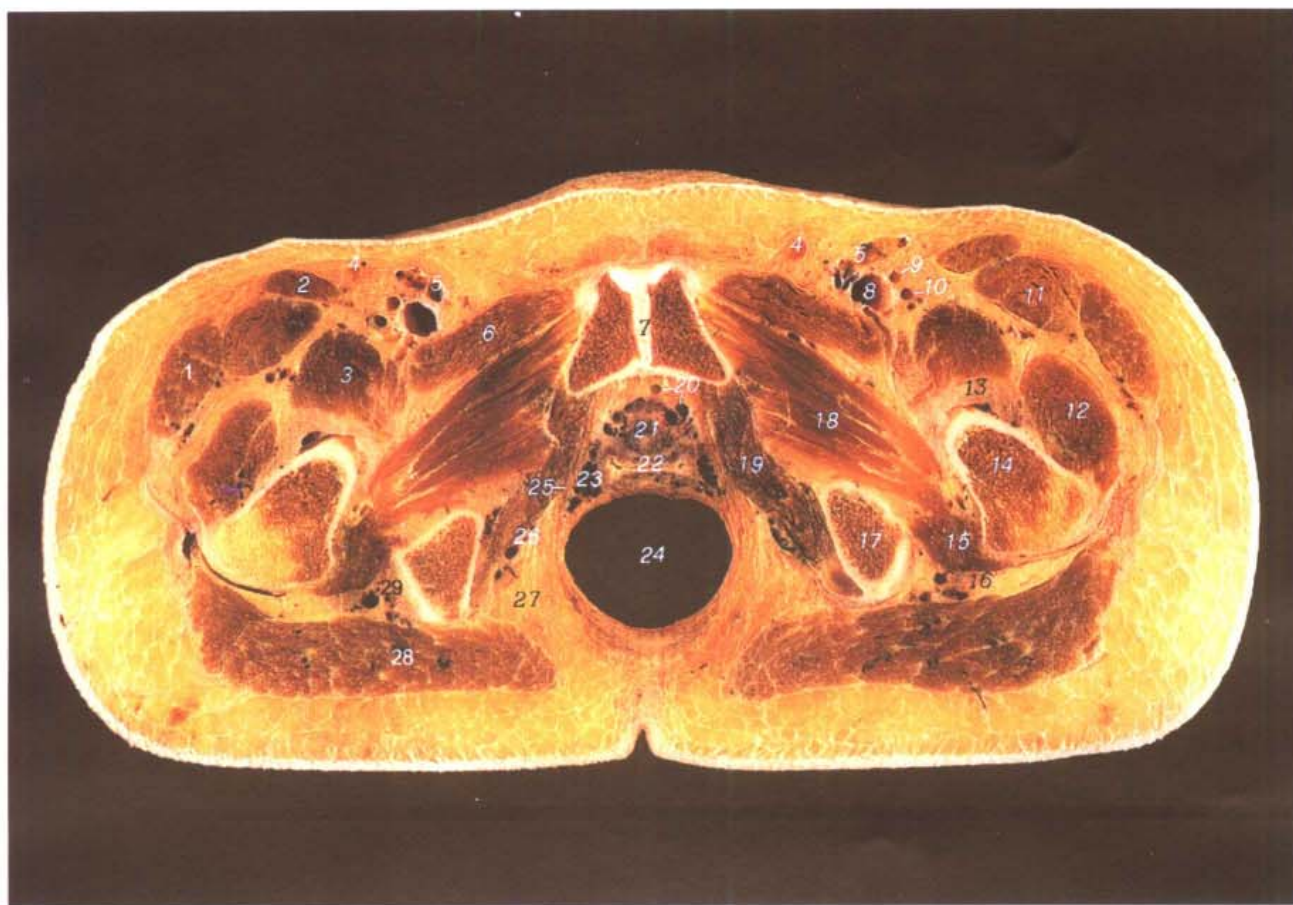


C. MRI T1WI

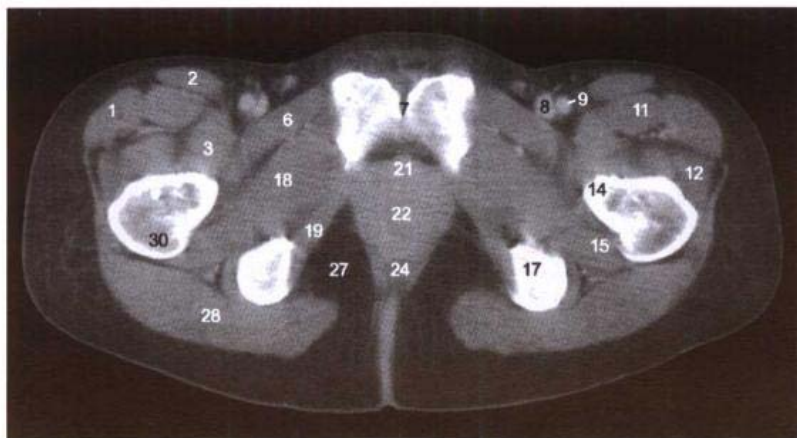
- | | |
|---|---|
| 1. 阔筋膜张肌 tensor fasciae latae | 18. 股骨颈 neck of femur |
| 2. 缝匠肌 sartorius | 19. 股骨头 head of femur |
| 3. 髂腰肌 iliopsoas | 20. 闭孔血管、神经 obturator vessels and nerve |
| 4. 腹股沟浅淋巴结 superficial inguinal lymph nodes | 21. 闭孔内肌 obturator internus |
| 5. 耻骨上支 superior ramus of pubis | 22. 女性尿道 female urethra |
| 6. 腹直肌 rectus abdominis | 23. 阴道 vagina |
| 7. 耻骨联合 pubic symphysis | 24. 阴道静脉丛 vaginal venous plexus |
| 8. 耻骨后间隙 retropubic space | 25. 肛管 anal canal |
| 9. 耻骨肌 pectineus | 26. 肛提肌 levator ani |
| 10. 股静脉 femoral vein | 27. 坐骨肛门窝 ischioanal fossa |
| 11. 股动脉 femoral artery | 28. 阴部内动、静脉 internal pudendal artery and vein |
| 12. 股深动脉 deep femoral artery | 29. 坐骨结节 ischial tuberosity |
| 13. 股直肌 rectus femoris | 30. 股方肌 quadratus femoris |
| 14. 髂股韧带 iliofemoral ligament | 31. 坐骨神经 sciatic nerve |
| 15. 股外侧肌 vastus lateralis | 32. 臀大肌 gluteus maximus |
| 16. 臀中肌 gluteus medius | 33. 膀胱 urinary bladder |
| 17. 大转子 greater trochanter | |

图 8-12 经耻骨联合中份的横断层

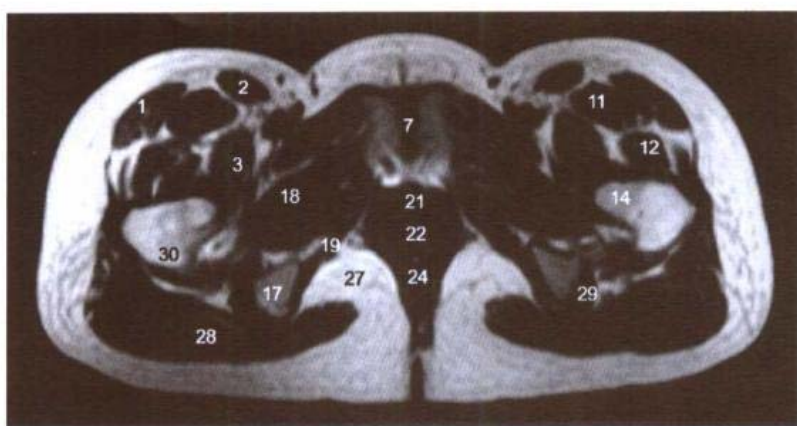
Fig.8-12 Transverse section through middle part of pubic symphysis



A. 断层标本 (sectional specimen)



B. CT

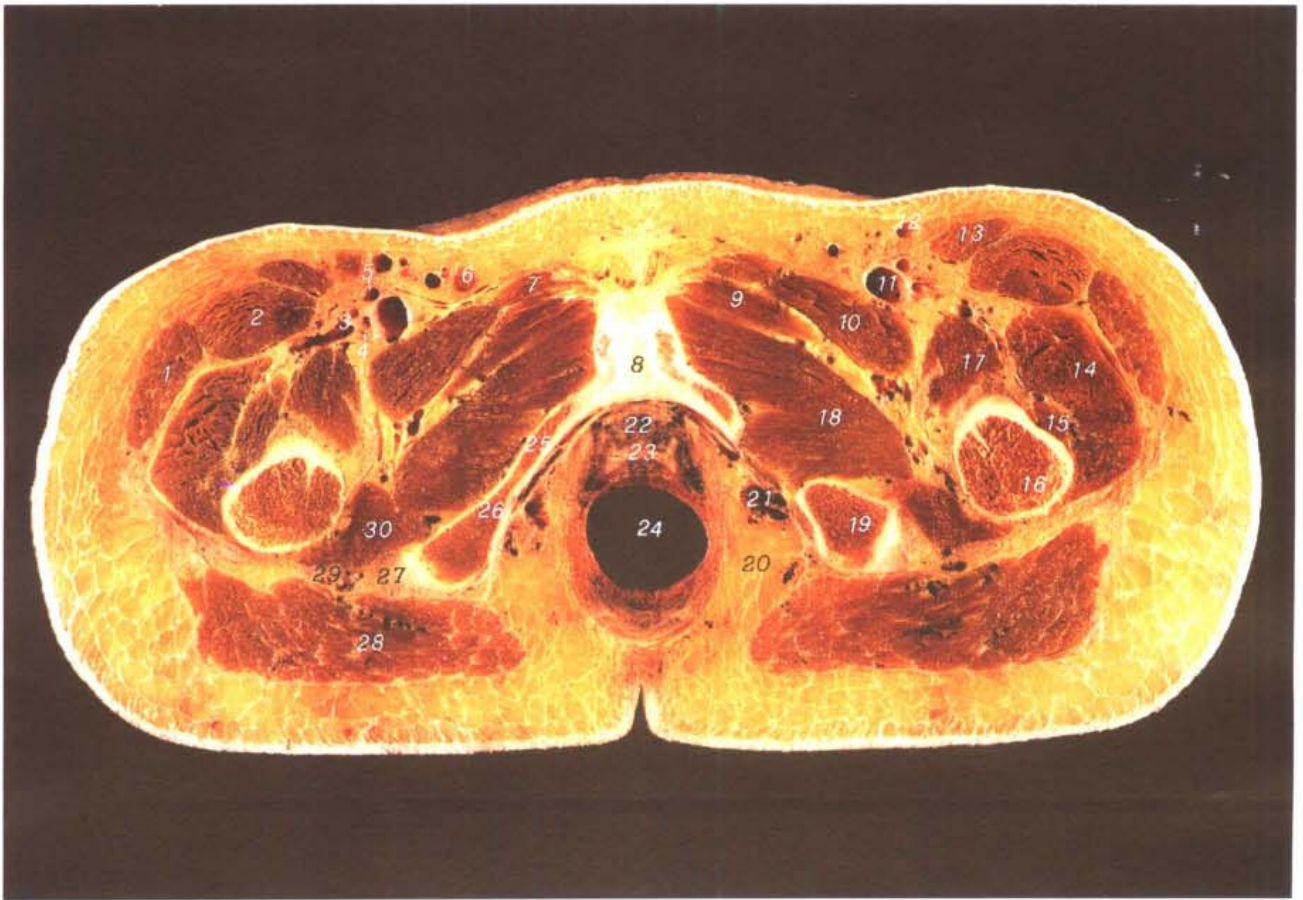


C. MRI T1WI

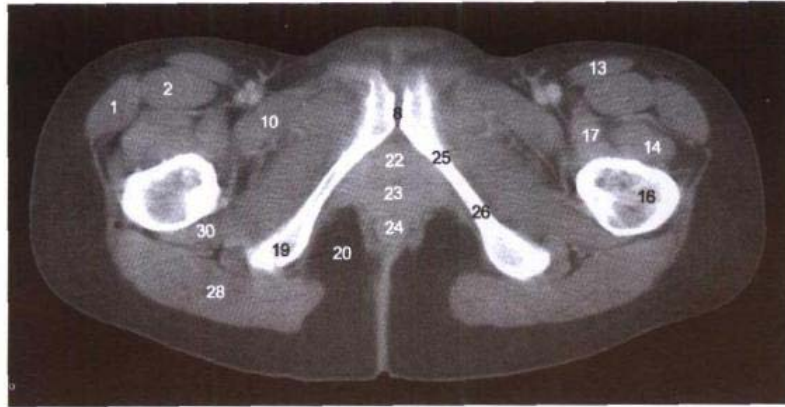
- | | |
|---|--|
| 1. 阔筋膜张肌 tensor fasciae latae | 17. 坐骨结节 ischial tuberosity |
| 2. 缝匠肌 sartorius | 18. 闭孔外肌 obturator externus |
| 3. 髂腰肌 iliopsoas | 19. 闭孔内肌 obturator internus |
| 4. 腹股沟浅淋巴结 superficial inguinal lymph nodes | 20. 膀胱静脉丛 vesical venous plexus |
| 5. 大隐静脉 great saphenous vein | 21. 女性尿道 female urethra |
| 6. 耻骨肌 pectineus | 22. 阴道 vagina |
| 7. 耻骨联合 pubic symphysis | 23. 阴道静脉丛 vaginal venous plexus |
| 8. 股静脉 femoral vein | 24. 肛管 anal canal |
| 9. 股动脉 femoral artery | 25. 肛提肌 levator ani |
| 10. 股深动脉 deep femoral artery | 26. 阴部内动、静脉 internal pudendal artery and vein |
| 11. 股直肌 rectus femoris | 27. 坐骨肛门窝 ischioanal fossa |
| 12. 股外侧肌 vastus lateralis | 28. 臀大肌 gluteus maximus |
| 13. 髋关节囊 capsule of hip joint | 29. 股后群肌腱 tendon of posterior muscles of thigh |
| 14. 股骨颈 neck of femur | 30. 大转子 greater trochanter |
| 15. 股方肌 quadratus femoris | |
| 16. 坐骨神经 sciatic nerve | |

图 8-13 经耻骨联合下份的横断层

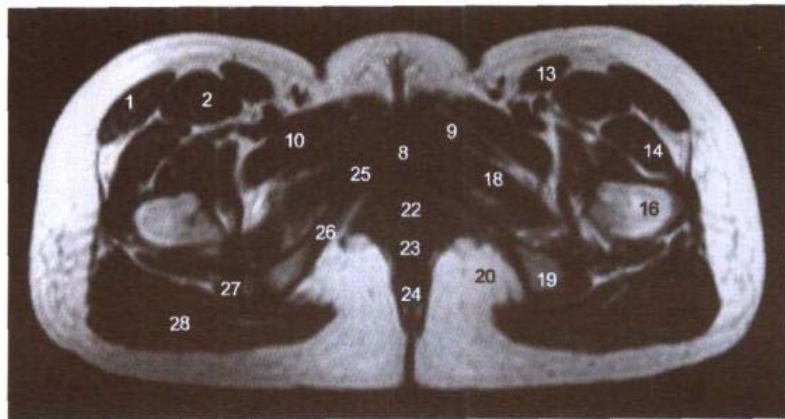
Fig.8-13 Transverse section through lower part of pubic symphysis



A. 断层标本 (sectional specimen)



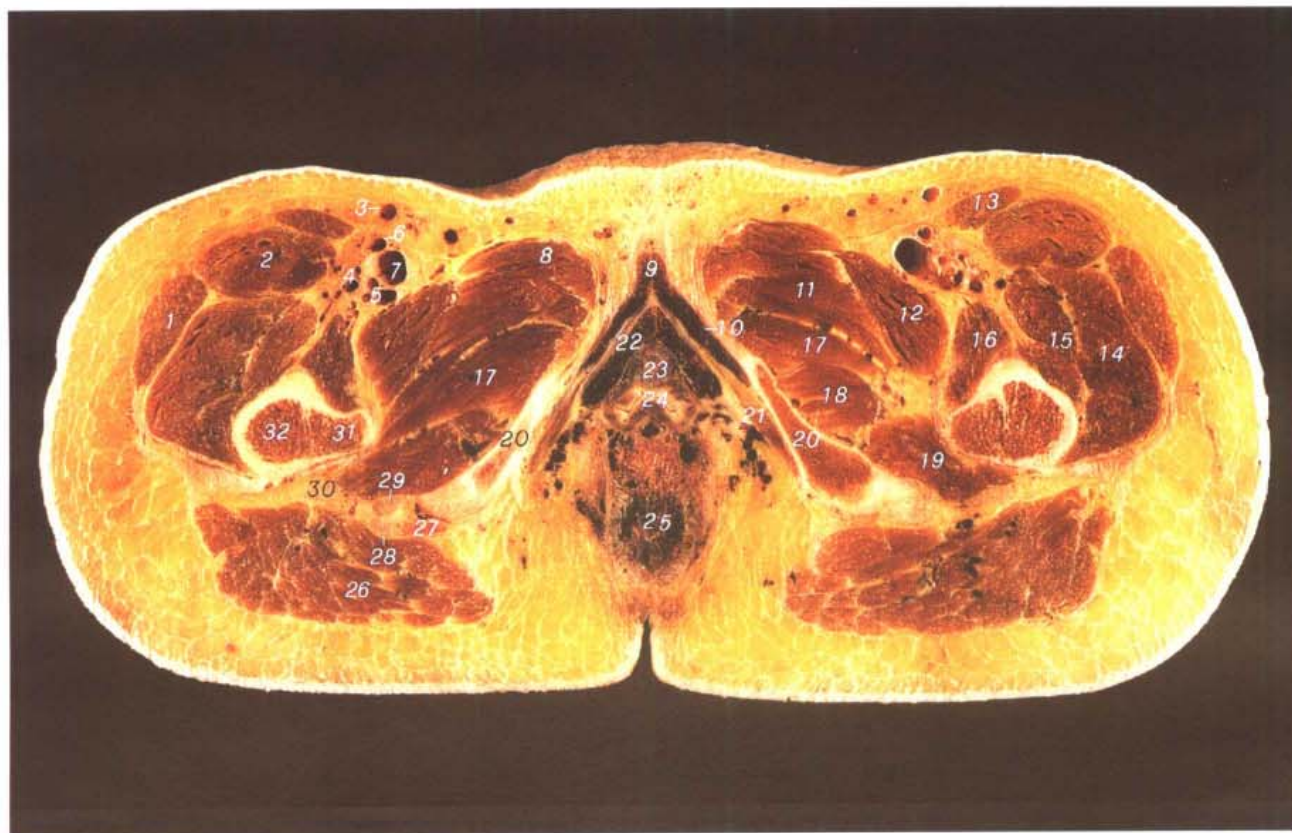
B. CT

C. MRI T₁-WI

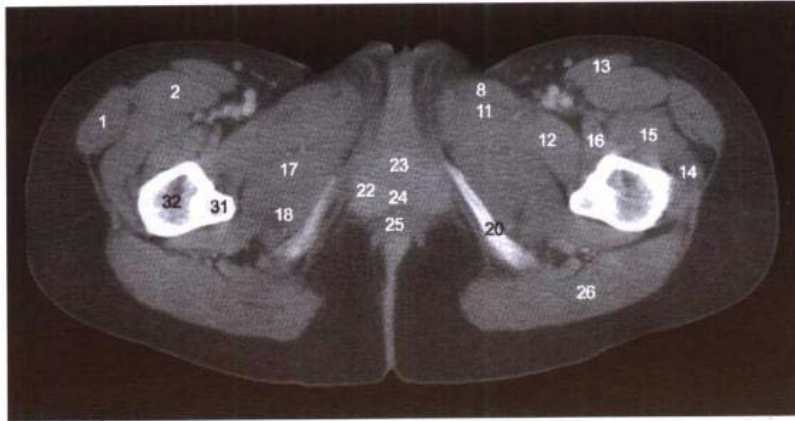
- | | |
|--|--|
| 1. 阔筋膜张肌 tensor fasciae latae | 16. 大转子 greater trochanter |
| 2. 股直肌 rectus femoris | 17. 髂腰肌 iliopsoas |
| 3. 旋股外侧动、静脉 lateral femoral circumflex artery and vein | 18. 闭孔外肌 obturator externus |
| 4. 股深动脉 deep femoral artery | 19. 坐骨结节 ischial tuberosity |
| 5. 股动脉 femoral artery | 20. 坐骨肛门窝 ischioanal fossa |
| 6. 腹股沟浅淋巴结 superficial inguinal lymph nodes | 21. 阴部内动、静脉 internal pudendal artery and vein |
| 7. 长收肌 adductor longus | 22. 女性尿道 female urethra |
| 8. 耻骨联合 pubic symphysis | 23. 阴道 vagina |
| 9. 短收肌 adductor brevis | 24. 肛管 anal canal |
| 10. 耻骨肌 pectineus | 25. 耻骨下支 inferior ramus of pubis |
| 11. 股静脉 femoral vein | 26. 坐骨支 ramus of ischium |
| 12. 大隐静脉 great saphenous vein | 27. 股后群肌腱 tendon of posterior muscles of thigh |
| 13. 缝匠肌 sartorius | 28. 臀大肌 gluteus maximus |
| 14. 股外侧肌 vastus lateralis | 29. 坐骨神经 sciatic nerve |
| 15. 股中间肌 vastus intermedius | 30. 股方肌 quadratus femoris |

图 8-14 经前庭球的横断层

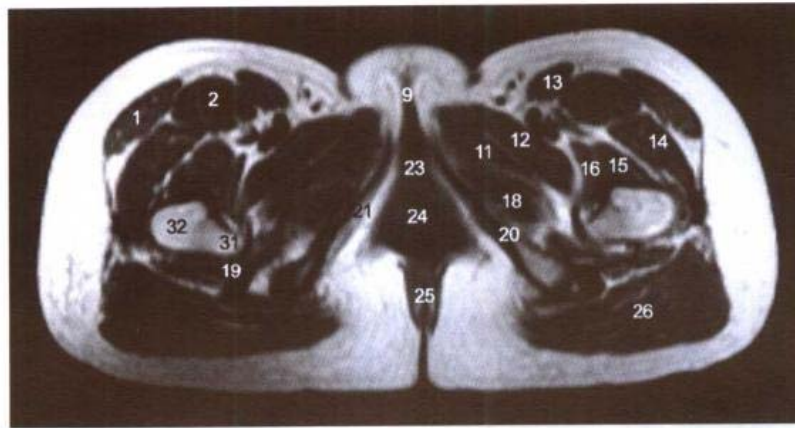
Fig.8-14 Transverse section through bulb of vestibule



A. 断层标本 (sectional specimen)



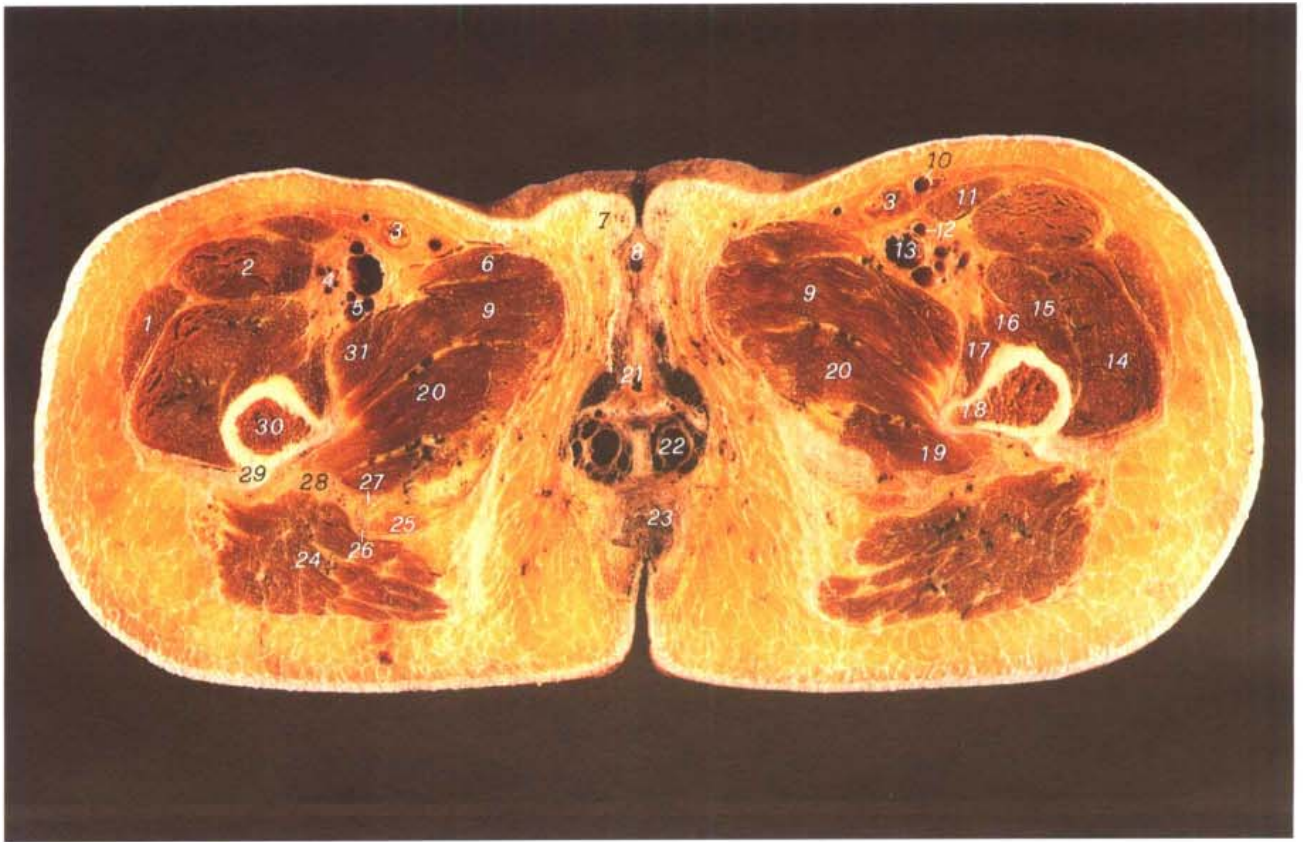B. CT

C. MRI T₁WI

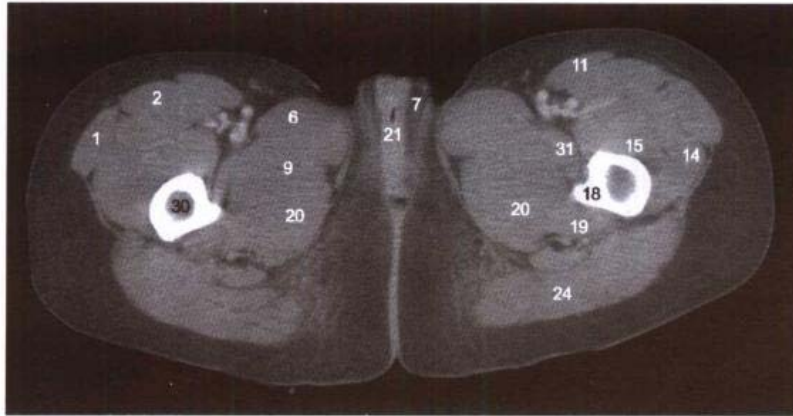
- | | |
|--|---|
| 1. 阔筋膜张肌 tensor fasciae latae | 17. 大收肌 adductor magnus |
| 2. 股直肌 rectus femoris | 18. 闭孔外肌 obturator externus |
| 3. 大隐静脉 great saphenous vein | 19. 股方肌 quadratus femoris |
| 4. 旋股外侧动、静脉 lateral femoral circumflex artery and vein | 20. 坐骨支 ramus of ischium |
| 5. 股深动、静脉 deep femoral artery and vein | 21. 坐骨海绵体肌 ischiocavernosus |
| 6. 股动脉 femoral artery | 22. 前庭球 bulb of vestibule |
| 7. 股静脉 femoral vein | 23. 女性尿道 female urethra |
| 8. 长收肌 adductor longus | 24. 阴道 vagina |
| 9. 阴蒂体 body of clitoris | 25. 肛门 anus |
| 10. 阴蒂脚 crus of clitoris | 26. 臀大肌 gluteus maximus |
| 11. 短收肌 adductor brevis | 27. 半腱肌 semitendinosus |
| 12. 耻骨肌 pectineus | 28. 股二头肌长头腱 tendon of long head of biceps femoris |
| 13. 缝匠肌 sartorius | 29. 半膜肌腱 tendon of semimembranosus |
| 14. 股外侧肌 vastus lateralis | 30. 坐骨神经 sciatic nerve |
| 15. 股中间肌 vastus intermedius | 31. 小转子 lesser trochanter |
| 16. 髂腰肌 iliopsoas | 32. 股骨 femur |

图 8-15 经大阴唇和阴蒂的横断层

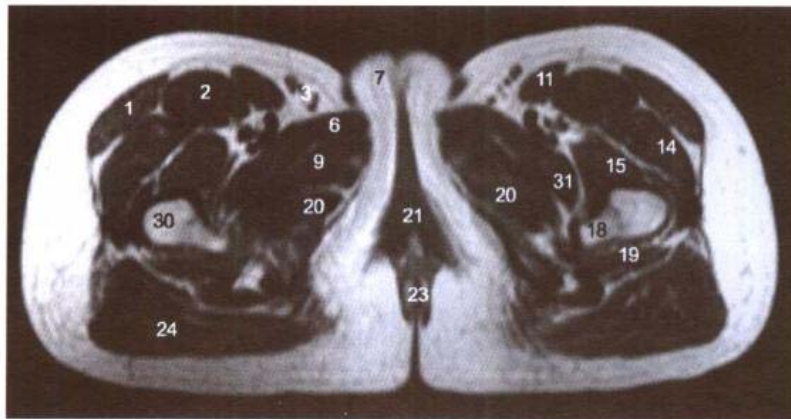
Fig.8-15 Transverse section through greater lip of pudendum and clitoris



A. 断层标本 (sectional specimen)



B. CT



C. MRI T1WI

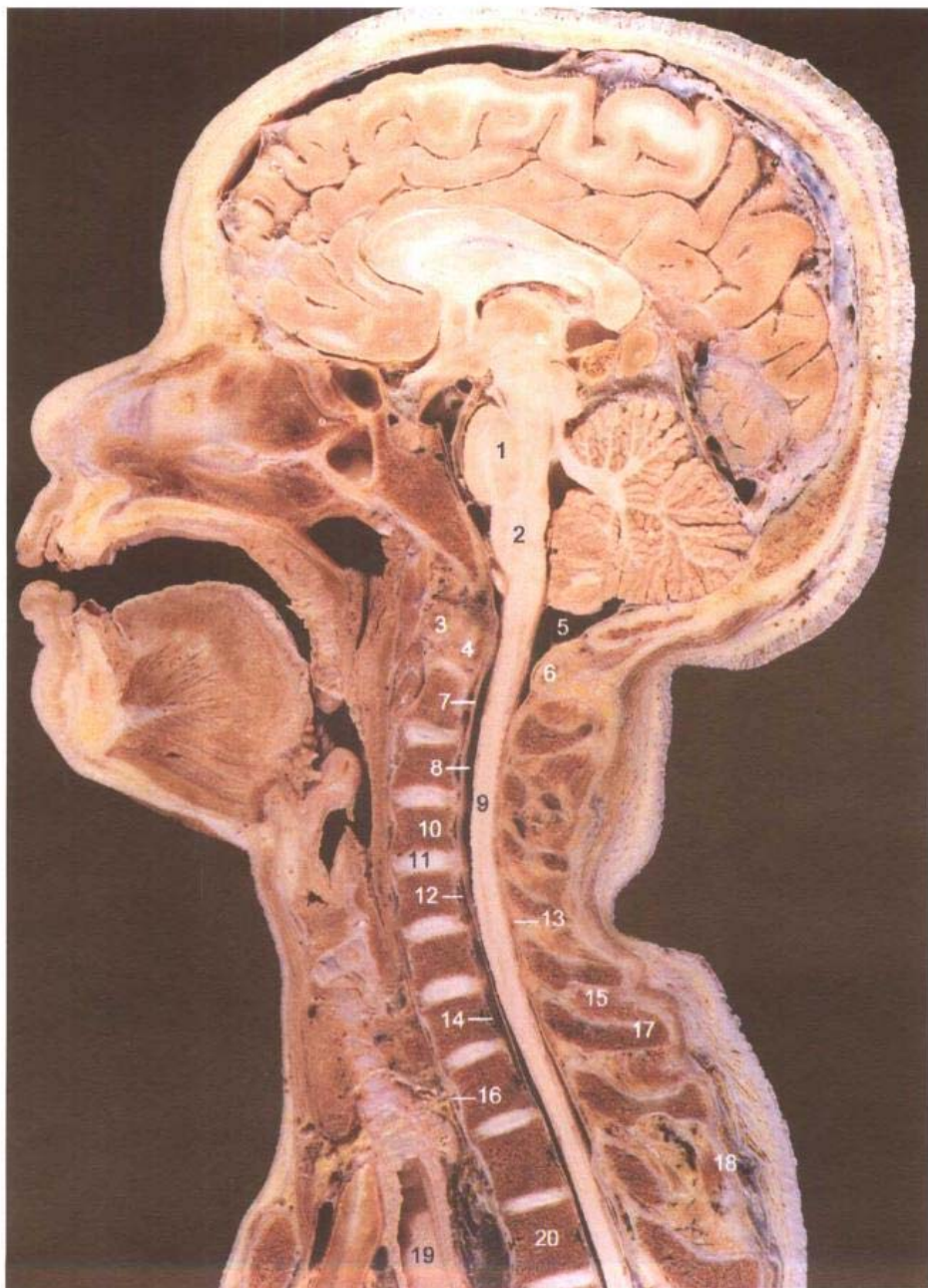
- | | |
|--|---|
| 1. 阔筋膜张肌 tensor fasciae latae | 17. 髂腰肌 iliopsoas |
| 2. 股直肌 rectus femoris | 18. 小转子 lesser trochanter |
| 3. 腹股沟浅淋巴结 superficial inguinal lymph nodes | 19. 股方肌 quadratus femoris |
| 4. 旋股外侧动、静脉 lateral femoral circumflex artery and vein | 20. 大收肌 adductor magnus |
| 5. 股深动、静脉 deep femoral artery and vein | 21. 阴道 vagina |
| 6. 长收肌 adductor longus | 22. 直肠静脉丛 rectal venous plexus |
| 7. 大阴唇 greater lip of pudendum | 23. 肛门外括约肌 sphincter ani externus |
| 8. 阴蒂 clitoris | 24. 臀大肌 gluteus maximus |
| 9. 短收肌 adductor brevis | 25. 半腱肌 semitendinosus |
| 10. 大隐静脉 great saphenous vein | 26. 股二头肌长头腱 tendon of long head of biceps femoris |
| 11. 缝匠肌 sartorius | 27. 半膜肌腱 tendon of semimembranosus |
| 12. 股动脉 femoral artery | 28. 坐骨神经 sciatic nerve |
| 13. 股静脉 femoral vein | 29. 股骨粗线 linea aspera of femur |
| 14. 股外侧肌 vastus lateralis | 30. 股骨 femur |
| 15. 股中间肌 vastus intermedius | 31. 耻骨肌 pectineus |
| 16. 股内侧肌 vastus medialis | |

第九章 脊柱区横、矢、冠状断层

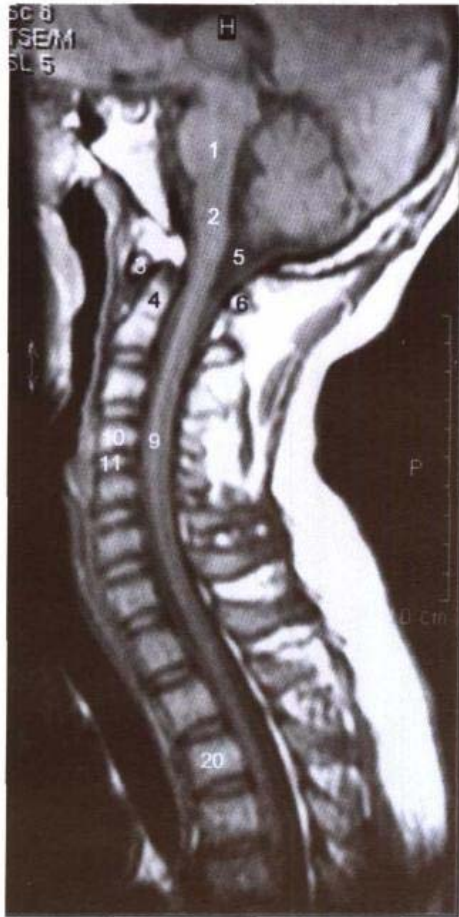Chapter 9 Transverse, Sagittal, and Coronal Sections Of Vertebral Region

图 9-1 脊柱区颈段正中矢状面

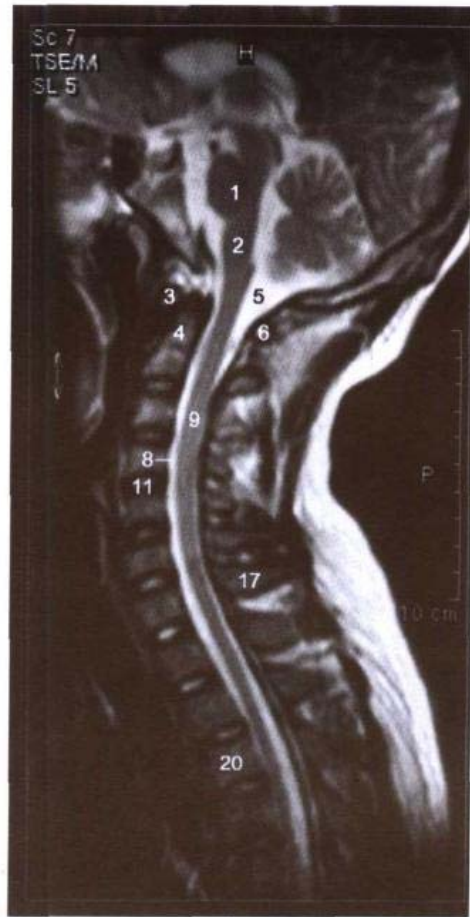Fig.9-1 Median sagittal plane of cervical vertebral region



A. 断层标本 (sectional specimen)



B. MRI T₁WI

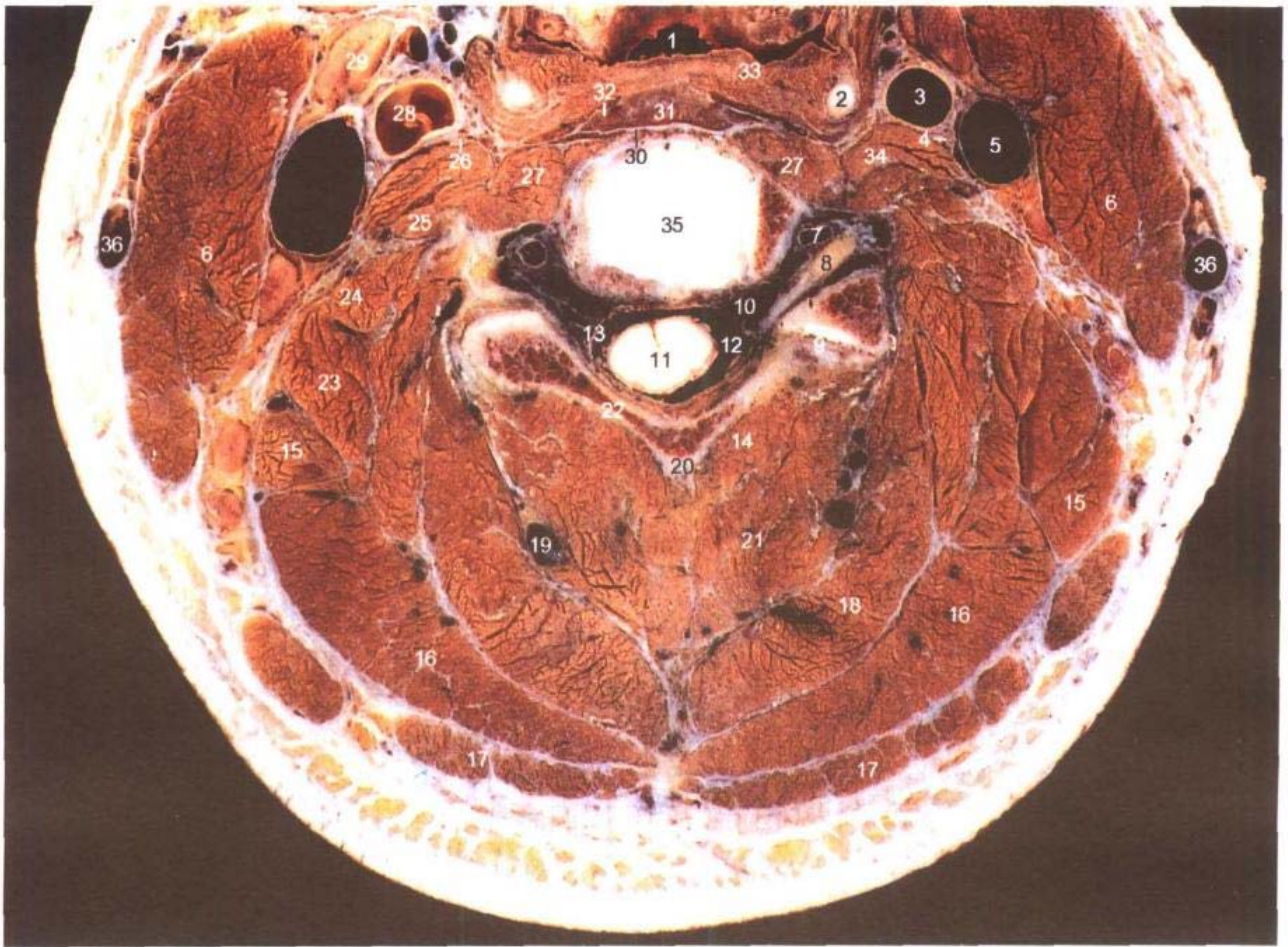

C. MRI T₂WI

- | | |
|--|--|
| <ol style="list-style-type: none"> 1. 脑桥 pons 2. 延髓 medulla oblongata 3. 寰椎前弓 anterior arch of atlas 4. 枢椎齿突 dens of axis 5. 小脑延髓池 cerebellomedullary cistern 6. 寰椎后弓 posterior arch of atlas 7. 硬脊膜 spinal dura mater 8. 蛛网膜下隙 subarachnoid space 9. 脊髓颈段 cervical segment of spinal cord 10. 第4颈椎 4th cervical vertebrae | <ol style="list-style-type: none"> 11. 第3颈椎间盘 3rd cervical intervertebral disc 12. 硬膜外隙 epidural space 13. 黄韧带 ligamenta flava 14. 后纵韧带 posterior longitudinal ligament 15. 棘间肌 interspinales 16. 前纵韧带 anterior longitudinal ligament 17. 第7颈椎棘突 spinous process of 7th cervical vertebrae 18. 棘上韧带 supraspinal ligament 19. 气管 trachea 20. 第3胸椎体 body of 3rd thoracic vertebrae |
|--|--|

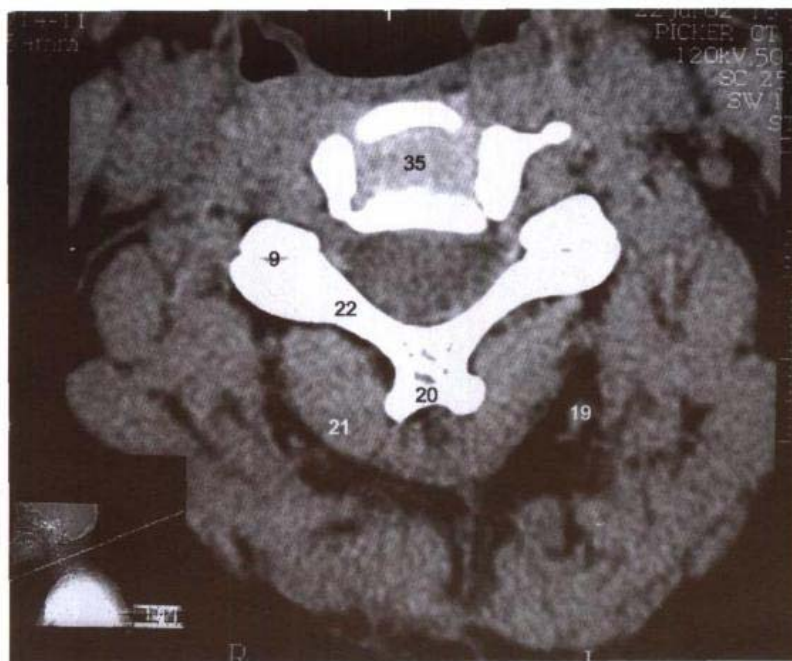图 9-2 经第 3 颈椎间盘的横断层

Fig.9-2 Transverse section through 3rd cervical intervertebral disc

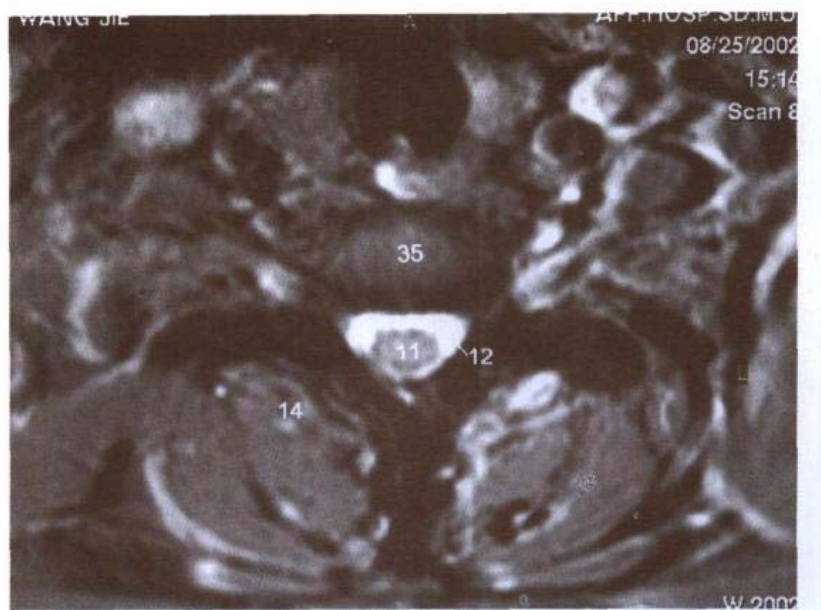


A. 断层标本 (sectional specimen)

- | | |
|--|-------------------------------|
| 1. 咽喉 laryngopharynx | 11. 脊髓 spinal cord |
| 2. 甲状软骨上角 superior horn of thyroid cartilage | 12. 蛛网膜下隙 subarachnoid space |
| 3. 颈总动脉 common carotid artery | 13. 硬脊膜 spinal dura mater |
| 4. 迷走神经 vagus nerve | 14. 多裂肌 multifidi |
| 5. 颈内静脉 internal jugular vein | 15. 肩胛提肌 levator scapulae |
| 6. 胸锁乳突肌 sternocleidomastoid | 16. 头夹肌 splenius capitis |
| 7. 椎动脉 vertebral artery | 17. 斜方肌 trapezius |
| 8. 脊神经节 spinal ganglion | 18. 头半棘肌 semispinalis capitis |
| 9. 关节突关节 zygapophysial joints | 19. 颈深静脉 deep cervical vein |
| 10. 椎内静脉丛 intervertebral venous plexus | 20. 棘突 spinous process |



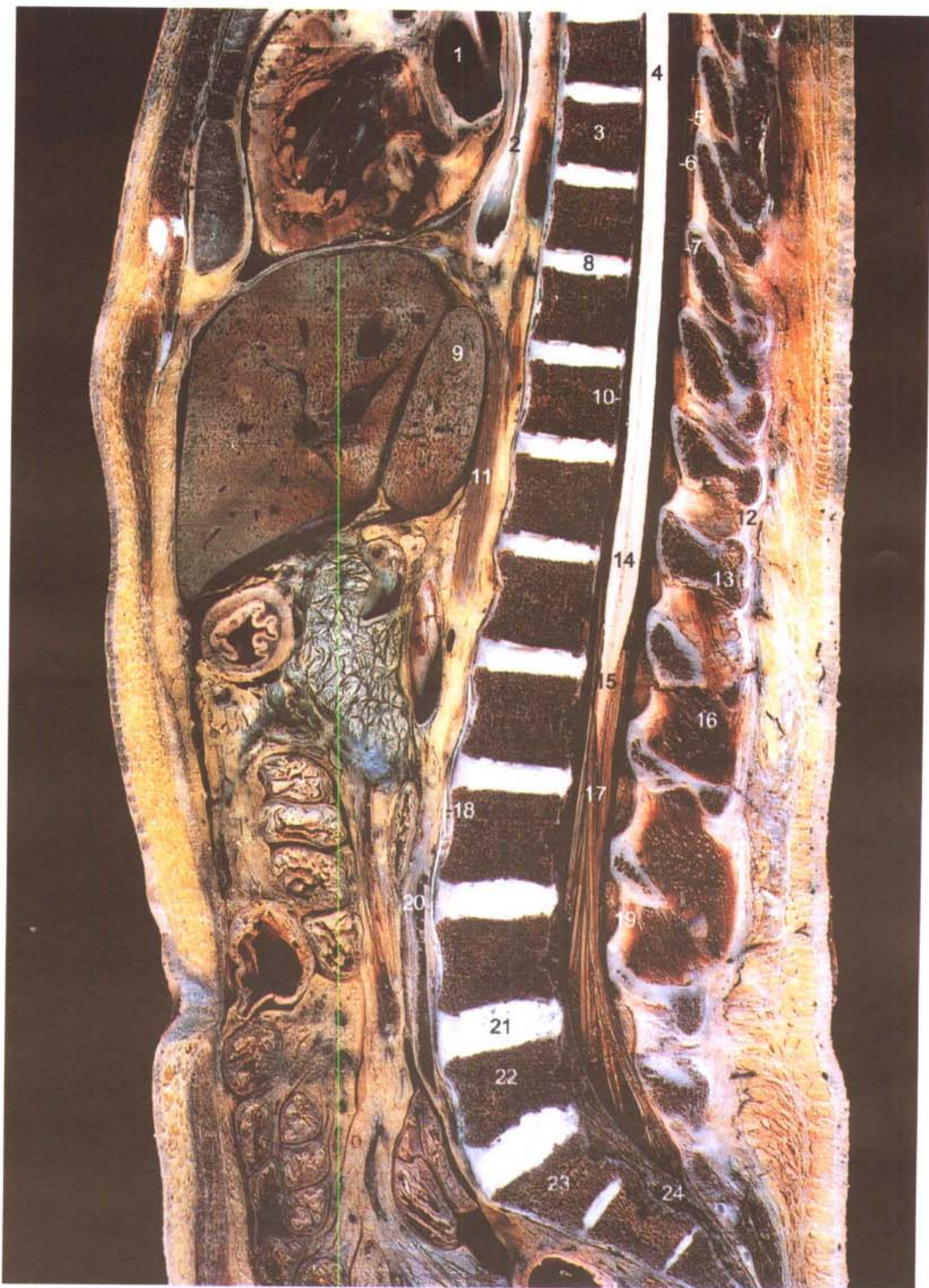
B. CT

C. MRI T₂WI

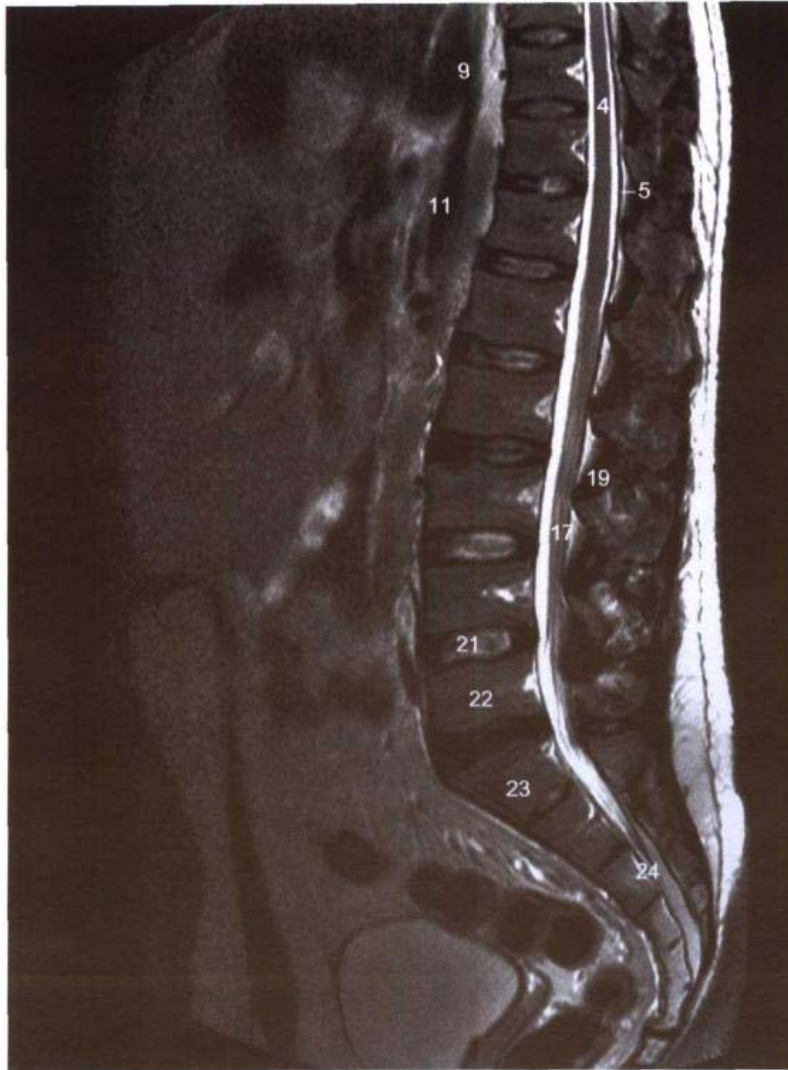- | | |
|--|---|
| 21. 颈半棘肌 semispinalis cervicis | nodes |
| 22. 椎弓板 lamina of vertebral arch | 30. 椎前筋膜 prevertebral fascia |
| 23. 后斜角肌 scalenus posterior | 31. 咽后间隙 retropharyngeal space |
| 24. 中斜角肌 scalenus medius | 32. 颊咽筋膜 buccopharyngeal fascia |
| 25. 前斜角肌 scalenus anterior | 33. 咽下缩肌 inferior constrictor of pharynx |
| 26. 交感干 sympathetic trunk | 34. 头长肌 longus capiti |
| 27. 颈长肌 longus colli | 35. 第3颈椎间盘 3rd cervical intervertebral disc |
| 28. 颈总动脉分叉处 bifurcation of common carotid artery | 36. 颈外静脉 external jugular vein |
| 29. 颈外侧深淋巴结 deep lateral cervical lymph | |

图 9-3 脊柱区腰段正中矢状面

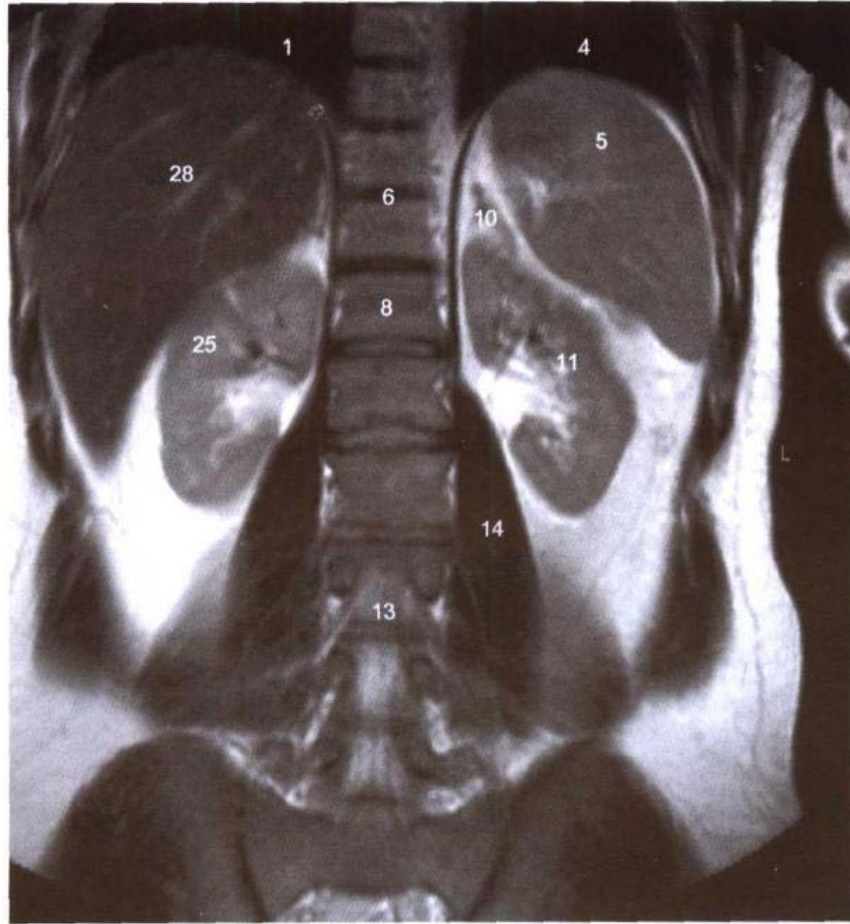
Fig.9-3 Median plane of lumbar vertebral region



A. 断层标本 (sectional specimen)

B. MRI T₂WI

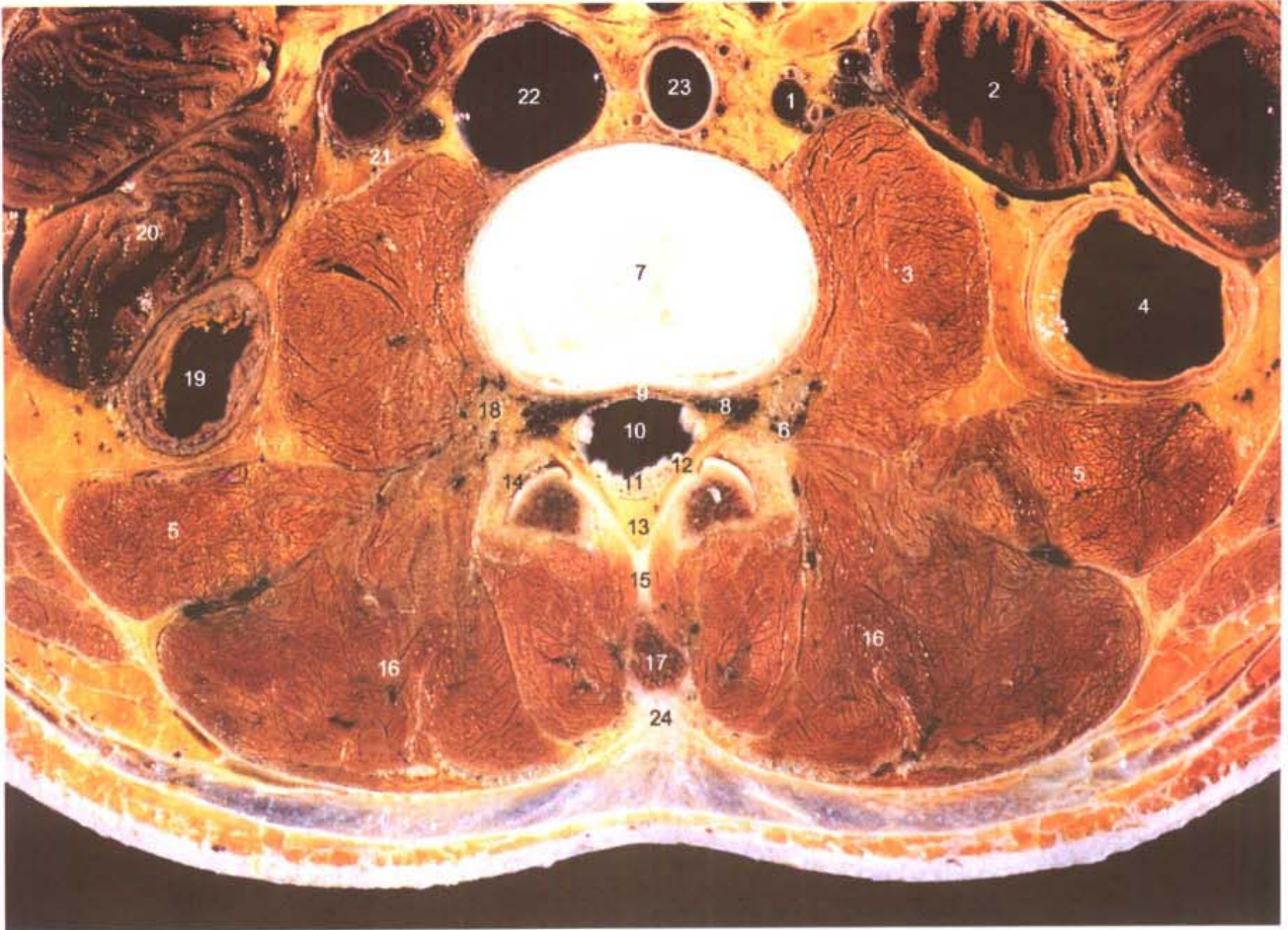
- | | |
|--|---|
| 1. 左心房 left atrium | thoracic vertebrae |
| 2. 食管 esophagus | 14. 脊髓腰骶膨大 lumbosacral enlargement of spinal cord |
| 3. 第8胸椎体 body of 8th thoracic vertebrae | 15. 脊髓圆锥 conus medullaris |
| 4. 脊髓 spinal cord | 16. 棘间肌 interspinales |
| 5. 硬脊膜 spinal dura mater | 17. 马尾 cauda equina |
| 6. 蛛网膜下隙 subarachnoid space | 18. 前纵韧带 anterior longitudinal ligament |
| 7. 硬膜外隙 epidural space | 19. 黄韧带 ligamenta flava |
| 8. 第9胸椎间盘 9th thoracic intervertebral disc | 20. 腹主动脉 abdominal aorta |
| 9. 肝尾状叶 caudate lobe of liver | 21. 第4腰椎间盘 4th lumbar intervertebral disc |
| 10. 后纵韧带 posterior longitudinal ligament | 22. 第5腰椎体 body of 5th lumbar vertebrae |
| 11. 膈 diaphragm | 23. 第1骶椎 1st sacral vertebrae |
| 12. 棘上韧带 supraspinal ligament | 24. 骶管 sacral canal |
| 13. 第12胸椎棘突 spinous process of 12th | |

B. MRI T₂WI

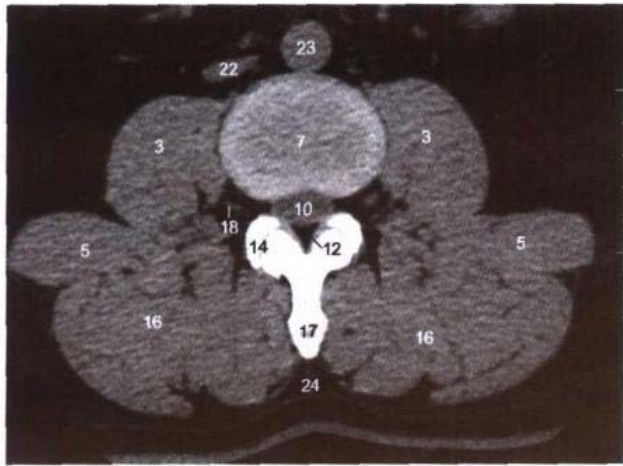
- | | |
|--|---|
| 1. 右肺下叶 inferior lobe of right lung | 3rd lumbar vertebrae |
| 2. 第9胸椎体 body of 9th thoracic vertebrae | 16. 黄韧带 ligamenta flava |
| 3. 肋头关节 joint of costal head | 17. 第4腰椎横突 transverse process of 4th lumbar vertebrae |
| 4. 左肺下叶 inferior lobe of left lung | 18. 横突间肌 intertransversarii |
| 5. 脾 spleen | 19. 腰方肌 quadratus lumborum |
| 6. 第10胸椎间盘 10th thoracic intervertebral disc | 20. 髂嵴 iliac crest |
| 7. 肋间后动、静脉 posterior intercostal artery and vein | 21. 蛛网膜下隙 subarachnoid space |
| 8. 第12胸椎体 body of 12th thoracic vertebrae | 22. 硬脊膜 spinal dura mater |
| 9. 左膈脚 left diaphragmatic crus | 23. 肾脂肪囊 fatty renal capsule |
| 10. 左肾上腺 left adrenal gland | 24. 第2腰神经 2nd lumbar nerve |
| 11. 左肾 left kidney | 25. 右肾 right kidney |
| 12. 硬膜外隙 epidural space | 26. 右膈脚 right diaphragmatic crus |
| 13. 马尾 cauda equina | 27. 右肾上腺 right suprarenal gland |
| 14. 腰大肌 psoas major | 28. 肝右叶 right lobe of liver |
| 15. 第3腰椎椎弓根 pedicle of vertebral arch of | |

图 9-5 经第 3 腰椎间盘的横断层

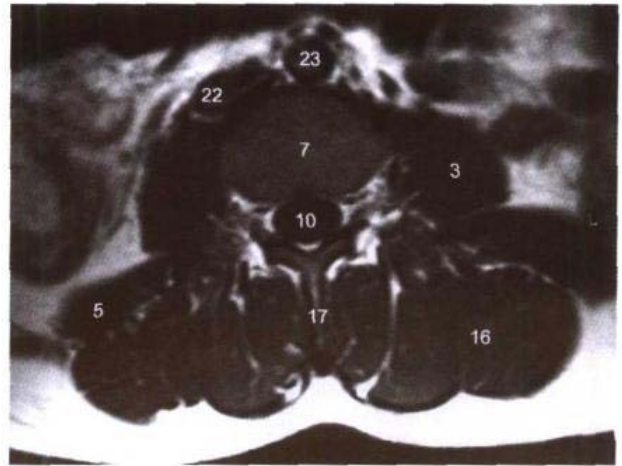
Fig.9-5 Transverse section through 3rd lumbar intervertebral disc



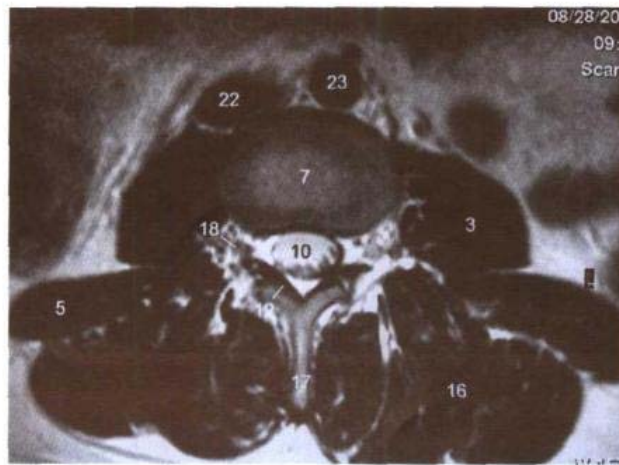
A. 断层标本 (sectional specimen)



B. CT

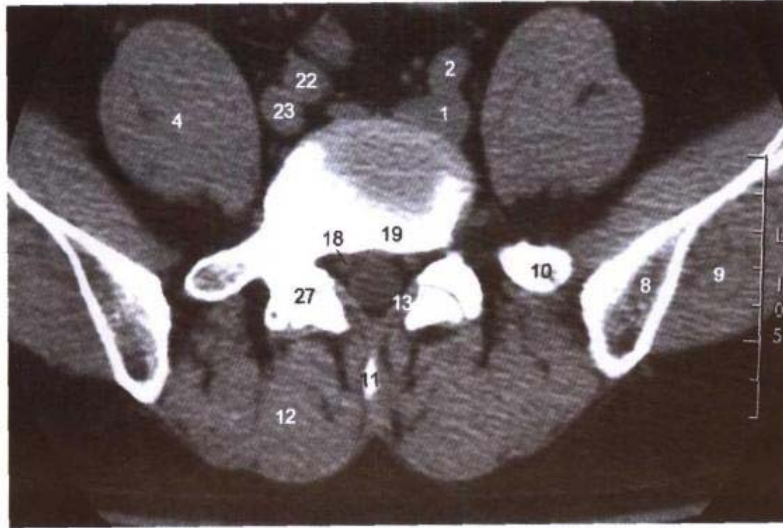


C. MRI T₁WI

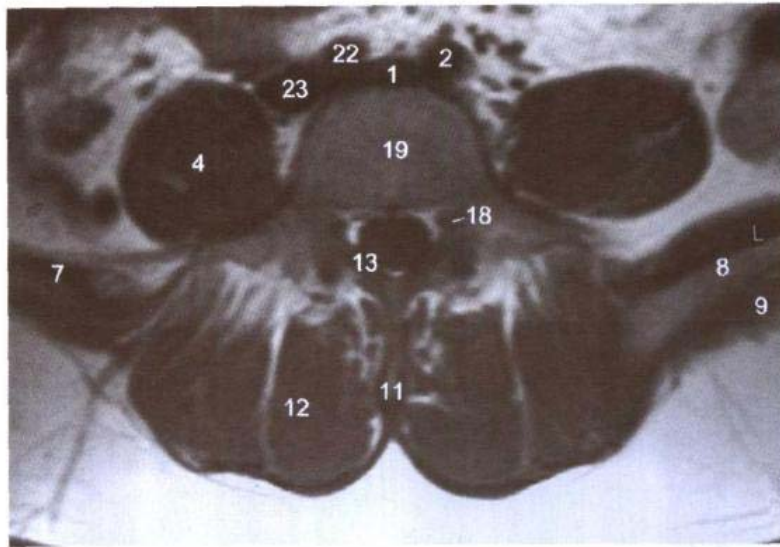


D. MRI T₂WI

- | | |
|--|-------------------------------|
| 1. 左睾丸动、静脉 left testicular artery and vein | 14. 关节突关节 zygapophysial joint |
| 2. 空肠 jejunum | 15. 棘间韧带 interspinal ligament |
| 3. 腰大肌 psoas major | 16. 竖脊肌 erector spinae |
| 4. 降结肠 descending colon | 17. 棘突 spinous process |
| 5. 腰方肌 quadratus lumborum | 18. 第3腰神经 3rd lumbar nerve |
| 6. 椎外静脉丛 external vertebral venous plexus | 19. 升结肠 ascending colon |
| 7. 第3腰椎间盘 3rd lumbar intervertebral disc | 20. 回肠 ileum |
| 8. 椎内静脉丛 internal vertebral venous plexus | 21. 右输尿管 right ureter |
| 9. 硬脊膜 spinal dura mater | 22. 下腔静脉 inferior vena cava |
| 10. 蛛网膜下隙 subarachnoid space | 23. 腹主动脉 abdominal aorta |
| 11. 马尾 cauda equina | 24. 棘上韧带 supraspinal ligament |
| 12. 黄韧带 ligamenta flava | |
| 13. 硬膜外隙 epidural space | |



B. CT



C. MRI T1WI

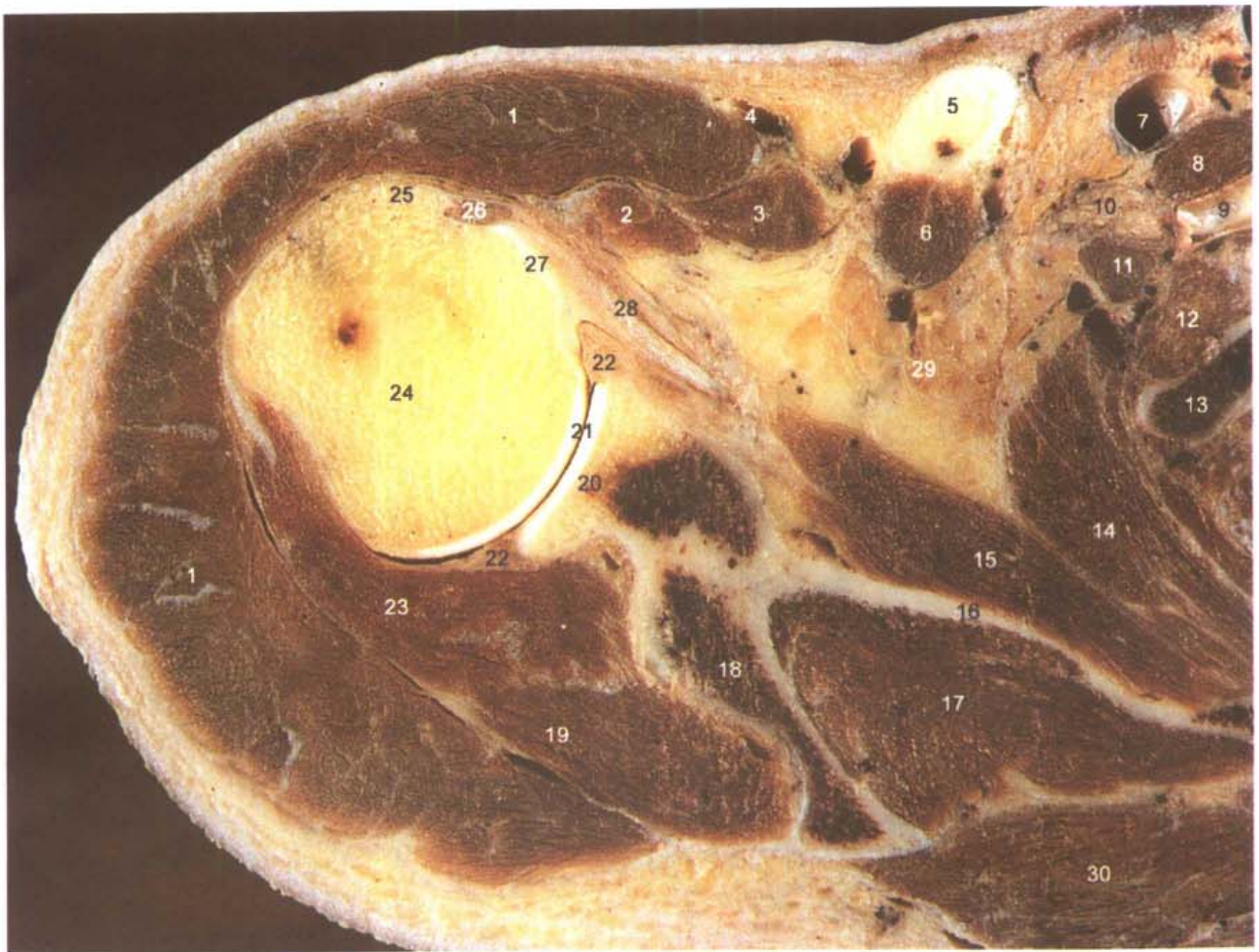
- | | |
|---|--|
| 1. 左髂总静脉 left common iliac vein | 15. 马尾 cauda equina |
| 2. 左髂总动脉 left common iliac artery | 16. 硬脊膜 spinal dura mater |
| 3. 左睾丸动脉、静脉 left testicular artery and vein | 17. 椎内静脉丛 internal vertebral venous plexus |
| 4. 腰大肌 psoas major | 18. 第5腰神经 5th lumbar nerve |
| 5. 乙状结肠 sigmoid colon | 19. 第5腰椎体 5th lumbar vertebral body |
| 6. 腰丛 lumbar plexus | 20. 盲肠 cecum |
| 7. 髂肌 iliacus | 21. 右输尿管 right ureter |
| 8. 髂骨翼 ala of ilium | 22. 右髂外动脉 right external iliac artery |
| 9. 臀中肌 gluteus medius | 23. 右髂总静脉 right common iliac vein |
| 10. 横突 transverse process | 24. 右髂内动脉 right internal iliac artery |
| 11. 棘突 spinous process | 25. 棘上韧带 supraspinal ligament |
| 12. 竖脊肌 erector spinae | 26. 空肠 jejunum |
| 13. 黄韧带 ligamenta flava | 27. 关节突关节 zygapophysial joints |
| 14. 椎弓板 lamina of vertebral arch | |

第十章 上肢横断层

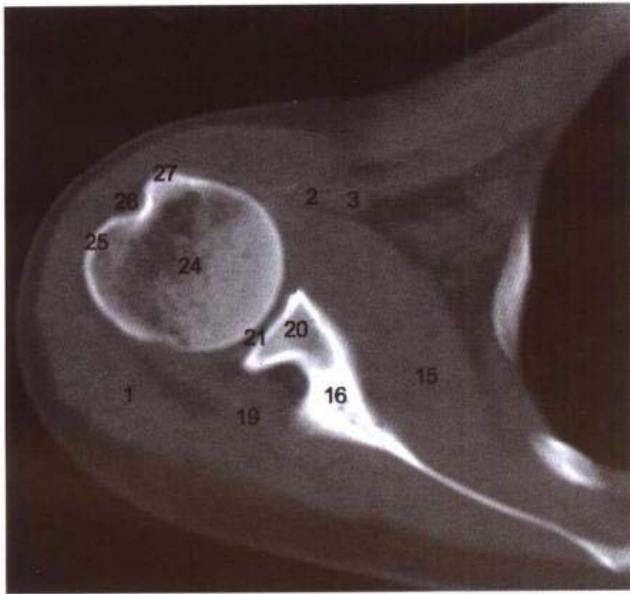Chapter 10 Transverse Sections of Upper Limb

图 10-1 经肩胛冈的横断层

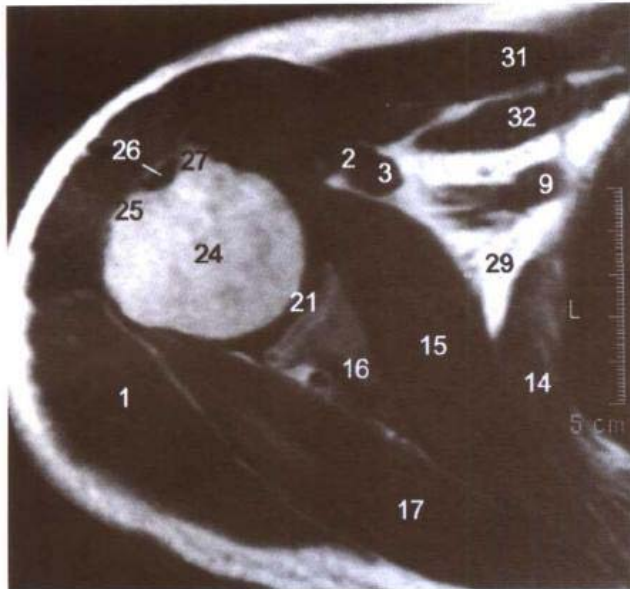
Fig.10-1 Transverse section through spine of scapula



A. 断层标本 (sectional specimen)



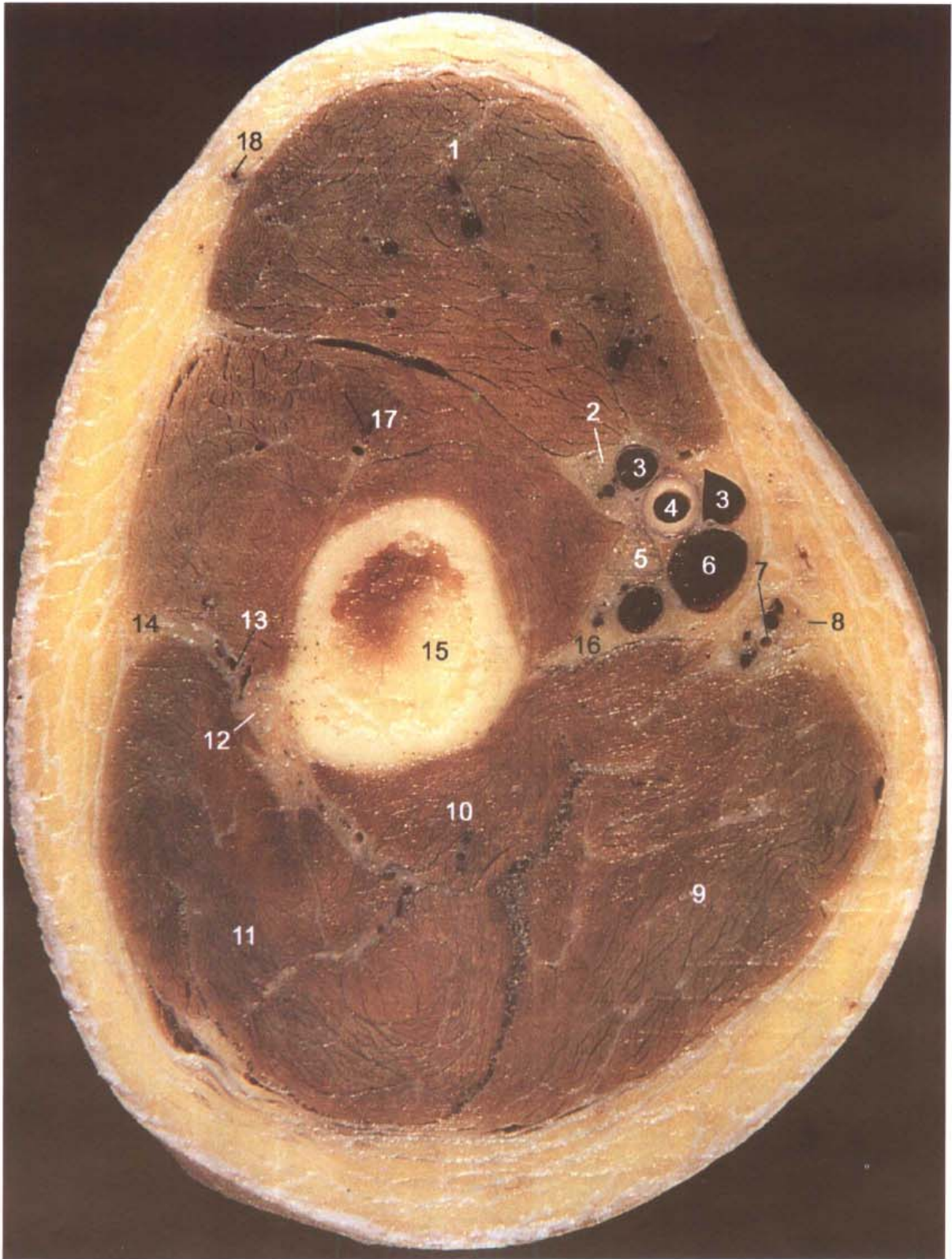
B. CT

C. MRI T₁WI

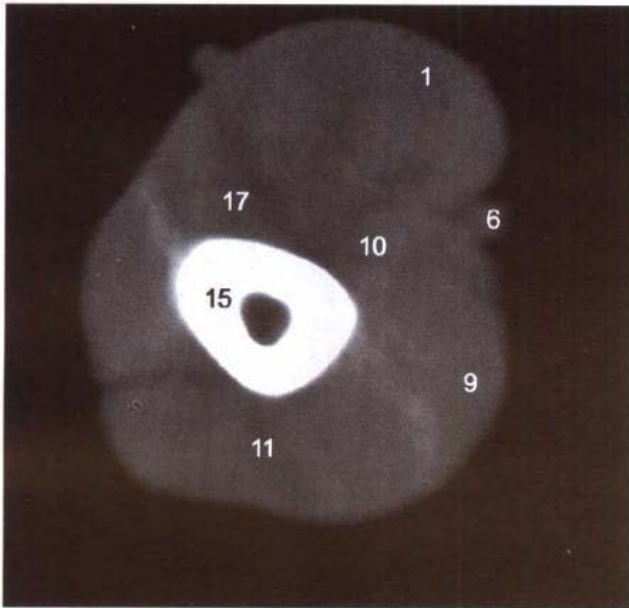
1. 三角肌 deltoid
2. 肱二头肌短头 short head of biceps brachii
3. 喙肱肌 coracobrachialis
4. 头静脉 cephalic vein
5. 锁骨 clavicle
6. 锁骨下肌 subclavius
7. 锁骨下静脉 subclavian vein
8. 前斜角肌 scalenus anterior
9. 锁骨下动脉 subclavian artery
10. 臂丛 brachial plexus
11. 中斜角肌 scalenus medius
12. 后斜角肌 scalenus posterior
13. 第1肋 1st rib
14. 前锯肌 serratus anterior
15. 肩胛下肌 subscapularis
16. 肩胛骨 scapula
17. 冈上肌 supraspinatus
18. 肩胛冈 spine of scapula
19. 冈下肌 infraspinatus
20. 关节盂 glenoid cavity
21. 肩关节腔 cavity of shoulder joint
22. 孟唇 glenoid labrum
23. 小圆肌 teres minor
24. 肱骨头 head of humerus
25. 肱骨大结节 greater tubercle of humerus
26. 肱二头肌长头腱 tendon of long head of biceps brachii
27. 肱骨小结节 lesser tubercle of humerus
28. 肩胛下肌腱 tendon of subscapularis
29. 腋窝脂肪组织 fat tissue in axillary fossa
30. 斜方肌 trapezius
31. 胸大肌 pectoralis major
32. 胸小肌 pectoralis minor

图 10-2 经臂中份的横断层

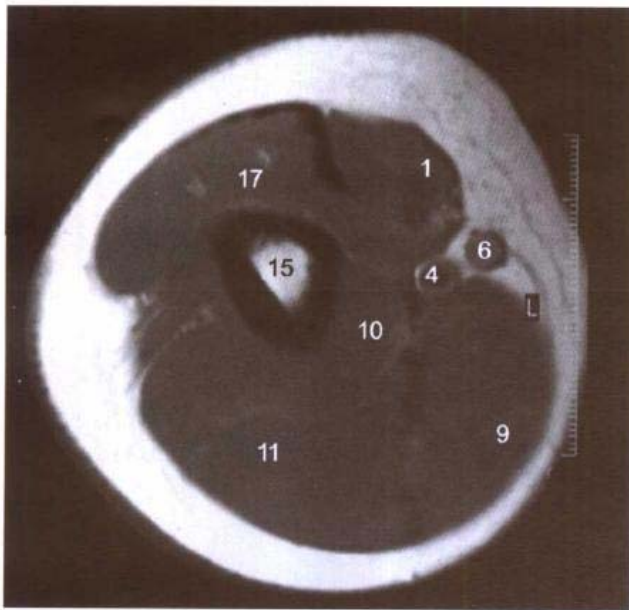
Fig.10-2 Transverse section through middle part of arm



A. 断层标本 (sectional specimen)



B. CT

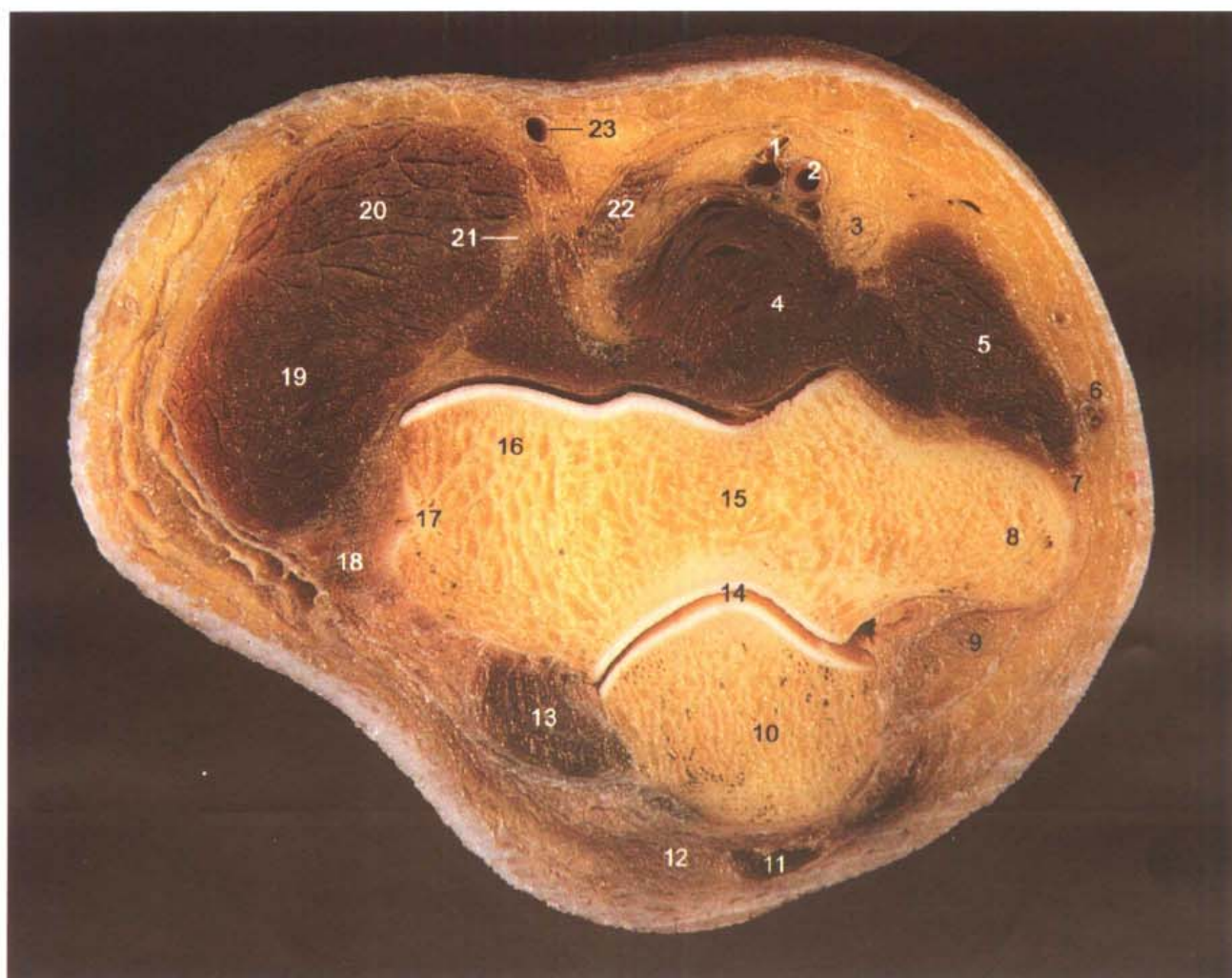

C. MRI T1WI

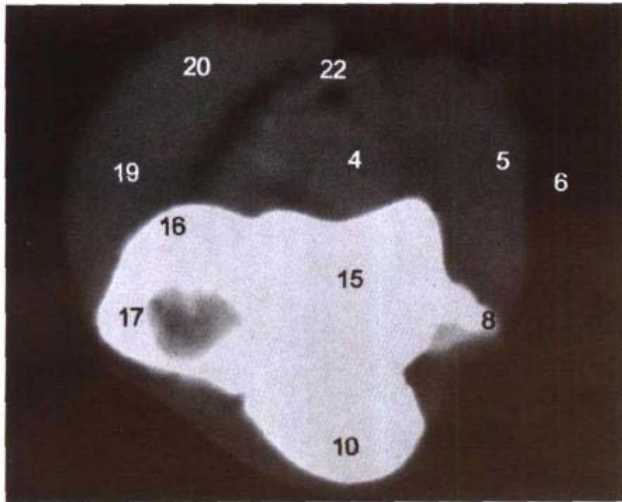
1. 肱二头肌 biceps brachii
2. 肌皮神经 musculocutaneous nerve
3. 肱静脉 brachial veins
4. 肱动脉 brachial artery
5. 正中神经 median nerve
6. 贵要静脉 basilic vein
7. 尺侧上副动脉 superior ulnar collateral artery
8. 尺神经 ulnar nerve
9. 肱三头肌长头 long head of triceps brachii
10. 肱三头肌内侧头 medial head of triceps brachii
11. 肱三头肌外侧头 lateral head of triceps brachii
12. 桡神经 radial nerve
13. 桡侧副动脉 radial collateral artery
14. 臂外侧肌间隔 lateral brachial intermuscular septum
15. 肱骨 humerus
16. 臂内侧肌间隔 medial brachial intermuscular septum
17. 肱肌 brachialis
18. 头静脉 cephalic vein

图 10-3 经肘关节上份的横断层

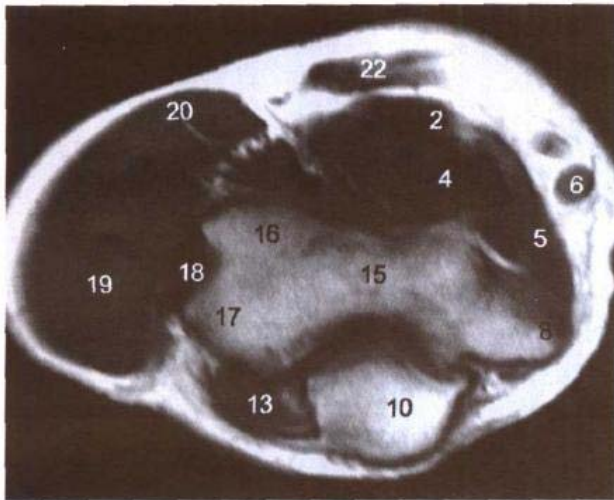
Fig.10-3 Transverse section through upper part of elbow joint



A. 断层标本 (sectional specimen)

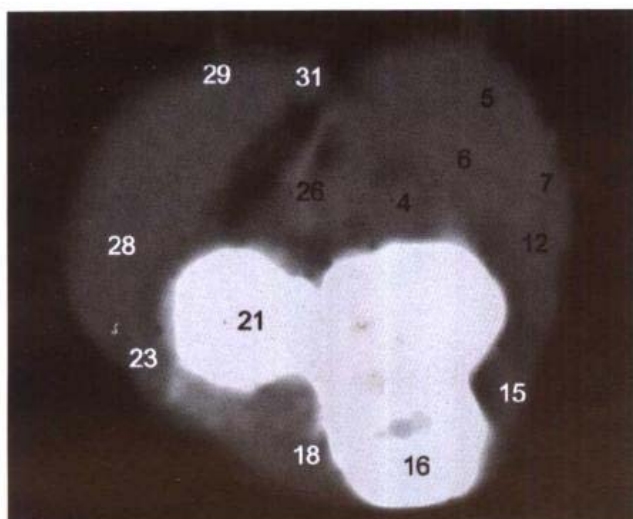


B. CT

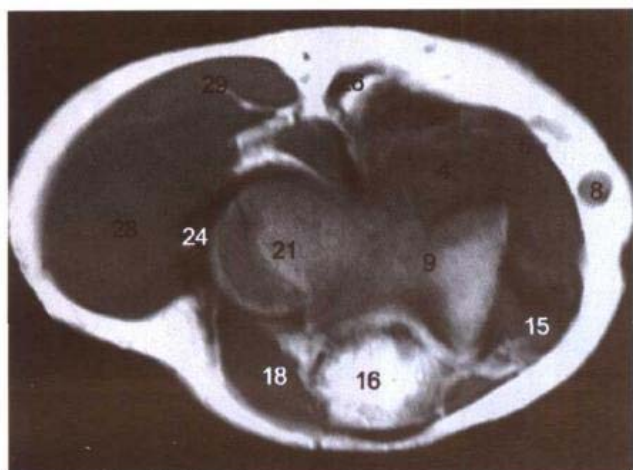


C. MRI T₁WI

1. 肱静脉 brachial vein
2. 肱动脉 brachial artery
3. 正中神经 median nerve
4. 肱肌 brachialis
5. 旋前圆肌 pronator teres
6. 贵要静脉 basilic vein
7. 尺侧副韧带 ulnar collateral ligament
8. 肱骨内上髁 medial epicondyle
9. 尺神经 ulnar nerve
10. 尺骨鹰嘴 ulnar olecranon
11. 鹰嘴皮下囊 subcutaneous bursa of olecranon
12. 肱三头肌腱 tendon of triceps brachii
13. 肘肌 anconeus
14. 肘关节腔 cavity of elbow joint
15. 肱骨滑车 trochlea of humerus
16. 肱骨小头 capitulum of humerus
17. 肱骨外上髁 lateral epicondyle
18. 桡侧副韧带 radial collateral ligament
19. 桡侧腕长、短伸肌 extensor carpi radialis longus and brevis
20. 肱桡肌 brachioradialis
21. 桡神经 radial nerve
22. 肱二头肌腱 tendon of biceps brachii
23. 头正中静脉 median cephalic vein



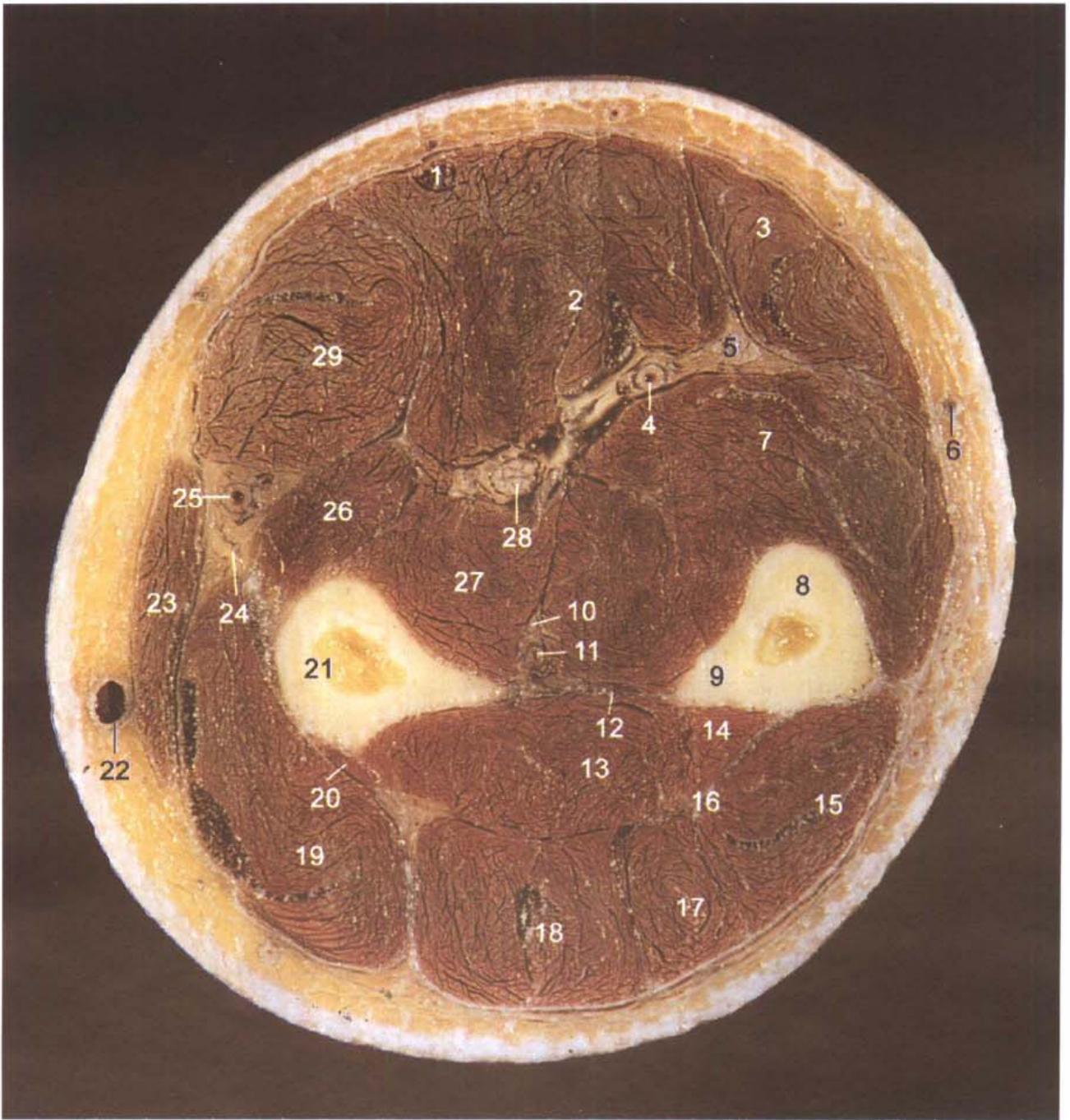
B. CT

C. MRI T₁WI

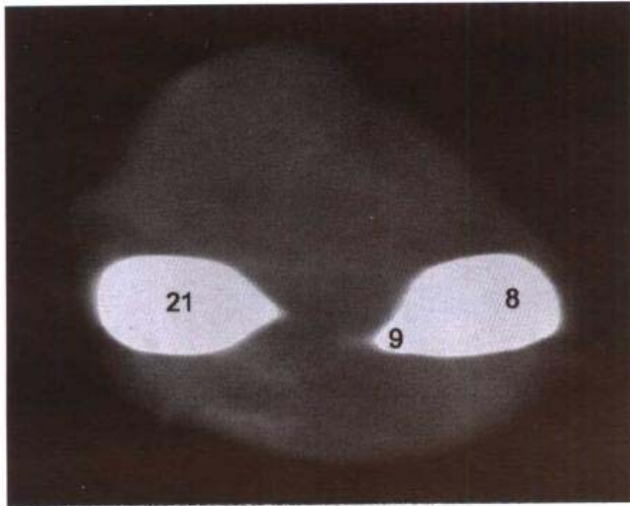
1. 肱静脉 brachial vein
2. 肱动脉 brachial artery
3. 正中神经 median nerve
4. 肱肌 brachialis
5. 旋前圆肌 pronator teres
6. 桡侧腕屈肌 flexor carpi radialis
7. 掌长肌 palmaris longus
8. 贵要静脉 basilic vein
9. 肱骨滑车 trochlear of humerus
10. 肱尺关节 humeroulnar joint
11. 肘关节囊 capsule of elbow joint
12. 指浅屈肌 flexor digitorum superficialis
13. 尺侧腕屈肌 flexor carpi ulnaris
14. 尺神经 ulnar nerve
15. 指深屈肌 flexor digitorum profundus
16. 尺骨鹰嘴 ulnar olecranon
17. 肱三头肌腱 tendon of triceps brachii
18. 肘肌 anconeus
19. 尺侧腕伸肌 extensor carpi ulnaris
20. 桡尺近侧关节 proximal radioulnar joint
21. 桡骨头 head of radius
22. 小指伸肌 extensor digiti minimi
23. 指伸肌 extensor digitorum
24. 桡骨环状韧带 annular ligament of radius
25. 旋后肌 supinator
26. 肱二头肌腱 tendon of biceps brachii
27. 桡神经深支 deep branch of radial nerve
28. 桡侧腕长、短伸肌 extensor carpi radialis longus and brevis
29. 肱桡肌 brachioradialis
30. 桡神经浅支 superficial branch of radial nerve
31. 头正中静脉 median cephalic vein

图 10-5 经前臂中份的横断层

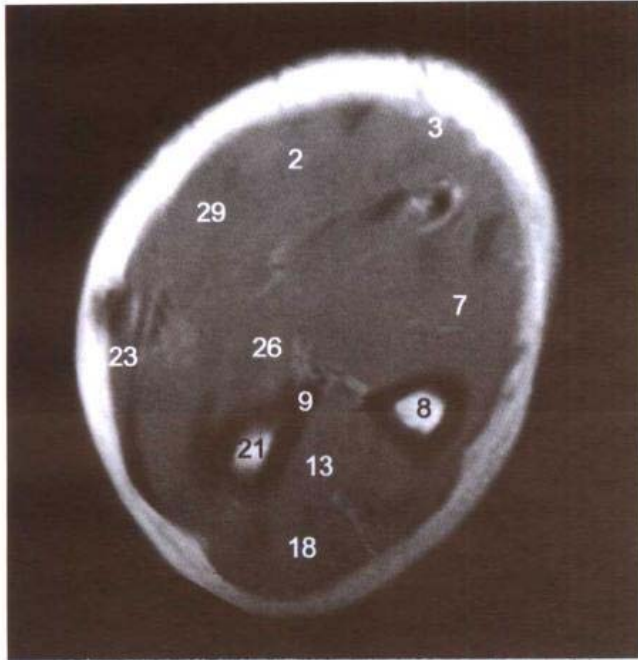
Fig.10-5 Transverse section through middle part of forearm



A. 断层标本 (sectional specimen)



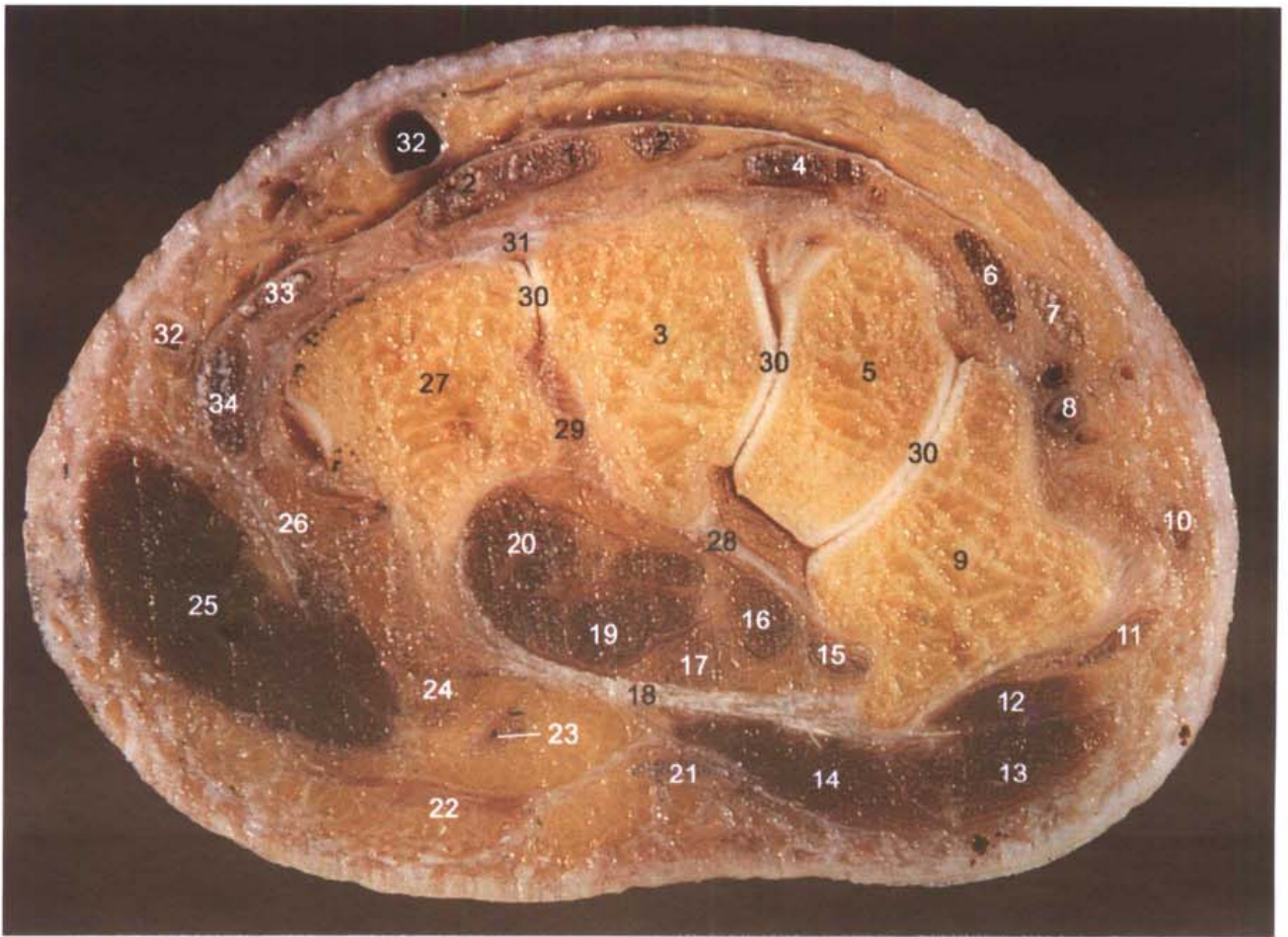
B. CT

C. MRI T₁WI

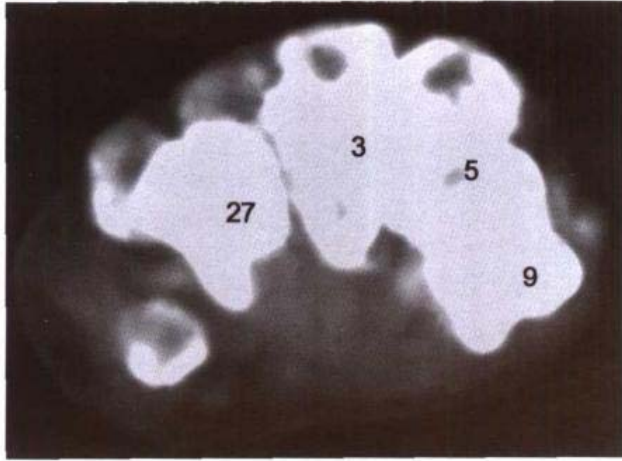
1. 掌长肌腱 tendon of palmaris longus
2. 指浅屈肌 flexor digitorum superficialis
3. 尺侧腕屈肌 flexor carpi ulnaris
4. 尺动脉 ulnar artery
5. 尺神经 ulnar nerve
6. 贵要静脉 basilic vein
7. 指深屈肌 flexor digitorum profundus
8. 尺骨 ulna
9. 骨间缘 interosseous border
10. 骨间前神经 anterior interosseous nerve
11. 骨间前动脉 anterior interosseous artery
12. 前臂骨间膜 interosseous membrane of forearm
13. 拇长展肌 abductor pollicis longus
14. 拇长伸肌 extensor pollicis longus
15. 尺侧腕伸肌 extensor carpi ulnaris
16. 骨间后动脉 posterior interosseous artery
17. 小指伸肌 extensor digiti minimi
18. 指伸肌 extensor digitorum
19. 桡侧腕长、短伸肌 extensor carpi radialis longus and brevis
20. 旋后肌 supinator
21. 桡骨 radius
22. 头静脉 cephalic vein
23. 肱桡肌 brachioradialis
24. 桡神经浅支 superficial branch of radial nerve
25. 桡动脉 radial artery
26. 旋前圆肌 pronator teres
27. 拇长屈肌 flexor pollicis longus
28. 正中神经 median nerve
29. 桡侧腕屈肌 flexor carpi radialis

图 10-6 经腕管的横断层

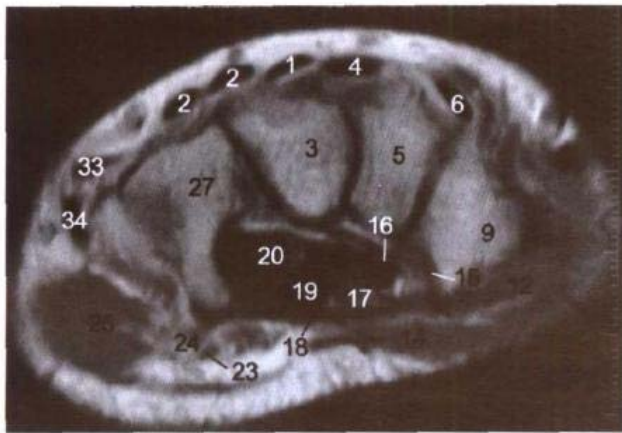
Fig.10-6 Transverse section through carpal canal



A. 断层标本 (sectional specimen)



B. CT

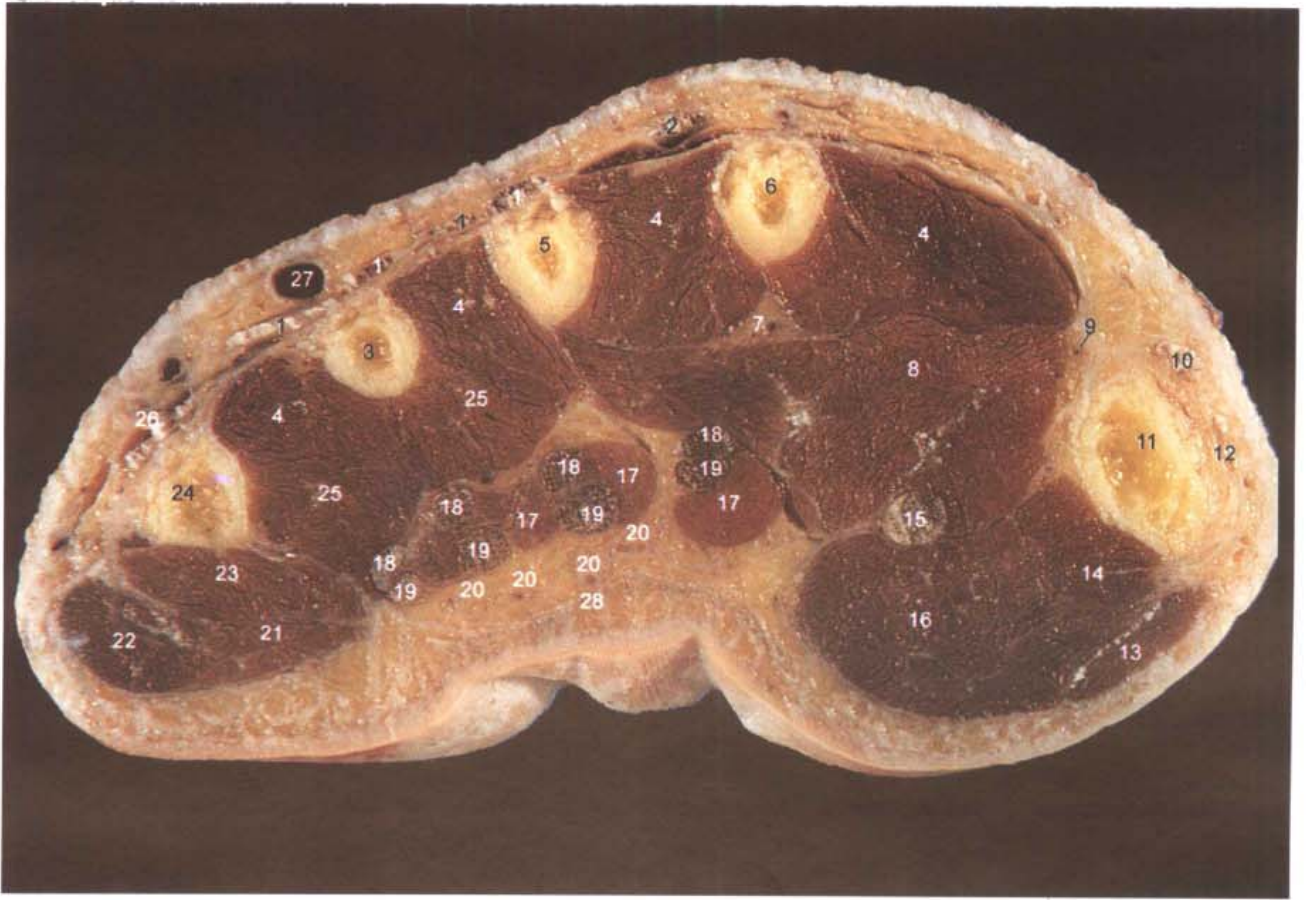


C. MRI T1WI

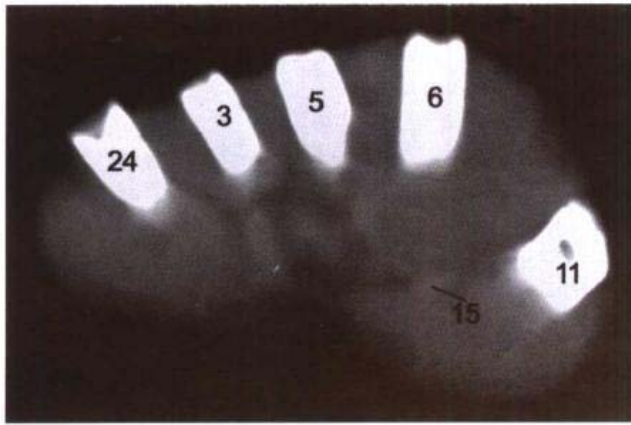
1. 示指伸肌腱 tendon of extensor indicis
2. 指伸肌腱 tendon of extensor digitorum
3. 头状骨 capitate bone
4. 桡侧腕短伸肌腱 tendon of extensor carpi radialis brevis
5. 小多角骨 trapezoid bone
6. 桡侧腕长伸肌腱 tendon of extensor carpi radialis longus
7. 拇长伸肌腱 tendon of extensor pollicis longus
8. 桡动脉 radial artery
9. 大多角骨 trapezium bone
10. 拇短伸肌腱 tendon of extensor pollicis brevis
11. 拇长展肌腱 tendon of abductor pollicis longus
12. 拇对掌肌 opponens pollicis
13. 拇短展肌 abductor pollicis brevis
14. 拇短屈肌 flexor pollicis brevis
15. 桡侧腕屈肌腱 tendon of flexor carpi radialis
16. 拇长屈肌腱 tendon of flexor pollicis longus
17. 正中神经 median nerve
18. 腕横韧带 transverse carpal ligament
19. 指浅屈肌腱 tendon of flexor digitorum superficialis
20. 指深屈肌腱 tendon of flexor digitorum profundus
21. 掌长肌腱 tendon of palmaris longus
22. 掌短肌 palmaris brevis
23. 尺动脉 ulnar artery
24. 尺神经 ulnar nerve
25. 小指展肌 abductor digiti minimi
26. 豆钩韧带和豆掌韧带 pisohamate and pisometacarpal ligaments
27. 钩骨 hamate bone
28. 腕骨间掌侧韧带 palmar intercarpal ligaments
29. 腕骨间骨间韧带 interosseous intercarpal ligaments
30. 腕骨间关节 intercarpal joints
31. 腕骨间背侧韧带 dorsal intercarpal ligaments
32. 手背静脉 dorsal vein of hand
33. 小指伸肌腱 tendon of extensor digiti minimi
34. 尺侧腕伸肌腱 tendon of extensor carpi ulnaris

图 10-7 经掌骨中份的横断层

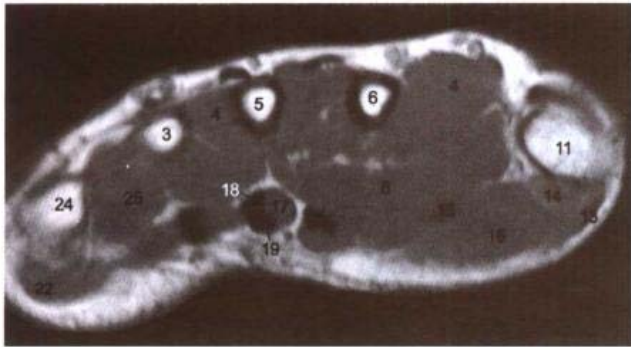
Fig.10-7 Transverse section through middle part of metacarpal bones



A. 断层标本 (sectional specimen)



B. CT

C. MRI T₁WI

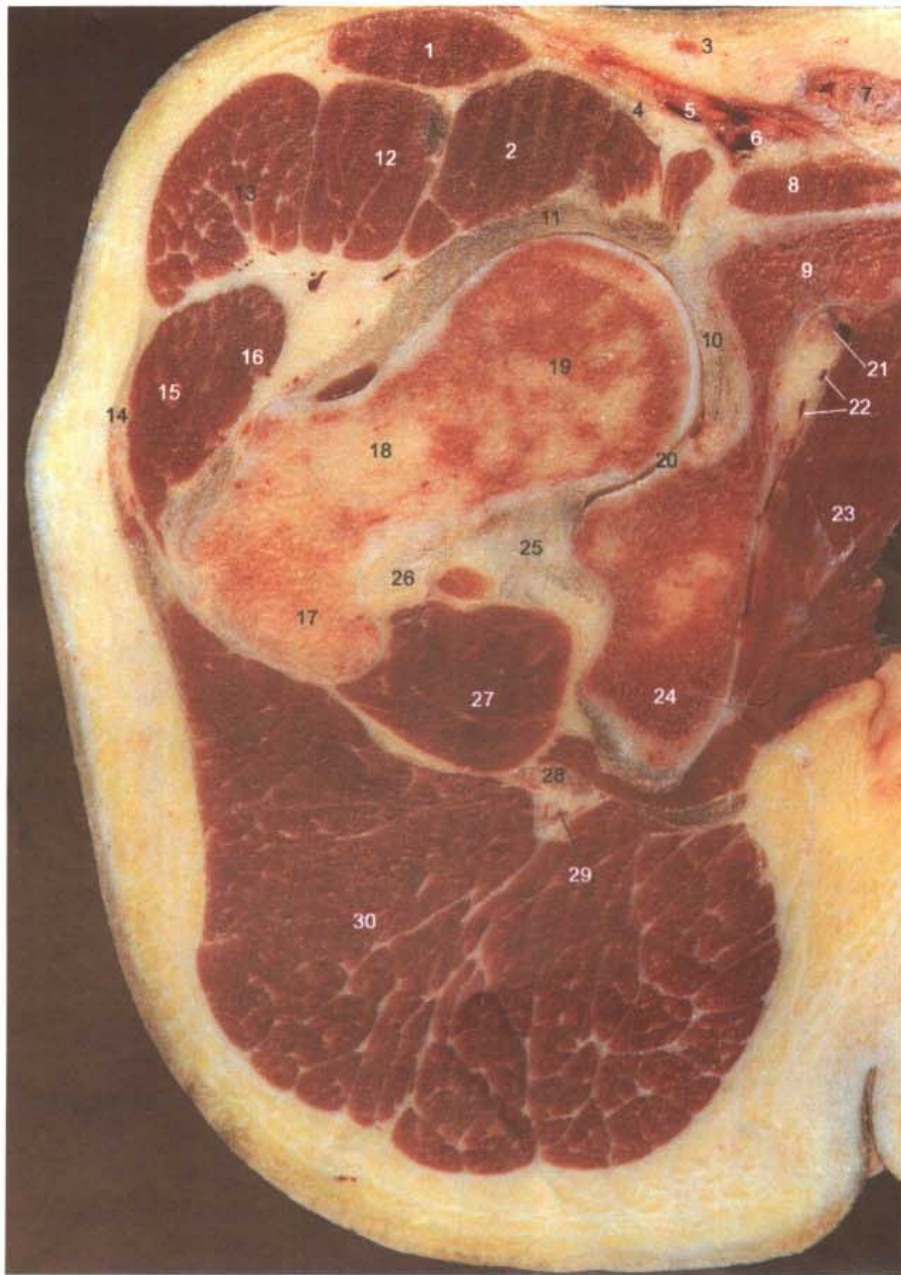1. 指伸肌腱 tendon of extensor digitorum
2. 示指伸肌腱 tendon of extensor indicis
3. 第4掌骨 4th metacarpal bone
4. 骨间背侧肌 dorsal interossei
5. 第3掌骨 3rd metacarpal bone
6. 第2掌骨 2nd metacarpal bone
7. 掌心动脉 palmar metacarpal artery
8. 拇收肌 adductor pollicis
9. 拇指尺掌侧动脉 ulnar palmar digital artery of thumb
10. 拇长伸肌腱 tendon of extensor pollicis longus
11. 第1掌骨 1st metacarpal bone
12. 拇短伸肌腱 tendon of extensor pollicis brevis
13. 拇短展肌 abductor pollicis brevis
14. 拇对掌肌 opponens pollicis
15. 拇长屈肌腱 tendon of flexor pollicis longus
16. 拇短屈肌 flexor pollicis brevis
17. 蚓状肌 lumbricales
18. 指深屈肌腱 tendon of flexor digitorum profundus
19. 指浅屈肌腱 tendon of flexor digitorum superficialis
20. 指掌侧总动脉及神经 common palmar digital arteries and nerves
21. 小指短屈肌 flexor digiti minimi brevis
22. 小指展肌 abductor digiti minimi
23. 小指对掌肌 opponens digiti minimi
24. 第5掌骨 5th metacarpal bone
25. 骨间掌侧肌 palmar interossei
26. 小指伸肌腱 tendon of extensor digiti minimi
27. 手背静脉 dorsal vein of hand
28. 掌腱膜 palmar aponeurosis

第十一章 下肢横、矢、冠状断层

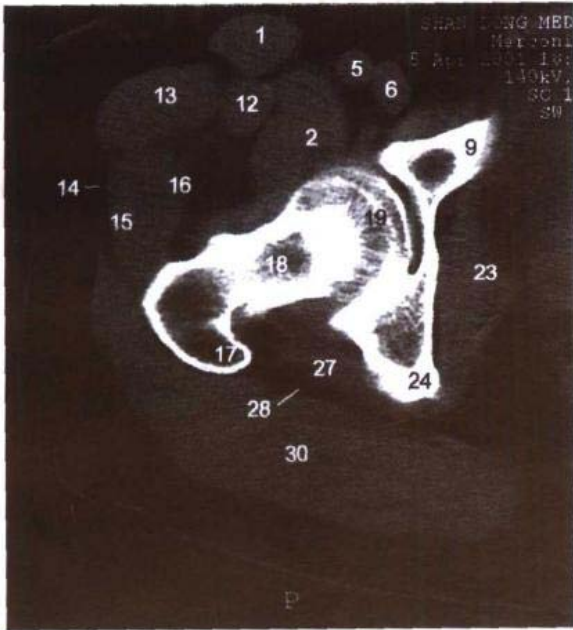
Chapter 11 Transverse, Sagittal, and Coronal Sections of Lower Limb

图 11-1 经髋关节的横断层

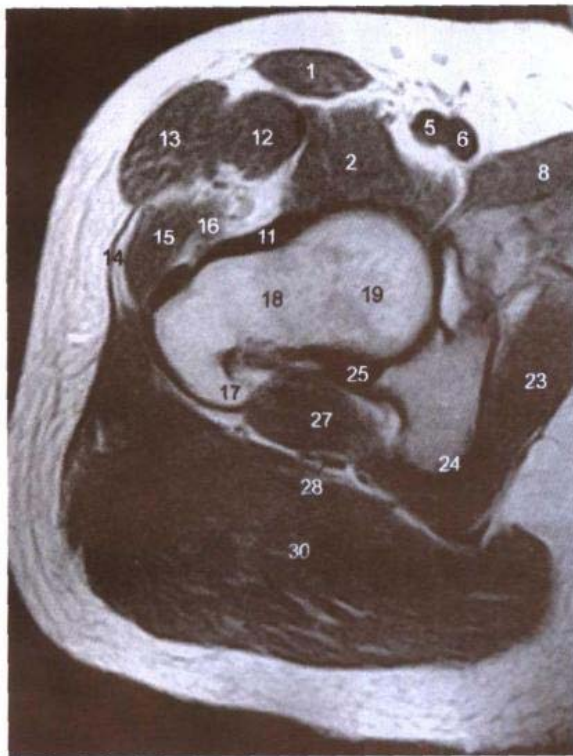
Fig.11-1 Transverse section through hip joint



A. 断层标本 (sectional specimen)



B. CT

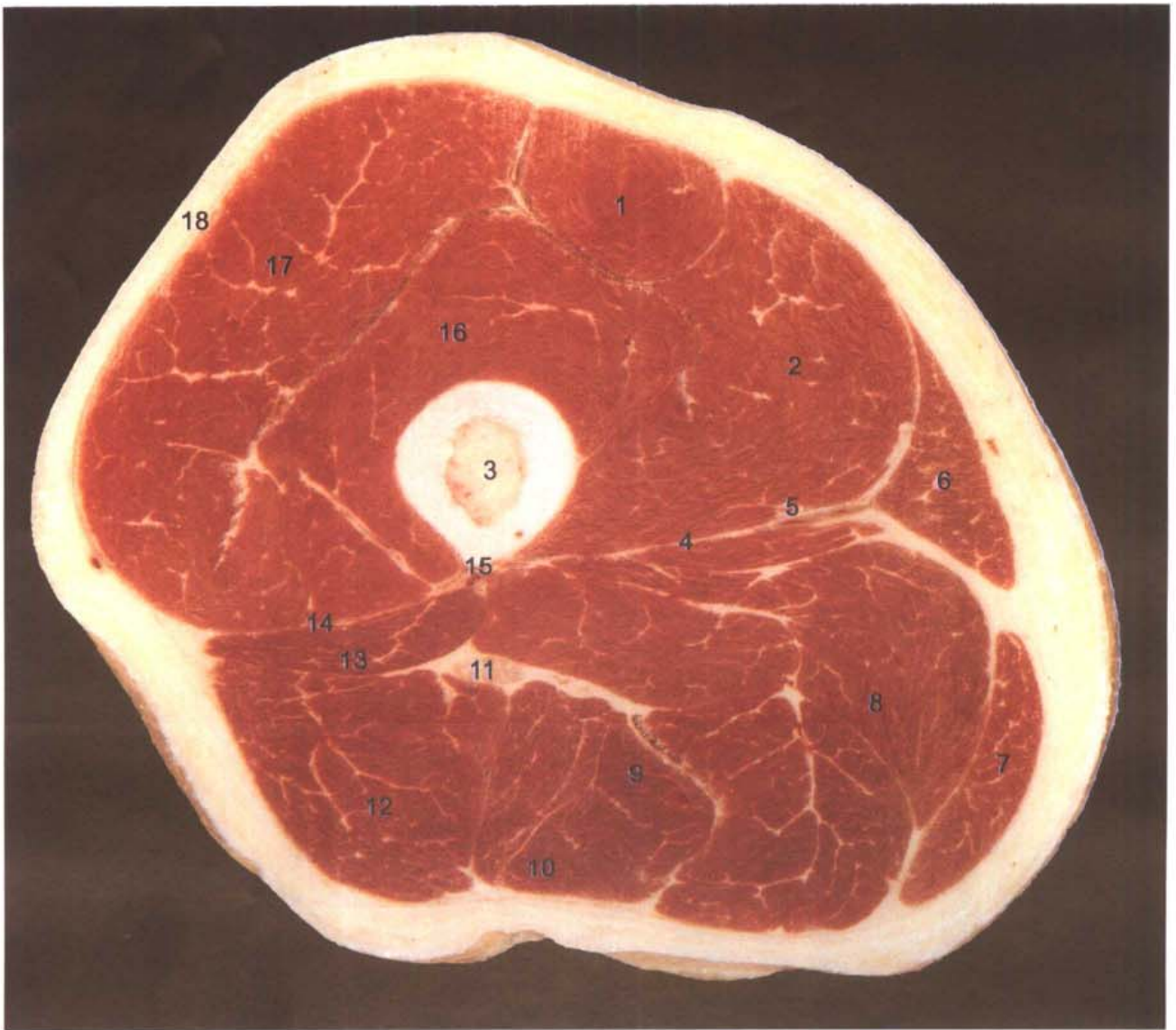


C. MRI T₁WI

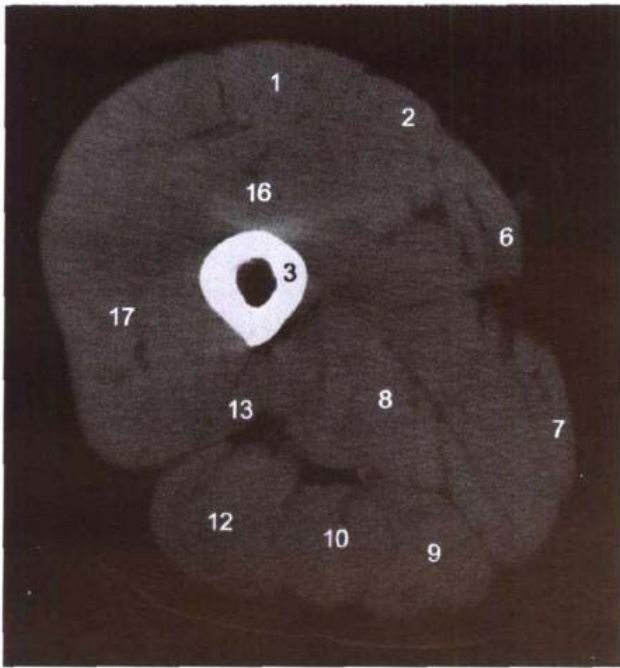
1. 缝匠肌 sartorius
2. 髂腰肌 iliopsoas
3. 腹股沟浅淋巴结 superficial inguinal lymph nodes
4. 股神经 femoral nerve
5. 股动脉 femoral artery
6. 股静脉 femoral vein
7. 精索 spermatic cord
8. 耻骨肌 pectineus
9. 耻骨上支 superior ramus of pubis
10. 髌白横韧带 transverse acetabular ligament
11. 髂股韧带 iliofemoral ligament
12. 股直肌 rectus femoris
13. 阔筋膜张肌 tensor fasciae latae
14. 髂胫束 iliotibial tract
15. 臀中肌 gluteus medius
16. 臀小肌 gluteus minimus
17. 大转子 greater trochanter
18. 股骨颈 neck of femur
19. 股骨头 femoral head
20. 髋关节腔 cavity of hip joint
21. 闭孔神经 obturator nerve
22. 闭膜管和闭孔动脉 obturator canal and artery
23. 闭孔内肌 obturator internus
24. 坐骨结节 ischial tuberosity
25. 坐股韧带 ischiofemoral ligament
26. 闭孔外肌腱 tendon of obturator externus
27. 股方肌 quadratus femoris
28. 坐骨神经 sciatic nerve
29. 臀下动、静脉 inferior gluteal artery and vein
30. 臀大肌 gluteus maximus

图 11-2 经股部中份的横断层

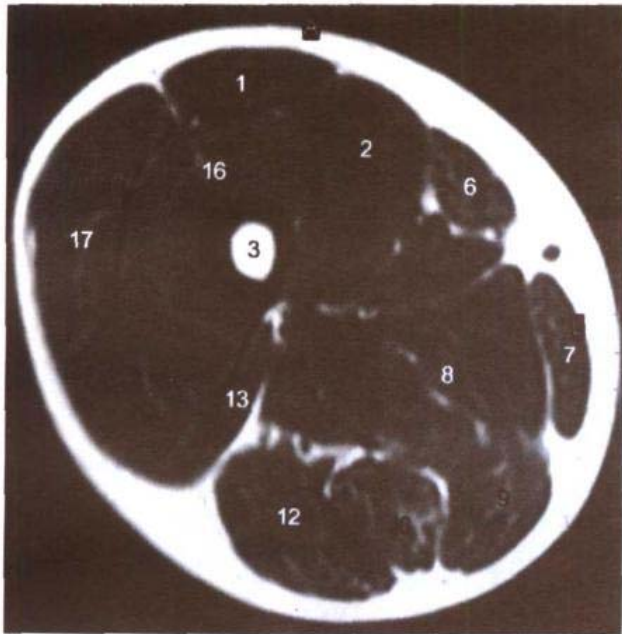
Fig.11-2 Transverse section through middle part of thigh



A. 断层标本 (sectional specimen)



B. CT

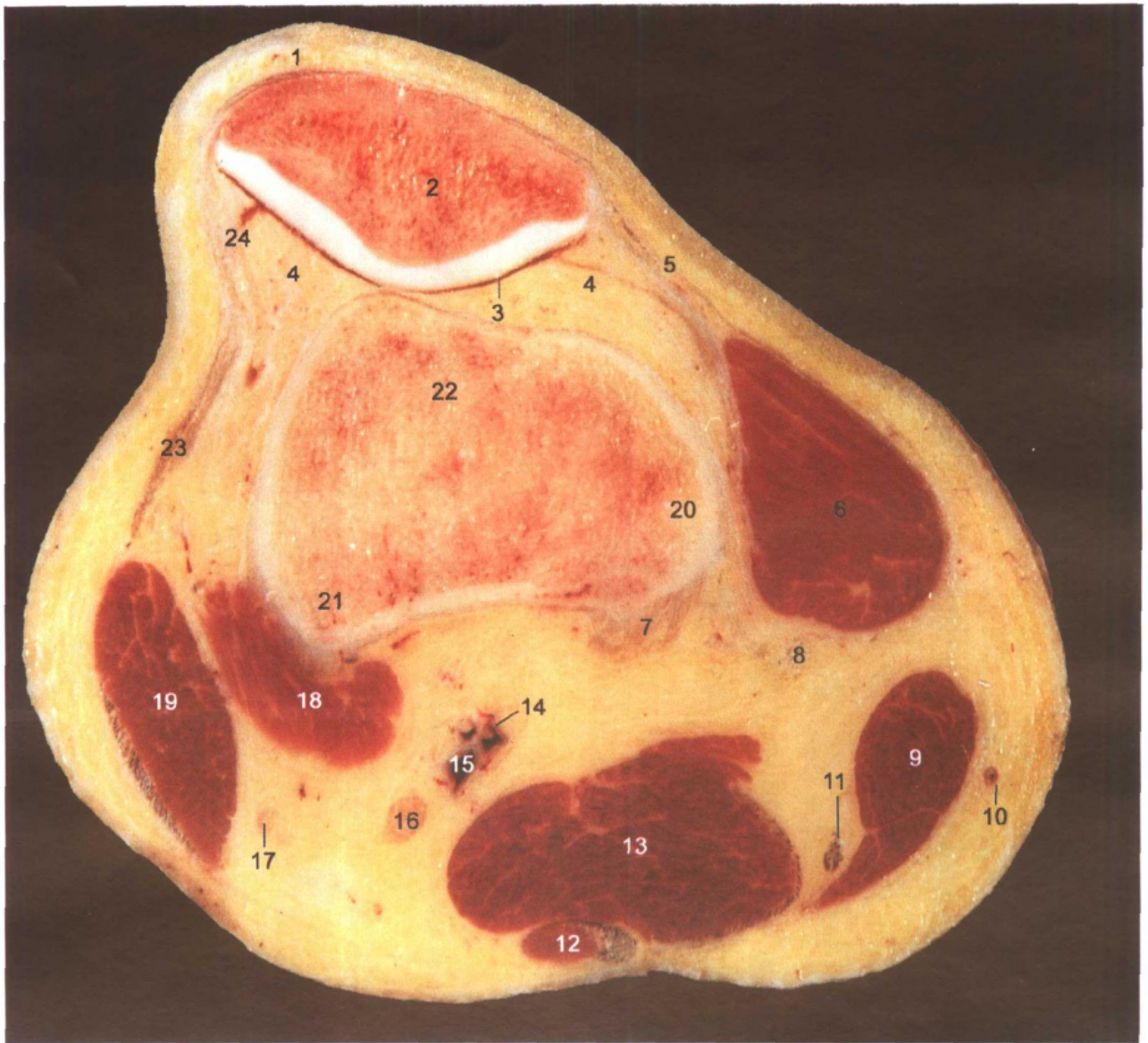


C. MRI T₁WI

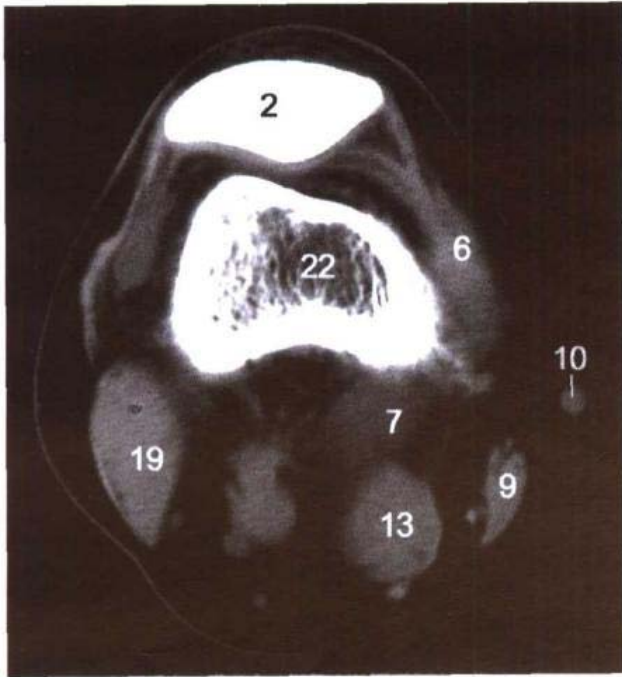
1. 股直肌 rectus femoris
2. 股内侧肌 vastus medialis
3. 股骨中份 middle part of femur
4. 内侧肌间隔 medial intermuscular septum
5. 股动脉、静脉 femoral artery and vein
6. 缝匠肌 sartorius
7. 股薄肌 gracilis
8. 大收肌 adductor magnus
9. 半膜肌 semimembranosus
10. 半腱肌 semitendinosus
11. 坐骨神经 sciatic nerve
12. 股二头肌(长头) long head of biceps femoris
13. 股二头肌(短头) short head of biceps femoris
14. 外侧肌间隔 lateral intermuscular septum
15. 股骨粗线 linea aspera
16. 股中间肌 vastus intermedius
17. 股外侧肌 vastus lateralis
18. 髂胫束 iliotibial tract

图 11-3 经髌骨的横断层

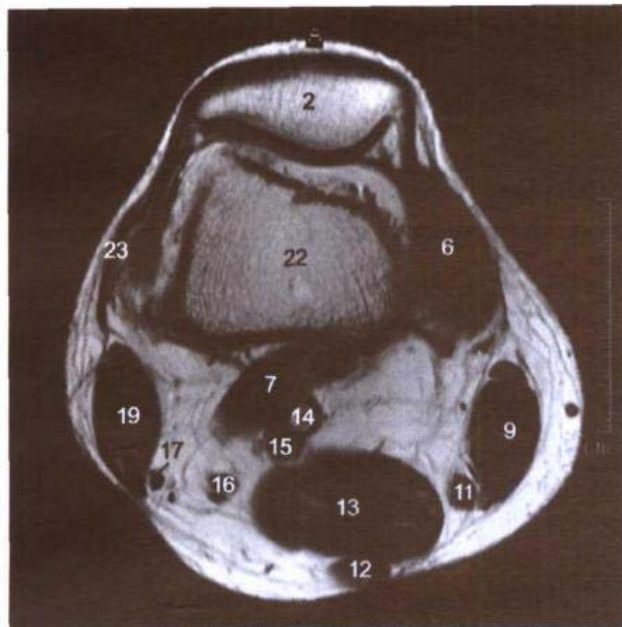
Fig.11-3 Transverse section through patella



A. 断层标本 (sectional specimen)



B. CT

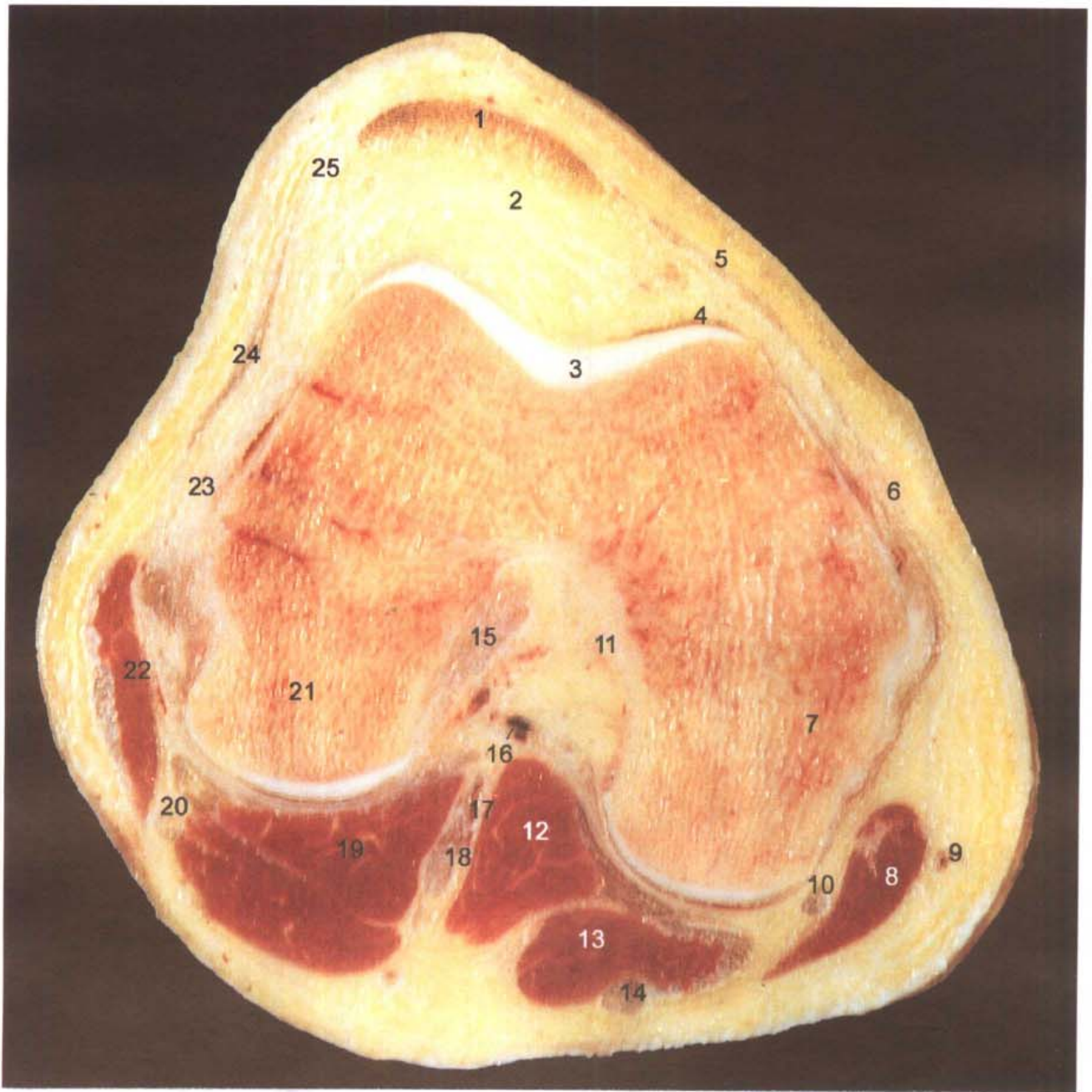

C. MRI T1WI

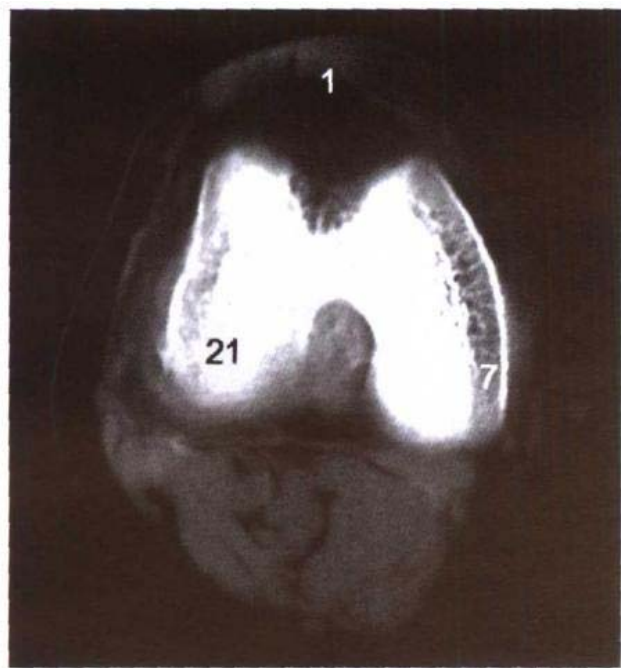1. 股四头肌腱 tendon of quadriceps femoris
2. 髌骨 patella
3. 膝关节腔 cavity of knee joint
4. 髌下脂体 infrapatellar fat pad
5. 髌内侧支持带 medial patellar retinaculum
6. 股内侧肌 vastus medialis
7. 腓肠肌内侧头 medial head of gastrocnemius
8. 大收肌腱 tendon of adductor magnus
9. 缝匠肌 sartorius
10. 大隐静脉 great saphenous vein
11. 股薄肌腱 tendon of gracilis
12. 半腱肌 semitendinosus
13. 半膜肌 semimembranosus
14. 腘动脉 popliteal artery
15. 腘静脉 popliteal vein
16. 胫神经 tibial nerve
17. 腓总神经 common peroneal nerve
18. 腓肠肌外侧头 lateral head of gastrocnemius
19. 股二头肌 biceps femoris
20. 股骨内上髁 medial epicondyle of femur
21. 股骨外上髁 lateral epicondyle of femur
22. 股骨 femur
23. 髂胫束 iliotibial tract
24. 髌外侧支持带 lateral patellar retinaculum

图 11-4 经髁间窝的横断层

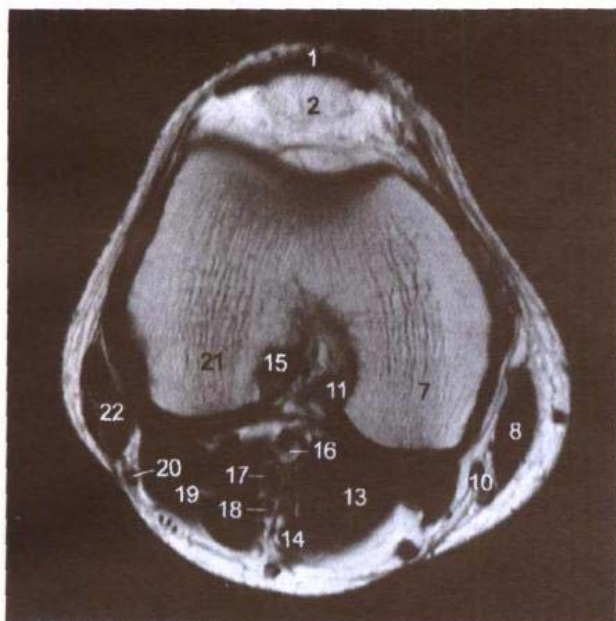
Fig.11-4 Transverse section through intercondylar fossa



A. 断层标本 (sectional specimen)



B. CT

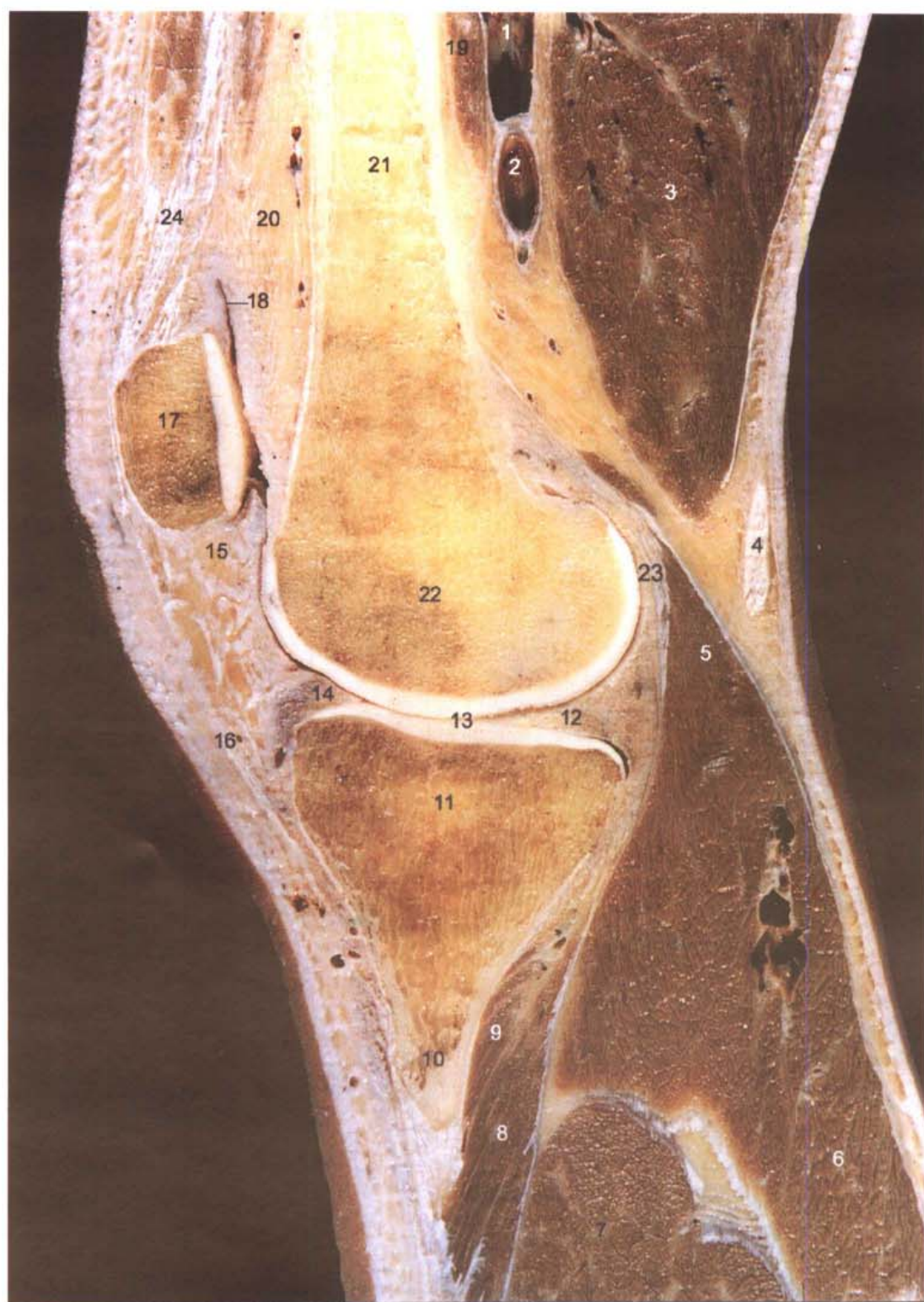


C. MRI T₁WI

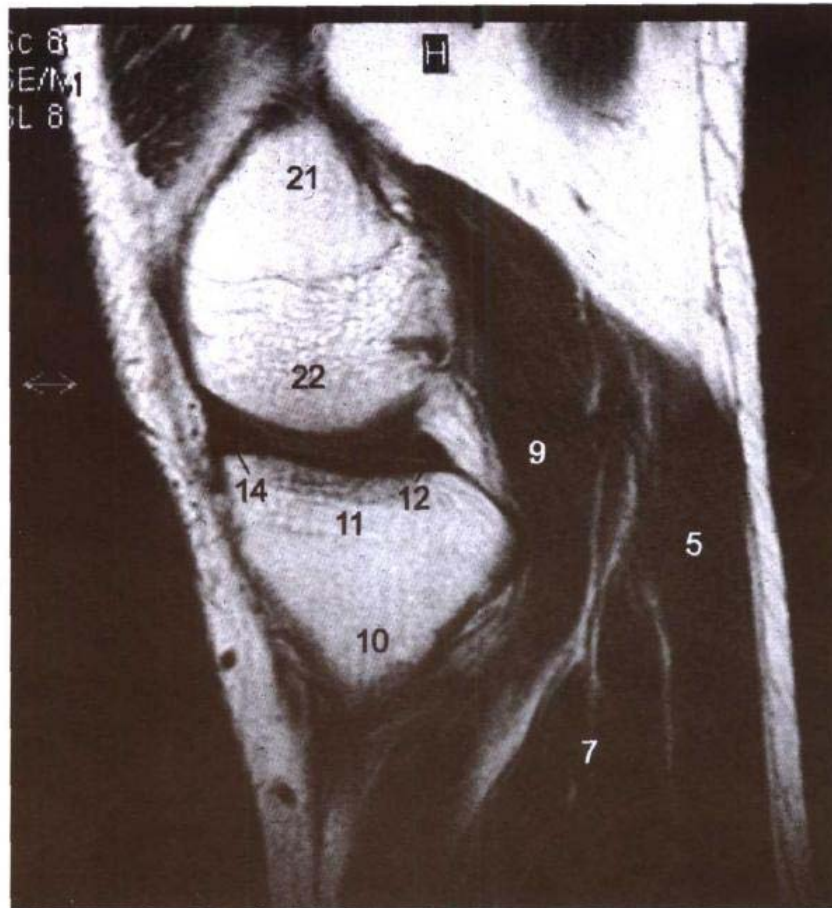
1. 髌韧带 patellar ligament
2. 髌下脂体 infrapatellar fat pad
3. 关节软骨 articular cartilage
4. 膝关节腔 cavity of knee joint
5. 髌内侧支持带 medial patellar retinaculum
6. 胫侧副韧带 tibial collateral ligament
7. 股骨内侧髁 medial condyle of femur
8. 缝匠肌 sartorius
9. 大隐静脉 great saphenous vein
10. 股薄肌腱 tendon of gracilis
11. 后交叉韧带 posterior cruciate ligament
12. 腓肠肌内侧头 medial head of gastrocnemius
13. 半膜肌 semimembranosus
14. 半腱肌腱 tendon of semitendinosus
15. 前交叉韧带 anterior cruciate ligament
16. 腘动脉 popliteal artery
17. 腘静脉 popliteal vein
18. 胫神经 tibial nerve
19. 腓肠肌外侧头 lateral head of gastrocnemius
20. 腓总神经 common peroneal nerve
21. 股骨外侧髁 lateral condyle of femur
22. 股二头肌 biceps femoris
23. 腓侧副韧带 fibular collateral ligament
24. 髂胫束 iliotibial tract
25. 髌外侧支持带 lateral patellar retinaculum

图 11-5 经股骨内侧髁的矢状断层

Fig.11-5 Sagittal section through medial condyle of femur



A. 断层标本 (sectional specimen)

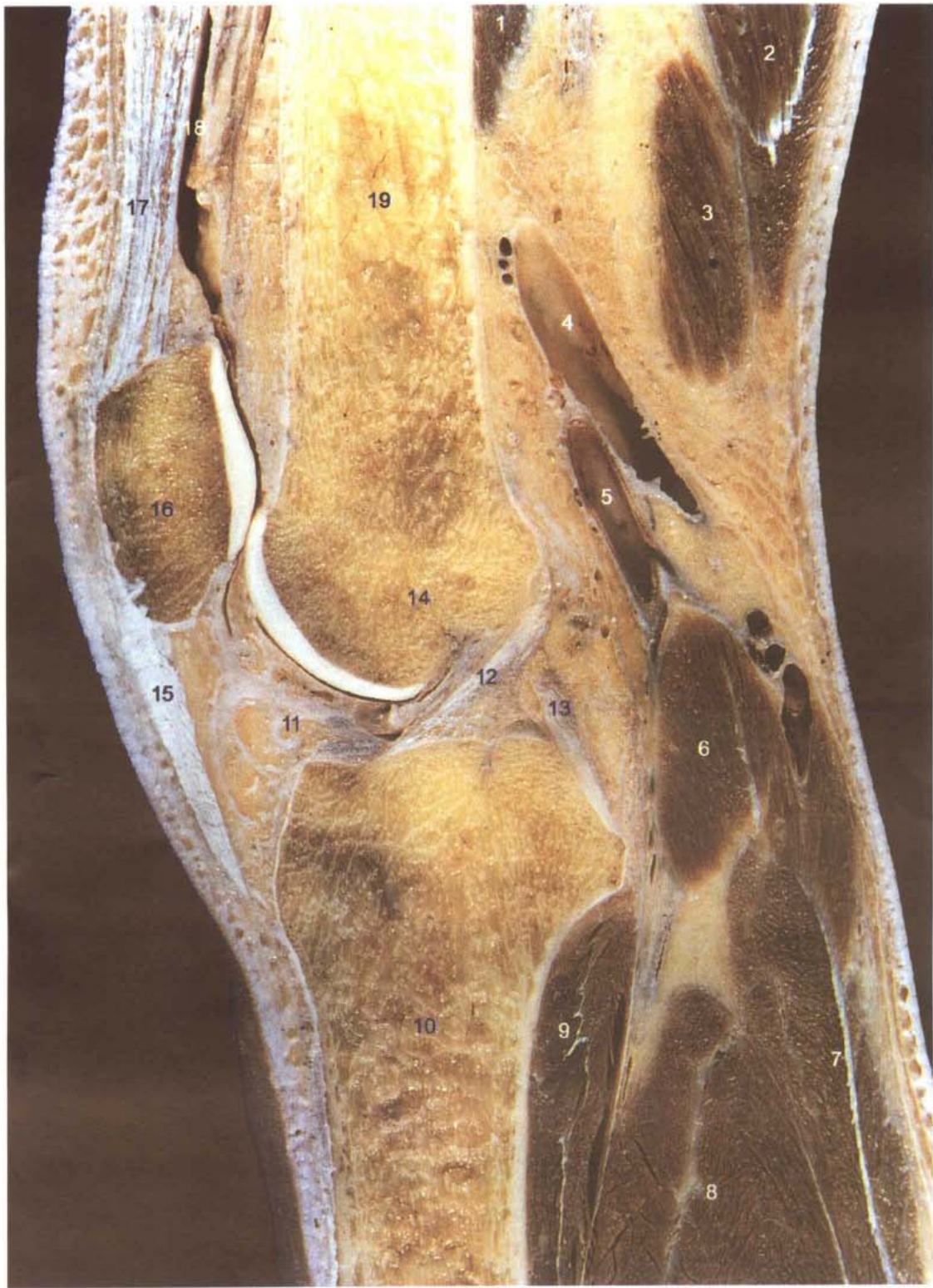

B. MRI T₁WI

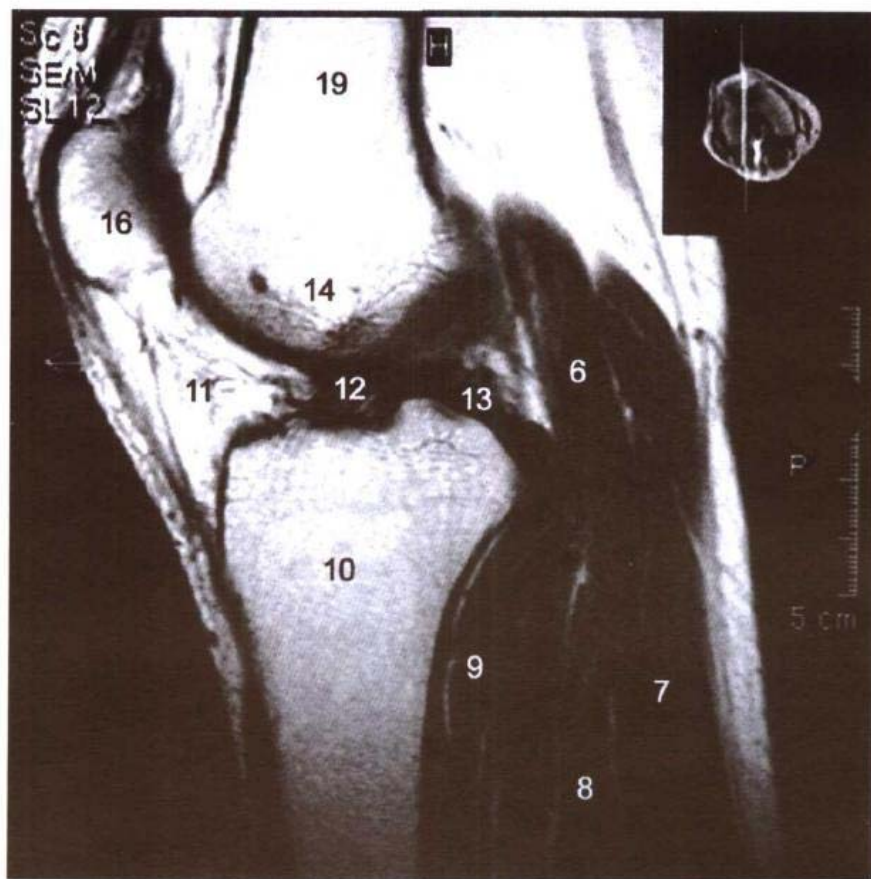
- | | |
|---|--|
| 1. 腘静脉 popliteal vein | 13. 关节腔 articular cavity |
| 2. 腘动脉 popliteal artery | 14. 内侧半月板前部 anterior part of medial meniscus |
| 3. 半膜肌 semimembranosus | 15. 翼状襞 alar fold |
| 4. 半腱肌腱 tendon of semitendinosus | 16. 髌韧带 patellar ligament |
| 5. 腓肠肌内侧头 medial head of gastrocnemius | 17. 髌骨 patella |
| 6. 腓肠肌 gastrocnemius | 18. 髌上囊 suprapatellar bursa |
| 7. 比目鱼肌 soleus | 19. 股内侧肌 vastus medialis |
| 8. 胫骨后肌 tibialis posterior | 20. 股前脂体 prefemoral fat pad |
| 9. 腘肌 popliteus | 21. 股骨 femur |
| 10. 胫骨 tibia | 22. 股骨内侧髁 medial condyle of femur |
| 11. 胫骨内侧髁 medial condyle of tibia | 23. 关节囊 articular capsule |
| 12. 内侧半月板后部 posterior part of medial meniscus | 24. 股四头肌腱 tendon of quadriceps femoris |

图 11-6 经前、后交叉韧带的矢状断层

Fig.11-6 Sagittal section through anterior and posterior cruciate ligaments



A. 断层标本 (sectional specimen)

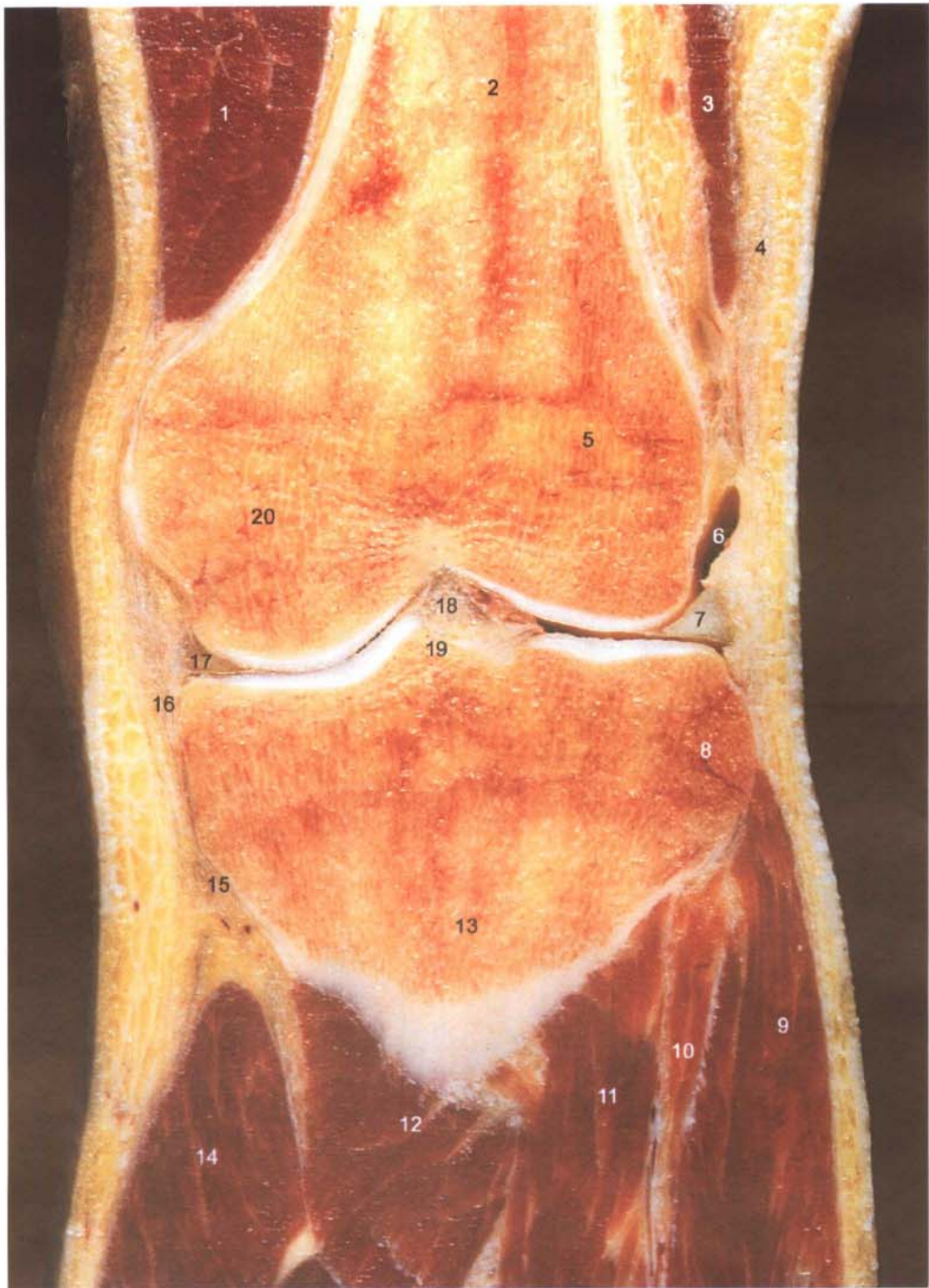

B. MRI T₁WI

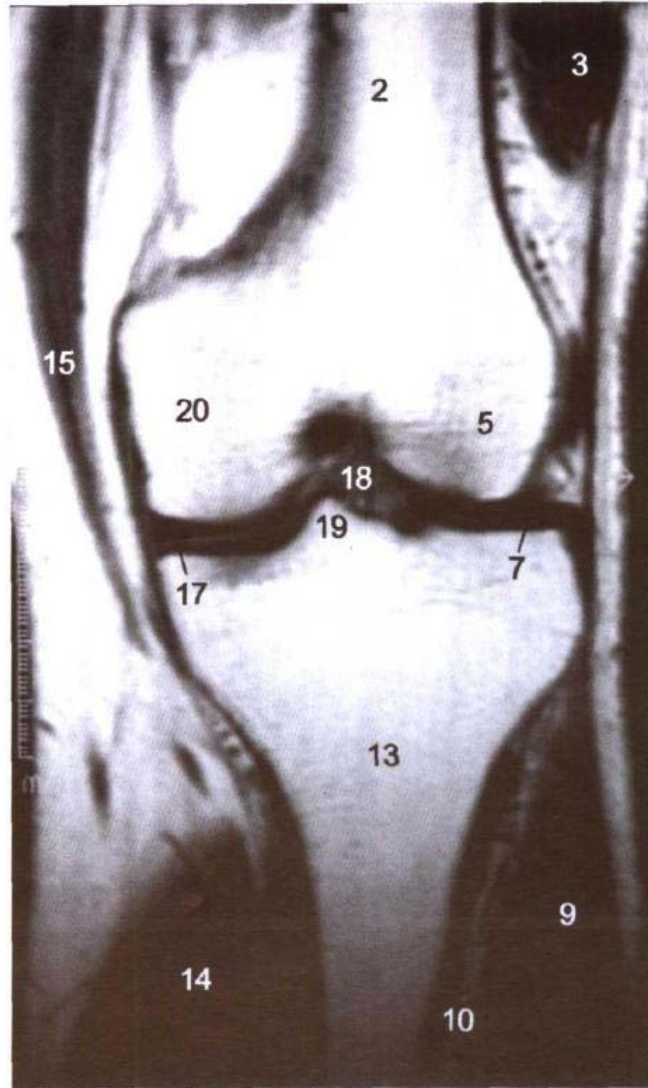
- | | |
|--|--|
| 1. 股内侧肌 vastus medialis | 11. 翼状襞 alar fold |
| 2. 半腱肌 semitendinosus | 12. 前交叉韧带 anterior cruciate ligament |
| 3. 半膜肌 semimembranosus | 13. 后交叉韧带 posterior cruciate ligament |
| 4. 腘静脉 popliteal vein | 14. 股骨外侧髁 lateral condyle of femur |
| 5. 腘动脉 popliteal artery | 15. 髌韧带 patellar ligament |
| 6. 腓肠肌内侧头 medial head of gastrocnemius | 16. 髌骨 patella |
| 7. 腓肠肌 gastrocnemius | 17. 股四头肌腱 tendon of quadriceps femoris |
| 8. 比目鱼肌 soleus | 18. 髌上囊 suprapatellar bursa |
| 9. 腘肌 popliteus | 19. 股骨 femur |
| 10. 胫骨 tibia | |

图 11-7 经胫骨髁间隆起和前交叉韧带的冠状断层

Fig.11-7 Coronal section through intercondylar eminence of tibia and anterior cruciate ligament



A. 断层标本(sectional specimen)

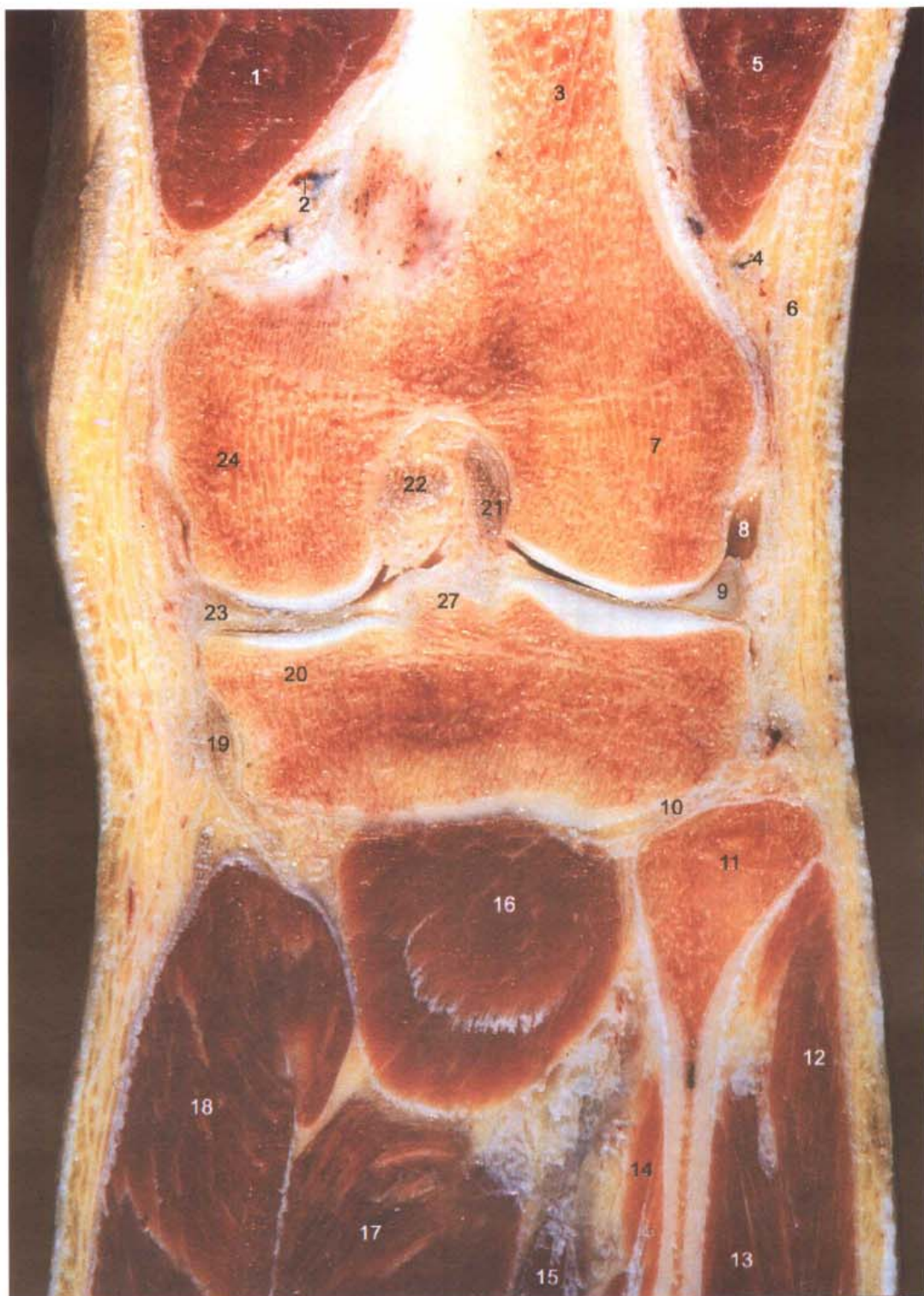

B. MRI T₁WI

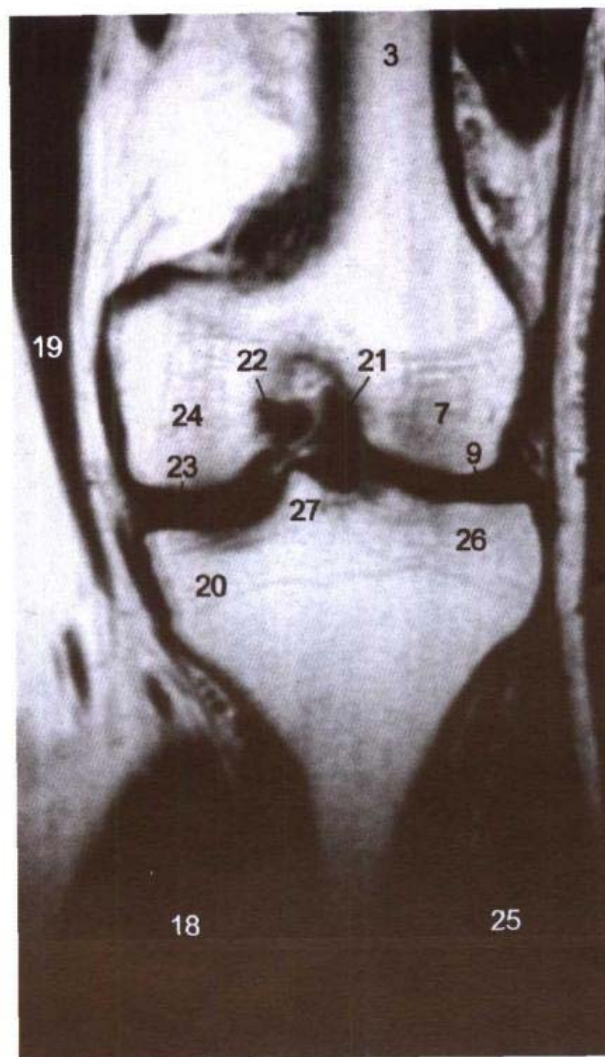
- | | |
|-----------------------------------|--|
| 1. 股内侧肌 vastus medialis | 11. 胫骨后肌 tibialis posterior |
| 2. 股骨体 shaft of femur | 12. 腘肌 popliteus |
| 3. 股外侧肌 vastus lateralis | 13. 胫骨 tibia |
| 4. 髂胫束 iliotibial tract | 14. 腓肠肌内侧头 medial head of gastrocnemius |
| 5. 股骨外侧髁 lateral condyle of femur | 15. 半膜肌腱 tendon of semimembranosus |
| 6. 膝关节腔 cavity of knee joint | 16. 胫侧副韧带 tibial collateral ligament |
| 7. 外侧半月板 lateral meniscus | 17. 内侧半月板 medial meniscus |
| 8. 胫骨外侧髁 lateral condyle of tibia | 18. 前交叉韧带 anterior cruciate ligament |
| 9. 趾长伸肌 extensor digitorum longus | 19. 胫骨髁间隆起 intercondylar eminence of tibia |
| 10. 胫骨前肌 tibialis anterior | 20. 股骨内侧髁 medial condyle of femur |

图 11-8 经前、后交叉韧带的冠状断层

Fig.11-8 Coronal section through anterior and posterior cruciate ligaments



A. 断层标本 (sectional specimen)

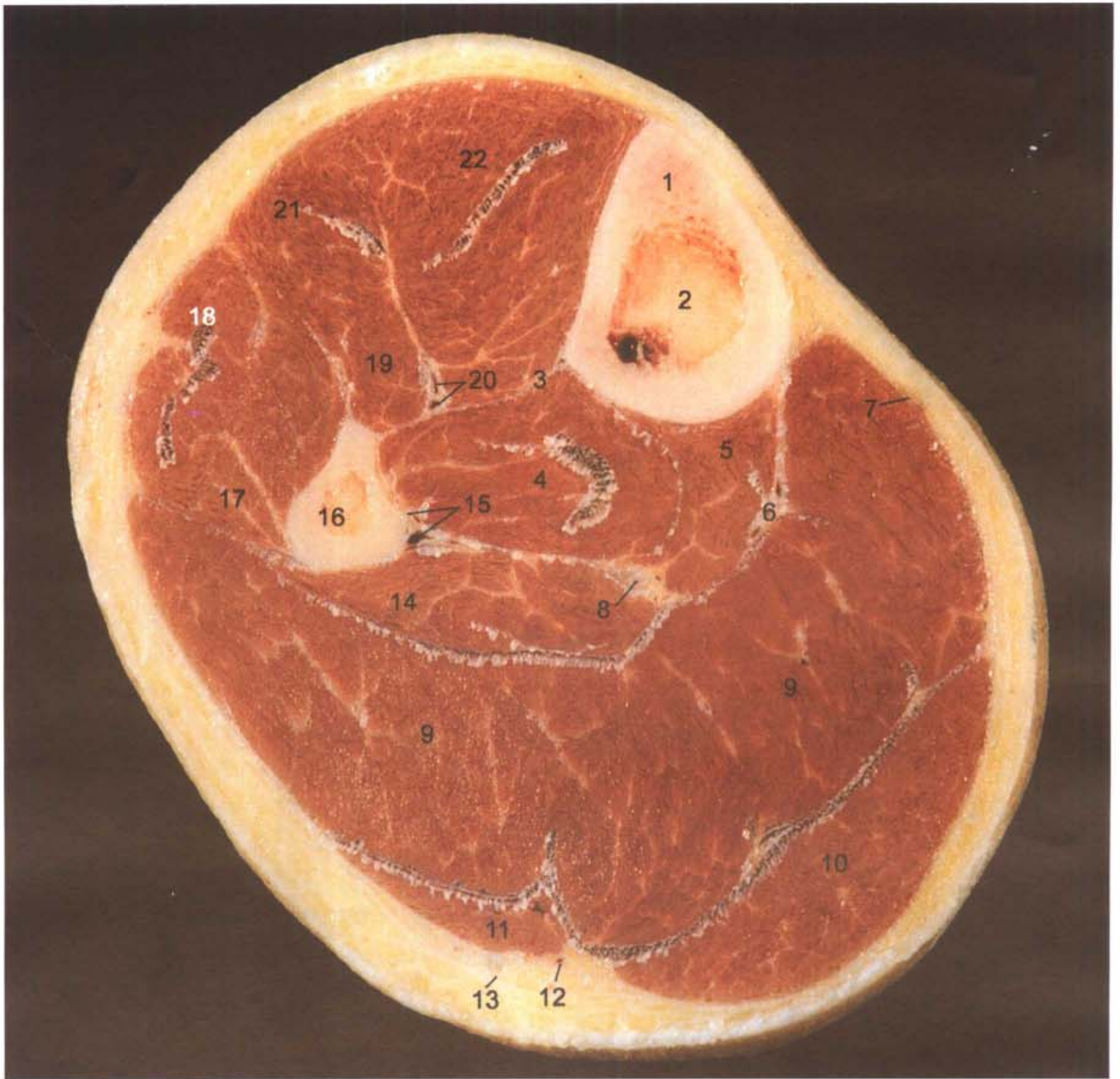

B. MRI T₁WI

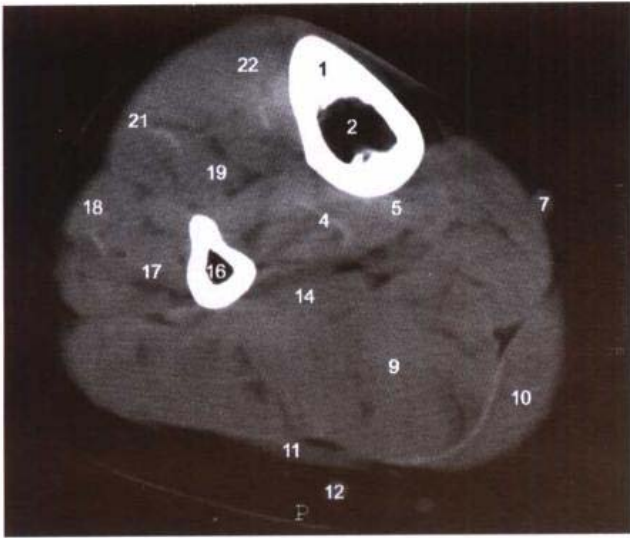
- | | |
|---|--|
| 1. 股内侧肌 vastus medialis | 14. 拇长屈肌 flexor hallucis longus |
| 2. 膝上内侧动、静脉 medial superior genicular artery and vein | 15. 胫骨后肌 tibialis posterior |
| 3. 股骨干 shaft of femur | 16. 腘肌 popliteus |
| 4. 膝上外侧动、静脉 lateral superior genicular artery、vein | 17. 比目鱼肌 soleus |
| 5. 股外侧肌 vastus lateralis | 18. 腓肠肌内侧头 medial head of gastrocnemius |
| 6. 髂胫束 iliotibial tract | 19. 半膜肌腱 tendon of semimembranosus |
| 7. 股骨外侧髁 lateral condyle of femur | 20. 胫骨内侧髁 medial condyle of tibia |
| 8. 膝关节腔 cavity of knee joint | 21. 前交叉韧带 anterior cruciate ligament |
| 9. 外侧半月板 lateral meniscus | 22. 后交叉韧带 posterior cruciate ligament |
| 10. 胫腓关节 tibiofibular joint | 23. 内侧半月板 medial meniscus |
| 11. 腓骨头 head of fibula | 24. 股骨内侧髁 medial condyle of femur |
| 12. 腓骨长肌 peroneus longus | 25. 腓肠肌外侧头 lateral head of gastrocnemius |
| 13. 腓骨短肌 peroneus brevis | 26. 胫骨外侧髁 lateral condyle of tibia |
| | 27. 胫骨髁间隆起 intercondylar eminence of tibia |

图 11-9 经小腿中份的横断层

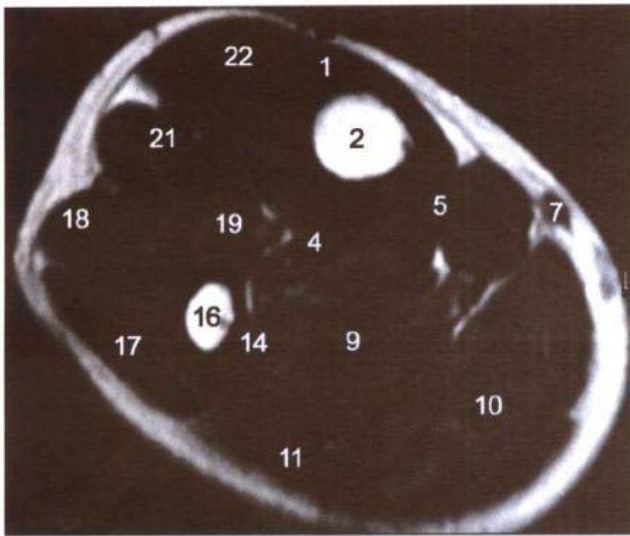
Fig.11-9 Transverse section through middle part of leg



A. 断层标本 (sectional specimen)



B. CT

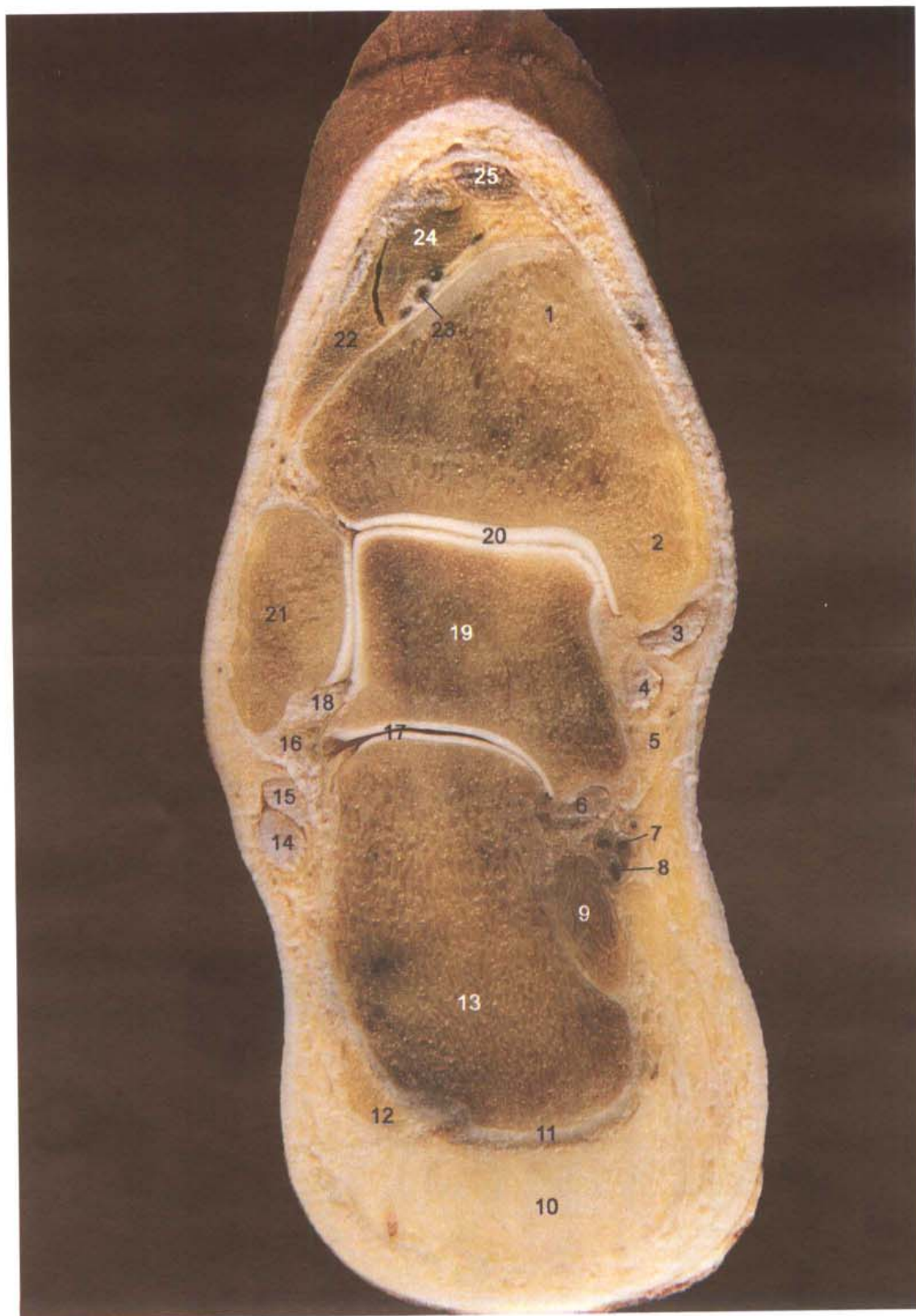

C. MRI T₁WI

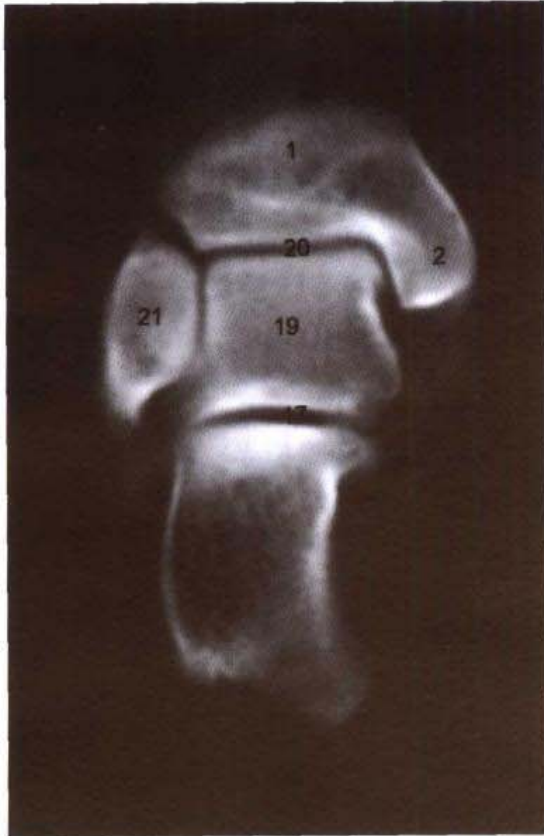
1. 胫骨 tibia
2. 胫骨骨髓腔 medullary cavity of tibia
3. 小腿骨间膜 crural interosseous membrane
4. 胫骨后肌 tibialis posterior
5. 趾长屈肌 flexor digitorum longus
6. 胫后动脉、静脉 posterior tibial artery and vein
7. 大隐静脉、隐神经 great saphenous vein and saphenous nerve
8. 胫神经 tibial nerve
9. 比目鱼肌 soleus
10. 腓肠肌内侧头 medial head of gastrocnemius
11. 腓肠肌外侧头 lateral head of gastrocnemius
12. 小隐静脉 small saphenous vein
13. 腓肠外侧皮神经 lateral sural cutaneous nerve
14. 趾长屈肌 flexor digitorum longus
15. 腓动脉、静脉 peroneal artery and vein
16. 腓骨 fibula
17. 腓骨短肌 peroneus brevis
18. 腓骨长肌 peroneus longus
19. 踇长伸肌 extensor hallucis longus
20. 腓深神经、胫前血管 deep peroneal nerve and anterior tibial artery and vein
21. 趾长伸肌 extensor digitorum longus
22. 胫骨前肌 tibialis anterior

图 11-10 经踝关节和跟距关节的横断层

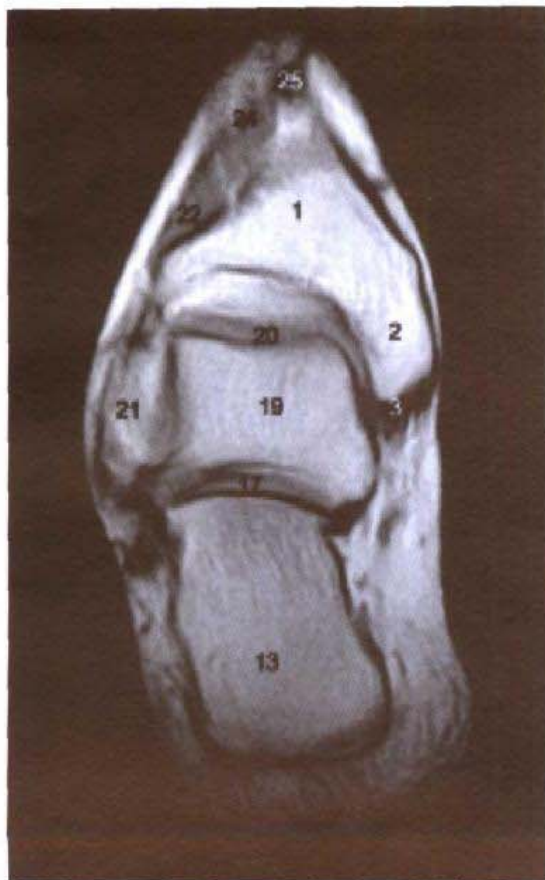
Fig.11-10 Transverse section through ankle joint and talocalcaneal joint



A. 断层标本 (sectional specimen)



B. CT

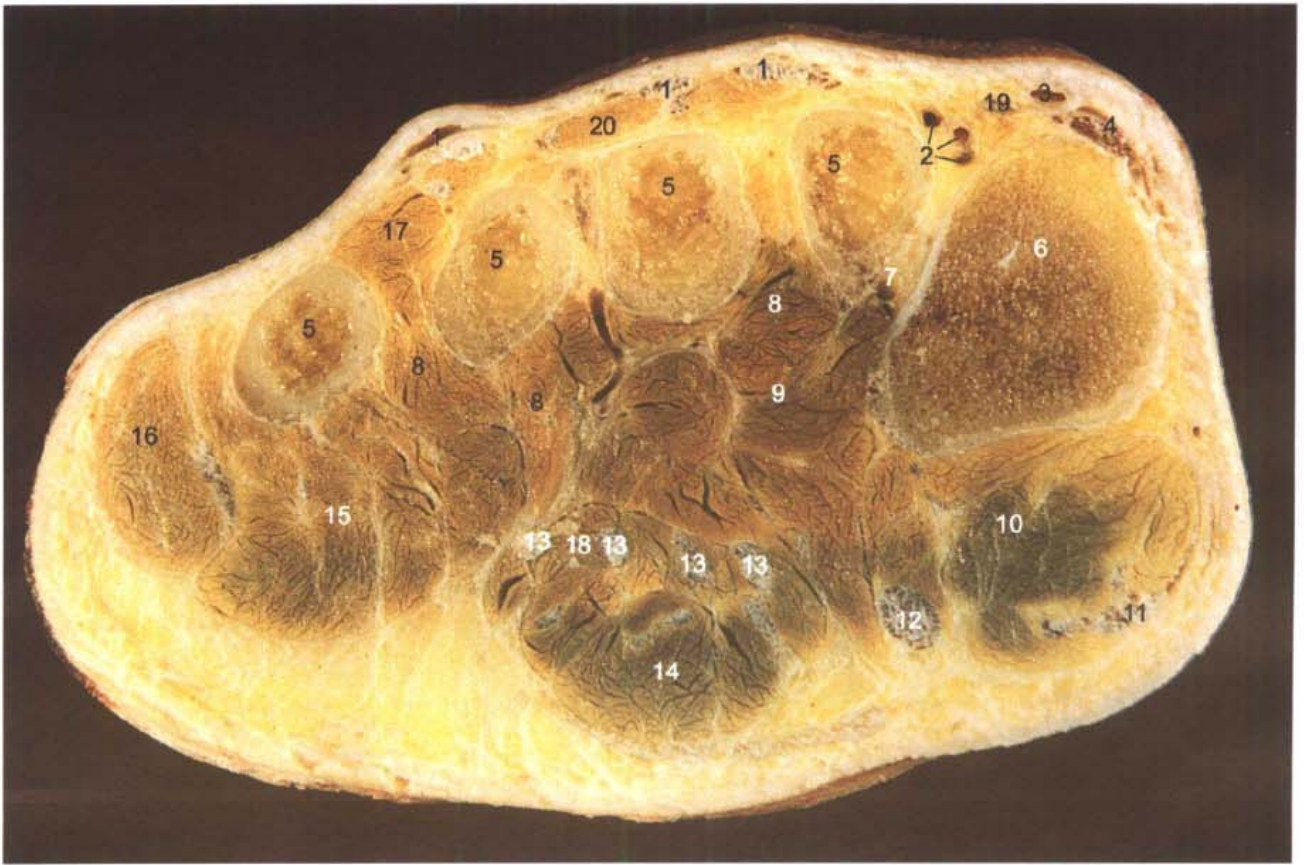

C. MRI T₁WI

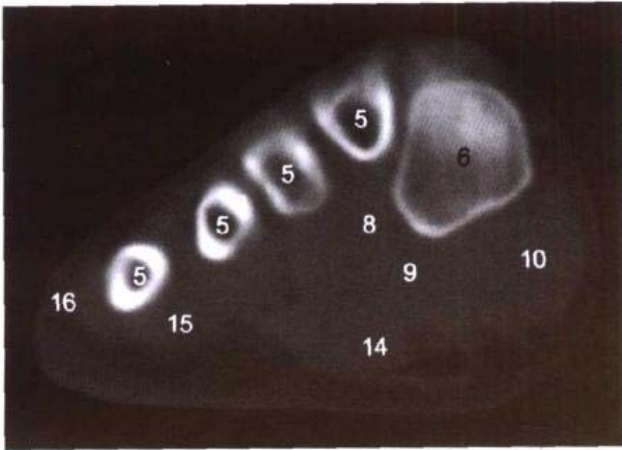
1. 胫骨 tibia
2. 内踝 medial maleolus
3. 胫骨后肌腱 tendon of tibialis posterior
4. 趾长屈肌腱 tendon of flexor digitorum longus
5. 胫神经 tibial nerve
6. 拇长屈肌腱 tendon of flexor hallucis
7. 胫后动脉 posterior tibial artery
8. 胫后静脉 posterior tibial vein
9. 足底方肌 quadratus plantae
10. 跟脂肪垫 fat pat of heel
11. 足底长韧带 long plantel ligament
12. 小趾展肌 abductor digiti minimi
13. 跟骨 calcaneus
14. 腓骨长肌腱 tendon of peroneus longus
15. 腓骨短肌腱 tendon of peroneus brevis
16. 跟腓韧带 calcaneofibular ligament
17. 距跟关节 subtalar joint
18. 距腓前韧带 anterior talofibular ligament
19. 距骨 talus
20. 踝关节 talocrural joint
21. 外踝 lateral maleolus
22. 趾长伸肌 extensor digitorum longus
23. 胫前动脉 anterior tibial artery
24. 拇长伸肌 extensor hallucis longus
25. 胫骨前肌 tibialis anterior

图 11-11 经足中份的横断层

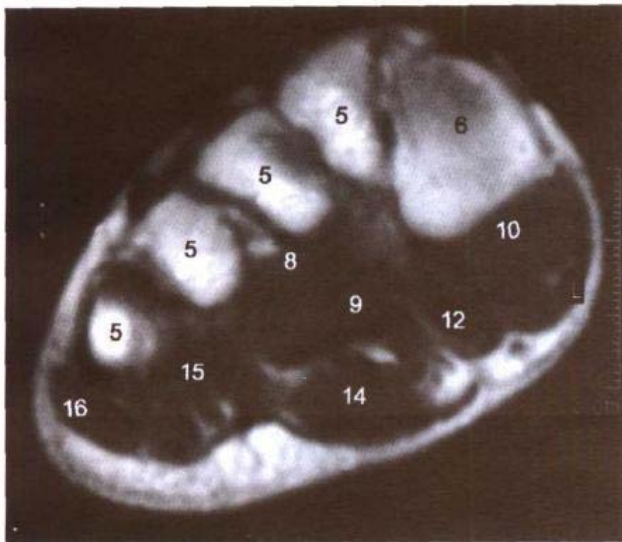
Fig.11-11 Transverse section through middle part of foot



A. 断层标本 (sectional specimen)



B. CT



C. MRI T₁WI

1. 第2~5趾长伸肌腱 tendon of 2~5th extensor digitorum longus
2. 足背动、静脉 dorsal artery and vein of foot
3. 足背静脉 dorsal vein of foot
4. 拇长伸肌腱 tendon of extensor hallucis longus
5. 第2~5跖骨体 body of 2~5th metatarsal bone
6. 第1跖骨体 body of 1st metatarsal bone
7. 第1趾足底血管、神经 1st plantar digital vessels and nerve
8. 骨间足底肌 plantar interossei
9. 拇收肌(斜头) oblique head of adductor hallucis
10. 拇短屈肌 flexor hallucis brevis
11. 拇展肌腱 tendon of abductor hallucis
12. 拇长屈肌腱 tendon of flexor hallucis longus
13. 第2~5趾屈肌腱 tendon of 2~5th flexor digitorum
14. 趾短屈肌 flexor digitorum brevis
15. 小趾短屈肌 flexor digiti minimi brevis
16. 小趾展肌 abductor digiti minimi
17. 第4骨间背侧肌 4th dorsal interossei
18. 蚓状肌 lumbricales
19. 拇短伸肌 extensor hallucis brevis
20. 趾短伸肌 extensor digitorum brevis

参 考 文 献

References

- 1 刘树伟. 断层解剖学. 北京: 人民卫生出版社, 1998
Liu SW. Sectional Anatomy. Beijing: People's Health Publishing House, 1998
- 2 吴德昌. 人体断层解剖学(横断断层). 北京: 科学出版社, 1988
Wu DC. Human Sectional Anatomy(transverse sections). Beijing: Science Publishing House, 1988
- 3 吴德昌. 人体断层解剖学(矢冠斜断断层). 北京: 科学出版社, 1994
Wu DC. Human Sectional Anatomy(sagittal, coronal, and oblique sections). Beijing: Science Publishing House, 1994
- 4 姜均本. 人体断面解剖学彩色图谱与 CT、MRI 应用. 北京: 科学出版社, 1997
Jiang JB. A Color Atlas of Human Sectional Anatomy and CT, MRI Application. Beijing: Science Publishing House, 1997
- 5 姜树学. 断面解剖与 MRI、CT、ECT 对照图谱. 沈阳: 辽宁科学技术出版社, 1998
Jiang SX. An Atlas of Sectional Anatomy Correlated with MRI, CT, and ECT Images. Shenyang: Liaoning Science and Technology Publishing House, 1998
- 6 Cahill DR, et al. Atlas of Human Cross-Sectional Anatomy with CT and MR Images, 3rd ed. New York: Wiley-Liss, 1998
- 7 Dean D and Herbener TE. Cross-Sectional Human Anatomy. Philadelphia: Lippincott Williams & Wilkins, 2000
- 8 Duvernoy HM. The Human Brain: Surface, Blood Supply, and Three-Dimensional Sectional Anatomy, 2nd ed. Wien: Springer, 1999
- 9 Ellis H, et al. Human Sectional Anatomy, 2nd ed. Boston: Butterworth-Heinemann, 1999
- 10 Jinkins JR. Atlas of Neuroradiologic Embryology, Anatomy, and Variants. Philadelphia: Lippincott Williams & Wilkins, 2000
- 11 Kelley LL and Petersen CM. Sectional Anatomy for Imaging Professionals. St Louis: Mosby-Year Book, Inc, 1997
- 12 Orrison Jr. WW. Neuroimaging. Philadelphia: W.B. Saunders Company, 2000
- 13 Pope TL and Lochr S. Atlas of Musculoskeletal Imaging. New York: Thieme, 2000
- 14 Spitzer VM and Whitlock DG. Atlas of Visible Human Male: Reverse Engineering of the Human Body. Boston: Jones and Bartlett Publishers, 1998
- 15 Wicke L. Atlas of Radiologic Anatomy, 5th ed. Philadelphia: Lea & Febiger, 1994

中文索引

Index (Chinese)

A

鞍背 20, 21
鞍上池 18, 19

B

半腱肌 158-163, 187-193, 222-235
半卵圆中心 8, 9
半膜肌 158-163, 187-193, 222-235
半奇静脉 108-113
背侧丘脑 12-15, 42-47, 68-73
背阔肌 111-151
鼻咽 42, 43, 62-65
鼻中隔 24-29, 42, 43, 54-61
比目鱼肌 228-231, 234-237
闭孔动脉 152-157, 180-185, 220, 221
闭孔内肌 152, 154-159, 178-187, 221
闭孔神经 152, 153, 182-185
闭孔外肌 154-161, 186-191
闭膜管 152, 153, 182-185
臂丛 38-41, 206, 207
髌骨 224, 225, 228-231
髌韧带 226-231
髌上囊 228-231

C

苍白球 14-15, 44-47, 68, 69
侧副沟 18-21, 48, 49, 66-81
侧脑室 10-19, 42-51, 62-77
侧副隆起 14, 15
长收肌 156-163, 189-193
肠系膜 150, 151, 164, 165
肠系膜上动脉 134-151
肠系膜上静脉 136-151
肠系膜下动脉 146-149
肠系膜下静脉 138, 139
尺侧副韧带 210, 211
尺侧腕屈肌 212-215
尺侧腕伸肌 212-215
尺动脉 214-217
尺骨 210-215
尺神经 208-217

齿状核 18, 19, 44, 45, 74-77
耻骨 152-159, 180-189
耻骨肌 152-163, 182-193, 220, 221
耻骨联合 152-157, 184-189
垂体 20, 21, 42, 43, 64-67
垂体柄 21, 66, 67

D

大多角骨 216, 217
大菱形肌 84-103
大脑大静脉 12, 13, 42, 43, 75
大脑后动脉 14-19, 72, 73
大脑镰 2-23, 42, 43, 56-83
大脑内静脉 12, 13, 74, 75
大脑前动脉 12-19, 62-65
大脑中动脉 14-21, 46-53, 64-73
大脑中浅静脉 26, 27
大收肌 158-163, 190-193
大隐静脉 224-227, 236, 237
大圆肌 100-111
大转子 152-157
胆囊 128-135
胆囊管 130-135
胆总管 136-145
岛叶 14-16, 48-51, 64-71
骶丛 166-177
骶骨 152, 153
骶管 164-175
骶髂骨间韧带 164-167
骶髂关节 166-171
骶神经 164-177
第三脑室 12-15, 68-71
第四脑室 18-23, 42, 43, 75
蝶窦 22-27, 42-45, 62, 63
蝶骨 14-23, 26-29, 62-67
顶骨 4-15, 44, 45, 74-83
顶内沟 2-7, 50, 51, 76-83
顶上小叶 2-7, 50, 51, 76-83
顶下沟 6-9, 76, 77
顶下小叶 2-7, 50, 51, 76-83
顶枕沟 4-9, 44-49, 80-83

动眼神经 18~21,24,25,42,43,64~69
 豆钩韧带 216,217
 豆掌韧带 216,217
 豆状核 14,15,44~47,68,69
 短收肌 156~163,188~193

E

额窦 18~23,42~45,54~59
 额骨 2~25,42~53,54~73
 额内侧回 2~19,56,57,62~75
 额上沟 4~19,56~73
 额上回 2~19,42~49,56~73
 额下沟 8~19,52,53,56~65
 额下回 10~19,48~53,56~65
 额中回 4~19,50~53,56~69
 腭扁桃体 44,45,64,65
 腭帆提肌 46,47,64,65
 腭帆张肌 28,29,64~67
 腭腺 44~47,60~63
 二腹肌 28~33,44~53,58~61,64~73
 二尖瓣 110,111

F

帆间池 11~13
 房间隔 106~111
 腓侧副韧带 226,227
 腓肠肌 224~237
 腓动脉 236,237
 腓骨 234~237
 腓骨长肌 234~239
 腓骨短肌 234~239
 腓深神经 236,237
 腓总神经 224~227
 肺动脉干 98~103
 肺动脉杈 98,99
 肺尖 84,85
 肺门淋巴结 94~109
 肺韧带 110,111
 肺韧带淋巴结 110,111
 缝匠肌 152~163,176~193
 附睾 162,163
 伏隔核 66,67
 腹股沟浅淋巴结 160~163,180~193,220,221
 腹横肌 142~151
 腹内斜肌 142~151
 腹腔干 132,133
 腹外斜肌 122~151

腹直肌 120~153,164~185
 腹主动脉 132~151

G

肝固有动脉 128~133
 肝镰状韧带 118~135
 肝淋巴结 132,133
 肝裸区 114~133
 肝门静脉 118~139
 肝门右切迹 130~139
 肝肾隐窝 134~145
 肝尾状叶 120~133,198,199
 肝尾状叶静脉 124,125
 肝胃韧带 126~135
 肝右管 128,129
 肝右后上缘静脉 120,121
 肝右后下静脉 131~135
 肝右后叶 118~143
 肝右静脉 118~140
 肝右前叶 118~143
 肝圆韧带 128~151
 肝圆韧带裂 128~135
 肝中静脉 118~139
 肝总管 130~135
 肝左管 128,129
 肝左静脉 118~131
 肝左内叶 118~139
 肝左外叶 118~135
 肝左叶间静脉 120,121
 冈上肌 84~87
 冈下肌 84~103
 肛管 160~163,184~189
 肛门外括约肌 160~163,192,193
 肛提肌 152~159,180~187
 睾丸 162,163
 膈 114~117
 膈下间隙 118~148
 跟腓韧带 238,239
 跟骨 238,239
 肱尺关节 210~213
 肱动脉 208~213
 肱二头肌 206~213
 肱骨 206~211
 肱肌 208~213
 肱静脉 208~213
 肱桡肌 210~215

肱三头肌 208~213
 钩 18~21,44~47,64~67
 钩骨 216,217
 股薄肌 222~227
 股动脉 152~163,181~193
 股二头肌 222~227
 股方肌 154~159,182~189
 股骨体 162, 163
 股骨颈 152~157, 182~187
 股骨头 152~155, 180~184
 股骨头韧带 152, 153, 182, 183
 股静脉 152~163, 181~193
 股深动脉 157~163, 186~193
 股神经 152~155, 164~185
 股四头肌 153~163, 182~193
 骨间背侧肌 218, 219
 骨间掌侧肌 218, 219
 骨间足底肌 240, 241
 鼓膜 70, 71
 鼓室 22, 23, 70, 71
 关节突关节 32, 33, 72~75, 150, 151, 196, 197,
 202~205
 冠状窦 111~115
 冠状缝 2~13, 42~45
 贵要静脉 208~215
 膈动脉 224~231
 膈肌 228~235
 膈静脉 224~231

H

海马 14~19, 48~51, 68~77
 海马旁回 14~17, 46, 47, 68~75
 海绵窦 20~23, 44~49, 64~69
 黑质 16, 17, 42~45, 70, 71
 横窦 16, 17, 42~53, 74~83
 横结肠 140~151
 横突 28~41
 横突间肌 200, 201
 横突孔 28~41
 红核 16, 17, 42, 43, 70, 71
 喉旁间隙 36, 37
 喉前庭 30~35
 喉下腔(声门下腔) 40, 41
 喉咽 30~43
 喉中间腔 36~39
 后床突 18~21, 42~45

后交叉韧带 226, 227, 230, 231, 234, 235
 后连合 14, 15, 42, 43
 后升动脉 100, 101
 后斜角肌 30~41
 后纵韧带 194,195,198,199
 滑车神经 16,17,62~67
 踝关节 238,239
 踝管 238,239
 环池 16,17,70~73
 环状软骨 40,41
 寰枢关节 26,27,42~47,68~75
 寰枕关节 26,27,42~47,68~75
 黄韧带 194,195,198~205
 灰结节 42,43
 回肠 164~179
 回盲瓣 164~167
 会厌 30~35,42,43
 会厌谷 30~33,42,43
 会厌前间隙 32~35,42,43
 会厌正中襞 30~33
 喙肱肌 206,207
 喙突 84,85

J

基底动脉 18~23,42,43
 棘间肌 194,195,198,199
 棘间韧带 42,43
 棘上韧带 42,43
 脊神经节 196,197
 脊髓 28~45,72~75,84~137,194~199
 脊髓圆锥 198,199
 颊肌 56~61
 颊咽筋膜 196,197
 甲杓肌 36,37
 甲状软骨 34~39,42~45
 甲状腺 34~41,42,43
 肩关节 206~207
 肩胛冈 84~87,206,207
 肩胛骨 84~109,206,207
 肩胛舌骨肌 32~41
 肩胛提肌 30~41
 肩胛下肌 86~107,206,207
 腱索 110~117
 继三角 14,15,42,43
 降结肠 140~151
 交叉池 18~21,42,43,64~67

角回 8-11,52,53,76-81
 脚间池 16,17,42,43,68,69
 茎突舌骨肌 26-29,48-51
 茎突舌肌 26-29,48-51
 茎突咽肌 26-29,48-51
 精囊 154,155
 精索 152-161
 颈半棘肌 32-41,46,47
 颈长肌 28-41
 颈动脉杈 30,31
 颈动脉鞘 26-41
 颈夹肌 30,31
 颈静脉孔 24,25
 颈静脉切迹 84,85
 颈阔肌 30-41
 颈内动脉 26-31,48-51,68-71
 颈内静脉 26-41,48-51,68-73
 颈前静脉 30-41
 颈深静脉 30-41
 颈外侧深淋巴结 30-41
 颈外动脉 26-32
 颈外静脉 30-41
 颈总动脉 32-41
 胫侧副韧带 226,227,232,233
 胫腓关节 234,235
 胫骨 228-237
 胫骨后肌 228,229, 232-239
 胫骨前肌 232,233,236-239
 胫后动脉 236-239
 胫前动脉 236,237
 胫神经 224-227,236-239
 静脉韧带裂 120-127
 距腓前韧带 238,239
 距跟关节 238,239
 距骨 238,239
 距状沟 10-15,42-49,74-83

K

颞舌肌 30,31,42-45,58-65
 壳 12-17,44-49,64-71
 空肠 140-151
 口咽 42,43
 扣带沟缘支 42-45
 扣带回 6-15,42,43,60-75
 扣带回峡 12-15,42-45,74,75
 髌关节 152-155

髌臼横韧带 220,221
 眶回 18-21,46-53,56-65
 阔筋膜张肌 152-163,176-193

L

阑尾 168-173
 肋膈隐窝 118-139
 肋纵隔隐窝 106-117
 泪腺 22-27,56-61
 梨状肌 170-177
 梨状隐窝 32-35
 犁骨 28,29
 菱形窝 18-23,42,43,75
 隆嵴下淋巴结 94-101
 漏斗 19,20,42,43
 卵巢 170-177
 卵巢动脉 164-173
 卵巢静脉 164-173
 卵圆窝 110,111

M

脉络丛 10-19,42-49,62-77
 盲肠 164-171
 门腔淋巴结 133,134
 迷走神经 30-41
 面动脉 30,31,60-67
 面神经 22,23
 拇长屈肌 214-219
 拇长伸肌 214-219
 拇长展肌 214-217
 拇短屈肌 216-219
 拇短伸肌 216-219
 拇短展肌 216-219
 拇对掌肌 216-219
 拇收肌 218,219
 踝长屈肌 234-241
 踝长伸肌 236-241
 踝短屈肌 240,241
 踝短伸肌 240,241
 踝收肌 240,241
 踝展肌 240,241

N

内侧半月板 228,229,232-235
 内囊 12-17,44-47,66-73
 内直肌 24-27,56-61
 脑膜中动脉 66,67

脑桥 20~23,42~45,68~73
 脑桥小脑角池 20~23,46,47,70,71
 尿道 184~191
 尿道海绵体 160~163
 尿道球 160~163
 颞骨 14~27,46~53,58~79
 颞横回 16,17,52,53,68~73
 颞肌 4~29,58~65
 颞浅动脉 24~27
 颞浅静脉 24~27
 颞上沟 16~21,52,53,64~81
 颞上回 16~21,52,53,64~81
 颞下颌关节 24~27,66~69
 颞下回 16~21,64~81
 颞中回 16~21,64~81

P

膀胱 152~155,178~183
 膀胱精囊角 154,155
 膀胱静脉丛 152~155
 脾 124~141
 脾动脉 132~135
 脾静脉 132~137
 脾肾隐窝 132~137
 胼胝体 10~15,42~45,62~75
 胼胝体辐射 8,9,46~49,60~75
 屏状核 12~17,64~71

Q

奇静脉 94~117
 奇静脉弓 92,93
 奇静脉食管隐窝 92~117
 气管杈 90~93
 髂股韧带 152~157,180~187
 髌骨 164~179
 髌肌 164~173
 髌胫束 220~227,232~235
 髌内动脉 164~173
 髌内静脉 164~173
 髌外动脉 164~180
 髌外静脉 164~180
 髌外淋巴结 170~178
 髌腰肌 152~161
 髌总动脉 204,205
 髌总静脉 204,205
 前床突 22,23,44,45,64,65
 前交叉韧带 226,227,230,231

前锯肌 84~117
 前连合 16,17,42,43
 前列腺 152~159
 前庭球 190,191
 前庭蜗神经 22,23
 前斜角肌 30~41
 前纵隔淋巴结 84~117
 前纵韧带 198,199
 桥池 20~23,42~45,68~73
 禽距 76,77
 穹窿 12~15,42,43,64~73
 丘脑间粘合 14,15,42,43
 丘脑枕 14,15,44~47,72,73
 颧弓 58~65
 颧骨 24~29,56~61

R

桡侧副韧带 210,211
 桡侧腕长伸肌 210~217
 桡侧腕短伸肌 210~217
 桡侧腕屈肌 212~217
 桡尺近侧关节 212,213
 桡动脉 214~217
 桡骨 212~215
 桡骨环状韧带 212,213
 桡神经 208~215
 人字缝 4~19
 绒球 20~23
 肉柱 116,117
 乳头肌 108~117
 乳头体 42,43

S

腮腺 26~29
 三叉神经 20~23,46,47
 三叉神经节 22,23,46,47
 三尖瓣 110~115
 三角肌 84~103
 杓横肌 36,37
 杓状会厌囊 30~35
 杓状软骨 34~37
 筛窦 24~29,44,45,58~61
 筛骨 24~29,44,45,58~61
 上鼻甲 58~61
 上颌动脉 48,49,68,69
 上颌窦 26~29,42~51,58~61
 上颌骨 26~29,42~51,58~61

上颌神经 62~67
 上睑提肌 22,23,48,49,58~63
 上腔静脉 90~99
 上丘 16,17,42,43
 上矢状窦 2~17,42,43,56~83
 上髓帆 16~19,42,43
 上斜肌 23,24,58~61
 上直肌 22,23,48,49,58~63
 上 I 肌 180,181
 舌动脉 46~49
 舌骨 30~33,42~47
 舌骨舌肌 46,47
 舌回 42~45
 舌神经 44,45
 舌下神经 46,47
 舌下腺 44~47
 舌咽神经 46,47
 射精管 156,157
 肾 132~151
 肾动脉 136~143
 肾静脉 136~147
 肾上腺 128~135
 肾盂 138~141
 升结肠 144~151
 升主动脉 98~103
 十二指肠 134~151
 食管 41,117
 食管旁淋巴结 84~117
 示指伸肌 216~219
 视辐射 10~15,74~81
 视交叉 20,21,42,43,66,67
 视神经 20~25,46,47,58~65
 视束 16~19,42,43,68~71
 室间隔 108~117
 室间孔 12~15,42,43,68,69
 输精管 152~155
 输卵管 172
 输尿管 142~151,164~181
 竖脊肌 84~151
 四叠体池(上池) 42,43
 松果体 13,42,43
 锁骨 84~87
 锁骨上淋巴结 38~41
 锁骨下动脉 84~89
 锁骨下静脉 84~89

T

毯 10~17,68~79
 听辐射 16,17,52,53,68~73
 听小骨 70,71
 头半棘肌 32~41,46,47
 头臂干 84~89
 头臂静脉 86~89
 头长肌 30~33
 头后大直肌 46,47
 头后小直肌 44,45
 头夹肌 30~39
 头静脉 84~89
 头下斜肌 46,47
 头正中静脉 212,213
 头状骨 216,217
 透明隔 12~15,42,43,64~71
 透明隔腔 64~71
 臀大肌 152~193
 臀下动脉 152~161,174~183
 臀下神经 152~161,174~183
 臀小肌 168~183
 臀中肌 164~185

W

外侧半月板 232~235
 外侧沟 10~21,46~53,64~79
 外侧膝状体 70,71
 外囊 12~17,64~71
 外直肌 24~27,56~63
 腕骨间背侧韧带 216,217
 腕骨间骨间韧带 216,217
 腕骨间关节 216,217
 腕骨间掌侧韧带 216,217
 腕管 216,217
 腕横韧带 216,217
 网膜孔 132,133
 网膜囊 120~139
 尾骨 154~157
 尾骨肌 154,155
 尾状核 10~19,42~47,64~73
 胃 118~149
 胃脾韧带 130~135
 胃脾隐窝 130~135
 胃十二指肠动脉 134,135
 胃左动脉 132~135
 胃左淋巴结 132~135

X

膝关节 224 ~ 235
 下鼻甲 42 ~ 45, 54 ~ 61
 下橄榄核 24, 25
 下颌骨 24 ~ 31, 42 ~ 53, 56 ~ 69
 下颌后静脉 28, 29
 下颌舌骨肌 30, 31, 42 ~ 47, 60 ~ 63
 下颌下淋巴结 30 ~ 33, 48 ~ 51, 62 ~ 67
 下颌下腺 30 ~ 33, 48 ~ 51, 62 ~ 67
 下腔静脉 114 ~ 151
 下丘 16, 17, 42, 43
 下斜肌 50, 51, 56, 57
 下牙槽神经 62, 63
 下直肌 26 ~ 29, 48 ~ 51, 56 ~ 61
 下口肌 182, 183
 小多角骨 216, 217
 小结 20, 21, 74, 75
 小脑半球 16 ~ 25, 42 ~ 53, 72 ~ 81
 小脑扁桃体 20, 21, 40, 45, 70, 77, 81

胸骨甲状肌 38 ~ 41
 胸骨角 94 ~ 97
 胸骨舌骨肌 38 ~ 41
 胸廓内动脉 84 ~ 117
 胸锁乳突肌 26 ~ 41
 胸腺 90 ~ 103
 胸小肌 86 ~ 105
 胸主动脉 94 ~ 117
 嗅束 42, 43, 58 ~ 63
 旋后肌 214, 215
 旋前圆肌 210 ~ 215

Y

咽鼓管软骨 26 ~ 29, 46, 47
 咽后间隙 32 ~ 35
 咽缩肌 30 ~ 41
 咽隐窝 64, 65
 延池 24 ~ 27, 42 ~ 45, 72, 73
 延髓 24 ~ 27, 42 ~ 45, 72, 73

阴道穹后部 180,181
 阴蒂 190~193
 阴茎 156~163
 阴囊 162,163
 蚓垂 74~77
 蚓状肌 218,219
 蚓锥体 20,21
 隐神经 236,237
 硬膜外隙 194~201
 右肺动脉 98~101
 右肺上叶 84~105
 右肺上叶动脉 94~99
 右肺上叶支气管 94,95
 右肺下叶 94~117
 右肺下叶动脉 102~105
 右肺下叶支气管 102~105
 右肺中叶 102~117
 右肺中叶动脉 102~105
 右肺中叶支气管 102~105
 右肝上间隙 118~149
 右冠状动脉 106~117
 右气管支气管淋巴结 92~95
 右上肺静脉 98~105
 右上气管旁淋巴结 84~89
 右下肺静脉 106~109
 右下气管旁淋巴结 90,91
 右心耳 100~105
 右心房 100~117
 右心室 106~117
 右主支气管 92~95
 缘上回 10~13,52,53,74~77
 月骨 216,217

Z

展神经 44,45,64~67
 掌长肌 212~215
 掌骨 218,219
 掌心动脉 218,219
 枕动脉 52,53,72~83
 枕额肌 56~59,80~83
 枕骨 4~29,42~53
 枕内嵴 42,43
 枕颞沟 68~79
 枕颞内侧回 68~79
 枕颞外侧回 68~79
 枕外隆凸 14~19,42,43,

枕叶 14,15,42,43
 正中神经 208~217
 直肠 152~159,170~183
 直窦 42,43,76~81
 直回 20,21,42~45,56~63
 跖骨 240,241
 指浅屈肌 212~219
 指伸肌 212~219
 指深屈肌 212~219
 指掌侧总神经 218,219
 趾长屈肌 236~241
 趾长伸肌 236~241
 趾短屈肌 240,241
 趾短伸肌 240,241
 中鼻甲 28,29,42~45,56~61
 中间支气管 98~101
 中脑 16,17,42~45,72,73
 中脑水管 16,17,42~45,72,73
 中斜角肌 30~41
 中央后沟 2~9,44~53,74~79
 中央后回 2~14,44~53,74~79
 中央旁沟 2,3,42,43
 中央前沟 2~13,44~53,66~73
 中央前回 2~15,44~53,66~73
 终纹 12~15,42,43,68~73
 肘关节 210~213
 肘肌 210~213
 肘正中静脉 210~213
 蛛网膜粒 72~75
 蛛网膜下隙 194~203
 主动脉肺动脉窗 94~97
 主动脉肺淋巴结 94~98
 主动脉弓 90~93
 主动脉下隐窝 104~107
 椎动脉 24~41,46,47,70~75
 椎间盘 194~203
 椎内静脉丛 202~205
 椎外静脉丛 202,203
 子宫底 170,171
 子宫颈 176~183
 子宫静脉丛 176~183
 子宫体 172~175
 子宫腔 172~179
 子宫主韧带 176~179
 足背动脉 240,241
 足背静脉 240,241

足底长韧带 238,239
最外囊 12-17,64-71
左肺动脉 96-103
左肺上叶 84-117
左肺上叶支气管 100-101
左肺下叶 94-117
左肺下叶动脉 100-107
左肝上前间隙 120-135
左冠状动脉 104,105
左上肺静脉 98-103
左上气管旁淋巴结 84-89
左下肺静脉 106,107
左下气管旁淋巴结 90-93
左心房 104-111
左心室 108-117
左支气管旁淋巴结 94-98
左主支气管 90-99
坐股韧带 152-155
坐骨 152-163,180-191
坐骨肛门窝 156-163,181-191
坐骨海绵体肌 160,161,190,191
坐骨棘 152,153,180,181
坐骨结节 154-161,181-189
坐骨神经 152-163,172-193

英文索引

Index (English)

A

abdominal aorta 132~151
 abducent nerve 44,45,64~67
 abductor digiti minimi 216~219
 abductor hallucis 240,241
 abductor pollicis brevis 216~219
 abductor pollicis longus 214~217
 acoustic radiation 16,17,52,53,68~73
 adductor brevis 156~163,188~193
 adductor hallucis 240,241
 adductor longus 156~163,189~193
 adductor magnus 158~163,190~193
 adductor pollicis 218,219
 adrenal gland 128~135
 amygdaloid body 18,19,46~49,66,67
 anal canal 160~163,184~189
 anconeus 210~213
 angular gyrus 8~11,52,53,76~81
 ankle canal 238,239
 ankle joint 238,239
 annular ligament of radius 212,213
 anterior cerebral artery 12~19,62~65
 anterior cervical vein 30~41
 anterior clinoid process 22,23,44,45,64,65
 anterior commissure 16,17,42,43
 anterior cruciate ligament 226,227,230,231
 anterior left suprahepatic space 120~135
 anterior longitudinal ligament 198,199
 anterior mediastinal lymph nodes 84~117
 anterior talofibular ligament 238,239
 anterior tibial artery 236,237
 aortic arch 90~93
 aorticopulmonary window 94~97
 aortopulmonary lymph nodes 94~98
 apex of lung 84,85
 arachnoid granulation 72~75
 arch of azygos vein 92,93
 aryepiglottic fold 30~35
 arytenoid cartilage 34~37
 ascending aorta 98~103

ascending colon 144~151
 atlantoaxial joint 26,27,42~47,68~75
 atlantooccipital joint 26,27,42~47,68~75
 auditory ossicles 70,71
 axillary artery 86~97
 axillary lymph node 86~97
 axillary vein 86~97
 azygoesophageal recess 92~117
 azygos vein 94~117

B

bare area of liver 114~133
 basilar artery 18~23,42,43
 basilic vein 208~215
 biceps brachii 206~213
 biceps femoris 222~227
 bicuspid valve 110,111
 bifurcation of pulmonary trunk 98,99
 bifurcation of trachea 90~93
 body of pancreas 132~141
 body of uterus 172~175
 brachial artery 208~213
 brachial plexus 38~41,206,207
 brachial vein 208~213
 brachialis 208~213
 brachiocephalic trunk 84~89
 brachiocephalic vein 84~89
 brachioradialis 210~215
 buccinator 56~61
 buccopharyngeal fascia 196,197
 bulb of urethra 160~163
 bulb of vestibule 190,191

C

calcaneofibular ligament 238,239
 calcaneus 238,239
 calcar avis 76,77
 calcarene sulcus 10~15,42~49,74~83
 capitate bone 216,217
 carotid sheath 26~41
 carpal canal 216,217

cartilage of auditory tube 26~29,46,47
 caudate hepatic veins 124,125
 caudate lobe of liver 120~133,198,199
 caudate nucleus 10~19,42~47,64~73
 cavernous body of urethra 160~163
 cavernous sinus 20~23,44~49,64~69
 cavity of septum pellucidum 64~71
 cavity of uterus 172~179
 cecum 164~171
 celiac trunk 132,133
 centrum semiovale 8,9
 cephalic vein 84~89
 cerebellar hemisphere 16~25,42~53,72~81
 cerebellomedullary cistern(cisterna magna) 42,43
 cerebral falx 2~23,42,43,56~83
 chiasmatic cistern 18~21,42,43,64~67
 chordae tendineae 110~117
 choroid plexus 10~19,42~49,62~77
 cingulate gyrus 6~15,42,43,60~75
 cingulate sulcus 4~15,42~45,60~79
 cistern of corpus quadrigemina(superior cistern) 42,43
 cistern of medulla oblongata 24~27,42~45,72,73
 cistern of pontocerebellar trigone 20~23,46,47,70,71
 cistern of velum interpositum 10,11
 cisterna ambiens 16,17,70~73
 claustrum 12~17,64~71
 clitoris 190~193
 coccyx 154~157,178~181
 coccygeus 154,155,176~179
 collateral eminence 14,15
 collateral sulcus 18~21,48,49,66~81
 common bile duct 136~145
 common carotid artery 32~41
 common hepatic duct 130~135
 common iliac vein 204,205
 common palmar digital nerves 218,219
 common peroneal nerve 236,237
 common iliac artery 204,205
 constrictor of pharynx 30~41
 conus medullaris 198,199
 coracobrachialis 210~215
 coracoid process 84,85
 coronary sinus 111~115
 corpus callosum 10~15,42~45,62~75
 costodiaphragmatic recess 118~139
 costomediastinal recess 106~117

cricoid cartilage 40,41
 cystic duct 130,135

D

deep cervical vein 30~41
 deep femoral artery 157~163,186~193
 deep lateral cervical lymph nodes 30~41
 deep peroneal nerve 236,237
 deltoid 84~103
 dentate nucleus 18,19,44,45,74~77
 descending colon 140~151
 diaphragm 114~117
 digastric 28~33,44~53,58~61,64~73
 dorsal artery of foot 240,241
 dorsal intercarpal ligaments 216,217
 dorsal thalamus 12~15,42~47,68~73
 dorsal vein of foot 240,241
 dorsum sellae 20,21
 ductus deferens 152~155
 duodenum 134~151

E

ejaculatory duct 156,157
 elbow joint 210~213
 epidural space 194~201
 epiglottic cartilage 30~35,42,43
 epiglottic vallecula 30~33,42,43
 epiglottis 30~35,42,43
 erector spinae 84~151
 esophagus 41~117
 ethmoid bone 24~29,44,45,58~61
 ethmoid sinus 24~29,44,45
 extensor carpi radialis longus 210~217
 extensor carpi radialis brevis 210~217
 extensor carpi ulnaris 212~215
 extensor digiti minimi 214~219
 extensor digitorum brevis 240,241
 extensor digitorum longus 236~241
 extensor hallucis brevis 240,241
 extensor hallucis longus 236~241
 extensor indicis 216~219
 extensor pollicis brevis 216~219
 extensor pollicis longus 214~219
 extensor digitorum 212~219
 external iliac lymph nodes 170~178
 external capsule 12~17,64~71
 external carotid artery 26~32

external jugular vein 20, 41

external jugular vein 190, 191

inferior lobe of right lung 94~117
 inferior mesenteric vein 138,139
 inferior mesenteric artery 146~149
 inferior nasal concha 42~45,54~61
 inferior obliquus 50,51,56,57
 inferior olivary nucleus 24,25
 inferior parietal lobule 2~7,50,51,76~83
 inferior petrosal sinus 46,47
 inferior rectus 26~29,48~51,56~61
 inferior temporal gyrus 16~21,64~81
 inferior vena cava 114~151
 inferior right posterior hepatic veins 131~135
 infraaortic recess 104~107
 infraglottic cavity 40,41
 infraspinalis 84~103
 infundibulum 19,20,42,43
 insula 14~16,48~51,64~71
 interatrial septum 106~111
 intercarpal joints 216,217
 interlobar artery 100,101
 intermedial cavity of larynx 36~39
 intermetacarpal joints 216,217
 internal capsule 12~17,44~47,66~73
 internal carotid artery 26~31,48~51,68~71
 internal cerebral veins 12,13,74,75
 internal iliac artery 164~173
 internal iliac vein 164~173
 internal jugular vein 26~41,48~51,68~73
 internal occipital crest 42,43
 internal pudendal artery 152~159
 internal vertebral venous plexus 202~205
 internal thoracic artery 84~117
 interosseous intercarpal ligament 216,217
 interosseous sacroiliac ligaments 164~167
 interpeduncular cistern 16,17,42,43,68,69
 interspinal ligament 42,43
 interthalamic adhesion 14,15,42,43
 interventricular foramen 12~15,42,43,68,69
 interventricular septum 108~117
 intervertebral disc 194~203
 intraparietal sulcus 2~7,50,51,76~83
 ischial tuberosity 154~161,181~189
 ischiocavernosus 160,161,190,191
 ischiofemoral ligament 152~155
 ischium 152~163,180~191

J

jejunum 140~151
 jugular foramen 24,25
 jugular notch 84,85

K

kidney 132~151
 knee joint 224~235

L

lacrimal gland 22~27,56~61
 laryngeal vestibule 30~35
 lateral geniculate body 70,71
 lateral occipitotemporal gyrus 68~79
 lateral pterygoid 26~29,48~53,62~67
 lateral rectus 24~27,56~63
 lateral sulcus 10~21,46~53,64~79
 lateral ventricle 10~19,42~51,62~77
 lateral meniscus 232~235
 latissimus dorsi 111~151
 left atrium 104~111
 left coronary artery 104,105
 left gastric artery 132~135
 left gastric lymph nodes 132~135
 left inferior lobar bronchus 100~107
 left inferior pulmonary vein 106,107
 left lateral lobe of liver 118~135
 left lower paratracheal lymph nodes 90~93
 left medial lobe of liver 118~139
 left pulmonary artery 96~103
 left superior lobar bronchus 100,101
 left superior pulmonary vein 98~103
 left upper paratracheal lymph nodes 84~89
 left ventricle 108~117
 left hepatic duct 128,129
 left hepatic vein 118~131
 left interlobar vein 120,121
 left principal bronchus 90~99
 lenticular nucleus 14,15,44~47,68,69
 lesser trochanter 158~161
 levator ani 152~159,180~187
 levator palpebrae superioris 22,23,48,49,58~63
 levator veli palatini 46,47,64,65
 levator scapulae 30~41
 ligament of head of femur 152,153,182,183
 ligamenta flava 194,195,198~205

ligamentum teres hepatis 128~151
 lingual gyrus 42~45
 lingual artery 46~49
 lingual nerve 44,45
 long plantar ligament 238,239
 longus capitis 30~33
 longus colli 30~41
 lumbar lymph nodes 142,143
 lumbricales 218,219
 lunate bone 216,217

M

mamillary body 42,43
 mandible 24~31,42~53,56~69
 marginal ramus of cingulate sulcus 42~45
 masseter 60~67
 maxilla 26~29,42~51,58~61
 maxillary artery 48,49,68,69
 maxillary nerve 62~67
 maxillary sinus 26~29,42~51,58~61
 medial cephalic vein 212,213
 medial frontal gyrus 2~19,56,57,62~75
 medial meniscus 228,229,232~235
 medial occipitotemporal gyrus 68~79
 medial pterygoid 28,29,46~53,62~67
 medial rectus 24~27,56~61
 median cubital vein 210~213
 median nerve 208~217
 medulla oblongata 24~27,42~45,72,73
 mesencephalic aqueduct 16,17,42~45,72,73
 mesentery 150,151,164,165
 metacarpal bones 218,219
 metatarsal bones 240,241
 midbrain 16,17,42~45,72,73
 middle lobar artery of right lung 102~105
 middle lobe of right lung 102~117
 middle cardiac vein 116,117
 middle cerebellar peduncle 20,21,44,45
 middle cerebral artery 14~21,46~53,64~73
 middle frontal gyrus 4~19,55~53,56~69,70,73
 middle meningeal artery 66,67
 middle nasal concha 28,29,42~45,56~61
 middle temporal gyrus 16~21,64~81
 middle hepatic vein 118~139

N

nasal septum 24~29,42,43,54~61

nasopharynx 42,43,62~65
 neck of femur 152~157,182~187
 neck of pancreas 134~141
 neck of uterus 176~183
 nodule 20,21,74,75
 nucleus accumbens septi 66,67

O

oblique sinus of pericardium 104~115
 obliquus capitis inferior 46,47
 obliquus externus abdominis 122~151
 obliquus internus abdominis 142~151
 obturator artery 152~157,180~185,220,221
 obturator canal 152,153,182~185
 obturator externus 154~161,186~191
 obturator internus 152,154~159,178~187,221
 obturator nerve 152,153,182~185
 occipital artery 52,53,72~83
 occipital bone 4~29,42~53
 occipital lobe 14,15,42,43
 occipitofrontalis 56~59,80~83
 occipitotemporal sulcus 68~79
 oculomotor nerve 18~21,24,25,42,43,64~69
 olfactory tract 42,43,58,63
 omental bursa 120~139
 omental foramen 132,133
 ophthalmic nerve 24,25
 opponens digiti minimi 218,219
 opponens pollicis 216~219
 optic chiasma 20,21,42,43,66,67
 optic nerve 20~25,46,47,58~65
 optic radiation 10~15,74~81
 optic tract 16~19,42,43,68~71
 orbital gyri 18~21,46~53,56~65
 oropharynx 42,43
 ovarian artery 164~173
 ovarian vein 164~173
 ovary 170~177

P

palatine glands 44~47,60~63
 palatine tonsil 44,45,64,65
 palmar intercarpal ligaments 216,217
 palmar interossei 218,219
 palmar metacarpal arteries 218,219
 palmaris longus 212~215

papillary muscle 108~117
 paracentral sulcus 2,3,42,43
 paraesophageal lymph nodes 84~117
 parahippocampal gyrus 14~17,46,47,68~75
 parietal bone 4~15,44,45,74~83
 parietooccipital sulcus 4~9,44~49,80~83
 parotid gland 26~29
 patella 224,225,228~231
 patellar ligament 226~231
 pectineus 152~163,182~193,220,221
 pectoralis major 84~117
 pectoralis minor 86~105
 penis 156~163
 peroneus brevis 234~239
 peroneus longus 234~239
 pharyngeal recess 64,65
 pineal body 13,42,43
 piriform recess 32~35
 piriformis 170~177
 pisohamate ligament 216,217
 pisometacarpal ligament 216,217
 pituitary gland 20,21,42,43,64~67
 pituitary stalk 21,66,67
 plantar interossei 240,241
 platysma 30~41
 pons 20~23,42~45,68~73
 pontine cistern 20~23,42~45,68~73
 popliteal artery 224~231
 popliteal vein 224~231
 popliteus 228~235
 portocaval lymph nodes 133,134
 postcentral gyrus 2~14,44~53,74~79
 postcentral sulcus 2~9,44~53,74~79
 posterior ascending artery 100,101
 posterior cerebral artery 14~19,72,73
 posterior clinoid process 18~21,42~45
 posterior commissure 14,15,42,43
 posterior cruciate ligament 226,227,230,231,234,235
 posterior longitudinal ligament 194,195,198,199
 posterior tibial artery 236~239
 precentral gyrus 2~15,44~53,66~73
 precentral sulcus 2~13,44~53,66~73
 precuneus 2~9,42~45,78~83
 preepiglottic space 32~35,42,43
 pronator teres 210~215
 proper hepatic artery 128~133

prostate 152~159
 proximal radioulnar joint 212,213
 psoas major 132~151,164~173,200~205
 pterion 14,15
 pterygopalatine fossa 26~29
 pubic symphysis 152~157,184~189
 pubis 152~159,180~189
 pudendal nerve 152~159
 pulmonary hilar lymph nodes 94~109
 pulmonary ligament lymph nodes 110,111
 pulmonary ligaments 110,111
 pulmonary trunk 98~103
 pulmonary artery 132~133
 pulvinar 14,15,44~47,72,73
 putamen 12~17,44~49,64~71
 pyramid of vermis 20,21

Q

quadratus femoris 154~159,182~189
 quadratus lumborum 134~151
 quadriceps femoris 153~163,182~193

R

radial artery 214~217
 radial collateral ligament 210,211
 radial nerve 208~215
 radiation of corpus callosum 8,9,46~49,60~75
 radius 212~215
 rectum 152~159,170~183
 rectus capitis posterior major 46,47
 rectus capitis posterior minor 44,45
 rectus abdominis 120~153,164~185
 red nucleus 16,17,42,43,70,71
 renal artery 136~143
 renal vein 136~147
 retromandibular vein 28,29
 retropharyngeal space 32~35
 rhomboid fossa 18~23,42,43,75
 rhomboideus major 84~103
 right anterior lobe of liver 118~143
 right atrium 100~117
 right auricle 100~105
 right hepatic duct 128,129
 right hepatic vein 118~140
 right inferior lobar bronchus 102~105
 right inferior pulmonary vein 106~109

right lower paratracheal lymph nodes 90,91
 right middle lobar bronchus 102~105
 right posterior lobe of liver 118~143
 right posterior supramarginal vein 120,121
 right pulmonary artery 98~101
 right superior lobar bronchus 94,95
 right superior pulmonary vein 98~105
 right suprahepatic space 118~149
 right tracheobronchial lymph nodes 92~95
 right upper paratracheal lymph nodes 84~89
 right ventricle 106~117
 right coronary artery 106~117
 right principal bronchus 92~95

S

sacral plexus 166~177
 sacral canal 164~175
 sacral nerves 166~177
 sacroiliac joint 166~171
 sacrum 152,153
 saphenous nerve 236,237
 sartorius 152~163,176~193
 scalenus anterior 30~41
 scalenus medius 30~41
 scalenus posterior 30~41
 scapula 84~109
 sciatic nerve 152~163,172~193
 scrotum 162,163
 semimembranosus 158~163,187~193,222~235
 seminal vesicle 154,155
 semispinalis capitis 32~41,46,47
 semispinalis cervicis 32~41,46,47
 semitendinosus 158~163,187~193,222~235
 septum pellucidum 12~15,42,43,64~71
 serratus anterior 84~117
 shoulder joint 206,207
 sigmoid colon 164~179
 sigmoid sinus 18~25,50,51,74,75
 small saphenous vein 236,237
 soleus 228~231,234~237
 spermatic cord 154,155
 sphenoid bone 14~23,26~29,62~67
 sphenoidal sinus 22~27,42~45,62,63
 sphincter ani externus 160~163,192,193
 spinal ganglia 196,197
 spinal cord 28~45,72~75,84~137,194~199

spleen 124~141
 splenic artery 132~135
 splenic vein 132~137
 splenius capitis 30~39
 splenorenal recess 132~137
 sternal angle 94~97
 sternocleidomastoid 26~41
 sternohyoid 38~41
 sternothyroid 38~41
 sternum 84~117
 stomach 118~149
 straight sinus 42,43,76~81
 styloglossus 26~29,48~51
 stylohyoid 26~29,48~51
 stylopharyngeus 26~29,48~51
 subarachnoid space 194~203
 subcarinal lymph nodes 94~101
 subclavian artery 84~89
 subclavian vein 84~89
 sublingual gland 44~47
 submandibular lymph nodes 30~33,48~51,62~87
 submandibular gland 30~33,48~51,62~67
 subparietal sulcus 6~9,76,77
 subphrenic space 118~148
 subscapularis 86~107
 substantia nigra 16,17,42~45,70,71
 superficial middle cerebral veins 26,27
 superficial temporal artery 24~27
 superficial temporal vein 24~27
 superficial inguinal ligament lymph nodes 160~163,
 180~193,220,221
 superior cerebellar peduncle 16~19,42,43
 superior frontal gyrus 2~19,42~49,56~73
 superior frontal sulcus 4~19,56~73
 superior lobar artery of right lung 94~99
 superior lobe of left lung 84~117
 superior lobe of right lung 84~105
 superior medullary velum 16~19,42,43
 superior mesenteric vein 136~151
 superior mesenteric artery 134~151
 superior nasal concha 58~61
 superior obliquus 23,24,58~61
 superior parietal lobule 2~7,50,5176~83
 superior recess of pericardium 90~99
 superior rectus 22,23,48,49,58~63
 superior sagittal sinus 2~17,42,43,56~83

superior temporal gyrus 16~21,52,53,64~81
 superior temporal sulcus 16~21,52,53,64~81
 superior vena cava 90~99
 supinator 214,215
 supraclavicular lymph nodes 38~41
 supramarginal gyrus 10~13,52,53,74~77
 suprapatellar bursa 228~231
 suprasellay cistern 18,19
 supraspinal ligament 42,43
 supraspinatus 84~87

T

tail of pancreas 134~138
 talocalcaneal joint 238,239
 talus 238,239
 temporal bone 14~27,46~53,58~79
 temporalis 4~29,58~65
 temporomandibular joint 24~27,66~69
 tensor fasciae latae 152~163,176~193
 tensor veli palatini 28,29,64~67
 tentorium of cerebellum 22~27,42~45,72~77
 teres major 100~111
 teres minor 96~99
 terminal stria 12~15,42,43,68~73
 testis 162,163
 third ventricle 12~15,68~71
 thoracic aorta 94~117
 thoracic duct 84~117
 thymus 90~103
 thyroarytenoid 36,37
 thyroid cartilage 34~39,42~45
 thyroid gland 34~41,42,43
 tibia 228~237
 tibialis anterior 232,233,236~239
 tibial collateral ligament 226,227,232,233
 tibial nerve 224~227,236~239
 tibialis posterior 228,229,232~239
 tibiofibular joint 234,235
 tonsil of cerebellum 22~27,42~45,72~77
 transverse acetabular ligament 220,221
 transverse arytenoid 36,37
 transverse carpal ligament 216,217
 transverse colon 140~151
 transverse foramen 28~41
 transverse process 28~41
 transverse sinus 16~17,42~53,74~83

transverse sinus of pericardium 102~107
 transverse temporal gyrus 16,17,52,53,68~73
 transversus abdominis 142~151
 trapezium bone 216,217
 trapezius 84~117
 trapezoid bone 216,217
 triceps brachii 208~213
 tricuspid valve 110~115
 trigeminal ganglion 22,23,46,47
 trigeminal nerve 20~23,46,47
 trochlear nerve 16,17,62~67
 tuber cinereum 42,43
 tympanic cavity 22,23,70,71
 tympanic membrane 70,71

U

ulna 210~215
 ulnar artery 214~217
 ulnar collateral ligament 210,211
 ulnar nerve 208~217
 uncinat process of pancreas 136~145
 uncus 18~21,44~47,64~67
 ureter 142~151,164~181
 urethra 184~191
 urinary bladder 152~155,178~183
 uterine tube 172
 uterine venous plexus 176~183
 uvula 74~77

V

vagina 180~193
 vaginal venous plexus 176~183
 vagus nerve 30~41
 vermiform appendix 168~173
 vermis 14~21,42,43,74~79
 vertebral artery 24~41,46,47,70~75
 vesical venous plexus 152~155
 vesicoseminal angle 154,155
 vestibulocochlear nerve 22,23
 vomer 28,29

Z

zygapophysial joints 32,33,72~75,150,151,196,197,
 202~205
 zygomatic arch 58~65
 zygomatic bone 24~29,56~61

