



第1章 运动系统 CHAPTER 1 THE LOCOMOTOR SYSTEM

图 1	全身骨骼(前和后面观) The skeleton(anterior and posterior aspect)	(2)
图 2	骨的分类 Classification of bones	(3)
图 3	骨的构造(A、B) Structure of the bone(A,B)	(3)
图 4	脊柱(A、B、C) The vertebral column(A,B,C)	(4)
图 5	寰椎(上和下面观) The atlas(superior and inferior aspect)	(5)
图 6	枢椎(上面观) The axis(superior aspect)	(5)
图 7	颈椎(上面观) A cervical vertebra(superior aspect)	(5)
图 8	胸椎(上和侧面观) A thoracic vertebra(superior and lateral aspect)	(6)
图 9	腰椎(上和侧面观) A lumbar vertebra(superior and lateral aspect)	(6)
图 10	骶骨和尾骨(前面观) The sacrum and coccyx(anterior aspect)	(7)
图 11	骶骨和尾骨(后面观) The sacrum and coccyx(posterior aspect)	(7)
图 12	第一(A)、二(B)、六(C)、十二(D)肋骨(上面观) The 1st(A), 2nd(B), 6th(C), 12th(D) ribs(superior aspect)	(8)
图 13	胸骨(前和侧面观) The sternum(anterior and lateral aspect)	(8)
图 14	颅(前面观) The skull(anterior aspect)	(9)
图 15	颅(上面观) The skull(superior aspect)	(9)
图 16	颅底外面观 The external aspect of the base of the skull	(10)
图 17	颅底内面观 The internal aspect of the base of the skull	(11)
图 18	颅(侧面观) The skull(lateral aspect)	(12)
图 19	婴儿颅(上和侧面观) The skull of an infant(superior and lateral aspect)	(12)
图 20	下颌骨(外侧面和后面观) The mandible(lateral and posterior aspect)	(13)
图 21	舌骨(上面观) The hyoid bone(superior aspect)	(13)
图 22	蝶骨(前、后和上面观) The sphenoid bone (anterior, posterior and superior aspect)	(14)
图 23	颞骨(外、内和下面观) The temporal bone(external, internal and inferior aspect)	(15)
图 24	额骨(前和内面观) The frontal bone(anterior and internal aspect)	(16)
图 25	筛骨(上和下面观) The ethmoid bone(superior and inferior aspect)	(16)
图 26	枕骨(外和内面观) The occipital bone(external and internal aspect)	(17)
图 27	上颌骨(前和内侧面观) The maxilla bone(anterior and medial aspect)	(18)
图 28	锁骨(上和下面观) The clavicle(superior and inferior aspect)	(19)
图 29	肩胛骨(外侧角) The scapula(lateral angle)	(19)
图 30	肩胛骨(前和后面观) The scapula(anterior and posterior aspect)	(20)

图 31	肱骨(前和后面观) The humerus(anterior and posterior aspect).....	(21)
图 32	尺骨(A. 右图, B. 左图) The ulna(A.the right figure,B.the left figure)	(22)
图 33	桡骨(A. 左图, B. 右图) The radius(A.the left figure,B.the right figure)	(22)
图 34	手骨(前和后面观) The bones of the hand(anterior and posterior aspect).....	(23)
图 35	髋骨(内和外面观) The hip bone(internal and external aspect)	(24)
图 36	婴儿髋骨(外面观) The hip bone of the infant(external aspect)	(24)
图 37	股骨(前和后面观) The femur (anterior and posterior aspect).....	(25)
图 38	髌骨(前和后面观) The patella(anterior and posterior aspect).....	(26)
图 39	胫骨与腓骨(前和后面观) The tibia and fibula(anterior and posterior aspect)	(26)
图 40	足骨(上和下面观) The bones of the foot(superior and inferior aspect)	(27)
图 41	足纵弓(侧面及上面观) The longitudinal arches of foot (lateral and superior aspect).....	(28)
图 42	椎骨间连结(A、B、C、D) Intervertebral joints (A,B,C,D).....	(29)
图 43	颅骨与椎骨连结(A、B、C) The joints of the skull and vertebra(A,B,C).....	(30)
图 44	肋与胸骨连结 The joints of ribs and the sternum	(31)
图 45	颞下颌关节(A、B、C) The temporomandibular joint(A,B,C)	(31)
图 46	肩关节(A、B、C) The shoulder joint(A,B,C).....	(32)
图 47	肘关节(A、B、C) The elbow joint(A,B,C).....	(33)
图 48	手骨连结(A、B、C) The joints of the hand(A,B,C)	(34)
图 49	骨盆的连结(前和后面观) The joints of the pelvis(anterior and posterior aspect)	(35)
图 50	髋关节(A,B,C,D) The hip joint(A,B,C,D).....	(37)
图 51	膝关节(前和后面观) The knee joint (anterior and posterior aspect)	(38)
图 52	膝关节(A、B)The knee joint (A,B).....	(39)
图 53	膝关节(切开) The knee joint(incision).....	(40)
图 54	膝关节(半月板) The knee joint(meniscuses).....	(40)
图 55	膝关节(矢状节面) The knee joint(sagittal section).....	(41)
图 56	小腿骨的连结 The joints of the leg.....	(41)
图 57	足骨的连结(上和下面观) The joints of the foot(superior and inferior aspect).....	(42)
图 58	足骨的连结(A、B) The joints of the foot(A,B)	(43)
图 59	肌的形态(A~H)Forms of muscles(A~H).....	(44)
图 60	背部的肌(I) Muscles of back(I).....	(45)
图 61	背部的肌(II) Muscles of back(II)	(46)

第2章 下肢 CHAPTER 2 THE LOWER LIMB.....(47)

图 62	股前内侧区的浅静脉 Superficial veins of anterior and medial region of the thigh.....	(48)
图 63	腹股沟浅淋巴结 Superficial inguinal lymph nodes.....	(48)
图 64	股前内侧区的肌、神经和血管(I)(A、B)Muscles,nerves and blood vessels of anterior and medial region of the thigh(I)(A,B).....	(49)
图 65	股鞘 Femoral sheath.....	(49)

图 66	股前内侧区的肌、神经和血管(Ⅱ) Muscles,nerves and blood vesseles of anterior and medial region of the thigh(Ⅱ).....	(50)
图 67	股前内侧区的肌、神经和血管(Ⅲ) Muscles,nerves and blood vesseles of anterior and medial region of the thigh(Ⅲ).....	(50)
图 68	股动脉及股深动脉 Femoral artery and deep femoral artery.....	(51)
图 69	股深动脉及其穿动脉 Deep femoral artery and perforating arteries.....	(51)
图 70	闭孔神经和血管 Obturator nerves and obturator vesseles.....	(52)
图 71	臀区和股后区的皮神经 Cutaneous nerves of the gluteal region and posterior region of the thigh.....	(52)
图 72	臀区和股后区的肌 Muscles of the gluteal region and posterior region of the thigh.....	(52)
图 73	臀区的肌、神经和血管(Ⅰ) Muscles,nerves and blood vesseles of the gluteal region(Ⅰ).....	(53)
图 74	臀区的肌、神经和血管(Ⅱ) Muscles,nerves and blood vesseles of the gluteal region(Ⅱ).....	(53)
图 75	股后区的肌 Muscles of posterior region of the thigh.....	(54)
图 76	股后区的肌、神经和血管 Muscles,nerves and blood vesseles of posterior region of the thigh.....	(54)
图 77	腘窝的神经和血管 Nerves and blood vesseles of the popliteal fossa.....	(55)
图 78	腘动脉的分支 Branches of the popliteal artery.....	(55)
图 79	膝关节网(A、B) Genicular articular rete(A,B).....	(56)
图 80	股部中段横切面(下面观) Transverse section through the middle of the thigh(inferior aspect).....	(57)
图 81	小腿的浅静脉(A、B) Superficial veins of the leg (A,B).....	(58)
图 82	小腿后区的肌、神经和血管(A、B、C) Muscles,nerves and blood vesseles of the posterior crural region(A,B,C).....	(59)
图 83	足底腱膜 Plantar aponeurosis.....	(60)
图 84	足底肌、神经和血管(Ⅰ) Muscles, nerves and blood vesseles of the sole of foot(Ⅰ).....	(60)
图 85	足底肌、神经和血管(Ⅱ) Muscles, nerves and blood vesseles of the sole of foot(Ⅱ).....	(60)
图 86	足底肌、神经和血管(Ⅲ) Muscles,nerves and blood vesseles of the sole of foot(Ⅲ).....	(61)
图 87	足底肌、神经和血管(Ⅳ) Muscles,nerves and blood vesseles of the sole of foot(Ⅳ).....	(61)
图 88	足底肌 Muscles of the sole of foot.....	(61)
图 89	踝管 Malleolar canal.....	(62)
图 90	小腿中部横断面(下面观) Transverse section through the middle of the leg (inferior aspect).....	(62)
图 91	小腿前外侧区和足背 Anteriolateral crural region and dorsum of foot.....	(63)

- 图 92 小腿伸肌支持带和腓骨肌支持带 Extensor retinaculum and peroneal retinaculum of the leg.(63)
- 图 93 足背的浅静脉(上面观) Superficial veins of the dorsum of foot(superior aspect).....(64)
- 图 94 足背的神经和动脉 Nerves and arteries of the dorsum of foot.....(64)
- 图 95 足肌(上面观) Muscles of the foot(superior aspect).....(64)

第3章 上肢 CHAPTER 3 THE UPPER LIMB.....(65)

- 图 96 腋窝前壁(A、B、C) Anterior wall of the axillary fossa (A,B,C).....(66)
- 图 97 腋窝的血管和神经(I) Blood vessels and nerves of the axillary fossa (I)(67)
- 图 98 腋窝的血管和神经(II) Blood vessels and nerves of the axillary fossa (II).....(68)
- 图 99 腋窝的血管和神经(III) Blood vessels and nerves of the axillary fossa (III)(69)
- 图 100 腋淋巴结 Axillary lymph nodes.....(69)
- 图 101 肩和臂前面的肌、血管和神经(A、B) Muscles,blood vessels and nerves of the anterior aspect of the shoulder and upper arm (A,B)(70)
- 图 102 肩胛区和臂后区的肌、血管和神经(A、B) Muscles,blood vessels and nerves of the scapular and posterior brachial region (A,B)(71)
- 图 103 肩胛区动脉 Arteries of the scapular region(72)
- 图 104 肘前区和前臂前区的肌、血管及神经(I)(A、B) Muscles,blood vessels and nerves of the anterior cubital region and anterior antebrachial region (I)(A,B).....(73)
- 图 105 肘前区和前臂前区的肌、血管及神经(II)(A、B) Muscles,blood vessels and nerves of the anterior cubital region and anterior antebrachial region (II)(A,B)(74)
- 图 106 肘前区和前臂前区的肌、血管及神经(III) Muscles,blood vessels and nerves of the anterior cubital region and anterior antebrachial region(III).....(75)
- 图 107 前臂前区的肌(A、B) Muscles of the anterior antebrachial region (A,B).....(76)
- 图 108 旋前和旋后的肌(A.后面观, B.前面观) Muscles of the pronation and supination (A.posterior aspect,B.anterior aspect)(77)
- 图 109 前臂后区的肌、血管和神经(A、B、C) Muscles,blood vessels and nerves of the posterior antebrachial region(A,B,C)(78)
- 图 110 手掌部浅层 Superficial layer of the palm of hand.....(79)
- 图 111 手掌深部(I) Deep layer of the palm of hand (I)(79)
- 图 112 手掌深部(II)(A、B) Deep layer of the palm of hand (II)(A,B)(80)
- 图 113 手掌深部(III) Deep layer of the palm of hand (III)(81)
- 图 114 手背的血管和神经(A,B) Blood vessels and nerves of the dorsum of hand(A,B).....(82)
- 图 115 手背的血管 Blood vessels of the dorsum of hand(83)
- 图 116 手肌(A、B、C、D) Muscles of hand(A,B,C,D)(84)
- 图 117 臂中部横断面 Transverse section through the middle of upper arm(85)
- 图 118 前臂中部横断面 Transverse section through the middle of forearm.....(85)

图 119	手的横断面 Transverse section of hand	(86)
图 120	手指屈肌腱 Tendons of flexor digitorum	(86)
第4章 胸部 CHAPTER 4 THE THORAX (87)		
图 121	呼吸系统概观 General arrangement of respiratory system	(88)
图 122	女性乳房 Female breast	(89)
图 123	胸前壁(内面观) Anterior thoracic wall(internal aspect)	(89)
图 124	膈(胸腔面) Diaphragm(thoracic surface)	(90)
图 125	肋间神经和血管 Intercostal nerves and blood vessels	(90)
图 126	心于原位(前面观) Heart in situ(anterior aspect)	(91)
图 127	纵隔(右侧面观) Mediastinum(left lateral aspect)	(92)
图 128	纵隔(右侧面观) Mediastinum(right lateral aspect)	(93)
图 129	头臂静脉、主动脉弓和右肺动脉 Brachiocephalic vein, arch of aorta and right pulmonary artery	(94)
图 130	上纵隔和后纵隔 Superior mediastinum and posterior mediastinum	(95)
图 131	奇静脉和胸导管 Azygos vein and thoracic duct	(96)
图 132	浆膜心包 Serous pericardium	(97)
图 133	冠状动脉和心的静脉(I) Coronary arteries and cardiac vein(I)	(97)
图 134	冠状动脉和心的静脉(II) Coronary arteries and cardiac vein(II)	(98)
图 135	冠状动脉和心的静脉(III) Coronary arteries and cardiac vein(III)	(98)
图 136	肺动脉半月瓣和肺动脉窦 Semilunar cusp of pulmonary valve and sinus of pulmonary trunk	(99)
图 137	右心室 Right ventricle	(99)
图 138	二尖瓣(左房室瓣) Mitral valve(left atrioventricular valve)	(100)
图 139	主动脉瓣和主动脉窦 Mitral valve and aortic sinuses	(100)
图 140	心的瓣膜(I) Valves of heart(I)	(101)
图 141	心的瓣膜(II) Valves of heart(II)	(101)
图 142	右肺(A. 外侧面观, B. 内侧面观) Right lung(A. lateral aspect, B. medial aspect)	(102)
图 143	左肺(A. 外侧面观, B. 内侧面观) Left lung(A. lateral aspect, B. medial aspect)	(103)
图 144	左肺支气管肺段(A. 外侧面观, B. 内侧面观) Bronchopulmonary segments of left lung(A. lateral aspect, B. medial aspect)	(104)
图 145	右肺支气管肺段(A. 外侧面观, B. 内侧面观) Bronchopulmonary segment of right lung(A. lateral aspect, B. medial aspect)	(105)
图 146	经肺动脉分叉平面横断面 The section at the level of the bifurcation of pulmonary trunk on transverse	(106)
图 147	经心长轴斜切面 The section at the long axis of the heart on oblique	(106)
图 148	经腹盆正中矢状切面 Sagittal section through the abdomen and pelvis in median plane	(107)
图 149	经齿突冠状断面 Coronal section through the level of the dens of axis(C2)	(108)

图 150	消化系统概观 General arrangement of the digestive apparatus	(110)
图 151	腹部皮下静脉(I) Abdominal subcutaneous veins(I)	(110)
图 152	腹部皮下静脉(II) Abdominal subcutaneous viens(II)	(111)
图 153	腹股沟区的腹壁层次 Layers of abdominal wall of the inguinal region	(111)
图 154	腹前外侧壁肌层 Musculature of the anterolateral abdominal wall	(112)
图 155	腹前外侧壁的神经和血管 Nerves and blood vessels of anterolateral wall of abdomen	(113)
图 156	腹股沟管(I) Inguinal canal(I)	(114)
图 157	腹股沟管(II) Inguinal canal(II)	(114)
图 158	腹前壁后面观(左) Posterior aspect of the anterior abdominal wall(left)	(115)
图 159	膈(下面观) Diaphragm(inferior aspect)	(115)
图 160	腹膜的配布(I) Arrangement of the peritoneum(I)	(116)
图 161	腹膜的配布(II) Arrangement of the peritoneum(II)	(117)
图 162	网膜 Omenta	(118)
图 163	网膜囊 Omental bursa	(118)
图 164	胃(I) Stomach(I)	(119)
图 165	胃(II) Stomach(II)	(119)
图 166	胃的神经、动脉 Nerves and arteries of stomach	(120)
图 167	胃的动脉 Arteries of stomach	(120)
图 168	腹腔动脉干及胰 Celiac trunk and pancreas	(121)
图 169	胰头及十二指肠的动脉 Arteries of the head of pancreas and duodenum	(121)
图 170	胰的动脉 Arteries of the pancreas	(122)
图 171	脾 Spleen	(122)
图 172	肝(脏面) Liver (visceral surface)	(123)
图 173	肝(上面观) Liver (superior aspect)	(123)
图 174	肝内的血管和胆管 The blood vessels and bile ducts in the liver	(124)
图 175	肝外胆道 Extrahepatic bile ducts	(124)
图 176	幽门平面横断面 Transverse section at level of pylorus	(125)
图 177	肠系膜上动脉 Superior mesenteric artery	(126)
图 178	回结肠动脉 Ileocolic artery	(126)
图 179	肠系膜下动脉 Inferior mesenteric artery	(127)
图 180	回盲部结构 Caecal region	(127)
图 181	消化管的一般结构 Layers of alimentary canal	(127)
图 182	肝门静脉 Hepatic portal vein	(128)
图 183	男性泌尿生殖器官 Organs of urogenital system of the male	(129)
图 184	肾(冠状切面) Kidney(coronal section)	(130)
图 185	肾(小叶) Kidney(renal lobes)	(130)
图 186	肾盏及肾盂 Renal calices and pelvis	(130)

图 187	肾上腺的动脉 Arteries of suprarenal gland	(131)
图 188	副肾动脉及双输尿管 Accessory renal artery and double ureter	(131)
图 189	马蹄肾 Horseshoe kidney	(131)
图 190	肾后面毗邻 Posterior relationship of kidney	(132)
图 191	腰静脉和腰动脉 Lumbar arteries and veins	(132)
图 192	腹后隙的血管和神经 Blood vessels and nerves in the retroperitoneal space	(133)
图 193	腹后隙的神经 Nerves in the retroperitoneal space	(134)
第6章 盆部与会阴 CHAPTER 6 THE PELVIS AND PERINEUM (135)		
图 194	男性盆部(上面观) Pelvis of the male(superior aspect)	(136)
图 195	男性盆部(正中矢状剖面) The pelvis of the male(median sagittal section)	(137)
图 196	男性盆腔(左侧面观) The pelvic cavity of the male(left lateral aspect)	(137)
图 197	男性盆部的动脉(上面观) Arteries of the pelvis of the male(superior aspect)	(138)
图 198	男性盆部的动脉(左侧面观) Arteries of the pelvis of the male(left lateral aspect)	(138)
图 199	男性盆部的神经(上面观) Nerves of the pelvis of the male(superior aspect)	(139)
图 200	男性膀胱(内面观) The male urinary bladder(internal aspect)	(140)
图 201	男性膀胱和生殖腺 The male urinary and genital glands	(140)
图 202	前列腺和精囊(后面观) The prostate and seminal vesicle(posterior aspect)	(141)
图 203	直肠(内面观) The rectum(internal aspect)	(141)
图 204	男性膀胱底(后面观) Fundus of the male urinary bladder(posterior aspect)	(142)
图 205	肛提肌(上面观) Levator ani(superior aspect)	(143)
图 206	女性盆部(正中矢状剖面)(I) The pelvis of the female (median sagittal section)(I)	(144)
图 207	女性盆部(正中矢状剖面)(II) The pelvis of the female (median sagittal section)(II)	(144)
图 208	女性内生殖器(膀胱面) Internal genital organs of the female(vesical surface)	(145)
图 209	女性盆部的动脉(上面观) Arteries of the female pelvis(superior aspect)	(146)
图 210	男性会阴浅隙和坐骨肛门窝(I) Superficial perineal space and ischioanal fossa of the male(I)	(147)
图 211	男性会阴浅隙和坐骨肛门窝(II) Superficial perineal space and ischioanal fossa of the male(II)	(148)
图 212	男性会阴深隙及坐骨肛门窝 Deep perineal space and ischioanal fossa of the male	(149)
图 213	睾丸和精索被膜 Testis and tunicae of spermatic cord	(150)
图 214	阴茎(A.尿道面, B.阴茎背) Penis(A.urethral surface,B.dorsum penis)	(150)
图 215	女性外生殖器(I) External genital organs of the female(I)	(151)
图 216	女性外生殖器(II) External genital organs of the female(II)	(151)
图 217	女性会阴浅隙及坐骨肛门窝(I) Superficial perineal space and	

	ischioanal fossa of the female(I).....	(151)
图 218	女性会阴浅隙及坐骨肛门窝(II) Superficial perineal space and ischioanal fossa of the female(II).....	(152)
第7章 颈部 CHAPTER 7 THE NECK (153)		
图 219	颈部三角 Traingle of cervical region	(154)
图 220	颈阔肌侧面观 Lateral aspect of platysma	(154)
图 221	颈前区浅层结构 Superficial structures of the anterior cervical region	(155)
图 222	颈阔肌前面观 Anterior aspect of platysma	(155)
图 223	颈深筋膜浅层 Superficial layer of cervical deep fascia.....	(156)
图 224	颈丛和颈浅静脉 Cervical plexus and superficial jugular veins	(156)
图 225	颈丛及其分支 Cervical plexus and it's branches.....	(157)
图 226	颈部浅静脉 Superficial veins of cervical region	(157)
图 227	第七颈椎间盘横切面 Transverse section at level of seventh cervical vertebral disc.....	(158)
图 228	甲状腺区前面观 Anterior aspect of the region of thyroid	(159)
图 229	颈浅静脉 Superficial cervical veins.....	(159)
图 230	颈部右侧面的肌、血管和神经(I) Muscles,blood vessels and nerves of the right lateral aspect of the neck(I).....	(160)
图 231	颈部右侧面的肌、血管和神经(II) Muscles,blood vessels and nerves of the right lateral aspect of the neck(II).....	(161)
图 232	颈部右侧面的肌、血管和神经(III) Muscles,blood vessels and nerves of the right lateral aspect of the neck(III).....	(162)
图 233	颈深部血管和神经 Deep blood vessels and nerves of the neck	(163)
图 234	椎动脉和颈椎前面观 Anterior aspect of vertebral artery and cervical vertebrae.....	(164)
图 235	椎动脉和颈椎侧面观 Lateral aspect of vertebral artery and cervical vertebrae.....	(164)
图 236	甲状腺区后面观 Posterior aspect of the region of thyroid gland.....	(165)
图 237	喉软骨前、后面观 Anterior and posterior aspect of the cartilages of larynx.....	(166)
图 238	喉的软骨和韧带(I) Cartilages and ligaments of larynx(I).....	(166)
图 239	喉右侧面观 Right lateral aspect of larynx.....	(167)
图 240	喉肌后面观 Posterior aspect of muscles of larynx.....	(167)
图 241	喉的软骨和韧带(II) Cartilages and ligaments of larynx(II).....	(168)
图 242	喉腔后面观 Posterior aspect of the cavity of larynx.....	(168)
第8章 头部 CHAPTER 8 THE HEAD..... (169)		
图 243	头颈的肌、血管和神经(I) Muscles,blood vessels and nerves of the head and neck(I).....	(170)
图 244	头颈的肌、血管和神经(II) Muscles,blood vessels and nerves of the head and neck(II).....	(171)

第

章

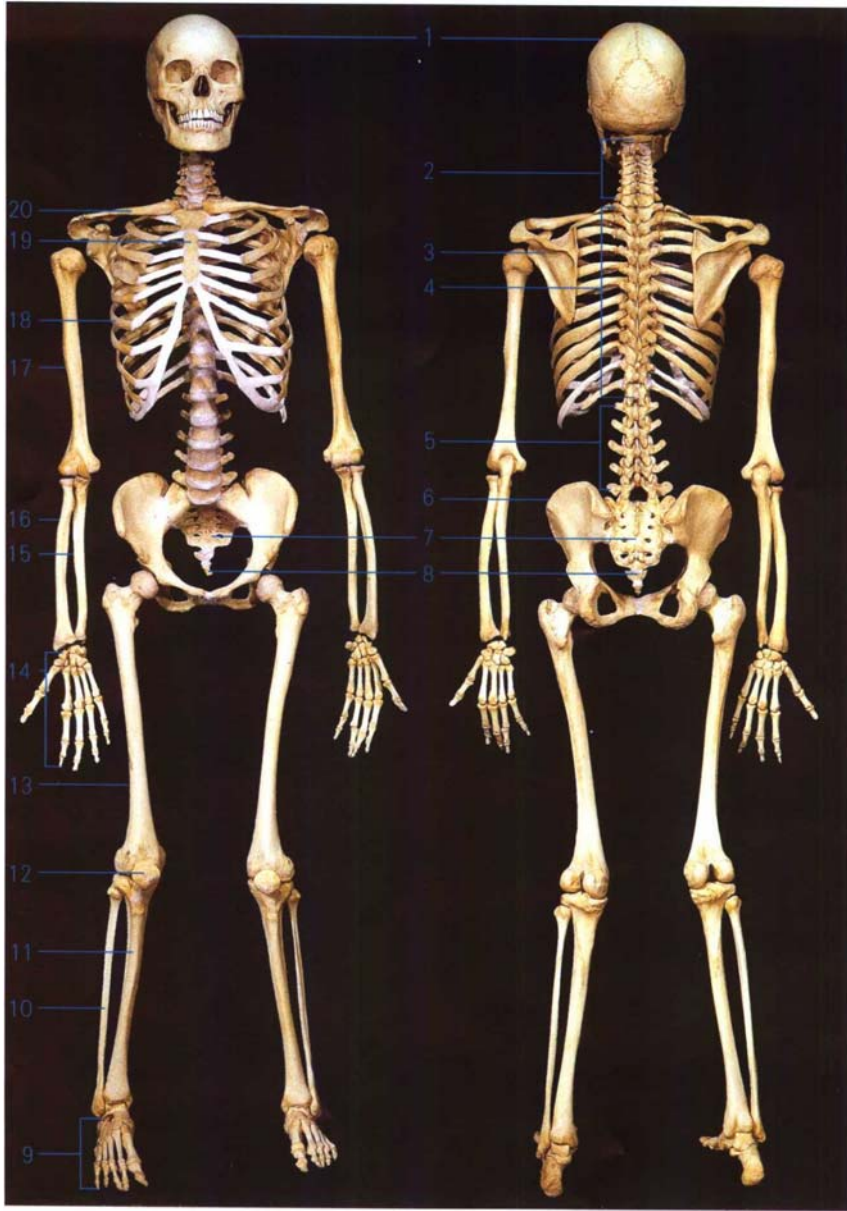1

运动系统

CHAPTER 1 THE LOCOMOTOR SYSTEM



PRACTICE COLOUR ATLAS OF HUMAN ANATOMY

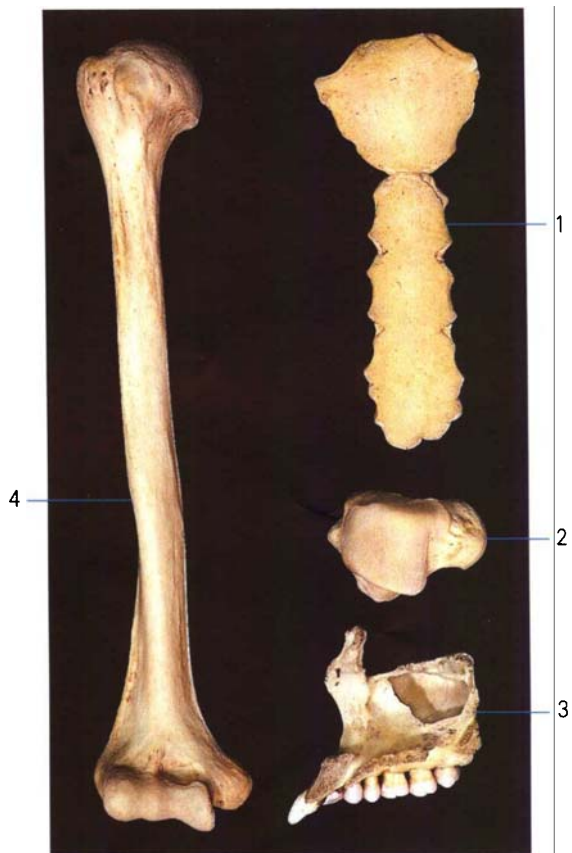


前面观

后面观

图1 全身骨骼(前和后面观)
The skeleton(anterior and posterior aspect)

- | | | | | | |
|--------|--------------------|--------|---------------|--------|----------|
| 1. 颅骨 | cranial bones | 8. 尾骨 | coccyx | 15. 尺骨 | ulna |
| 2. 颈椎 | cervical vertebrae | 9. 足骨 | bones of foot | 16. 桡骨 | radius |
| 3. 肩胛骨 | scapula | 10. 腓骨 | fibula | 17. 肱骨 | humerus |
| 4. 胸椎 | thoracic vertebrae | 11. 胫骨 | tibia | 18. 肋 | ribs |
| 5. 腰椎 | lumbar vertebrae | 12. 髌骨 | patella | 19. 胸骨 | sternum |
| 6. 髌骨 | hip bone | 13. 股骨 | femur | 20. 锁骨 | clavicle |
| 7. 骶骨 | sacrum | 14. 手骨 | bones of hand | | |



- 1. 扁骨 flat bone
- 2. 短骨 short bone
- 3. 不规则骨 irregular bone
- 4. 长骨 long bone

图2 骨的分类
Classification of bones

- a. 股骨上端剖面 The upper part of the femur section
- b. 跟骨剖面 Section of the calcaneus
- c. 顶骨剖面 Section of the parietal bone
- d. 椎骨剖面 Section of the vertebral

- 1. 松质 Spongy
- 2. 密质 compact
- 3. 骨髓 bone marrow
- 4. 骨膜 periosteum
- 5. 关节软骨 articular cartilage
- 6. 外板 outer plate
- 7. 板障 diploe
- 8. 内板 inner plate

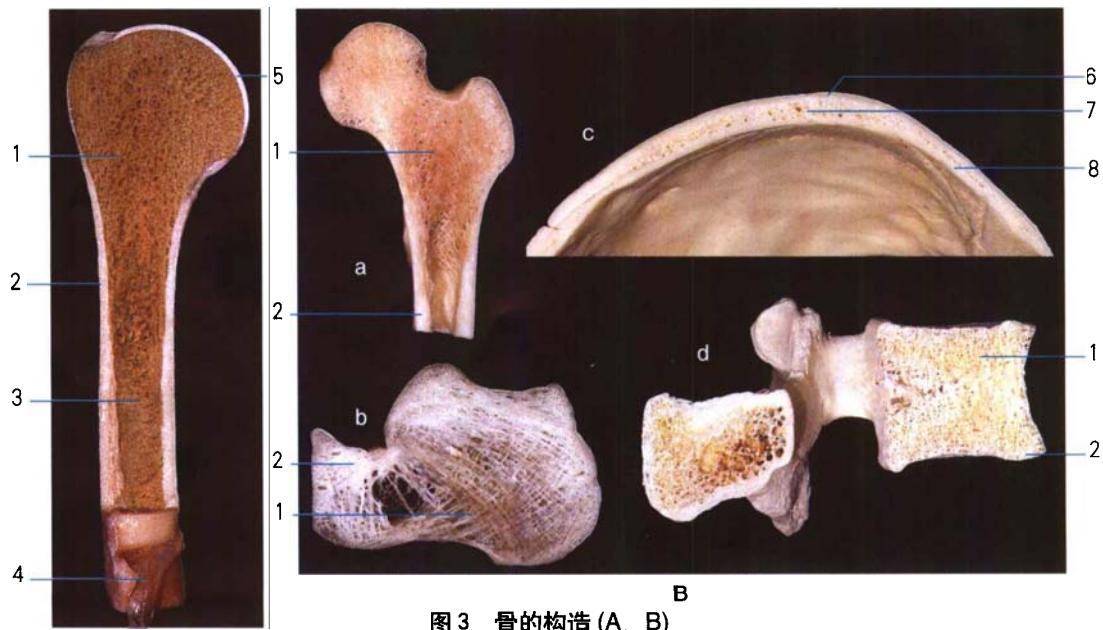


图3 骨的构造 (A, B)
Structure of the bone (A, B)

第

章

1

运动系统

CHAPTER 1 THE LOCOMOTOR SYSTEM



PRACTICE COLOUR ATLAS OF HUMAN ANATOMY

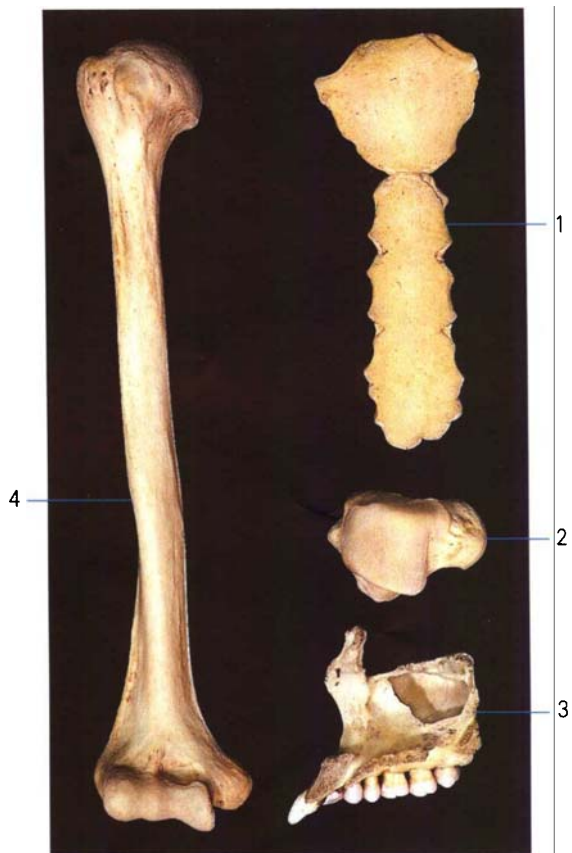


前面观

后面观

图1 全身骨骼(前和后面观)
The skeleton(anterior and posterior aspect)

- | | | | | | |
|--------|--------------------|--------|---------------|--------|----------|
| 1. 颅骨 | cranial bones | 8. 尾骨 | coccyx | 15. 尺骨 | ulna |
| 2. 颈椎 | cervical vertebrae | 9. 足骨 | bones of foot | 16. 桡骨 | radius |
| 3. 肩胛骨 | scapula | 10. 腓骨 | fibula | 17. 肱骨 | humerus |
| 4. 胸椎 | thoracic vertebrae | 11. 胫骨 | tibia | 18. 肋 | ribs |
| 5. 腰椎 | lumbar vertebrae | 12. 髌骨 | patella | 19. 胸骨 | sternum |
| 6. 髌骨 | hip bone | 13. 股骨 | femur | 20. 锁骨 | clavicle |
| 7. 骶骨 | sacrum | 14. 手骨 | bones of hand | | |



- 1. 扁骨 flat bone
- 2. 短骨 short bone
- 3. 不规则骨 irregular bone
- 4. 长骨 long bone

图2 骨的分类
Classification of bones

- a. 股骨上端剖面 The upper part of the femur section
- b. 跟骨剖面 Section of the calcaneus
- c. 顶骨剖面 Section of the parietal bone
- d. 椎骨剖面 Section of the vertebral

- 1. 松质 Spongy
- 2. 密质 compact
- 3. 骨髓 bone marrow
- 4. 骨膜 periosteum
- 5. 关节软骨 articular cartilage
- 6. 外板 outer plate
- 7. 板障 diploe
- 8. 内板 inner plate

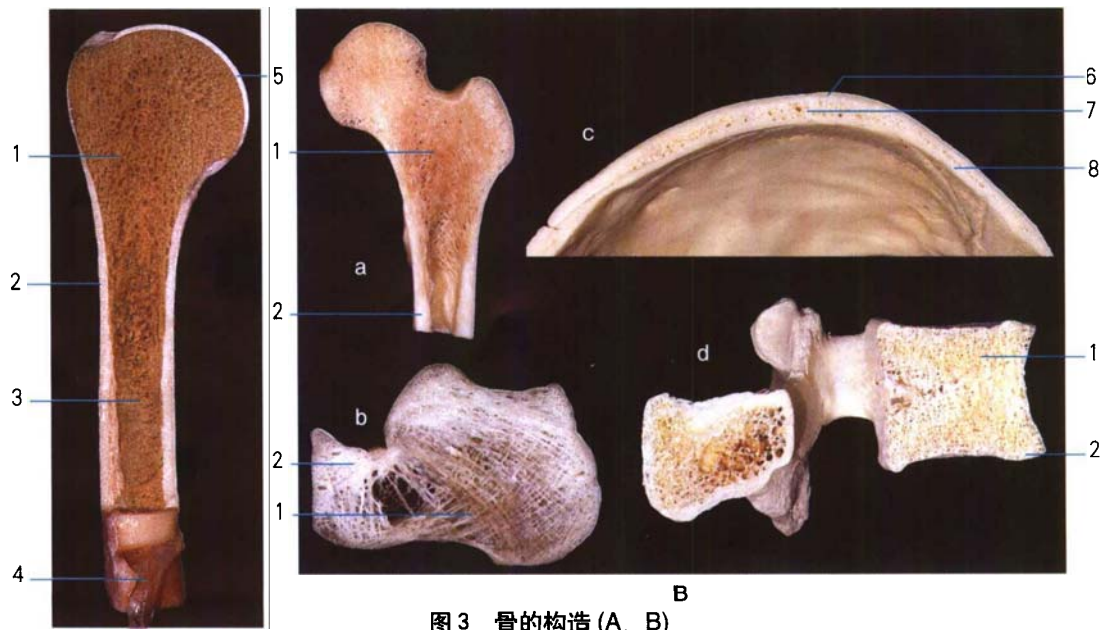


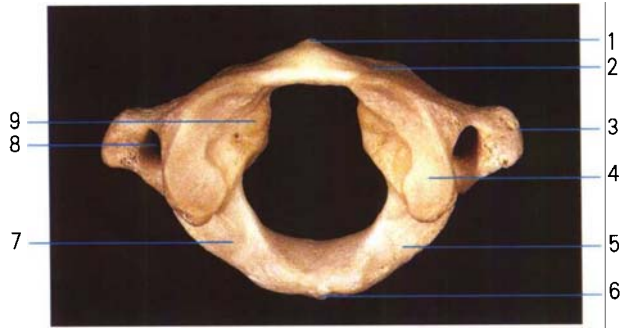
图3 骨的构造 (A, B)
Structure of the bone(A,B)

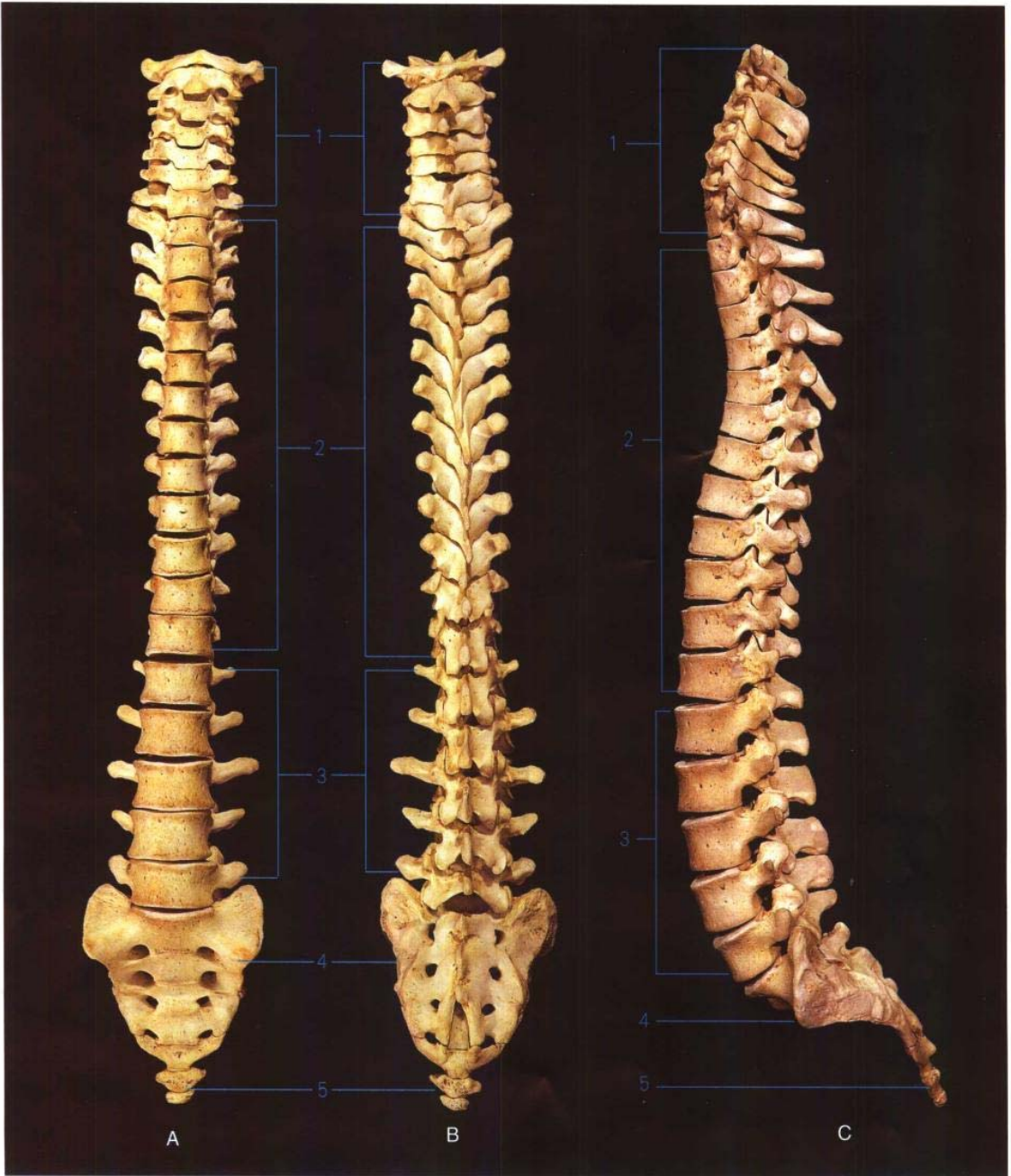

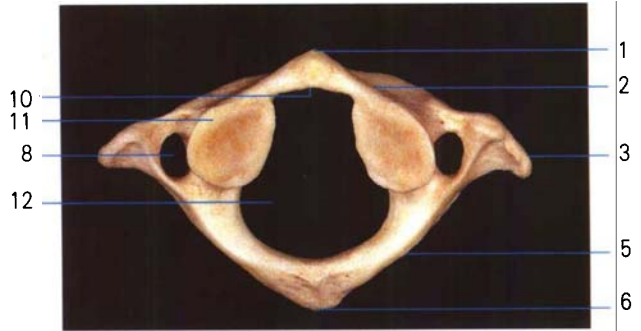
图4 脊柱(A、B、C)
The vertebral column(A,B,C)

- | | | | |
|--------|--------------------|-------|--------------------|
| A. 前面观 | Anterior aspect | 2. 胸椎 | thoracic vertebrae |
| B. 后面观 | Posterior aspect | 3. 腰椎 | lumbar vertebrae |
| C. 侧面观 | Lateral aspect | 4. 骶骨 | sacrum |
| 1. 颈椎 | cervical vertebrae | 5. 尾骨 | coccyx |

1. 前结节 anterior tubercle
2. 前弓 anterior arch
3. 横突 transverse process
4. 上关节凹 superior articular fovea
5. 后弓 posterior arch
6. 后结节 posterior tubercle
7. 椎动脉沟 groove for vertebral a.
8. 横突孔 transverse foramen
9. 侧块 lateral mass
10. 齿突凹 dental fovea
11. 下关节凹 inferior articular fovea
12. 椎孔 Vertebral foramen



上面观



下面观

图5 寰椎(上和下面观)
The atlas(superior and inferior aspect)

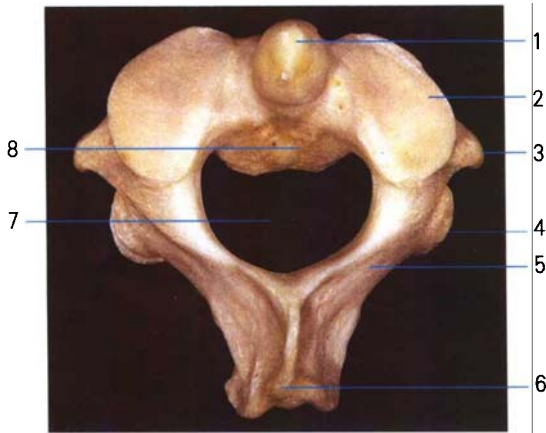


图6 枢椎(上面观)
The axis(superior aspect)

1. 齿突 dens
2. 上关节面 superior articular surface
3. 横突 transverse process
4. 下关节突 inferior articular process
5. 椎弓 vertebral arch
6. 棘突 spinous process
7. 椎孔 vertebral foramen
8. 椎体 vertebral body

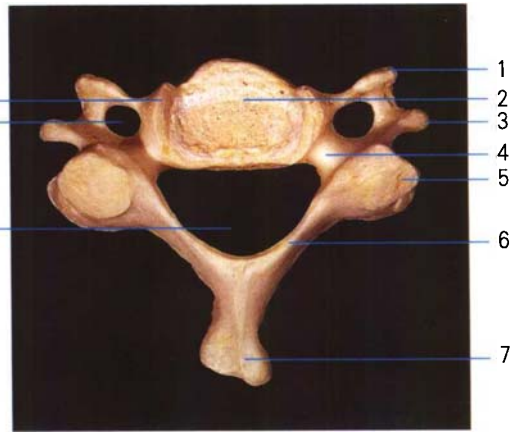


图7 颈椎(上面观)
A cervical vertebra(superior aspect)

1. 前结节 anterior tubercle
2. 椎体 vertebral body
3. 后结节 posterior tubercle
4. 椎弓根 pedicle of vertebral arch
5. 上关节突 superior articular process
6. 椎弓 vertebral arch
7. 棘突 spinous process
8. 椎孔 vertebral foramen
9. 横突孔 transverse foramen
10. 椎体钩 uncus of vertebral body

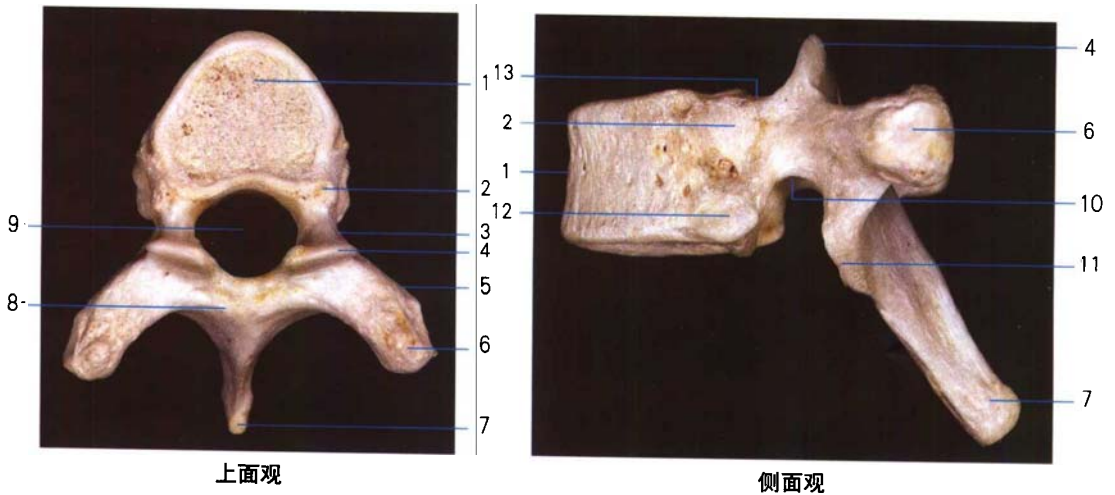


图8 胸椎(上和侧面观)
A thoracic vertebra(superior and lateral aspect)

- | | |
|------------------------------------|-------------------------------------|
| 1. 椎体 vertebral body | 8. 椎弓板 lamina of vertebral arch |
| 2. 上肋凹 superior costal fovea | 9. 椎孔 vertebral foramen |
| 3. 椎弓根 pedicle of vertebral arch | 10. 椎下切迹 inferior vertebral notch |
| 4. 上关节突 superior articular process | 11. 下关节突 inferior articular process |
| 5. 横突 transverse process | 12. 下肋凹 inferior costal fovea |
| 6. 横突肋凹 transverse costal fovea | 13. 椎上切迹 superior vertebral notch |
| 7. 棘突 spinous process | |

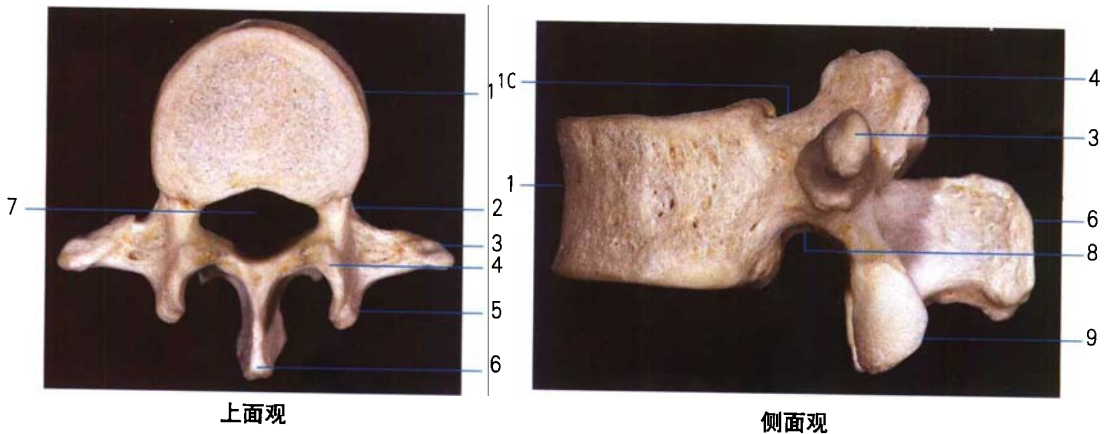


图9 腰椎(上和侧面观)
A lumbar vertebra(superior and lateral aspect)

- | | |
|------------------------------------|------------------------------------|
| 1. 椎体 vertebral body | 6. 棘突 spinous process |
| 2. 椎弓根 pedicle of vertebral arch | 7. 椎孔 vertebral foramen |
| 3. 横突 transverse process | 8. 椎下切迹 inferior vertebral notch |
| 4. 上关节突 superior articular process | 9. 下关节突 inferior articular process |
| 5. 乳突 mamillary process | 10. 椎上切迹 superior vertebral notch |

1. 上关节突 superior articular process
2. 岬 promontory
3. 骶翼 ala of sacrum
4. 骶前孔 anterior sacrum foramen
5. 横线 transverse line
6. 骶骨尖 apex of sacrum
7. 尾骨角 coccygeal cornu

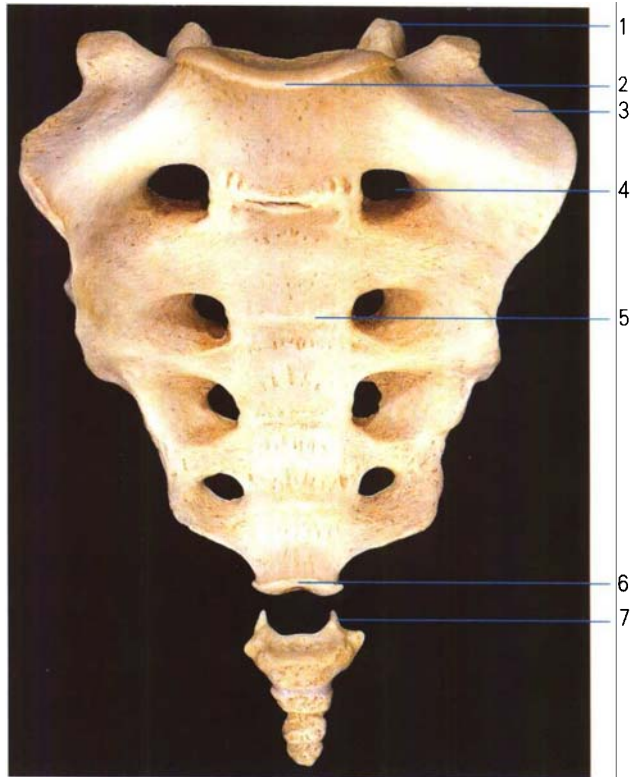
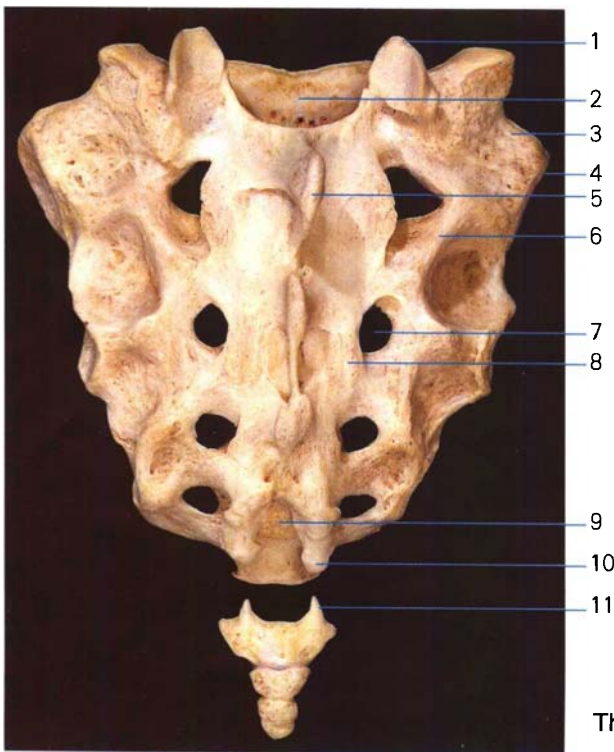
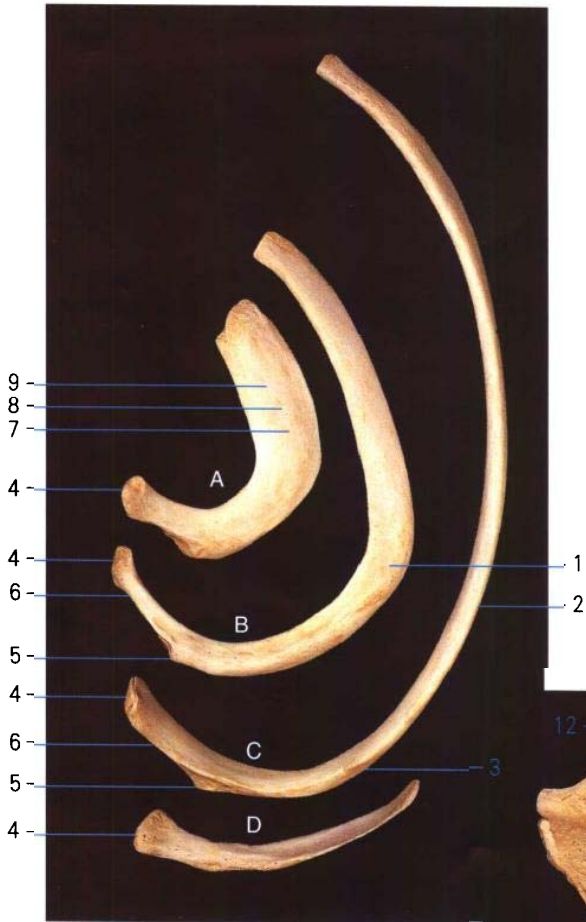


图10 骶骨和尾骨(前面观)
The sacrum and coccyx(anterior aspect)



1. 上关节突 superior articular process
2. 骶管 sacral canal
3. 骶粗隆 sacral trberosity
4. 耳状面 auricular surface
5. 骶正中嵴 median sacral crest
6. 骶外侧嵴 lateral sacral crest
7. 骶后孔 posterior sacral foramen
8. 骶中间嵴 intermediate sacral crest
9. 骶管裂孔 sacral hiatus
10. 骶角 sacral cornu
11. 尾骨角 coccygeal cornu

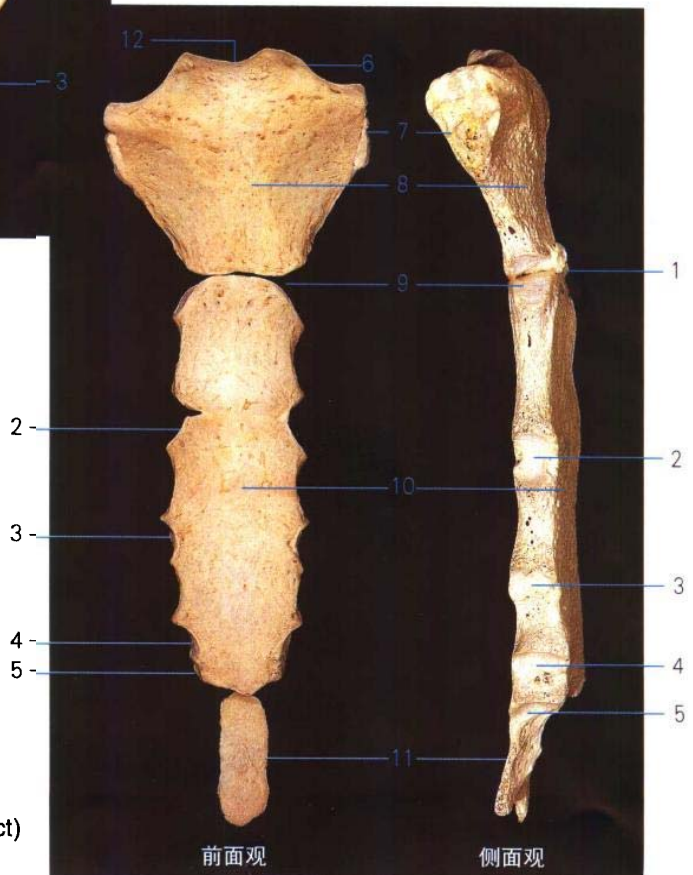
图11 骶骨和尾骨(后面观)
The sacrum and coccyx(posterior aspect)



1. 前锯肌粗隆 tuberosity for serratus anterior
2. 肋体 shaft of rib
3. 肋角 costal angle
4. 肋头 costal head
5. 肋结节 costal tubercle
6. 肋颈 costal neck
7. 锁骨下动脉沟 sulcus for subclavian a.
8. 前斜角肌结节 tubercle for scalenus anterior
9. 锁骨下静脉沟 sulcus for subclavian v.

图 12 第一(A)、二(B)、六(C)、十二(D)肋骨(上面观)
The 1st(A), 2nd(B), 6th(C), 12th(D) ribs (superior aspect)

1. 胸骨角 sternal angle
2. 第三肋切迹 3rd costal notch
3. 第四肋切迹 4th costal notch
4. 第五肋切迹 5th costal notch
5. 第六、七肋切迹 6,7th costal notches
6. 锁切迹 clavicular notch
7. 第一肋切迹 1st costal notch
8. 胸骨柄 sternal manubrium
9. 第二肋切迹 2nd costal notch
10. 胸骨体 sternal body
11. 剑突 xiphoid process
12. 颈静脉切迹 jugular notch



前面观

侧面观

图 13 胸骨(前和侧面观)
The sternum (anterior and lateral aspect)

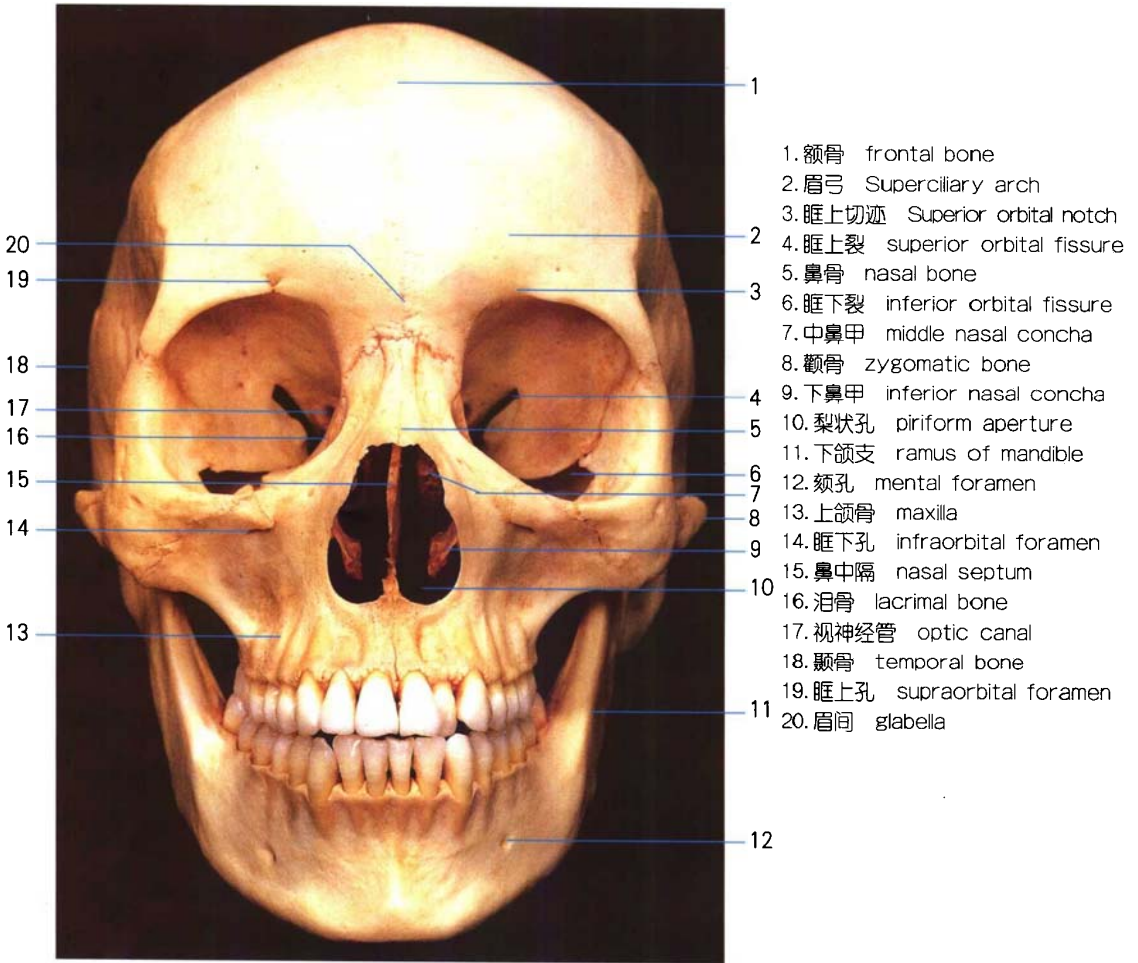


图 14 颅(前面观)
The skull(anterior aspect)

- 1. 枕骨 occipital bone
- 2. 顶孔 parietal foramen
- 3. 顶骨 parietal bone
- 4. 额骨 frontal bone
- 5. 冠状缝 coronal suture
- 6. 矢状缝 sagittal suture
- 7. 人字缝 lambdoid suture

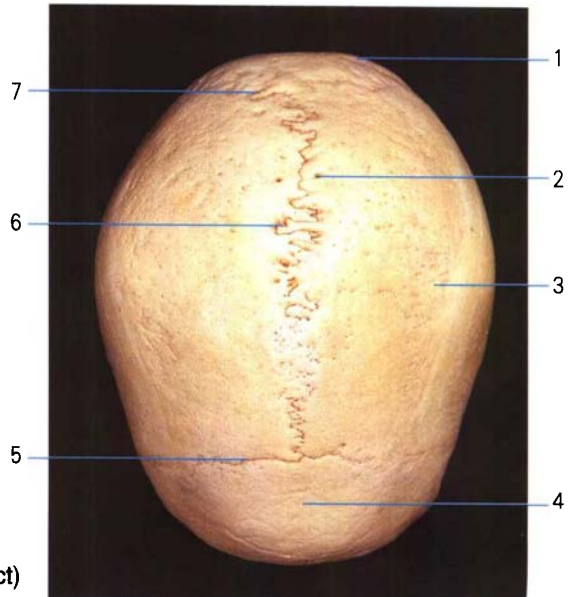


图 15 颅(上面观)
The skull(superior aspect)

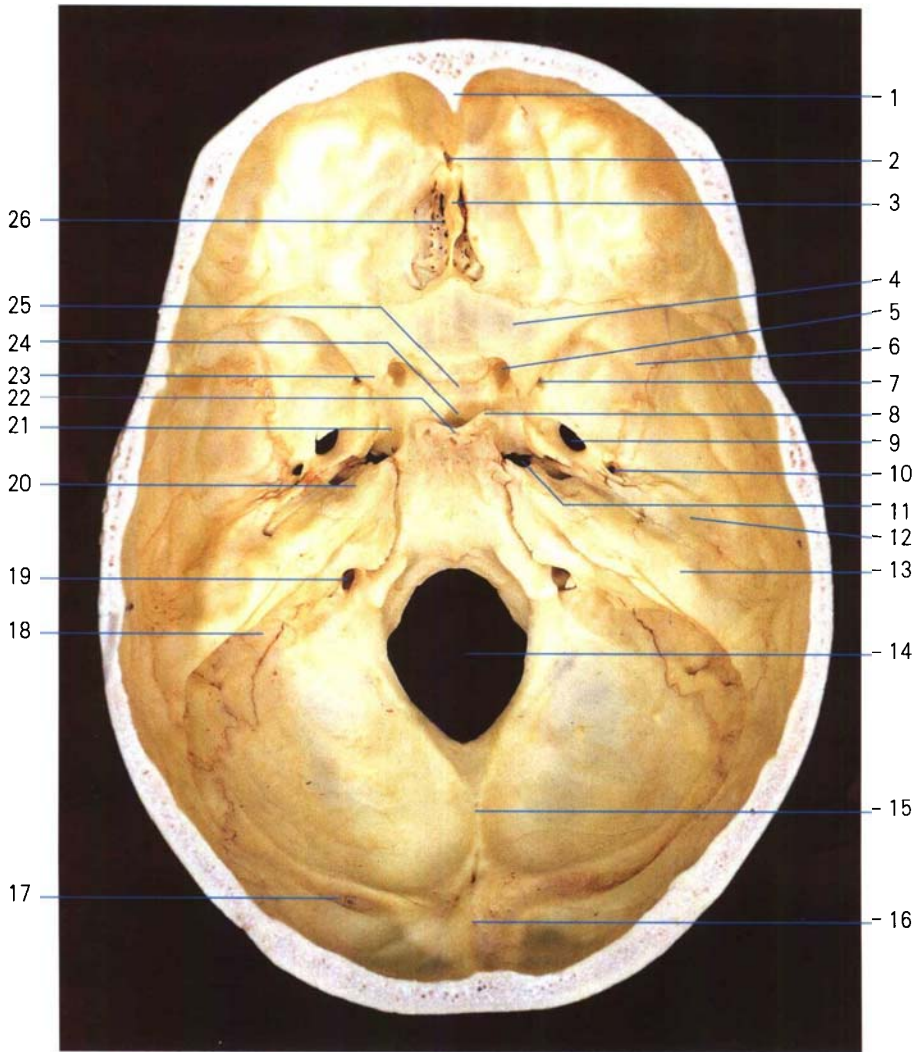


图 17 颅底内面观

The internal aspect of the base of the skull

- | | |
|----------------------------------|--|
| 1. 额峭 frontal crest | 14. 枕骨大孔 foramen magnum |
| 2. 盲孔 foramen caecum | 15. 枕内峭 internal occipital crest |
| 3. 鸡冠 crista galli | 16. 枕内隆凸 internal occipital protuberance |
| 4. 小翼 lesser wing | 17. 横窦沟 sulcus for transverse sinus |
| 5. 视神经管 optic canal | 18. 乙状窦沟 sulcus for sigmoid sinus |
| 6. 大翼 greater wing | 19. 颈静脉孔 jugular foramen |
| 7. 圆孔 foramen rotundum | 20. 三叉神经压迹 trigeminal impression |
| 8. 后床突 posterior clinoid process | 21. 颈动脉沟 carotid sulcus |
| 9. 卵圆孔 foramen ovale | 22. 鞍背 dorsum sellae |
| 10. 棘孔 foramen spinosum | 23. 前床突 anterior clinoid process |
| 11. 破裂孔 foramen lacerum | 24. 垂体窝 hypophysial fossa |
| 12. 鼓室盖 tegmen tympani | 25. 交叉前沟 sulcus prechiasmaticus |
| 13. 弓状隆起 arcuata eminence | 26. 筛板 cribriform plate |

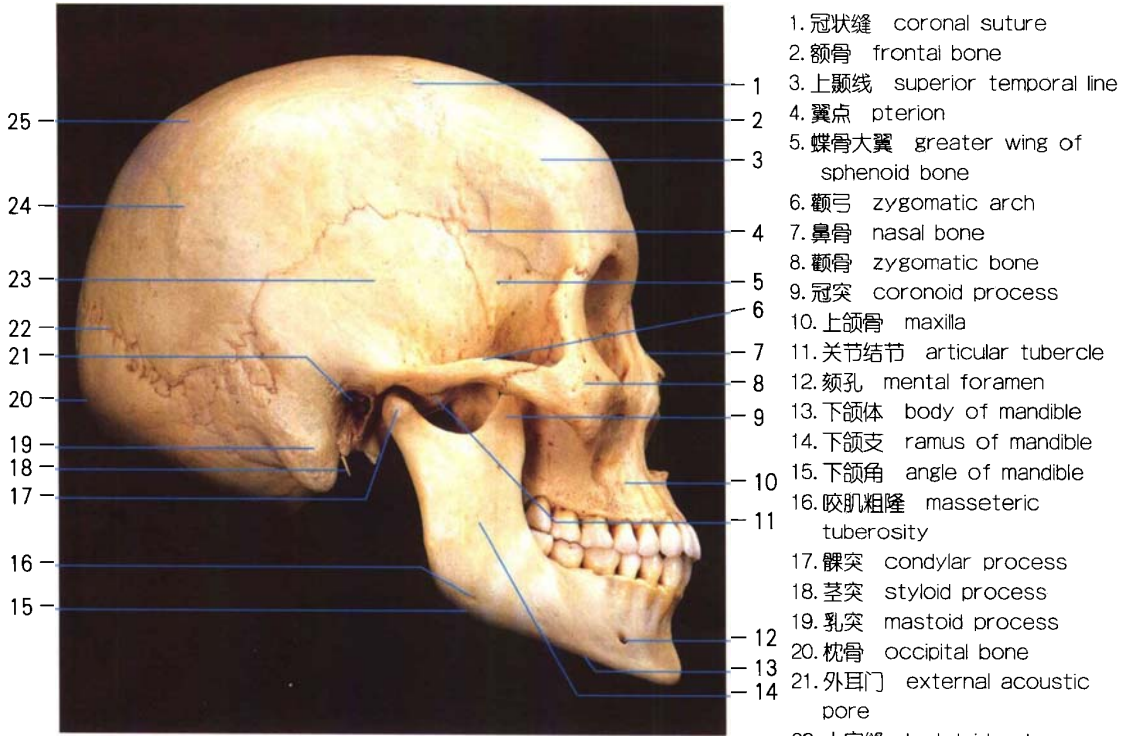
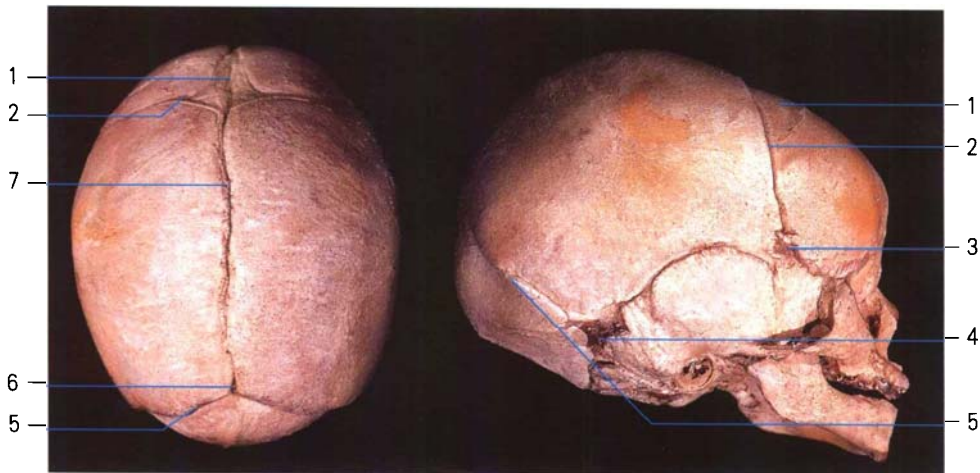


图 18 颅(侧面观)
The skull(lateral aspect)

1. 冠状缝 coronal suture
2. 额骨 frontal bone
3. 上颞线 superior temporal line
4. 翼点 pterion
5. 蝶骨大翼 greater wing of sphenoid bone
6. 颧弓 zygomatic arch
7. 鼻骨 nasal bone
8. 颧骨 zygomatic bone
9. 冠突 coronoid process
10. 上颌骨 maxilla
11. 关节结节 articular tubercle
12. 颏孔 mental foramen
13. 下颌体 body of mandible
14. 下颌支 ramus of mandible
15. 下颌角 angle of mandible
16. 咬肌粗隆 masseteric tuberosity
17. 髁突 condylar process
18. 茎突 styloid process
19. 乳突 mastoid process
20. 枕骨 occipital bone
21. 外耳门 external acoustic pore
22. 人字缝 lambdoid suture
23. 颞骨 temporal bone
24. 下颞线 inferior temporal line
25. 顶骨 parietal bone



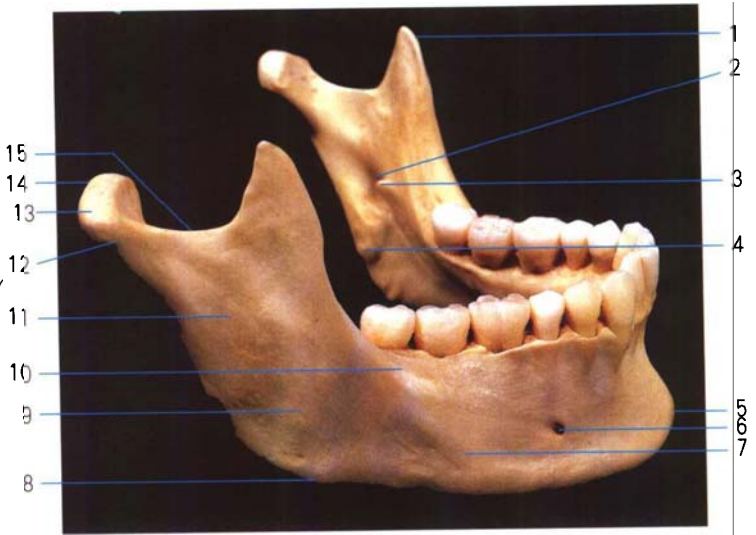
上面观

侧面观

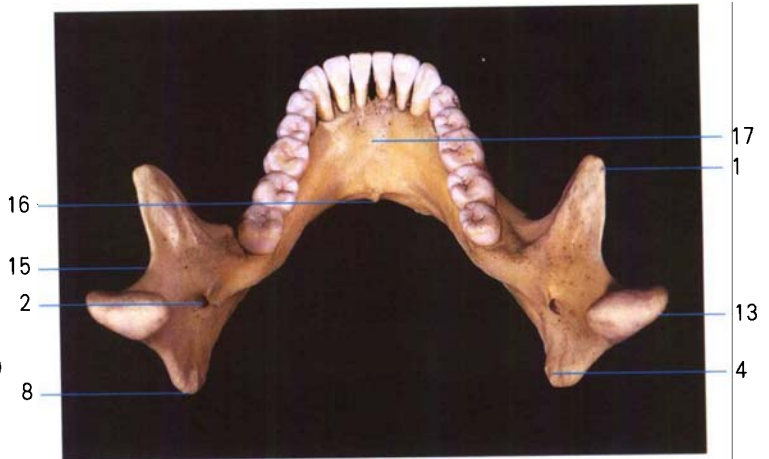图 19 婴儿颅(上面和侧面观)
The skull of a infant(superior and lateral aspect)

- | | |
|-----------------------------------|----------------------------|
| 1. 前囟 anterior fontanelle | 5. 人字缝 lambdoid suture |
| 2. 冠状缝 coronal suture | 6. 后囟 posterior fontanelle |
| 3. 前外侧囟 anterolateral fontanelle | 7. 矢状缝 sagittal suture |
| 4. 后外侧囟 posterolateral fontanelle | |

- 1.冠突 coronoid process
- 2.下颌孔 mandibular foramen
- 3.下颌小舌 mandibular lingula
- 4.翼肌粗隆 pterygoid tuberosity
- 5.颏隆凸 mental protuberance
- 6.颏孔 mental foramen
- 7.下颌体 body of mandible
- 8.下颌角 angle of mandible
- 9.咬肌粗隆 masseteric tuberosity
- 10.斜线 oblique line
- 11.下颌支 ramus of mandible
- 12.下颌颈 neck of mandible
- 13.下颌头 head of mandible
- 14.髁突 condylar process
- 15.下颌切迹 mandibular notch
- 16.颏棘 mental spine
- 17.舌下腺凹 sublingual fovea

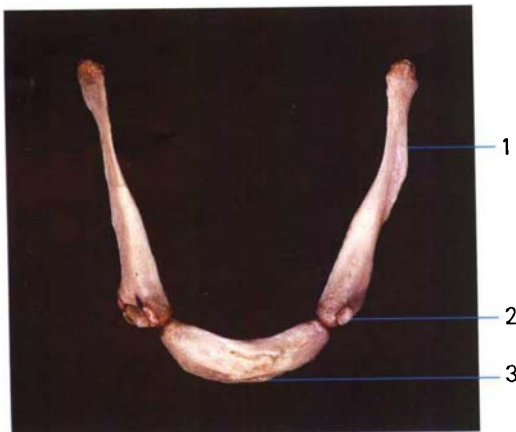

外侧面观



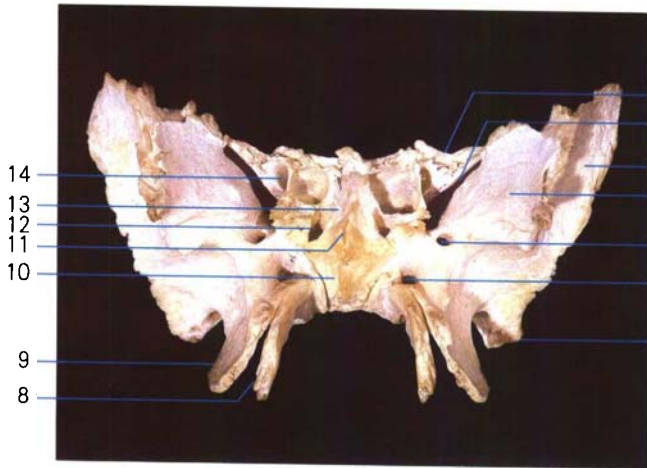
后面观

图20 下颌骨(外侧面和后面观)
The mandible(lateral and posterior aspect)



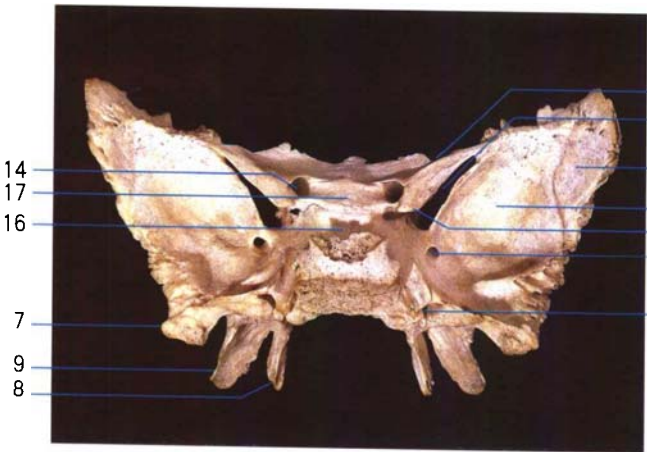
- 1.大角 greater horn
- 2.小角 lesser horn
- 3.舌骨体 body of hyoid bone

图21 舌骨(上面观)
The hyoid bone(superior aspect)



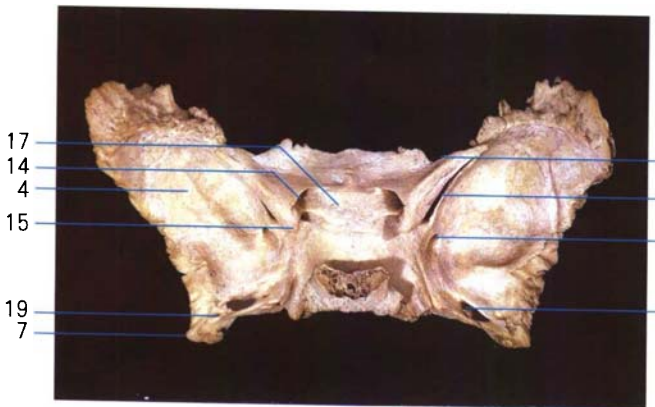
前面观

- 1 小翼 lesser wing
- 2 眶上裂 superior orbital fissure
- 3 大翼 greater wing
- 4 眶面 orbital surface
- 5 圆孔 foramen rotundum
- 6 翼管 pterygoid canal
- 7 蝶棘 spine of sphenoid bone
- 8 翼突内侧板 medial pterygoid plate
- 9 翼突外侧板 lateral pterygoid plate
- 10 体 body
- 11 蝶嵴 sphenoid crest
- 12 蝶窦口 aperture of sphenoidal sinus
- 13 蝶甲 sphenoidal concha
- 14 视神经管 optic canal
- 15 前床突 anterior clinoid process
- 16 垂体窝 hypophysial fossa
- 17 交叉前沟 sulcus prechiasmaticus
- 18 卵圆孔 foramen ovale
- 19 棘孔 foramen spinosum



后面观

- 1 小翼 lesser wing
- 2 眶上裂 superior orbital fissure
- 3 大翼 greater wing
- 4 眶面 orbital surface
- 5 圆孔 foramen rotundum
- 6 翼管 pterygoid canal
- 7 蝶棘 spine of sphenoid bone
- 8 翼突内侧板 medial pterygoid plate
- 9 翼突外侧板 lateral pterygoid plate
- 10 体 body
- 11 蝶嵴 sphenoid crest
- 12 蝶窦口 aperture of sphenoidal sinus
- 13 蝶甲 sphenoidal concha
- 14 视神经管 optic canal
- 15 前床突 anterior clinoid process
- 16 垂体窝 hypophysial fossa
- 17 交叉前沟 sulcus prechiasmaticus
- 18 卵圆孔 foramen ovale
- 19 棘孔 foramen spinosum

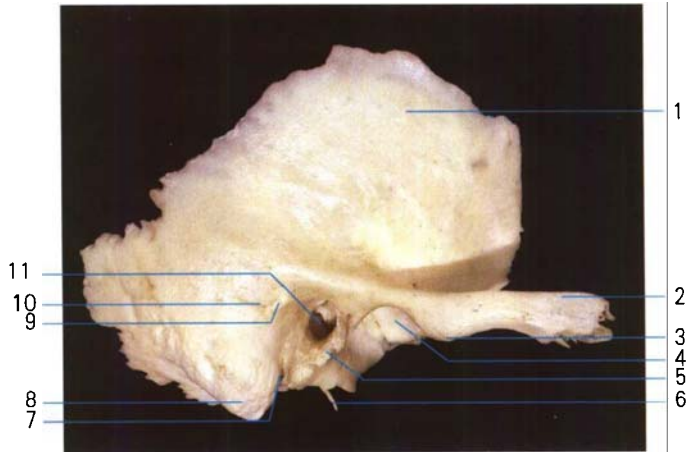


上面观

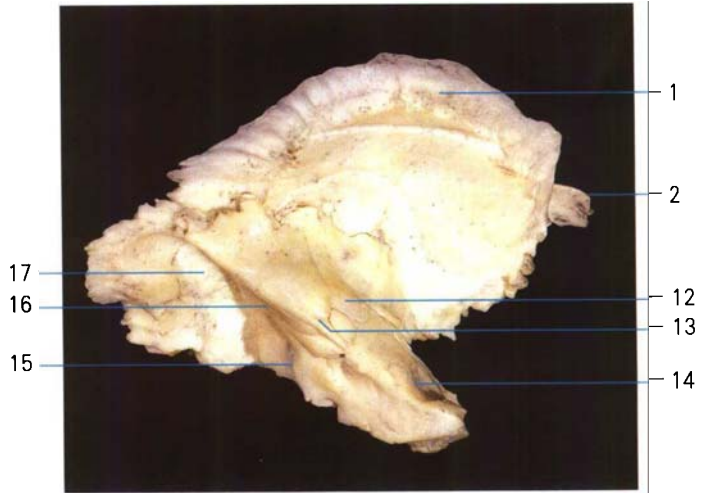
- 1 小翼 lesser wing
- 2 眶上裂 superior orbital fissure
- 3 大翼 greater wing
- 4 眶面 orbital surface
- 5 圆孔 foramen rotundum
- 6 翼管 pterygoid canal
- 7 蝶棘 spine of sphenoid bone
- 8 翼突内侧板 medial pterygoid plate
- 9 翼突外侧板 lateral pterygoid plate
- 10 体 body
- 11 蝶嵴 sphenoid crest
- 12 蝶窦口 aperture of sphenoidal sinus
- 13 蝶甲 sphenoidal concha
- 14 视神经管 optic canal
- 15 前床突 anterior clinoid process
- 16 垂体窝 hypophysial fossa
- 17 交叉前沟 sulcus prechiasmaticus
- 18 卵圆孔 foramen ovale
- 19 棘孔 foramen spinosum

图 22 蝶骨(前、后和上面观)
The sphenoid bone (anterior, posterior and superior aspect)

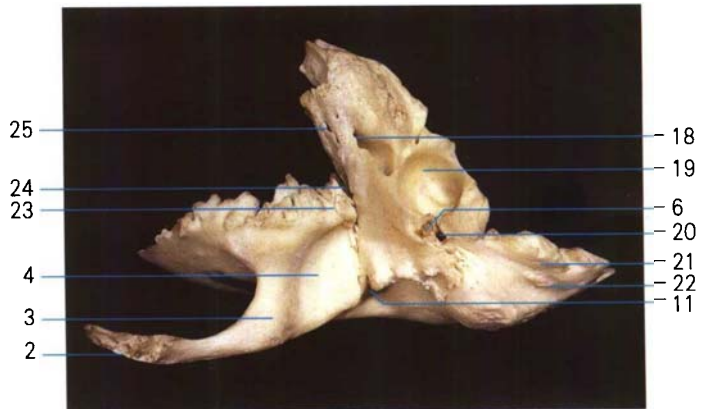
1. 鳞部 squamous part
2. 颧突 zygomatic process
3. 关节结节 articular tubercle
4. 下颌窝 mandibular fossa
5. 鼓部 tympanic part
6. 茎突 styloid process
7. 鼓乳裂 tympanomastoid fissure
8. 乳突 mastoid process
9. 道上嵴 superameatal spine
10. 道上小凹 superameatal foveola
11. 外耳门 external acoustic pore
12. 鼓室盖 tegmen tympani
13. 弓状隆起 arcuate eminence
14. 三叉神经压迹 trigeminal impression
15. 前庭水管外口 external aperture of aqueduct of vestibule
16. 岩上窦沟 suclus for superior petrosal sinus
17. 乙状窦沟 Suclus for sigmoid sinus
18. 颈动脉管 carotid canal
19. 颈静脉窝 jugular fossa
20. 茎乳孔 styломastoid foramen
21. 枕动脉沟 occipital groove
22. 乳突切迹 mastoid notch
23. 岩鳞裂 petrosquamous fissure
24. 岩鼓裂 petrotympanic fissure
25. 肌咽鼓管 musculotubal canal



外面观



内面观



下面观

图 23 颞骨(外、内和下面观)
The temporal bone(external,internal
and inferior aspect)

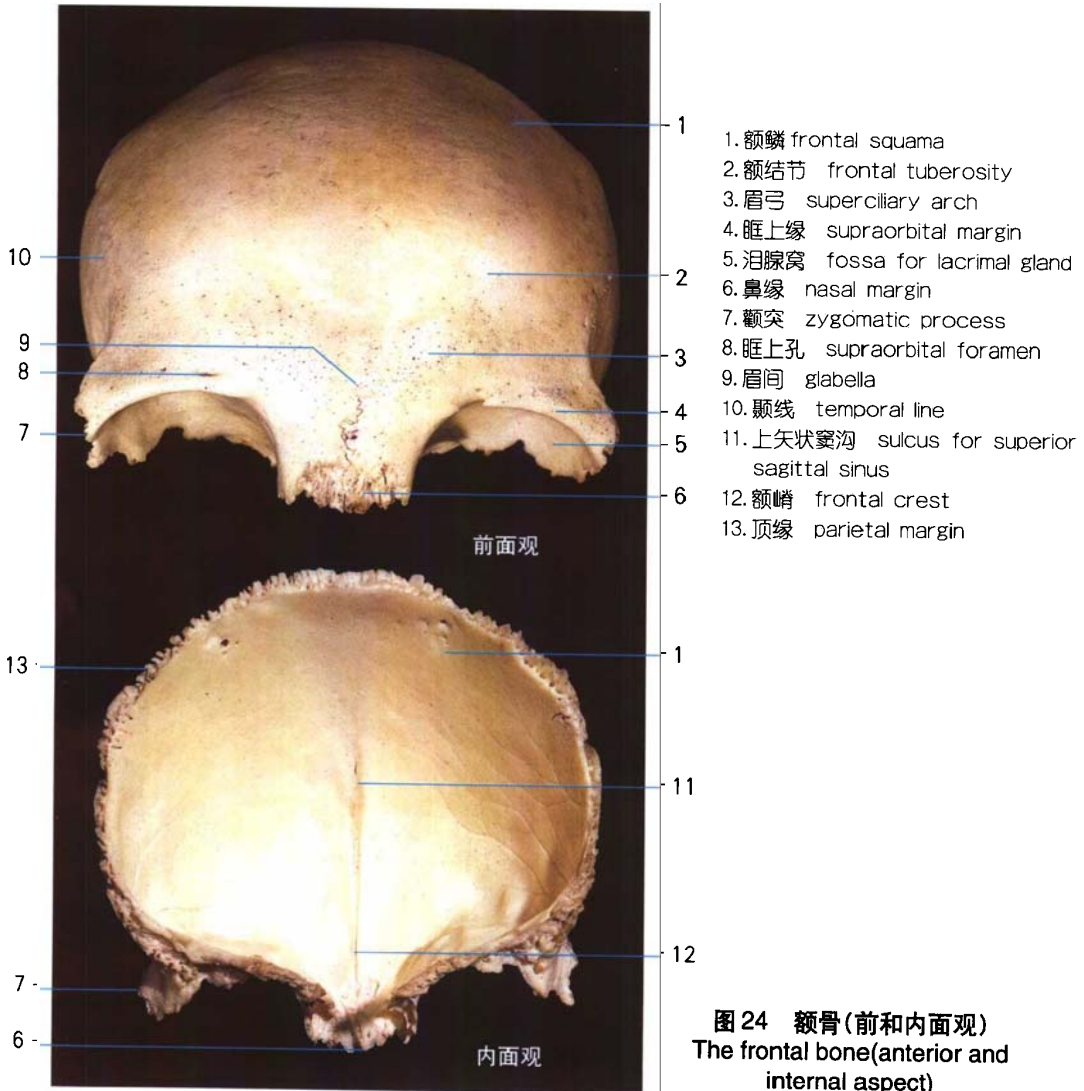


图 24 额骨(前和内面观)
The frontal bone(anterior and internal aspect)

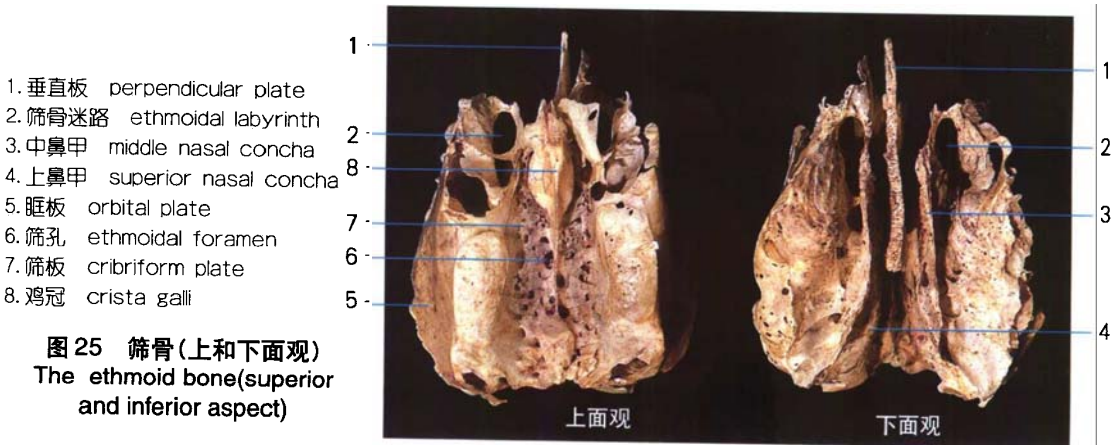


图 25 筛骨(上和下面观)
The ethmoid bone(superior and inferior aspect)

1. 枕鳞 occipital squama
2. 枕外隆凸 external occipital protuberance
3. 枕外嵴 external occipital crest
4. 髁管 condylar canal
5. 枕髁 occipital condyle
6. 咽结节 pharyngeal tubercle
7. 大孔 foramen magnum
8. 下项线 inferior nuchal line
9. 上项线 superior nuchal line
10. 最上项线 highest nuchal line
11. 大脑窝 cerebral fossa
12. 枕内隆凸 internal occipital protuberance
13. 枕内嵴 internal occipital crest
14. 小脑窝 cerebellar fossa
15. 基底部分 basilar part
16. 横窦沟 sulcus for transverse sinus
17. 上矢状窦沟 Sulcus for superior sagittal sinus

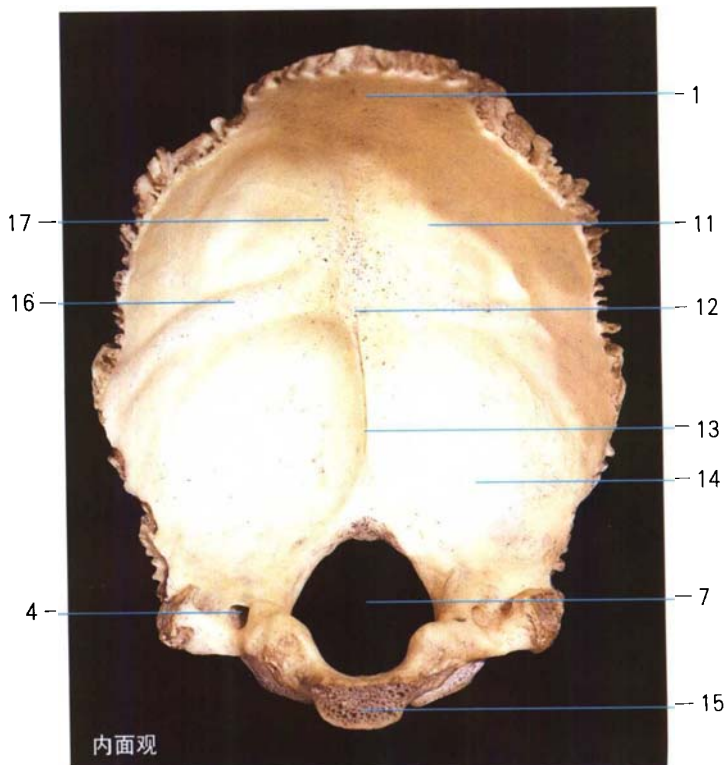
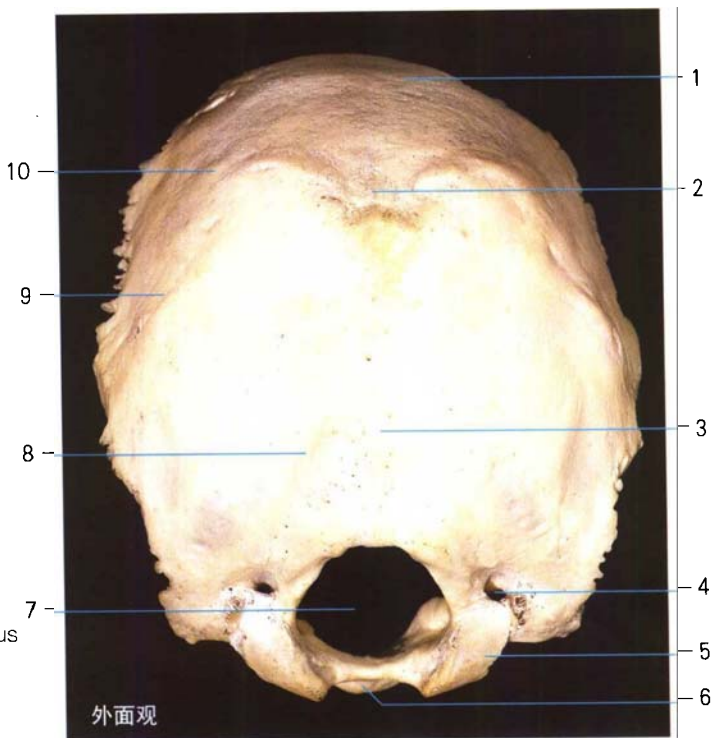
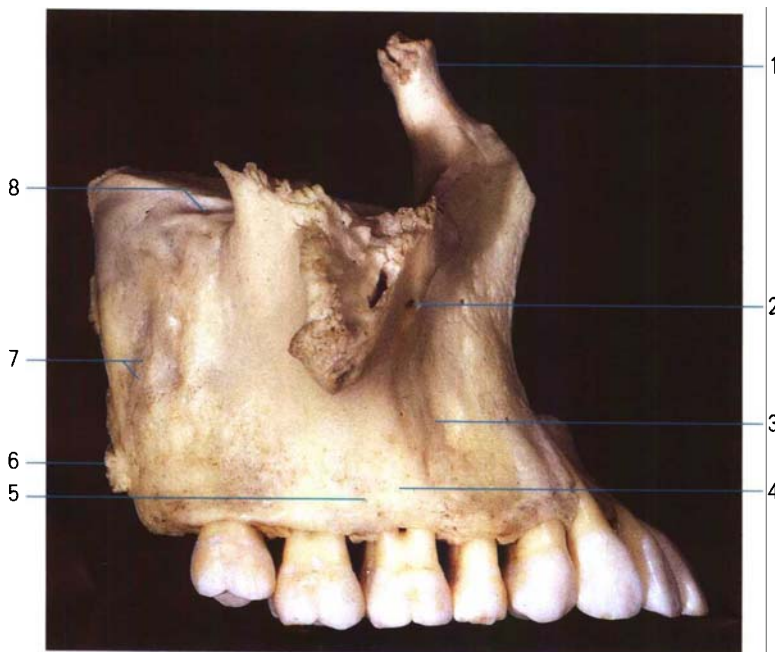
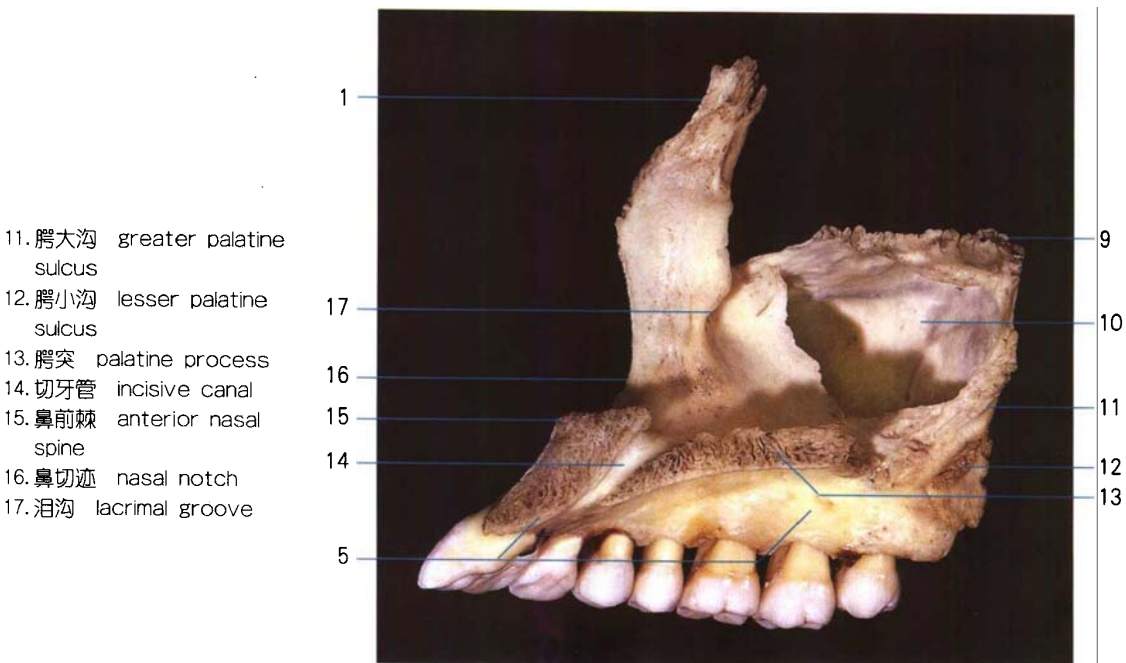


图 26 枕骨(外和内面观)
The occipital bone(external and internal aspect)



- 1. 额突 frontal process
- 2. 眶下孔 infraorbital foramen
- 3. 尖牙窝 canine fossa
- 4. 牙槽嵴 juga alveolaria
- 5. 牙槽突 alveolar process
- 6. 上颌结节 maxillary tubercle
- 7. 牙槽孔 alveolar foramen
- 8. 眶下沟 infraorbital groove
- 9. 颧突 zygomatic process
- 10. 上颌窦裂孔 maxillary hiatus

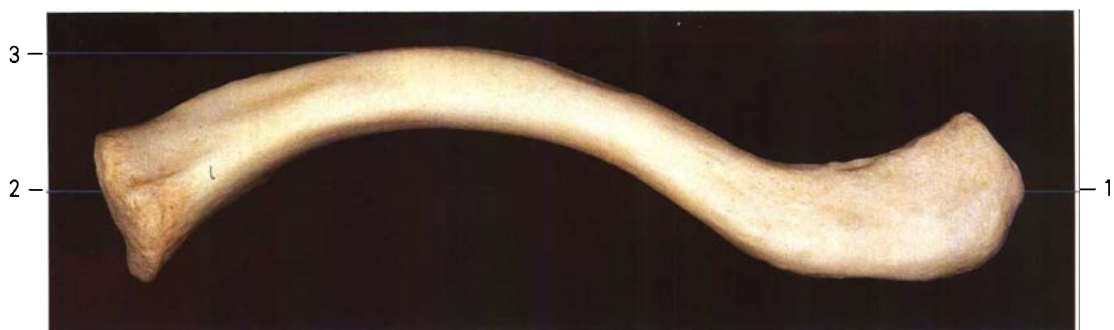前面观



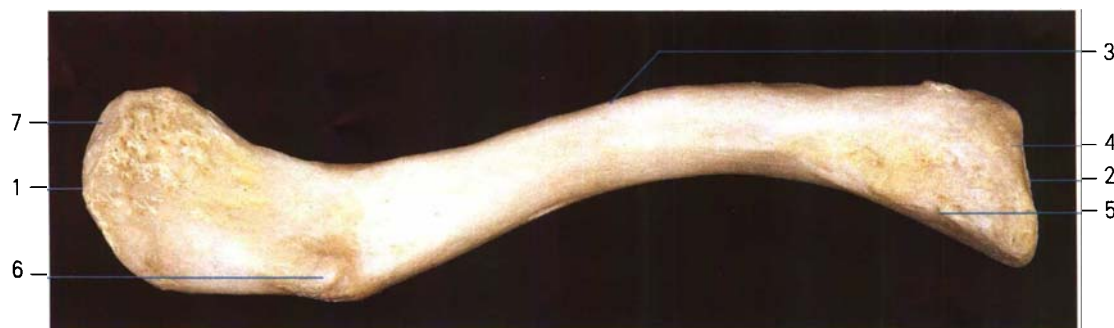
- 11. 腭大沟 greater palatine sulcus
- 12. 腭小沟 lesser palatine sulcus
- 13. 腭突 palatine process
- 14. 切牙管 incisive canal
- 15. 鼻前棘 anterior nasal spine
- 16. 鼻切迹 nasal notch
- 17. 泪沟 lacrimal groove

内侧面观

图 27 上颌骨(前和内侧面观)
The maxilla bone(anterior and medial aspect)



上面观

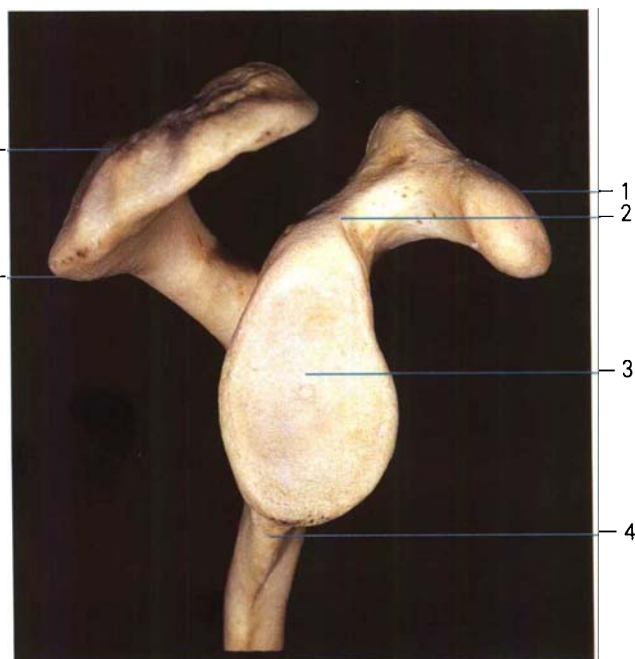


下面观

图 28 锁骨(上和下面观)

The clavicle(superior and inferior aspect)

- 1. 肩峰端 acromial end
- 2. 胸骨端 sternal end
- 3. 锁骨体 shaft of clavicle
- 4. 胸骨关节面 articular surface for sternum
- 5. 肋锁韧带压迹 impression for costoclavicular lig.
- 6. 锥状结节 conoid tubercle
- 7. 肩峰关节面 acromial articular surface



- 1. 喙突 coracoid process
- 2. 孟上结节 supraglenoid tubercle
- 3. 关节盂 glenoid cavity
- 4. 孟下结节 infraglenoid tubercle
- 5. 肩峰角 acromial angle
- 6. 肩峰 acromion

图 29 肩胛骨(外侧角)
The scapula(lateral angle)

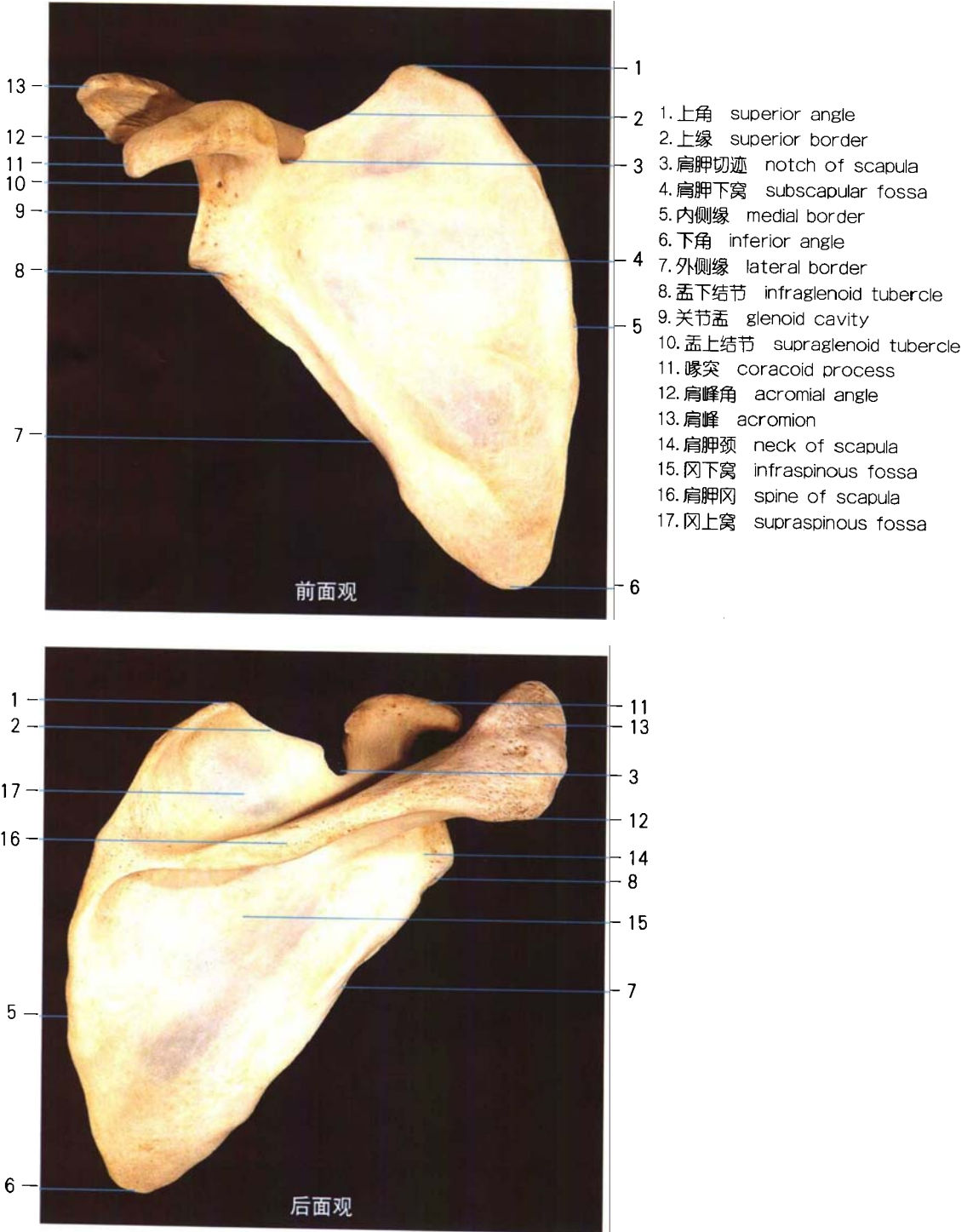


图 30 肩胛骨(前和后面观)
The scapula(anterior and posterior aspect)

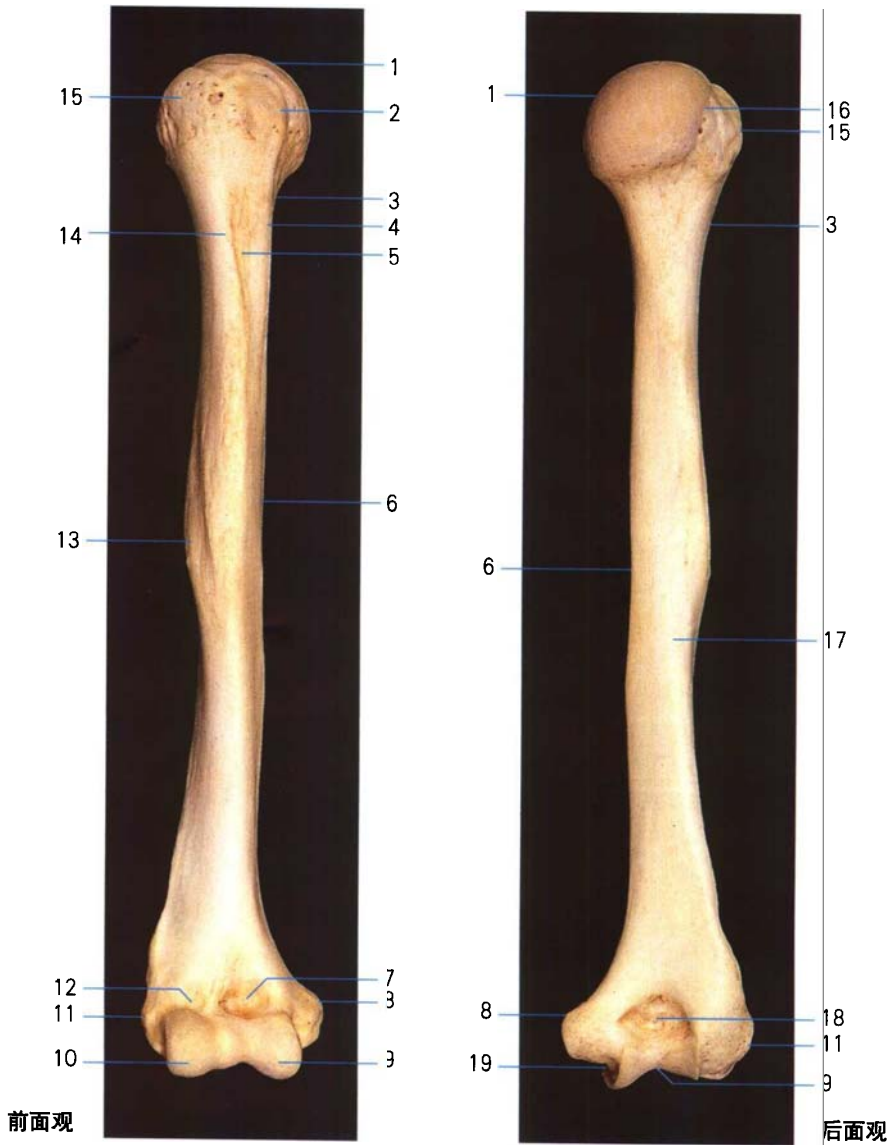
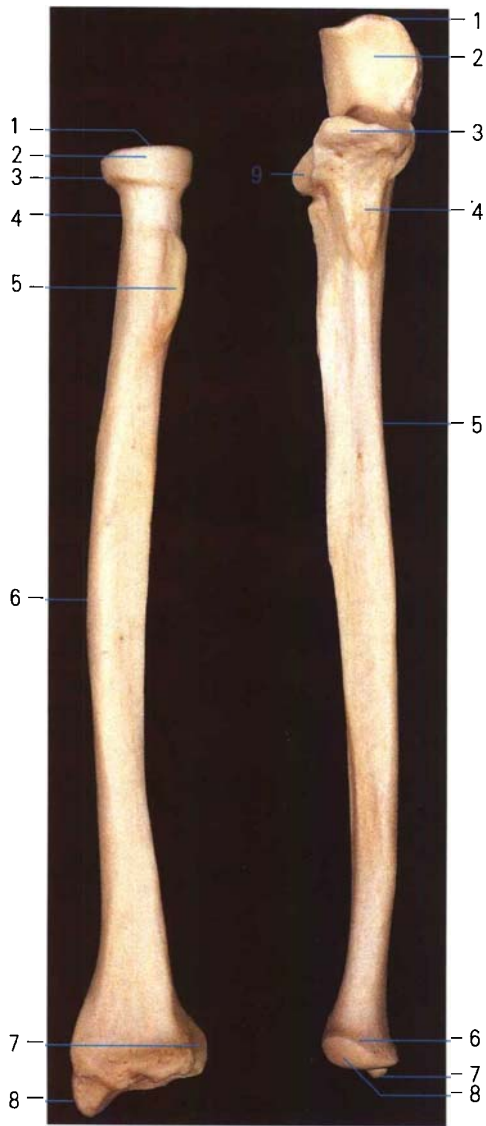


图31 肱骨(前和后面观)
The humerus(anterior and posterior aspect)

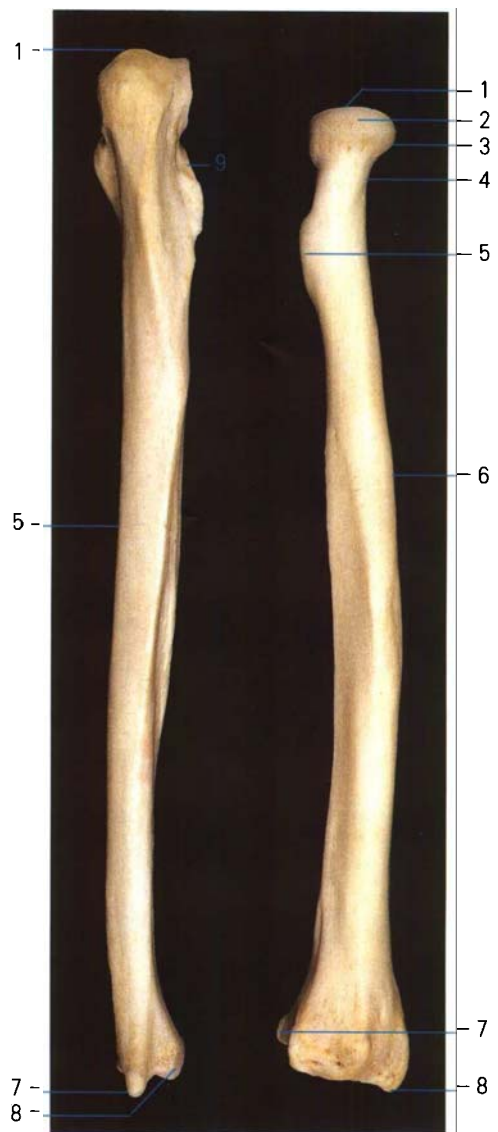
- | | |
|----------------------------------|------------------------------------|
| 1. 肱骨头 head of humerus | 11. 外上髁 lateral epicondyle |
| 2. 小结节 lesser tubercle | 12. 桡窝 radial fossa |
| 3. 外科颈 Surgical neck | 13. 三角肌粗隆 deltoid tuberosity |
| 4. 小结节嵴 crest of lesser tubercle | 14. 大结节嵴 crest of greater tubercle |
| 5. 结节间沟 intertubercular sulcus | 15. 大结节 greater tubercle |
| 6. 肱骨体 shaft of humerus | 16. 解剖颈 anatomical neck |
| 7. 冠突窝 coronoid fossa | 17. 桡神经沟 sulcus for radial n. |
| 8. 内上髁 medial epicondyle | 18. 鹰嘴窝 olecranon fossa |
| 9. 肱骨滑车 trochlea of humerus | 19. 尺神经沟 sulcus for ulnar n. |
| 10. 肱骨小头 capitulum of humerus | |



A. 前面观

图 32 尺骨(A.右图, B.左图)
The ulna(A.the right figure,B.the left figure)

1. 鹰嘴 olecranon
2. 滑车切迹 trochlear notch
3. 冠突 coronoid process
4. 尺骨粗隆 ulnar tuberosity
5. 尺骨体 shaft of ulna
6. 尺骨头 head of ulna
7. 茎突 styloid process
8. 环状关节面 articular circumference
9. 桡切迹 radius notch

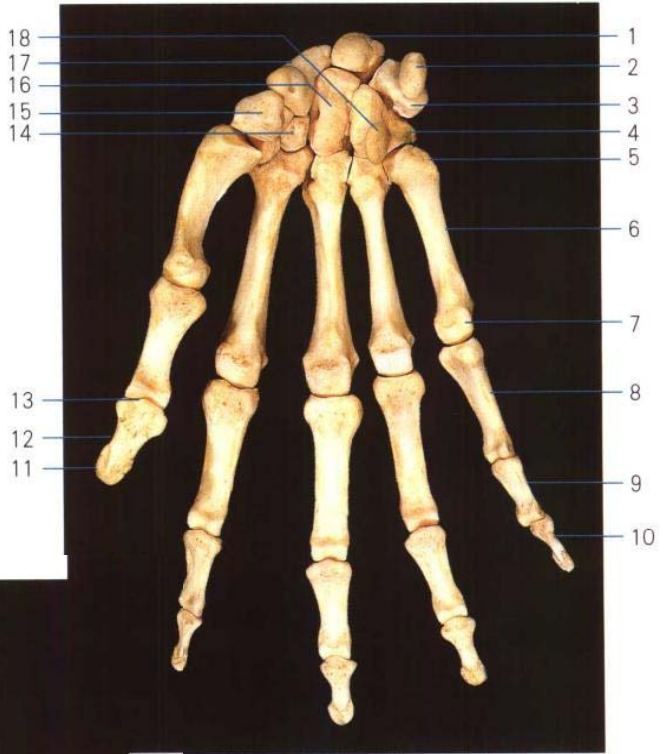


B. 后面观

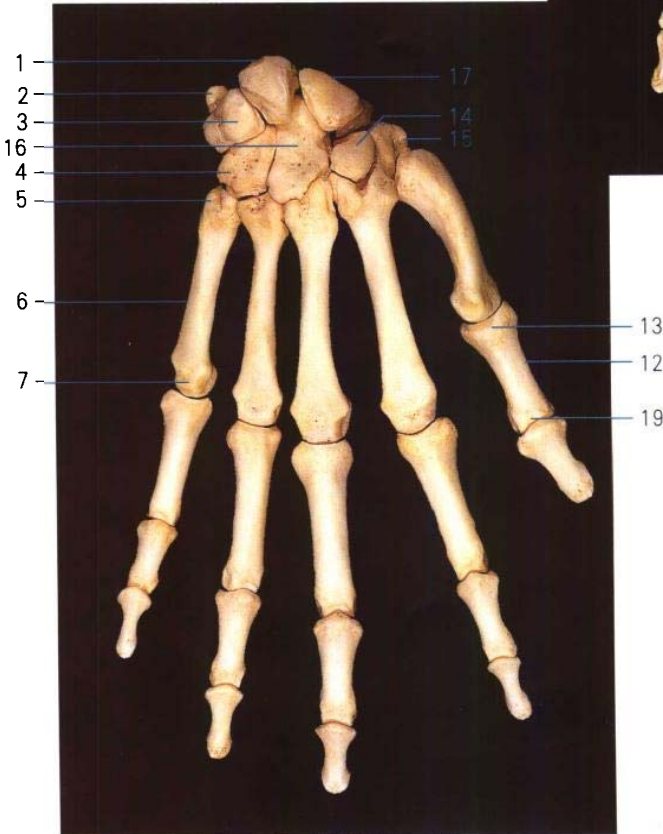
图 33 桡骨(A.左图, B.右图)
The radius(A.the left figure,B.the right figure)

1. 关节凹 articular fovea
2. 环状关节面 articular circumference
3. 桡骨头 head of radius
4. 桡骨颈 neck of radius
5. 桡骨粗隆 radius tuberosity
6. 桡骨体 shaft of radius
7. 尺切迹 ulnar notch
8. 茎突 styloid process

- 1. 月骨 lunate bone
- 2. 豌豆骨 pisiform bone
- 3. 三角骨 triquetral bone
- 4. 钩骨 hamate bone
- 5. 掌骨底 base of metacarpal bone
- 6. 掌骨体 shaft of metacarpal bone
- 7. 掌骨头 head of metacarpal bone
- 8. 近节指骨 proximal phalanx
- 9. 中节指骨 middle phalanx
- 10. 远节指骨 distal phalanx
- 11. 指骨粗隆 tuberosity of phalanx
- 12. 指骨体 shaft of phalanx



前面观



后面观

- 13. 指骨底 base of phalanx
- 14. 小多角骨 trapezoid bone
- 15. 大多角骨 trapezium bone
- 16. 头状骨 capitate bone
- 17. 手舟骨 scaphoid bone
- 18. 钩骨钩 hamulus of hamate bone
- 19. 指骨滑车 trochlea of phalanx

图34 手骨(前和后面观)
The bones of the hand(anterior and posterior aspect)

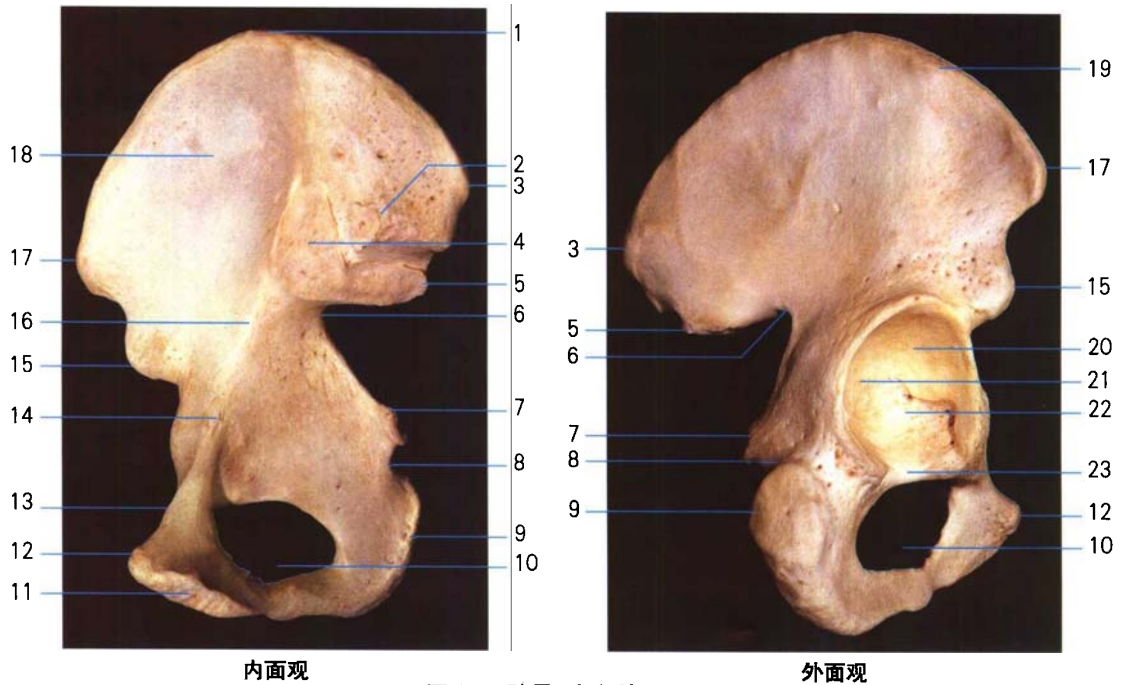


图 35 髋骨(内和外面观)
The hip bone(internal and external aspect)

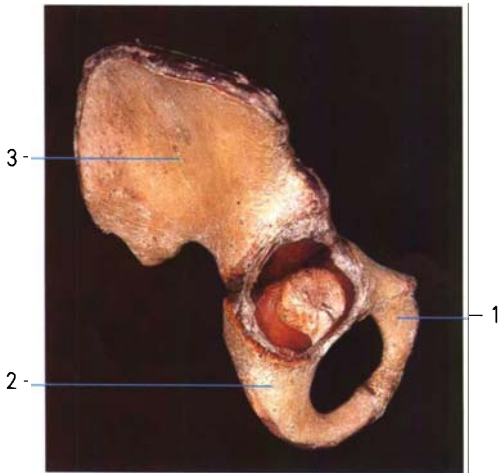


图 36 婴儿髋骨(外面观)
The hip bone of the infant(external aspect)

- 1. 耻骨 pubis
- 2. 坐骨 ischium
- 3. 髌骨 ilium

- 1. 髌嵴 iliac crest
- 2. 髌粗隆 iliac trberosity
- 3. 髌后上棘 posterior superior iliac spine
- 4. 耳状面 auricular surface
- 5. 髌右下棘 posterior inferior iliac spine
- 6. 坐骨大切迹 greater sciatic notch
- 7. 坐骨棘 ischial spine
- 8. 坐骨小切迹 lesser sciatic notch
- 9. 坐骨结节 ischial tuberosity
- 10. 闭孔 obturator foramen
- 11. 耻骨联合面 symphyseal surface
- 12. 耻骨结节 pubic tubercle
- 13. 耻骨梳 pecten of pubis
- 14. 髌耻隆起 iliopubic eminence
- 15. 髌前下棘 anterior inferior iliac spine
- 16. 弓状线 arcuate line
- 17. 髌前上棘 anterior superior iliac spine
- 18. 髌窝 iliac fossa
- 19. 髌结节 iliac tubercle
- 20. 髌臼 acetabulum
- 21. 月状面 lunate surface
- 22. 髌臼窝 acetabular fossa
- 23. 髌臼切迹 acetabular notch

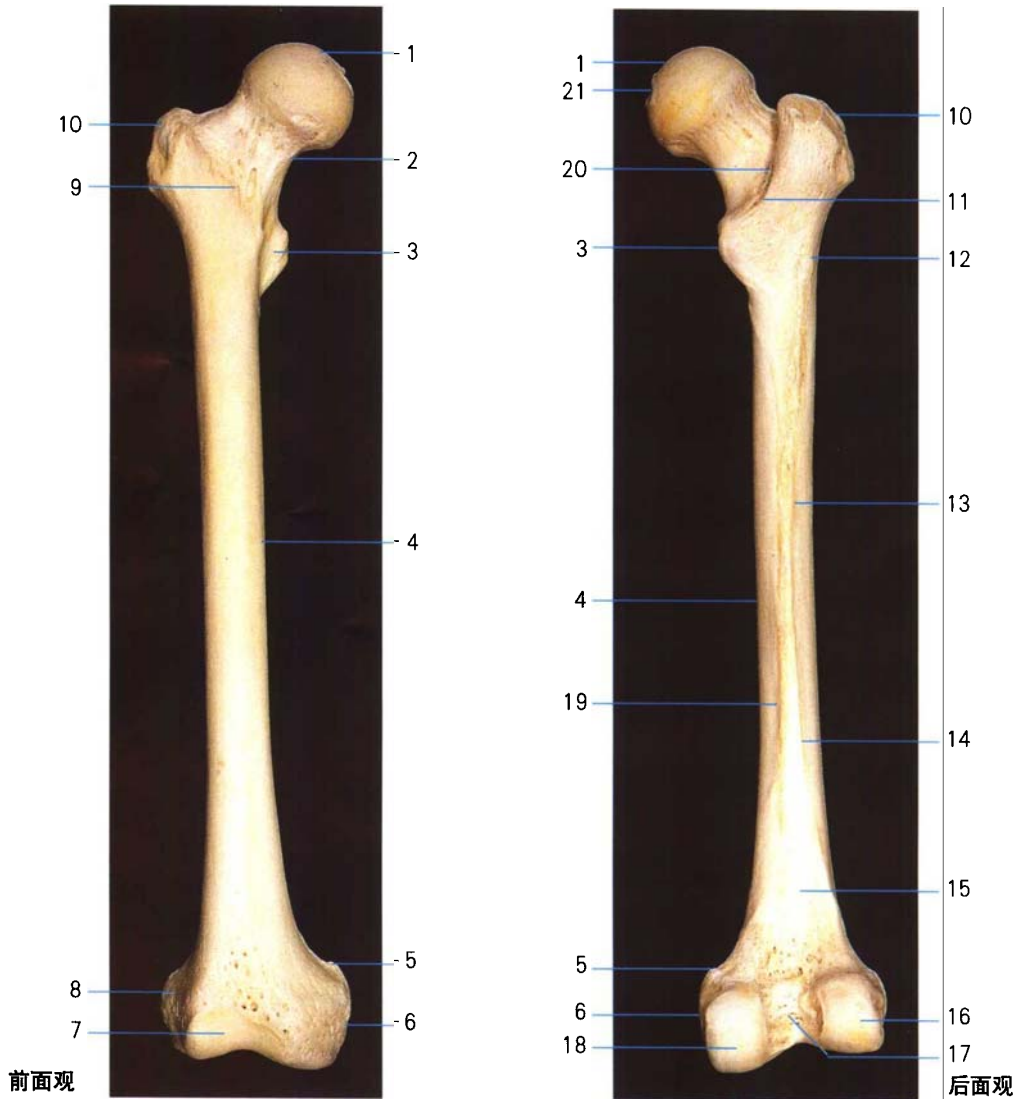


图 37 股骨(前和后面观)
The femur(anterior and posterior aspect)

- 1. 股骨头 head of femer
- 2. 股骨颈 neck of femur
- 3. 小转子 lesser trochanter
- 4. 股骨体 shaft of femur
- 5. 收股结节 adductor tubercle
- 6. 内上髁 medial epicondyle
- 7. 髌面 patellar surface
- 8. 外上髁 lateral epicondyle
- 9. 转子间线 intertrochanteric line
- 10. 大转子 greater trochanter
- 11. 转子间嵴 intertrochanteric crest

- 12. 臀肌粗隆 glutral trberosity
- 13. 粗线 linea aspera
- 14. 外侧唇 external lip
- 15. 腓面 popliteal surface
- 16. 外侧髁 lateral condyle
- 17. 髁间窝 intercondylar fossa
- 18. 内侧髁 medial condyle
- 19. 内侧唇 internal lip
- 20. 转子窝 trochanteric fossa
- 21. 股骨头凹 fovea of femoral head

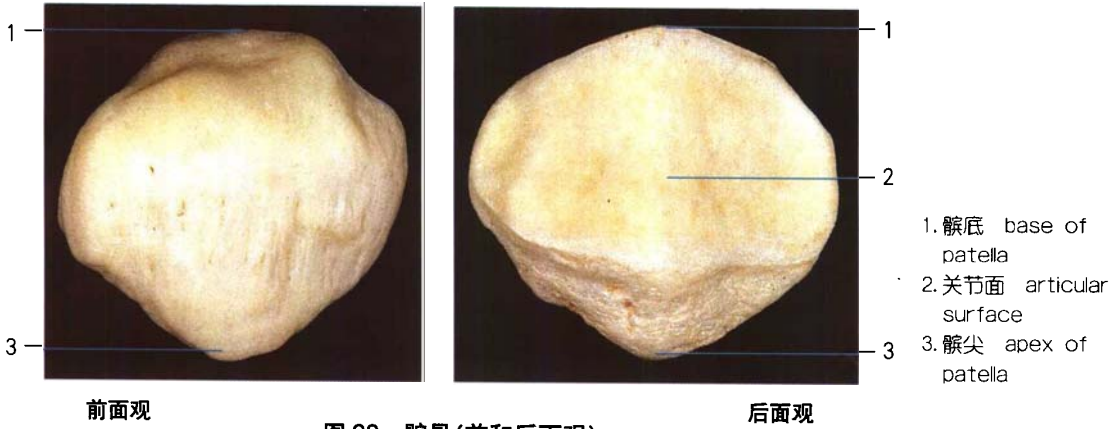

图 38 髌骨(前和后面观)
The patella(anterior and posterior aspect)

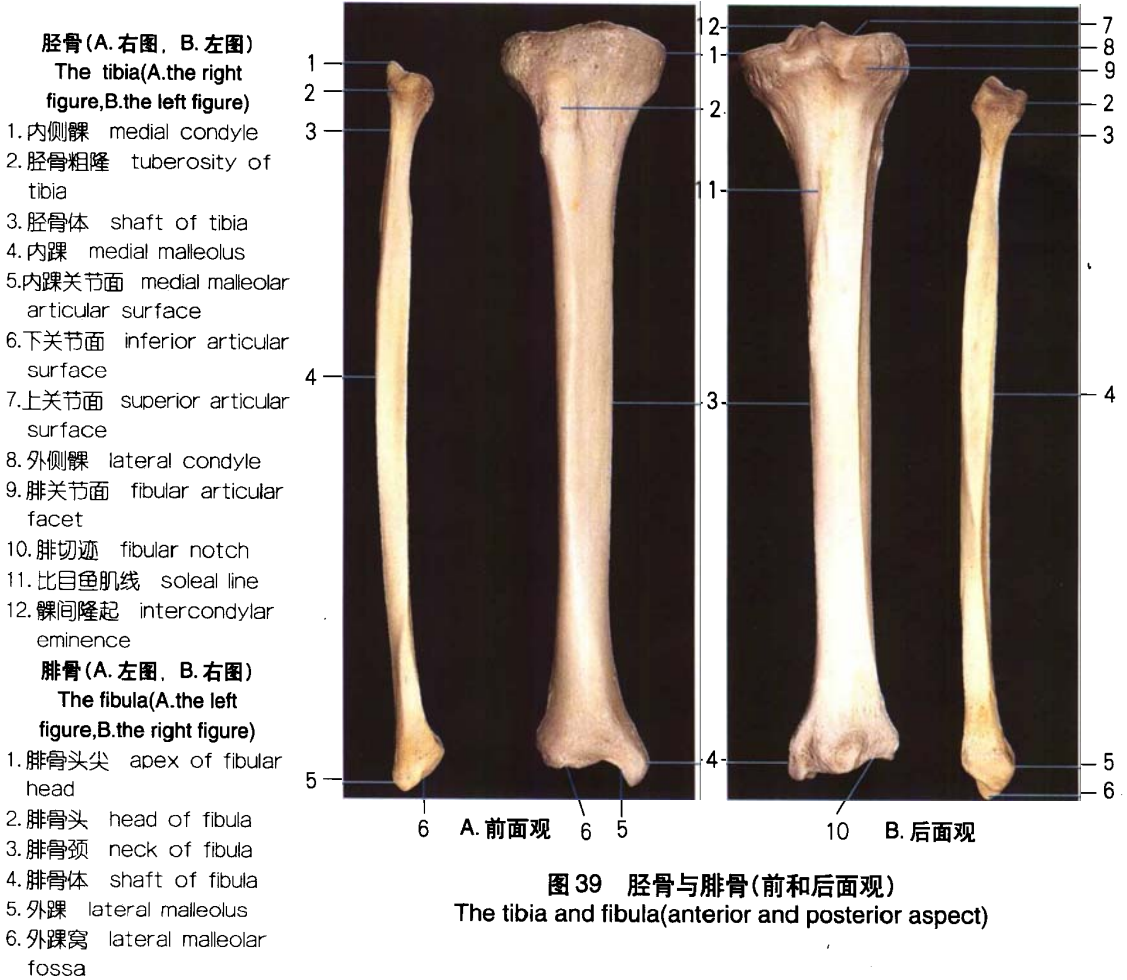
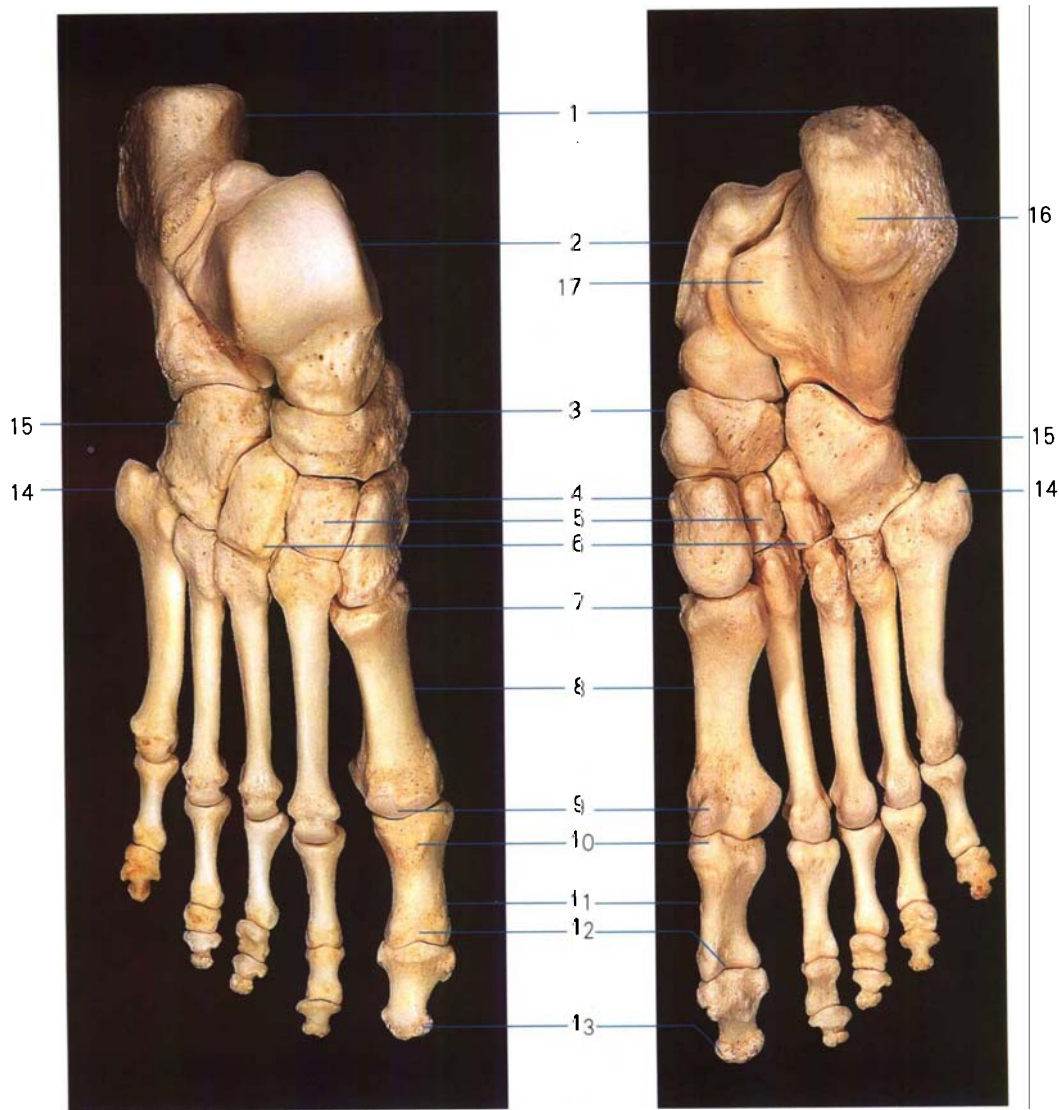


图 39 胫骨与腓骨(前和后面观)
The tibia and fibula(anterior and posterior aspect)



上面观

下面观

图 40 足骨(上和下面观)

The bones of the foot(superior and inferior aspect)

- | | |
|-------------------------------------|--|
| 1. 跟骨 calcaneus | 10. 趾骨底 base of phalanx |
| 2. 距骨 talus | 11. 趾骨体 shaft of phalanx |
| 3. 足舟骨 navicular bone | 12. 趾骨滑车 trochlea of phalanx |
| 4. 内侧楔骨 medial cuneiform bone | 13. 趾骨粗隆 tuberosity of phalanx |
| 5. 中间楔骨 intermediate cuneiform bone | 14. 第五跖骨粗隆 tuberosity of 5th metatarsal bone |
| 6. 外侧楔骨 lateral cuneiform bone | 15. 骰骨 cuboid bone |
| 7. 跖骨底 base of metatarsal bone | 16. 跟骨结节 calcaneal tuberosity |
| 8. 跖骨体 shaft of metatarsal bone | 17. 载距突 sustentaculum tale |
| 9. 跖骨头 head of metatarsal bone | |

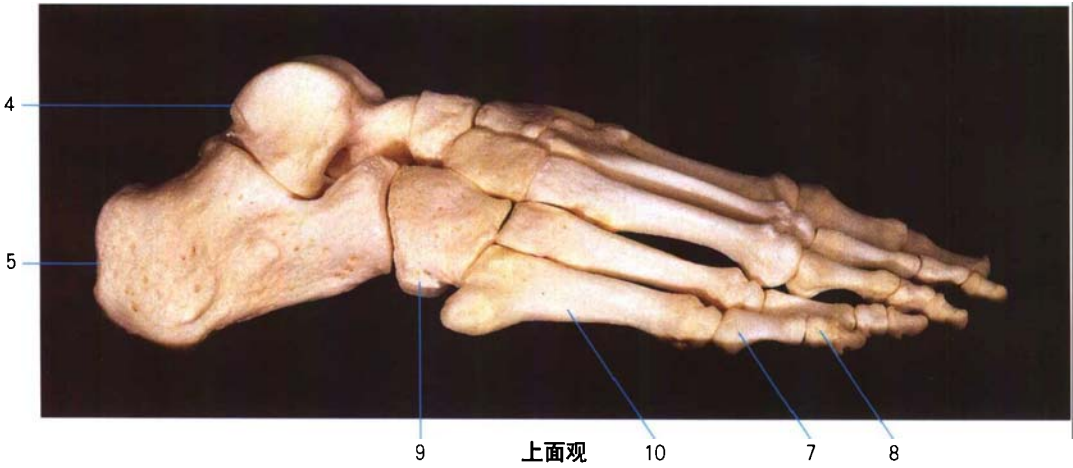
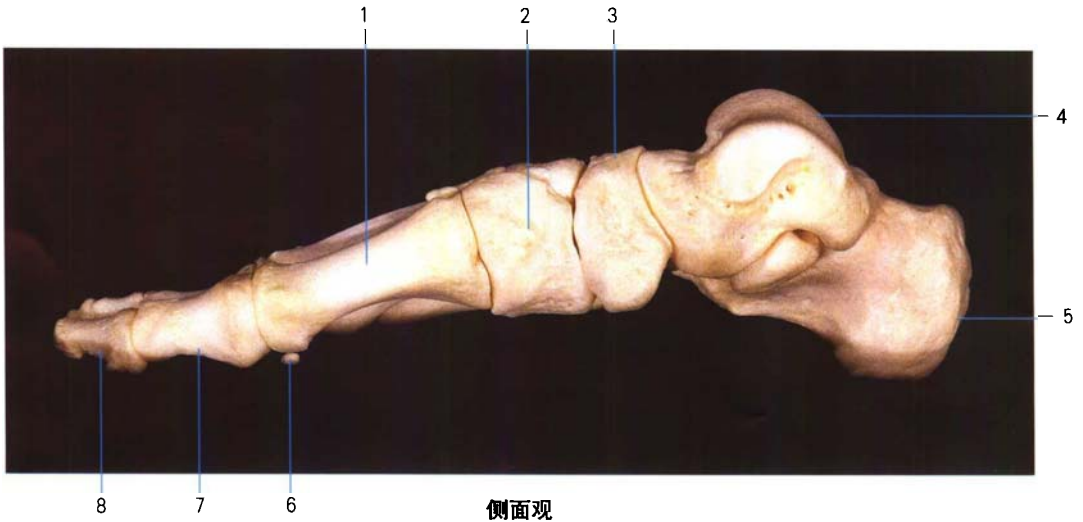

图 41 足纵弓(侧面及上面观)
The longitudinal arches of foot(lateral and superior aspect)

- | | |
|-------------------------------|------------------------------|
| 1. 第一跖骨 1st metatarsal bone | 6. 籽骨 sesamoid bone |
| 2. 内侧楔骨 medial cuneiform bone | 7. 近节趾骨 proximal phalanx |
| 3. 足舟骨 navicular bone | 8. 远节趾骨 distal phalanx |
| 4. 距骨 talus | 9. 骰骨 cuboid bone |
| 5. 跟骨 calcaneus | 10. 第五跖骨 5th metatarsal bone |

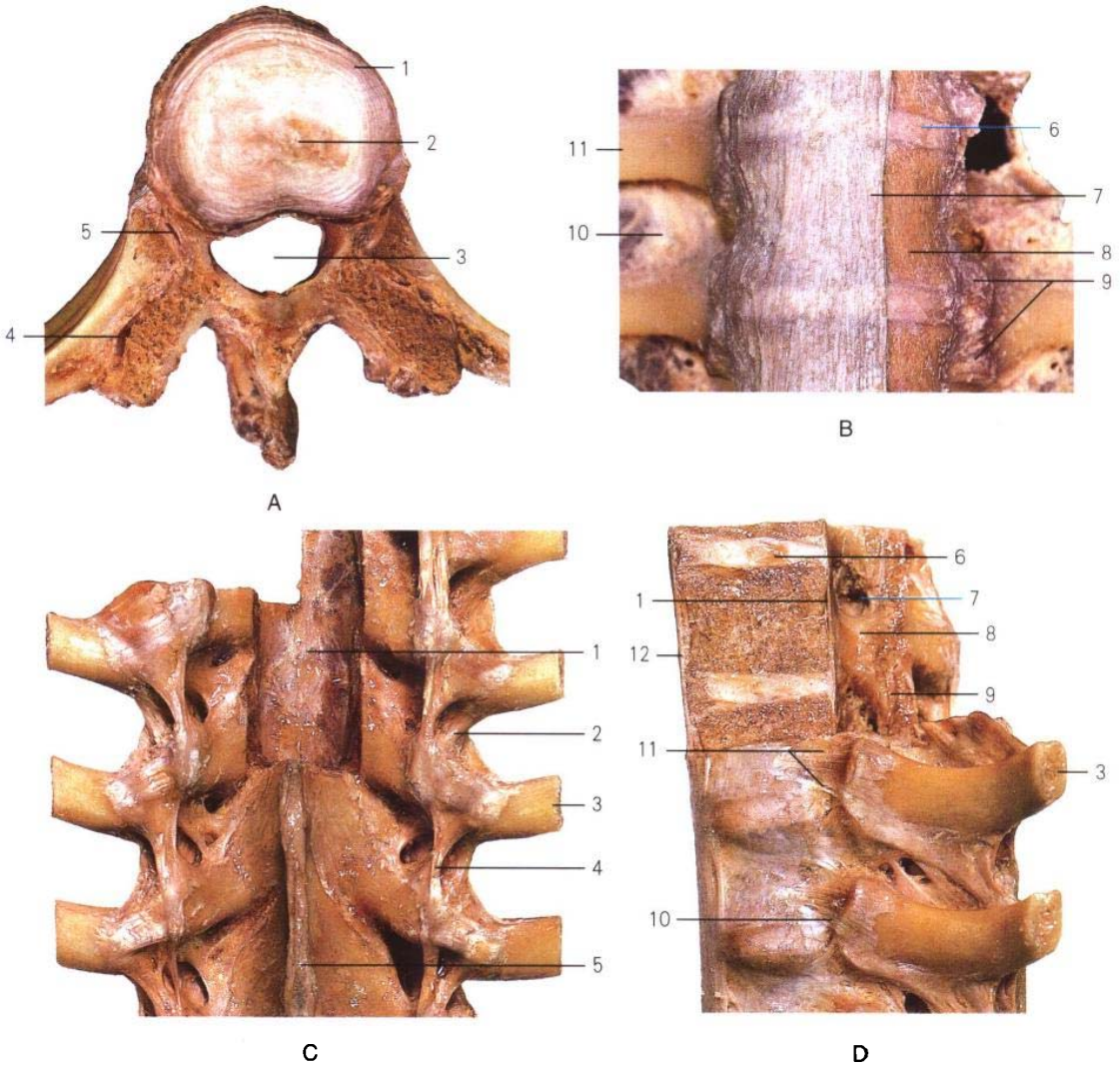


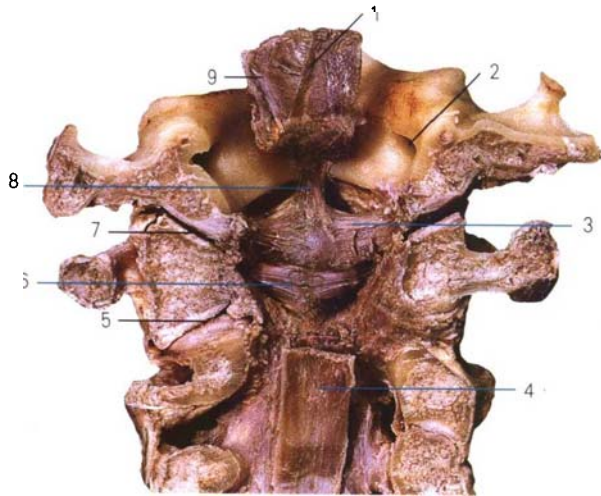
图 42 椎骨间连结 (A、B、C、D)
Intervertebral joints(A,B,C,D)

图 A、B

1. 纤维环 anulus fibrosus
2. 髓核 nucleus pulposus
3. 椎孔 vertebral foramen
4. 肋横突关节 costotransverse joint
5. 肋头关节 joint of costal head

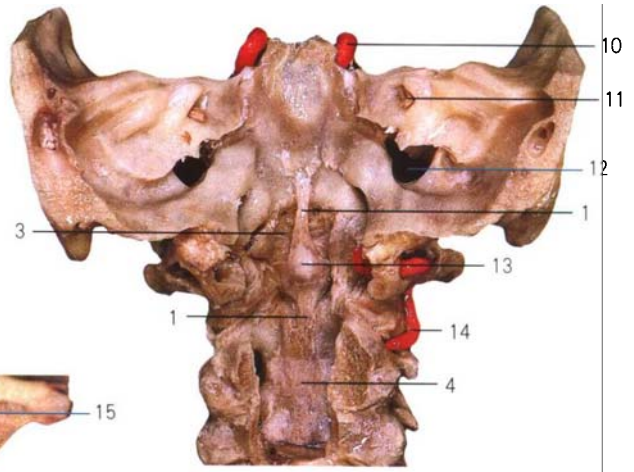
图 C、D

1. 后纵韧带 posterior longitudinal lig.
2. 肋横突上韧带 superior costotransverse lig.
3. 肋骨 costal bone
4. 横突间韧带 intertransverse lig.
5. 棘上韧带 supraspinal lig.
6. 椎间盘 intervertebral disc
7. 椎间孔 intervertebral foramen
8. 椎弓板 lamina of vertebral arch
9. 黄韧带 ligamenta flava
10. 肋头关节 joint of costal head
11. 肋头辐状韧带 radiate lig.of costal head
12. 前纵韧带 anterior longitudinal lig.



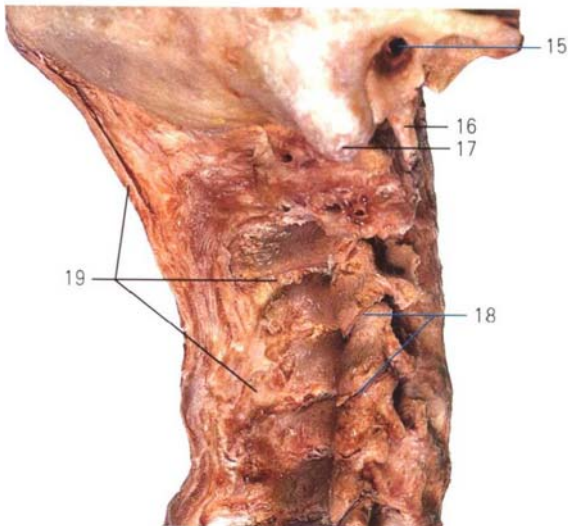
A

1. 纵束 longitudinal bands
2. 舌下神经管 hypoglossal canal
3. 翼状韧带 alar lig.of dens
4. 后纵韧带 posterior longitudinal lig.
5. 寰枢外侧关节 lateral atlantoaxial joint
6. 寰椎横韧带 transverse lig.of atlas
7. 寰枕关节 atlantooccipital joint
8. 齿突尖韧带 apical lig.of dens
9. 覆膜 tectorial membrane
10. 颈内动脉 internal carotid a.



B

11. 内耳门 internal acoustic pore
12. 颈静脉孔 jugular foramen
13. 寰椎十字韧带 cruciform lig.of atlas
14. 椎动脉 vertebral a.
15. 外耳门 external acoustic pore
16. 茎突 styloid process
17. 乳突 mastoid process
18. 关节突关节 zygapophysial joints
19. 项韧带 ligamentum nuchae



C

图 43 颅骨与椎骨连结 (A、B、C)
The joints of the skull and vertebra(A,B,C)

1. 关节盘 articular disc
2. 第一肋肋结合 sternocostal synchondrosis of first rib
3. 肋肋关节 sternocostal joints
4. 肋软骨 costochondral joints
5. 剑突 xiphoid process
6. 软骨间关节 interchondral joints
7. 胸骨下角 infrasternal angle
8. 肋弓 costal arch
9. 肋间隙 intercostal space
10. 肋肋辐状韧带 radiate sternocostal lig.
11. 胸骨角 sternal angle
12. 胸锁关节 sternoclavicular joint

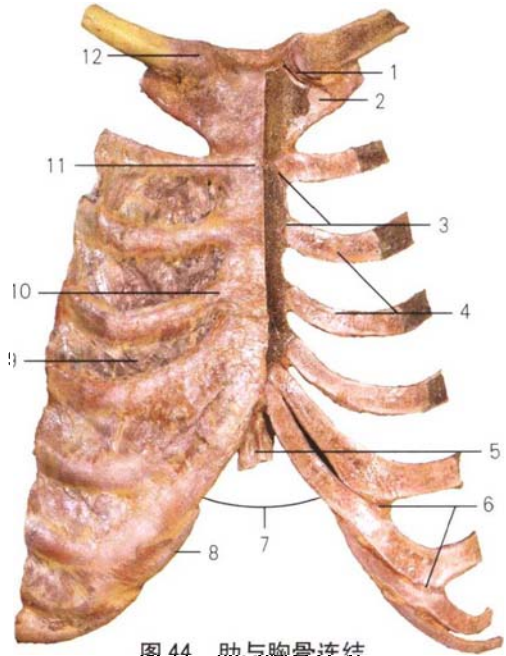
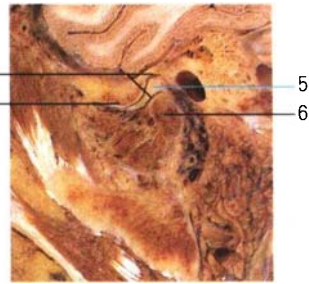
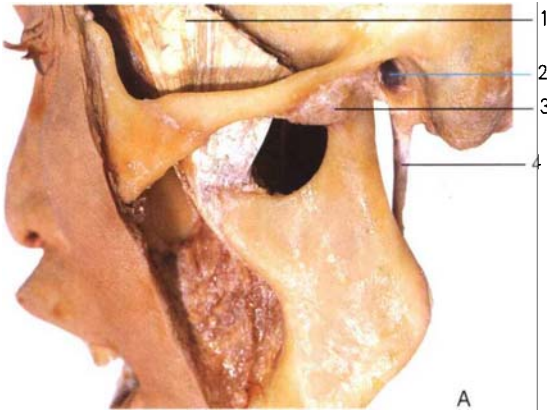
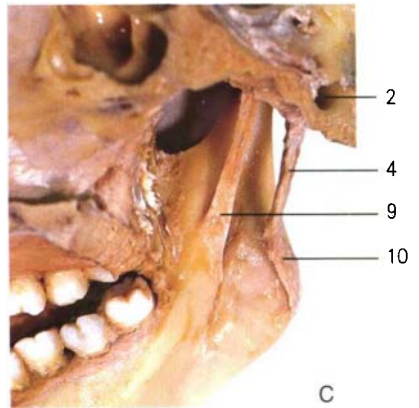


图 44 肋与胸骨连结
The joints of ribs and the sternum



B



C

- A. 外面观 Lateral aspect
1. 颞肌 temporalis
2. 外耳道 external acoustic meatus
3. 关节囊 articular capsule
4. 茎突 styloid process
- B. 矢状剖面 Sagittal section
5. 关节盘 articular disc
6. 髁突 condylar process
7. 关节结节 articular tubercle
8. 关节腔 articular cavity
- C. 内面观 medial aspect
9. 蝶下颌韧带 sphenomandibular lig.
10. 茎突下颌韧带 tylomandibular lig.

图 45 颞下颌关节 (A、B、C)
The temporomandibular joint (A, B, C)

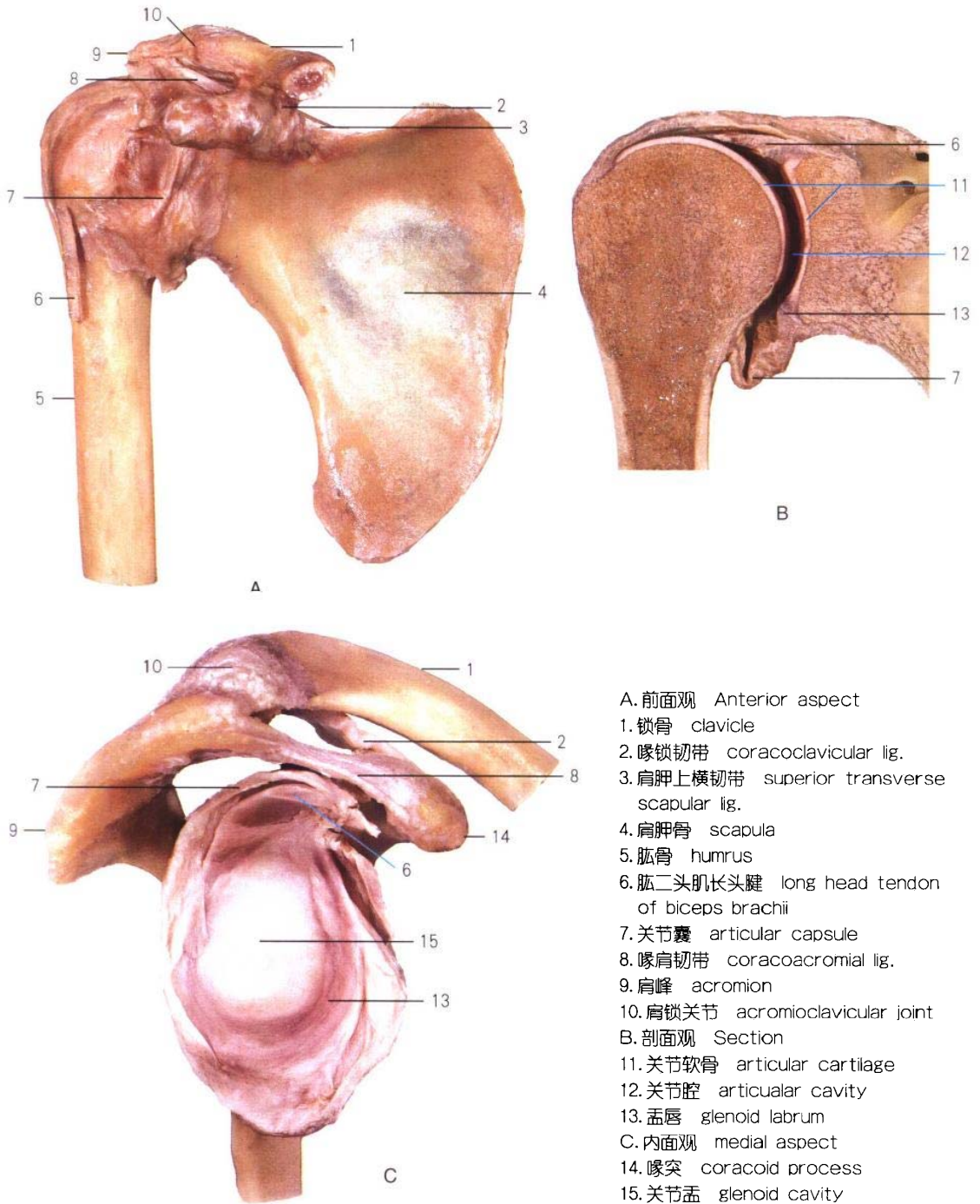
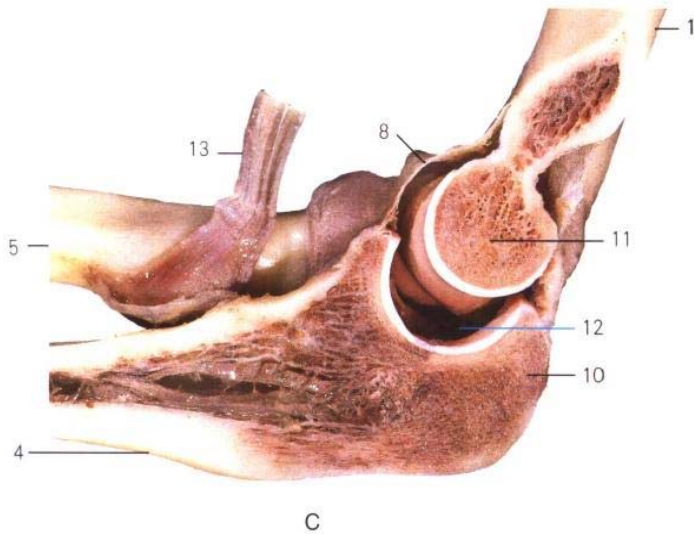
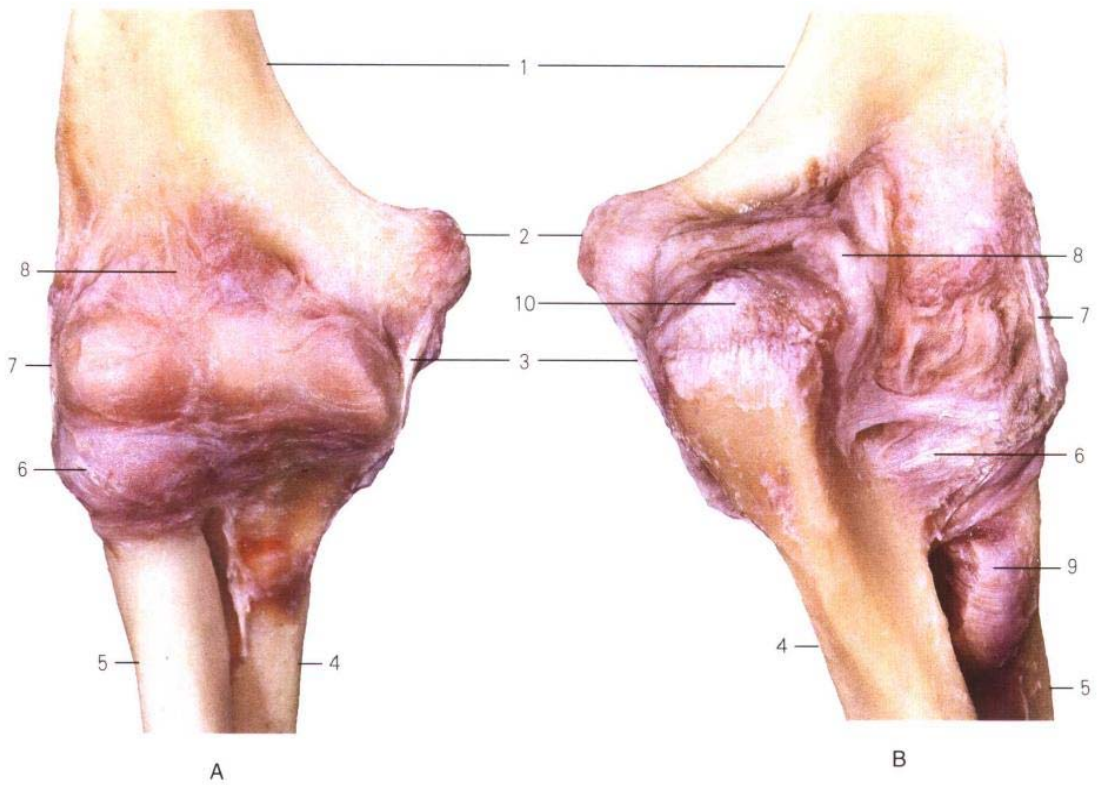
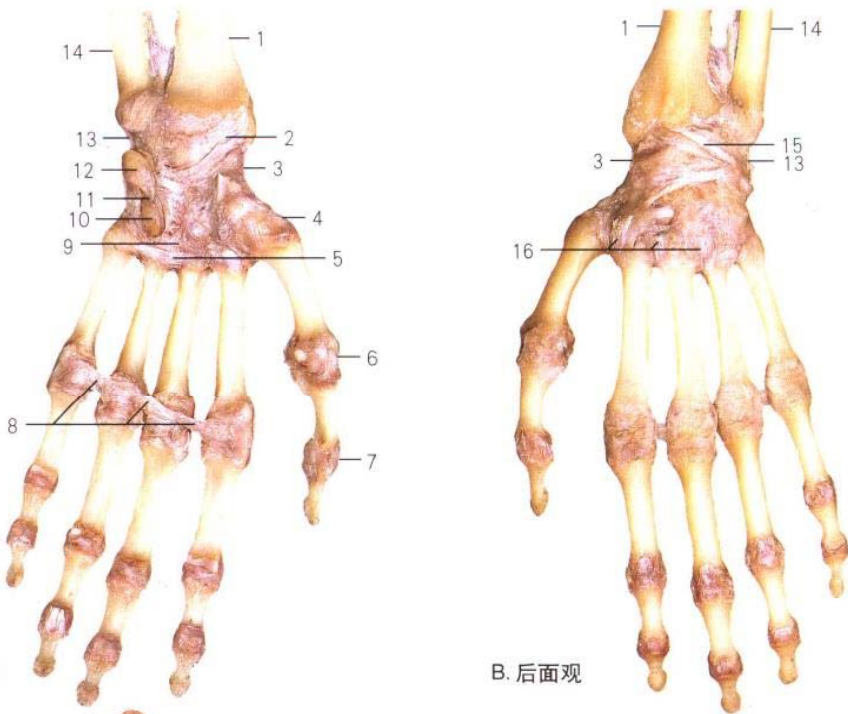


图 46 肩关节 (A、B、C)
The shoulder joint(A,B,C)



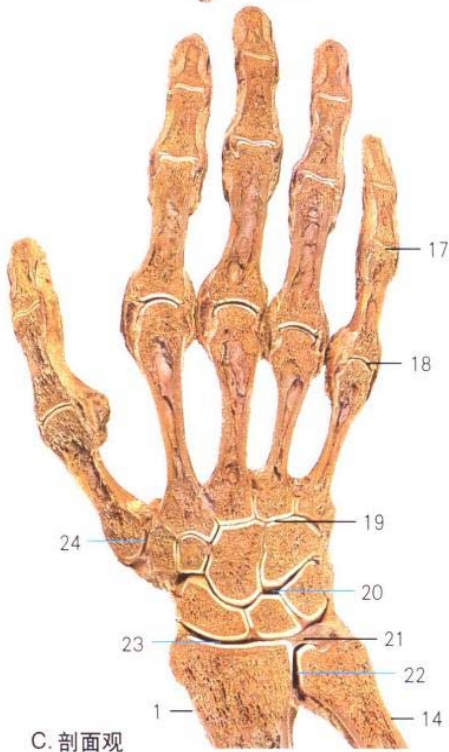- A. 前面观 Anterior aspect
 1. 肱骨 humerus
 2. 内上髁 medial epicondyle
 3. 尺侧副韧带 ulnar collateral lig.
 4. 尺骨 ulna
 5. 桡骨 radius
 6. 桡骨环状韧带 annular lig.of radius
 7. 桡侧副韧带 radial collateral lig.
 8. 关节囊 articular capsule
 B. 后面观 Posterior aspect
 9. 桡骨粗隆 radial taberosity
 10. 鹰嘴 olecranon
 C. 剖面观 Section
 11. 肱骨滑车 trochlea of humerus
 12. 关节腔 articular cavity
 13. 肱二头肌腱 bicipital tendon

图 47 肘关节(A、B、C)
 The elbow joint(A,B,C)



A. 前面观

B. 后面观



C. 剖面观

A. 前面观 Anterior aspect

1. 桡骨 radius
2. 腕腕掌侧韧带 palmar radiocarpal lig.
3. 腕桡侧副韧带 collateral carporadial lig.
4. 拇指腕掌关节 carpometacarpal joint of thumb
5. 掌骨间韧带 interosseous metacarpal lig.
6. 第一掌指关节 first metacarpophalangeal joint
7. 指间关节 interphalangeal joint of hand
8. 掌骨深横韧带 deep transverse metacarpal lig.
9. 腕掌掌侧韧带 palmar carpometacarpal lig.
10. 钩骨钩 hamulus of hamate bone
11. 豆钩韧带 pisohamate lig.
12. 豌豆骨 pisiform bone
13. 腕尺侧副韧带 carpoulnar collateral lig.
14. 尺骨 ulna

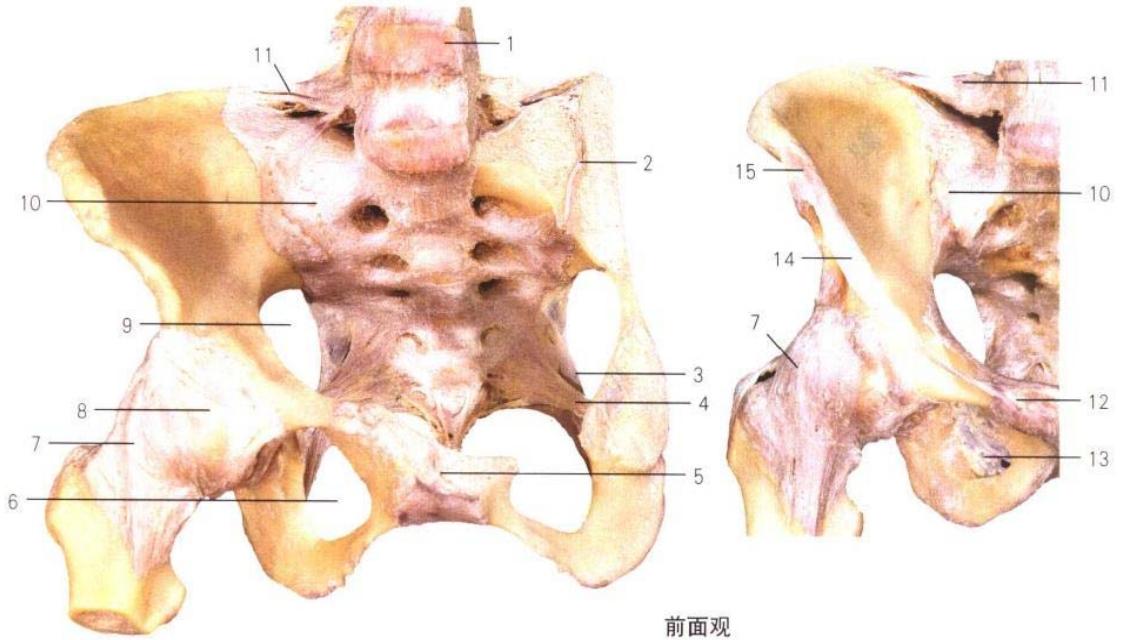
B. 后面观 Posterior aspect

15. 腕腕背侧韧带 dorsal radiocarpal lig.
16. 腕掌背侧韧带 dorsal carpometacarpal lig.

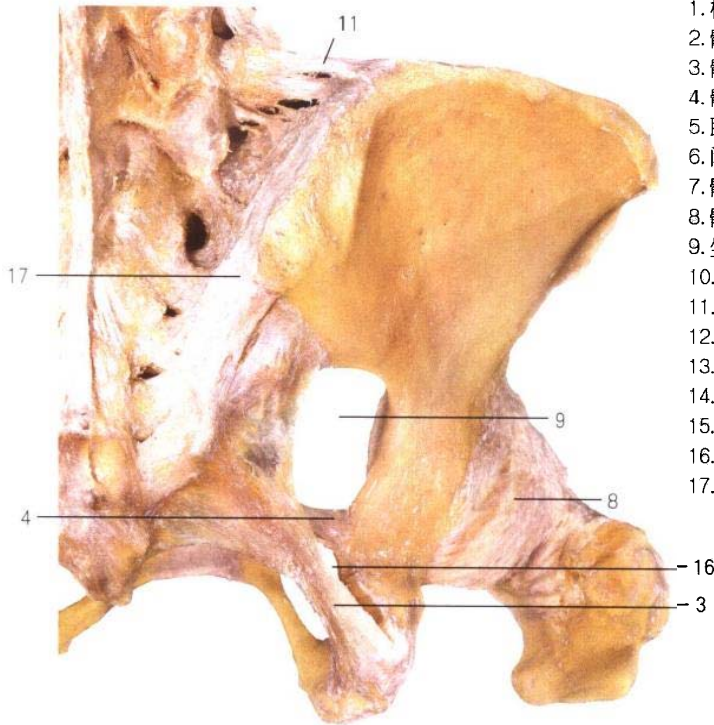
C. 剖面观 Section

17. 指间关节腔 interphalangeal joint cavity
18. 掌指关节腔 metacarpophalangeal joint cavity
19. 腕掌关节腔 carpometacarpal joint cavity
20. 腕骨间关节腔 intercarpal joint cavity
21. 关节盘 articular disc
22. 桡尺远侧关节腔 distal radioulnar joint cavity
23. 腕腕关节腔 radiocarpal joint cavity
24. 拇指腕掌关节腔 carpometacarpal joint cavity of thumb

图 48 手骨连结 (A, B, C)
The joints of the hand (A, B, C)



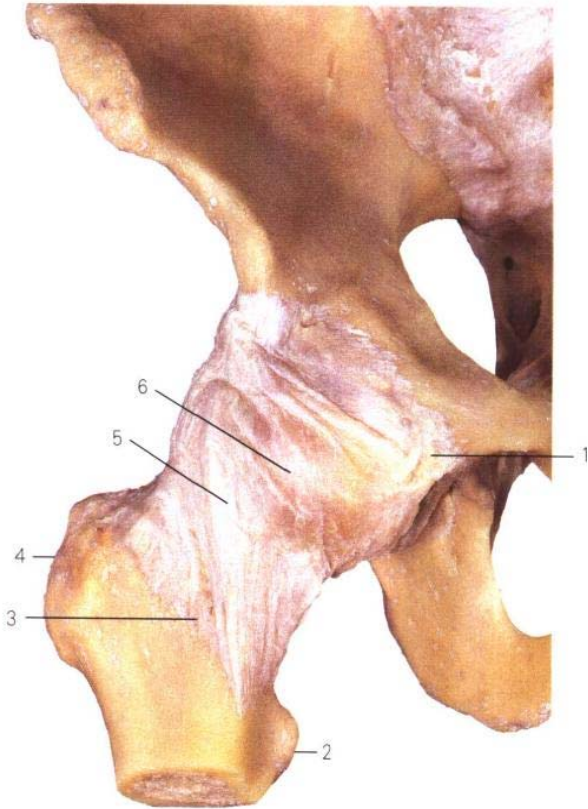
前面观



后面观

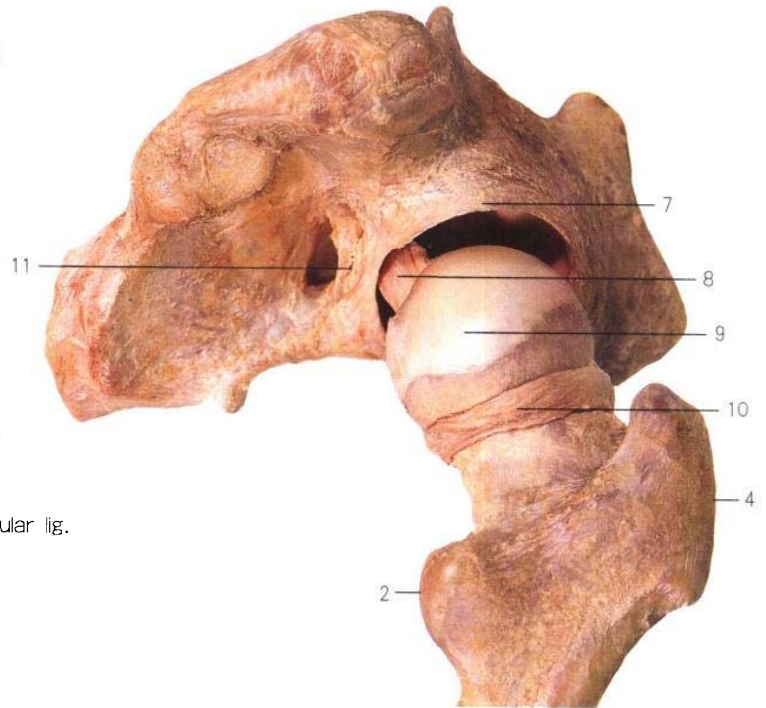
1. 椎间盘 intervertebral discs
2. 骶髂关节 sacroiliac joint
3. 骶结韧带 sacrotuberous lig.
4. 骶棘韧带 sacrospinous lig.
5. 耻骨联合腔 pubic symphysis cavity
6. 闭孔 obturator foramen
7. 髂股韧带 iliofemoral lig.
8. 髋关节囊 hip articular capsule
9. 坐骨大孔 greater sciatic foramen
10. 骶髂腹侧韧带 ventral sacroiliac lig.
11. 髂腰韧带 iliolumbar lig.
12. 耻骨结节 pubic tubercle
13. 闭孔膜 obturator membrane
14. 腹股沟韧带 inguinal lig.
15. 髂前上棘 anterior superior iliac spine
16. 坐骨小孔 lesser sciatic foramen
17. 骶髂背侧韧带 dorsal sacroiliac lig.

图 49 骨盆的连接(前和后面观)
The joints of the pelvis(anterior and posterior aspect)



A. 前面观 Anterior aspect
 1. 耻骨韧带 pubofemoral lig.
 2. 小转子 lesser trochanter
 3. 转子间线 intertrochanteric line
 4. 大转子 greater trochanter
 5. 髂股韧带 iliofemoral lig.
 6. 关节囊 articular capsule

A



B. 切开 Incision
 7. 髋臼唇 acetabular labrum
 8. 股骨头韧带 lig. of head of femur
 9. 股骨头 femur head
 10. 轮匝带 zona orbicularis
 11. 髋臼横韧带 transverse acetabular lig.

B

C. 后面观 Posterior aspect
12. 股骨颈 neck of femur
13. 坐股韧带 ischiofemoral lig.
D. 剖面 section

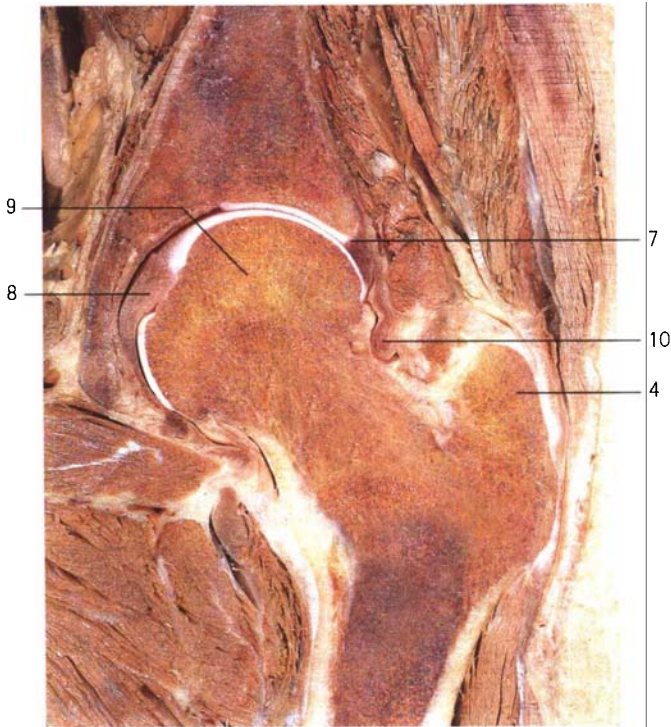
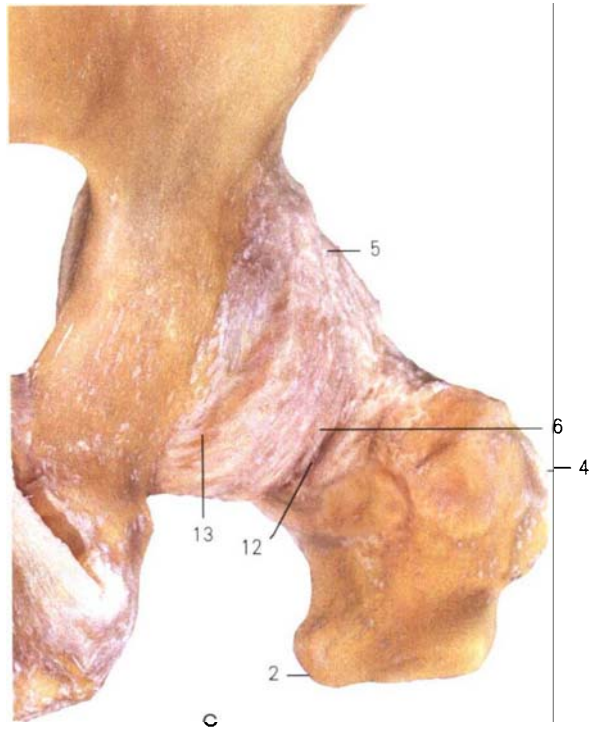
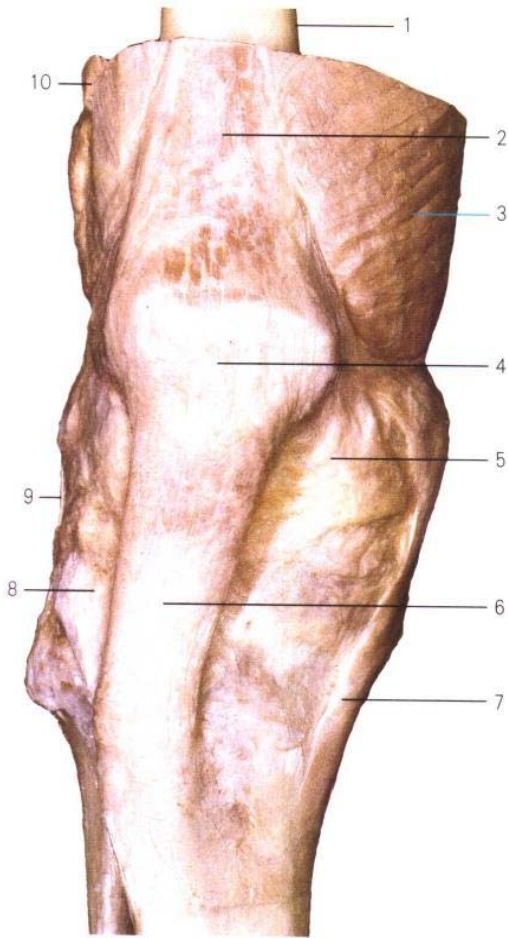
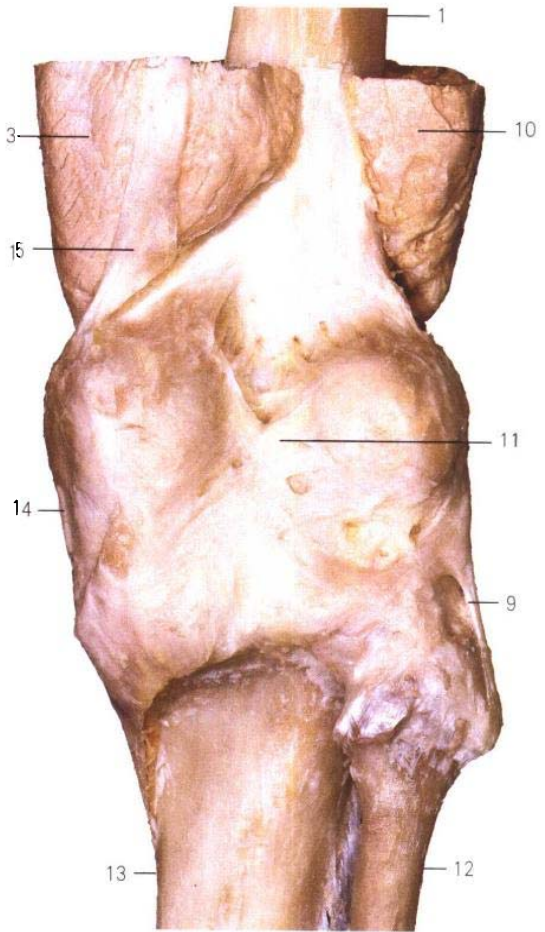


图50 髋关节(A、B、C、D)
The hip joint(A,B,C,D)



前面观

1. 股骨 femur
2. 股直肌 rectus femoris
3. 股内侧肌 vastus medialis
4. 髌骨 patella
5. 髌内侧支持带 medial patellar retinaculum
6. 髌韧带 patellar lig.
7. 缝匠肌腱 sartorius tendon
8. 髌外侧支持带 lateral patellar retinaculum



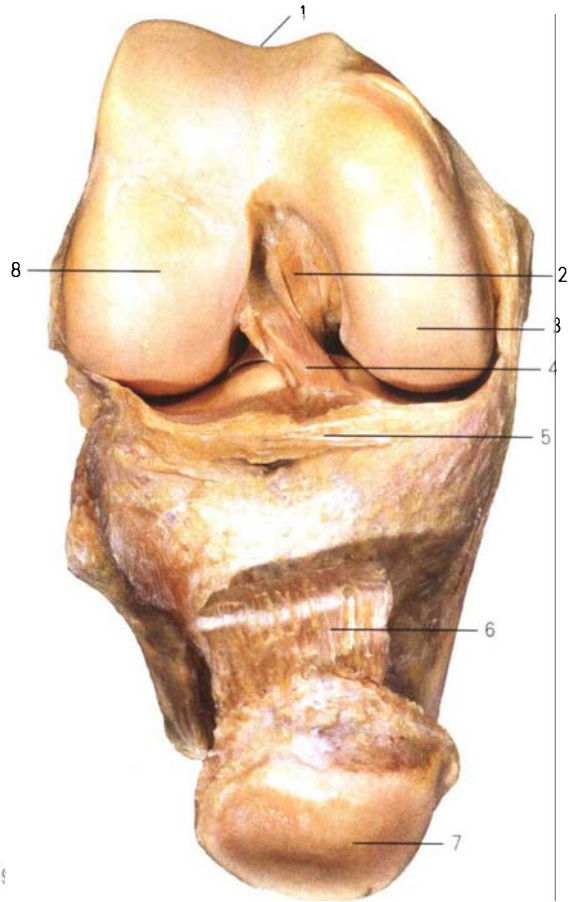
后面观

9. 腓侧副韧带 fibular collateral lig.
10. 股外侧肌 vastus lateralis
11. 腓斜韧带 oblique popliteal lig.
12. 腓骨 fibula
13. 胫骨 tibia
14. 胫侧副韧带 tibial collateral lig.
15. 大收肌腱 adductor magnus tendon

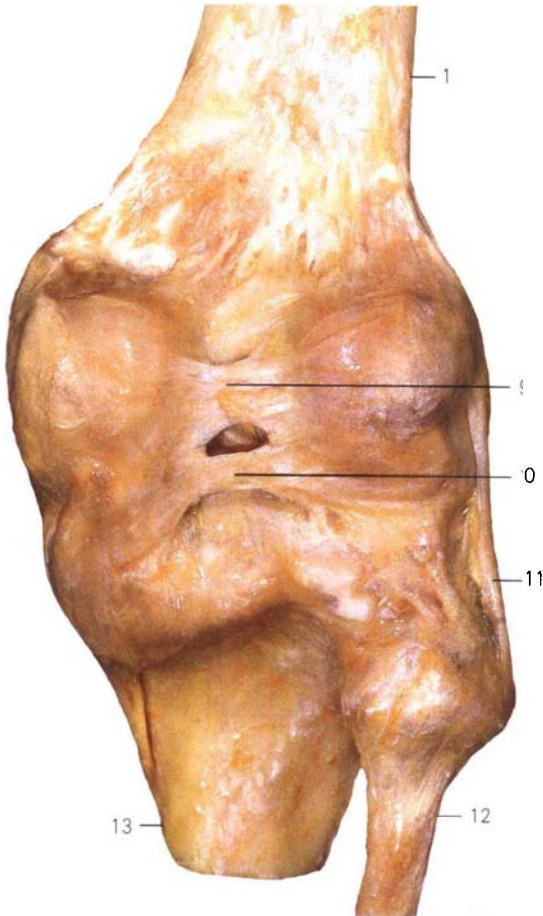
图 51 膝关节(前和后面观)
The knee joint(anterior and posterior aspect)

A. 切开 Incision

- 1. 髌面 patella surface
- 2. 后交叉韧带 posterior cruciate lig.
- 3. 内侧髌 medial condyle
- 4. 前交叉韧带 anterior cruciate lig.
- 5. 膝横韧带 transverse lig. of knee
- 6. 髌韧带 patellar lig.
- 7. 髌关节面 patellar articular surface
- 8. 外侧髌 lateral condyle



A. 切开



B. 后面观

B. 后面观 Posterior aspect

- 9. 腓斜韧带 oblique popliteal lig.
- 10. 腓弓状韧带 arcuate popliteal lig.
- 11. 腓侧副韧带 fibular collateral lig.
- 12. 腓骨 fibula
- 13. 胫骨 tibia

图 52 膝关节 (A、B)

The knee joint (A,B)

1. 股骨 femur
2. 髌上囊 suprapatellar capsule
3. 股四头肌腱 quadriceps femoris tendon
4. 髌骨 patella
5. 翼状襞 alar folds
6. 髌韧带 patellar lig.
7. 胫骨 tibia




图 56 小腿骨的连结
The joints of the leg

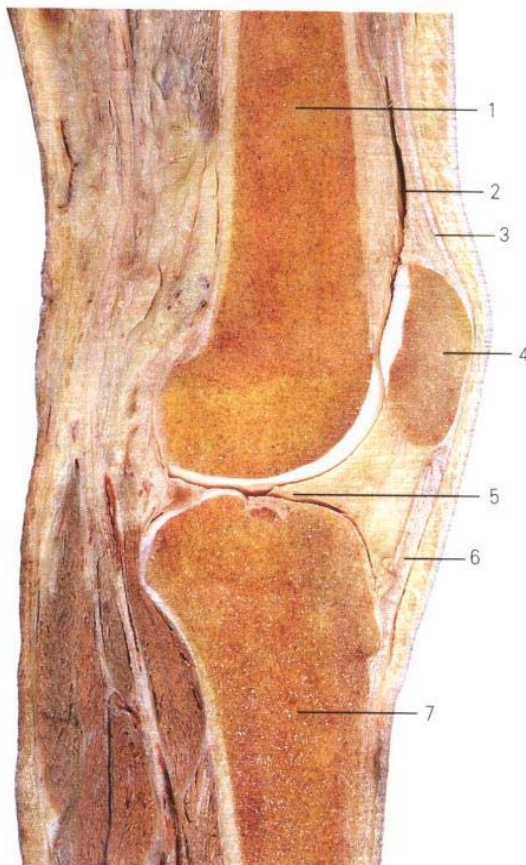


图 55 膝关节(矢状节面)
The knee joint(sagittal section)

1. 胫骨 tibia
2. 小腿骨间膜 crural interosseous membrane
3. 胫腓前韧带 anterior tibiofibular lig.
4. 腓骨 fibula
5. 胫腓关节 tibiofibular joint

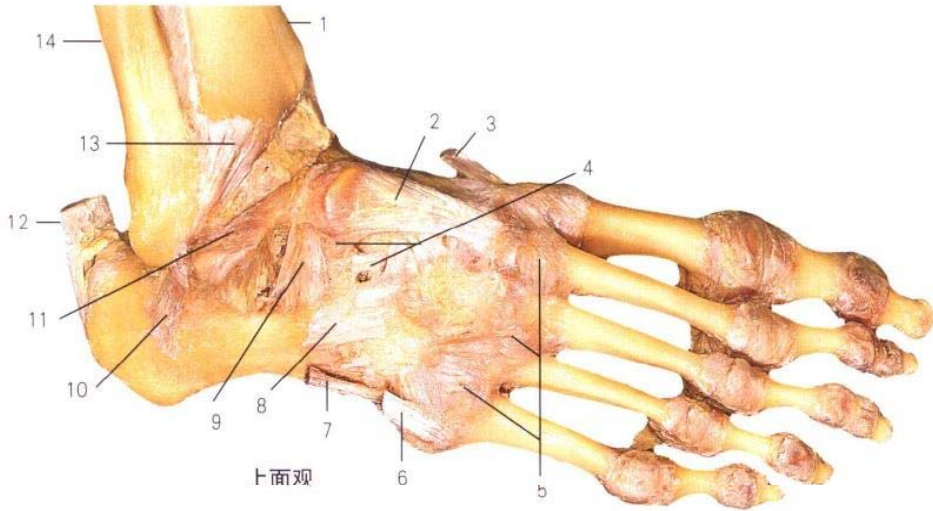
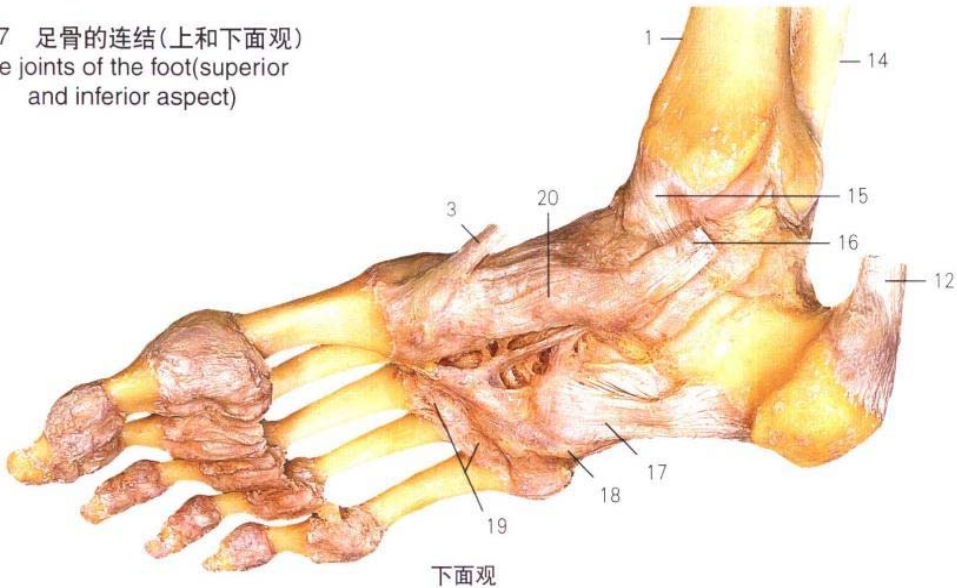
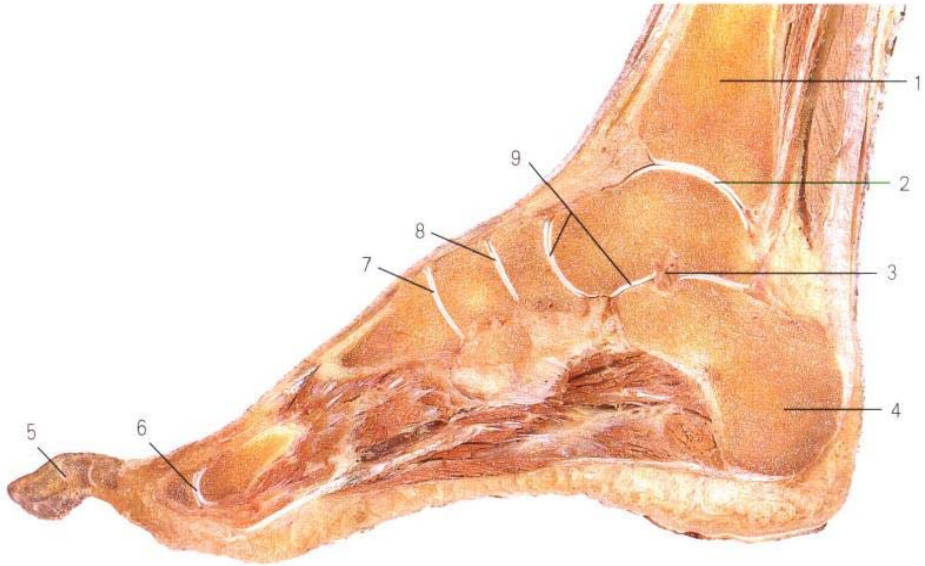


图 57 足骨的连结(上和下面观)
The joints of the foot (superior and inferior aspect)

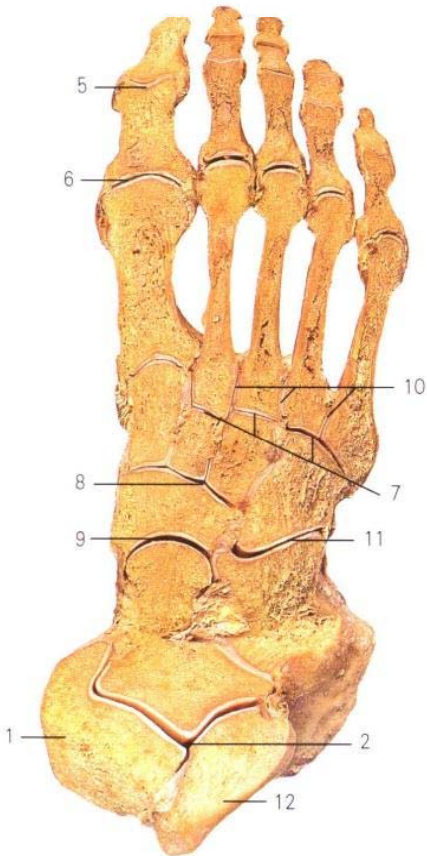


1. 胫骨 tibia
2. 楔舟背侧韧带 dorsal cuneonavicular lig.
3. 胫骨前肌腱 tibialis anterior tendon
4. 分歧韧带 bifurcated lig.
5. 跗跖背侧韧带 dorsal tarsometatarsal lig.
6. 腓骨短肌腱 peroneus brevis tendon
7. 腓骨长肌腱 peroneus longus tendon
8. 跟骰背侧韧带 dorsal calcaneocuboid lig.
9. 距跟骨间韧带 interosseous talocalcaneal lig.
10. 跟腓韧带 calcaneofibular lig.

11. 距腓前韧带 anterior talofibular lig.
12. 跟腱 tendo calcaneus
13. 胫腓前韧带 anterior tibiofibular lig.
14. 腓骨 fibula
15. 内侧(三角)韧带 medial (deltoid) lig.
16. 胫骨后肌腱 tibialis posterior tendon
17. 足底长韧带 long plantar lig.
18. 腓骨长肌腱 peroneus longus tendon
19. 跗骨足底韧带 plantar metatarsal lig.
20. 跗跖足底韧带 plantar tarsometatarsal lig.



A. 矢状剖面观



B. 冠状剖面观

1. 股骨 tibia
2. 距小腿关节(踝关节) talocrural (ankle) joint
3. 距跟骨间韧带 interosseous talocalcaneal lig.
4. 跟骨 calcaneus
5. 趾骨间关节 interphalangeal joint
6. 跖趾关节 metatarsophalangeal joint
7. 跗跖关节 tarsometatarsal joints
8. 楔舟关节 cuneonavicular joint
9. 距跟舟关节 talocalcaneonavicular joint
10. 跖骨间关节 intermetatarsal joints
11. 跟骰关节 calcaneocuboid joint
12. 腓骨 fibula

图 58 足骨的连结 (A、B)
The joints of the foot(A,B)

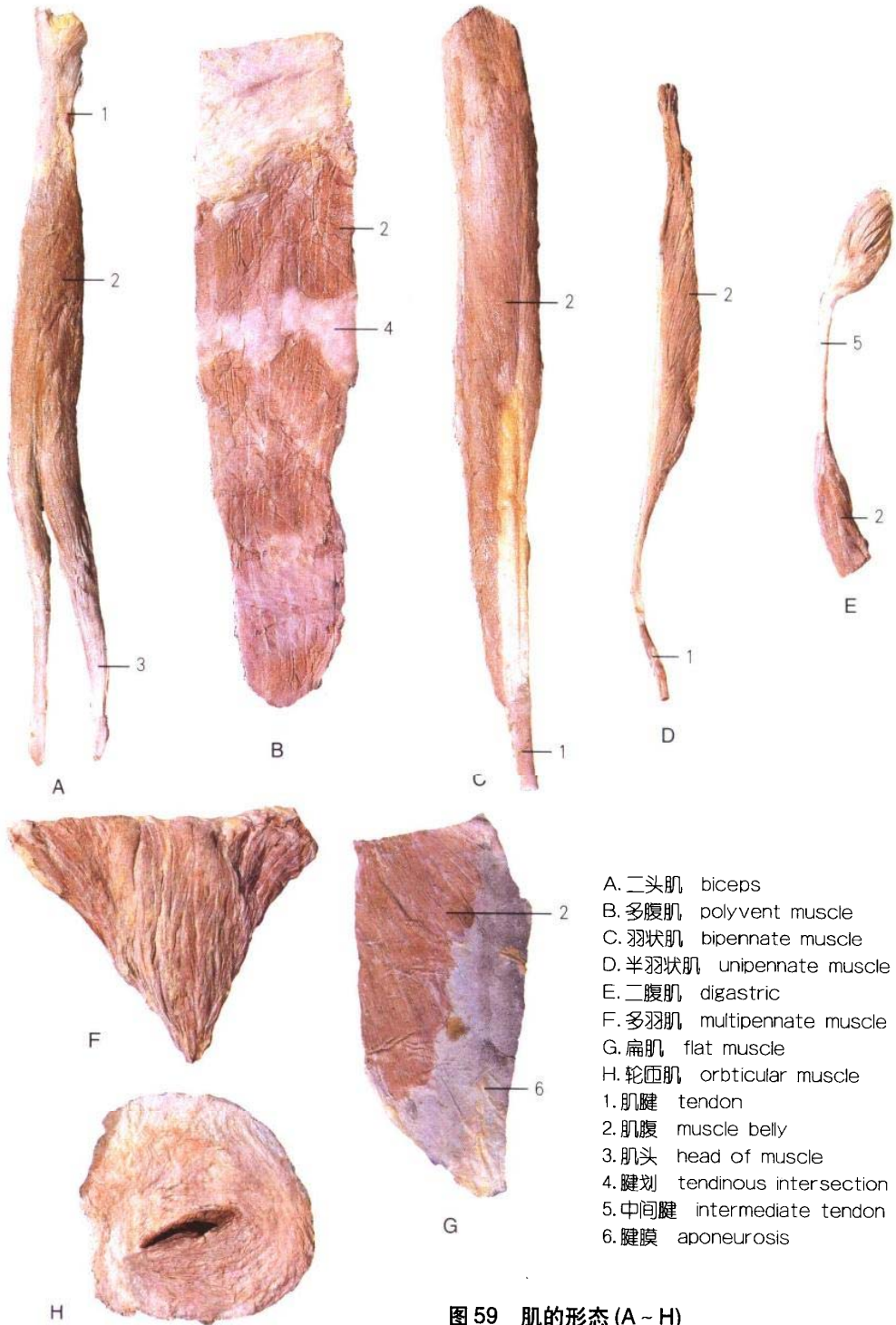


图 59 肌的形态 (A ~ H)
Forms of muscles (A ~ H)

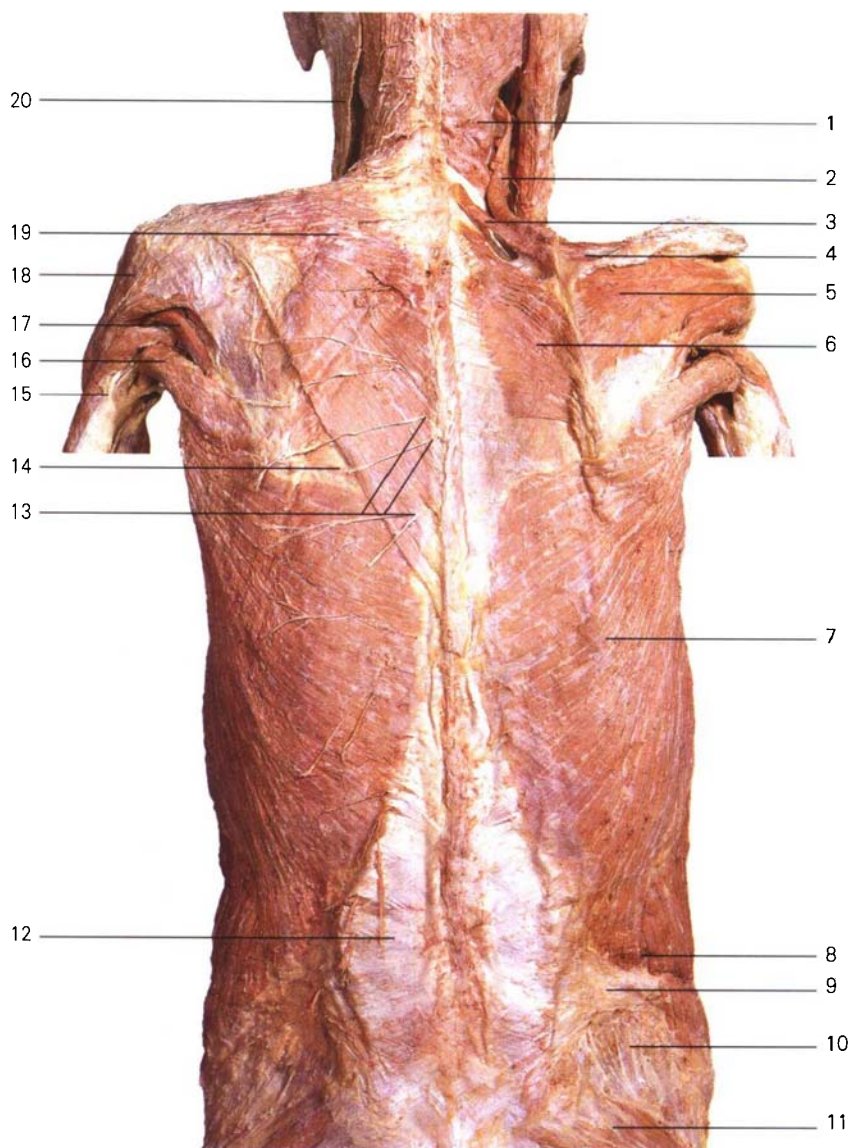
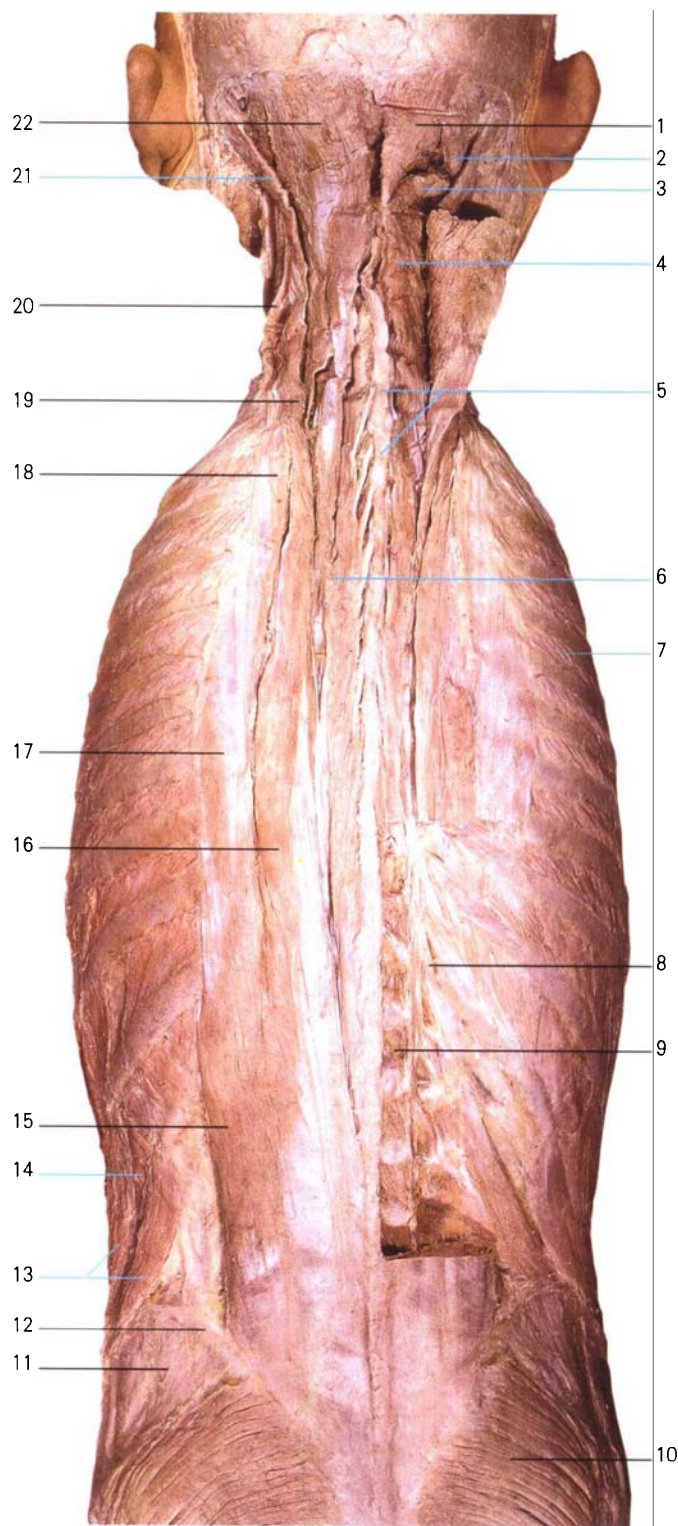


图 60 背部的肌 (I)
Muscles of back (I)

- | | |
|---------------------------|---|
| 1. 头夹肌 splenius capitis | 11. 臀大肌 gluteus maximus |
| 2. 肩胛提肌 levator scapulae | 12. 胸腰筋膜 thoracolumbar fascia |
| 3. 小菱形肌 rhomboideus minor | 13. 胸神经后支 posterior branches of thoracic n. |
| 4. 冈上肌 supraspinatus | 14. 听诊三角 triangle of auscultation |
| 5. 冈下肌 infraspinatus | 15. 肱三头肌 triceps brachii |
| 6. 大菱形肌 rhomboideus major | 16. 大圆肌 teres major |
| 7. 背阔肌 latissimus dorsi | 17. 小圆肌 teres minor |
| 8. 腰三角 lumbar triangle | 18. 三角肌 deltoid |
| 9. 髂嵴 iliac crest | 19. 斜方肌 trapezius |
| 10. 臀中肌 gluteus medius | 20. 胸锁乳突肌 sternocleidomastoid |



1. 头后大直肌, rectus capitis posterior major
2. 头上斜肌, obliquus capitis superior
3. 头下斜肌, obliquus capitis inferior
4. 颈半棘肌, semispinalis cervicis
5. 棘间肌, interspinales
6. 棘肌, spinalis
7. 肋间外肌, intercostales externi
8. 肋提肌, levatores costarum
9. 横突间肌, intertransversarii
10. 臀大肌, gluteus maximus
11. 臀中肌, gluteus medius
12. 髂嵴, iliac crest
13. 腹外斜肌, obliquus externus abdominis
14. 腹内斜肌, obliquus internus abdominis
15. 腰髂肋肌, iliocostalis lumborum
16. 胸最长肌, longissimus thoracis
17. 胸髂肋肌, iliocostalis thoracis
18. 颈髂肋肌, iliocostalis cervicis
19. 颈最长肌, longissimus cervicis
20. 后斜角肌, scalenus posterior
21. 头最长肌, longissimus capitis
22. 头半棘肌, semispinalis capitis

图 61 背部的肌(II)
Muscles of back(II)

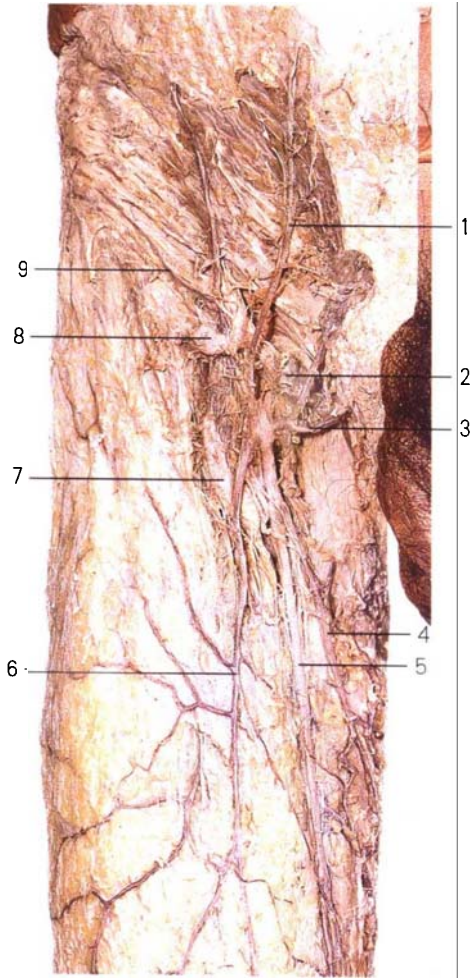
第

章

2

下肢

CHAPTER 2 THE LOWER LIMB



1. 腹壁浅静脉 superficial epigastric v.
2. 腹股沟上内侧浅淋巴结 superomedial superficial inguinal lymph nodes
3. 阴部外静脉 external pudendal v.
4. 股内侧浅静脉 medial superficial femoral v.
5. 大隐静脉 great saphenous v.
6. 股外侧浅静脉 lateral superficial femoral v.
7. 腹股沟下浅淋巴结 inferior superficial inguinal lymph nodes
8. 腹股沟上外侧浅淋巴结 superolateral superficial inguinal lymph nodes
9. 旋髂浅静脉 superficial iliac circumflex v.

图 62 股前内侧区的浅静脉
Superficial veins of anterior and medial region of the thigh

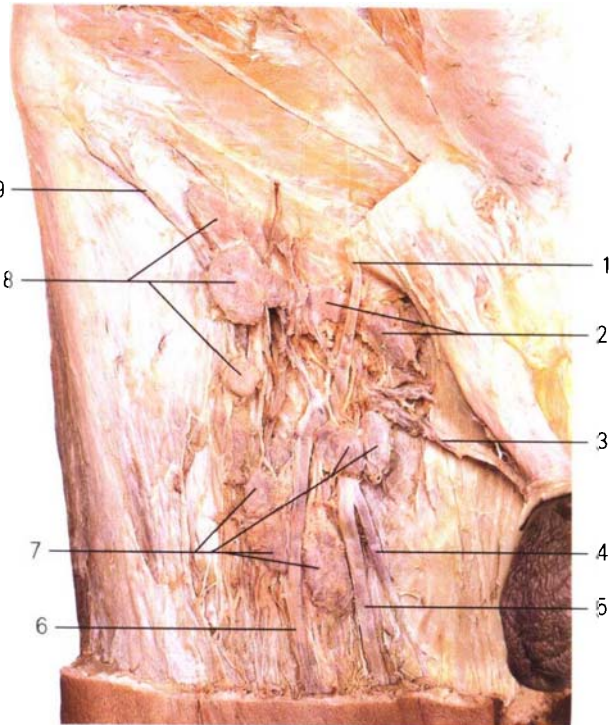


图 63 腹股沟浅淋巴结
Superficial inguinal lymph nodes

1. 腹股沟韧带 inguinal lig.
2. 股静脉 femoral v.
3. 耻骨肌 pectineus
4. 精索 spermatic cord
5. 大隐静脉 great saphenous v.
6. 长收肌 adductor longus
7. 股薄肌 gracilis
8. 缝匠肌 sartorius
9. 股直肌 rectus femoris
10. 股内侧肌 vastus medialis

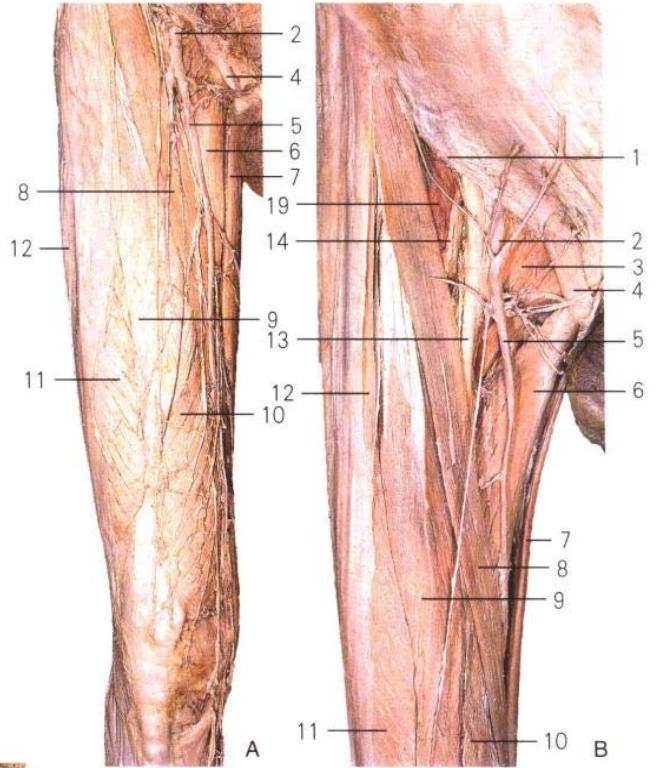


图64 股前内侧区的肌、神经和血管(I)(A, B)
Muscles, nerves and blood vessels of anterior and medial region of the thigh(I)(A, B)

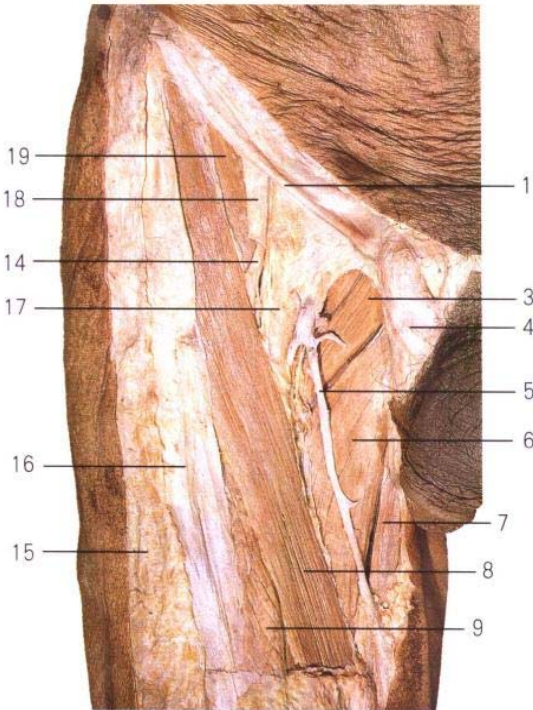


图65 股鞘
Femoral sheath

11. 股外侧肌 vastus lateralis
12. 阔筋膜张肌 tensor fasciae latae
13. 股动脉 femoral a.
14. 股神经 femoral n.
15. 浅筋膜 superficial fascial
16. 阔筋膜 fascia lata
17. 股鞘 femoral sheath
18. 髂筋膜 iliac fascia
19. 髂腰肌 iliopsoas

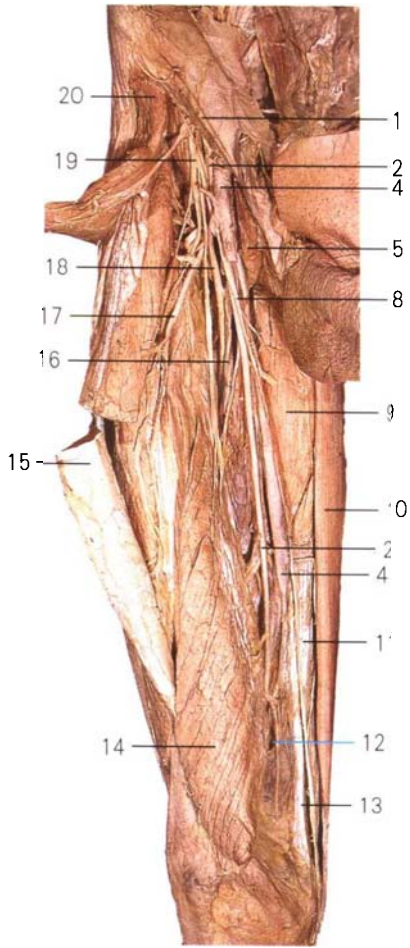


图 66 股前内侧区的肌、神经和血管(Ⅱ)
Muscles, nerves and blood vessels of anterior and medial region of the thigh (II)

1. 腹股沟韧带 inguinal lig.
2. 股动脉 femoral a.
3. 股管及腹股沟深淋巴结 femoral canal and deep inguinal lymph nodes
4. 股静脉 femoral v.
5. 耻骨肌 pectineus
6. 短收肌 adductor brevis
7. 闭孔神经(前支) obturator n.(anterior branch)
8. 隐神经 saphenous n.
9. 长收肌 adductor longus
10. 股薄肌 gracilis
11. 大收肌 adductor magnus
12. 收肌腱裂孔 adductor tendinous opening
13. 大收肌(腱) adductor magnus (tendon)

14. 股内侧肌 vastus medialis
15. 股直肌 rectus femoris
16. 股深静脉 deep femoral v.
17. 旋股外侧动脉 lateral femoral circumflex a.
18. 股深动脉 deep femoral a.
19. 股神经 femoral n.
20. 缝匠肌 sartorius

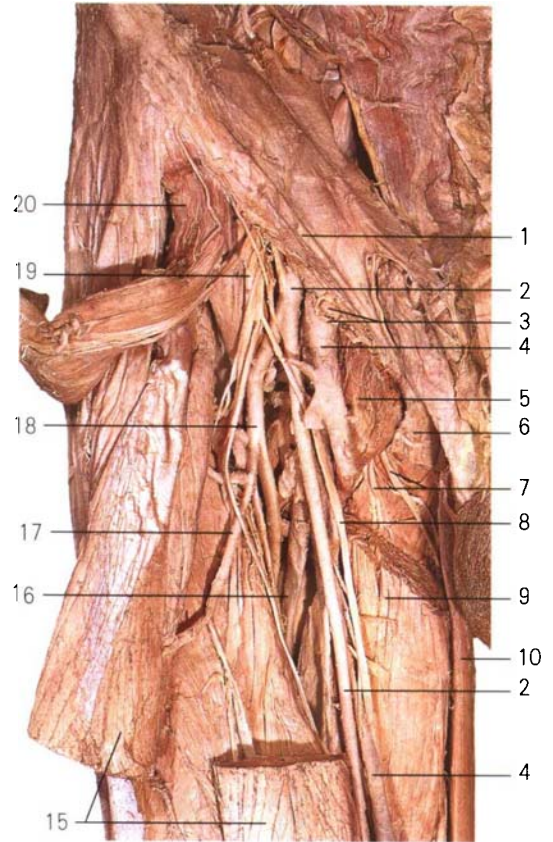


图 67 股前内侧区的肌、神经和血管(Ⅲ)
Muscles, nerves and blood vessels of anterior and medial region of the thigh (III)

1. 耻骨肌 pectineus
2. 股静脉 femoral v.
3. 旋股内侧动脉 medial femoral circumflex a.
4. 闭孔外肌 obturator externus
5. 闭孔神经 obturator n.
6. 短收肌 adductor brevis
7. 股深静脉 deep femoral v.
8. 穿动脉 perforating a.
9. 大收肌 adductor magnus
10. 股薄肌 gracilis
11. 隐神经 saphenous n.

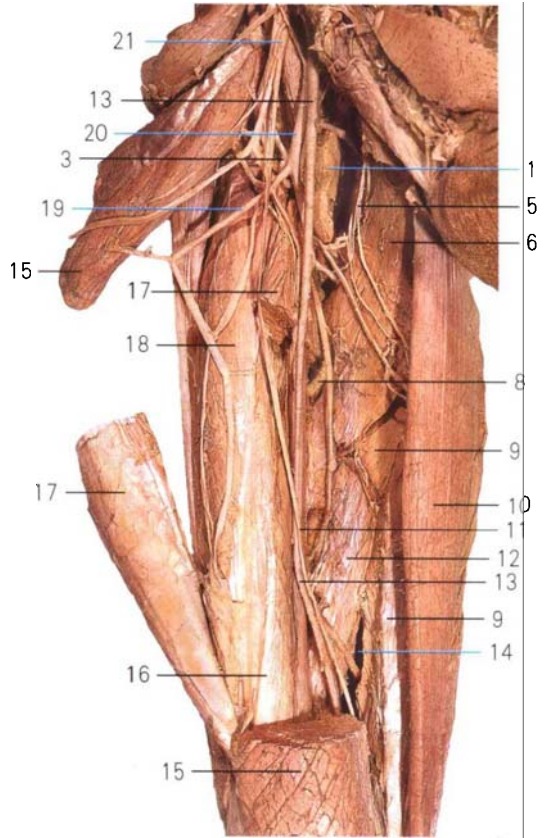


图 68 股动脉及股深动脉
Femoral artery and deep femoral artery

12. 长收肌 adductor longus
13. 股动脉 femoral a.
14. 收肌腱裂孔 adductor tendinous opening
15. 股直肌 rectus femoris
16. 股内侧肌 vastus medialis
17. 股中间肌 vastus intermedius
18. 股外侧肌 vastus lateralis
19. 旋股外侧动脉 lateral femoral circumflex a.
20. 股深动脉 deep femoral a.
21. 股神经 femoral n.

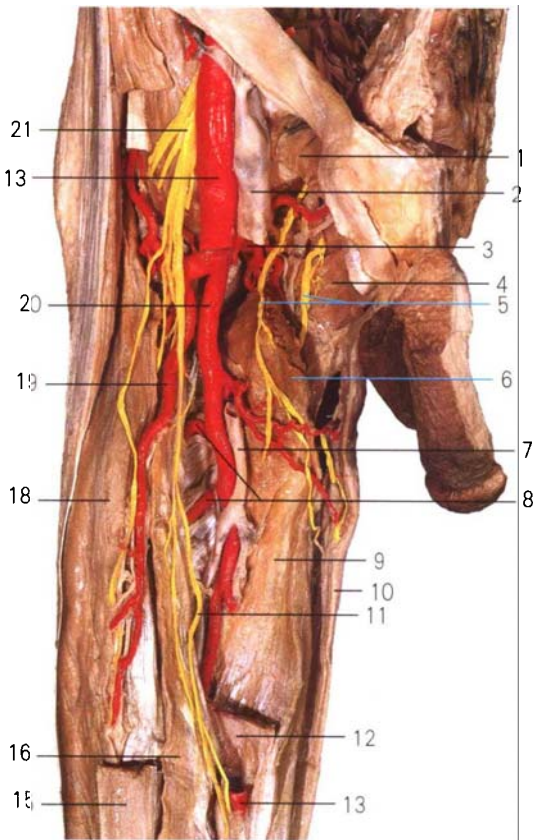


图 69 股深动脉及其穿动脉
Deep femoral artery and perforating arteries

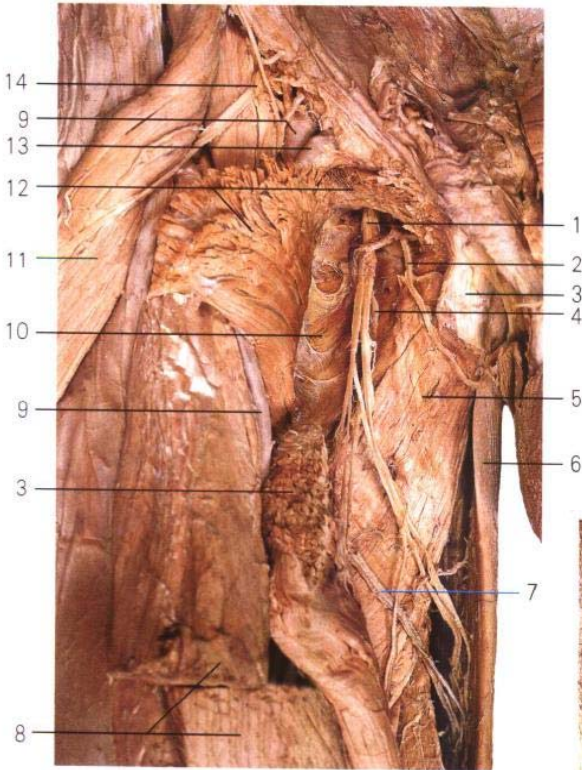


图 70 闭孔神经和血管
Obturator nerves and obturator vessels

1. 闭孔神经 obturator n.
2. 闭孔动脉(前支) obturator a.(anterior branch)
3. 长收肌 adductor longus
4. 闭孔动脉(后支) obturator a.(posterior branch)
5. 短收肌 adductor brevis
6. 股薄肌 gracilis
7. 旋股内侧动脉(深支) medial femoral circumflex a. (deep branch)
8. 股直肌 rectus femoris
9. 股动脉 femoral a.
10. 闭孔外肌 obturator externus
11. 缝匠肌 sartorius
12. 耻骨肌 pectineus
13. 股静脉 femoral v.
14. 股神经 femoral n.

1. 臀上皮神经 superior clunial n.
2. 臀内侧皮神经 medial clunial n.
3. 臀下皮神经 inferior clunial n.
4. 股后皮神经 posterior femoral cutaneous n.

1. 臀中肌 gluteus medius
2. 髂后上棘 posterior superior iliac spine
3. 臀大肌 gluteus maximus
4. 股骨大转子 greater trochanter
5. 股二头肌 biceps femoris
6. 髂胫束 iliotibial tract
7. 半膜肌 semimembranosus
8. 半腱肌 semitendinosus
9. 股薄肌 gracilis

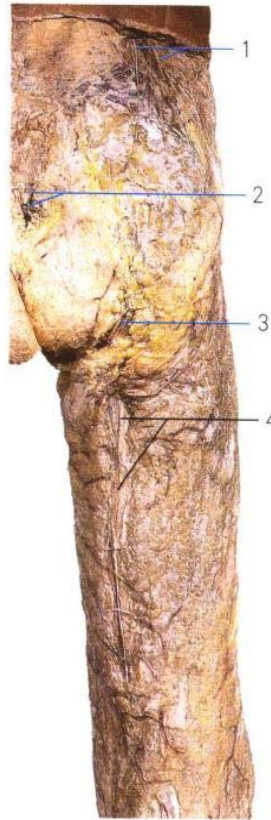


图 71 臀区和股后区的皮神经
Cutaneous nerves of the gluteal region and posterior region of the thigh

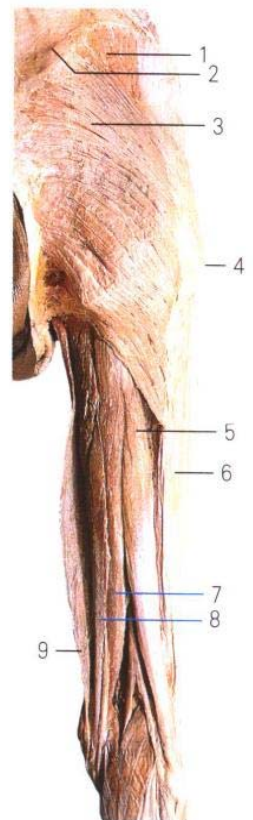


图 72 臀区和股后区的肌
Muscles of the gluteal region and posterior region of the thigh

1. 臀中肌 gluteus medius
2. 臀小肌 gluteus minimus
3. 梨状肌 piriformis
4. 上孖肌 gemellus superior
5. 闭孔内肌(腱) obturator internus (tendon)
6. 下孖肌 gemellus inferior
7. 股方肌 quadratus femoris
8. 阴部神经 pudendal n.
9. 阴部内动脉 internal pudendal a.
10. 股后皮神经 posterior femoral cutaneous n.
11. 骶结节韧带 sacrotuberous lig.
12. 坐骨神经 sciatic n.
13. 臀下神经 inferior gluteal n.
14. 臀下动脉 inferior gluteal a.
15. 臀上神经 superior gluteal n.
16. 臀上动脉 superior gluteal a.
17. 臀大肌 gluteus maximus

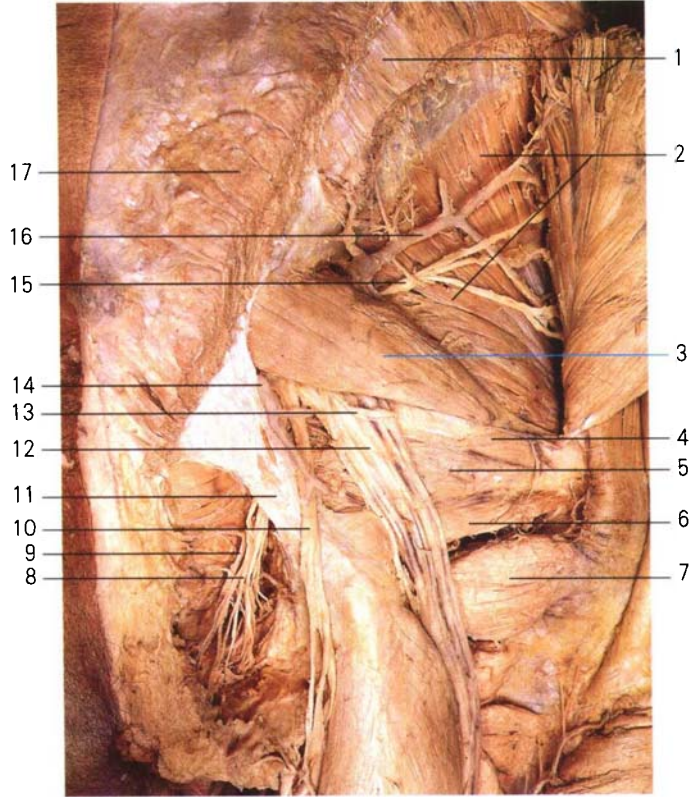


图 73 臀区的肌、神经和血管(I)
Muscles, nerves and blood vessels of the gluteal region(I)

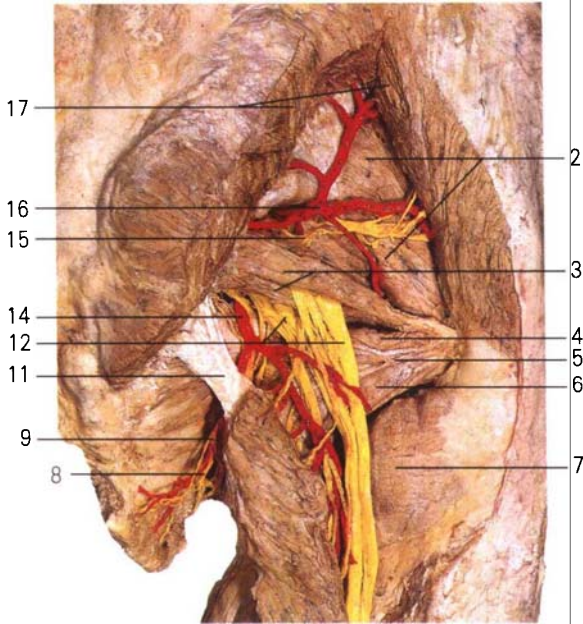
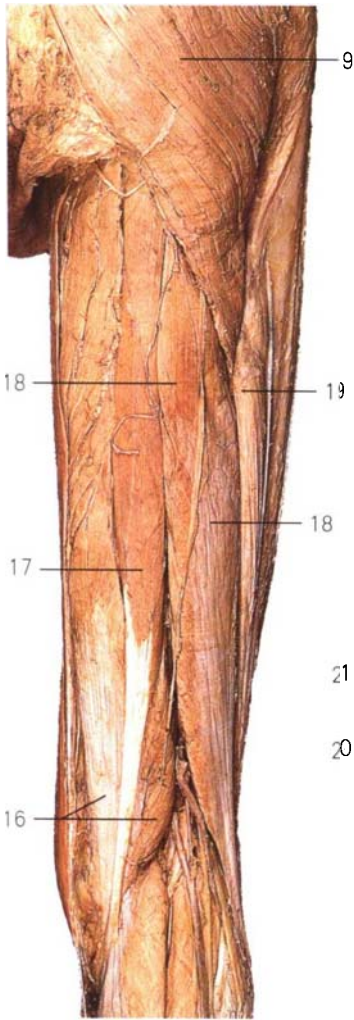


图 74 臀区的肌、神经和血管(II)
Muscles, nerves and blood vessels of the gluteal region(II)



1. 臀中肌 gluteus medius
2. 梨状肌 piriformis
3. 上孖肌 gemellus superior
4. 闭孔内肌(腱) obturator internus (tendon)
5. 下孖肌 gemellus inferior
6. 股方肌 quadratus femoris
7. 旋股内侧动脉 medial femoral circumflex a.
8. 臀下动脉 inferior gluteal a.
9. 臀大肌 gluteus maximus
10. 大收肌 adductor magnus
11. 第一穿动脉 first perforating a.
12. 第二穿动脉 2nd perforating a.
13. 第三穿动脉 3rd perforating a.

图 75 股后区的肌
Muscles of posterior region of the thigh

14. 坐骨神经 sciatic n.
15. 股二头肌(短头) biceps femoris (short head)
16. 半膜肌 semimembranosus
17. 半腱肌 semitendinosus
18. 股二头肌(长头) biceps femoris (long head)
19. 阔筋膜张肌 tensor fasciae latae
20. 股后皮神经 posterior femoral cutaneous n.
21. 骶结韧带 sacrotuberous lig.

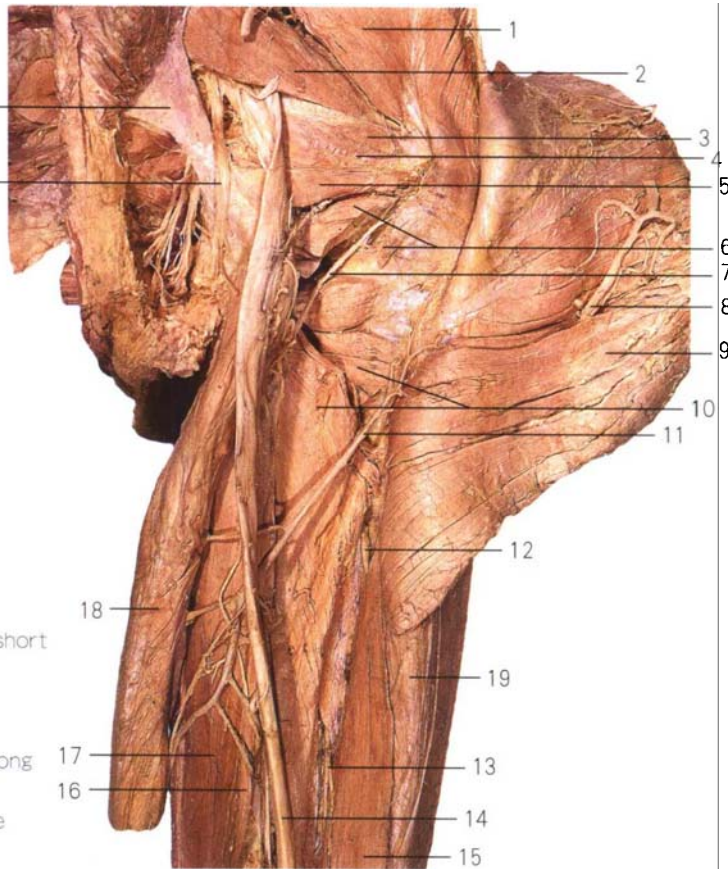


图 76 股后区的肌、神经和血管
Muscles, nerves and blood vessels of posterior region of the thigh

1. 坐骨神经 sciatic n.
2. 股二头肌 biceps femoris
3. 腓静脉 popliteal v.
4. 腓动脉 popliteal a.
5. 腓总神经 common peroneal n.
6. 膝上外侧动脉 lateral superior genicular a.
7. 胫神经 tibial n.
8. 小隐静脉 small saphenous v.
9. 腓肠肌(外侧头) gastrocnemius (lateral head)
10. 膝下外侧动脉 lateral inferior genicular a.
11. 腓肠外侧皮神经 lateral sural cutaneous n.

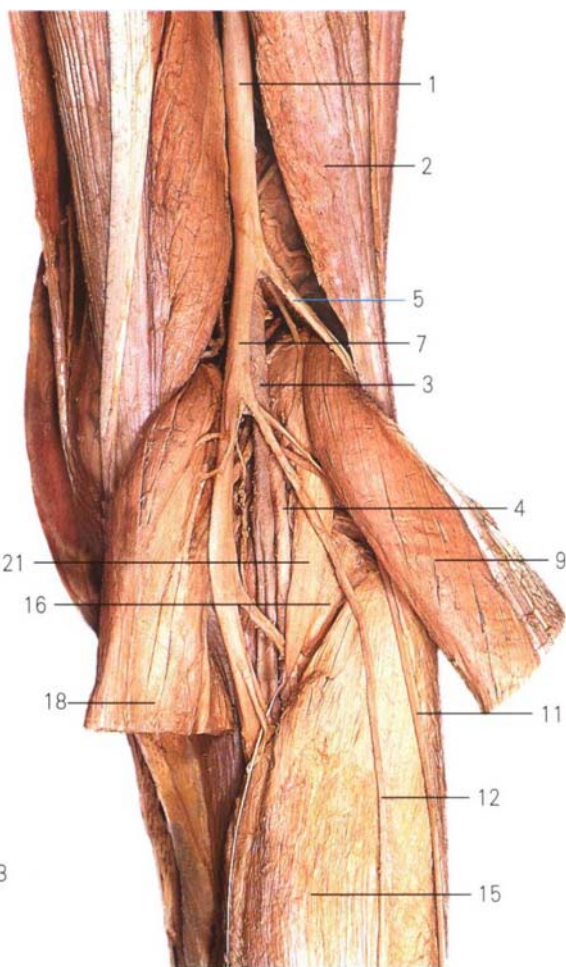


图 77 腓窝的神经和血管
Nerves and blood vessels of the popliteal fossa

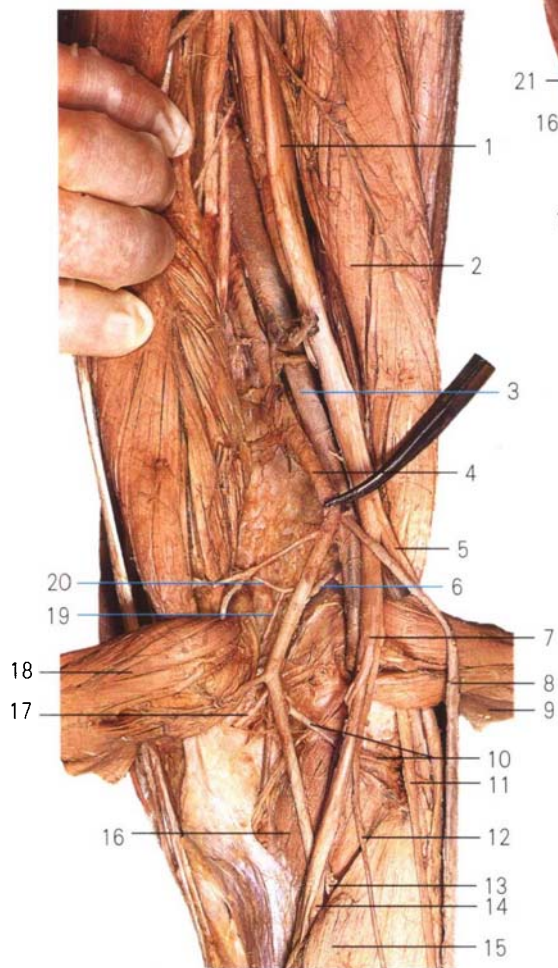
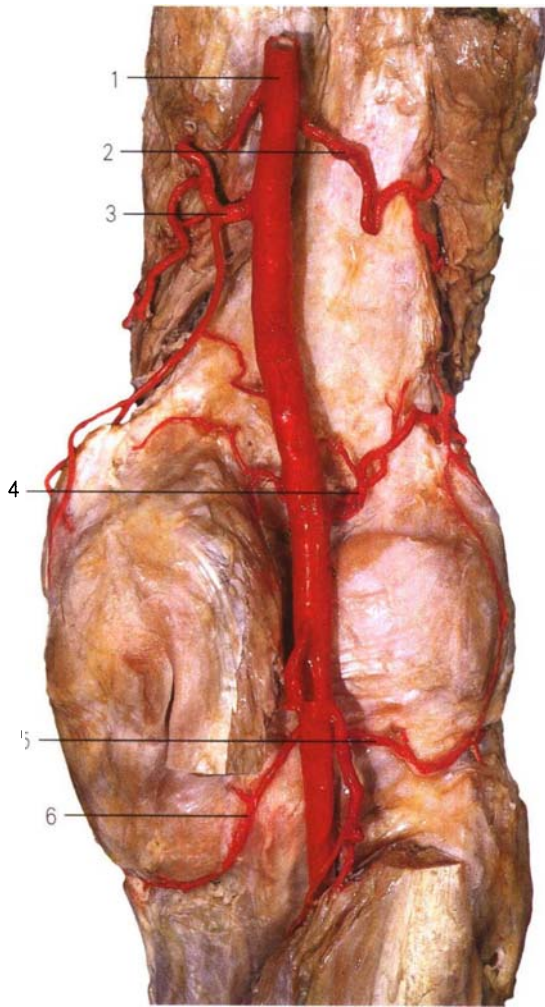
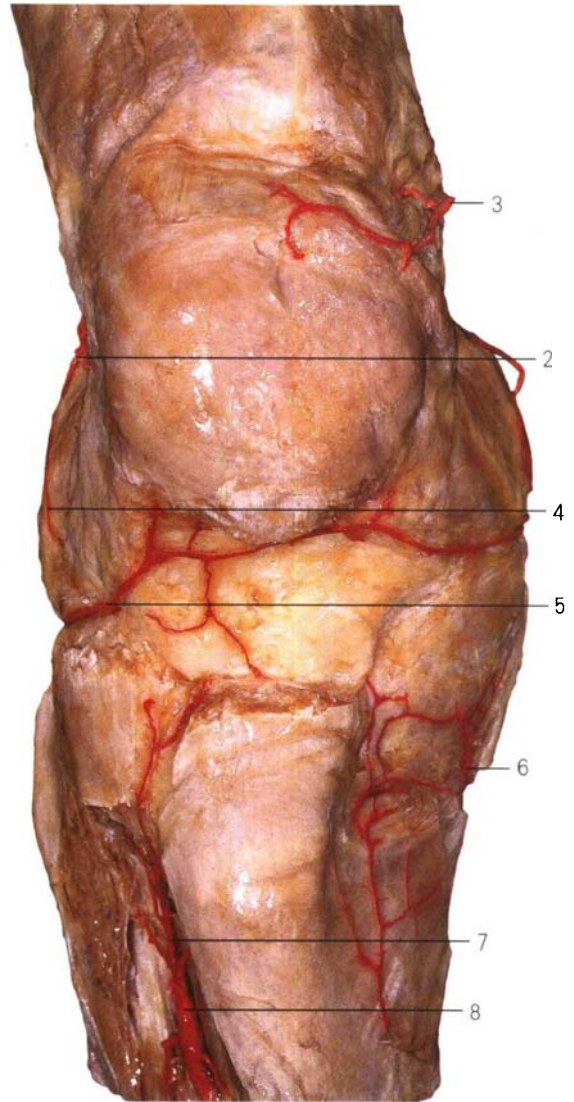


图 78 腓动脉的分支
Branches of the popliteal artery

12. 腓肠内侧皮神经 medial sural cutaneous n.
13. 胫前动脉 anterior tibial a.
14. 胫后动脉 posterior tibial a.
15. 比目鱼肌 soleus
16. 腓肌 popliteus
17. 膝下内侧动脉 medial inferior genicular a.
18. 腓肠肌(内侧头) gastrocnemius (medial head)
19. 膝中动脉 middle genicular a.
20. 膝上内侧动脉 medial superior genicular a.
21. 跖肌 plantaris



A. 后面观



B. 前面观

1. 腘动脉 popliteal a.
2. 膝上外侧动脉 lateral superior genicular a.
3. 膝上内侧动脉 medial superior genicular a.
4. 膝中动脉 middle genicular a.
5. 膝下外侧动脉 lateral inferior genicular a.
6. 膝下内侧动脉 medial inferior genicular a.
7. 胫前返动脉 anterior tibial recurrent a.
8. 胫前动脉 anterior tibial a.

图 79 膝关节网 (A、B)
Genicular articular rete(A,B)

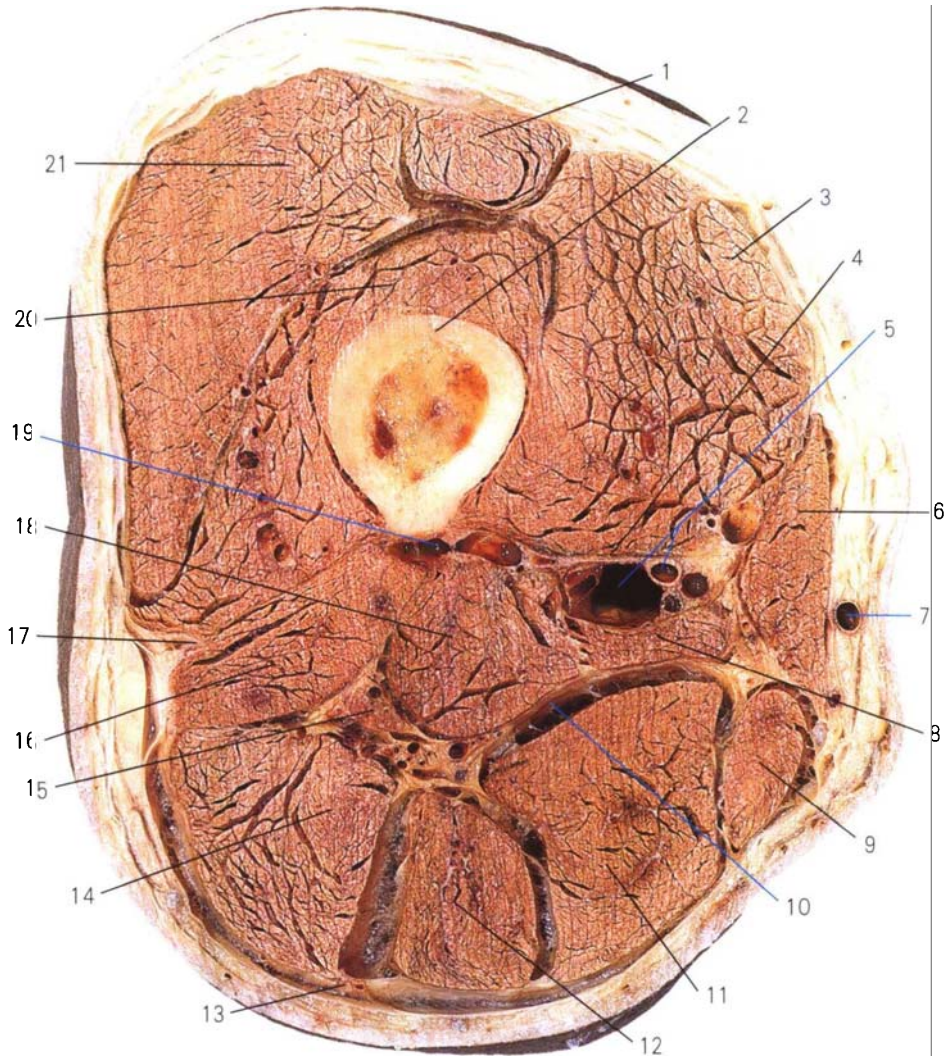


图 80 股部中段横切面(下面观)

Transverse section through the middle of the thigh (inferior aspect)

- | | |
|--|---|
| 1. 股直肌 rectus femoris | 12. 半腱肌 semitendinosus |
| 2. 股骨 femur | 13. 股后皮神经 posterior femoral cutaneous n. |
| 3. 股内侧肌 vastus medialis | 14. 股二头肌(长头) biceps femoris (long head) |
| 4. 股内侧肌间隔 medial femoral intermuscular septum | 15. 坐骨神经 sciatic n. |
| 5. 股静脉、股动脉 femoral v. and a. | 16. 股二头肌(短头) biceps femoris (short head) |
| 6. 缝匠肌 sartorius | 17. 股外侧肌间隔 lateral femoral intermuscular septum |
| 7. 大隐静脉 great saphenous v. | 18. 大收肌 adductor magnus |
| 8. 长收肌 adductor longus | 19. 股深动脉及穿动脉 deep femoral a. and perforating a. |
| 9. 股薄肌 gracilis | 20. 股中间肌 vastus intermedius |
| 10. 股后肌间隔 posterior femoral intermuscular septum | 21. 股外侧肌 vastus lateralis |
| 11. 半膜肌 semimembranosus | |

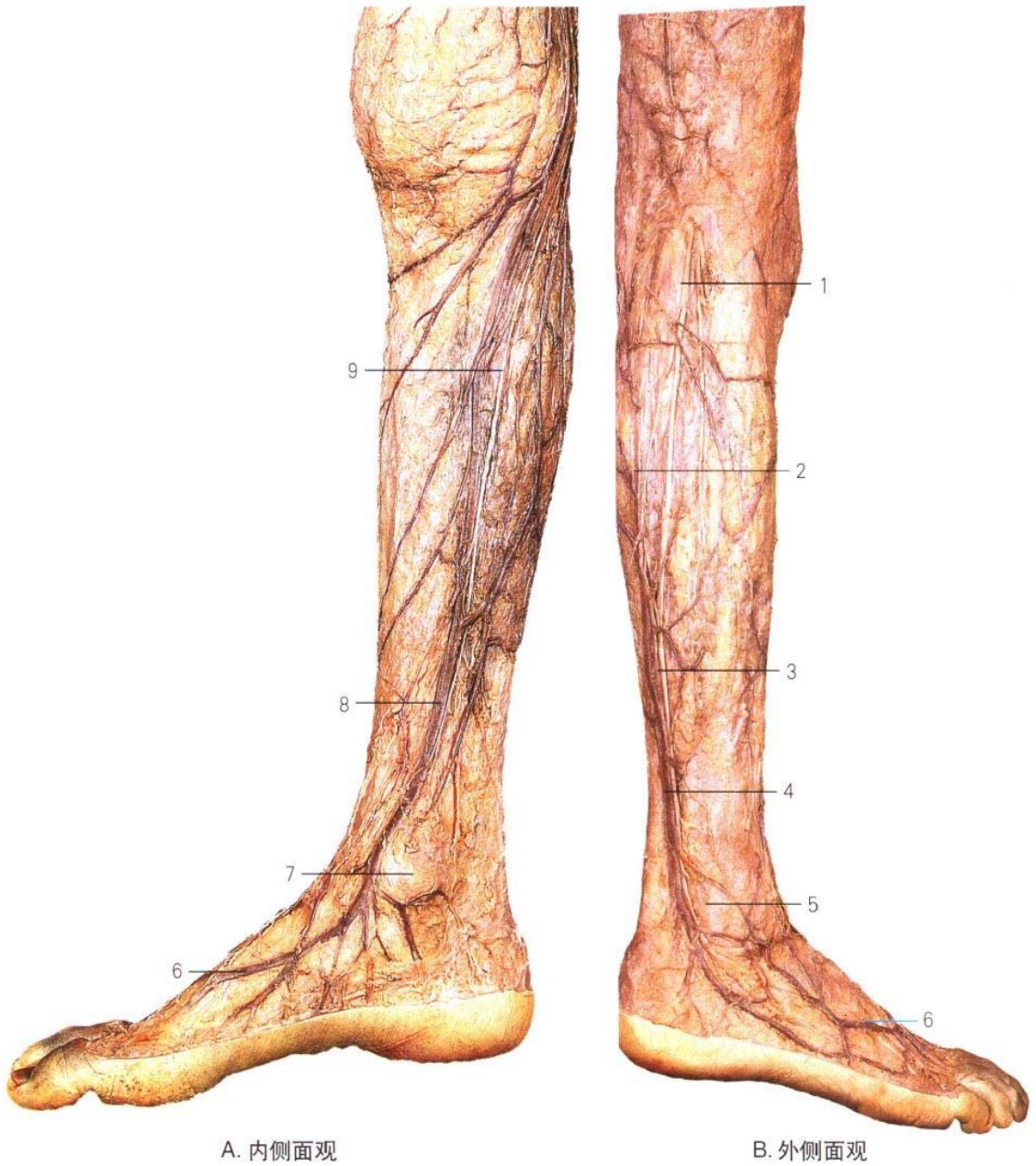

图 81 小腿的浅静脉 (A, B)
Superficial veins of the leg (A, B)

- 1. 腓肠外侧皮神经 lateral sural cutaneous n.
- 2. 腓肠内侧皮神经 medial sural cutaneous n.
- 3. 腓肠神经 sural n.
- 4. 小隐静脉 small saphenous v.
- 5. 外踝 lateral malleolus

- 6. 足背静脉弓 dorsal venous arch of foot
- 7. 内踝 medial malleolus
- 8. 大隐静脉 great saphenous v.
- 9. 隐神经 saphenous n.

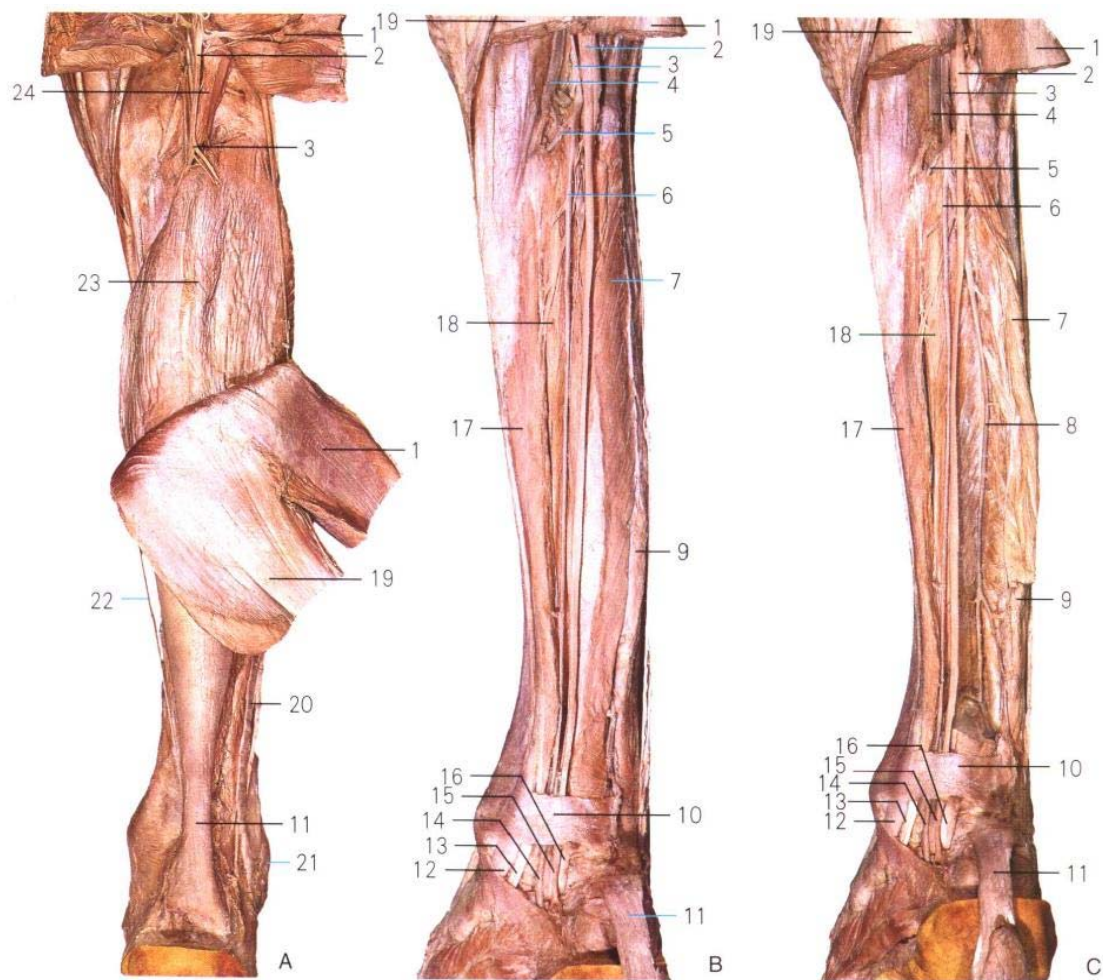


图 82 小腿后区的肌、神经和血管 (A、B、C)
Muscles, nerves and blood vessels of the posterior crural region (A, B, C)

- | | |
|--|--|
| 1. 腓肠肌(外侧头) gastrocnemius (lateral head) | 13. 趾长屈肌(腱) flexor digitorum longus (tendon) |
| 2. 胫神经 tibial n. | 14. 胫后动脉 posterior tibial a. |
| 3. 腓动脉 popliteal a. | 15. 胫神经 tibial n. |
| 4. 腓静脉 popliteal v. | 16. 拇长屈肌(腱) flexor hallucis longus (tendon) |
| 5. 胫前动脉 anterior tibial a. | 17. 趾长屈肌 flexor digitorum longus |
| 6. 胫后动脉 posterior tibial a. | 18. 胫骨后肌 tibialis posterior |
| 7. 拇长屈肌 flexor hallucis longus | 19. 腓肠肌(内侧头) gastrocnemius (medial head) |
| 8. 腓动脉 peroneal a. | 20. 大隐静脉 great saphenous v. |
| 9. 腓骨长肌 peroneus longus | 21. 外踝 lateral malleolus |
| 10. 屈肌支持带 flexor retinaculum | 22. 跖肌(腱) plantaris (tendon) |
| 11. 跟腱 tendo calcaneus | 23. 比目鱼肌 soleus |
| 12. 胫骨后肌(腱) tibialis posterior (tendon) | 24. 跖肌 plantaris |

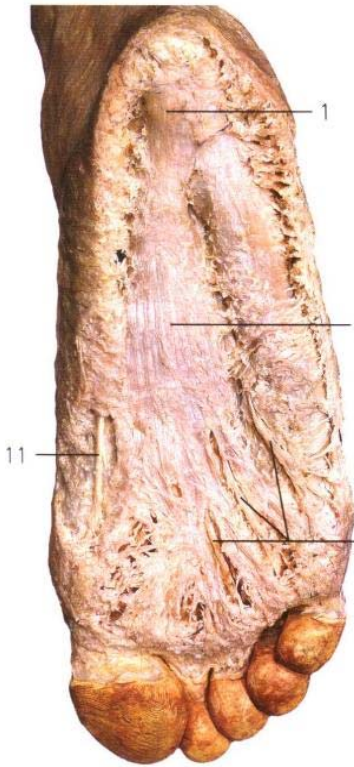


图 83 足底腱膜
Plantar aponeurosis

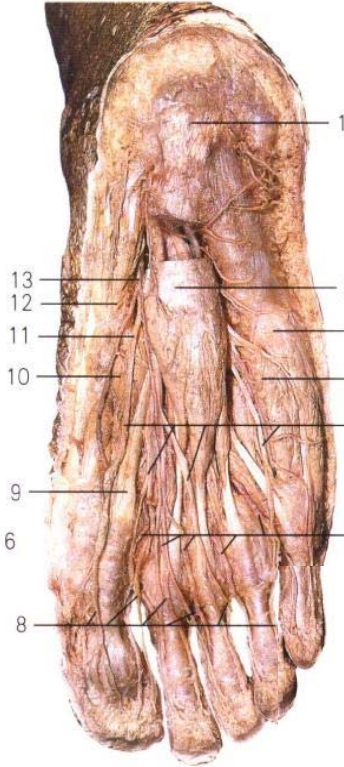


图 84 足底肌、神经和血管(I)
Muscles, nerves and blood vessels
of the sole of foot(I)

1. 跟骨 calcaneus
2. 足底腱膜 plantar aponeurosis
3. 趾短屈肌, flexor digitorum brevis
4. 小趾展肌, abductor digiti minimi
5. 小趾短屈肌, flexor digiti minimi brevis
6. 趾足底总神经 common plantar digital n.
7. 趾足底总动脉 common plantar digital a.
8. 趾足底固有动脉、神经 proper plantar digital a. & n.
9. 拇长屈肌(腱) flexor hallucis longus (tendon)
10. 拇短屈肌, flexor hallucis brevis

11. 足底内侧神经 medial plantar n.
12. 拇展肌, abductor hallucis
13. 足底内侧动脉 medial plantar a.
14. 足底外侧神经 lateral plantar n.
15. 足底方肌, quadratus plantae
16. 蚓状肌, lumbricales
17. 趾长屈肌(腱) flexor digitorum longus (tendon)
18. 胫后动脉 posterior tibial a.
19. 胫骨后肌(腱) tibialis posterior(tendon)

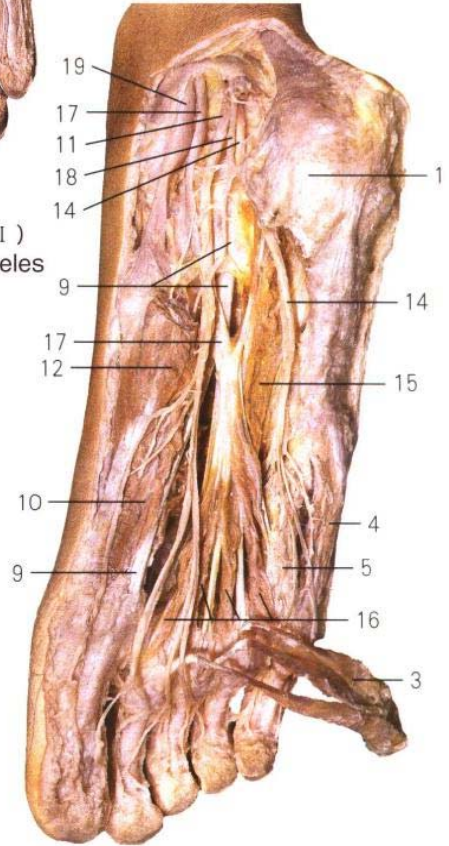


图 85 足底肌、神经和血管(II)
Muscles, nerves and blood vessels
of the sole of foot(II)

1. 跟腱 tendo calcaneus
2. 跟骨 calcaneus
3. 足底外侧神经 lateral plantar n.
4. 足底外侧动脉 lateral plantar a.
5. 拇长屈肌(腱) flexor hallucis longus (tendon)
6. 足底方肌 quadratus plantae
7. 趾长屈肌(腱) flexor digitorum longus (tendon)
8. 腓骨长肌(腱) peroneus longus (tendon)
9. 拇收肌(斜头) adductor hallucis (oblique head)
10. 小趾展肌 abductor digiti minimi
11. 小趾短屈肌 flexor digiti minimi brevis
12. 趾短屈肌 flexor digitorum brevis

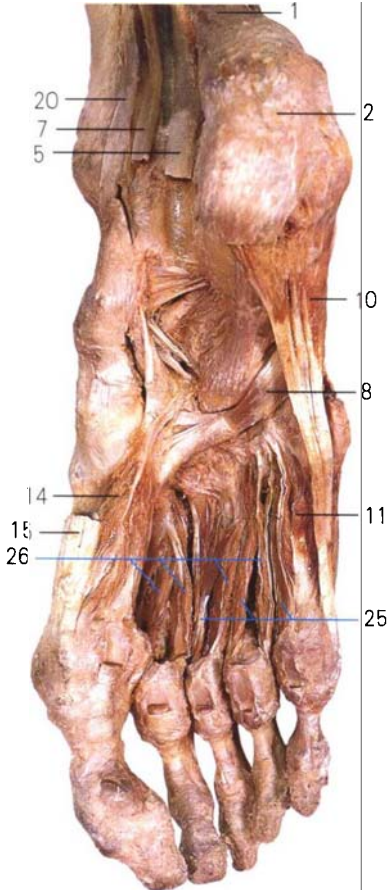


图 88 足底肌
Muscles of the sole of foot

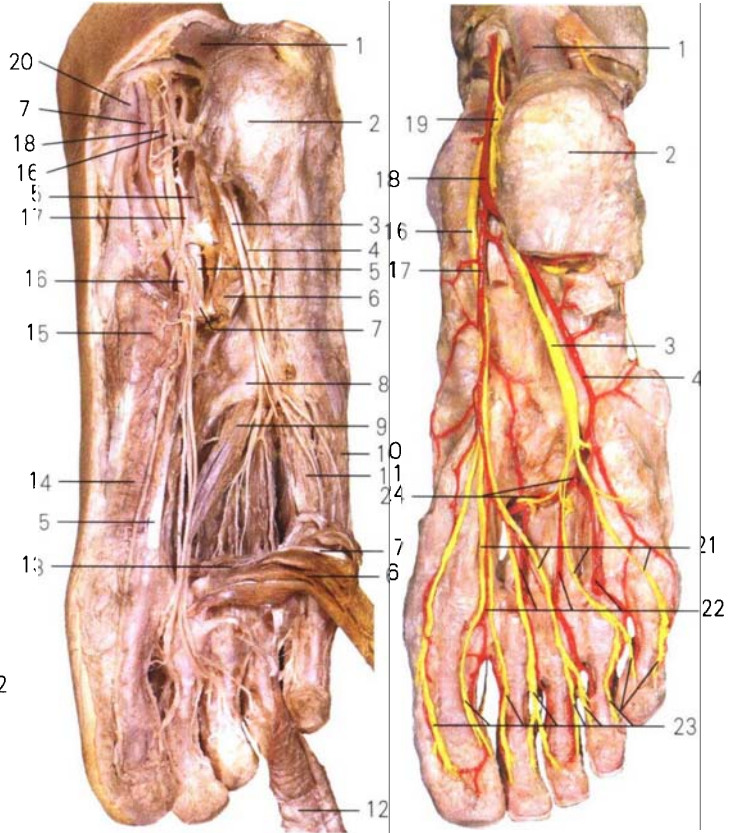
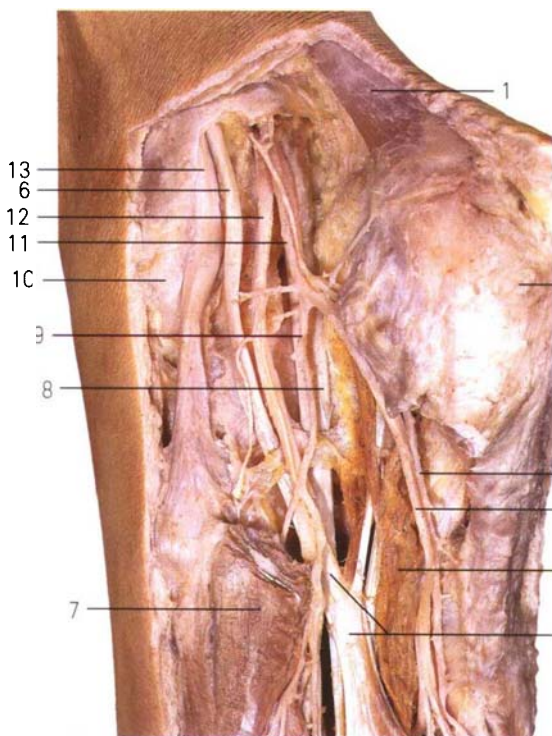


图 86 足底肌、神经和血管(Ⅲ)
Muscles, nerves and blood vessels of the sole of foot (Ⅲ)

图 87 足底肌、神经和血管(Ⅳ)
Muscles, nerves and blood vessels of the sole of foot (Ⅳ)

13. 拇收肌(横头) adductor hallucis (transverse head)
14. 拇短屈肌 flexor hallucis brevis
15. 拇展肌 abductor hallucis
16. 足底内侧神经 medial plantar n.
17. 足底内侧动脉 medial plantar a.
18. 胫后动脉 posterior tibial a.
19. 胫神经 tibial n.
20. 胫骨后肌(腱) tibialis posterior (tendon)
21. 趾足底总神经 common plantar digital n.
22. 趾足底总动脉 common plantar digital a.
23. 趾足底固有神经、动脉 proper plantar digital n. & a.
24. 足底深弓 deep plantar arch
25. 骨间足底肌 plantar interossei
26. 骨间背侧肌 dorsal interossei



1. 跟腱 tendo calcaneus
2. 跟骨 calcaneus
3. 足底外侧动脉 lateral plantar a.
4. 足底外侧神经 lateral plantar n.
5. 足底方肌 quadratus plantae
6. 趾长屈肌(腱) flexor digitorum longus (tendon)
7. 拇展肌 abductor hallucis
8. 拇长屈肌(腱) flexor hallucis longus (tendon)
9. 足底内侧动脉 medial plantar a.
10. 内踝 medial malleolus
11. 胫后动脉 posterior tibial a.
12. 足底内侧神经 medial plantar n.
13. 胫骨后肌(腱) tibialis posterior (tendon)

图 89 踝管
Malleolar canal

1. 胫骨前肌 tibialis anterior
2. 胫骨 tibia
3. 胫前动脉 anterior tibial a.
4. 小腿骨间膜 crural interosseous membrane
5. 胫骨后肌 tibialis posterior
6. 趾长屈肌 flexor digitorum longus
7. 胫神经及胫后动脉 tibial n. and posterior tibial a.
8. 比目鱼肌 soleus
9. 腓肠肌(腱膜) gastrocnemius (aponeurosis)
10. 小隐静脉 small saphenous v.
11. 腓动脉、静脉 peroneal a. & v.
12. 拇长屈肌 flexor hallucis longus
13. 小腿后肌间隔 posterior crural intermuscular septum
14. 腓骨 fibula
15. 腓骨长肌和短肌 peroneus longus and brevis
16. 小腿前肌间隔 anterior crural intermuscular septum
17. 拇长伸肌 extensor hallucis longus
18. 趾长伸肌 extensor digitorum longus

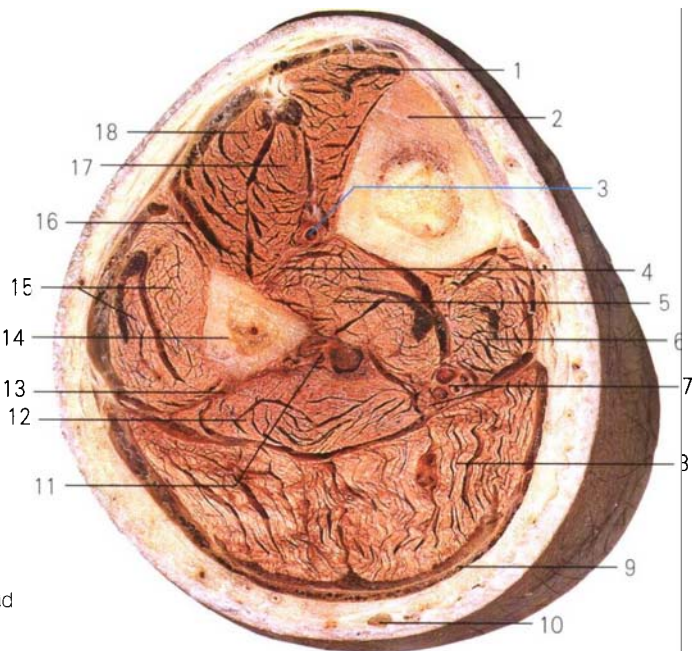


图 90 小腿中部横断面(下面观)
Transverse section through the middle of the leg (inferior aspect)

1. 腓深神经 deep peroneal n.
2. 胫前动脉 anterior tibial a.
3. 胫骨前肌 tibialis anterior
4. 踇长伸肌 extensor hallucis longus
5. 趾长伸肌 extensor digitorum longus
6. 伸肌上支持带 superior extensor retinaculum
7. 腓浅神经 superficial peroneal n.
8. 伸肌下支持带 inferior extensor retinaculum
9. 趾短伸肌 extensor digitorum brevis
10. 第五跖骨粗隆 tuberosity of fifth metatarsal bone
11. 第三腓骨肌(腱) peroneus tertius (tendon)
12. 腓骨短肌(腱) peroneus brevis (tendon)

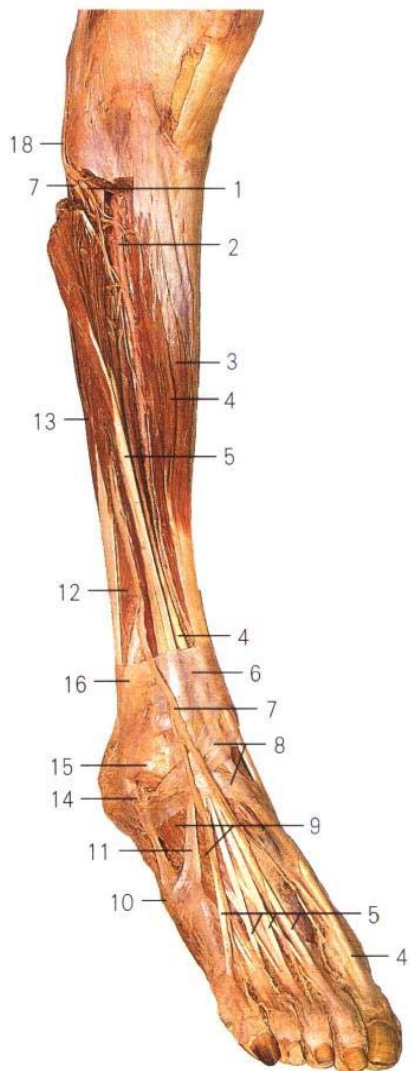


图91 小腿前外侧区和足背
Anteriolateral crural region and
dorsum of foot

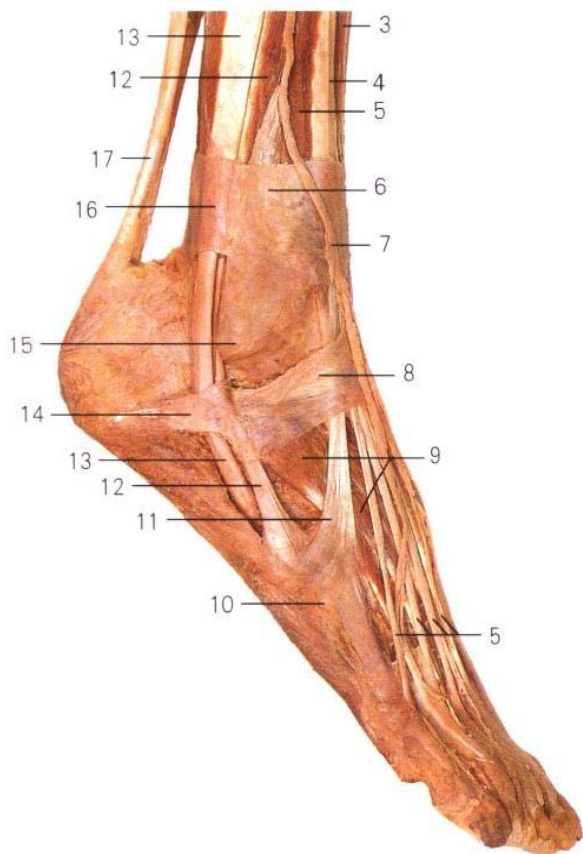


图92 小腿伸肌支持带和腓骨肌支持带
Extensor retinaculum and peroneal
retinaculum of the leg.

3. 腓骨长肌(腱) peroneus longus (tendon)
4. 腓骨肌下支持带 inferior peroneal retinaculum
5. 外踝 lateral malleolus
6. 腓骨肌上支持带 superior peroneal retinaculum
7. 跟腱 tendo calcaneus
8. 腓总神经 common peroneal n.

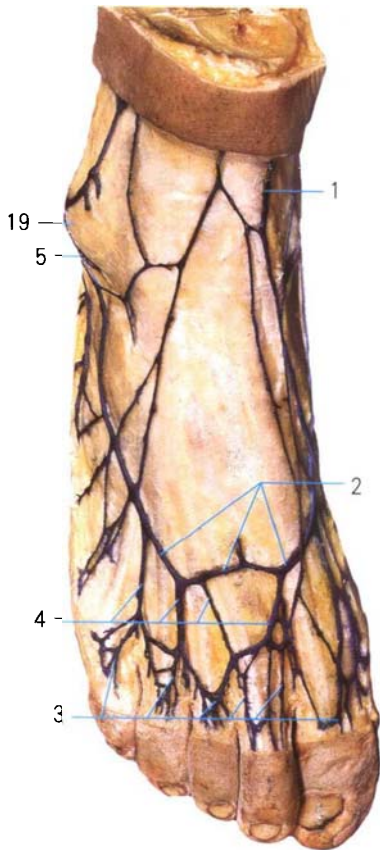


图 93 足背的浅静脉(上面观)
Superficial veins of the dorsum of foot(superior aspect)

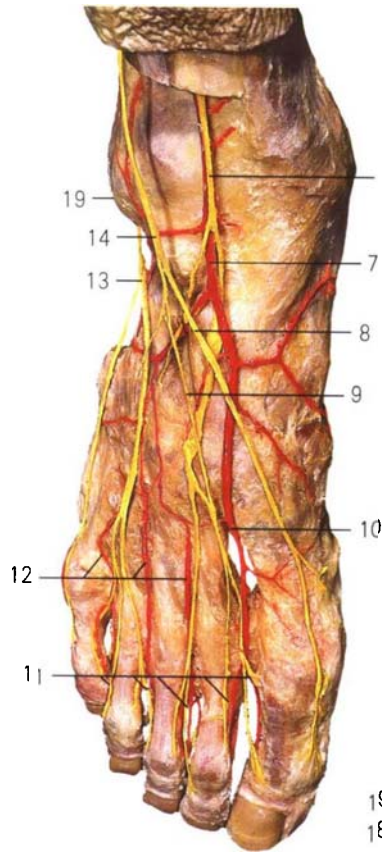


图 94 足背的神经和动脉
Nerves and arteries of the dorsum of foot

1. 大隐静脉 great saphenous v.
2. 足背静脉弓 dorsal venous arch of foot
3. 趾背静脉 dorsal digital v. of foot
4. 跖背静脉 dorsal metatarsal v.
5. 小隐静脉 small saphenous v.
6. 腓深神经 deep peroneal n.
7. 足背动脉 dorsal a. of foot
8. 足背内侧皮神经 medial dorsal cutaneous n. of foot
9. 足背中间皮神经 intermediate dorsal cutaneous n. of foot
10. 第一跖背动脉 first dorsal metatarsal a.
11. 趾背神经和动脉 dorsal digital n. and a. of foot

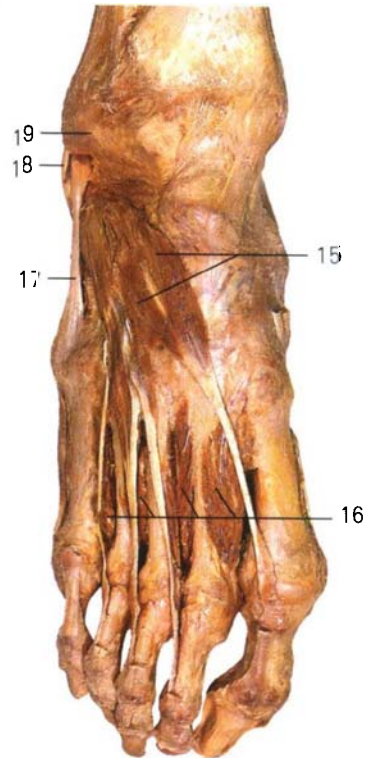


图 95 足肌(上面观)
Muscles of the foot(superior aspect)

12. 跖背动脉 dorsal metatarsal a.
13. 足背外侧皮神经 lateral dorsal cutaneous n. of foot
14. 腓浅神经 superficial peroneal n.
15. 趾短伸肌 extensor digitorum brevis
16. 骨间背侧肌 dorsal interossei
17. 腓骨短肌(腱) peroneus brevis (tendon)
18. 腓骨长肌(腱) peroneus longus (tendon)
19. 外踝 lateral malleolus

第

章

3

上肢

CHAPTER 3 THE UPPER LIMB



PRACTICE COLOUR ATLAS OF HUMAN ANATOMY

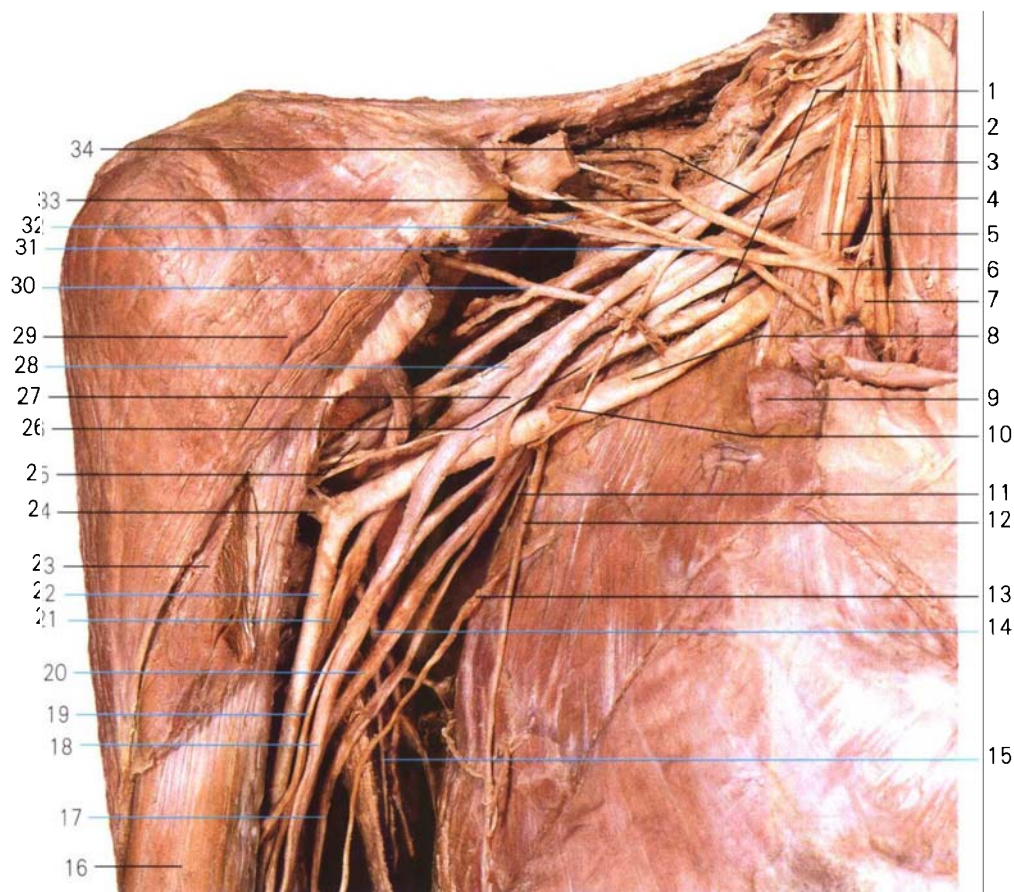


图 97 腋窝的血管和神经(I)

Blood vessels and nerves of the axillary fossa (I)

- | | |
|--|--|
| 1. 臂丛根 roots of the brachial plexus | 18. 正中神经 median n. |
| 2. 颈升动脉 ascending cervical a. | 19. 肌皮神经 musculocutaneous n. |
| 3. 迷走神经 vagus n. | 20. 尺神经 ulnar n. |
| 4. 前斜角肌 scalenus anterior | 21. 桡神经 radial n. |
| 5. 膈神经 phrenic n. | 22. 肱动脉 brachial a. |
| 6. 甲状腺颈干 thyrocervical trunk | 23. 胸大肌 pectoralis major |
| 7. 锁骨下动脉 subclavian a. | 24. 旋肱后动脉 posterior humeral circumflex a. |
| 8. 腋动脉 axillary a. | 25. 腋神经 axillary n. |
| 9. 锁骨下静脉 subclavian v. | 26. 臂丛内侧束 medial cord of brachial plexus |
| 10. 胸肩峰动脉 thoracoacromial a. | 27. 臂丛外侧束 lateral cord of brachial plexus |
| 11. 胸长神经 long thoracic n. | 28. 臂丛后束 posterior cord of brachial plexus |
| 12. 胸外侧动脉 lateral thoracic a. | 29. 三角肌 deltoid |
| 13. 肋间臂神经 intercostobrachial n. | 30. 三角肌支 branch of deltoid |
| 14. 胸背动脉 thoracodorsal a. | 31. 肩胛上动脉 suprascapular a. |
| 15. 胸背神经 thoracodorsal n. | 32. 肩胛上神经 suprascapular n. |
| 16. 肱二头肌 biceps brachii | 33. 颈横动脉 transverse cervical a. |
| 17. 前臂内侧皮神经 medial antebrachial cutaneous n. | 34. 中斜角肌, scalenus medius |

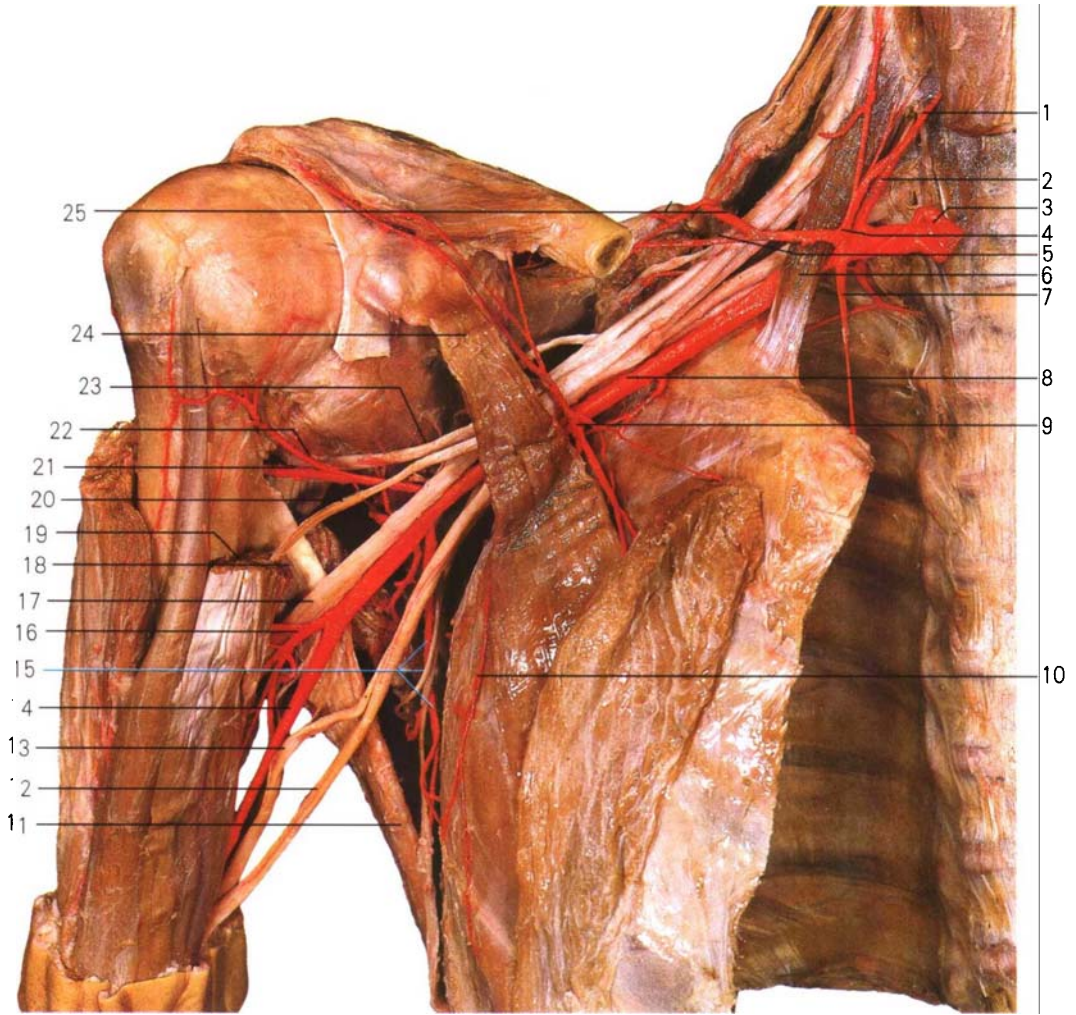


图 98 腋窝的血管和神经(II)
Blood vessels and nerves of the axillary fossa(II)

- | | |
|-------------------------------|---|
| 1. 甲状腺下动脉 inferior thyroid a. | 14. 肱动脉 brachial a. |
| 2. 椎动脉 vertebral a. | 15. 胸背动脉和胸背神经 thoracodorsal a.and n. |
| 3. 锁骨下动脉 subclavian a. | 16. 肱深动脉 deep brachial a. |
| 4. 甲状腺干 thyrocervical trunk | 17. 桡神经 radial n. |
| 5. 肩胛上动脉 suprascapular a. | 18. 喙肱肌 coracobrachialis |
| 6. 前斜角肌 scalenus anterior | 19. 肱二头肌 biceps brachii |
| 7. 胸廓内动脉 internal thoracic a. | 20. 肌皮神经 musculocutaneous n. |
| 8. 腋动脉 axillary a. | 21. 旋肱后动脉 posterior humeral circumflex a. |
| 9. 胸肩峰动脉 thoracoacromial a. | 22. 旋肱前动脉 anterior humeral circumflex a. |
| 10. 胸外侧动脉 lateral thoracic a. | 23. 腋神经 axillary n. |
| 11. 背阔肌 latissimus dorsi | 24. 胸小肌 pectoralis minor |
| 12. 正中神经 median n. | 25. 颈浅动脉与肩胛提肌 superficial cervical a.and levator scapulae |
| 13. 尺神经 ulnar n. | |

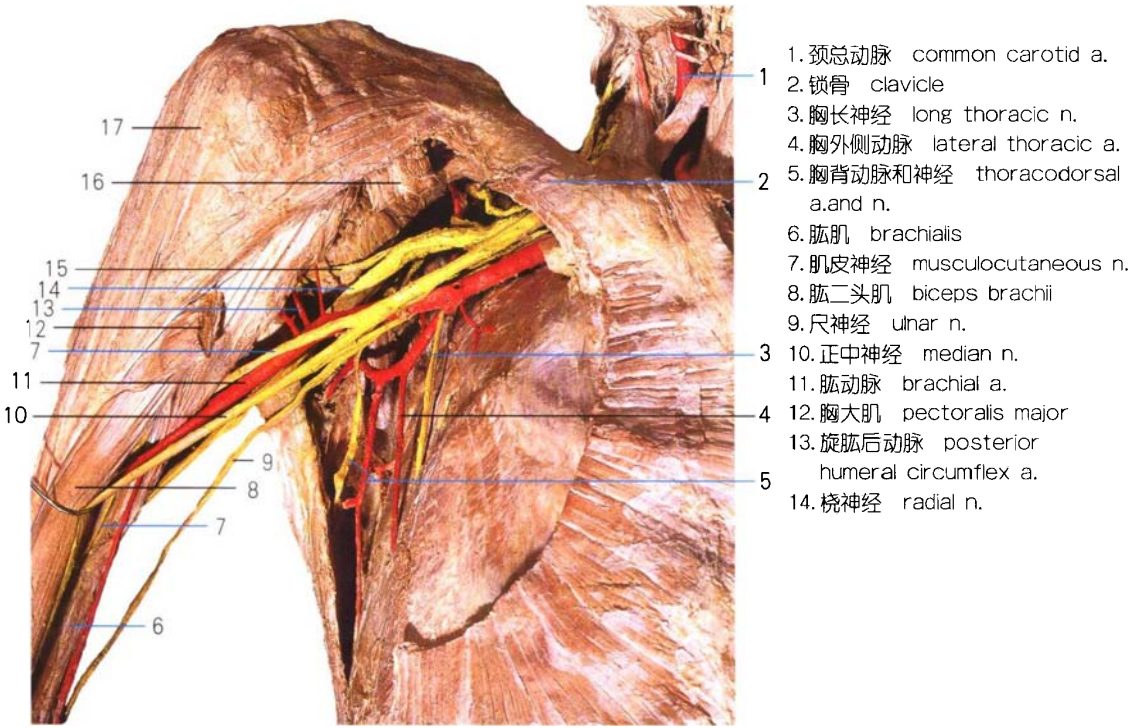


图99 腋窝的血管和神经(Ⅲ)
 Blood vessels and nerves of the axillary fossa (Ⅲ)

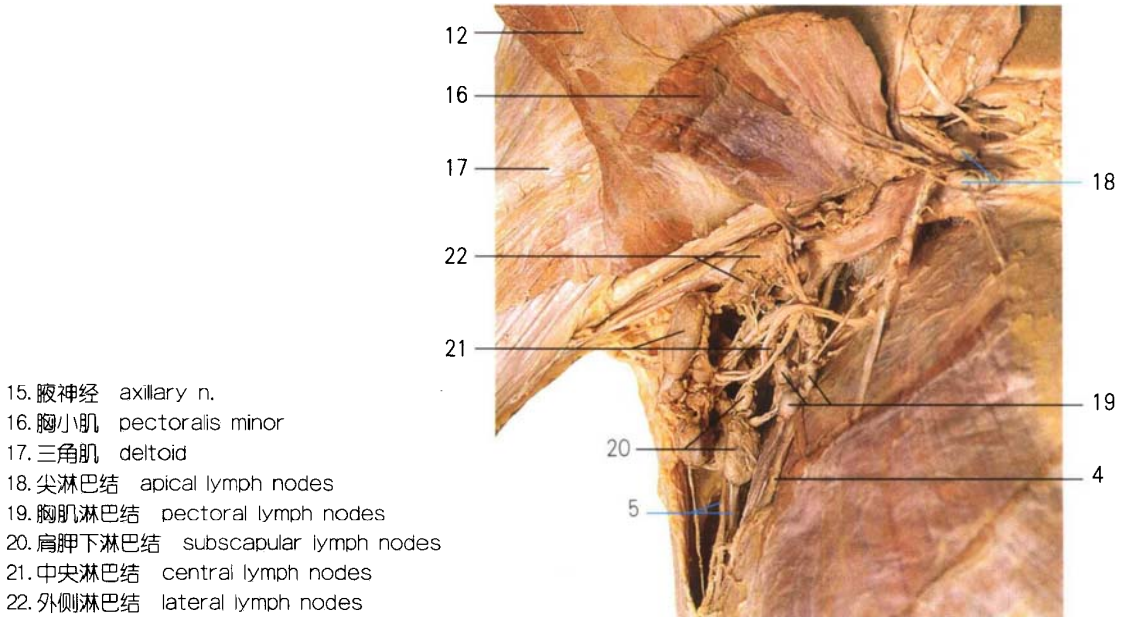
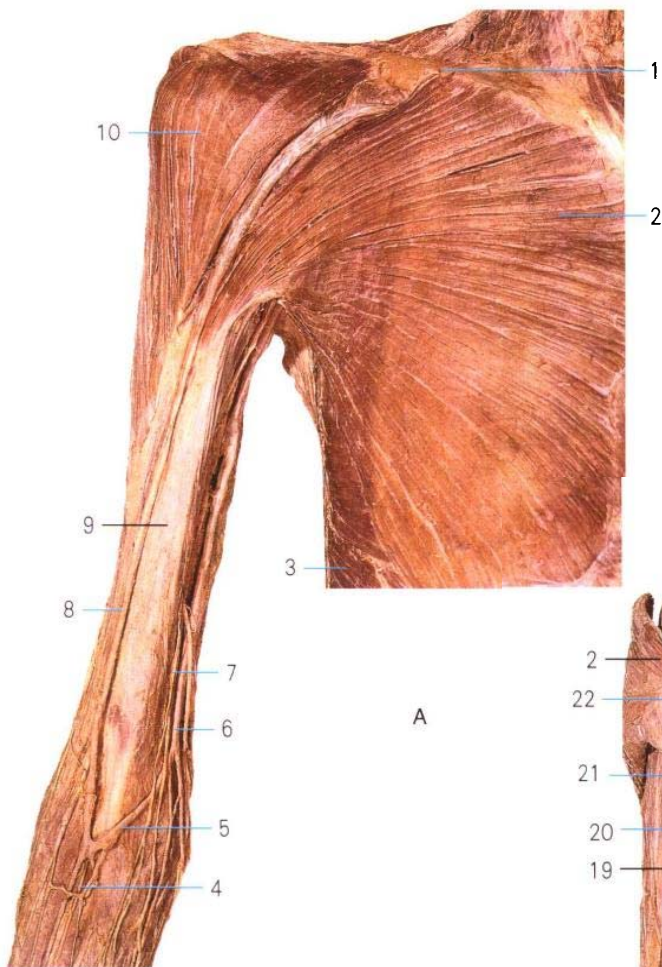
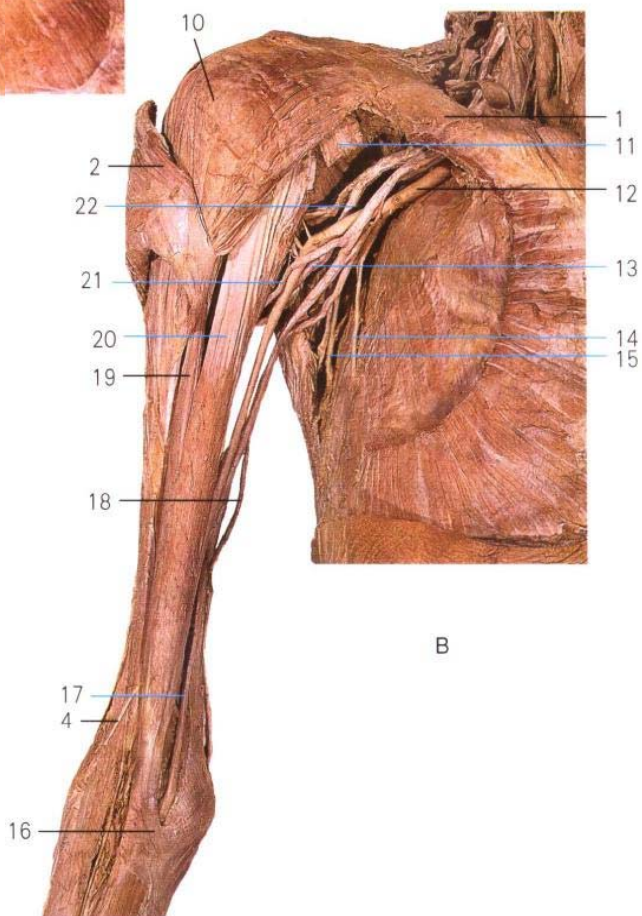


图100 腋淋巴结
 Axillary lymph nodes

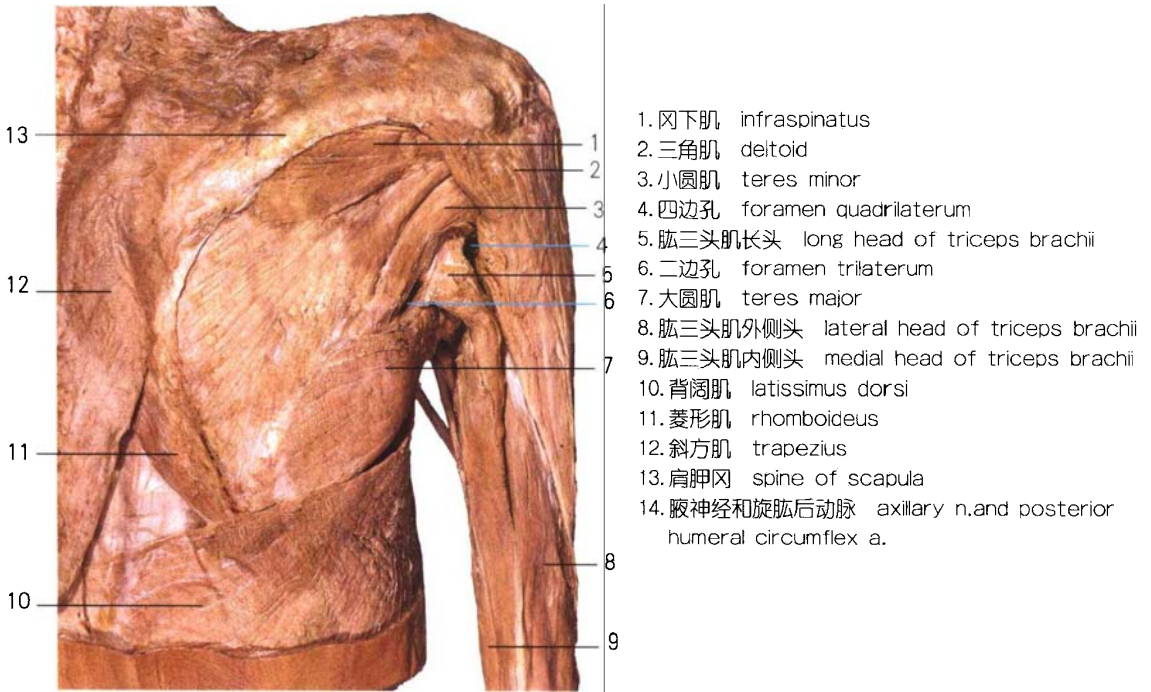


1. 锁骨 clavicle
2. 胸大肌 pectoralis major
3. 前锯肌 serratus anterior
4. 前臂外侧皮神经 lateral antebrachial cutaneous n.
5. 肘正中静脉 median cubital v.
6. 贵要静脉 basilic v.
7. 前臂内侧皮神经 medial antebrachial cutaneous n.
8. 头静脉 cephalic v.

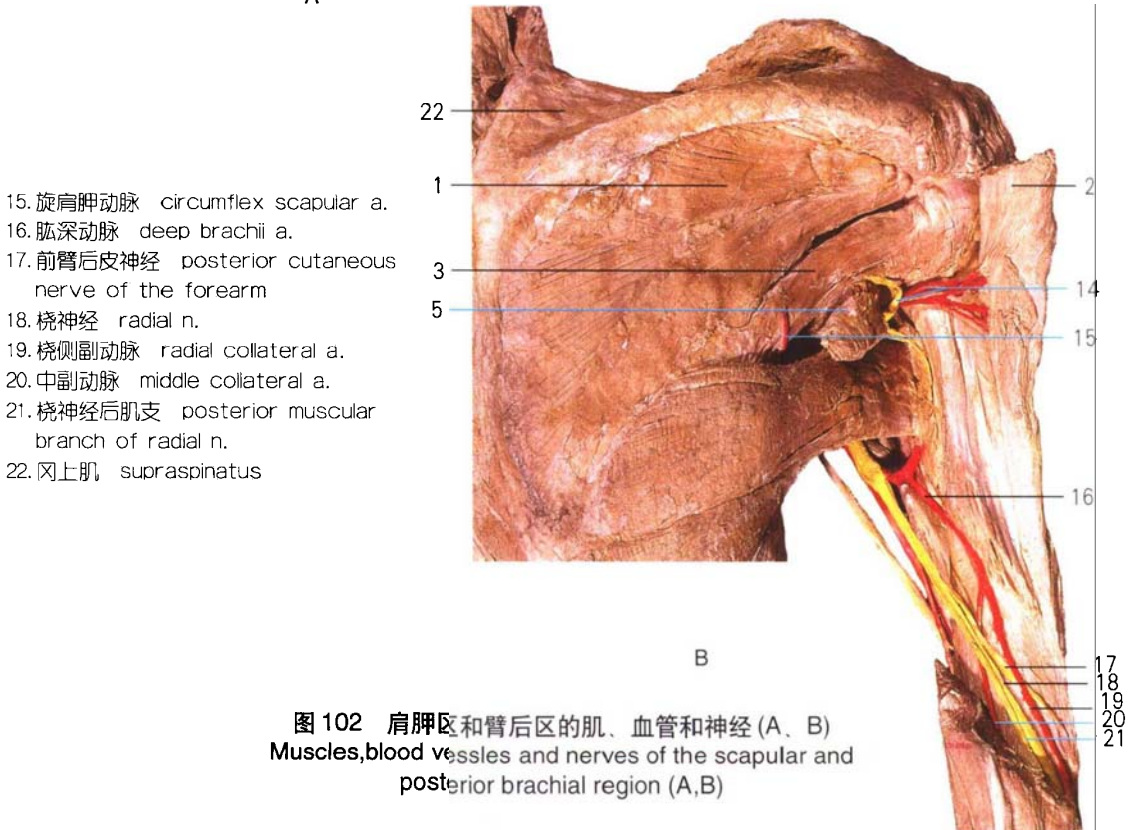


9. 肱二头肌 biceps brachii
10. 三角肌 deltoid
11. 胸小肌 pectoralis minor
12. 腋动脉 axillary a.
13. 桡神经 radial n.
14. 胸外侧动脉 Lateral thoracic a.
15. 胸背动脉 thoracodorsal a.
16. 肱二头肌腱膜 bicipital aponeurosis
17. 正中神经 median n.
18. 尺神经 ulnar n.
19. 肱二头肌长头 long head of biceps brachii
20. 肱二头肌短头 short head of biceps brachii
21. 肌皮神经 musculocutaneous n.
22. 腋神经 axillary n.

图 101 肩和臂前面的肌、血管和神经 (A、B)
Muscles, blood vessels and nerves of the anterior aspect of the shoulder and upper arm (A,B)



A



B

图 102 肩胛区和臂后区的肌、血管和神经 (A、B)
 Muscles, blood vessels and nerves of the scapular and posterior brachial region (A, B)

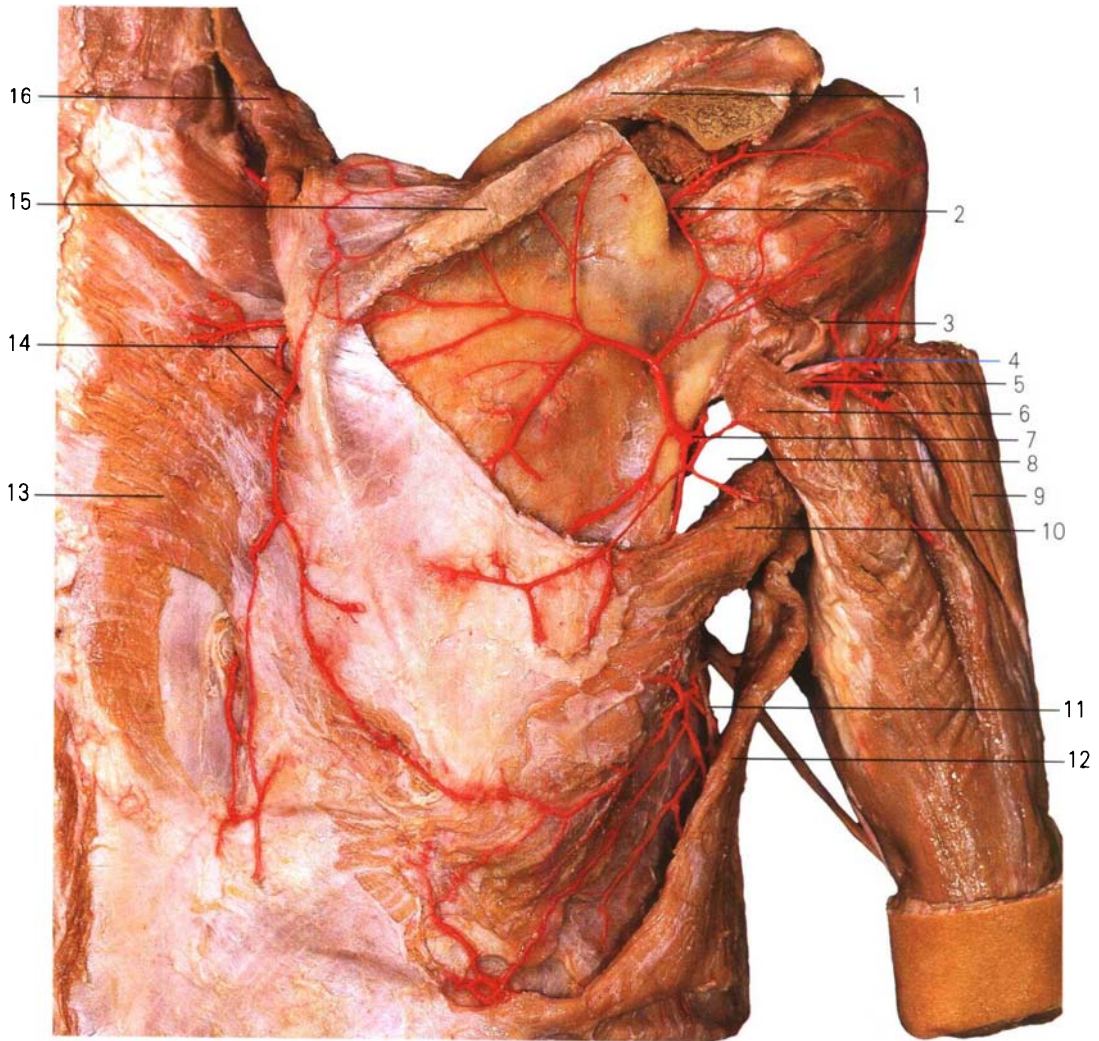


图 103 肩胛区动脉
Arteries of the scapular region

- | | |
|--|------------------------------|
| 1. 锁骨 clavicle | 9. 三角肌 deltoid |
| 2. 肩胛上动脉 suprascapular a. | 10. 大圆肌 teres major |
| 3. 腋神经 axillary n. | 11. 胸背神经 thoracodorsal n. |
| 4. 四边孔 foramen quadrilaterum | 12. 背阔肌 latissimus dorsi |
| 5. 旋肱后动脉 posterior humeral circumflex a. | 13. 菱形肌 rhomboideus |
| 6. 肱三头肌长头 long head of triceps brachii | 14. 肩胛背动脉 dorsal scapular a. |
| 7. 旋肩胛动脉 circumflex scapular a. | 15. 肩胛冈 spine of scapula |
| 8. 三边孔 foramen triaterum | 16. 肩胛提肌 levator scapulae |

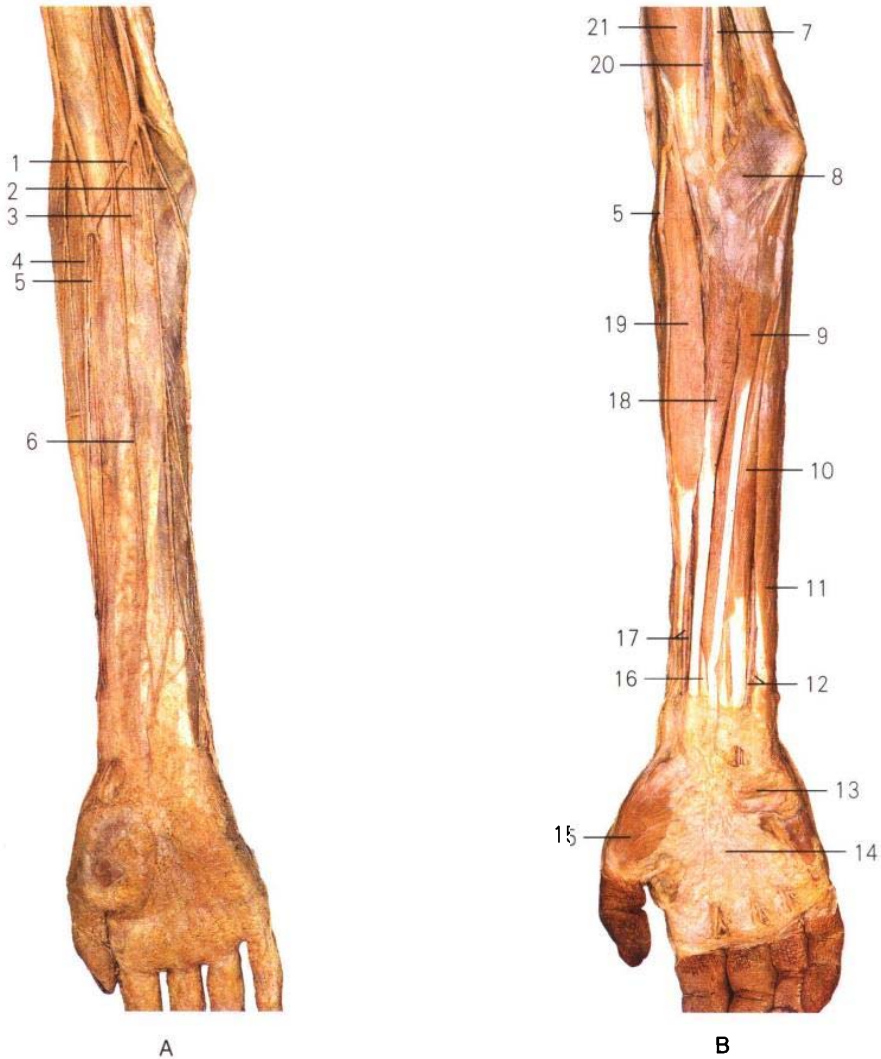
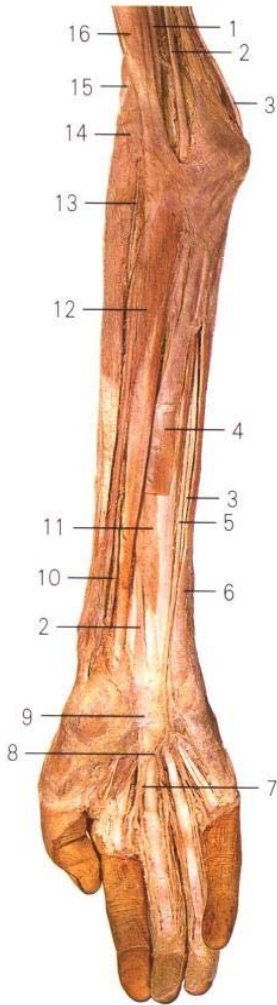


图 104 肘前区和前臂前区的肌、血管及神经(I)(A、B)
Muscles, blood vessels and nerves of the anterior cubital region and anterior antebrachial region (I)(A,B)

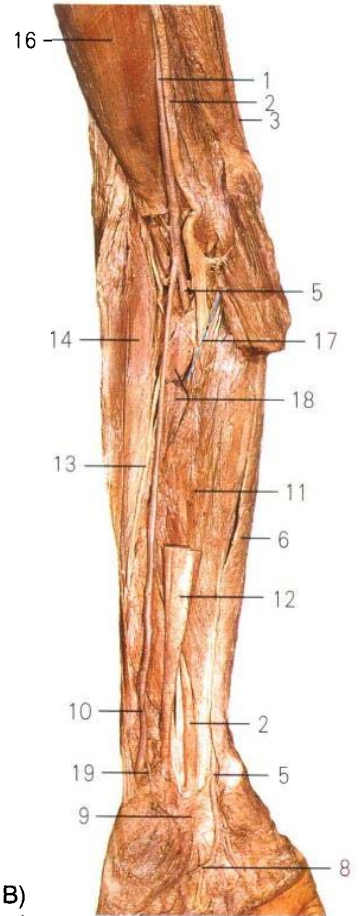
- | | |
|--|-----------------------------------|
| 1. 肘正中静脉 median cubital v. | 12. 尺动脉和尺静脉 ulnar a. and v. |
| 2. 贵要静脉 basilic v. | 13. 掌短肌 palmaris brevis |
| 3. 前臂正中静脉 median antebrachial v. | 14. 掌腱膜 palmar aponeurosis |
| 4. 头静脉 cephalic v. | 15. 拇短展肌 abductor pollicis brevis |
| 5. 前臂外侧皮神经 lateral antebrachial cutaneous n. | 16. 正中神经 median n. |
| 6. 前臂内侧皮神经 medial antebrachial cutaneous n. | 17. 桡动脉和静脉 radial a. and v. |
| 7. 正中神经 median n. | 18. 桡侧腕屈肌 flexor carpi radialis |
| 8. 旋前圆肌 pronator teres | 19. 肱桡肌 brachioradialis |
| 9. 掌长肌 palmaris longus | 20. 肱动脉 brachial a. |
| 10. 指浅屈肌 flexor digitorum superficialis | 21. 肱二头肌 biceps brachii |
| 11. 尺侧腕屈肌 flexor carpi ulnaris | |



A

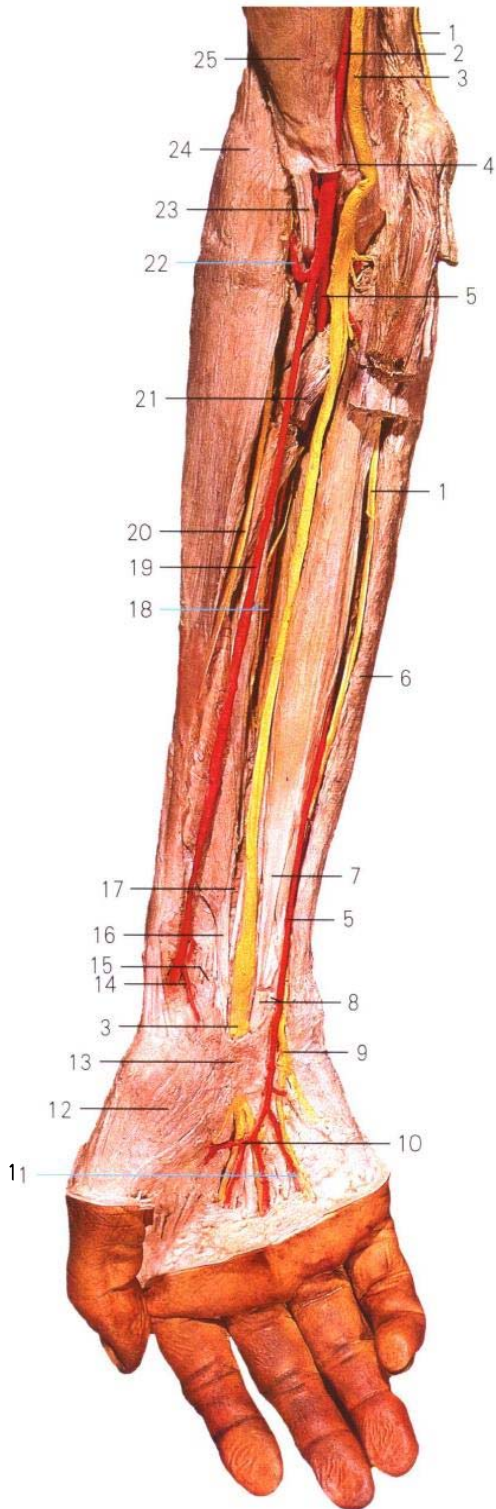
1. 肱动脉 brachial a.
2. 正中神经 median n.
3. 尺神经 ulnar n.
4. 掌长肌 palmaris longus
5. 尺动脉 ulnar a.
6. 尺侧腕屈肌 flexor carpi ulnaris
7. 指掌侧总动脉和神经 common palmar digital a.and n.
8. 掌浅弓 superficial palmar arch
9. 屈肌支持带 flexor retinaculum
10. 桡动脉 radial a.
11. 指浅屈肌 flexor digitorum superficialis
12. 桡侧腕屈肌 flexor carpi radialis
13. 桡神经浅支 superficial branch of radial n.

14. 肱桡肌 brachioradialis
15. 前臂外侧皮神经 lateral antebrachial cutaneous n.
16. 肱二头肌 biceps brachii
17. 指浅屈肌腱弓 tendinous arch of flexor digitorum superficialis
18. 旋前圆肌 pronator teres
19. 掌浅支 superficial palmar branch of radial a.



B

图 105 肘前区和前臂前区的肌、血管及神经(Ⅱ)(A、B)
Muscles, blood vessels and nerves of the anterior cubital region and anterior antebrachial region (Ⅱ)(A,B)



1. 尺神经 ulnar n.
2. 肱动脉 brachial a.
3. 正中神经 median n.
4. 肱二头肌腱膜 bicipital aponeurosis
5. 尺动脉 ulnar a.
6. 尺侧腕屈肌 flexor carpi ulnaris
7. 指深屈肌 flexor digitorum profundus
8. 指浅屈肌腱 tendon of the flexor digitorum superficialis
9. 尺神经浅支 superficial branch of ulnar n.
10. 掌浅弓 superficial palmar arch
11. 指掌侧总动脉及神经 common palmar digital a. and n.
12. 拇短展肌 abductor pollicis brevis
13. 屈肌支持带 flexor retinaculum
14. 桡动脉掌浅支 superficial palmar branch of radial a.
15. 桡侧腕屈肌腱 tendon of flexor carpi radialis
16. 拇长屈肌腱 tendon of flexor pollicis longus
17. 旋前方肌 pronator quadratus
18. 骨间前动脉和神经 interosseus anterior a. and n.
19. 桡动脉 radial a.
20. 桡神经浅支 superficial branch of radial n.
21. 旋前圆肌 pronator teres
22. 桡侧返动脉 radial recurrent a.
23. 肱二头肌腱 tendon of biceps brachii
24. 肱桡肌 brachioradialis
25. 肱二头肌 biceps brachii

图 106 肘前区和前臂前区的肌、血管及神经(Ⅲ)
Muscles, blood vessels and nerves of the anterior
subital region and anterior antebrachial region(Ⅲ)

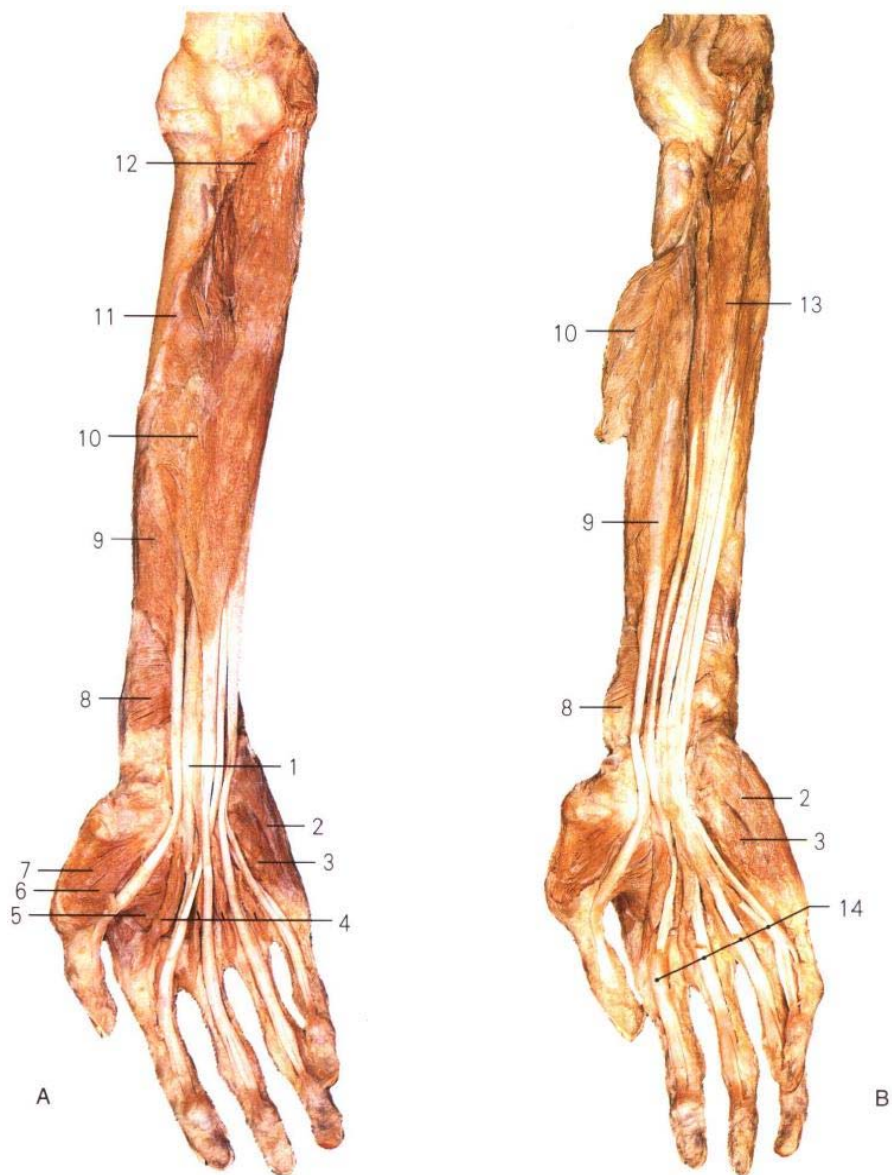


图 107 前臂前区的肌 (A、B)
Muscles of the anterior antebrachial region (A,B)

- | | |
|---|--|
| 1. 指深屈肌腱 tendon of flexor digitorum profundus | 10. 指浅屈肌 flexor digitorum superficialis |
| 2. 小指展肌 abductor digiti minimi | 11. 指浅屈肌桡头 radial head of flexor digitorum superficialis |
| 3. 小指短屈肌 flexor digiti minimi brevis | 12. 指浅屈肌肱尺头 humeroulnar head of flexor digitorum superficialis |
| 4. 蚓状肌 lumbricales | 13. 指深屈肌 flexor digitorum profundus |
| 5. 拇收肌 adductor pollicis | 14. 指浅屈肌腱 tendons of flexor digitorum superficialis |
| 6. 拇短屈肌 flexor pollicis brevis | |
| 7. 拇对掌肌 opponens pollicis | |
| 8. 旋前方肌 pronator quadratus | |
| 9. 拇长屈肌 flexor pollicis longus | |

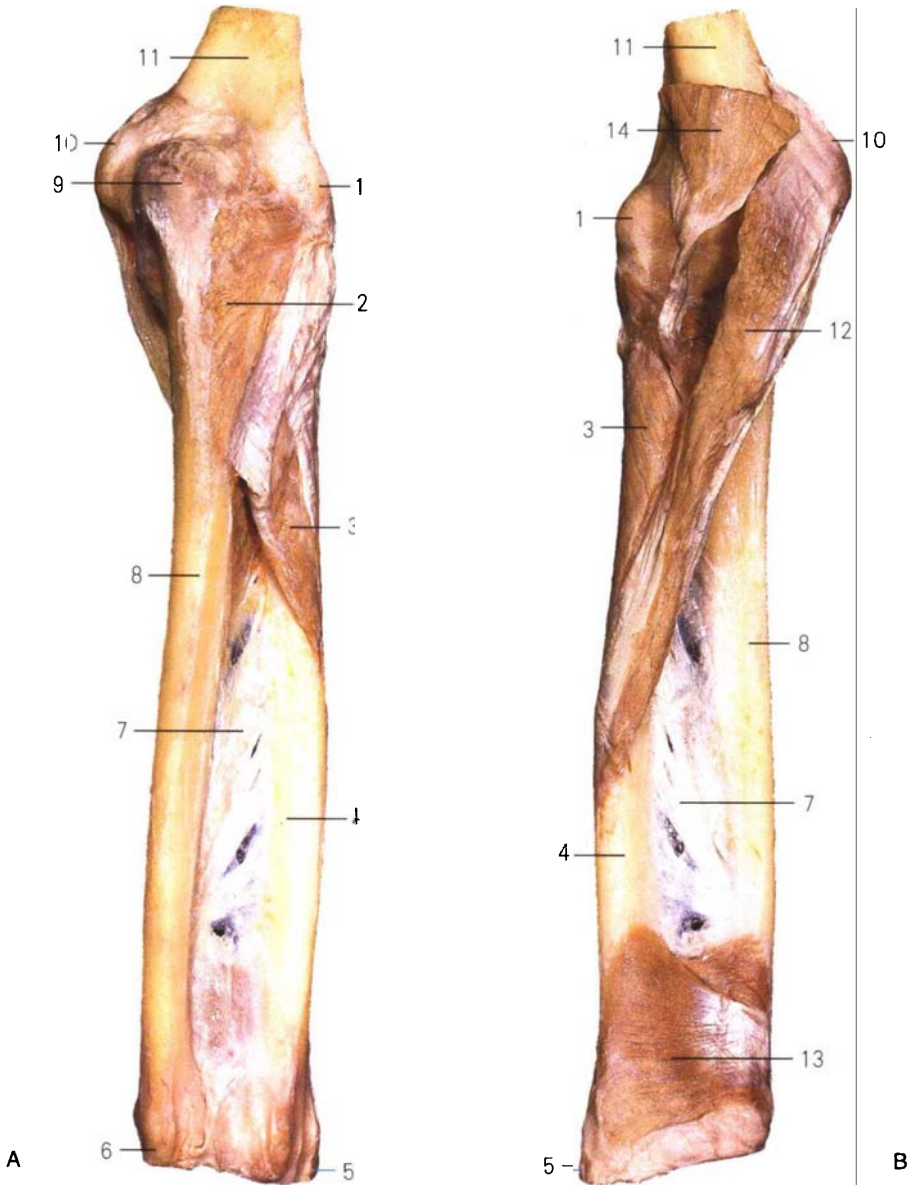
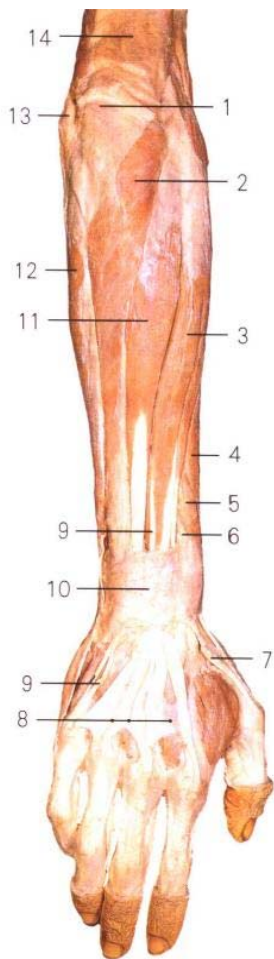
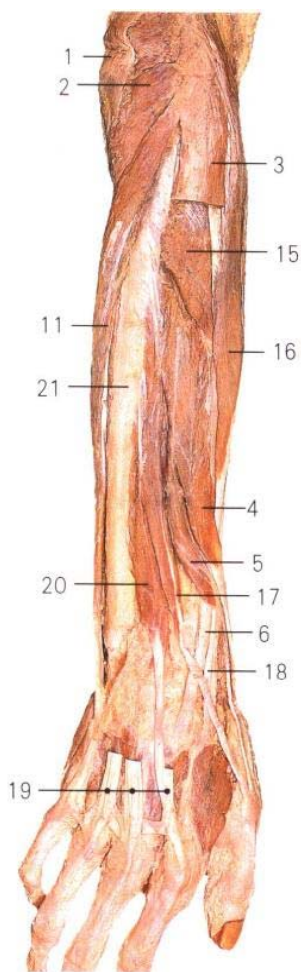


图 108 旋前和旋后的肌(A.后面观, B.前面观)
Muscles of the pronation and supination (A.posterior aspect,B.anterior aspect)

- | | |
|---|--|
| 1. 肱骨外上髁 lateral epicondyle of humerus | 8. 尺骨 ulnar |
| 2. 肘肌 anconeus | 9. 鹰咀 olecranon |
| 3. 旋后肌 supinator | 10. 肱骨内上髁 medial epicondyle of humerus |
| 4. 桡骨 radius | 11. 肱骨 humerus |
| 5. 桡骨茎突 styloid process of radius | 12. 旋前圆肌 pronator teres |
| 6. 尺骨茎突 styloid process of ulnar | 13. 旋前方肌 pronator quadratus |
| 7. 前臂骨间膜 interosseous membrane of forearm | 14. 肱二头肌 biceps brachii |

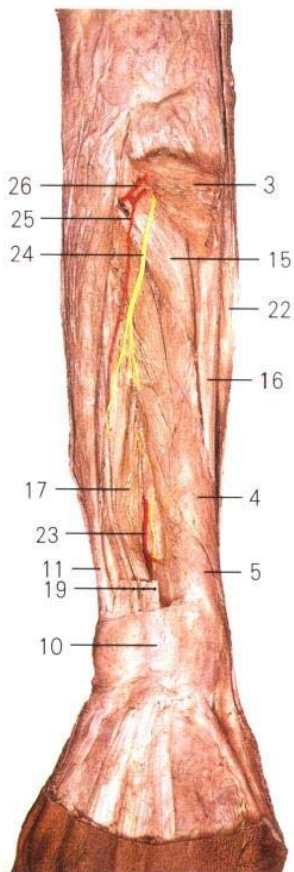


A



B

1. 鹰咀 olecranon
2. 肘肌 anconeus
3. 指伸肌 extensor digitorum
4. 拇长展肌 abductor pollicis longus
5. 拇短伸肌 extensor pollicis brevis
6. 桡侧腕短伸肌腱 tendon of extensor carpi radialis brevis
7. 拇长伸肌腱 tendon of extensor pollicis longus
8. 腱间结合 intertendinous connections
9. 小指伸肌 extensor digiti minimi
10. 伸肌支持带 extensor retinaculum
11. 尺侧腕伸肌 extensor carpi ulnaris
12. 尺侧腕屈肌 flexor carpi ulnaris
13. 尺神经 ulnar n.



C

14. 肱三头肌 triceps brachii
15. 旋后肌 supinator
16. 桡侧腕短伸肌 extensor carpi radialis brevis
17. 拇长伸肌 extensor pollicis longus
18. 桡侧腕长伸肌腱 tendon of extensor carpi radialis longus
19. 指伸肌腱 tendon of extensor digitorum
20. 示指伸肌 extensor indicis
21. 尺骨 ulnar
22. 桡侧腕长伸肌 extensor carpi radialis longus
23. 骨间前动脉后支 posterior branch of anterior interosseous a.
24. 骨间后神经 posterior interosseous n.
25. 骨间后动脉 posterior interosseous a.
26. 骨间返动脉 recurrent interosseous a.

图 109 前臂后区的肌、血管和神经 (A、B、C)
Muscles, blood vessels and nerves of the posterior antebrachial region (A,B,C)

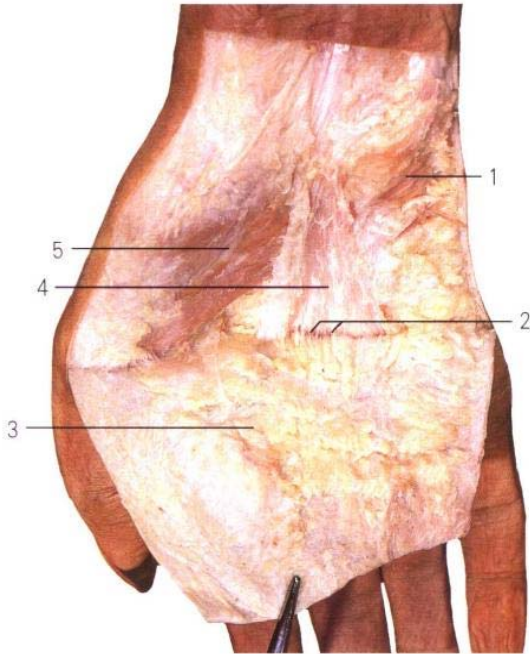


图 110 手掌部浅层
Superficial layer of the palm of hand

1. 掌短肌 palmaris brevis
2. 纤维隔 fibrous septa
3. 皮肤与浅筋膜 skin and superficial fascia
4. 掌腱膜 palmar aponeurosis
5. 鱼际 thenar

1. 贵要静脉 basilic v.
2. 尺侧腕屈肌腱 tendon of flexor carpi ulnaris
3. 尺动脉 ulnar a.
4. 指浅屈肌腱 tendon of flexor digitorum superficialis
5. 尺神经深支及尺动脉掌深支 deep branch of ulnar n. and deep palmar branch of ulnar a.
6. 尺神经浅支 superficial branch of ulnar n.
7. 掌浅弓 superficial palmar arch
8. 指掌侧总神经 common palmar digital n.
9. 小指尺掌侧固有动脉及神经 ulnar palmar a. and n. of little finger
10. 指掌侧总动脉 common palmar digital a.
11. 指掌侧固有动脉及神经 proper palmar digital a. and n.
12. 蚓状肌 lumbricales
13. 拇短屈肌 flexor pollicis
14. 正中神经返支 recurrent branch of median n.
15. 桡动脉掌浅支 superficial palmar branch of radial a.
16. 拇短展肌 abductor pollicis brevis
17. 屈肌支持带 flexor retinaculum
18. 正中神经 median n.
19. 桡侧腕屈肌腱 tendon of flexor carpi radialis
20. 桡动脉 radial a.

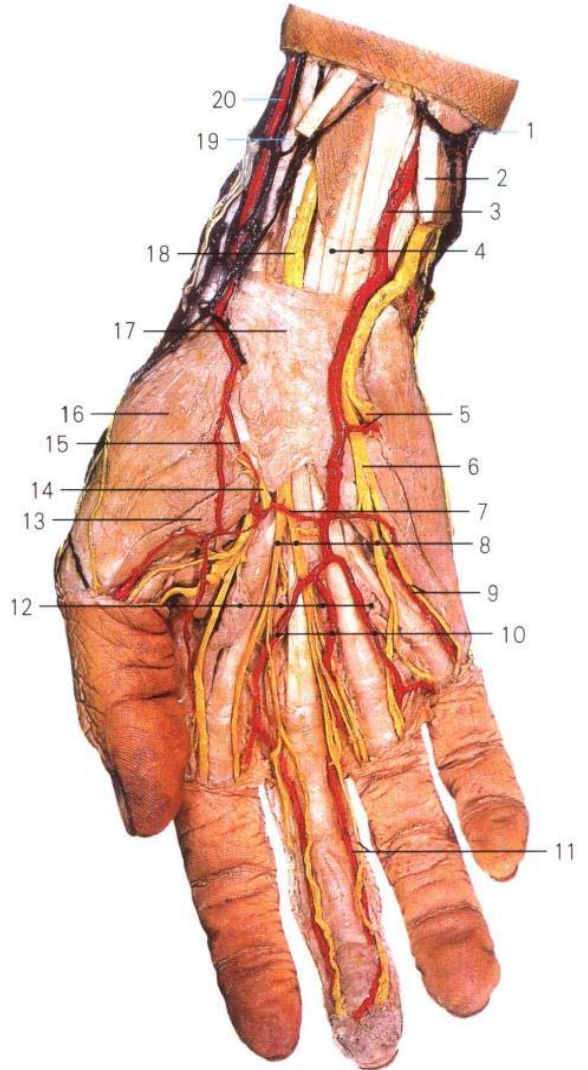
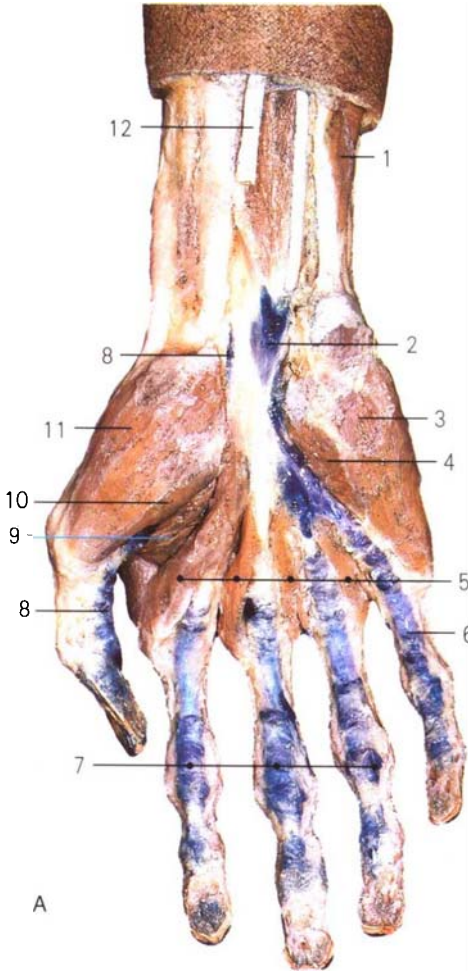


图 111 手掌深部(I)
Deep layer of the palm of hand (I)



1. 尺动脉 ulnar a.
2. 尺神经深支 deep branch of ulnar n.
3. 骨间掌侧肌 palmar interossei
4. 腱纤维鞘 fibrous flexor sheaths
5. 指掌侧固有动脉及神经 proper palmar digital a. & n.
6. 掌心动脉 palmar metacarpal a.
7. 掌深弓 deep palmar arch
8. 桡动脉掌浅支 superficial branch of radial n.
9. 肱桡肌腱 tendon of brachioradialis
10. 桡侧腕屈肌腱 tendon of flexor carpi radialis
11. 桡动脉 radial a.

1. 尺侧腕屈肌 flexor carpi ulnaris
2. 屈肌总腱鞘 common flexor synovial sheath
3. 小指展肌 abductor digiti minimi
4. 小指短屈肌 flexor digiti minimi brevis
5. 蚓状肌 lumbricales
6. 小指屈肌腱鞘 synovial sheath of little finger
7. 指屈肌腱鞘 digital synovial sheath
8. 拇长屈肌腱鞘 synovial sheath of flexor pollicis longus
9. 拇收肌 adductor pollicis
10. 拇短屈肌 flexor pollicis brevis
11. 拇短展肌 abductor pollicis brevis
12. 掌长肌腱 tendon of palmaris longus

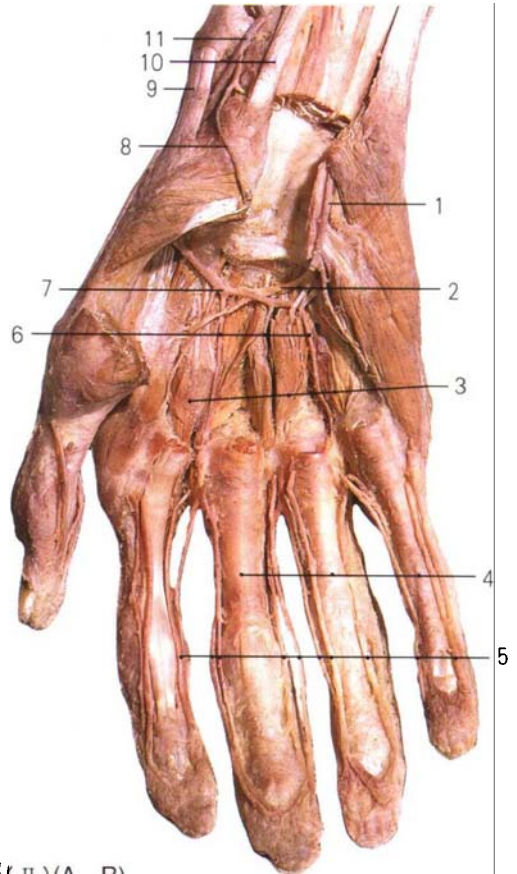


图 112 手掌深部(Ⅱ)(A、B)
Deep layer of the palm of hand (Ⅱ)(A,B)

B

1. 指浅屈肌腱 tendons of flexor digitorum superficialis
2. 尺侧腕屈肌腱 tendon of flexor carpi ulnaris
3. 尺神经手背支 dorsal branch of ulnar n.
4. 豌豆骨 pisiform
5. 尺动脉掌深支及尺神经深支 deep palmar branch of ulnar a. and deep branch of ulnar n.
6. 尺神经浅支 superficial branch of ulnar n.
7. 正中神经 median n.
8. 尺神经深支 deep branch of ulnar n.
9. 掌心动脉 palmar metacarpal a.
10. 小指尺掌侧动脉及神经 ulnar palmar a. and n. of little finger
11. 指掌侧总动脉及神经 common palmar digital a. & n.
12. 指掌侧固有动脉和神经 proper palmar digital a. & n.
13. 掌浅弓 superficial palmar arch
14. 拇主要动脉 principal artery of thumb
15. 掌深弓 deep palmar arch
16. 正中神经返支 recurrent branch of median n.
17. 桡动脉掌浅支 superficial palmar branch of radial a.
18. 屈肌支持带 flexor retinaculum
19. 桡动脉 radial a.
20. 桡侧腕屈肌腱 tendon of flexor carpi radialis
21. 肱桡肌腱 tendon of brachioradialis

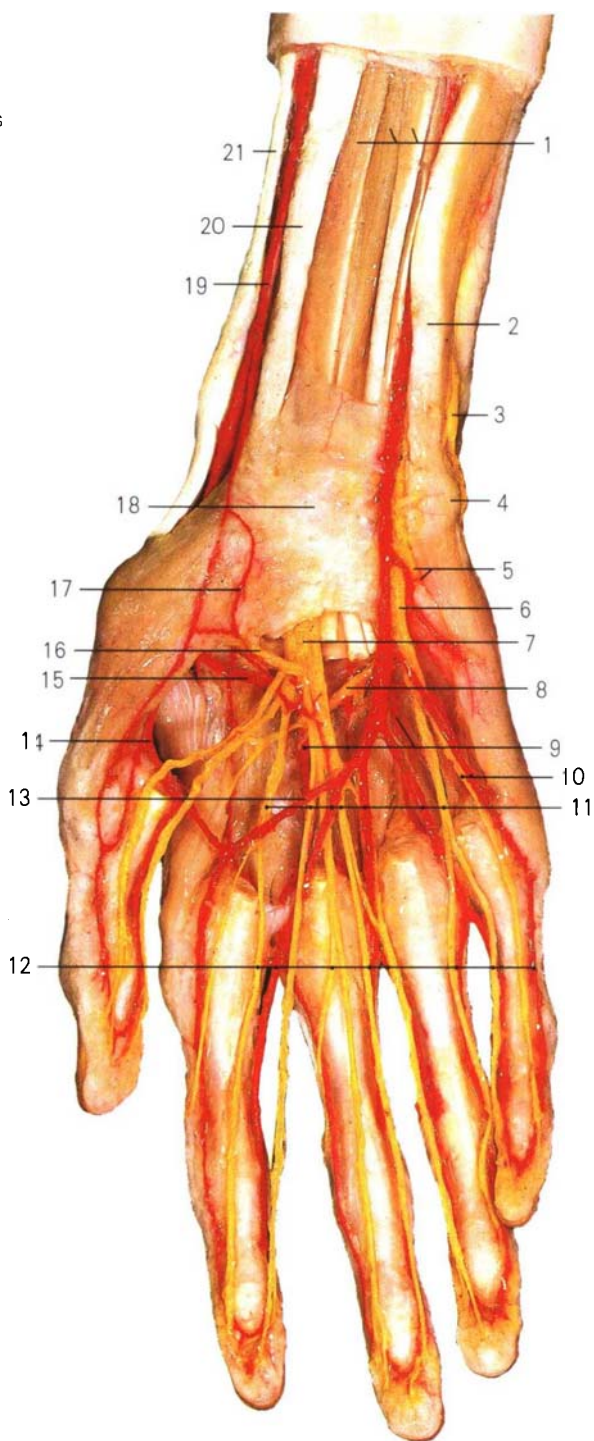
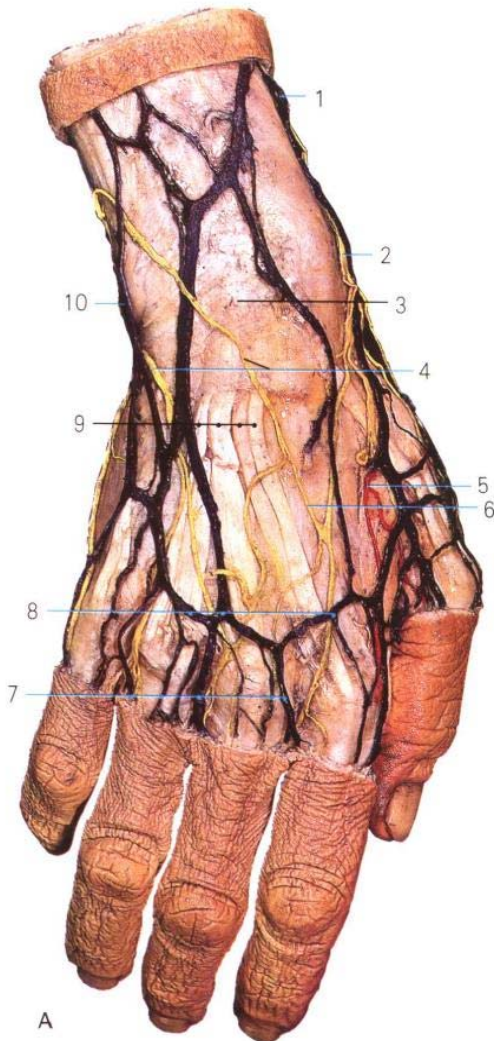
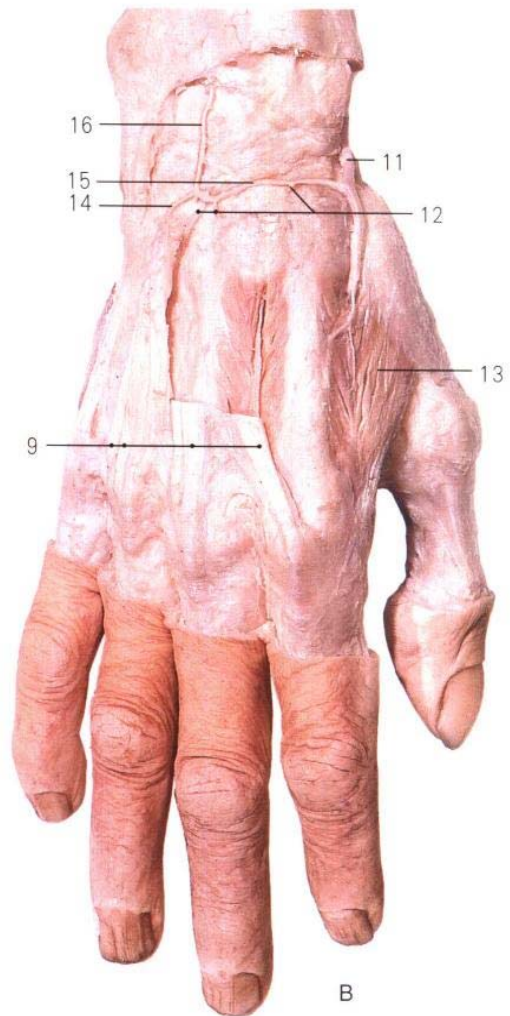


图 113 手掌深部(Ⅲ)
Deep layer of the palm of hand (Ⅲ)



1. 头静脉 cephalic v.
2. 桡神经浅支 superficial branch of radial n.
3. 伸肌支持带 extensor retinaculum
4. 尺神经手背支 dorsal branch of ulnar n.
5. 第一掌背动脉 first dorsal metacarpal a.
6. 尺神经交通支 communicating branch with ulnar n.
7. 指背静脉网 dorsal venous rete of fingers
8. 手背静脉网 dorsal venous rete of hand
9. 指伸肌腱 tendons of extensor digitorum
10. 贵要静脉 basilic v.



11. 桡动脉 radial a.
12. 掌背动脉 dorsal palmar a.
13. 第一骨间背侧肌 first dorsal interossei
14. 尺动脉腕背支 dorsal carpal branch of ulnar a.
15. 腕背弓 posterior carpal arch
16. 骨间后动脉终支 terminal branch of posterior interosseous a.

图 114 手背的血管和神经 (A, B)
Blood vessels and nerves of the dorsum of hand (A, B)

1. 拇短伸肌腱 tendon of extensor pollicis brevis
2. 桡动脉 radial a.
3. 桡动脉腕背支 dorsal carpal branch of radial a.
4. 桡侧腕长伸肌腱 tendon of extensor carpi radialis longus
5. 桡侧腕短伸肌 tendon of extensor carpi radialis brevis
6. 拇长伸肌腱 tendon of extensor pollicis longus
7. 掌背动脉 dorsal palmar arteries
8. 腱间结合 intertendinous connections
9. 指伸肌腱 tendons of extensor digitorum
10. 小指伸肌腱 tendon of extensor digiti minimi
11. 示指伸肌腱 tendon of extensor indicis
12. 伸肌支持带 extensor retinaculum
13. 腕背骨纤维管 osseofibrous canal of posterior region of wrist

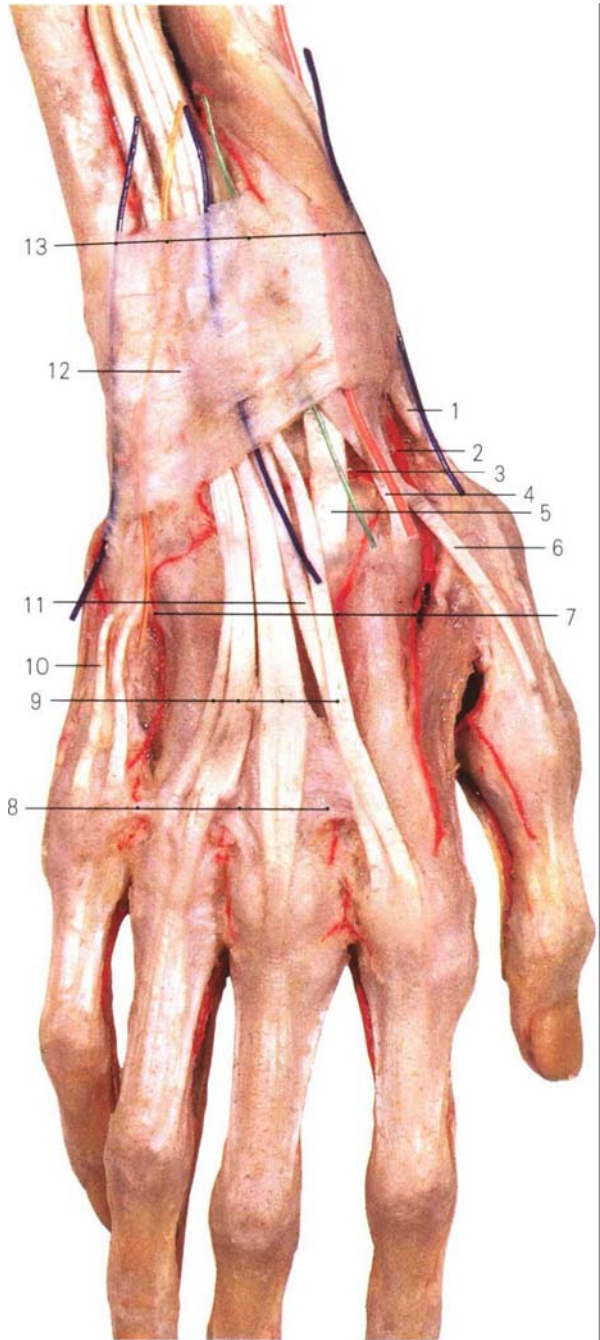
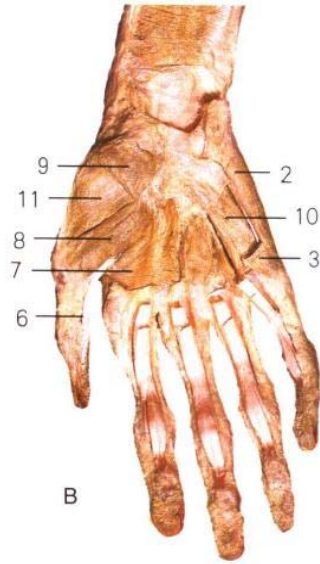
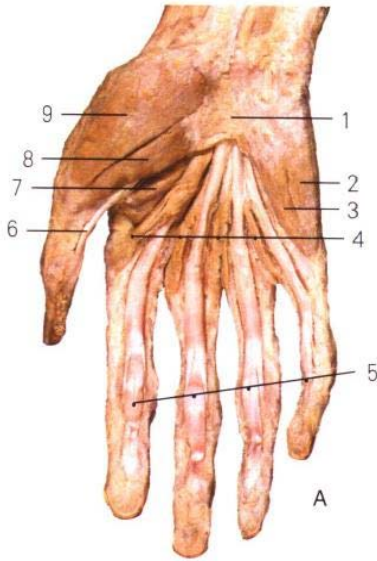
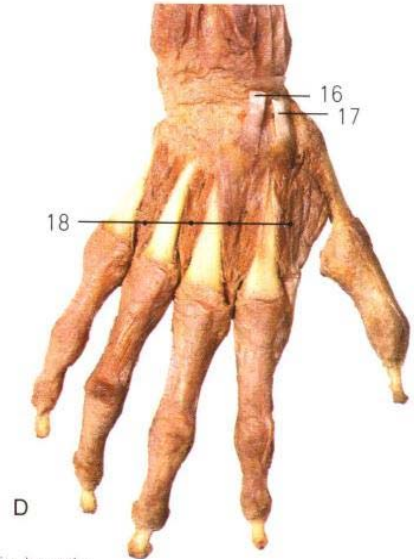
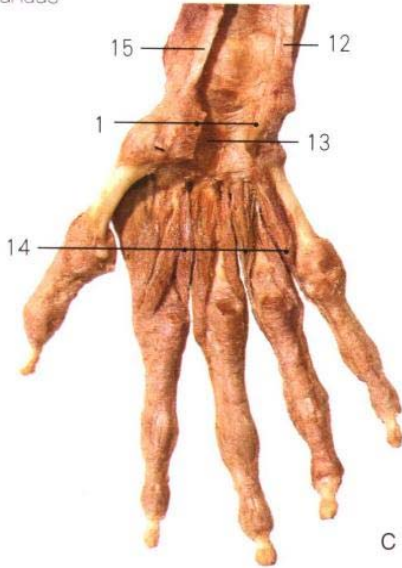


图 115 手背的血管
Blood vessels of the dorsum of hand



- 1. 屈肌支持带 flexor retinaculum
- 2. 小指展肌 abductor digiti minimi
- 3. 小指短屈肌 flexor digiti minimi brevis
- 4. 蚓状肌 lumbricales
- 5. 指深屈肌腱 tendons of flexor digitorum profundus

- 6. 拇长屈肌腱 tendon of flexor pollicis longus
- 7. 拇收肌 adductor pollicis
- 8. 拇短屈肌 flexor pollicis brevis
- 9. 拇短展肌 abductor pollicis brevis
- 10. 小指对掌肌 opponens digiti minimi
- 11. 拇对掌肌 opponens pollicis



- 12. 尺侧腕屈肌腱 tendon of flexor carpi ulnaris
- 13. 腕管 canalis carpalis (carpal canal)
- 14. 骨间掌侧肌 palmar interossei
- 15. 桡侧腕屈肌 tendon of flexor carpi radialis
- 16. 桡侧腕短伸肌腱 tendon of extensor carpi radialis brevis

- 17. 桡侧腕长伸肌腱 tendon of extensor carpi radialis longus
- 18. 骨间背侧肌 dorsal interossei

图 116 手肌 (A, B, C, D)
Muscles of hand (A, B, C, D)

1. 正中神经 median n.
2. 贵要静脉 basilic v.
3. 肱动脉及静脉 brachial a. & v.
4. 尺神经与尺侧上副动脉 ulnar n. and superior ulnar collateral a.
5. 肱三头肌内侧头 medial head of triceps brachii
6. 肱三头肌长头 long head of triceps brachii
7. 肱三头肌外侧头 lateral head of triceps brachii
8. 桡神经 radial n.
9. 肱深动脉及静脉 deep brachial a. & v.
10. 肱肌 brachialis
11. 肌皮神经 musculocutaneous n.
12. 头静脉 cephalic v.
13. 肱二头肌 biceps brachii

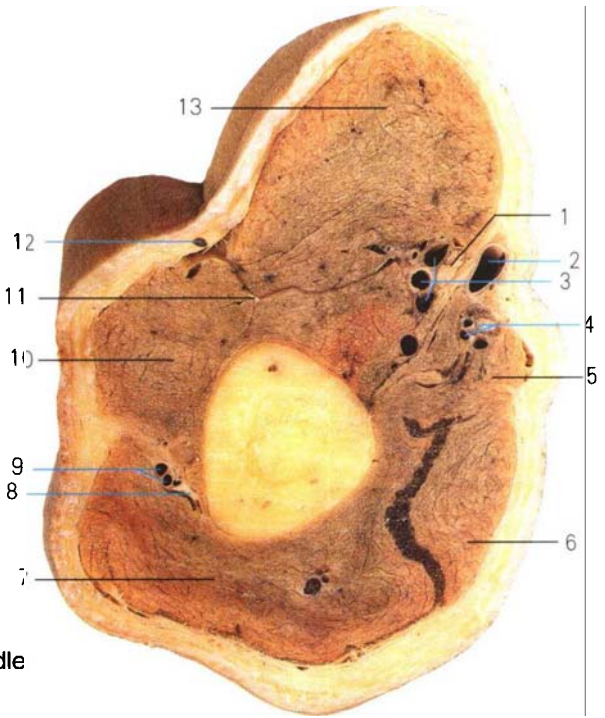


图 117 臂中部横断面
Transverse section through the middle of upper arm

1. 尺神经及动脉 ulnar n. & a.
2. 贵要静脉 basilic v.
3. 指深屈肌 flexor digitorum profundus
4. 尺骨 ulna
5. 骨间前动脉及静脉 anterior interosseous a. & v.
6. 前臂骨间膜 interosseous membrane of forearm
7. 尺侧腕伸肌 extensor carpi ulnaris
8. 骨间后动脉及静脉 posterior interosseous a. & v.
9. 小指伸肌 extensor digiti minimi
10. 指伸肌 extensor digitorum
11. 桡侧腕短伸肌 extensor carpi radialis brevis
12. 旋后肌 supinator
13. 桡骨 radius
14. 头静脉 cephalic v.
15. 拇长屈肌 flexor pollicis longus
16. 正中神经 median n.
17. 桡神经 radial n.
18. 肱桡肌 brachioradialis
19. 桡动脉及静脉 radial a. & v.
20. 指浅屈肌 flexor digitorum superficialis

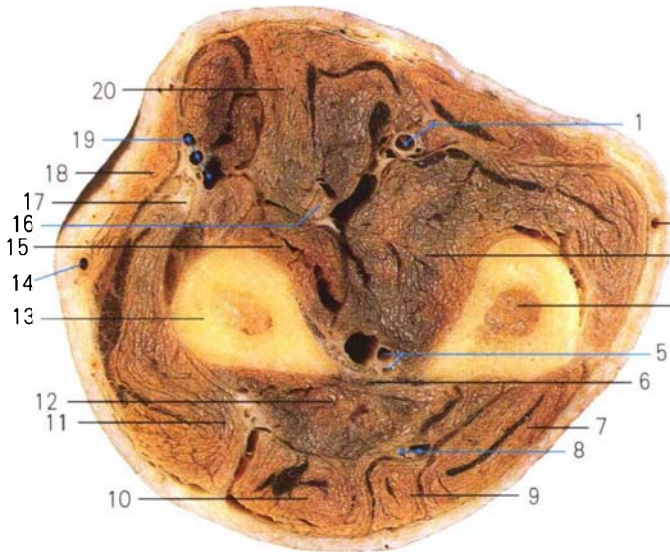


图 118 前臂中部横断面
Transverse section through the middle of forearm

第

章

4

胸部

CHAPTER 4 THE THORAX

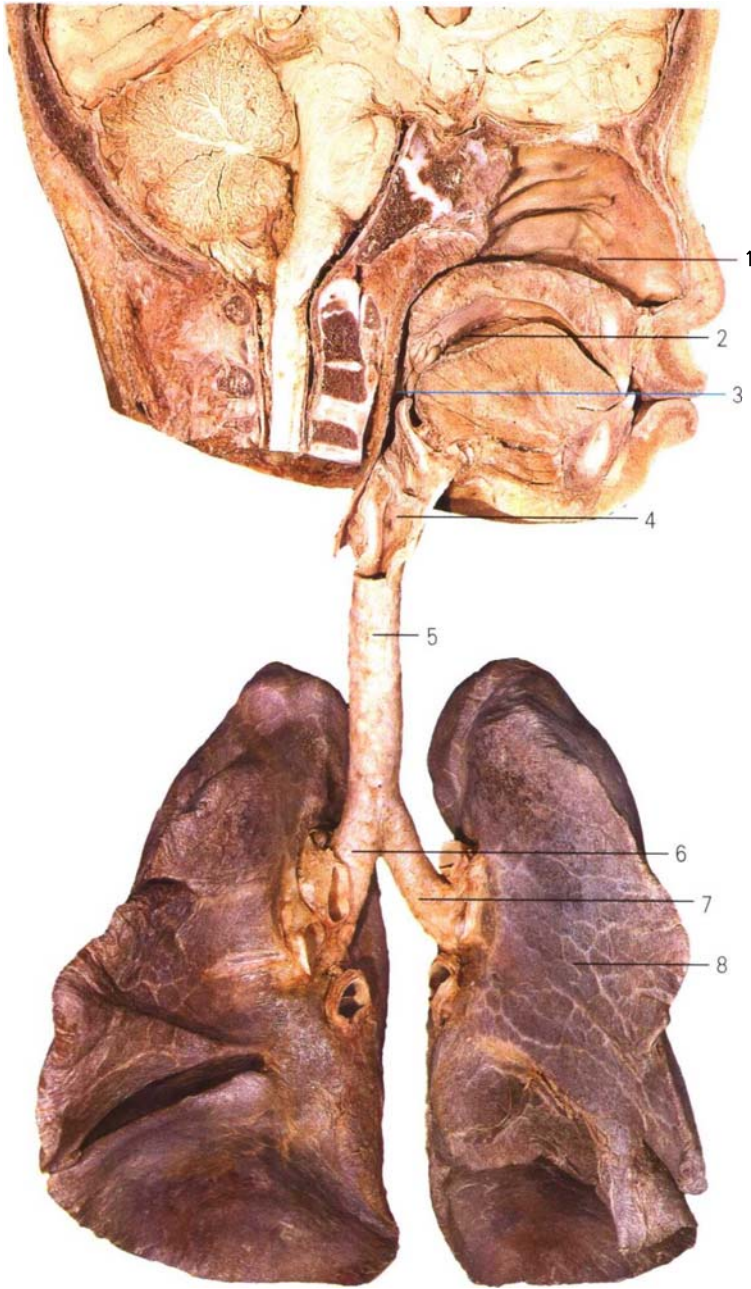


图 121 呼吸系统概观
General arrangement of respiratory system

- 1. 鼻腔 nasal cavity
- 2. 口腔 oral cavity
- 3. 咽 pharynx
- 4. 喉腔 larynx cavity

- 5. 气管 trachea
- 6. 右主支气管 right principal bronchus
- 7. 左主支气管 left principal bronchus
- 8. 肺 lung

1. 乳晕 areola
2. 乳头 nipple
3. 输乳管 lactiferous ducts
4. 输乳管窦 ampulla
5. 脂肪 fat
6. 乳腺小叶 gland lobules

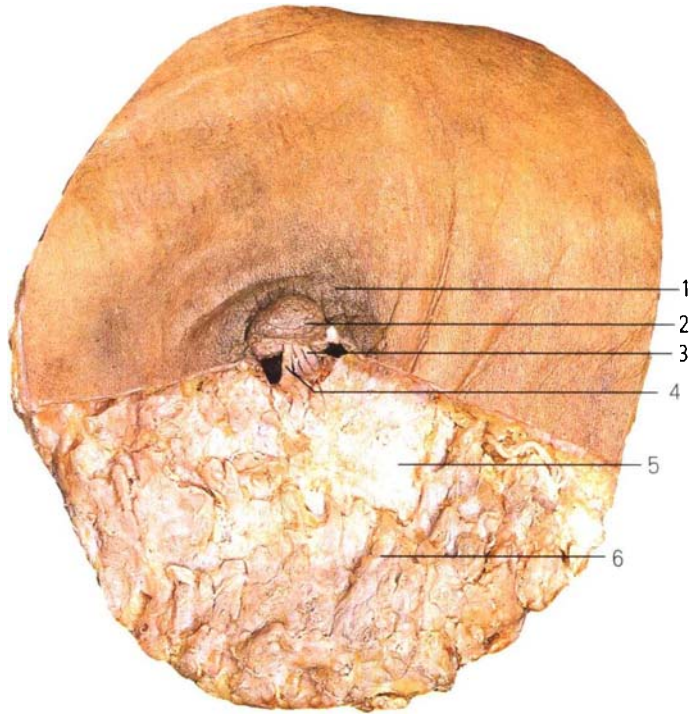
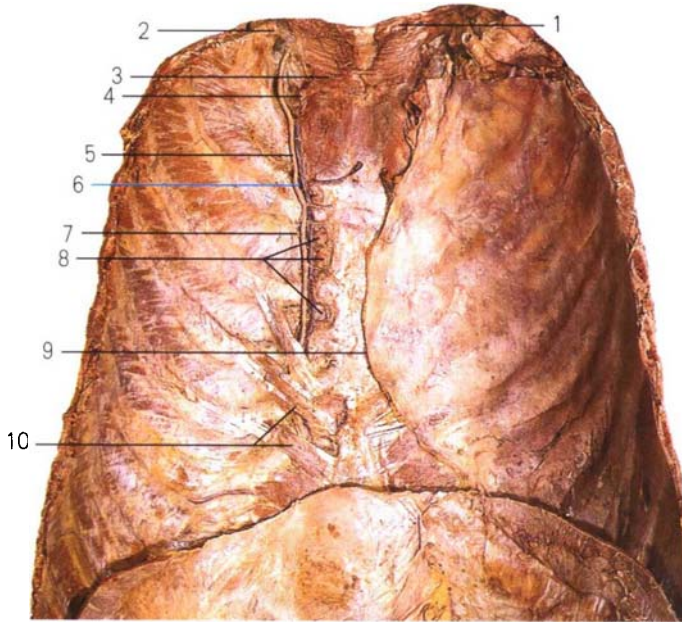


图 122 女性乳房
Female breast



1. 胸骨舌骨肌 sternohyoid
2. 右锁骨下动脉 right subclavian a.
3. 胸骨甲状肌 sternothyroid
4. 右头臂静脉 right brachiocephalic v.
5. 胸廓内动脉 internal thoracic a.
6. 胸廓内静脉 internal thoracic v.
7. 穿支 perforating branch of internal thoracic a.
8. 胸骨旁淋巴结 parasternal lymphatic nodes
9. 胸膜前反折线 anterior pleural reflex
10. 胸横肌 transversus thoracis m.

图 123 胸前壁(内面观)
Anterior thoracic wall(internal aspect)

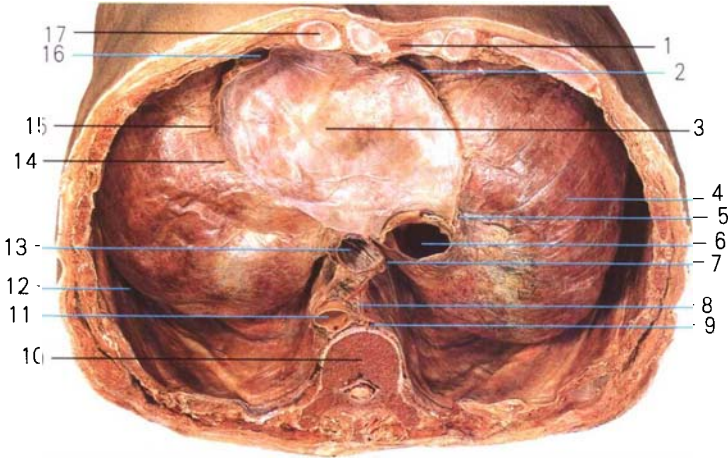


图 124 膈(胸腔面)
Diaphragm(thoracic surface)

1. 胸骨 sternum
2. 右肋隔隐窝
right costodiaphragmatic recess
3. 膈中心腱中叶(被纤维心包覆盖) middle
leaflet of central tendon covered
by pericardium
4. 膈肌 diaphragmatic m.
5. 右膈神经和心包膈动脉、静脉 right
phrenic n. and pericardiophrenic
a. & v.
6. 下腔静脉 inferior vena cava
7. 食管隐窝 esophageal recess
8. 胸导管 thoracic duct
9. 奇静脉 azygos v.
10. 胸椎椎体 thoracic vertebral
body
11. 胸主动脉 thoracic aorta
12. 左肋隔隐窝
left costodiaphragmatic recess
13. 食管 esophagus
14. 纤维心包(切断处)
fibrous pericardium(cut)
15. 左膈神经和心包膈动脉、静脉 left
phrenic n. and pericardiophrenic
a. & v.
16. 左肋纵隔窝 left costomedial
recess
17. 肋软骨 costal cartilage

1. 竖脊肌, erector spinal muscle
2. 后纵隔淋巴结 posterior
mediasternal lymph nodes
3. 奇静脉 azygos v.
4. 胸主动脉 thoracic a.
5. 肋 rib
6. 肋间最内肌 innermost
intercostal m.
7. 肋间内肌 internal
intercostal m.
8. 肋间外肌 external
intercostal m.
9. 胸廓内动脉 internal
thoracic a.
10. 腹直肌 rectus abdominis
11. 胸骨 sternum
12. 胸导管 thoracic duct
13. 内脏大神经 greater
splanchnic n.
14. 交感干 sympathetic trunk
15. 肋间后动脉 posterior
intercostal a.
16. 肋间后静脉 posterior
intercostal v.
17. 脊神经前支 anterior branch
of spinal n.

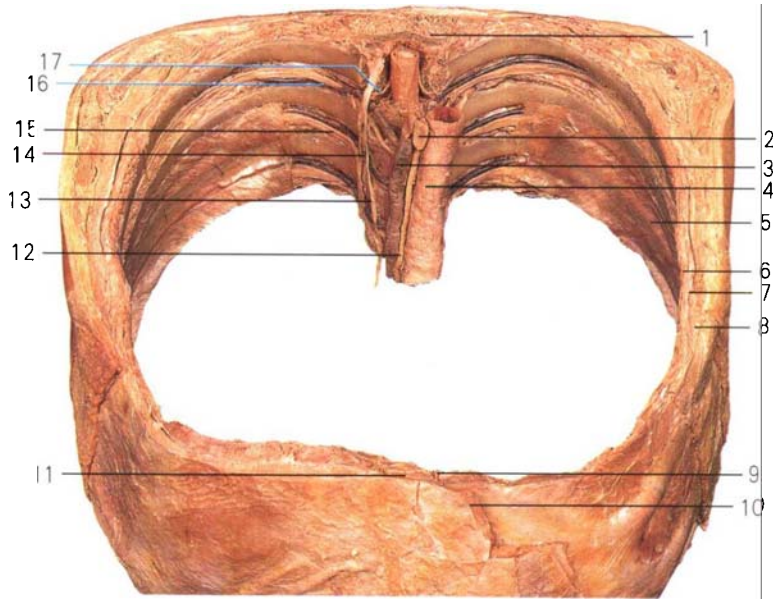


图 125 肋间神经和血管
Intercostal nerves and blood vessels

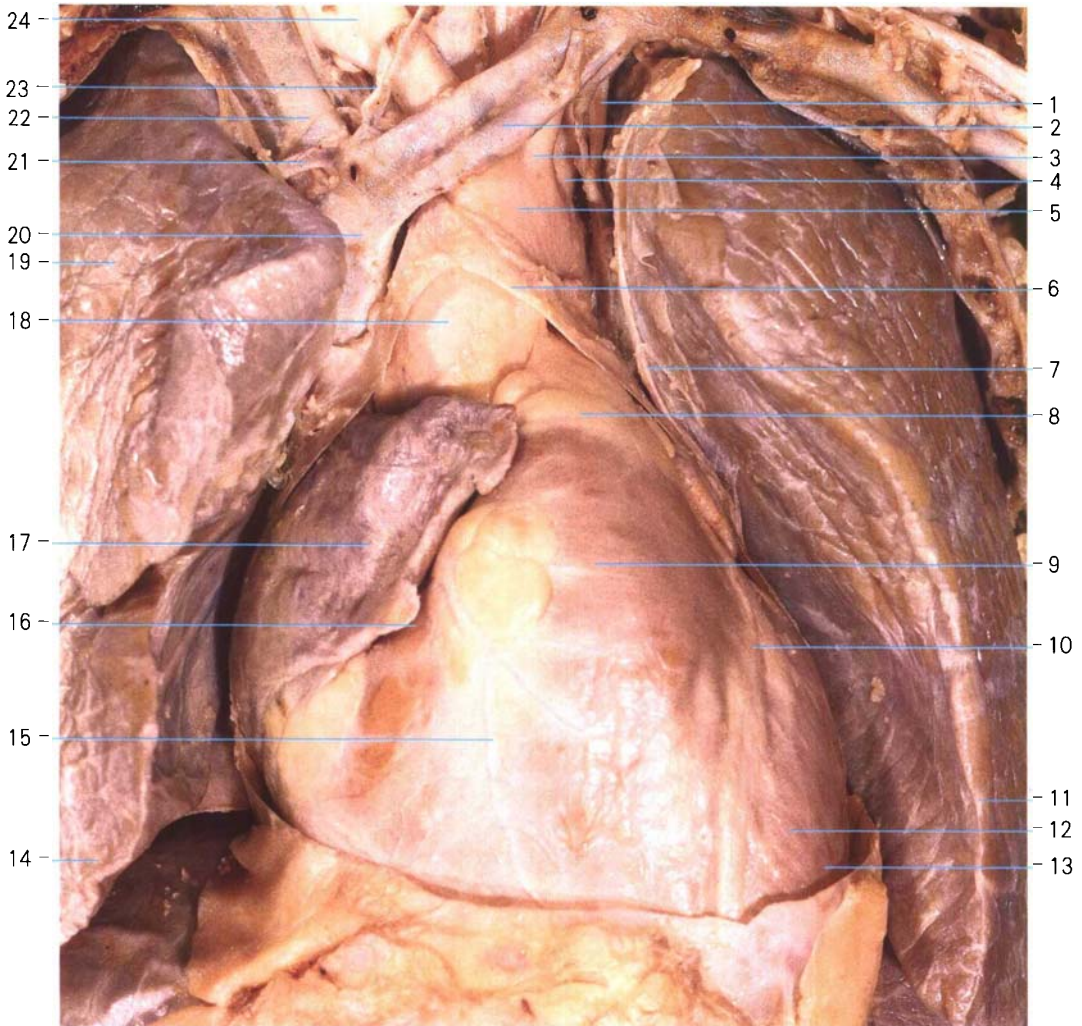


图 126 心于原位(前面观)
Heart in situ(anterior aspect)

- | | |
|--|---|
| 1. 左迷走神经 left vagus n. | 13. 心尖 apex of heart |
| 2. 左头臂静脉 left brachiocephalic v. | 14. 右肺中叶 middle lobe of right lung |
| 3. 左颈总动脉 left common carotid a. | 15. 右室前壁 anterior wall of right ventricle |
| 4. 左锁骨下动脉 left subclavian a. | 16. 右冠状沟 right coronary sulcus |
| 5. 主动脉弓 arch of aorta | 17. 右心耳 right auricle |
| 6. 纤维心包及其反折处 fibrous pericardium and reflection from great vessels | 18. 升主动脉 ascending aorta |
| 7. 左膈神经 left phrenic n. | 19. 右肺上叶 superior lobe of right lung |
| 8. 肺动脉干 pulmonary trunk | 20. 上腔静脉 superior vena cava |
| 9. 动脉圆锥 conus arteriosus | 21. 胸廓内静脉 internal thoracic v. |
| 10. 前室间沟 anterior interventricular sulcus | 22. 右头臂静脉 right brachiocephalic v. |
| 11. 左肺下叶 inferior lobe of left lung | 23. 甲状腺下静脉 inferior thyroid v. |
| 12. 左室前壁 anterior wall of left ventricle | 24. 头臂干 Brachiocephalic trunk |

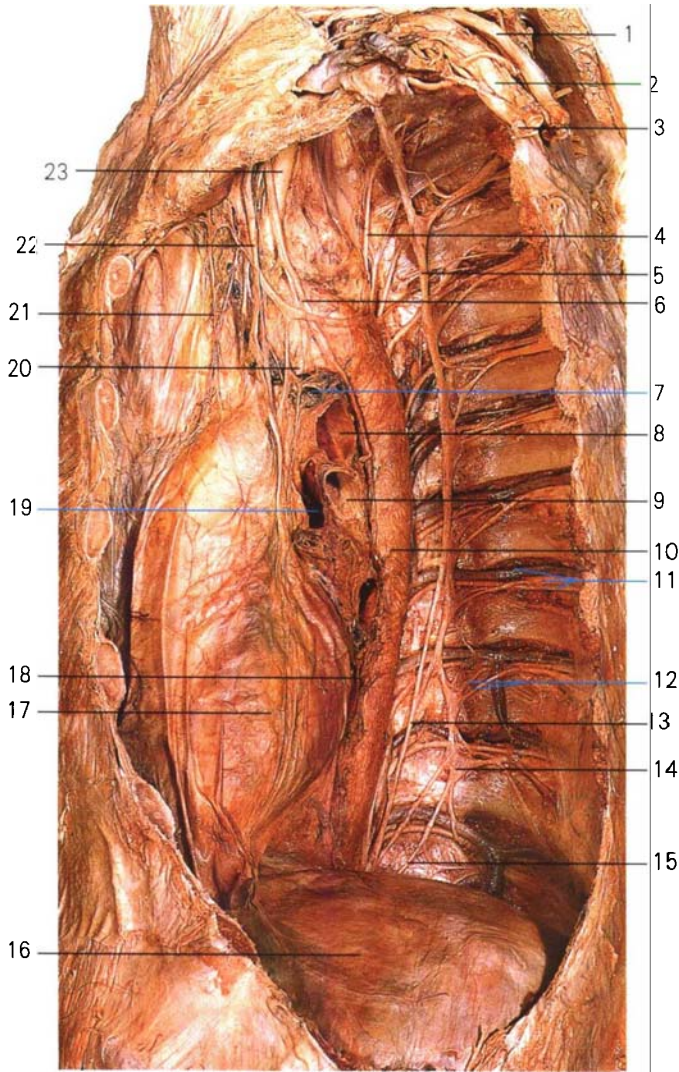


图 127 纵隔(右侧面观)
Mediastinum(left lateral aspect)

- | | |
|---|---------------------------------|
| 1. 臂丛外侧束 lateral cord of brachial plexus | 13. 内脏大神经 greater splanchnic n. |
| 2. 腋动脉 axillary a. | 14. 交感神经节 sympathetic ganglion |
| 3. 臂丛内侧束 medial cord of brachial plexus | 15. 内脏小神经 lesser splanchnic n. |
| 4. 肋间动脉 intercostal a. | 16. 膈 diaphragm |
| 5. 交感干 sympathetic trunk | 17. 心包 fibrous pericardium |
| 6. 迷走神经 vagus n. | 18. 肺韧带 pulmonary ligament |
| 7. 淋巴结 lymph node | 19. 左肺静脉 left pulmonary v. |
| 8. 左肺动脉 left pulmonary trunk | 20. 动脉韧带 ligamentum arteriosum |
| 9. 左主支气管 left principal bronchus | 21. 心包膈动脉 pericardiophrenic a. |
| 10. 胸主动脉 thoracic aorta | 22. 膈神经 phrenic n. |
| 11. 肋间静脉、动脉和神经 intercostal v., a. & n. | 23. 左锁骨下动脉 left subclavian a. |
| 12. 灰白交通支 gray and white rami communicantes | |

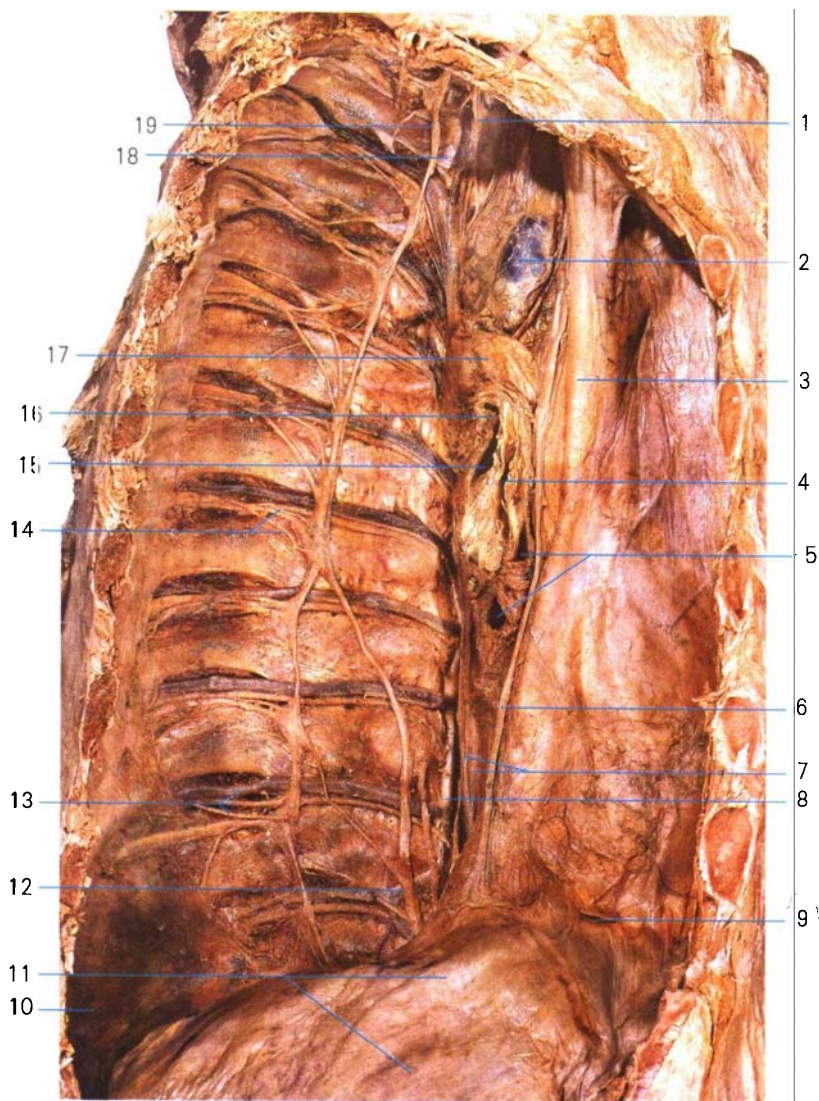


图 128 纵隔(右侧面观)
Mediastinum(right lateral aspect)

- | | |
|---|--|
| 1. 右迷走神经 right vagus n. | 11. 膈(覆盖膈胸膜) diaphragm(covered by pleural) |
| 2. 奇静脉弓淋巴结 lymph nodes of azygos arch | 12. 内脏大神经 greater splanchnic n. |
| 3. 上腔静脉 superior vena cava | 13. 肋间神经血管 intercostal nerve and vessels |
| 4. 右肺动脉 right pulmonary a. | 14. 灰白交通支 gray and white rami communicantes |
| 5. 右肺静脉 right pulmonary v. | 15. 中间支气管 intermediate bronchus |
| 6. 右膈神经 right phrenic n. | 16. 右肺上叶支气管 superior lobar bronchi of right lung |
| 7. 食管及神经丛 Esophagus and plexus | 17. 奇静脉弓 arch of azygos v. |
| 8. 奇静脉 azygos v. | 18. 右肋间最上静脉 right highest intercostal v. |
| 9. 下腔静脉 inferior vena cava | 19. 胸交感干 sympathetic trunk |
| 10. 右肋膈隐窝 right costodiaphragmatic recess of pleura | |

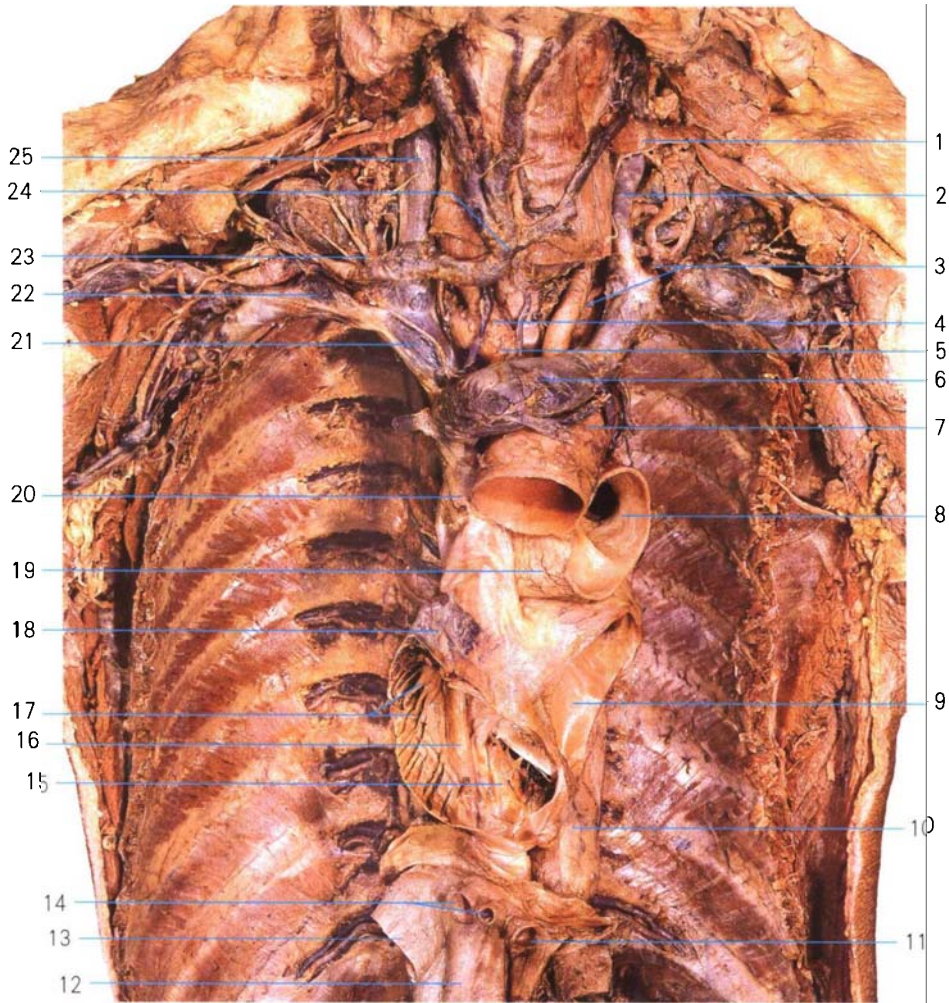


图 129 头臂静脉、主动脉弓和右肺动脉
Brachiocephalic vein, arch of aorta and right pulmonary artery

- | | |
|---|------------------------------------|
| 1. 颈深下淋巴结 inferior cervical lymphatic nodes | 14. 肝中静脉 middle hepatic v. |
| 2. 左颈内静脉 left jugular v. | 15. 右心房 right atrium |
| 3. 胸导管 thoracic duct | 16. 界嵴 crista terminalis |
| 4. 右颈总动脉 right common carotid a. | 17. 梳状肌 pectinate m. |
| 5. 头臂干 brachiocephalic trunk | 18. 右心耳 right auricle |
| 6. 左头臂静脉 left brachiocephalic v. | 19. 右肺动脉 right pulmonary a. |
| 7. 主动脉弓 arch of aorta | 20. 上腔静脉 superior vena cava |
| 8. 左肺动脉 left pulmonary a. | 21. 右头臂静脉 right brachiocephalic v. |
| 9. 左心房 left atrium | 22. 右锁骨下静脉 right subclavian v. |
| 10. 食管 esophagus | 23. 右淋巴导管 right lymphatic duct |
| 11. 肝左静脉 left hepatic v. | 24. 甲状腺下静脉 inferior thyroid v. |
| 12. 下腔静脉 inferior vena cava | 25. 右颈内静脉 right jugular v. |
| 13. 肝右静脉 right hepatic v. | |

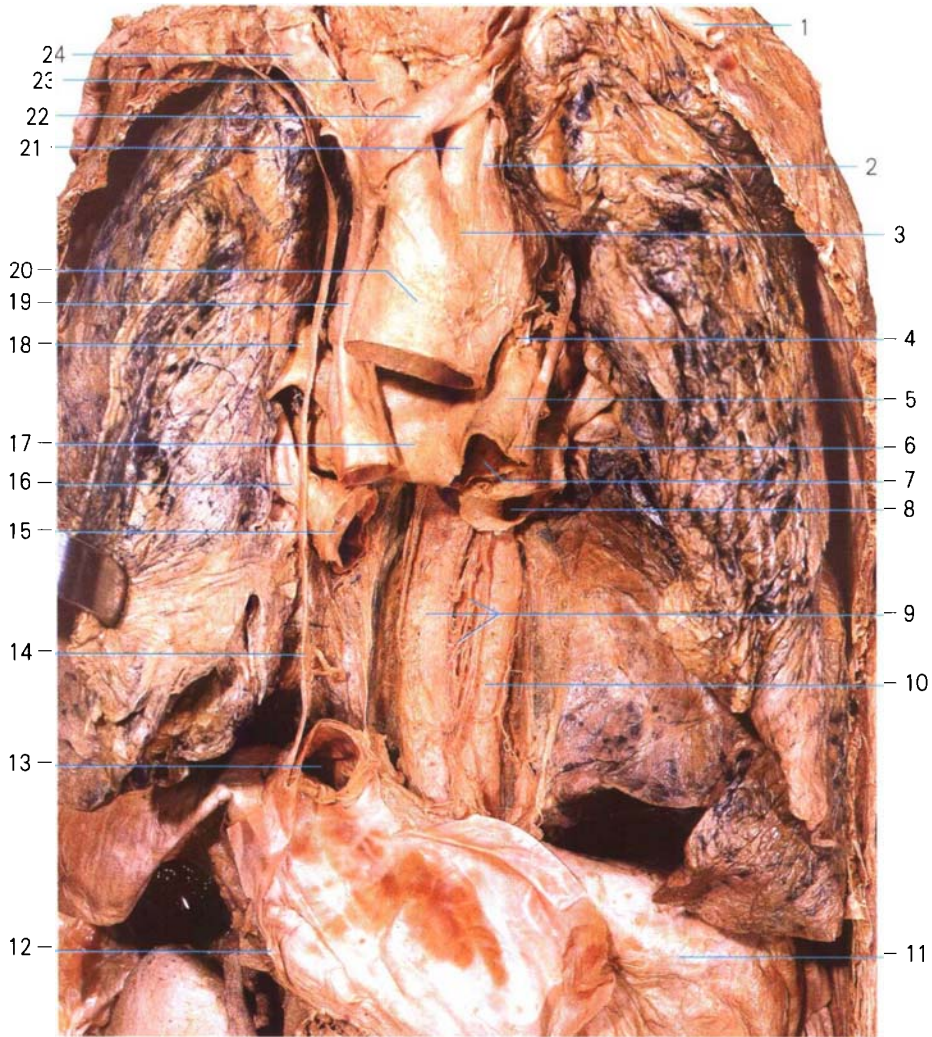
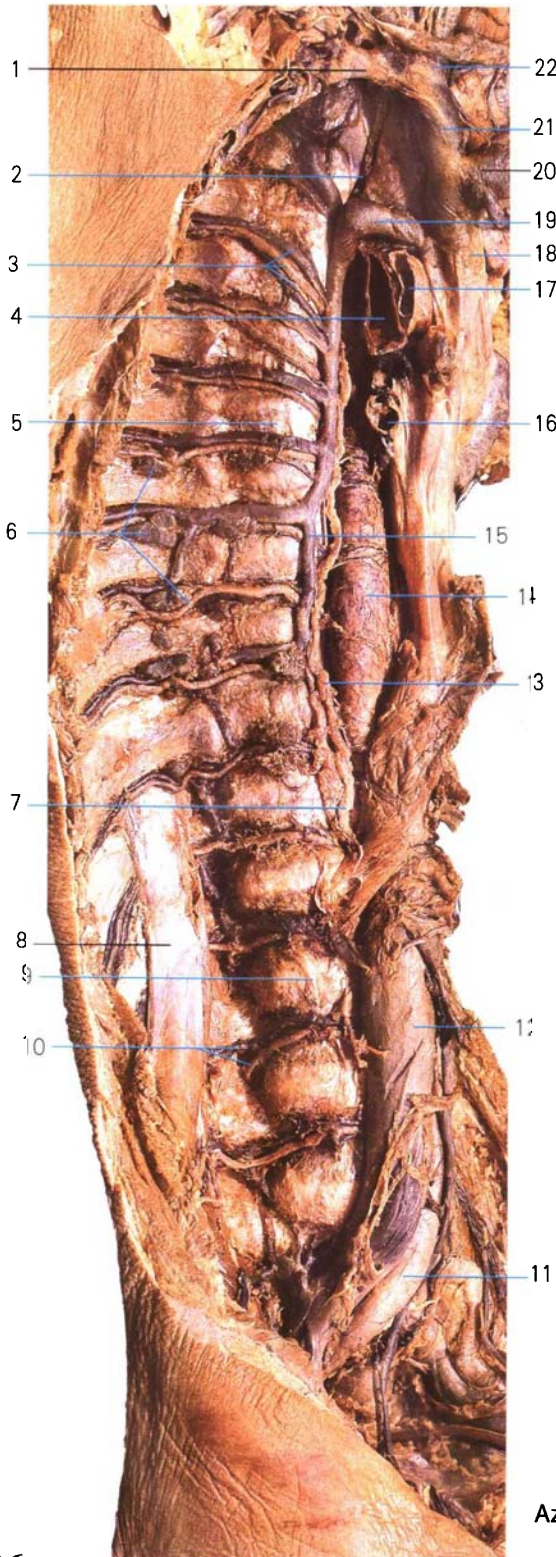


图 130 上纵隔和后纵隔
Superior mediastenum and posterior
mediastenum

- | | |
|--|---|
| 1. 腋动脉 axillary a. | 13. 下腔静脉 inferior vena cava |
| 2. 左锁骨下动脉 left subclavian a. | 14. 右膈神经 right phrenic n. |
| 3. 主动脉弓 arch of aorta | 15. 右肺静脉 right pulmonary v. |
| 4. 动脉韧带 ligamentum arteriosum | 16. 右肺下叶支 inferior lobar branches of right lung |
| 5. 左肺动脉 left pulmonary a. | 17. 右肺动脉 right pulmonary a. |
| 6. 左迷走神经 left vagus n. | 18. 右肺上叶支 superior lobar branches of right lung |
| 7. 肺动脉干 pulmonary trunk | 19. 上腔静脉 superior vena cava |
| 8. 左肺静脉 left pulmonary v. | 20. 升主动脉 ascending aorta |
| 9. 食管及其神经丛 esophagus and esophageal plexus | 21. 左颈总动脉 left carotid a. |
| 10. 胸主动脉 thoracic aorta | 22. 左头臂静脉 left brachiocephalic v. |
| 11. 膈胸膜 diaphragmatic pleura | 23. 头臂干 brachiocephalic trunk |
| 12. 纤维心包(切断处)fibrous pericardium(cut) | 24. 右头臂静脉 right brachiocephalic v. |



1. 右锁骨下静脉 right subclavian v.
2. 右最上肋间静脉 right highest intercostal v.
3. 肋间神经血管 intercostal nerve vessels
4. 右主支气管 right principal bronchus
5. 胸椎椎体 thoracic vertebral body
6. 肋间后淋巴结 posterior intercostal lymph nodes
7. 乳糜池 cisterna chyli
8. 腰方肌 quadratus lumborum
9. 腰椎椎体 lumbar vertebral body
10. 腰动、静脉 lumbar artery and v.
11. 右髂总动脉 right common iliac a.
12. 下腔静脉 inferior vena cava
13. 胸导管 thoracic duct
14. 食管 esophagus
15. 奇静脉 azygos v.
16. 右肺静脉 right pulmonary v.
17. 右肺动脉 right pulmonary a.
18. 上腔静脉 superior vena cava
19. 奇静脉弓 arch of azygos v.
20. 左头臂静脉 left brachiocephalic v.
21. 右头臂静脉 right brachiocephalic v.
22. 右颈内静脉 right jugular v.

图 131 奇静脉和胸导管
Azygos vein and thoracic duct

1. 胸腺 thymus
2. 肺动脉干 pulmonary trunk
3. 左腔静脉襞 fold of left vena cava
4. 心包横窦 transverse pericardial sinus
5. 左肺静脉 left pulmonary v.
6. 心包斜窦 oblique sinus of pericardium
7. 下腔静脉 inferior vena cava
8. 后室间沟 posterior interventricular sulcus
9. 左房斜静脉 oblique vein of left atrium
10. 左心房 left atrium
11. 左心耳 left auricle
12. 心包横窦 transverse pericardial sinus
13. 上腔静脉 superior vena cava
14. 升主动脉 ascending aorta

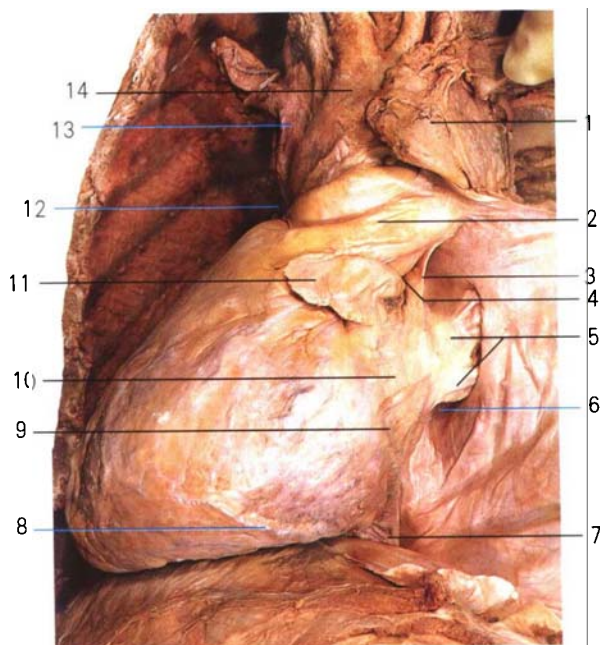
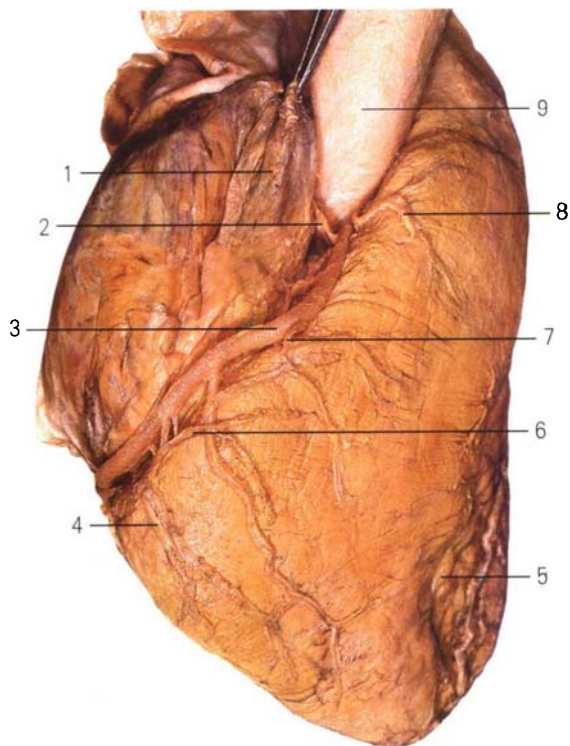
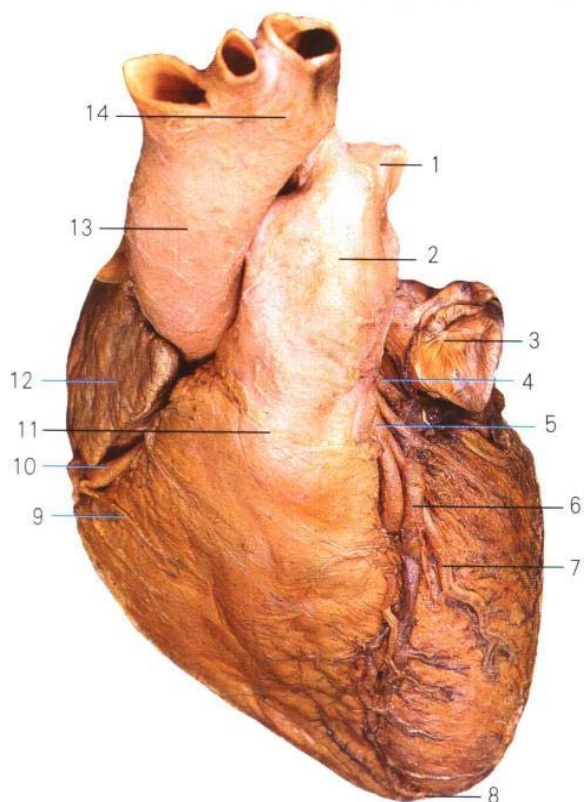


图 132 浆膜心包
Serous pericardium



1. 右心耳 right auricle
2. 窦房结支 branch to sinoatrial node
3. 右冠状动脉 right coronary a.
4. 右缘支 right marginal branch
5. 前室间支 anterior interventricular branch
6. 心前静脉 anterior cardiac v.
7. 右室前支 anterior branch of right ventricle
8. 动脉圆锥支 conus branch
9. 升主动脉 ascending aorta

图 133 冠状动脉和心的静脉 (I)
Coronary arteries and cardiac vein (I)



1. 左肺动脉 left pulmonary a.
2. 肺动脉干 pulmonary trunk
3. 左心耳 left auricle
4. 旋支 circumflex branch
5. 前室间支 anterior interventricular branch
6. 心大静脉 great cardiac v.
7. 左室前支 anterior branch of left ventricle
8. 心尖切迹 cardiac apical incisure
9. 右缘支 right marginal branch
10. 右冠状动脉 right coronary a.
11. 动脉圆锥 conus arteriosus
12. 右心耳 right auricle
13. 升主动脉 ascending aorta
14. 主动脉弓 arch of aorta

图 134 冠状动脉和心的静脉(Ⅱ)
Coronary arteries and cardiac vein(Ⅱ)

1. 左上肺静脉 left superior pulmonary v.
2. 左心房 left atrium
3. 左下肺静脉 left inferior pulmonary v.
4. 冠状窦 coronary sinus
5. 旋支 circumflex branch
6. 左缘支 left marginal branch
7. 旋支后支 posterior branch of circumflex branch
8. 左心室后壁 posterior wall of left ventricle
9. 右心室后壁 posterior wall of right ventricle
10. 后室间支 posterior interventricular branch
11. 心中静脉 middle cardiac v.
12. 右冠状动脉 right coronary a.
13. 心小静脉 small cardiac v.
14. 下腔静脉 inferior vena cava

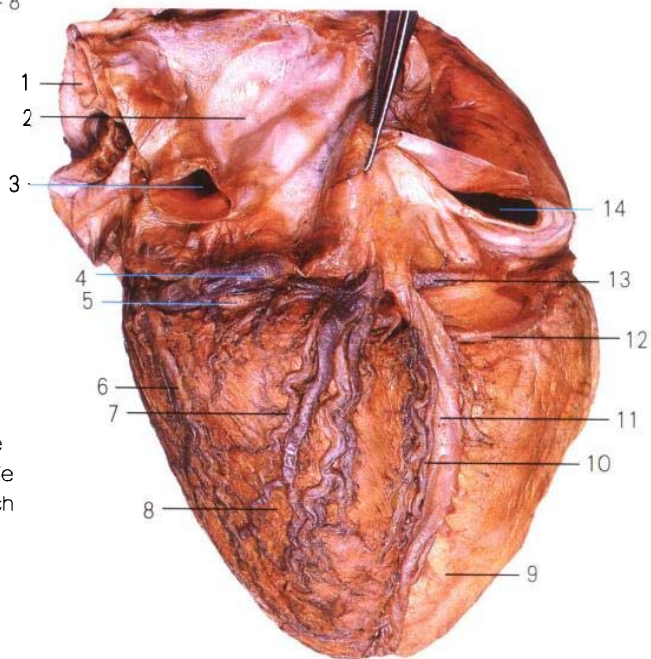


图 135 冠状动脉和心的静脉(Ⅲ)
Coronary arteries and cardiac vein(Ⅲ)

1. 肺动脉半月瓣 semilunar cusp of pulmonary valve
2. 肺动脉窦 sinus of pulmonary trunk
3. 动脉圆锥 conus arteriosus
4. 室上嵴 supra-ventricular crest
5. 隔侧乳头肌 septal papillary m.
6. 三尖瓣前瓣 anterior cusp of tricuspid valve
7. 前乳头肌 anterior papillary m.
8. 前室间动脉 anterior interventricular branch
9. 后乳头肌 posterior papillary m.

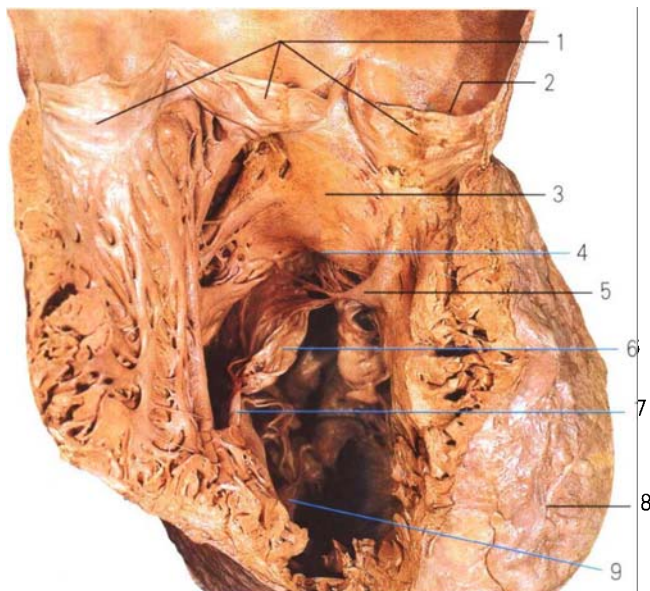
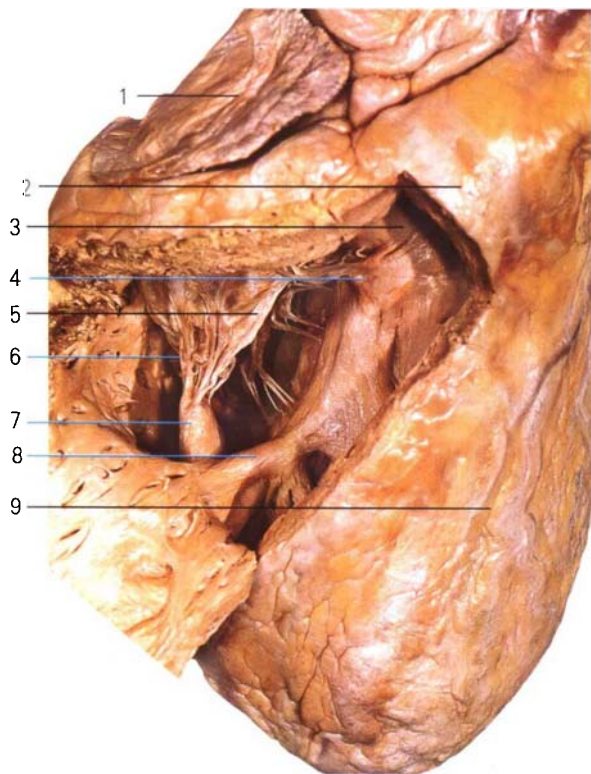
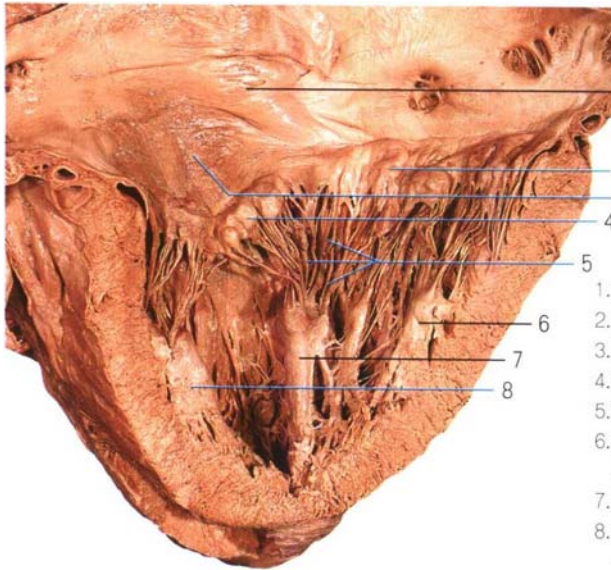


图 136 肺动脉半月瓣和肺动脉窦
Semilunar cusp of pulmonary valve
and sinus of pulmonary trunk



1. 右心耳 right auricle
2. 肺动脉干 pulmonary trunk
3. 动脉圆锥 conus arteriosus
4. 室上嵴 supra-ventricular crest
5. 三尖瓣前瓣 anterior cusp of tricuspid valve
6. 腱索 chordae tendineae
7. 前乳头肌 anterior papillary m.
8. 隔缘肉柱 septomarginal trabecula
9. 前室间沟 anterior interventricular sulcus

图 137 右心室
Right ventricle



1. 左心房 left auricle
2. 二尖瓣后瓣 posterior cusp of mitral valve
3. 二尖瓣前瓣 anterior cusp of mitral valve
4. 纤维小结节 fibrous (Albini's) nodules
5. 腱索 chordae tendineae
6. 前乳头肌(已切开) anterior papillary m. (sectioned)
7. 后乳头肌 posterior papillary muscle
8. 前乳头肌(已切开) anterior papillary m. (sectioned)

图 138 二尖瓣(左房室瓣)
Mitral valve(left atrioventricular valve)

1. 左冠状动脉口 orifice of left coronary a.
2. 主动脉窦 aortic sinuses (of valsalva)
3. 右冠状动脉口 orifice of right coronary a.
4. 半月瓣小结 nodule of semilunar valve
5. 室间隔膜部 membranous part of interventricular septum
6. 二尖瓣前瓣 anterior cusp of mitral valve
7. 腱索 chordae tenineae
8. 室间隔肌性部 muscular part of interventricular septum
9. 前乳头肌 anterior papillary m.
10. 后乳头肌 posterior papillary m.

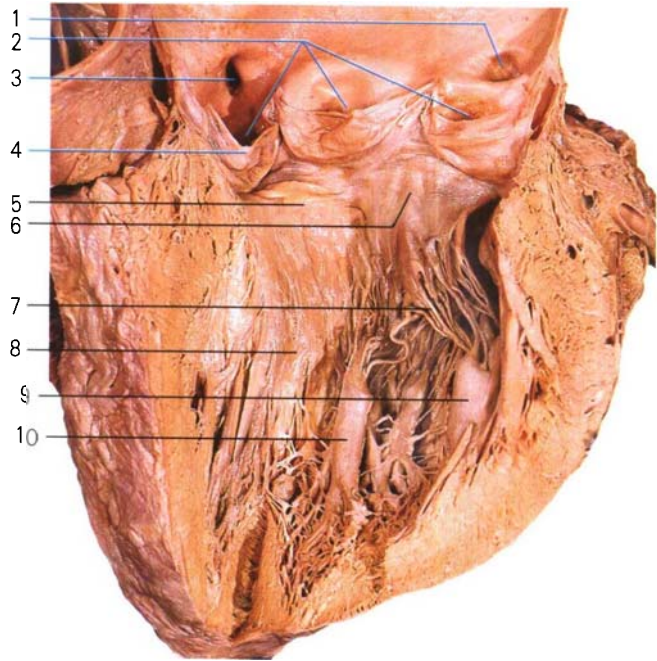


图 139 主动脉瓣和主动脉窦
Mitral valve and aortic sinuses

1. 肺动脉窦 sinus of pulmonary trunk
2. 肺动脉半月瓣 semilunar cusp of pulmonary valve
3. 纤维环 annulus fibrosus
4. 主动脉半月瓣 semilunar cusp of aortic valve
5. 二尖瓣后瓣 posterior cusp of mitral valve
6. 主动脉窦 sinus of aorta
7. 右心耳 right auricle
8. 三尖瓣前瓣 anterior cusp of tricuspid valve
9. 三尖瓣隔侧瓣 septal cusp of tricuspid valve
10. 三尖瓣后瓣 posterior cusp of tricuspid valve

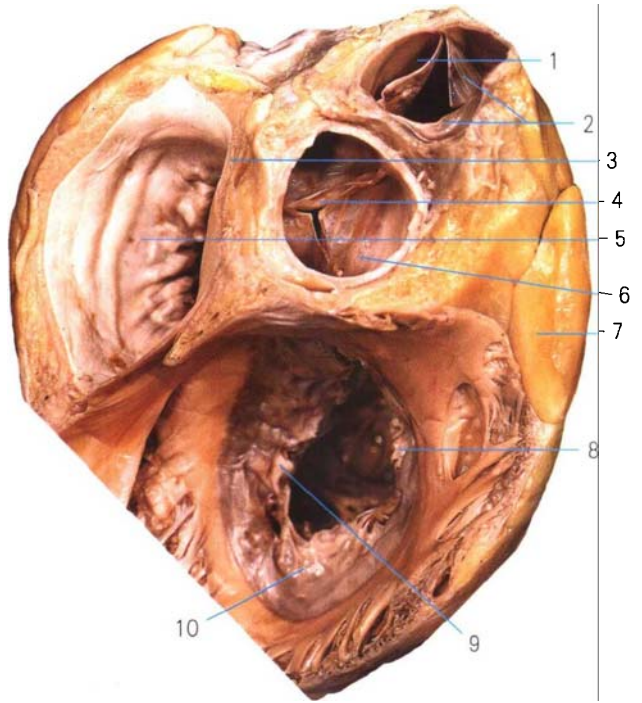


图 140 心的瓣膜(I)
Valves of heart(I)

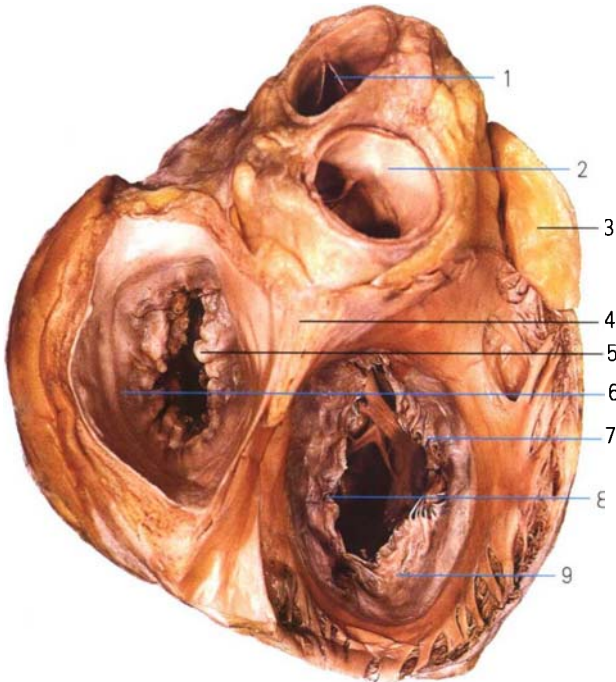
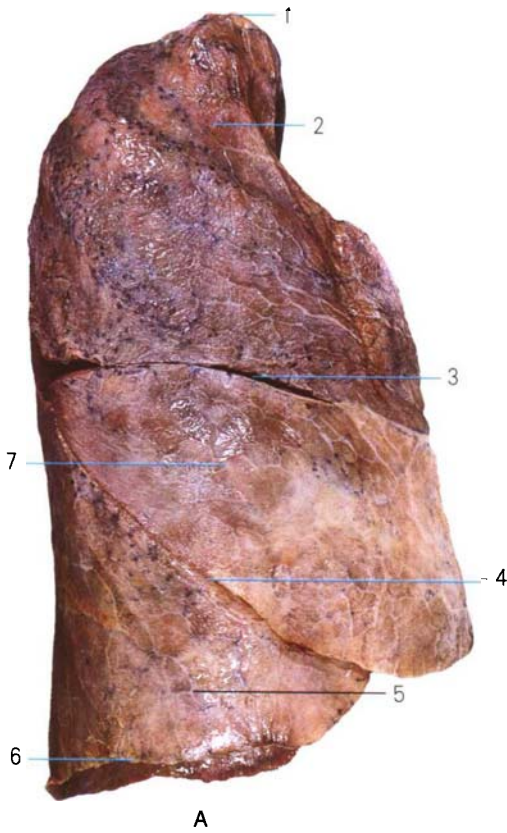
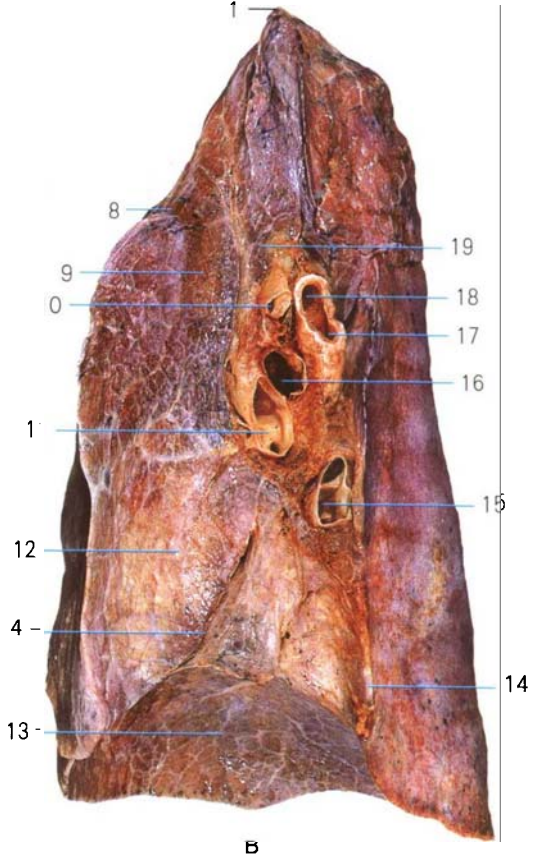


图 141 心的瓣膜(II)
Valves of heart(II)

1. 肺动脉半月瓣 semilunar cusp of pulmonary trunk
2. 升主动脉 ascending aorta
3. 右心耳 right auricle
4. 右纤维三角 right fibrous trigone
5. 二尖瓣前瓣 anterior cusp of mitral valve
6. 二尖瓣后瓣 posterior cusp of mitral valve
7. 三尖瓣前瓣 posterior cusp of tricuspid valve
8. 三尖瓣隔瓣 anterior cusp of tricuspid valve
9. 三尖瓣后瓣 posterior cusp of tricuspid valve



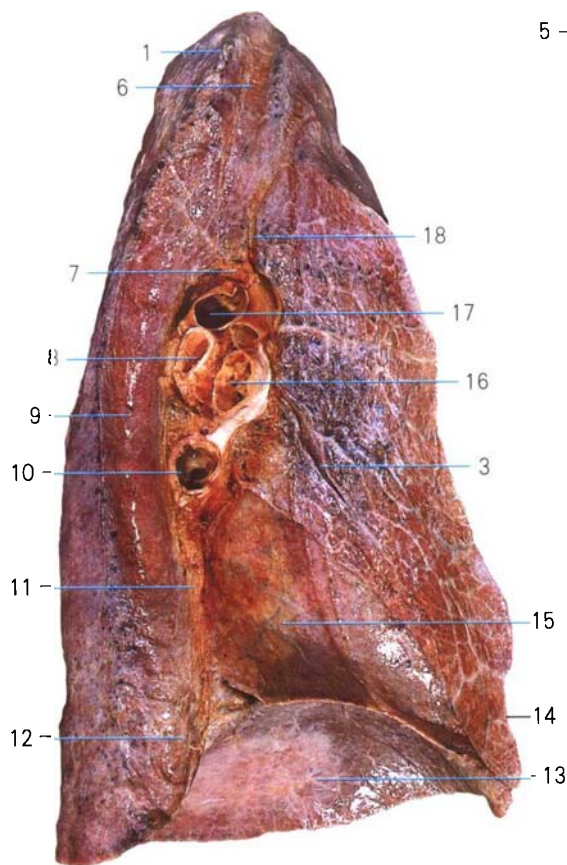
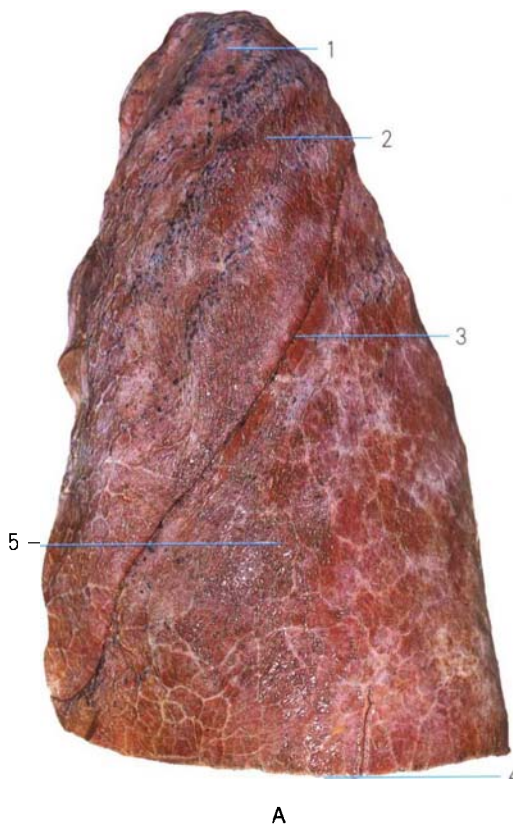
1. 肺尖 apex
2. 上叶 upper lobe
3. 水平裂 horizontal fissure
4. 斜裂 oblique fissure
5. 下叶 lower lobe
6. 下缘 inferior margin
7. 中叶 middle lobe
8. 第一肋压迹 impression for first rib
9. 上腔静脉压迹 impression for superior vena cava
10. 上叶支 superior lobar bronchus
11. 上肺静脉 superior pulmonary v.
12. 心压迹 cardiac impression
13. 膈面 diaphragmatic surface



14. 肺韧带 pulmonary ligament
15. 下肺静脉 inferior pulmonary v.
16. 肺动脉叶间部 interlobular part of pulmonary a.
17. 中间支气管 intermediate bronchus
18. 上叶支气管 superior lobar bronchus
19. 奇静脉压迹 impression for azygos v.

图 142 右肺(A.外侧面观, B.内侧面观)
Right lung(A.lateral aspect,B.medial aspect)

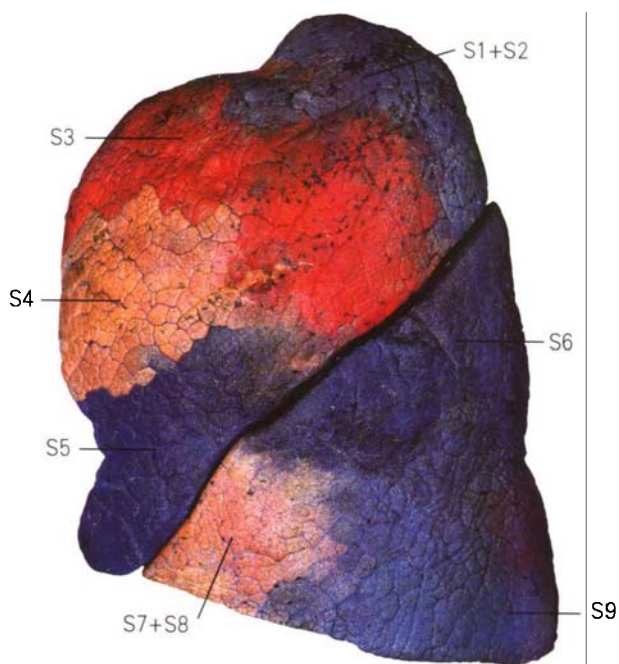
1. 肺尖 apex
2. 上叶 upper lobe
3. 斜裂 oblique fissure
4. 下缘 inferior margin
5. 下叶 lower lobe
6. 食管压迹 impression for esophagus
7. 主动脉弓压迹 impression for arch of aorta
8. 左主支气管 left principal bronchus
9. 降主动脉压迹 impression for descending aorta
10. 下肺静脉 inferior vena cava
11. 肺韧带 pulmonary ligament
12. 食管压迹 impression for esophagus
13. 膈面 diaphragmatic surface



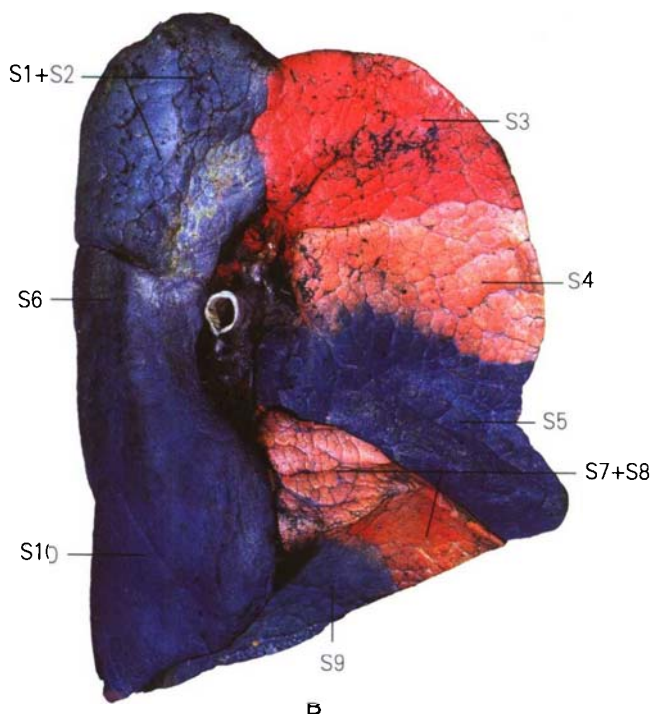
14. 心切迹 cardiac notch
15. 心压迹 cardiac impression
16. 上肺静脉 superior pulmonary v.
17. 左肺动脉 left pulmonary a.
18. 左锁骨下动脉压迹 impression for left subclavian a.

B

图 143 左肺(A. 外侧面观, B. 内侧面观)
Left lung(A.lateral aspect,B.medial aspect)



A



B

- S1 + S2. 尖后段 apicoposterior segment
- S3. 前段 anterior segment
- S4. 上舌段 superior lingular segment
- S5. 下舌段 inferior lingular segment
- S6. 上段 superior segment
- S7 + S8. 内侧底段又称“心底段” medial basal segment(cardac basal segmental +前底段 anterior basal segment)
- S9. 外侧底段 lateral basal segmental
- S10. 后底段 posterior basal segmental

图 144 左肺支气管肺段(A. 外侧面观, B. 内侧面观)
Bronchopulmonary segments of left lung
(A.lateral aspect,B.medial aspect)

- S1. 尖段 apical segment
 S2. 后段 posterior segment
 S3. 前段 anterior segment
 S4. 外侧段 lateral segment
 S5. 内侧段 medial segmental
 S6. 上段 superior segment
 S7. 内侧底段又称“心底段” medial segment (cardiac basal segment)
 S8. 前底段 anterior basal segment
 S9. 外侧底段 lateral basal segment
 S10. 后底段支气管 posterior basal segment

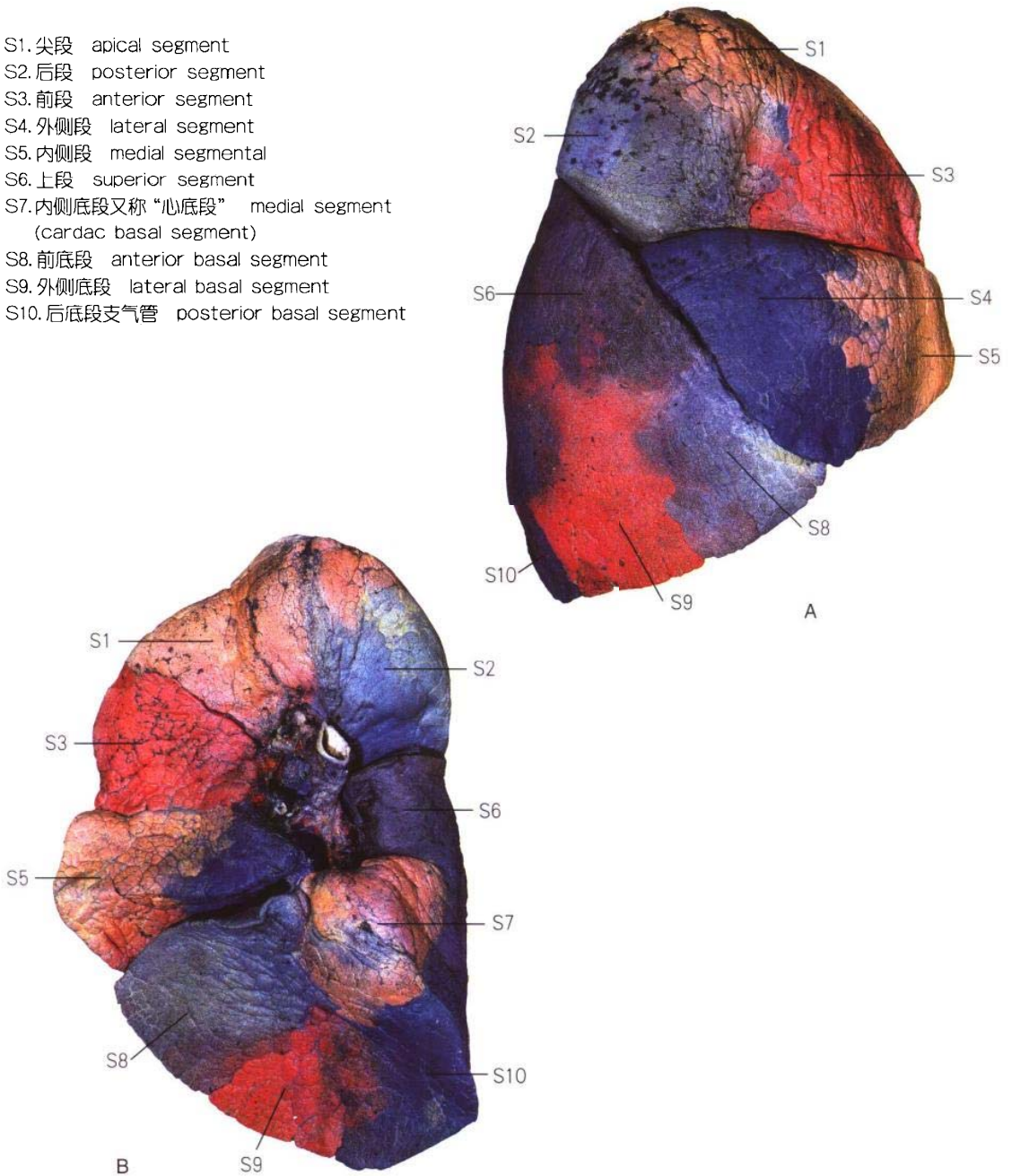
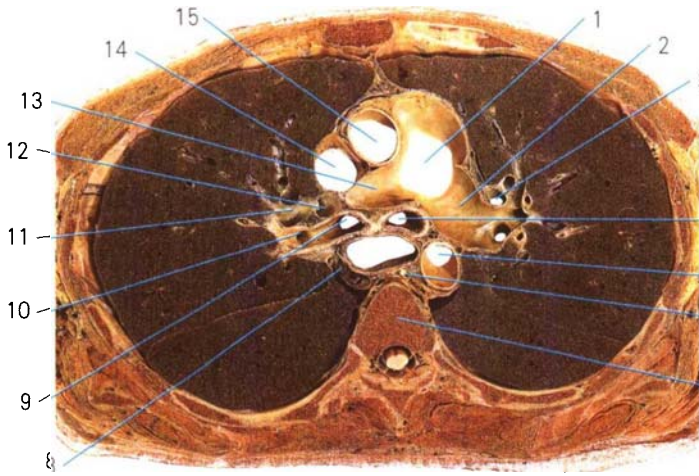


图 145 右肺支气管肺段(A. 外侧面观, B. 内侧面观)
 Bronchopulmonary segment of right lung
 (A.lateral aspect, B.medial aspect)



1. 肺动脉干 pulmonary trunk
2. 左肺动脉 left pulmonary a.
3. 左肺上静脉 left pulmonary v.
4. 左主支气管 left principal bronchus
5. 胸主动脉 thoracic aorta
6. 胸导管 thoracic duct
7. 胸椎椎体 vertebral body
8. 奇静脉 azygos v.
9. 右主支气管 right principal bronchus
10. 右肺上叶支气管 right superior lobar bronchus
11. 右上肺静脉 right superior pulmonary v.
12. 右肺上叶动脉 right superior pulmonary a.
13. 右肺动脉 right pulmonary a.
14. 上腔静脉 superior vena cava
15. 升主动脉 ascending aorta

图 146 经肺动脉分权平面横断面
The section at the level of the bifurcation of pulmonary trunk on transverse

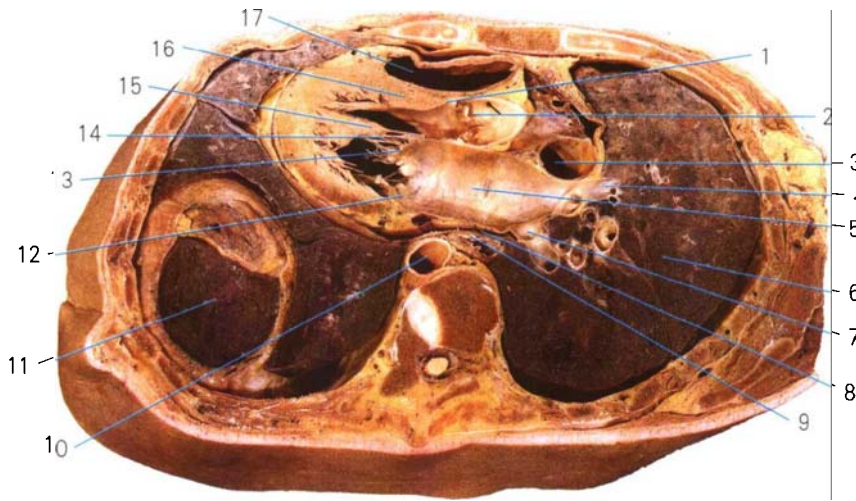


图 147 经心长轴斜切面
The section at the long axis of the heart on oblique

- | | |
|---|---|
| <ol style="list-style-type: none"> 1. 室间隔膜部 interventricular membranous part 2. 主动脉右前窦、右冠状动脉口 right aortic sinus of (valsalva)and orifice of right coronary a. 3. 上腔静脉 superior vena cava 4. 右上肺静脉 pulmonary trunk 5. 左心房 left atrium 6. 右肺上叶 superior lobar of right lung 7. 右肺下静脉 right inferior pulmonary v. 8. 心包斜窦 oblique pericardial sinus | <ol style="list-style-type: none"> 9. 食管 esophagus 10. 胸主动脉 thoracic aorta 11. 脾 spleen 12. 二尖瓣后瓣 posterior cusp of mitral valve 13. 二尖瓣前瓣 anterior cusp of mitral valve 14. 腱索 chordae tendineae 15. 前乳头肌 anterior papillary m. 16. 室间隔肌性部 interventricular muscular part 17. 右心室 right ventricle |
|---|---|

1. 第一胸椎椎体 first thoracic vertebral body
2. 头臂干 brachiocephalic trunk
3. 右肺动脉 right pulmonary a.
4. 左心房 left auricle
5. 食管 esophagus
6. 右心房 right auricle
7. 下腔静脉 inferior vena cava
8. 冠状韧带上层 superior layer of coronary ligament
9. 肝尾状叶 caudate lobe
10. 静脉韧带裂及肝胃韧带 fissure for ligamentum venosum and hepatogastric ligament
11. 第一腰椎椎体 the first lumbar vertebral body
12. 胰 pancreas
13. 第五腰椎椎体 fifth lumbar vertebral body
14. 尾骨 coccygeal vertebrae
15. 直肠 rectum
16. 肛门 anus
17. 睾丸 testis
18. 阴茎 penis
19. 耻骨联合 pubic symphysis
20. 膀胱 urinary bladder
21. 骶岬 promontory
22. 小肠 jejunum
23. 横结肠 transverse colon
24. 横结肠系膜 transverse mesocolon
25. 胃 stomach
26. 肝胃韧带 hepatogastric ligament
27. 肝 liver
28. 右心室 right ventricle
29. 心包腔 serous pericardial cavity
30. 右心耳 right auricle
31. 升主动脉 ascending aorta
32. 胸骨角 sternal angle
33. 左头臂静脉 left brachiocephalic vein
34. 气管 trachea

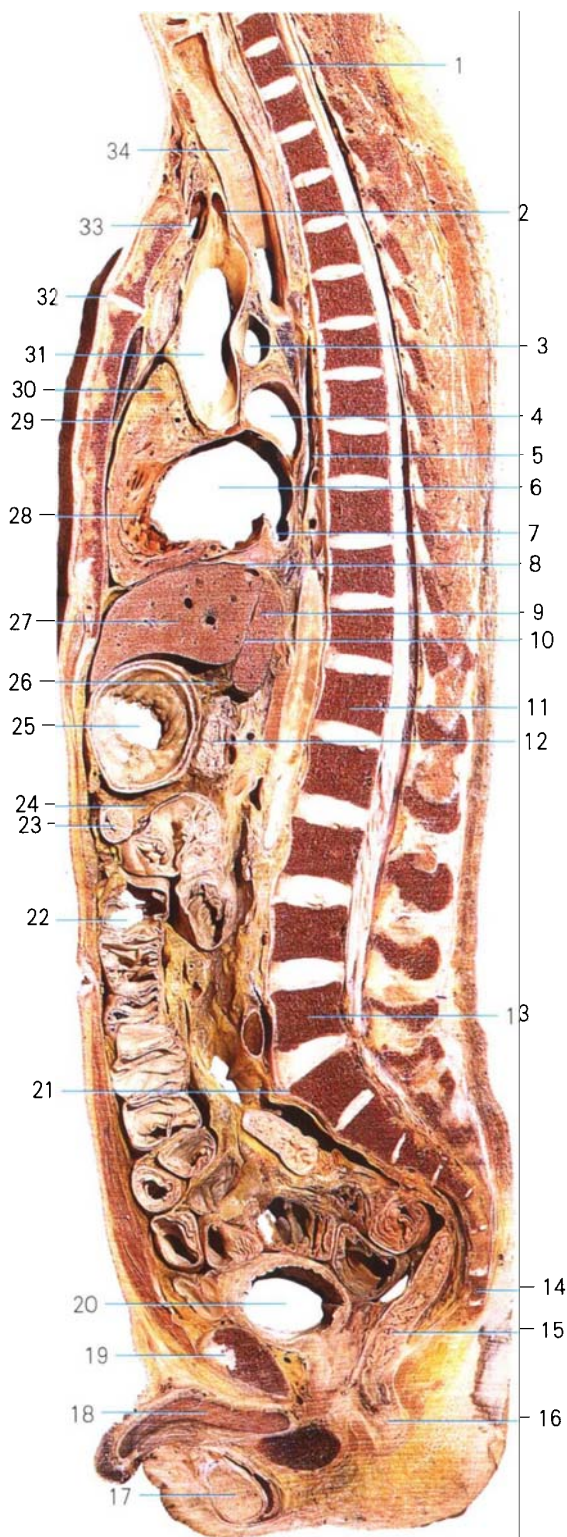
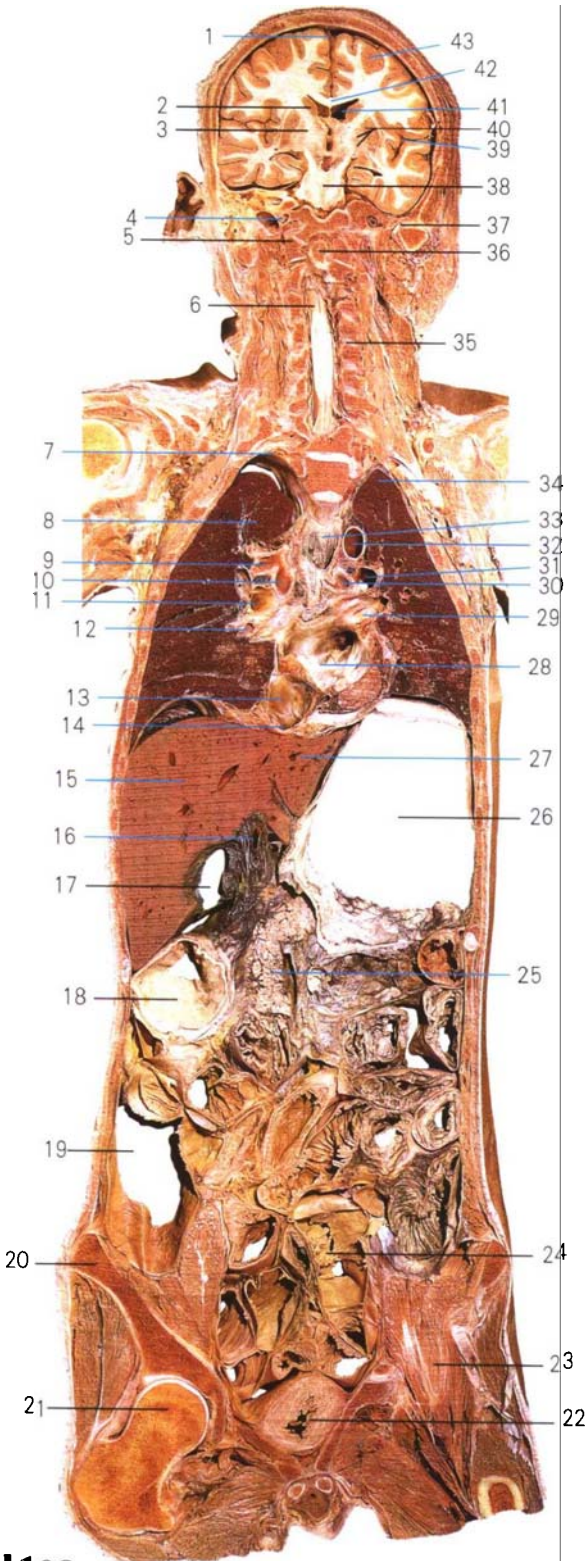
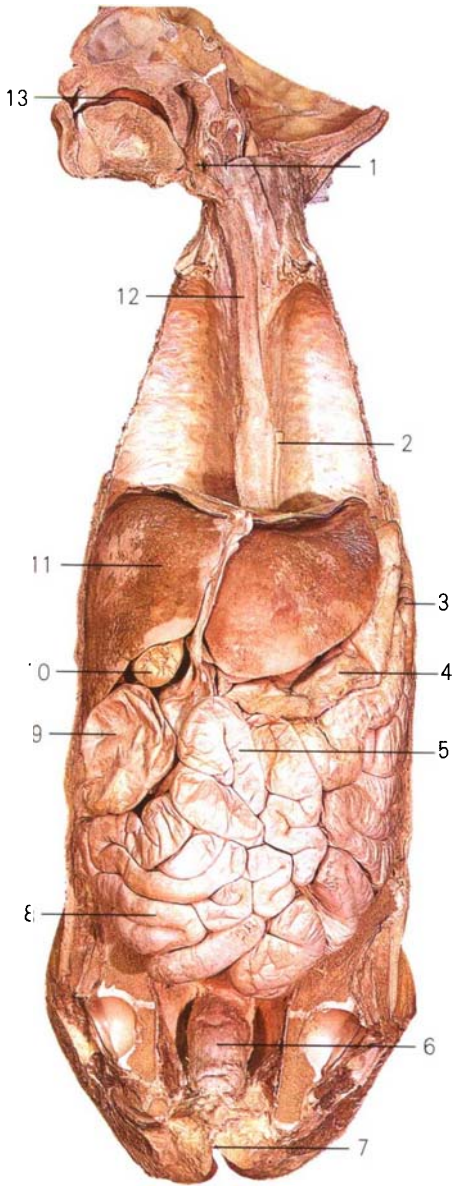


图 148 经腹盆正中矢状切面
Sagittal section through the abdomen
and pelvis in median plane



1. 大脑镰 falx cerebri
2. 尾状核 caudate nucleus
3. 内囊 internal capsule
4. 颈内动脉 internal carotid a.
5. 寰枕关节 atlantooccipital joint
6. 脊髓 spinal cord
7. 胸膜顶(颈胸膜) cupula(cervical pleura)
8. 右肺上叶 superior lobe of right lung
9. 右肺下叶支气管 right superior lobar bronchus
10. 中间支气管 intermediate bronchus
11. 右肺动脉 right pulmonary a.
12. 右肺下叶支气管 right inferior lobar bronchus
13. 右心房 right atrium
14. 下腔静脉 inferior vena cava
15. 肝右叶 right hepatic lobe
16. 肝门静脉 hepatic portal v.
17. 胆囊 gall bladder
18. 横结肠 transverse colon
19. 升结肠 ascending colon
20. 髌骨 ilium
21. 股骨头 head of femur
22. 膀胱 urinary bladder
23. 髂腰肌 iliopsoas
24. 空肠 jejunum
25. 胰 pancreas
26. 胃 stomach
27. 肝左叶 left lobe of liver
28. 左心房 left atrium
29. 左肺静脉 left pulmonary v.
30. 左主支气管 left principal bronchus
31. 左肺动脉 left pulmonary a.
32. 主动脉弓 arch of aorta
33. 食管 esophagus
34. 左肺尖 apex of lung
35. 颈椎椎间关节 cervical intervertebral joint
36. 齿突 dens
37. 颞下颌关节盘 articular disc of temporomandibular joint
38. 桥脑 pons
39. 外侧沟 lateral(sylvian)sulcus
40. 豆状核 lentiform nucleus
41. 侧脑室 lateral ventricle
42. 胼胝体 corpus callosum
43. 顶叶 parietal lobule

图 149 经齿突冠状断面
Coronal section through the level
of the dens of axis(C2)



1. 咽 pharynx
2. 胸主动脉 thoracic aorta
3. 脾 spleen
4. 胃 stomach
5. 空肠 jejunum
6. 直肠 rectum
7. 肛门 anus
8. 回肠 ileum
9. 结肠右曲 right colic flexure
10. 胆囊 gallbladder
11. 肝 liver
12. 食管 esophagus
13. 口腔 oral cavity
14. 胸腹壁静脉 thoracoepigastric v.
15. 脐 umbilicus
16. 腹壁浅静脉 superficial epigastric v.
17. 旋髂浅静脉 superficial iliac circumflex v.
18. 大隐静脉 great saphenous v.

图 150 消化系统概观
General arrangement of the digestive apparatus

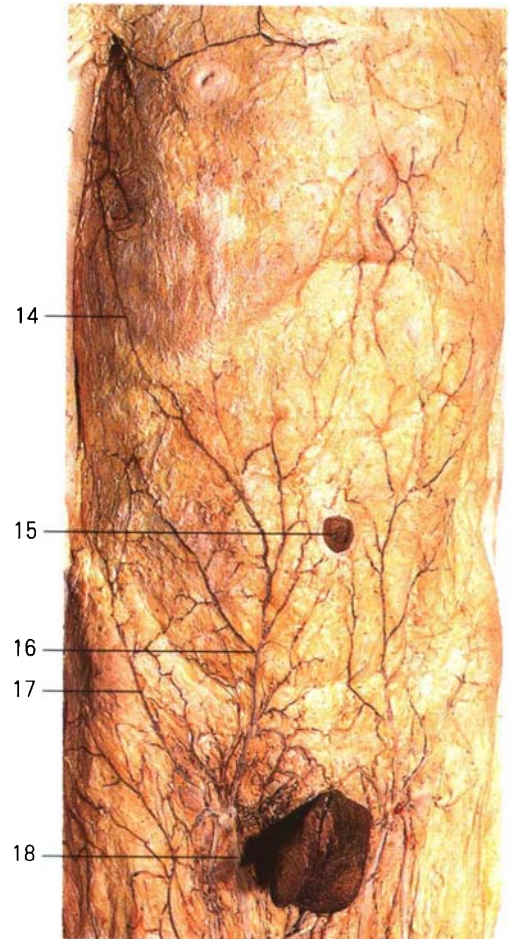


图 151 腹部皮下静脉 (I)
Abdominal subcutaneous veins (I)

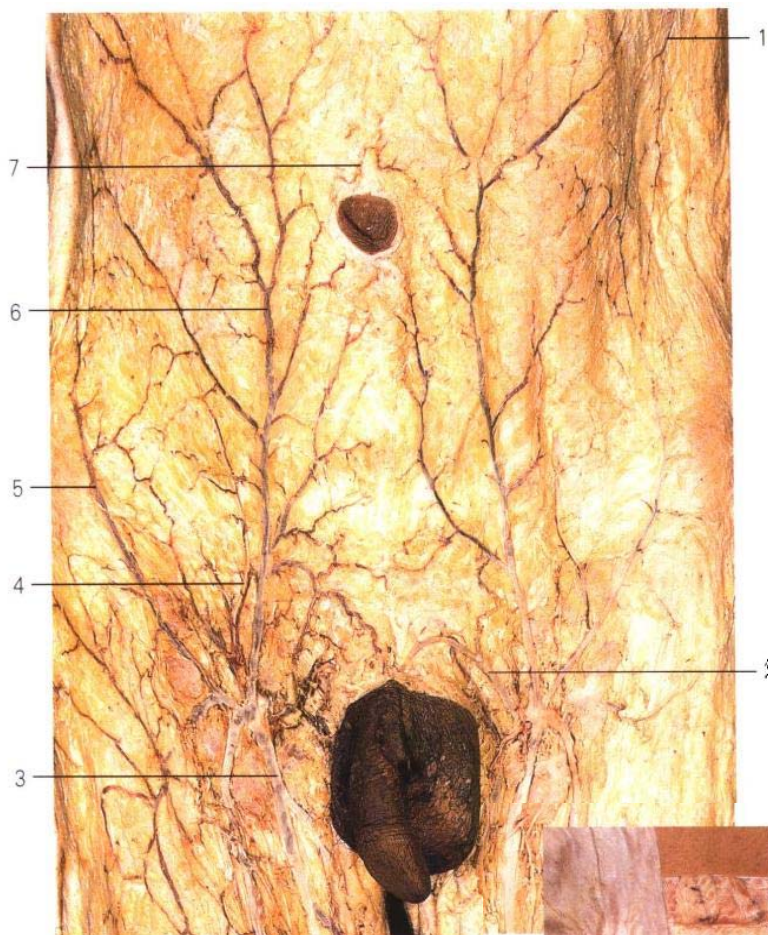


图 152 腹部皮下静脉(II)
Abdominal subcutaneous
veins(II)

1. 胸腹壁静脉 thoracoepigastric v.
2. 阴部外静脉 external pudendal v.
3. 大隐静脉 great saphenous v.
4. 腹壁浅动脉 superficial epigastric a.
5. 旋髂浅静脉 superficial iliac circumflex v.
6. 腹壁浅静脉 superficial epigastric v.
7. 附脐静脉 paraumbilical v.
8. 皮肤 skin
9. 浅筋膜脂性层 camper fascia
10. 浅筋膜膜层 scarpa fascia
11. 腹外斜肌腱膜 aponeurosis of obliquus externus abdominis
12. 腹股沟韧带 inguinal ligament
13. 精索 spermatic cord
14. 阴茎 penis
15. 睾丸 testis

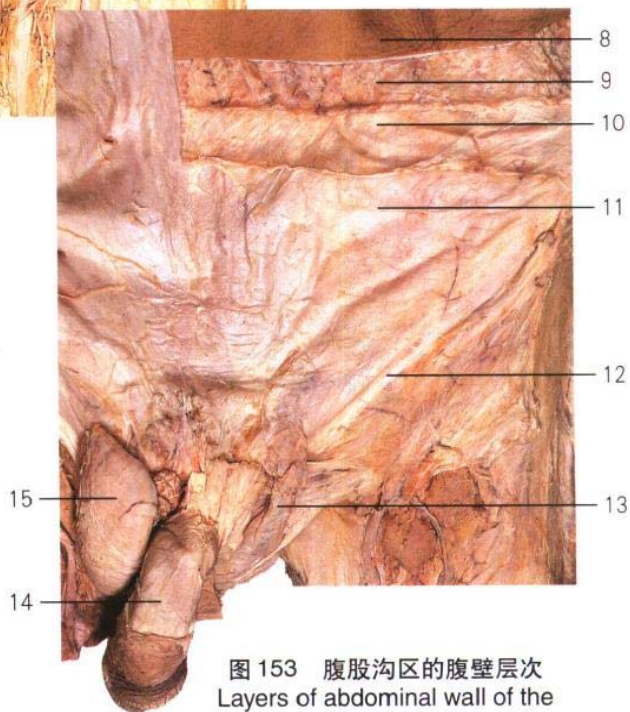


图 153 腹股沟区的腹壁层次
Layers of abdominal wall of the
inguinal region

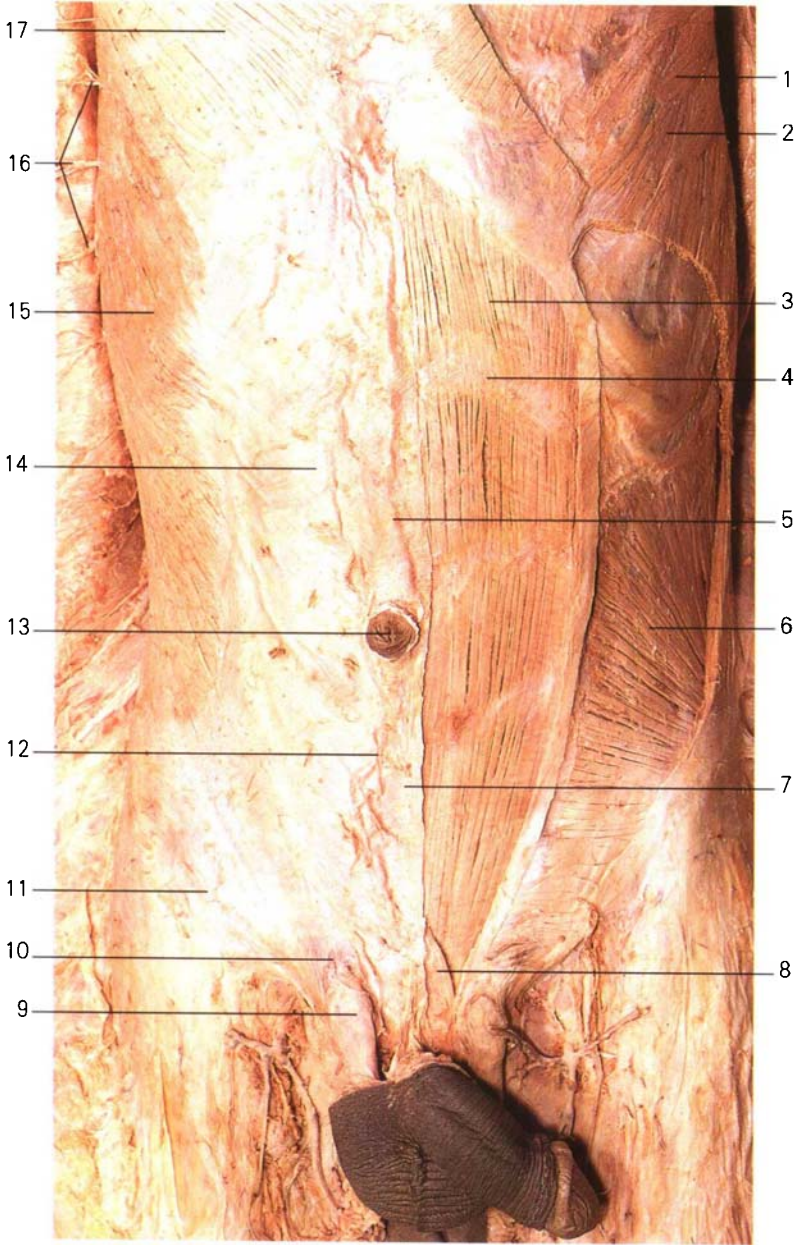


图 154 腹前外侧壁肌层
Musculature of the
anterolateral abdominal wall

- 1. 前锯肌, serratus anterior
- 2. 15. 腹外斜肌, obliquus externus abdominis
- 3. 腹直肌, rectus abdominis
- 4. 腱划, tendinous intersections
- 5. 7. 腹白线, linea alba
- 6. 腹内斜肌, obliquus internus abdominis
- 8. 锥状肌, pyramidalis
- 9. 精索, spermatic cord
- 10. 腹股沟管浅环, superficial inguinal ring

- 11. 腹股沟韧带, inguinal ligament
- 12. 胸神经前皮支, anterior cutaneous branch(T.11)
- 13. 脐, umbilicus
- 14. 腹直肌鞘前层, anterior layer of sheath of rectus abdominis
- 16. 外侧皮支(胸神经), lateral cutaneous branches (thoracic nerves)
- 17. 胸大肌, pectoralis major

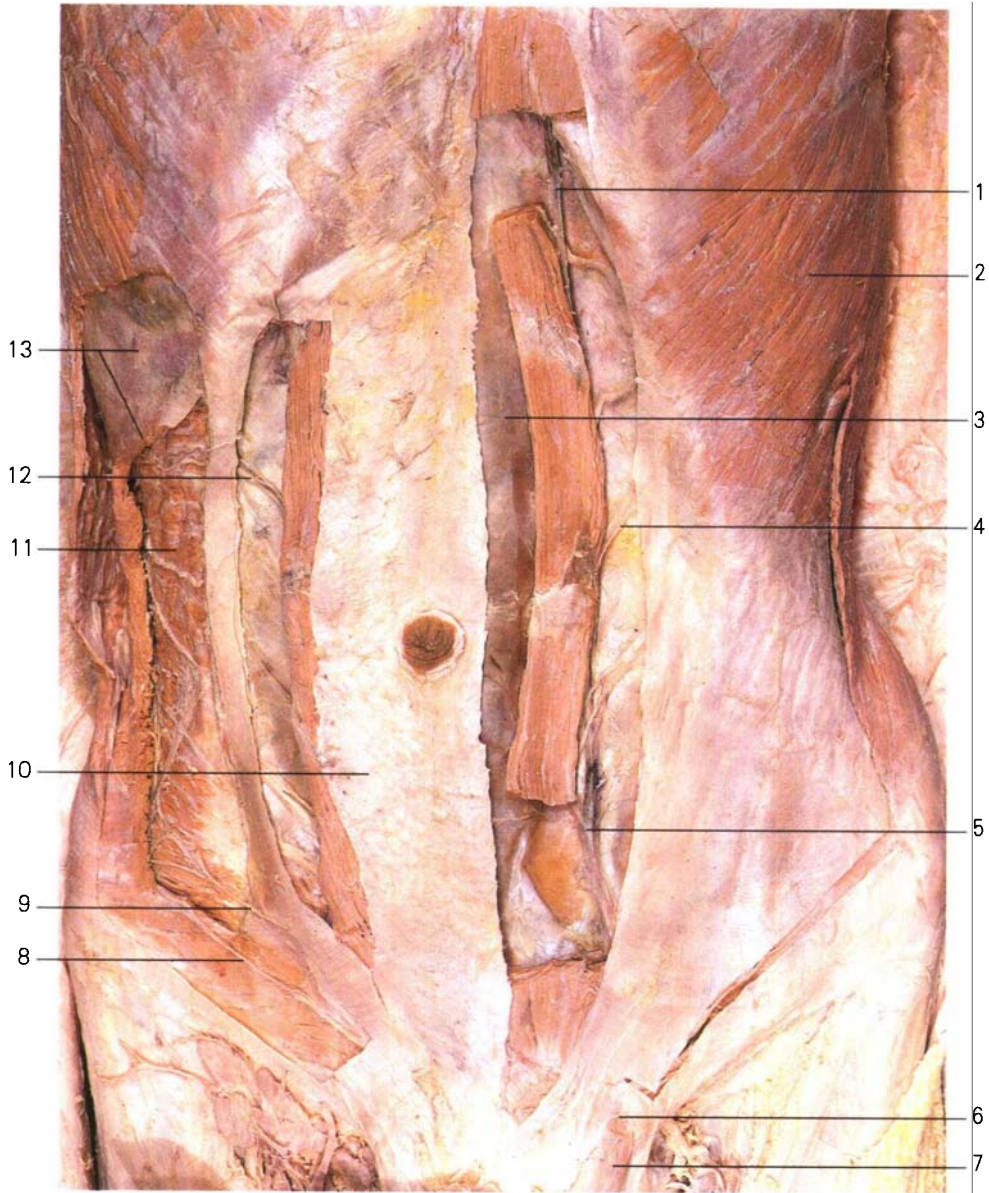
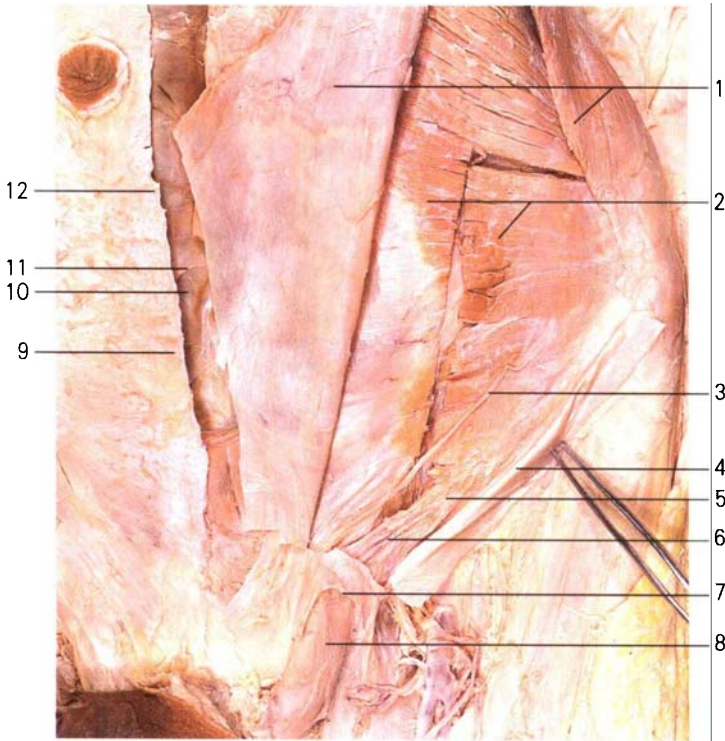

图 155 腹前外侧壁的神和血管
Nerves and blood vessels of anterolateral wall of abdomen

- | | |
|---|---|
| 1. 腹壁上动脉、静脉 superior epigastric a. & v. | 8. 髂腹股沟神经 ilioinguinal n. |
| 2. 腹外斜肌 abliquus externus abdominis | 9. 髂腹下神经 iliohypogastric n. |
| 3. 腹直肌鞘后层 posterior layer of sheath of rectus abdominis | 10. 腹直肌鞘前层 anterior layer of sheath of rectus abdominis |
| 4. 第10胸神经 thoracic n.(T.10) | 11. 腹横肌 transversus abdominis |
| 5. 腹壁下动脉、静脉 inferior epigastric a. & v. | 12. 第十胸神经及血管 10th thoracic n. and blood vessels |
| 6. 腹股沟管浅环 superficial inguinal ring | 13. 腹内斜肌 obliquus internus abdominis |
| 7. 精索 spermatic cord | |



- 1. 腹外斜肌 obliquus externus abdominis
- 2.15. 腹内斜肌 obliquus internus abdominis
- 3. 髂股下神经 iliohypogastric n.
- 4. 腹股沟韧带 inguinal ligament
- 5.8.19. 精索 spermatic cord
- 6. 髂腹沟神经 ilioinguinal n.
- 7.20. 浅环 superficial inguinal ring
- 9. 腹直鞘前层 anterior layer of sheath of rectus abdominis
- 10.14.24. 腹横筋膜 transversalis fascia
- 11.25. 弓状线 arcuate line
- 12.26. 腹直肌鞘后层 posterior layer of sheath of rectus abdominis

图 156 腹股沟管 (I)
Inguinal canal (I)

- 13.16. 腹横肌 transversus abdominis
- 17. 腹股沟管深环 deep inguinal ring
- 18. 凹间韧带 interfoveolar lig.
- 21. 联合腱 conjoined tendon
- 22. 锥状肌 pyramidalis
- 23. 腹直肌 rectus abdominis

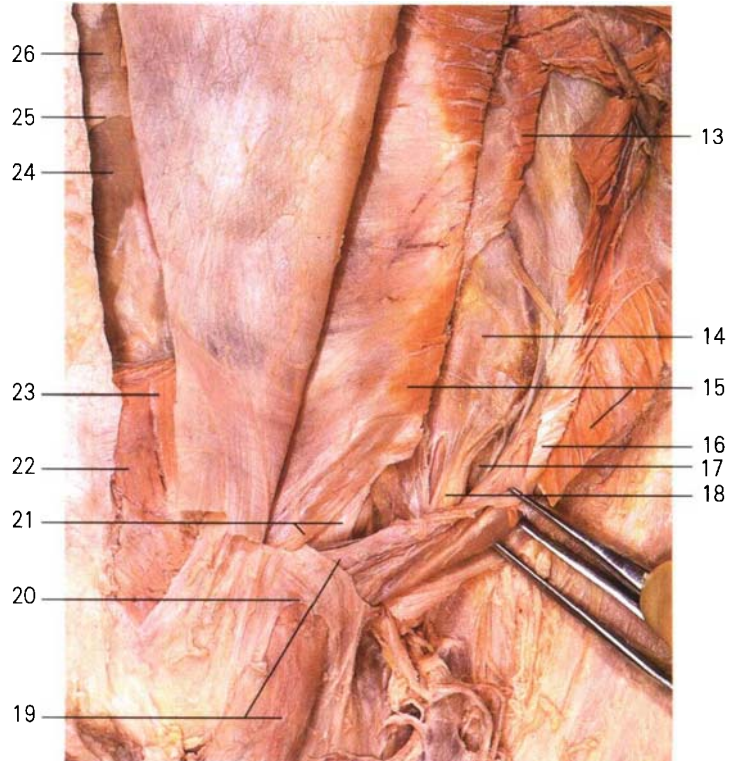


图 157 腹股沟管 (II)
Inguinal canal (II)

1. 脐内侧韧带 medial umbilical ligament
2. 腹膜 peritoneum
3. 腹膜外脂 extraperitoneal fat
4. 膀胱尖 apex of urinary bladder
5. 髂外静脉 external iliac v.
6. 髂外动脉 external iliac a.
7. 腹壁下动静脉 inferior epigastric a. & v.
8. 腹横肌 transversus abdominis
9. 腹直肌 rectus abdominis
10. 中心腱 central tendon
11. 食管腹段 abdominal part of esophagus
12. 左膈下动脉 left inferior phrenic a.
13. 主动脉裂 aortic hiatus
14. 腹主动脉 abdominal aorta
15. 左、右膈足 left and right crus
16. 右膈下动脉 right inferior phrenic a.
17. 腔静脉孔 vena caval foramen

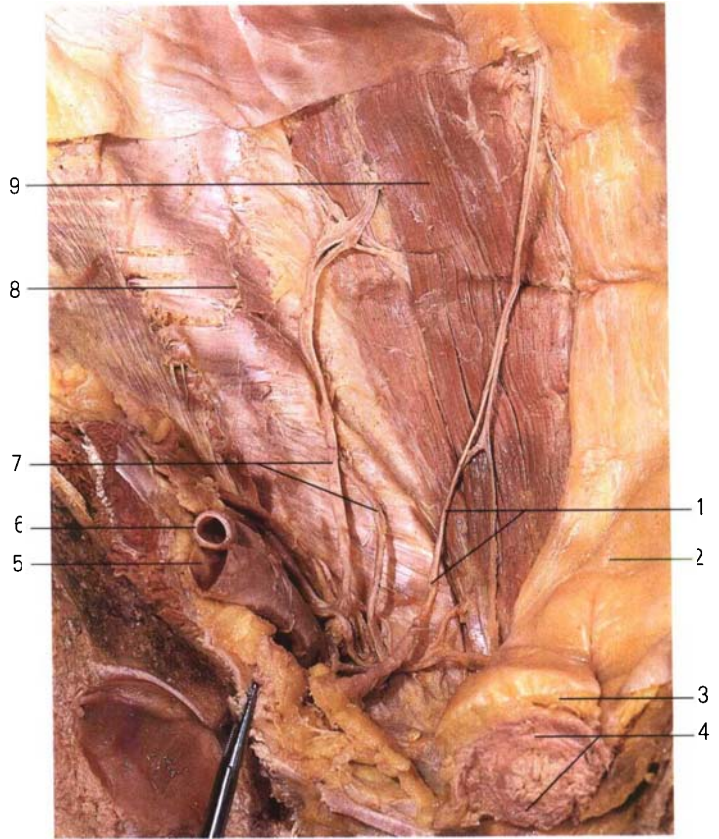


图 158 腹前壁后面观(左)
Posterior aspect of the anterior abdominal wall(left)

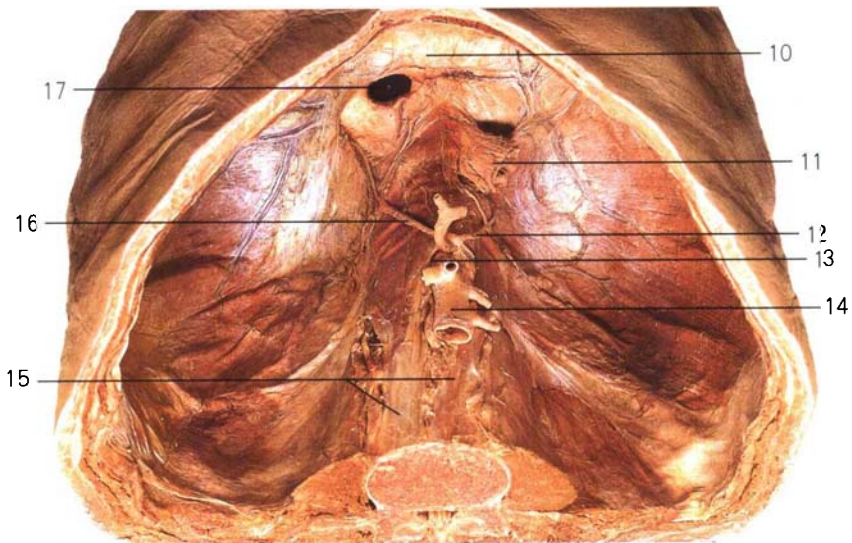


图 159 膈(下面观)
Diaphragm(inferior aspect)

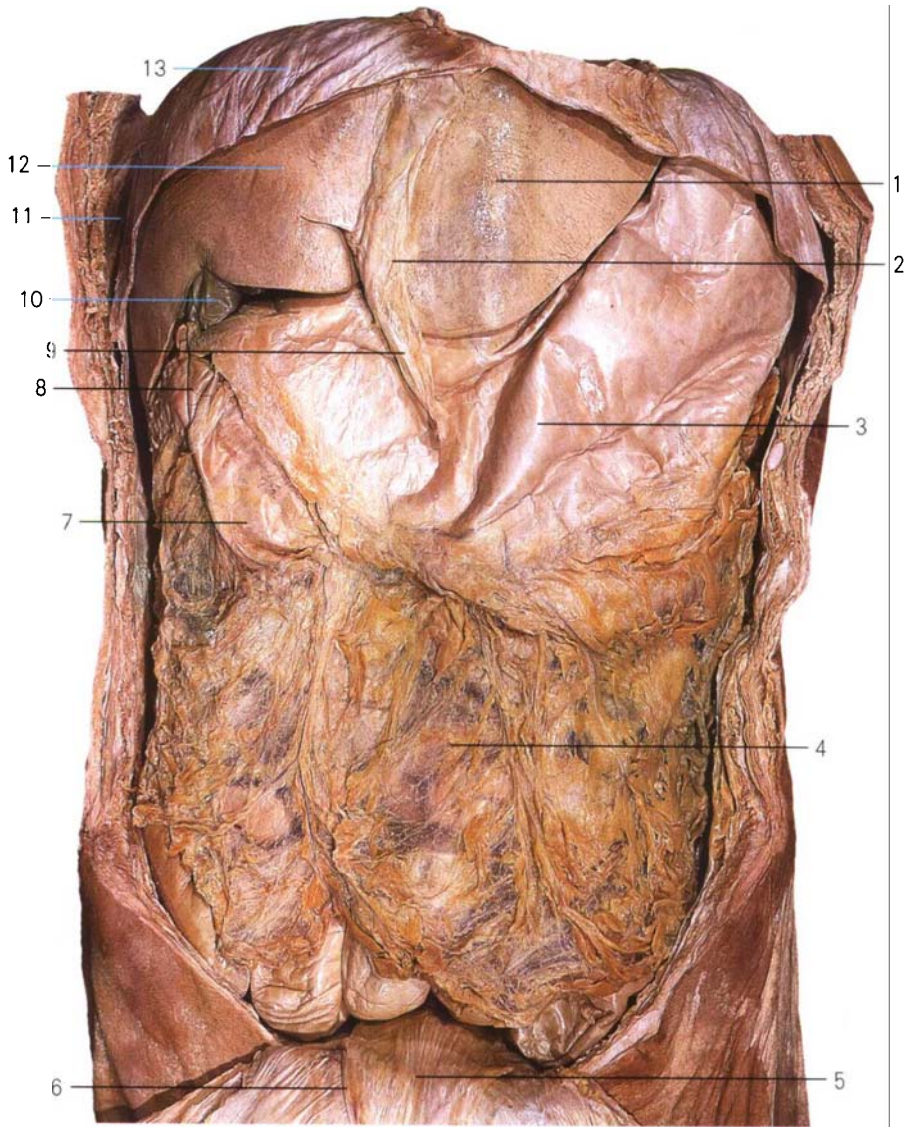


图 160 腹膜的配布(I)
Arrangement of the peritoneum(I)

- | | |
|-------------------------------------|------------------------------------|
| 1. 肝左叶 left lobe of liver | 8. 结肠右曲 right colic flexure |
| 2. 镰状韧带 falciform ligament of liver | 9. 肝圆韧带 ligament teres hepatis |
| 3. 胃 stomach | 10. 胆囊 gall bladder |
| 4. 大网膜 greater omentum | 11. 肋膈隐窝 costodiaphragmatic recess |
| 5. 脐正中襞 median umbilical fold | 12. 肝右叶 right lobe of liver |
| 6. 左脐内侧襞 left medial umbilical fold | 13. 膈 diaphragm |
| 7. 横结肠 transverse colon | |

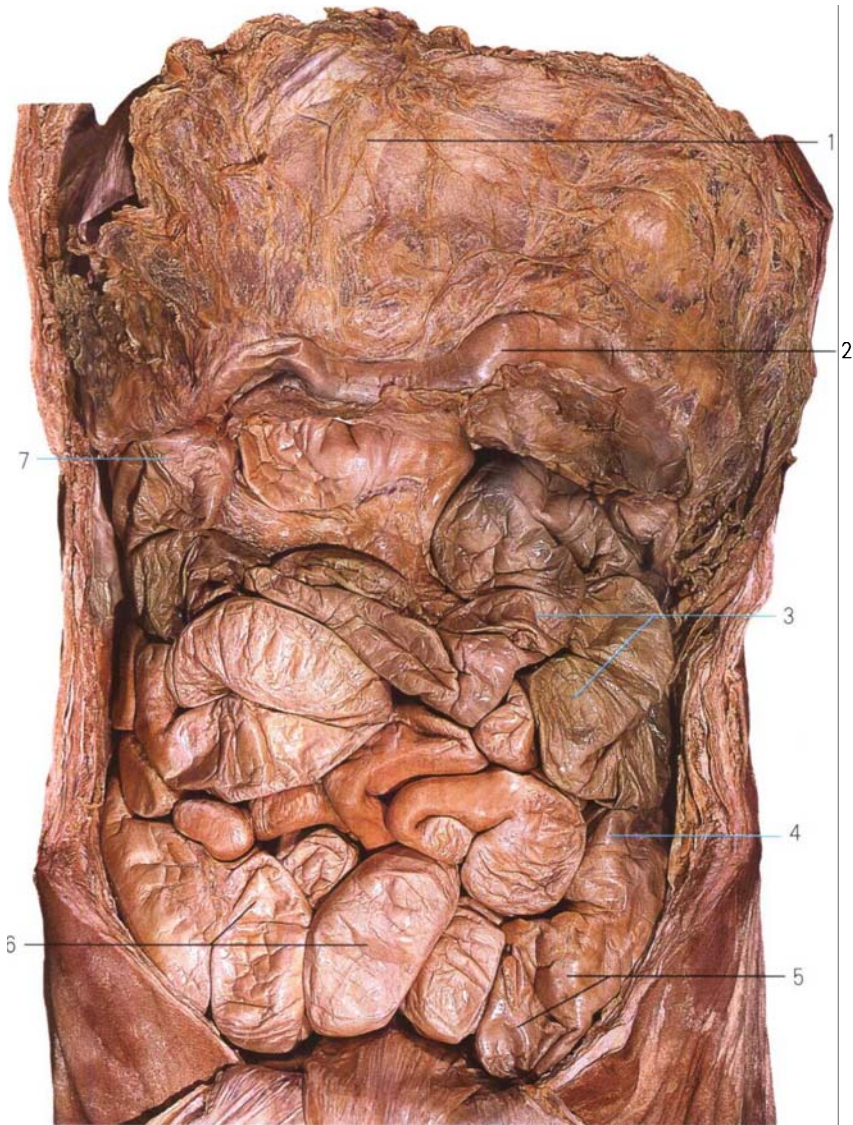


图 161 腹膜的配布(Ⅱ)
Arrangement of the peritoneum (Ⅱ)

1. 大网膜 greater omentum
2. 横结肠 transverse colon
3. 空肠 jejunum
4. 降结肠 descending colon

5. 乙状结肠 sigmoid colon
6. 回肠 ileum
7. 结肠右曲 right colic flexure

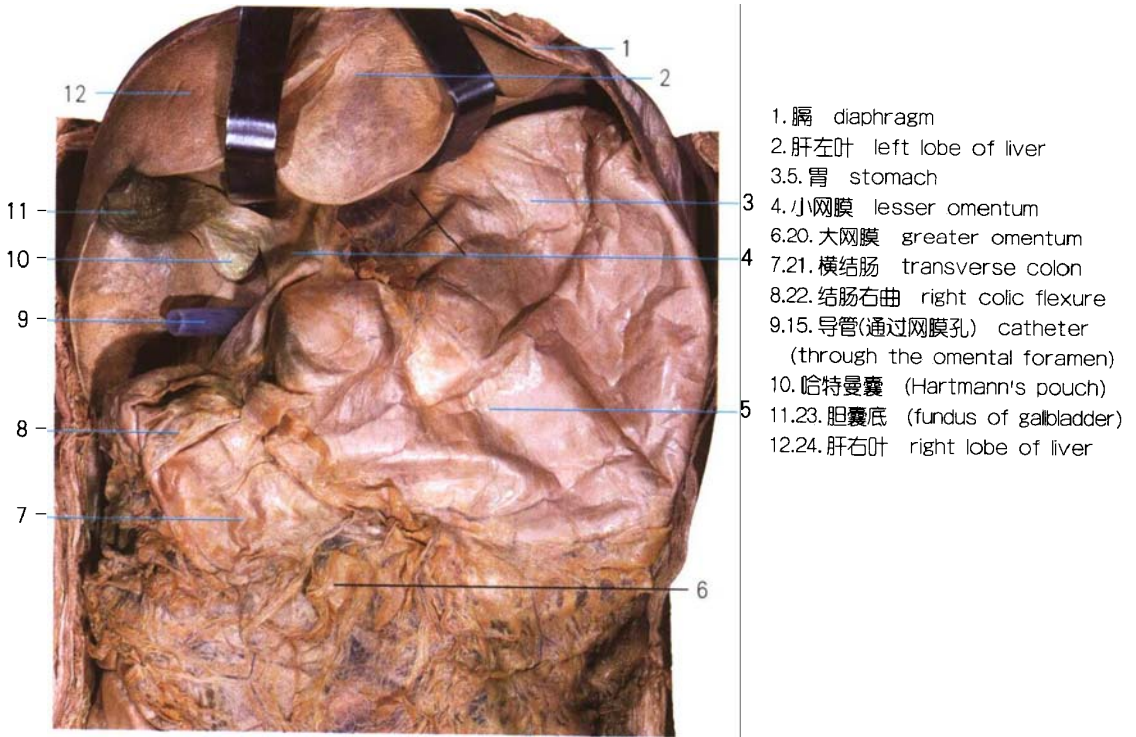


图 162 网膜
Omenta

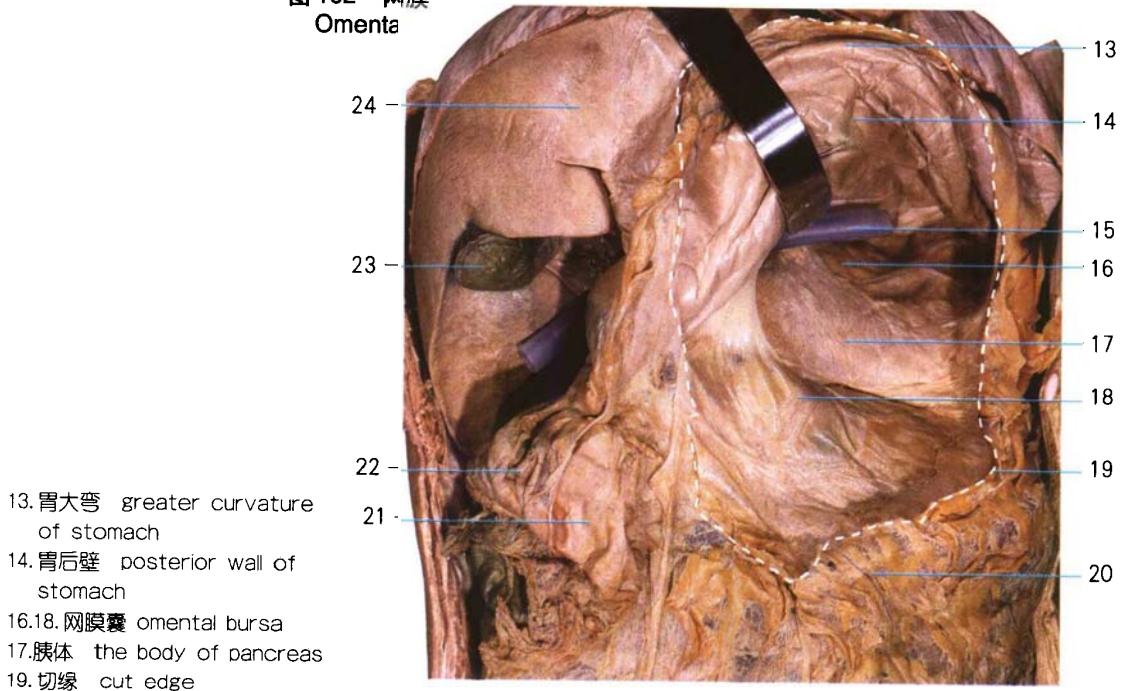


图 163 网膜囊
Omental bursa

1. 胃底 fundus of stomach
2. 贲门切迹 cardiac incisure
3. 胃体 body of stomach
4. 胃大弯 greater curvature of stomach
5. 胃肌层 musculature of stomach
6. 幽门窦 pyloric antrum
7. 幽门管 pyloric canal
8. 幽门 pylorus
9. 十二指肠上部 superior part of duodenum
10. 角切迹 angular incisure
11. 胃小弯 lesser curvature
12. 贲门 cardia
13. 食管腹部 abdominal part of esophagus

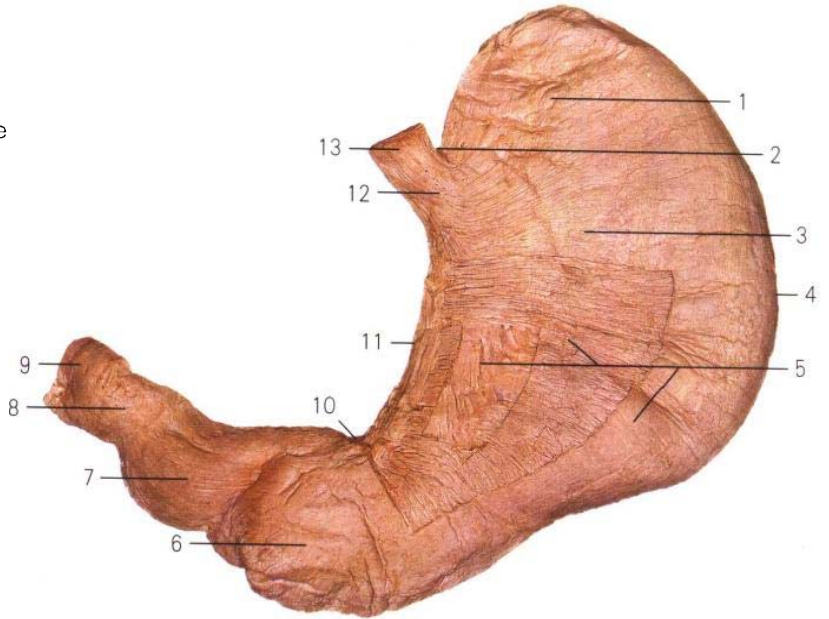


图 164 胃(I)
Stomach(I)

14. 胃粘膜皱襞 gastric folds
- 15.16. 胃小凹 gastric pit
17. 幽门括约肌 pyloric sphincter
18. 十二指肠皱襞 folds of duodenum
19. 胃路 gastric canal
20. 食管纵皱襞 longitudinal folds of esophagus

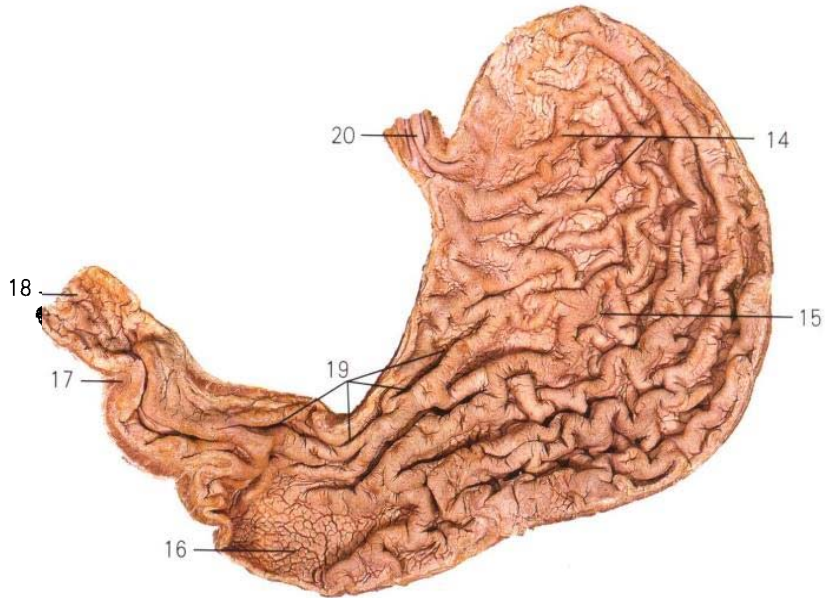


图 165 胃(II)
Stomach(II)

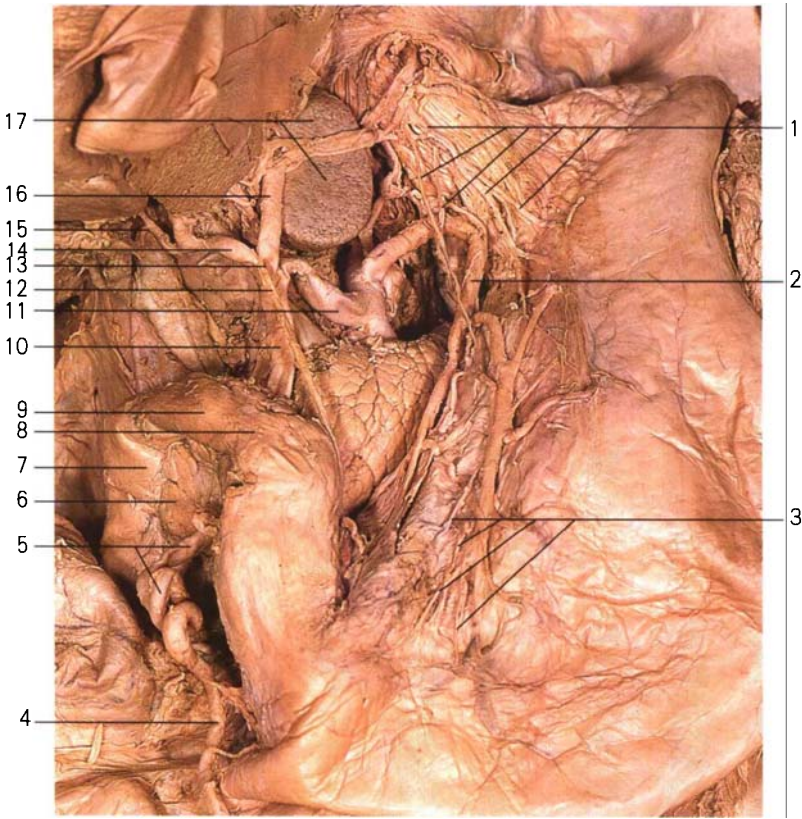


图 166 胃的神经、动脉
Nerves and arteries of stomach

- 1. 迷走神经前干分支
branches of anterior vagal trunk
- 2.28. 胃左动脉 left gastric a.
- 3. 至幽门部分支
branches to pyloric part
- 4.24. 胃网膜右动脉 right gastroepiploic a.
- 5.10.25. 胃十二指肠动脉
gastroduodenal a.
- 6. 胰头 head of pancreas
- 7. 十二指肠降部
part of duodenum

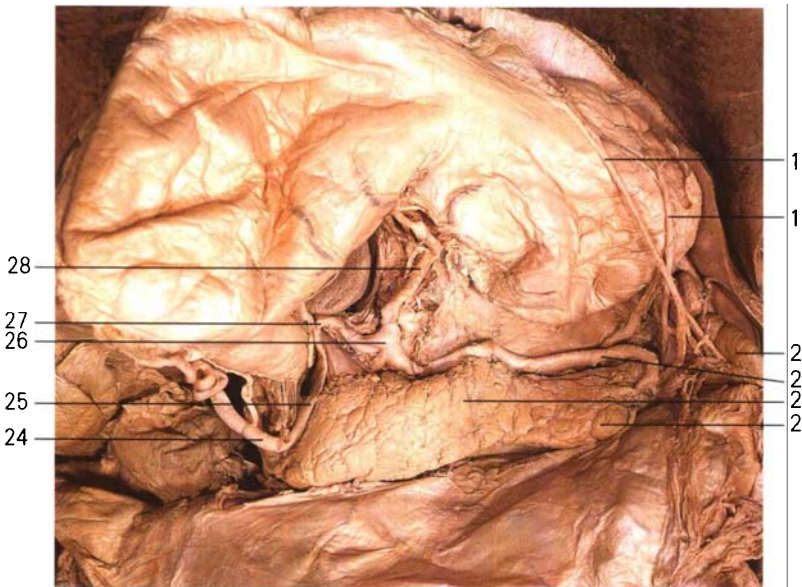
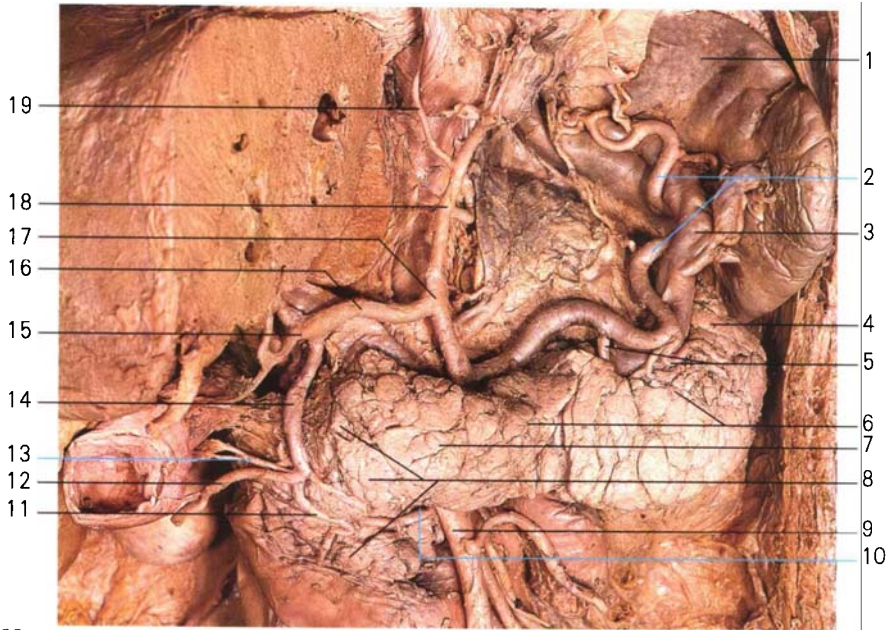


图 167 胃的动脉
Arteries of stomach

- 8. 幽门 pylorus
- 9. 十二指肠上部
superior part of duodenum
- 11.27. 肝总动脉 common
hepatic a.
- 12. 胃右动脉 right gastric a.
- 13. 肝固有动脉 proper
hepatic a.
- 14. 肝右动脉 right branch
of proper hepatic a.
- 15. 胆囊动脉 cystic a.
- 16. 肝左动脉 left branch of
proper hepatic a.
- 17. 肝尾叶 caudate lobe
- 18. 胃网膜左动脉 left
gastroepiploic a.
- 19. 胃短动脉 short gastric a.
- 20. 脾 spleen
- 21. 脾动脉 splenic a.
- 22. 胰体 body of pancreas
- 23. 胰尾 tail of pancreas
- 26. 腹腔动脉干 celiac trunk



- 1.脾 spleen
- 2.脾动脉 splenic a.
- 3.脾静脉 splenic v.
- 4.胰尾 tail of pancreas
- 5.胰支 pancreatic branches
- 6.胰体 body of pancreas
- 7.胰颈 neck of pancreas
- 8.胰头 head of pancreas
- 9.21.肠系膜上动脉 superior mesenteric a.
- 10.20.肠系膜上静脉 superior mesenteric v.
- 11.29.胰十二指肠前上动脉 anterior superior pancreaticoduodenal a.
- 12.28.胃网膜右动脉 right gastroepiploic a.
- 13.胰十二指肠后上动脉 posterior superior pancreaticoduodenal a.
- 14.30.胃十二指肠动脉 gastroduodenal a.
- 15.31.肝固有动脉 proper hepatic a.
- 16.肝总动脉 common hepatic a.
- 17.腹腔动脉干 celiac trunk
- 18.胃左动脉 left gastric a.
- 19.食管支 esophageal branches
- 22.胰十二指肠前下动脉 anterior inferior pancreaticoduodenal a.
- 23.十二指肠空肠曲 duodenojejunal flexure
- 24.胰十二指肠后下动脉 posterior inferior pancreaticoduodenal a.
- 25.十二指肠升部 ascending part
- 26.十二指肠下部 inferior part
- 27.十二指肠降部 descending part

图 168 腹腔动脉干及胰
Celiac trunk and pancreas

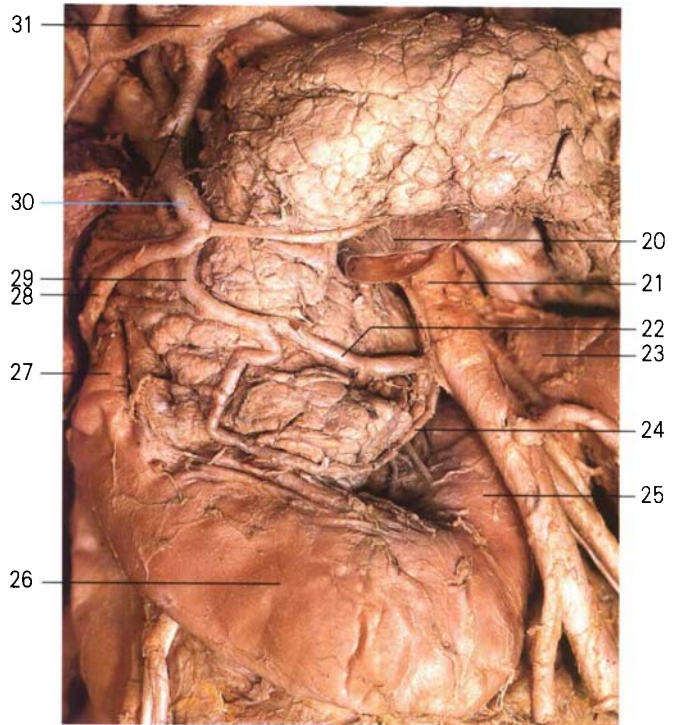


图 169 胰头及十二指肠的动脉
Arteries of the head of pancreas and duodenum

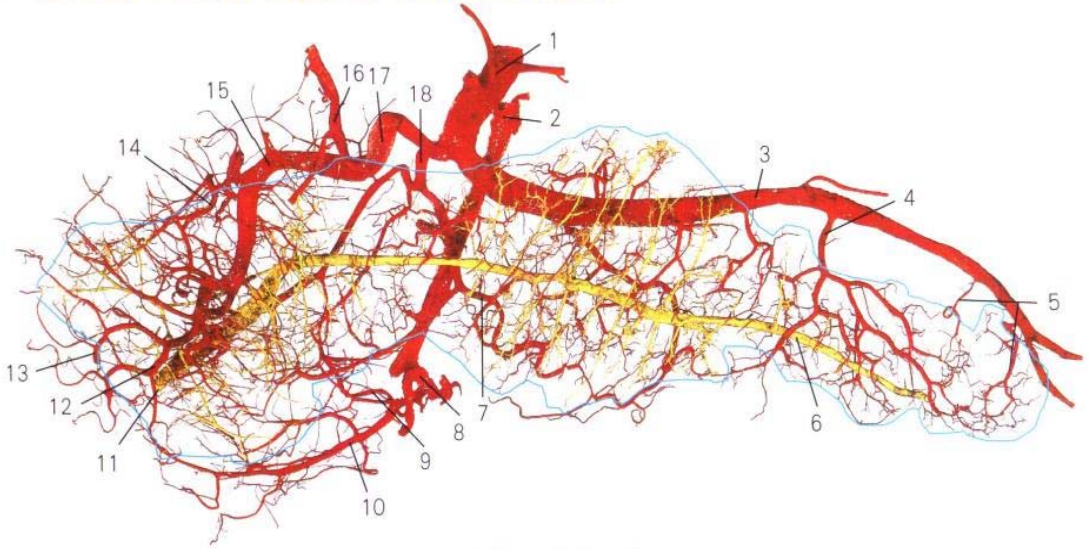


图 170 胰的动脉
Arteries of the pancreas

- | | | |
|----------------------------------|---|-------------------------------|
| 1. 腹腔干 celiac trunk | 9,10. 胰十二指肠下动脉 inferior pancreaticoduodenal a. | 16. 肝固有动脉 proper hepatic a. |
| 2. 肠系膜上动脉 superior mesenteric a. | 12. 胰十二指肠上前动脉 anterior superior pancreaticoduodenal a. | 17. 肝总动脉 common hepatic a. |
| 3. 脾动脉 splenic a. | 13. 胃网膜右动脉 right gastroepiploic a. | 18. 胰背动脉 dorsal pancreatic a. |
| 4. 胰大动脉 great pancreatic a. | 14. 胰十二指肠上后动脉 posterior superior pancreaticoduodenal a. | 19,28. 脾切迹 splenic notches |
| 5. 胰尾动脉 caudal pancreatic a. | 15. 胃十二指肠动脉 gastroduodenal a. | 20,27. 前端 anterior extremity |
| 6,11. 胰管 pancreatic duct | | 21,29. 脾静脉 splenic v. |
| 7. 胰下动脉 inferior pancreatic a. | | 22,30. 脾动脉 splenic a. |
| 8. 空肠动脉 jejunal a. | | 23. 脏面 visceral surface |
| | | 24,32. 后端 posterior extremity |
| | | 25. 膈面 diaphragmatic surface |
| | | 26. 下缘 inferior border |
| | | 31. 上缘 superior border |

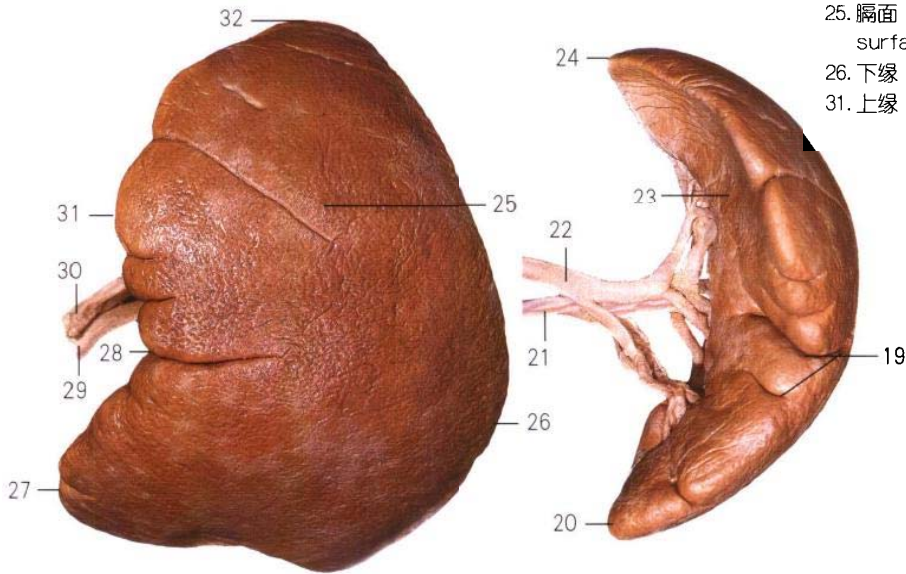


图 171 脾
Spleen

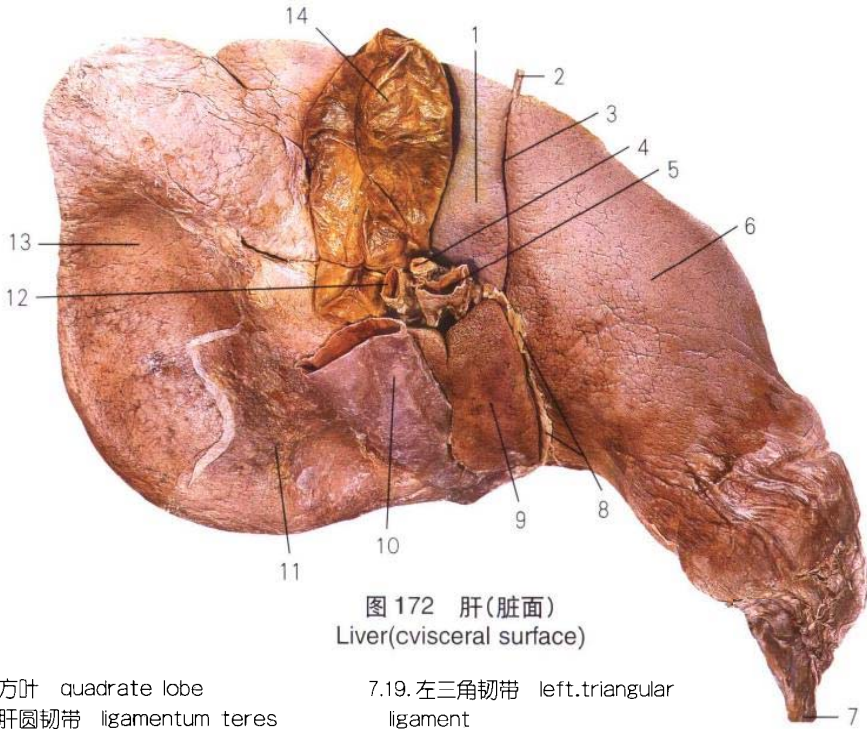


图 172 肝(脏面)
Liver(visceral surface)

- | | | |
|---|-----------------------------------|-----------------------------|
| 1. 方叶 quadrate lobe | 7. 左三角韧带 left triangular ligament | 12. 胆总管 common bile duct |
| 2. 肝圆韧带 ligamentum teres hepatis | 8. 肝胃韧带 hepatogastric ligament | 13. 肝右叶 right lobe of liver |
| 3. 肝圆韧带裂 fissure for ligamentum teres hepatis | 9. 尾状叶 caudate lobe | 14. 胆囊 gall bladder |
| 4. 肝固有动脉 proper hepatic a. | 10. 下腔静脉 inferior vena cava | 15. 主动脉 aorta |
| 5. (肝)门静脉 portal v. | 11. 肝裸区 bare area of liver | 16. 食管 esophagus |
| 6. 肝左叶 left lobe of liver | | 17. 脾 spleen |

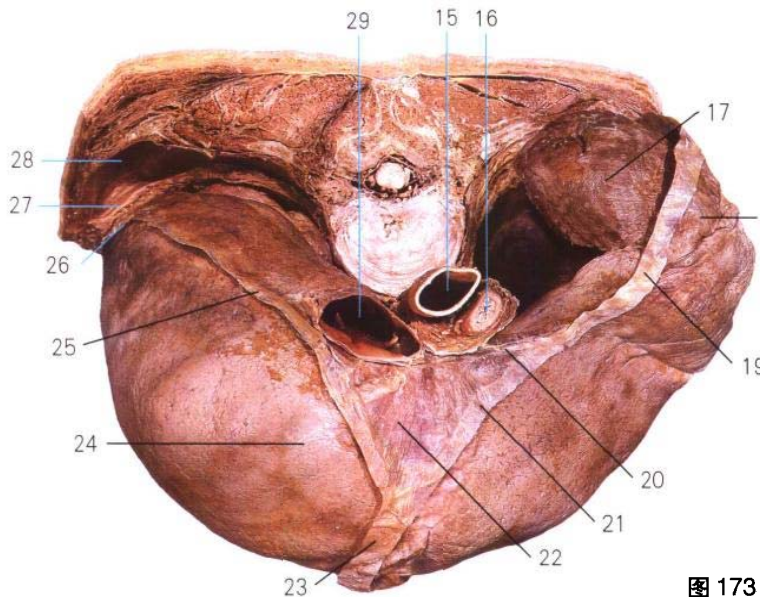


图 173 肝(上面观)
Liver(superior aspect)

- | | |
|---|---|
| 20. 左冠状韧带后层 posterior layer of left coronary ligament | 21. 左冠状韧带前层 anterior layer of left coronary ligament |
| 22. 镰状韧带 falciform ligament of liver | 23. 右冠状韧带上层 superior layer of right coronary ligament |
| 24. 右三角韧带 right triangular ligament | 25. 膈 diaphragm |
| 26. 肋膈隐窝 costodiaphragmatic recess | 27. 膈 diaphragm |
| 28. 肋膈隐窝 costodiaphragmatic recess | 29. 左冠状韧带后层 posterior layer of left coronary ligament |

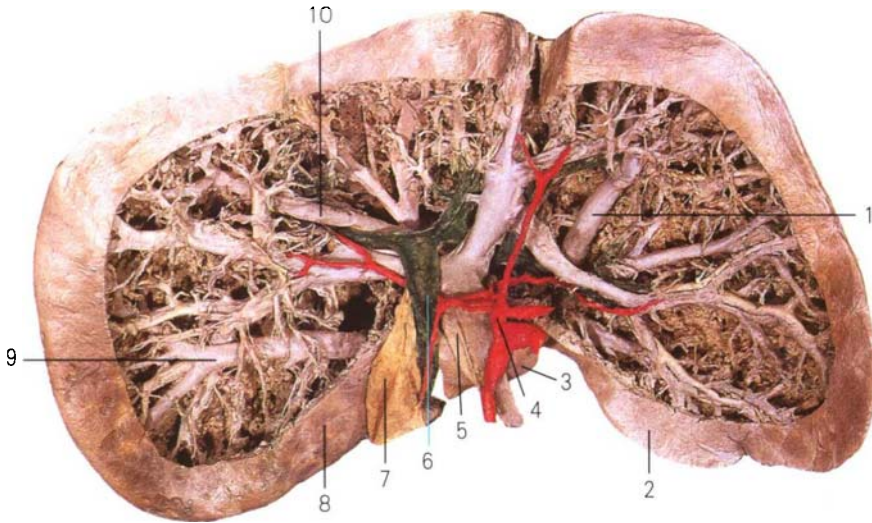
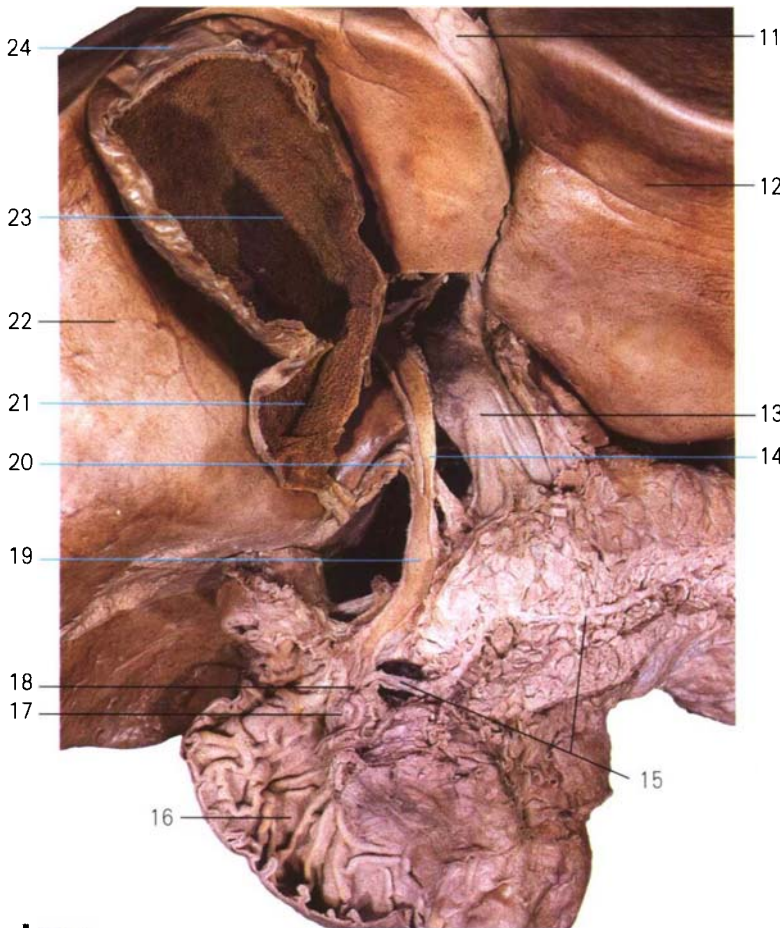


图 174 肝内的血管和胆管
The blood vessels and bile ducts in the liver



- 1.9.10. 肝静脉 hepatic v.
- 2.12. 肝左叶 left lobe of liver
- 3. 尾状叶 caudate lobe of liver
- 4. 肝固有动脉 proper hepatic a.
- 5.13. 门静脉 portal v.
- 6.14. 肝总管 common hepatic duct
- 7. 胆囊 gall bladder
- 8.22. 肝右叶 right lobe of liver
- 11. 肝圆韧带 ligamentum teres hepatis
- 15. 胰管 pancreatic duct
- 16. 十二指肠降部 descending part of duodenum
- 17. 十二指肠大乳头 major duodenal papilla
- 18. 肝胰腹壶 hepatopancreatic ampulla
- 19. 胆总管 common bile duct
- 20. 胆囊管 cystic duct
- 21. 胆囊颈 neck of gallbladder
- 23. 胆囊体 body of gallbladder
- 24. 胆囊底 fundus of gallbladder

图 175 肝外胆道
Extrahepatic bile ducts

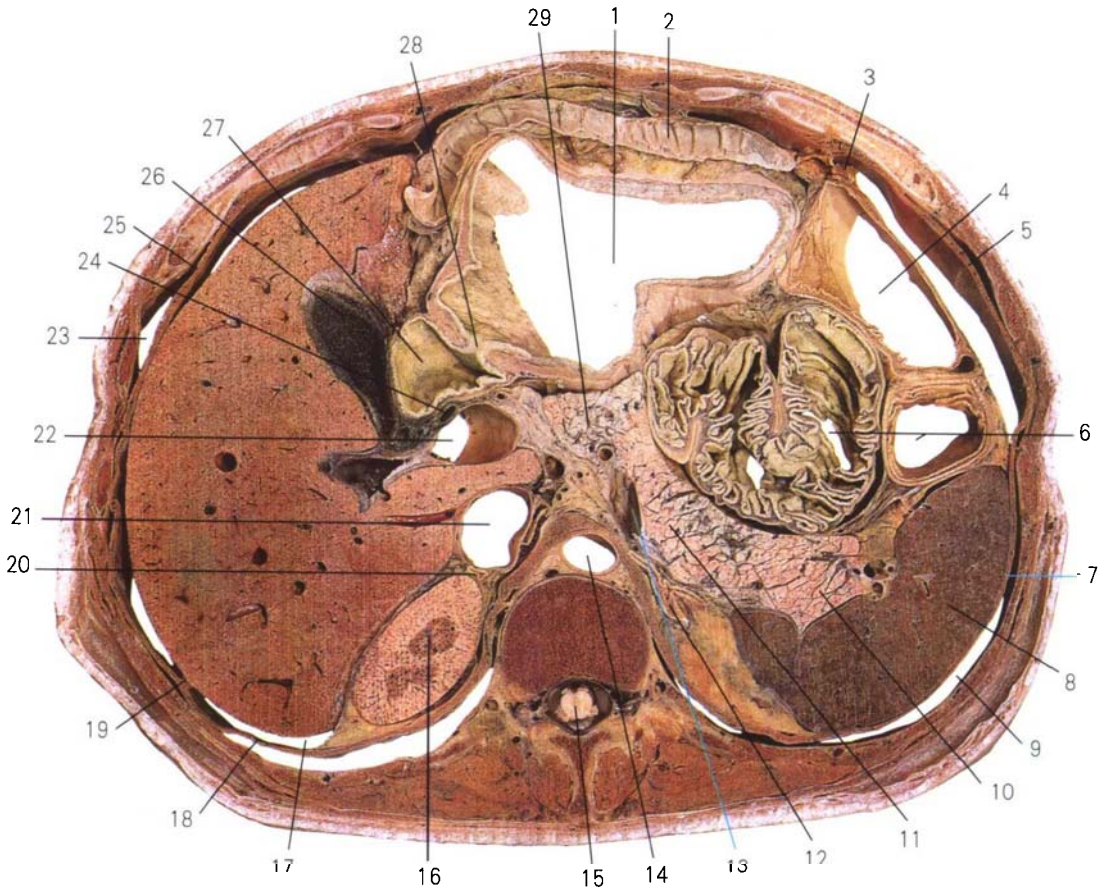


图 176 幽门平面横断面
Transverse section at level of pylorus

- | | |
|--------------------------------------|---------------------------------------|
| 1. 胃 stomach | 15. 脊髓 spinal cord |
| 2. 回肠 ileum | 16. 右肾 right kidney |
| 3. 膈结肠韧带 phrenicocolic ligament | 17. 肝肾隐窝(囊) hepatorenal recess(pouch) |
| 4. 结肠左曲 left colic flexure | 19. 右三角韧带 right triangular ligament |
| 5.7.18.25. 膈 diaphragm | 20. 右肾上腺 right suprarenal gland |
| 6. 空肠 jejunum | 21. 下腔静脉 inferior vena cava |
| 8. 脾 spleen | 22.(肝)门静脉 portal v. |
| 9.23. 肋膈隐窝 costodiaphragmatic recess | 24. 胆总管 common bile duct |
| 10. 胰尾 tail of pancreas | 26. 胆囊 gall bladder |
| 11. 胰体 body of pancreas | 27. 十二指肠上部 superior part of duodenum |
| 12. 左肾上腺 left suprarenal gland | 28. 幽门口 pyloric orifice |
| 13. 脾静脉 splenic v. | 29. 胰头 head of pancreas |
| 14. 腹主动脉 abdominal aorta | |

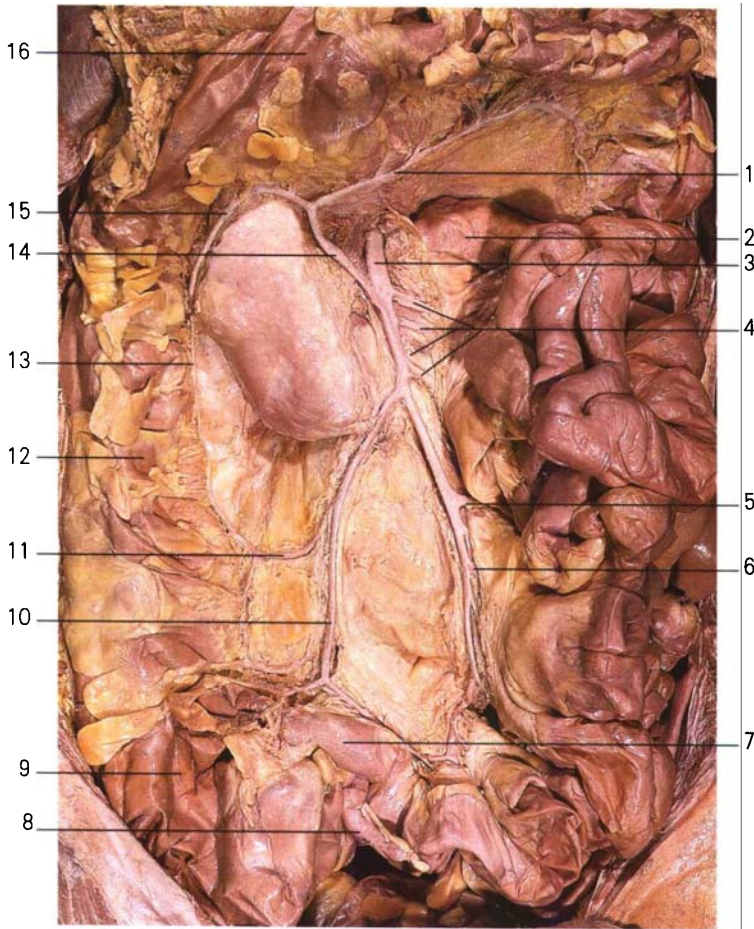


图 177 肠系膜上动脉
Superior mesenteric artery 24

- 1. 左支 left branch
- 2. 十二指肠空肠曲 duodenojejunal flexure
- 3. 肠系膜上动脉 superior mesenteric a.
- 4.5. 空肠动脉 jejunal a.
- 6. 回肠动脉 ileal a.
- 7.19. 回肠 ileum
- 8.22. 阑尾 vermiform appendix
- 9.23. 盲肠 cecum
- 10.17. 回结肠动脉 ileocolic a.
- 11. 右结肠动脉 right colic a.
- 12.24. 升结肠 ascending colon
- 13. 边缘动脉 marginal a.
- 14. 中结肠动脉 middle colic a.
- 15. 右支 right branch
- 16. 横结肠 transverse colon
- 18.20. 阑尾动脉, 静脉 appendicular a. & v.
- 21. 阑尾系膜 mesoappendix

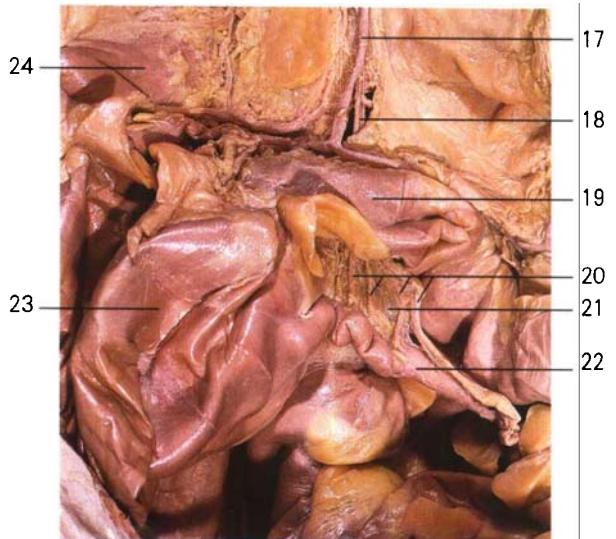


图 178 回结肠动脉
Ileocolic artery

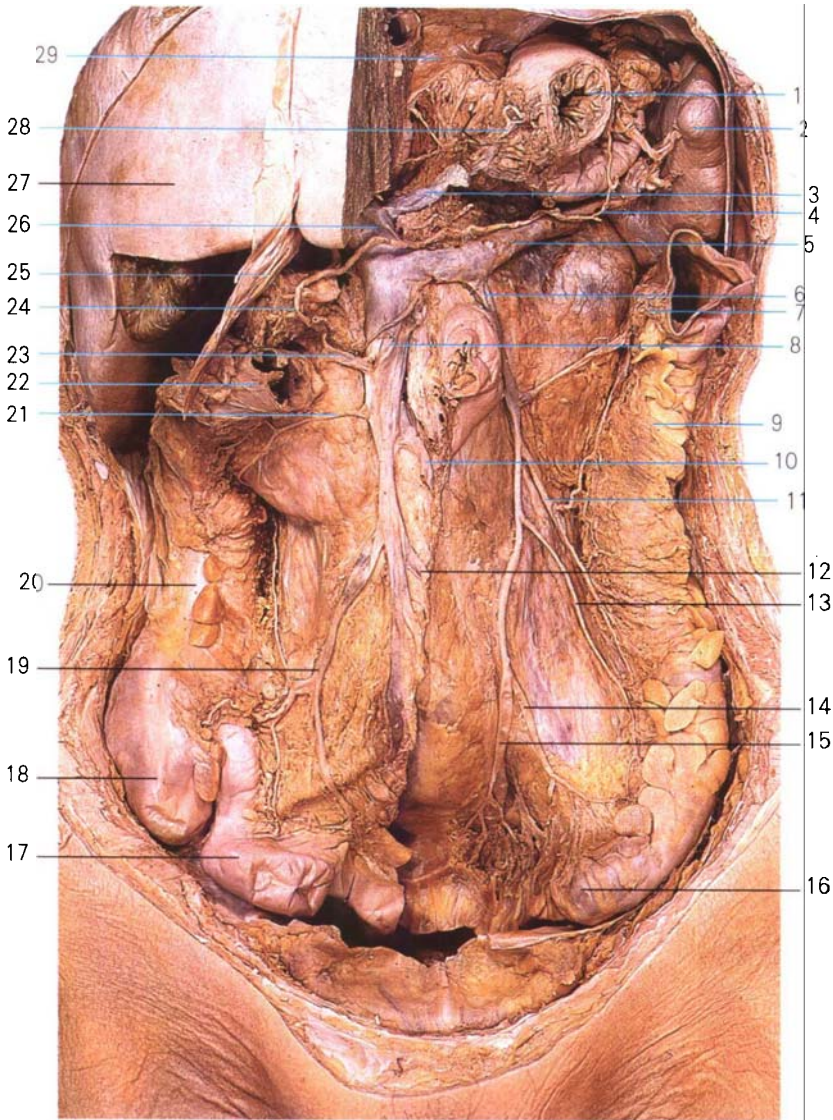


图 182 肝门静脉
Hepatic portal vein

- | | | |
|----------------------------------|------------------------------|--------------------------------------|
| 1. 胃底 fundus of stomach | 10.12. 空肠静脉 jejunal v. | 23. 中结肠静脉 middle colic v. |
| 2. 脾 spleen | 11. 右结肠静脉 right colic v. | 24. 胃网膜右静脉 right gastroepiploic v. |
| 3. 胃左静脉 left gastric v. | 13.14. 乙状结肠静脉 sigmoid v. | 25. 肝圆韧带 ligamentum teres hepatis |
| 4. 胃网膜左静脉 left gastroepiploic v. | 15. 直肠上静脉 superior rectal v. | 26. 肝门静脉 hepatic portal v. |
| 5. 脾静脉 splenic v. | 16. 乙状结肠 sigmoid colon | 27. 肝右叶 right lobe of liver |
| 6. 肠系膜下静脉 inferior mesenteric v. | 17. 回肠 ileum | 28. 胃底部静脉 viens of fundus of stomach |
| 7. 结肠左曲 left colic flexure | 18. 盲肠 cecum | 29. 食管腹段 abdominal part of esophagus |
| 8. 肠系膜上静脉 superior mesenteric v. | 19. 回结肠静脉 ileocolic v. | |
| 9. 降结肠 descending colon | 20. 升结肠 ascending colon | |
| | 21. 右结肠静脉 right colic v. | |
| | 22. 结肠右曲 right colic flexure | |

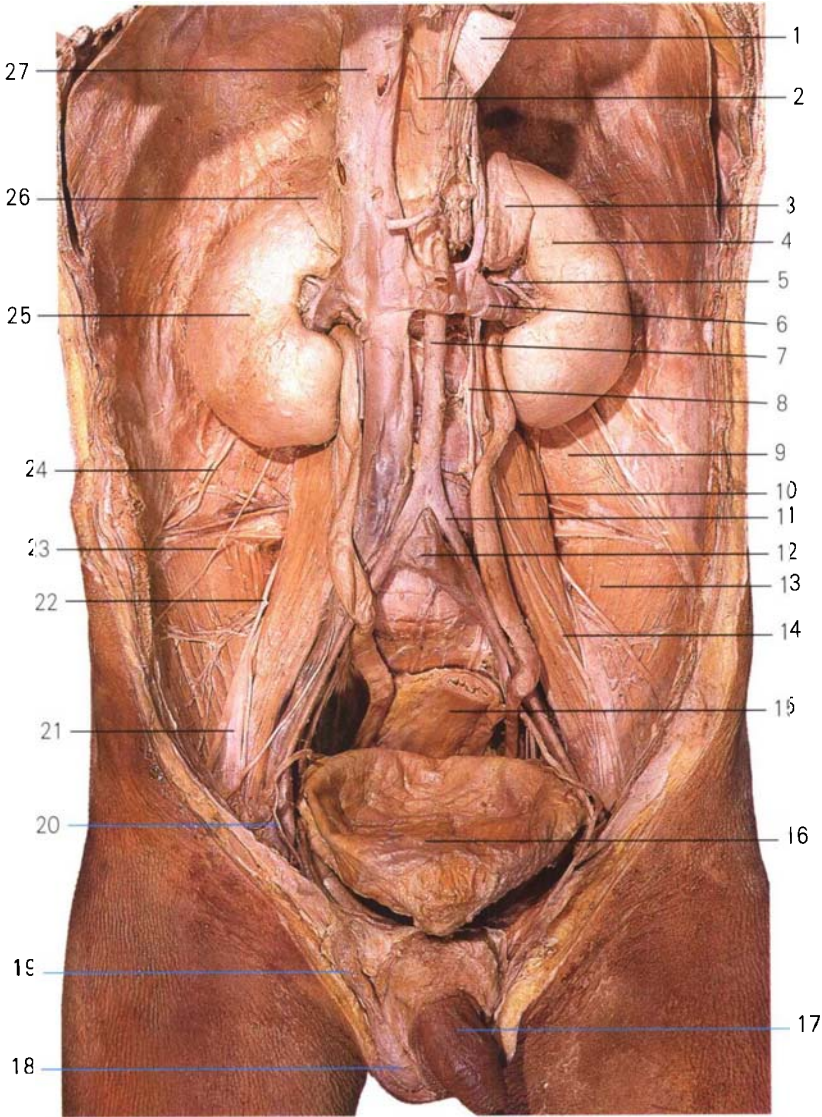


图 183 男性泌尿生殖器官
Organs of urogenital system of the male

- | | | |
|-------------------------------------|--------------------------------|---|
| 1. 食管腹段 abdominal part of esophagus | 10. 腰大肌 psoas major | 20. 输精管 ductus deferens |
| 2. 膈 diaphragm | 11. 左髂总动脉 left common iliac a. | 21. 股神经 femoral n. |
| 3. 左肾上腺 left suprarenal gland | 12. 左髂总静脉 left common iliac v. | 22. 股外侧皮神经 lateral femoral cutaneous n. |
| 4. 左肾 left kidney | 13. 髂肌 iliacus | 23. 髂腹股沟神经 ilioinguinal n. |
| 5. 左肾动脉 left renal a. | 14. 生殖股神经 genitofemoral n. | 24. 髂腹下神经 iliohypogastric n. |
| 6. 左肾静脉 left renal v. | 15. 直肠 rectum | 25. 右肾 right kidney |
| 7. 腹主动脉 abdominal aorta | 16. 膀胱 urinary bladder | 26. 右肾上腺 right suprarenal gland |
| 8. 腰交感神经节 lumbar ganglia | 17. 阴茎 penis | 27. 下腔静脉 inferior vena cava |
| 9. 腰方肌 quadratus lumborum | 18. 睾丸 testis | |
| | 19. 精索 spermatic cord | |

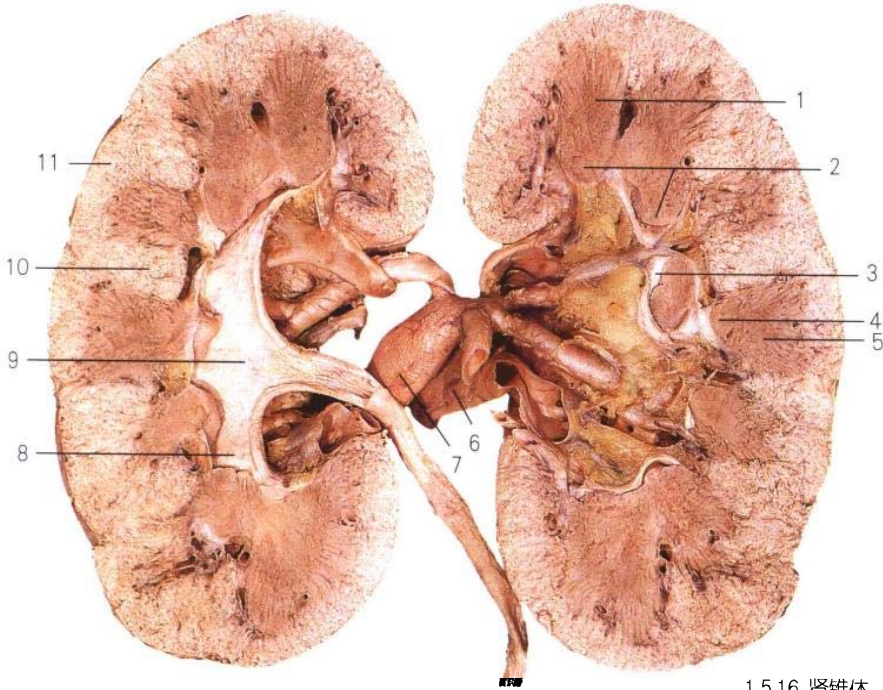


图 184 肾(冠状切面)
Kidney(coronal section)

- 1.5.16. 肾锥体 renal pyramids
- 2.4.23. 肾乳头 renal papillae
- 3.12.19.21. 肾小盏 minor renal calices
- 6. 肾静脉 renal v.
- 7. 肾动脉 renal a.
- 8.13.20. 肾大盏 major renal calices
- 9.14.17. 肾盂 renal pelvis
- 10. 肾柱 renal columns
- 11.22. 肾皮质 renal cortex
- 15.18. 输尿管 ureter

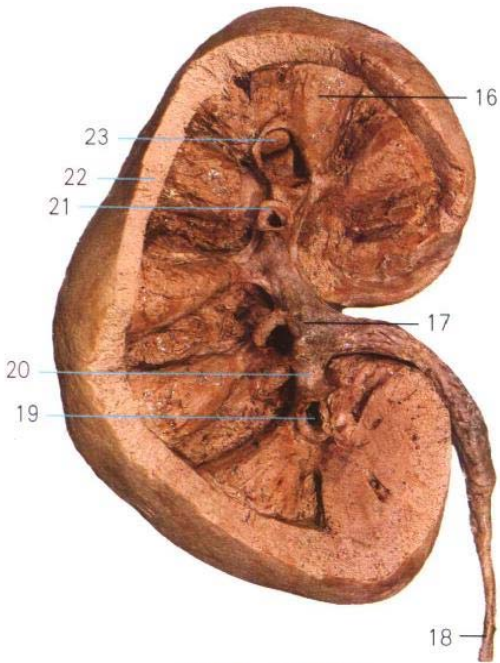


图 185 肾(小叶)
Kidney(renal lobes)

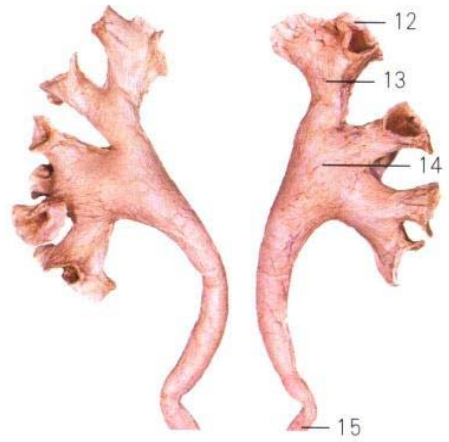
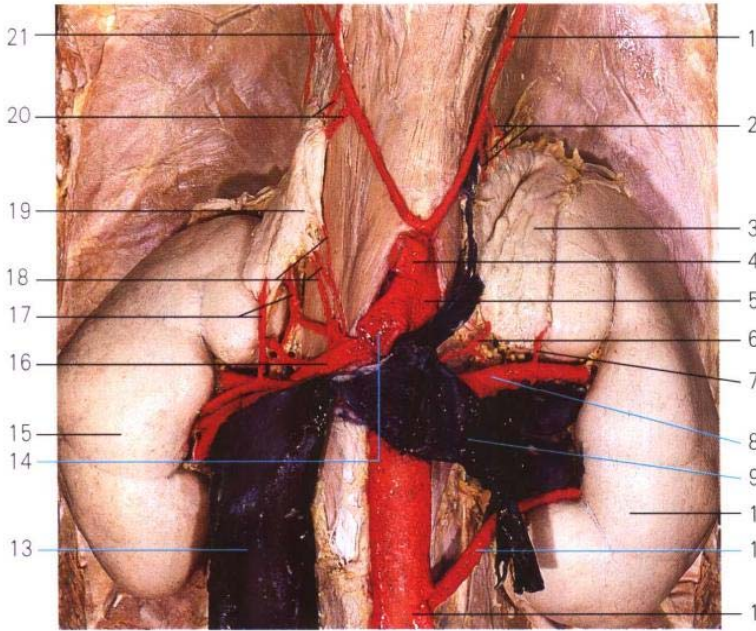


图 186 肾盏及肾盂
Renal calices and pelvis



1. 左膈下动脉 left inferior phrenic a.
2. 20. 肾上腺上动脉 superior suprarenal a.
3. 左肾上腺 left suprarenal gland
4. 腹腔干 celiac trunk
5. 12. 26. 腹主动脉 abdominal aorta
6. 18. 肾上腺中动脉 middle suprarenal a.
7. 17. 肾上腺下动脉 inferior suprarenal a.
8. 16. 肾动脉 renal a.
9. 左肾静脉 left renal v.
10. 左肾 left kidney
11. 22. 25. 副肾动脉 accessory renal a.
13. 下腔静脉 inferior vena cava
14. 肠系膜上动脉 superior mesenteric a.
15. 右肾 right kidney
19. 右肾上腺 right suprarenal gland
21. 右膈下动脉 right inferior phrenic a.

图 187 肾上腺的动脉
Arteries of suprarenal gland

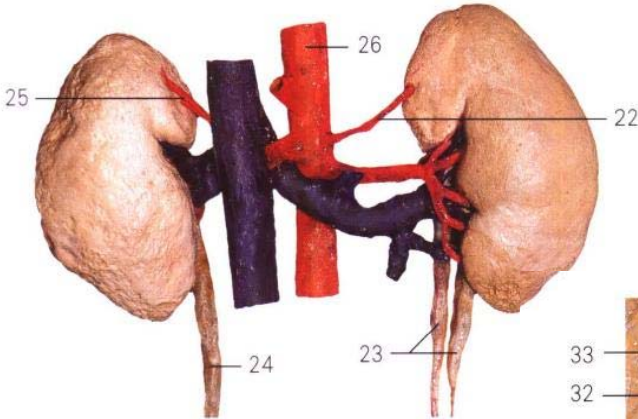


图 188 副肾动脉及双输尿管
Accessory renal artery and double ureter

23. 24. 28. 29. 30. 输尿管 ureter
27. 马蹄肾 horseshoe kidney
31. 肾盂 renal pelvis
32. 腹腔神经节 celiac ganglia
33. 内脏大、小神经 greater and lesser splanchnic n.

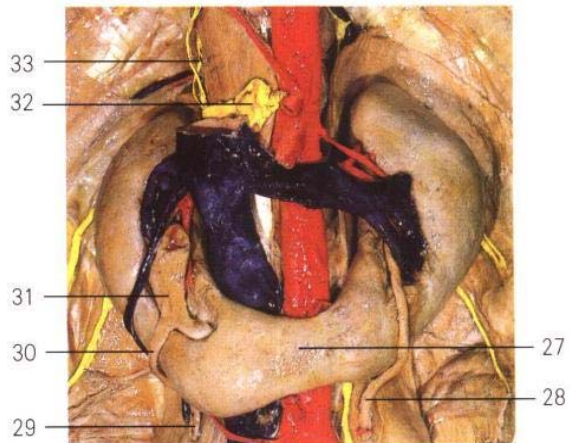


图 189 马蹄肾
Horseshoe kidney

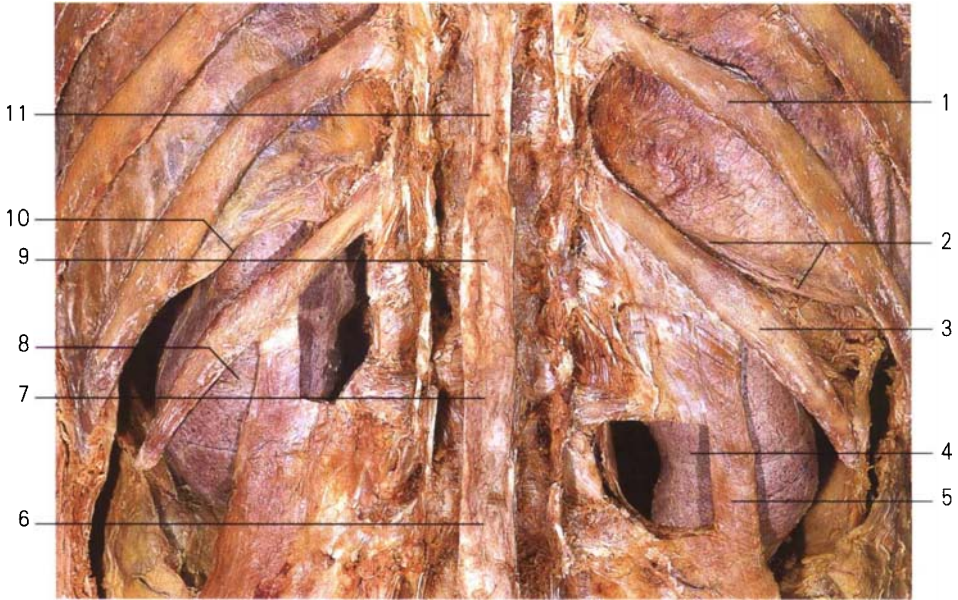


图 190 肾后面毗邻
Posterior relationship of kidney

1. 第十一肋 11th rib
- 2.10. 胸膜下缘 inferior margin of pleura
- 3.22. 第十二肋 12th rib
4. 右肾 right kidney
5. 腰方肌 quadratus lumborum
- 6.7. 棘突(L2, L1) spinous process(L2,L1)
8. 左肾 left kidney
- 9.11 棘突(T12, T11) spinous process(T12,T11)
12. 胸导管 thoracic duct
13. 乳糜池 cisterna chyli
14. 右膈足 right crus of diaphragm
15. 下腔静脉 inferior vena cava
- 16.17.18. 腰静脉 lumbar v.
19. 盆内静脉丛 venous plexuses of pelvis
20. 腰动脉 lumbar a.
21. 肋下动脉 subcostal a.
23. 腰升静脉 ascending lumbar v.
24. 肋间后动脉 posterior intercostal a.
25. 奇静脉 azygos v.
26. 肋间后静脉 posterior intercostal v.
27. 胸主动脉 thoracic aorta

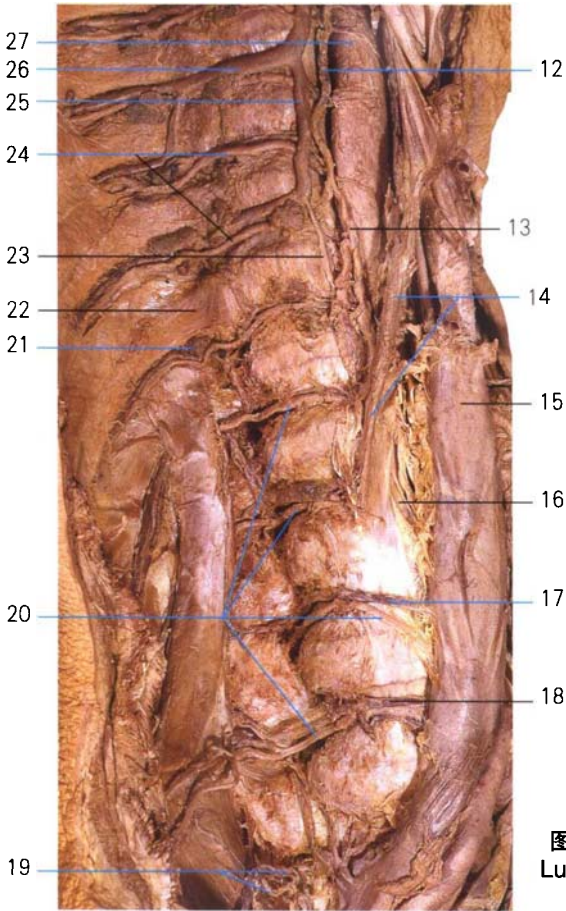


图 191 腰静脉和腰动脉
Lumbar arteries and veins

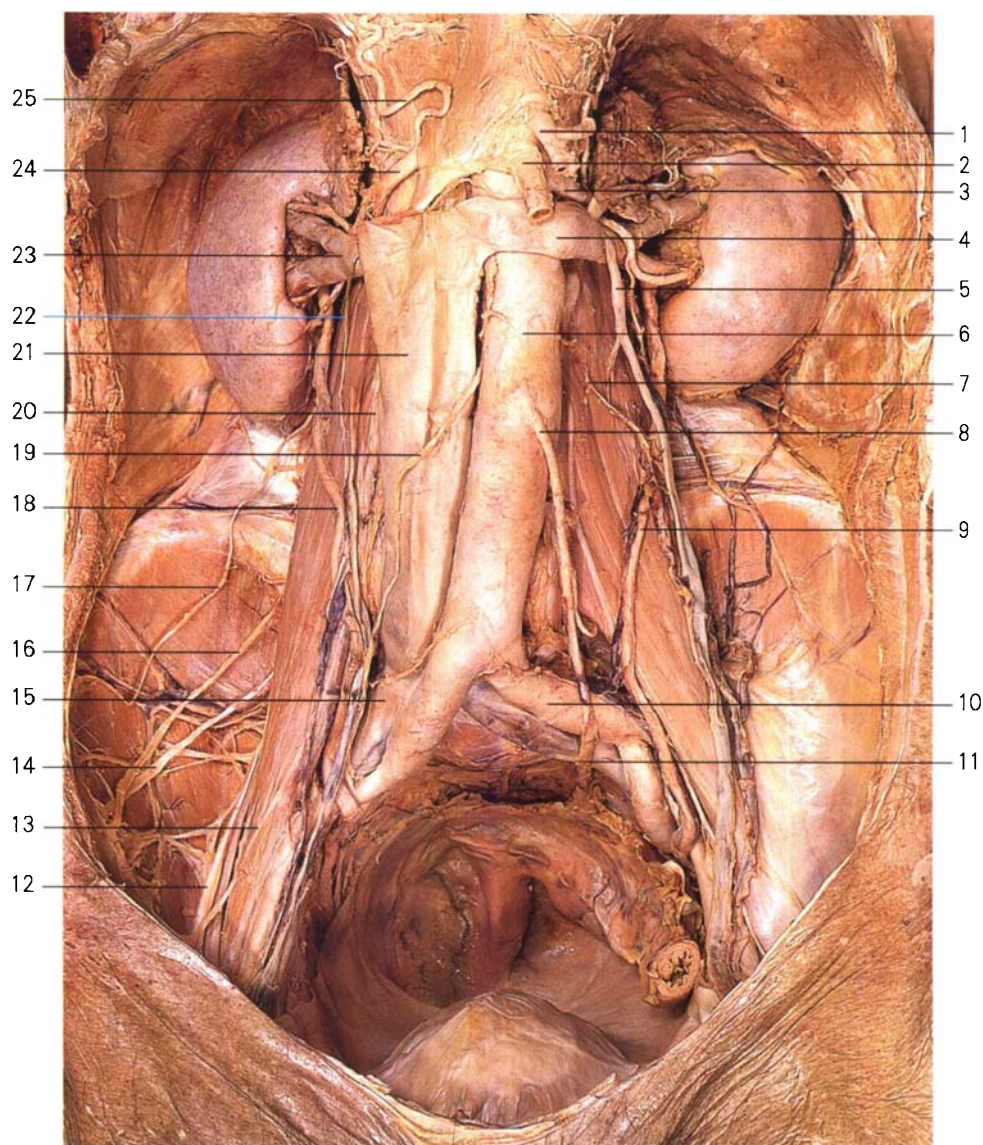


图 192 腹后隙的血管和神经
Blood vessels and nerves in the retroperitoneal space

- | | | |
|----------------------------------|---|-------------------------------------|
| 1. 腹腔动脉干 celiac trunk | 9. 输尿管 ureter | 19. 左睾丸动脉 left testicular a. |
| 2. 肠系膜上动脉 superior mesenteric a. | 10. 左髂总动脉 left common iliac a. | 20. 左睾丸静脉 left testicular v. |
| 3. 左肾动脉 left renal a. | 11. 直肠上动脉 superior rectal a. | 21. 下腔静脉 inferior vena cava |
| 4. 左肾静脉 left renal v. | 12. 股神经 femoral n. | 22. 副睾丸动脉 accessory testicular a. |
| 5. 左睾丸静脉 left testicular v. | 13. 生殖股神经 genitofemoral n. | 23. 右肾静脉 right renal v. |
| 6. 腹主动脉 abdominal aorta | 14. 股外侧皮神经 lateral femoral cutaneous n. | 24. 右肾动脉 right renal a. |
| 7. 左睾丸动脉 left testicular a. | 15. 右髂总静脉 right common iliac v. | 25. 右膈下动脉 right inferior phrenic a. |
| 8. 肠系膜下动脉 inferior mesenteric a. | 16. 髂腹股沟神经 ilioinguinal n. | |
| | 17. 髂腹下神经 iliohypogastric n. | |

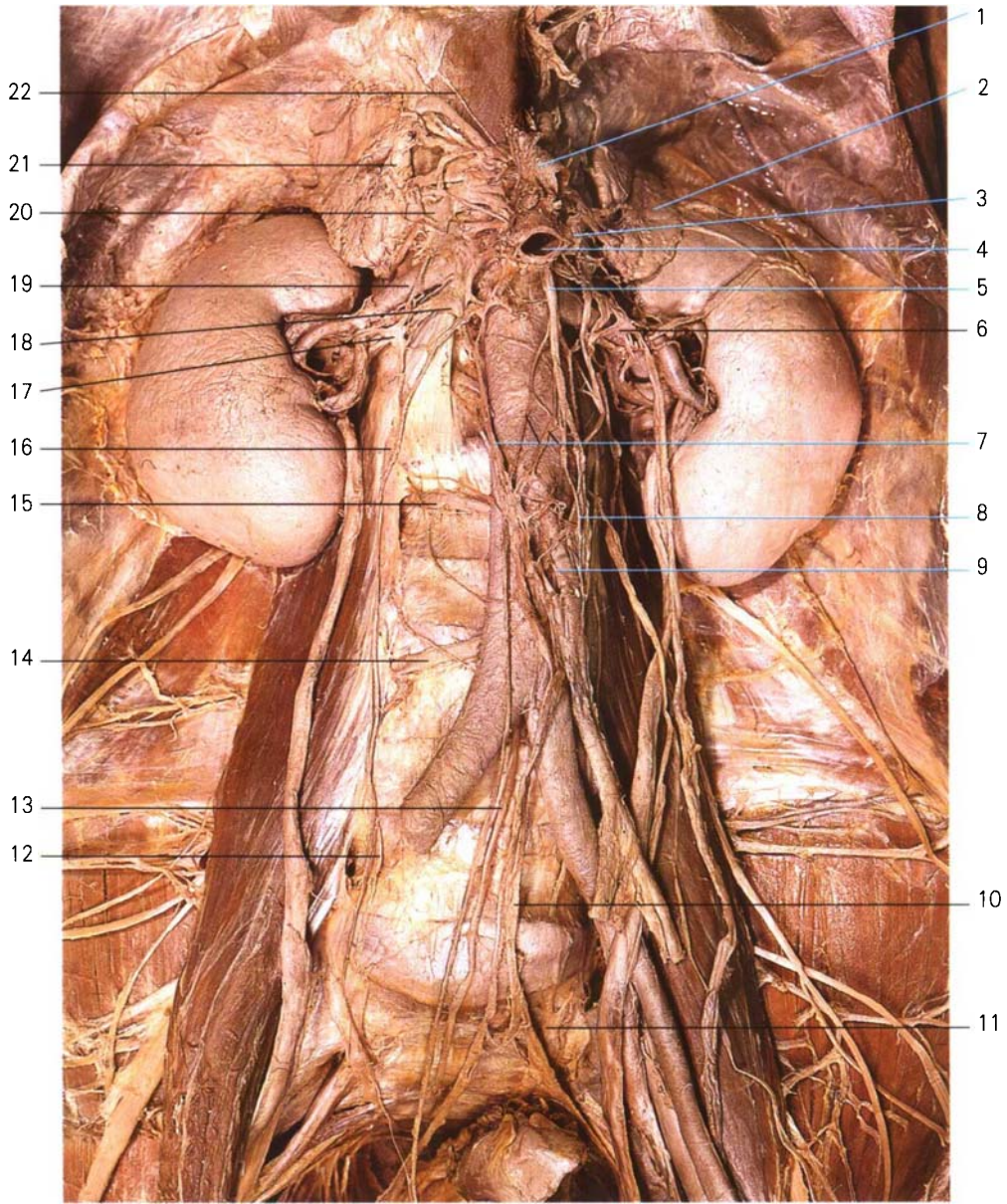


图 193 腹后隙的神经
Nerves in the retroperitoneal space

- | | | |
|-------------------------------------|--------------------------------------|-----------------------------------|
| 1. 腹腔动脉干 celiac trunk | 7. 主动脉丛 aortic plexus | 12.16. 腰交感神经节 lumbar ganglia |
| 2. 左肾上腺 left suprarenal gland | 8. 肠系膜下丛 inferior mesenteric plexus | 13. 骶正中动脉 median sacral a. |
| 3.20. 腹腔神经节 celiac ganglia | 9. 肠系膜下动脉 inferior mesenteric a. | 14.15. 腰动脉 lumbar a. |
| 4. 肠系膜上动脉 superior mesenteric a. | 10. 上腹下丛 superior hypogastric plexus | 17.18. 主动脉肾节 aorticorenal ganglia |
| 5. 肠系膜上丛 superior mesenteric plexus | 11. 骶交感神经节 sacral ganglia | 19. 右肾动脉 right renal a. |
| 6. 肾丛 renal plexus | | 21. 右肾上腺 right suprarenal gland |
| | | 22. 膈神经 phrenic n. |

第

章

6

盆部与会阴

CHAPTER 6 THE PELVIS AND PERINEUM



PRACTICE COLOUR ATLAS OF HUMAN ANATOMY

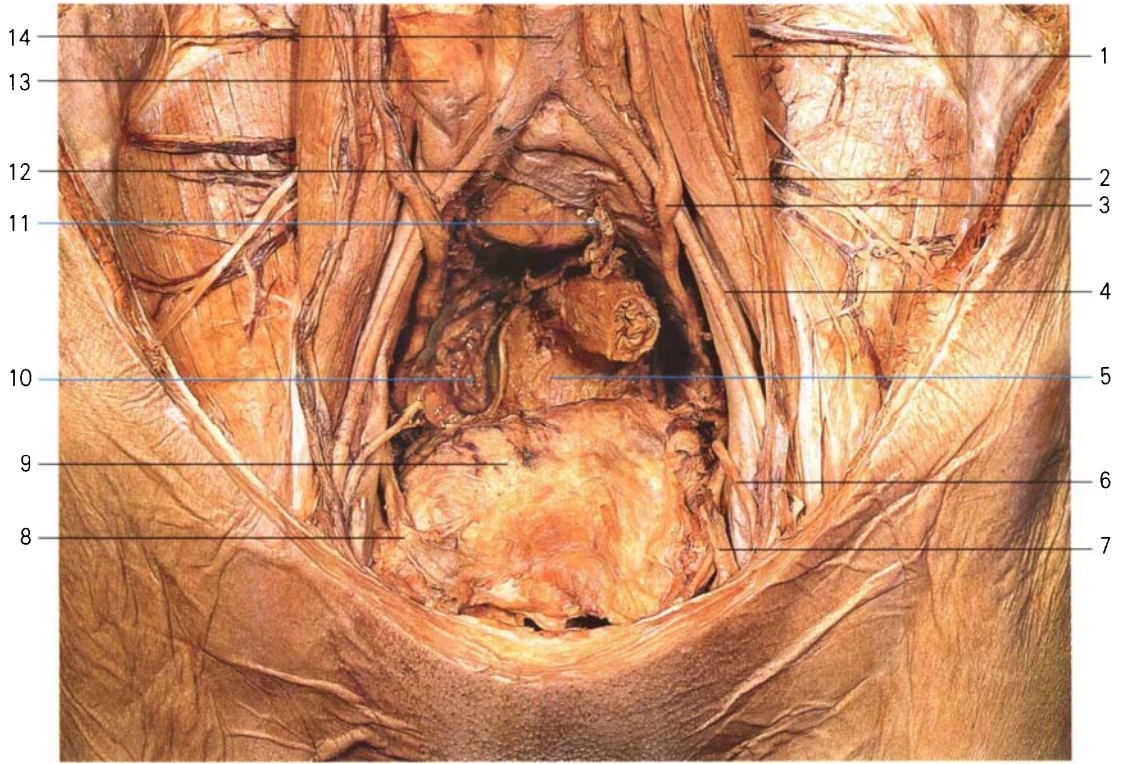


图 194 男性盆部(上面观)
Pelvis of the male(superior aspect)

- | | |
|---|--------------------------------------|
| 1. 腰大肌 psosas major | 8. 脐内侧韧带 medial umbilical ligament |
| 2. 睾丸动脉和静脉 testicular a. & v. | 9. 膀胱 urinary bladder |
| 3. 输尿管 ureter | 10. 精囊 seminal vesicle |
| 4. 髂外动脉和静脉 external iliac a. & v. | 11. 直肠上动脉和静脉 superior rectal a. & v. |
| 5. 直肠 rectum | 12. 髂内动脉 internal iliac a. |
| 6. 输精管 ductus deferens | 13. 下腔静脉 inferior vena cava |
| 7. 腹壁下动脉和静脉 inferior epigastric a. & v. | 14. 腹主动脉 abdominal aorta |

1. 直肠 rectum
2. 直肠膀胱陷凹 rectovesical pouch
3. 精囊 seminal vesicle
4. 前列腺(中叶) prostate(middle lobe)
5. 射精管 ejaculatory duct
6. 前列腺(后叶) prostate(posterior lobe)
7. 尿生殖膈 urogenital diaphragm
8. 尿道球 bulb of urathra
9. 阴囊中隔 septum of scrotum
10. 尿道(海绵体部) male urethra(cavernous part)
11. 尿道(膜部) male urethra(membranous part)
12. 前列腺(前叶) prostate(anterior lobe)
13. 尿道(前列腺部) male urethra(prastatic part)

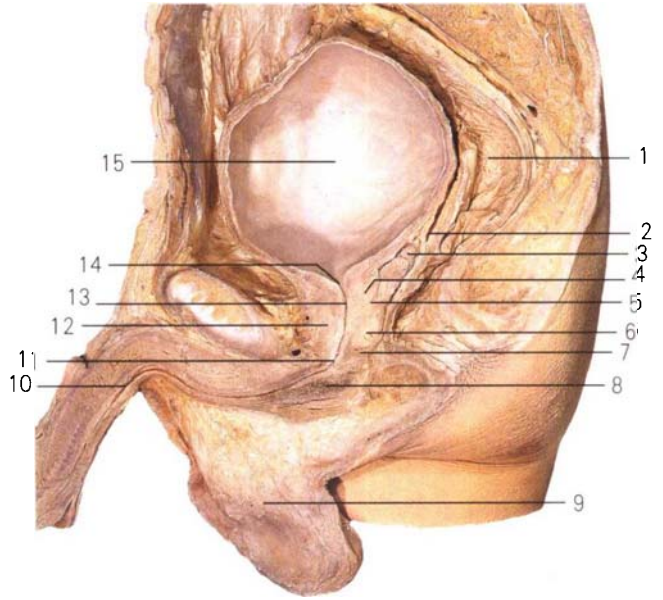
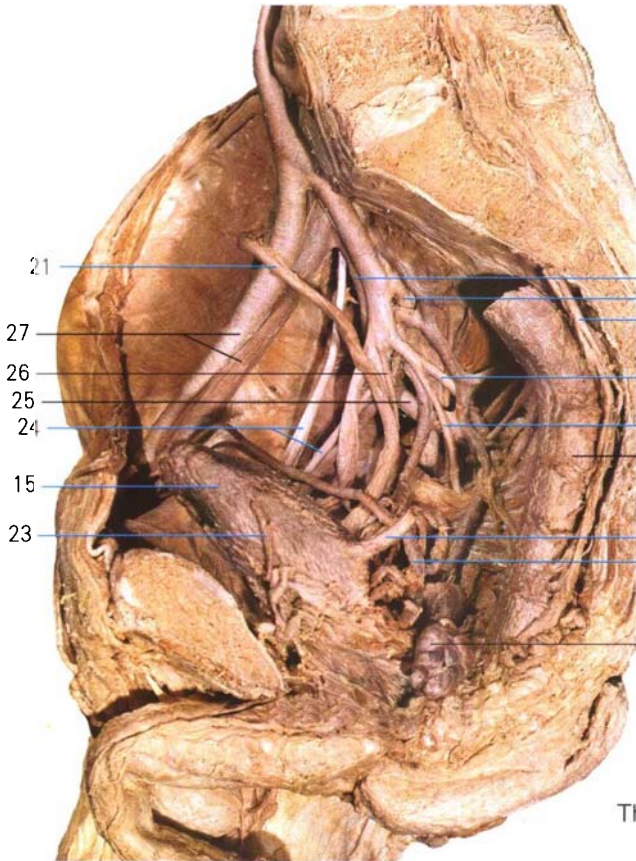


图 195 男性盆部(正中矢状剖面)
The pelvis of the male(median sagittal section)



14. 尿道内口 internal urethral orifice
15. 膀胱 urinary bladder
16. 髂内动脉、静脉 internal iliac a. & v.
17. 臀上动脉 superior gluteal a.
18. 直肠上动脉、静脉 superior rectal a. & v.
19. 阴部内动脉 internal pudendal a.
20. 直肠下动脉 inferior rectal a.
21. 输尿管 ureter
22. 输精管 ductus deferens
23. 膀胱上动脉 superior vesical a.
24. 闭孔神经、动脉 obturator n. & a.
25. 臀下动脉 inferior gluteal a.
26. 膀胱下动脉 inferior vesical a.
27. 髂外动、静脉 external iliac a. & v.

图 196 男性盆腔(左侧面观)
The pelvic cavity of the male(left lateral aspect)

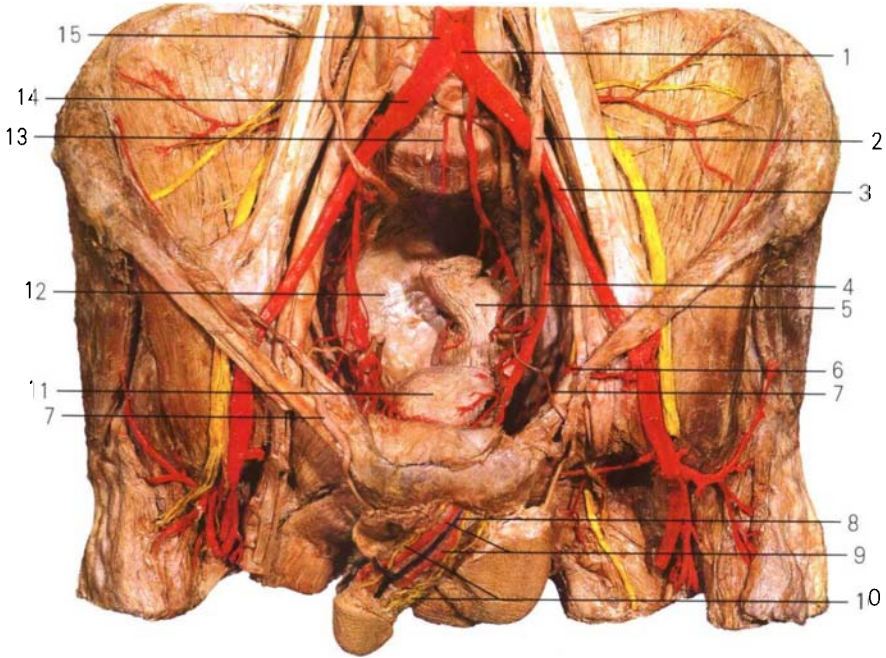
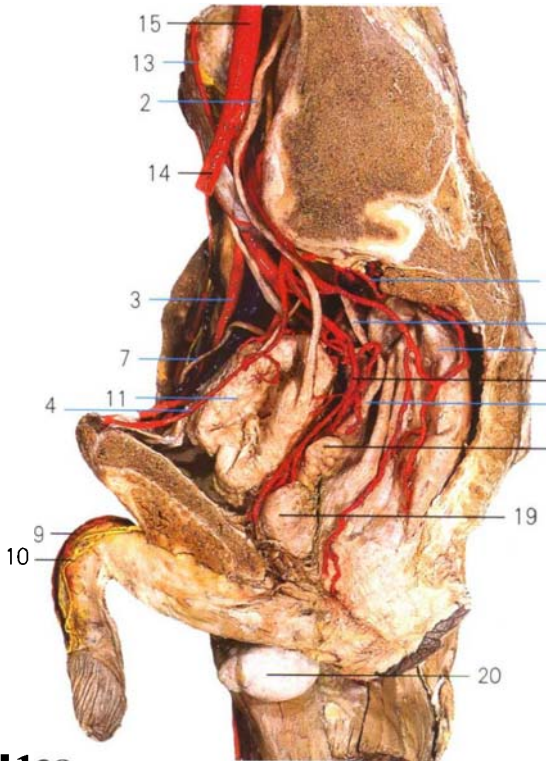


图 197 男性盆部的动脉(上面观)
Arteries of the pelvis of the male(superior aspect)



1. 直肠上动脉 superior rectal a.
2. 输尿管 ureter
3. 髂外动脉 external iliac a.
4. 脐动脉 umbilical a.
5. 乙状结肠 sigmoid colon
6. 腹壁下动脉闭孔支(副闭孔动脉) obturator branch of inferior epigastric a.(accessory . obturator a.)
7. 输精管 ductus deferens
8. 阴茎背深静脉 deep dorsal v.of penis
9. 阴茎背动脉 dorsal a.of penis
10. 阴茎背神经 dorsal n.of penis
11. 膀胱 urinary bladder
12. 直肠 rectum
13. 骶正中动脉 median sacral a.
14. 髂总动脉 common iliac a.
15. 腹主动脉 abdominal aorta
16. 膀胱下动脉 inferior vesical a.
17. 输精管壶腹 ampulla ductus deferentis
18. 精囊 seminal vesicle
19. 前列腺 prostate
20. 睾丸 testis

图 198 男性盆部的动脉(左侧面观)
Arteries of the male pelvis of the male(left lateral aspect)

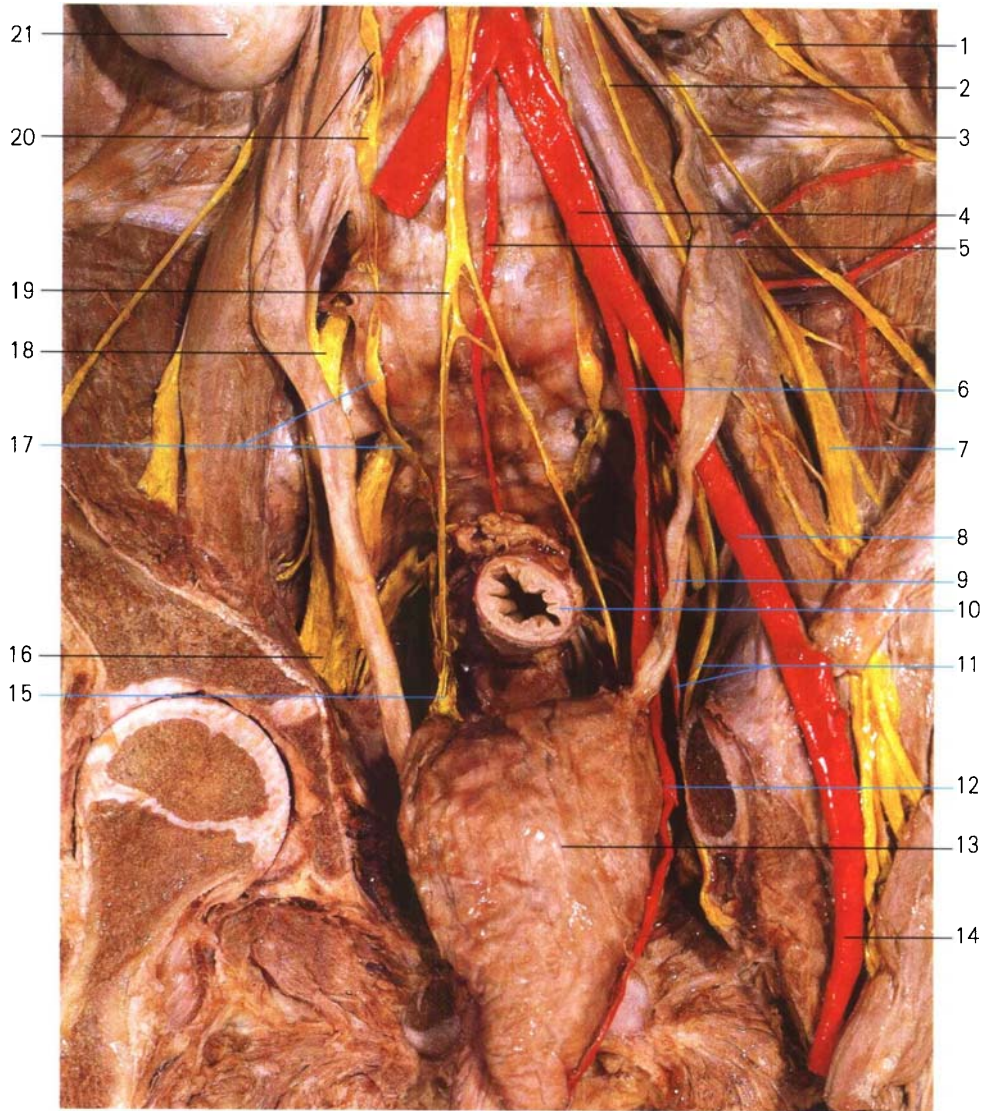
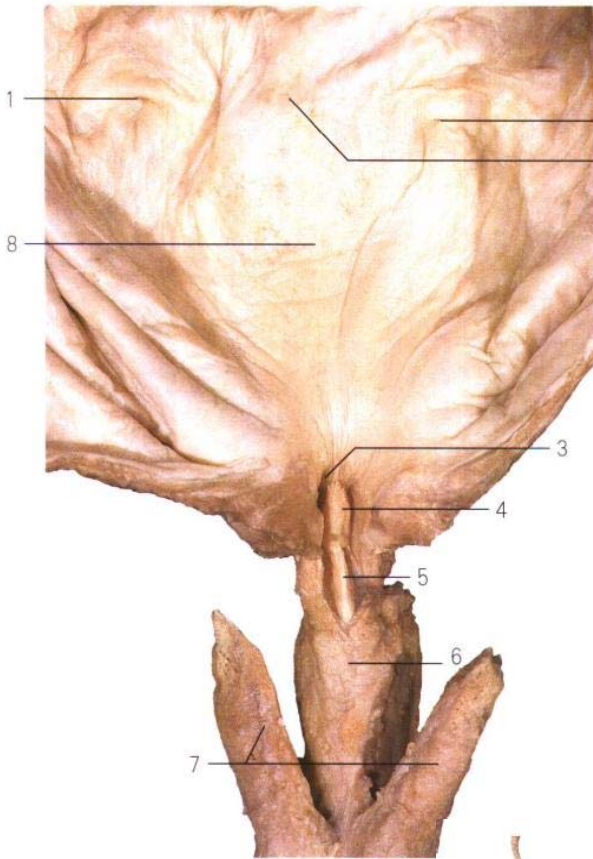


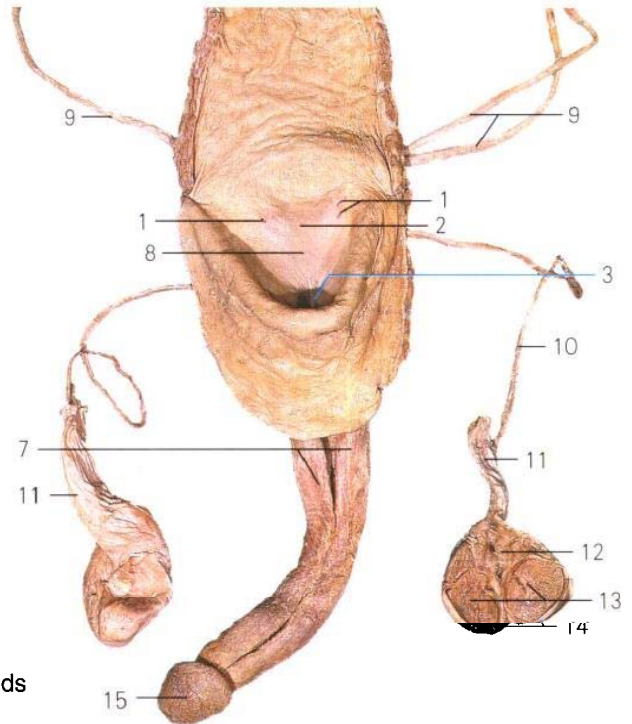
图 199 男性盆部的神经(上面观)
Nerves of the pelvis of the male(superior aspect)

- | | |
|--|--------------------------------------|
| 1. 髂腹股沟神经 ilioinguinal n. | 12. 脐动脉 umbilical a. |
| 2. 生殖股神经 genitofemoral n. | 13. 膀胱 urinary bladder |
| 3. 股外侧皮神经 lateral femoral cutaneous n. | 14. 股动脉 femoral a. |
| 4. 髂总动脉 common iliac a. | 15. 下腹下丛 inferior hypogastric plexus |
| 5. 骶正中动脉 median sacral a. | 16. 骶丛 sacral plexus |
| 6. 髂内动脉 internal iliac a. | 17. 骶神经节 sacral ganglia |
| 7. 股神经 femoral n. | 18. 腰骶干 lumbosacral trunk |
| 8. 髂外动脉 external iliac a. | 19. 上腹下丛 superior hypogastric plexus |
| 9. 输尿管 ureter | 20. 腰神经节 lumbar ganglia |
| 10. 直肠 rectum | 21. 肾 kidney |
| 11. 闭孔神经、动脉 obturator n. & a. | |



1. 输尿管口 ureteric orifice
2. 输尿管间襞 interureteric fold
3. 尿道内口 internal urathral orifice
4. 精阜 seminal colliculus
5. 尿道嵴 urethral ridge
6. 尿道海绵体 cavernous body of urethra
7. 阴茎脚 crus penis
8. 膀胱三角 trigone of bladder

图 200 男性膀胱(内面观)
The male urinary bladder(internal aspect)



9. 输尿管 ureter
10. 输精管 ductus deferens
11. 精索 spermatic cord
12. 附睾 epididymis
13. 睾丸 testis
14. 白膜 tunica albuginea
15. 阴茎头 glans penis

图 201 男性膀胱和生殖腺
The male urinary and genital glands

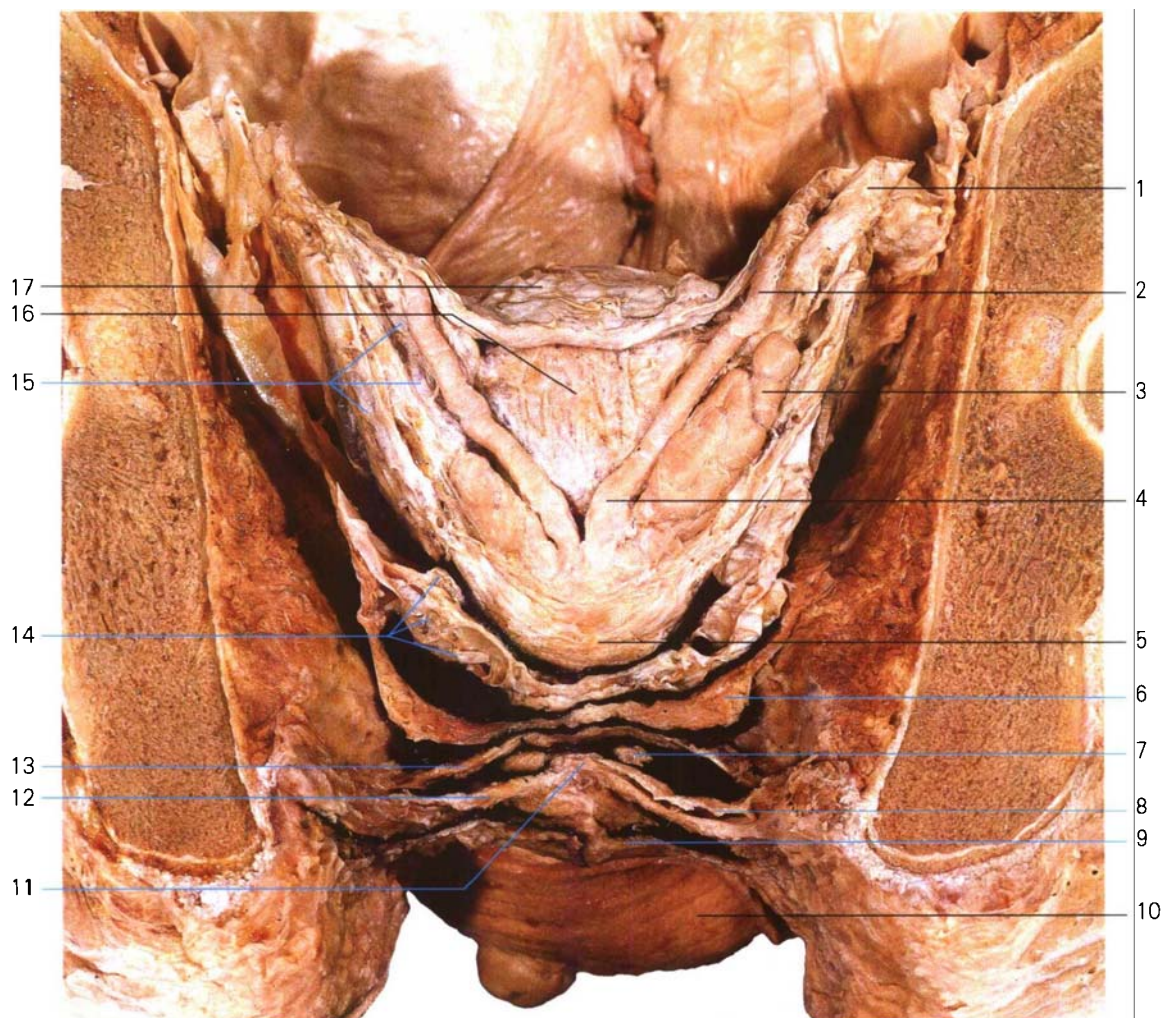


图 204 男性膀胱底(后面观)
Fundus of the male urinary bladder(posterior aspect)

- | | |
|---|--|
| 1. 输尿管 ureter | 12. 会阴浅横肌 superficial transverse muscle of perineum |
| 2. 输精管 ductus deferens | 13. 会阴深横肌和尿生殖膈上筋膜 deep transverse muscle of perineum and superior fascia of urogenital diaphragm |
| 3. 精囊 seminal vesicle | 14. 前列腺静脉丛 prostatic venous plexus |
| 4. 输精管壶腹 ampulla ductus deferentis | 15. 膀胱静脉丛 vesical venous plexus |
| 5. 前列腺 prostate | 16. 膀胱 urinary bladder |
| 6. 肛提肌(盆膈) levator ani(pelvic diaphragm) | 17. 脏腹膜 visceral peritoneum |
| 7. 尿道球腺 bulbourethral gland | |
| 8. 尿生殖膈下筋膜 inferior fascia of urogenital | |
| 9. 会阴浅筋膜 superficial fascia of perineum | |
| 10. 阴囊 scrotum | |
| 11. 会阴体(会阴中心腱) perineal body(perineal central tendon) | |

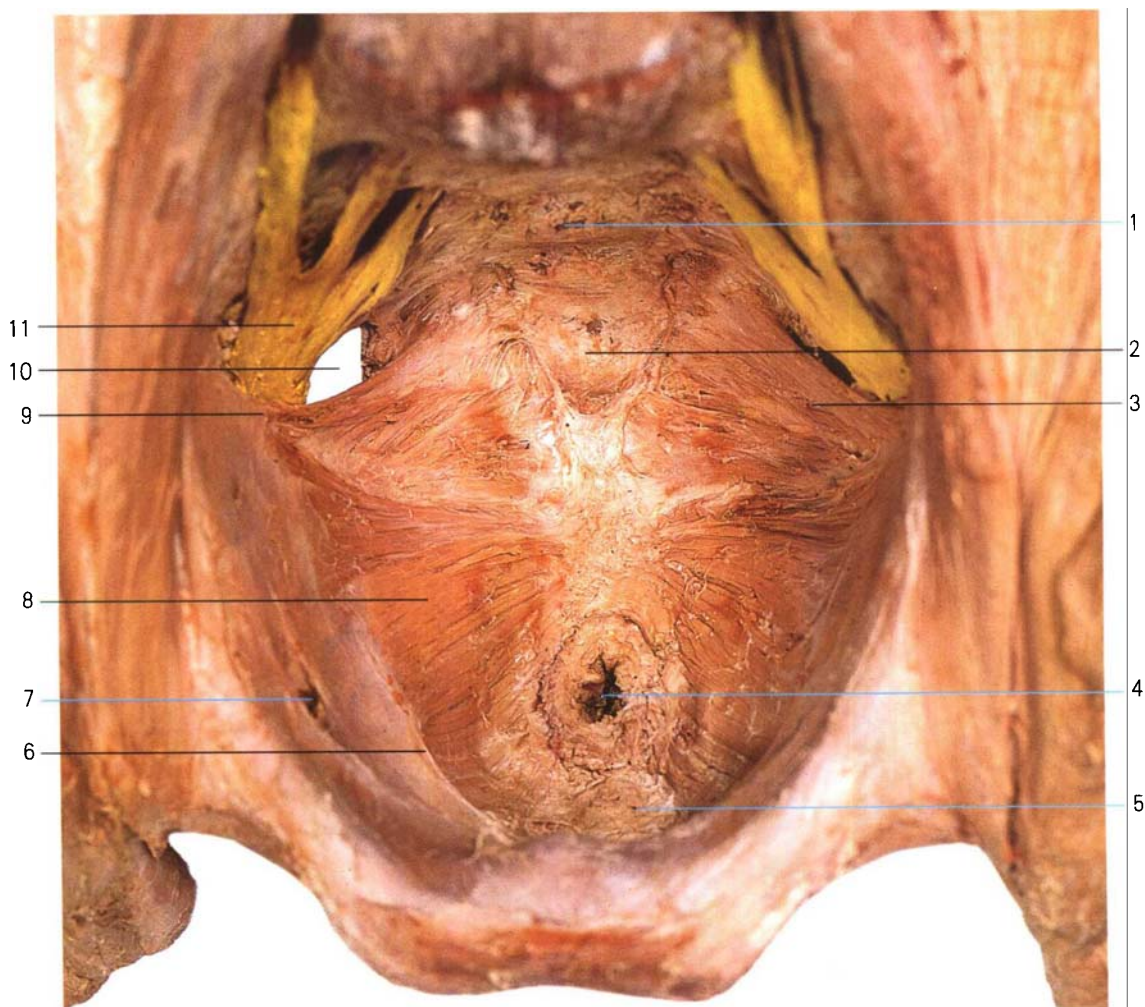


图 205 肛提肌(上面观)
Levator ani(superior aspect)

- | | |
|--|----------------------------------|
| 1. 骶骨 sacrum | 7. 闭孔 obturator foramen |
| 2. 尾骨 coccyx | 8. 肛提肌 levator ani |
| 3. 尾骨肌 coccygeus | 9. 坐骨棘 ischial spine |
| 4. 直肠 rectum | 10. 坐骨大孔 greater sciatic foramen |
| 5. 男尿道(膜部) male urethra(membranous part) | 11. 骶丛 sacral plexus |
| 6. 肛提肌腱弓 tendinous arch of levator ani | |

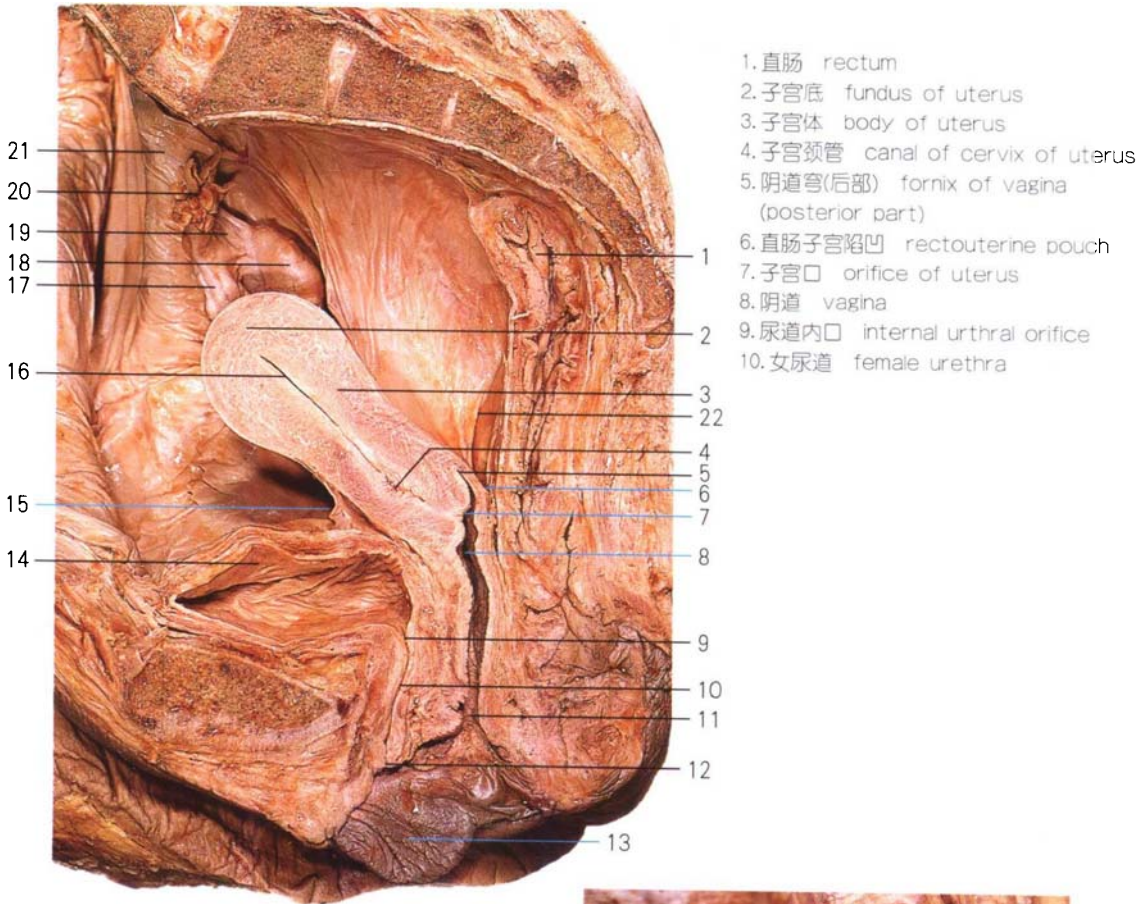


图 206 女性盆部(正中矢状剖面)(I)
 The pelvis of the female
 (median sagittal section)(I)

11. 阴道口 vaginal orifice
 12. 尿道外口 external orifice of urethra
 13. 小阴唇 lesser lip of pudendum
 14. 膀胱 urinary bladder
 15. 膀胱子宫陷凹 vesicouterine pouch
 16. 子宫腔 cavity of uterus
 17. 输卵管 uterine tube
 18. 卵巢 ovary
 19. 卵巢系膜 mesovarium
 20. 输卵管伞 fimbriae of uterine tube
 21. 卵巢悬韧带 suspensory lig.of ovary
 22. 直肠子宫襞 rectouterine fold

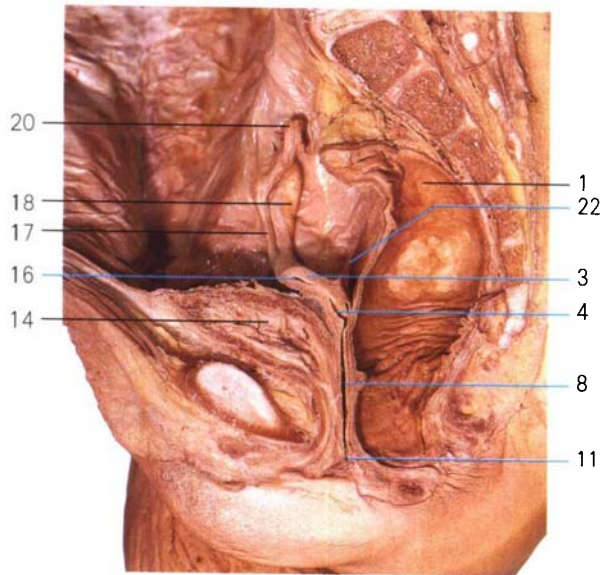


图 207 女性盆部(正中矢状剖面)(II)
 The pelvis of the female(median sagittal section)(II)

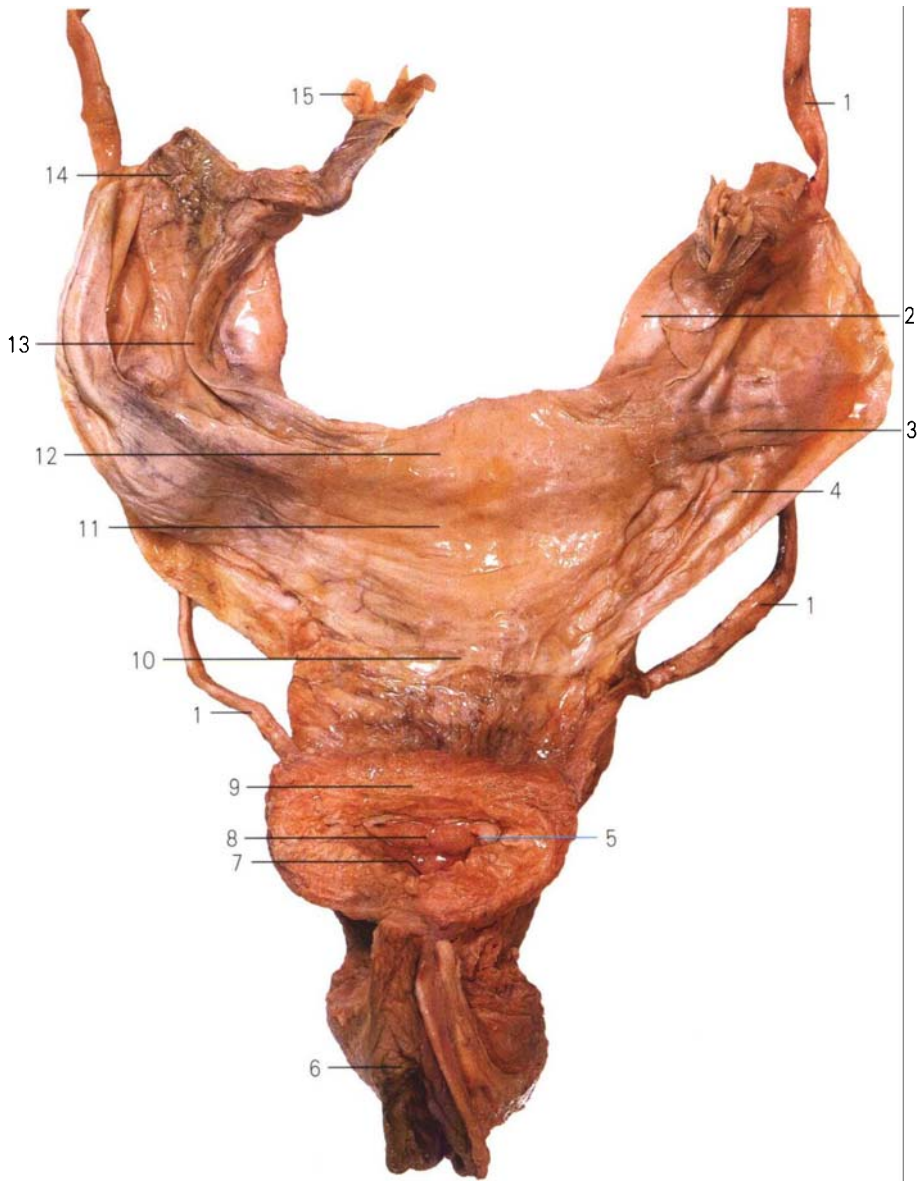


图 208 女性内生殖器(膀胱面)
Internal genital organs of the female(vesical surface)

- | | |
|-----------------------------------|--|
| 1. 输尿管 ureter | 9. 膀胱 urinary bladder |
| 2. 卵巢 ovary | 10. 子宫颈 neck of uterus |
| 3. 子宫圆韧带 round ligament of uterus | 11. 子宫体 body of uterus |
| 4. 子宫阔韧带 broad ligament of uterus | 12. 子宫底 fundus of uterus |
| 5. 输尿管口 ureteric orifice | 13. 输卵管 uterine tube |
| 6. 女阴 female pudendum | 14. 卵巢悬韧带 suspensory ligament of ovary |
| 7. 尿道内口 internal urethral orifice | 15. 输卵管伞 fimbriae of uterine tube |
| 8. 输尿管间襞 interureteric fold | |

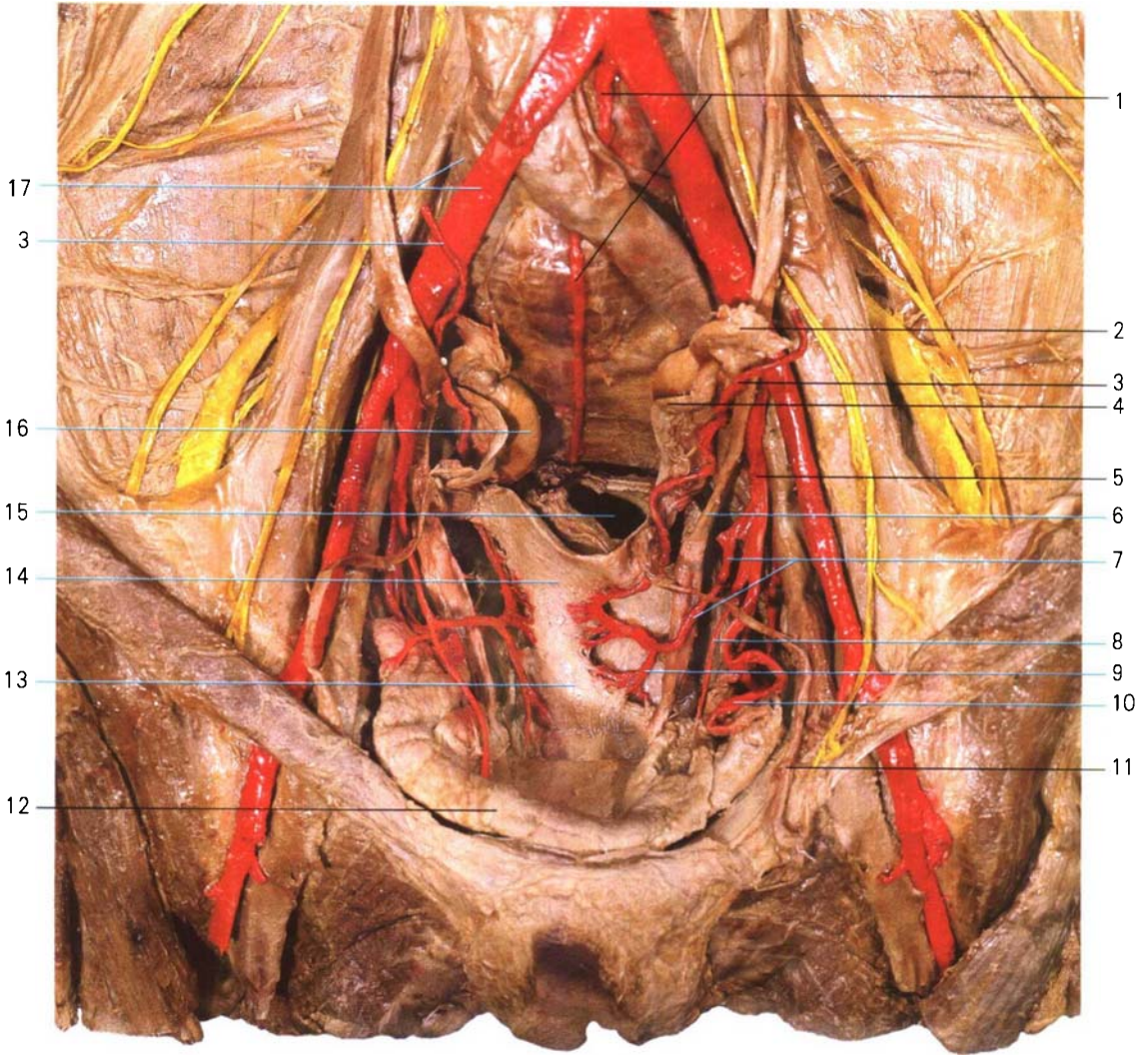


图 209 女性盆部的动脉(上面观)
Arteries of the female pelvis(superior aspect)

- | | |
|---|------------------------------------|
| 1. 骶正中动脉 median sacral a. | 10. 脐动脉 umbilical a. |
| 2. 输卵管伞 fimbriae of uterine tube | 11. 子宫圆韧带 round ligament of uterus |
| 3. 卵巢动脉 ovarian a. | 12. 膀胱 urinary bladder |
| 4. 输卵管 uterine tube | 13. 子宫颈 neck of uterus |
| 5. 髂内动脉 internal iliac a. | 14. 子宫体 body of uterus |
| 6. 输尿管 ureter | 15. 直肠 rectum |
| 7. 子宫动脉 uterine a. | 16. 卵巢 ovary |
| 8. 膀胱下动脉 inferior vesical a. | 17. 髂总动脉、静脉 common iliac a. & v. |
| 9. 子宫动脉(阴道支) uterine a.(vaginal branches) | |

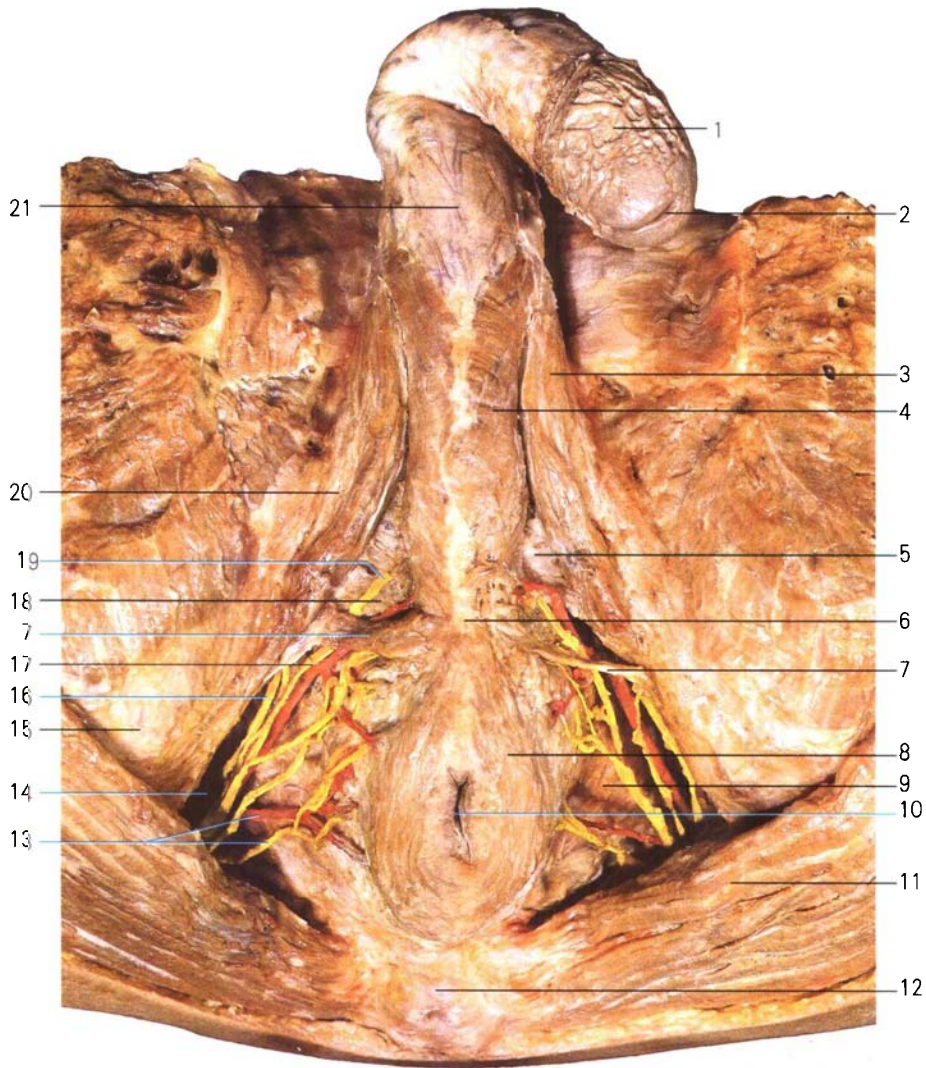


图210 男性会阴浅隙和坐骨肛门窝(I)
Superficial perineal space and ischioanal fossa of the male(I)

- | | |
|--|--|
| 1. 阴茎头 glans penis | 11. 臀大肌 gluteus maximus |
| 2. 尿道外口 external orifice of urathra | 12. 尾骨 coccyx |
| 3. 坐骨海绵体肌 ischiocavernosus | 13. 肛神经、动脉 anal n. & a. |
| 4. 球海绵体肌 bulbocavernosus | 14. 坐骨肛门窝 ischioanal fossa |
| 5. 尿生殖膈下筋膜 inferior fascia of urogenital diaphragm | 15. 坐骨结节 ischial tuberosity |
| 6. 会阴体 perineal body | 16. 阴茎背神经 dorsal nerve of penis |
| 7. 会阴浅横肌 superficial transverse muscle of perineum | 17. 会阴神经、动脉 perineal n. & a. |
| 8. 肛门外括约肌 sphincter ani externus | 18. 会阴深横肌 deep transverse muscle of perineum |
| 9. 肛提肌 levator ani | 19. 阴囊后神经 posterior scrotal n. |
| 10. 肛门 anus | 20. 耻骨弓 pubic arch |
| | 21. 尿道海绵体 spongy body of penis |

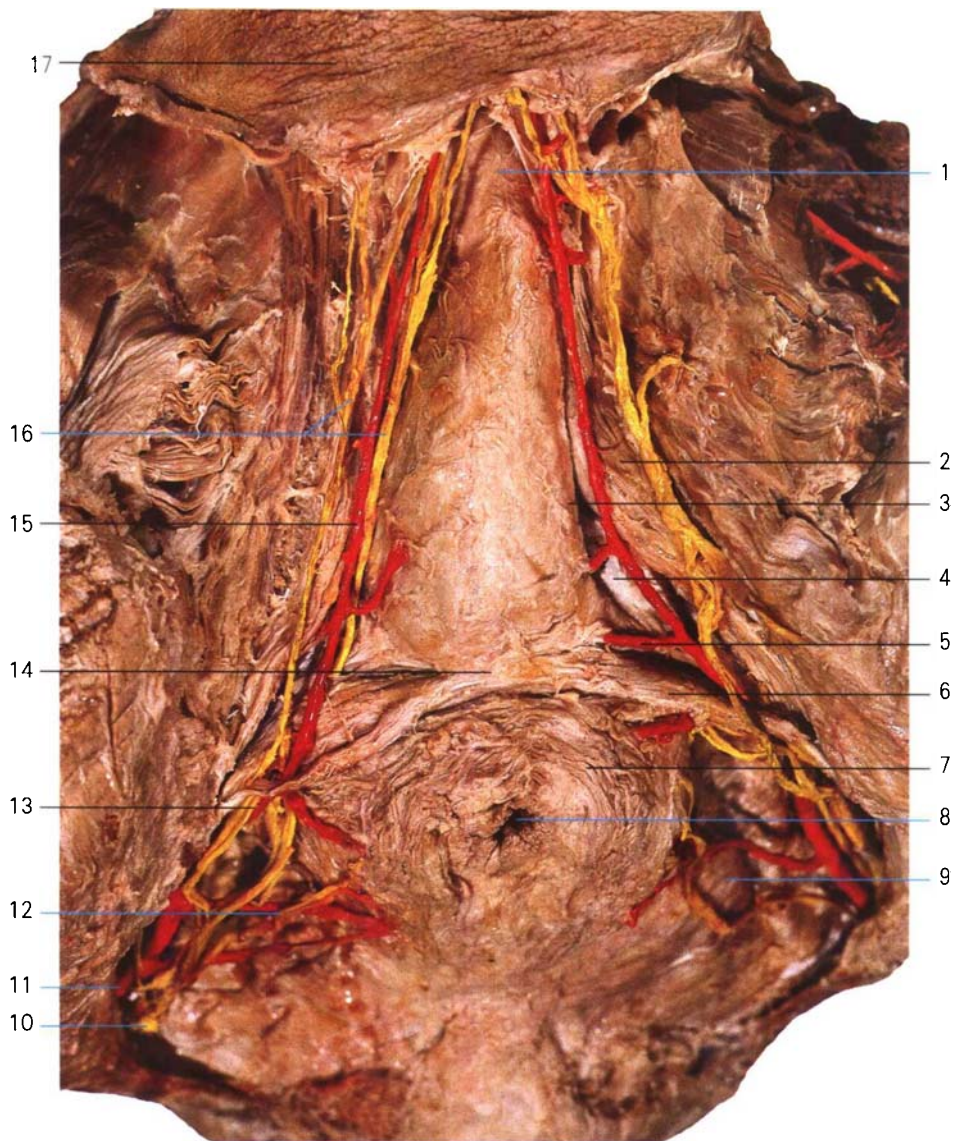


图 211 男性会阴浅隙和坐骨肛门窝(Ⅱ)
Superficial perineal space and ischioanal fossa of the male(Ⅱ)

- | | |
|--|-------------------------------------|
| 1. 尿道海绵体 spongy body of penis | 9. 肛提肌 levator ani |
| 2. 坐骨海绵体肌 ischiocavernosus | 10. 阴部神经 pudendal n. |
| 3. 球海绵体肌 bulbocavernosus | 11. 阴部内动脉 internal pudendal a. |
| 4. 尿生殖膈下筋膜 inferior fascia of urogenital diaphragm | 12. 肛神经、动脉 anal n. & a. |
| 5. 尿道球动脉 urethral bulbar a. | 13. 会阴神经、动脉 perineal n. & a. |
| 6. 会阴浅横肌 superficial transverse muscle of perineum | 14. 会阴体 perineal body |
| 7. 肛门外括约肌 sphincter ani externus | 15. 阴囊后支 posterior scrotal branches |
| 8. 肛门 anus | 16. 阴囊后神经 posterior scrotal n. |
| | 17. 阴囊 scrotum |

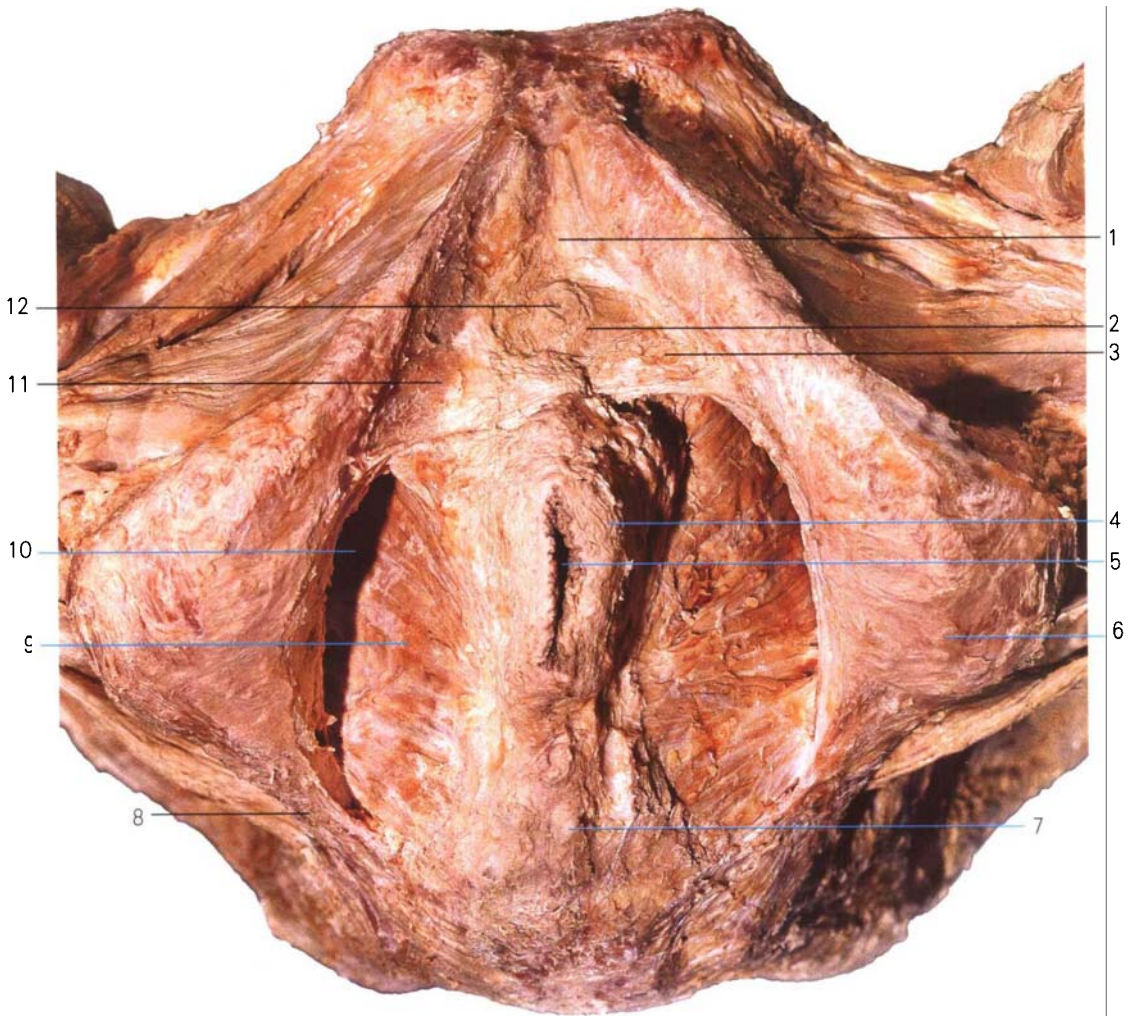

图 212 男性会阴深隙及坐骨肛门窝
Deep perineal space and ischioanal fossa of the male

- | | |
|---|---|
| 1. 尿生殖膈 urogenital diaphragm | 7. 尾骨 coccyx |
| 2. 尿道括约肌 sphincter of urethra | 8. 骶结节韧带 sacrotuberous ligament |
| 3. 会阴深横肌 deep transverse muscle of perineum | 9. 肛提肌 levator ani |
| 4. 肛门外括约肌 sphincter ani externus | 10. 坐骨肛门窝 ischioanal fossa |
| 5. 肛门 anus | 11. 尿生殖膈下筋膜 inferior fascia of urogenital |
| 6. 坐骨结节 ischial tuberosity | 12. 男尿道(膜部) male urethra(membranous part) |

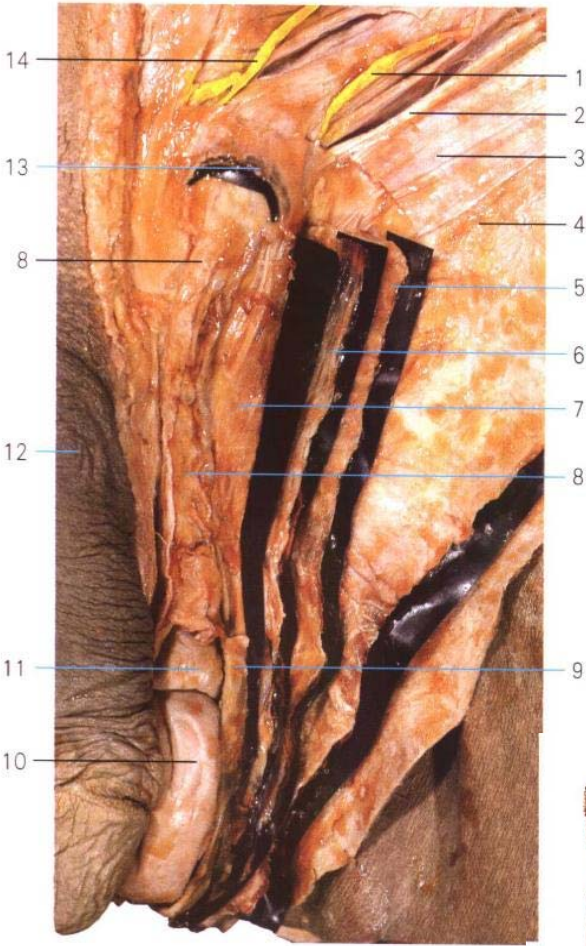


图 213 睾丸和精索被膜
Testis and tunicae of spermatic cord

1. 髂腹股沟神经 ilioinguinal n.
2. 腹股沟韧带 inguinal ligament
3. 腹外斜肌(腱膜) obliquus externus abdominis (aponeurosis)
4. 浅筋膜 superficial fascia
5. 精索外筋膜 external spermatic fascia
6. 提睾肌筋膜 cremasteric fascia
7. 精索内筋膜 internal spermatic fascia
8. 精索 spermatic cord
9. 睾丸鞘膜(壁层) tunica vaginalis of testis (parietal layer)
10. 睾丸 testis
11. 副睾头 head of epididymis
12. 阴茎 penis
13. 腹股沟管浅环 superficial inguinal ring
14. 髂腹下神经 iliohypogastric n.

1. 阴茎背神经 dorsal nerve of penis
2. 阴茎背动脉 dorsal artery of penis
3. 阴茎背深静脉 deep dorsal vein of penis
4. 阴茎深筋膜 deep fascia of penis
5. 阴茎浅筋膜 superficial fascia of penis
6. 皮肤 skin
7. 阴茎包皮 prepuce of penis
8. 阴茎颈 neck of penis
9. 阴茎头 glans penis
10. 尿道球 bulb of urethra
11. 阴茎脚 crus penis
12. 阴茎海绵体白膜 albuginea of cavernous body of penis
13. 尿道海绵体 cavernous body of urethra
14. 男尿道 male urethra
15. 阴茎深动脉 deep artery of penis
16. 阴茎海绵体 cavernous body of penis
17. 阴茎背深静脉 deep dorsal vein of penis

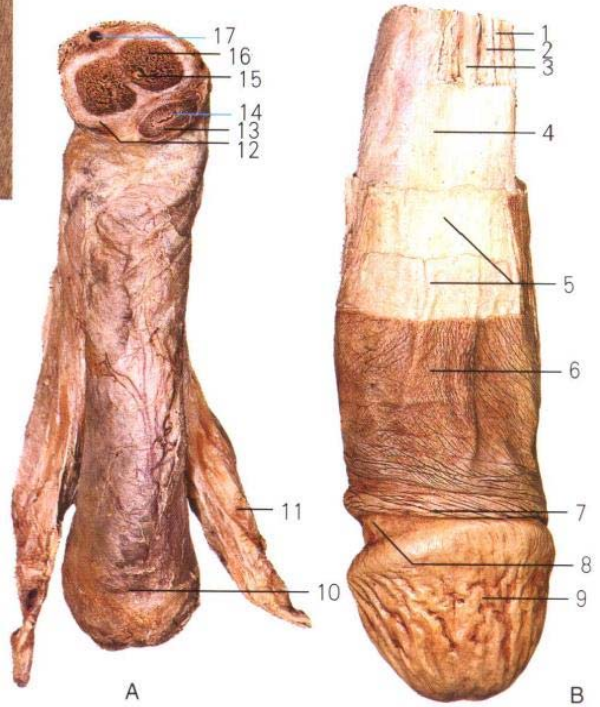


图 214 阴茎(A.尿道面, B.阴茎背)
Penis(A.urethral surface,B.dorsum penis)

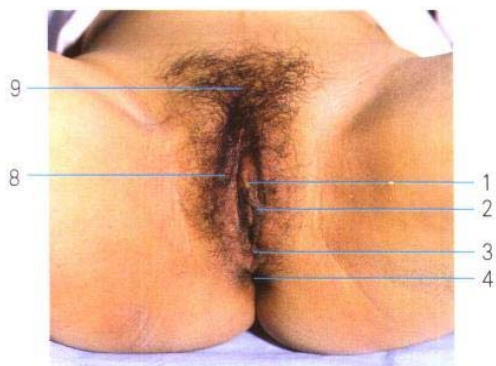

图 215 女性外生殖器(I)
External genital organs of the female(I)

1. 阴蒂及阴蒂包皮 clitoris and prepuce of clitoris
2. 小阴唇 lesser lip of pudendum
3. 阴唇系带 frenulum of pudendal labia
4. 肛门 anus
5. 会阴 perineum
6. 阴道口及处女膜痕 vaginal orifice and carunculae hymenales
7. 尿道外口 external orifice of urethra
8. 大阴唇 greater lip of pudendum
9. 阴阜 mons pubis

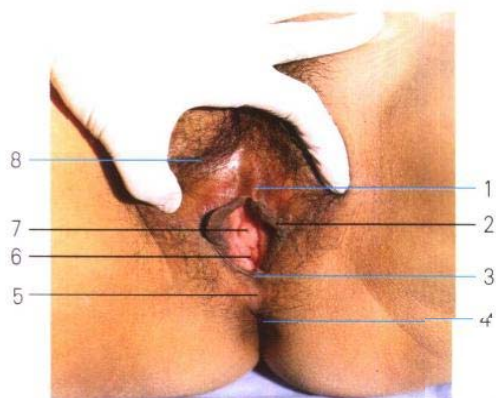

图 216 女性外生殖器(II)
External genital organs of the female(II)

1. 阴蒂海绵体 cavernous body of clitoris
2. 阴蒂及阴蒂包皮 clitoris and prepuce of clitoris
3. 阴蒂脚 crus of clitoris
4. 球海绵体肌 bulbocavernosus
5. 前庭球 bulb of vestibule
6. 坐骨海绵体肌 ischiocavernosus
7. 会阴浅横肌 superficial transverse muscle of perineum
8. 肛提肌 levator ani
9. 肛门外括约肌 sphincter ani externus
10. 臀大肌 gluteus maximus
11. 肛门 anus
12. 坐骨肛门窝 ischioanal fossa
13. 前庭大腺 greater vestibular gland
14. 阴道口 vaginal orifice
15. 小阴唇 lesser lip of pudendum
16. 尿道外口 external orifice of urethra
17. 阴蒂系带 frenulum of clitoris

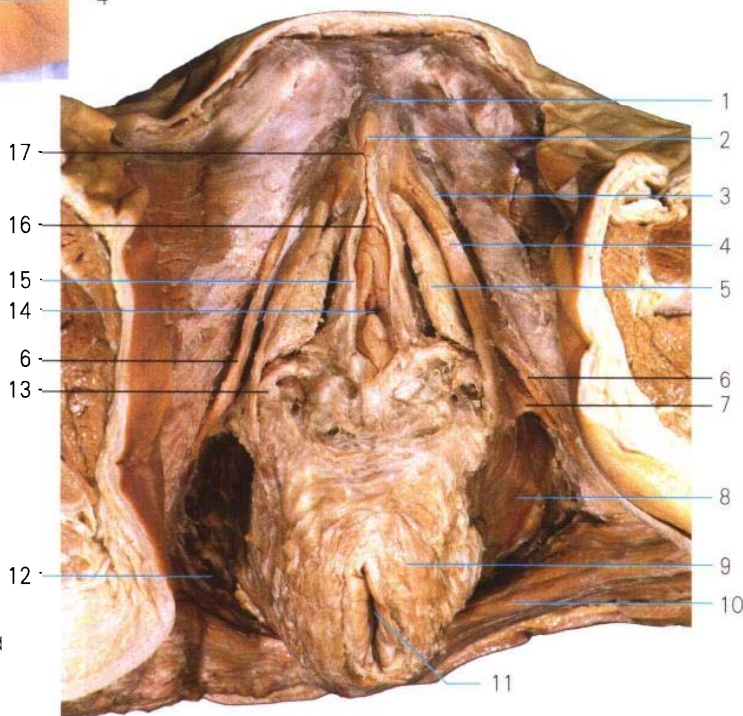


图 217 女性会阴浅隙及坐骨肛门窝(I)
Superficial perineal space and ischioanal fossa of the female(I)

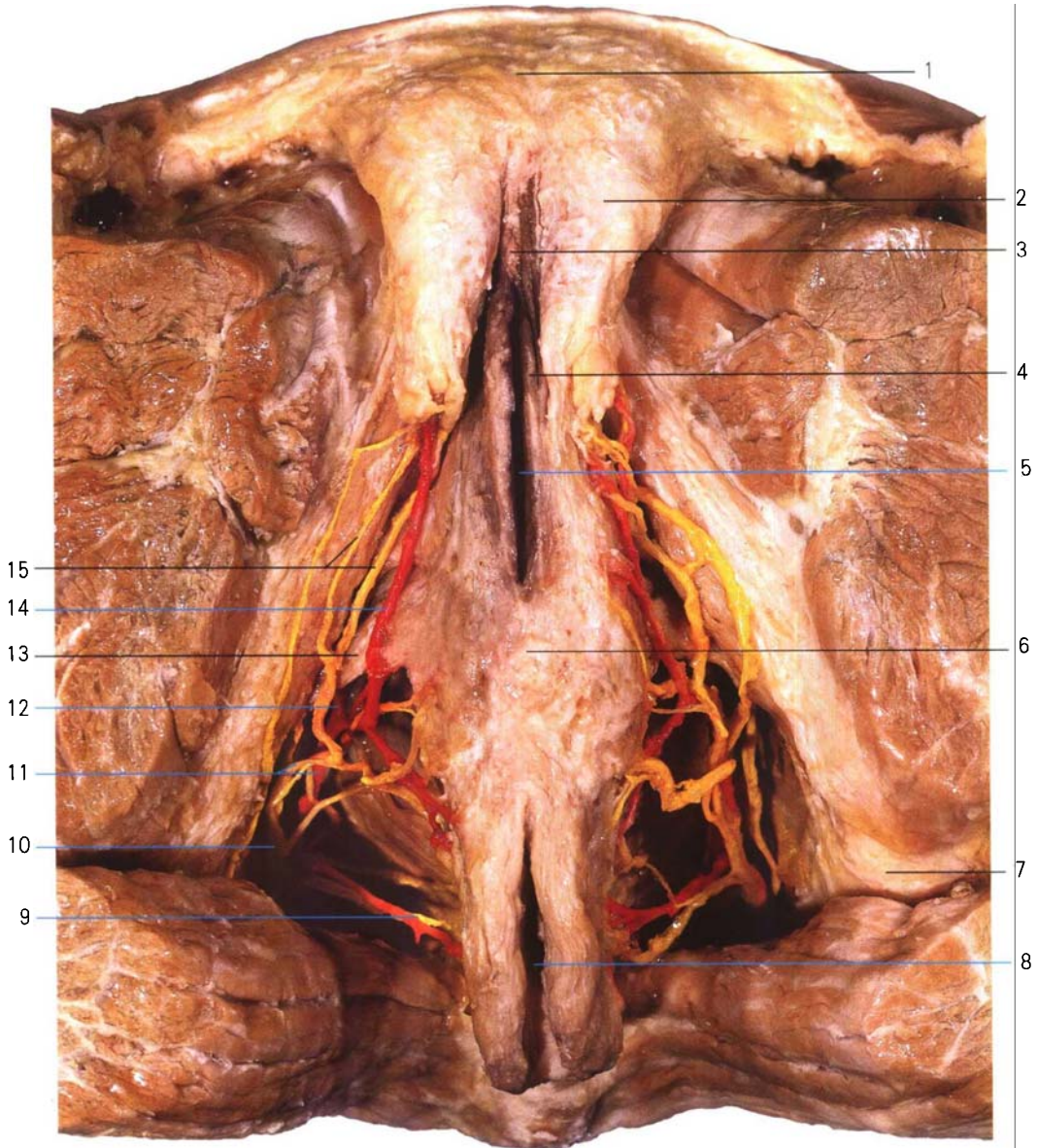


图 218 女性会阴浅隙及坐骨肛门窝(Ⅱ)
Superficial perineal space and ischioanal fossa of the female (Ⅱ)

- | | |
|--------------------------------|---|
| 1. 阴阜 mons pubis | 9. 肛动脉和神经 anal a.n. |
| 2. 大阴唇 greater lip of pudendum | 10. 阴部神经 pudendal n. |
| 3. 阴蒂 clitoris | 11. 会阴神经、动脉 perineal n.a. |
| 4. 小阴唇 lesser lip of pudendum | 12. 阴蒂深动脉 deep artery of clitoris |
| 5. 阴道口 vaginal orifice | 13. 会阴浅横肌 superficial transverse muscle of perineum |
| 6. 会阴体 perineal body | 14. 阴唇后支 posterior labial branches |
| 7. 坐骨结节 ischial tuberosity | 15. 阴唇后神经 posterior labial n. |
| 8. 肛门 anus | |

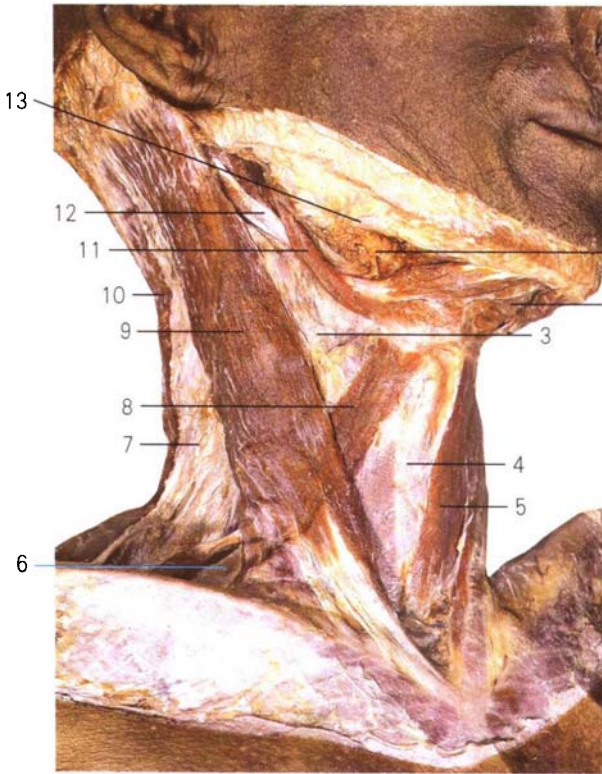
第

章



颈 部

CHAPTER 7 THE NECK



1. 下颌下三角 submandibular triangle
2. 颏下三角 submental triangle
3. 颈动脉三角 carotid triangle
4. 肌三角 muscular triangle
5. 胸骨舌骨肌 sternohyoid
6. 锁骨上大窝 greater supraclavicular fossa
7. 枕三角 occipital triangle
8. 肩胛舌骨肌上腹 superior belly of the omohyoid

图 219 颈部三角
Triangle of cervical region

9. 胸锁乳突肌 sternocleidomastoid
10. 斜方肌 trapezius
11. 茎突舌骨肌 stylohyoid
12. 二腹肌后腹 posterior belly of the digastric
13. 下颌骨下缘 inferior margin of the mandible
14. 颈阔肌 platysma

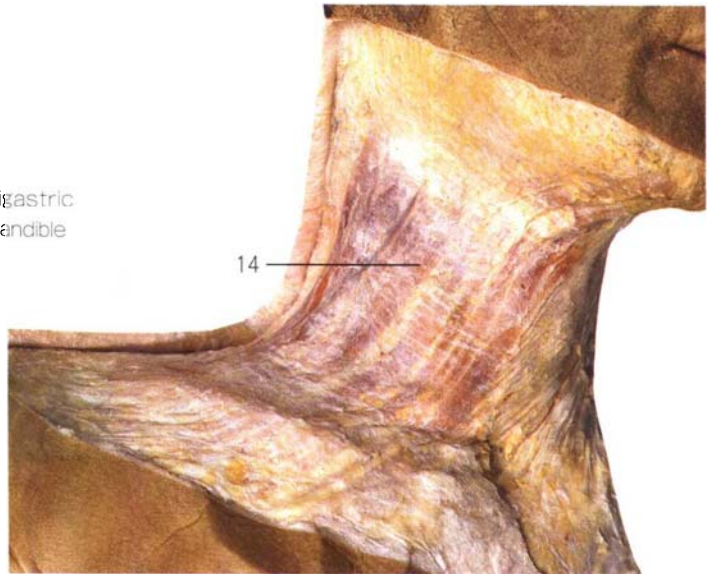


图 220 颈阔肌侧面观
Lateral aspect of platysma

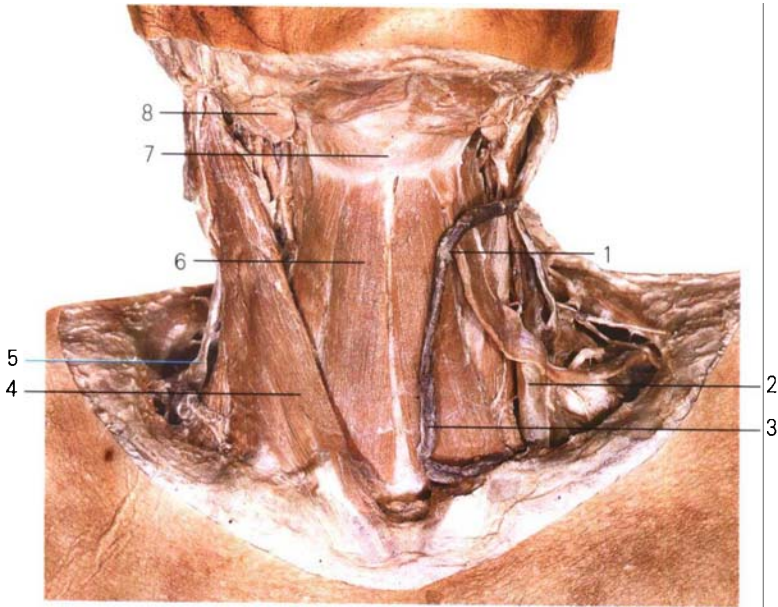
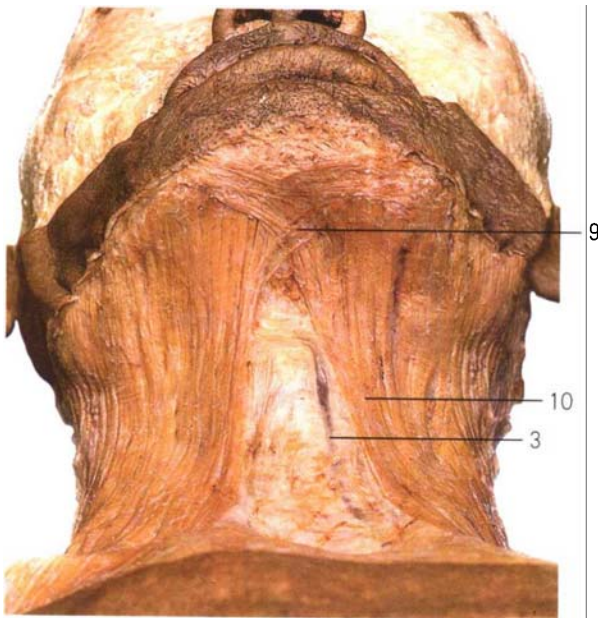


图 221 颈前区浅层结构
Superficial structures of the anterior
cervical region



1. 肩胛舌骨肌 omohyoid
2. 颈内静脉 internal jugular v.
3. 颈前静脉 anterior jugular v.
4. 胸锁乳突肌 sternocleidomastoid
5. 颈外静脉 external jugular v.
6. 胸骨舌骨肌 sternohyoid
7. 舌骨 hyoid bone
8. 下颌下腺 submandibular gland
9. 颈阔肌交叉纤维 cross fiber of platysma
10. 颈阔肌 platysma

图 222 颈阔肌前面观
Anterior aspect of platysma

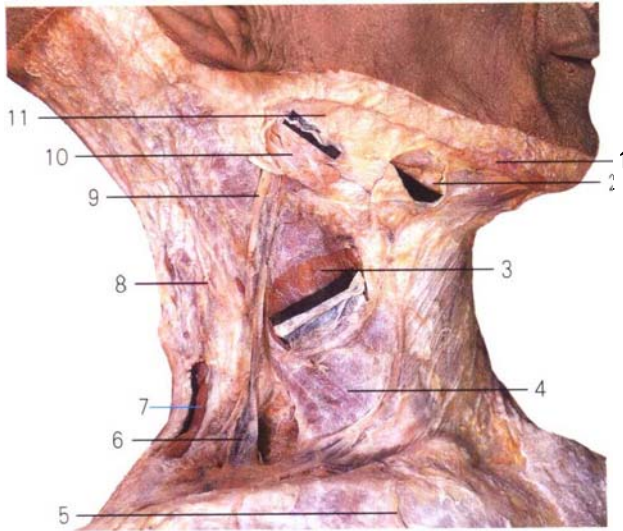


图 223 颈深筋膜浅层
Superficial layer of cervical deep fascia

1. 颈阔肌 platysma
2. 下颌下腺 submandibular gland
3. 胸锁乳突肌 sternocleidomastoid
4. 颈深筋膜浅层 superficial layer of the cervical deep fascia
5. 锁骨上神经 supraclavicular n.
6. 颈外静脉 external jugular v.
7. 斜方肌 trapezius
8. 枕小神经 lesser occipital n.
9. 耳大神经 greater auricular n.
10. 腮腺 parotid gland
11. 腮腺筋膜 parotid fascia
12. 舌骨 hyoid bone
13. 颈前静脉 anterior jugular v.
14. 胸骨舌骨肌 sternohyoid
15. 颈横动脉 transeverse jugular a.
16. 肩胛舌骨肌 omohyoid
17. 颈内静脉 interior jugular v.
18. 颈丛 cervical plexus

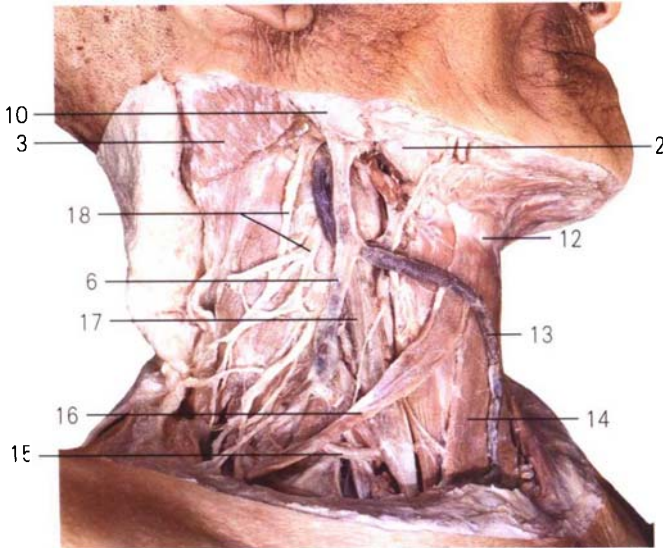
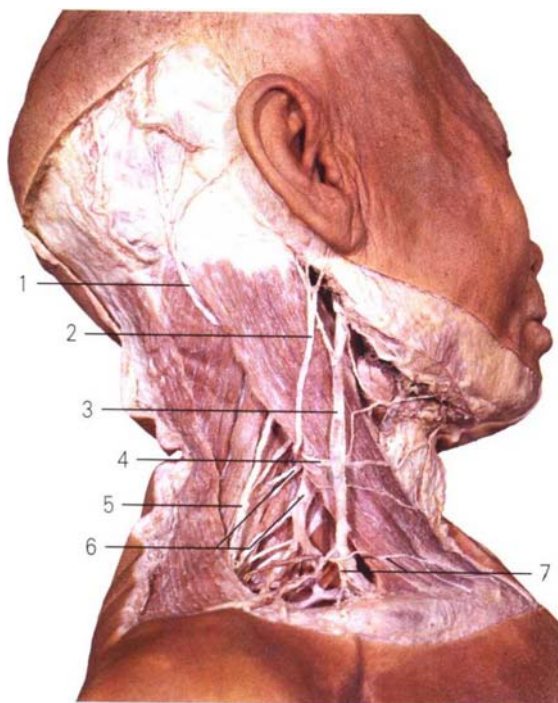


图 224 颈丛和颈浅静脉
Cervical plexus and superficial jugular veins



1. 枕小神经 lesser occipital n.
2. 耳大神经 great auricular n.
3. 颈外静脉 external jugular v.
4. 颈横神经 transverse nerve of neck
5. 副神经 accessory n.
6. 颈丛 cervical plexus
7. 锁骨上神经 supraclavicular n.
8. 肩胛舌骨肌 omohyoid
9. 胸骨舌骨肌 sternohyoid
10. 颈内静脉 internal jugular v.
11. 颈静脉弓 jugular venous arch
12. 胸锁乳突肌 sternocleidomastoid
13. 颈前静脉 anterior jugular v.

图 225 颈丛及其分支
Cervical plexus and it's branches

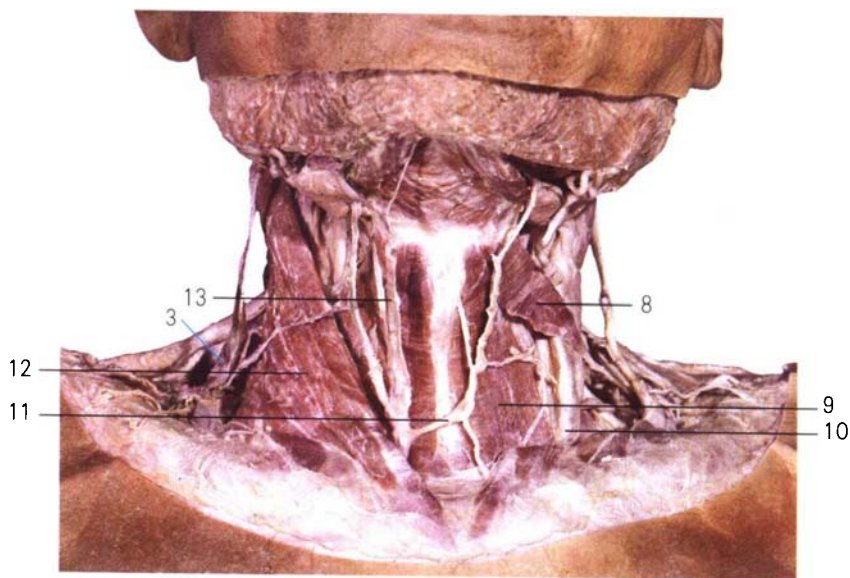


图 226 颈部浅静脉
Superficial veins of cervical region

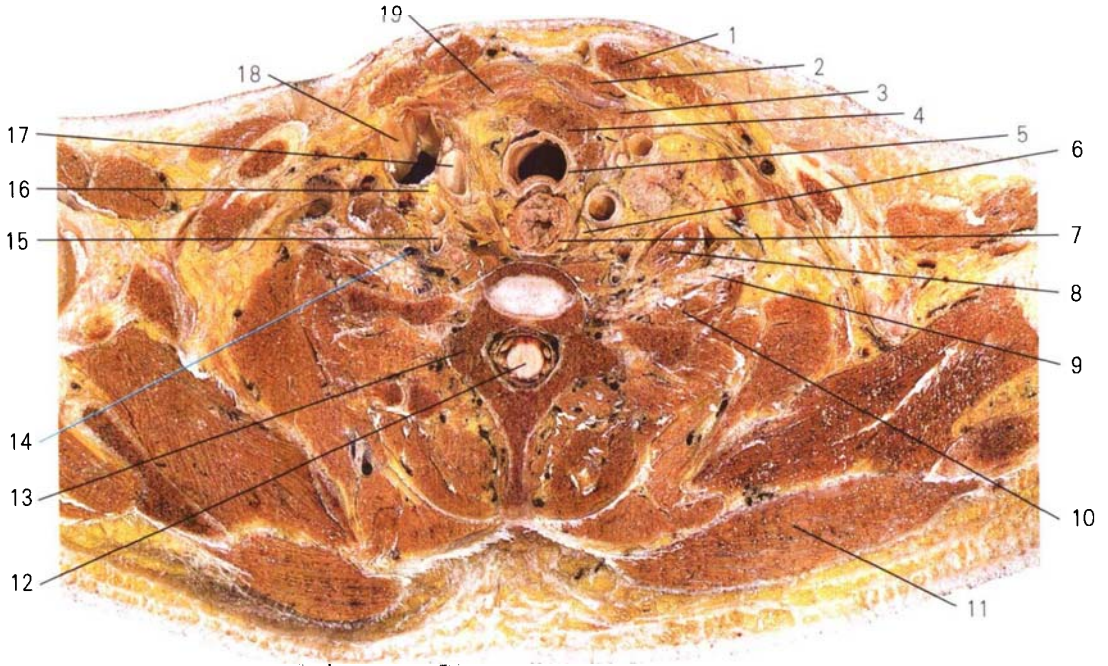


图 227 第七颈椎间盘横切面
Transverse section at level of seventh
cervical vertebral disc

- | | |
|--------------------------------------|------------------------------------|
| 1. 胸锁乳突肌 sternocleidomastoid | 11. 斜方肌 trapezius |
| 2. 胸骨舌骨肌 sternohyoid | 12. 脊髓 spinal cord |
| 3. 肩胛舌骨肌 omohyoid | 13. 第七颈椎 seventh cervical vertebra |
| 4. 甲状腺 thyroid gland | 14. 椎静脉 vertebral v. |
| 5. 气管 trachea | 15. 椎动脉 vertebral a. |
| 6. 左喉返神经 left recurrent laryngeal n. | 16. 迷走神经 vagus n. |
| 7. 食管 esophagus | 17. 颈总动脉 common carotid a. |
| 8. 前斜角肌 scalenus anterior | 18. 颈内静脉 internal jugular v. |
| 9. 臂丛 brachial plexus | 19. 胸骨甲状肌 sternothyroid |
| 10. 中斜角肌 scalenus medius | |

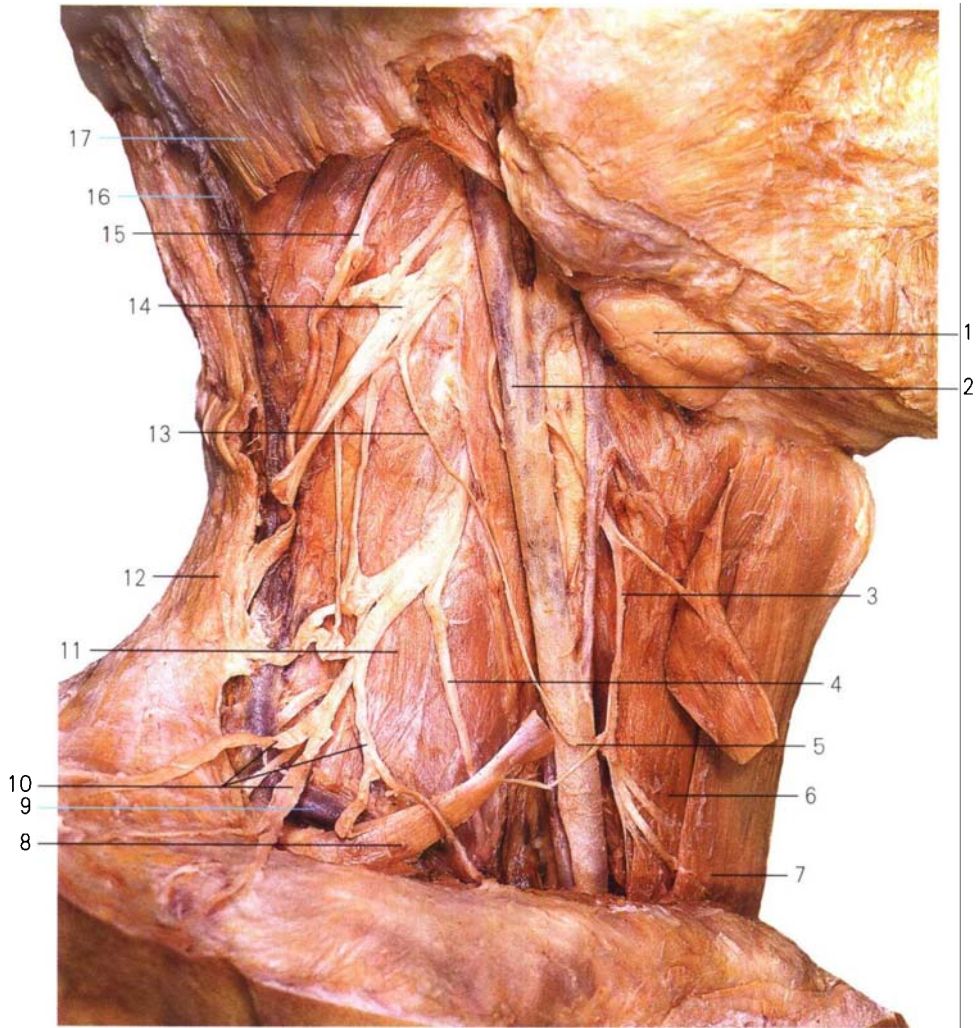


图 230 颈部右侧面的肌、血管和神经(I)
Muscles, blood vessels and nerves of the
right lateral aspect of the neck(I)

- | | |
|-----------------------------|-------------------------------|
| 1. 下颌下腺 submandibular gland | 10. 锁骨上神经 supraclavicular n. |
| 2. 颈内静脉 internal jugular v. | 11. 肩胛提肌 levator scapulae |
| 3. 上根 superior root | 12. 斜方肌 trapezius |
| 4. 膈神经 phrenic n. | 13. 下根 inferior root |
| 5. 颈襻 ansa cervicalis | 14. 颈丛 cervical plexus |
| 6. 胸骨甲状肌 sternothyroid | 15. 副神经 accessory n. |
| 7. 胸骨舌骨肌 sternohyoid | 16. 枕静脉 occipital v. |
| 8. 肩胛舌骨肌 omohyoid | 17. 胸锁乳突肌 sternocleidomastoid |
| 9. 锁骨下静脉 subclavian v. | |

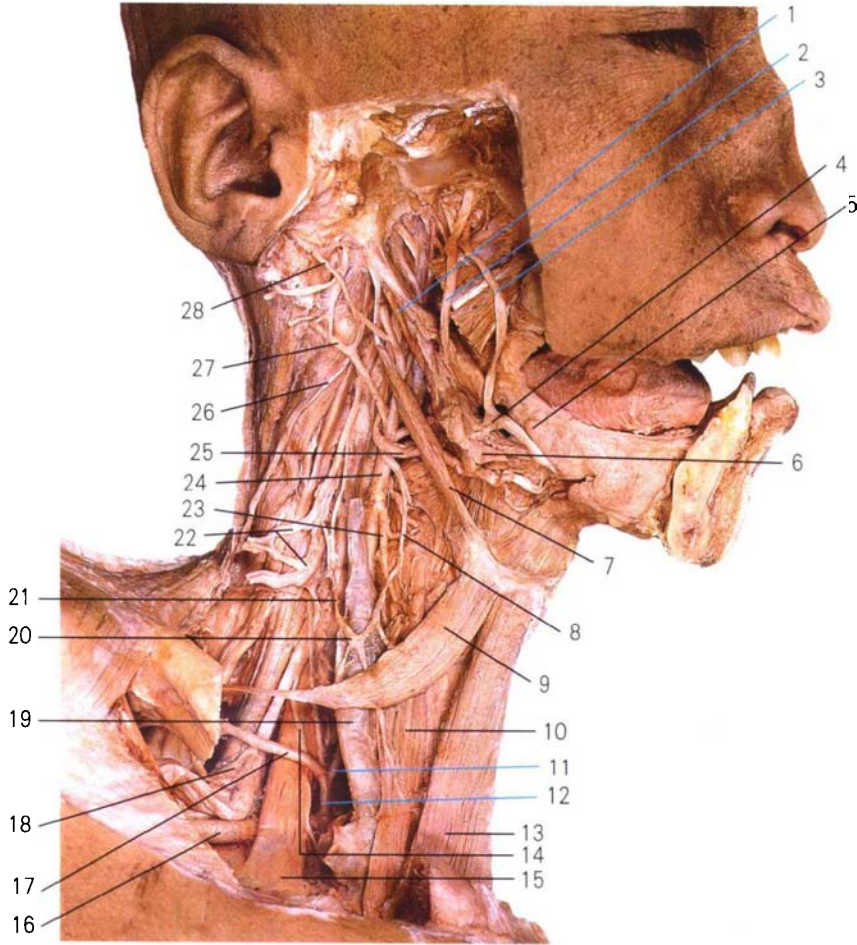


图 231 颈部右侧面的肌、血管和神经(Ⅱ)
Muscles; blood vessels and nerves of the
right lateral aspect of the neck (Ⅱ)

- | | |
|--------------------------------|---------------------------------|
| 1. 舌咽神经 glossopharyngeal n. | 15. 前斜角肌 scalenus anterior |
| 2. 下牙槽神经 inferior alveolar n. | 16. 锁骨下动脉 subclavian a. |
| 3. 舌神经 lingual n. | 17. 颈横动脉 transverse cervical a. |
| 4. 下颌下节 submandibular ganglion | 18. 臂丛 brachial plexus |
| 5. 舌下腺 sublingual gland | 19. 颈内静脉 internal jugular v. |
| 6. 下颌下腺 submandibular gland | 20. 颈襻 ansa cervicalis |
| 7. 茎突舌骨肌 stylohyoid | 21. 下根 inferior root |
| 8. 上根 superior root | 22. 颈丛 cervical plexus |
| 9. 肩胛舌骨肌 omohyoid | 23. 甲状腺上动脉 superior thyroid a. |
| 10. 胸骨甲状肌 sternothyroid | 24. 颈外动脉 external jugular a. |
| 11. 甲状腺下动脉 inferior thyroid a. | 25. 舌下神经 hypoglossal n. |
| 12. 甲状颈干 thyrocervical trunk | 26. 副神经 accessory n. |
| 13. 胸骨舌骨肌 sternohyoid | 27. 枕动脉 occipital a. |
| 14. 膈神经 phrenic n. | 28. 耳后动脉 posterior auricular a. |

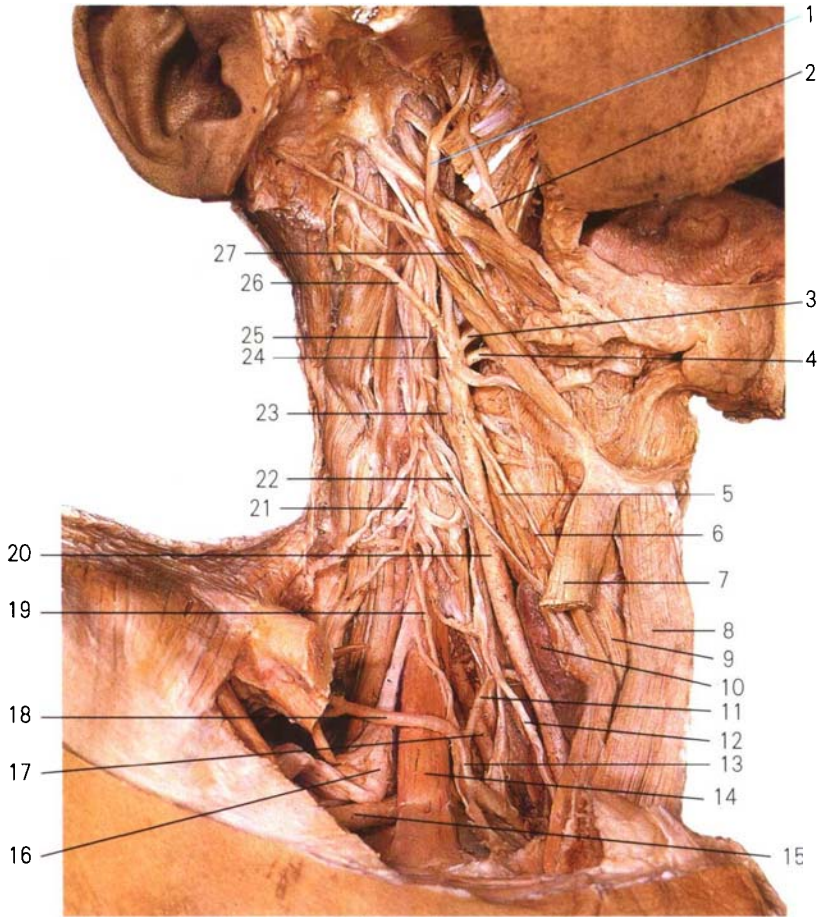


图 232 颈部右侧面的肌、血管和神经(Ⅲ)
Muscles, blood vessels and nerves of the right lateral aspect of the neck(Ⅲ)

- | | |
|--------------------------------|--------------------------------|
| 1. 下牙槽神经 inferior alveolar n. | 15. 锁骨下动脉 subclavian a. |
| 2. 舌神经 lingual n. | 16. 臂丛 brachial plexus |
| 3. 面动脉 facial a. | 17. 椎动脉 vertebral a. |
| 4. 舌动脉 lingual a. | 18. 颈横动脉 tranverse cervical a. |
| 5. 甲状腺上动脉 superior thyroid a. | 19. 膈神经 phrenic n. |
| 6. 上根 superior root | 20. 颈总动脉 common carotid a. |
| 7. 肩胛舌骨肌 omohyoid | 21. 颈丛 cervical plexus |
| 8. 胸骨舌骨肌 sternohyoid | 22. 下根 inferior root |
| 9. 胸骨甲状肌 sternothyroid | 23. 颈动脉窦 carotid sinus |
| 10. 甲状腺 thyroid gland | 24. 舌下神经 hypoglossal n. |
| 11. 甲状腺下动脉 inferior thyroid a. | 25. 副神经 accessory n. |
| 12. 迷走神经 vagus n. | 26. 枕动脉 occipital a. |
| 13. 甲状颈干 thyrocervical trunk | 27. 舌咽神经 glossopharyngeal n. |
| 14. 前斜角肌 scalenus anterior | |

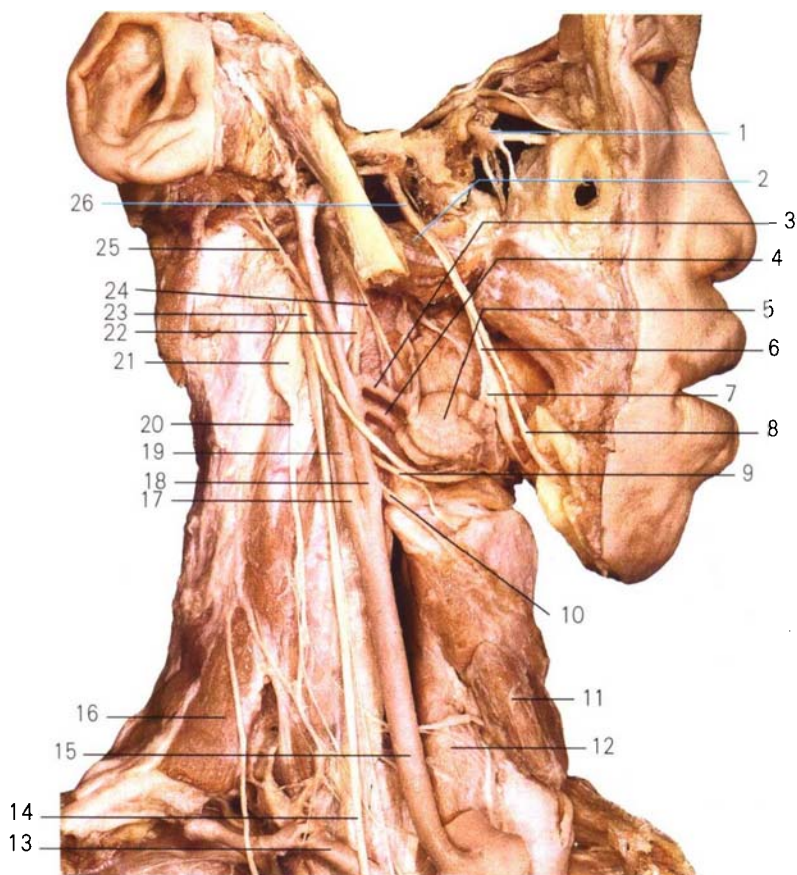


图 233 颈深部血管和神经
Deep blood vessels and nerves of the neck

- | | |
|--------------------------------|--------------------------------------|
| 1. 上颌神经 maxillary n. | 14. 迷走神经 vagus n. |
| 2. 翼外肌 lateral pterygoid | 15. 颈总动脉 common carotid a. |
| 3. 面动脉 facial a. | 16. 斜方肌 trapezius |
| 4. 舌动脉 lingual a. | 17. 颈动脉窦 carotid sinus |
| 5. 下颌下腺 submandibular gland | 18. 颈外动脉 external carotid a. |
| 6. 舌神经 facial a. | 19. 颈内动脉 internal carotid a. |
| 7. 下颌下节 submandibular ganglion | 20. 交感干 sympathetic trunk |
| 8. 下牙槽神经 inferior alveolar n. | 21. 交感颈上节 superior cervical ganglion |
| 9. 喉上神经 superior laryngeal n. | 22. 咽升动脉 ascending pharyngeal a. |
| 10. 甲状腺上动脉 superior thyroid a. | 23. 舌下神经 sublingual n. |
| 11. 甲状腺 thyroid gland | 24. 舌咽神经 glossopharyngeal n. |
| 12. 咽 pharynx | 25. 枕动脉 occipital a. |
| 13. 锁骨下动脉 subclavian a. | 26. 下颌神经 submandibular n. |

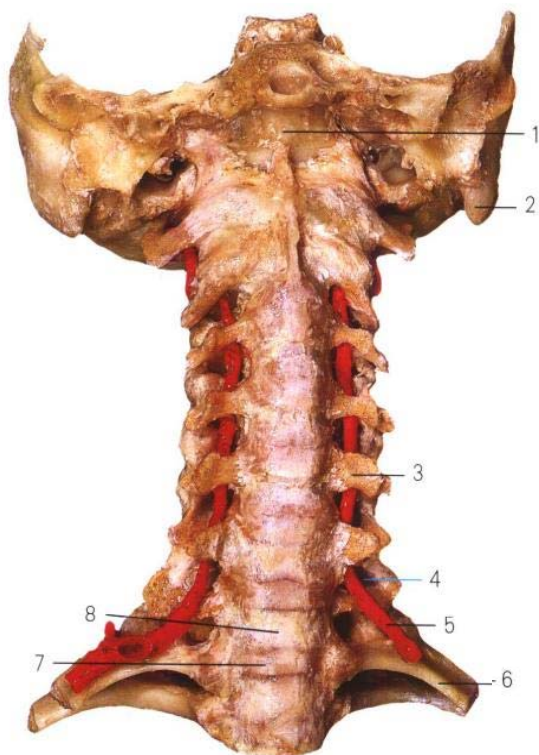


图 234 椎动脉和颈椎前面观
Anterior aspect of vertebral artery
and cervical vertebrae

1. 枕骨 occipital bone
2. 乳突 mastoid process
3. 横突 transverse process
4. 横突孔 transverse foramen
5. 椎动脉 vertebral a.
6. 第一肋 first rib
7. 椎体 vertebral body
8. 椎间盘 intervertebral discs
9. 外耳门 external acoustic pore
10. 项韧带 ligamentum nuchae
11. 棘突 spinous process

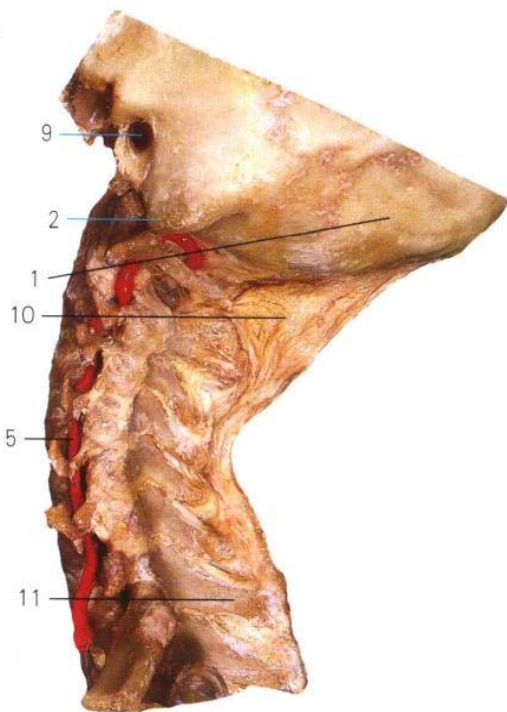


图 235 椎动脉和颈椎侧面观
Lateral aspect of vertebral artery and
cervical vertebrae

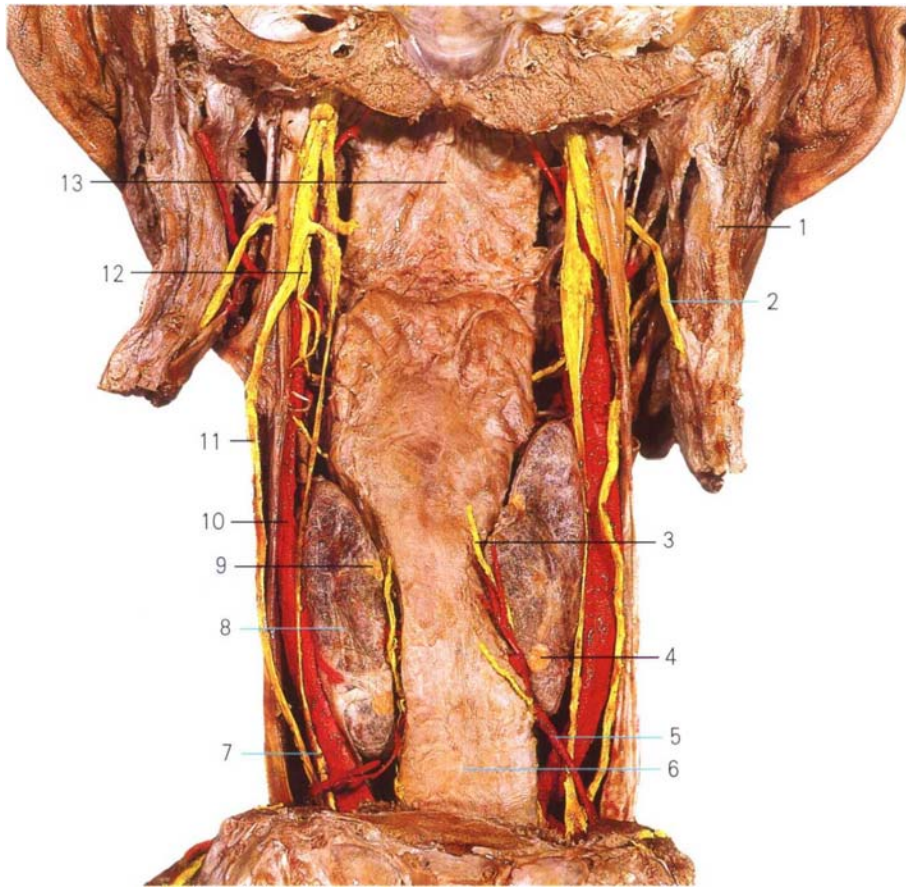
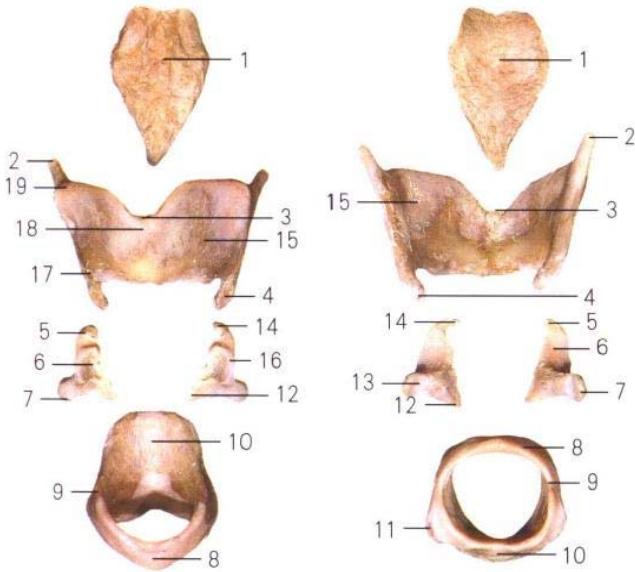


图 236 甲状腺区后面观
Posterior aspect of the region of thyroid gland

- | | |
|--|-------------------------------------|
| 1. 胸锁乳突肌 sternocleidomastoid | of vagus n. |
| 2. 副神经 accessory n. | 8. 甲状腺 thyroid gland |
| 3. 右喉返神经 right recurrent laryngeal n. | 9. 上甲状旁腺 superior parathyroid gland |
| 4. 下甲状旁腺 inferior parathyroid gland | 10. 颈总动脉 common carotid a. |
| 5. 甲状腺下动脉 inferior thyroid a. | 11. 迷走神经 vagus n. |
| 6. 食管颈部 cervical part of the esophagus | 12. 喉上神经 superior laryngeal n. |
| 7. 迷走神经颈心支 cervical cardiac branches | 13. 咽 pharynx |



1. 会厌软骨 epiglottic cartilage
2. 上角 superior cornu
3. 上切迹 superior thyroid notch
4. 下角 inferior cornu
5. 杓状软骨尖 apex of arytenoid cartilage
6. 杓状软骨 arytenoid cartilage
7. 肌突 muscular process
8. 环状软骨弓 arch of cricoid cartilage
9. 环状软骨 cricoid cartilage
10. 环状软骨板 lamina of cricoid cartilage
1. 甲关节面 thyroid articular surface
2. 声带突 vocal process
3. 关节面 articular surface
4. 小角软骨 corniculate cartilage
5. 甲状软骨板 lamina of thyroid cartilage
6. 弓状嵴 arcuate crest
7. 下结节 inferior thyroid tubercle
8. 喉结 laryngeal prominence
9. 上结节 superior thyroid tubercle

图 237 喉软骨前、后面观
Anterior and posterior aspect of the cartilages of larynx

1. 会厌软骨 epiglottic cartilage
2. 舌骨大角 greater horn
3. 甲状舌骨膜 thyrohyoid membrane
4. 甲状软骨 thyroid cartilage
5. 杓状软骨 arytenoid cartilage
6. 肌突 muscular process
7. 环状软骨板 lamina of cricoid cartilage
8. 气管软骨 tracheal cartilages
9. 下角 inferior cornu
10. 声带突 vocal process
11. 小角软骨 corniculate cartilage
12. 上角 superior cornu
13. 舌骨体 body of hyoid bone
14. 甲状舌骨正中韧带 median thyrohyoid lig.
15. 上切迹 superior thyroid notch
16. 喉结 laryngeal prominence
17. 环状软骨 cricoid cartilage
18. 环韧带 annular ligaments
19. 环甲韧带 cricothyroid lig.

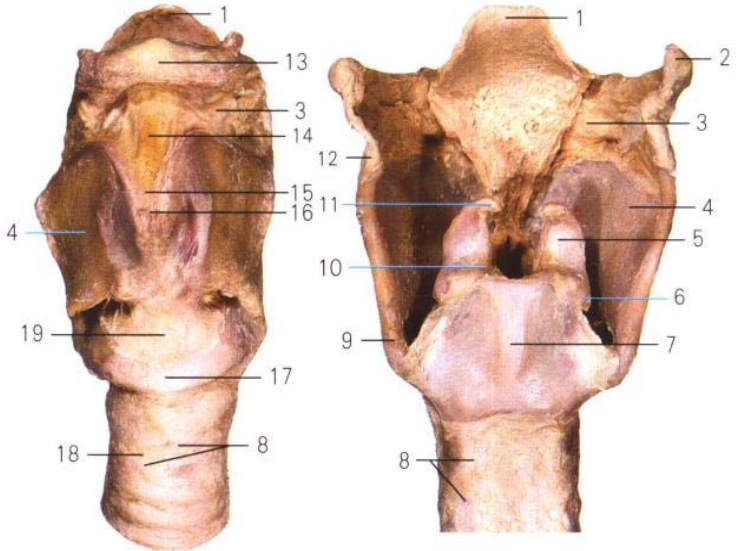


图 238 喉的软骨和韧带 (I)
Cartilages and ligaments of larynx (I)

1. 舌骨体 body of hyoid bone
2. 上切迹 superior thyroid notch
3. 喉结 laryngeal prominence
4. 甲杓肌 thyroarytenoid
5. 气管软骨 tracheal cartilage
6. 环甲关节面 thyroid articular surface of cricoid cartilage
7. 环状软骨 cricoid cartilage
8. 环杓后肌 posterior cricoarytenoid
9. 环杓侧肌 lateral cricoarytenoid
10. 甲会厌肌 thyroepiglottis

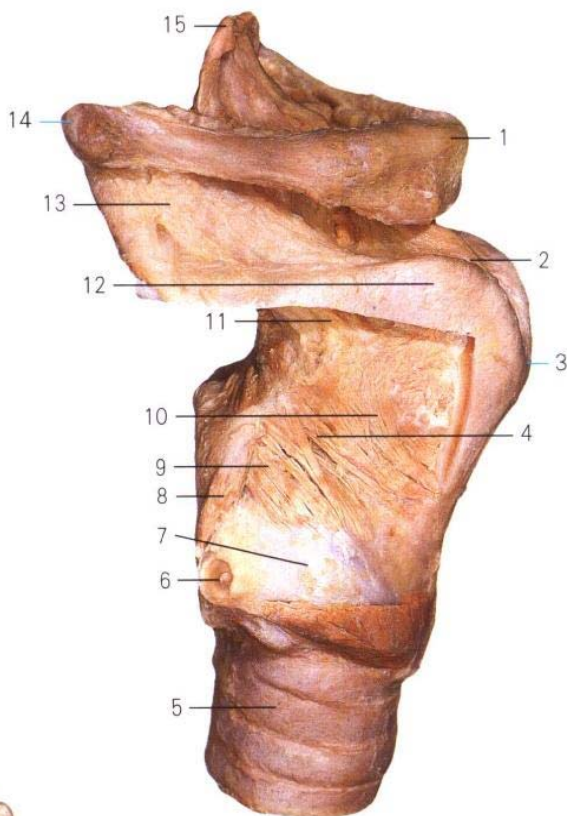


图 239 喉右侧面观
Right lateral aspect of larynx

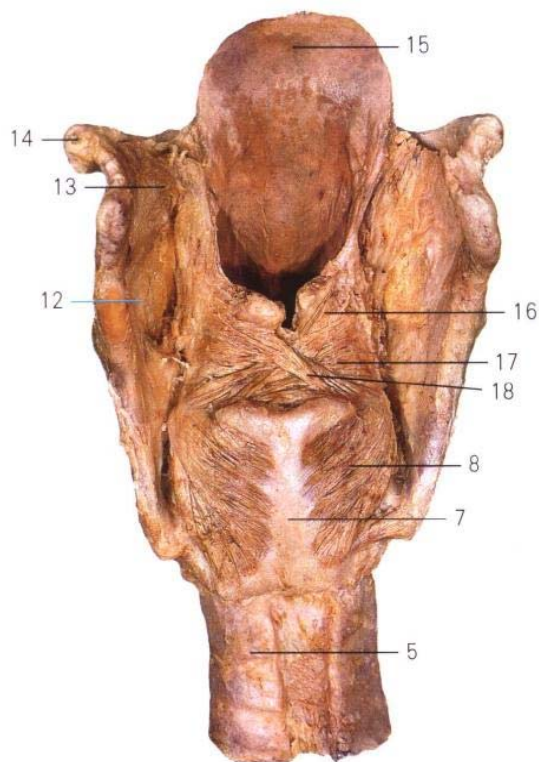
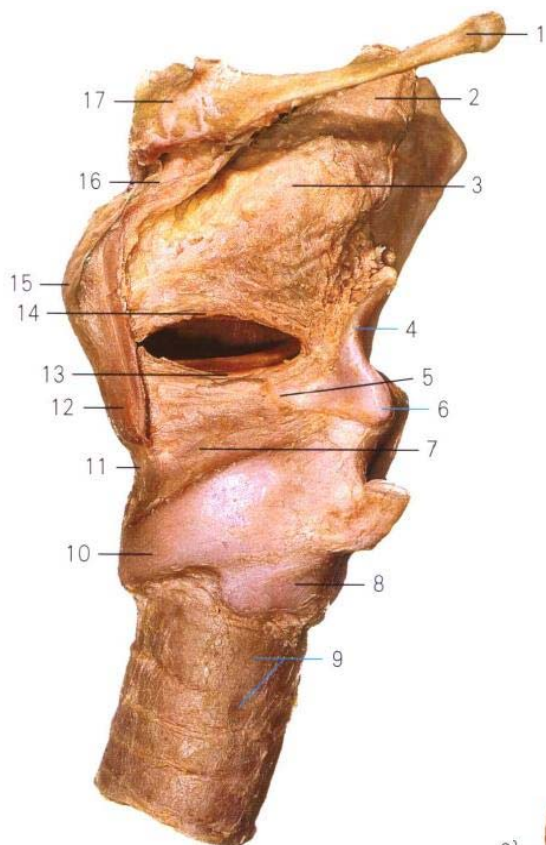


图 240 喉肌后面观
Posterior aspect of muscles of larynx

11. 方形膜 quadrangular membrane
12. 甲状软骨板 lamina of thyroid cartilage
13. 甲状舌骨膜 thyrohyoid membrane
14. 舌骨大角 greater horn
15. 会厌 epiglottis
16. 杓会厌肌 aryepiglottis
17. 杓横肌 transeverse arytenoid
18. 杓斜肌 oblique arytenoid



1. 舌骨大角 greater horn
2. 会厌 epiglottis
3. 方形膜 quadrangular membrane
4. 杓状软骨尖 apex of arytenoid cartilage
5. 声带突 vocal process
6. 肌突 muscular process
7. 弹性圆锥 conus elasticus
8. 环状软骨板 lamina of cricoid cartilage
9. 气管软骨 tracheal cartilage
10. 环状软骨弓 arch of cricoid cartilage
11. 环甲韧带 cricothyroid lig.
12. 甲状软骨 thyroid cartilage
13. 声韧带 vocal lig.

图 241 喉的软骨和韧带(II)
Cartilages and ligaments of larynx(II)

14. 前庭韧带 vestibular lig.
15. 喉结 laryngeal prominence
16. 甲舌膜 thyrohyoid membrane
17. 舌骨体 body of hyoid bone
18. 杓会厌襞 aryepiglottic fold
19. 梨状隐窝 piriform recess
20. 前庭襞 vestibular fold
21. 声襞 vocal fold
22. 声门下腔 infraglottic cavity
23. 喉前庭 laryngeal vestibule

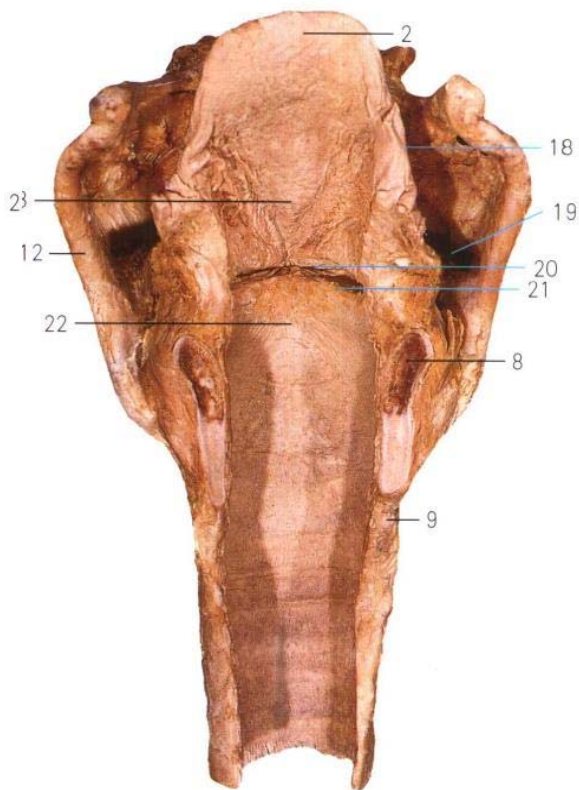


图 242 喉腔后面观
Posterior aspect of the cavity of larynx

第

章

8

头 部

CHAPTER 8 THE HEAD

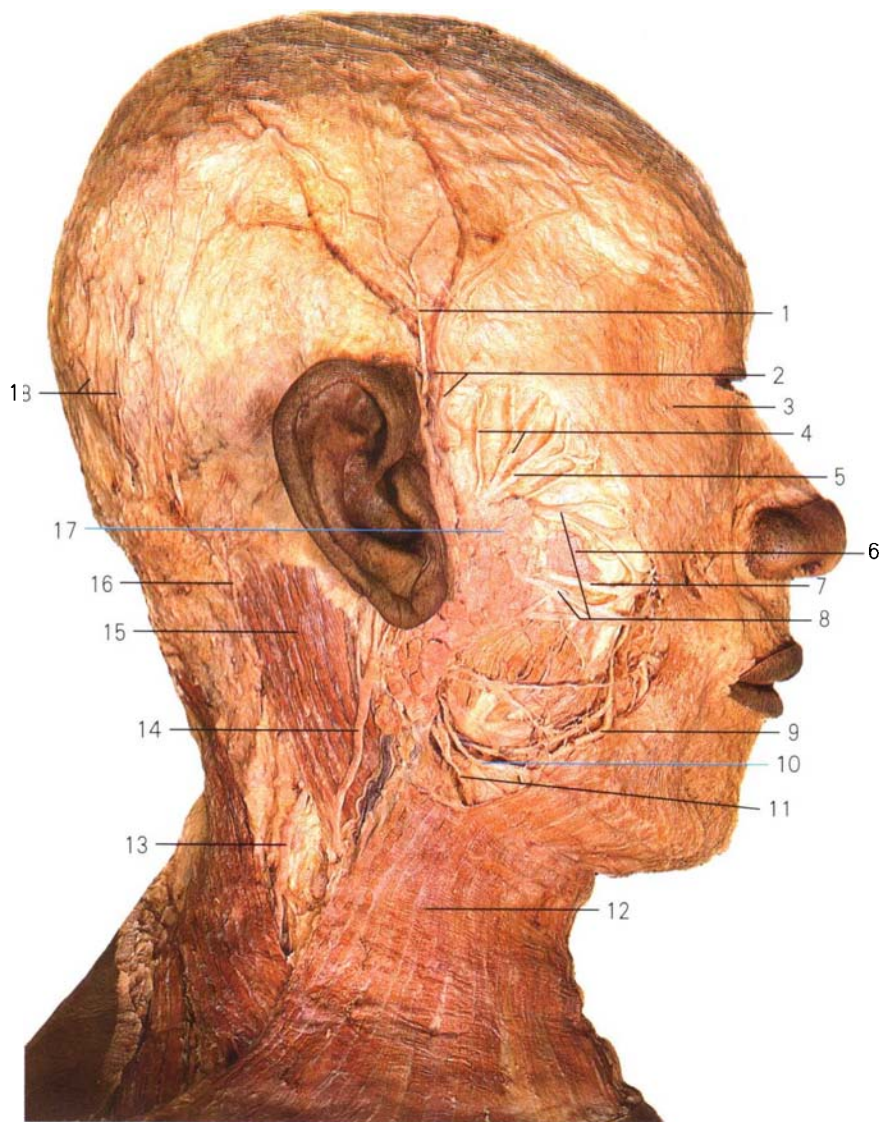


图 243 头颈的肌、血管和神经(I)
Muscles, blood vessels and nerves of the head and neck(I)

- | | |
|---|--|
| 1. 耳颞神经 auriculotemporal n. | 10. 下颌缘支 marginal mandibular branch |
| 2. 颞浅动脉和静脉 superficial temporal a. and v. | 11. 颈支 cervical branch |
| 3. 眼轮匝肌 orbicularis oculi | 12. 颈阔肌 platysma |
| 4. 颞支 temporal branches | 13. 副神经 accessory n.(XI) |
| 5. 颧支 zygomatic branches | 14. 耳大神经 great auricular n. |
| 6. 副腮腺 accessory parotid gland | 15. 胸锁乳突肌 sternocleidomastoid |
| 7. 腮腺导管 parotid duct | 16. 枕小神经 lesser occipital n. |
| 8. 颊支 buccal branches | 17. 腮腺 parotid gland |
| 9. 面动脉 facial a. | 18. 枕大神经和枕动脉 greater occipital n. and occipital a. |

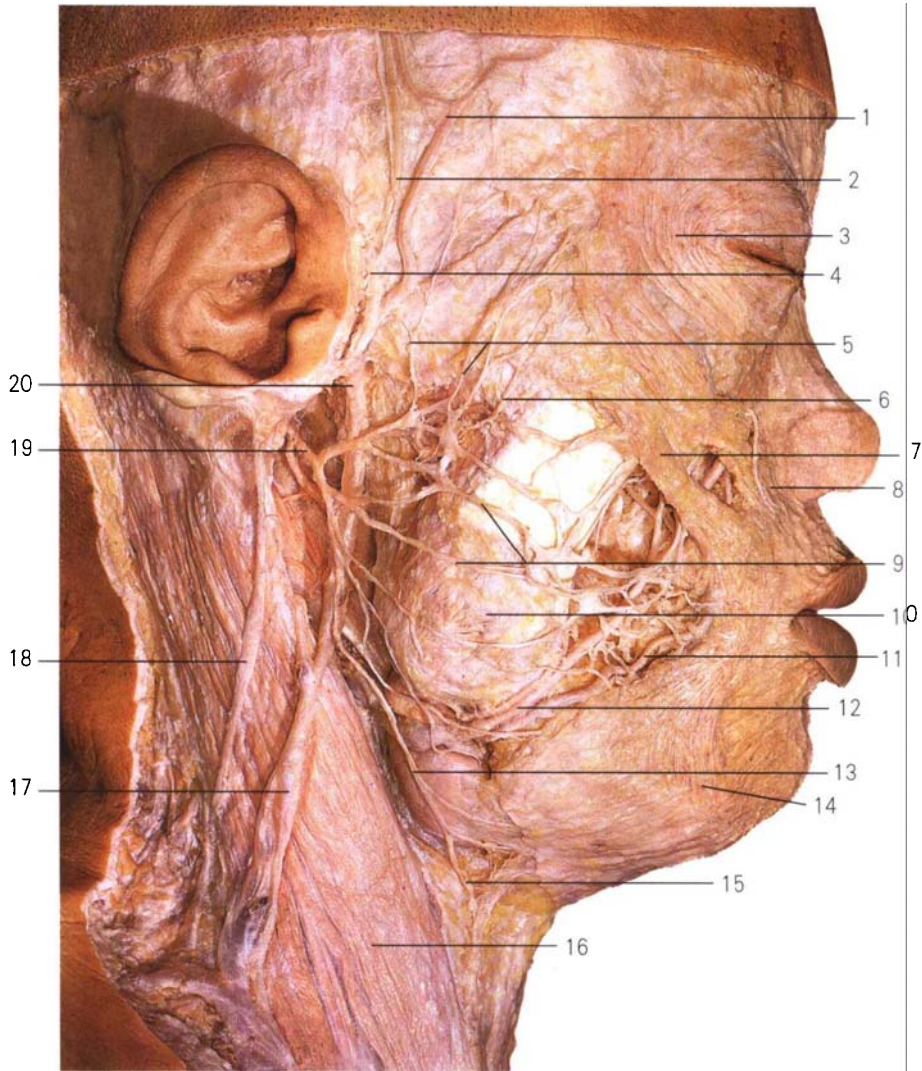


图 244 头颈的肌、血管和神经(Ⅱ)
Muscles, blood vessels and nerves of the head and neck(Ⅱ)

- | | |
|----------------------------------|-------------------------------------|
| 1. 颞浅动脉 superficial temporal a. | 11. 面动脉 facial a. |
| 2. 颞浅静脉 superficial temporal v. | 12. 面静脉 facial v. |
| 3. 眼轮匝肌 orbicularis oculi | 13. 下颌缘支 marginal mandibular branch |
| 4. 耳颞神经 auriculotemporal n. | 14. 降口角肌 depressor anguli oris |
| 5. 颞支 temporal branches | 15. 颈支 cervical branch |
| 6. 颧支 zygomatic branches | 16. 胸锁乳突肌 sternocleidomastoid |
| 7. 颧大肌 zygomaticus major | 17. 颈外静脉 external jugular v. |
| 8. 提上唇肌 levator labii superioris | 18. 耳大神经 great auricular n. |
| 9. 颊支 buccal branches | 19. 面神经 facial n. |
| 10. 咬肌 masseter | 20. 下颌后静脉 ratromandibular v. |

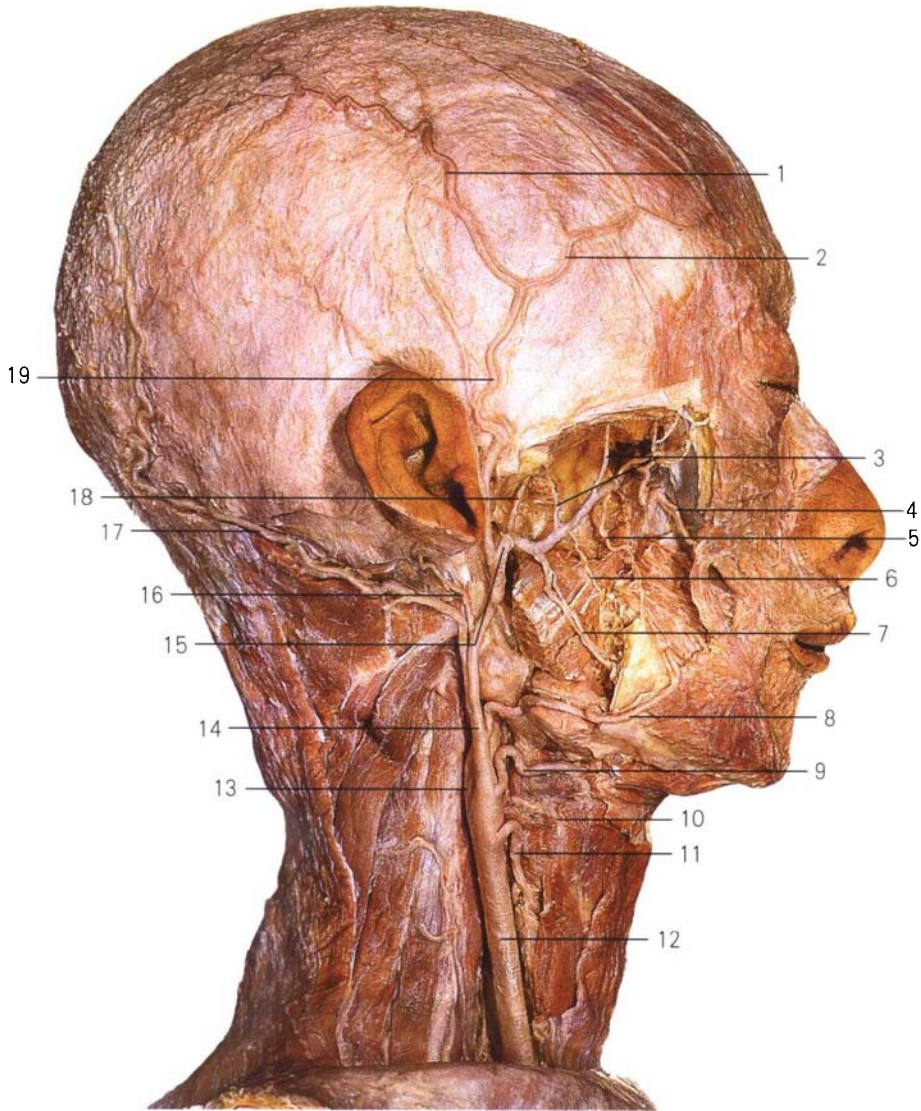


图 245 颈外动脉分支(右侧)
The branches of external carotid artery (right side)

- | | |
|--|----------------------------------|
| 1. 顶支 parietal branch | 10. 喉上动脉 superior laryngeal a. |
| 2. 额支 frontal branch | 11. 甲状腺上动脉 superior thyroid a. |
| 3. 颞深前、后动脉 anterior posterior deep temporal a. | 12. 颈总动脉 common carotid a. |
| 4. 上牙槽后动脉 posterior superior alveolar a. | 13. 颈内动脉 internal carotid a. |
| 5. 颊动脉 buccal a. | 14. 颈外动脉 external carotid a. |
| 6. 翼肌支 pterygoid branches | 15. 上颌动脉 maxillary a. |
| 7. 下牙槽动脉 inferior alveolar a. | 16. 耳后动脉 posterior auricular a. |
| 8. 面动脉 facial a. | 17. 枕动脉 occipital a. |
| 9. 舌动脉 lingual a. | 18. 脑膜中动脉 middle meningeal a. |
| | 19. 颞浅动脉 superficial temporal a. |

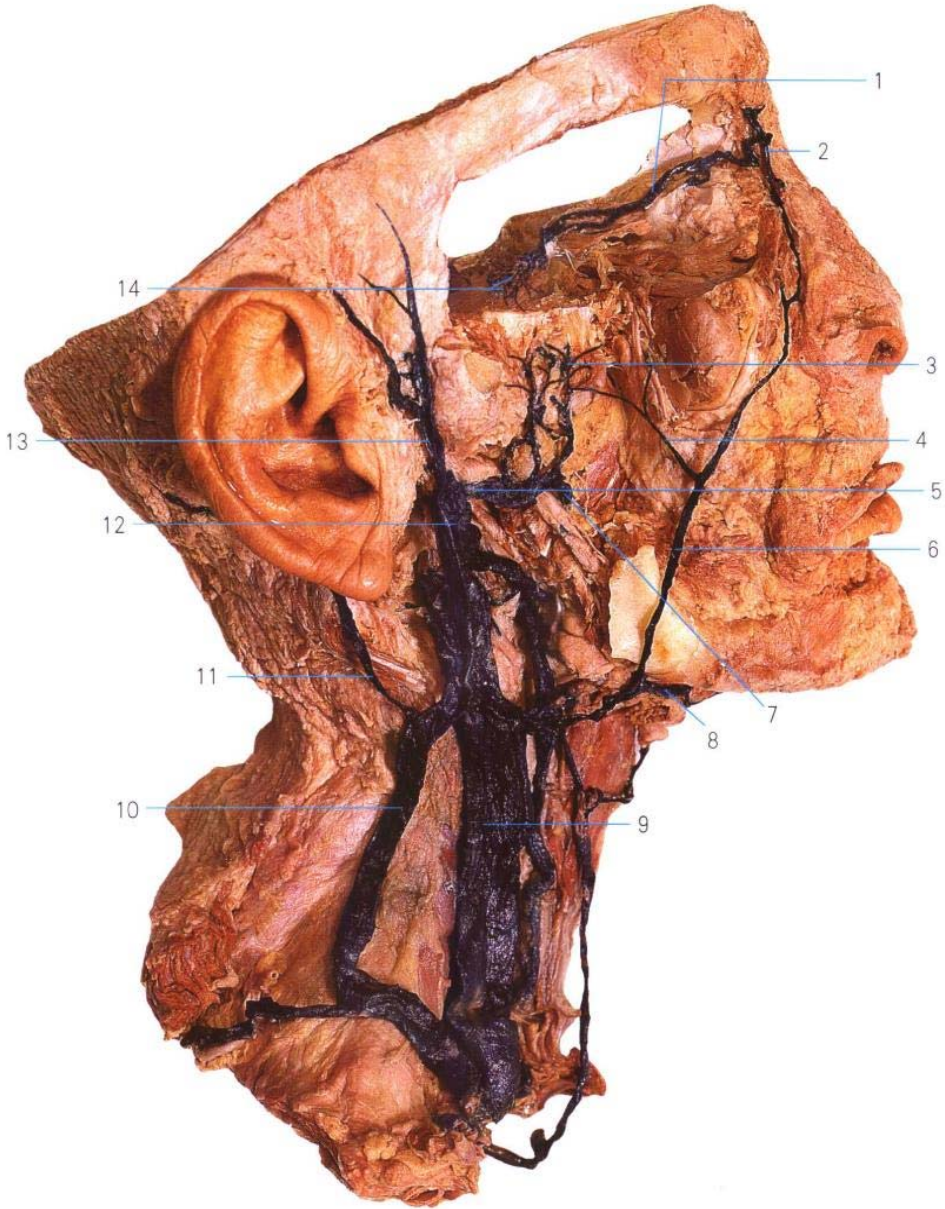

图 246 头颈部的静脉(右侧)
Veins of the head and neck(right side)

- | | | | |
|----------|-------------------------|-----------|-------------------------|
| 1. 眼上静脉 | superior ophthalmic v. | 8. 颌下静脉 | submental v. |
| 2. 内眦静脉 | angular v. | 9. 颈内静脉 | internal jugular v. |
| 3. 翼静脉丛 | pterygoid venous plexus | 10. 颈外静脉 | external jugular v. |
| 4. 面深静脉 | deep facial v. | 11. 耳后静脉 | posterior auricular v. |
| 5. 上颌静脉 | maxillary v. | 12. 下颌后静脉 | retromandibular v. |
| 6. 面静脉 | facial v. | 13. 颞浅静脉 | superficial temporal v. |
| 7. 下牙槽静脉 | inferior alveolar v. | 14. 海绵窦 | cavernous sinus |

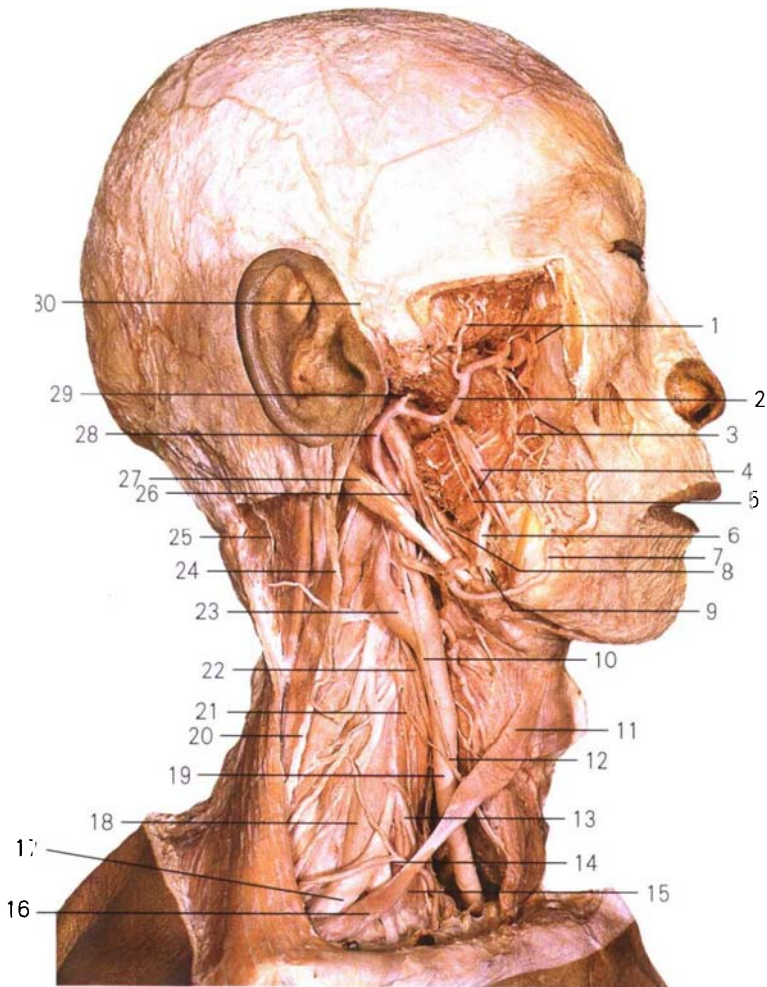
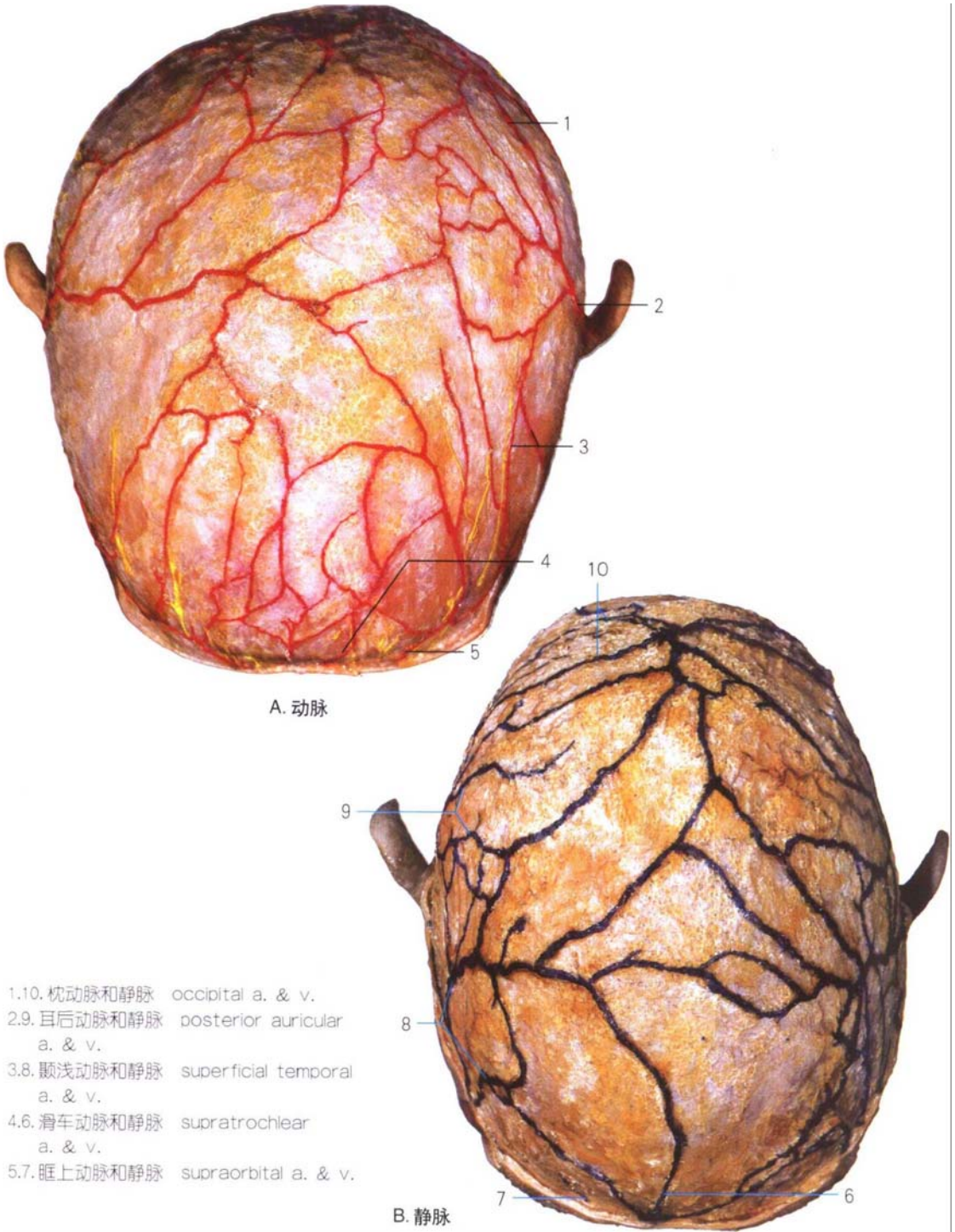


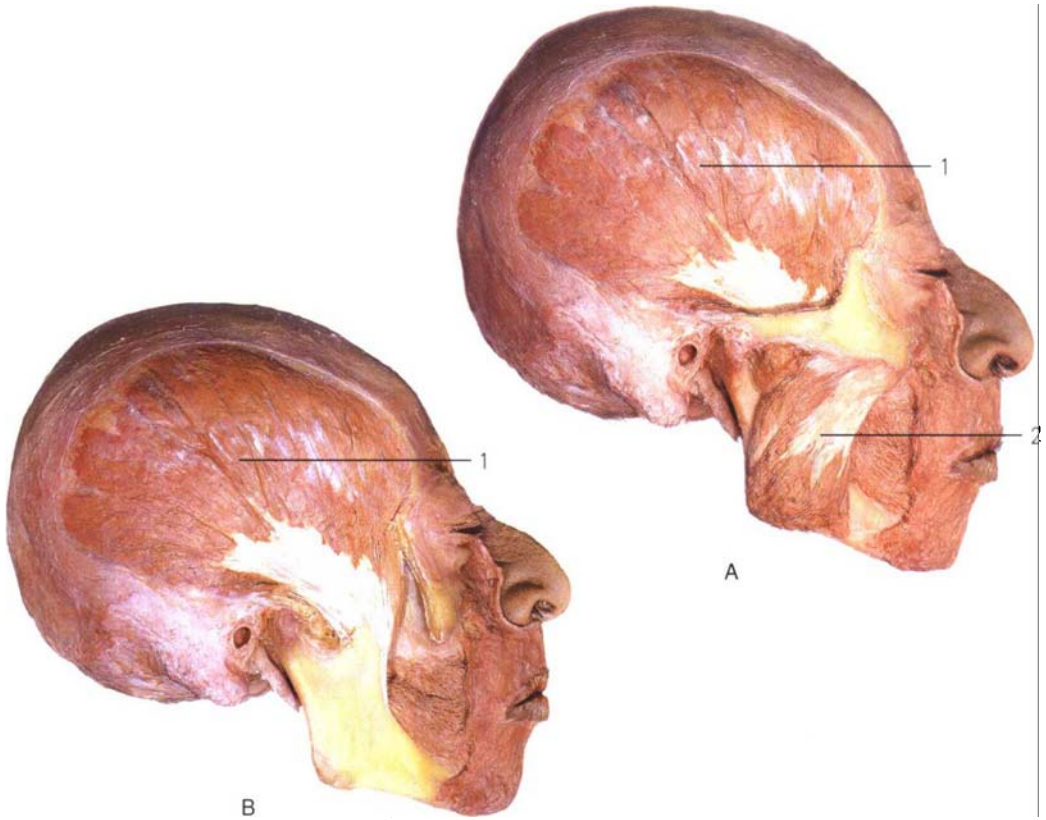
图 247 面颈肌、神经和血管(右侧)
Muscles, nerves and blood vessels of facial and neck(right side)

- | | |
|---|---|
| 1. 颞深前、后动脉 anterior, posterior deep temporal a. | 16. 肩胛舌骨肌下腹 inferior belly of omohyoid |
| 2. 上颌动脉 maxillary a. | 17. 臂丛 brachial plexus |
| 3. 颊动脉和神经 buccal a. and n. | 18. 中斜角肌 scalenus medius |
| 4. 下牙槽神经和动脉 inferior alveolar n. and a. | 19. 颈总动脉 common carotid a. |
| 5. 下颌舌骨肌神经 mylohyoid n. | 20. 副神经 accessory n(XI) |
| 6. 舌神经 lingual n. | 21. 颈攀下根 inferior root of ansa cervicalis |
| 7. 面动脉 facial a. | 22. 迷走神经 vagus n(X) |
| 8. 茎突舌肌 styloglossus | 23. 颈动脉窦 carotid sinus |
| 9. 下颌下神经节 submandibular ganglion | 24. 耳大神经 great auricular n. |
| 10. 颈攀上根 superior root of ansa cervicalis | 25. 枕小神经 lesser occipital n. |
| 11. 肩胛舌骨肌上腹 superior belly of omohyoid | 26. 茎突舌骨肌 stylohyoid |
| 12. 颈攀 ansa cervicalis | 27. 二腹肌后腹 posterior belly of digastric |
| 13. 膈神经 phrenic n. | 28. 颈外动脉 external carotid a. |
| 14. 颈横动脉 transverse cervical a. | 29. 脑膜中动脉 middle meningeal a. |
| 15. 前斜角肌 scalenus anterior | 30. 颞浅动脉 superficial temporal a. |



- 1.10. 枕动脉和静脉 occipital a. & v.
- 2.9. 耳后动脉和静脉 posterior auricular a. & v.
- 3.8. 颞浅动脉和静脉 superficial temporal a. & v.
- 4.6. 滑车动脉和静脉 supratrochlear a. & v.
- 5.7. 眶上动脉和静脉 supraorbital a. & v.

图 250 颅顶的血管(A、B)
 Roof blood vessels of the skull(A,B)



- 1. 颞肌, temporalis
- 2. 咬肌, masseter
- 3. 翼内肌, medial pterygoid
- 4. 翼外肌, lateral pterygoid

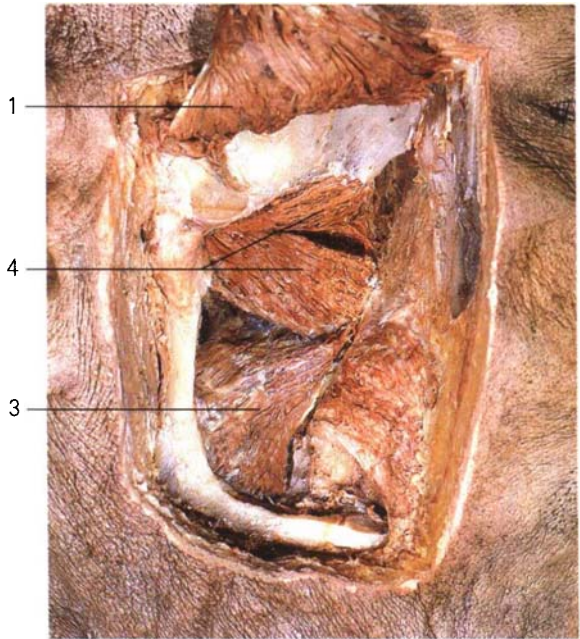


图 251 右侧咀嚼肌 (A、B、C)
Masseter of right side(A,B,C)

C

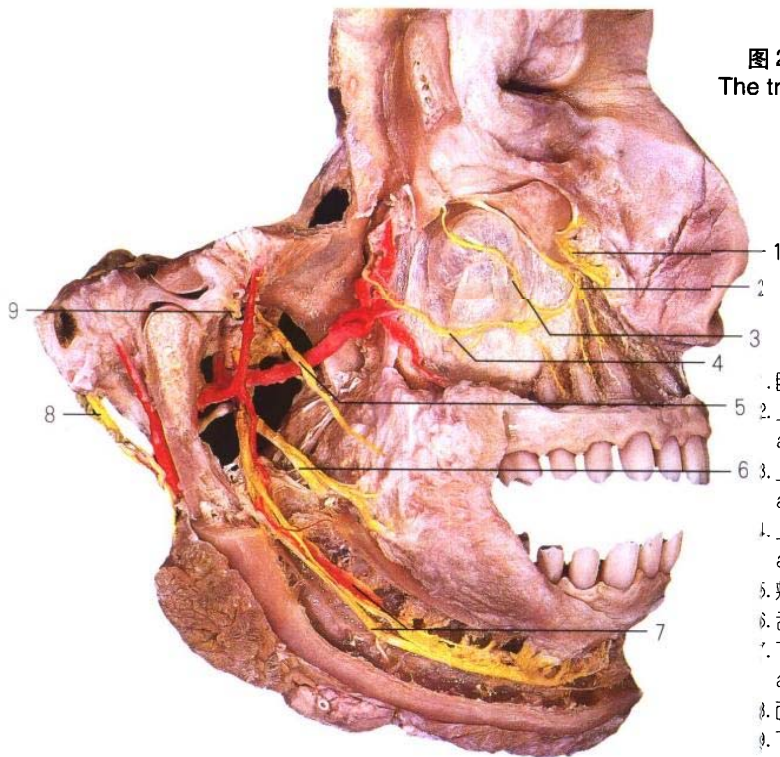


图 252 三叉神经(右侧面观)
The trigeminal nerve(right aspect)

1. 眶下神经 infraorbital n.
2. 上牙槽前支 anterior superior alveolar branch
3. 上牙槽中支 middle superior alveolar branch
4. 上牙槽后支 posterior superior alveolar branch
5. 颊神经 buccal n.
6. 舌神经 lingual n.
7. 下牙槽神经和动脉 inferior alveolar n. and a.
8. 面神经 facial n.
9. 下颌神经 mandibular n.

1. 泪腺 lacrimal gland
2. 上颌神经 maxillary n.
3. 翼腭神经节 pterygopalatine ganglion
4. 鼻腭粘膜腺 glands of nasal and palatal
5. 耳神经节 otic ganglion
6. 腮腺 parotid gland
7. 下颌神经 mandibular n.
8. 舌神经 lingual n.
9. 舌 tongue
10. 下颌下神经节 submandibular ganglion
11. 舌下腺 sublingual gland
12. 下颌下腺 submandibular gland.
13. 耳颞神经 auriculotemporal n.
14. 舌咽神经 glossopharyngeal n.(IX)
15. 面神经 facial n.(VII)
16. 鼓索 chorda tympani
17. 鼓室丛 tympanic plexus
18. 膝神经节 geniculate ganglion
19. 孤束核 nucleus of solitary tract
20. 孤束 solitary tract
21. 面神经核 nucleus of facial n.
22. 展神经核 nucleus of abducent n.
23. 岩大神经 greater petrosal n.
24. 岩小神经 lesser petrosal n.

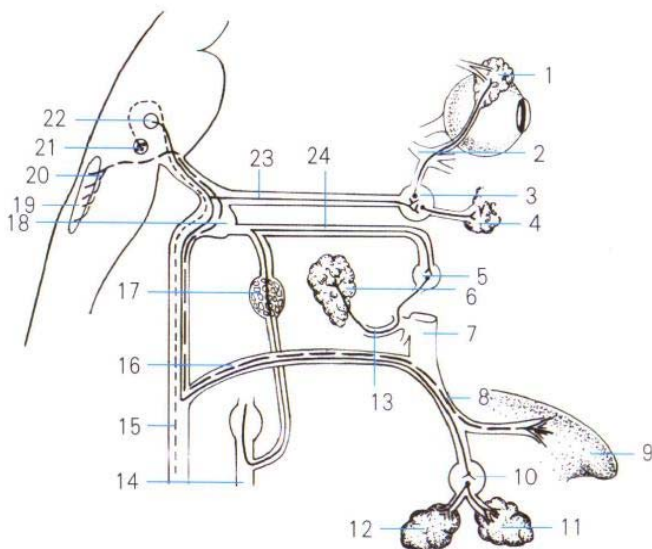
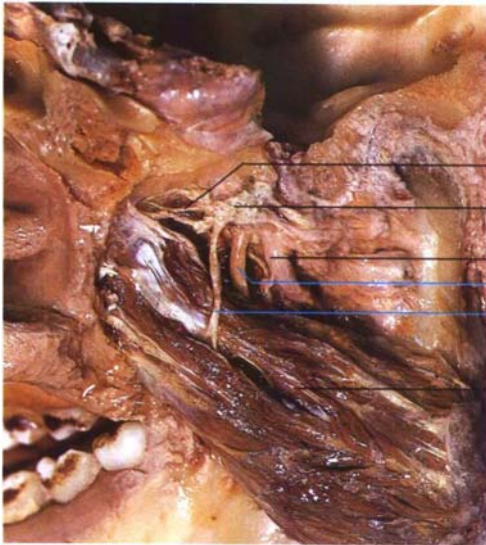
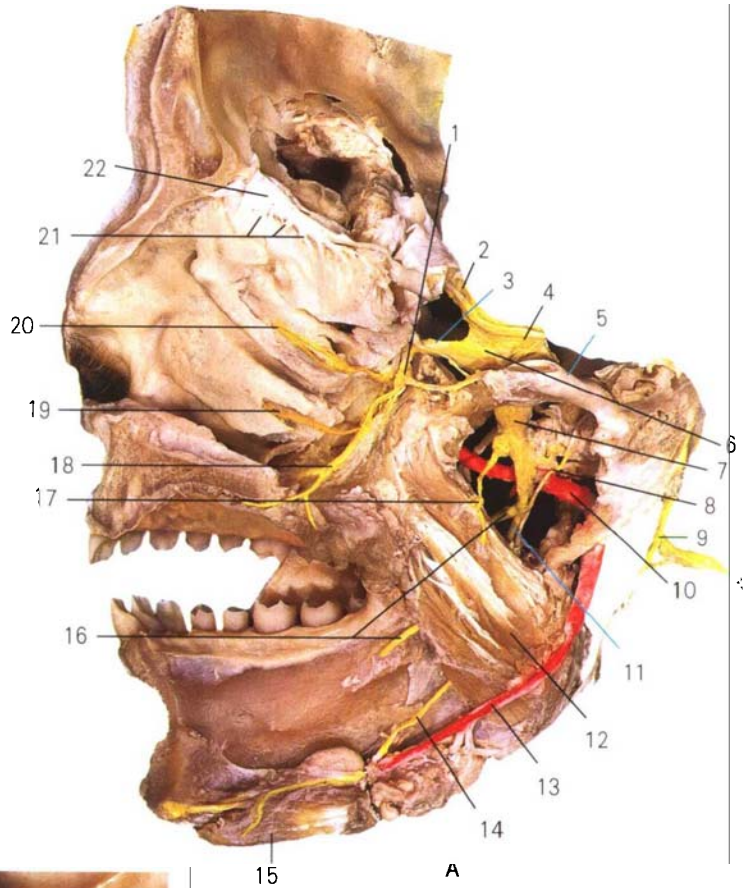


图 253 面神经和舌咽神经的副交感纤维分布模式图
Diagram of the distribution of the parasympathetic fibers in facial and glossopharyngeal nerve

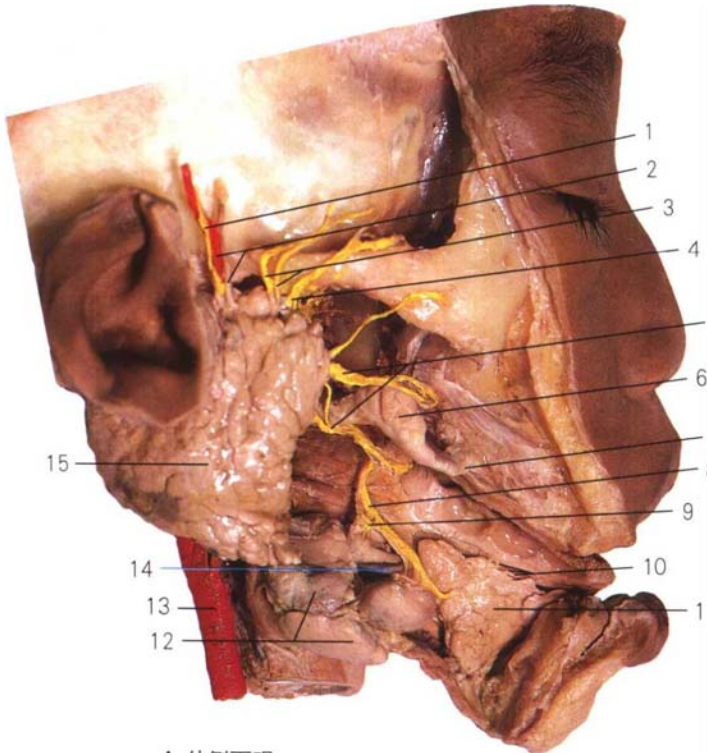
- 1.翼腭神经节 pterygopalatine ganglion
- 2.眼神经 ophthalmic n.
- 3.上颌神经 maxillary n.
- 4.三叉神经 trigeminal n.(V)
- 5.颈内动脉 common carotid a.
- 6.三叉神经节 trigeminal ganglion
- 7.下颌神经 mandibular n.
- 8.鼓索 chorda tympani
- 9.面神经 facial n.
- 10.上颌动脉 maxillary a.
- 11.下牙槽神经 inferior alveolar n.



- 12.翼内肌 medial pterigoid
- 13.下颌舌骨肌 mylohyoid
- 14.下颌舌骨肌神经 mylohyoid n.
- 15.二腹肌前腹 anterior belly of digastric
- 16.舌神经 lingual n.
- 17.翼内肌神经 medial pterigoid n.
- 18.腭大神经 greater palatine n.
- 19.鼻后下支 posterior inferior nasal branches
- 20.鼻后上外侧支 lateral posterior superior nasal branches
- 21.嗅神经 olfactory n(I)
- 22.嗅球 olfactory bulb
- 23.岩大神经 greater petrosal n.
- 24.耳神经节 otic ganglion

B

图 254 三叉神经(内侧面观)(A、B)
The trigeminal nerve(medial aspect)(A,B)

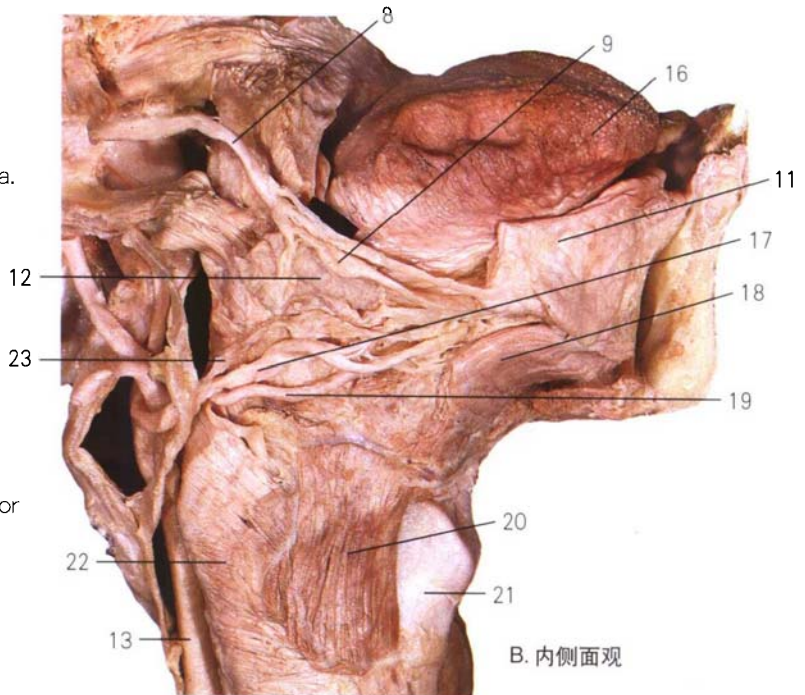


A. 外侧面观

图 255 大唾液腺 (A、B)
The large salivary glands (A, B)

1. 耳颞神经 auriculotemporal n.
2. 颞浅动脉和静脉 superficial temporal a. & v.
3. 颞支 temporal branches
4. 颧支 zygomatic branches
5. 颊支 buccal branches
6. 副腮腺 accessory parotid gland
7. 腮腺管 parotid duct
8. 舌神经 lingual n.
9. 下颌下神经节 submandibular ganglion
10. 舌下腺管 sublingual duct
11. 舌下腺 sublingual gland
12. 下颌下腺 submandibular gland

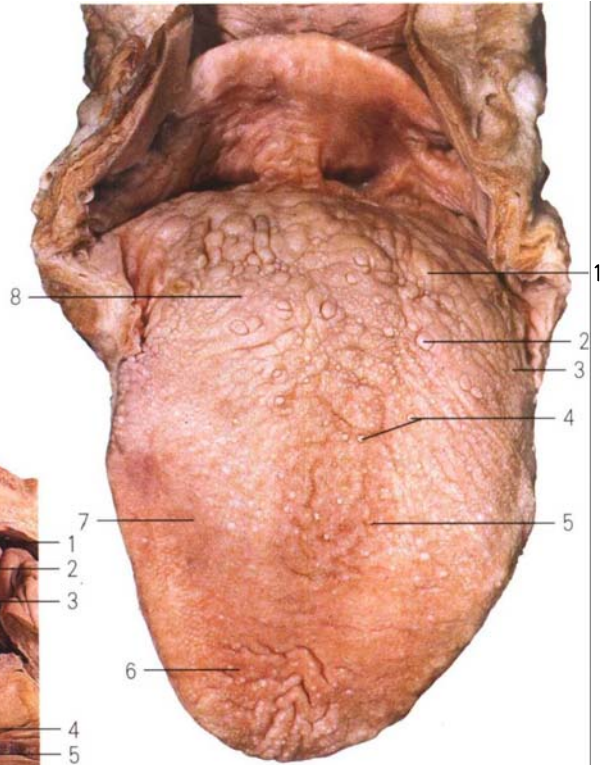
13. 颈总动脉 common carotid a.
14. 下颌下腺管 submandibular duct
15. 腮腺 parotid gland
16. 舌 tongue
17. 舌下神经 hypoglossal n.(XII)
18. 颏舌骨肌 genioboid
19. 舌动脉 lingual a.
20. 甲状舌骨肌 thyrohyoid
21. 甲状软骨 thyroid cartilage
22. 咽下缩肌 inferior constrictor of pharynx
23. 舌静脉 lingual v.



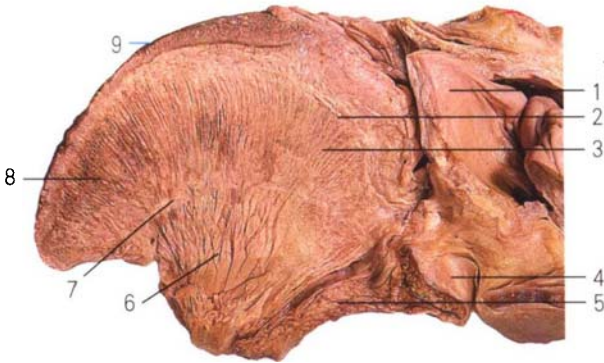
B. 内侧面观

A. 舌背面 The dorsum of the tongue

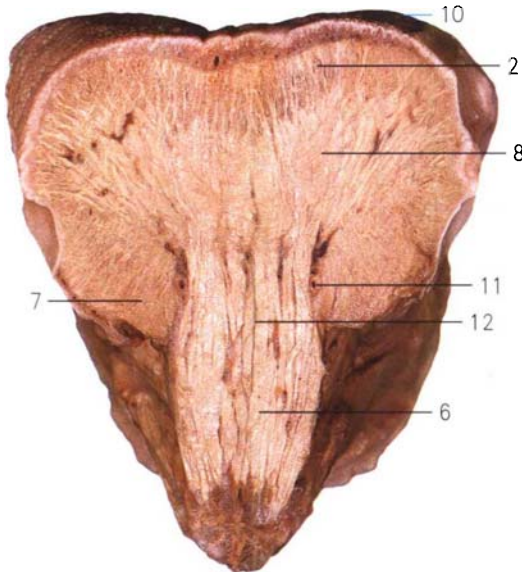
1. 舌扁桃体 lingual tonsil
2. 轮廓乳头 vallate papillae
3. 叶状乳头 filiate papillae
4. 菌状乳头 fungiform papillae
5. 丝状乳头 filiform papillae
6. 舌尖 apex of tongue
7. 舌体 body of tongue
8. 舌根 root of tongue



A. 舌背面



B. 舌矢状切面



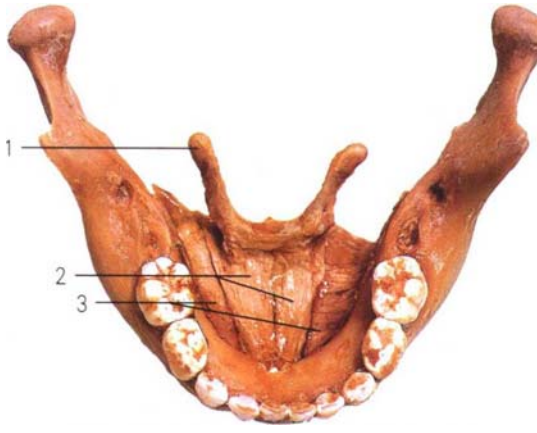
C. 舌冠状切面

B. 舌矢状切面 Sagittal section through tongue

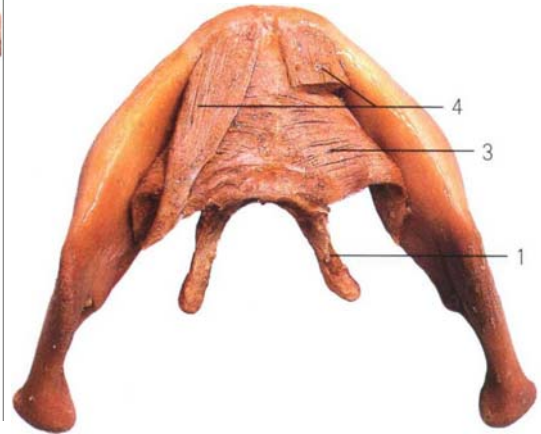
C. 舌冠状切面 Coronal section through tongue

1. 会厌 epiglottis
2. 上纵肌 superior longitudinal muscle
3. 舌垂直肌 vertical muscle of tongue
4. 舌骨 hyoid bone
5. 颈舌骨肌, geniohyoid
6. 颈舌肌 genioglossus
7. 下纵肌 inferior longitudinal muscle
8. 舌横肌 transverse muscle of tongue
9. 舌背 dorsum of tongue
10. 舌粘膜 lingual mucous membrane
11. 舌动脉 lingual artery
12. 舌中隔 septum of tongue

图 256 舌 (A、B、C)
Tongue (A, B, C)



A. 上面观



B. 下面观

图 257 口腔底肌 (A、B)
Base muscles of the oral cavity(A,B)

- 1. 舌骨 hyoid bone
- 2. 颏舌骨肌 genioid

- 3. 下颌舌骨肌 mylohyoid
- 4. 二腹肌前腹 anterior belly of digstric

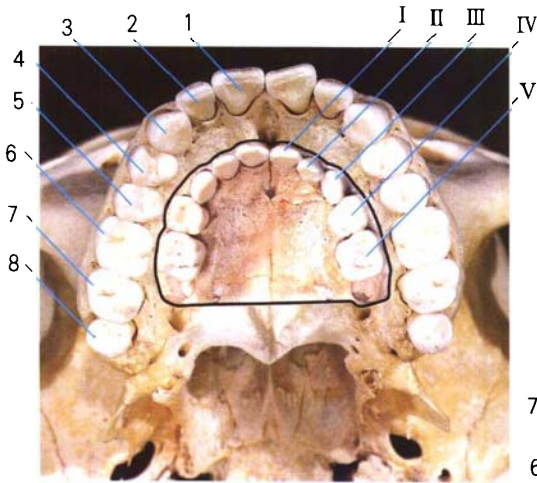


图 258 上颌恒、乳牙(下面观)
Upper permanent and deciduous teeth
(inferior aspect)

- 1. 中切牙 central incisor
- 2. 侧切牙 lateral inisor
- 3. 尖牙 canine
- 4. 第一前磨牙 premolars I
- 5. 第二前磨牙 premolars II
- 6. 第一磨牙 molars I
- 7. 第二磨牙 molars II

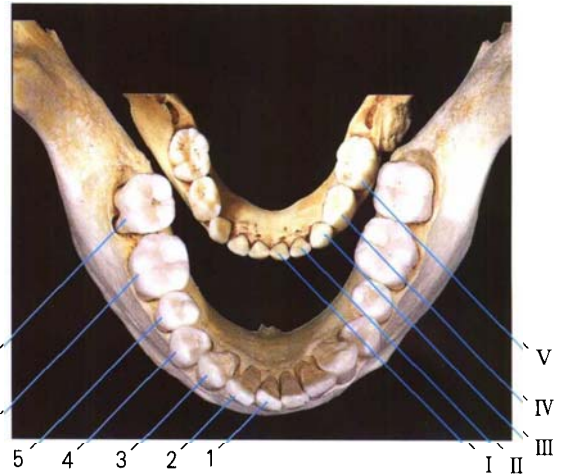

图 259 下颌恒、乳牙(上面观)
Lower permanent and deciduous teeth
(superior aspect)

- 8. 第三磨牙 molars III
- I. 乳中切牙 deciduous central incisor
- II. 乳侧切牙 deciduous lateral inisor
- III. 乳尖牙 deciduous canine
- IV. 第一乳磨牙 deciduous molars I
- V. 第二乳磨牙 deciduous molars II

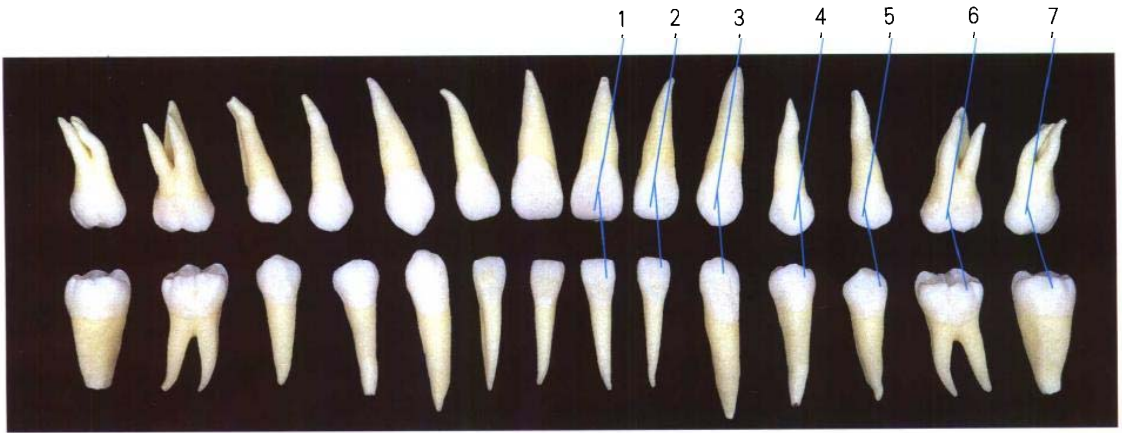

图 260 恒牙 Permanent teeth

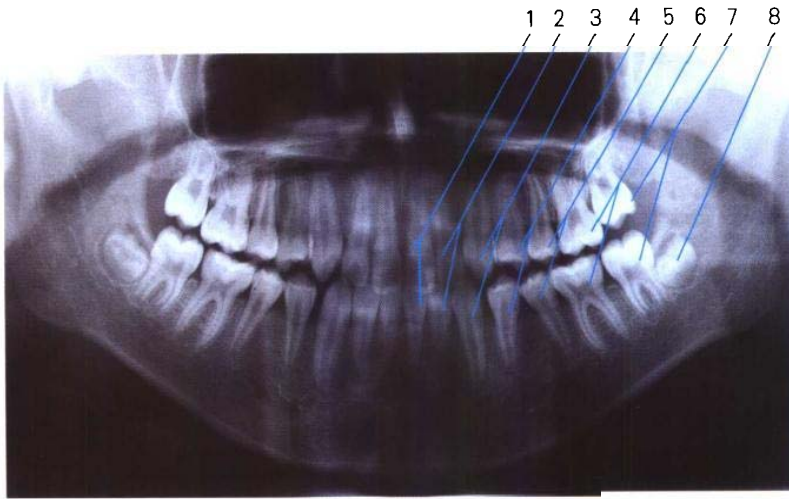


图 261 曲面断层 X 线片
Panoramic

1. 中切牙 medial incisor
2. 侧切牙 lateral incisor
3. 尖牙 canine teeth
4. 第一前磨牙 premolars I
5. 第二前磨牙 premolars II
6. 第一磨牙 molars I
7. 第二磨牙 molars II
8. 第三磨牙 molars III
9. 釉质 enamel
10. 牙本质 dentine
11. 牙髓 dental pulp
12. 牙骨质 cement
13. 牙根管 root canal
14. 牙周膜 periodontal membrane
15. 牙根尖孔 apical fora
16. 牙槽骨 alveolar bone
17. 牙龈 gum
18. 牙腔 dental cavity

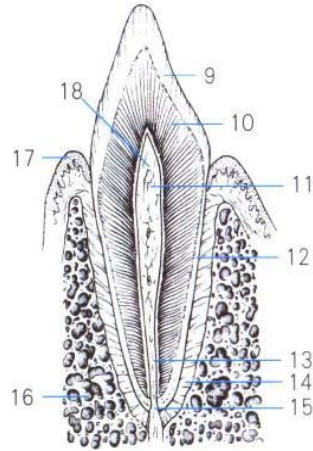
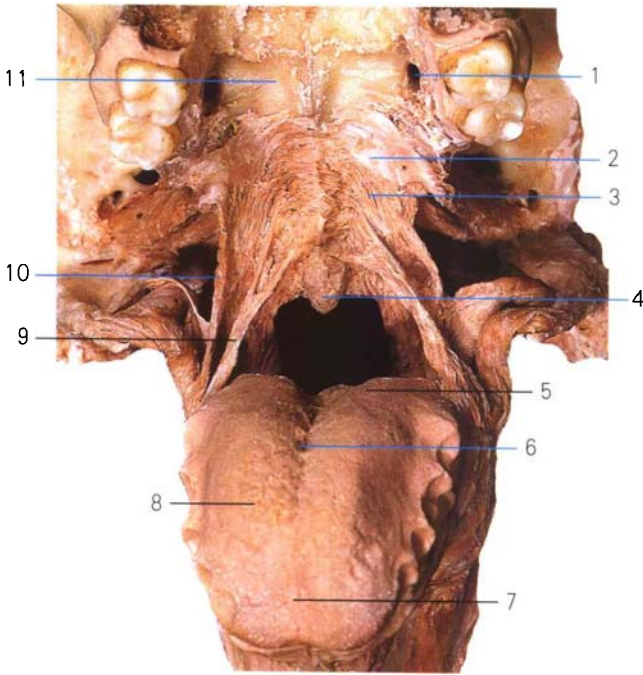
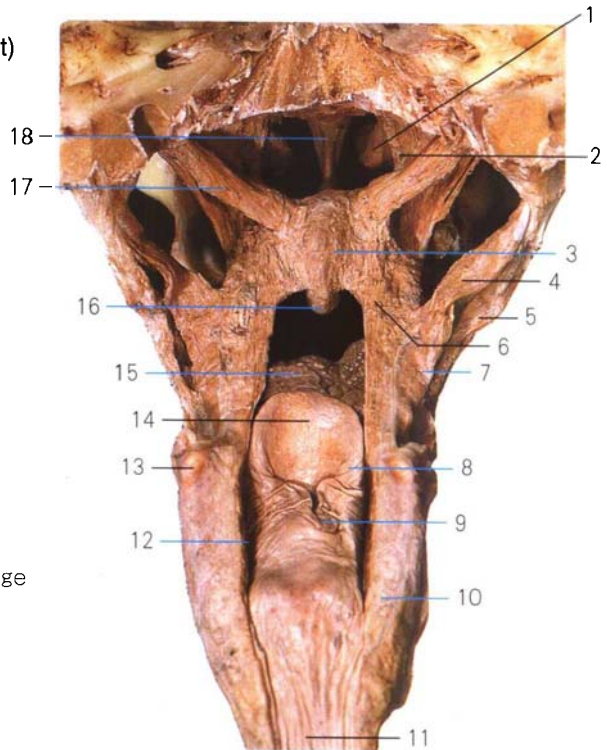


图 262 牙的构造模式图(纵切)
Diagram of the structure of a
tooth(sagittal section)



1. 腭大孔 greater palatine foramen
2. 腭帆张肌 tensor veli palatini
3. 软腭 soft palate
4. 腭垂 uvula
5. 舌根 root of tongue
6. 舌正中沟 median sulcus of tongue
7. 舌尖 apex of tongue
8. 舌体 body of tongue
9. 腭舌弓 palatoglossal arch
10. 腭咽弓 palatopharyngeal arch
11. 腭骨水平板 horizontal palate of palatine bone

图 263 咽腔(前面观)
The pharyngeal cavity(anterior aspect)



1. 下鼻甲 inferior nasal concha
2. 腭帆张肌 tensor veli palatini
3. 软腭 soft palate
4. 茎突咽肌 stylopharyngeus
5. 茎突舌骨肌 stylohyoid
6. 腭咽肌 palatopharyngeus
7. 咽上缩肌 superior constrictor of pharynx
8. 杓状会厌襞 aryepiglottic fold
9. 杓间切迹 interarytenoid notch
10. 咽下缩肌 inferior constrictor of pharynx
11. 食管 esophagus
12. 梨状隐窝 piriform recess
13. 甲状软骨上角 superior horn of thyroid cartilage
14. 会厌 epiglottis
15. 舌 tongue
16. 腭垂肌 musculus uvulae
17. 腭帆提肌 levator veli palatini
18. 鼻中隔 nasal septum

图 264 咽腔(后面观)
The pharyngeal cavity(posterior aspect)

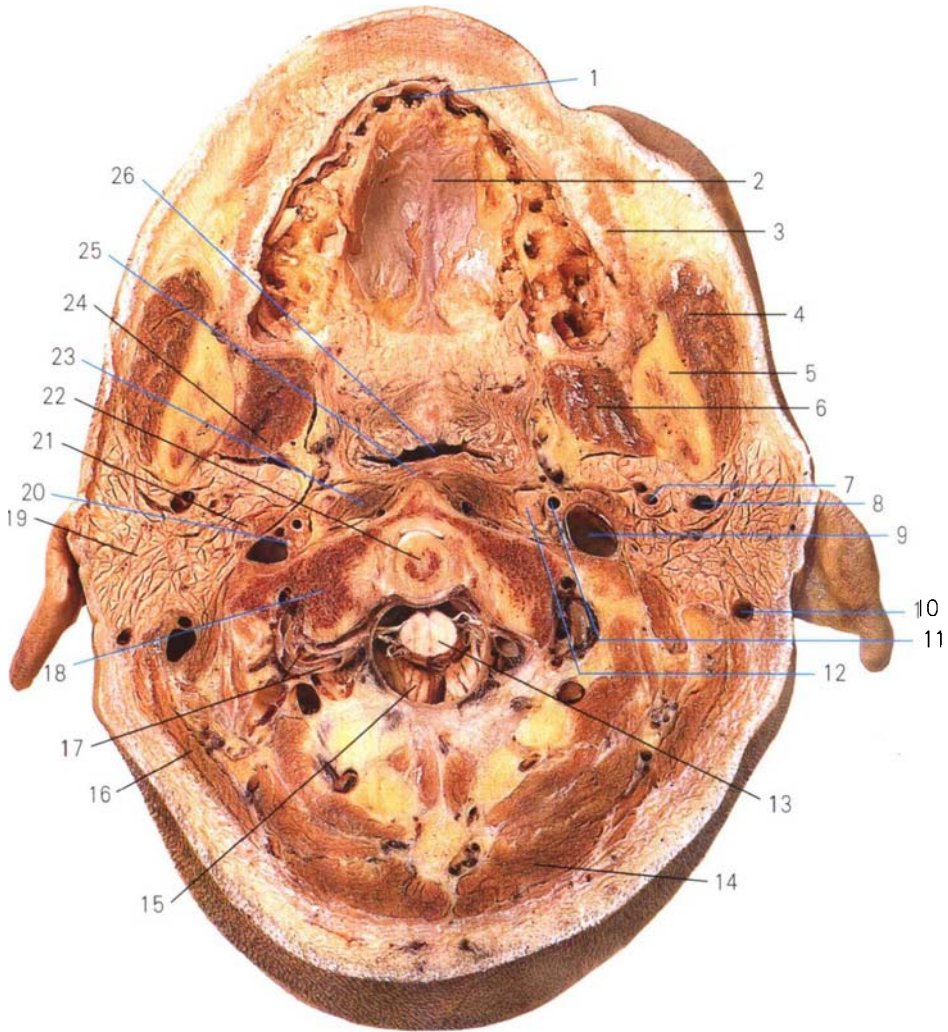


图 265 经口腔水平断面
Horizontal section through oral cavity

- | | |
|--------------------------------------|--|
| 1. 上颌牙槽 superior alveoli | 14. 斜方肌 trapezius |
| 2. 硬腭 hard palate | 15. 小脑 cerebellum |
| 3. 颊肌 buccinator | 16. 胸锁乳突肌 sternocleidomastoid |
| 4. 咬肌 masseter | 17. 椎动脉和静脉 vertebral a. & v. |
| 5. 下颌支 ramus of mandible | 18. 寰椎 Atlas |
| 6. 翼内肌 medial pterygoid | 19. 腮腺 parotid gland |
| 7. 颈外动脉 external carotid a. | 20. 迷走神经 vagus n. |
| 8. 下颌后静脉 retromandibular v. | 21. 茎突 styloid process |
| 9. 颈内静脉 internal jugular V. | 22. 齿突 dens |
| 10. 耳后静脉 posterior auricular v. | 23. 头长肌 longus capitis |
| 11. 颈内动脉 internal carotid a. | 24. 翼外肌 lateral pterygoid |
| 12. 颈上神经节 superior cervical ganglion | 25. 咽上缩肌 superior constrictor of pharynx |
| 13. 脊髓 spinal cord | 26. 咽 pharynx |

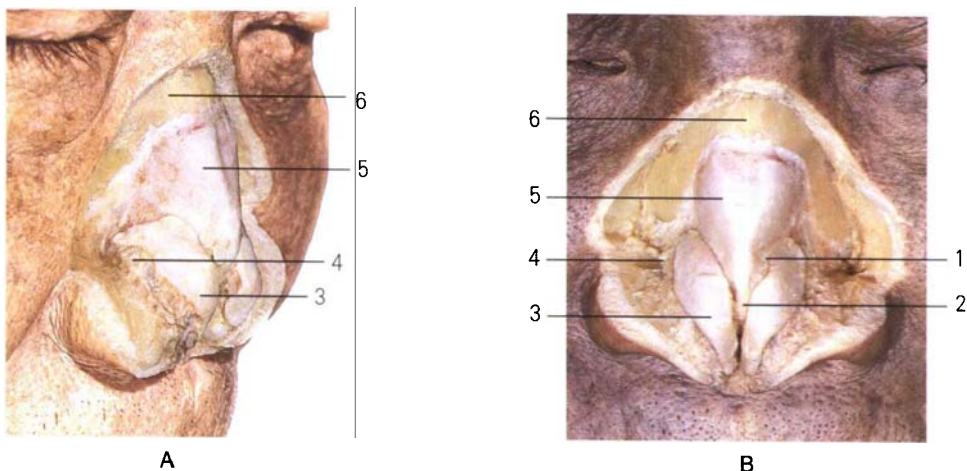


图 266 鼻软骨 (A, B)
Nasal cartilage(A,B)

- | | | | |
|----------|----------------------------|----------|--------------------------|
| 1. 鼻副软骨 | accessory nasal cartilages | 4. 鼻翼小软骨 | minor alar cartilages |
| 2. 鼻中隔软骨 | septal cartilage of nose | 5. 鼻外侧软骨 | lateral nasal cartilages |
| 3. 鼻翼大软骨 | major alar cartilage | 6. 鼻骨 | nasal bone |

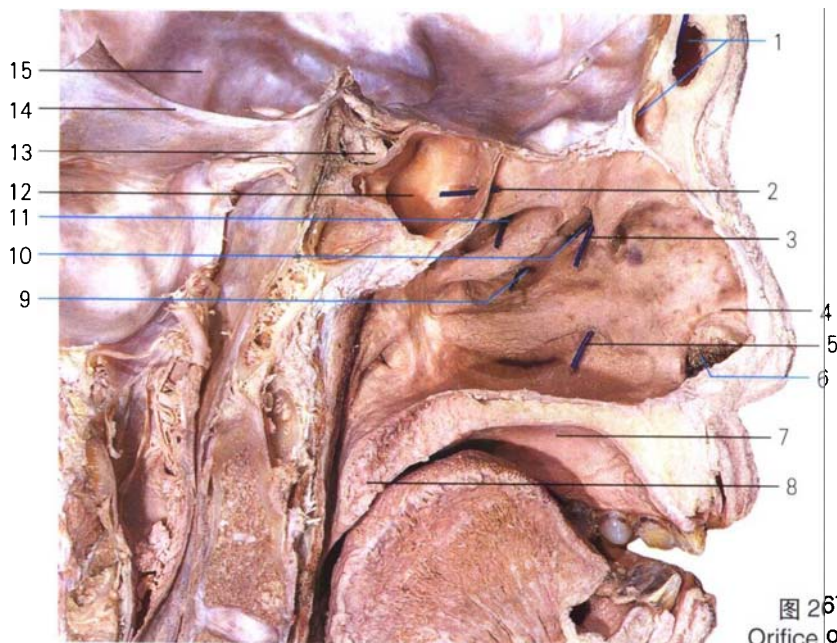

图 267 鼻旁窦的开口
Orifice of paranasal sinuses

- | | | | |
|----------|------------------------------|------------|--|
| 1. 额窦 | frontal sinus | 8. 软腭 | soft palate |
| 2. 蝶窦开口 | orifice of sphenoidal sinus | 9. 上颌窦开口 | orifice of maxillary sinus |
| 3. 额窦开口 | orifice of frontal sinus | 10. 筛窦前群开口 | orifice of anterior ethmoidal sinuses |
| 4. 鼻咽 | limen nasi | 11. 筛窦后群开口 | orifice of posterior ethmoidal sinuses |
| 5. 鼻泪管开口 | orifice of nasolacrimal duct | 12. 蝶窦 | sphenoidal sinus |
| 6. 鼻前庭 | nasal vestibule | 13. 垂体 | hypophysis |
| 7. 硬腭 | hard palate | 14. 小脑幕 | tentorium of cerebellum |
| | | 15. 硬脑膜 | cerebral dura mater |

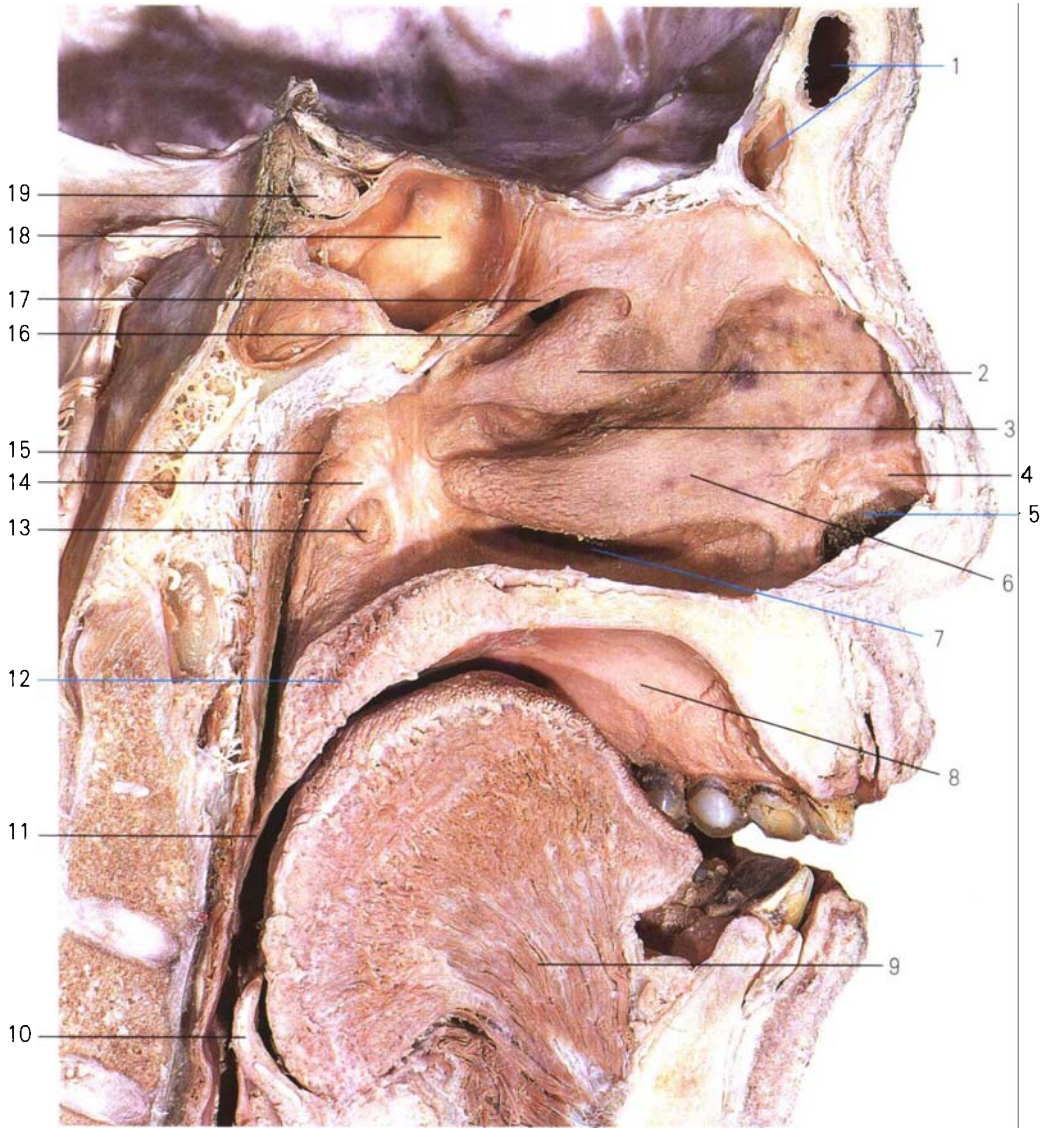


图 268 鼻腔外侧壁
Lateral wall of nasal cavity

- | | |
|------------------------------|---|
| 1. 额窦 frontal sinus | 11. 腭咽弓 palatopharyngeal arch |
| 2. 中鼻甲 middle nasal concha | 12. 软腭 soft palate |
| 3. 中鼻道 middle nasal meatus | 13. 咽鼓管咽口 pharyngeal opening of auditory tube |
| 4. 鼻咽 limen nasi | 14. 咽鼓管圆枕 tubal torus |
| 5. 鼻前庭 nasal vestibule | 15. 咽隐窝 pharyngeal recess |
| 6. 下鼻甲 inferior nasal concha | 16. 上鼻道 superior nasal meatus |
| 7. 下鼻道 inferior nasal meatus | 17. 上鼻甲 superior nasal concha |
| 8. 硬腭 hard palate | 18. 蝶窦 sphenoidal sinus |
| 9. 颊舌肌 genioglossus | 19. 垂体 hypophysis |
| 10. 会厌 epiglottis | |

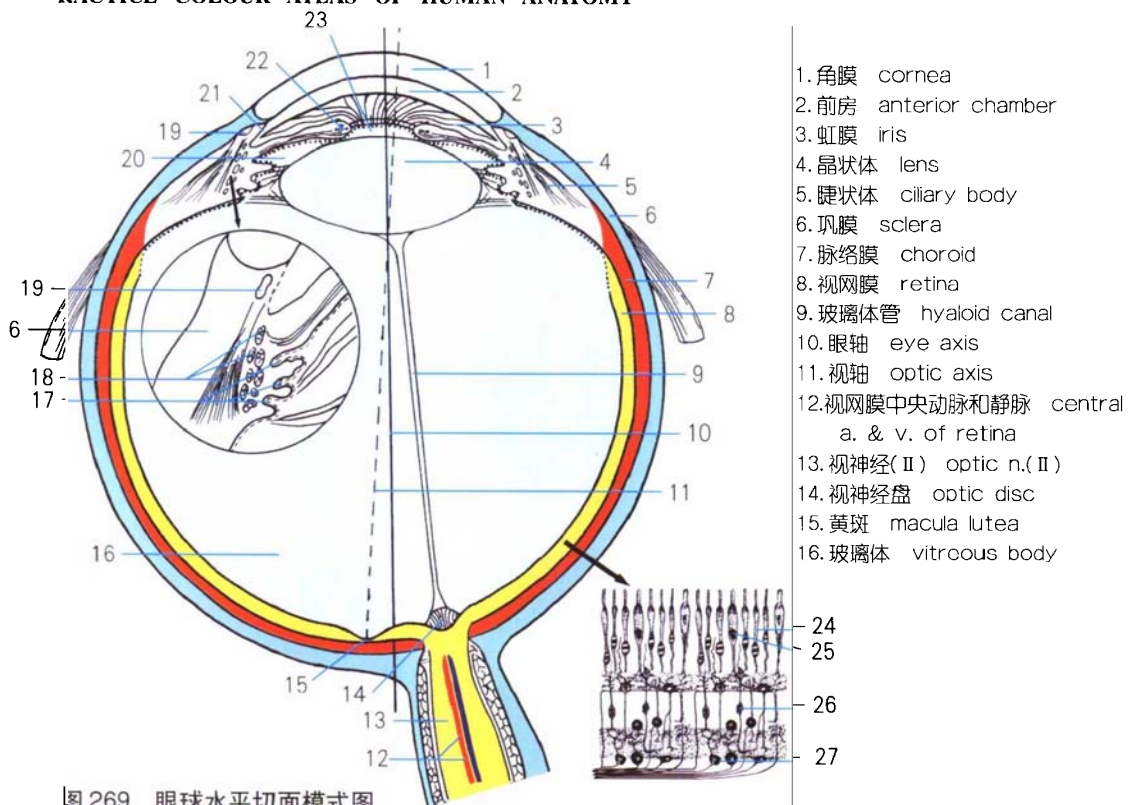


图 269 眼球水平切面模式图
 Diagram of horizontal section through the eyeball

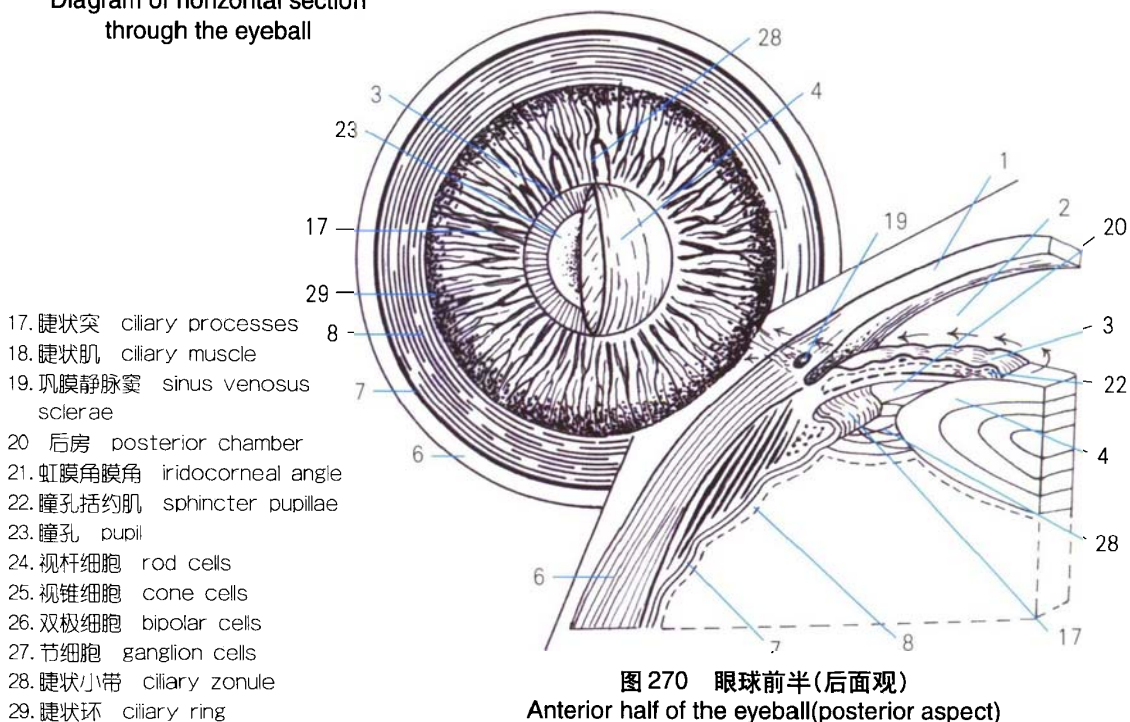


图 270 眼球前半(后面观)
 Anterior half of the eyeball (posterior aspect)

1. 中央凹 fovea centralis
2. 视网膜颞侧下小动脉 inferior temporal arteriole of retina
3. 视网膜颞侧下小静脉 inferior temporal venule of retina
4. 视网膜鼻侧下小动脉 inferior nasal arteriole of retina
5. 视网膜鼻侧下小静脉 inferior nasal venule of retina
6. 黄斑下血管 inferior macular vessel
7. 视神经盘 optic disc
8. 视网膜鼻侧上小动脉 superior nasal arteriole of retina
9. 视网膜鼻侧上小静脉 superior nasal venule of retina
10. 视网膜颞侧上小动脉 superior temporal arteriole of retina
11. 视网膜颞侧上小静脉 superior temporal venule of retina
12. 黄斑上血管 superior macular vessel

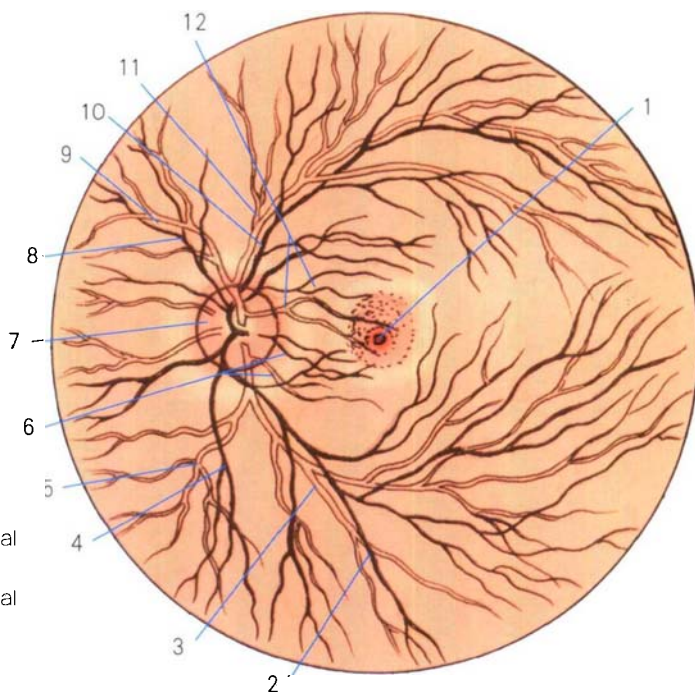


图 271 眼底的血管
Blood vessel of eyeball fundus

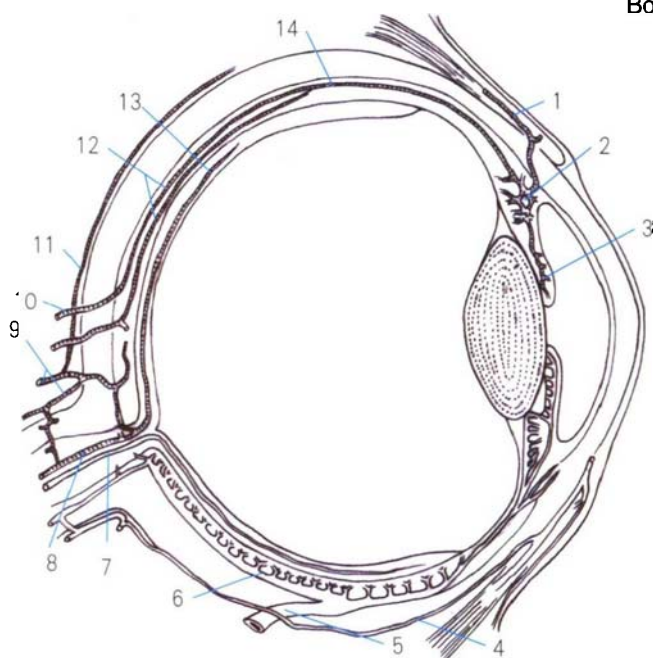
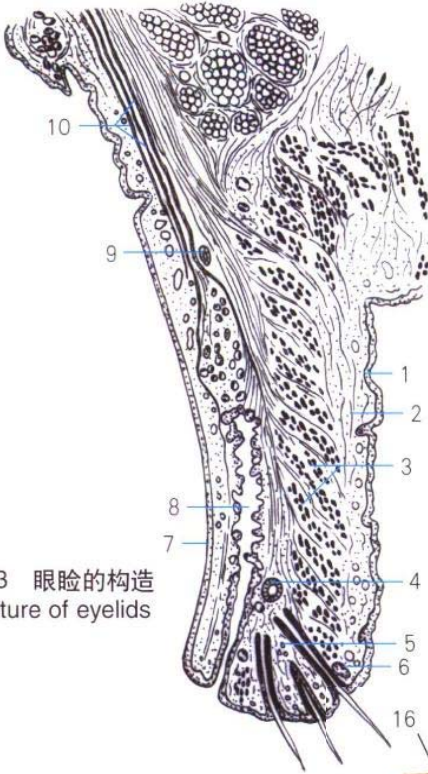

图 272 眼球壁的血管分布模式图
Diagram to show the distribution of the blood vessels of the eyeball wall

1. 睫状前动脉 anterior ciliary a.
2. 虹膜大环动脉 greater ring arterial of iris
3. 虹膜动脉小环 lesser ring arterial of iris
4. 巩膜外静脉 episcleral v.
5. 涡静脉 vorticosse v.
6. 脉络膜毛细血管 capillaries of choroid
7. 视网膜中央静脉 centralis retina v.
8. 视网膜中央动脉 centralis retina a.
9. 睫后长动脉 long posterior ciliary a.
10. 睫后短动脉 short posterior ciliary a.
11. 巩膜动脉 scleral a.
12. 脉络膜动脉 arterial of choroid
13. 视网膜动脉 retinal a.
14. 睫状后动脉 posterior ciliary a.



1. 皮肤 skin
2. 皮下组织 subcutaneous tissue
3. 眼轮匝肌 orbicularis oculi
4. 下动脉弓 inferior arterial arch
5. 睫毛腺 ciliary glands
6. 皮脂腺 sebaceous glands
7. 睑结膜 palpebral conjunctiva
8. 睑板 tarsus
9. 上动脉弓 superior arterial arch
10. 米勒肌 muller muscle

图 273 眼睑的构造
Structure of eyelids

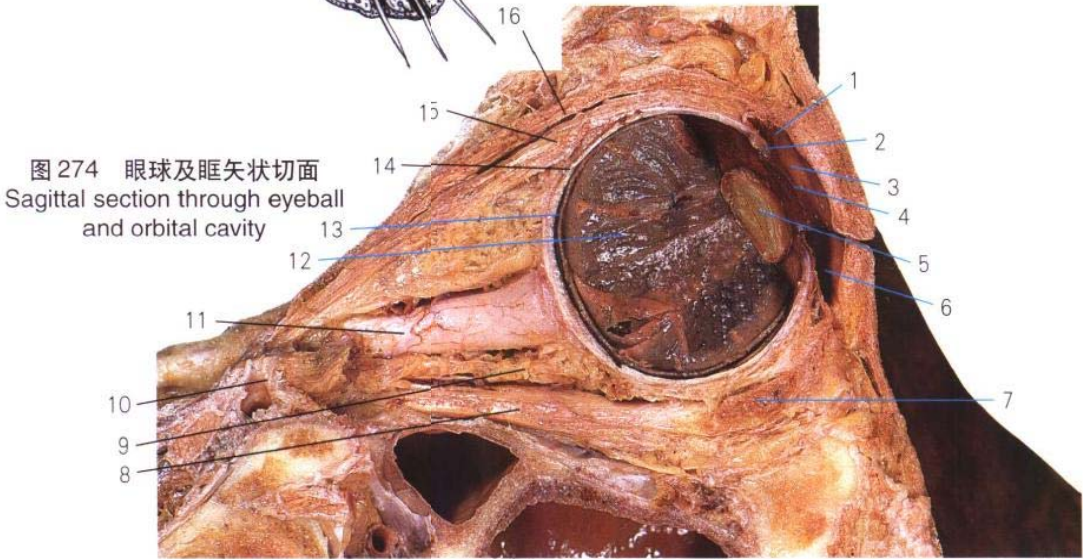


图 274 眼球及眶矢状切面
Sagittal section through eyeball
and orbital cavity

- | | |
|--------------------------------------|--------------------------------------|
| 1. 结膜上穹 superior conjunctival fornix | 9. 眶脂体 adipose body of orbit |
| 2. 虹膜 iris | 10. 总腱环 common tendinous ring |
| 3. 睑结膜 palpebral conjunctiva | 11. 视神经(II) optic n.(II) |
| 4. 角膜 cornea | 12. 视网膜 retina |
| 5. 晶状体 lens | 13. 脉络膜 choroid |
| 6. 结膜下穹 inferior conjunctival fornix | 14. 巩膜 sclera |
| 7. 下斜肌 inferior oblique | 15. 上直肌 superior rectus |
| 8. 下直肌 inferior rectus | 16. 上睑提肌 levator palpebrae superiors |

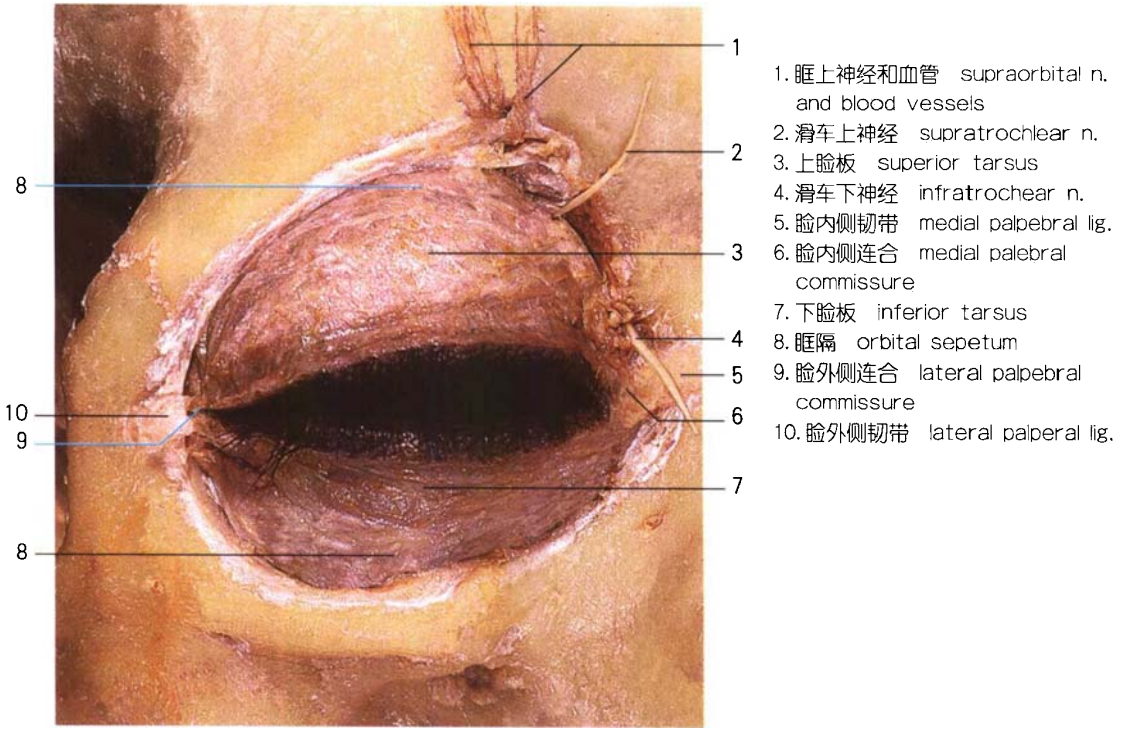


图 275 右眼眶隔
Orbital septum of the right eye

1. 眶上神经和血管 supraorbital n. and blood vessels
2. 滑车上神经 supratrochlear n.
3. 上睑板 superior tarsus
4. 滑车下神经 infratrochlear n.
5. 睑内侧韧带 medial palpebral lig.
6. 睑内侧连合 medial palpebral commissure
7. 下睑板 inferior tarsus
8. 眶隔 orbital septum
9. 睑外侧连合 lateral palpebral commissure
10. 睑外侧韧带 lateral palpebral lig.

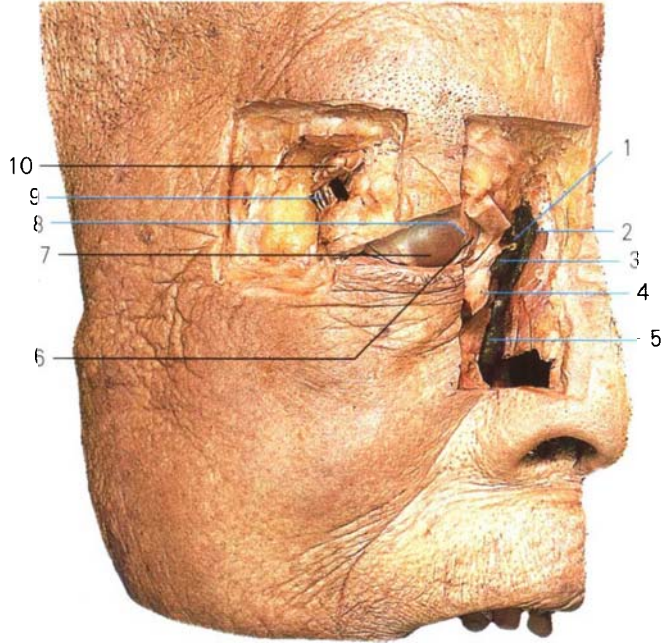
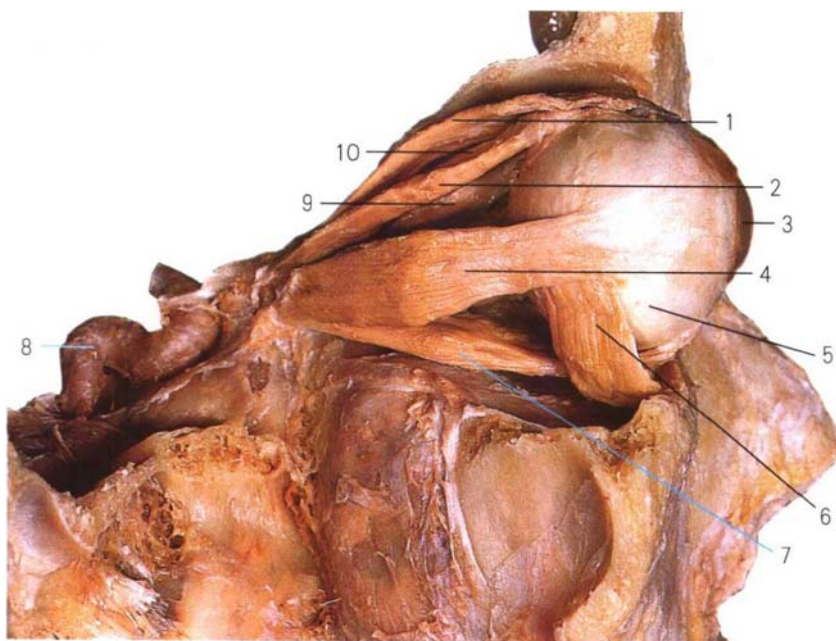


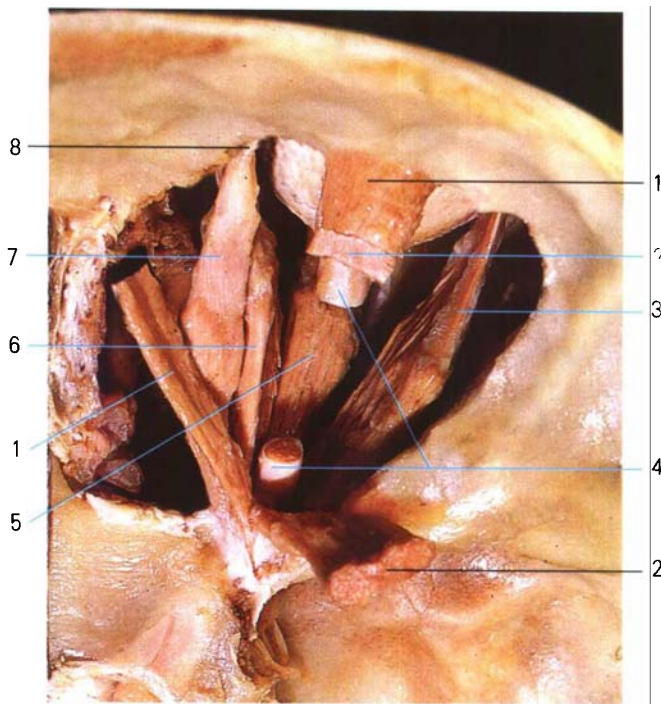
图 276 泪器(右侧)
The lacrimal apparatus(right side)

1. 上泪小管 upper lacrimal ductule
2. 泪囊 lacrimal sac
3. 下泪小管 lower lacrimal punctum
4. 下泪点 lower lacrimal punctum
5. 鼻泪管 nasolacrimal duct
6. 泪湖 lacrimal lacus
7. 角膜 cornea
8. 结膜半月襞 conjunctival semilunar fold
9. 泪腺排泄小管 excretory ductules of lacrimal
10. 泪腺 lacrimal gland



1. 上睑提肌 levator palpebrae superioris
2. 上直肌 superior rectus
3. 角膜 cornea
4. 外直肌 lateral rectus
5. 眼球 eyeball
6. 下斜肌 inferior obliquus
7. 下直肌 inferior rectus
8. 颈内动脉 internal carotid a.
9. 内直肌 medial rectus
10. 上斜肌 superior obliquus

图 277 眼球外肌(外侧观)
The ocular muscles(lateral aspect)



1. 上睑提肌 levator palpebrae superior
2. 上直肌 superior rectus
3. 外直肌 lateral rectus
4. 视神经(II) optic n.(II)
5. 下直肌 inferior rectus
6. 内直肌 medial rectus
7. 上斜肌 superior obliquus
8. 滑轮 trochlea

图 278 眼球外肌(上面观)
The ocular muscles(supeior aspect)

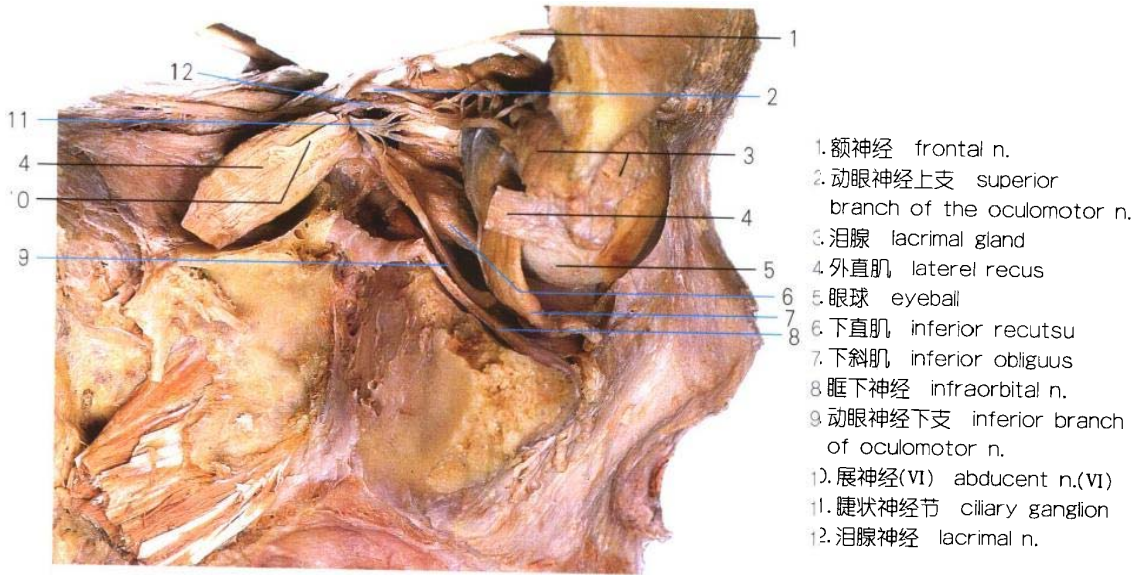


图 279 右眼眶内容(外侧面)
 Right orbital contents(lateral aspect)

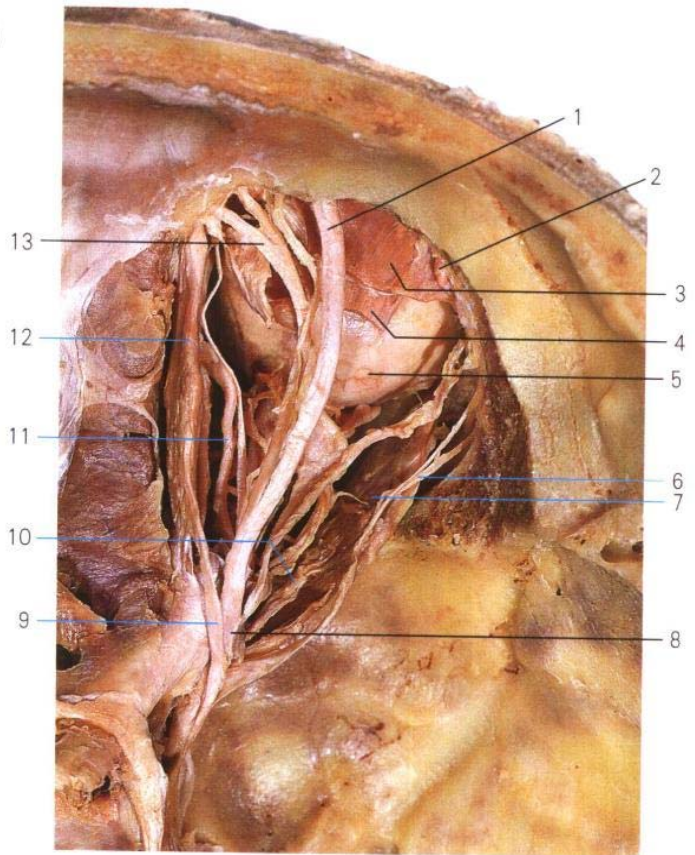


图 280 右眼眶内容(上面观)
 Right orbital contents(superior aspect)

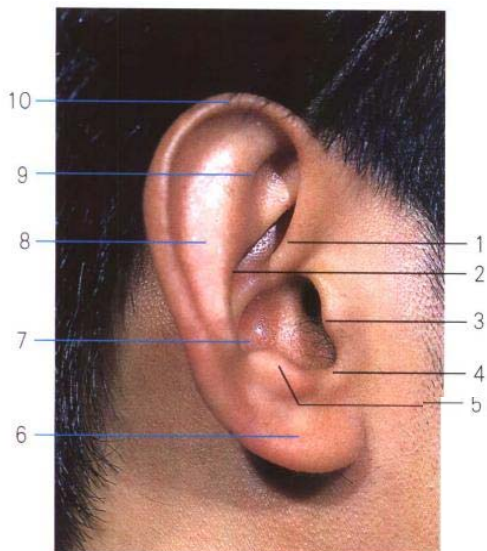


图 281 耳廓
Auricle

1. 耳轮脚 crus of helix
2. 对耳轮脚 crura of antihelix
3. 耳屏 tragus
4. 耳屏间切迹 intertragic notch
5. 对耳屏 antitragus
6. 耳垂 auricular lobule
7. 耳甲 auricular concha
8. 耳舟 scapha
9. 对耳轮 antihelix
10. 耳轮 helix

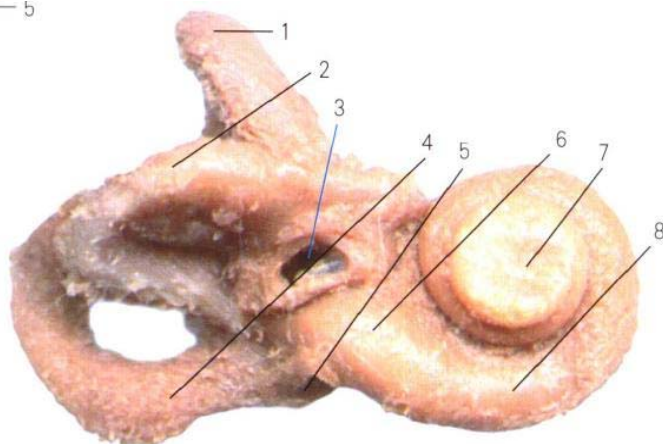


图 282 骨迷路
Bony labyrinth

1. 前骨半规管 anterior semicircular canal
2. 外骨半规管 lateral semicircular canal
3. 前庭窗 fenestra vestibuli
4. 后骨半规管 posterior semicircular canal
5. 蜗窗 fenestra cochleae
6. 前庭 vestibule
7. 蜗顶 cupula of cochlea
8. 耳蜗 cochlea

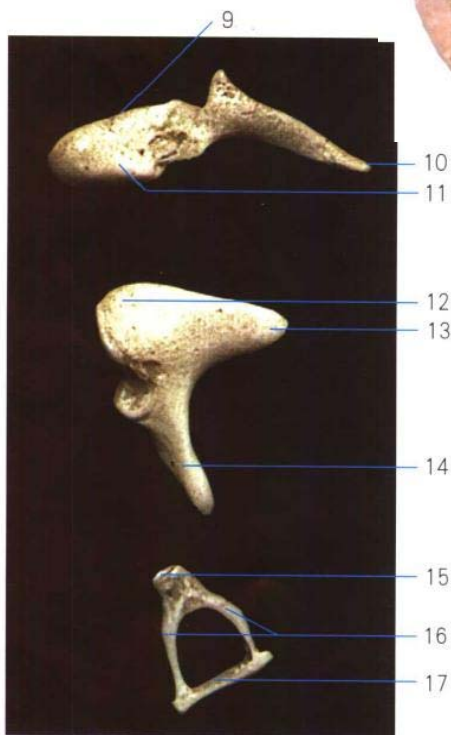

图 283 听小骨
Auditory ossicles

9. 锤骨 malleus
10. 锤骨柄 manubrium of malleus
11. 锤骨头 head of malleus
12. 砧骨 incus
13. 短脚 short crus
14. 长脚 long crus
15. 镫骨 stapes
16. 镫骨脚 crus of stapes
17. 镫骨底 base of stapes

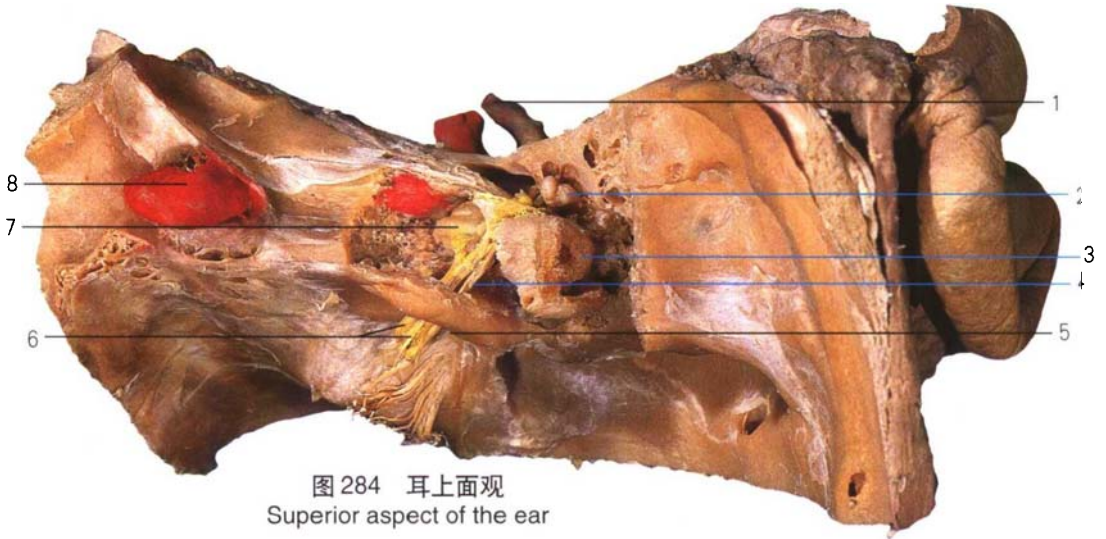


图 284 耳上面观
Superior aspect of the ear

- | | |
|----------------------------------|----------------------------------|
| 1. 茎突 styloid process | 10. 咽鼓管 auditory tube |
| 2. 听小骨 auditory ossicles | 11. 迷走神经 vagus n. |
| 3. 骨半规管 bony semicircular canals | 12. 颈内静脉 internal carotid a. |
| 4. 面神经 facial n. | 13. 胸锁乳突肌 sternocleidomastoid |
| 5. 内耳门 internal acoustic pore | 14. 乳突 mastoid process |
| 6. 前庭蜗神经 vestibulocochlear n. | 15. 耳廓 auricle |
| 7. 耳蜗 cochlea | 16. 外耳道 external acoustic meatus |
| 8. 颈内动脉 internal carotid a. | 17. 鼓膜 tympanic membrane |
| 9. 鼓膜张肌 tensor tympani | |

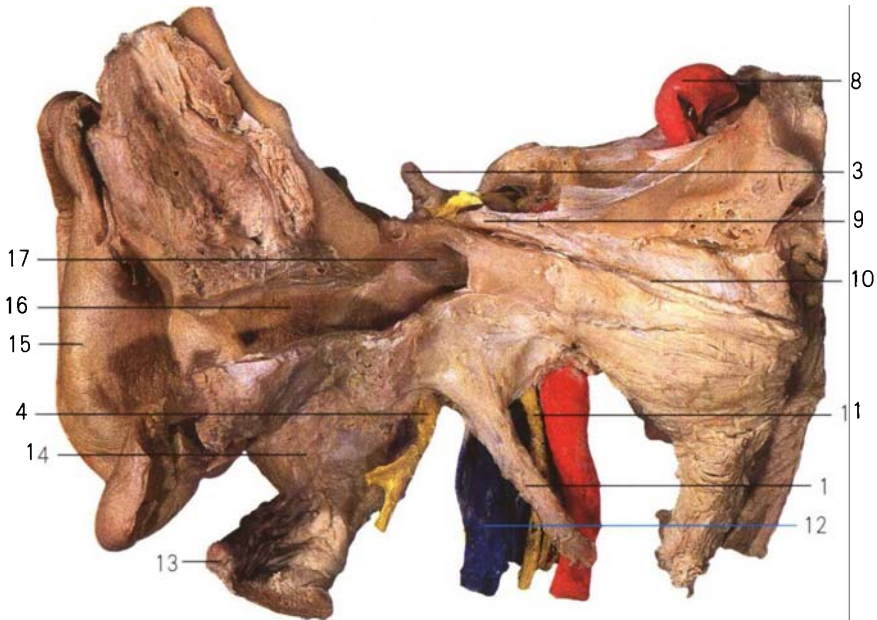


图 285 耳前面观
Anterior aspect of the ear

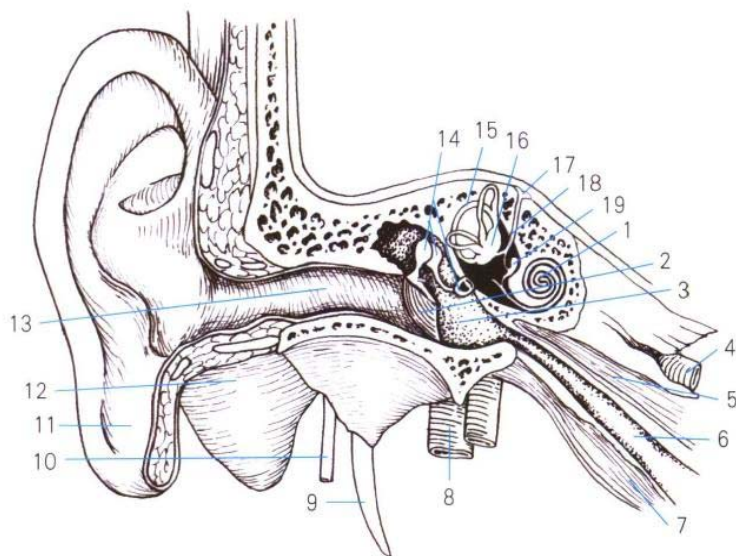


图 286 位听器模式图(右侧)
Diagram of the organs of hearing and equalization (right side)

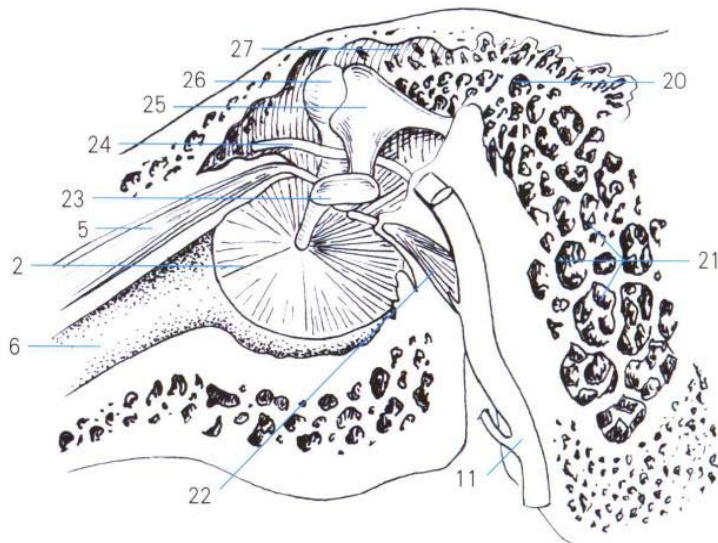


图 287 鼓室外侧壁(右侧)
Lateral wall of the tympanic cavity(right side)

- 1. 耳蜗 cochlea
- 2. 鼓膜 tympanic membrane
- 3. 鼓室 tympanic cavity
- 4. 颈内动脉 internal carotid a.
- 5. 鼓膜张肌 tensor tympani
- 6. 咽鼓管 auditory tube
- 7. 腭帆提肌 levator veli palatini
- 8. 颈内静脉 internal carotid v.
- 9. 茎突 styloid process
- 10. 面神经(VII) facial n.(VII)
- 11. 耳垂 auricular lobule
- 12. 乳突 mastoid process
- 13. 外耳道 external acoustic meatus
- 14. 听小骨 auditory ossicles

- 15. 骨半规管 bony semicircular canals
- 16. 椭圆囊 utricle
- 17. 内淋巴囊 endolymphatic sac
- 18. 内淋巴管 endolymphatic duct
- 19. 球囊 saccule
- 20. 乳突窦 mastoid antrum
- 21. 乳突小房 tympanic cells
- 22. 镫骨肌 stapedius
- 23. 镫骨 stapes
- 24. 鼓索 chorda tympani
- 25. 砧骨 incus
- 26. 锤骨 malleus
- 27. 鼓室上隐窝 superior recess of tampanic

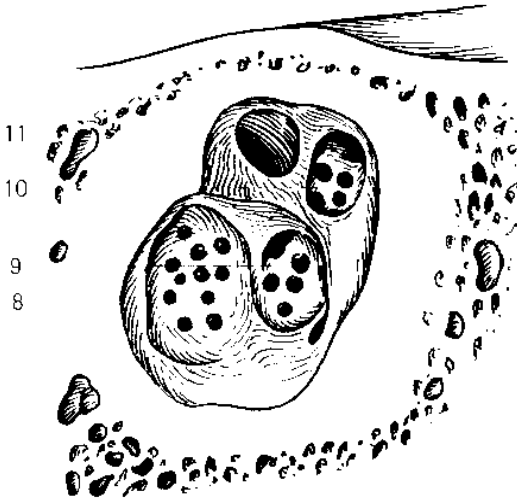


图 288 右侧内耳道底
Bottom of the right internal acoustic meatus

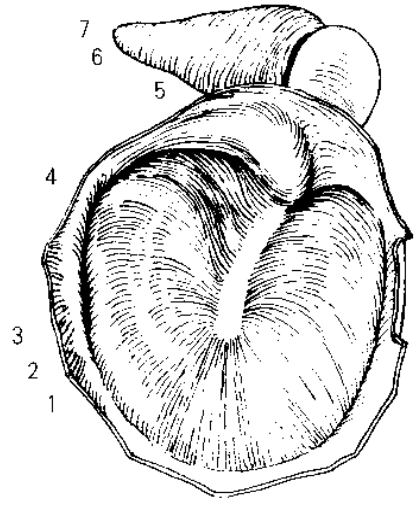


图 289 右侧鼓膜
The right tympanic membrane

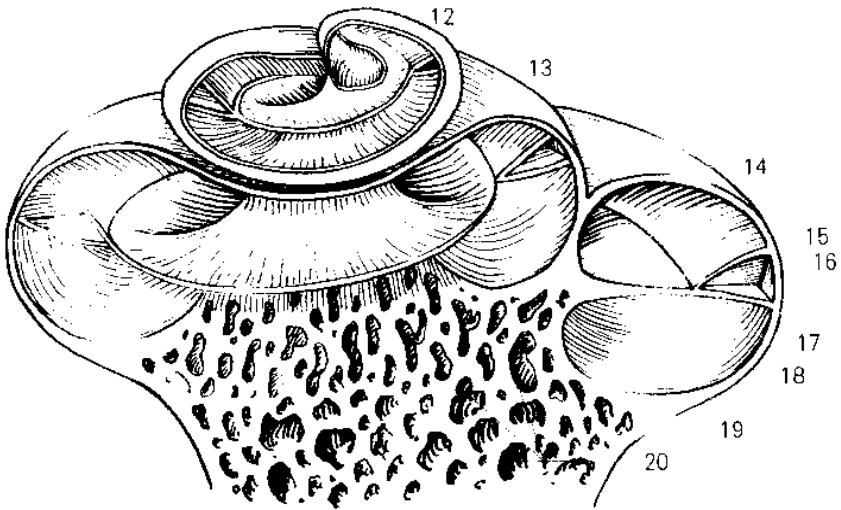
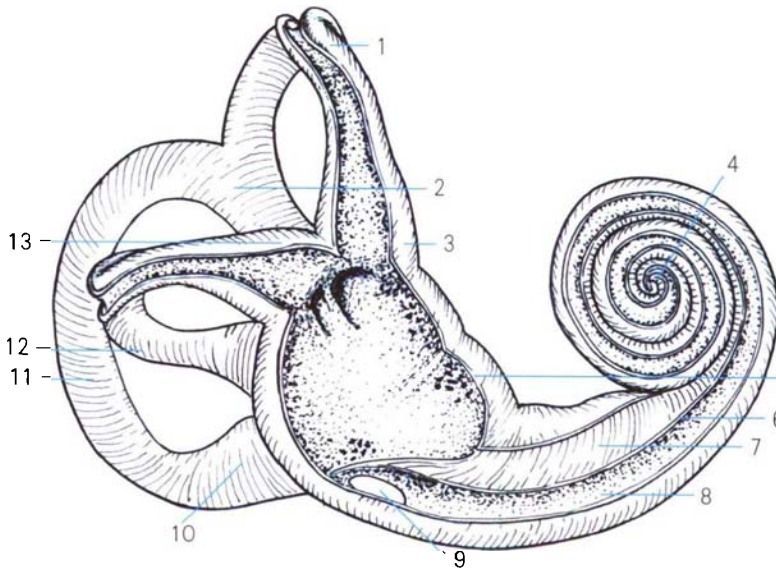


图 290 耳蜗(通过蜗轴的剖面)
Cochlea section through the modiolus

- | | |
|-----------------------------------|-----------------------------------|
| 1. 光锥 light cone | 11. 面神经区 area of facial nerve |
| 2. 紧张部 tense part | 12. 蜗顶 cupula of cochlea |
| 3. 鼓膜脐 umbo of tympanic membrane | 13. 螺旋板钩 hamulus of spira. lamina |
| 4. 松弛部 flaccid part | 14. 骨螺旋板 osseous spiral lamina |
| 5. 锤骨头 head of stapes | 15. 前庭阶 scala vestibuli |
| 6. 砧锤关节 incudomalleolar joint | 16. 前庭膜 vestibular membrane |
| 7. 砧骨体 body of incus | 17. 蜗管 cochlear duct |
| 8. 蜗区 cochlear area | 18. 螺旋膜 spiral membrane |
| 9. 前庭下区 inferior vestibular area | 19. 鼓阶 scala tympani |
| 10. 前庭上区 superior vestibular area | 20. 蜗轴 cochlear axis |



1. 前骨半规管 anterior semicircular canals
2. 总骨脚 common bony crus
3. 前骨壶腹 anterior bony ampulla
4. 蜗顶 cupula of cochlea
5. 前庭 vestibule
6. 骨螺旋板 osseous spiral lamina
7. 前庭阶 scala vestibuli
8. 鼓阶 scala tympani
9. 蜗窗 fenestra cochleae
10. 后骨壶腹 posterior bony ampulla
11. 后骨半规管 posterior semicircular canal
12. 外骨半规管 lateral semicircular canal

图 291 右侧骨迷路内面
Interior aspect of the right bony labyrinth

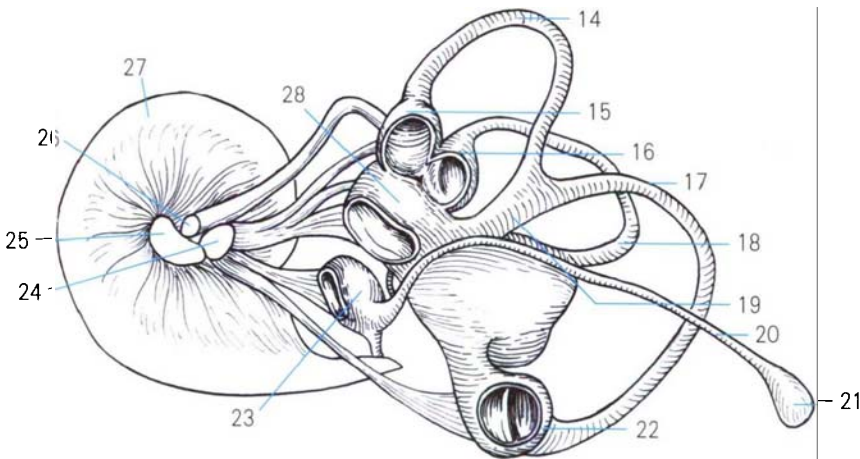


图 292 右侧膜迷路
Right membranous labyrinth

- | | |
|---------------------------------------|---------------------------------------|
| 13. 外骨壶腹 lateral bony ampulla | 21. 内淋巴囊 endolymphatic sac |
| 14. 前膜半规管 anterior semicircular duct | 22. 后膜壶腹 posterior membranous empulla |
| 15. 前膜壶腹 anterior membranous ampulla | 23. 球囊 saccula |
| 16. 外膜壶腹 lateral membranous ampulla | 24. 前庭神经 vestibular n. |
| 17. 后膜半规管 posterior semicircular duct | 25. 蜗神经 cochlear n. |
| 18. 外膜半规管 lateral semicircular duct | 26. 面神经 facial n. |
| 19. 总膜脚 common membranous crus | 27. 蜗管 cochlear duct |
| 20. 内淋巴管 endolymphatic duct | 28. 椭圆囊 utricle |

第

章

9

中枢神经系统

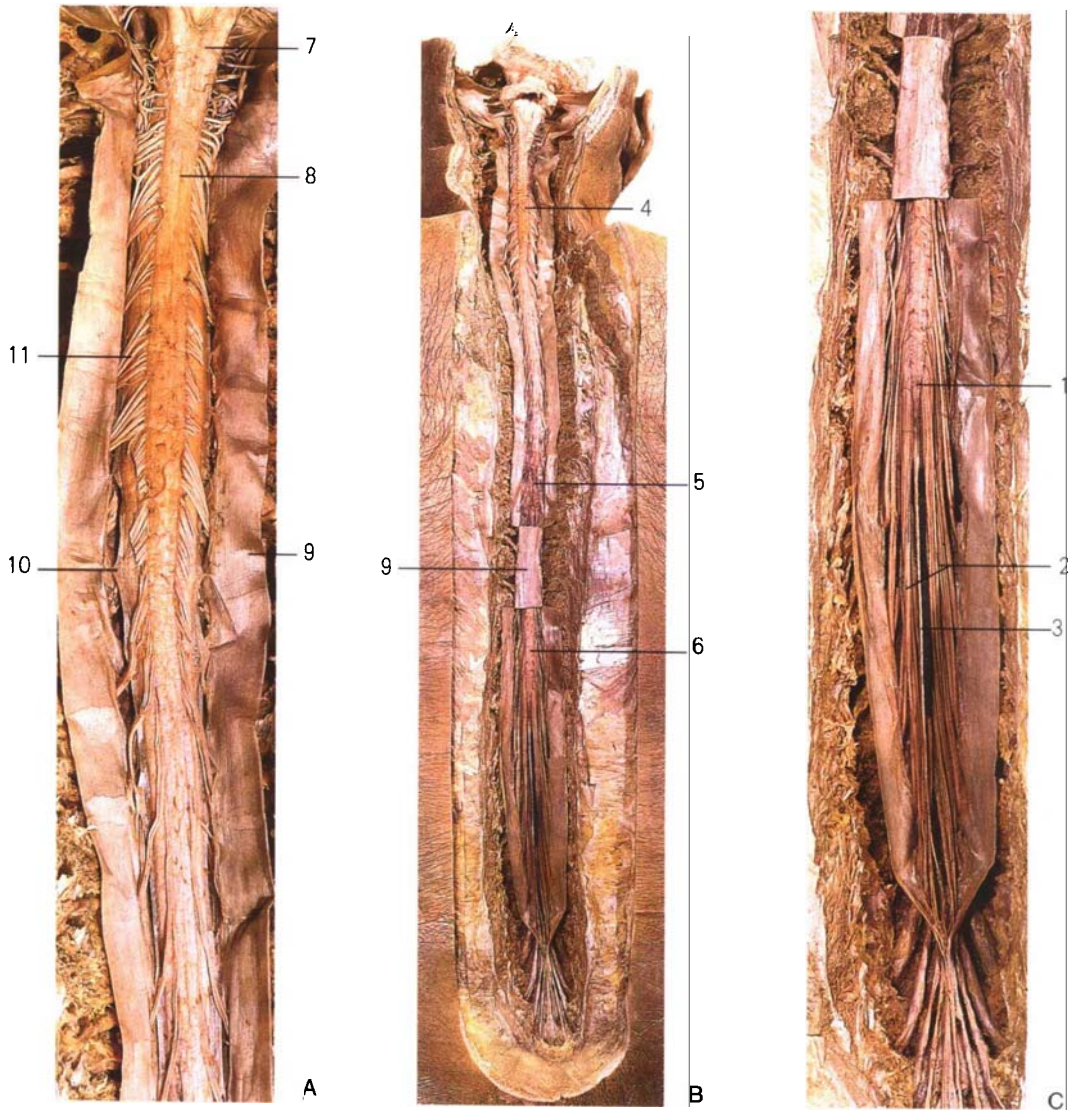
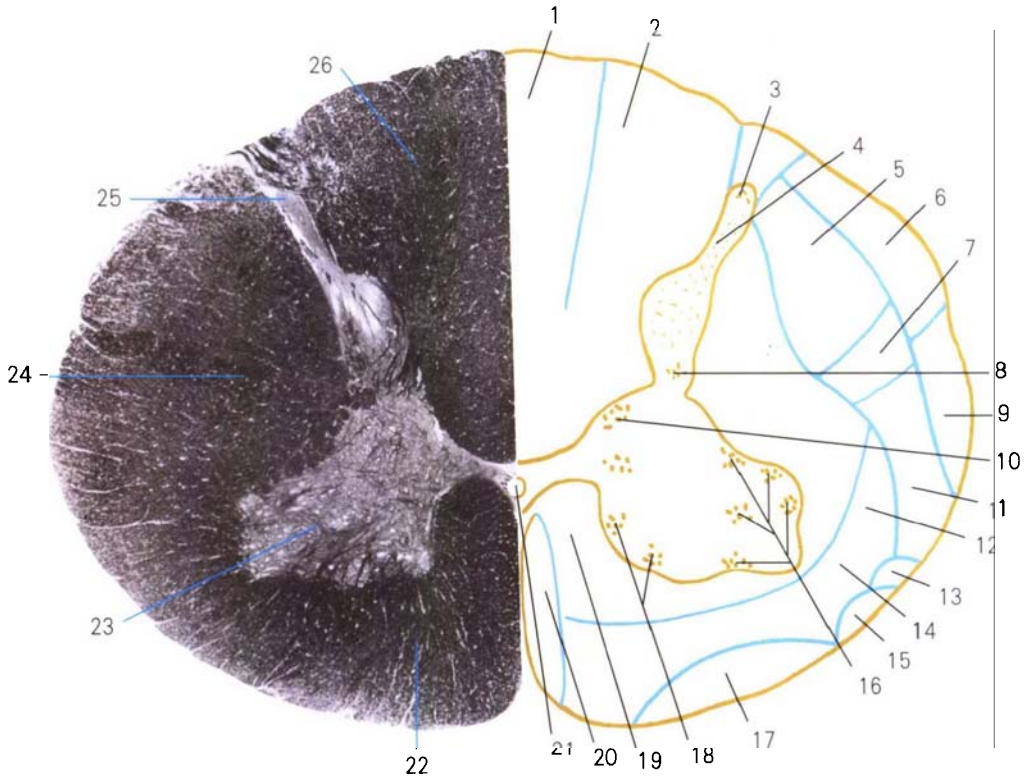


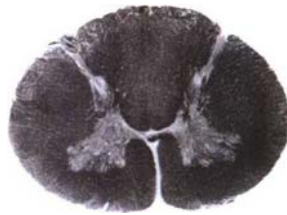图 293 脊髓的外形和被膜 (A、B、C)
External features and meninges of the spinal cord(A,B,C)

- | | |
|---------------------------------|---------------------------------|
| 1. 脊髓圆锥 conus medullaris | 7. 延髓 medulla oblongata |
| 2. 马尾 cauda equina | 8. 后正中沟 posterior median sulcus |
| 3. 终丝 filum terminale | 9. 硬脊膜 spinal dura mater |
| 4. 颈膨大 cervical enlargement | 10. 齿状韧带 denticulate ligament |
| 5. 脊髓蛛网膜 spinal arachnoid mater | 11. 后根 posterior root |
| 6. 腰骶膨大 lumbosacral enlargement | |

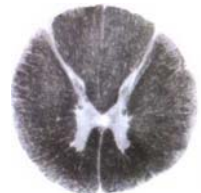

1. 薄束 fasciculus gracilis
2. 楔束 fasciculus cuneatus
3. 缘层 marginal layer
4. 胶状质 substantia gelatinosa
5. 皮质脊髓侧束 lateral corticospinal tract
6. 脊髓小脑后束 posterior spinocerebellar tract
7. 红核脊髓束 rubrospinal tract
8. 后脚固有核 nucleus proprius
9. 脊髓小脑前束 anterior spinocerebellar tract
10. 胸核 nucleus thoracicus
11. 脊髓丘脑束 spinothalamic tract
12. 网状脊髓束 reticulospinal tract
13. 脊髓顶盖束 spinotectal tract
14. 顶盖脊髓束 tectospinal tract
15. 橄榄脊髓束 olivospinal tract
16. 外侧核 lateral nucleus
17. 前庭脊髓束 vestibulospinal tract
18. 内侧核 medial nucleus
19. 内侧纵束 medial longitudinal fasciculus
20. 皮质脊髓前束 anterior corticospinal tract
21. 中央管 central canal
22. 前索 anterior funiculus
23. 前角 anterior horn
24. 外侧索 lateral funiculus
25. 后角 posterior horn
26. 后索 posterior funiculus

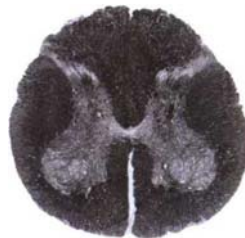A. 颈段
Cervical segment



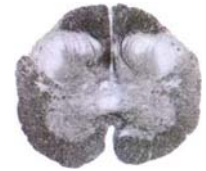
B. 颈段
Cervical segment



C. 胸段
Thoracic segment



D. 腰段
Lumbar segment



E. 骶段
Sacral segment

图 294 脊髓横切面(A, B, C, D, E)
Transverse section of spinal cord(A, B, C, D, E)

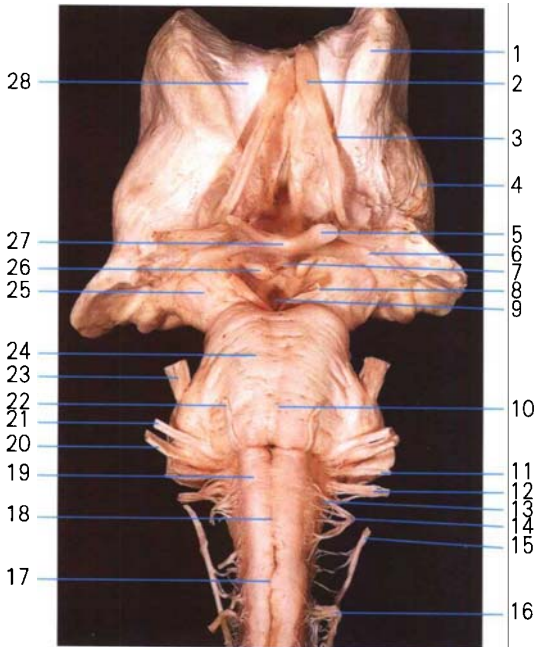


图 295 脑干腹面观
Ventral aspect of brain stem

1. 背侧丘脑 dorsal thalamus
2. 下丘 inferior colliculus
3. 滑车神经(IV) trochlear n.(IV)
4. 前髓帆 anterior medullary velum
5. 内侧隆起 medial eminence
6. 正中沟 median sulcus
7. 界沟 sulcus limitans
8. 前庭区 vestibular area
9. 髓纹 striae medullares
10. 舌下神经三角 hypoglossal triangle
11. 迷走神经三角 vagal triangle
12. 楔束结节 cuneate tubercle
13. 后正中沟 posterior median sulcus
14. 薄束结节 gracile tubercle
15. 副神经(XI) accessory n.(XI)
16. 舌下神经(XII) hypoglossal n.(XII)
17. 迷走神经(X) vagus n.(X)
18. 小脑下脚 inferior cerebellar peduncle
19. 小脑中脚 middle cerebellar peduncle
20. 面神经丘 facial colliculus
21. 小脑上脚 superior cerebellar peduncle
22. 上丘 superior colliculus
23. 内侧膝状体 medial geniculate body
24. 松果体 pineal body
25. 彗三角 habenular trigone
26. 丘脑髓纹 thalamic medullary stria
27. 胼胝体 corpus callosum

1. 辐射冠 corona radiata
2. 嗅球 olfactory bulb
3. 嗅束 olfactory tract
4. 豆状核 lentiform nucleus
5. 视神经(II) optic n.(II)
6. 视束 optic tract
7. 漏斗 infundibulum
8. 动眼神经(III) oculomotor n.(III)
9. 脚间窝 interpeduncular fossa
10. 基底沟 basilar sulcus
11. 舌咽神经(IX) glossopharyngeal n.(IX)
12. 迷走神经(X) vagus n.(X)
13. 橄榄 olive
14. 舌下神经(XII) hypoglossal n.(XII)
15. 副神经(XI) accessory n.(XI)
16. 第一颈神经 first cervical n.
17. 锥体交叉 decussation of pyramid
18. 前正中裂 anterior median fissure
19. 锥体 pyramid
20. 前庭蜗(位听)神经(VIII) vestibulocochlear n.(VIII)
21. 面神经(VII) facial n.(VII)
22. 展神经(VI) abducent n.(VI)
23. 三叉神经(V) trigeminal n.(V)
24. 脑桥 pons
25. 大脑脚 cerebral peduncle
26. 乳头体 mamilary body
27. 视交叉 optic chiasma
28. 尾状核 caudate nucleus

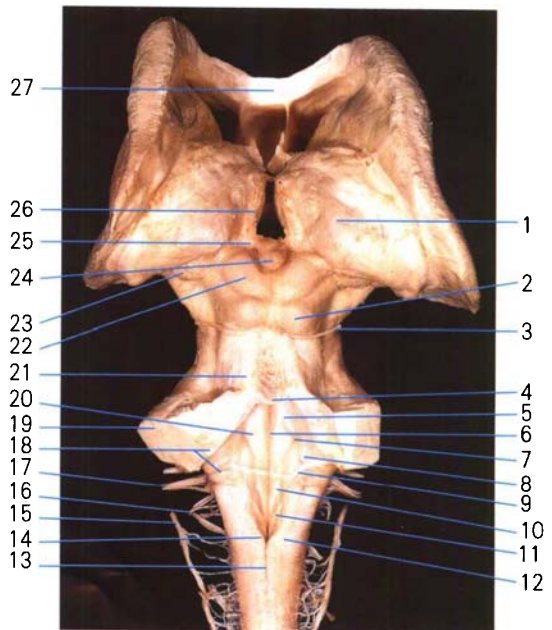


图 296 脑干背面观
Dorsal aspect of brain stem

1. 外侧膝状体 lateral geniculate body
2. 内侧膝状体 medial geniculate body
3. 上丘 superior colliculus
4. 下丘 inferior colliculus
5. 滑车神经(IV) trochlear n.(IV)
6. 小脑中脚 middle cerebellar peduncle
7. 小脑下脚 inferior cerebellar peduncle
8. 橄榄 olive
9. 锥体 pyramid
10. 脑桥 pons
11. 三叉神经(V) trigeminal n.(V)
12. 动眼神经(III) oculomotor n.(III)
13. 大脑脚 cerebral peduncle
14. 视束 optic tract
15. 杏仁体 amygdaloid body
16. 豆状核 lentiform nucleus
17. 辐射冠 corona radiata

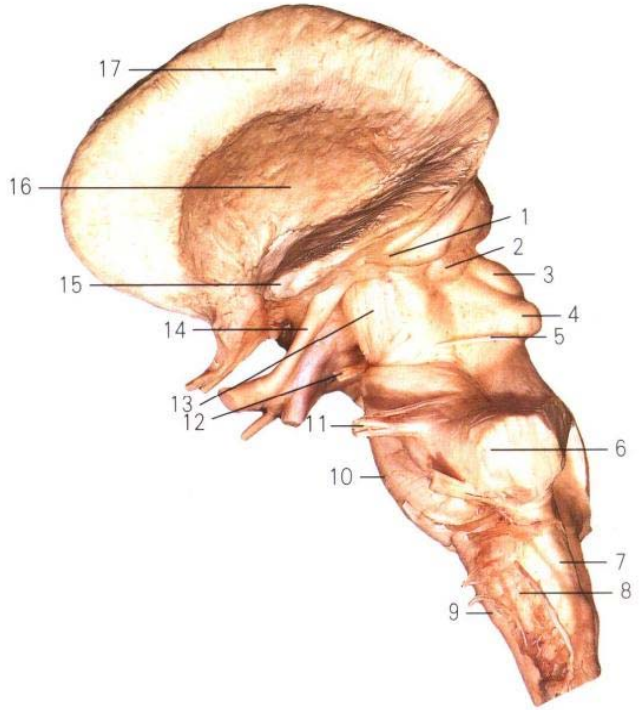


图 297 脑干侧面观
Lateral aspect of the brain stem

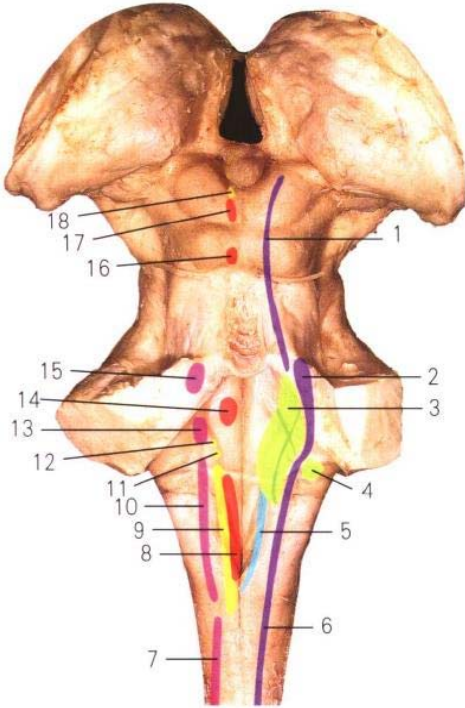


图 298 脑神经核模式图(背面观)
Diagram of the nuclei of the cranial nerves(dorsal aspect)

1. 三叉神经中脑核 mesencephalic nucleus of trigeminal n.
2. 三叉神经脑桥核 pontine nucleus of trigeminal n.
3. 前庭神经核 vestibular nuclei
4. 蜗神经核 cochlear nuclei
5. 孤束核 nucleus of solitary tract
6. 三叉神经脊核 spinal nucleus of trigeminal n.
7. 副神经核 accessory nucleus
8. 舌下神经核 nucleus of hypoglossal n.
9. 迷走神经背核 dorsal nucleus of vagus n.
10. 疑核 nucleus ambiguus
11. 下涎核 inferior salivatory nucleus
12. 上涎核 superior salivatory nucleus
13. 面神经核 nucleus of facial n.
14. 展神经核 nucleus of abducent n.
15. 三叉神经运动核 motor nucleus of trigeminal n.
16. 滑车神经核 nucleus of trochlear n.
17. 动眼神经核 nucleus of oculomotor n.
18. 动眼神经副核 accessory nucleus of oculomotor n.

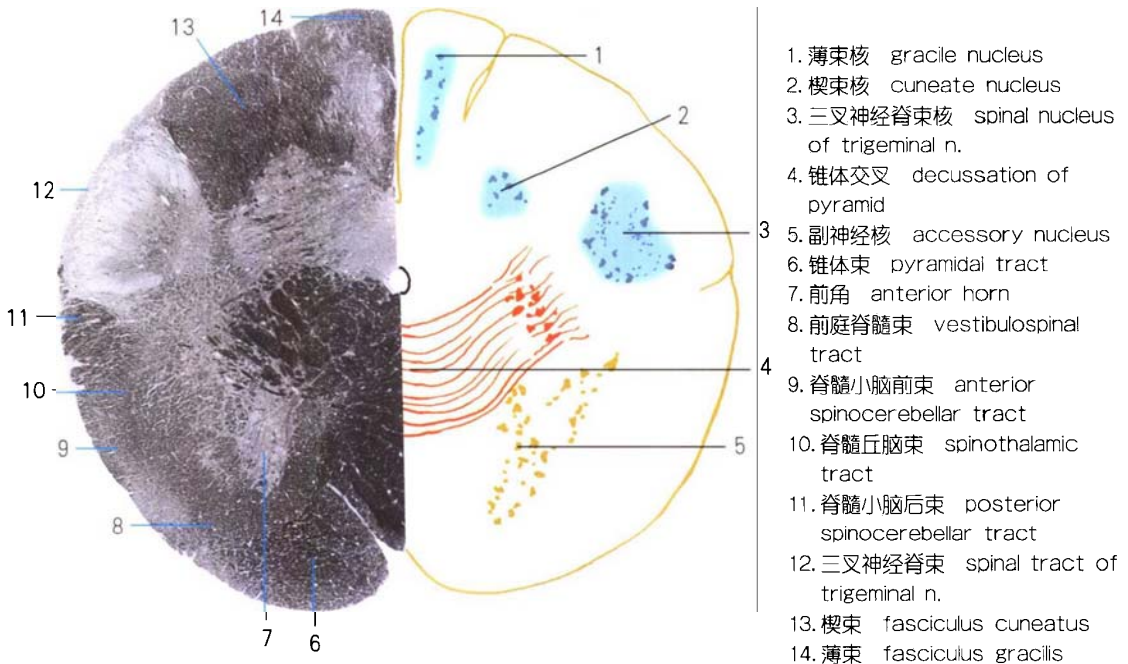


图 299 延髓横切面(经锥体交叉)
Transverse section of the medulla oblongata(through the pyramidal decussation)

1. 薄束核 gracile nucleus
2. 楔束核 cuneate nucleus
3. 三叉神经脊束核 spinal nucleus of trigeminal n.
4. 锥体交叉 decussation of pyramid
5. 副神经核 accessory nucleus
6. 锥体束 pyramidal tract
7. 前角 anterior horn
8. 前庭脊髓束 vestibulospinal tract
9. 脊髓小脑前束 anterior spinocerebellar tract
10. 脊髓丘脑束 spinothalamic tract
11. 脊髓小脑后束 posterior spinocerebellar tract
12. 三叉神经脊束 spinal tract of trigeminal n.
13. 楔束 fasciculus cuneatus
14. 薄束 fasciculus gracilis

1. 薄束核 gracile nucleus
2. 楔束核 cuneate nucleus
3. 三叉神经脊束核 spinal nucleus of trigeminal n.
4. 疑核 nucleus ambiguus
5. 舌下神经核 nucleus of hypoglossal n.
6. 内侧丘系交叉 decussation of medial lemniscus
7. 内侧副橄榄核 medial accessory olivary nucleus
8. 锥体束 pyramidal tract
9. 脊髓小脑前束 anterior spinocerebellar tract
10. 脊髓丘脑束 spinothalamic tract
11. 脊髓小脑后束 posterior spinocerebellar tract
12. 内弓状纤维 internal arcuate fibers
13. 三叉神经脊束 spinal tract of trigeminal n.
14. 楔束 fasciculus cuneatus
15. 薄束 fasciculus gracilis

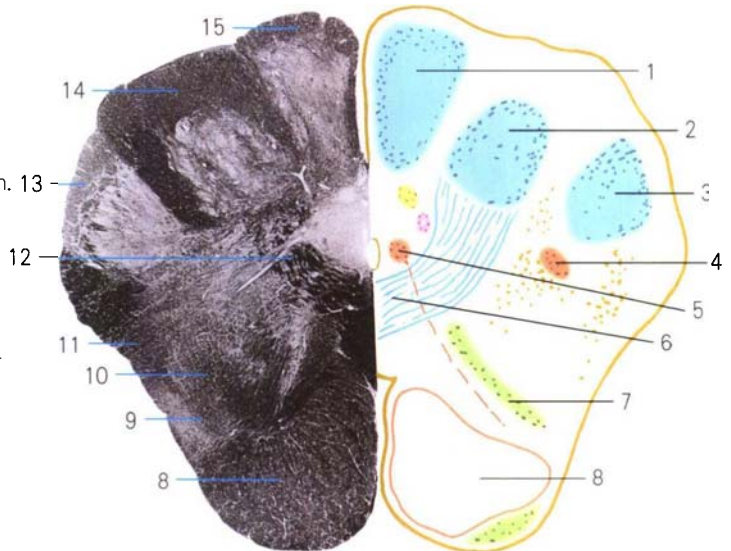


图 300 延髓横切面(经内侧丘系交叉)
Transverse section of the medulla oblongata(through the decussation of the medial lemniscus)

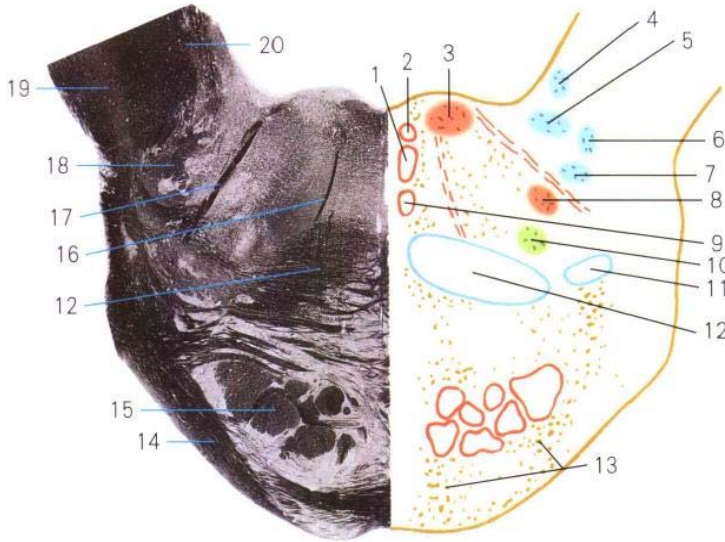


图 303 脑桥横切面(经面丘)
Transverse section of the pons(through the facial colliculus)

- | | |
|--|--|
| 1. 内侧纵束 medial longitudinal tract | 12. 内侧丘系和斜方体 medial lemniscus and trapezoid body |
| 2. 面神经膝 genu of facial n. | 13. 脑桥核 pontine nucleus |
| 3. 展神经核 nucleus of abducent n. | 14. 脑桥横纤维 transverse fibers of pons |
| 4. 前庭神经上核 superior vestibular nucleus | 15. 锥体束 pyramidal tract |
| 5. 前庭神经内侧核 medial vestibular nucleus | 16. 展神经(VI) abducent n.(VI) |
| 6. 前庭神经外侧核 lateral vestibular nucleus | 17. 面神经(VII) facial n.(VII) |
| 7. 三叉神经脊束核 spinal nucleus of trigeminal n. | 18. 三叉神经脊束 spinal tract of trigeminal n. |
| 8. 面神经核 nucleus of facial n. | 19. 小脑中脚 middle cerebellar peduncle |
| 9. 顶盖脊髓束 tectospinal tract | 20. 小脑上脚 superior cerebellar peduncle |
| 10. 上橄榄核 superior olivary nucleus | |
| 11. 外侧丘系 lateral lemniscus | |

- | | |
|---|---------------------------------------|
| 1. 内侧纵束 medial longitudinal fasciculus | 12. 小脑中脚 middle cerebellar peduncle |
| 2. 网状结构 reticular formation | 13. 小脑上脚 superior cerebellar peduncle |
| 3. 三叉神经中脑核 mesencephalic nucleus of trigeminal n. | |
| 4. 三叉神经脑桥核 pontine nucleus of trigeminal n. | |
| 5. 三叉神经运动核 motor nucleus of trigeminal n. | |
| 6. 外侧丘系 lateral lemniscus | |
| 7. 顶盖脊髓束 tectospinal tract | |
| 8. 内侧丘系 medial lemniscus | |
| 9. 脑桥核 pontine nucleus | |
| 10. 锥体束 pyramidal tract | |
| 11. 脑桥横行纤维 transverse fibers of pons | |

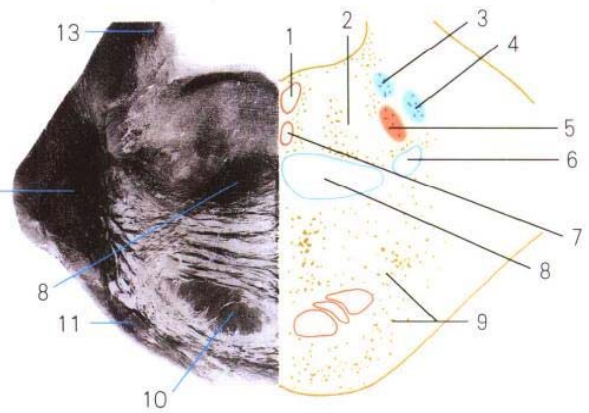


图 304 脑桥横切面(经三叉运动核)
Transverse section of the pons(through the motor nucleus of the trigeminal nerve)

1. 三叉神经中脑核 mesencephalic nucleus of trigeminal n.
2. 滑车神经核 nucleus of trochlear n.
3. 内侧纵束 medial longitudinal fasciculus
4. 内侧丘系 medial lemniscus
5. 大脑脚底 crus cerebri
6. 黑质 substantia nigra
7. 小脑上脚交叉 decussation of superior cerebellar peduncle
8. 顶盖脊髓束 tectospinal tract
9. 中央灰质 central gray matter
10. 外侧丘系 lateral lemniscus
11. 中脑水管 mesencephalic aqueduct
12. 下丘核 nucleus of inferior colliculus

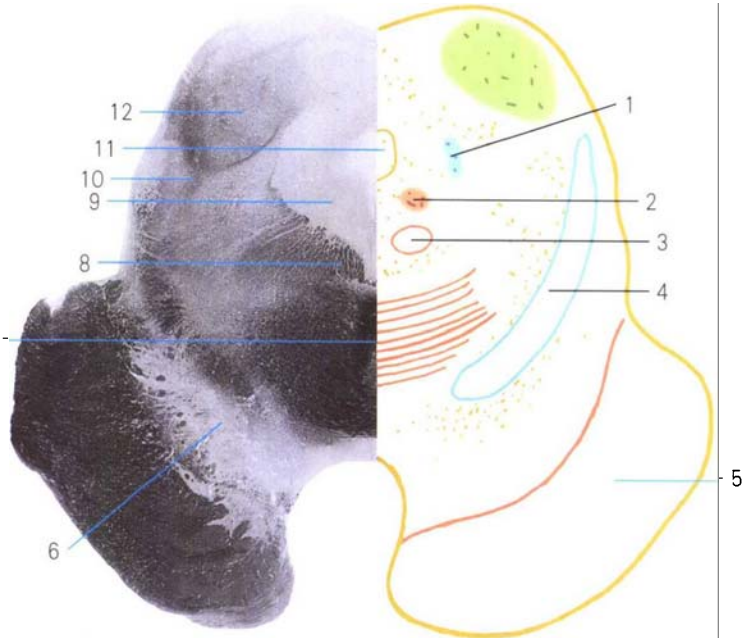


图 305 中脑横切面(经下丘)
Transverse section of the midbrain(through the inferior colliculus)

1. 上丘层 gray matter layer of superior colliculus
2. 中央灰质 central gray matter
3. 动眼神经副核 accessory nucleus of oculomotor n.
4. 三叉神经中脑核 mesencephalic nucleus of trigeminal n.
5. 动眼神经核 nucleus of oculomotor n.
6. 红核 red nucleus
7. 黑质 substantia nigra
8. 顶颞桥束 parietotemporo-pontine tract
9. 锥体束 pyramidal tract
10. 额桥束 frontopontine tract
11. 动眼神经(Ⅲ) oculomotor n.(Ⅲ)
12. 大脑脚底 crus cerebri
13. 内侧丘系 medial lemniscus
14. 中脑水管 mesencephalic aqueduct

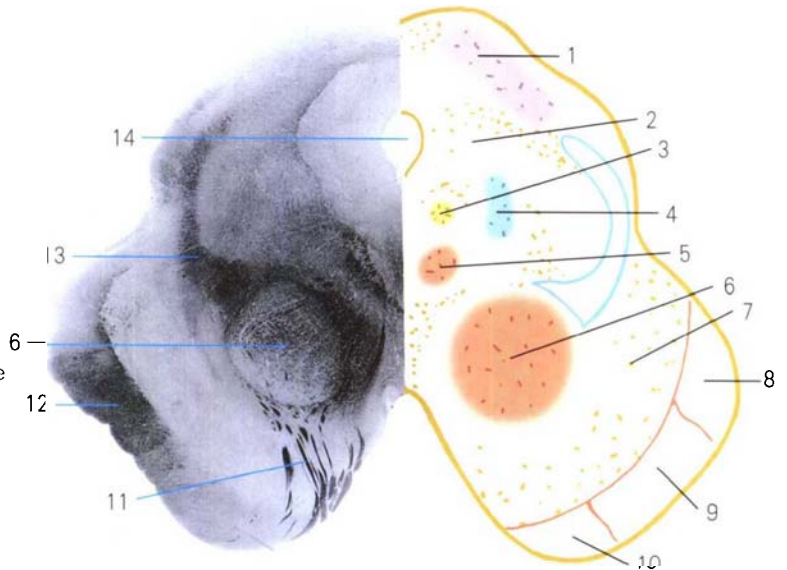


图 306 中脑横切面(经上丘)
Transverse section of the midbrain(through the superior colliculus)

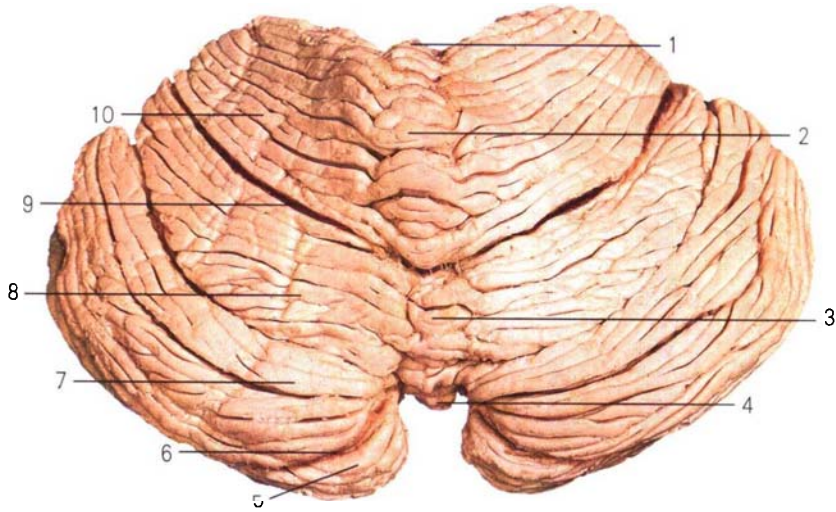


图 307 小脑(上面观)
The cerebellum(superior aspect)

- | | |
|------------------------------------|---|
| 1. 中央小叶 central lobule | 6. 水平裂 horizontal fissure |
| 2. 山顶 culmen | 7. 上半月小叶 superior semilunar lobule |
| 3. 山坡 declive | 8. 方形小叶(后部) posterior quadrangular lobule |
| 4. 蚓叶 folium of vermis | 9. 原裂 primary fissure |
| 5. 下半月小叶 inferior semilunar lobule | 10. 方形小叶(前部) anterior quadrangular lobule |

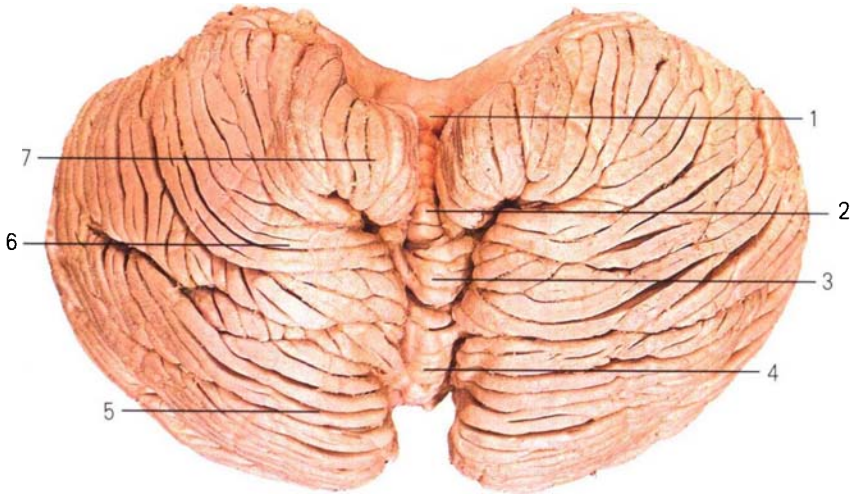


图 308 小脑(下面观)
The cerebellum(inferior aspect)

- | | |
|--------------------------|------------------------------------|
| 1. 小结 nodule | 5. 下半月小叶 inferior semilunar lobule |
| 2. 蚓垂 uvula of vermis | 6. 二腹小叶 biventral lobule |
| 3. 蚓锥体 pyramid of vermis | 7. 小脑扁桃体 tonsil of cerebellum |
| 4. 蚓结节 tuber of vermis | |

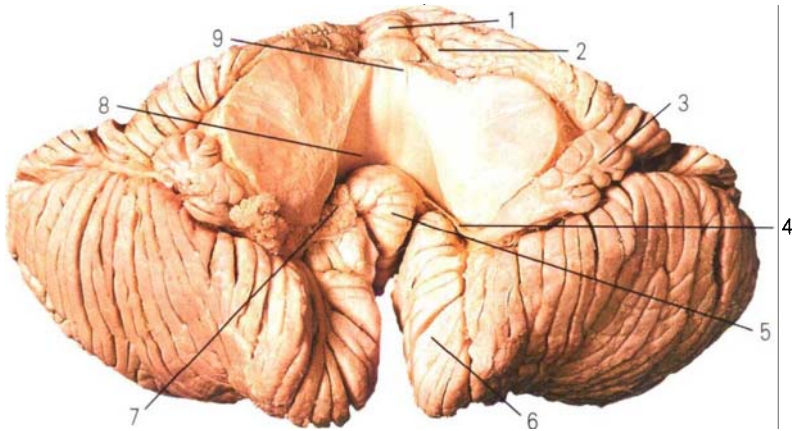


图 309 小脑(前面观)
The cerebellum(anterior aspect)

- | | |
|--------------------------------|---|
| 1. 中央小叶 central lobule | 6. 小脑扁桃体 tonsil of cerebellum |
| 2. 中央小叶翼 ala of central lobule | 7. 第四脑室脉络丛 choroid plexus of fourth ventricle |
| 3. 绒球 flocculus | 8. 第四脑室 fourth ventricle |
| 4. 绒球脚 peduncle of flocculus | 9. 前髓帆 anterior medullary velum |
| 5. 小结 nodule | |

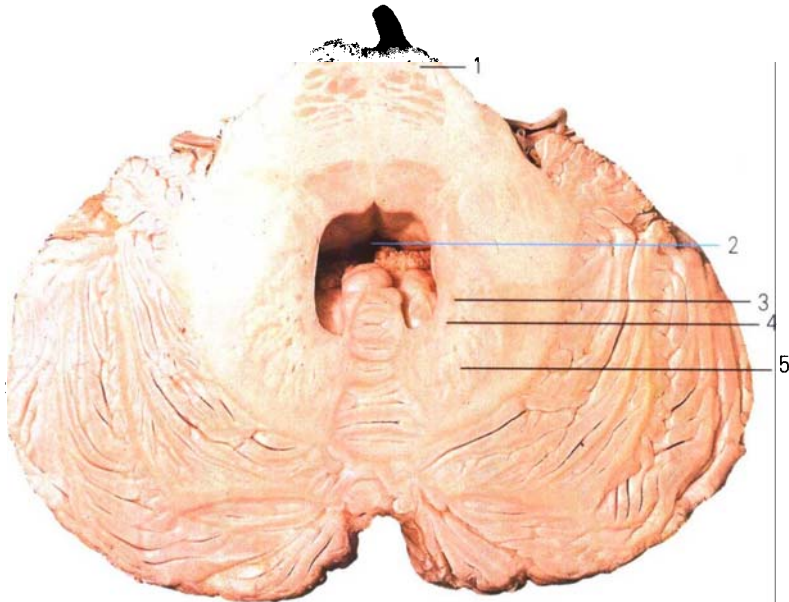
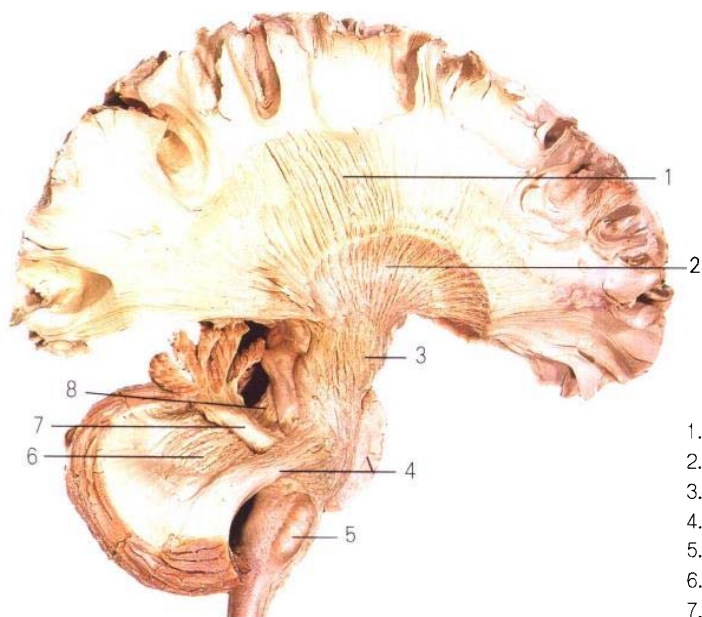


图 310 小脑横断面
Transverse section of the cerebellum

- | | |
|--------------------------|---------------------------|
| 1. 脑桥 pons | 4. 栓状核 emboliform nucleus |
| 2. 第四脑室 fourth ventricle | 5. 齿状核 dentate nucleus |
| 3. 球状核 globose nucleus | |



1. 辐射冠 corona radiata
2. 内囊 internal capsule
3. 锥体束 pyramidal tract
4. 小脑中脚 middle cerebellar peduncle
5. 橄榄 olive
6. 齿状核 dentate nucleus
7. 小脑下脚 inferior cerebellar peduncle
8. 小脑上脚 superior cerebellar peduncle

图 311 小脑脚及锥体束
The peduncles of cerebellum and the pyramidal tract

1. 尾状核 caudate nucleus
2. 豆状核 lentiform nucleus
3. 杏仁体 amygdaloid body
4. 视束 optic tract
5. 视神经(Ⅱ) optic n.(Ⅱ)
6. 漏斗 infundibulum
7. 大脑脚 cerebral peduncle
8. 脑桥 pons
9. 三叉神经(V) trigeminal n.(V)
10. 前庭蜗神经(XⅡ) vestibulocochlear n.(XⅡ)
11. 小脑中脚 middle cerebellar peduncle
12. 齿状核 dentate nucleus
13. 小脑上脚 superior cerebellar peduncle
14. 下丘 inferior colliculus
15. 内侧膝状体 medial geniculate body
16. 上丘 superior colliculus
17. 外侧膝状体 lateral geniculate body

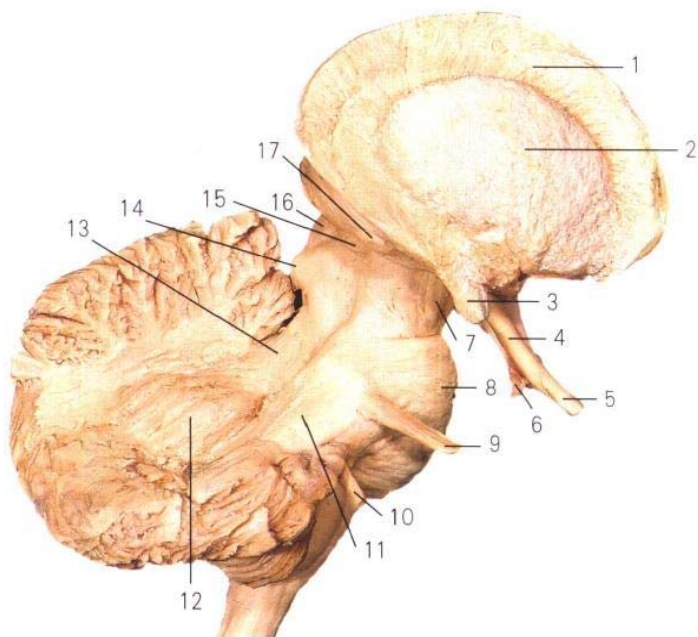


图 312 基底核和脑干
The basal nuclei and the brain stem

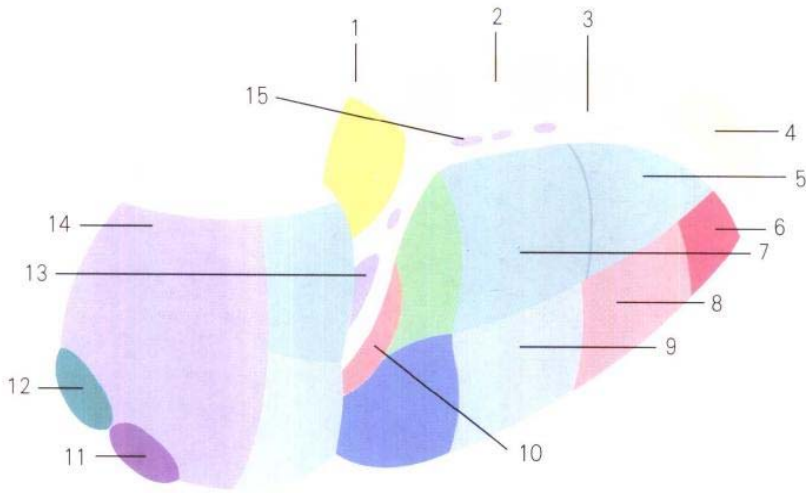


图 313 丘脑核团模式图
Diagram of the thalamic nuclei

- | | |
|--------------------------------------|---|
| 1. 中线核群 midline nuclear group | 9. 腹后外侧核 ventral posterolateral nucleus |
| 2. 内侧背核 mediodorsal nucleus | 10. 腹后内侧核 ventral posteromedial nucleus |
| 3. 内髓板 internal medullary lamina | 11. 外侧膝状体 lateral geniculate body |
| 4. 前核 anterior nucleus | 12. 内侧膝状体 medial geniculate body |
| 5. 外侧背核 lateral dorsal nucleus | 13. 中央中核 centromedian nucleus |
| 6. 腹前核 ventral anterior nucleus | 14. 枕核 nuclei pulvinare |
| 7. 外侧后核 lateral posterior nucleus | 15. 板内核群 intralaminar nuclear group |
| 8. 腹中间核 ventral intermediate nucleus | |

- | |
|------------------------------------|
| 1. 室间孔 interventricular foramen |
| 2. 丘脑间粘合 interthalamic adhesion |
| 3. 背内侧核 dorsomedial nucleus |
| 4. 下丘脑沟 hypothalamic sulcus |
| 5. 后核 posterior nucleus |
| 6. 腹内侧核 ventromedial nucleus |
| 7. 乳头体 mammillary body |
| 8. 弓状核 arcuate nucleus |
| 9. 视上核 supraoptic nucleus |
| 10. 视交叉 optic chiasma |
| 11. 视前内侧核 medial preoptic nucleus |
| 12. 视前外侧核 lateral preoptic nucleus |
| 13. 前核 anterior nucleus |
| 14. 室旁核 paraventricular nucleus |

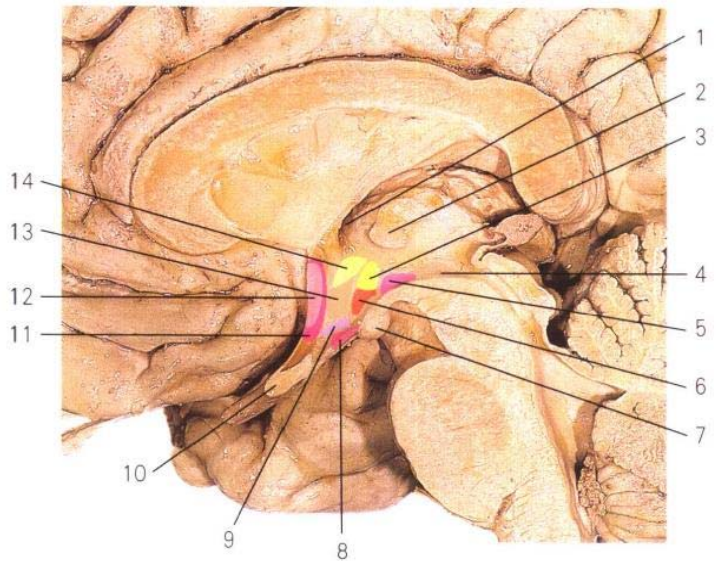


图 314 下丘脑核团模式图
Diagram of the hypothalamic nuclei

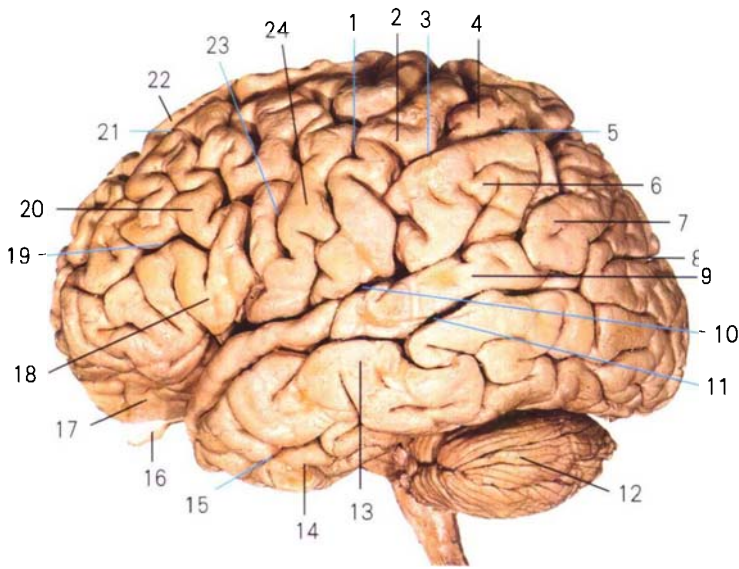


图 315 脑的外侧面
Lateral surface of the brain

1. 中央沟 central sulcus
2. 中央后回 postcentral gyrus
3. 中央后沟 postcentral sulcus
4. 顶上小叶 superior parietal lobule
5. 顶内沟 intraparietal sulcus
6. 缘上回 supramarginal gyrus
7. 角回 angular gyrus
8. 顶枕沟 parietooccipital sulcus
9. 颞上回 superior temporal gyrus
10. 外侧沟 lateral sulcus
11. 颞上沟 superior temporal sulcus
12. 小脑 cerebellum
13. 颞中回 middle temporal gyrus
14. 颞下回 inferior temporal gyrus
15. 颞下沟 inferior temporal sulcus
16. 嗅球 olfactory bulb
17. 眶回 orbital gyri
18. 额下回 inferior frontal gyrus
19. 额下沟 inferior frontal sulcus
20. 额中回 middle frontal gyrus
21. 额上沟 superior frontal sulcus
22. 额上回 superior frontal gyrus
23. 中央前沟 precentral sulcus
24. 中央前回 precentral gyrus

1. 中央旁小叶 paracentral lobule
2. 中央旁沟 paracentral sulcus
3. 扣带回 cingulate gyrus
4. 胼胝体 corpus callosum
5. 额上回 superior frontal gyrus
6. 透明隔 septum pellucidum
7. 扣带沟 cingulate sulcus
8. 室间孔 interventricular foramen
9. 丘脑间粘合 interthalamic adhesion
10. 下丘脑沟 hypothalamic sulcus
11. 乳头体 mamillary body
12. 嗅球 olfactory bulb
13. 视交叉 optic chiasma
14. 中脑水管 mesencephalic aqueduct
15. 中脑 midbrain
16. 脑桥 pons
17. 延髓 medulla oblongata
18. 小脑 cerebellum
19. 第四脑室 fourth ventricle
20. 松果体 pineal body
21. 舌回 lingual gyrus
22. 距状沟 calcarine sulcus
23. 楔叶 cuneus
24. 顶枕沟 parietooccipital sulcus
25. 楔前叶 precuneus
26. 缘支 marginal ramus

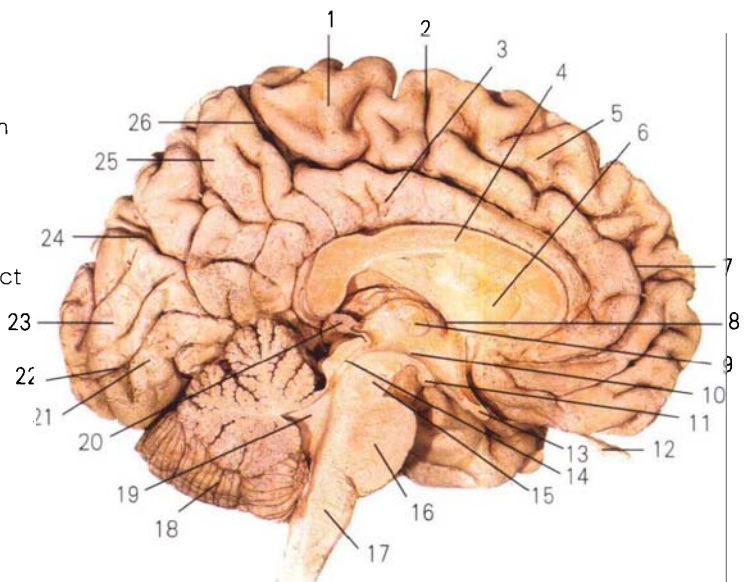


图 316 脑的正中矢状切面
Median sagittal section of the brain

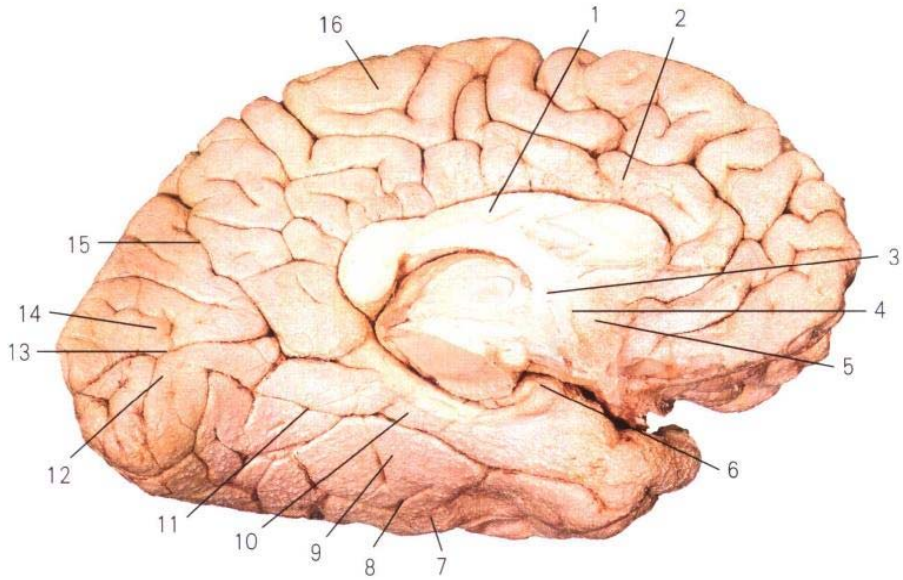
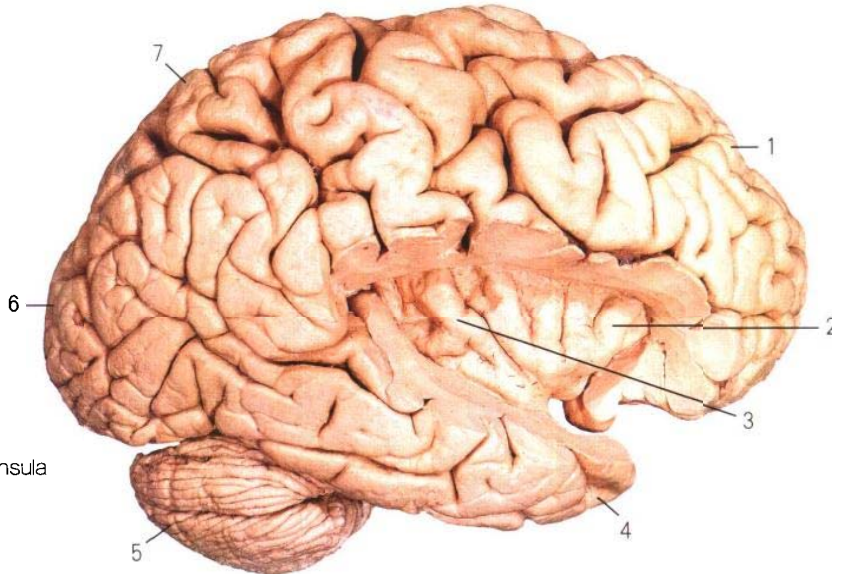


图 317 大脑半球内侧面
Medial surface of the cerebral hemisphere

- | | |
|---|--|
| 1. 胼胝体 corpus callosum | 9. 枕颞内侧回 medial occipitotemporal gyrus |
| 2. 扣带回 cingulate gyrus | 10. 海马旁回 parahippocampal gyrus |
| 3. 前连合 anterior commissure | 11. 侧副沟 collateral sulcus |
| 4. 终板旁回 paraterminal gyrus | 12. 舌回 lingual gyrus |
| 5. 胼胝体下区 subcallosal area | 13. 距状沟 calcarine sulcus |
| 6. 钩 uncus | 14. 楔叶 cuneus |
| 7. 枕颞外侧回 lateral occipitotemporal gyrus | 15. 顶枕沟 parietooccipital sulcus |
| 8. 枕颞沟 occipitotemporal sulcus | 16. 中央旁小叶 paracentral lobule |



- | |
|------------------------------|
| 1. 额叶 frontal lobe |
| 2. 岛短回 short gyrus of insula |
| 3. 岛长回 long gyrus of insula |
| 4. 颞叶 temporal lobe |
| 5. 小脑 cerebellum |
| 6. 枕叶 occipital lobe |
| 7. 顶叶 parietal lobe |

图 318 脑岛
The insula

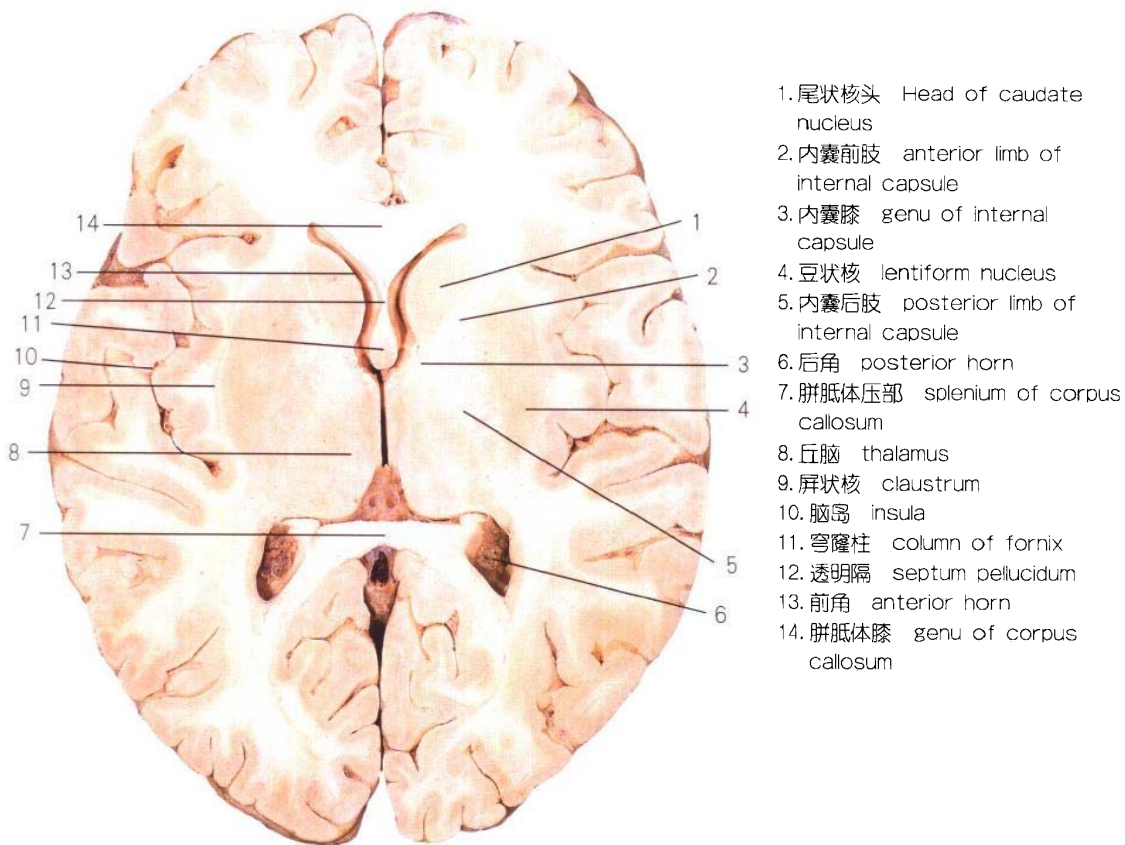
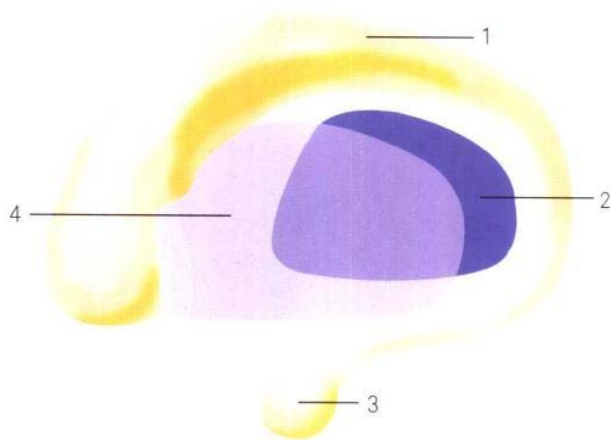


图 319 脑的水平切面
Horizontal section of the brain



- 1. 尾状核 caudate nucleus
- 2. 背侧丘脑 dorsal thalamus
- 3. 杏仁体 amygdaloid body
- 4. 豆状核 lentiform nucleus

图 320 基底神经核
The basal nuclei

1. 尾状核 caudate nucleus
2. 内囊 internal capsule
3. 豆状核 lentiform nucleus
4. 脑岛 insula
5. 第三脑室 third ventricle
6. 背侧丘脑 dorsal thalamus
7. 苍白球 globus pallidus
8. 壳 putamen
9. 屏状核 claustrum
10. 穹窿 fornix
11. 透明隔 septum pellucidum
12. 侧脑室 lateral ventricle
13. 胼胝体 corpus callosum

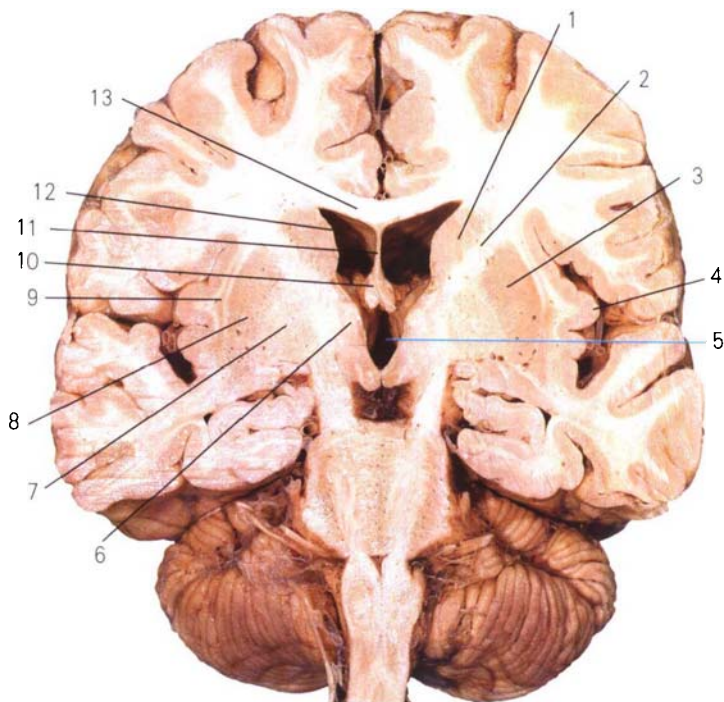
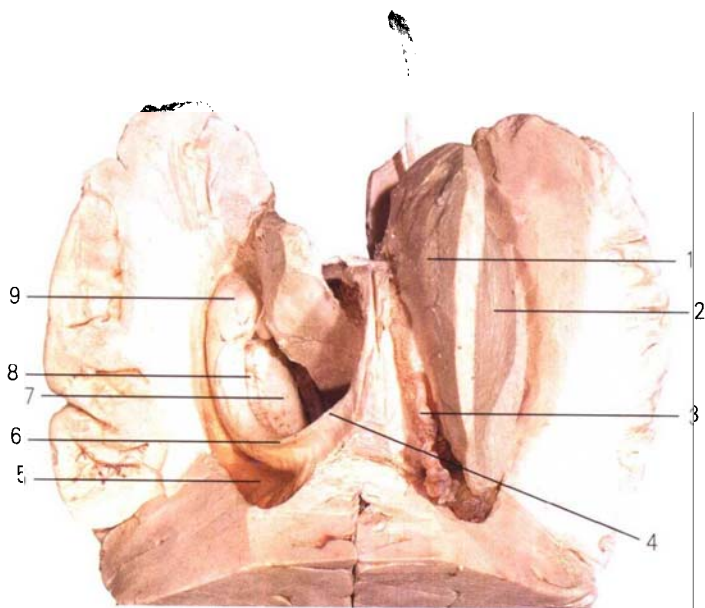


图 321 脑的冠状切面
Coronal section of the brain



1. 尾状核 caudate nucleus
2. 豆状核 lentiform nucleus
3. 侧脑脉络丛 choroid plexus of lateral ventricle
4. 穹窿脚 crus of fornix
5. 侧副三角 collateral trigone
6. 海马伞 fimbria of hippocampus
7. 海马旁回 parahippocampal gyrus
8. 齿状回 dentate gyrus
9. 海马 hippocampus

图 322 侧脑室下角
Inferior horn of lateral ventricle

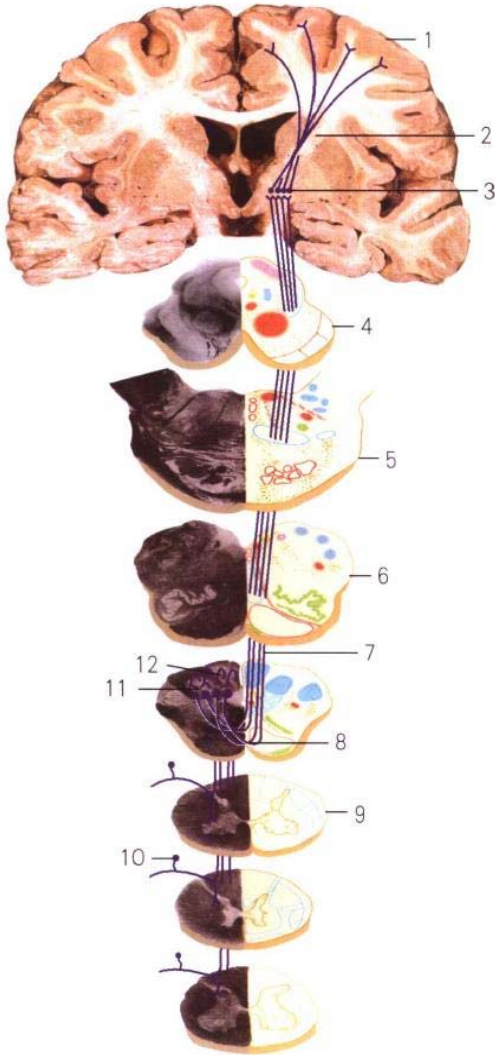


图 323 本体感觉传导道
Pathway of the proprioceptive sensibility

1. 中央后回 postcentral gyrus
2. 内囊 internal capsule
3. 腹后外侧核 ventral posterolateral nucleus
4. 中脑 midbrain
5. 脑桥 pons
6. 延髓 medulla oblongata
7. 内侧丘系 medial lemniscus
8. 内侧丘系交叉 decussation of medial lemniscus
9. 脊髓 spinal cord
10. 脊神经节 spinal ganglion
11. 楔束核 cuneate nucleus
12. 薄束核 gracile nucleus

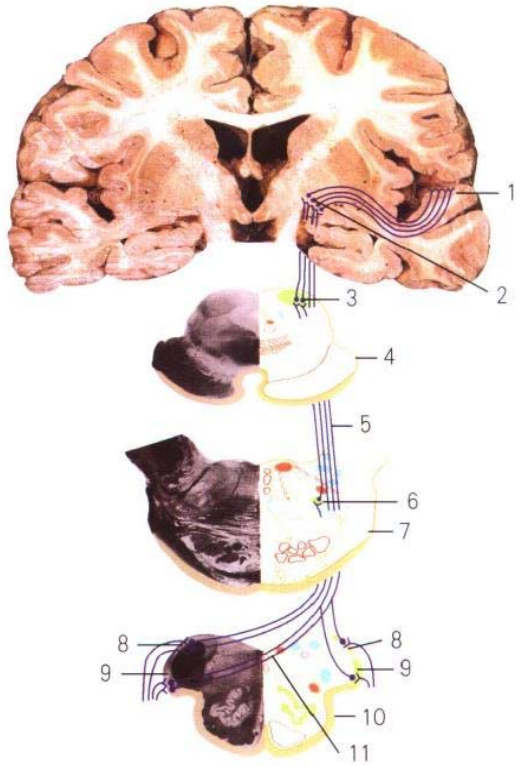
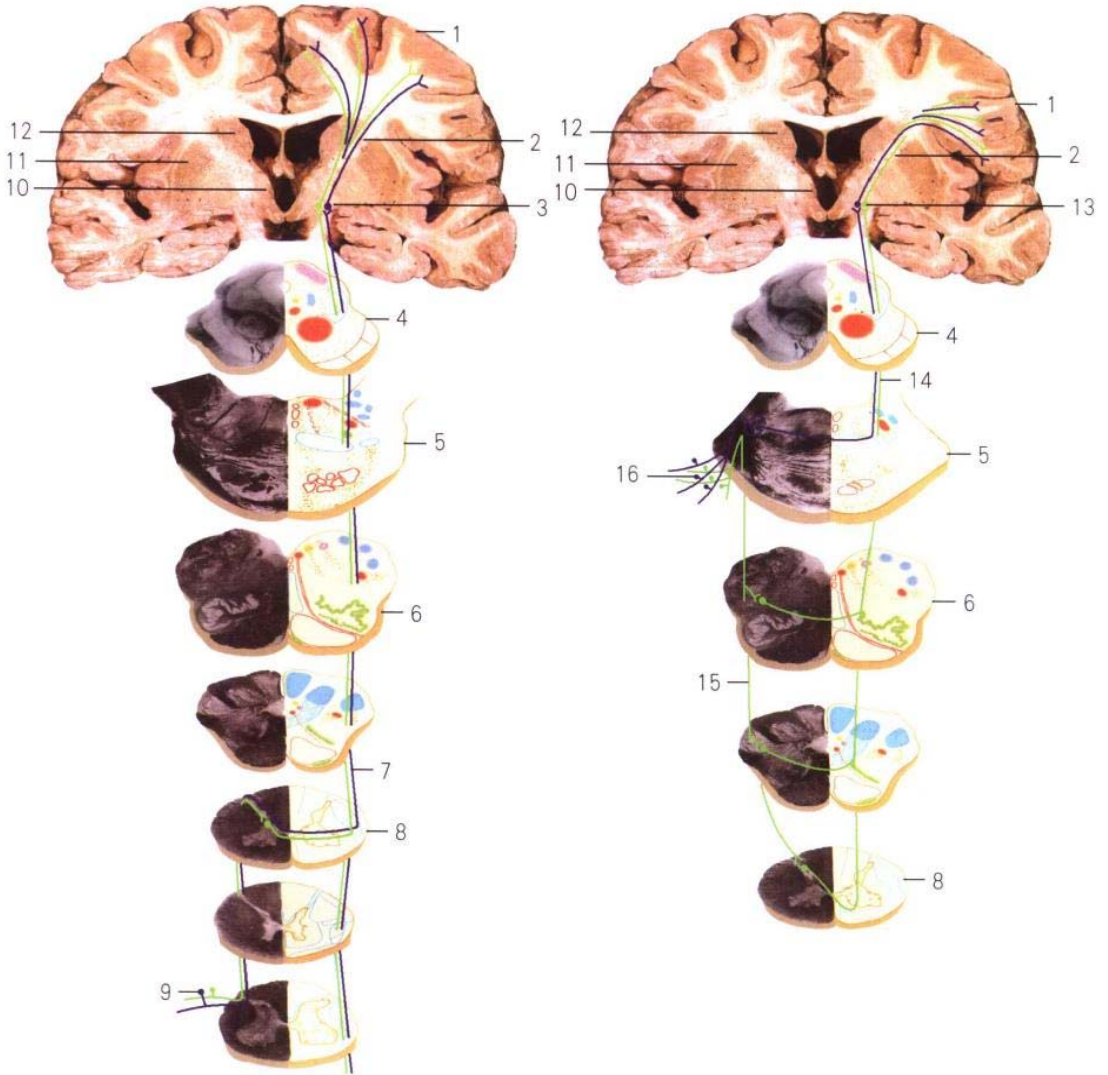


图 324 听觉传导道
The auditory pathway

1. 颞横回 transverse temporal gyri
2. 内侧膝状体 medial geniculate body
3. 下丘核 nucleus of inferior colliculus
4. 中脑 midbrain
5. 外侧丘系 lateral lemniscus
6. 上橄榄核 superior olivary nucleus
7. 脑桥 pons
8. 蜗背侧核 dorsal cochlear nucleus
9. 蜗腹侧核 ventral cochlear nucleus
10. 延髓 medulla oblongata
11. 斜方体 trapezoid body



A. 脊髓丘系
Spinal lemniscus

B. 三叉丘系
Trigeminal lemniscus

图 325 浅感觉传导道 (A, B)
Pathway of the exteroceptive sensibility (A, B)

- 1. 中央后回 postcentral gyrus
- 2. 内囊 internal capsule
- 3. 腹后外侧核 ventral posterolateral nucleus
- 4. 中脑 midbrain
- 5. 脑桥 pons
- 6. 延髓 medulla oblongata
- 7. 脊髓丘脑束 spinothalamic tract
- 8. 脊髓 spinal cord

- 9. 脊神经节 spinal ganglion
- 10. 背侧丘脑 dorsal thalamus
- 11. 豆状核 lentiform nucleus
- 12. 尾状核 caudate nucleus
- 13. 腹后内侧核 ventral posteromedial nucleus
- 14. 三叉丘系 trigeminal lemniscus
- 15. 三叉神经脊束 spinal tract of trigeminal n.
- 16. 三叉神经节 trigeminal ganglion

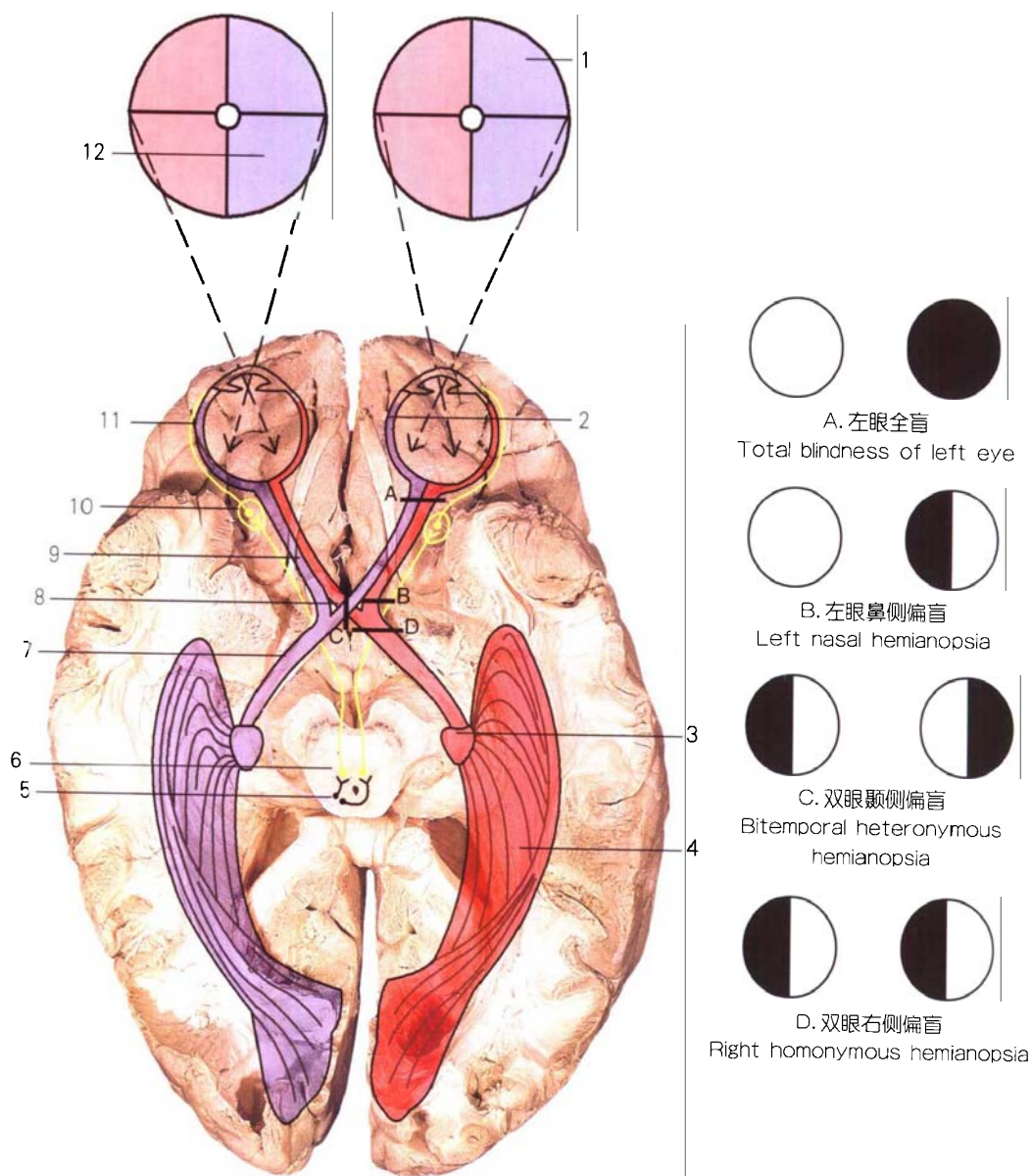


图 326 视觉传导道(下面观)
The visual pathway(inferior aspect)

- 1. 颞侧视野 temporal visual field
- 2. 鼻侧视网膜 nasal retina
- 3. 外侧膝状体 lateral geniculate body
- 4. 视辐射 optic radiation
- 5. 顶盖前区 pretectal area
- 6. 动眼神经副核 accessory nucleus of oculomotor n.

- 7. 视束 optic tract
- 8. 视交叉 optic chiasma
- 9. 视神经(Ⅱ) optic n.(Ⅱ)
- 10. 睫状神经节 ciliary ganglion
- 11. 颞侧视网膜 temporal retina
- 12. 鼻侧视野 nasal visual field

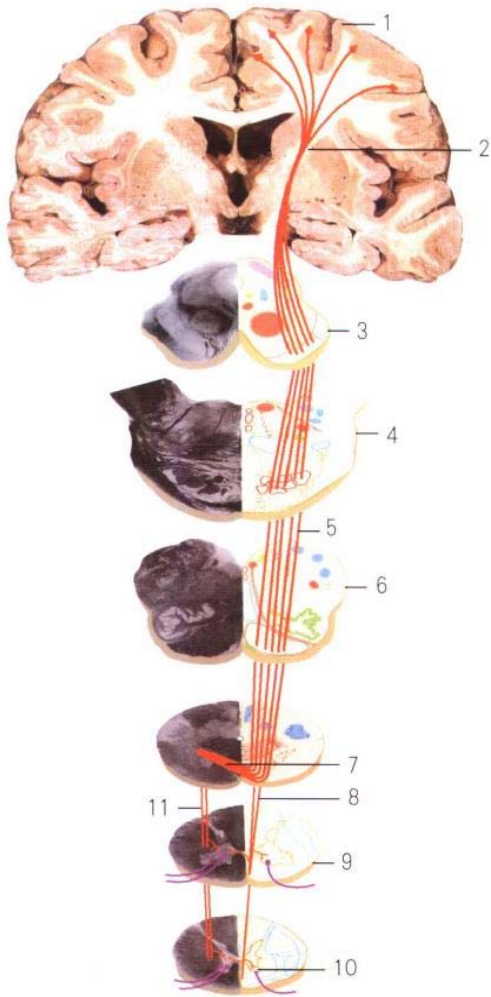


图 327 锥体系(皮质脊髓束)
Pyramidal system(corticospinal tracts)

1. 中央前回 precentral gyrus
2. 内囊 internal capsule
3. 中脑 midbrain
4. 脑桥 pons
5. 皮质脊髓束 corticospinal tracts
6. 延髓 medulla oblongata
7. 锥体交叉 decussation of pyramid
8. 皮质脊髓前束 anterior corticospinal tract
9. 脊髓 spinal cord
10. 前角 anterior horn
11. 皮质脊髓侧束 lateral corticospinal tract

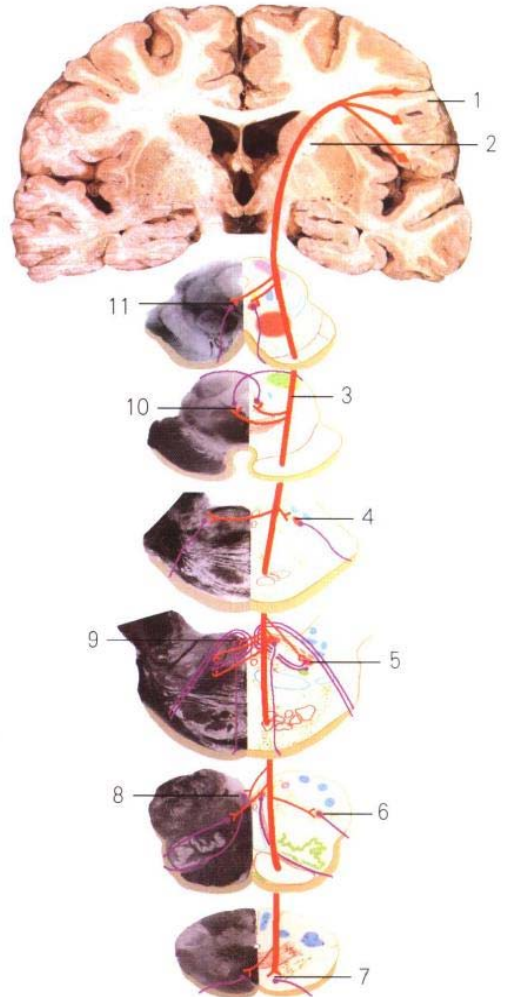
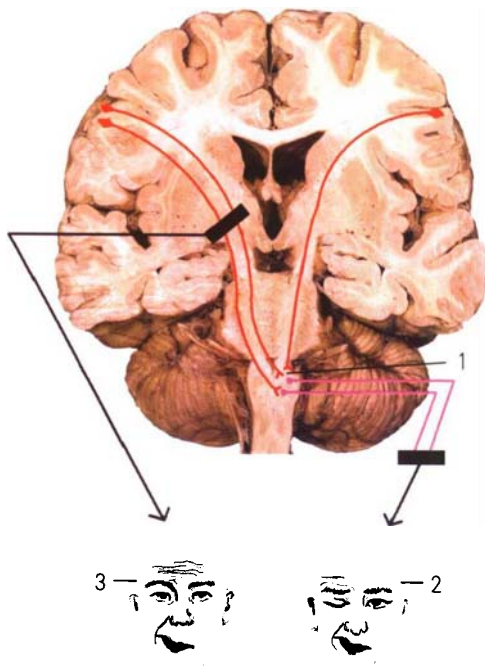


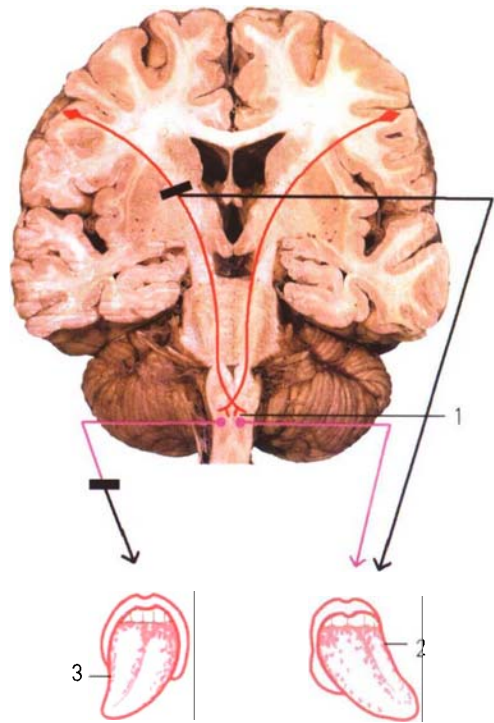
图 328 锥体系(皮质核束)
Pyramidal system(corticonuclear tract)

1. 中央前回 precentral gyrus
2. 内囊 internal capsule
3. 皮质核束 corticonuclear tract
4. 三叉神经运动核 motor nucleus of trigeminal n.
5. 面神经核 nucleus of facial n.
6. 疑核 nucleus ambiguus
7. 副神经核 nucleus of accessory n.
8. 舌下神经核 nucleus of hypoglossal n.
9. 展神经核 nucleus of abducent n.
10. 滑车神经核 nucleus of trochlear n.
11. 动眼神经核 nucleus of oculomotor n.



1. 面神经核 nucleus of facial n.
2. 面神经核下瘫 infranuclear paralysis
3. 面神经核上瘫 supranuclear paralysis

图 329 面神经瘫
 Paralysis of the facial nerve



1. 舌下神经核 nucleus of hypoglossal n.
2. 舌下神经核上瘫 supranuclear paralysis
3. 舌下神经核下瘫 infranuclear paralysis

图 330 舌下神经瘫
 Paralysis of the hypoglossal nerve

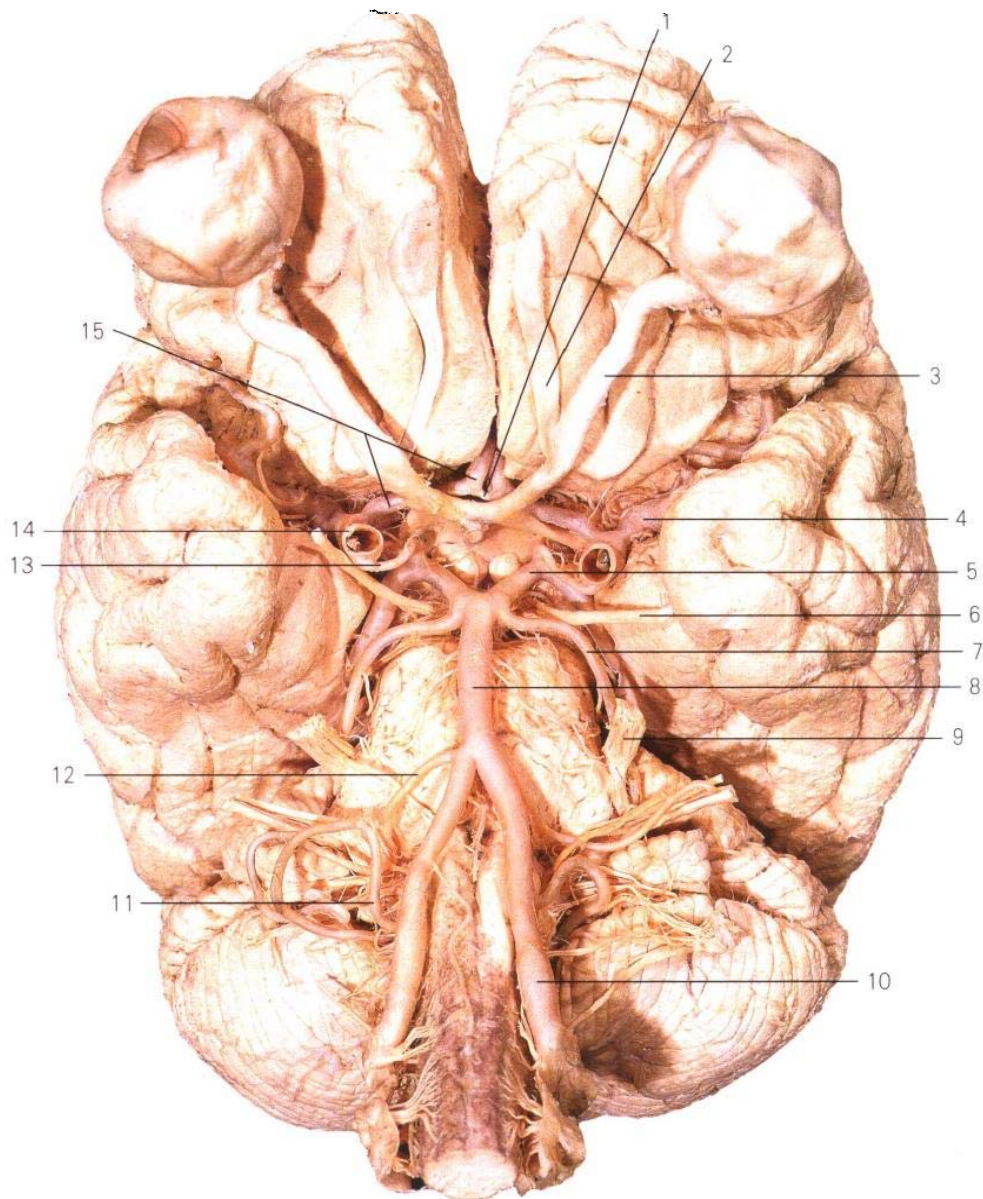


图 333 脑底的动脉
Arteries at the base of brain

- | | |
|------------------------------------|---|
| 1. 前交通动脉 anterior communicating a. | 9. 三叉神经(V) trigeminal n.(V) |
| 2. 嗅束 olfactory tract | 10. 椎动脉 vertebral a. |
| 3. 视神经(II) optic n.(II) | 11. 小脑后下动脉 posterior inferior cerebellar a. |
| 4. 大脑中动脉 middle cerebral a. | 12. 小脑前下动脉 anterior inferior cerebellar a. |
| 5. 大脑后动脉 posterior cerebral a. | 13. 后交通动脉 posterior communicating a. |
| 6. 动眼神经(III) oculomotor n.(III) | 14. 颈内动脉 internal carotid a. |
| 7. 小脑上动脉 superior cerebellar a. | 15. 大脑前动脉 anterior cerebral a. |
| 8. 基底动脉 basilar a. | |

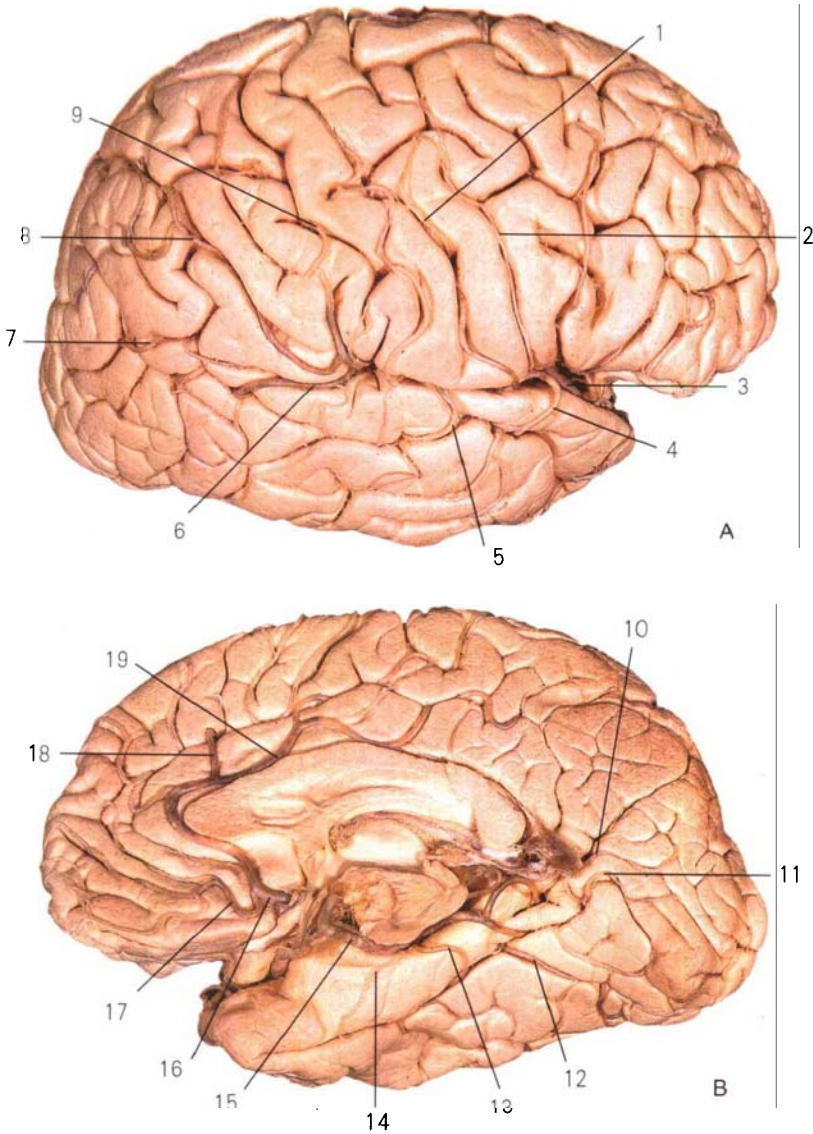
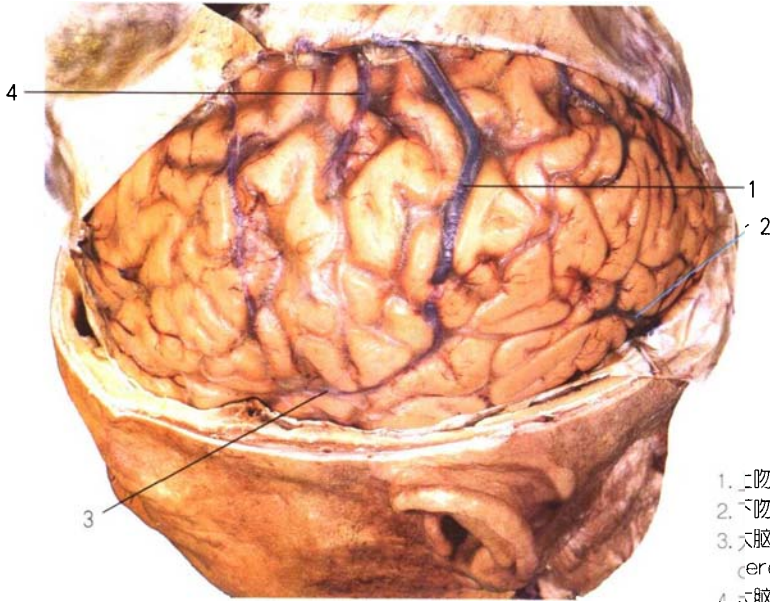


图334 大脑半球的动脉(A.外侧面, B.内侧面)
Arteries of the cerebral hemisphere(A.lateral surface,B.medial surface)

- | | |
|-----------------------------------|--|
| 1.中央沟动脉 a. of central sulcus | 11.距状沟支 calcarine branch |
| 2.中央前沟动脉 a. of precentral sulcus | 12.颞后支 posterior temporal branches |
| 3.大脑中动脉 middle cerebral a. | 13.颞中间支 intermediate temporal branches |
| 4.颞前动脉 anterior temporal a. | 14.颞前支 anterior temporal branches |
| 5.颞中动脉 middle temporal a. | 15.大脑后动脉 posterior cerebral a. |
| 6.颞后动脉 posterior temporal a. | 16.大脑前动脉 anterior cerebral a. |
| 7.角回动脉 a. of angular gyrus | 17.额极动脉 frontopolar a. |
| 8.顶后动脉 posterior parietal artery | 18.胼缘动脉 callosomarginal a. |
| 9.中央后沟动脉 a. of postcentral sulcus | 19.胼胝体周动脉 pericallosal a. |
| 10.顶枕支 parietooccipital branch | |



- 1. 上吻合静脉 superior anastomotic v.
- 2. 下吻合静脉 inferior anastomotic v.
- 3. 大脑中浅静脉 superficial middle cerebral v.
- 4. 大脑上静脉 superior cerebral v.

图 335 大脑半球外侧面的静脉
Veins of the lateral surface of cerebral hemisphere

- 1. 大脑中动脉 middle cerebral a.
- 2. 大脑内静脉 internal cerebral v.
- 3. 大脑大静脉 great cerebral v.
- 4. 直窦 rectus sinuss
- 5. 小脑幕 tentorium of cerebellum
- 6. 大脑后动脉 posterior cerebral a.
- 7. 侧脑室脉络丛 choroid plexus of lateral ventricle

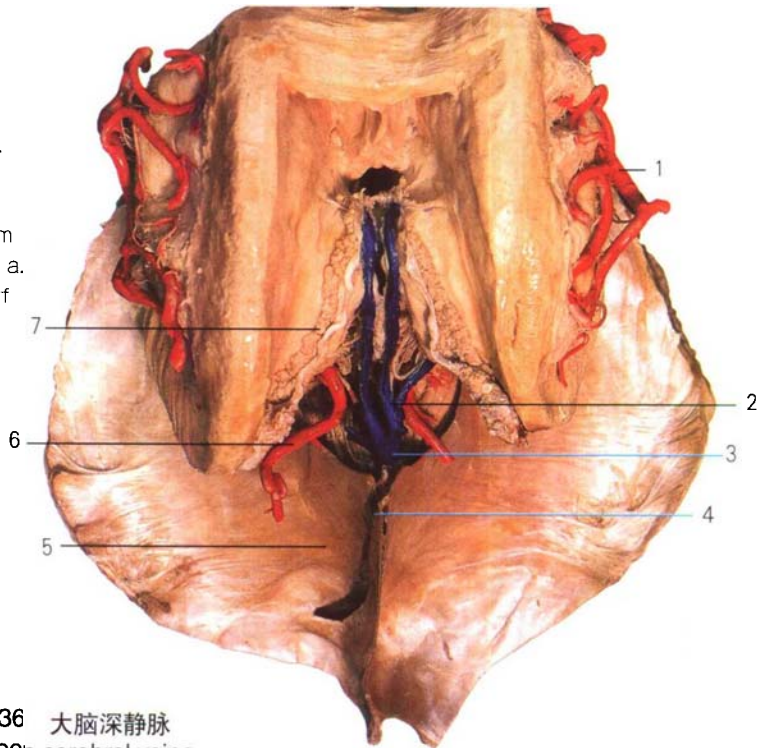
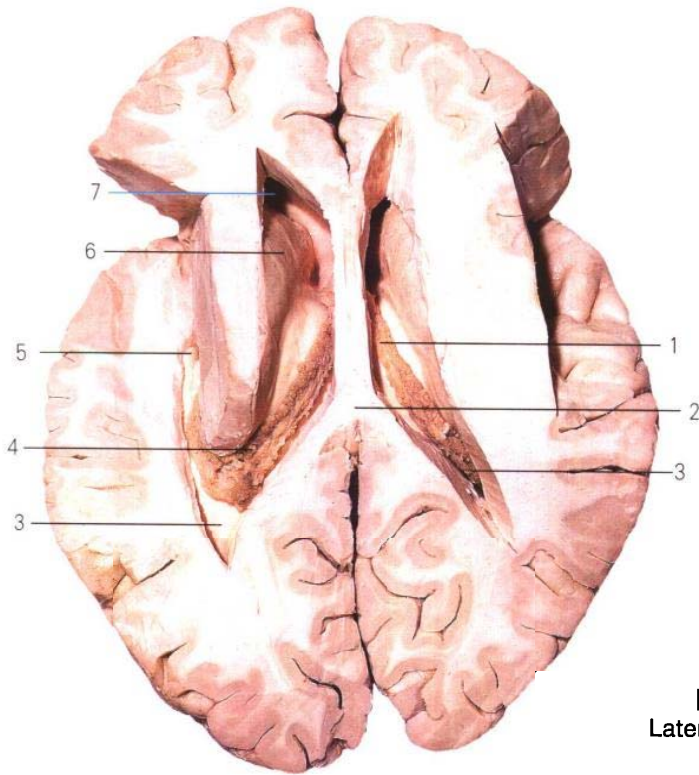
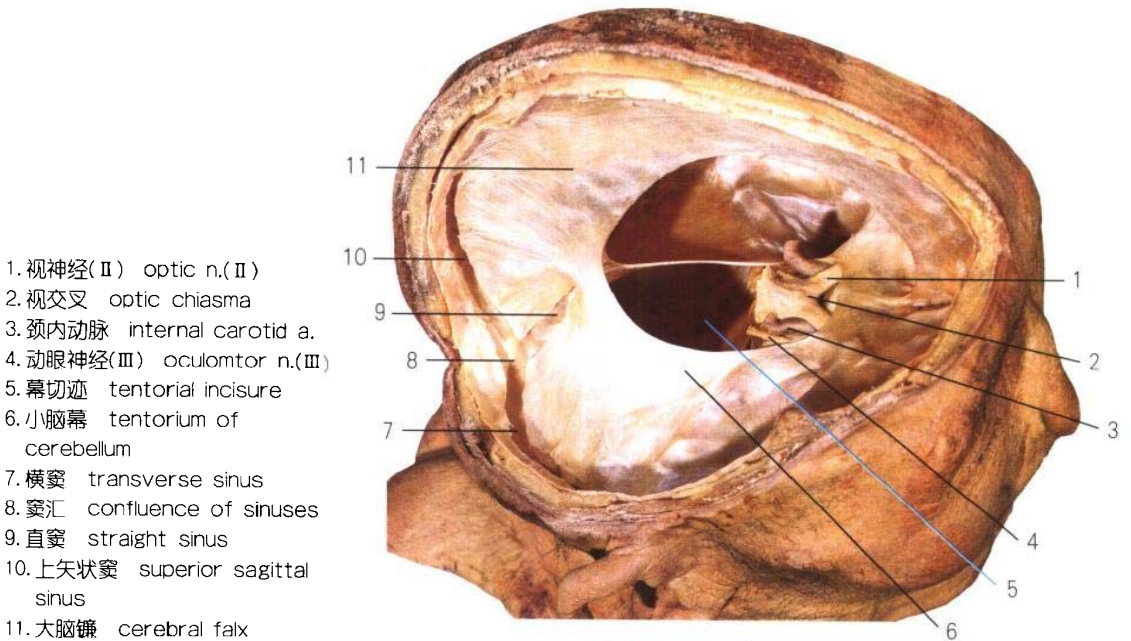


图 336 大脑深静脉
The deep cerebral veins



1. 侧脑室中央部 central part of lateral ventricle
2. 胼胝体压部 splenium of corpus callosum
3. 侧脑室后角 posterior horn of lateral ventricle
4. 侧脑室脉络丛 choroid plexus of lateral ventricle
5. 海马 hippocampus
6. 尾状核头 head of caudate nucleus
7. 侧脑室前角 anterior horn of lateral ventricle

图 337 侧脑室(上面观)
Lateral ventricle(superior aspect)



1. 视神经(Ⅱ) optic n.(Ⅱ)
2. 视交叉 optic chiasma
3. 颈内动脉 internal carotid a.
4. 动眼神经(Ⅲ) oculomotor n.(Ⅲ)
5. 幕切迹 tentorial incisure
6. 小脑幕 tentorium of cerebellum
7. 横窦 transverse sinus
8. 窦汇 confluence of sinuses
9. 直窦 straight sinus
10. 上矢状窦 superior sagittal sinus
11. 大脑镰 cerebral falx

图 338 硬脑膜及硬脑膜窦
Cerebral dura mater and sinuses of dura mater

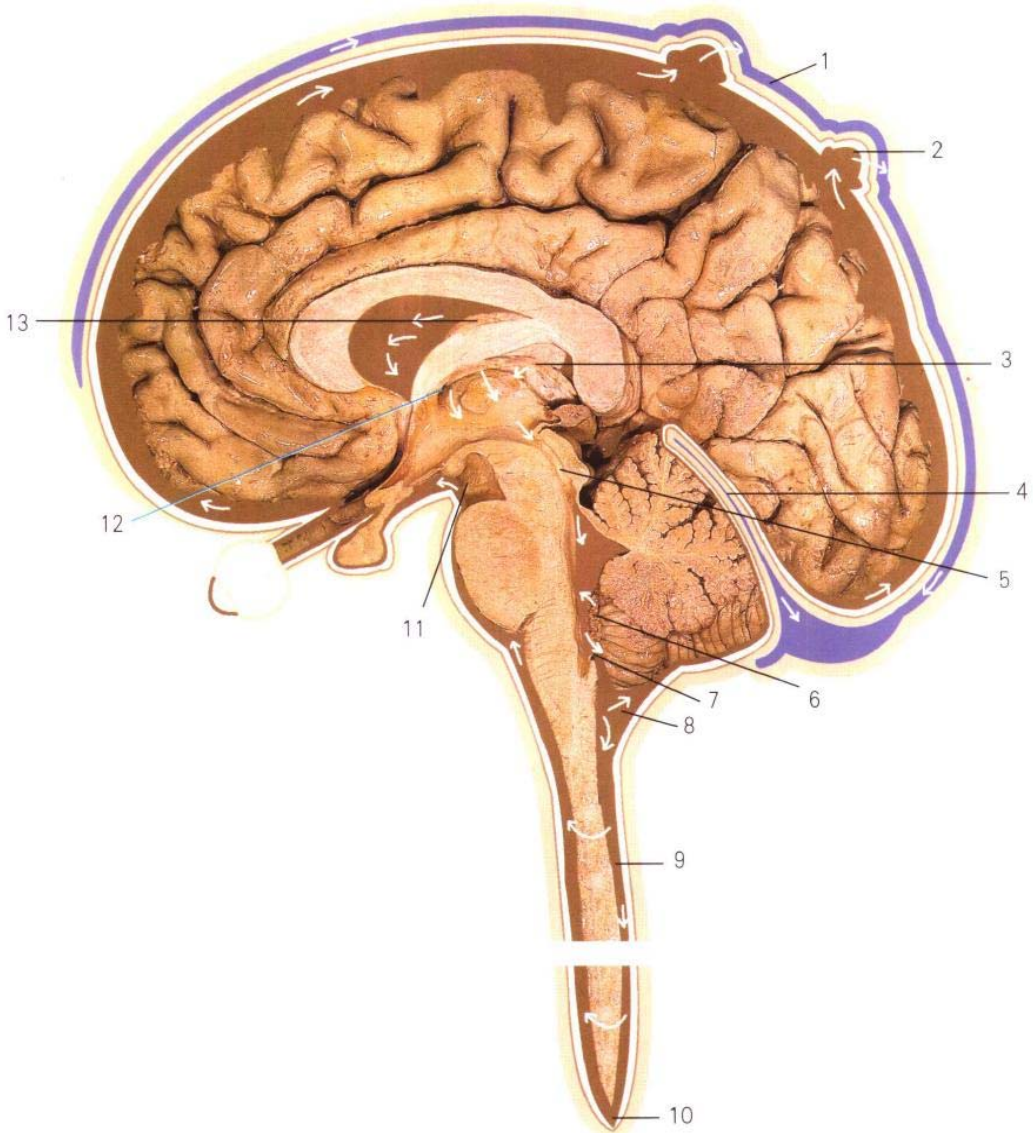


图 339 脑脊液循环模式图
Diagram of cerebrospinal fluid circulation

- | | |
|--|--|
| 1. 上矢状窦 superior sagittal sinus | 8. 小脑延髓池 cerebellomedullary cistern |
| 2. 蛛网膜粒 arachnoid granulations | 9. 蛛网膜下腔 subarachnoid space |
| 3. 第三脑室脉络丛 choroid plexus of third ventricle | 10. 终池 terminal cistern |
| 4. 直窦 straight sinus | 11. 脚间池 interpeduncular cistern |
| 5. 中脑导水管 mesencephalic aqueduct | 12. 室间孔 interventricular foramen |
| 6. 第四脑室脉络丛 choroid plexus of fourth ventricle | 13. 侧脑室脉络丛 choroid plexus of lateral ventricle |
| 7. 第四脑室正中孔 median aperture of fourth ventricle | |

索引

A

鞍背 dorsum sellae 11

B

白膜 tunica albuginea 140,150

板内核群 intralaminar nuclear group 211

板障 diploe 3

半腱肌 semimembranosus 52,54,57

半膜肌 semimembranosus 52,54,57

半羽状肌 unipennate muscle 44

半月瓣小结 nodule of semilunar valve 100

膀胱 urinary bladder 136 - 142,144 - 146,107,108,129

膀胱尖 apex of urinary bladder 115

膀胱静脉丛 vesical venous plexus 142

膀胱三角 trigone of bladder 140

膀胱上动脉 superior vesical a. 137 ~ 139,146

膀胱下动脉 inferior vesical a. 137,138,146

膀胱子宫陷凹 vesicouterine pouch 144

背侧丘脑 dorsal thalamus 214,215,217,221

背阔肌 latissimus dorsi 68,71,72

背内侧核 dorsomedial nucleus 211

贲门 cardia 119

贲门切迹 cardiac incisure 119

鼻侧视网膜 nasal retina 218

鼻侧视野 nasal visual field 218

鼻腭粘膜腺 glands of nose and palatum 178

鼻副软骨 accessory nasal cartilages 186

鼻骨 nasal bone 9,12,186

鼻后孔 posterior nasal aperture 10

鼻后上外侧支 lateral posterior superior nasal branches 179

鼻后下支 posterior inferior nasal branches 178

鼻泪管 nasolacrimal duct 191

鼻泪管开口 orifice of nasolacrimal duct 186

鼻前棘 anterior nasal spine 18

鼻前庭 nasal vestibule 186,187

鼻腔 nasal cavity 88

鼻切迹 nasal notch 18

鼻外侧软骨 lateral nasal cartilages 186

鼻翼大软骨 major alar cartilage 186

鼻翼小软骨 minor alar cartilages 180

鼻阈 limen nasi 186,187

鼻中隔 nasal septum 9,184

鼻中膈软骨 septal cartilage of nose 186

比目鱼肌 soleus 55,59,62

比目鱼肌线 soleal line 26

闭孔 obturator foramen 24,35,143

闭孔动脉(后支) obturator a.(posterior branch) 52

闭孔动脉(前支) obturator a.(anterior branch) 52

闭孔膜 obturator membrane 35

闭孔内肌(腱) obturator internus (tendon) 53,54

闭孔神经 obturator n. 51,52

闭孔神经(前支) obturator n.(anterior branch) 50

闭孔神经、动脉 obturator n. & a. 137,139

闭孔外肌 obturator externus 51,52

臂丛 brachial plexus 66,158,159,161,162

臂丛根 roots of the brachial flexus 67

臂丛后束 posterior cord of brachial plexus 67

臂丛内侧束 medial cord of brachial plexus 67,92

臂丛外侧束 lateral cord of brachial plexus 67,92

边缘动脉 marginal a. 126,127

扁骨 flat bone 3

扁肌 flat muscle 44

杓横肌 transverse arytenoid 167

杓会厌襞 aryepiglottic fold 168,184

杓会厌肌 aryepiglottis 167

杓间切迹 interarytenoid notch 184

杓斜肌 oblique arytenoid 167

杓状会厌襞 aryepiglottic fold 184

杓状软骨 arytenoid cartilage 166

杓状软骨尖 apex of arytenoid cartilage 166,168

髌底 base of patella 26

髌骨 patella 2,26

髌关节面 patellar articular surface 26

髌尖 apex of patella 26

髌面 patellar surface 25,39
髌内侧支持带 medial patellar retinaculum 38
髌韧带 patellar lig. 38,39,40,41
髌上囊 suprapatellar capsule 41
髌外侧支持带 lateral patellar retinaculum 38
玻璃体 vitreous body 188
玻璃体管 hyaloid canal 188
薄束 fasciculus gracilis 201,204
薄束核 gracile nucleus 204,216
薄束结节 gracile tubercle 202
不规则骨 irregular bone 3

C

苍白球 globus pallidus 215
侧副沟 collateral sulcus 213
侧副三角 collateral trigone 215
侧块 lateral mass 5
侧脑室 lateral ventricle 108
侧脑室后角 posterior horn of lateral ventricle 225
侧脑室脉络丛 choroid plexus of
lateral ventricle 224,225,226
侧脑室前角 anterior horn of lateral ventricle 225
侧脑室中央部 central part of lateral ventricle 225
侧切牙 lateral incisor 182
长脚 long crus 194
长收肌 adductor longus 49 ~ 52,57
肠系膜上丛 superior mesenteric plexus 134
肠系膜上动脉 superior
mesenteric a. 121,122,126,131,133,134
肠系膜上静脉 superior mesenteric v. 121,128
肠系膜下丛 inferior mesenteric plexus 134
肠系膜下动脉 inferior mesenteric a. 127,133,134
肠系膜下静脉 inferior mesenteric v. 128
尺侧副韧带 ulnar collateral lig. 33
尺侧腕屈肌 flexor carpi ulnaris 73 ~ 75,80
尺侧腕屈肌腱 tendon of flexor carpi ulnaris 79,81,84
尺侧腕伸肌 extensor carpi ulnaris 78,85
尺动脉 ulnar a. 74,75,79,80
尺动脉和尺静脉 ulnar a. & v. 73
尺动脉腕背支 dorsal carpal branch of ulnar a. 82
尺动脉掌深支及尺神经深支 deep palmar branch
of ulnar a. and deep branch of ulnar n. 79,80,81
尺骨 ulna 2,22,33,34,77
尺骨粗隆 ulnar tuberosity 22

尺骨茎突 styloid process of ulna 22,77
尺骨体 shaft of ulna 22
尺骨头 head of ulna 22
尺切迹 ulnar notch 22
尺神经 ulnar n. 67 ~ 70,74,75,85
尺神经沟 sulcus for ulnar n. 21
尺神经及动脉 ulnar n. & a. 75,85
尺神经交通支 communicating branch with ulnar n. 82
尺神经浅支 superficial branch of ulnar n. 79,81
尺神经深支 deep branch of ulnar n. 79 ~ 81
尺神经深支及尺动脉掌深支 deep branch of ulnar
n. and deep palmar branch of ulnar a. 79
尺神经手背支 dorsal branch of ulnar n. 81
尺神经与尺侧上副动脉 ulnar n. and superior
ulnar collateral a. 85
齿突 dens 5,108,185
齿突凹 dental fovea 5
齿突尖韧带 apical lig of dens 30
齿状核 dentate nucleus 209,210,221
齿状红核束 dentatorubral tract 221
齿状回 dentate gyrus 215
齿状丘脑束 dentatohalamic tract 221
齿状韧带 denticulate ligament 200
耻骨 pubis 24
耻骨弓 pubic arch 147
耻骨结节 pubic tubercle 24,35
耻骨联合 pubic symphysis 107
耻骨联合面 symphyseal surface 24
耻骨联合腔 pubic symphysis cavity 35
耻股韧带 pubofemoral lig. 36
耻骨梳 pecten of pubis 24
穿动脉 perforating a. 51
穿支 perforating branch 66,89
垂体 hypophysis 186,187
垂体窝 hypophysial fossa 11,14
垂直板 perpendicular plate 16
锤骨 malleus 194,196
锤骨柄 manubrium of malleus 194
锤骨头 head of malleus 194
粗线 linea aspera 25

D

大多角骨 trapezium bone 23
大角 greater horn 13,168

- 大结节 greater tubercle 21
 大结节嵴 crest of greater tubercle 21
 大菱形肌 rhomboideus major 45
 大脑大静脉 great cerebral v. 224
 大脑后动脉 posterior cerebral a. 222 ~ 224
 大脑脚 cerebral peduncle 202,203,210
 大脑脚底 crus cerebri 207
 大脑镰 falx cerebri 108,225
 大脑内静脉 internal cerebral v. 224
 大脑皮质 cerebral cortex 221
 大脑前动脉 anterior cerebral a. 222,223
 大脑上静脉 superior cerebral v. 224
 大脑窝 cerebral fossa 17
 大脑中动脉 middle cerebral a. 222 ~ 224
 大脑中浅静脉 superficial middle cerebral v. 224
 大收肌 adductor magnus 50,51,54
 大收肌腱 adductor magnus tendon 38,50
 大网膜 greater omentum 116 ~ 118
 大翼 greater wing 11,14
 大阴唇 greater lip of pudendum 151,152
 大隐静脉 great saphenous v. 48,49,57,58,59,64,110,111
 大圆肌 teres major 45
 大转子 greater trochanter 25,36,37
 胆囊 gall bladder 110,116,123,124,125
 胆囊底 fundus of gallbladder 118,124
 胆囊动脉 cystic a. 120
 胆囊管 cystic duct 124
 胆囊颈 neck of gallbladder 124
 胆囊体 body of gallbladder 124
 胆总管 common bile duct 123 ~ 125
 弹性圆锥 conus elasticus 168
 导管(通过网膜孔) catheter
 (through the omental foramen) 118
 岛长回 long gyrus of insula 213
 岛短回 short gyrus of insula 213
 道上嵴 superameatal spine 15
 道上小凹 superameatal foveola 15
 镫骨 stapes 194,196
 镫骨底 base of stapes 194
 镫骨肌 stapedius 196
 镫骨脚 crus of stapes 194
 底丘脑核 subthalamic nucleus 221
 骶丛 sacral plexus 139
 骶粗隆 sacral tuberosity 7
 骶骨 sacrum 2,4,7,143
 骶骨尖 apex of sacrum 7
 骶管 sacral canal 7
 骶管裂孔 sacral hiatus 7
 骶后孔 posterior sacral foramen 7
 骶棘韧带 sacrospinous lig. 35
 骶交感神经节 sacral ganglia 134
 骶角 sacral cornu 7
 骶结节韧带 sacrotuberous lig. 35
 骶髂背侧韧带 dorsal sacroiliac lig. 35
 骶髂腹侧韧带 ventral sacroiliac lig. 35
 骶髂关节腔 sacroiliac joint cavity 35
 骶前孔 anterior sacrum foramen 7
 骶神经节 sacral ganglia 139
 骶外侧嵴 lateral sacral crest 7
 骶翼 ala of sacrum 7
 骶正中动脉 median sacral a. 134,138,139,146
 骶正中嵴 median sacral crest 7
 骶中间嵴 intermediate sacral crest 7
 骶骨 sacrum 2,7,143
 第二穿动脉 2nd perforating a. 54
 第二磨牙 molar II 182,183
 第二前磨牙 premolar II 182,183
 第二肋切迹 2nd costal notch 8
 第二乳磨牙 deciduous molar II 182
 第六、七肋切迹 6,7th costal notches 8
 第三穿动脉 3rd perforating a. 54
 第三磨牙 molar III 182,183
 第三腓骨肌(腱) peroneus tertius (tendon) 63
 第三肋切迹 3rd costal notch 8
 第三脑室 third ventricle 215
 第三脑室脉络丛 choroid plexus of third ventricle 226
 第十胸神经 10th thoracic nerve 113
 第十胸神经及血管 10th thoracic n.
 and blood vessels 113
 第十二肋 12th rib 8,132
 第十一肋 11th rib 132
 第四肋切迹 4th costal notch 8
 第四脑室 fourth ventricle 209,212
 第四脑室脉络丛 choroid plexus of fourth
 ventricle 209,226
 第四脑室正中孔 median aperture of fourth ventricle 226
 第五掌骨 fifth metacarpal 86
 第五肋切迹 5th costal notch 8
 第五腰椎椎体 the fifth lumbar vertebral body 107
 第五跖骨 5th metatarsal bone 28

第五跖骨粗隆 tuberosity of 5th metatarsal bone 27,63
第一颈神经 first cervical n. 202
第一肋 first rib 8
第一肋切迹 1st costal notch 8
第一肋压迹 impression for first rib 102
第一磨牙 molar I 182,183
第一前磨牙 premolar I 182,183
第一乳磨牙 deciduous molar I 182
第一胸肋结合 sternocostal synchondrosis of first rib 31
第一胸椎椎体 first thoracic vertebral body 107
第一腰椎椎体 first lumbar vertebral body 107
第一掌指关节 first metacarpophalangeal joint 34
第一跖骨 1st metatarsal bone 28
第一穿动脉 first perforating a. 54
第一骨间背侧肌 first dorsal interossei 82
第一掌背动脉 first dorsal metacarpal a. 82
第一跖背动脉 first dorsal metatarsal a. 64
蝶窦 sphenoidal sinus 186
蝶窦开口 orifice of sphenoidal sinus 186
蝶窦口 aperture of sphenoid sinus 186
蝶骨大翼 greater wing of sphenoid 12
蝶棘 spine of sphenoid bone 14
蝶嵴 sphenoid crest 14
蝶甲 sphenoidal concha 14
蝶下颌韧带 sphenomandibular lig. 31
顶盖脊髓束 tectospinal tract 201,205,206,207
顶盖前区 pretectal area 218
顶骨 parietal bone 9
顶骨剖面 Section of the parietal bone 3
顶后动脉 posterior parietal artery 223
顶孔 parietal foramen 9
顶颞桥束 parietotemporo-pontine tract 207
顶上小叶 superior parietal lobule 212
顶叶 parietal lobe 108,213
顶缘 parietal margin 16
顶枕沟 parietooccipital sulcus 212,213
顶枕支 parietooccipital branch 223
顶支 parietal branch 172
动脉韧带 ligamentum arteriosum 92,95
动脉圆锥 conus arteriosus 91,98,99
动脉圆锥支 conus branch 97
动眼神经 Oculomotor n.(Ⅲ) 193,202,203,207,222,225
动眼神经副核 accessory nucleus of oculomotor n. 203,207,218
动眼神经核 nucleus of oculomotor n. 203,207,219

动眼神经上支 superior branch of the oculomotor n. 193
动眼神经下支 inferior branch of oculomotor n. 193
豆钩韧带 pisohamate lig. 34
豆状核 lentiform nucleus 108,202,203,214,215,217,221
窦房结支 branch to sinoatrial node 97
窦汇 confluence of sinuses 225
短骨 short bone 3
短收肌 adductor brevis 50,51,52
对耳轮 antihelix 194
对耳轮脚 crura of antihelix 194
对耳屏 antitragus 194
多腹肌 polyvent muscle 44
多羽肌 multipennate muscle 44

E

额窦 frontal sinus 187
额窦开口 orifice of frontal sinus 186
额骨 frontal bone 9,12,16
额极动脉 frontopolar a. 223
额嵴 frontal crest 16
额结节 frontal tuber 16
额鳞 frontal squama 16
额桥束 frontopontine tract 207
额上沟 superior frontal sulcus 212
额上回 superior frontal gyrus 212
额神经 frontal n. 193
额突 frontal process 18
额下沟 inferior frontal sulcus 212
额下回 inferior frontal gyrus 212
额叶 frontal lobe 212
额支 frontal branch 172
额中回 middle frontal gyrus 212
腭垂 uvula 184
腭垂肌 musculus uvulae 184
腭大沟 greater palatine sulcus 18
腭大孔 greater palatine foramen 10,184
腭大神经 greater palatine n. 179
腭帆提肌 levator veli palatini 184
腭帆张肌 tensor veli palatini 184
腭骨水平板 horizontal palate of palatine bone 10,184
腭横缝 transverse palatine suture 10
腭舌弓 palatoglossal arch 184
腭突 palatine process 18
腭小沟 lesser palatine sulcus 18

腭小孔 lesser palatine foramen 10
 腭咽弓 palatopharyngeal arch 184
 腭咽肌 palatopharyngeus 184
 腭正中缝 median palatine suture 10
 耳垂 auricular lobule 194
 耳大神经 great auricular n. 156,157,170,171,174
 耳后动脉 posterior auricular a. 161,172,176
 耳后静脉 posterior auricular v. 173,176,185
 耳甲 auricular concha 194
 耳廓 auricle 194
 耳轮 helix 194
 耳轮脚 crus of helix 194
 耳颞神经 auriculotemporal n. 170,171,178,180
 耳屏 tragus 194
 耳屏间切迹 intertragic notch 194
 耳神经节 otic ganglion 178,179
 耳蜗 cochlea 194
 耳舟 scapha 194
 耳状面 auricular surface 7
 二腹肌 digastric 44
 二腹肌后腹 posterior belly of the digastric 154,174
 二腹肌前腹 anterior belly of digstric 179
 二腹小叶 biventral lobule 208
 二尖瓣后瓣 posterior cusp of mitral valve 100,101,106
 二尖瓣前瓣 anterior cusp of mitral valve 100,101,106
 二头肌 biceps 44

F

方形膜 quadrangular menbrane 167,168
 方形小叶(后部) posterior quadrangular lobule 208
 方形小叶(前部) anterior quadrangular lobule 208
 方叶 quadrate lobe 123
 腓侧副韧带 fibular collateral lig. 38,39
 腓肠肌(腱膜) gastrocnemius (aponeurosis) 62
 腓肠肌(内侧头) gastrocnemius (medial head) 55,59
 腓肠肌(外侧头) gastrocnemius (lateral head) 55,59
 腓肠内侧皮神经 medial sural cutaneous n. 55,58
 腓肠神经 sural n. 58
 腓肠外侧皮神经 lateral sural cutaneous n. 55,58
 腓动脉 peroneal a. 59
 腓动脉、静脉 peroneal a. & v. 59,62
 腓骨 fibula 2,26,38,39,40,41,62
 腓骨长肌 peroneus longus 59,61
 腓骨长肌(腱) peroneus longus (tendon) 61,63
 腓骨长肌和短肌 peroneus longus and brevis 62
 腓骨短肌(腱) peroneus brevis (tendon) 63
 腓骨肌上支持带 superior peroneal retinaculum 63
 腓骨肌下支持带 inferior peroneal retinaculum 63
 腓骨颈 neck of fibula 26
 腓骨体 shaft of fibula 26
 腓骨头 head of fibula 26
 腓骨头尖 apex of fibular head 26
 腓关节面 fibular articular facet 26
 腓浅神经 superficial peroneal n. 63
 腓切迹 fibular notch 26
 腓深神经 deep peroneal n. 62,63,64
 腓总神经 common peroneal n. 55,63
 肺动脉半月瓣 semilunar cusp of pulmonary valve 99,101
 肺动脉半月瓣和肺动脉窦 semilunar cups of pulmonary valve and sinus of pulmonary trunk 99
 肺动脉窦 sinus of pulmonary trunk 99,101
 肺动脉干 pulmonary trunk 91,99,95,97,98,99,106
 肺动脉叶间部 interlobular part of pulmonary artery 102
 肺尖 apex of lung 102,103
 肺韧带 pulmonary ligament 92,102,103
 分岐韧带 bifurcated lig. 42
 缝匠肌 sartorius 49,50,52,57
 缝匠肌腱 sartorius tendon 38
 跗跖背侧韧带 dorsal tarsometatarsal lig. 42
 跗跖关节 tarsometatarsal joints 43
 跗跖足底韧带 plantar tarsometatarsal lig. 42
 辐射冠 corona radiata 202,203,210
 附睾 epididymis 140
 附脐静脉 paraumbilical v. 111
 副睾头 head of epididymis 150,133
 副睾丸动脉 accessory testicular a. 133
 副腮腺 accessory parotid gland 170,179
 副神经(XI) accessory n.(XI) 157,160,161,162,165,170,174,202
 副神经核 nucleus of accessory n. 203,204,219
 副肾动脉 accessory renal a. 131
 腹白线 linea alba 112
 腹壁浅动脉 superficial epigastric a. 111
 腹壁浅静脉 superficial epigastric v. 48,110,111
 腹壁上动脉、静脉 superior epigastric a. & v. 113
 腹壁下动、静脉 inferior epigastric a. & v. 113,115,136
 腹壁下动脉闭孔支(副闭孔动脉) obturator branch of inferior epigastric a.(accessory obturator a) 138
 腹股沟管浅环 superficial inguinal ring 112,113,114,150

腹股沟韧带 inguinal ligament 49,50,111,112,114,150
 腹股沟上内侧浅淋巴结 superomedial superficial
 inguinal lymph nodes 48
 腹股沟下浅淋巴结 inferior superficial
 inguinal lymph nodes 48
 腹横肌 transversus abdominis 113,114,115
 腹横筋膜 transversalis fascia 114
 腹后内侧核 ventral posteromedial nucleus 211,217
 腹后外侧核 ventral posterolateral nucleus 211,216,217
 腹腔神经节 celiac ganglia 131,134
 腹膜 peritoneum 115 ~ 117,142
 腹膜外脂 extraperitoneal fat 115
 腹内侧核 ventromedial nucleus 211
 腹内斜肌 obliquus internus abdominis 112,113,114
 腹前核 ventral anterior nucleus 211
 腹腔动脉干 celiac trunk 120 ~ 122,131,133,134
 腹外斜肌 obliquus externus abdominis 112 ~ 114
 腹外斜肌(腱膜) obliquus externus abdominis
 (aponeurosis) 111,150
 腹直肌 rectus abdominis 90,112,114,115
 腹直肌鞘后层 posterior layer of sheath of
 rectus abdominis 113,114
 腹直肌鞘前层 anterior layer of sheath of
 rectus abdominis 112 ~ 114
 腹中间核 ventral intermediate nucleus 211
 腹主动脉 abdominal aorta 115,125,127,129,131,133,136,138
 覆膜 tectorial membrane 30

G

肝 liver 107,110,123
 肝固有动脉 proper hepatic a. 120 ~ 124
 肝静脉 hepatic v. 124
 肝裸区 bare area of liver 123
 肝门静脉 hepatic portal vein 108,123 ~ 125,128
 肝肾隐窝(囊) hepatorenal recess(pouch) 125
 肝尾状叶 caudate lobe 107,120,123,124
 肝胃韧带 hepatogastric ligament 123
 肝胰腹壶 hepatopancreatic ampulla 124
 肝右动脉 right branch of proper hepatic a. 120
 肝右静脉 right hepatic vein 94
 肝右叶 right lobe of liver 108,116,118,123,124,128
 肝圆韧带 ligamentum teres hepatis 116,123,124,128
 肝圆韧带裂 fissure for ligamentum teres hepatis 123
 肝中静脉 middle hepatic v. 94

肝总动脉 common hepatic a. 120 ~ 122
 肝总管 common hepatic duct 124
 肝左动脉 left branch of proper hepatic a. 120
 肝左静脉 left hepatic vein 94
 肝左叶 left lobe of liver 108,116,118,123,124
 橄榄 olive 202,203,210
 橄榄脊髓束 olivospinal tract 201
 冈上肌 supraspinatus 45,77
 冈上窝 supraspinous fossa 20
 冈下肌 infraspinatus 45,77
 冈下窝 infraspinous fossa 20
 肛瓣 anal valves 141
 肛窦 anal sinuses 141
 肛门 anus 107,110,147 ~ 149,151,152
 肛门外括约肌 sphincter ani externus 141,147,148,149,151
 肛门外括约肌 sphincter ani internus 141
 肛神经、动脉 anal n. & a. 147,148,152
 肛提肌 levator ani 143,147,148,149
 肛提肌(盆膈) levator ani(pelvic diaphragm) 142,151
 肛提肌腱弓 tendinous arch of levator ani 143
 肛柱 anal column 141
 睾丸 testis 107,111,129,138,140,150
 睾丸动脉和静脉 testicular a. & v. 136
 睾丸鞘膜(壁层) tunica vaginalis of testis
 (parietal layer) 150
 隔膜肉柱 septomarginal trabecula 99
 膈 diaphragm 92,115,116,118,123,125,129
 膈(覆盖膈胸膜) diaphragm(covered by pleural) 93
 膈侧乳头肌 septal papillary muscle 99
 膈肌 diaphragmatic muscle 90
 膈结肠韧带 phrenicocolic ligament 125
 膈面 diaphragmatic surface 102,103,122
 膈神经 phrenic nerve 67,92,134,174
 膈胸膜 diaphragmatic pleura 95
 膈中心腱中叶(被纤维心包覆盖) middle leaflet
 of central tendon (covered by pericardium) 90
 跟腓韧带 calcaneofibular lig. 42
 跟骨 calcaneus 27,28,43,60 ~ 61
 跟骨结节 calcaneal tuberosity 217
 跟骨剖面 Section of the calcaneus 3
 跟腱 tendo calcaneus 43,59,61 ~ 63
 跟骰背侧韧带 dorsal calcaneocuboid lig. 42
 跟骰关节 calcaneocuboid joint 43
 弓状嵴 arcuate crest 166
 弓状核 arcuate nucleus 205,211

- 弓状隆起 arcuate eminence 15
 弓状线 arcuate line 24,114
 肱动脉 brachial a. 67-69
 肱动脉及静脉 brachial a. & v. 85
 肱二头肌 biceps brachii 67-70,73-75,77
 肱二头肌长头 long head of biceps brachii 70
 肱二头肌长头腱 long head of biceps brachii(tendon) 32
 肱二头肌短头 short head of biceps brachii 70
 肱二头肌腱 tendon of biceps brachii 33,75
 肱二头肌腱膜 bicipital aponeurosis 75
 肱骨 humerus 2,21,32,33,77
 肱骨滑车 trochlea of humerus 21,33
 肱骨内上髁 medial epicondyle of humerus 21,77
 肱骨体 shaft of humerus 21
 肱骨头 head of humerus 21
 肱骨外上髁 lateral epicondyle of humerus 21,77
 肱骨小头 capitulum of humerus 21
 肱肌 brachialis 69
 肱桡肌 brachioradialis 73,74,75
 肱桡肌腱 tendon of brachioradialis 80,81
 肱三头肌 triceps brachii 78
 肱三头肌长头 long head of triceps brachii 71,72,85
 肱三头肌内侧头 medial head of triceps brachii 71,85
 肱三头肌外侧头 lateral head of triceps brachii 71,85
 肱深动脉 deep brachial a. 68,71
 肱深动脉及静脉 deep brachial a. & v. 85
 巩膜 sclera 188
 巩膜动脉 scleral a. 189
 巩膜静脉窦 sinus venosus sclerae 188
 巩膜外静脉 episcleral v. 189
 钩 uncus 213
 钩骨 hamate bone 23
 钩骨钩 hamulus of hamate bone 23
 孤束 solitary tract 178,205
 孤束核 nucleus of solitary tract 178,203,205
 股薄肌 gracilis 49-52,57
 股动脉 femoral a. 49-52,139
 股二头肌(长头) biceps femoris (long head) 54,57
 股二头肌 biceps femoris 52,54
 股二头肌(短头) biceps femoris (short head) 54,57
 股方肌 quadratus femoris 53,55
 股骨 femur 2,25
 股骨大转子 greater trochanter 25,52
 股骨颈 neck of femur 25
 股骨上端剖面 The upper part of the femur.section 3
 股骨体 shaft of femur 25
 股骨头 head of femur 25
 股骨头凹 fovea of femoral head 25
 股骨头韧带 lig.of head of femur 36
 股管及腹股沟深淋巴结 femoral canal
 and deep inguinal lymph nodes 50
 股后肌间隔 posterior femoral intermuscular septum 57
 股后皮神经 posterior femoral cutaneous n. 52,53,54,57
 股静脉 femoral v. 49,50,51,52
 股静脉、股动脉 femoral v. & a. 57
 股内侧肌 vastus medialis 50,51,57
 股内侧肌间隔 medial femoral intermuscular septum 57
 股内侧浅静脉 medial superficial femoral v. 48
 股鞘 femoral sheath 49
 股深动脉 deep femoral a. 50,51
 股深动脉及穿动脉 deep femoral a. and
 perforating a. 57
 股深静脉 deep femoral v. 50,51
 股神经 femoral n. 49-52,129,133,139
 股四头肌腱 quadriceps femoris tendon 41
 股外侧肌 vastus lateralis 38,49,51,57
 股外侧肌间隔 lateral femoral intermuscular septum 57
 股外侧皮神经 lateral femoral cutaneous n. 129,133,139
 股外侧浅静脉 lateral superficial femoral v. 48
 股直肌 rectus femoris 38,49-52,57
 股中间肌 vastus intermedius 51,57
 骨半规管 bony semicircular canals 195,196
 骨间背侧肌 dorsal interossei 61,64,84,86
 骨间返动脉 recurrent interosseous a. 78
 骨间后动脉 posterior interosseous a. 78
 骨间后动脉及静脉 posterior interosseous a. & v. 85
 骨间后动脉终支 terminal branch of posterior
 interosseous a. 82
 骨间后神经 posterior interosseous n. 78
 骨间前动脉和神经 interosseus anterior a. & n. 75
 骨间前动脉后支 posterior branch of anterior
 interosseous a. 78
 骨间前动脉及静脉 anterior interosseous a. & v. 85
 骨间掌侧肌 palmar interossei 84,86
 骨间足底肌 plantar interossei 61
 骨螺旋板 osseous spiral lamina 197
 骨膜 periosteum 3
 骨髓 bone marrow 3
 鼓部 tympanic part 15
 鼓阶 scala tympani 197

- 鼓膜 tympanic membrane 195,196
 鼓膜脐 umbo of tympanic membrane 197
 鼓膜张肌 tensor tympani 195,196
 鼓乳裂 tympanomastoid fissure 15
 鼓室 tympanic cavity 196
 鼓室丛 tympanic plexus 178
 鼓室盖 tegmen tympani 15
 鼓室上隐窝 superior recess of tampanic cavity 196
 鼓索 chorda tympani 178,179
 关节凹 articular fovea 5
 关节结节 articular tubercle 10,15
 关节面 articular surface 31,32,33,36
 关节囊 articular capsule 31,32
 关节盘 articular disc 31
 关节腔 articualar cavity 31
 关节软骨 articular cartilage 32
 关节突关节 zygapophysial joints 30
 关节盂 glenoid cavity 32
 冠突 coronoid process 22
 冠突窝 coronoid fossa 21
 冠状窦 coronary sinus 98
 冠状缝 coronal suture 9,12
 冠状韧带上层 superior layer of coronary ligament 107
 光锥 light cone 197
 贵要静脉 basilic v. 70,73,79,82,85
 腭弓状韧带 arcuate popliteal lig. 39
 腭斜韧带 oblique popliteal lig. 38,39
 腭肌 popliteus 55
 腭静脉 popliteal v. 55,59
 腭面 popliteal surface 25
- H**
- 哈特曼囊 Hartmann's pouch 118
 海绵窦 cavernous sinus 173
 海马 hippocampus 215,225
 海马旁回 parahippocampal gyrus 213,215
 海马伞 fimbria of hippocampus 215
 黑质 substantia nigra 207
 横窦 transverse sinus 225
 横窦沟 sulcus for transverse sinus 11,17
 横结肠 transverse colon 107,108,116,117,118,126,127
 横结肠系膜 transverse mesocolon 107
 横突 transverse process 5,6
 横突间肌 intertransversarii 46
 横突间韧带 intertransverse lig. 29
 横突孔 transverse foramen 5
 横突肋凹 transverse costal fovea 6
 红核 red nucleus 207,221
 红核脊髓束 rubrospinal tract 201,221
 虹膜 iris 188,190
 虹膜动脉大环 greater ring arterial of iris 189
 虹膜动脉小环 lesser ring arterial of iris 189
 虹膜角膜角 iridocorneal angle 188
 喉结 laryngeal prominence 166,167,168
 喉前庭 laryngeal vestibule 168
 喉上动脉 superior laryngeal a. 172
 喉上神经 superior laryngeal n. 159,163,165
 后床突 posterior clinoid process 11
 后底段 posterior basal segment 104,105
 后底段支气管 posterior basal segmental bronchus 105
 后端 posterior extremity 122
 后段 posterior segment 105
 后房 posterior chamber 188
 后弓 posterior arch 5
 后骨半规管 posterior bony semicircular bony canal 194,198
 后骨壶腹 posterior of bony ampulla 194,198
 后核 posterior nucleus 211
 后交叉韧带 posterior cruciate lig. 39,40
 后交通动脉 posterior communicating a. 222
 后角 posterior horn 201,214
 后角固有核 nucleus proprius 201
 后结节 posterior tubercle 5
 后膜半规管 posterior membranous semicircular duct 198
 后膜壶腹 posterior membranous ampulla 198
 后乳头肌 posterior papillary muscle 99,100
 后室间沟 posterior interventricular sulcus 97
 后室间支 posterior interventricular branch 78
 后索 posterior funiculus 201
 后外侧窗 posterolateral fontanelle 12
 后斜角肌 scalenus posterior 46
 后窗 posterior fontanelle 12
 后正中沟 posterior median sulcus 200,202
 后纵膈淋巴结 posterior mediasternal lymph nodes 90
 后纵韧带 posterior longitudinal lig. 29,30
 滑车 trochlea 21
 滑车切迹 trochlear notch 22
 滑车上神经 supratrochlear n. 191,203
 滑车神经(IV) trochlear n.(IV) 202,203
 滑车神经核 nucleus of trochlear n. 202,203,207,219

- 滑车下神经 infratrochlear n. 191
 滑车上动、静脉 supratrochlear a. & v. 176
 环杓侧肌 lateral cricoarytenoid 167
 环杓后肌 posterior cricoarytenoid 167
 环肌层 stratum circularis of muscularis 127
 环甲关节面 thyroid articular surface of cricoid cartilage 167
 环甲肌 cricothyroid 159
 环甲韧带 cricothyroid ligament 166,168
 环韧带 annular ligament 166
 环状关节面 articular circumference 22
 环状软骨 cricoid cartilage 166,167
 环状软骨板 lamina of cricoid cartilage 166,168
 环状软骨弓 arch of cricoid cartilage 166,168
 寰枢外侧关节 lateral atlantoaxial joint 30
 寰枕关节 alantooccipital joint 30,108
 寰椎 Atlas 5,185
 寰椎横韧带 transverse lig. of atlas 30
 寰椎十字韧带 cruciform lig. of atlas 30
 黄斑 macula lutea 188
 黄斑上血管 superior macular vessel 189
 黄斑下血管 inferior macular vessel 189
 黄韧带 ligamenta flava 29
 灰白交通支 gray and white communicating branches 92,93
 回肠 ileum 110,117,125~128
 回肠动脉 ileal a. 126
 回结肠动脉 ileocolic a. 126
 回结肠静脉 ileocolic v. 128
 回盲瓣 ileocecal valve 127
 会厌 epiglottis 167,168,187
 会厌软骨 epiglottic cartilage 166
 会阴 perineum 151
 会阴浅横肌 superficial transverse muscle of perineum 142,147,148,152
 会阴浅筋膜 superficial fascia of perineum 142
 会阴深横肌 deep transverse muscle of perineum 147,149
 会阴深横肌和尿生殖膈上筋膜 deep transverse muscle of perineum and superior fascia of urogenital diaphragm 142
 会阴神经、动脉 perineal n. & a. 147,148,152
 会阴体 perineal body 142,147,148,152
 喙肱肌 coracobrachialis 168
 喙肩韧带 coracoacromial lig. 32
 喙锁韧带 coracoclavicular lig. 32
 喙突 coracoid process 20,32
- ## J
- 肌腹 muscle belly 44
 肌腱 tendon 44
 肌皮神经 musculocutaneous n. 67~70
 肌三角 muscular triangle 154
 肌头 head of muscle 44
 肌突 muscular process 166,168
 肌咽鼓管 musculotubal canal 15
 鸡冠 crista galli 11,16
 基底部 basilar part 17
 基底动脉 basilar a. 222
 基底沟 basilar sulcus 202
 茎突 styloid process 10,12,15,22,195
 棘肌 spinalis 46
 棘间肌 interspinales 46
 棘孔 foramen spinosum 9,11,14
 棘上韧带 supraspinal lig. 29
 棘突 spinous process 5,6,132
 脊神经节 spinal ganglion 216,217
 脊神经前支 anterior branch of spinal nerve 90
 脊髓 spinal cord 108,125,158,185,216,217,219,221
 脊髓顶盖束 spinotectal tract 201
 脊髓丘脑束 spinothalamic tract 201,204,205,217
 脊髓小脑后束 posterior spinocerebellar tract 201,204,221
 脊髓小脑前束 anterior spinocerebellar tract 201,204,205
 脊髓圆锥 conus medullaris 200
 脊髓蛛网膜 spinal arachnoid mater 200
 岬 promontory 7,107
 颊动脉 buccal a. 172
 颊动脉和神经 buccal a. & n. 174
 颊肌 buccinator 185
 颊神经 buccal n. 178
 颊支 buccal branches 170,171,179
 甲杓肌 thyroarytenoid 167
 甲关节面 thyroid articular surface 166
 甲会厌肌 thyroepiglottis 167
 甲舌膜 thyrohyoid membrane 168
 甲状颈干 thyrocervical trunk 67,68,161,162
 甲状软骨 thyroid cartilage 159,166,168,180
 甲状软骨板 lamina of thyroid cartilage 166,167

- 甲状软骨上角 superior horn of thyroid cartilage 166,184
 甲状舌骨肌 thyrohyoid 159,180
 甲状舌骨膜 thyrohyoid membrane 166,167
 甲状舌骨正中韧带 median thyrohyoid ligament 166
 甲状腺 thyroid gland 158,162,163,165
 甲状腺侧叶 lateral lobe of thyroid gland 159
 甲状腺上动脉 superior thyroid a. 159,161 ~ 163,172
 甲状腺峡部 isthmus of thyroid gland 159
 甲状腺下动脉 inferior thyroid a. 68,161,162
 甲状腺下静脉 inferior thyroid v. 91,94,159
 尖段 apical segment 105
 尖后段 apicoposterior segment 104
 尖淋巴结 apical lymph nodes 69
 尖牙 canine 82
 尖牙窝 canine fossa 18
 肩峰 acromion 20
 肩峰端 acromial end 19
 肩峰关节面 acromial articular surface 19
 肩峰角 acromial angle 19,20
 肩胛背动脉 dorsal scapular a. 72
 肩胛冈 spine of scapula 20,71
 肩胛骨 scapula 2,20,32
 肩胛颈 neck of scapula 20
 肩胛切迹 notch of scapula 20
 肩胛上动脉 suprascapular a. 67,68,72
 肩胛上横韧带 superior transverse scapular lig. 32
 肩胛上神经 suprascapular n. 67
 肩胛舌骨肌 omohyoid 155 ~ 158,160 ~ 162
 肩胛舌骨肌上腹 superior belly of the omohyoid 154,174
 肩胛舌骨肌下腹 inferior belly of omohyoid 174
 肩胛提肌 levator scapulae 45,68,72,160
 肩胛下肌 subscapularis 66
 肩胛下淋巴结 subscapular lymph nodes 69
 肩胛下窝 subscapular fossa 20
 肩锁关节 acromioclavicular joint 32
 睑板 tarsus 190
 睑结膜 palpebral conjunctiva 190
 睑内侧连合 medial palpebral commissure 191
 睑内侧韧带 medial palpebral ligament 175,191
 睑外侧连合 lateral palpebral commissure 191
 睑外侧韧带 lateral palpebral ligament 175,191
 剑突 xiphoid process 8,31
 腱划 tendinous intersection 44,112
 腱间结合 intertendinous connections 78,83
 腱膜 aponeurosis 44
 腱纽 vincula tendinum 86
 腱索 chordae tendineae 99,100,106
 腱纤维鞘 fibrous flexor sheaths 80
 浆膜层 serosa 127
 疆三角 habenular trigone 202
 降结肠 descending colon 117,127,128
 降口角肌 depressor anguli oris 175
 降下唇肌 depressor labii inferioris 175
 降主动脉压迹 impression for descending aorta 103
 交叉前沟 sulcus prechiasmaticus 11,14
 交感干 sympathetic trunk 90,92,163
 交感颈上节 superior cervical ganglion 163,185
 交感神经节 sympathetic ganglion 92
 胶状质 substantia gelatinosa 201
 角回 angular gyrus 212
 角回动脉 artery of angular gyrus 223
 角膜 cornea 191
 角切迹 angular incisure 119
 脚间池 interpeduncular cistern 226
 脚间窝 interpeduncular fossa 202
 节细胞 ganglion cells 188
 结肠右曲 right colic flexure 110,116,117,118,128
 结肠左曲 left colic flexure 125,127,128
 结节间沟 inter tubercular sulcus 21
 结膜半月襞 conjunctival semilunar fold 191
 结膜上穹 superior conjunctival fornix 190
 结膜下穹 inferior conjunctival fornix 190
 睫后长动脉 long posterior ciliary a. 189
 睫后短动脉 short posterior ciliary a. 189
 睫毛腺 ciliary glands 190
 睫状后动脉 posterior ciliary a. 189
 睫状环 ciliary ring 188
 睫状肌 ciliary muscle 188
 睫状前动脉 anterior ciliary a. 189
 睫状神经节 ciliary ganglion 193,218
 睫状体 ciliary body 188
 睫状突 ciliary processes 188
 睫状小带 ciliary zonule 188
 解剖颈 anatomical neck 21
 界沟 sulcus limitans 202
 界嵴 crista terminalis 94
 深筋膜浅层 superficial layer of deep fascia 156
 紧张部 tense part 197
 近节指骨 proximal phalanx 23
 经齿突冠状断层 coronal section through

- the level of the dens of axis(C2) 108
 经肺动脉分叉平面横断层 the section at
 the level of the bifurcation pulmonary
 on transverse 106
 经腹腔正中矢状切面 sagittal section through
 abdomen and pelvis in median plane 107
 经心长轴斜切面 the section at the long
 axis of the heart on oblique 106
 茎乳孔 stylomastoid foramen 10,15
 茎突 styloid process 10,12,15,22,185,195
 茎突舌骨肌 stylohyoid 154,161,174
 茎突舌肌 styloglossus 174
 茎突下颌韧带 stylomandibular lig. 31
 茎突咽肌 stylopharyngeus 184
 晶状体 lens 188
 精阜 seminal colliculus 140
 精囊 seminal vesicle 136,137,138,141,142
 精囊排泄管 seminal vesicle excretory duct 141
 精索 spermatic cord 49,111,112,113,114,129,140,150
 精索内筋膜 internal spermatic fascia 150
 精索外筋膜 external spermatic fascia 150
 颈半棘肌 semispinalis cervicis 46
 颈动脉窦 carotid sinus 162,163,174
 颈动脉沟 carotid sulcus 11
 颈动脉管 carotid canal 35
 颈动脉管外口 external aperture of carotid canal 10
 颈动脉三角 carotid triangle 154
 颈横动脉 tranverse cervical a. 67,156,161,162,174
 颈横神经 tranverse nerve of neck 157
 颈静脉弓 jugular venous arch 157,159
 颈静脉孔 jugular foramen 11
 颈静脉窝 jugular fossa 10,15
 颈阔肌 platysma 154,155,170,175
 颈阔肌交叉纤维 cross fiber of platysma 155
 颈内动脉 internal carotid
 artery 108,172,179,185,195,222,225
 颈内静脉 interior
 jugular v. 155,156,157,158,159,160,161,173,185
 颈襻 ansa cervicalis 160,161,174
 颈襻上根 superior root of ansa cervicalis 161,162,174
 颈襻下根 inferior root of ansa cervicalis 161,162,174
 颈膨大 cervical enlargement 200
 颈肋肋肌 iliocostalis cervicis 46
 颈前静脉 anterior jugular v 155,156,157,159
 颈浅动脉与肩胛提肌 superficial cervical
 a.and levator scapulae 45,68,160
 颈上神经节 superior cervical ganglion 163,185
 颈深筋膜浅层 superficial layer of
 the cervical deep fascia 156,159
 颈深下淋巴结 inferior cervical lymphatic nodes 94
 颈升动脉 ascending cervical a. 67
 颈外动脉 external carotid a. 161,163,172,174,185
 颈外静脉 external jugular v. 155,156,157,171,173
 颈支 cervical branch 171
 颈椎 cervical vertebrae 2,4,5
 颈椎椎间关节 cervical intervertebral joint 108
 颈总动脉 common
 carotid a. 69,158,159,162,163,165,172,174,179
 颈最长肌 longissimus cervicis 46
 胫侧副韧带 tibial collateral lig. 38
 胫腓关节 tibiofibular joint 41
 胫腓前韧带 anterior tibiofibular lig. 42
 胫骨 tibia 2,26,41,42,43,62
 胫骨粗隆 tuberosity of tibia 26
 胫骨后肌 tibialis posterior 59,62
 胫骨后肌(腱) tibialis posterior (tendon) 42,59,60,61,62
 胫骨前肌 tibialis anterior 62,63
 胫骨前肌腱 tibialis anterior (tendon) 42
 胫骨体 shaft of tibia 26
 胫后动脉 posterior tibial a. 55,59,60,61,62
 胫前动脉 anterior tibial a. 55,56,59,62,63
 胫前返动脉 anterior tibial recurrent a. 56
 胫神经 tibial n. 55,59,61,62
 胫神经及胫后动脉 tibial n. and posterior tibial a. 62
 静脉韧带裂及肝胃韧带 fissure for ligamentum
 venosum and hepatogastric ligament 107
 距腓前韧带 anterior talofibular lig. 42
 距跟骨间韧带 interosseous talocalcaneal lig. 42
 距跟舟关节 talocalcaneonavicular joint 43
 距骨 talus 27,28
 距小腿关节(踝关节) talocrural (ankle) joint 43
 距状沟 calcarine sulcus 212,213
 距状沟支 calcarine branch 223
 菌状乳头 fungiform papillae 181
- ## K
- 颞棘 mental spine 13
 颞孔 mental foramen 13
 颞隆凸 mental protuberance 13

- 颞舌骨肌 geniohyoid 180,181
 颞舌肌 genioglossus 181,187
 颞下静脉 submental v. 173
 颞下三角 submental triangle 154
 髁管 condylar canal 10
 髁间隆起 intercondylar eminence 26
 髁间窝 intercondylar fossa 25
 髁突 condylar process 13,31
 壳 putamen 215
 空肠 jejunum 107,108,110,117,125
 空肠动脉 jejunal a. 122,126
 空肠静脉 jejunal v. 128
 口轮匝肌 orbicularis oris 175
 口腔 oral cavity 88,110
 扣带沟 cingulate sulcus 212
 扣带回 cingulate gyrus 212,213
 髌骨 hip bone 21
 髌关节囊 hip articular capsule 35,36
 髌臼 acetabulum 24
 髌臼唇 acetabular labrum 36
 髌臼横韧带 transverse acetabular lig. 36
 髌臼切迹 acetabular notch 24
 髌臼窝 acetabular fossa 24
 眶板 orbital plate 16
 眶隔 orbital septum 191
 眶回 orbital gyri 212
 眶面 orbital surface 14
 眶上动、静脉 supraorbital a. & v. 176
 眶上孔 supraorbital foramen 9
 眶上裂 superior orbital fissure 9,14
 眶上切迹 Supraorbital notch 9
 眶上神经和血管 supraorbital n. and blood vessels 191
 眶上缘 supraorbital margin 16
 眶下沟 infraorbital groove 18
 眶下孔 infraorbital foramen 9
 眶下裂 inferior orbital fissure 9
 眶下神经 infraorbital n. 178
 眶脂体 adipose body of orbit 190
 阔筋膜 fascia lata 49
 阔筋膜张肌 tensor fasciae latae 49,54
 阑尾 vermiform appendix 126,127
 阑尾系膜 mesoappendix 126,127
 肋 rib 2,90
 肋膈隐窝 costodiaphragmatic recess 116,123,125
 肋弓 costal arch 31
 肋骨 costal bone 8
 肋横突关节 costotransverse joint 29
 肋横突上韧带 superior costotransverse lig. 29
 肋间臂神经 intercostobrachial n. 67
 肋间动脉 intercostal artery 92
 肋间后动脉 posterior intercostal artery 90,132
 肋间后静脉 posterior intercostal vein 90,132
 肋间后淋巴结 posterior intercostal lymph nodes 96
 肋间静脉、动脉和神经 intercostal vein, artery and nerve 92
 肋间内肌 internal intercostal muscle 90
 肋间神经、血管 intercostal nerve and vessels 93,96
 肋间外肌 intercostales externi 90
 肋间最内肌 innermost intercostal muscle 91
 肋角 costal angle 8
 肋结节 costal tubercle 8
 肋颈 costal neck 8
 肋软骨 costal cartilage 31,90
 肋锁韧带压迹 impression for costoclavicular lig. 19
 肋提肌 levatores costarum 46
 肋体 shaft of rib 8
 肋头 costal head 8
 肋头辐状韧带 radiate lig. of costal head 29
 肋头关节 joint of costal head 29
 肋下动脉 subcostal a. 132
 泪沟 lacrimal groove 18
 泪骨 lacrimal bone 9
 泪湖 lacrimal lacus 191
 泪囊 lacrimal sac 191
 泪腺 lacrimal gland 191
 泪腺排泄小管 excretory ductules of lacrimal gland 191
 泪腺神经 lacrimal n. 193
 泪腺窝 fossa for lacrimal gland 16
 梨状肌 piriformis 53,54
 梨状孔 piriform aperture 9
 梨状隐窝 piriform recess 184
 犁骨 vomer 10
 镰状韧带 falciform ligament of liver 116,123
 淋巴结 lymph node 92
 鳞部 squamous part 15

L

- 阑尾 vermiform appendix 126,127
 阑尾动脉、静脉 appendicular a. & v. 126

漏斗 infundibulum 202,210
 颅盖 calvaria 175
 颅骨 cranial bones 2
 颅骨膜 pericranium 175
 卵巢 ovary 144,145,146
 卵巢动脉 ovarian a. 146
 卵巢系膜 mesovarium 144
 卵巢悬韧带 suspensory ligament of ovary 144,145
 卵圆孔 foramen ovale 10,11
 轮廓乳头 vallate papillae 181
 轮匝带 zona orbicularis 36
 轮匝肌 orbicular muscle 44
 螺旋板钩 hamulus of spiral lamina 197
 螺旋膜 spiral membrane 197
 马蹄肾 horseshoe kidney 131
 马尾 cauda equina 200

M

脉络膜 choroid 188
 脉络膜动脉 arteries of choroid 189
 脉络膜毛细血管 capillaries of choroid 189
 盲肠 cecum 126,127,128
 盲孔 foramen caecum 11
 帽状腱膜 galea aponeurotica 175
 帽状腱膜下间隙 subaponeurotic space 175
 眉弓 superciliary arch 9
 眉间 glabella 9
 米勒肌 müller muscle 190
 迷走神经(X) vagus
 nerve(X) 67,92,158,159,162,163,165,174,185,195,202
 迷走神经背核 dorsal nucleus of vagus n. 203,205
 迷走神经颈心支 cervical cardiac branches of vagus n. 165
 迷走神经前干分支 branches of anterior vagal trunk 120
 迷走神经三角 vagal triangle 202
 密质 compact 3
 面动脉 facial a. 162,163,170,171,172,174
 面静脉 facial v. 171,173
 面深静脉 deep facial v. 173
 面神经(VII) facial n.(VII) 171,178,179,202,206,219
 面神经核 nucleus of facial n. 178,203,206,220
 面神经核上瘫 supranuclear paralysis 220
 面神经核下瘫 infranuclear paralysis 220
 面神经丘 facial colliculus 202
 面神经区 area of facial nerve 197

面神经膝 genu of facial n. 206
 拇长屈肌 flexor pollicis longus 76
 拇长屈肌腱 tendon of flexor pollicis longus 75,84,86
 拇长屈肌腱鞘 synovial sheath of flexor
 pollicis longus 80
 拇长伸肌 extensor pollicis longus 83
 拇长伸肌腱 tendon of extensor
 pollicis longus 83
 拇长展肌 abductor pollicis longus 80,78
 拇短屈肌 flexor pollicis brevis 76,79,80,84
 拇短伸肌 extensor pollicis brevis 78
 拇短伸肌腱 tendon of extensor pollicis brevis 83
 拇短展肌 abductor pollicis brevis 75,79,84
 拇对掌肌 opponens pollicis 76,84
 拇收肌 adductor pollicis 76,80,84,86
 拇指腕掌关节 carpometacarpal joint of thumb 34
 拇指腕掌关节腔 carpometacarpal joint cavity of thumb 34
 拇主要动脉 principal artery of thumb 81
 踇长屈肌 flexor hallucis longus 59,62
 踇长屈肌(腱) flexor hallucis longus (tendon) 59~62
 踇长伸肌 extensor hallucis longus 62
 踇收肌(横头) adductor hallucis
 (transverse head) 61
 踇收肌(斜头) adductor hallucis
 (oblique head) 61
 幕切迹 tentorial incisure 225

N

内板 inner plate 3
 内侧(三角)韧带 medial (deltoid) lig. 42
 内侧半月板 medial meniscus 40
 内侧背核 mediodorsal nucleus 211
 内侧唇 internal lip 25
 内侧底段又称“心底段” medial segment
 (cardiac basal segment) 104,105
 前底段 anterior basal segment 104,105
 内侧段 medial segmental 105
 内侧副橄榄核 medial accessory olivary nucleus 204
 内侧核 medial nucleus 201
 内侧髁 medial condyle 26
 内侧隆起 medial eminence 202
 内侧丘系 medial lemniscus 205,206,207,216
 内侧丘系和斜方体 medial lemniscus and
 trapezoid body 206

内侧丘系交叉 decussation of medial lemniscus 204,216
 内侧膝状体 medial geniculate body 202,203,210,211,216
 内侧楔骨 medial cuneiform bone 27,28
 内侧缘 medial border 20
 内侧纵束 medial longitudinal fasciculus 201,205,206,207
 内耳门 internal acoustic pore 195
 内弓状纤维 internal arcuate fibers 204
 内踝 medial malleolus 26
 内踝关节面 medial malleolar articular surface 26
 内淋巴管 endolymphatic duct 198
 内淋巴囊 endolymphatic sac 196,198
 内囊 internal capsule 108,210,215,216,217,219
 内囊后肢 posterior limb of internal capsule 214
 内囊前肢 anterior limb of internal capsule 214
 内囊膝 genu of internal capsule 214
 内上髁 medial epicondyle 25
 内髓板 internal medullary lamina 211
 内脏大、小神经 greater and lesser
 splanchnic n. 131
 内脏大神经 greater splanchnic nerve 90,92,93
 内脏小神经 lesser splanchnic nerve 92
 内直肌 medial rectus 192
 内眦静脉 angular v. 173
 男尿道 male urethra 150
 男尿道(膜部) male urethra(membranous part) 143,149
 脑岛 insula 214,215
 脑膜中动脉 middle meningeal a. 172,174
 脑桥 pons 202,203,206,209,210,212,216,217,219
 脑桥核 pontine nucleus 221
 脑桥横纤维 transverse fibers of pons 206
 脑桥小脑束 pontocerebellar tract 221
 尿道(女) female urethra (female) 144
 尿道(膜部) male urethra (membranous part) 137
 尿道(前列腺部) male urethra(prastatic part) 137
 尿道(海绵体部) male urethra (cavernous part) 137
 尿道海绵体 cavernous body of urethra 150
 尿道海绵体 spongy body of penis 147,148
 尿道嵴 urethral ridge 140
 尿道括约肌 sphincter of urethra 149
 尿道内口 internal urethral orifice 137,140,144,145
 尿道球 bulb of urethra 137,141,150
 尿道球动脉 urethral bulbar a. 148
 尿道球腺 bulbourethral gland 142
 尿道外口 external orifice of urethra 144,147,151
 尿生殖膈 urogenital diaphragm 137,149

尿生殖膈下筋膜 inferior fascia of
 urogenital diaphragm 142,147,148,149
 颞侧视网膜 temporal retina 218
 颞侧视野 temporal visual field 218
 颞骨 temporal bone 9,12,15
 颞横回 transverse temporal gyri 216
 颞后动脉 posterior temporal a. 223
 颞后支 posterior temporal branches 223
 颞肌 temporalis 31
 颞前动脉 anterior temporal a. 223
 颞前支 anterior temporal branches 223
 颞浅动脉和静脉 superficial temporal
 a. & v. 170,176,180
 颞浅动脉 superficial temporal a. 171,174
 颞浅静脉 superficial temporal v. 171,173
 颞上回 superior temporal gyrus 212
 颞深前、后动脉 anterior, posterior
 deep temporal a. 172,174
 颞下沟 inferior temporal sulcus 212
 颞下颌关节盘 articular disc of
 temporomandibular joint 31,108
 颞下回 inferior temporal gyrus 212
 颞线 temporal line 12
 颞叶 temporal lobe 213
 颞支 temporal branches 170,171,179
 颞中动脉 middle temporal a. 223
 颞中回 middle temporal gyrus 212
 颞中间支 intermediate temporal branches 223
 女阴 female pudendum 145

P

盆内静脉丛 venous plexuses of pelvis 132
 皮肤 skin 111,150,175,190
 皮肤与浅筋膜 skin and superficial fascia 79
 皮下部 subcutaneous part 141
 皮下组织 subcutaneous tissue 175
 皮脂腺 sebaceous glands 190
 皮质核束 corticonuclear tract 219
 皮质脊髓侧束 lateral corticospinal tract 219
 皮质脊髓束 corticospinal tracts 201,219
 脾 spleen 106,110,120,121,122,123,125
 脾动脉 splenic a. 120,121,122
 脾静脉 splenic v. 121,122,125,128
 脾切迹 splenic notches 122

前庭区 vestibular area 202
前庭韧带 vestibular ligament 168
前庭上区 superior vestibular area 197
前庭神经核 vestibular nuclei 195,203
前庭神经内侧核 medial vestibular nucleus 205,206
前庭神经上核 superior vestibular nucleus 206
前庭神经外侧核 lateral vestibular nucleus 206
前庭神经下核 inferior vestibular nucleus 205
前庭水管外口 external aperture of aqueduct of vestibule 15
前庭蜗(位听)神经(VIII) vestibulocochlear n.(VIII) 195,202,210
前庭下区 inferior vestibular area 197
前外侧窝 anterolateral fontanelle 12
前斜角肌 scalenus anterior 158,161,162
前斜角肌结节 tubercle for scalenus anterior 8
前窝 anterior fontanelle 12
前正中裂 anterior median fissure 202
前纵韧带 anterior longitudinal lig. 29
浅部 superficial part 140
浅环 superficial inguinal ring 150
浅筋膜 superficial fascia 49,150
浅筋膜膜层 scarpa fascia 111
浅筋膜脂性层 camper fascia 111
桥脑 pons 108
切牙管 incisive canal 18
切牙孔 incisive foramina 10
切缘 cut edge 118
穹窿 fornix 215
穹窿脚 crus of fornix 215
穹窿柱 column of fornix 214
丘脑 thalamus 214
丘脑间粘合 interthalamic adhesion 211,212
丘脑髓纹 thalamic medulary stria 202
球海绵体肌 bulbocavernosus 147,148,151
球囊 sacculle 198
球状核 globose nucleus 209
屈肌支持带 flexor retinaculum 59,74,75,79,81,84
屈肌总腱鞘 common flexor synovial sheath 80
壳 putamen 215
颧大肌 zygomaticus major 171,175
颧弓 zygomatic arch 10
颧骨 zygomatic bone 9,12
颧突 zygomatic process 15
颧小肌 zygomaticus minor 175

颧支 zygomatic branches 170,171,179

R

桡侧运动脉 radial recurrent a. 75
桡侧副动脉 radial collateral a. 71
桡侧副韧带 radial collateral lig. 33
桡侧腕长伸肌 extensor carpi radialis longus 78
桡侧腕长伸肌腱 tendon of extensor carpi radialis longus 78,83,84
桡侧腕短伸肌 extensor carpi radialis brevis 78
桡侧腕短伸肌腱 tendon of extensor carpi radialis brevis 78
桡侧腕屈肌 flexor carpi radialis 73,74,84
桡侧腕屈肌腱 tendon of flexor carpi radialis 75,79,80,81
桡尺远侧关节腔 distal radioulnar joint cavity 34
桡动脉 radial a. 74,75,79,80,82,83
桡动脉和静脉 radial a. & v. 73,85
桡动脉腕背支 dorsal carpal branch of radial a. 83
桡动脉掌浅支 superficial palmar branch of radial a. 75,79,80,81
桡骨 radius 22,33,34,85
桡骨粗隆 radial tuberosity 22,33
桡骨环状韧带 annular lig. of radius 33
桡骨茎突 styloid process of radius 22,77
桡骨颈 neck of radius 22
桡骨体 shaft of radius 22
桡骨头 head of radius 22
桡切迹 radius notch 22
桡神经 radial n. 67,68,69,70,71,85
桡神经沟 sulcus for radial n. 21
桡神经后肌支 posterior muscular branch of radial n. 71
桡神经浅支 superficial branch of radial n. 74,75,82
桡腕背侧韧带 dorsal radiocarpal lig. 34
桡腕关节腔 radiocarpal joint cavity 34
桡腕掌侧韧带 palmar radiocarpal lig. 34
桡窝 radial fossa 21
人字缝 lambdoid suture 8,12
绒球 flocculus 209
绒球脚 peduncle of flocculus 209
乳侧切牙 deciduous lateral incisor 182
乳尖牙 deciduous canine 182
乳糜池 cisterna chyli 96,132
乳头 mammary papilla 66,89
乳头 nipple 89

乳头体 mamillary body 202,211,212
 乳突 mastoid process 10,12,15,164
 乳突窦 mastoid antrum 196
 乳突孔 mastoid foramen 10
 乳突切迹 mastoid notch 15
 乳突小房 tympanic cells 196
 乳腺小叶 gland lobules 89
 乳晕 areola of breast 66,89
 乳晕静脉丛 areola venous plexus 66
 乳中切牙 deciduous central incisor 182
 软腭 soft palate 184,186
 软骨间关节 interchondral joints 31

S

腮腺 parotid gland 156,170,178,180,185
 腮腺导管 parotid duct 170,179
 腮腺筋膜 parotid fascia 156
 三边孔 foramen trilaterum 71,72
 三叉丘系 trigeminal lemniscus 217
 三叉神经 trigeminal n.(V) 179,202,203,210,222
 三叉神经脊束 spinal tract of trigeminal n. 204,205,206,217
 三叉神经脊束核 spinal nucleus of trigeminal n. 203,204,205,206
 三叉神经节 trigeminal ganglion 179,217
 三叉神经脑桥核 pontine nucleus of trigeminal n. 203,206
 三叉神经压迹 trigeminal impression 15
 三叉神经运动核 motor nucleus of trigeminal n. 203,206,219
 三叉神经中脑核 mesencephalic nucleus of trigeminal n. 203,206,207
 三尖瓣隔侧瓣 septal cusp of tricuspid valve 101
 三尖瓣后瓣 posterior cusp of tricuspid valve 101
 三尖瓣前瓣 anterior cusp of tricuspid valve 101
 三角骨 triquetral bone 23
 三角肌 deltoid 67,69,70,71,72
 三角肌粗隆 deltoid tuberosity 21
 三角肌支 branch of deltoid 67
 筛板 cribriform plate 11,16
 筛窦后群开口 orifice of posterior ethmoidal sinuses 186
 筛窦前群开口 orifice of anterior ethmoidal sinuses 186
 筛骨迷路 ethmoidal labyrinth 16
 筛孔 ethmoidal foramen 16
 山顶 culmen 208
 山坡 declive 208
 上半月小叶 superior semilunar lobule 208
 上鼻道 superior nasal meatus 187
 上鼻甲 superior nasal concha 16,187
 上动脉弓 superior arterial arch 190
 上段 superior segment 104,105
 上肺静脉 superior pulmonary vein 102,103
 上腹下丛 superior hypogastric plexus 134,139
 上橄榄核 superior olivary nucleus 206,216
 上根 superior root 160,161,162
 上关节凹 superior articular fovea 5
 上关节面 superior articular surface 5
 上关节突 superior articular process 5,6
 上颌动脉 maxillary a. 172,174,179
 上颌窦开口 orifice of maxillary sinus 180
 上颌窦裂孔 maxillary hiatus 18
 上颌骨 maxilla 9,12,18
 上颌结节 maxillary tubercle 18
 上颌静脉 maxillary v. 173
 上颌神经 maxillary n. 163,178
 上颌牙槽 superior alveoli 185
 上甲状旁腺 superior parathyroid gland 165
 上睑板 superior tarsus 191
 上睑提肌 levator palpebrae superior 192
 上角 superior cornu 166
 上结节 superior thyroid tubercle 166
 上肋凹 superior costal fovea 6
 上泪小管 upper lacrimal ductule 191
 上涎涎核 superior salivatory nucleus 203
 上颞线 superior temporal line 12
 上腔静脉 superior vena cava 91,93,94,95,96,97,106
 上腔静脉压迹 impression for superior vena cava 102
 上切迹 superior thyroid notch 6,166,167
 上丘 superior colliculus 202,203,210
 上丘层 gray matter layer of superior colliculus 207
 上舌段 superior lingular segment 104
 上矢状窦 superior sagittal sinus 225,226
 上矢状窦沟 sulcus for superior sagittal sinus 17
 上吻合静脉 superior anastomotic v. 224
 上颈线 superior nucha line 17
 上斜肌 superior obliquus 192
 上牙槽后动脉 posterior superior alveolar a. 172
 上牙槽后支 posterior superior alveolar branch 178
 上牙槽前支 anterior superior alveolar branch 178



- 上牙槽中支 middle superior alveolar branch 178
 上叶 upper lobe 102,103
 上叶支 superior lobar branche 102
 上叶支气管 superior lobar bronchus 102
 上缘 superior border 122
 上直肠横襞 superior transverse folds of rectum 141
 上直肌 superior rectus 190,192,193
 上孖肌 gemellus superior 53,54
 上纵肌 superior longitudinal muscle 181
 舌 tongue 178,180,184
 舌背 dorsum of tongue 181
 舌扁桃体 lingual tonsil 181
 舌垂直肌 vertical muscle of tongue 181
 舌动脉 lingual a. 162,163,172,180,181
 舌动脉 lingual artery 172
 舌根 root of tongue 181,184
 舌骨 hyoid bone 13,155,156,181,182
 舌骨大角 greater horn 13,166,167,168
 舌骨体 body of hyoid bone 13,166,167,168
 舌横肌 transverse muscle of tongue 181
 舌回 lingual gyrus 212,213
 舌尖 apex of tongue 181
 舌静脉 lingual v. 180
 舌神经 lingual n. 161,162,163,174,178,179,180
 舌下神经(XII) hypoglossal n.(XII) 161,162,163,180,202,205
 舌下神经核 nucleus of hypoglossal n. 203,204,205,219,220
 舌下神经核上瘫 supranuclear paralysis 220
 舌下神经核下瘫 infranuclear paralysis 220
 舌下神经三角 hypoglossal triangle 202
 舌下腺 sublingual gland 161,178,179
 舌下腺凹 sublingual fovea 13
 舌下腺管 sublingual duct 180
 舌咽神经(X) glossopharyngeal n.(IX) 161,162,163,178,202
 舌粘膜 lingual mucous membrane 181
 舌正中沟 median sulcus of tongue 184
 舌中隔 septum of tongue 181
 射精管 ejaculatory duct 137,141
 伸肌上支持带 superior extensor retinaculum 63
 伸肌支持带 extensor retinaculum 63,78,83
 肾 kidney 125,129,139
 肾丛 renal plexus 134
 肾大盏 major renal calices 130
 肾动脉 renal a. 130,131,
 肾静脉 renal v. 130
 肾皮质 renal cortex 130
 肾乳头 renal papillae 130
 肾上腺上动脉 superior suprarenal a. 131
 肾上腺下动脉 inferior suprarenal a. 131
 肾上腺中动脉 middle suprarenal a. 131
 肾小盏 minor renal calices 130
 肾盂 renal pelvis 130
 肾柱 renal columns 130
 肾锥体 renal pyramids 130
 升结肠 ascending colon 108,126,127,128
 升主动脉 ascending aorta 91,95,97,98,101,106,107
 生殖股神经 genitofemoral n. 129,133,139
 声襞 vocal fold 168
 声带突 vocal process 166,168
 声门下腔 infraglottic cavity 168
 声韧带 vocal ligament 168
 十二指肠大乳头 major duodenal papilla 124
 十二指肠降部 descending part of duodenum 120,121,124
 十二指肠空肠曲 duodenoejejunal flexure 121,126,127
 十二指肠上部 superior part of duodenum 119,120,125
 十二指肠升部 ascending part 121
 十二指肠下部 inferior part 121
 十二指肠皱襞 folds of duodenum 119
 食管 esophagus 90,94,96,106,107,108,110,123,158,184
 食管腹段 abdominal part of esophagus 115,119,128,129
 食管及其神经丛 esophagus and esophageal plexus 93
 食管颈部 cervical part of the esophagus 165
 食管压迹 impression for esophagus 103
 食管隐窝 esophageal recess 90
 食管纵皱襞 longitudinal folds of esophagus 119
 矢状缝 sagittal suture 9,12
 示指伸肌 extensor indicis 78
 示指伸肌腱 tendon of extensor indicis 83
 视辐射 optic radiation 218
 视杆细胞 rod cells 188
 视交叉 optic chiasma 202,211,212,218,225
 视前内侧核 medial preoptic nucleus 211
 视前外侧核 lateral preoptic nucleus 211
 视上核 supraoptic nucleus 211
 视神经(Ⅱ) optic n.(Ⅱ) 189,202,210,218,222,225
 视神经管 optic canal 14,19
 视神经盘 optic disc 189
 视束 optic tract 202,203,210,218
 视网膜 retina 189
 视网膜鼻侧上小动脉 superior nasal

- arteriole of retina 189
 视网膜鼻侧上小静脉 superior nasal venule of retina 189
 视网膜鼻侧下小动脉 inferior nasal arteriole of retina 189
 视网膜鼻侧下小静脉 inferior nasal infnasal
 venule of retina 189
 视网膜动脉 retinal a. 189
 视网膜颞侧上小动脉 superior temporal
 arteride of retina 189
 视网膜颞侧上小静脉 superior temporal
 venule of retina 189
 视网膜颞侧下小动脉 inferior temporal
 arteriole of retina 189
 视网膜颞侧下小静脉 inferior temporal
 venule of retina 189
 视网膜中央动、静脉 central artery and
 vein of retina 188
 视网膜中央动脉 centralis retina a. 189
 视网膜中央静脉 centralis retina v. 189
 视轴 optic axis 188
 视锥细胞 cone cells 188
 室间隔肌性部 muscular part of
 interventricular septum 100,106
 室间隔膜部 membranous part of
 interventricular septum 100,106
 室间孔 interventricular foramen 211,212,226
 室旁核 paraventricular nucleus 211
 室上嵴 supraventricular crest 99
 收肌结节 adductor tubercle 25
 收肌腱裂孔 adductor tendinous opening 50
 手背静脉网 dorsal venous rete of hand 82
 手骨 bones of hand 23
 手舟骨 scaphoid bone 23
 梳状肌 pectinate muscle 54
 输精管 ductus deferens 129,136,137,138,140,141,142
 输精管壶腹 ampulla of ductus deferens 138,141,142
 输卵管 uterine tube 144,145,146
 输卵管伞 fimbriae of uterine tube 144,145,146
 输尿管 ureter 130,131,133,136 - 142,145,146
 输尿管间襞 interureteric fold 140,145
 输尿管口 ureteric orifice 140,145
 输乳管 lactiferous ducts 89
 输乳管窦 ampulla 89
 栓状核 emboliform nucleus 209
 双极细胞 bipolar cells 188
 双眼颞侧偏盲 bitemporal heteronymous hemianopsia 218
 双眼右侧偏盲 right homonymous hemianopsia 218
 水平板 horizontal plate 10
 水平裂 horizontal fissure 102,208
 丝状乳头 filiform papillae 181
 四边孔 foramen quadrilaterum 71,72
 松弛部 flaccid part 197
 松果体 pineal body 202,212
 松质 spongy 3
 髓核 nucleus pulposus 2
 髓纹 striae medullares 202
 锁骨 clavicle 19,66,70
 锁骨上大窝 greater supraclavicular fossa 154
 锁骨上神经 supraclavicular n. 156,157,160
 锁骨体 shaft of clavicle 19
 锁骨下动脉 subclavian a. 67,161,162,163
 锁骨下动脉沟 sulcus for subclavian a. 8
 锁骨下静脉 subclavian v. 67,160
 锁骨下静脉沟 sulcus for subclavian v. 8
 锁切迹 clavicular notch 8
 锁胸筋膜 clavipectoral fascia 66
- ## T
- 提睾肌筋膜 cremasteric fascia 150
 提上唇鼻翼肌 levator labii superioris alaeque nasi 175
 提上唇肌 levator labii superioris 175
 听小骨 auditory ossicles 196
 听诊三角 triangle of auscultation 45
 瞳孔 pupil 188
 瞳孔括约肌 sphincter pupillae 188
 头半棘肌 semispinalis capitis 46
 头臂干 brachiocephalic trunk 91,94,95
 头长肌 longus capitis 46
 头后大直肌 rectus capitis posterior major 46
 头夹肌 splenius capitis 46
 头静脉 cephalic v. 70,73,82
 头上斜肌 obliquus capitis superior 46
 头下斜肌 obliquus capitis inferior 46
 头状骨 capitate bone 23
 头最长肌 longissimus capitis 46
 骰骨 cuboid bone 27
 透明隔 septum pellucidum 212,214,215
 近节趾骨 proximal phalanx 23
 臀大肌 gluteus maximus 52,53,54,147
 臀肌粗隆 gluteal tuberosity 25

臀内侧皮神经 medial clunial n. 52
 臀上动脉 superior gluteal a. 53,137
 臀上皮神经 superior clunial n. 52
 臀上神经 superior gluteal n. 53
 臀下动脉 inferior gluteal a. 53,54,137
 臀下皮神经 inferior clunial n. 52
 臀下神经 inferior gluteal n. 53
 臀小肌 gluteus minimus 53
 臀中肌 gluteus medius 52,53,54
 椭圆囊 utricle 198

W

外板 outer plate 3
 外侧半月板 lateral meniscus 40
 外侧背核 lateral dorsal nucleus 211
 外侧唇 external lip 25
 外侧底段 lateral basal segment 104,105
 外侧段 lateral segment 105
 外侧沟 lateral sulcus 108,212
 外侧核 lateral nucleus 201
 外侧后核 lateral posterior nucleus 211
 外侧髁 lateral condyle 26
 外侧淋巴结 lateral lymph nodes 69
 外侧皮支 lateral cutaneous branches
 (Thoracic Nerves) 112
 外侧丘系 lateral lemniscus 206,207,216
 外侧索 lateral funiculus 201
 外侧膝状体 lateral geniculate body 203,210,211,218
 外侧楔骨 lateral cuneiform bone 27
 外侧缘 lateral border 20
 外耳道 external acoustic meatus 195,196
 外耳孔 external acoustic pore 12,15
 外骨半规管 lateral bony semicircular canal 194,198
 外骨壶腹 lateral bony ampulla 198
 外踝 lateral malleolus 26,59,63
 外踝窝 lateral malleolar fossa 26
 外科颈 Surgical neck 21
 外膜半规管 lateral semicircular duct 198
 外膜壶腹 lateral membranous ampulla 198
 外上髁 lateral epicondyle 25
 外直肌 lateral rectus 192,193
 豌豆骨 pisiform bone 23,81
 腕背弓 posterior carpal arch 82
 腕背骨纤维管 osseofibrous canal of
 posterior region of wrist 83
 腕尺侧副韧带 carpal collateral lig. 34
 腕骨间关节腔 intercarpal joint cavity 34
 腕管 canalis carpalis (carpal canal) 84
 腕桡侧副韧带 collateral carporadial lig. 34
 腕掌背侧韧带 dorsal carpometacarpal lig. 34
 腕掌关节腔 carpometacarpal joint cavity 34
 腕掌掌侧韧带 palmar carpometacarpal lig. 34
 网膜囊 omental bursa 118
 网状脊髓束 reticulospinal tract 201
 网状结构 reticular formation 205,206,221
 尾骨 coccyx 2,4,7,107,143,149
 尾骨 coccygeal vertebrae 107
 尾骨肌 coccygeus 143
 尾骨角 coccygeal cornu 7
 尾状核 caudate nucleus 108,202,210,214,215,217,221
 尾状核头 head of caudate nucleus 214,225
 胃 stomach 107,108,110,116,118,119,125
 胃大弯 greater curvature of stomach 118,119
 胃底 fundus of stomach 119,128
 胃底部静脉 veins of fundus of stomach 128
 胃短动脉 short gastric a. 120
 胃路 gastric canal 119
 胃后壁 posterior wall of stomach 118
 胃肌层 musculature of stomach 119
 胃十二指肠动脉 gastroduodenal a. 121,122
 胃体 body of stomach 119
 胃网膜右动脉 right gastroepiploic a. 120,121,122
 胃网膜右静脉 right gastroepiploic v. 128
 胃网膜左动脉 left gastroepiploic a. 120
 胃网膜左静脉 left gastroepiploic v. 128
 胃小凹 gastric pit 119
 胃小弯 lesser curvature 119
 胃右动脉 right gastric a. 120
 胃粘膜皱襞 gastric folds 119
 胃左动脉 left gastric a. 120,121
 胃左静脉 left gastric v. 128
 涡静脉 vorticosae v. 189
 蜗背侧核 dorsal cochlear nucleus 205,216
 蜗窗 fenestra cochleae 194,198
 蜗顶 cupula of cochlea 194,197,198
 蜗腹侧核 ventral cochlear nucleus 205,216
 蜗管 cochlear duct 197,198
 蜗区 cochlear area 197
 蜗神经 cochlear n. 198

蜗神经核 cochlear nuclei 203

蜗轴 cochlear axis 197

X

斜方肌 trapezius 154,156,158,160,163,185

膝横韧带 transverse lig. of knee 39,40

膝上内侧动脉 medial superior genicular a. 55,56

膝上外侧动脉 lateral superior genicular a. 55,56

膝神经节 geniculate ganglion 178

膝下内侧动脉 medial inferior genicular a. 55,56

膝下外侧动脉 lateral inferior genicular a. 55,56

膝中动脉 middle genicular a. 55,56

下半月小叶 inferior semilunar lobule 208

下鼻道 inferior nasal meatus 187

下鼻甲 inferior nasal concha 9,187

下动脉弓 inferior arterial arch 190

下肺静脉 inferior pulmonary vein 102,103

下腹下丛 inferior hypogastric plexus 139

下橄榄核 inferior olivary nucleus 205

下根 inferior root 106,161,162

下关节凹 inferior articular fovea 5

下关节突 inferior articular process 5,6

下颌骨下缘 inferior margin of the mandible 154

下颌后静脉 ratromandibular v. 171,173 ~ 185

下颌角 angle of mandible 13

下颌颈 neck of mandible 13

下颌孔 mandibular foramen 13

下颌切迹 mandibular notch 13

下颌舌骨肌 mylohyoid 174,179

下颌舌骨肌神经 mylohyoid n. 179

下颌神经 submandibular n. 178

下颌体 body of mandible 13

下颌头 head of mandible 13

下颌窝 mandibular fossa 10

下颌下节 submandibular ganglion 161,163,174,180

下颌下三角 submandibular triangle 154

下颌下腺 submandibular gland 155,156,159,160,161,163,178

下颌下腺管 submandibular duct 179

下颌小舌 mandibular lingula 13

下颌缘支 marginal mandibular branch 170,171

下颌支 ramus of mandible 13,185

下甲状旁腺 inferior parathyroid gland 165

下睑板 inferior tarsus 191

下角 inferior angle 20

下角 inferior cornu 166

下结节 inferior thyroid tubercle 166

下肋凹 inferior costal fovea 6

下泪点 lower lacrimal punctum 191

下涎核 inferior salivatory nucleus 203

下颞线 inferior temporal line 12

下腔静脉 inferior vena cava 90,93 ~ 98,107,108,123,125, 129,131 ~ 133,136

下腔静脉孔 vena caval foramen 115

下丘 inferior colliculus 202,203

下丘核 nucleus of inferior colliculus 207,216

下丘脑沟 hypothalamic sulcus 211,212

下舌段 inferior lingular segment 104

下吻合静脉 inferior anastomotic v. 224

下项线 inferior nucha line 17

下斜肌 inferior obliquus 190,192

下牙槽动脉 inferior alveolar a. 172

下牙槽静脉 inferior alveolar v. 173

下牙槽神经 inferior alveolar n. 161,162,163,179

下牙槽神经和动脉 inferior alveolar n. and a. 174,178,179

下叶 lower lobe 102,103

下叶支气管 inferior lobar bronchus 102

下直肠横襞 inferior transverse folds of rectum 141

下直肌 inferior rectus 190,192

下孪肌 gemellus inferior 53,54

下纵肌 inferior longitudinal muscle 181

纤维隔 fibrous septa 79

纤维环 annulus fibrosus 101

纤维小结节 fibrous (Albini's) nodules 100

纤维心包(切断处) fibrous pericardium(cut) 90,95

项韧带 ligamentum nuchae 30,164

小多角骨 trapezoid bone 23

小角 lesser horn 13

小角软骨 corniculate cartilage 166

小结 nodule 208,209

小结节 lesser tubercle 21

小结节嵴 crest of lesser tubercle 21

小脑 cerebellum 185,212,213

小脑扁桃体 tonsil of cerebellum 208,209

小脑后下动脉 posterior inferior cerebellar a. 222

小脑幕 tentorium of cerebellum 224,225

小脑前下动脉 anterior inferior cerebellar a. 222

小脑上动脉 superior cerebellar a. 222

小脑上脚 superior cerebellar peduncle 202,206,210

小脑上脚交叉 decussation of superior



- cerebellar peduncle 207
- 小脑窝 cerebellar fossa 17
- 小脑下脚 inferior cerebellar peduncle 202,203,205,210
- 小脑延髓池 cerebellomedullary cistem 226
- 小脑中脚 middle cerebellar peduncle 202,203,206,210
- 小腿骨间膜 crural interosseous membrane 41,62
- 小腿后肌间隔 posterior crural intermuscular septum 62
- 小腿前肌间隔 anterior crural intermuscular septum 62
- 小网膜 lesser omentum 118
- 小翼 lesser wing 11,14
- 小阴唇 lesser lip of pudendum 144,151,152
- 小隐静脉 small saphenous v. 58,62,64
- 小圆肌 teres minor 45
- 小指尺掌侧动脉及神经 ulnar palmar a. & n.of little finger 79
- 小指尺掌侧固有动脉及神经 ulnar palmar a. & n.of little finger 79
- 小指短屈肌 flexor digiti minimi brevis 79,80,84
- 小指对掌肌 opponens digiti minimi 84
- 小指屈肌腱鞘 synovial sheath of little finger 80
- 小指伸肌 extensor digiti minimi 78
- 小指伸肌腱 tendon of extensor digiti minimi 83
- 小指展肌 abductor digiti minimi 76,80,84,86
- 小趾短屈肌 flexor digiti minimi brevis 60
- 小趾展肌 abductor digiti minimi 60
- 小转子 lesser trochanter 25,36,37
- 楔前叶 precuneus 212
- 楔束 fasciculus cuneatus 201,204
- 楔束副核 accessory cuneate nucleus 205
- 楔束核 cuncate nucleus 204,216
- 楔束结节 cuneate tubercle 202
- 楔叶 cuneus 212,213
- 楔舟背侧韧带 dorsal cuneonavicular lig. 42
- 楔舟关节 cuneonavicular joint 43
- 斜方肌 trapezius 45,156,158,163,185
- 斜方体 trapezoid body 216
- 斜角肌 scalenus anterior 46
- 斜裂 oblique fissure 102,103
- 纤维心包 fibrous pericardium 92
- 心包膈动脉 pericardiophrenic artery 92
- 心包横窦 transverse pericardial sinus 97
- 心包腔 serous pericardium cavity 107
- 心包斜窦 oblique pericardial sinus 97,106
- 心大静脉 great cardiac vein 98
- 心尖 apex of heart 91
- 心尖切迹 cardiac apical incisure 98
- 心前静脉 anterior cardiac vein 97
- 心切迹 cardiac notch 103
- 心小静脉 small cardiac vein 98
- 心压迹 cardiac impression 102,103
- 心中静脉 middle cardiac vein 98
- 杏仁体 amygdaloid body 203,214
- 胸背动脉 thoracodorsal a. 68,69
- 胸背神经 thoracodorsal n. 68,69,70,72
- 胸长神经 long thoracic n. 67,69
- 胸大肌 pectoralis major 66,67,69,70,112
- 胸导管 thoracic duct 90,94,96,106,132
- 胸腹壁静脉 thoracoepigastric v. 66,110,111
- 胸骨 sternum 8,90
- 胸骨柄 sternal manubrium 8
- 胸骨端 sternal end 19
- 胸骨甲状肌 sternothyroid 89,160,161,162
- 胸骨角 sternal angle 8,107
- 胸骨旁淋巴结 parasternal lymphatic nodes 89
- 胸骨上窝 suprasternal fossa 159
- 胸骨舌骨肌 sternohyoid muscle 89,154 - 158,160,161,162
- 胸骨体 sternal body 8
- 胸骨下角 infrasternal angle 31
- 胸核 nucleus thoracicus 201
- 胸横肌 transversus thoracis muscle 89
- 胸肌淋巴结 pectoral lymph nodes 69
- 胸肩峰动脉 thoracoacromial a. 66,67,68
- 胸交感干 sympathetic trunk of thorax 93
- 胸廓内动脉 internal thoracic artery 68,89,90
- 胸廓内静脉 internal thoracic vein 89,90,91
- 胸肋辐状韧带 radiate sternocostal lig. 31
- 胸肋关节 sternocostal joints 31
- 胸膜顶(颈胸膜) cupula(cervical pleura) 108
- 胸膜前反折线 anterior plural reflex 89
- 胸膜下缘 inferior margin of pleura 132
- 胸内侧神经 medial pectoral n. 66
- 胸髂肋肌 iliocostalis thoracis 46
- 胸神经前皮支 anterior cutaneous branch(T.11) 112
- 胸锁关节 sternoclavicular joint 31
- 胸锁乳突肌 sternocleidomastoid 154,155,156,157,158,160,165,170,171,185
- 胸外侧动脉 lateral thoracic a. 67,68,69
- 胸腺 thymus 97
- 胸小肌 pectoralis minor 66,68,69,70
- 胸腰筋膜 thoracolumbar fascia 45

- 胸主动脉 thoracic aorta 90,92,95,106,110,132
 胸椎 thoracic vertebrae 2,4,6
 胸椎椎体 thoracic vertebral body 6,90,96,106
 胸最长肌 longissimus thoracis 46
 嗅球 olfactory bulb 179,202,212
 嗅神经 olfactory n(I) 179
 嗅束 olfactory tract 202,222
 旋肱后动脉 posterior humeral circumflex a. 67,68,69,71,72
 旋肱前动脉 anterior humeral circumflex a. 68
 旋股内侧动脉 medial femoral circumflex a. 51
 旋股内侧动脉(深支) medial femoral circumflex a.(deep branch) 52
 旋股外侧动脉 lateral femoral circumflex a. 50,51
 旋后肌 supinator 78
 旋肩胛动脉 circumflex scapular a. 71,72
 旋髂浅静脉 superficial inguinal circumflex v. 48,111,110
 旋前方肌 pronator quadratus 75,76,77
 旋前圆肌 pronator teres 74,75,77
 旋支 circumflex branch 98
- Y**
- 牙本质 dentine 183
 牙槽轭 juga alveolaria 18
 牙槽孔 alveolar foramen 18
 牙槽突 alveolar process 18
 牙龈 gum 183
 牙根管 root canal 183
 牙根尖孔 apical foramen 183
 牙骨质 cement 183
 牙腔 dental cavity 183
 牙髓 dental pulp 183
 牙周膜 periodontal membrane 183
 咽 pharynx 88,110,163,165,185
 咽鼓管 auditory tube 195
 咽鼓管咽口 pharyngeal opening of auditory tube 187
 咽鼓管咽枕 tubal torus 187
 咽结节 pharyngeal tubercle 10,17
 咽升动脉 ascending pharyngeal a. 163
 咽下缩肌 inferior constrictor of pharynx 180,184
 延髓 medulla oblongata 200,212,216,217,219,221
 岩大神经 greater petrosal n. 178,179
 岩鼓裂 petrotympanic fissure 15
 岩鳞裂 petrosquamous fissure 15
 岩上窦沟 sulcus for superi of petrosal sinus 15
 岩小神经 lesser petrosal n. 178
 眼动脉 ophthalmic a. 193
 眼轮匝肌 orbicularis oculi 170,171
 眼轮匝肌眶部 orbital part of orbicularis oculi 175
 眼轮匝肌睑部 palpebral part of orbicularis oculi 175
 眼球 eyeball 192
 眼上静脉 superior ophthalmic v. 173
 眼神经 ophthalmic n. 179
 眼轴 eye axis 188
 腰大肌 psoas major 129,136
 腰椎干 lumbosacral trunk 139
 腰动脉 lumbar a. 96,132,134,135
 腰方肌 quadratus lumborum 96,132
 腰交感神经节 lumbar ganglion 129
 腰静脉 lumbar v. 96,132
 腰髂肋肌 iliocostalis lumborum 46
 腰三角 lumbar triangle 45
 腰神经节 lumbar ganglia 134,139
 腰升静脉 ascending lumbar v. 132
 腰椎 lumbar vertebrae 2,4,6
 腰椎椎体 lumbar vertebral body 6,96
 咬肌 masseter 171,177
 咬肌粗隆 masseteric tuberosity 13
 叶状乳头 filiate papillae 181
 腋动脉 axillary artery 67,68,70,91,95
 腋神经 axillary n. 67,68,69,70,72
 腋神经和旋肱后动脉 axillary n.and posterior humeral circumflex a. 71
 胰 pancreas 107,108
 胰背动脉 dorsal pancreatic a. 122
 胰大动脉 great pancreatic a. 122
 胰管 pancreatic duct 122,124
 胰颈 neck of pancreas 121
 胰十二指肠后上动脉 posterior superior pancreaticoduodenal a. 121,122
 胰十二指肠后下动脉 posterior inferior pancreatico duodenal a. 121
 胰十二指肠前上动脉 anterior superior pancreaticoduodenal a. 121,122
 胰十二指肠前下动脉 anterior inferior pancreaticoduodenal a. 121
 胰十二指肠下动脉 inferior pancreaticoduodenal a. 122
 胰体 the body of pancreas 118,120,121,125
 胰头 head of pancreas 120,121,125
 胰尾 tail of pancreas 120,121,125



- 胰尾动脉 caudal pancreatic a. 122
 胰下动脉 inferior pancreatic a. 122
 疑核 nucleus ambiguus 205
 乙状窦沟 Sulcus for sigmoid sinus 15
 乙状结肠 sigmoid colon 117,127,128,138
 乙状结肠动脉 sigmoid a. 127
 乙状结肠静脉 sigmoid v. 128
 翼点 pterion 12
 翼腭神经节 pterygopalatine ganglion 178,179
 翼管 pterygoid canal 14
 翼肌粗隆 pterygoid tuberosity 13
 翼肌支 pterygoid branches 172,179
 翼静脉丛 pterygoid venous plexus 173
 翼内肌 medial pterygoid 177,179,185
 翼内肌神经 medial pterygoid n. 179
 翼突内侧板 medial pterygoid plate 10,14
 翼突外侧板 lateral pterygoid plate 10,14
 翼外肌 lateral pterygoid 177,185
 翼窝 pterygoid fossa 10
 翼状襞 alar folds 41
 翼状韧带 alar lig of dens 30
 阴部内动脉 internal pudendal a. 53,137,148
 阴部神经 pudendal n. 53,148,152
 阴唇后神经 posterior labial n. 152
 阴唇后支 posterior labial branches 152
 阴唇系带 frenulum of pudendum labia 151
 阴道 vagina 144
 阴道口 vaginal orifice 144,151,152
 阴道口及处女膜痕 vaginal orifice and carunculæ hymenales 151
 阴道穹(后部) fornix of vagina(posterior part) 144
 阴蒂 clitoris 152
 阴蒂海绵体 cavernous body of clitoris 151
 阴蒂及阴蒂包皮 clitoris and prepuce of clitoris 151
 阴蒂脚 crus of clitoris 151
 阴蒂深动脉 deep artery of clitoris 152
 阴蒂系带 frenulum of clitoris 151
 阴阜 mons pubis 151,152
 阴茎 penis 107,111,129,150
 阴茎包皮 prepuce of penis 150
 阴茎背动脉 dorsal artery of penis 138,150
 阴茎背深静脉 deep dorsal vein of penis 138,150
 阴茎背神经 dorsal nerve of penis 138,147,150
 阴茎海绵体 cavernous body of penis 150
 阴茎海绵体白膜 albuginea of cavernous body of penis 150
 阴茎脚 crus penis 140,141,150
 阴茎颈 neck of penis 150
 阴茎浅筋膜 superficial fascia of penis 150
 阴茎深动脉 deep artery of penis 150
 阴茎深筋膜 deep fascia of penis 150
 阴茎头 glans penis 140,147,150
 阴囊 scrotum 142,148
 阴囊后神经 posterior scrotal n. 147,148
 阴囊后支 posterior scrotal branches 148
 阴囊中隔 septum of scrotum 137
 蚓垂 uvula of vermis 208
 蚓结节 tuber of vermis 208
 蚓叶 folium 208
 蚓锥体 pyramid of vermis 208
 隐神经 saphenous n. 50,59
 鹰咀 olecranon 22,33,77,78
 鹰嘴窝 olecranon fossa 21
 硬腭 hard palate 185,186,187
 硬脊膜 spinal dura mater 200
 硬脑膜 cerebral dura mater 225
 幽门 pylorus 119
 幽门窦 pyloric antrum 119
 幽门管 pyloric canal 119
 幽门口 pyloric orifice 125
 幽门括约肌 pyloric sphincter 119
 右肺动脉 right pulmonary artery 93,94,95,96,106,107,108
 右肺静脉 right pulmonary veins 93,95,96
 右肺上叶 superior lobar of right lung 91,106,108
 右肺上叶动脉 right superior pulmonary artery 106
 右肺上叶支 superior lobar branches of right lung 95
 右肺上叶支气管 superior lobar bronchi of right lung 93,106,108
 右肺下静脉 right inferior pulmonary vein 106
 右肺下叶支 inferior lobar branches of right lung 95,108
 右肺支气管肺段 bronchopulmonary segments of right lung 105
 右肺下叶 inferior lobe of right lung 102
 右膈神经 right phrenic nerve 93,95
 右膈神经和心包膈动脉、静脉 right phrenic nerve and pericardiophrenic artery and vein 90
 右膈下动脉 right inferior phrenic a. 115,131,133
 右膈足 right crus of diaphragm 132
 右冠状动脉 right coronary artery 97,98
 右冠状动脉口 orifice of right coronary artery 100
 右冠状沟 right coronary sulcus 91

右冠状韧带上层 superior layer of right coronary ligament 123
 右喉返神经 right recurrent laryngeal n. 165
 右结肠动脉 right colic a. 126
 右结肠静脉 right colic v. 128
 右颈内静脉 right jugular vein 94,96
 右颈总动脉 right common carotid artery 94
 右肋膈隐窝 right costodiaphragmatic recess 90
 右肋膈隐窝 right costodiaphragmatic recess of pleura 90,93
 右肋间最上静脉 right highest intercostal vein 93
 右淋巴导管 right lymphatic duct 94
 右迷走神经 right vagus nerve 93
 右髂总动脉 right common iliac artery 96
 右髂总静脉 right common iliac v. 136
 右睾丸动脉 right testicular a. 133
 右睾丸静脉 right testicular v. 133
 右三角韧带 right triangular ligament 123,125
 右上肺静脉 right superior pulmonary vein 106
 右肾 right kidney 125,131,132
 右肾动脉 right renal a. 133,134
 右肾静脉 right renal v. 133
 右肾上腺 right suprarenal gland 125,131,134
 右室前壁 anterior wall of right ventricle 91
 右室前支 anterior branch of right ventricle 97
 右锁骨下动脉 right subclavian artery 89
 右锁骨下静脉 right subclavian vein 89,94,96
 右头臂静脉 right brachiocephalic vein 89,91,94,95,96
 右纤维三角 right fibrous trigone 101
 右心耳 right auricle 91,94,97,98,99,101,107
 右心房 right atrium 94,108
 右心室 right ventricle 106,107
 右心室后壁 posterior wall of right ventricle 98
 右缘支 right marginal branch 97,98
 右支 right branch 126
 右主支气管 right principal bronchus 88,96,106
 右最上肋间静脉 right highest intercostal vein 96
 釉质 enamel 183
 盂唇 glenoid labrum 32
 孟上结节 supraglenoid tubercle 20
 孟下结节 infraglenoid tubercle 20
 鱼际 thenar 79
 羽状肌 bipennate muscle 44
 原裂 primary fissure 208
 圆孔 foramen rotundum 11,14

缘层 marginal layer 201
 缘上回 supramarginal gyrus 212
 缘支 marginal ramus 212
 远节指骨 distal phalanx 23
 远节趾骨 distal phalanx 28
 月骨 lunate bone 23
 月状面 lunate surface 24

Z

载距突 sustentaculum tale 27
 脏腹膜 visceral peritoneum 142
 脏面 visceral surface 122
 粘膜 mucosa 127
 粘膜下层 submucosa 127
 展神经 abducent n(VI) 193,202,206
 展神经核 nucleus of abducent n. 203,206,219
 掌背动脉 dorsal palmar a. 82
 掌长肌 palmaris longus 73,74
 掌长肌腱 tendon of palmaris longus 80
 掌短肌 palmaris brevis 73,79
 掌骨底 base of metacarpal bone 23
 掌骨间韧带 interosseous metacarpal lig. 34
 掌骨深横韧带 deep transverse metacarpal lig. 34
 掌骨体 shaft of metacarpal bone 23
 掌骨头 head of metacarpal bone 23
 掌腱膜 palmar aponeurosis 73,79,86
 掌浅弓 superficial palmar arch 74,75,81
 掌浅支 superficial palmar branch of radial a. 74,79,81
 掌深弓 deep palmar arch 80,81,86
 掌心动脉 palmar metacarpal a. 80
 掌指关节腔 metacarpophalangeal joint cavity 34
 掌中隔 midpalmar septum 86
 掌中间隙 midpalmar space 86
 砧锤关节 incudomalleolar joint 197
 砧骨 incus 194,196
 砧骨体 body of incus 197
 枕大神经和枕动脉 greater occipital n. & occipital a. 170
 枕动、静脉 occipital a. & v. 176
 枕动脉 occipital a. 161,162,163,172
 枕动脉沟 occipital groove 15
 枕额肌额腹 frontal belly of occipitofrontalis 175
 枕骨 occipital bone 9,12,164
 枕骨大孔 foramen magnum 10,11
 枕核 nuclei pulvinares 211

- 枕静脉 occipital v. 160,176
 枕髁 occipital condyle 10,17
 枕鳞 occipital squama 17
 枕内嵴 internal occipital crest 11,17
 枕内隆凸 internal occipital protuberance 11,17
 枕颞沟 occipitotemporal sulcus 213
 枕颞内侧回 medial occipitotemporal gyrus 213
 枕颞外侧回 lateral occipitotemporal gyrus 213
 枕三角 occipital triangle 154
 枕外嵴 external occipital crest 10,17
 枕外隆凸 external occipital protuberance 10,17
 枕小神经 lesser occipital n. 156,157,170,174
 枕叶 occipital lobe 213
 正中沟 median sulcus 202
 正中神经 median n. 67 ~ 70,73 ~ 75,79,81,85
 正中神经反支 recurrent branch of median n. 79,81
 正中神经分支 branches of median n. 86
 脂肪 fat 89
 直肠 rectum 107,110,127,129,136 ~ 139,143,144,146
 直肠膀胱陷凹 rectovesical pouch 137
 直肠上动脉 superior rectal a. 127,133,136,137,138
 直肠上静脉 superior rectal v. 128,136,137
 直肠下动脉 inferior rectal a. 137
 直肠子宫襞 rectouterine fold 144
 直肠子宫陷凹 rectouterine pouch 144
 直窦 straight sinus 224,225,226
 跖背动脉 dorsal metatarsal a. 64
 跖背静脉 dorsal metatarsal v. 64
 跖骨底 base of metatarsal bone 27
 跖骨间关节 intermetatarsal joints 43
 跖骨体 shaft of metatarsal bone 27
 跖骨头 head of metatarsal bone 27
 跖骨足底韧带 plantar metatarsal lig. 42
 跖肌 plantaris 56,59
 跖肌(腱) plantaris (tendon) 59
 跖趾关节 metatarso-phalangeal joint 43
 指背静脉网 dorsal venous rete of fingers 82
 指骨粗隆 tuberosity of phalanx 23
 指骨底 base of phalanx 23
 指骨滑车 trochlea of phalanx 23
 指骨体 shaft of phalanx 23
 指间关节 interphalangeal joint of hand 34
 指间关节腔 interphalangeal joint cavity 34
 指浅屈肌 flexor digitorum superficialis 73,76,81
 指浅屈肌腱尺头 humeroulnar head of flexor digitorum superficialis 76
 指浅屈肌腱 tendon of flexor digitorum superficialis 75,81
 指浅屈肌腱弓 tendinous arch of flexor digitorum superficialis 74,79
 指浅屈肌桡头 radial head of flexor digitorum superficialis 76
 指屈肌腱鞘 digital synovial sheath 80
 指伸肌 extensor digitorum 78
 指伸肌腱 tendons of extensor digitorum 78
 指深屈肌 flexor digitorum profundus 75,76
 指深屈肌腱 tendons of flexor digitorum profundus 76
 指掌侧总动脉 common palmar digital a. 79
 指掌侧总动脉及神经 common palmar digital a. & n. 74,81
 指掌侧总神经 common palmar digital n. 79
 趾背静脉 dorsal digital v. of foot 64
 趾背神经和动脉 dorsal digital n. & a. of foot 64
 趾长屈肌 flexor digitorum longus 59,62
 趾长屈肌(腱) flexor digitorum longus (tendon) 59 ~ 62
 趾长伸肌 extensor digitorum longus 62,63
 趾短屈肌 flexor digitorum brevis 60,61
 趾短伸肌 extensor digitorum brevis 63,64
 趾骨粗隆 tuberosity of phalanx 27
 趾骨底 base of phalanx 27
 趾骨滑车 trochlea of phalanx 27
 趾骨间关节 interphalangeal joint 43
 趾骨体 shaft of phalanx 27
 趾足底固有神经、动脉 proper plantar digital n.a. 60,61
 趾足底总动脉 common plantar digital a. 60,61
 趾足底总神经 common plantar digital n. 60,61
 至幽门部分支 branches to pyloric part 120
 中鼻道 middle nasal meatus 187
 中鼻甲 middle nasal concha 9,16,187
 中副动脉 middle collateral a.
 中间楔骨 intermediate cuneiform bone 27
 中间支气管 intermediate bronchus 93,102,108
 中节指骨 middle phalanx 23
 中结肠动脉 middle colic a. 126,127
 中结肠静脉 middle colic v. 128
 中脑 midbrain 212,216,217,219,221
 中脑水管 mesencephalic aqueduct 207,212,226
 中切牙 central incisor 183
 中线核群 midline nuclear group 211
 中斜角肌 scalenus medius 159

- 中心腱 central tendon 115
 中央凹 fovea centralis 189
 中央沟 central sulcus 212
 中央沟动脉 artery of central sulcus 223
 中央管 central canal 201
 中央后沟 postcentral sulcus 212
 中央后沟动脉 artery of postcentral sulcus 223
 中央后回 postcentral gyrus 212,216,217
 中央灰质 central gray matter 267
 中央淋巴结 central lymph nodes 69
 中央旁沟 paracentral sulcus 212
 中央旁小叶 paracentral lobule 212,213
 中央前沟 precentral sulcus 212
 中央前沟动脉 artery of precentral sulcus 223
 中央前回 precentral gyrus 212,219
 中央小叶 central lobule 208,209
 中央小叶翼 ala of central lobule 209
 中央中核 centromedian nucleus 211
 中叶 middle lobe 102
 中直肠横襞 middle transverse folds of rectum 141
 终板旁回 paraterminal gyrus 213
 终池 terminal cistern 226
 终丝 filum terminale 200
 肘肌 anconeus 77,78
 肘正中静脉 median cubital v. 73
 蛛网膜粒 arachnoid granulations 226
 蛛网膜下腔 subarachnoid space 226
 主动脉 aorta 123
 主动脉半月瓣 semilunar cusp of aortic valve 101
 主动脉丛 aortic plexus 134
 主动脉窦 aortic sinuses(of valsalva) 100,101
 主动脉弓 arch of aorta 91,94,95,98,108
 主动脉弓压迹 impression for arch of aorta 103
 主动脉裂 aortic hiatus 135
 主动脉肾节 aorticorenal ganglia 134
 主动脉右前窦、右冠状动脉口 right aortic sinus of (valsalva)and orifice of right coronary artery 106
 转子间嵴 intertrochanteric crest 25
 转子间线 intertrochanteric line 25
 转子窝 trochanteric fossa 25
 椎动脉和静脉 vertebral a. & v. 185
 椎动脉 vertebral a. 158,162,222
 椎动脉沟 groove for vertebral a. 5
 椎弓 vertebral arch 5
 椎弓板 lamina of vertebral arch 6
 椎弓根 pedicle of vertebral arch 5,6
 椎骨剖面 Section of the vertebral 3
 椎间孔 intervertebral foramen 29
 椎间盘 intervertebral discs 29,164
 椎静脉 vertebral v. 158
 椎孔 vertebral foramen 5,6
 椎上切迹 superior vertebral notch 6
 椎体 vertebral body 5,6,164
 椎体钩 uncus of vertebral body 5
 锥体 pyramid 202,203
 锥体交叉 decussation of pyramid 202,204
 锥体束 pyramidal tract 204,206,207,210
 锥状肌 pyramidalis 112,114
 籽骨 sesamoid bone 28
 子宫底 fundus of uterus 144,145
 子宫动脉 uterine a. 146
 子宫动脉(阴道支) uterine a. (vaginal branches) 146
 子宫颈 neck of uterus 145,146
 子宫颈管 cervical canal of uterus 144
 子宫口 orifice of uterus 144
 子宫阔韧带 broad ligament of uterus 145
 子宫体 body of uterus 144,145,146
 子宫体腔 uterine cavity 144
 子宫圆韧带 round ligament of uterus 145,146
 总骨脚 common bony crus 198
 总腱环 common tendinous ring 190
 总膜脚 common membranous crus 198
 纵肌层 stratum longitudinalis of muscularis 127
 纵束 longitudinal bands 30
 足背动脉 dorsal a. of foot 64
 足背静脉弓 dorsal venous arch of foot 59,64
 足背内侧皮神经 medial dorsal cutaneous n. of foot 64
 足背外侧皮神经 lateral dorsal cutaneous n. of foot 64
 足背中间皮神经 intermediate dorsal cutaneous n. of foot 64
 足底长韧带 long plantar lig. 42
 足底方肌 quadratus plantae 60,61,62
 足底腱膜 plantar aponeurosis 60
 足底内侧动脉 medial plantar a. 60,61,62
 足底内侧神经 medial plantar n. 60,61,62
 足底深弓 deep plantar arch 61
 足底外侧动脉 lateral plantar a. 61,62
 足底外侧神经 lateral plantar n. 61,62
 足底外侧神经、动脉 lateral plantar n.a. 60
 足骨 bones of foot 27
 足舟骨 navicular bone 27

- 最上项线 highest nuchal line 17
- 左、右膈足 left and right crus 115
- 左房斜静脉 oblique vein of left atrium 97
- 左肺动脉 left pulmonary artery 92 ~ 95,98,103,106,108
- 左肺尖 apex of lung 108
- 左肺静脉 left pulmonary vein 92,95,97,108
- 左肺上静脉 left pulmonary vein 106
- 左肺下叶 inferior lobe of left lung 91
- 左睾丸动脉 left testicular a. 133
- 左睾丸静脉 left testicular v. 133
- 左膈神经 left phrenic nerve 91
- 左膈神经和心包膈动脉、静脉 left phrenic nerve and pericardiophrenic artery and vein 90
- 左膈下动脉 left inferior phrenic a. 131,135
- 左冠状动脉口 orifice of left coronary artery 100
- 左冠状韧带后层 posterior layer of left coronary ligament 123
- 左冠状韧带前层 anterior layer of left coronary ligament 123
- 左喉返神经 left recurrent laryngeal n. 158
- 左结肠动脉 left colic a. 127
- 左颈内静脉 left jugular vein 94
- 左颈总动脉 left common carotid artery 91,95
- 左肋纵隔窝 left costomediastinal recess 90
- 左迷走神经 left vagus nerve 91,95
- 左脐内侧襞 left medial umbilical fold 116
- 左髂总动脉 left common iliac a. 133
- 左髂总静脉 left common iliac v. 133
- 左腔静脉襞 fold of left vena cava 97
- 左三角韧带 left triangular ligament 123
- 左上肺静脉 left superior pulmonary vein 98
- 左肾 left kidney 129,131,132
- 左肾动脉 left renal a. 129,133
- 左肾静脉 left renal v. 125,129,131,133
- 左肾上腺 left supra renal gland 129,131,134
- 左室前壁 anterior wall of left ventricle 91
- 左室前支 anterior branch of left ventricle 98
- 左锁骨下动脉 left subclavian artery 91,92,95
- 左锁骨下动脉压迹 impression for left subclavian artery 103
- 左头臂静脉 left brachiocephalic vein 91,93,95,96,97
- 左心耳 left auricle 97,98
- 左心房 left atrium 94,97,98,100,106,107,108
- 左心室后壁 posterior wall of left ventricle 98
- 左眼鼻侧偏盲 left nasal hemianopsia 218
- 左眼全盲 total blindness of left eye 218
- 左缘支 left marginal branch 98
- 左支 left branch 126
- 左主支气管 left principal bronchus 88,92,103,106,108
- 坐股韧带 ischiofemoral lig. 37
- 坐骨 ischium 24
- 坐骨大孔 greater sciatic foramen 35,143
- 坐骨大切迹 greater sciatic notch 24
- 坐骨肛门窝 ischioanal fossa 147,149,151
- 坐骨海绵体肌 ischiocavernosus 147,148,151
- 坐骨棘 ischial spine 24,143
- 坐骨结节 ischial tuberosity 24,147,149
- 坐骨神经 sciatic n. 53,54,55
- 坐骨小孔 lesser sciatic foramen 35
- 坐骨小切迹 lesser sciatic notch 24

