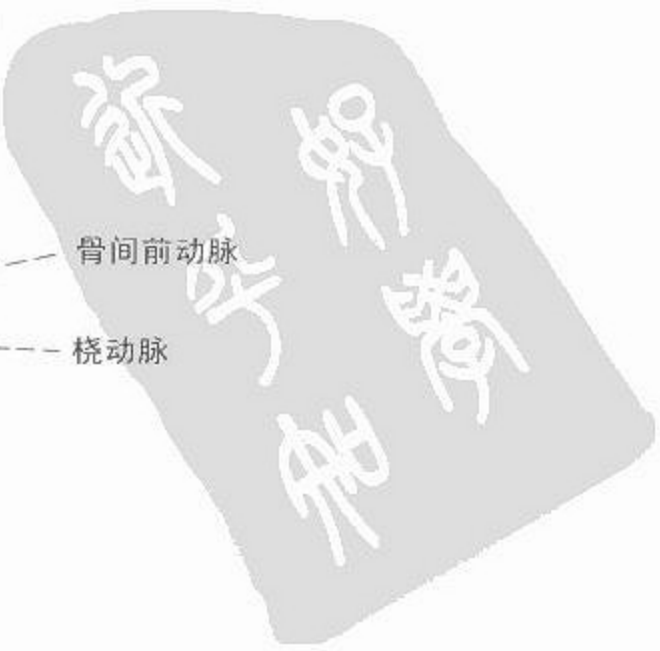



# 血管造影

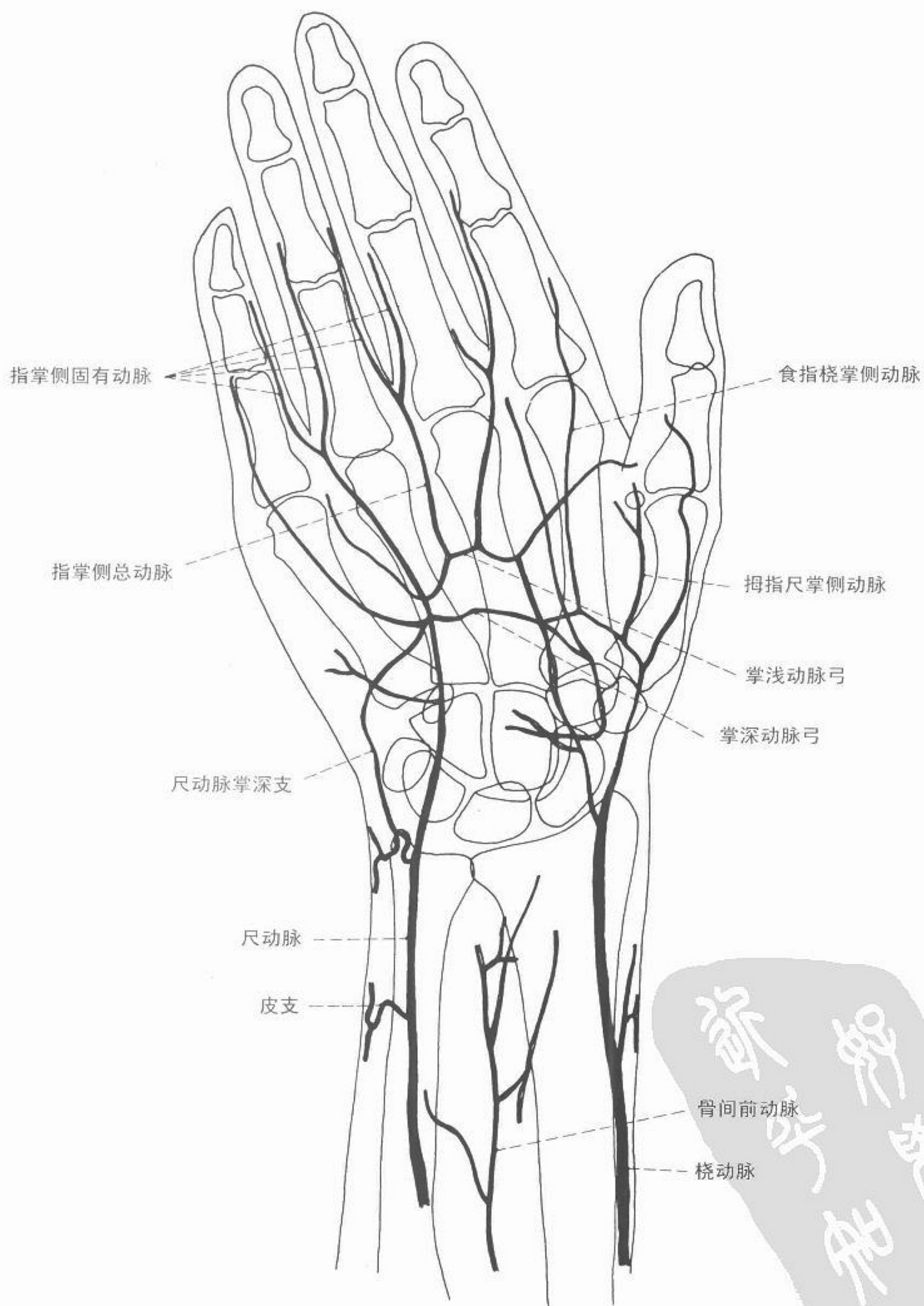

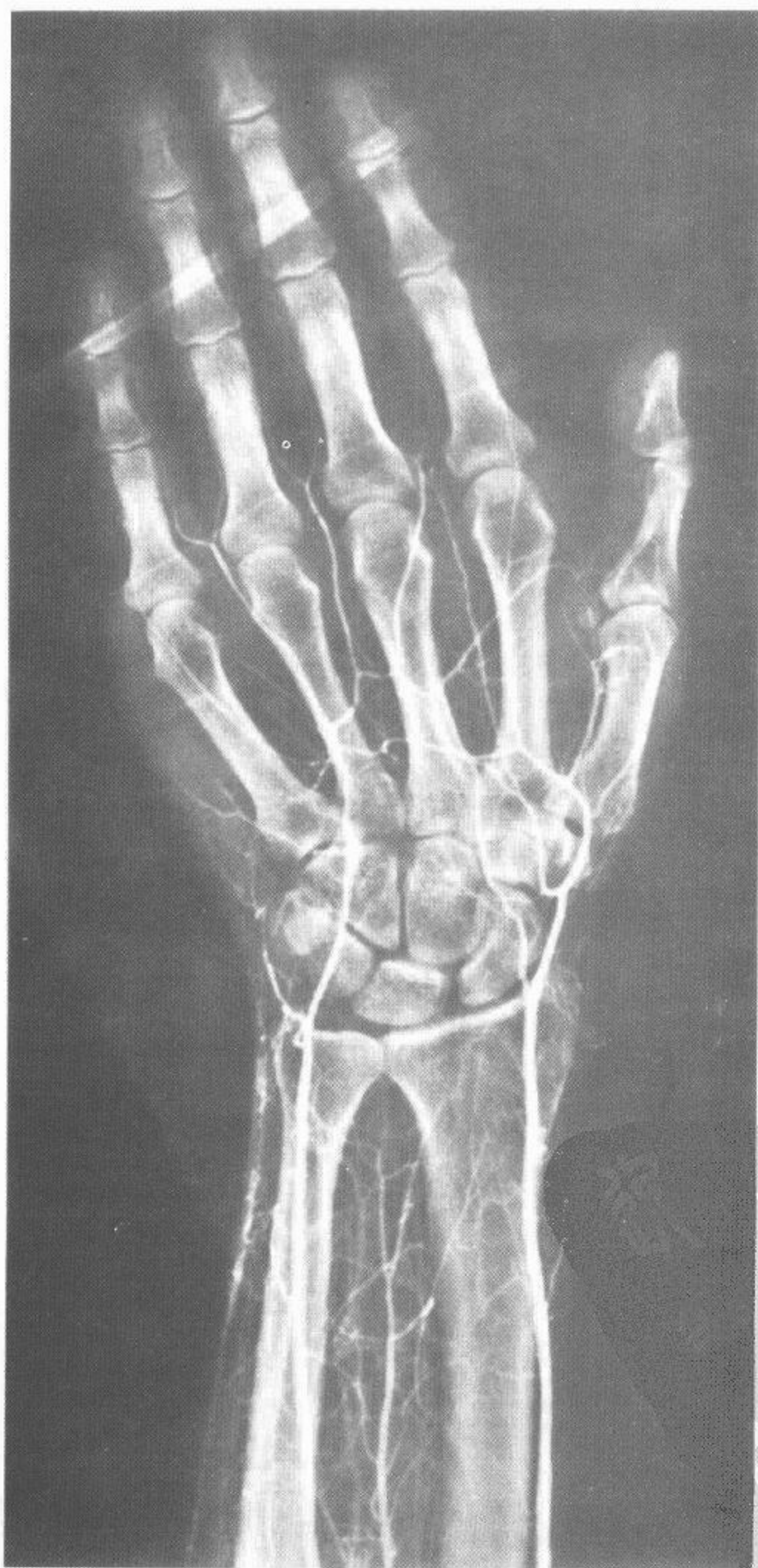
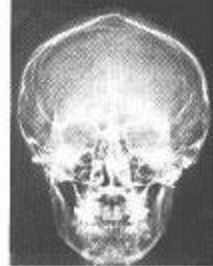
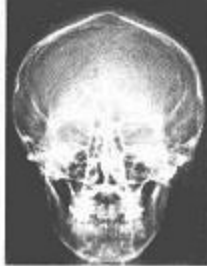
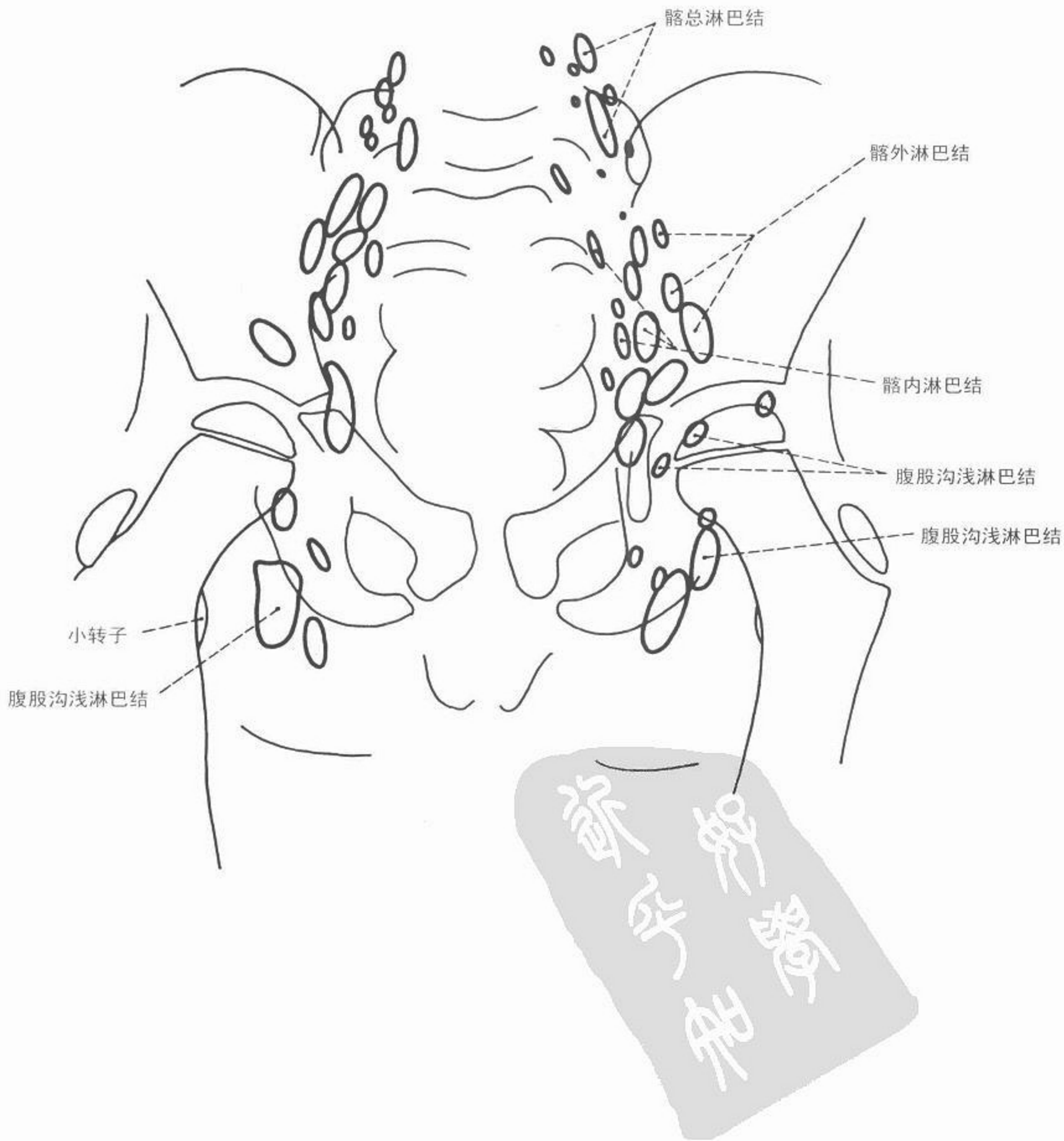图 115 手部血管造影

医学影像



# 淋巴系造影

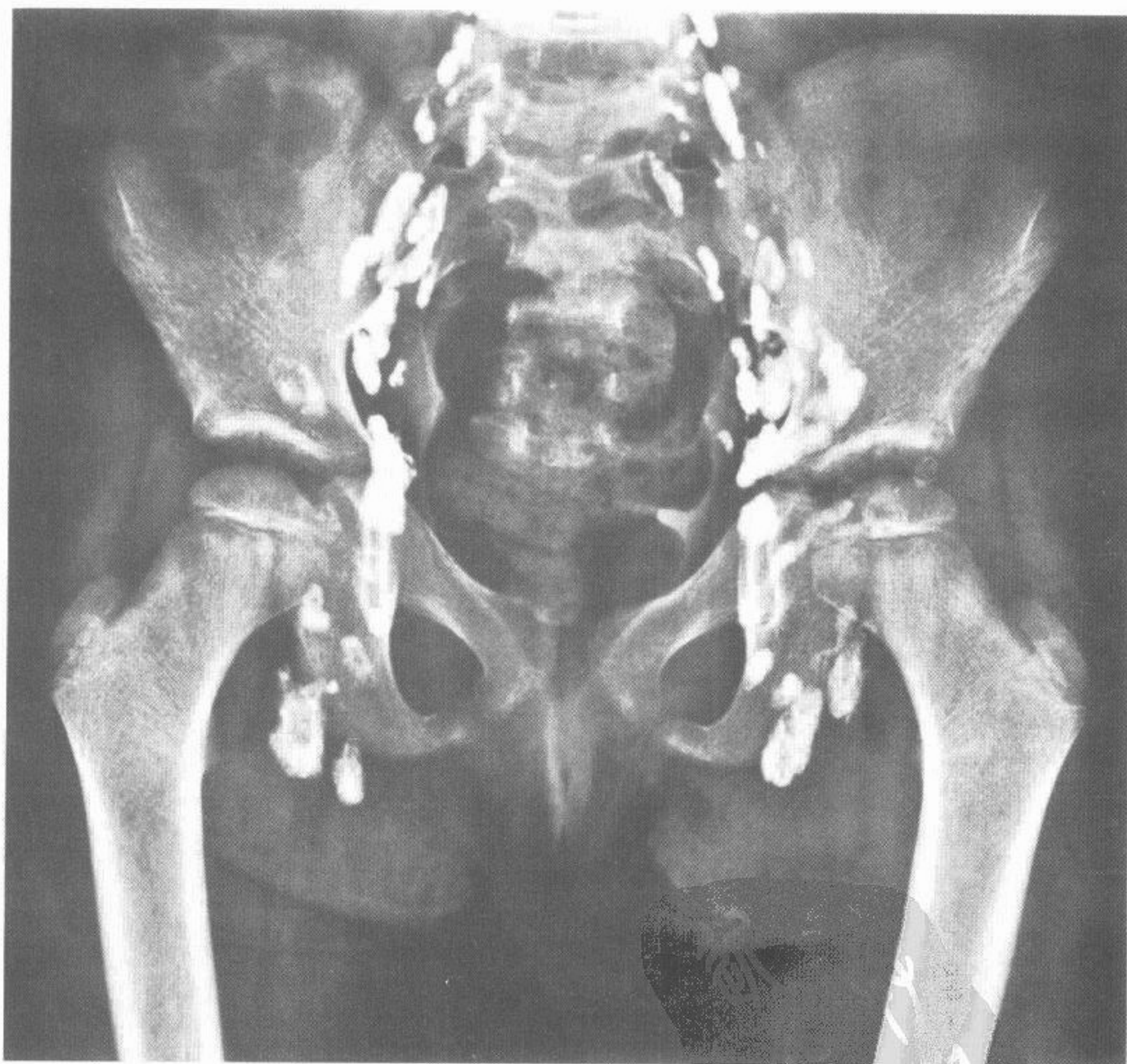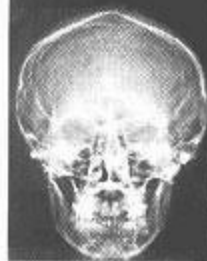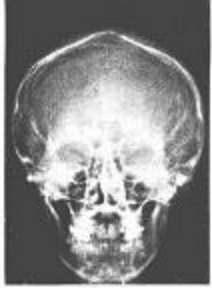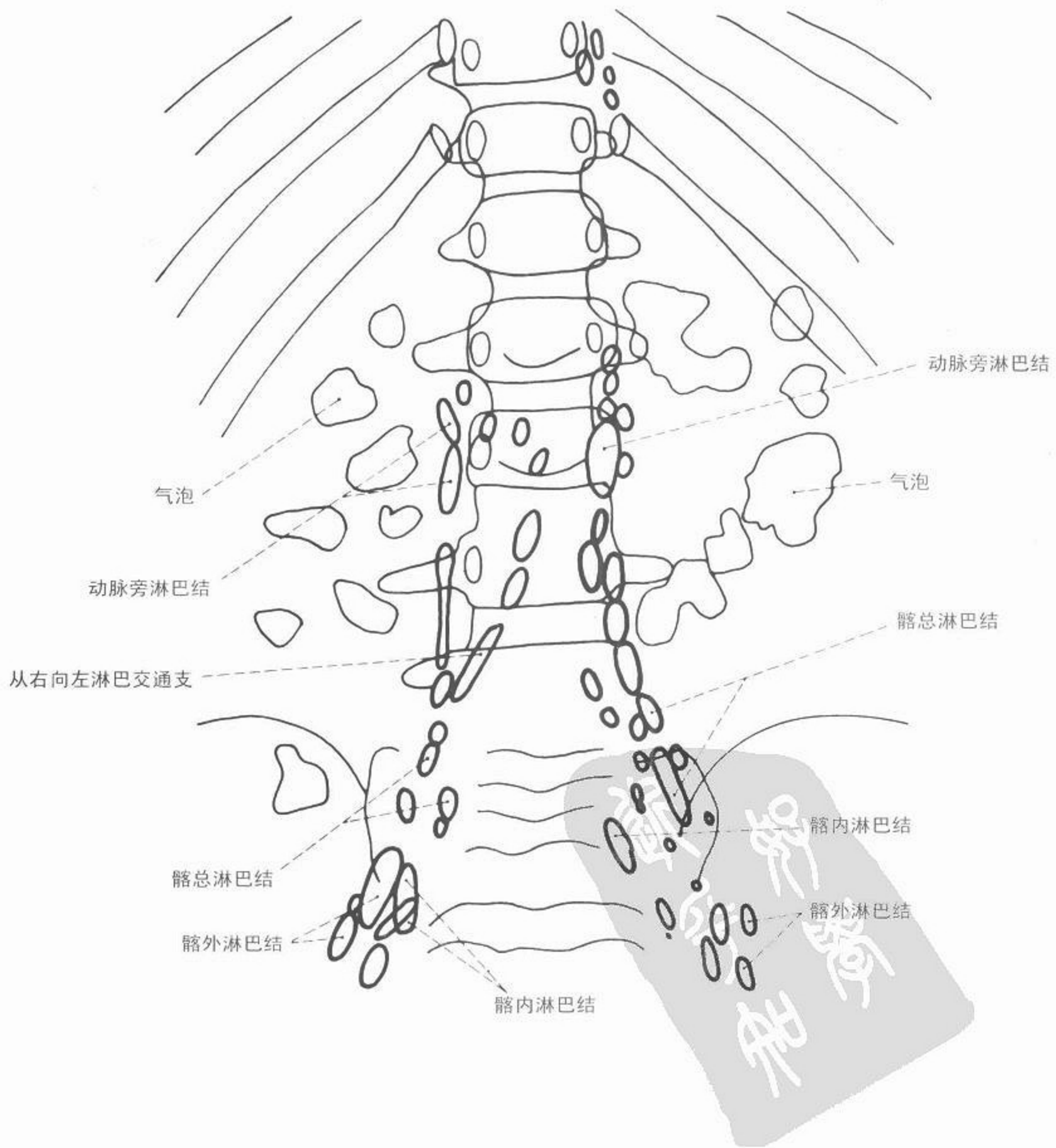




图 116 盆腔淋巴造影(储存期) 前后位



# 淋巴系造影



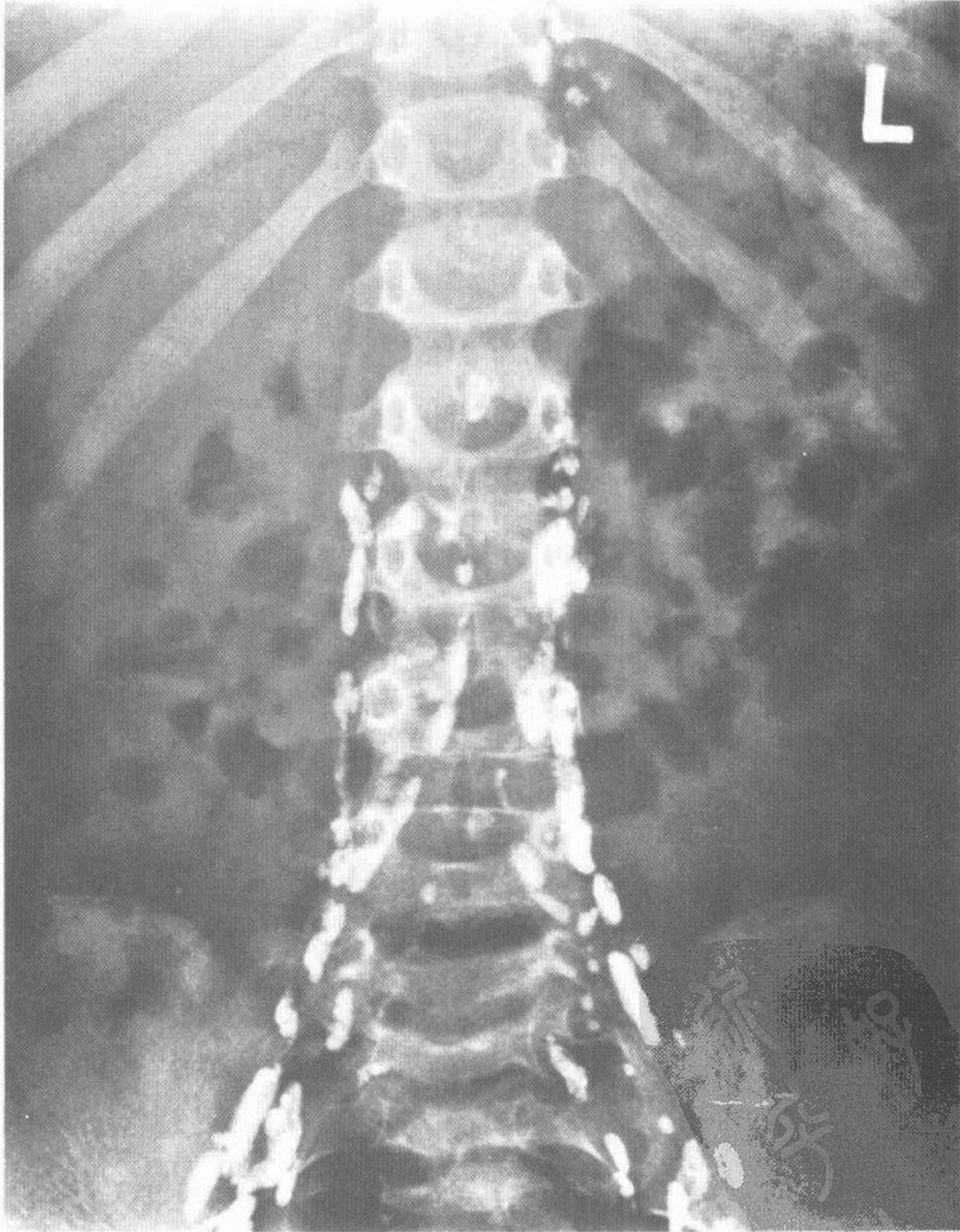
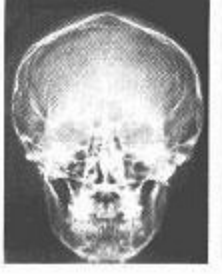
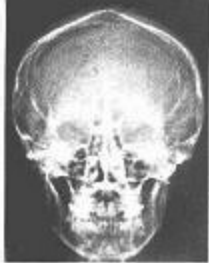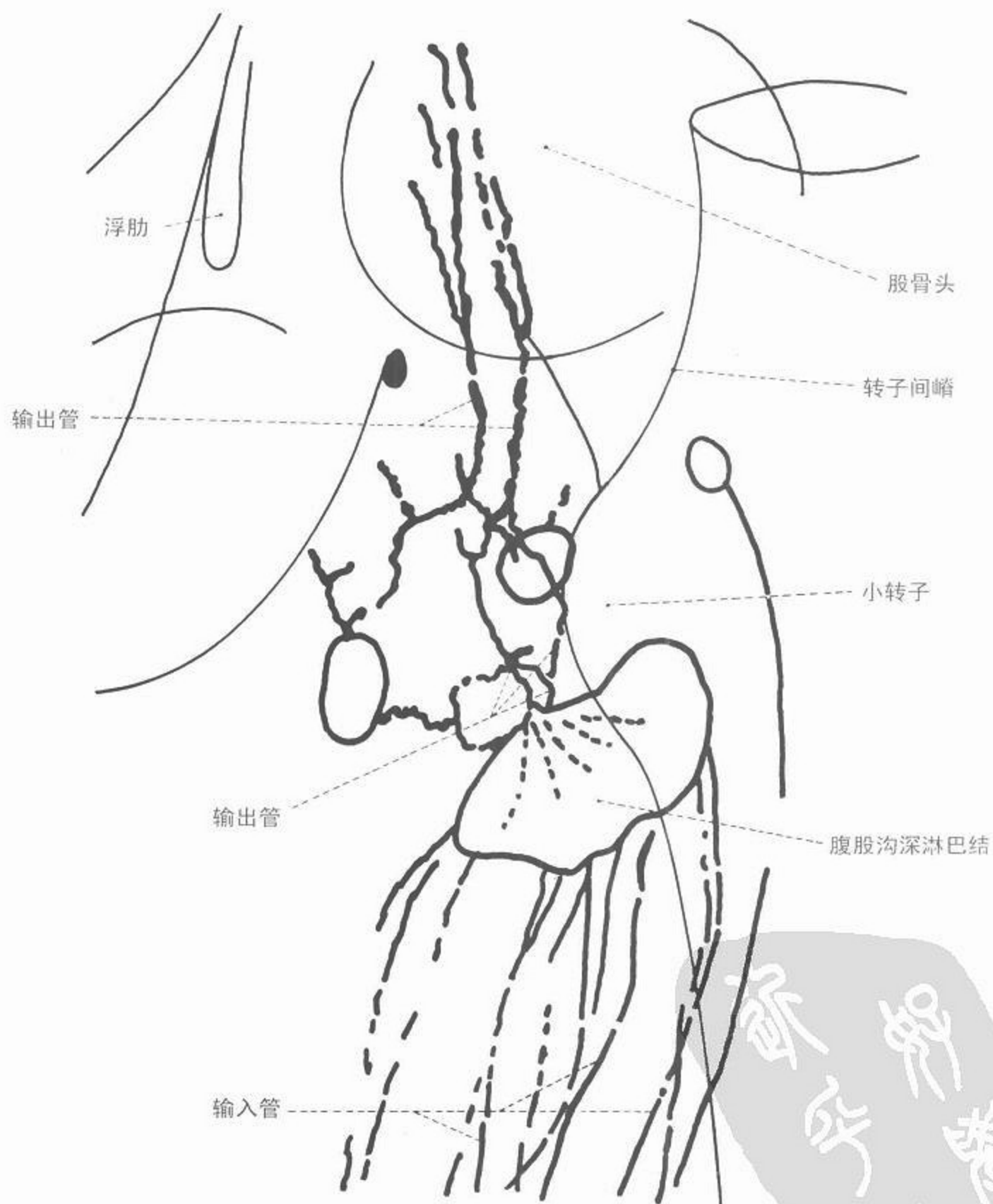


图 117 主动脉旁淋巴造影(储存期) 前后位



# 淋巴系造影



医学影像

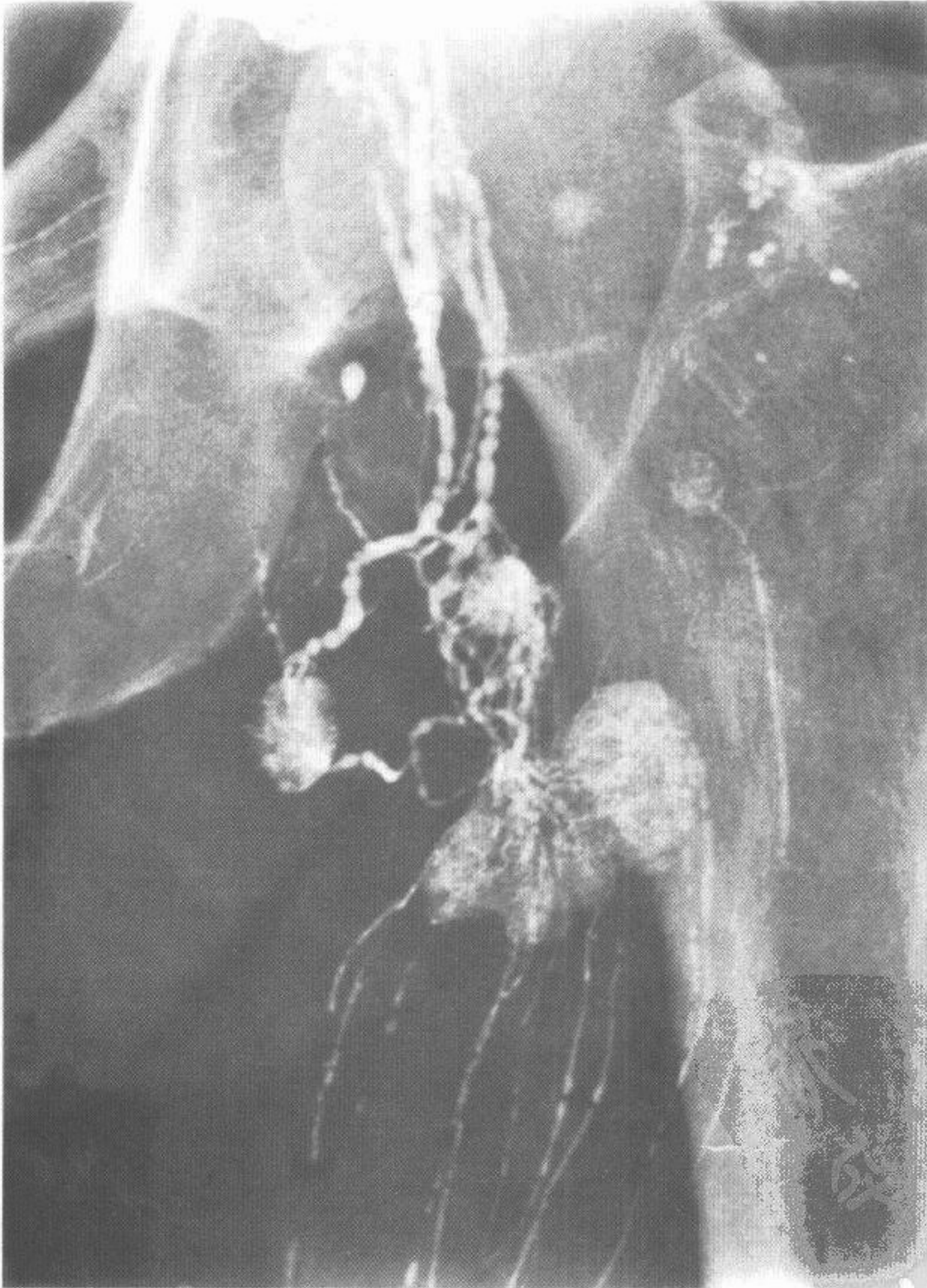
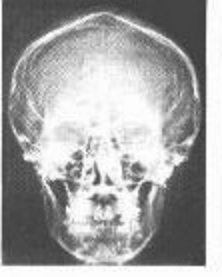
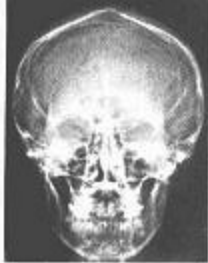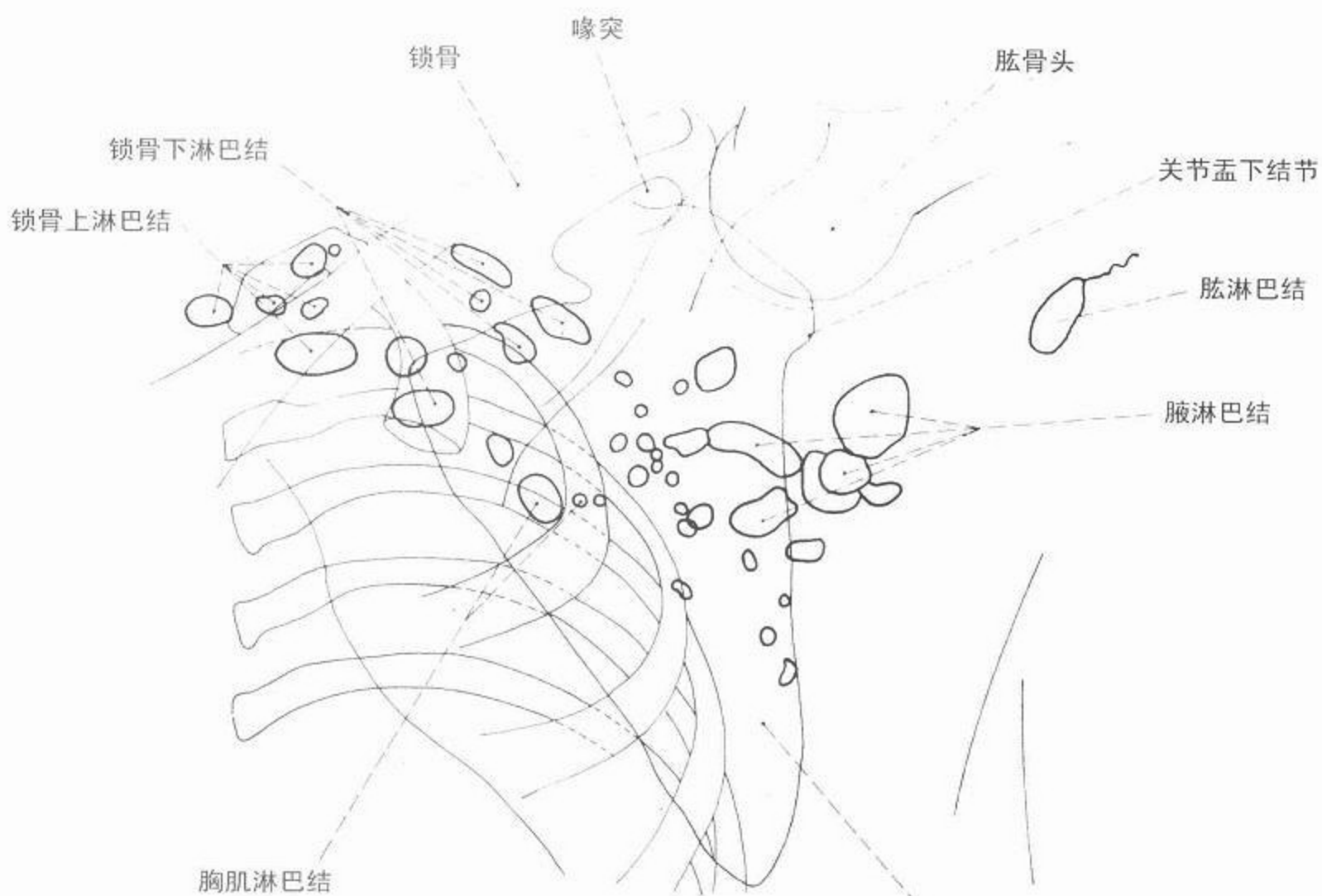


图 118 腹股沟区淋巴造影(充盈期)





# 淋巴系造影



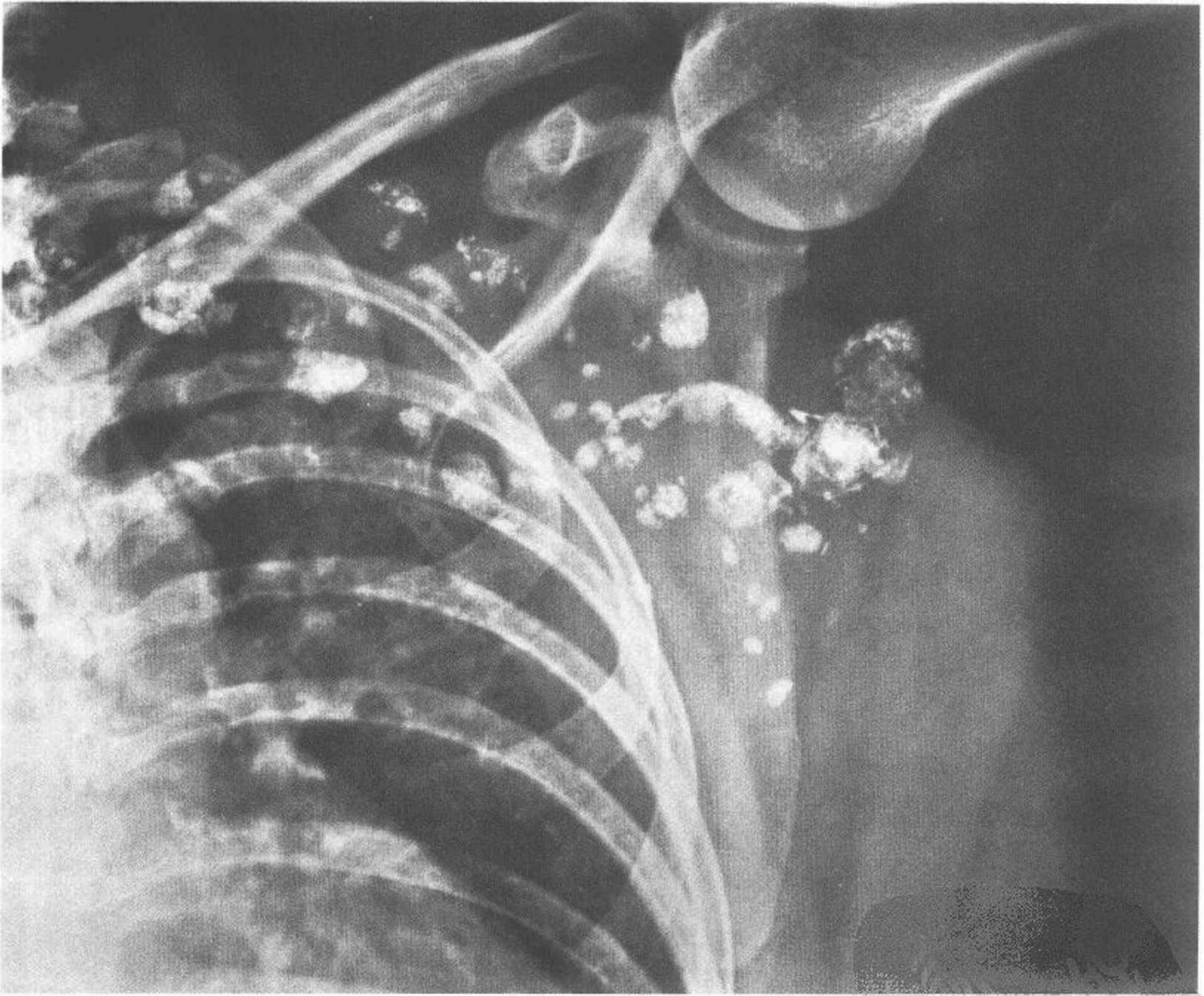
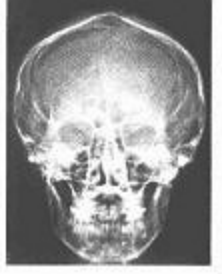
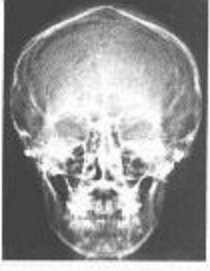

图 119 腋窝淋巴造影(储存期)





妇产科



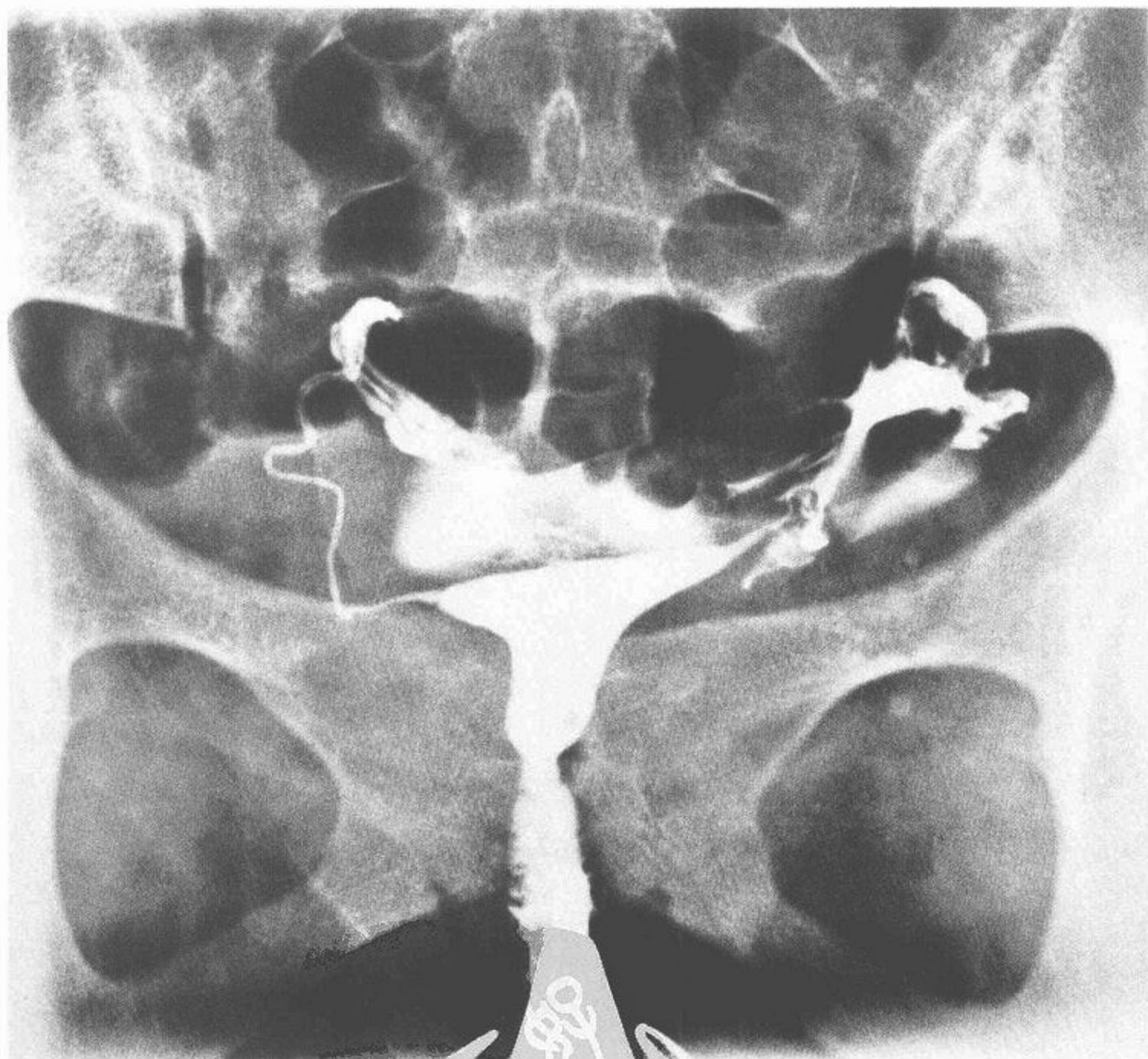
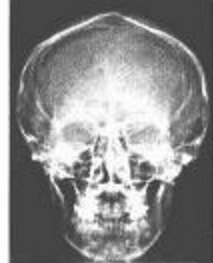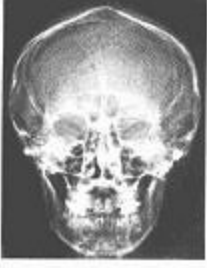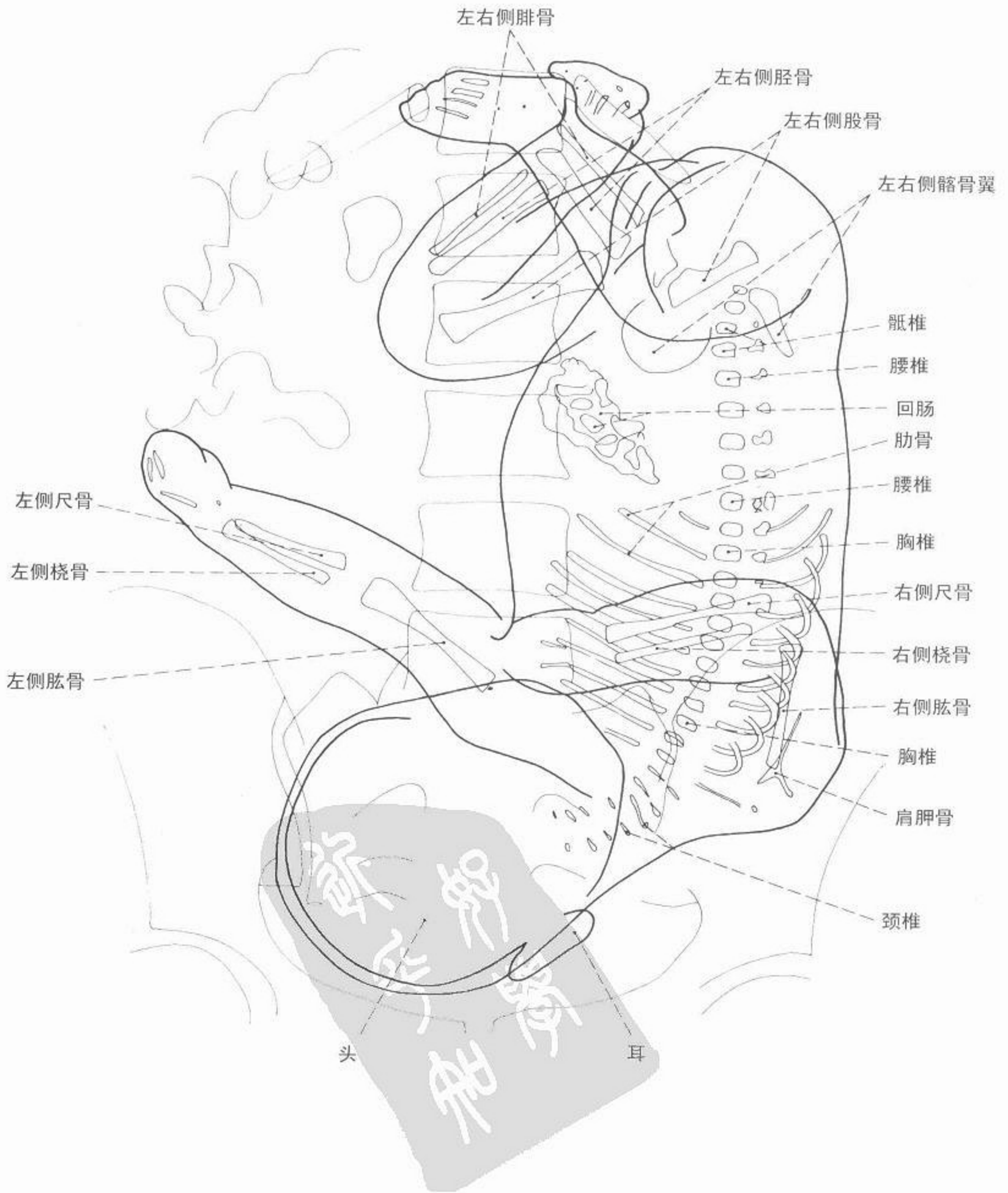


图 120 子宫输卵管造影 仰卧前后位

子宫  
输卵管



妇产科



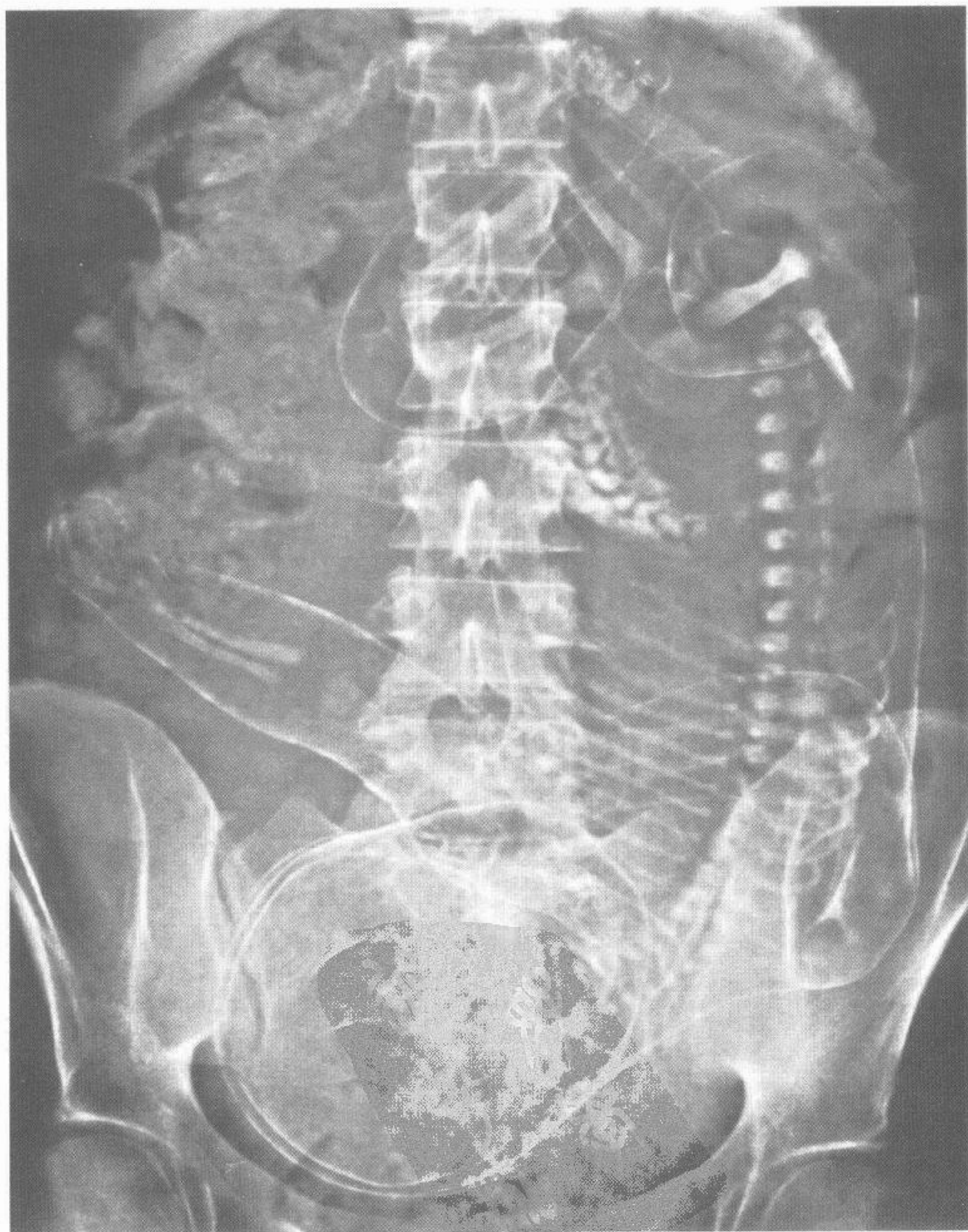
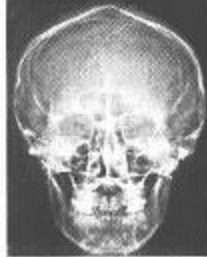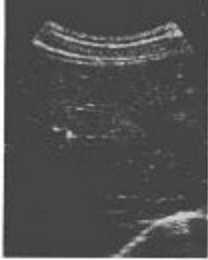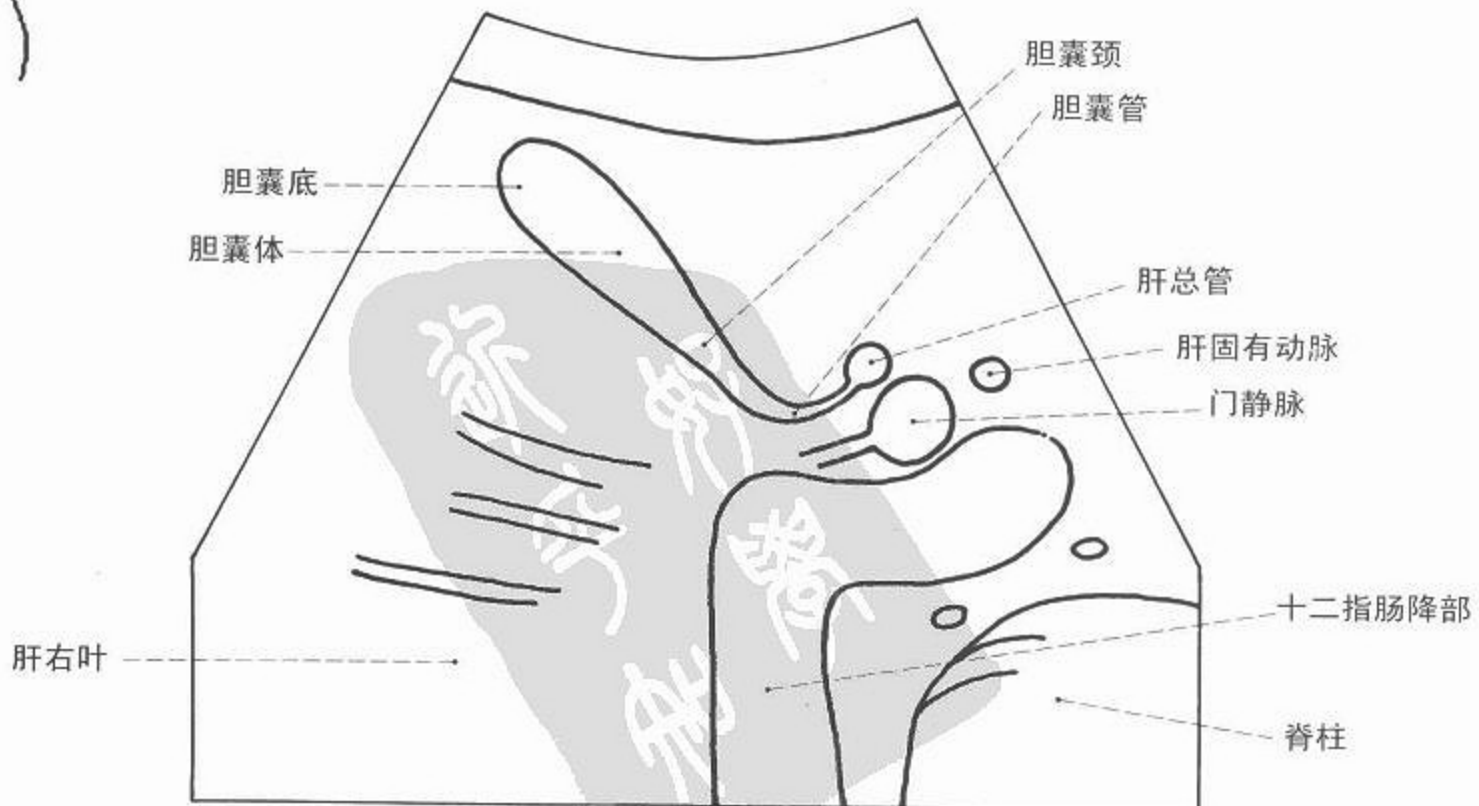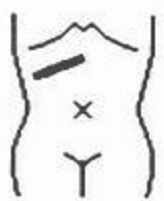
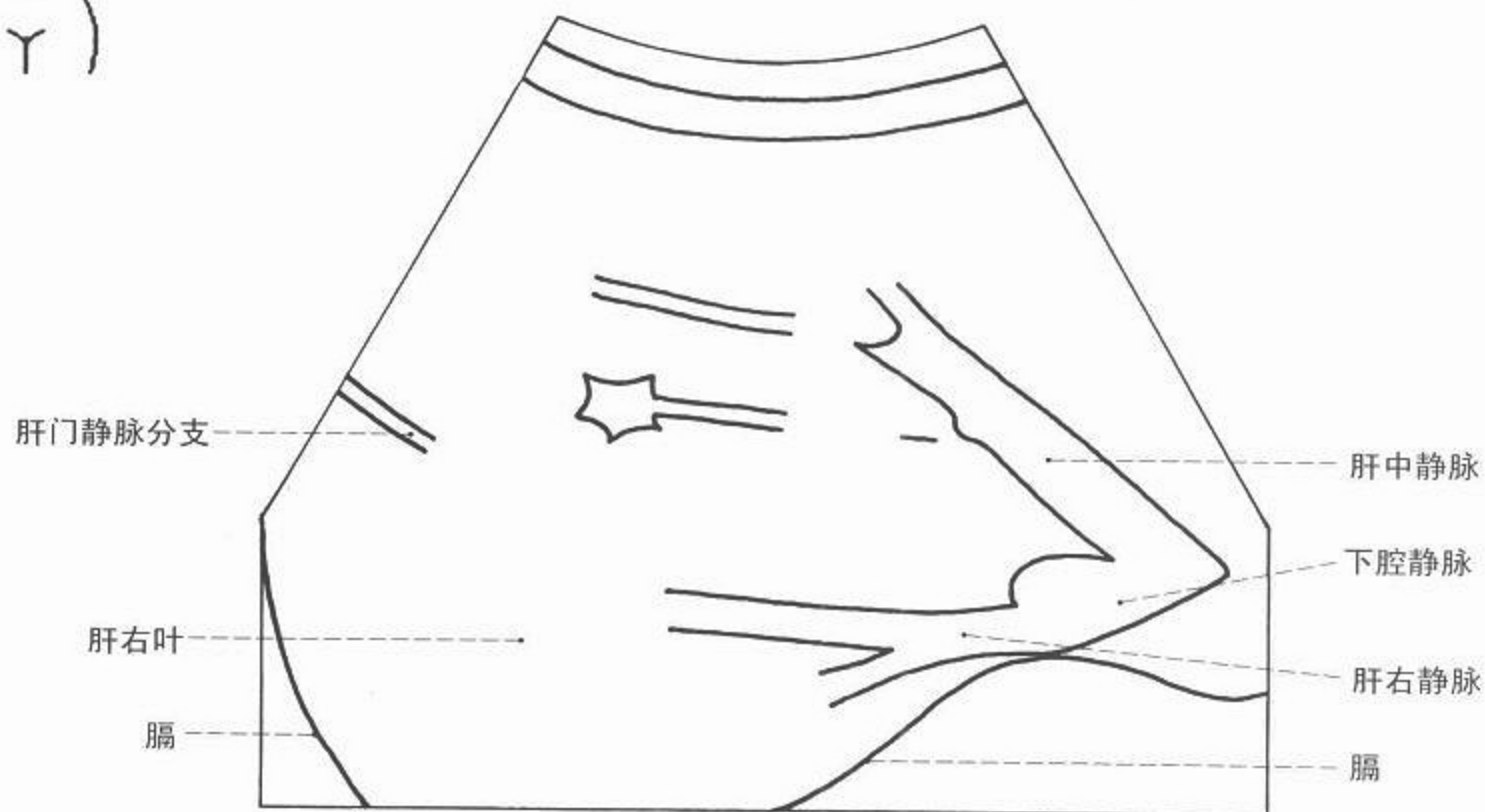


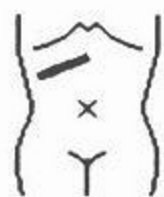图 121 胎儿造影



超声



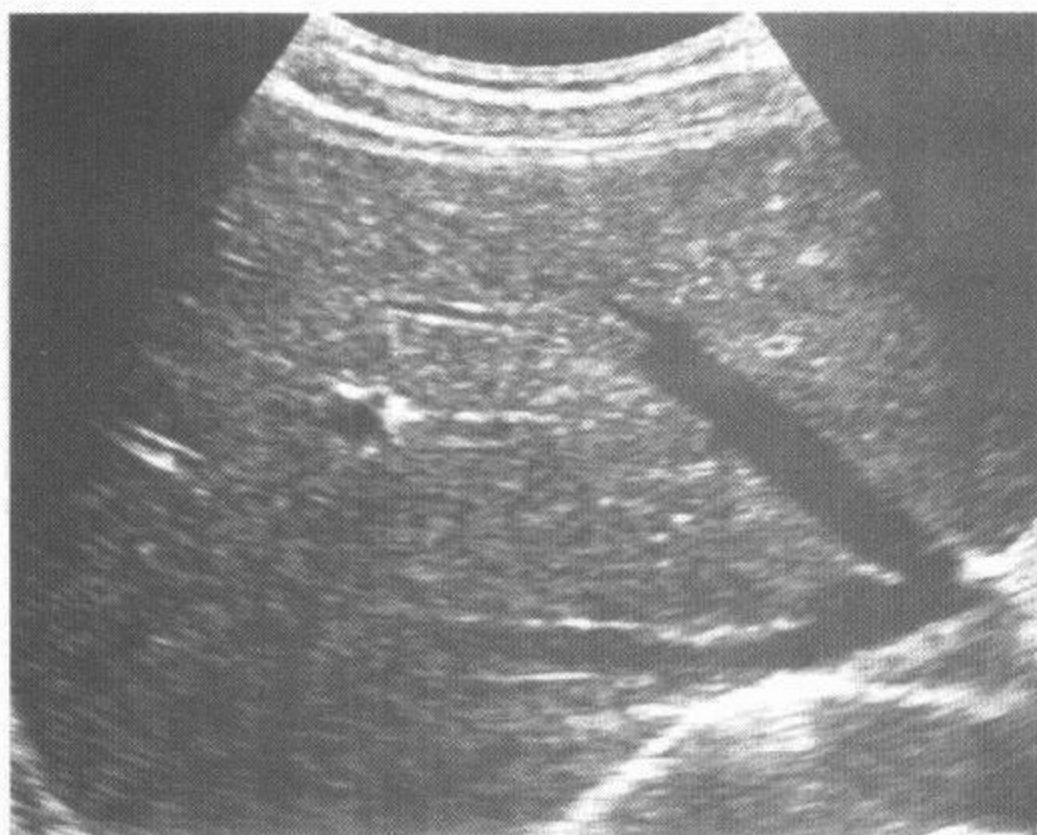
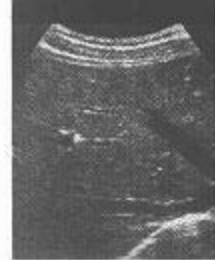

图 122 肝脏和肝静脉超声

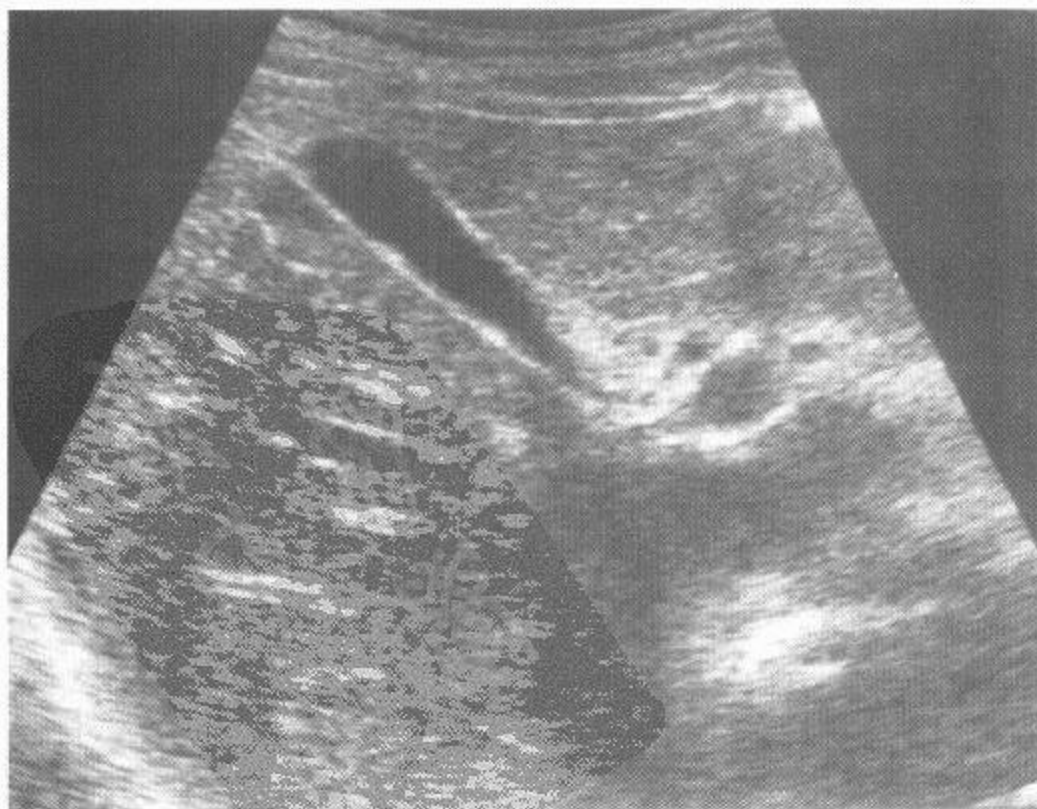
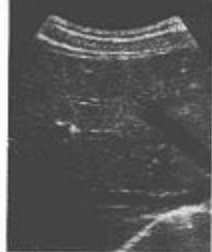

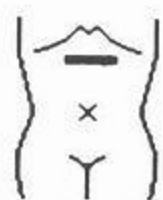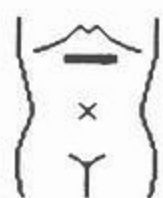图 123 胆囊与胆囊管超声





超声

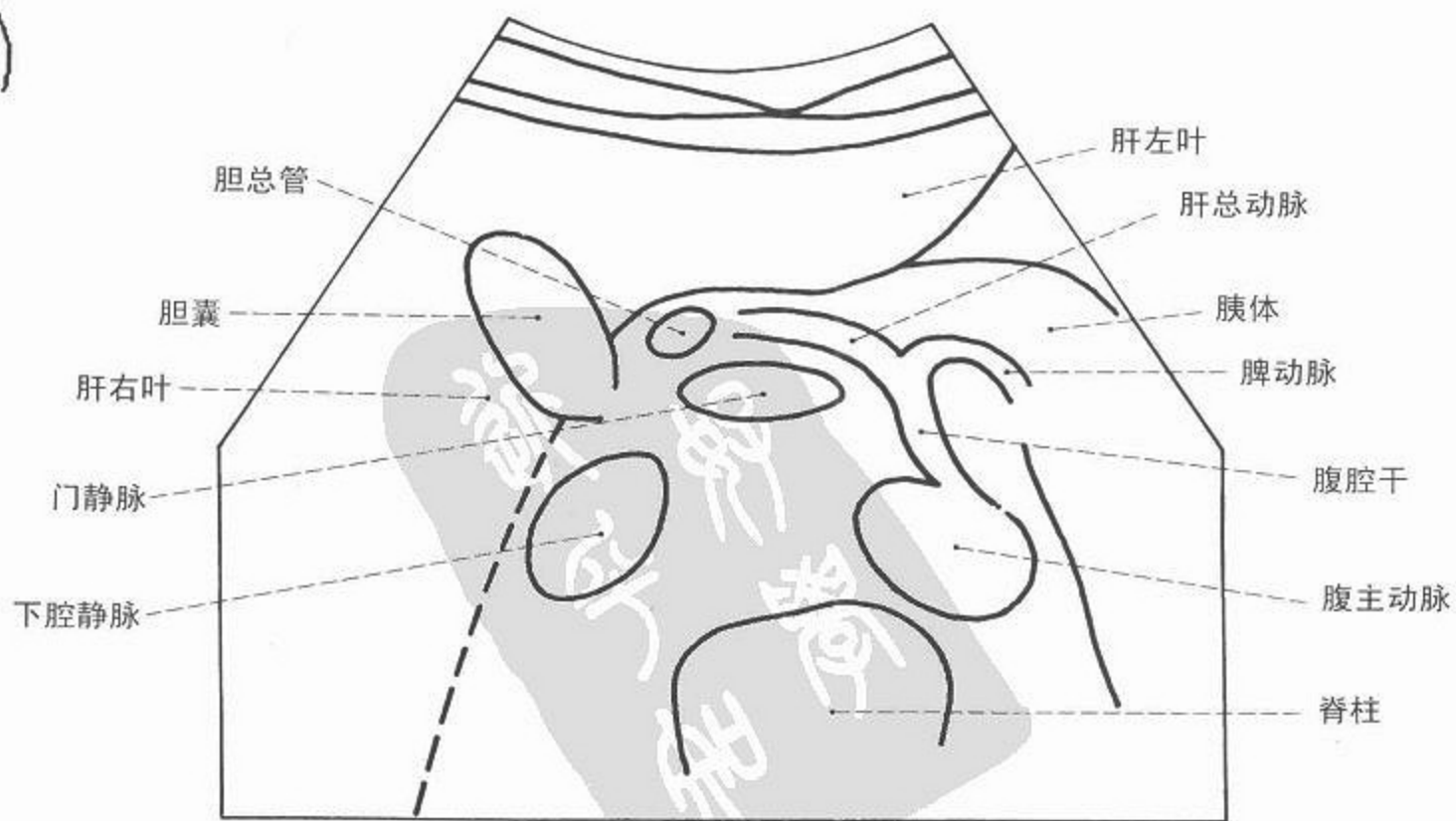
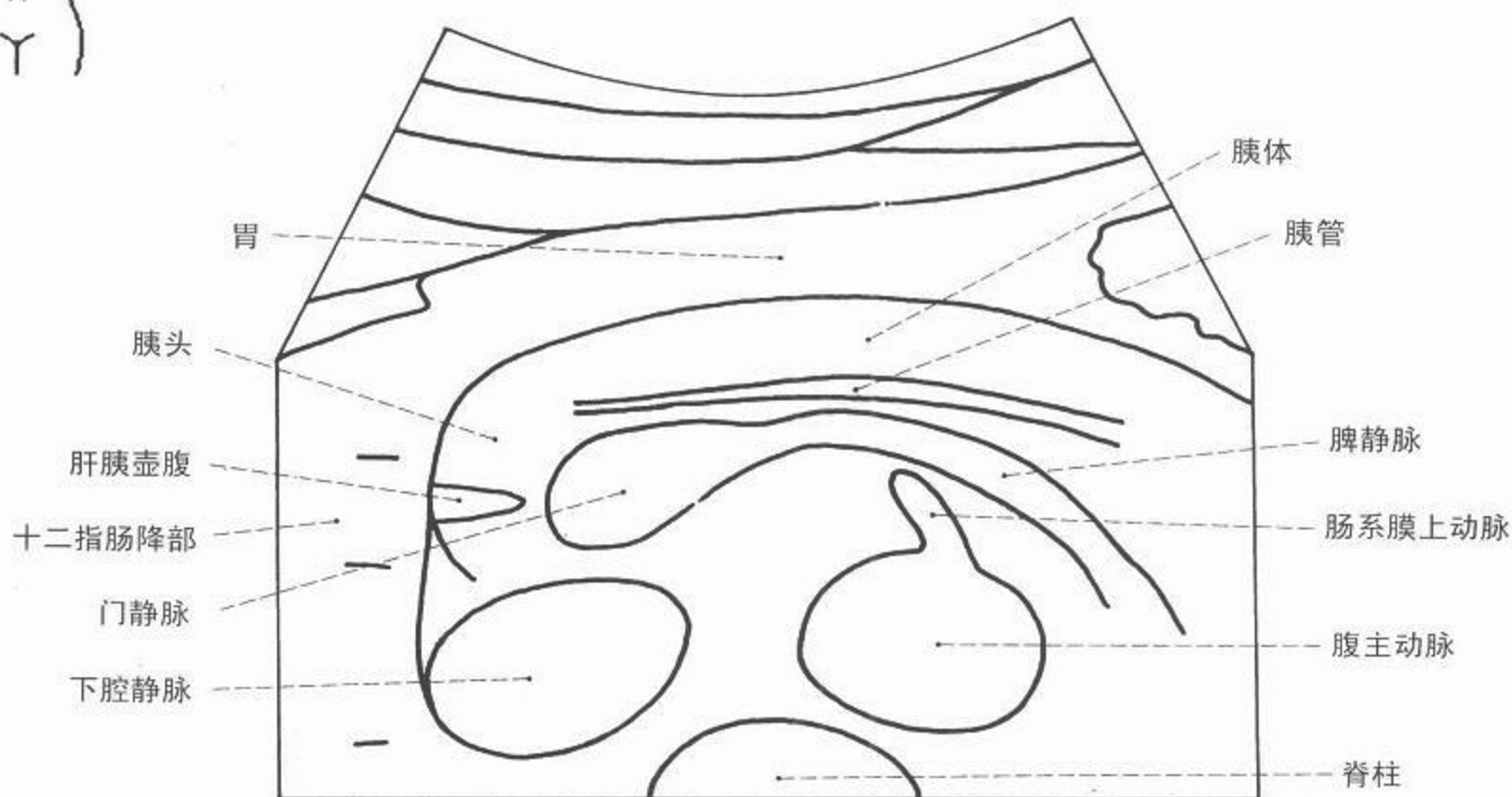
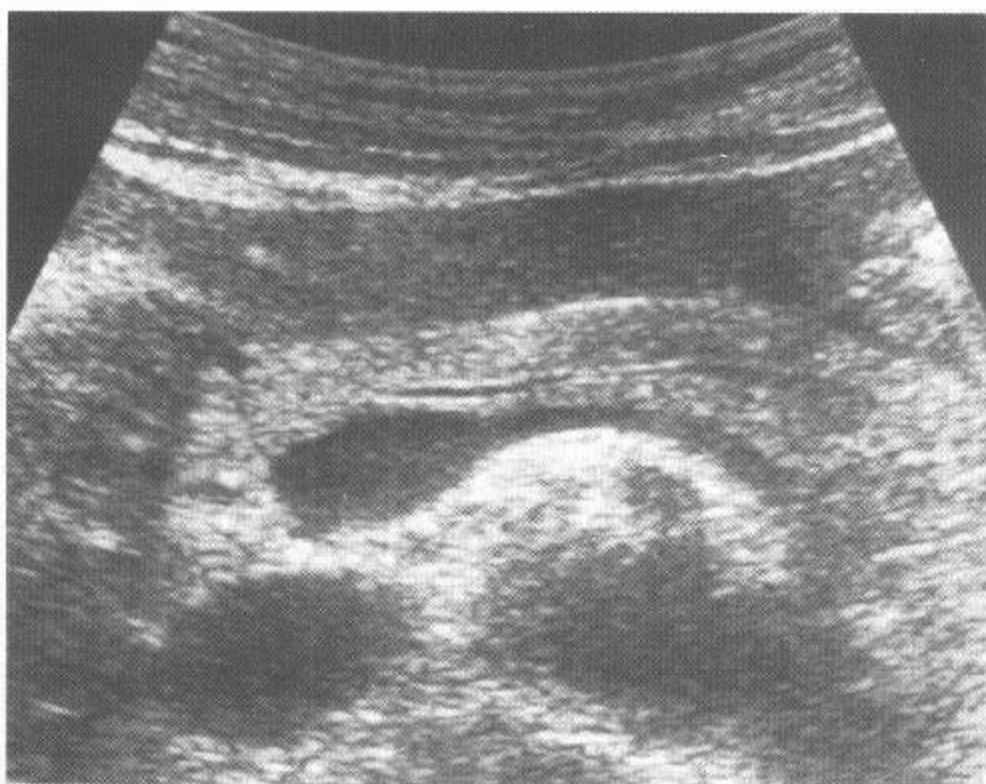
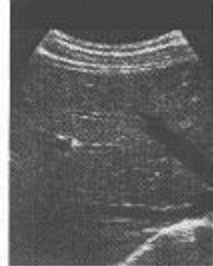


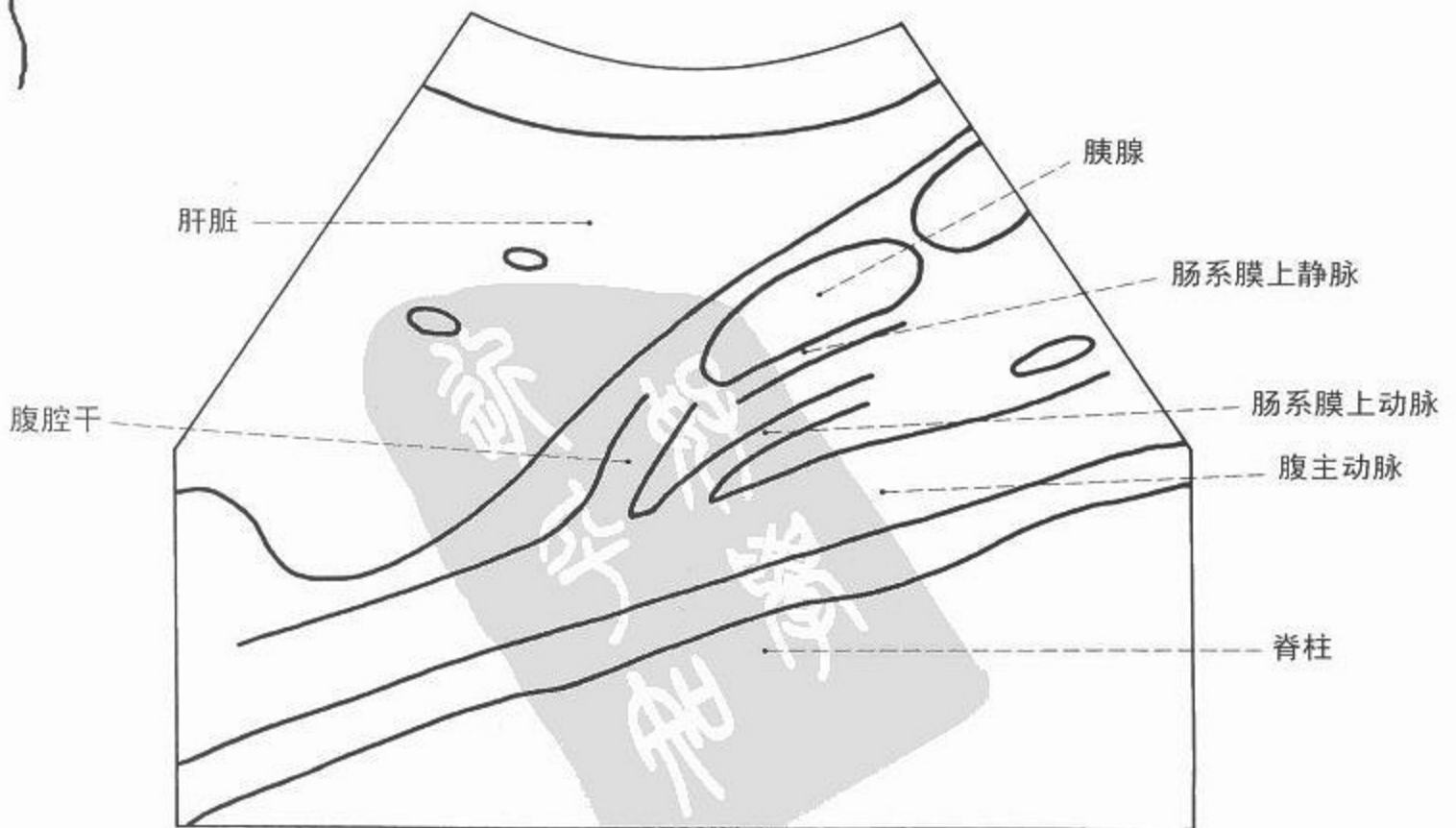
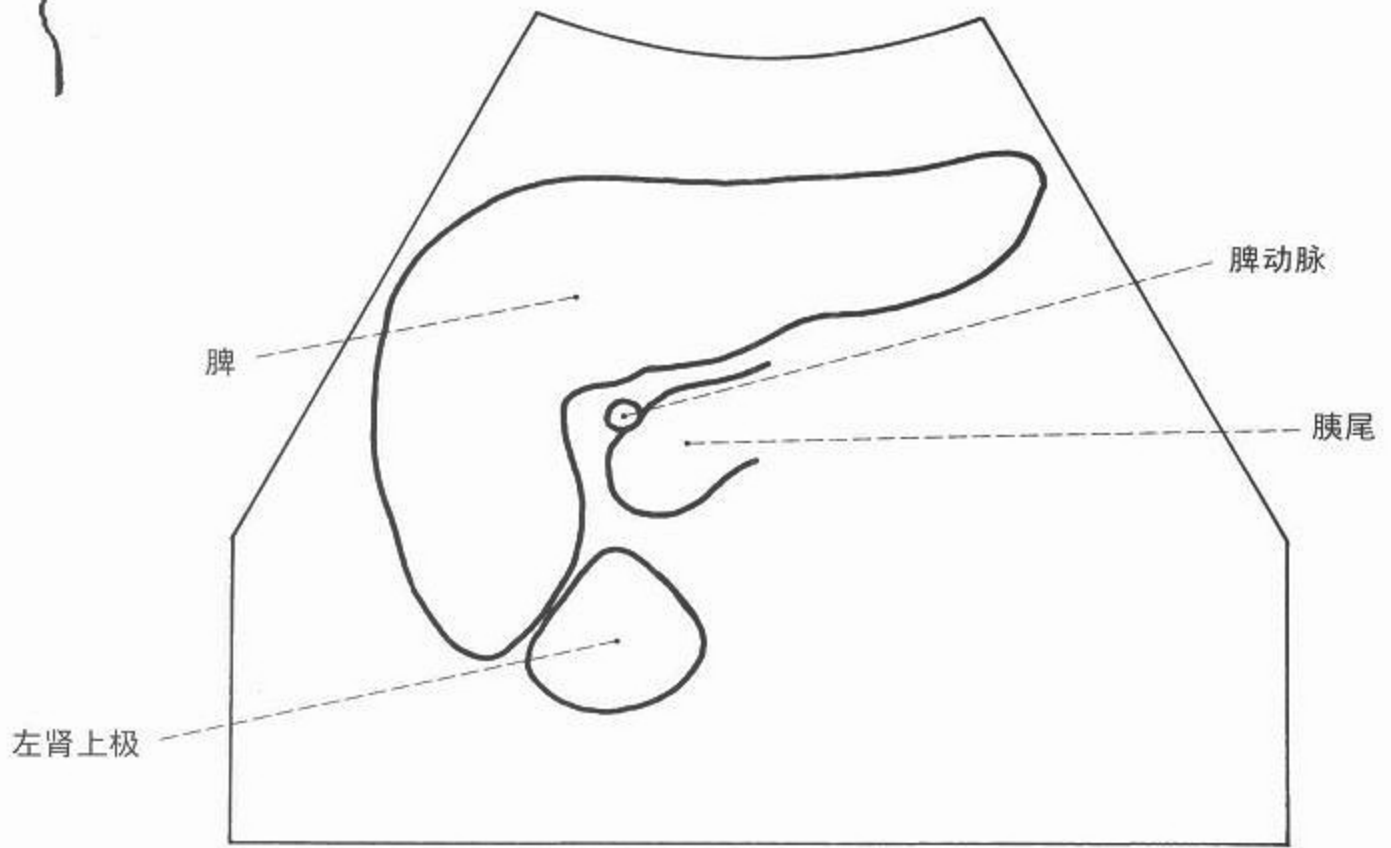
图 124 胰腺超声

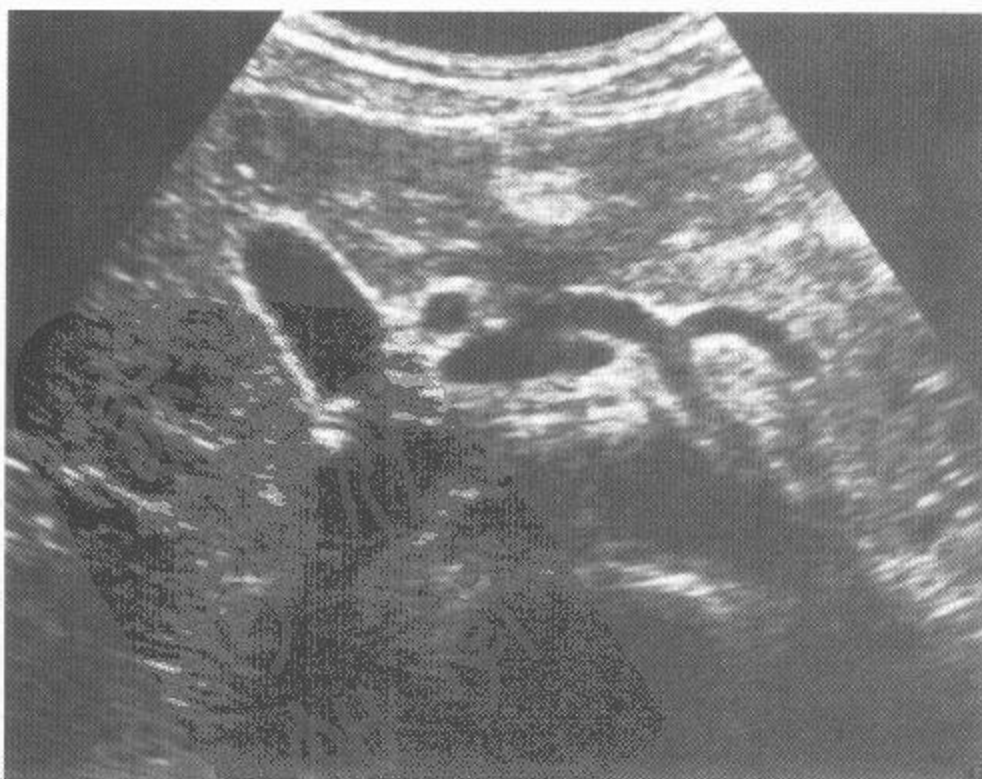
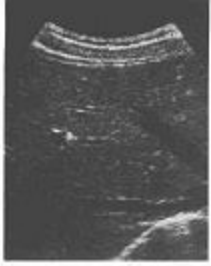
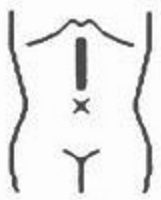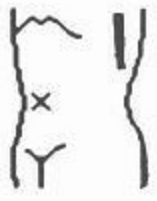图 125 腹腔干超声



超声



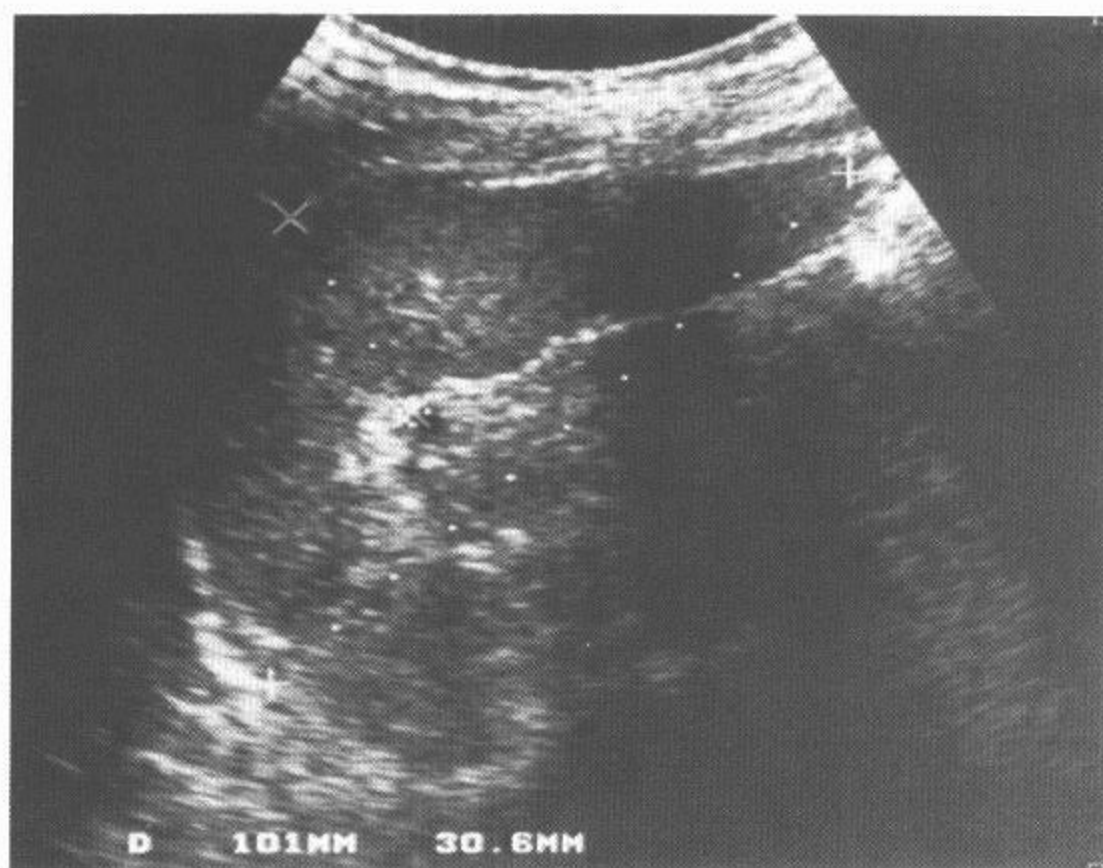
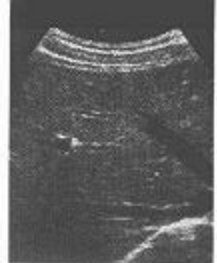

图 126 脾脏超声

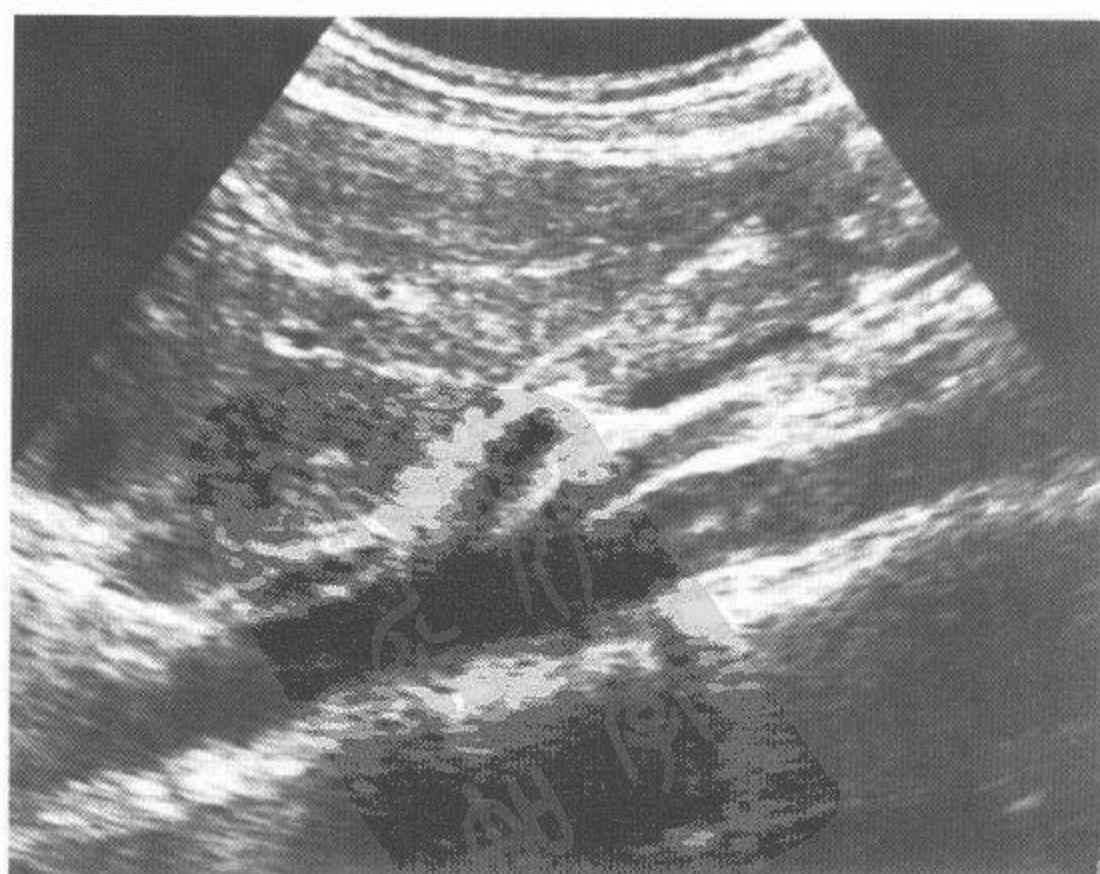
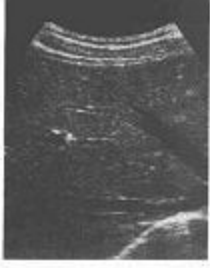
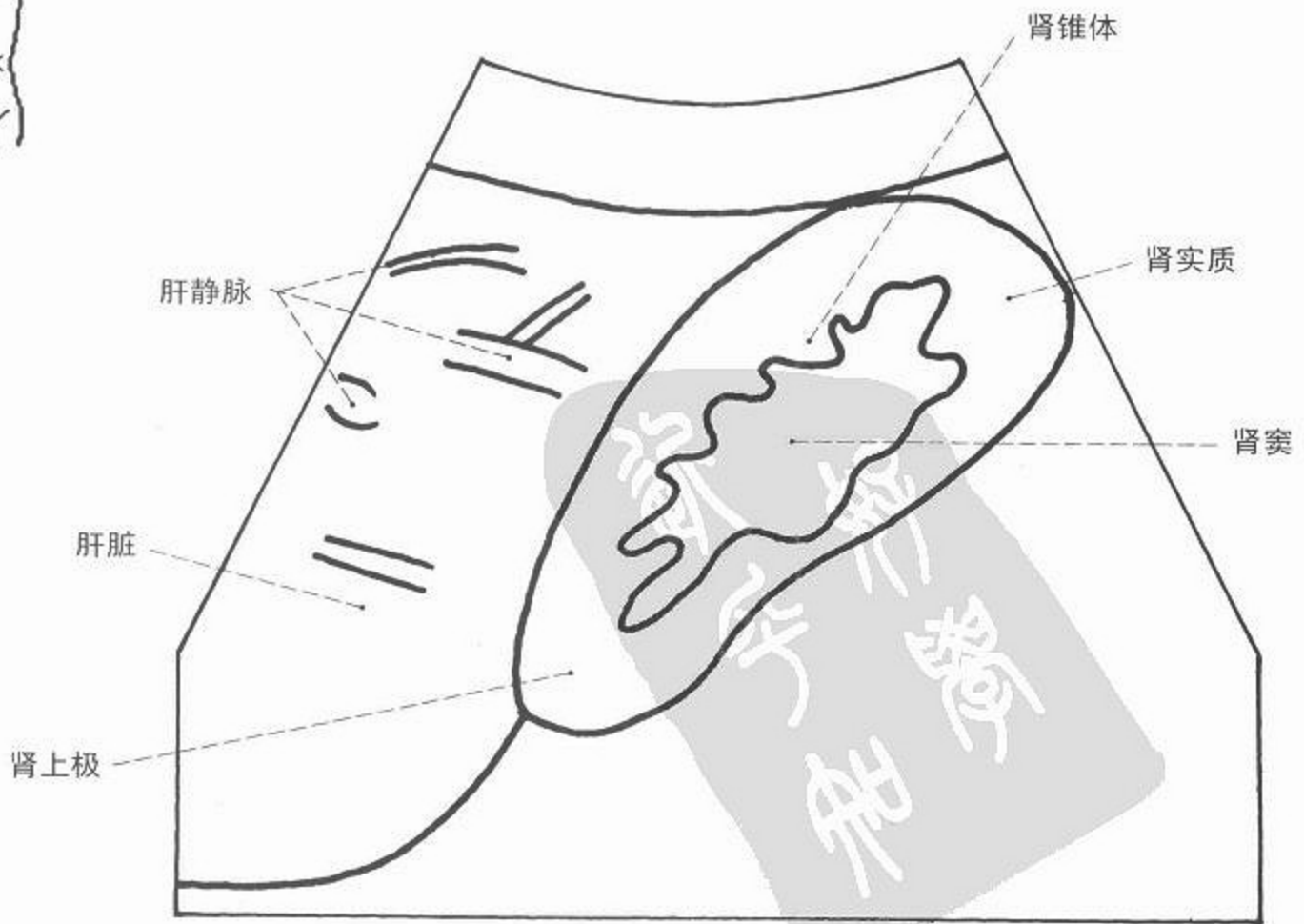
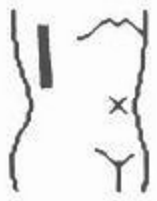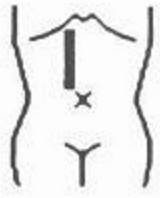图 127 腹主动脉超声



超声

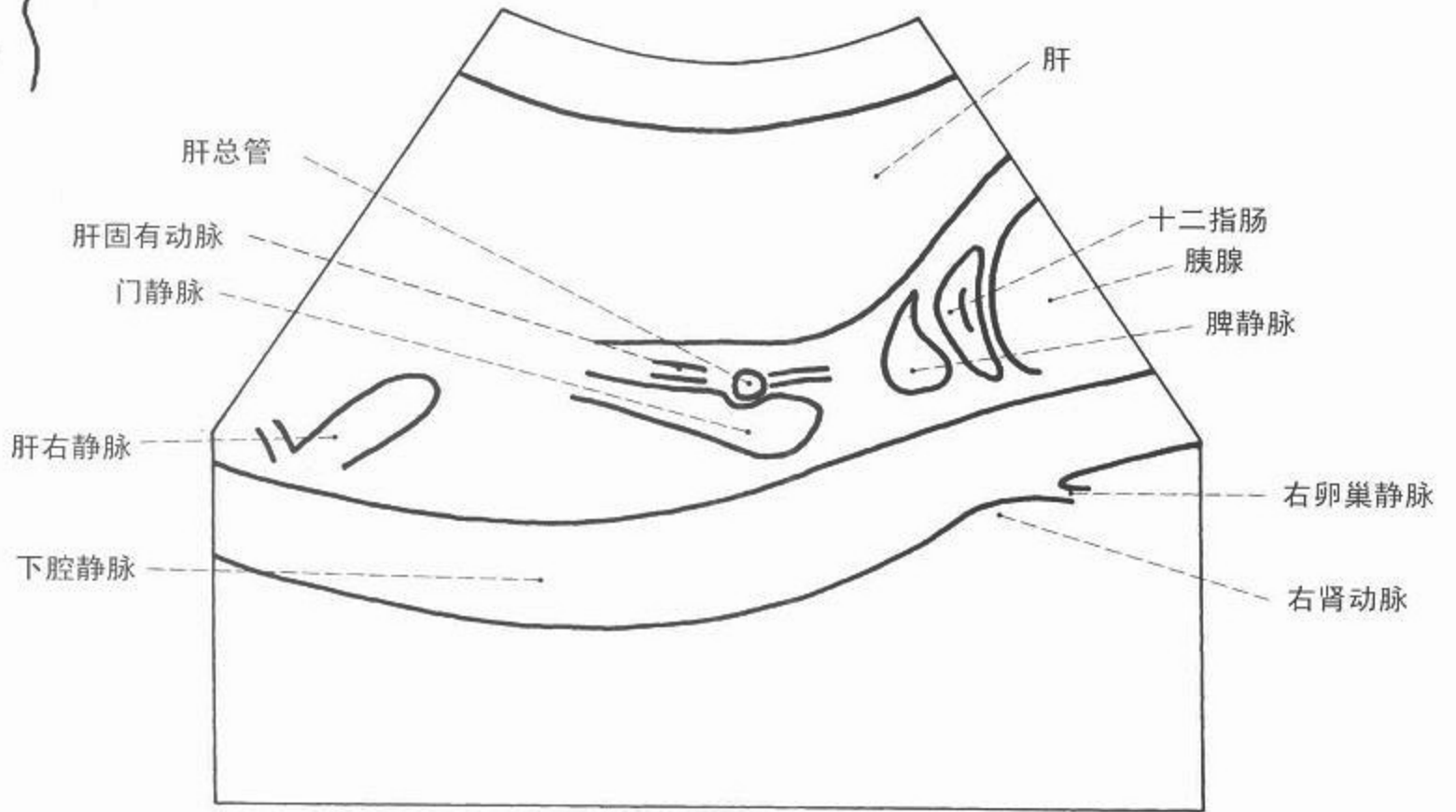

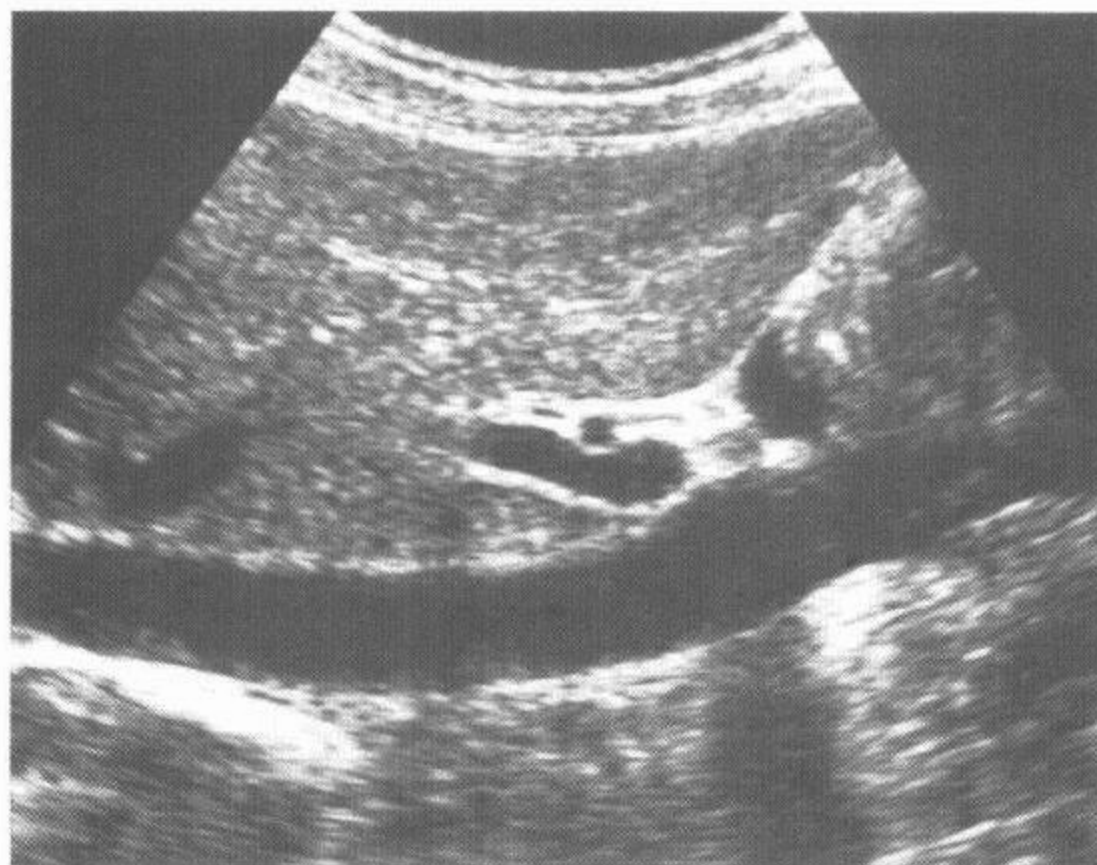
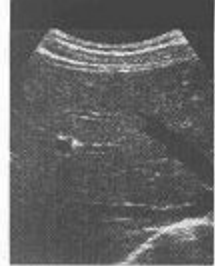

图 128 下腔静脉超声

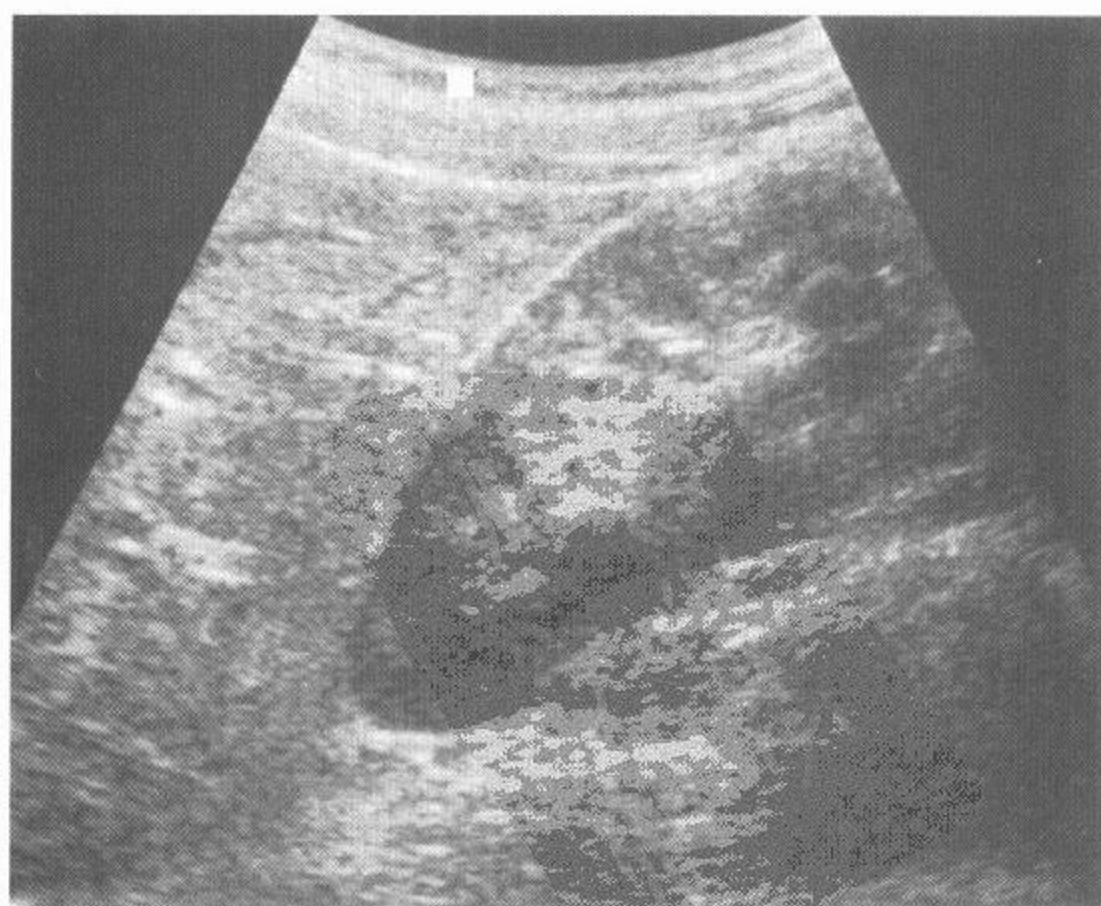
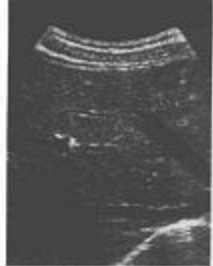
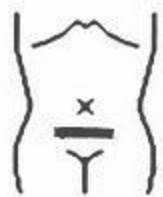图 129 右肾超声



超声

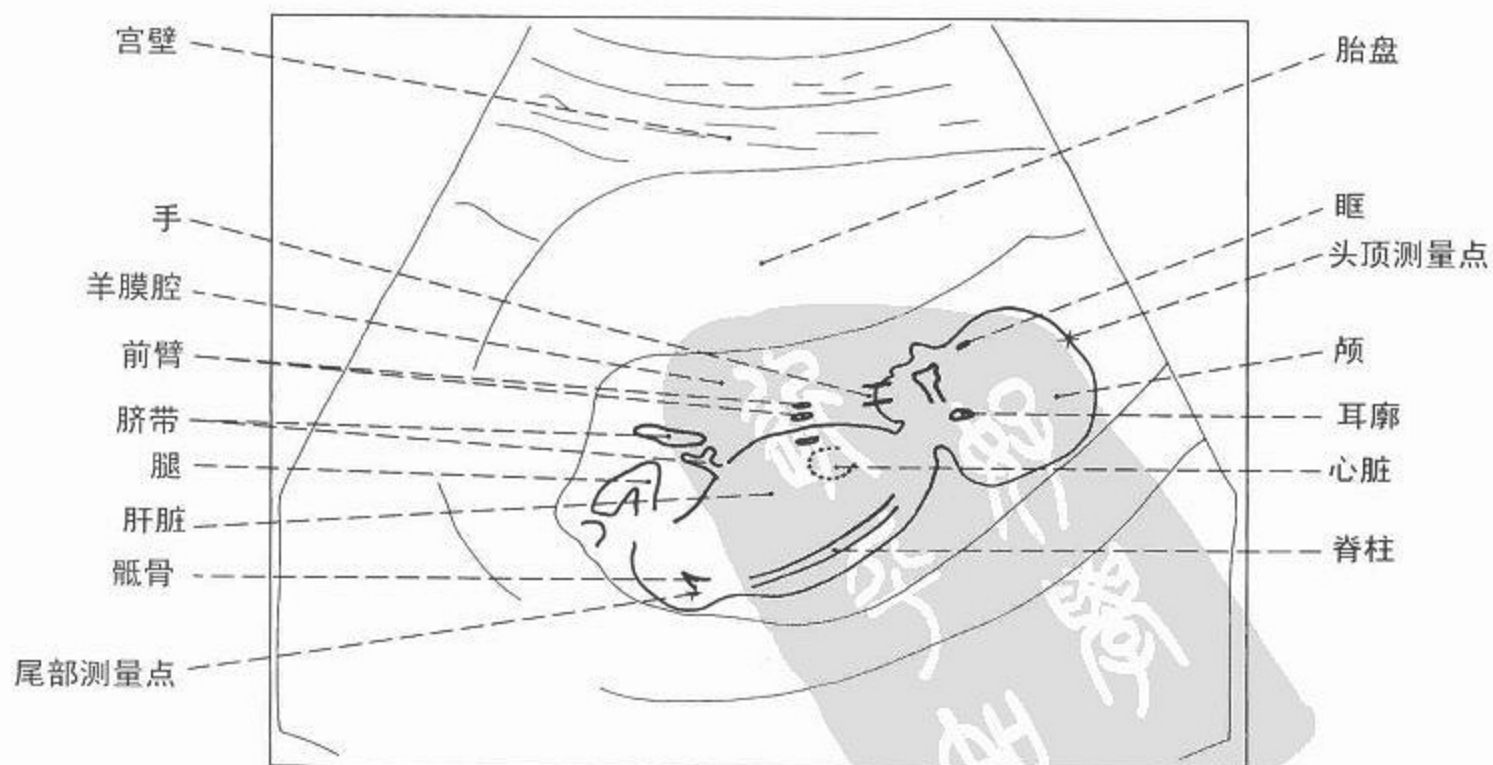
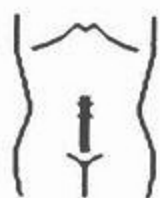
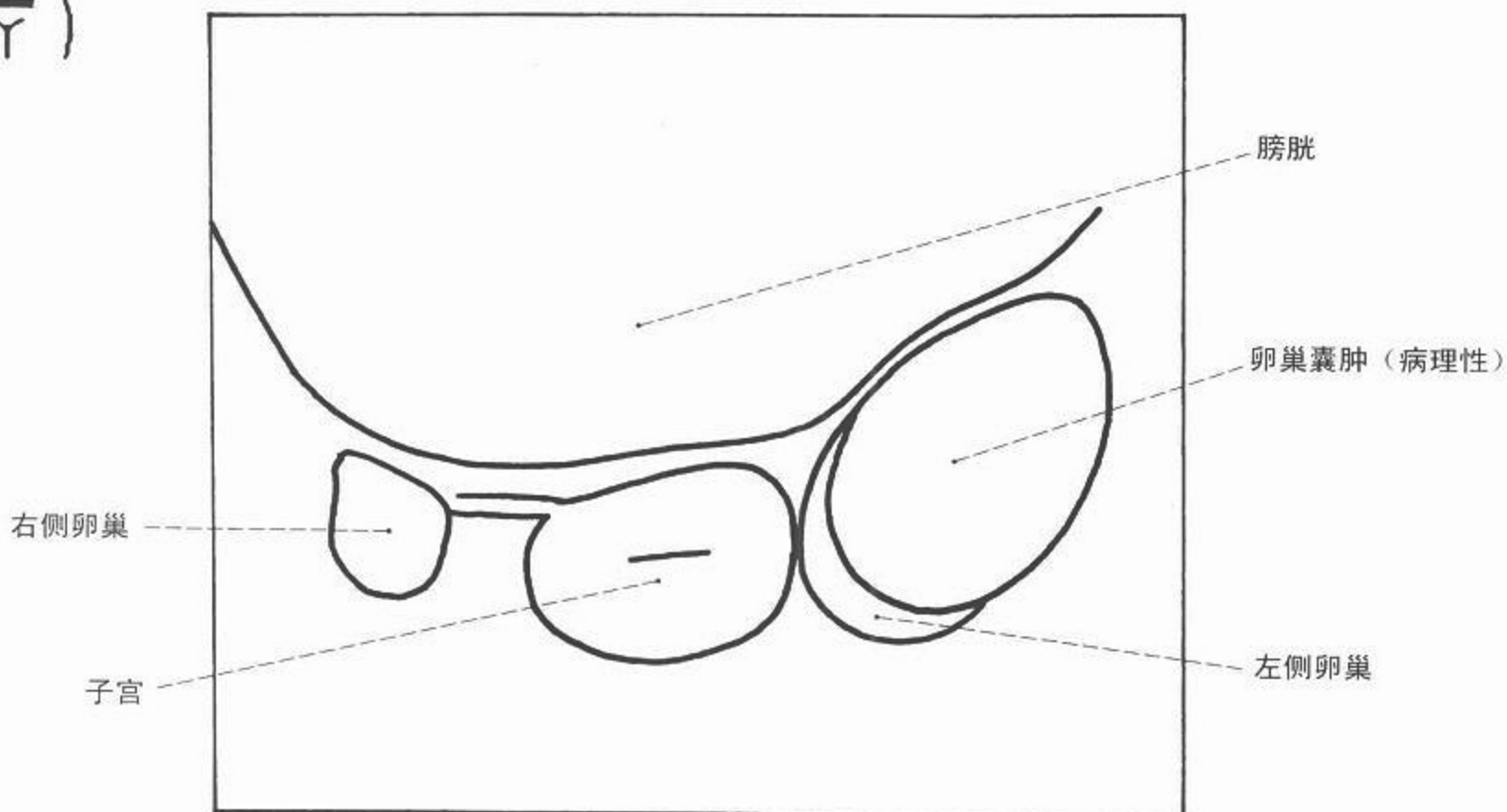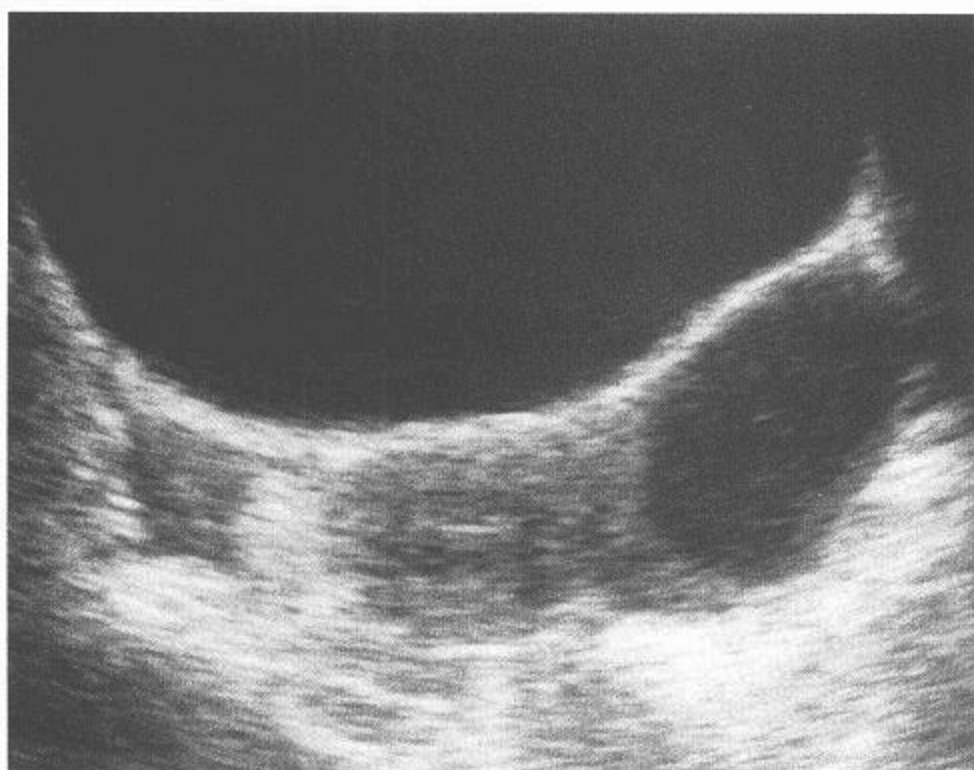
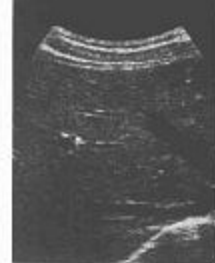



图 130 女性盆腔超声

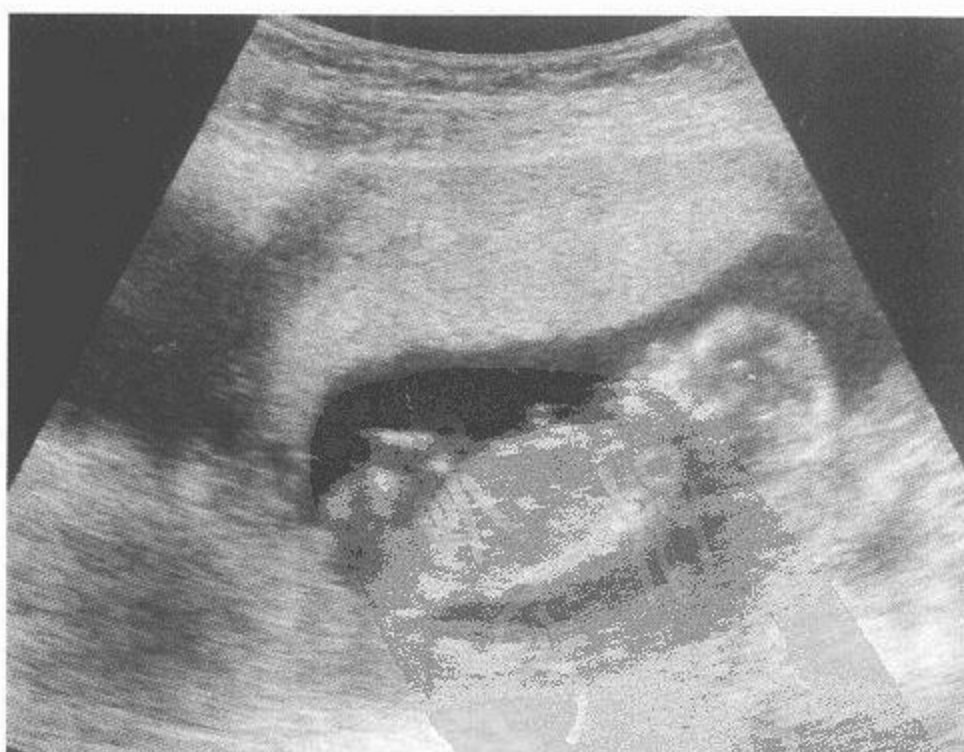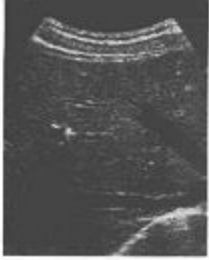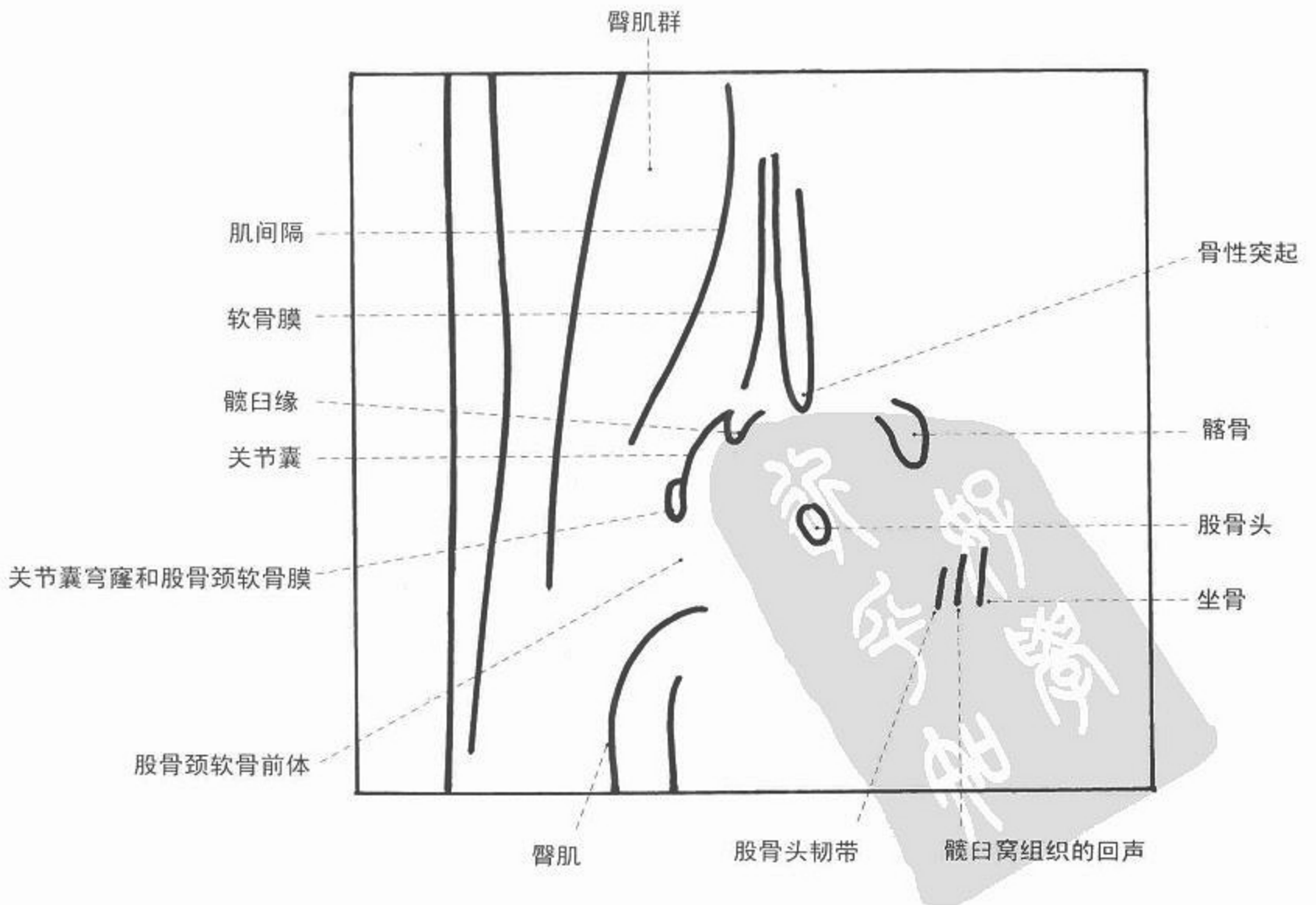
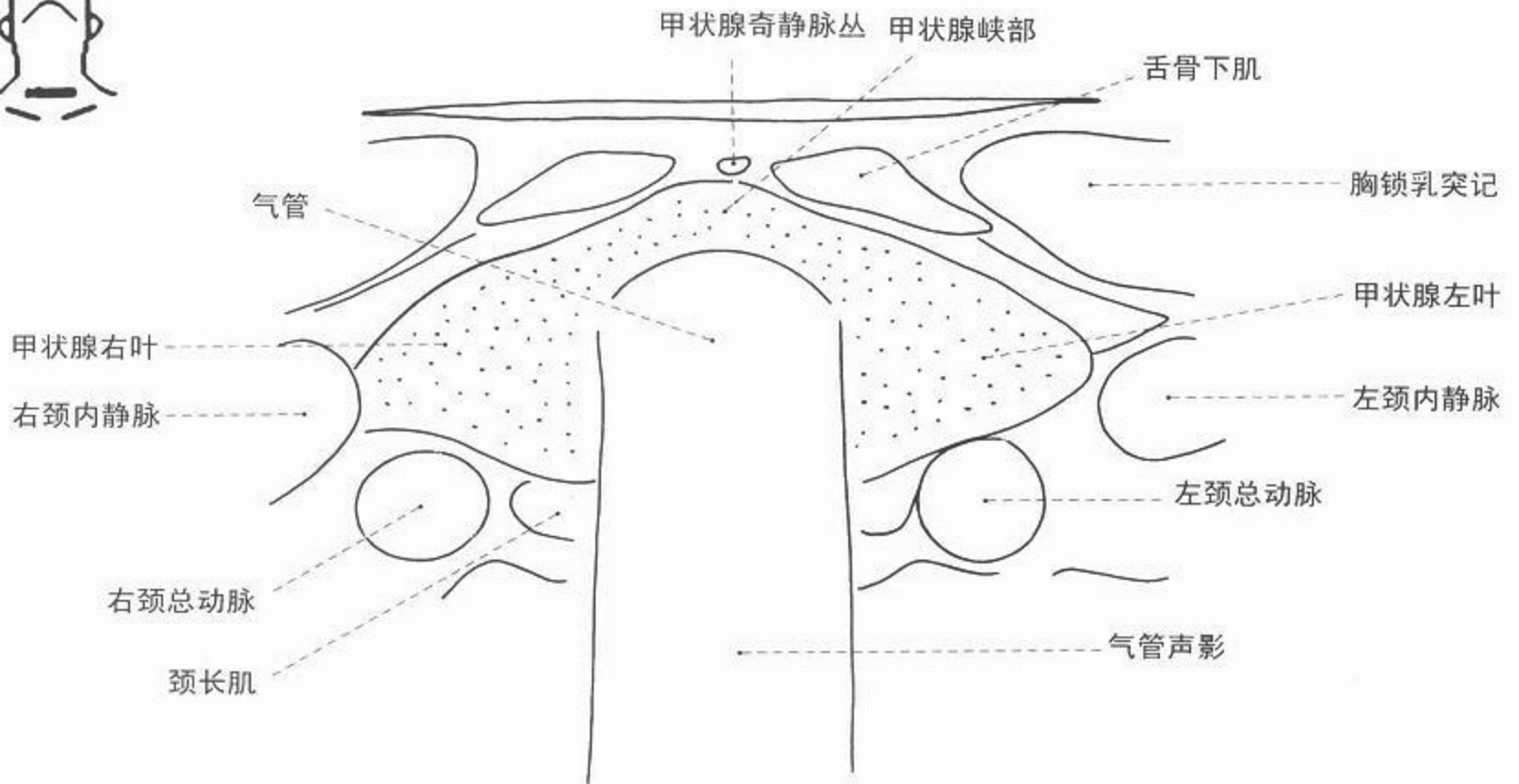


图 131 妊娠(孕 13~14 周)超声





超声



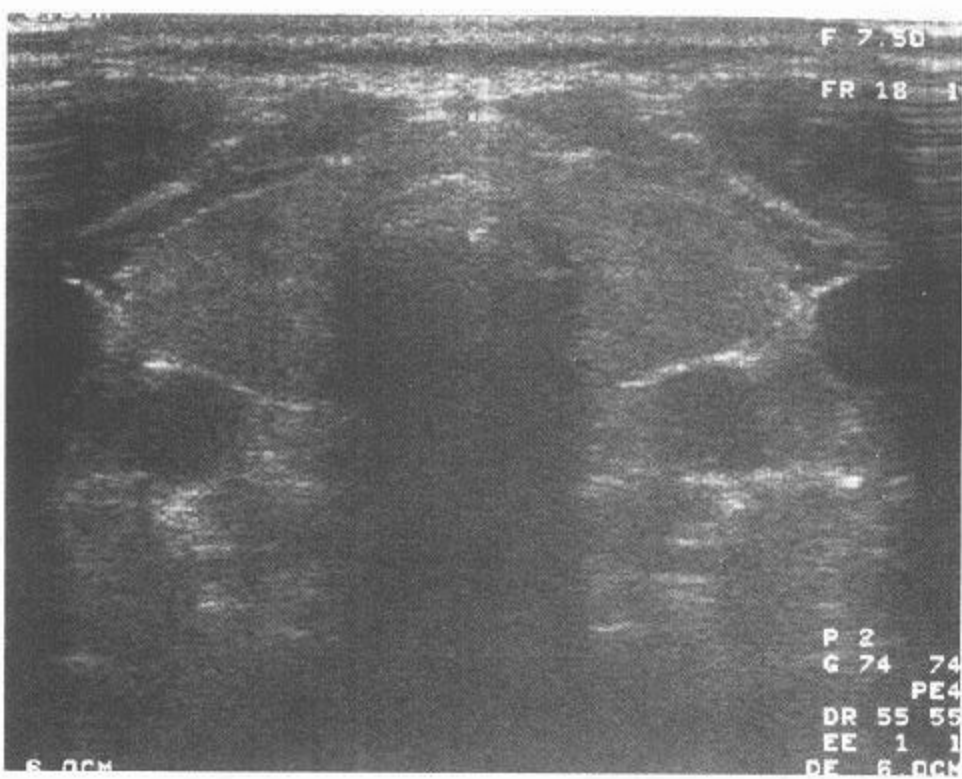
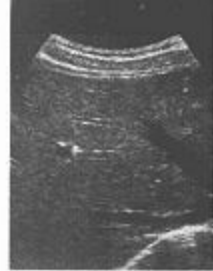

图 132 甲状腺超声

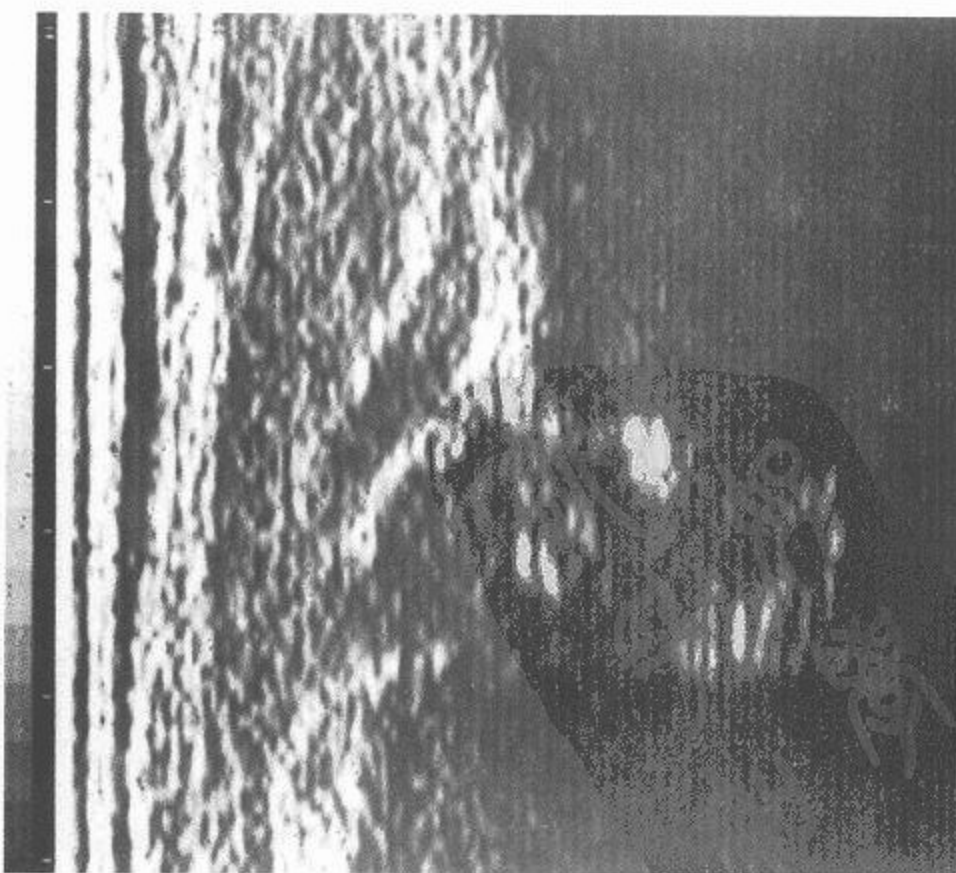
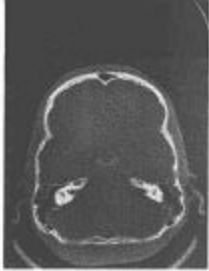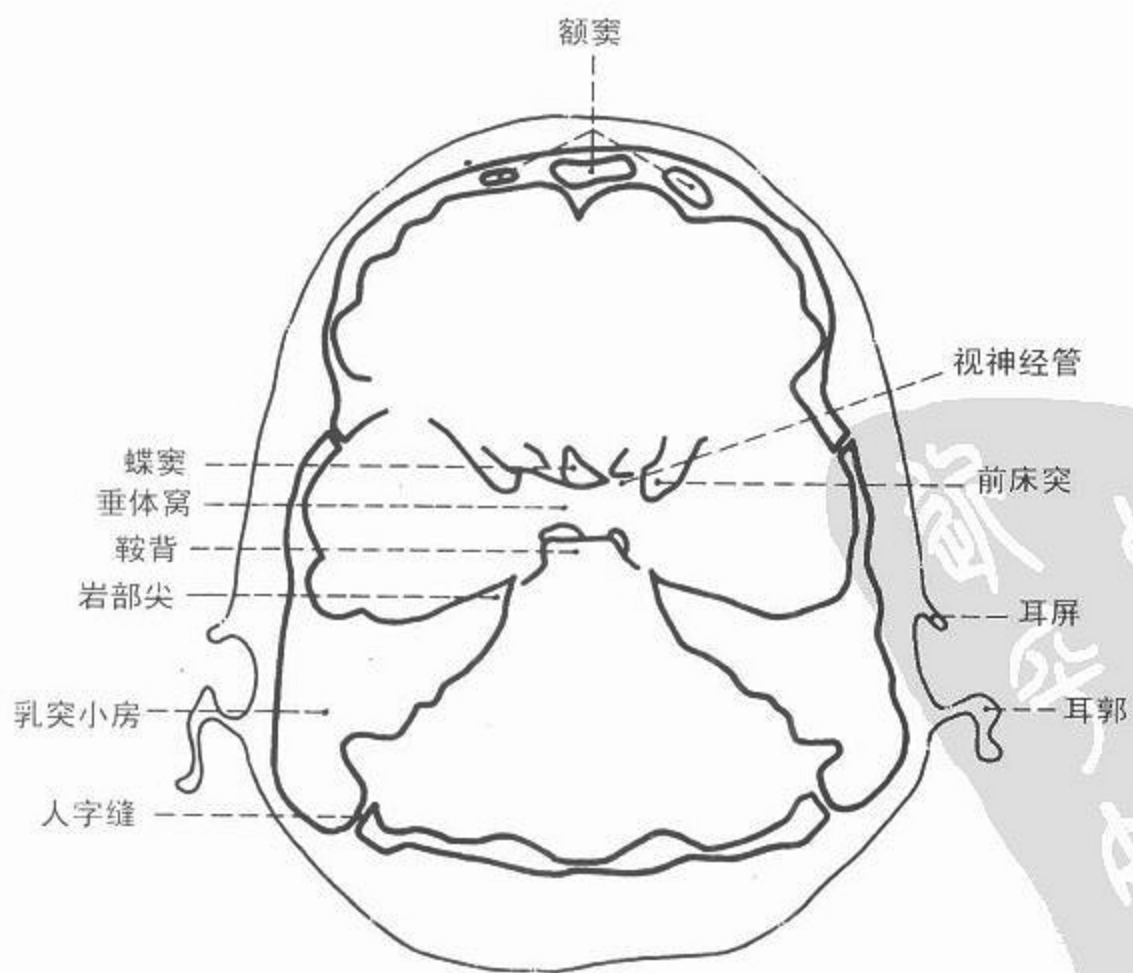
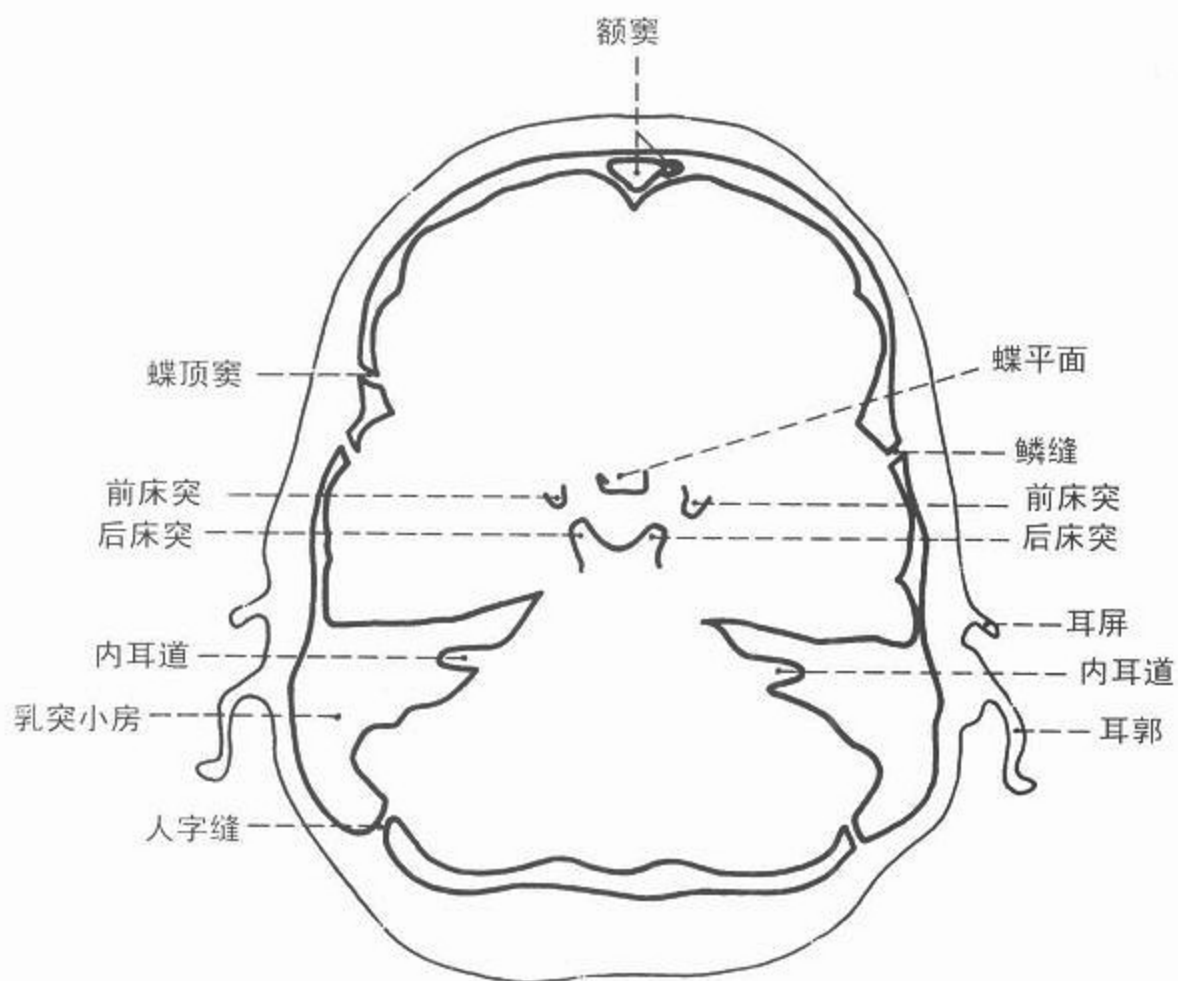


图 133 新生儿髋部超声



CT



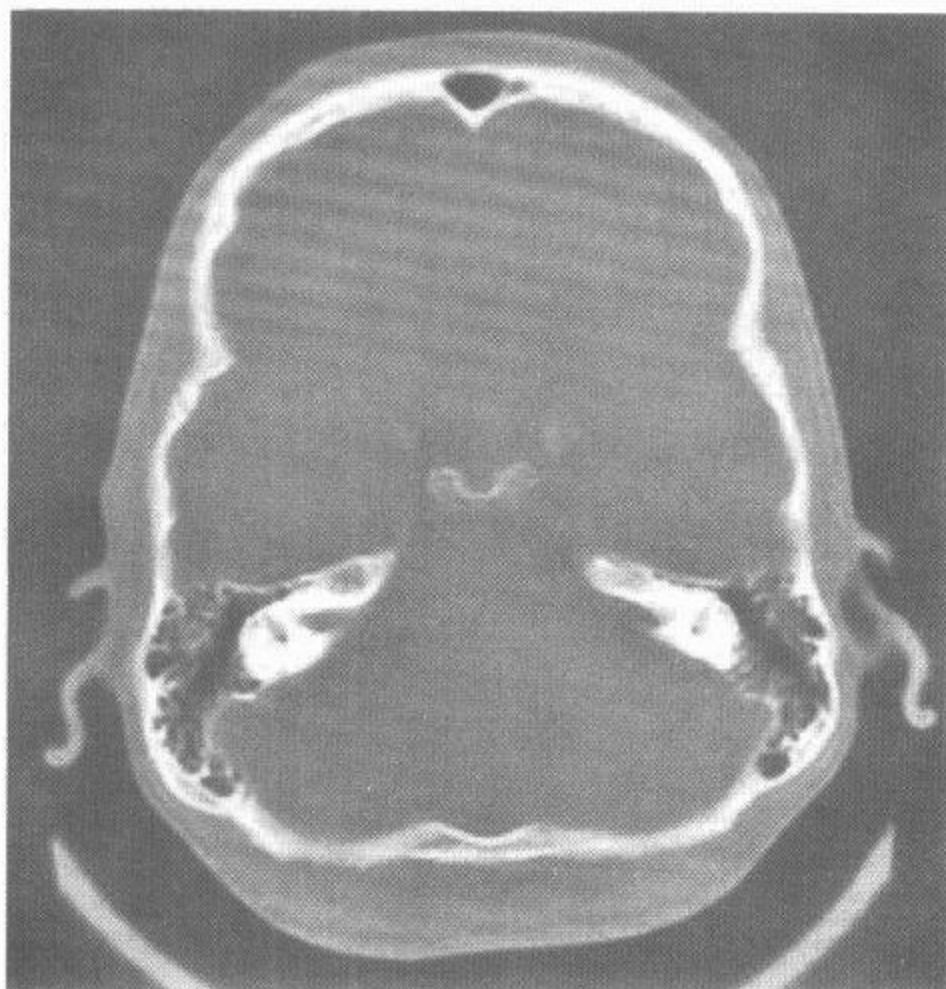
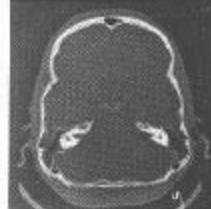

图 134 轴位头部 CT 像 骨窗

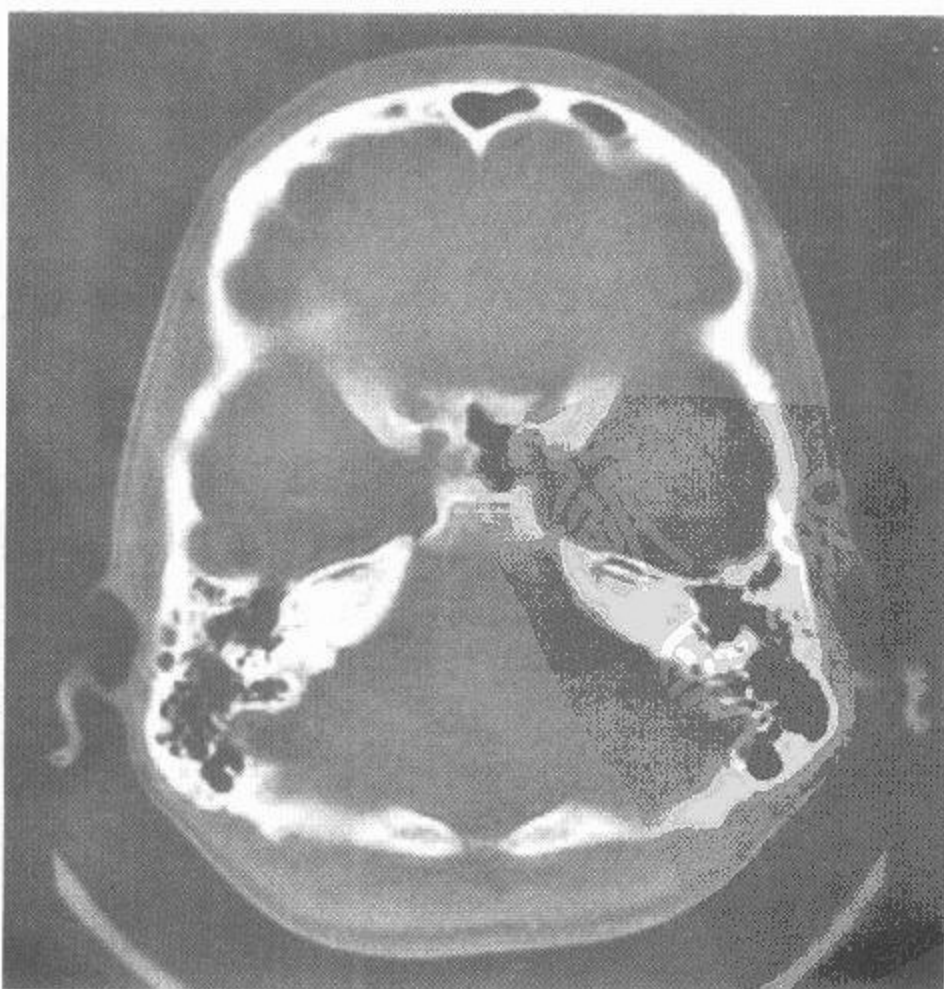
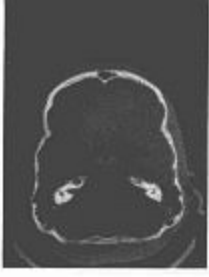
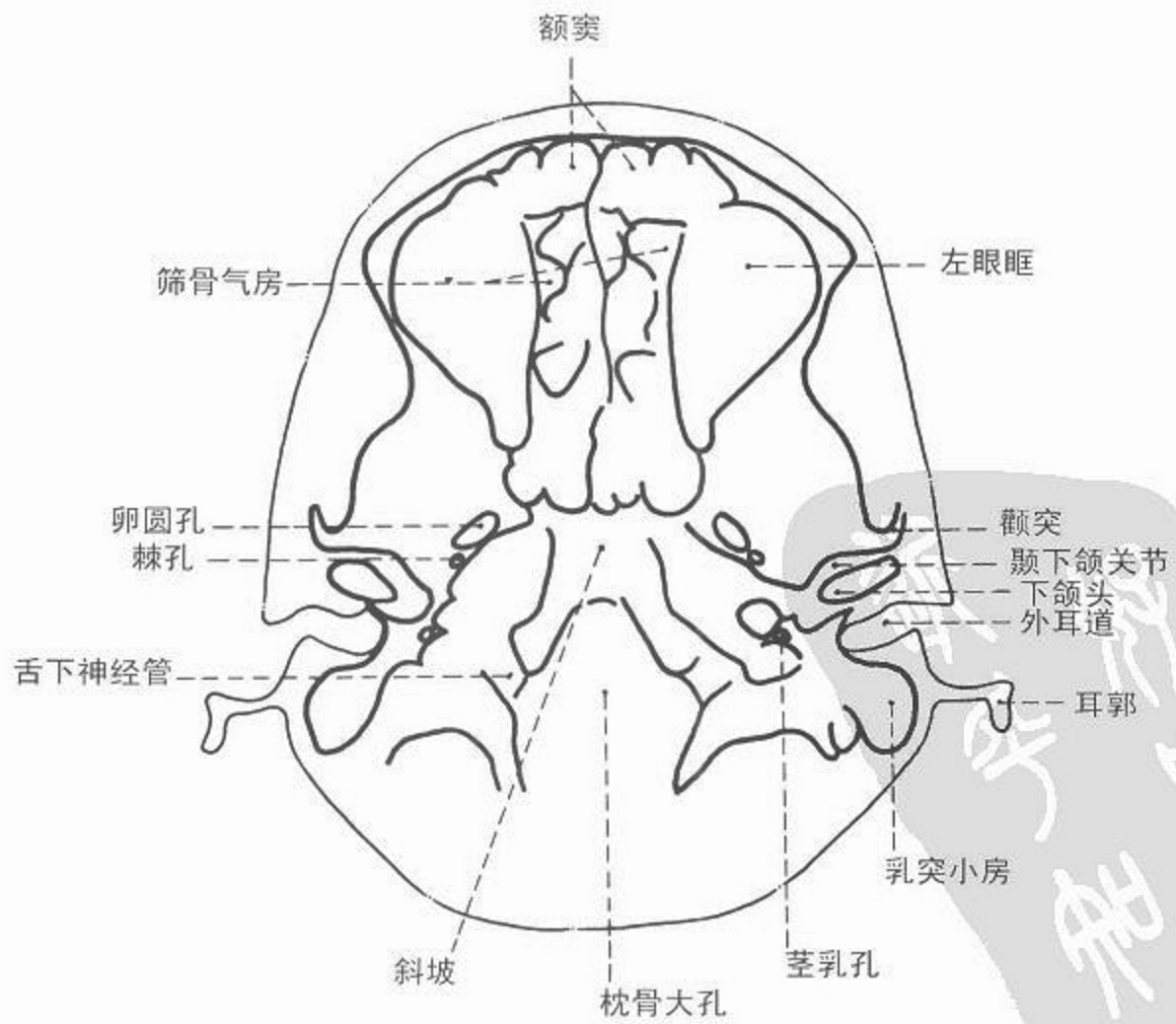
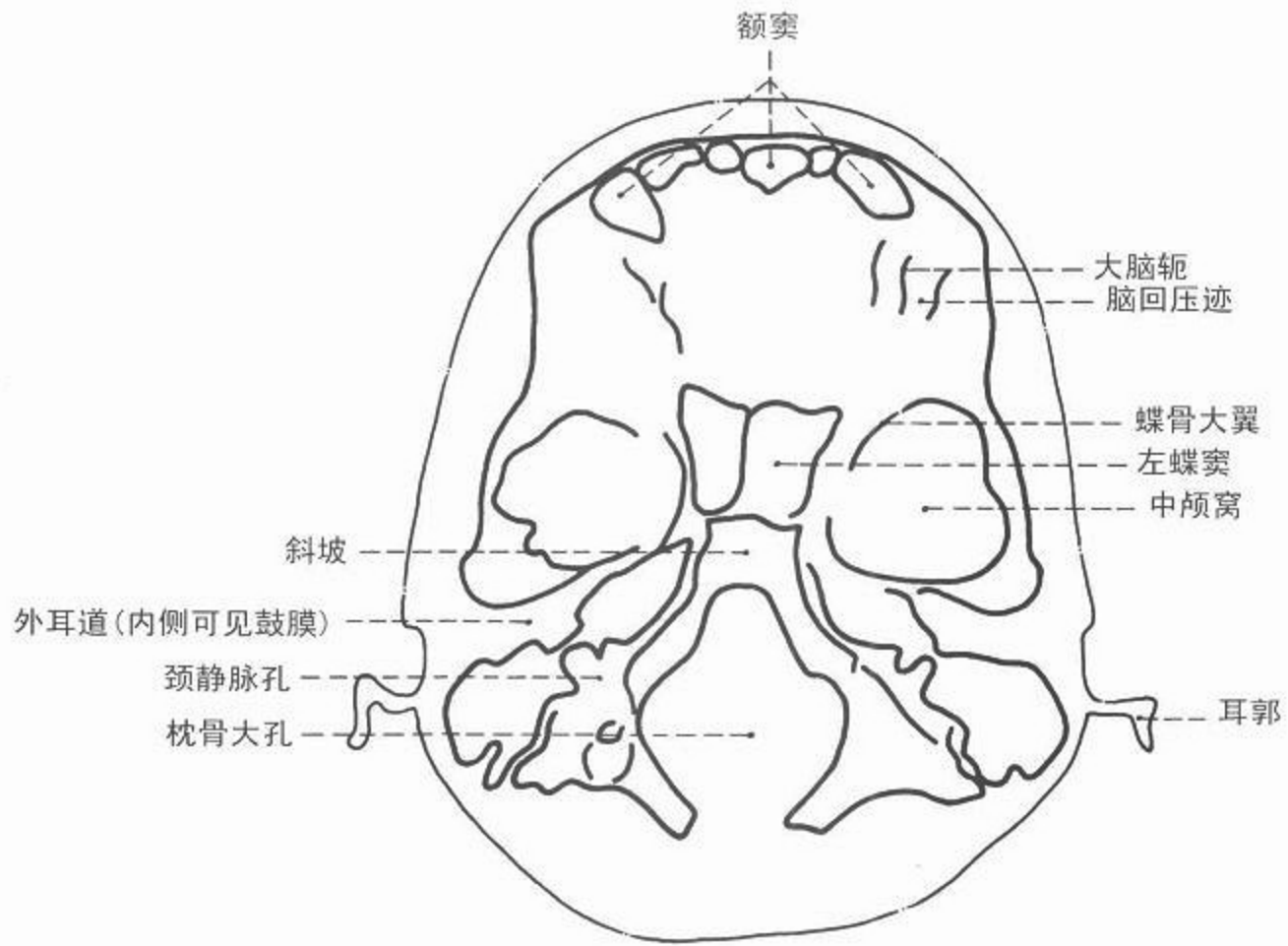


图 135 轴位头部 CT 像 骨窗



CT



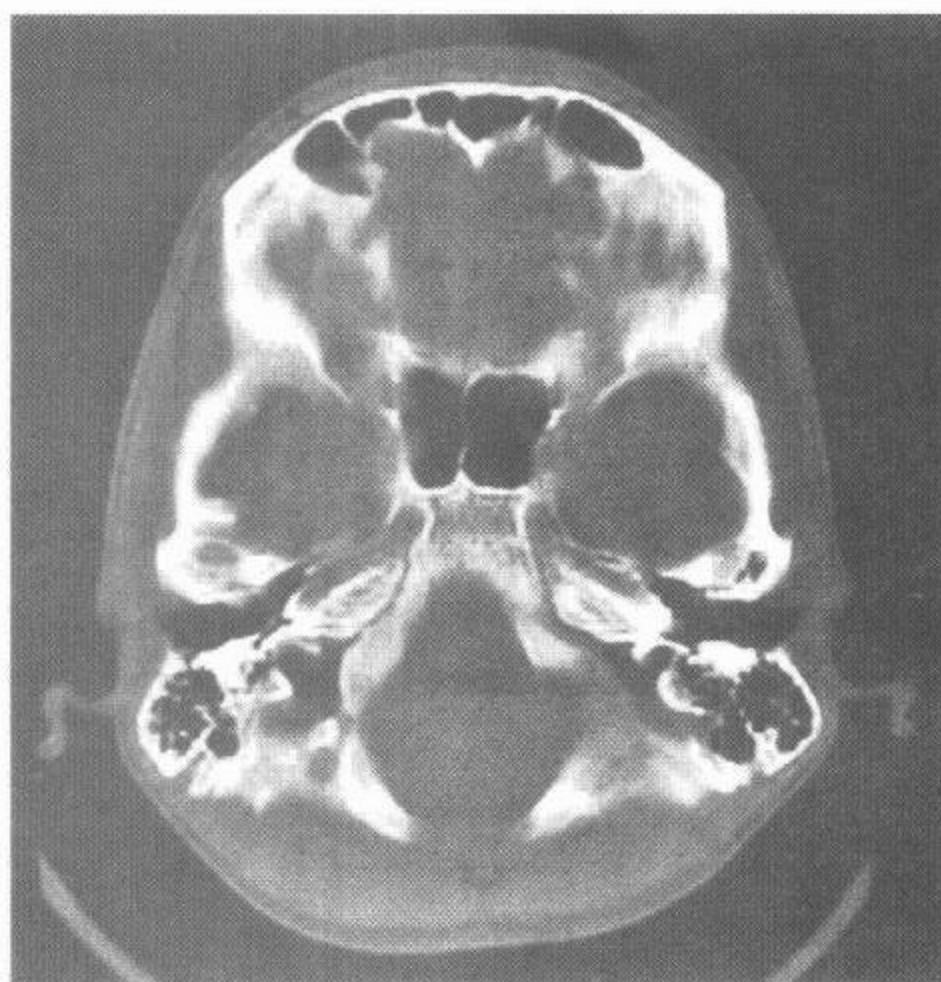
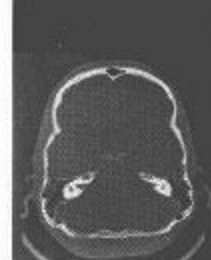

图 136 轴位头部 CT 像 骨窗

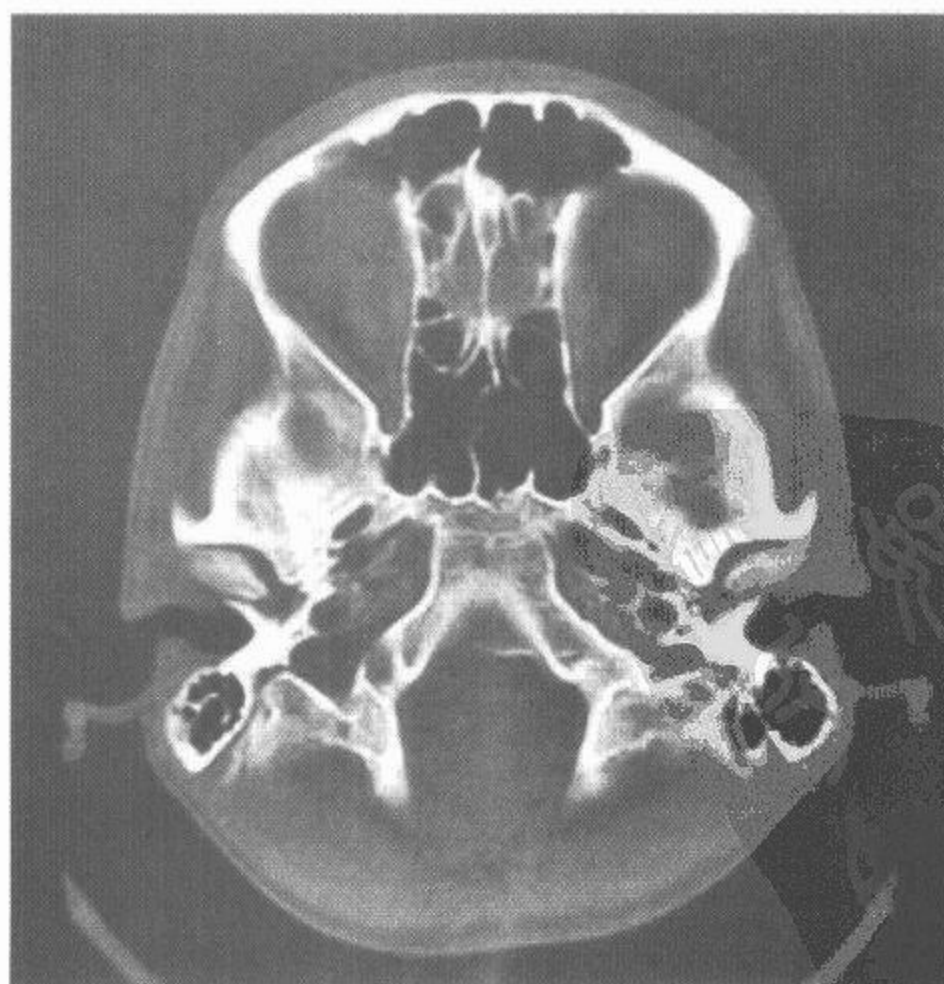
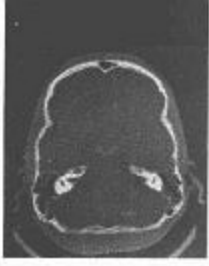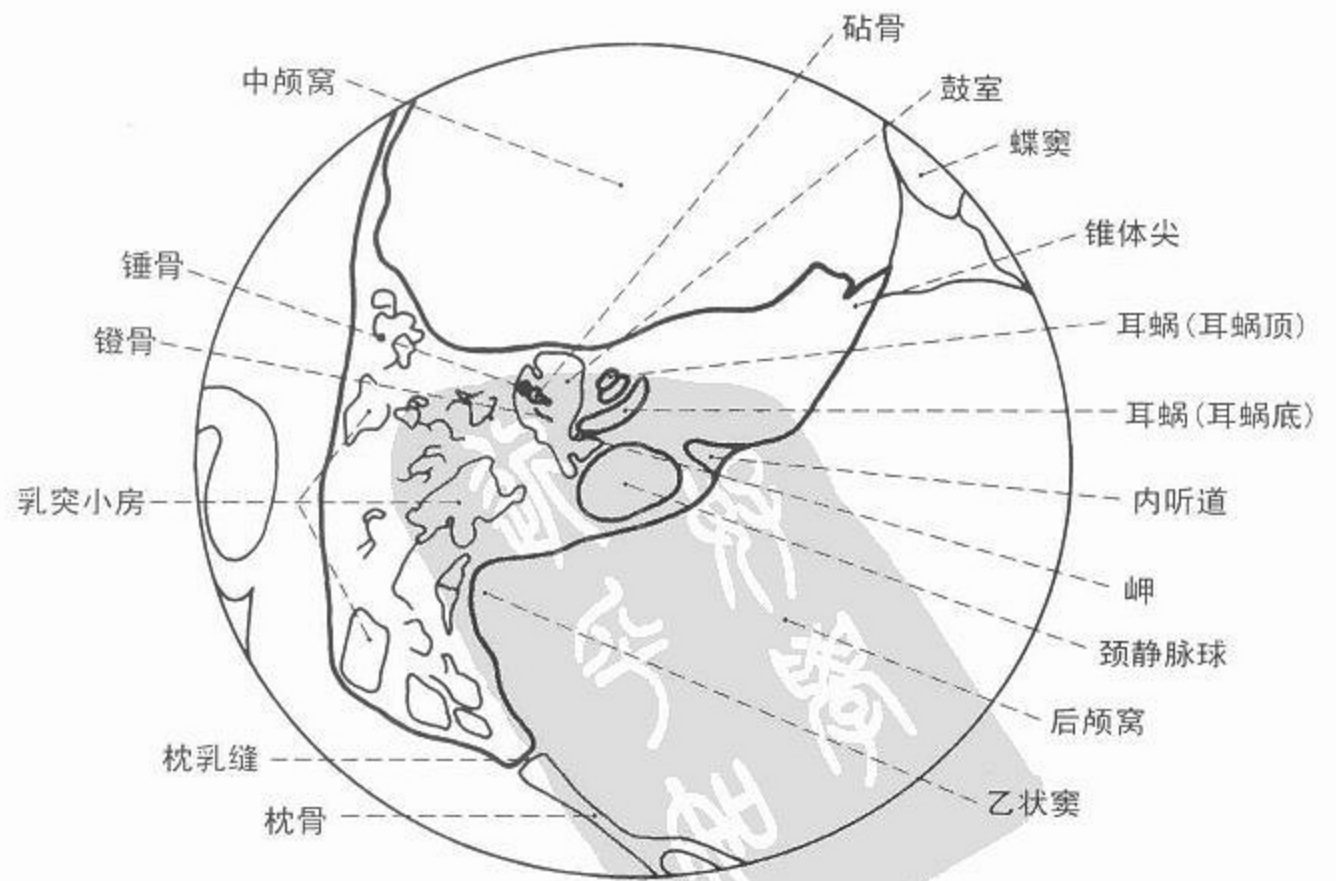
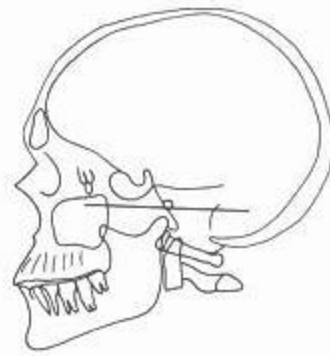
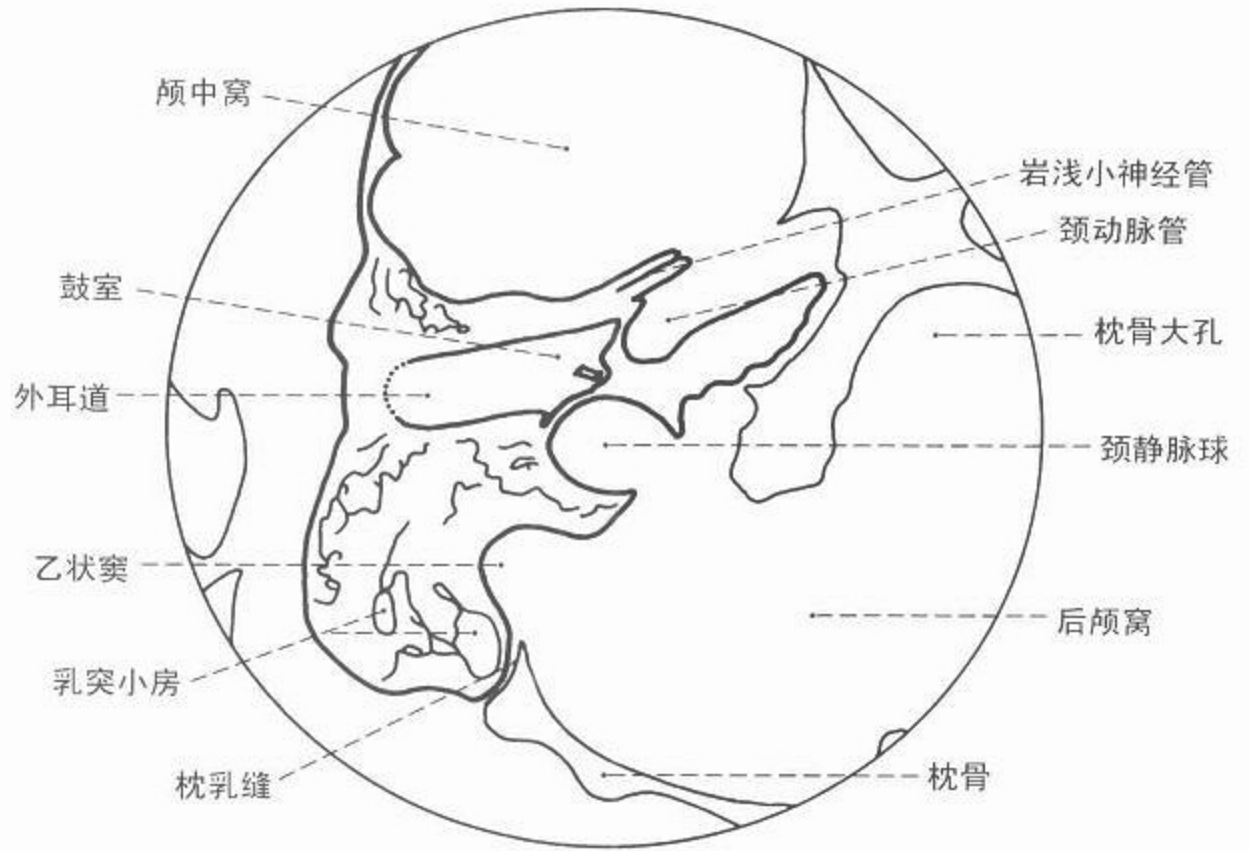
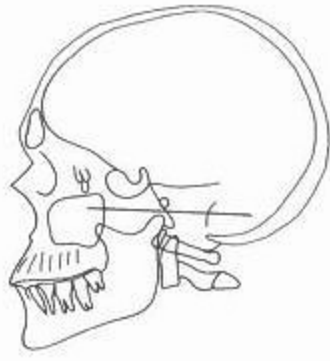


图 137 轴位头部 CT 像 骨窗



CT



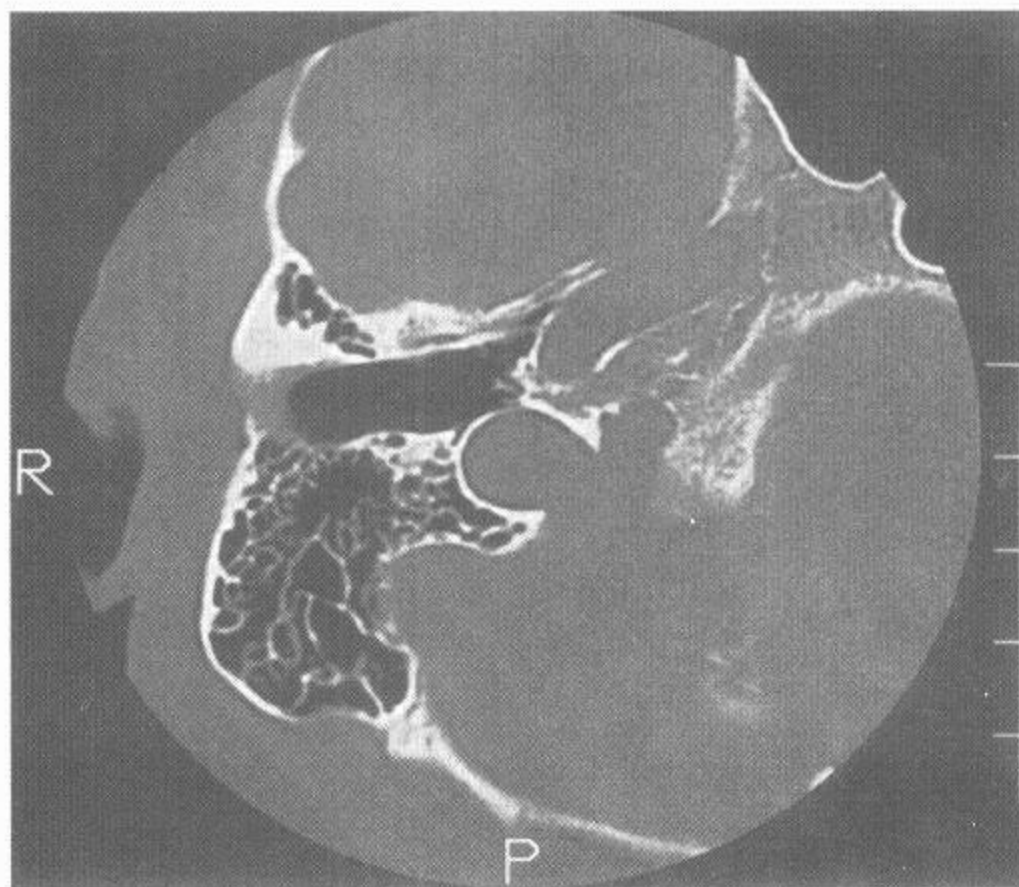
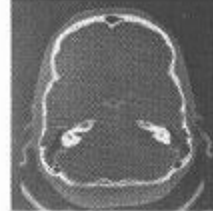


图 138 轴位(横轴)颞骨 CT 像 骨窗

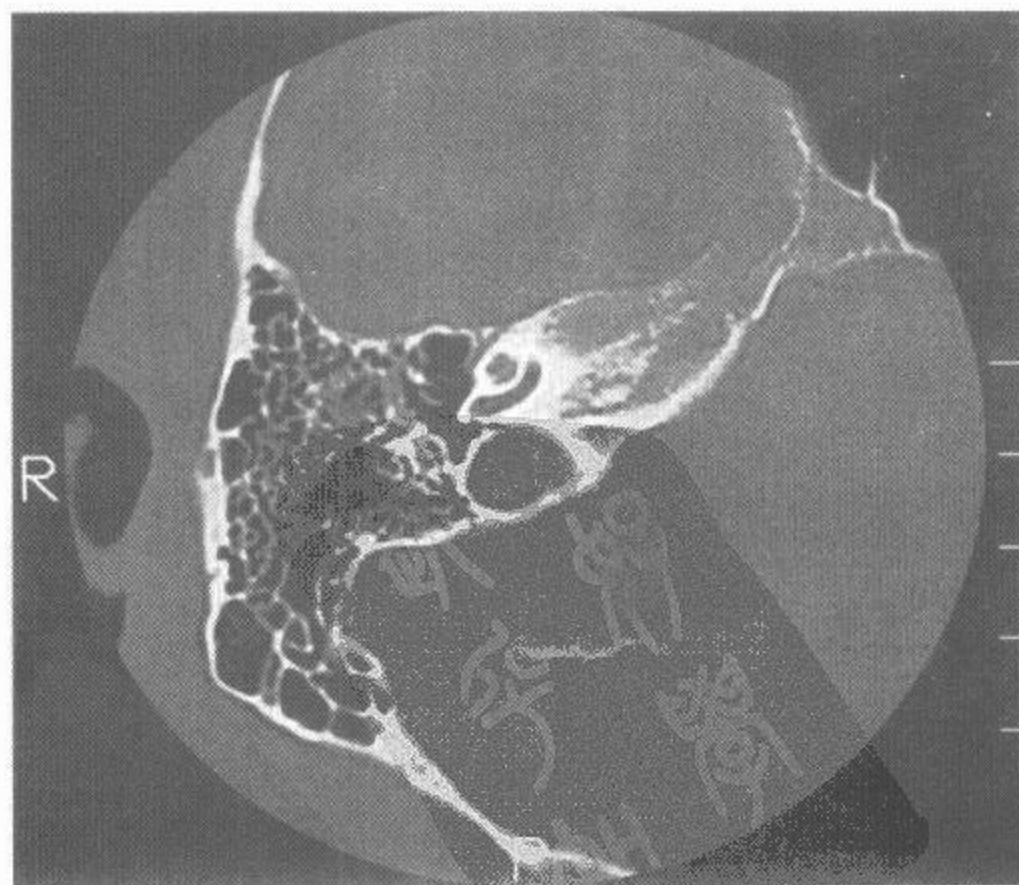
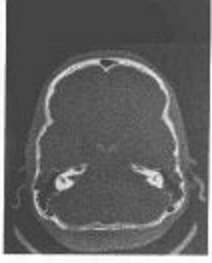
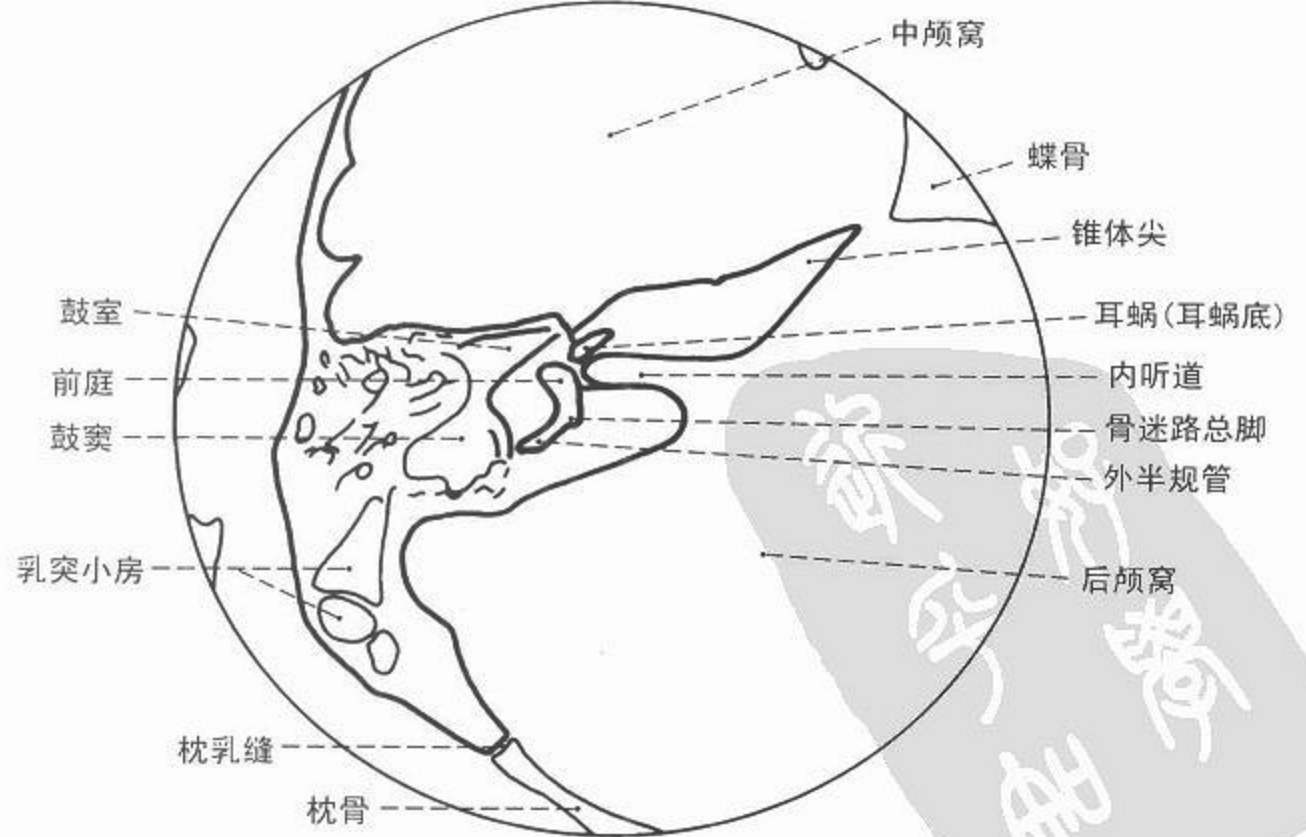
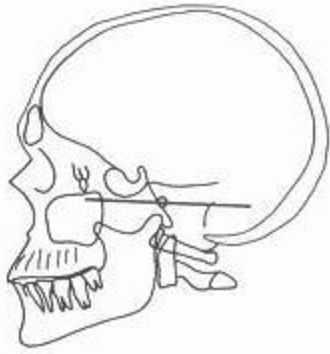
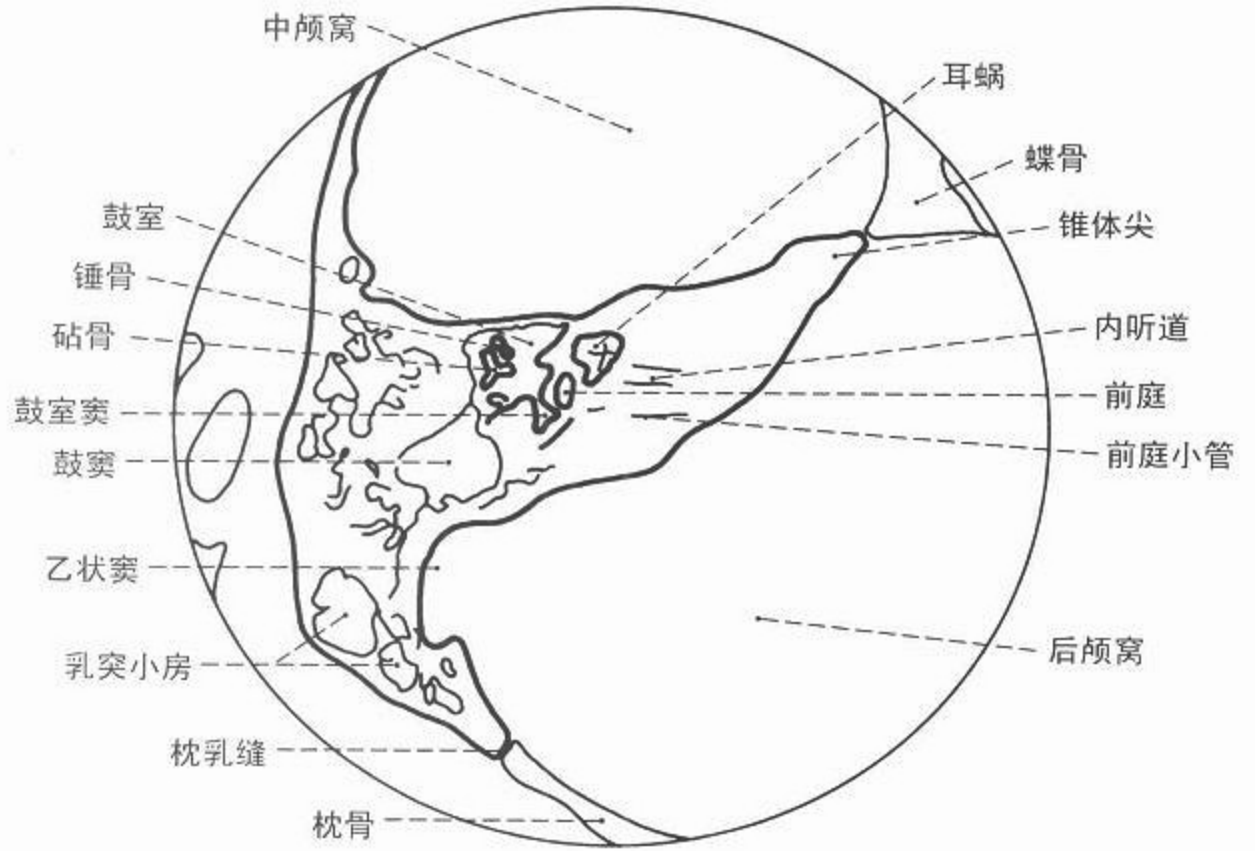
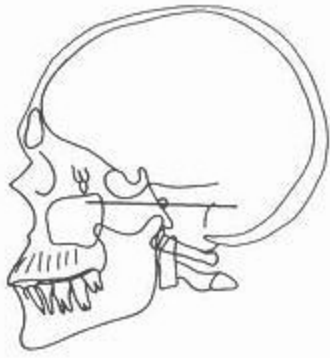


图 139 轴位(横轴)颞骨 CT 像 骨窗





CT



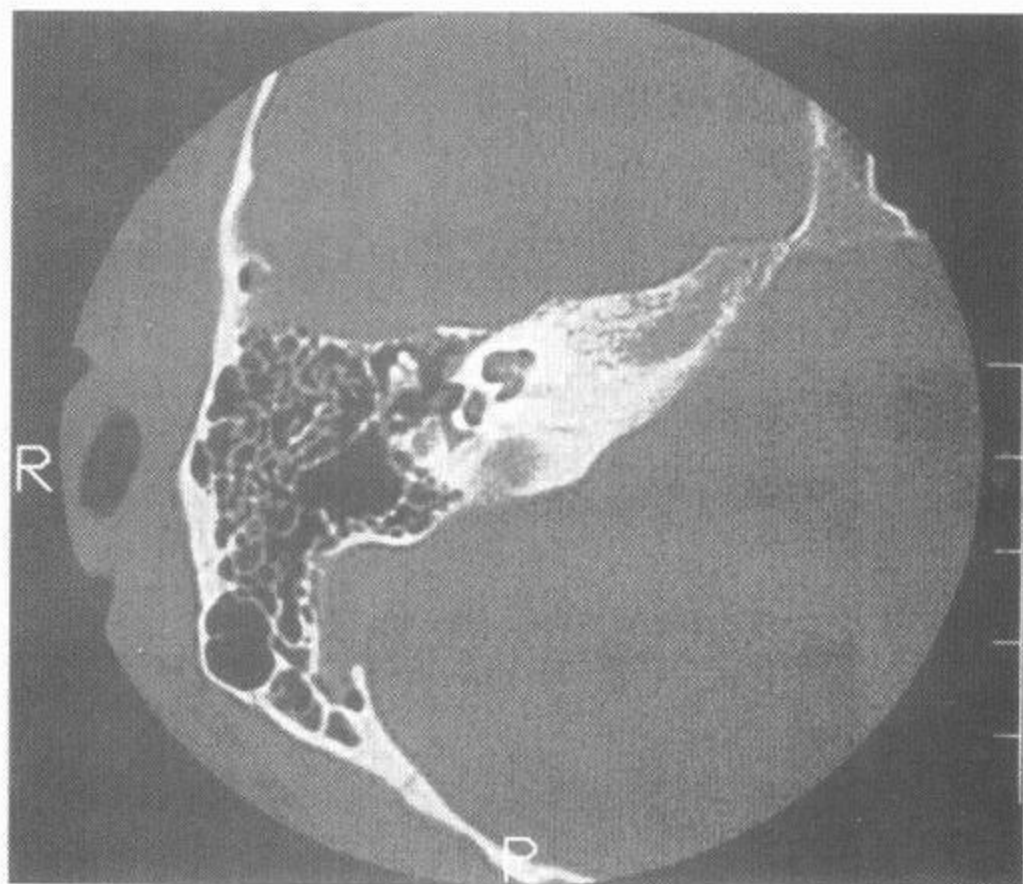
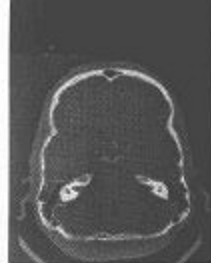

图 140 轴位(横轴)颞骨 CT 像 骨窗

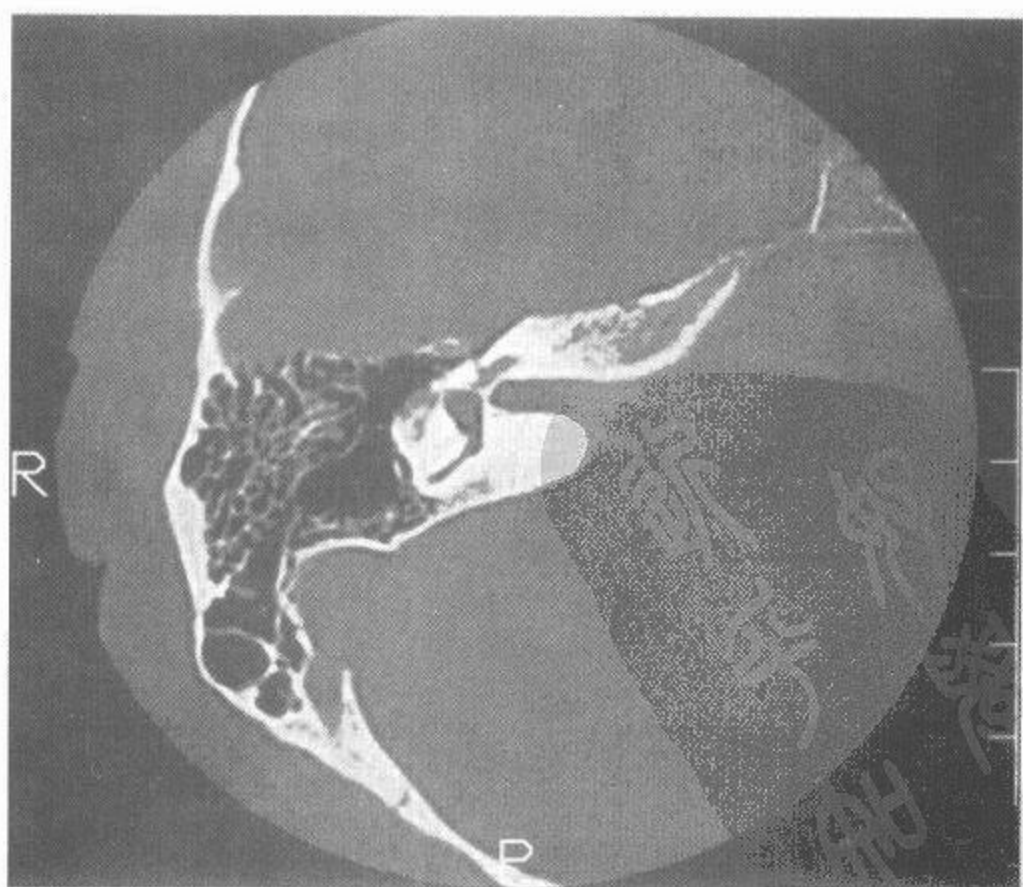
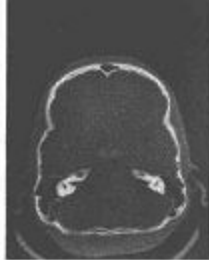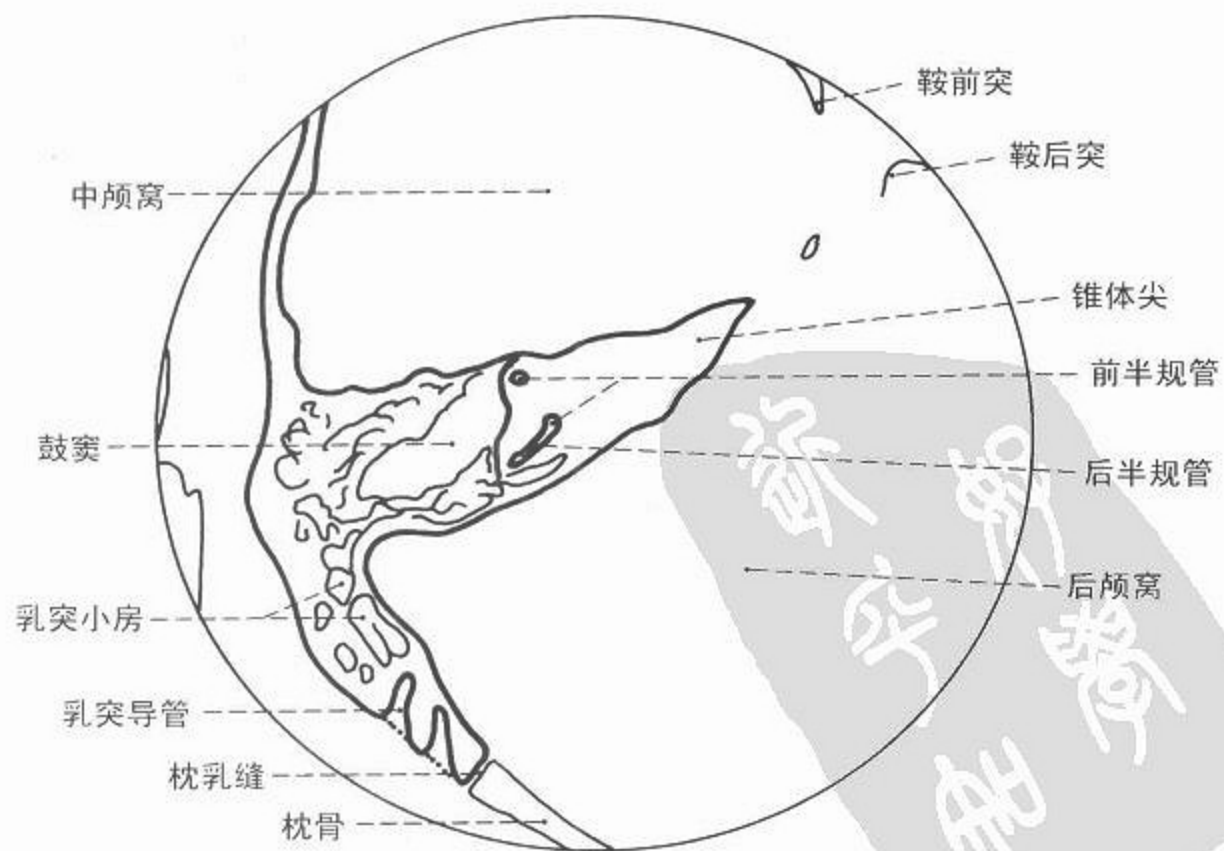
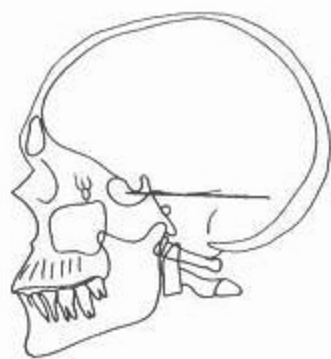
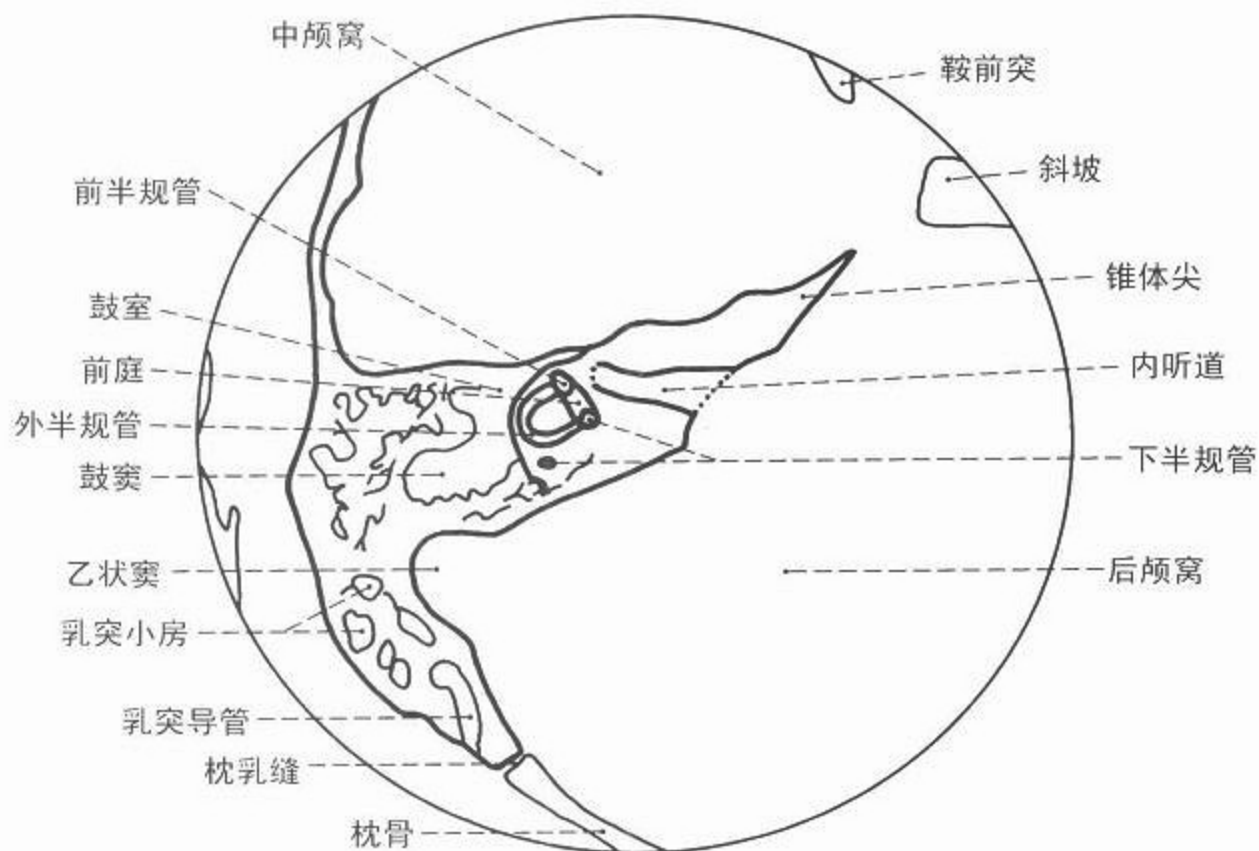
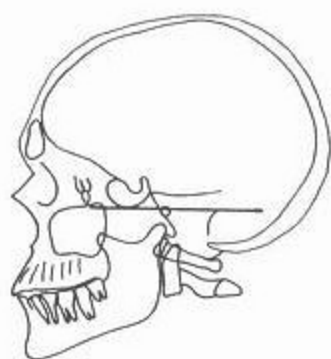


图 141 轴位(横轴)颞骨 CT 像 骨窗



CT



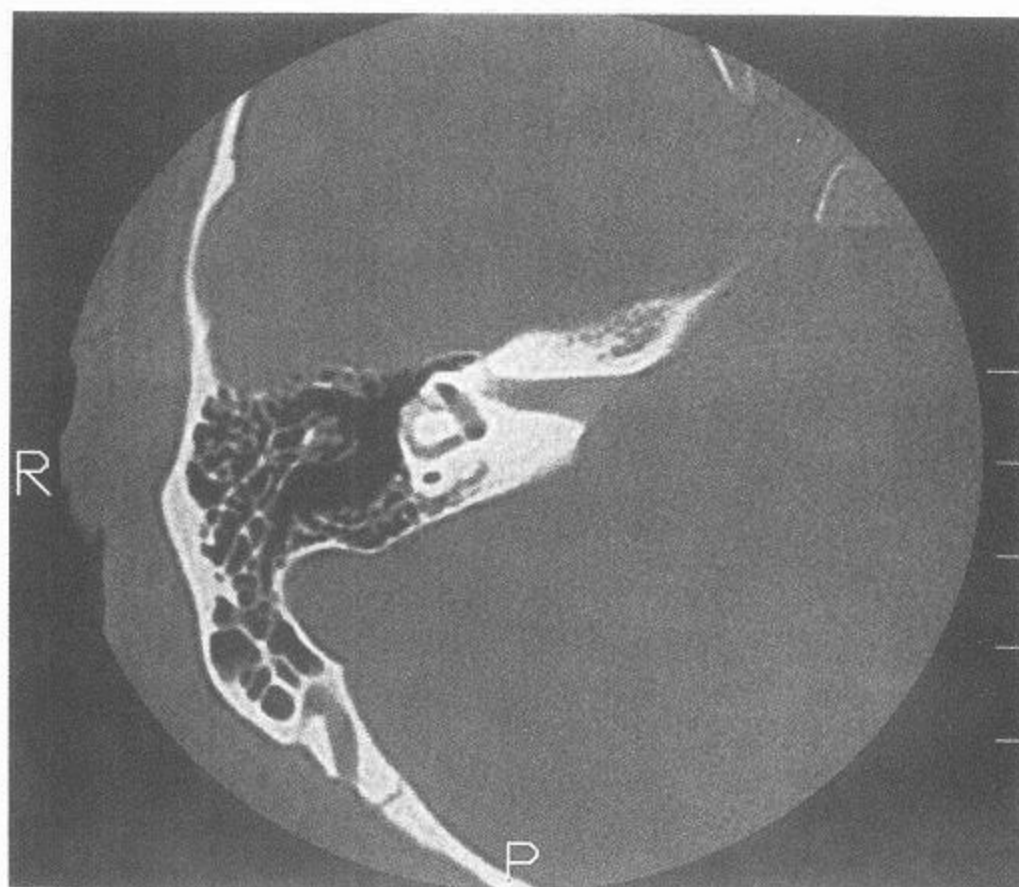
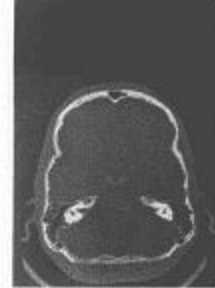

图 142 轴位(横轴)颞骨 CT 像 骨窗

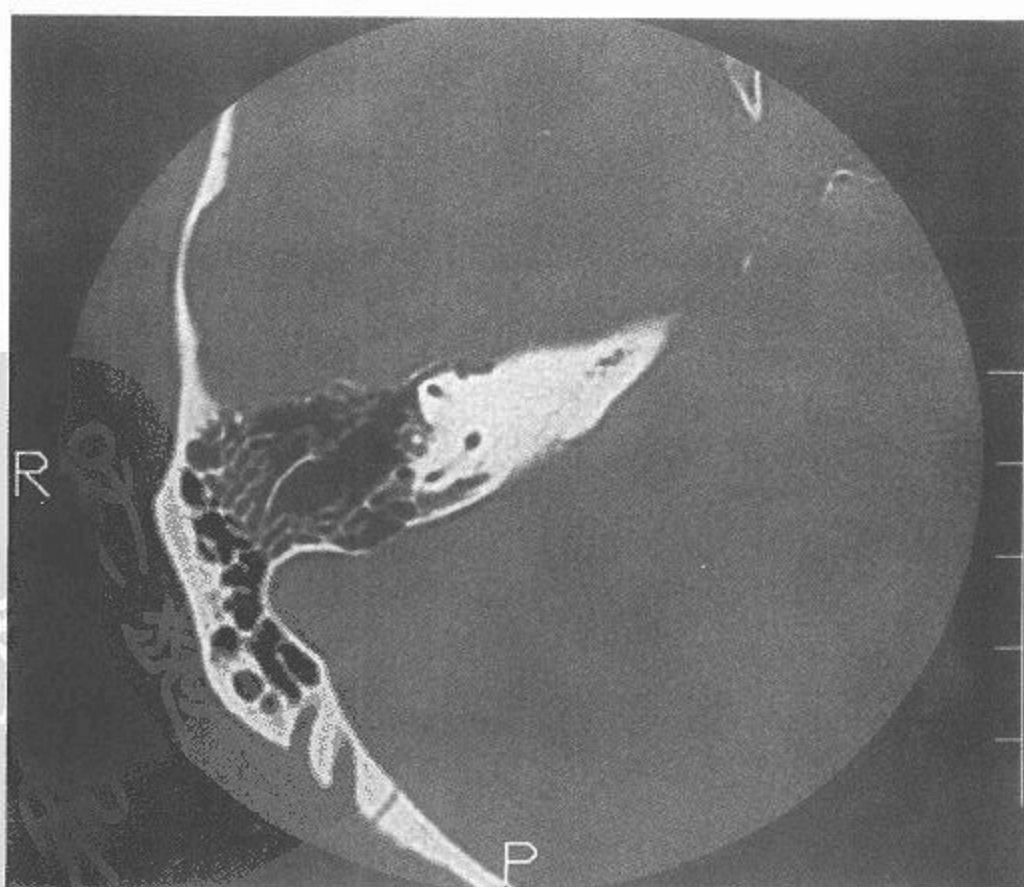
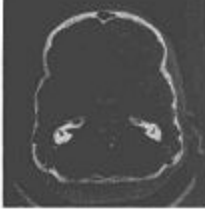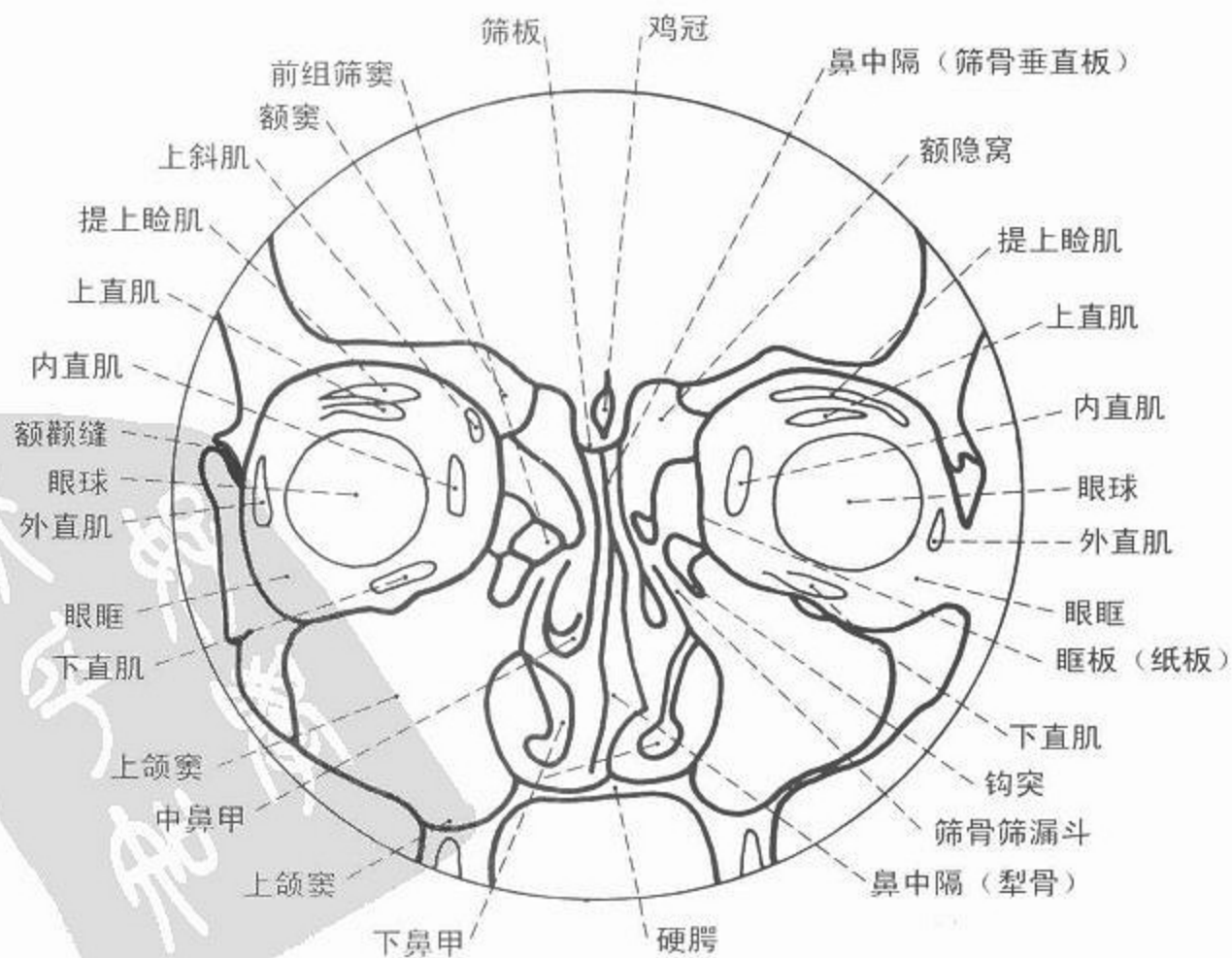
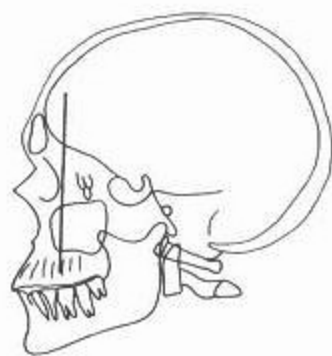
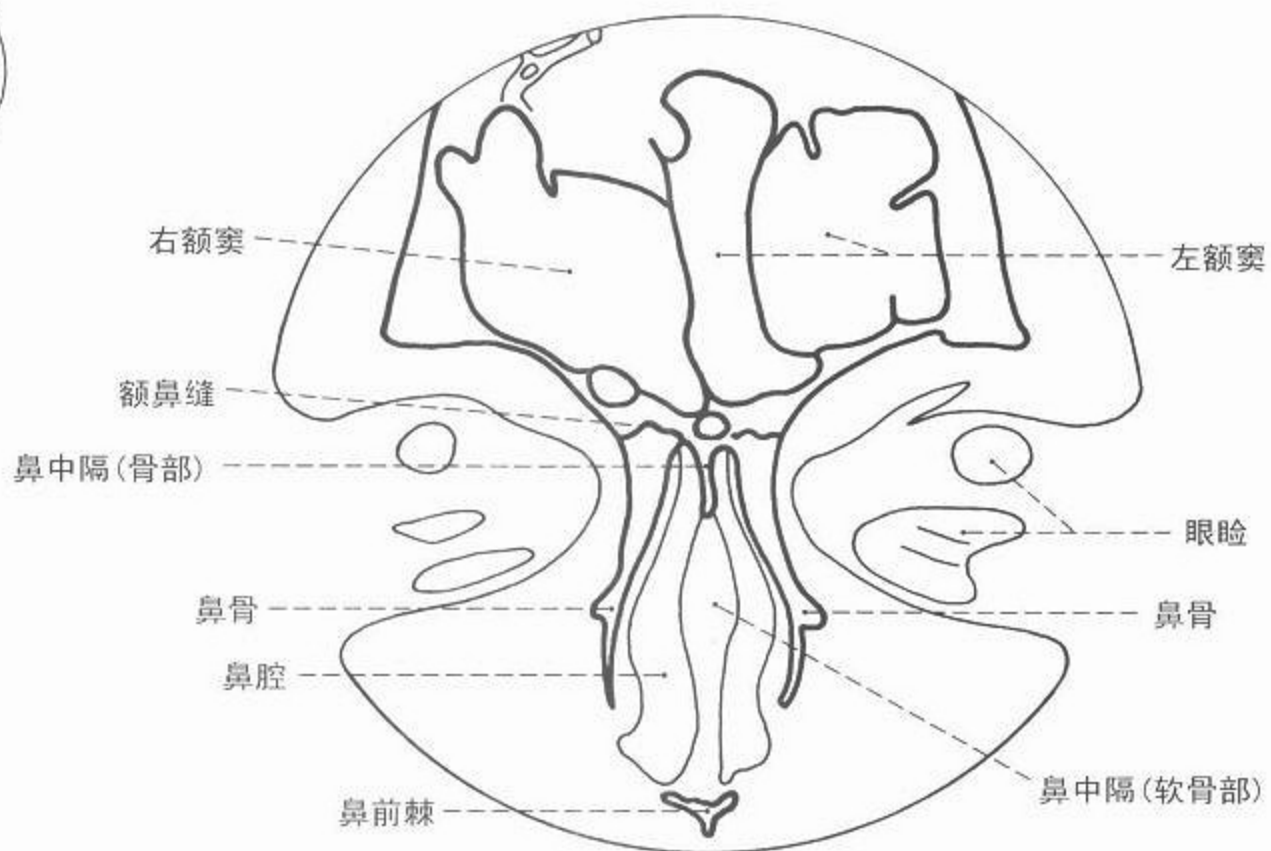
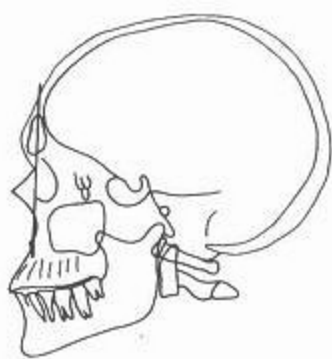


图 143 轴位(横轴)颞骨 CT 像 骨窗



CT



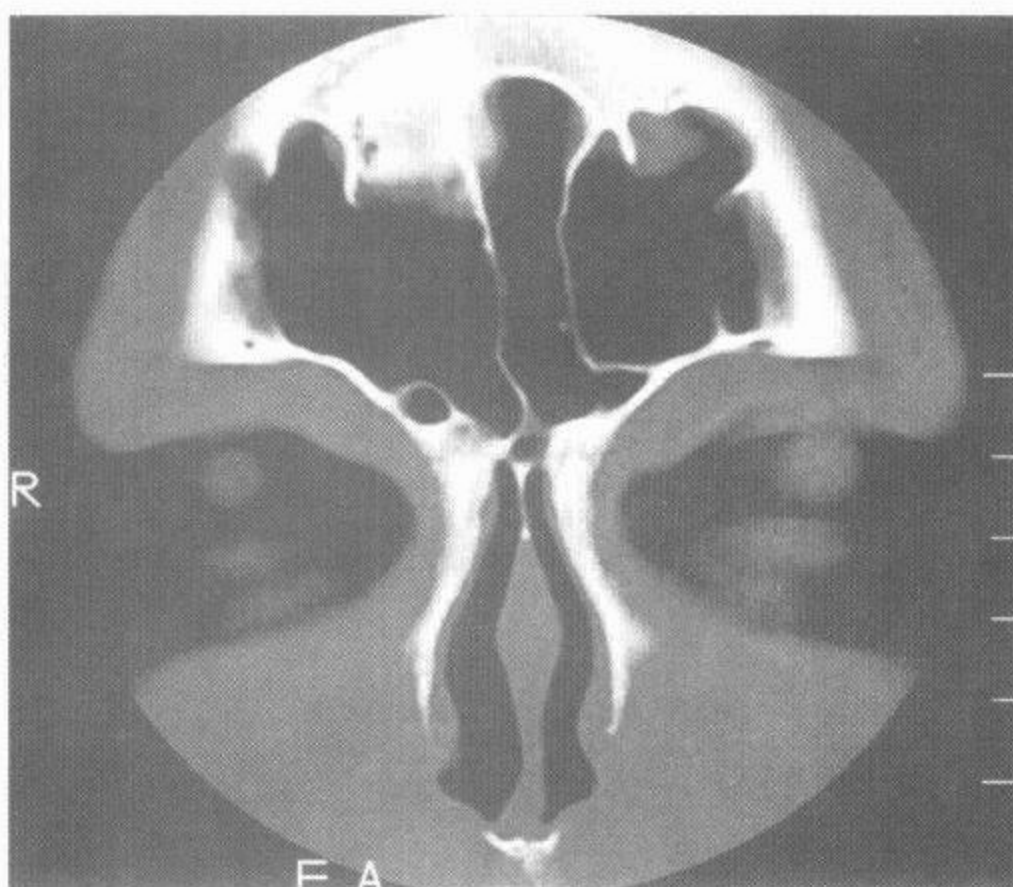
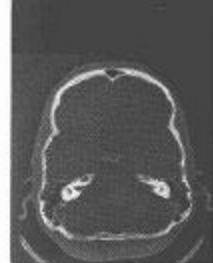

图 144 冠位鼻窦 CT 像

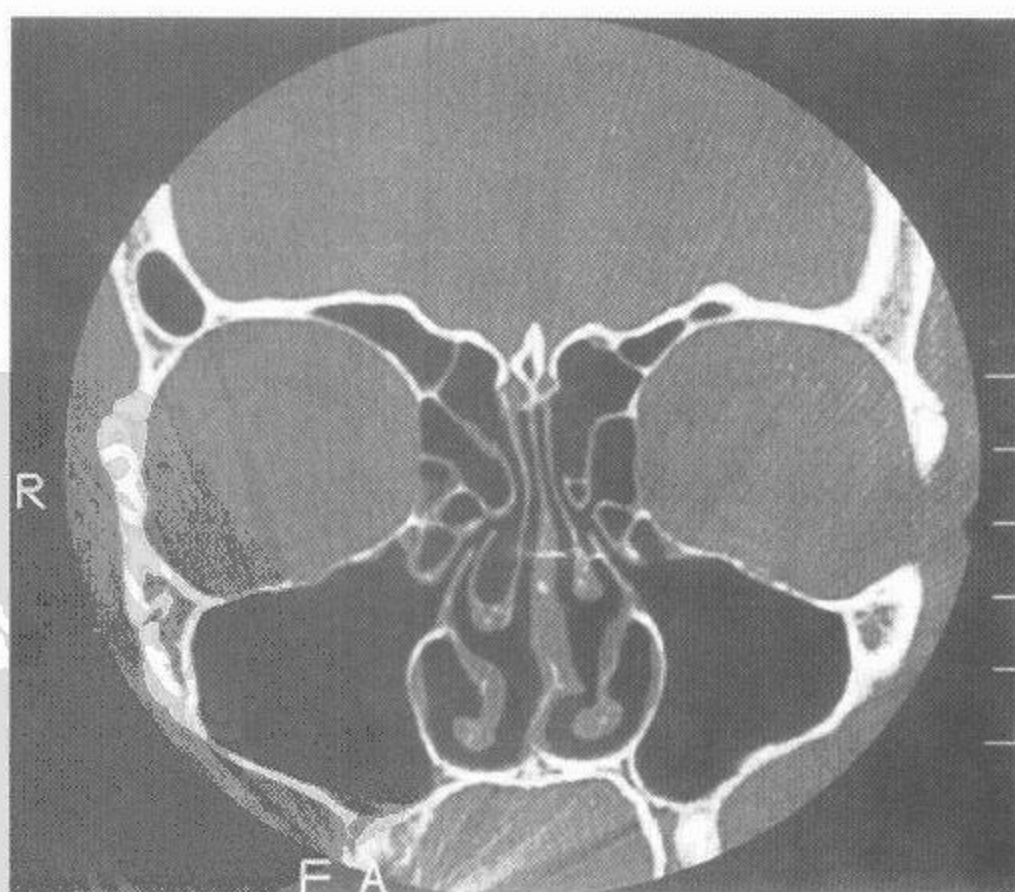
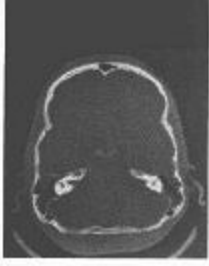
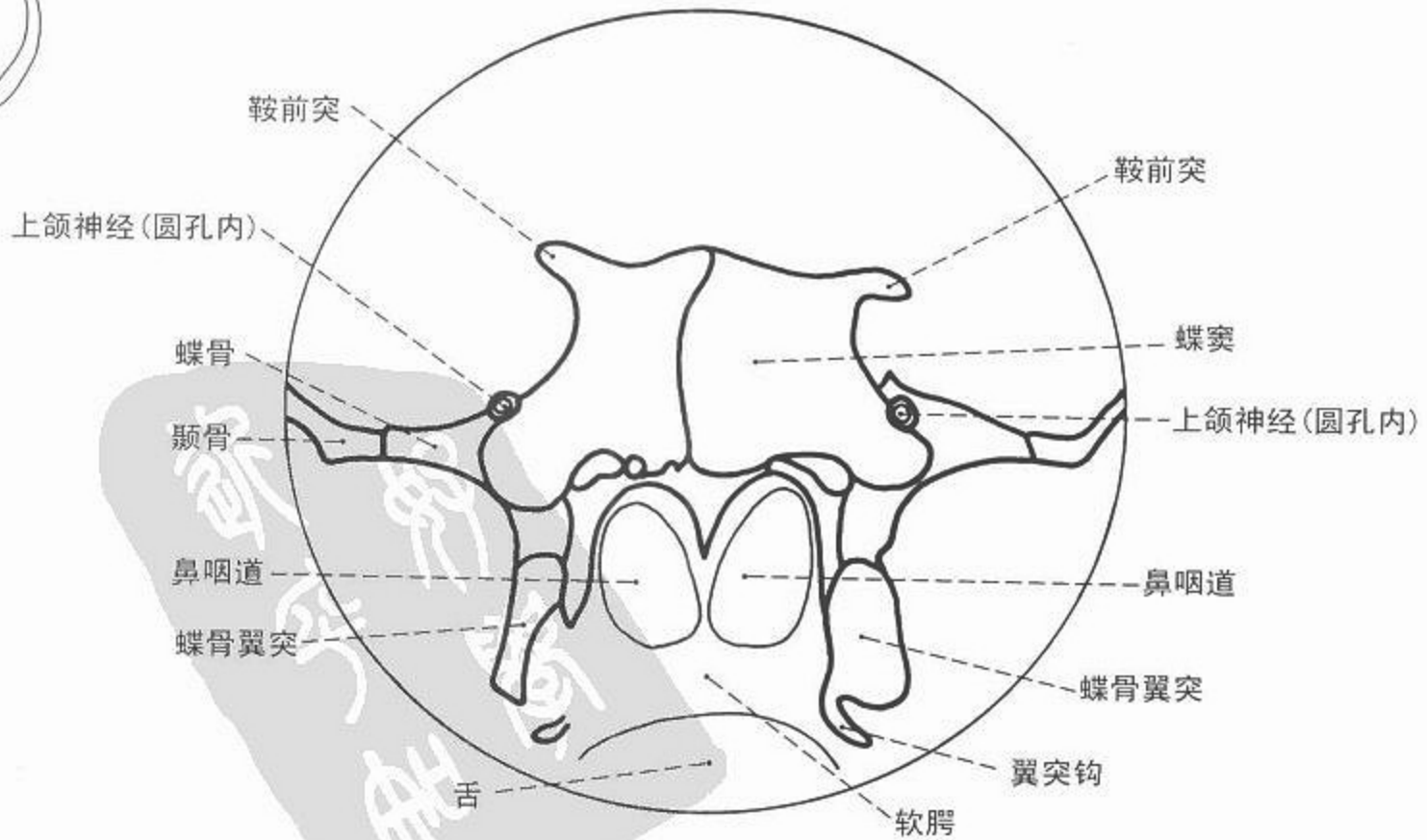
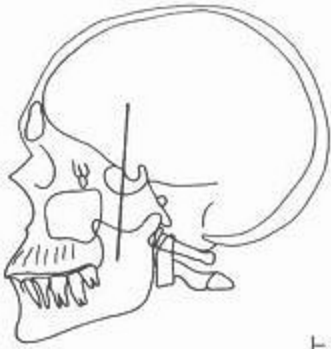
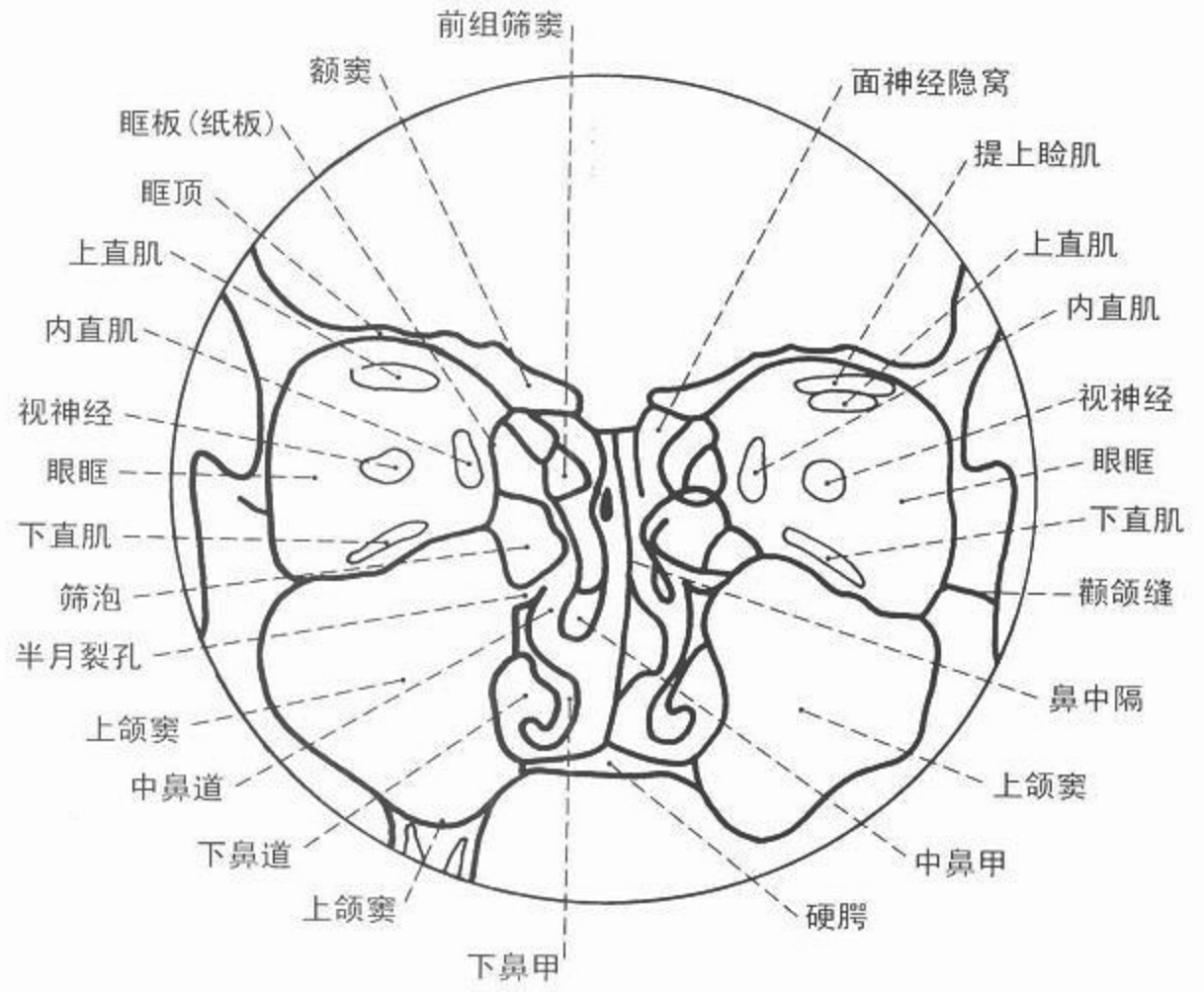
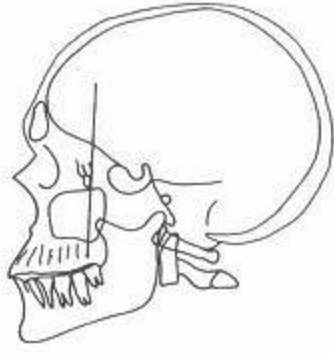


图 145 冠位鼻窦 CT 像



CT



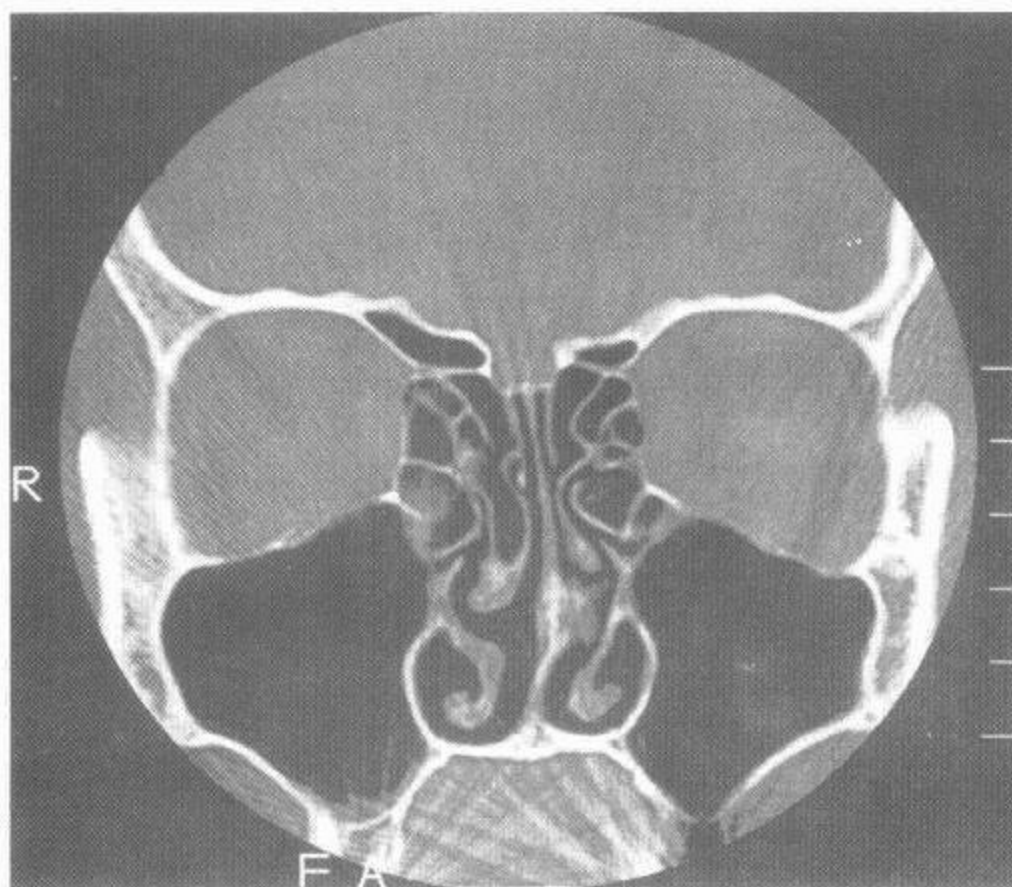
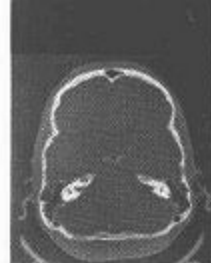

图 146 冠位鼻窦 CT 像

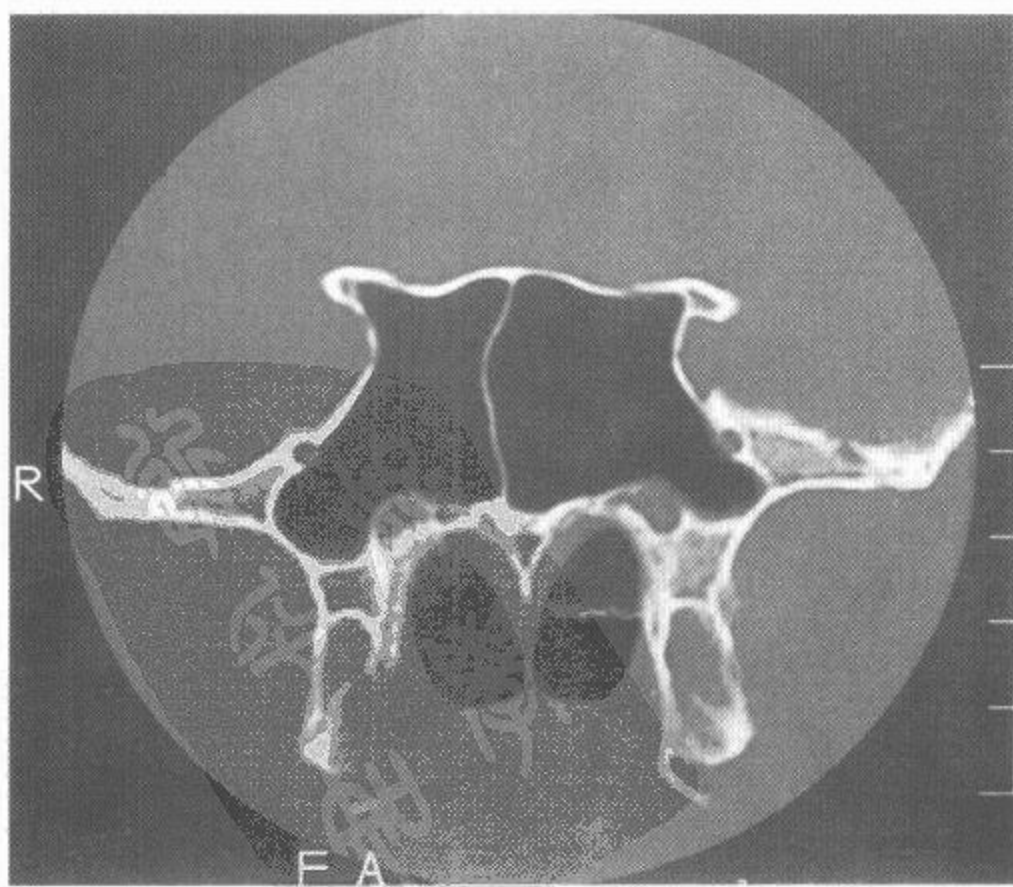
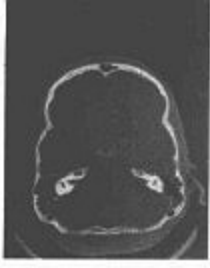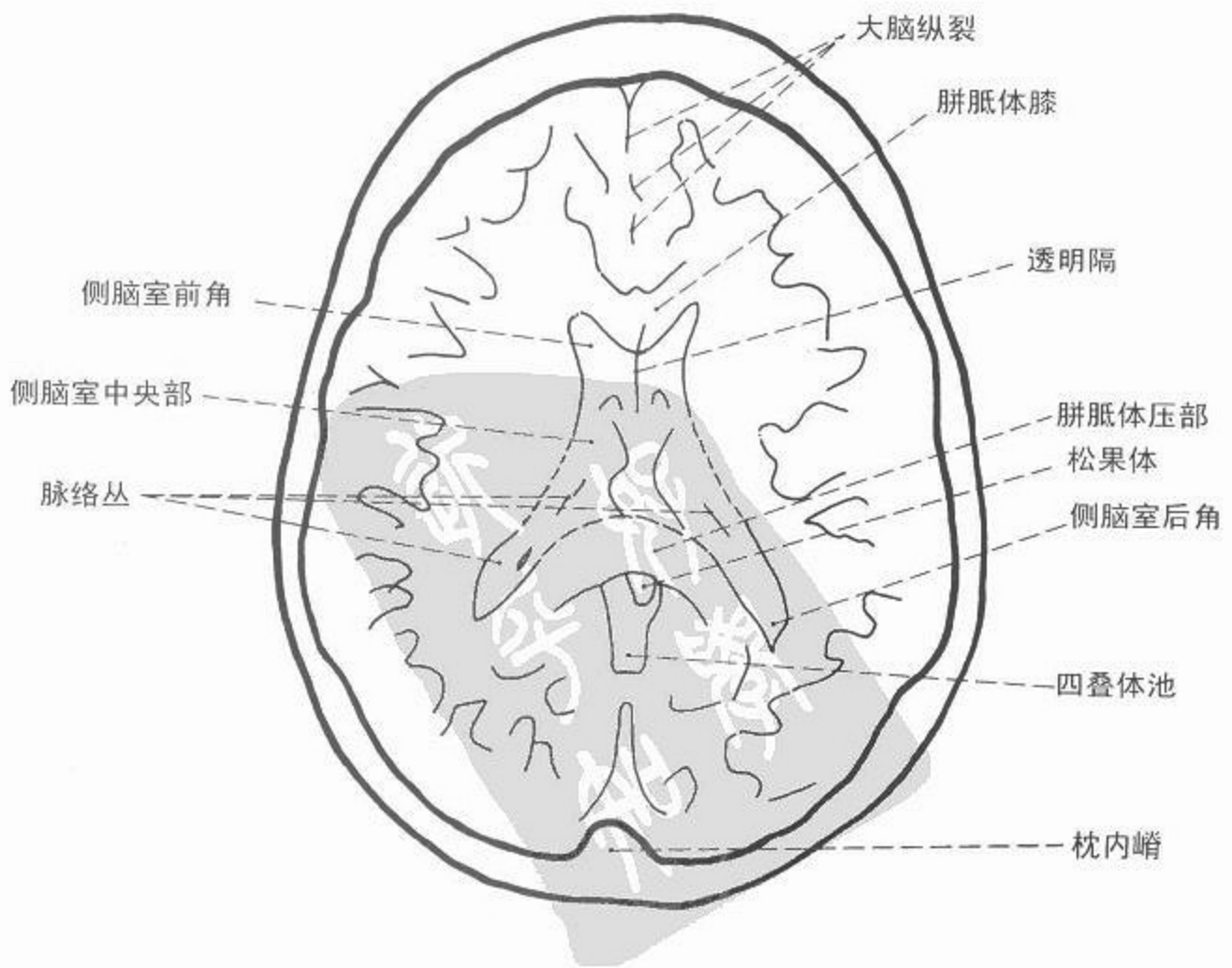
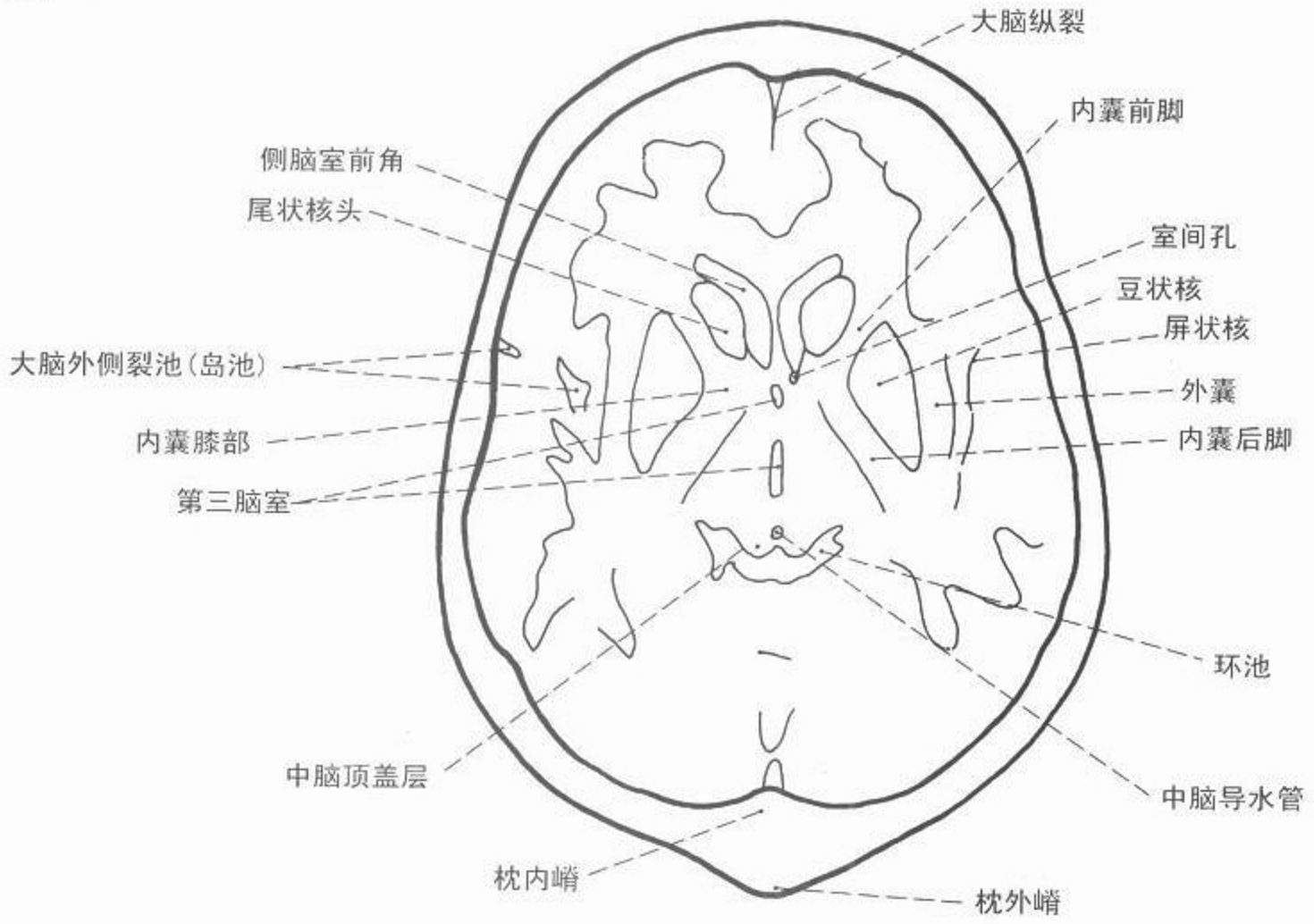


图 147 冠位鼻窦 CT 像





CT



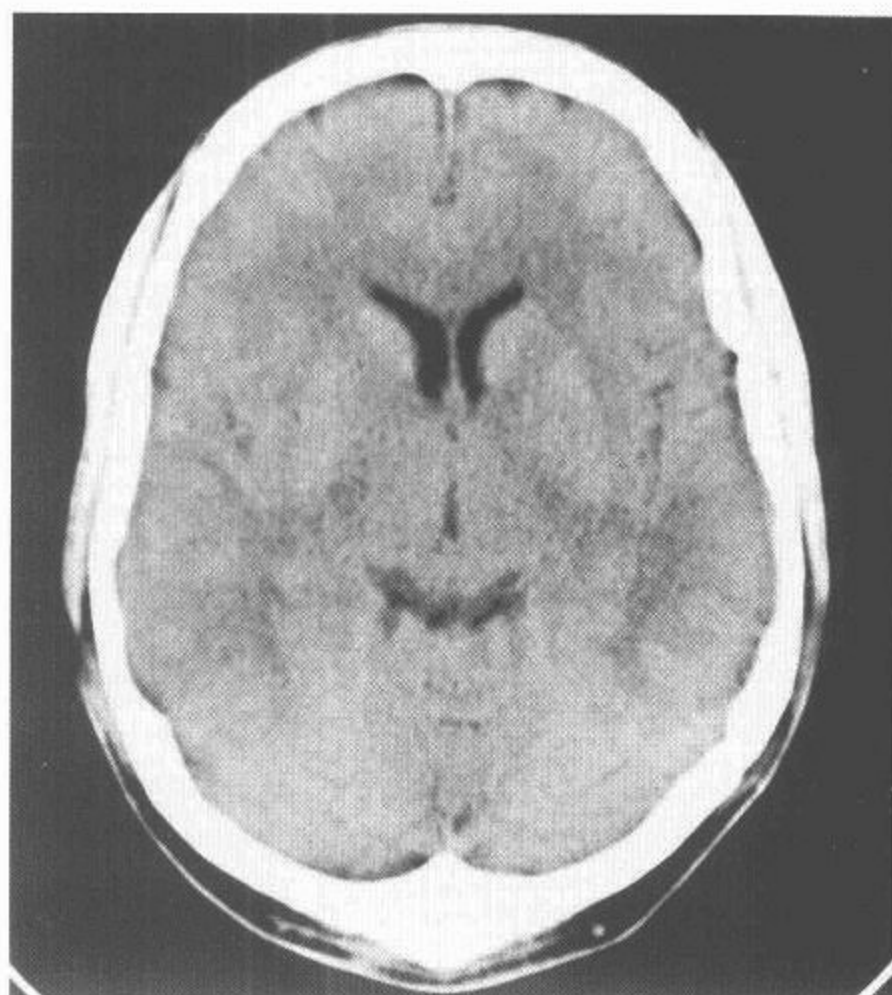
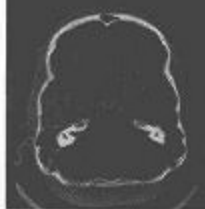


图 148 脑轴位 CT 像

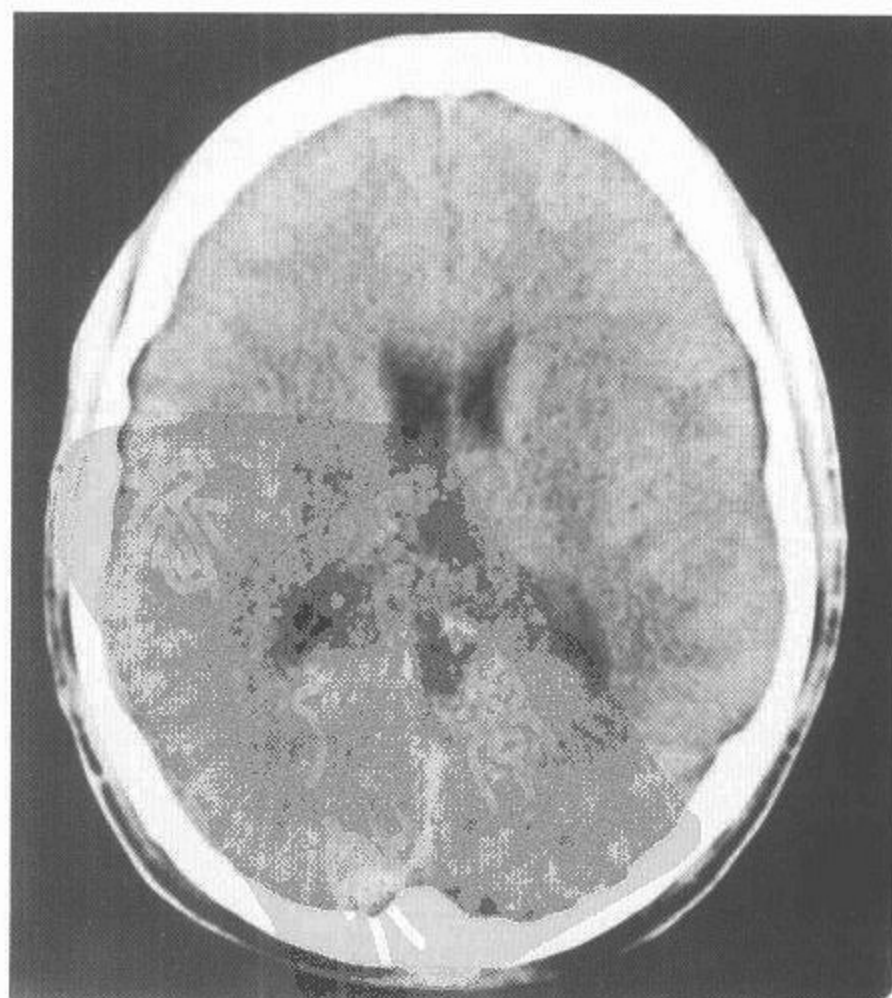
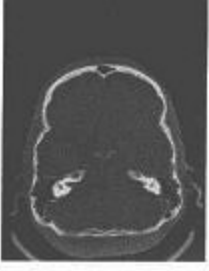
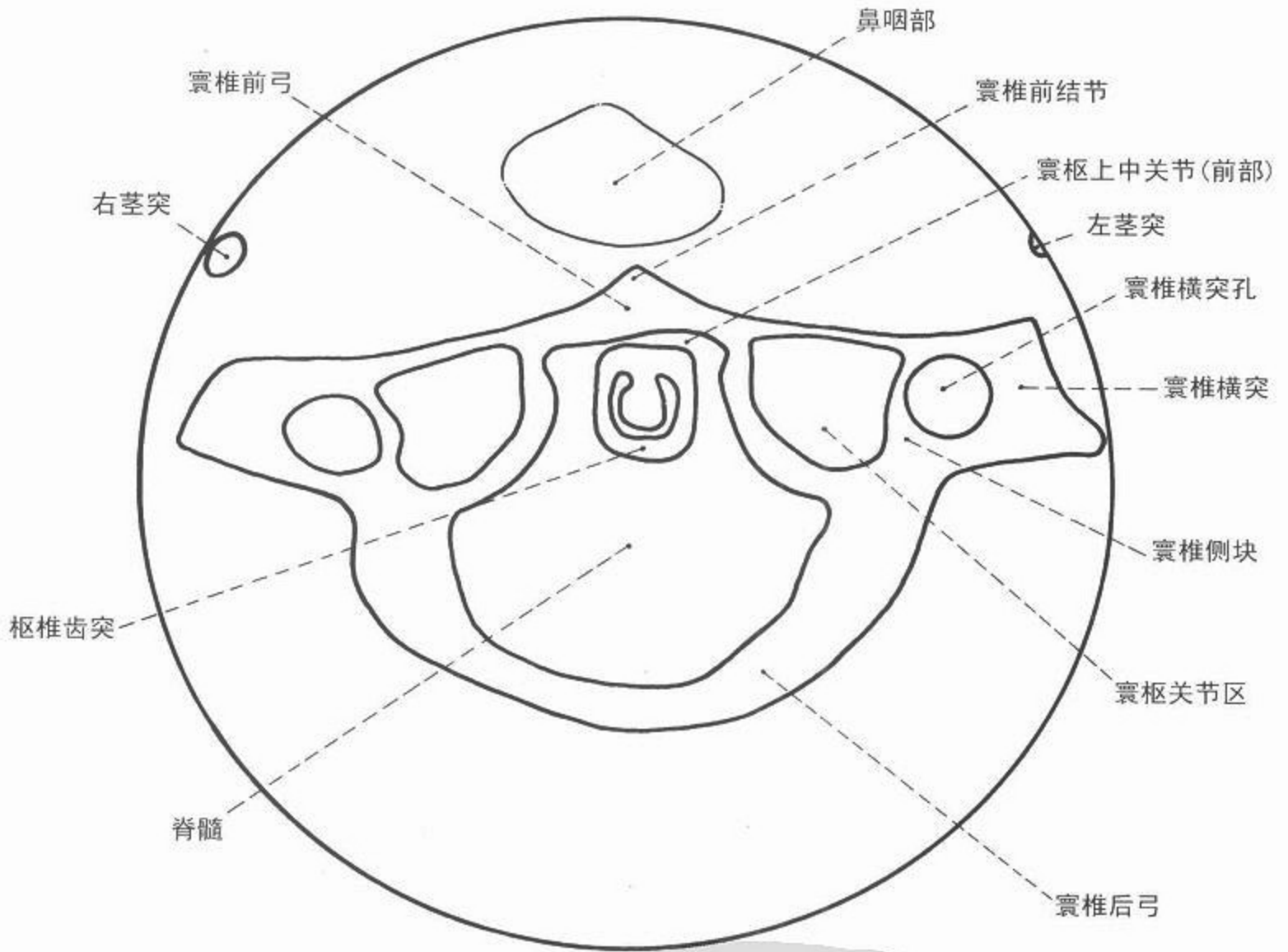


图 149 脑轴位 CT 像



CT



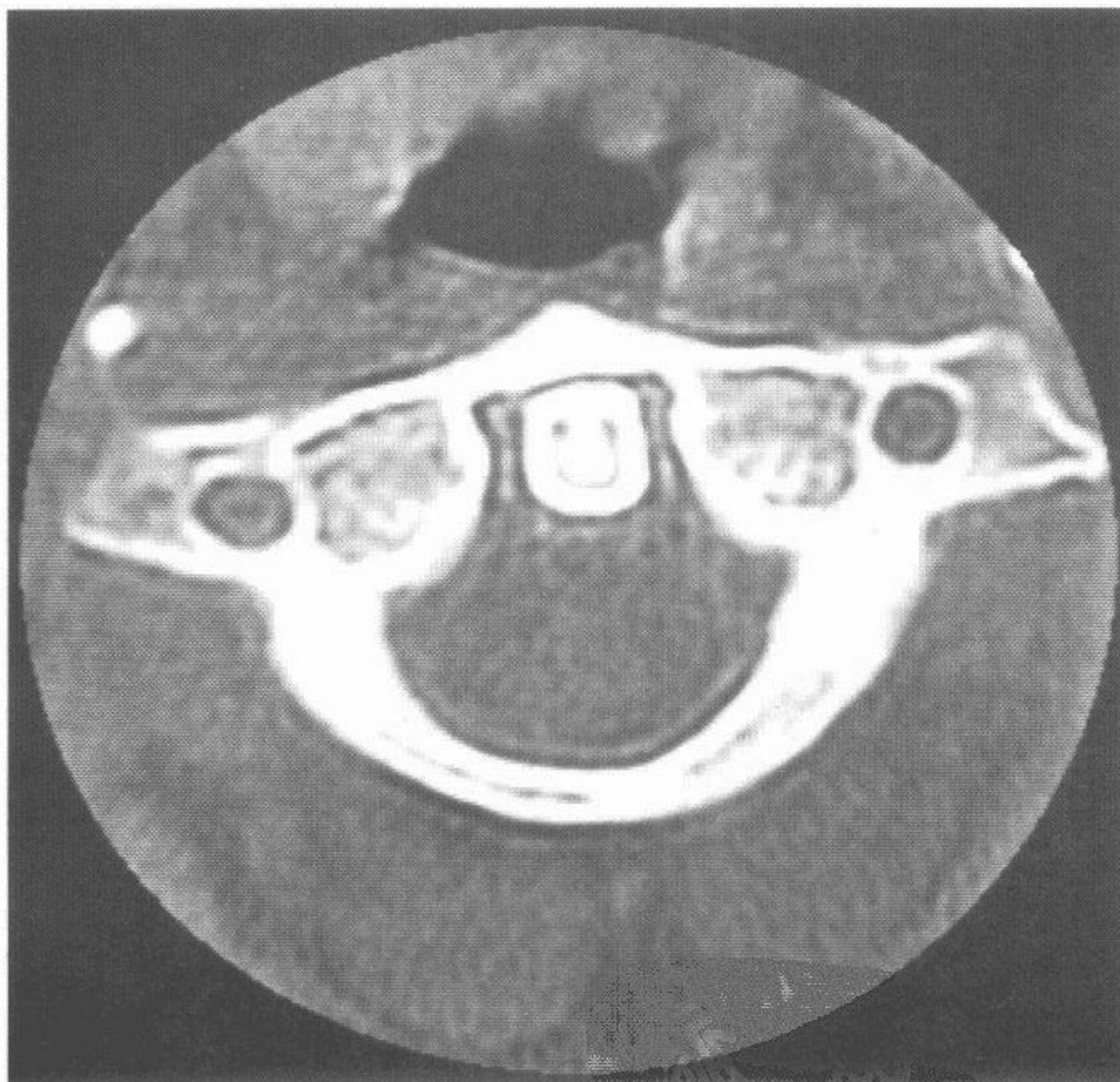
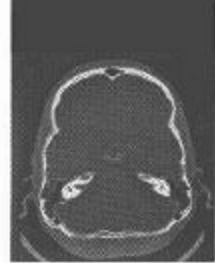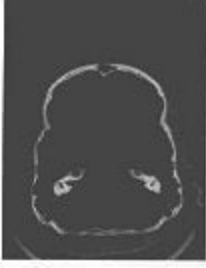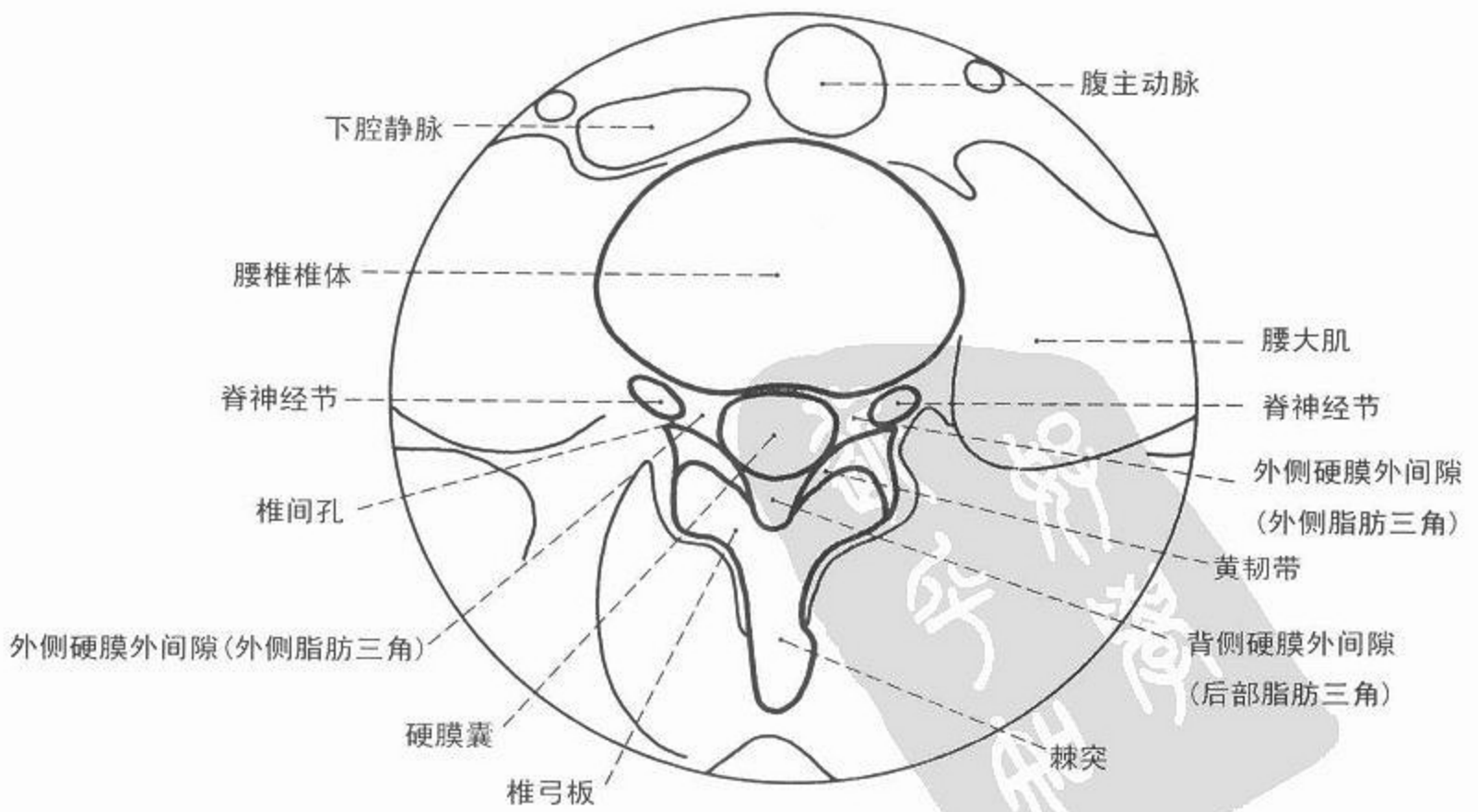
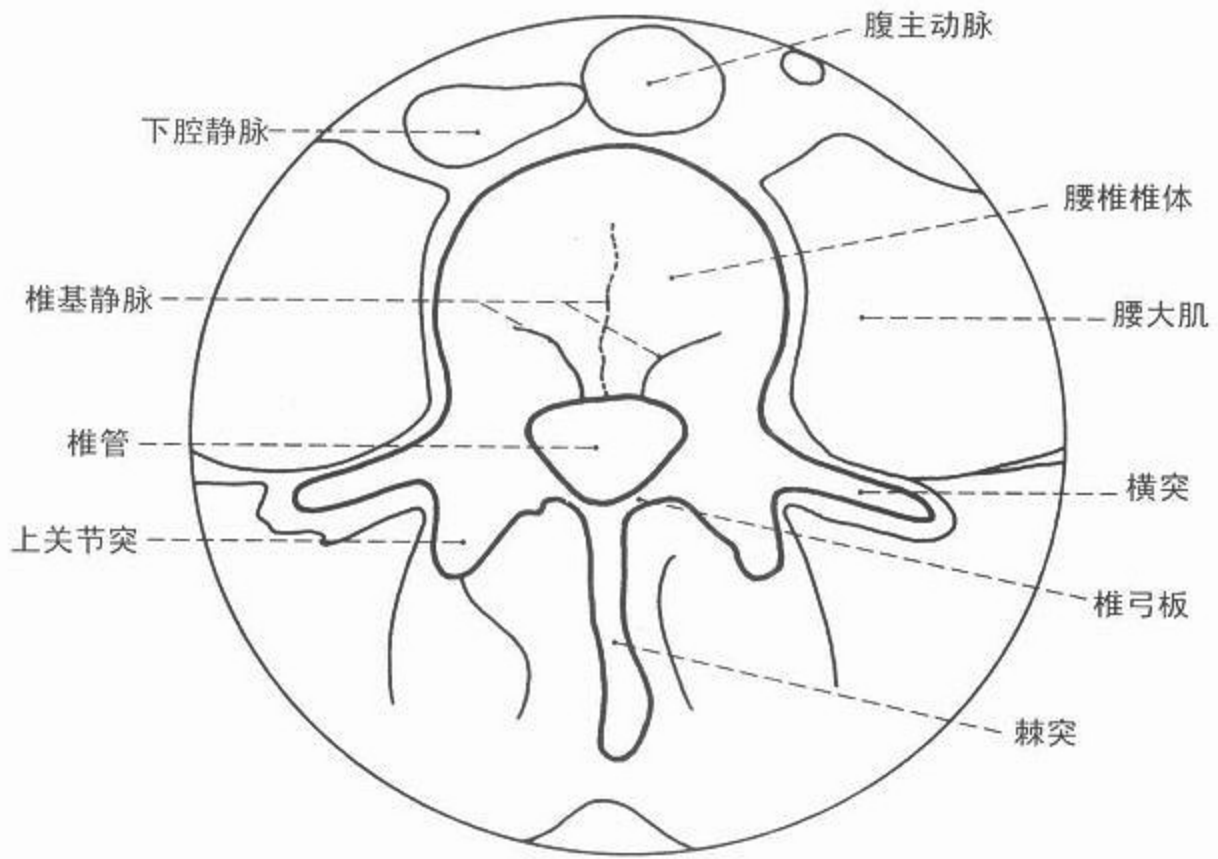


图 150 前部寰枢关节轴位 CT 像



CT



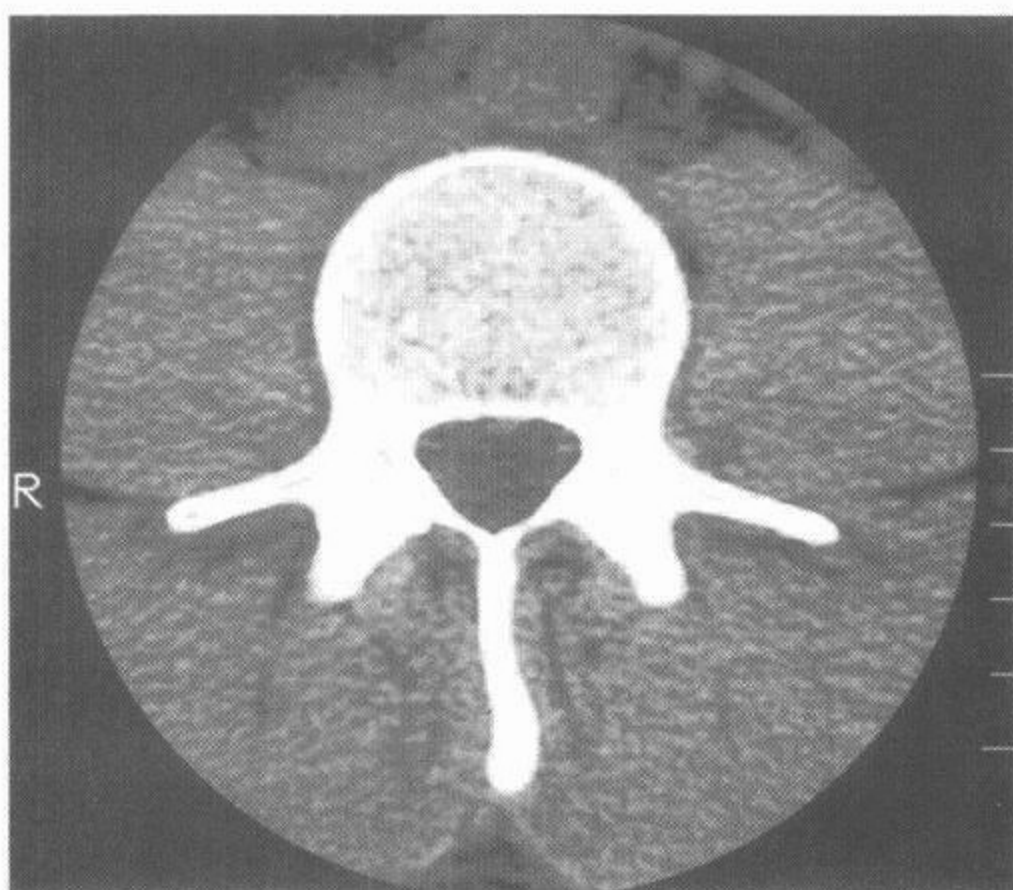
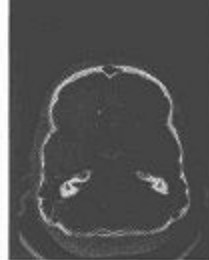

图 151 第四腰椎轴位(横轴位)CT 像

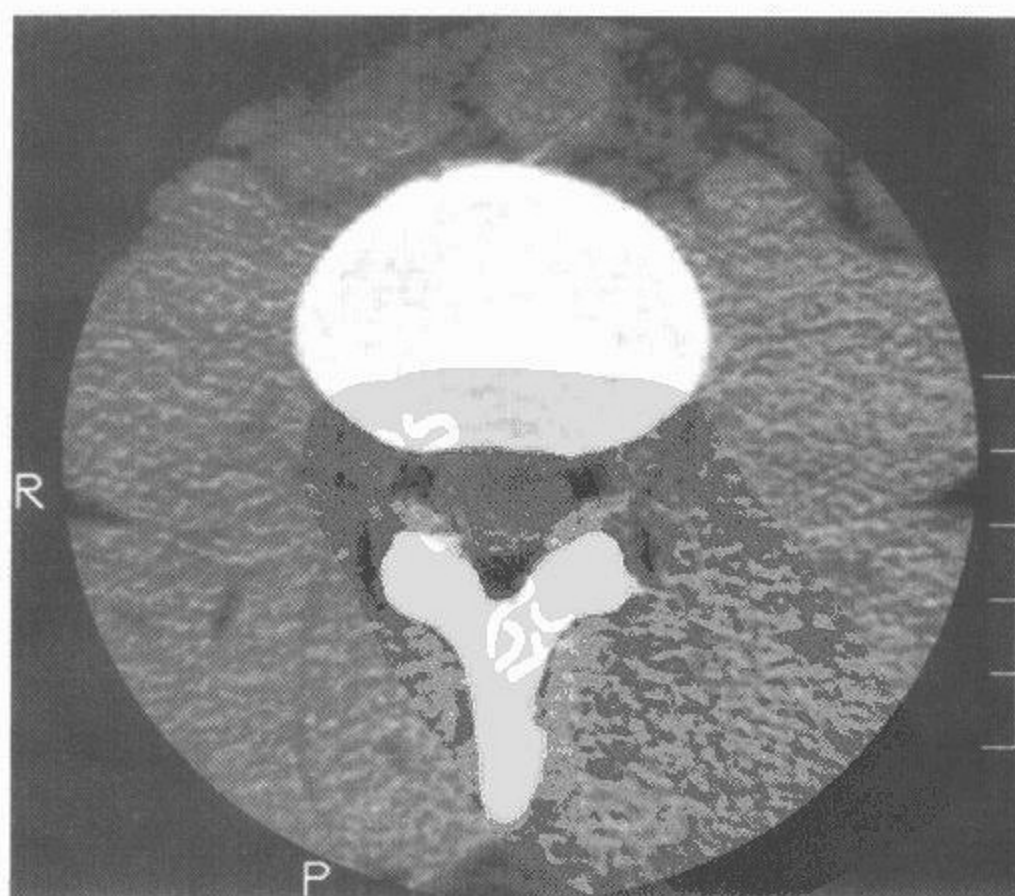
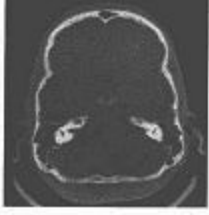
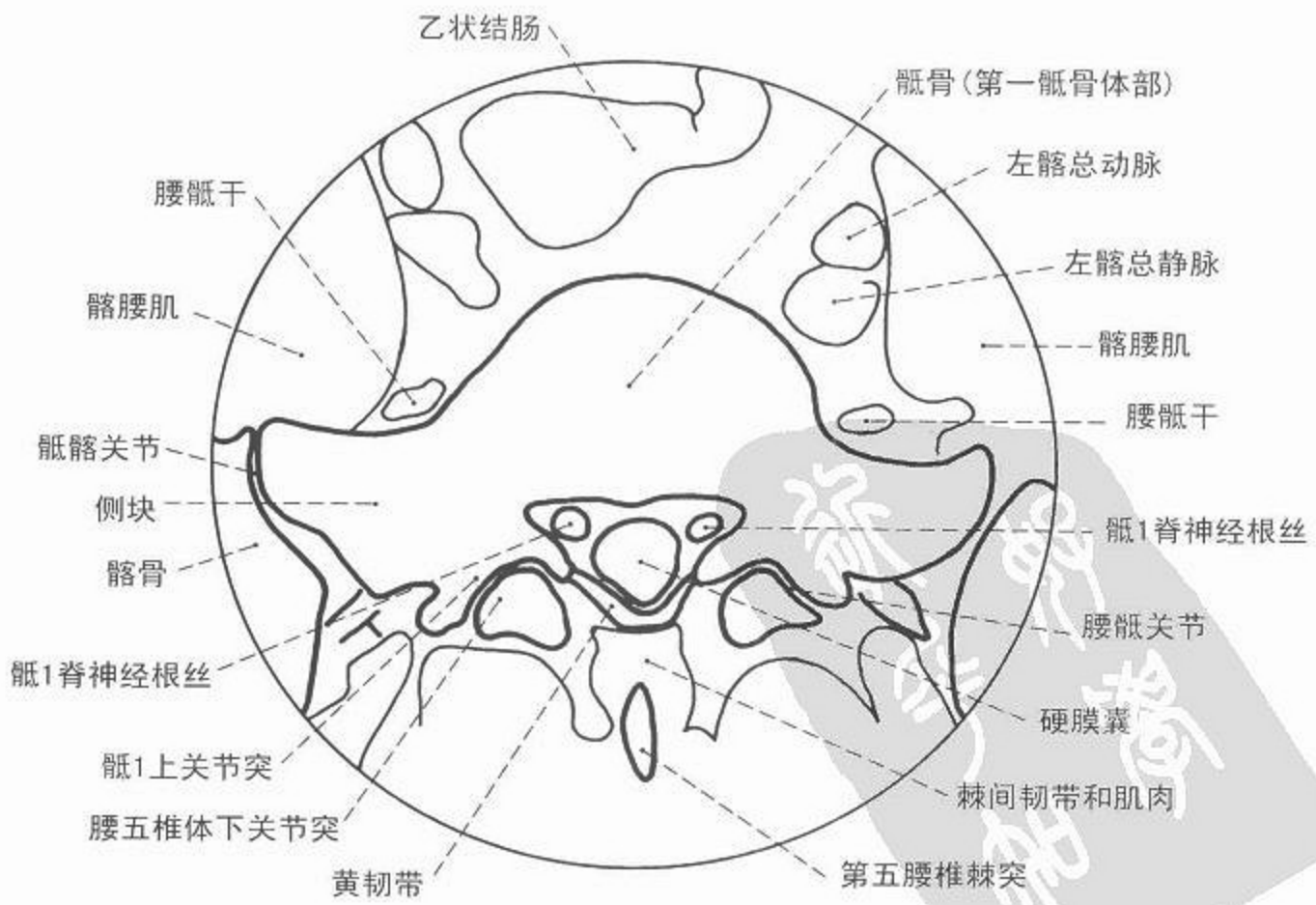
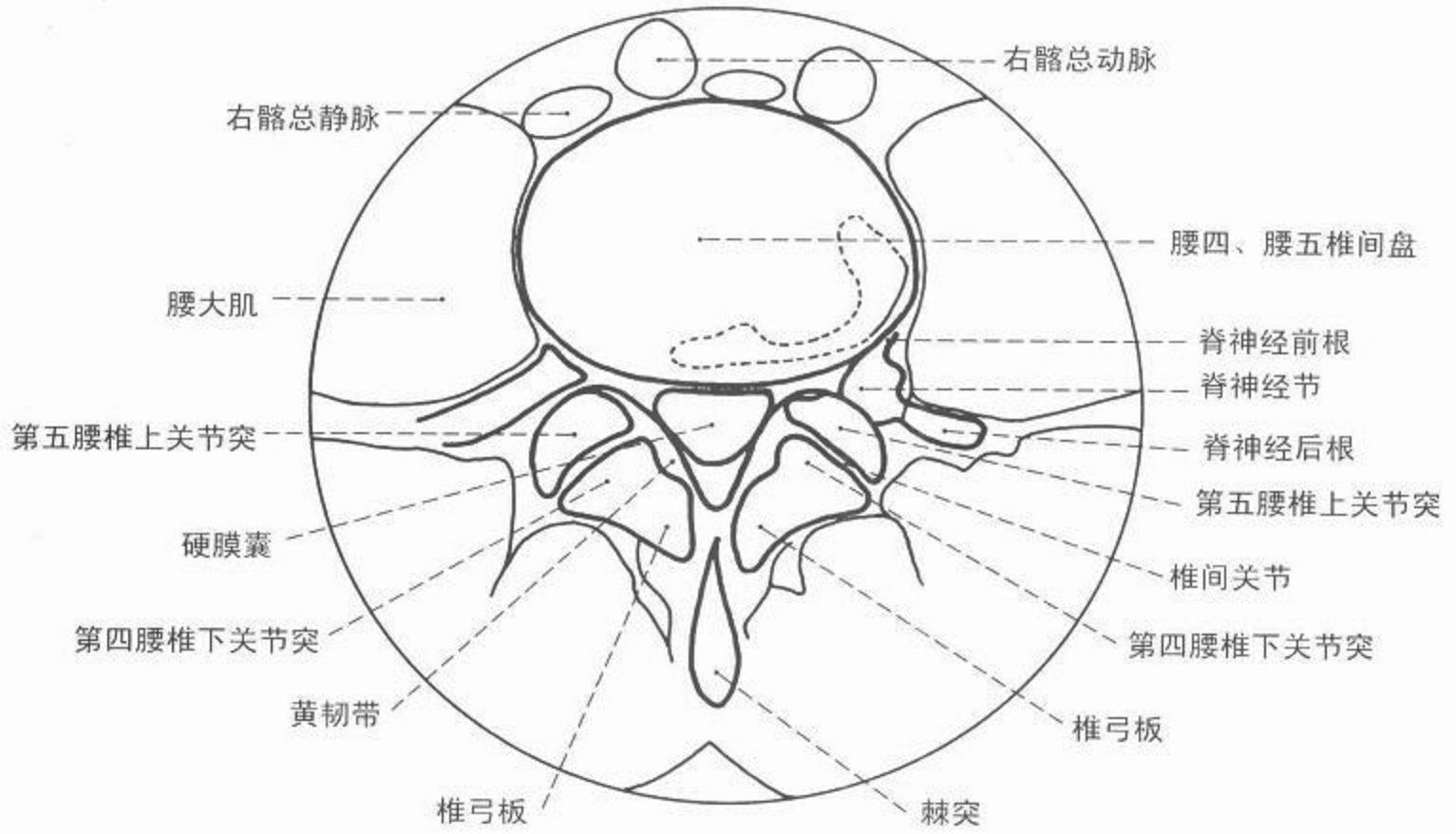


图 152 椎间孔轴位(横轴位)CT 像



CT



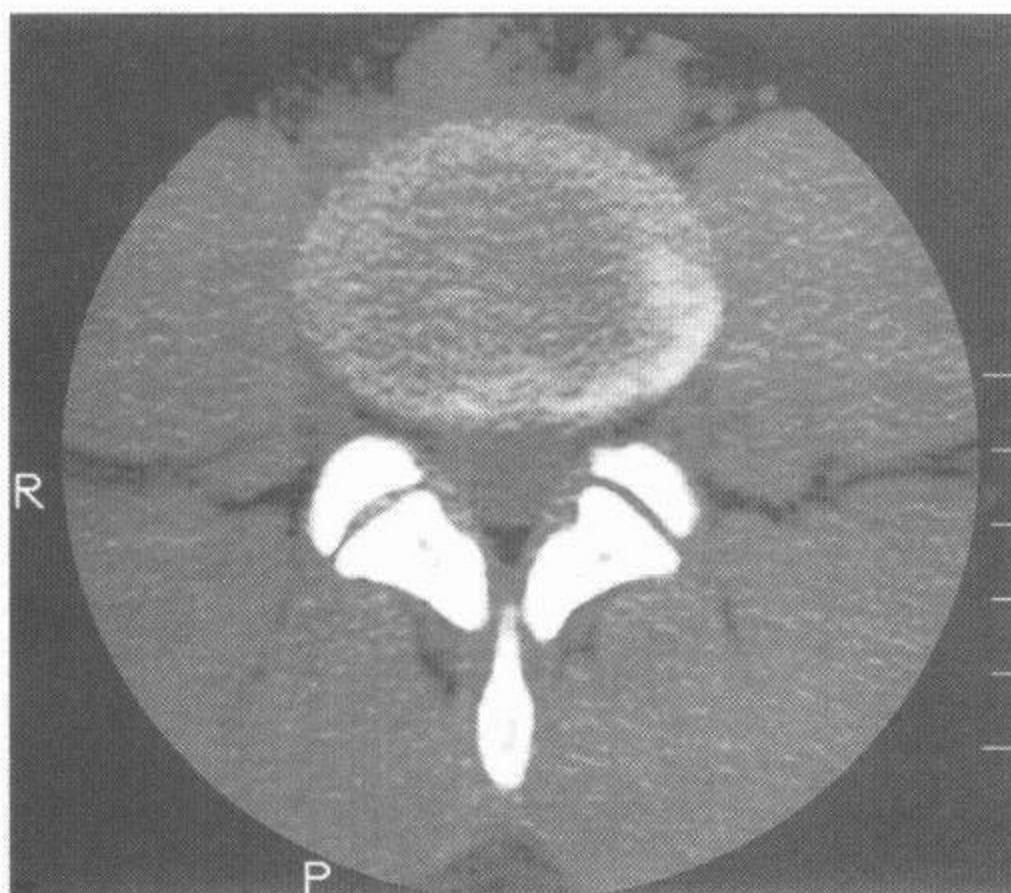
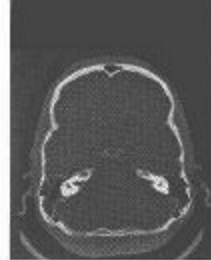


图 153 第四、第五腰椎间盘轴位(横轴位)CT 像

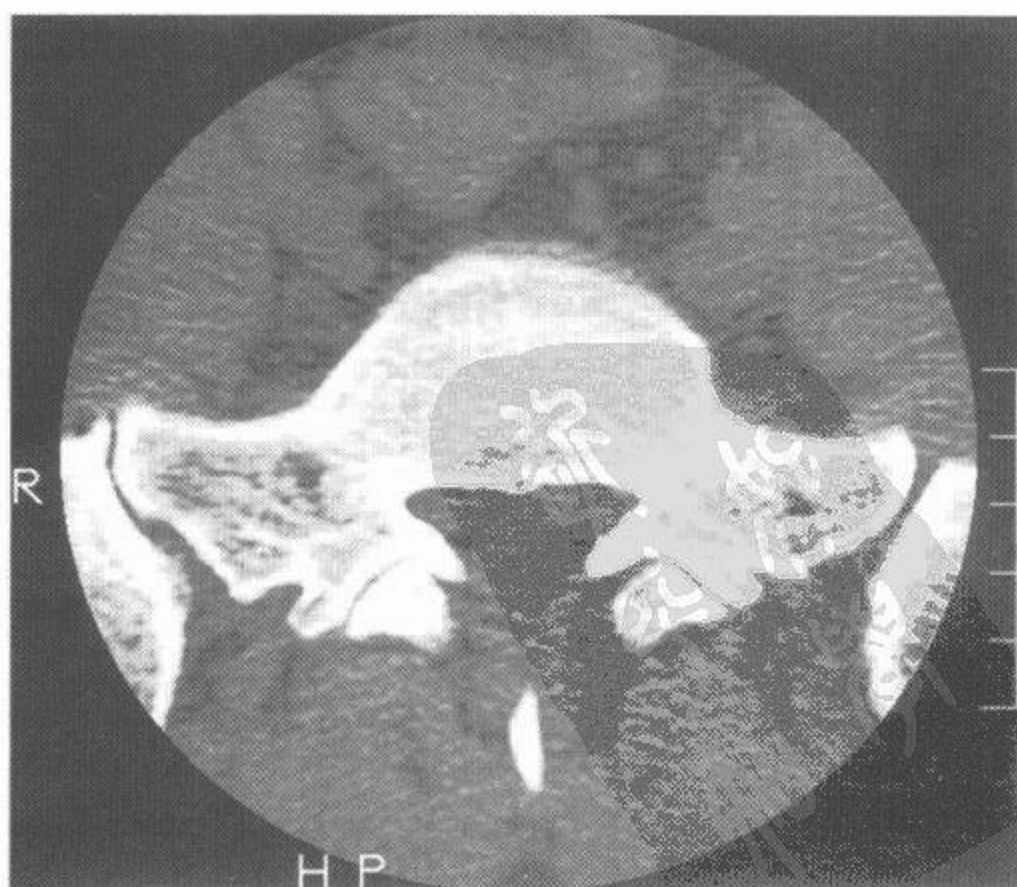
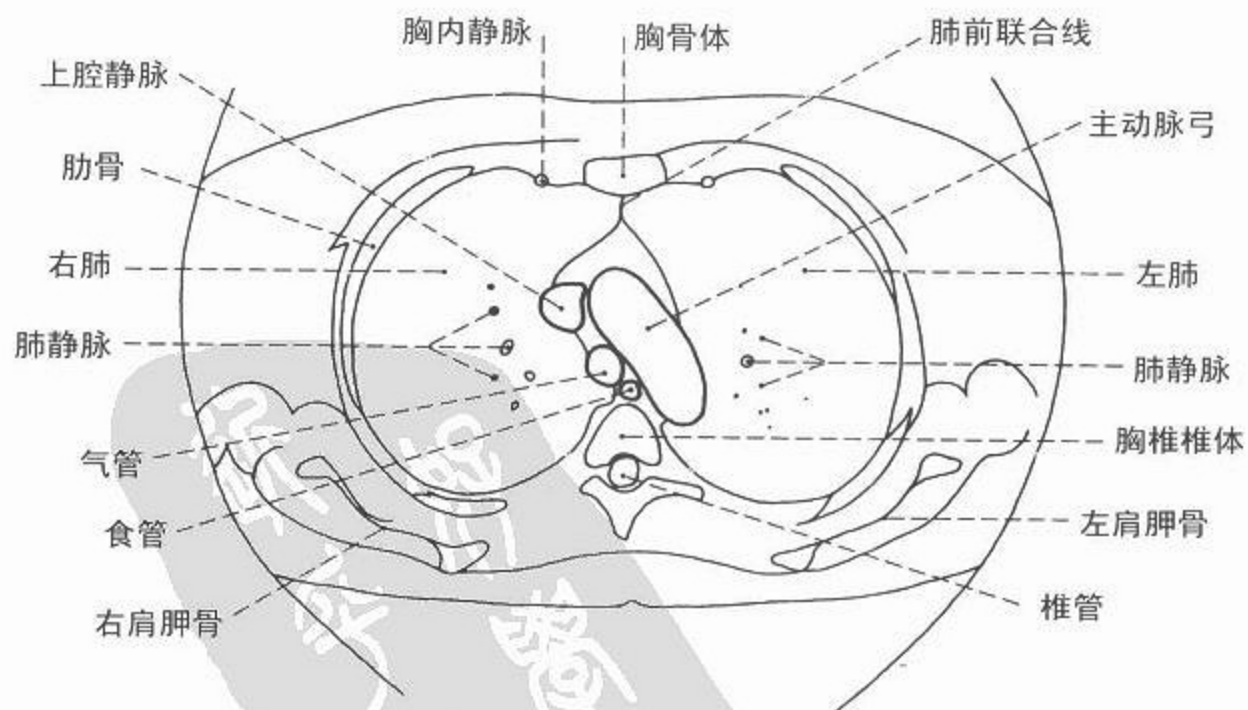
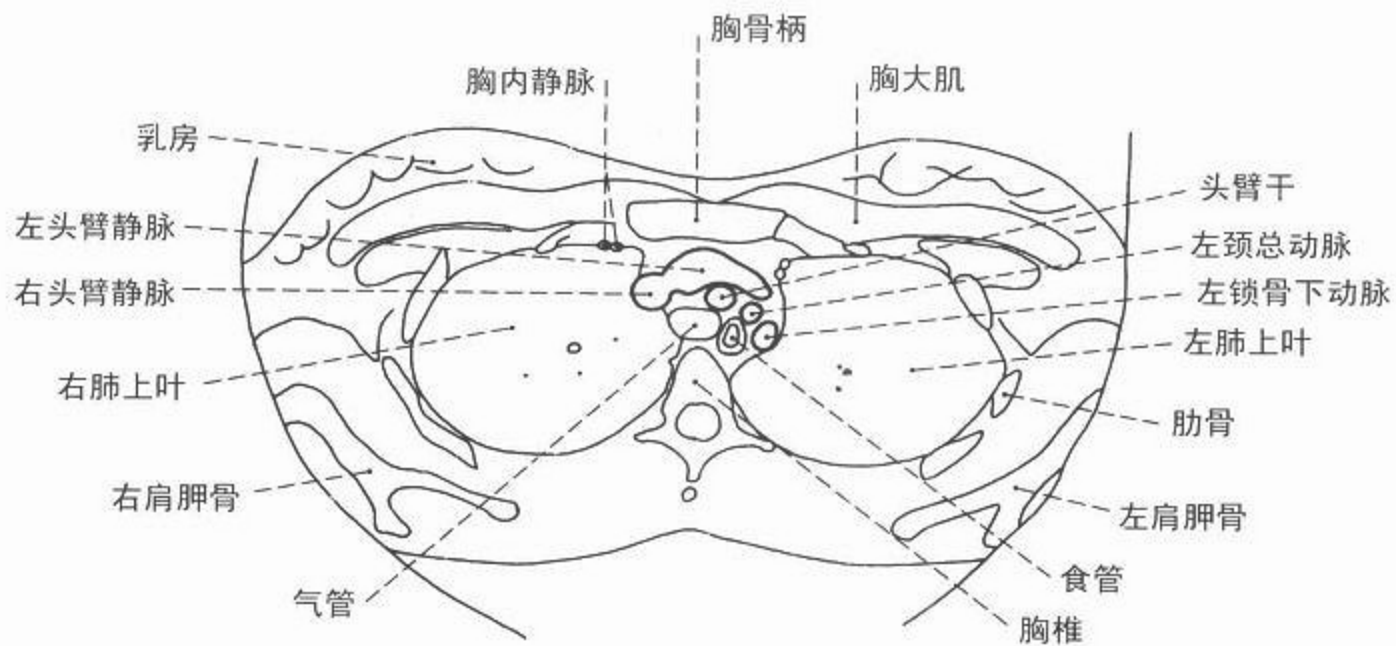


图 154 骶 1 节段轴位(横轴位)CT 像





CT



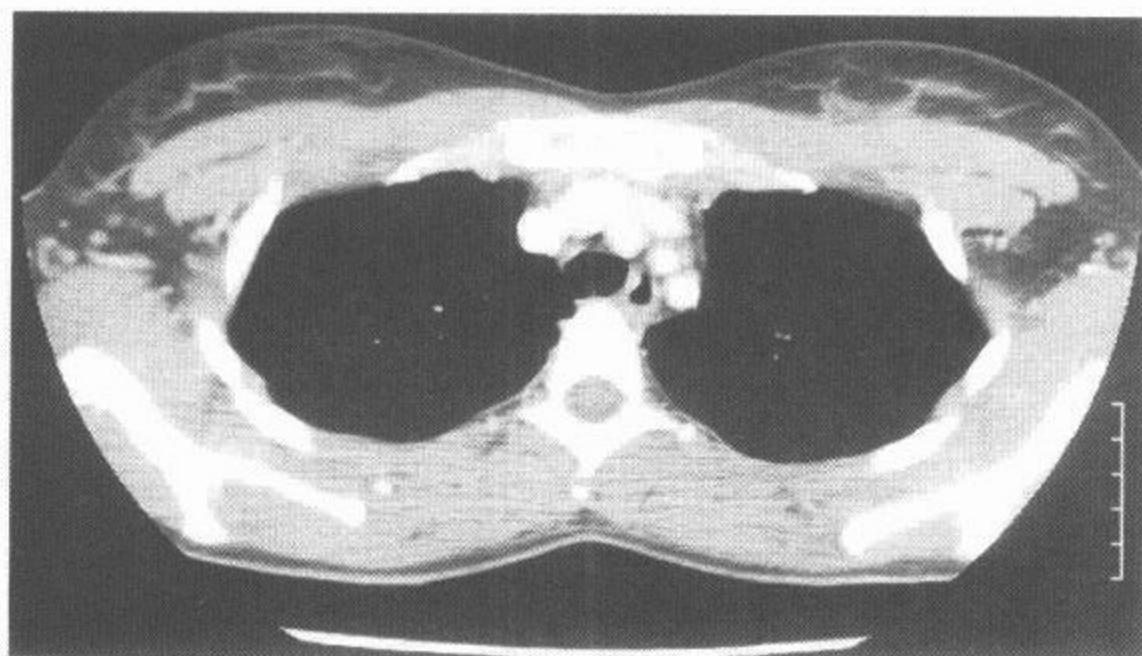
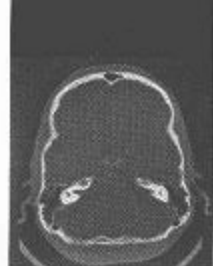

图 155 胸部轴位(横断面),  
头臂静脉层面(纵隔窗)

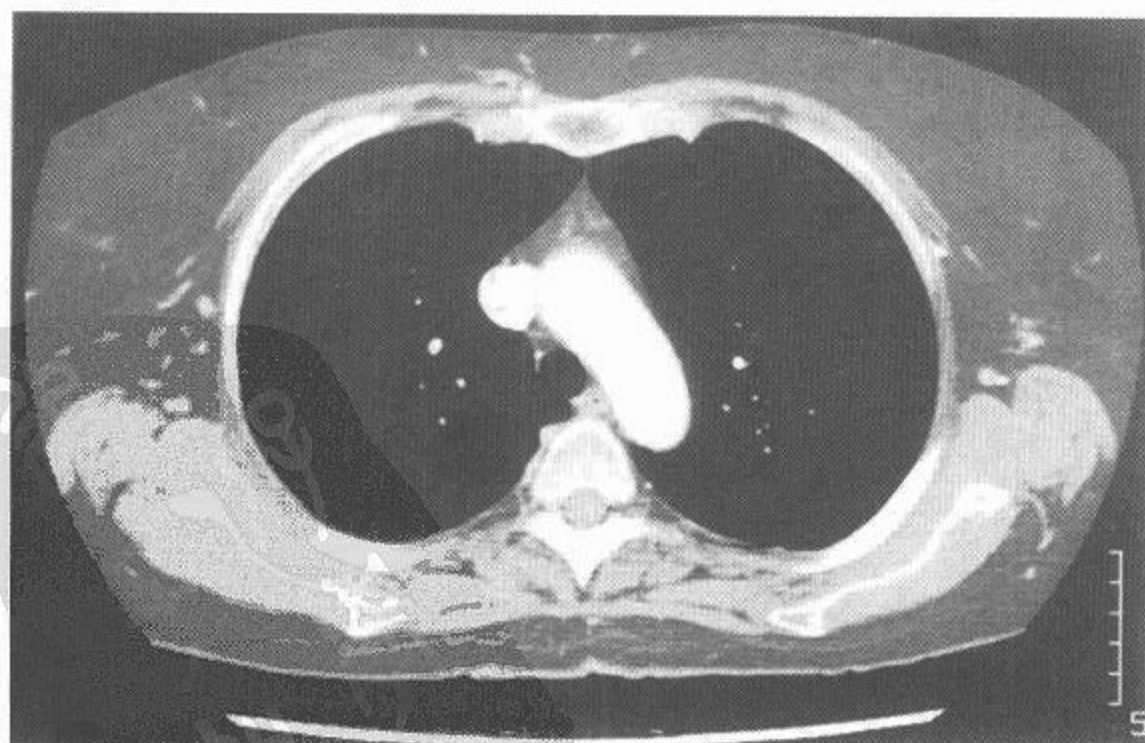
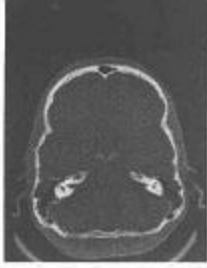
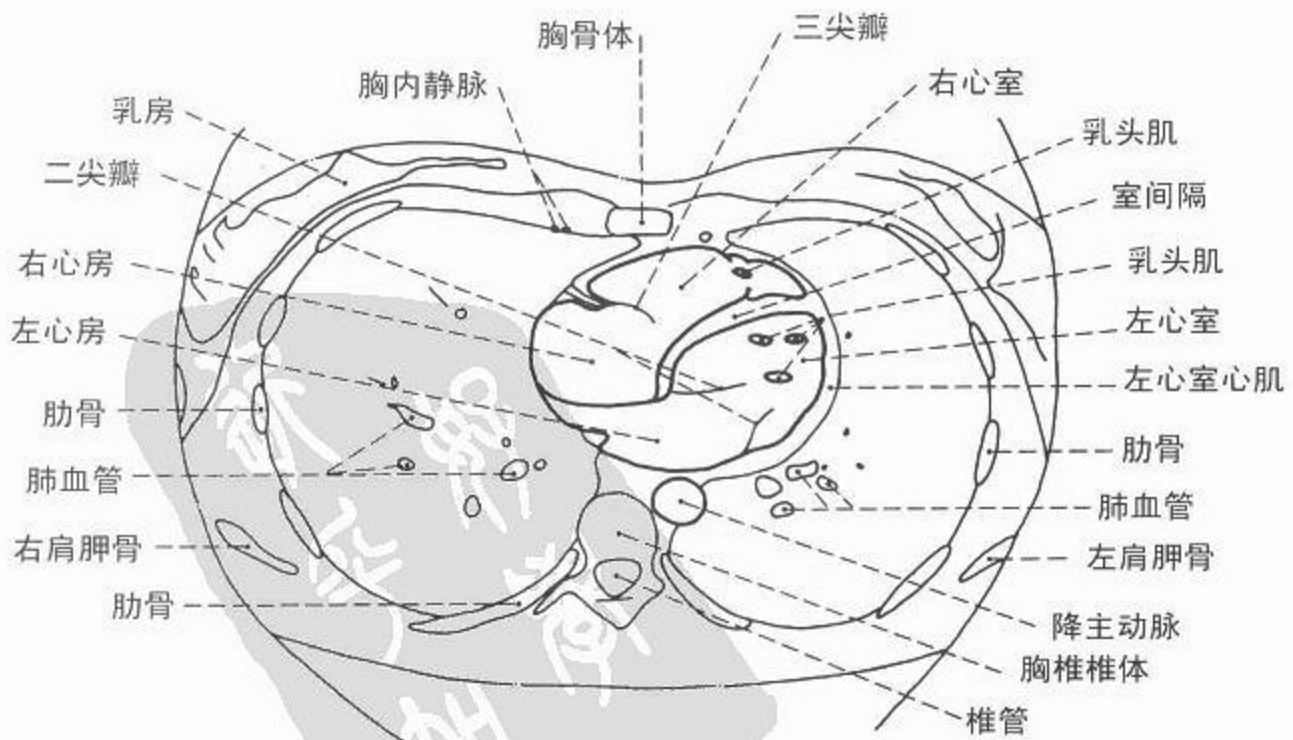
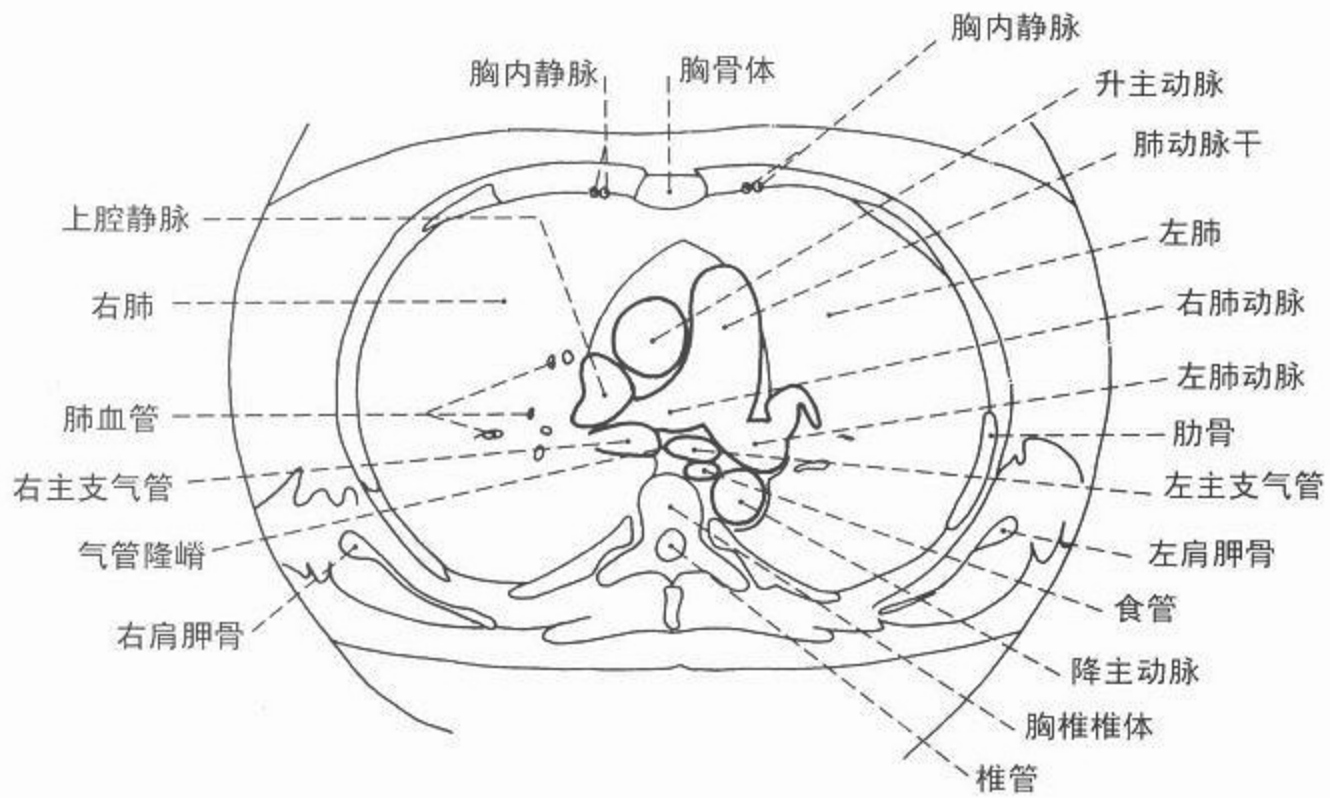


图 156 胸部轴位(横断面),  
主动脉弓层面(纵隔窗)



CT



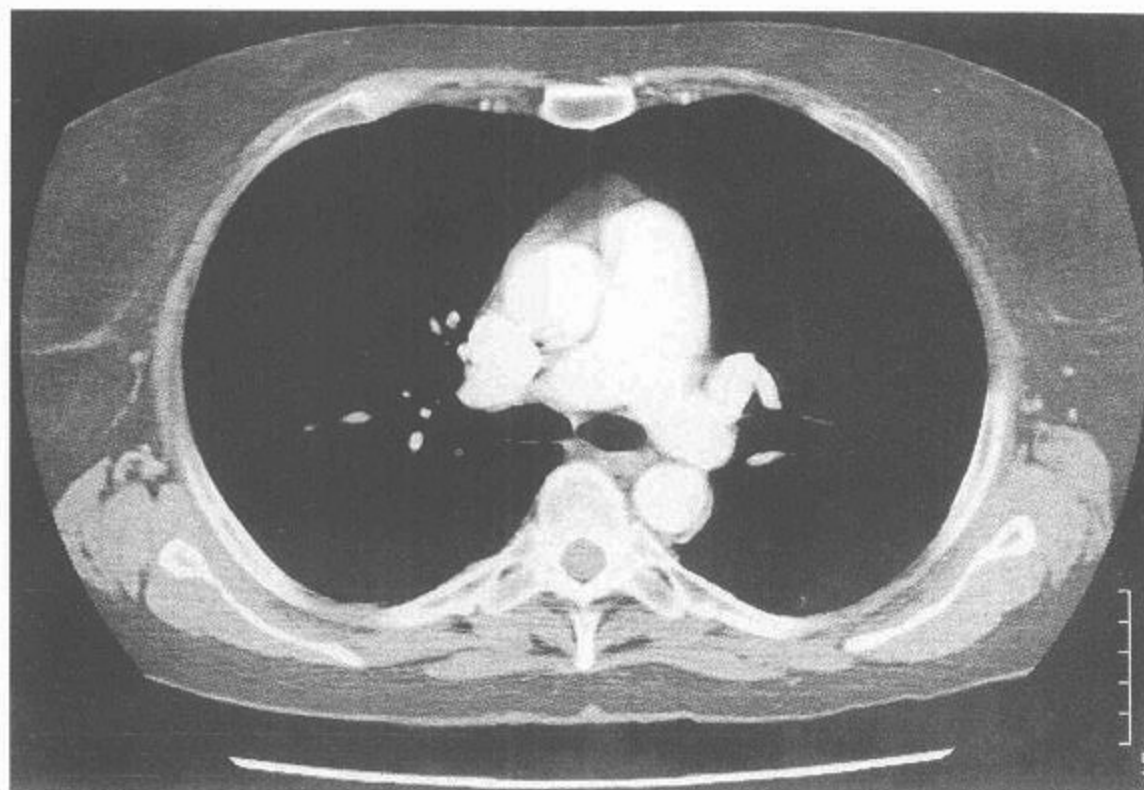
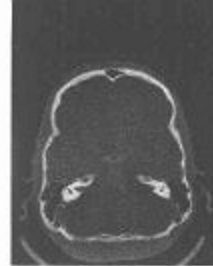

图 157 胸部轴位(横断面),  
肺动脉层面(纵隔窗)

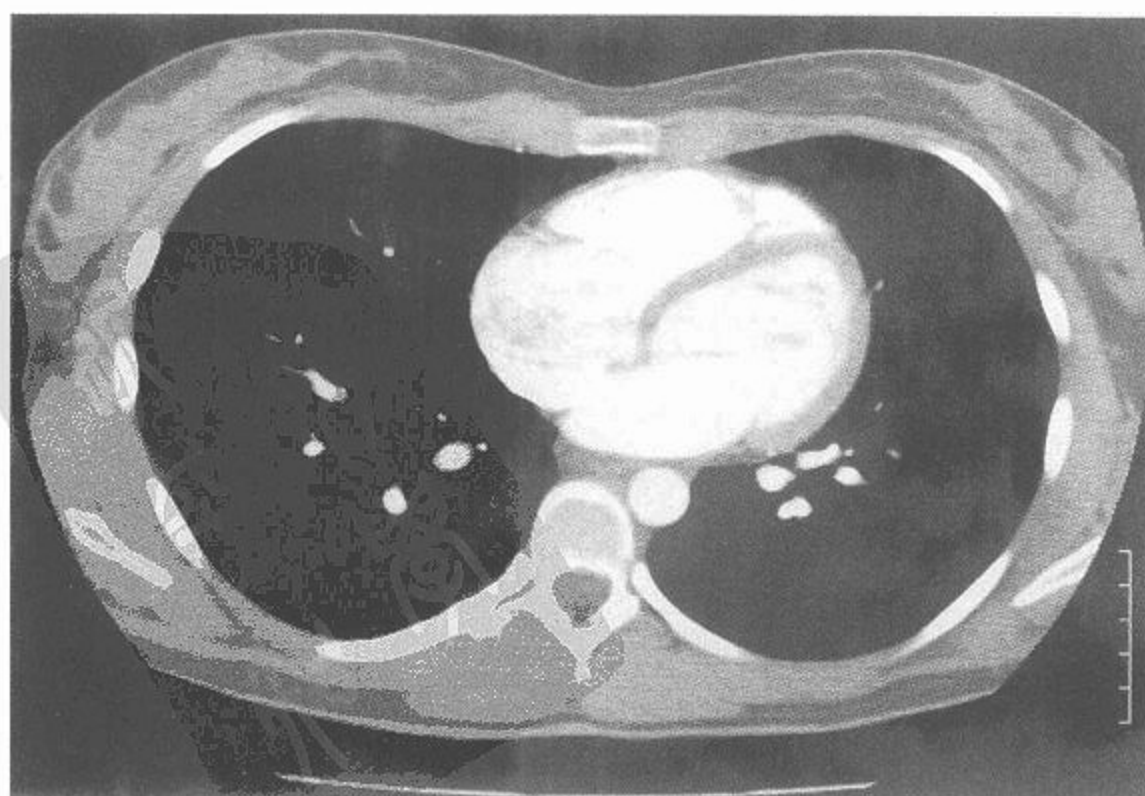
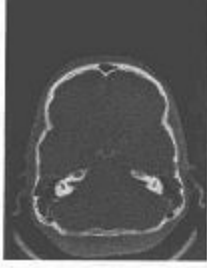
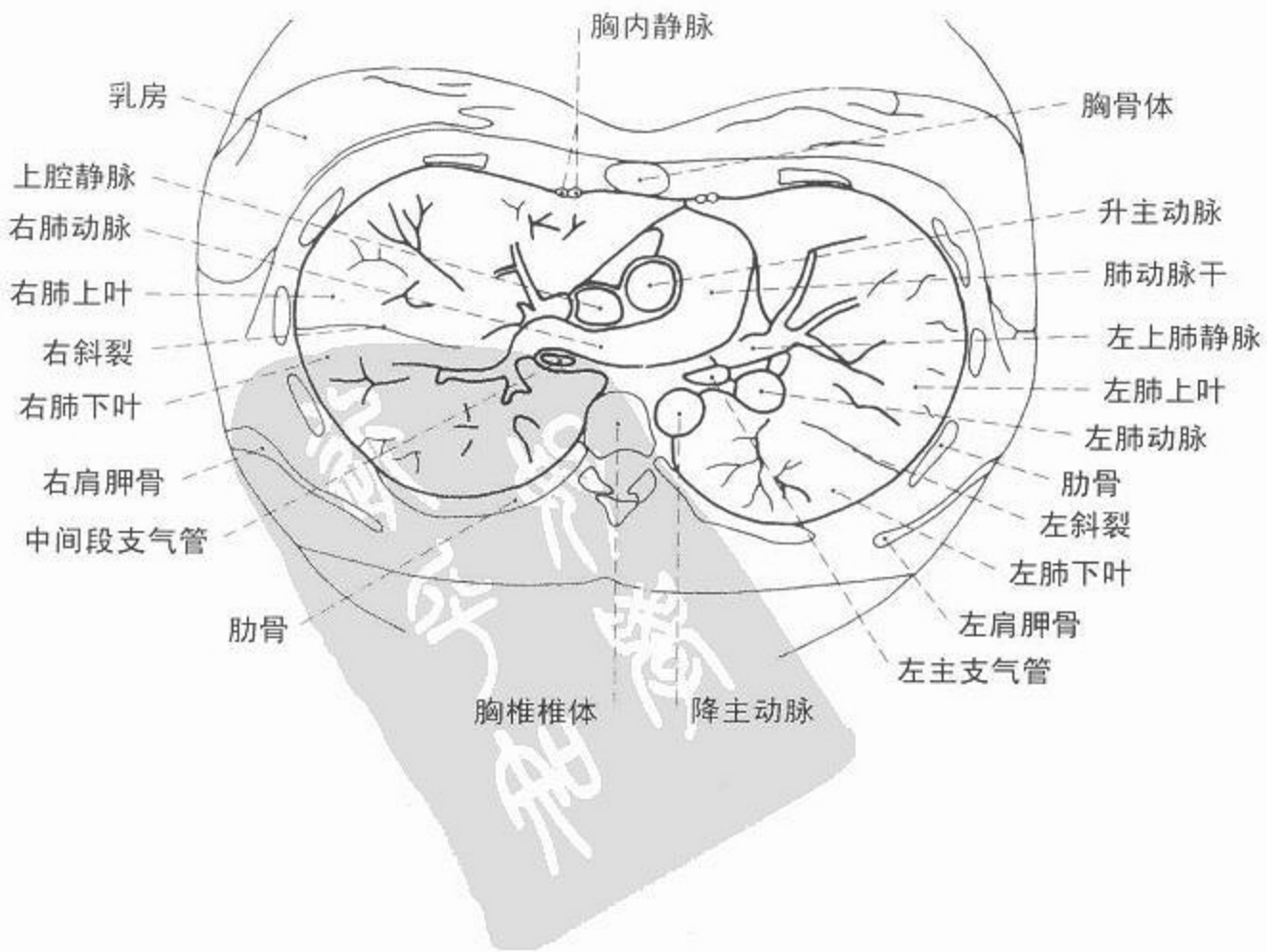
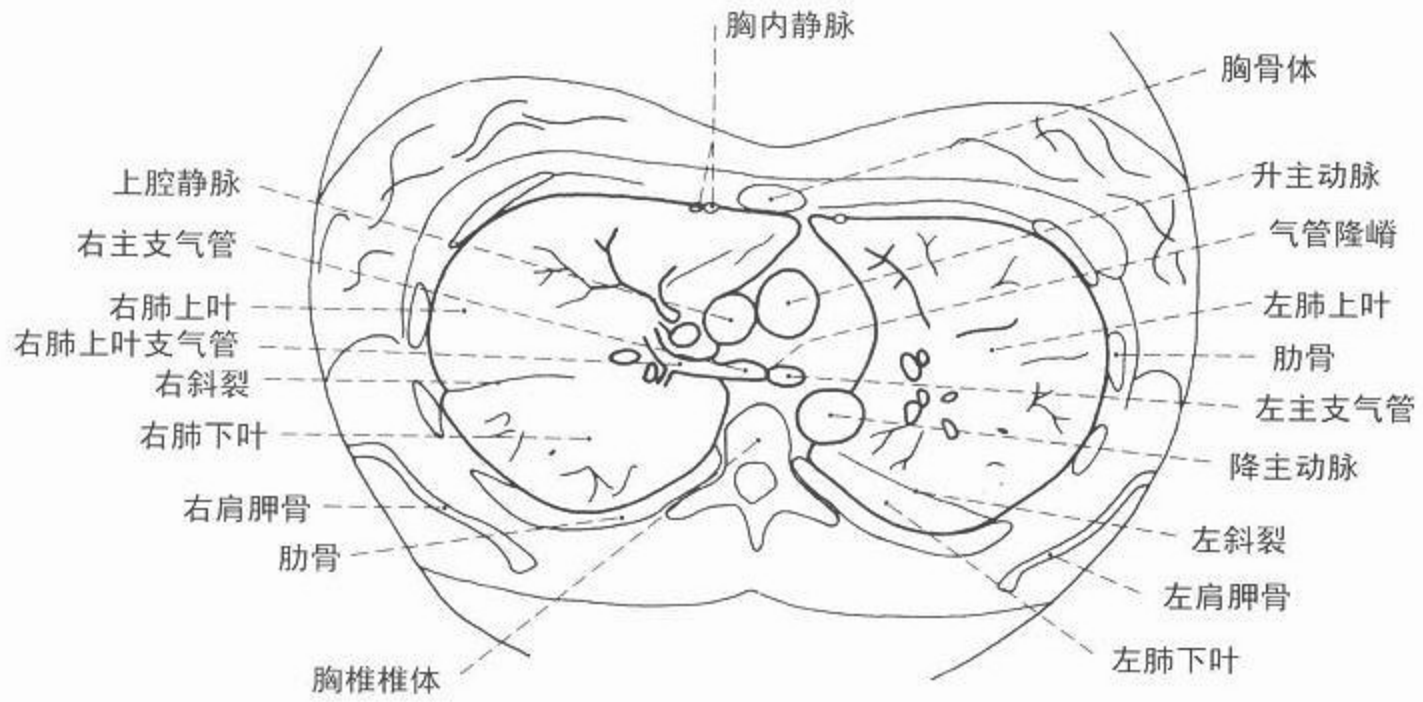


图 158 胸部轴位(横断面),  
心室层面(纵隔窗)



CT



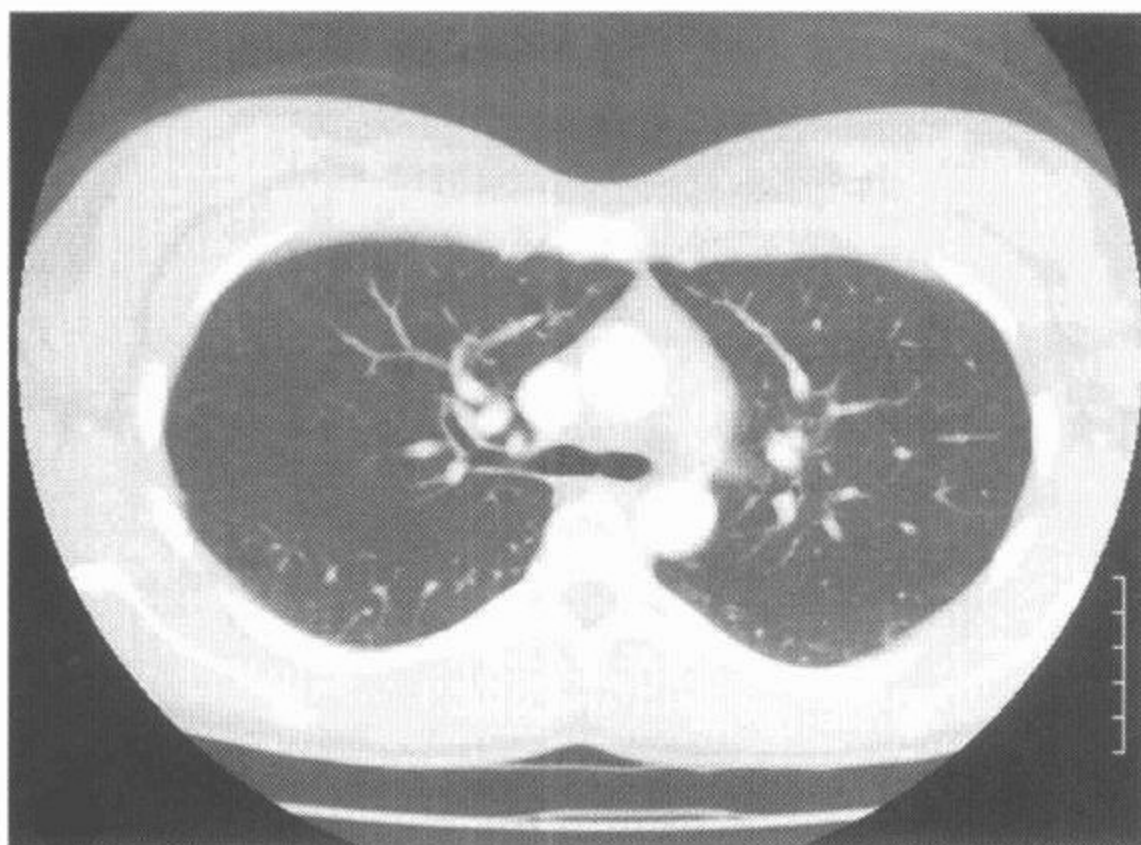
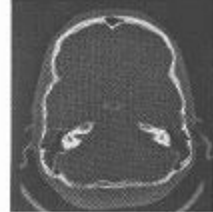


图 159 胸部轴位(横断面),  
气管分叉层面(肺窗)

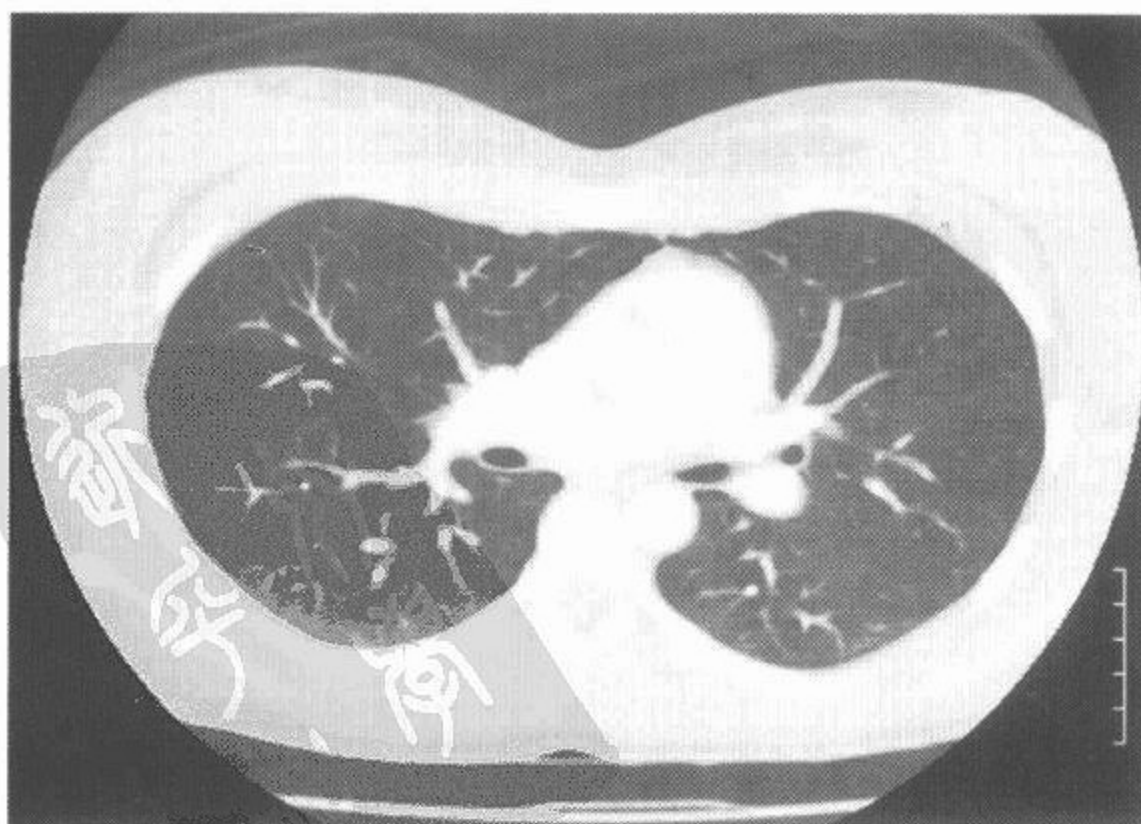
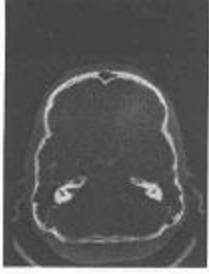
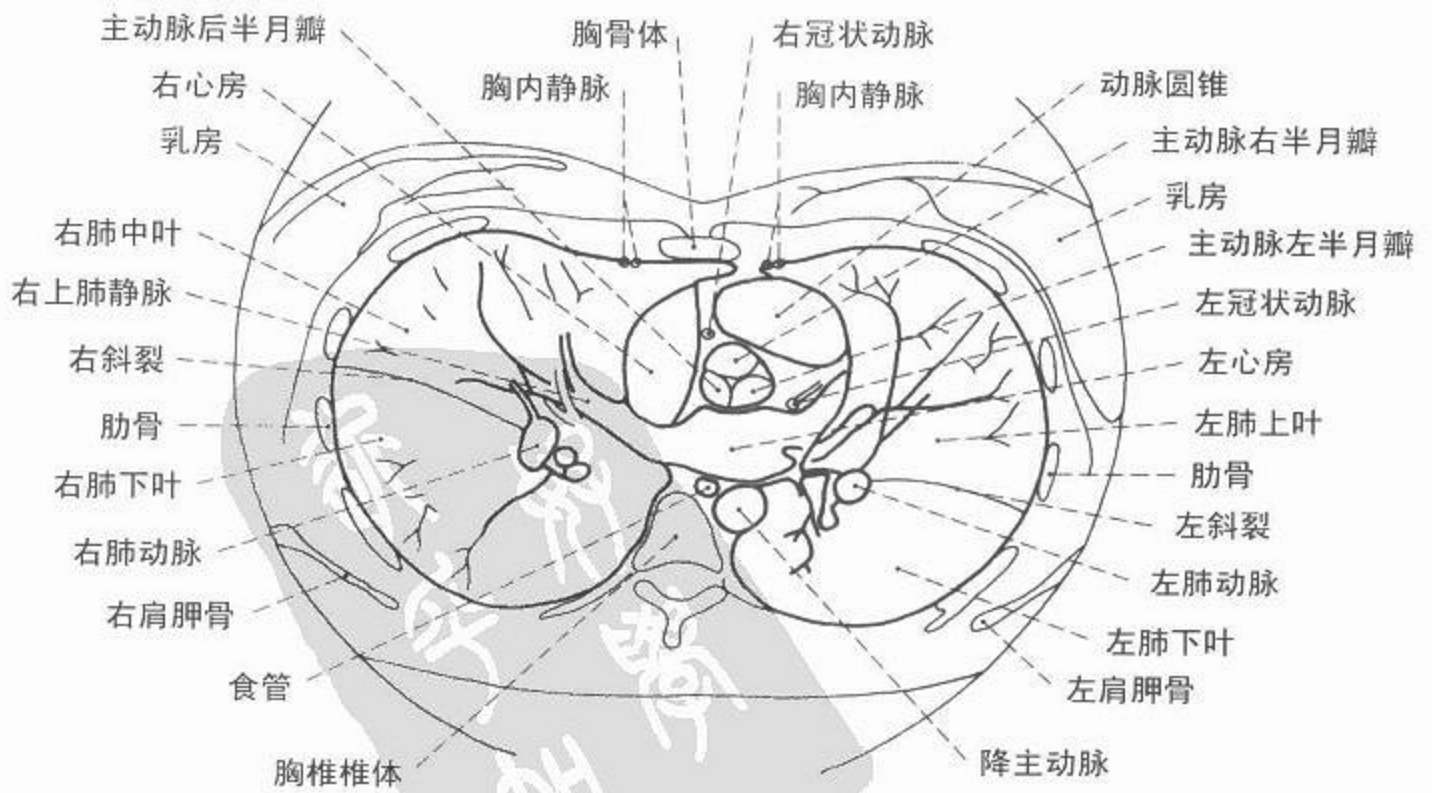
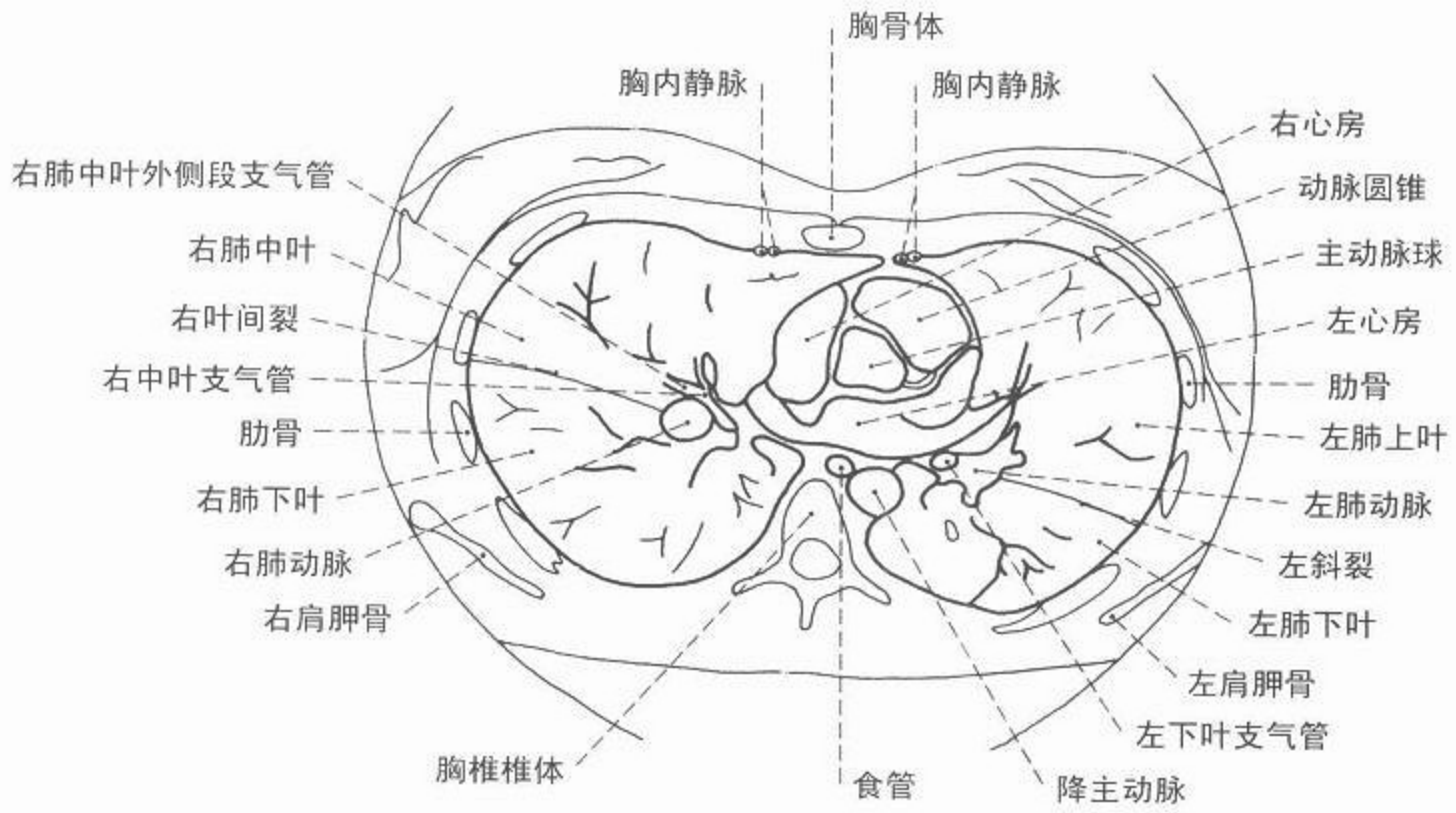


图 160 胸部轴位(横断面),  
肺动脉层面(肺窗)



CT



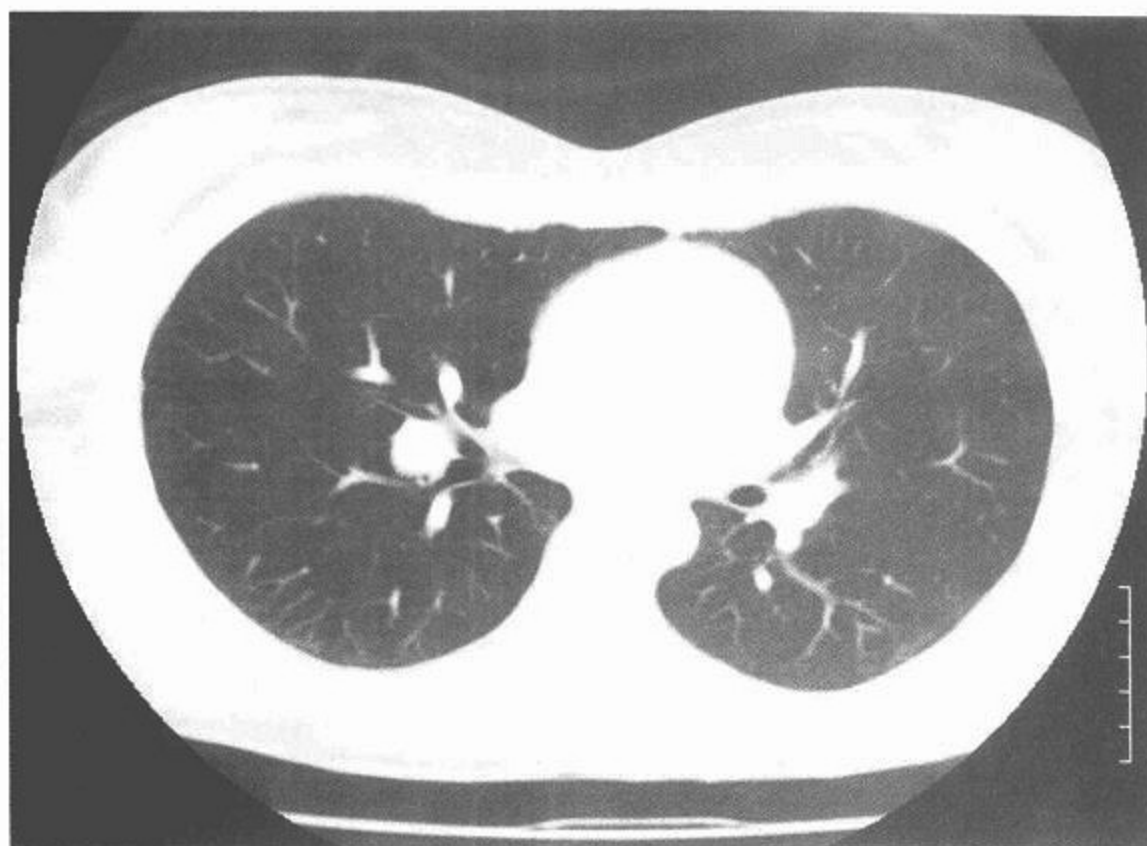
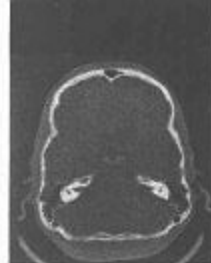

图 161 胸部轴位(横断面),  
肺门层面(肺窗)

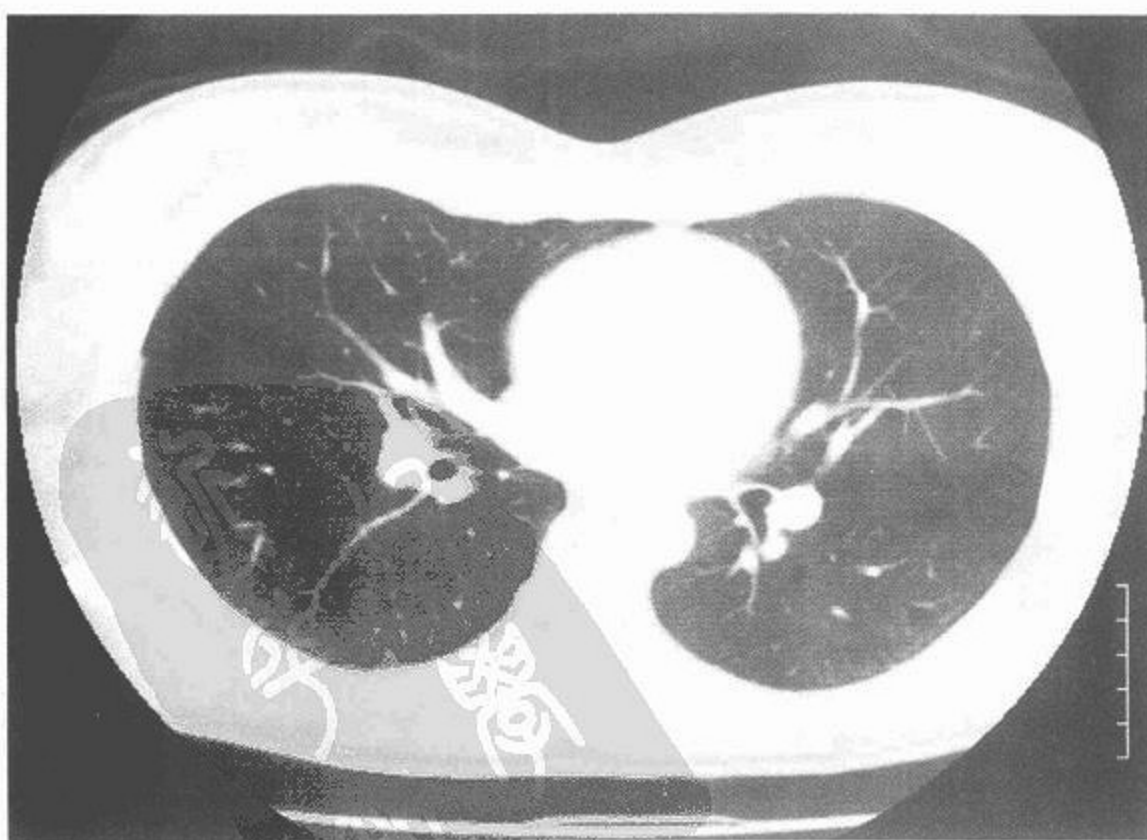
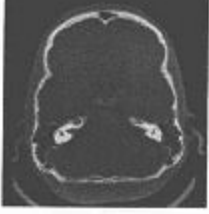
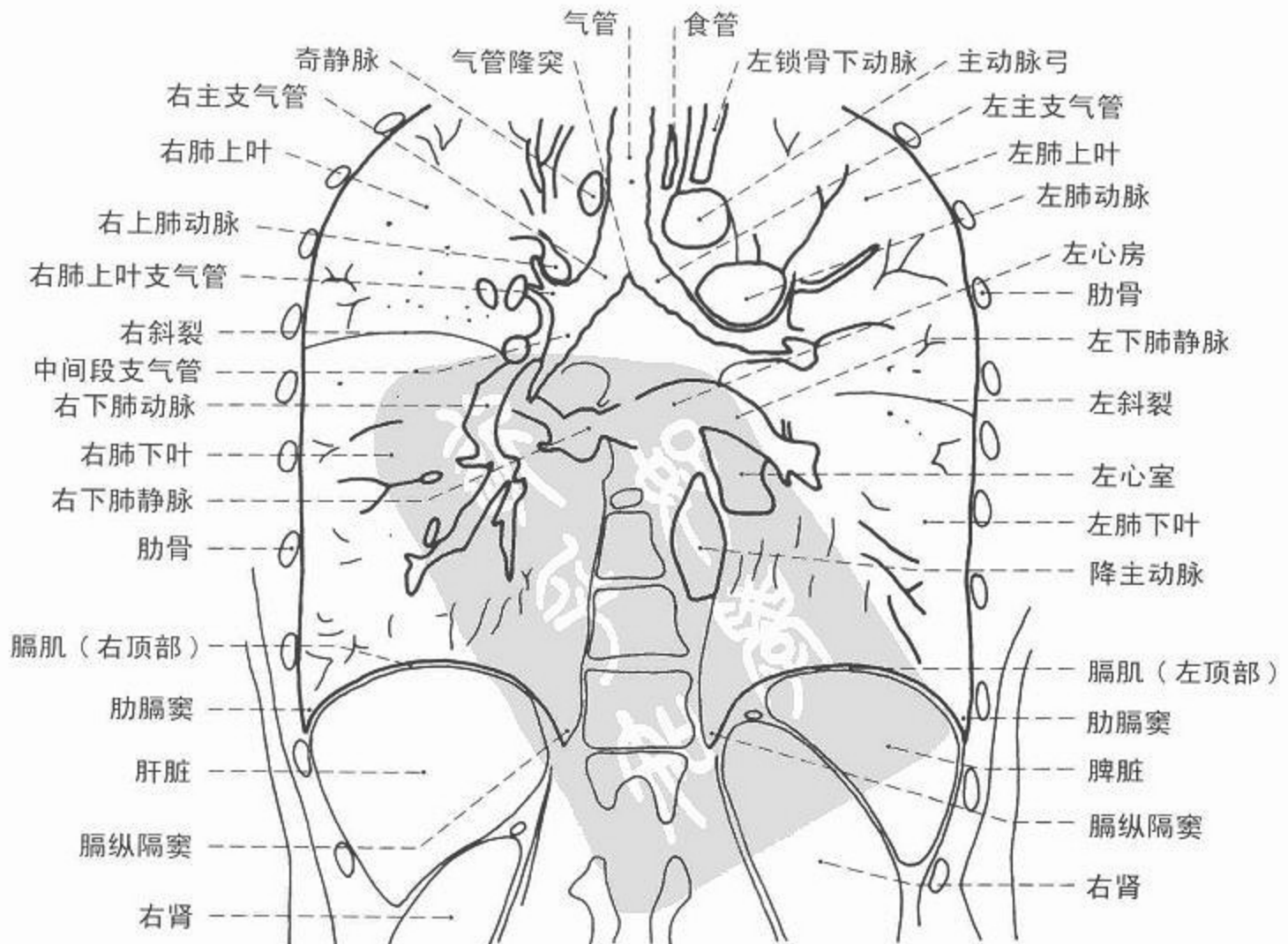
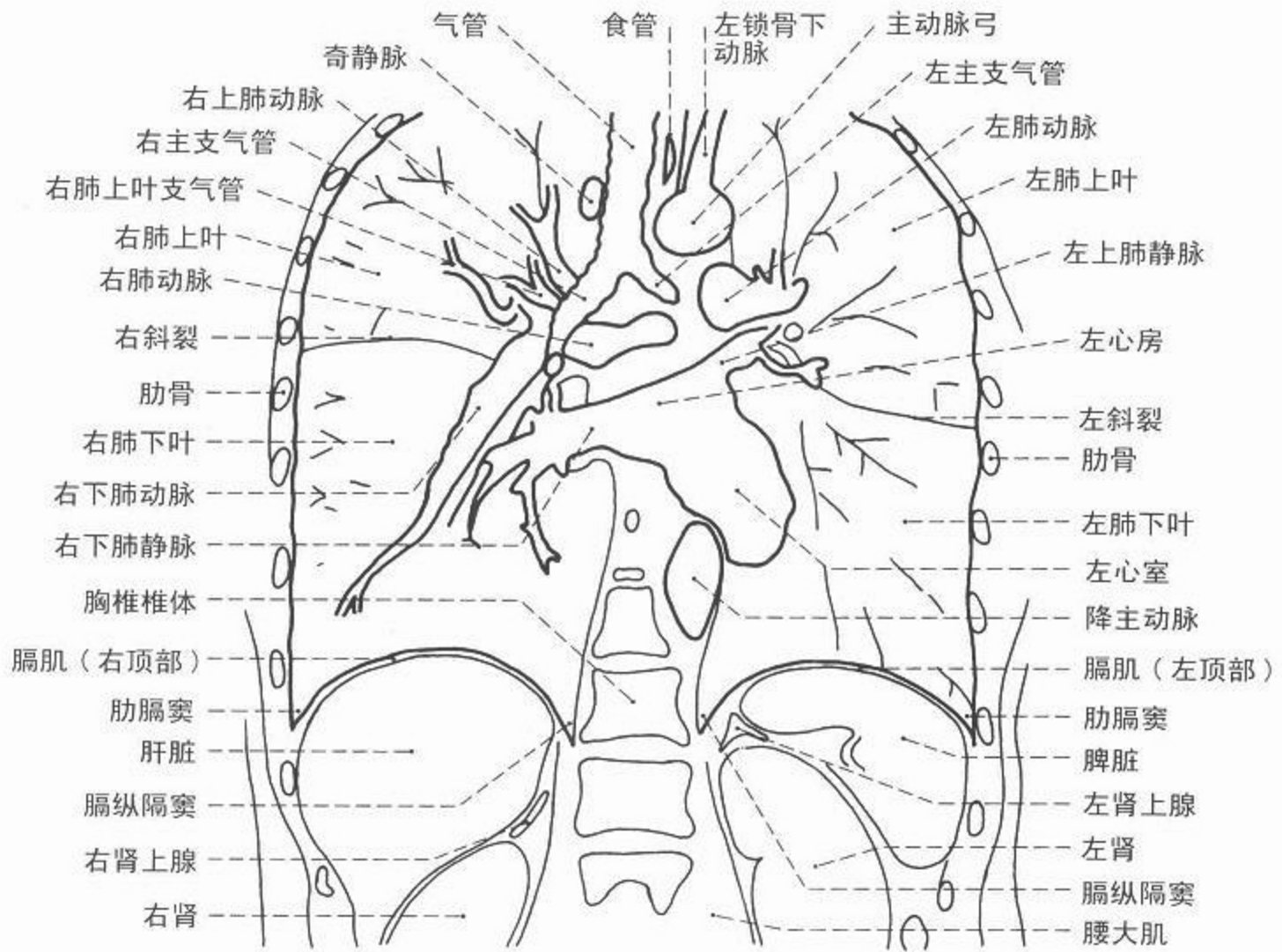


图 162 胸部轴位(横断面),  
主动脉瓣层面(肺窗)





CT



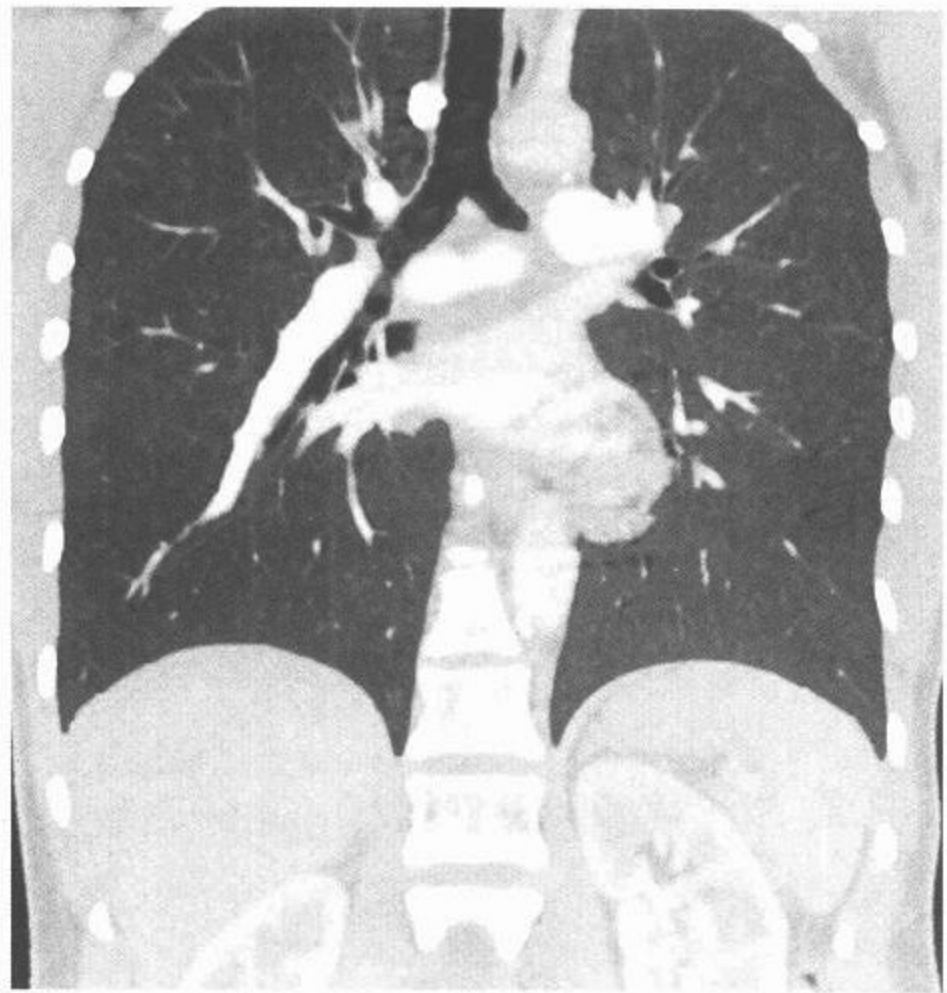
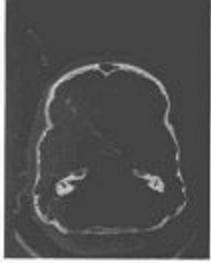


图 163 胸部冠状面(额状面)重建,左心房肺门层面

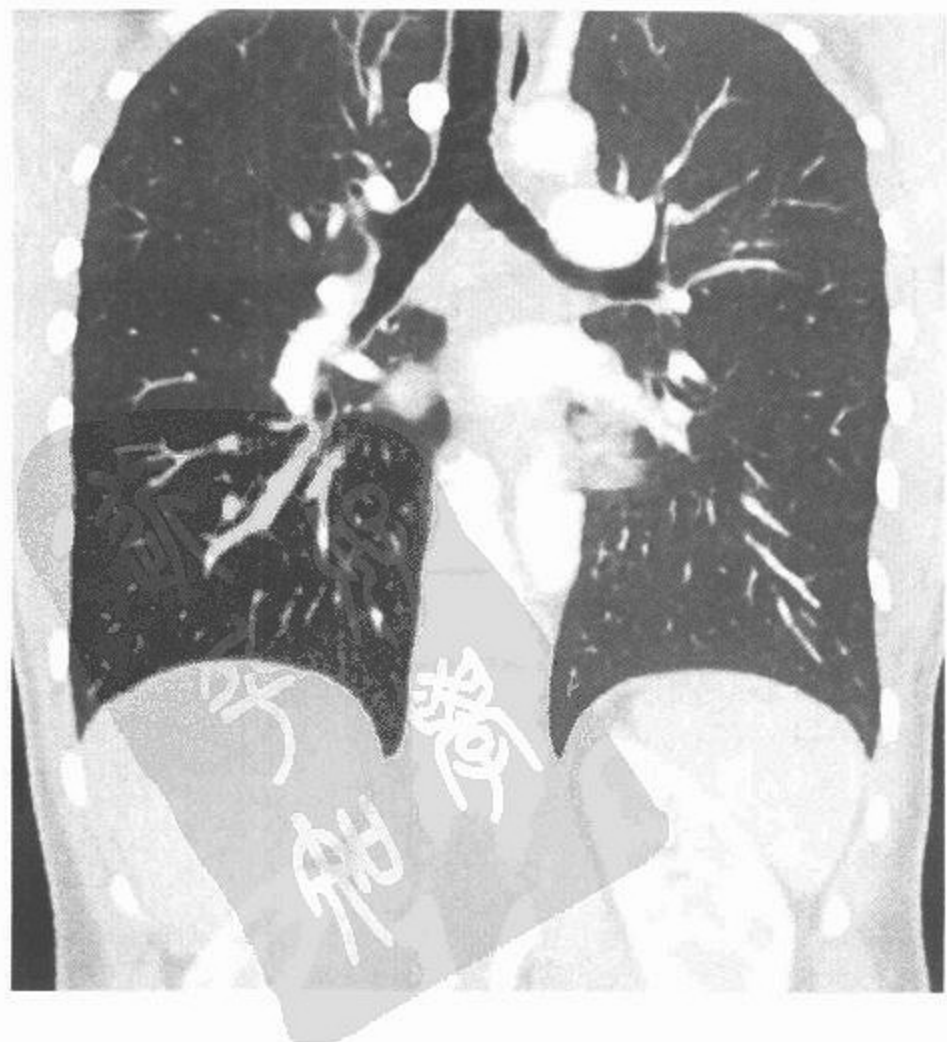
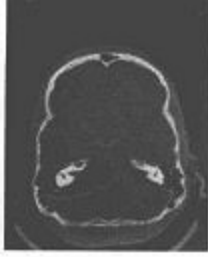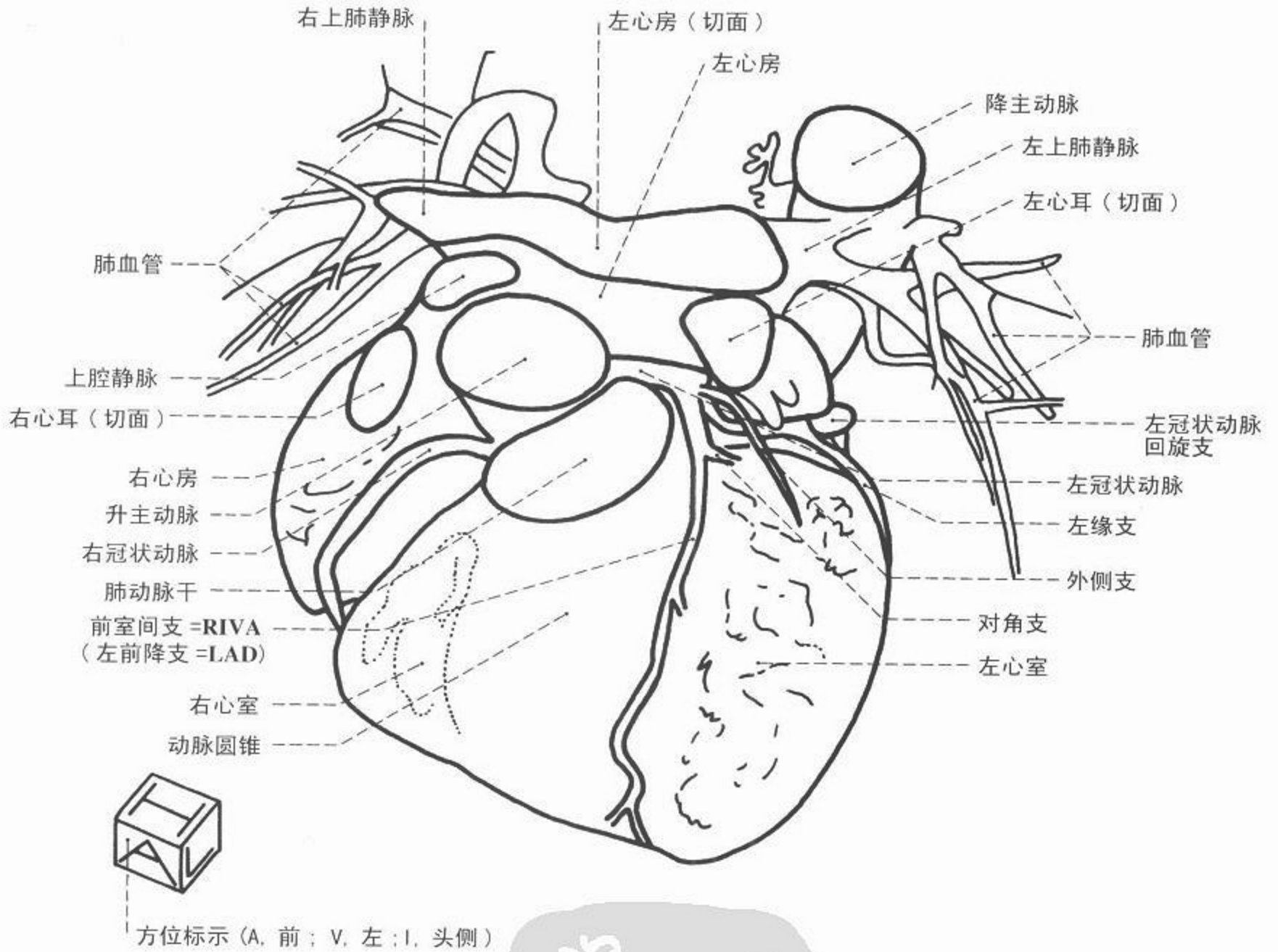


图 164 胸部冠状面(额状面)重建,气管分叉层面



CT



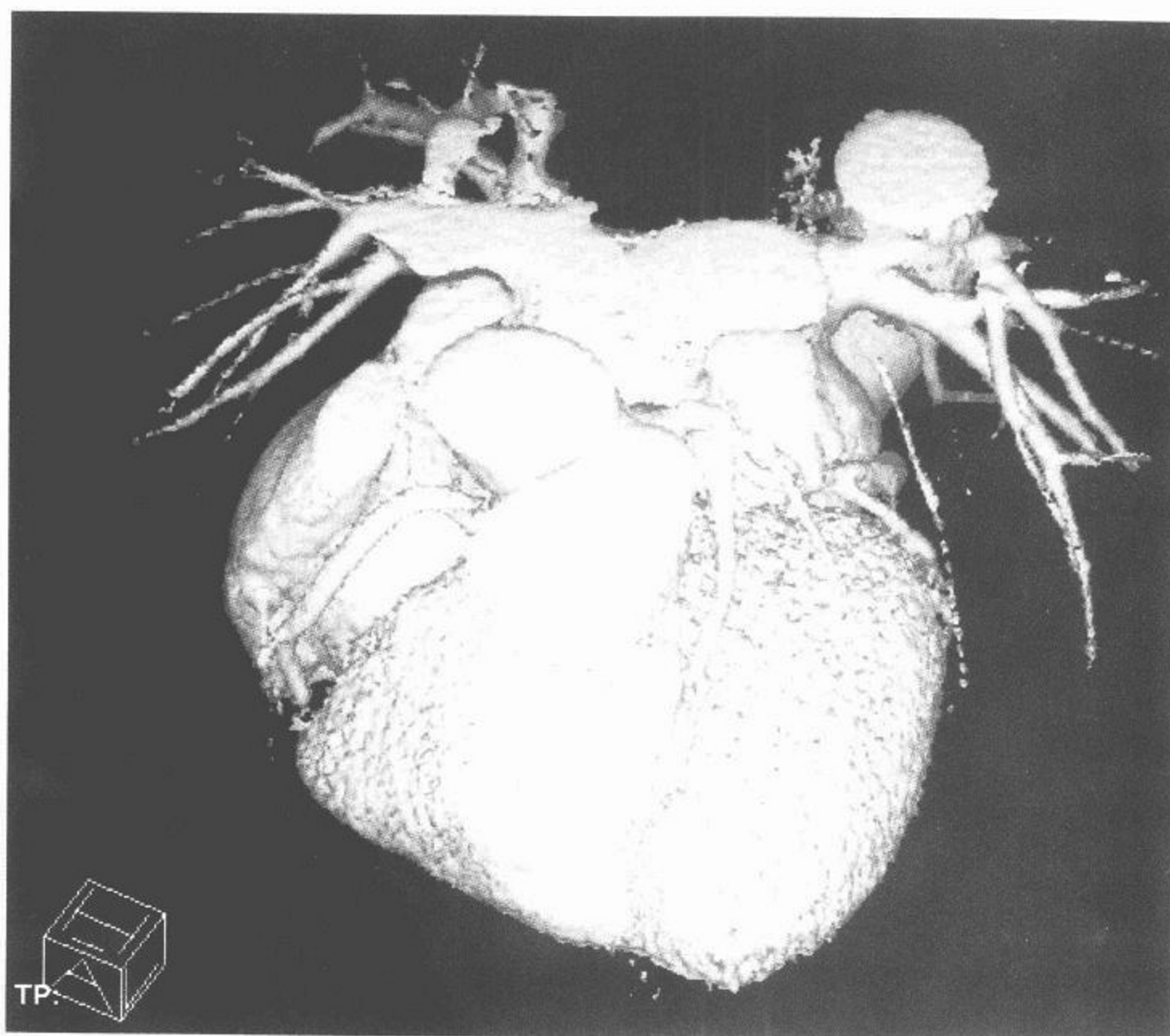
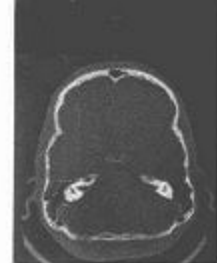
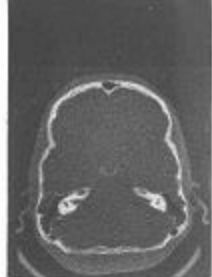
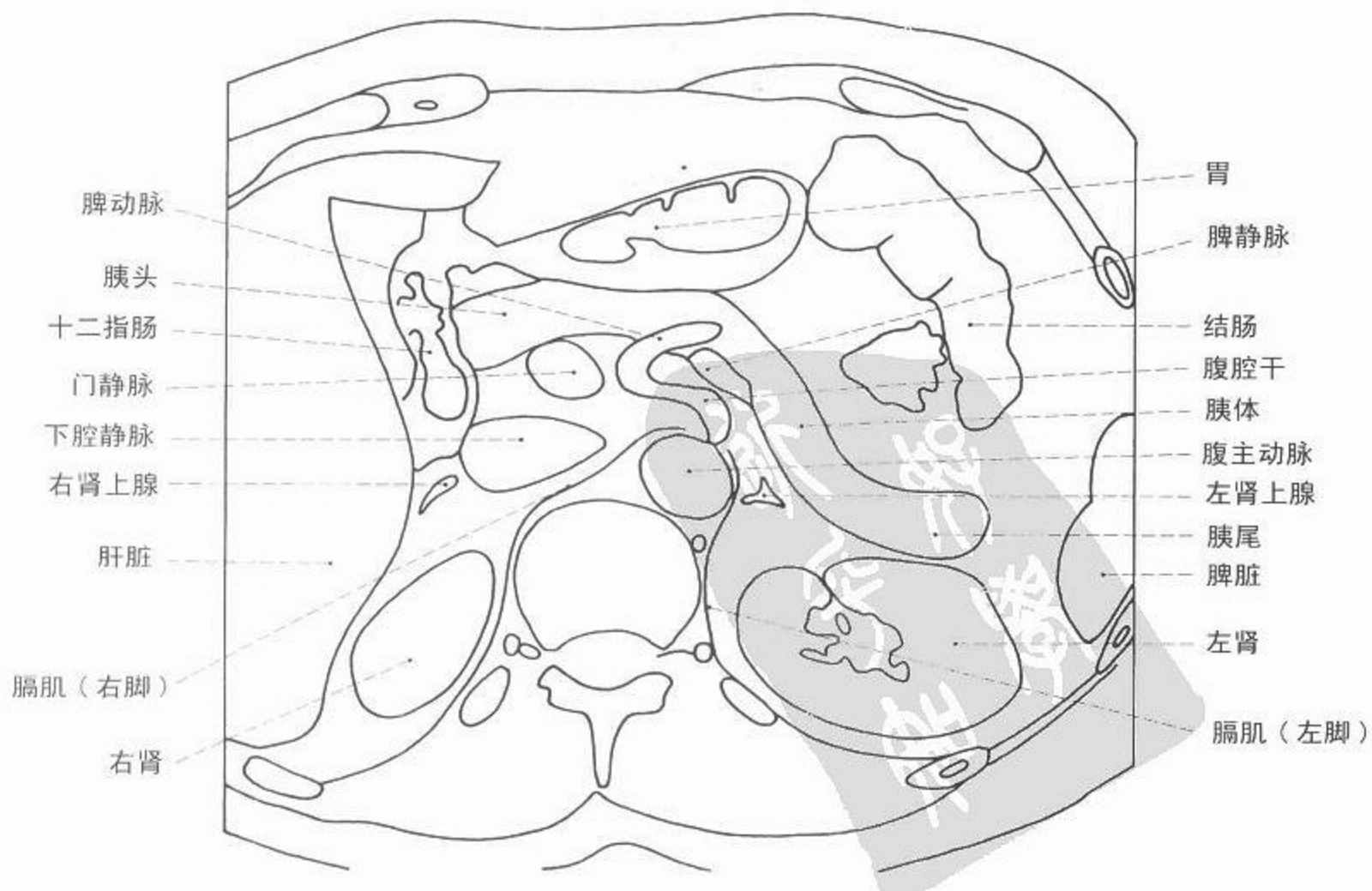
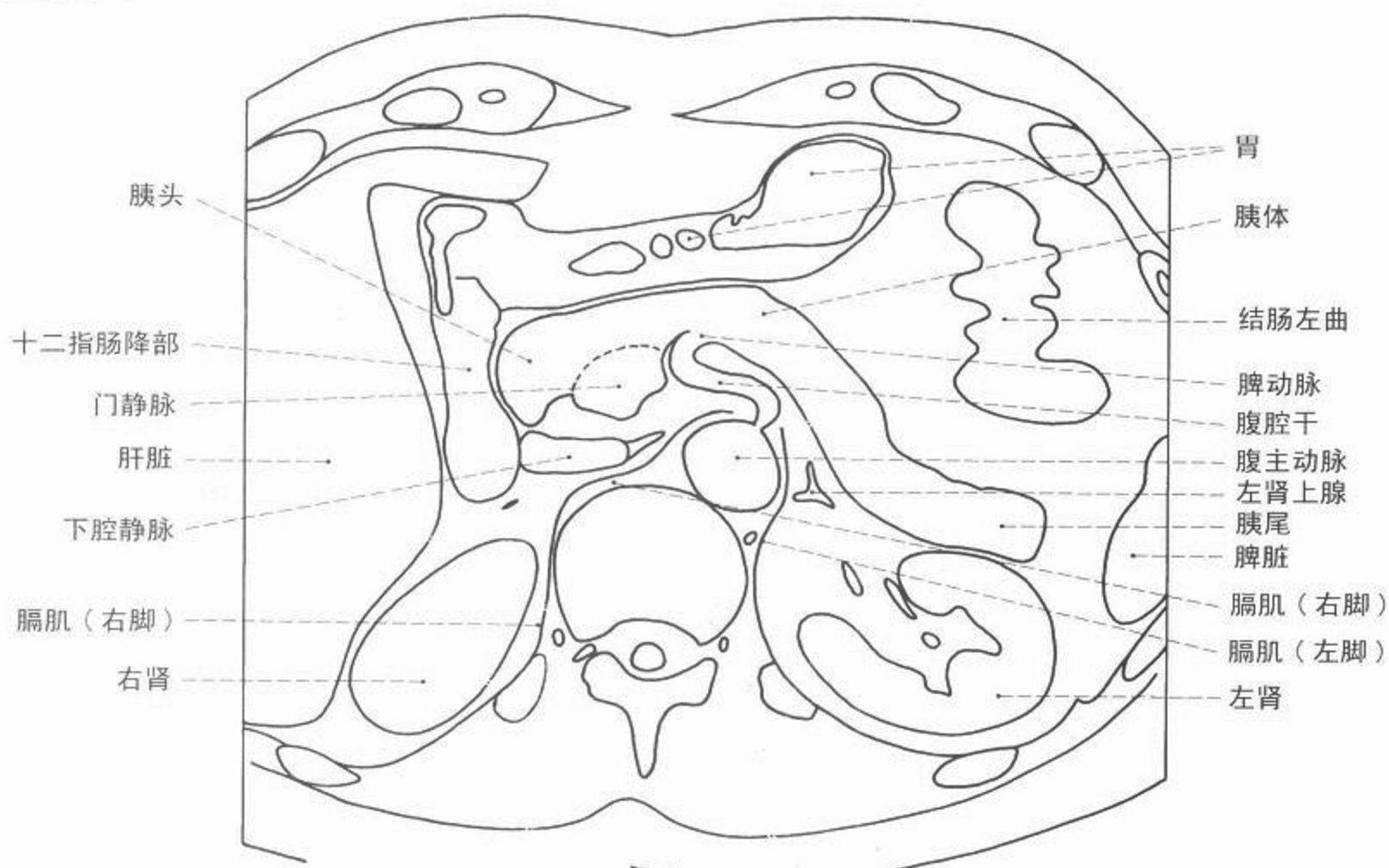


图 165 心脏,超快 CT 造影 3 维重建图(电子束 CT)





CT



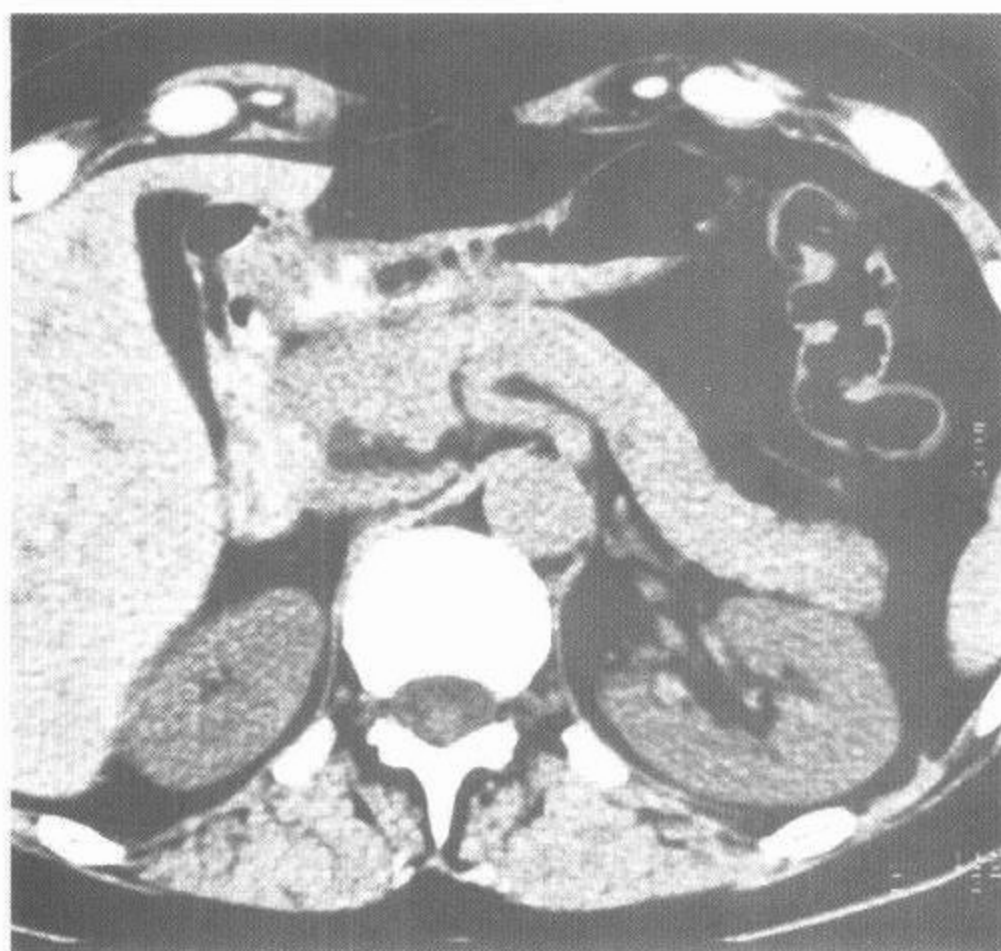
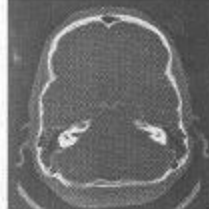

图 166 上腹部 CT 断面(平扫)

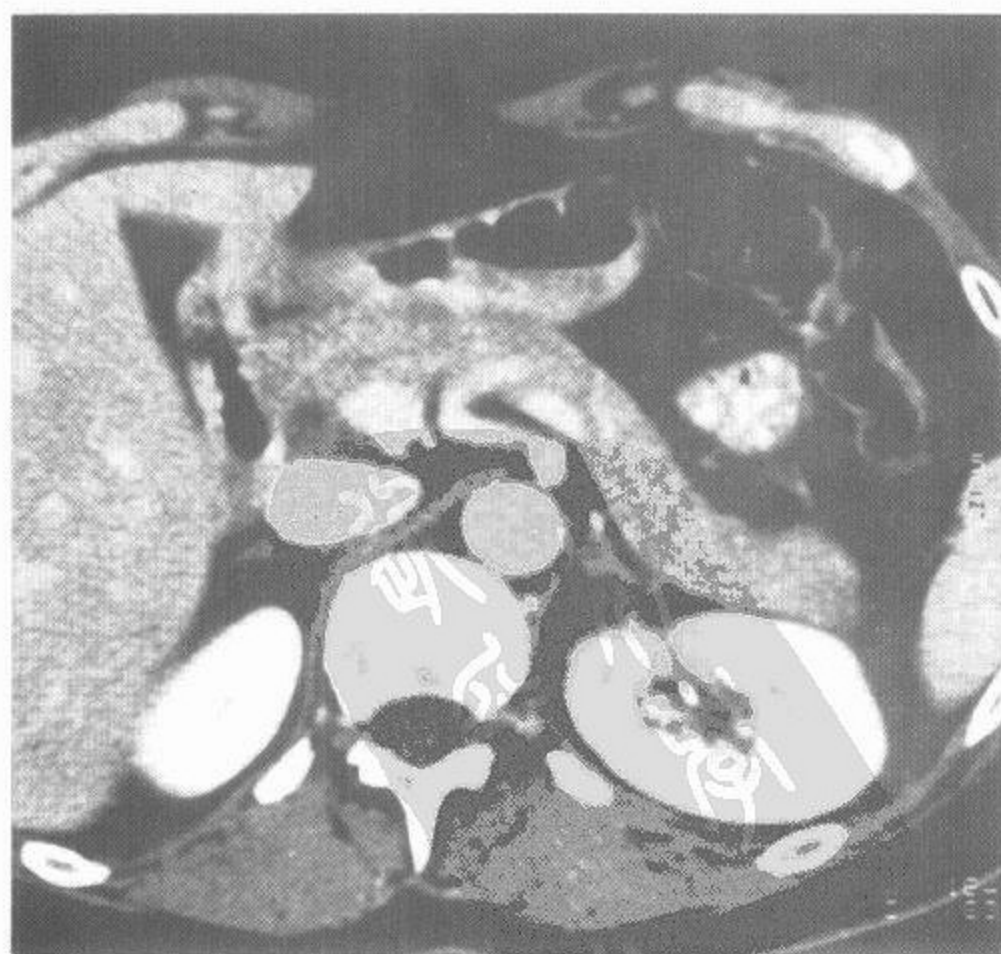
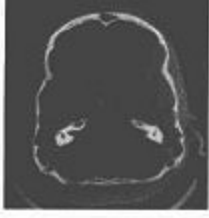
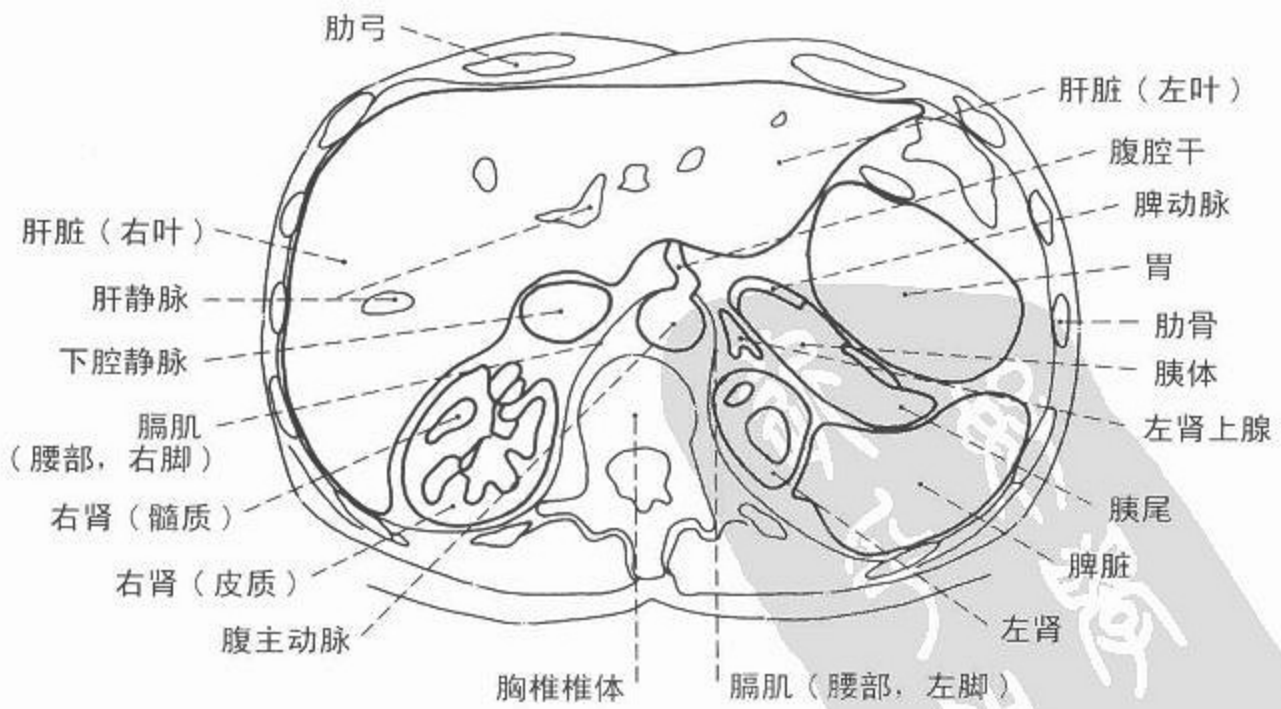
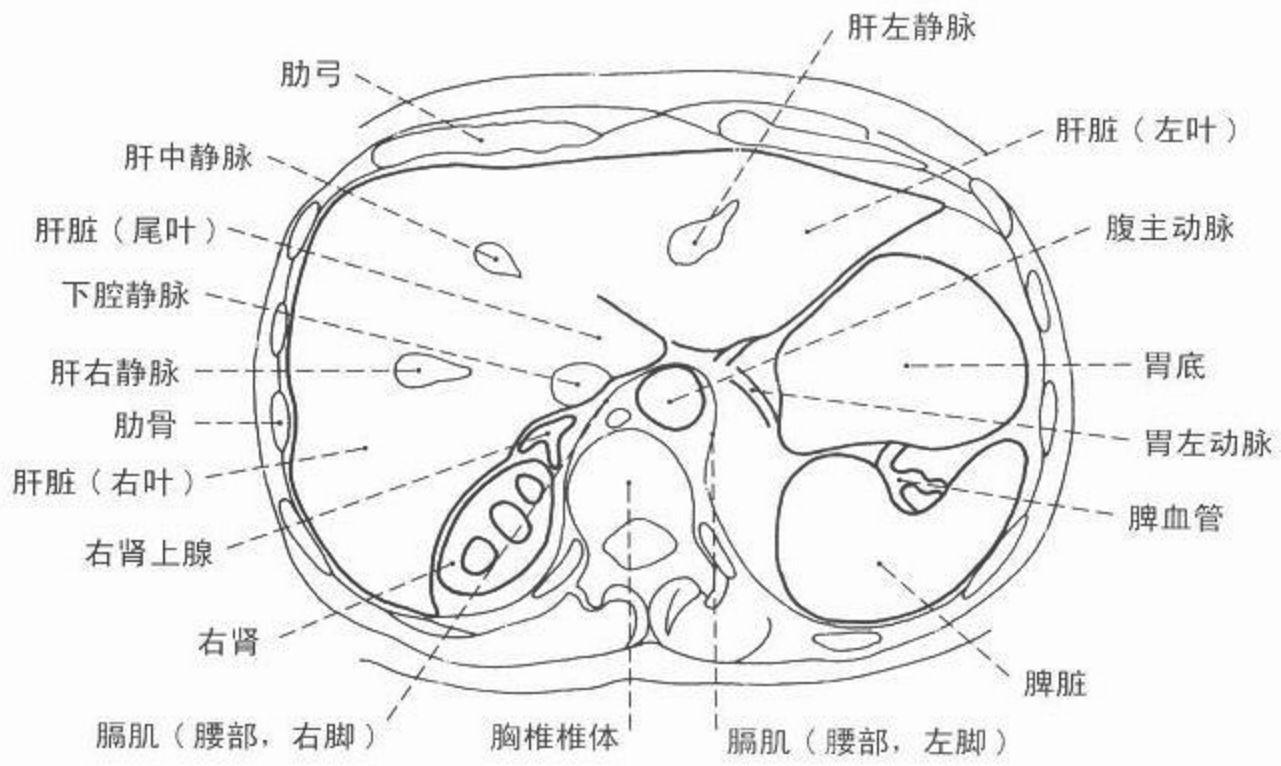


图 167 上腹部 CT 断面(增强)



CT



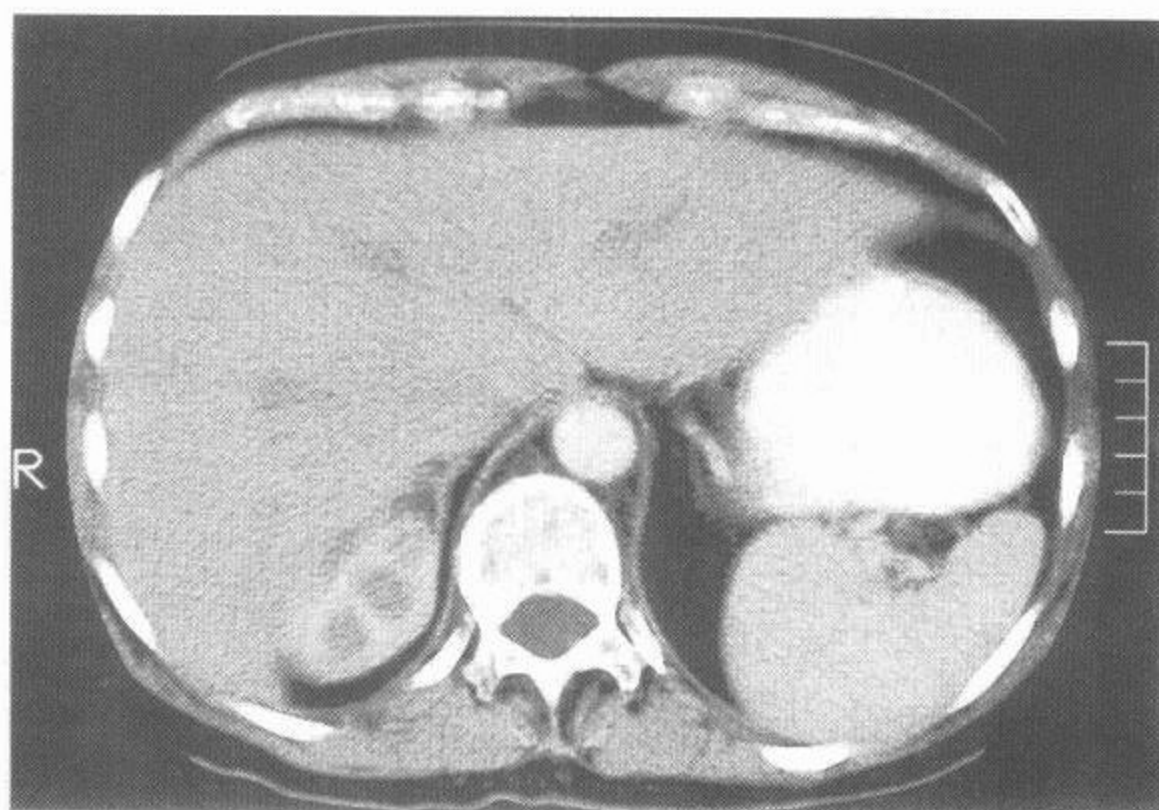
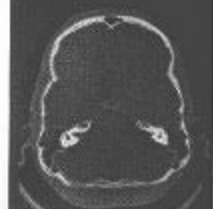

图 168 腹部 CT 轴位像，  
右肾层面

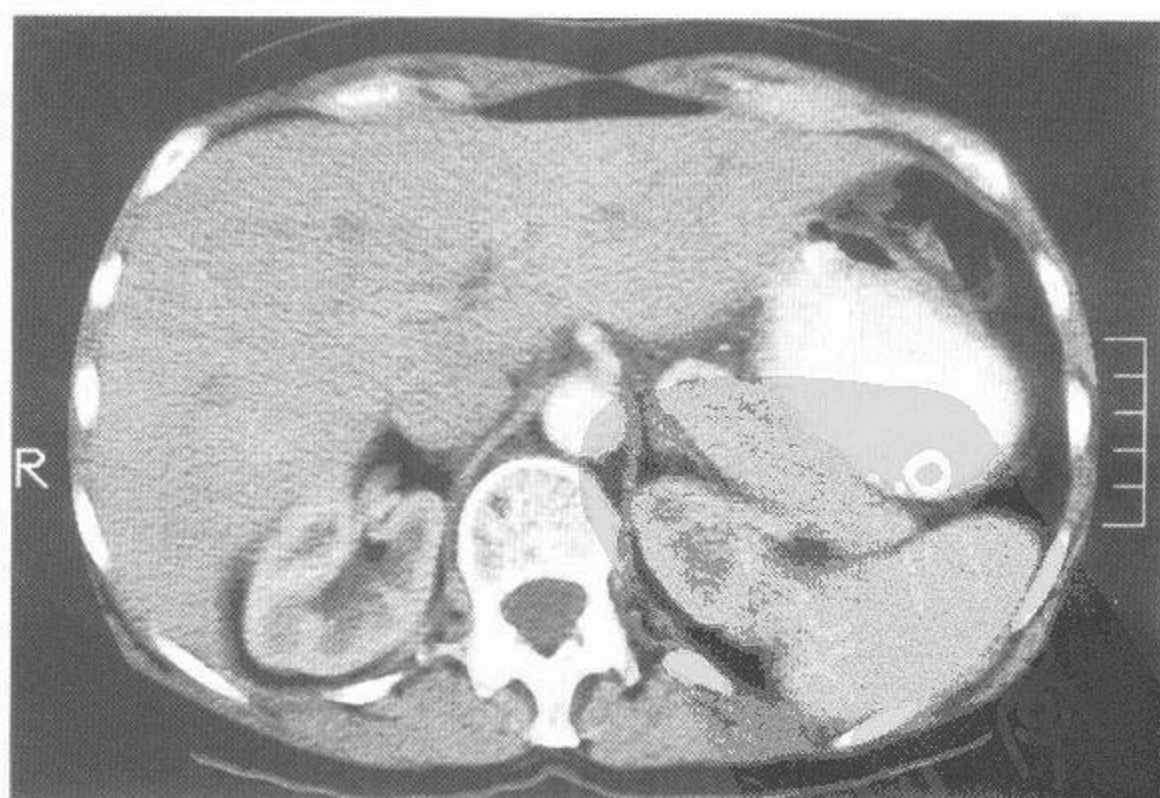
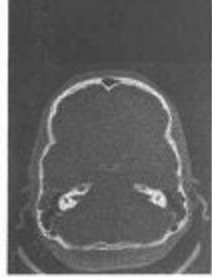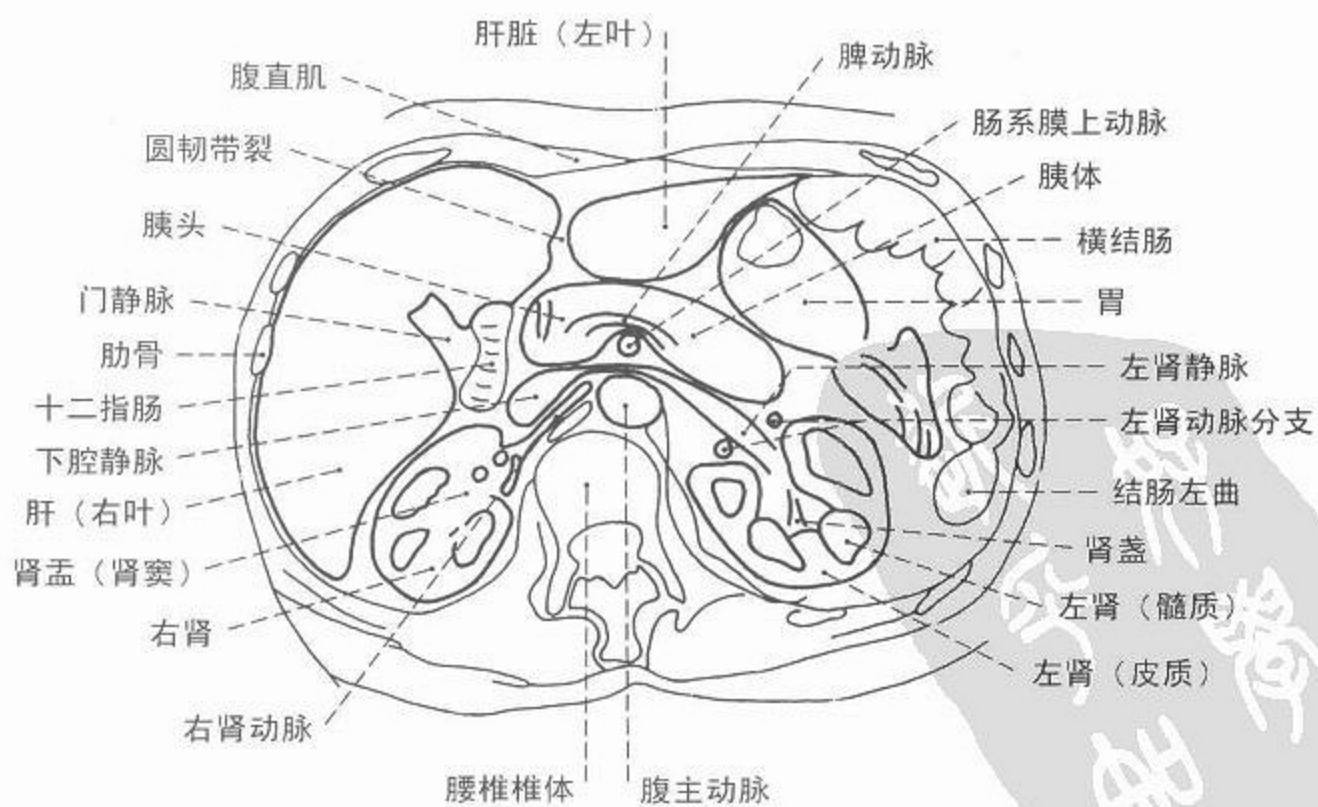
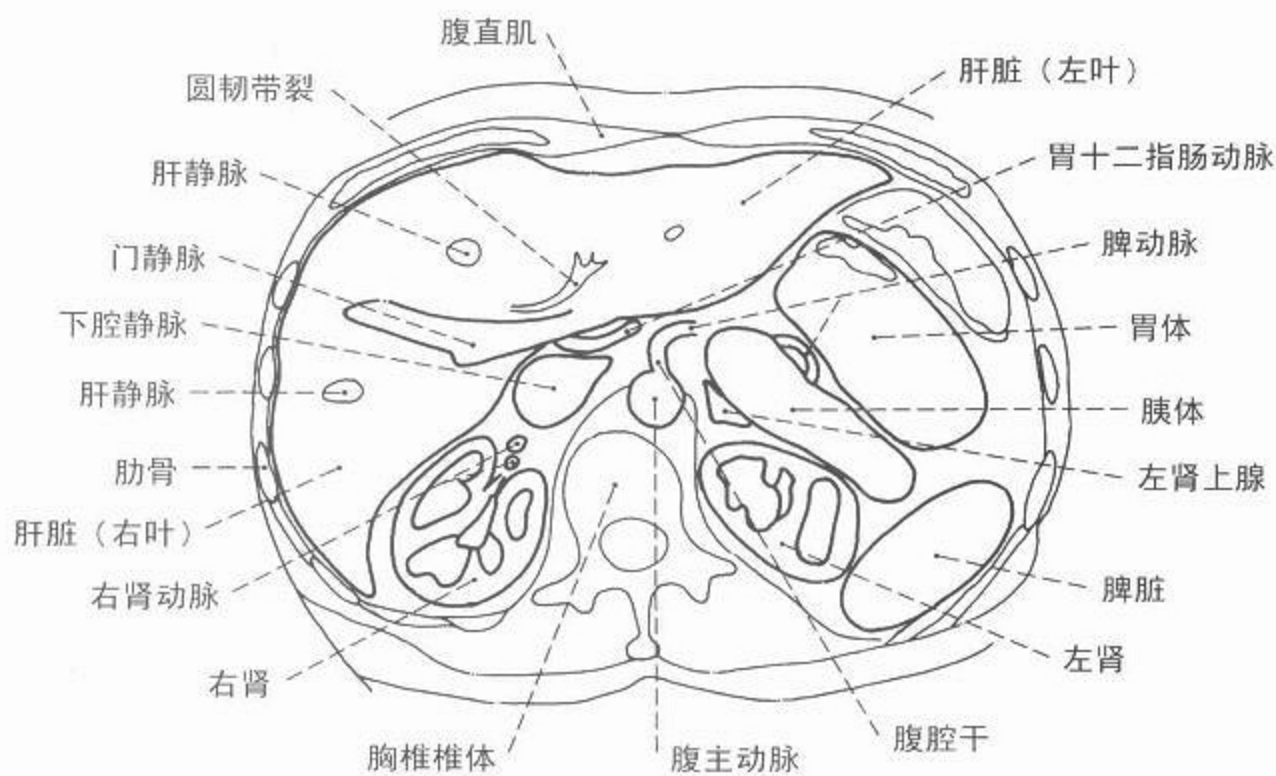


图 169 腹部 CT 轴位像，  
腹腔干层面





CT



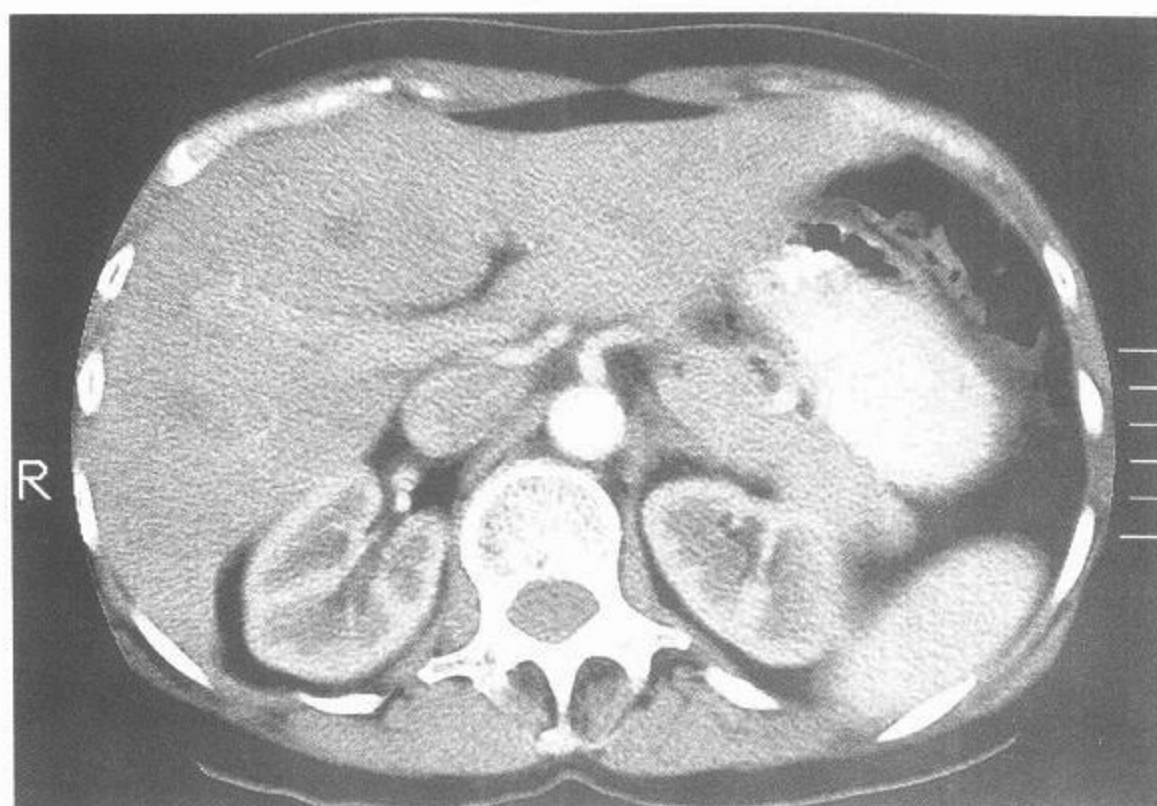
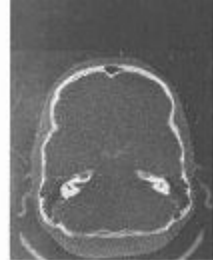

图 170 腹部 CT 轴位像,肝门层面

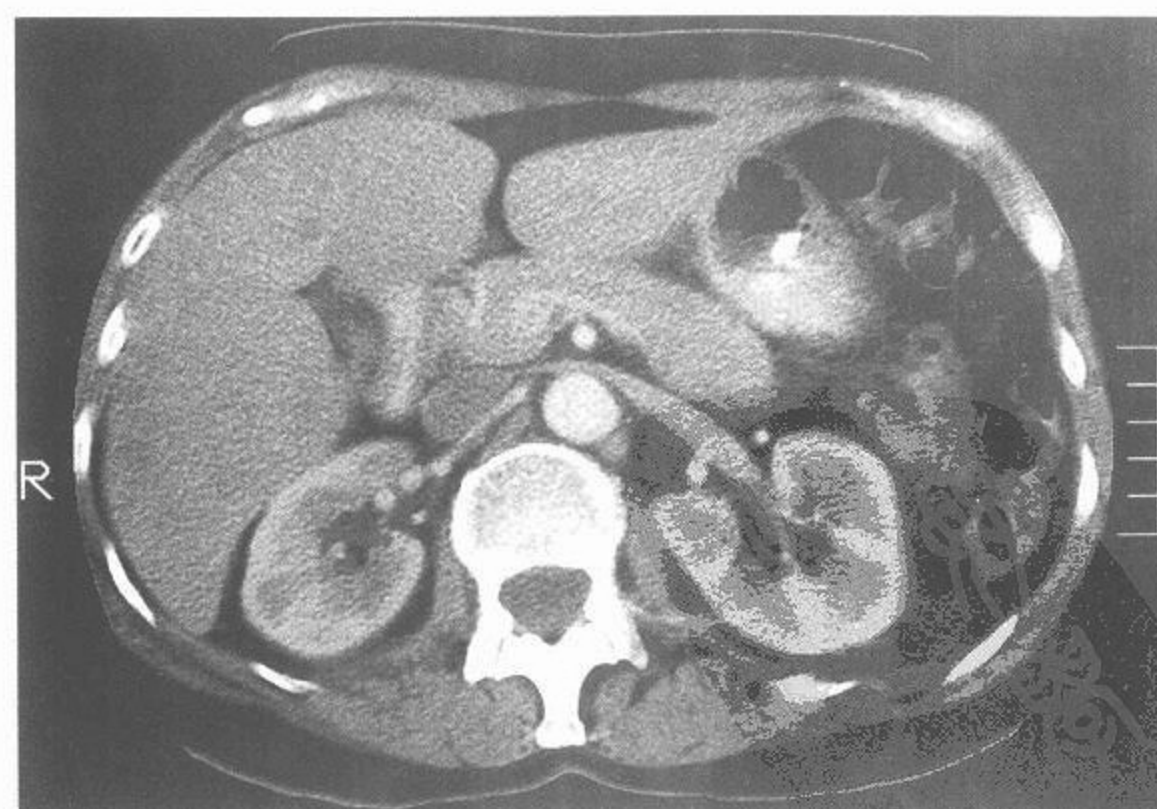
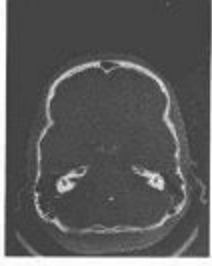
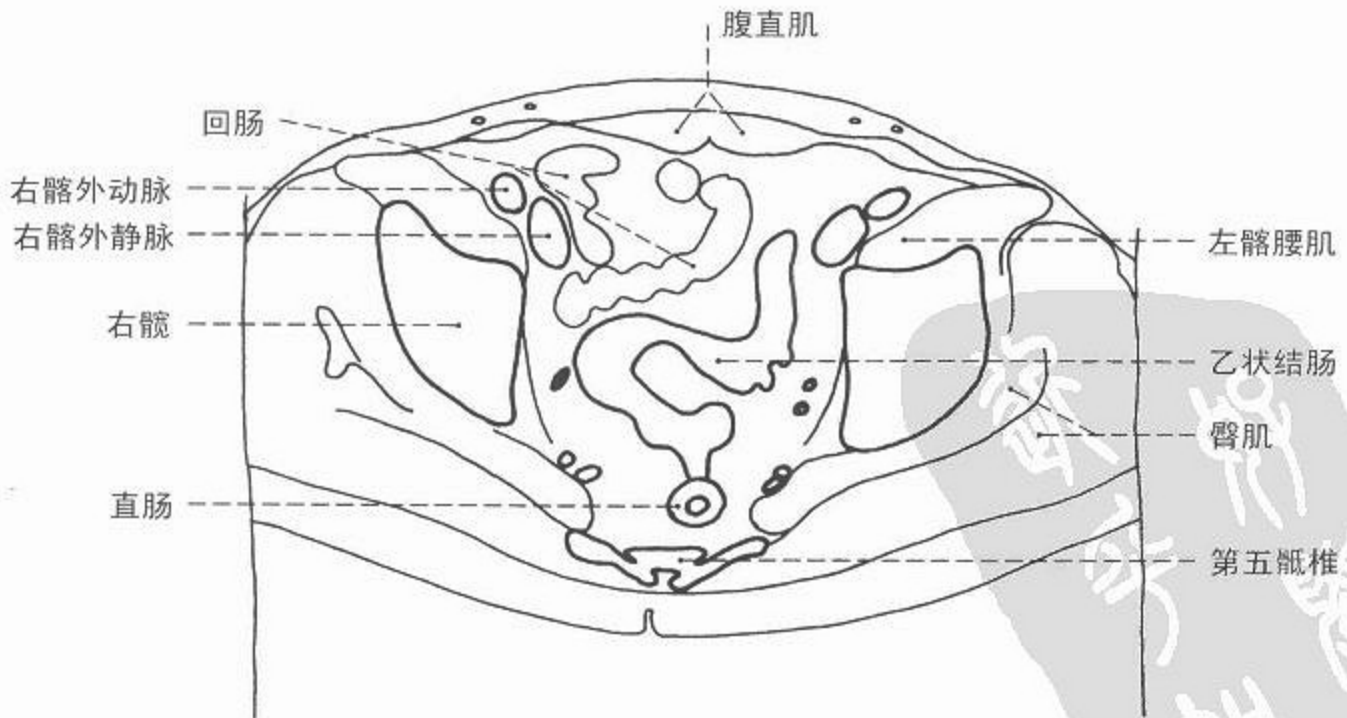
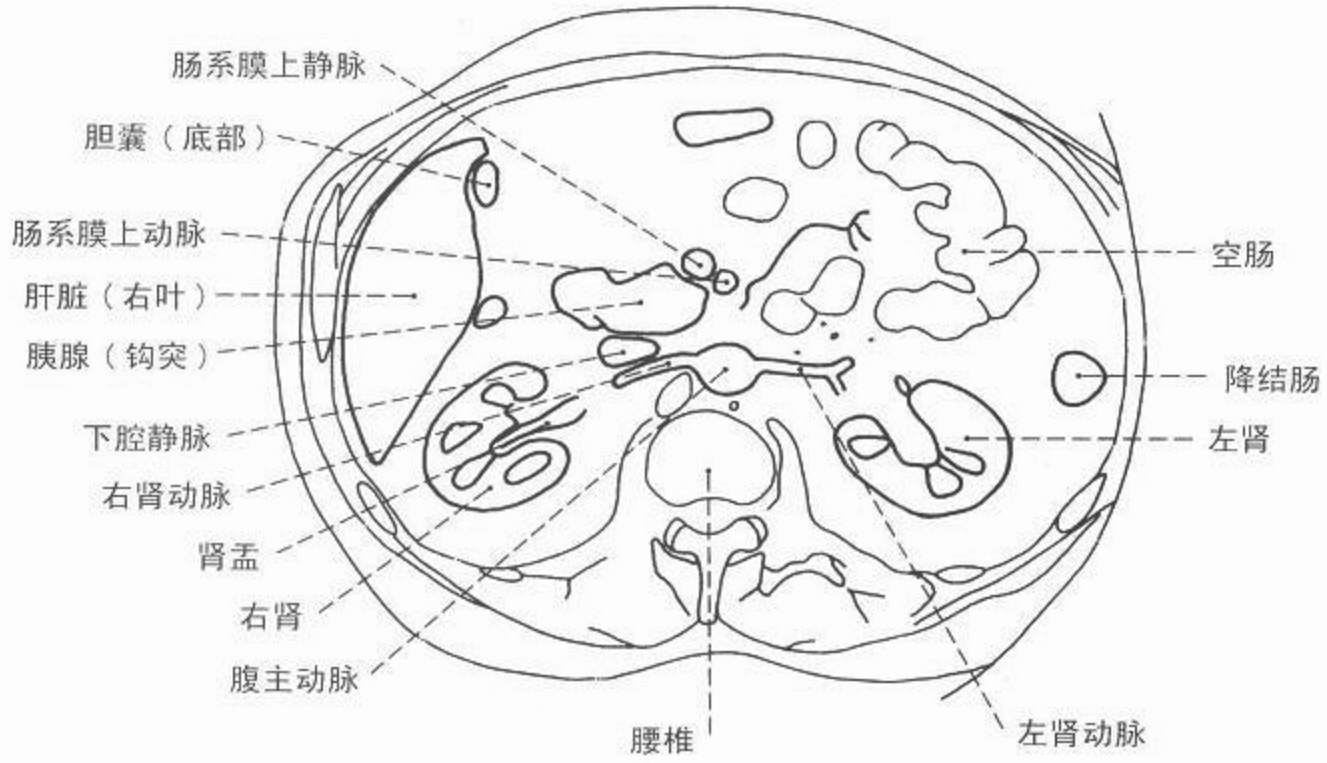


图 171 腹部 CT 轴位像,胰腺层面



CT



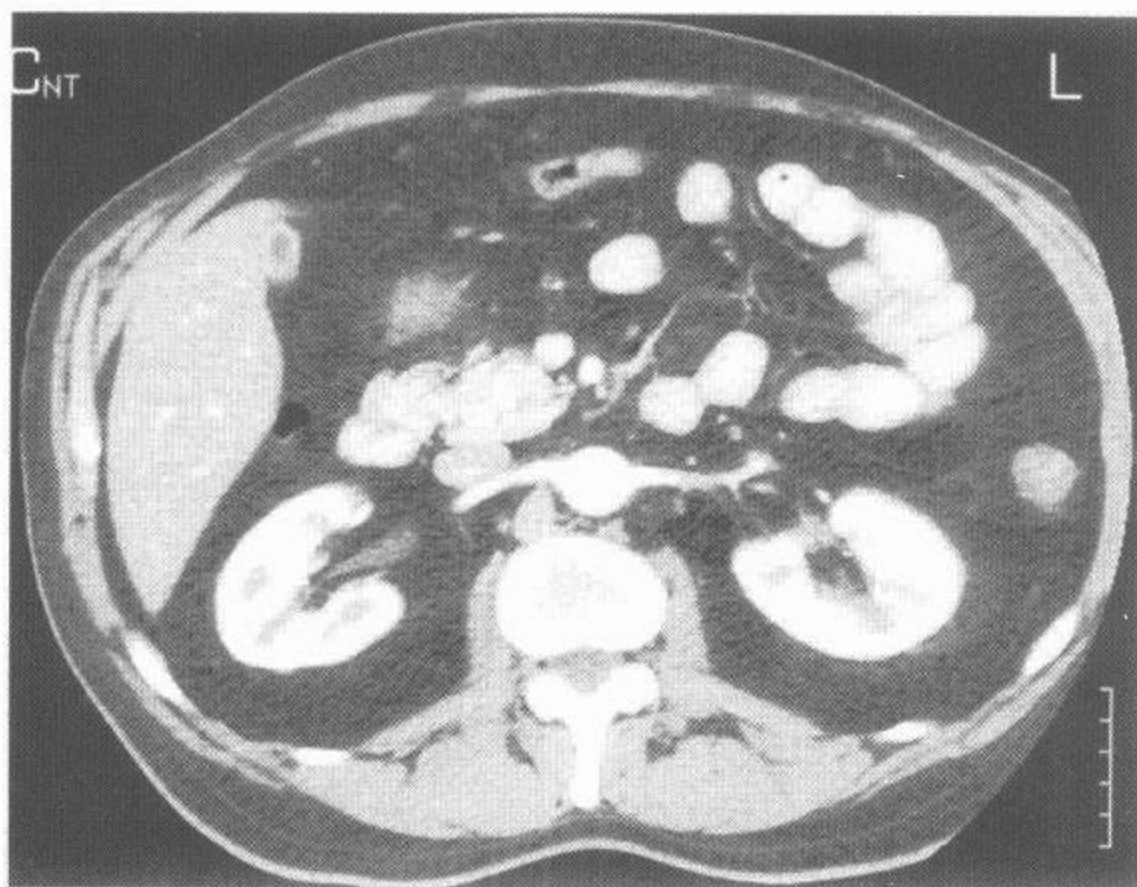
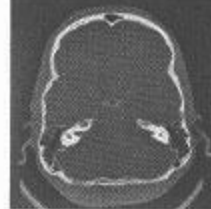

图 172 腹部 CT 轴位像，  
肾动脉层面

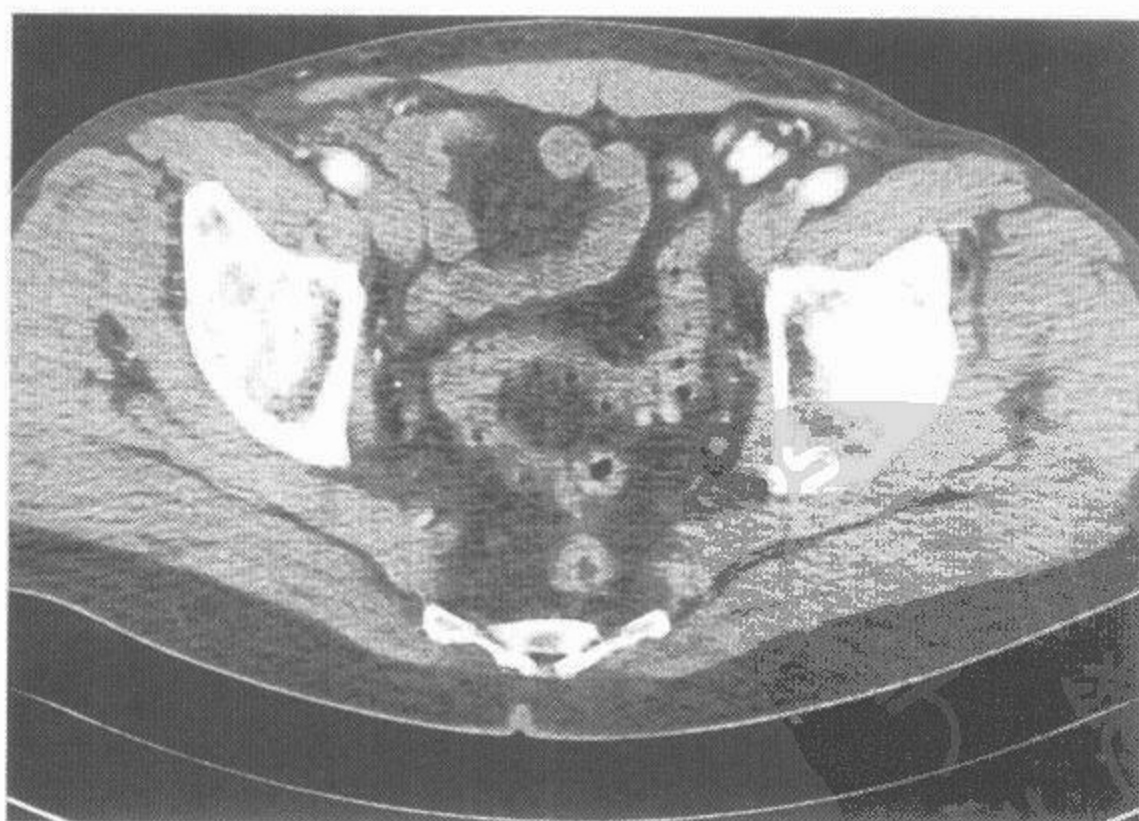
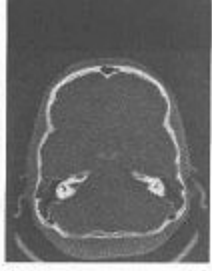
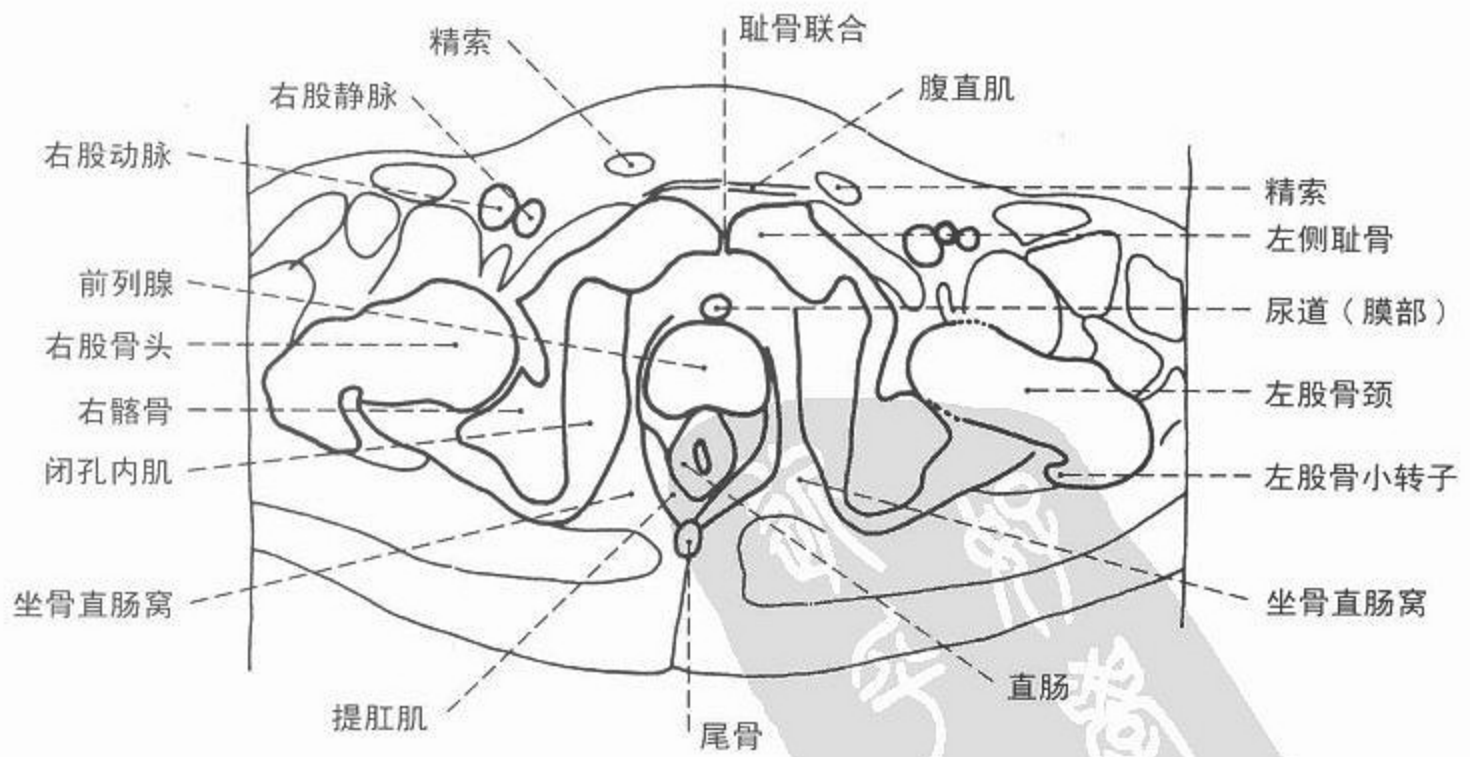
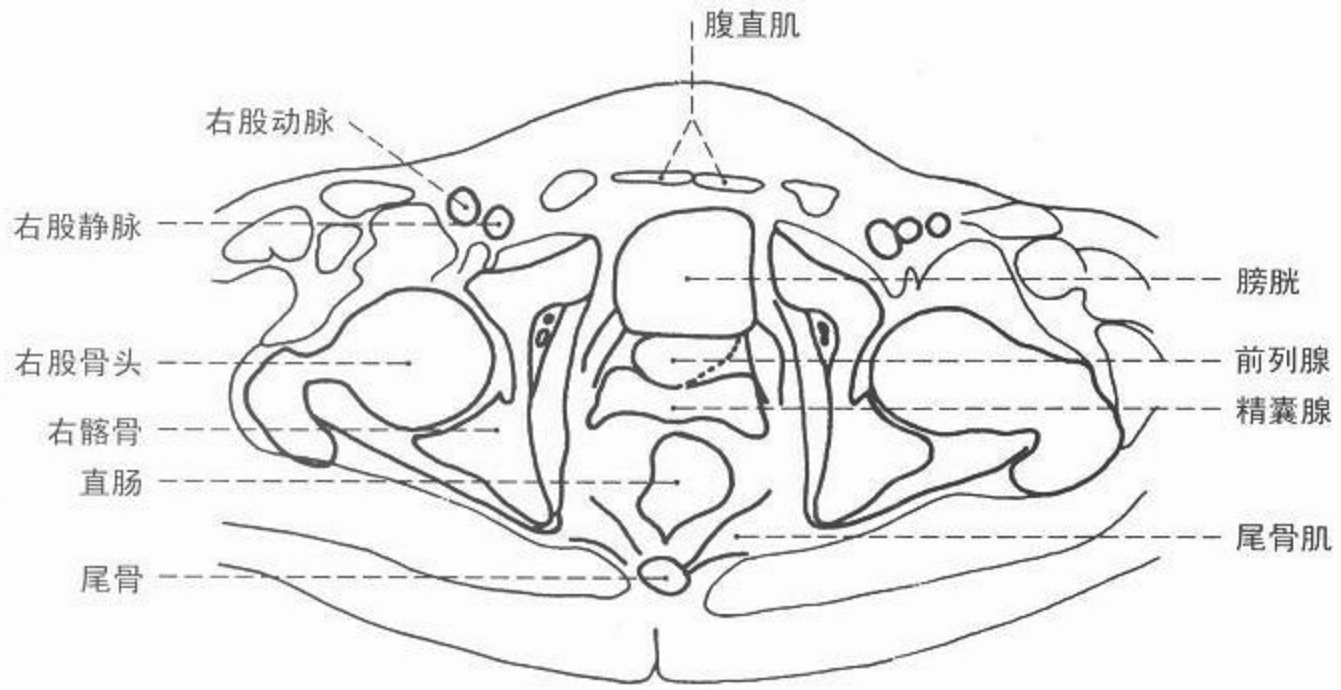


图 173 盆腔 CT 轴位像，  
髌臼顶层面



CT



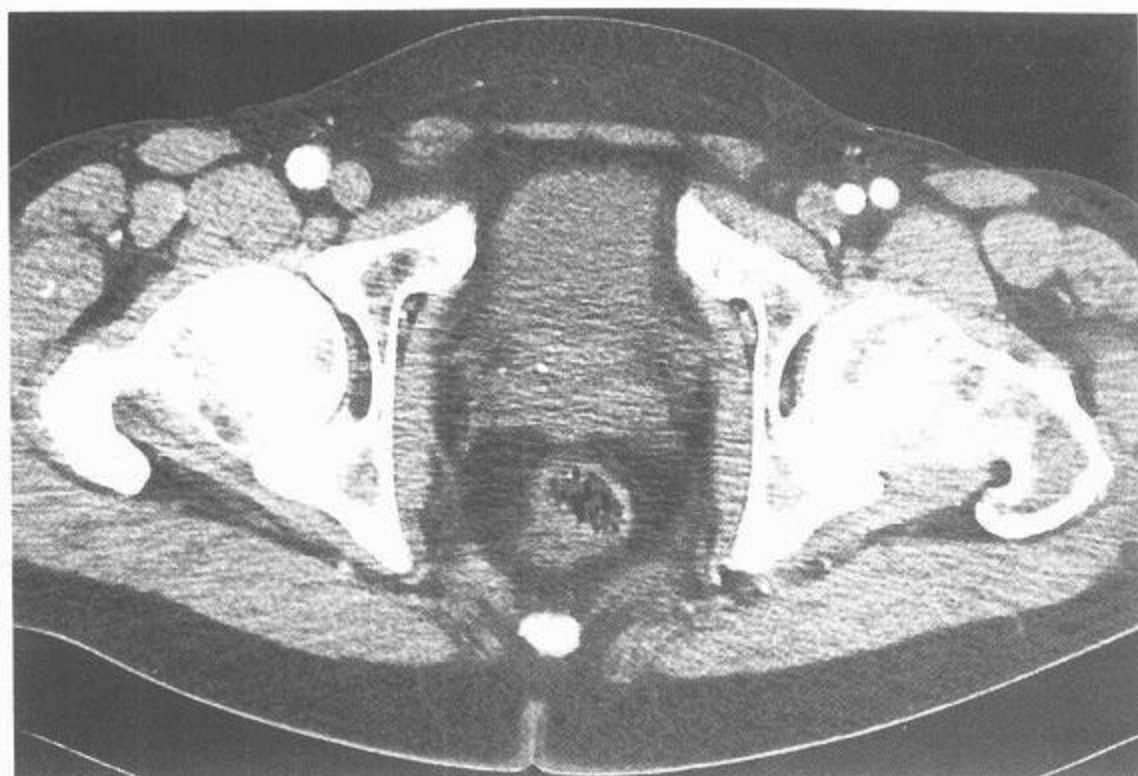
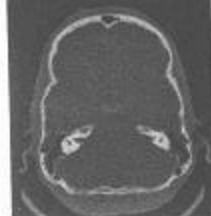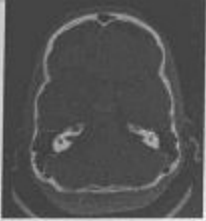


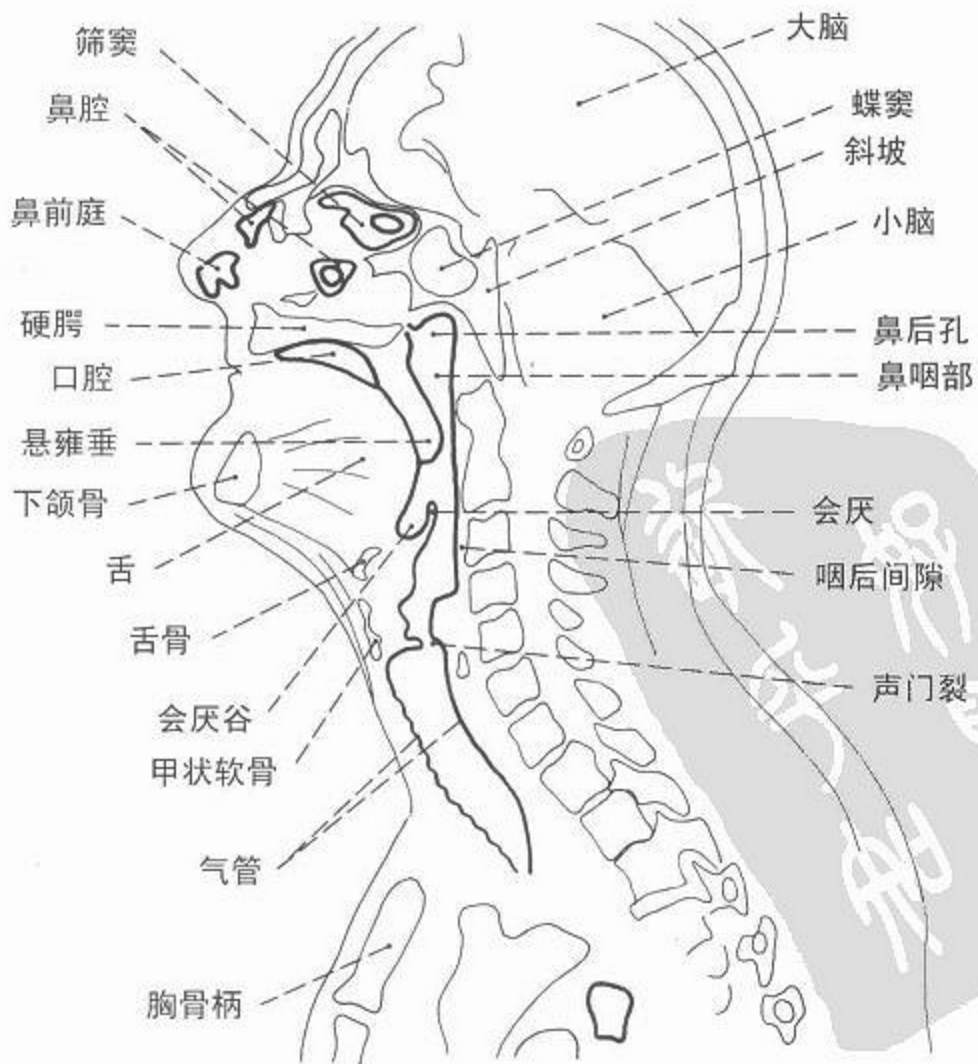
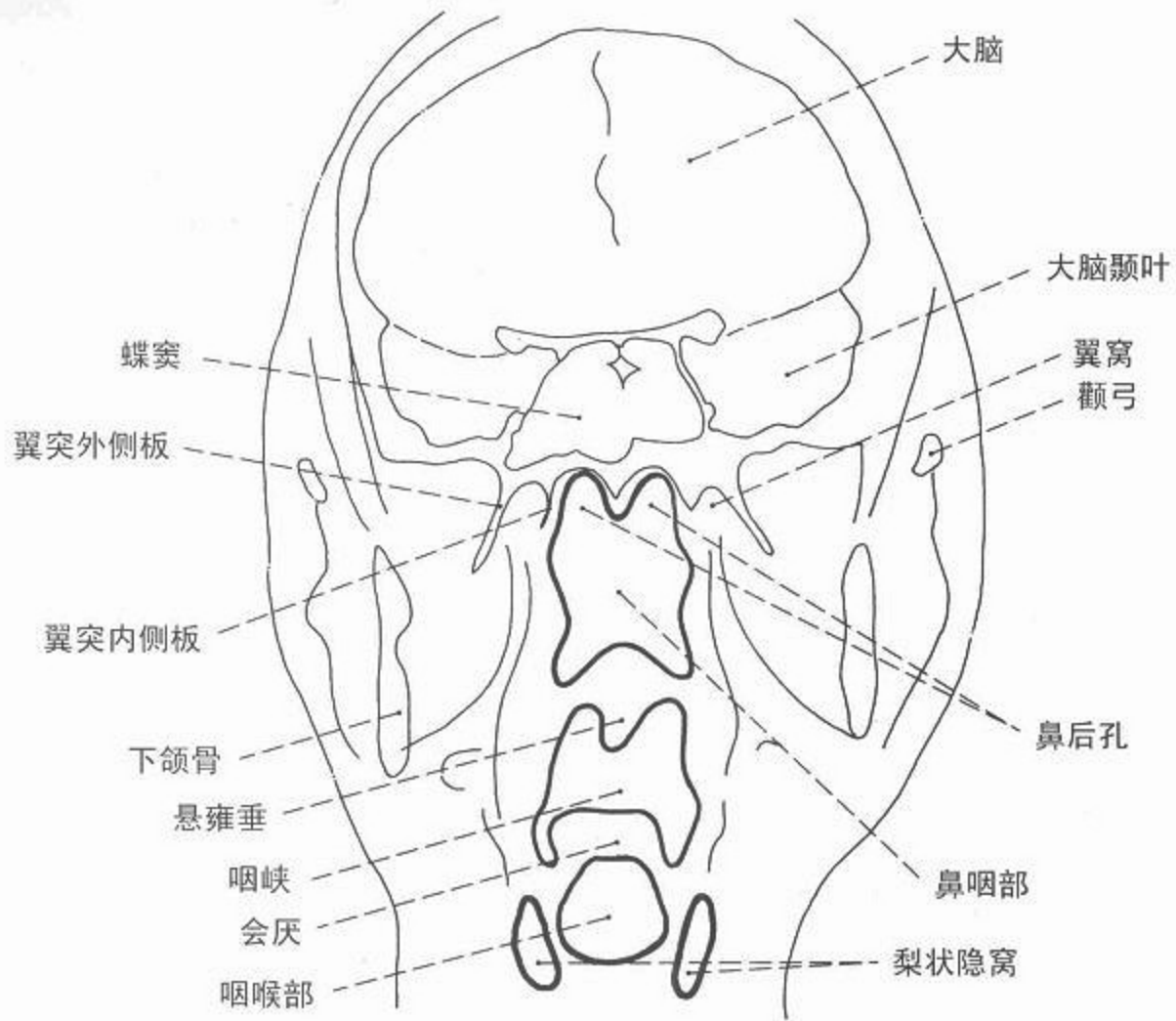
图 174 男性盆腔 CT 轴位像，  
精囊腺层面

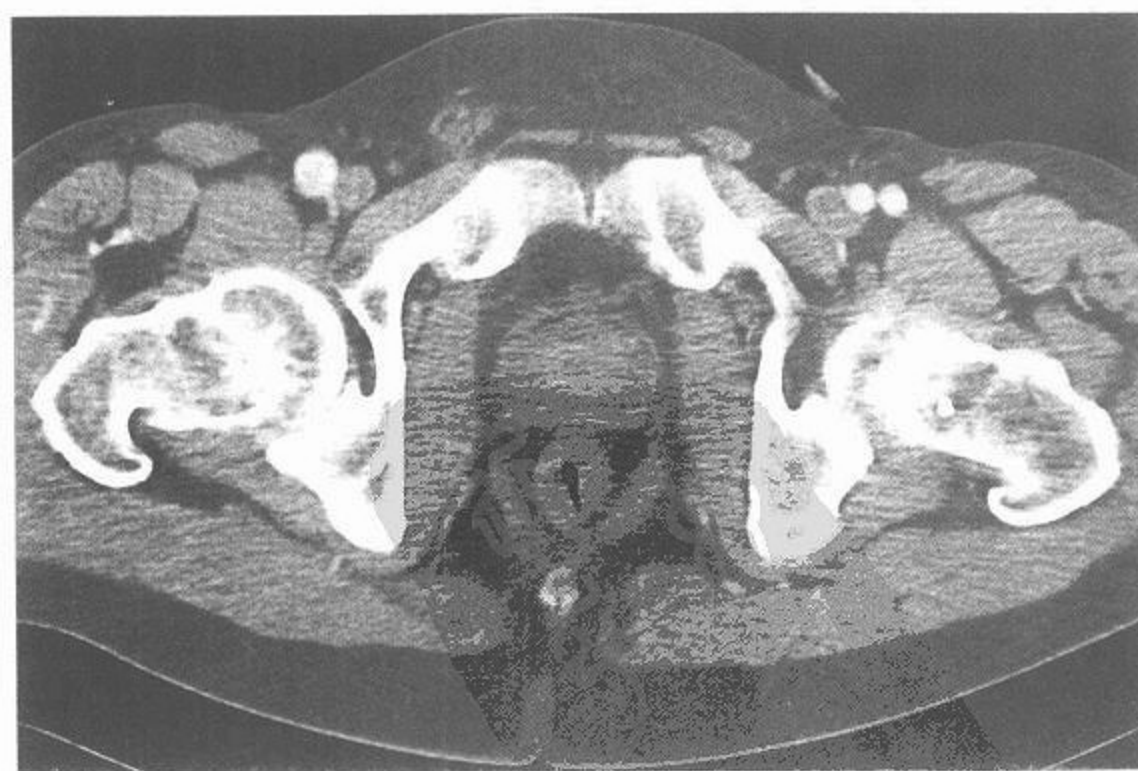

图 175 男性盆腔 CT 轴位像，  
前列腺层面



CT



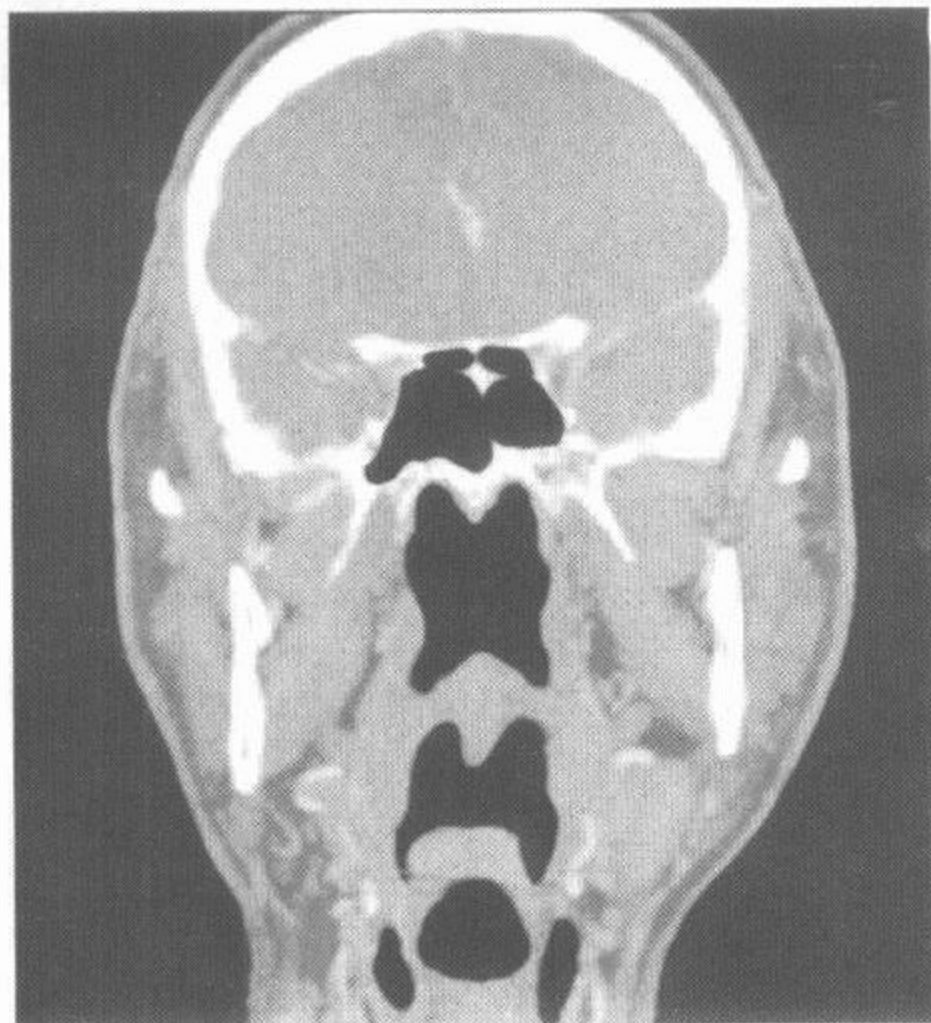
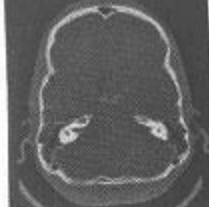

图 176 颈部,冠状面(多排螺旋 CT 重建图)

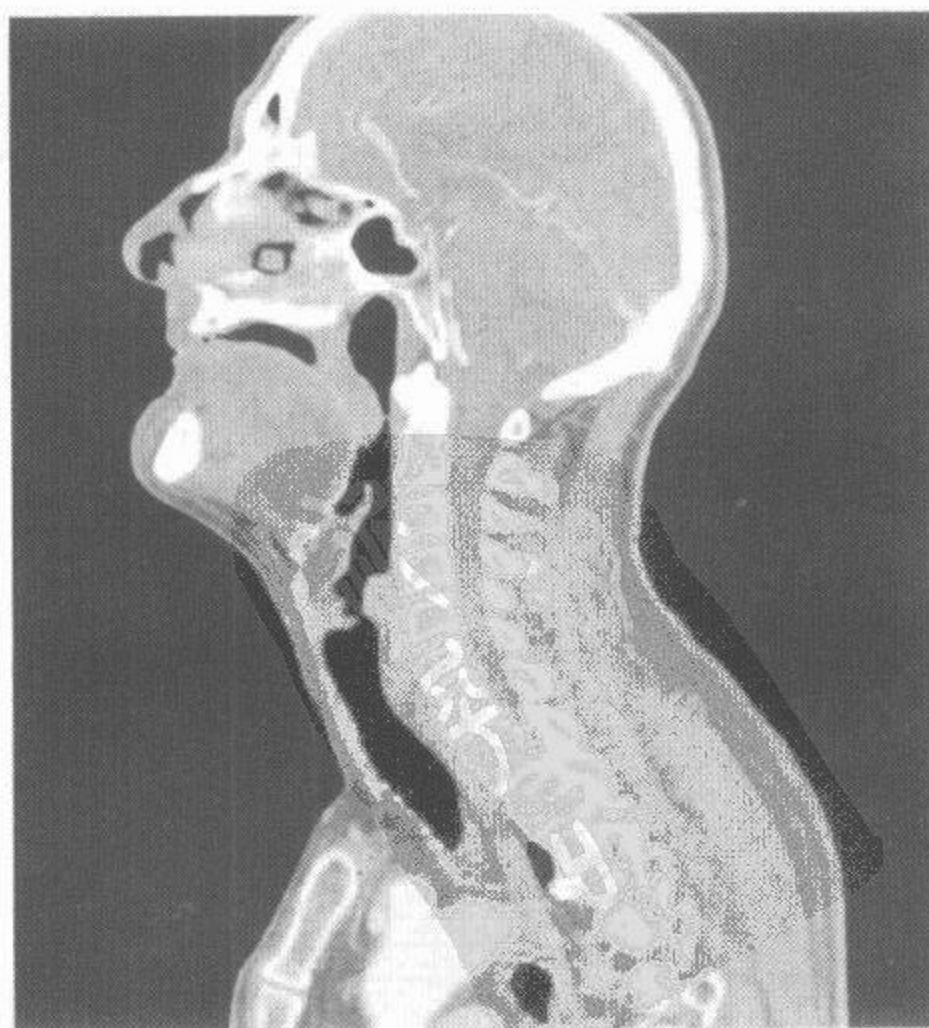
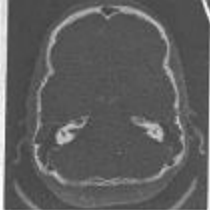
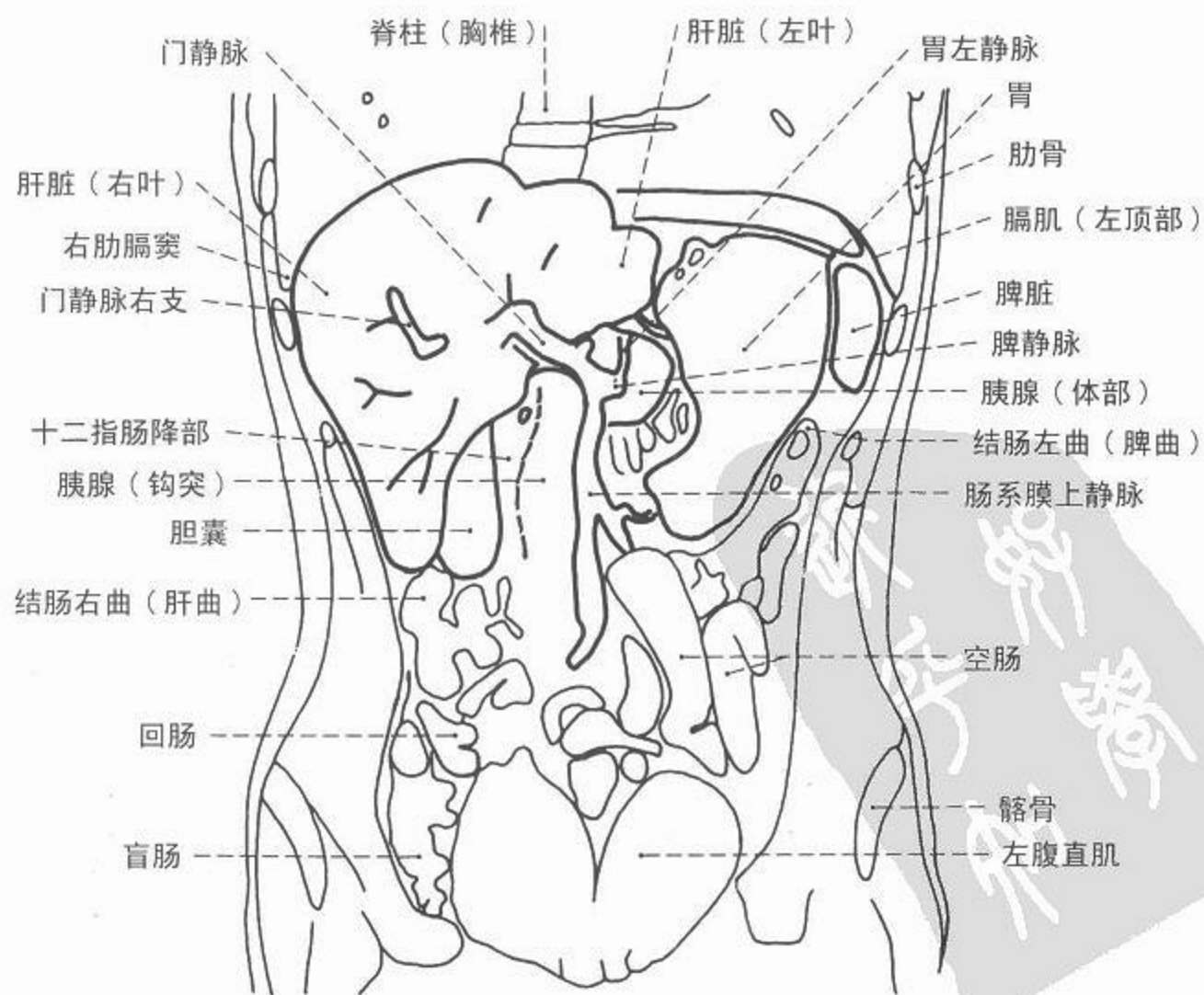
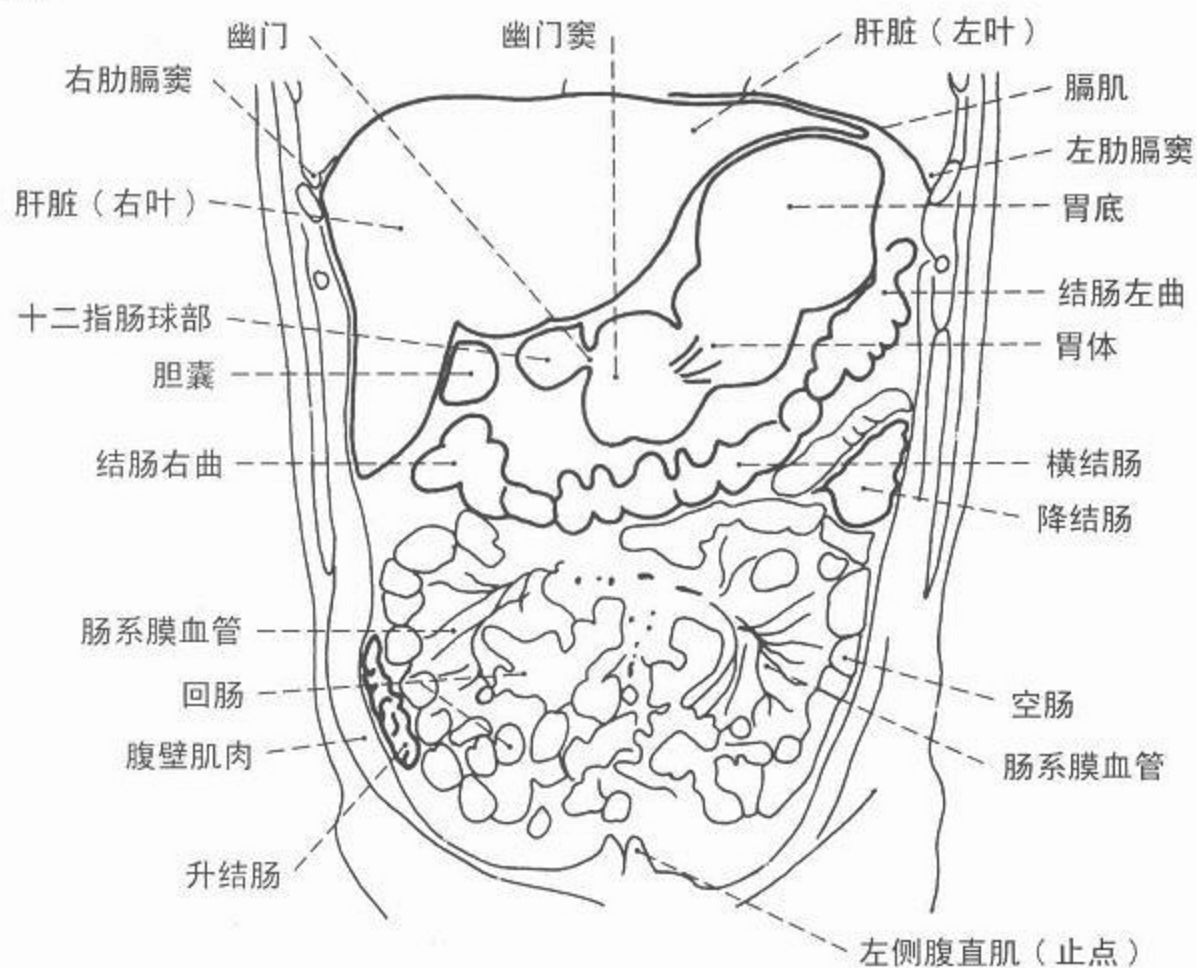


图 177 颈部,正中矢状面(多排螺旋 CT 重建图)





CT



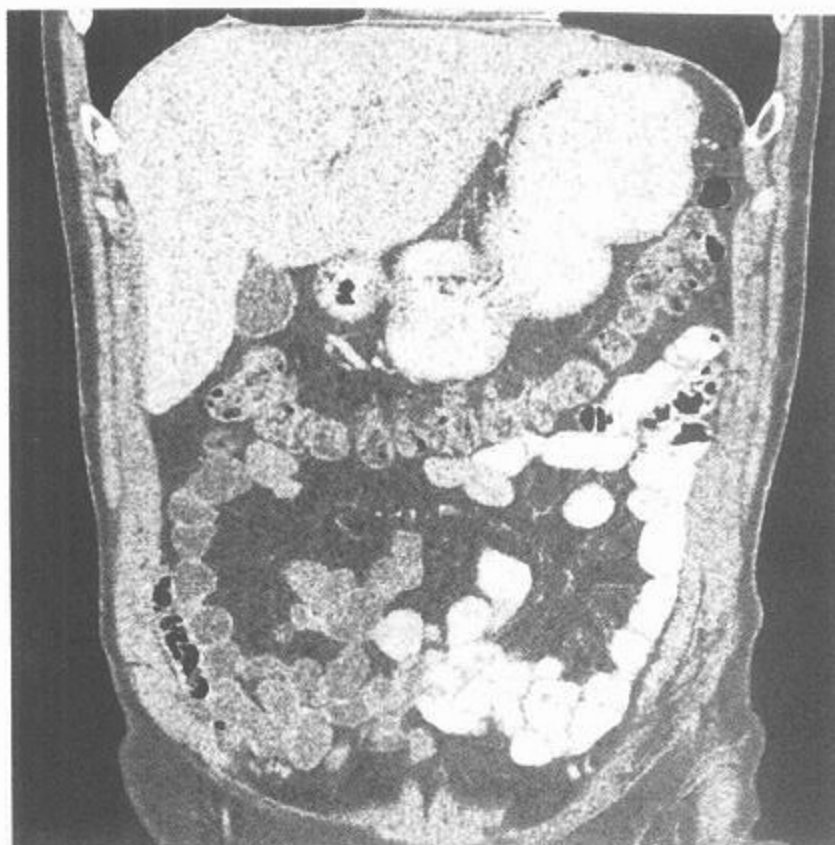
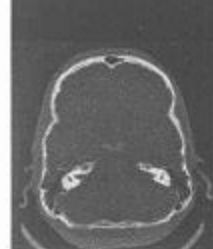
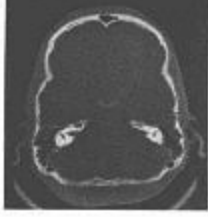


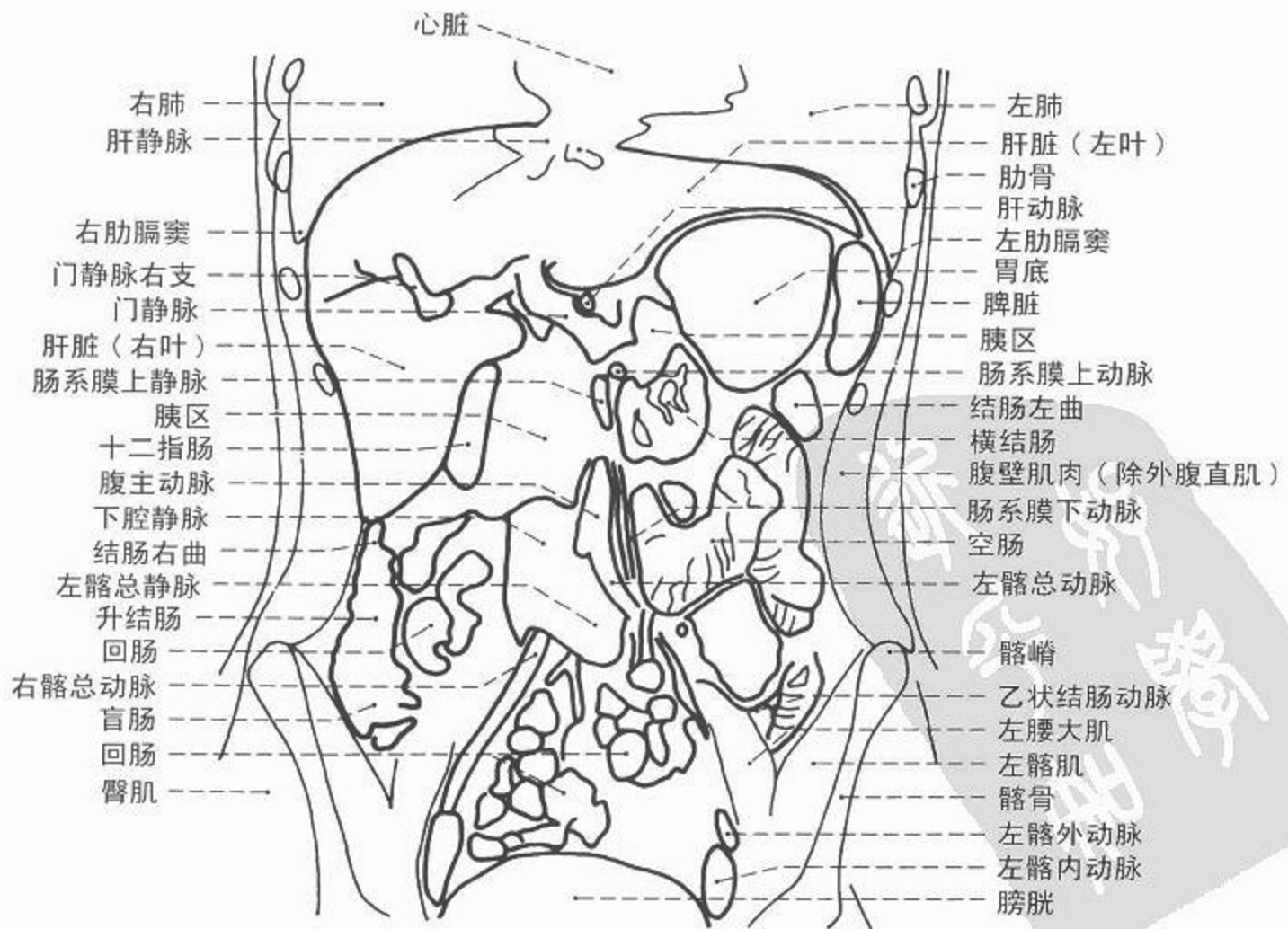
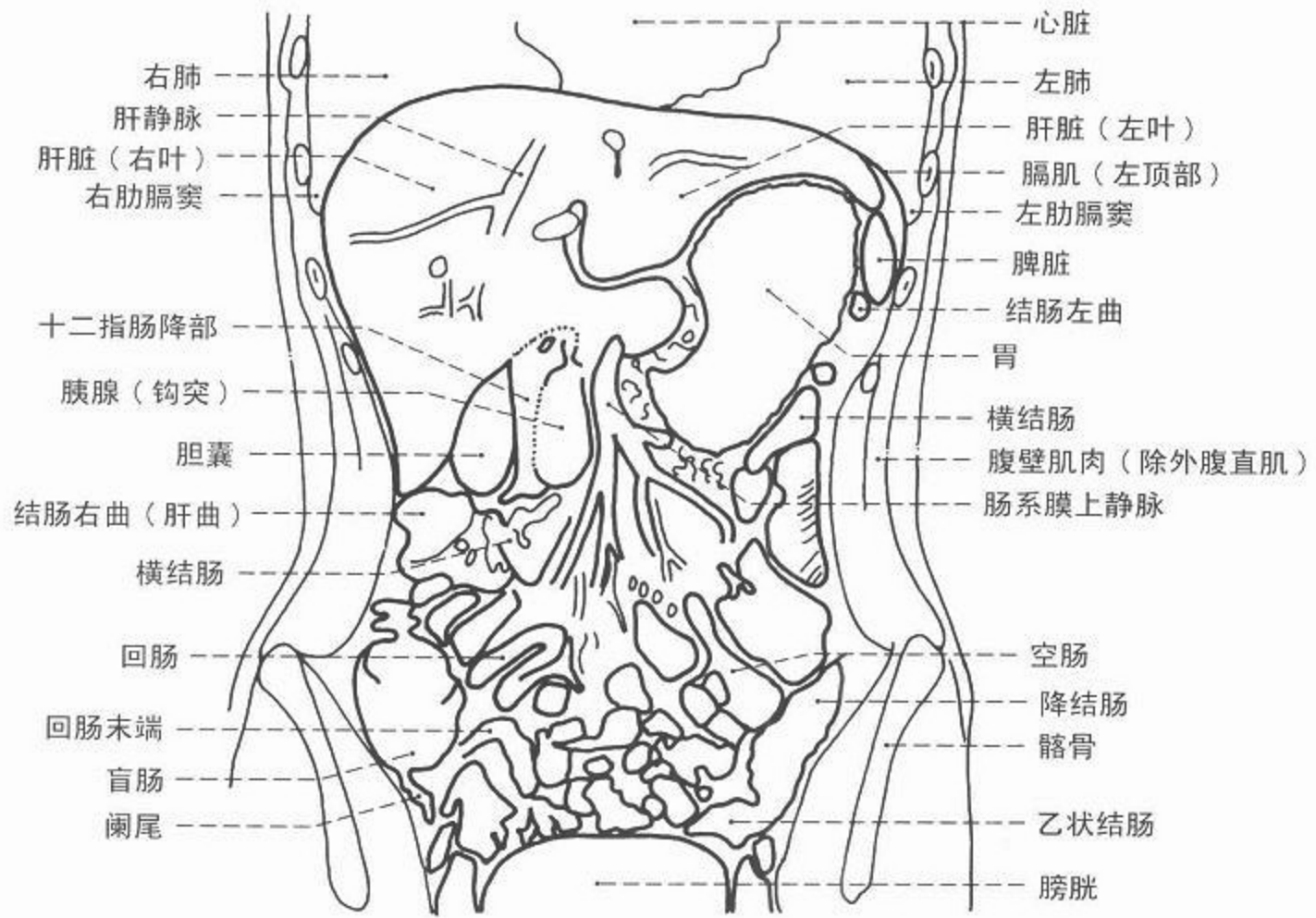
图 178 腹部冠状面(多排螺旋CT重建图),耻骨联合前层面

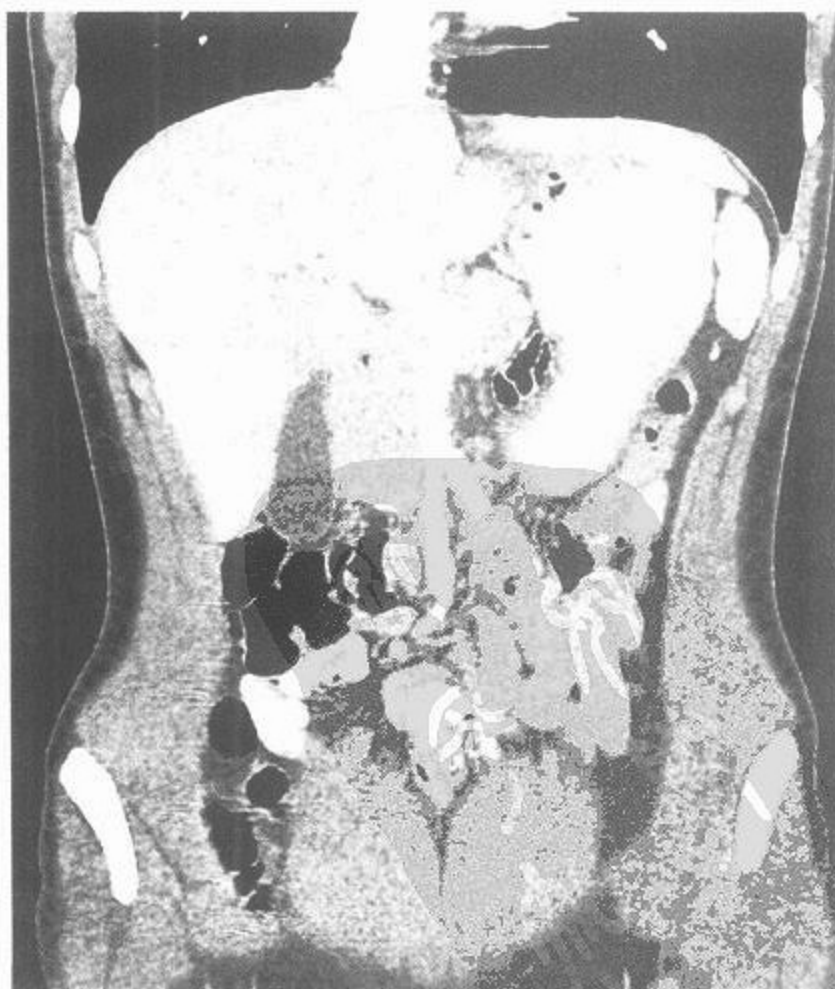

图 179 腹部冠状面(多排螺旋CT重建图),门静脉层面



CT



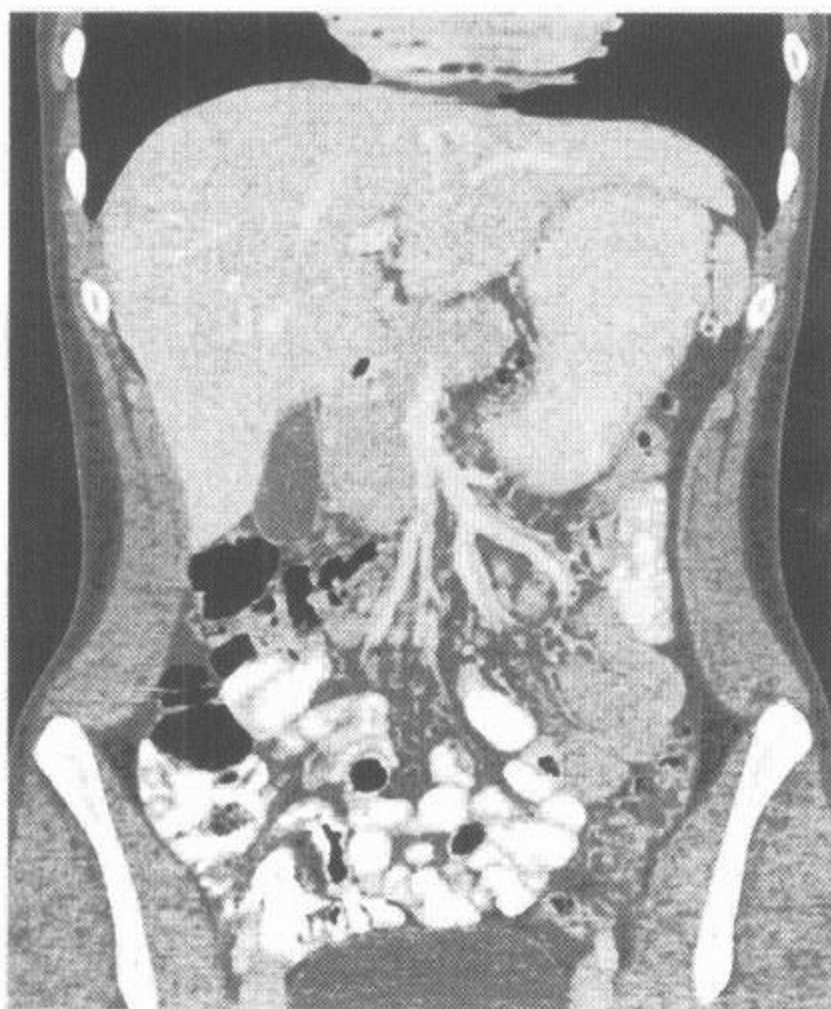
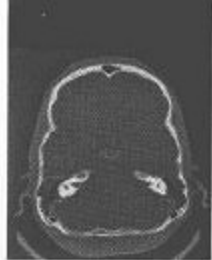

图 180 腹部冠状面(多排螺旋 CT 重建图),  
肠系膜上静脉层面

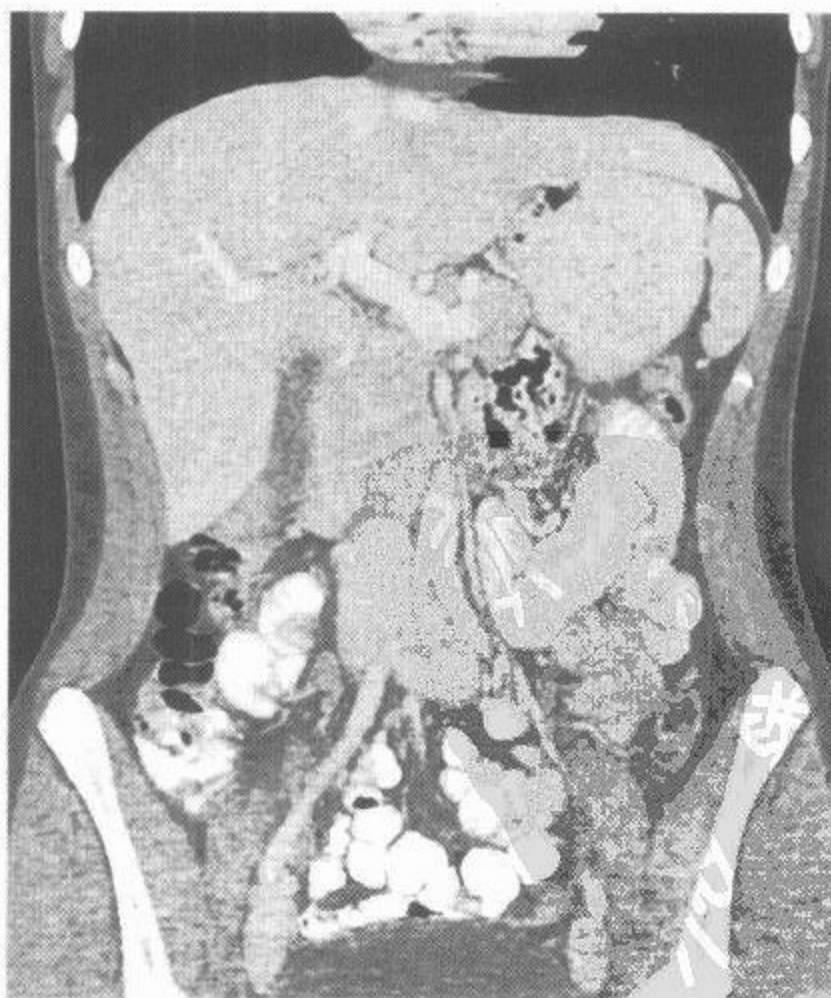
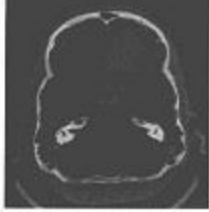
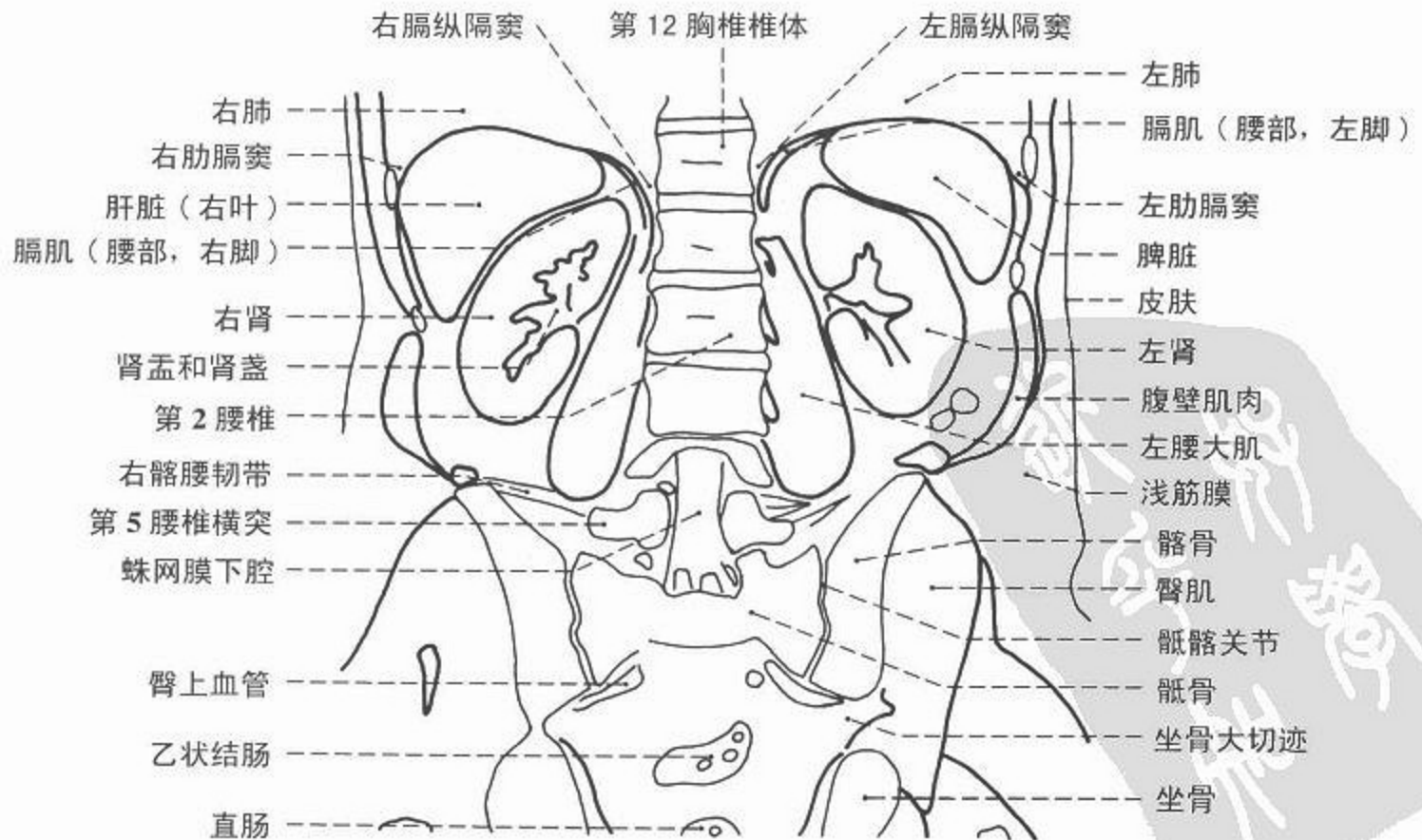
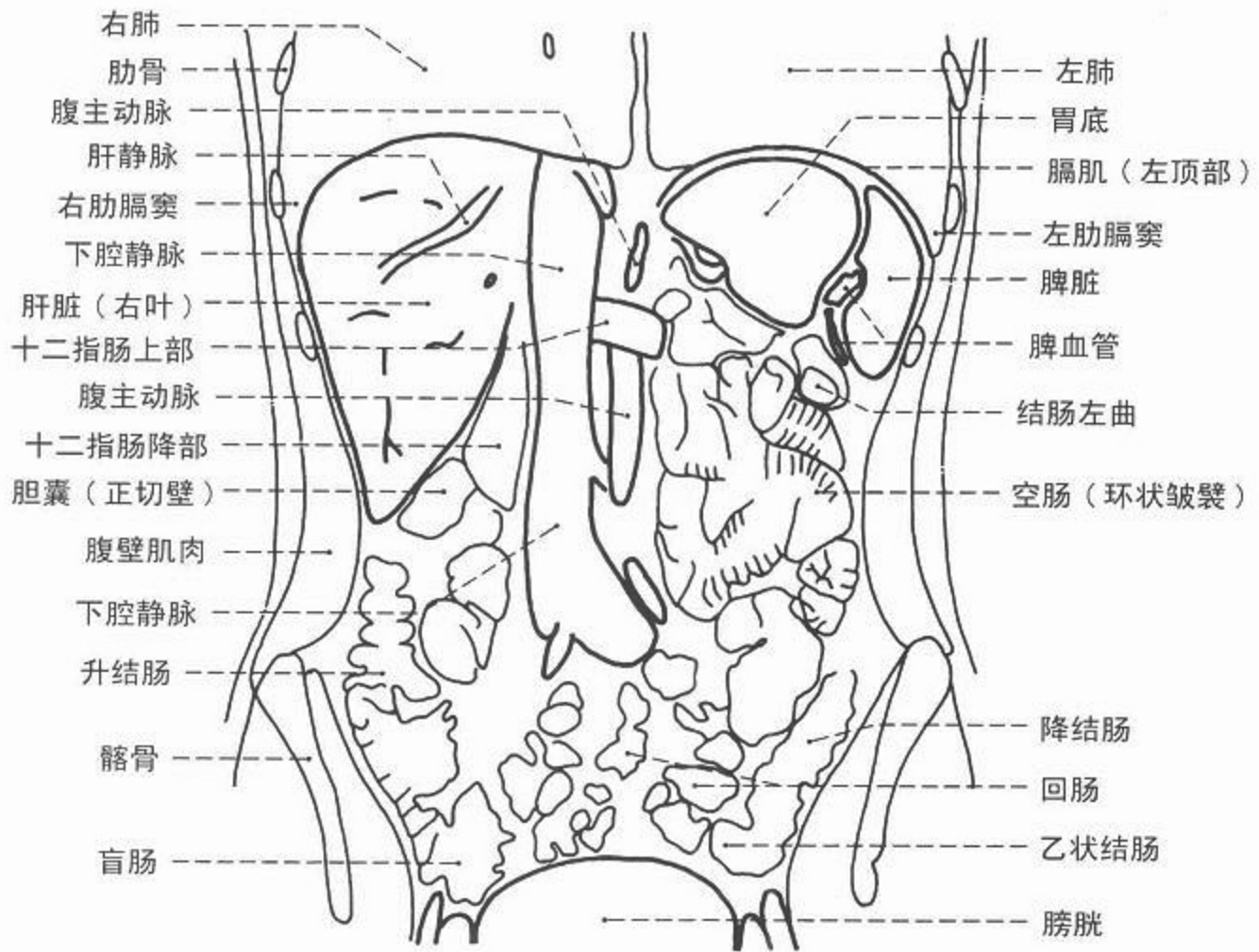


图 181 腹部冠状面(多排螺旋 CT 重建图),  
腹主动脉分叉层面



# CT



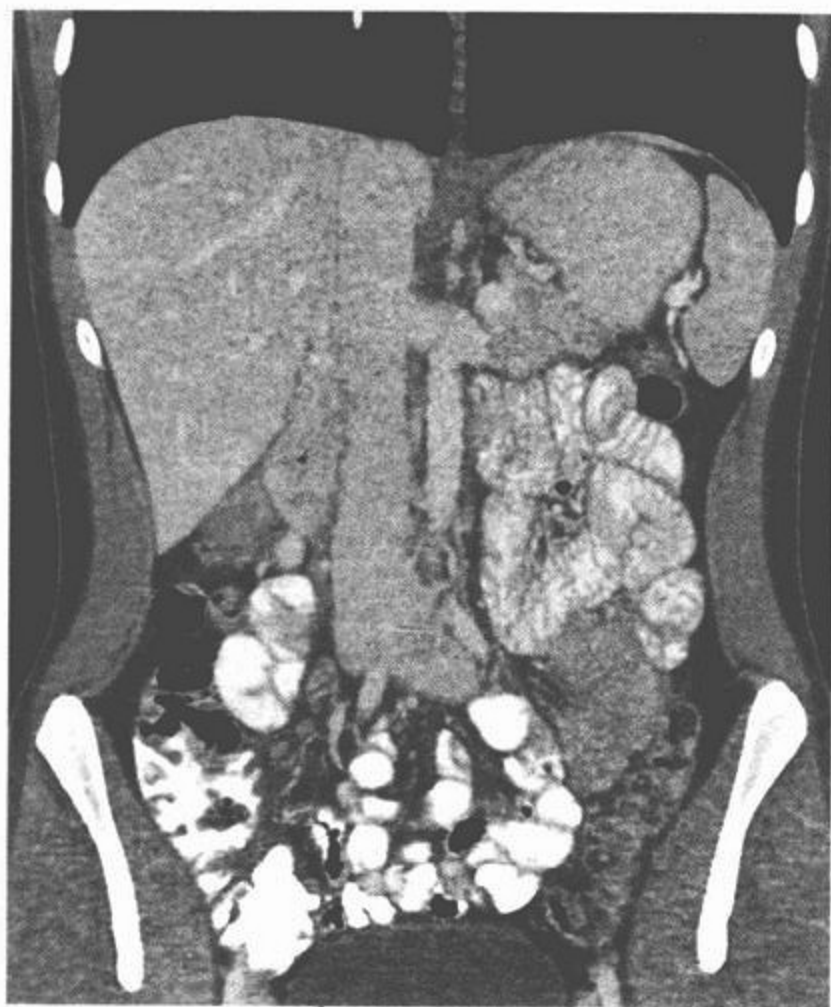


图 182 腹部冠状面(多排螺旋CT重建图),下腔静脉层面

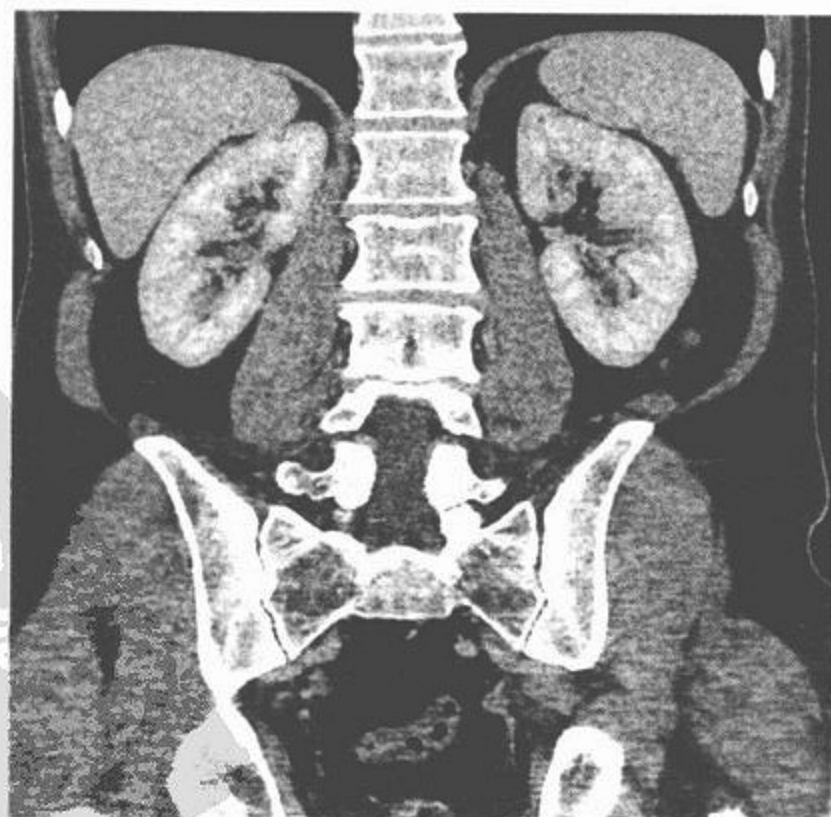
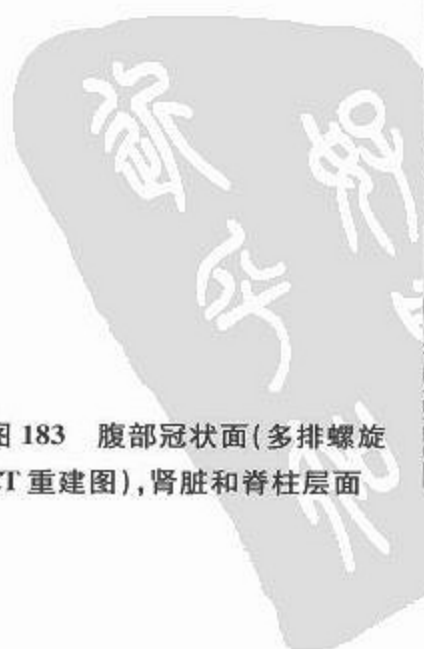
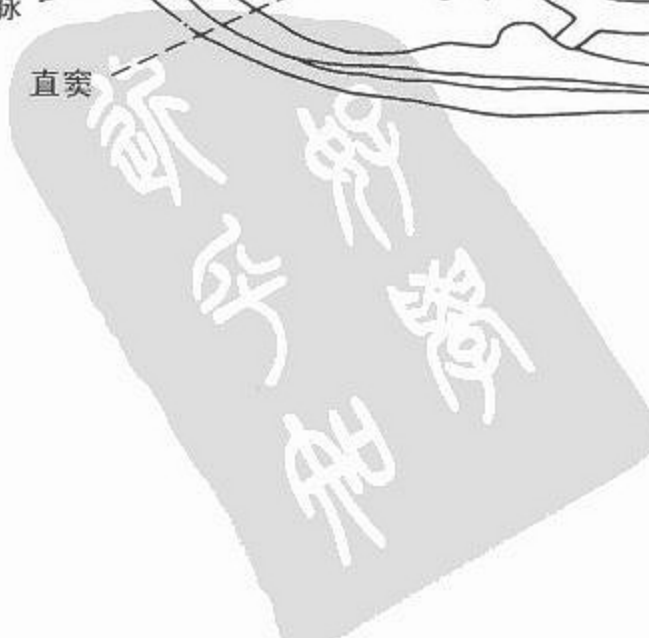
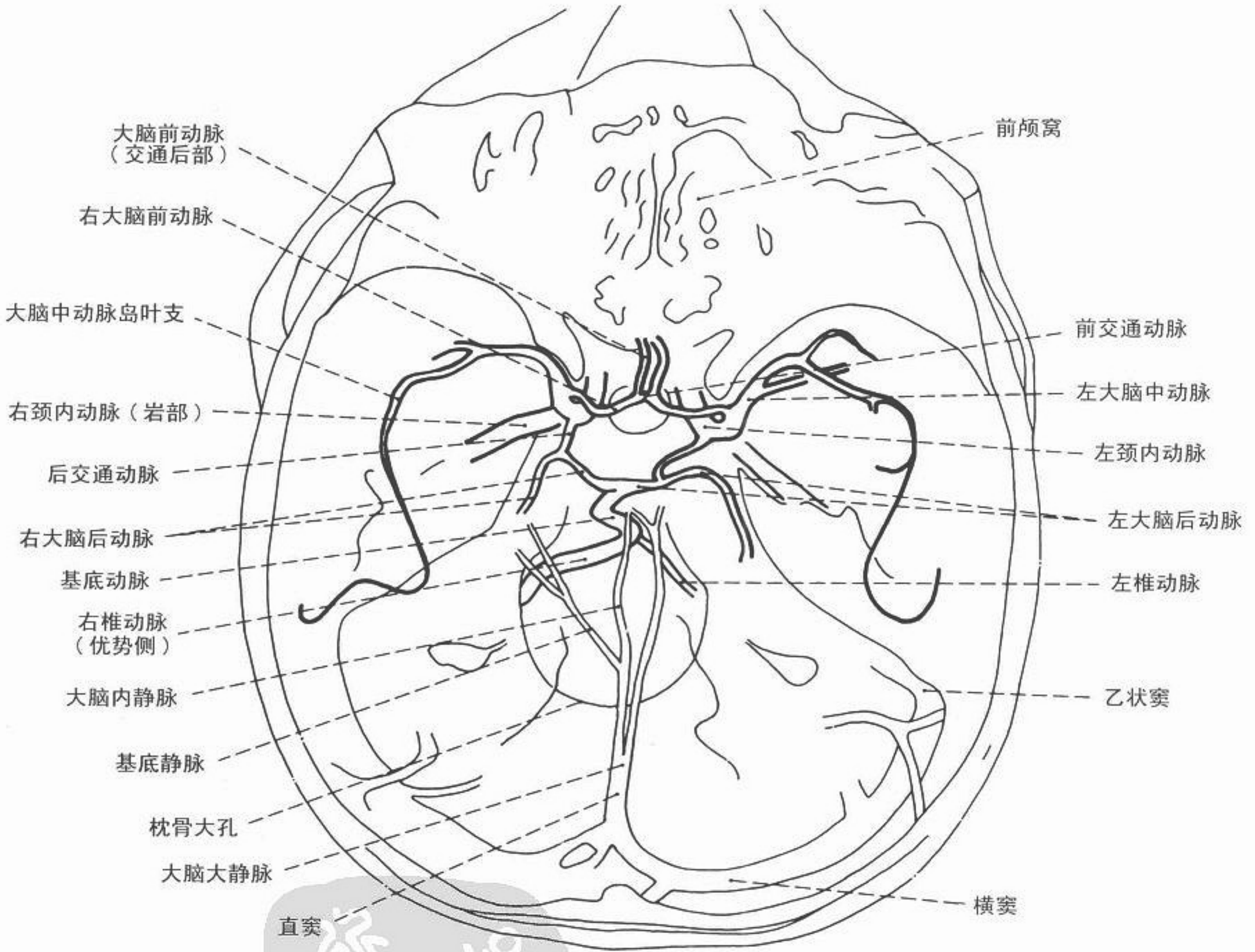


图 183 腹部冠状面(多排螺旋CT重建图),肾脏和脊柱层面



# CT 血管造影



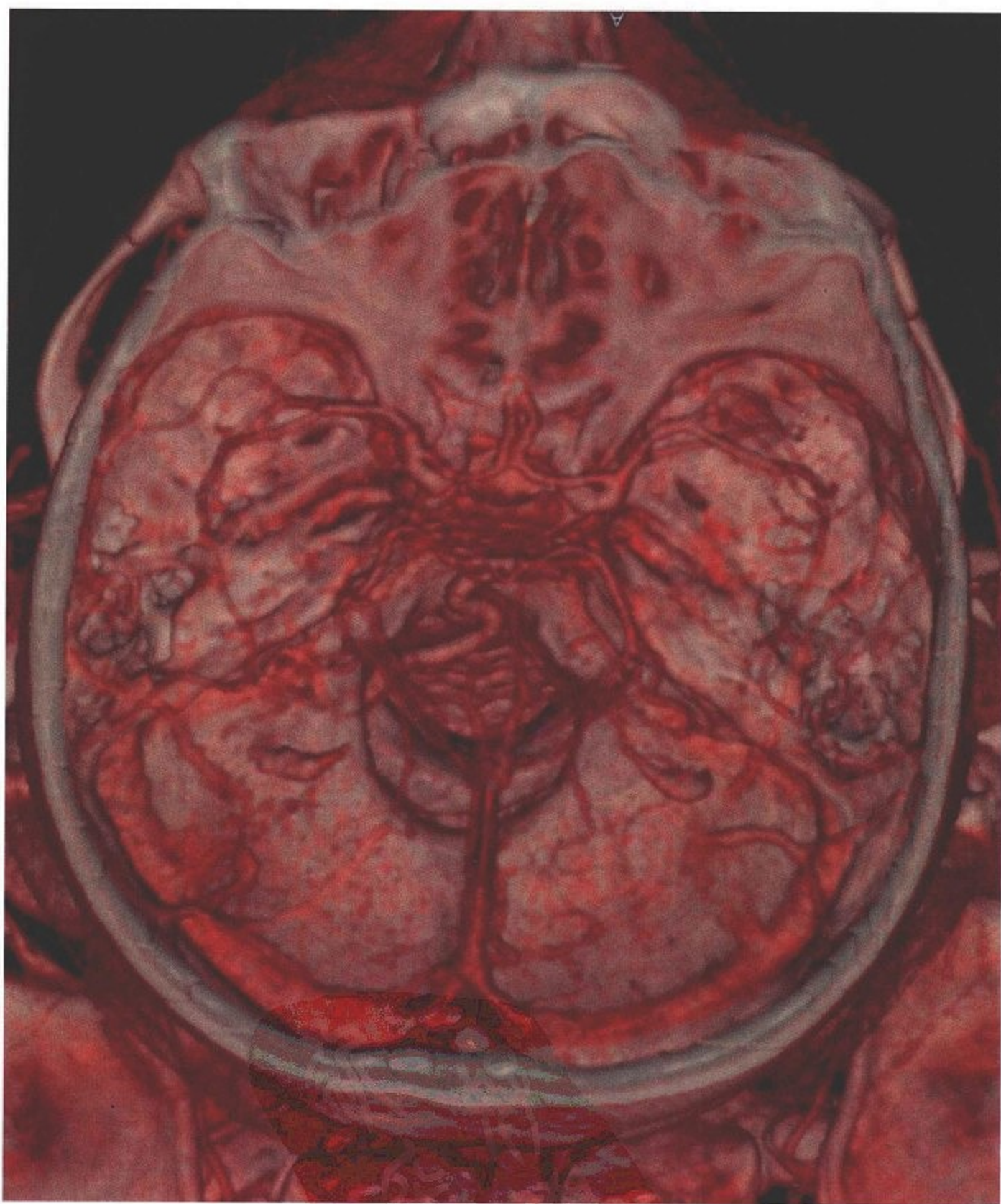
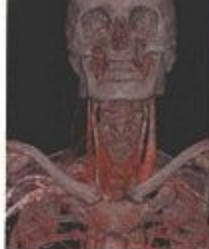
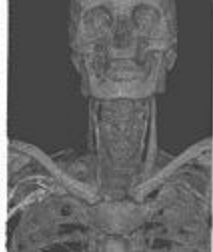
图 184 大脑动脉环(Willisii 环)(多排螺旋 CT 容积再现)





# CT 血管造影

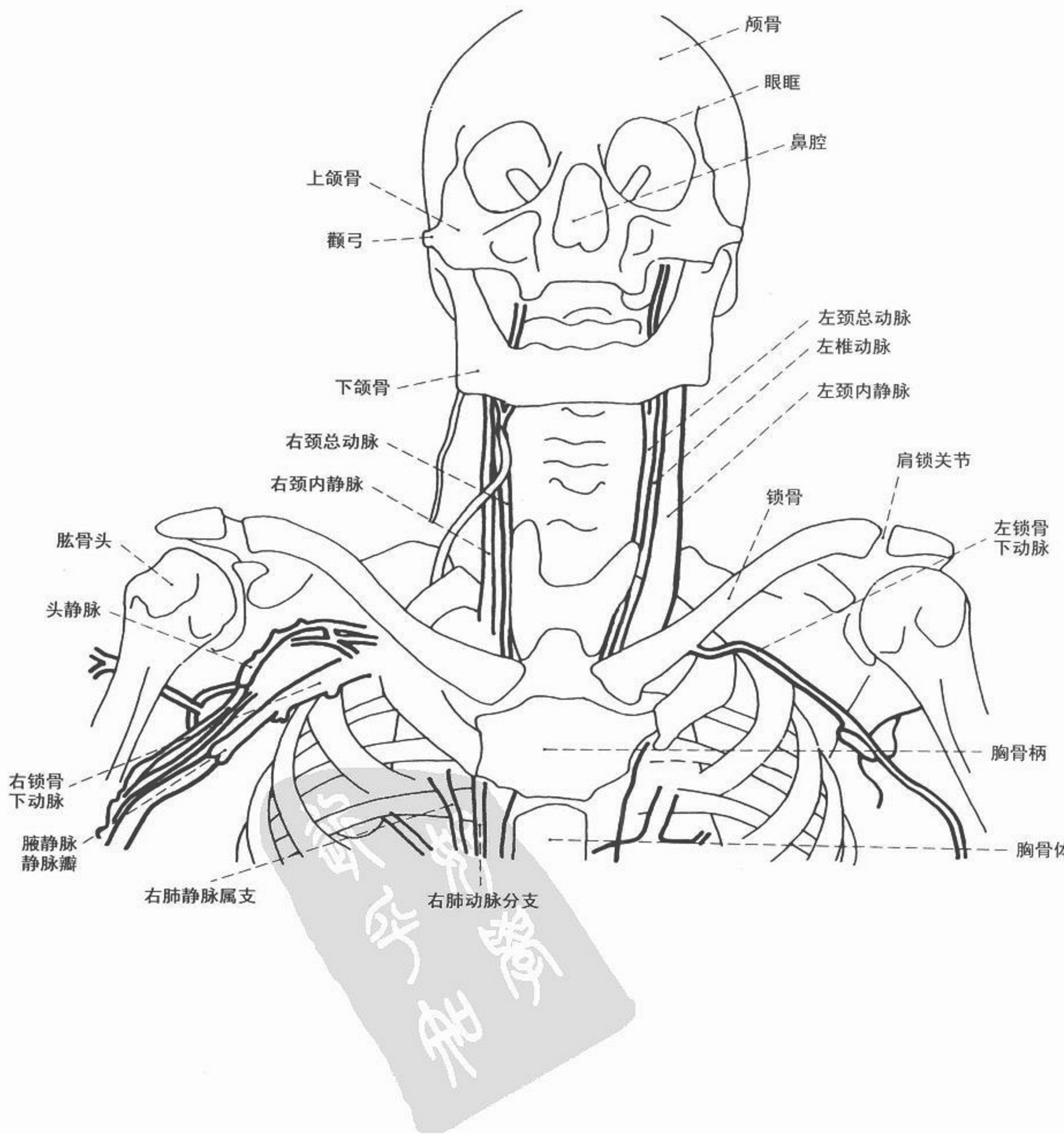

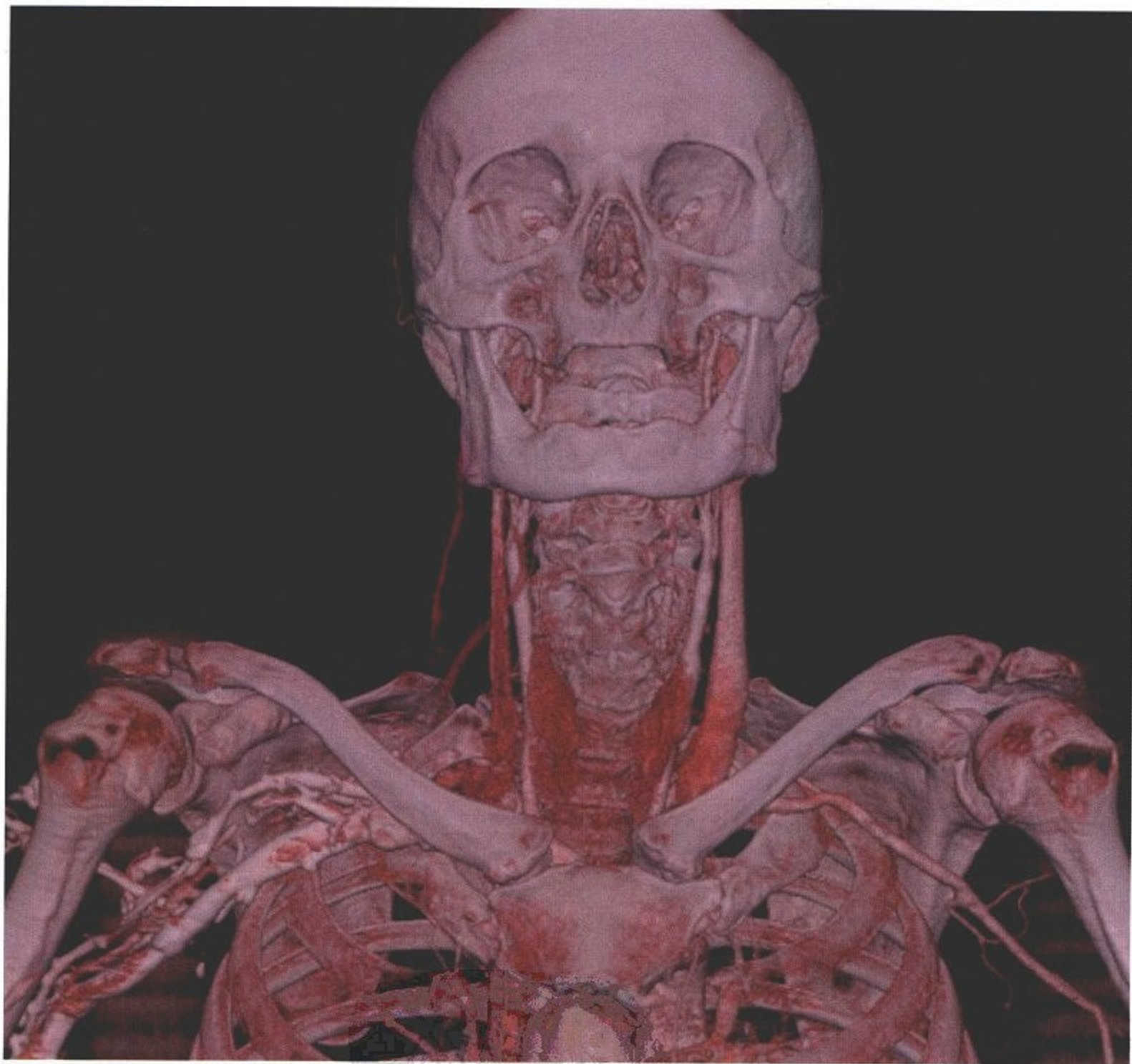
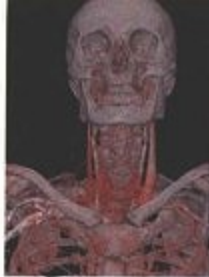
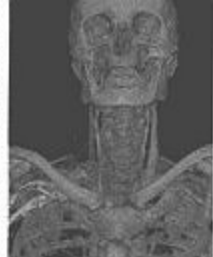
图 185 胸廓入口处血管造影(多排螺旋 CT 容积再现技术)

中华  
医学



# CT 血管造影

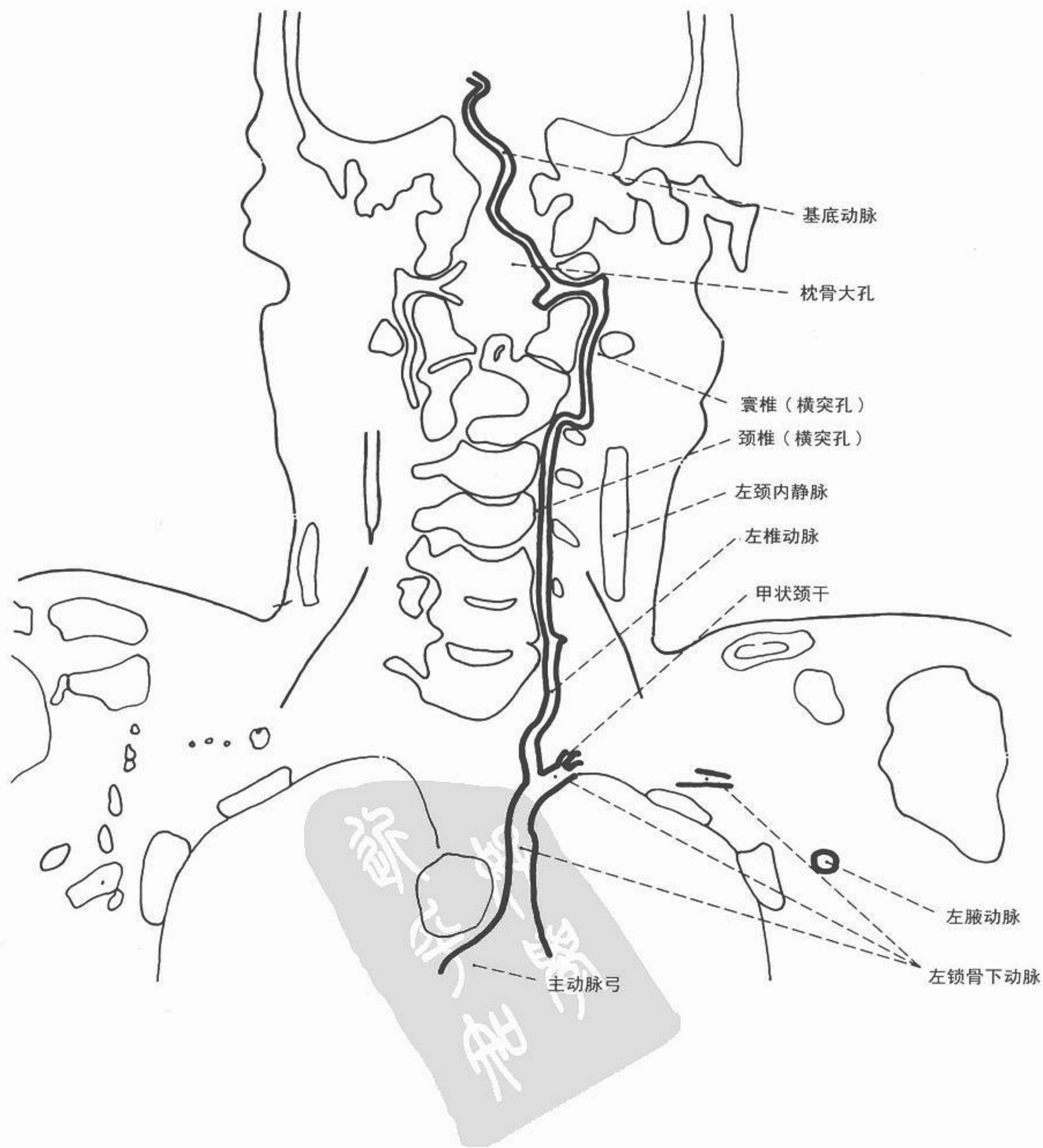

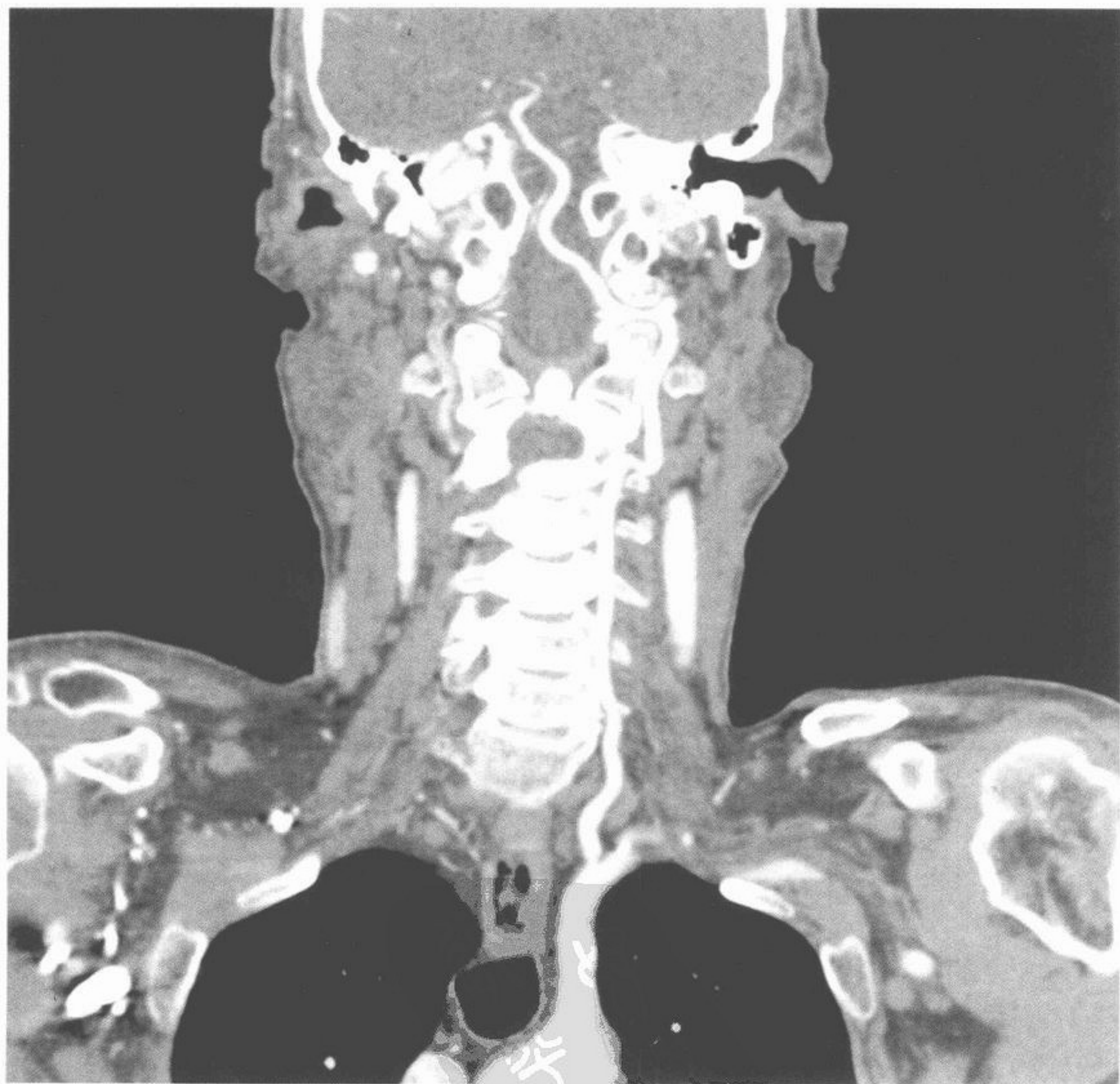
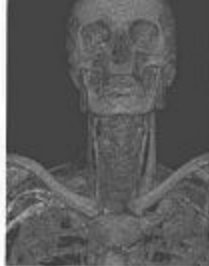
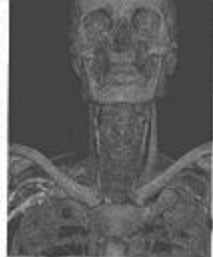
图 186 椎动脉血管造影(多排螺旋 CT 曲面重建技术)



# CT 血管造影

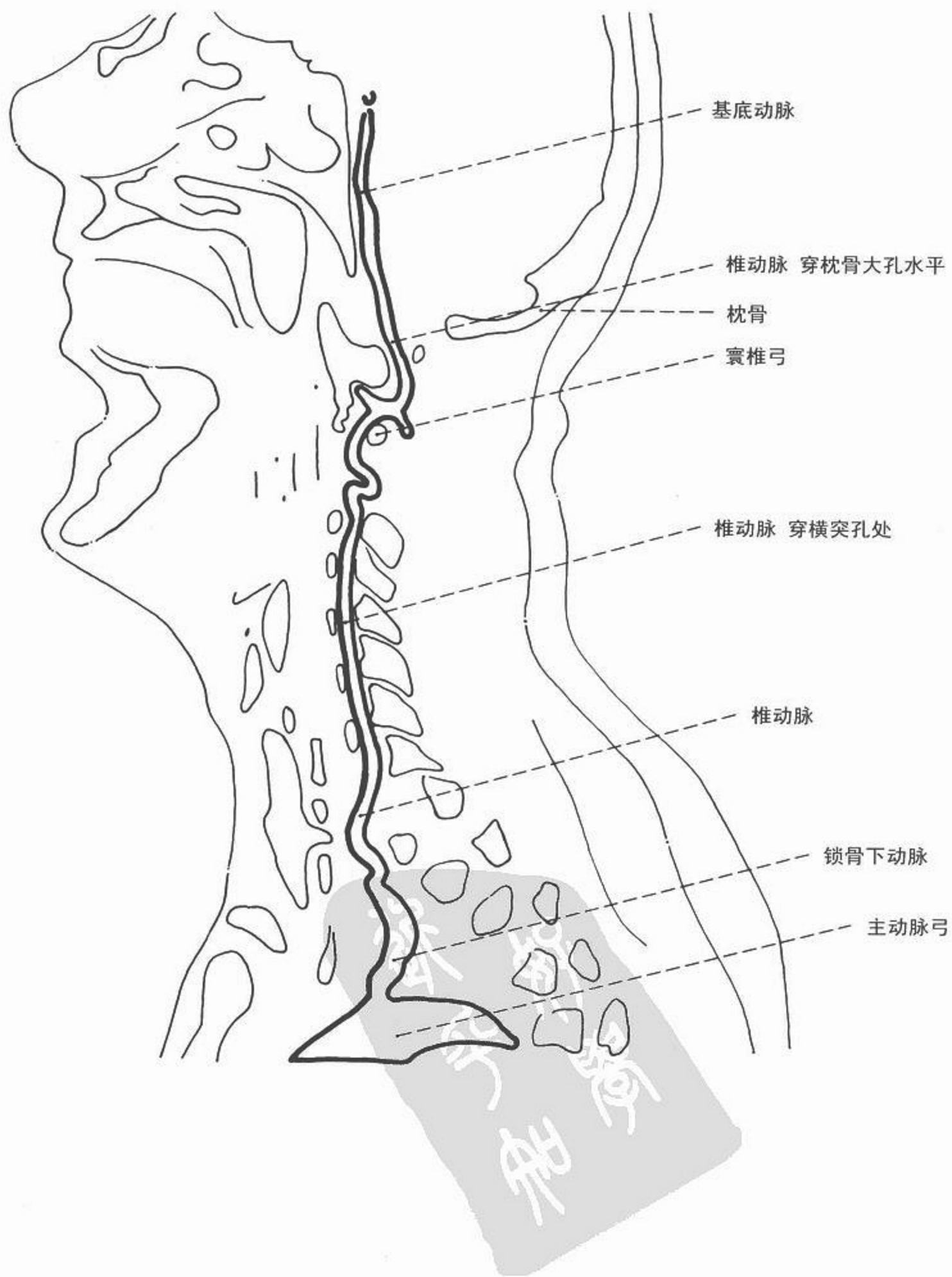
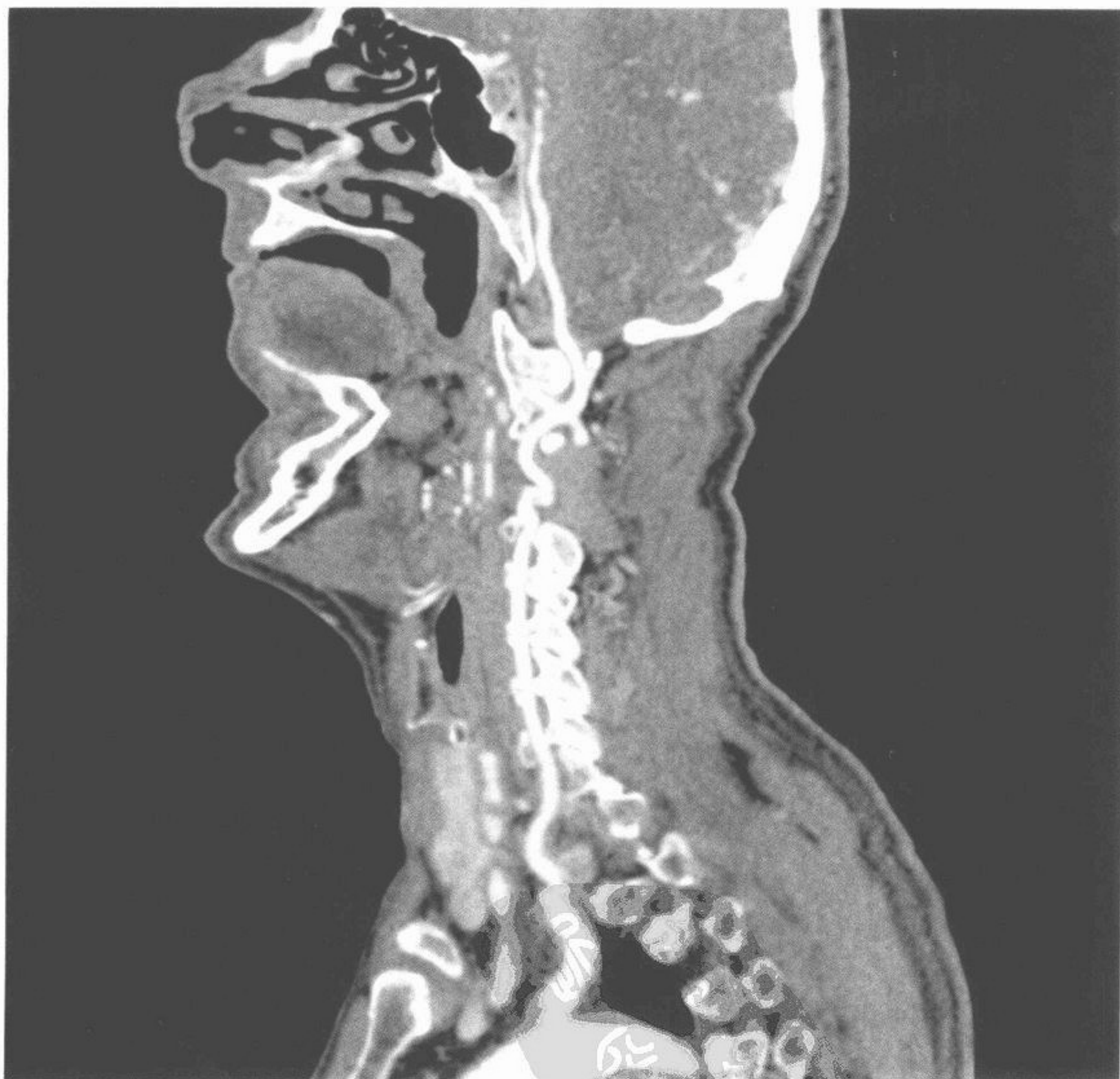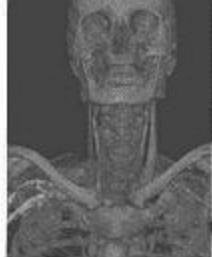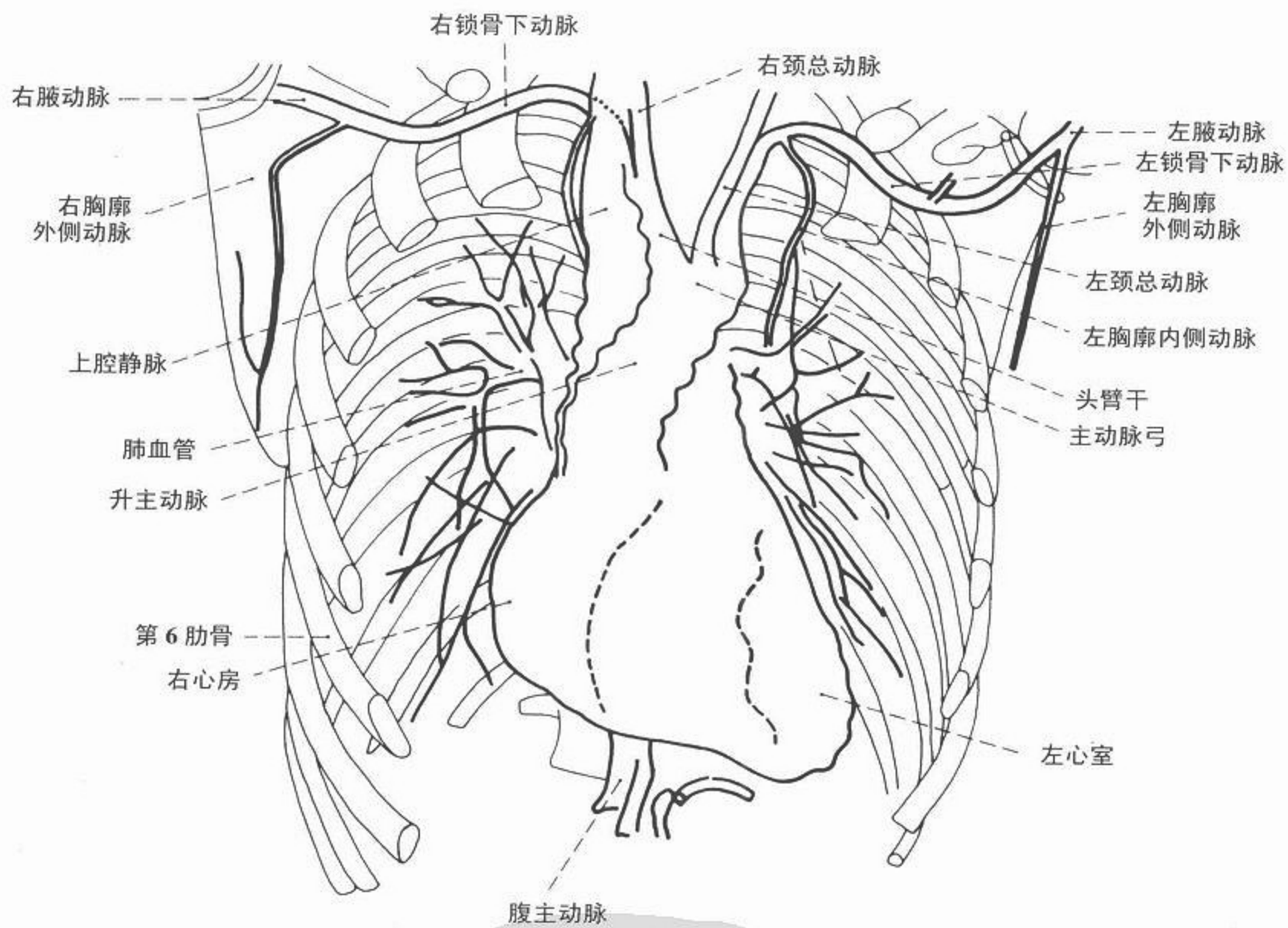




图 187 椎动脉血管造影,侧位(多排螺旋 CT 曲面重建技术)

# CT 血管造影



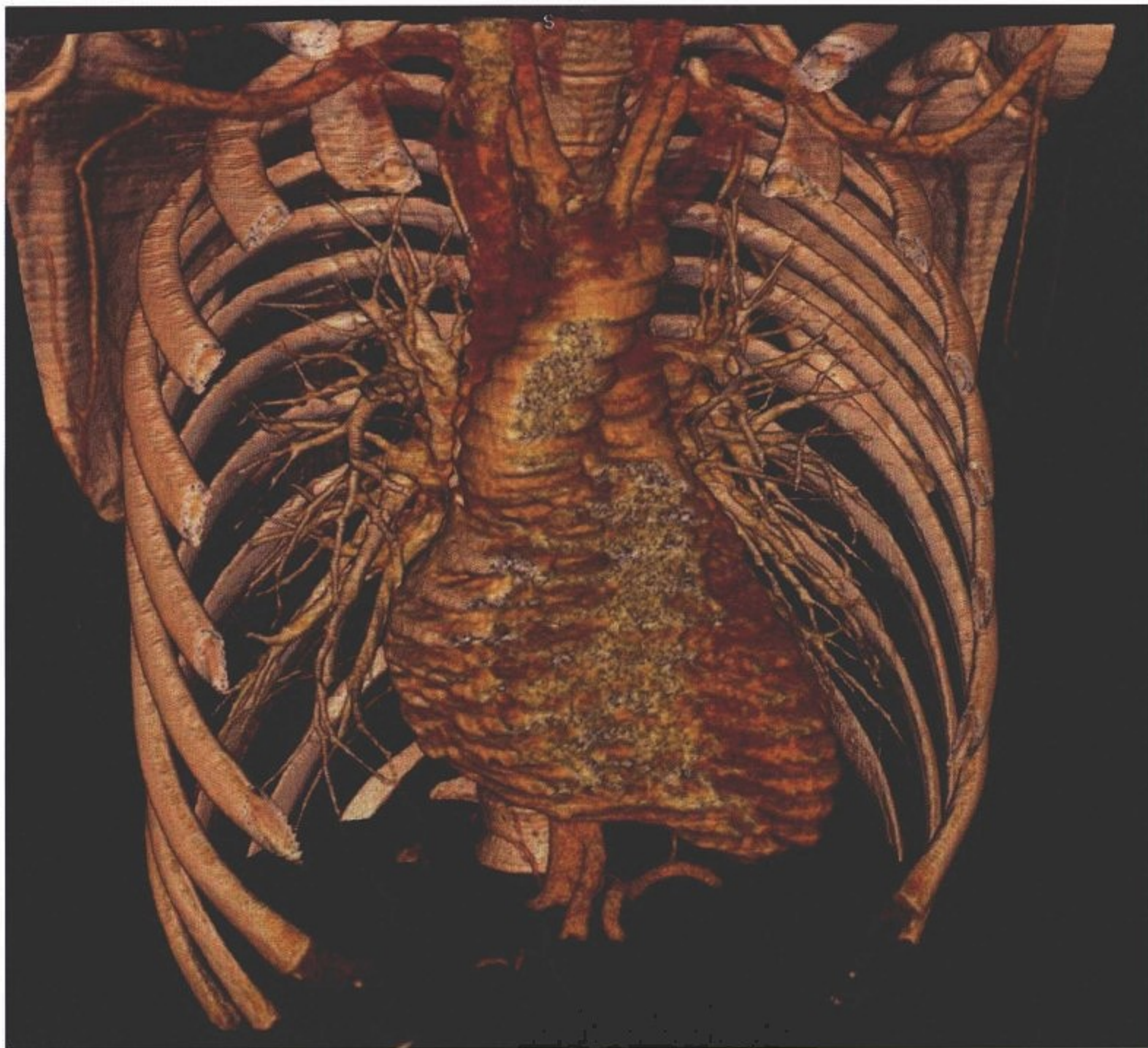
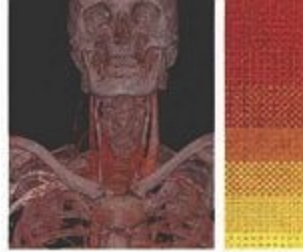
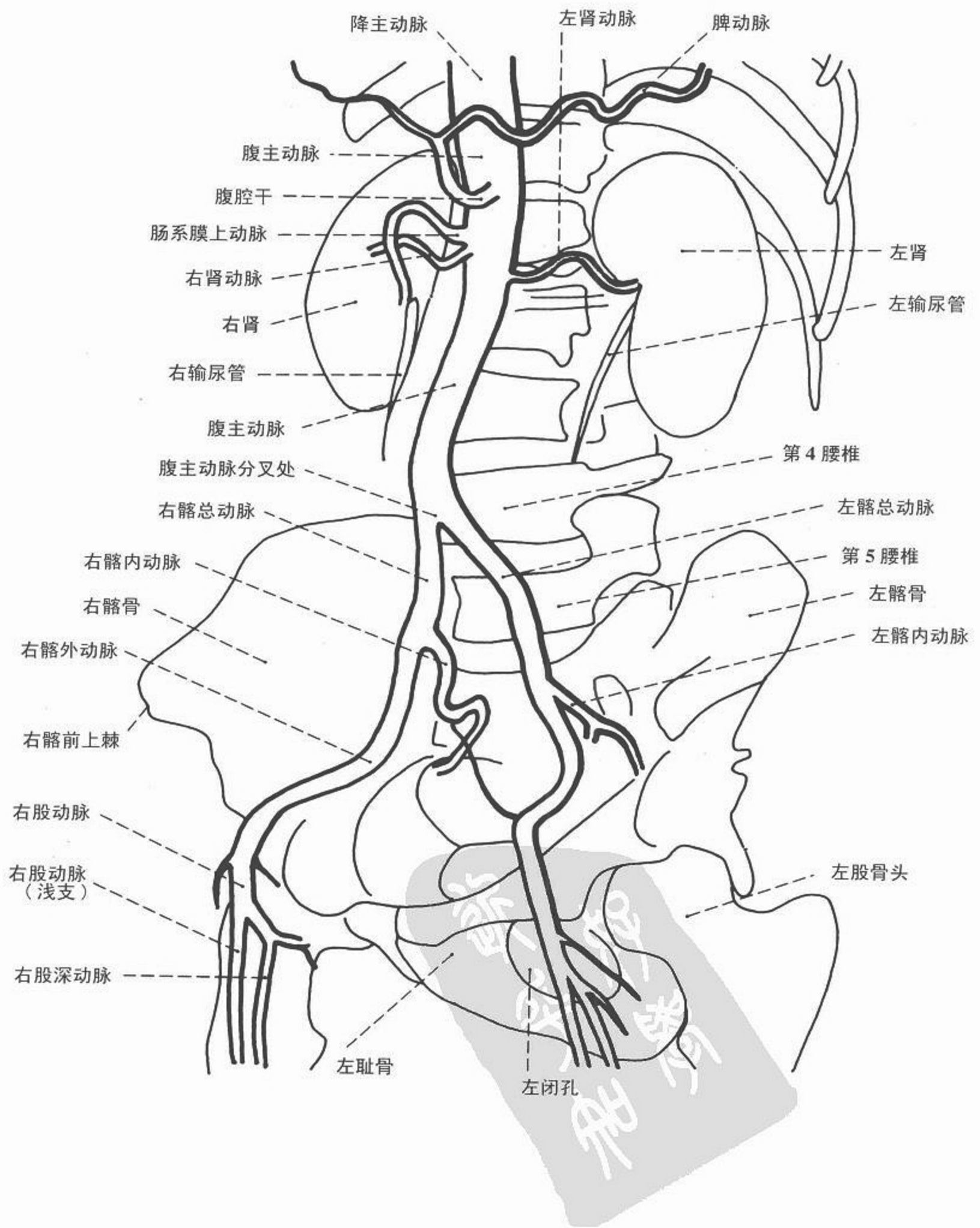


图 188 胸部血管造影(多排螺旋 CT 容积再现技术)

醫學  
影像  
學



# CT 血管造影



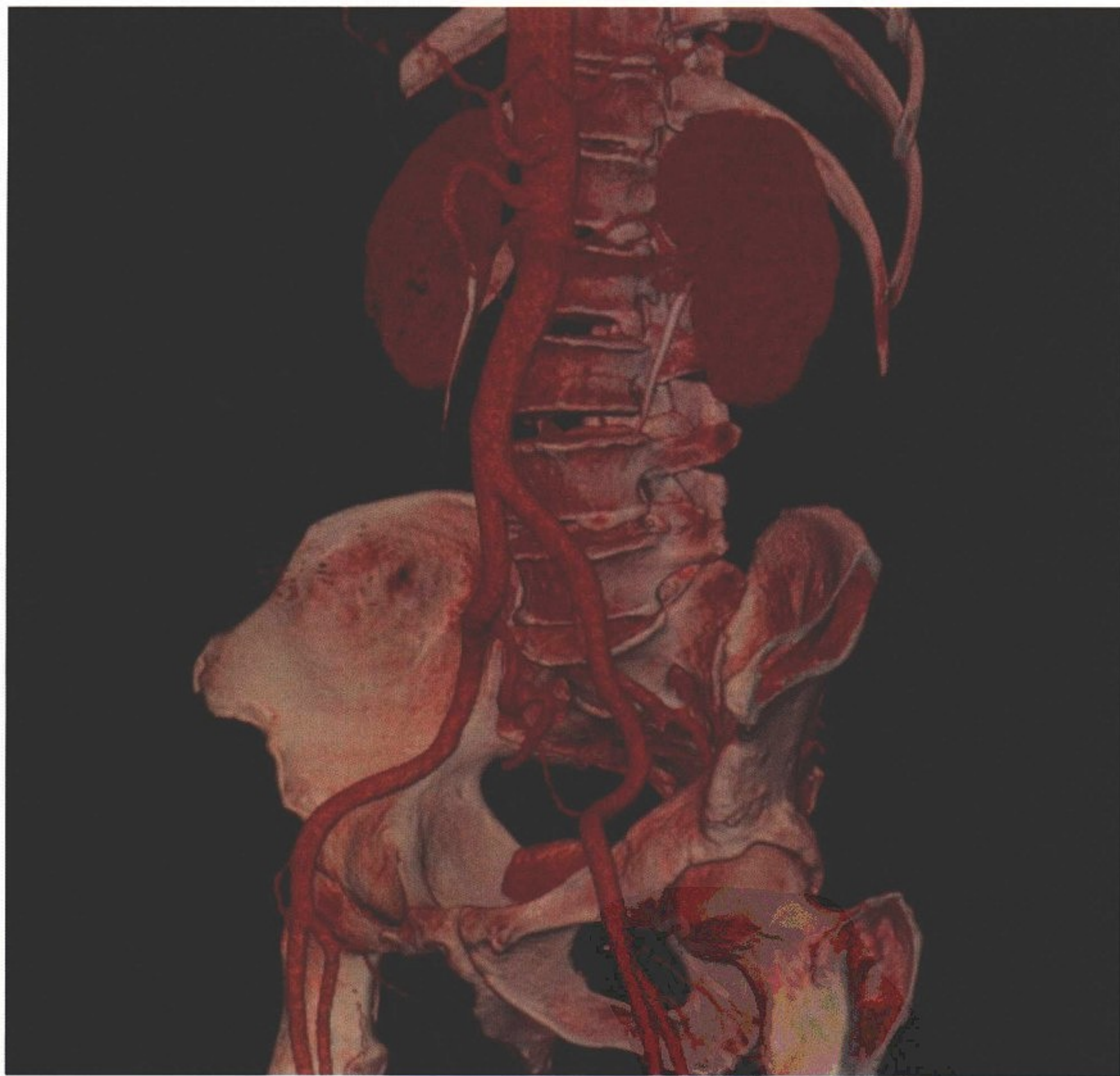
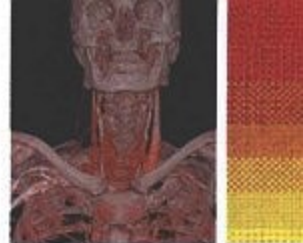
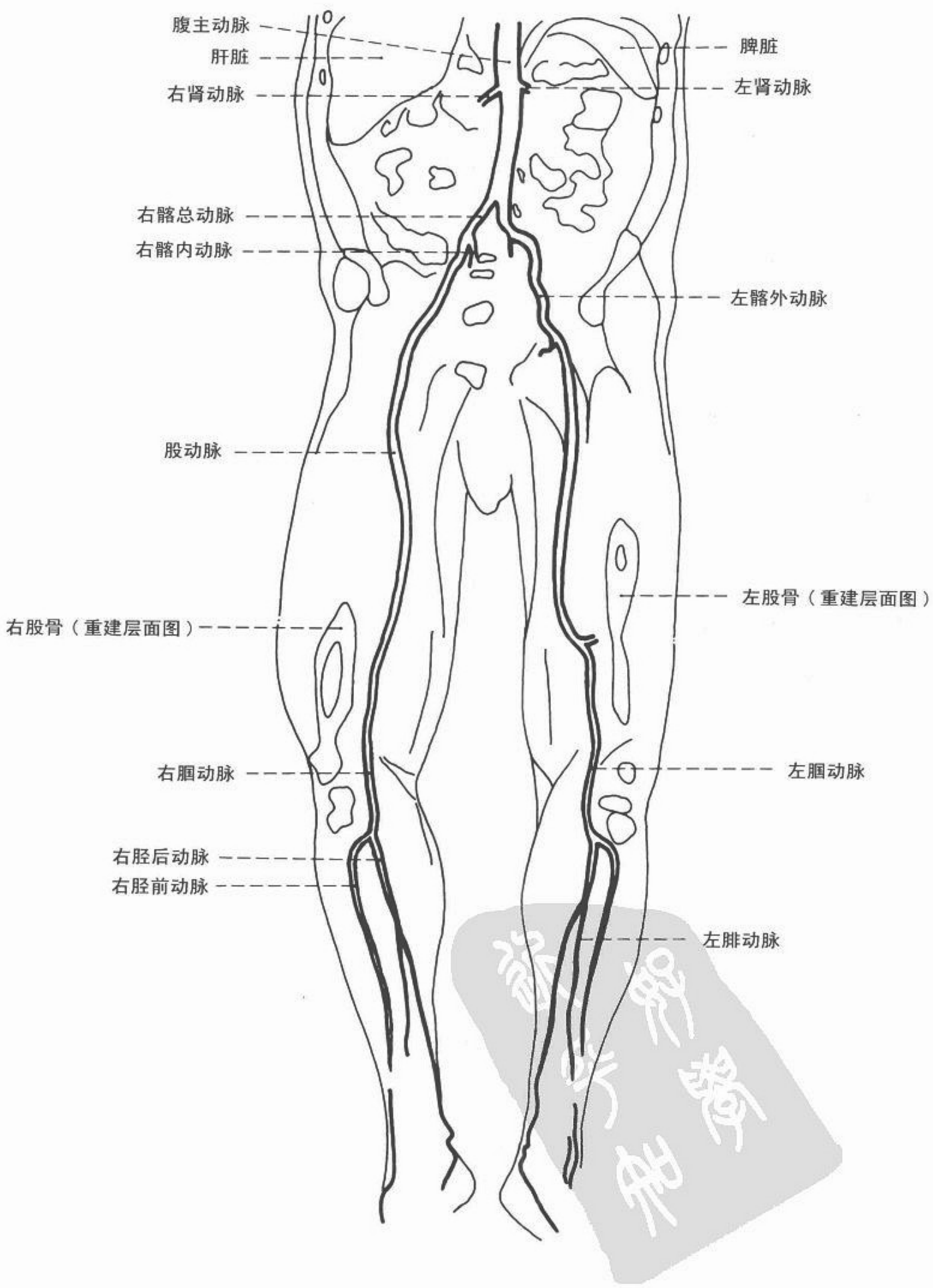


图 189 腹部和盆腔血管造影(多排螺旋 CT 容积再现技术)



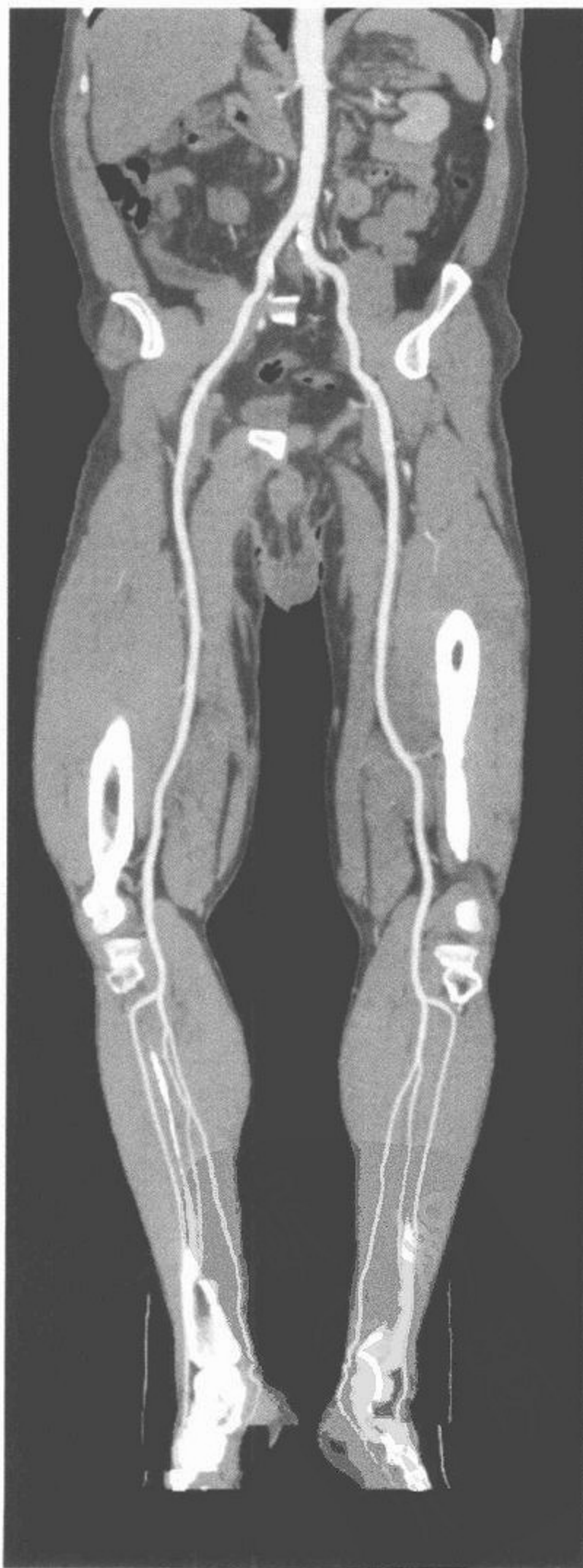
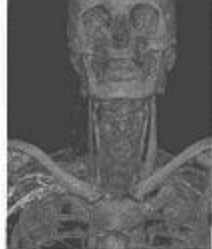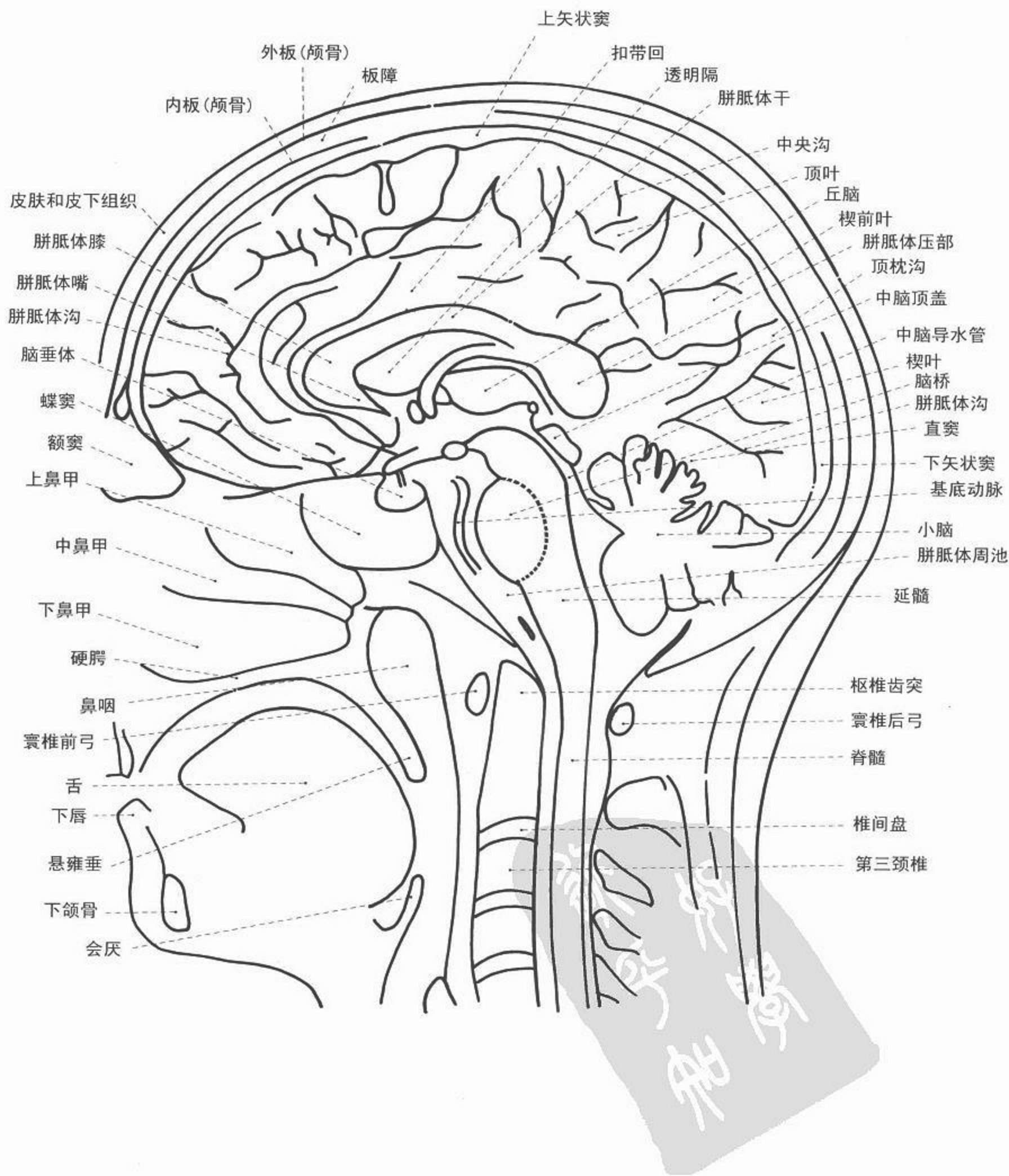

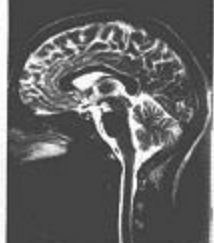
图 190 盆腔与下肢的血管造影  
(多排螺旋 CT 曲面重建, CPR)



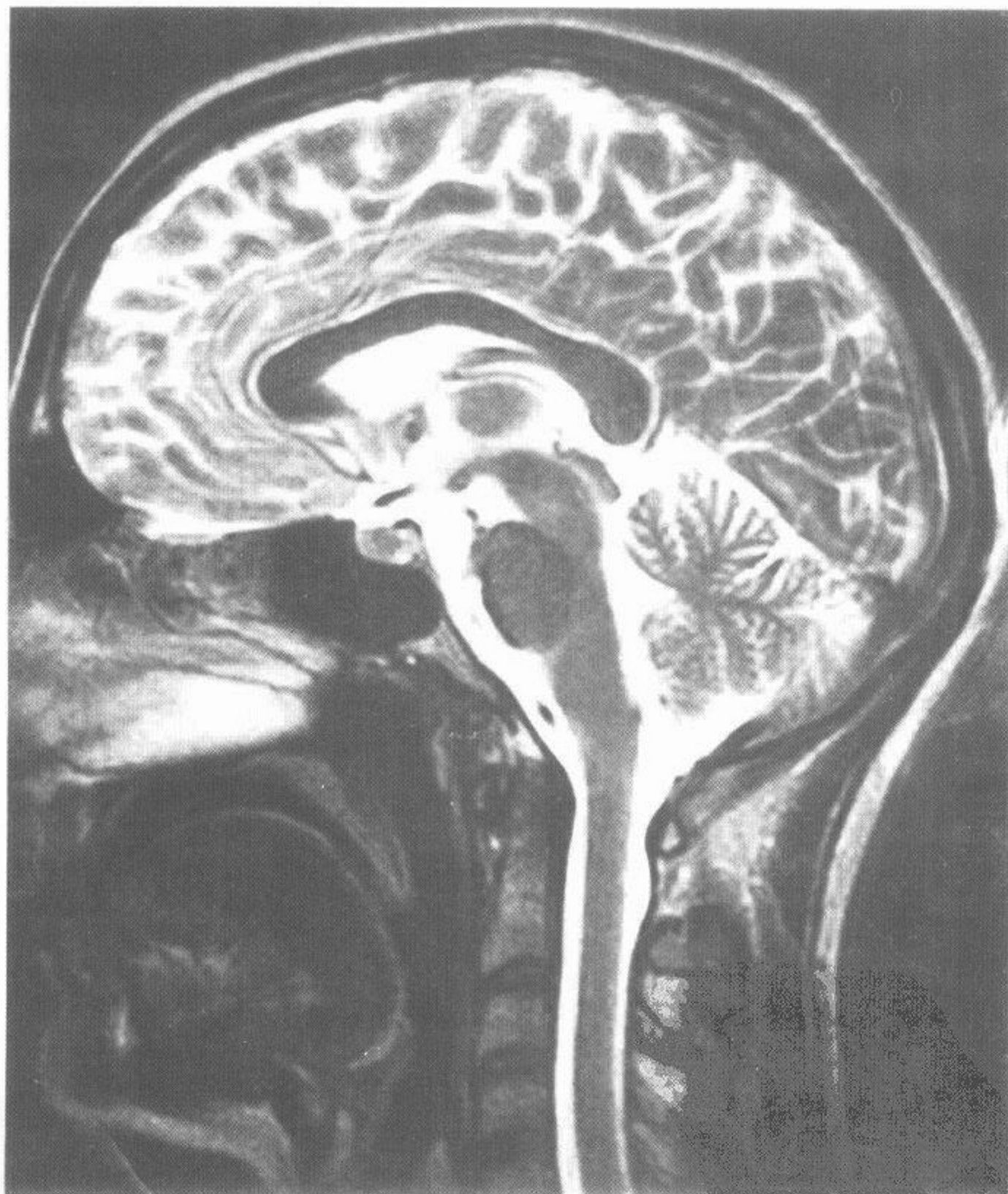
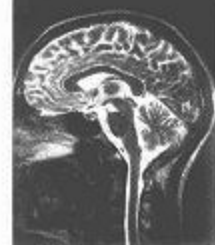
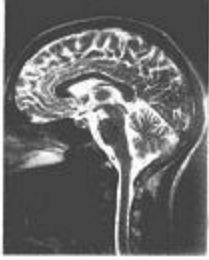
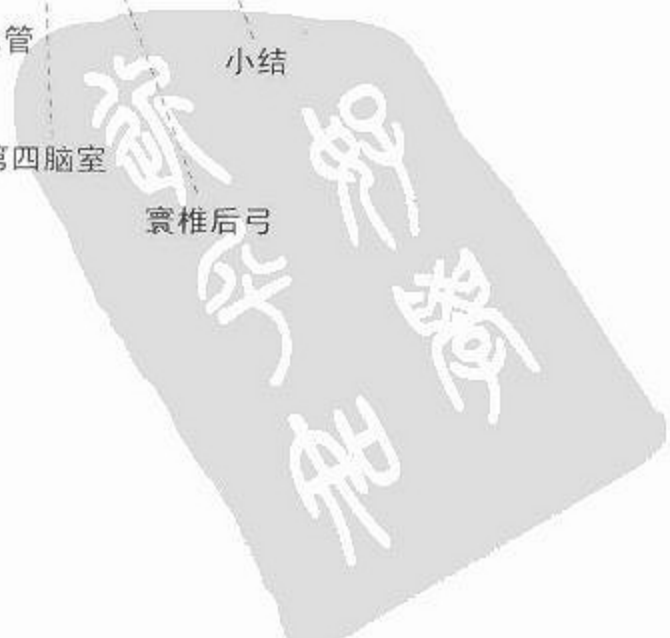图 191 脑磁共振 T<sub>2</sub> 正中矢状图(全貌)



MRI

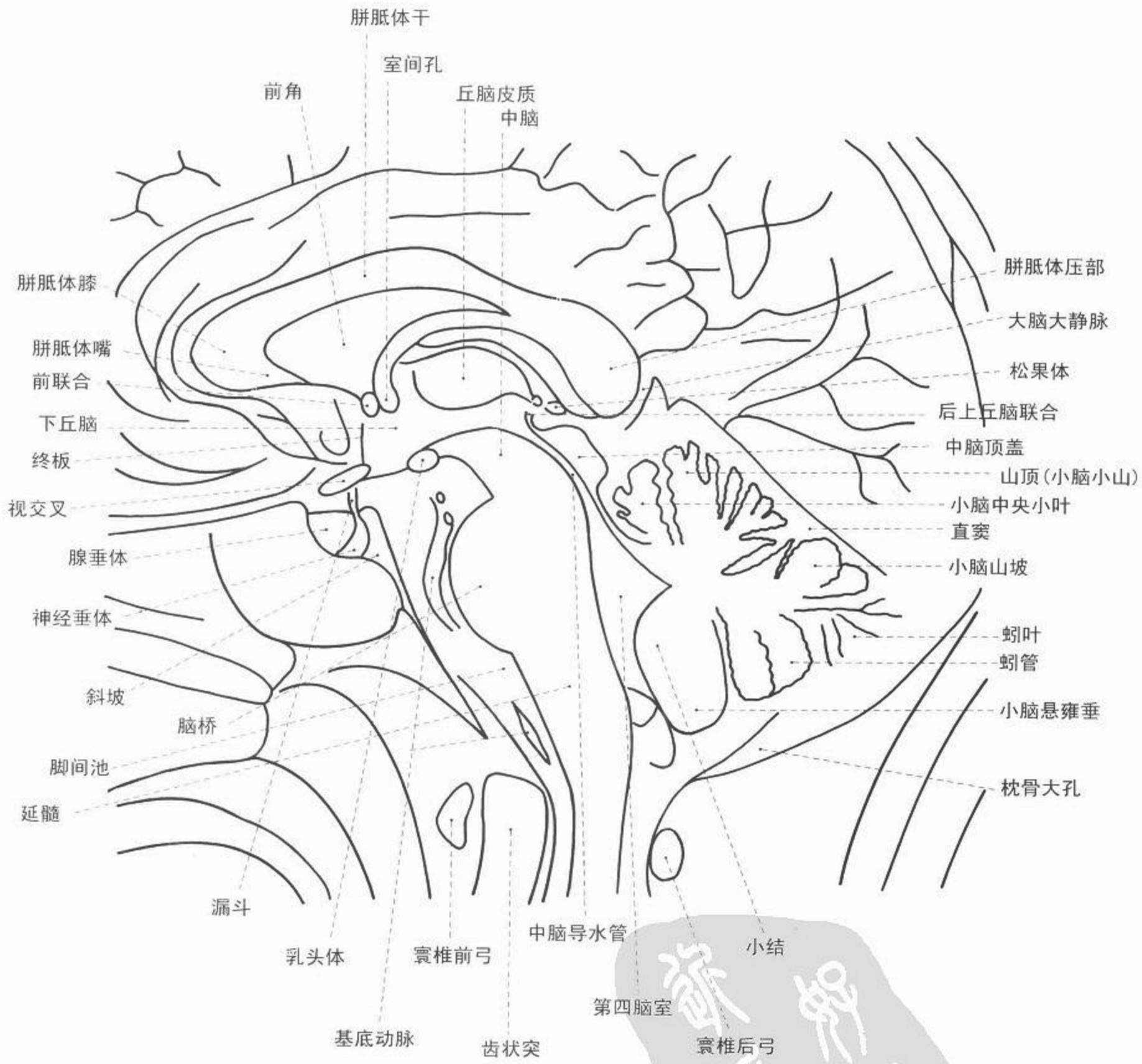

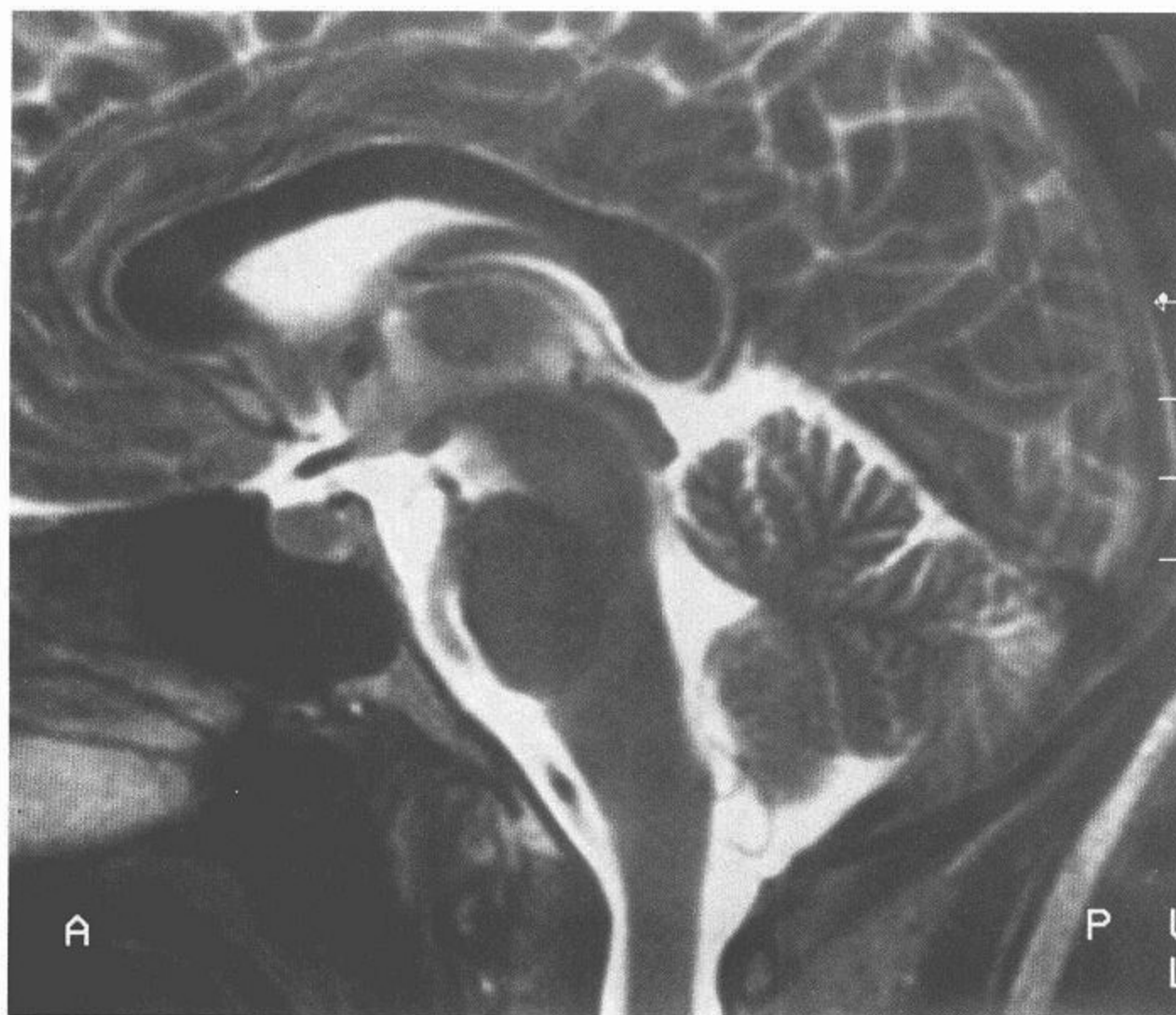
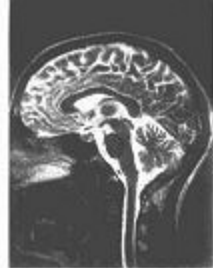
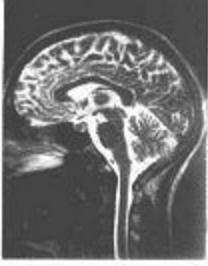
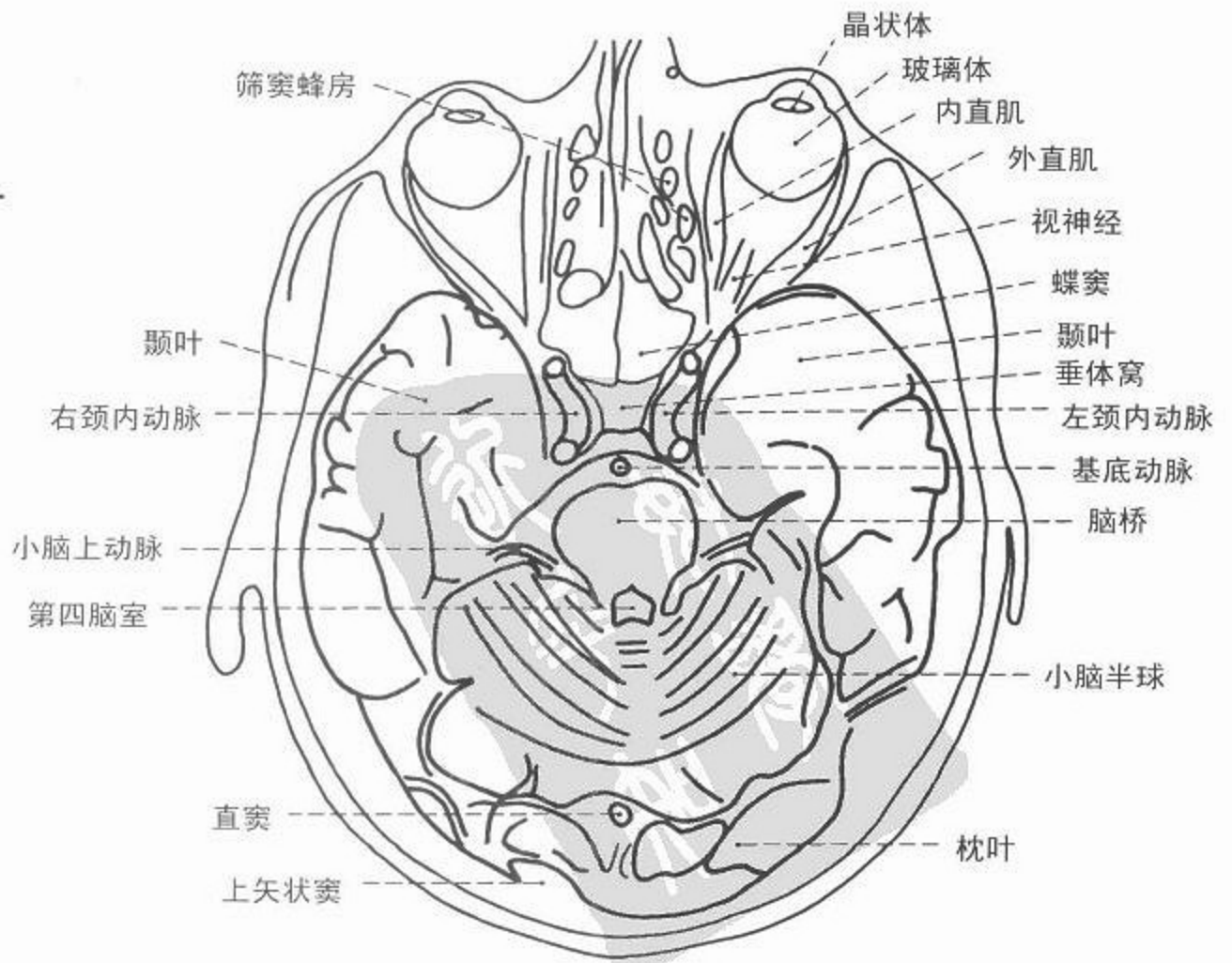
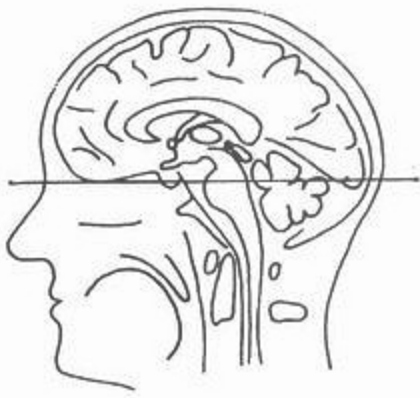
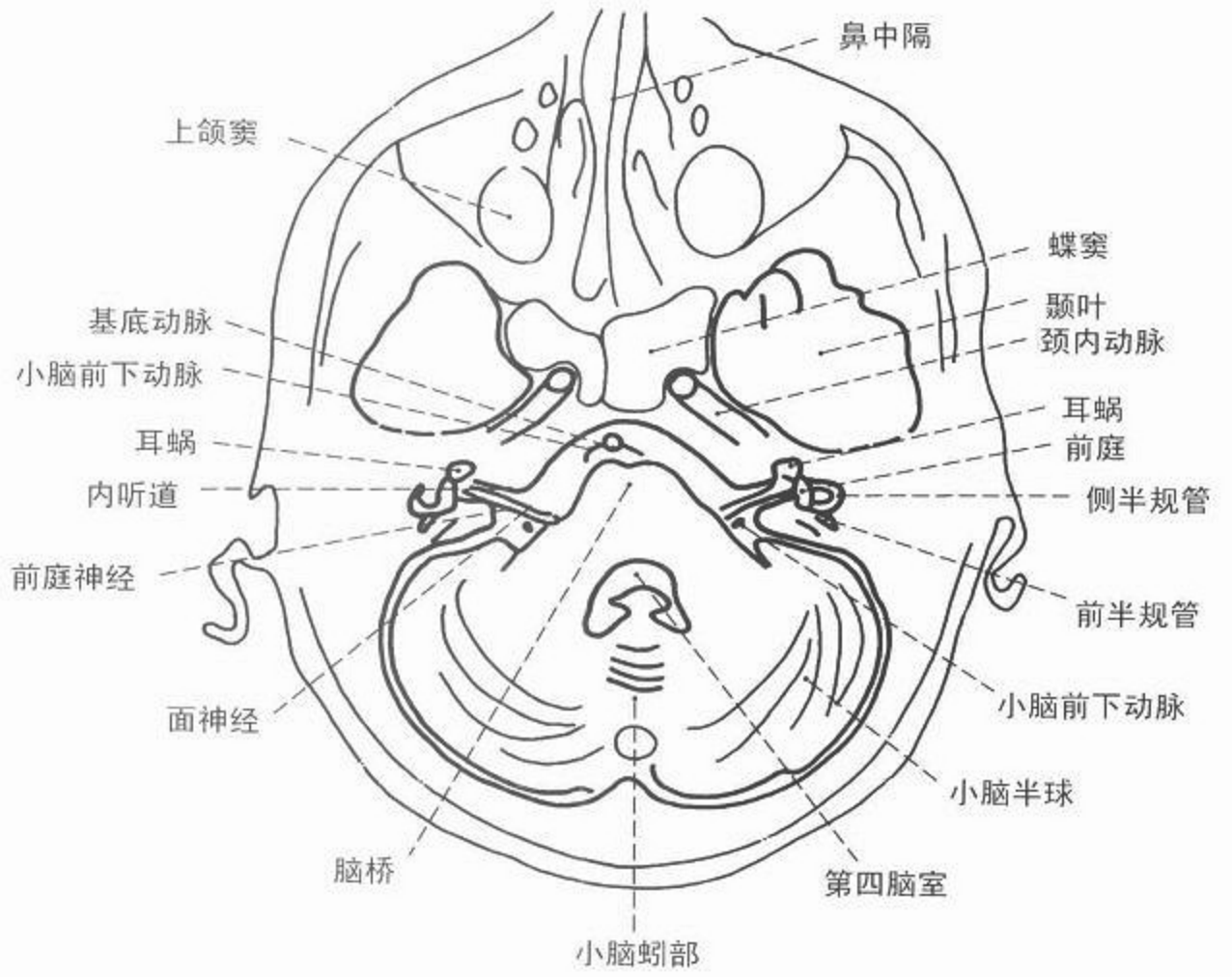
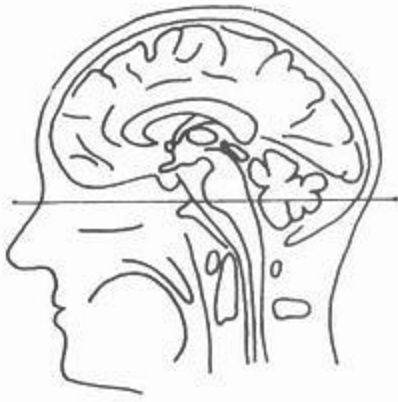图 192 脑磁共振 T<sub>2</sub> 正中矢状图(细节)







MRI



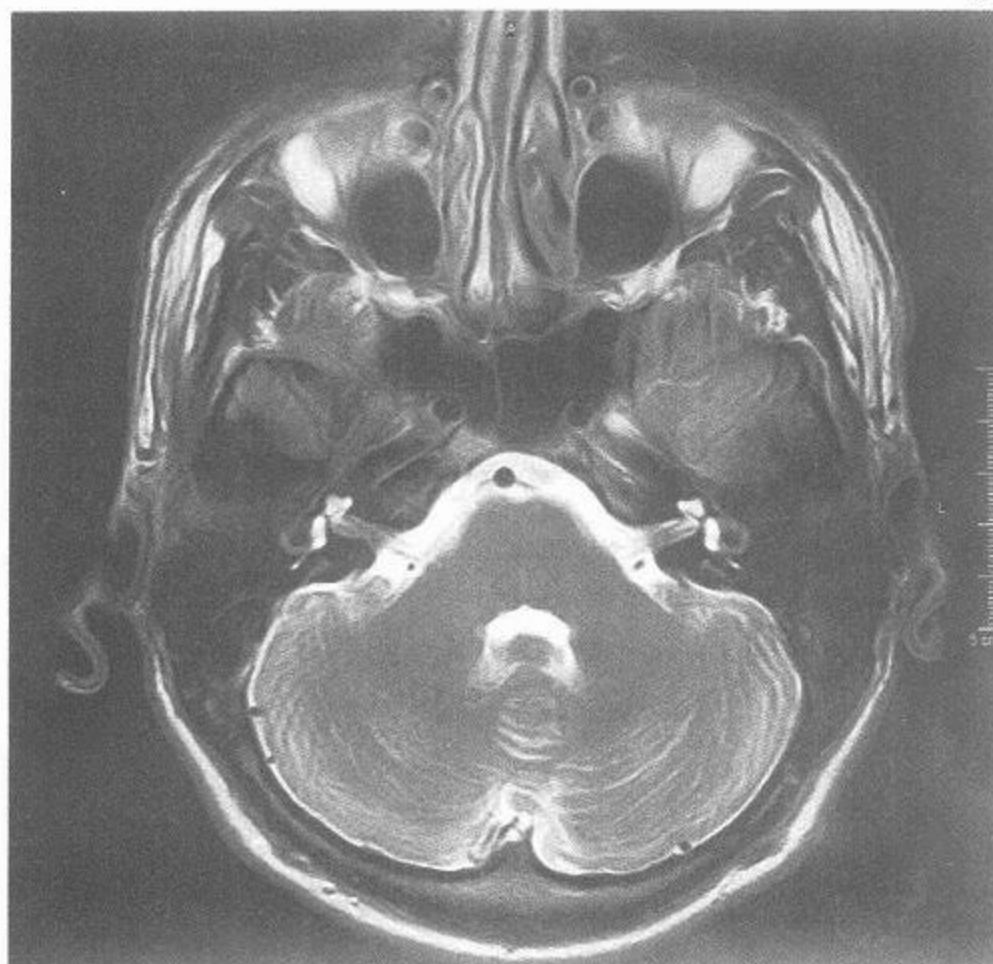
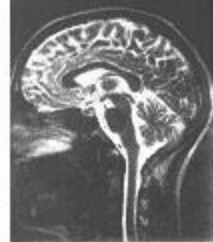

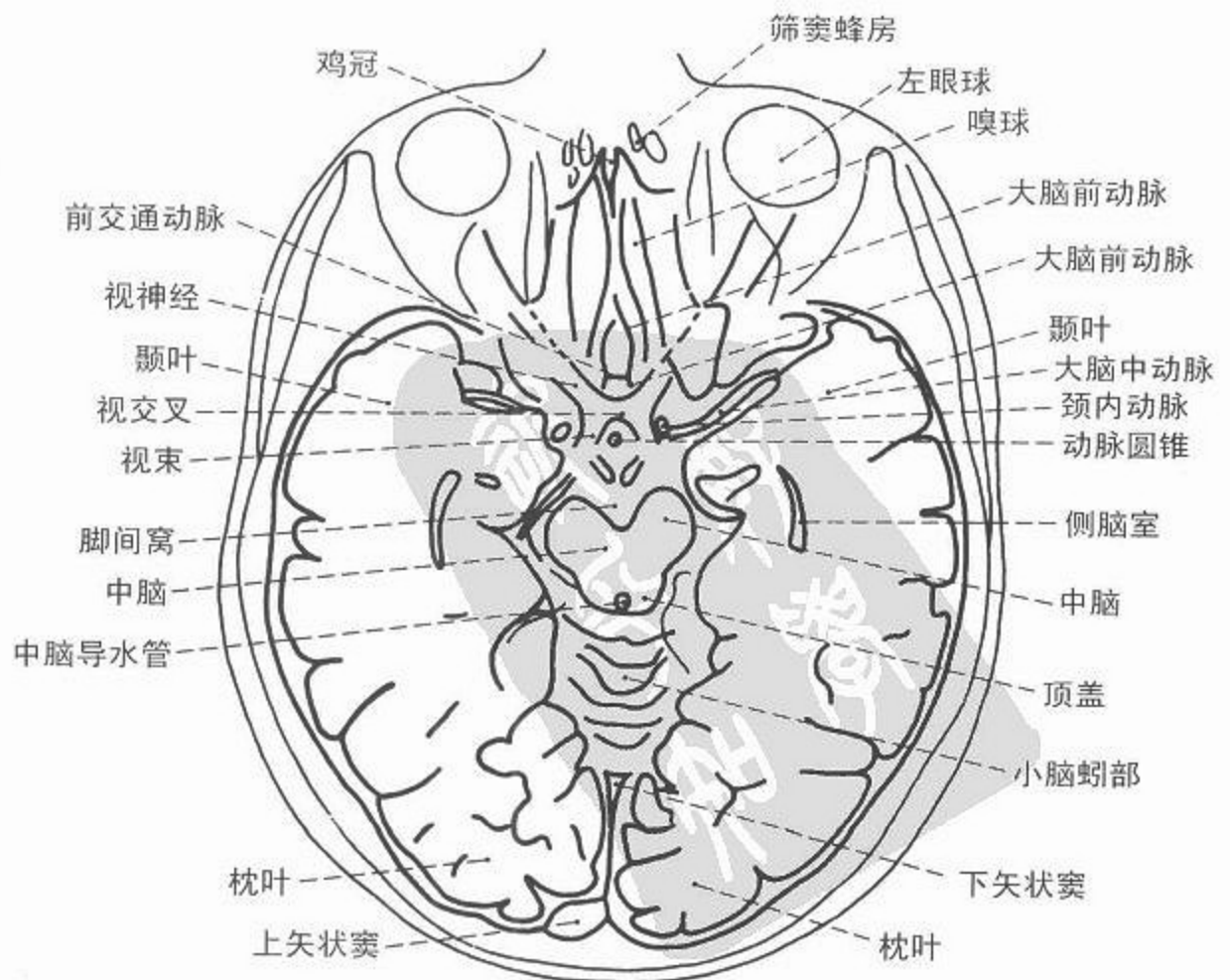
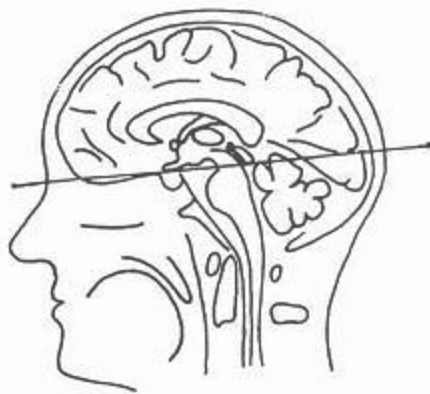
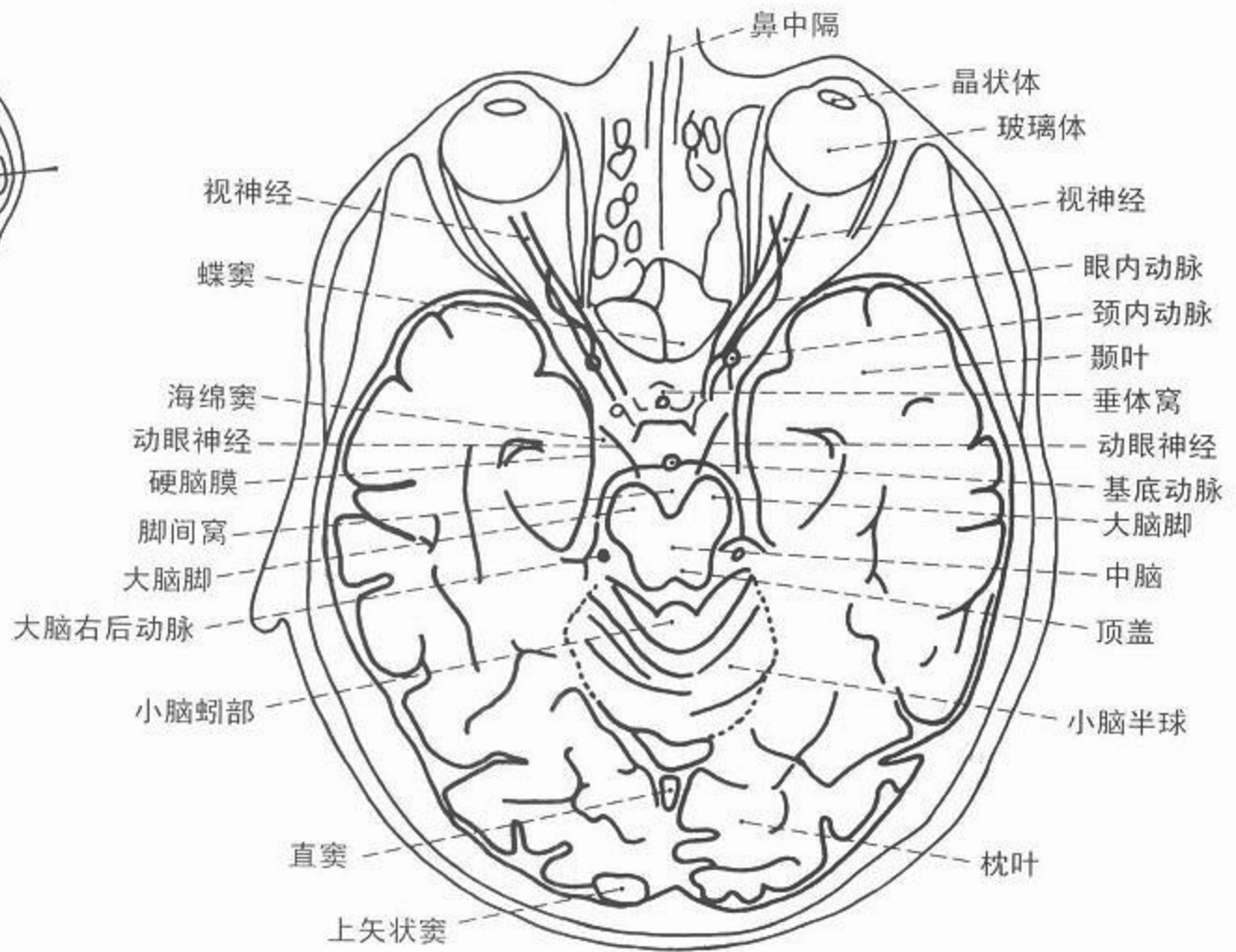
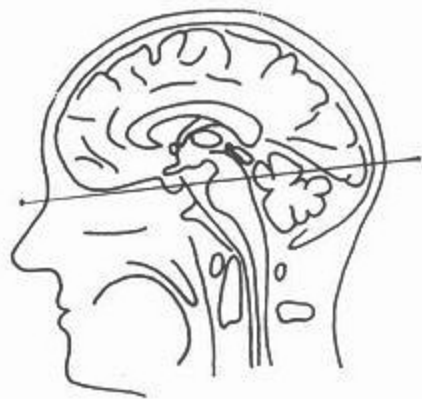
图 193 脑磁共振 T<sub>2</sub> 轴位图(横断面)

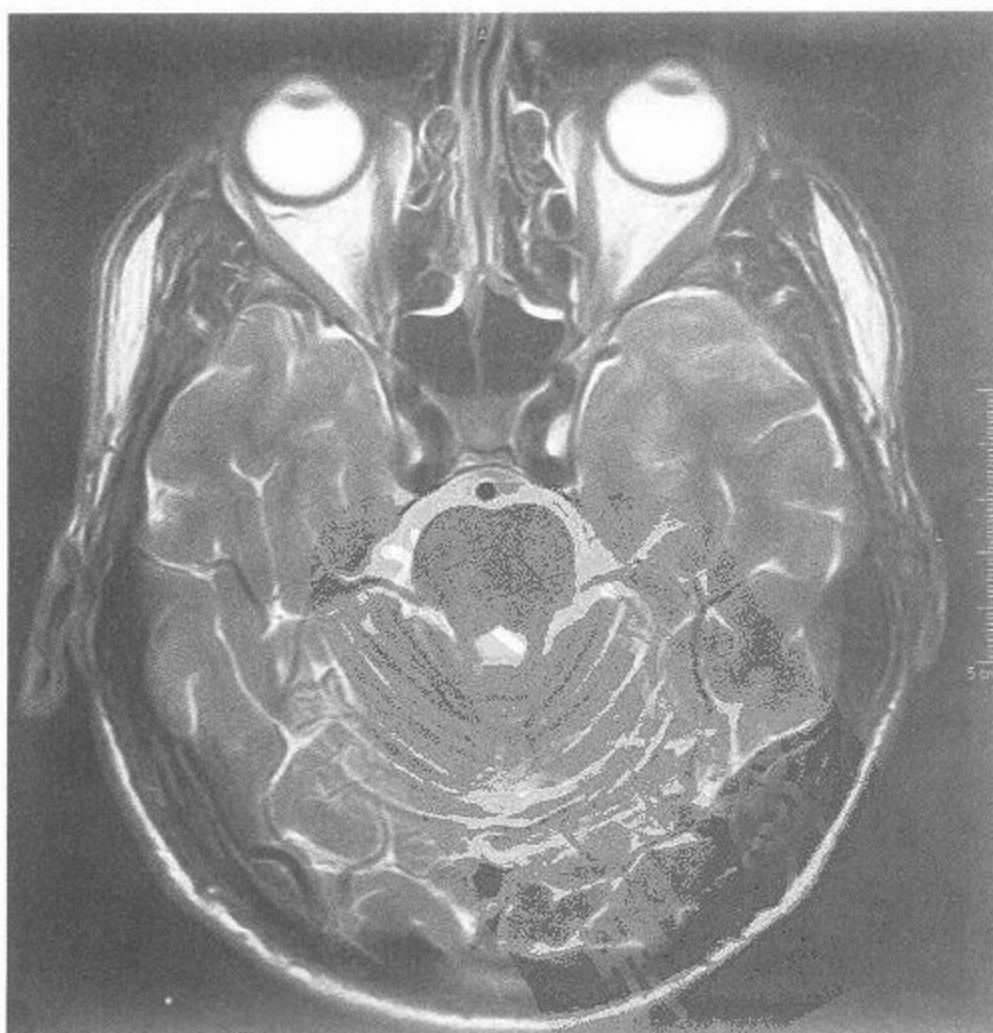
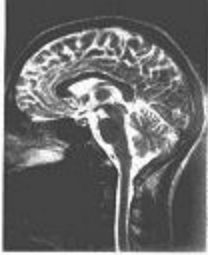
图 194 脑磁共振 T<sub>2</sub> 轴位图(横断面)



MRI



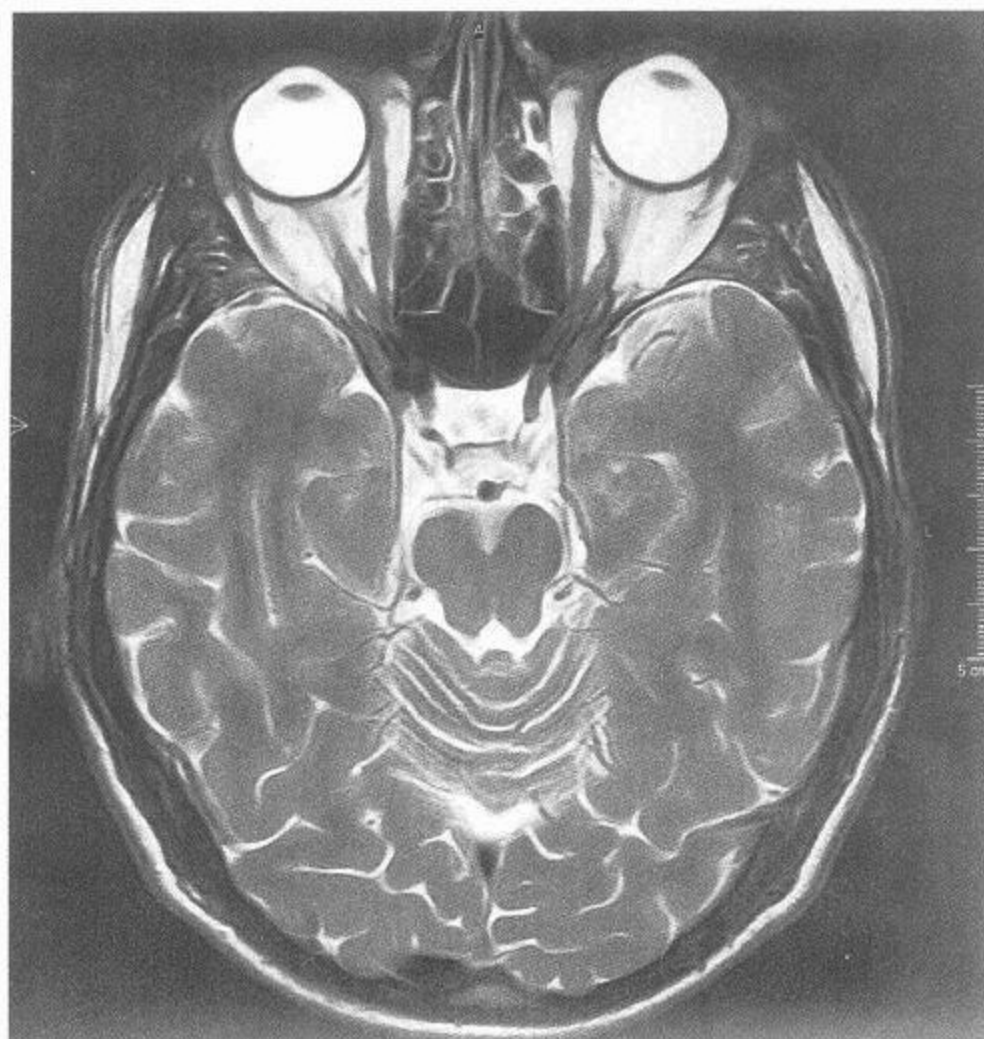
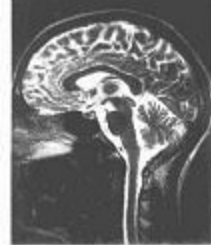

图 195 脑磁共振 T<sub>2</sub> 轴位图(横断面)

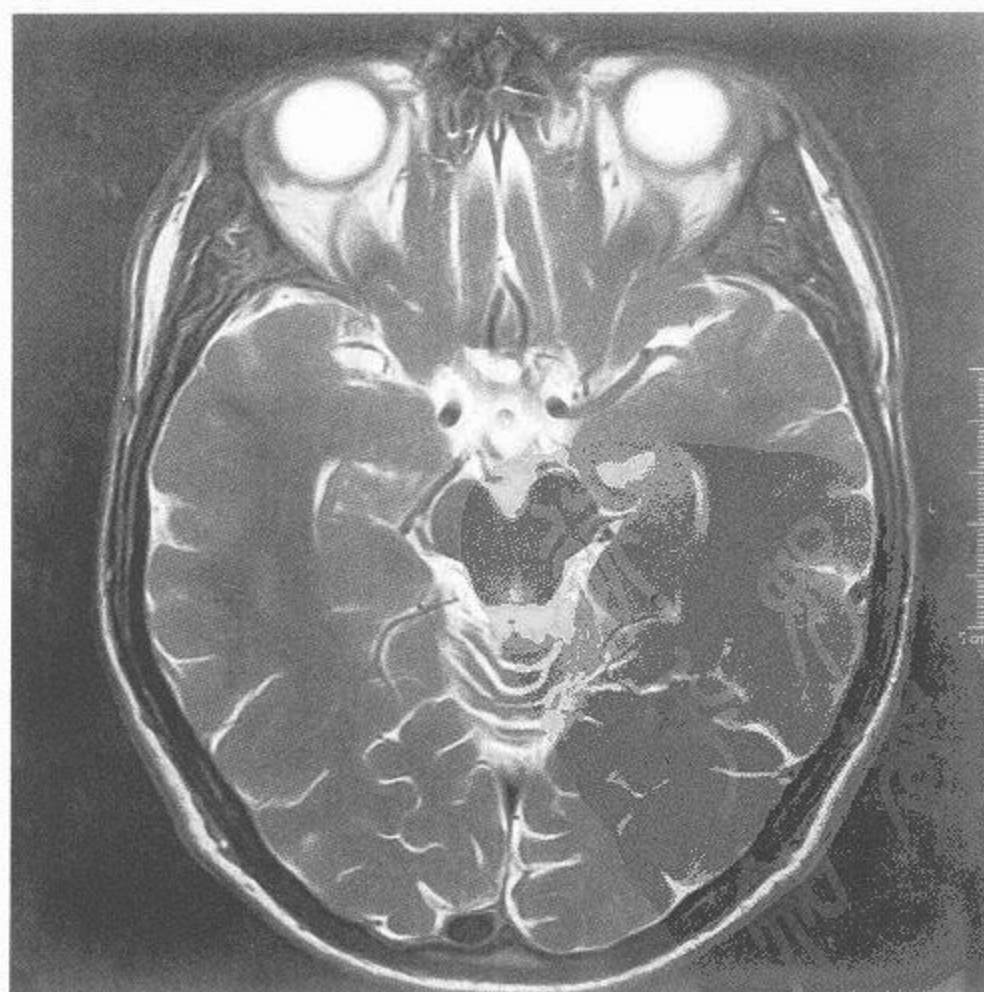

图 196 脑磁共振 T<sub>2</sub> 轴位图(横断面)