

编委会

- 主 编** CHIEF EDITORS
姜树学 Jiang Shuxue 马述盛 Ma Shusheng
- 副主编** VICE EDITORS
陈金宝 Chen Jinbao 吴振华 Wu Zhenhua
- 审 阅** REVISER
陈炽贤 Chen Chixian
- 编 者** EDITORS
姜树学 Jiang Shuxue 马述盛 Ma Shusheng
陈金宝 Chen Jinbao 吴振华 Wu Zhenhua
王振宇 Wang Zhenyu 李佩玲 Li Peiling
姜拥军 Jiang Yongjun 黎 庶 Li Shu
王书轩 Wang Shuxuan 苏惠群 Su Huiqun
王 顺 Wang Shun 姜爱民 Jiang Aimin
- 摄 影** PHOTOGRAPHER
邵 郢 Shao Ying
- 电子排版** ELECTRONIC COMPOSITION
陈树刚 Chen Shugang 杜龙梅 Du Longmei
刘克江 Liu Kejiang 姜树学 Jiang Shuxue

改版说明

ABOUT CHIEF EDITOR

改版说明

ABOUT CHIEF EDITOR

《断面解剖与MRI CT ECT对照图谱》已出版7年了，进行了4次印刷。作者也收到了一些读者的建议，认为该书部头较大、较厚、不利于携带和阅读。为了满足不同医学专业读者的需要，该书又增添了小的版本印刷，分两册装订：《断面解剖与MRI CT ECT对照图谱①——头颈部、胸部》与《断面解剖与MRI CT ECT对照图谱②——腹部、盆部、四肢部》，彩图变成黑白图，精装变成简装，这样更适合于部分读者的需要。该书这样改版如何，敬请读者多提宝贵意见。

姜树学 马述盛

2005年9月 于沈阳

前 言

随着医学检测手段的迅速发展, B型超声、CT已得到普及, MRI与ECT设备相继出现于市级医院。传统的投影成像(X线成像), 已变成二维或三维的断面成像, 如CT、MRI和超声成像。与此同时, 医学影像工作者的队伍逐年扩大, 各科医生都在积极学习和运用医学影像知识为患者服务。读CT、MRI片必须以断面解剖学知识为基础, 然而, 过去没有断面解剖学的教育, 临床工作的医生大都缺乏这方面的知识。为了满足临床医务工作者的诊断和医学院校影像教学的急需, 我们编写了《断面解剖与MRI CT ECT对照图谱》, 为读者提供了宝贵的图像资料。

两书精选出180幅断面解剖图、337幅MRI图、105幅CT图、40幅ECT图和3幅MRA图。每两页为一单元, 一页为彩色断面解剖图、ECT图及定位图。另一页为CT及MRI图。每一单元图都处于同一断面上, 切线相同, 结构相同, 便于读者学习和应用。本图谱不仅对从事医学影像的学者是一本不可缺少的读物, 而且对其他各科临床医生阅读CT、MRI图像也是极有价值的参考书。断面解剖标本是用健康国人尸体冰冻切片制成的。胸、腹、盆部的横断面(水平断面)及头颈部、膝关节的断面等层厚为1cm; 胸、腹、盆部的冠状断面及矢状断面层厚为2cm。CT、MRI及ECT等各种影像图都是用健康国人扫描制成的。

CT图是用第四代CT机扫描、激光照相制成的。头颈部与胸部用平扫图像; 腹部与盆部用增强扫描图像。

MRI图像(T_1WI 、 T_2WI 及PDWI)是用1.5T、2.0T磁共振仪、自旋回波(SE)序列采集的。

名词以全国自然科学名词审定委员会1991年公布的人体解剖学名词为准, 中英文对照。

本图谱是断面解剖学与医学影像学相结合的产物, 经过几年的努力终于和读者见面了, 我们感到很欣慰。本书在编著过程中, 得到王淀教授、曹郁琦教授等人的帮助, 特此表示衷心的感谢。

尽管诸位编者尽心尽力, 精益求精, 但是仍有不足之处, 敬请各位读者指正。

姜树学 马述盛
2005年9月于沈阳

PREFACE

With the rapid development of modern sophisticated imaging modalities, the conventional projection imaging as radiography is now changed to sectional imaging such as B-mode US, CT and MRI. Now, in China most of hospitals are equipped with such imaging modalities. Doctors and technicians in the department of Radiology and physicians in other departments are interested in studying the fundamental knowledge of human sectional anatomy. However, in the past few medical school offered the course of sectional anatomy so that most of the radiologists and clinical physicians are not familiar with this. To meet the urgent need for the clinical medical workers and training of students, we compiled this book "Atlas of Sectional Anatomy Correlated with the MRI, CT and ECT" with hope that it would be easier for them to learn.

One hundred and eighty illustrations of sectional anatomy together with corresponding 337 MR images, 105 CT images and 40 ECT pictures were carefully chosen for the atlas. Each unit is composed of two pages, one shows the colored illustration of sectional anatomy and ECT image as well as a locator of section, while another page depicts the CT and MR images of the corresponding section. This atlas is not only indispensable for radiologists but also essential to all clinical physicians in interpreting CT and MR imaging.

All the anatomic sections were made from normal Chinese cadavers with frozen section method. The thickness of horizontal section for the thorax, abdomen, pelvis and the thickness of sections for head and neck, knee joint were 1.0 cm, and the thickness of frontal and sagittal sections was 2.0 cm for the thorax, abdomen and pelvis. The CT, MRI and ECT images were obtained from scanning normal Chinese volunteers.

All CT examinations were performed with PQ-2000 (Picker International, Cleveland, Ohio, U.S.A.) and laser printer. The images of head and neck, chest were non-enhanced, while the images of abdomen and pelvis were enhanced. The slice thickness was 1.0 cm.

MR images including T₁ weighted, T₂ weighted and proton density images were performed on 1.5T scanner (Signa, GE Medical Systems, Milwaukee, Wis., U.S.A.) and 2.0 T scanner (Prestige, Elscint Ltd, Israel) with spin echo (SE) sequence. The slice thickness was 1.0 cm.

Terms are used according to the Human Anatomic Terms published in 1991 by the National Examination and Approval Committee on Natural Scientific Terminology with corresponding English terms.

After several years, the authors appreciated very much that this book was eventually compiled and published. We hope that the readers will find this book interesting and helpful.

We would like to express our thanks to Prof. Wang Dian and Prof. Cao Yuqi, whose assistance and co-operation made this publication possible.

Shenyang Jiang Shuxue
 Ma Shusheng
 September, 2005

使用说明

一、本图谱分头颈部、胸部、腹部、盆部和四肢五个部分。每两页为一单元，一页为彩色断面解剖图、ECT图及定位图。定位图的白色线为断面的切线，蓝色线为基准线。另一页为黑白的CT图、MRI T₁加权图、MRI T₂加权图及该单元的中英文名词。每一单元的所有图像都处于同一断面上。

二、参考平面

1. 头颈部水平断面的参考平面为眶下缘至外耳门的平面。
2. 头颈部额状断面的参考平面为垂直于眼耳平面的断面。
3. 头颈部矢状断面的参考平面为正中矢状断面。
4. 胸腹盆及四肢水平断面的参考平面为经过胸骨角或脐的水平断面。
5. 胸腹盆及膝关节的矢状断面的参考平面为躯干和膝关节的正中矢状面。
6. 胸腹盆及膝关节的额状断面的参考平面为经过腋中线和膝关节的侧中线的额状面。

三、英文名词缩写

Fig.Figure	HHorizontal
CCephalo-cervical	SSagittal
FFrontal	TThoracic Vertebrae
LLumbar Vertebrae	SSacral Vertebrae
CoCoccyx	AAbdomen
PPelvis	KKnee
ULUpper Limb	LLLower Limb
PDProton Density	ffemale
mmale	a.artery
v.vein	n.nerve

INSTRUCTIONS

1. There are five regions in this atlas including head and neck, thorax, abdomen, pelvis and limbs. Every unit is composed of two pages. One page shows a colored sectional anatomic picture, ECT image and a locator of sections in which the white line represents cutting plane, and the blue line represents basic plane. Another page shows CT and MRI (T₁WI and T₂WI) images with Chinese-English anatomical terms of this section. Pictures and images of one unit are all at the same plane.

2. The plane of reference

a. The plane of reference for horizontal sections of head and neck is at the eye-ear plane (Frankfurt horizontal, orbito-meatal line).

b. The plane of reference for frontal sections of head and neck is the plane perpendicular to the eye-ear plane (Frankfurt horizontal, orbitomeatal line).

c. The plane of reference for sagittal sections of head and neck is median sagittal plane.

d. The plane of reference for horizontal sections of thorax, abdomen, pelvis and limbs is the horizontal plane passing through sternal angle or umbilicus.

e. The plane of reference for sagittal sections of thorax, abdomen, pelvis or knee joint is the median sagittal plane of trunk or knee joint.

f. The plane of reference for frontal sections of thorax, abdomen, pelvis or knee joint is the plane passing through midaxillary line or lateral median line of knee joint.

3. Abbreviations:

Fig.Figure	HHorizontal
CCephalo-cervical	SSagittal
FFrontal	TThoracic Vertebrae
LLumbar Vertebrae	SSacral Vertebrae
CoCoccyx	AAbdomen
PPelvis	KKnee
ULUpper Limb	LLLower Limb
PDProton Density	ffemale
mmale	a.artery
v.vein	n.nerve

目 录

腹 部

水平断面 HA	176
额状断面 FA	206
矢状断面 SA	222
磁共振成像(胆、胰管和输尿管)MRI	244

盆 部

女盆水平断面 HPf	246
男盆水平断面 HPm	274
女盆额状断面 FPF	292
男盆矢状断面 SPm	304
磁共振成像(前列腺)MRI	316

四肢部

左上肢水平断面 HUL	318
左下肢水平断面 HLL	330
左膝关节额状断面 FK(L)	342
右膝关节矢状断面 SK(R)	356

CONTENTS

Abdomen (Abdomen and Pelvis)

Horizontal Sections HA	176
Frontal Sections FA	206
Sagittal Sections SA	222
MRI (cystic, pancreatic duct and ureter)	244

Pelvis

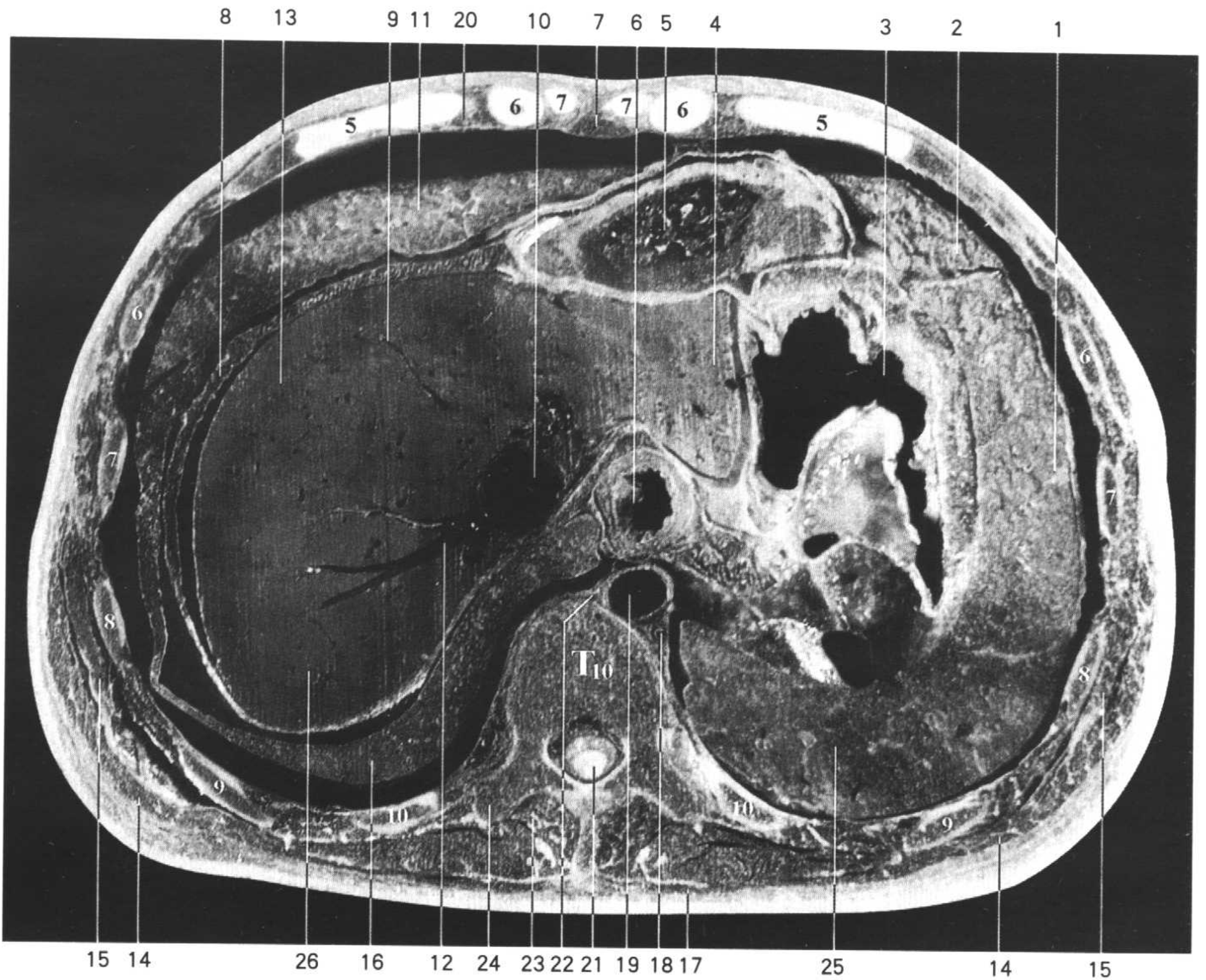
Horizontal Sections, female HPf	246
Horizontal Sections, male HPm	274
Frontal Sections, female FPf	292
Sagittal Sections, male SPm	304
MRI (prostate)	316

Limbs

Horizontal Sections of the Left Upper Limb HUL	318
Horizontal Sections of the Left lower Limb HLL	330
Frontal Sections of the Left Knee FK(L)	342
Sagittal Sections of the Right Knee SK(R)	356

ABDOMEN

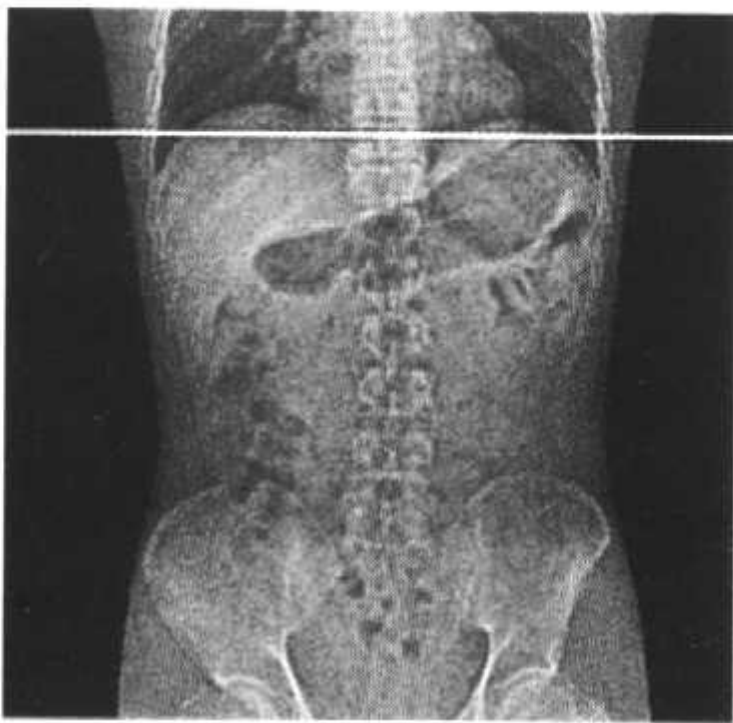
腹部

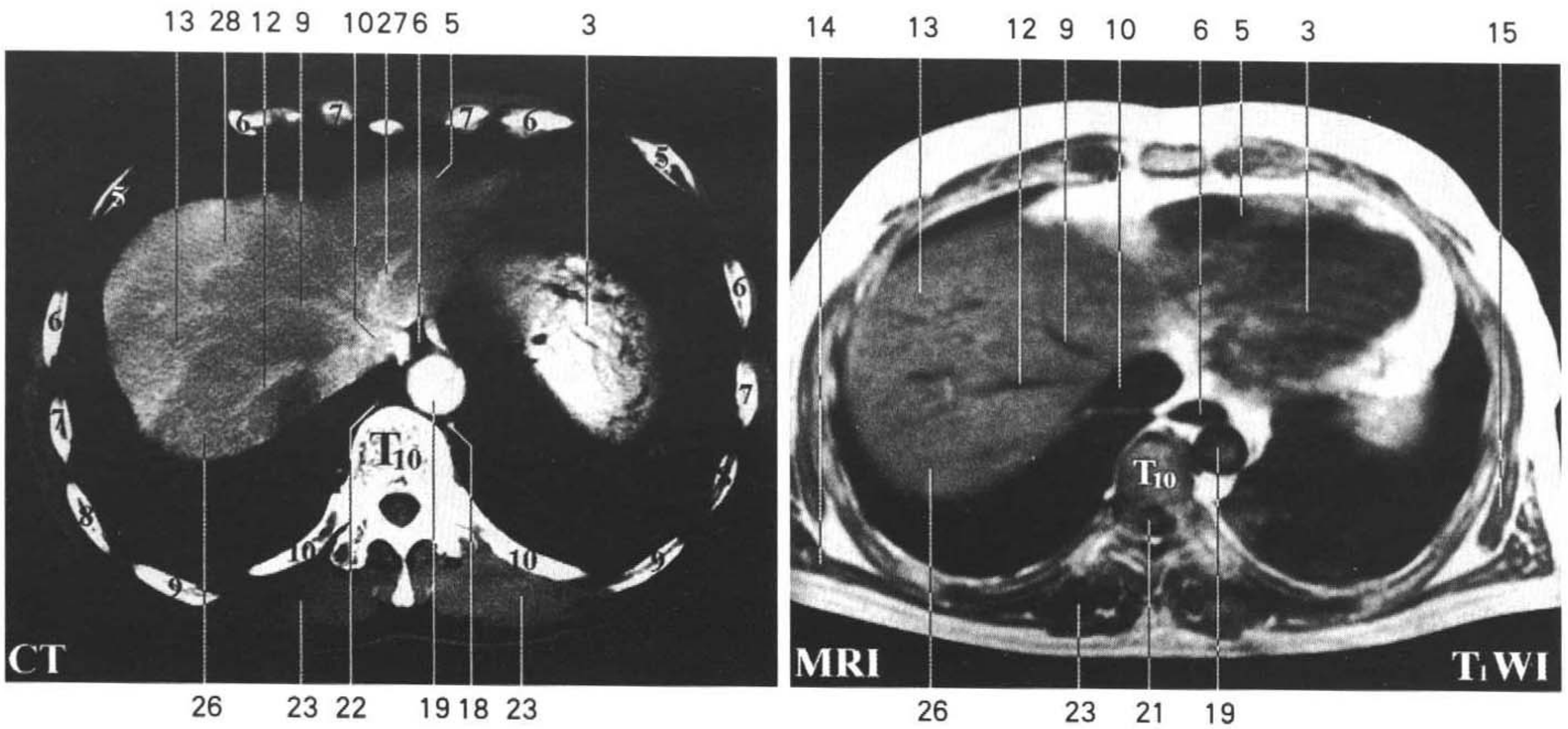


水平断面 HA

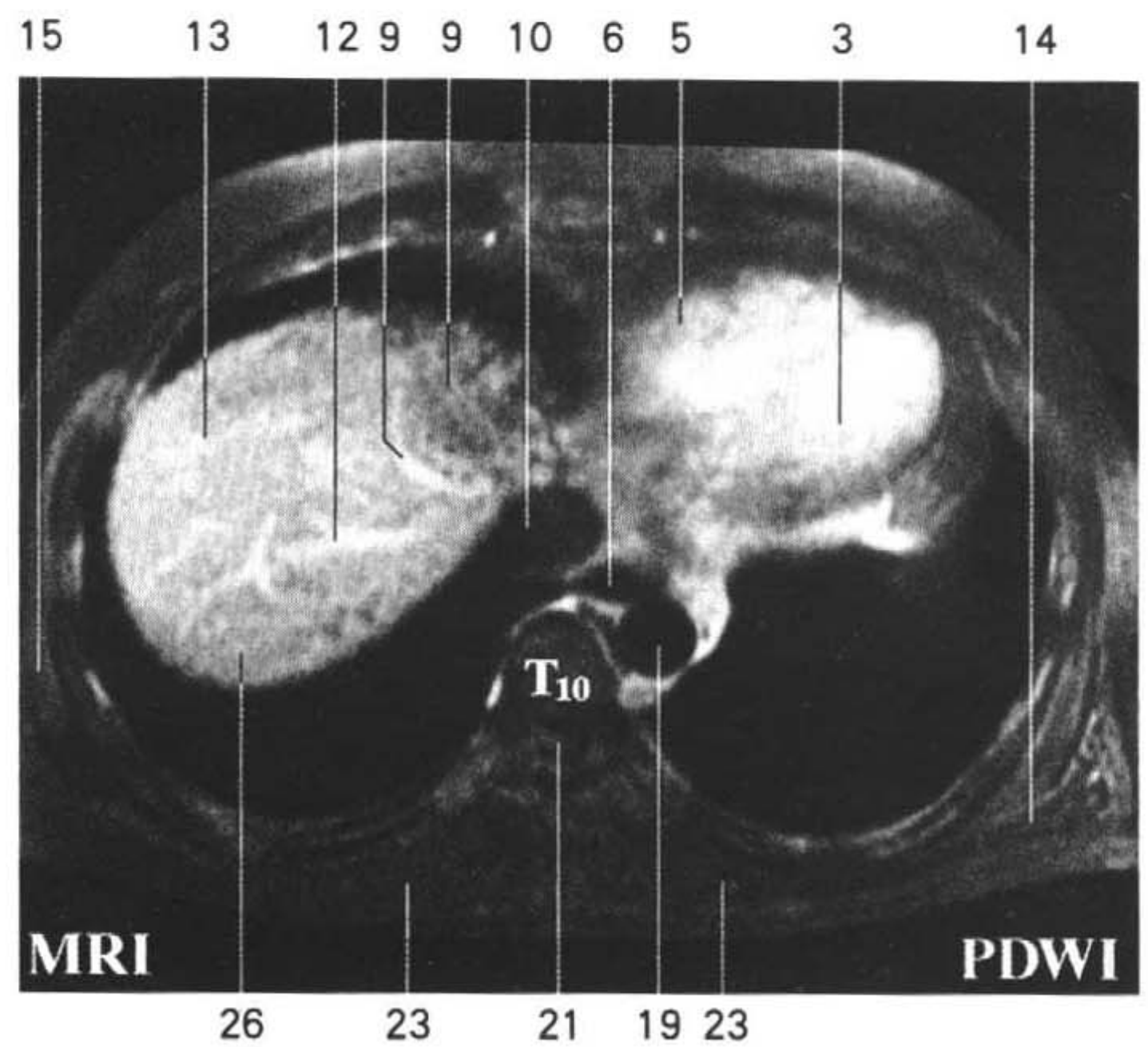
Fig.HA1

1. 外侧底段 (S_{ix}) lateral basal segment (S_{ix})
2. 下舌段 (S_v) inferior lingual segment (S_v)
3. 胃底 fundus of stomach
4. 左外叶 left lateral lobe
5. 右心室 right ventricle
6. 食管 esophagus
7. 剑突 xiphoid process
8. 膈 diaphragm
9. 肝中间静脉 intermediate hepatic v.
10. 下腔静脉 inferior vena cava





11. 内侧段 (S_v) medial segment (S_v)
12. 肝右静脉 right hepatic v.
13. 右前叶 right anterior lobe
14. 背阔肌 latissimus dorsi
15. 前锯肌 serratus anterior
16. 后底段 (S_x) posterior basal segment (S_x)
17. 斜方肌 trapezius
18. 半奇静脉 semiazygos v.
19. 胸主动脉 thoracic aorta
20. 胸廓内动脉 internal thoracic a.
21. 脊髓 spinal cord
22. 奇静脉 azygos v.
23. 竖脊肌 erector spinae
24. 第10胸椎横突 transverse process (T₁₀)
25. 后底段 (S_x) posterior basal segment (S_x)
26. 右后叶 right posterior lobe
27. 肝左静脉 left hepatic v.
28. 左内叶 left medial lobe



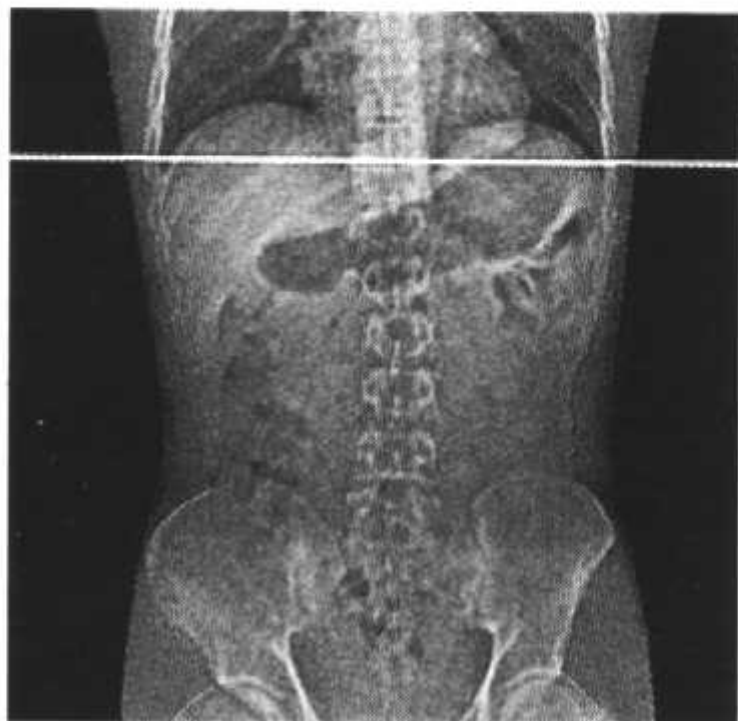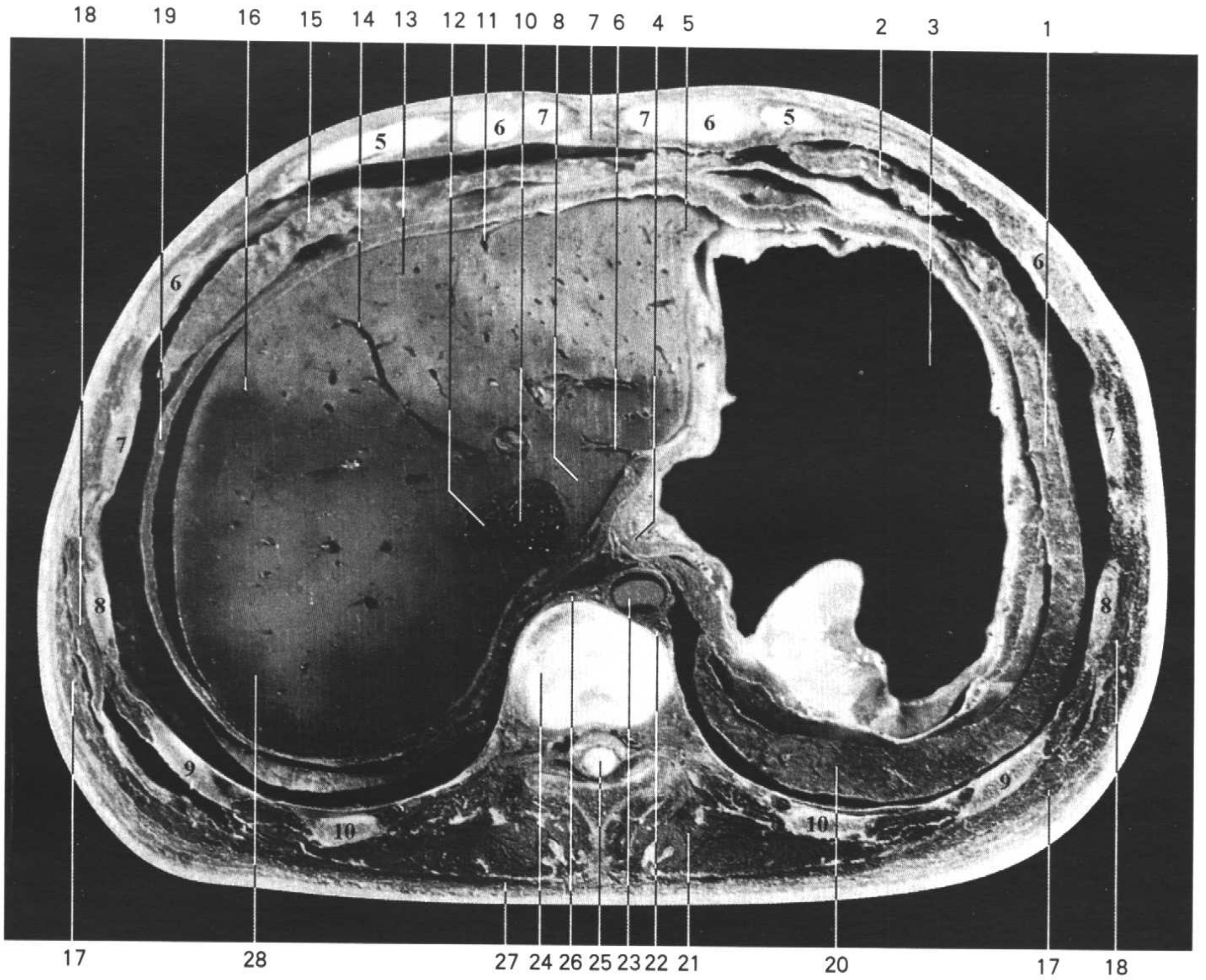
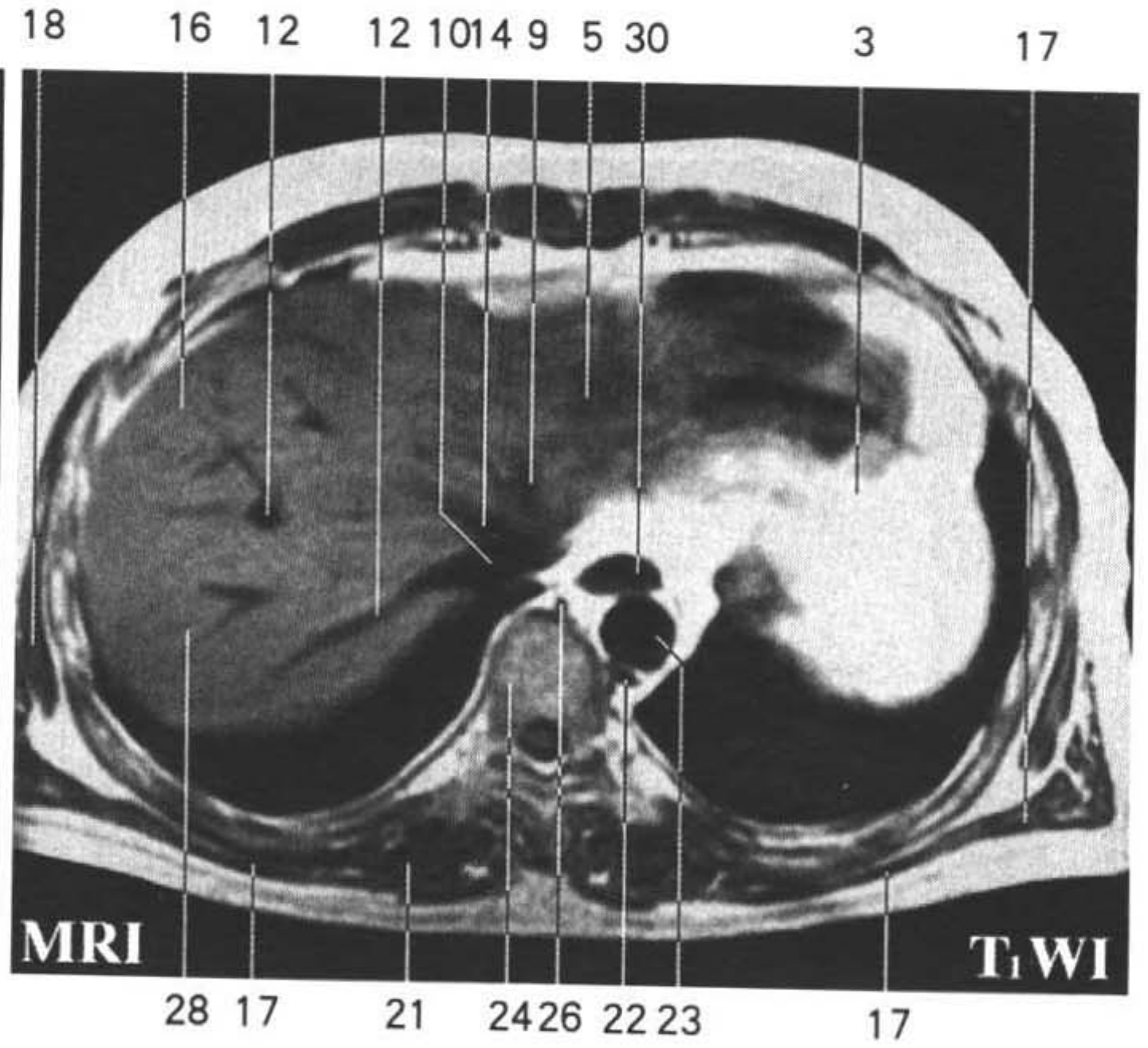
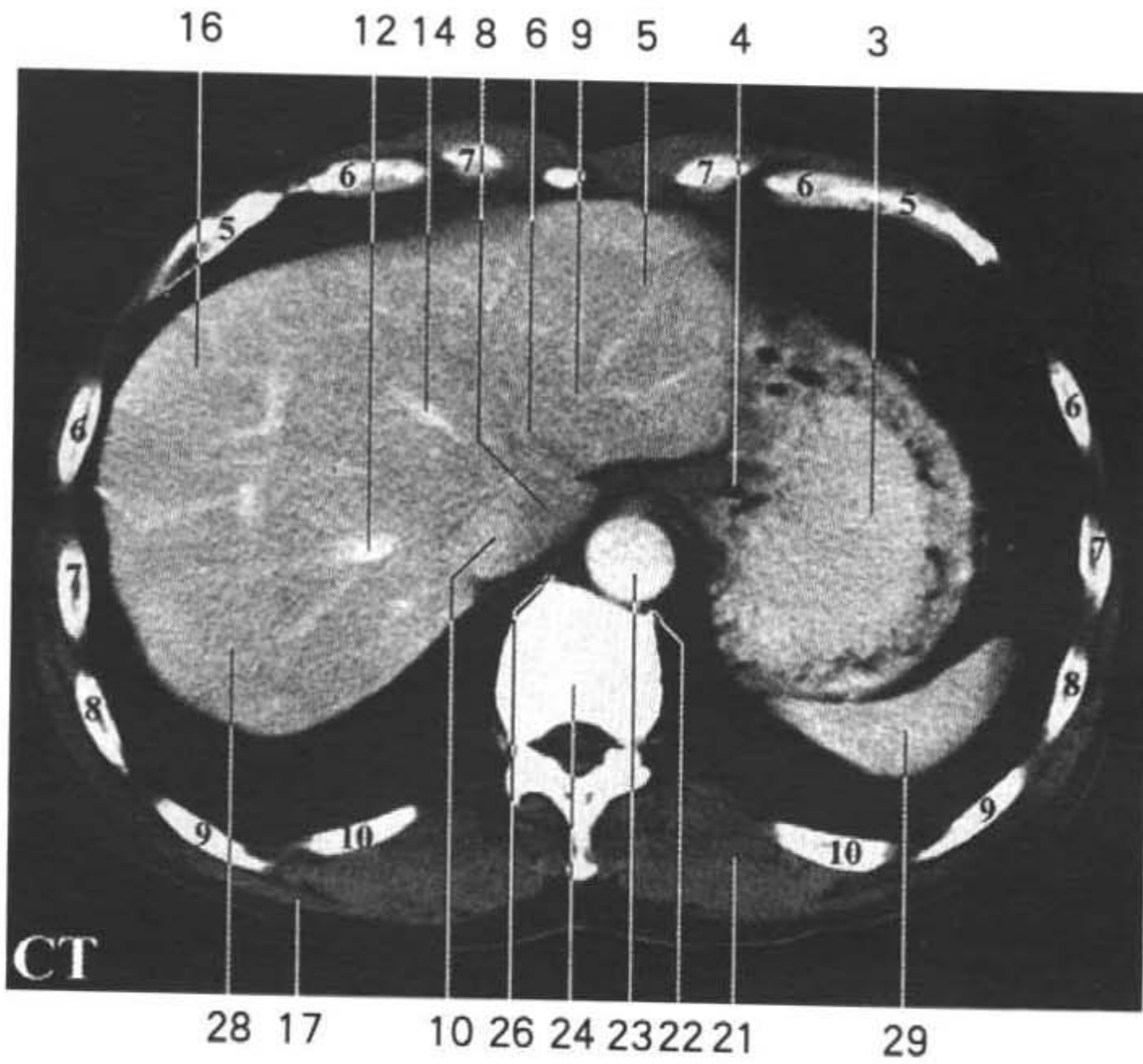
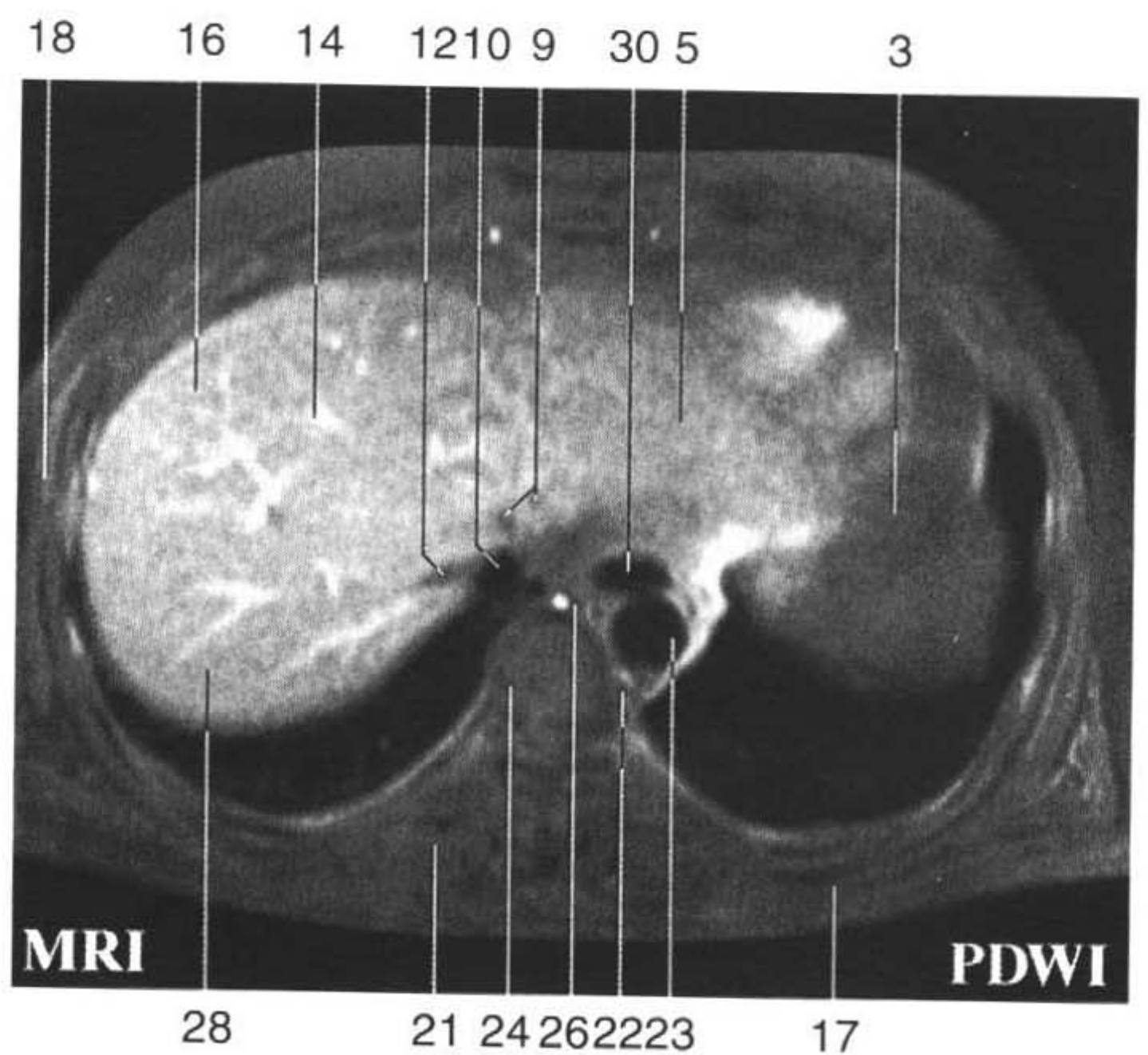


Fig.HA2

1. 外侧底段 (S_Ⅹ) lateral basal segment (S_Ⅹ)
2. 下舌段 (S_Ⅴ) inferior lingual segment (S_Ⅴ)
3. 胃 stomach
4. 贲门 cardia
5. 左外叶 left lateral lobe
6. 静脉韧带裂 fissure for ligamentum venosum
7. 剑突 xiphoid process
8. 尾状叶 caudate lobe
9. 肝左静脉 left hepatic v.
10. 下腔静脉 inferior vena cava



11. 肝圆韧带裂 fissure for ligamentum teres hepatis
12. 肝右静脉 right hepatic v.
13. 左内叶 left medial lobe
14. 肝中间静脉 intermediate hepatic v.
15. 内侧段 (S_v) medial segment (S_v)
16. 右前叶 right anterior lobe
17. 背阔肌 latissimus dorsi
18. 前锯肌 serratus anterior
19. 膈 diaphragm
20. 后底段 (S_x) posterior basal segment (S_x)
21. 竖脊肌 erector spinae
22. 半奇静脉 semiazygos v.
23. 胸主动脉 thoracic aorta
24. 10、11 胸椎间盘 intervertebral disc (T₁₀₋₁₁)
25. 脊髓 spinal cord
26. 奇静脉 azygos v.
27. 斜方肌 trapezius
28. 右后叶 right posterior lobe
29. 脾 spleen
30. 食管 esophagus



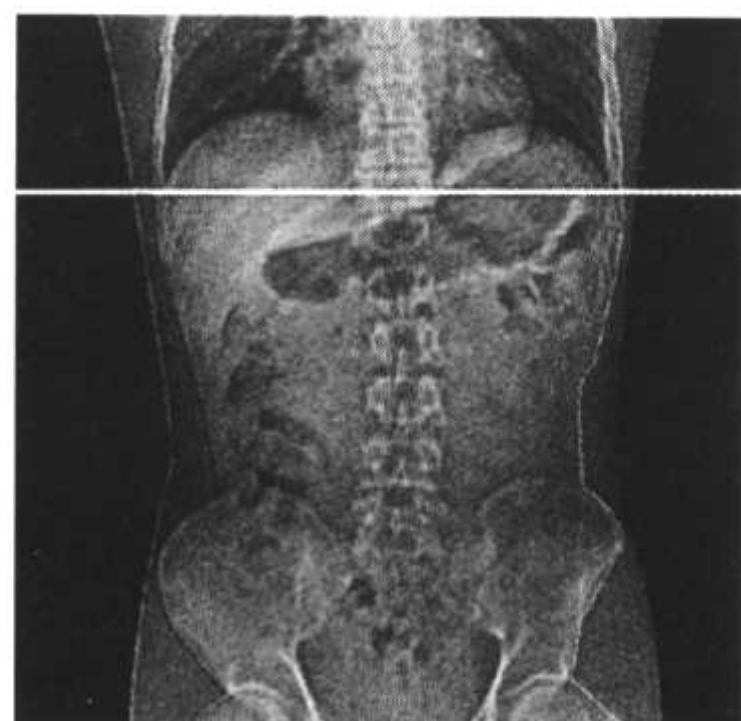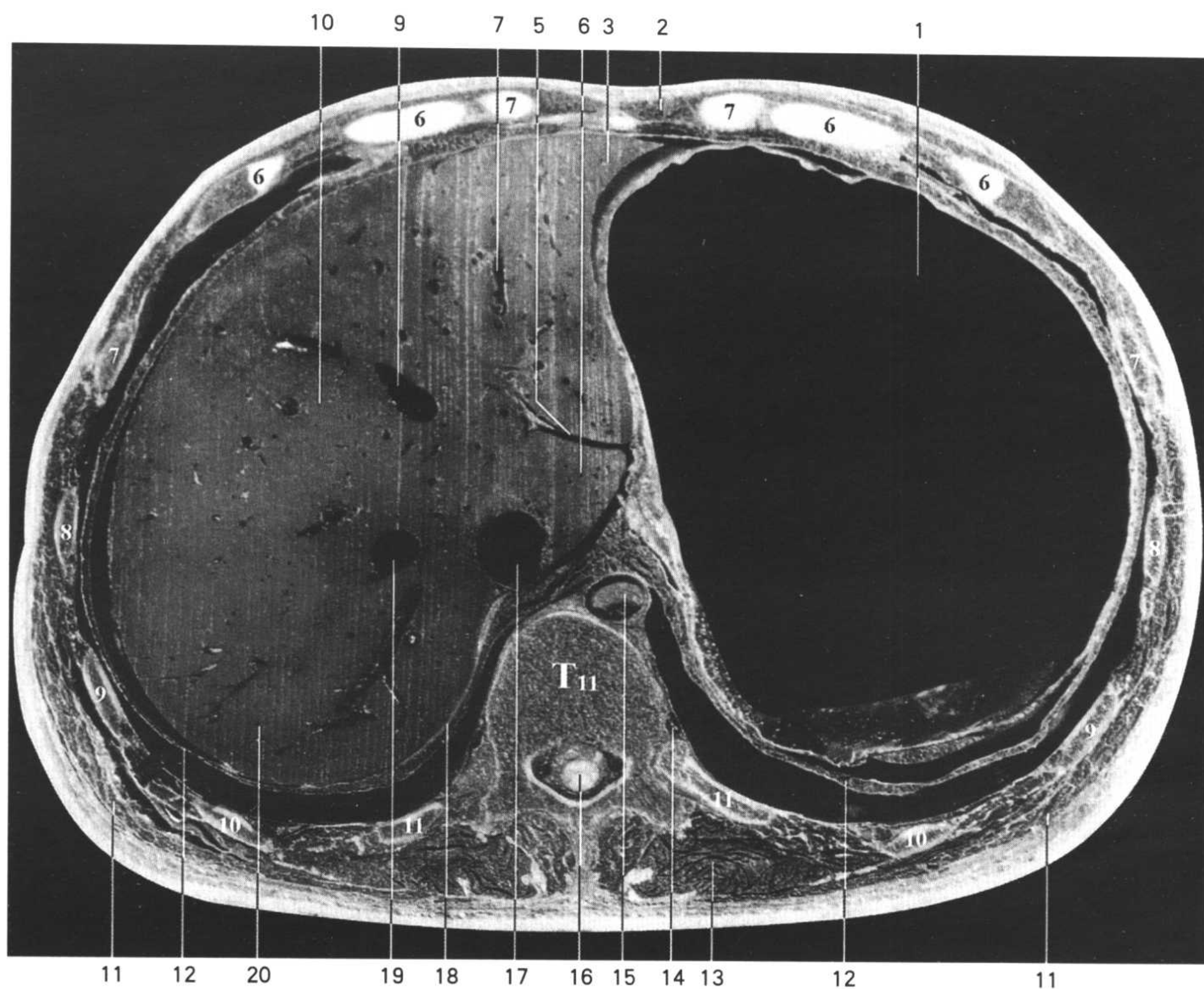
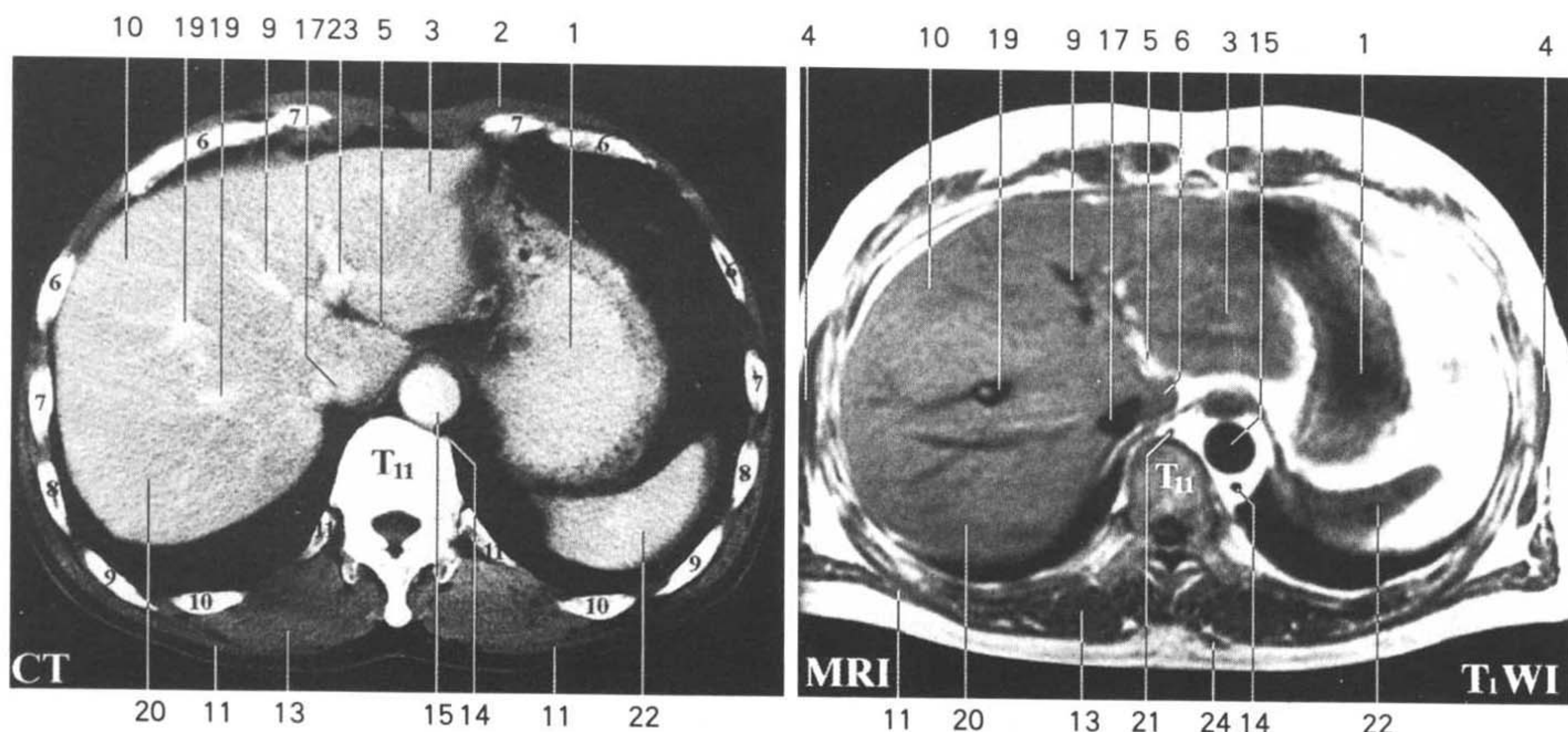
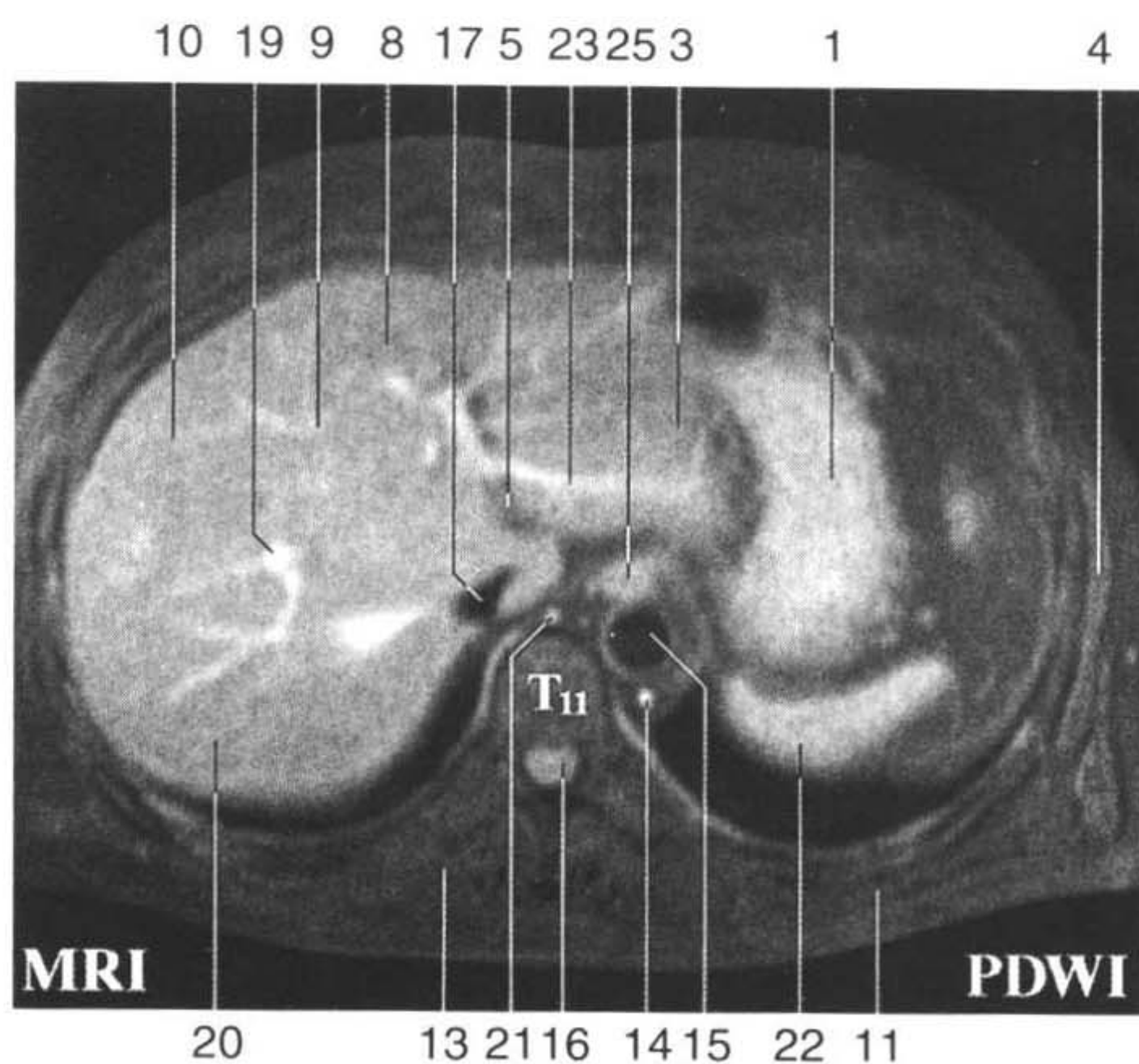


Fig.HA3

1. 胃 stomach
2. 腹直肌 rectus abdominis
3. 左外叶 left lateral lobe
4. 前锯肌 serratus anterior
5. 静脉韧带裂 fissure for ligamentum venosum
6. 尾状叶 caudate lobe
7. 肝左静脉 left hepatic v.
8. 左内叶 left medial lobe
9. 肝中间静脉 intermediate hepatic v.
10. 右前叶 right anterior lobe



- 11. 背阔肌 latissimus dorsi
- 12. 膈 diaphragm
- 13. 竖脊肌 erector spinae
- 14. 半奇静脉 semiazygos v.
- 15. 胸主动脉 thoracic aorta
- 16. 脊髓 spinal cord
- 17. 下腔静脉 inferior vena cava
- 18. 右肾上腺 right suprarenal gland
- 19. 肝右静脉 right hepatic v.
- 20. 右后叶 right posterior lobe
- 21. 奇静脉 azygos v.
- 22. 脾 spleen
- 23. 肝门静脉左支 left branch of hepatic portal v.
- 24. 斜方肌 trapezius
- 25. 食管 esophagus



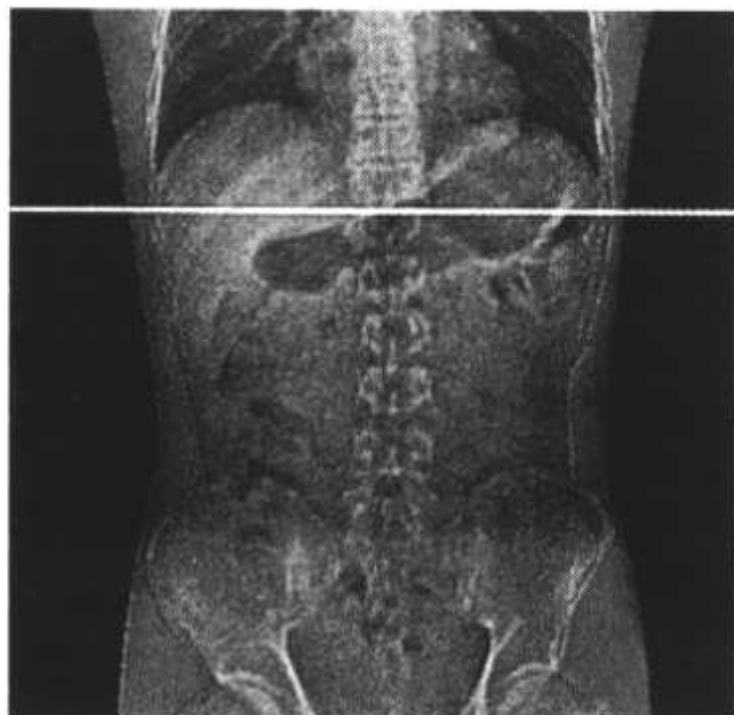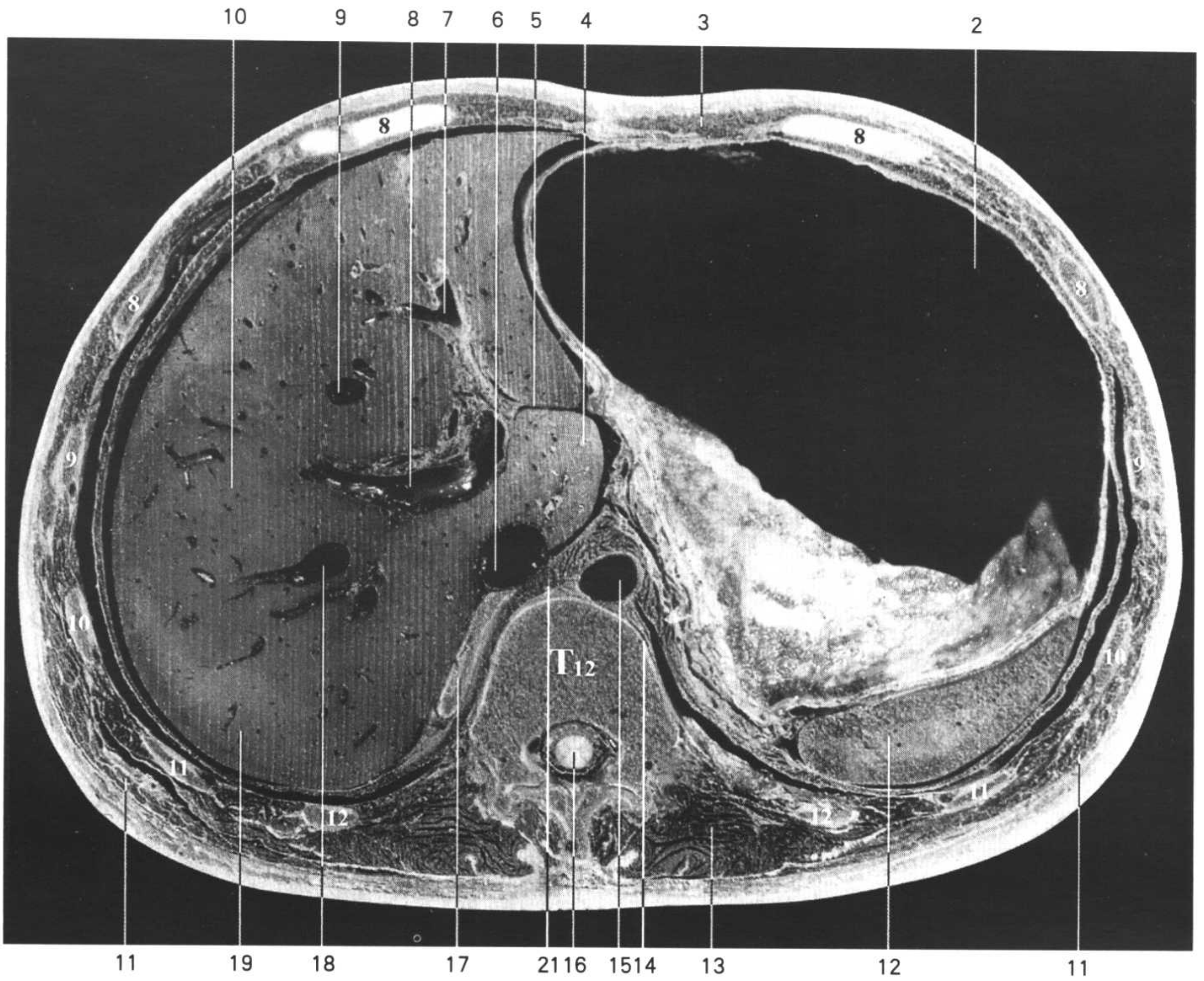
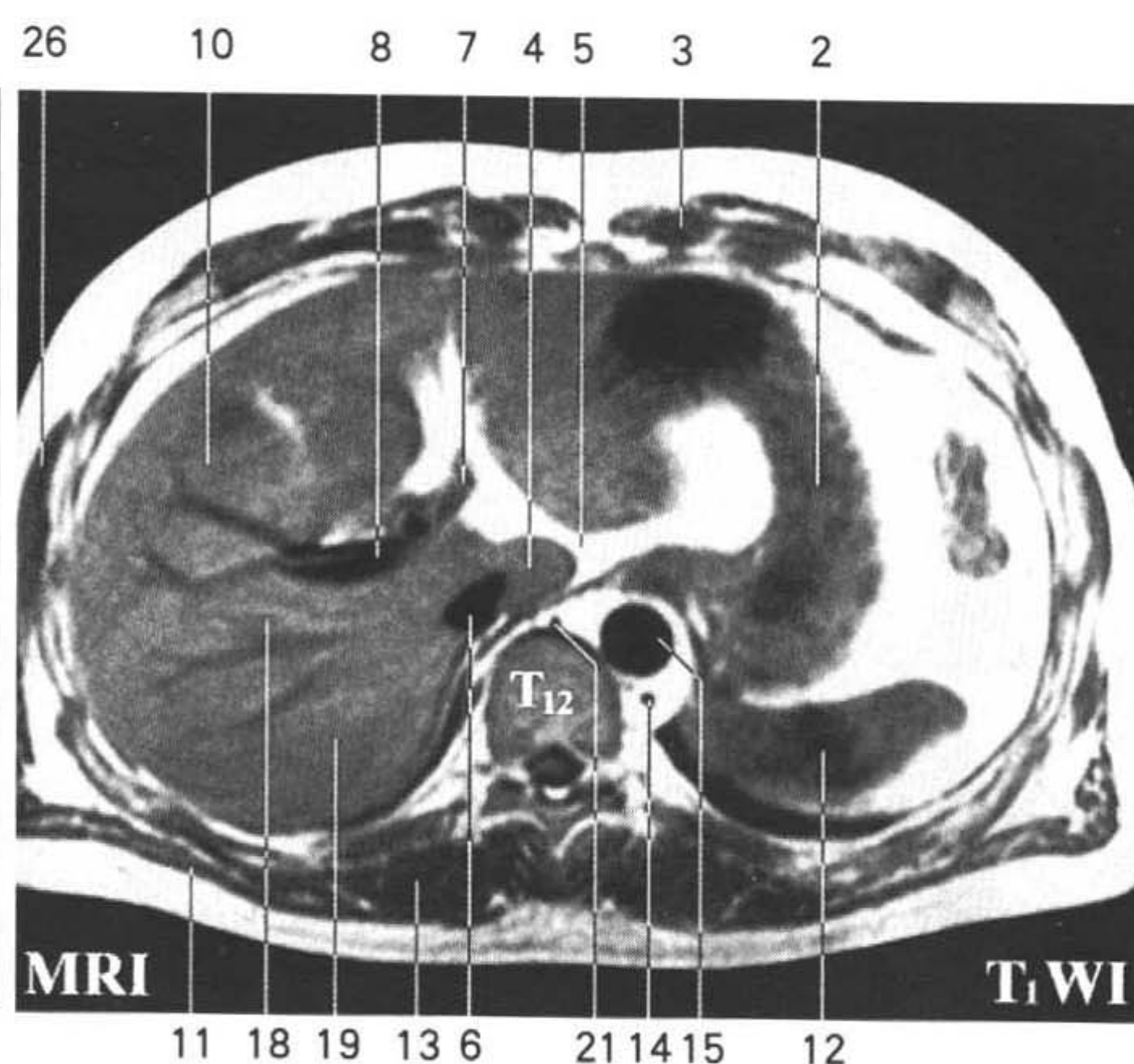
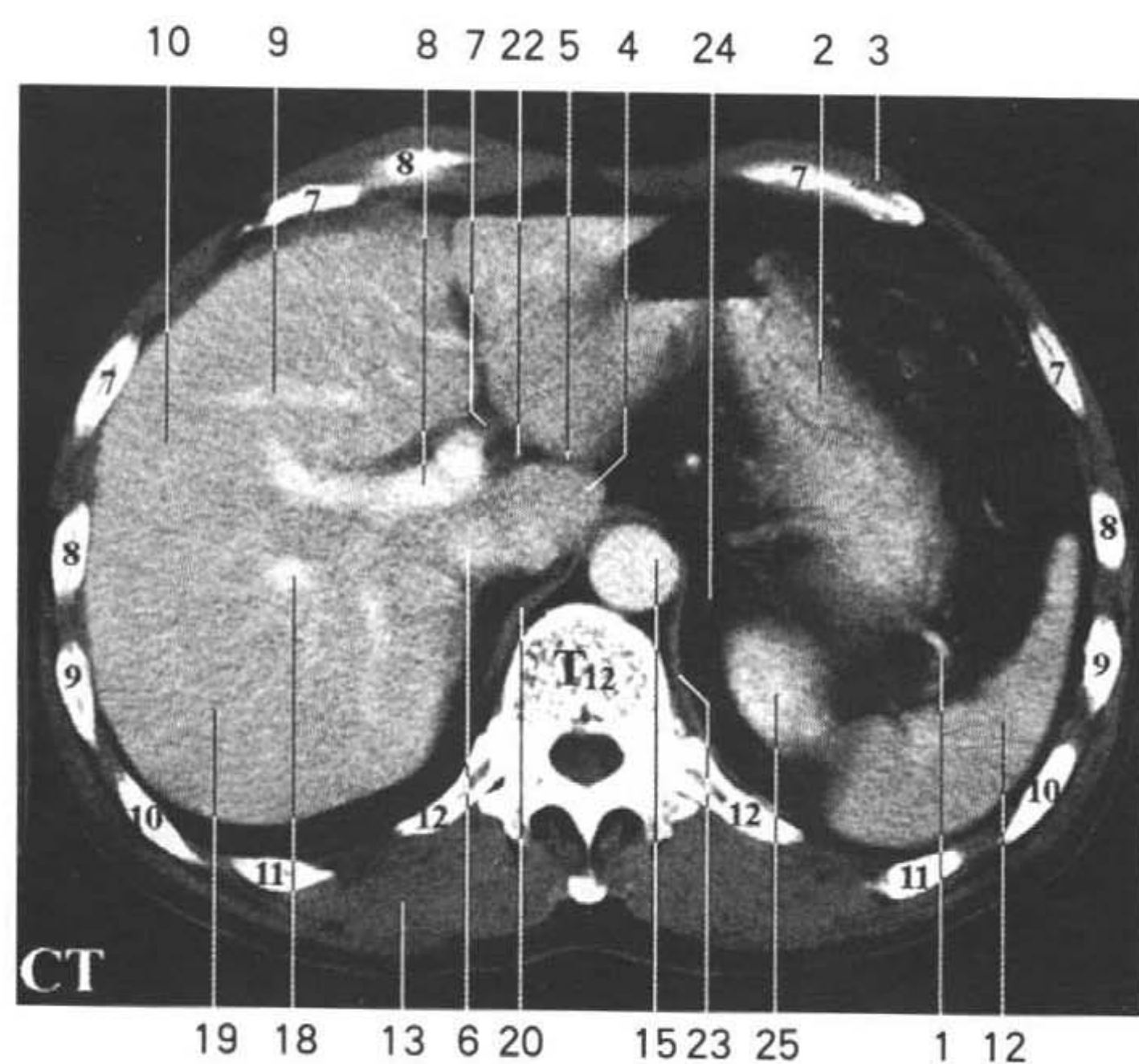
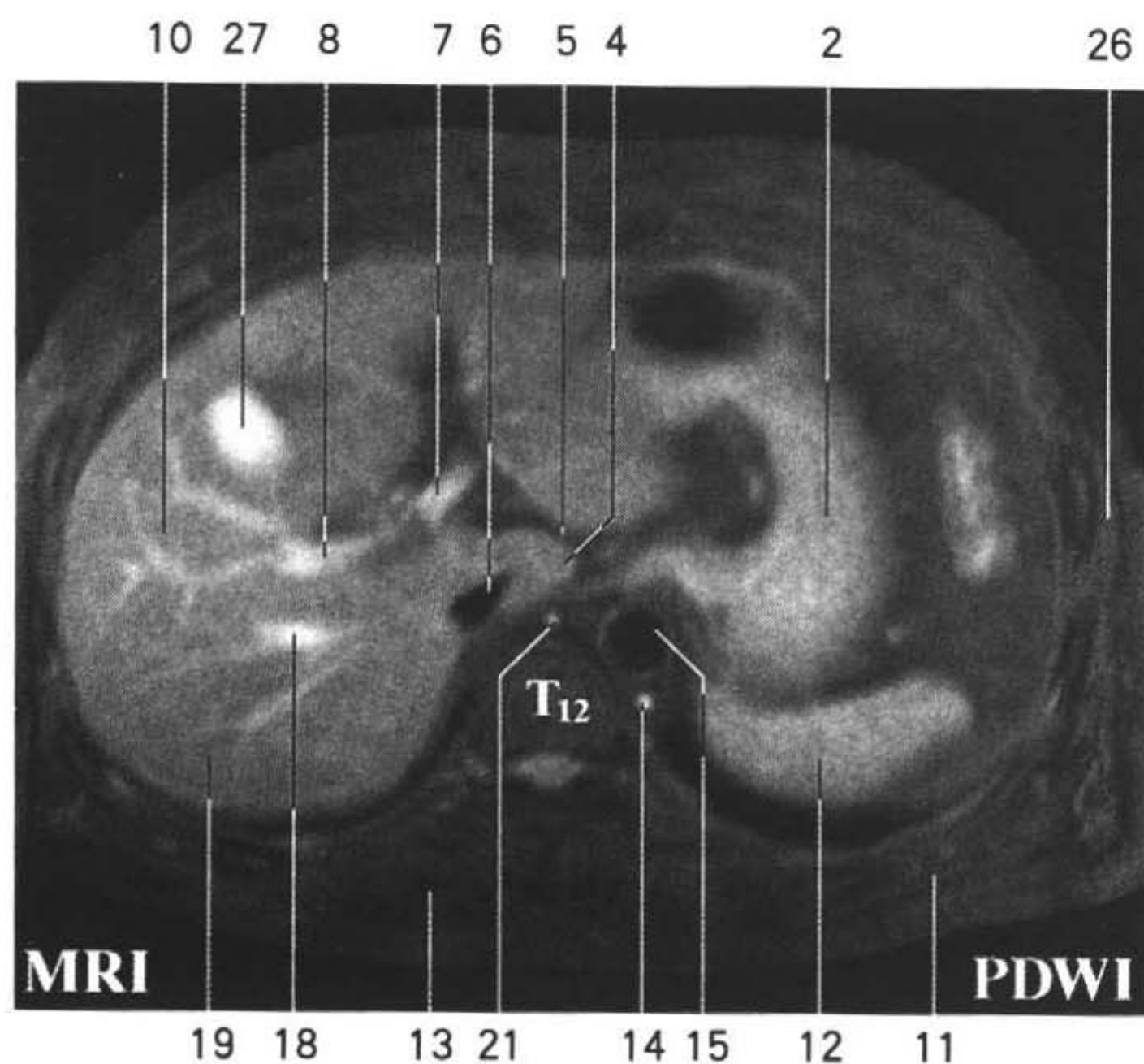


Fig.HA4

1. 脾动脉 splenic a.
2. 胃 stomach
3. 腹直肌 rectus abdominis
4. 尾状叶 caudate lobe
5. 静脉韧带裂 fissure for ligamentum venosum
6. 下腔静脉 inferior vena cava
7. 肝门静脉左支 left branch of hepatic portal v.
8. 肝门静脉右支 right branch of hepatic portal v.
9. 肝中间静脉 intermediate hepatic v.
10. 右前叶 right anterior lobe



11. 背阔肌 latissimus dorsi
12. 脾 spleen
13. 竖脊肌 erector spinae
14. 半奇静脉 semiazygos v.
15. 胸主动脉 thoracic aorta
16. 脊髓 spinal cord
17. 右肾上腺 right suprarenal gland
18. 肝右静脉 right hepatic v.
19. 右后叶 right posterior lobe
20. 膈右脚 right crus of diaphragm
21. 奇静脉 azygos v.
22. 肝固有动脉 proper hepatic a.
23. 膈左脚 left crus of diaphragm
24. 左肾上腺 left suprarenal gland
25. 左肾 left kidney
26. 前锯肌 serratus anterior
27. 胆囊 gallbladder



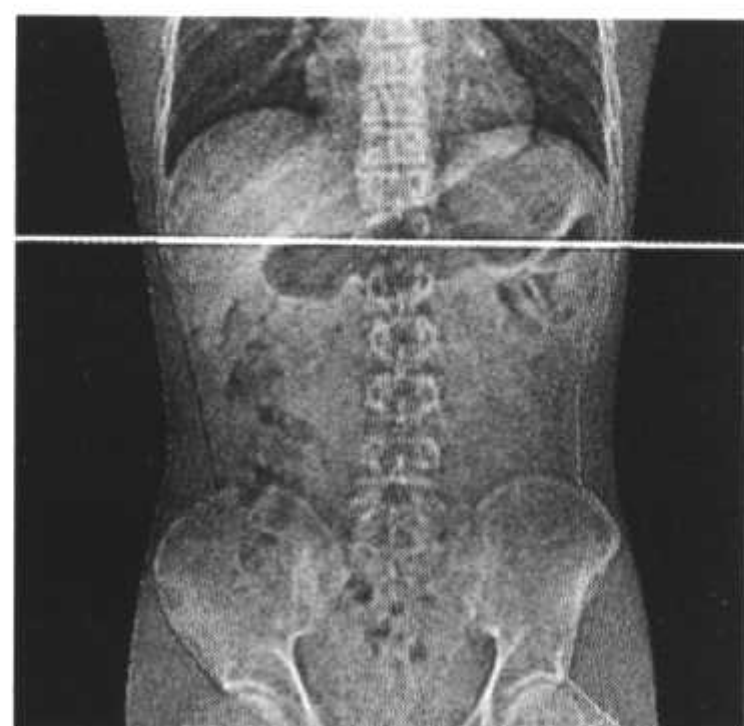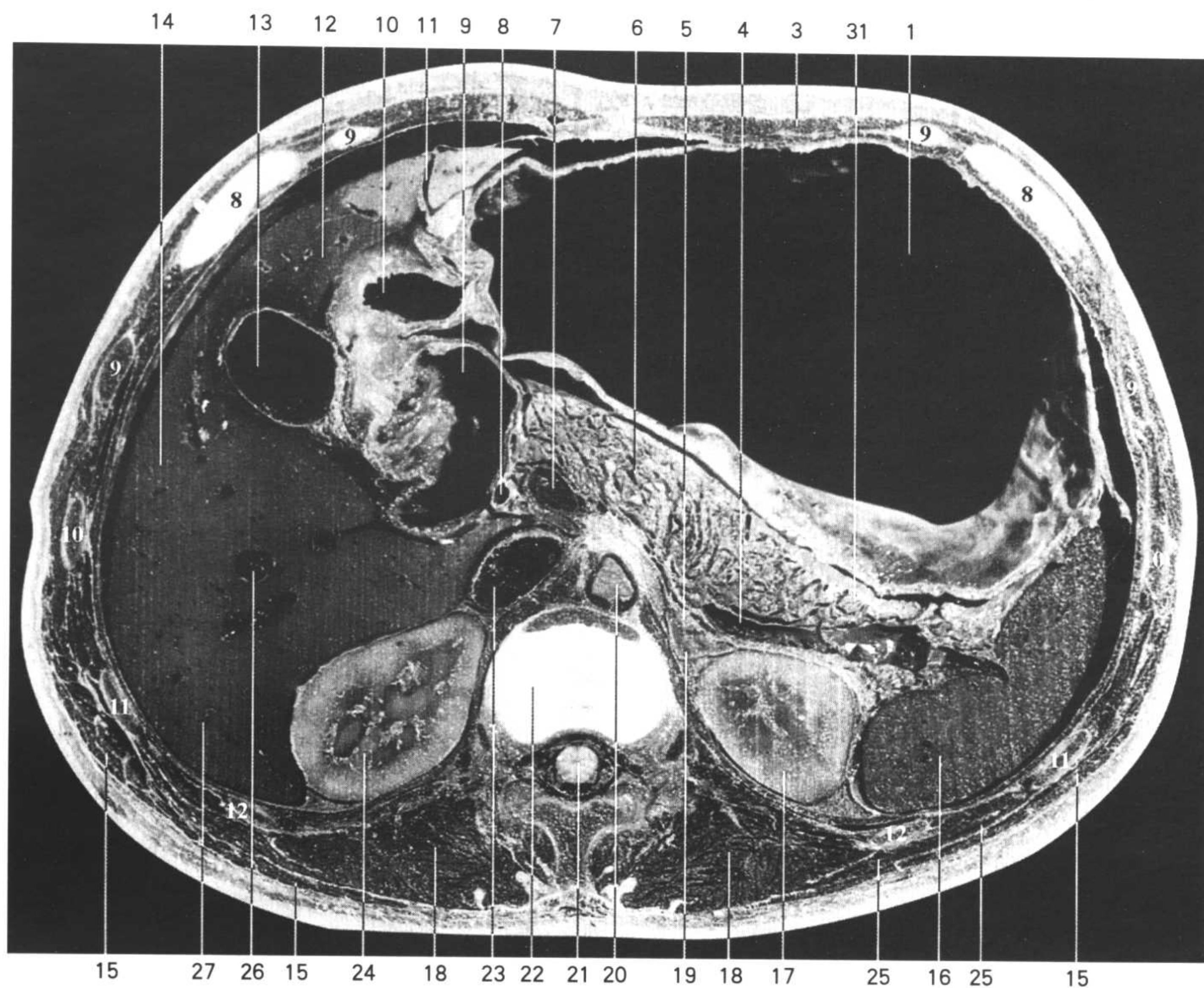

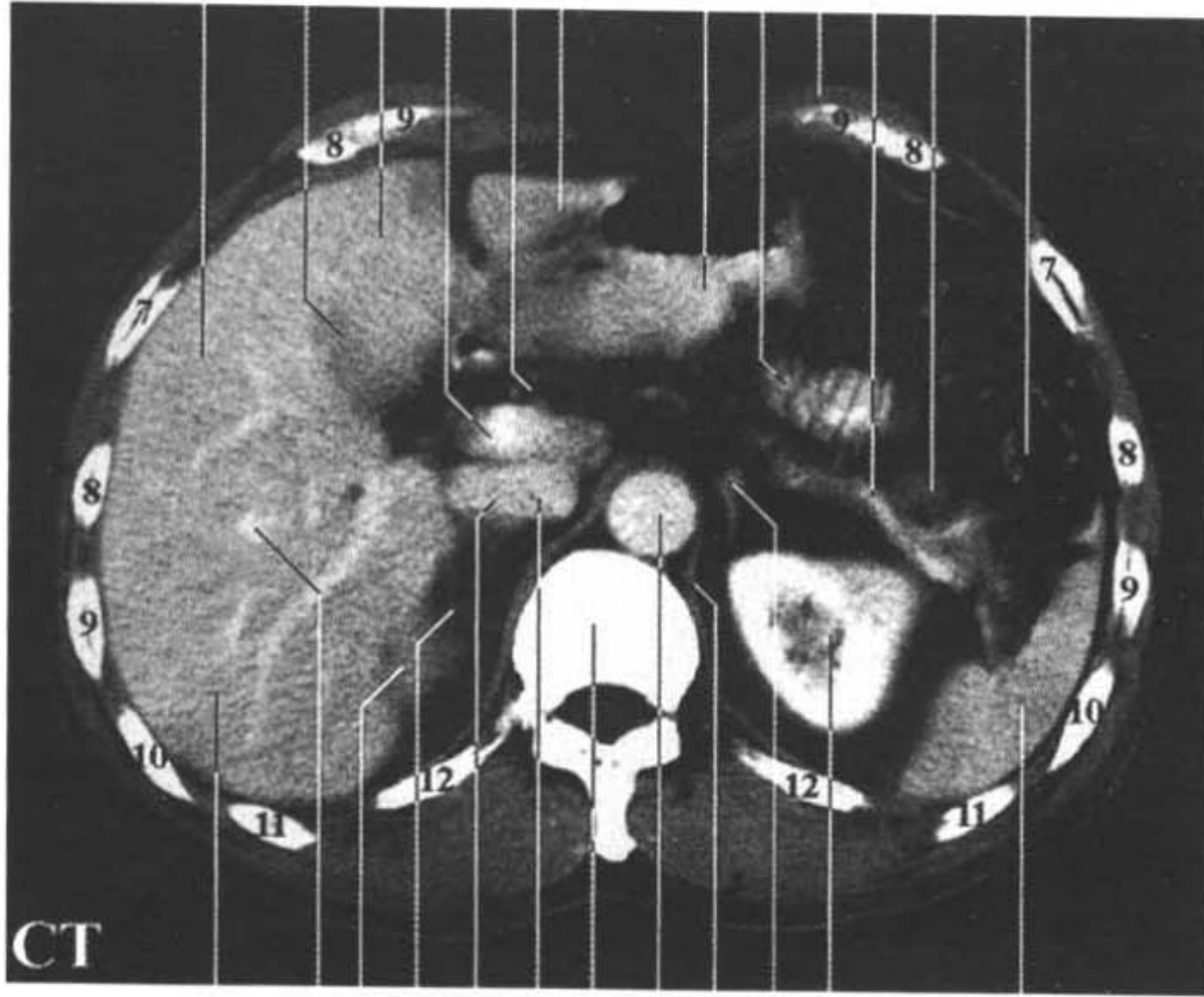
Fig.HA5

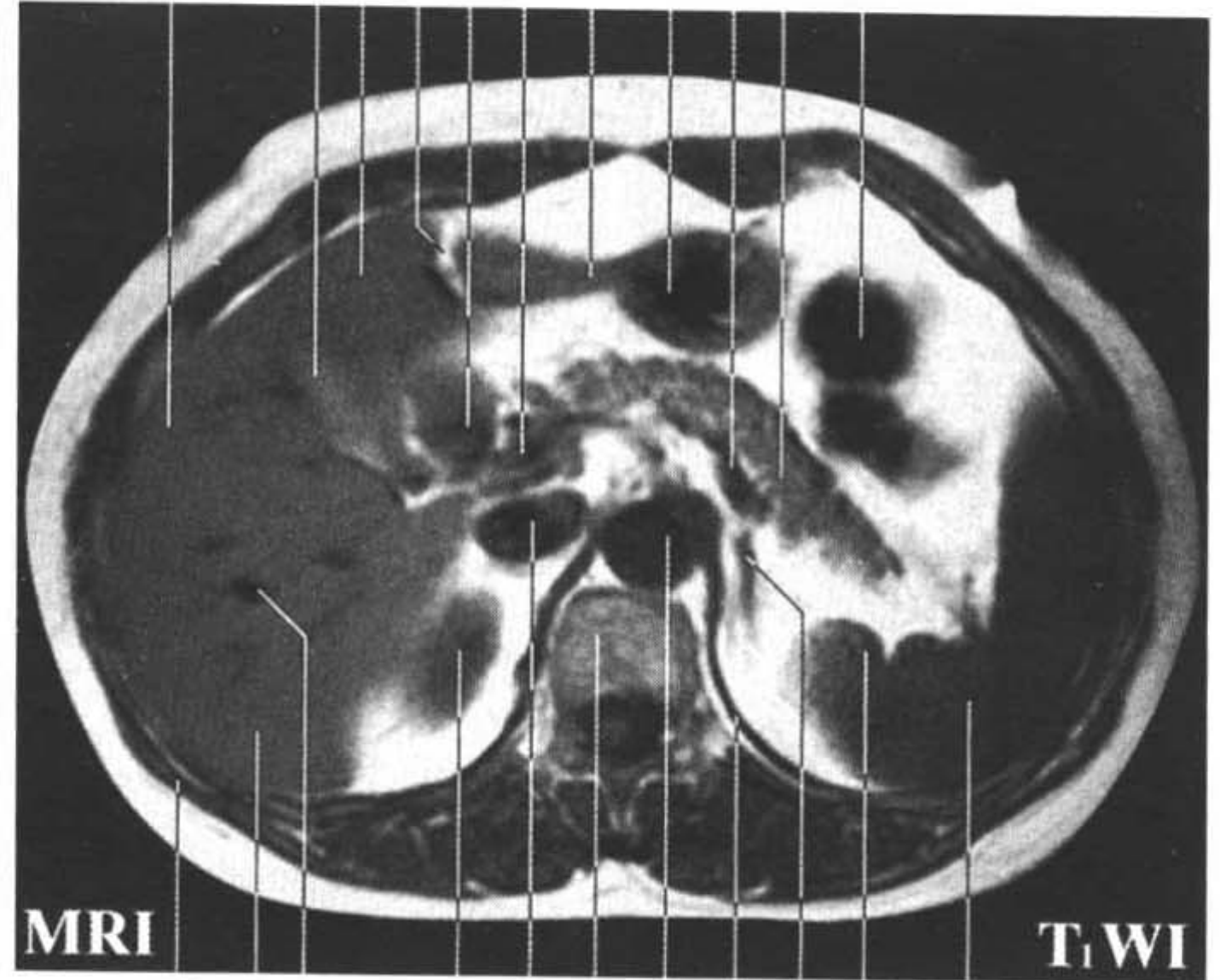
1. 胃 stomach
2. 结肠左曲 left colic flexure
3. 腹直肌 rectus abdominis
4. 脾静脉 splenic v.
5. 左肾动脉 left renal a.
6. 胰体 body of pancreas
7. 肝门静脉 hepatic portal v.
8. 胆总管 common bile duct
9. 十二指肠降部 descending part of duodenum
10. 幽门窦 pyloric antrum

14 13 12 7 3328 1 32 3 4 31 2



27 262430 34 2322 20 29 19 17 16

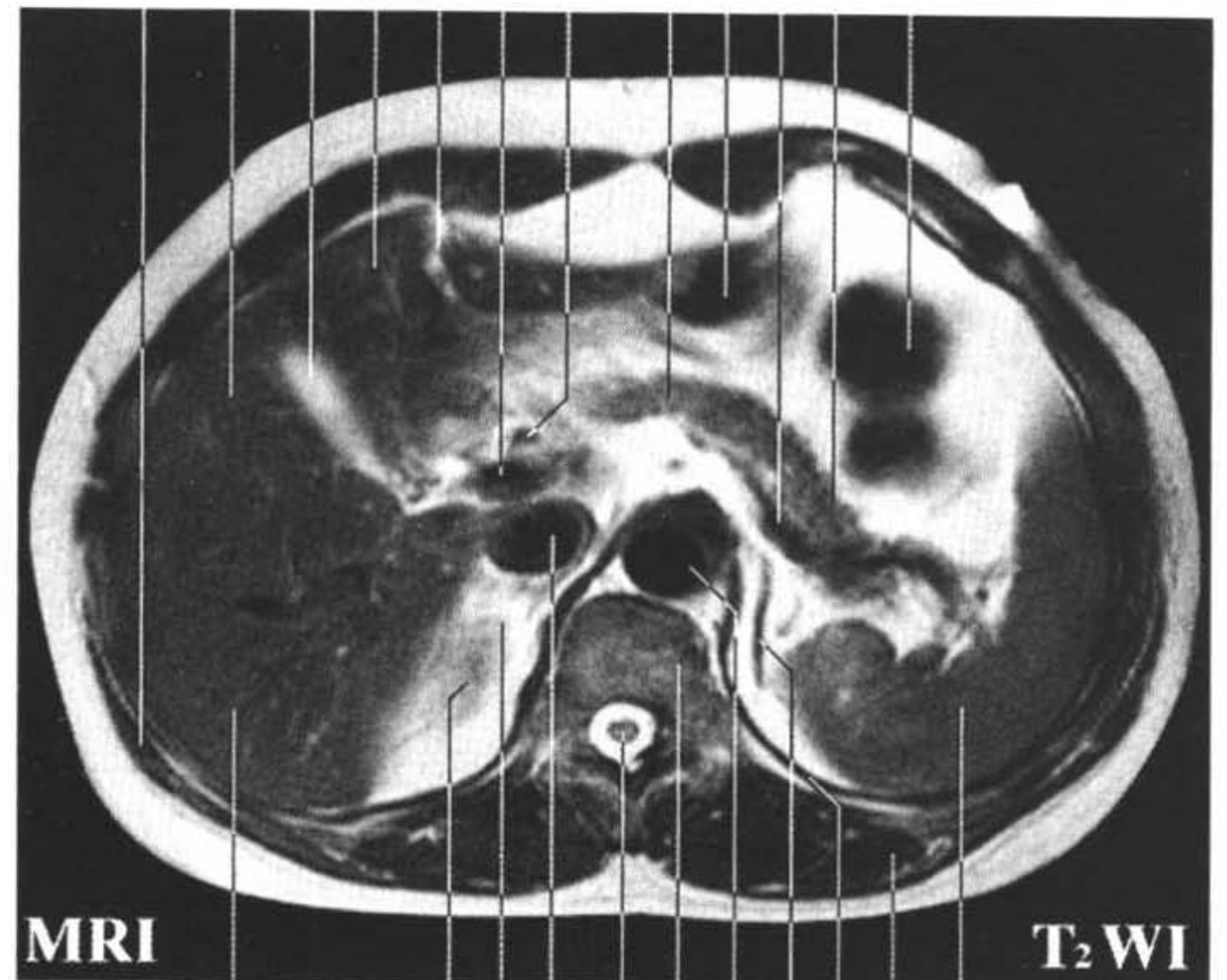
14 13121110 7 28 1 4 31 2



15 2726 24 23 22 20 29 19 17 16

11. 肝圆韧带裂 fissure for ligamentum teres hepatis
12. 左内叶 left medial lobe
13. 胆囊 gallbladder
14. 右前叶 right anterior lobe
15. 背阔肌 latissimus dorsi
16. 脾 spleen
17. 左肾 left kidney
18. 竖脊肌 erector spinae
19. 左肾上腺 left suprarenal gland
20. 腹主动脉 abdominal aorta
21. 脊髓 spinal cord
22. 第12胸椎与第1腰椎间盘 intervertebral disc (T₁₂-L₁)
23. 下腔静脉 inferior vena cava
24. 右肾 right kidney
25. 下后锯肌 serratus posterior inferior
26. 肝右静脉 right hepatic v.
27. 右后叶 right posterior lobe
28. 左外叶 left lateral lobe
29. 膈左脚 left crus of diaphragm
30. 右肾上腺 right suprarenal gland
31. 胰尾 tail of pancreas
32. 十二指肠空肠曲 duodenojejunal flexure
33. 肝固有动脉 proper hepatic a.
34. 尾状叶 caudate lobe

15 14 13 12 11 7 8 6 1 4 31 2



27 243023 21 22 20 19 29 18 16

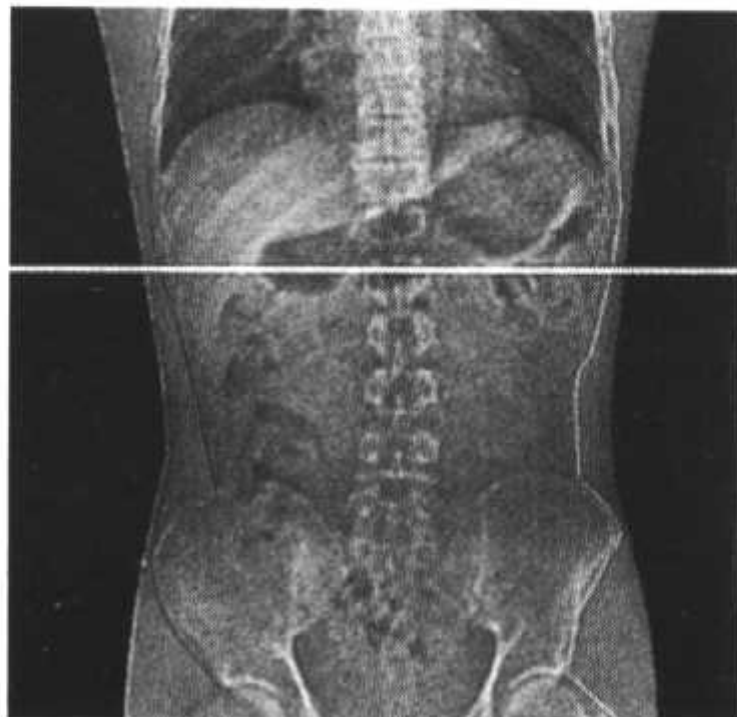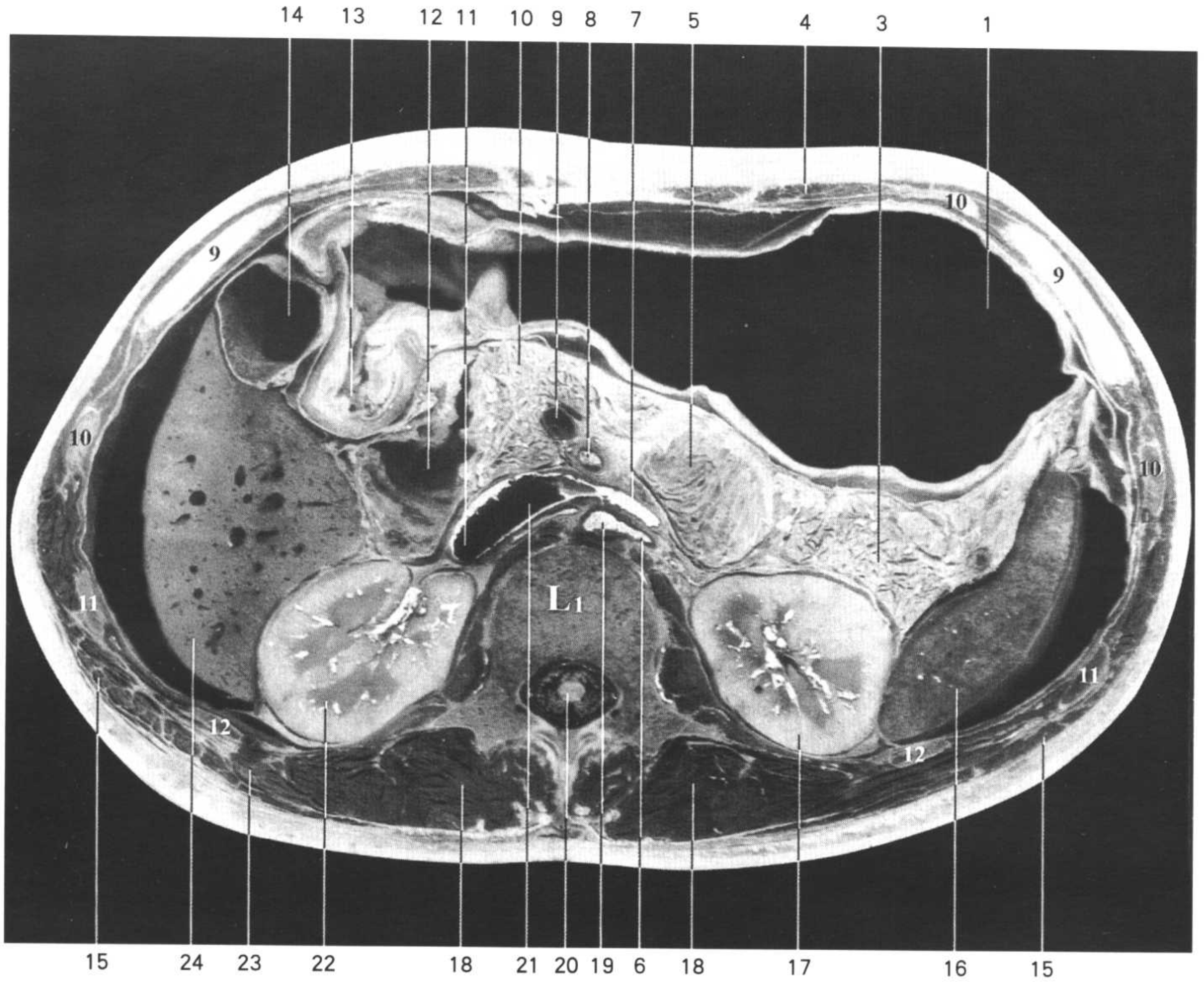
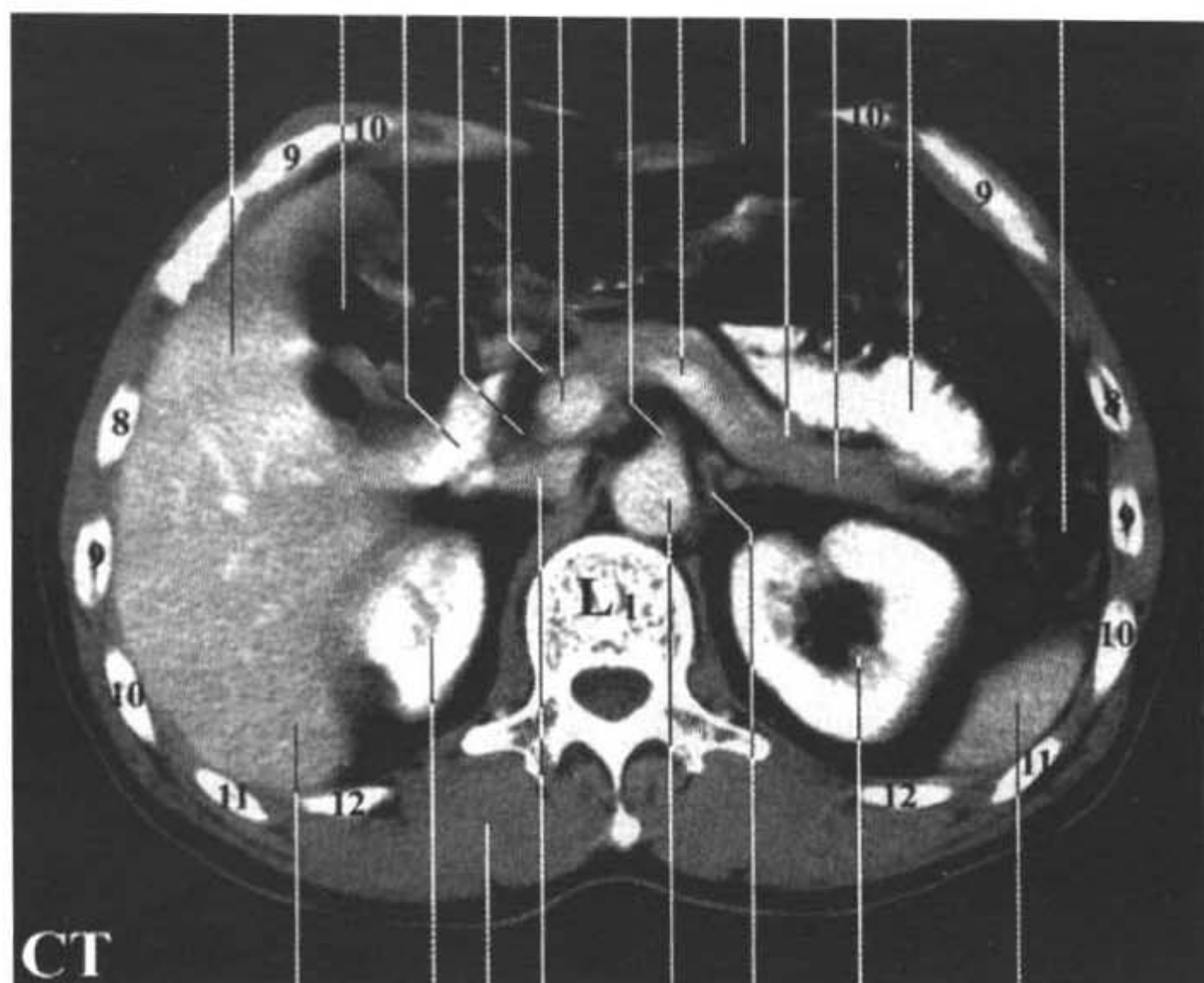


Fig.HA6

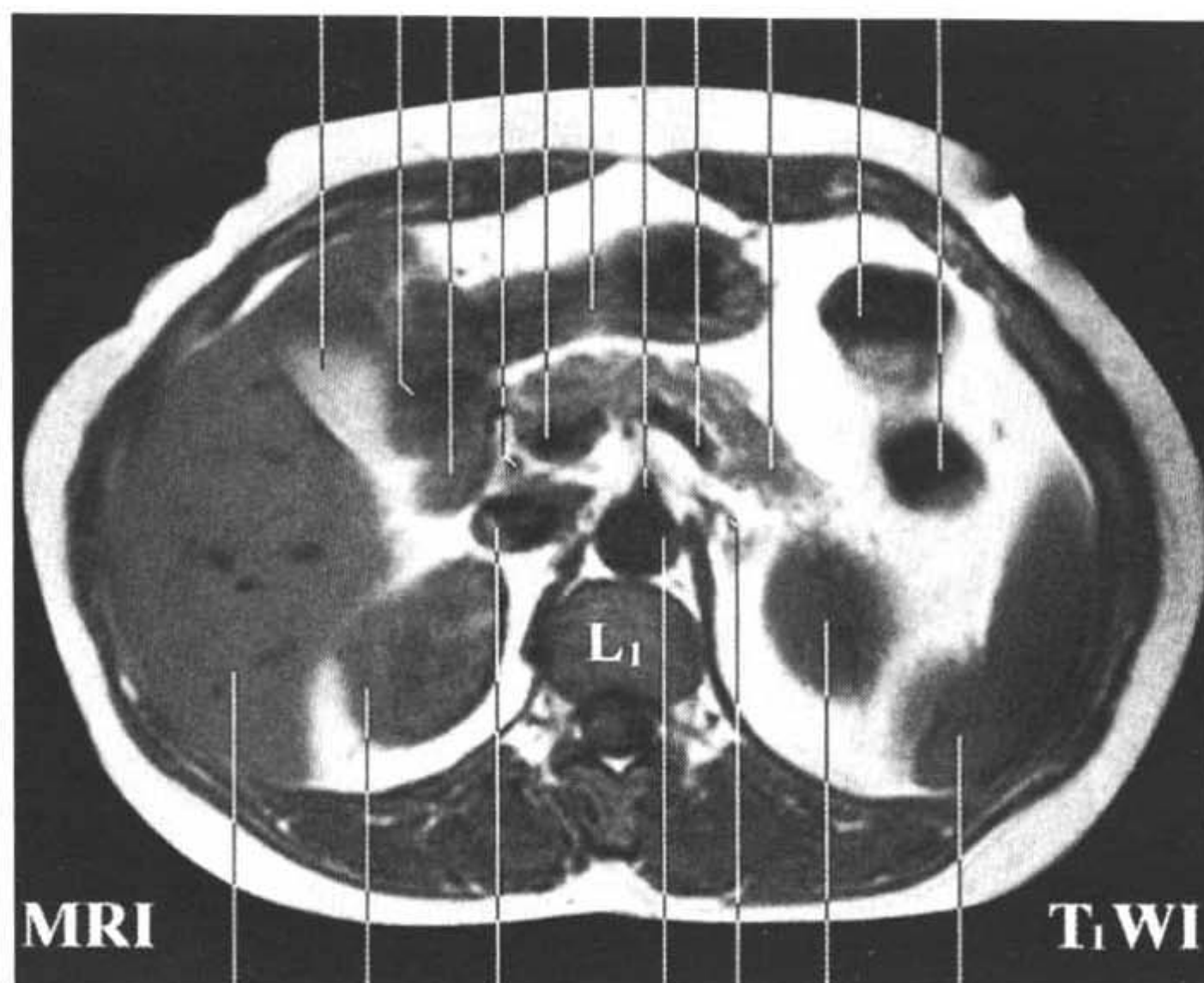1. 胃 stomach
2. 左肾上腺 left suprarenal gland
3. 胰尾 tail of pancreas
4. 腹直肌 rectus abdominis
5. 空肠 jejunum
6. 左肾动脉 left renal a.
7. 左肾静脉 left renal v.
8. 肠系膜上动脉 superior mesenteric a.
9. 肠系膜上静脉 superior mesenteric v.
10. 胰头 head of pancreas

32 14 12 27 31 25 8 28 4 26 3 5 30



24 22 18 21 19 2 17 16

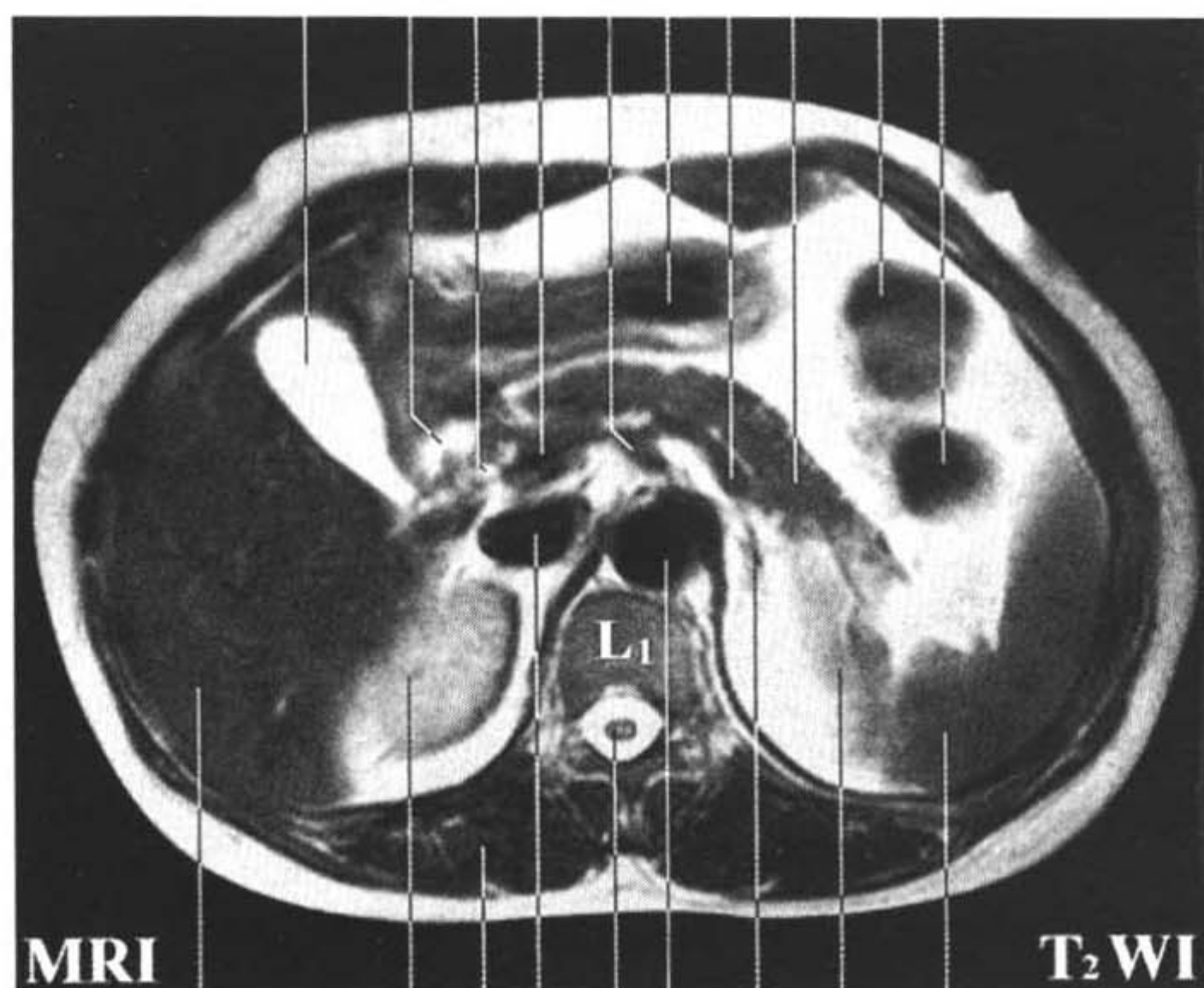
14 13 12 27 25 1 8 28 3 29 30



24 22 21 19 2 17 16

11. 右肾静脉 right renal v.
12. 十二指肠降部 descending part of duodenum
13. 幽门 pylorus
14. 胆囊 gallbladder
15. 背阔肌 latissimus dorsi
16. 脾 spleen
17. 左肾 left kidney
18. 竖脊肌 erector spinae
19. 腹主动脉 abdominal aorta
20. 脊髓 spinal cord
21. 下腔静脉 inferior vena cava
22. 右肾 right kidney
23. 下后锯肌 serratus posterior inferior
24. 右后叶 right posterior lobe
25. 肝门静脉 hepatic portal v.
26. 胰体 body of pancreas
27. 胆总管 common bile duct
28. 脾静脉 splenic v.
29. 横结肠 transverse colon
30. 降结肠 descending colon
31. 肝固有动脉 proper hepatic a.
32. 右前叶 right anterior lobe

14 12 27 25 8 1 28 3 29 30



24 22 18 21 20 19 2 17 16

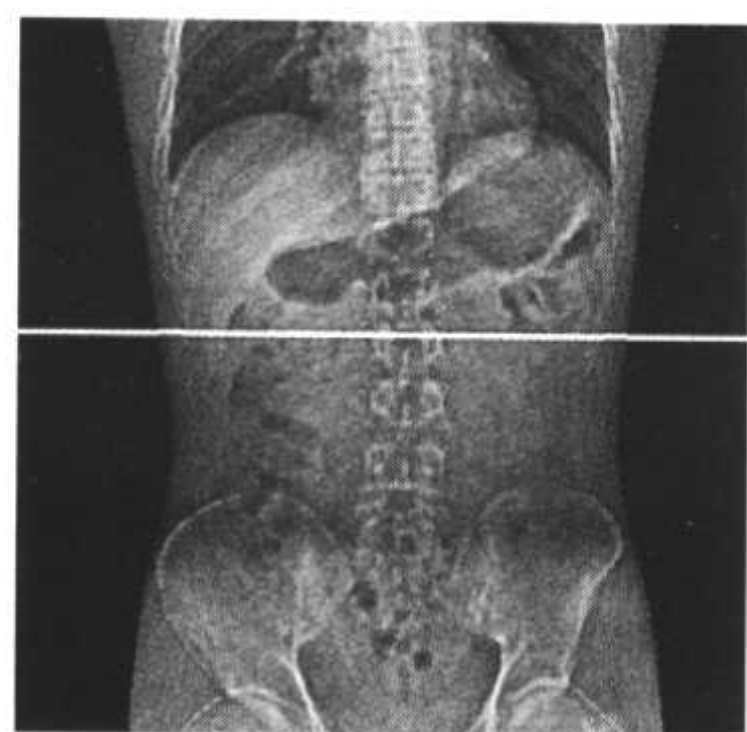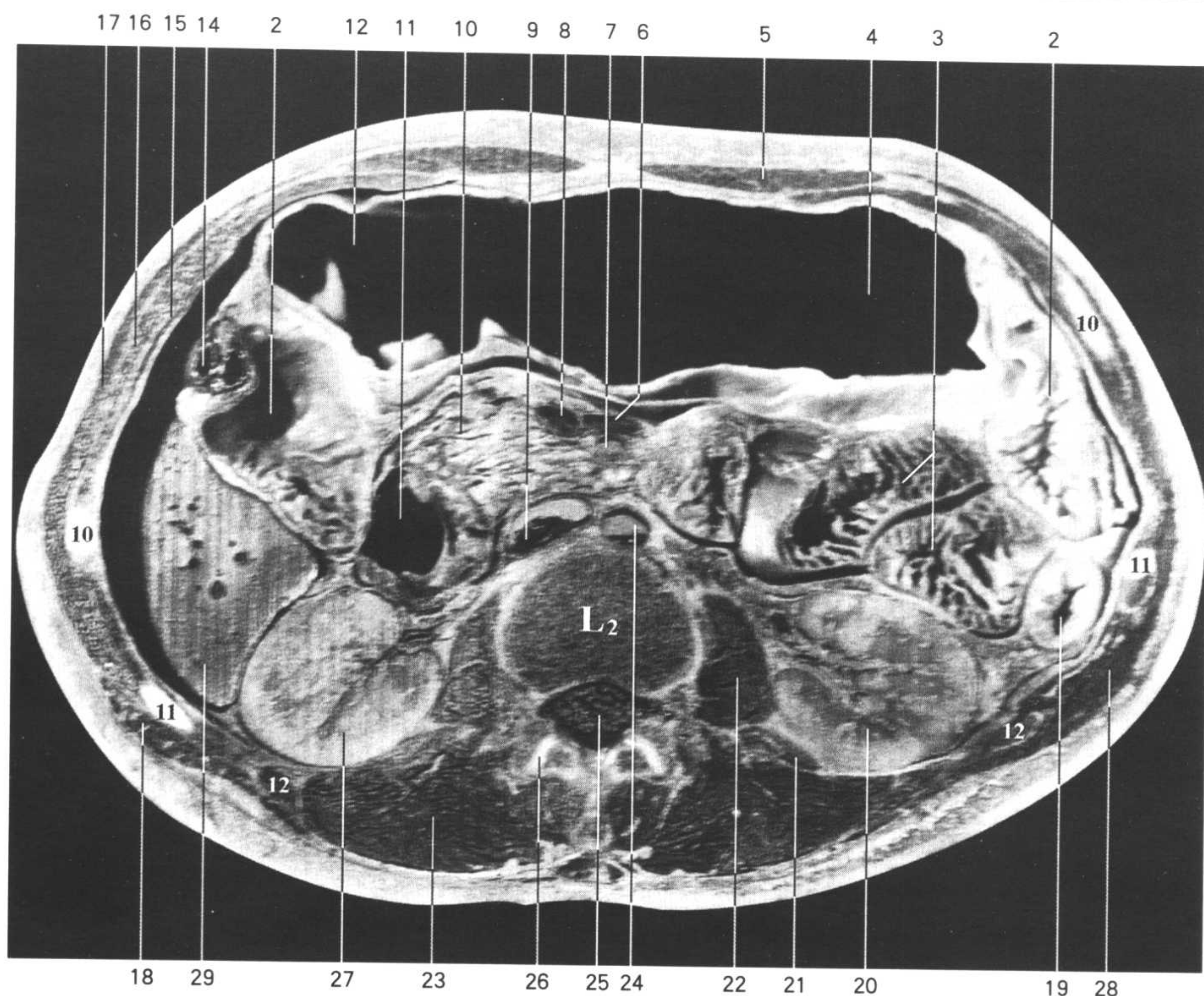
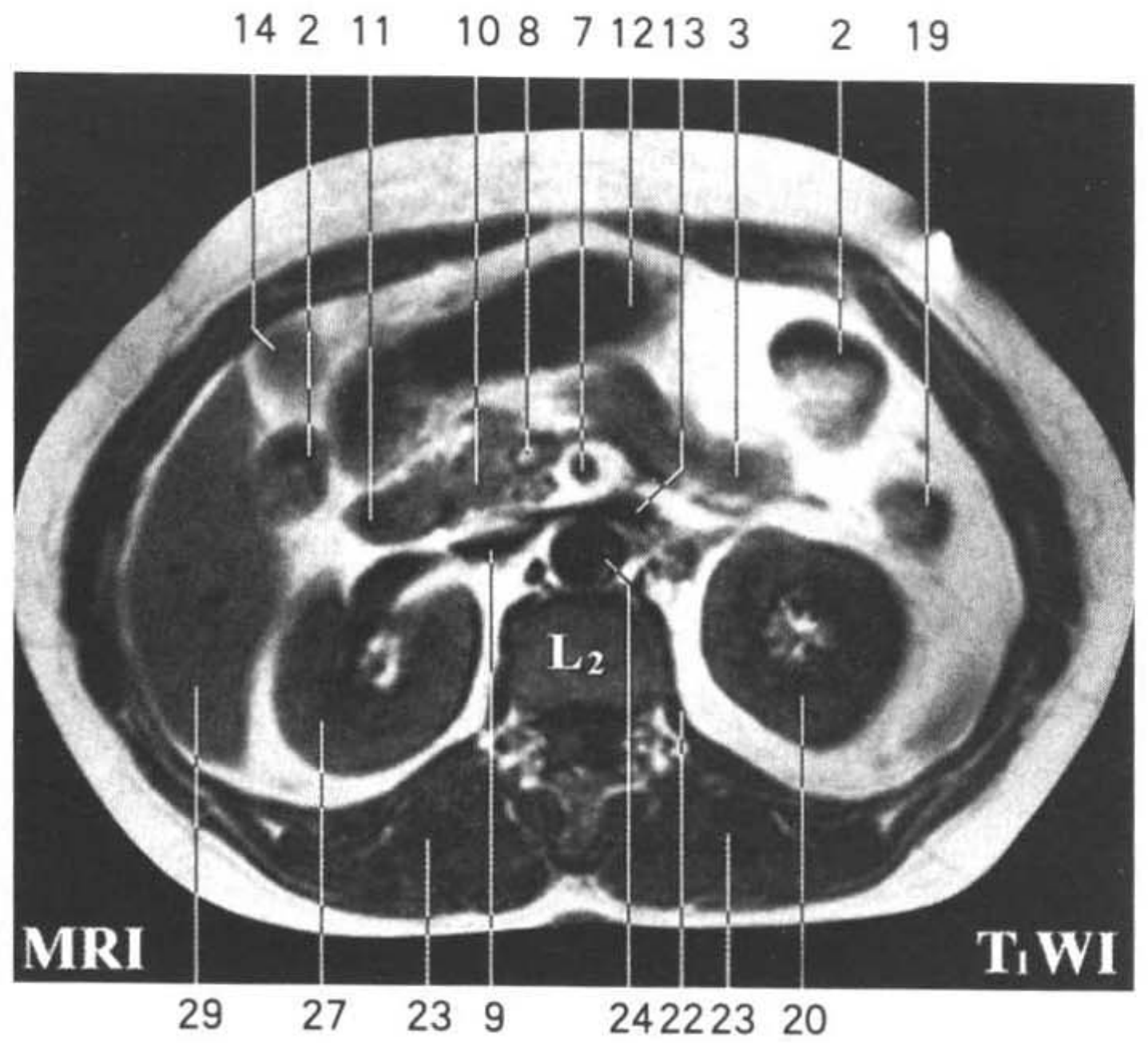
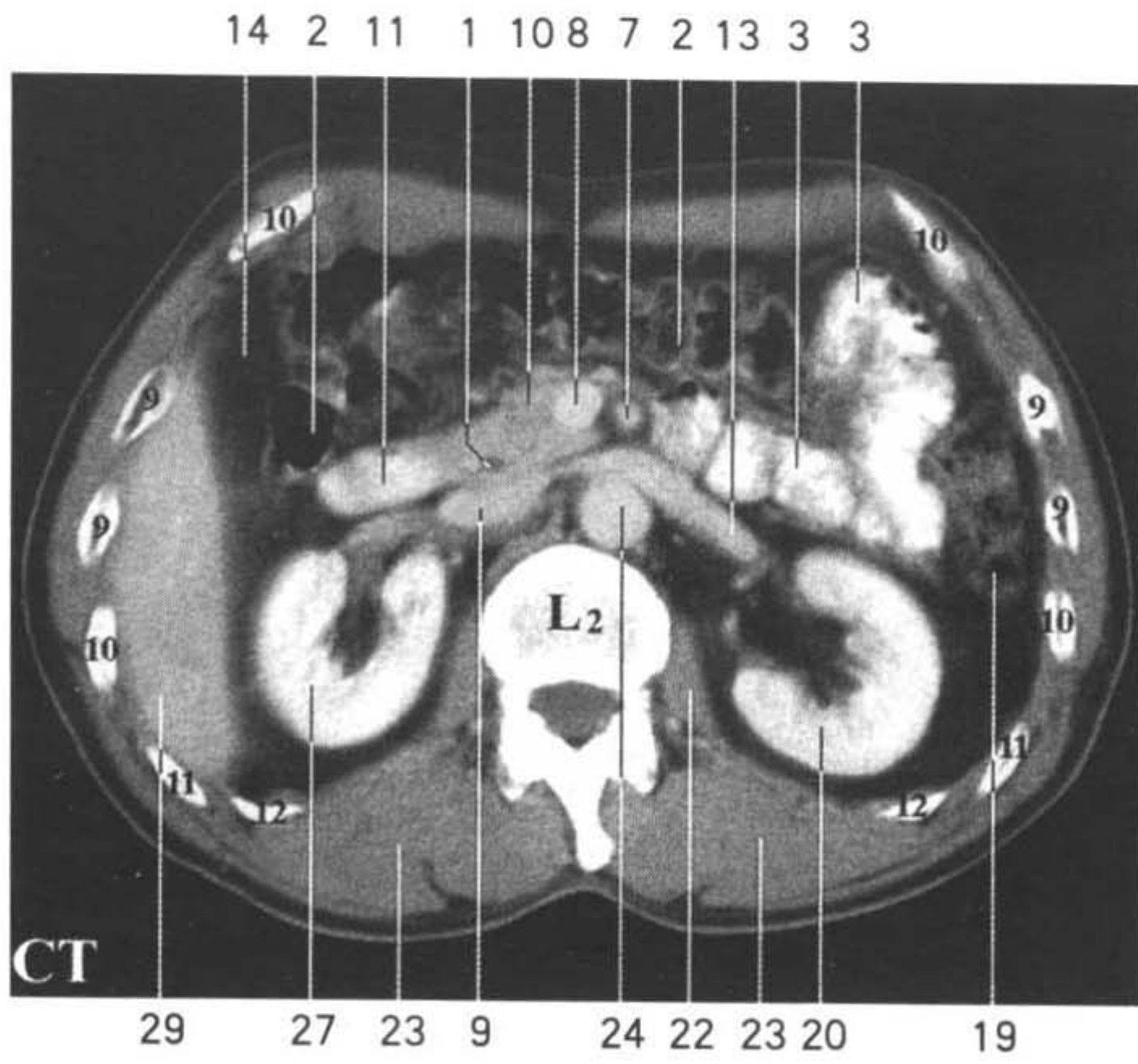
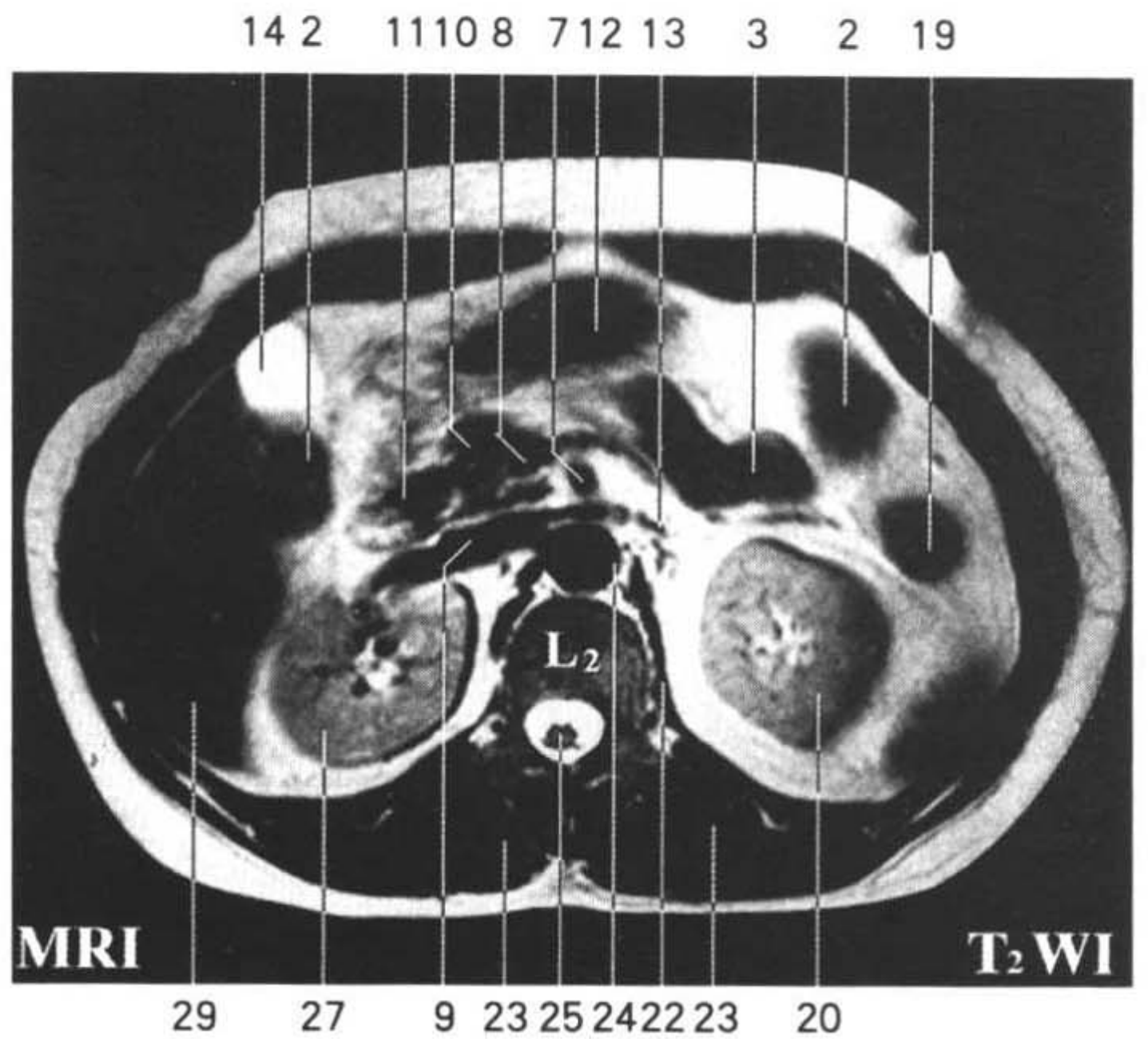


Fig.HA7

1. 胆总管 common bile duct
2. 横结肠 transverse colon
3. 空肠 jejunum
4. 胃 stomach
5. 腹直肌 rectus abdominis
6. 脾静脉 splenic v.
7. 肠系膜上动脉 superior mesenteric a.
8. 肠系膜上静脉 superior mesenteric v.
9. 下腔静脉 inferior vena cava
10. 胰头 head of pancreas



11. 十二指肠降部 descending part of duodenum
12. 胃 stomach
13. 左肾静脉 left renal v.
14. 胆囊 gallbladder
15. 腹横肌 transversus abdominis
16. 腹内斜肌 obliquus internus
17. 腹外斜肌 obliquus externus
18. 背阔肌 latissimus dorsi
19. 降结肠 descending colon
20. 左肾 left kidney
21. 腰方肌 quadratus lumborum
22. 腰大肌 psoas major
23. 竖脊肌 erector spinae
24. 腹主动脉 abdominal aorta
25. 马尾 cauda equina
26. 1、2腰椎关节突关节 zygapophysial joint (L₁-L₂)
27. 右肾 right kidney
28. 下后锯肌 serratus posterior inferior
29. 右后叶 right posterior lobe



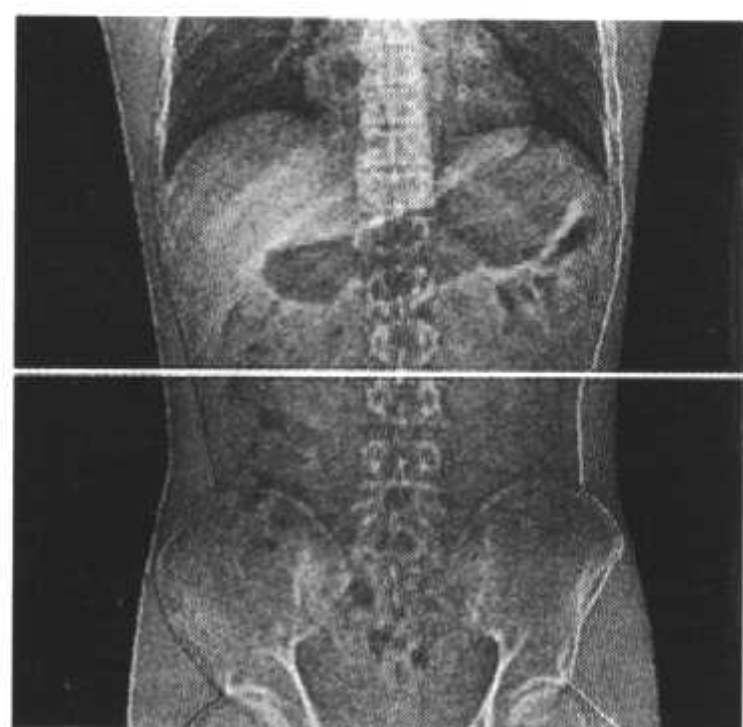
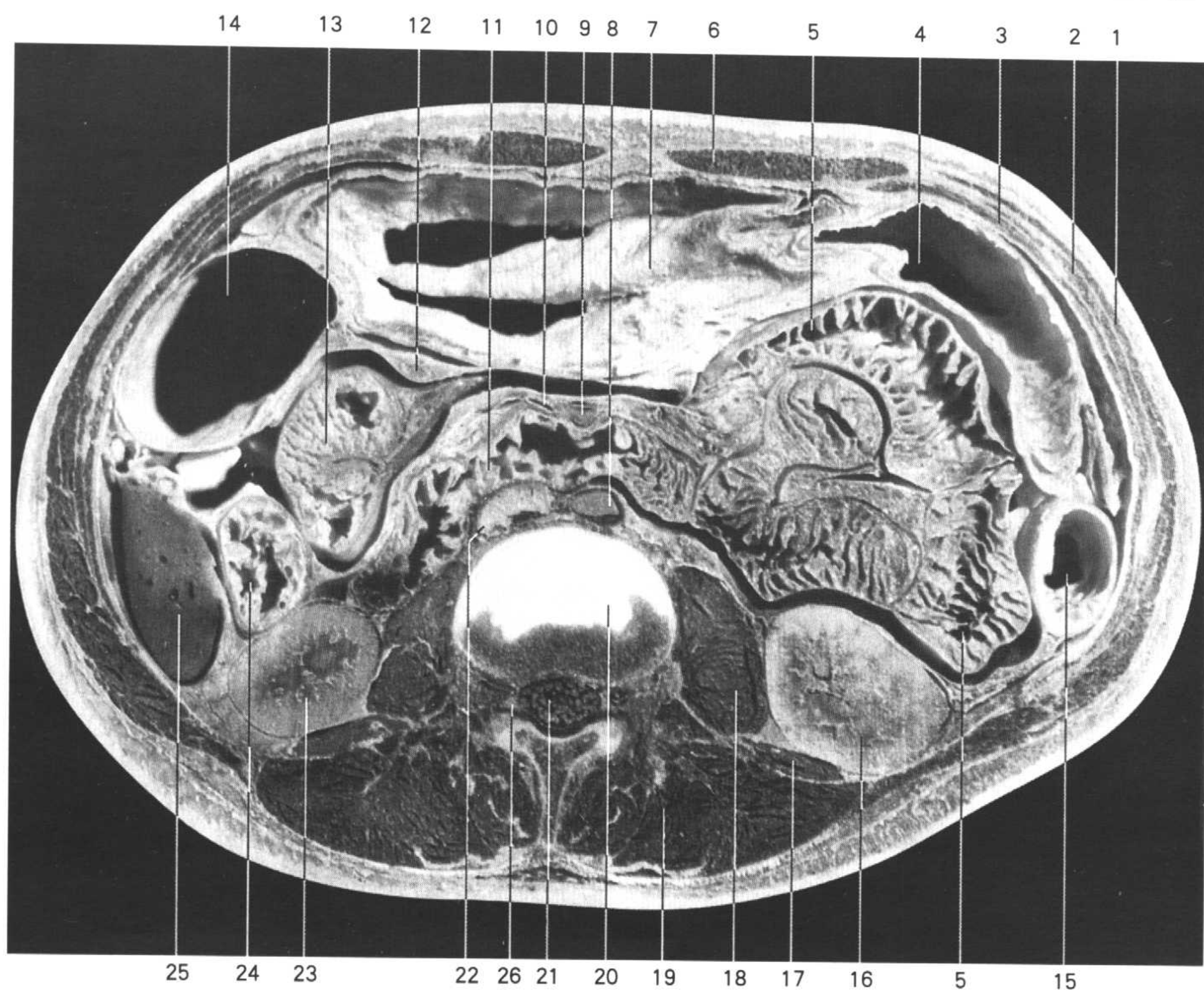
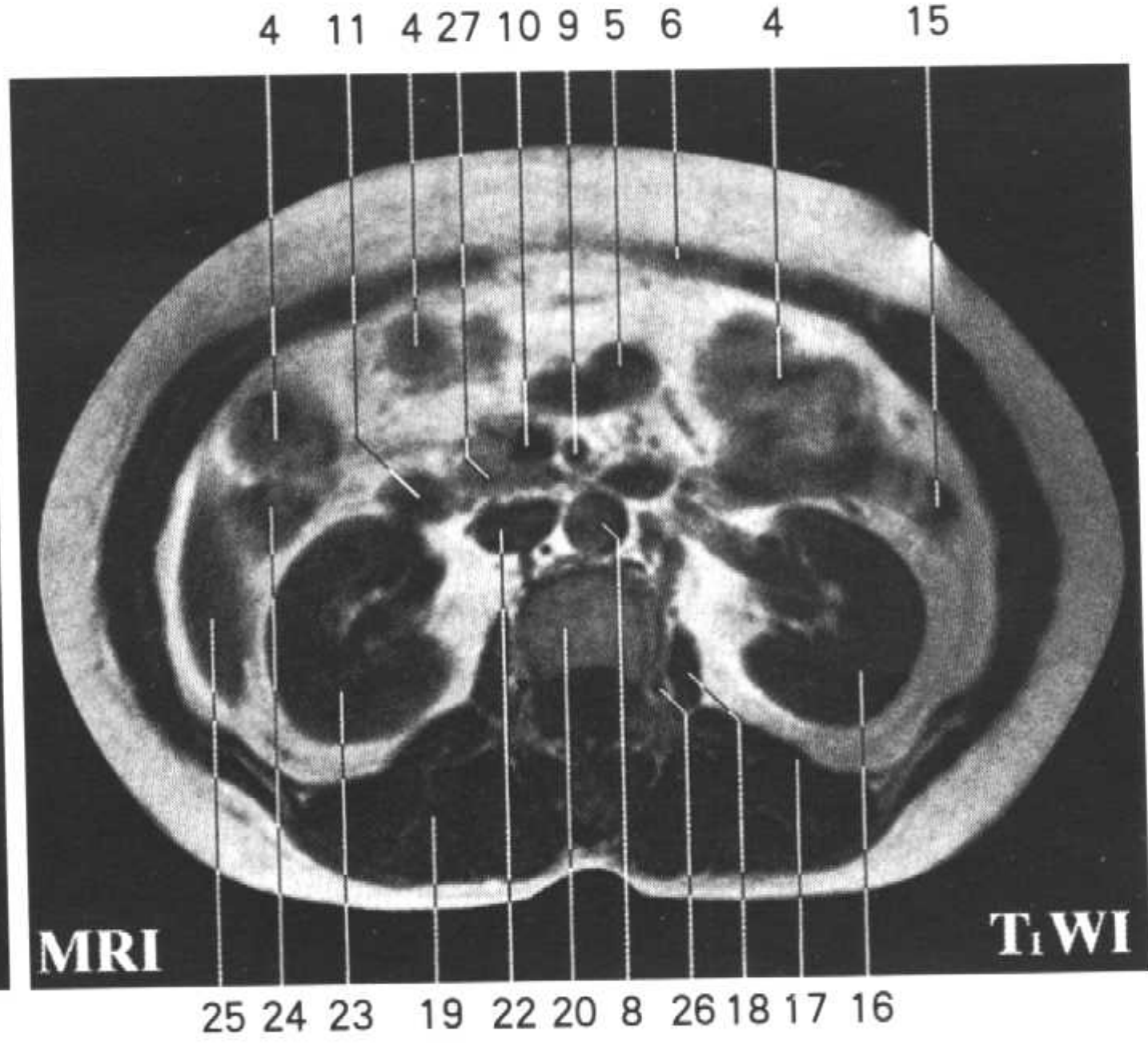
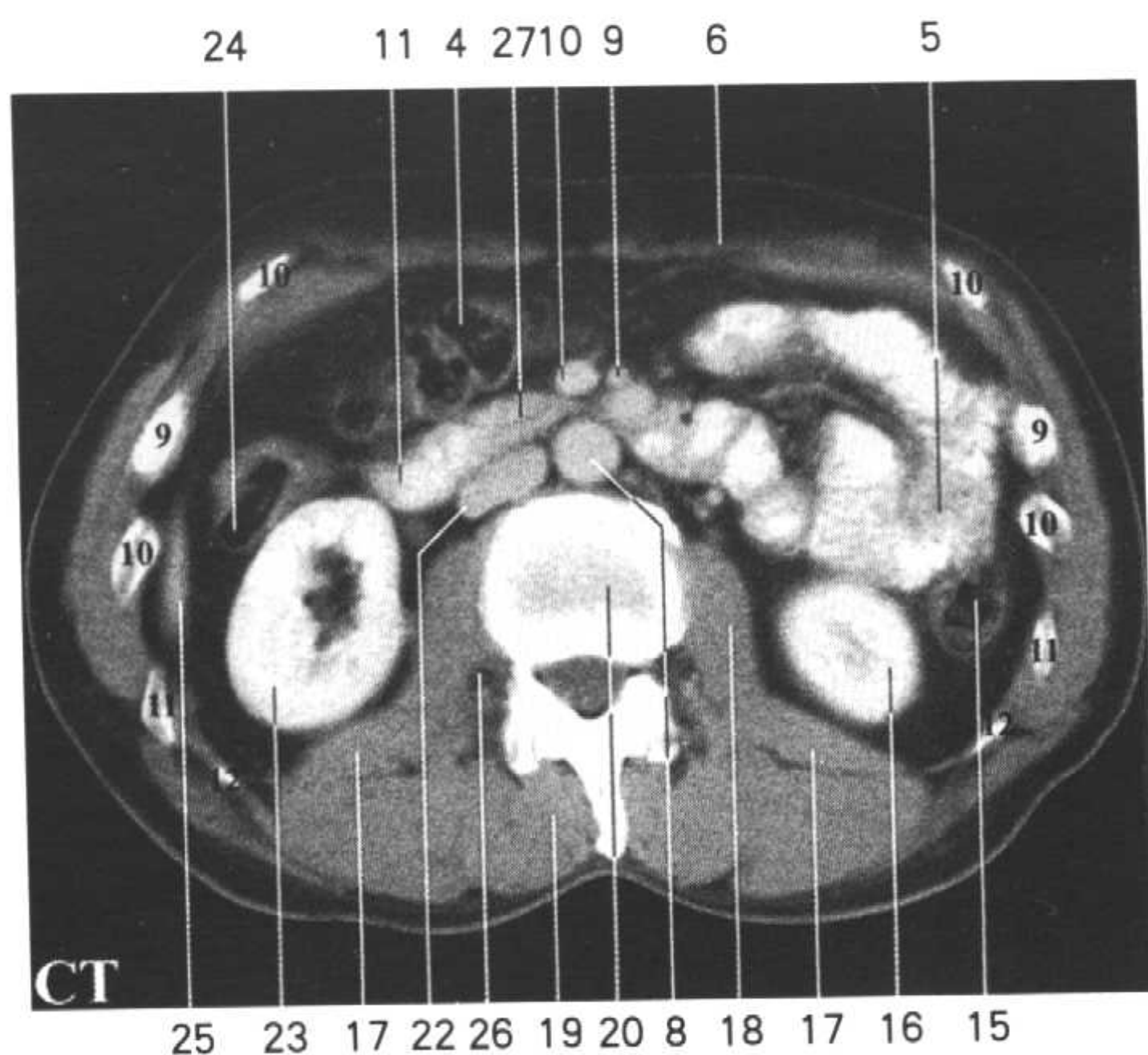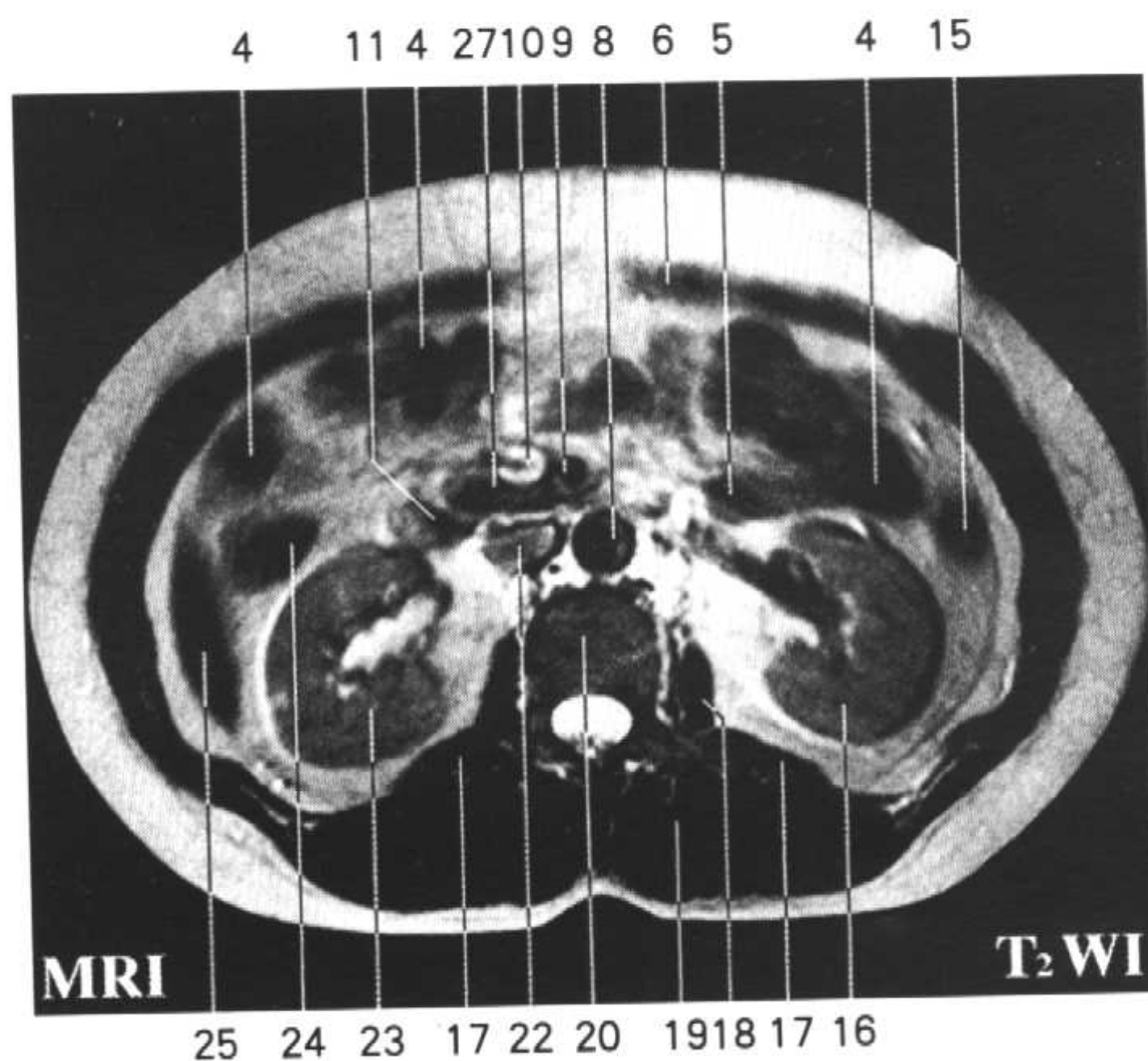


Fig.HA8

1. 腹外斜肌 *obliquus externus abdominis*
2. 腹内斜肌 *obliquus internus abdominis*
3. 腹横肌 *transversus abdominis*
4. 横结肠 *transverse colon*
5. 空肠 *jejunum*
6. 腹直肌 *rectus abdominis*
7. 胃 *stomach*
8. 腹主动脉 *abdominal aorta*
9. 肠系膜上动脉 *superior mesenteric a.*
10. 肠系膜上静脉 *superior mesenteric v.*



- 11. 十二指肠水平部 horizontal part of duodenum
- 12. 肠系膜 mesentery
- 13. 回肠 ileum
- 14. 横结肠 transverse colon
- 15. 降结肠 descending colon
- 16. 左肾 left kidney
- 17. 腰方肌 quadratus lumborum
- 18. 腰大肌 psoas major
- 19. 竖脊肌 erector spinae
- 20. 2、3 腰椎间盘 intervertebral disc (L₂-L₃)
- 21. 马尾 cauda equina
- 22. 下腔静脉 inferior vena cava
- 23. 右肾 right kidney
- 24. 升结肠 ascending colon
- 25. 右后叶 right posterior lobe
- 26. 第2 腰神经 2nd lumbar n.
- 27. 钩突 uncinat process



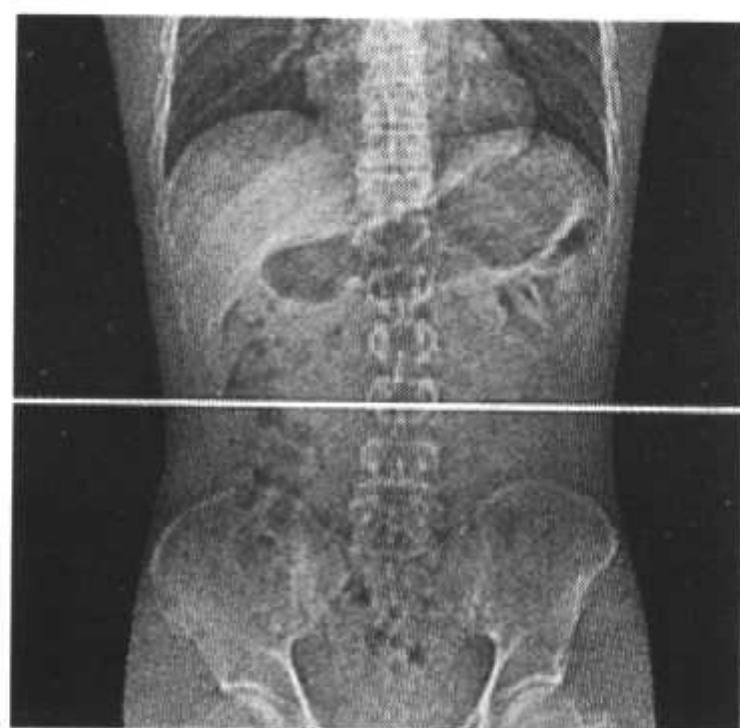
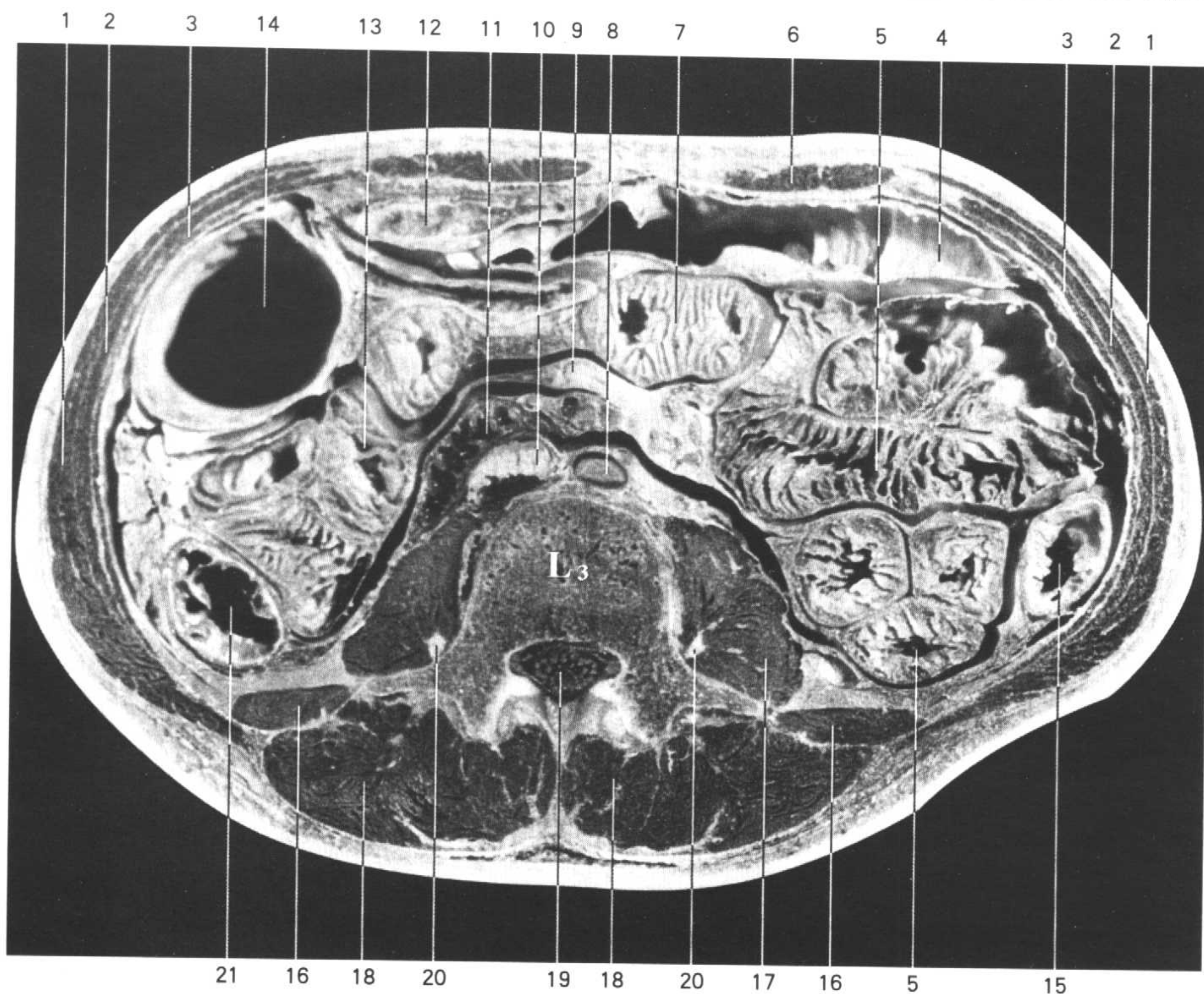
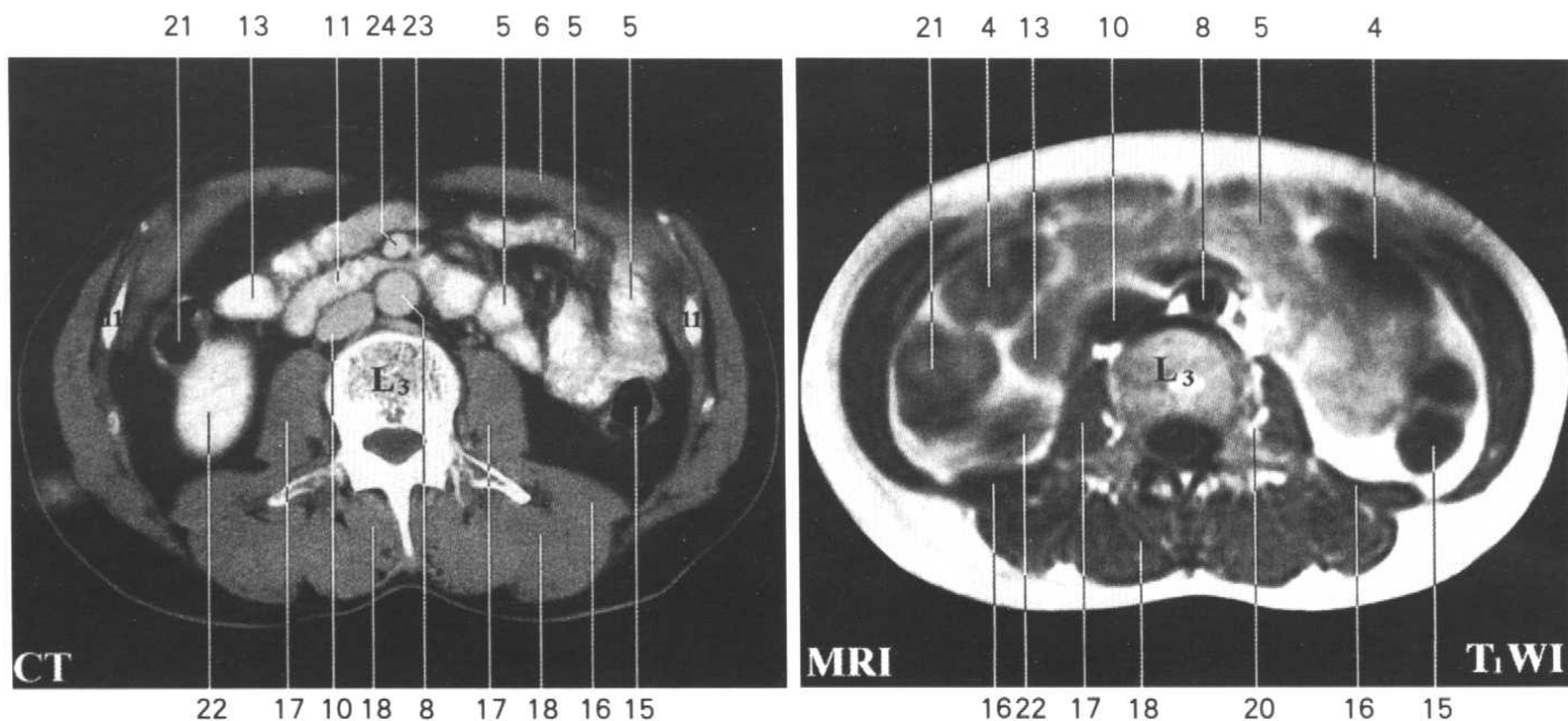
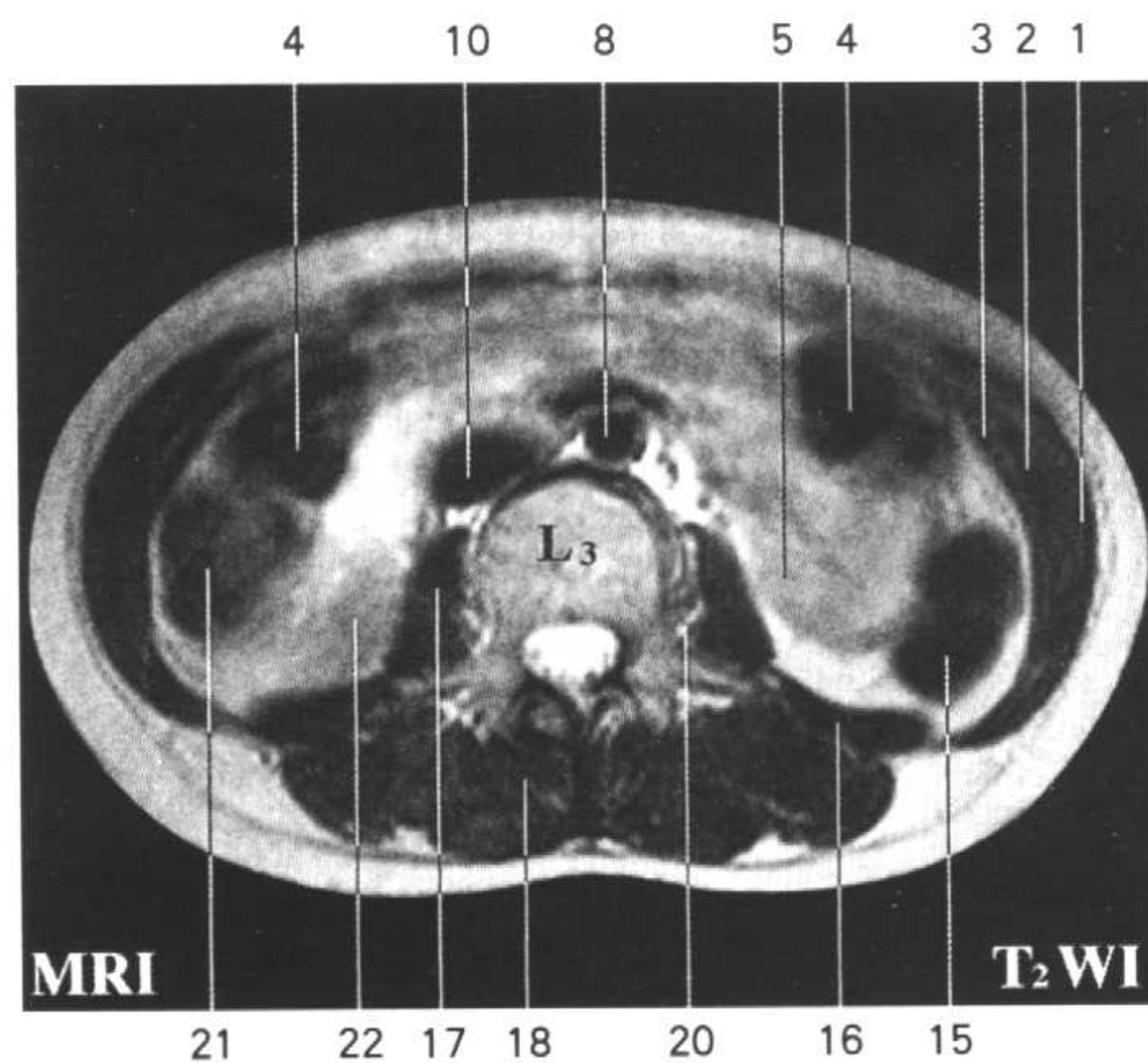


Fig.HA9

1. 腹外斜肌 *obliquus externus abdominis*
2. 腹内斜肌 *obliquus internus abdominis*
3. 腹横肌 *transversus abdominis*
4. 横结肠 *transverse colon*
5. 空肠 *jejunum*
6. 腹直肌 *rectus abdominis*
7. 空肠 *jejunum*
8. 腹主动脉 *abdominal aorta*
9. 肠系膜 *mesentery*
10. 下腔静脉 *inferior vena cava*



- 11. 十二指肠水平部 horizontal part of duodenum
- 12. 胃 stomach
- 13. 回肠 ileum
- 14. 横结肠 transverse colon
- 15. 降结肠 descending colon
- 16. 腰方肌 quadratus lumborum
- 17. 腰大肌 psoas major
- 18. 竖脊肌 erector spinae
- 19. 马尾 cauda equina
- 20. 第3腰神经 3rd lumbar n.
- 21. 升结肠 ascending colon
- 22. 右肾 right kidney
- 23. 肠系膜上动脉 superior mesenteric a.
- 24. 肠系膜上静脉 superior mesenteric v.



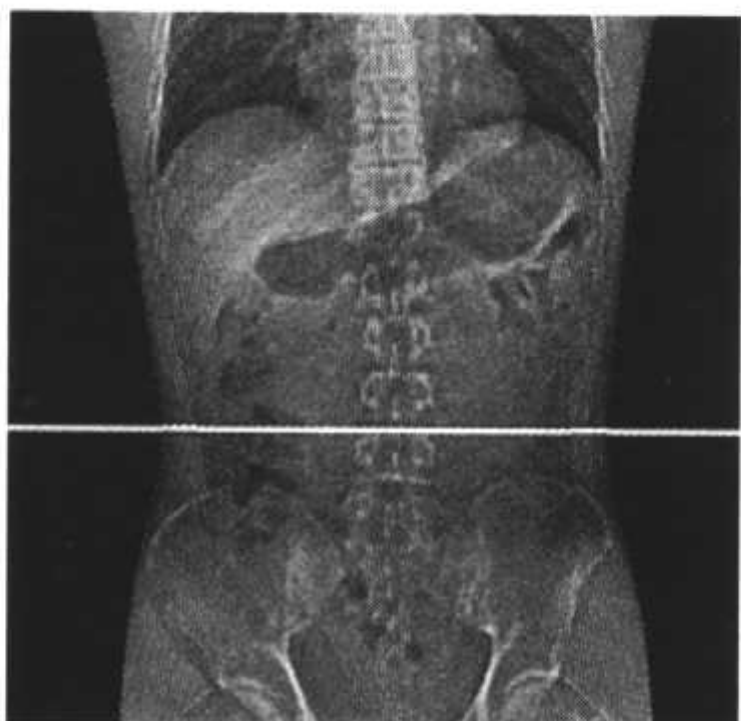
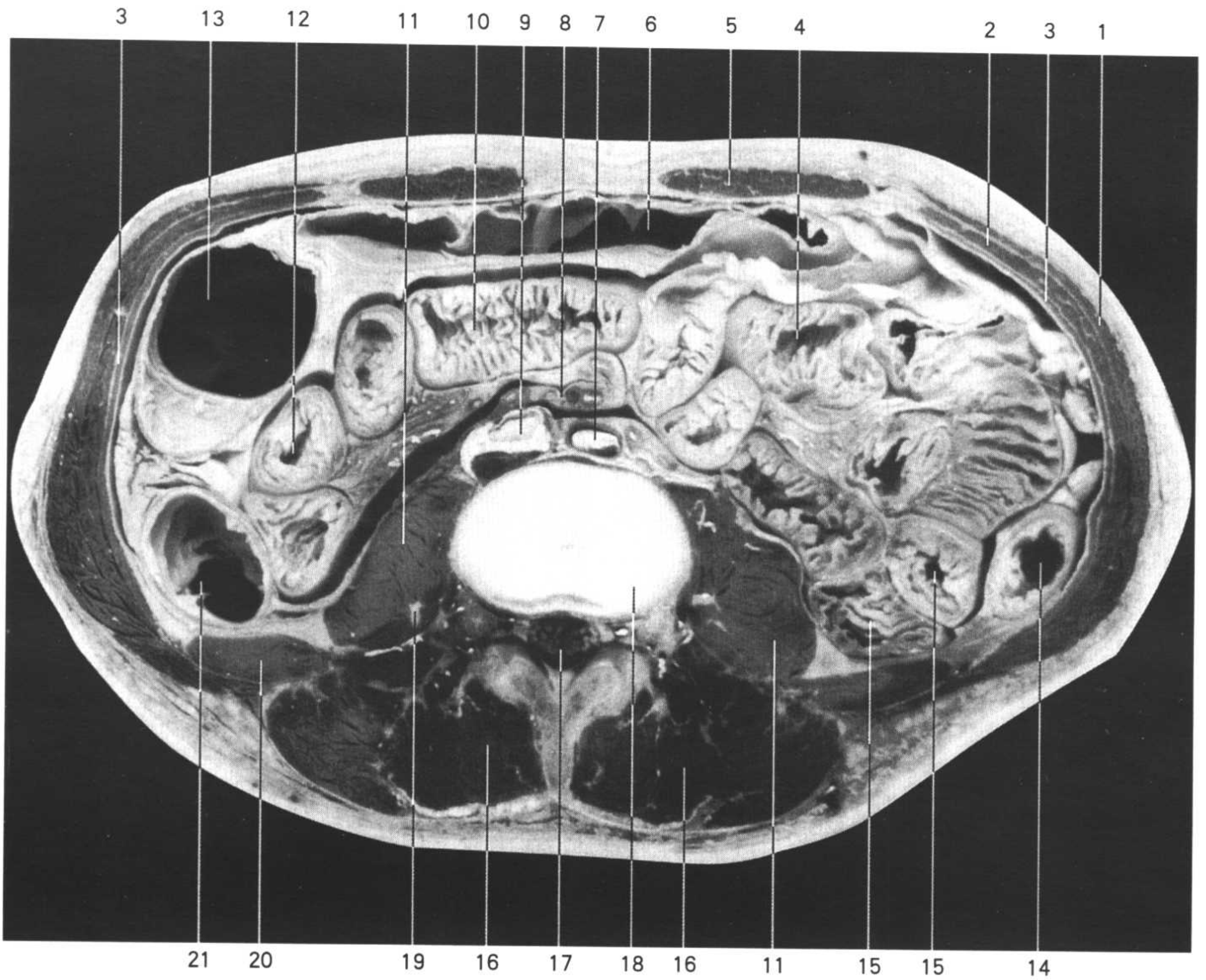
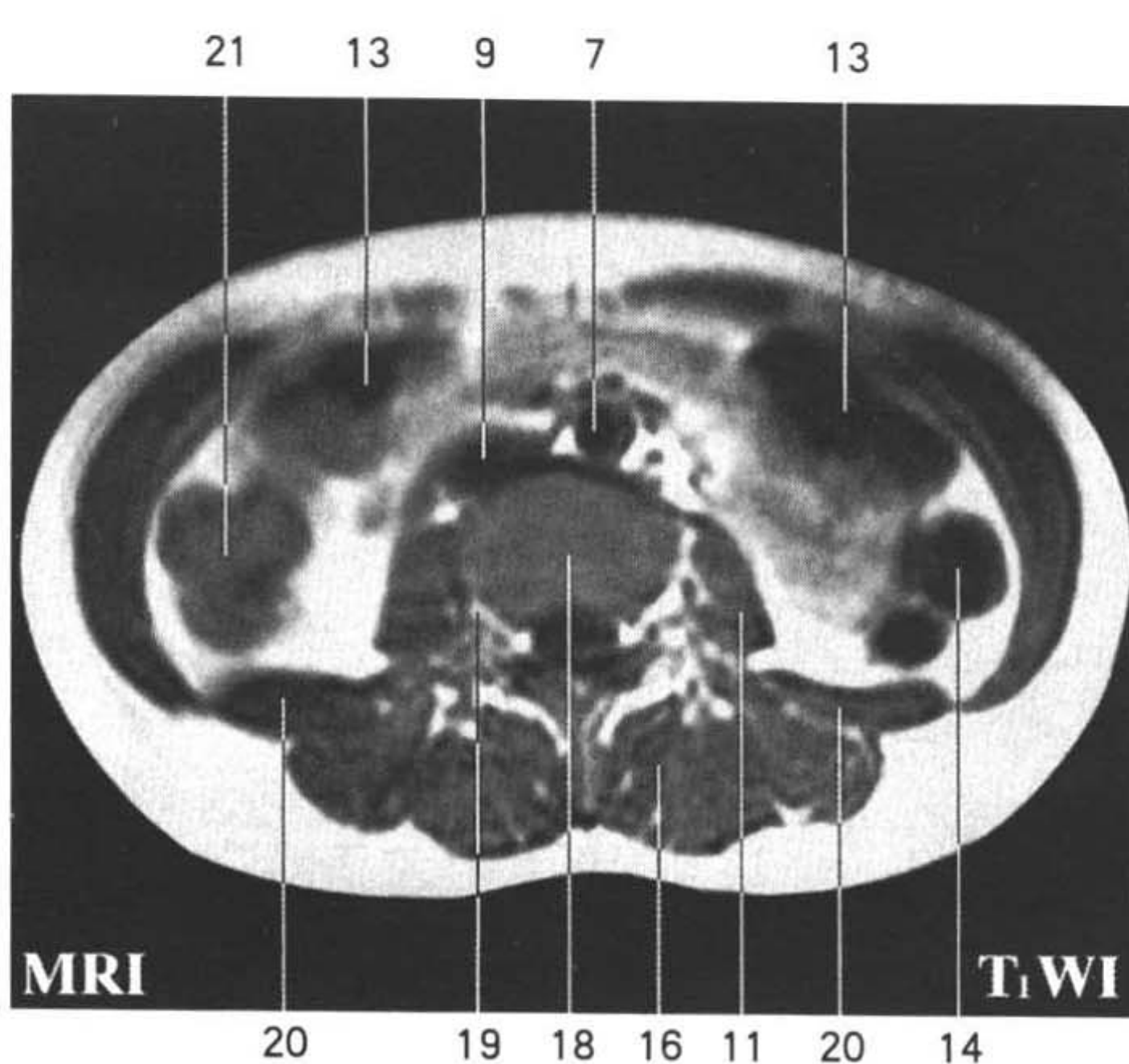
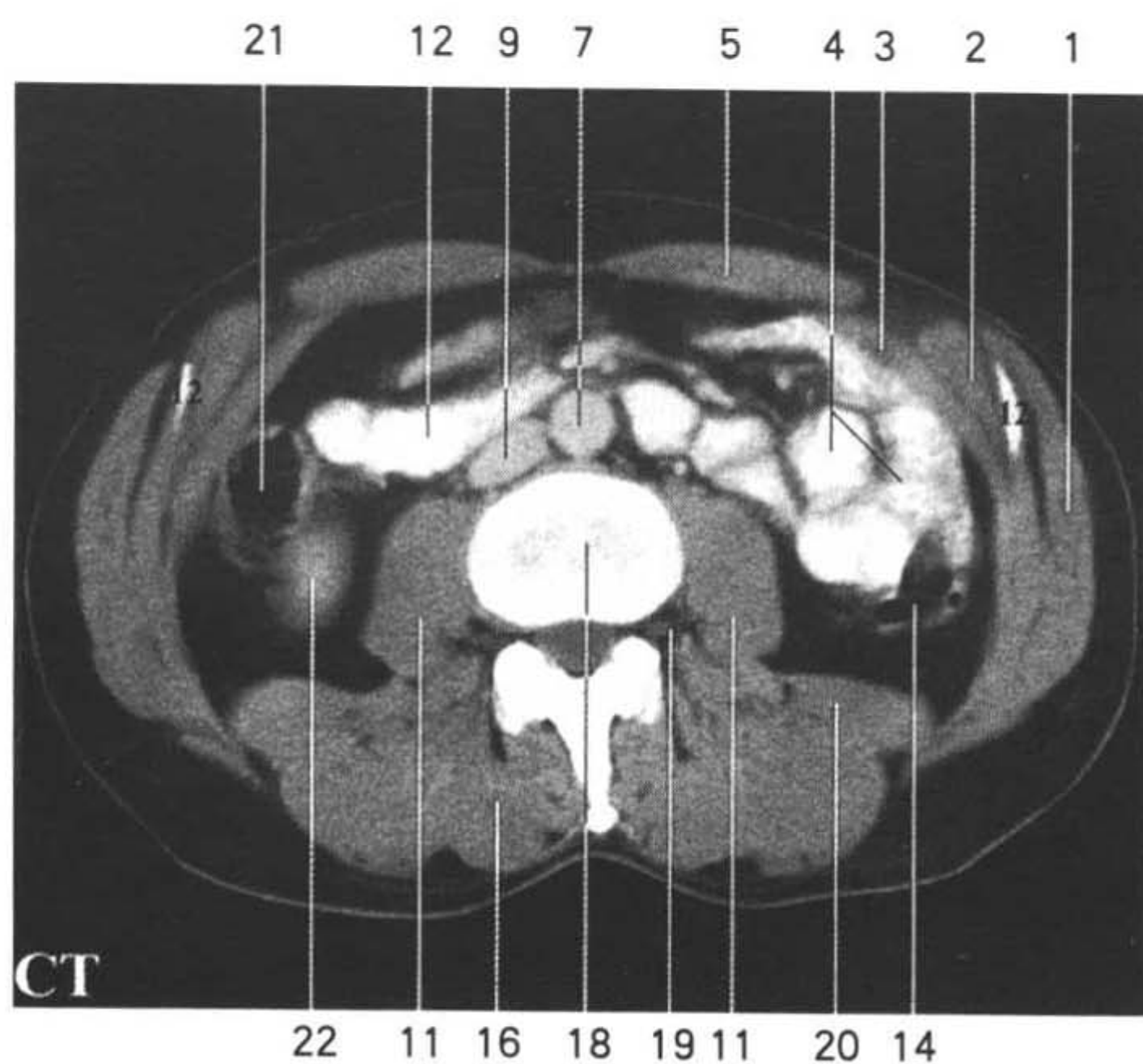
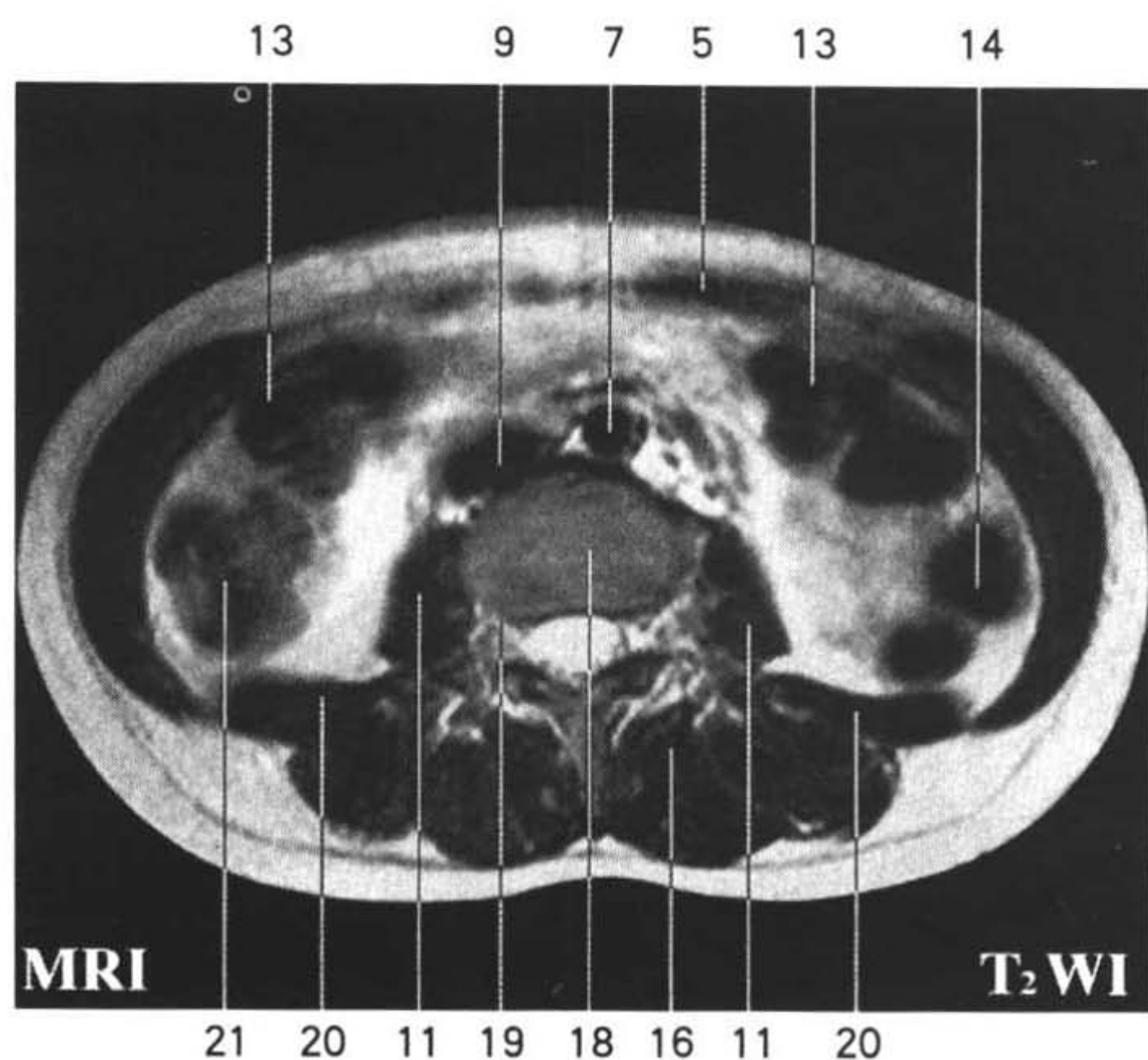


Fig.HA10

1. 腹外斜肌 *obliquus externus abdominis*
2. 腹内斜肌 *obliquus internus abdominis*
3. 腹横肌 *transversus abdominis*
4. 空肠 *jejunum*
5. 腹直肌 *rectus abdominis*
6. 横结肠 *transverse colon*
7. 腹主动脉 *abdominal aorta*
8. 肠系膜 *mesentery*
9. 下腔静脉 *inferior vena cava*
10. 空肠 *jejunum*



- 11. 腰大肌 *psoas major*
- 12. 回肠 *ileum*
- 13. 横结肠 *transverse colon*
- 14. 降结肠 *descending colon*
- 15. 空肠 *jejunum*
- 16. 竖脊肌 *erector spinae*
- 17. 马尾 *cauda equina*
- 18. 3、4 腰椎间盘 *intervertebral disc (T₃-T₄)*
- 19. 第3 腰神经 *3rd lumbar n.*
- 20. 腰方肌 *quadratus lumborum*
- 21. 升结肠 *ascending colon*
- 22. 右肾 *right kidney*



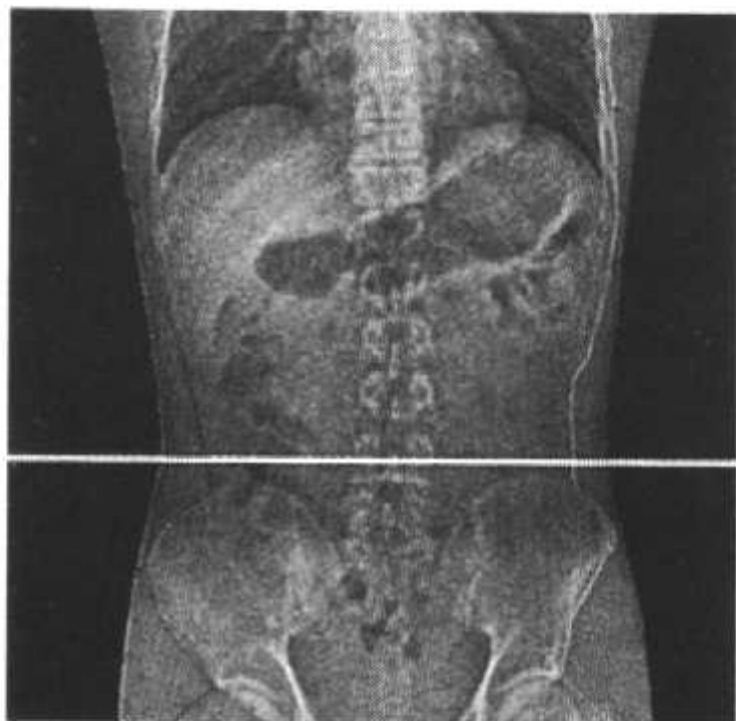
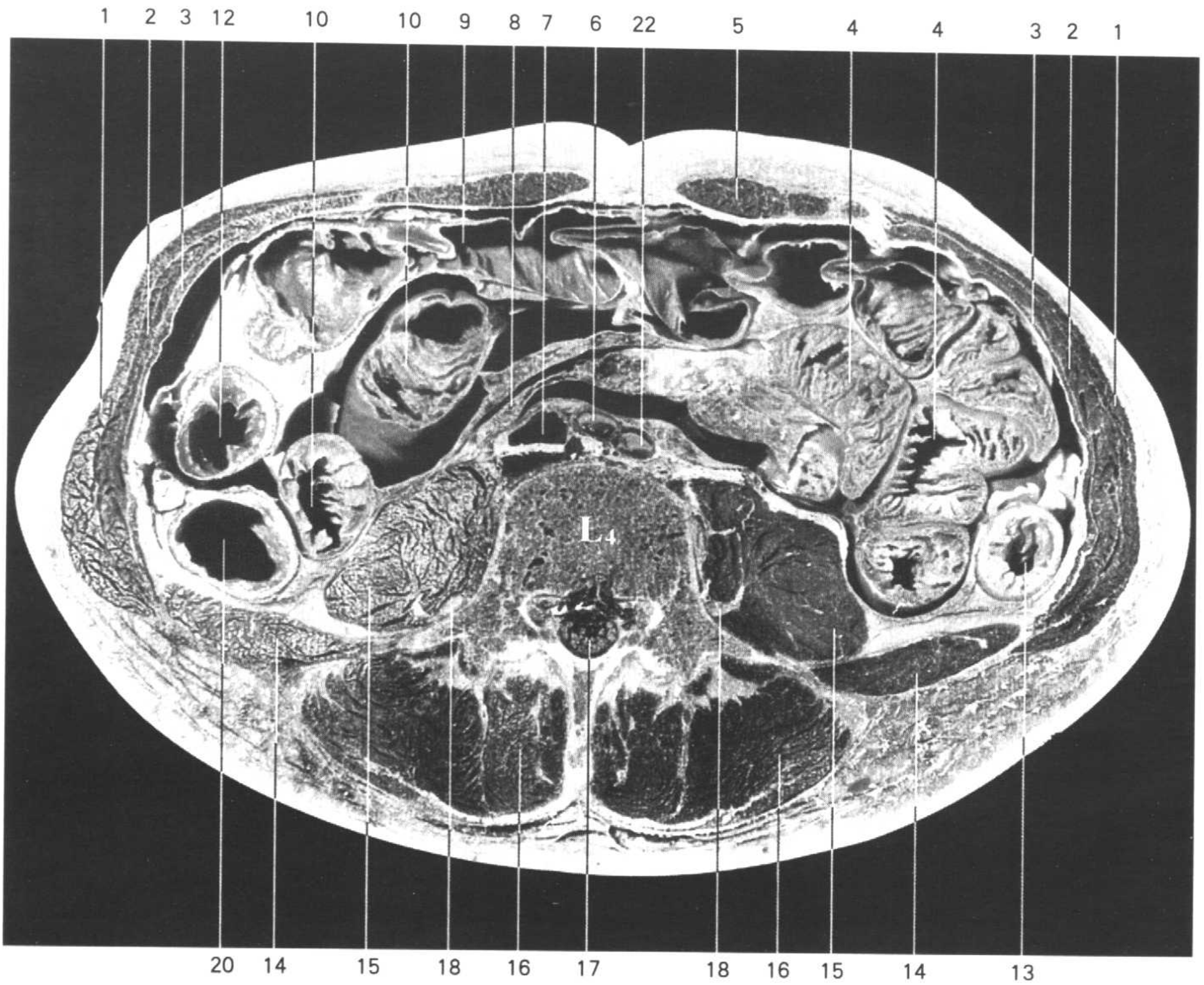
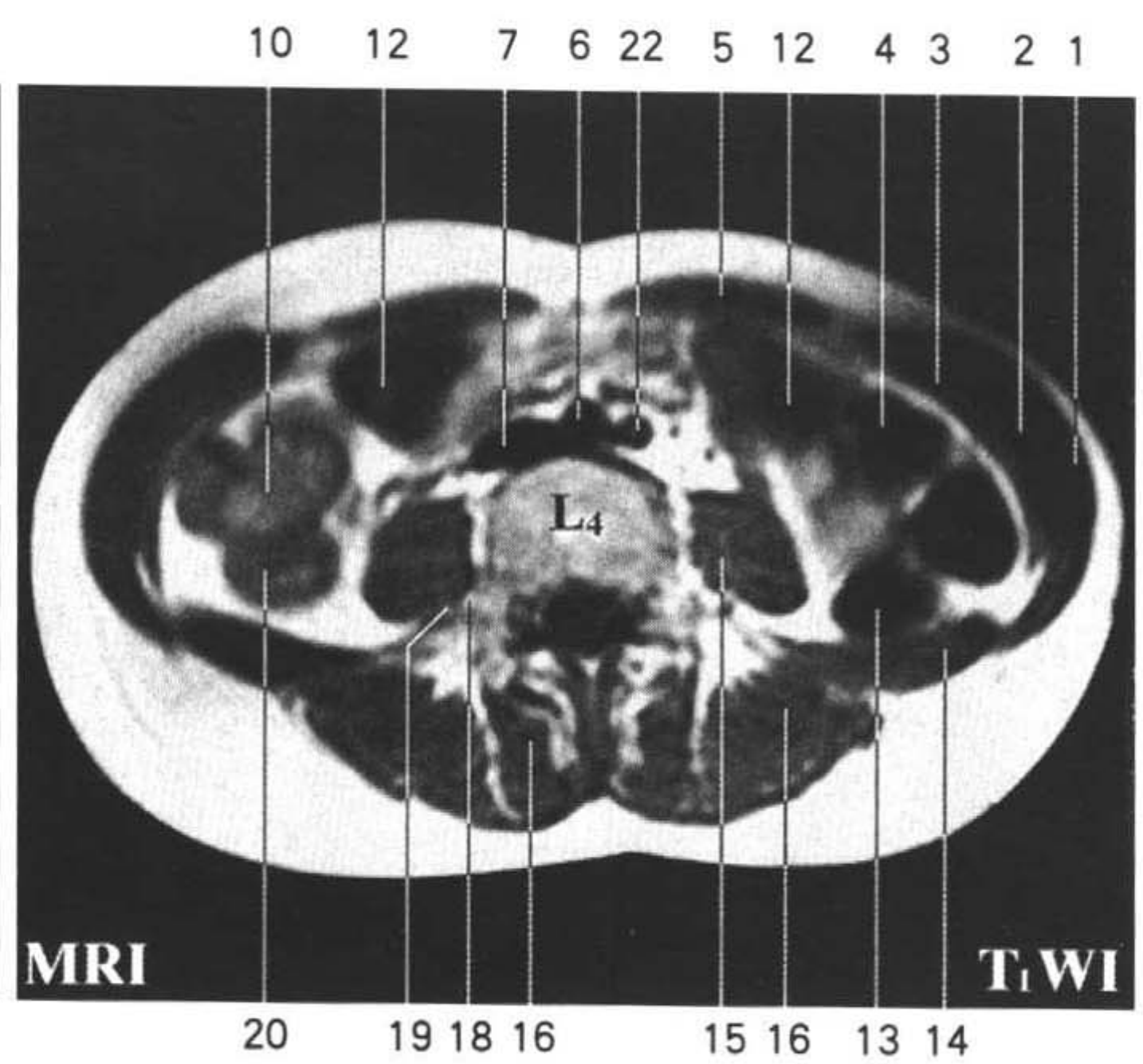
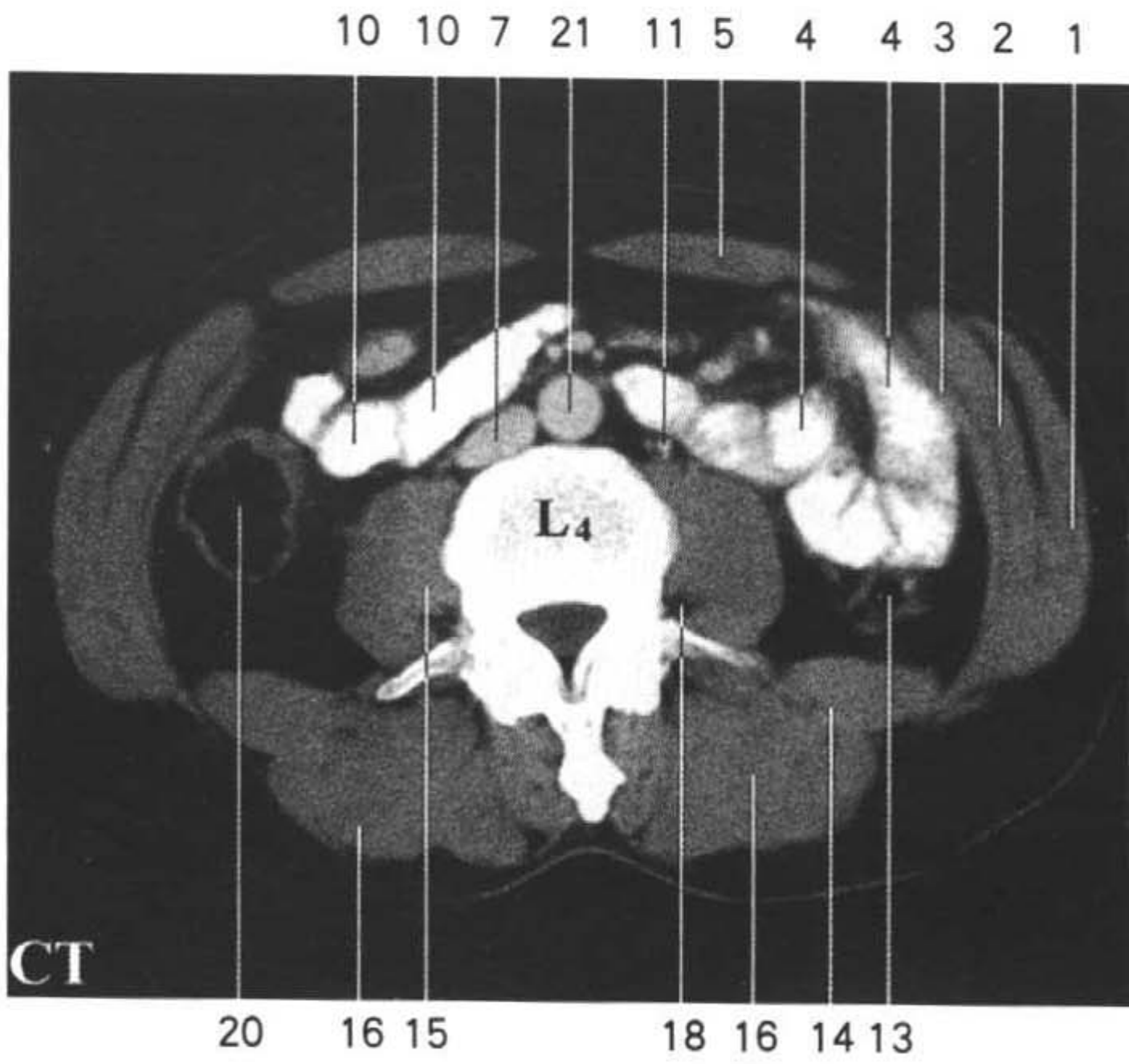
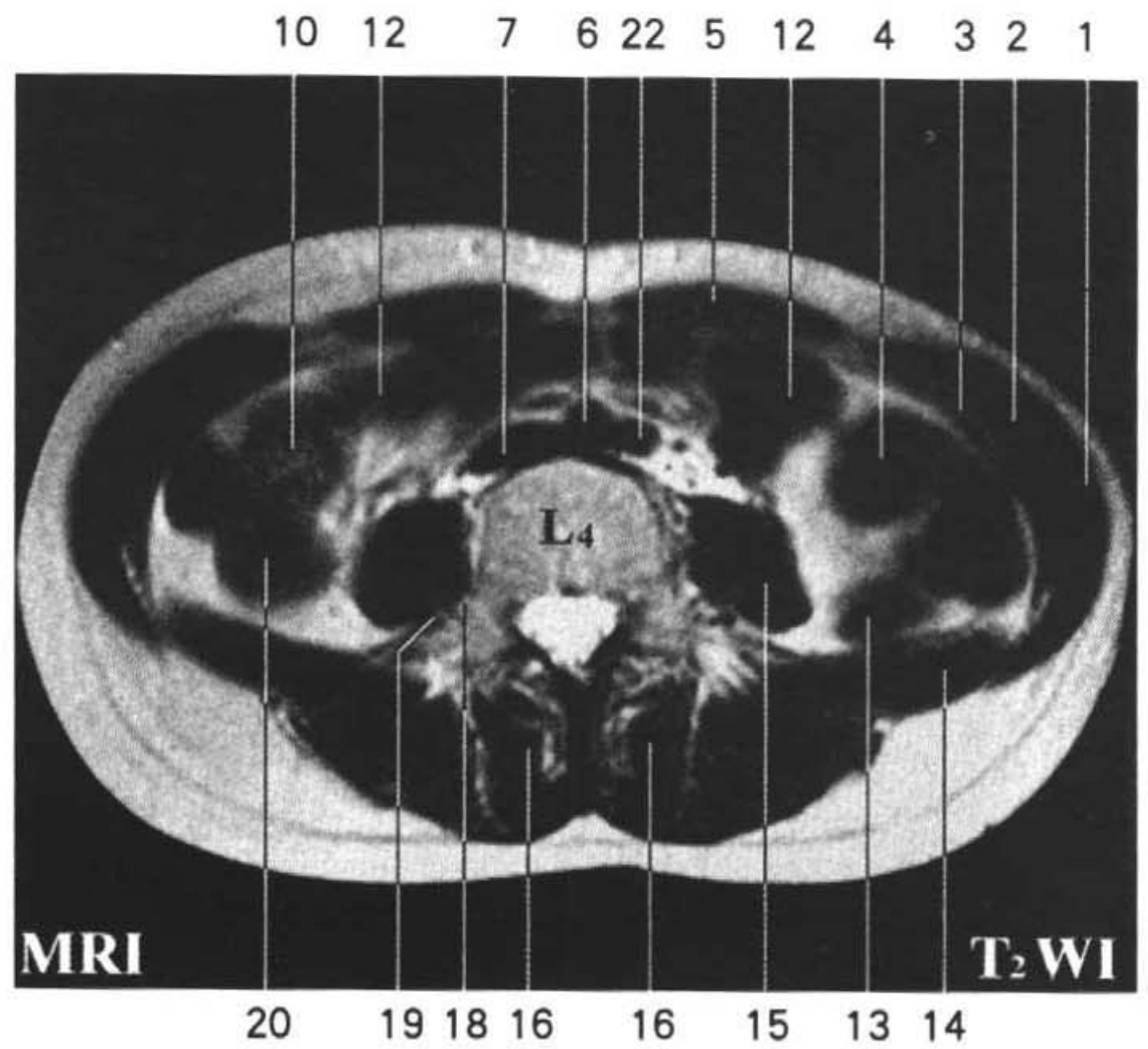


Fig.HA11

1. 腹外斜肌 obliquus externus abdominis
2. 腹内斜肌 obliquus internus abdominis
3. 腹横肌 transversus abdominis
4. 空肠 jejunum
5. 腹直肌 rectus abdominis
6. 右髂总动脉 right common iliac a.
7. 下腔静脉 inferior vena cava
8. 肠系膜 mesentery
9. 横结肠 transverse colon
10. 回肠 ileum



11. 输尿管 ureter
12. 横结肠 transverse colon
13. 降结肠 descending colon
14. 腰方肌 quadratus lumborum
15. 腰大肌 psoas major
16. 竖脊肌 erector spinae
17. 马尾 cauda equina
18. 第4腰神经 4th lumbar n.
19. 第3腰神经 3rd lumbar n.
20. 升结肠 ascending colon
21. 腹主动脉 abdominal aorta
22. 左髂总动脉 left common iliac a.



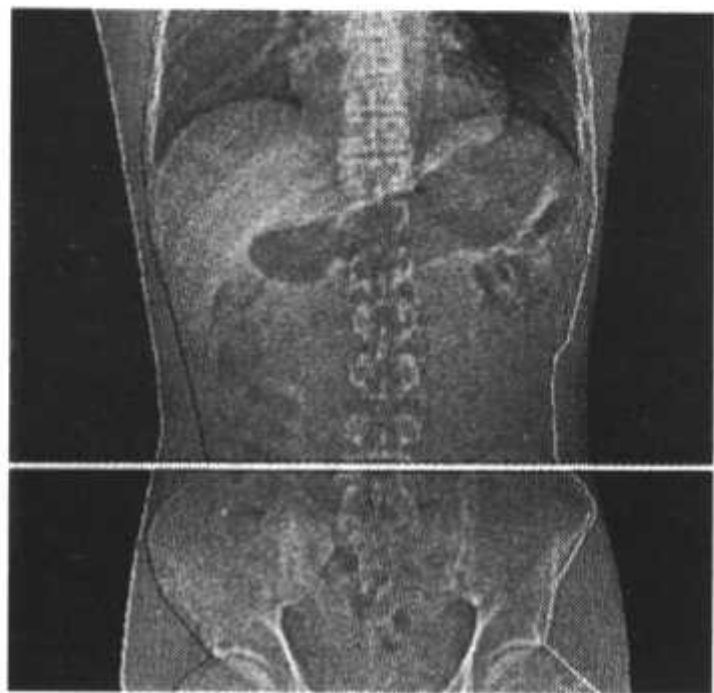
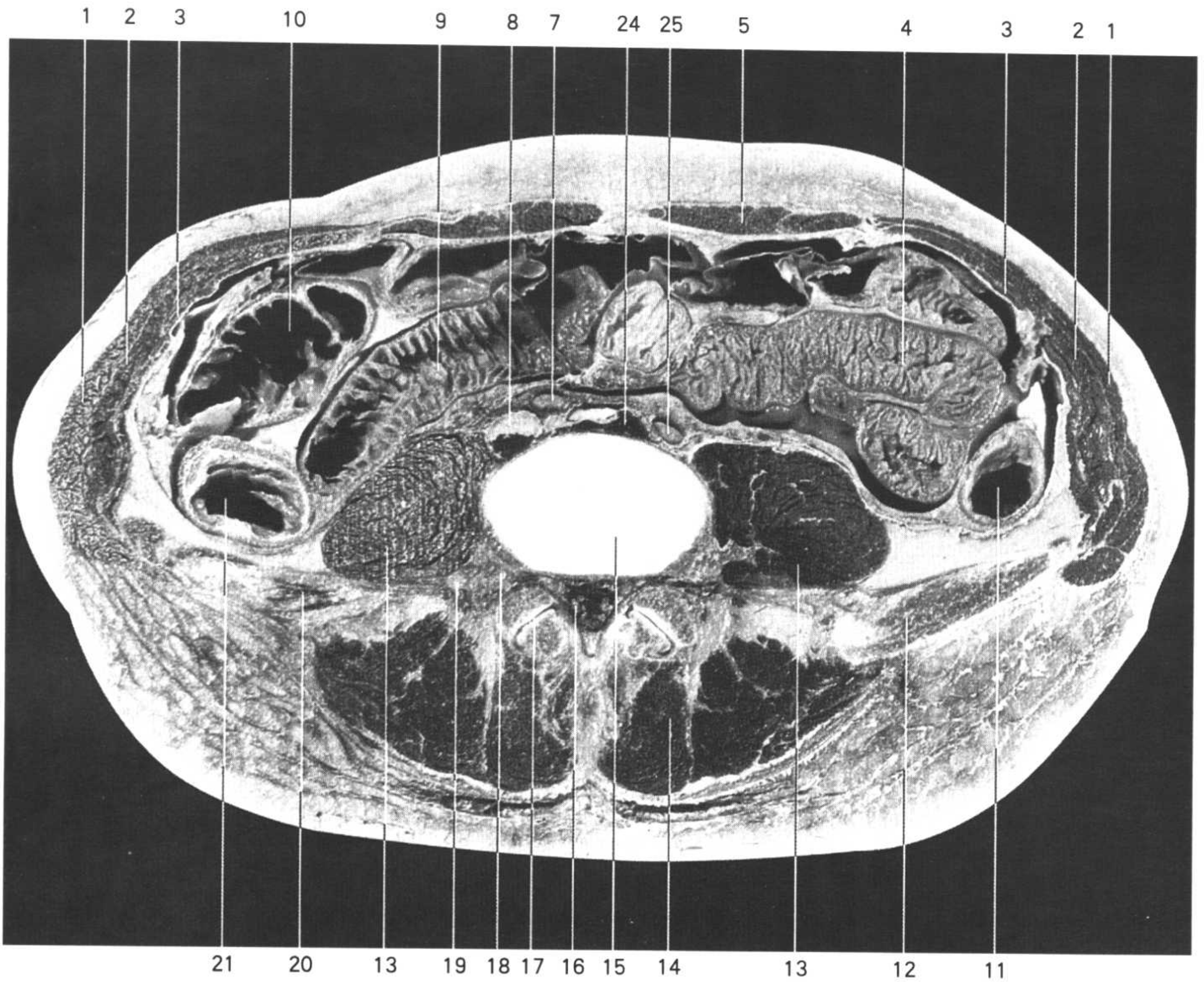
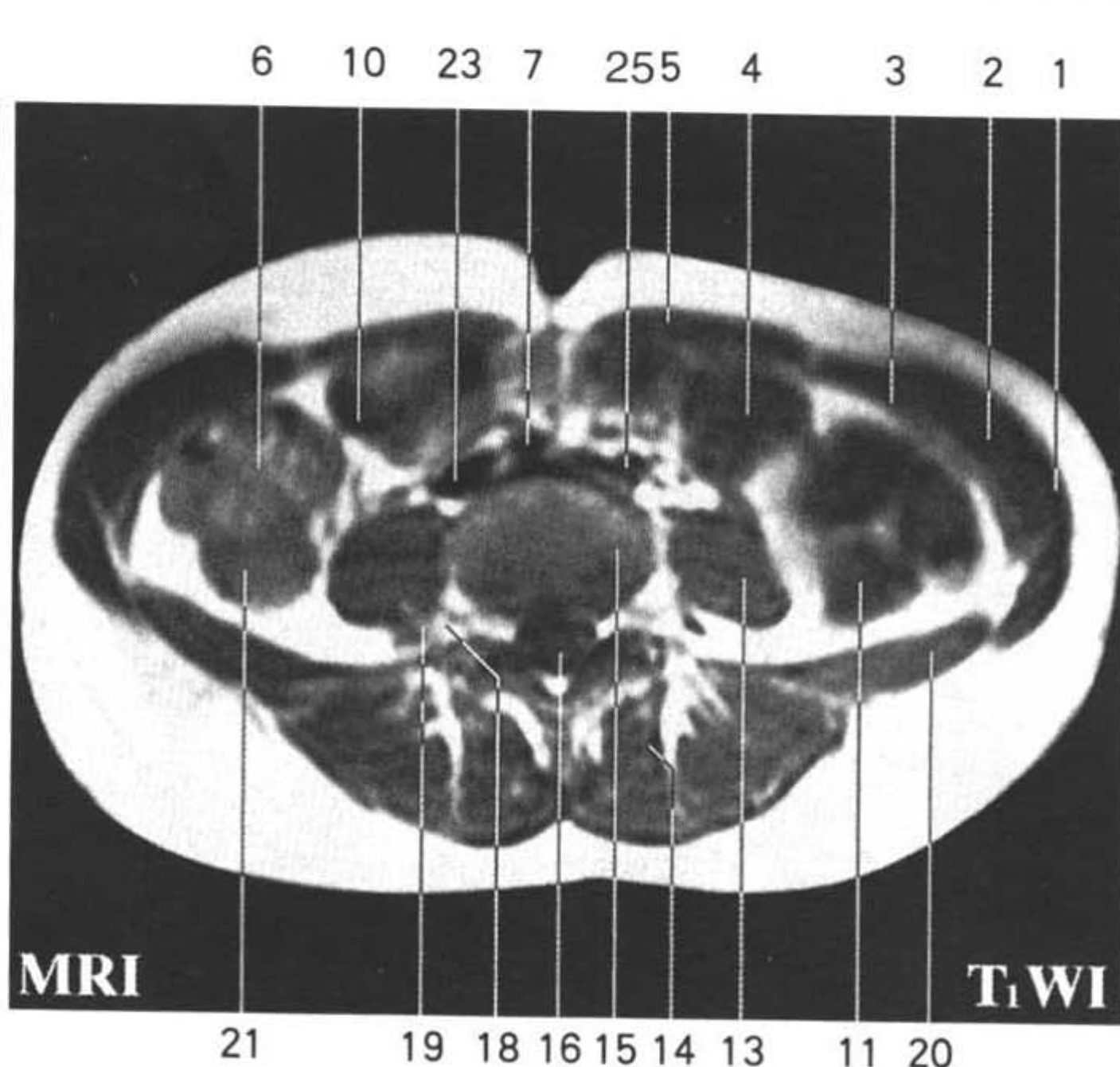
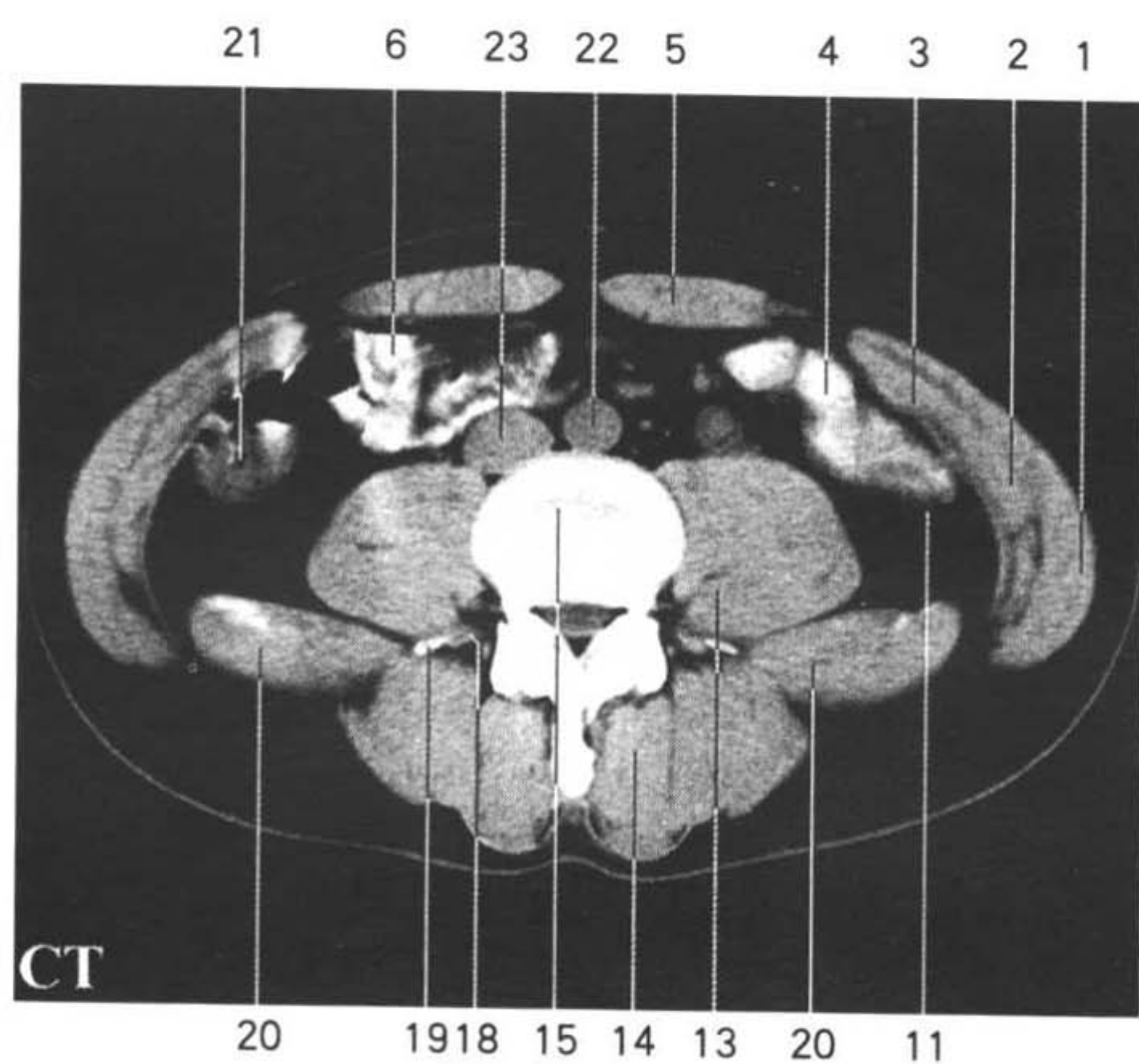
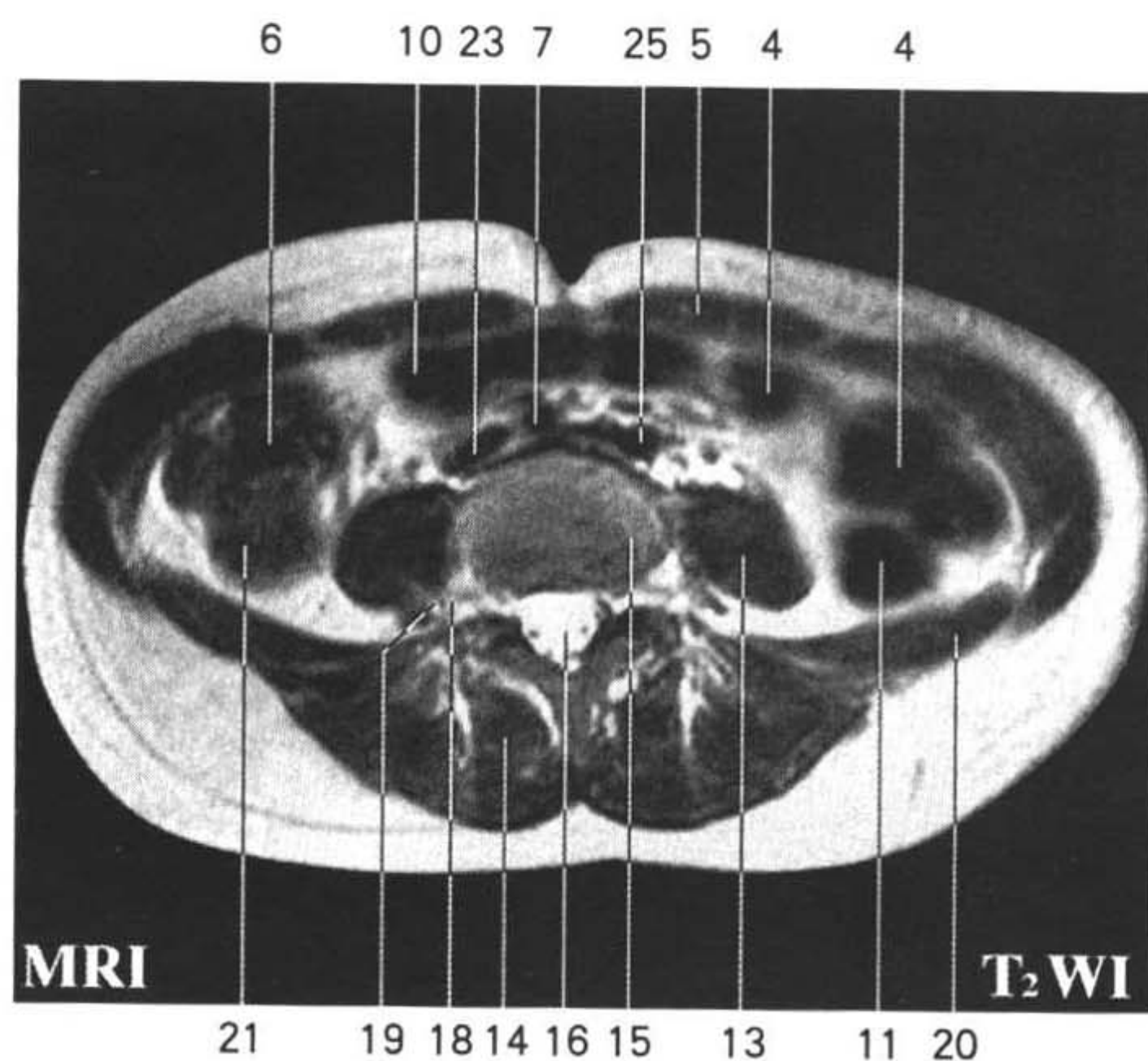


Fig.HA12

1. 腹外斜肌 obliquus externus abdominis
2. 腹内斜肌 obliquus internus abdominis
3. 腹横肌 transversus abdominis
4. 空肠 jejunum
5. 腹直肌 rectus abdominis
6. 回肠 ileum
7. 右髂总动脉 right common iliac a.
8. 右髂总静脉 right common iliac v.
9. 空肠 jejunum
10. 横结肠 transverse colon



11. 降结肠 descending colon
12. 髂嵴 iliac crest
13. 腰大肌 psoas major
14. 竖脊肌 erector spinae
15. 4、5 腰椎间盘 intervertebral disc (L₄-L₅)
16. 马尾 cauda equina
17. 4、5 腰椎关节突关节 zygapophysial joint (L₄-L₅)
18. 第4腰神经 4th lumbar n.
19. 第3腰神经 3rd lumbar n.
20. 腰方肌 quadratus lumborum
21. 升结肠 ascending colon
22. 腹主动脉 abdominal aorta
23. 下腔静脉 inferior vena cava
24. 左髂总静脉 left common iliac v.
25. 左髂总动脉 left common iliac a.



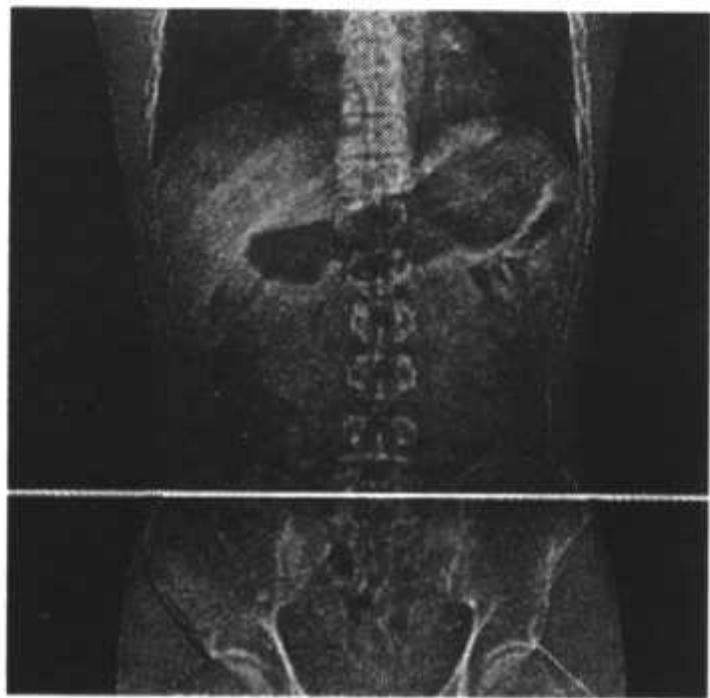
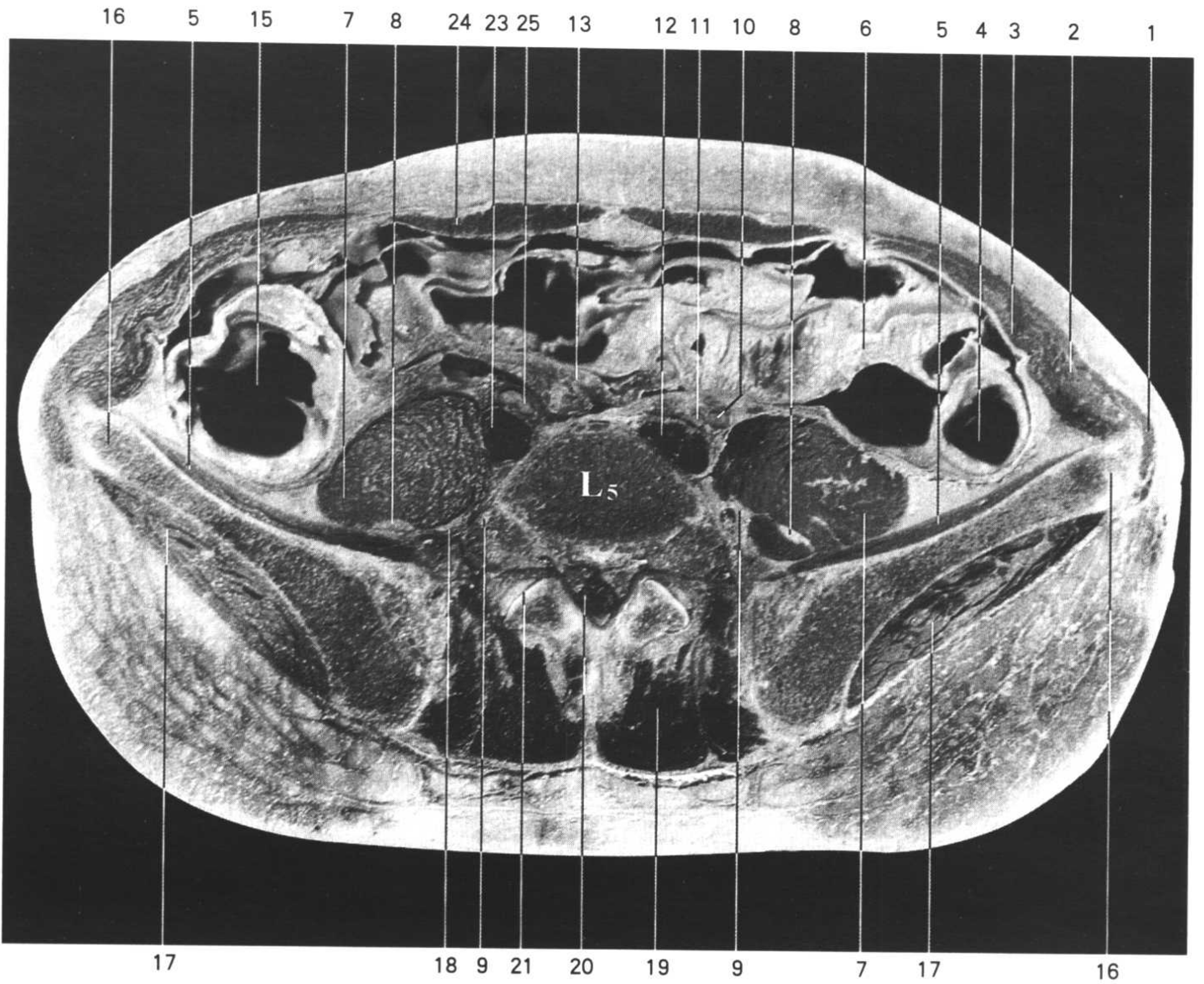
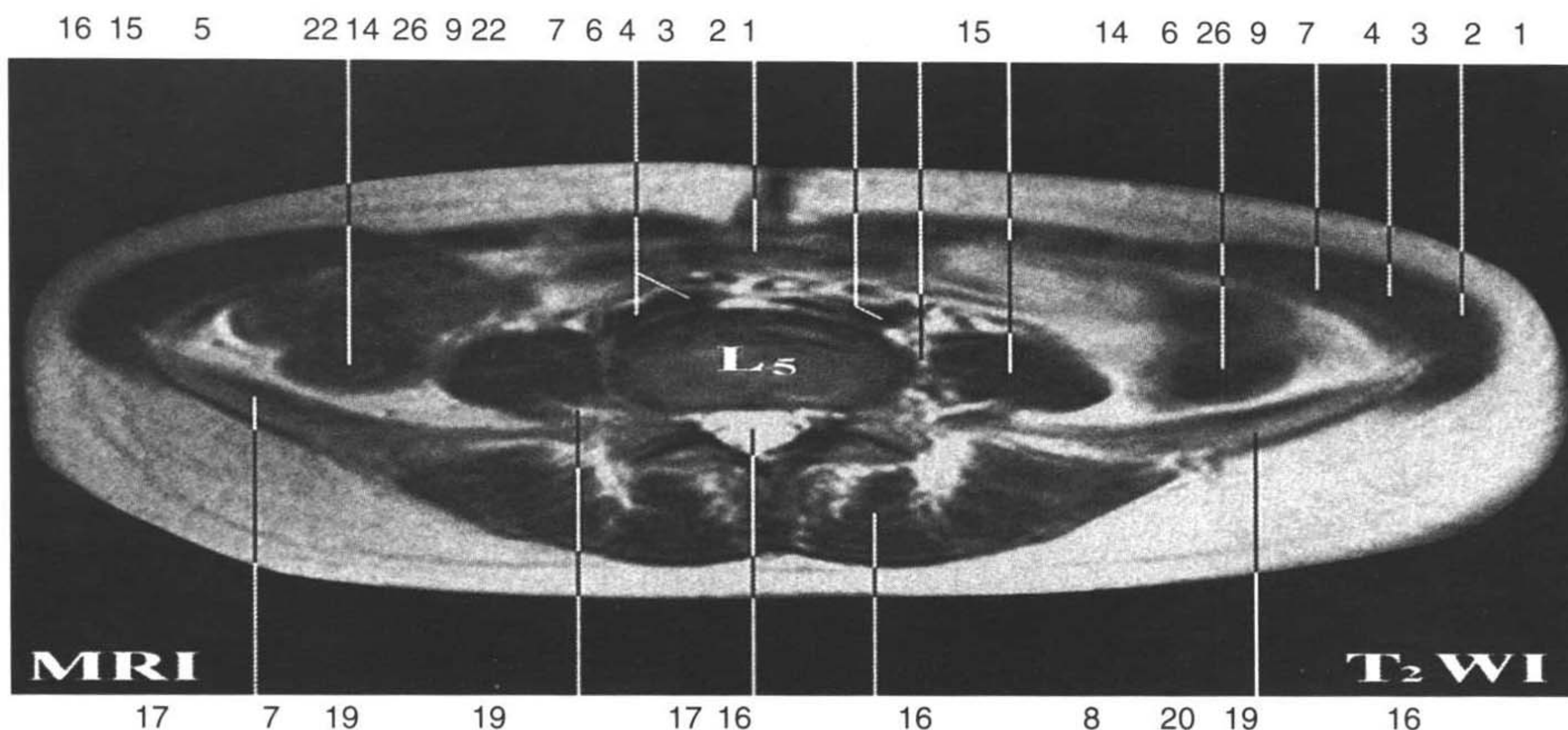
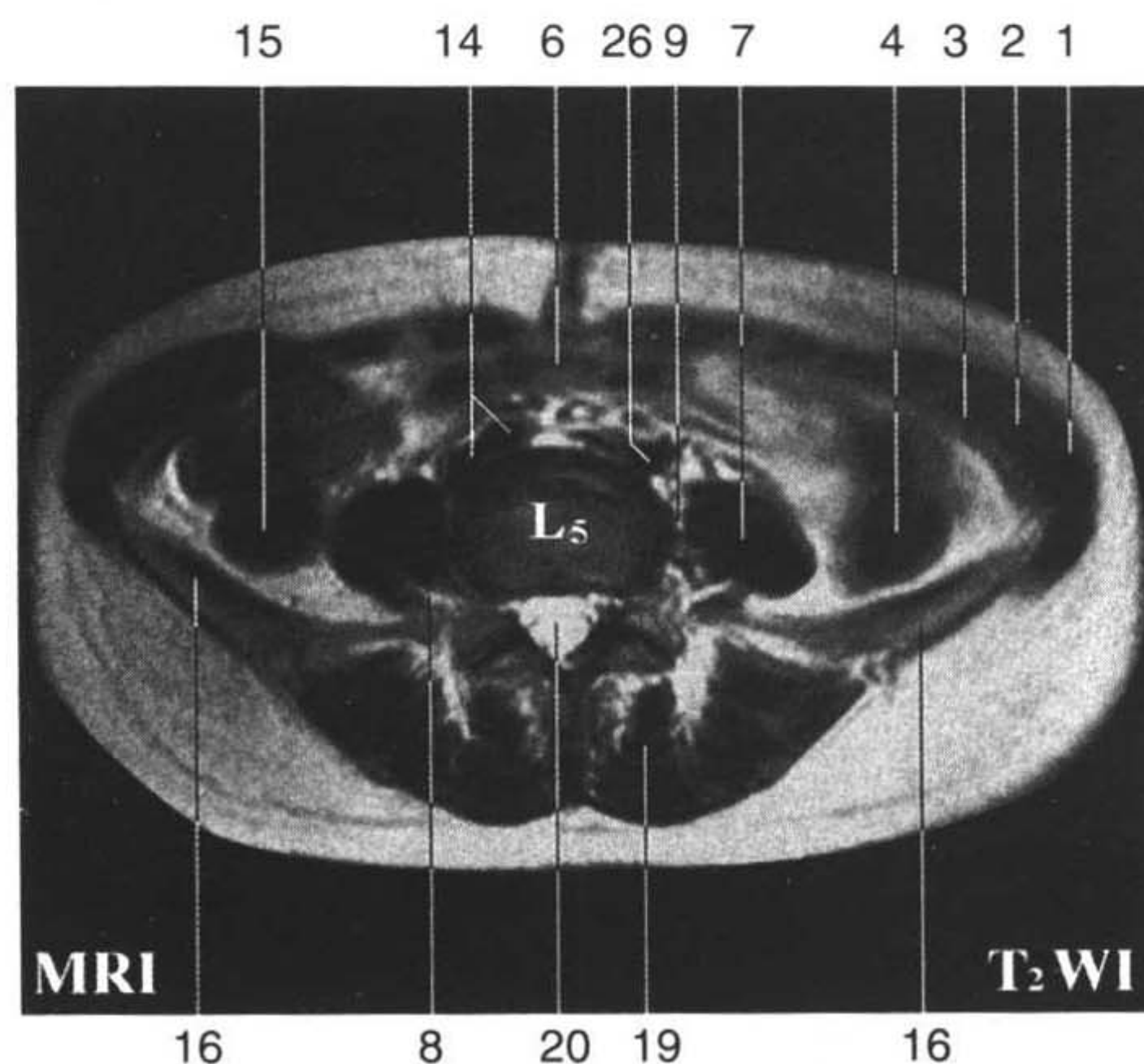


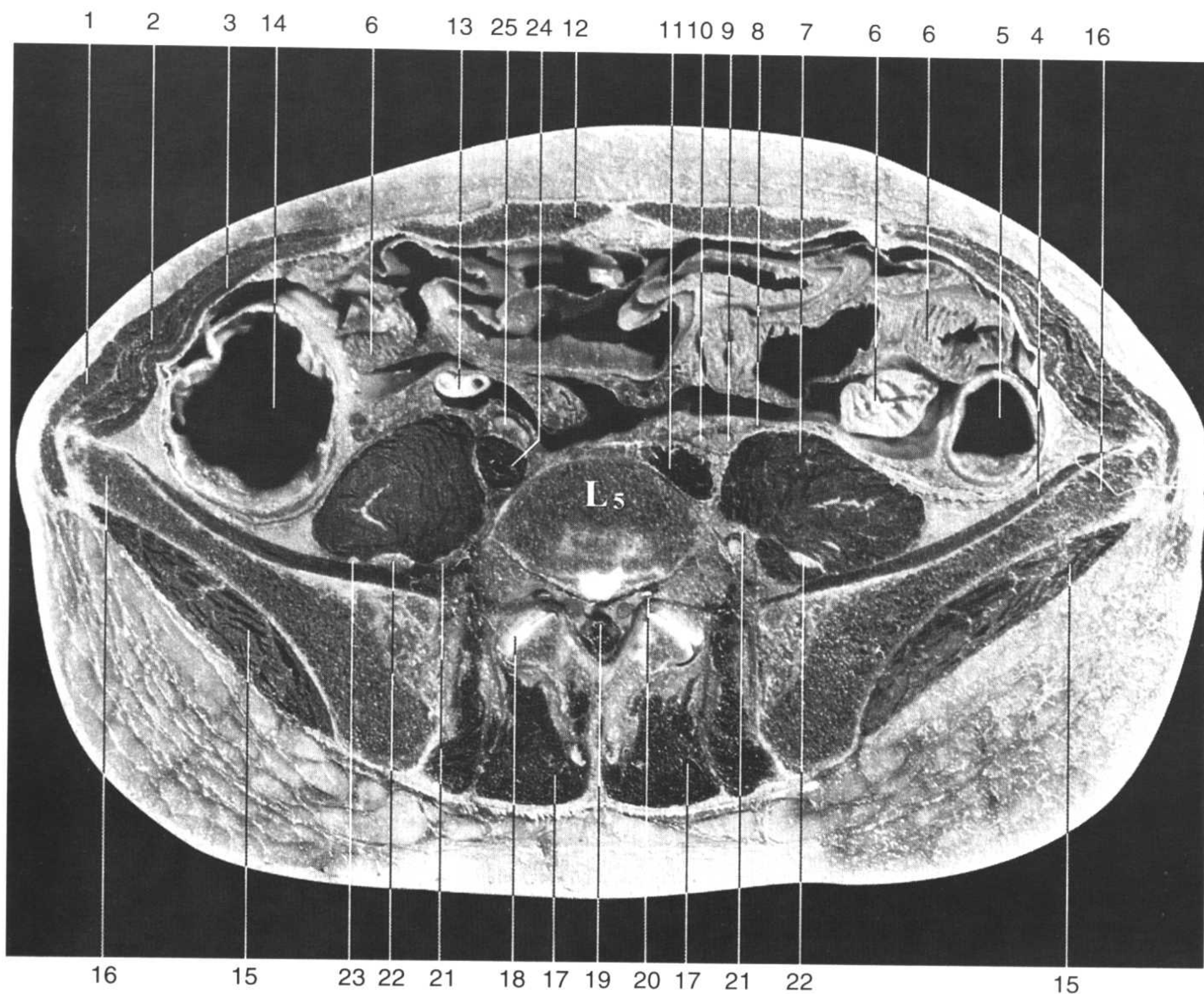
Fig.HA13

1. 腹外斜肌 obliquus externus abdominis
2. 腹内斜肌 obliquus internus abdominis
3. 腹横肌 transversus abdominis
4. 乙状结肠 sigmoid colon
5. 髂肌 iliacus
6. 回肠 ileum
7. 腰大肌 psoas major
8. 股神经 femoral n.
9. 闭孔神经 obturator n.
10. 左髂外动脉 left external iliac a.



11. 左髂内动脉 left internal iliac a.
12. 左髂总静脉 left common iliac v.
13. 肠系膜 mesentery
14. 右髂总动、静脉 right common iliac a. and v.
15. 升结肠 ascending colon
16. 髂骨翼 ala of ilium
17. 臀中肌 gluteus medius
18. 第4腰神经 4th lumbar n.
19. 竖脊肌 erector spinae
20. 马尾 cauda equina
21. 4、5 腰椎关节突关节
zygapophysial joint (L₄-L₅)
22. 输尿管 ureter
23. 右髂总静脉 right common iliac v.
24. 腹直肌 rectus abdominis
25. 右髂总动脉 right common iliac a.
26. 左髂总动、静脉 left common iliac a. and v.





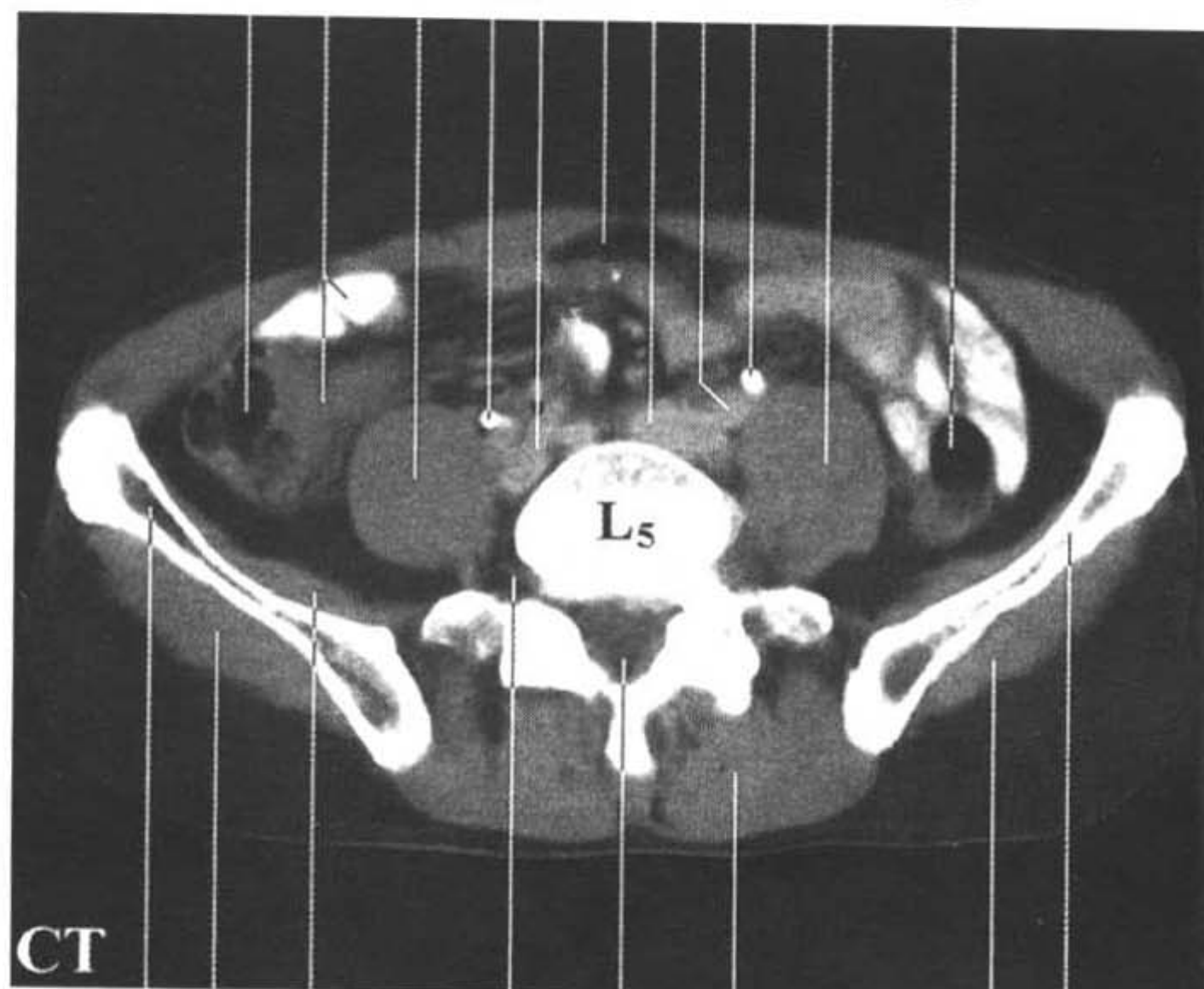
16 15 23 22 21 18 17 19 20 17 21 22 15

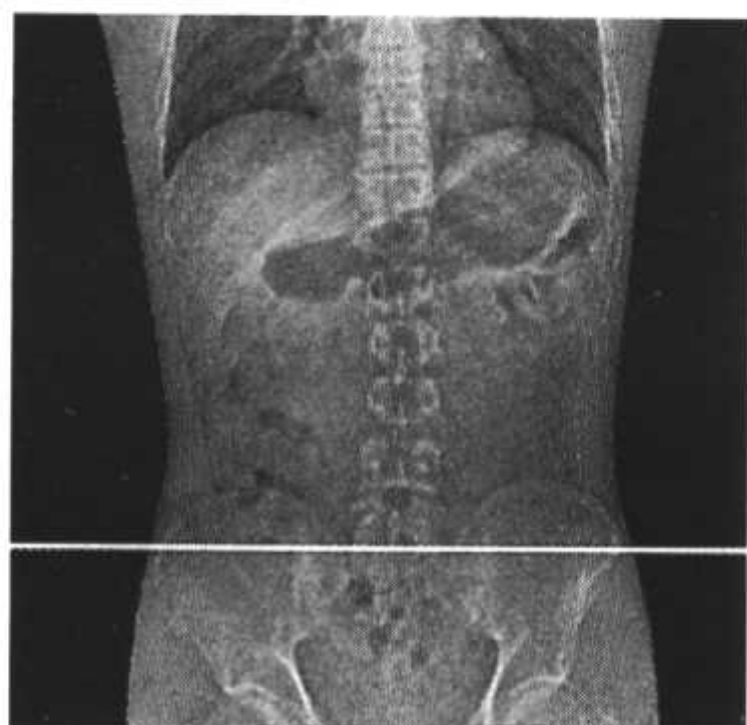

Fig.HA14

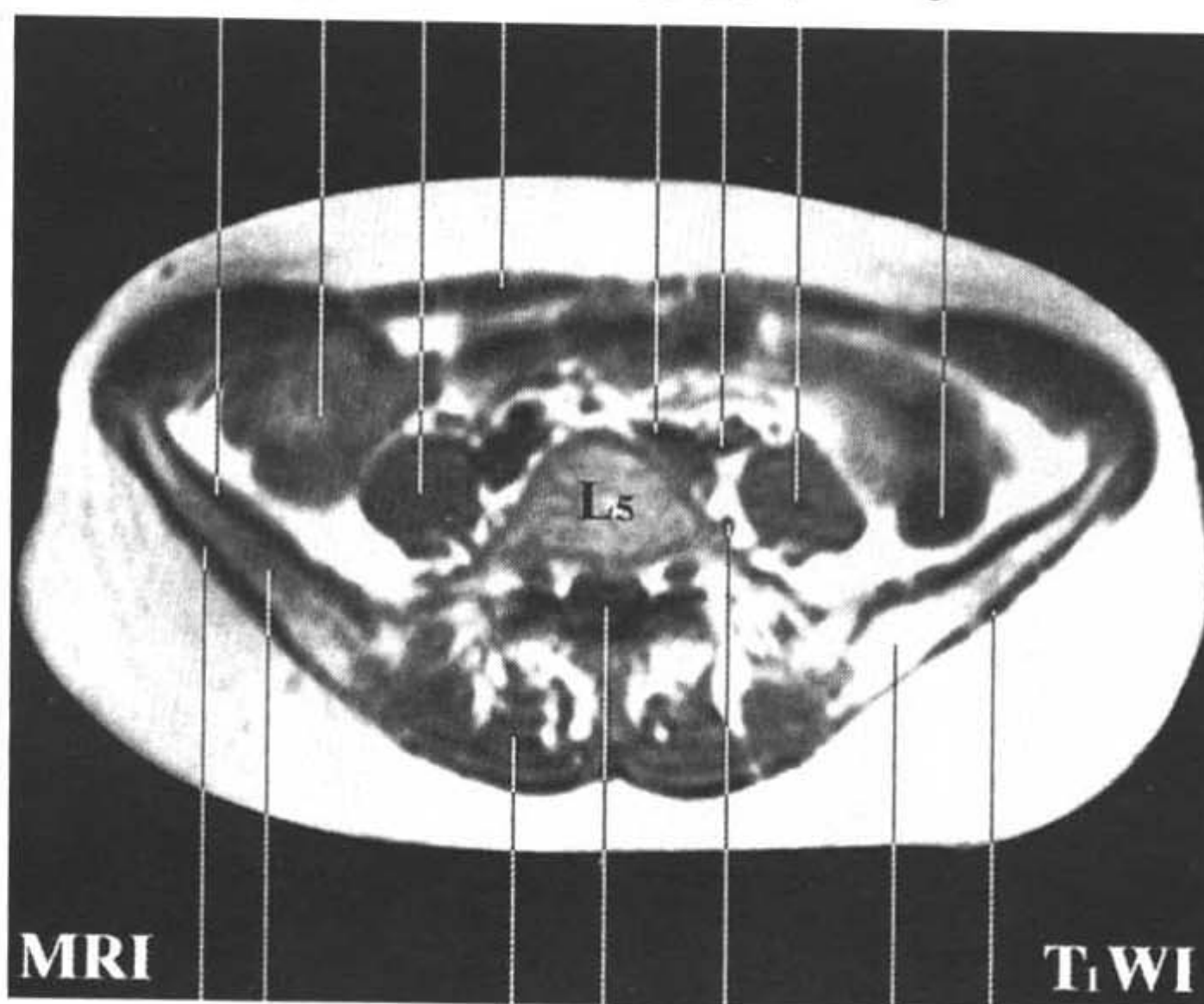
1. 腹外斜肌 obliquus externus abdominis
2. 腹内斜肌 obliquus internus abdominis
3. 腹横肌 transversus abdominis
4. 髂肌 iliacus
5. 乙状结肠 sigmoid colon
6. 回肠 ileum
7. 腰大肌 psoas major
8. 输尿管 ureter
9. 左髂外动脉 left external iliac a.
10. 左髂内动脉 left internal iliac a.

14 6 7 8 24 12 11 10 8 7 5



16 15 4 20 19 17 15 16

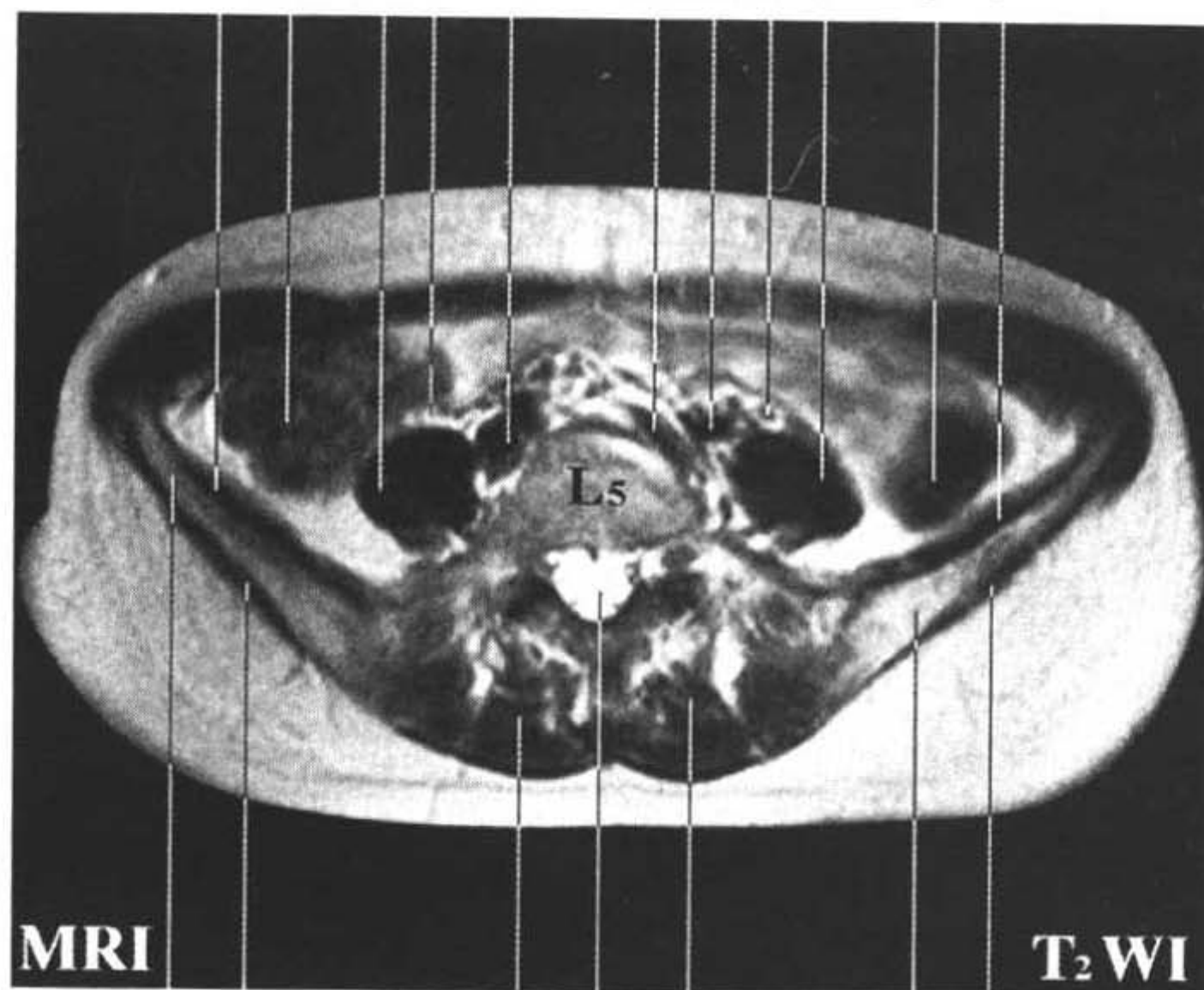
4 14 7 12 11 10 7 5



15 16 17 19 20 16 15

11. 左髂总静脉 left common iliac v.
12. 腹直肌 rectus abdominis
13. 阑尾 vermiform appendix
14. 升结肠 ascending colon
15. 臀中肌 gluteus medius
16. 髂骨翼 ala of ilium
17. 竖脊肌 erector spinae
18. 第5腰椎与第1骶椎关节突关节 zygapophysial joint (L₅-S₁)
19. 马尾 cauda equina
20. 第5腰神经 5th lumbar n.
21. 第4腰神经 4th lumbar n.
22. 股神经 femoral n.
23. 第2腰神经 2nd lumbar n.
24. 右髂总静脉 right common iliac v.
25. 右髂总动脉 right common iliac a.

4 14 7 8 24 11 10 9 7 5 4



16 15 17 19 17 16 15

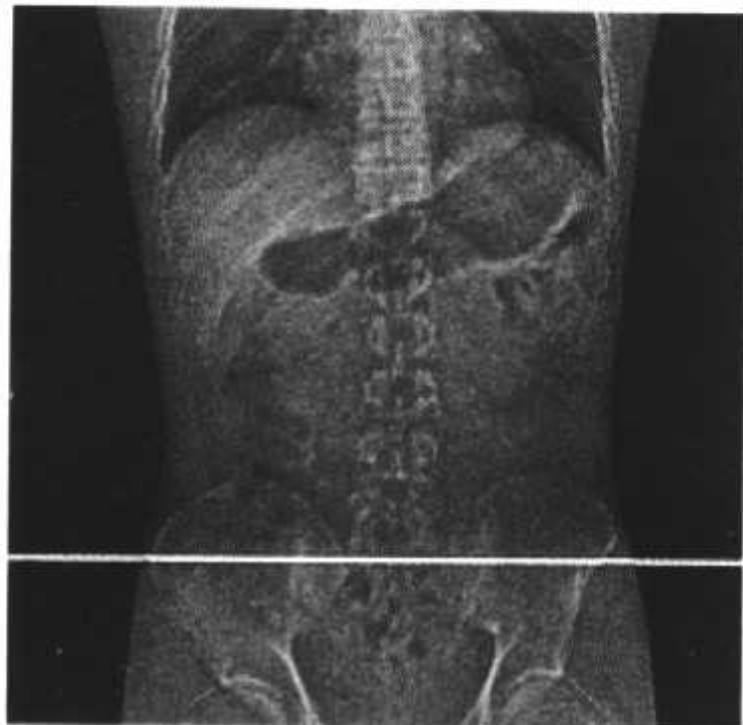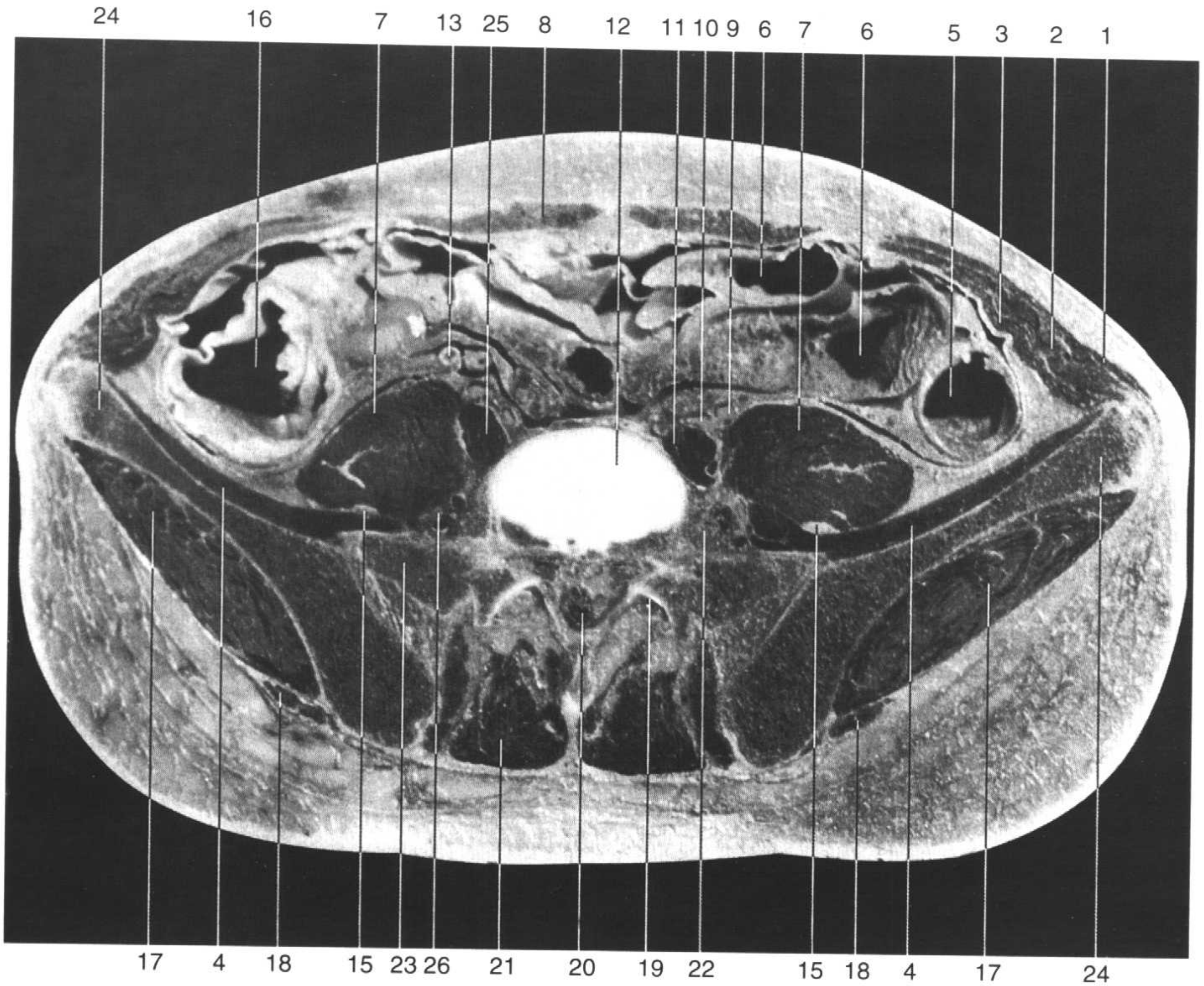
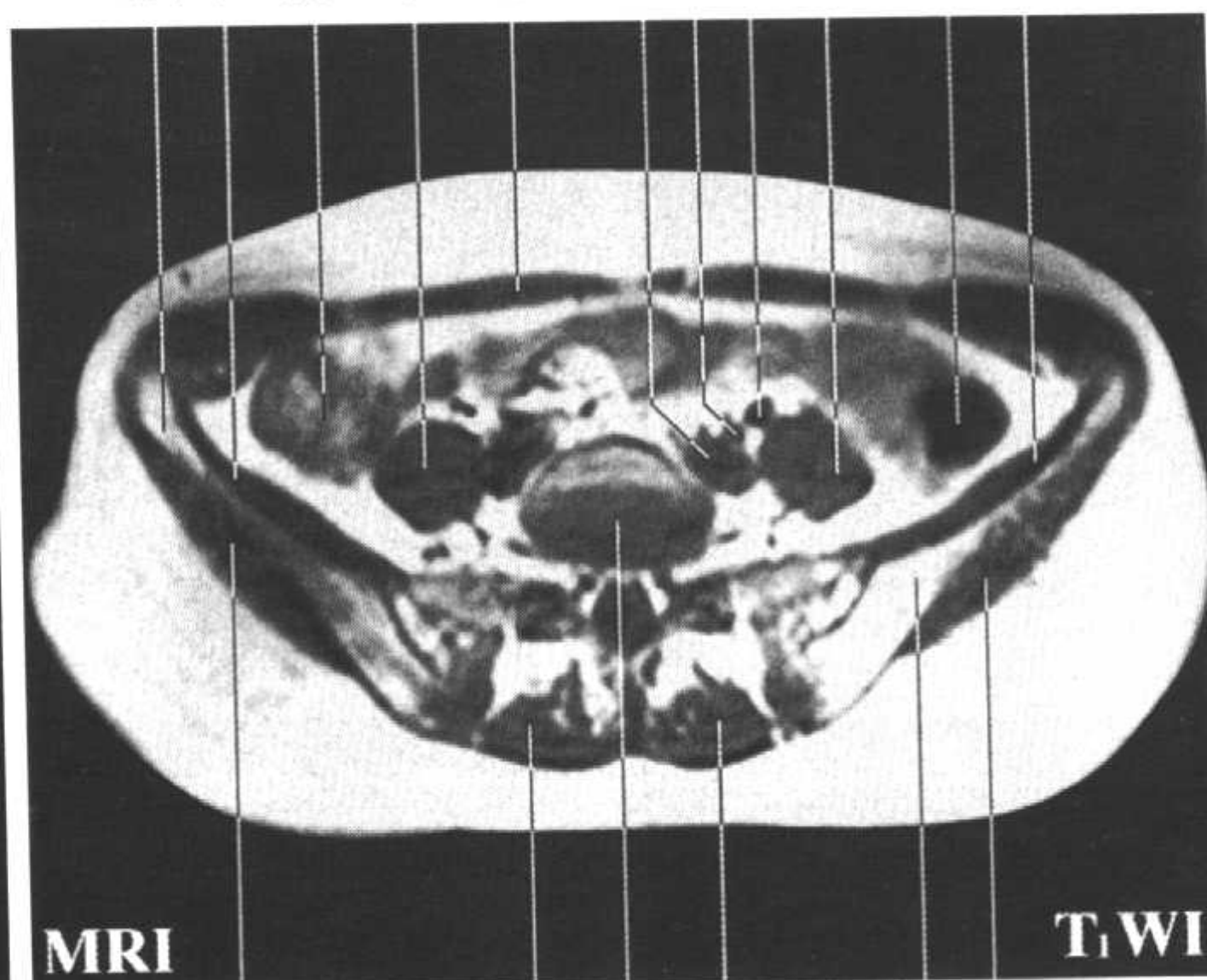
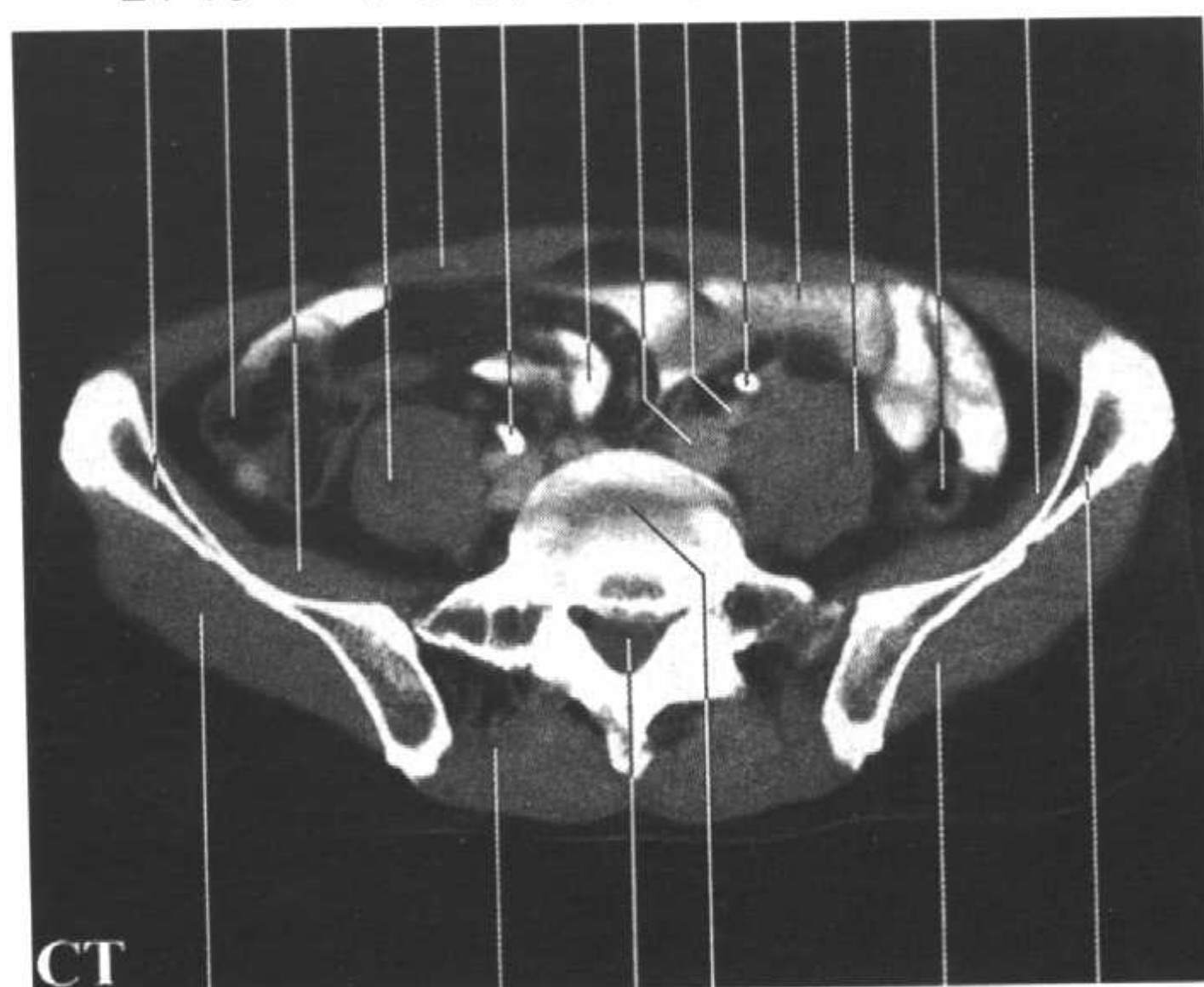


Fig.HT15

1. 腹外斜肌 obliquus externus abdominis
2. 腹内斜肌 obliquus internus abdominis
3. 腹横肌 transversus abdominis
4. 髂肌 iliacus
5. 乙状结肠 sigmoid colon
6. 回肠 ileum
7. 腰大肌 psoas major
8. 腹直肌 rectus abdominis
9. 左髂外动脉 left external iliac a.
10. 左髂内动脉 left internal iliac a.

24 16 4 7 8 14 6 11 10 14 6 7 5 4

24 4 16 7 8 11 10 9 7 5 4



CT

MRI

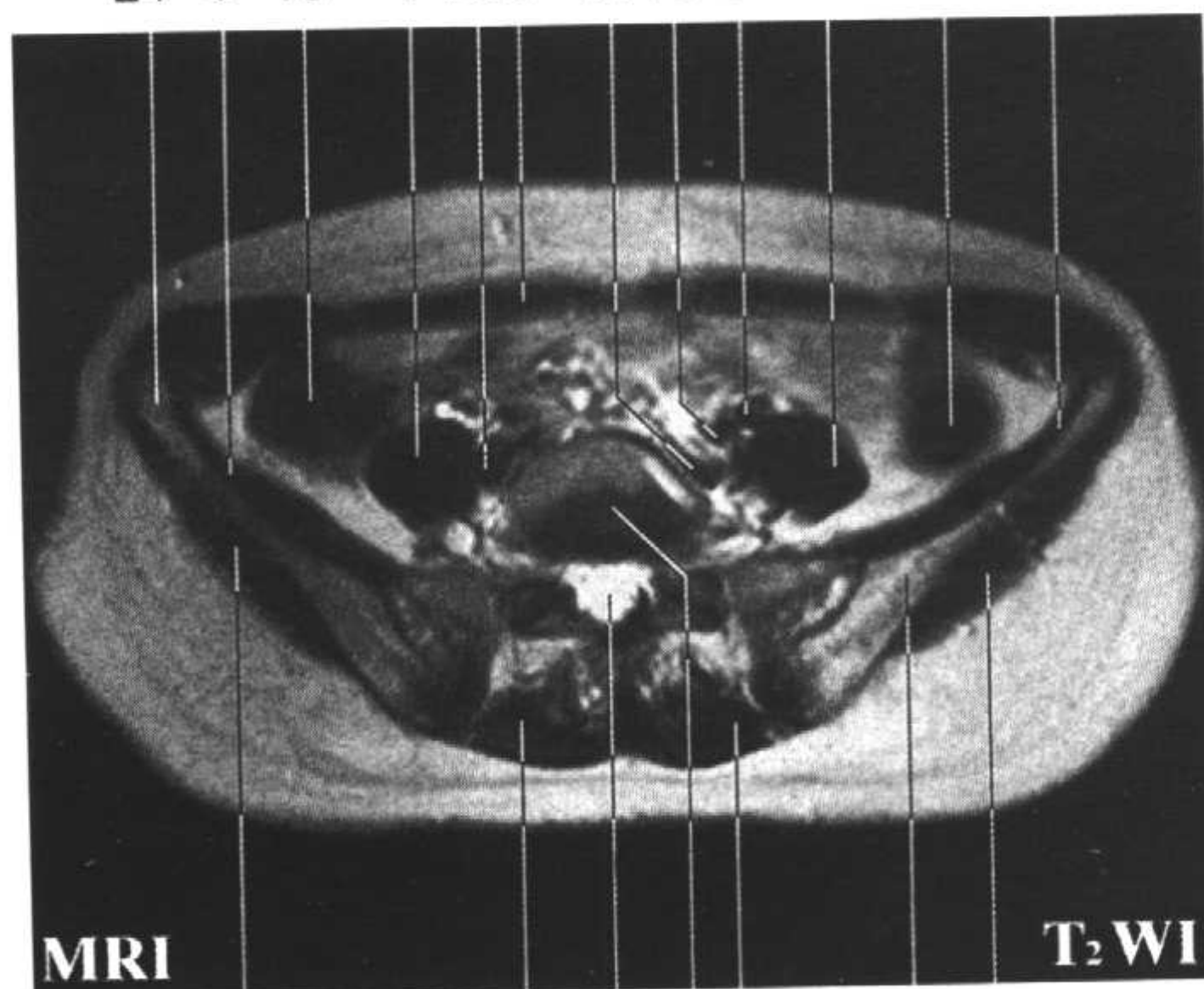
T₁WI

17 21 20 12 17 24

17 21 12 21 24 17

11. 左髂总静脉 left common iliac v.
12. 第5腰椎与第1骶椎间盘 intervertebral disc (L₅-S₁)
13. 阑尾 vermiform appendix
14. 输尿管 ureter
15. 股神经 femoral n.
16. 升结肠 ascending colon
17. 臀中肌 gluteus medius
18. 臀大肌 gluteus maximus
19. 第5腰椎与第1骶椎关节突关节 zygapophysial joint (L₅-S₁)
20. 马尾 cauda equina
21. 竖脊肌 erector spinae
22. 腰骶干 lumbosacral trunk
23. 骶翼 ala of sacrum
24. 髂骨翼 ala of ilium
25. 右髂总静脉 right common iliac v.
26. 闭孔神经 obturator n.

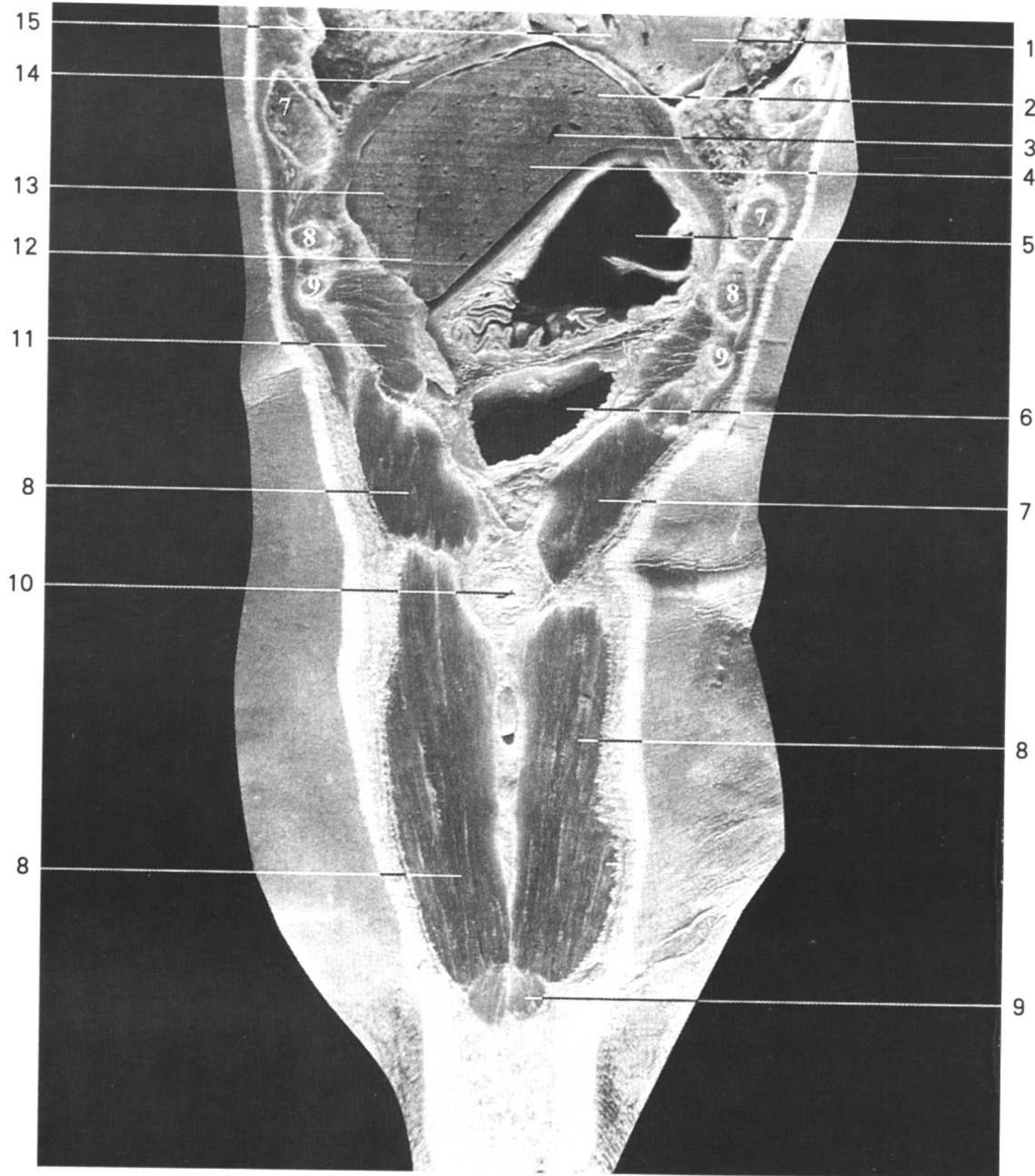
24 4 16 7 25 8 11 10 9 7 5 4



MRI

T₂WI

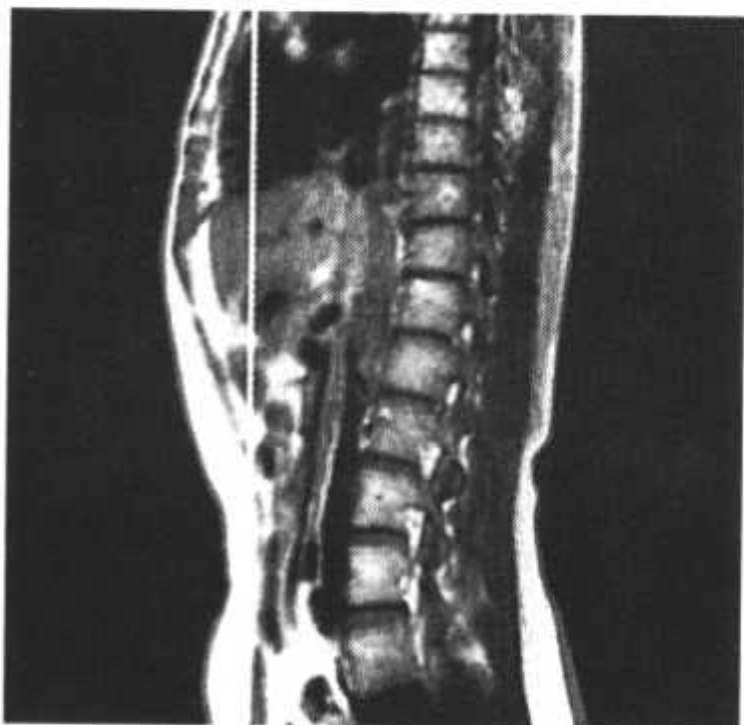17 21 20 12 21 24 17



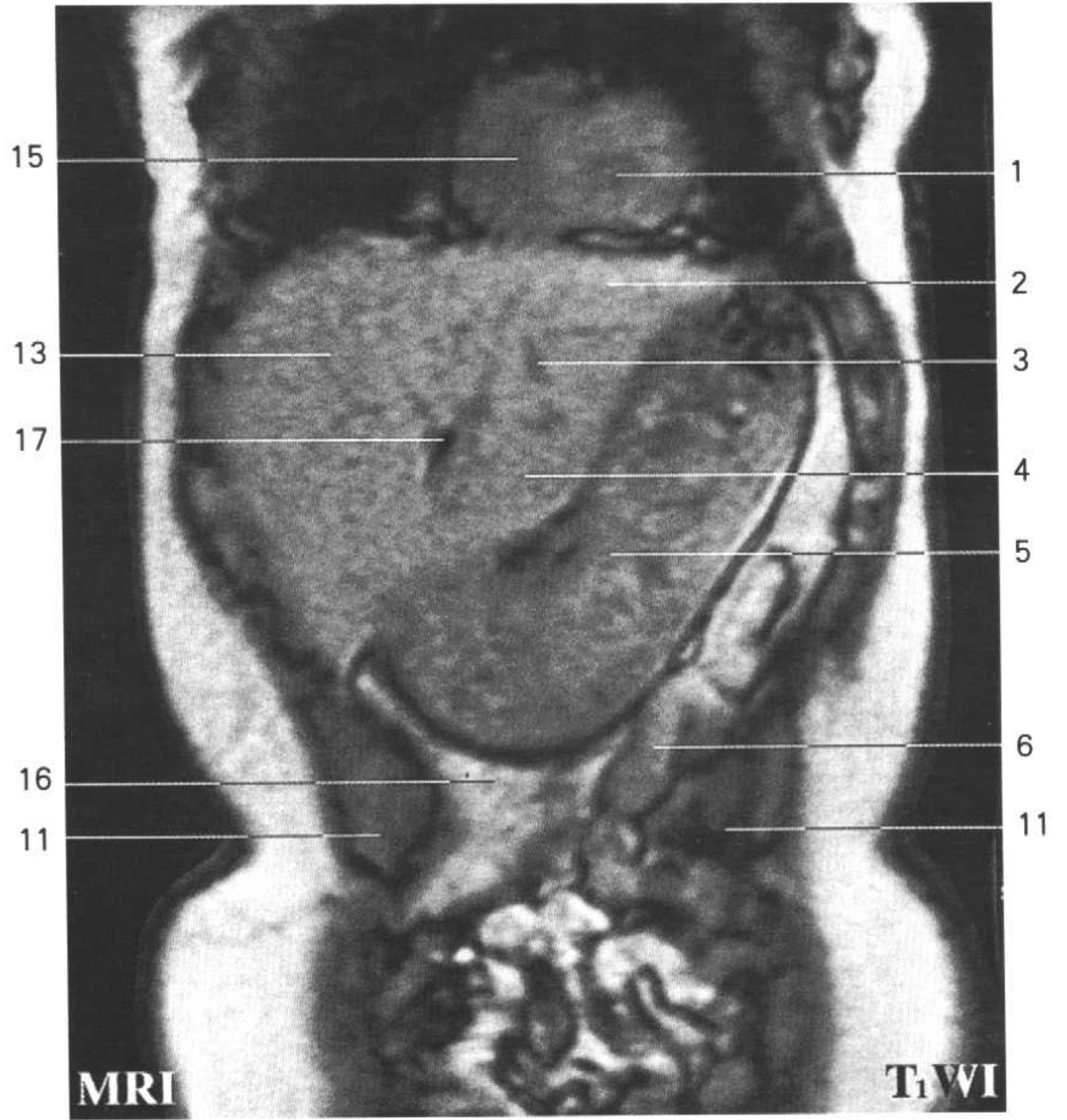额状断面 FA

Fig.FA1

1. 左心室 left ventricle
2. 左外叶上段 superior segment of left lateral lobe
3. 肝左静脉 left hepatic v.
4. 左外叶下段 inferior segment of left lateral lobe
5. 胃 stomach
6. 横结肠 transverse colon
7. 腹直肌 rectus abdominis
8. 腹直肌 rectus abdominis
9. 锥状肌 pyramidalis
10. 脐 umbilicus



- 11. 腹横肌 transversus abdominis
- 12. 肝圆韧带裂 fissure for
ligamentum teres hepatis
- 13. 左内叶 left medial lobe
- 14. 膈 diaphragm
- 15. 右心室 right ventricle
- 16. 大网膜 greater omentum
- 17. 肝门静脉左支 left branch
of hepatic portal v.

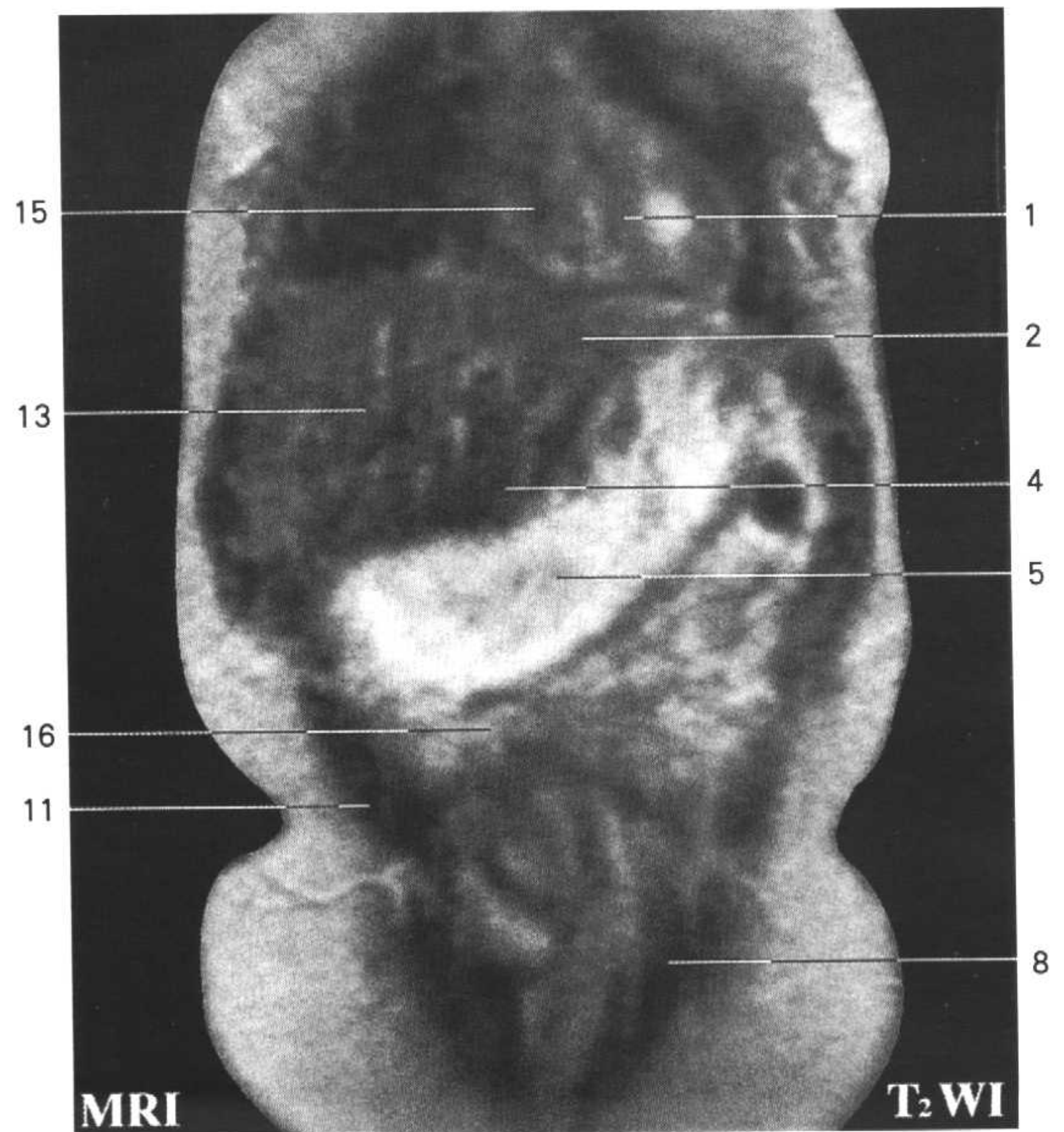
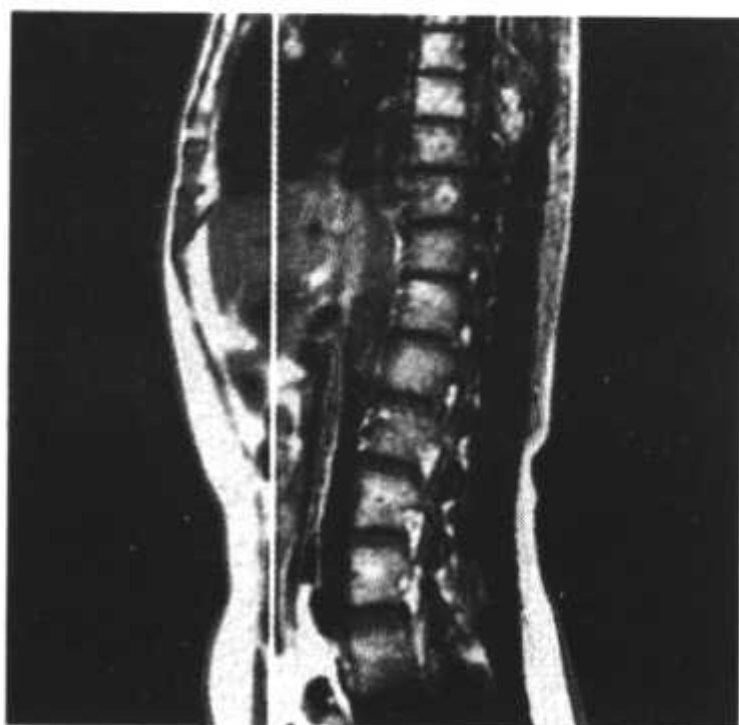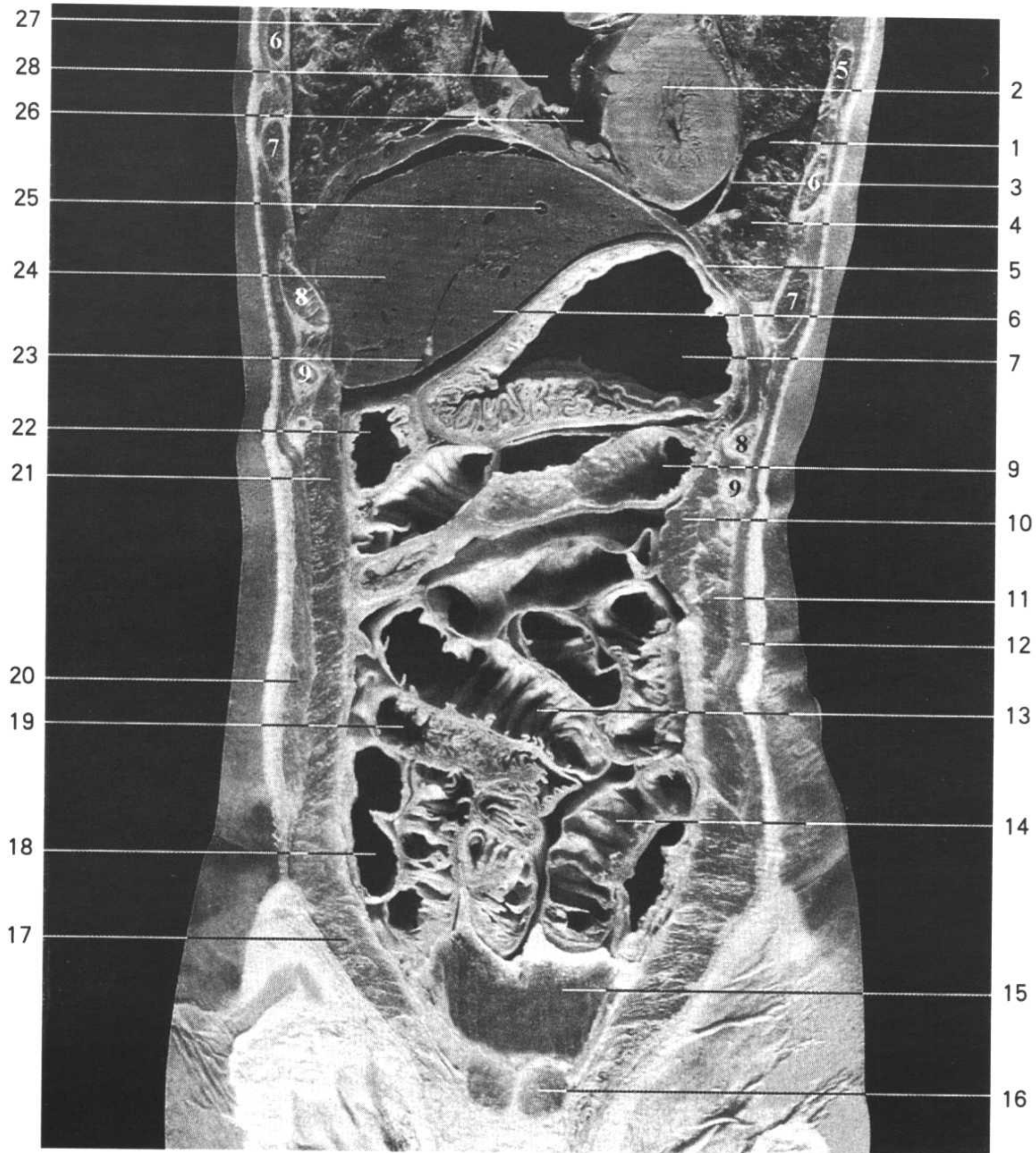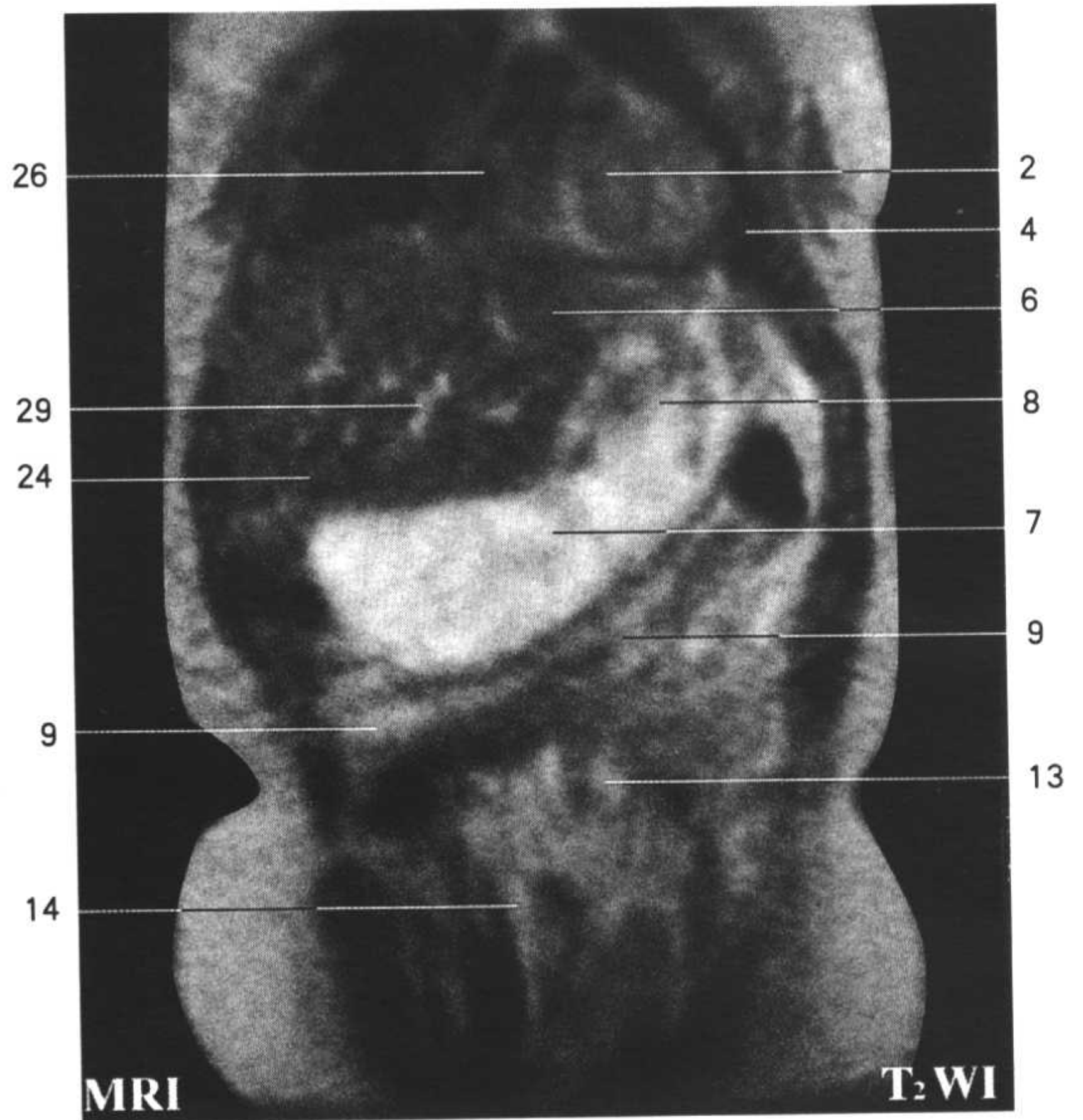



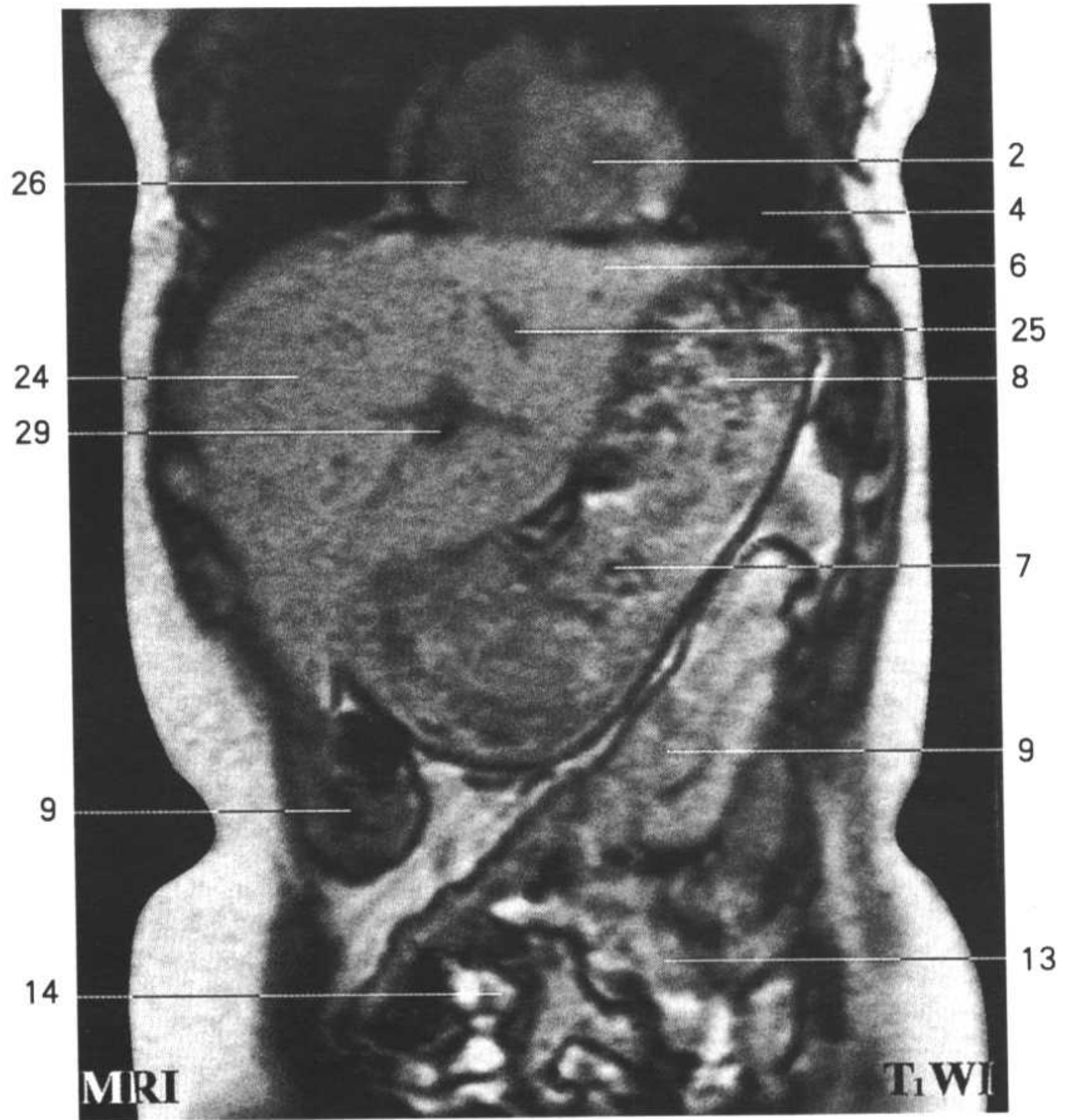
Fig.FA2

1. 斜裂 oblique fissure
2. 左心室 left ventricle
3. 心包 pericardium
4. 左肺下叶 inferior lobe of left lung
5. 膈 diaphragm
6. 左外叶 left lateral lobe
7. 胃体 body of stomach
8. 胃底 fundus of stomach
9. 横结肠 transverse colon
10. 腹横肌 transversus abdominis

- 11. 腹内斜肌 obliquus internus abdominis
- 12. 腹外斜肌 obliquus externus abdominis
- 13. 空肠 jejunum
- 14. 空肠 jejunum
- 15. 腹直肌 rectus abdominis
- 16. 锥状肌 pyramidalis
- 17. 腹内斜肌 obliquus internus abdominis
- 18. 升结肠 ascending colon
- 19. 回肠 ileum
- 20. 腹外斜肌 obliquus externus abdominis
- 21. 腹横肌 transversus abdominis
- 22. 幽门窦 pyloric antrum
- 23. 肝圆韧带裂 fissure for ligamentum teres hepatis
- 24. 左内叶 left medial lobe
- 25. 肝左静脉 left hepatic v.
- 26. 右心室 right ventricle
- 27. 右肺中叶 middle lobe of right lung
右心房 right atrium
- 28. 肝门静脉左支 left branch
- 29. of hepatic portal v.



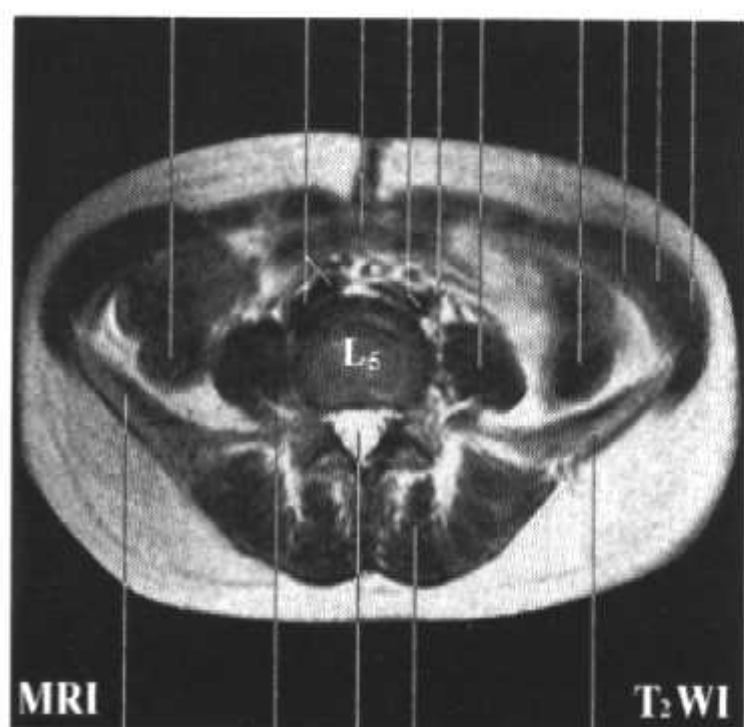
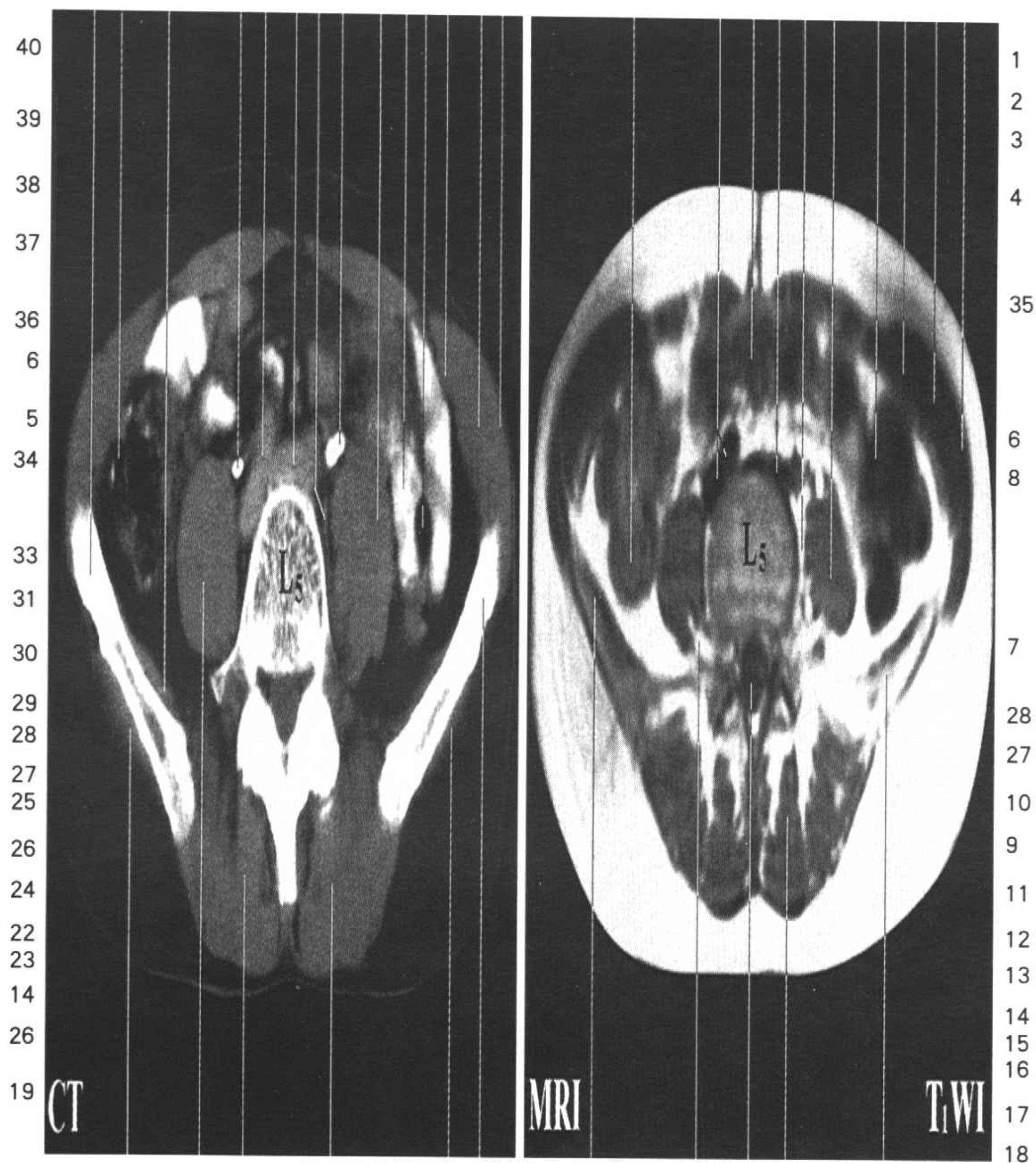
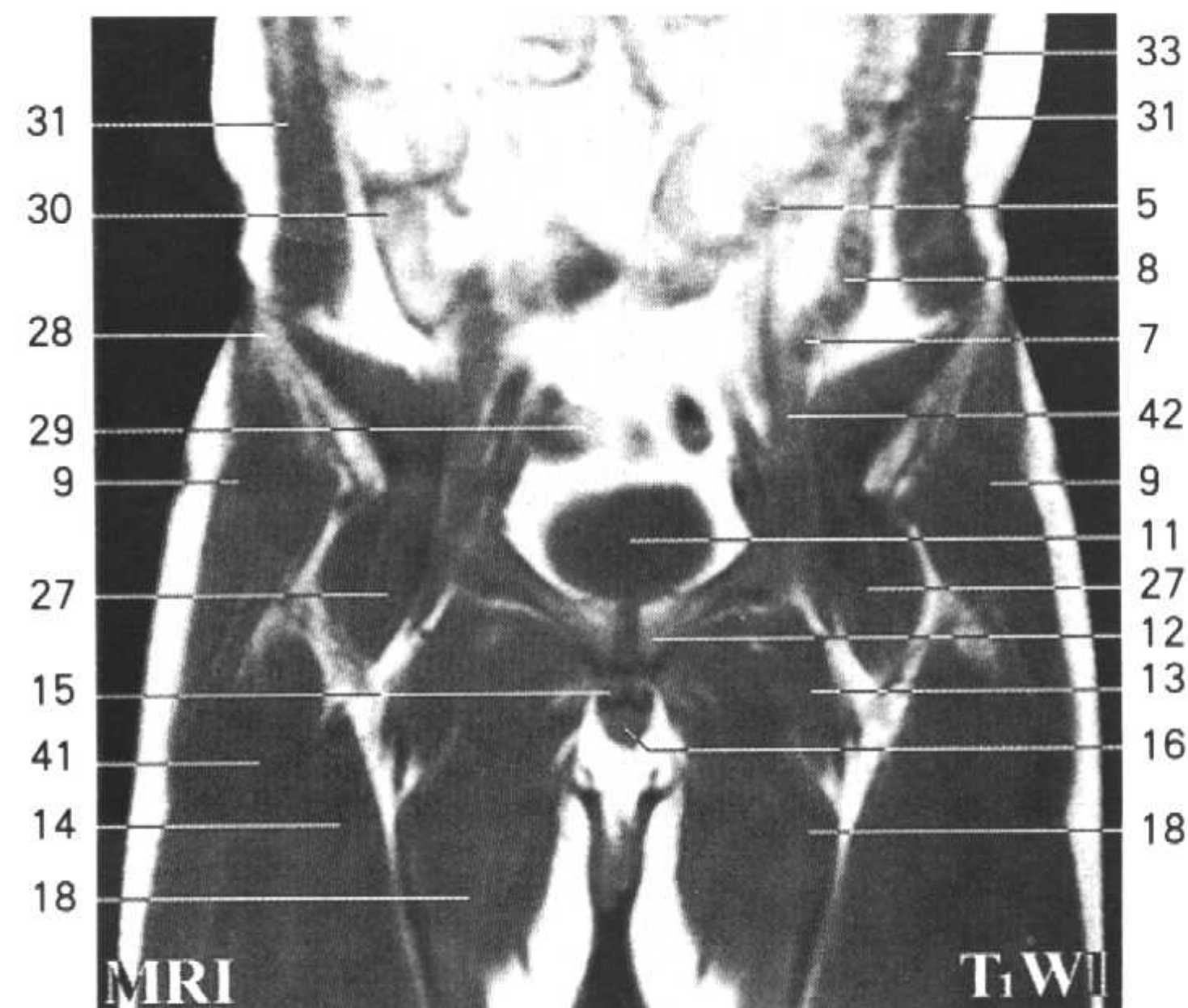
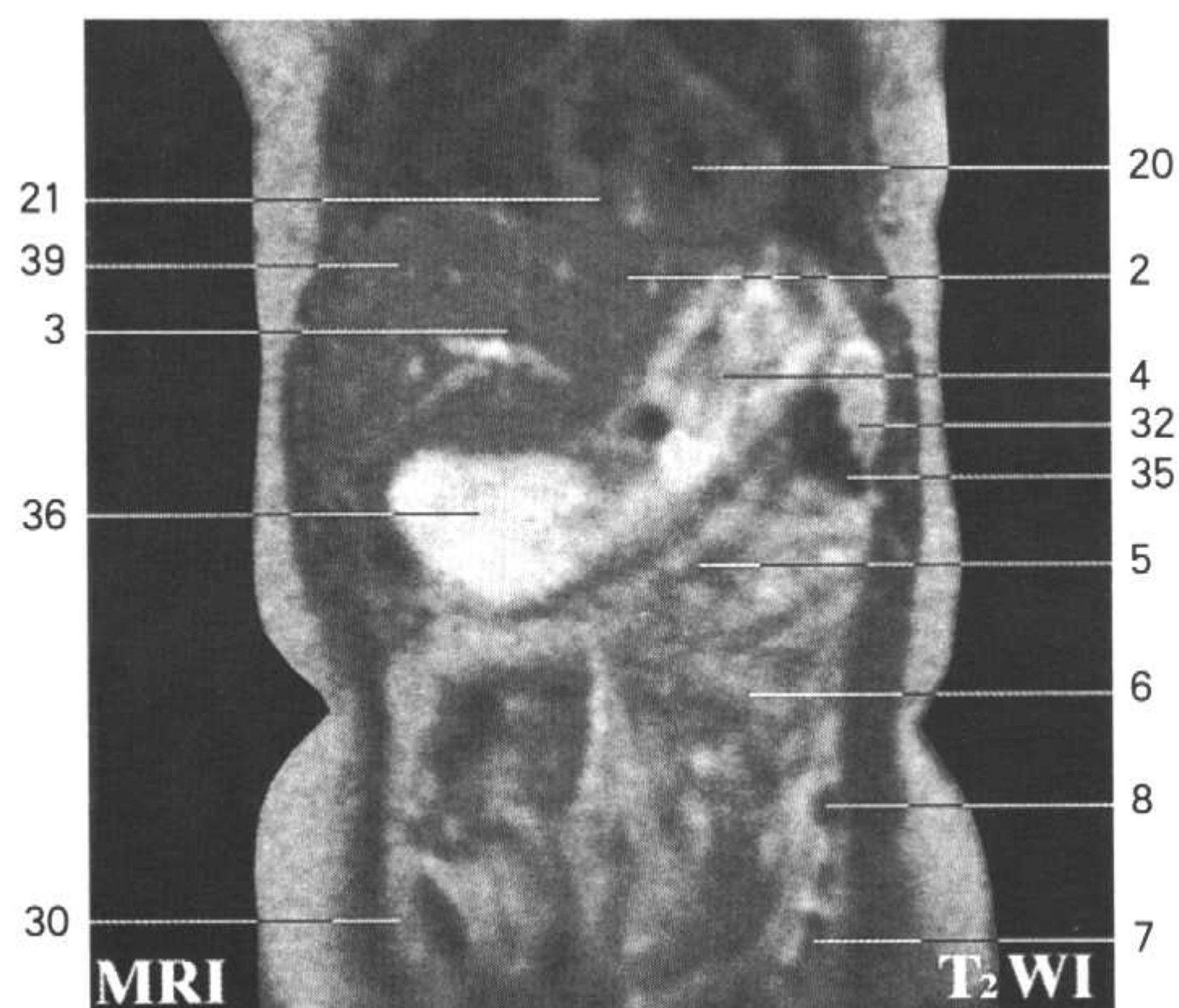
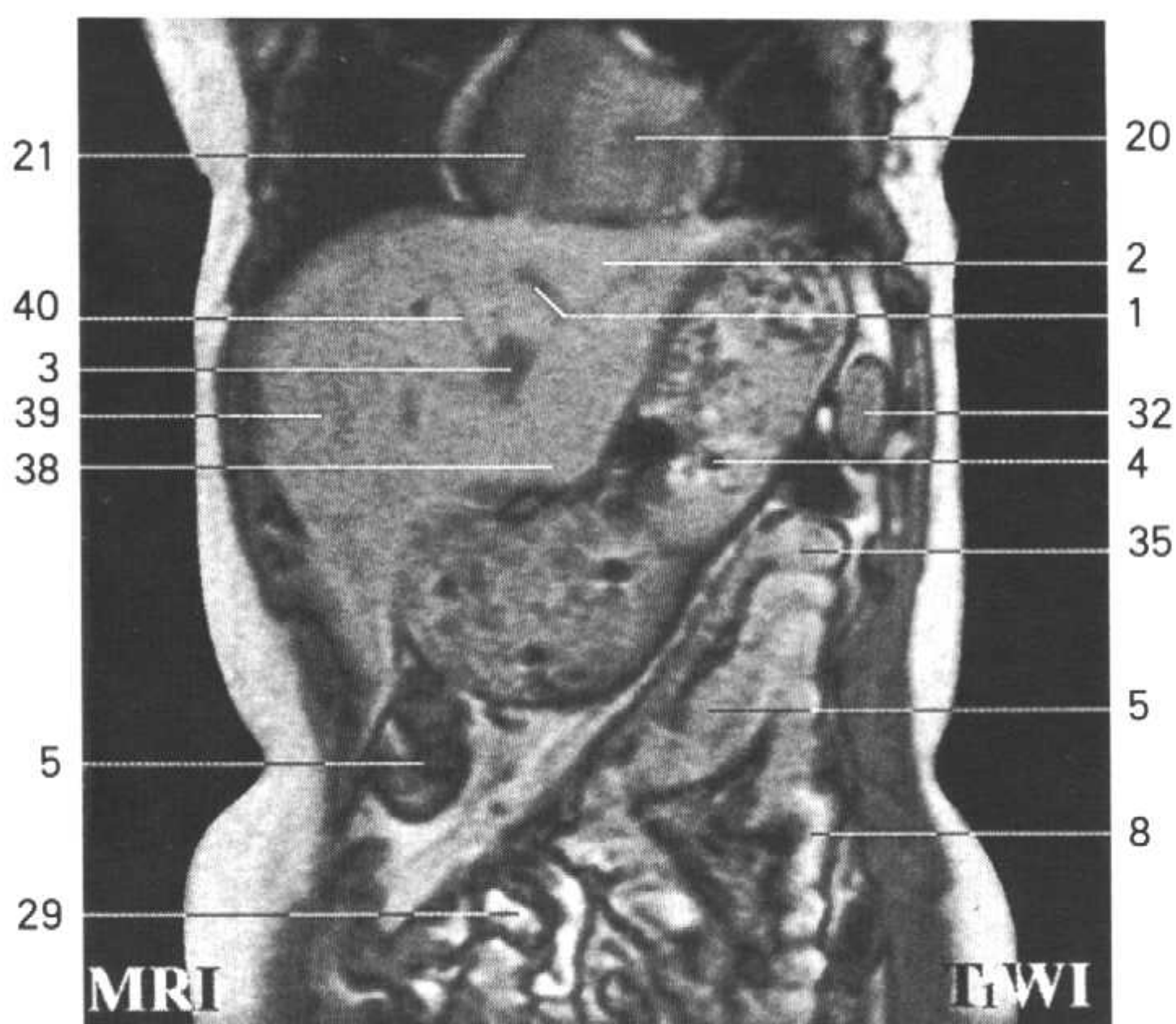


Fig.FA3

1. 肝左静脉 left hepatic v.
2. 左外叶 left lateral lobe
3. 肝门静脉左支脐部 umbilical part of left branch of hepatic portal v.
4. 胃 stomach
5. 横结肠 transverse colon
6. 空肠 jejunum
7. 乙状结肠 sigmoid colon
8. 降结肠 descending colon
9. 阔筋膜张肌 tensor fasciae latae

- 10. 缝匠肌 sartorius
- 11. 膀胱 urinary bladder
- 12. 耻骨 pubis
- 13. 耻骨肌 pectineus
- 14. 股直肌 rectus femoris
- 15. 阴茎脚 crus penis
- 16. 尿道海绵体 cavernous body of urethra
- 17. 股中间肌 vastus intermedius
- 18. 长收肌 adductor longus
- 19. 睾丸 testis
- 20. 左心室 left ventricle
- 21. 右心房 right atrium
- 22. 股静脉 femoral v.
- 23. 股深动脉 deep femoral a.
- 24. 股动脉 femoral a.
- 25. 阔筋膜张肌 tensor fasciae latae
- 26. 缝匠肌 sartorius
- 27. 髂腰肌 iliopsoas
- 28. 髂前上棘 anterior superior iliac spine
- 29. 回肠 ileum
- 30. 升结肠 ascending colon
- 31. 腹外斜肌 obliquus externus abdominis
- 32. 脾 spleen
- 33. 腹内斜肌 obliquus internus abdominis
- 34. 腹横肌 transversus abdominis
- 35. 结肠左曲 left colic flexure
- 36. 幽门窦 pyloric antrum
- 37. 胆囊 gallbladder
- 38. 肝圆韧带裂 fissure for ligamentum teres hepatis
- 39. 右前叶 right anterior lobe
- 40. 左内叶 left medial lobe
- 41. 股外侧肌 vastus lateralis
- 42. 腰大肌 psoas major



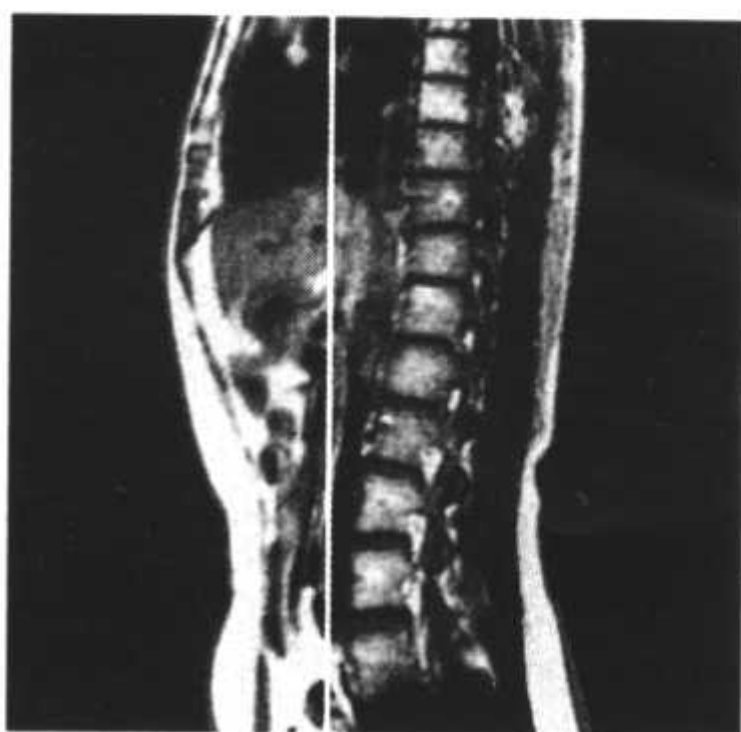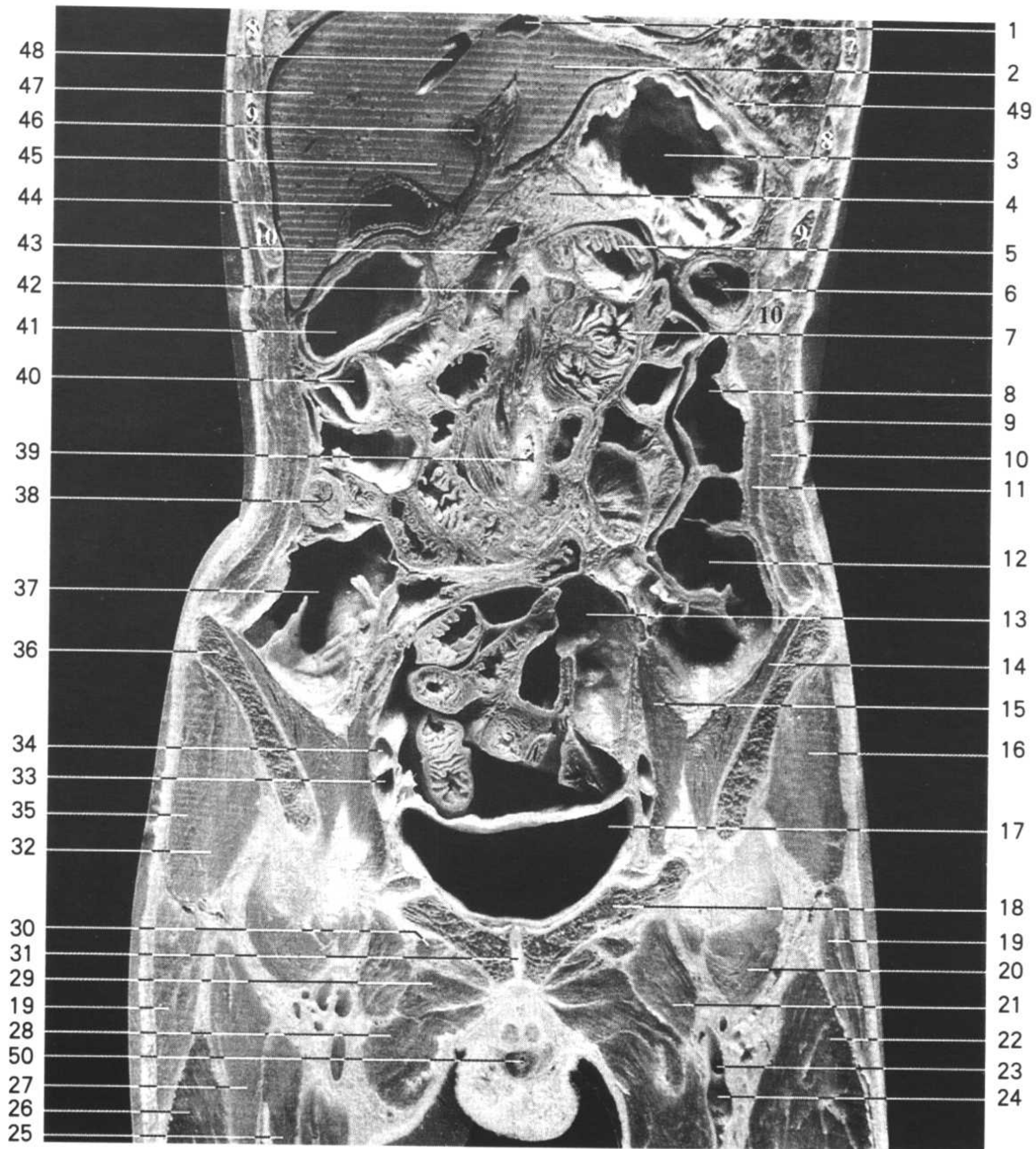
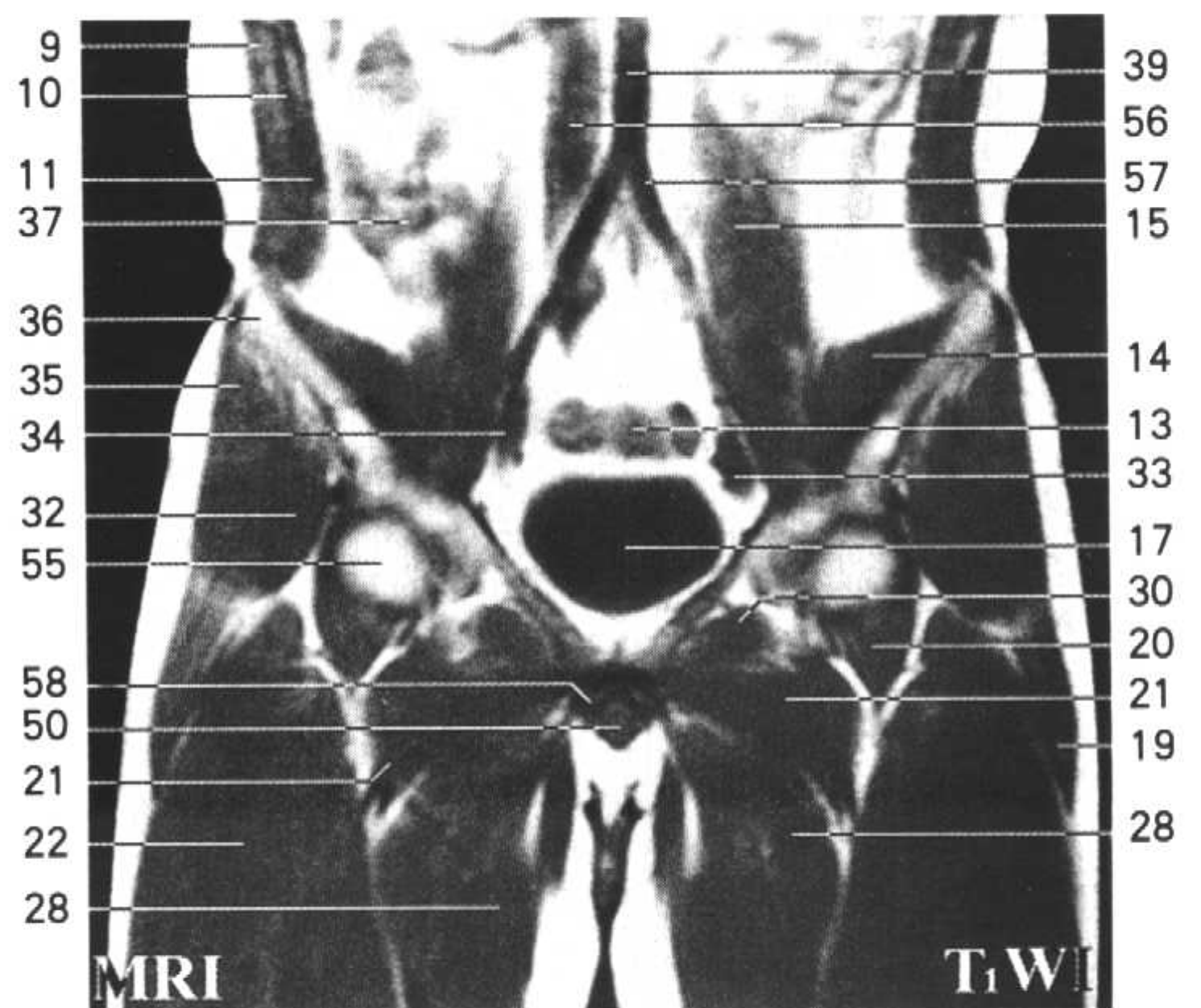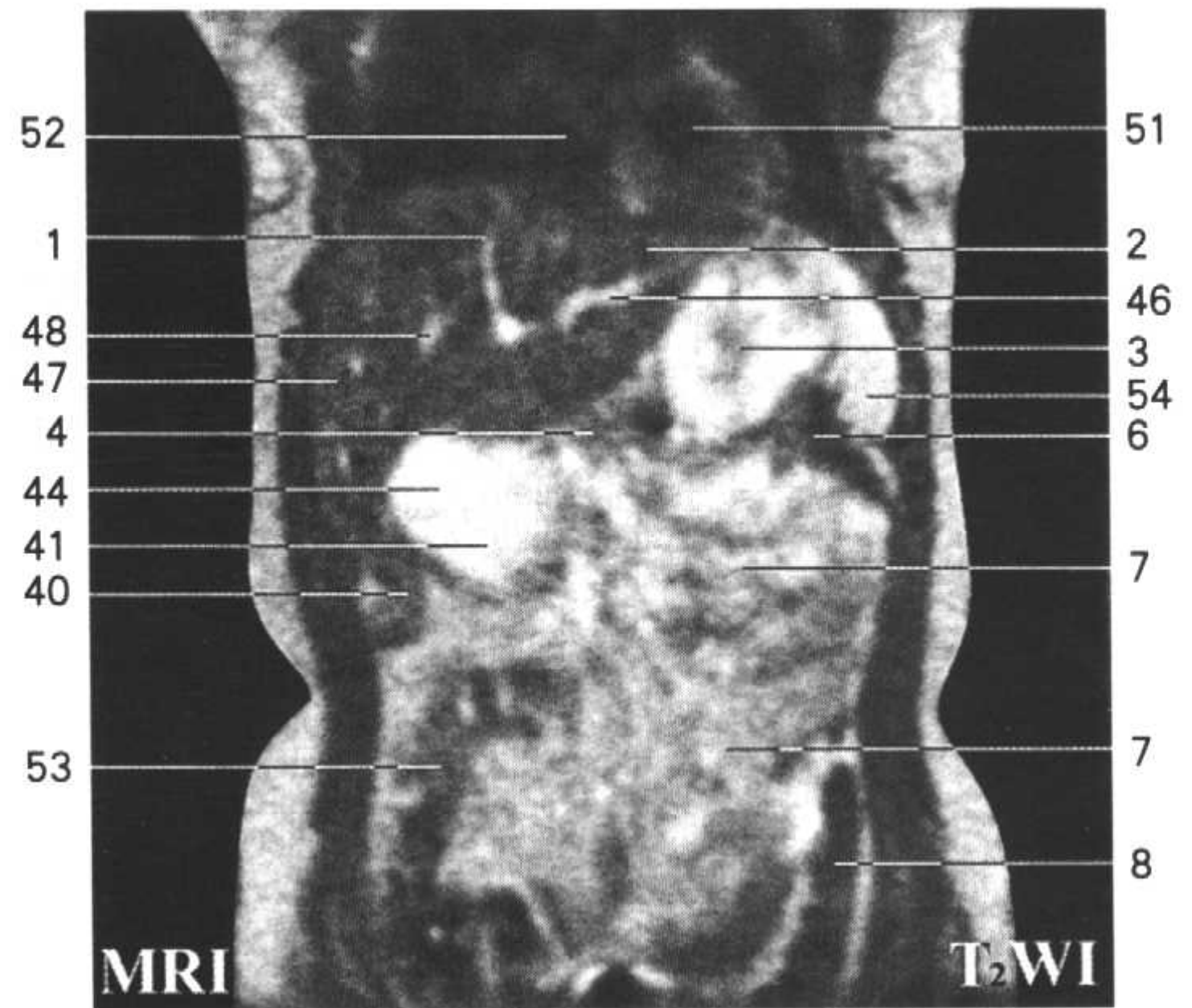


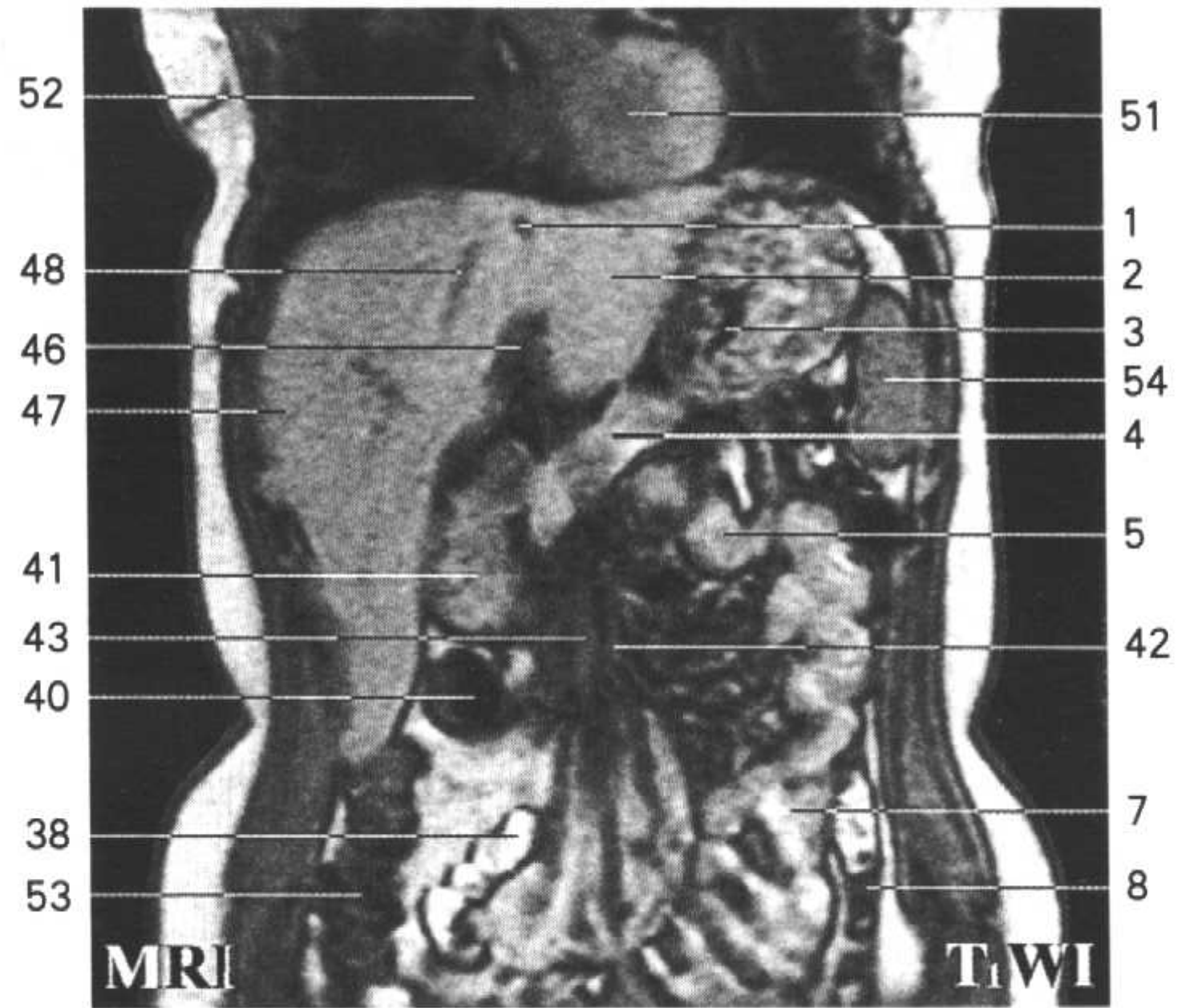Fig.FA4

1. 肝左静脉 left hepatic v.
2. 左外叶 left lateral lobe
3. 胃底 fundus of stomach
4. 胰 pancreas
5. 空肠 jejunum
6. 横结肠 transverse colon
7. 空肠 jejunum
8. 降结肠 descending colon
9. 腹外斜肌 obliquus externus abdominis
10. 腹内斜肌 obliquus internus abdominis

11. 腹横肌 transversus abdominis
12. 乙状结肠 sigmoid colon
13. 乙状结肠 sigmoid colon
14. 髂肌 iliacus
15. 腰大肌 psoas major
16. 臀中肌 gluteus medius
17. 膀胱 urinary bladder
18. 耻骨上支 superior ramus of pubis
19. 阔筋膜张肌 tensor fasciae latae
20. 髂腰肌 iliopsoas
21. 耻骨肌 pectineus
22. 股直肌 rectus femoris
23. 股深动脉 deep femoral a.
24. 股动脉 femoral a.
25. 缝匠肌 sartorius
26. 股外侧肌 vastus lateralis
27. 股直肌 rectus femoris
28. 长收肌 adductor longus
29. 短收肌 adductor brevis
30. 闭孔外肌 obturator externus
31. 耻骨联合 pubic symphysis
32. 臀小肌 gluteus minimus
33. 髂外静脉 external iliac v.
34. 髂外动脉 external iliac a.
35. 臀中肌 gluteus medius
36. 髂嵴 iliac crest
37. 盲肠 cecum
38. 回肠 ileum
39. 腹主动脉 abdominal aorta
40. 横结肠 transverse colon
41. 幽门窦 pyloric antrum
42. 肠系膜上动脉 superior mesenteric a.
43. 肠系膜上静脉 superior mesenteric v.
44. 胆囊 gallbladder
45. 左内叶 left medial lobe
46. 肝门静脉左支脐部 umbilical part of left branch of hepatic portal v.
47. 右前叶 right anterior lobe
48. 肝中间静脉 intermediate hepatic v.
49. 膈 diaphragm
50. 尿道海绵体 cavernous body of urethra
51. 左心室 left ventricle
52. 右心房 right atrium
53. 升结肠 ascending colon
54. 脾 spleen
55. 股骨头 femoral head
56. 下腔静脉 inferior vena cave
57. 髂总动脉 common iliac a.
58. 阴茎脚 crus penis



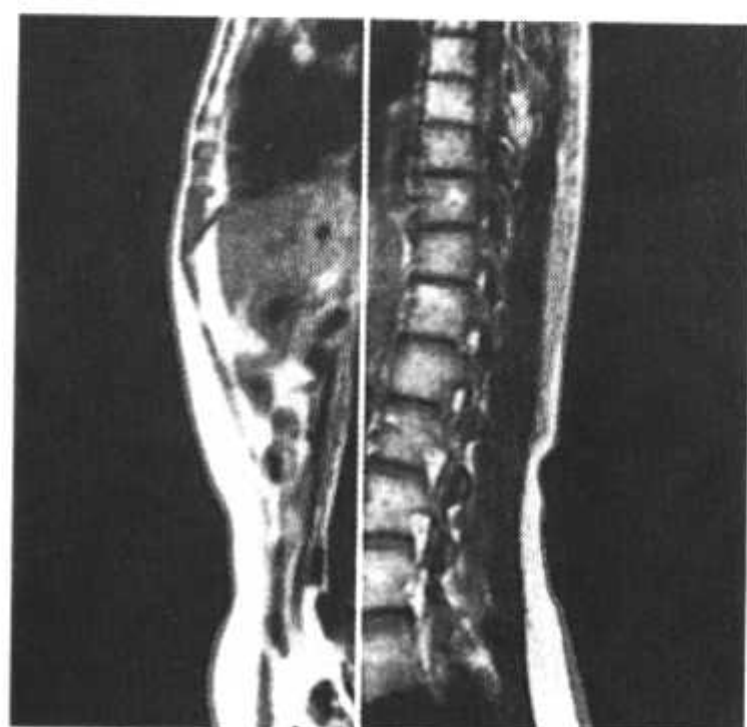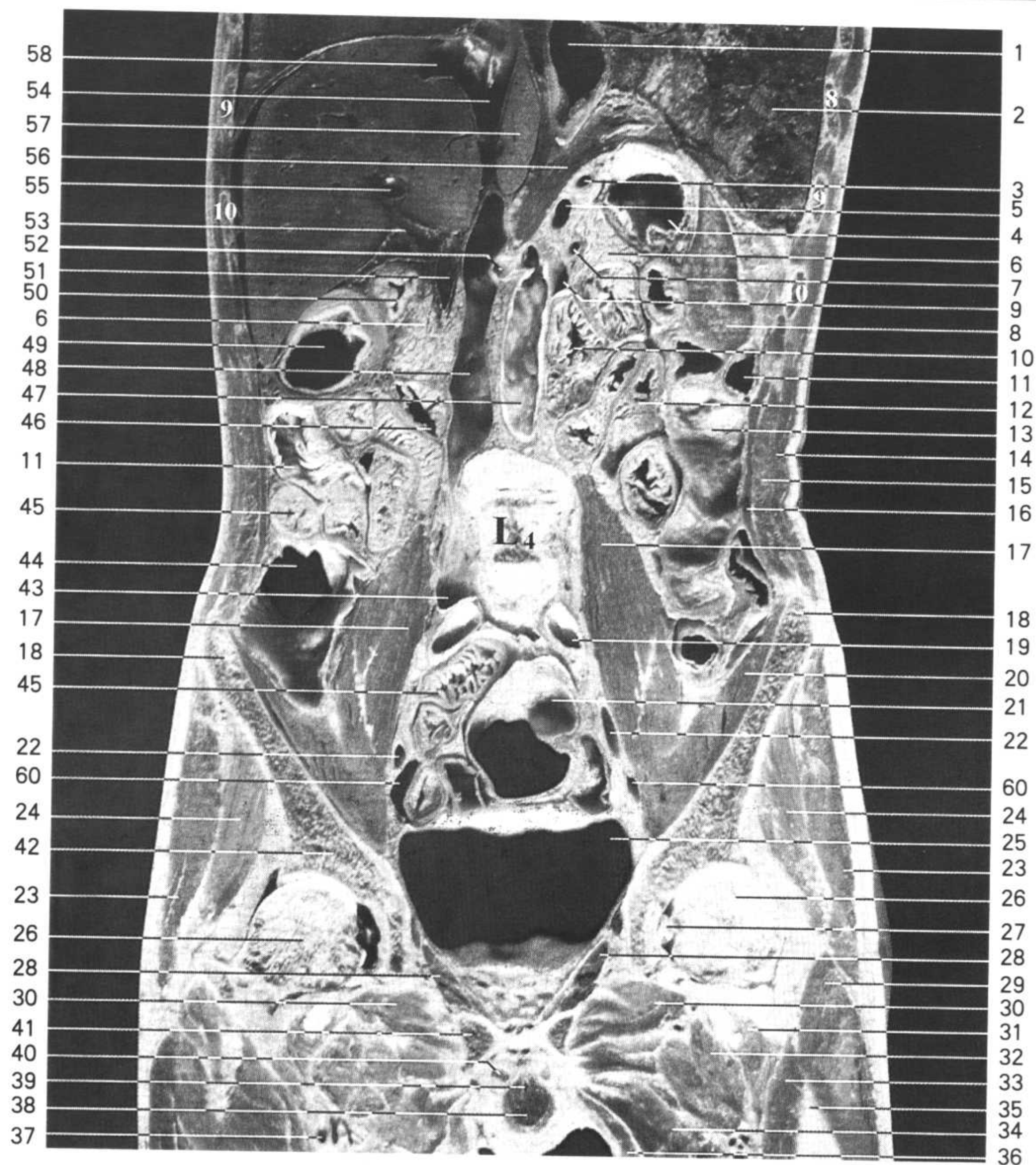
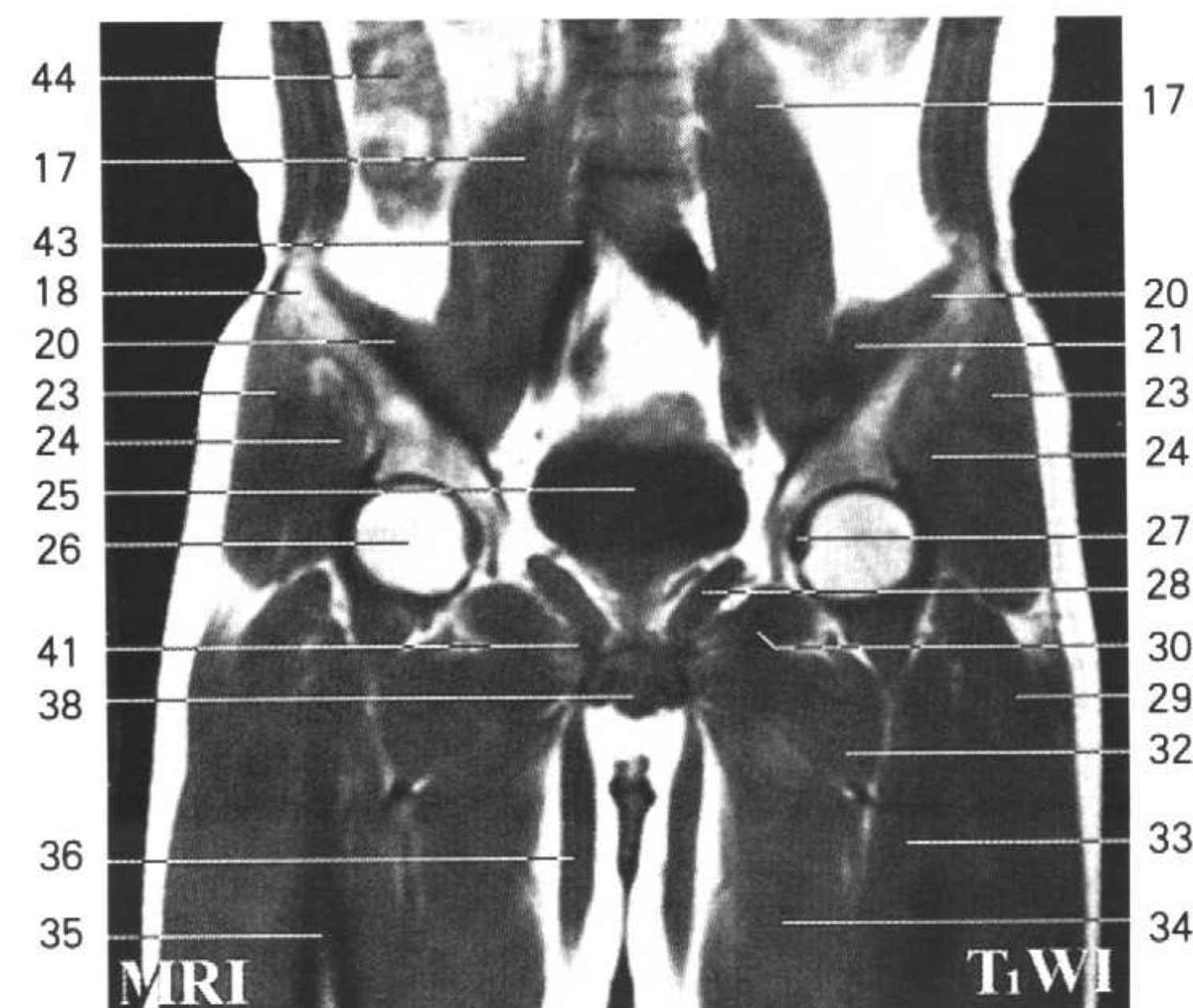
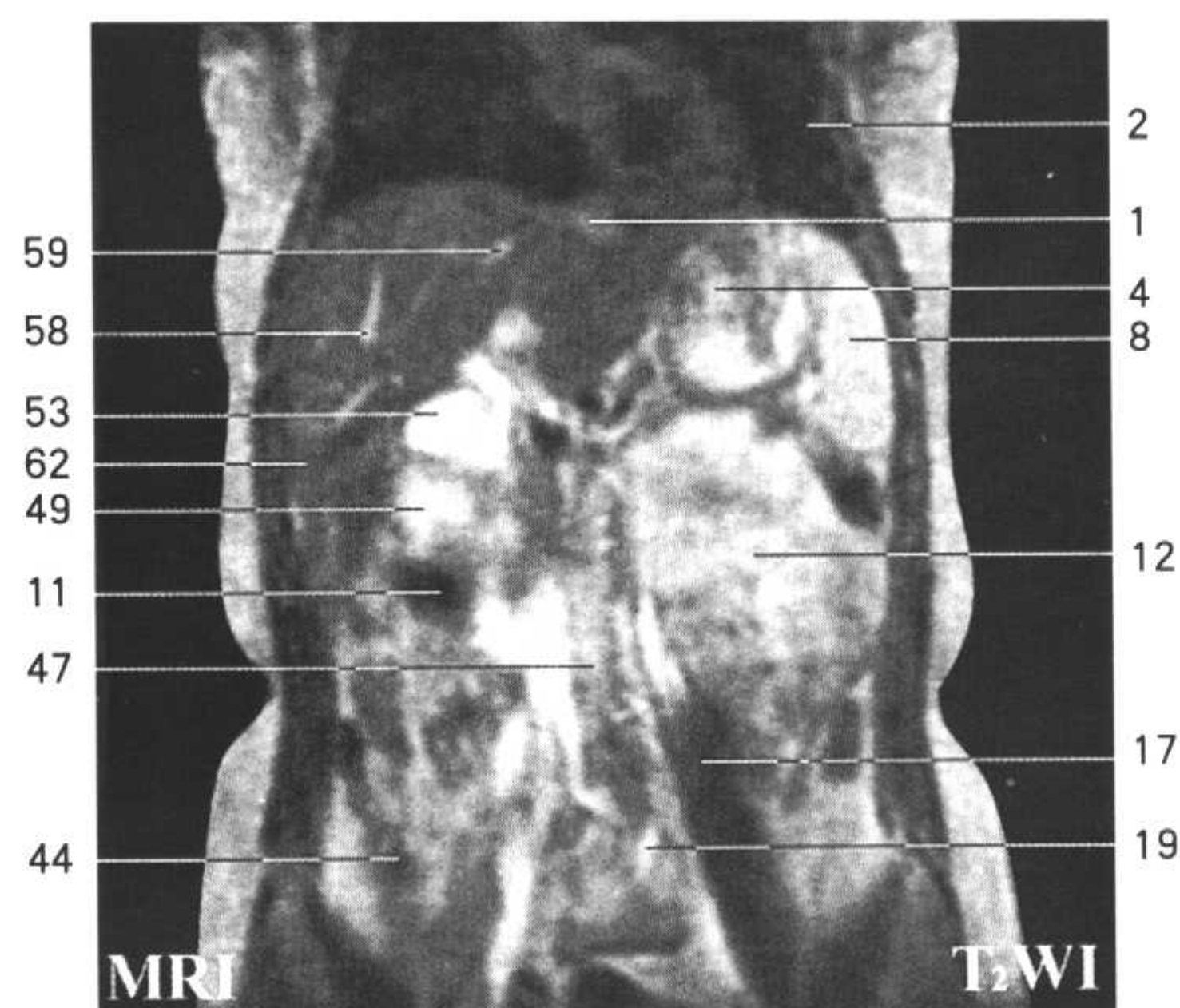
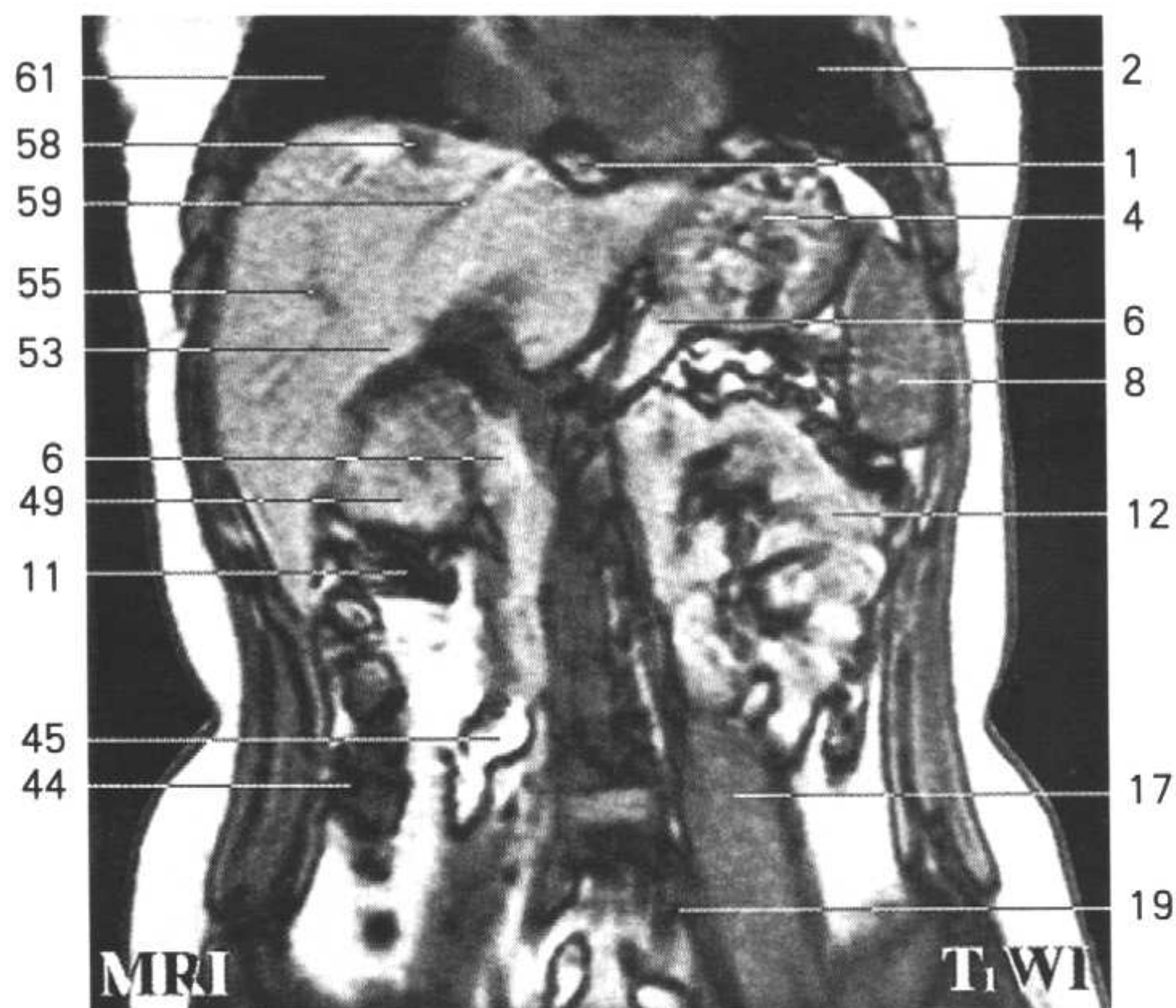


Fig.FA5

1. 食管 esophagus
2. 左肺下叶 inferior lobe of left lung
3. 腹腔干 celiac trunk
4. 贲门 cardia
5. 肠系膜上动脉 superior mesenteric a.
6. 胰 pancreas
7. 脾动脉 splenic a.
8. 脾 spleen
9. 左肾静脉 left renal v.
10. 十二指肠水平部 horizontal part of duodenum
11. 横结肠 transverse colon

12. 空肠 jejunum
13. 降结肠 descending colon
14. 腹外斜肌 obliquus externus abdominis
15. 腹内斜肌 obliquus internus abdominis
16. 腹横肌 transversus abdominis
17. 腰大肌 psoas major
18. 髂嵴 iliac crest
19. 髂总动脉 common iliac a.
20. 髂肌 iliacus
21. 乙状结肠 sigmoid colon
22. 髂外动脉 external iliac a.
23. 臀中肌 gluteus medius
24. 臀小肌 gluteus minimus
25. 膀胱 urinary bladder
26. 股骨头 femoral head
27. 股骨头韧带 ligament of head of femur
28. 闭孔内肌 obturator externus
29. 股外侧肌 vastus lateralis
30. 闭孔外肌 obturator externus
31. 髂腰肌 iliopsoas
32. 耻骨肌 pectineus
33. 股内侧肌 vastus medialis
34. 大收肌 adductor magnus
35. 股骨 femur
36. 股薄肌 gracilis
37. 股深动、静脉 deep femoral a. and v.
38. 尿道海绵体 cavernous body of urethra
39. 男尿道 male urethra
40. 阴茎脚 crus penis
41. 耻骨下支 inferior ramus of pubis
42. 髂骨体 body of ilium
43. 右髂总静脉 right common iliac v.
44. 升结肠 ascending colon
45. 回肠 ileum
46. 十二指肠降部 descending part of duodenum
47. 腹主动脉 abdominal aorta
48. 下腔静脉 inferior vena cava
49. 幽门管 pyloric canal
50. 十二指肠上部 superior part of duodenum
51. 胆总管 common bile duct
52. 右肾动脉 right renal a.
53. 胆囊 gallbladder
54. 下腔静脉 inferior vena cava
55. 肝门静脉右支 right branch of hepatic portal v.
56. 膈左脚 left crus of diaphragm
57. 尾状叶 caudate lobe
58. 肝右静脉 right hepatic v.
59. 肝中间静脉 intermediate hepatic v.
60. 髂外静脉 external iliac v.
61. 右肺下叶 inferior lobe of right lung
62. 右后叶 right posterior lobe



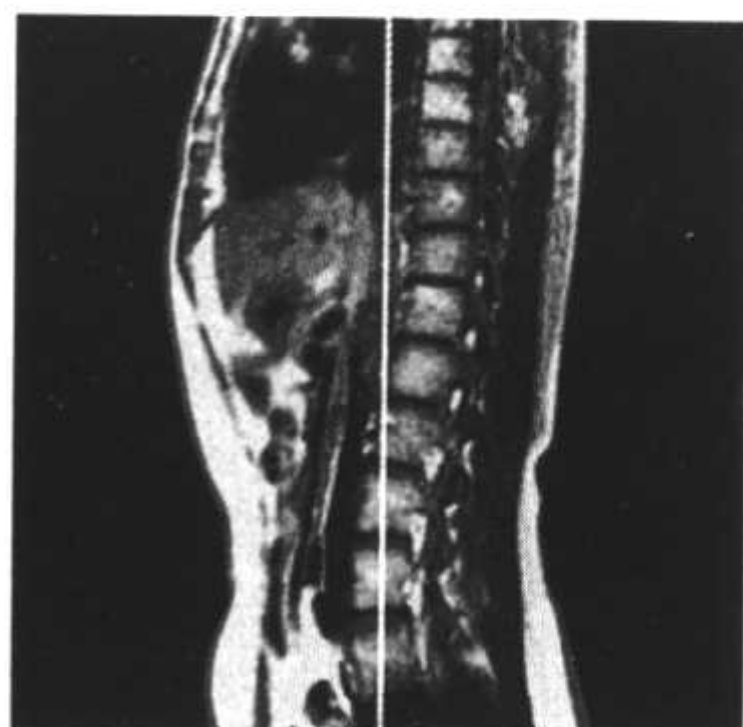
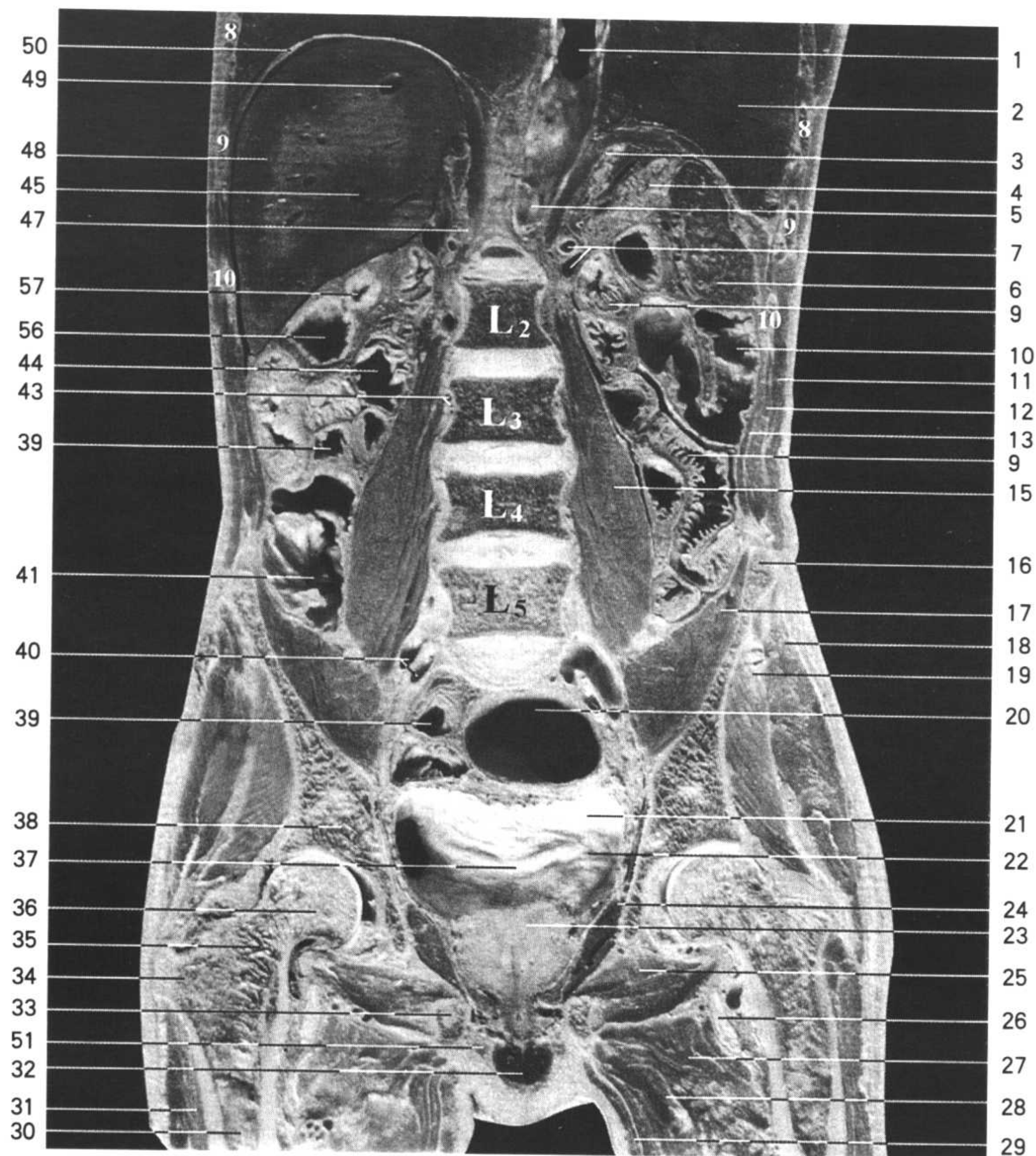
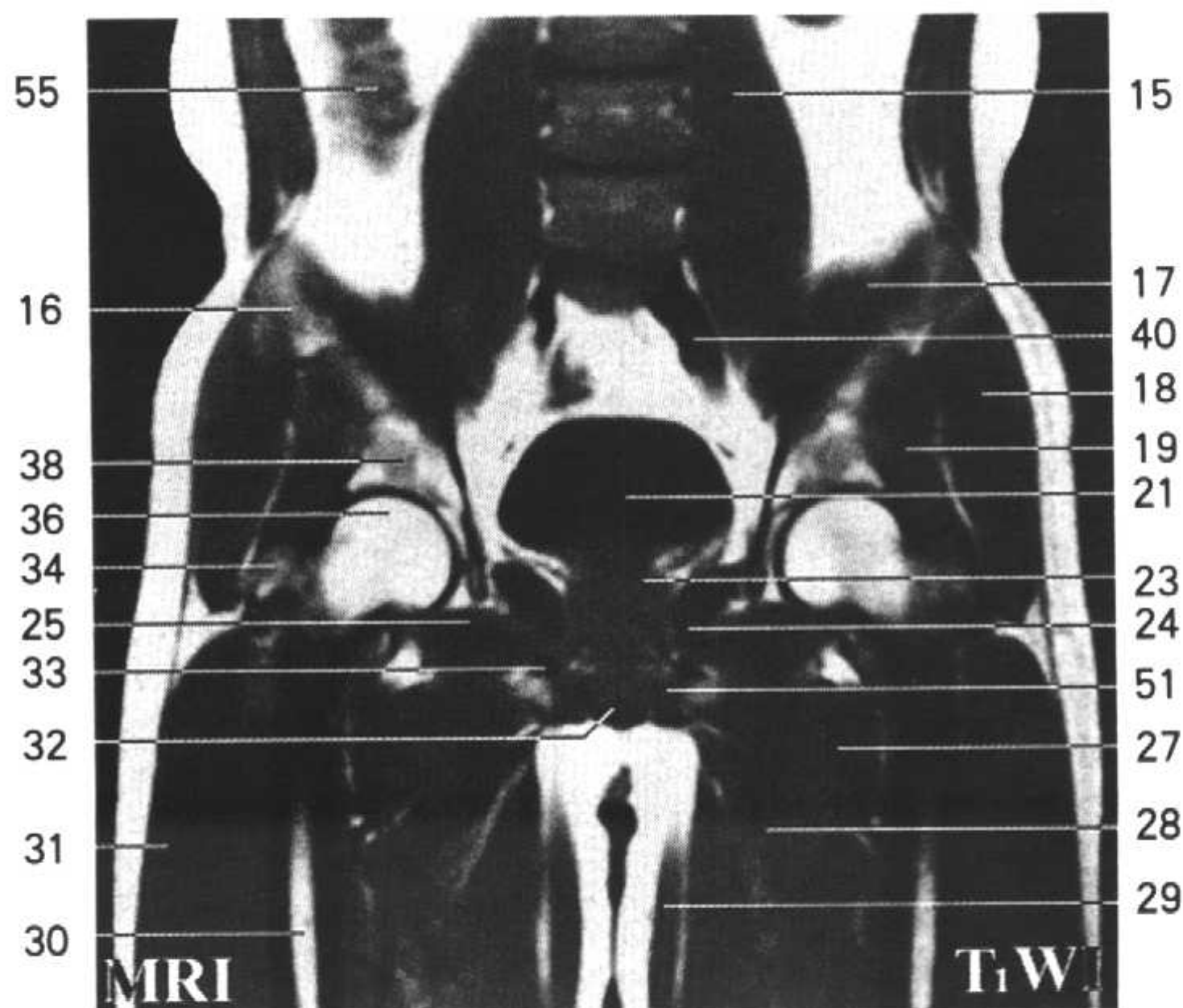
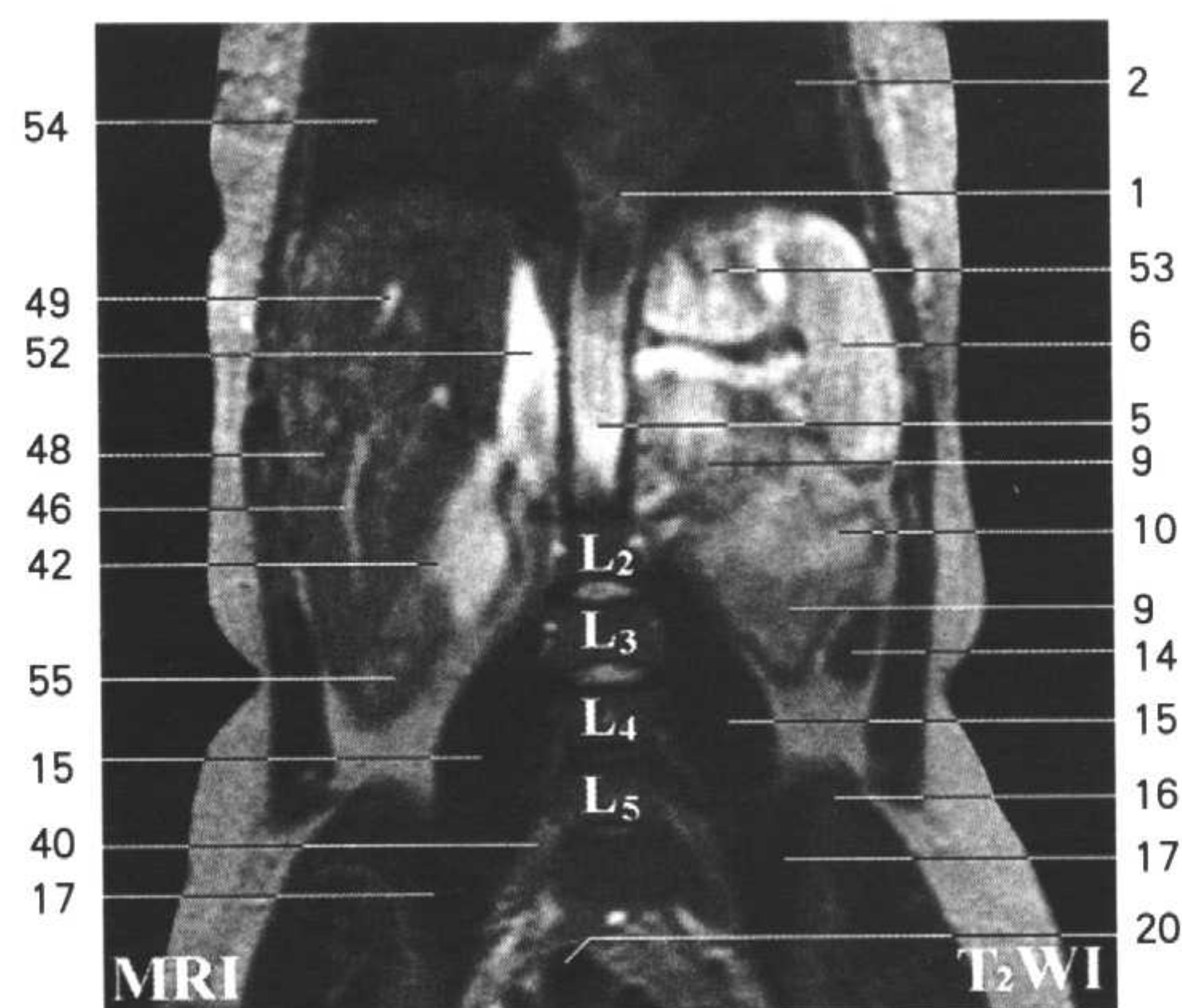
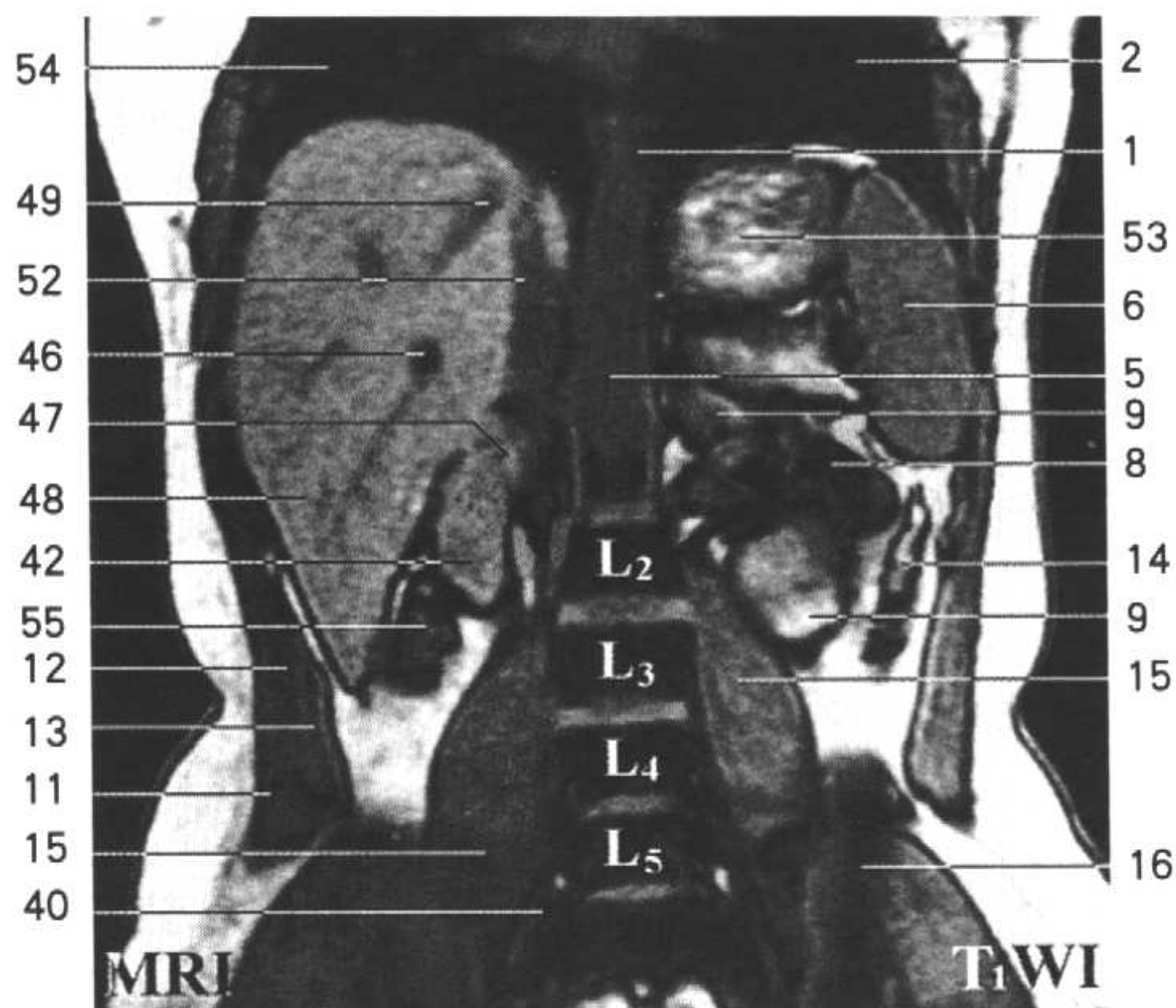


Fig.FA6

1. 胸主动脉 thoracic aorta
2. 左肺下叶 inferior lobe of left lung
3. 左肾上腺 left suprarenal gland
4. 胰 pancreas
5. 腹主动脉 abdominal aorta
6. 脾 spleen
7. 左肾动、静脉 left renal a. and v.
8. 横结肠 transverse colon
9. 空肠 jejunum
10. 结肠左曲 left colic flexure

11. 腹外斜肌 obliquus externus abdominis
12. 腹内斜肌 obliquus internus abdominis
13. 腹横肌 transversus abdominis
14. 降结肠 descending colon
15. 腰大肌 psoas major
16. 髂嵴 iliac crest
17. 髂肌 iliacus
18. 臀中肌 gluteus medius
19. 臀小肌 gluteus minimus
20. 乙状结肠 sigmoid colon
21. 膀胱 urinary bladder
22. 输尿管口 ureteric orifice
23. 前列腺 prostate gland
24. 闭孔内肌 obturator internus
25. 闭孔外肌 obturator externus
26. 髂腰肌腱 tendon of iliopsoas
27. 短收肌 adductor brevis
28. 大收肌 adductor magnus
29. 股薄肌 gracilis
30. 股骨 femur
31. 股外侧肌 vastus lateralis
32. 尿道球 bulb of urethra
33. 坐骨支 ramus of ischium
34. 大转子 greater trochanter
35. 股骨颈 neck of femur
36. 股骨头 femoral head
37. 输尿管间襞 interureteric fold
38. 髌骨体 body of ilium
39. 回肠 ileum
40. 右髂总动、静脉 right common iliac
a. and v.
41. 盲肠 cecum
42. 右肾 right kidney
43. 腰动、静脉 lumbar a. and v.
44. 十二指肠降部 descending part of duodenum
45. 肝右静脉 right hepatic v.
46. 右前叶静脉 right anterior lobar v.
47. 右肾上腺 right suprarenal gland
48. 右后叶 right posterior lobe
49. 肝右静脉 right hepatic v.
50. 膈 diaphragm
51. 阴茎脚 crus penis
52. 下腔静脉 inferior vena cava
53. 胃底 fundus of stomach
54. 右肺下叶 inferior lobe of left lung
55. 升结肠 ascending colon
56. 幽门管 pyloric canal
57. 幽门 pylorus



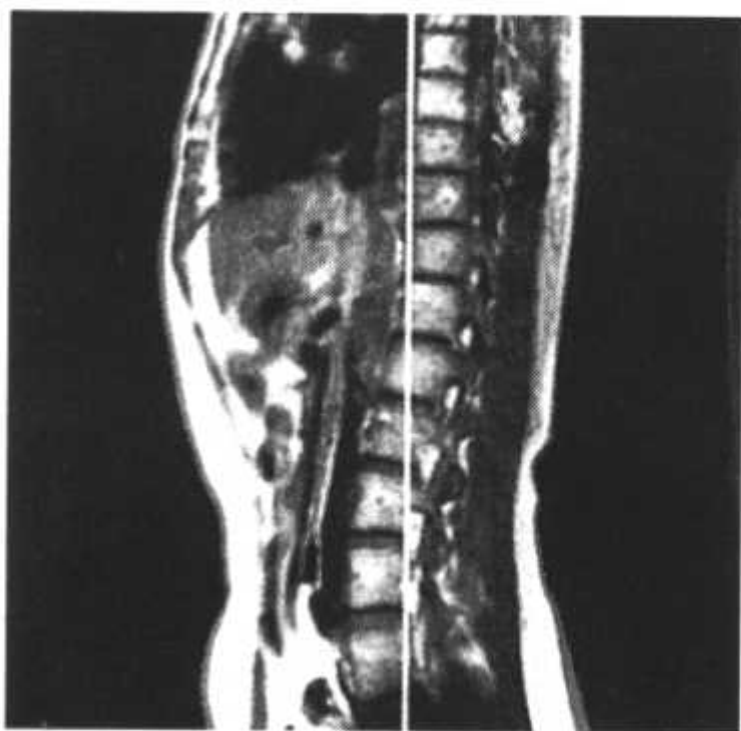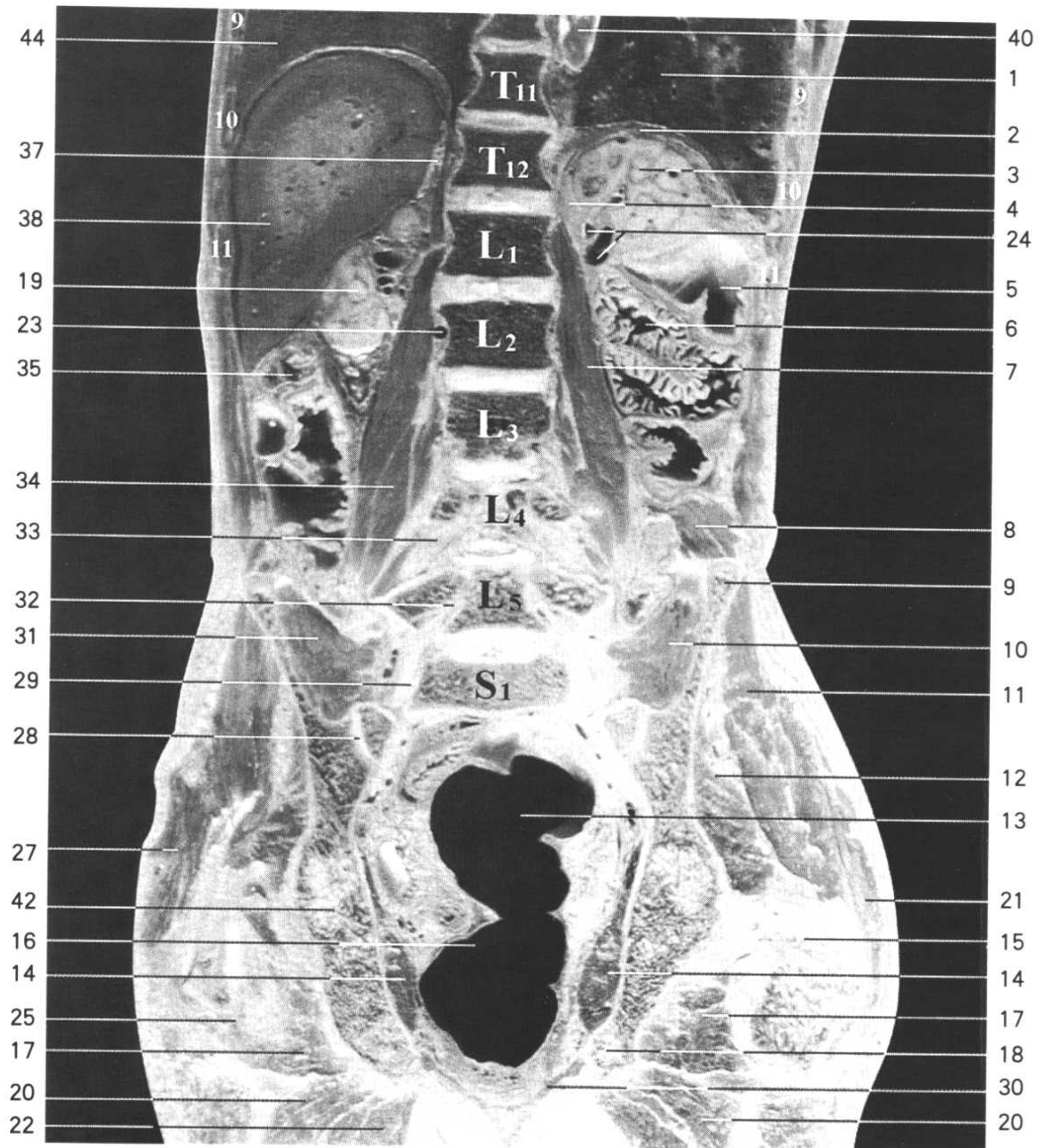
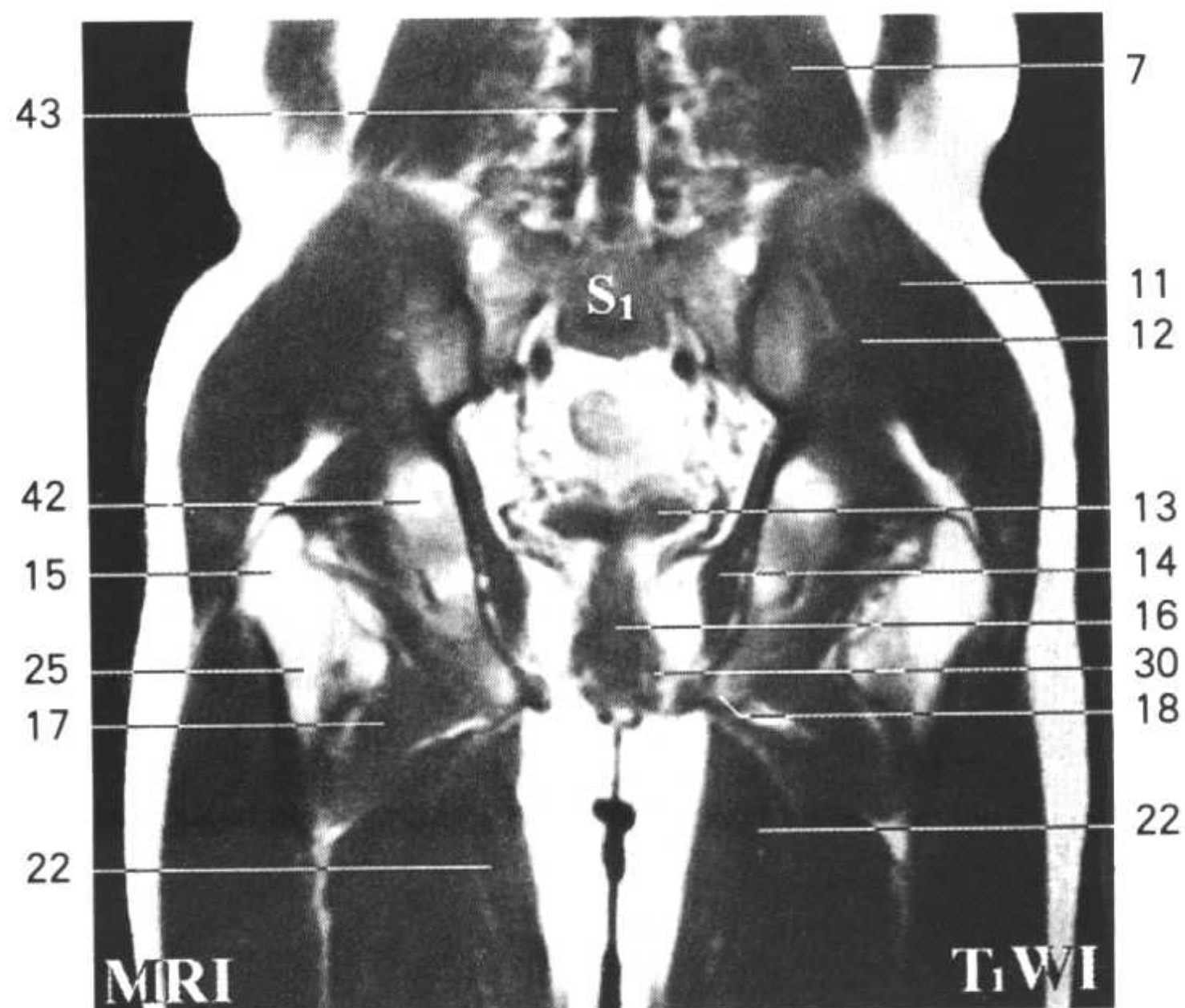
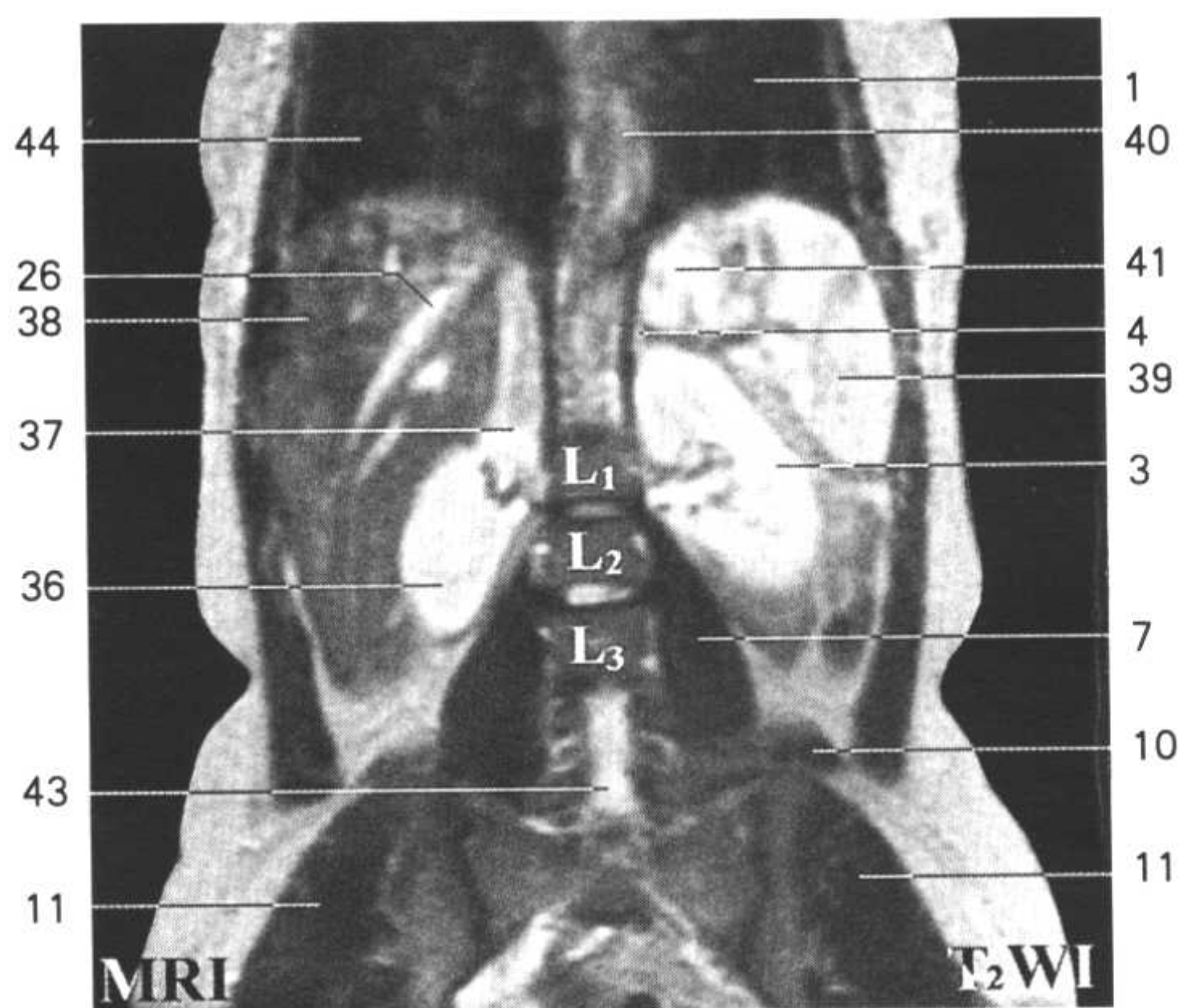
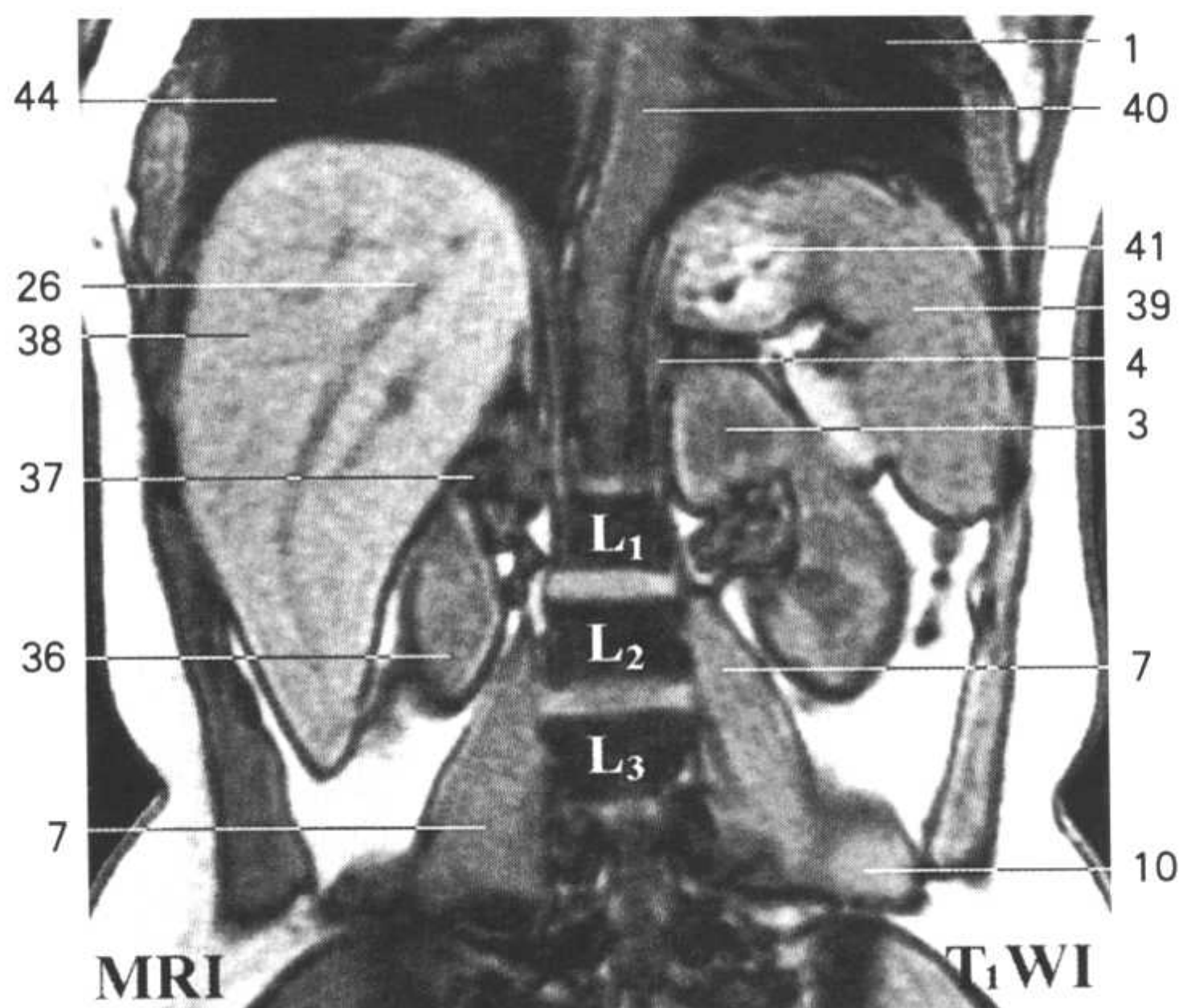


Fig.FA7

1. 左肺下叶 inferior lobe of left lung
2. 膈 diaphragm
3. 左肾 left kidney
4. 左肾上腺 left suprarenal gland
5. 横结肠 transverse colon
6. 空肠 jejunum
7. 腰大肌 psoas major
8. 腰方肌 quadratus lumborum
9. 髂嵴 iliac crest
10. 髂肌 iliacus

11. 臀中肌 gluteus medius
12. 臀小肌 gluteus minimus
13. 乙状结肠 sigmoid colon
14. 闭孔内肌 obturator internus
15. 大转子 greater trochanter
16. 直肠 rectum
17. 股方肌 quadratus femoris
18. 坐骨结节 ischial tuberosity
19. 右肾 right kidney
20. 半腱肌 semitendinosus
21. 臀大肌 gluteus maximus
22. 大收肌 adductor magnus
23. 腰动脉 lumbar a.
24. 左肾动、静脉 left renal a. and v.
25. 股骨 femur
26. 肝右静脉 right hepatic v.
27. 臀大肌 gluteus maximus
28. 骶髂关节 sacroiliac joint
29. 第1骶神经 1st sacral n.
30. 肛提肌 levator ani
31. 髂肌 iliacus
32. 第5腰神经 5th lumbar n.
33. 第4腰神经 4th lumbar n.
34. 腰大肌 psoas major
35. 横结肠 transverse colon
36. 右肾 right kidney
37. 右肾上腺 right suprarenal gland
38. 右后叶 right posterior lobe
39. 脾 spleen
40. 胸主动脉 thoracic aorta
41. 胃底 fundus of stomach
42. 坐骨 ischium
43. 脊髓 spinal cord
44. 右肺下叶 inferior lobe of right lung



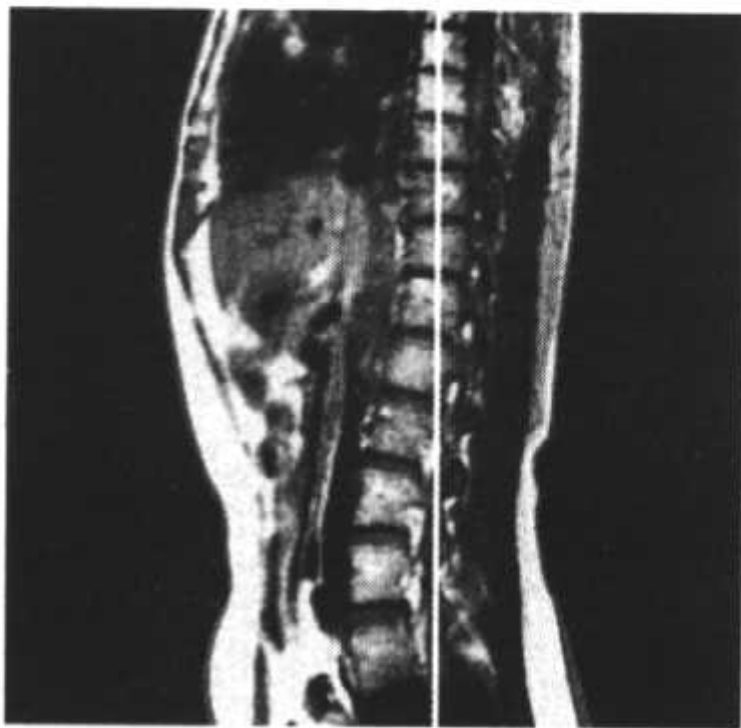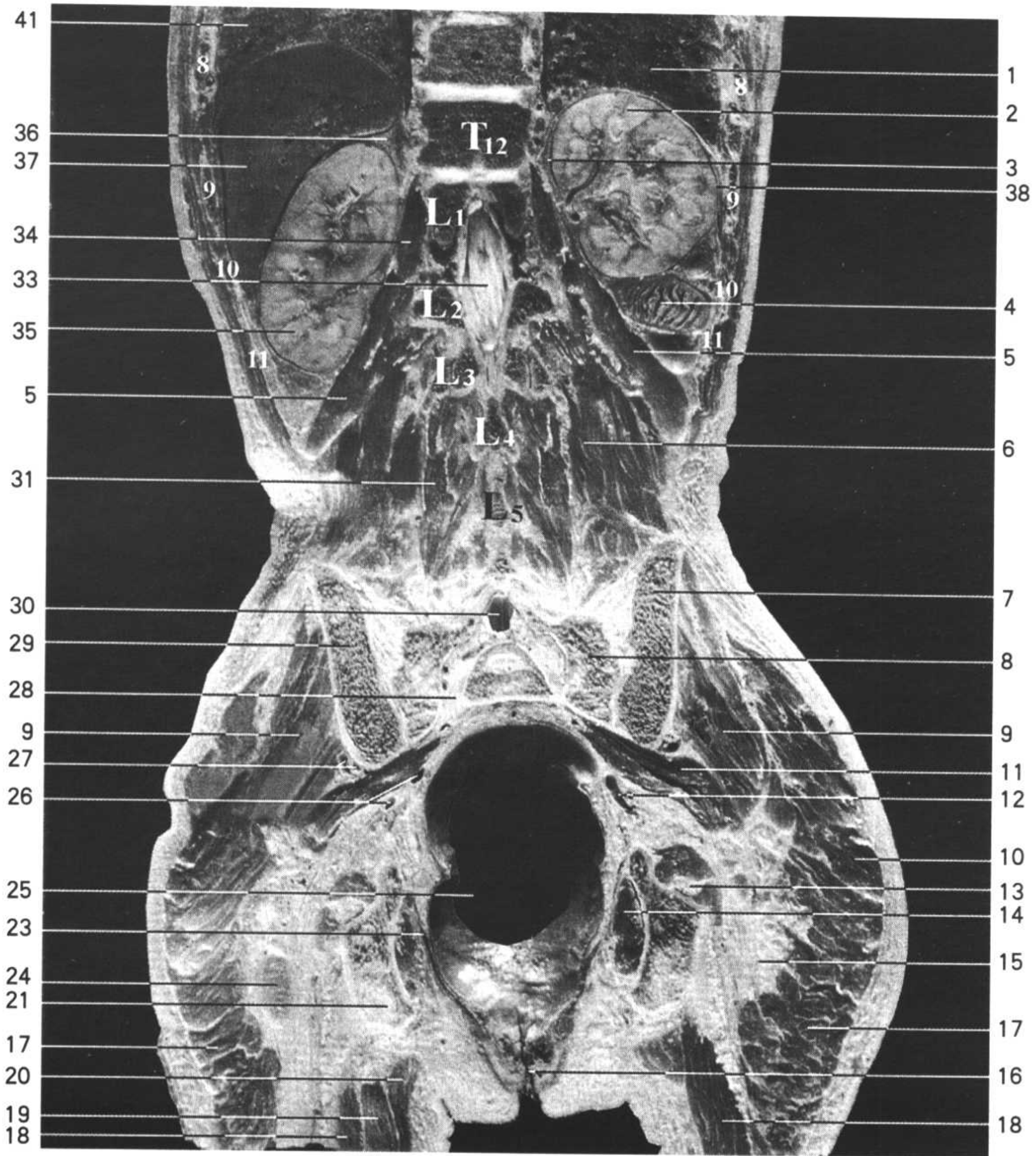
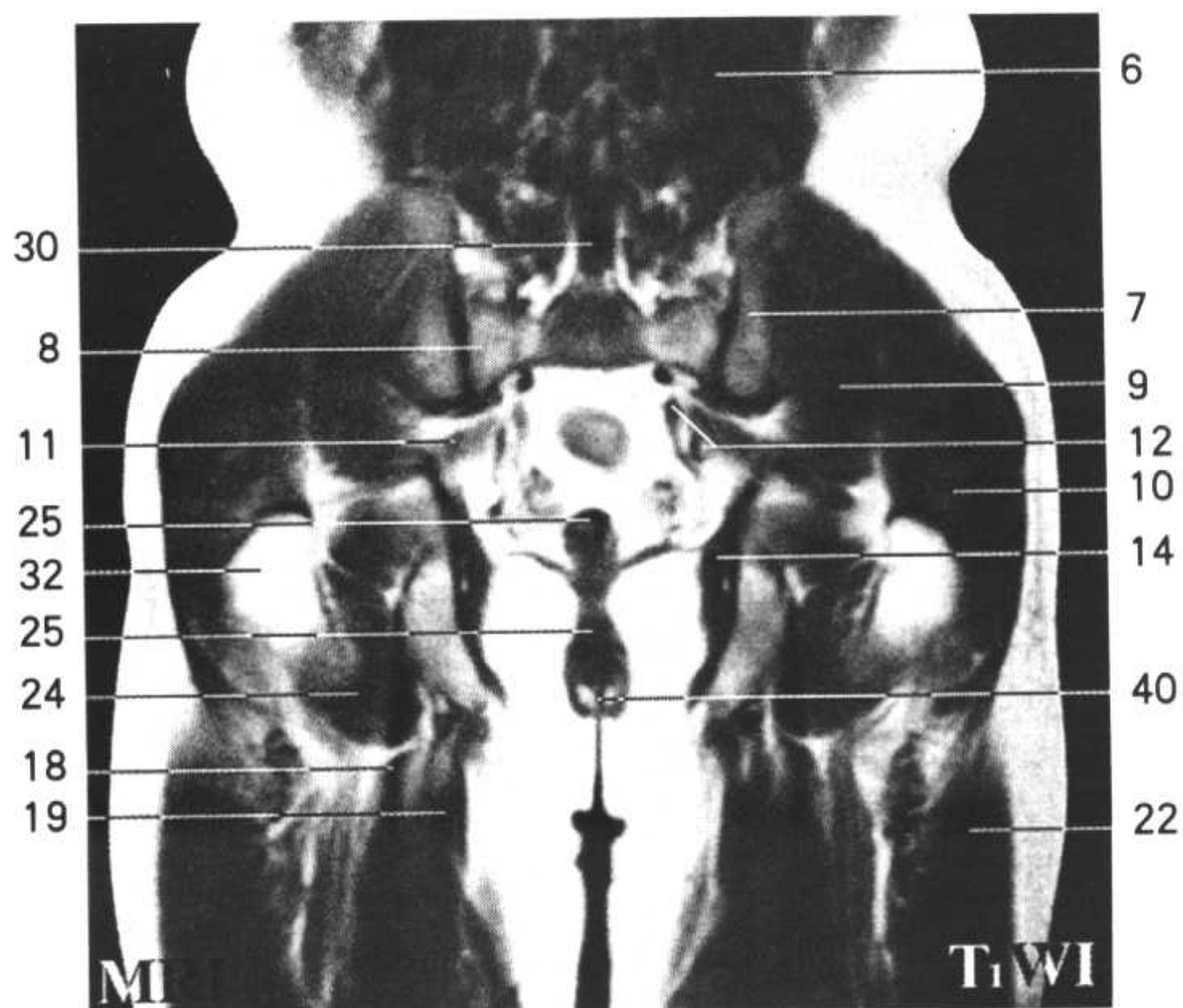
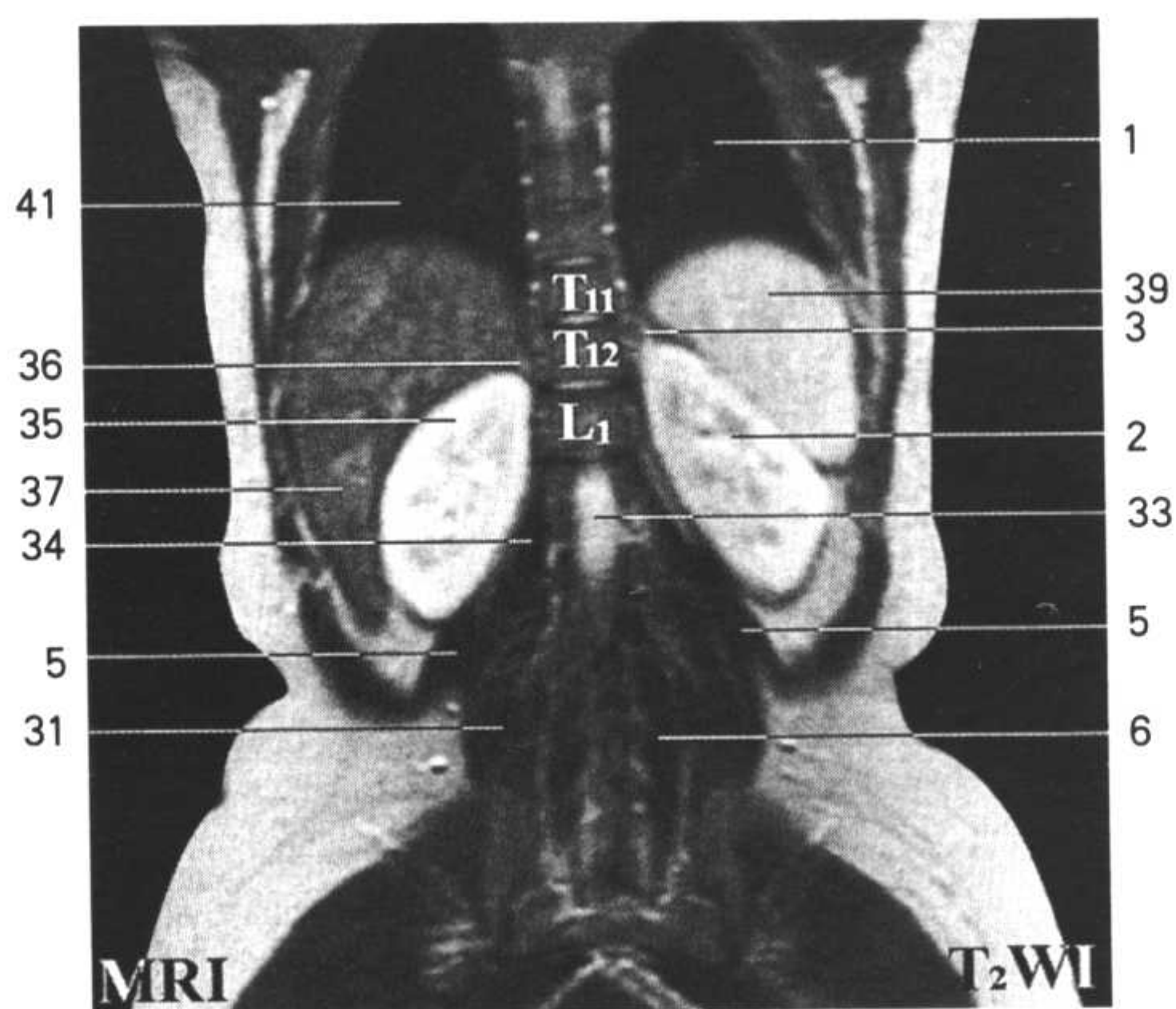
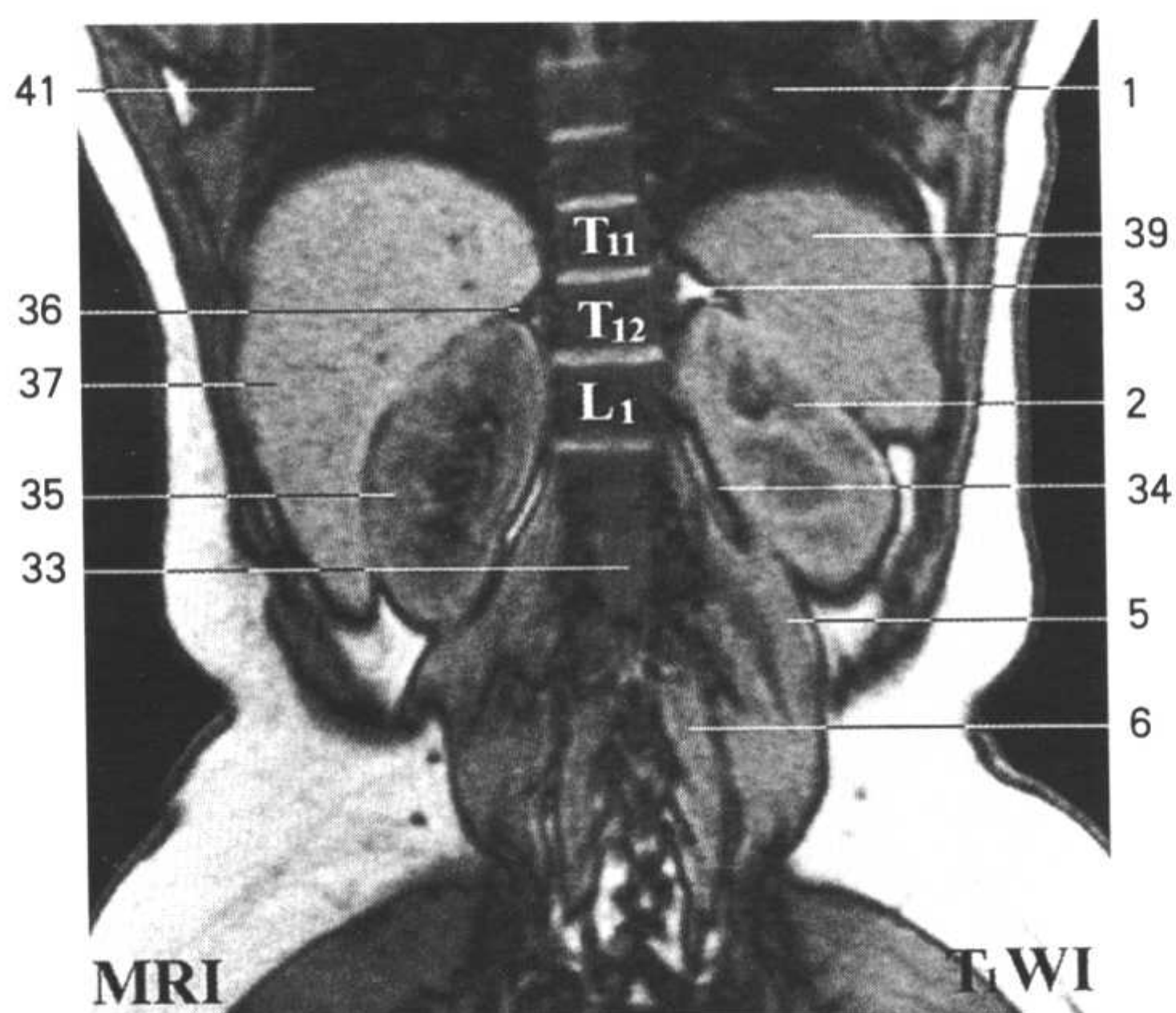
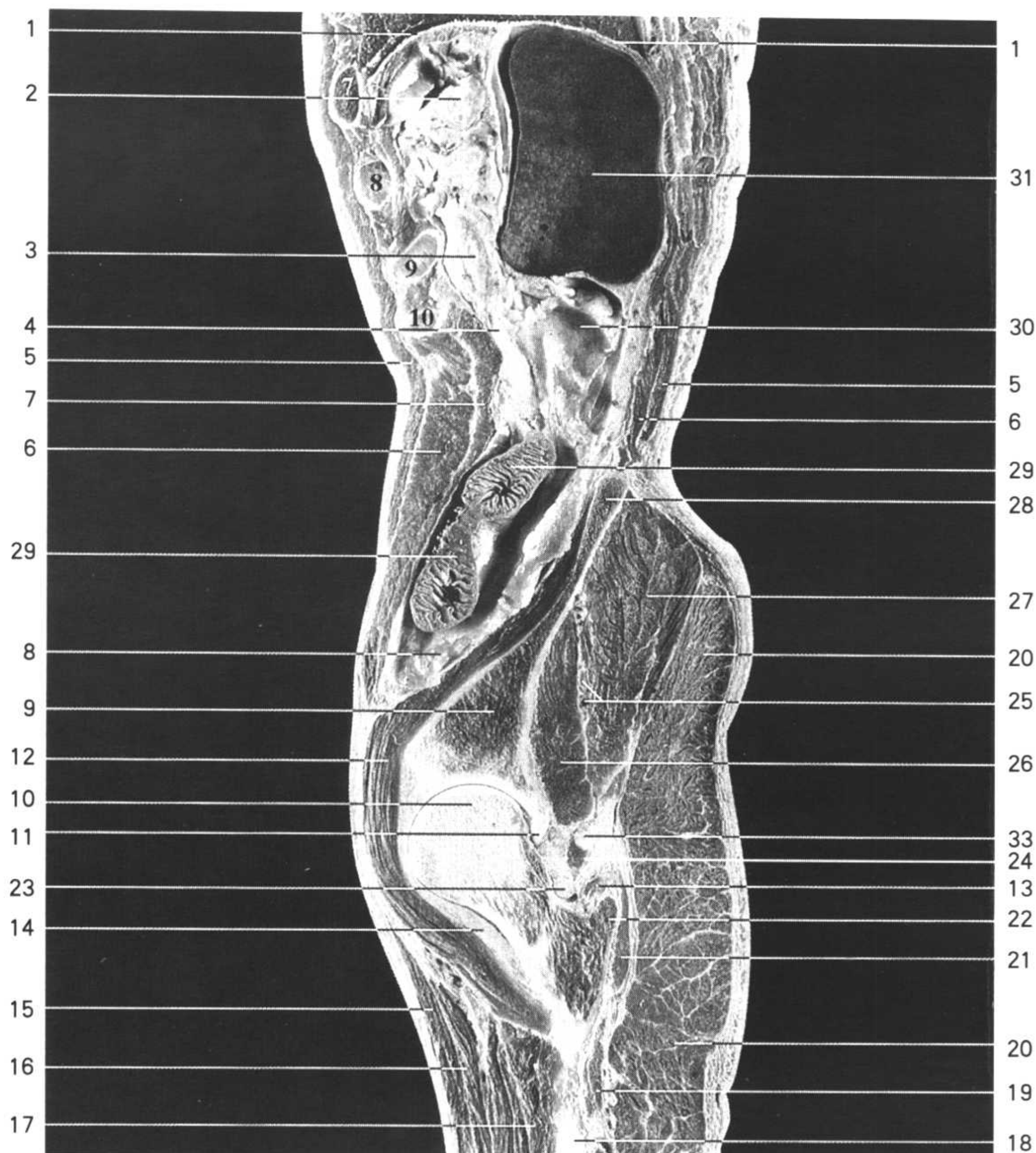


Fig.FA8

1. 左肺下叶 inferior lobe of left lung
2. 左肾 left kidney
3. 左肾上腺 left suprarenal gland
4. 空肠 jejunum
5. 腰方肌 quadratus lumborum
6. 竖脊肌 erector spinae
7. 髂骨翼 ala of ilium
8. 骶翼 ala of sacrum
9. 臀中肌 gluteus medius
10. 臀大肌 gluteus maximus
11. 梨状肌 piriformis

12. 臀下动、静脉 inferior gluteal a. and v.
13. 闭孔内肌腱 tendon of obturator internus
14. 闭孔内肌 obturator internus
15. 坐骨神经 sciatic n.
16. 肛门 anus
17. 臀大肌 gluteus maximus
18. 股二头肌长头 long head of biceps femoris
19. 半腱肌 semitendinosus
20. 大收肌 adductor magnus
21. 坐骨 ischium
22. 股外侧肌 vastus lateralis
23. 肛提肌 levator ani
24. 股方肌 quadratus femoris
25. 直肠 rectum
26. 臀下动、静脉 inferior gluteal a. and v.
27. 臀上动、静脉 superior gluteal a. and v.
28. 骶前孔 anterior sacral foramen
29. 髂骨翼 ala of ilium
30. 骶管 sacral canal
31. 竖脊肌 erector spinae
32. 大转子 greater trochanter
33. 脊髓 spinal cord
34. 腰大肌 psoas major
35. 右肾 right kidney
36. 右肾上腺 right suprarenal gland
37. 右后叶 right posterior lobe
38. 膈 diaphragm
39. 脾 spleen
40. 肛门外括肌 sphincter ani externus
41. 右肺下叶 inferior lobe of right lung

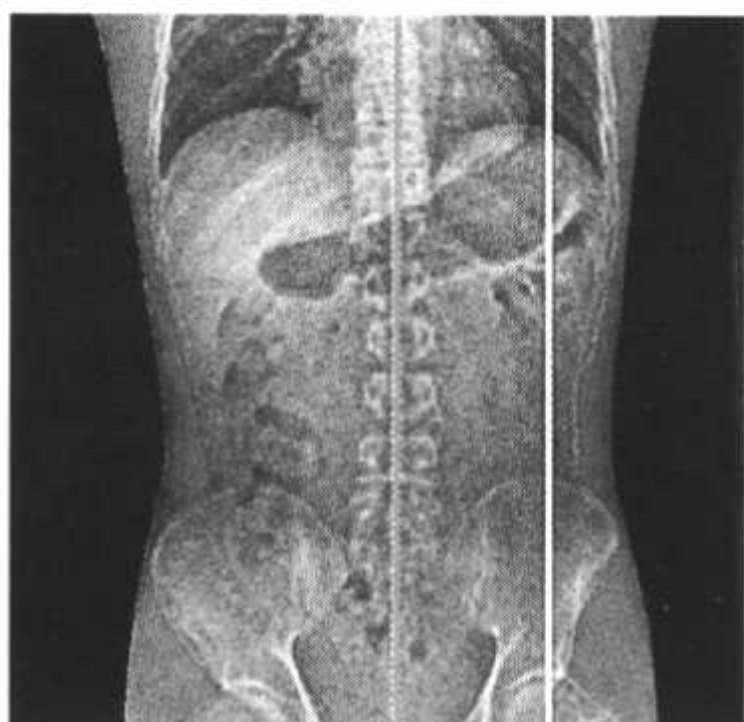




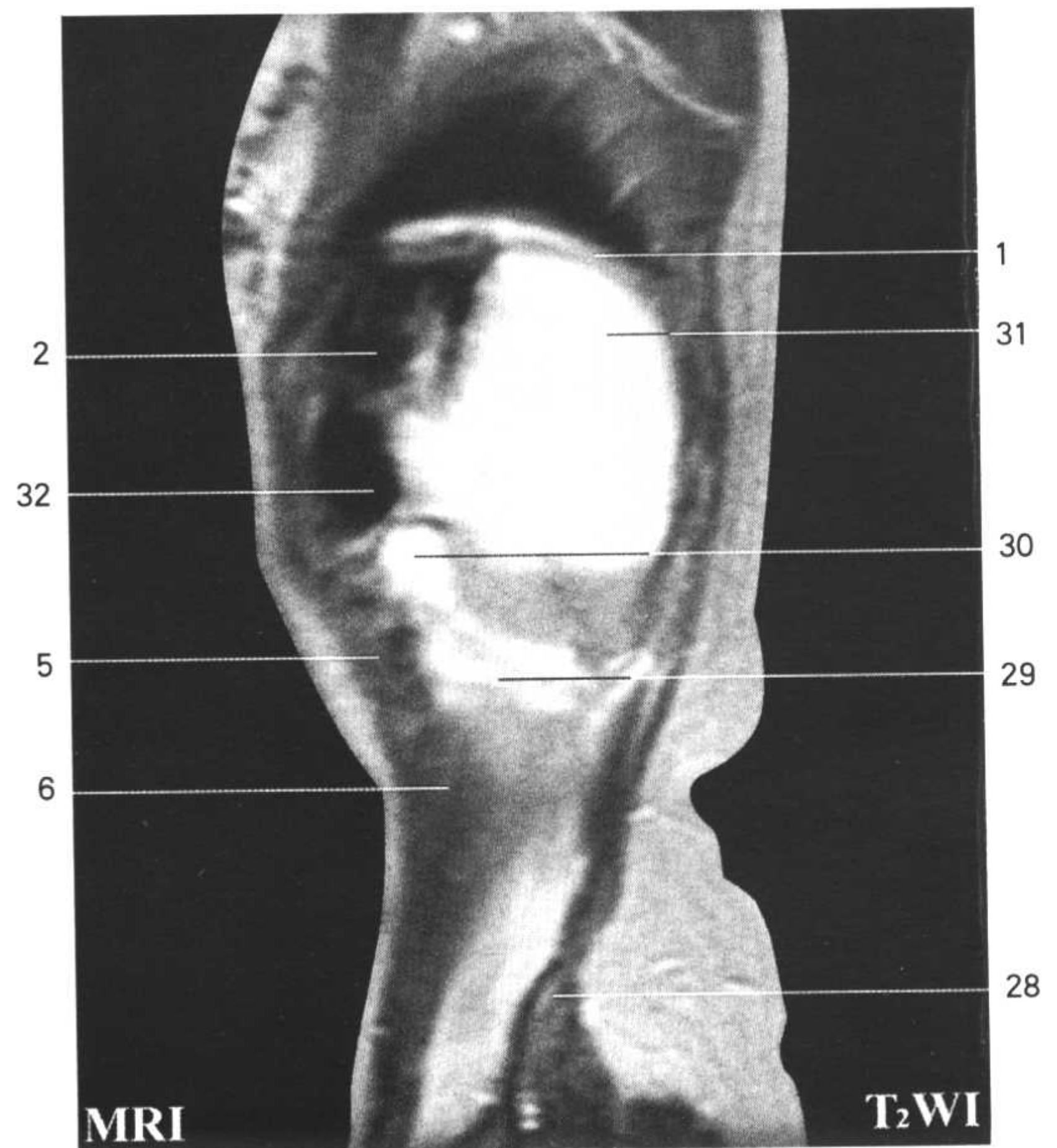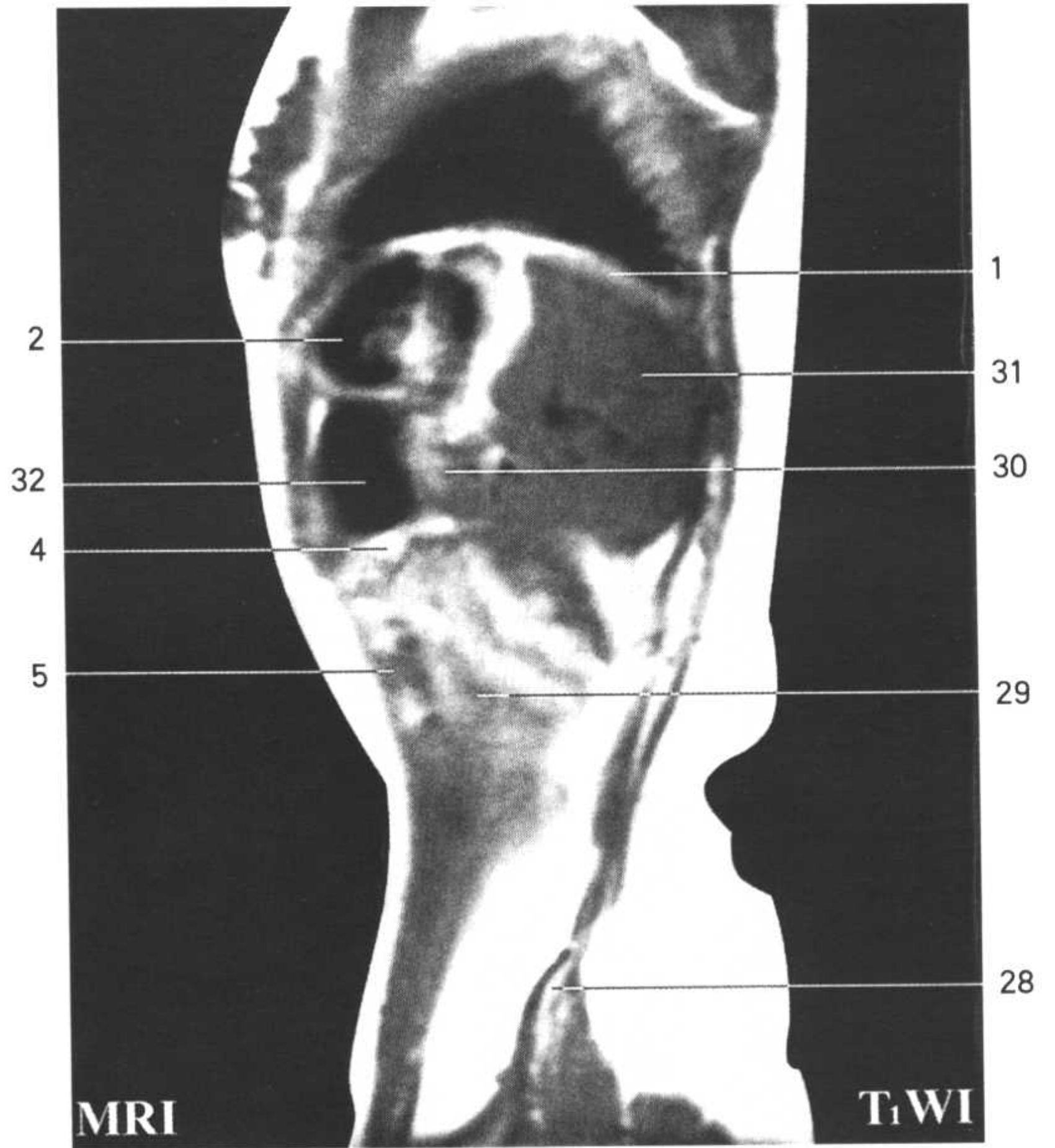
矢状断面 SA

Fig.SA1

1. 膈 diaphragm
2. 胃底 fundus of stomach
3. 横结肠 transverse colon
4. 大网膜 greater omentum
5. 腹外斜肌 obliquus externus abdominis
6. 腹内斜肌 obliquus internus abdominis
7. 腹横肌 transversus abdominis
8. 乙状结肠 sigmoid colon
9. 髌骨体 body of ilium
10. 股骨头 femoral head



11. 髋臼唇 acetabular labrum
12. 髂腰肌 iliopsoas
13. 闭孔外肌腱 tendon of obturator externus
14. 关节囊 articular capsule
15. 缝匠肌 sartorius
16. 股直肌 rectus femoris
17. 股中间肌 vastus intermedius
18. 股骨 femur
19. 半腱肌 semitendinosus
20. 臀大肌 gluteus maximus
21. 股方肌 quadratus femoris
22. 大转子 greater trochanter
23. 闭孔内肌腱 tendon of obturator internus
24. 梨状肌 piriformis
25. 臀上动、静脉 superior gluteal a. and v.
26. 臀小肌 gluteus minimus
27. 臀中肌 gluteus medius
28. 髂嵴 iliac crest
29. 空肠 jejunum
30. 结肠左曲 left colic flexure
31. 脾 spleen
32. 胃体 body of stomach
33. 梨状肌腱 tendon of piriformis



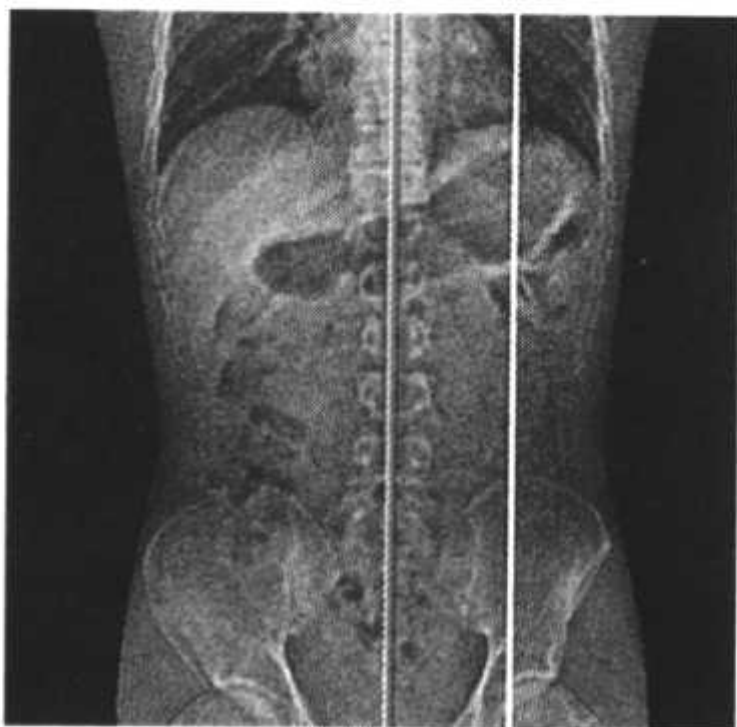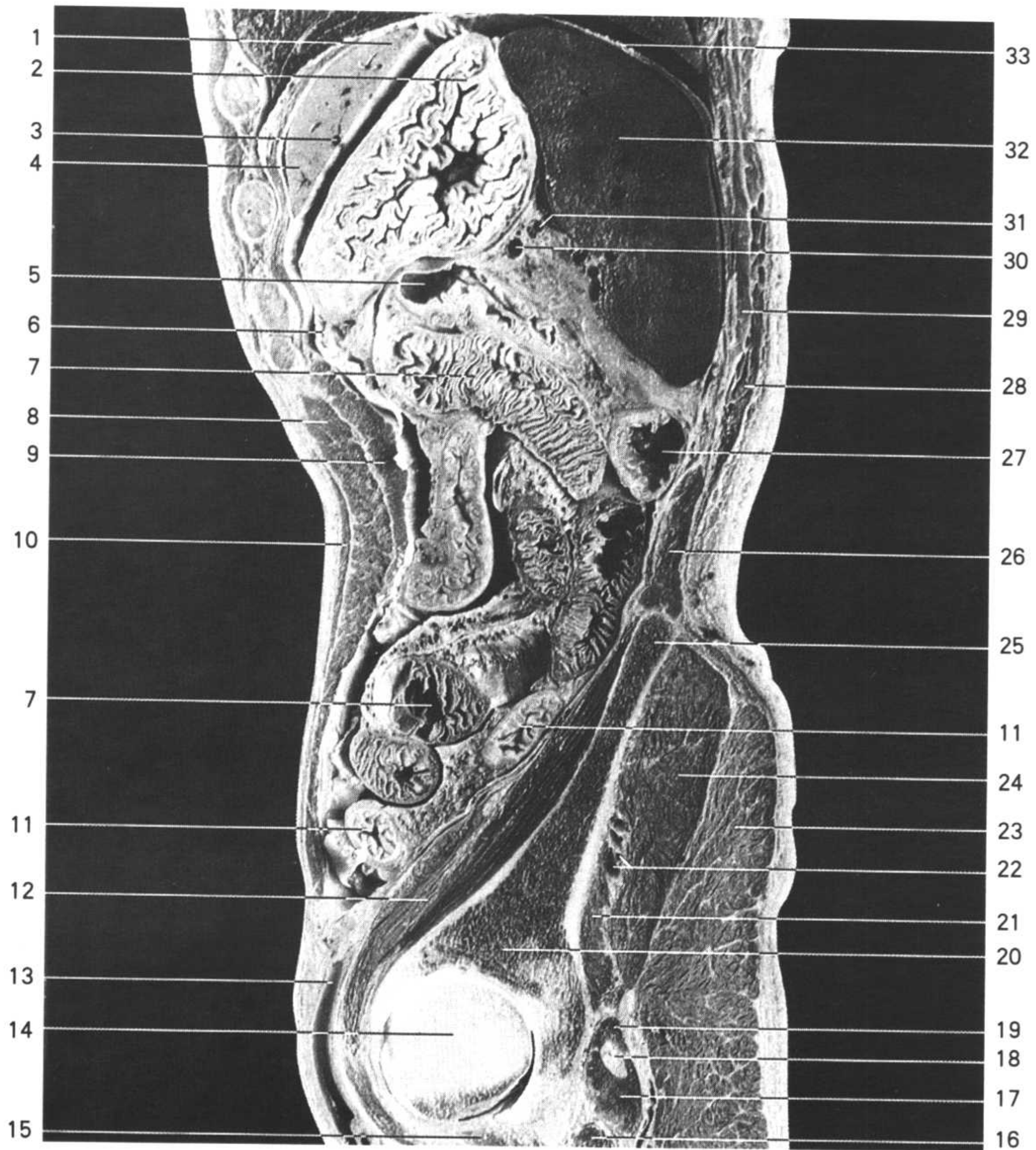
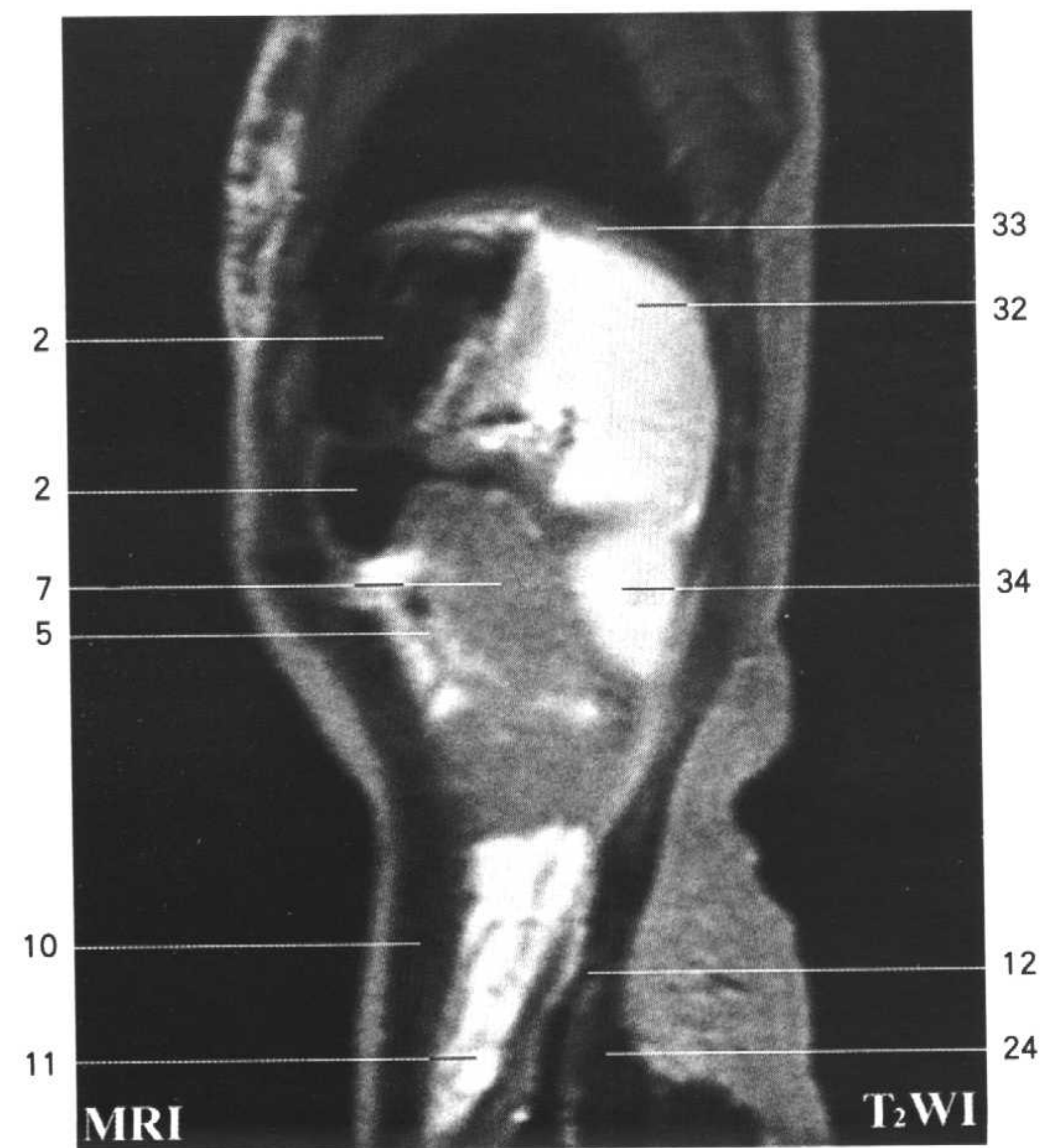
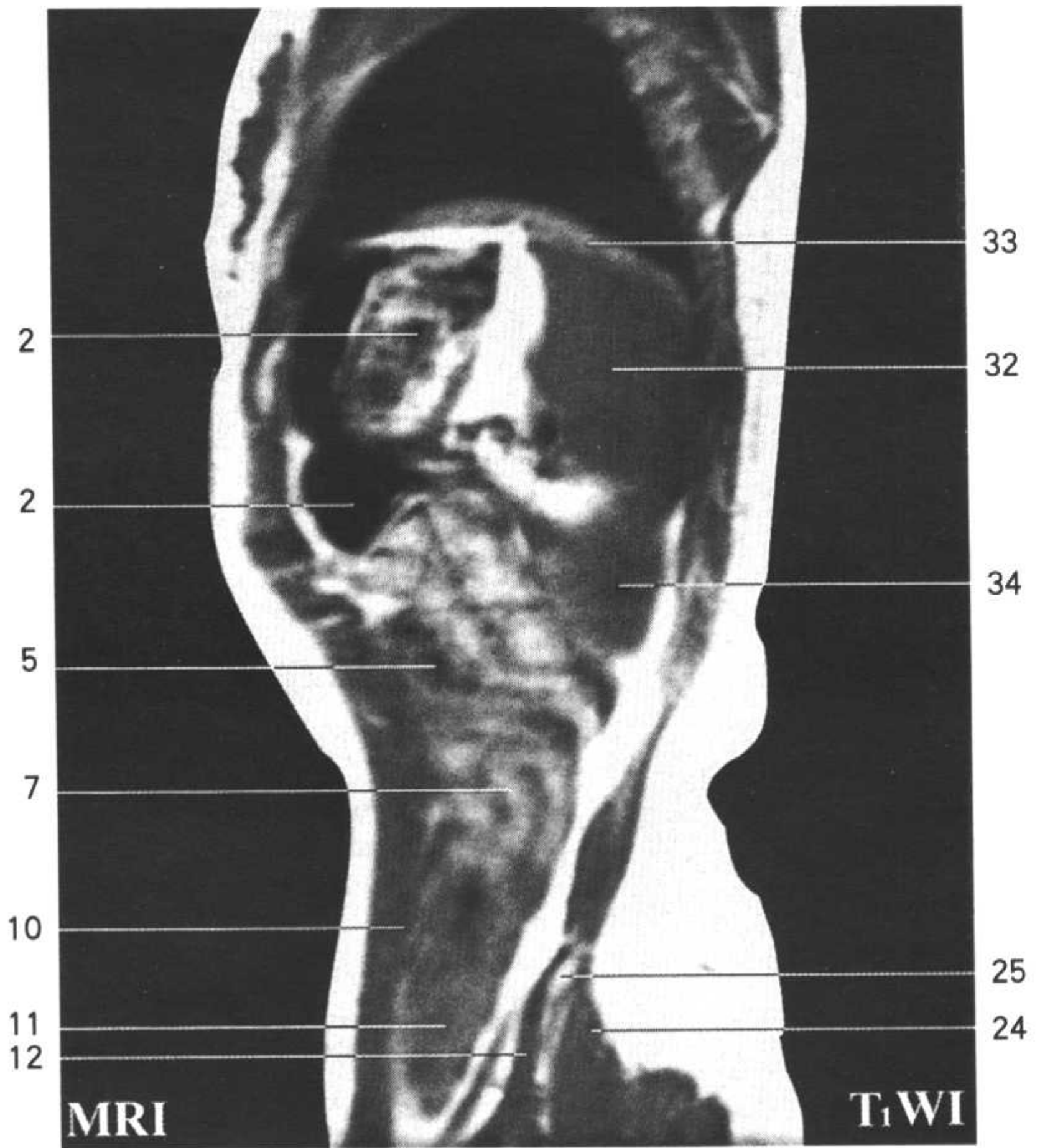


Fig.SA2

1. 左外叶上段 superior segment of left lateral lobe
2. 胃 stomach
3. 肝左静脉 left hepatic v.
4. 左外叶下段 inferior segment of left lateral lobe
5. 横结肠 transverse colon
6. 大网膜 greater omentum
7. 空肠 jejunum
8. 腹内斜肌 obliquus internus abdominis
9. 腹横肌 transversus abdominis

- 10. 腹外斜肌 obliquus externus abdominis
- 11. 乙状结肠 sigmoid colon
- 12. 髂肌 iliacus
- 13. 股动脉 femoral a.
- 14. 股骨头 femoral head
- 15. 闭孔外肌 obturator externus
- 16. 股方肌 quadratus femoris
- 17. 下孖肌 gemellus inferior
- 18. 梨状肌腱 tendon of piriformis
- 19. 上孖肌 gemellus superior
- 20. 髂骨体 body of ilium
- 21. 臀小肌 gluteus minimus
- 22. 臀上动、静脉 superior gluteal a. and v.
- 23. 臀大肌 gluteus maximus
- 24. 臀中肌 gluteus medius
- 25. 髂嵴 iliac crest
- 26. 腰方肌 quadratus lumborum
- 27. 结肠左曲 left colic flexure
- 28. 腹外斜肌 obliquus externus abdominis
- 29. 腹内斜肌 obliquus internus abdominis
- 30. 脾静脉 splenic v.
- 31. 脾动脉 splenic a.
- 32. 脾 spleen
- 33. 膈 diaphragm
- 34. 左肾 left kidney



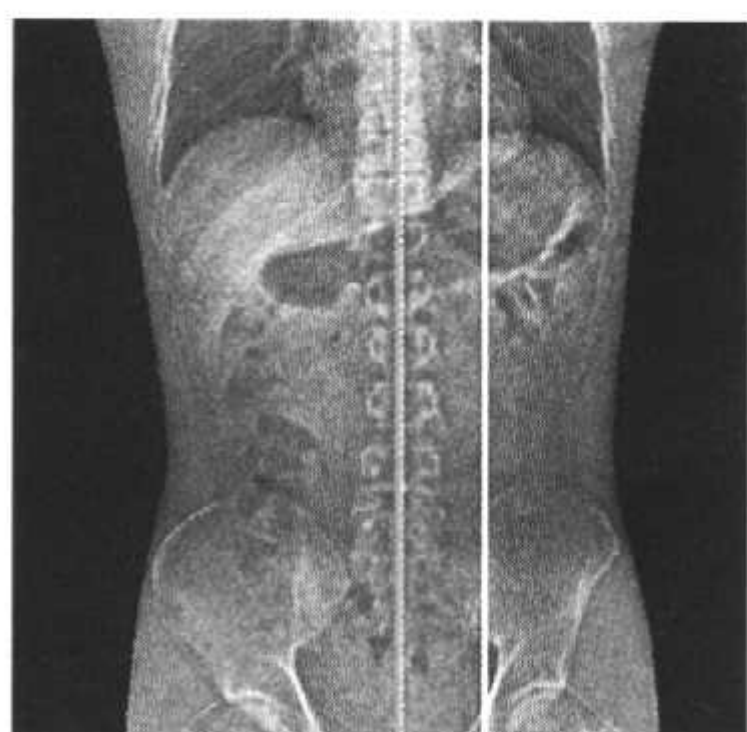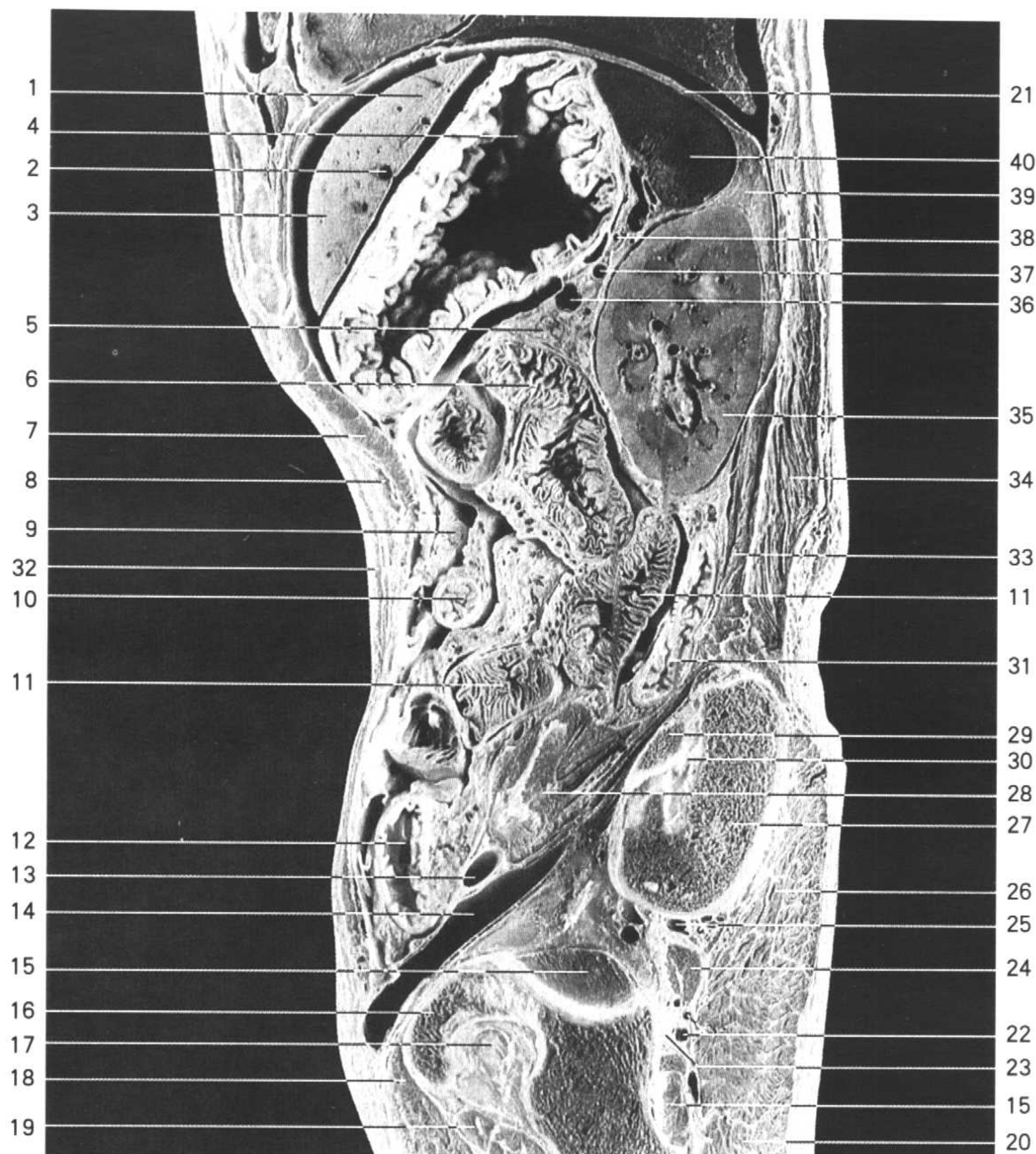
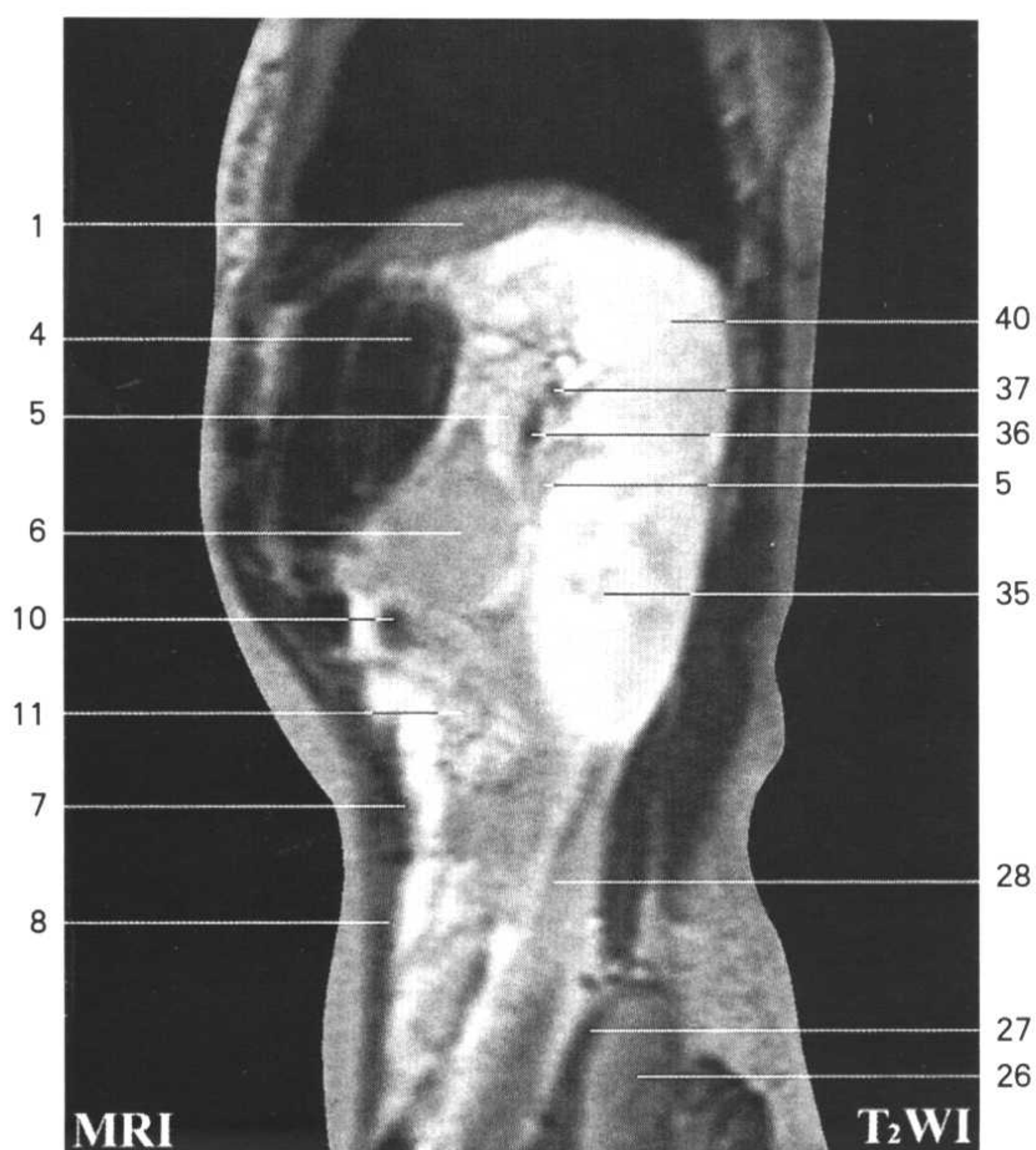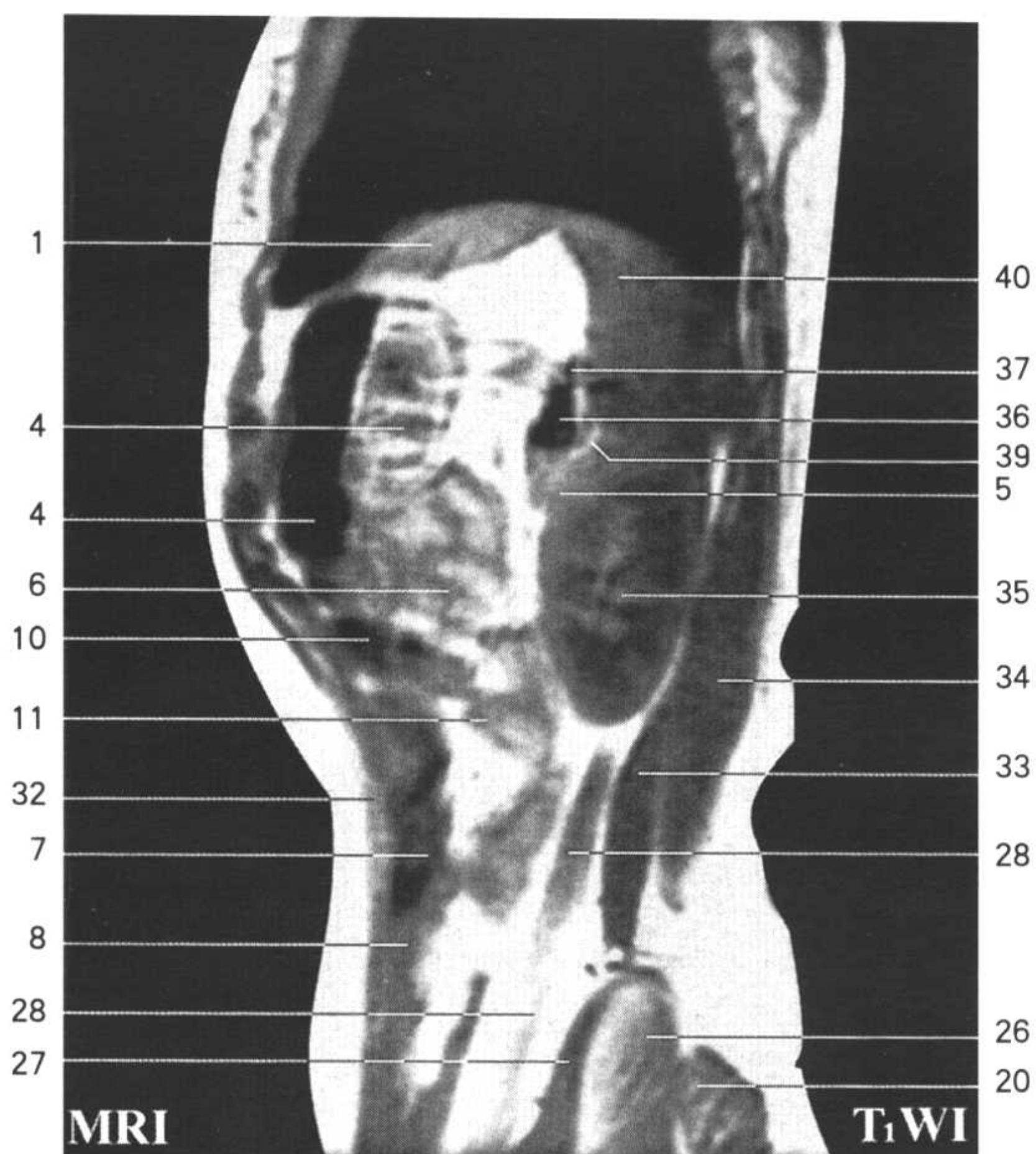


Fig.SA3

1. 左外叶上段 superior segment of left lateral lobe
2. 肝左静脉 left hepatic v.
3. 左外叶下段 inferior segment of left lateral lobe
4. 胃体 body of stomach
5. 胰 pancreas
6. 空肠 jejunum
7. 腹横肌 transversus abdominis
8. 腹内斜肌 obliquus internus abdominis
9. 大网膜 greater omentum

10. 横结肠 transverse colon
11. 空肠 jejunum
12. 乙状结肠 sigmoid colon
13. 左髂外动脉 left external iliac a.
14. 左髂外静脉 left external iliac v.
15. 闭孔内肌 obturator internus
16. 耻骨体 body of pubis
17. 股骨头 femoral head
18. 耻骨肌 pectineus
19. 闭孔外肌 obturator externus
20. 臀大肌 gluteus maximus
21. 膈 diaphragm
22. 臀下动、静脉 inferior gluteal a. and v.
23. 坐骨神经 sciatic n.
24. 梨状肌 piriformis
25. 臀上动、静脉 superior gluteal a. and v.
26. 臀中肌 gluteus medius
27. 髌骨 ilium
28. 腰大肌 psoas major
29. 骶骨 sacrum
30. 骶髂关节 sacroiliac joint
31. 降结肠 descending colon
32. 腹外斜肌 obliquus externus abdominis
33. 腰方肌 quadratus lumborum
34. 竖脊肌 erector spinae
35. 左肾 left kidney
36. 脾静脉 splenic v.
37. 脾动脉 splenic a.
38. 胃短动脉 short gastric a.
39. 左肾上腺 left suprarenal gland
40. 脾 spleen



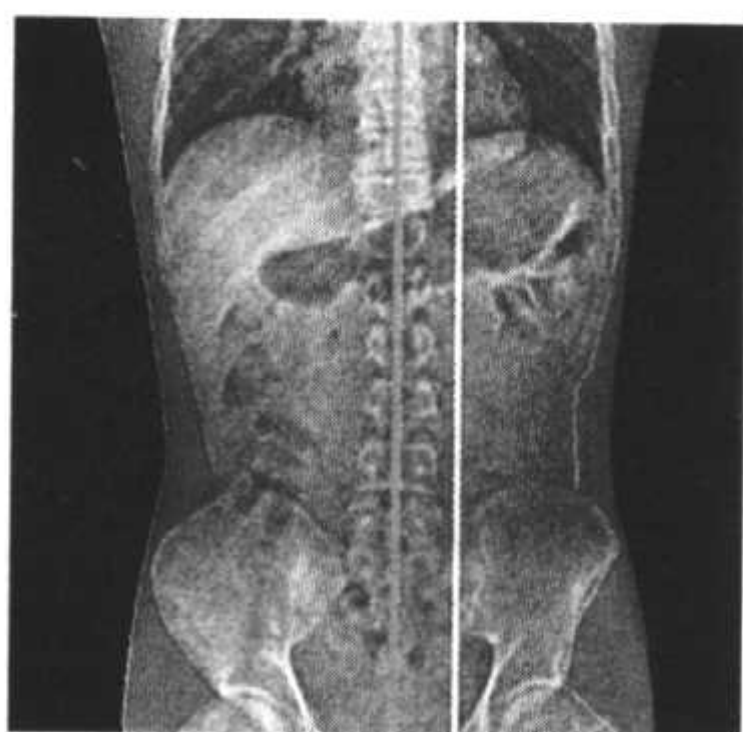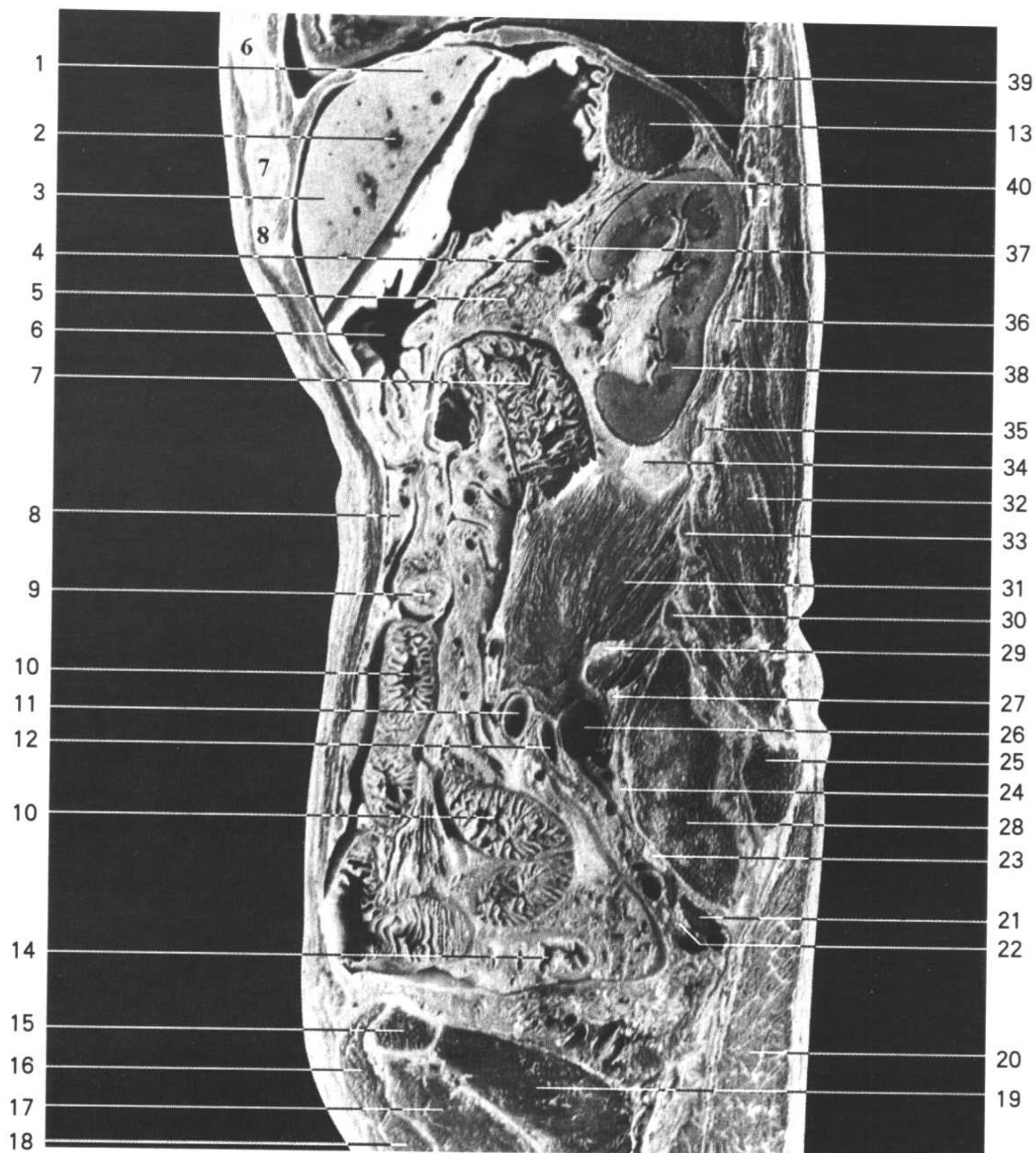
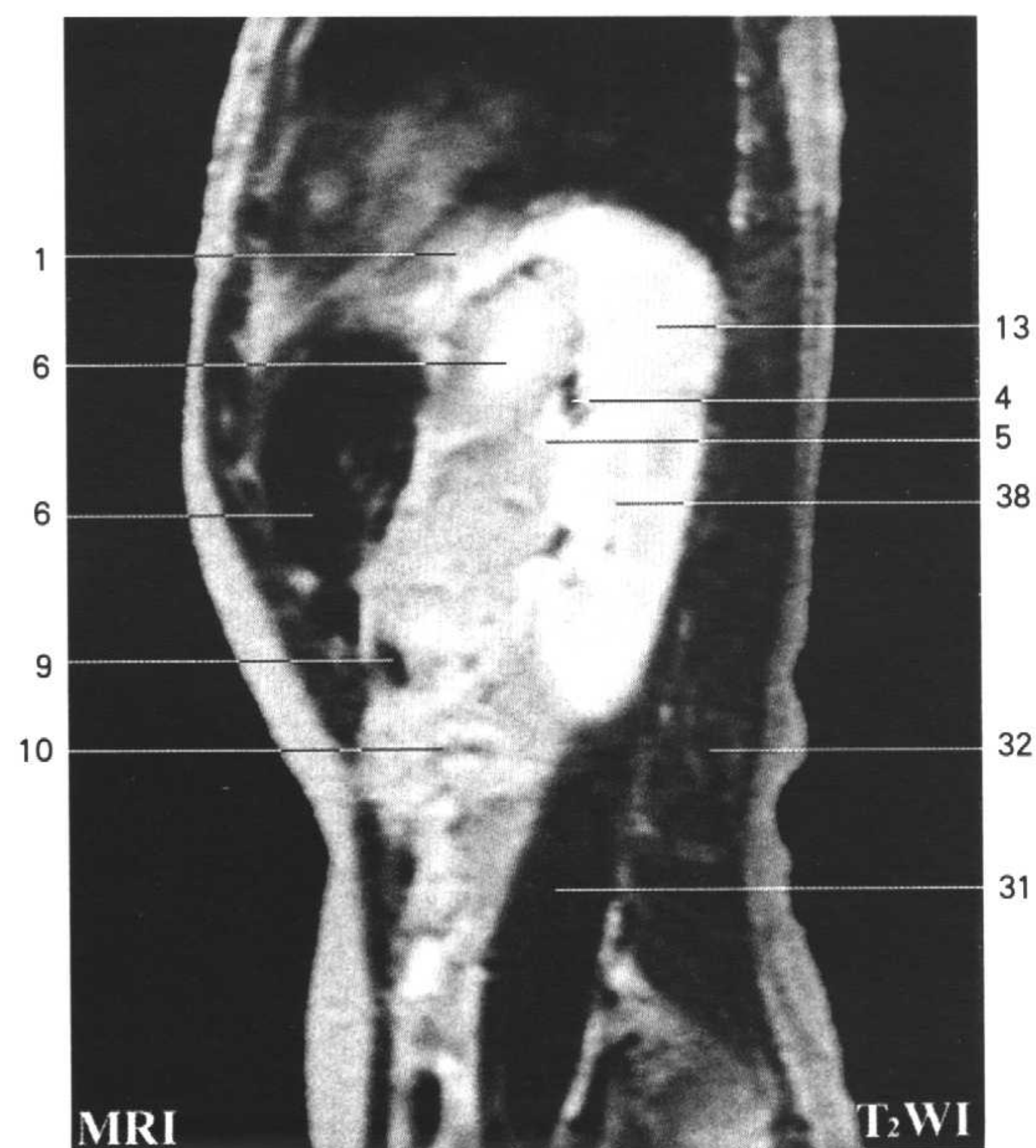
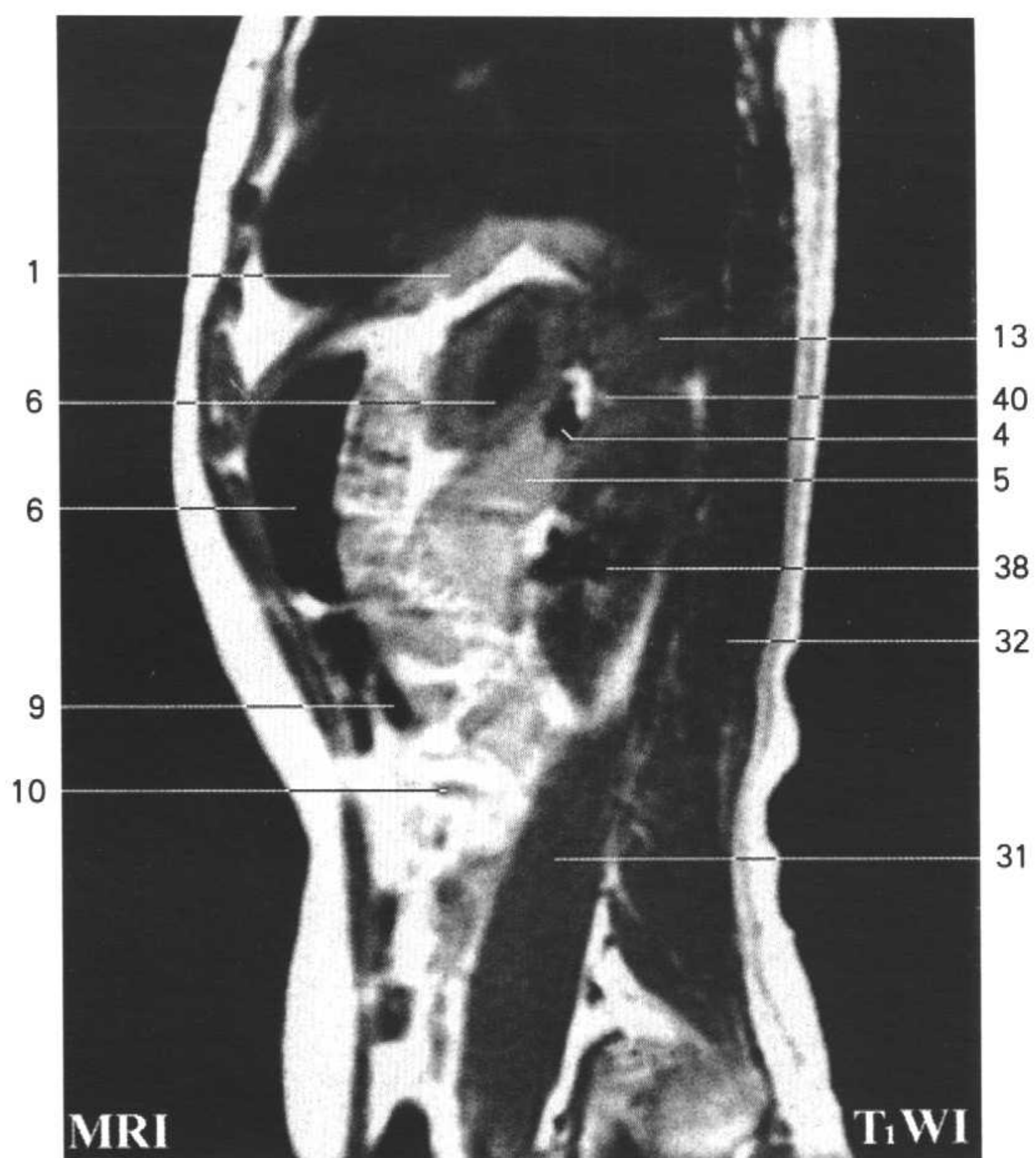


Fig.SA4

1. 左外叶上段 superior segment of left lateral lobe
2. 肝左静脉 left hepatic v.
3. 左外叶下段 inferior segment of left lateral lobe
4. 脾静脉 splenic v.
5. 胰 pancreas
6. 胃体 body of stomach
7. 空肠 jejunum
8. 大网膜 greater omentum
9. 横结肠 transverse colon
10. 空肠 jejunum

11. 左髂外动脉 left external iliac a.
12. 左髂内动脉 left internal iliac a.
13. 脾 spleen
14. 乙状结肠 sigmoid colon
15. 耻骨上支 superior ramus of pubis
16. 耻骨肌 pectineus
17. 闭孔外肌 obturator externus
18. 长收肌 adductor longus
19. 闭孔内肌 obturator internus
20. 臀大肌 gluteus maximus
21. 梨状肌 piriformis
22. 第2骶神经 2nd sacral n.
23. 第1骶神经 1st sacral n.
24. 腰骶干 lumbosacral trunk
25. 髌骨 ilium
26. 左髂总静脉 left common iliac v.
27. 闭孔神经 obturator n.
28. 骶骨 sacrum
29. 股神经 femoral n.
30. 第4腰椎横突 transverse process (L₄)
31. 腰大肌 psoas major
32. 竖脊肌 erector spinae
33. 第3腰椎横突 transverse process (L₃)
34. 脂肪囊 fatty renal capsule
35. 第2腰椎横突 transverse process (L₂)
36. 第1腰椎横突 transverse process (L₁)
37. 脾动脉 splenic a.
38. 左肾 left kidney
39. 膈 diaphragm
40. 左肾上腺 left suprarenal gland



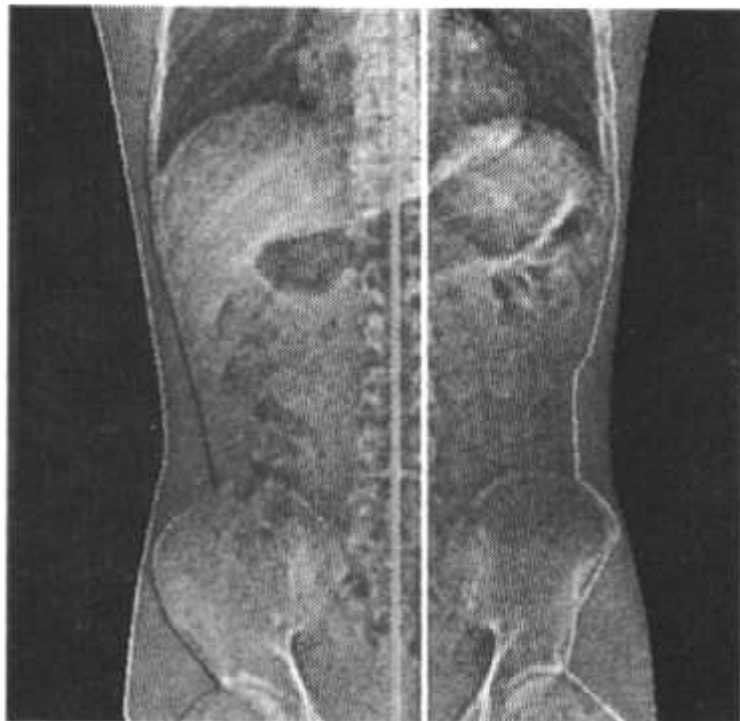
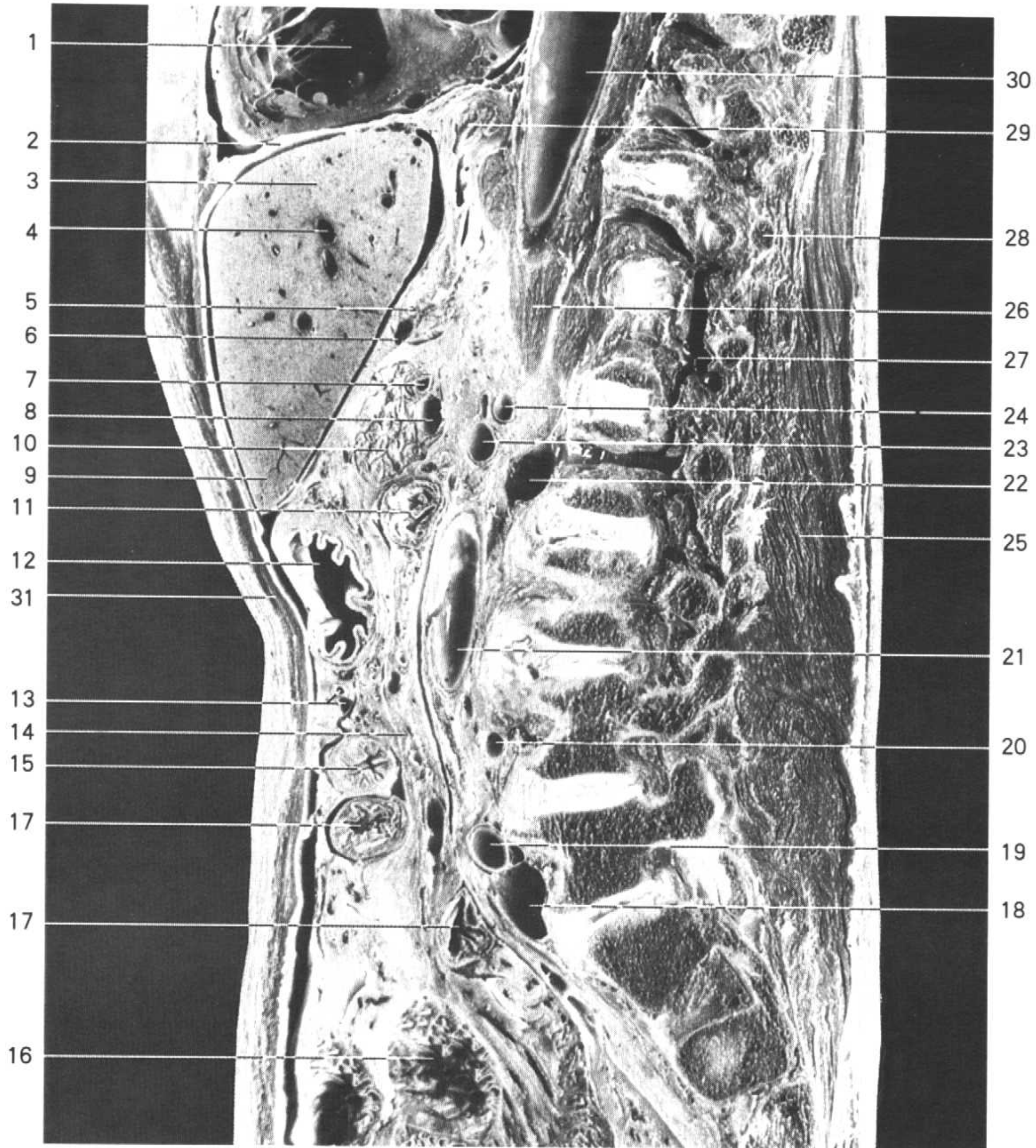
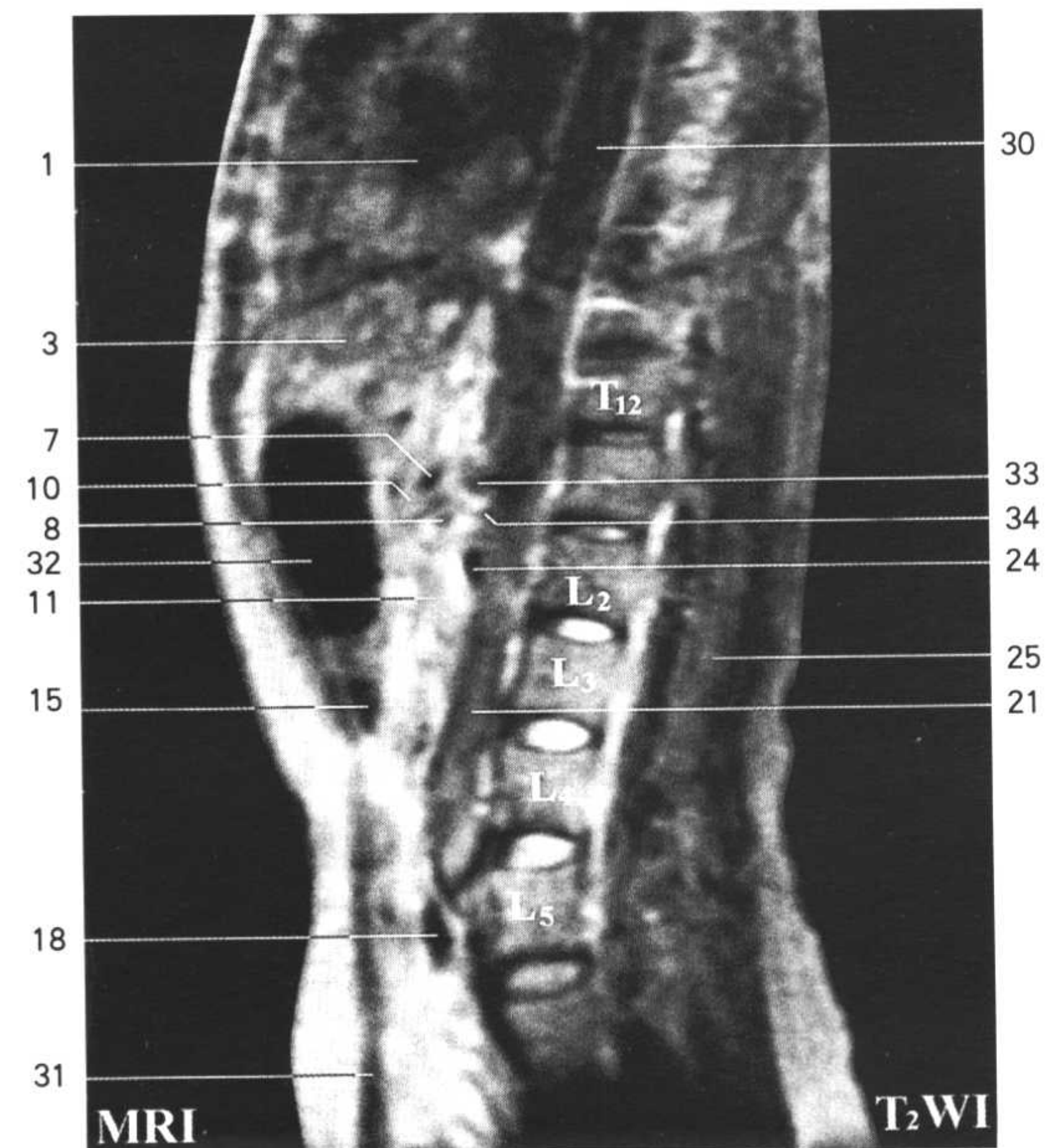
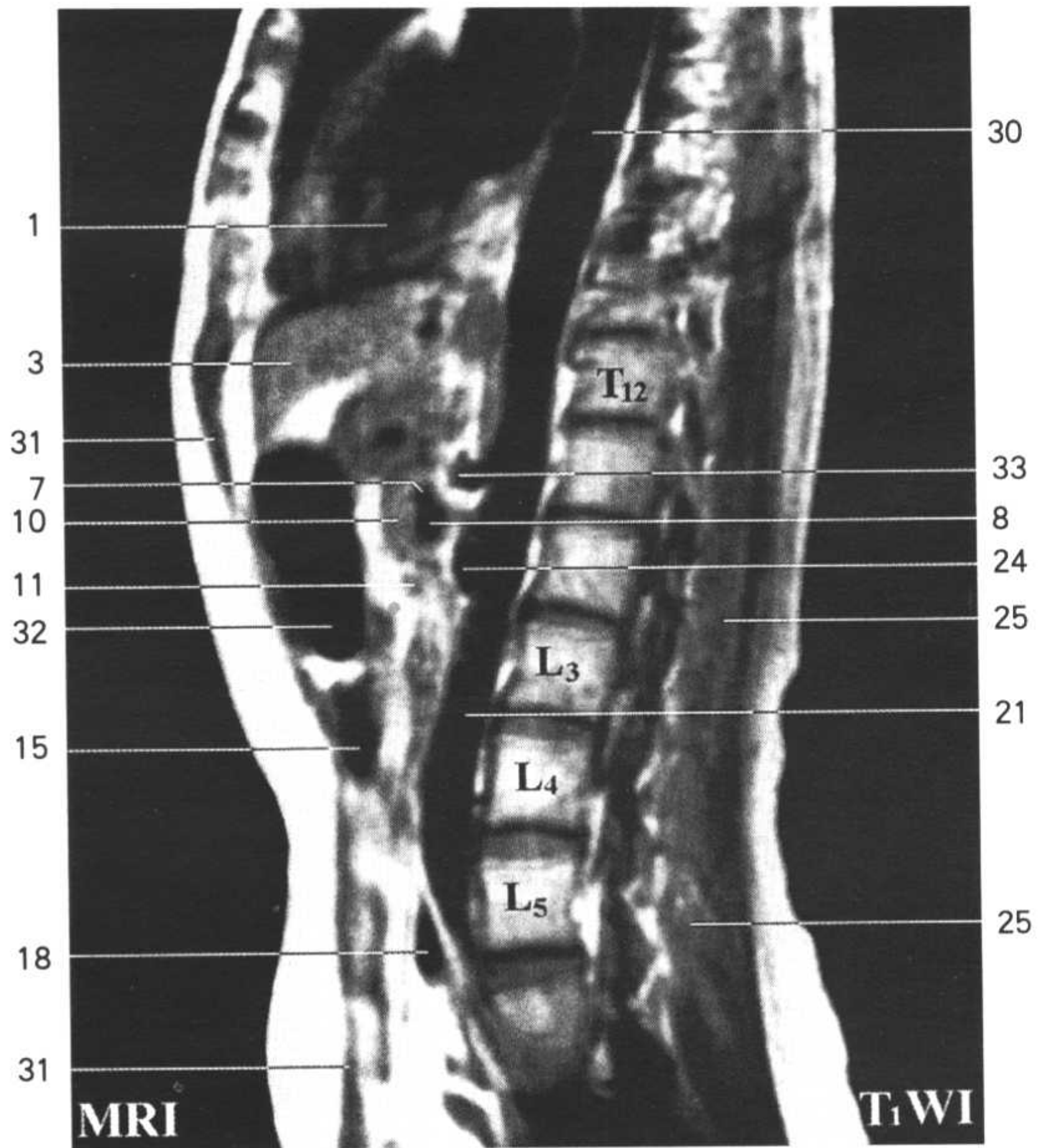


Fig.SA5

1. 右心室 right ventricle
2. 膈 diaphragm
3. 左外叶 left lateral lobe
4. 肝左静脉 left hepatic v.
5. 胃左动脉 left gastric a.
6. 胃左静脉 left gastric v.
7. 脾动脉 splenic a.
8. 脾静脉 splenic v.
9. 左外叶下段 inferior segment of left lateral lobe

10. 胰 pancreas
11. 十二指肠水平部 horizontal part of duodenum
12. 幽门窦 pyloric antrum
13. 胃网膜右动、静脉 right gastroepiploic a. and v.
14. 肠系膜 mesentery
15. 横结肠 transverse colon
16. 空肠 jejunum
17. 空肠 jejunum
18. 左髂总静脉 left common iliac v.
19. 左髂总动脉 left common iliac a.
20. 腰动脉 lumbar a.
21. 腹主动脉 abdominal aorta
22. 第3腰静脉 3rd lumbar v.
23. 左肾静脉 left renal v.
24. 左肾动脉 left renal a.
25. 竖脊肌 erector spinae
26. 膈左脚 left crus of diaphragm
27. 椎外静脉丛 external vertebral venous plexus
28. 第12胸椎横突 transverse process (T₁₂)
29. 食管 esophagus
30. 胸主动脉 thoracic aorta
31. 腹直肌 rectus abdominis
32. 胃体 body of stomach
33. 腹腔干 celiac trunk
34. 肠系膜上动脉 superior mesenteric a.



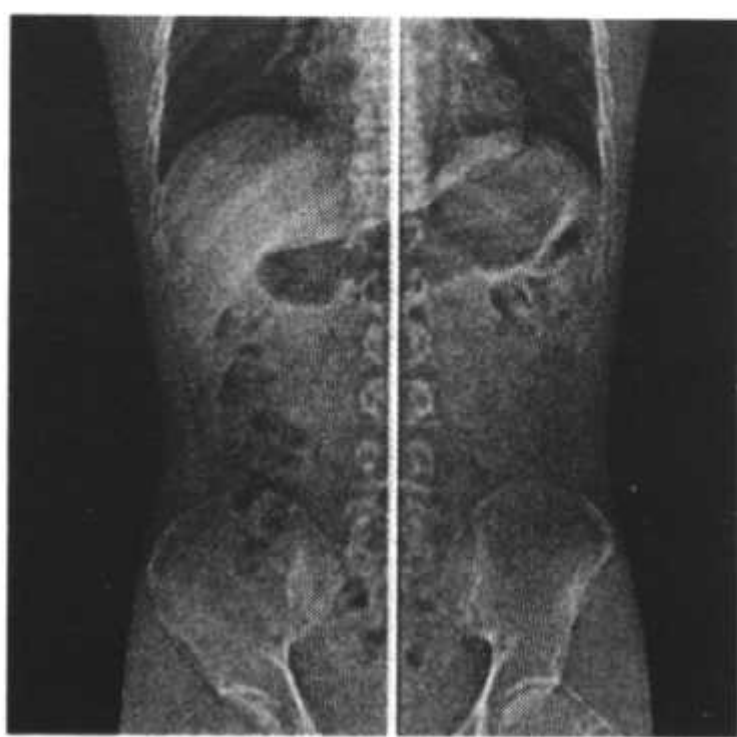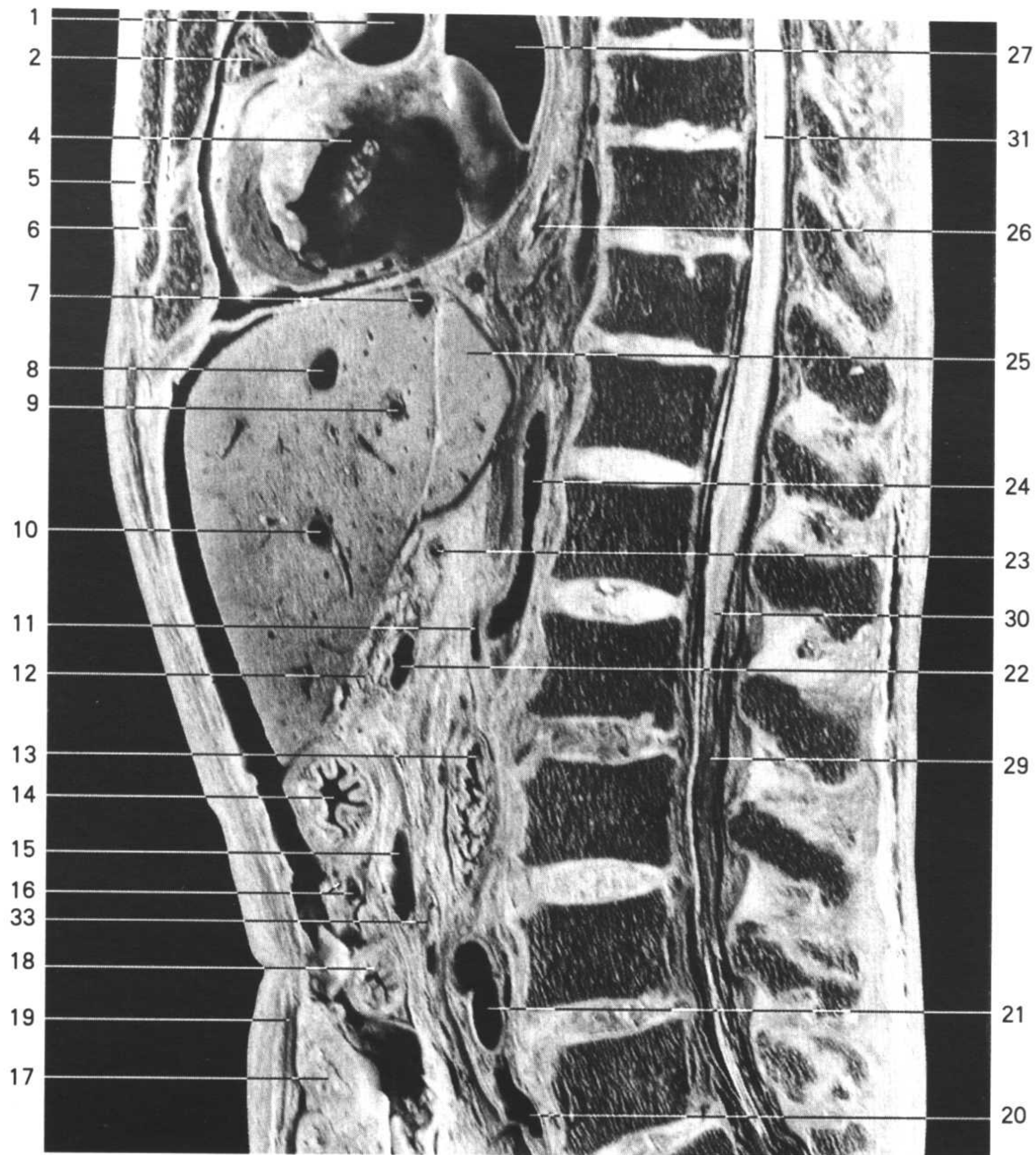
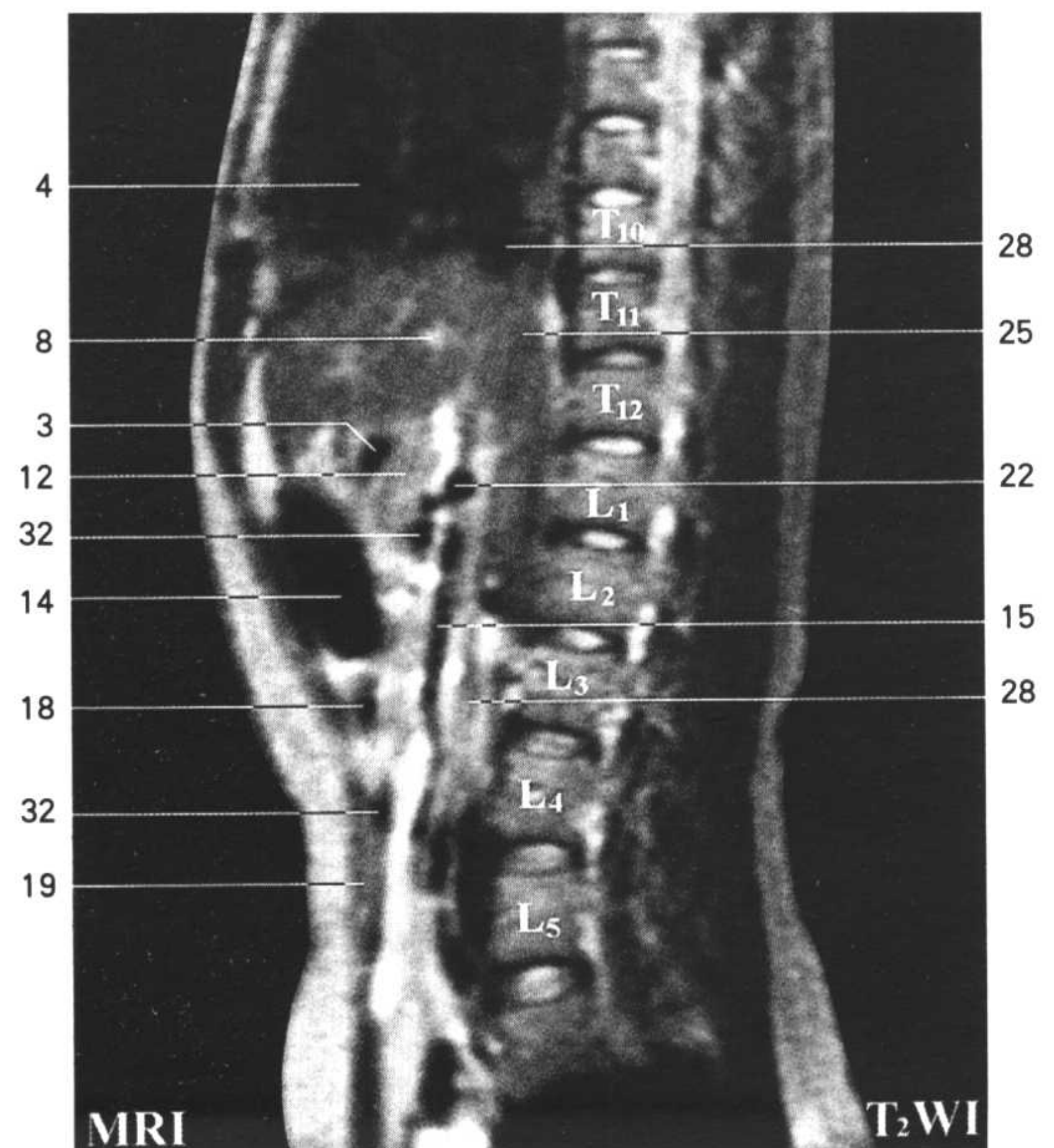
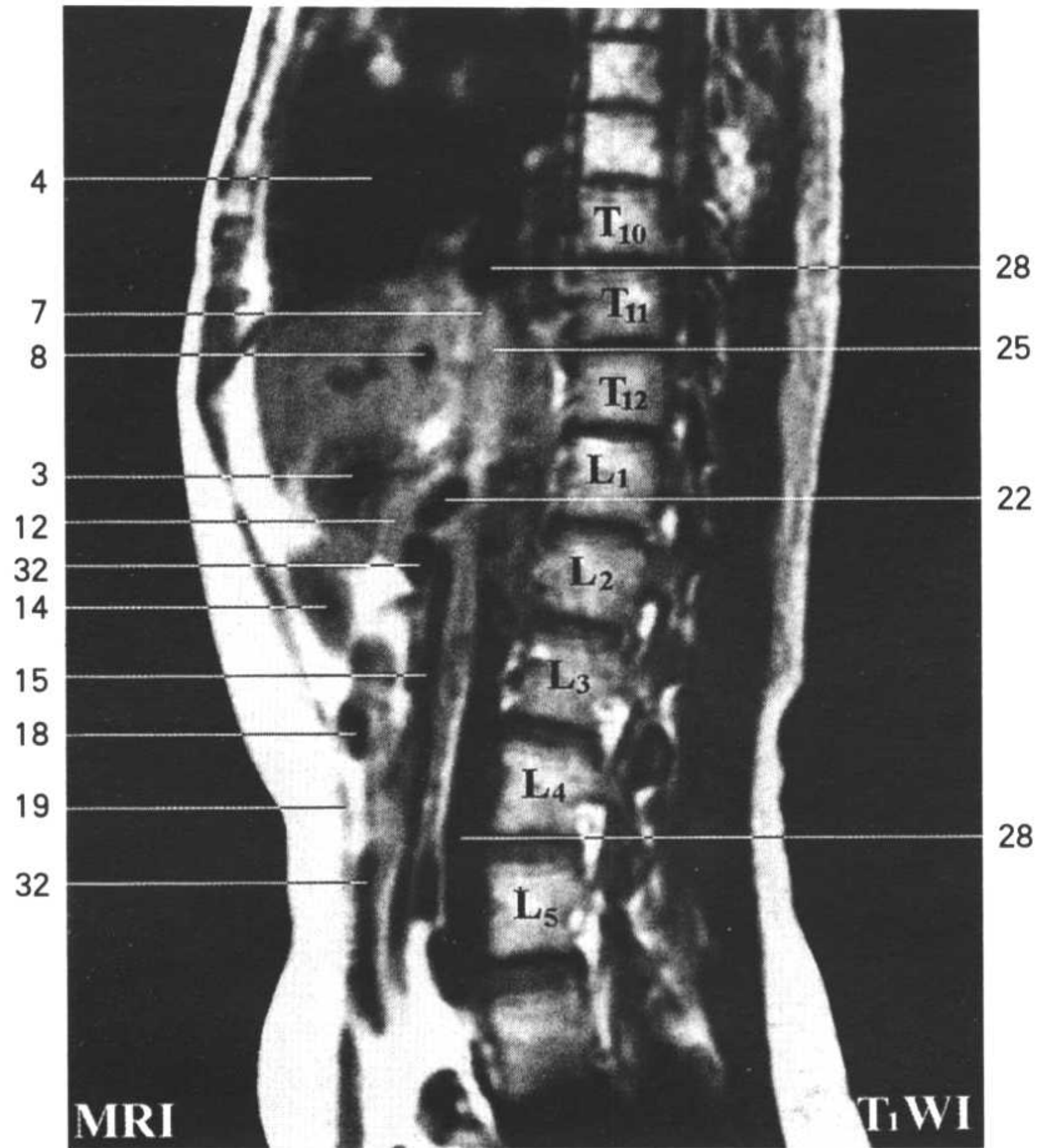


Fig.SA6

1. 升主动脉 ascending aorta
2. 右心耳 right auricle
3. 胃 stomach
4. 右心房 right atrium
5. 胸骨体 body of sternum
6. 右肺中叶 middle lobe of right lung
7. 肝中间静脉 intermediate hepatic v.
8. 肝左静脉 left hepatic v.
9. 左外叶上段静脉 superior segmental v. of left lateral lobe

10. 左外叶下段静脉 inferior segmental v. of left lateral lobe
11. 左肾静脉 left renal v.
12. 胰 pancreas
13. 十二指肠水平部 horizontal part of duodenum
14. 幽门管 pyloric canal
15. 肠系膜上静脉 superior mesenteric v.
16. 胃网膜右动、静脉 right gastroepiploic a. and v.
17. 大网膜 greater omentum
18. 横结肠 transverse colon
19. 腹直肌 rectus abdominis
20. 左髂总静脉 left common iliac v.
21. 左髂总动脉 left common iliac a.
22. 肝门静脉 hepatic portal v.
23. 肝总动脉 common hepatic a.
24. 腹主动脉 abdominal aorta
25. 尾状叶 caudate lobe
26. 食管 esophagus
27. 左心房 left atrium
28. 下腔静脉 inferior vena cava
29. 马尾 cauda equina
30. 脊髓圆锥 conus medullaris
31. 脊髓 spinal cord
32. 肠系膜上动脉 superior mesenteric a.
33. 空肠 jejunum



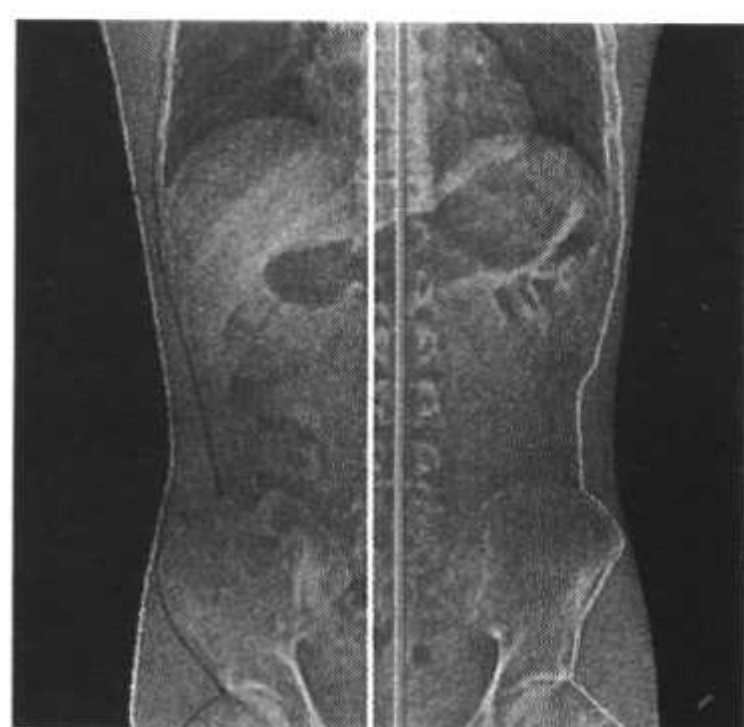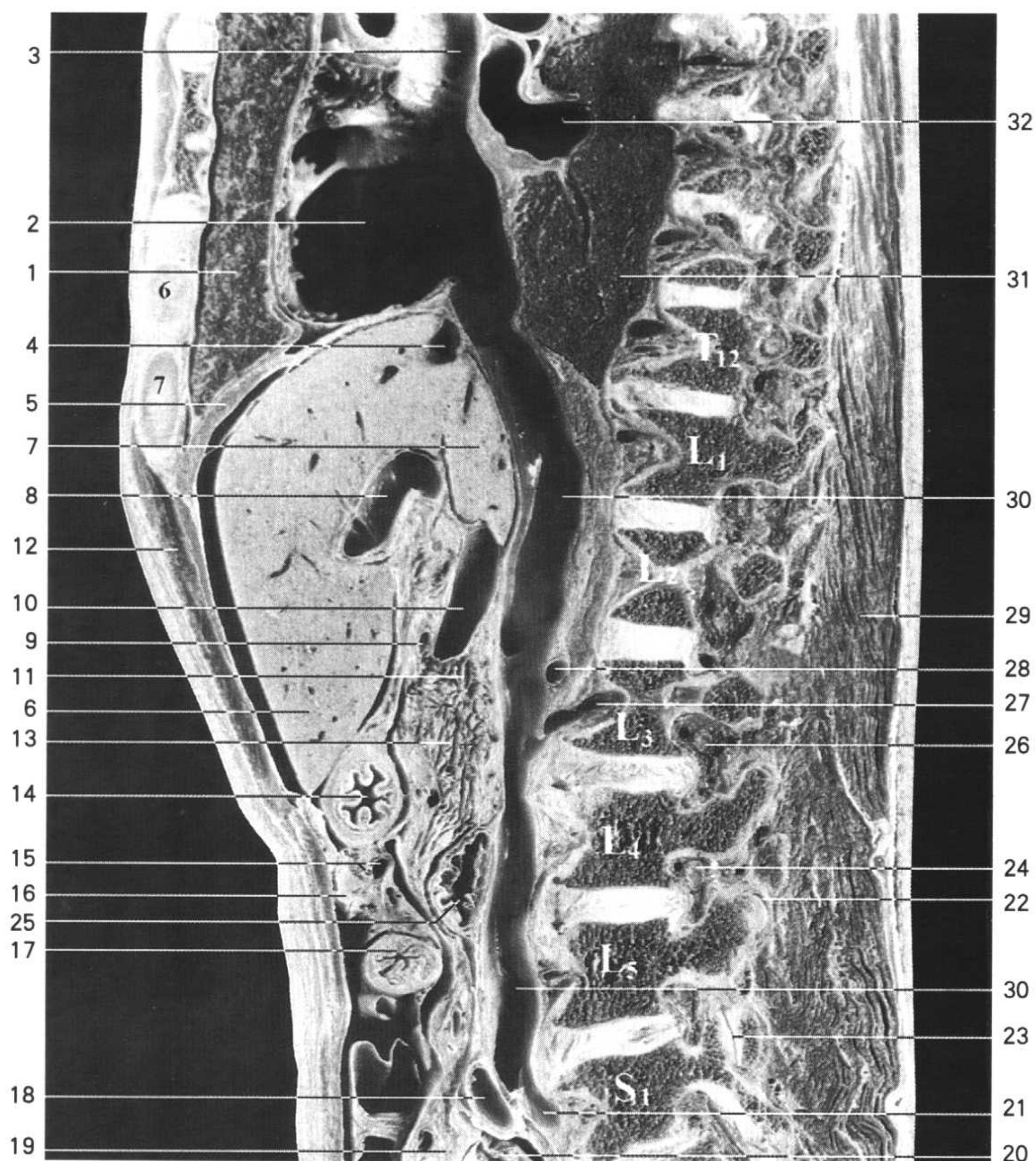
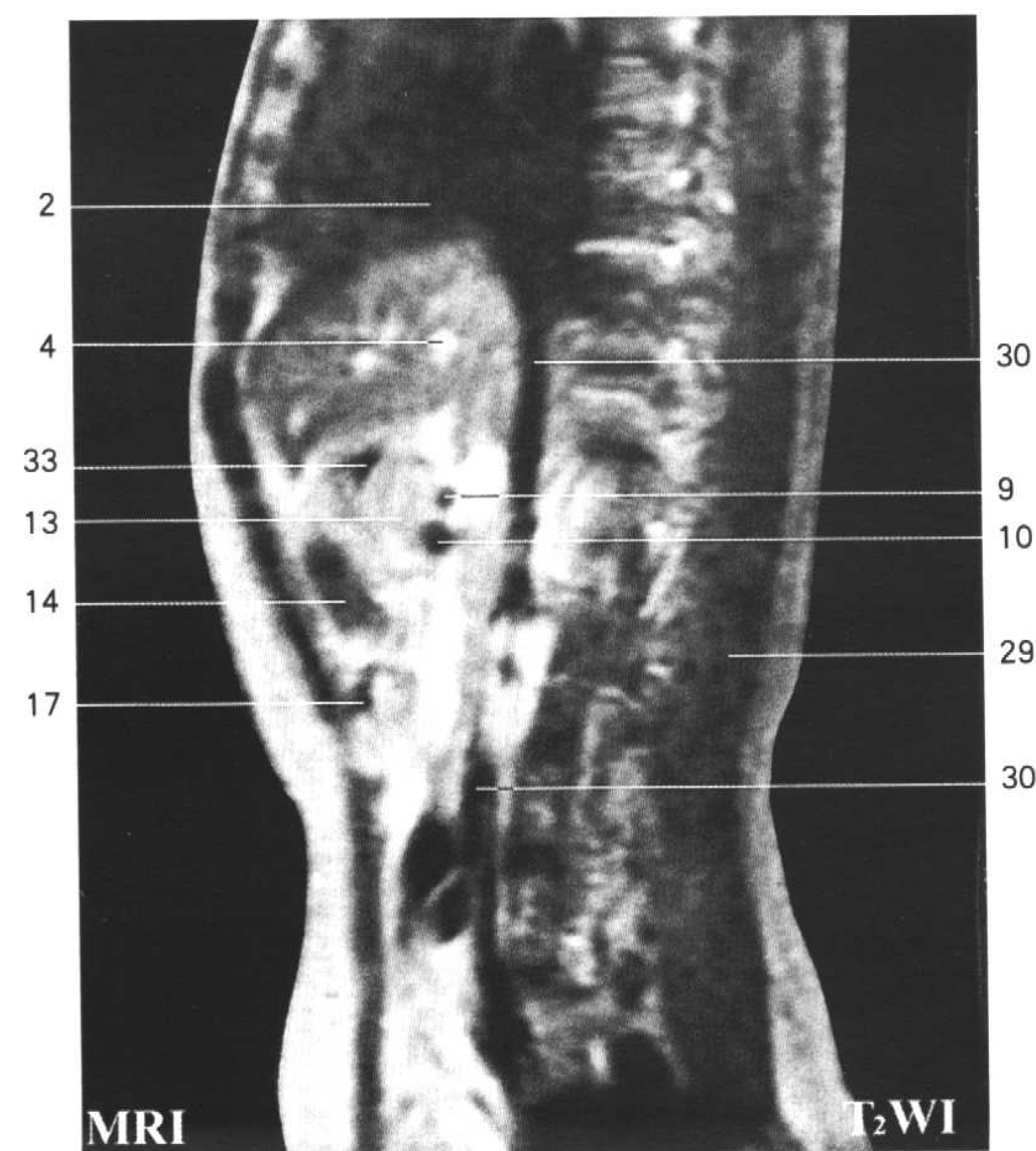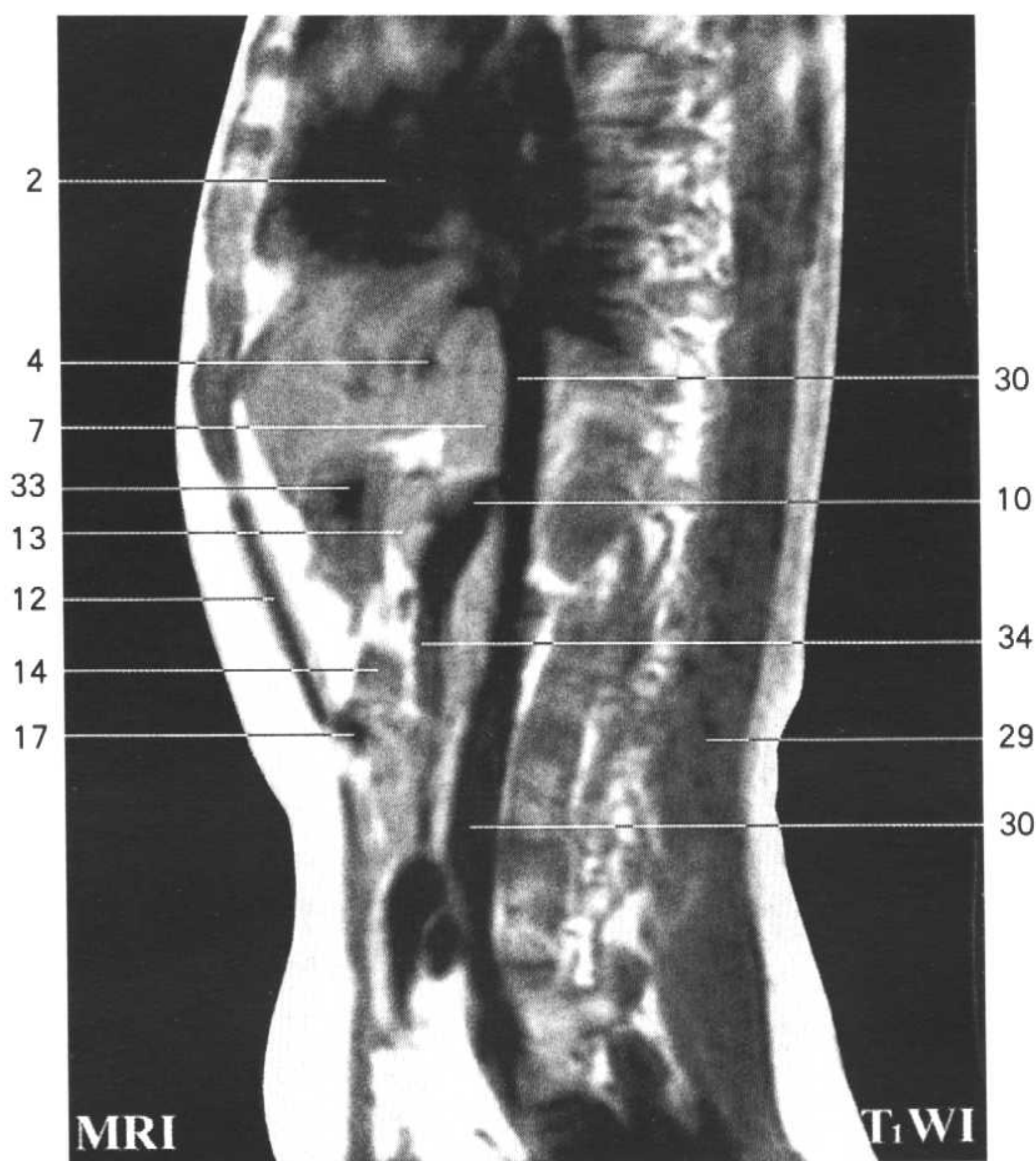


Fig.SA7

1. 右肺中叶 middle lobe of right lung
2. 右心房 right atrium
3. 上腔静脉 superior vena cava
4. 肝中间静脉 intermediate hepatic v.
5. 膈 diaphragm
6. 左外叶 left lateral lobe
7. 尾状叶 caudate lobe
8. 肝门静脉左支脐部 umbilical part of left branch of hepatic portal v.
9. 肝固有动脉 proper hepatic a.

10. 肝门静脉 hepatic portal v.
11. 胆总管 common bile duct
12. 腹直肌 rectus abdominis
13. 胰头 head of pancreas
14. 幽门管 pyloric canal
15. 胃网膜右动、静脉 right gastroepiploic a. and v.
16. 大网膜 greater omentum
17. 横结肠 transverse colon
18. 右髂总动脉 right common iliac a.
19. 肠系膜 mesentery
20. 空肠 jejunum
21. 右髂总静脉 right common iliac v.
22. 4、5 腰椎关节突关节 zygapophysial joint (L₄-L₅)
23. 第 5 腰椎、第 1 骶椎关节突关节 zygapophysial joint (L₅-S₁)
24. 第 4 腰神经 4th lumbar n.
25. 十二指肠水平部 horizontal part of duodenum
26. 第 3 腰神经 3rd lumbar n.
27. 第 3 腰静脉 3rd lumbar v.
28. 右肾动脉 right renal a.
29. 竖脊肌 erector spinae
30. 下腔静脉 inferior vena cava
31. 右肺下叶 inferior lobe of right lung
32. 左心房 left atrium
33. 胃 stomach
34. 肠系膜上静脉 superior mesenteric v.



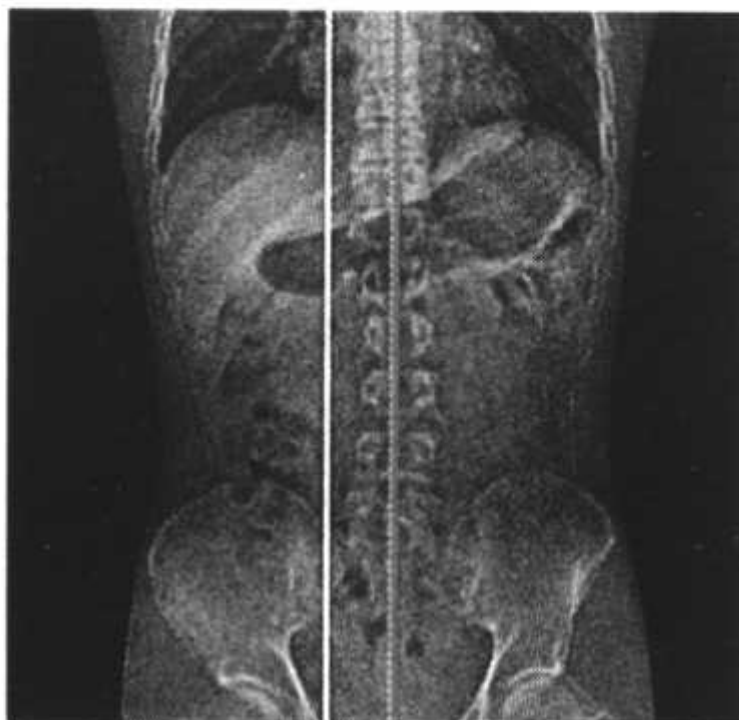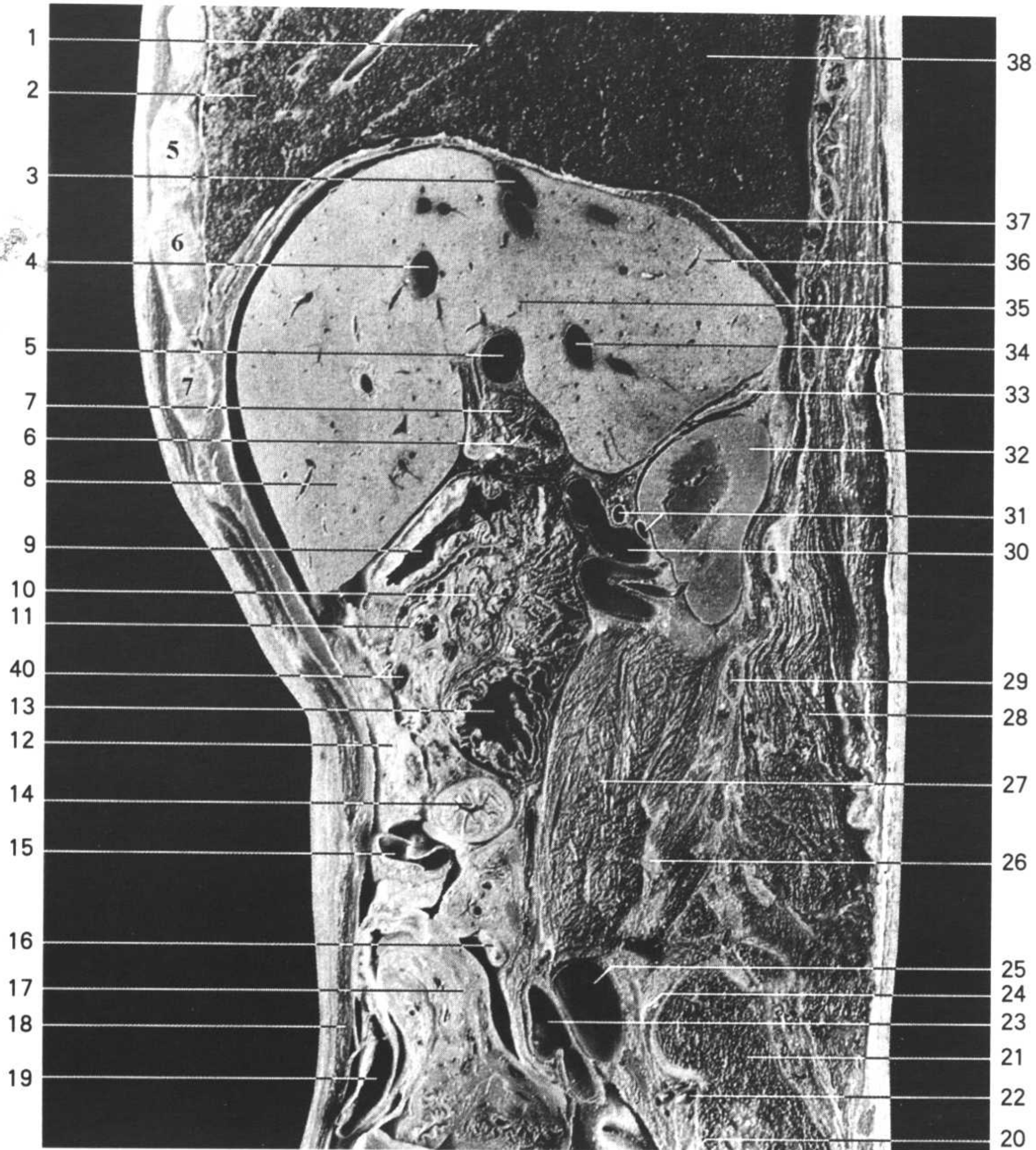
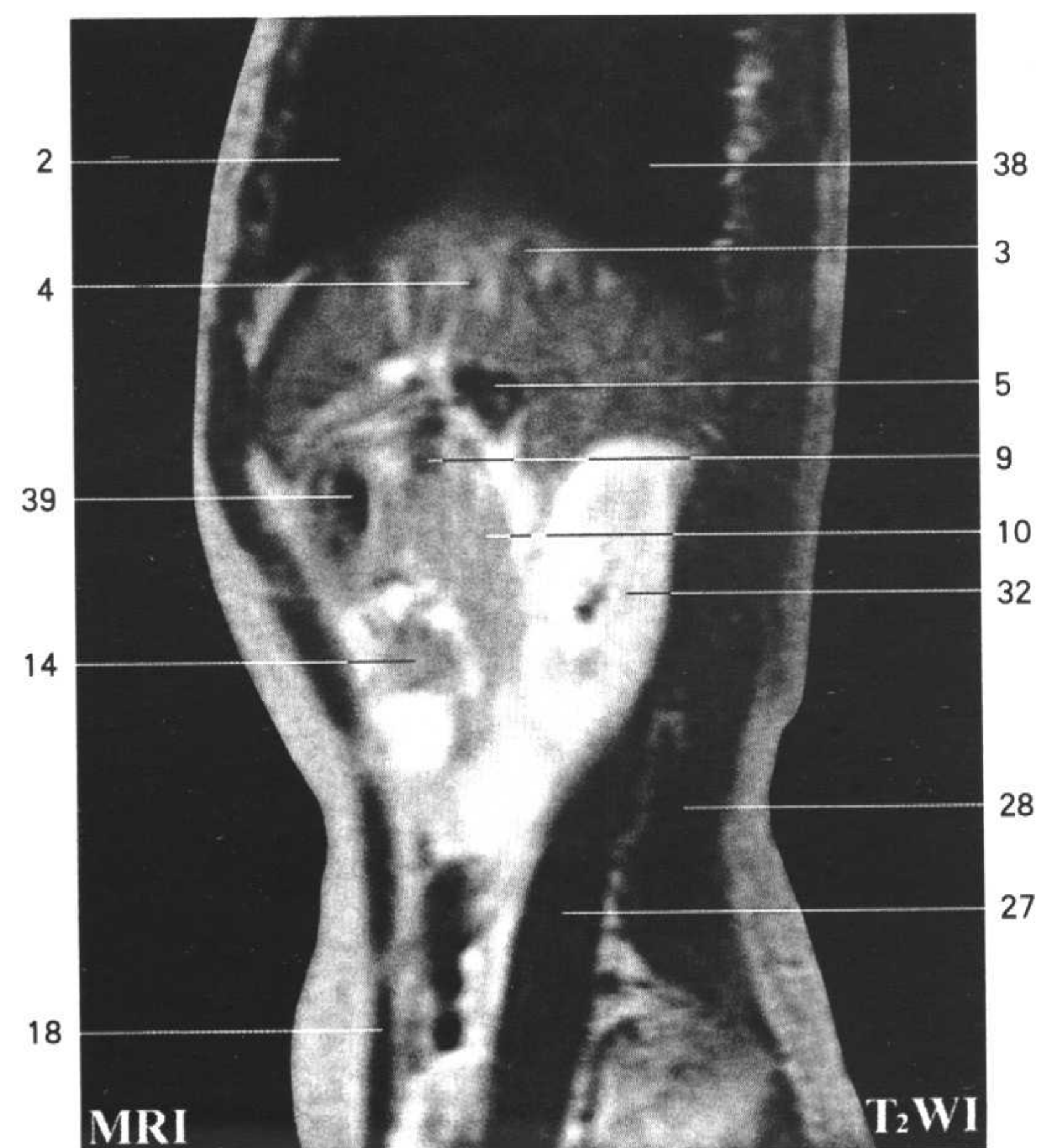
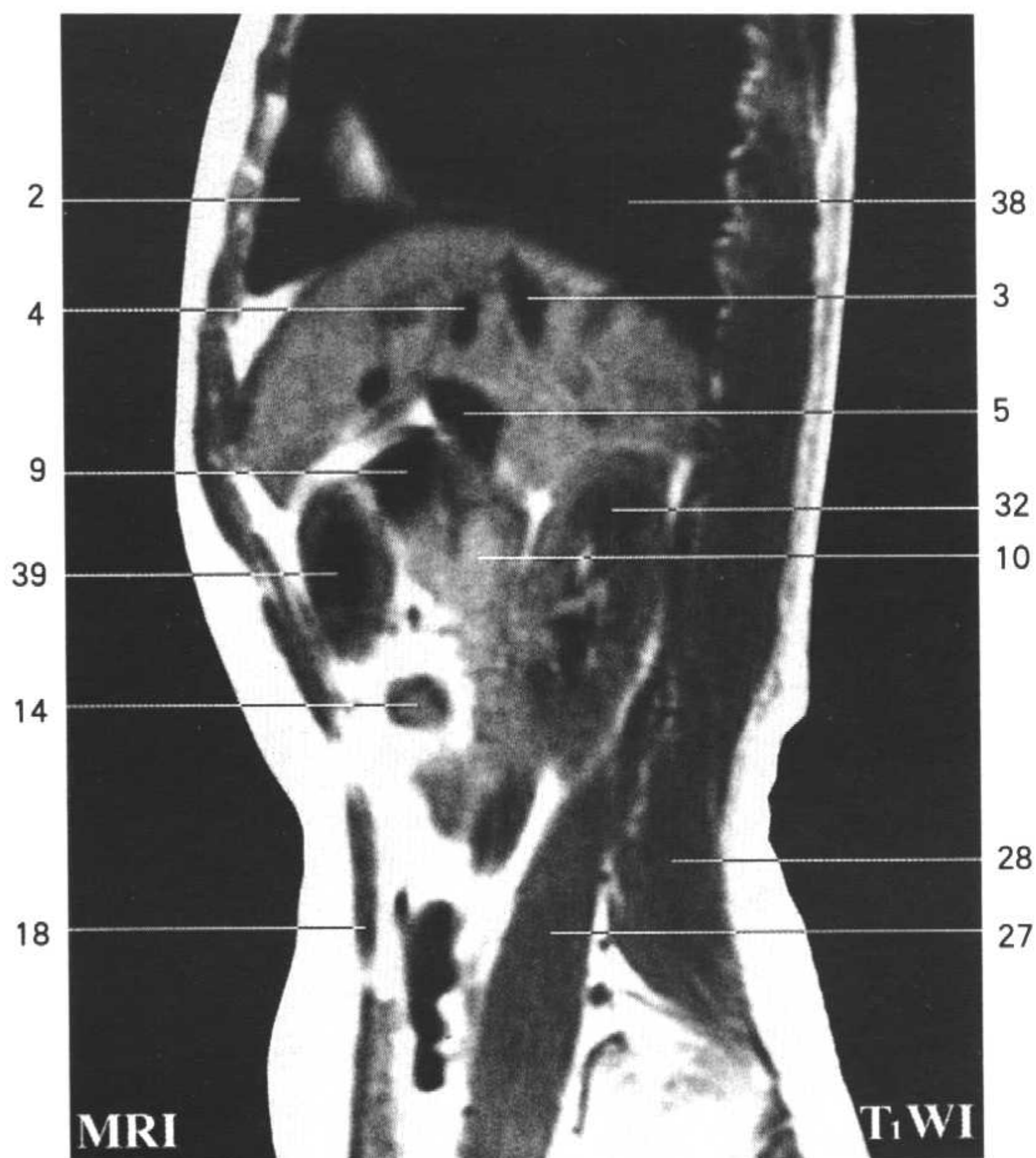


Fig.SA8

1. 斜裂 oblique fissure
2. 右肺中叶 middle lobe of right lung
3. 肝右静脉 right hepatic v.
4. 肝中间静脉 intermediate hepatic v.
5. 肝门静脉 hepatic portal v.
6. 肝固有动脉 proper hepatic a.
7. 胆总管 common bile duct
8. 左内叶 left medial lobe
9. 十二指肠上部 superior part of duodenum
10. 胰头 head of pancreas

11. 胰十二指肠动脉
pancreaticoduodenal a.
12. 大网膜 greater omentum
13. 十二指肠降部 descending part
of duodenum
14. 横结肠 transverse colon
15. 回肠 ileum
16. 阑尾 vermiform appendix
17. 肠系膜 mesentery
18. 腹直肌 rectus abdominis
19. 回肠 ileum
20. 骶丛 sacral plexus
21. 骶骨 sacrum
22. 骶外侧动脉 lateral sacral a.
23. 右髂总动脉 right common
iliac a.
24. 第5腰神经 5th lumbar n.
25. 右髂总静脉 right common
iliac v.
26. 股神经 femoral n.
27. 腰大肌 psoas major
28. 竖脊肌 erector spinae
29. 第3腰椎横突 transverse
process (L₃)
30. 右肾静脉 right renal v.
31. 右肾动脉 right renal a.
32. 右肾 right kidney
33. 右肾上腺 right suprarenal gland
34. 右后肝静脉 right posterior
hepatic v.
35. 右前叶 right anterior lobe
36. 右后叶 right posterior lobe
37. 膈 diaphragm
38. 右肺下叶 inferior lobe
of right lung
39. 胃 stomach
40. 胃网膜右动、静脉 right
gastroepiploic a. and v.



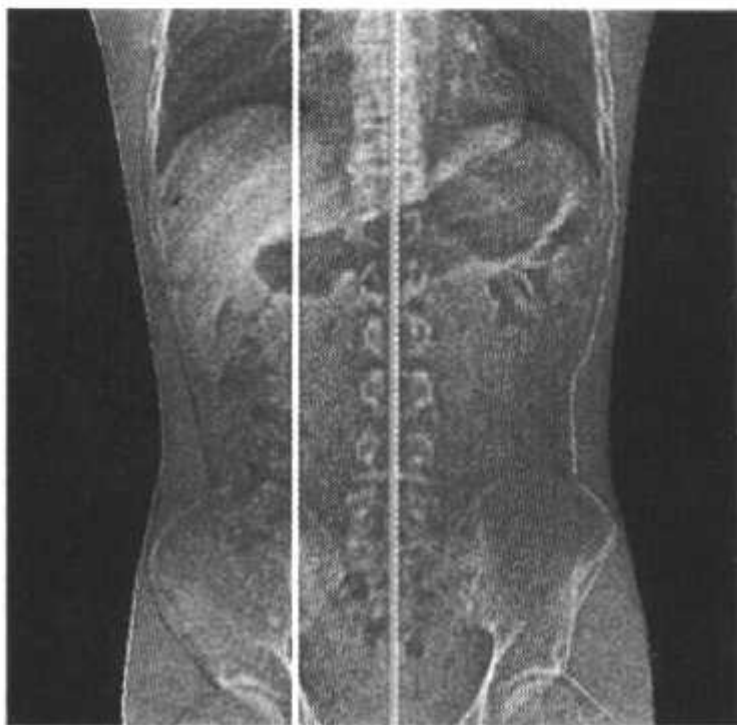
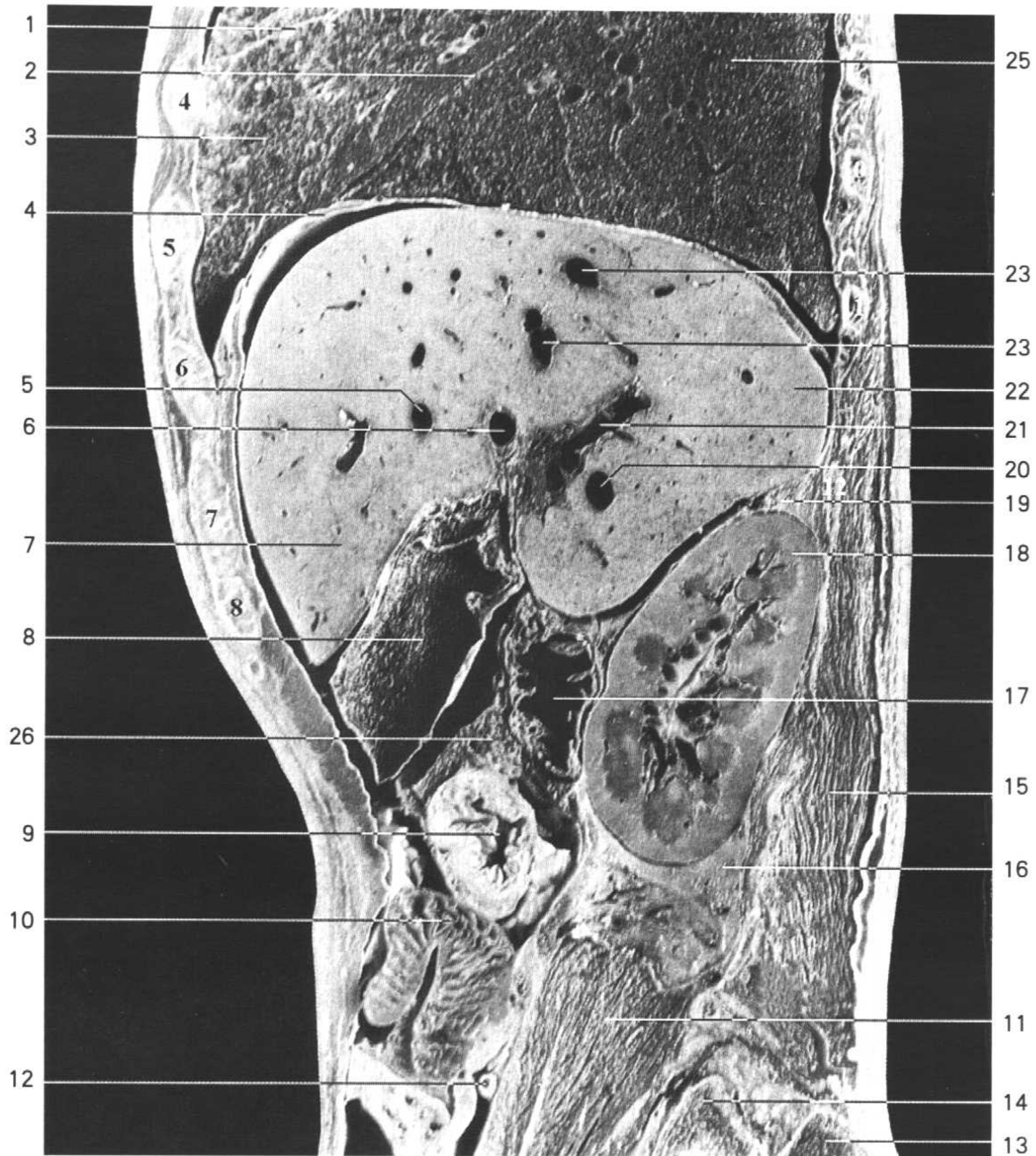
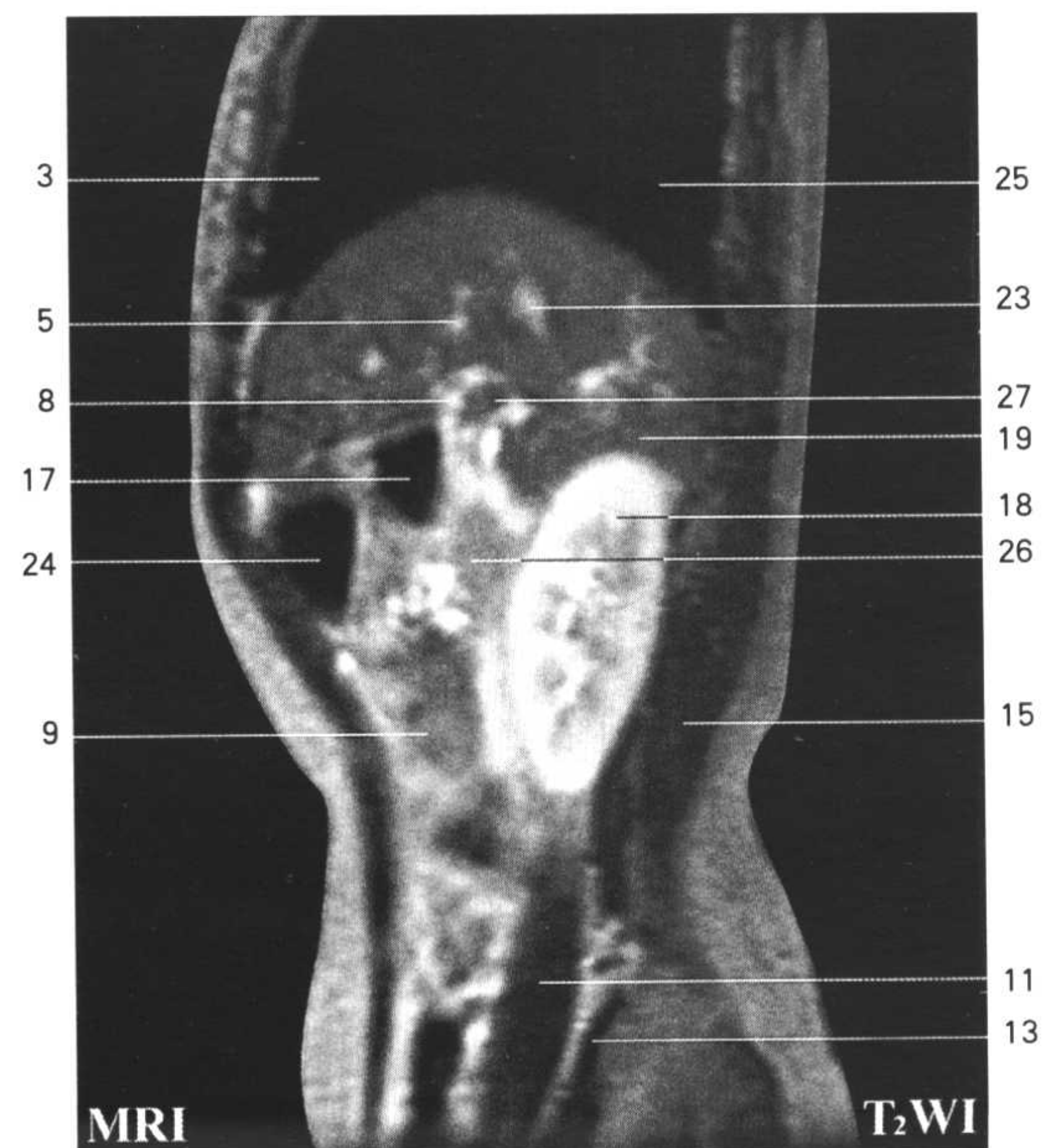
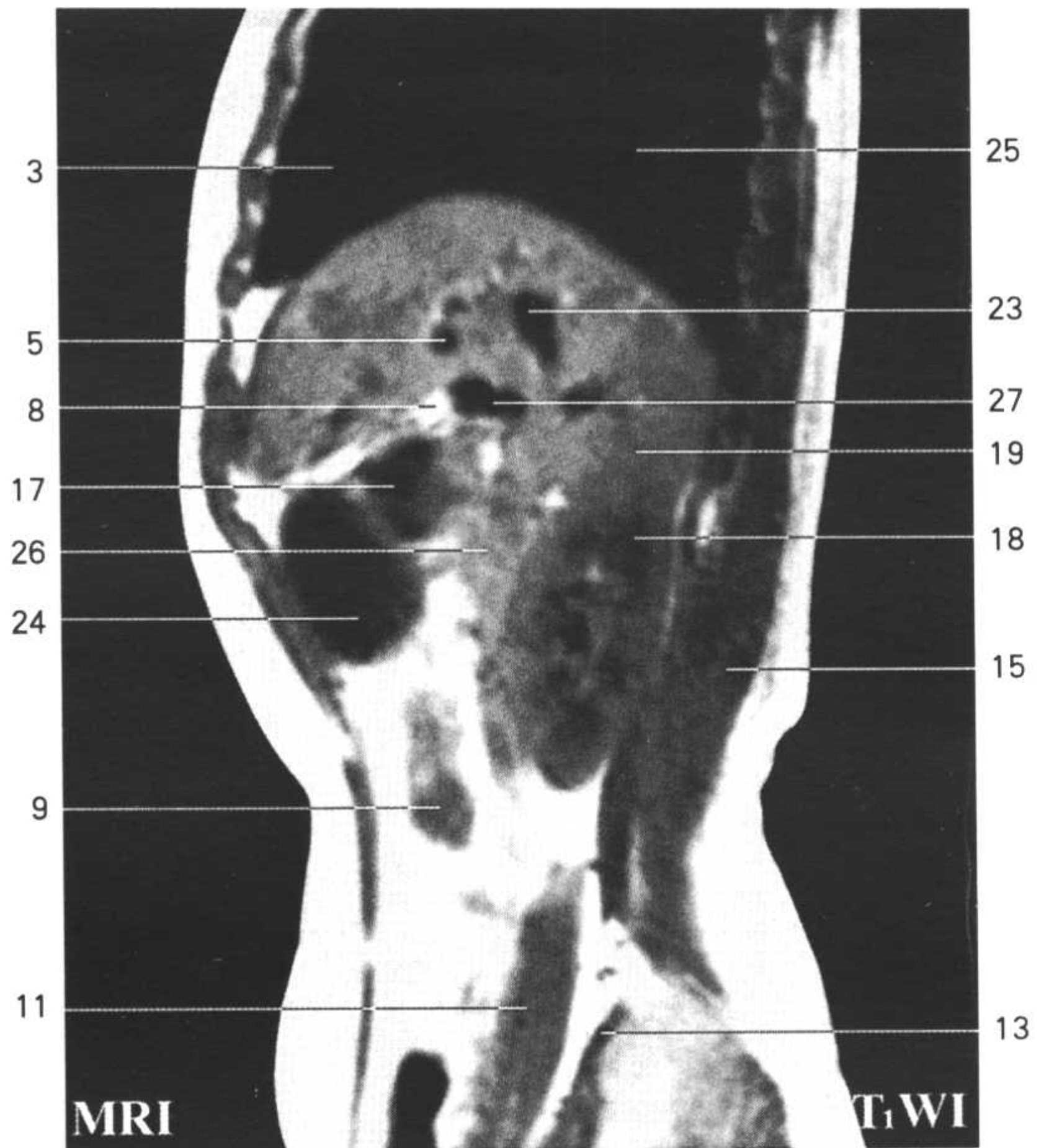Fig.SA9

1. 右肺水平裂 horizontal fissure of right lung
2. 斜裂 oblique fissure
3. 右肺中叶 middle lobe of right lung
4. 膈 diaphragm
5. 肝中间静脉 intermediate hepatic v.
6. 肝门静脉左支横部 transverse part of left branch of hepatic portal v.
7. 左内叶 left medial lobe
8. 胆囊 gallbladder
9. 横结肠 transverse colon

10. 回肠 ileum
11. 腰大肌 psoas major
12. 阑尾 vermiform appendix
13. 髂骨 ilium
14. 骶骨 sacrum
15. 竖脊肌 erector spinae
16. 脂肪囊 fatty renal capsule
17. 十二指肠降部 descending part of duodenum
18. 右肾 right kidney
19. 右肾上腺 right suprarenal gland
20. 右后肝静脉 right posterior hepatic v.
21. 肝门静脉右支 right branch of hepatic portal v.
22. 右后叶 right posterior lobe
23. 肝右静脉 right hepatic v.
24. 胃 stomach
25. 右肺下叶 inferior lobe of right lung
26. 胰头 head of pancreas
27. 肝门静脉 hepatic portal v.



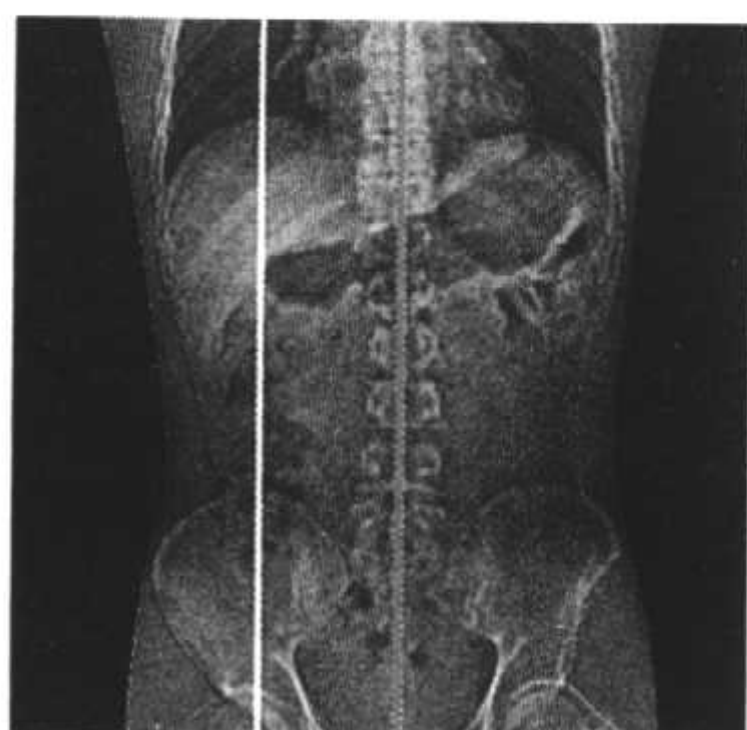
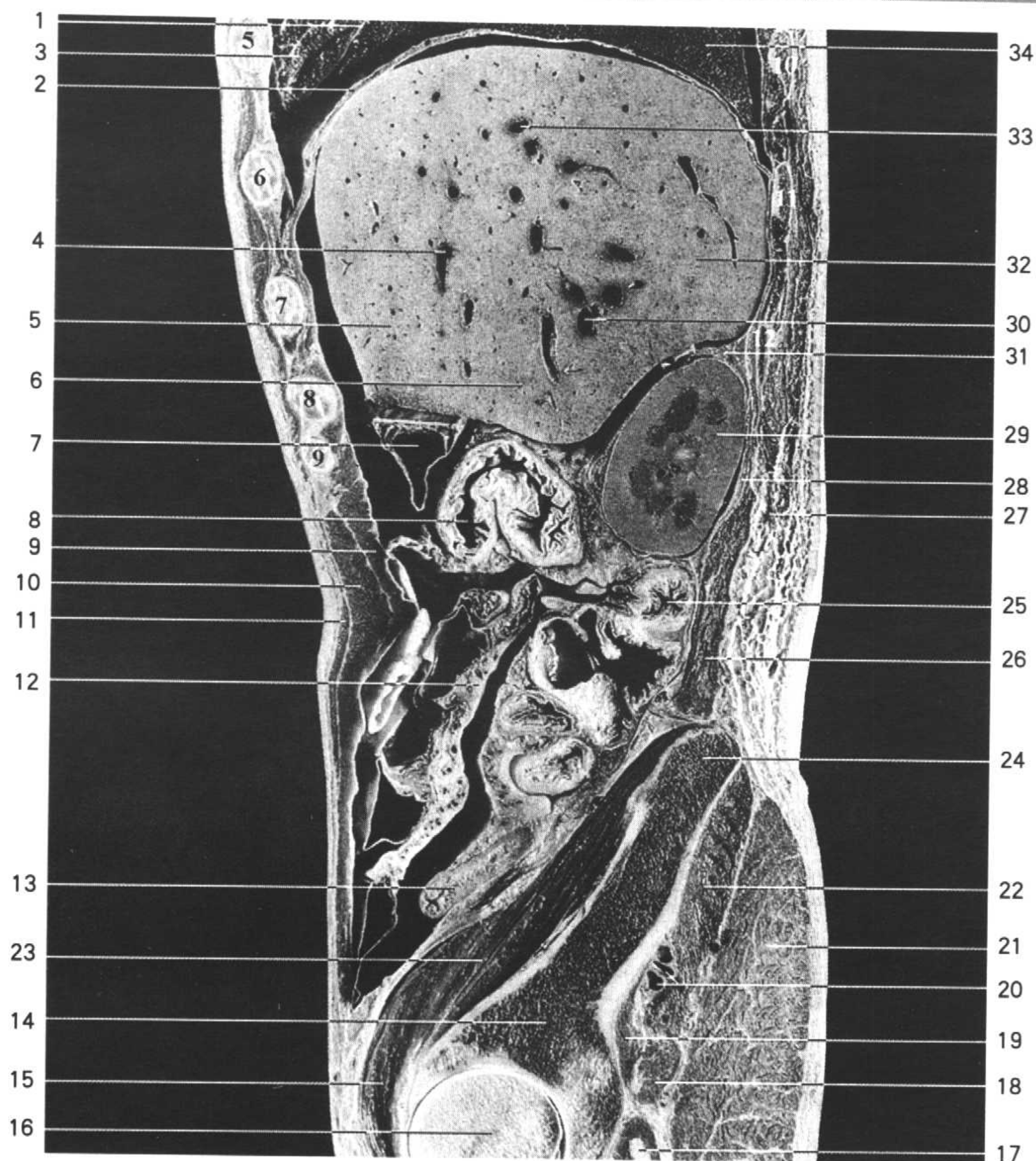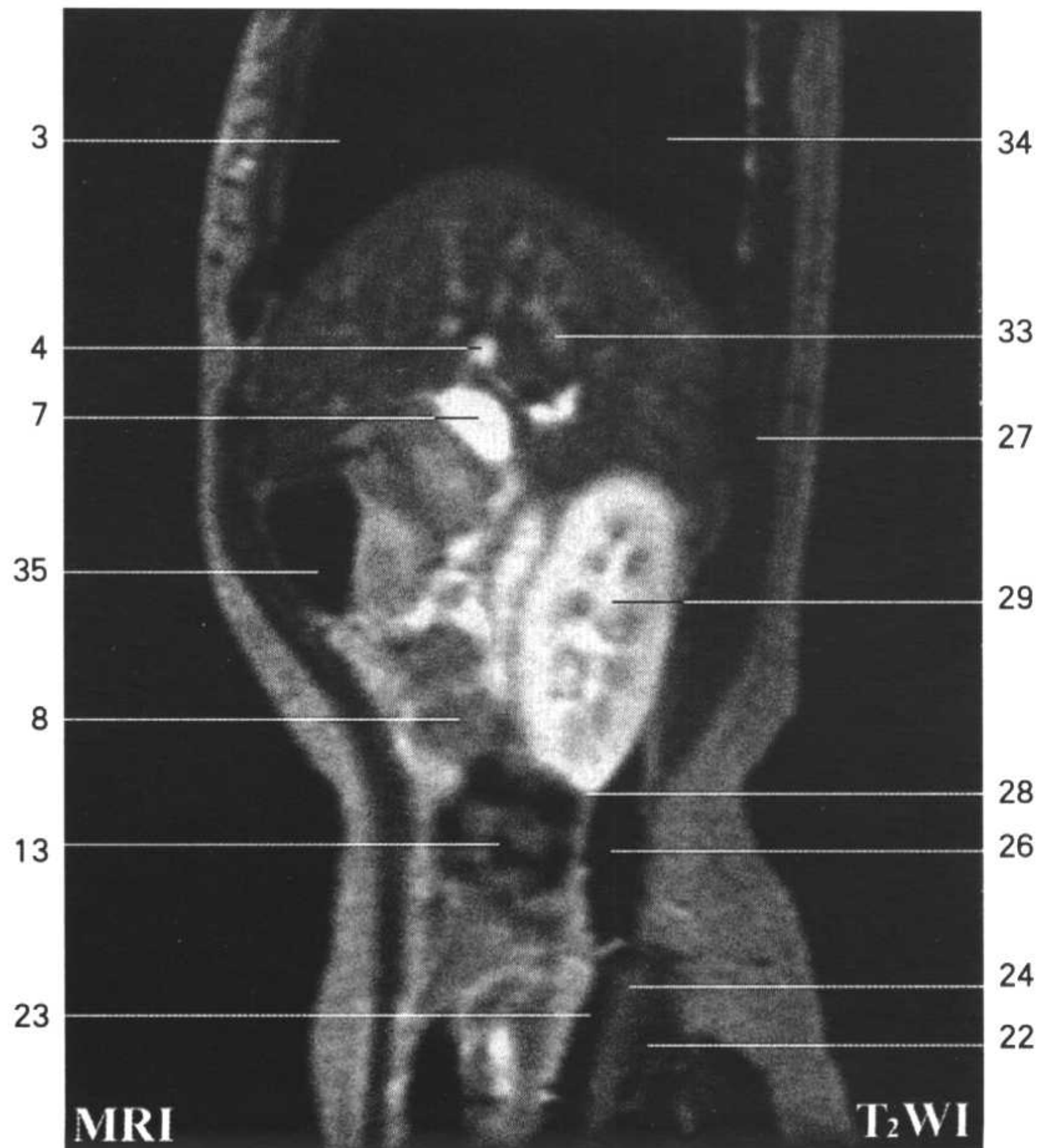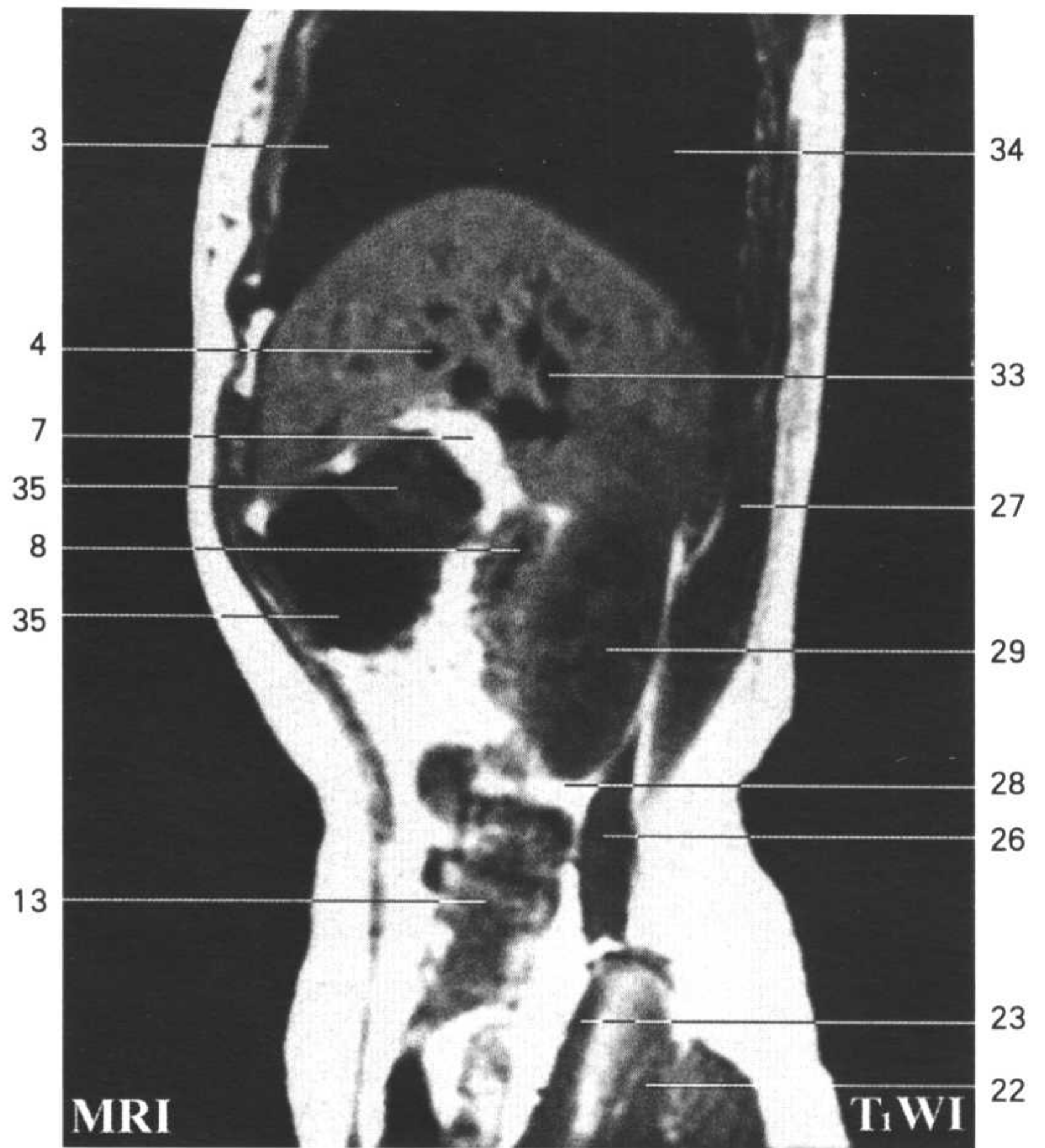


Fig.SA10

1. 斜裂 oblique fissure
2. 膈 diaphragm
3. 右肺中叶 middle lobe of right lung
4. 肝中间静脉 intermediate hepatic v.
5. 左内叶 left medial lobe
6. 右前叶 right anterior lobe
7. 胆囊 gallbladder
8. 横结肠 transverse colon
9. 腹横肌 transversus abdominis
10. 腹内斜肌 obliquus internus abdominis

11. 腹外斜肌 obliquus externus abdominis
12. 肠系膜 mesentery
13. 回肠 ileum
14. 髌骨体 body of ilium
15. 髌腰肌 iliopsoas
16. 股骨头 femoral head
17. 闭孔内肌腱 tendon of obturator internus
18. 梨状肌 piriformis
19. 臀小肌 gluteus minimus
20. 臀上动、静脉 superior gluteal a. and v.
21. 臀大肌 gluteus maximus
22. 臀中肌 gluteus medius
23. 髌肌 iliacus
24. 髌嵴 iliac crest
25. 升结肠 ascending colon
26. 腰方肌 quadratus lumborum
27. 竖脊肌 erector spinae
28. 脂肪囊 fatty renal capsule
29. 右肾 right kidney
30. 右后叶静脉 right posterior lobar v.
31. 右肾上腺 right suprarenal gland
32. 右后叶 right posterior lobe
33. 肝右静脉 right hepatic v.
34. 右肺下叶 inferior lobe of right lung
35. 胃 stomach



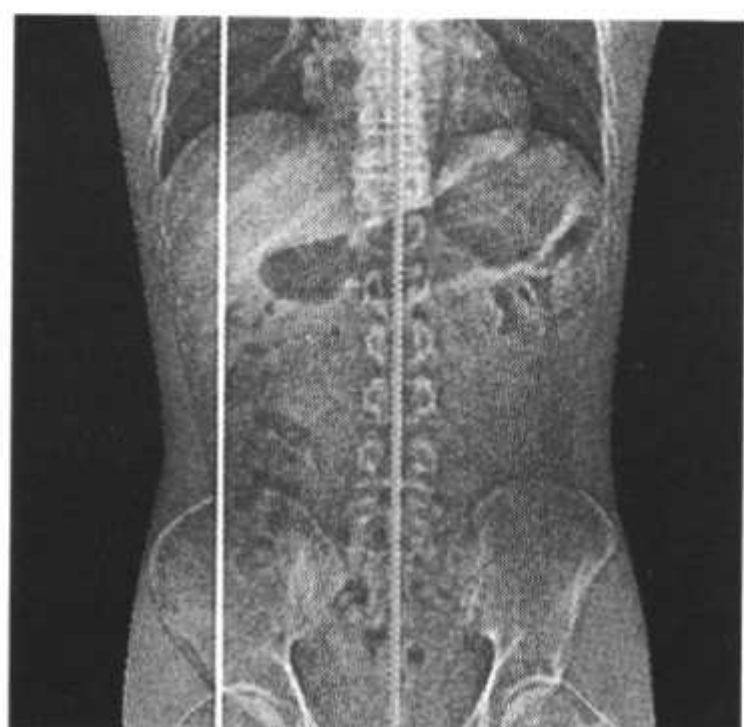
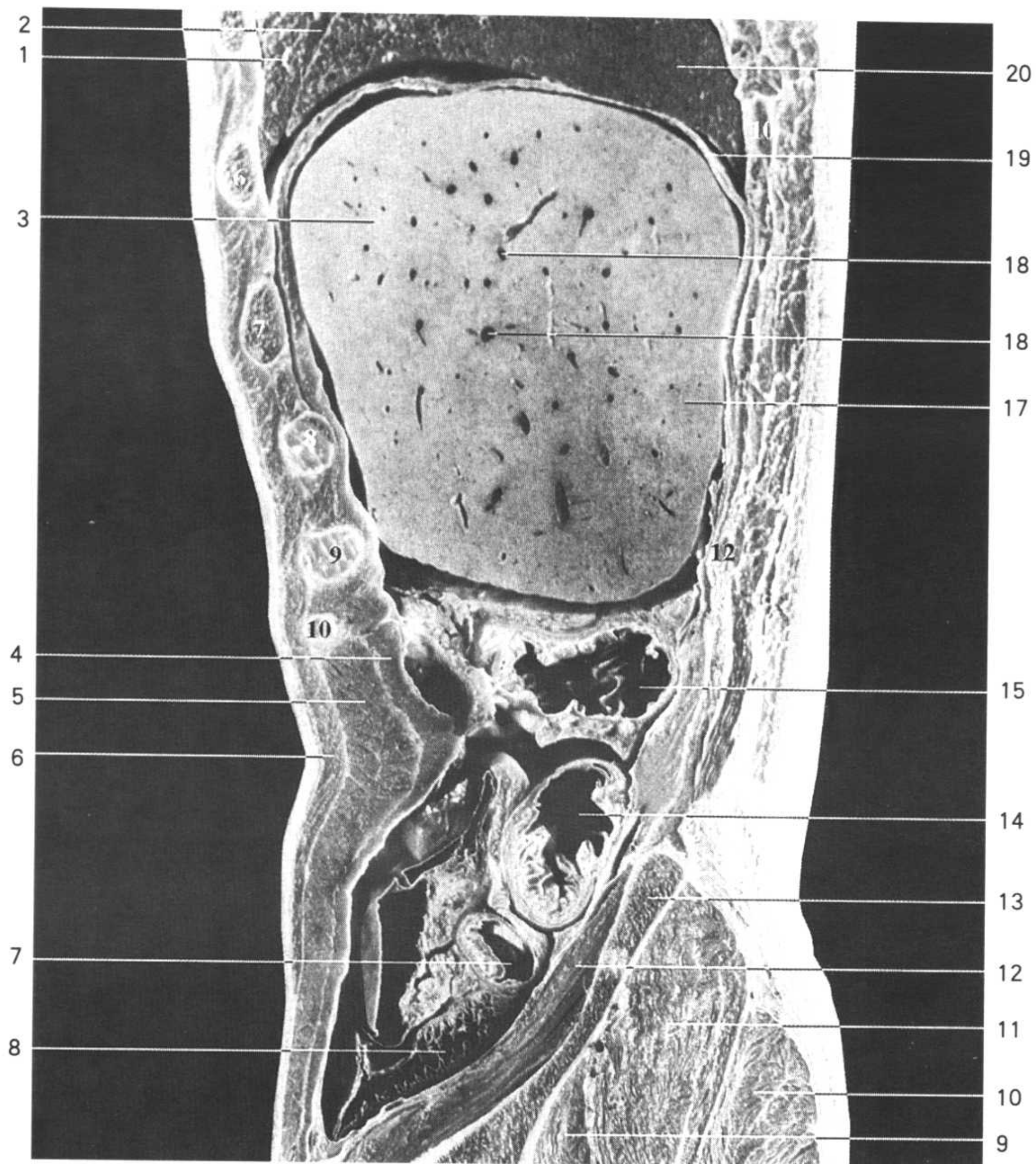
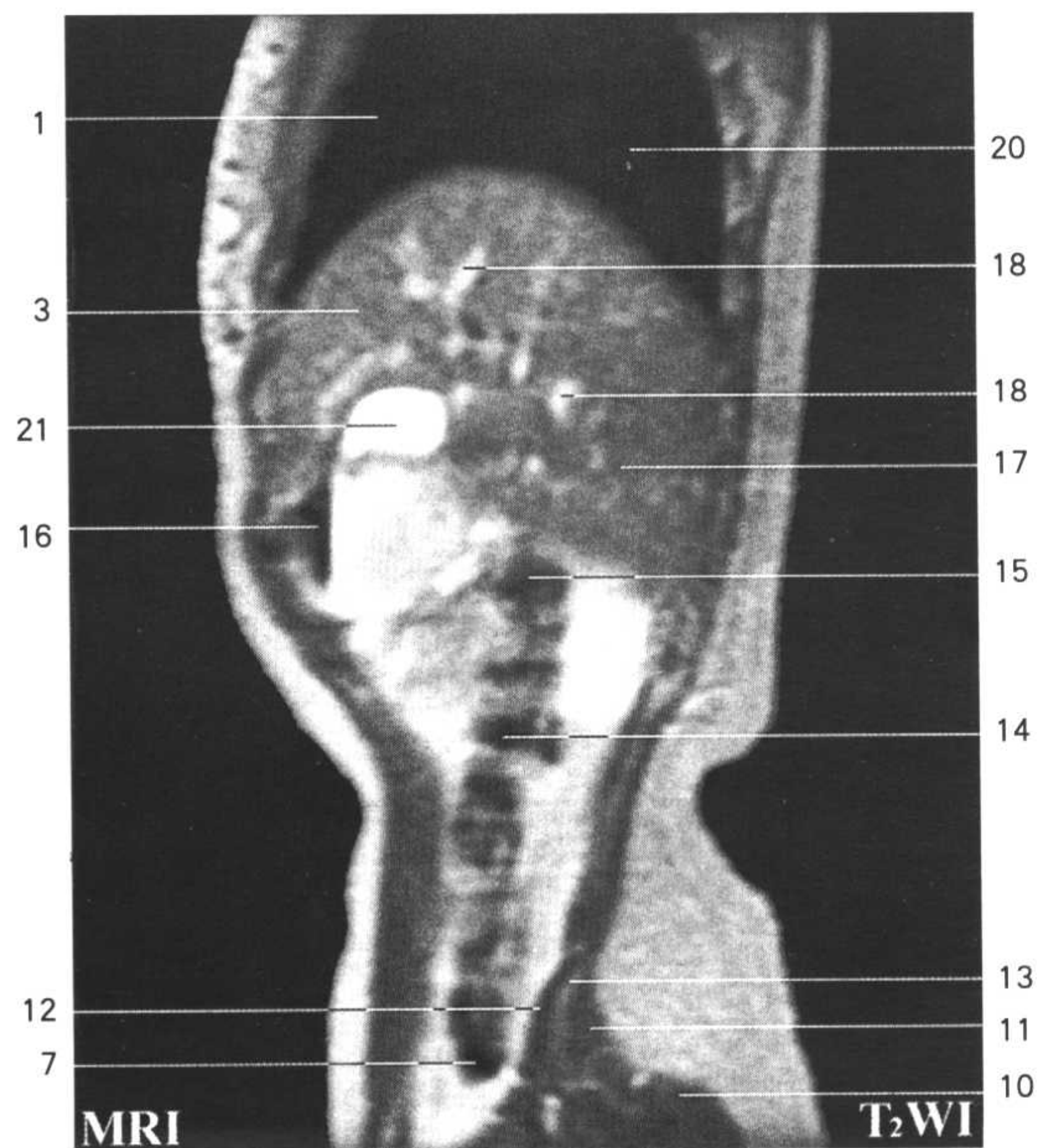
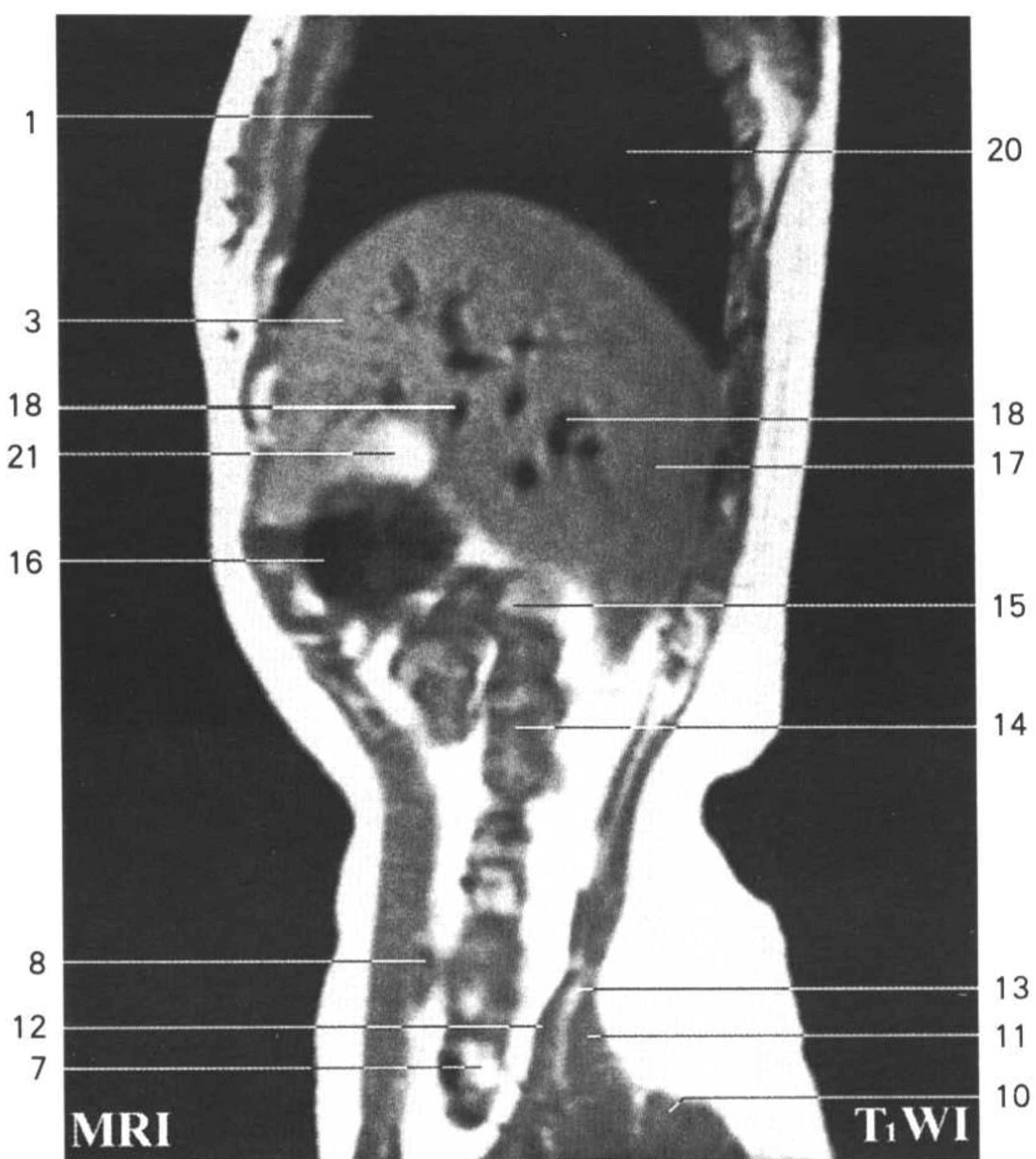

Fig.SA11

1. 右肺中叶 middle lobe of right lung
2. 斜裂 oblique fissure
3. 右前叶 right anterior lobe
4. 腹横肌 transversus abdominis
5. 腹内斜肌 obliquus internus abdominis
6. 腹外斜肌 obliquus externus abdominis
7. 盲肠 cecum
8. 回肠 ileum
9. 臀小肌 gluteus minimus
10. 臀大肌 gluteus maximus

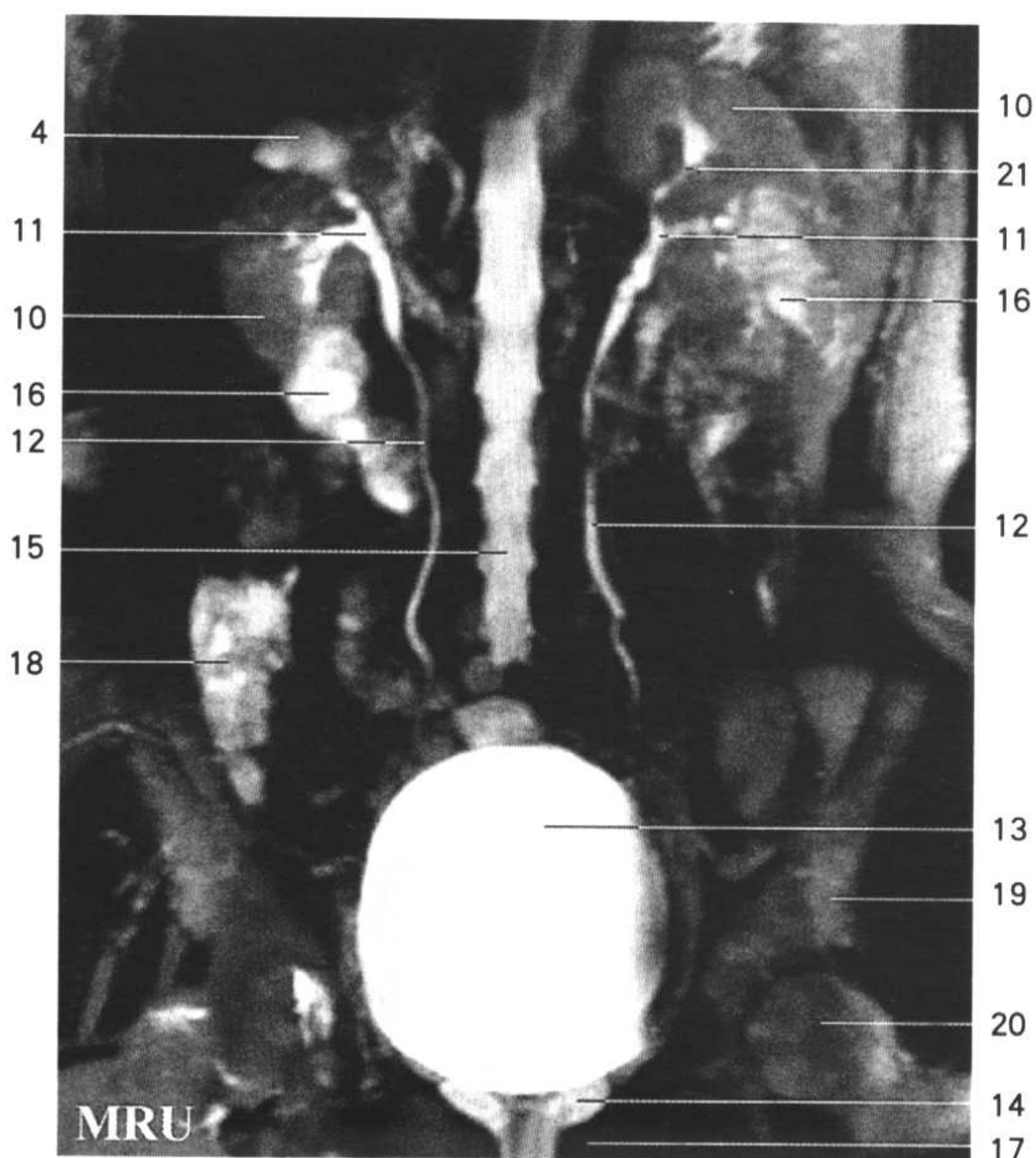
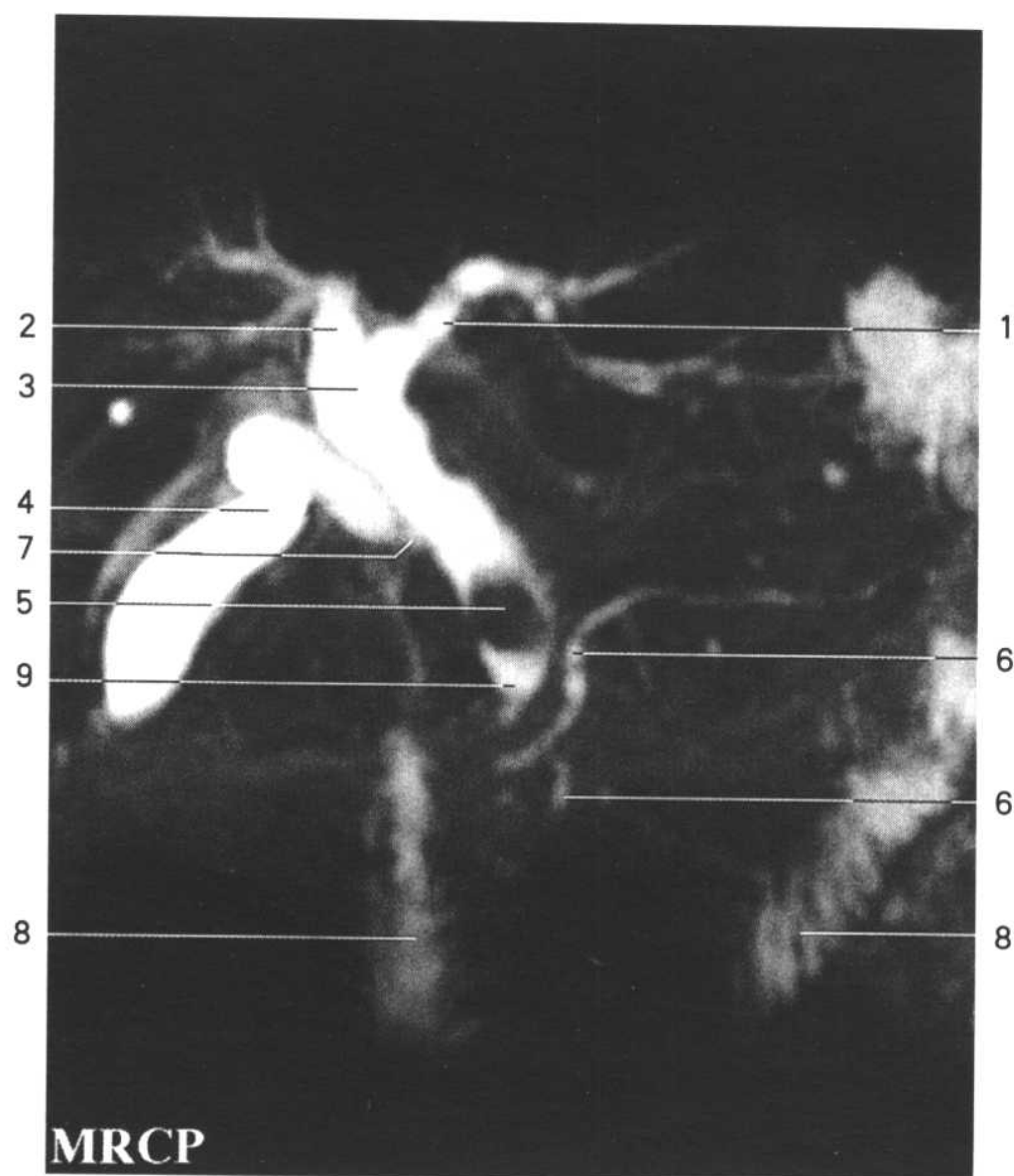
- 11. 臀中肌 gluteus medius
- 12. 髂肌 iliacus
- 13. 髂嵴 iliac crest
- 14. 升结肠 ascending colon
- 15. 结肠右曲 right colic flexure
- 16. 胃 stomach
- 17. 右后叶 right posterior lobe
- 18. 肝右静脉 right hepatic v.
- 19. 膈 diaphragm
- 20. 右肺下叶 inferior lobe of right lung
- 21. 胆囊 gallbladder



磁共振成像(胆、胰管和输尿管)MRI

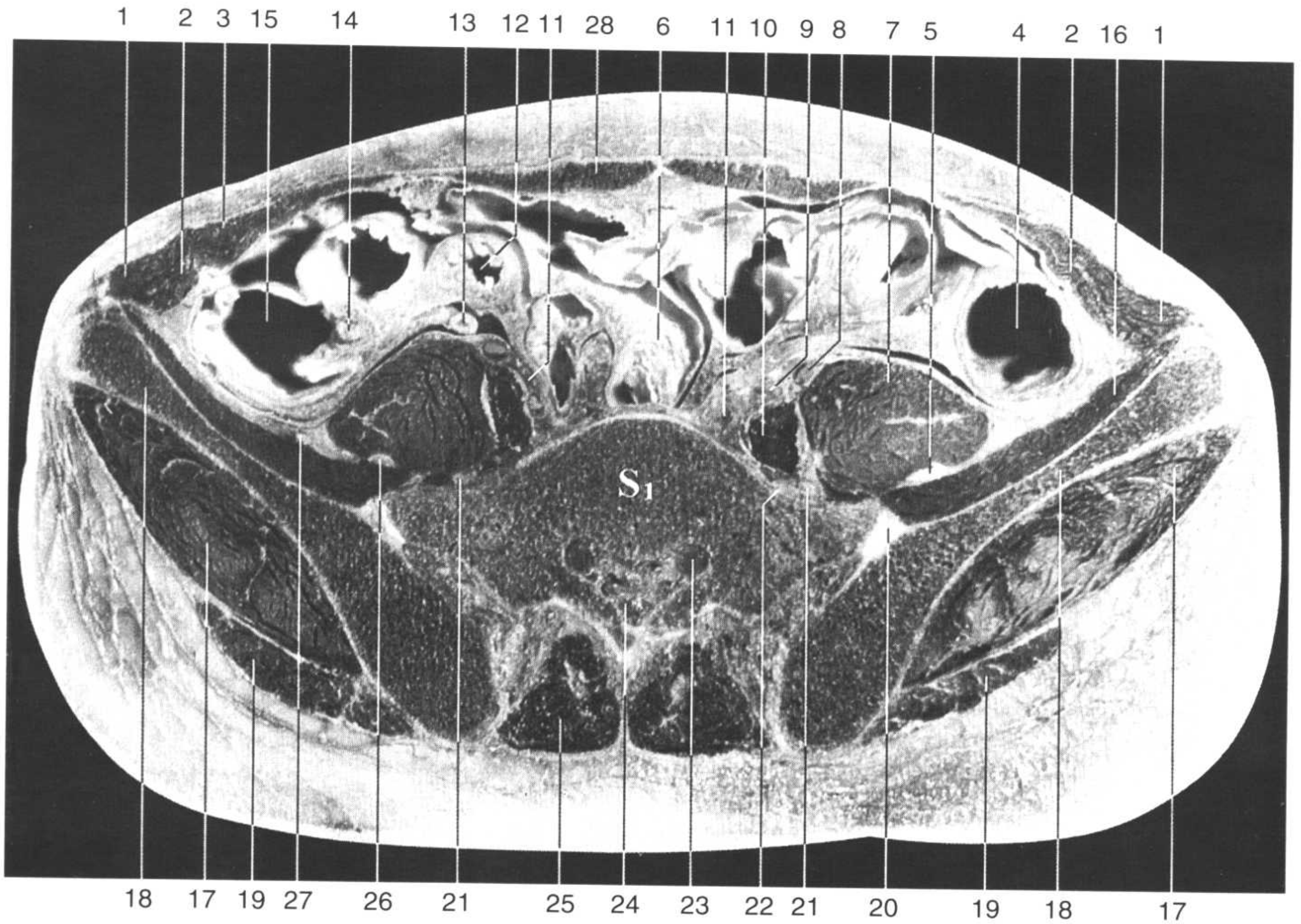
Fig.MRI

1. 肝左管 left hepatic duct
2. 肝右管 right hepatic duct
3. 肝总管 common hepatic duct
4. 胆囊 gallbladder
5. 胆结石 cholelith
6. 胰管 pancreatic duct
7. 胆囊管 cystic duct
8. 十二指肠 duodenum
9. 胆总管 common bile duct
10. 肾 kidney
11. 肾盂 renal pelvis
12. 输尿管 ureter
13. 膀胱 urinary bladder
14. 精囊 seminal vesicle
15. 蛛网膜下隙 subarachnoid space
16. 横结肠 transverse colon
17. 坐骨支 ramus of ischium
18. 升结肠 ascending colon
19. 髌骨 ilium
20. 股骨头 femoral head
21. 肾大盏 major renal calices



PELVIS

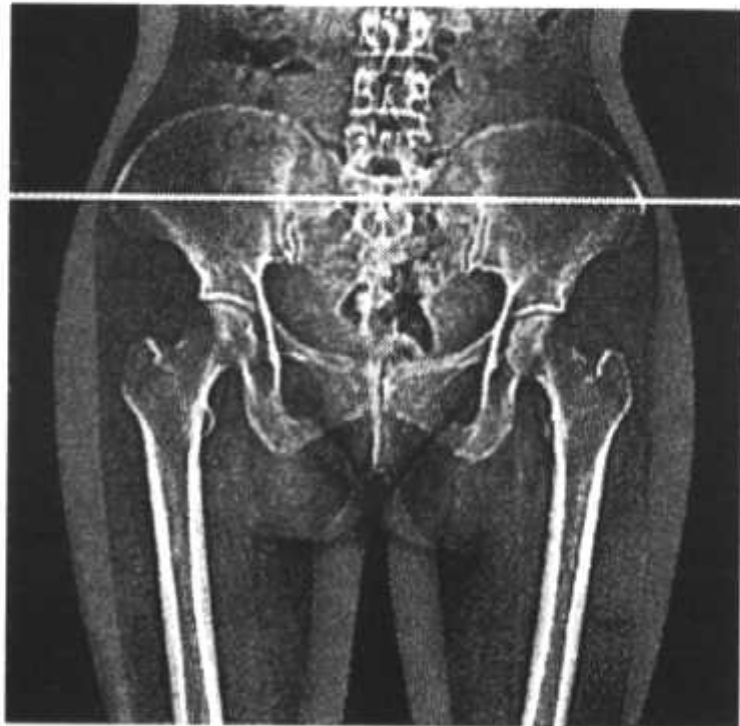盆 部



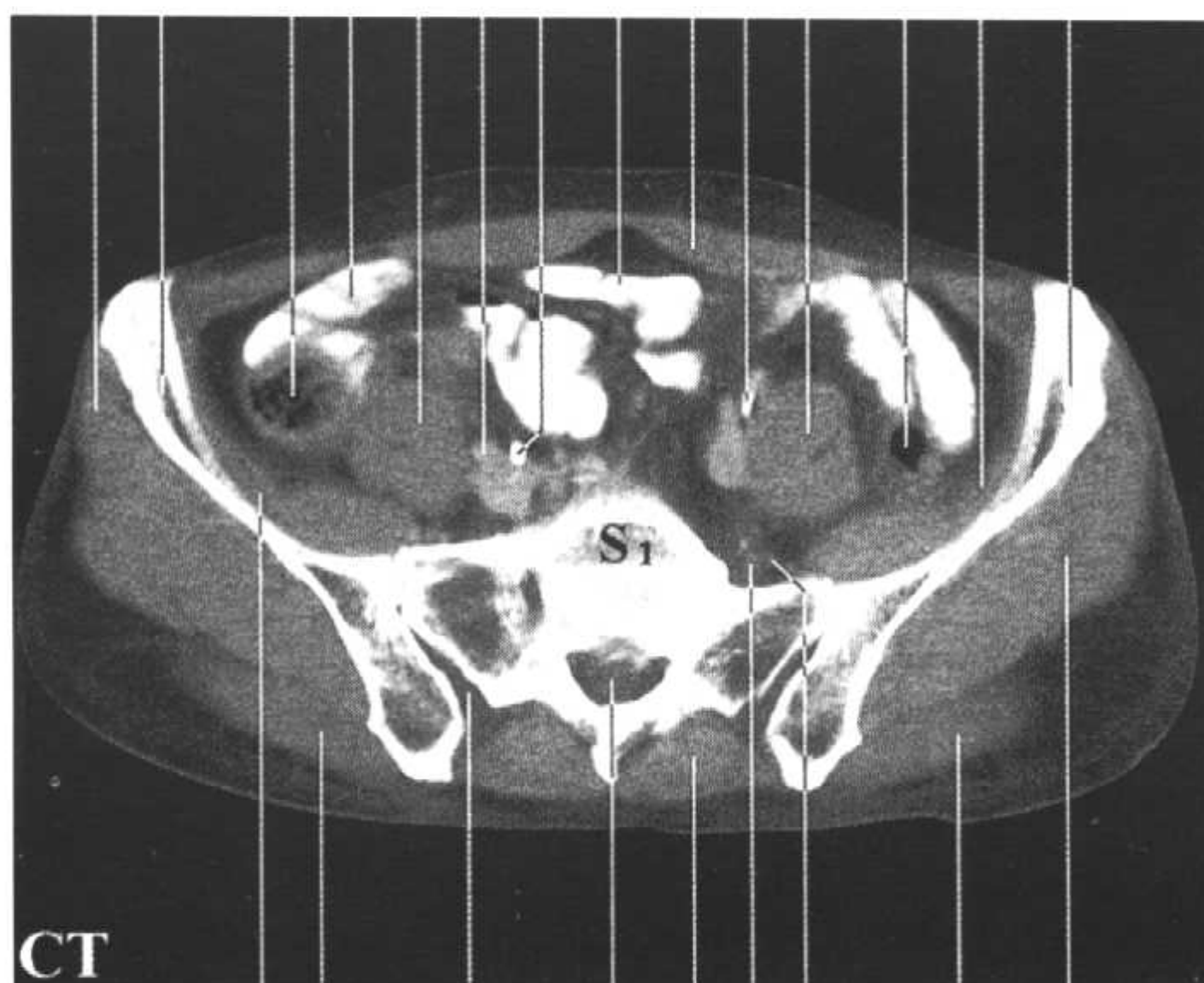女盆水平断面 HPf

Fig.HPf1

1. 腹内斜肌 obliquus internus abdominis
2. 腹横肌 transversus abdominis
3. 腹外斜肌 obliquus externus abdominis
4. 乙状结肠 sigmoid colon
5. 股神经 femoral n.
6. 回肠 ileum
7. 腰大肌 psoas major
8. 左髂外动脉 left external iliac a.
9. 左髂内动脉 left internal iliac a.
10. 左髂总静脉 left common iliac v.

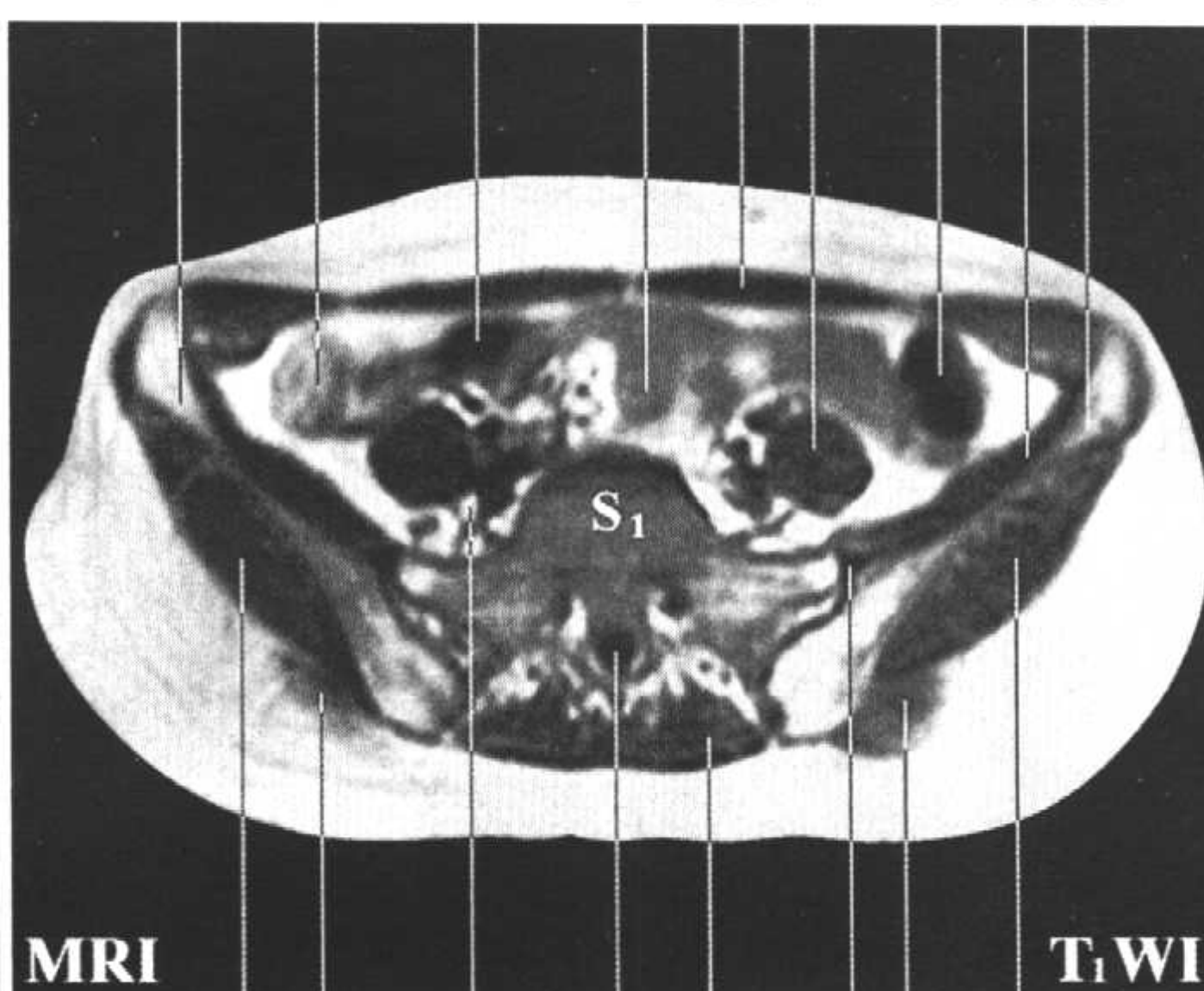


17 18 15 12 7 29 11 12 28 11 7 4 16 18



16 19 20 24 25 22 21 19 17

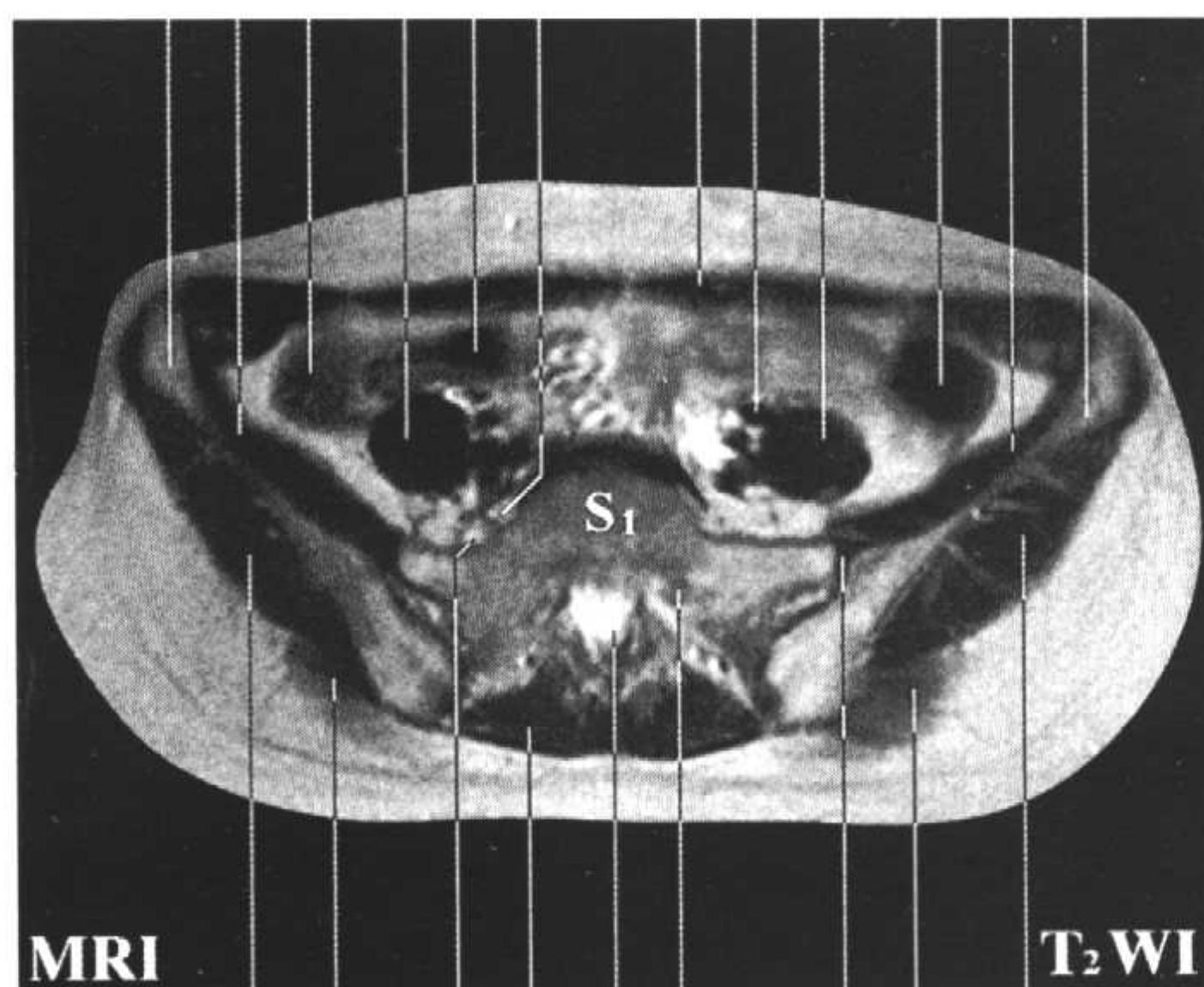
18 15 12 6 28 7 4 16 18



17 19 21 24 25 20 19 17

11. 输尿管 ureter
12. 回肠 ileum
13. 阑尾 vermiform appendix
14. 回盲瓣 ileocecal valve
15. 盲肠 cecum
16. 髂肌 iliacus
17. 臀中肌 gluteus medius
18. 髂骨翼 ala of ilium
19. 臀大肌 gluteus maximus
20. 骶髂关节 sacroiliac joint
21. 闭孔神经 obturator n.
22. 腰骶干 lumbosacral trunk
23. 第1骶神经 1st sacral n.
24. 马尾 cauda equina
25. 竖脊肌 erector spinae
26. 股神经 femoral n.
27. 股外侧皮神经 lateral femoral cutaneous n.
28. 腹直肌 rectus abdominis
29. 右髂外动脉 right external iliac a.

18 16 15 7 12 22 28 8 7 4 16 18



17 19 21 25 24 23 20 19 17

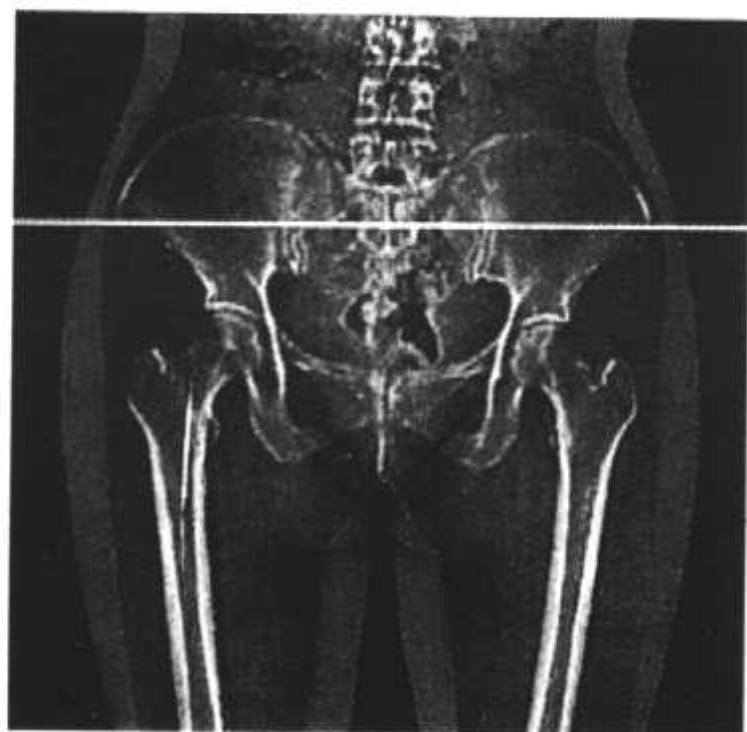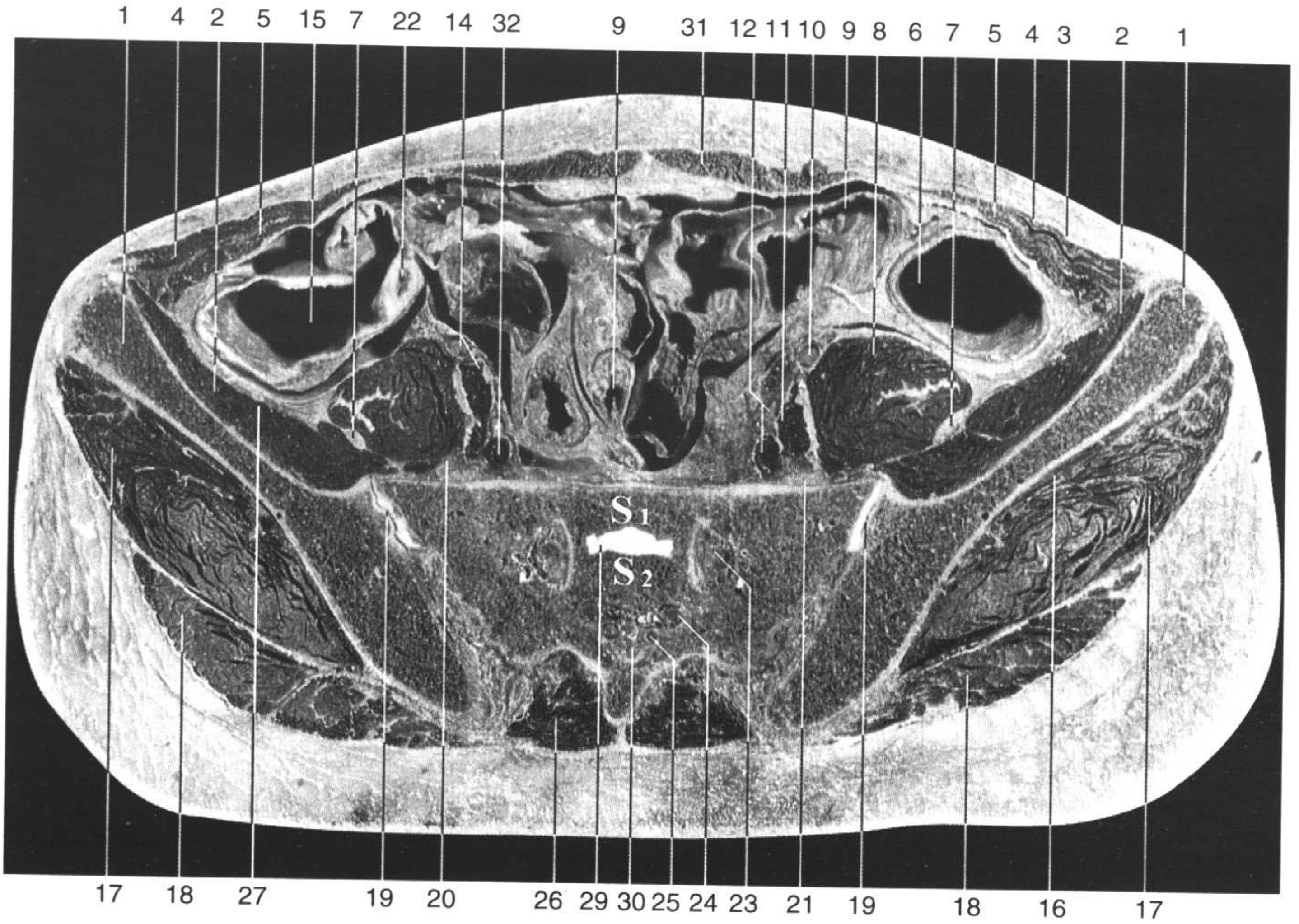
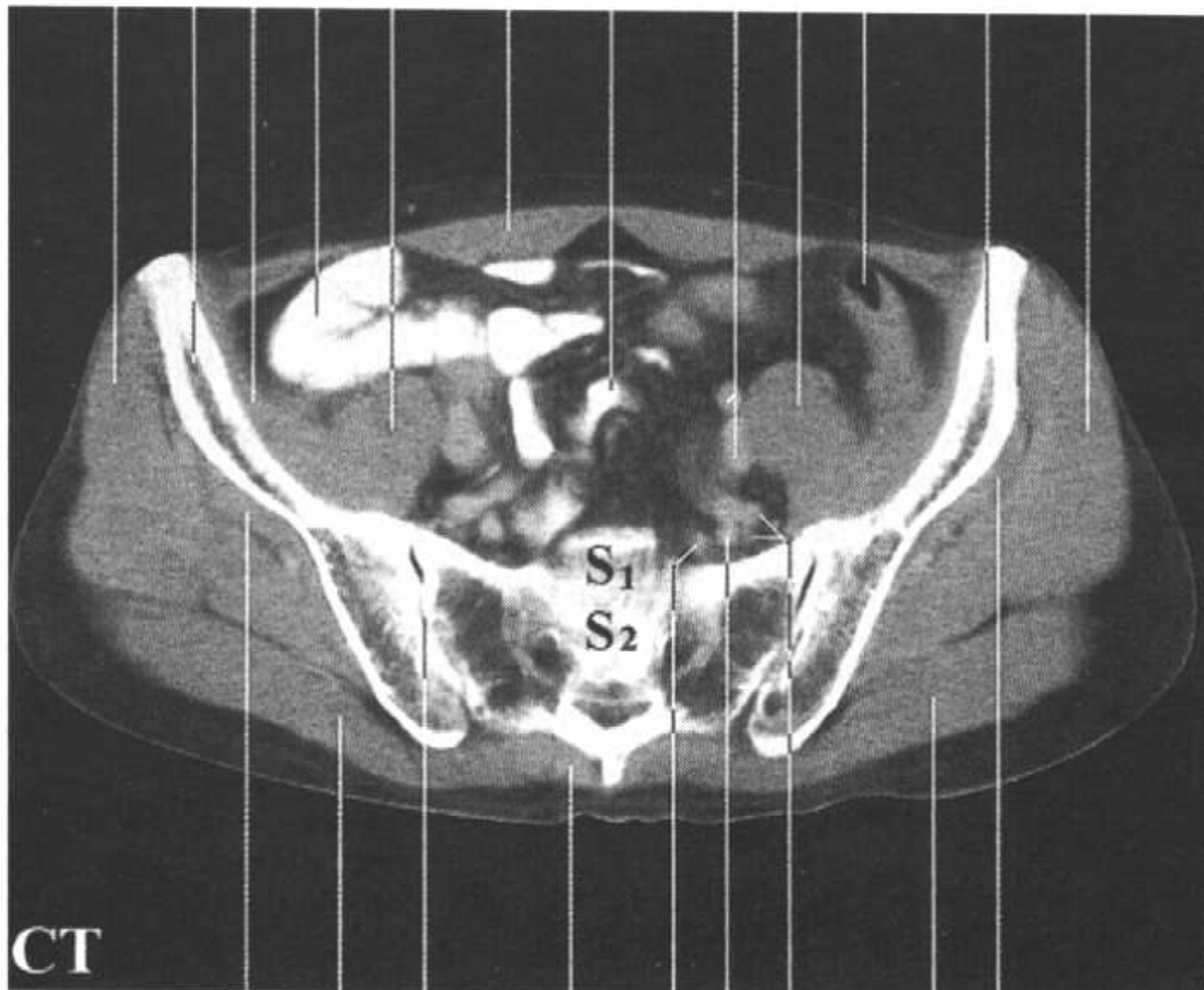


Fig.HPf2

1. 髂骨翼 ala of ilium
2. 髂肌 iliacus
3. 腹外斜肌腱膜 aponeurosis of obliquus externus abdominis
4. 腹内斜肌 obliquus internus abdominis
5. 腹横肌 transversus abdominis
6. 乙状结肠 sigmoid colon
7. 股神经 femoral n.
8. 腰大肌 psoas major
9. 回肠 ileum

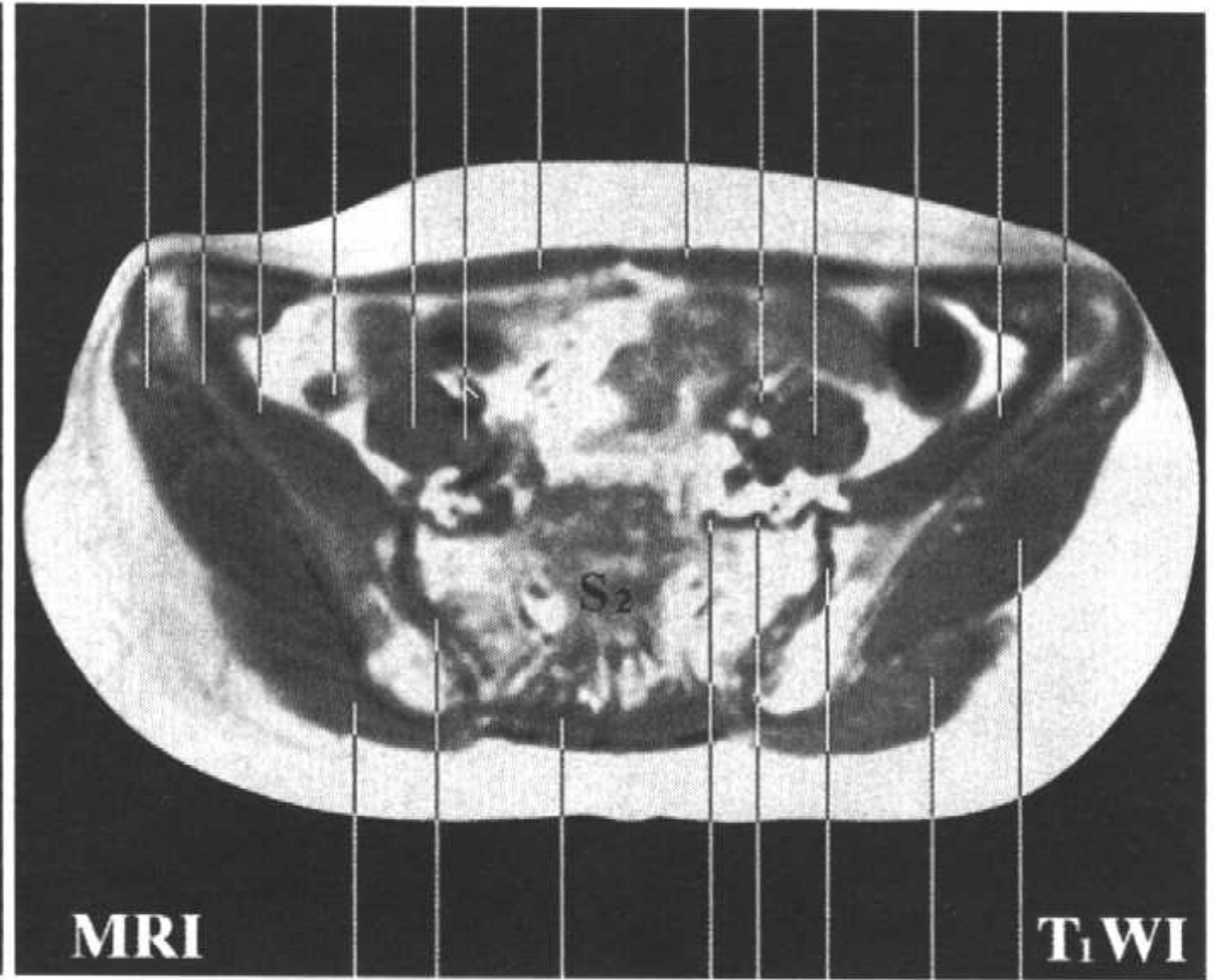
17 1 2 28 8 31 13 11 8 6 1 17

17 1 2 9 8 14 31 31 10 8 6 2 1



CT

16 18 19 26 21 20 12 18 16



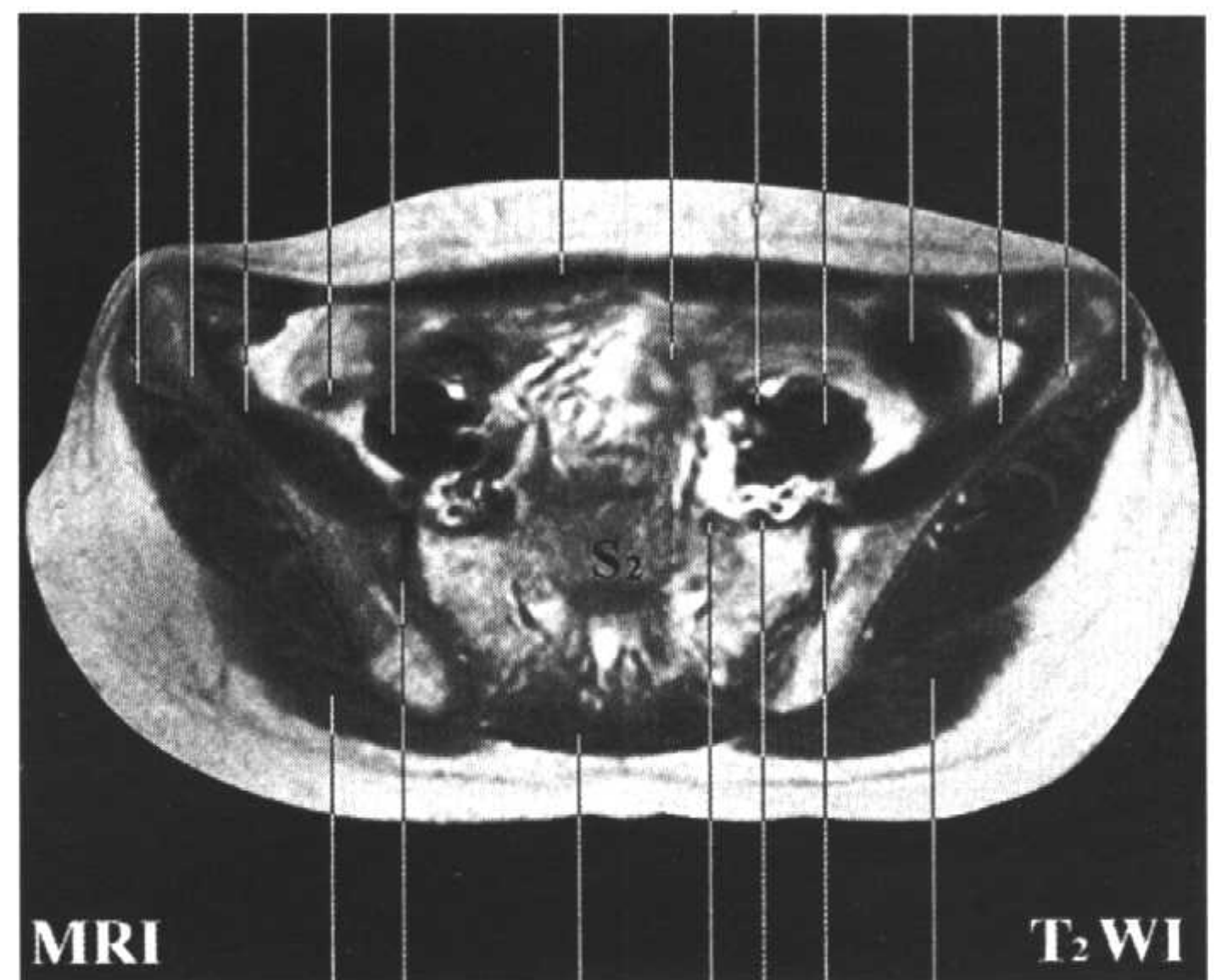
MRI

T₁WI

18 19 26 21 20 19 18 17

10. 左髂外动脉 left external iliac a.
11. 左髂外静脉 left external iliac v.
12. 左髂内动、静脉 left internal iliac a. and v.
13. 回肠 ileum
14. 右髂外动、静脉 right external iliac a. and v.
15. 盲肠 cecum
16. 臀小肌 gluteus minimus
17. 臀中肌 gluteus medius
18. 臀大肌 gluteus maximus
19. 骶髂关节 sacroiliac joint
20. 闭孔神经 obturator n.
21. 腰骶干 lumbosacral trunk
22. 阑尾 vermiform appendix
23. 第1骶神经 1st sacral n.
24. 第2骶神经 2nd sacral n.
25. 第3骶神经 3rd sacral n.
26. 竖脊肌 erector spinae
27. 股外侧皮神经 lateral femoral cutaneous n.
28. 回肠 ileum
29. 1、2骶椎间盘 intervertebral disc (S₁-S₂)
30. 第4骶神经 4th sacral n.
31. 腹直肌 rectus abdominis
32. 右髂内动、静脉 right medial iliac a. and v.

17 1 2 9 8 31 9 10 8 6 2 1 17



MRI

T₂WI

18 19 26 21 20 19 18

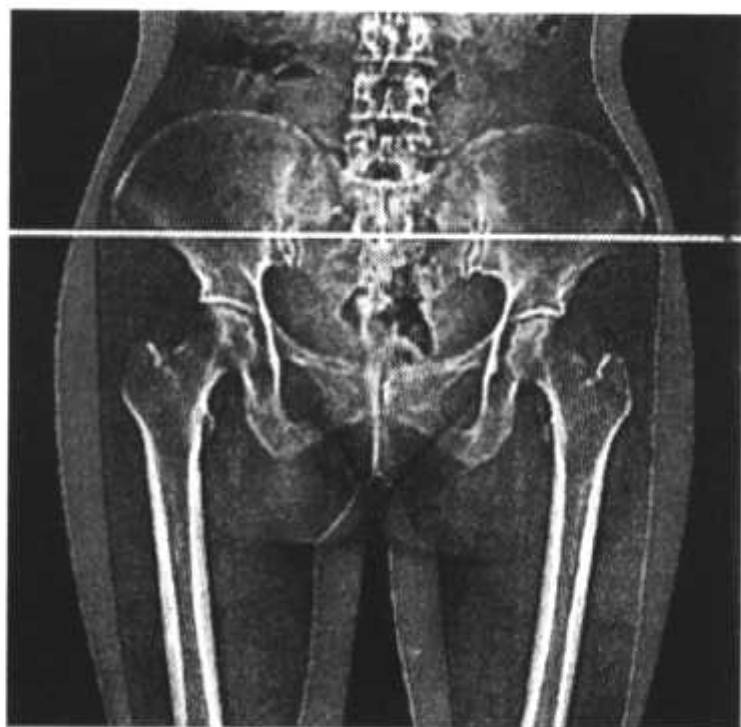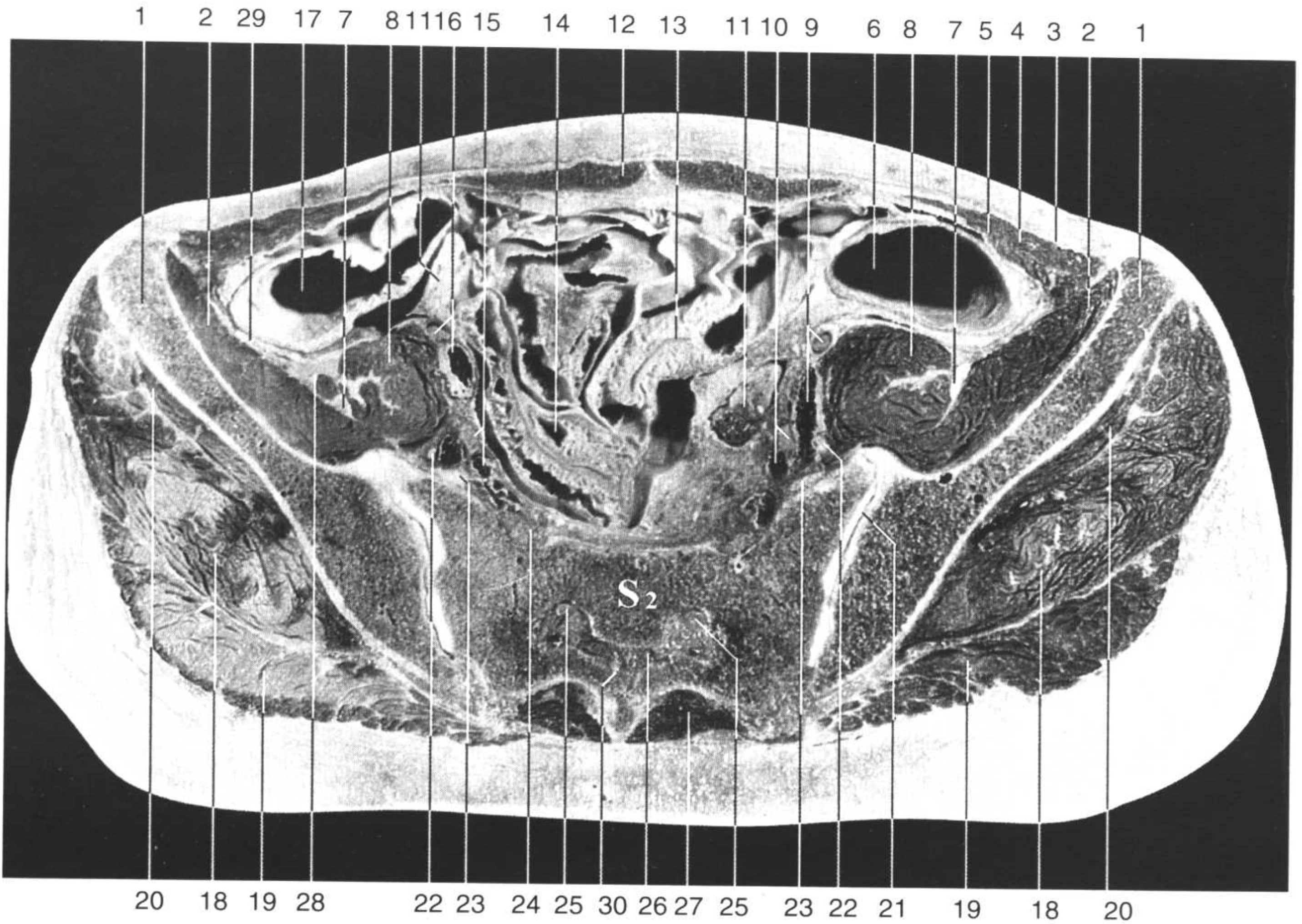
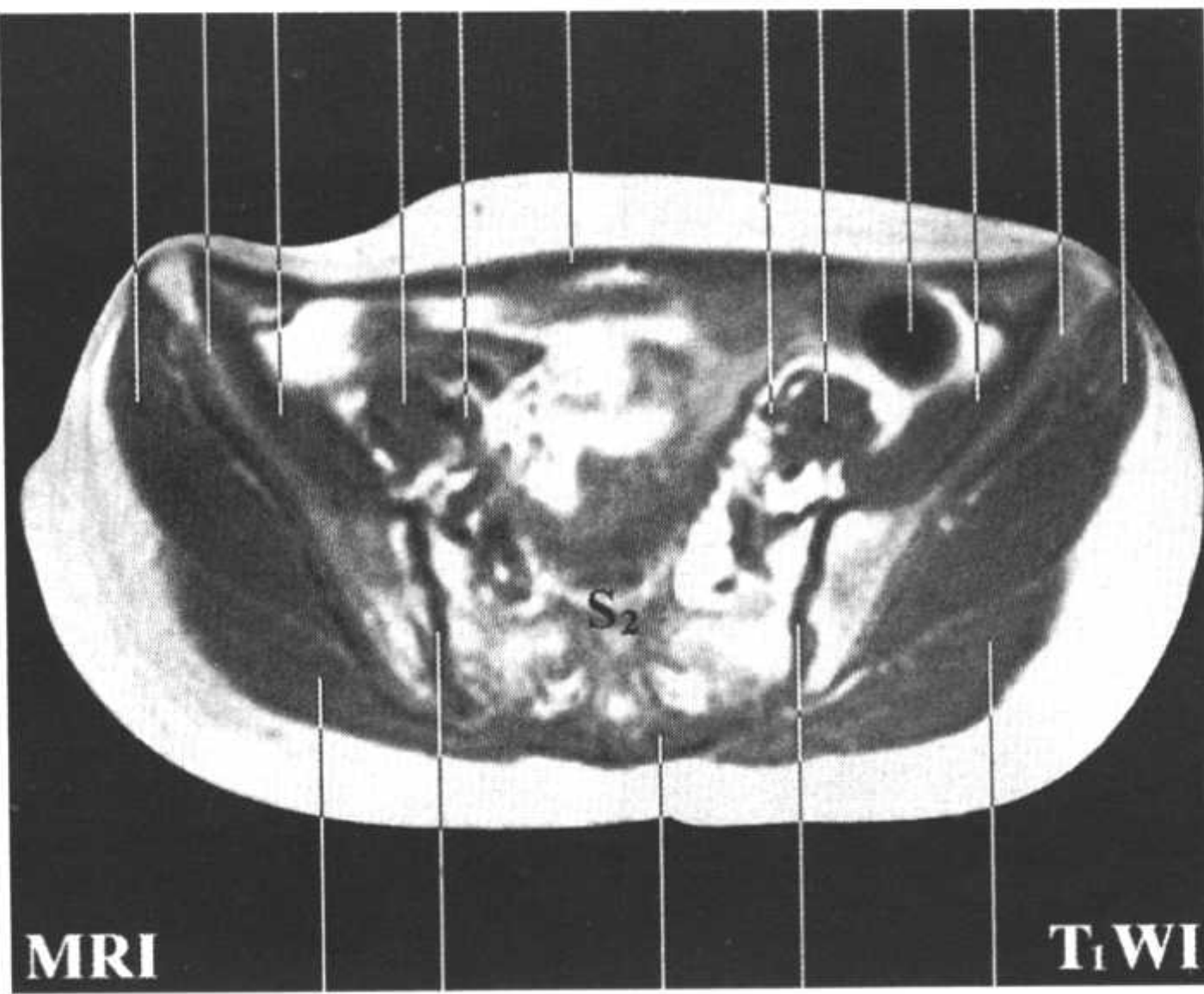
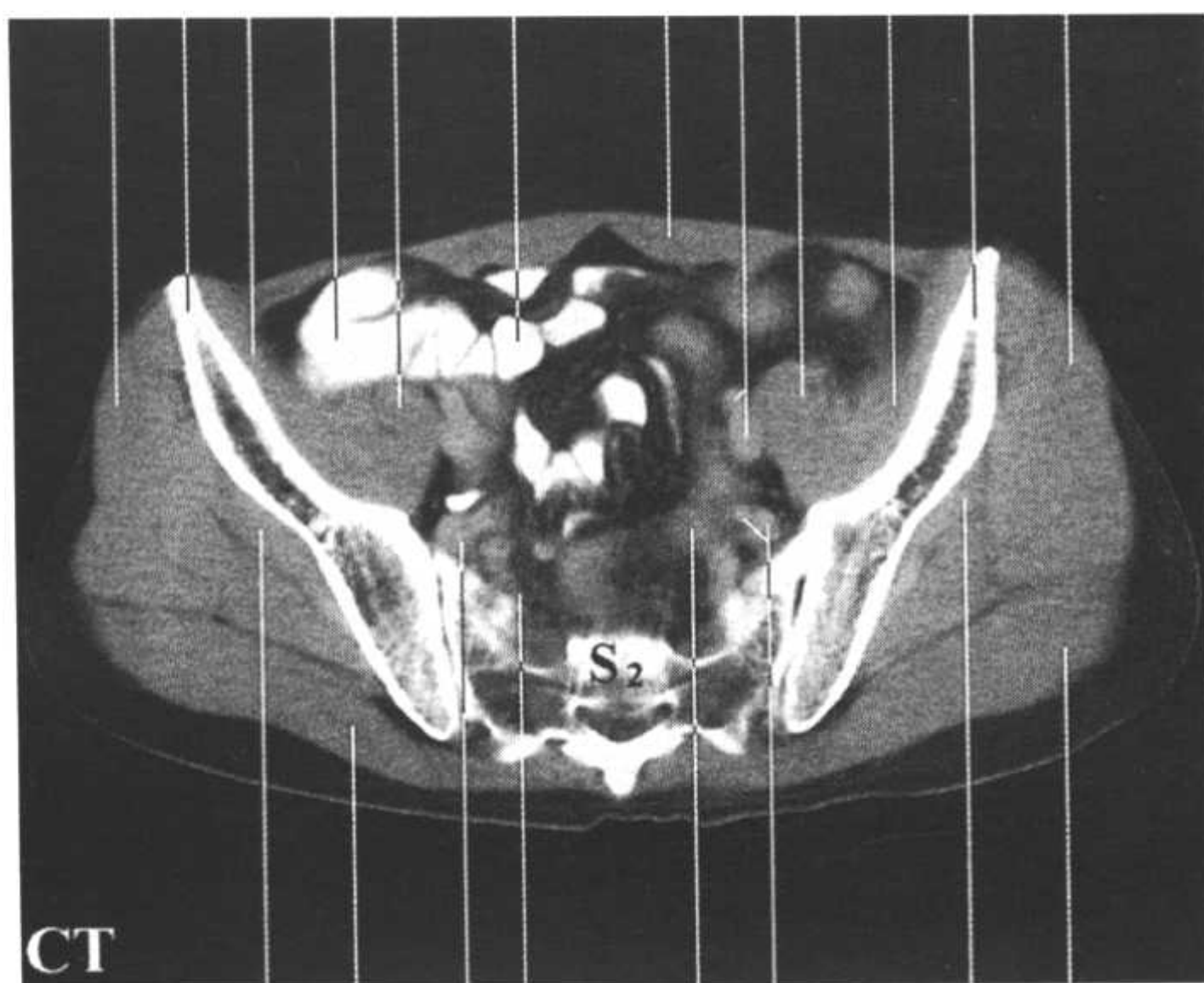


Fig.HPf3

1. 髂骨翼 ala of ilium
2. 髂肌 iliacus
3. 腹外斜肌腱膜 aponeurosis of obliquus externus abdominis
4. 腹内斜肌 obliquus internus abdominis
5. 腹横肌 transversus abdominis
6. 乙状结肠 sigmoid colon
7. 股神经 femoral n.
8. 腰大肌 psoas major
9. 左髂外动、静脉 left external iliac a.and v.

18 1 2 13 8 14 12 9 8 2 1 18

18 1 2 8 16 12 9 8 6 2 1 18

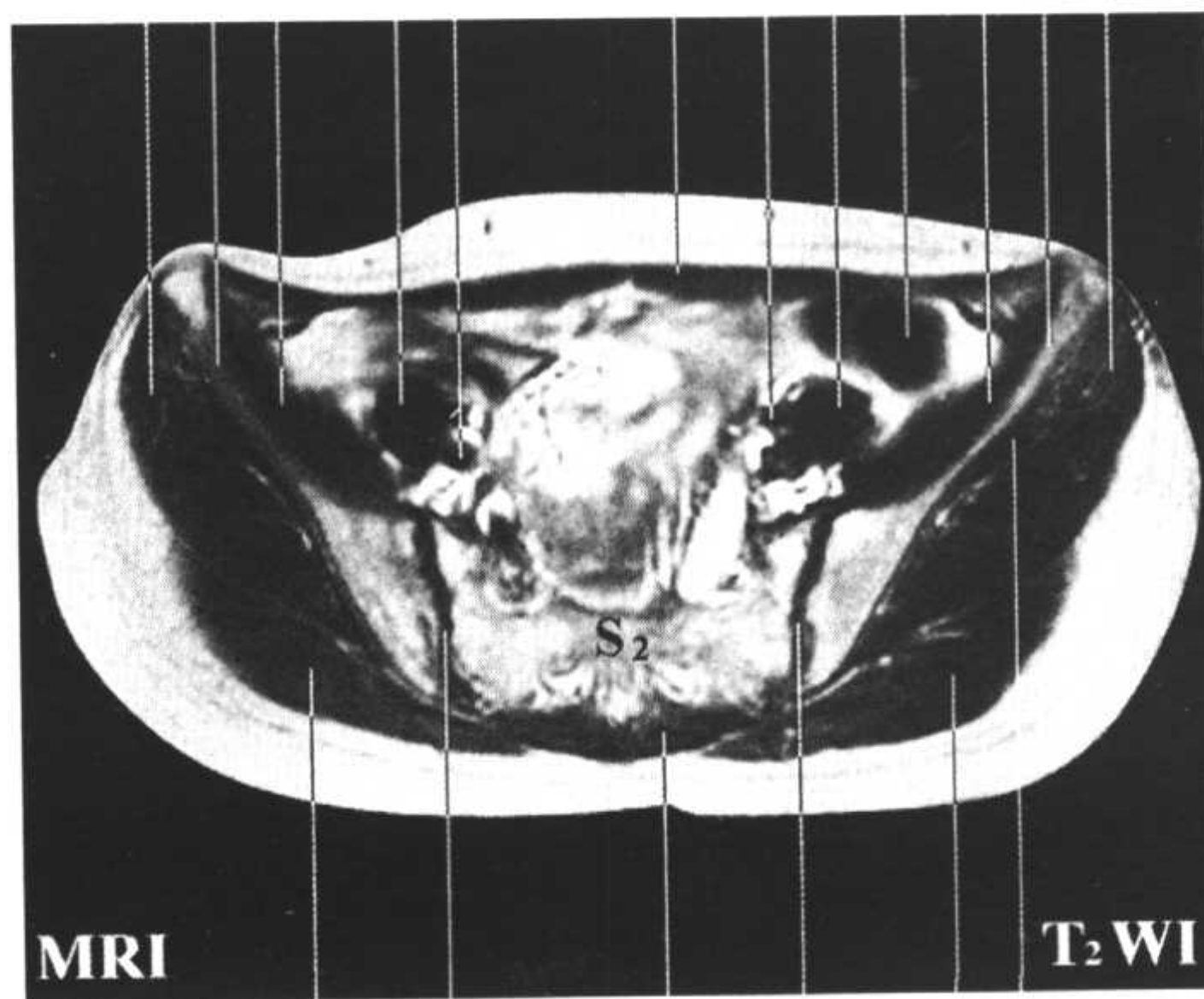


20 19 23 24 6 10 20 19

19 21 27 21 19

10. 左髂内动、静脉 left internal iliac a. and v.
11. 卵巢 ovary
12. 腹直肌 rectus abdominis
13. 回肠 ileum
14. 回肠 ileum
15. 右髂内动、静脉 right internal iliac a. and v.
16. 右髂外动、静脉 right external iliac a. and v.
17. 盲肠 cecum
18. 臀中肌 gluteus medius
19. 臀大肌 gluteus maximus
20. 臀小肌 gluteus minimus
21. 骶髂关节 sacroiliac joint
22. 闭孔神经 obturator n.
23. 腰骶干 lumbosacral trunk
24. 第1骶神经 1st sacral n.
25. 第2骶神经 2nd sacral n.
26. 第3骶神经 3rd sacral n.
27. 竖脊肌 erector spinae
28. 股外侧皮神经 lateral femoral cutaneous n.
29. 髂腹股沟神经 ilioinguinal n.
30. 第4骶神经 4th sacral n.

18 1 2 8 16 12 9 8 6 2 1 18



19 21 27 21 19 20

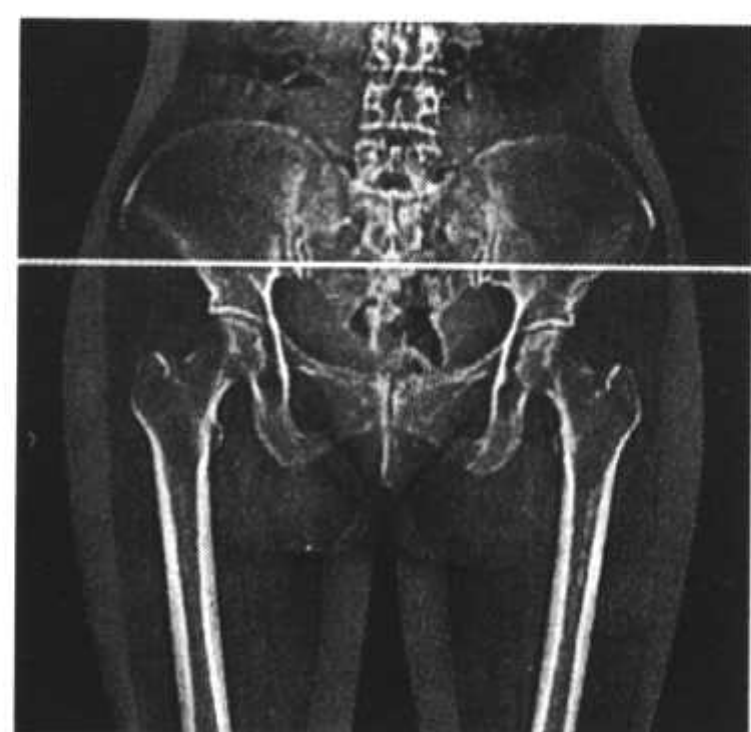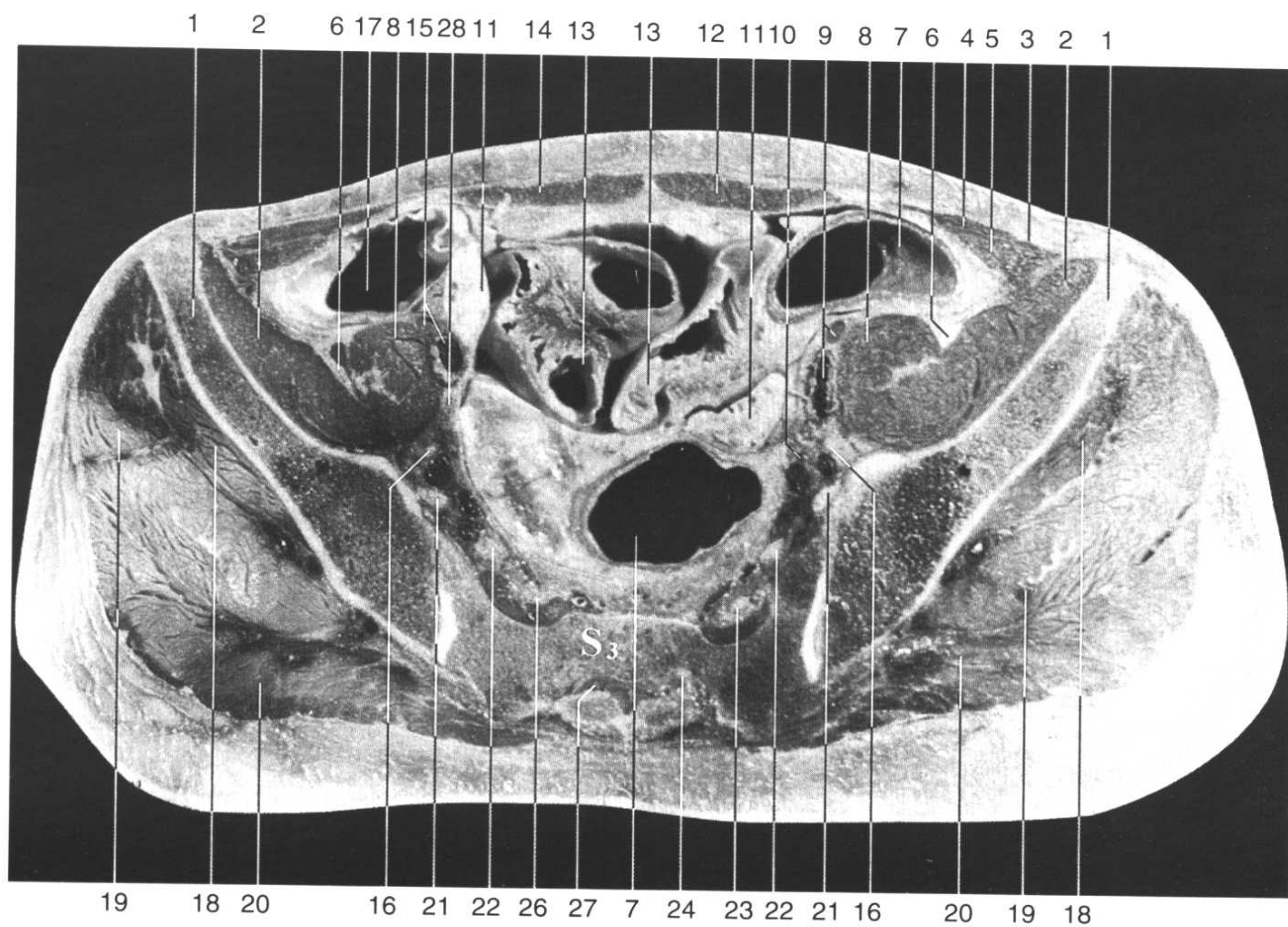
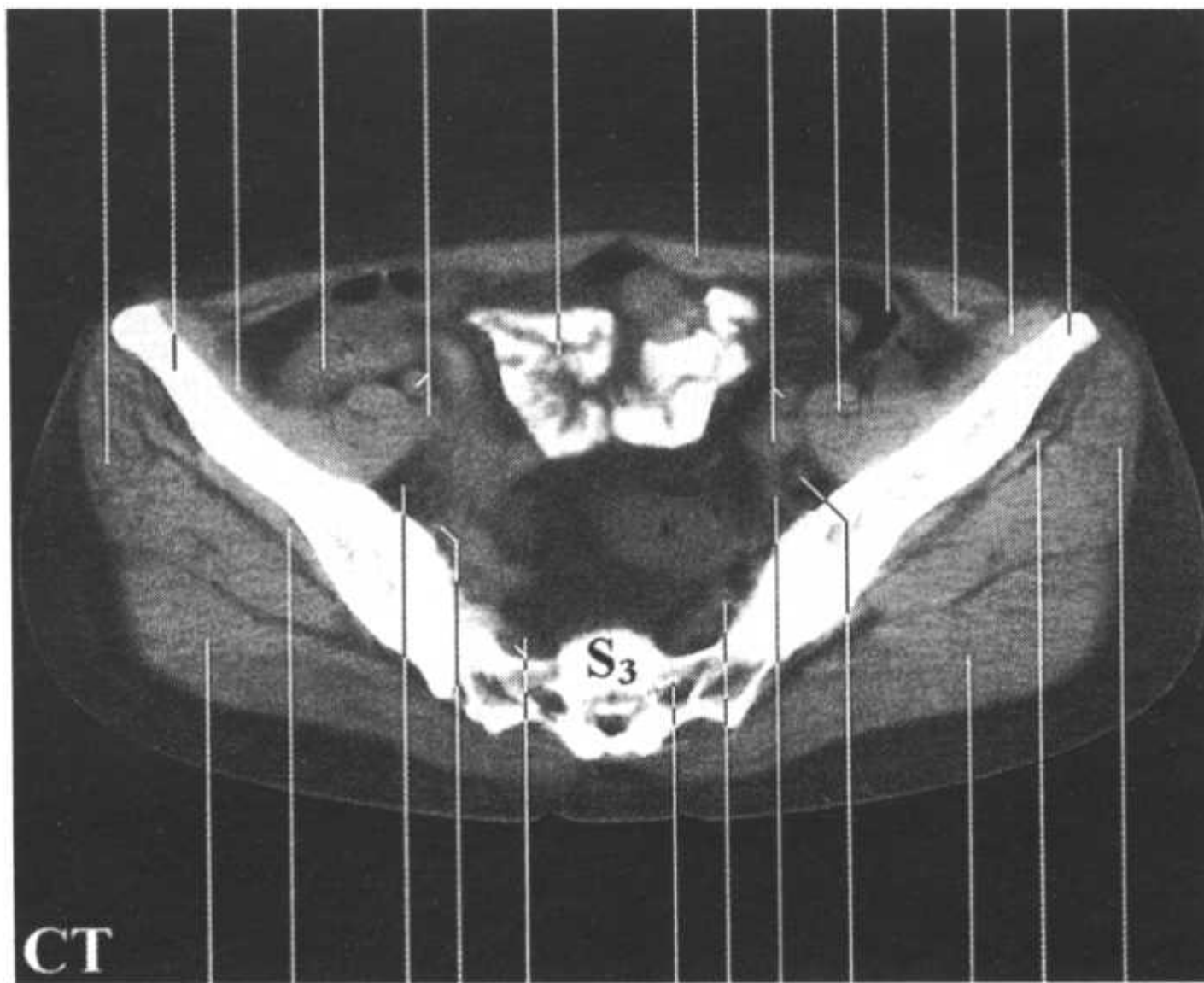


Fig.HPf4

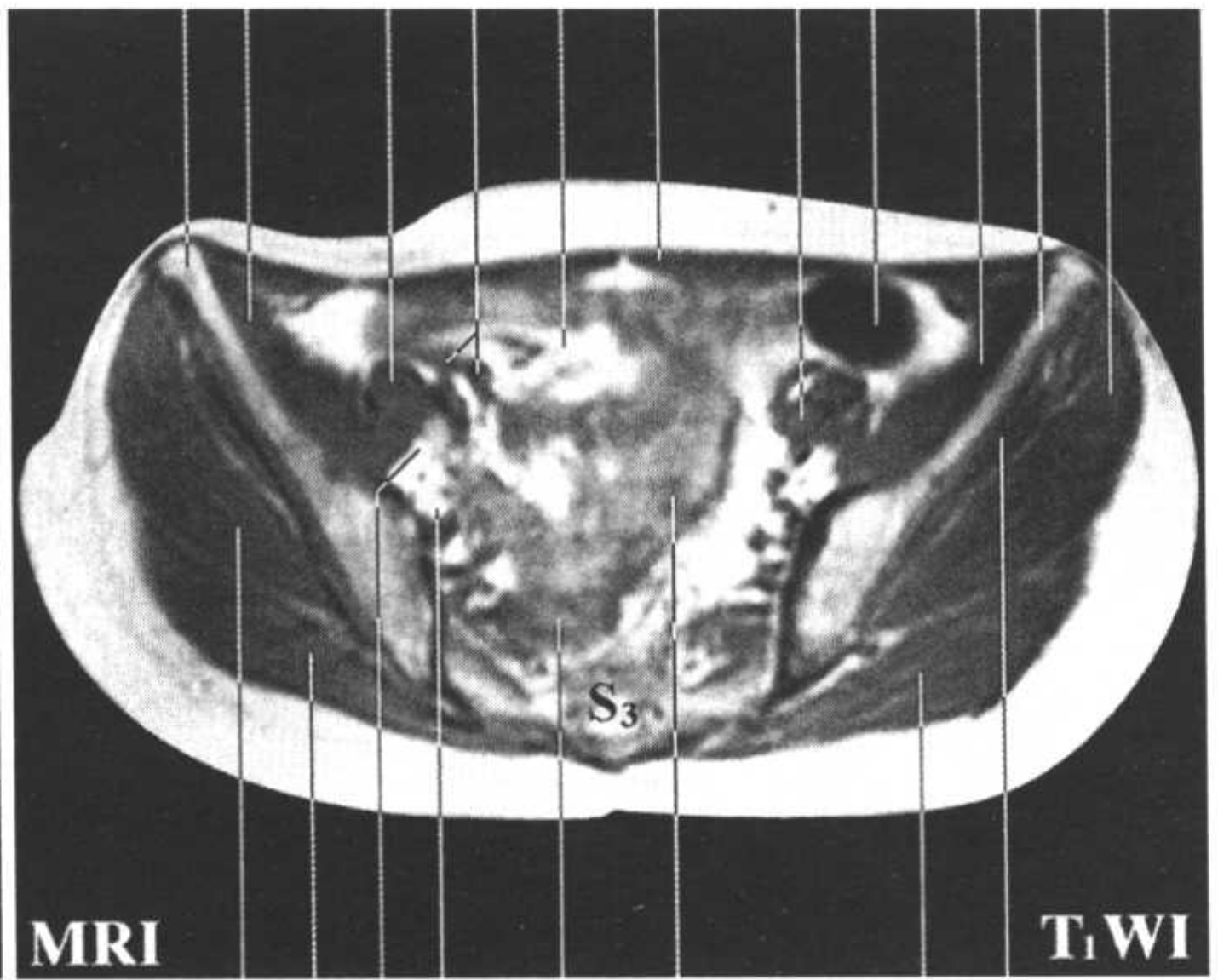
1. 髂骨翼 ala of ilium
2. 髂肌 iliacus
3. 腹外斜肌腱膜 aponeurosis of obliquus externus abdominis
4. 腹内斜肌 obliquus internus abdominis
5. 腹横肌 transversus abdominis
6. 股神经 femoral n.
7. 乙状结肠 sigmoid colon
8. 腰大肌 psoas major
9. 左髂外动、静脉 left external iliac a. and v.

19 1 2 17 15 13 12 9 8 25 5 2 1



20 18 16 21 26 27 22 21 16 20 18 19

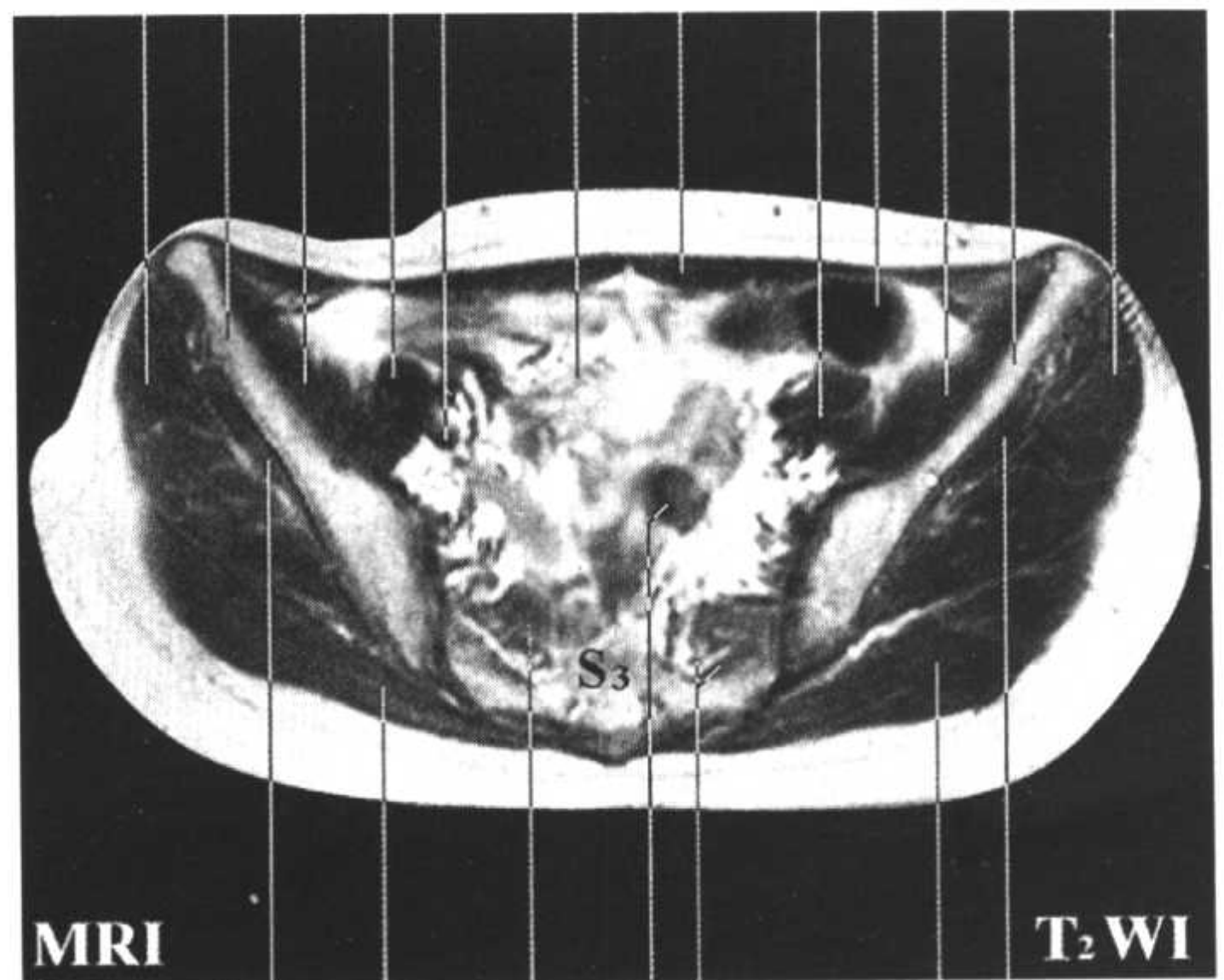
1 2 8 15 13 12 8 7 2 1 19



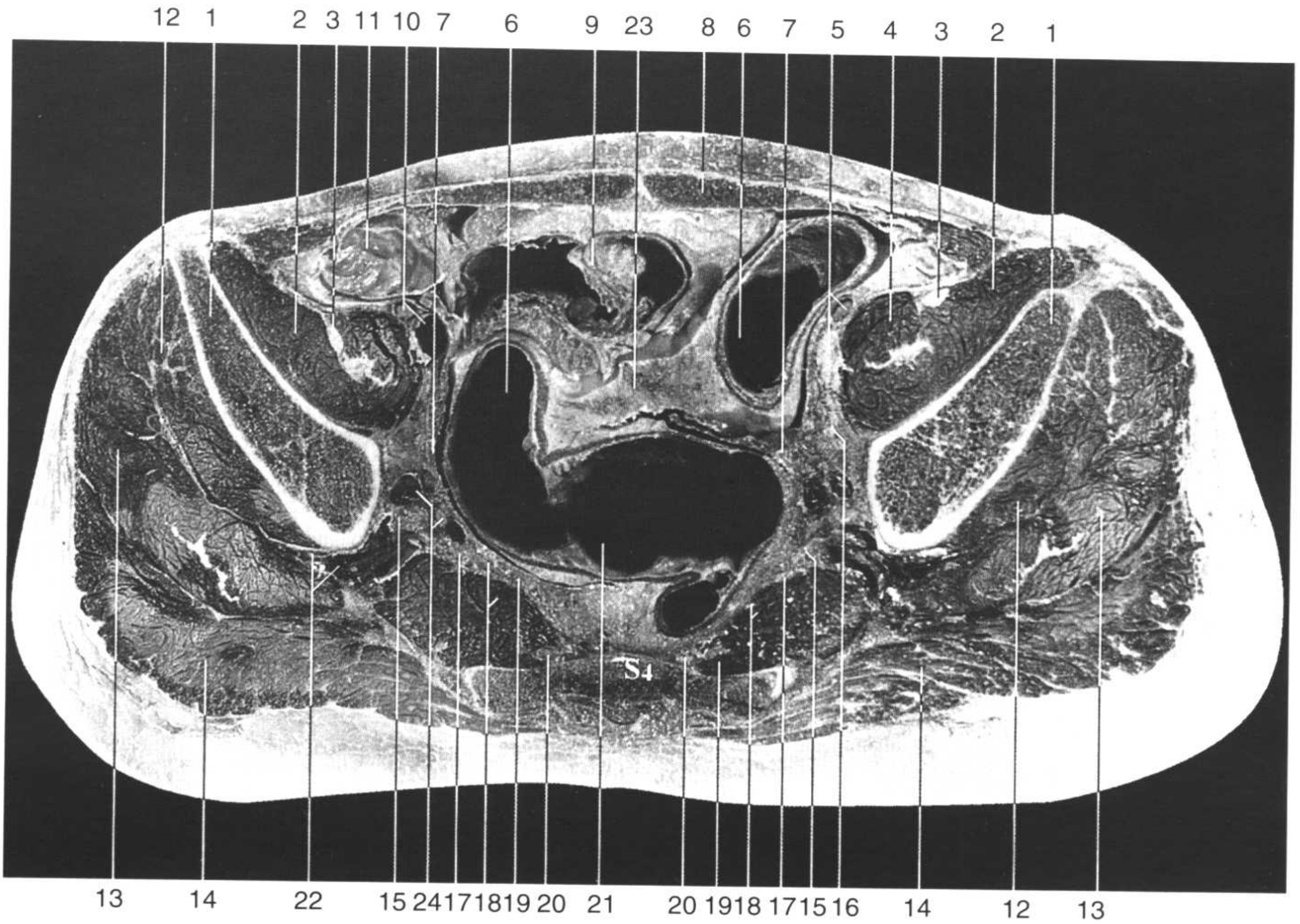
19 20 16 21 26 7 20 18

10. 输尿管 ureter
11. 卵巢 ovary
12. 腹直肌 rectus abdominis
13. 回肠 ileum
14. 腹直肌 rectus abdominis
15. 右髂外动、静脉 right external iliac a. and v.
16. 闭孔神经 obturator n.
17. 盲肠 cecum
18. 臀小肌 gluteus minimus
19. 臀中肌 gluteus medius
20. 臀大肌 gluteus maximus
21. 腰骶干 lumbosacral trunk
22. 第1骶神经 1st sacral n.
23. 第2骶神经 2nd sacral n.
24. 第3骶神经 3rd sacral n.
25. 乙状结肠 sigmoid colon
26. 第2骶神经与梨状肌 2nd sacral n. and piriformis
27. 第4骶神经 4th sacral n.
28. 右髂内动脉 right internal iliac a.

19 1 2 8 15 13 12 8 7 2 1 19



18 20 26 7 26 20 18

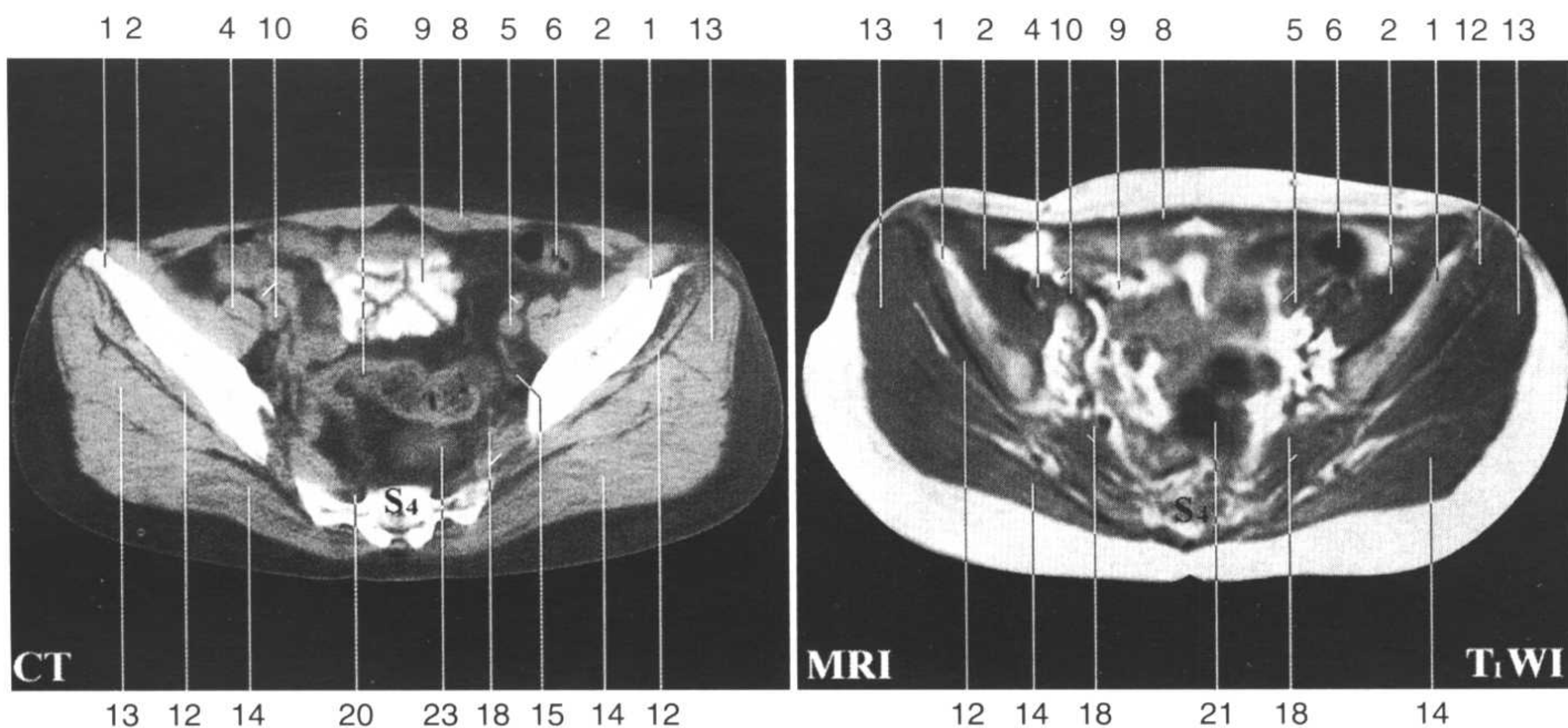


12 1 2 3 11 10 7 6 9 23 8 6 7 5 4 3 2 1
13 14 22 15 24 17 18 19 20 21 20 19 18 17 15 16 14 12 13

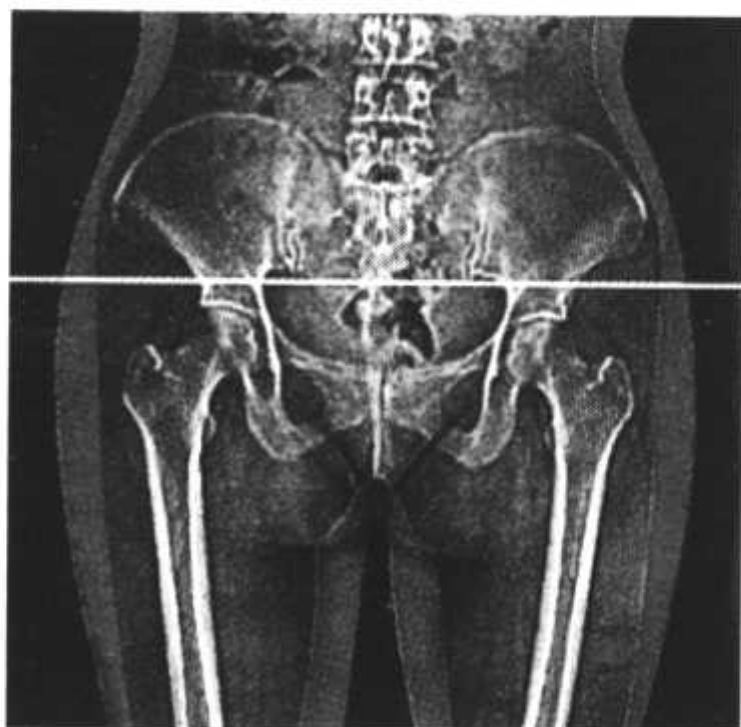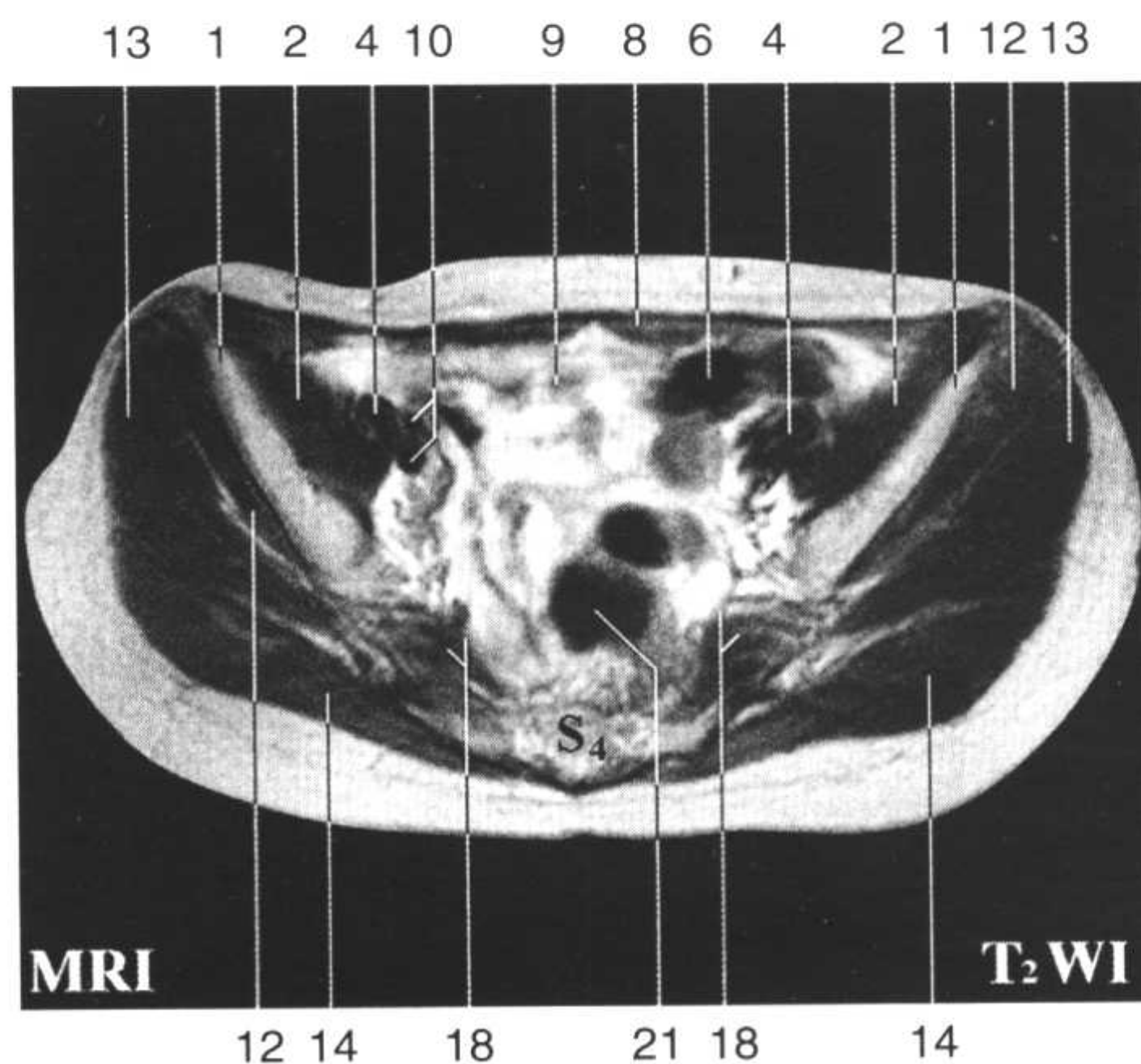


Fig.HPf5

1. 髂骨翼 ala of ilium
2. 髂肌 iliacus
3. 股神经 femoral n.
4. 腰大肌 psoas major
5. 左髂外动、静脉 left external iliac a. and v.
6. 乙状结肠 sigmoid colon
7. 输尿管 ureter
8. 腹直肌 rectus abdominis
9. 回肠 ileum
10. 右髂外动、静脉 right external iliac a. and v.



- 11. 盲肠 cecum
- 12. 臀小肌 gluteus minimus
- 13. 臀中肌 gluteus medius
- 14. 臀大肌 gluteus maximus
- 15. 腰骶干 lumbosacral trunk
- 16. 闭孔神经 obturator n.
- 17. 第1骶神经 1st sacral n.
- 18. 第2骶神经与梨状肌 2nd sacral n. and piriformis
- 19. 第3骶神经 3rd sacral n.
- 20. 第4骶神经 4th sacral n.
- 21. 直肠 rectum
- 22. 臀上动、静脉 superior gluteal a. and v.
- 23. 子宫 uterus
- 24. 右髂内动脉、静脉 right internal iliac a. and v.



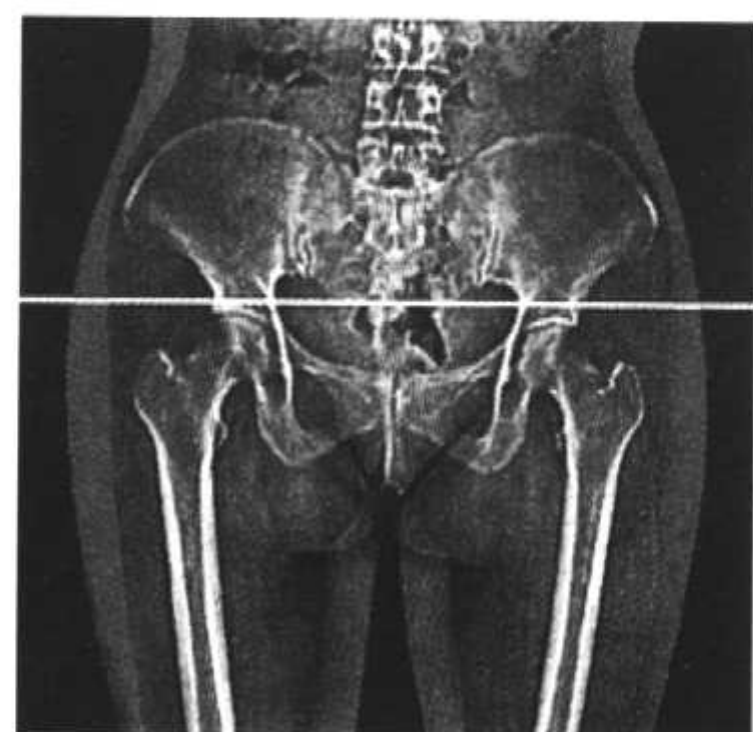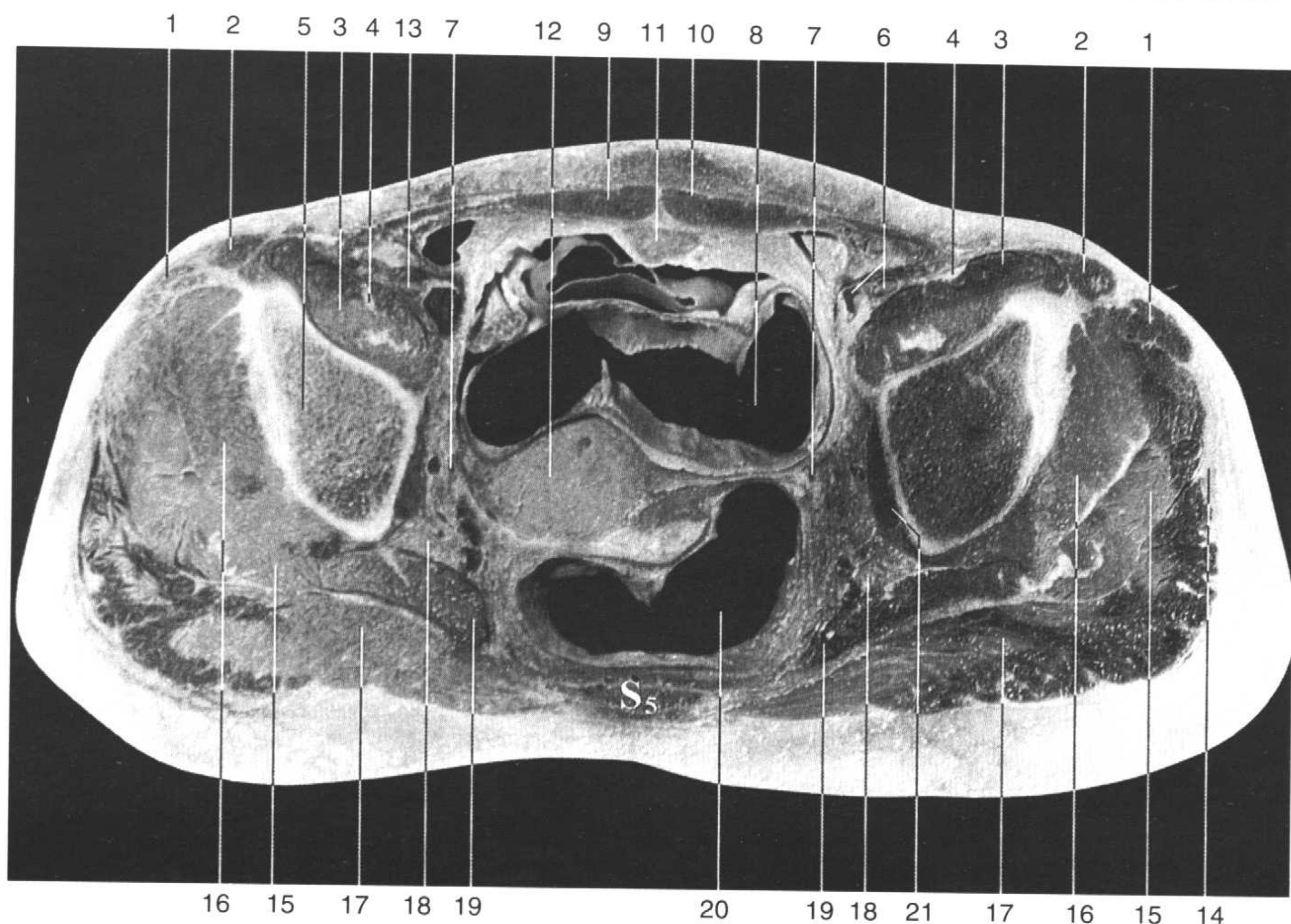


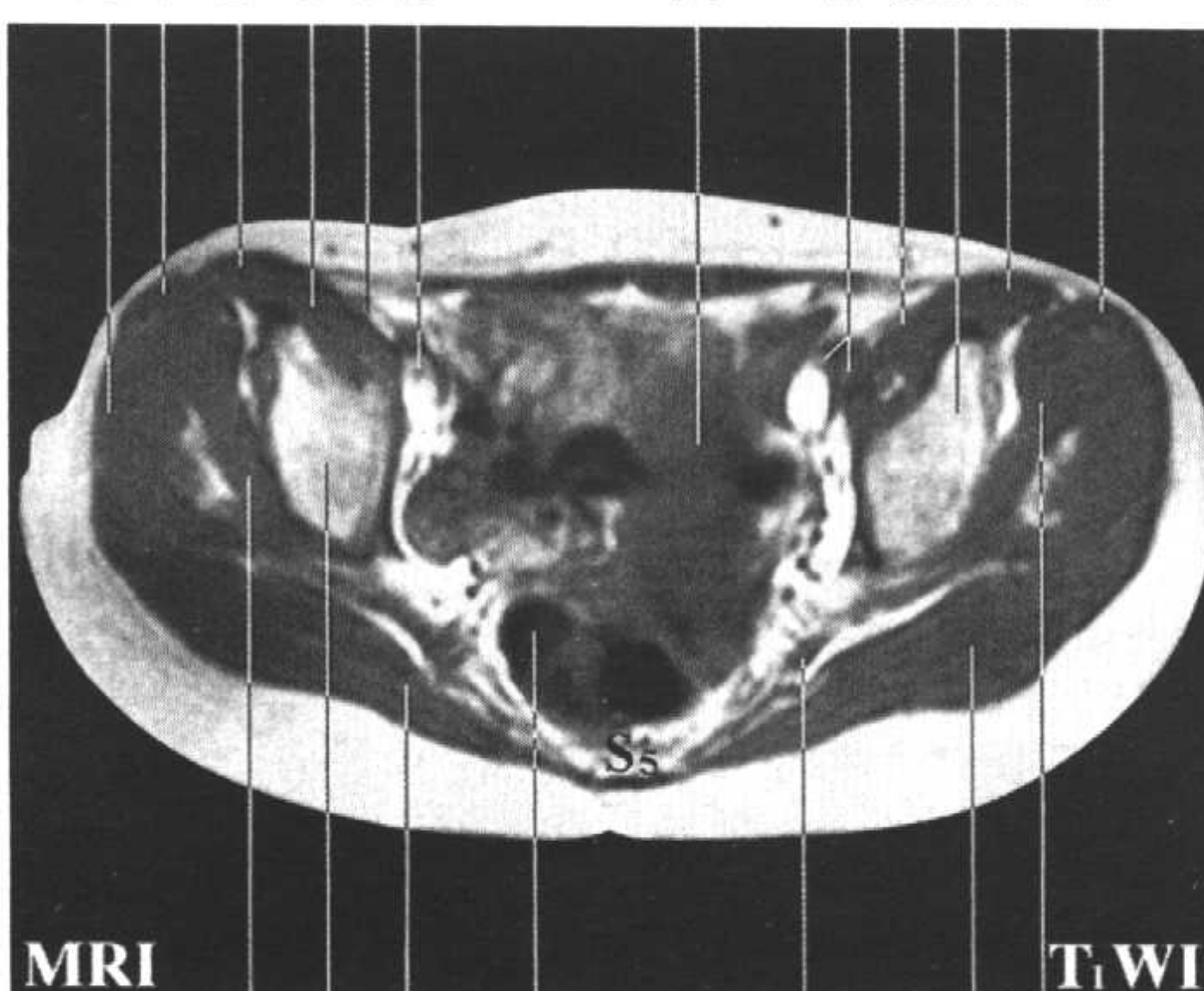
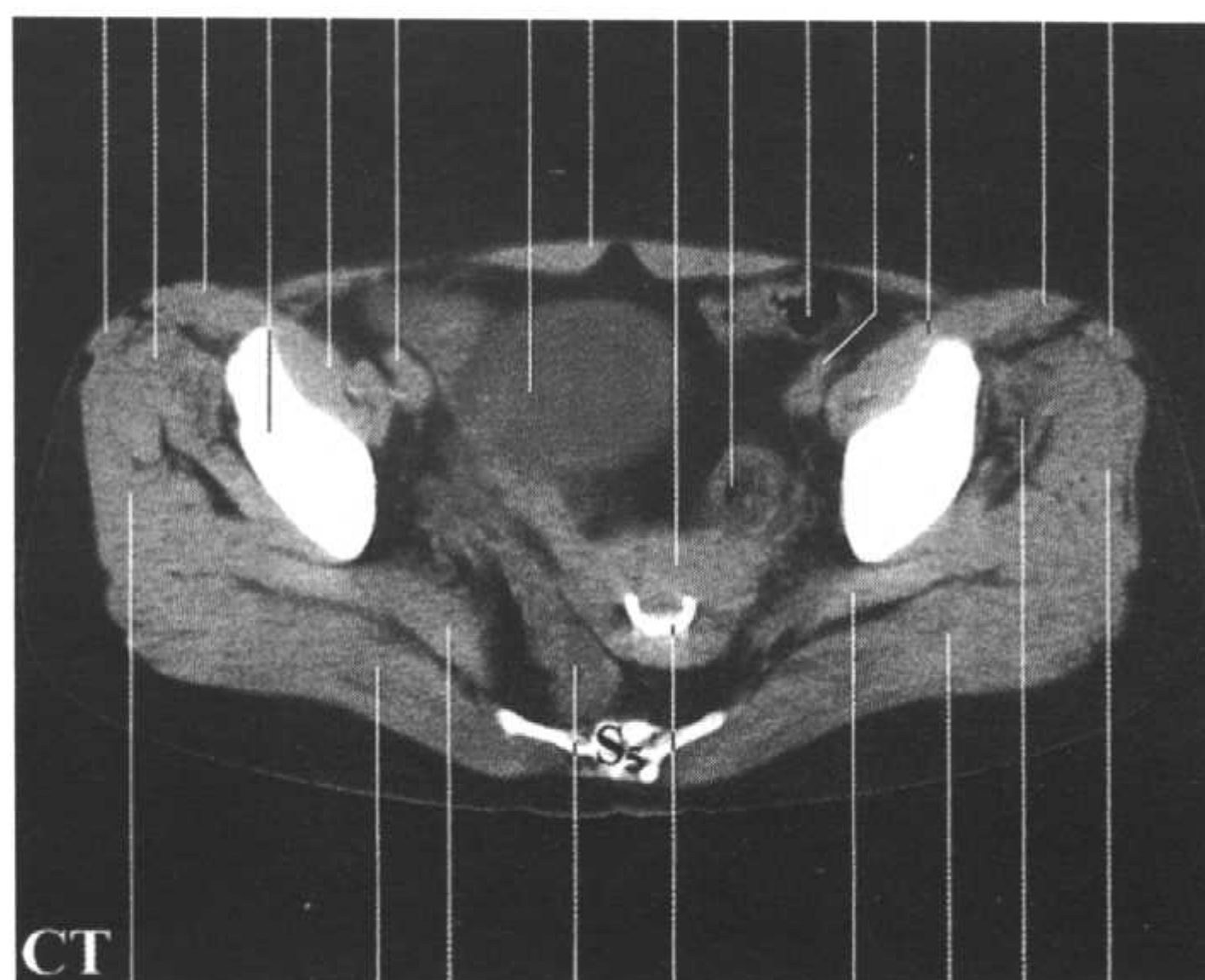
Fig.HPf6

1. 阔筋膜张肌 tensor fasciae latae
2. 缝匠肌 sartorius
3. 髂腰肌 iliopsoas
4. 股神经 femoral n.
5. 髂骨体 body of ilium
6. 髂外动、静脉 external iliac a. and v.
7. 输尿管 ureter
8. 乙状结肠 sigmoid colon
9. 腹直肌 rectus abdominis

116 2 5 3 13 11 10 12 8 8 6 3 2 1

15 1 2 3 4 13

12 6 3 5 2 1



CT

MRI

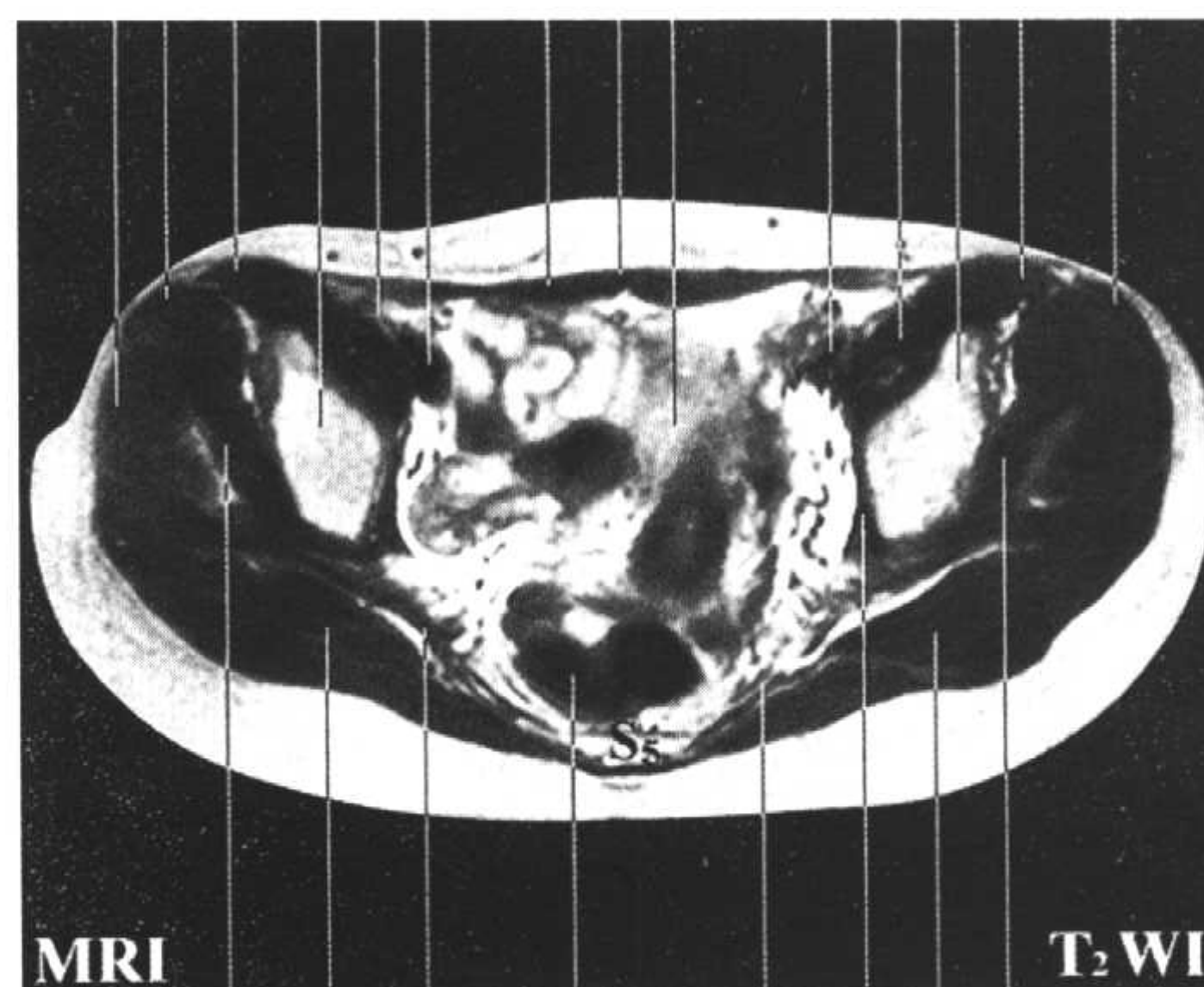
T₁WI

15 17 19 20 22 19 17 16 15

16 5 17 20 19 17 16

10. 锥状肌 pyramidalis
11. 膀胱尖 apex of bladder
12. 子宫底 fundus of uterus
13. 右髂外动脉 right external iliac a.
14. 髂胫束 iliotibial tract
15. 臀中肌 gluteus medius
16. 臀小肌 gluteus minimus
17. 臀大肌 gluteus maximus
18. 坐骨神经 sciatic n.
19. 梨状肌 piriformis
20. 直肠 rectum
21. 闭孔内肌 obturator internus
22. 节育环 contraceptive ring

15 1 2 5 4 13 9 10 12 6 3 5 2 1



MRI

T₂WI

16 17 19 20 19 21 17 16

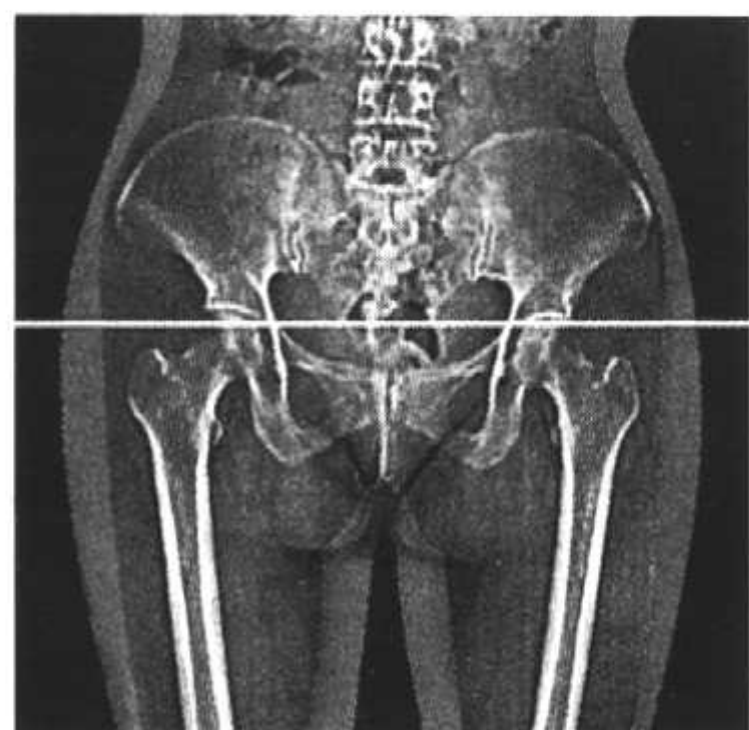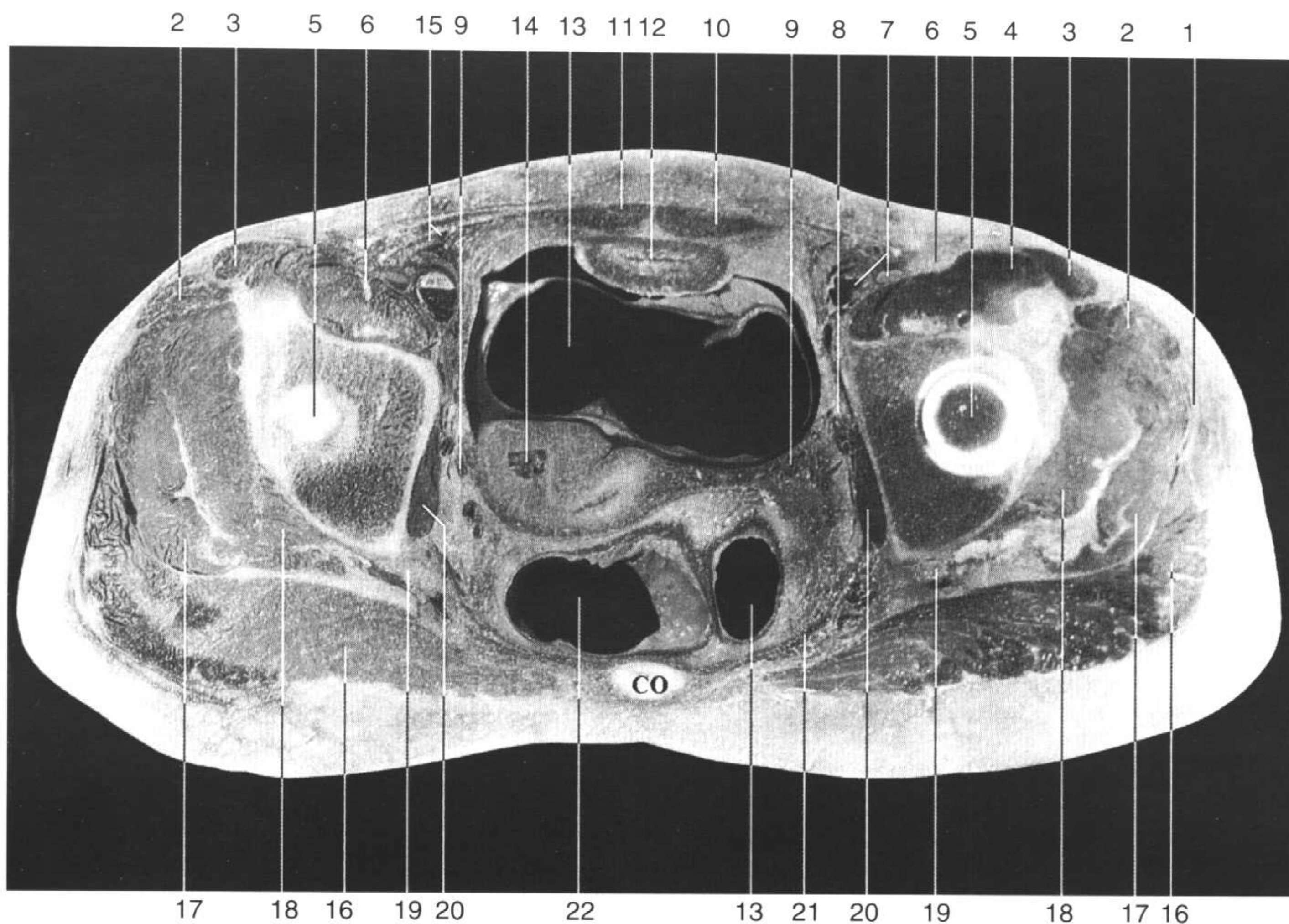
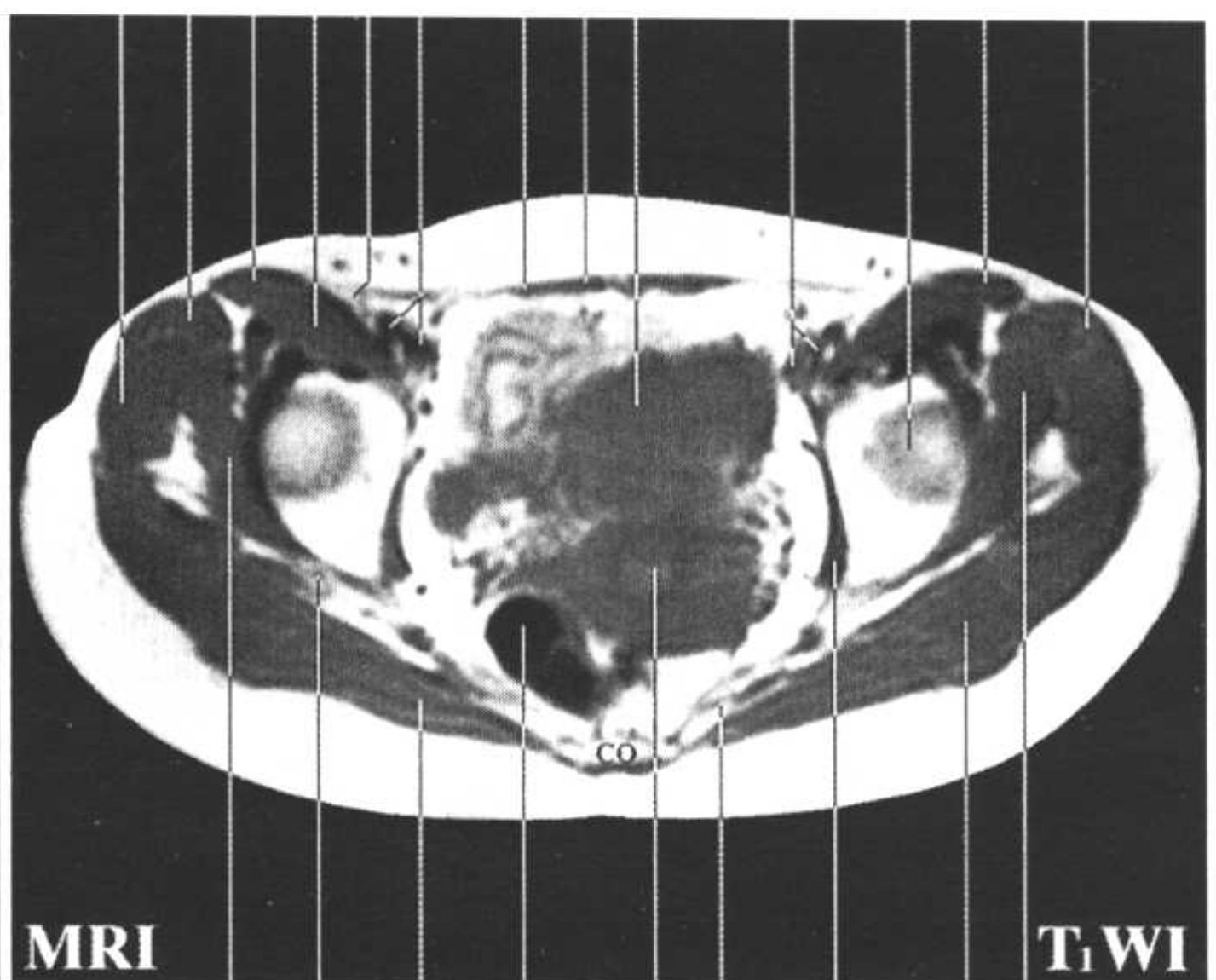
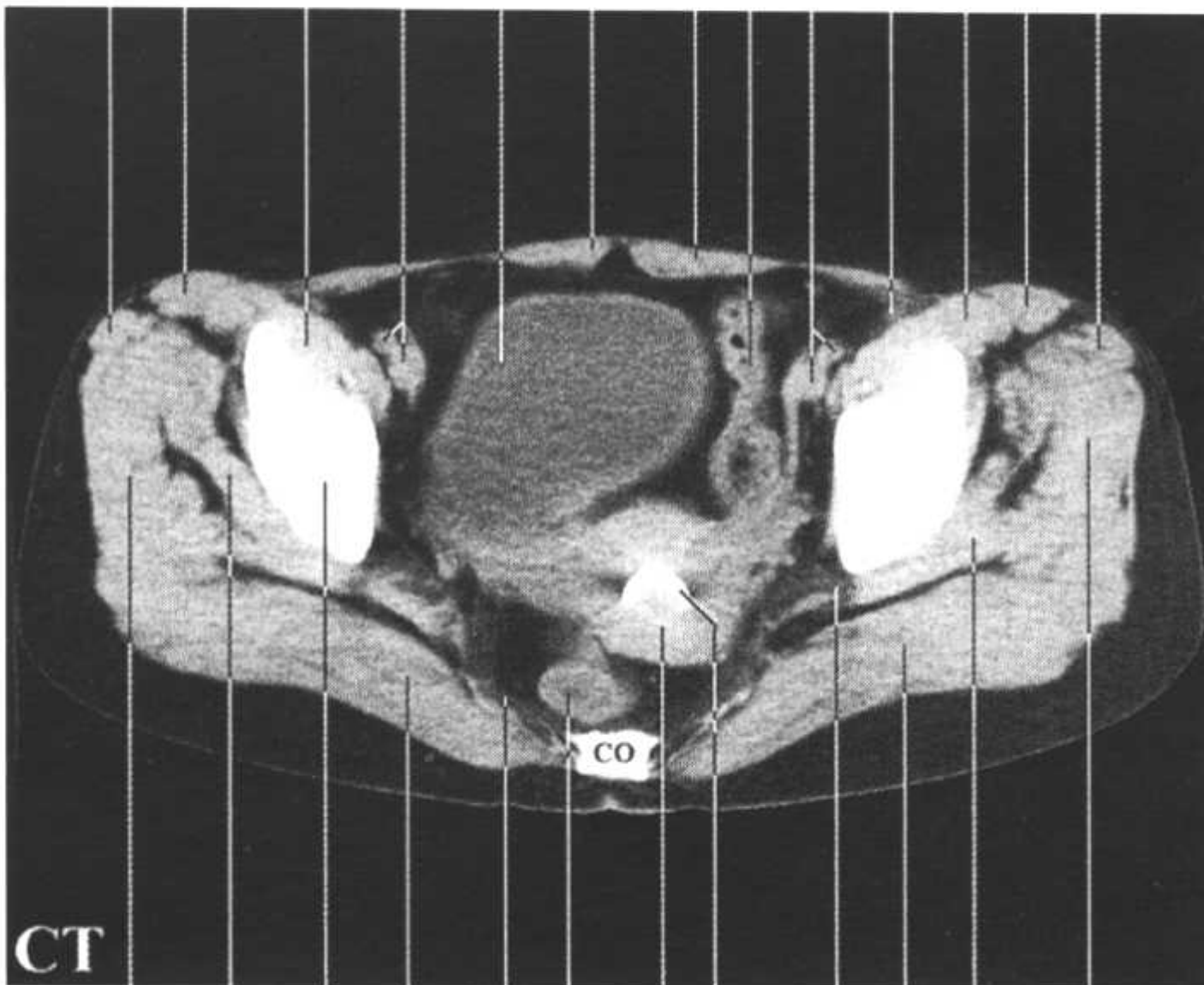


Fig.HP7

1. 髂胫束 iliotibial tract
2. 阔筋膜张肌 tensor fasciae latae
3. 缝匠肌 sartorius
4. 髂腰肌 iliopsoas
5. 股骨头 femoral head
6. 股神经 femoral n.
7. 髂外动、静脉 external iliac a. and v.
8. 闭孔神经 obturator n.
9. 输尿管 ureter

2 3 4 7 12 11 10 13 7 6 4 3 2

17 2 3 4 6 7 10 11 25 7 5 3 2

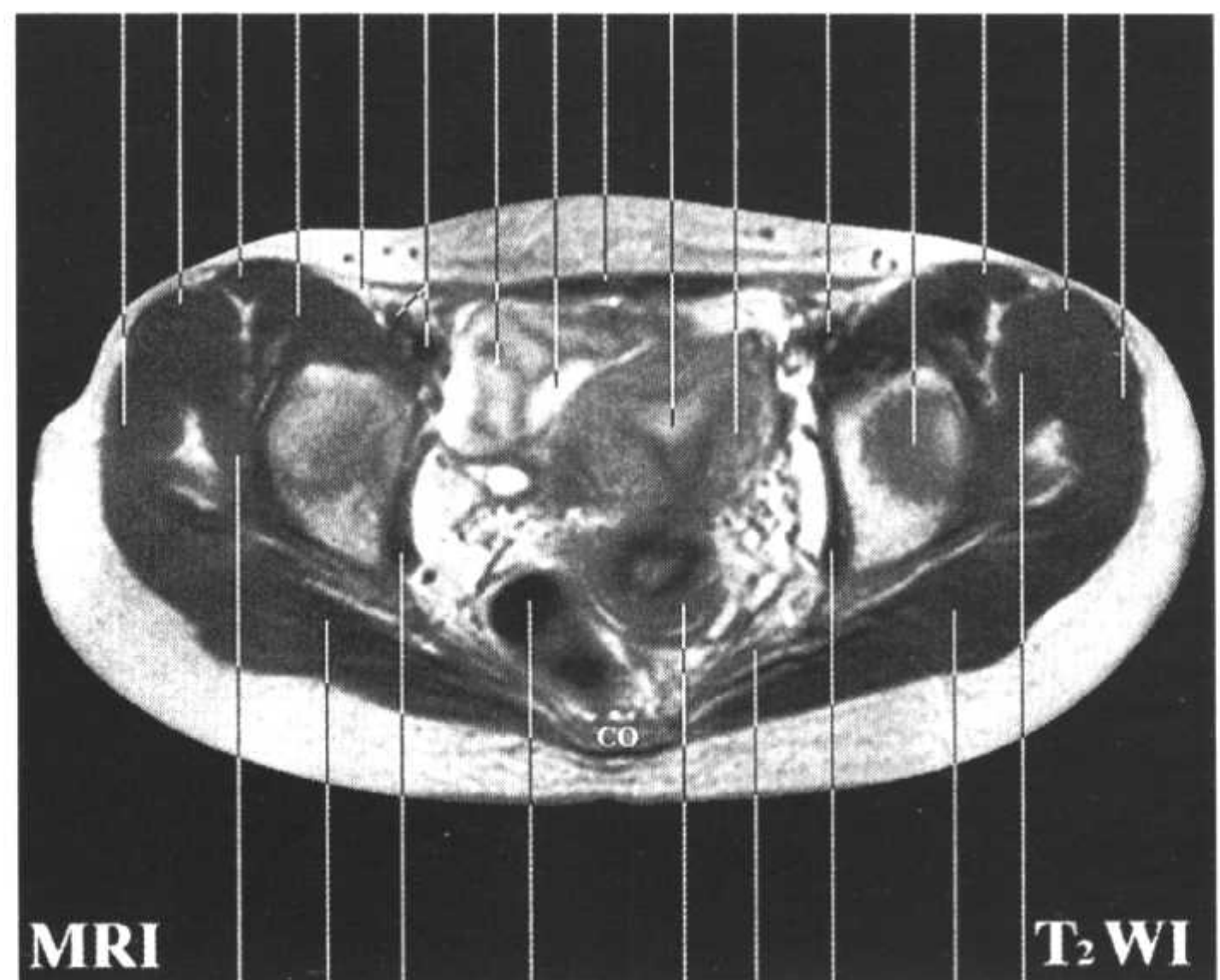


17 18 27 16 21 22 25 23 19 16 18 17

18 19 16 22 26 21 20 16 18

- 10. 腹直肌 rectus abdominis
- 11. 锥状肌 pyramidalis
- 12. 膀胱 urinary bladder
- 13. 乙状结肠 sigmoid colon
- 14. 子宫腔 cavity of uterus
- 15. 腹壁下动、静脉 inferior epigastric a. and v.
- 16. 臀大肌 gluteus maximus
- 17. 臀中肌 gluteus medius
- 18. 臀小肌 gluteus minimus
- 19. 坐骨神经 sciatic n.
- 20. 闭孔内肌 obturator internus
- 21. 尾骨肌 coccygeus
- 22. 直肠 rectum
- 23. 节育环 contraceptive ring
- 24. 回肠 ileum
- 25. 子宫体 body of uterus
- 26. 子宫颈 neck of uterus
- 27. 髌骨体 body of ilium

17 2 3 4 6 7 24 12 11 14 25 7 5 3 2 17



18 16 20 22 26 21 20 16 18

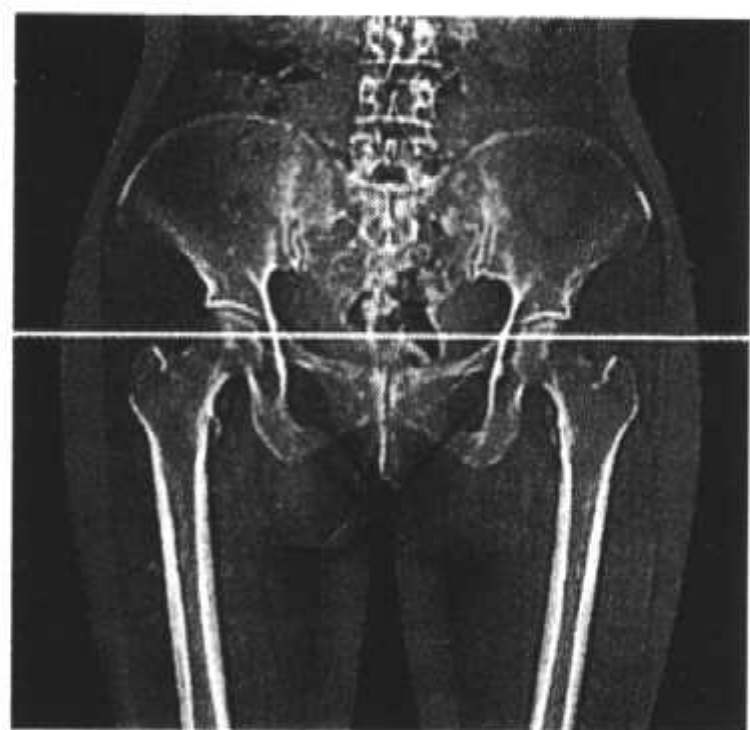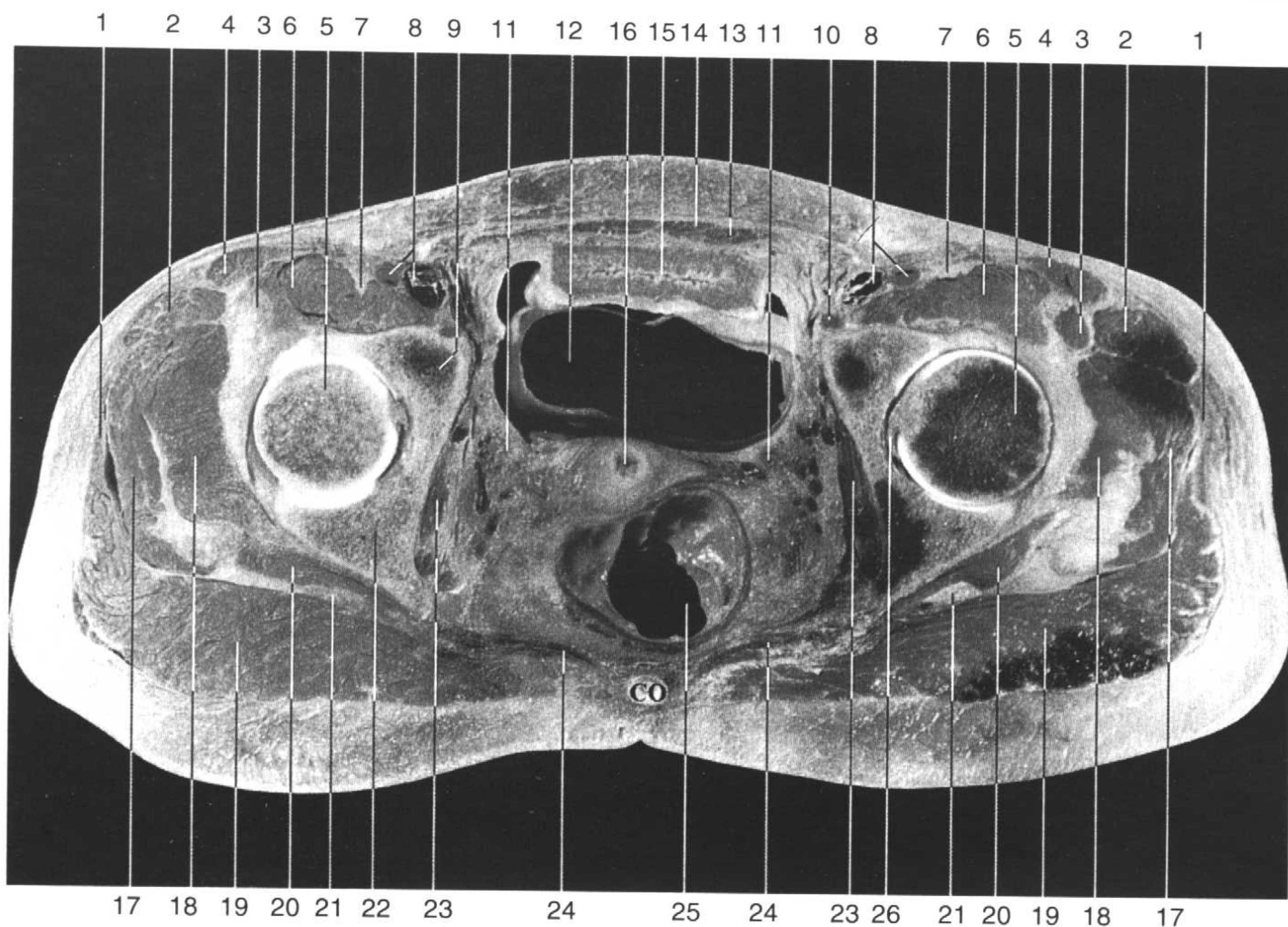
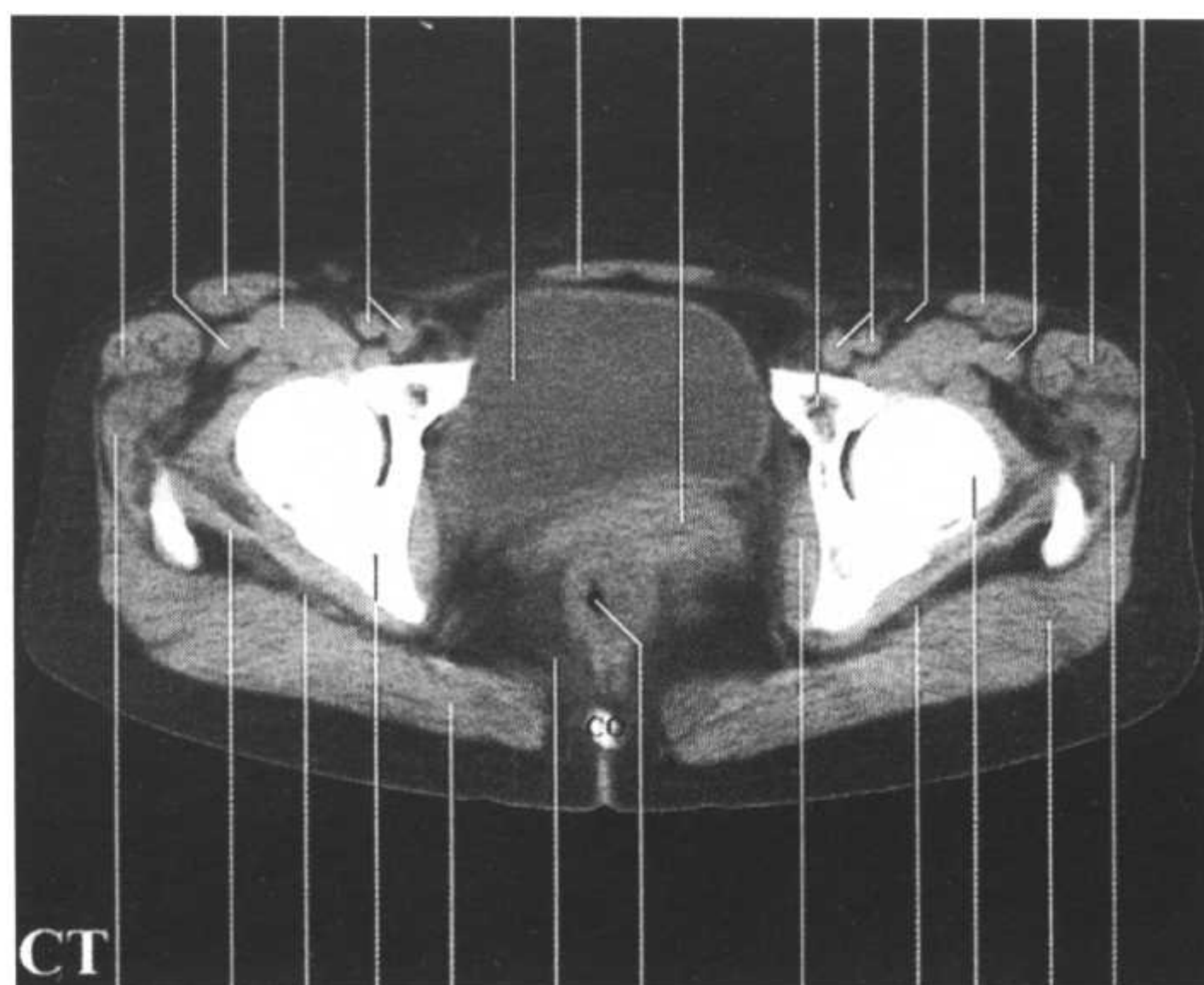


Fig.HPf8

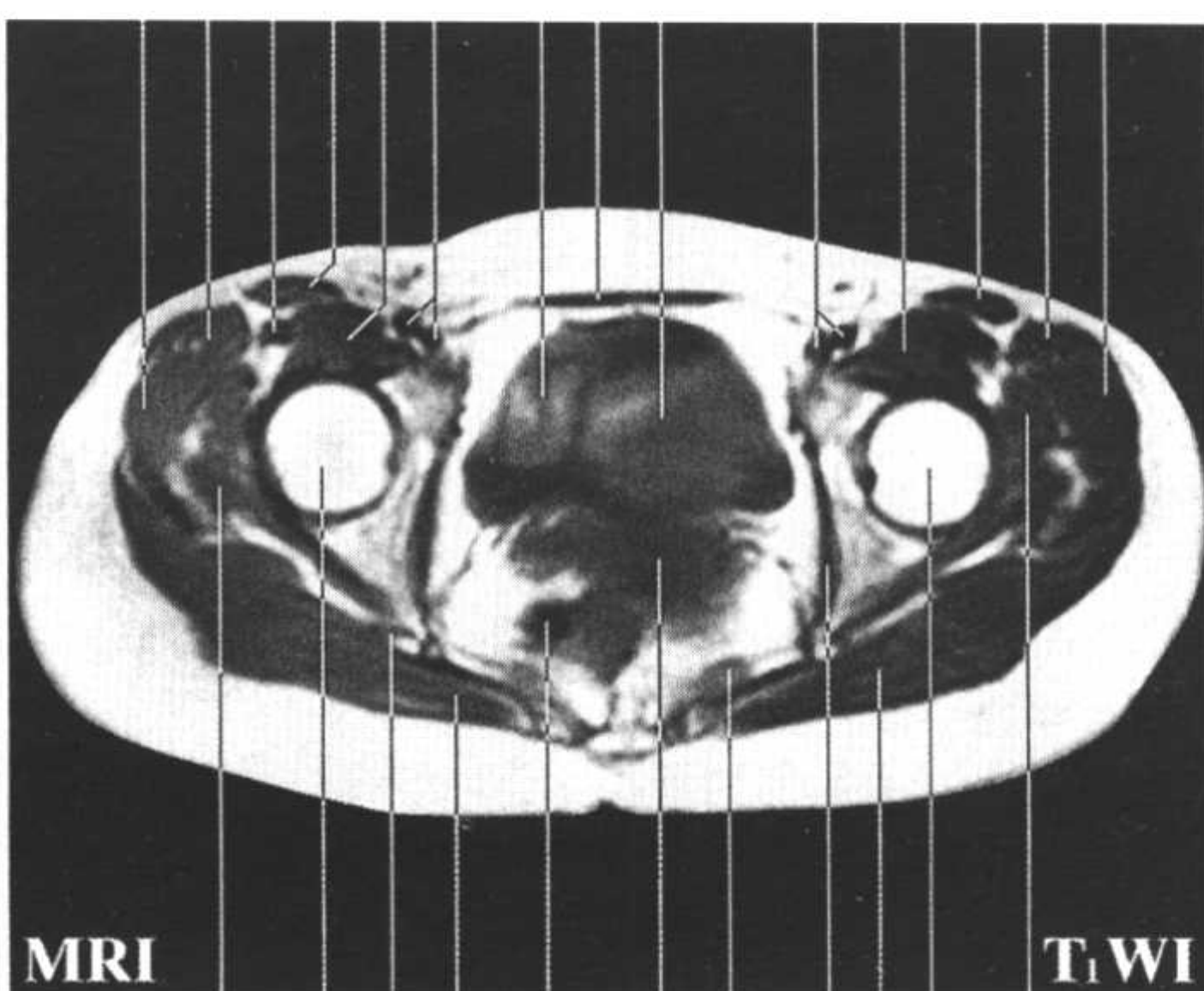
1. 髂胫束 iliotalibial tract
2. 阔筋膜张肌 tensor fasciae latae
3. 股直肌 rectus femoris
4. 缝匠肌 sartorius
5. 股骨头 femoral head
6. 髂腰肌 iliopsoas
7. 股神经 femoral n.
8. 股动、静脉 femoral a. and v.
9. 耻骨体 body of pubis
10. 耻骨肌 pectineus

2 3 4 6 8 15 13 16 9 8 7 4 3 2 1

17 2 3 4 6 8 15 14 27 8 6 4 2 17



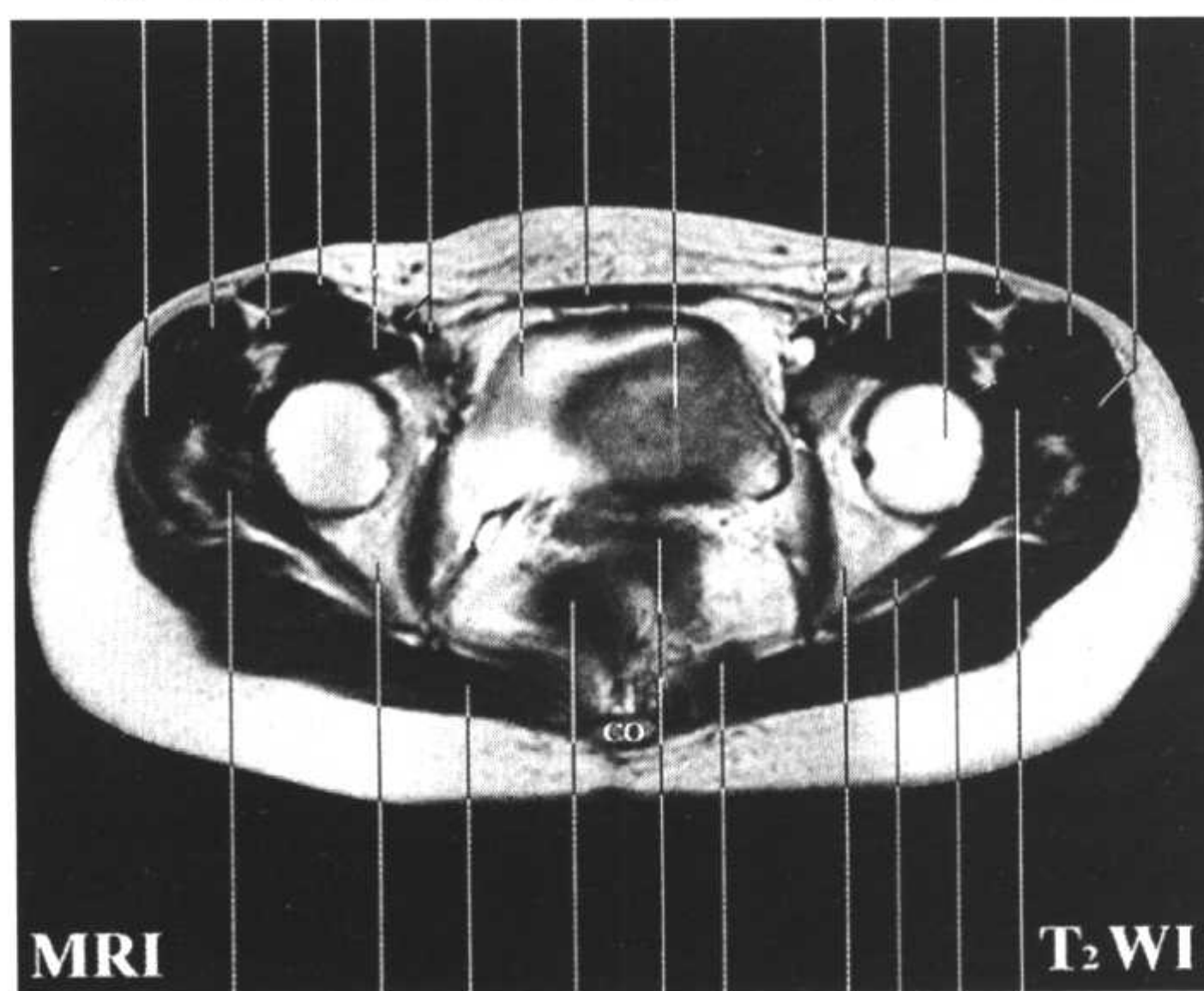
17 20 21 22 19 24 25 23 21 5 19 17



18 5 21 19 25 16 24 23 19 5 18

11. 输尿管 ureter
12. 乙状结肠 sigmoid colon
13. 腹直肌 rectus abdominis
14. 锥状肌 pyramidalis
15. 膀胱 urinary bladder
16. 子宫颈管 canal of cervix of uterus
17. 臀中肌 gluteus medius
18. 臀小肌 gluteus minimus
19. 臀大肌 gluteus maximus
20. 上孖肌 gemellus superior
21. 坐骨神经 sciatic n.
22. 坐骨体 body of ischium
23. 闭孔内肌 obturator internus
24. 尾骨肌 coccygeus
25. 直肠 rectum
26. 股骨头韧带 ligament of head of femur
27. 子宫体 body of uterus

17 2 3 4 6 8 15 14 27 8 6 5 4 2 17



18 22 19 25 16 24 22 20 19 18

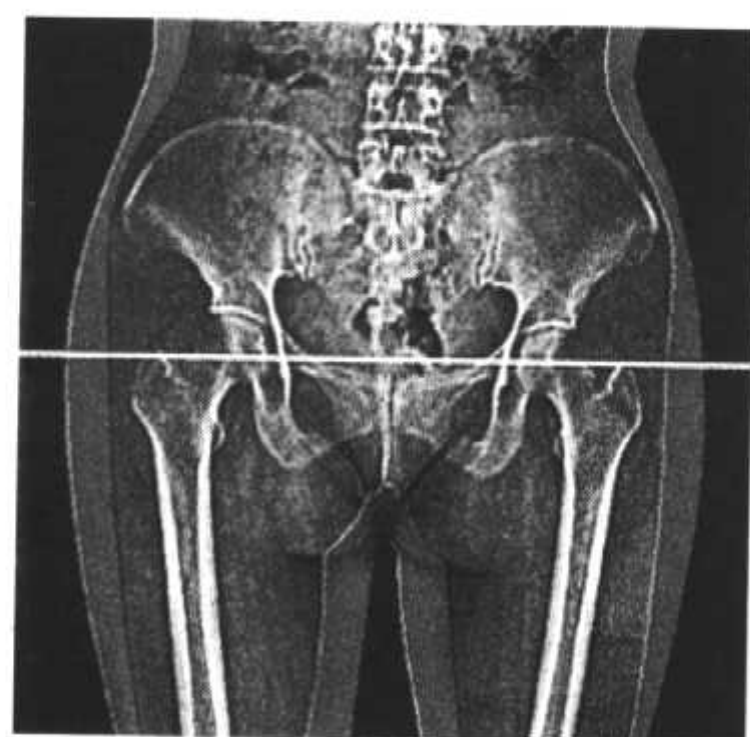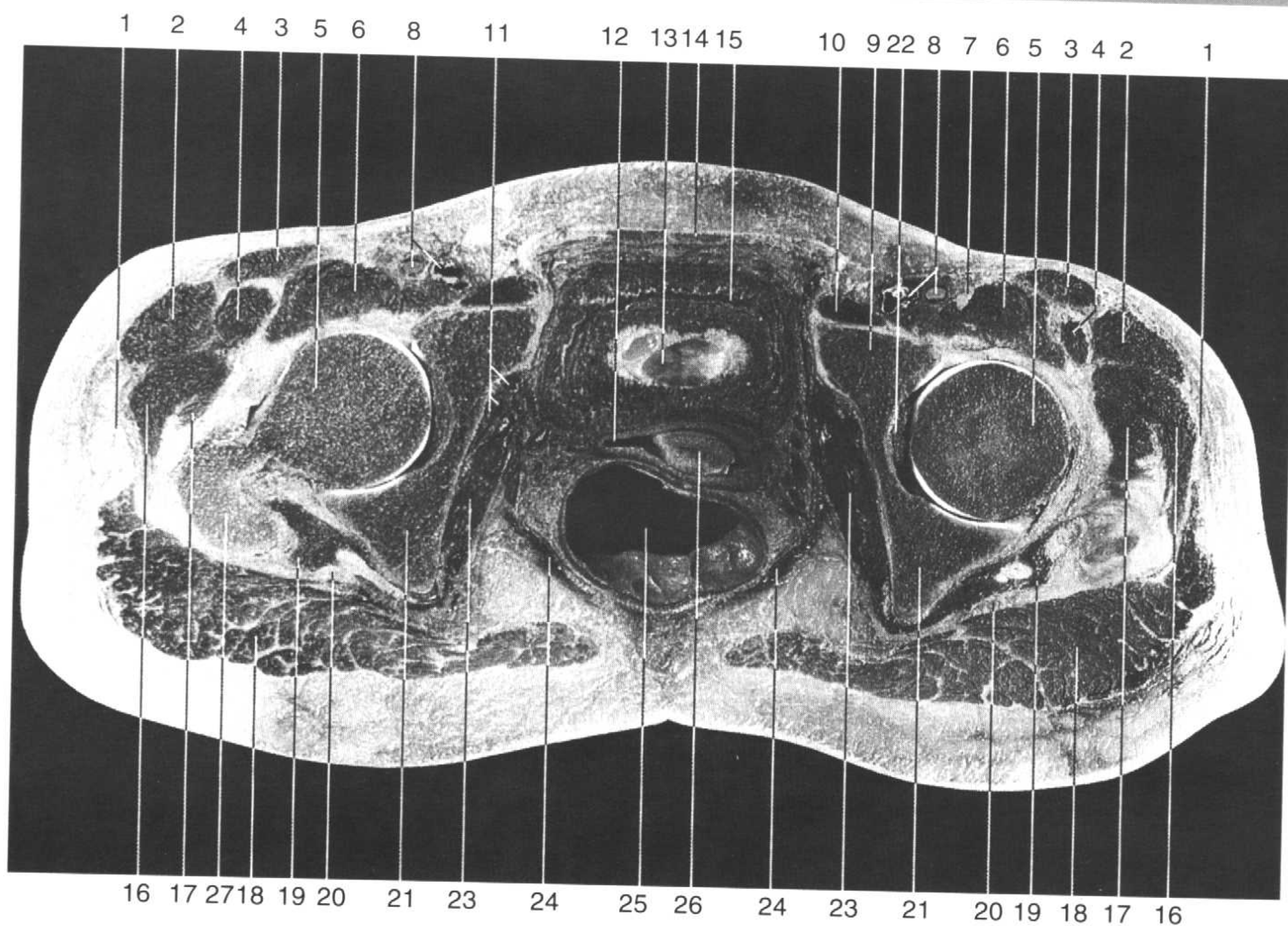

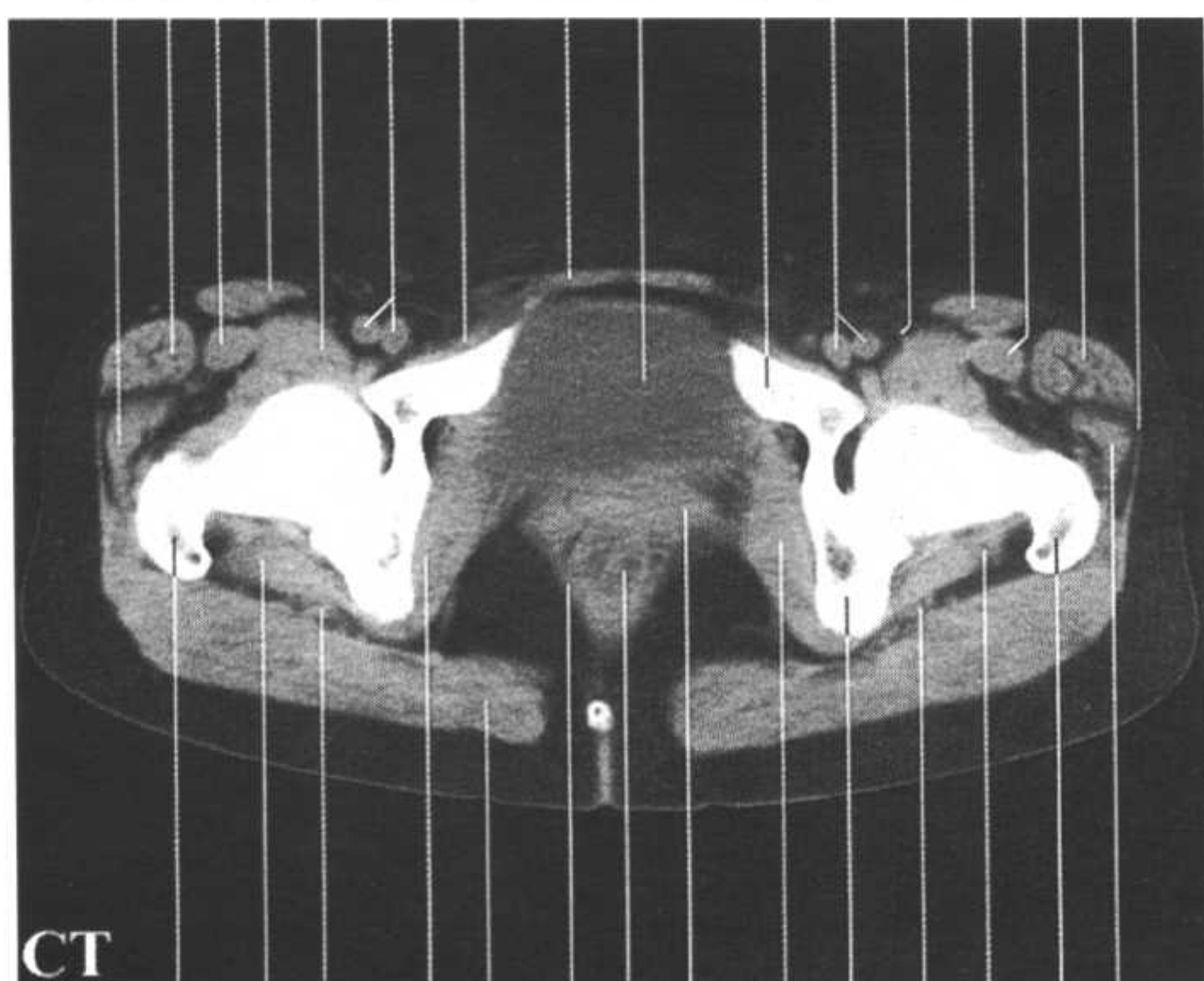
Fig.HPf9

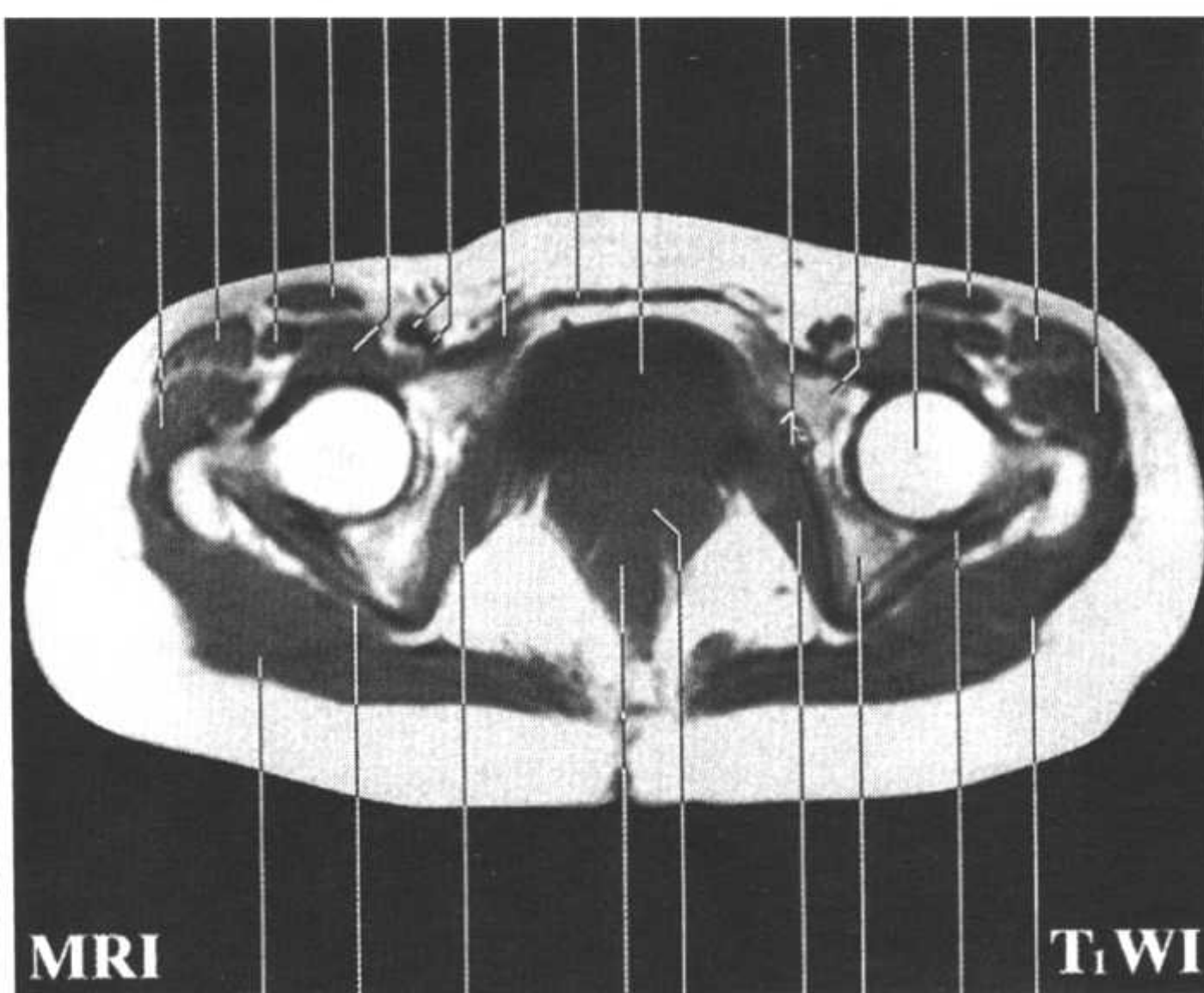
1. 髂胫束 iliotibial tract
2. 阔筋膜张肌 tensor fasciae latae
3. 缝匠肌 sartorius
4. 股直肌 rectus femoris
5. 股骨头 femoral head
6. 髂腰肌 iliopsoas
7. 股神经 femoral n.
8. 股动、静脉 femoral a. and v.
9. 耻骨体 body of pubis
10. 耻骨肌 pectineus

16 2 4 3 6 8 10 14 15 9 8 7 3 4 2 1



27 19 20 23 18 24 25 12 23 21 20 19 27 16

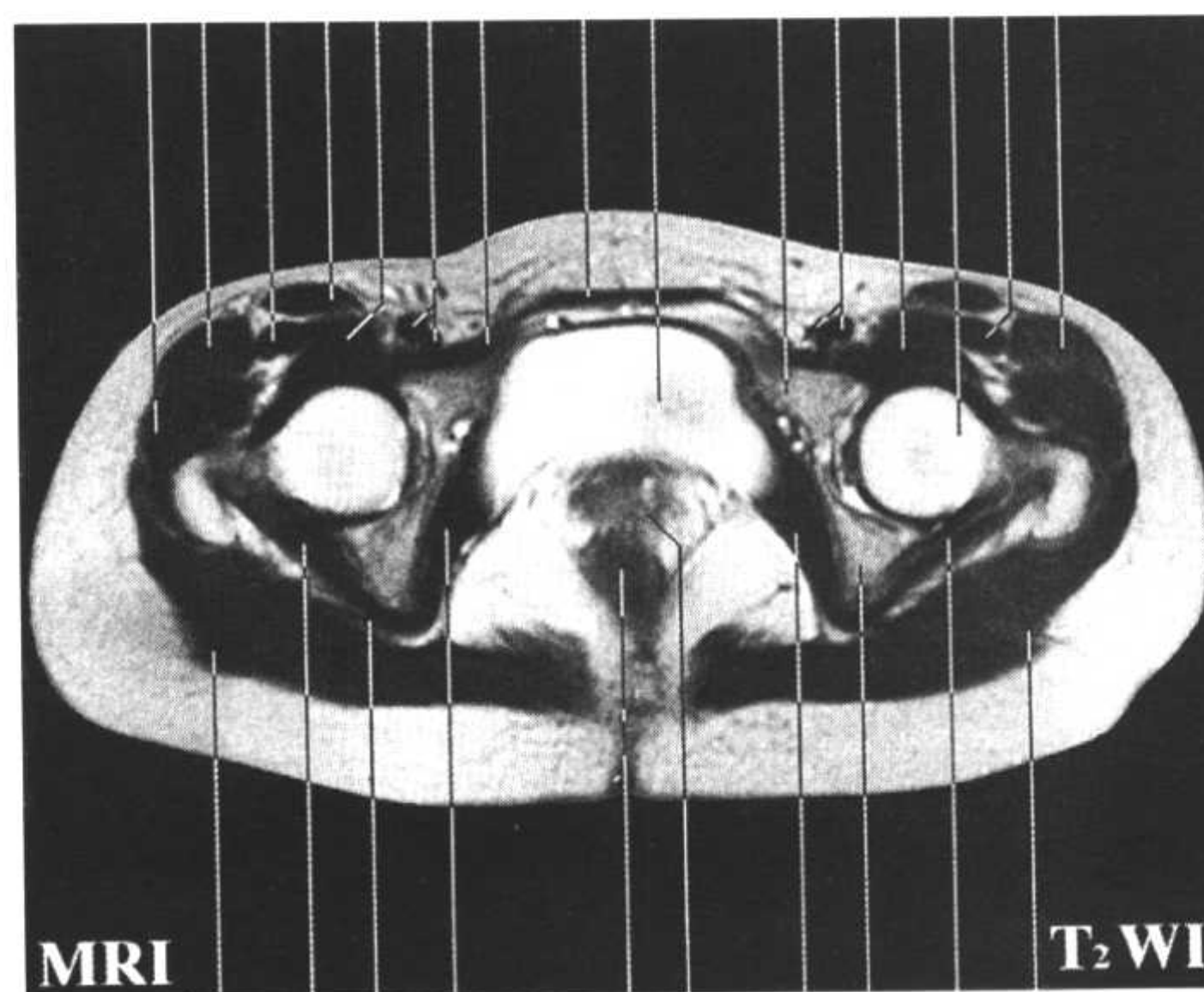
16 2 4 3 6 8 10 14 15 11 9 5 3 2 16



18 20 23 25 12 23 21 19 18

11. 闭孔动、静脉与闭孔神经 obturator a., v. and obturator n.
12. 阴道 vagina
13. 乙状结肠 sigmoid colon
14. 锥状肌 pyramidalis
15. 膀胱 urinary bladder
16. 臀中肌 gluteus medius
17. 臀小肌 gluteus minimus
18. 臀大肌 gluteus maximus
19. 上孖肌 gemellus inferior
20. 坐骨神经 sciatic n.
21. 坐骨体 body of ischium
22. 股骨头韧带 ligament of head of femur
23. 闭孔内肌 obturator internus
24. 肛提肌 levator ani
25. 直肠 rectum
26. 子宫颈阴道部 vaginal part of cervix
27. 大转子 greater trochanter

16 2 4 3 6 8 10 14 15 9 8 6 5 4 2



18 19 20 23 25 12 23 21 19 18

2 3 4 5 7 8 30 29 11 17 28 16 15 14 13 12 11 10 9 8 7 5 4 2 3 1

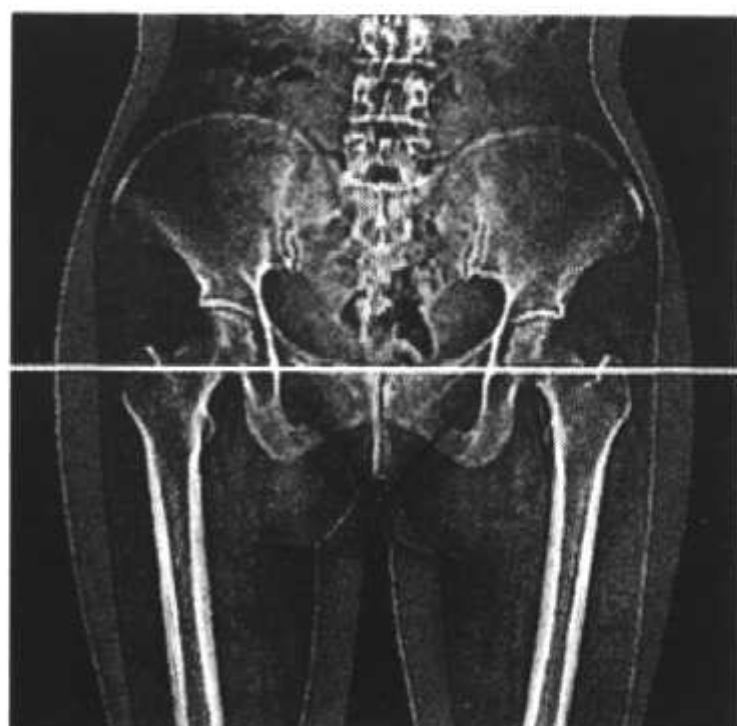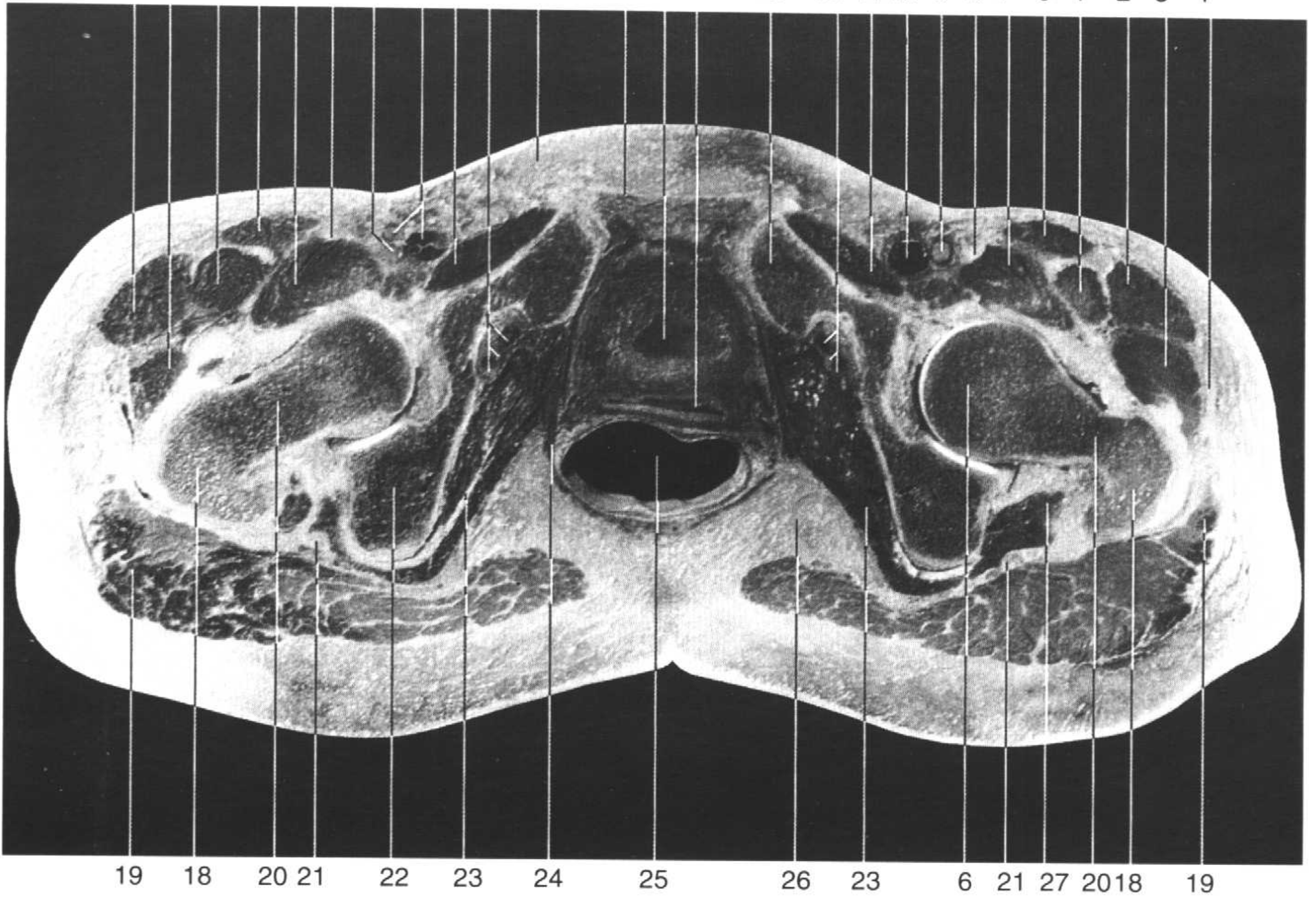
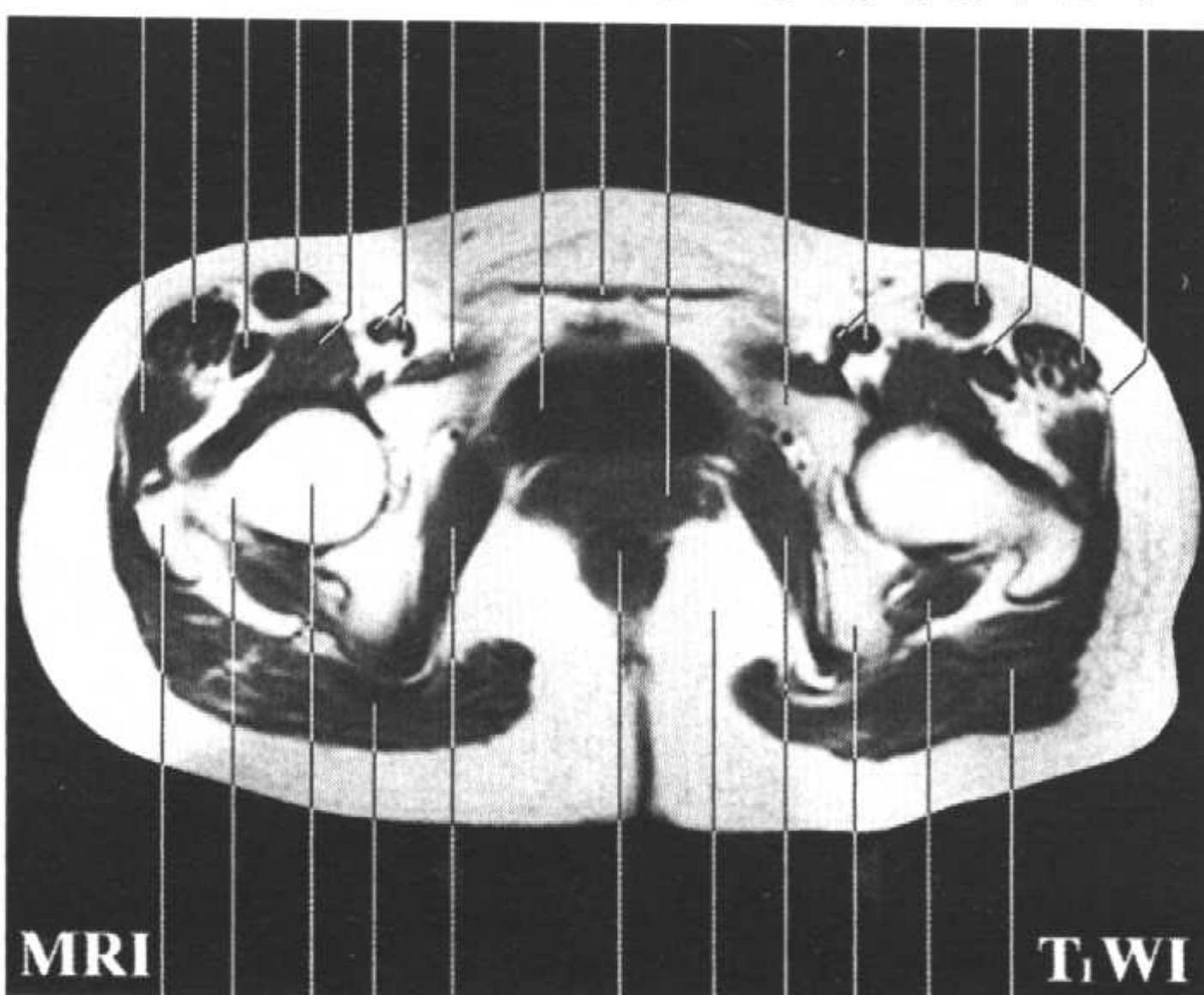

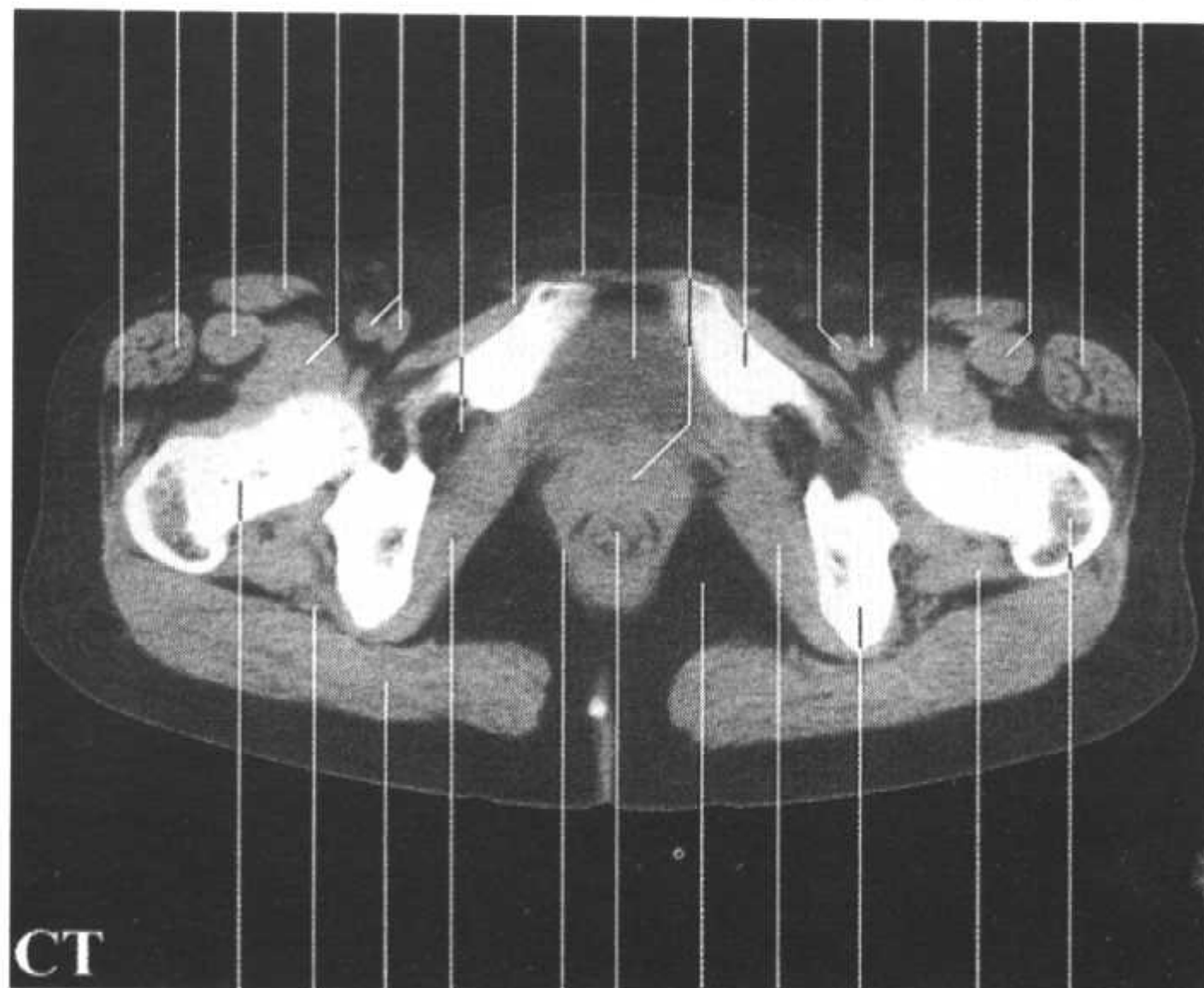
Fig.HPf10

1. 髂胫束 iliotibial tract
2. 阔筋膜张肌 tensor fasciae latae
3. 臀中肌 gluteus medius
4. 股直肌 rectus femoris
5. 缝匠肌 sartorius
6. 股骨头 femoral head
7. 髂腰肌 iliopsoas
8. 股神经 femoral n.
9. 股动脉 femoral a.
10. 股静脉 femoral v.

3 2 4 5 7 29 12 11 16 15 14 13 10 9 7 5 4 2 1

3 2 4 5 7 29 11 15 16 14 13 29 8 5 4 2 1

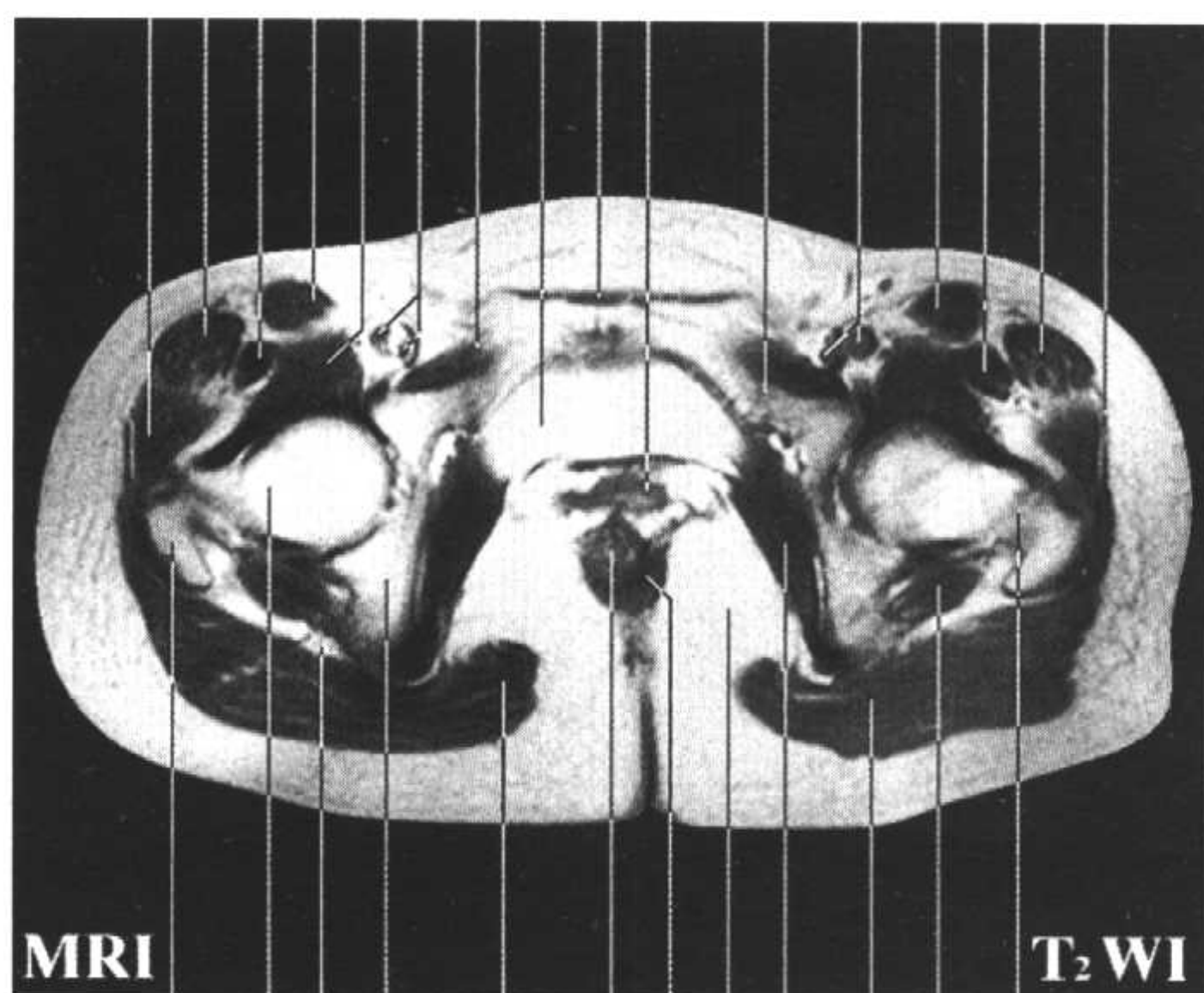


20 21 19 23 24 25 26 23 22 27 18

18 20 6 19 23 25 26 23 22 27 19

11. 耻骨肌 pectineus
12. 闭孔神经 (闭膜管) obturator n. (obturator canal)
13. 耻骨上支 superior ramus of pubis
14. 阴道 vagina
15. 膀胱 urinary bladder
16. 锥状肌 pyramidalis
17. 闭孔动、静脉 (闭膜管) obturator a. and v. (obturator canal)
18. 大转子 greater trochanter
19. 臀大肌 gluteus maximus
20. 股骨颈 neck of femur
21. 坐骨神经 sciatic n.
22. 坐骨体 body of ischium
23. 闭孔内肌 obturator internus
24. 肛提肌 levator ani
25. 直肠 rectum
26. 坐骨肛门窝脂体 adipose body of ischioanal fossa
27. 股方肌 quadratus femoris
28. 阴阜 mons pubis
29. 股动、静脉 femoral a. and v.
30. 股深动脉 deep femoral a.

3 2 4 5 7 29 11 15 16 14 13 29 5 4 2 1



18 6 21 22 19 25 24 26 23 19 27 20

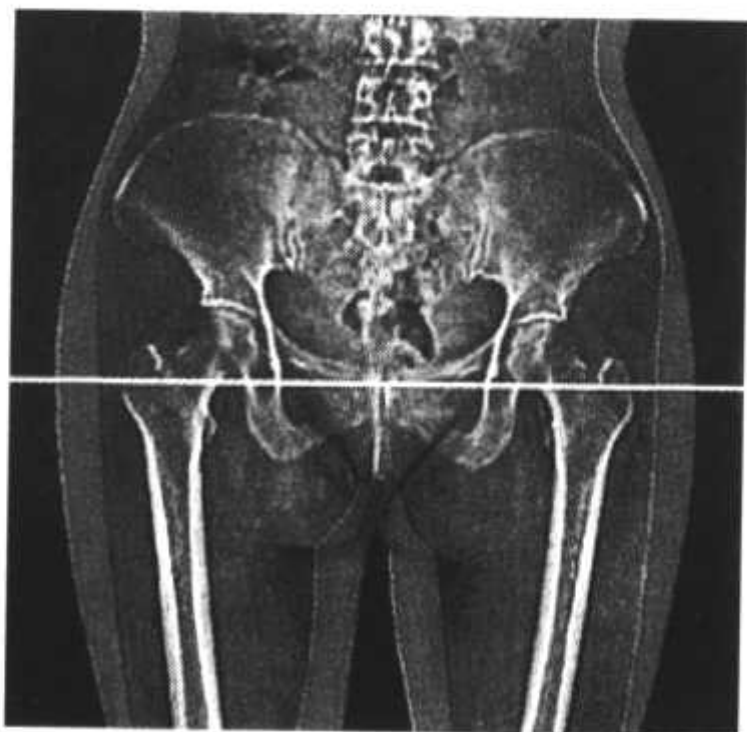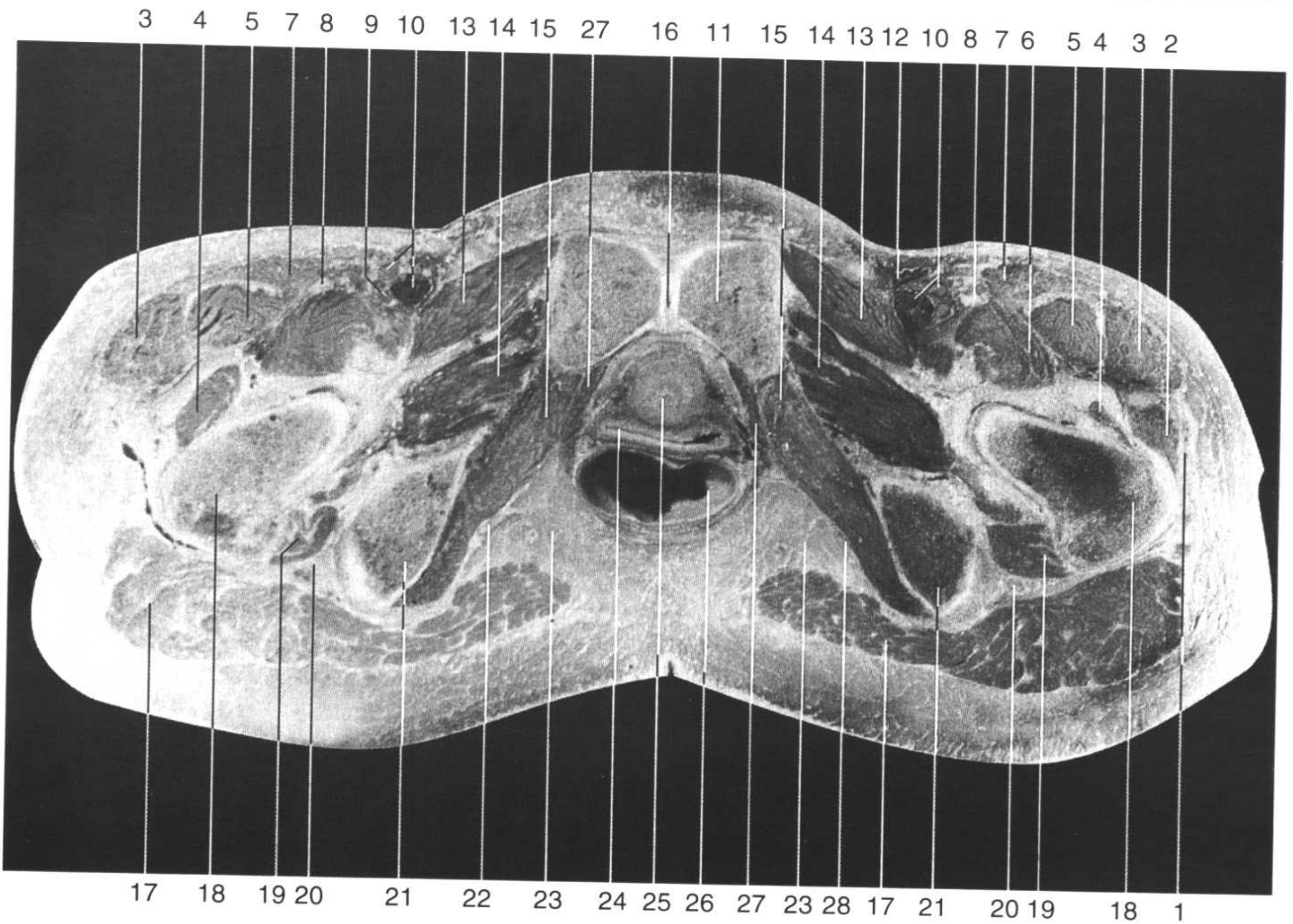
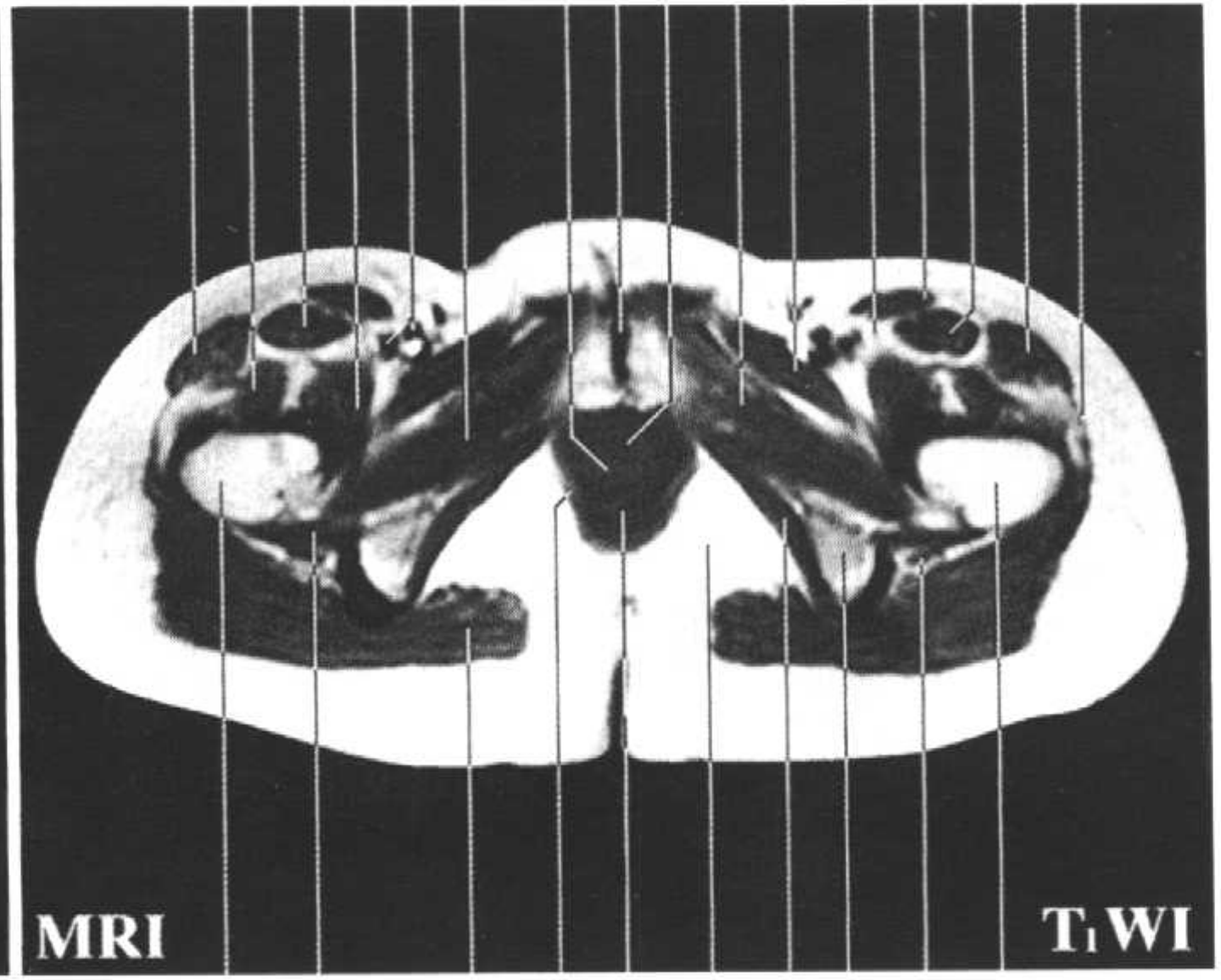
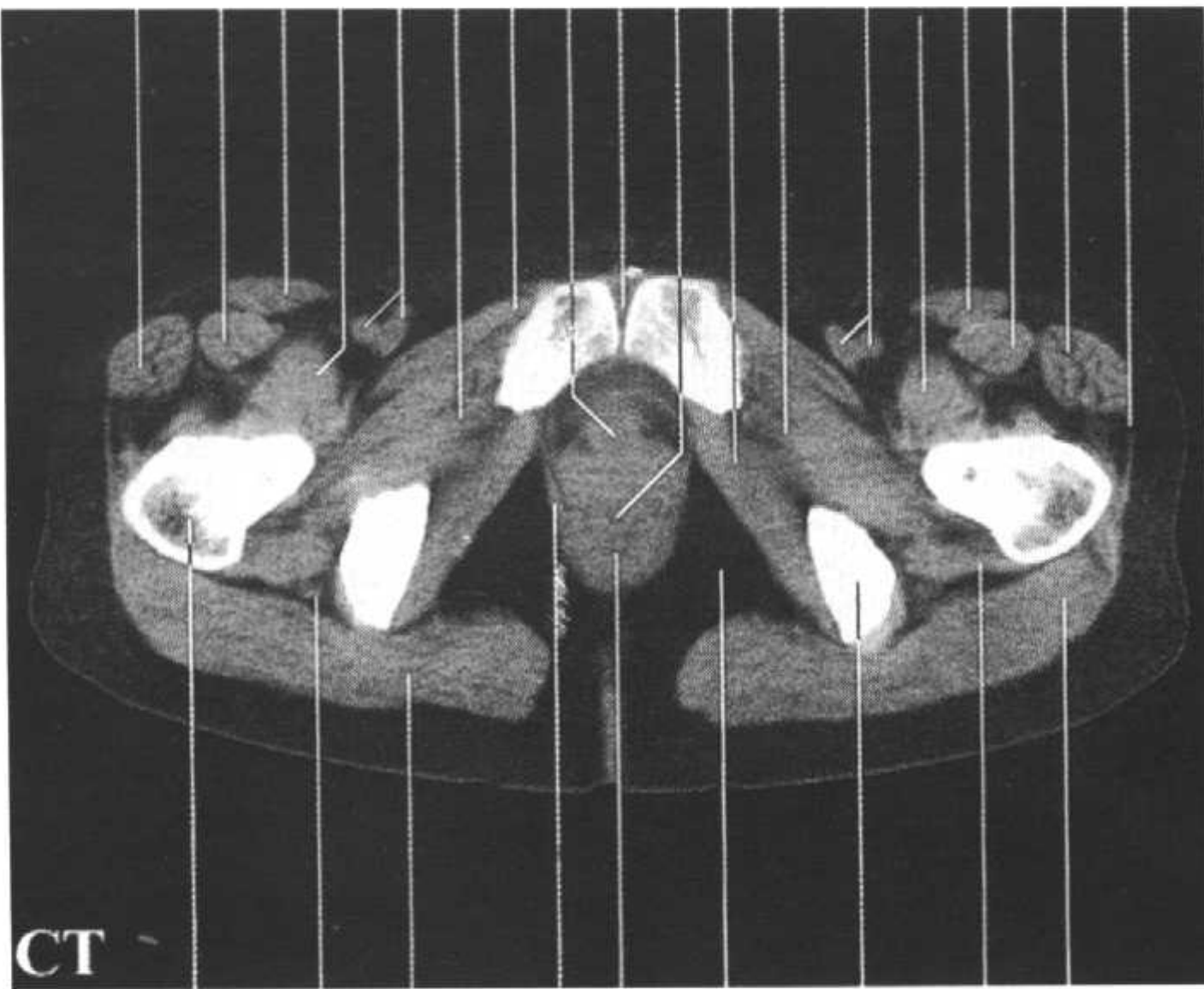


Fig.HPf11

1. 髂胫束 iliotibial tract
2. 臀中肌 gluteus medius
3. 阔筋膜张肌 tensor fasciae latae
4. 股外侧肌 vastus lateralis
5. 股直肌 rectus femoris
6. 髂腰肌 iliopsoas
7. 缝匠肌 sartorius
8. 股神经 femoral n.
9. 股深动脉 deep femoral a.
10. 股动、静脉 femoral a. and v.

3 5 7 6 10 14 13 25 16 24 15 14 10 6 7 5 3 1

3 4 5 6 10 14 24 16 25 14 13 8 7 5 3 1

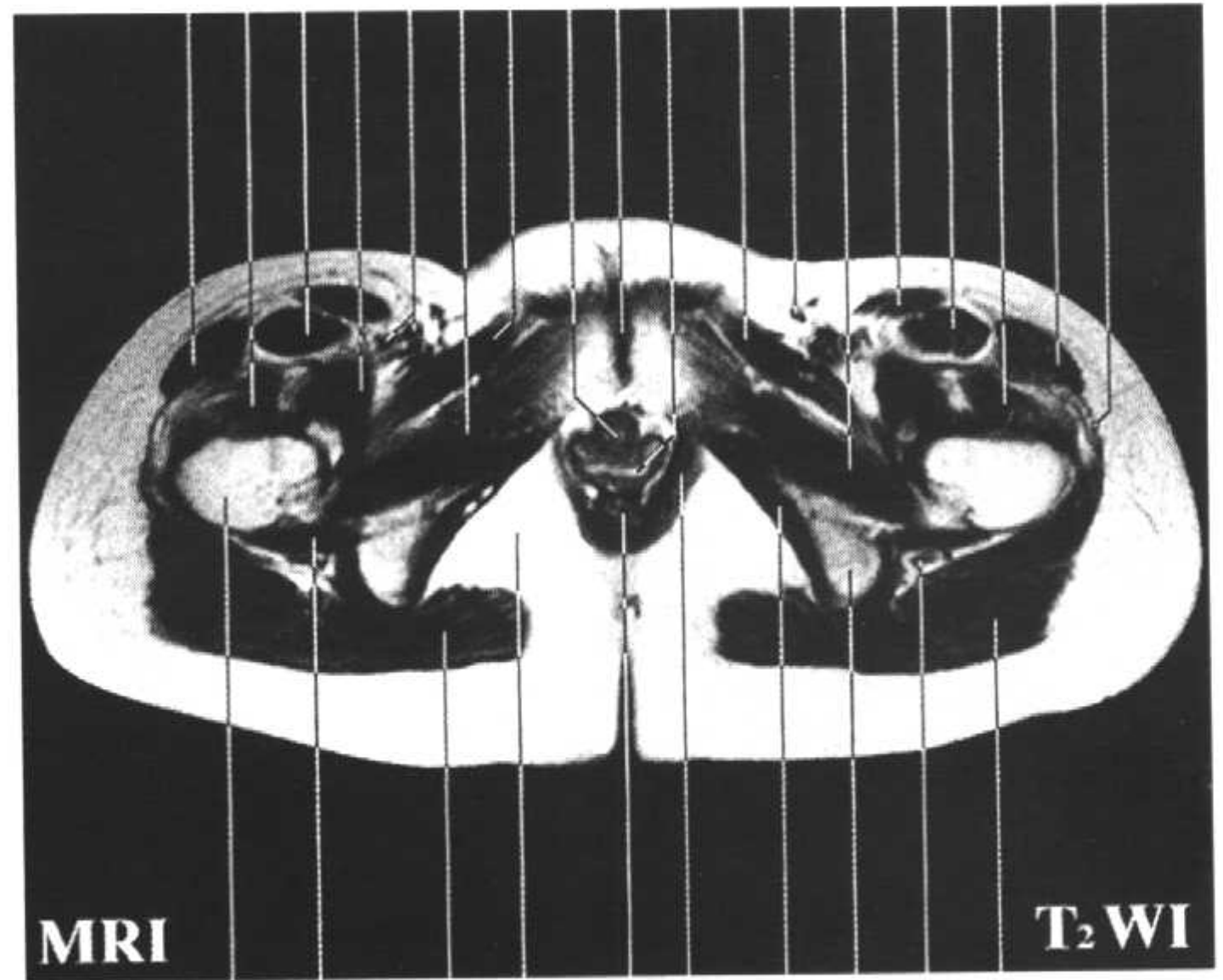


18 20 17 27 26 23 21 19 17

18 19 17 27 26 23 15 21 20 18

11. 耻骨上支 superior ramus of pubis
12. 大隐静脉 great saphenous v.
13. 耻骨肌 pectineus
14. 闭孔外肌 obturator externus
15. 闭孔内肌 obturator internus
16. 耻骨联合 pubic symphysis
17. 臀大肌 gluteus maximus
18. 大转子 greater trochanter
19. 股方肌 quadratus femoris
20. 坐骨神经 sciatic n.
21. 坐骨结节 ischial tuberosity
22. 阴部管 pudendal canal
23. 坐骨肛门窝脂体 adipose body of ischioanal fossa
24. 阴道 vagina
25. 女尿道 female urethra
26. 直肠 rectum
27. 肛提肌 levator ani
28. 阴部内动、静脉与阴部神经 internal pudendal a., v. and pudendal n.

3 4 5 6 10 14 13 25 16 24 13 12 14 7 5 4 3 1



18 19 17 23 26 27 15 21 20 17

1 2 3 10 4 5 6 8 9 11 12 13 15 17 16 12 14 13 11 8 9 7 4 5 2 1

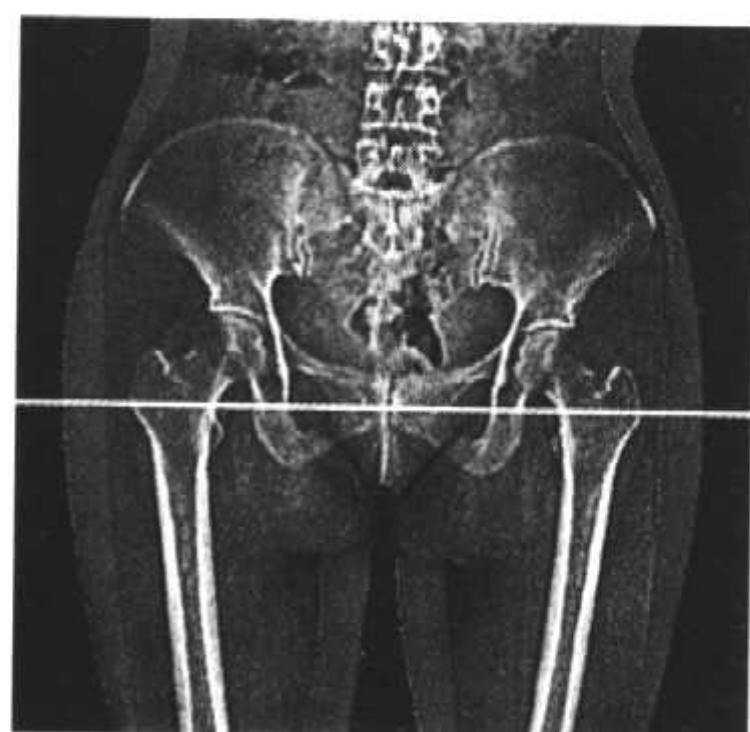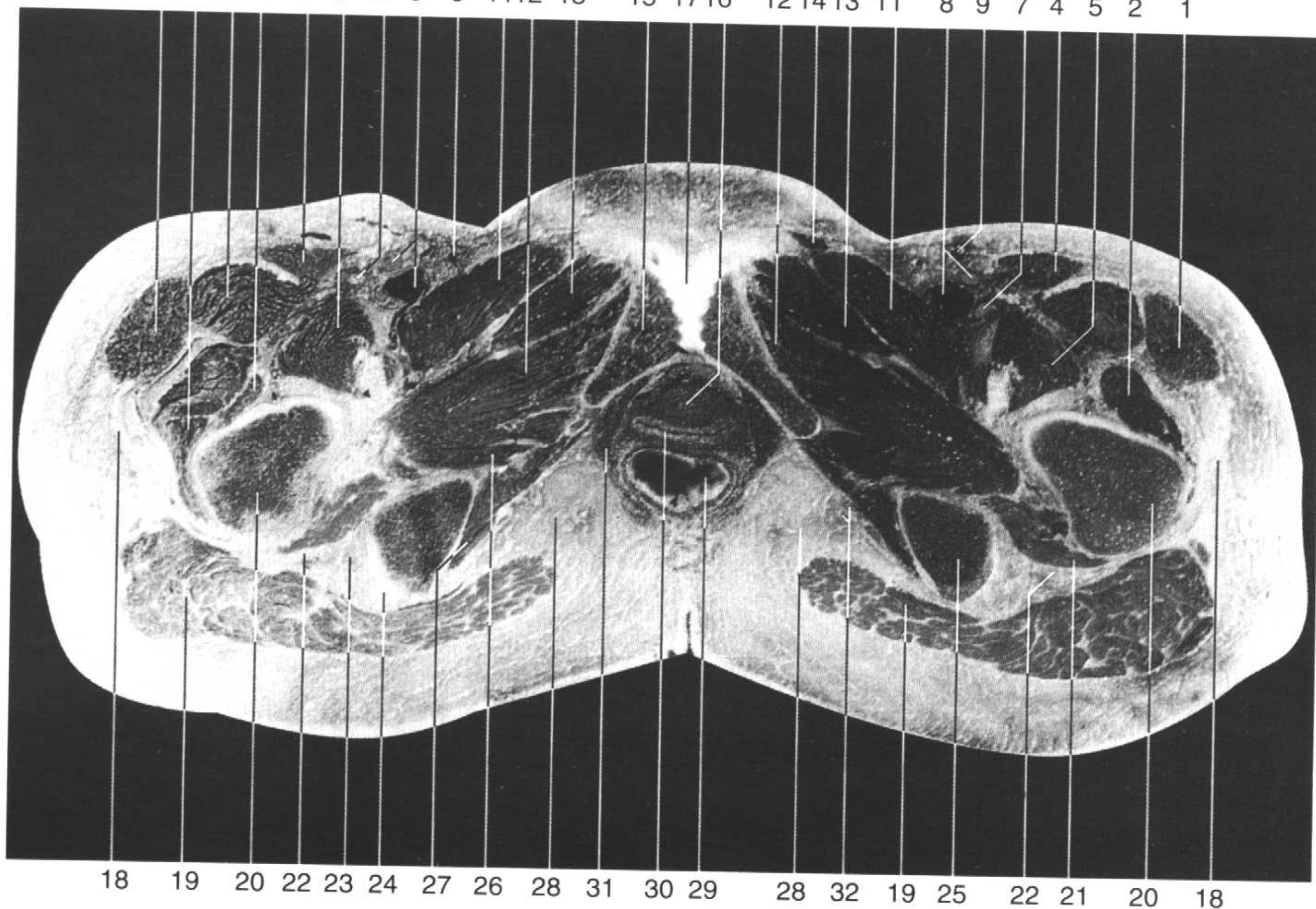
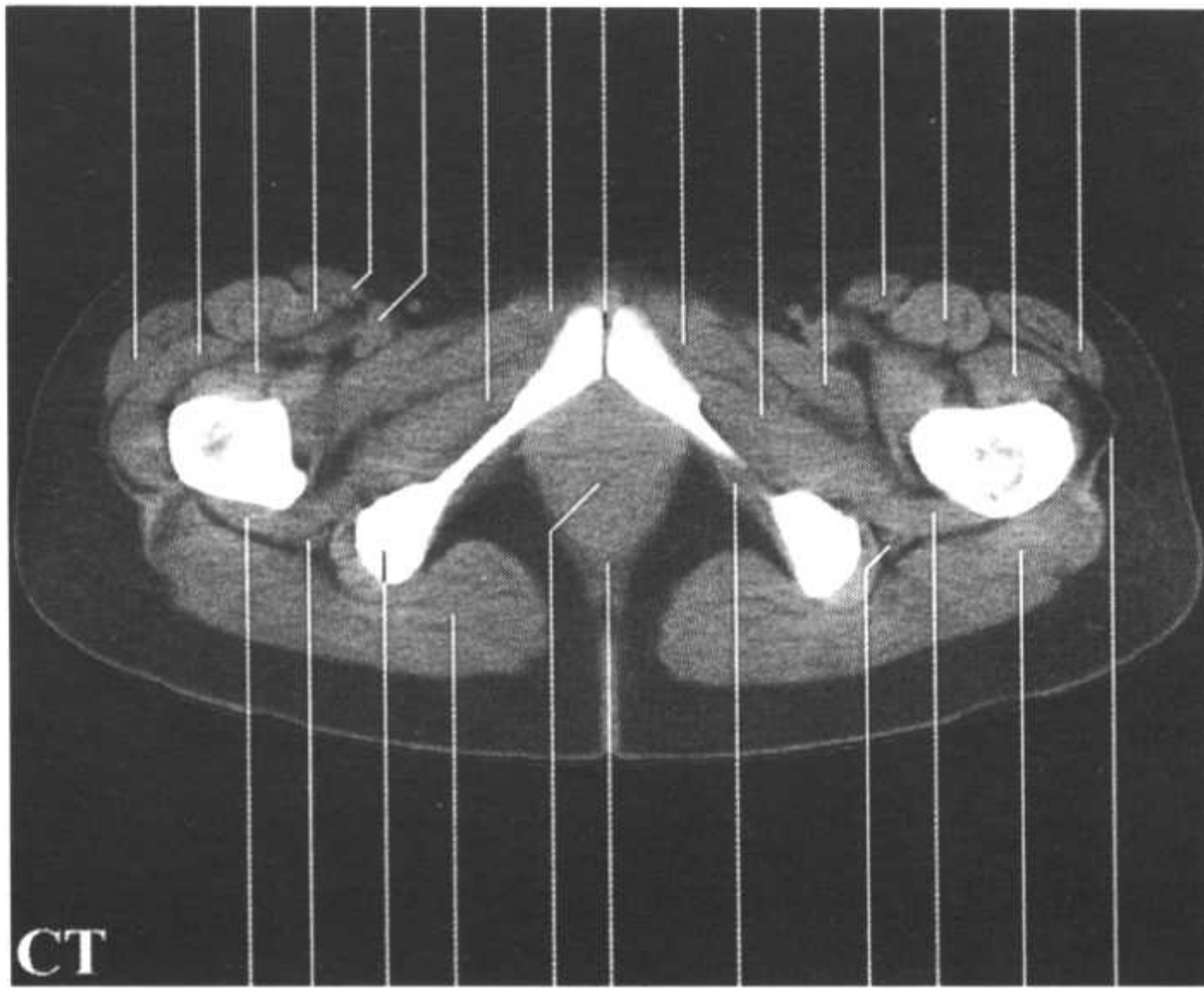


Fig.HPf12

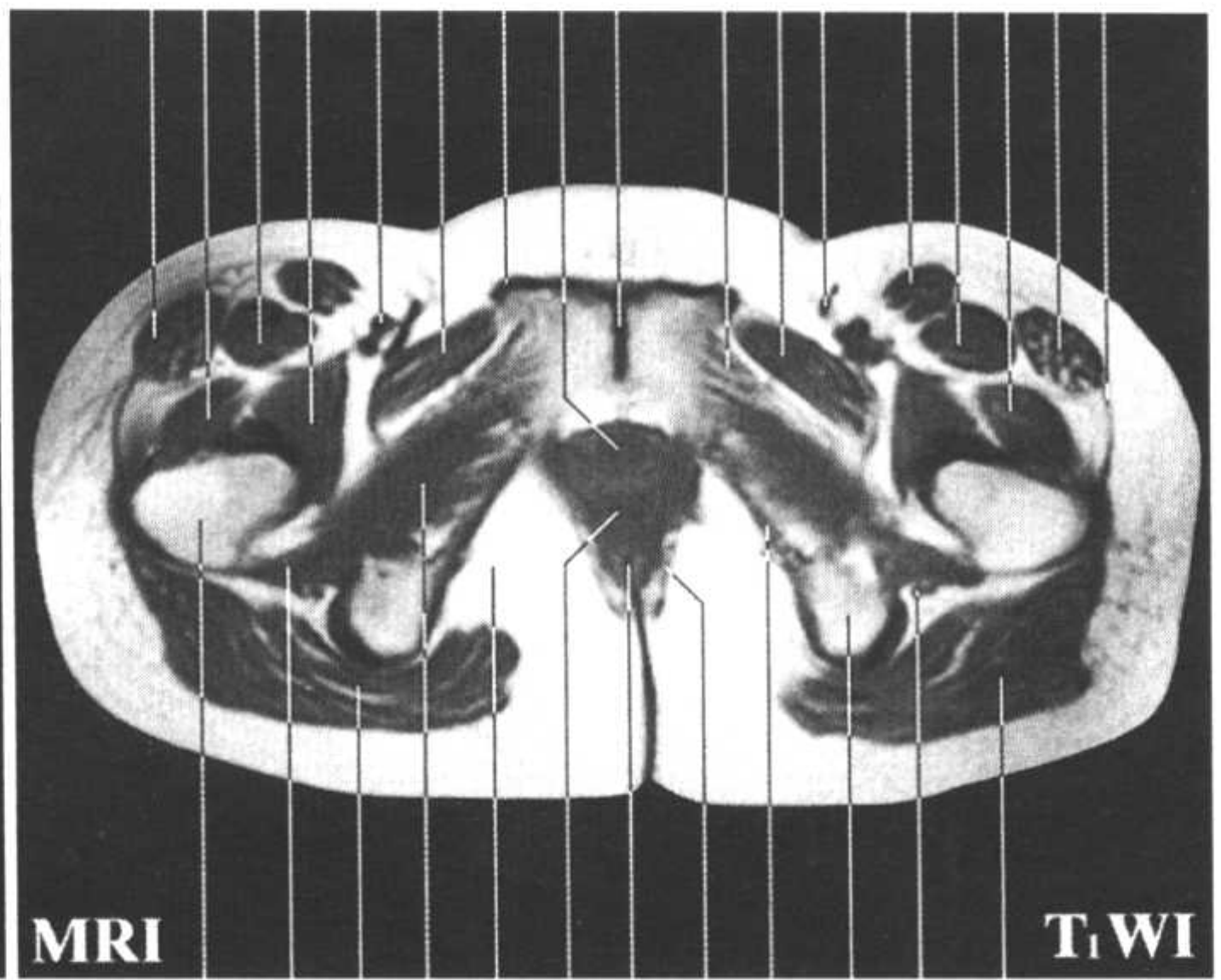
1. 阔筋膜张肌 tensor fasciae latae
2. 股外侧肌 vastus lateralis
3. 股直肌 rectus femoris
4. 缝匠肌 sartorius
5. 髂腰肌 iliopsoas
6. 股神经 femoral n.
7. 股深动脉 deep femoral a.
8. 股动、静脉 femoral a. and v.
9. 大隐静脉 great saphenous v.
10. 股中间肌 vastus intermedius

1 2 10 3 4 8 12 14 17 13 12 11 4 3 2 1



21 22 25 19 30 29 27 22 21 19 18

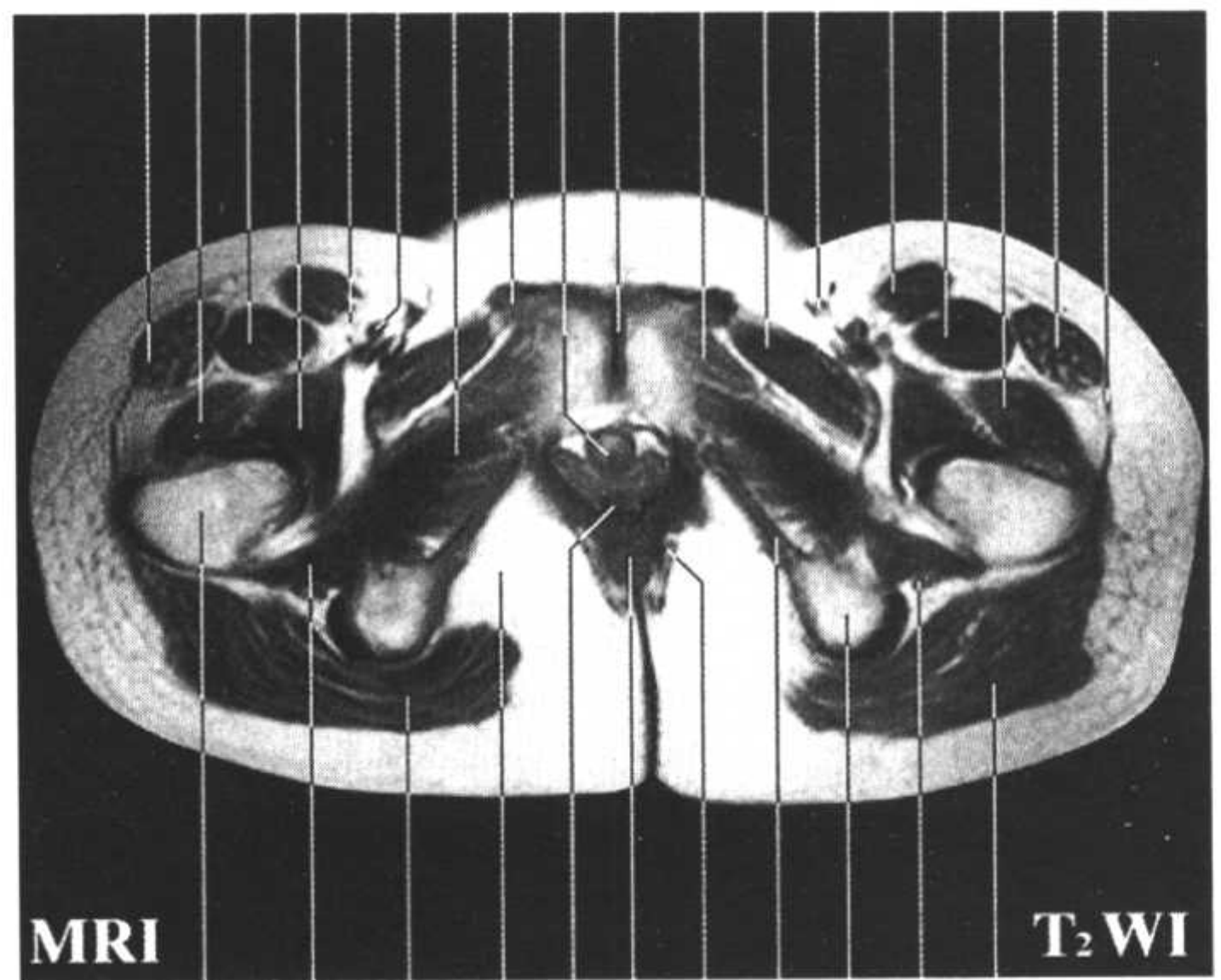
1 2 3 5 8 11 14 16 17 13 11 9 4 3 2 1 18



20 21 19 12 28 30 29 31 27 25 22 19

- 11. 耻骨肌 pectineus
- 12. 大收肌 adductor magnus
- 13. 短收肌 adductor brevis
- 14. 长收肌 adductor longus
- 15. 耻骨下支 inferior ramus of pubis
- 16. 女尿道 female urethra
- 17. 耻骨联合 pubic symphysis
- 18. 髂胫束 iliotibial tract
- 19. 臀大肌 gluteus maximus
- 20. 大转子 greater trochanter
- 21. 股方肌 quadratus femoris
- 22. 坐骨神经 sciatic n.
- 23. 半膜肌腱 tendon of semimembranosus
- 24. 半腱肌与股二头肌长头腱 tendon of semitendinosus and long head of biceps femoris
- 25. 坐骨结节 ischial tuberosity
- 26. 闭孔外肌 obturator externus
- 27. 闭孔内肌 obturator internus
- 28. 坐骨肛门窝脂体 adipose body of ischioanal fossa
- 29. 直肠 rectum
- 30. 阴道 vagina
- 31. 肛提肌 levator ani
- 32. 阴部管 pudendal canal

1 2 3 5 6 8 12 14 16 17 13 11 9 4 3 2 1 18



20 21 19 28 30 29 31 27 25 22 19

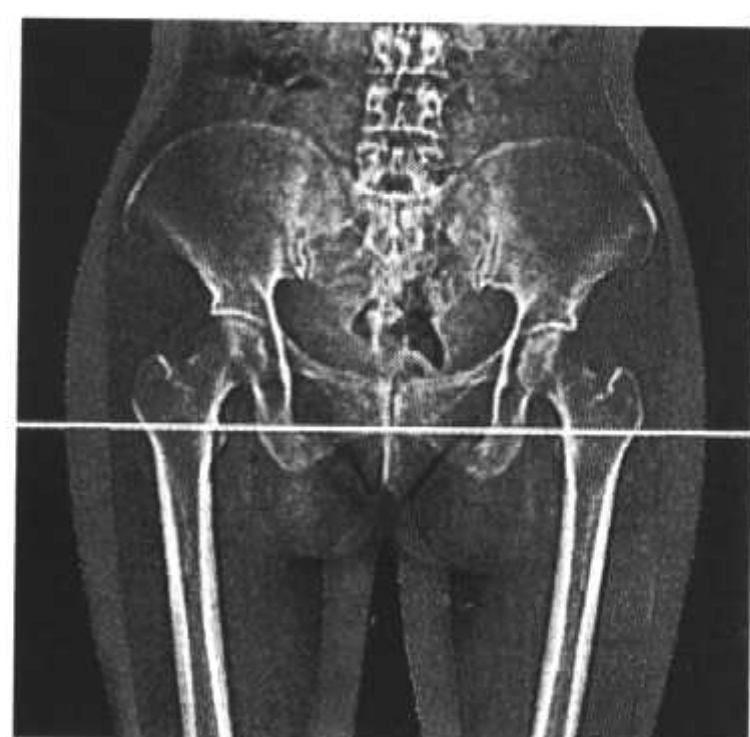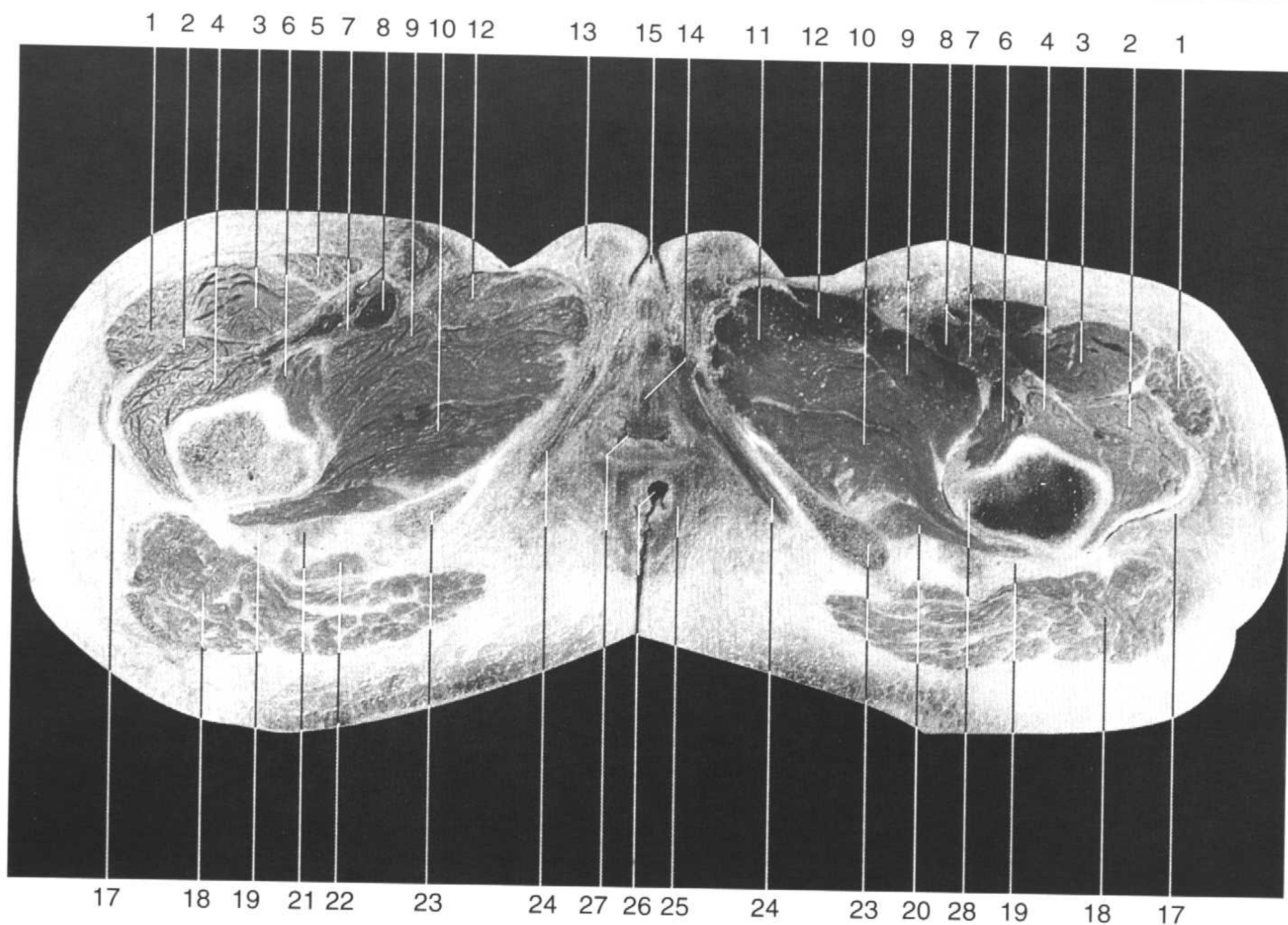

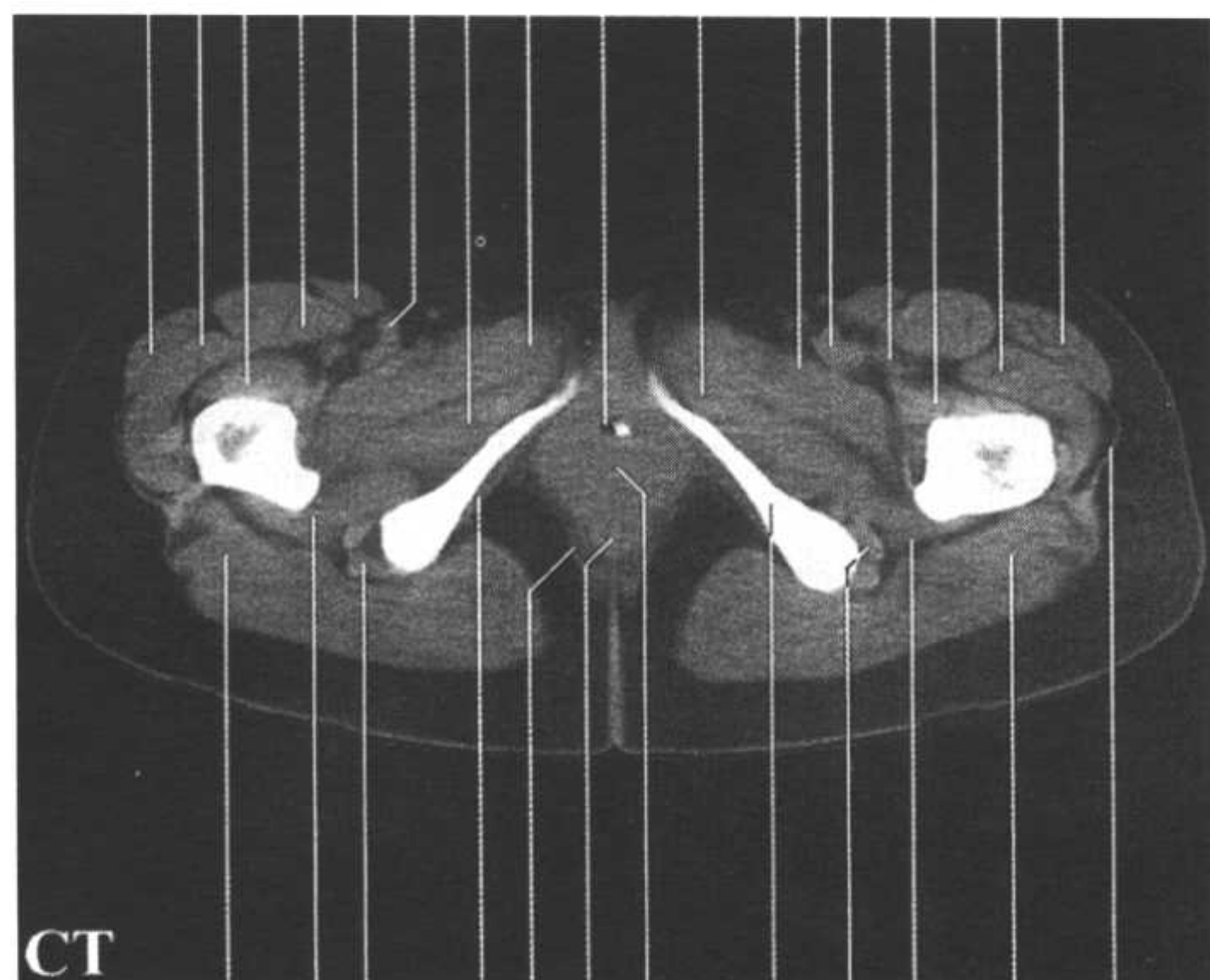
Fig.HPf13

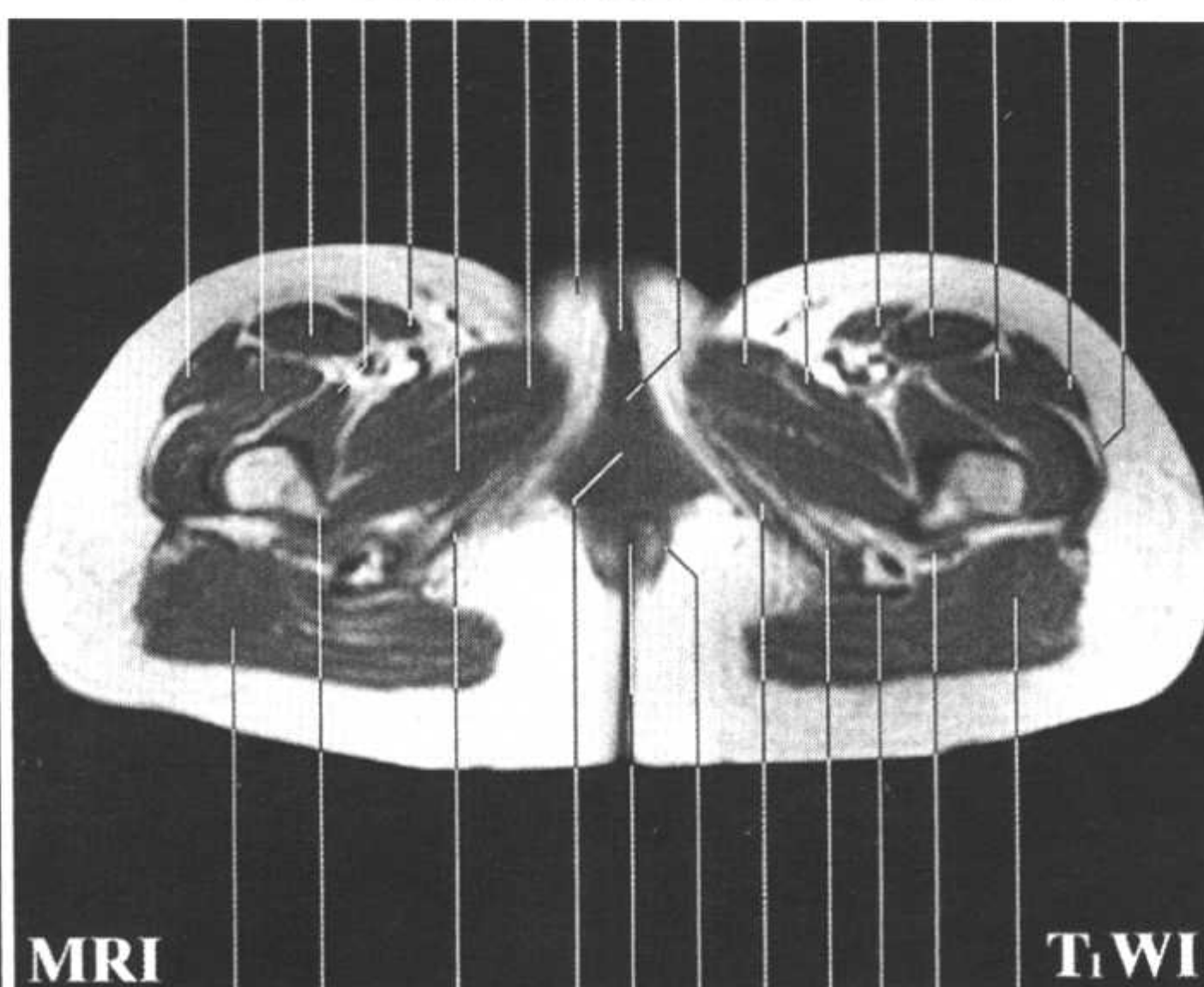
1. 阔筋膜张肌 tensor fasciae latae
2. 股外侧肌 vastus lateralis
3. 股直肌 rectus femoris
4. 股中间肌 vastus intermedius
5. 缝匠肌 sartorius
6. 髂腰肌 iliopsoas
7. 股深动脉 deep femoral a.
8. 股动、静脉 femoral a. and v.
9. 耻骨肌 pectineus

1 2 4 3 5 8 10 12 14 11 9 8 7 6 2 1



18 20 22 24 25 26 27 23 21 19 18 17

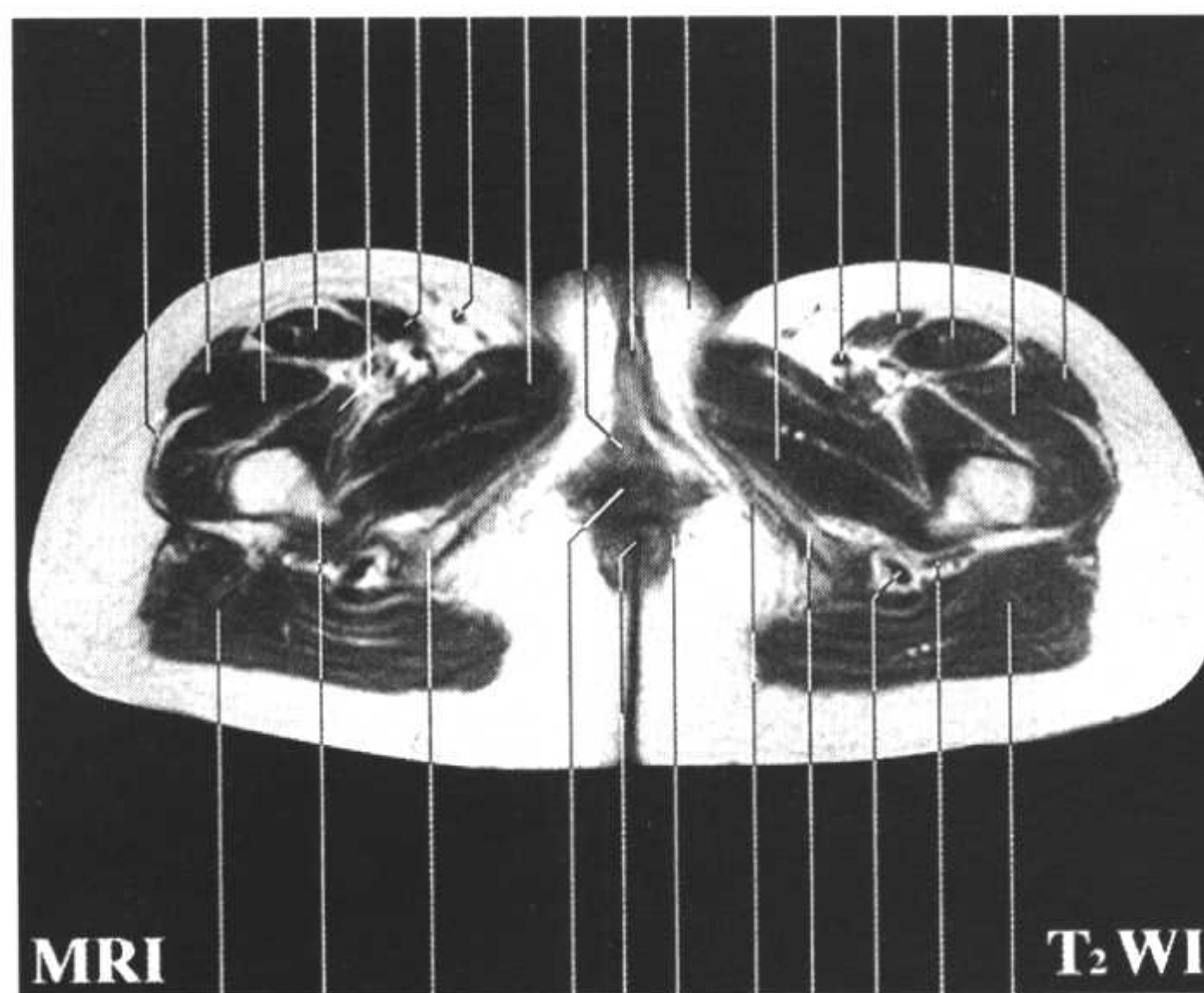
1 2 3 4 5 10 11 13 15 14 12 9 5 3 2 1 17



18 28 24 27 26 25 24 23 21 19 18

10. 大收肌 adductor magnus
11. 短收肌 adductor brevis
12. 长收肌 adductor longus
13. 大阴唇 greater lip of pudendum
14. 女尿道 female urethra
15. 阴蒂 clitoris
16. 大隐静脉 great saphenous v.
17. 髂胫束 iliotibial tract
18. 臀大肌 gluteus maximus
19. 坐骨神经 sciatic n.
20. 股方肌 quadratus femoris
21. 半膜肌腱 tendon of semimembranosus
22. 半腱肌与股二头肌长头腱 semitendinosus and tendon of long head of biceps femoris
23. 坐骨支 ramus of ischium
24. 坐骨海绵体肌 ischiocavernosus
25. 肛门外括约肌 sphincter ani externus
26. 肛门 anus
27. 阴道 vagina
28. 小转子 lesser trochanter

17 1 2 3 4 5 16 11 14 15 13 10 8 5 3 2 1



18 28 23 27 26 25 24 23 21 19 18

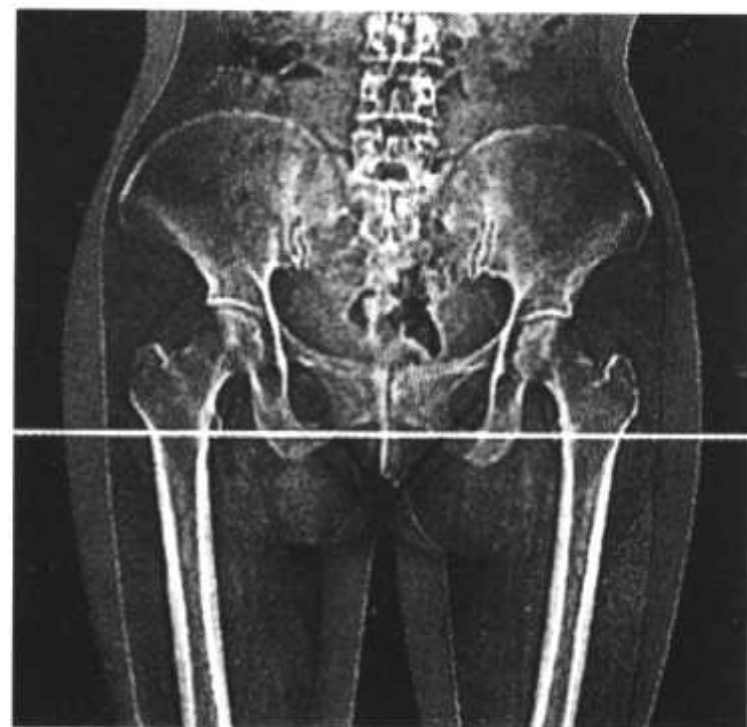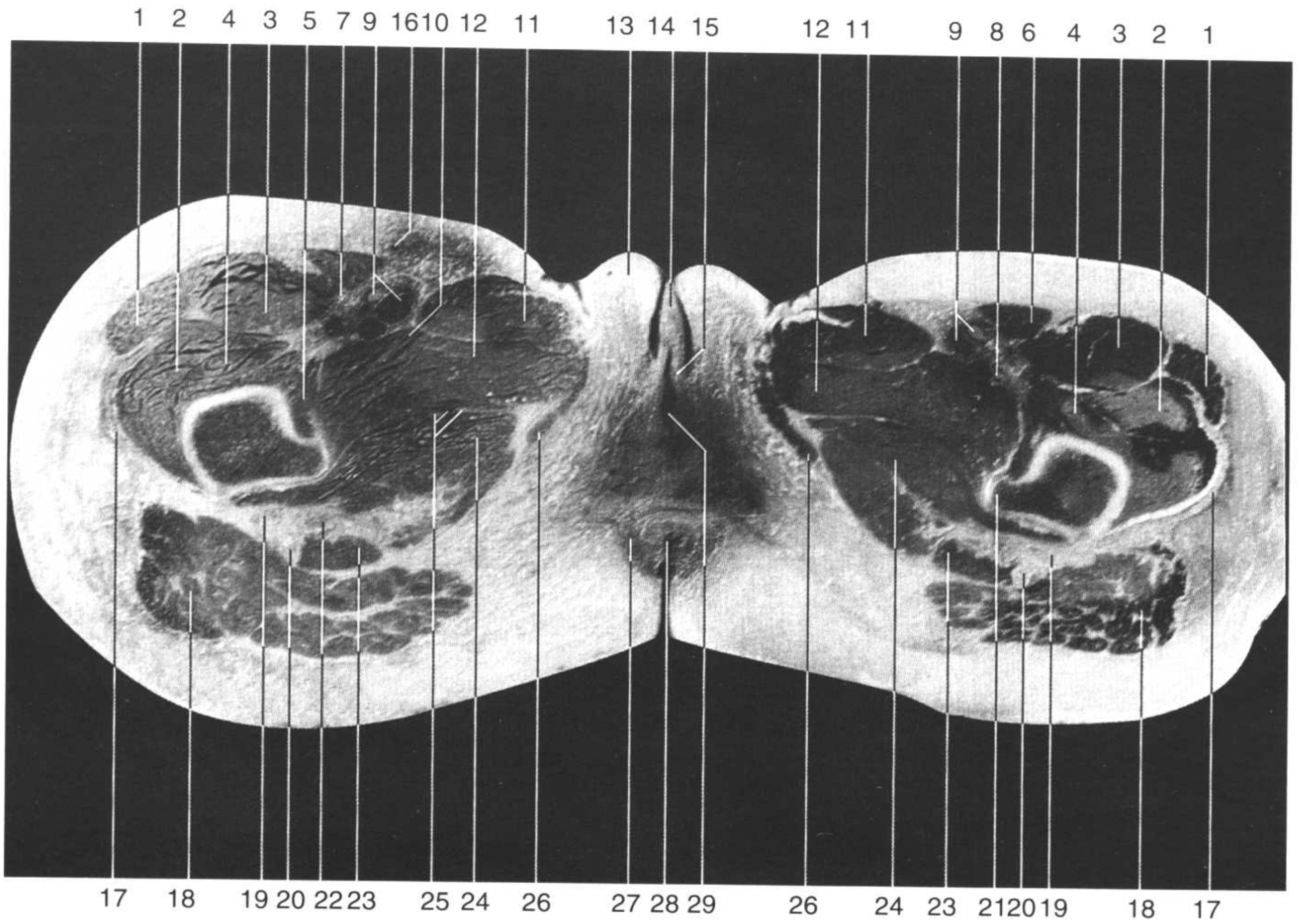
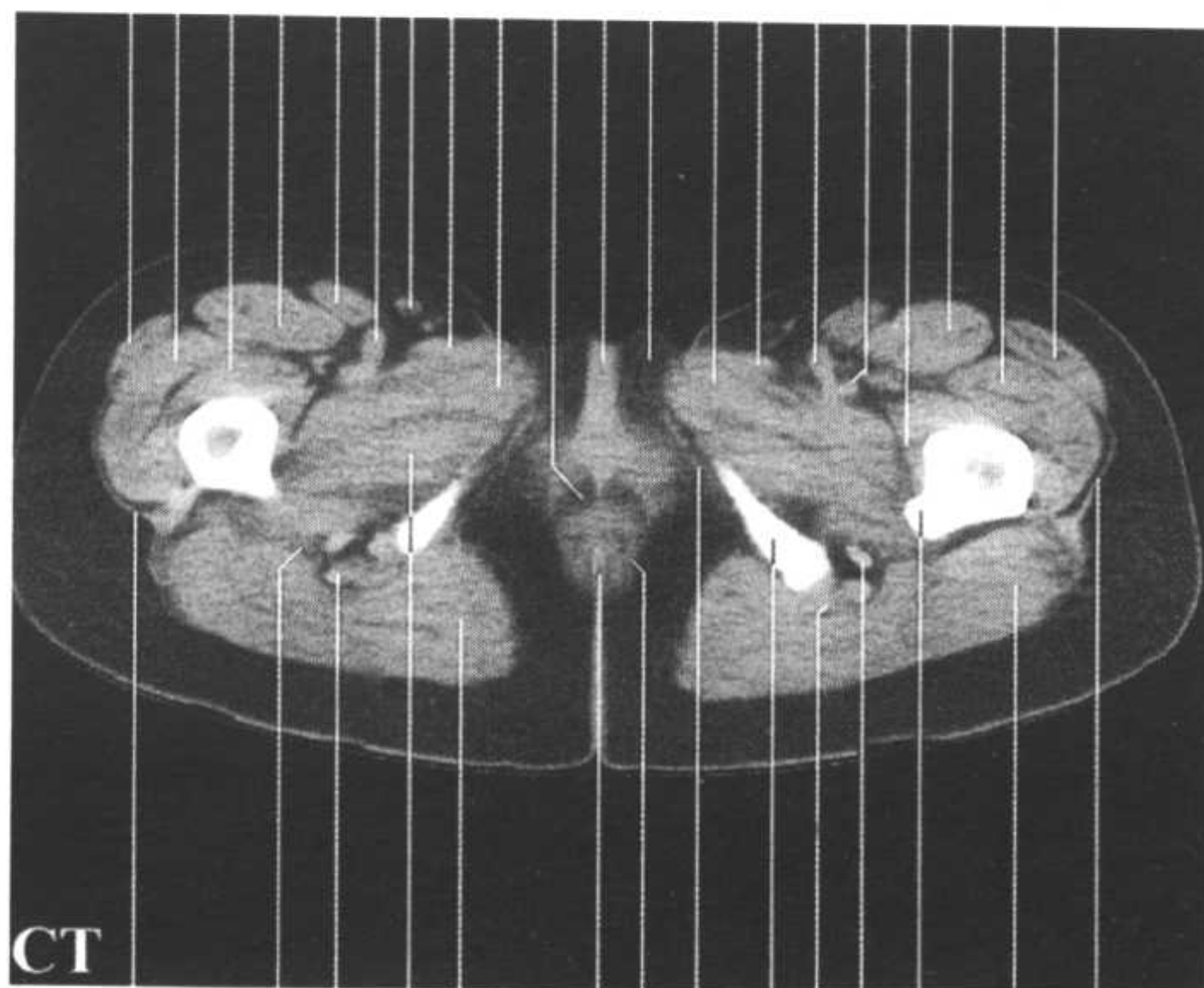


Fig. HPf14

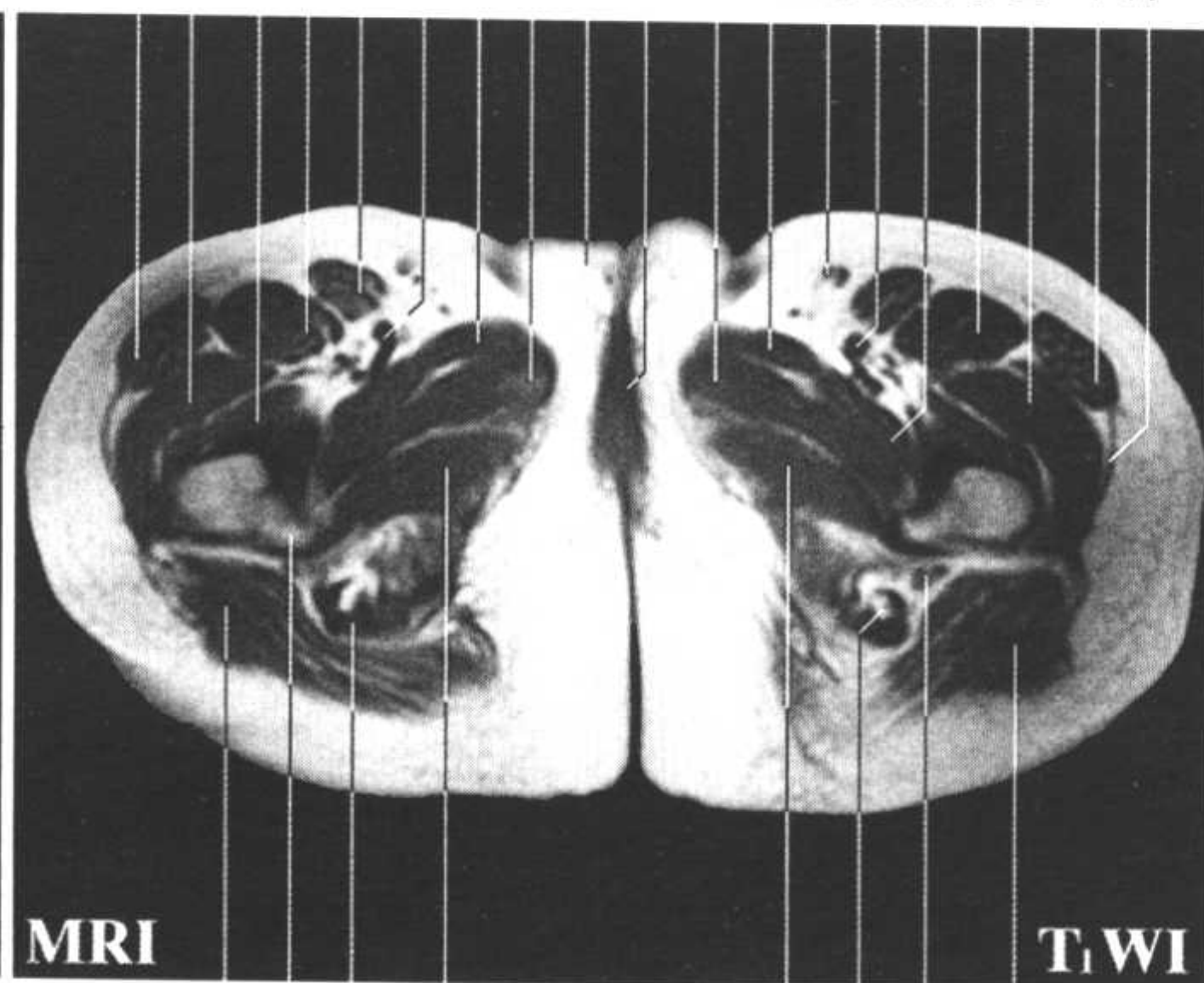
1. 阔筋膜张肌 tensor fasciae latae
2. 股外侧肌 vastus lateralis
3. 股直肌 rectus femoris
4. 股中间肌 vastus intermedius
5. 髂腰肌 iliopsoas
6. 缝匠肌 sartorius
7. 股神经 femoral n.
8. 股深动、静脉 deep femoral a. and v.
9. 股动、静脉 femoral a. and v.
10. 耻骨肌 pectineus

1 2 4 3 6 9 16 11 12 29 14 13 12 11 9 8 5 3 2 1



17 19 20 24 18 28 27 26 30 23 22 21 18 17

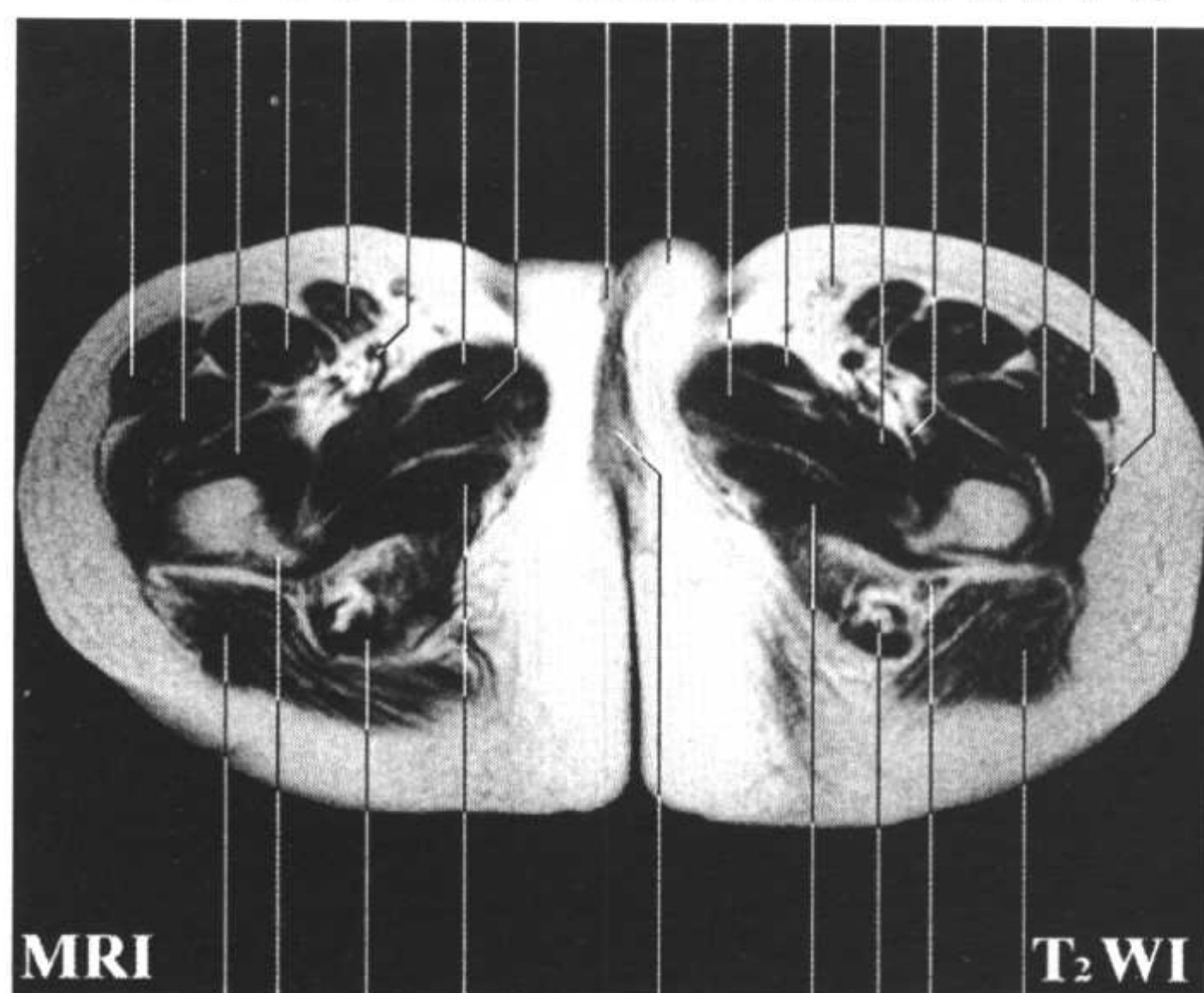
1 2 4 3 6 9 11 12 13 29 12 11 16 9 10 3 2 1 17



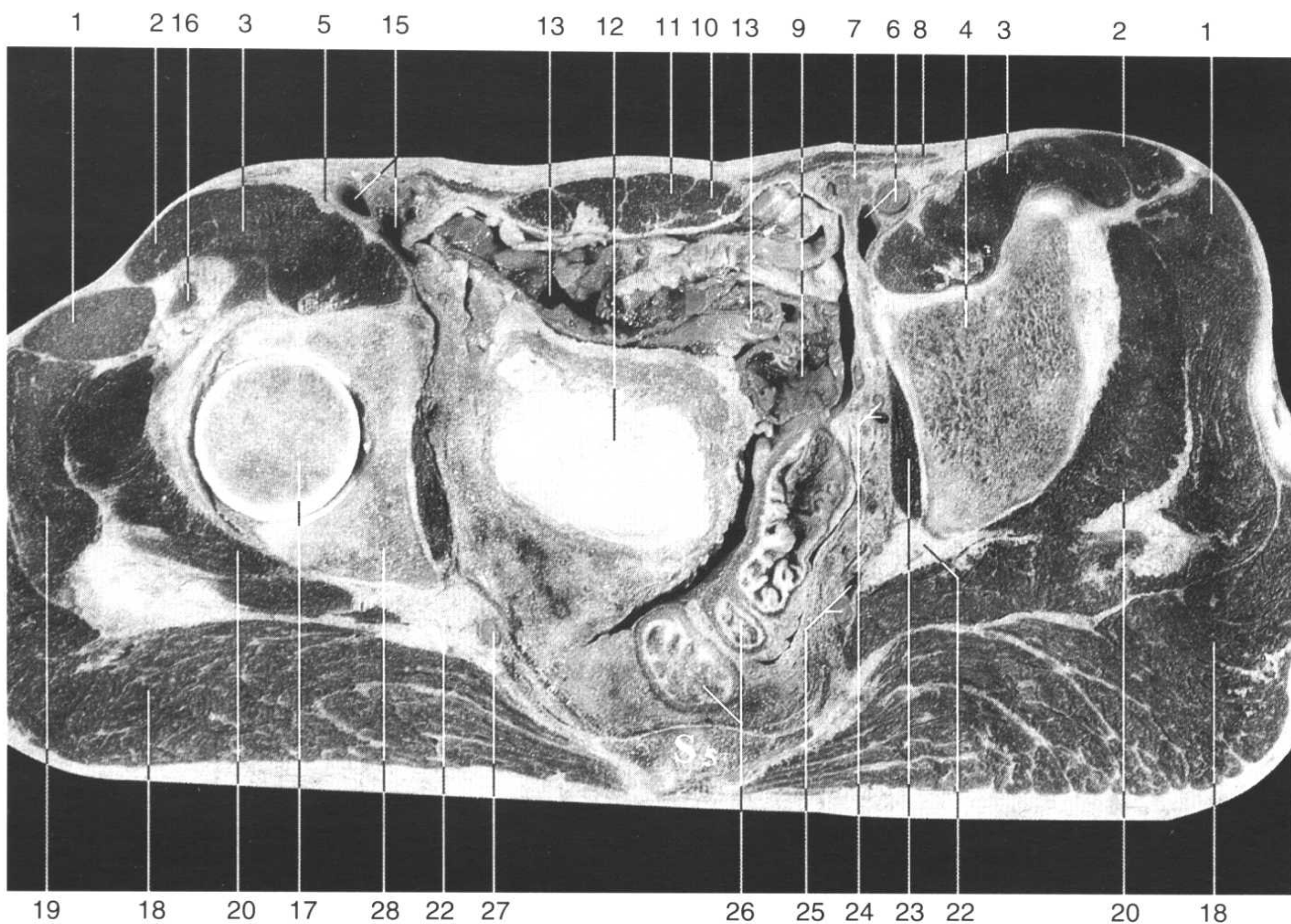
18 21 20 24 24 22 19 18

11. 长收肌 adductor longus
12. 短收肌 adductor brevis
13. 大阴唇 greater lip of pudendum
14. 阴蒂 clitoris
15. 小阴唇 lesser lip of pudendum
16. 大隐静脉 great saphenous v.
17. 髂胫束 iliotibial tract
18. 臀大肌 gluteus maximus
19. 坐骨神经 sciatic n.
20. 股二头肌长头腱 tendon of long head of biceps femoris
21. 小转子 lesser trochanter
22. 半膜肌腱 tendon of semimembranosus
23. 半腱肌 semitendinosus
24. 大收肌 adductor magnus
25. 闭孔动、静脉与神经 obturator a., v. and n.
26. 股薄肌 gracilis
27. 肛门外括约肌 sphincter ani externus
28. 肛门 anus
29. 阴道前庭 vaginal vestibule
30. 坐骨支 ramus of ischium

1 2 4 3 6 9 11 12 15 13 12 11 16 10 5 3 2 1 17



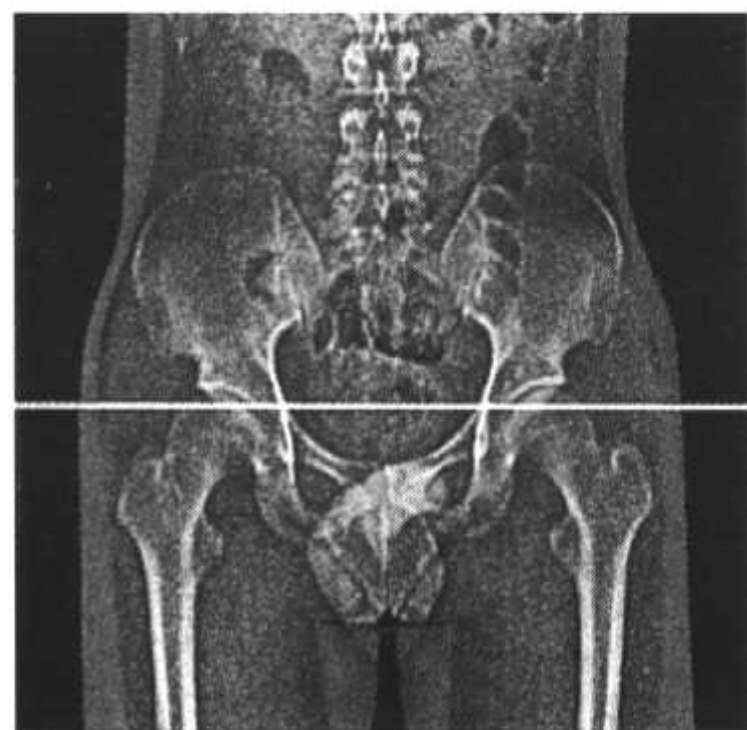18 21 23 24 29 24 22 19 18

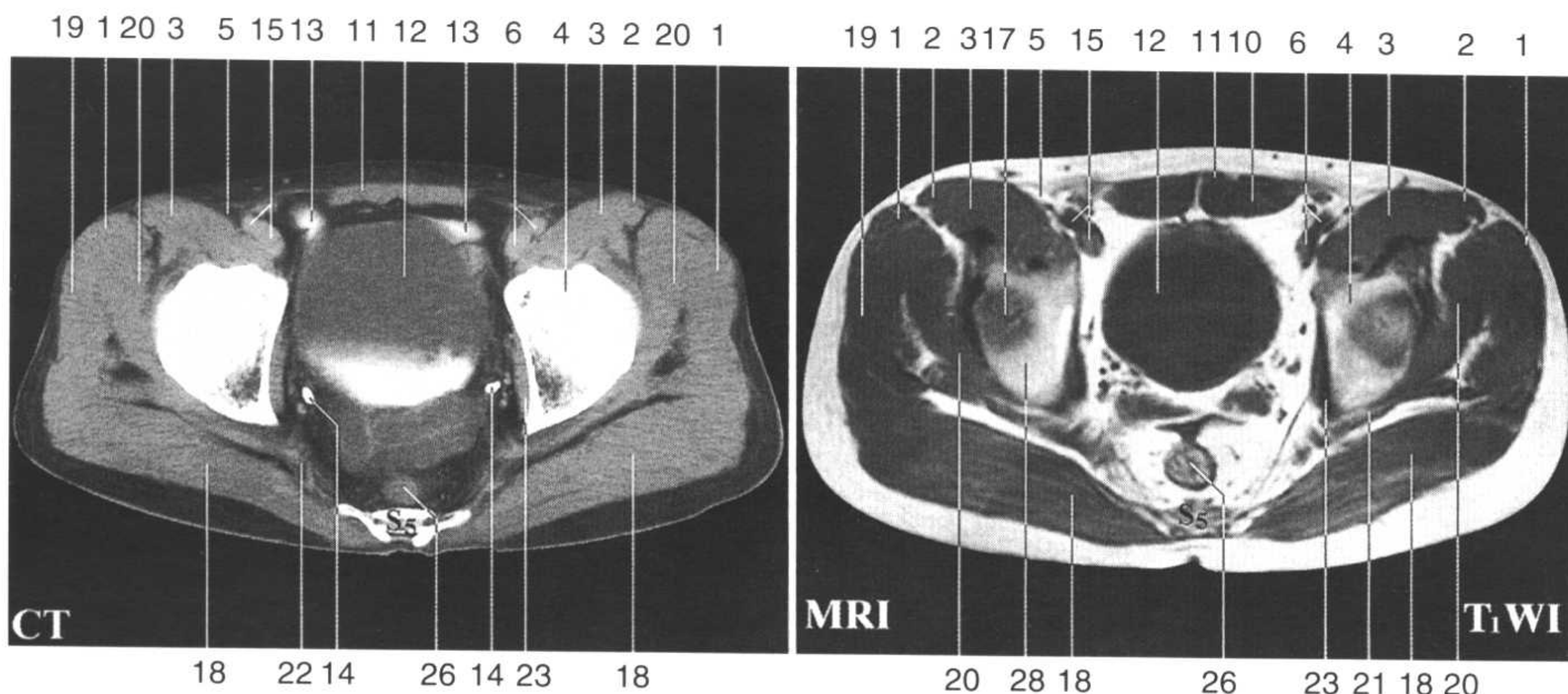


男盆水平断面 HPm

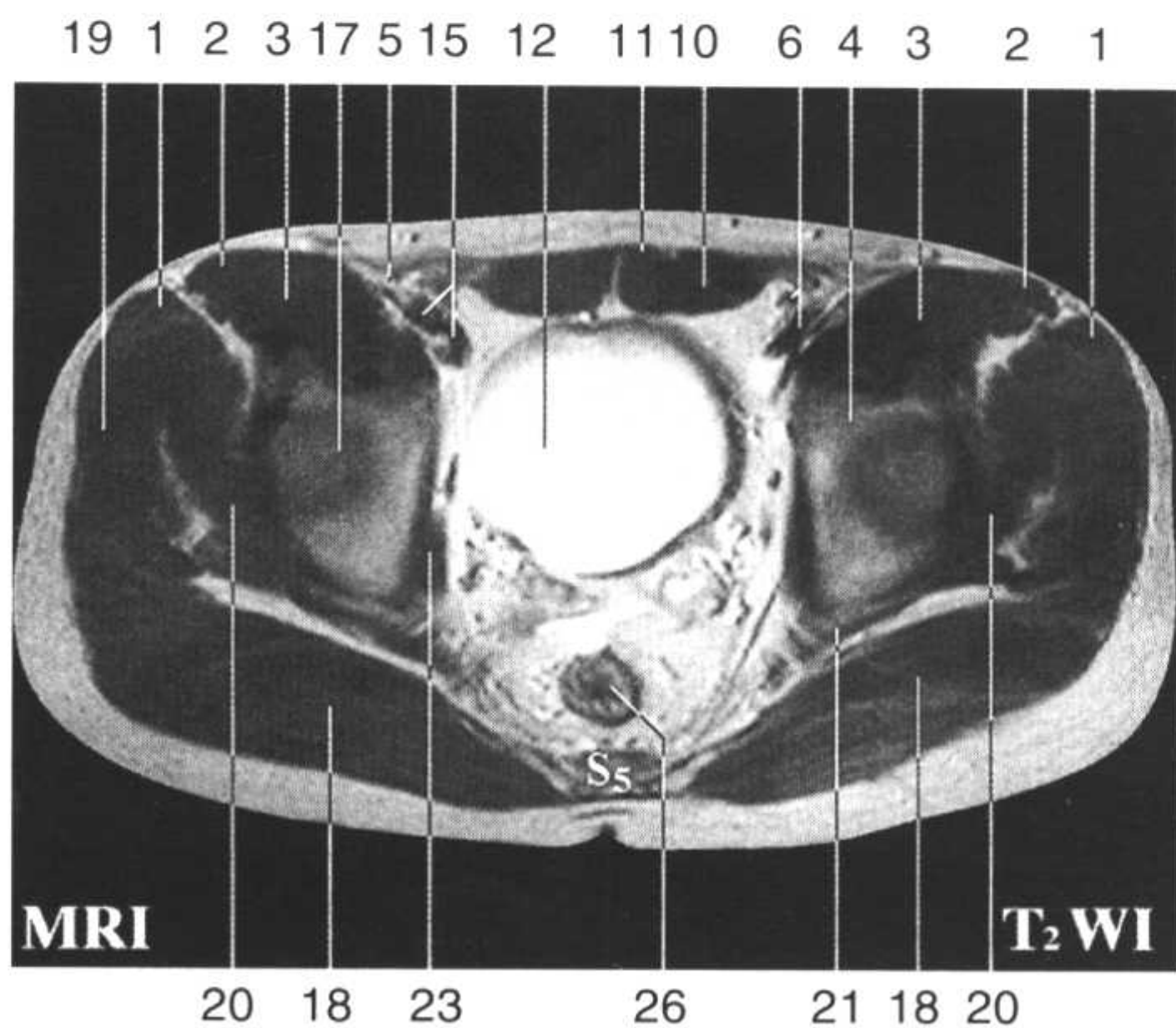
Fig.HPm1

1. 阔筋膜张肌 tensor fasciae latae
2. 缝匠肌 sartorius
3. 髂腰肌 iliopsoas
4. 髌骨体 body of ilium
5. 股神经 femoral n.
6. 左髂外动、静脉 left external iliac a. and v.
7. 精索 spermatic cord
8. 腹内斜肌 obliquus internus abdominis
9. 乙状结肠 sigmoid colon
10. 腹直肌 rectus abdominis





11. 锥状肌 pyramidalis
12. 膀胱 urinary bladder
13. 回肠 ileum
14. 输尿管 ureter
15. 右髂外动、静脉 right external iliac a. and v.
16. 股直肌 rectus femoris
17. 股骨头 femoral head
18. 臀大肌 gluteus maximus
19. 臀中肌 gluteus medius
20. 臀小肌 gluteus minimus
21. 梨状肌 piriformis
22. 坐骨神经 sciatic n.
23. 闭孔内肌 obturator internus
24. 闭孔动、静脉 obturator a. and v.
25. 臀下动、静脉 inferior gluteal a. and v.
26. 直肠 rectum
27. 阴部内动、静脉 internal pudendal a. and v.
28. 坐骨体 body of ischium



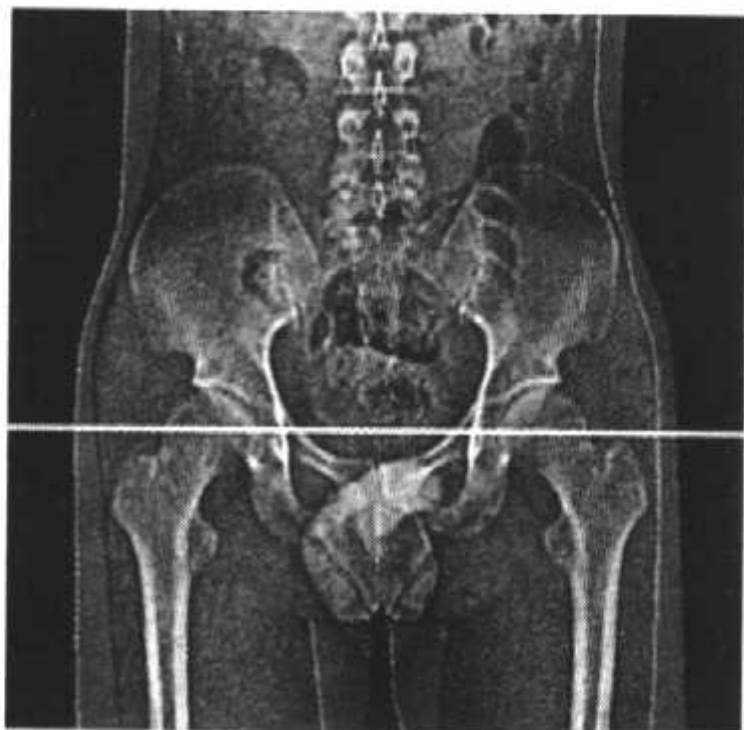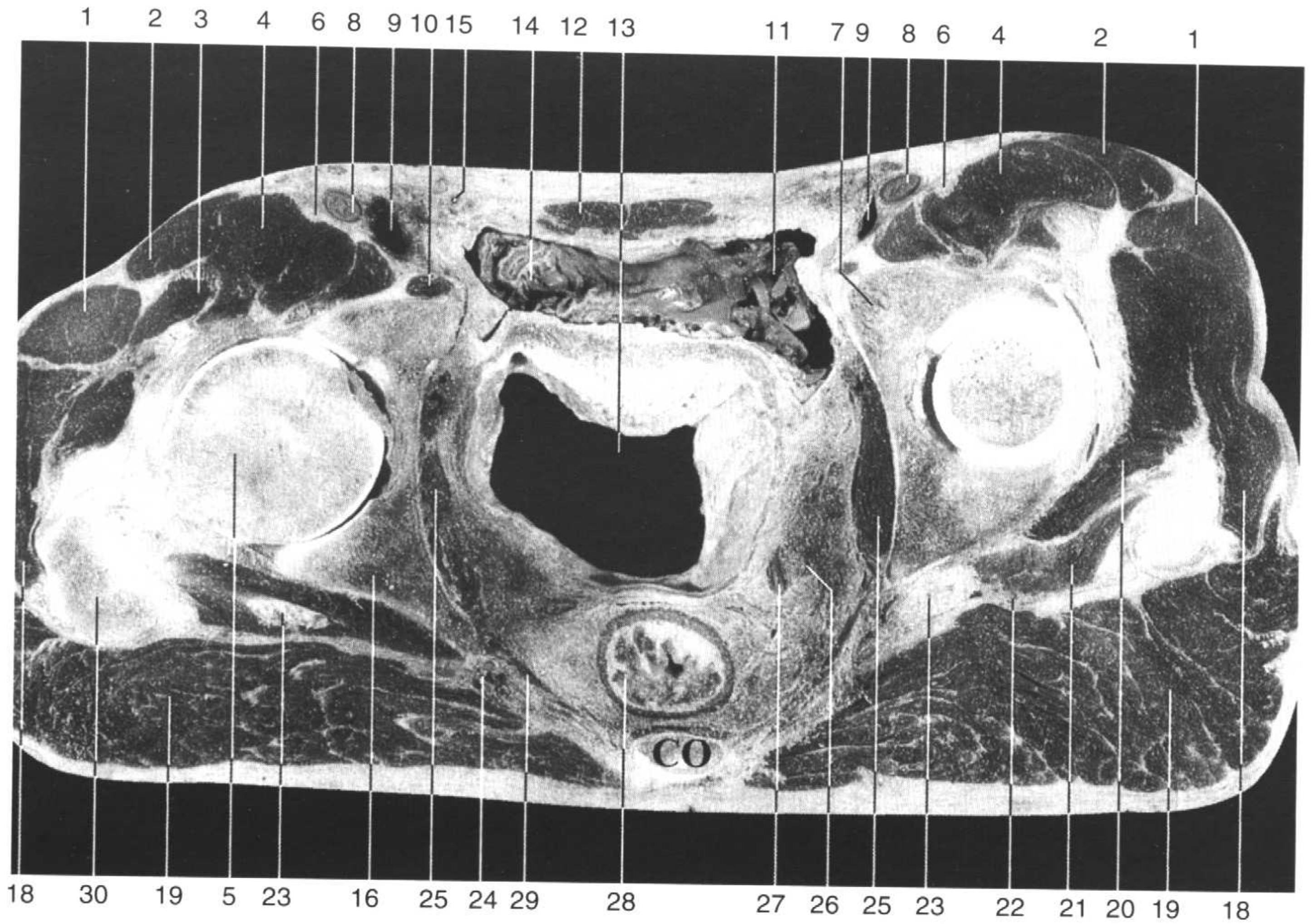
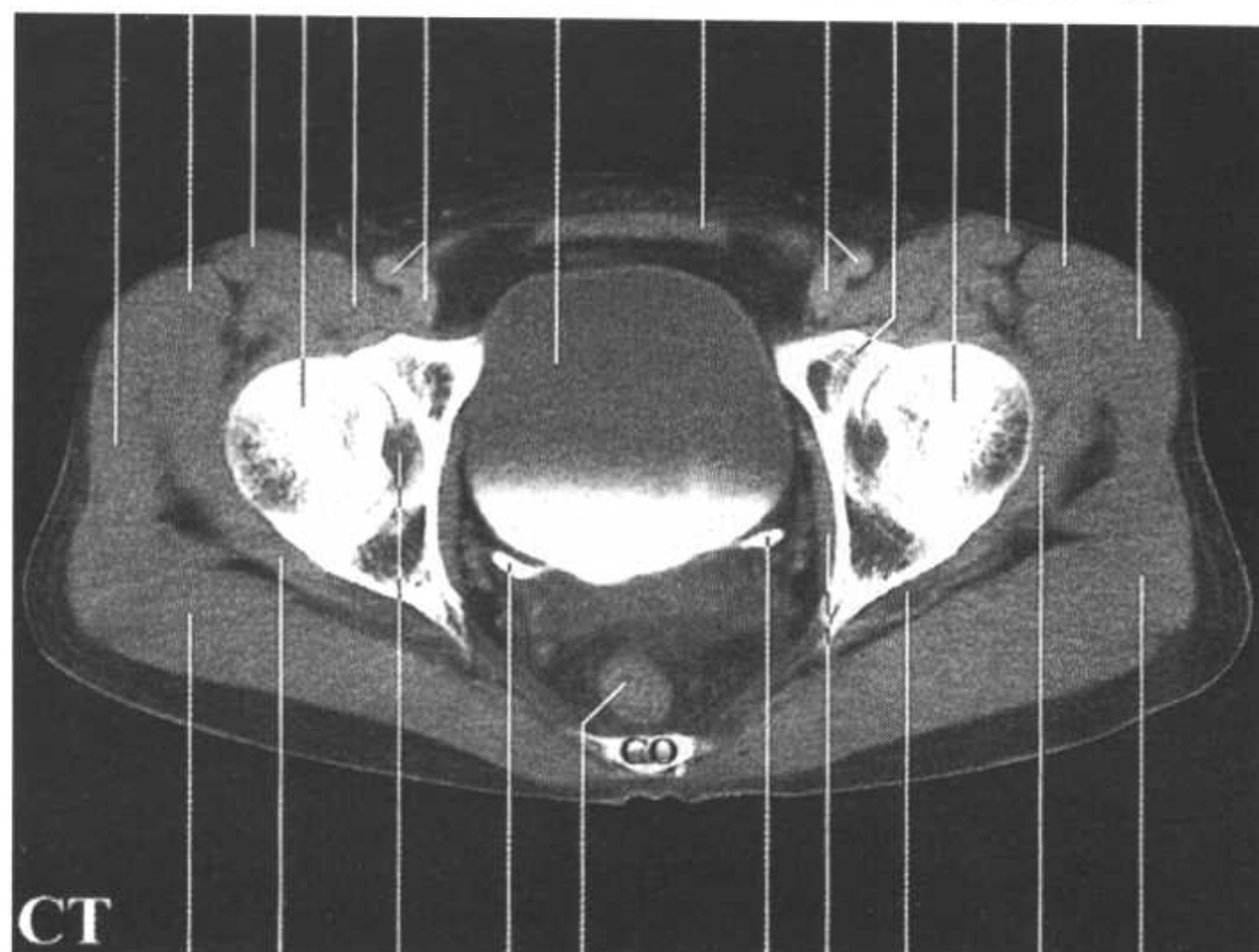


Fig.HPm2

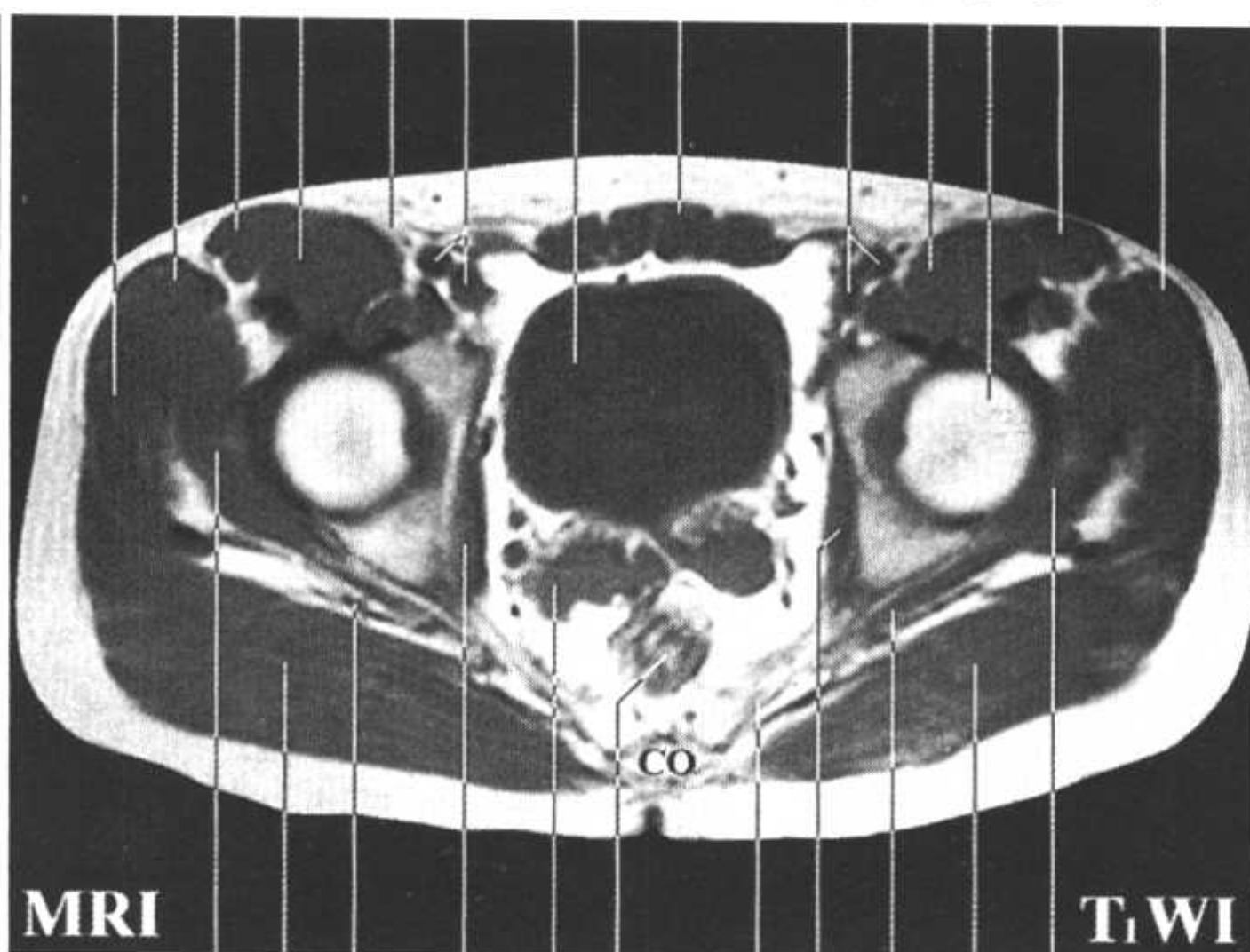
1. 阔筋膜张肌 tensor fasciae latae
2. 缝匠肌 sartorius
3. 股直肌 rectus femoris
4. 髂腰肌 iliopsoas
5. 股骨头 femoral head
6. 股神经 femoral n.
7. 耻骨体 body of pubis
8. 股动脉 femoral a.
9. 股静脉 femoral v.
10. 耻骨肌 pectineus

18 1 2 5 4 33 13 12 33 7 5 2 1 18



19 20 32 26 28 26 25 21 20 19

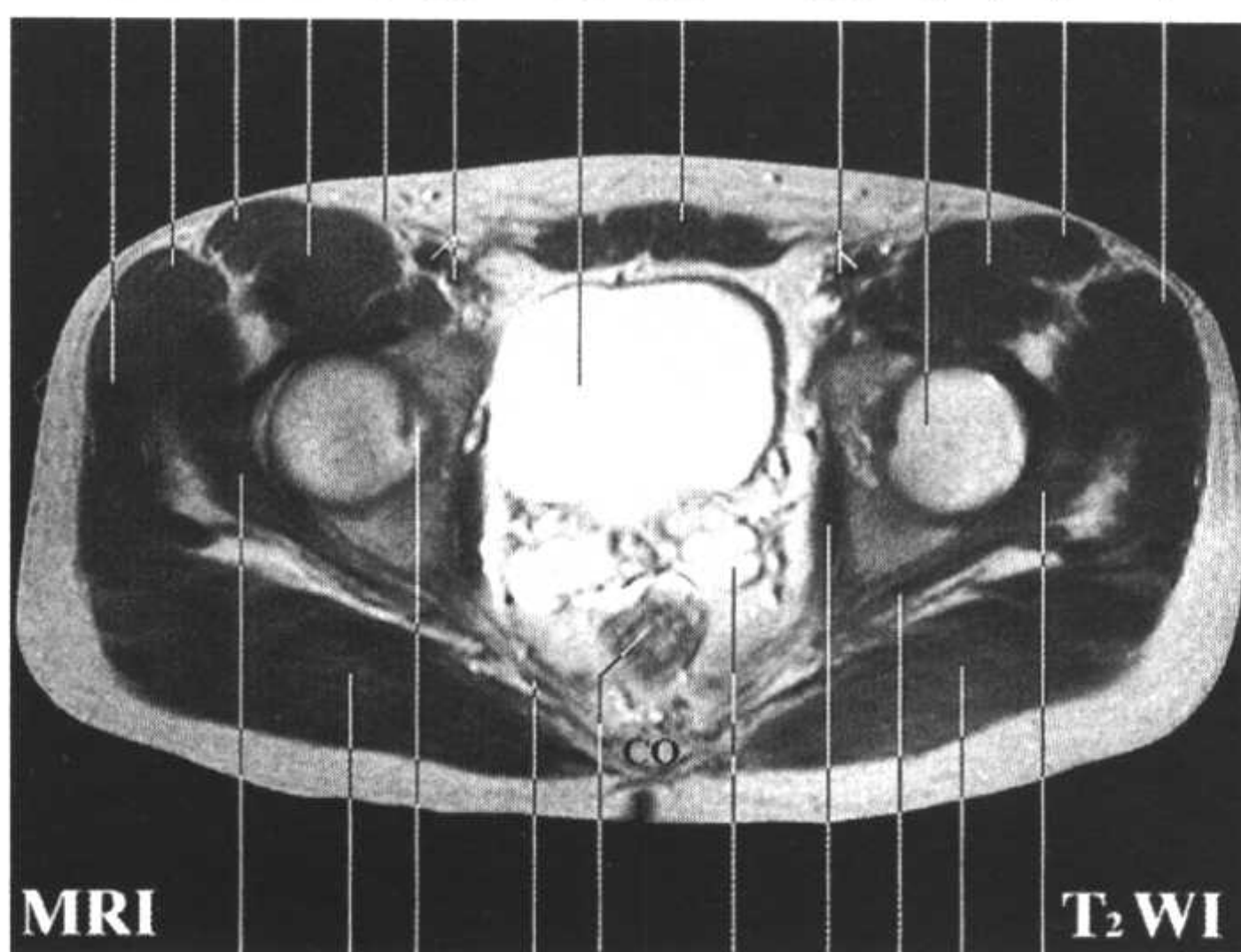
18 1 2 4 6 33 13 12 33 4 5 2 1



20 19 22 25 31 28 29 25 21 19 20

11. 乙状结肠 sigmoid colon
12. 锥状肌 pyramidalis
13. 膀胱 urinary bladder
14. 回肠 ileum
15. 精索 spermatic cord
16. 坐骨体 body of ischium
17. 股骨头韧带 ligament of head of femur
18. 臀中肌 gluteus medius
19. 臀大肌 gluteus maximus
20. 臀小肌 gluteus minimus
21. 上孖肌 gemellus superior
22. 坐骨神经 sciatic n.
23. 闭孔内肌腱 tendon of obturator internus
24. 臀下动、静脉 inferior gluteal a. and v.
25. 闭孔内肌 obturator internus
26. 输尿管 ureter
27. 输精管 ductus deferens
28. 直肠 rectum
29. 尾骨肌 coccygeus
30. 大转子 greater trochanter
31. 精囊 seminal vesicle
32. 股骨头韧带 ligament of head of femur
33. 股动、静脉 femoral a. and v.

18 1 2 4 6 33 13 12 33 5 4 2 1



20 19 17 29 28 31 25 21 19 20

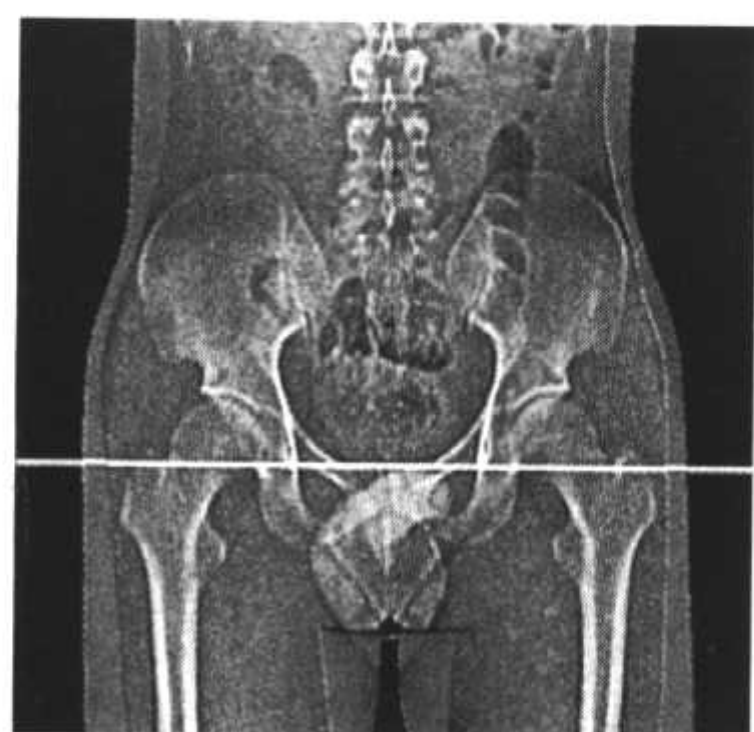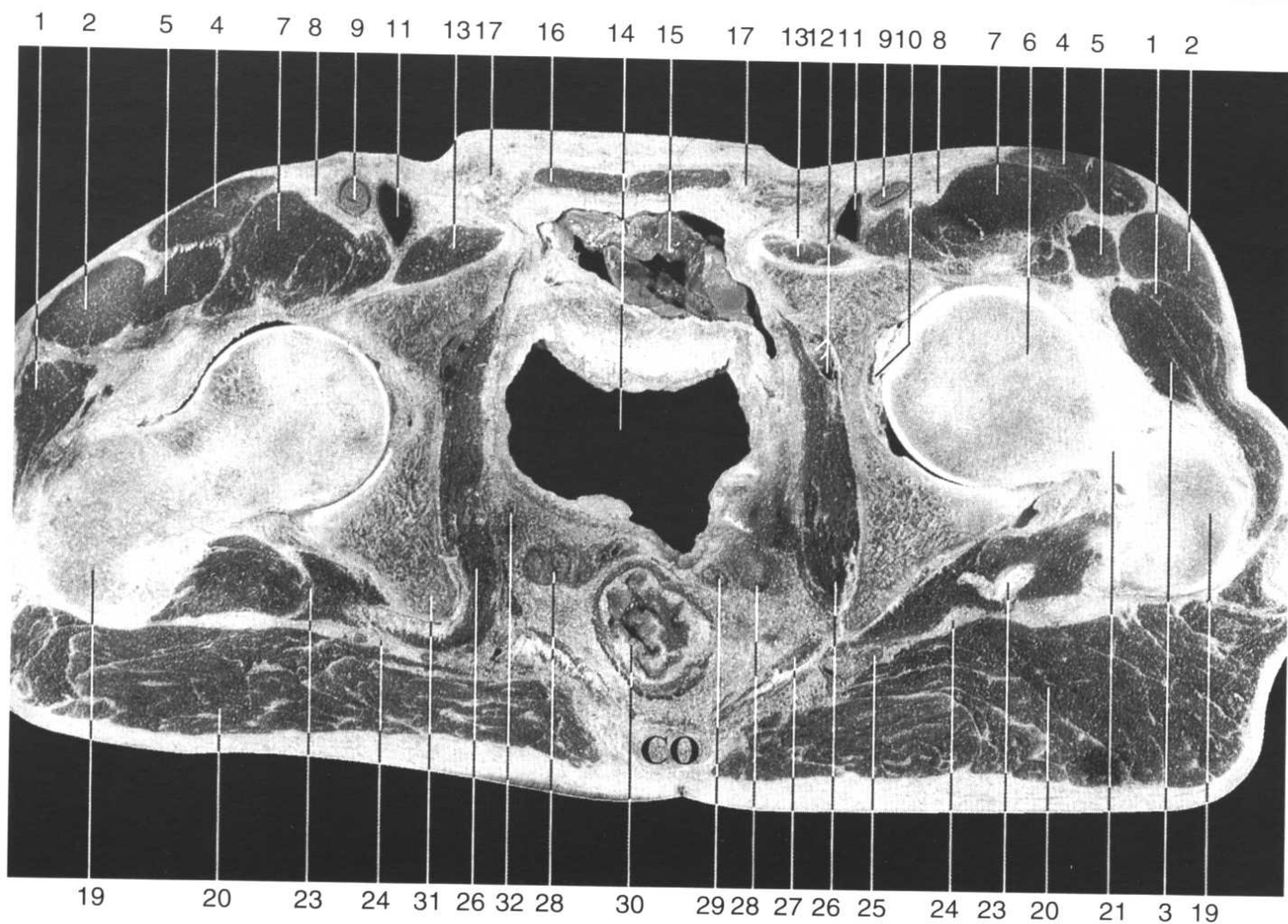
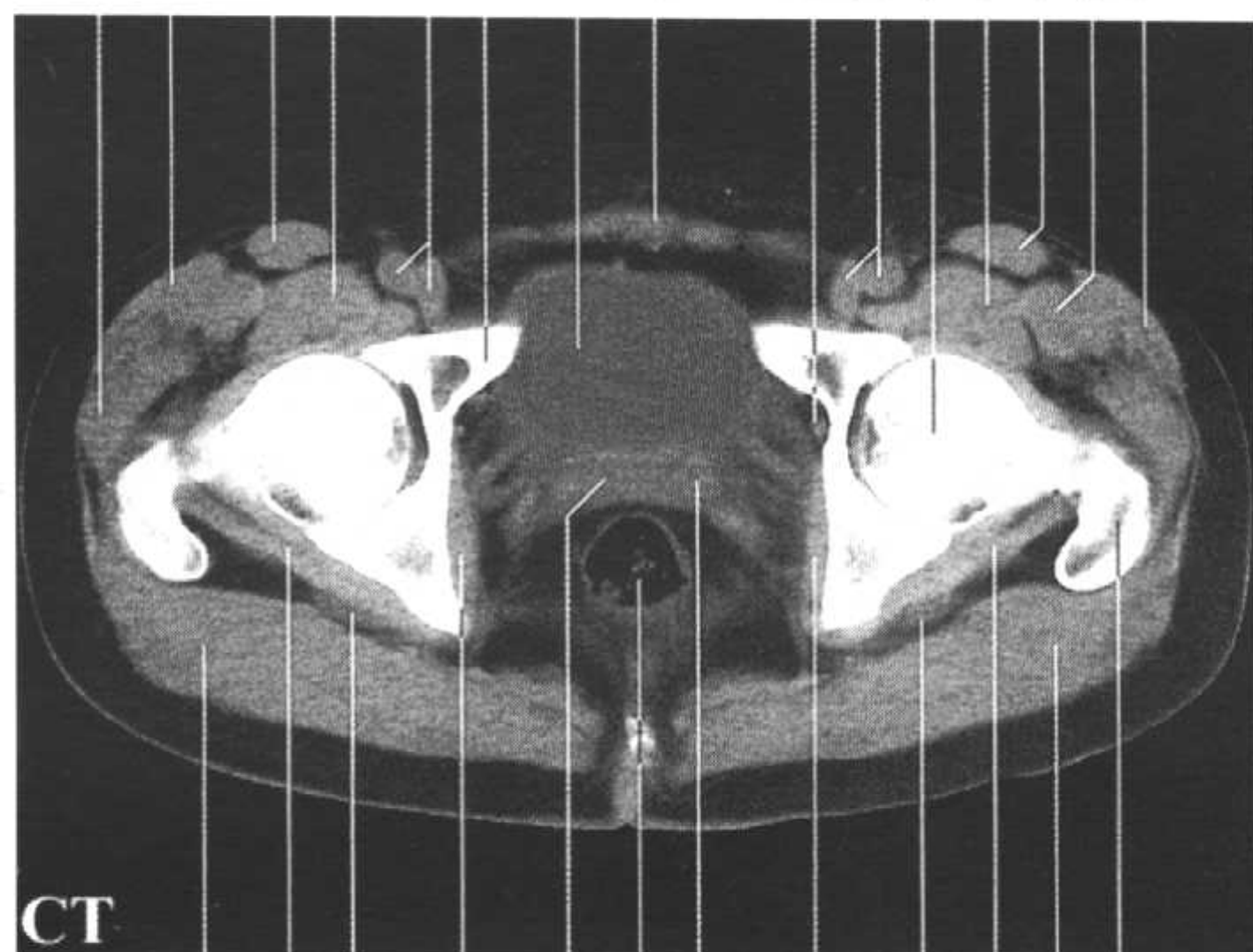


Fig.HPm3

1. 臀中肌 *gluteus medius*
2. 阔筋膜张肌 *tensor fasciae latae*
3. 臀小肌 *gluteus minimus*
4. 缝匠肌 *sartorius*
5. 股直肌 *rectus femoris*
6. 股骨头 *femoral head*
7. 髂腰肌 *iliopsoas*
8. 股神经 *femoral n.*
9. 股动脉 *femoral a.*
10. 股骨头韧带 *ligament of head of femur*

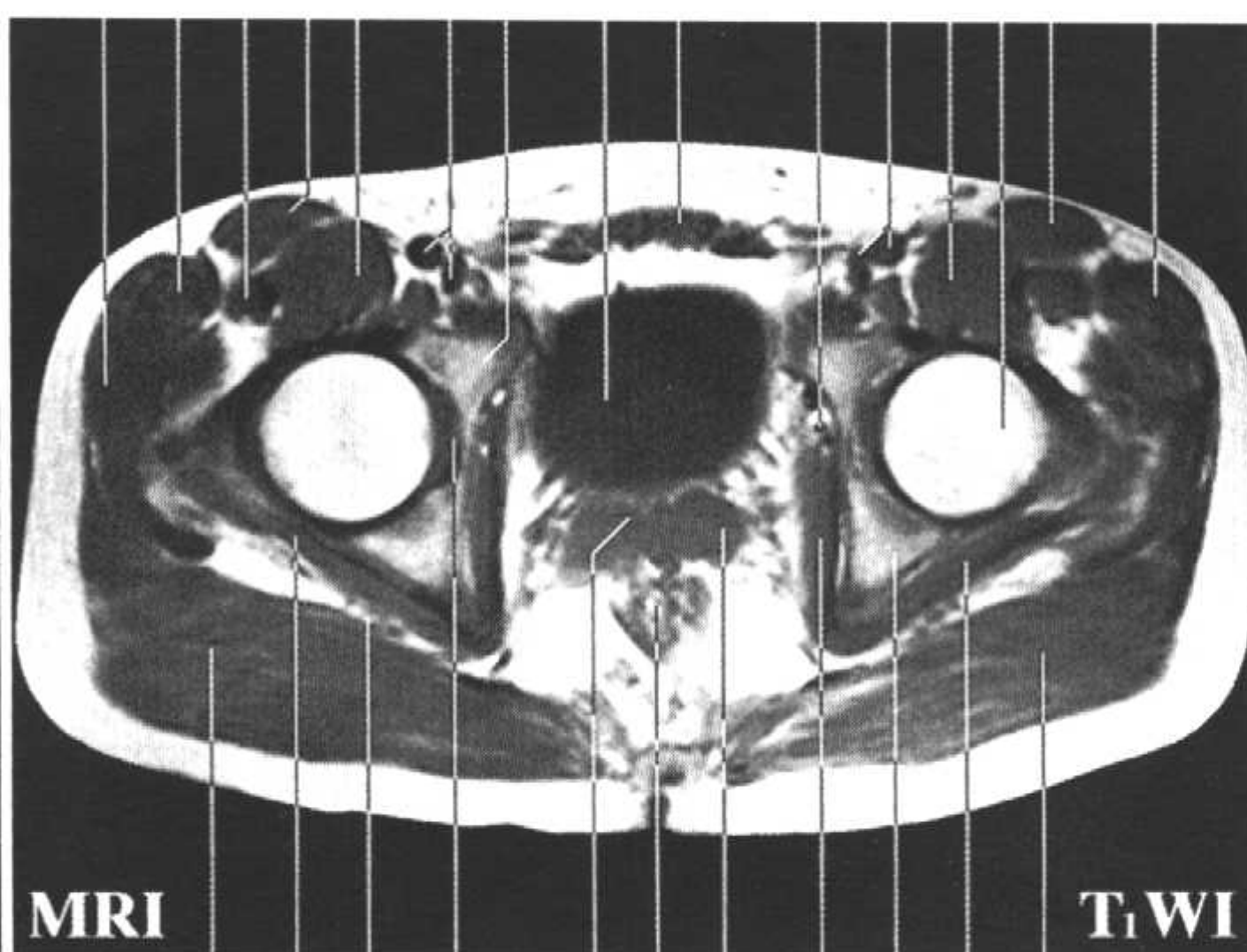
1 2 4 7 33 18 14 16 12 33 6 7 4 5 2



CT

20 22 24 26 29 30 28 26 24 22 20 19

1 2 5 4 7 33 18 14 16 12 33 7 6 4 2



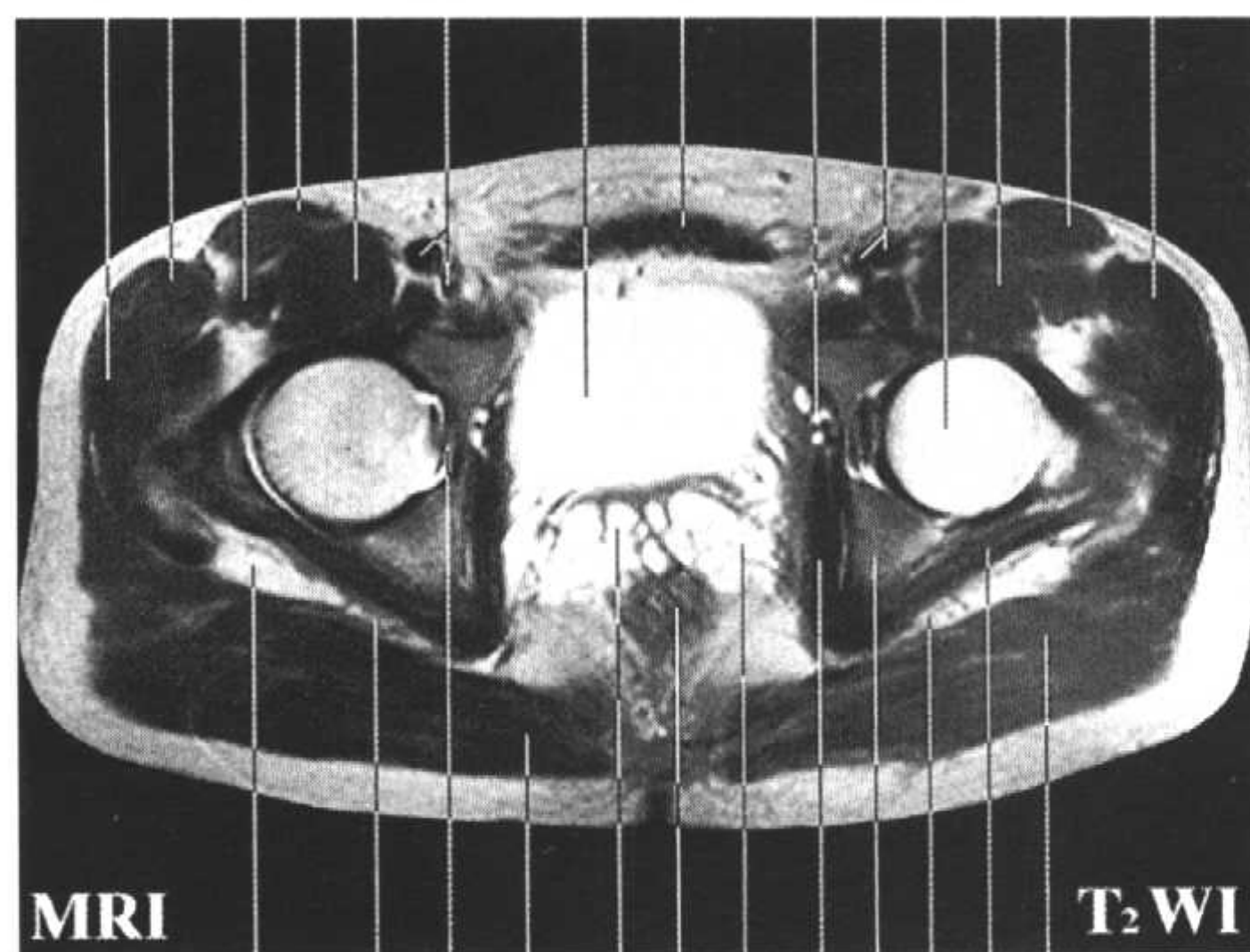
MRI

T₁WI

20 22 24 10 29 30 28 26 31 22 20

11. 股静脉 femoral v.
12. 闭膜管 obturator canal
13. 耻骨肌 pectineus
14. 膀胱 urinary bladder
15. 乙状结肠 sigmoid colon
16. 锥状肌 pyramidalis
17. 精索 spermatic cord
18. 耻骨体 body of pubis
19. 大转子 greater trochanter
20. 臀大肌 gluteus maximus
21. 股骨颈 neck of femur
22. 下孖肌 gemellus inferior
23. 闭孔内肌腱 tendon of obturator internus
24. 坐骨神经 sciatic n.
25. 臀下动、静脉 inferior gluteal a. and v.
26. 闭孔内肌 obturator internus
27. 尾骨肌 coccygeus
28. 精囊 seminal vesicle
29. 输精管壶腹 ampulla ductus deferentis
30. 直肠 rectum
31. 坐骨体 body of ischium
32. 输尿管 ureter
33. 股动、静脉 femoral a. and v.

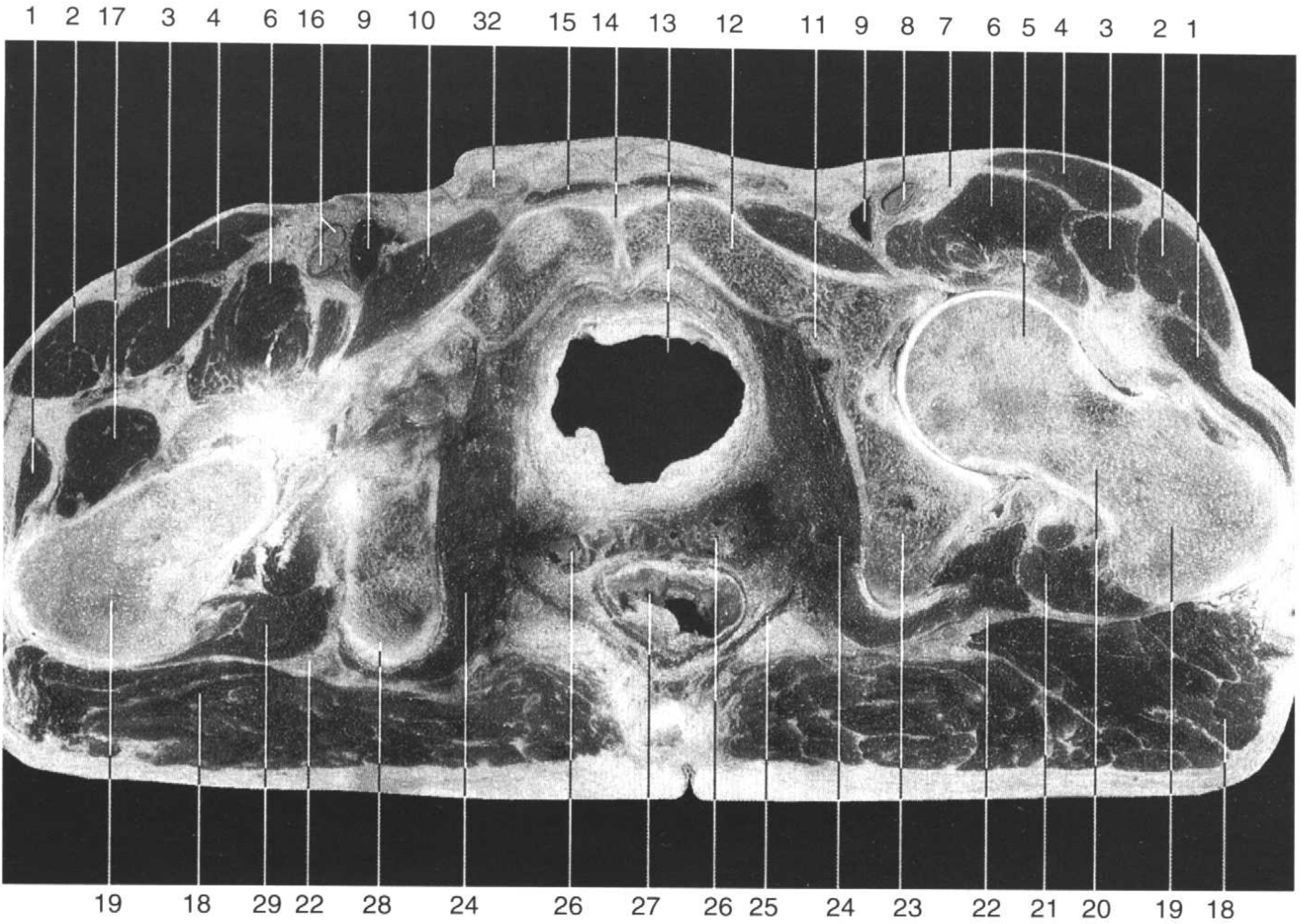
1 2 5 4 7 33 14 16 12 33 6 7 4 2



MRI

T₂WI

23 24 10 20 29 30 28 26 31 24 22 20



19 18 29 22 28 24 26 27 26 25 24 23 22 21 20 19 18

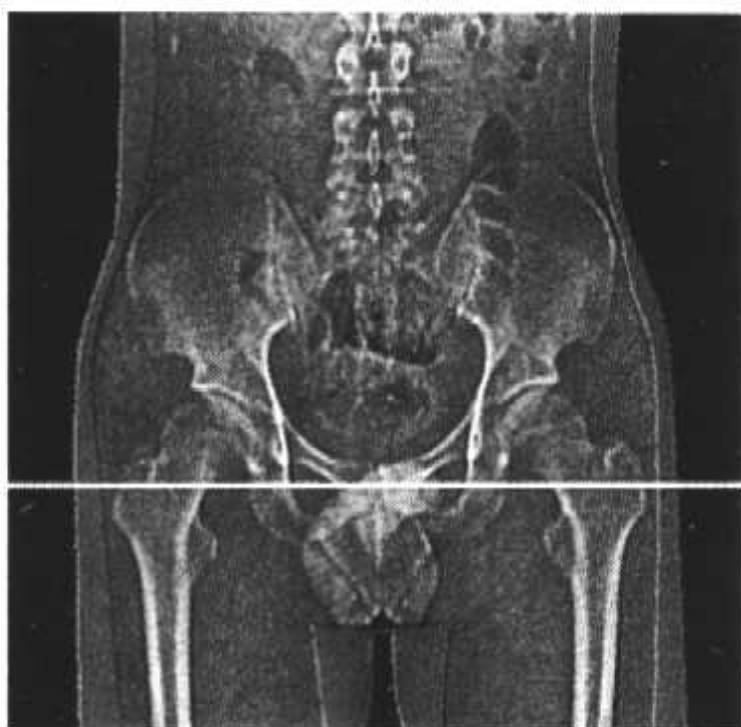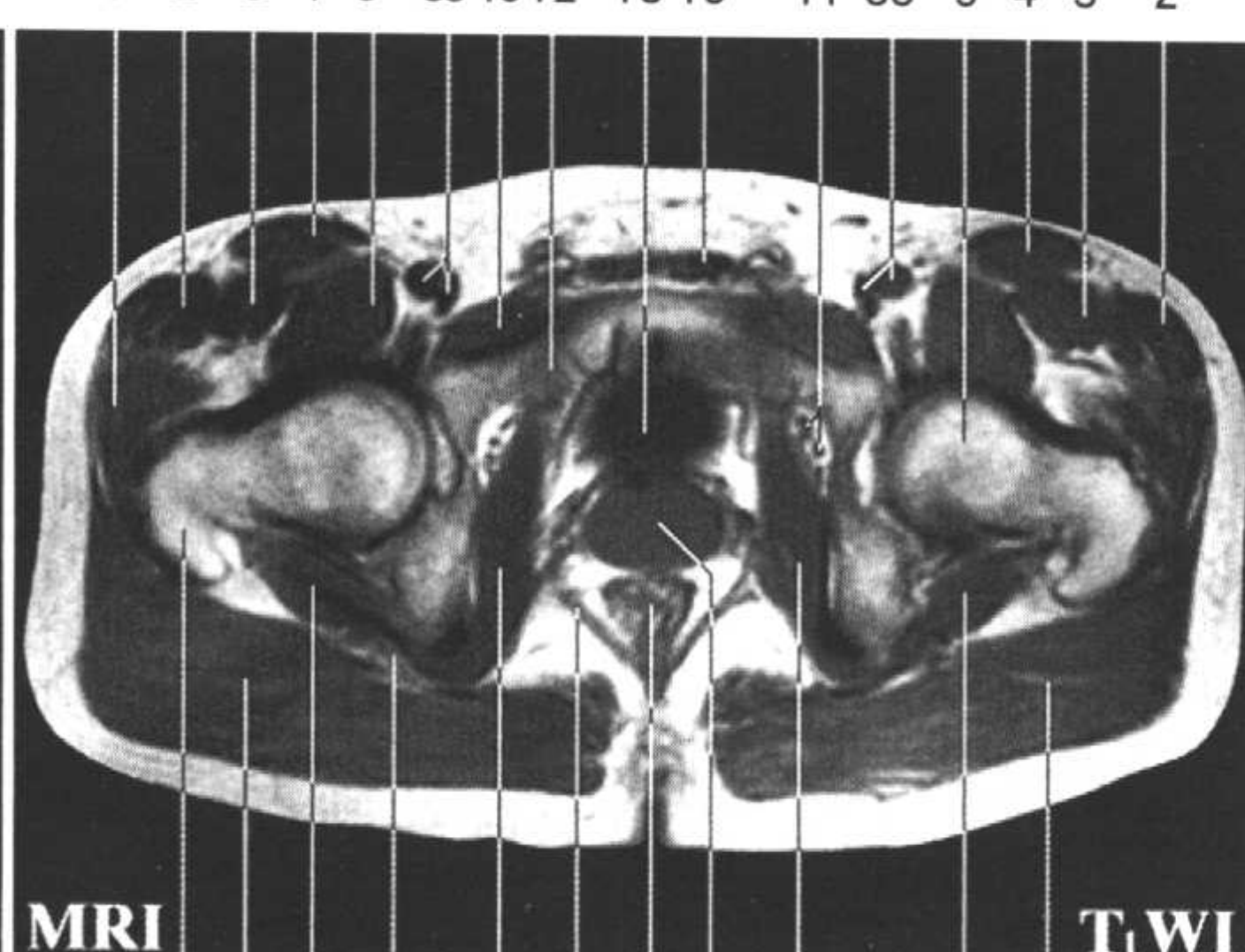
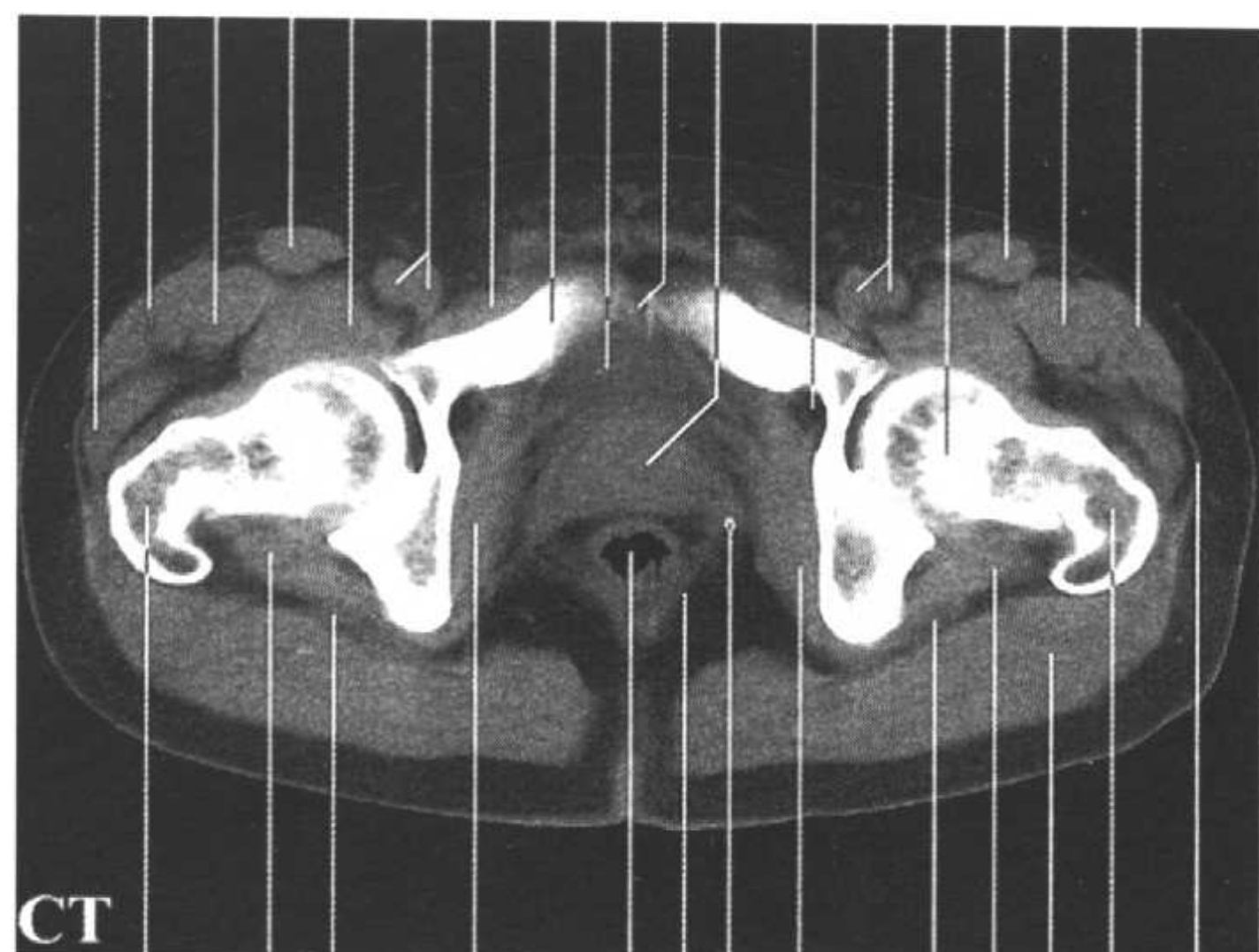


Fig.HPm4

1. 臀中肌 gluteus medius
2. 阔筋膜张肌 tensor fasciae latae
3. 股直肌 rectus femoris
4. 缝匠肌 sartorius
5. 股骨头 femoral head
6. 髂腰肌 iliopsoas
7. 股神经 femoral n.
8. 股动脉 femoral a.
9. 股静脉 femoral v.
10. 耻骨肌 pectineus

1 2 3 4 6 33 10 12 13 14 30 11 33 5 4 3 2

1 2 3 4 6 33 10 12 13 15 11 33 5 4 3 2

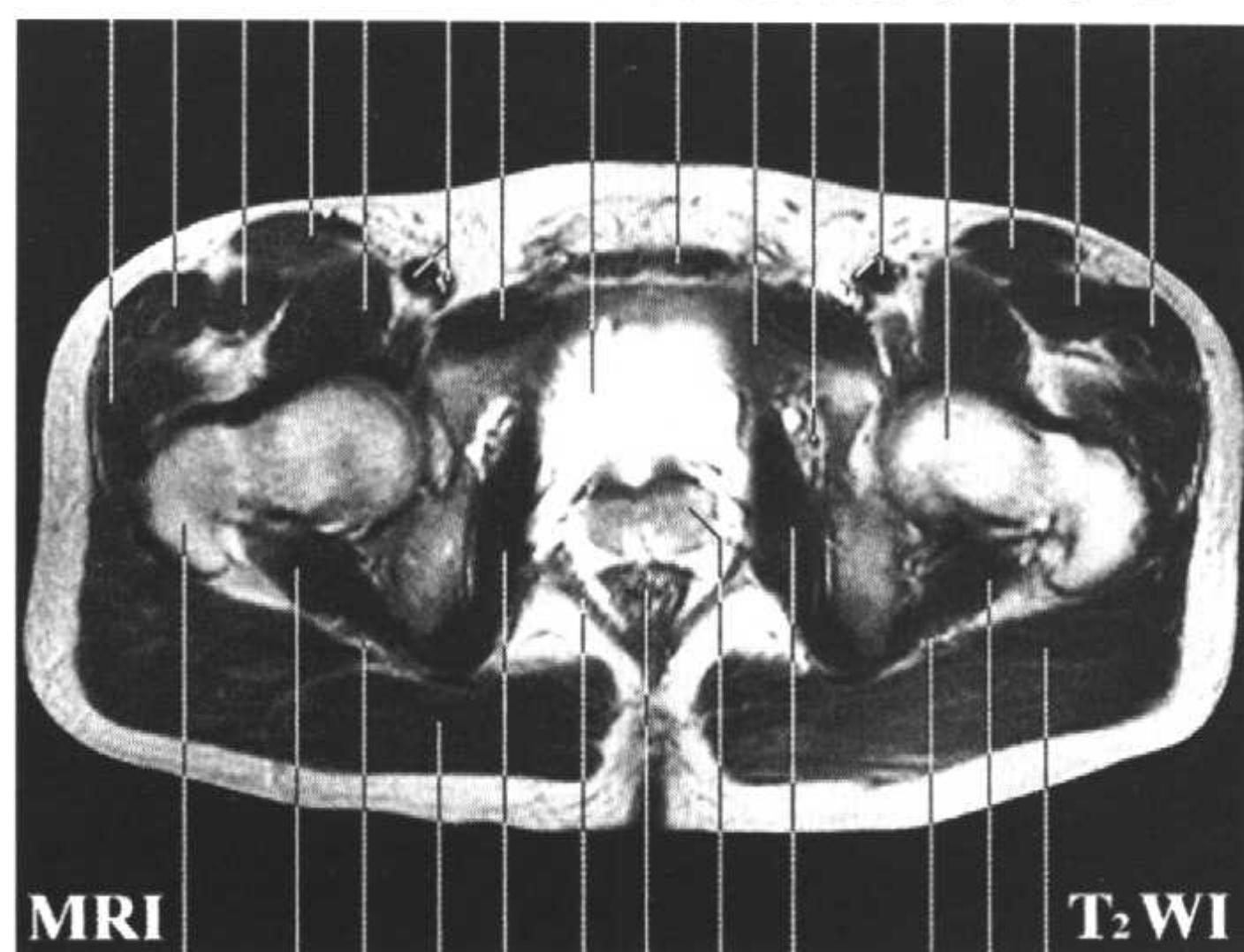


19 29 22 24 27 25 31 24 22 29 18 19 34

19 18 29 22 24 25 27 30 24 29 18

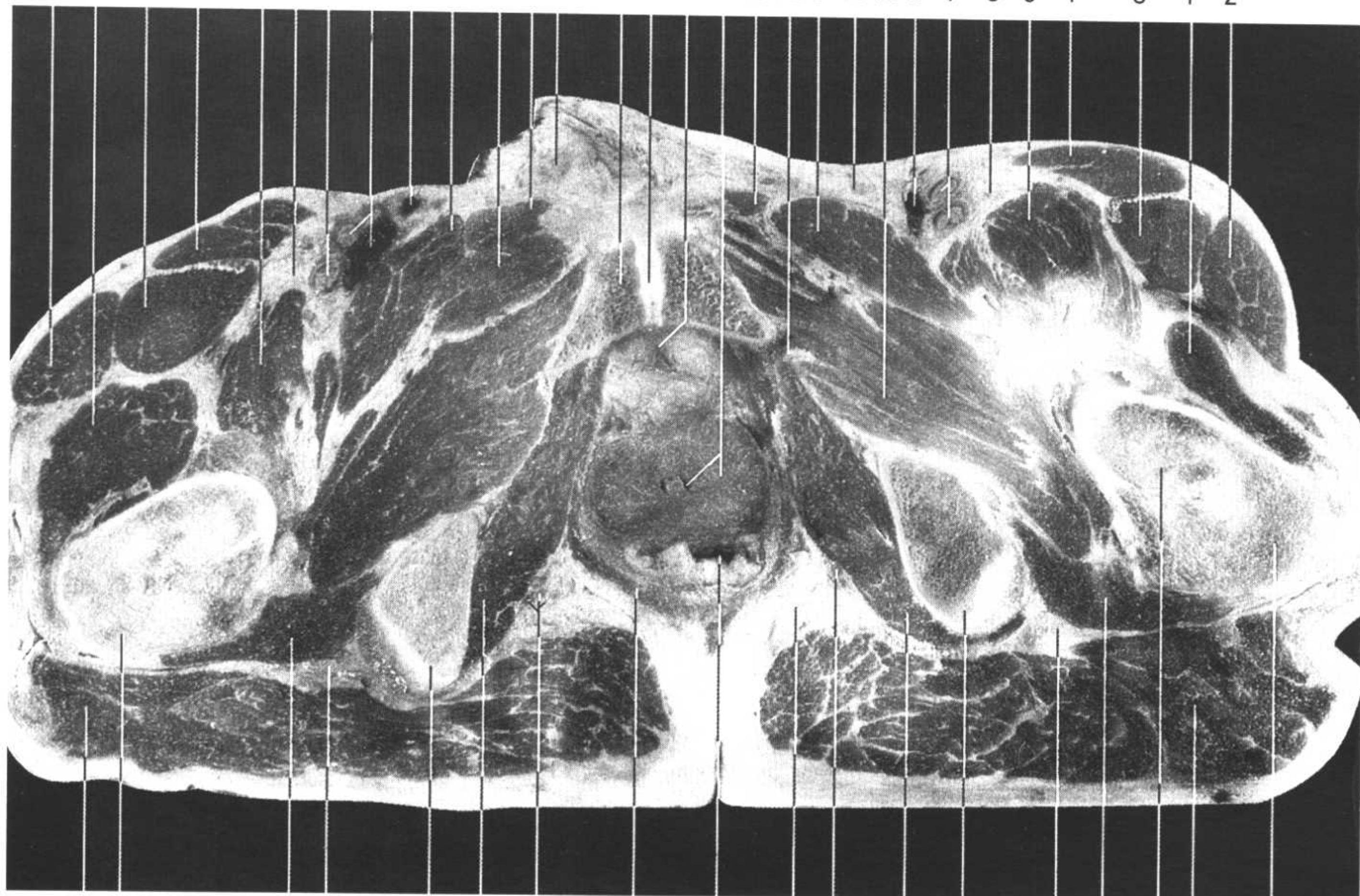
- 11. 闭膜管 obturator canal
- 12. 耻骨上支 superior ramus of pubis
- 13. 膀胱 urinary bladder
- 14. 耻骨联合 pubic symphysis
- 15. 锥状肌 pyramidalis
- 16. 股动脉与股深动脉 femoral a. and deep femoral a.
- 17. 股外侧肌 vastus lateralis
- 18. 臀大肌 gluteus maximus
- 19. 大转子 greater trochanter
- 20. 股骨颈 neck of femur
- 21. 下孖肌 gemellus inferior
- 22. 坐骨神经 sciatic n.
- 23. 坐骨体 body of ischium
- 24. 闭孔内肌 obturator internus
- 25. 肛提肌 levator ani
- 26. 精囊 seminal vesicle
- 27. 直肠 rectum
- 28. 坐骨结节 ischial tuberosity
- 29. 股方肌 quadratus femoris
- 30. 前列腺 prostate
- 31. 静脉石 phlebolith
- 32. 精索 spermatic cord
- 33. 股动、静脉 femoral a. and v.
- 34. 髂胫束 iliotibial tract

1 2 3 4 6 33 10 13 15 12 11 33 5 4 3 2



19 29 22 18 24 25 27 30 24 22 29 18

2 1 3 4 5 6 21 20 19 9 18 13 17 16 15 35 14 13 12 9 11 10 8 7 6 5 4 3 1 2



24 23 25 26 27 28 32 34 31 30 29 28 27 26 25 33 24 23

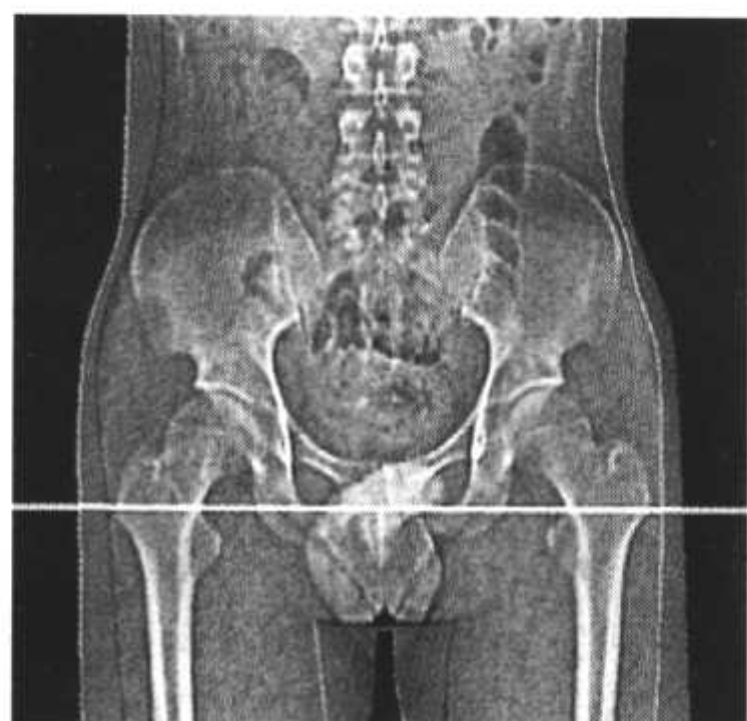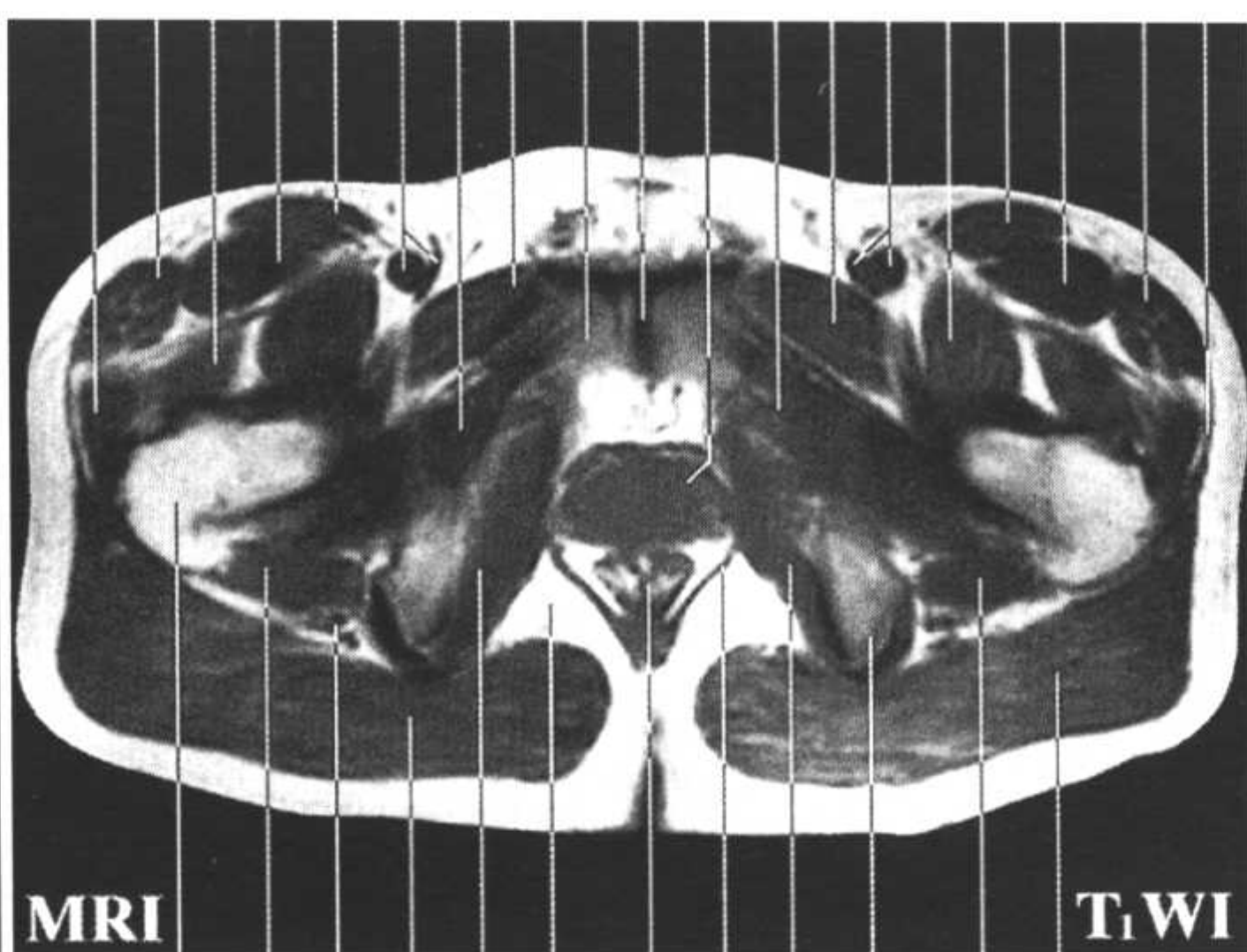
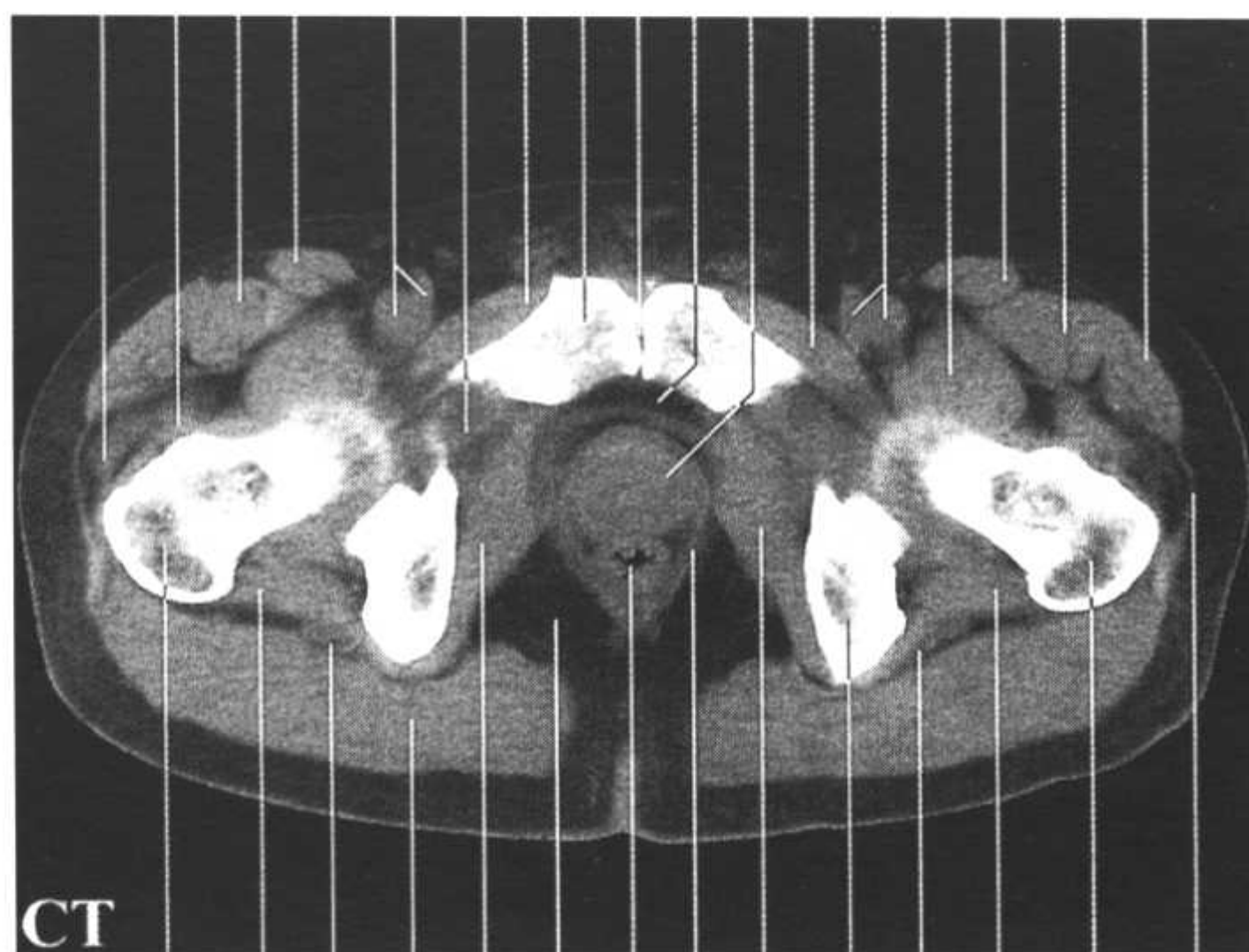


Fig.HPm5

1. 股外侧肌 vastus lateralis
2. 阔筋膜张肌 tensor fasciae latae
3. 股直肌 rectus femoris
4. 缝匠肌 sartorius
5. 髂腰肌 iliopsoas
6. 股神经 femoral n.
7. 股动脉与股深动脉 femoral a. and deep femoral a.
8. 股静脉 femoral v.
9. 耻骨肌 pectineus
10. 闭孔外肌 obturator externus

1 22 3 4 20 10 9 16 15 35 14 9 20 5 4 3 2

1 2 22 3 4 20 10 9 16 15 14 10 9 20 5 4 3 2 36

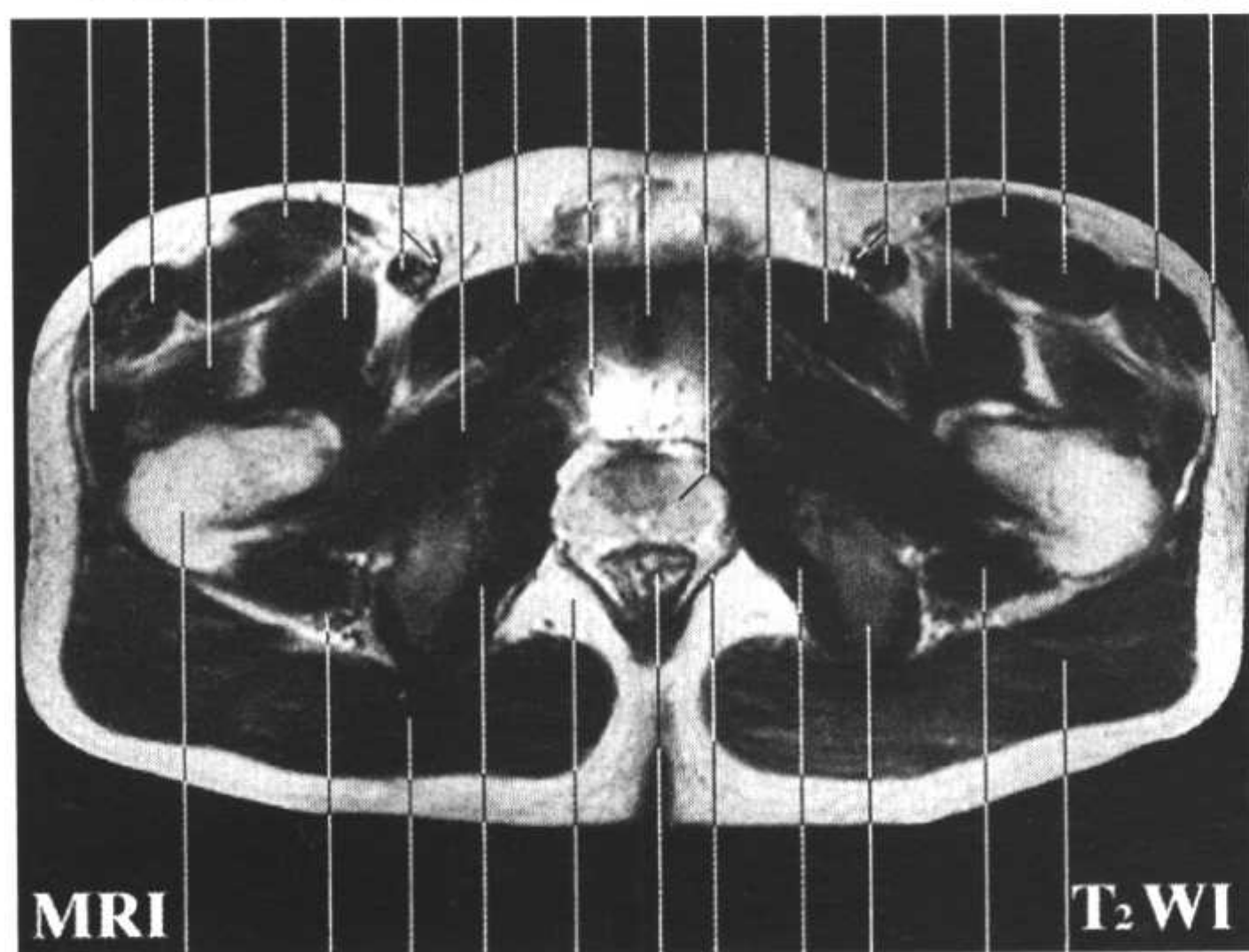


23 25 26 24 28 30 31 34 28 27 26 25 23 36

23 25 26 24 28 30 31 34 28 27 25 24

11. 腹股沟浅淋巴结 superficial inguinal lymph node
12. 闭孔神经 obturator n.
13. 长收肌 adductor longus
14. 前列腺与尿道 prostate and urethra
15. 耻骨联合 pubic symphysis
16. 耻骨上支 superior ramus of pubis
17. 精索 spermatic cord
18. 短收肌 adductor brevis
19. 大隐静脉 great saphenous v.
20. 股动、静脉 femoral a. and v.
21. 股深动脉 deep femoral a.
22. 股中间肌 vastus intermedius
23. 大转子 greater trochanter
24. 臀大肌 gluteus maximus
25. 股方肌 quadratus femoris
26. 坐骨神经 sciatic n.
27. 坐骨结节 ischial tuberosity
28. 闭孔内肌 obturator internus
29. 阴部管 pudendal canal
30. 坐骨肛门窝脂体 adipose body of ischioanal fossa
31. 直肠 rectum
32. 阴部内动、静脉与阴部神经 internal pudendal a., v. and pudendal n.
33. 股骨颈 neck of femur
34. 肛提肌 levator ani
35. 耻骨后 [间] 隙 retropubic space
36. 髂胫束 iliotibial tract

1 2 22 4 5 20 10 9 35 15 14 10 9 20 5 4 3 2 36



23 26 24 28 30 31 34 28 27 25 24

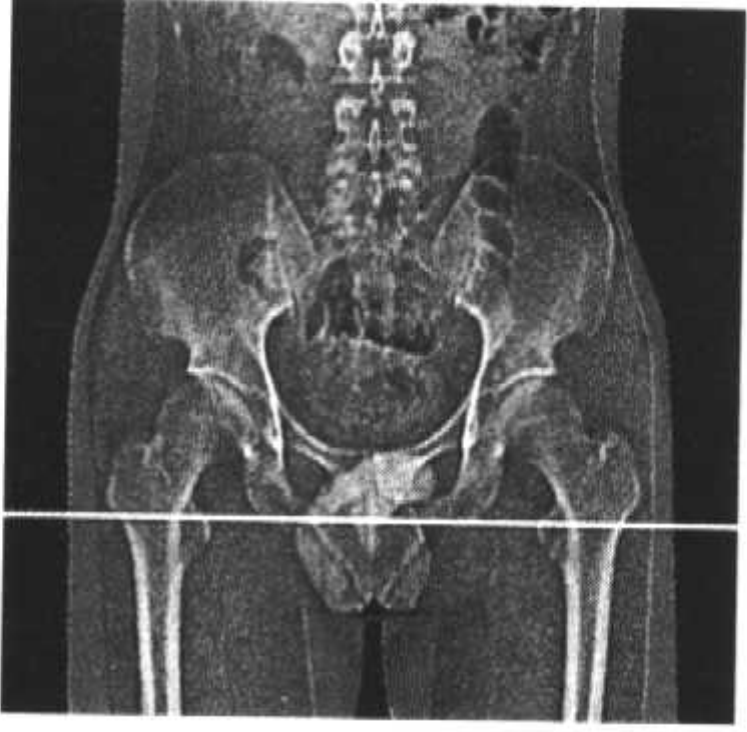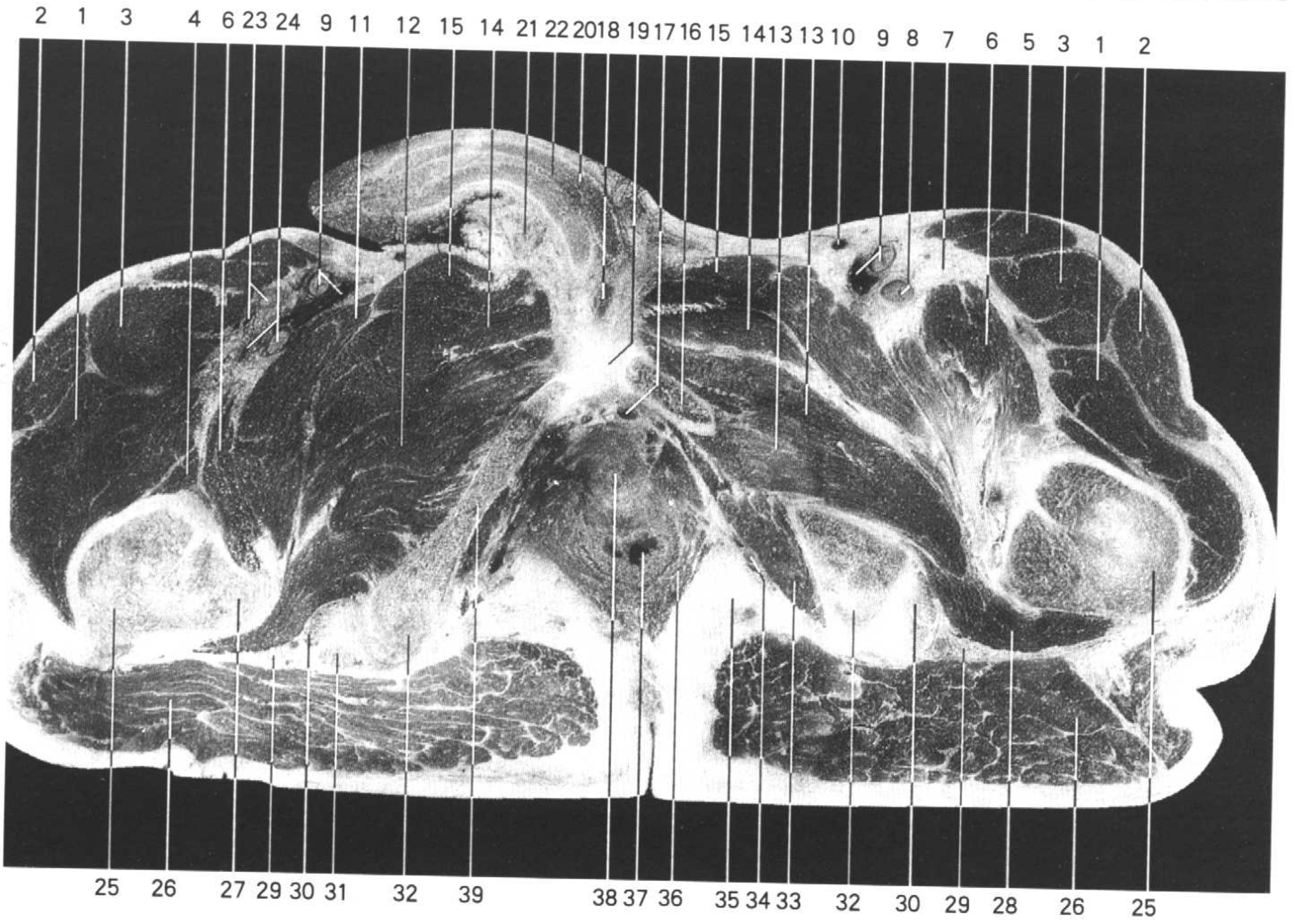
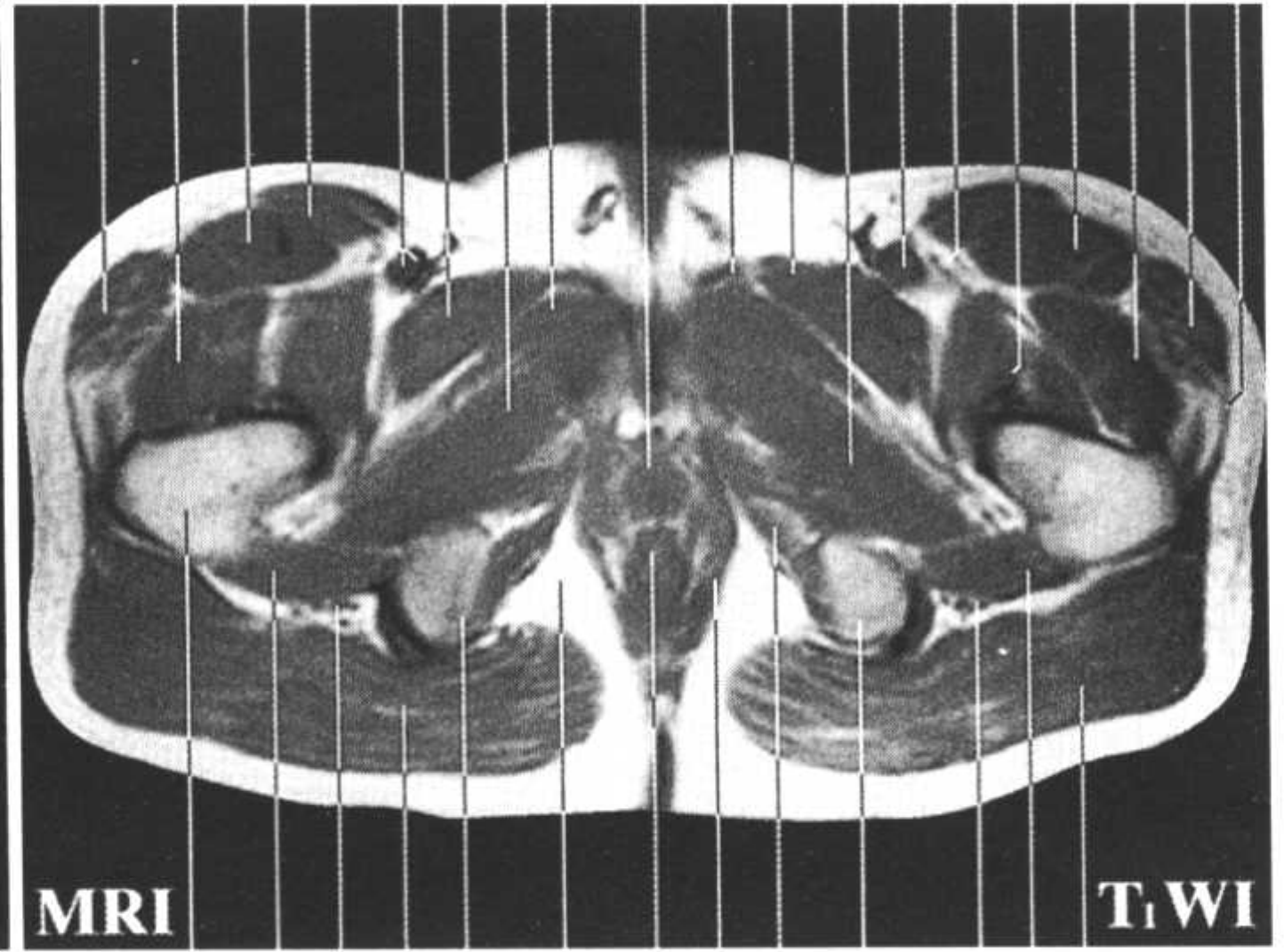
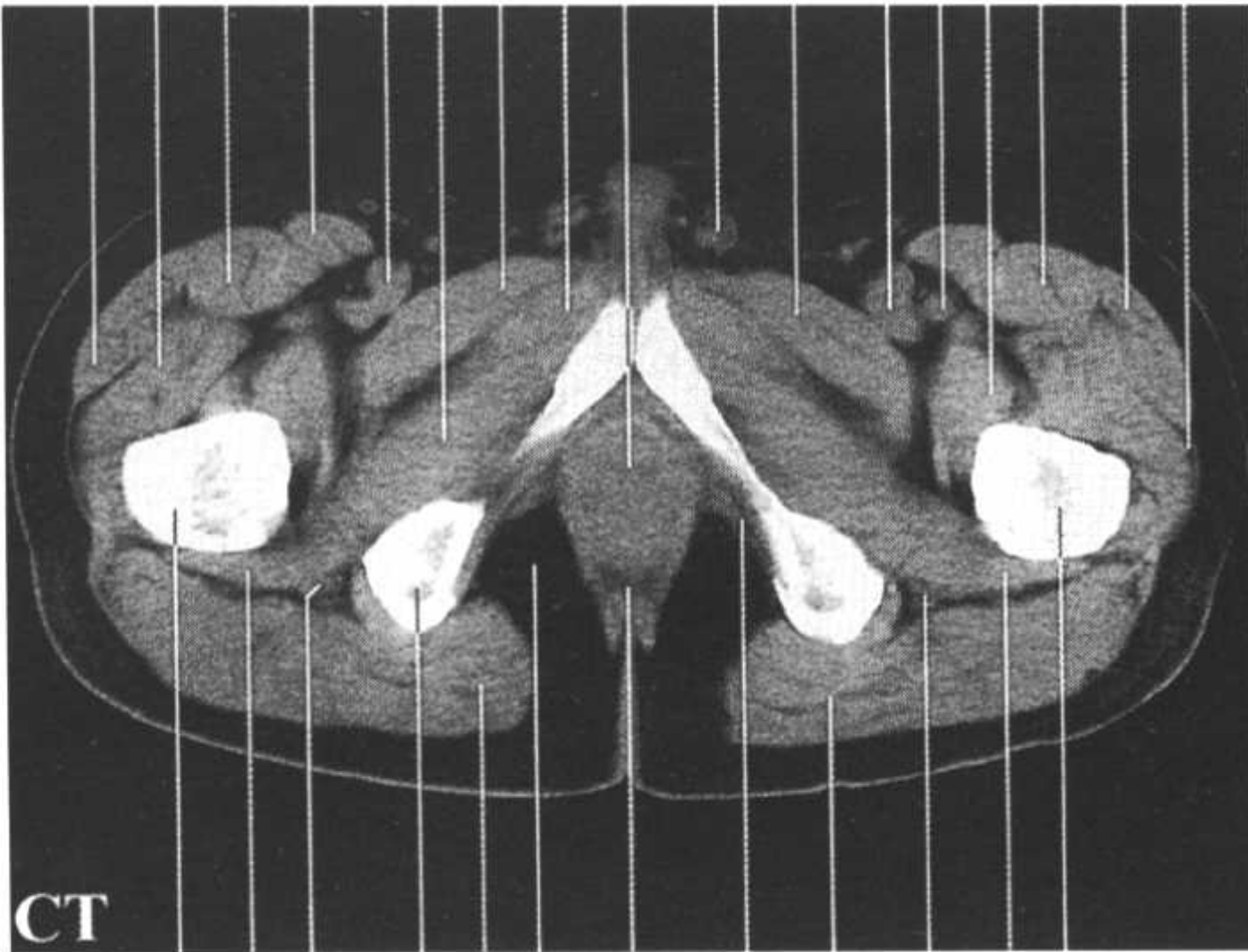


Fig.HPm6

1. 股外侧肌 vastus lateralis
2. 阔筋膜张肌 tensor fasciae latae
3. 股直肌 rectus femoris
4. 股中间肌 vastus intermedius
5. 缝匠肌 sartorius
6. 髂腰肌 iliopsoas
7. 股神经 femoral n.
8. 股深动脉 deep femoral a.
9. 股动、静脉 femoral a. and v.
10. 大隐静脉 great saphenous v.
11. 耻骨肌 pectineus
12. 大收肌 adductor magnus

2 1 3 5 9 12 11 14 38 21 11 9 8 6 3 2 40

2 1 3 5 9 11 12 14 38 15 11 12 9 7 6 3 1 2 40

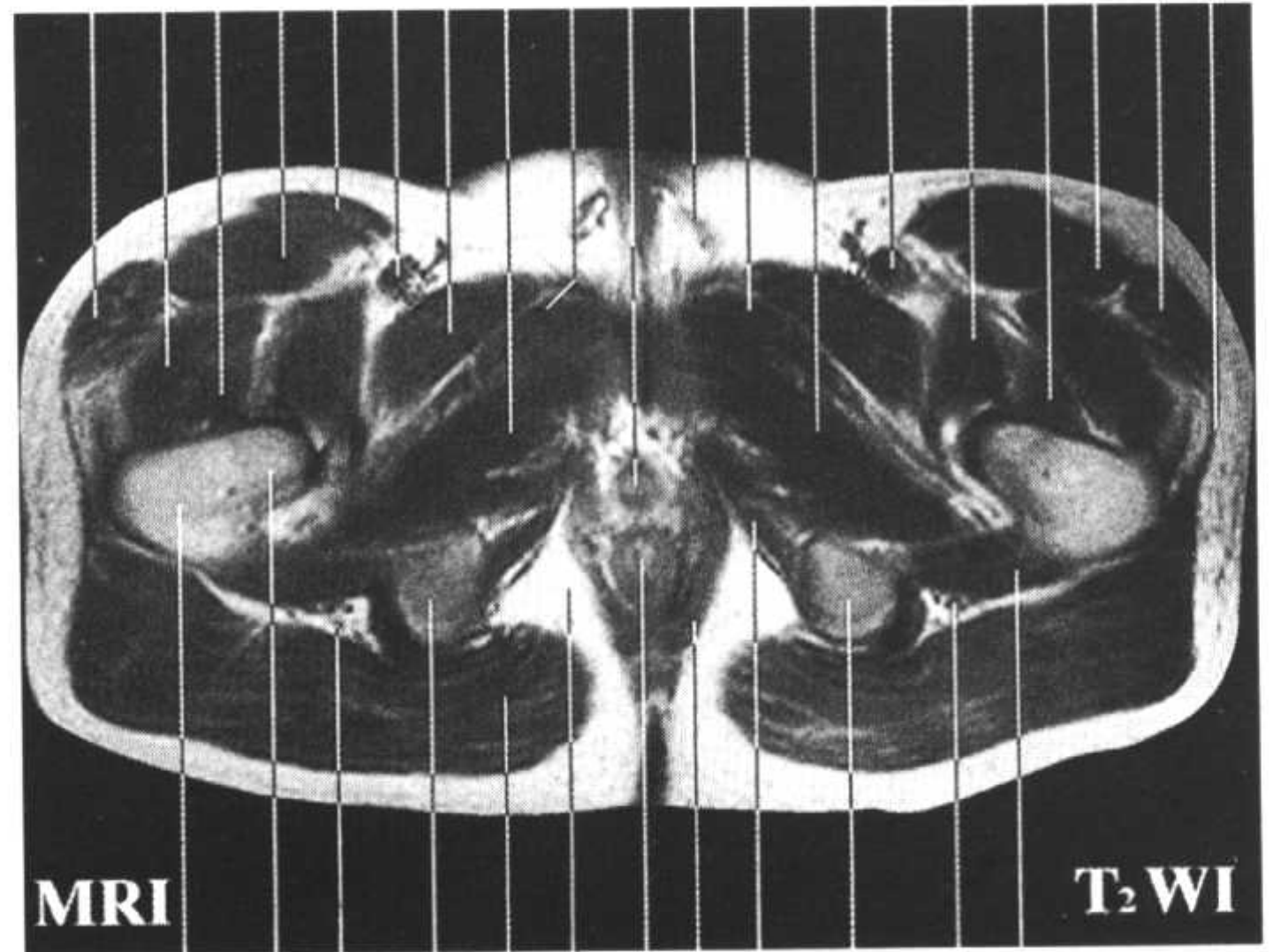


25 28 29 32 26 35 37 33 26 29 28 25

25 28 29 26 32 35 37 36 33 32 29 28 26

13. 闭孔外肌 obturator externus
14. 短收肌 adductor brevis
15. 长收肌 adductor longus
16. 耻骨下支 inferior ramus of pubis
17. 前列腺静脉丛 prostatic venous plexus
18. 尿道 urethra
19. 耻骨联合 pubic symphysis
20. 阴茎海绵体 cavernous body of penis
21. 精索 spermatic cord
22. 尿道海绵体 cavernous body of urethra
23. 旋股外侧动、静脉 lateral femoral circumflex a. and v.
24. 股深动、静脉 deep femoral a. and v.
25. 股骨 femur
26. 臀大肌 gluteus maximus
27. 小转子 lesser trochanter
28. 股方肌 quadratus femoris
29. 坐骨神经 sciatic n.
30. 半膜肌腱 tendon of semimembranosus
31. 股二头肌长头腱与半腱肌腱 tendon of long head of biceps femoris and semitendinosus
32. 坐骨结节 ischial tuberosity
33. 闭孔内肌 obturator internus
34. 阴部管 pudendal canal
35. 坐骨肛门窝脂体 adipose body of ischioanal fossa
36. 肛提肌 levator ani
37. 直肠 rectum
38. 前列腺与尿道 prostate and urethra
39. 坐骨支 ramus of ischium
40. 髂胫束 iliotibial tract

2 1 4 3 5 9 11 12 14 38 21 14 12 9 6 4 3 2 40



25 27 29 32 26 35 37 36 33 32 29 28

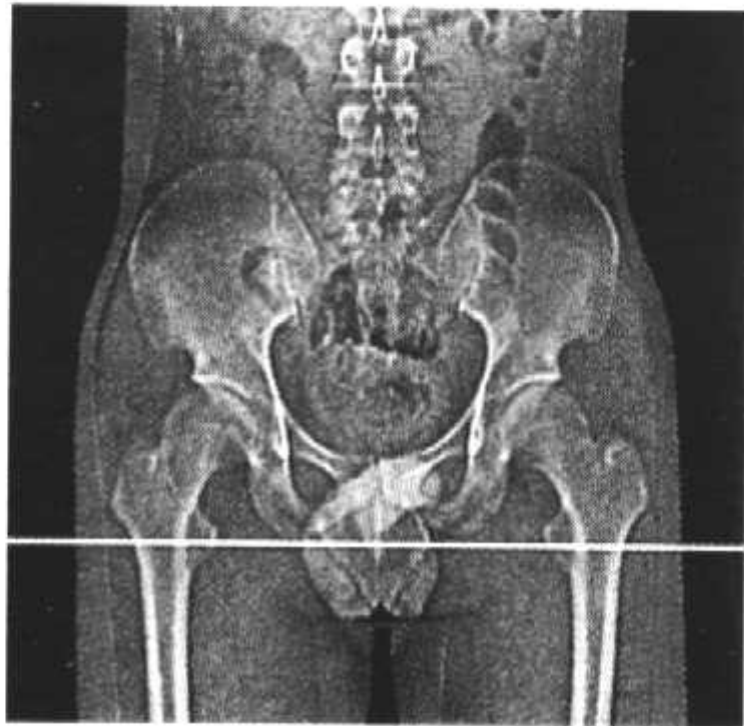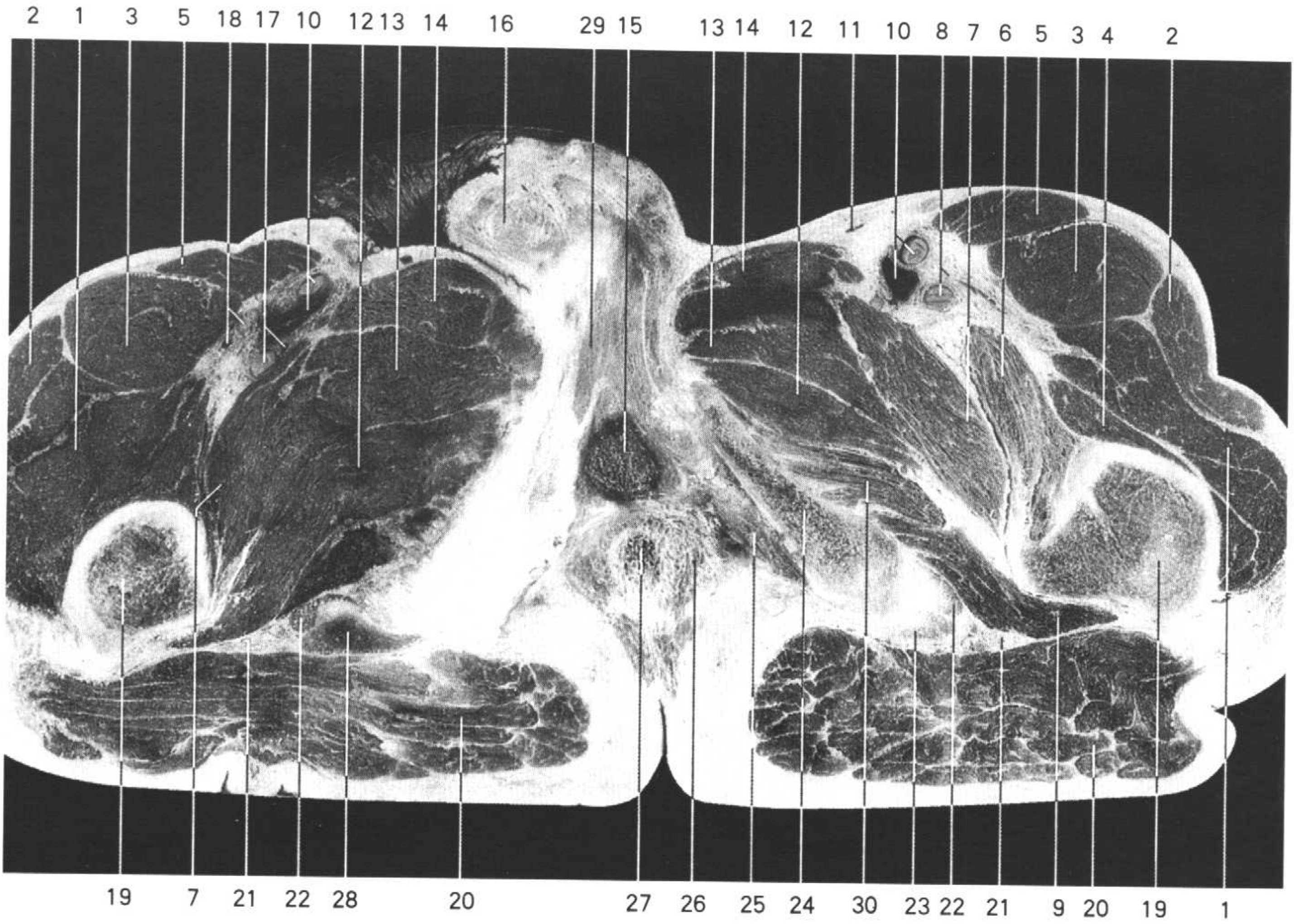
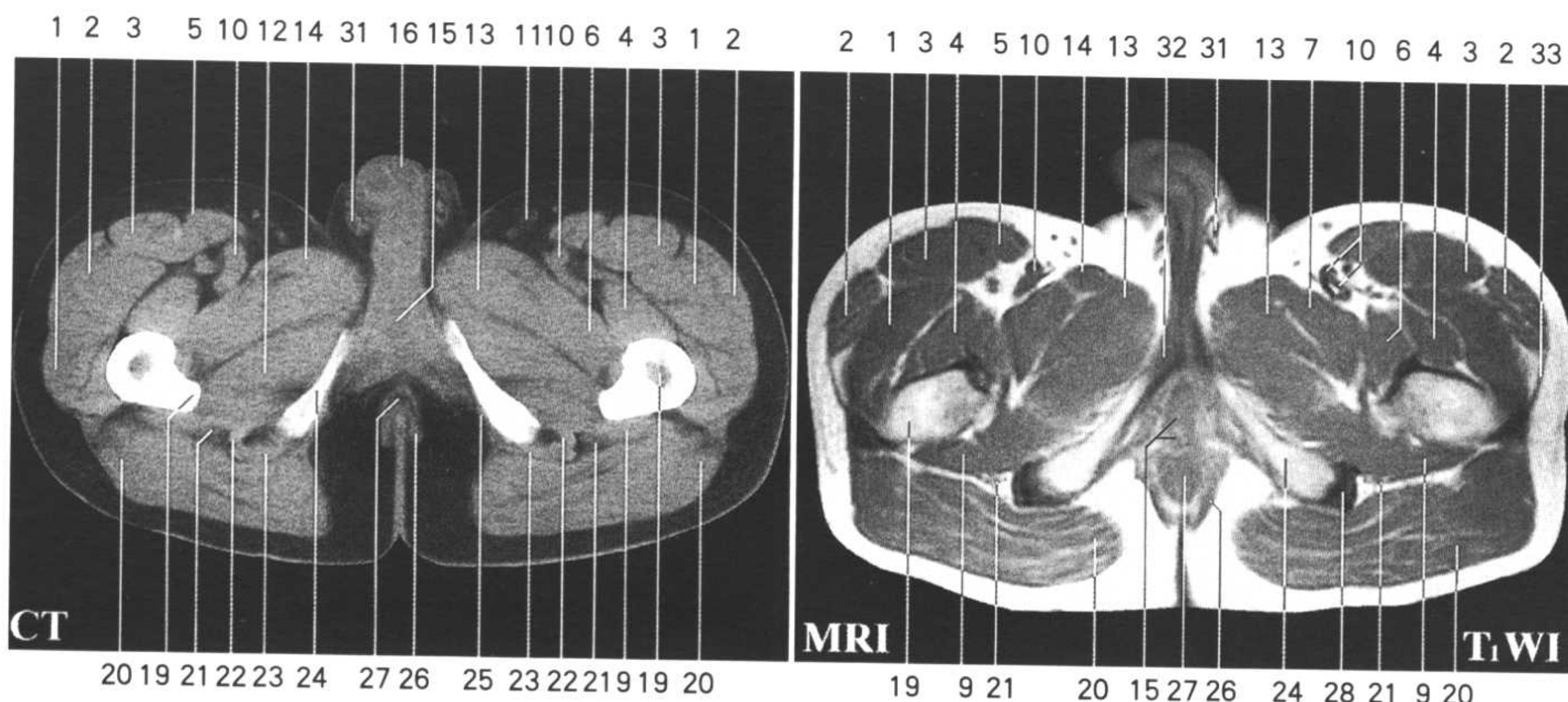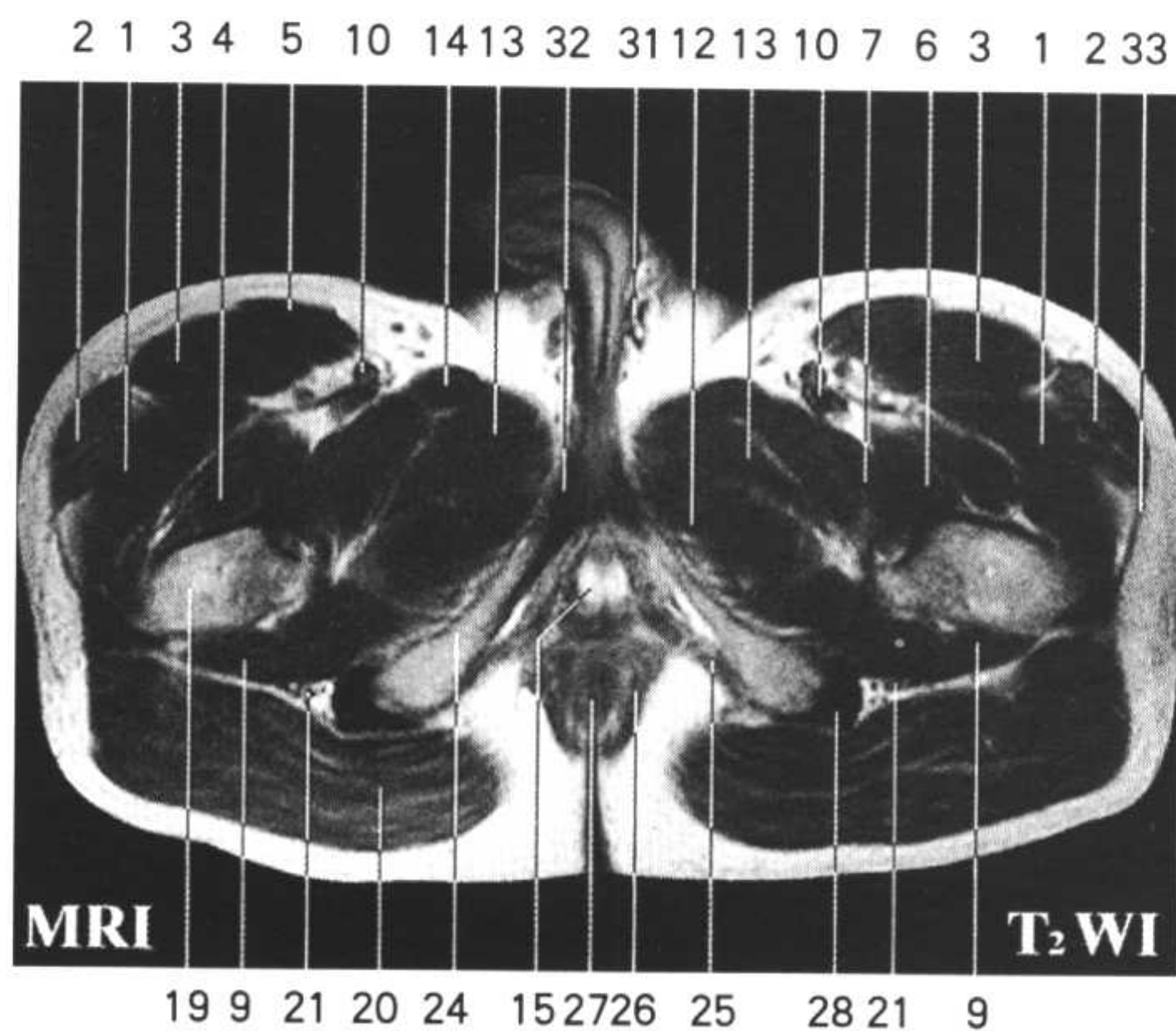


Fig.HPm7

1. 股外侧肌 vastus lateralis
2. 阔筋膜张肌 tensor fasciae latae
3. 股直肌 rectus femoris
4. 股中间肌 vastus intermedius
5. 缝匠肌 sartorius
6. 髂腰肌 iliopsoas
7. 耻骨肌 pectineus
8. 股深动脉与股神经 deep femoral a. and femoral n.
9. 股方肌 quadratus femoris
10. 股动、静脉 femoral a. and v.



11. 大隐静脉 great saphenous v.
12. 大收肌 adductor magnus
13. 短收肌 adductor brevis
14. 长收肌 adductor longus
15. 尿道球 bulb of urethra
16. 睾丸 testis
17. 股深动、静脉 deep femoral a. and v.
18. 旋股外侧动、静脉 lateral femoral circumflex a. and v.
19. 股骨 femur
20. 臀大肌 gluteus maximus
21. 坐骨神经 sciatic n.
22. 半膜肌腱 tendon of semimembranosus
23. 股二头肌长头腱与半腱肌腱 tendon of long head of biceps femoris and semitendinosus
24. 坐骨支 ramus of ischium
25. 坐骨海绵体肌 ischiocavernosus
26. 肛门括约肌 sphincter ani externus
27. 肛管 anal canal
28. 半腱肌 semitendinosus
29. 阴茎海绵体 cavernous body of penis
30. 大收肌 adductor magnus
31. 精索 spermatic cord
32. 球海绵体肌 bulbocavernosus
33. 髂胫束 iliotibial tract



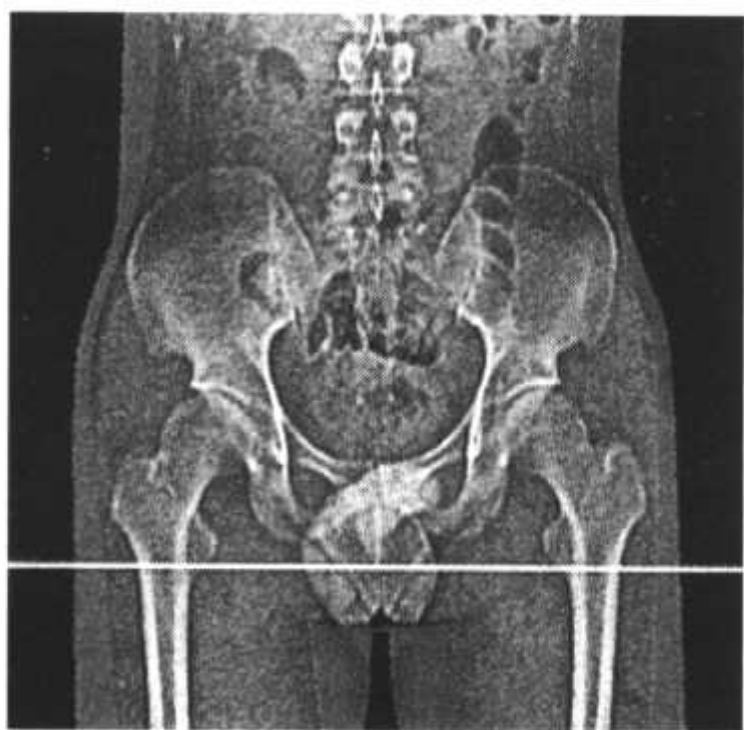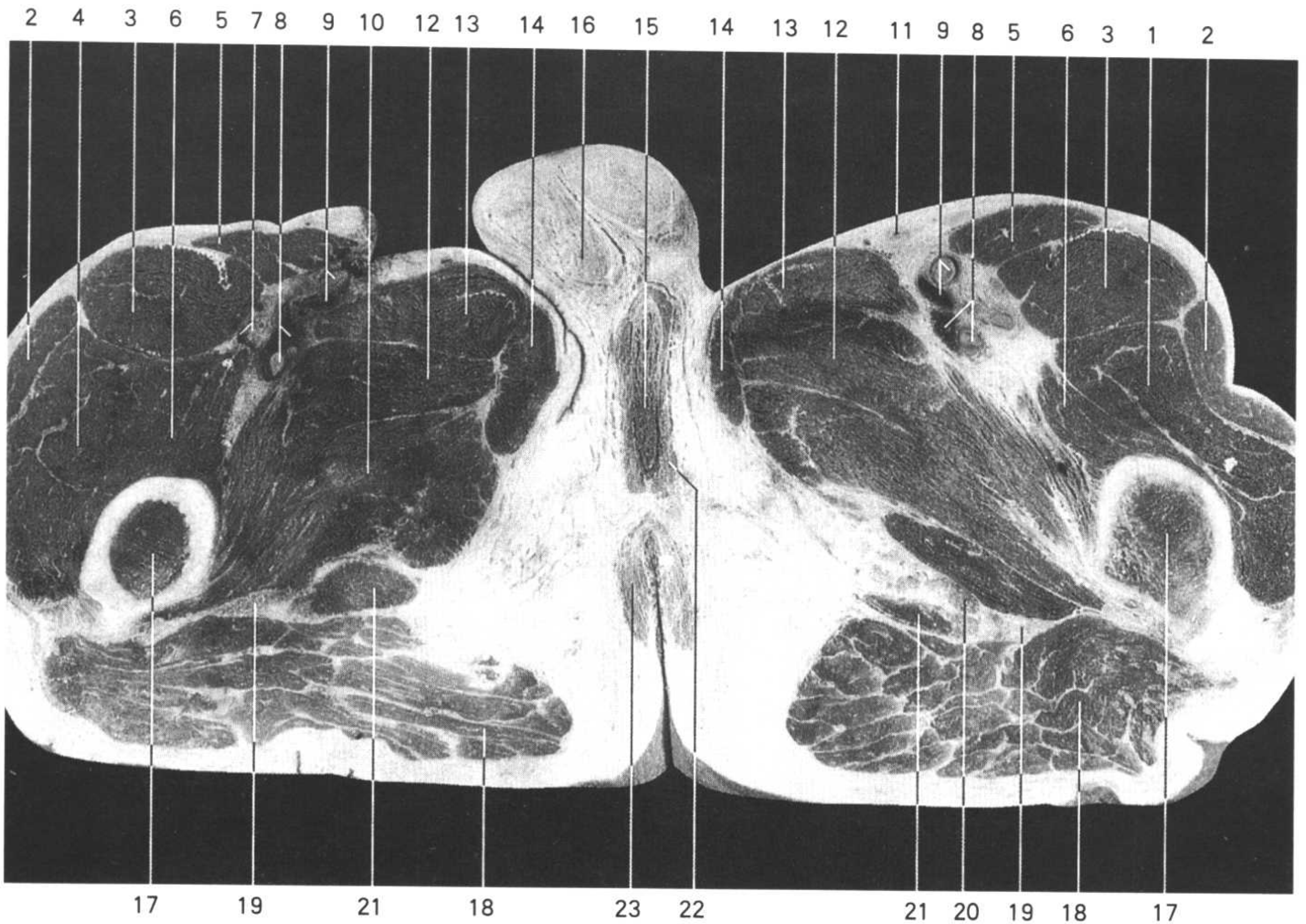
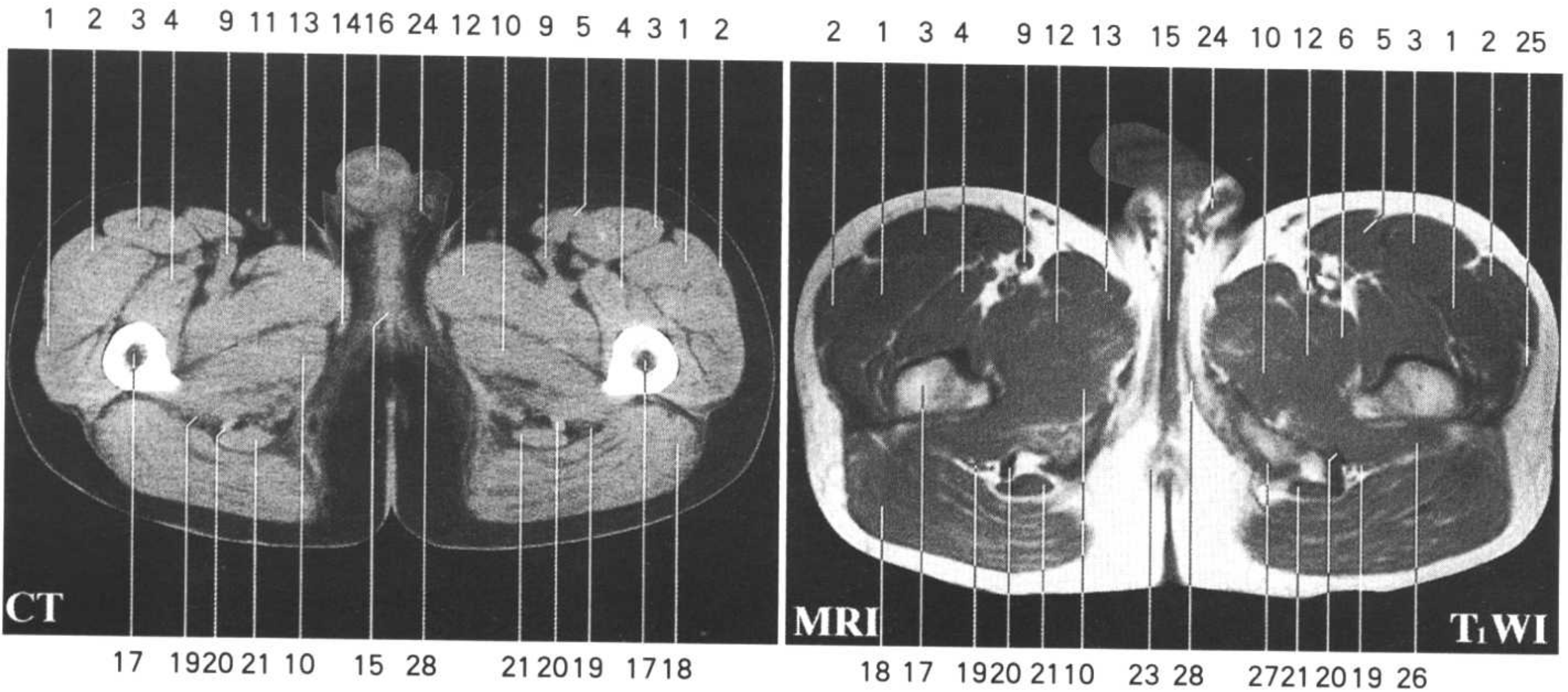


Fig.HPm8

1. 股外侧肌 vastus lateralis
2. 阔筋膜张肌 tensor fasciae latae
3. 股直肌 rectus femoris
4. 股中间肌 vastus intermedius
5. 缝匠肌 sartorius
6. 耻骨肌 pectineus
7. 旋股外侧动、静脉 lateral femoral circumflex a. and v.
8. 股深动、静脉 deep femoral a. and v.
9. 股动、静脉 femoral a. and v.
10. 大收肌 adductor magnus



11. 大隐静脉 great saphenous v.
12. 短收肌 adductor brevis
13. 长收肌 adductor longus
14. 股薄肌 gracilis
15. 尿道海绵体 cavernous body of urethra
16. 睾丸 testis
17. 股骨 femur
18. 臀大肌 gluteus maximus
19. 坐骨神经 sciatic n.
20. 半膜肌腱 tendon of semimembranosus
21. 股二头肌长头腱与半腱肌 tendon of long head of biceps femoris and semitendinosus
22. 球海绵体肌 bulbocavernosus
23. 肛门外括约肌 sphincter ani externus
24. 精索 spermatic cord
25. 髂胫束 iliotibial tract
26. 股方肌 quadratus femoris
27. 坐骨支 ramus of ischium
28. 坐骨海绵体肌 ischiocavernosus
29. 髂腰肌 iliopsoas

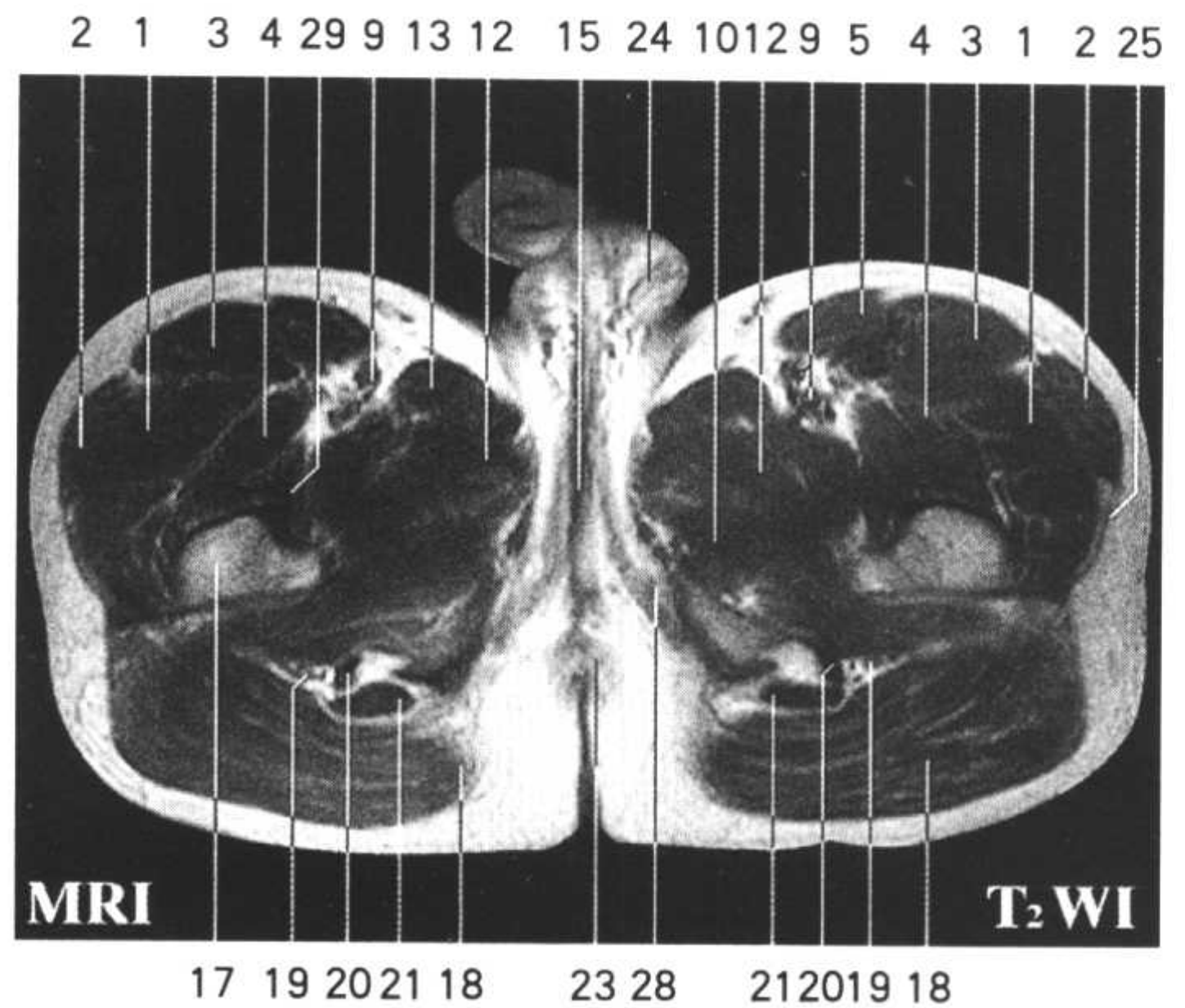
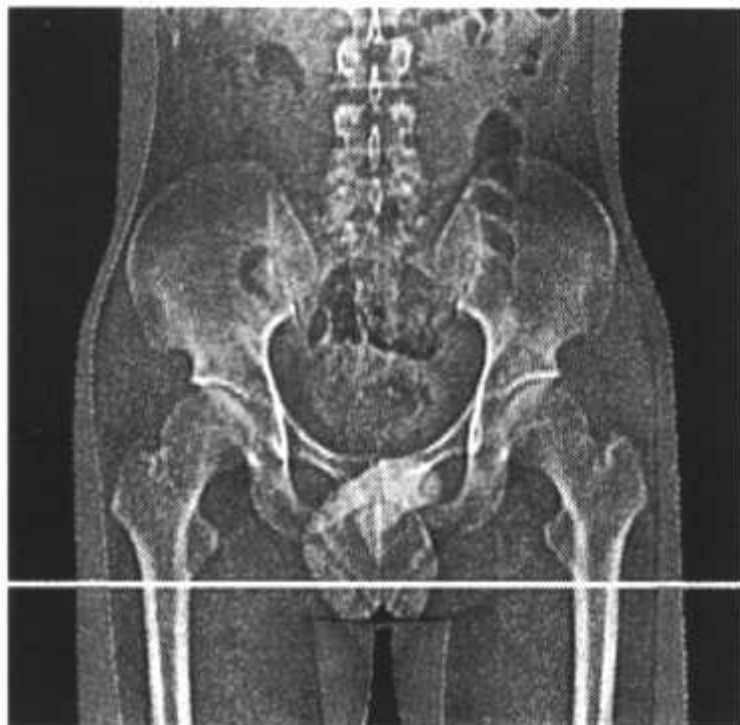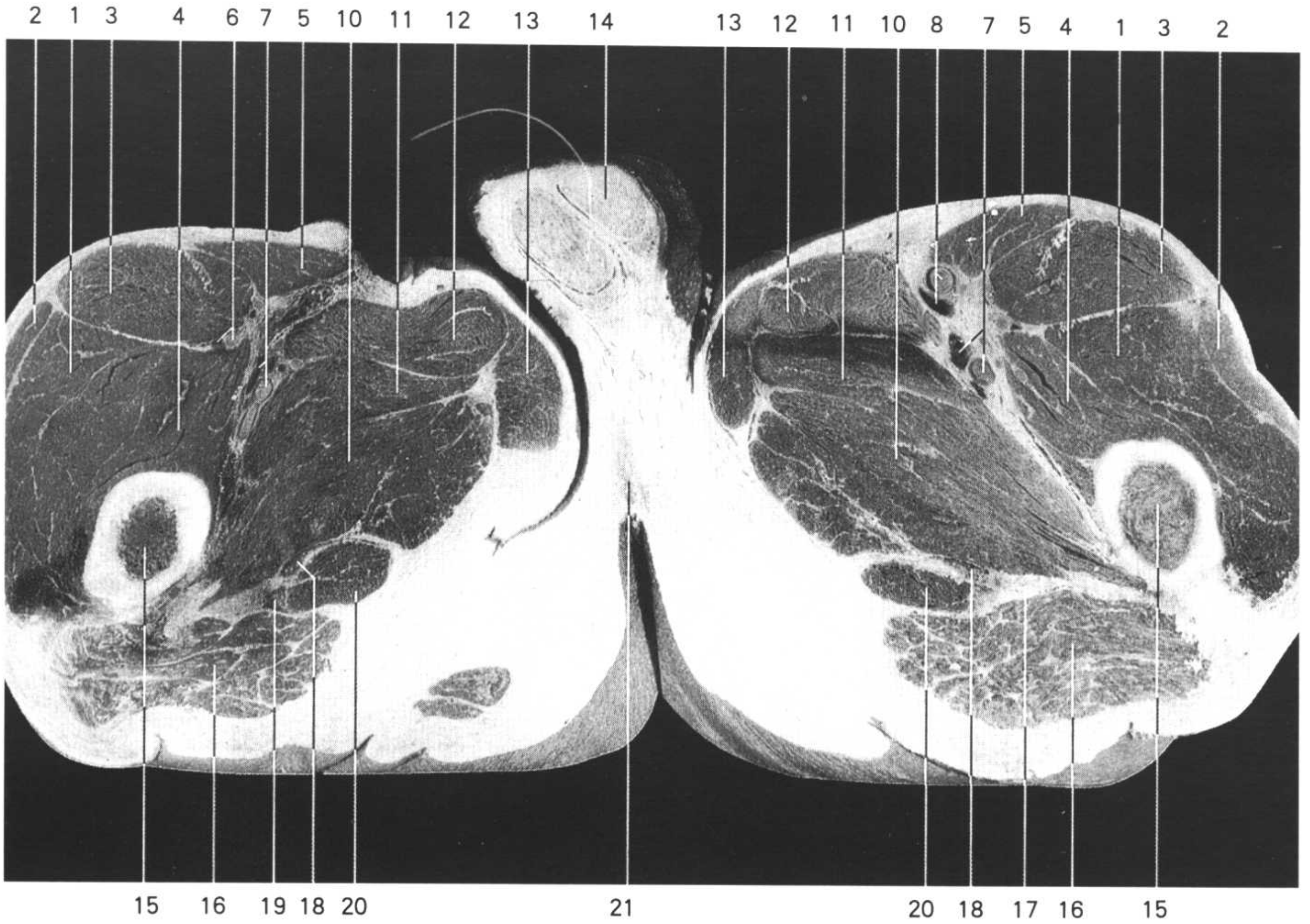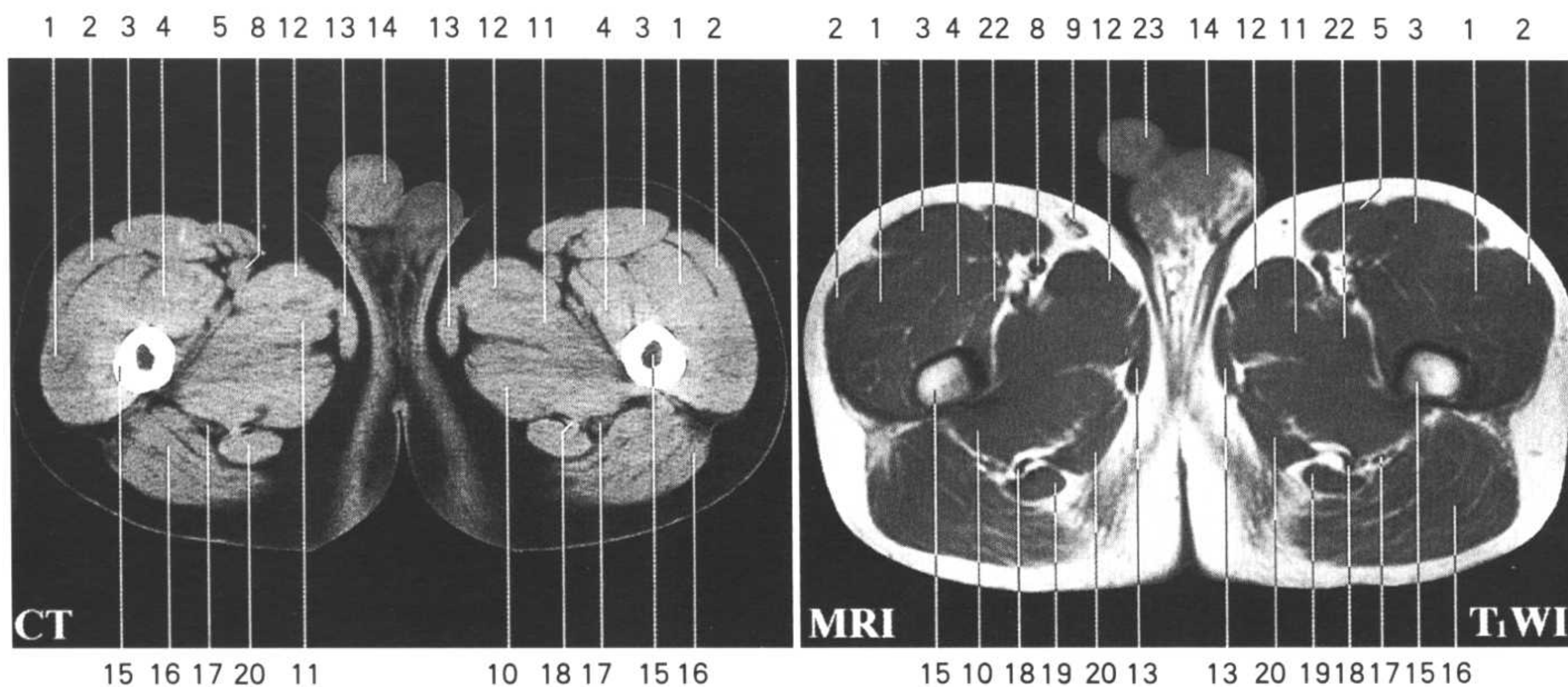


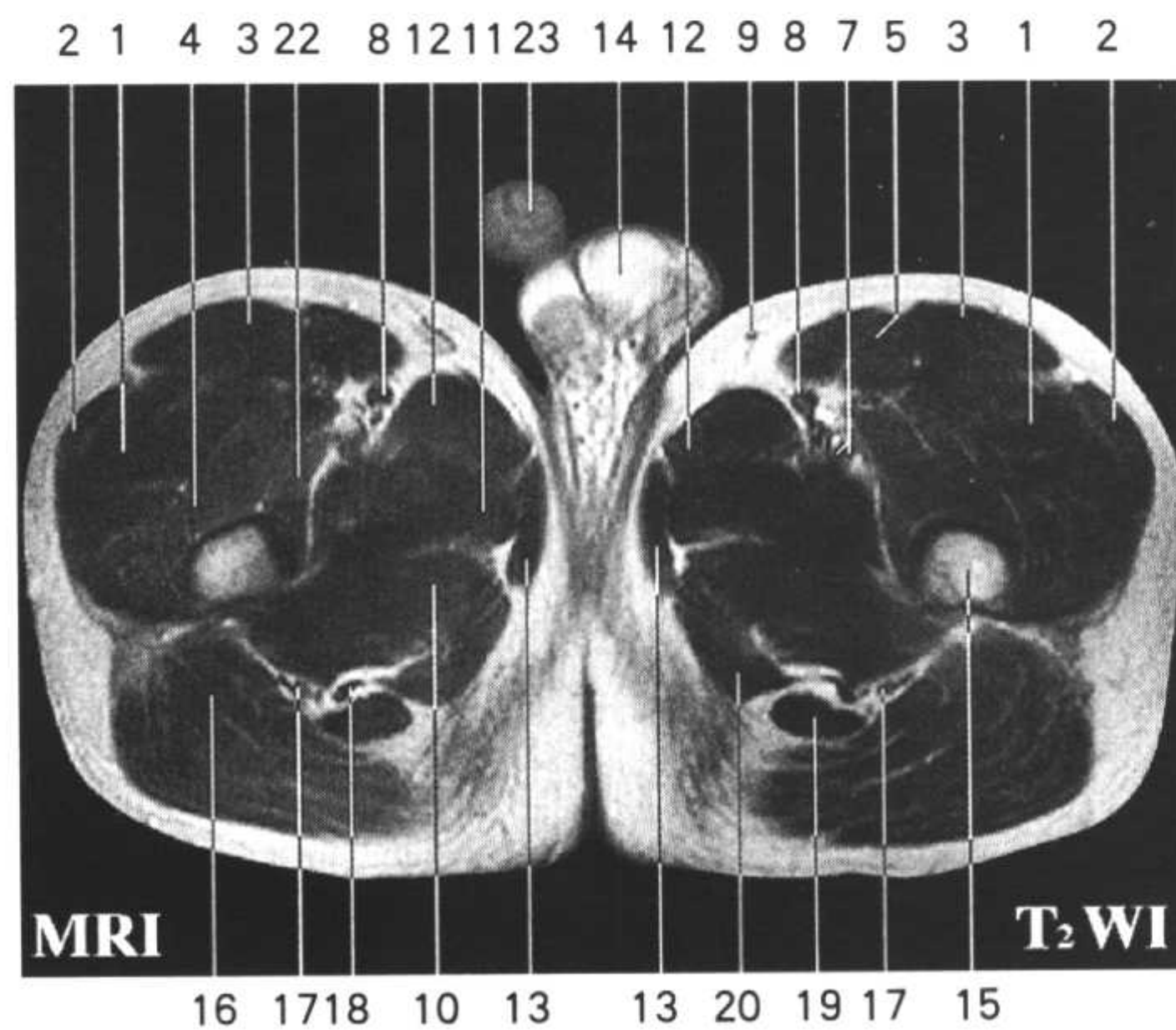


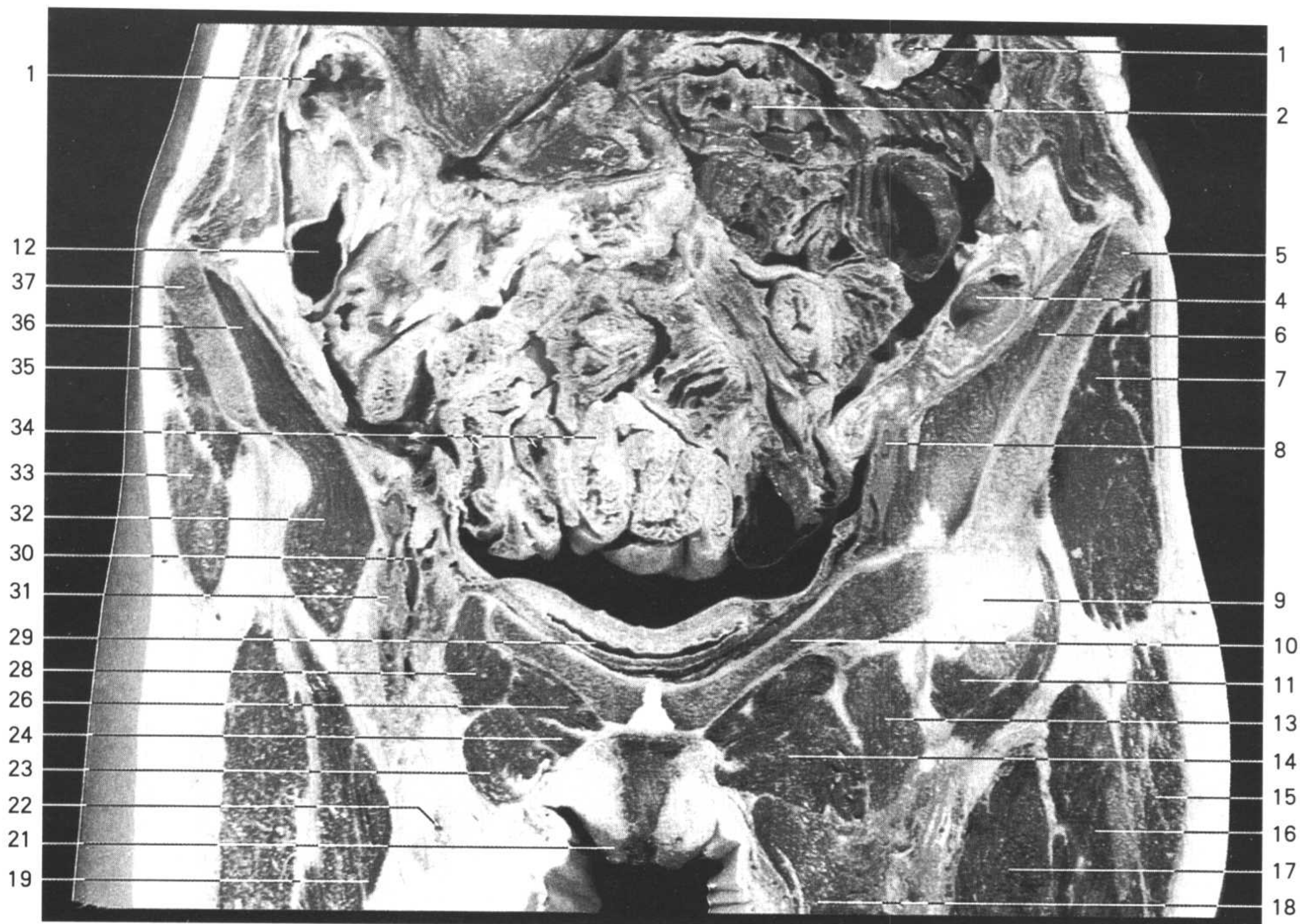Fig. HPm9

1. 股外侧肌 vastus lateralis
2. 阔筋膜张肌 tensor fasciae latae
3. 股直肌 rectus femoris
4. 股中间肌 vastus intermedius
5. 缝匠肌 sartorius
6. 旋股外侧动、静脉 lateral femoral circumflex a. and v.
7. 股深动、静脉 deep femoral a. and v.
8. 股动、静脉 femoral a. and v.
9. 大隐静脉 great saphenous v.
10. 大收肌 adductor magnus



- 11. 短收肌 adductor brevis
- 12. 长收肌 adductor longus
- 13. 股薄肌 gracilis
- 14. 睾丸 testis
- 15. 股骨 femur
- 16. 臀大肌 gluteus maximus
- 17. 坐骨神经 sciatic n.
- 18. 半膜肌 semimembranosus
- 19. 股二头肌长头腱 tendon of long head of biceps femoris
- 20. 半腱肌 semitendinosus
- 21. 球海绵体肌 bulbocavernosus
- 22. 耻骨肌 pectineus
- 23. 阴茎 penis

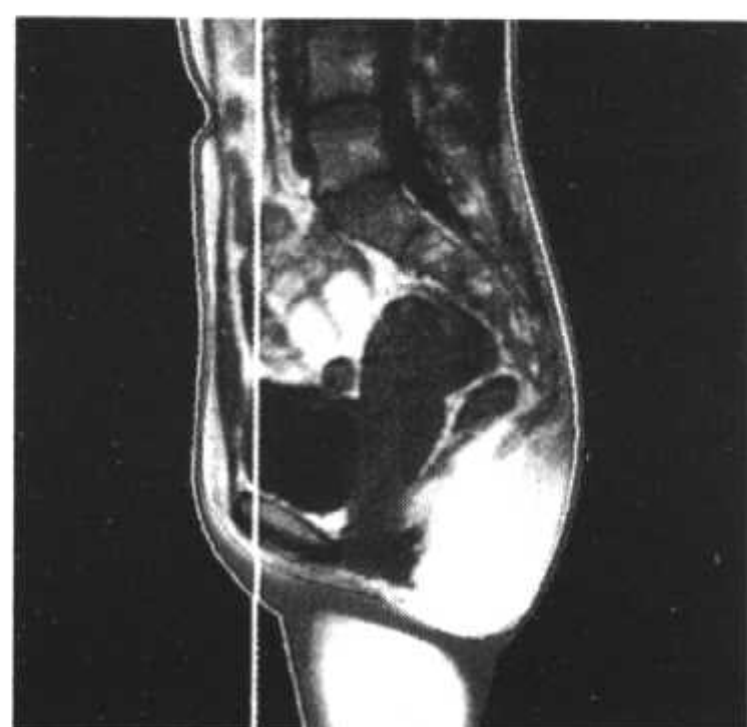



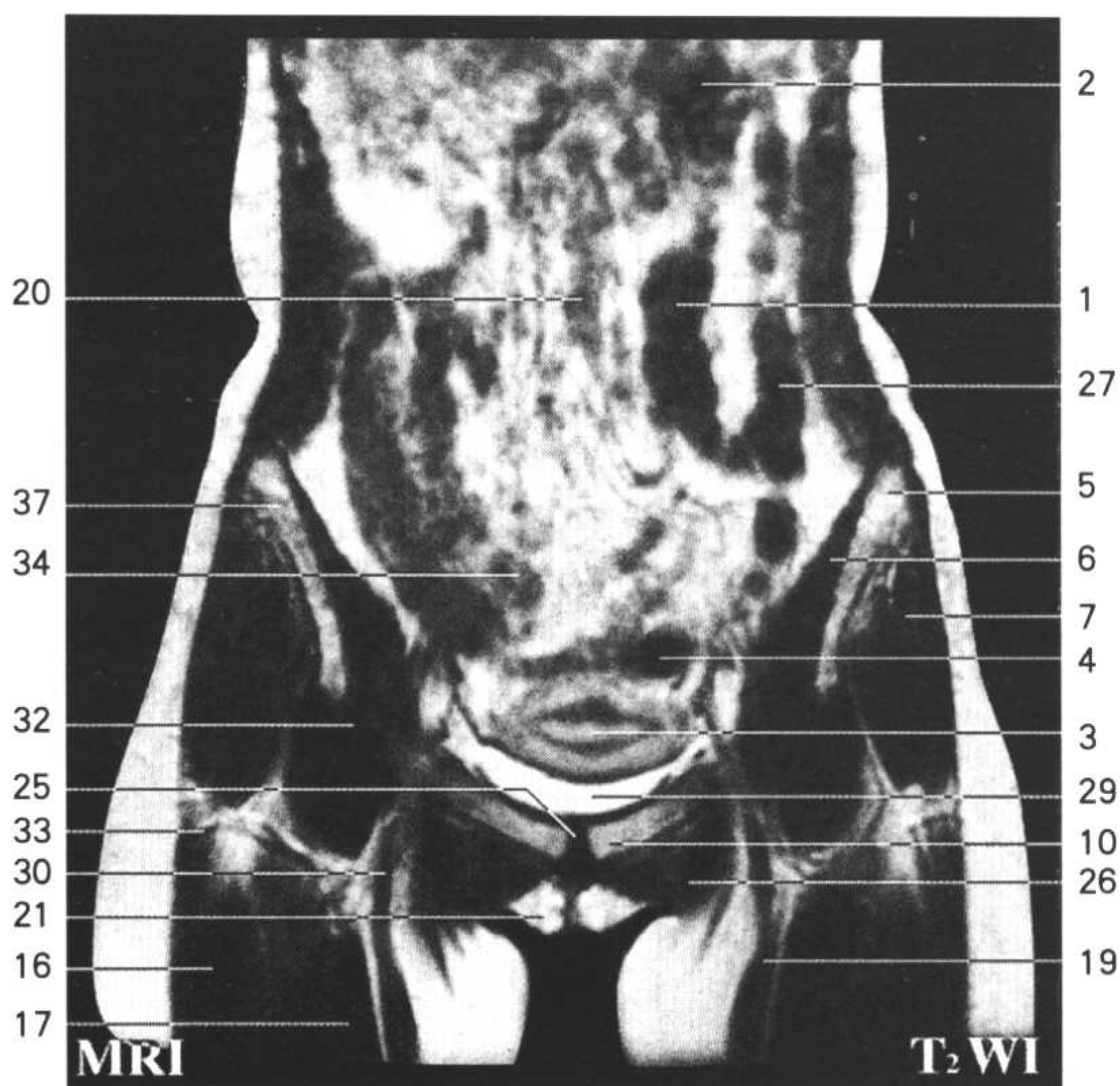
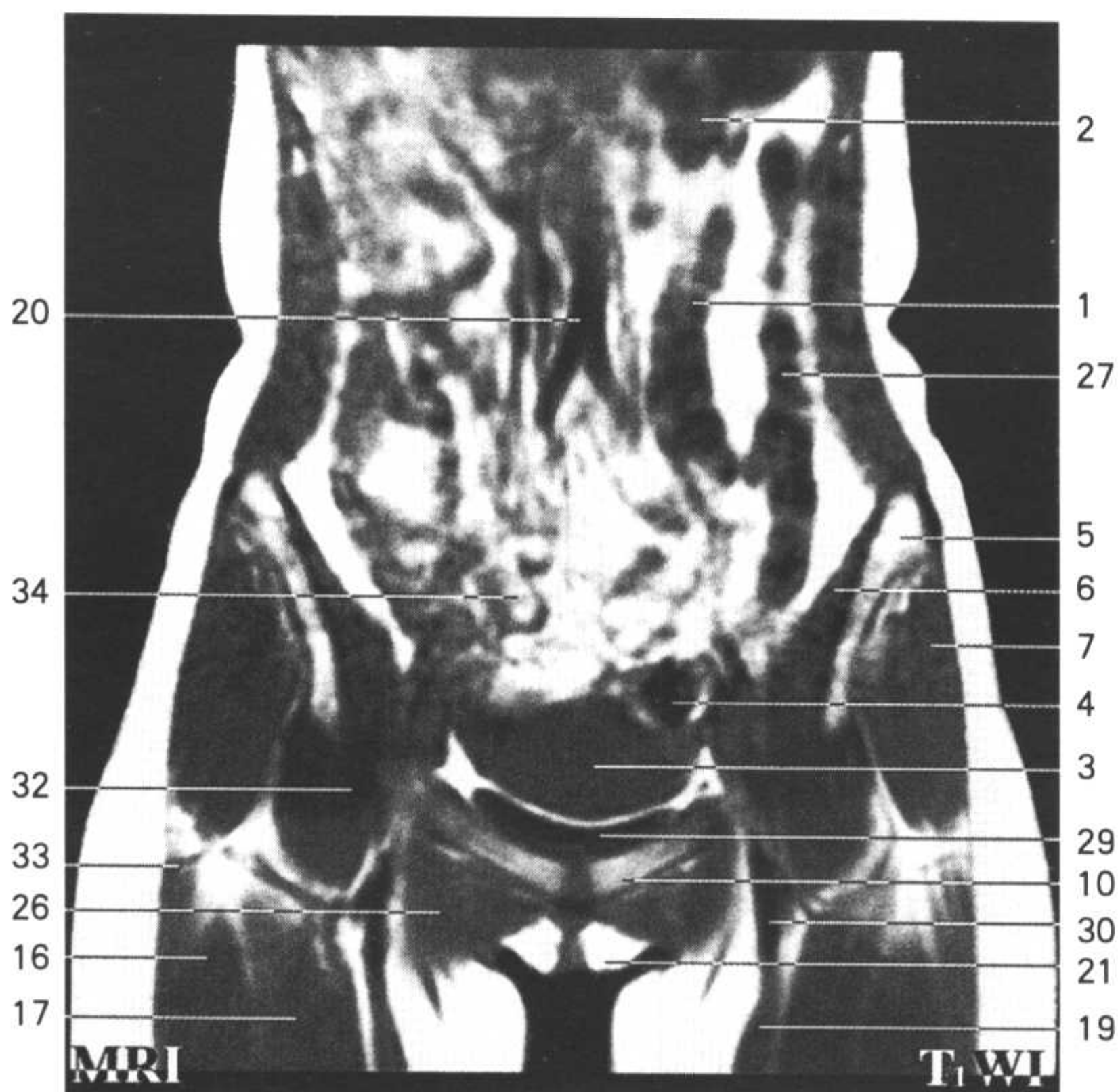
女盆额状断面 FPf

Fig.FPf1

1. 横结肠 transverse colon
2. 空肠 jejunum
3. 子宫 uterus
4. 乙状结肠 sigmoid colon
5. 髂骨翼 ala of ilium
6. 髂肌 iliacus
7. 臀中肌 gluteus medius
8. 髂外动脉 external iliac a.
9. 股骨头 femoral head
10. 耻骨上支 superior ramus of pubis



- 11. 髂腰肌 iliopsoas
- 12. 盲肠 cecum
- 13. 耻骨肌 pectineus
- 14. 短收肌 adductor brevis
- 15. 阔筋膜张肌 tensor fasciae latae
- 16. 股直肌 rectus femoris
- 17. 股内侧肌 vastus medialis
- 18. 长收肌 adductor longus
- 19. 缝匠肌 sartorius
- 20. 腹主动脉 abdominal aorta
- 21. 大阴唇 greater lip of pudendum
- 22. 大隐静脉 great saphenous v.
- 23. 长收肌 adductor longus
- 24. 短收肌 adductor brevis
- 25. 耻骨联合 pubic symphysis
- 26. 闭孔外肌 obturator externus
- 27. 降结肠 descending colon
- 28. 耻骨肌 pectineus
- 29. 膀胱 urinary bladder
- 30. 股静脉 femoral v.
- 31. 股动脉 femoral a.
- 32. 髂腰肌 iliopsoas
- 33. 阔筋膜张肌 tensor fasciae latae
- 34. 回肠 ileum
- 35. 臀中肌 gluteus medius
- 36. 髂肌 iliacus
- 37. 髂嵴 iliac crest



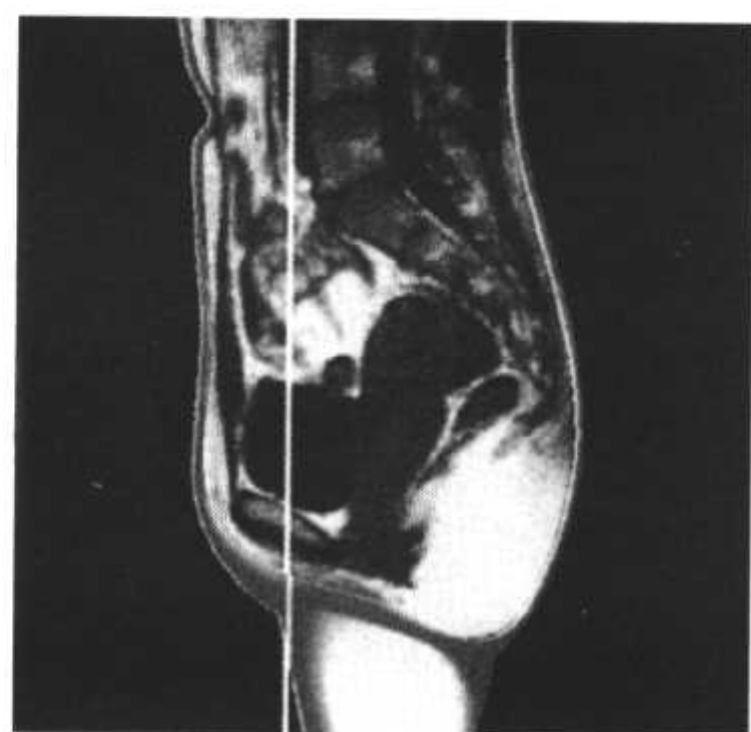
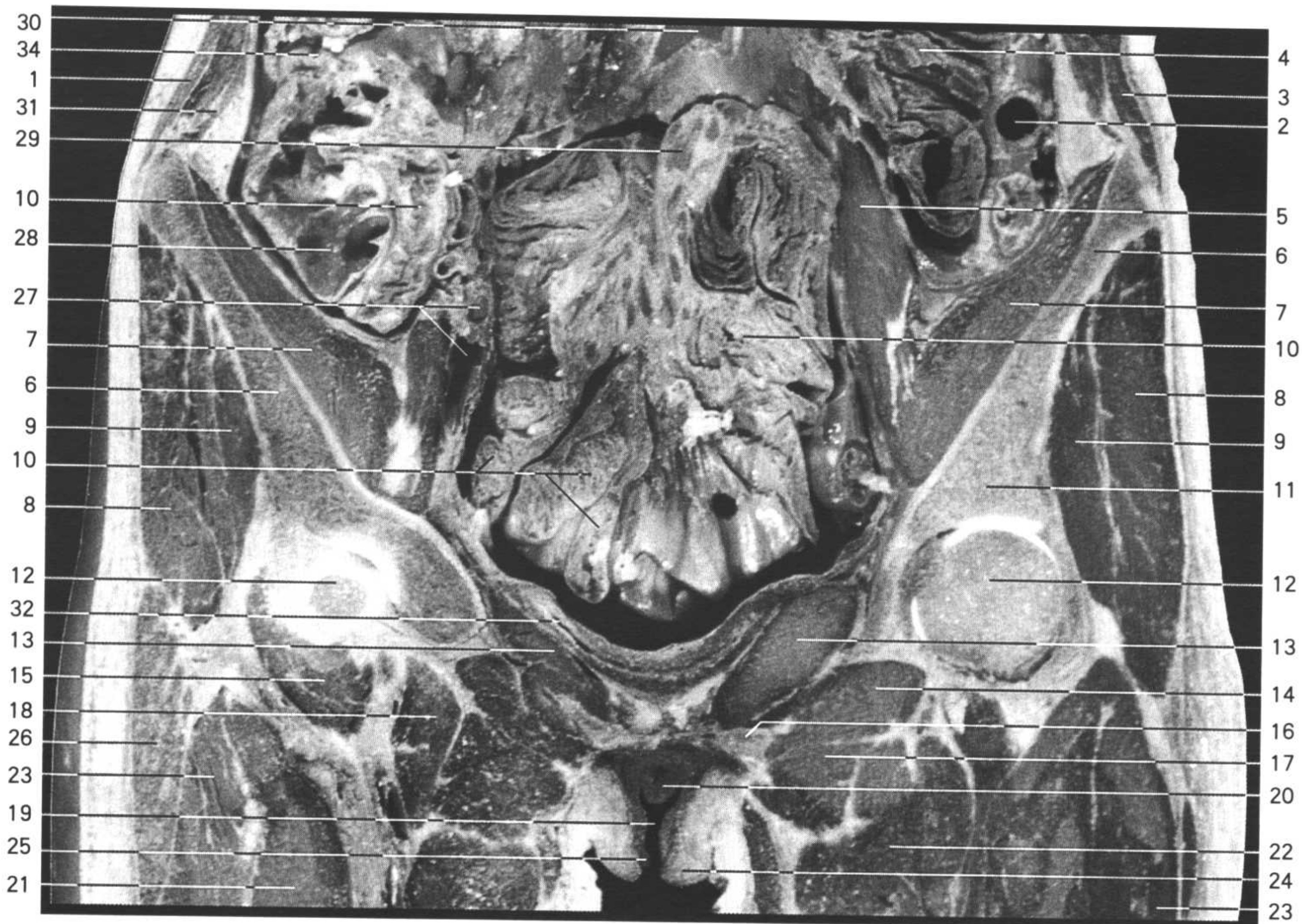
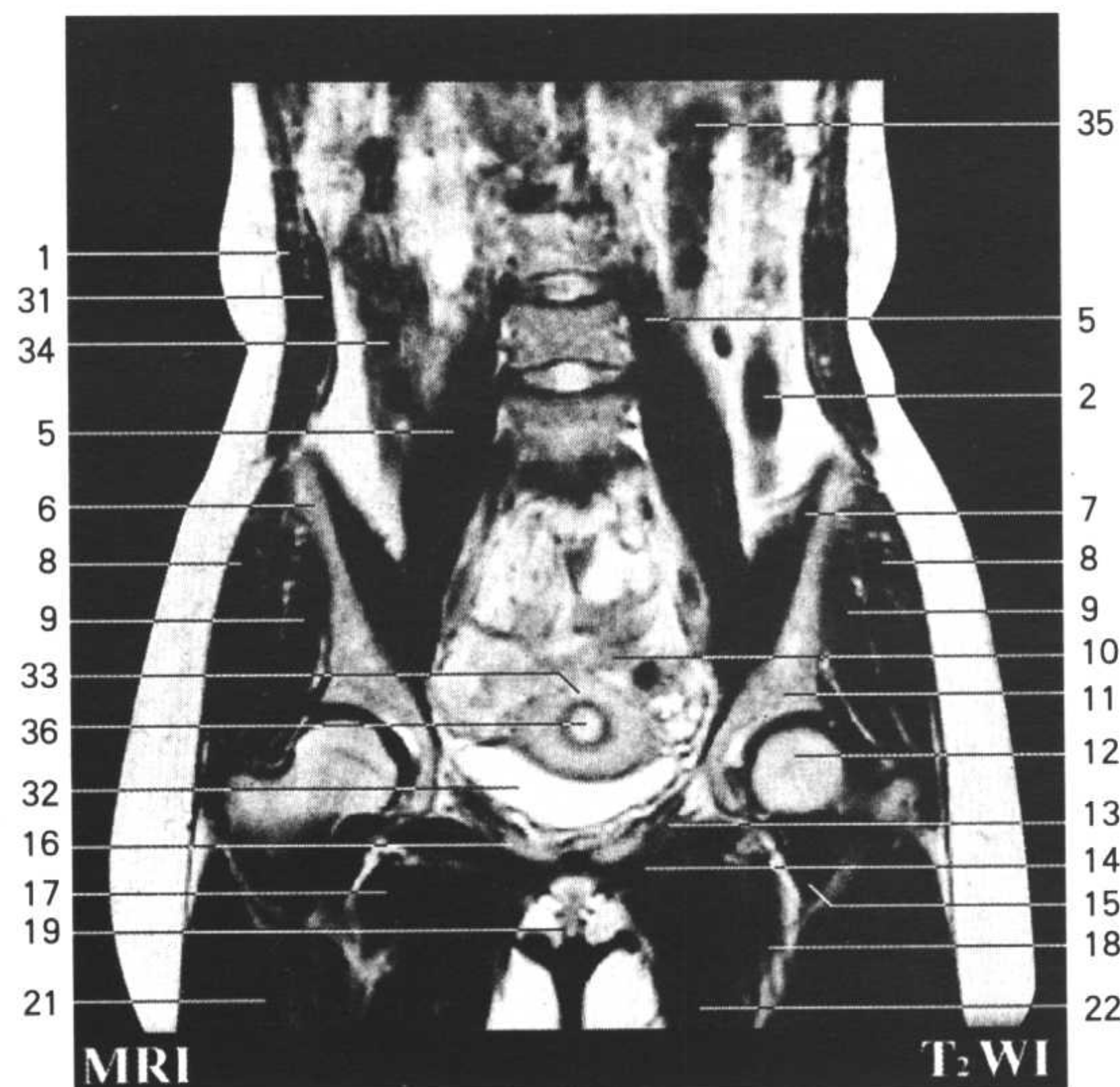
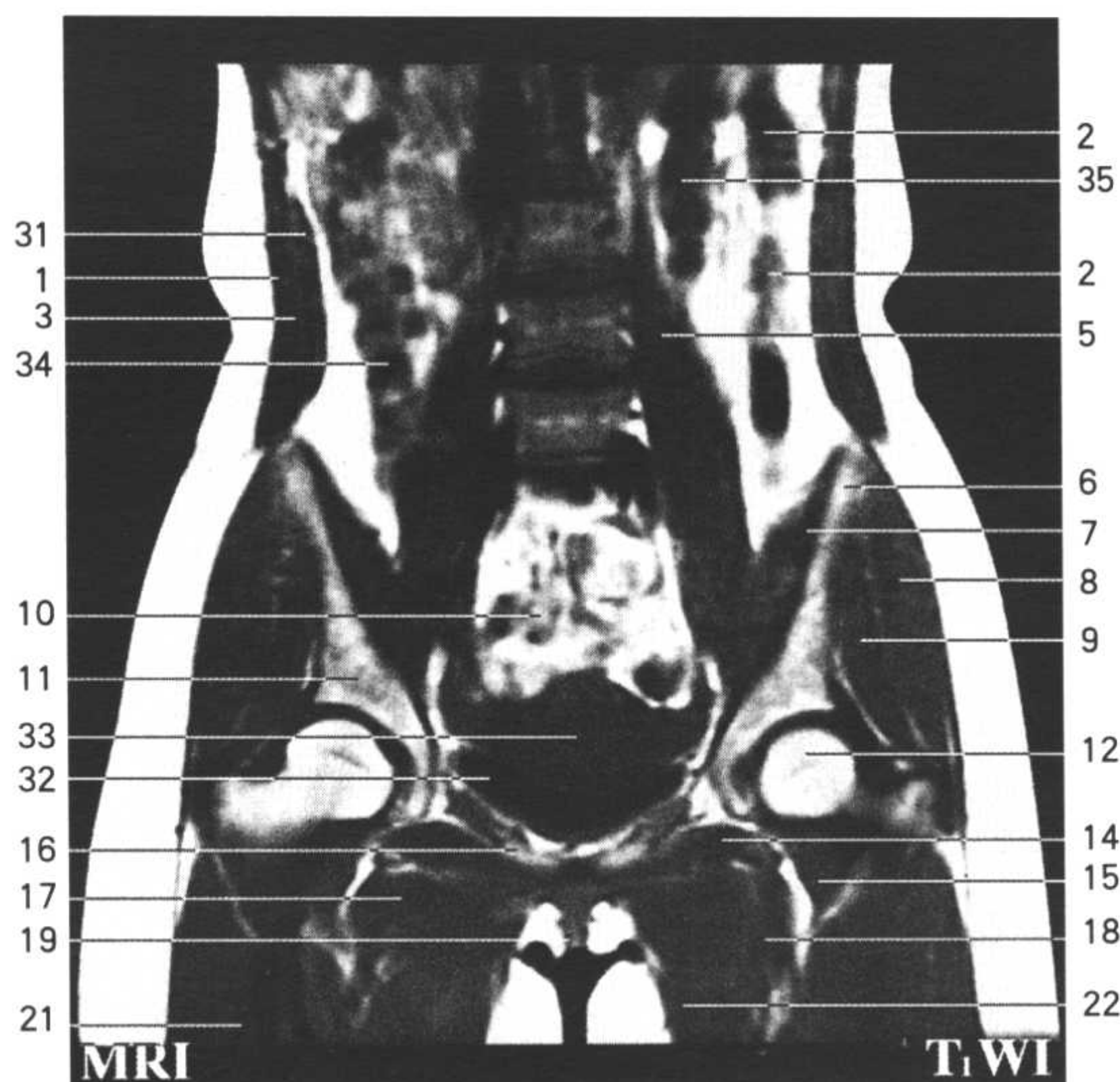

Fig.FPf2

1. 腹外斜肌 *obliquus externus abdominis*
2. 降结肠 *descending colon*
3. 腹内斜肌 *obliquus internus abdominis*
4. 空肠 *jejunum*
5. 腰大肌 *psoas major*
6. 髂骨翼 *ala of ilium*
7. 髂肌 *iliacus*
8. 臀中肌 *gluteus medius*
9. 臀小肌 *gluteus minimus*
10. 回肠 *ileum*

11. 髂骨体 body of ilium
12. 股骨头 femoral head
13. 闭孔内肌 obturator internus
14. 闭孔外肌 obturator externus
15. 髂腰肌 iliopsoas
16. 耻骨下支 inferior ramus of pubis
17. 短收肌 adductor brevis
18. 耻骨肌 pectineus
19. 阴道前庭 vaginal vestibule
20. 阴道 vagina
21. 股中间肌 vastus intermedius
22. 长收肌 adductor longus
23. 股外侧肌 vastus lateralis
24. 大阴唇 greater lip of pudendum
25. 小阴唇 lesser lip of pudendum
26. 阔筋膜张肌 tensor fasciae latae
27. 右髂外动、静脉 right external iliac
a. and v.
28. 盲肠 cecum
29. 肠系膜 mesentery
30. 腹主动脉 abdominal aorta
31. 腹横肌 transversus abdominis
32. 膀胱 urinary bladder
33. 子宫 uterus
34. 升结肠 ascending colon
35. 横结肠 transverse colon
36. 子宫腔 cavity of uterus



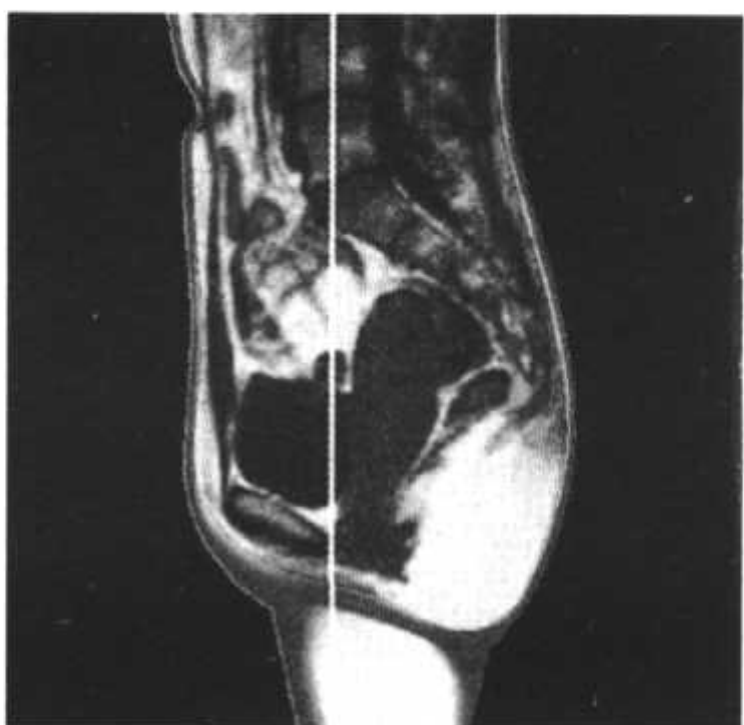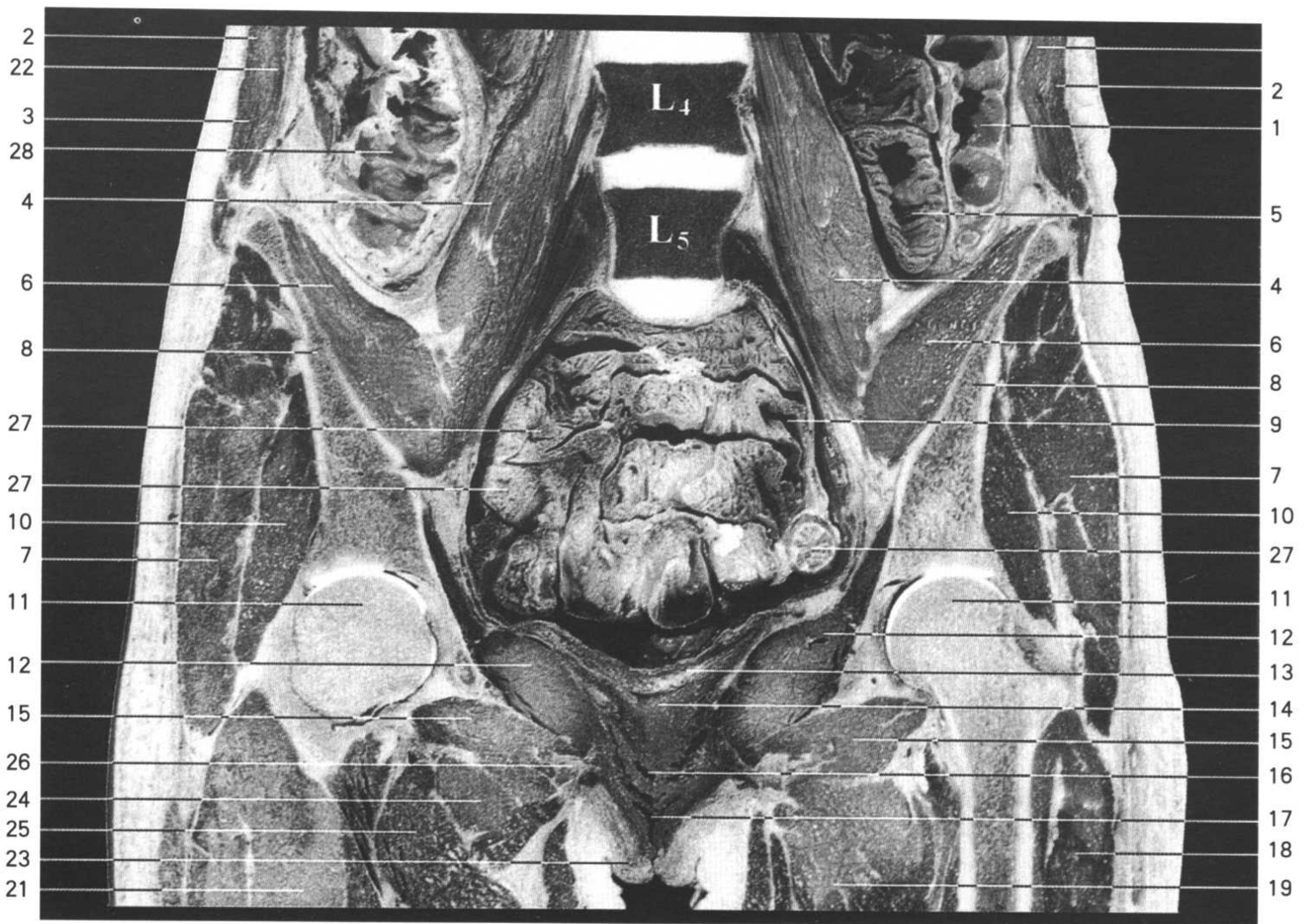

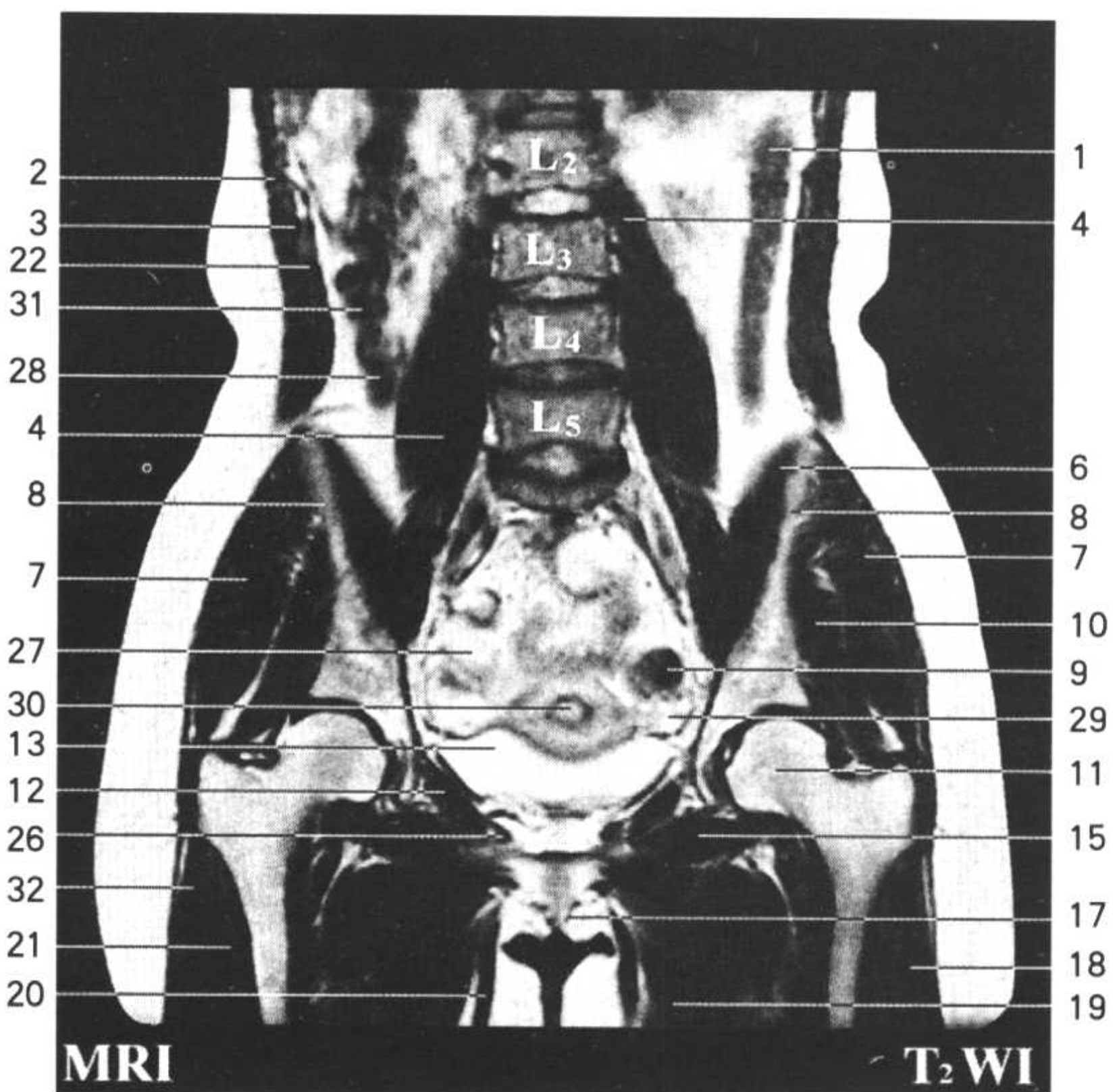
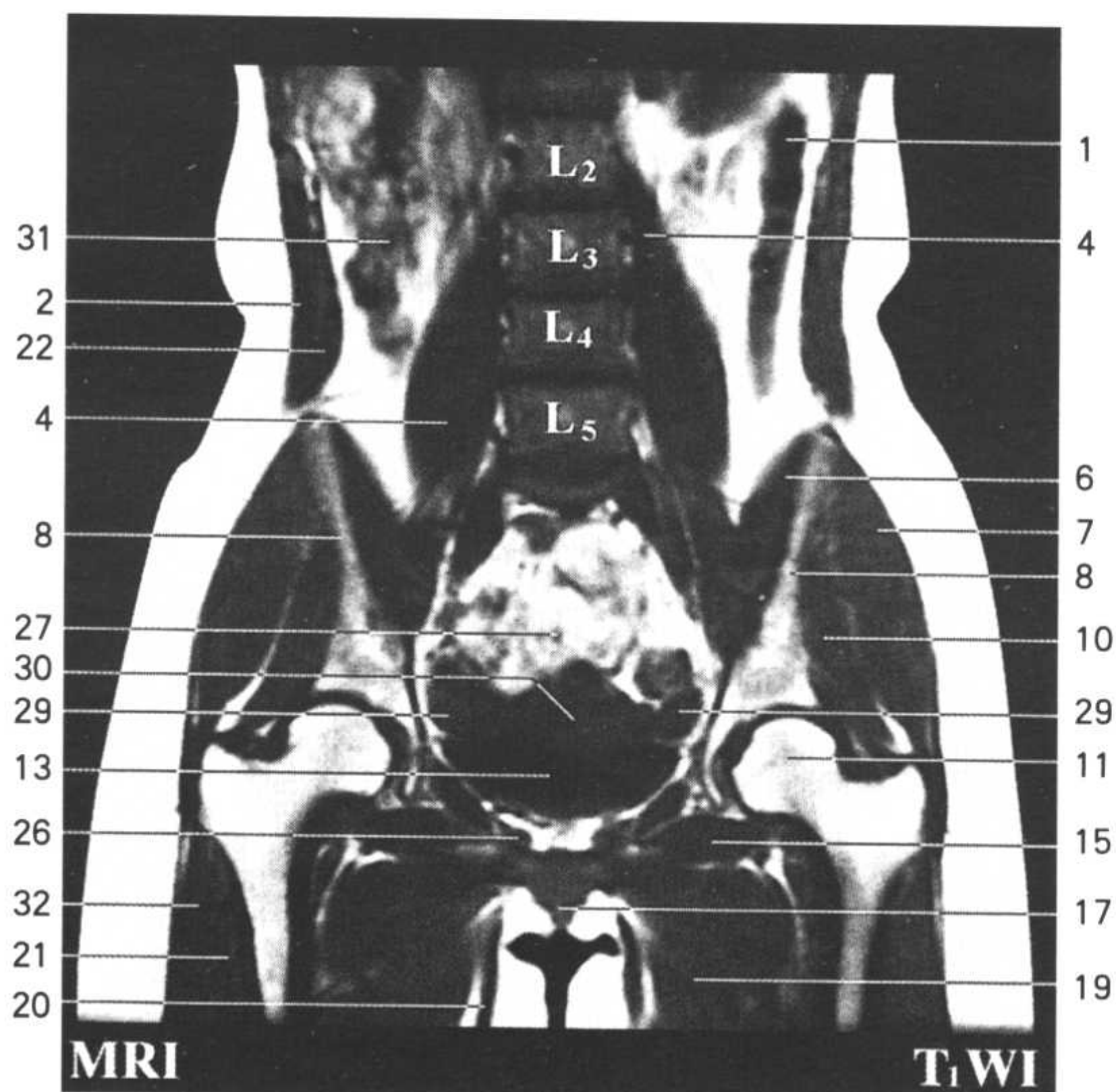Fig.FPf3

1. 降结肠 descending colon
2. 腹外斜肌 obliquus externus abdominis
3. 腹内斜肌 obliquus internus abdominis
4. 腰大肌 psoas major
5. 空肠 jejunum
6. 髂肌 iliacus
7. 臀中肌 gluteus medius
8. 髂骨翼 ala of ilium
9. 乙状结肠 sigmoid colon
10. 臀小肌 gluteus minimus

11. 股骨头 femoral head
12. 闭孔内肌 obturator internus
13. 膀胱 urinary bladder
14. 阴道前壁 anterior wall of vagina
15. 闭孔外肌 obturator externus
16. 阴道 vagina
17. 阴道前庭 vaginal vestibule
18. 股外侧肌 vastus lateralis
19. 大收肌 adductor magnus
20. 股薄肌 gracilis
21. 股中间肌 vastus intermedius
22. 腹横肌 transversus abdominis
23. 大阴唇 greater lip of pudendum
24. 短收肌 adductor brevis
25. 长收肌 adductor longus
26. 耻骨下支 inferior ramus of pubis
27. 回肠 ileum
28. 盲肠 cecum
29. 卵巢 ovary
30. 子宫 uterus
31. 升结肠 ascending colon
32. 股外侧肌 vastus lateralis



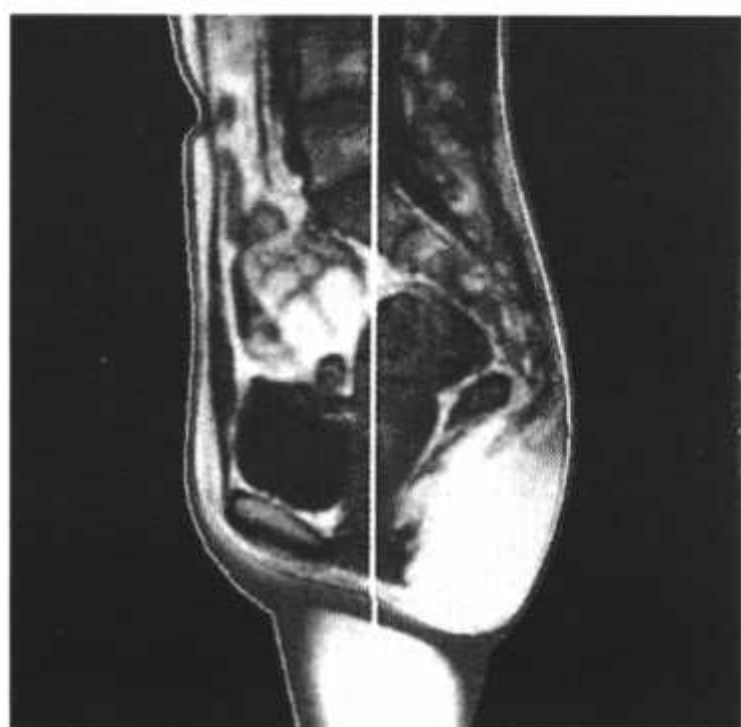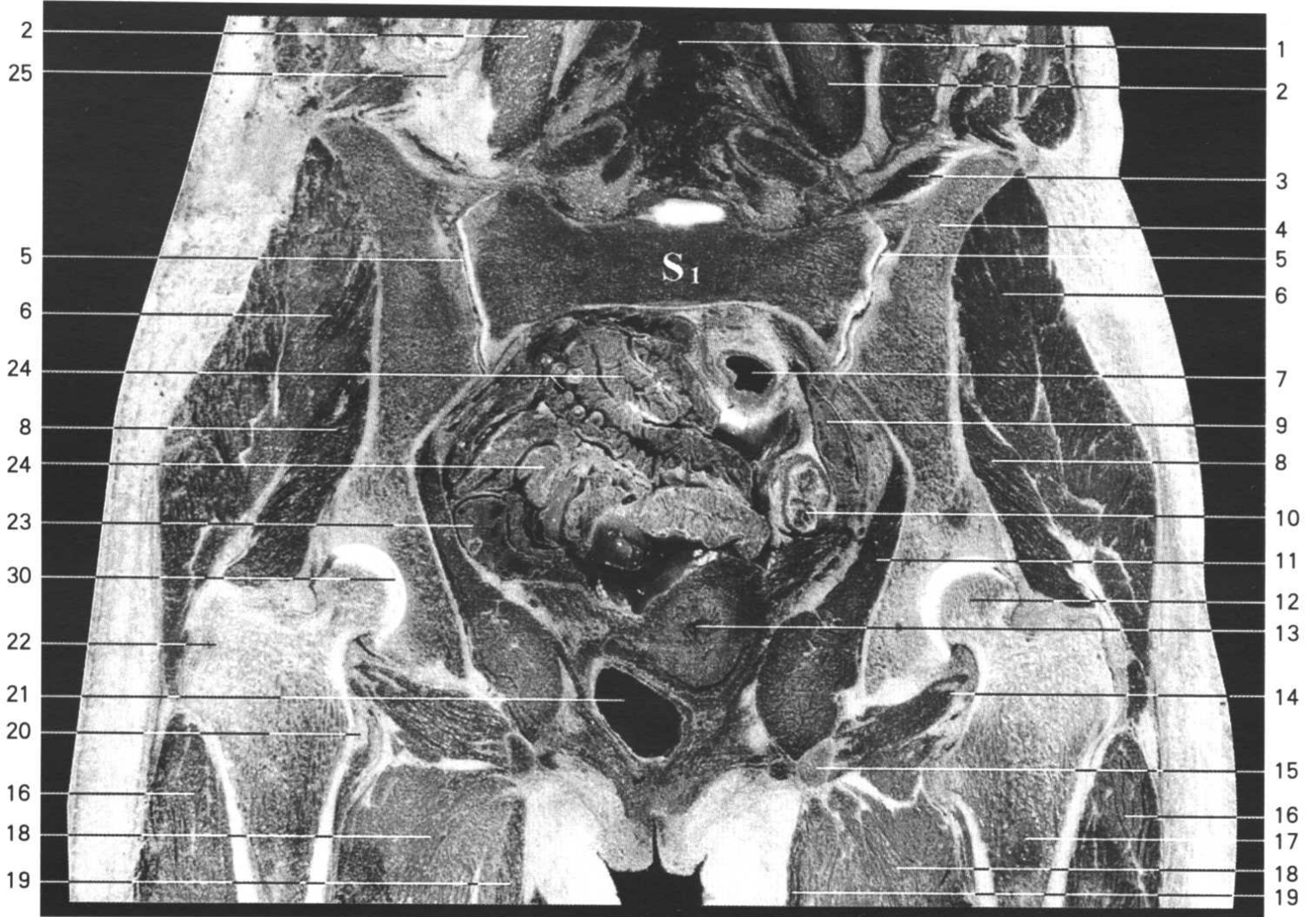
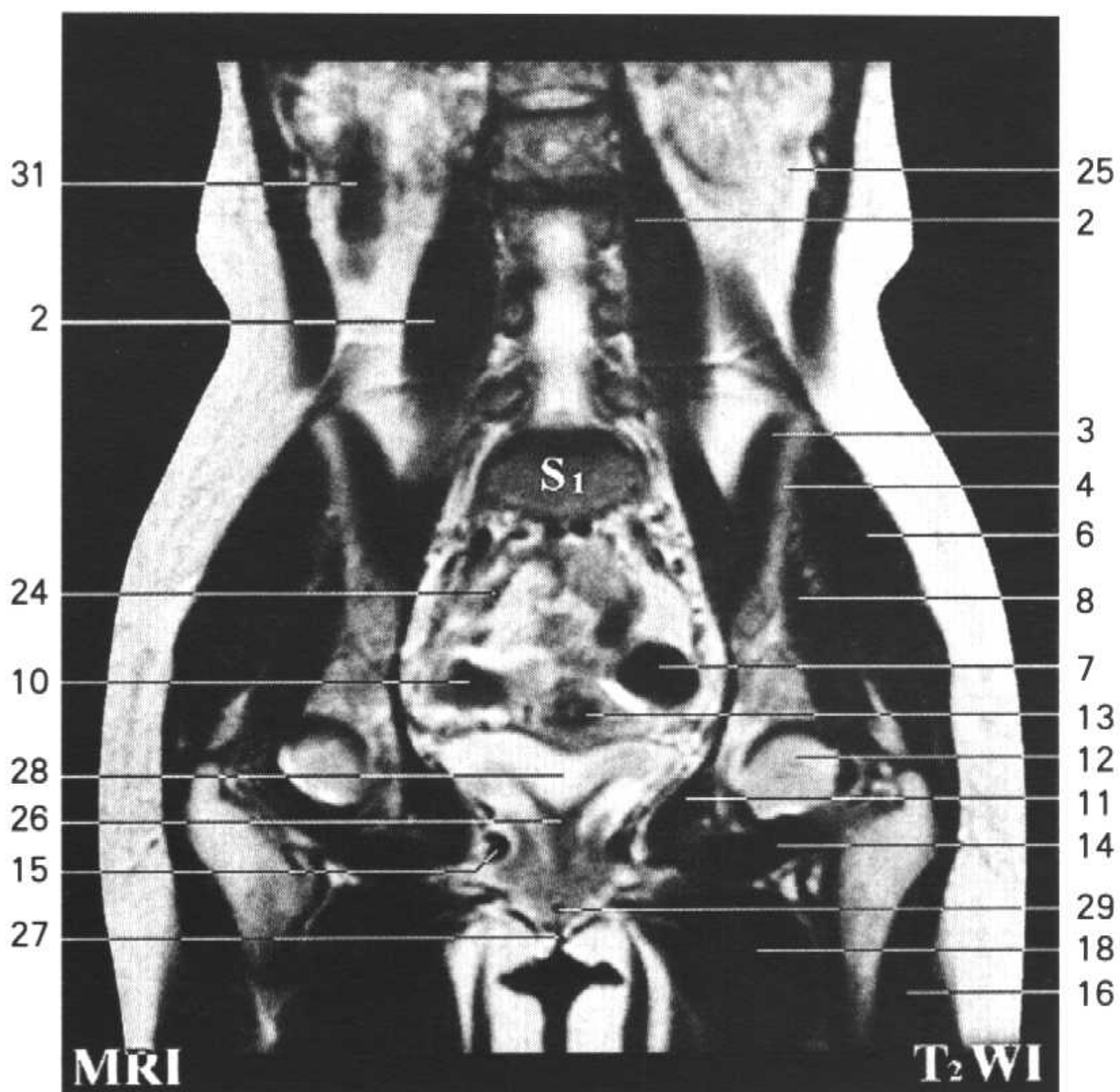

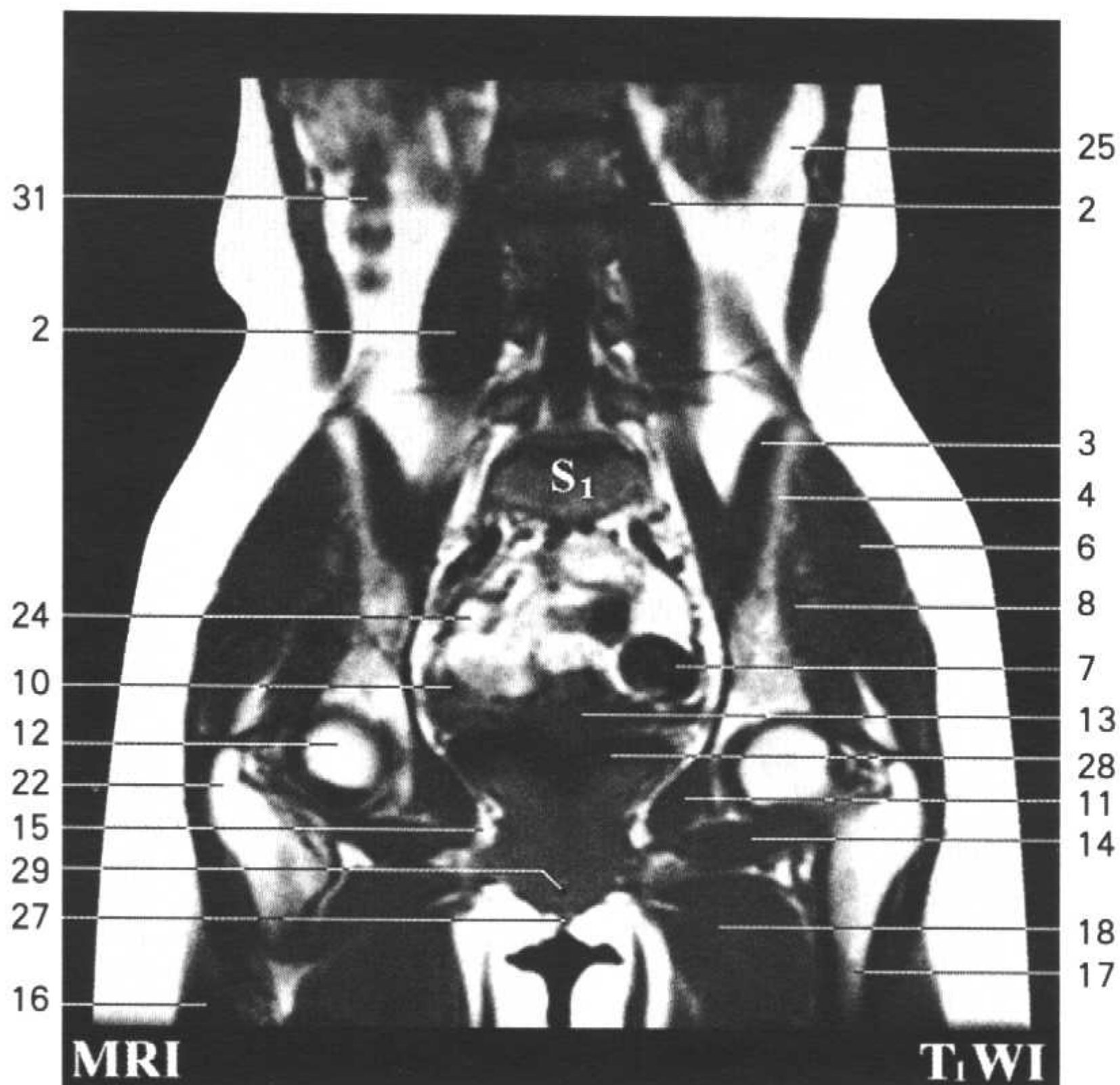
Fig.FPf 4

1. 后纵韧带 posterior longitudinal ligament
2. 腰大肌 psoas major
3. 髂肌 iliacus
4. 髂骨翼 ala of ilium
5. 骶髂关节 sacroiliac joint
6. 臀中肌 gluteus medius
7. 乙状结肠 sigmoid colon
8. 臀小肌 gluteus minimus
9. 卵巢 ovary
10. 回肠 ileum

11. 闭孔内肌 obturator internus
12. 股骨头 femoral head
13. 子宫 uterus
14. 闭孔外肌 obturator externus
15. 坐骨支 ramus of ischium
16. 股外侧肌 vastus lateralis
17. 股骨 femur
18. 大收肌 adductor magnus
19. 股薄肌 gracilis
20. 小转子 lesser trochanter
21. 直肠 rectum
22. 大转子 greater trochanter
23. 输卵管 uterine tube
24. 回肠 ileum
25. 脂肪囊 fatty renal capsule
26. 阴道 vagina
27. 阴道前庭 vaginal vestibule
28. 膀胱 urinary bladder
29. 尿道外口 external orifice of urethra
30. 髋关节 hip joint
31. 升结肠 ascending colon



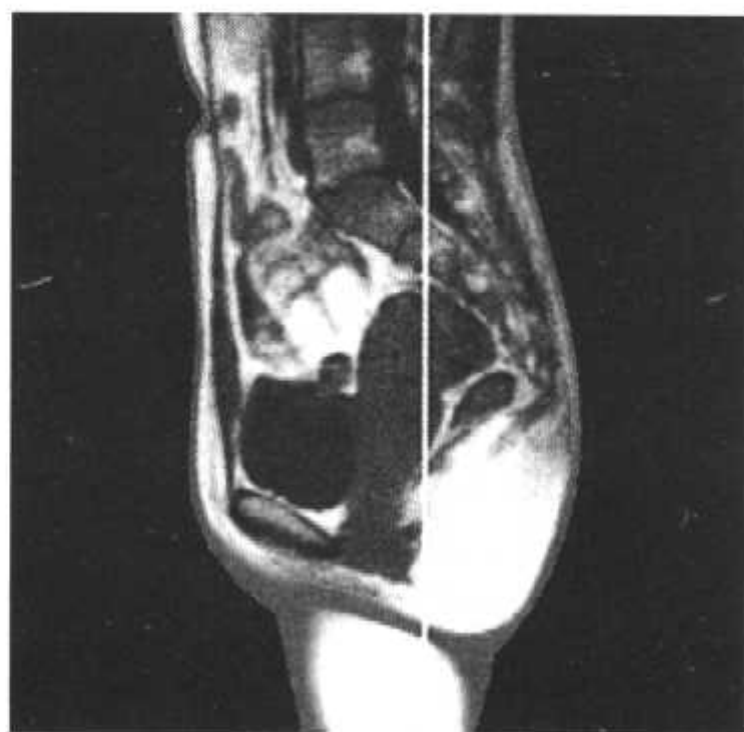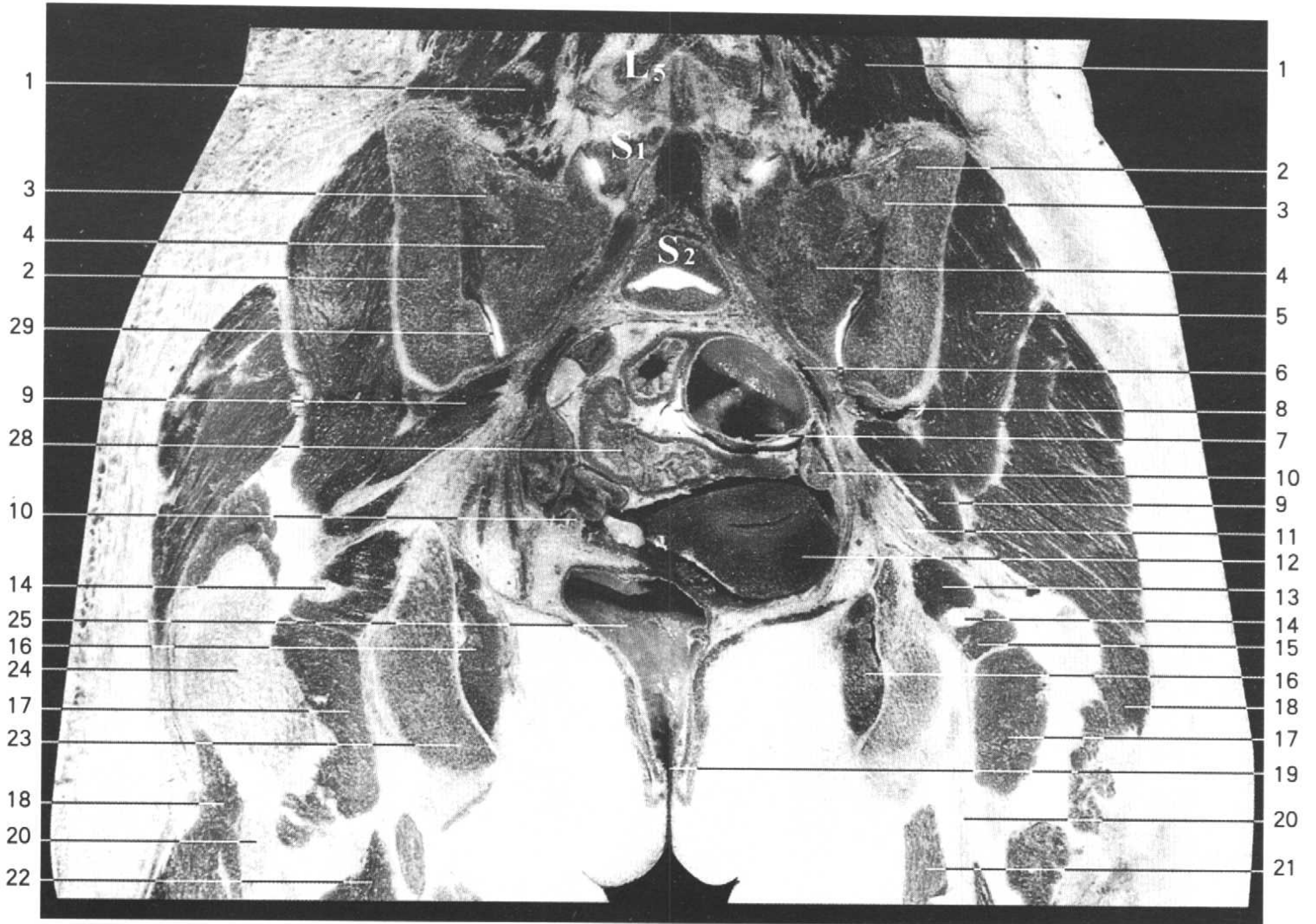
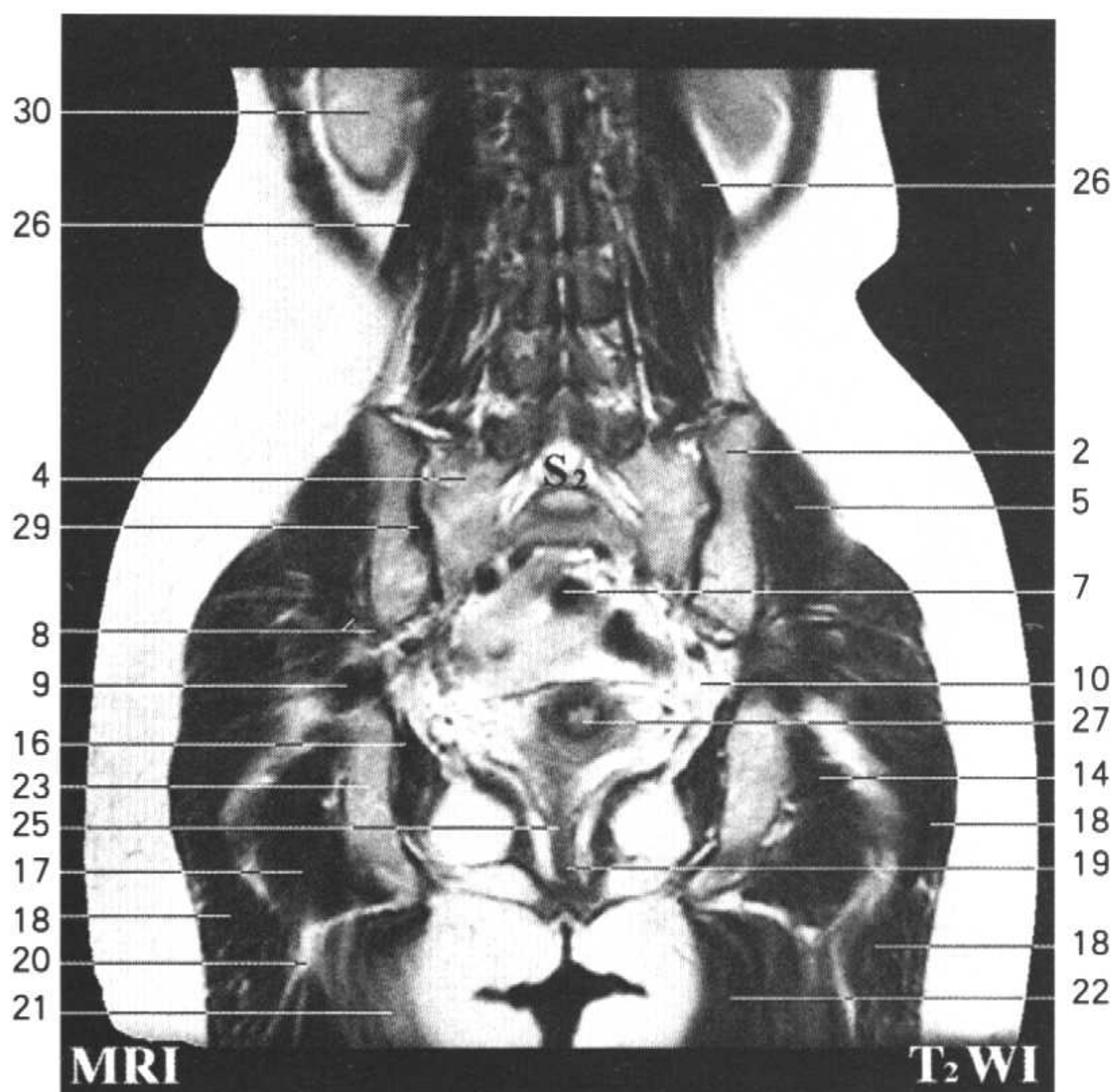
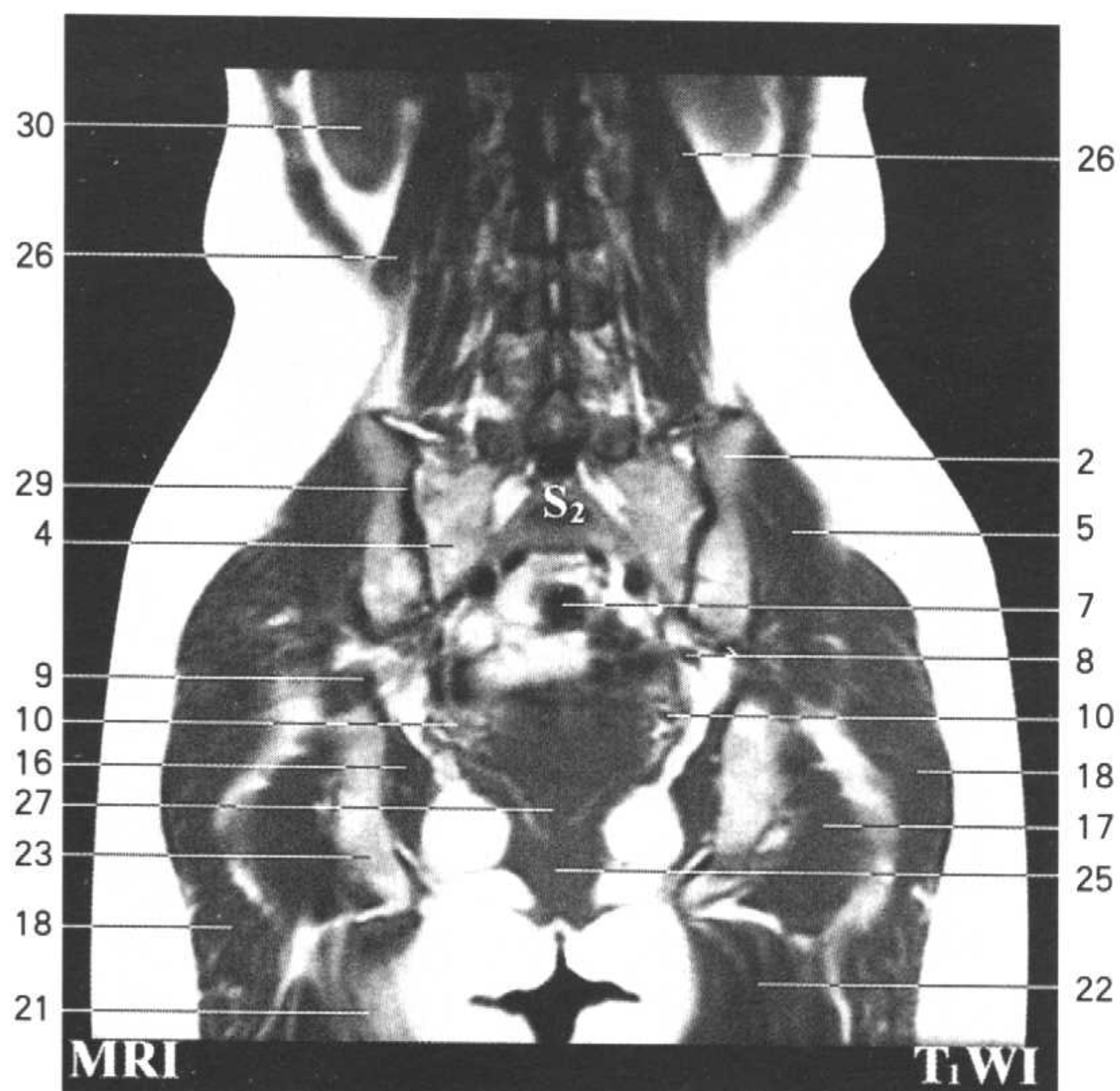


Fig.FPf 5

1. 横突棘肌 transversospinales
2. 髂骨翼 ala of ilium
3. 骶髂骨间韧带 interosseous sacroiliac ligaments
4. 骶粗隆 sacral tuberosity
5. 臀中肌 gluteus medius
6. 髂内静脉 internal iliac v.
7. 乙状结肠 sigmoid colon
8. 臀上动、静脉 superior gluteal a. and v.
9. 梨状肌 piriformis
10. 卵巢 ovary

11. 坐骨神经 sciatic n.
12. 子宫体 body of uterus
13. 上孖肌 gemellus superior
14. 闭孔内肌腱 tendon of obturator internus
15. 下孖肌 gemellus inferior
16. 闭孔内肌 obturator internus
17. 股方肌 quadratus femoris
18. 臀大肌 gluteus maximus
19. 肛管 anal canal
20. 坐骨神经 sciatic n.
21. 半腱肌 semitendinosus
22. 大收肌 adductor magnus
23. 坐骨 ischium
24. 大转子 greater trochanter
25. 直肠 rectum
26. 腰方肌 quadratus lumborum
27. 子宫颈 neck of uterus
28. 回肠 ileum
29. 骶髂关节 sacroiliac joint
30. 肾 kidney



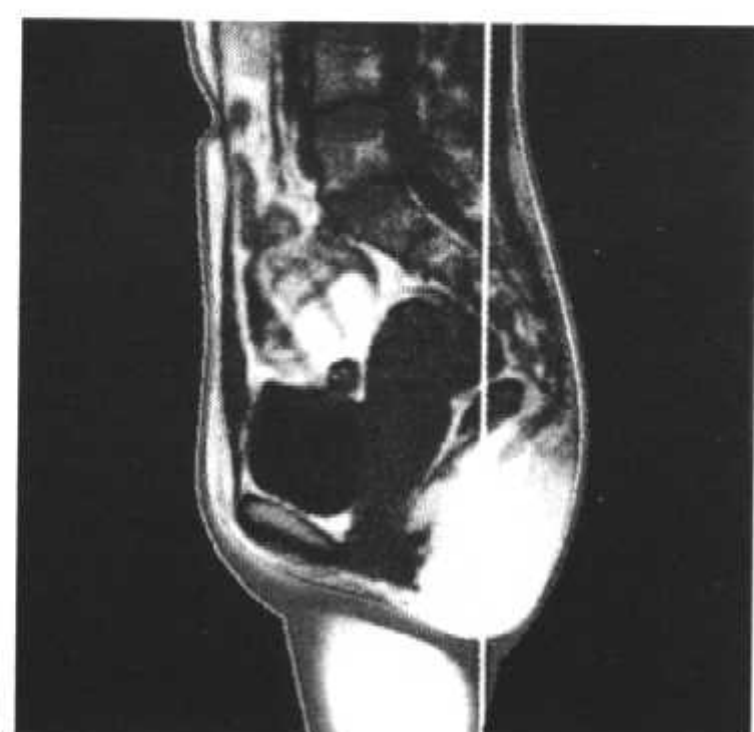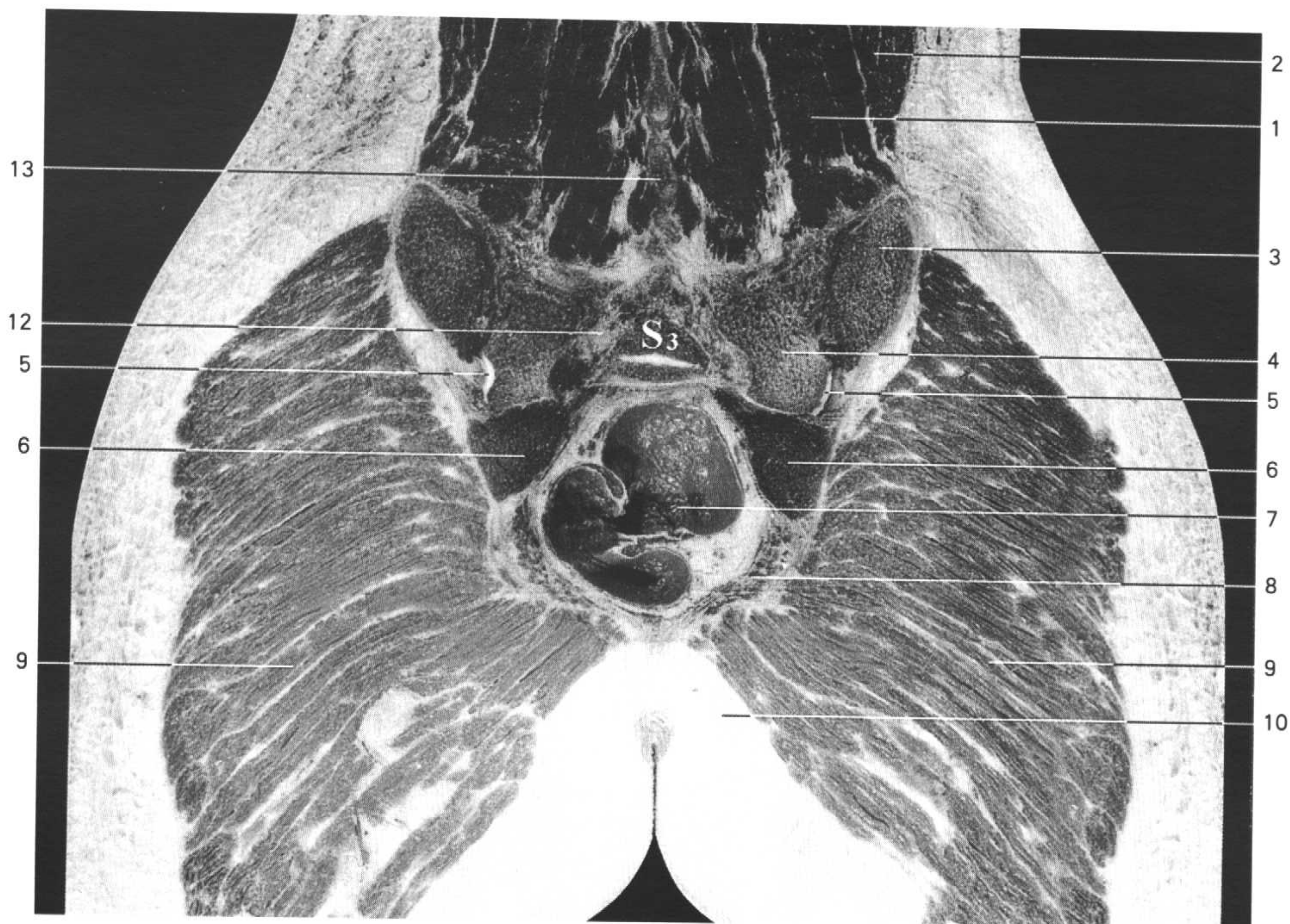
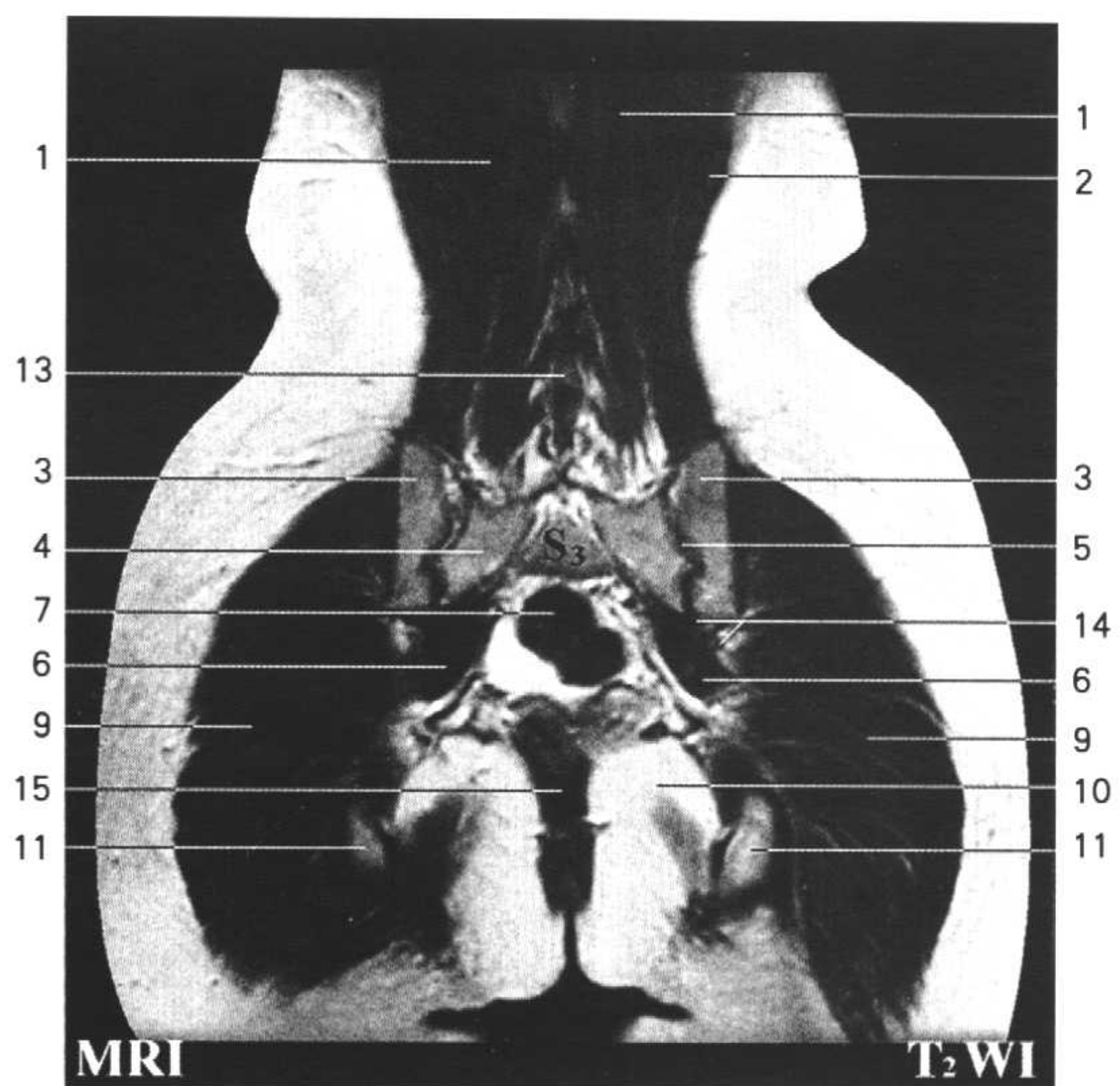
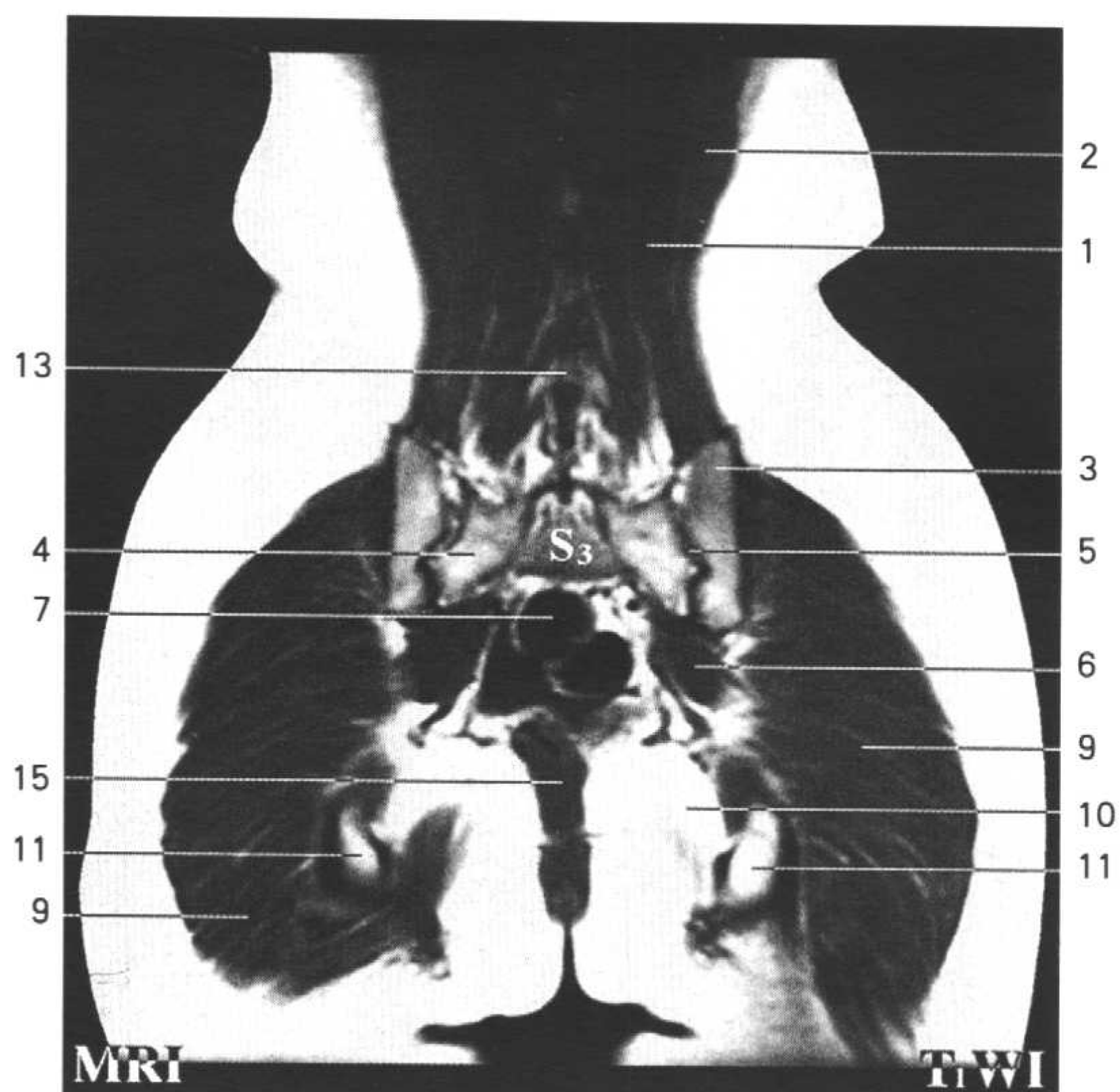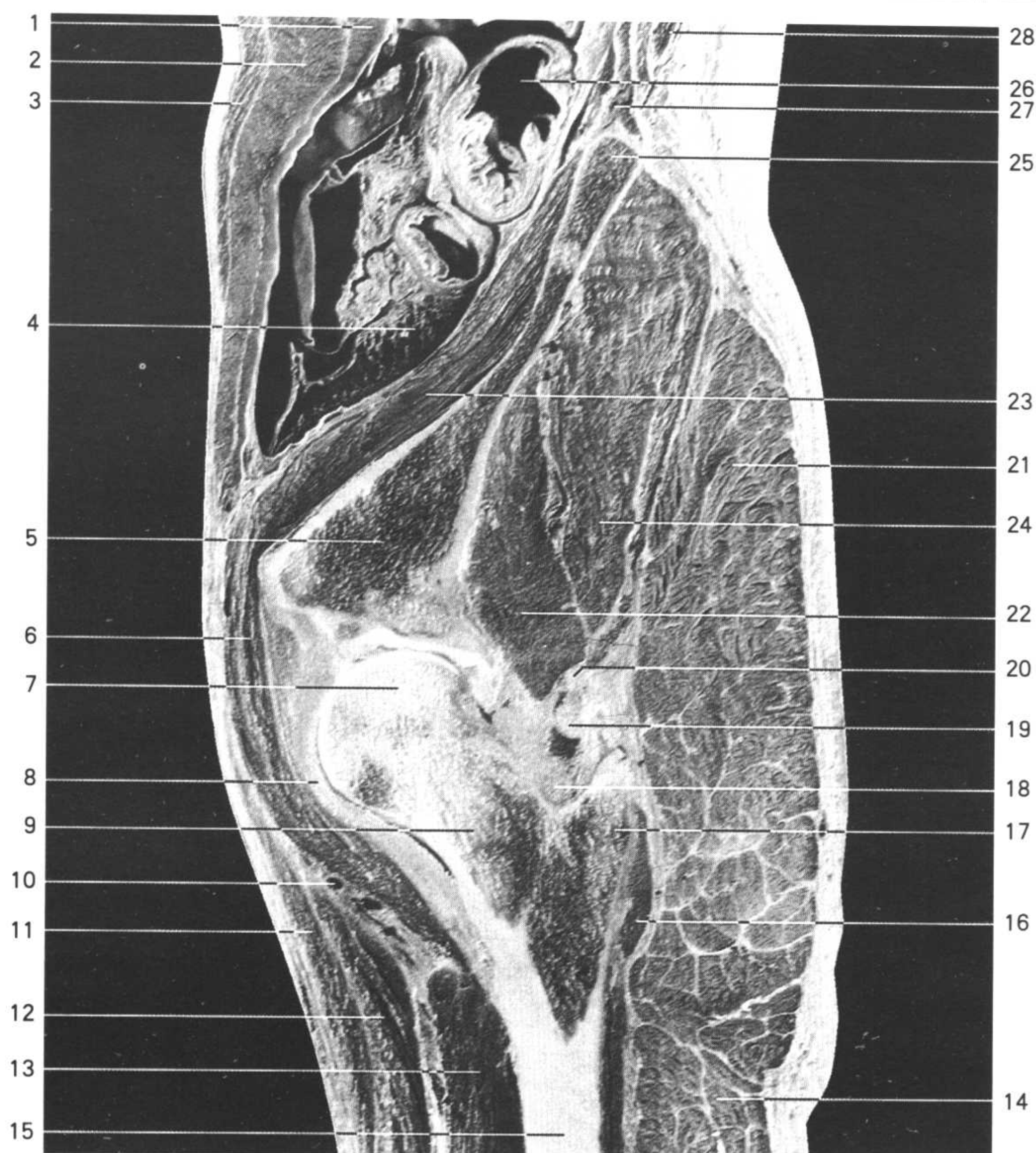


Fig.FPf 6

1. 竖脊肌 erector spinae
2. 背阔肌 latissimus dorsi
3. 髂骨翼 ala of ilium
4. 骶翼 ala of sacrum
5. 骶髂关节 sacroiliac joint
6. 梨状肌 piriformis
7. 直肠壶腹 ampulla of rectum
8. 肛提肌 levator ani
9. 臀大肌 gluteus maximus
10. 坐骨肛门窝 ischioanal fossa

- 11. 坐骨结节 ischial tuberosity
- 12. 第2骶神经 2nd sacral n.
(ventral ramus)
- 13. 第5腰椎棘突 spinous process (L₅)
- 14. 臀上动脉 superior gluteal a.
- 15. 直肠 rectum

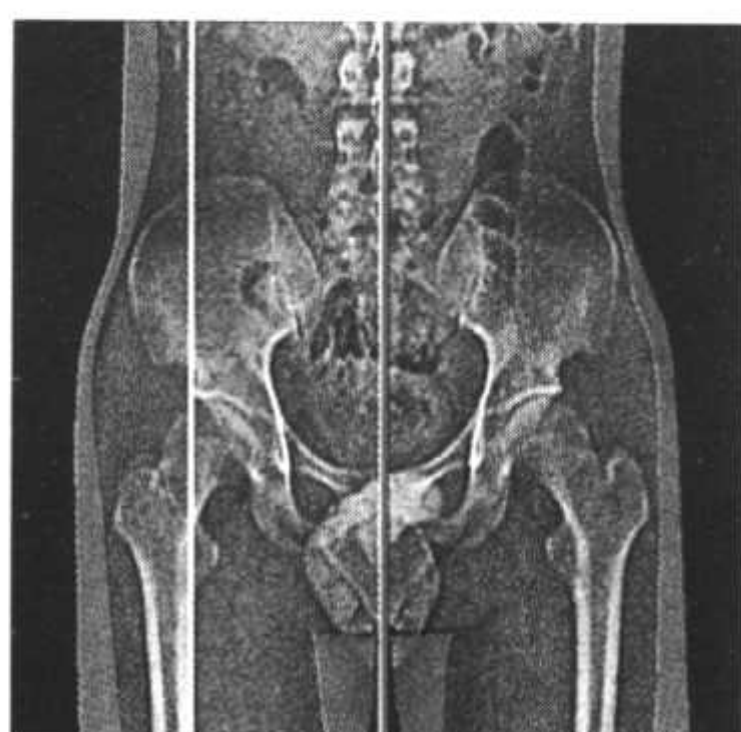




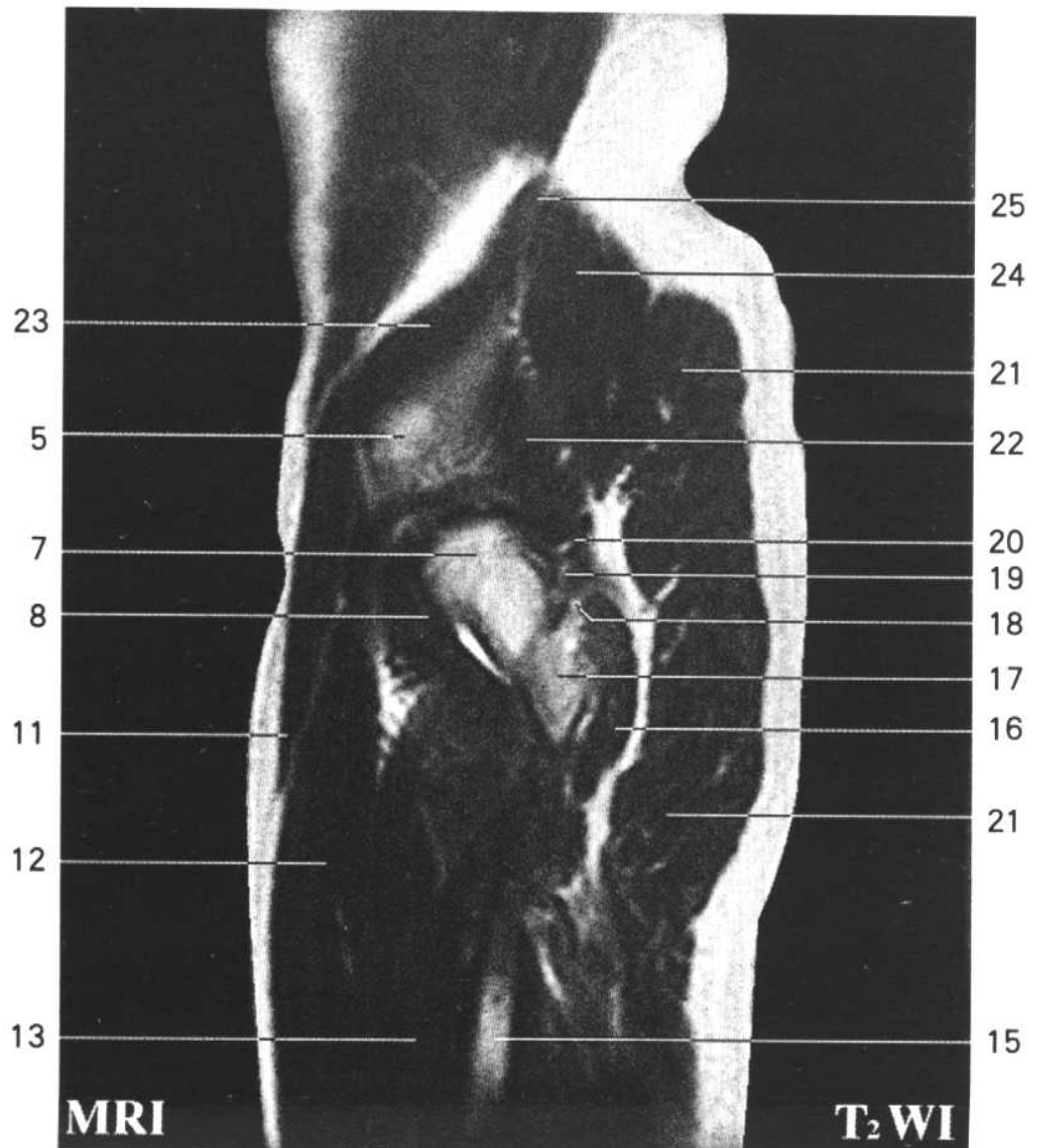
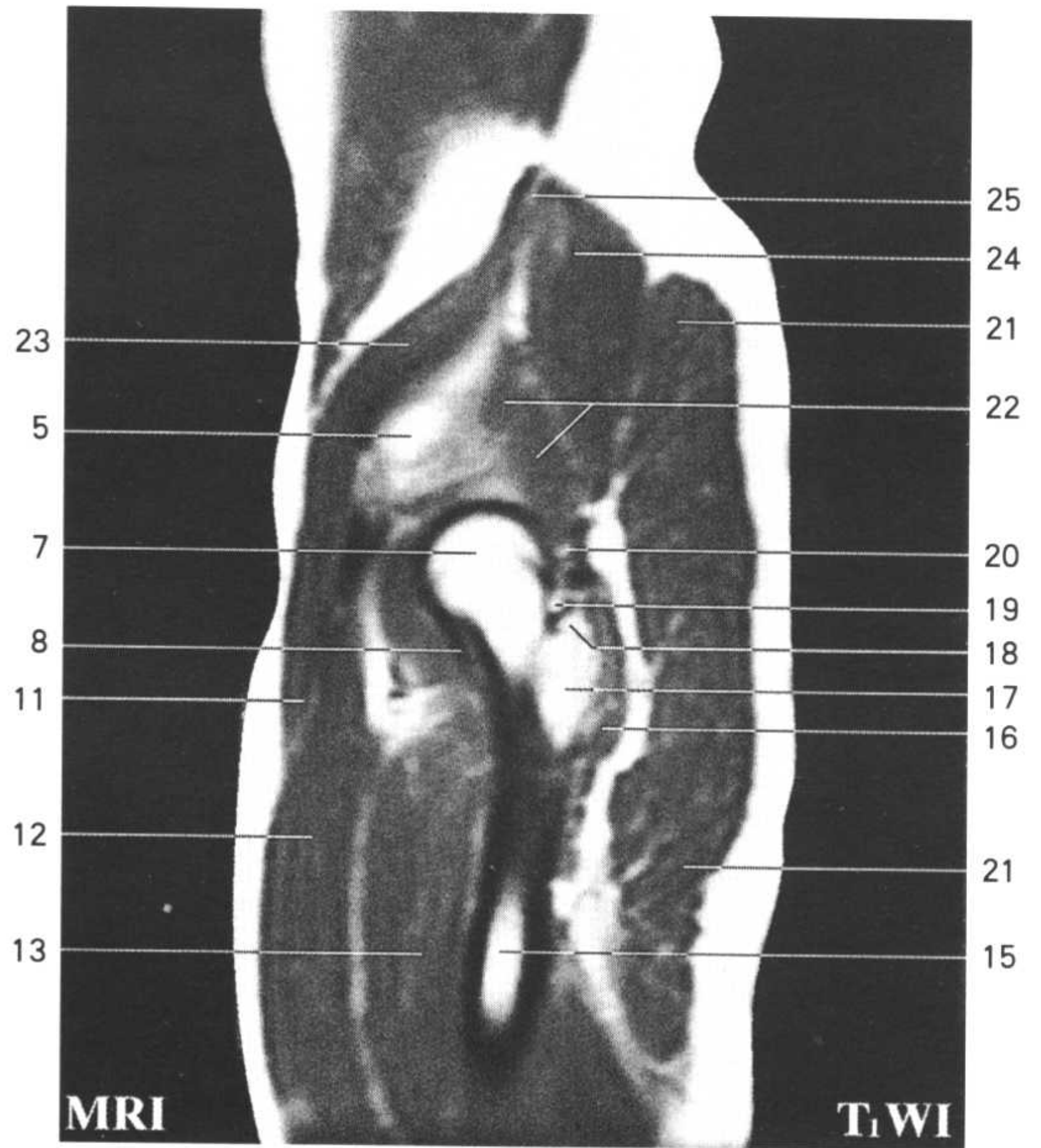
男盆矢状断面 SPm

Fig.SPm 1

1. 腹横肌 transversus abdominis
2. 腹内斜肌 obliquus internus abdominis
3. 腹外斜肌 obliquus externus abdominis
4. 回肠 ileum
5. 髂骨体 body of ilium
6. 髂腰肌 iliopsoas
7. 股骨头 femoral head
8. 关节囊 articular capsule
9. 股骨颈 neck of femur
10. 旋股外侧动脉 lateral femoral circumflex a.



11. 缝匠肌 sartorius
12. 股直肌 rectus femoris
13. 股中间肌 vastus intermedius
14. 臀大肌 gluteus maximus
15. 股骨体 shaft of femur
16. 股方肌 quadratus femoris
17. 大转子 greater trochanter
18. 闭孔外肌腱 tendon of obturator externus
19. 闭孔内肌腱 tendon of obturator internus
20. 梨状肌腱 tendon of piriformis
21. 臀大肌 gluteus maximus
22. 臀小肌 gluteus minimus
23. 髂肌 iliacus
24. 臀中肌 gluteus medius
25. 髂嵴 iliac crest
26. 升结肠 ascending colon
27. 腰方肌 quadratus lumborum
28. 背阔肌 latissimus dorsi



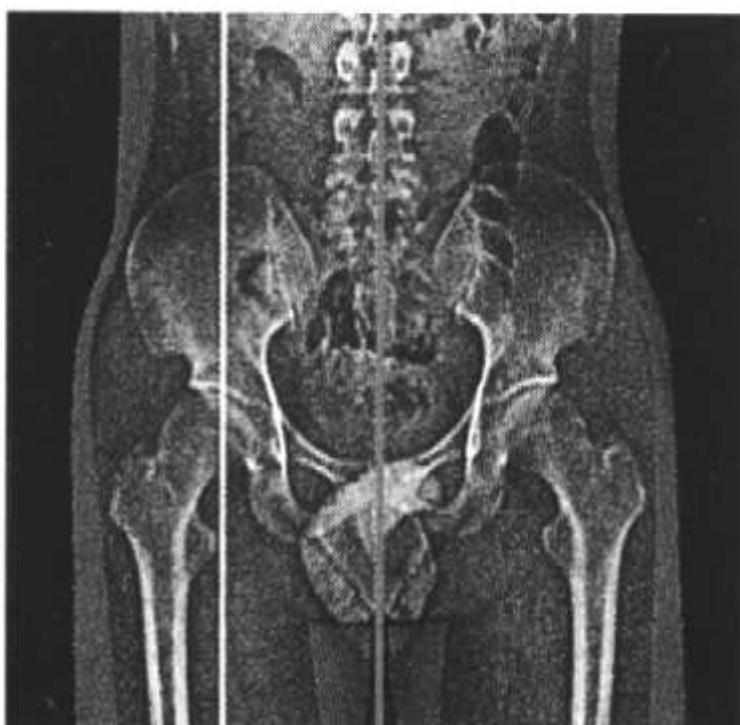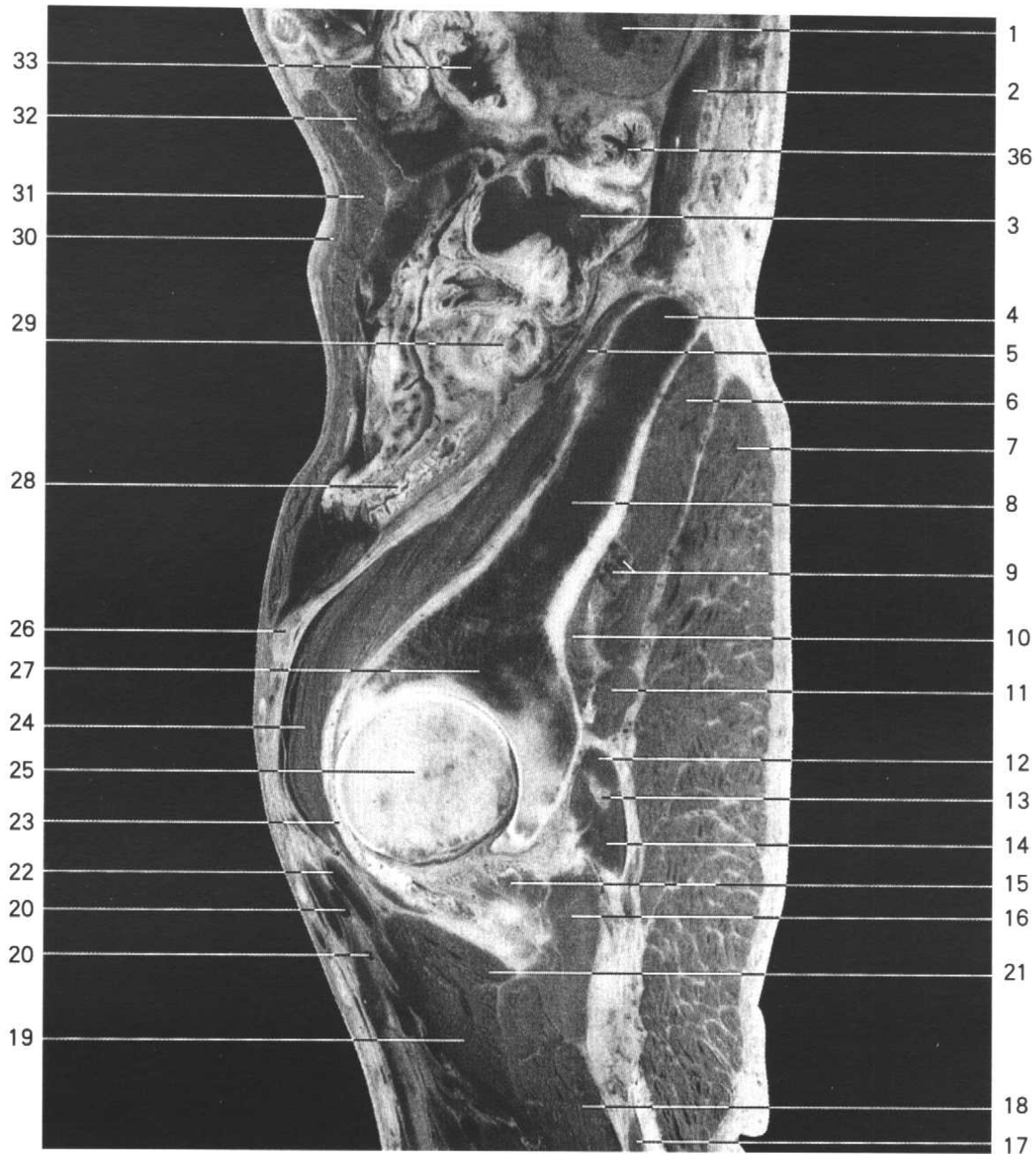
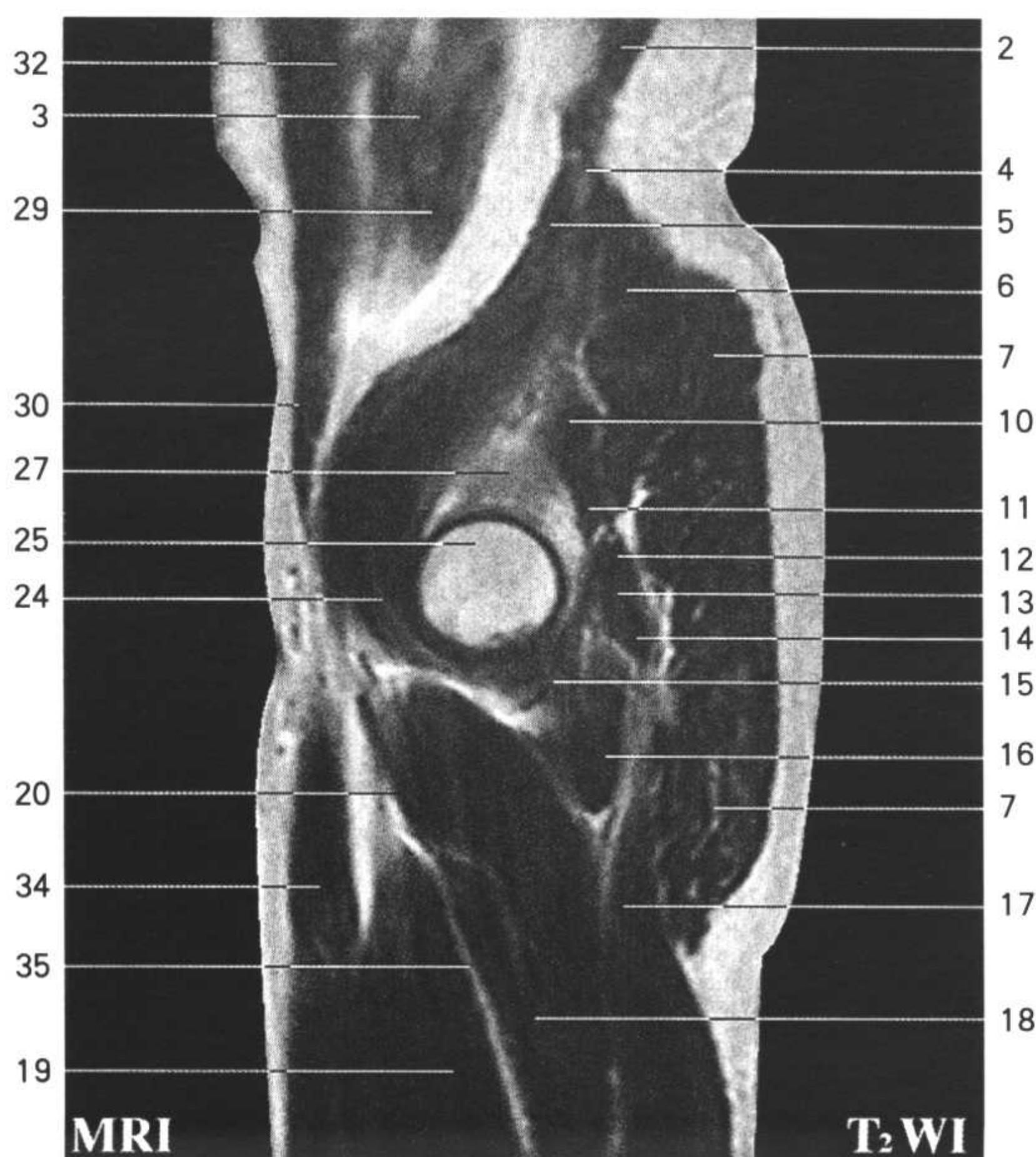
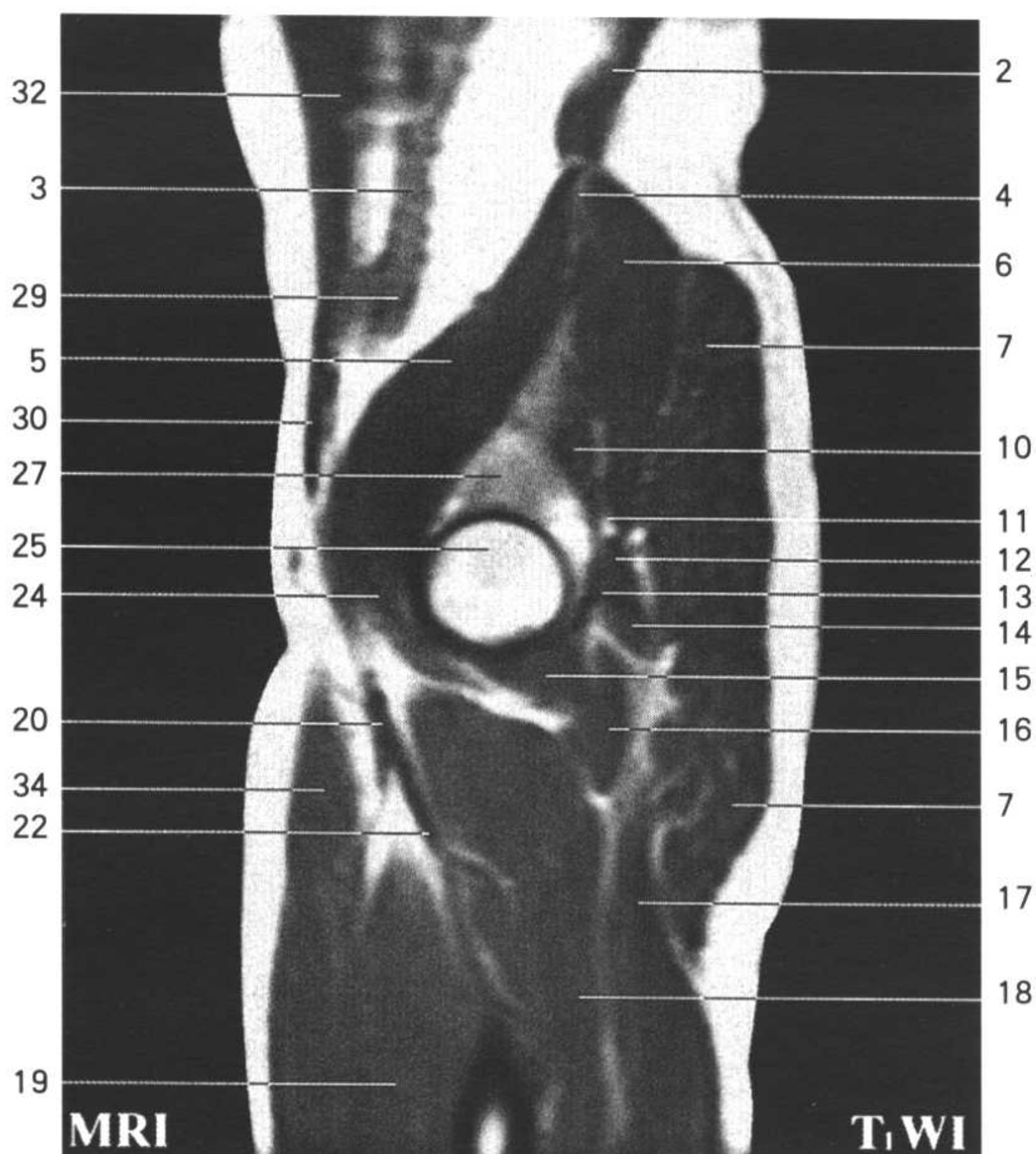


Fig.SPm 2

1. 右肾 right kidney
2. 腰方肌 quadratus lumborum
3. 升结肠 ascending colon
4. 髂嵴 iliac crest
5. 髂肌 iliacus
6. 臀中肌 gluteus medius
7. 臀大肌 gluteus maximus
8. 髂骨翼 ala of ilium
9. 臀上动脉 superior gluteal a.
10. 臀小肌 gluteus minimus

11. 梨状肌 piriformis
12. 上孖肌 gemellus superior
13. 闭孔内肌腱 tendon of obturator internus
14. 下孖肌 gemellus inferior
15. 闭孔外肌 obturator externus
16. 股方肌 quadratus femoris
17. 半腱肌 semitendinosus
18. 大收肌 adductor magnus
19. 长收肌 adductor longus
20. 股动脉 femoral a.
21. 短收肌 adductor brevis
22. 股深动脉 deep femoral a.
23. 关节囊 articular capsule
24. 髂腰肌 iliopsoas
25. 股骨头 femoral head
26. 腹股沟韧带 inguinal ligament
27. 髌骨体 body of ilium
28. 回肠 ileum
29. 盲肠 cecum
30. 腹外斜肌 obliquus externus abdominis
31. 腹内斜肌 obliquus internus abdominis
32. 腹横肌 transversus abdominis
33. 横结肠 transverse colon
34. 缝匠肌 sartorius
35. 肌间隔 intermuscular septum
36. 升结肠 ascending colon



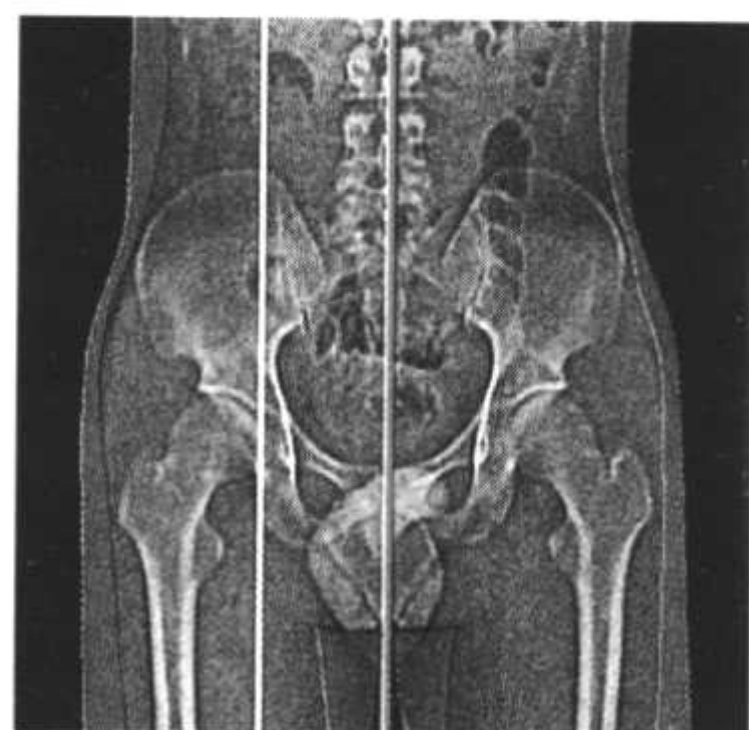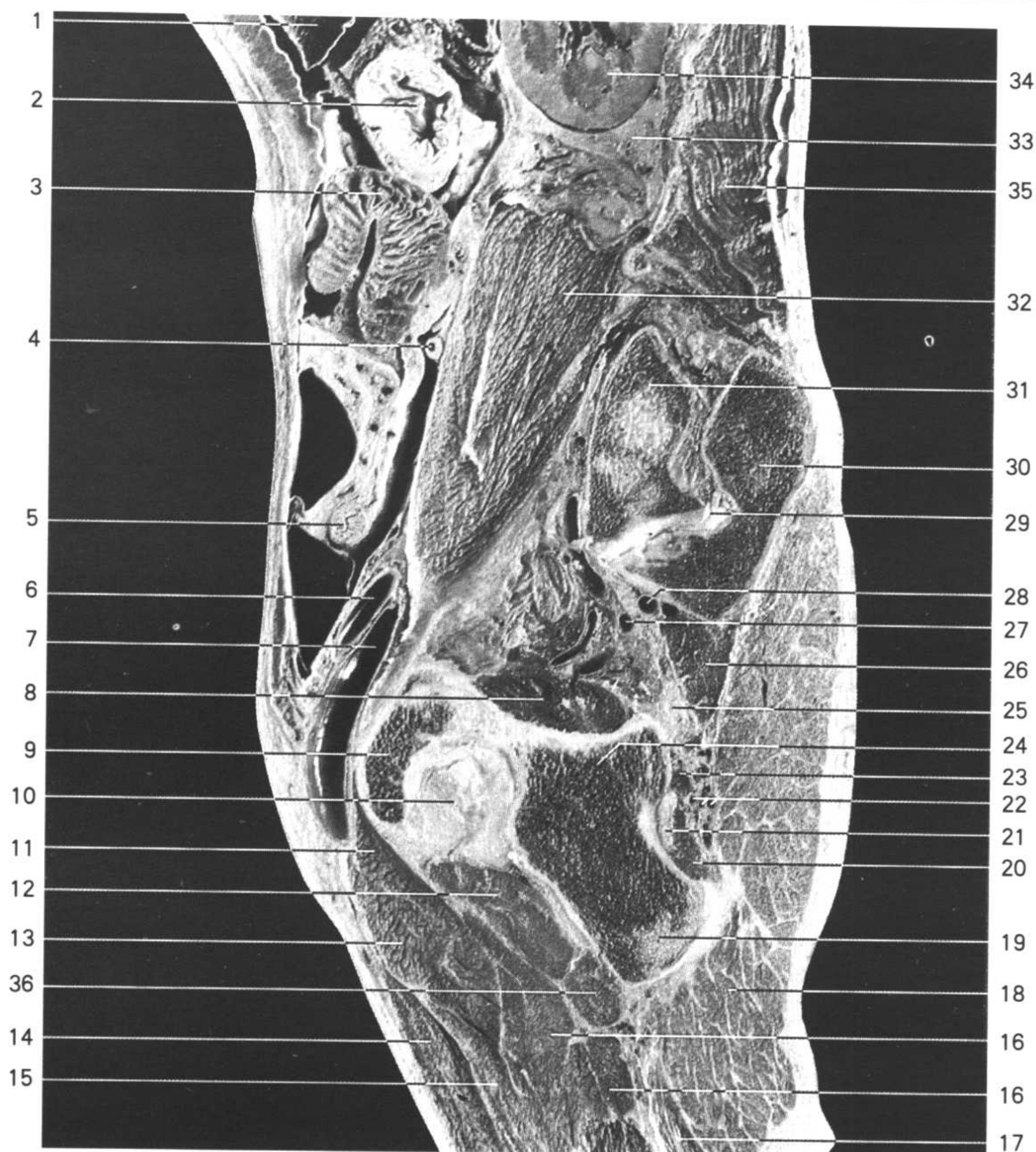


Fig.SPm 3

1. 胆囊 gallbladder
2. 横结肠 transverse colon
3. 回肠 ileum
4. 阑尾 vermiform appendix
5. 回肠 ileum
6. 右髂外动脉 right external iliac a.
7. 右髂外静脉 right external iliac v.
8. 闭孔内肌 obturator internus
9. 耻骨体 body of pubis
10. 股骨头 femoral head

11. 耻骨肌 pectineus
12. 闭孔外肌 obturator externus
13. 耻骨肌 pectineus
14. 长收肌 adductor longus
15. 短收肌 adductor brevis
16. 大收肌 adductor magnus
17. 半腱肌 semitendinosus
18. 臀大肌 gluteus maximus
19. 坐骨结节 ischial tuberosity
20. 下孖肌 gemellus inferior
21. 闭孔内肌腱 tendon of obturator internus
22. 臀下动脉、静脉 inferior gluteal a. and v.
23. 上孖肌 gemellus superior
24. 坐骨体 body of ischium
25. 坐骨神经 ischial n.
26. 梨状肌 piriformis
27. 臀下动脉 inferior gluteal a.
28. 臀上动脉 superior gluteal a.
29. 骶髂关节 sacroiliac joint
30. 髌骨 ilium
31. 骶骨 sacrum
32. 腰大肌 psoas major
33. 脂肪囊 fatty renal capsule
34. 右肾 right kidney
35. 竖脊肌 erector spinae
36. 股方肌 quadratus femoris
37. 髌骨体 body of ilium
38. 髌肌 iliacus
39. 腰方肌 quadratus lumborum
40. 缝匠肌 sartorius
41. 臀中肌 gluteus medius

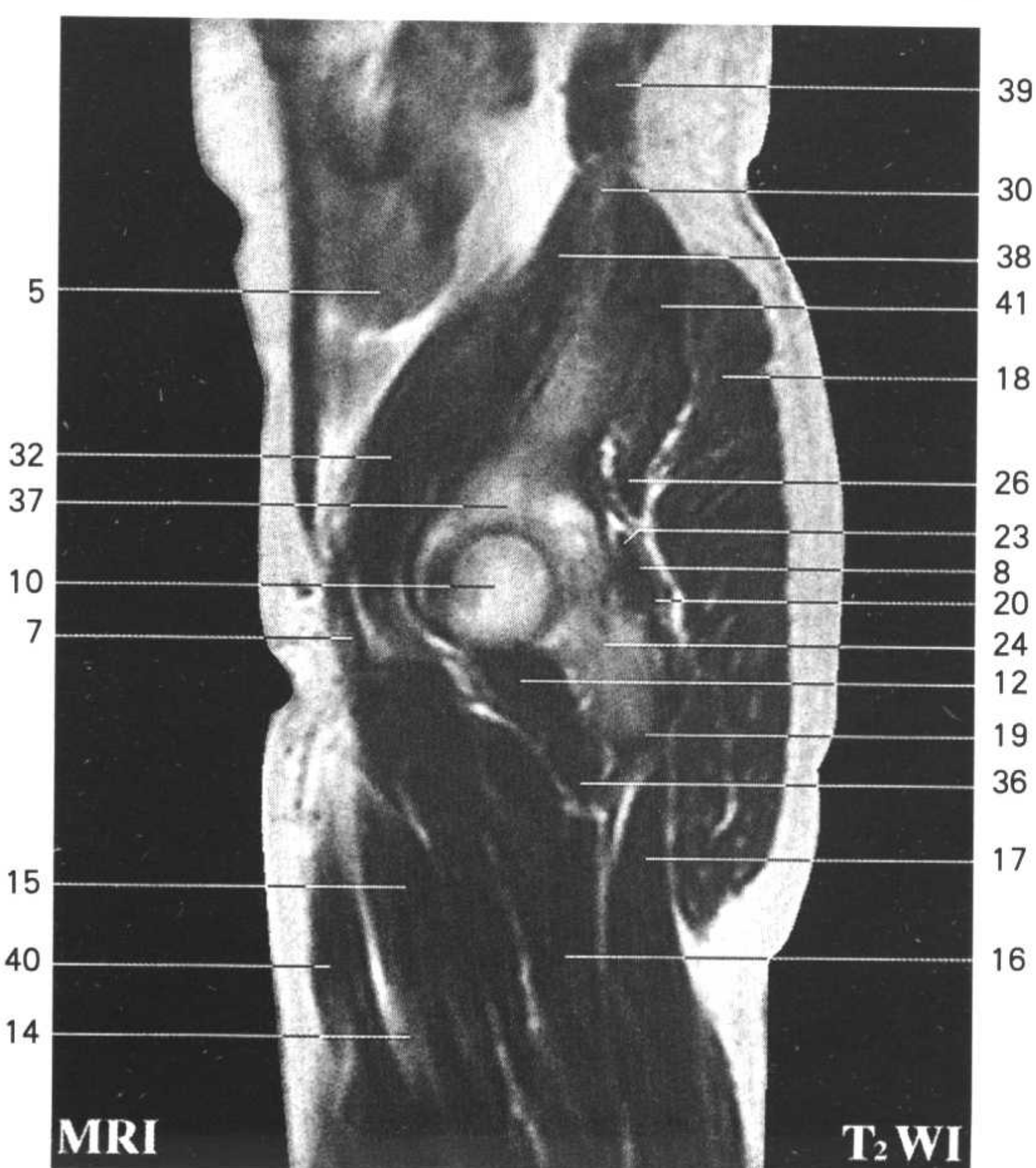
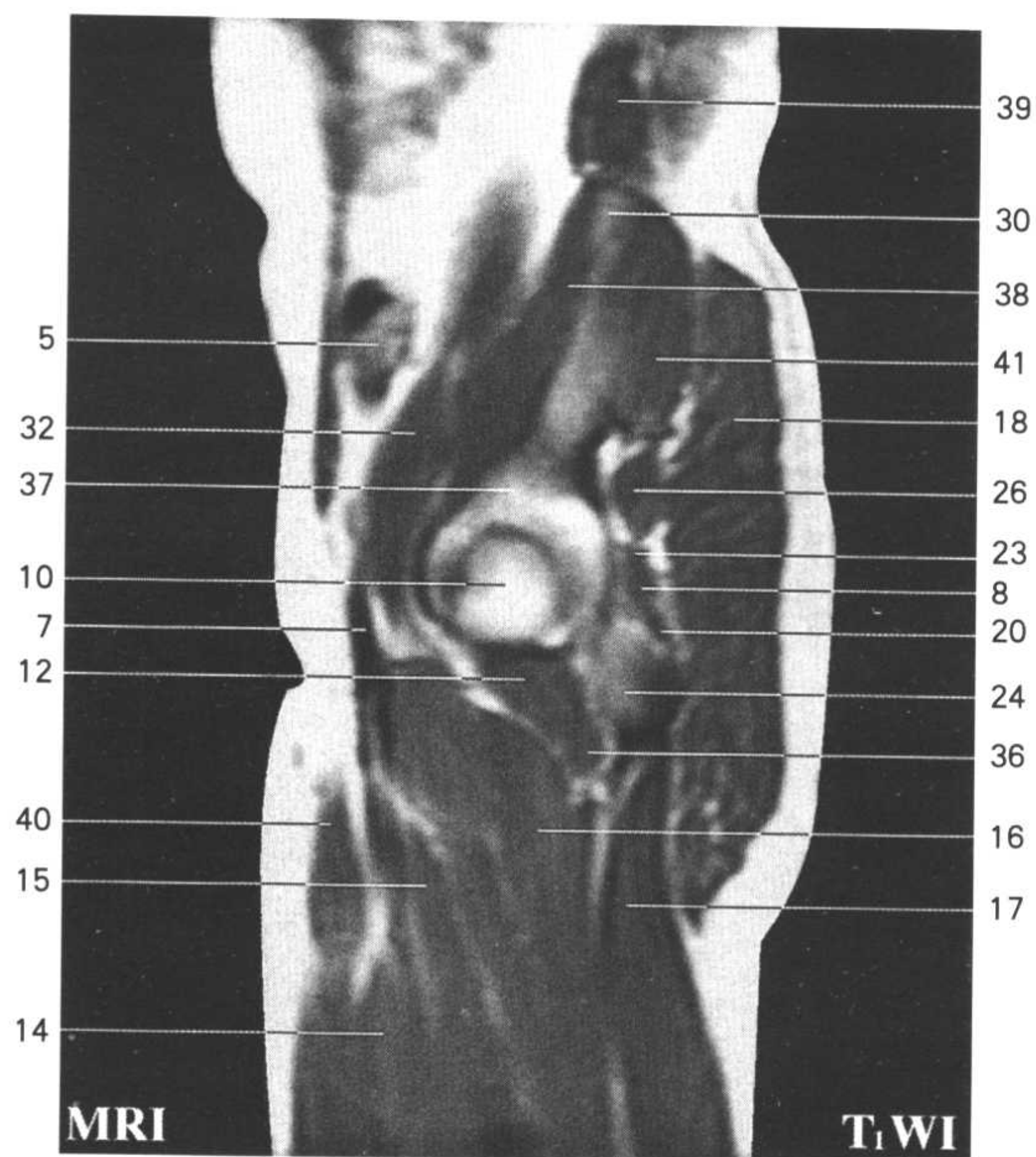
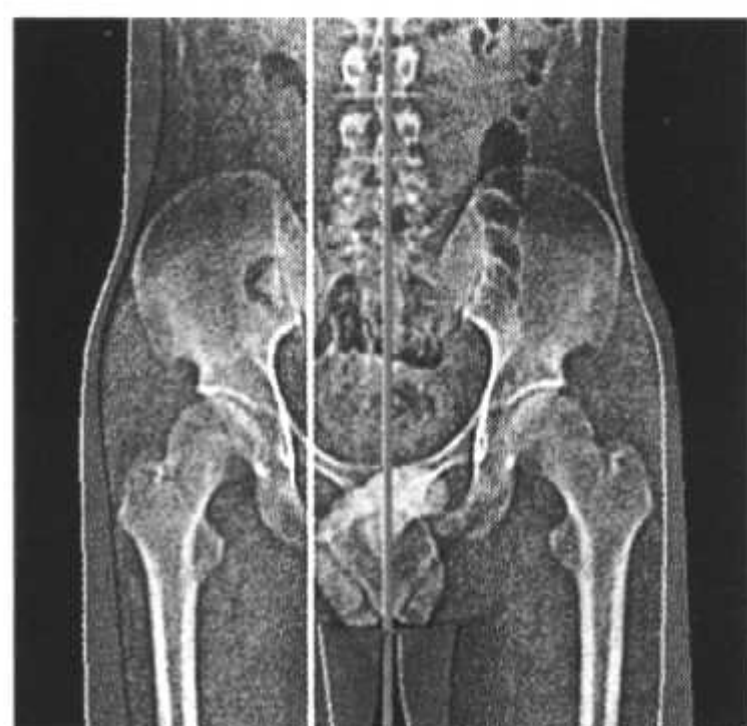
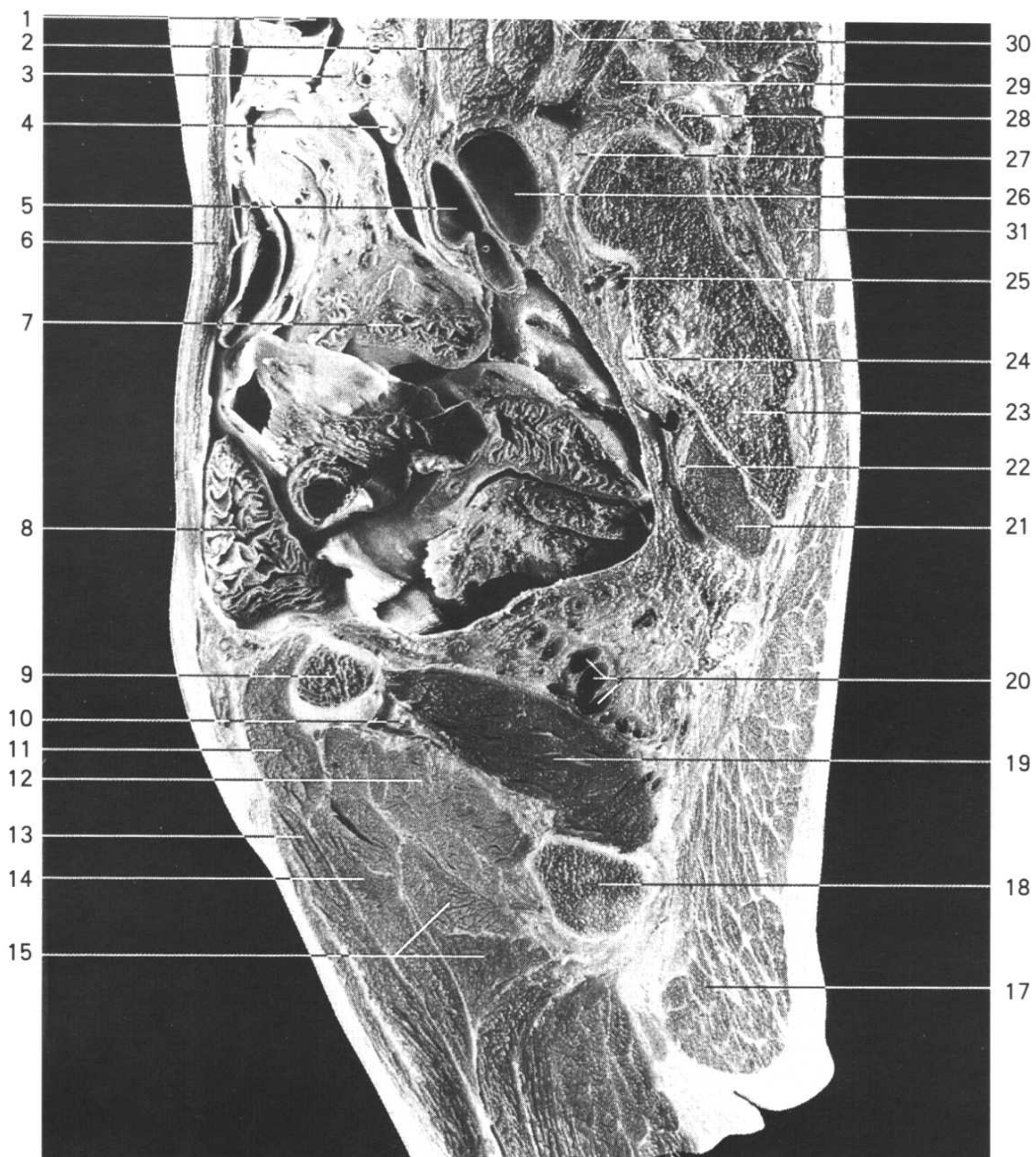
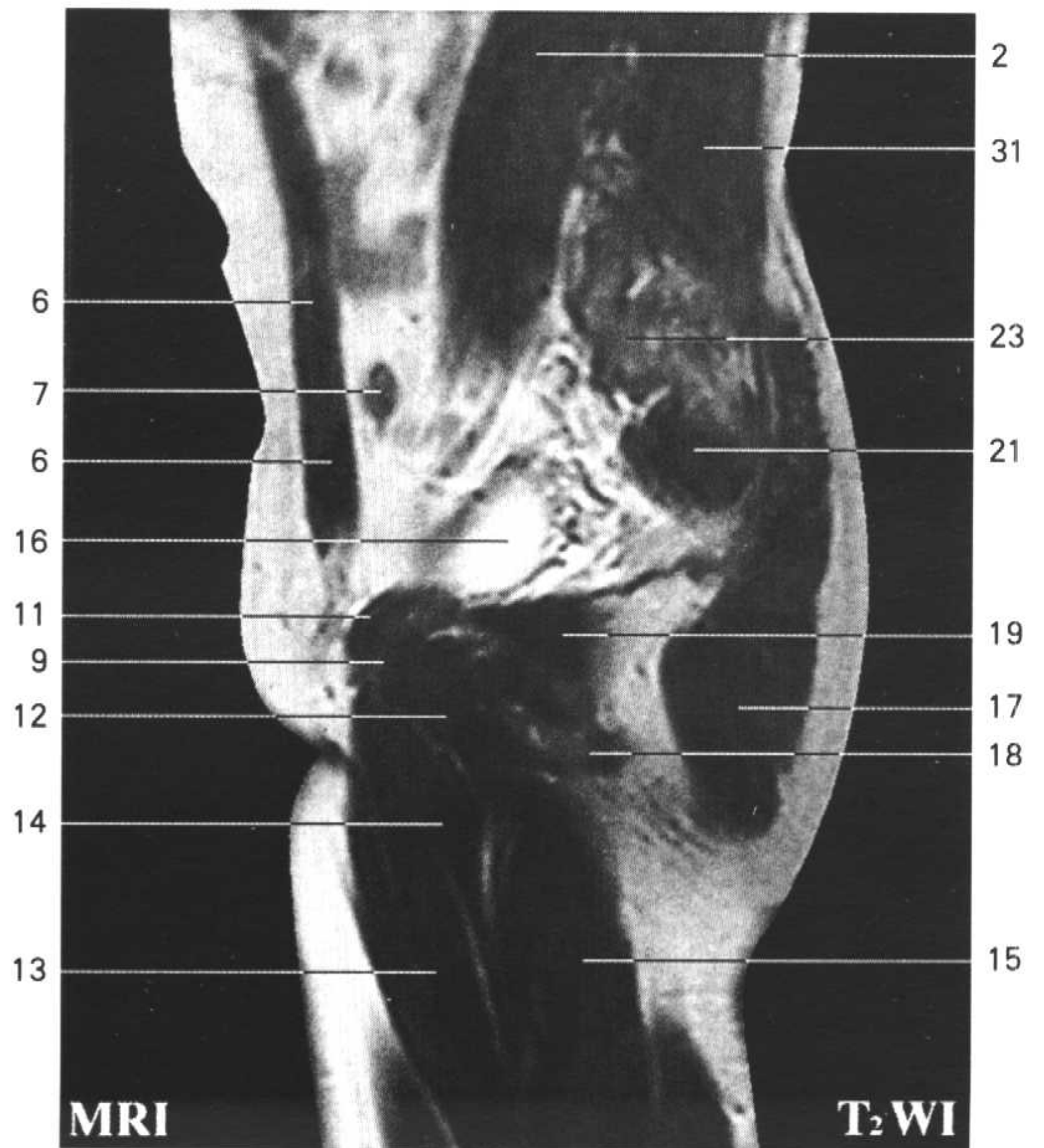
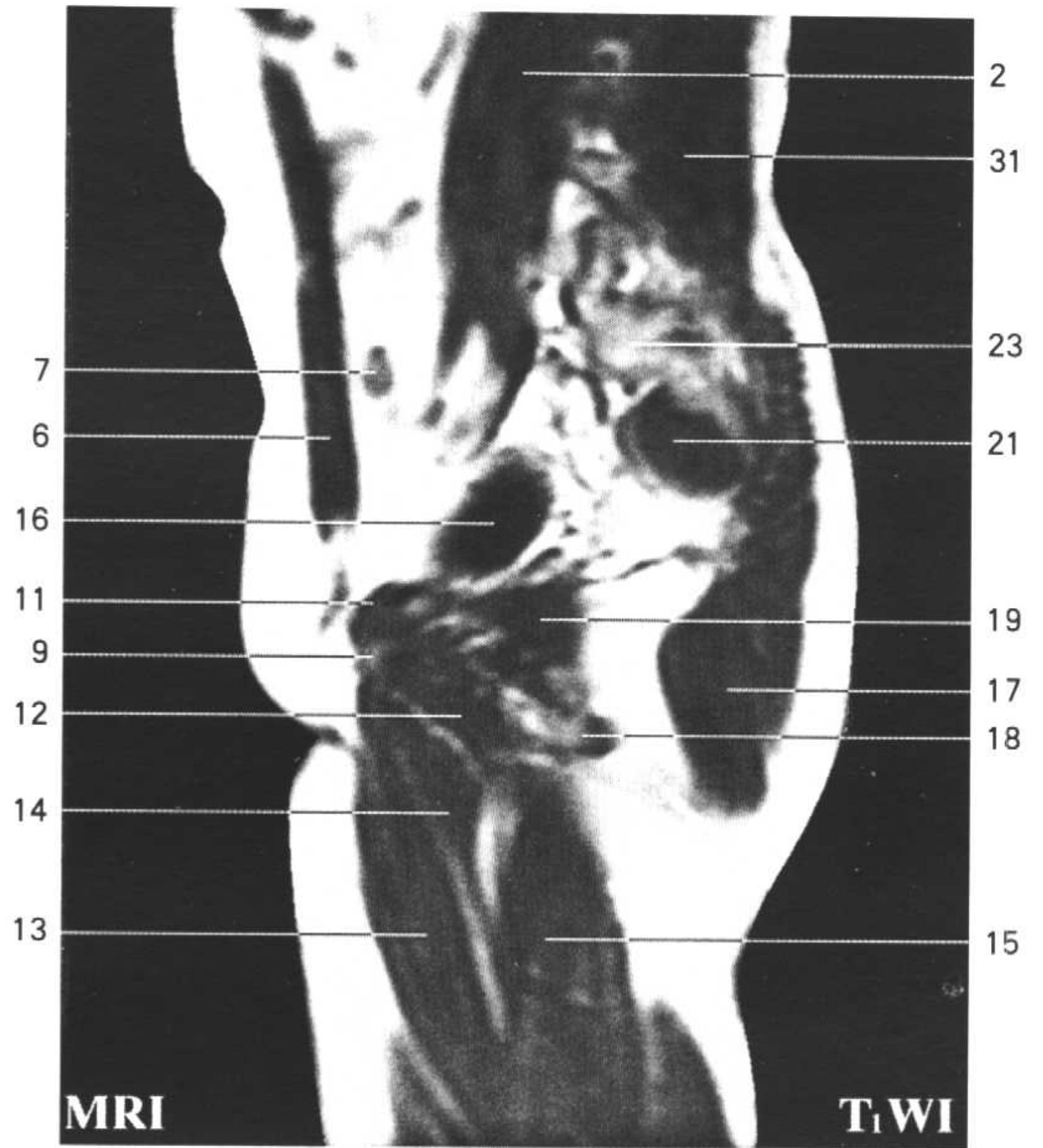
Fig.SPm 4

1. 横结肠 transverse colon
2. 腰大肌 psoas major
3. 肠系膜淋巴结 mesenteric lymph nodes
4. 阑尾 vermiform appendix
5. 右髂总动脉 right common iliac a.
6. 腹直肌 rectus abdominis
7. 回肠 ileum
8. 回肠 ileum
9. 耻骨上支 superior ramus of pubis
10. 闭孔动、静脉 obturator a. and v.

11. 耻骨肌 pectineus
12. 闭孔外肌 obturator externus
13. 长收肌 adductor longus
14. 短收肌 adductor brevis
15. 大收肌 adductor magnus
16. 膀胱 urinary bladder
17. 臀大肌 gluteus maximus
18. 坐骨支 ramus of ischium
19. 闭孔内肌 obturator internus
20. 膀胱静脉丛 vesical venous plexus
21. 梨状肌 piriformis
22. 第3骶神经 3rd sacral n.
23. 骶骨 sacrum
24. 第2骶神经 2nd sacral n.
25. 骶外侧动脉 lateral sacral a.
26. 右髂总静脉 right common iliac v.
27. 第5腰神经 5th lumbar n.
28. 髌骨 ilium
29. 第5腰椎横突 transverse process(L₅)
30. 股神经 femoral n.
31. 竖脊肌 erector spinae



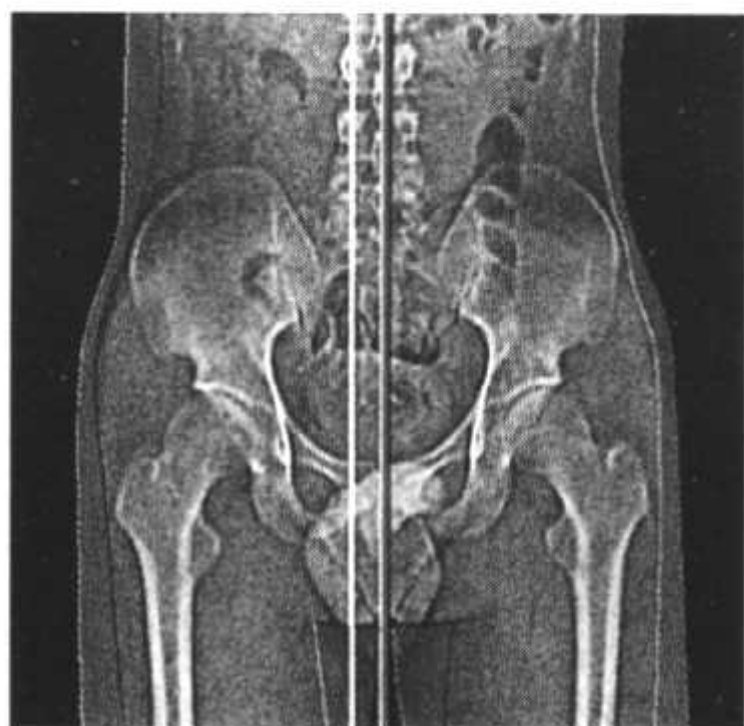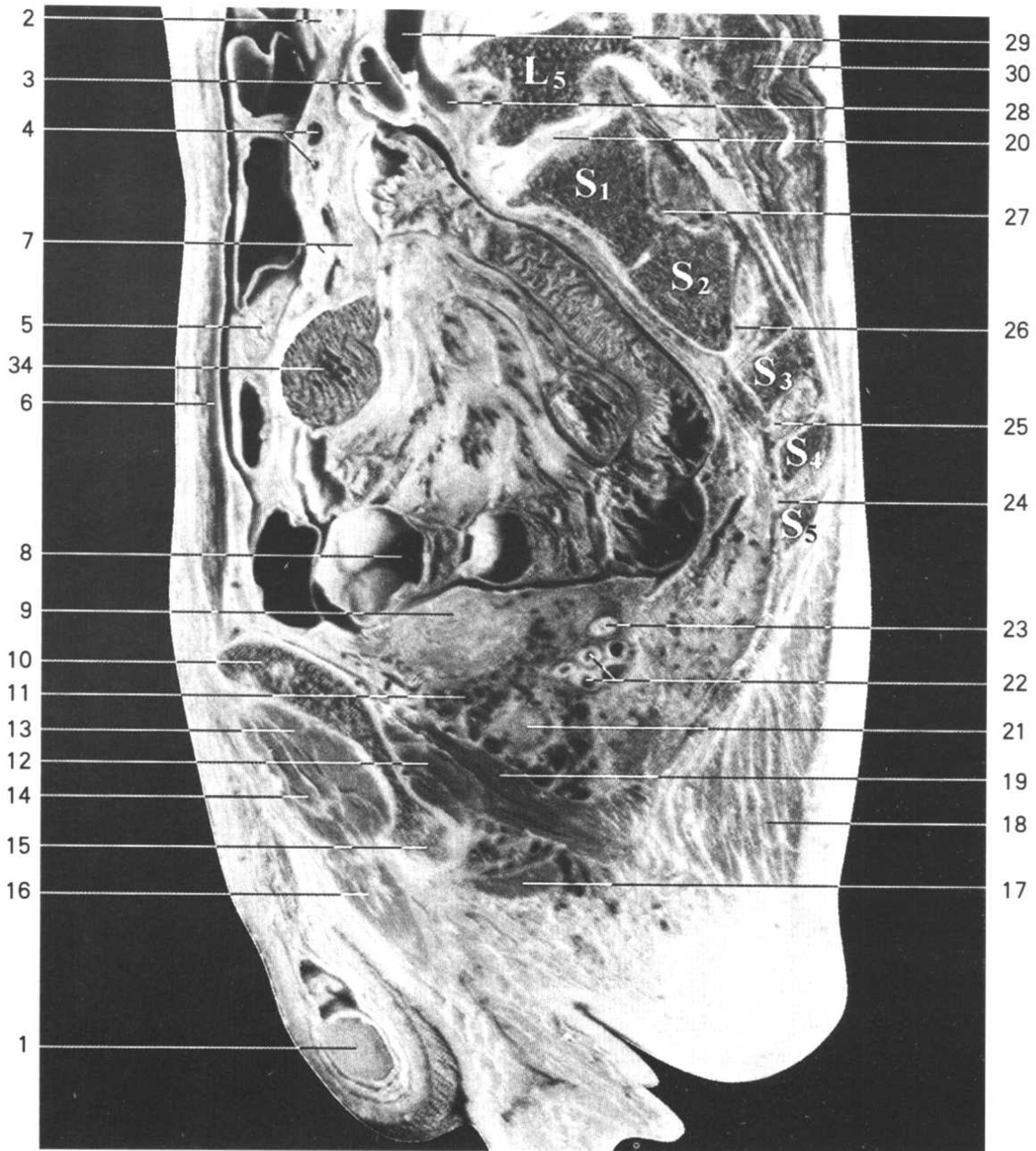
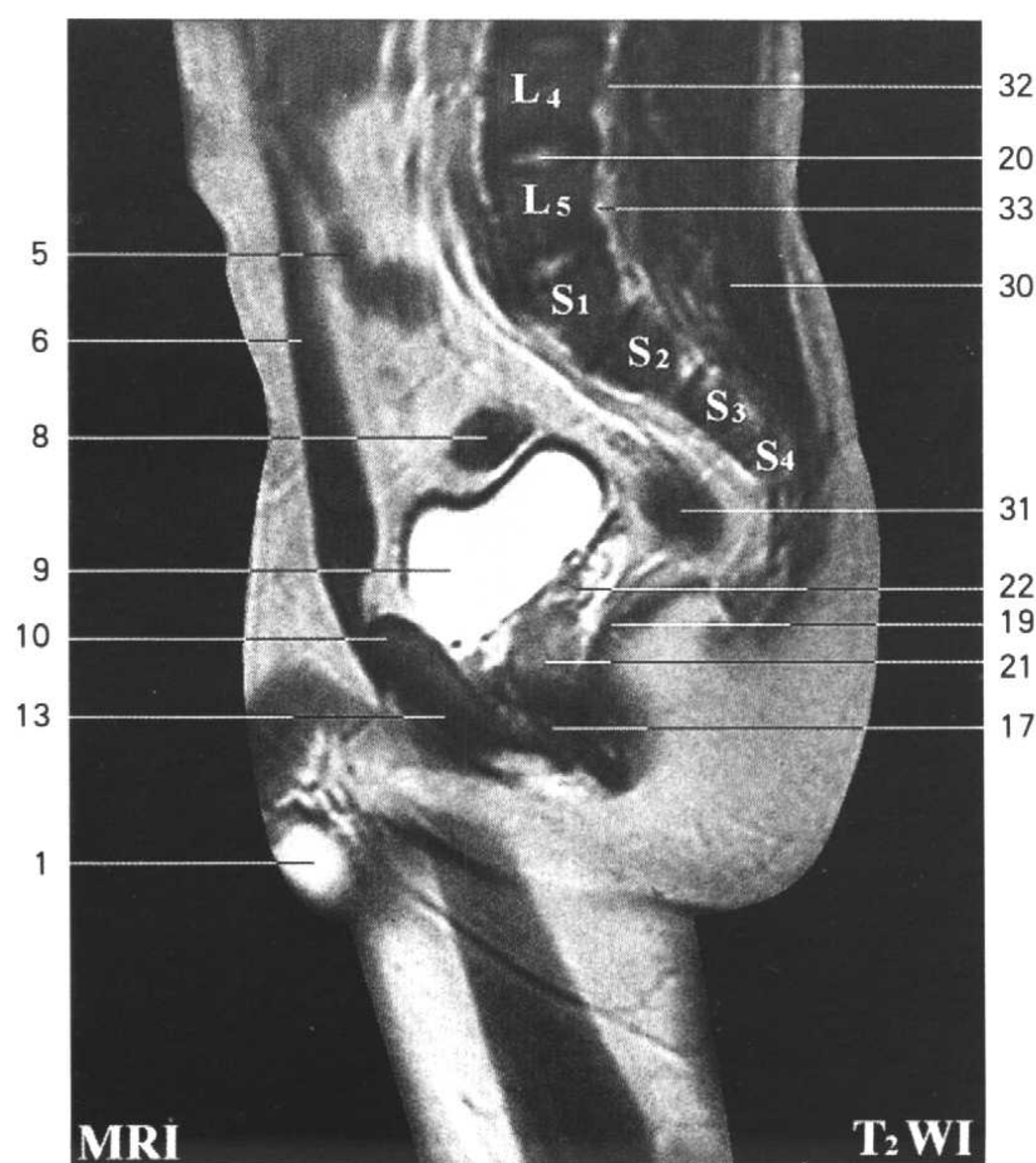
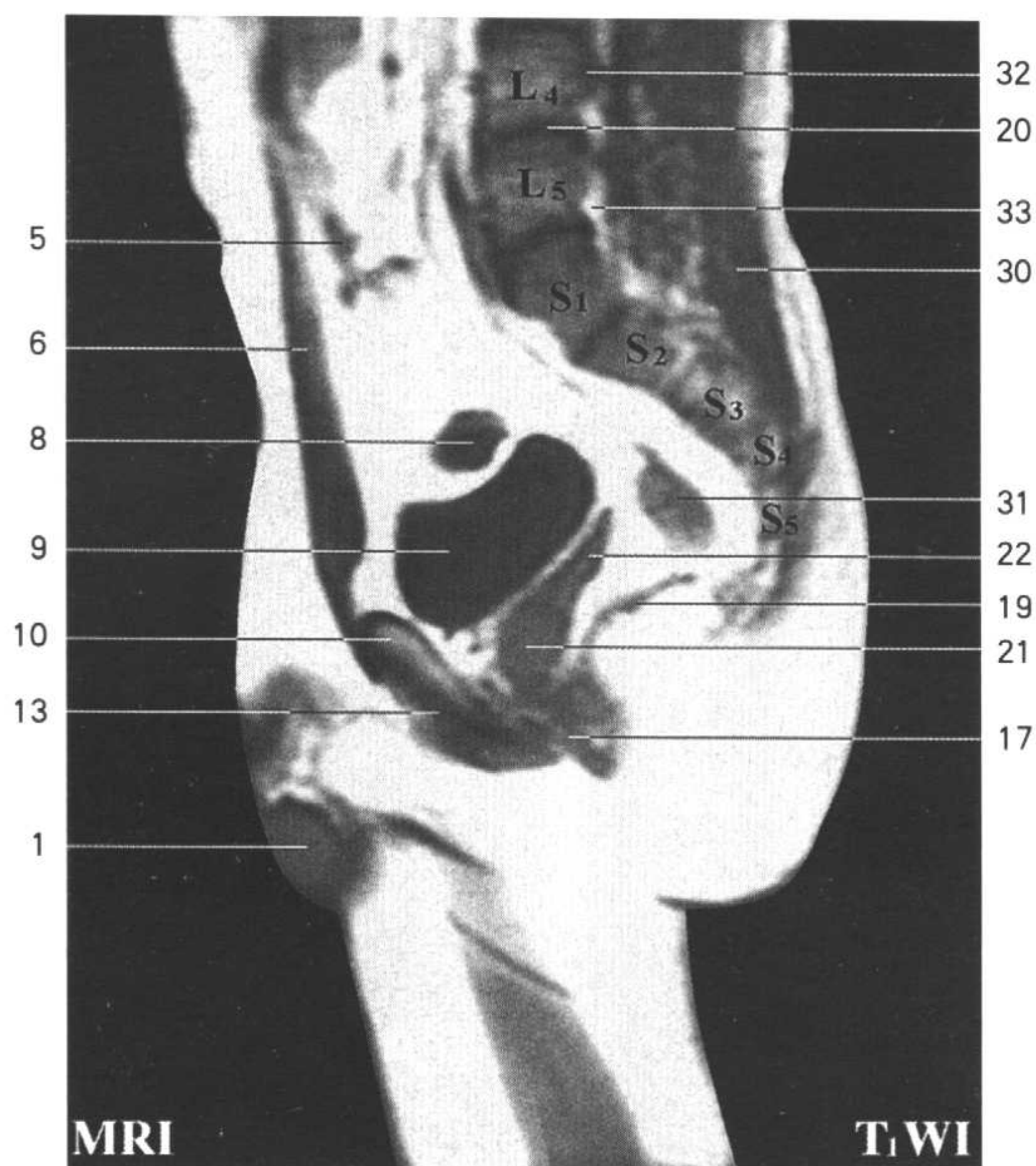


Fig.SPM 5

1. 睾丸 testis
2. 肠系膜淋巴结 mesenteric lymph nodes
3. 右髂总动脉 right common iliac a.
4. 肠系膜动、静脉 mesenteric a. and v.
5. 回肠 ileum
6. 腹直肌 rectum abdominis
7. 肠系膜 mesentery
8. 乙状结肠 sigmoid colon
9. 膀胱 urinary bladder
10. 耻骨上支 superior ramus of pubis

11. 膀胱静脉丛 vesical venous plexus
12. 闭孔内肌 obturator internus
13. 闭孔外肌 obturator externus
14. 耻骨肌 pectineus
15. 耻骨下支 inferior ramus of pubis
16. 长收肌 adductor longus
17. 球海绵体肌 bulbocavernosus
18. 臀大肌 gluteus maximus
19. 肛提肌 levator ani
20. 椎间盘 intervertebral disc
21. 前列腺 prostate
22. 精囊 seminal vesicle
23. 输精管壶腹 ampulla ductus deferentis
24. 第4骶神经 4th sacral n.
25. 第3骶神经 3rd sacral n.
26. 第2骶神经 2nd sacral n.
27. 第1骶神经 1st sacral n.
28. 右髂总静脉 right common iliac v.
29. 下腔静脉 inferior vena cava
30. 竖脊肌 erector spinae
31. 直肠 rectum
32. 椎弓根 pedicle of vertebral arch
33. 椎间孔 intervertebral foramina
34. 空肠 jejunum



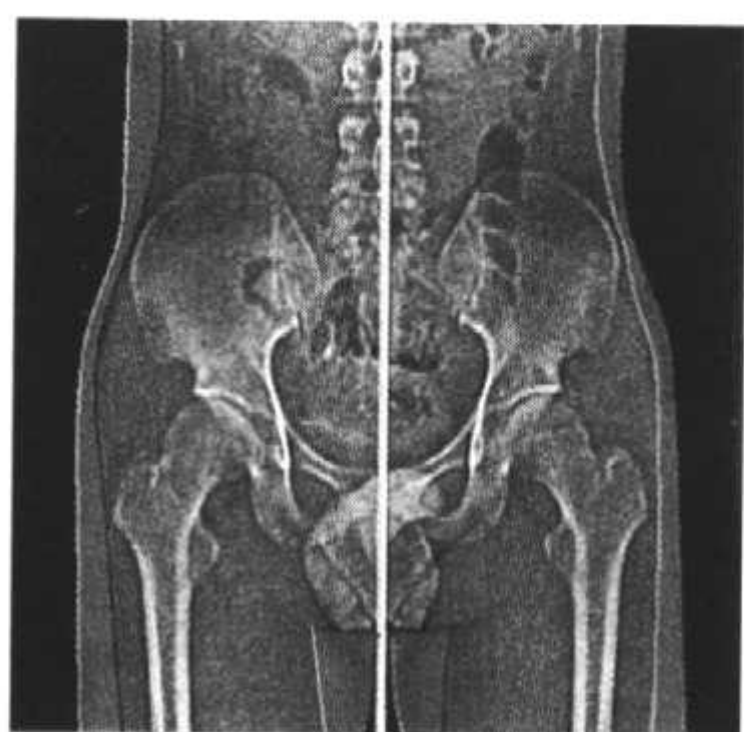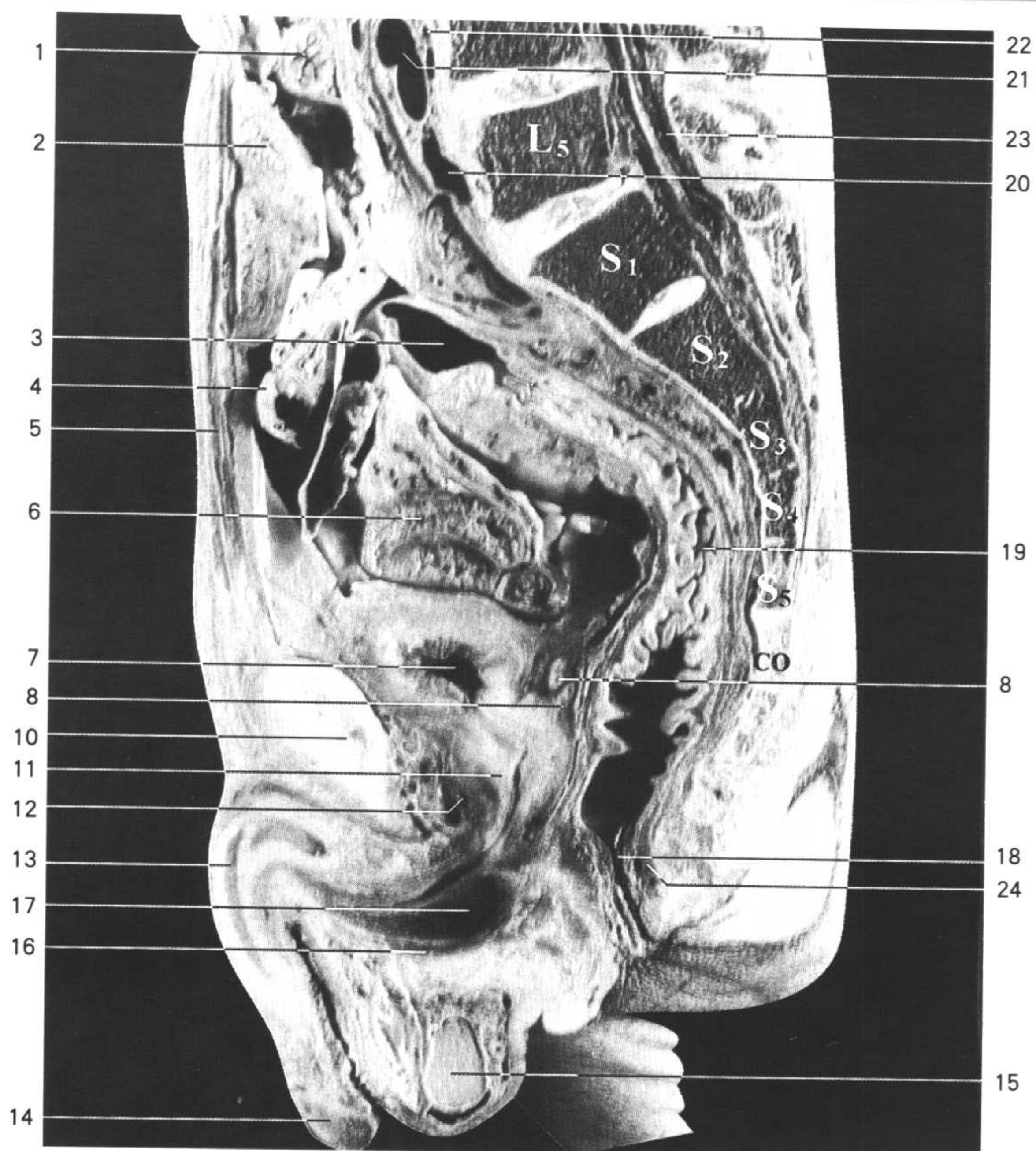
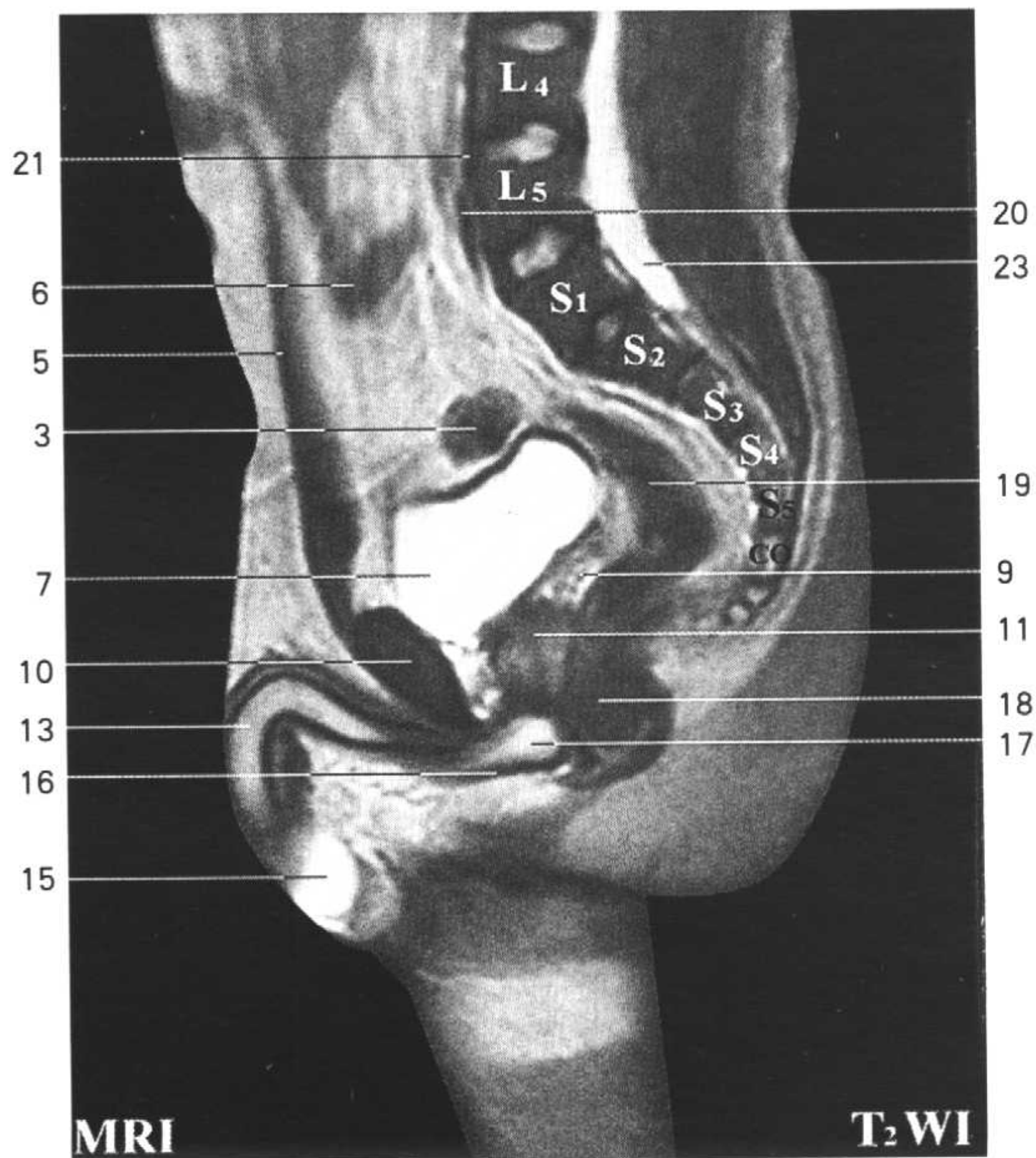
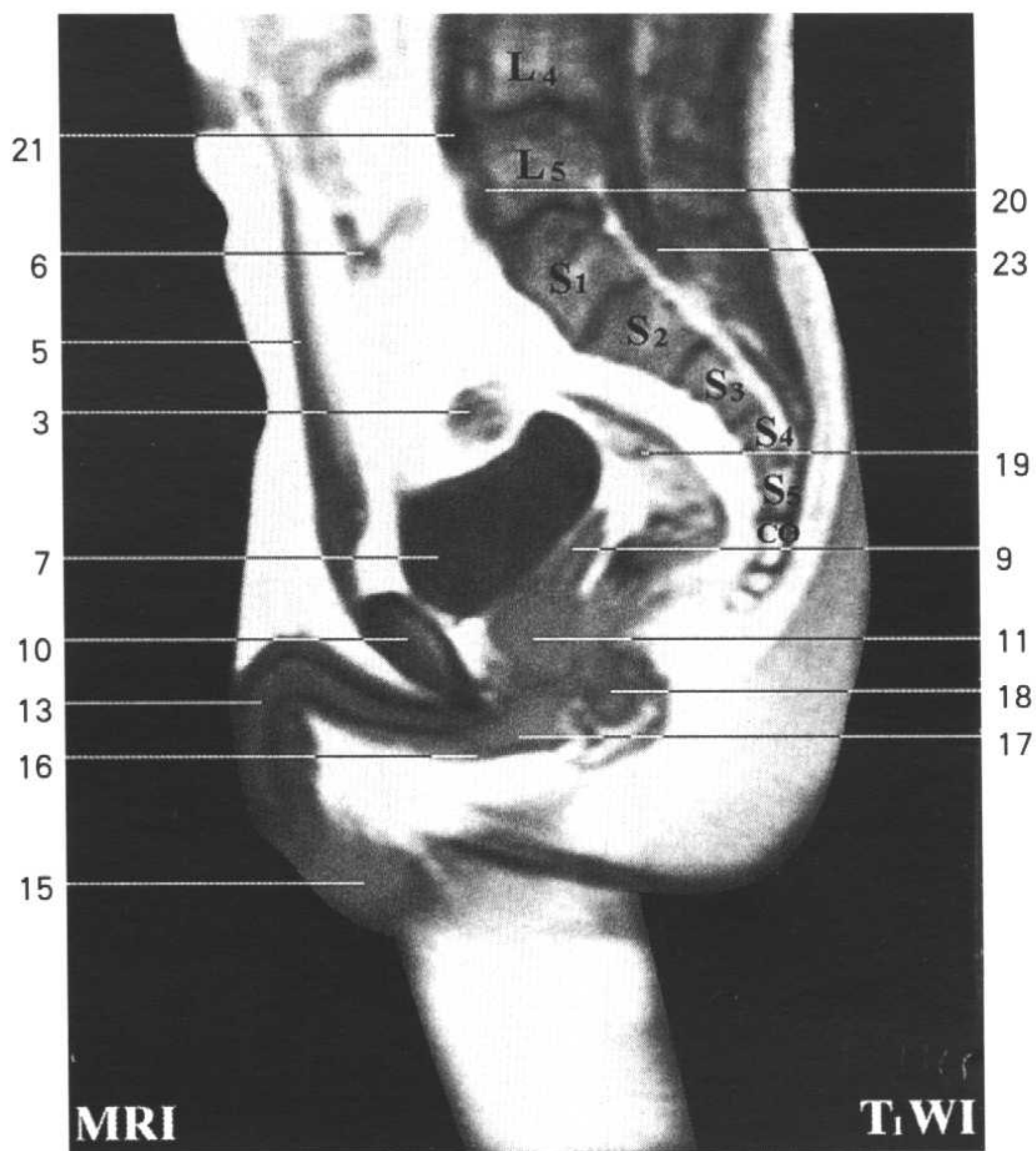
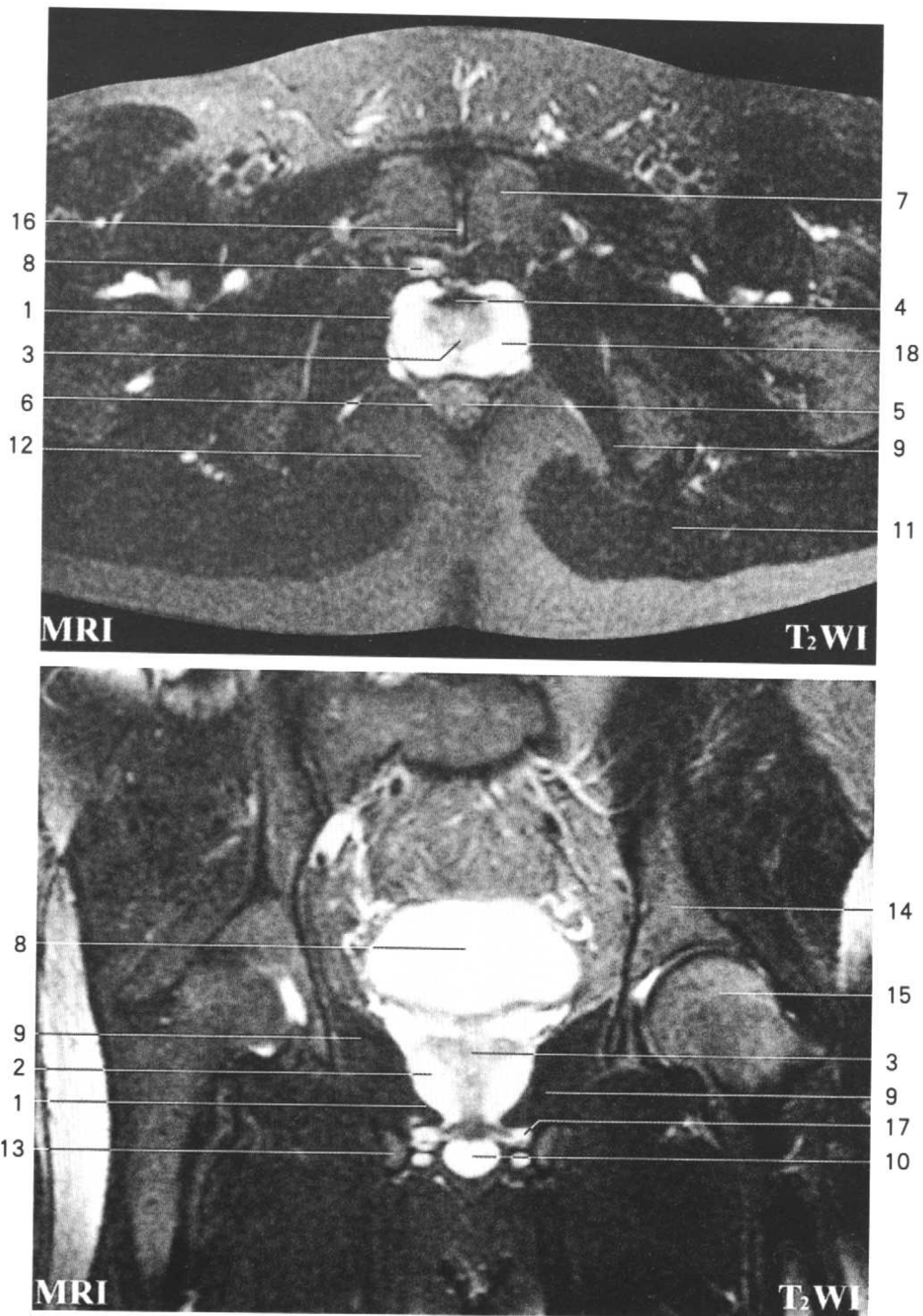


Fig.SPm 6

1. 空肠 jejunum
2. 空肠 jejunum
3. 乙状结肠 sigmoid colon
4. 大网膜 greater omentum
5. 腹直肌 rectus abdominis
6. 回肠 ileum
7. 膀胱 urinary bladder
8. 输精管壶腹 ampulla ductus deferentis
9. 精囊 seminal vesicle

- 10. 耻骨联合 pubic symphysis
- 11. 前列腺 prostate
- 12. 前列腺静脉丛 prostatic venous plexus
- 13. 阴茎 penis
- 14. 阴茎头 glans penis
- 15. 睾丸 testis
- 16. 球海绵体肌 bulbocavernosus
- 17. 尿道球 bulb of urethra
- 18. 肛管 anal canal
- 19. 直肠 rectum
- 20. 右髂总静脉 right common iliac v.
- 21. 右髂总动脉 right common iliac a.
- 22. 腰动脉 lumbar a.
- 23. 骶管 sacral canal
- 24. 肛门外括约肌 sphincter ani externus





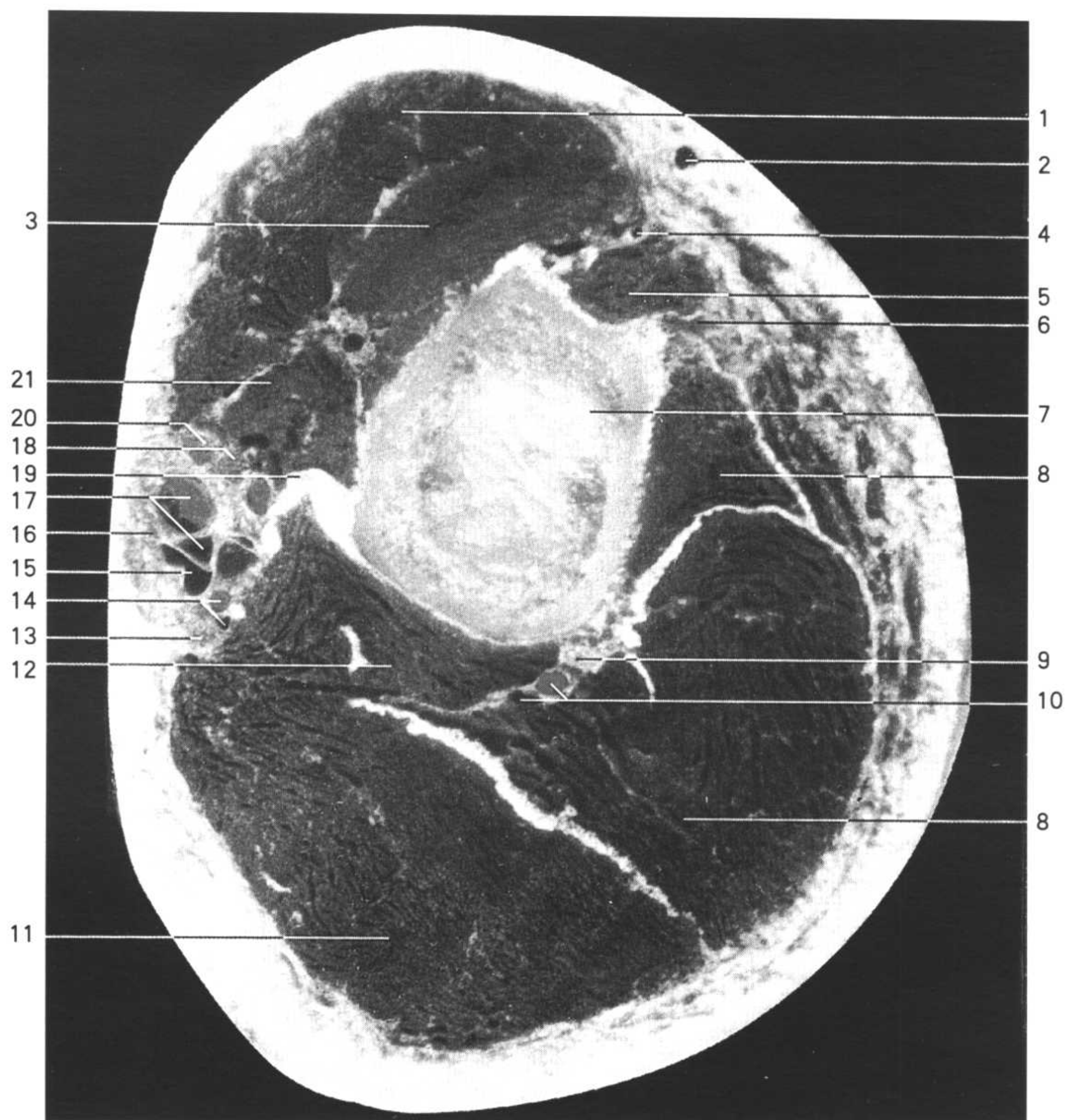
磁共振成像（前列腺）MRI

Fig.MRI

- | | |
|---|--|
| 1. 前列腺 [纤维] 囊 prostatic capsule | 9. 闭孔内肌 obturator internus |
| 2. 前列腺右叶 right lobe of prostate | 10. 尿道海绵体 cavernous body of urethra |
| 3. 前列腺中叶 middle lobe of prostate | 11. 臀大肌 gluteus maximus |
| 4. 前列腺肌质 muscular substance of prostate | 12. 坐骨肛门窝脂体 adipose body of ischioanal fossa |
| 5. 直肠 rectum | 13. 坐骨支 ramus of ischium |
| 6. 肛提肌 levator ani | 14. 髌骨体 body of ilium |
| 7. 耻骨 pubis | 15. 股骨头 femoral head |
| 8. 膀胱 urinary bladder | 16. 耻骨联合 pubic symphysis |
| | 17. 阴茎脚 crus penis |
| | 18. 前列腺左叶 left lobe of prostate |

LIMBS

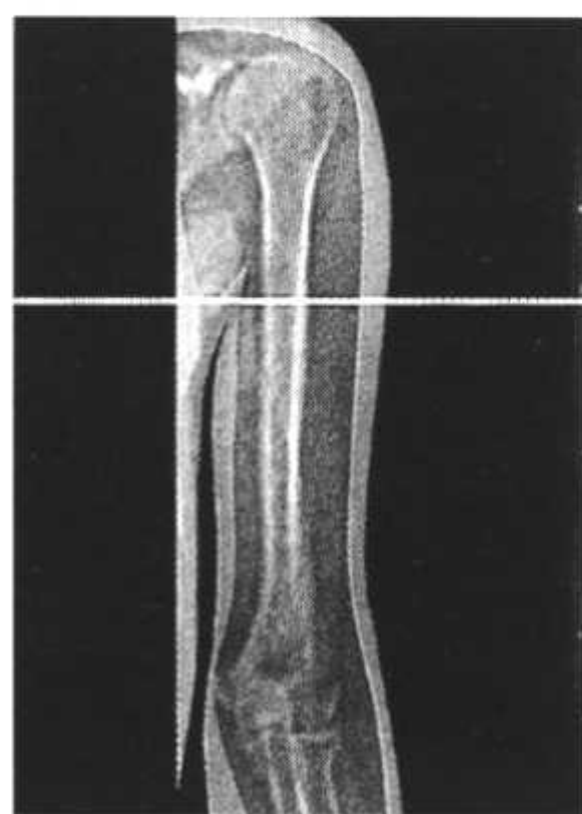
四肢部



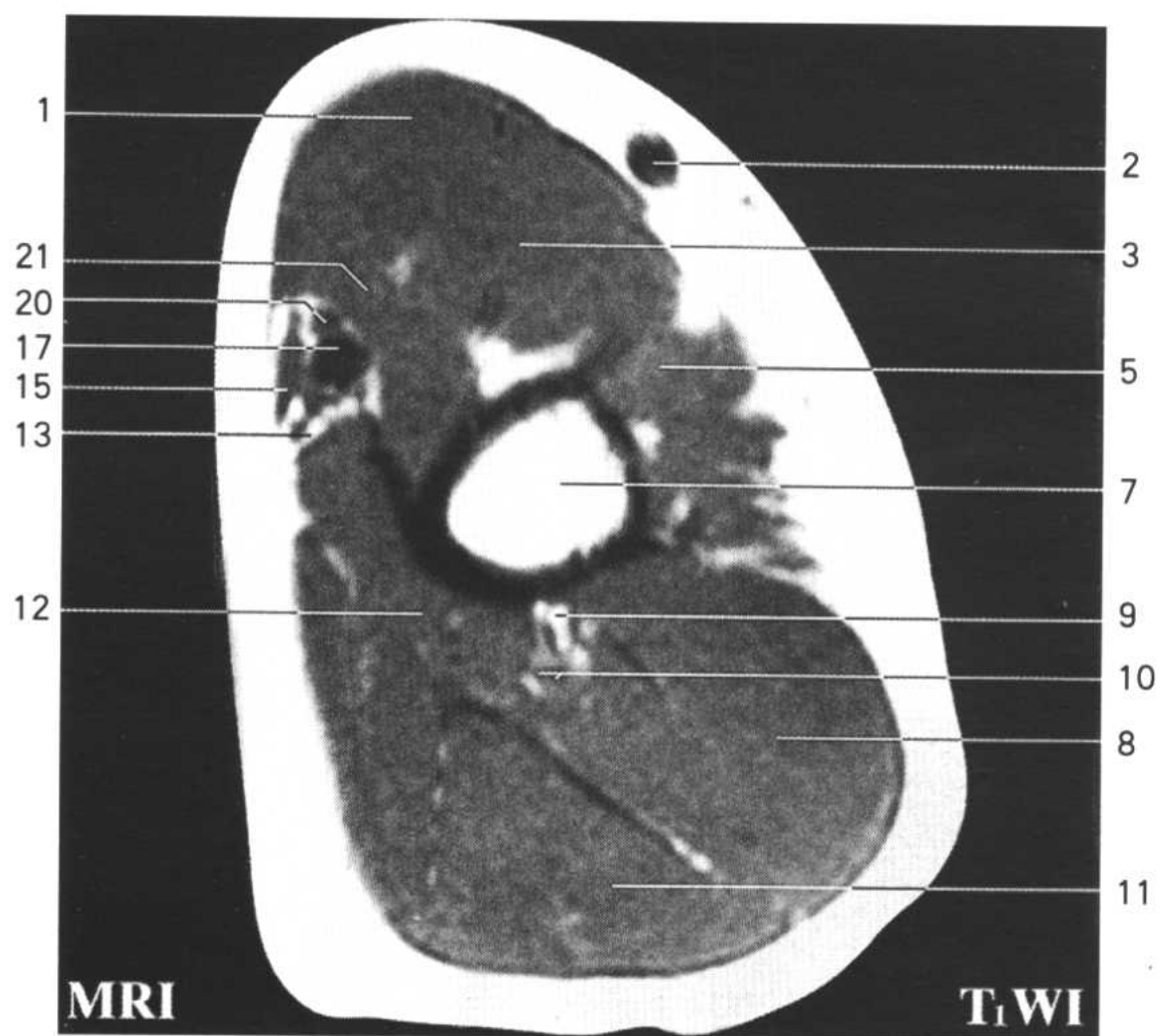
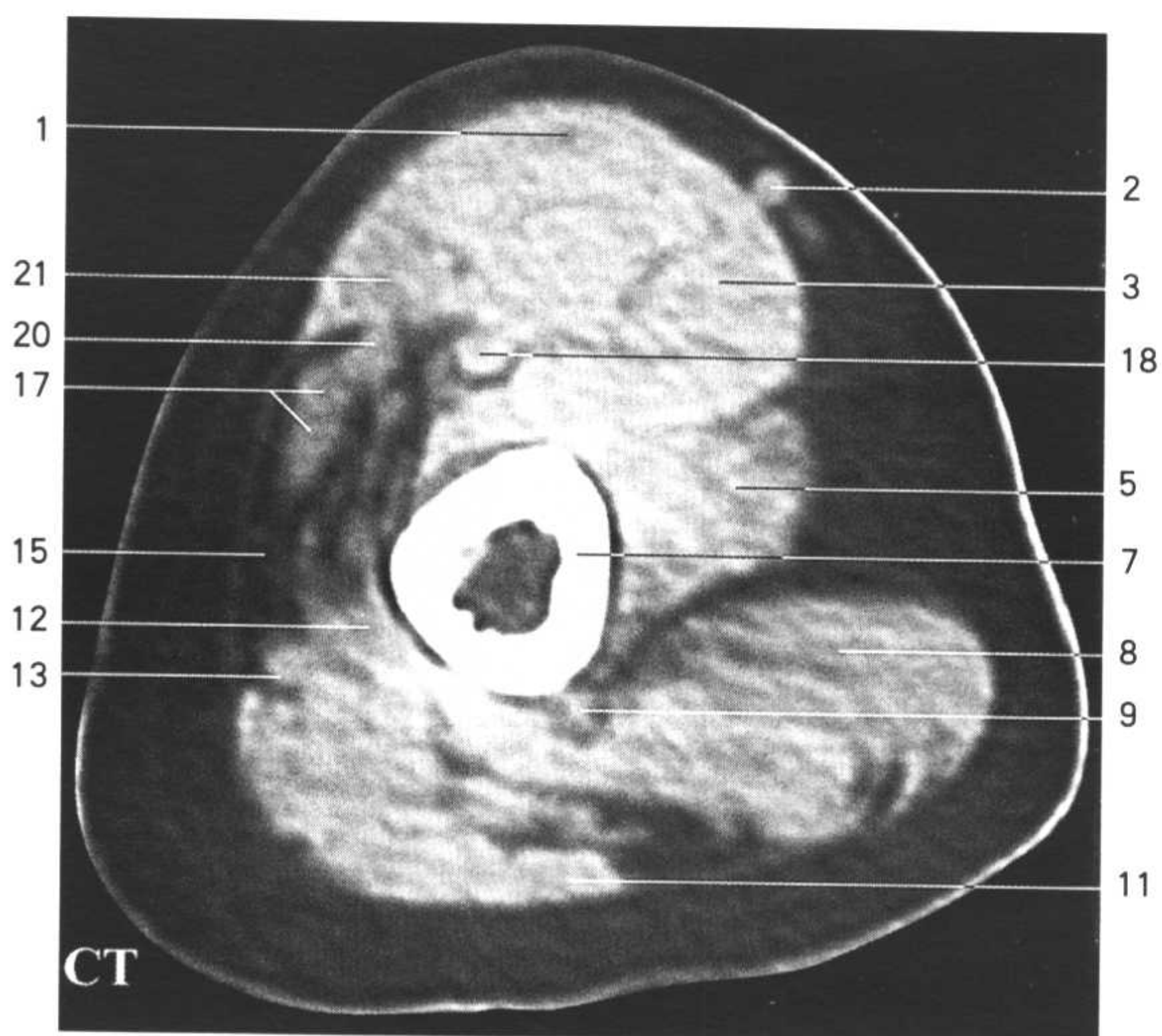
左上肢水平断面 HUL

Fig.HUL 1

1. 肱二头肌短头 short head of biceps brachii
2. 头静脉 cephalic v.
3. 肱二头肌长头 long head of biceps brachii
4. 肱深动脉三角肌支 deltoid branch of deep brachial a.
5. 三角肌 deltoid
6. 臂外侧肌间隔 lateral brachial intermuscular septum
7. 肱骨 humerus
8. 肱三头肌外侧头 lateral head of triceps brachii
9. 桡神经 radial n.
10. 肱深动、静脉 deep brachial a. and v.



11. 肱三头肌长头 long head of triceps brachii
12. 肱三头肌内侧头 medial head of triceps brachii
13. 尺神经 ulnar n.
14. 尺侧上副动、静脉 superior ulnar collateral a. and v.
15. 贵要静脉 basilic v.
16. 前臂内侧皮神经 medial antebrachial cutaneous n.
17. 肱动、静脉 brachial a. and v.
18. 肌皮神经 musculocutaneous n.
19. 臂内侧肌间隔 medial brachial intermuscular septum
20. 正中神经 median n.
21. 喙肱肌 coracobrachialis



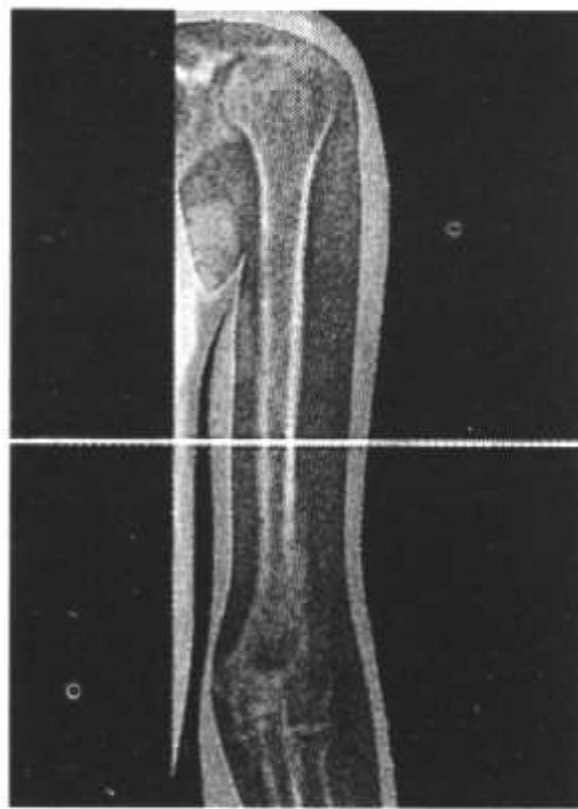
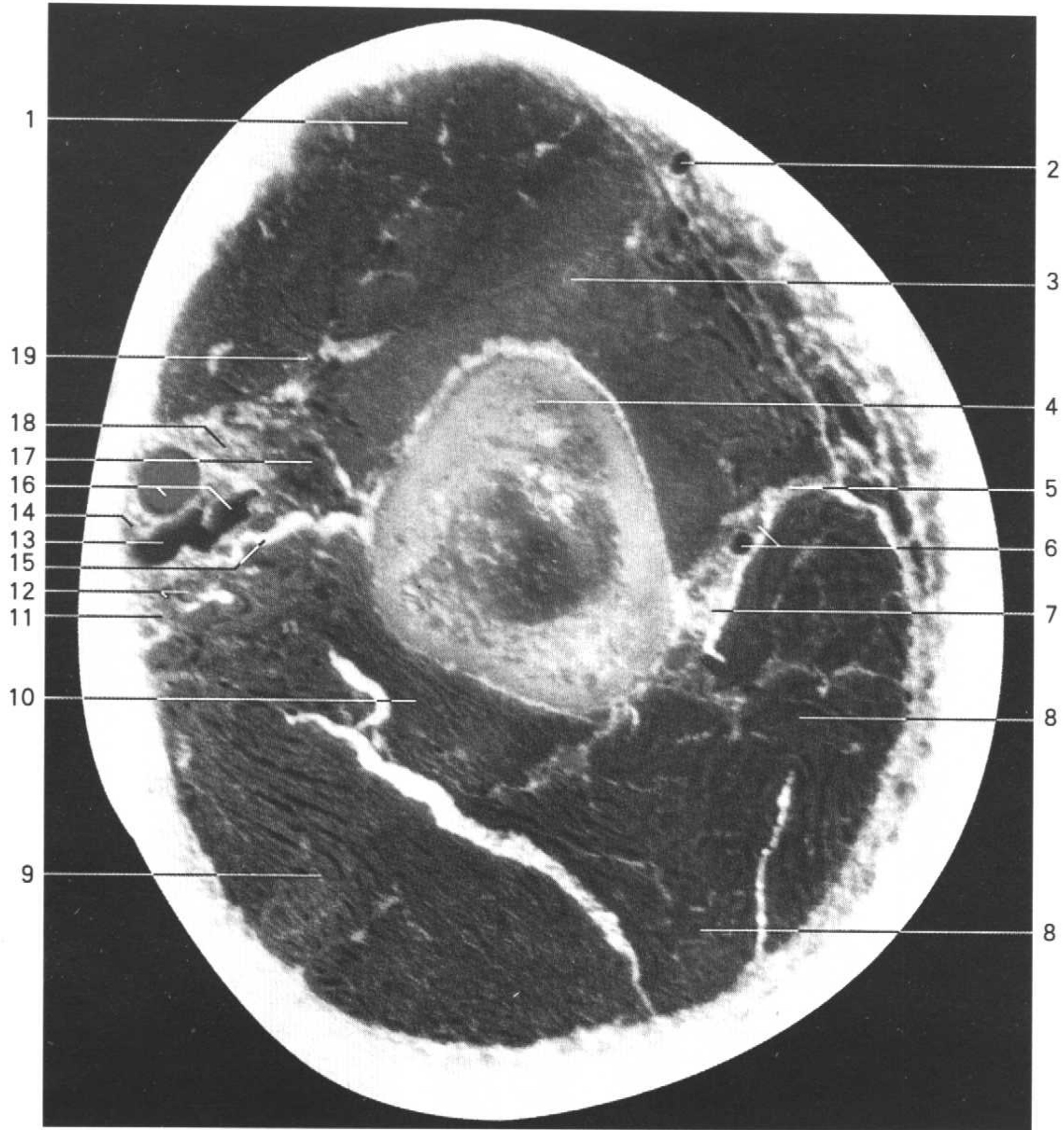
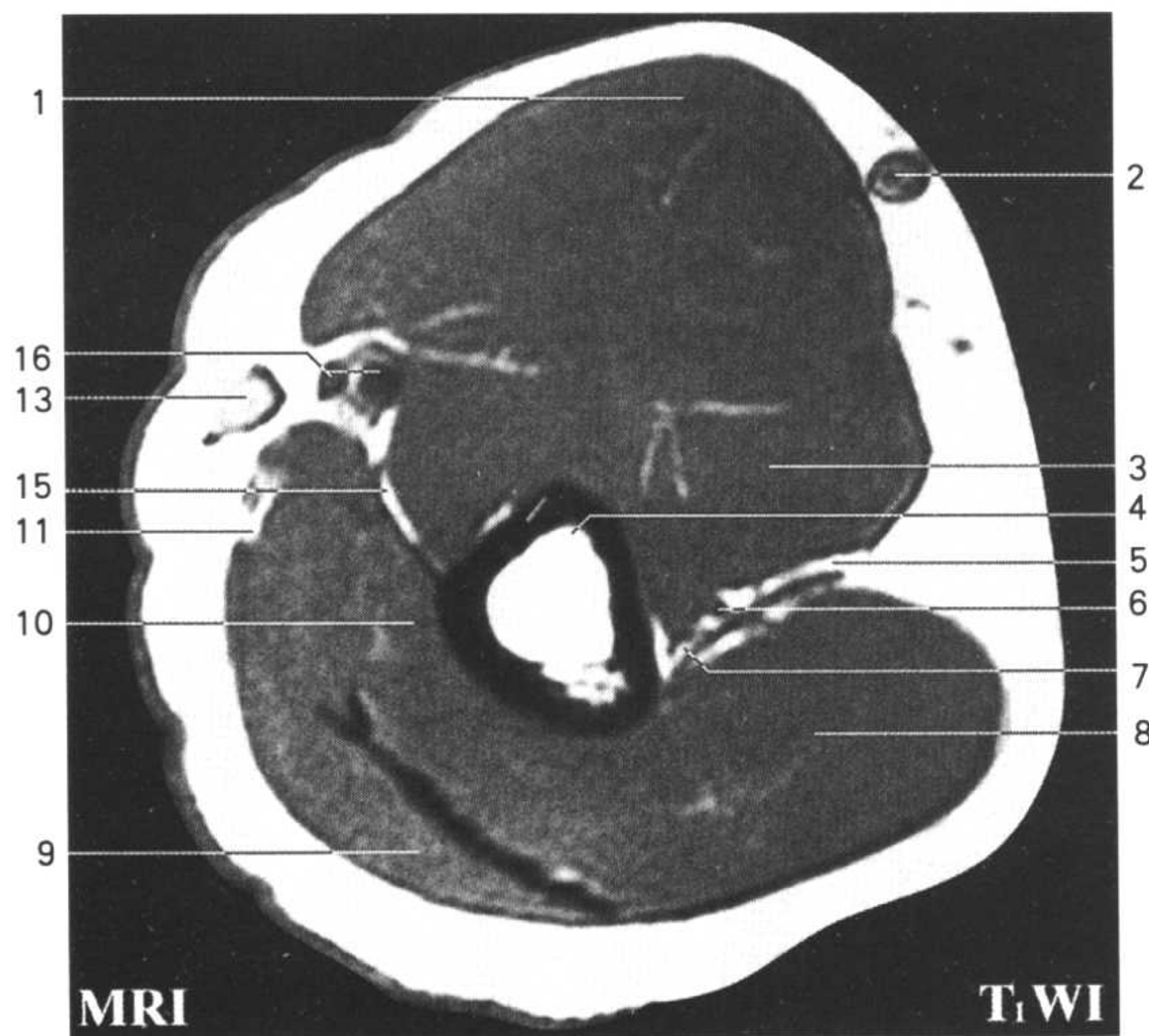
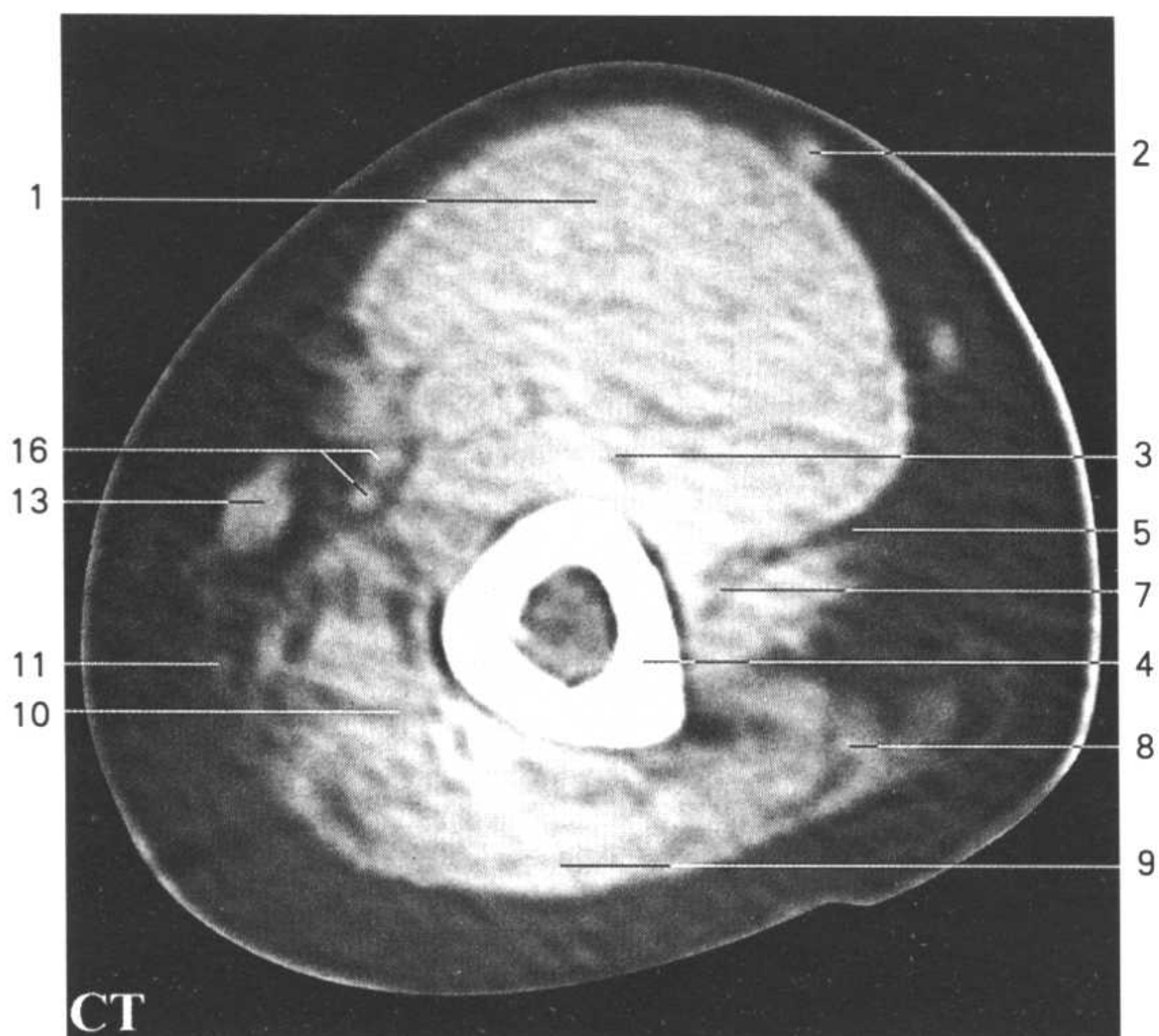


Fig.HUL 2

1. 肱二头肌 biceps brachii
2. 头静脉 cephalic v.
3. 肱肌 brachialis
4. 肱骨 humerus
5. 臂外侧肌间隔 lateral brachial intermuscular septum
6. 肱深动、静脉 deep brachial a. and v.
7. 桡神经 radial n.
8. 肱三头肌外侧头 lateral head of triceps brachii
9. 肱三头肌长头 long head of triceps brachii
10. 肱三头肌内侧头 medial head of triceps brachii

- 11. 尺神经 ulnar n.
- 12. 尺侧上副动、静脉 superior ulnar collateral a. and v.
- 13. 贵要静脉 basilic v.
- 14. 前臂内侧皮神经 medial antebrachial cutaneous n.
- 15. 臂内侧肌间隔 medial brachial intermuscular septum
- 16. 肱动、静脉 brachial a. and v.
- 17. 喙肱肌 coracobrachialis
- 18. 正中神经 median n.
- 19. 肌皮神经 musculocutaneous n.



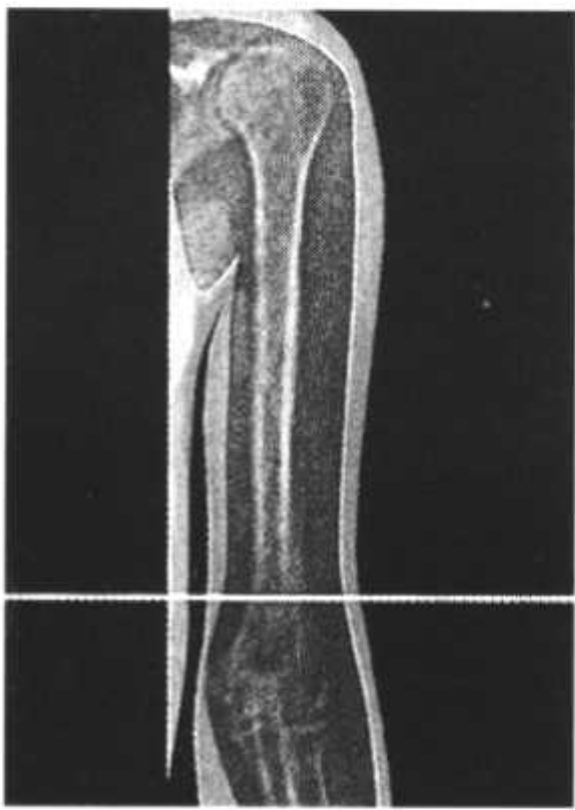
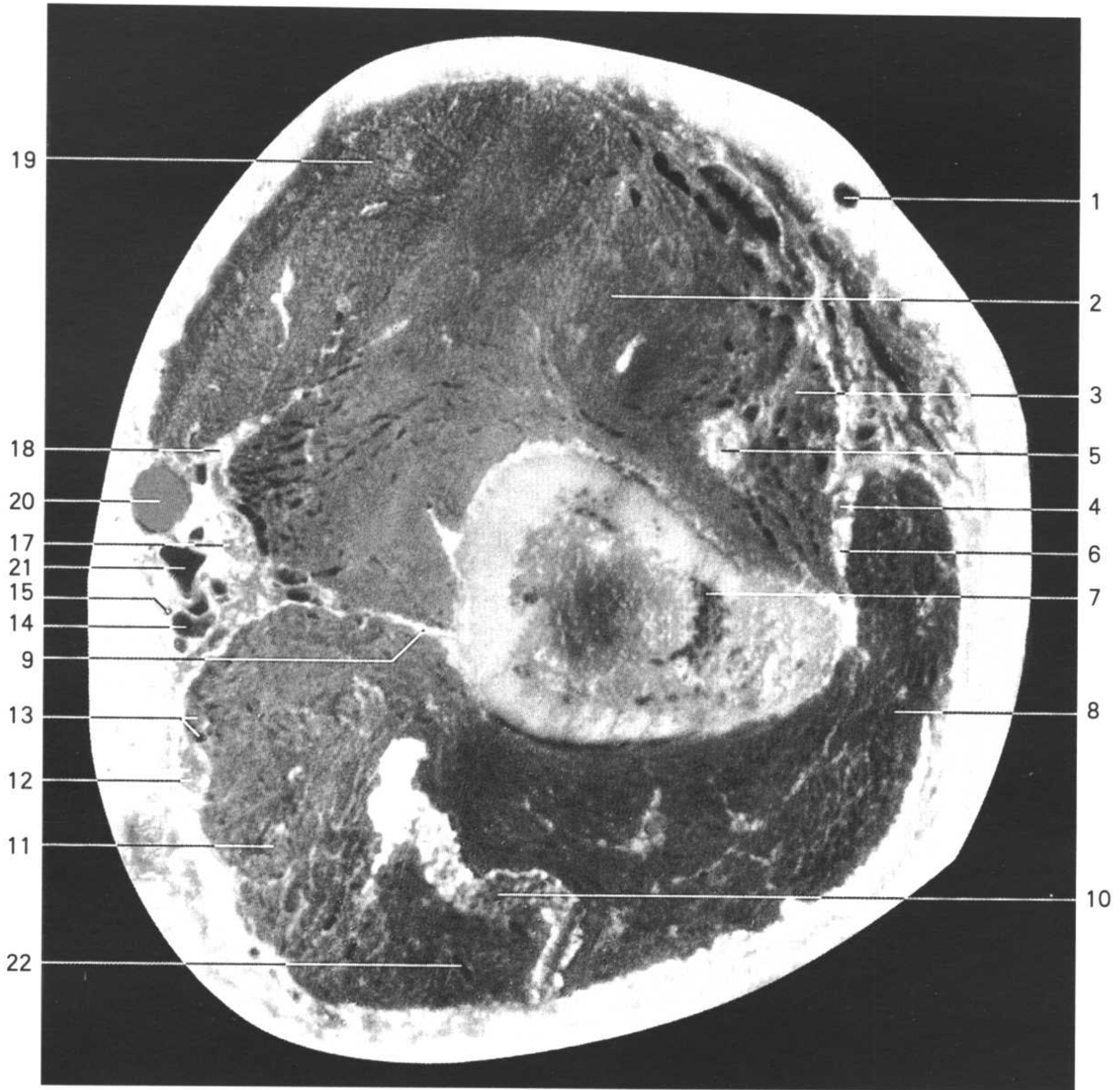
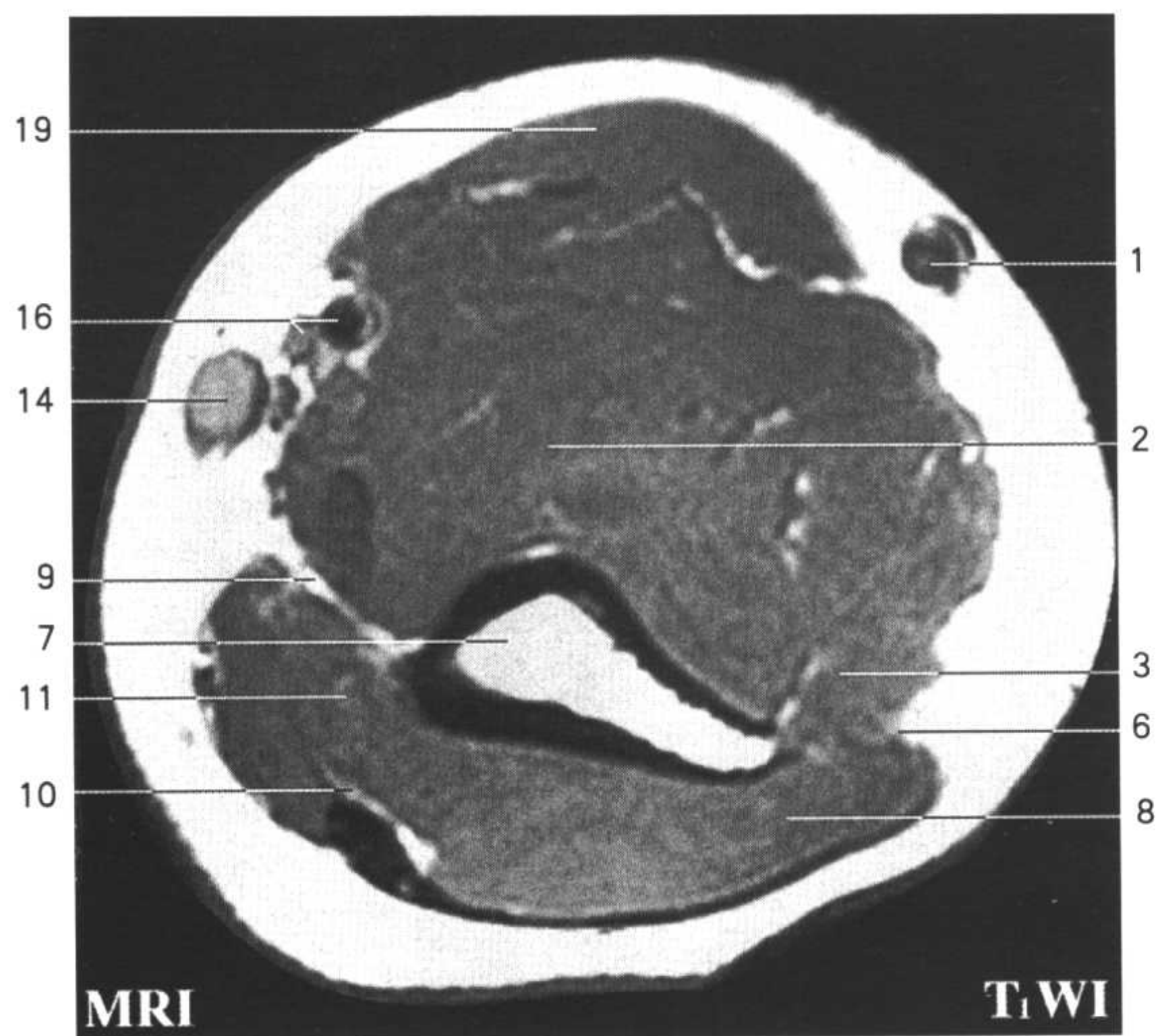
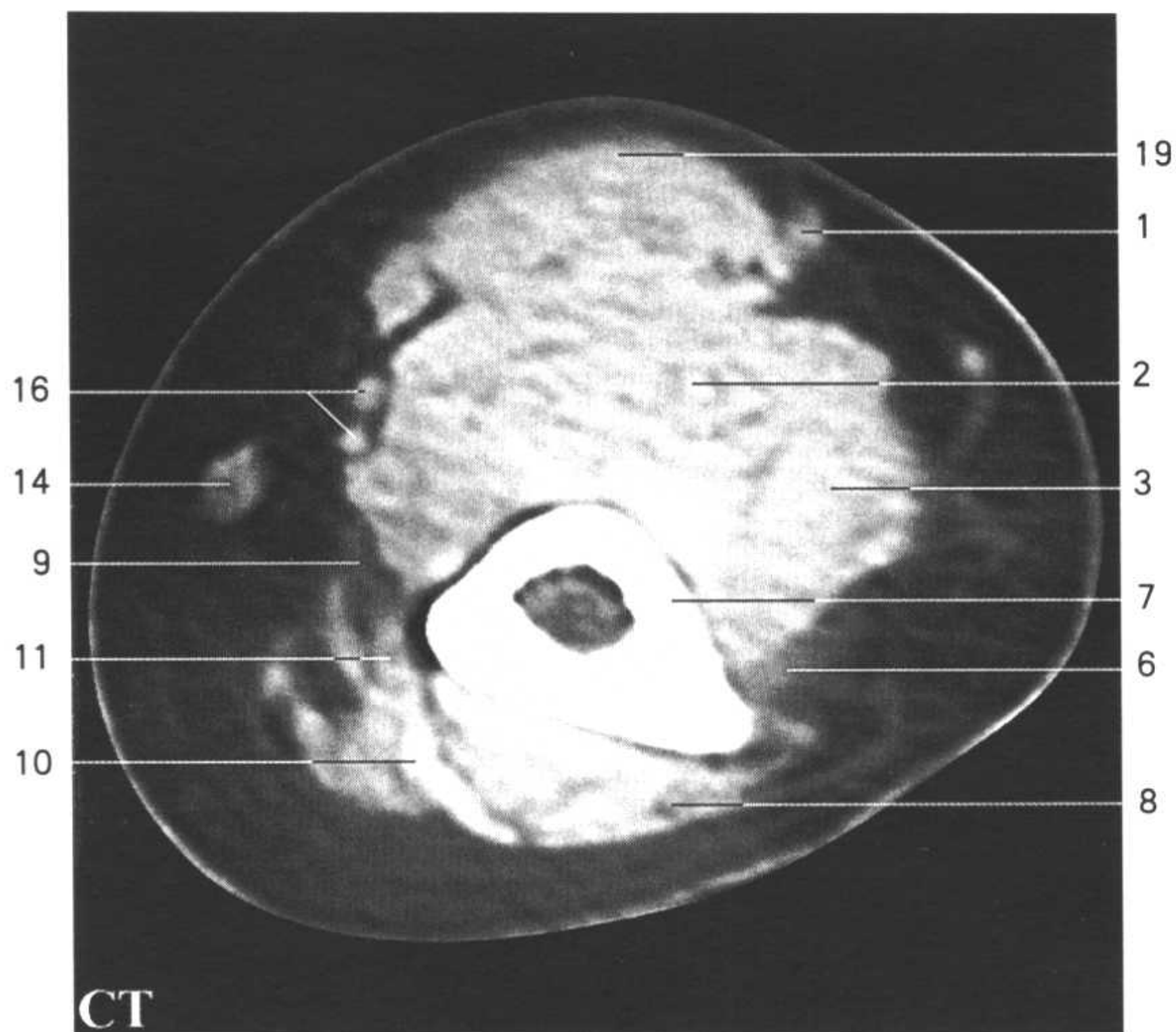


Fig.HUL 3

1. 头静脉 cephalic v.
2. 肱肌 brachialis
3. 肱桡肌 brachioradialis
4. 桡侧副动、静脉 radial collateral a. and v.
5. 桡神经 radial n.
6. 臂外侧肌间隔 lateral brachial intermuscular septum
7. 肱骨 humerus
8. 肱三头肌外侧头 lateral head of triceps brachii
9. 臂内侧肌间隔 medial brachial intermuscular septum
10. 肱三头肌腱 tendon of triceps brachii

11. 肱三头肌内侧头 medial head of triceps brachii
12. 尺神经 ulnar n.
13. 尺侧上副动、静脉 superior ulnar collateral a. and v.
14. 贵要静脉 basilic v.
15. 前臂内侧皮神经 medial antebrachial cutaneous n.
16. 肱动、静脉 brachial a. and v.
17. 正中神经 median n.
18. 肌皮神经 musculocutaneous n.
19. 肱二头肌 biceps brachii
20. 肱动脉 brachial a.
21. 肱静脉 brachial v.
22. 肱三头肌长头 long head of triceps brachii



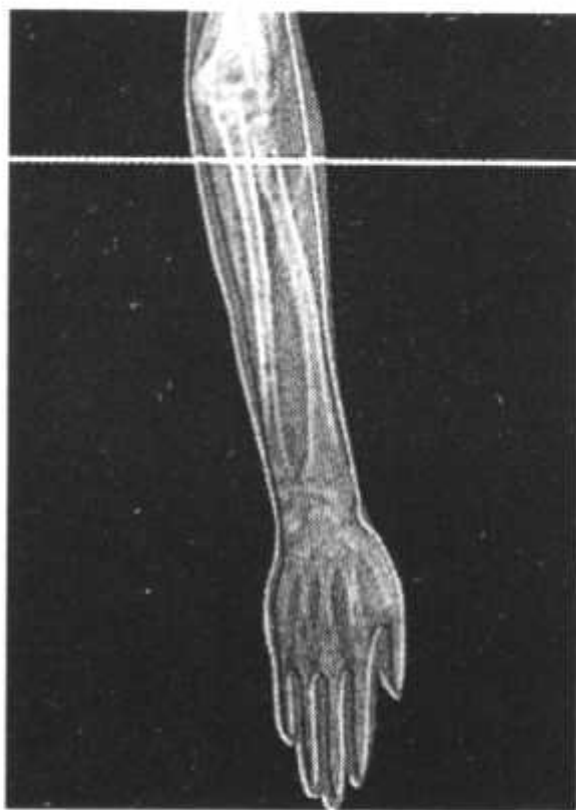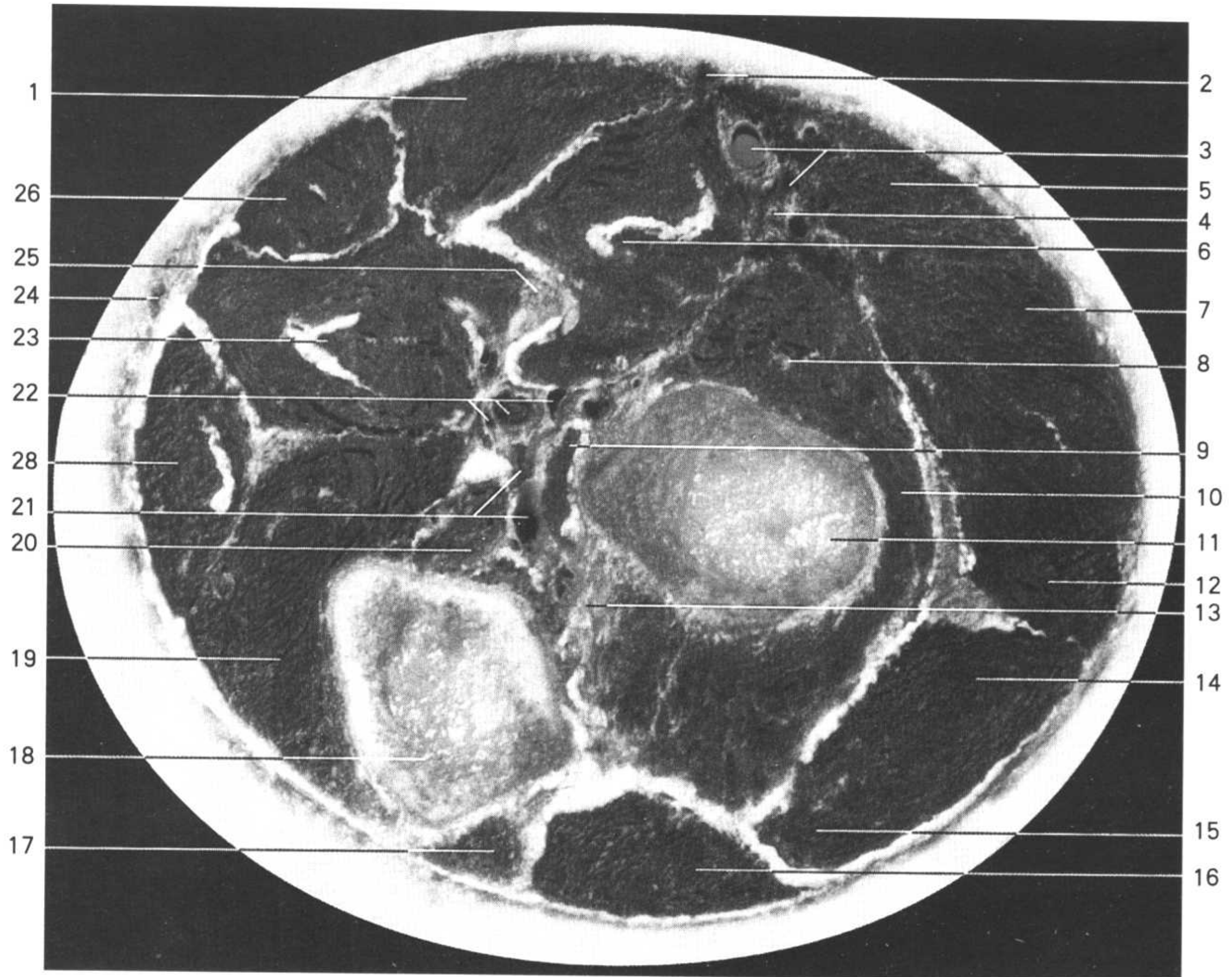
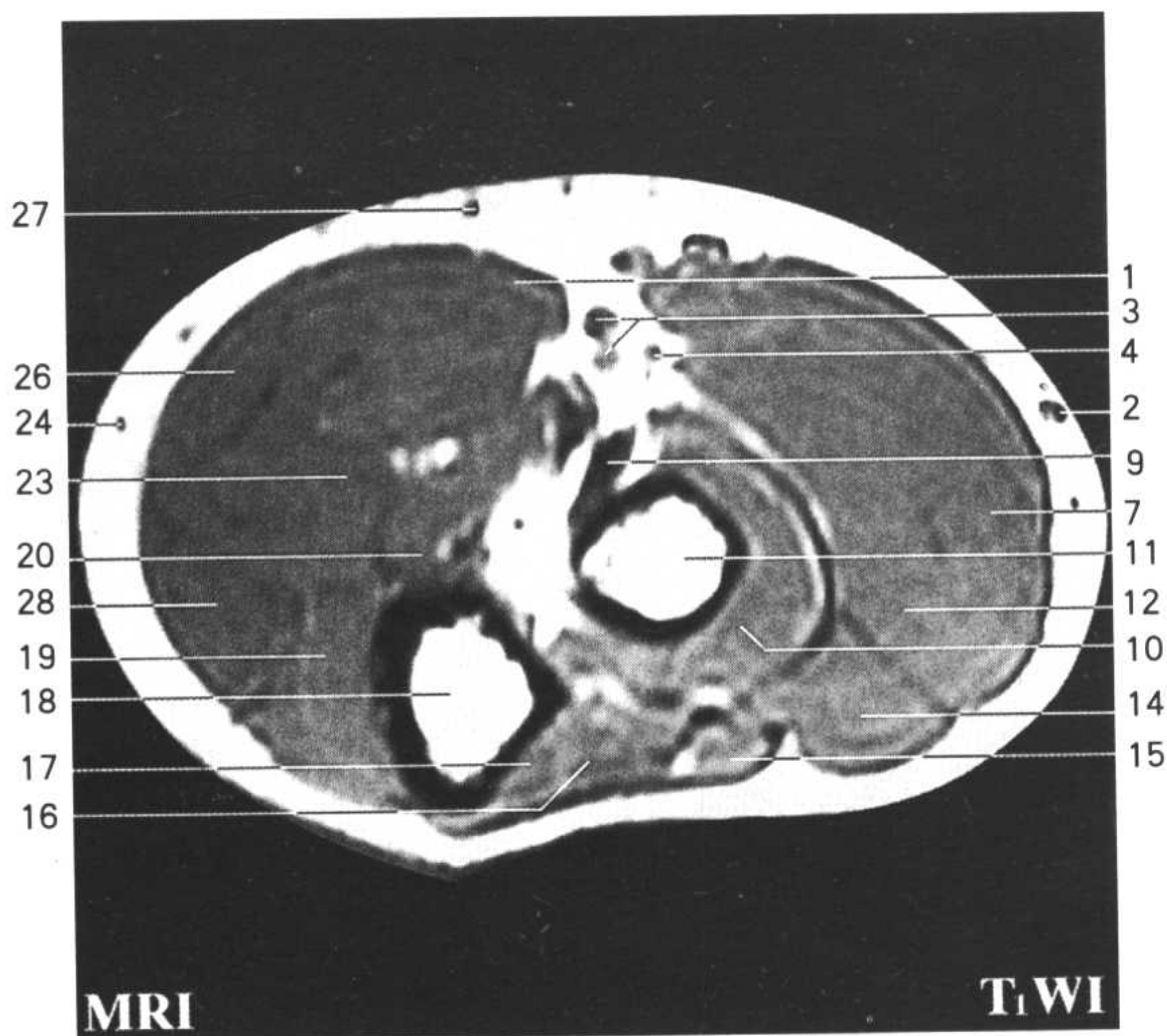
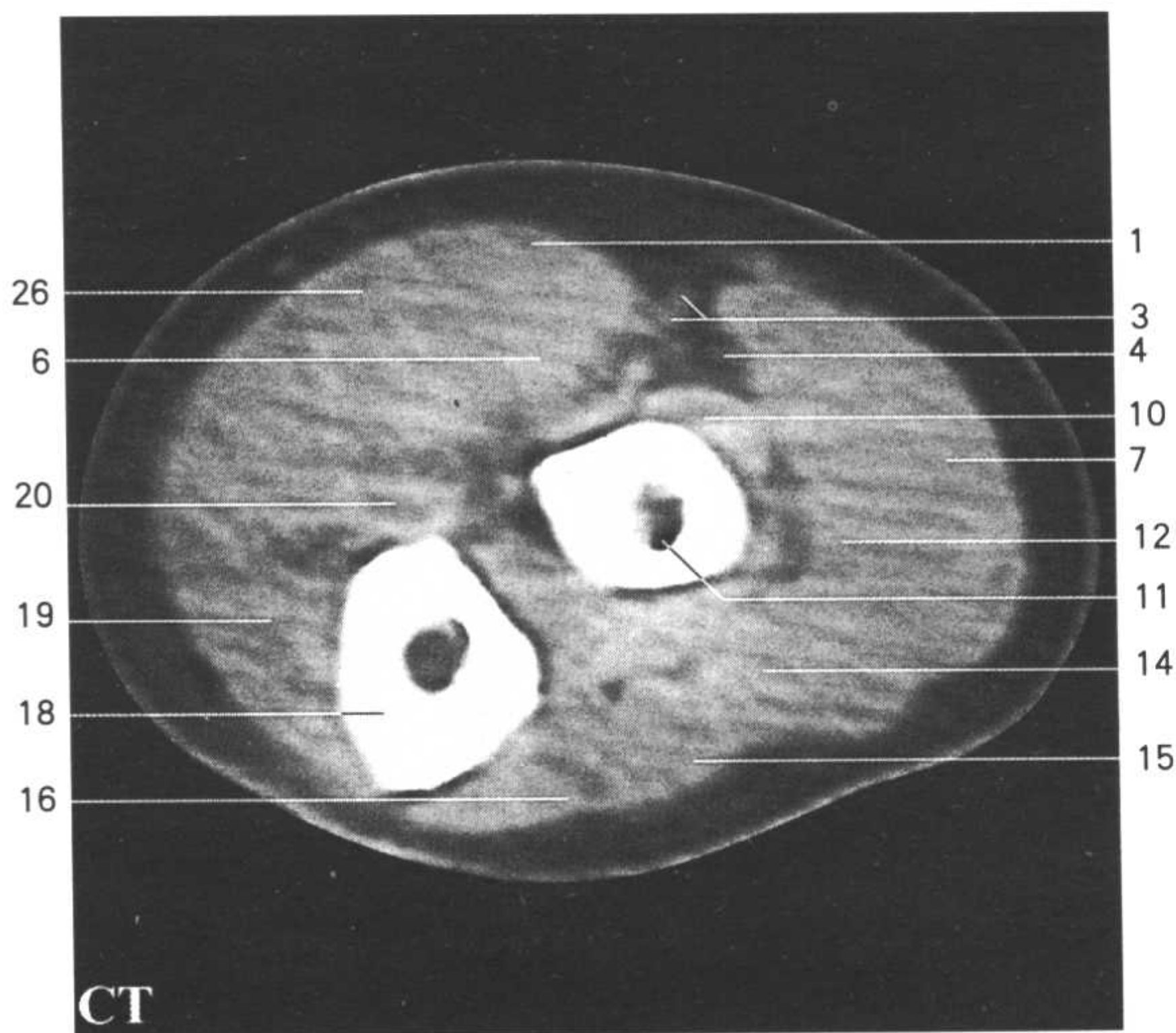


Fig.HUL 4

1. 桡侧腕屈肌 flexor carpi radialis
2. 头静脉 cephalic v.
3. 桡动、静脉 radial a. and v.
4. 桡神经浅支 superficial branch of radial n.
5. 肱桡肌 brachioradialis
6. 旋前圆肌 pronator teres
7. 桡侧腕长伸肌 extensor carpi radialis longus
8. 桡神经深支 deep branch of radial n.
9. 肱二头肌 biceps brachii
10. 旋后肌 supinator

- 11. 桡骨 radius
- 12. 桡侧腕短伸肌 extensor carpi radialis brevis
- 13. 前臂骨间膜 interosseous membrane of forearm
- 14. 指伸肌 extensor digitorum
- 15. 小指伸肌 extensor digiti minimi
- 16. 尺侧腕伸肌 extensor carpi ulnaris
- 17. 肘肌 anconeus
- 18. 尺骨 ulna
- 19. 指深屈肌 flexor digitorum profundus
- 20. 肱肌 brachialis
- 21. 骨间总动、静脉 common interosseous a. and v.
- 22. 尺动、静脉 ulnar a. and v.
- 23. 指浅屈肌 flexor digitorum superficialis
- 24. 贵要静脉 basilic v.
- 25. 正中神经 median n.
- 26. 掌长肌 palmaris longus
- 27. 前臂正中静脉 median antebrachial v.
- 28. 尺侧腕屈肌 flexor carpi ulnaris



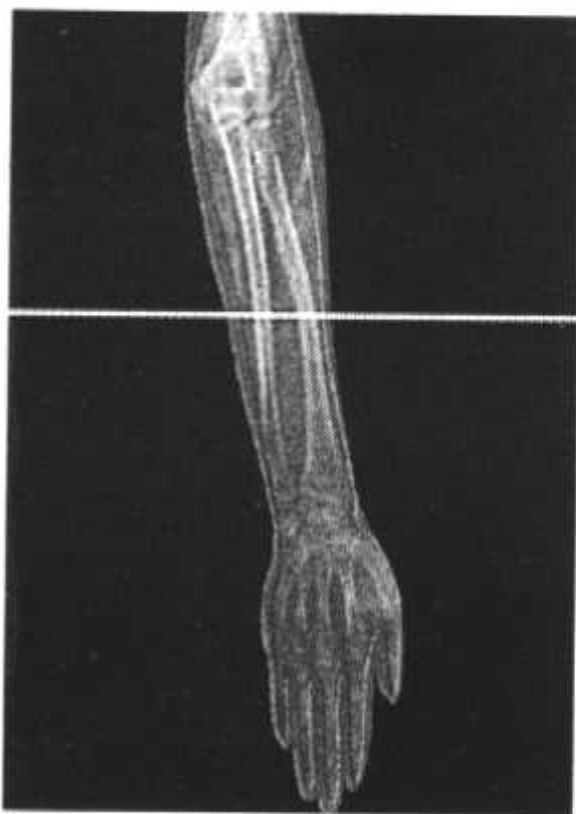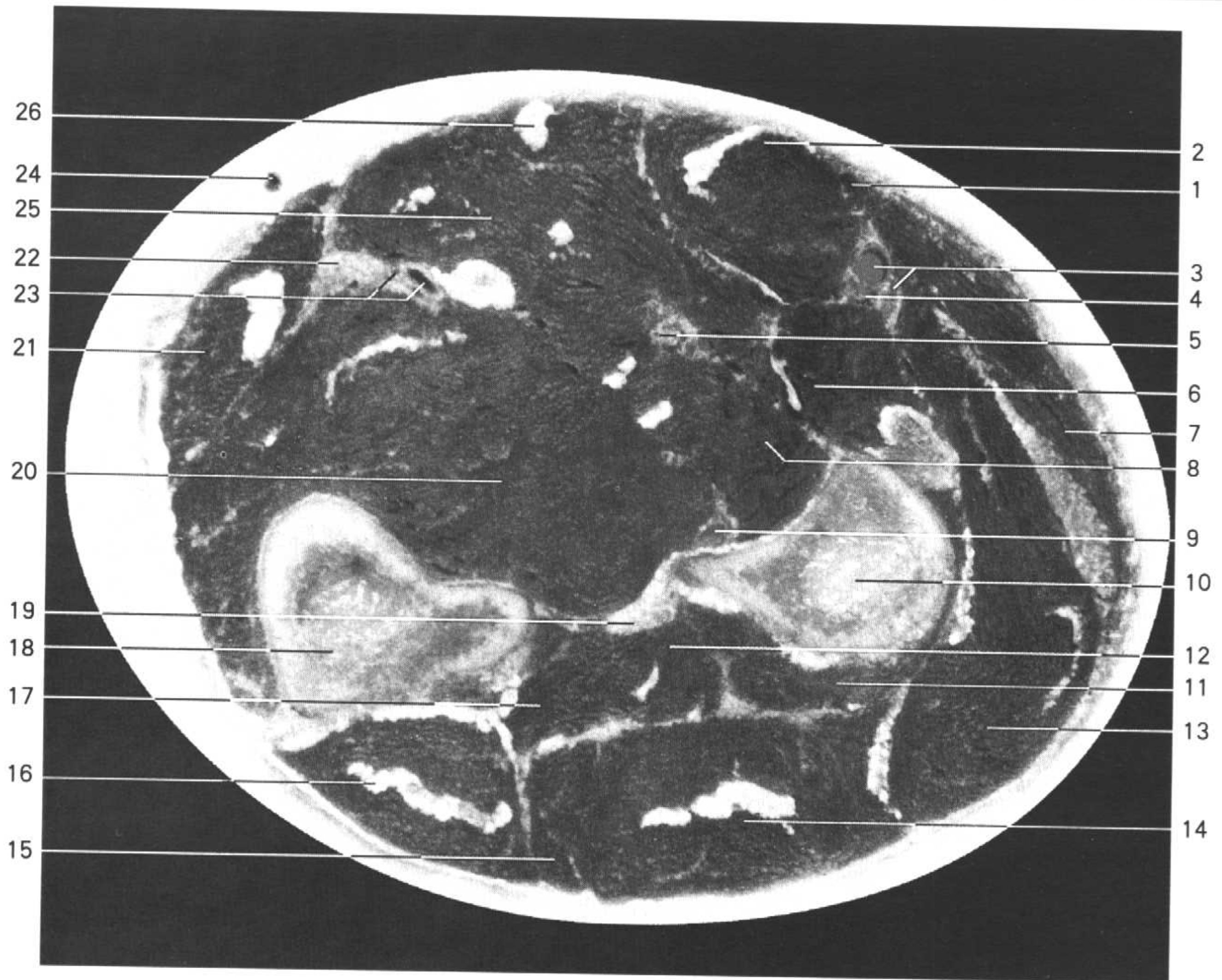
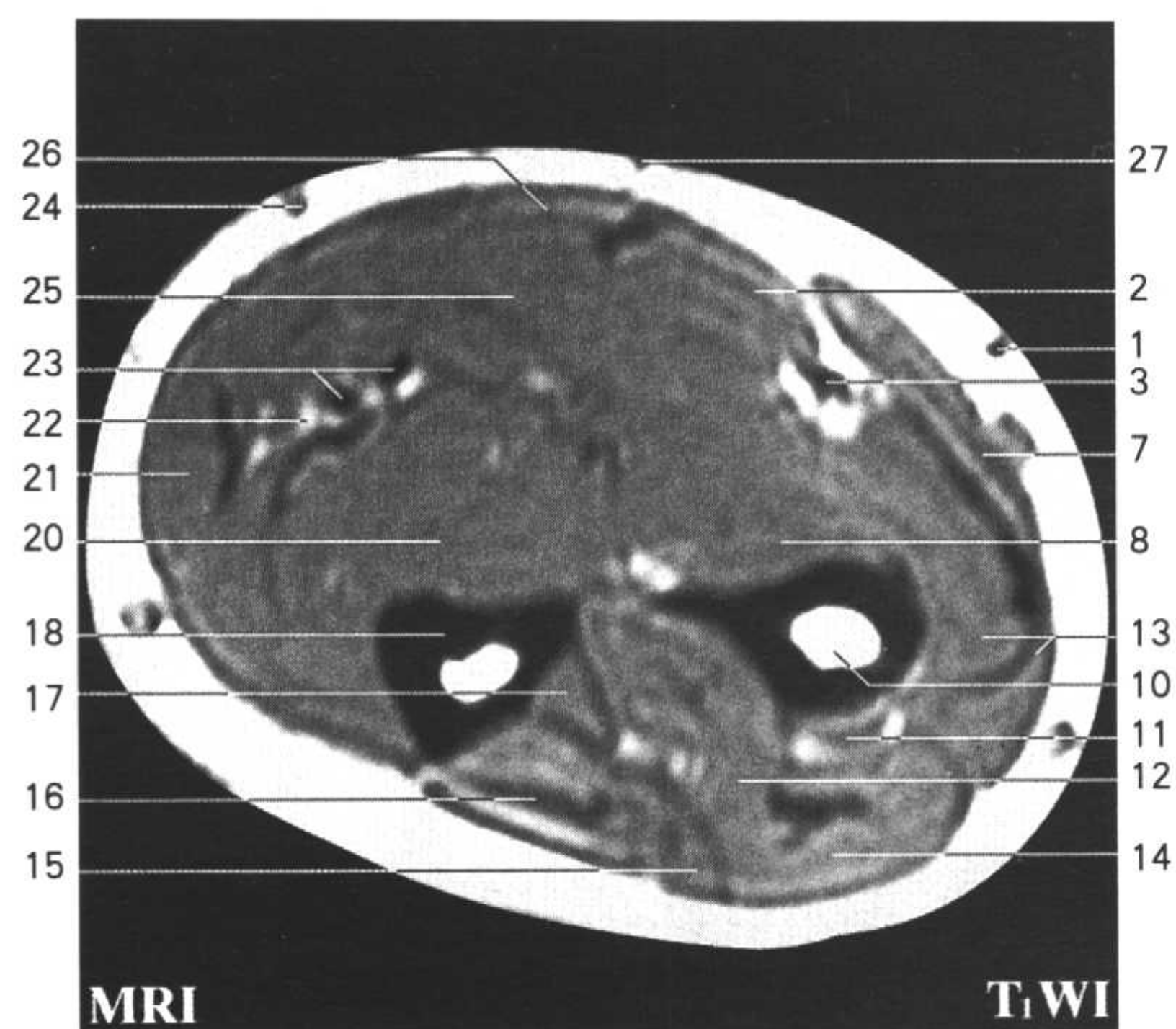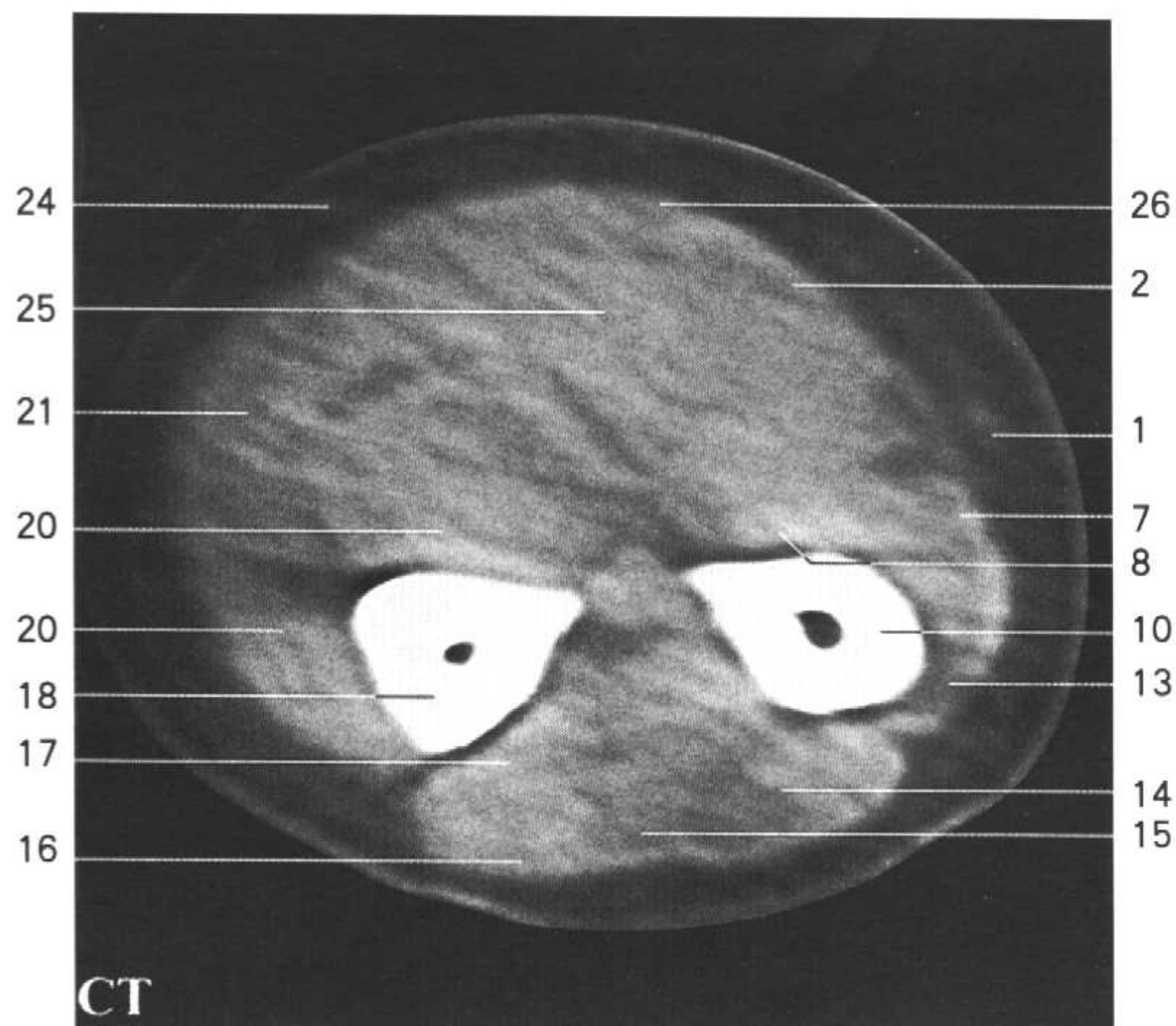


Fig.HUL 5

1. 头静脉 cephalic v.
2. 桡侧腕屈肌 flexor carpi radialis
3. 桡动、静脉 radial a. and v.
4. 桡神经浅支 superficial branch of radial n.
5. 正中神经 median n.
6. 旋前圆肌 pronator teres
7. 肱桡肌 brachioradialis
8. 拇长屈肌 flexor pollicis longus
9. 骨间前动、静脉 anterior interosseous a. and v.
10. 桡骨 radius

11. 旋后肌 supinator
12. 拇长展肌 abductor pollicis longus
13. 桡侧腕长、短伸肌 extensor carpi radialis longus and brevis
14. 指伸肌 extensor digitorum
15. 小指伸肌 extensor digiti minimi
16. 尺侧腕伸肌 extensor carpi ulnaris
17. 拇长伸肌 extensor pollicis longus
18. 尺骨 ulna
19. 前臂骨间膜 interosseous membrane of forearm
20. 指深屈肌 flexor digitorum profundus
21. 尺侧腕屈肌 flexor carpi ulnaris
22. 尺神经 ulnar n.
23. 尺动、静脉 ulnar a. and v.
24. 贵要静脉 basilic v.
25. 指浅屈肌 flexor digitorum superficialis
26. 掌长肌 palmaris longus
27. 前臂正中静脉 median antebrachial v.



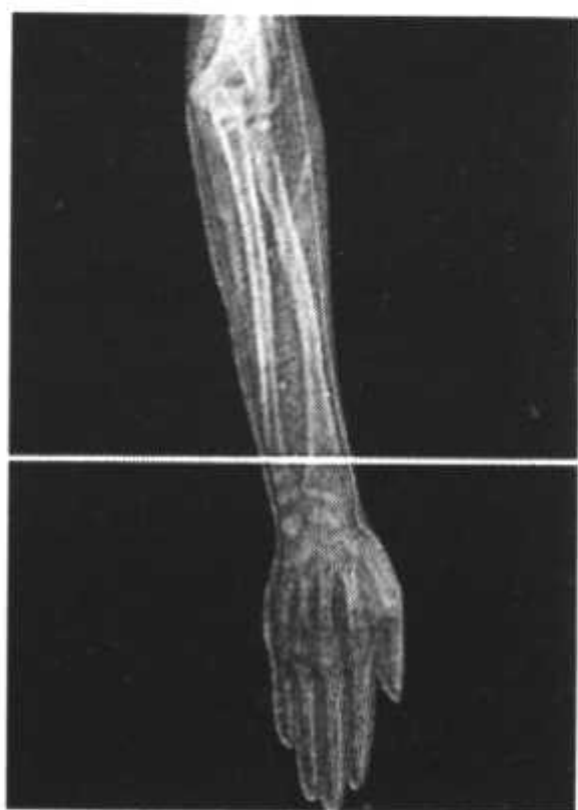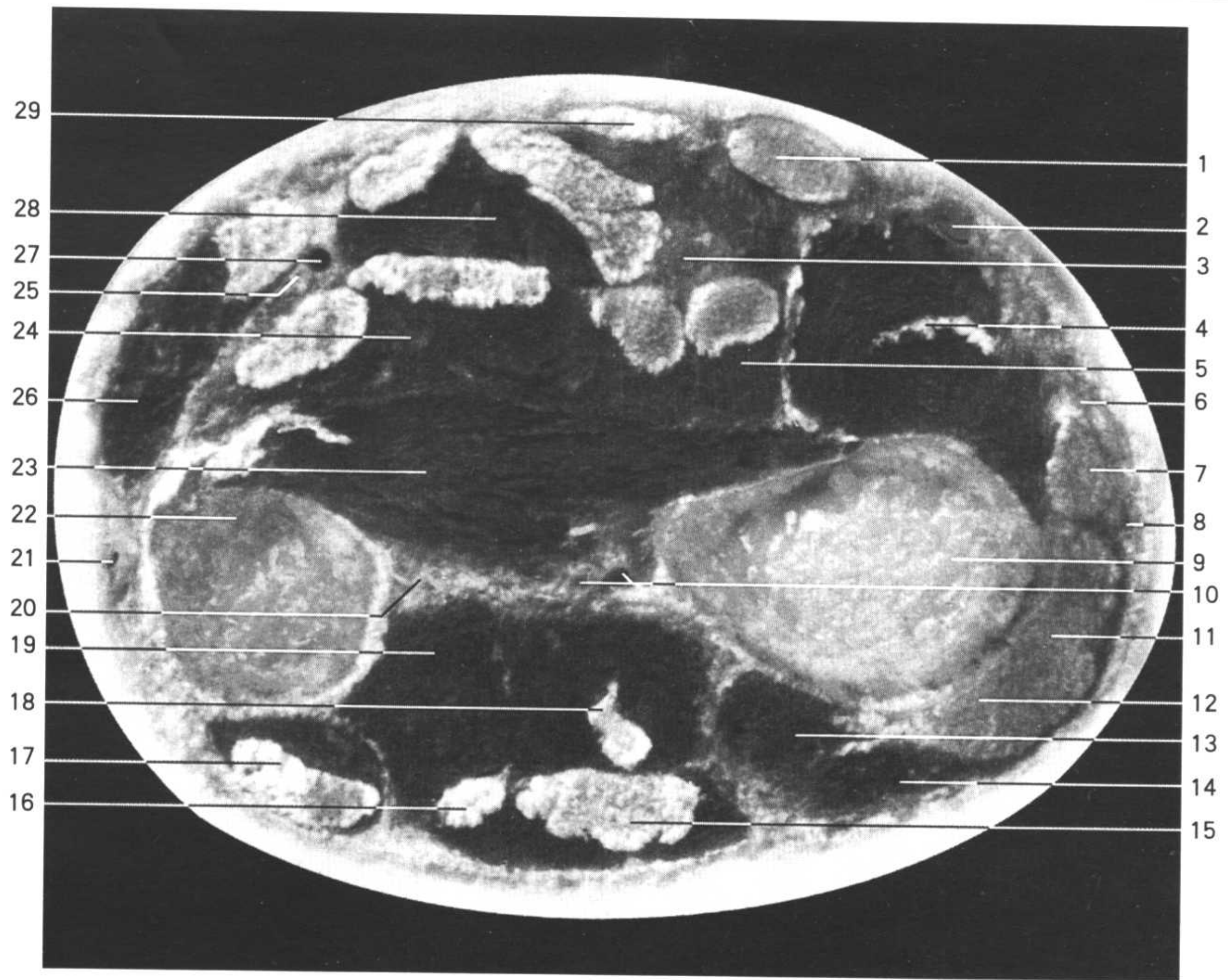
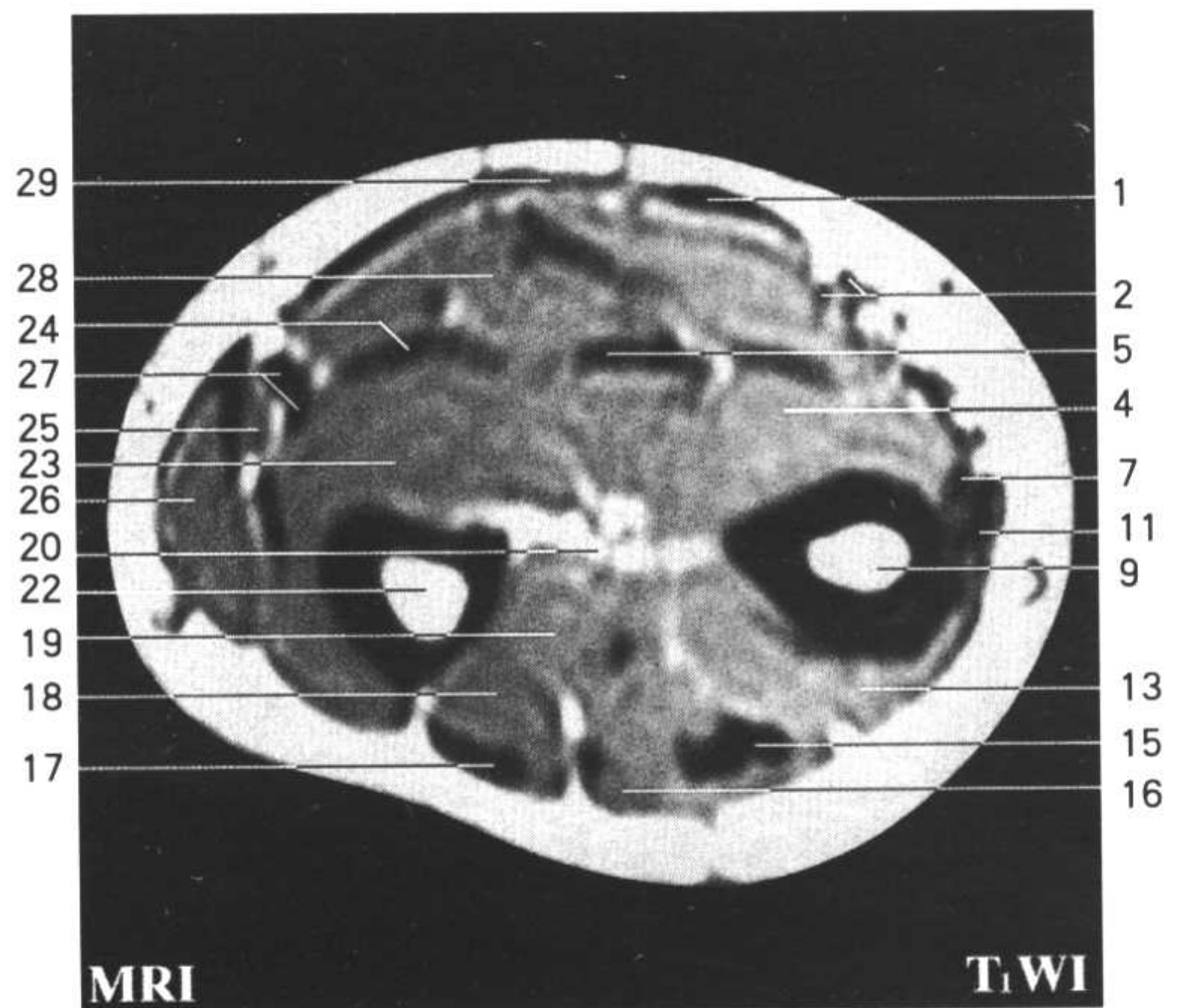
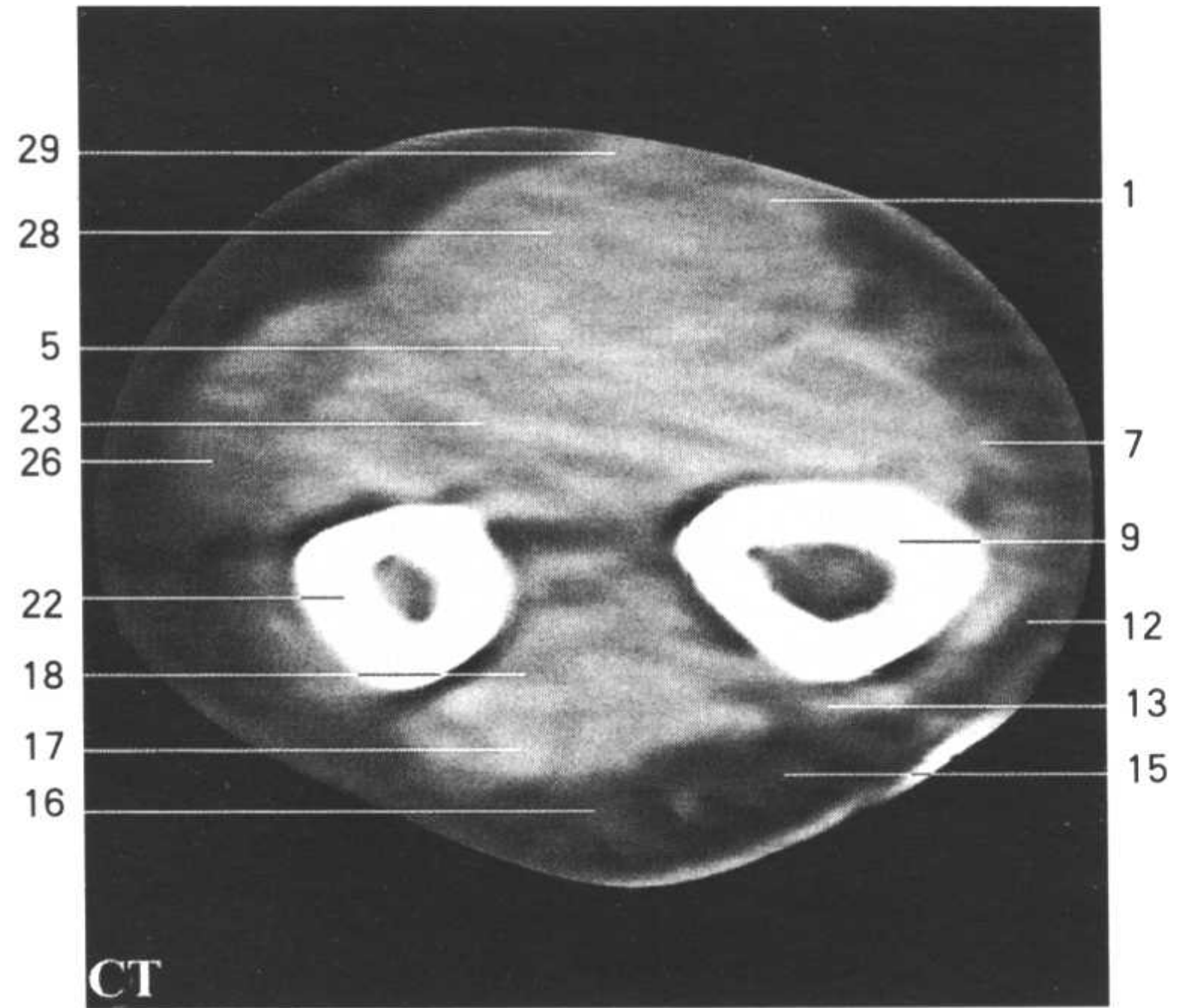
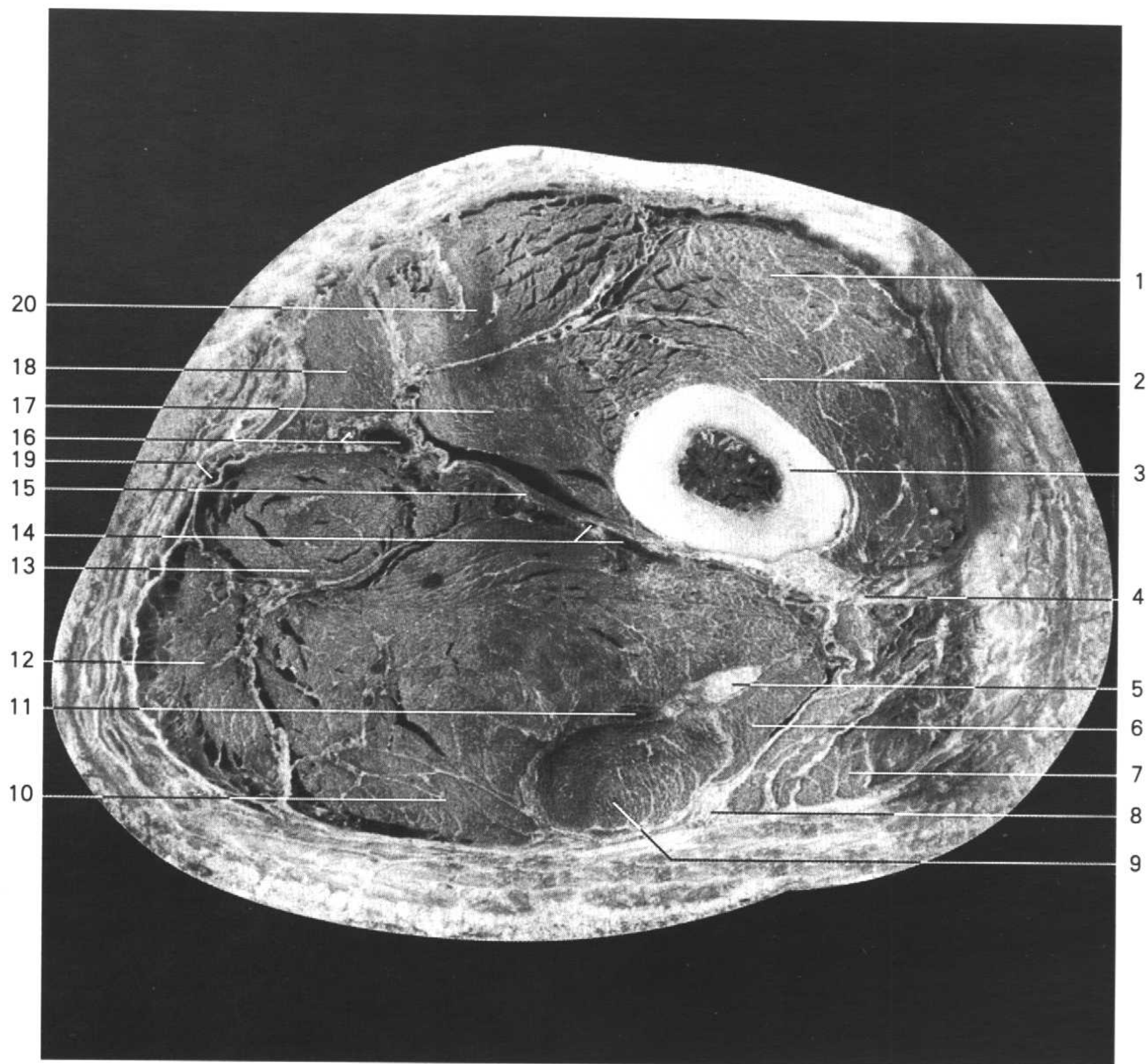


Fig.HUL 6

1. 桡侧腕屈肌 flexor carpi radialis
2. 桡动、静脉 radial a. and v.
3. 正中神经 median n.
4. 拇长屈肌 flexor pollicis longus
5. 指深屈肌 flexor digitorum profundus
6. 桡神经浅支 superficial branch of radial n.
7. 肱桡肌腱 tendon of brachioradialis
8. 头静脉 cephalic v.
9. 桡骨 radius
10. 骨间前动、静脉 anterior interosseous a. and v.

11. 桡侧腕长伸肌腱 tendon of extensor carpi radialis longus
12. 桡侧腕短伸肌腱 tendon of extensor carpi radialis brevis
13. 拇长展肌腱 tendon of abductor pollicis longus
14. 拇短伸肌 extensor pollicis brevis
15. 指伸肌腱 tendon of extensor digitorum
16. 小指伸肌腱 tendon of extensor digiti minimi
17. 尺侧腕伸肌 extensor carpi ulnaris
18. 拇长伸肌 extensor pollicis longus
19. 食指伸肌 extensor indicis
20. 前臂骨间膜 interosseous membrane of forearm
21. 贵要静脉 basilic v.
22. 尺骨 ulna
23. 旋前方肌 pronator quadratus
24. 指深屈肌 flexor digitorum profundus
25. 尺神经 ulnar n.
26. 尺侧腕屈肌 flexor carpi ulnaris
27. 尺动、静脉 ulnar a. and v.
28. 指浅屈肌 flexor digitorum superficialis
29. 掌长肌腱 tendon of palmaris longus

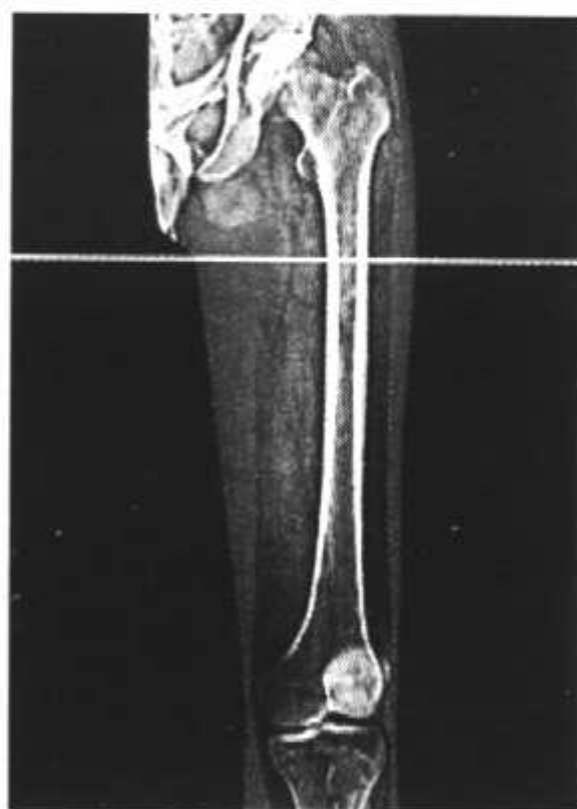



左下肢水平断面 HLL

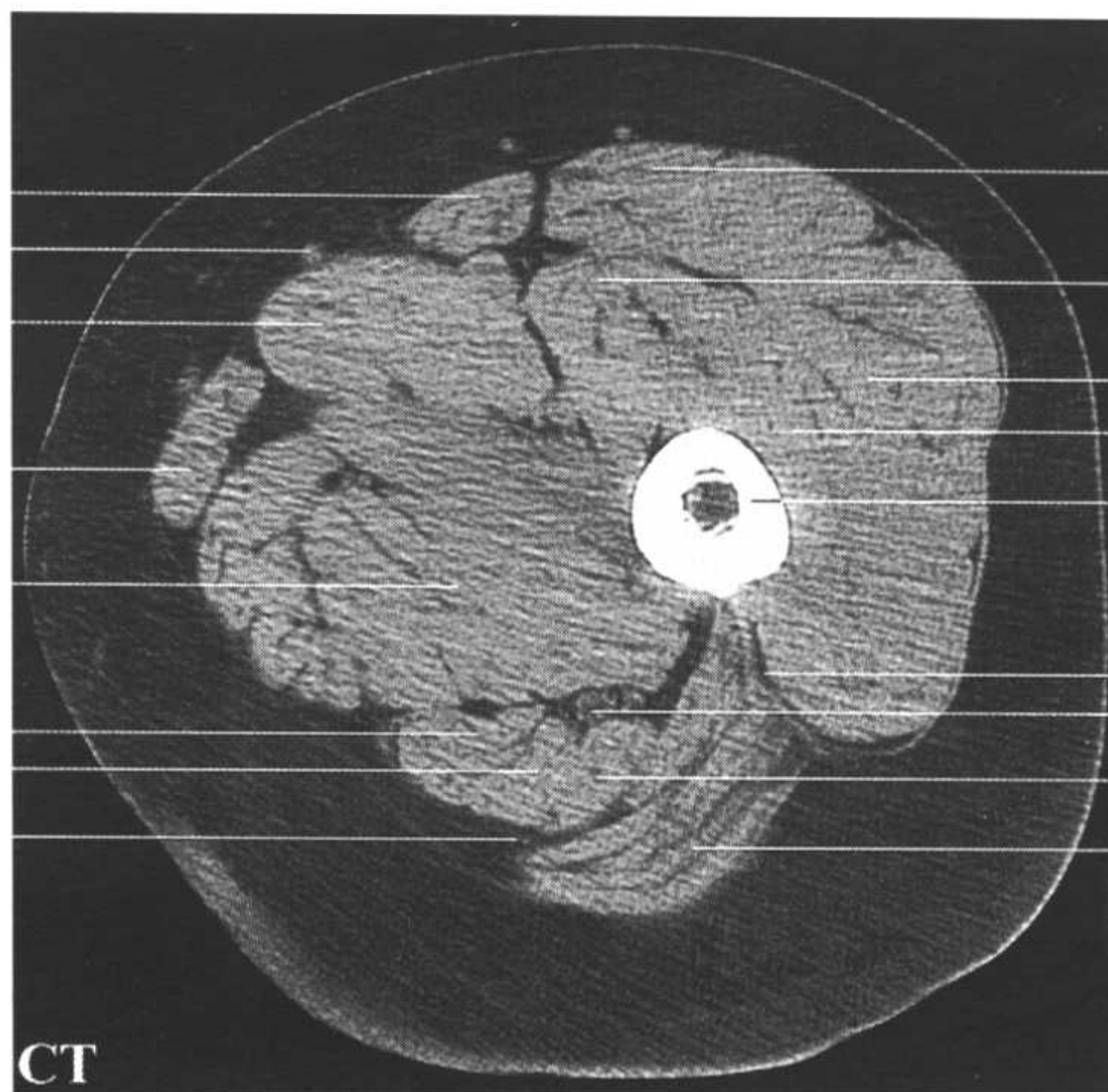
Fig.HLL1

1. 股外侧肌 vastus lateralis
2. 肌中间肌 vastus intermedius
3. 股骨 femur
4. 股外侧肌间隔 lateral femoral intermuscular septum
5. 坐骨神经 sciatic n.
6. 股二头肌长头 long head of biceps femoris
7. 臀大肌 gluteus maximus
8. 股后皮神经 posterior femoral cutaneous n.
9. 半腱肌 semitendinosus
10. 大收肌 adductor magnus



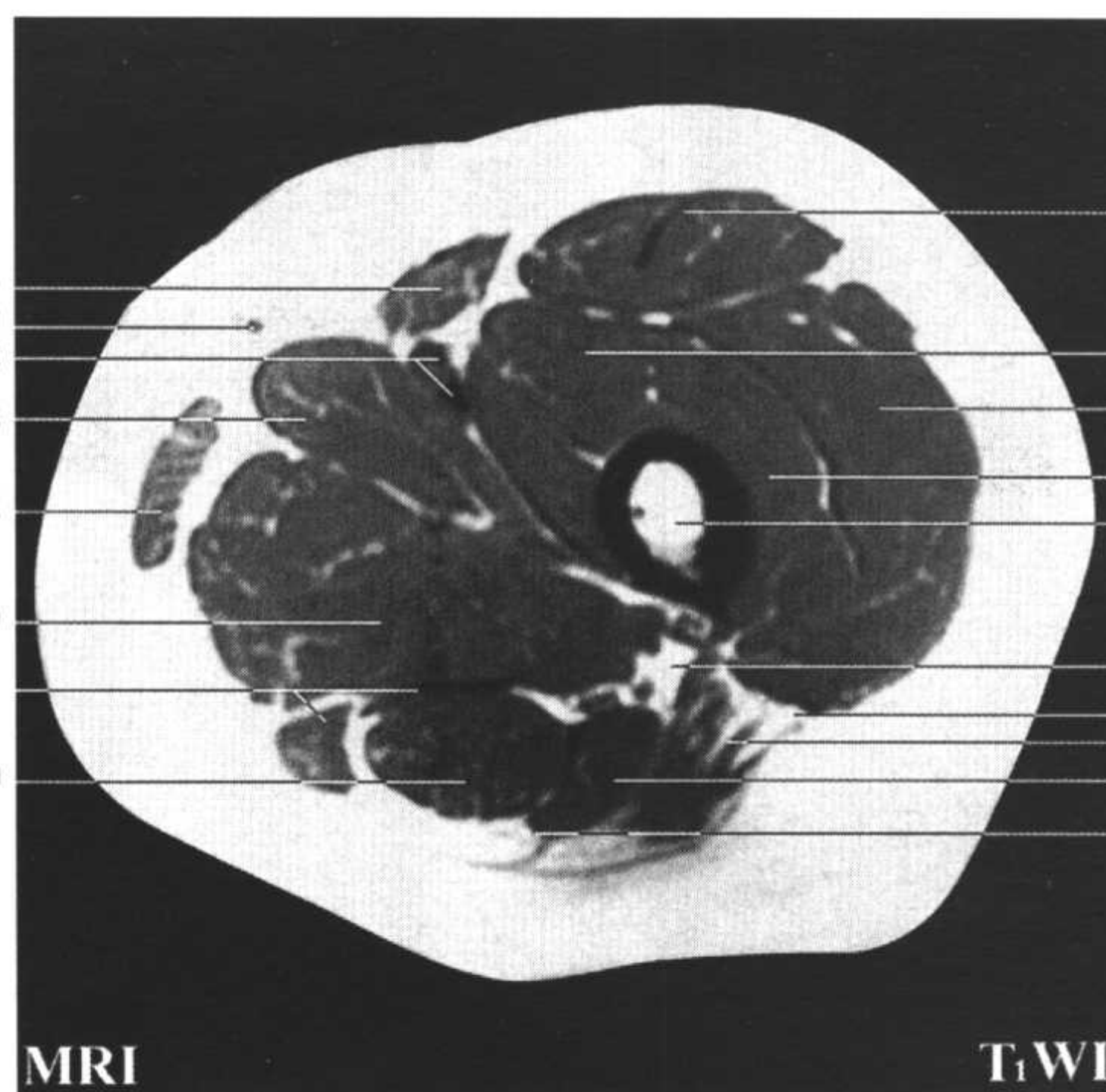
- 11. 半膜肌 semimembranosus
- 12. 股薄肌 gracilis
- 13. 长收肌 adductor longus
- 14. 股深动、静脉 deep femoral a. and v.
- 15. 股内侧肌间隔 medial femoral intermuscular septum
- 16. 股动、静脉 femoral a. and v.
- 17. 股内侧肌 vastus medialis
- 18. 缝匠肌 sartorius
- 19. 大隐静脉 great saphenous v.
- 20. 股直肌 rectus femoris

18
19
13
12
10
11
9
8



20
17
1
2
3
4
5
6
7

18
19
16
13
12
10
11
9



20
17
1
2
3
5
4
7
6
8

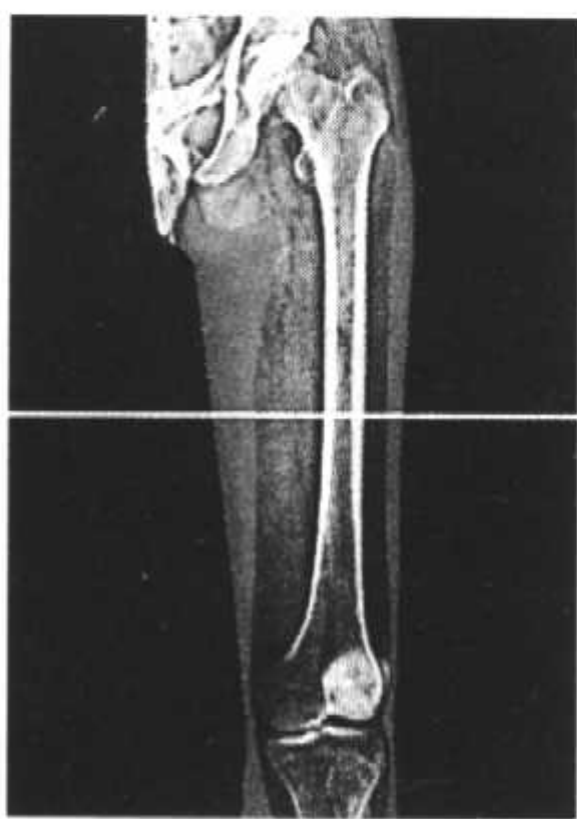
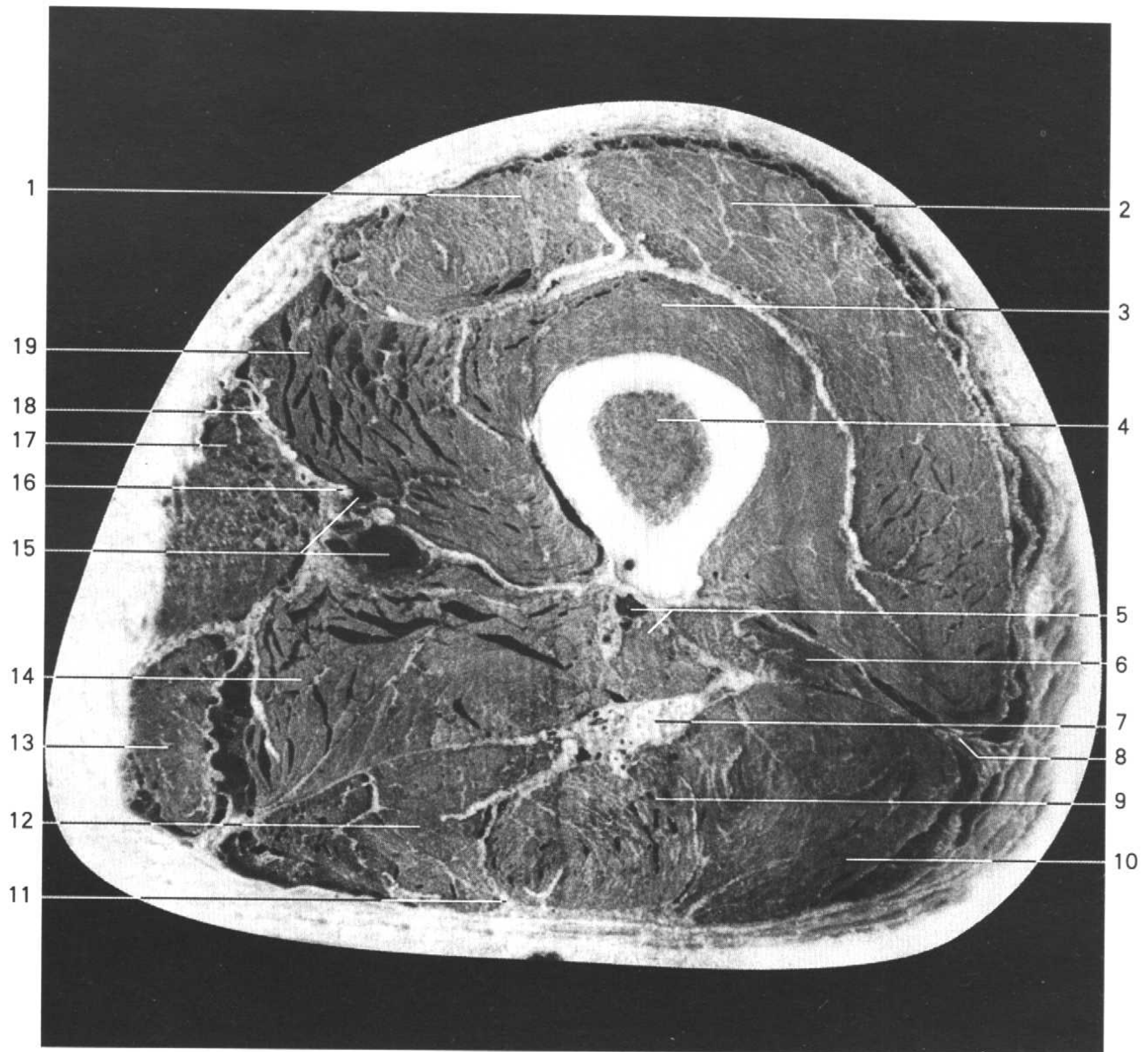
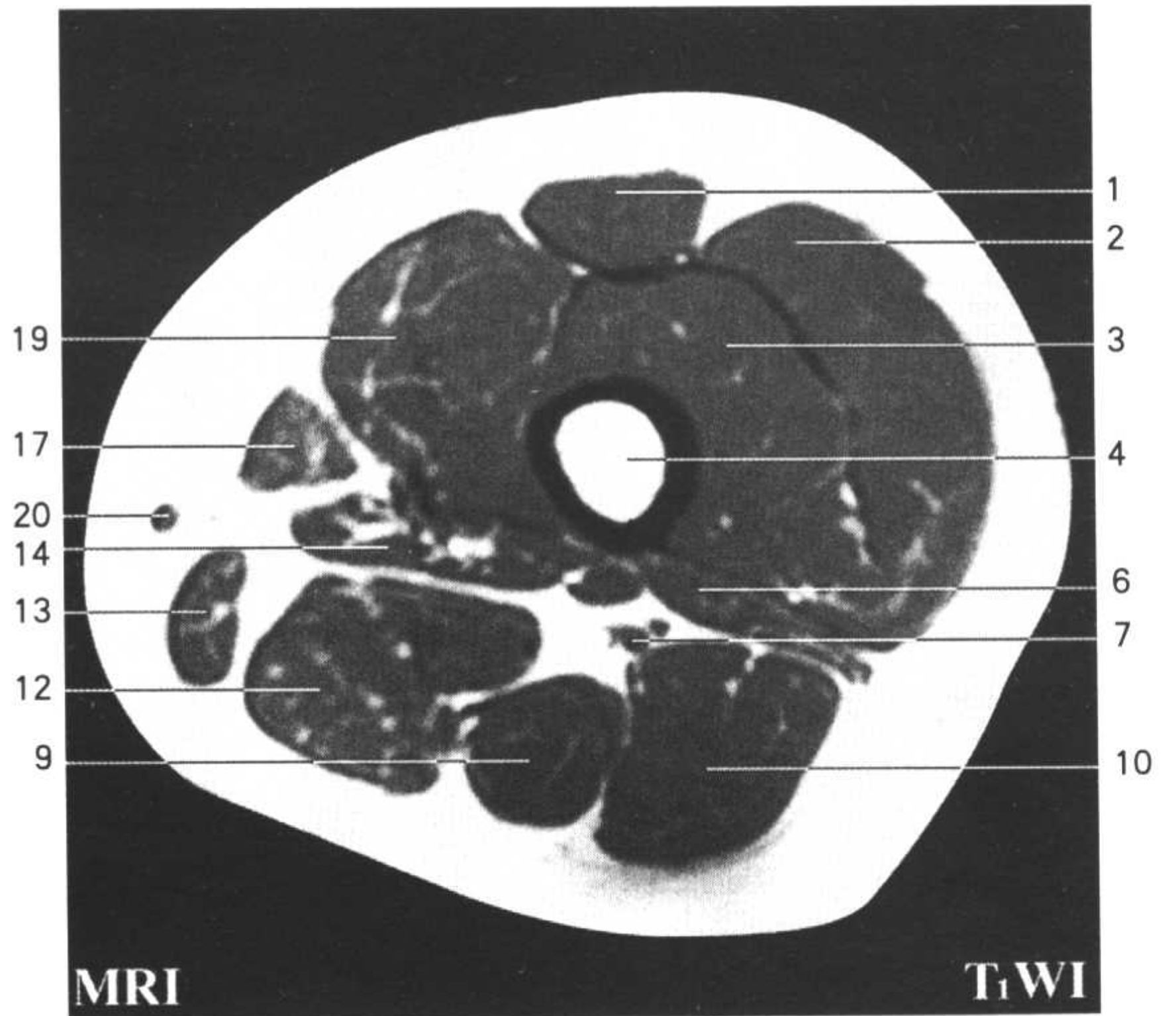
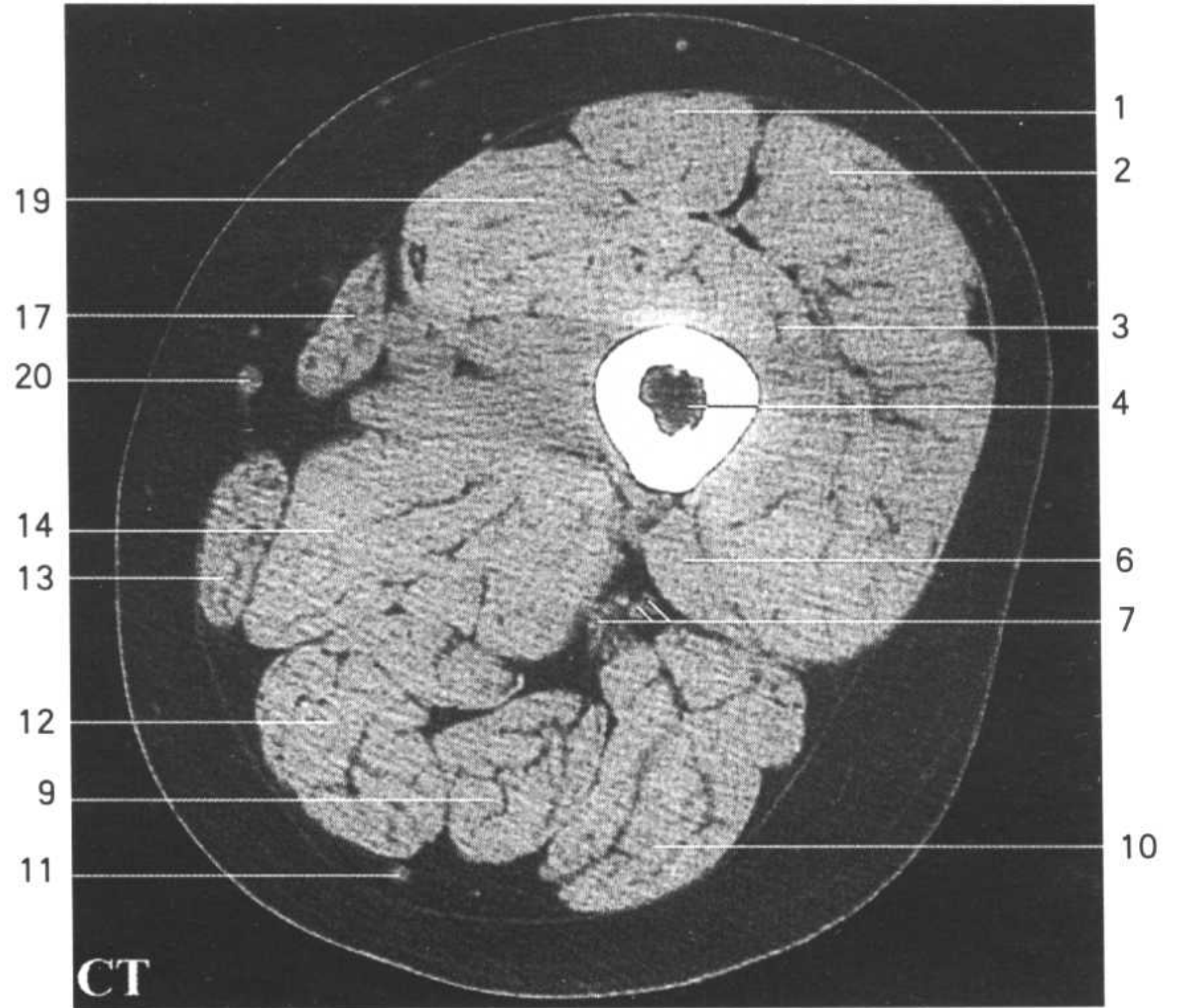


Fig.HLL 2

1. 股直肌 rectus femoris
2. 股外侧肌 vastus lateralis
3. 股中间肌 vastus intermedius
4. 股骨 femur
5. 股深动、静脉 deep femoral a. and v.
6. 股二头肌短头 short head of biceps femoris
7. 坐骨神经及坐骨神经伴行动、静脉 sciatic n. and accompanying a. and v.
8. 股外侧肌间隔 lateral femoral intermuscular septum
9. 半腱肌 semitendinosus

- 10. 股二头肌长头 long head of biceps femoris
- 11. 股后皮神经 posterior femoral cutaneous n.
- 12. 半膜肌 semimembranosus
- 13. 股薄肌 gracilis
- 14. 大收肌 adductor magnus
- 15. 股动、静脉 femoral a. and v.
- 16. 隐神经 saphenous n.
- 17. 缝匠肌 sartorius
- 18. 股内侧肌间隔 medial femoral intermuscular septum
- 19. 股内侧肌 vastus medialis
- 20. 大隐静脉 great saphenous v.



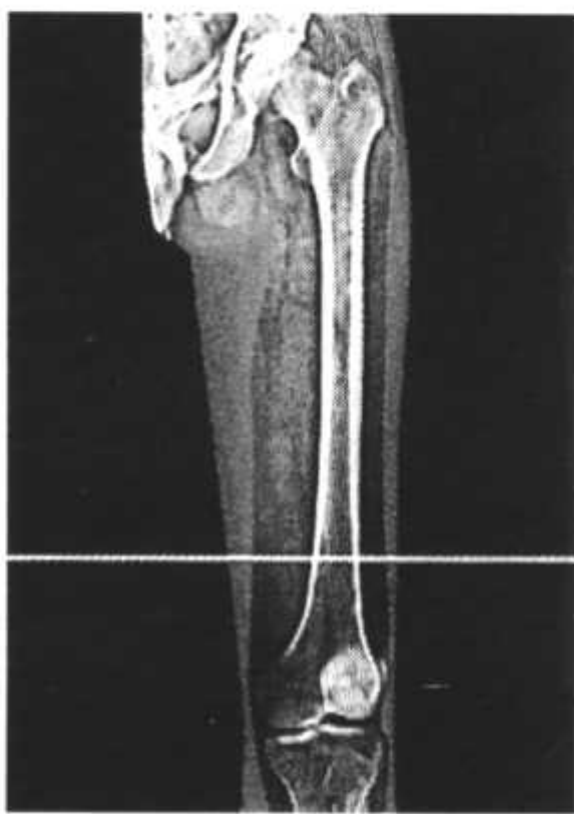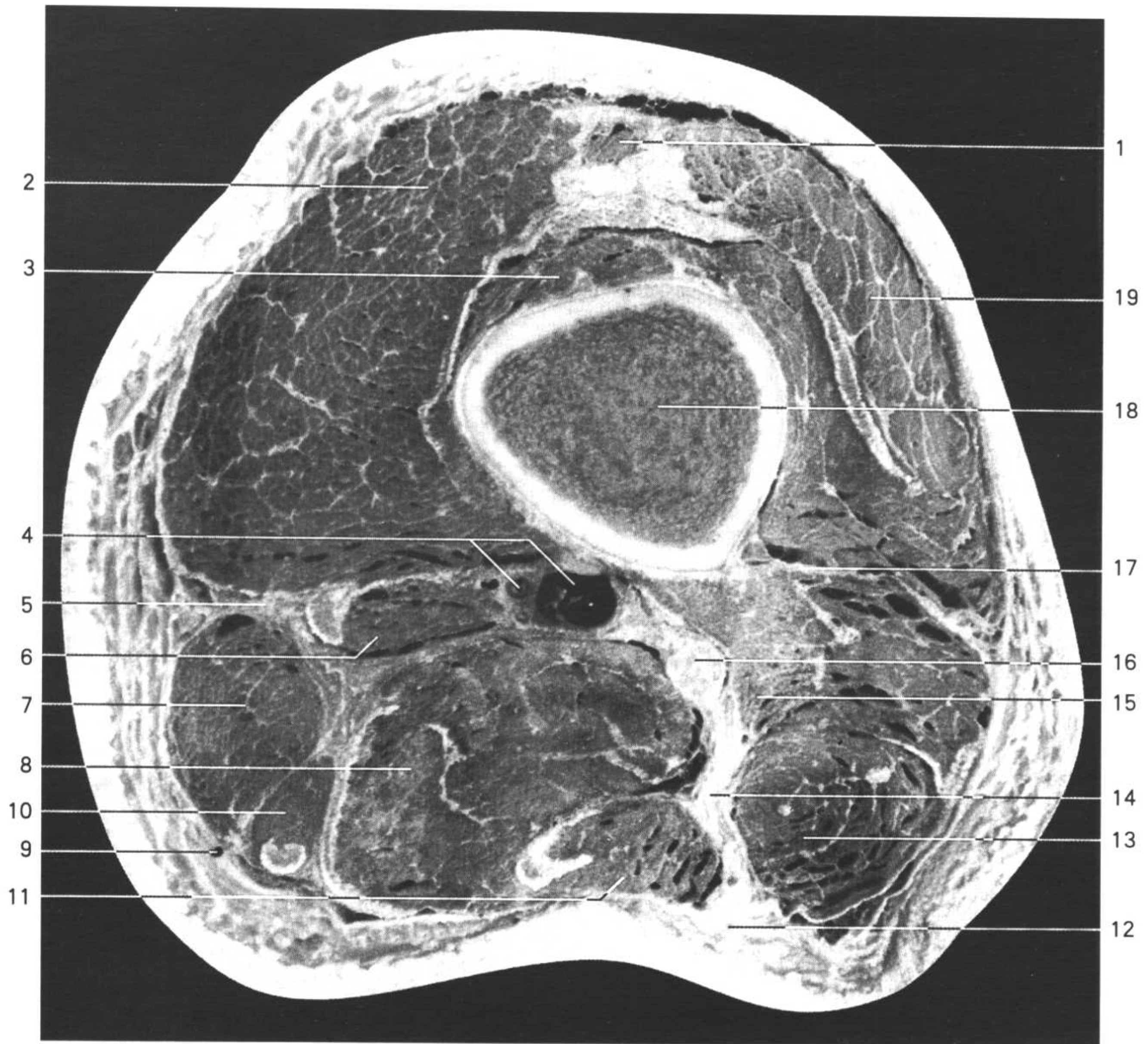
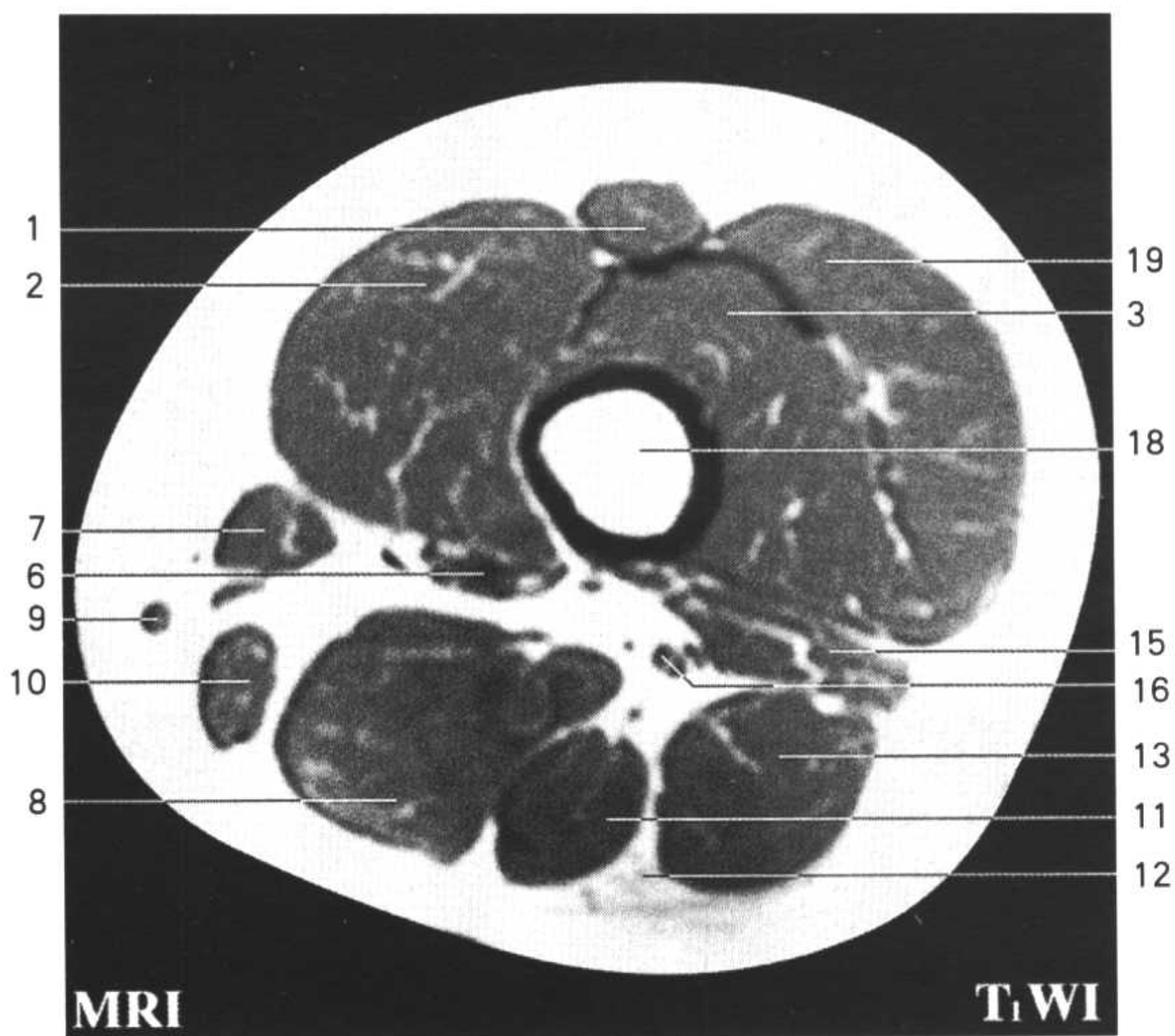
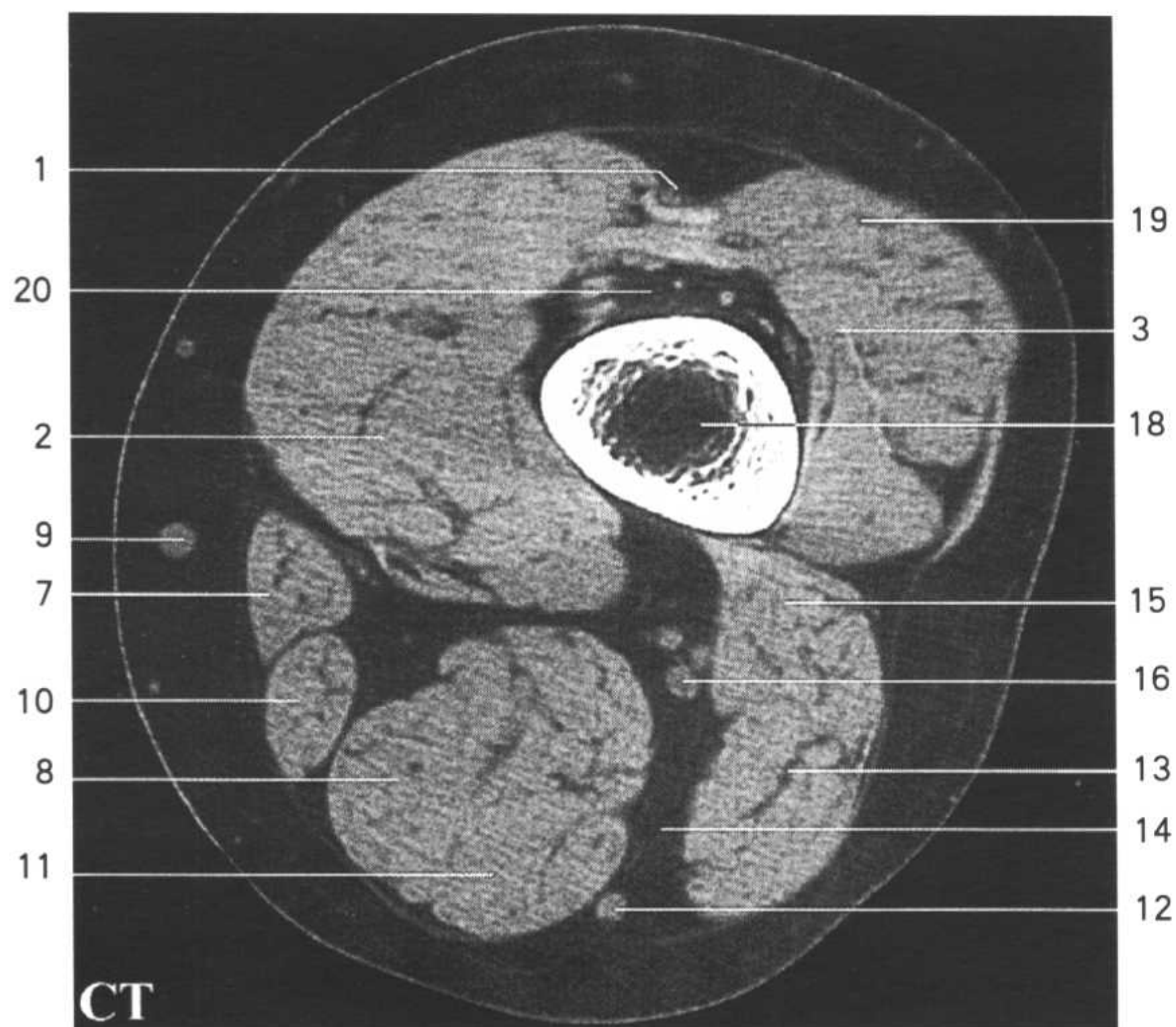


Fig.HLL 3

1. 股直肌 rectus femoris
2. 股内侧肌 vastus medialis
3. 股中间肌 vastus intermedius
4. 股动、静脉 femoral a. and v.
5. 股内侧肌间隔 medial femoral intermuscular septum
6. 大收肌 adductor magnus
7. 缝匠肌 sartorius
8. 半膜肌 semimembranosus
9. 大隐静脉 great saphenous v.

- 10. 股薄肌 gracilis
- 11. 半腱肌 semitendinosus
- 12. 股后皮神经 posterior femoral cutaneous n.
- 13. 股二头肌长头 long head of biceps femoris
- 14. 股后肌间隔 posterior femoral intermuscular septum
- 15. 股二头肌短头 short head of biceps femoris
- 16. 坐骨神经 sciatic n.
- 17. 股外侧肌间隔 lateral femoral intermuscular septum
- 18. 股骨 femur
- 19. 股外侧肌 vastus lateralis
- 20. 髌上囊 suprapatellar bursa



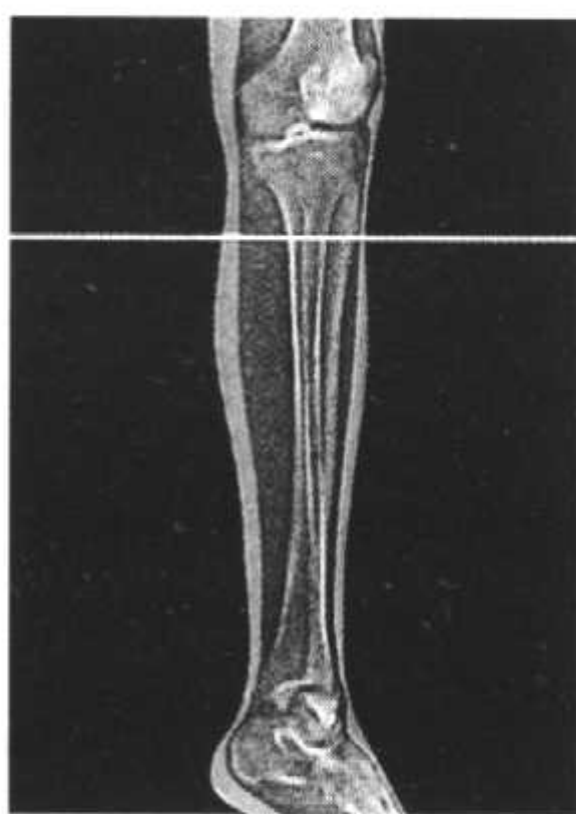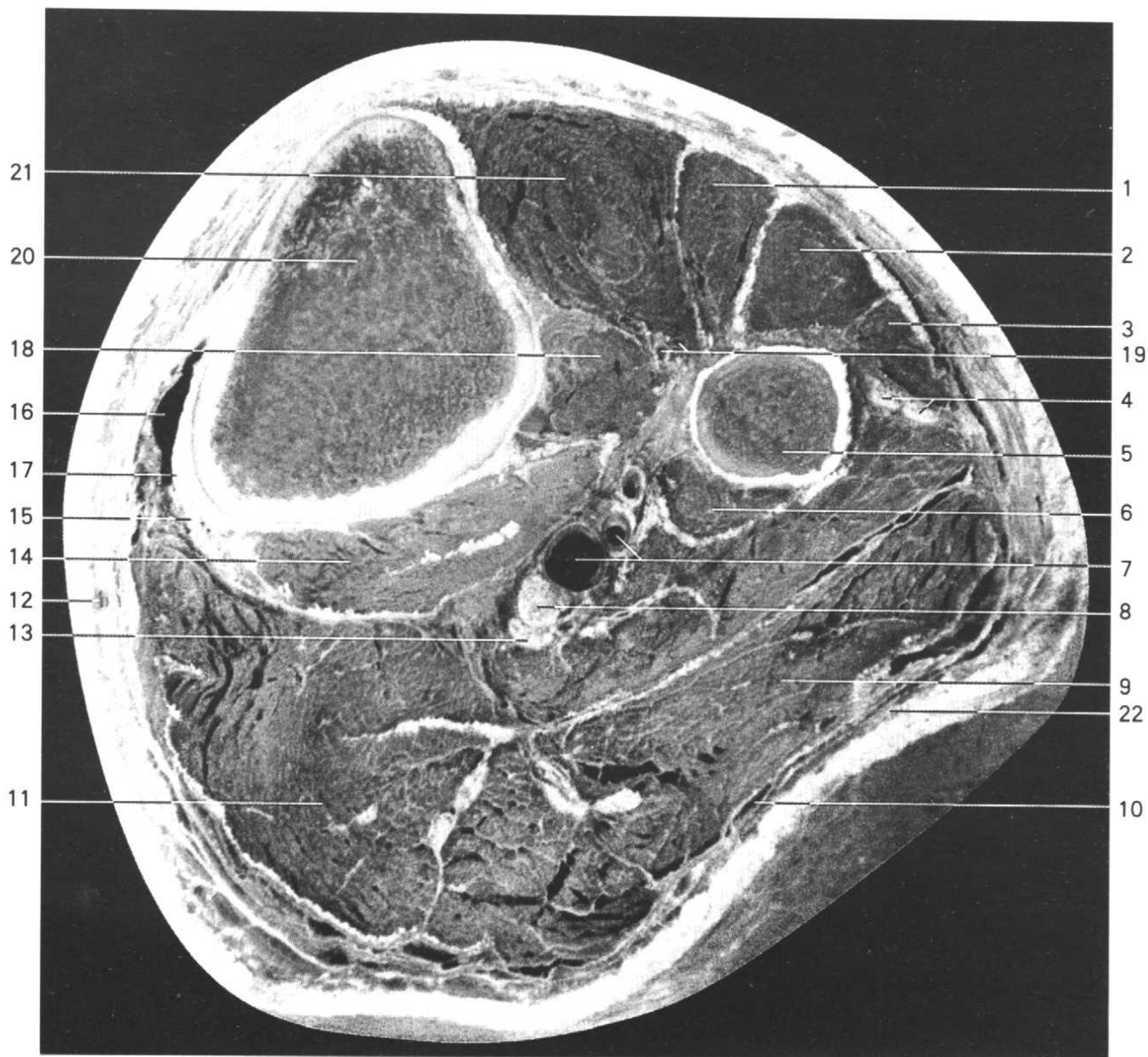
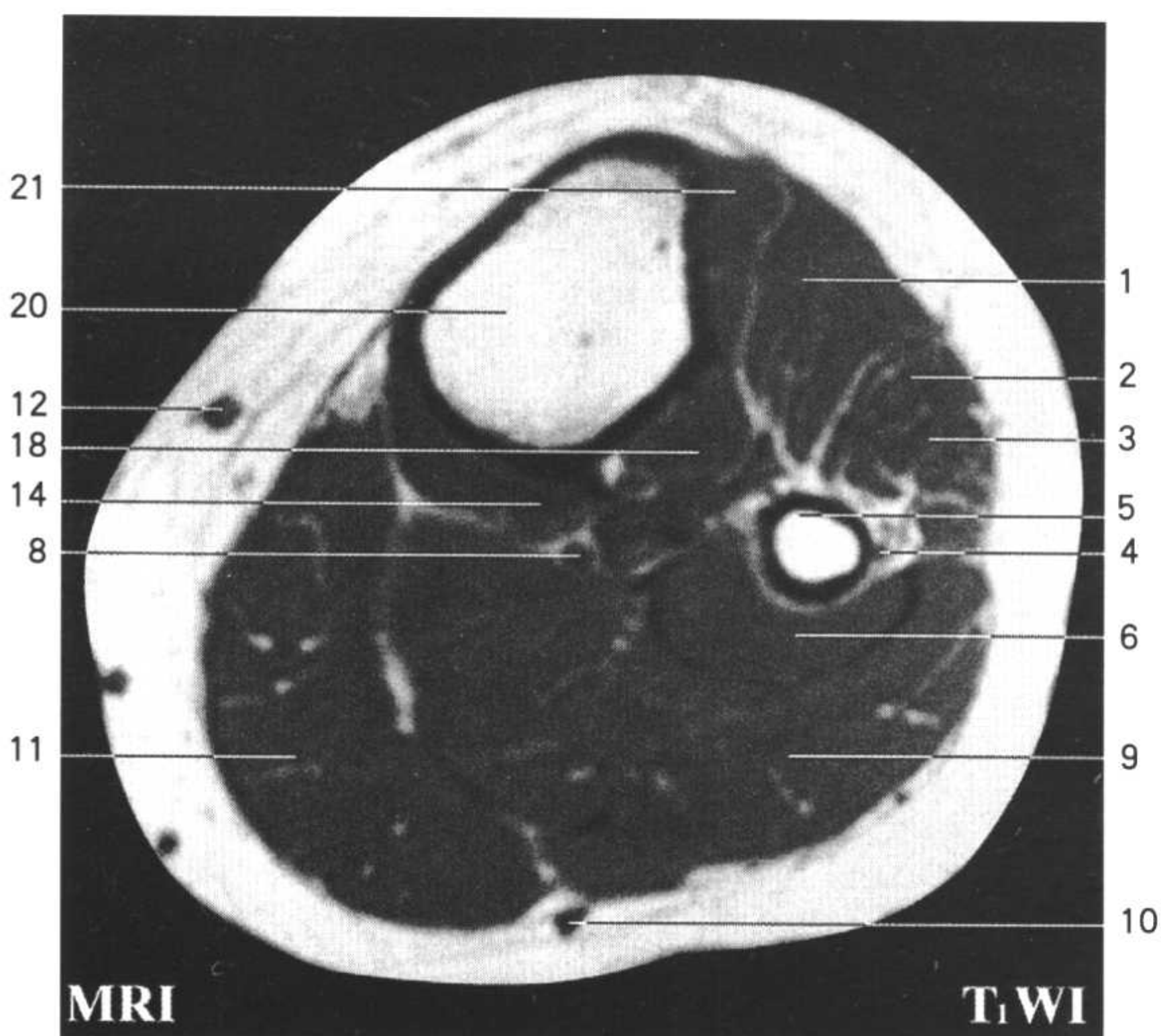
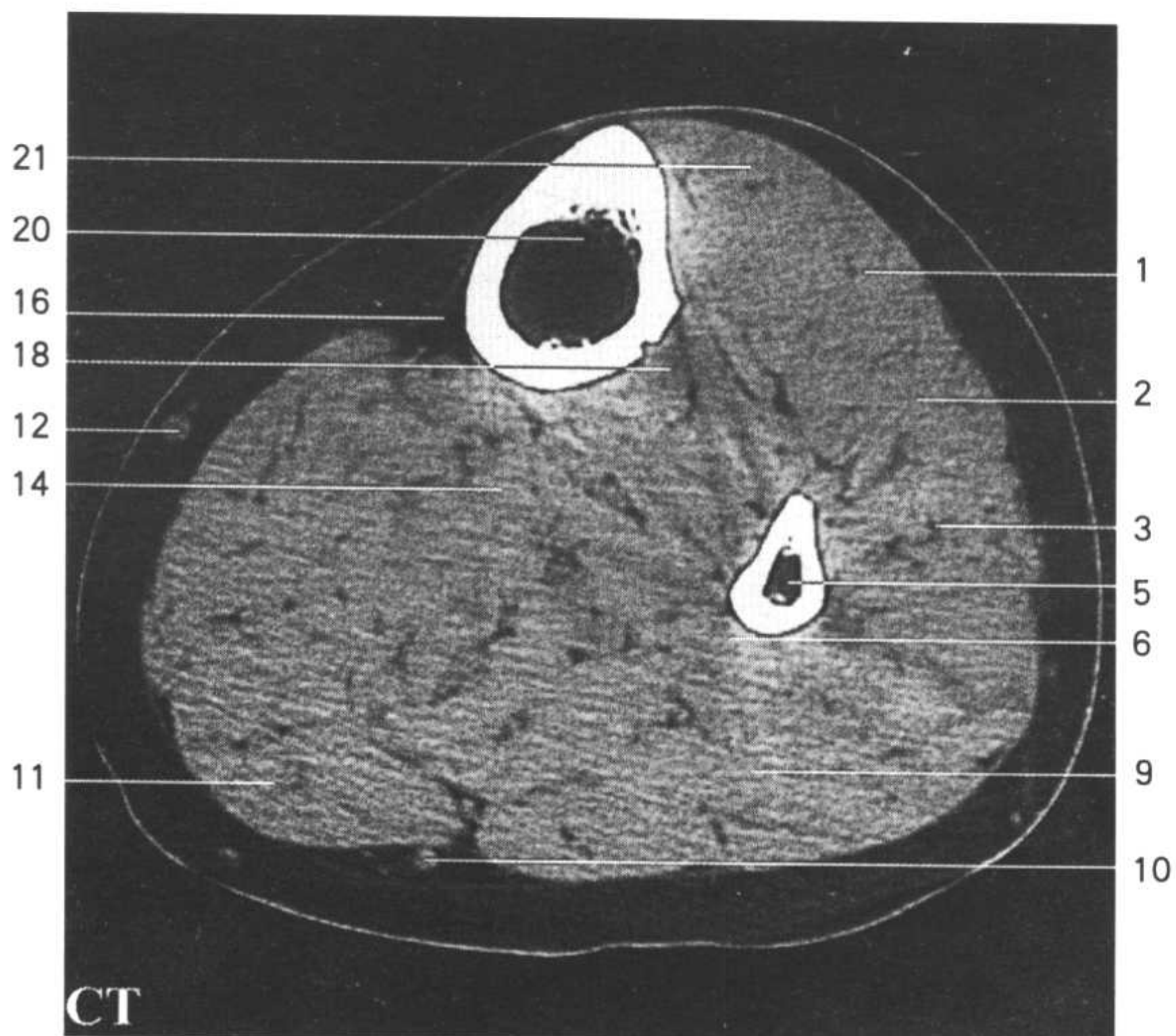


Fig.HLL 4

1. 趾长伸肌 extensor digitorum longus
2. 腓骨长肌 peroneus longus
3. 腓骨短肌 peroneus brevis
4. 腓总神经 common peroneal n.
5. 腓骨 fibula
6. 比目鱼肌 soleus
7. 胫后动、静脉 posterior tibial a. and v.
8. 胫神经 tibial n.
9. 腓肠肌外侧头 lateral head of gastrocnemius
10. 小隐静脉 small saphenous v.

- 11. 腓肠肌内侧头 medial head of gastrocnemius
- 12. 大隐静脉 great saphenous v.
- 13. 跖肌 plantaris
- 14. 腓肌 popliteus
- 15. 半膜肌、半腱肌腱 tendon of semimembranosus and svemi-tendinosus
- 16. 鹅足囊 anserine bursa
- 17. 缝匠肌、股薄肌腱 tendon of sartorius and gracilis
- 18. 胫骨后肌 tibialis posterior
- 19. 胫前动、静脉 anterior tibial a. and v.
- 20. 胫骨 tibia
- 21. 胫骨前肌 tibialis anterior
- 22. 腓肠外侧皮神经 lateral sural cutaneous n.



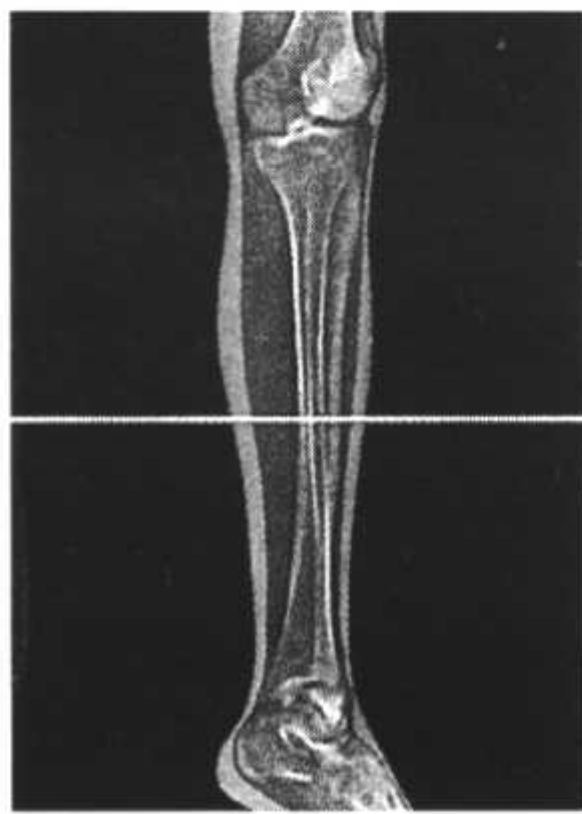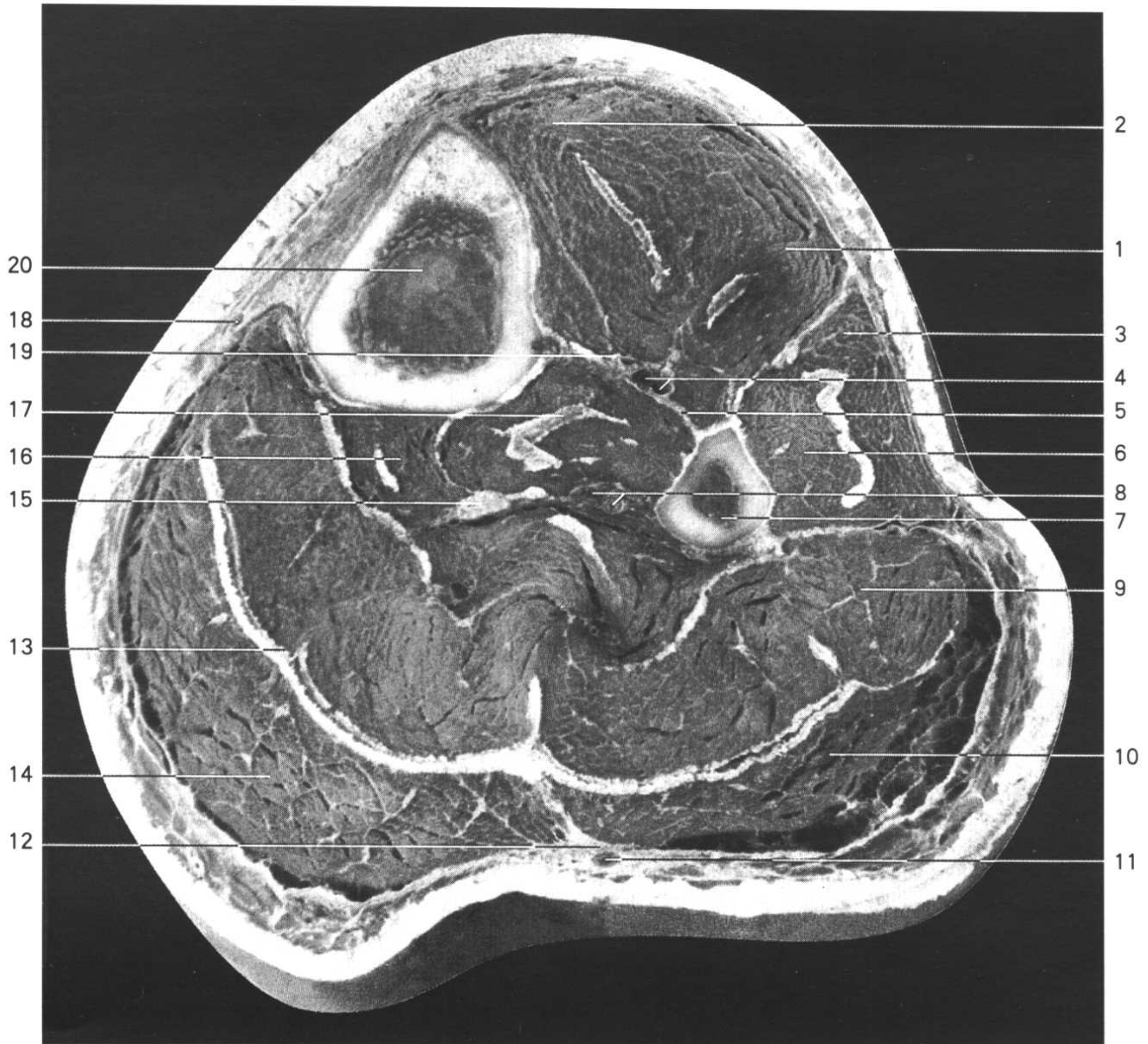
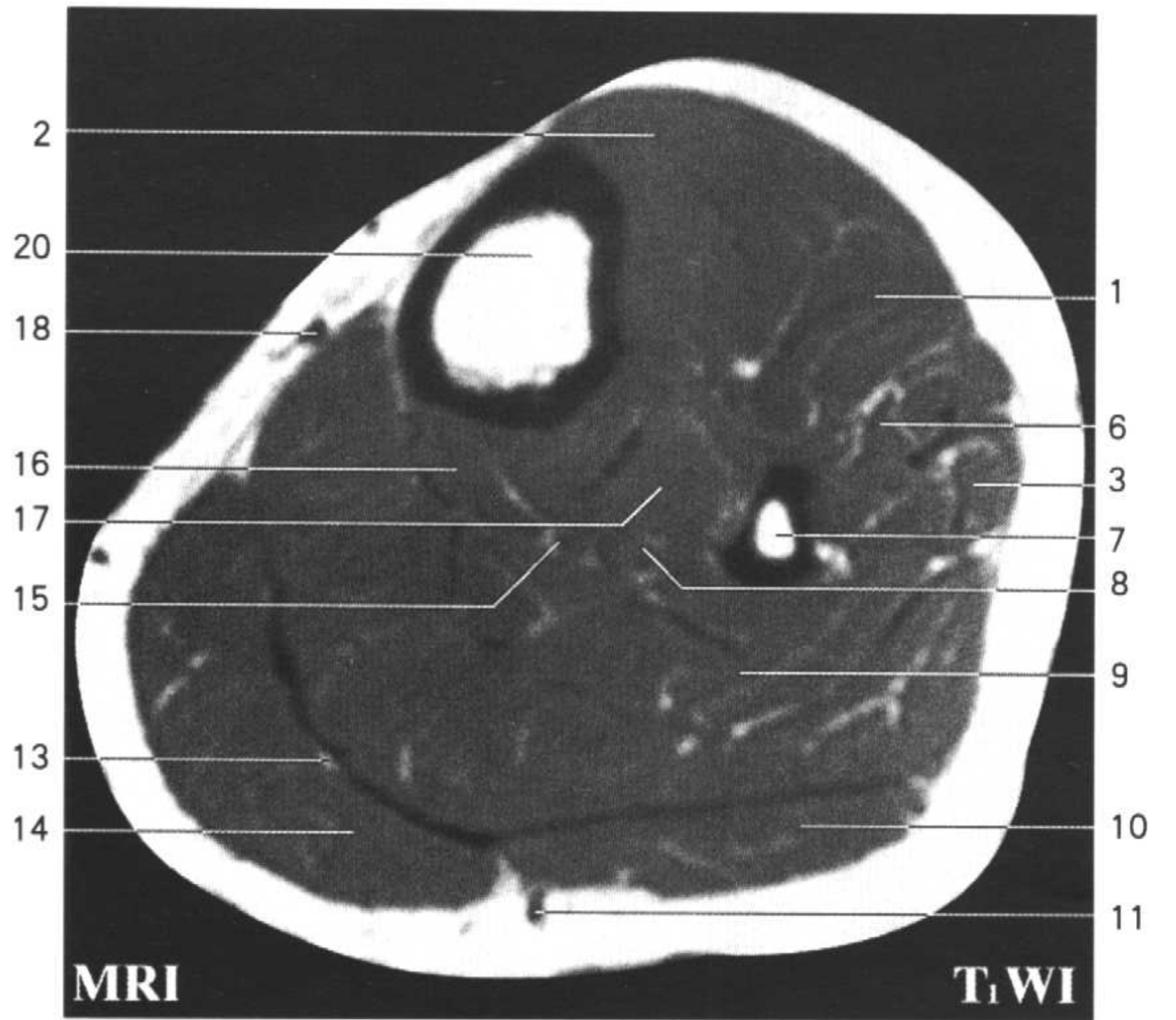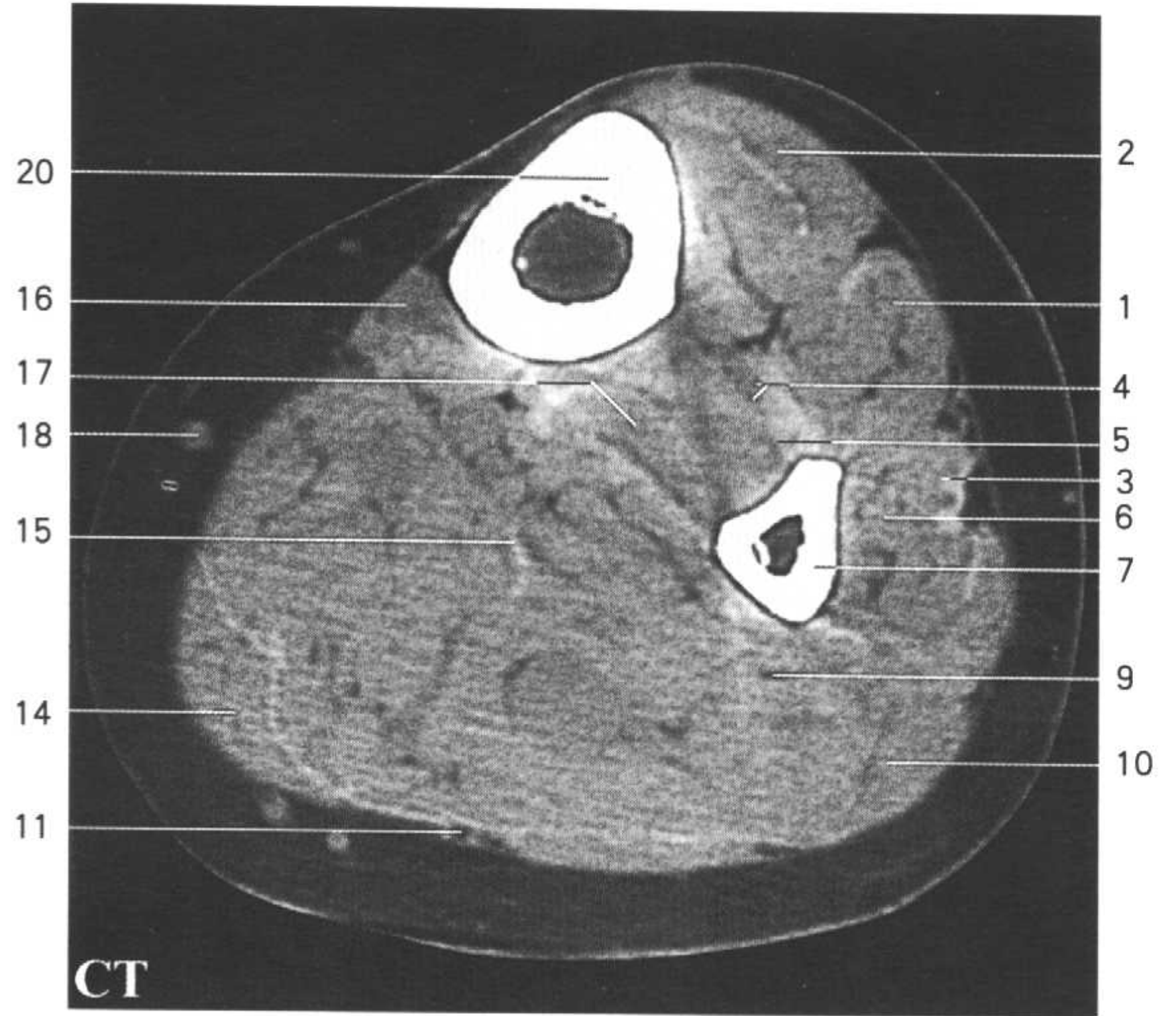


Fig.HLL 5

1. 趾长伸肌 extensor digitorum longus
2. 胫骨前肌 tibialis anterior
3. 腓骨长肌 peroneus longus
4. 胫前动、静脉 anterior tibial a. and v.
5. 小腿骨间膜 crural interosseous membrane
6. 腓骨短肌 peroneus brevis
7. 腓骨 fibula
8. 胫后动、静脉 posterior tibial a. and v.
9. 比目鱼肌 soleus
10. 腓肠肌外侧头 lateral head of gastrocnemius

- 11. 小隐静脉 small saphenous v.
- 12. 腓肠内侧皮神经 medial sural cutaneous n.
- 13. 跖肌腱 tendon of plantaris
- 14. 腓肠肌内侧头 medial head of gastrocnemius
- 15. 胫神经 tibial n.
- 16. 趾长屈肌 flexor digitorum longus
- 17. 胫骨后肌 tibialis posterior
- 18. 大隐静脉 great saphenous v.
- 19. 腓深神经 deep peroneal n.
- 20. 胫骨 tibia



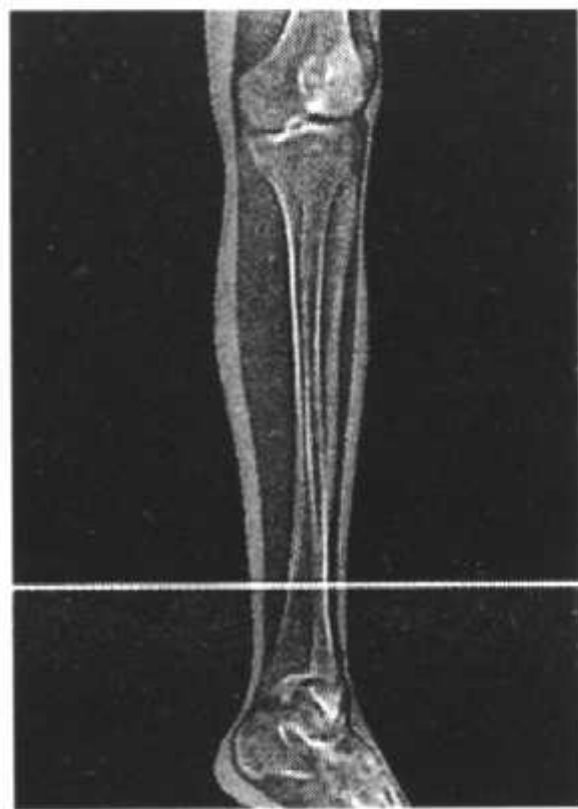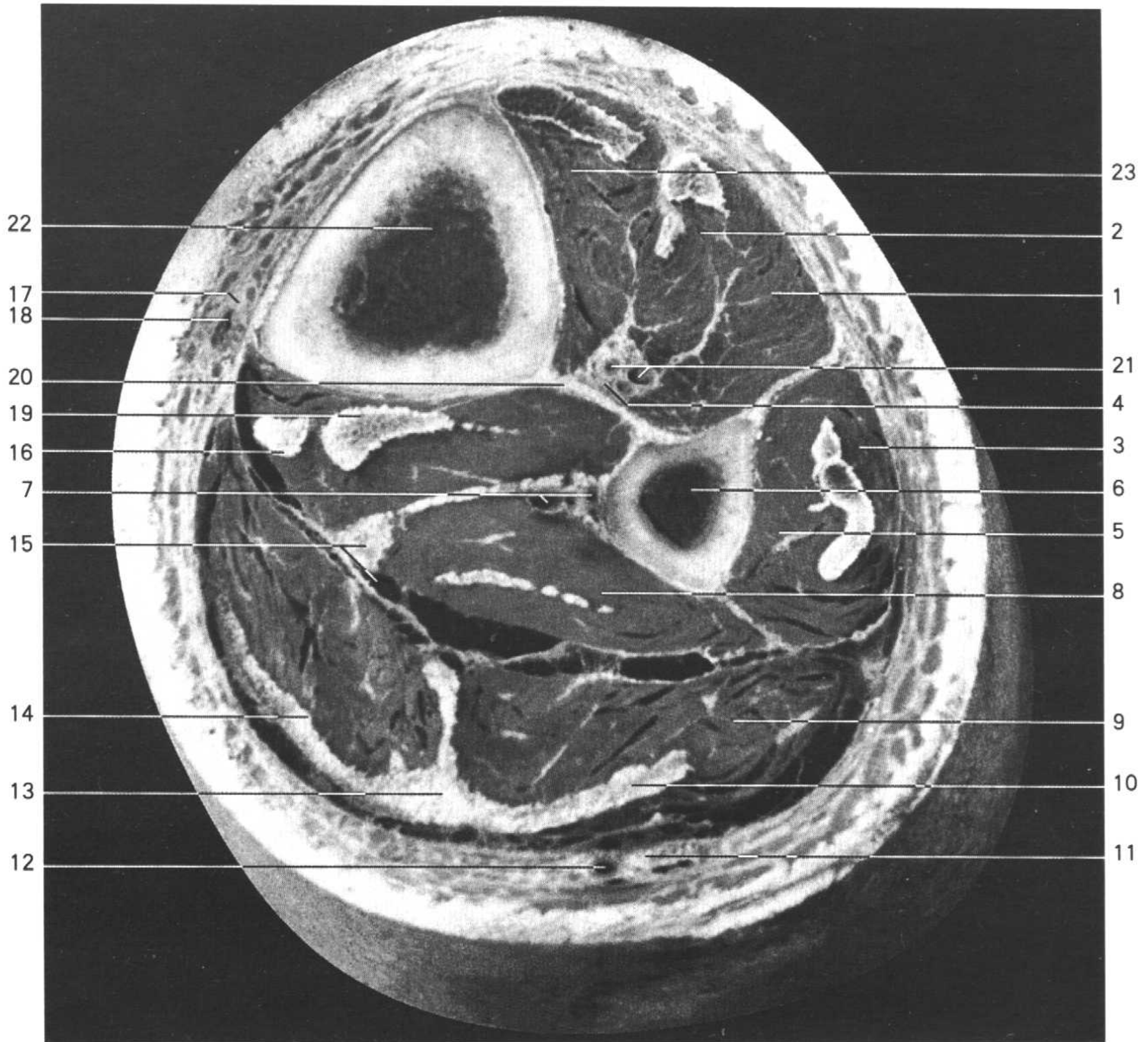
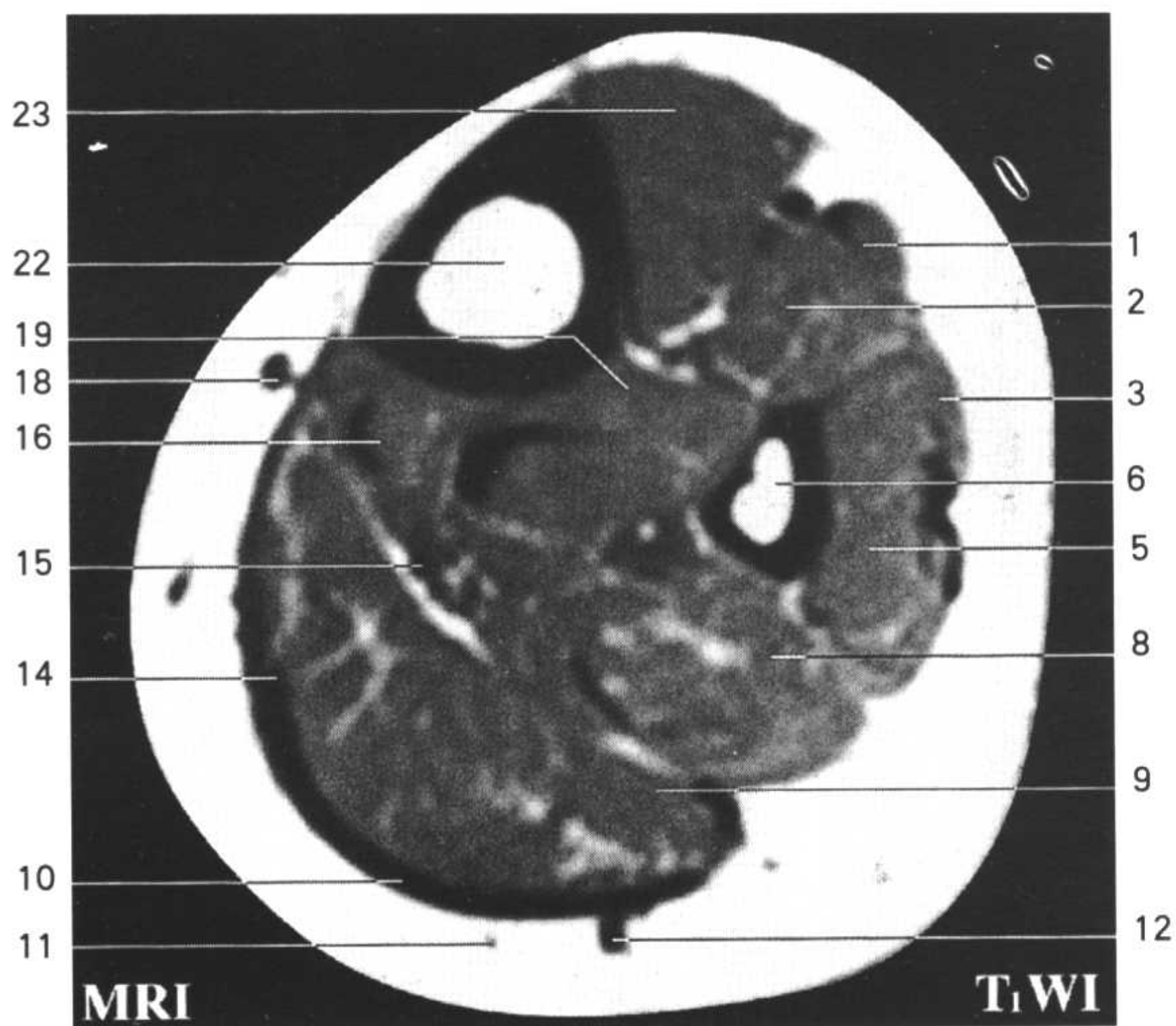
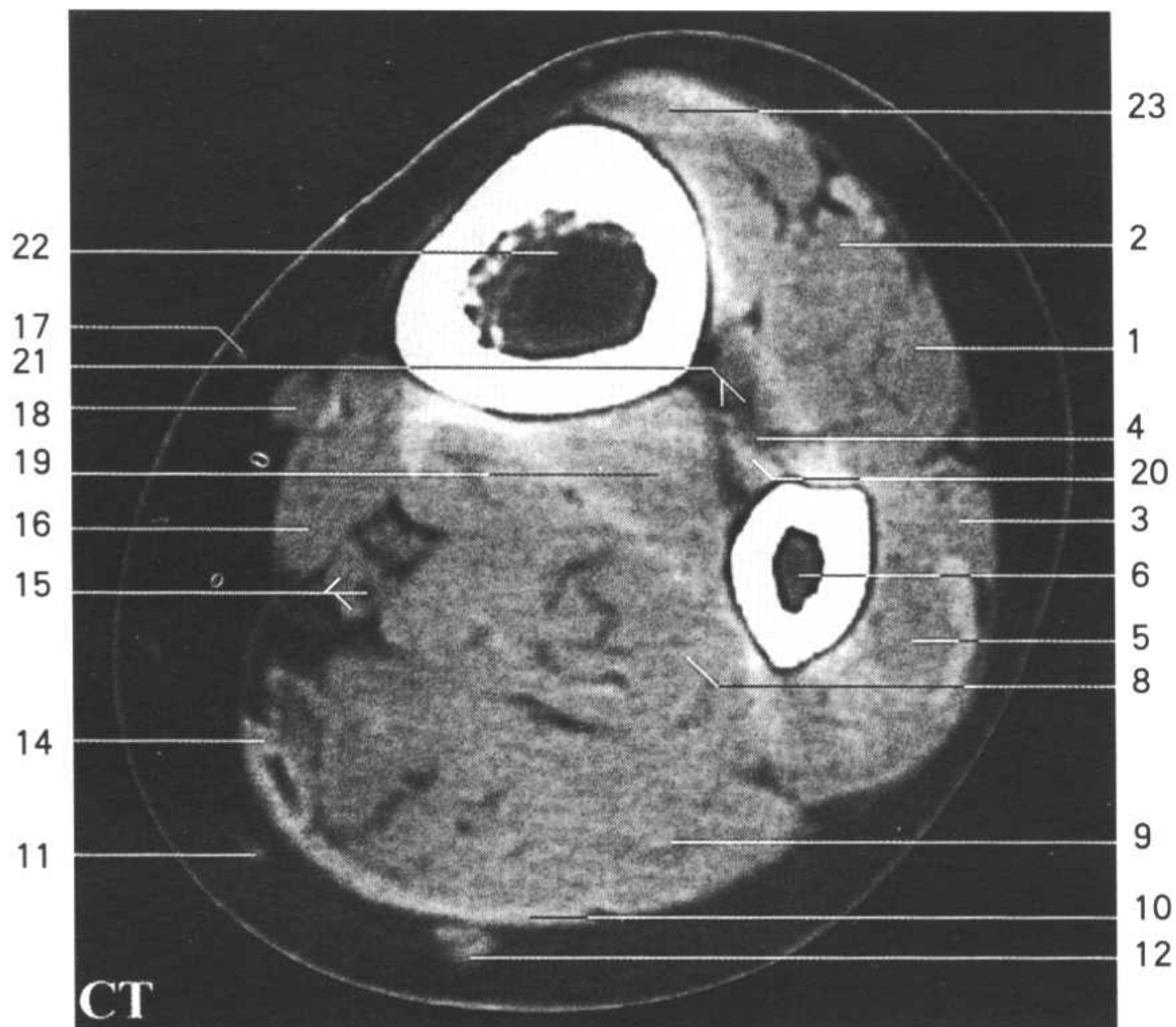

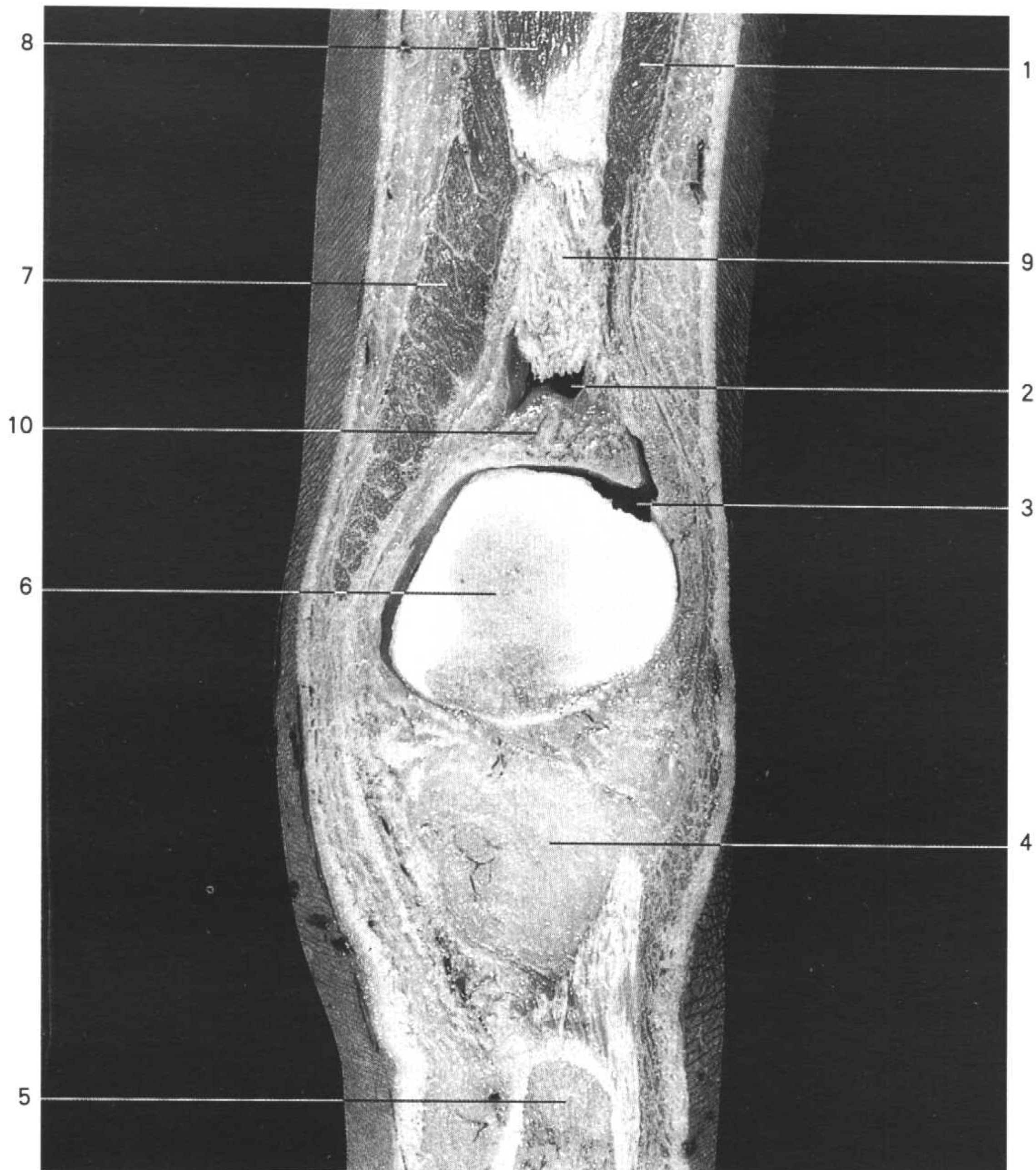
Fig.HLL 6

1. 趾长伸肌 extensor digitorum longus
2. 踇长伸肌 extensor hallucis longus
3. 腓骨长肌 peroneus longus
4. 腓深神经 deep peroneal n.
5. 腓骨短肌 peroneus brevis
6. 腓骨 fibula
7. 腓动、静脉 peroneal a. and v.
8. 踇长屈肌 flexor hallucis longus
9. 比目鱼肌 soleus
10. 腓肠肌腱 tendon of gastrocnemius

- 11. 腓肠神经 sural n.
- 12. 小隐静脉 small saphenous v.
- 13. 腓肠肌腱 tendon of gastrocnemius
- 14. 跖肌腱 tendon of plantaris
- 15. 胫神经与胫后动、静脉 tibial n. and posterior tibial a., v.
- 16. 趾长屈肌 flexor digitorum longus
- 17. 隐神经 saphenous n.
- 18. 大隐静脉 great saphenous v.
- 19. 胫骨后肌 tibialis posterior
- 20. 小腿骨间膜 crural interosseous membrane
- 21. 胫前动、静脉 anterior tibial a. and v.
- 22. 胫骨 tibia
- 23. 胫骨前肌 tibialis anterior

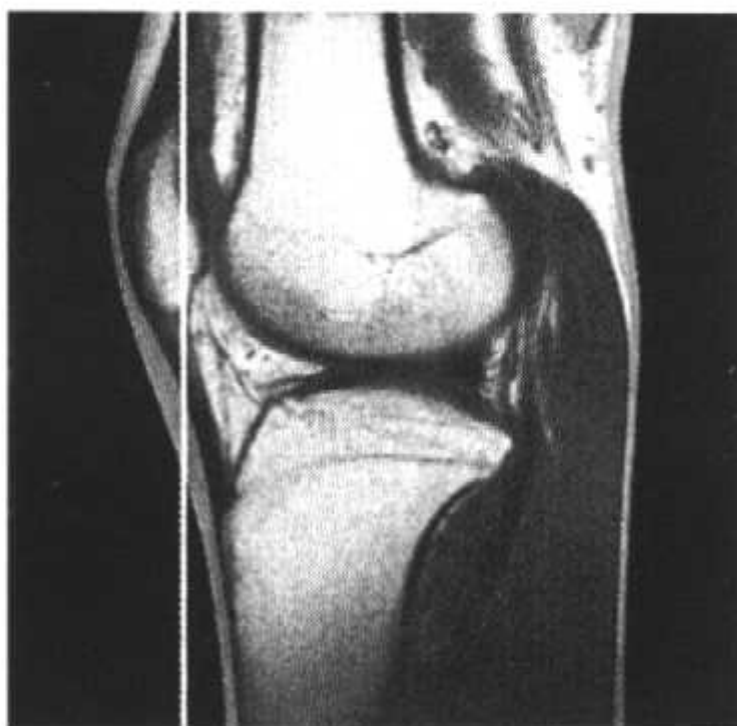



左膝关节额状断面FK(L)

Fig.FK(L) 1

1. 股外侧肌 vastus lateralis
2. 髌上囊 suprapatellar bursa
3. 膝关节腔 articular cavity of knee joint
4. 髌下脂体 infrapatellar fat pad
5. 髌韧带 patellar ligament
6. 髌骨 patella
7. 股内侧肌 vastus medialis
8. 股直肌 rectus femoris
9. 股四头肌腱 tendon of quadriceps femoris
10. 髌上脂体 suprapatellar fat pad



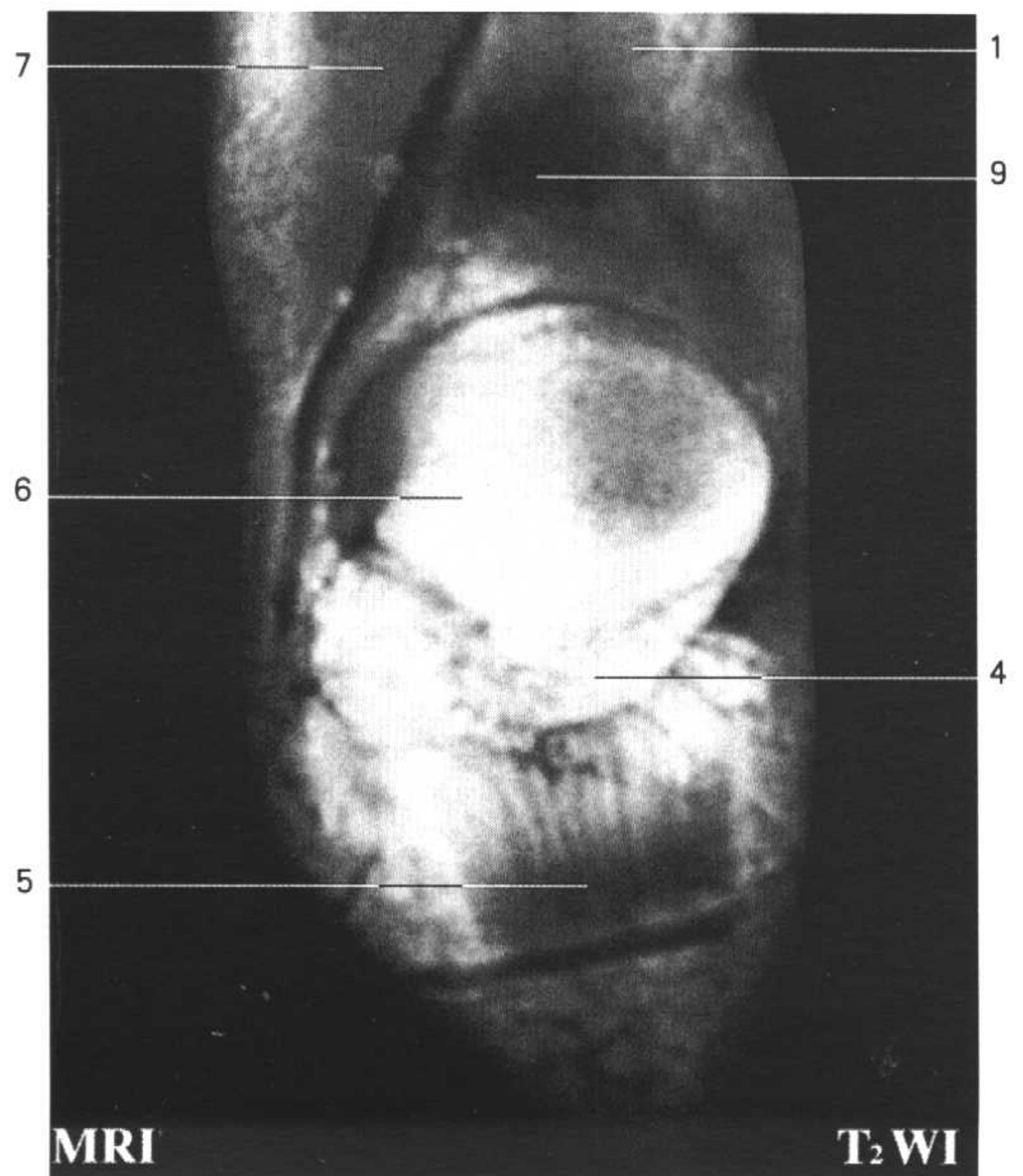
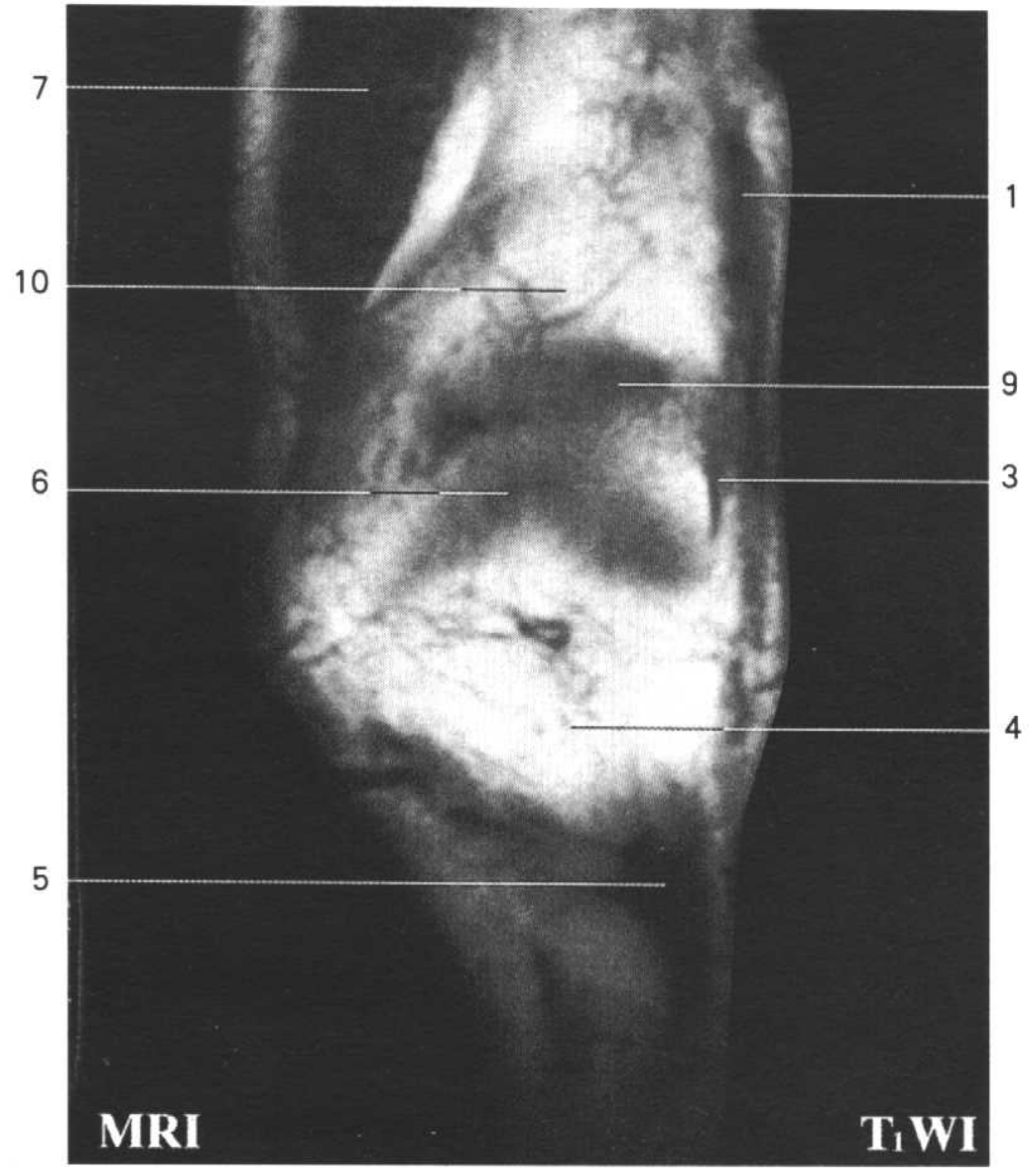
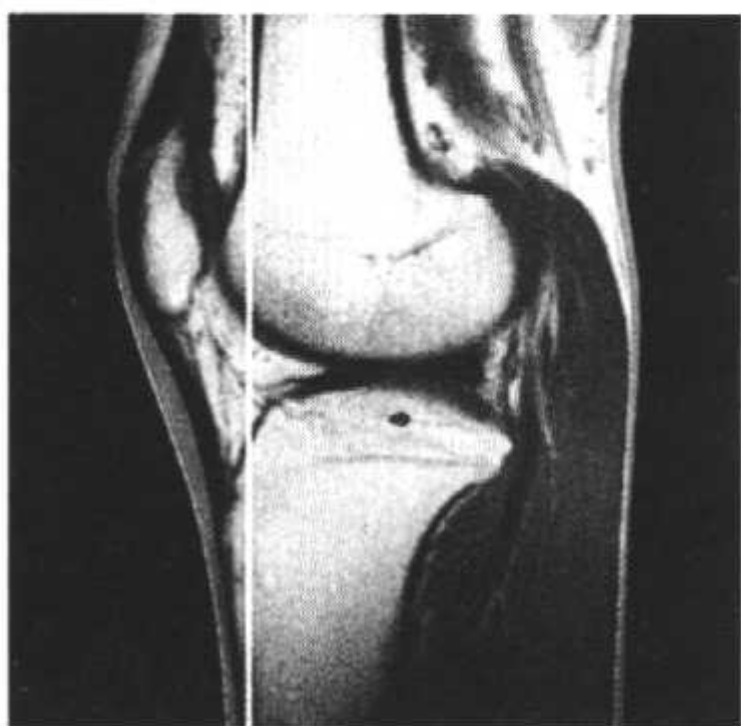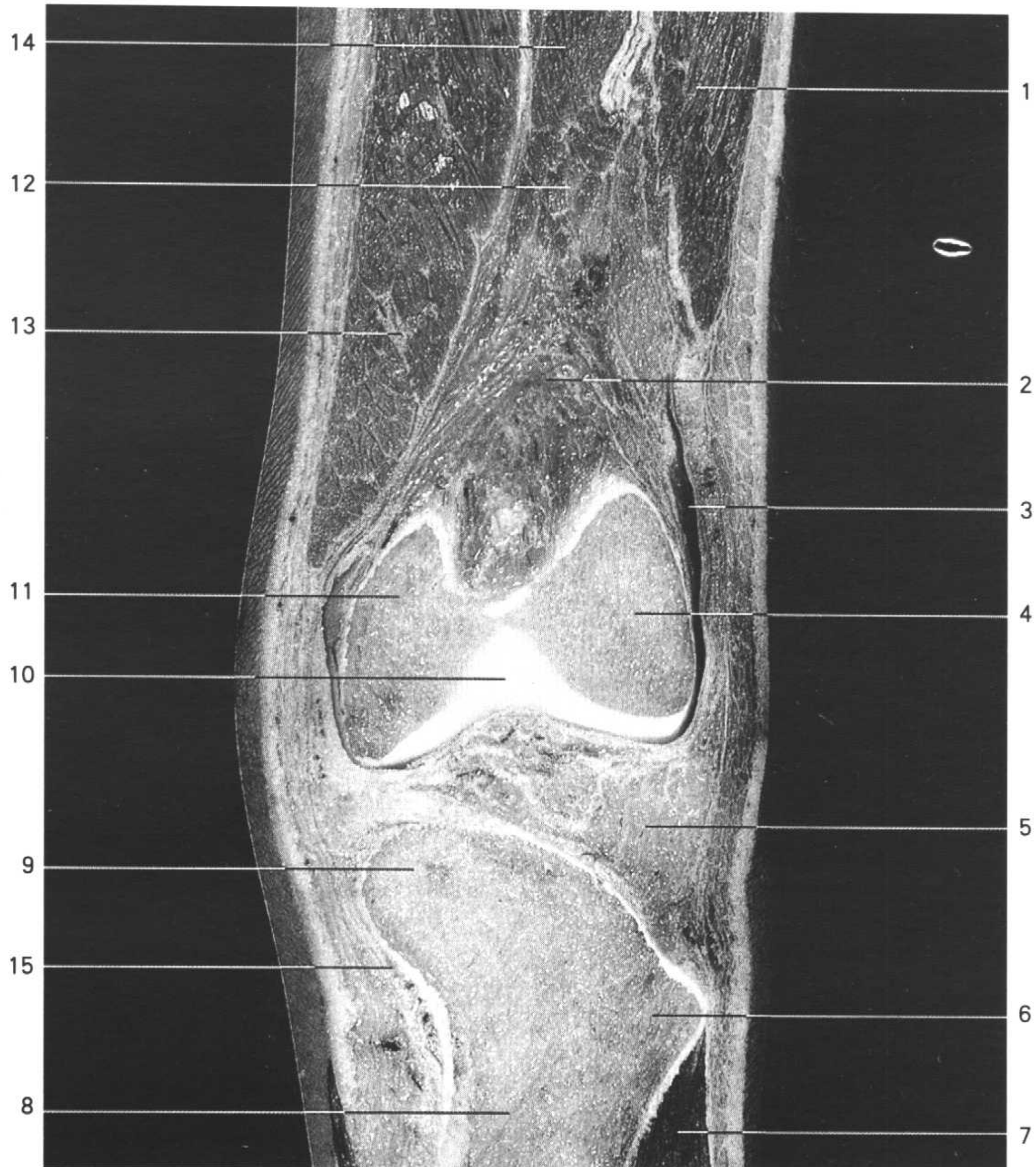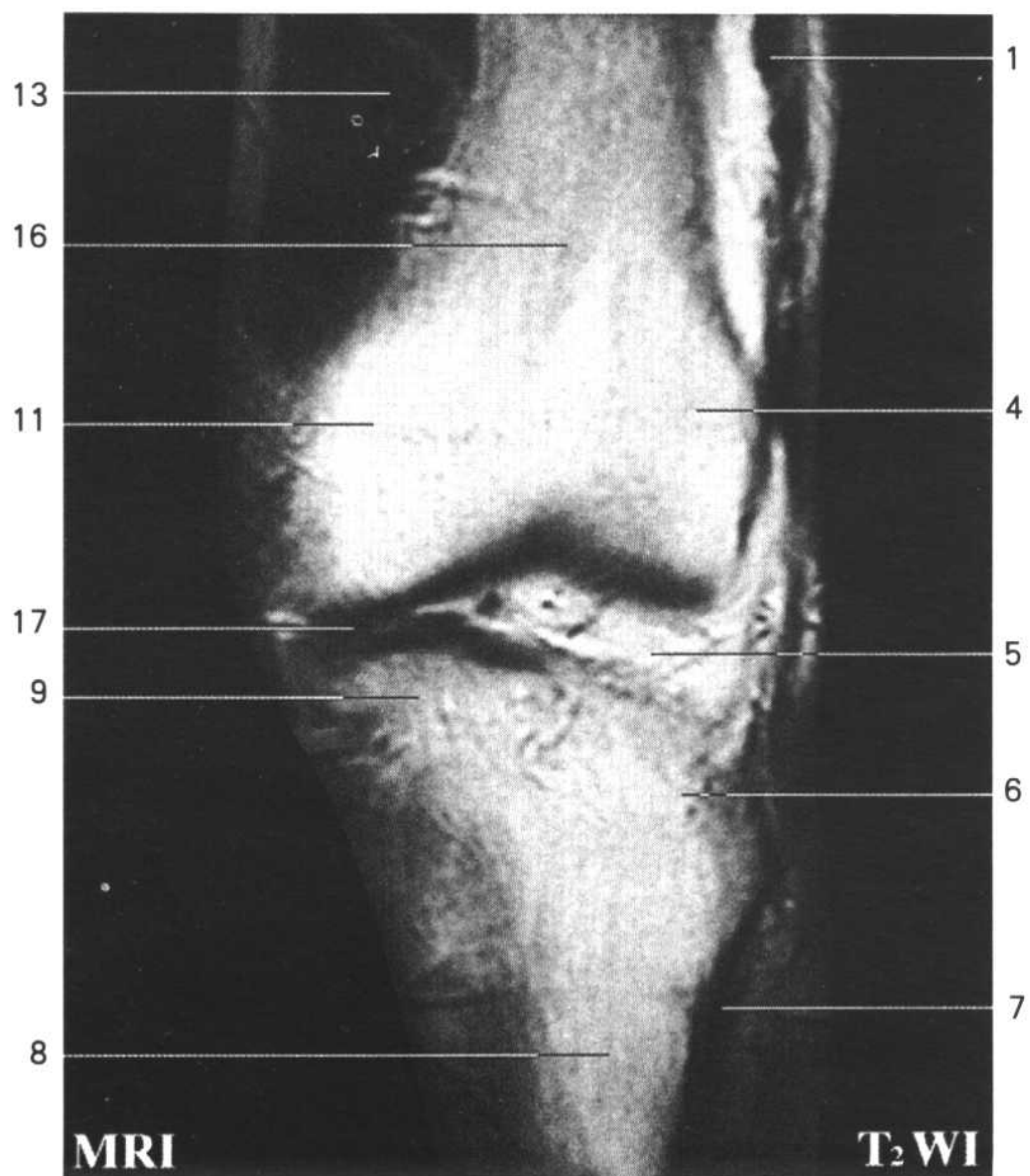
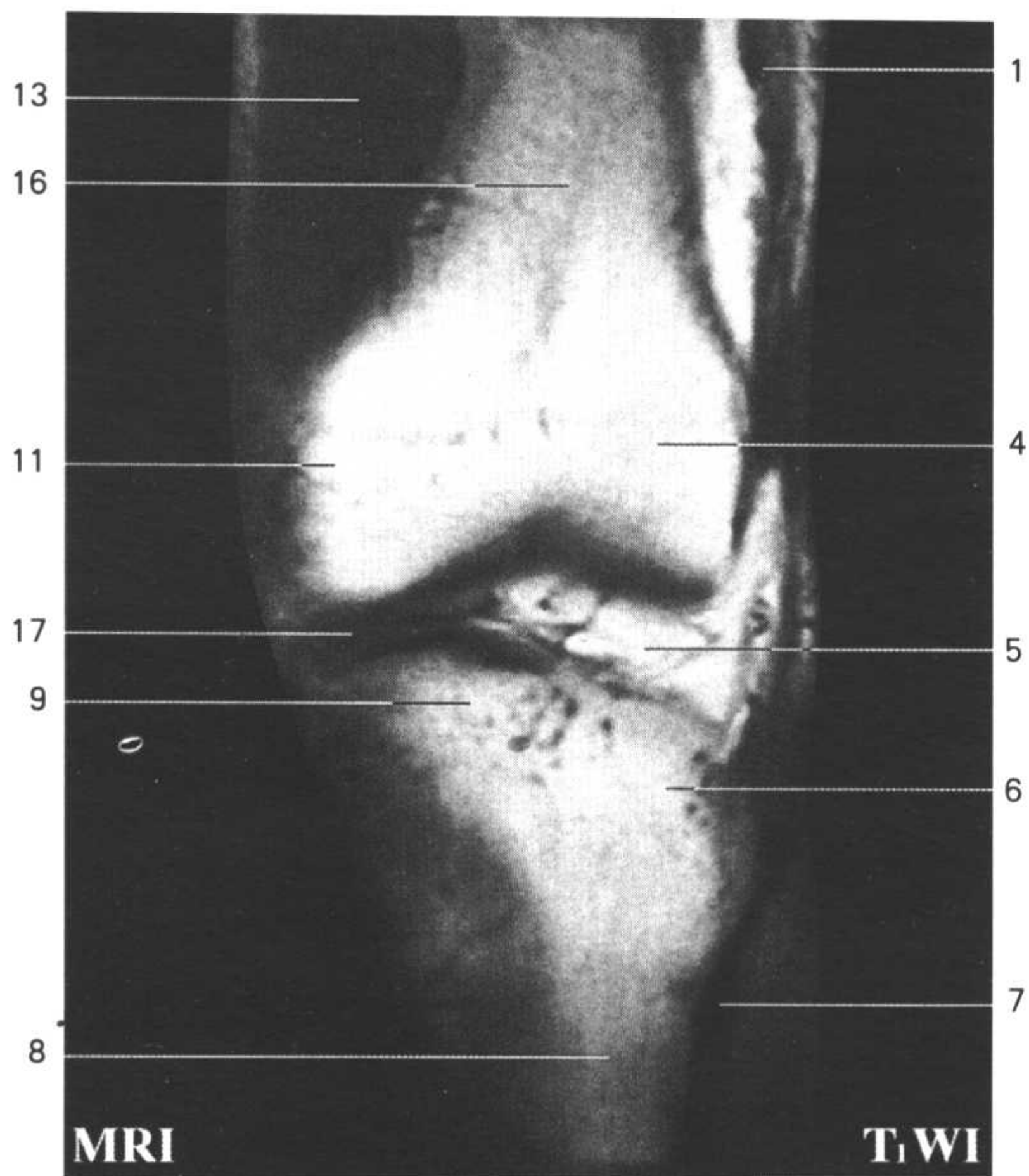




Fig.FK(L) 2

1. 股外侧肌 vastus lateralis
2. 膝关节肌 articularis genus
3. 关节腔 articular cavity
4. 股骨外侧髁 lateral condyle of femur
5. 髌下脂体 infrapatellar fat pad
6. 胫骨外侧髁 lateral condyle of tibia
7. 胫骨前肌 tibialis anterior
8. 胫骨 tibia
9. 胫骨内侧髁 medial condyle of tibia
10. 髌面 patellar surface

- 11. 股骨内侧髁 medial condyle of femur
- 12. 膝关节肌 articularis genus
- 13. 股内侧肌 vastus medialis
- 14. 股中间肌 vastus intermedius
- 15. 缝匠肌与股薄肌腱 tendon of satorius and gracilis
- 16. 股骨 femur
- 17. 内侧半月板 medial meniscus



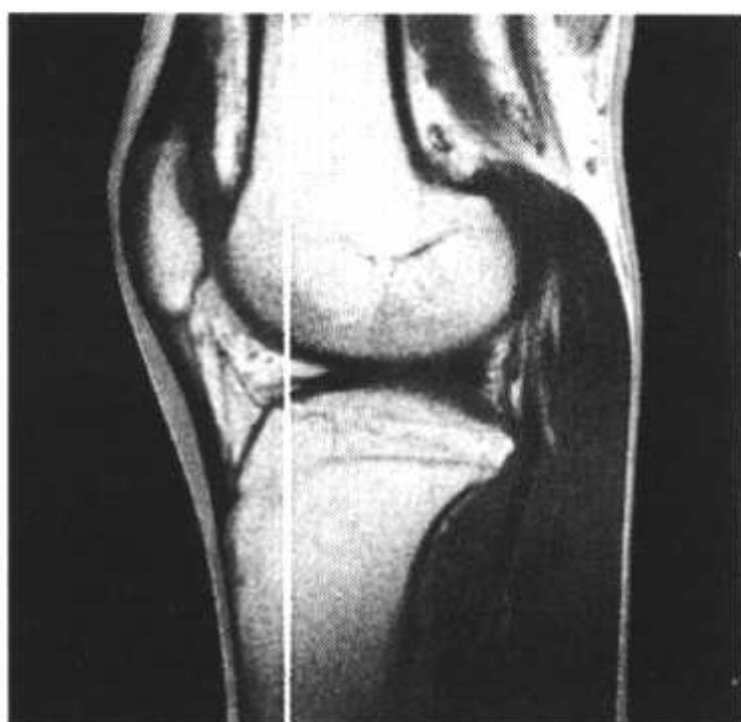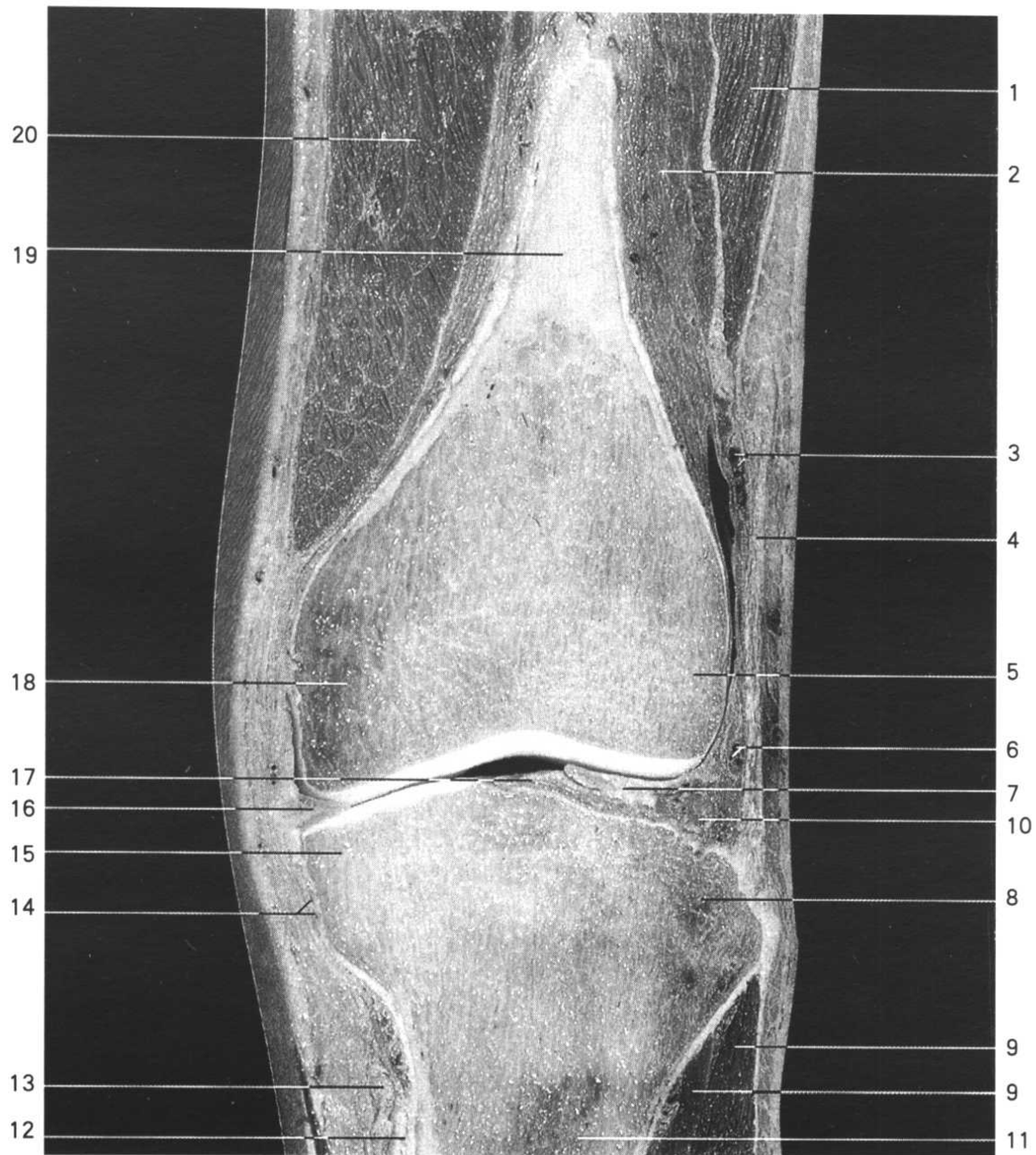
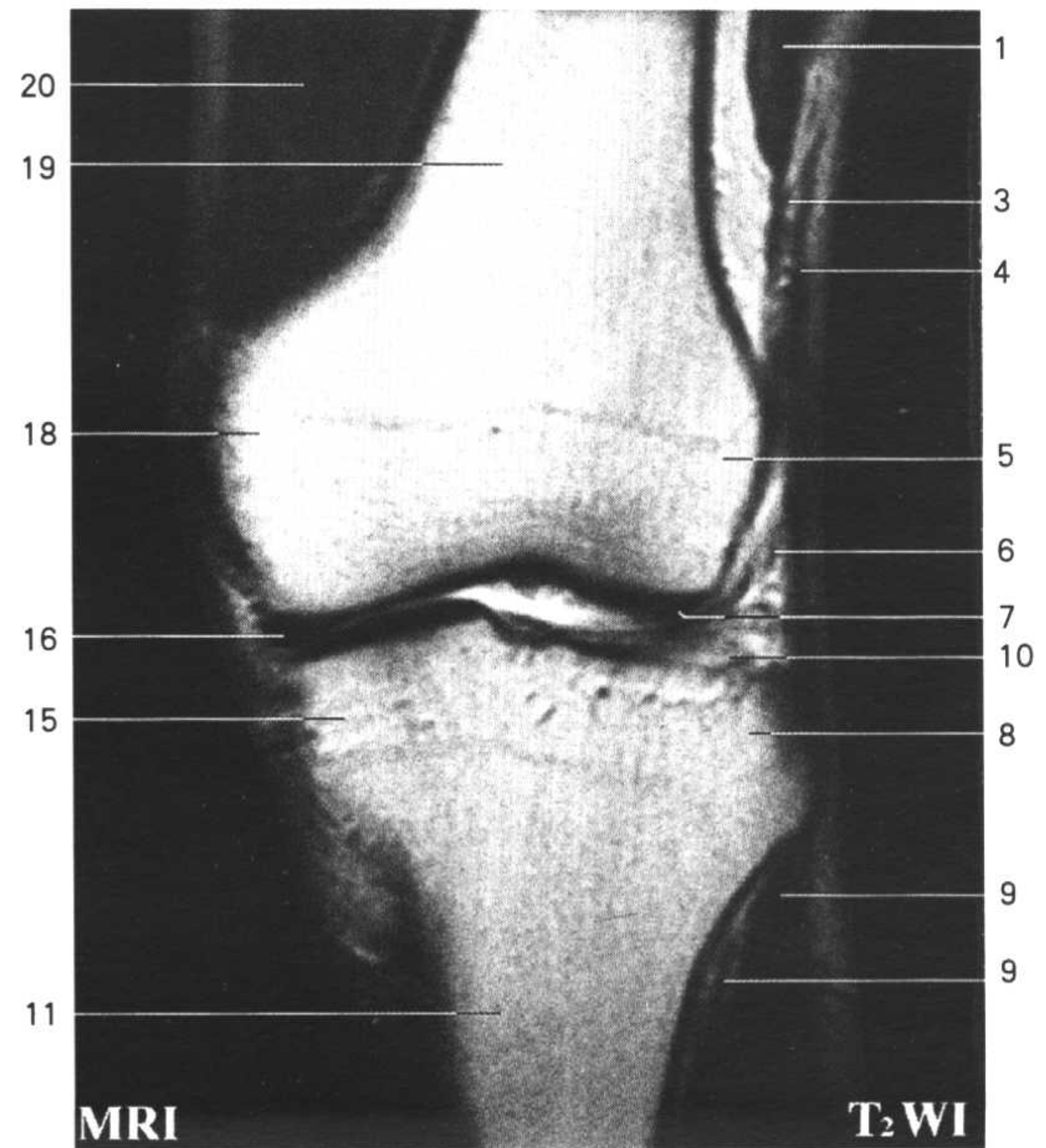
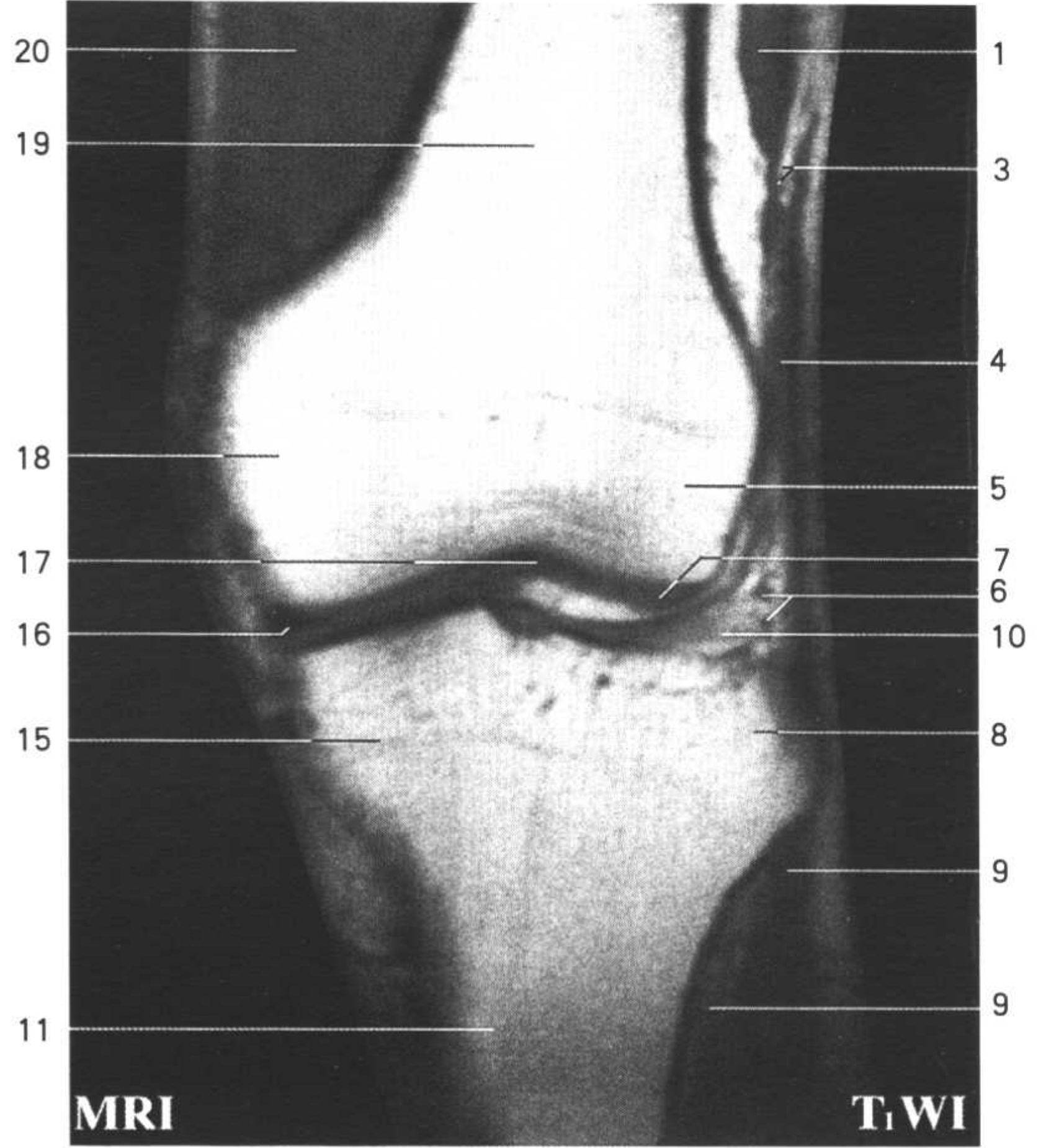


Fig.FK(L) 3

1. 股外侧肌 vastus lateralis
2. 股中间肌 vastus intermedius
3. 膝上外侧动、静脉 lateral superior genicular a. and v.
4. 髂胫束 iliotibial tract
5. 股骨外侧髁 lateral condyle of femur
6. 膝下外侧动、静脉 lateral inferior genicular a. and v.
7. 外侧半月板 lateral meniscus
8. 胫骨外侧髁 lateral condyle of tibia
9. 胫骨前肌 tibialis anterior

- 10. 髌下脂体 infrapatellar fat pad
- 11. 胫骨 tibia
- 12. 半腱肌腱 tendon of semitendinosus
- 13. 半膜肌腱 tendon of semimembranosus
- 14. 缝匠肌及股薄肌腱 tendon of sartorius and gracilis
- 15. 胫骨内侧髁 medial condyle of tibia
- 16. 内侧半月板 medial meniscus
- 17. 膝横韧带 transverse ligament of knee
- 18. 股骨内侧髁 medial condyle of femur
- 19. 股骨 femur
- 20. 股内侧肌 vastus medialis



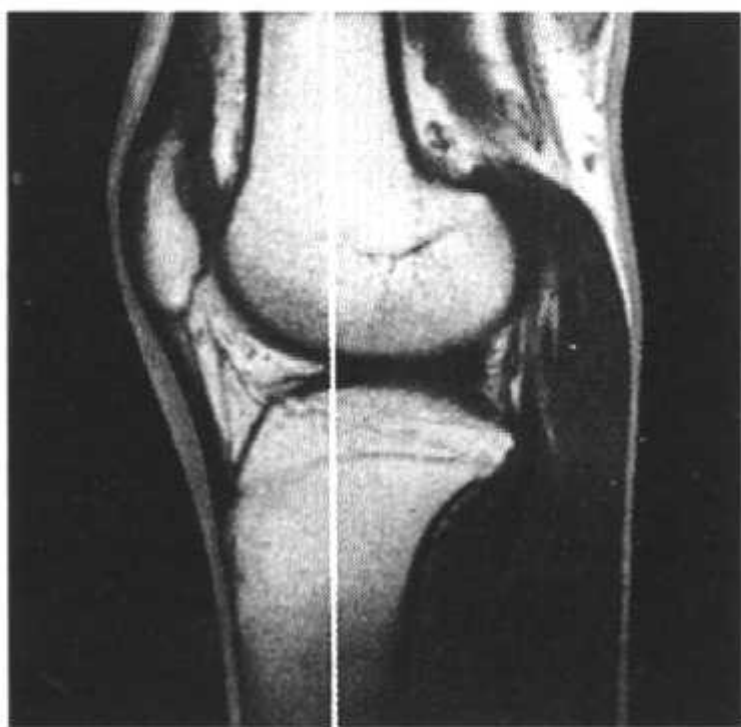
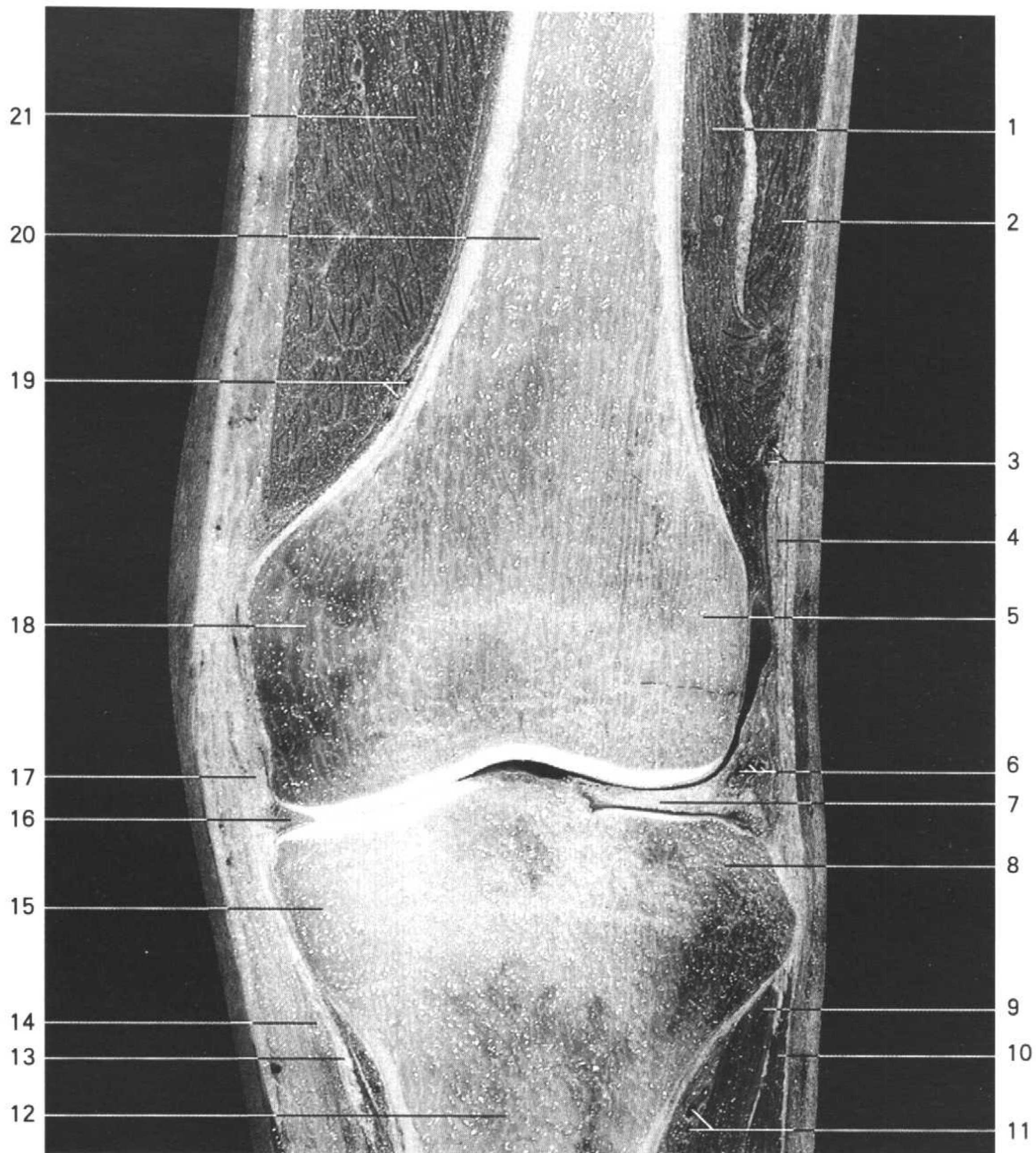
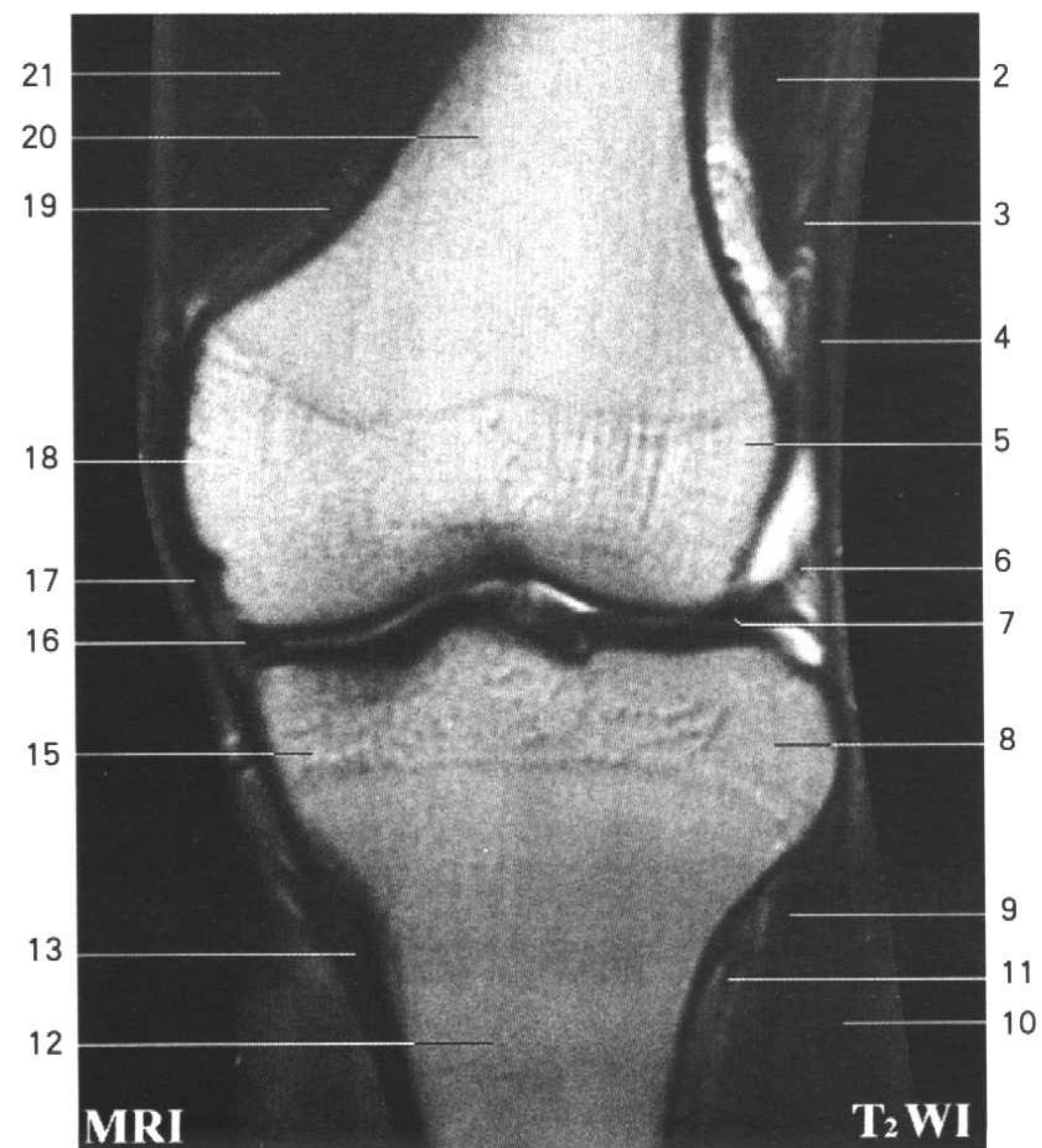
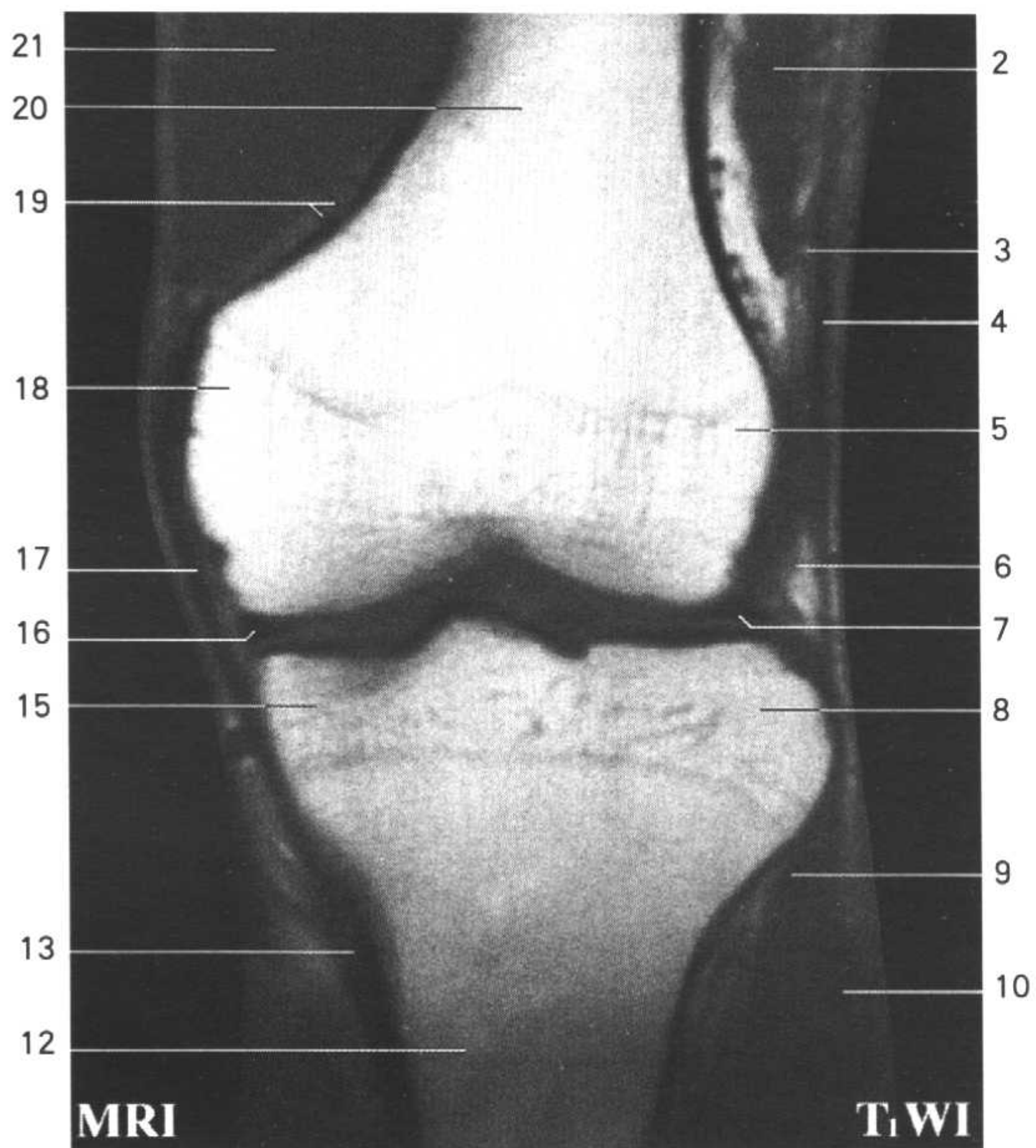


Fig.FK(L) 4

1. 股中间肌 vastus intermedius
2. 股外侧肌 vastus lateralis
3. 膝上外侧动、静脉 lateral superior genicular a. and v.
4. 髂胫束 iliotibial tract
5. 股骨外侧髁 lateral condyle of femur
6. 膝下外侧动、静脉 lateral inferior genicular a. and v.
7. 外侧半月板 lateral meniscus
8. 胫骨外侧髁 lateral condyle of tibia
9. 胫骨前肌 tibialis anterior
10. 趾长伸肌 extensor digitorum longus

- 11. 胫前动、静脉 anterior tibial a. and v.
- 12. 胫骨 tibia
- 13. 半膜肌与半腱肌腱 tendon of semimembranosus and semitendinosus
- 14. 缝匠肌腱 tendon of sartorius
- 15. 胫骨内侧髁 medial condyle of tibia
- 16. 内侧半月板 medial meniscus
- 17. 胫侧副韧带 tibial collateral ligament
- 18. 股骨内侧髁 medial condyle of femur
- 19. 膝上内侧动、静脉 medial superior genicular a. and v.
- 20. 股骨 femur
- 21. 股内侧肌 vastus medialis



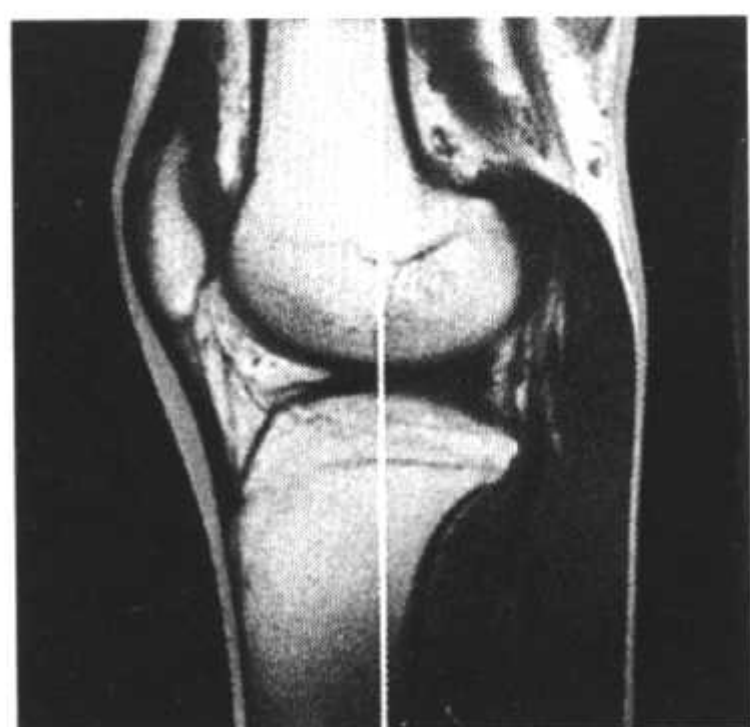
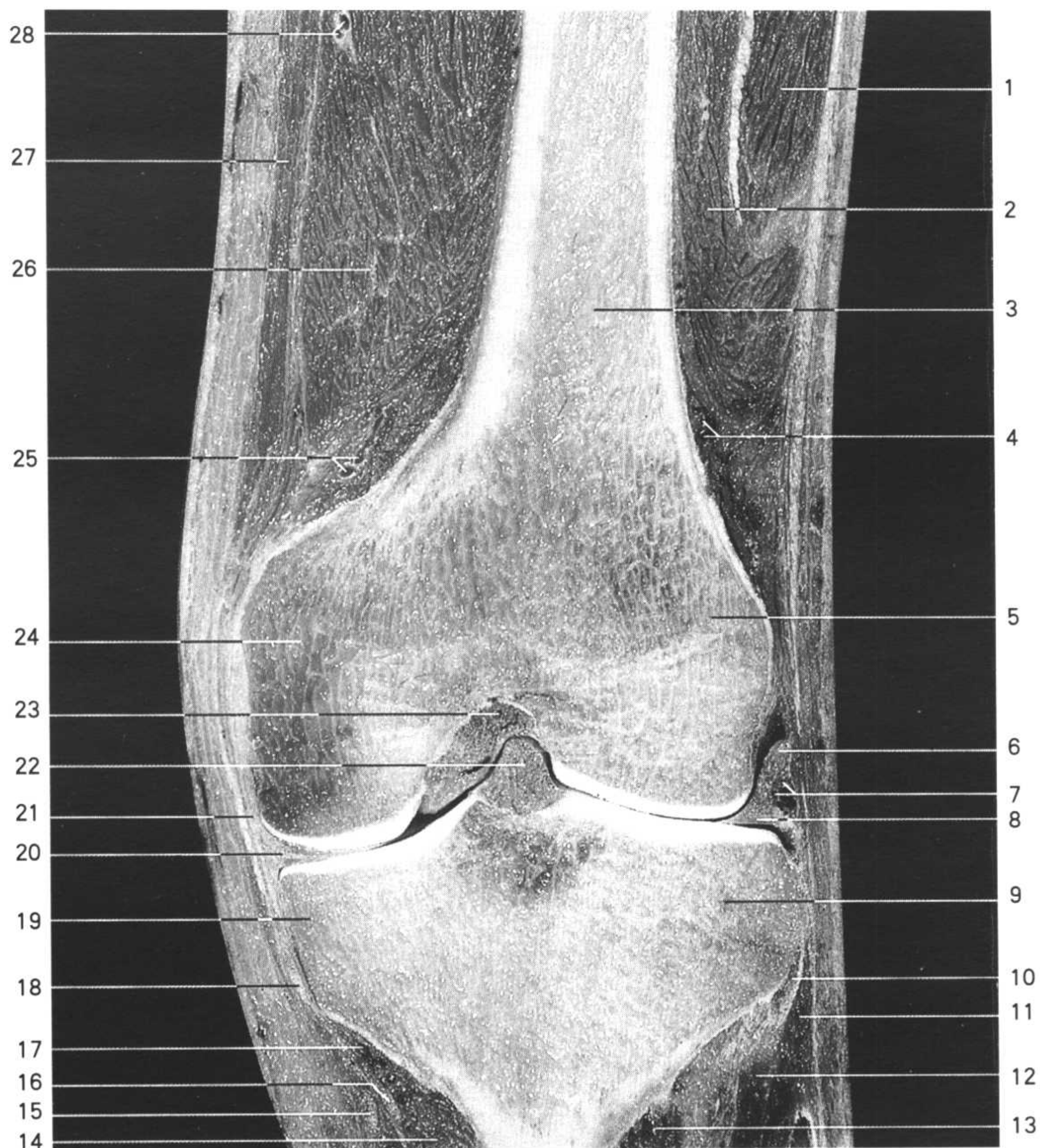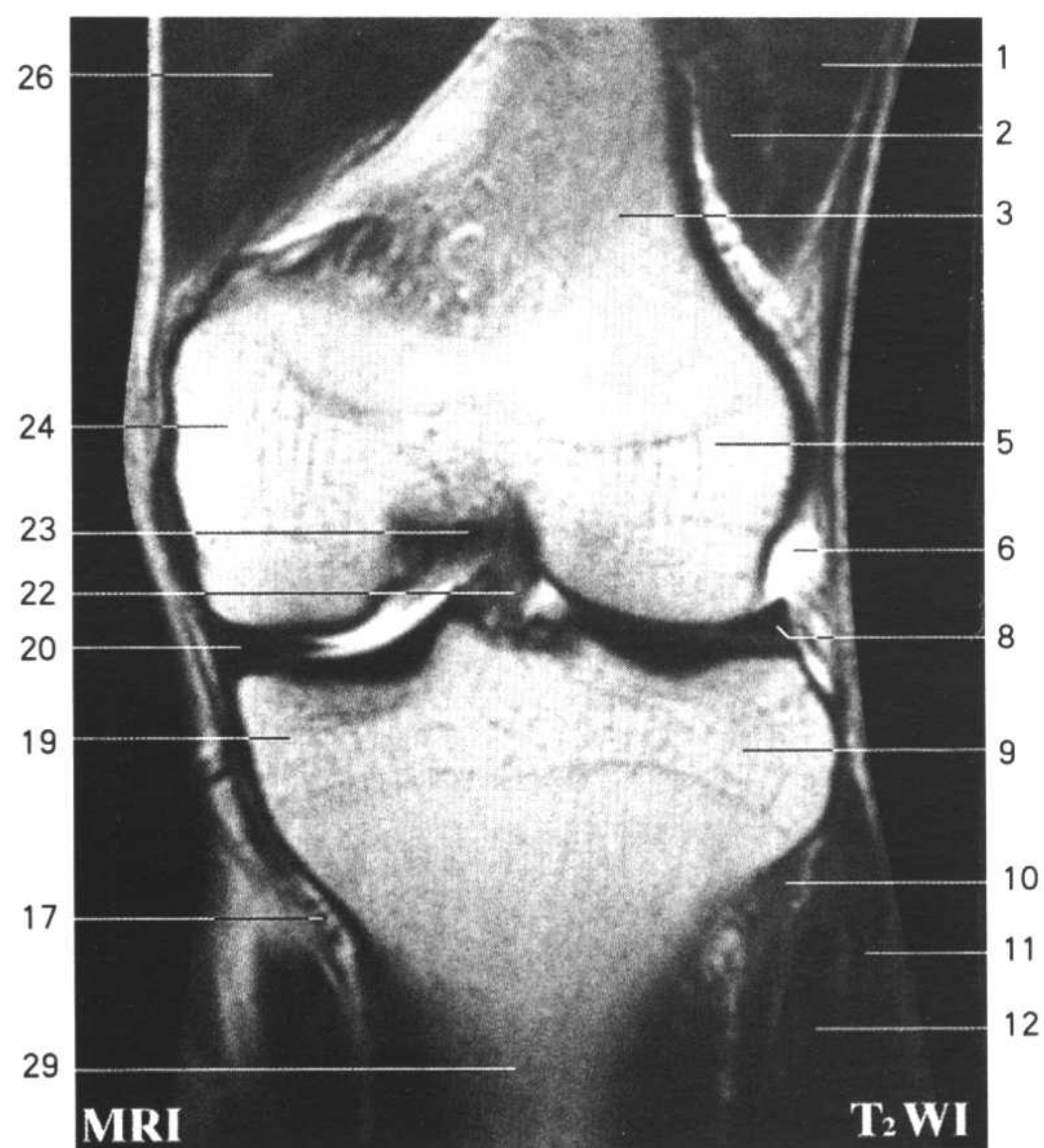
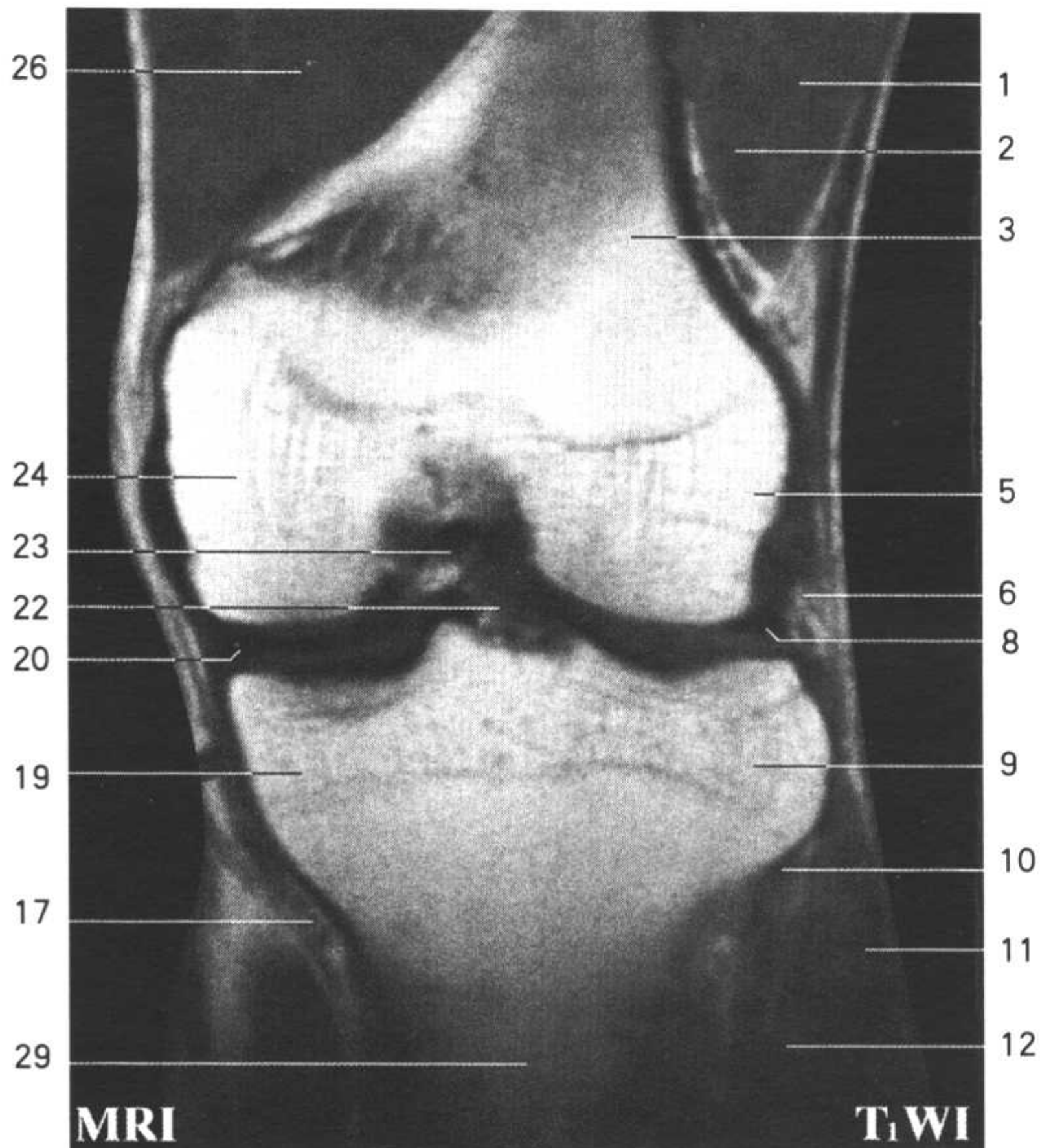


Fig.FK(L) 5

1. 股外侧肌 vastus lateralis
2. 股中间肌 vastus intermedius
3. 股骨 femur
4. 膝上外侧动、静脉 lateral superior genicular a. and v.
5. 股骨外侧髁 lateral condyle of femur
6. 腓肌腱 tendon of popliteus
7. 膝下外侧动、静脉 lateral inferior genicular a. and v.
8. 外侧半月板 lateral meniscus
9. 胫骨外侧髁 lateral condyle of tibia
10. 股二头肌腱 tendon of biceps femoris

11. 趾长伸肌 extensor digitorum longus
12. 胫骨前肌 tibialis anterior
13. 胫骨后肌 tibialis posterior
14. 腘肌 popliteus
15. 半腱肌腱 tendon of semitendinosus
16. 半膜肌腱 tendon of semimembranosus
17. 膝下内侧动、静脉 medial inferior genicular a. and v.
18. 缝匠肌腱 tendon of sartorius
19. 胫骨内侧髁 medial condyle of tibia
20. 内侧半月板 medial meniscus
21. 胫侧副韧带 tibial collateral ligament
22. 前交叉韧带 anterior cruciate ligament
23. 后交叉韧带 posterior cruciate ligament
24. 股骨内侧髁 medial condyle of femur
25. 膝上内侧动、静脉 medial superior genicular a. and v.
26. 股内侧肌 vastus medialis
27. 缝匠肌 sartorius
28. 降膝动、静脉 descending genicular a. and v.
29. 胫骨 tibia



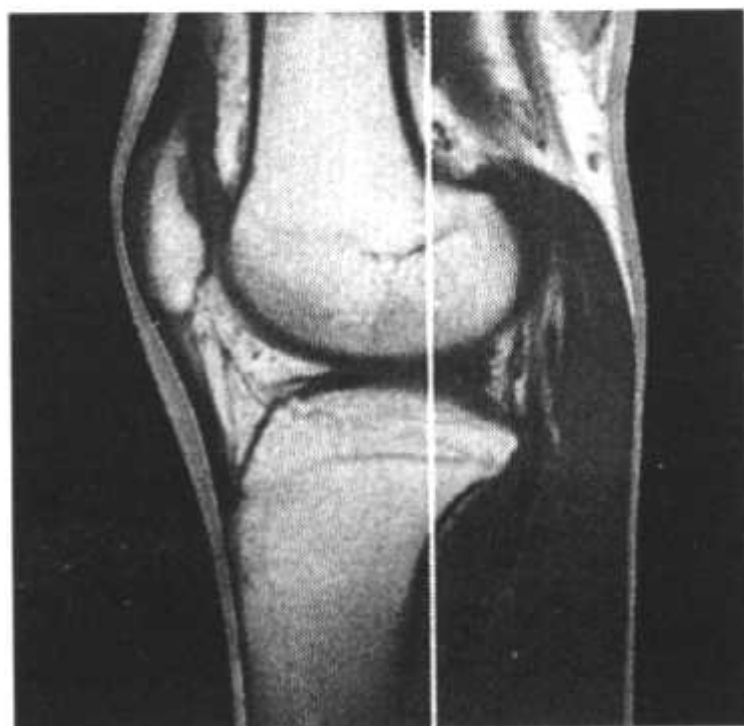
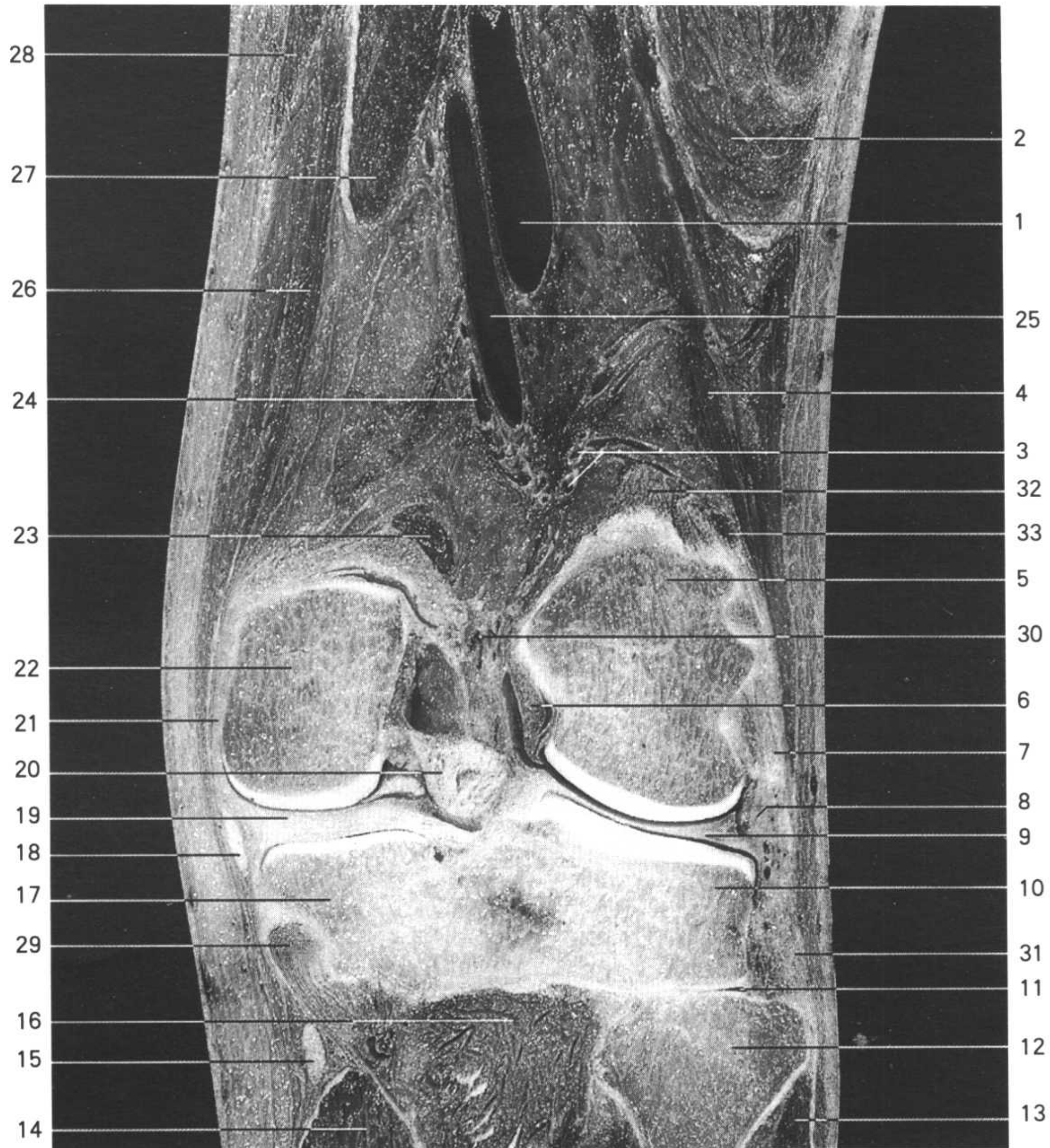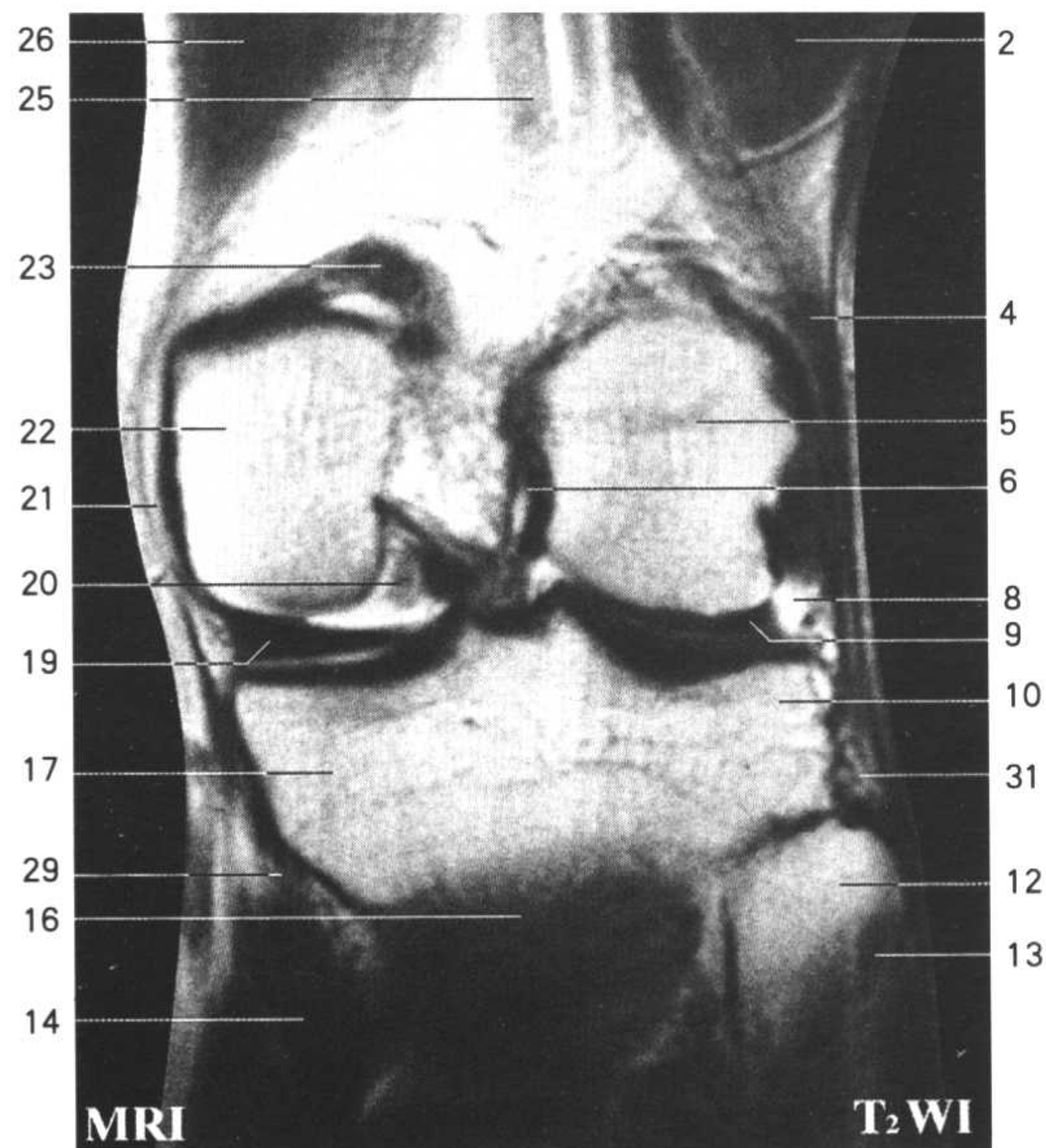
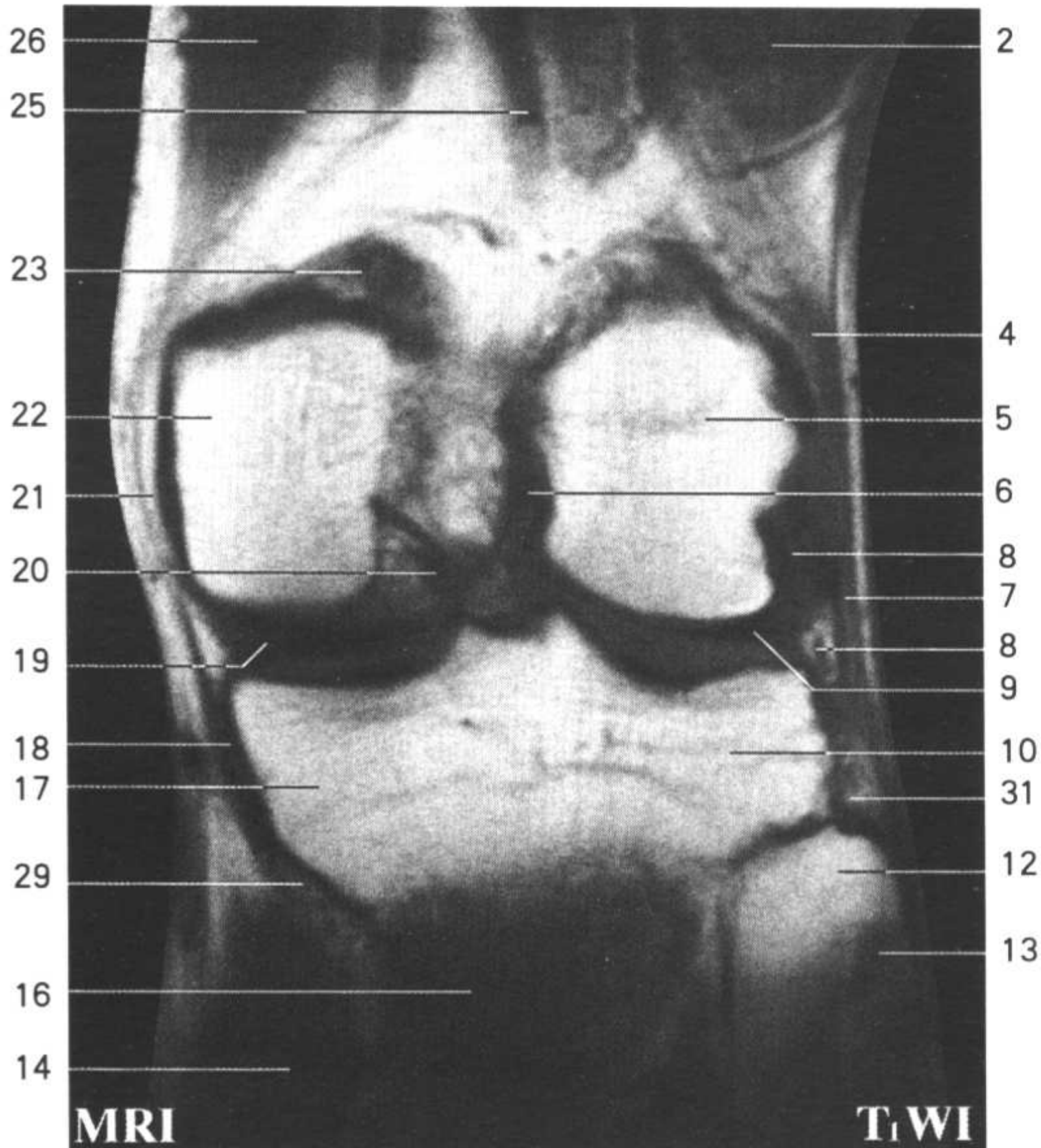


Fig.FK(L) 6

1. 腘静脉 popliteal v.
2. 股外侧肌 vastus lateralis
3. 膝上外侧动、静脉 lateral superior genicular a. and v.
4. 股二头肌 biceps femoris
5. 股骨外侧髁 lateral condyle of femur
6. 前交叉韧带 anterior cruciate ligament
7. 腓侧副韧带 fibular collateral ligament
8. 腘肌腱 tendon of popliteus
9. 外侧半月板 lateral meniscus

- 10. 胫骨外侧髁 lateral condyle of tibia
- 11. 胫腓关节 tibiofibular joint
- 12. 腓骨头 fibular head
- 13. 腓骨长肌 peroneus longus
- 14. 比目鱼肌 soleus
- 15. 半膜肌腱 tendon of semimembranosus
- 16. 腘肌 popliteus
- 17. 胫骨内侧髁 medial condyle of tibia
- 18. 缝匠肌腱 tendon of sartorius
- 19. 内侧半月板 medial meniscus
- 20. 后交叉韧带 posterior cruciate ligament
- 21. 胫侧副韧带 tibial collateral ligament
- 22. 股骨内侧髁 medial condyle of femur
- 23. 腓肠肌内侧头 medial head of gastrocnemius
- 24. 膝上内侧动脉 medial superior genicular a.
- 25. 腘动脉 popliteal a.
- 26. 缝匠肌 sartorius
- 27. 股内侧肌 vastus medialis
- 28. 股薄肌 gracilis
- 29. 半膜肌腱 tendon of semimembranosus
- 30. 膝下外侧动、静脉 lateral inferior genicular a. and v.
- 31. 股二头肌腱 tendon of biceps femoris
- 32. 跖肌 plantaris
- 33. 腓肠肌外头 lateral head of gastrocnemius



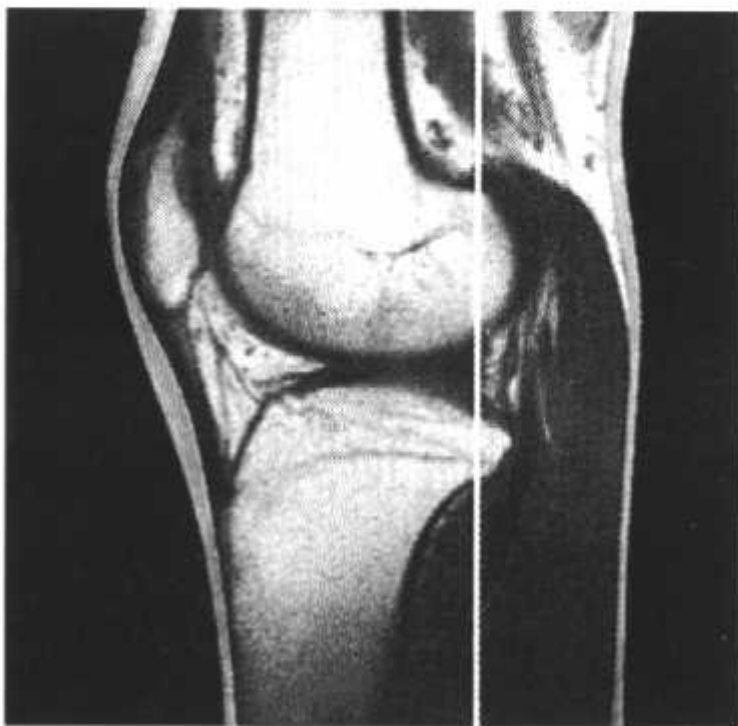
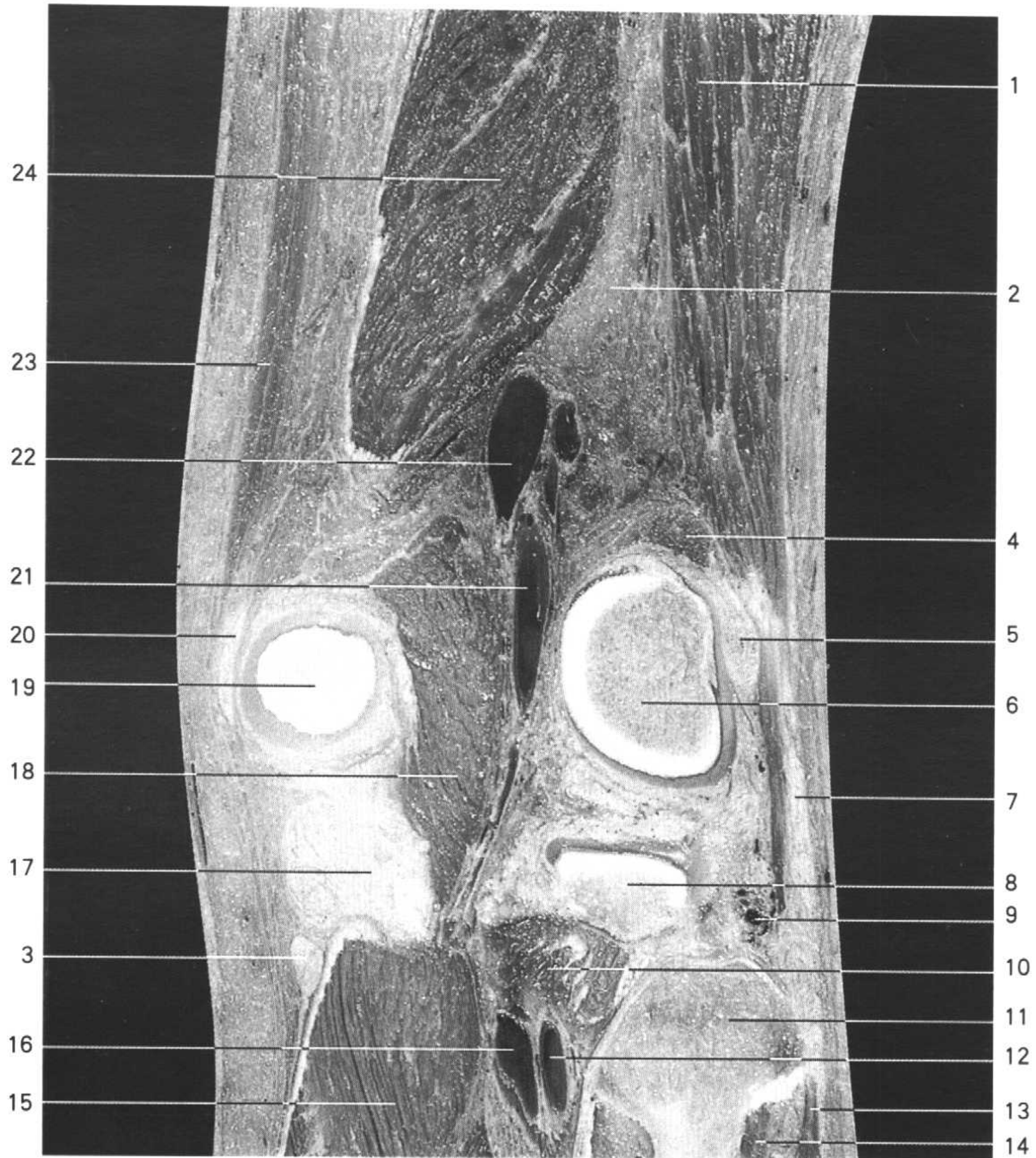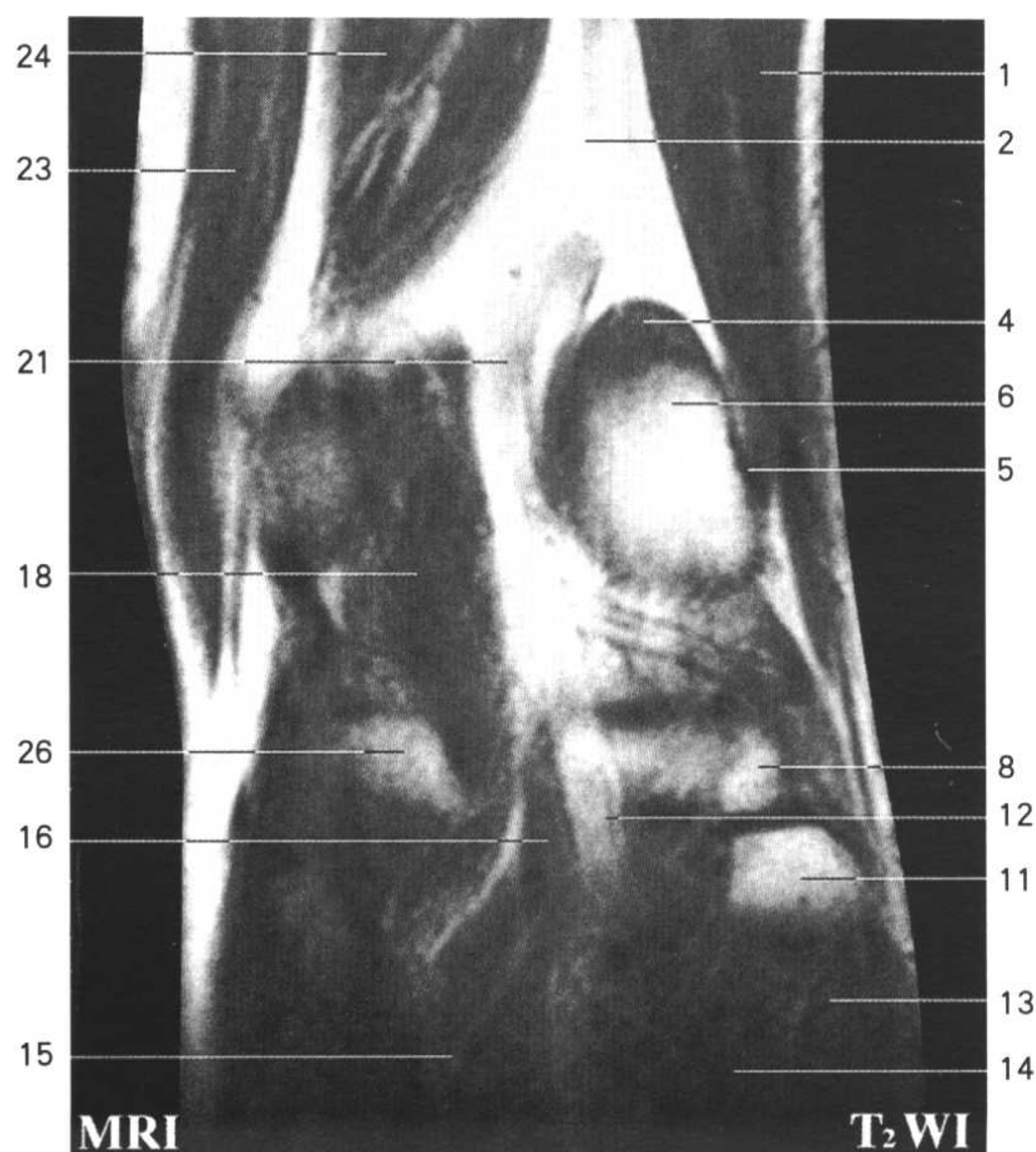
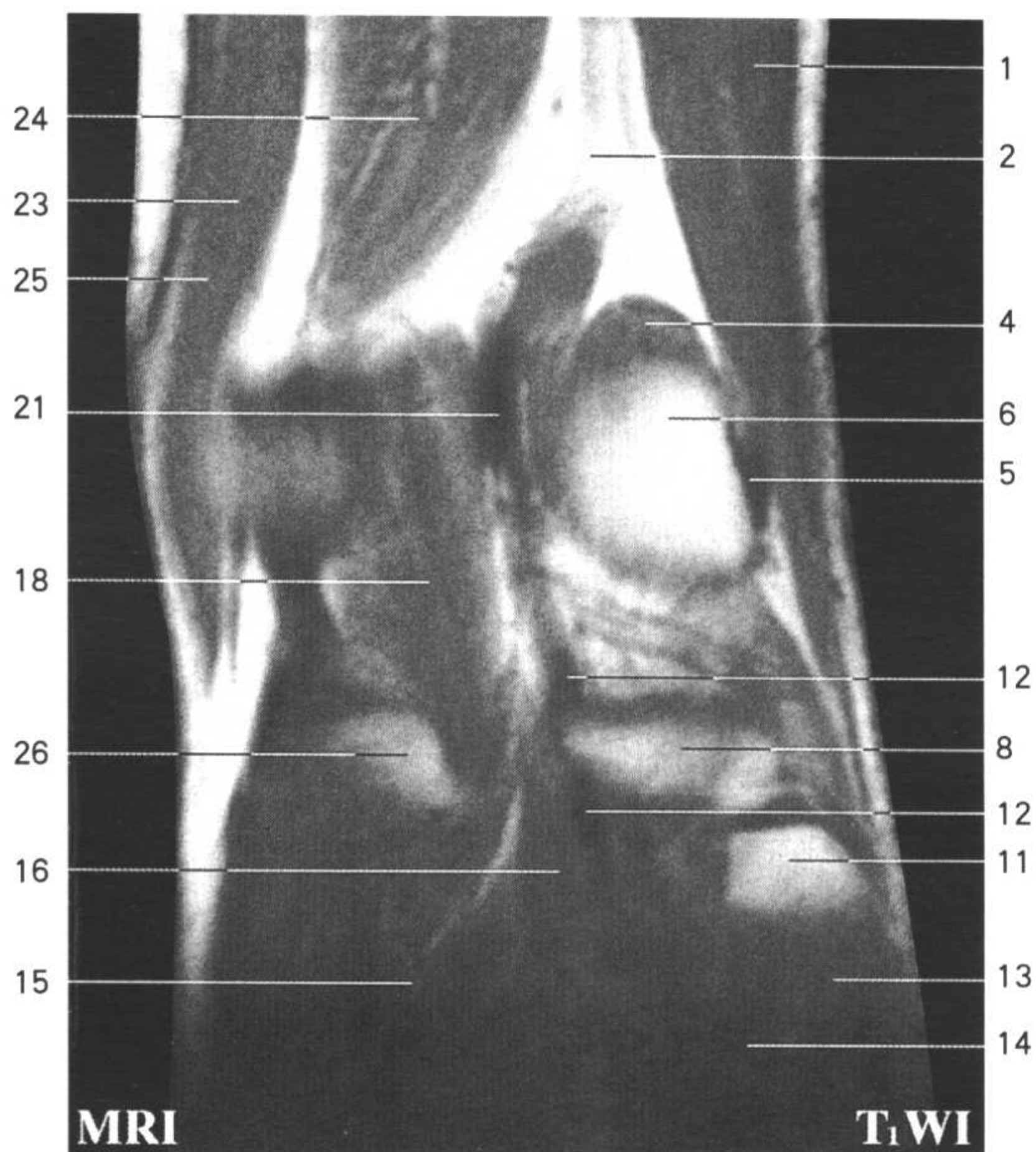
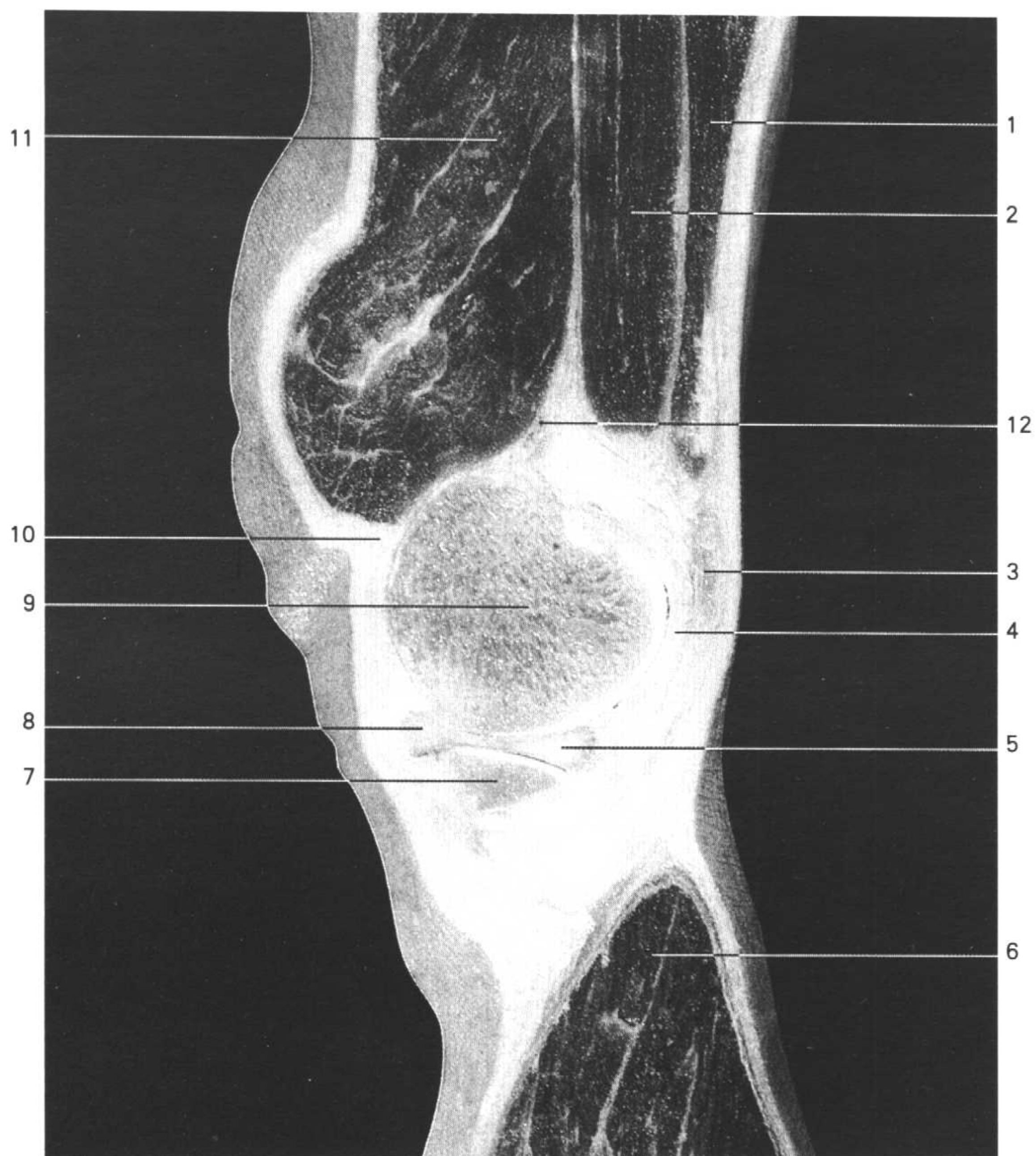


Fig.FK(L) 7

1. 股二头肌 biceps femoris
2. 腘窝 popliteal fossa
3. 半膜肌腱 tendon of semimembranosus
4. 腓肠肌外侧头 lateral head of gastrocnemius
5. 腘肌腱 tendon of popliteus
6. 股骨外侧髁 lateral condyle of femur
7. 腓侧副韧带 fibular collateral ligament
8. 胫骨外侧髁 lateral condyle of tibia
9. 膝下外侧动、静脉 lateral inferior genicular a. and v.
10. 跖肌 plantaris

- 11. 腓骨头 fibular head
- 12. 腘动脉 popliteal a.
- 13. 腓骨长肌 peroneus longus
- 14. 腓骨短肌 peroneus brevis
- 15. 腓肠肌 gastrocnemius
- 16. 腘静脉 popliteal v.
- 17. 关节囊 articular capsule
- 18. 腓肠肌内侧头 medial head of gastrocnemius
- 19. 股骨内侧髁 medial condyle of femur
- 20. 股薄肌与缝匠肌腱 tendon of gracilis and sartorius
- 21. 腘动脉 popliteal a.
- 22. 腘静脉 popliteal v.
- 23. 缝匠肌 sartorius
- 24. 大收肌 adductor magnus
- 25. 股薄肌 gracilis
- 26. 胫骨内侧髁 medial condyle of tibia

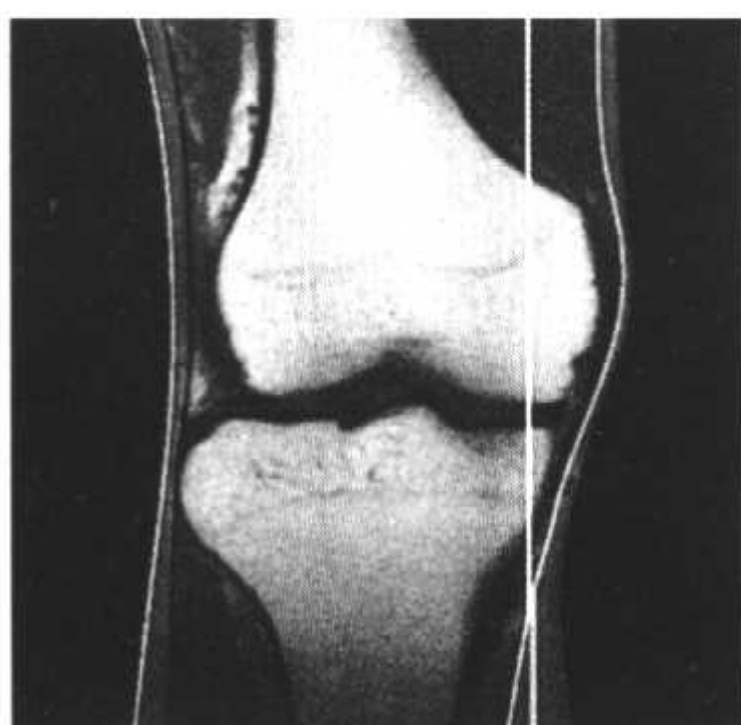




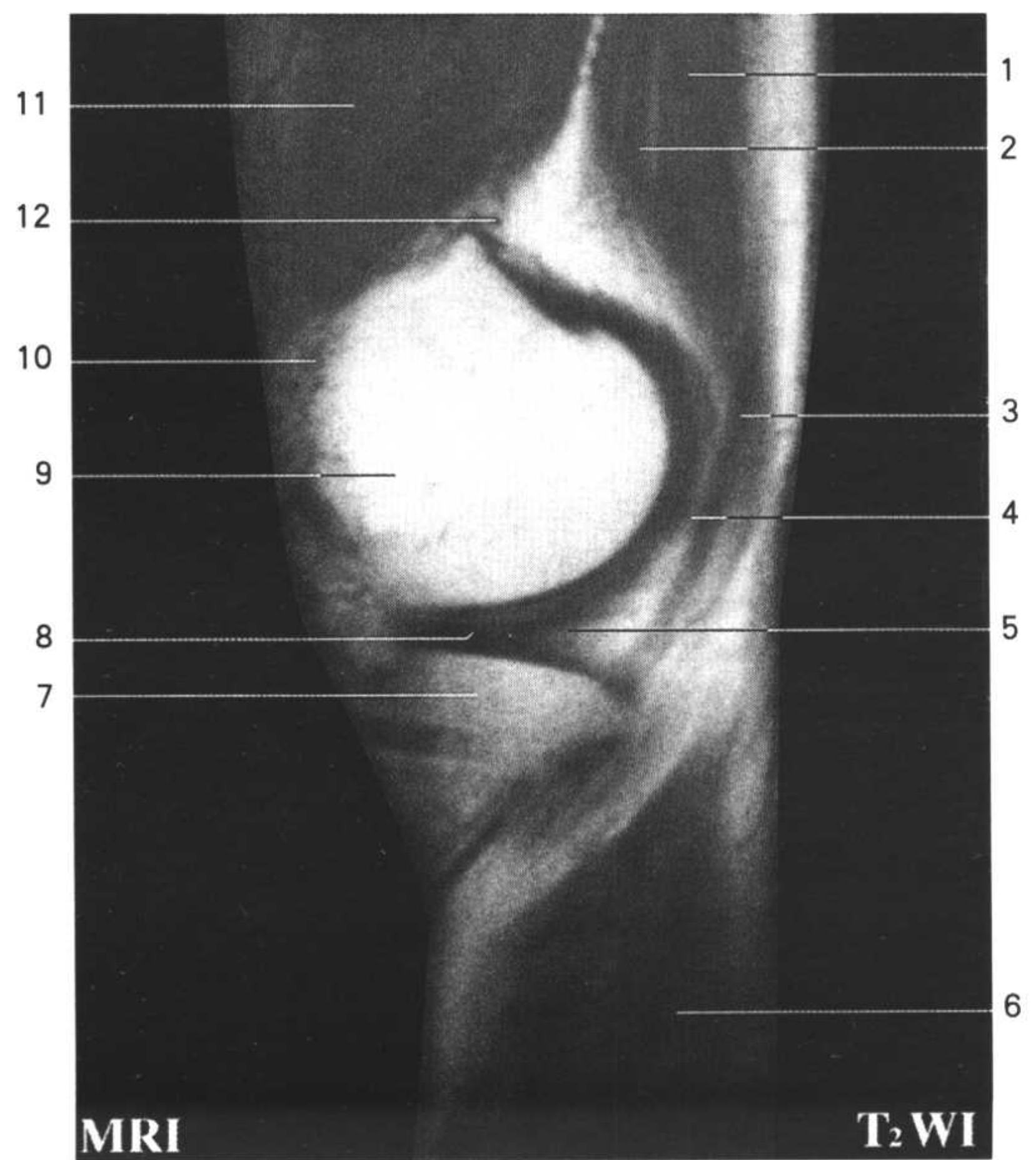
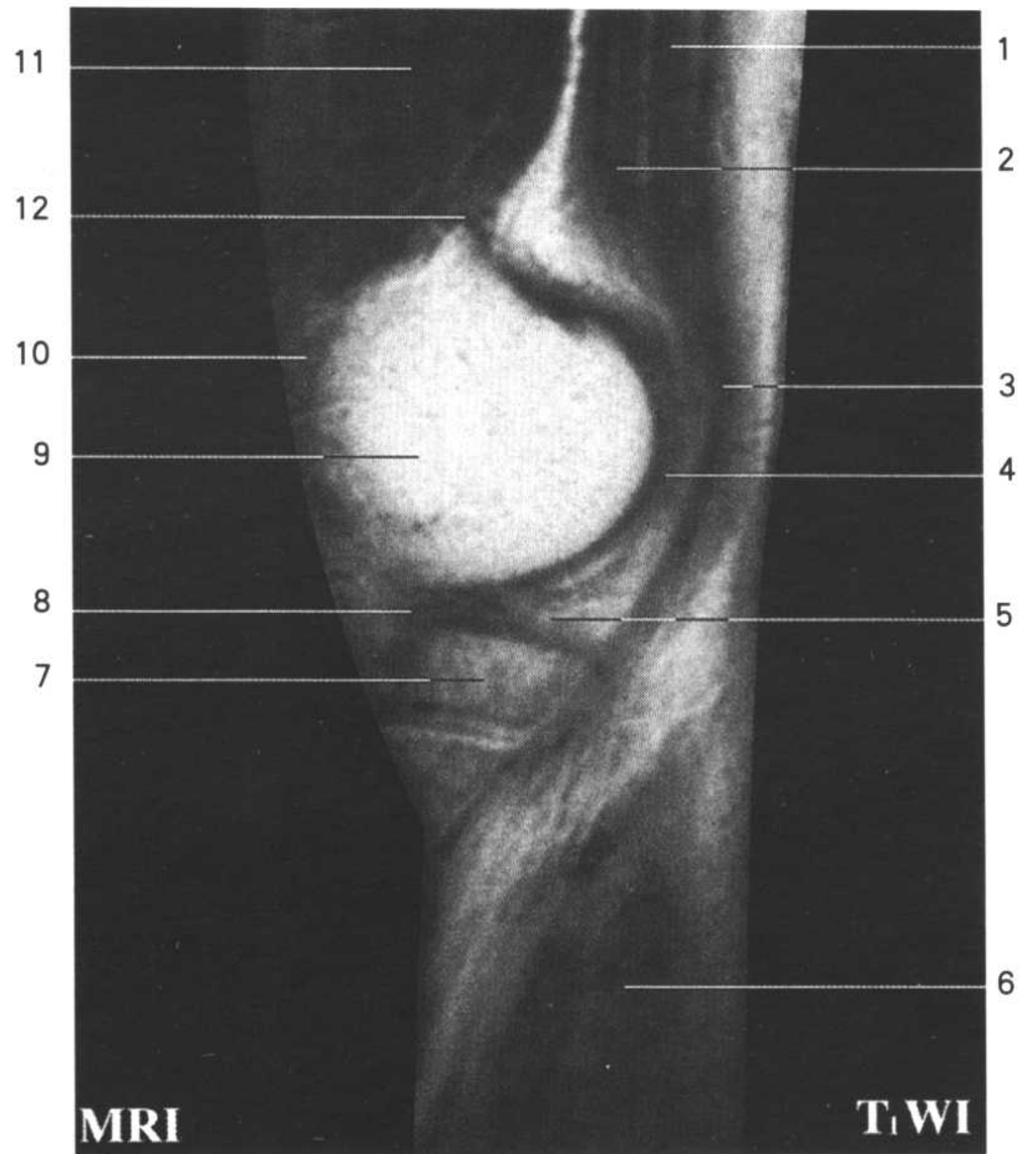
右膝关节矢状断面 SK(R)

Fig.SK(R) 1

1. 股薄肌 gracilis
2. 缝匠肌 sartorius
3. 半腱肌腱 tendon of semitendinosus
4. 关节囊 articular capsule
5. 内侧半月板后部 posterior part of medial meniscus
6. 腓肠肌内侧头 medial head of gastrocnemius
7. 胫骨内侧髁 medial condyle of tibia
8. 内侧半月板前部 anterior part of medial meniscus
9. 股骨内侧髁 medial condyle of femur



- 10. 髌内侧支持带 medial patellar retinaculum
- 11. 股内侧肌 vastus medialis
- 12. 膝上内侧动脉 medial superior genicular a.



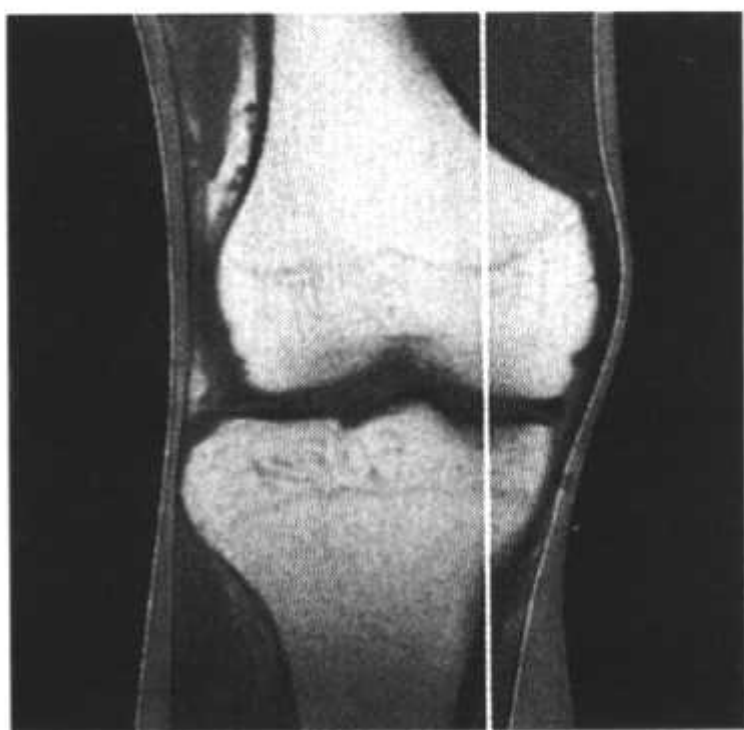
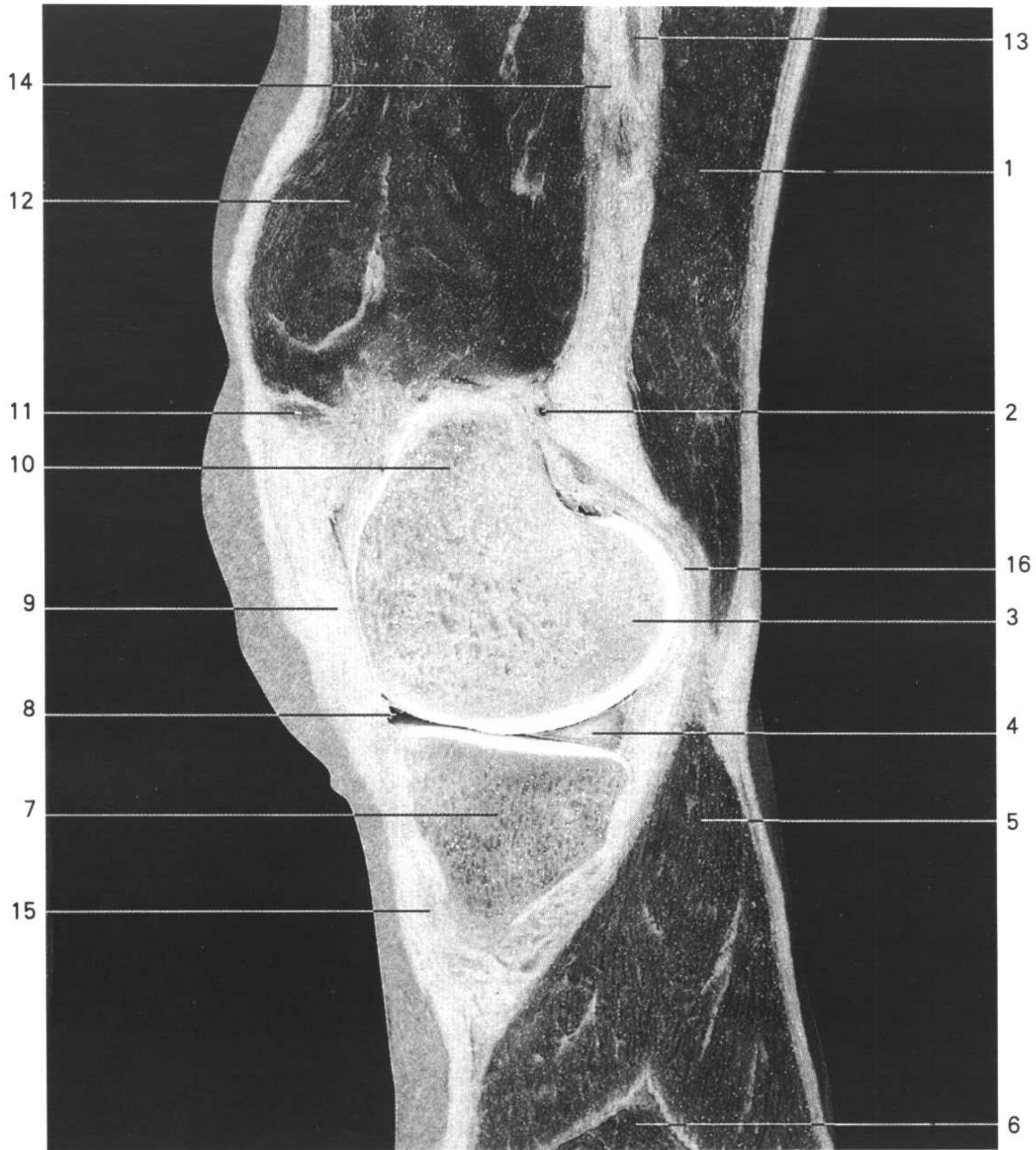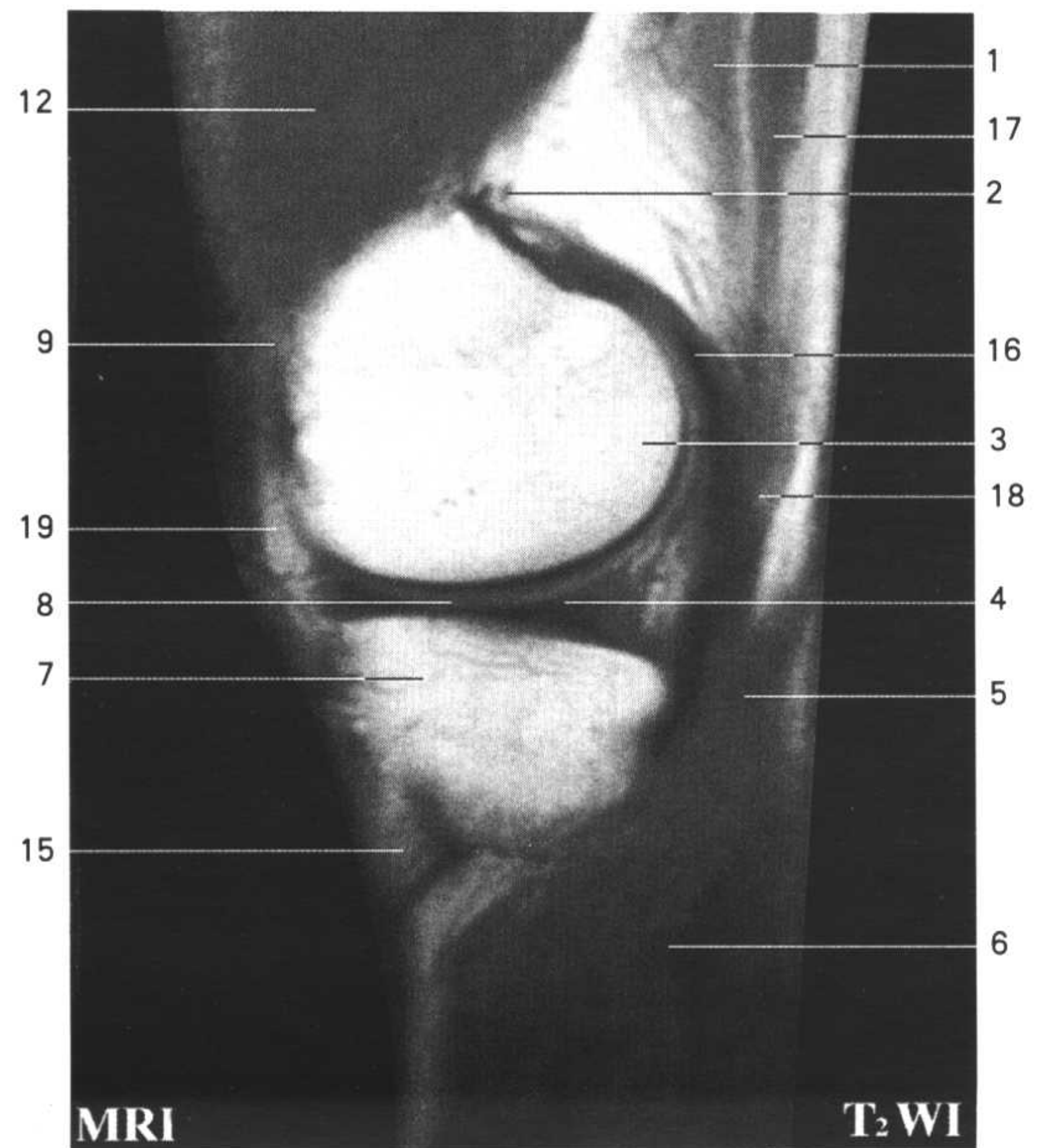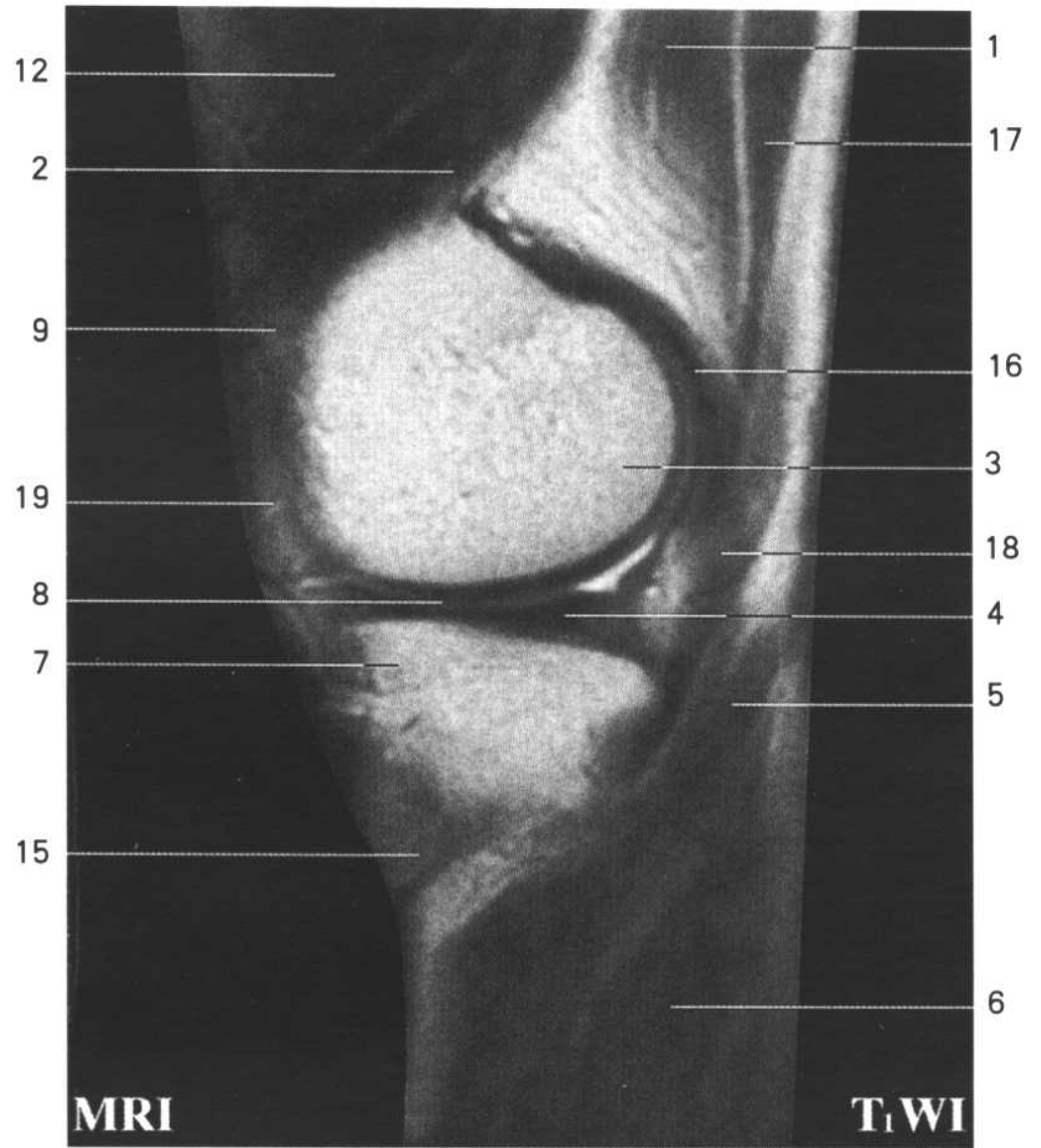


Fig.SK(R) 2

1. 半膜肌 semimembranosus
2. 膝上内侧动脉 medial superior genicular a.
3. 股骨内侧髁 medial condyle of femur
4. 内侧半月板后部 posterior part of medial meniscus
5. 腓肠肌内侧头 medial head of gastrocnemius
6. 比目鱼肌 soleus
7. 胫骨内侧髁 medial condyle of tibia
8. 关节腔 articular cavity
9. 髌韧带 patellar ligament
10. 股骨 femur

- 11. 髌骨 patella
- 12. 股内侧肌 vastus medialis
- 13. 大收肌 adductor magnus
- 14. 肌内侧肌间隔 medial femoral intermuscular septum
- 15. 缝匠肌腱 tendon of sartorius
- 16. 关节囊 articular capsule
- 17. 半腱肌 semitendinosus
- 18. 半膜肌腱 tendon of semimembranosus
- 19. 髌内侧支持带 medial patellar retinaculum



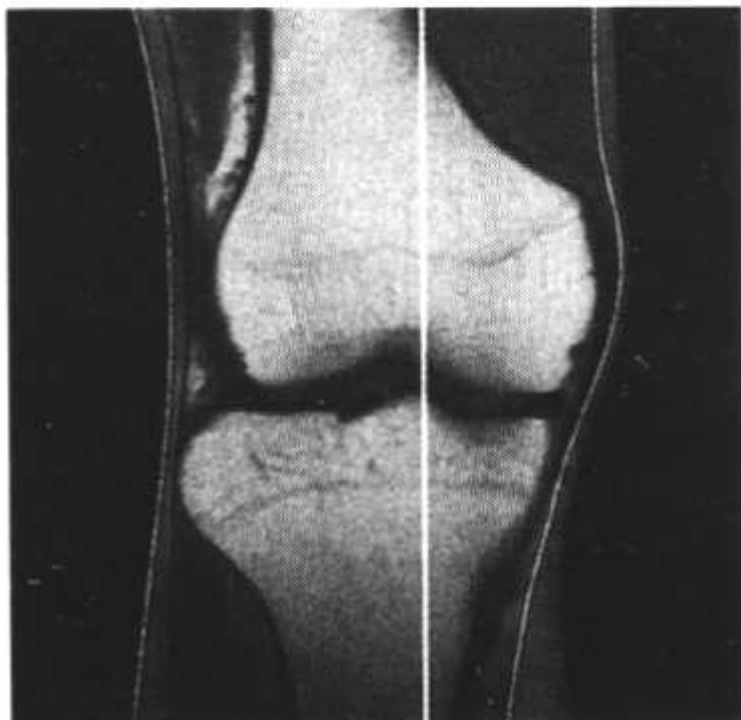
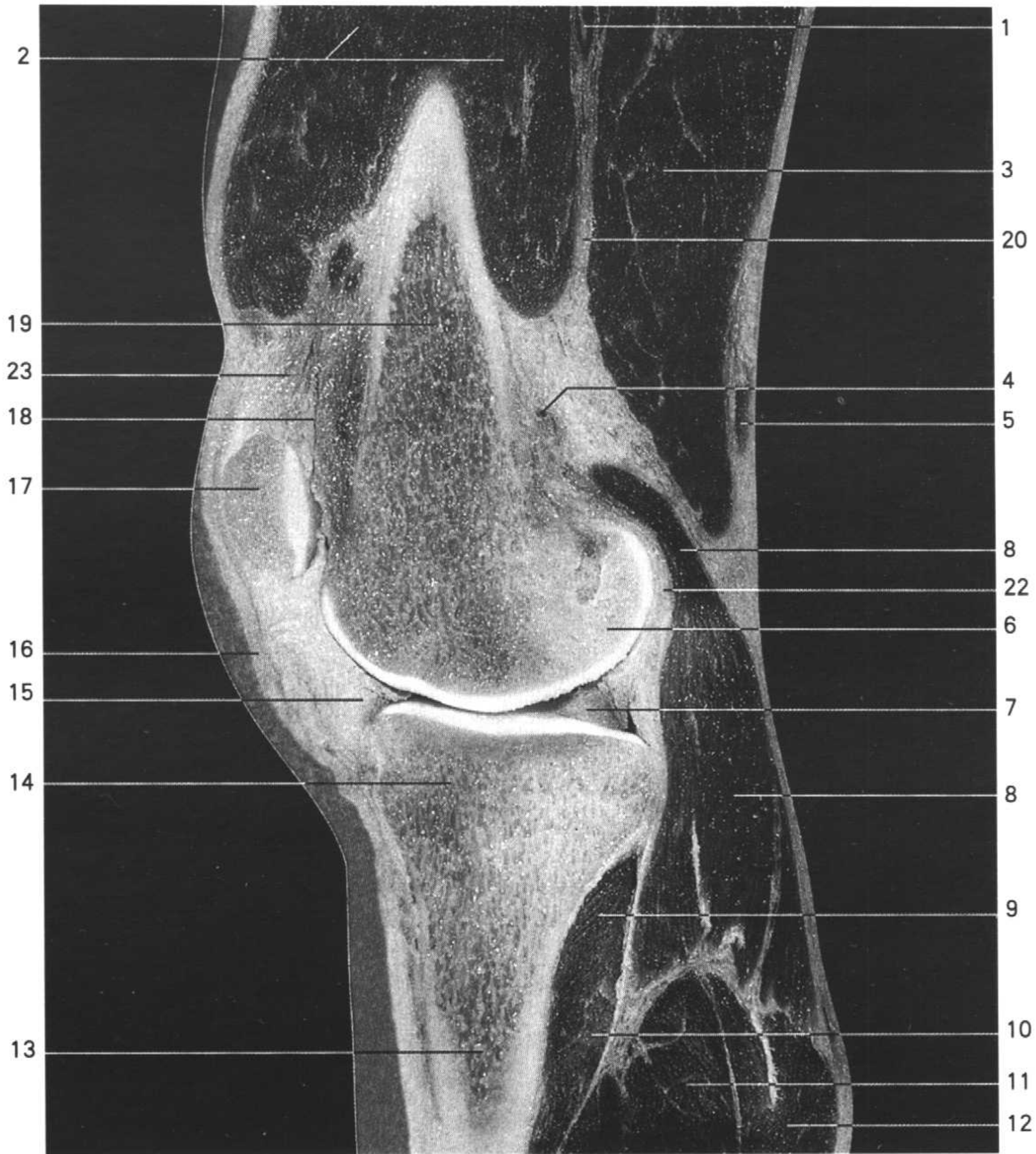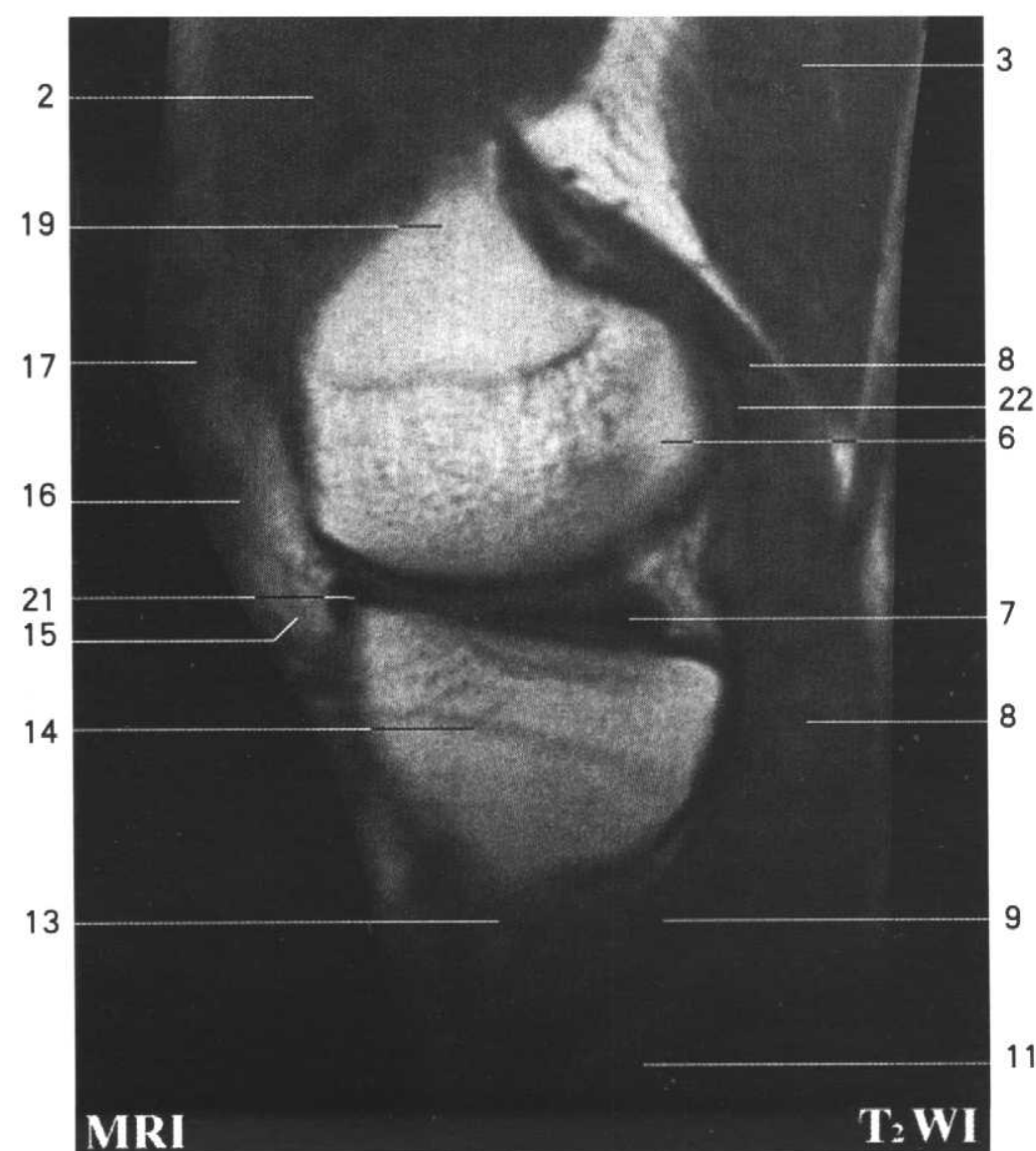

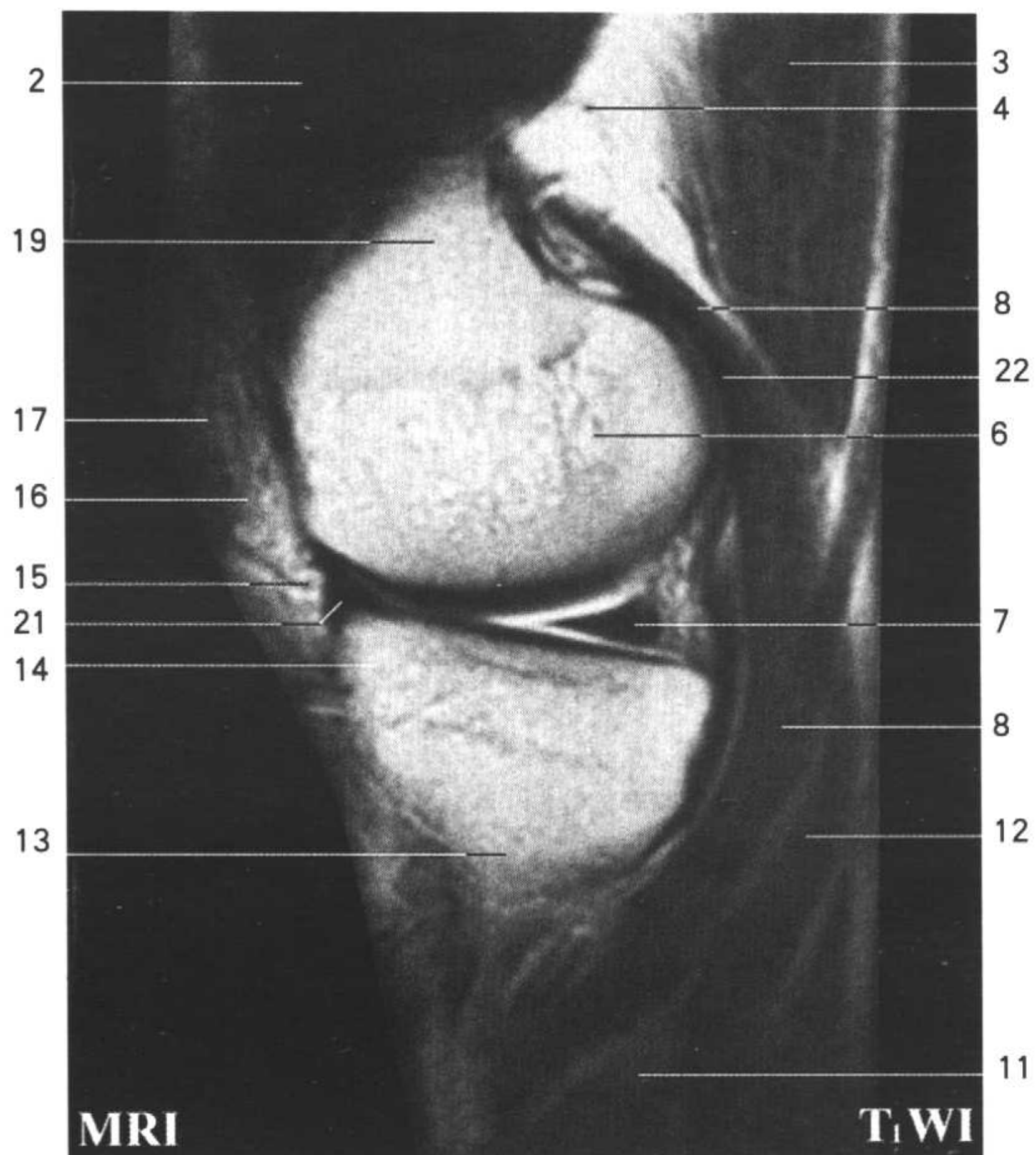
Fig.SK(R) 3

1. 股动脉 femoral a.
2. 股内侧肌 vastus medialis
3. 半膜肌 semimembranosus
4. 膝上内侧动脉 medial superior genicular a.
5. 半腱肌 semitendinosus
6. 股骨内侧髁 medial condyle of femur
7. 内侧半月板后部 posterior part of medial meniscus
8. 腓肠肌内侧头 medial head of gastrocnemius
9. 腓肌 popliteus

- 10. 胫骨后肌 tibialis posterior
- 11. 比目鱼肌 soleus
- 12. 腓肠肌 gastrocnemius
- 13. 胫骨 tibia
- 14. 胫骨内侧髁 medial condyle of tibia
- 15. 翼状襞 alar fold
- 16. 髌韧带 patellar ligament
- 17. 髌骨 patella
- 18. 髌上囊 suprapatellar bursa
- 19. 股骨 femur
- 20. 股内侧肌间隔 medial femoral intermuscular septum
- 21. 内侧半月板前部 anterior part of medial meniscus
- 22. 关节囊 articular capsule
- 23. 髌上脂体 suprapatellar fat pad



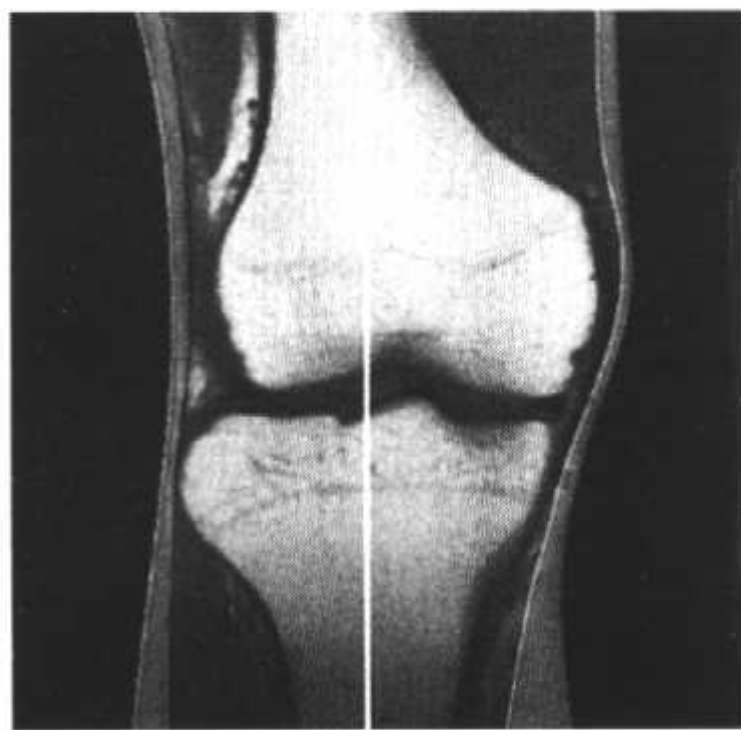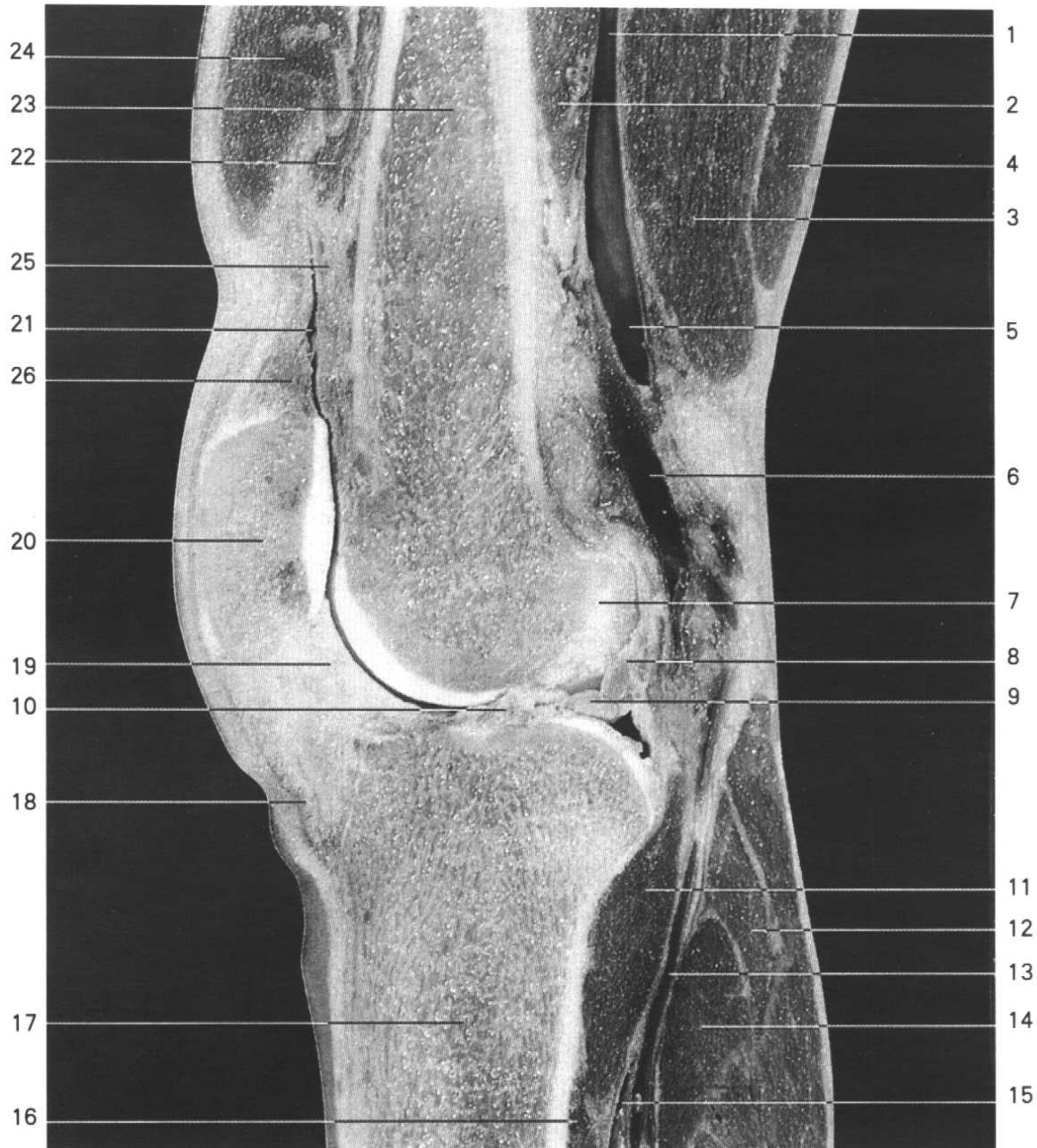
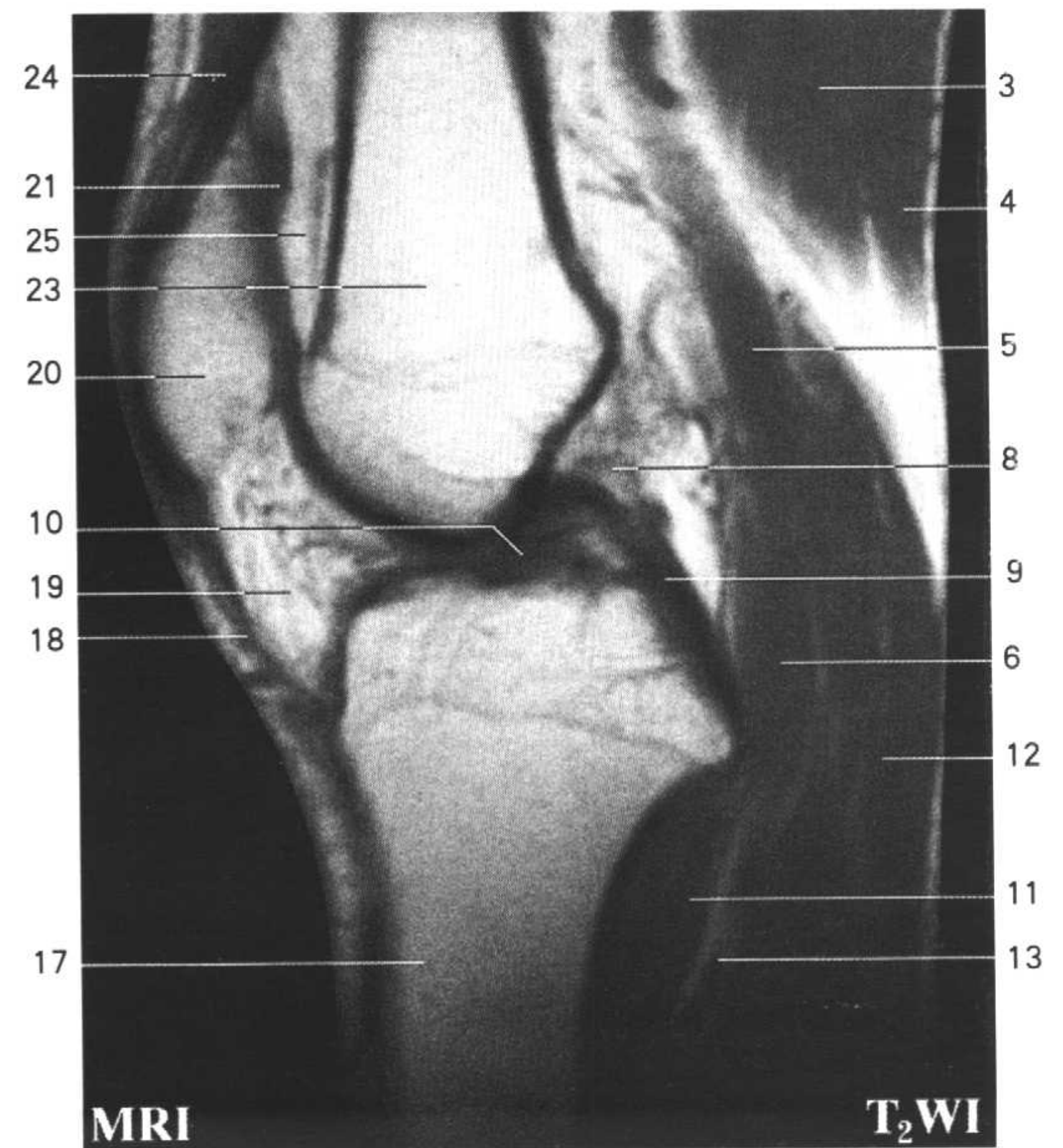
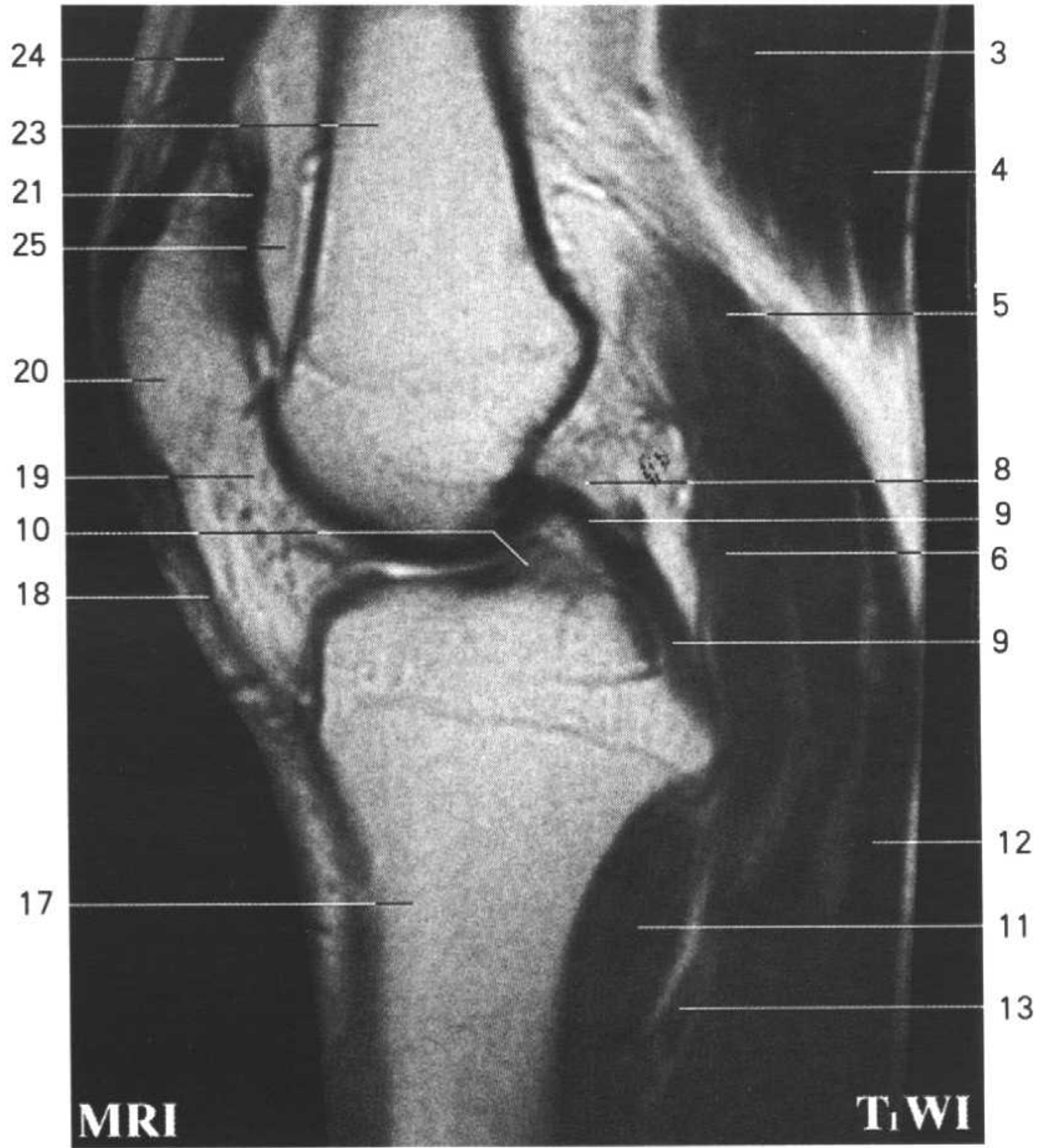


Fig.SK(R) 4

1. 股静脉 femoral v.
2. 股内侧肌 vastus medialis
3. 半膜肌 semimembranosus
4. 半腱肌 semitendinosus
5. 腘静脉 popliteal v.
6. 腘动脉 popliteal a.
7. 股骨外侧髁 lateral condyle of femur
8. 板股后韧带 posterior menisiofemoral ligament
9. 后交叉韧带 posterior cruciate ligament

- 10. 前交叉韧带 anterior cruciate ligament
- 11. 腓肌 popliteus
- 12. 腓肠肌 gastrocnemius
- 13. 胫后静脉 posterior tibial v.
- 14. 比目鱼肌 soleus
- 15. 胫后动脉 posterior tibial a.
- 16. 胫骨后肌 tibialis posterior
- 17. 胫骨 tibia
- 18. 髌韧带 patellar ligament
- 19. 翼状襞 alar fold
- 20. 髌骨 patella
- 21. 髌上囊 suprapatellar bursa
- 22. 膝关节肌 articularis genus
- 23. 股骨 femur
- 24. 股直肌 rectus femoris
- 25. 股前脂体 prefemoral fat pad
- 26. 髌上脂体 suprapatellar fat pad



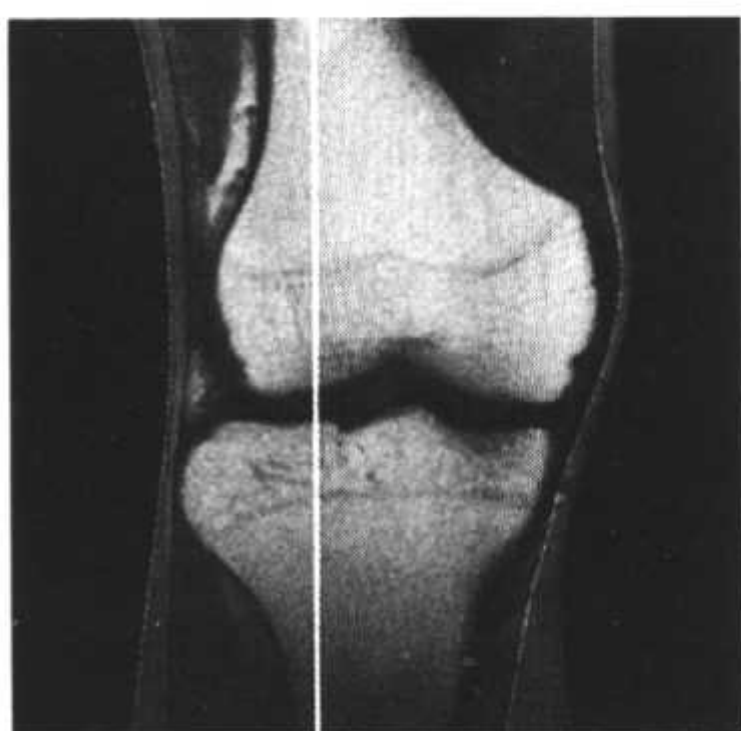
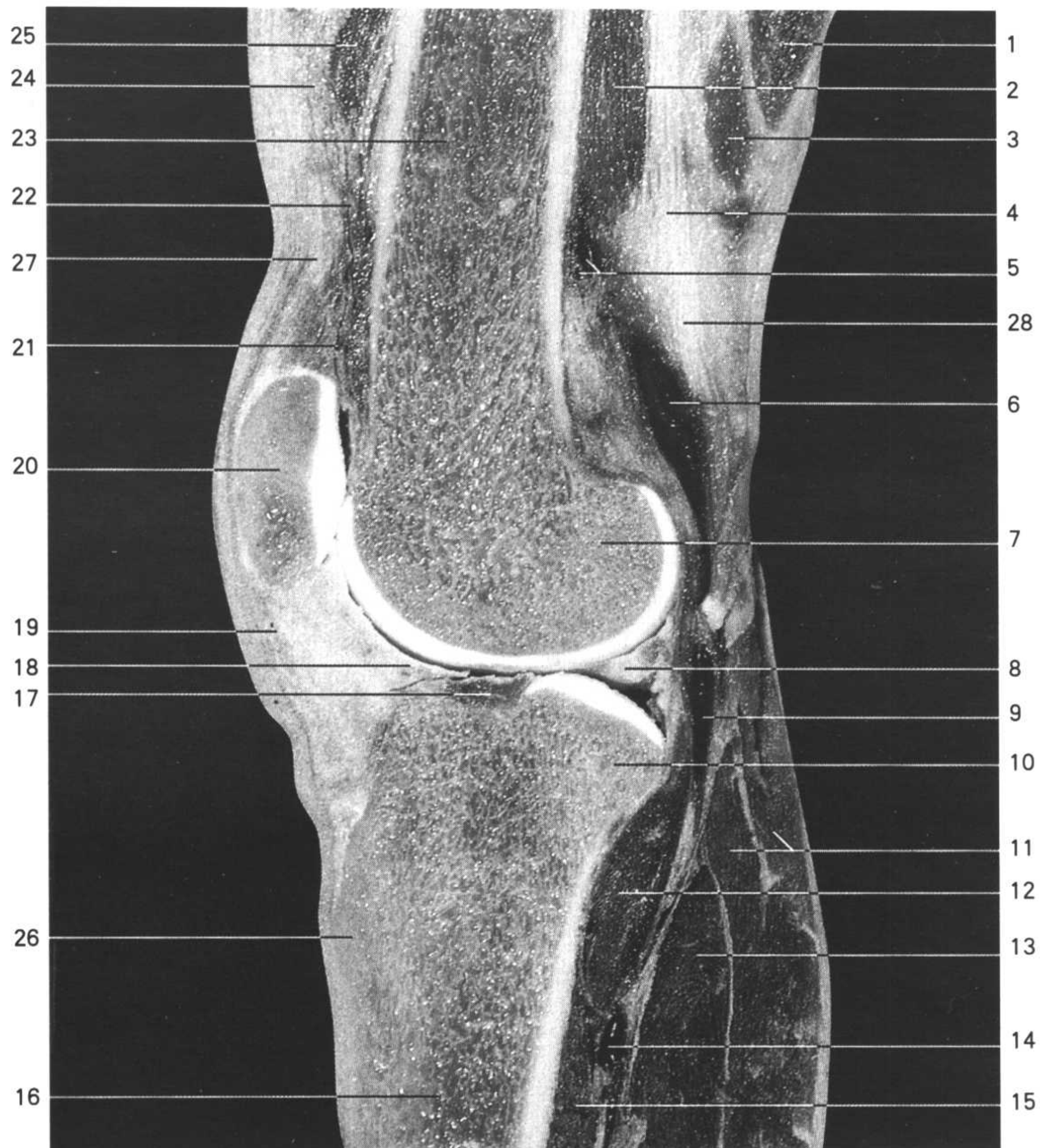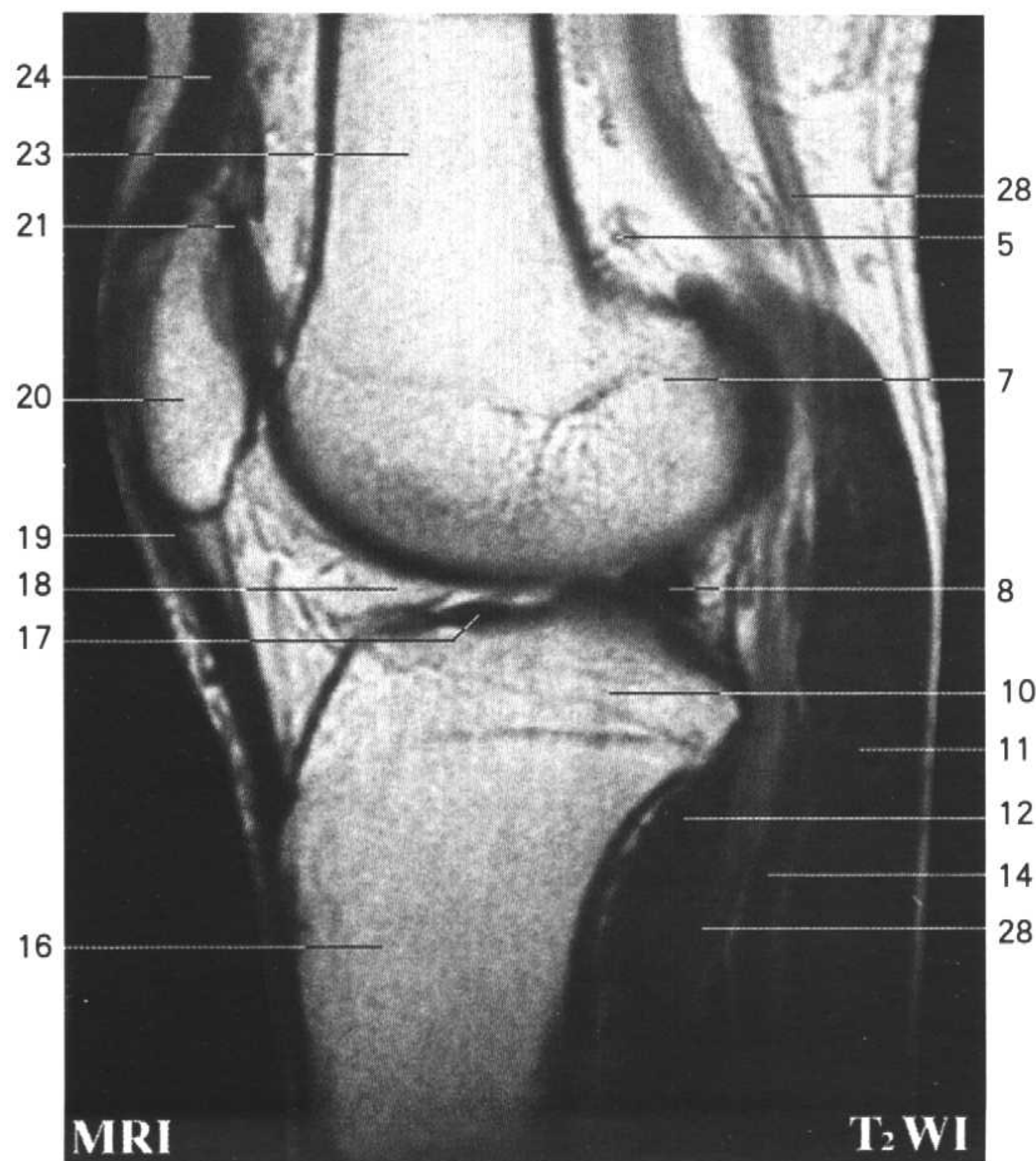
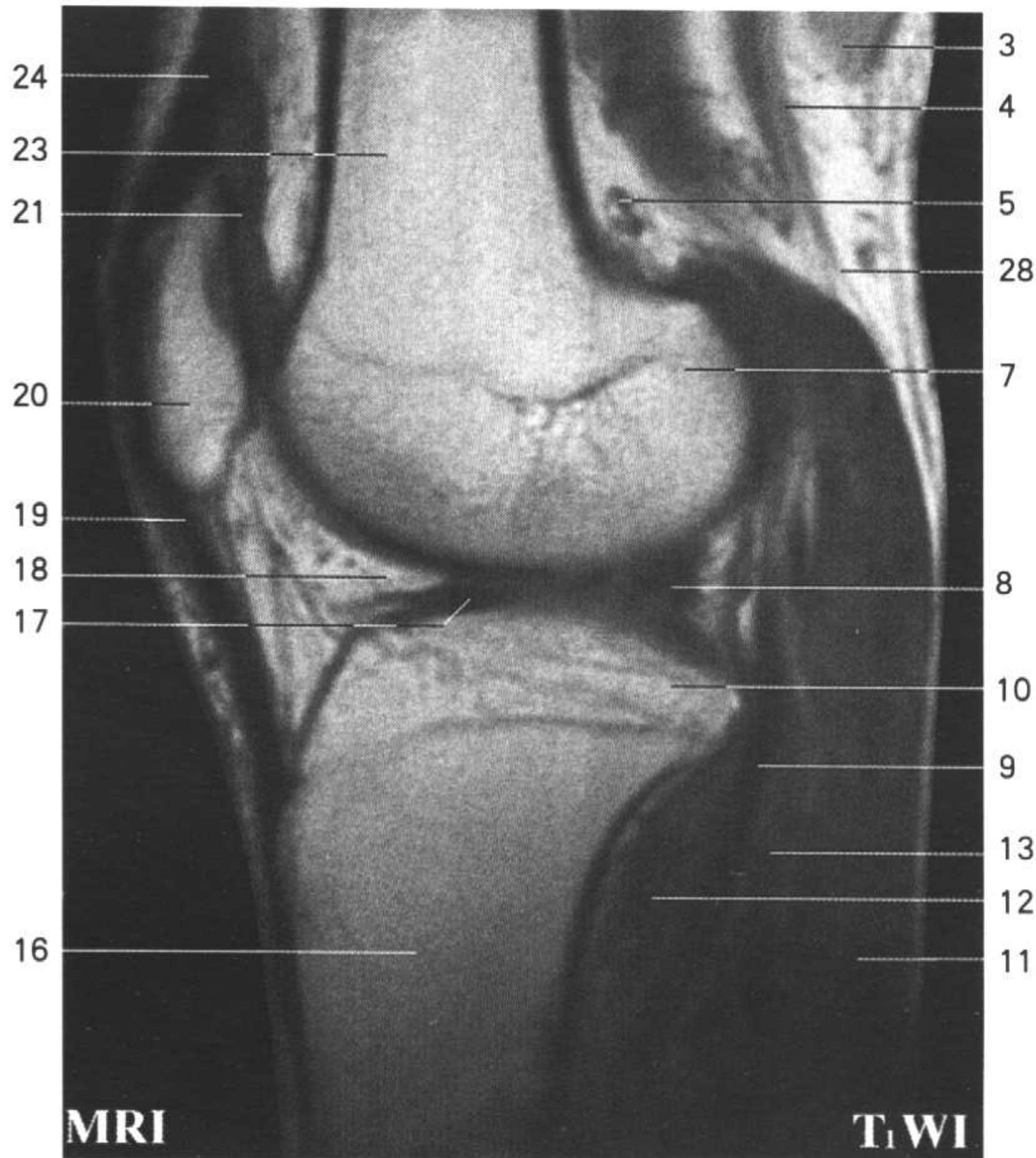


Fig.SK(R) 5

1. 股二头肌长头 long head of biceps femoris
2. 股二头肌短头 short head of biceps femoris
3. 半膜肌 semimembranosus
4. 坐骨神经 sciatic n.
5. 膝上外侧动、静脉 lateral superior genicular a. and v.
6. 腓静脉 popliteal v.
7. 股骨外侧髁 lateral condyle of femur
8. 外侧半月板后部 posterior part of lateral meniscus
9. 腓动脉 popliteal a.

- 10. 胫骨外侧髁 lateral condyle of tibia
- 11. 腓肠肌 gastrocnemius
- 12. 腘肌 popliteus
- 13. 比目鱼肌 soleus
- 14. 胫后动脉 posterior tibial a.
- 15. 胫骨后肌 tibialis posterior
- 16. 胫骨 tibia
- 17. 前交叉韧带 anterior cruciate ligament
- 18. 髌下滑膜襞 infrapatellar synovial fold
- 19. 髌韧带 patellar ligament
- 20. 髌骨 patella
- 21. 髌上囊 suprapatellar bursa
- 22. 膝关节肌 articularis genus
- 23. 股骨 femur
- 24. 股直肌腱 tendon of rectus femoris
- 25. 股中间肌 vastus intermedius
- 26. 胫骨粗隆 tibial tuberosity
- 27. 股四头肌腱 tendon of quadriceps femoris
- 28. 胫神经 tibial n.



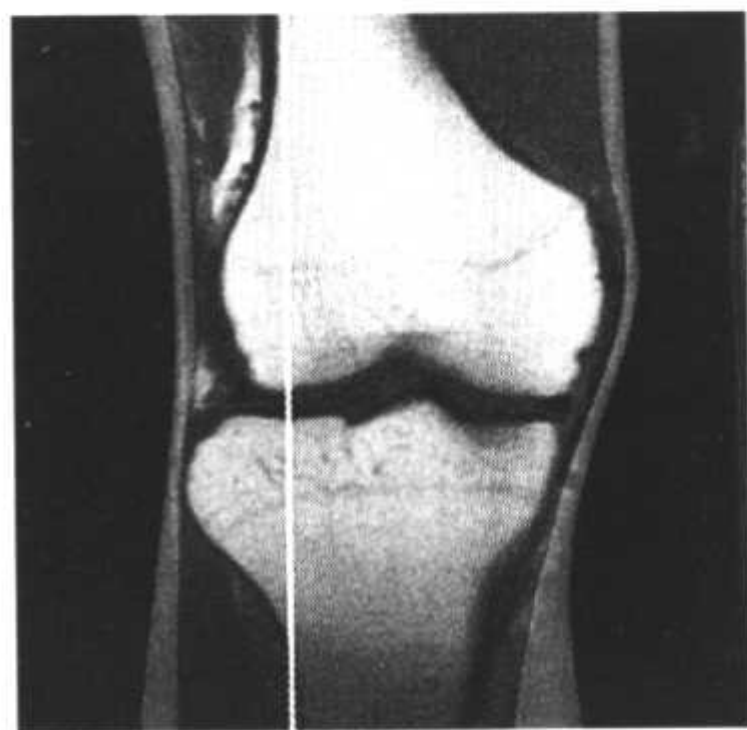
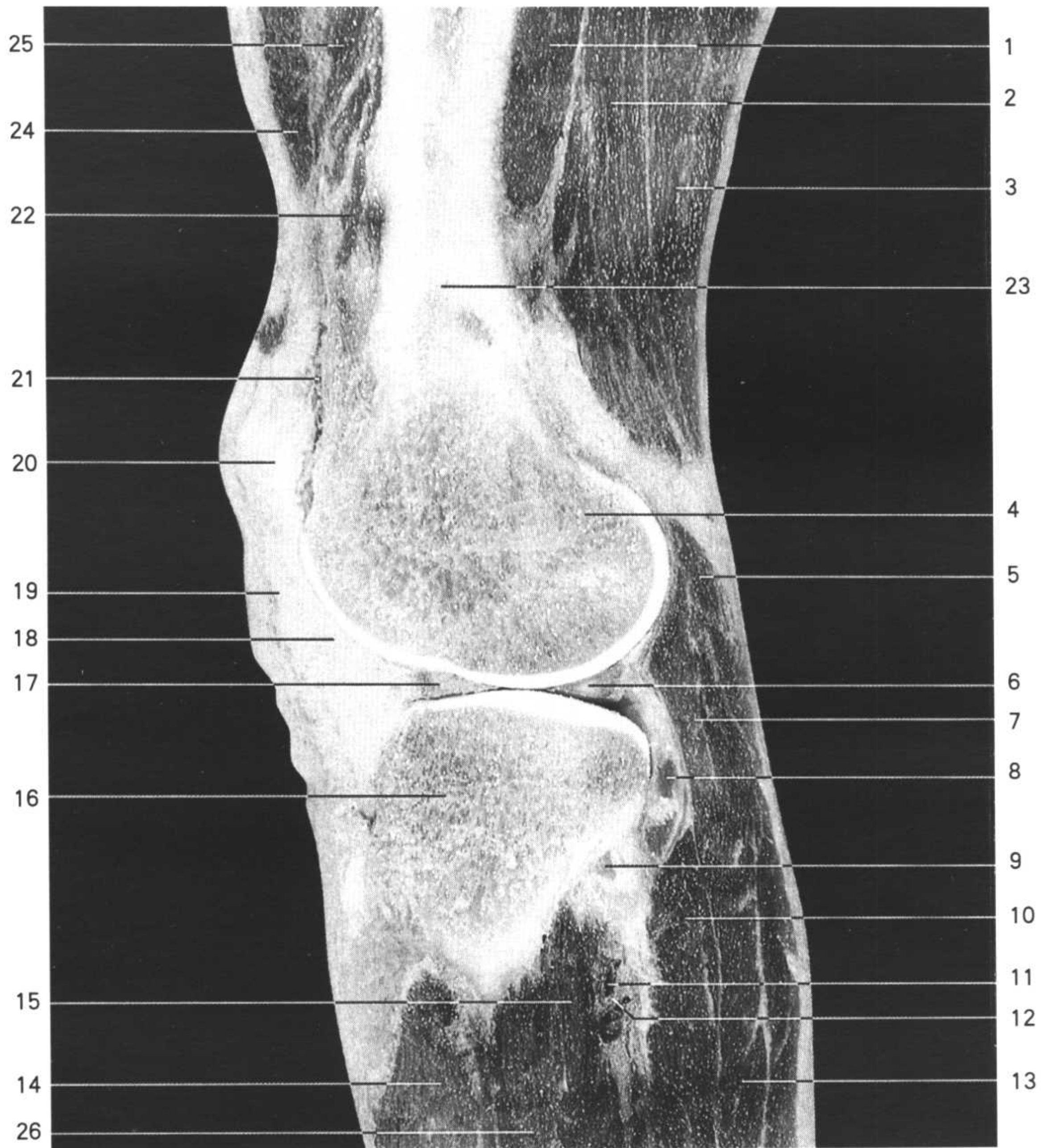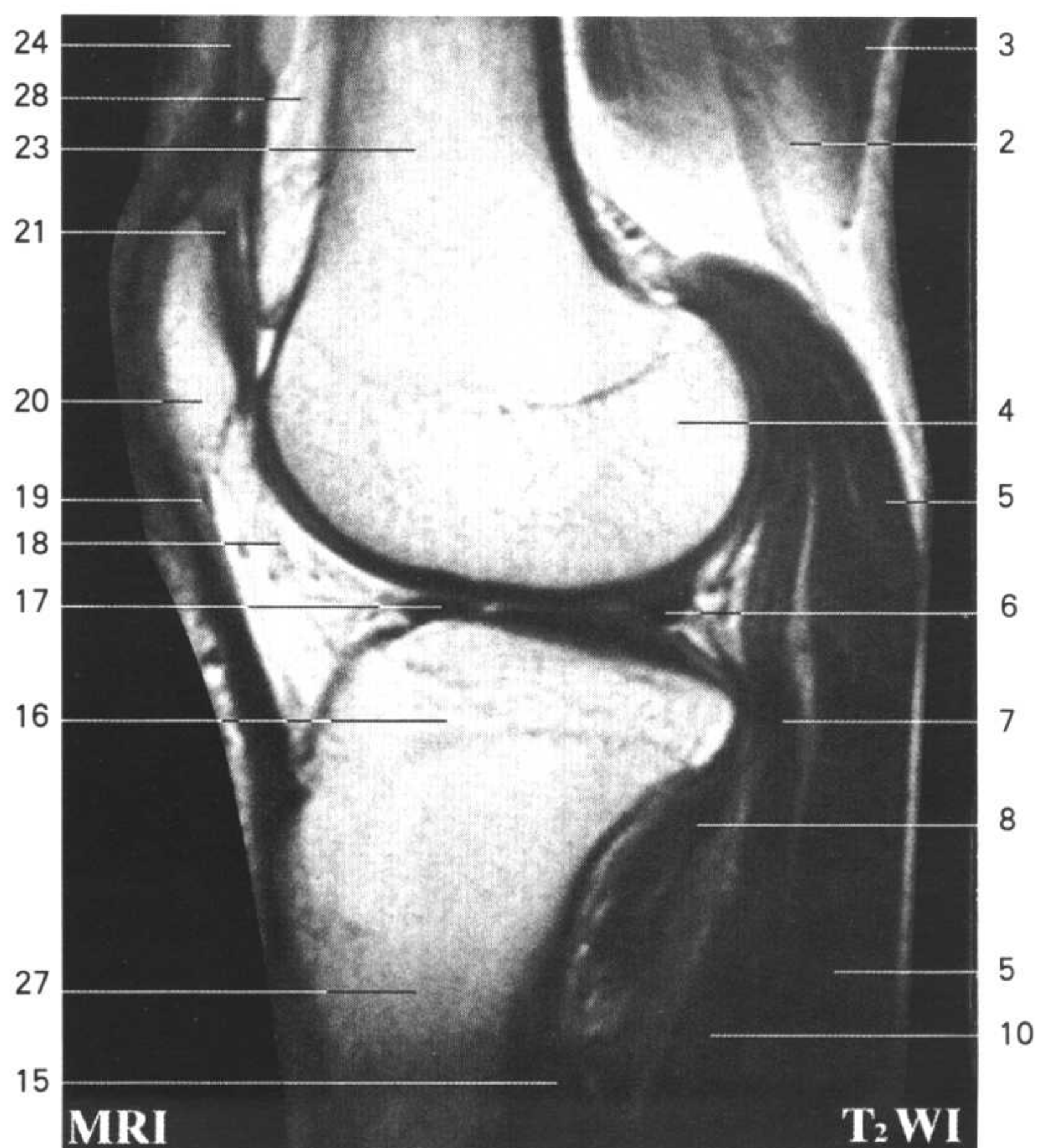
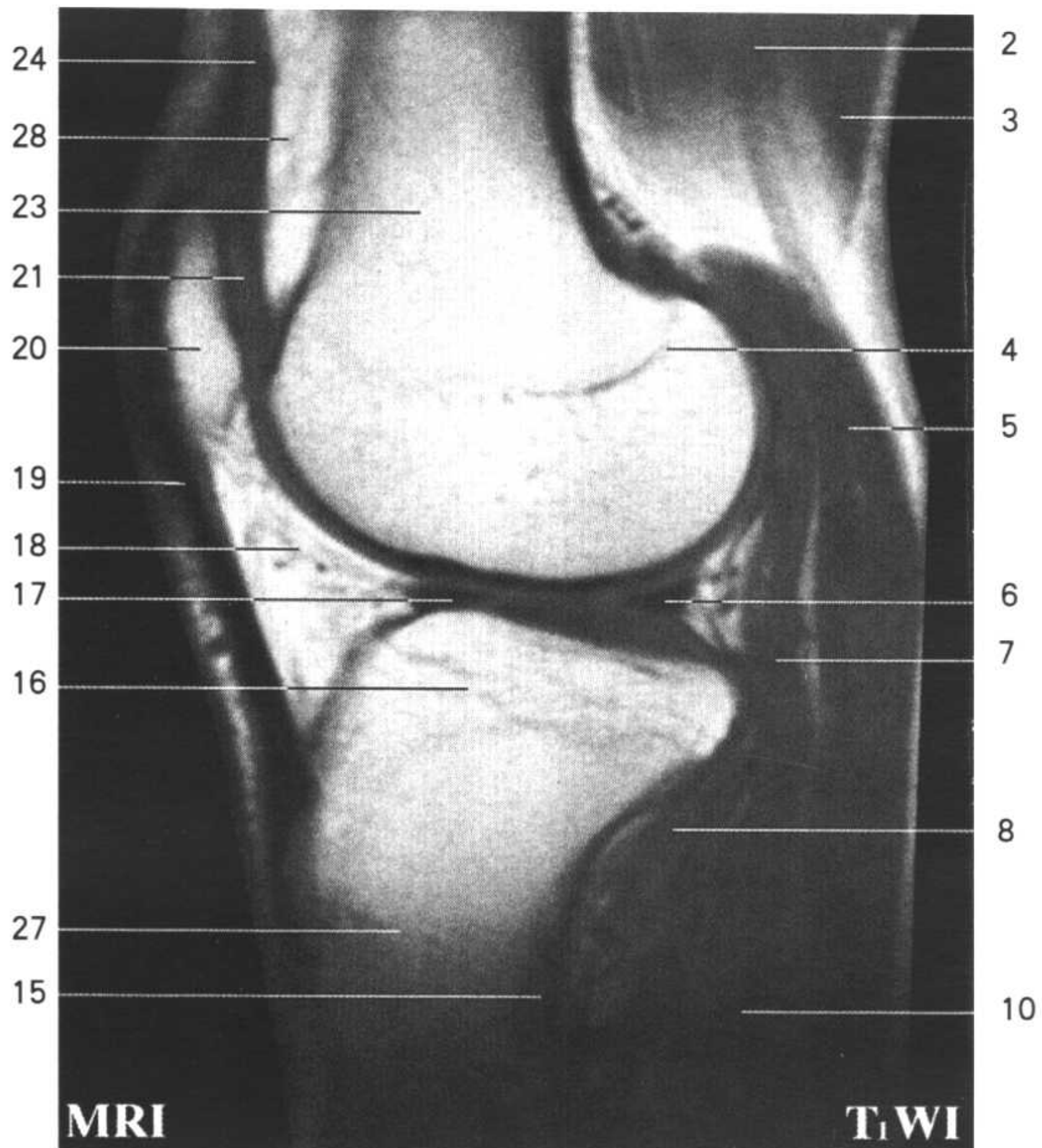


Fig.SK(R) 6

1. 股中间肌 vastus intermedius
2. 股二头肌短头 short head of biceps femoris
3. 股二头肌长头 long head of biceps femoris
4. 股骨外侧髁 lateral condyle of femur
5. 腓肠肌外侧头 lateral head of gastrocnemius
6. 外侧半月板后部 posterior part of lateral meniscus
7. 跖肌 plantaris
8. 腓肌 popliteus
9. 腓骨头 fibular head
10. 比目鱼肌 soleus

- 11. 胫后动、静脉 posterior tibial a. and v.
- 12. 胫神经 tibial n.
- 13. 腓肠肌 gastrocnemius
- 14. 胫骨前肌 tibialis anterior
- 15. 胫骨后肌 tibialis posterior
- 16. 胫骨外侧髁 lateral condyle of tibia
- 17. 外侧半月板前部 anterior part of lateral meniscus
- 18. 翼状襞 alar fold
- 19. 髌韧带 patellar ligament
- 20. 髌骨 patella
- 21. 髌上囊 suprapatellar bursa
- 22. 膝关节肌 articularis genus
- 23. 股骨 femur
- 24. 股直肌 rectus femoris
- 25. 股中间肌 vastus intermedius
- 26. 趾长伸肌 extensor digitorumlongus
- 27. 胫骨 tibia
- 28. 股前脂体 prefemoral fat pad



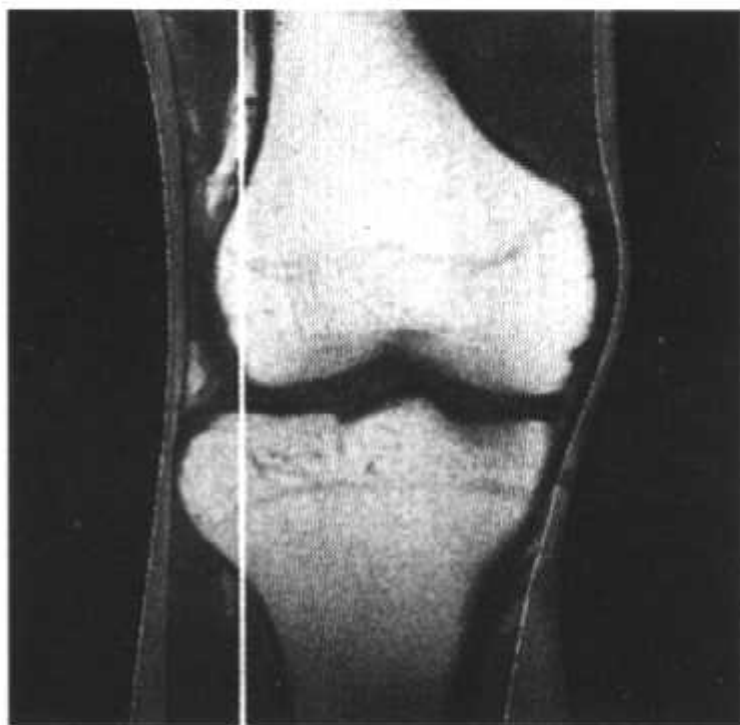
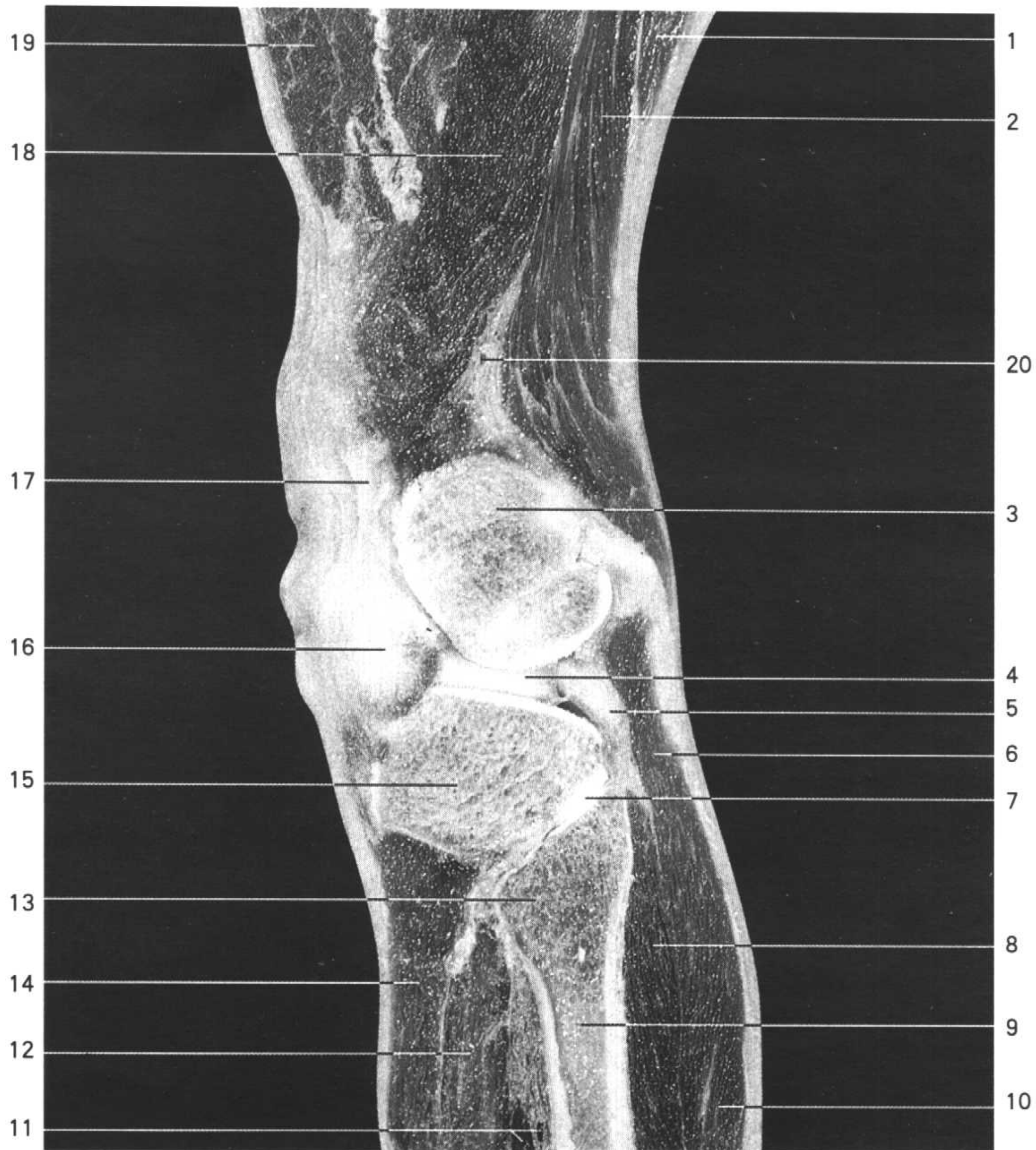

Fig.SK(R) 7

1. 股二头肌长头 long head of biceps femoris
2. 股二头肌短头 short head of biceps femoris
3. 股骨外侧髁 lateral condyle of femur
4. 外侧半月板 lateral meniscus
5. 腘肌腱 tendon of popliteus
6. 腓肠肌外侧头 lateral head of gastrocnemius
7. 胫腓关节 tibiofibular joint
8. 比目鱼肌 soleus
9. 腓骨 fibula
10. 腓肠肌 gastrocnemius

11. 胫前动、静脉 anterior tibial a. and v.
12. 趾长伸肌 extensor digitorum longus
13. 腓骨头 fibular head
14. 胫骨前肌 tibialis anterior
15. 胫骨外侧髁 lateral condyle of tibia
16. 翼状襞 alar fold
17. 髌外侧支持带 lateral patellar retinaculum
18. 股中间肌 vastus intermedius
19. 肌外侧肌 vastus lateralis
20. 膝上外侧动、静脉 lateral superior genicular a. and v.
21. 髌骨 patella

