

图书在版编目(CIP)数据

简明人体解剖彩色图谱 / 李瑞祥主编: —北京:
人民卫生出版社, 2001
ISBN 7-117-04586-8

I . 简 ... II . 李 ... III . 人体解剖学—图谱
IV . R322-64

中国版本图书馆 CIP 数据核字(2001)第 075543 号

简明人体解剖彩色图谱

主 编: 李 瑞 祥
出版发行: 人民卫生出版社 (中继线 67616688)
地 址: (100078) 北京市丰台区方庄芳群园3区3号楼
网 址: [http://www. pmph. com](http://www.pmph.com)
E-mail: [pmph @ pmph. com](mailto:pmph@pmph.com)
制版印刷: 四川新华印刷厂
经 销: 新华书店
开 本: 889 × 1194 1/32 印张: 8.25
字 数: 420千字
版 次: 2001年11月第1版 2001年11月第1版第1次印刷
印 数: 00 001—10 050
标准书号: ISBN 7-117-04586-8/R · 4587
定 价: 48.00元

著作权所有, 请勿擅自用本书制作各类出版物, 违者必究
(凡属质量问题请与本社发行部联系退换)

使用说明

本图谱共分运动系统、消化系统、呼吸系统、泌尿生殖系统、心血管系统、淋巴系统、感觉器、内分泌系统、中枢神经系统和局部解剖等10章，其中前9章为系统解剖部分，第10章为局部解剖部分，是对系统解剖中的部分内容如各部的肌、血管和周围神经等，按局部解剖方式予以综合展示。

每幅图中，器官的结构，采用引线、标号，其外中英文对照标。图中的解剖学名词，按全国自然科学名词审定委员会1991年公布的《人体解剖学名词》为准，尚未公布的结构名词，则按规划教材标注。某些英文名词作了缩写，如artery缩写为a.,vein缩写为v.,nerve缩写为n.,muscle缩写为m.,ligament缩写为lig.。为了方便读者查阅，附有以汉语拼音为序的中英文解剖学名词索引。

前 言

为了配合医学教育改革,培养面向二十一世纪不同层次医务工作者的需要,根据《人体解剖学》课程和教材的要求,我们继出版《实用人体解剖彩色图谱》后,编著了这部《简明人体解剖彩色图谱》。前者以局部解剖为主,系统解剖为辅;后者以系统解剖为主,辅为局部解剖,按《人体解剖学》教学内容编排。本图谱主要供医学本科生、大专生、中专生学习使用,也适用于成人教育、继续教育学生和临床医务工作人员,是一部简明、系统、全面和实用的医学工具书。

本图谱以人体系统解剖的实物标本图像为主,按运动系统、消化系统、呼吸系统、泌尿生殖系统、心血管系统、淋巴系统、感觉器、内分泌系统、中枢神经系统和局部解剖为序编排。全书共10章,共有390幅实地解剖标本彩图(共297个图号)。所有彩图均根据当前解剖学教学中所要求的内容,精心设计、制作实物标本,经专业摄影师拍制而成,力求每幅彩图具有科学性、真实性、艺术性和立体感,真实反映和清晰展示人体各器官系统的形态结构。图谱以系统解剖为主,局部解剖为辅,并有部分断层解剖图、铸型标本图及少量示意图;除正常解剖图外,亦有少量解剖变异图。图谱中的解剖学名词按中英文标注,并以全国自然科学名词审定委员会1991年公布的《人体解剖学名词》为准,尚未公布的结构名词,则按规划教材标注。为了方便读者查阅,附有以汉语拼音为序的中英文解剖学名词索引。

编者虽在标本设计、制作、摄影及编排等方面做了努力,力求适合教学实际的需要,但由于我们水平有限,难免有不妥之处,敬请广大读者及同道指正。

编 者

2001年10月

目 录

第1章 运动系统 Locomotor System	1
图1 全身骨骼(前和后面观) The skeleton(anterior and posterior aspect)	2
图2 骨的分类 Classification of bones	3
图3 骨的构造 (A、B) Structure of the bone(A,B)	3
图4 脊柱(A、B、C) The vertebral column(A,B,C)	4
图5 寰椎(上和下面观) The atlas(superior and inferior aspect)	5
图6 枢椎(上面观) The axis (superior aspect)	5
图7 颈椎(上面观) A cervical vertebra(superior aspect)	6
图8 胸椎(上和侧面观) A thoracic vertebra(superior and lateral aspect)	6
图9 腰椎(上和侧面观) A lumbar vertebra(superior and lateral aspect)	7
图10 骶骨和尾骨(前面观) The sacrum and coccyx(anterior aspect)	8
图11 骶骨和尾骨(后面观) The sacrum and coccyx(posterior aspect)	8
图12 第一(A)、二(B)、六(C)、十二(D)肋骨(上面观) The 1st(A),2nd(B), 6th(C),12th(D) ribs(superior aspect)	9
图13 胸骨(前和侧面观) The sternum(anterior and lateral aspect)	9
图14 颅(前面观) The skull(anterior aspect)	10
图15 颅(上面观) The skull(superior aspect)	10
图16 颅底外面观 The external aspect of the base of the skull	11
图17 颅底内面观 The internal aspect of the base of the skull	12
图18 颅(侧面观) The skull(lateral aspect)	13
图19 婴儿颅(上和侧面观) The skull of a infant (superior and lateral aspect)	13
图20 下颌骨(外侧面和后面观) The mandible (lateral and posterior aspect)	14
图21 舌骨(上面观) The hyoid bone(superior aspect)	14
图22 蝶骨(前和上面观) The sphenoid bone(anterior and superior aspect)	15
图23 颞骨(外、内和下面观) The temporal bone (external,internal and inferior aspect)	16
图24 筛骨(上和下面观) The ethmoid bone (superior and inferior aspect)	17
图25 枕骨(外和内面观) The occipital bone(external and internal aspect)	17
图26 上颌骨(前和内侧面观) The maxilla bone (anterior and medial aspect)	18

图 27	锁骨(上和下面观) The clavicle(superior and inferior aspect)	19
图 28	肩胛骨(外侧角) The scapula(lateral angle)	19
图 29	肩胛骨(前和后面观) The scapula(anterior and posterior aspect)	20
图 30	肱骨(前和后面观) The humerus(anterior and posterior aspect)	21
图 31	尺骨(A. 右图, B. 左图) The ulna (A.the right figure,B.the left figure)	22
图 32	桡骨(A. 左图, B. 右图) The radius (A.the left figure,B.the right figure)	22
图 33	手骨(前和后面观) The bones of the hand (anterior and posterior aspect)	23
图 34	髌骨(内和外面观) The hip bone(internal and external aspect)	24
图 35	婴儿髌骨(外面观) The hip bone of the infant(external aspect)	24
图 36	股骨(前和后面观) The femur(anterior and posterior aspect)	25
图 37	髌骨(前和后面观) The patella(anterior and posterior aspect)	26
图 38	胫骨与腓骨(前和后面观) The tibia and fibula (anterior and posterior aspect)	27
图 39	足骨(上和下面观) The bones of the foot (superior and inferior aspect)	28
图 40	足纵弓(侧面及上面观) The logitudinal arches of the foot (lateral and superior aspect)	29
图 41	椎骨间连结(A、B、C、D) Intervertebral joints(A,B,C,D)	31
图 42	颅骨与椎骨连结(A、B、C) The joints of the skull and vertebra(A,B,C)	32
图 43	肋与胸骨连结 The joints of ribs and the sternum	33
图 44	颞下颌关节(A、B、C) The temporomandibular joint(A,B,C)	33
图 45	肩关节(A、B、C) The shoulder joint(A,B,C)	34
图 46	肘关节(A、B、C) The elbow joint(A,B,C)	35
图 47	手骨连结(A、B、C) The joints of the hand(A,B,C)	36
图 48	骨盆的连结(前和后面观) The joints of the pelvis (anterior and posterior aspect)	37
图 49	髋关节(A、B、C、D) The hip joint(A,B,C,D)	39
图 50	膝关节(前和后面观) The knee joint (anterior and posterior aspect)	40
图 51	膝关节(A、B) The knee joint (A,B)	41
图 52	膝关节(切开) The knee joint(incision)	42
图 53	膝关节(半月板) The knee joint(meniscuses)	42
图 54	膝关节(矢状切面) The knee joint(sagittal section)	43

图 55 小腿骨的连结 The joints of the leg	43
图 56 足骨的连结(上和下面观) The joints of the foot (superior and inferior aspect)	44
图 57 足骨的连结(A、B) The joints of the foot(A,B)	45
图 58 肌的形态(A~H) Forms of muscles(A~H)	46
图 59 背部的肌(Ⅰ) Muscles of the back(Ⅰ)	47
图 60 背部的肌(Ⅱ) Muscles of the back(Ⅱ)	48
第2章 消化系统 Digestive System	49
图 61 消化系统概观 General arrangement of the digestive apparatus	50
图 62 恒牙 Permanent teeth	51
图 63 曲面断层 X 线片 Panoramic	51
图 64 牙的构造模式图(纵切) Diagram of the structure of a tooth (sagittal section)	51
图 65 上颌恒、乳牙(下面观) Upper permanent and deciduous teeth (inferior aspect)	52
图 66 下颌恒、乳牙(上面观) Lower permanent and deciduous teeth(superior aspect)	52
图 67 舌(A、B、C) Tongue(A,B,C)	53
图 68 大唾液腺(A、B) The large salivary glands(A,B)	54
图 69 咽腔(前面观) The pharyngeal cavity(anterior aspect)	55
图 70 咽腔(后面观) The pharyngeal cavity(posterior aspect)	55
图 71 咽肌(后面观) Muscles of pharynx(posterior aspect)	56
图 72 食管 Esophagus	56
图 73 胃(Ⅰ) Stomach(Ⅰ)	57
图 74 胃(Ⅱ) Stomach(Ⅱ)	57
图 75 十二指肠 Duodenum	58
图 76 回盲部结构 Caecal region	58
图 77 消化管的一般结构 Layers of alimentary canal	59
图 78 直肠(内面观) The rectum(internal aspect)	59
图 79 肝(脏面) Liver(visceral surface)	60
图 80 肝(上面观) Liver(superior aspect)	60
图 81 肝内的血管和胆管 The blood vessels and bile ducts in the liver	61
图 82 肝外胆道 Extrahepatic bile ducts	61
图 83 腹膜的配布(Ⅰ) Arrangement of the peritoneum(Ⅰ)	62
图 84 腹膜的配布(Ⅱ) Arrangement of the peritoneum(Ⅱ)	63
图 85 网膜 Omenta	64

图 86 网膜囊 Omental bursa	64
第 3 章 呼吸系统 Respiratory System	65
图 87 呼吸系统概观 General arrangement of respiratory system	66
图 88 鼻软骨(A、B) Nasal cartilages(A,B)	67
图 89 鼻中隔 Nasal septum	67
图 90 鼻甲和鼻道 Nasal conchae and meatuses	68
图 91 鼻腔外侧壁 Lateral wall of nasal cavity	68
图 92 鼻旁窦的开口 Orifices of paranasal sinuses	69
图 93 喉软骨前、后面观 Anterior and posterior aspect of the cartilages of larynx	70
图 94 喉的软骨和韧带(I) Cartilages and ligaments of larynx(I)	70
图 95 喉的软骨和韧带(II) Cartilages and ligaments of larynx(II)	71
图 96 喉的软骨和韧带(III) Cartilages and ligaments of larynx(III)	71
图 97 喉肌右侧观(A、B 甲状软骨右板被切除) Right aspect of muscles of larynx(A,B Right lamina of thyroid cartilage is removed)	72
图 98 喉肌后面观 Posterior aspect of muscles of larynx	73
图 99 喉腔后面观 Posterior aspect of cavity of larynx (right half of membrane is removed)	73
图 100 喉、气管和支气管 Larynx, trachea and bronchi	74
图 101 肺叶和肺段支气管(后面观) Lobar and segmental bronchi (posterior aspect)	75
图 102 右肺(A. 外侧面观, B. 内侧面观) Right lung (A. lateral aspect, B. medial aspect)	76
图 103 左肺(A. 外侧面观, B. 内侧面观) Left lung (A. lateral aspect, B. medial aspect)	77
图 104 右肺支气管肺段(A. 外侧面观, B. 内侧面观) Bronchopulmonary segments of right lung(A. lateral aspect, B. medial aspect)	78
图 105 左肺支气管肺段(A. 外侧面观, B. 内侧面观) Bronchopulmonary segments of left lung(A. lateral aspect, B. medial aspect)	79
图 106 胸膜和胸膜腔 Pleura and pleural cavity	80
图 107 肺根和肺韧带(右侧) Root of lung and pulmonary ligament (Right side)	80
第 4 章 泌尿生殖系统 Urogenital System	81
图 108 男性泌尿生殖系统概观 General arrangement of the urogenital system of male	82

图 109 女性泌尿生殖系统概观 General arrangement of the urogenital system of female	83
图 110 肾和输尿管位置(A、B) Location of kidneys and ureters(A,B)	85
图 111 肾(冠状切面) Kidney(coronal section)	86
图 112 肾(小叶) Kidney(renal lobes)	86
图 113 肾盏及肾盂 Renal calices and pelvis	86
图 114 (左)肾的被膜 The coverings of (left) kidney	87
图 115 膀胱、前列腺和精囊(A、B、C、D) The urinary bladder, prostate and seminal vesicle(A,B,C,D)	89
图 116 男性膀胱底(后面观) Fundus of the male urinary bladder (posterior aspect)	90
图 117 男性盆部(正中矢状剖面) The pelvis of the male (median sagittal section)	91
图 118 睾丸与附睾(A、B、C) Testis and epididymis (A,B,C)	92
图 119 阴囊的层次 The coverings of scrotum	93
图 120 阴茎(A、B) Penis(A,B)	94
图 121 女性内生殖器 The female internal genital organs	95
图 122 女性盆部(正中矢状剖面) The pelvis of the female (median sagittal section)	96
图 123 女性外生殖器 The female external organs	97
图 124 女性会阴浅隙及坐骨肛门窝 Superficial perineal space and ischioanal fossa of the female	97
图 125 女性乳房 Female breast	98
图 126 男性会阴肌 The male perineum	98
第 5 章 心血管系统 Cardiovascular System	99
图 127 心前面观 Heart anterior aspect	100
图 128 心的前面或胸肋面 The anterior or sternocostal surface of the heart	101
图 129 心底和膈面(Ⅰ) The base and diaphragmatic surface of the heart(Ⅰ)	102
图 130 心底和膈面(Ⅱ) The base and diaphragmatic surface of the heart(Ⅱ)	102
图 131 右心房内部结构(前面观) Internal structures of the right atrium (viewed from front)	103
图 132 右心室内结构(前面观) Internal structures of the right ventricle (viewed from front)	103

图 133	肺动脉半月瓣和肺动脉窦 Semilunar cusps of pulmonary valve and sinus of pulmonary trunk	104
图 134	左心室内部结构(前面观) Internal structures of left ventricle (viewed from front)	104
图 135	经心长轴斜切面 The section at the long axis of the heart on oblique	105
图 136	经左心室冠状切面 The coronary section through the left ventricle	106
图 137	主动脉瓣和主动脉窦 Mitral valve and aortic sinuses	106
图 138	心的瓣膜(I) Valves of heart(I)	107
图 139	心的瓣膜(II) Valves of heart(II)	107
图 140	心包 The pericardium	108
图 141	浆膜心包 Serous pericardium	109
图 142	心肌构筑 The myocardiac architecture	109
图 143	心冠状动脉红色铸型 The color red resin of the coronary arteries of the heart	110
图 144	心传导系统 The cardiac conducting system	110
第6章 淋巴系统 Lymphatic System 111		
图 145	颈部深淋巴结 Deep lymph nodes of the neck	112
图 146	胸腔脏器淋巴结 Lymph nodes of the thoracic viscera	113
图 147	胸导管颈段 Cervical part of the thoracic duct	113
图 148	乳糜池 Cisterna chyli	114
图 149	肝和胃的淋巴结 Lymph nodes around liver and stomach	114
图 150	髂内、外淋巴结 External and internal iliac lymph nodes	115
图 151	肠系膜上淋巴结 Superior mesenteric lymph nodes	115
图 152	肠系膜下淋巴结 Inferior mesenteric lymph nodes	116
图 153	腹后壁淋巴结 Lymph nodes of the posterior abdominal wall	116
图 154	胸导管胸段 Thoracic part of the thoracic duct	117
图 155	脾(A. 膈面、B. 脏面) Spleen(A. diaphragmatic surface, B. visceral surface)	118
图 156	腋淋巴结 Axillary lymph nodes	119
图 157	腹股沟浅淋巴结 Superficial inguinal lymph nodes	119
图 158	头颈部浅淋巴结(前分) Superficial lymph nodes of the head and neck (anterior part)	120
图 159	头颈部浅淋巴结(后分) Superficial lymph nodes of the head and neck (posterior part)	120

第7章 感觉器 Sense Organs	121
图 160 眼(右侧)的前面观(A、B) Anterior aspect of the eye (right side)(A,B)	122
图 161 睑(矢状切面) The eyelid(sagittal section)	123
图 162 眶(前面观) The orbit(anterior aspect)	123
图 163 右侧眼眶水平断面(上面观) Horizontal section through orbit(superior aspect)	124
图 164 眼球前半(后面观) Anterior half of the eyeball(posterior aspect)	124
图 165 眼底的血管 Blood vessel of the eyeball fundus	125
图 166 眼球及眶矢状切面 Sagittal section through eyeball and orbital cavity	125
图 167 眼外肌 The extraocular muscles	126
图 168 右眼眶隔 Orbital septum of the right eye	127
图 169 泪器(右侧) The lacrimal apparatus(right side)	127
图 170 眼球后的结构(A、B) Posterior structural of eyeball(A,B)	128
图 171 眼球外肌(外侧观) The ocularal muscles(lateral aspect)	129
图 172 眼球外肌(上面观) The ocularal muscles(superior aspect)	129
图 173 右眼眶内容(外侧面) Right orbital contents(lateral aspect)	130
图 174 右眼眶内容(上面观) Right orbital contents(superior aspect)	130
图 175 耳廓 Auricle	131
图 176 听小骨(A、B) Auditory ossicles(A,B)	131
图 177 外、中、内耳(冠状切面) External middle internal of the ear(coronal section)	132
图 178 耳上后面观 Superior posterior aspect of the ear	133
图 179 鼓室内侧壁(右侧) Medial wall of the tympanic cavity(right side)	134
图 180 骨迷路 Bony labyrinth	135
图 181 螺旋器 The spiral organ	135
图 182 位觉斑 The macula of utricle and macula of saccule	136
图 183 壶腹嵴 The ampullary crest	136
第8章 内分泌系统 Endocrine System	137
图 184 全身主要内分泌器官 The endocrine organs of body	138
图 185 垂体与松果体 Hypophysis and pineal body	139
图 186 胸腺 Thymus	139
图 187 甲状腺(前面观) Thyroid gland(anterior aspect)	140

图 188 肾上腺 Suprarenal gland	140
第 9 章 中枢神经系统 Central Nervous System	141
图 189 神经系统 Nervous system	142
图 190 脊髓的外形和被膜(A、B、C) External features and meninges of the spinal cord(A,B,C)	143
图 191 神经元模式图(A、B、C) Diagram of the neurons(A,B,C)	144
图 192 脊神经的组成 The constitution of spinal nerve	144
图 193 脊髓横切面(A、B、C、D、E) Transverse section of spinal cord(A,B,C,D,E)	145
图 194 脑干腹面观 Ventral aspect of brain stem	146
图 195 脑干背面观 Dorsal aspect of brain stem	146
图 196 脑干侧面观 Lateral aspect of the brain stem	147
图 197 脑神经核模式图(背面观) Diagram of the nuclei of the cranial nerves (dorsal aspect)	147
图 198 延髓横切面(经锥体交叉) Transverse section of the medulla oblongata (through the pyramidal decussation)	148
图 199 延髓横切面(经内侧丘系交叉) Transverse section of the medulla oblongata(through the decussation of the medial lemniscus)	148
图 200 延髓横切面(经过下橄榄核中部) Transverse section of the medulla oblongata(through the middle part of the inferior olive)	149
图 201 延髓横切面(经过蜗神经核) Transverse section of the medulla oblongata(through the cochlear nuclei)	149
图 202 脑桥横切面(经面丘) Transverse section of the pons (through the facial colliculus)	150
图 203 脑桥横切面(经三叉运动核) Transverse section of the pons (through the motor nucleus of the trigeminal nerve)	150
图 204 中脑横切面(经下丘) Transverse section of the midbrain (through the inferior colliculus)	151
图 205 中脑横切面(经上丘) Transverse section of the midbrain (through the superior colliculus)	151
图 206 小脑(上面观) The cerebellum(superior aspect)	152
图 207 小脑(下面观) The cerebellum(inferior aspect)	152
图 208 小脑(前面观) The cerebellum(anterior aspect)	153
图 209 小脑横断面 Transverse section of the cerebellum	153
图 210 小脑脚及锥体束 The peduncles of cerebellum and the pyramidal tract	154

图 211 基底核和脑干 The basal nuclei and the brain stem	154
图 212 丘脑核团模式图 Diagram of the thalamic nuclei	155
图 213 下丘脑核团模式图 Diagram of the hypothalamic nuclei	155
图 214 脑的外侧面 Lateral surface of the brain	156
图 215 脑的正中矢状切面 Median sagittal section of the brain	156
图 216 大脑半球内侧面 Medial surface of the cerebral hemisphere	157
图 217 脑岛 The insula	157
图 218 脑的水平切面 Horizontal section of the brain	158
图 219 基底神经核 The basal nuclei	158
图 220 脑的冠状切面 Coronal section of the brain	159
图 221 侧脑室下角 Inferior horn of lateral ventricle	159
图 222 本体感觉传导道 Pathway of the proprioceptive sensibility	160
图 223 浅感觉传导道(A、B) Pathway of the exteroceptive sensibility(A,B)	161
图 224 视觉传导道(下面观) The visual pathway(inferior aspect)	162
图 225 锥体系(皮质脊髓束) Pyramidal system(corticospinal tract)	163
图 226 锥体系(皮质核束) Pyramidal system(corticonuclear tract)	164
图 227 面神经瘫 Paralysis of the facial nerve	165
图 228 舌下神经瘫 Paralysis of the hypoglossal nerve	165
图 229 锥体外系(纹状体苍白球系) Extrapyramidal system (striopallidal system)	166
图 230 锥体外系(皮质脑桥小脑系) Extrapyramidal system (corticopontocerebellar system)	166
图 231 脑底的动脉 Arteries at the base of the brain	167
图 232 大脑半球的动脉(A. 外侧面、B. 内侧面) Arteries of the cerebral hemisphere(A.lateral surface,B.medial surface)	168
图 233 大脑半球外侧面的静脉 Veins of the lateral surface of cerebral hemisphere	169
图 234 大脑深静脉 The deep cerebral veins	169
图 235 侧脑室(上面观) Lateral ventricle(superior aspect)	170
图 236 硬脑膜及硬脑膜窦 Cerebral dura mater and sinuses of the dura mater	170
图 237 海绵窦的冠状切面 Coronal section of the cavernous sinus	171
图 238 脑的冠状切面(经过小脑幕切迹) Coronal section of the brain (through the tentorial incisure of cerebellum)	171
图 239 脑脊液循环模式图 Diagram of the cerebrospinal fluid circulation	172

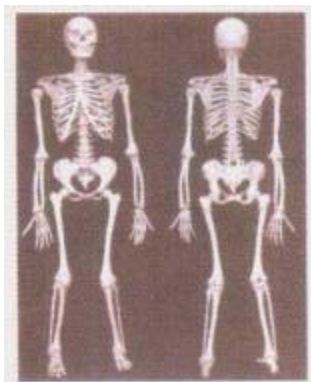
第 10 章 局部解剖 Topograph	173
图 240 腋窝的血管和神经 Blood vessels and nerves of the axillary fossa	174
图 241 肩和臂前面的肌、血管和神经 Muscles, blood vessels and nerves of the anterior aspect of the shoulder and upper arm	175
图 242 肩胛区和臂后区的肌、血管和神经 Muscles, blood vessels and nerves of the scapular and posterior brachial region	175
图 243 肘前区和前臂前区的肌、血管及神经(I)(A、B) Muscles, blood vessels and nerves of the anterior cubital region and anterior antebrachial region (I)(A,B)	176
图 244 肘前区和前臂前区的肌、血管及神经(II) Muscles, blood vessels and nerves of the anterior cubital region and anterior antebrachial region(II)	177
图 245 前臂后区的肌、血管和神经(A、B) Muscles, blood vessels and nerves of the posterior antebrachial region (A,B)	178
图 246 手背的血管和神经 Blood vessels and nerves of the dorsum of hand	179
图 247 手掌深部 Deep layer of the palm of hand	180
图 248 手肌(A、B、C) Muscles of hand (A,B,C)	181
图 249 颈丛及其分支 Cervical plexus and it's branches	182
图 250 颈部右侧面的肌、血管和神经(I) Muscles, blood vessels and nerves of the right lateral aspect of the neck(I)	183
图 251 颈部右侧面的肌、血管和神经(II) Muscles, blood vessels and nerves of the right lateral aspect of the neck(II)	184
图 252 颈深部血管和神经 Deep blood vessels and nerves of the neck	185
图 253 甲状腺区前面观 Anterior aspect of the region of thyroid	186
图 254 甲状腺区后面观 Posterior aspect of the region of thyroid gland	187
图 255 头颈的肌、血管和神经 Muscles, blood vessels and nerves of the head and neck	188
图 256 颈外动脉分支(右侧) The branches of external carotid artery (right side)	189
图 257 表情肌 Muscles of facial expression	189
图 258 右侧咀嚼肌(A、B、C) Masseter of right side(A,B,C)	190
图 259 纵隔(左侧面观) Mediastinum(left lateral aspect)	191
图 260 纵隔(右侧面观) Mediastinum(right lateral aspect)	192
图 261 上纵隔和后纵隔 Superior mediastenum and posterior mediastenum	193
图 262 膈(胸腔面) Diaphragm(thoracic surface)	194

图 263 肋间神经和血管 Intercostal nerves and blood vessels	194
图 264 经肺动脉分叉平面横断面 The section at the level of the bifurcation of pulmonary trunk on transverse	195
图 265 肩袖肌前面观 Anterior aspect of rotator cuff muscles	195
图 266 肩袖肌后面观 Posterior aspect of rotator cuff muscles	196
图 267 胸前壁(内面观) Anterior thoracic wall(internal aspect)	196
图 268 腹前外侧壁的肌、神经和血管 Muscles,nerves and blood vessels of anterolateral wall of abdomen	197
图 269 腹股沟管(A、B、C、D) Inguinal canal(A,B,C,D)	199
图 270 腹前壁后面观(左) Posterior aspect of the anterior abdominal wall(left)	200
图 271 膈(下面观) Diaphragm(inferior aspect)	200
图 272 腹腔干 Celiac trunk	201
图 273 幽门平面横断面 Transverse section at level of pylorus	202
图 274 肠系膜上动脉 Superior mesenteric artery	203
图 275 回结肠动脉 Ileocolic artery	203
图 276 肠系膜下动脉 Inferior mesenteric artery	204
图 277 肝门静脉 Hepatic portal vein	205
图 278 腹后隙的肌、血管和神经 Muscles blood vessels and nerves in the retroperitoneal space	206
图 279 男性盆部的动脉(上面观) Arteries of the pelvis of the male (superior aspect)	207
图 280 女性盆部的动脉(上面观) Arteries of the female pelvis (superior aspect)	208
图 281 肛提肌(上面观) Levator ani(superior aspect)	209
图 282 男性会阴浅隙和坐骨肛门窝 Superficial perineal space and ischioanal fossa of the male	210
图 283 下肢的浅静脉(A、B) Superficial veins of the lower limb(A、B)	211
图 284 股鞘 Femoral sheath	212
图 285 股前内侧区的肌、神经和血管(Ⅰ) Muscles,nerves and blood vessels of anterior medial region of the thigh(Ⅰ)	212
图 286 股前内侧区的肌、神经和血管(Ⅱ) Muscles,nerves and blood vessels of anterior and medial region of the thigh(Ⅱ)	213
图 287 臀区的肌、神经和血管 Muscles,nerves and blood vessels of the gluteal region	214
图 288 腘窝的神经和血管 Nerves and blood vessels of the popliteal fossa	214
图 289 小腿后区的肌、神经和血管(A、B、C) Muscles,nerves and blood	

vessels of the posterior crural region(A,B,C)	215
图 290 足底腱膜 Plantar aponeurosis	216
图 291 足底肌、神经和血管(I) Muscles,nerves and blood vessels of the sole of foot(I)	216
图 292 足底肌、神经和血管(II) Muscles,nerves and blood vessels of the sole of foot(II)	216
图 293 小腿前外侧区和足背 Anteriolateral crural region and dorsum of foot	217
图 294 小腿伸肌支持带和腓骨肌支持带 Extensor retinaculum and peroneal retinaculum of the leg.	217
图 295 足背的浅静脉(上面观) Superficial veins of the dorsum of foot (superior aspect)	218
图 296 足背的神经和动脉 Nerves and arteries of the dorsum of foot	218
图 297 足肌(上面观) Muscles of the foot(superior aspect)	218
索引 INDEX	219

1

LOCOMOTOR SYSTEM



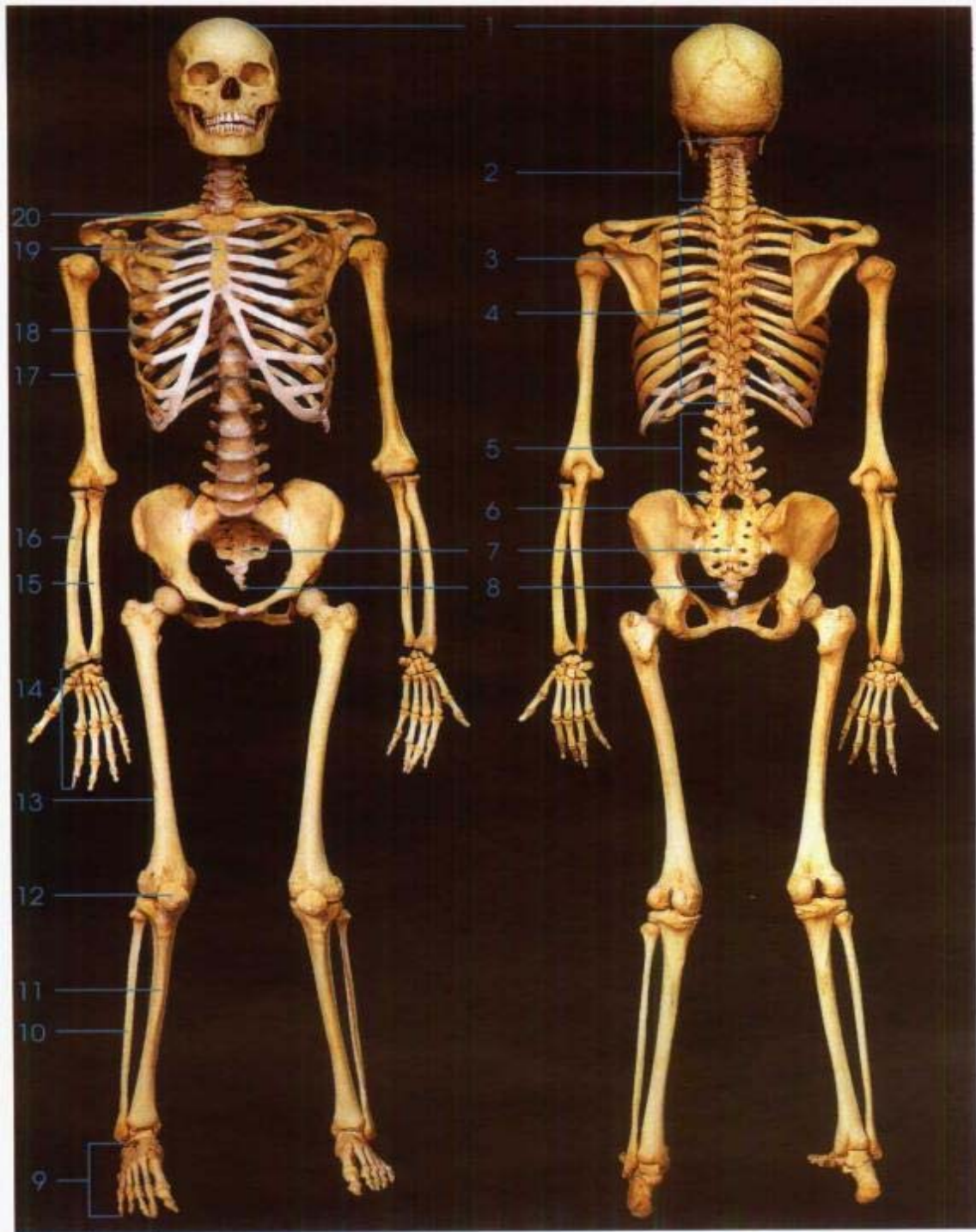
第1章

运

动

系

统



前面观

后面观

图1 全身骨骼(前和后面观)

The skeleton (anterior and posterior aspect)

- | | | | | | |
|--------|--------------------|--------|---------------|--------|----------|
| 1. 颅骨 | cranial bones | 8. 尾骨 | coccyx | 15. 尺骨 | ulna |
| 2. 颈椎 | cervical vertebrae | 9. 足骨 | bones of foot | 16. 桡骨 | radius |
| 3. 肩胛骨 | scapula | 10. 腓骨 | fibula | 17. 肱骨 | humerus |
| 4. 胸椎 | thoracic vertebrae | 11. 胫骨 | tibia | 18. 肋 | ribs |
| 5. 腰椎 | lumbar vertebrae | 12. 髌骨 | patella | 19. 胸骨 | sternum |
| 6. 髌骨 | hip bone | 13. 股骨 | femur | 20. 锁骨 | clavicle |
| 7. 骶骨 | sacrum | 14. 手骨 | bones of hand | | |

1. 扁骨 flat bone
2. 短骨 short bone
3. 不规则骨 irregular bone
4. 长骨 long bone

图2 骨的分类
Classification of bones

- a. 股骨上端剖面 The upper part of the femur section
- b. 跟骨剖面 Section of the calcaneus
- c. 顶骨剖面 Section of the parietal bone
- d. 椎骨剖面 Section of the vertebral

1. 松质 Spongy
2. 密质 compact
3. 骨髓 bone marrow
4. 骨膜 periosteum
5. 关节软骨 articular cartilage
6. 外板 outer plate
7. 板障 diploe
8. 内板 inner plate

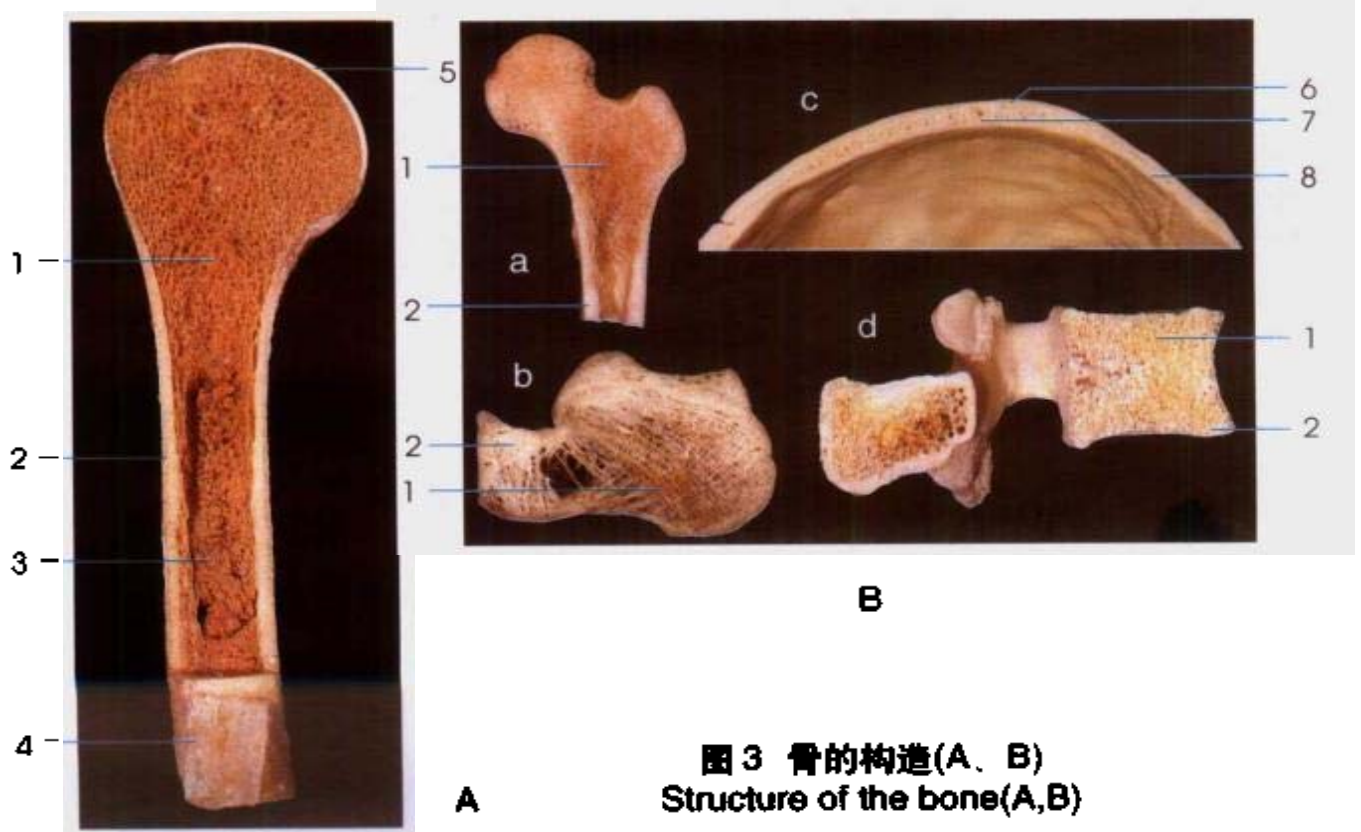
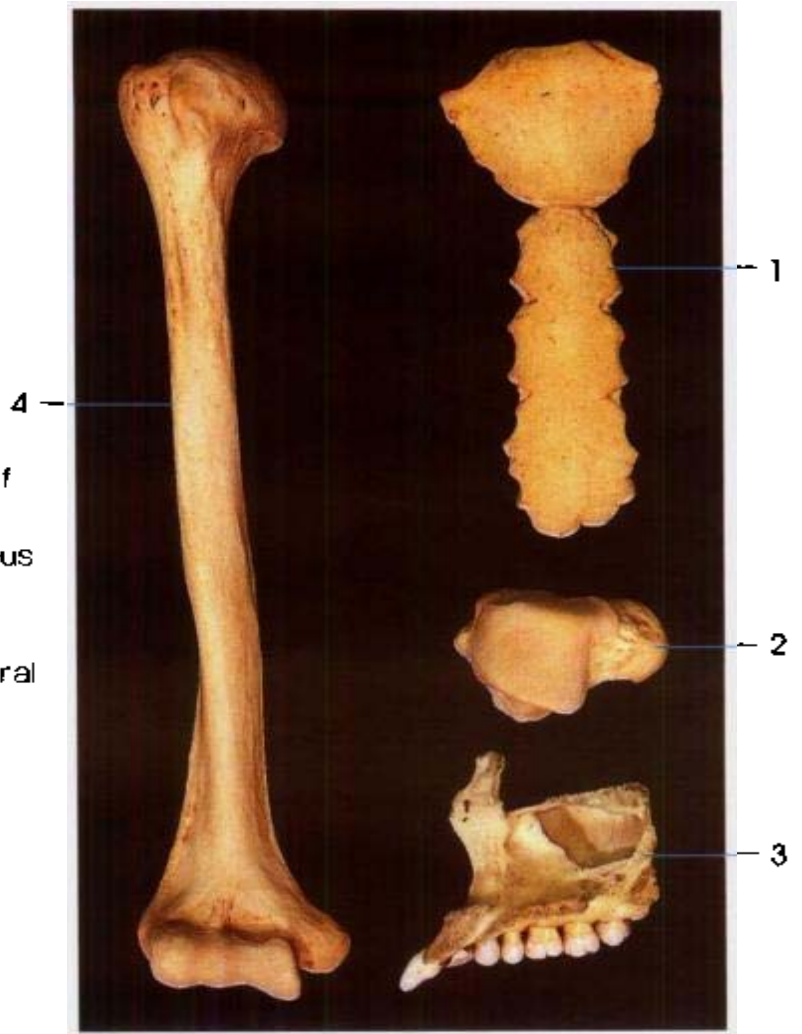


图3 骨的构造(A、B)
Structure of the bone(A,B)

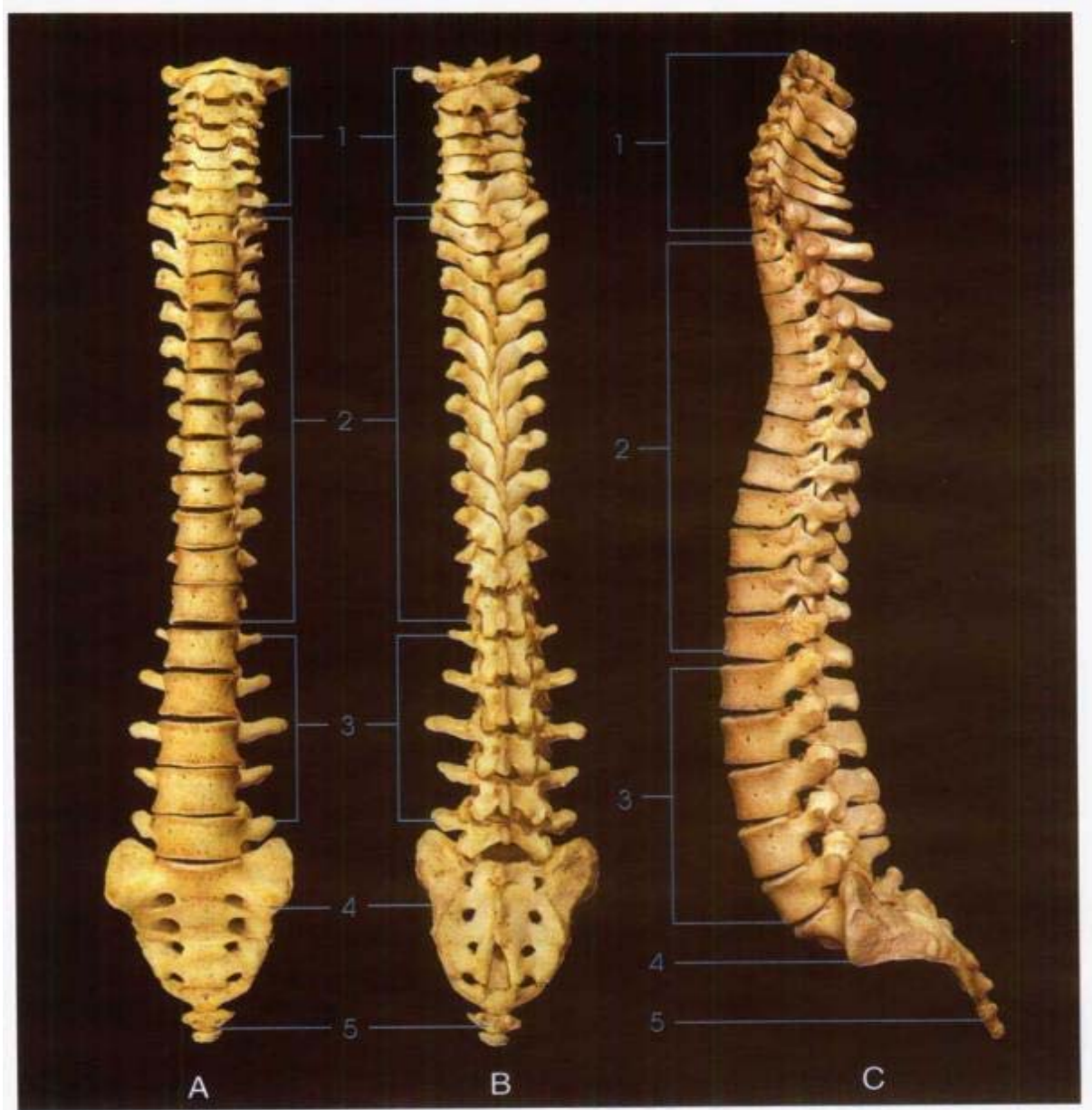
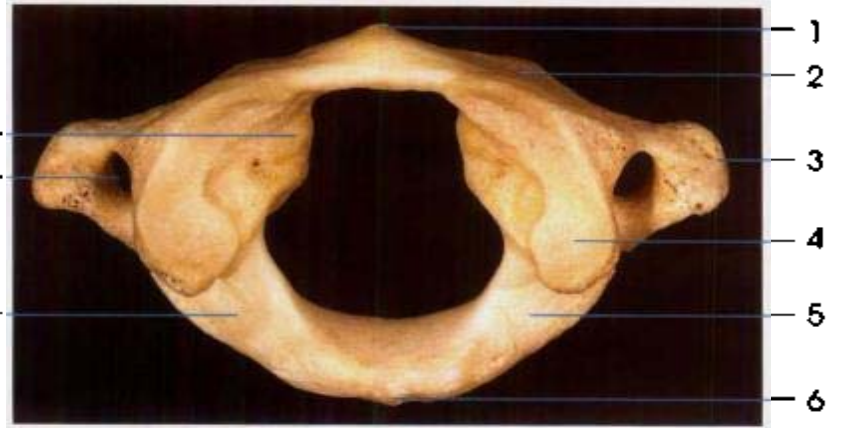


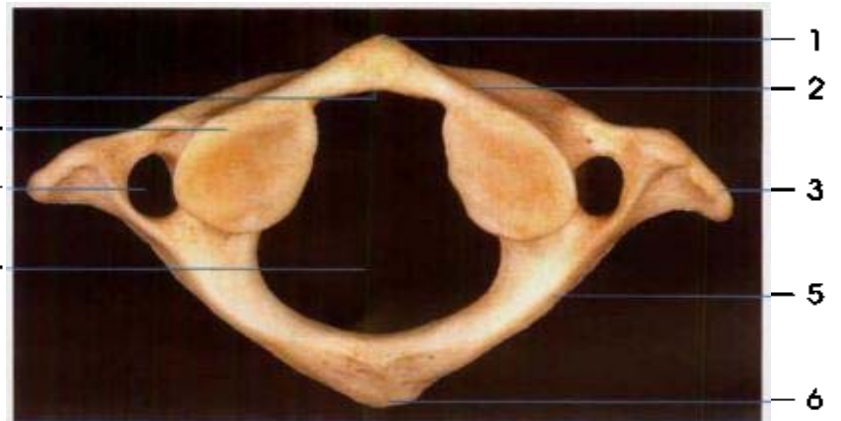
图4 脊柱(A、B、C)
The vertebral column(A,B,C)

- | | |
|--------------------------|--------------------------|
| A. 前面观 Anterior aspect | 2. 胸椎 thoracic vertebrae |
| B. 后面观 Posterior aspect | 3. 腰椎 lumbar vertebrae |
| C. 侧面观 Lateral aspect | 4. 骶骨 sacrum |
| 1. 颈椎 cervical vertebrae | 5. 尾骨 coccyx |

1. 前结节 anterior tubercle
2. 前弓 anterior arch
3. 横突 transverse process
4. 上关节凹 superior articular fovea
5. 后弓 posterior arch
6. 后结节 posterior tubercle
7. 椎动脉沟 groove for vertebral a.
8. 横突孔 transverse foramen
9. 侧块 lateral mass
10. 齿突凹 dental fovea
11. 下关节凹 inferior articular fovea
12. 椎孔 Vertebral foramen



上面观



下面观

图5 寰椎(上和下面观)
The atlas(superior and inferior aspect)

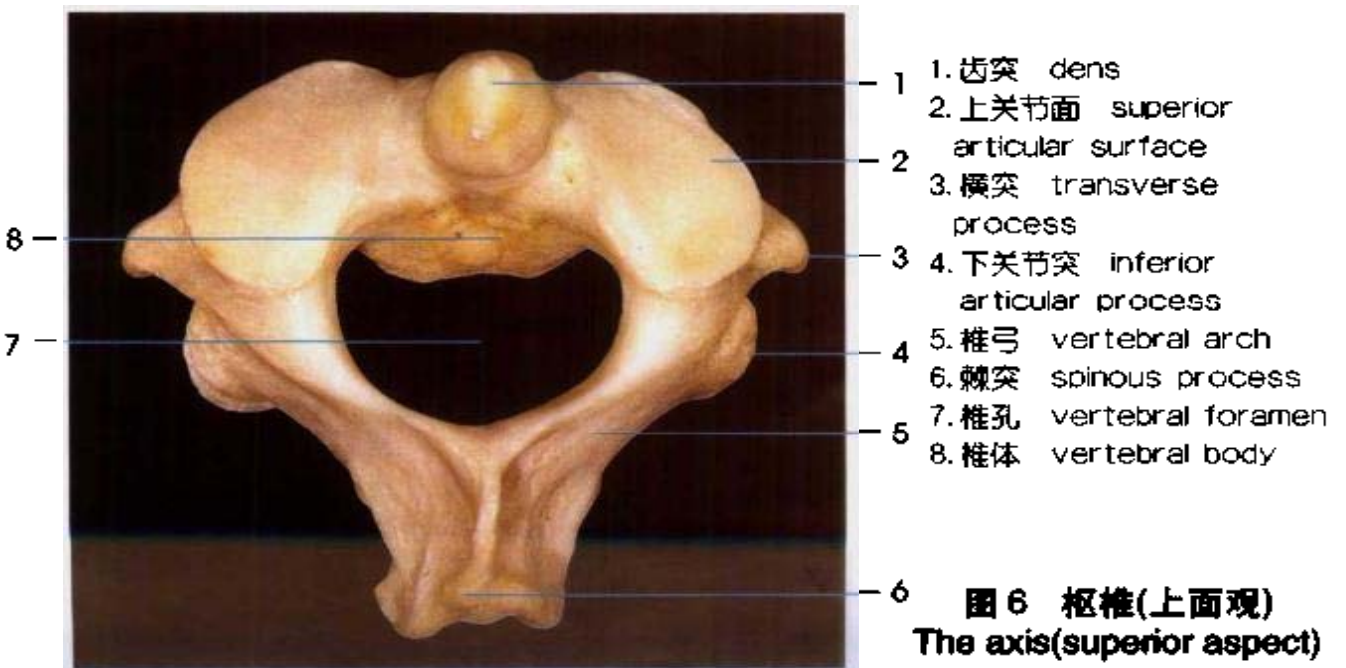


图6 枢椎(上面观)
The axis(superior aspect)

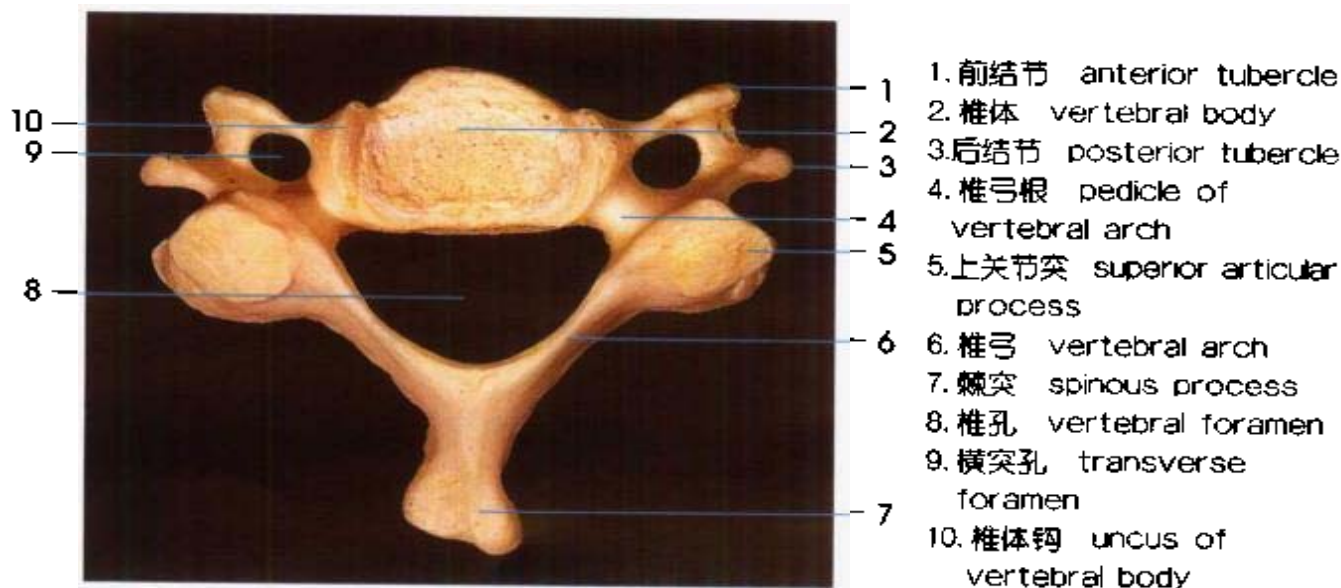



图7 颈椎(上面观)
 A cervical vertebra(superior aspect)

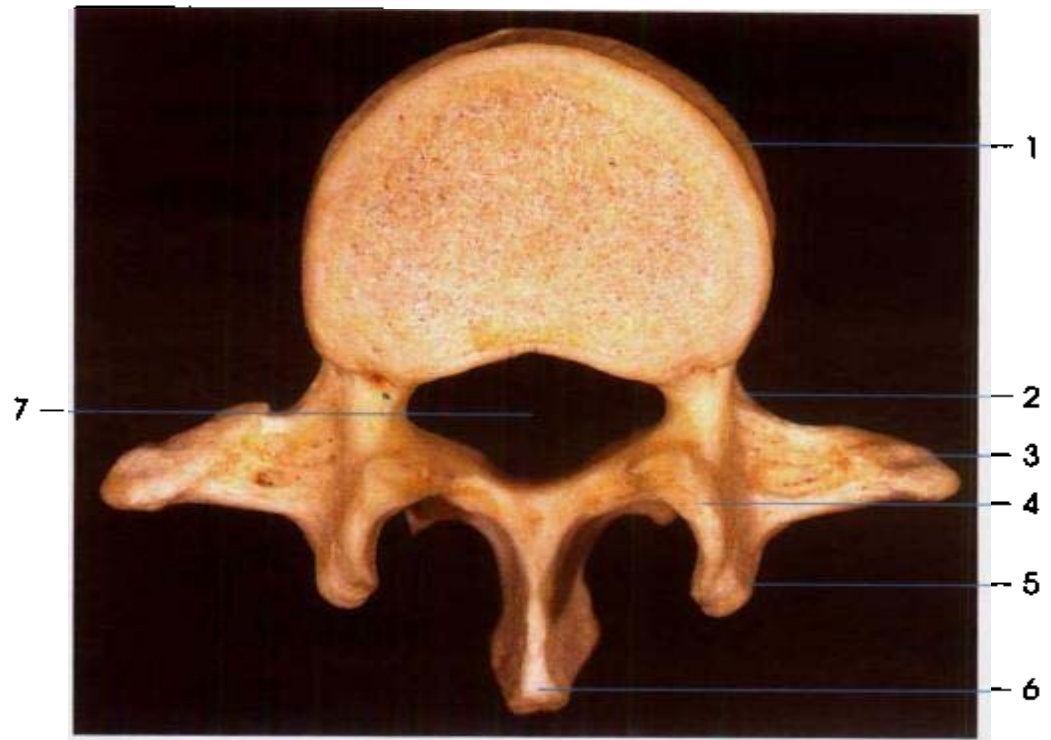


上面观

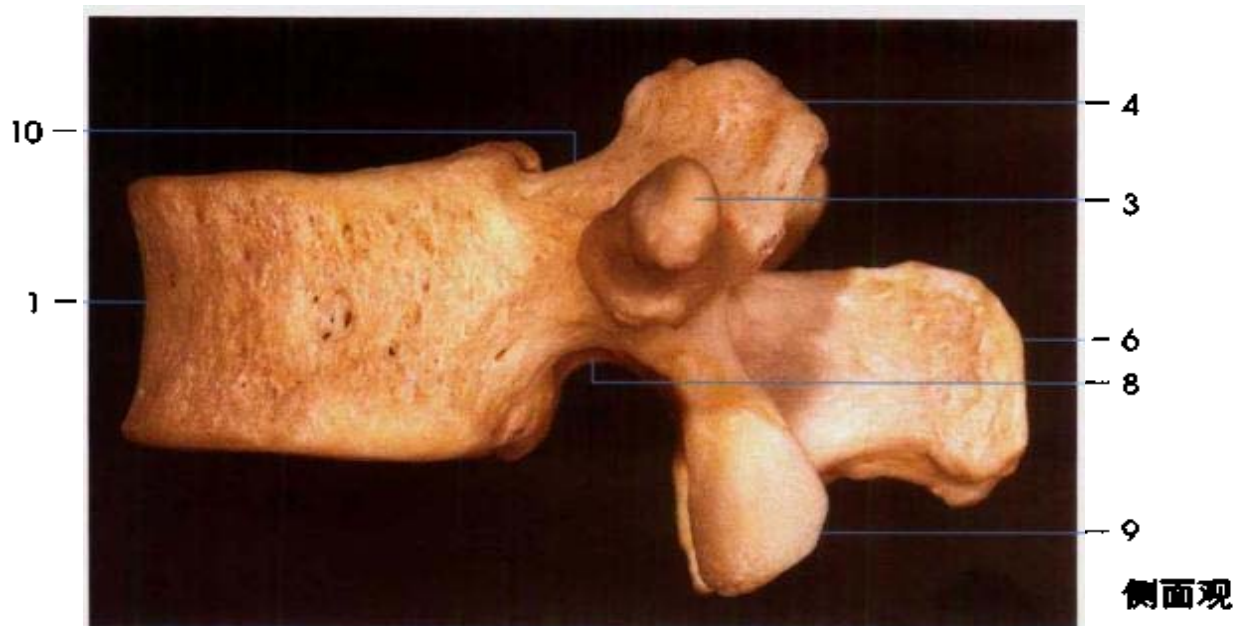
侧面观

图8 胸椎(上和侧面观)
 A thoracic vertebra(superior and lateral aspect)

- | | |
|------------------------------------|-------------------------------------|
| 1. 椎体 vertebral body | 8. 椎弓板 lamina of vertebral arch |
| 2. 上肋凹 superior costal fovea | 9. 椎孔 vertebral foramen |
| 3. 椎弓根 pedicle of vertebral arch | 10. 椎下切迹 inferior vertebral notch |
| 4. 上关节突 superior articular process | 11. 下关节突 inferior articular process |
| 5. 横突 transverse process | 12. 下肋凹 inferior costal fovea |
| 6. 横突肋凹 transverse costal fovea | 13. 椎上切迹 superior vertebral notch |
| 7. 棘突 spinous process | |



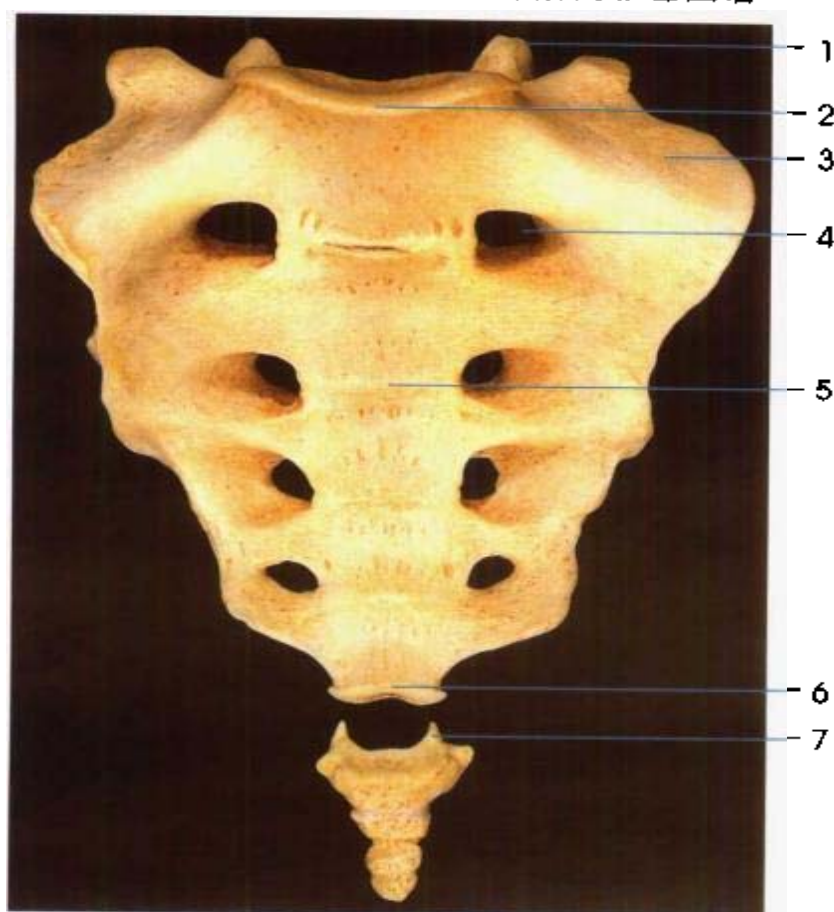
上面观



侧面观

图9 腰椎(上和侧面观)
A lumbar vertebra(superior and lateral aspect)

- | | |
|------------------------------------|------------------------------------|
| 1. 椎体 vertebral body | 6. 棘突 spinous process |
| 2. 椎弓根 pedicle of vertebral arch | 7. 椎孔 vertebral foramen |
| 3. 横突 transverse process | 8. 椎下切迹 inferior vertebral notch |
| 4. 上关节突 superior articular process | 9. 下关节突 inferior articular process |
| 5. 乳突 mamillary process | 10. 椎上切迹 superior vertebral notch |



- 1. 上关节突 superior articular process
- 2. 岬 promontory
- 3. 骶翼 ala of sacrum
- 4. 骶前孔 anterior sacral foramina
- 5. 横线 transverse line
- 6. 骶骨尖 apex of sacrum
- 7. 尾骨角 coccygeal cornu

图 10 骶骨和尾骨(前面观)
The sacrum and coccyx (anterior aspect)

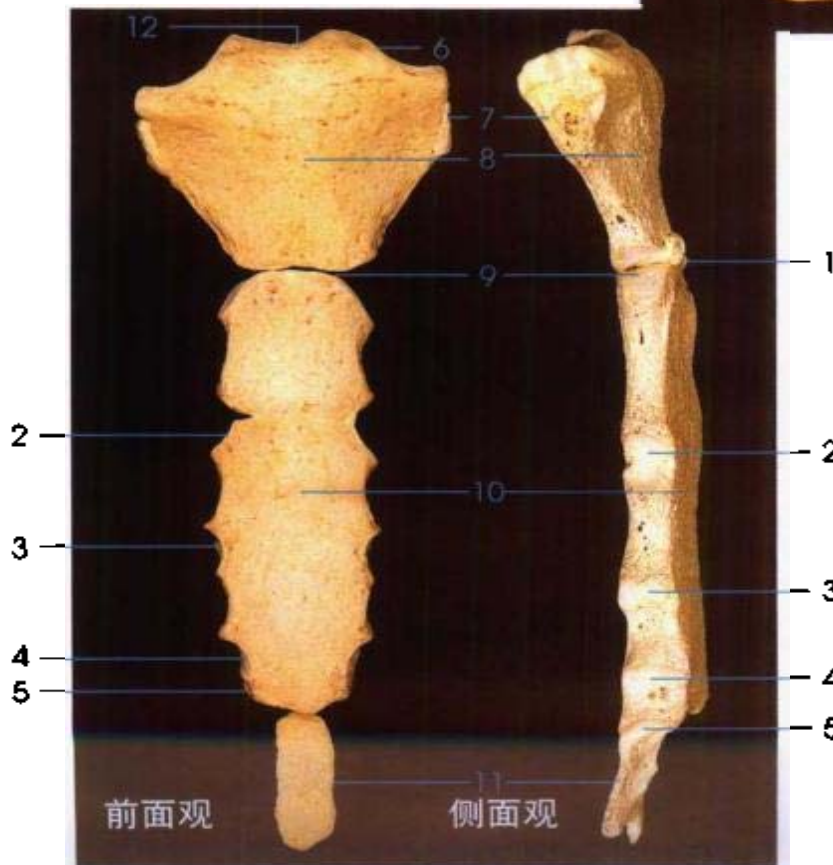- 1. 上关节突 superior articular process
- 2. 骶管 sacral canal
- 3. 骶粗隆 sacral tuberosity
- 4. 耳状面 auricular surface
- 5. 骶正中嵴 median sacral crest
- 6. 骶外侧嵴 lateral sacral crest
- 7. 骶后孔 posterior sacral foramina
- 8. 骶中间嵴 intermediate sacral crest
- 9. 骶管裂孔 sacral hiatus
- 10. 骶角 sacral cornu
- 11. 尾骨角 coccygeal cornu





图 11 骶骨和尾骨(后面观)
The sacrum and coccyx (posterior aspect)

1. 前锯肌粗隆 tuberosity for serratus anterior
2. 肋体 shaft of rib
3. 肋角 costal angle
4. 肋头 costal head
5. 肋结节 costal tubercle
6. 肋颈 costal neck
7. 锁骨下动脉沟 sulcus for subclavian a.
8. 前斜角肌结节 tubercle for scalenus anterior
9. 锁骨下静脉沟 sulcus for subclavian v.

图 12 第一(A)、二(B)、六(C)、十二(D)肋骨(上面观)
The 1st(A), 2nd(B), 6th(C), 12th(D) ribs (superior aspect)



1. 胸骨角 sternal angle
2. 第三肋切迹 3rd costal notch
3. 第四肋切迹 4th costal notch
4. 第五肋切迹 5th costal notch
5. 第六、七肋切迹 6,7th costal notches
6. 锁切迹 clavicular notch
7. 第一肋切迹 1st costal notch
8. 胸骨柄 sternal manubrium
9. 第二肋切迹 2nd costal notch
10. 胸骨体 sternal body
11. 剑突 xiphoid process
12. 颈静脉切迹 jugular notch

图 13 胸骨(前和侧面观)
The sternum (anterior and lateral aspect)

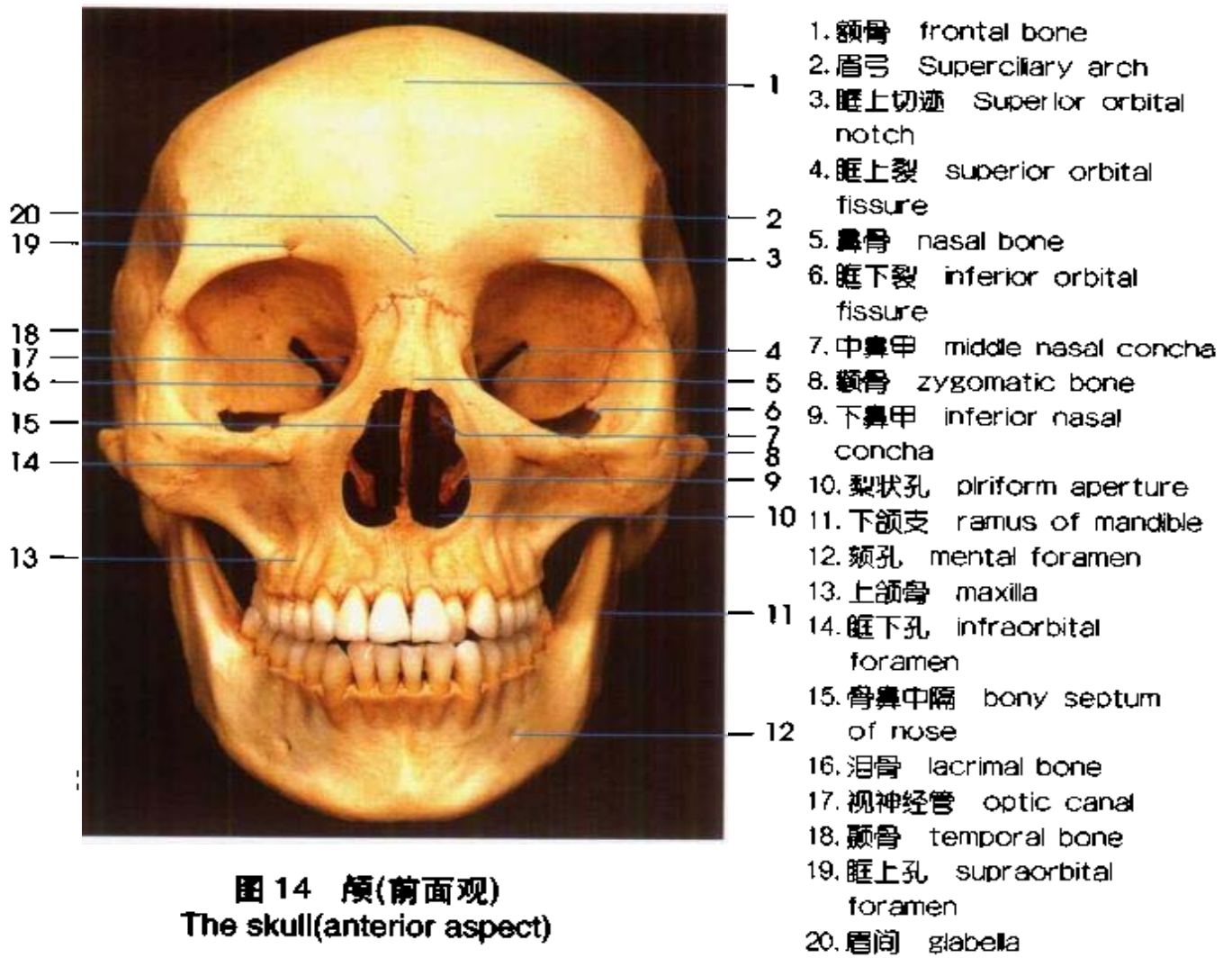


图 14 颅(前面观)
The skull (anterior aspect)

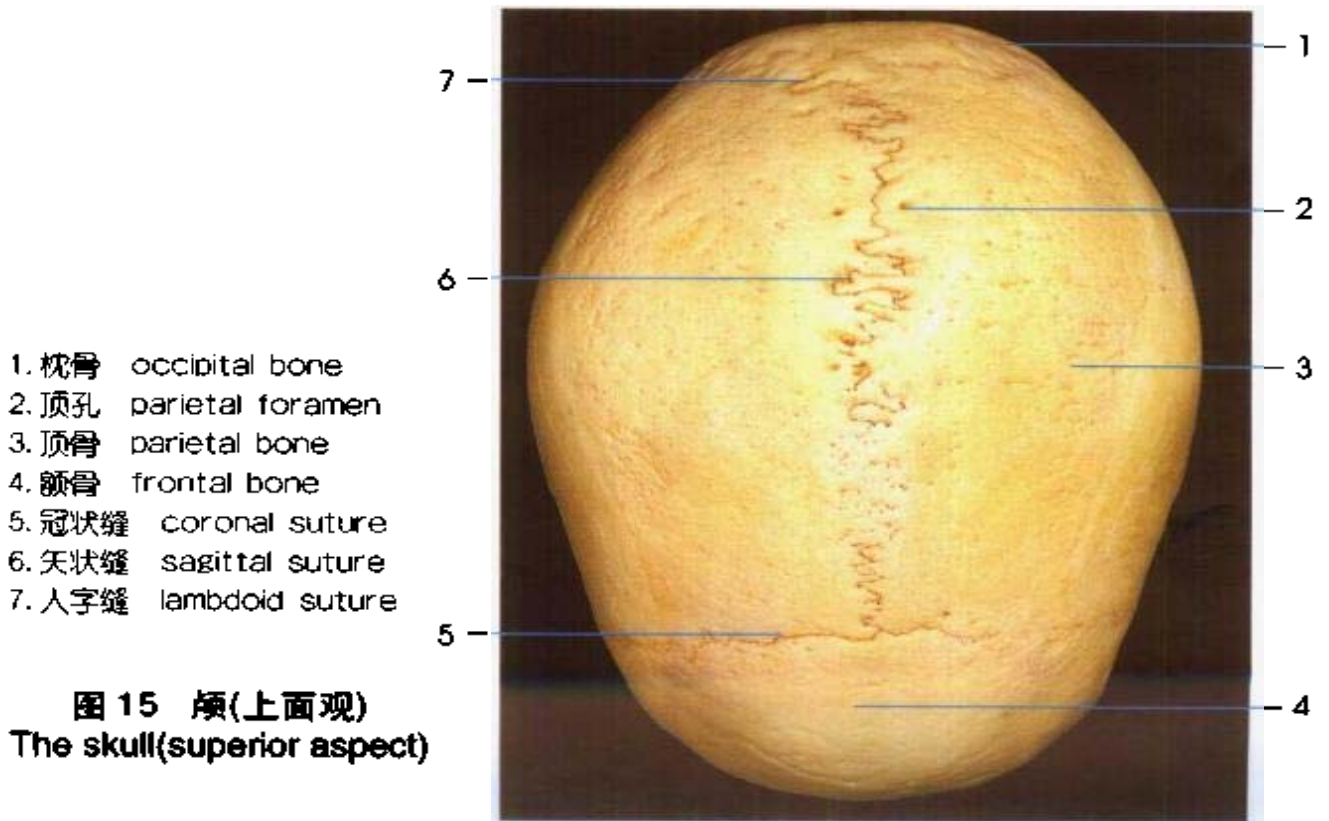


图 15 颅(上面观)
The skull (superior aspect)

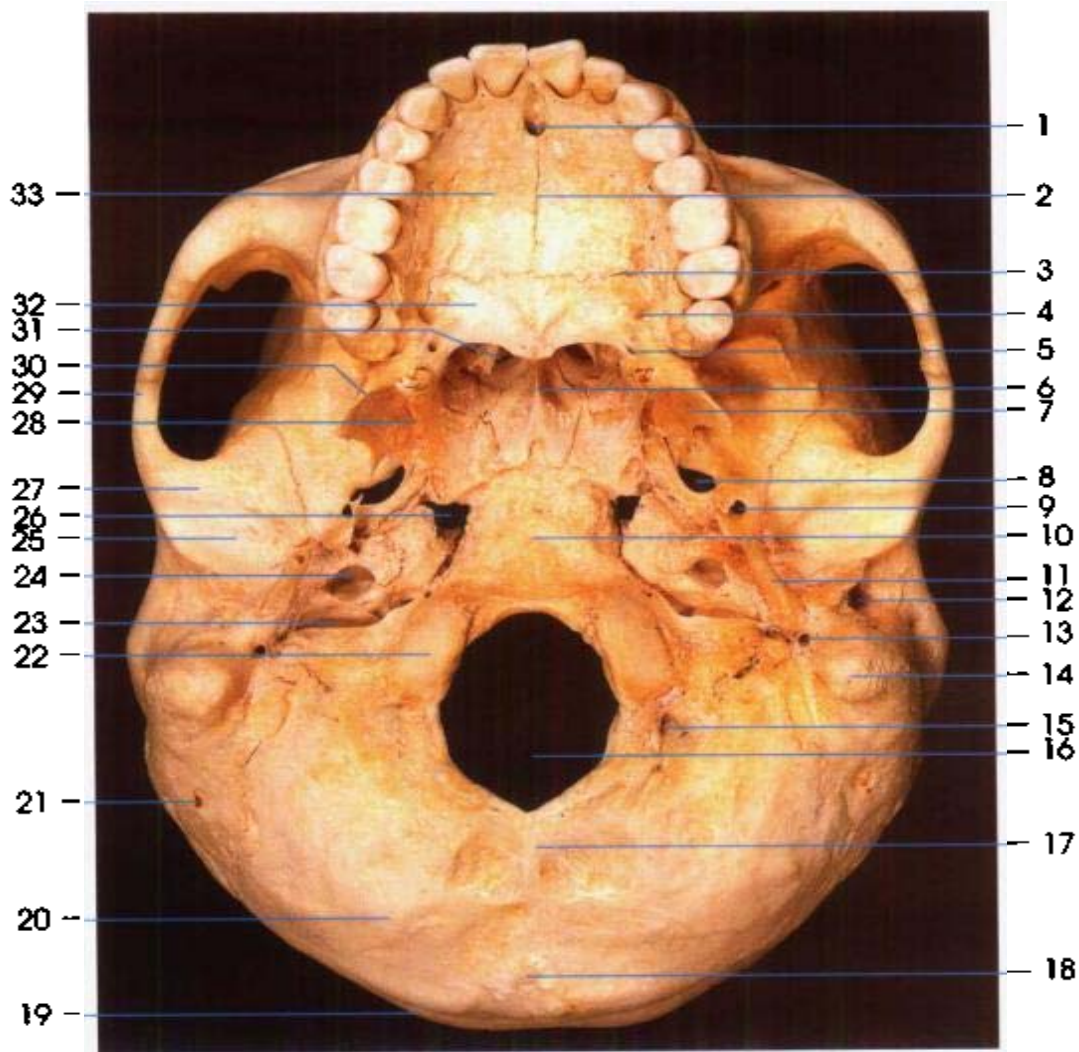


图 16 颅底外面观
The external aspect of the base of the skull

- | | |
|-----------------------------------|---|
| 1. 切牙孔 incisive foramina | 18. 枕外隆凸 external occipital protuberance |
| 2. 腭正中缝 median palatine suture | 19. 上顶线 superior nucha line |
| 3. 腭横缝 transverse palatine suture | 20. 下顶线 inferior nucha line |
| 4. 腭大孔 greater palatine foramen | 21. 乳突孔 mastoid foramen |
| 5. 腭小孔 lesser palatine foramen | 22. 枕髁 occipital condyle |
| 6. 犁骨 vomer | 23. 颈静脉窝 jugular fossa |
| 7. 翼窝 pterygoid fossa | 24. 颈动脉管外口 external aperture of carotid canal |
| 8. 卵圆孔 foramen ovale | 25. 下颌窝 mandibular fossa |
| 9. 棘孔 foramen spinosum | 26. 破裂孔 foramen lacerum |
| 10. 咽结节 pharyngeal tubercle | 27. 关节结节 articular tubercle |
| 11. 茎突 styloid process | 28. 翼突内侧板 medial pterygoid plate |
| 12. 外耳门 external acoustic pore | 29. 颧弓 zygomatic arch |
| 13. 茎乳孔 stylomastoid foramen | 30. 翼突外侧板 lateral pterygoid plate |
| 14. 乳突 mastoid process | 31. 鼻后孔 posterior nasal aperture |
| 15. 髁管 condylar canal | 32. 水平板 horizontal plate |
| 16. 枕骨大孔 foramen magnum | 33. 腭突 palatine process |
| 17. 枕外嵴 external occipital crest | |

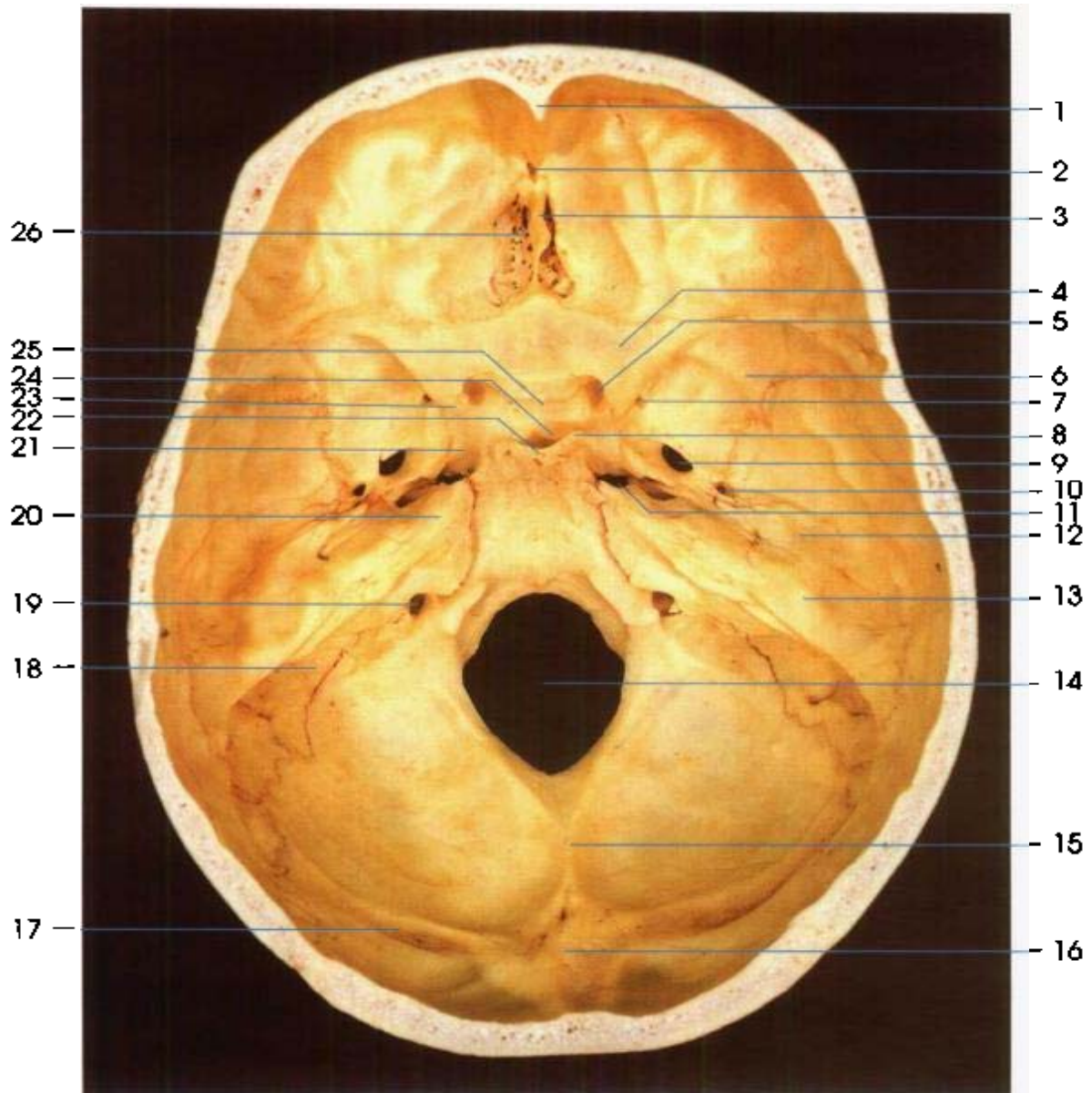
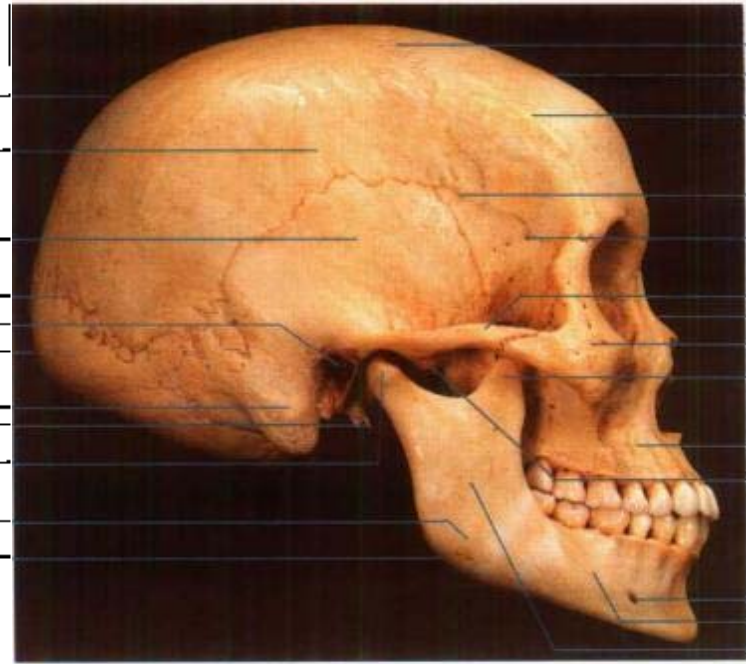


图 17 颅底内面观
The internal aspect of the base of the skull

- | | | | |
|----------|---------------------------|------------|---------------------------------|
| 1. 额嵴 | frotal crest | 15. 枕内嵴 | internal occipital crest |
| 2. 盲孔 | foramen caecum | 16. 枕内隆凸 | internal occipital protuberance |
| 3. 鸡冠 | crista galli | 17. 横窦沟 | sulcus for transverse sinus |
| 4. 小翼 | lesser wing | 18. 乙状窦沟 | sulcus for sigmoid sinus |
| 5. 视神经管 | optic canal | 19. 颈静脉孔 | jugular foramen |
| 6. 大翼 | greater wing | 20. 三叉神经压迹 | trigeminal impression |
| 7. 圆孔 | foramen rotundum | 21. 颈动脉沟 | carotid sulcus |
| 8. 后床突 | posterior clinoid process | 22. 鞍背 | dorsum sellae |
| 9. 卵圆孔 | foramen ovale | 23. 前床突 | anterior clinoid process |
| 10. 棘孔 | foramen spinosum | 24. 垂体窝 | hypophysial fossa |
| 11. 破裂孔 | foramen lacerum | 25. 交叉前沟 | sulcus prechiasmaticus |
| 12. 鼓室盖 | tegmen tympani | 26. 筛板 | cribriform plate |
| 13. 弓状隆起 | arcuata eminence | | |
| 14. 枕骨大孔 | foramen magnum | | |

1. 冠状缝 coronal suture
2. 额骨 frontal bone
3. 上颞线 superior temporal line
4. 翼点 pterion
5. 蝶骨大翼 greater wing of sphenoid bone
6. 颧弓 zygomatic arch
7. 鼻骨 nasal bone
8. 颧骨 zygomatic bone
9. 冠突 coronoid process
10. 上颌骨 maxilla
11. 关节结节 articular tubercle
12. 颏孔 mental foramen
13. 下颌体 body of mandible
14. 下颌支 ramus of mandible
15. 下颌角 angle of mandible
16. 咬肌粗隆 masseteric tuberosity
17. 髁突 condylar process
18. 茎突 styloid process
19. 乳突 mastoid process
20. 枕骨 occipital bone
21. 外耳门 external acoustic pore

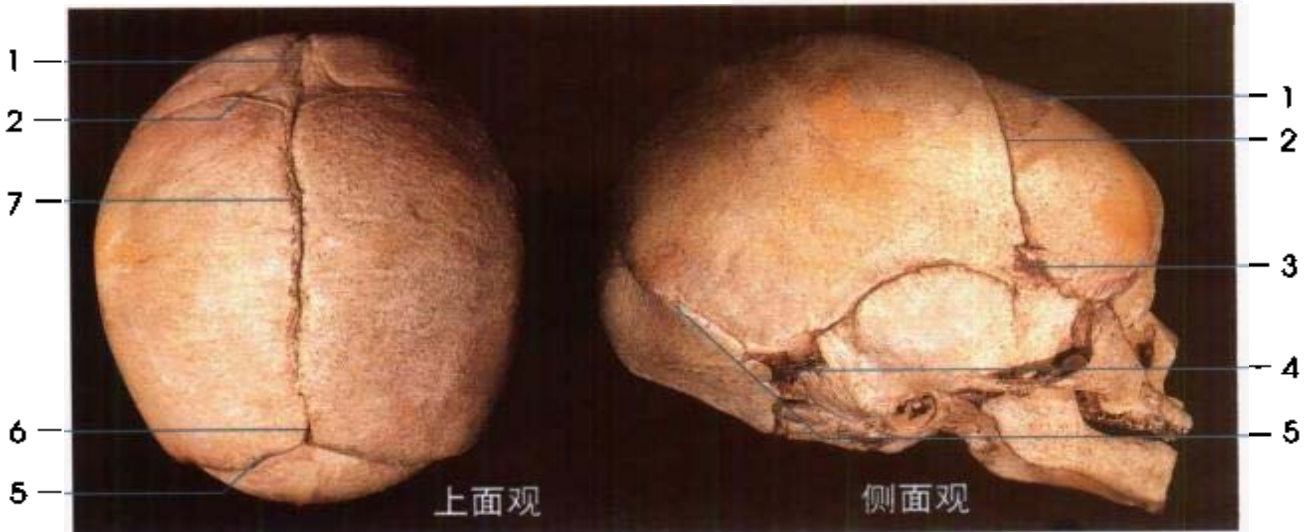25
24
23
22
21
20
19
18
17
16
15



1
2
3
4
5
6
7
8
9
10
11
12
13
14

图 18 颅(侧面观)
The skull(lateral aspect)

22. 人字缝 lambdoid suture
23. 颞骨 temporal bone
24. 下颞线 inferior temporal line
25. 顶骨 parietal bone

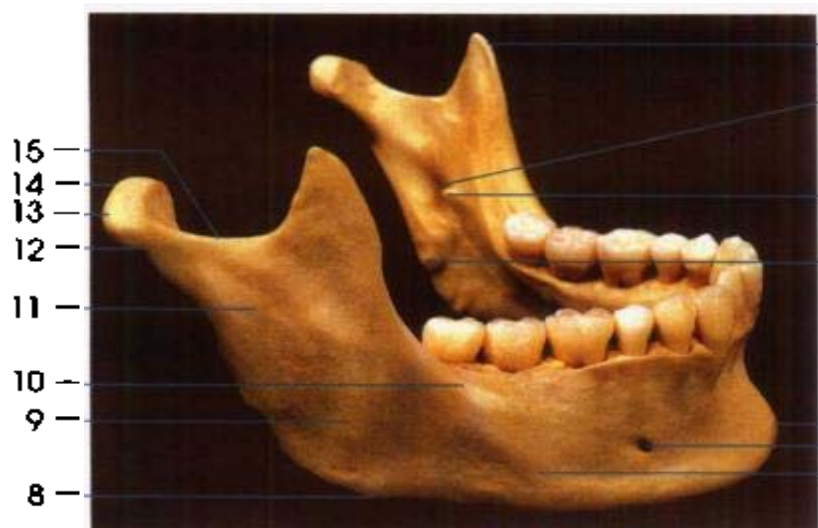


1
2
7
6
5

1
2
3
4
5

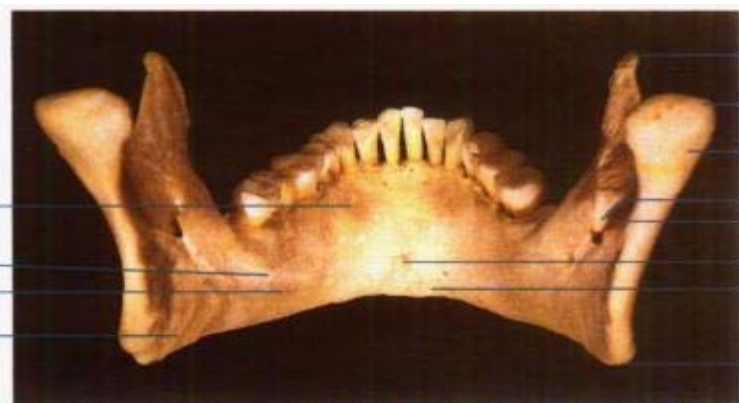
图 19 婴儿颅(上面和侧面观)
The skull of a infant(superior and lateral aspect)

1. 前囟 anterior fontanelle
2. 冠状缝 coronal suture
3. 前外侧囟 anterolateral fontanelle
4. 后外侧囟 posterolateral fontanelle
5. 人字缝 lambdoid suture
6. 后囟 posterior fontanelle
7. 矢状缝 sagittal suture



外侧面观

- 1. 冠突 coronoid process
- 2. 下颌孔 mandibular foramen
- 3. 下颌小舌 mandibular lingula
- 4. 翼肌粗隆 pterygoid tuberosity
- 5. 颏隆凸 mental protuberance
- 6. 颏孔 mental foramen
- 7. 下颌体 body of mandible
- 8. 下颌角 angle of mandible
- 9. 咬肌粗隆 masseteric tuberosity
- 10. 斜线 oblique line
- 11. 下颌支 ramus of mandible
- 12. 下颌颈 neck of mandible
- 13. 下颌头 head of mandible



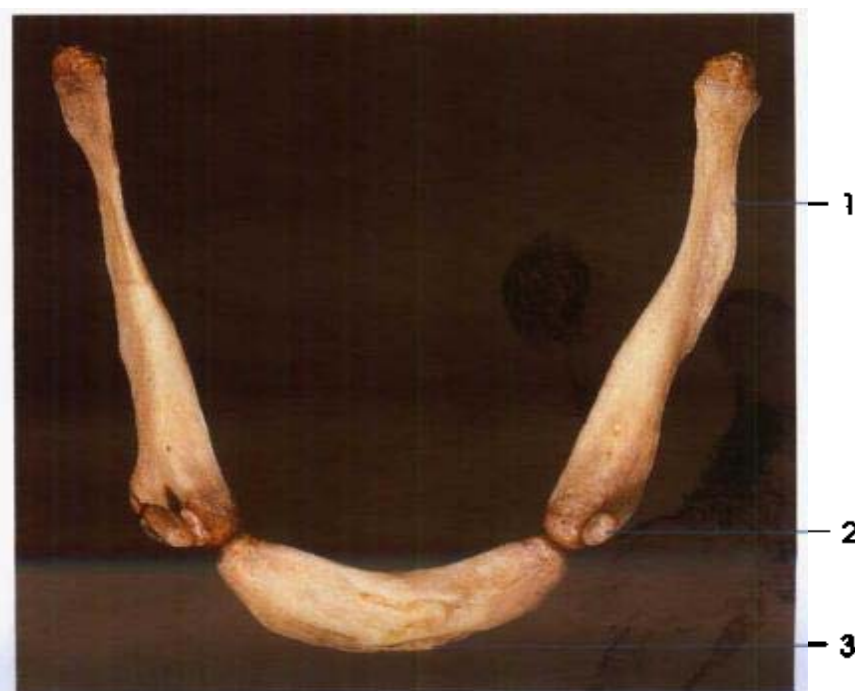
后面观

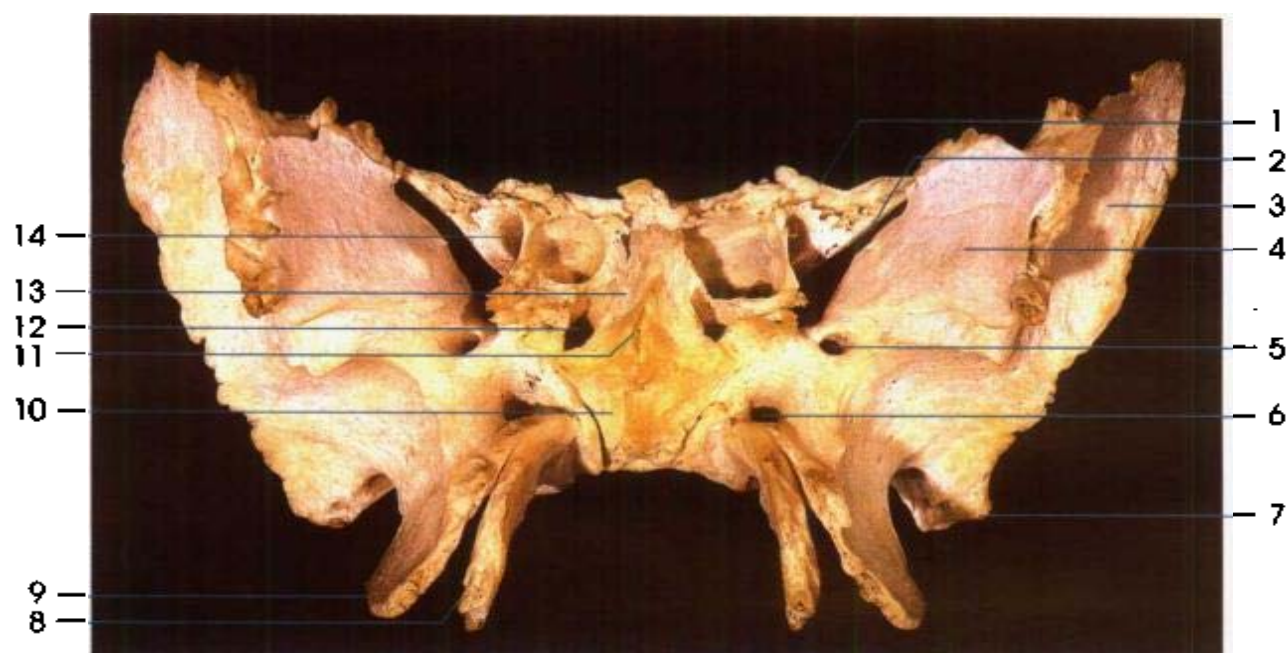
- 14. 髁突 condylar process
- 15. 下颌切迹 mandibular notch
- 16. 颏棘 mental spine
- 17. 舌下腺凹 sublingual fovea
- 18. 二腹肌窝 digastric fossa
- 19. 下颌下腺凹 submandibular fovea
- 20. 下颌舌骨肌线 mylohyoid line

图 20 下颌骨(外侧面和后面观)
The mandible(lateral and posterior aspect)

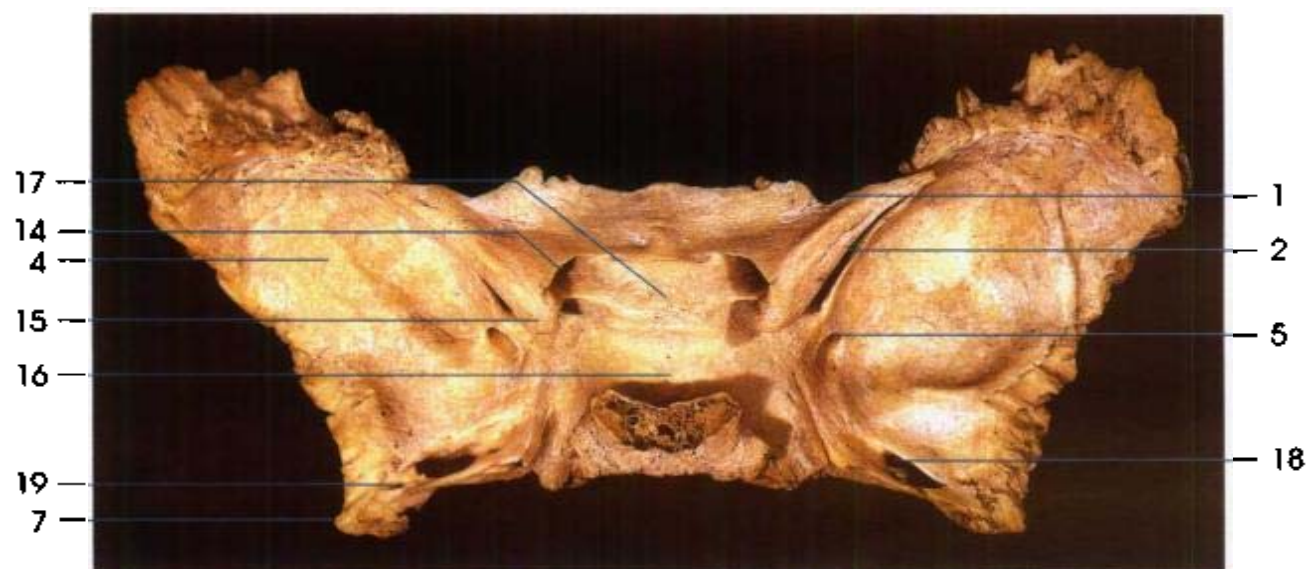
- 1. 大角 greater horn
- 2. 小角 lesser horn
- 3. 舌骨体 body of hyoid bone

图 21 舌骨(上面观)
The hyoid bone
(superior aspect)





前面观

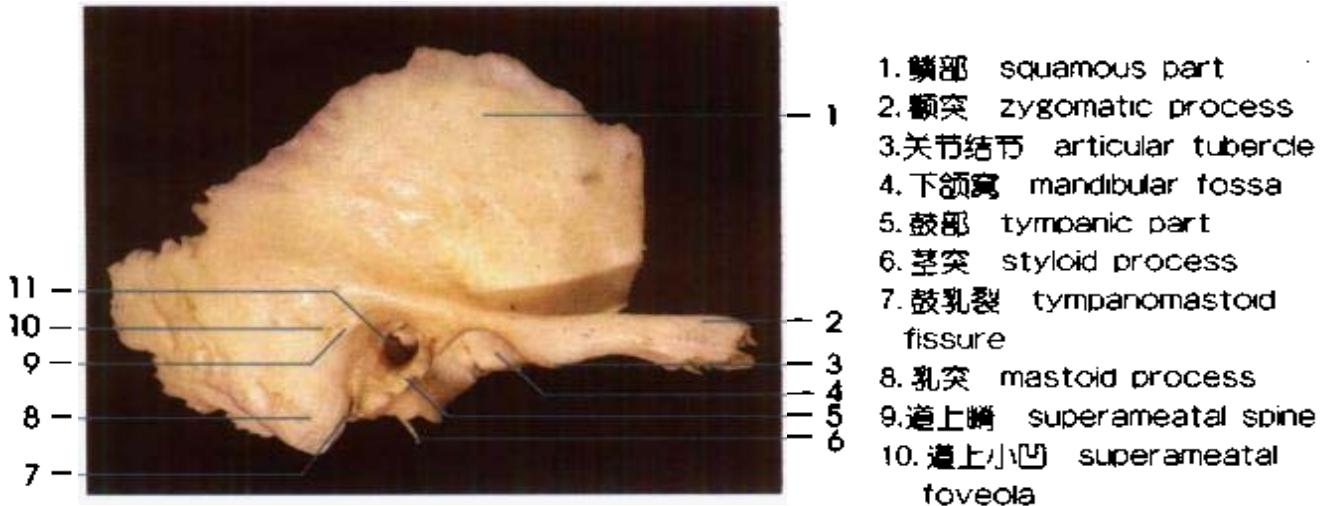


上面观

图 22 蝶骨(前和上面观)

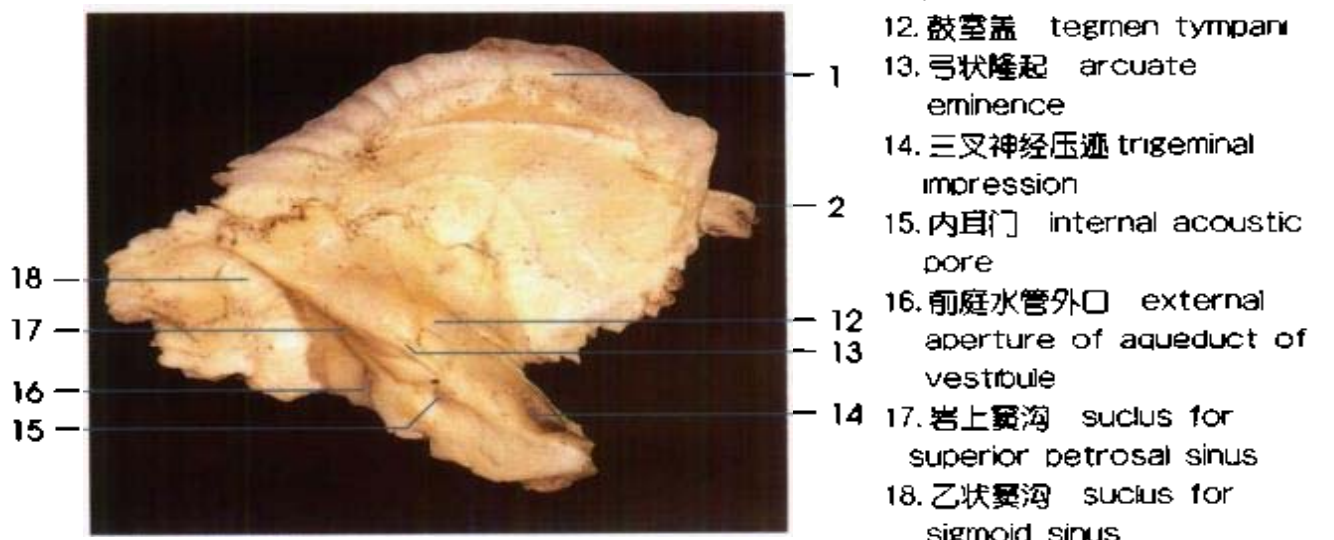
The sphenoid bone(anterior and superior aspect)

- | | |
|---------------------------------|-------------------------------------|
| 1.小翼 lesser wing | 11.蝶嵴 sphenoid crest |
| 2.眶上裂 superior orbital fissure | 12.蝶窦口 aperture of sphenoidal sinus |
| 3.大翼 greater wing | 13.蝶甲 sphenoidal concha |
| 4.眶面 orbital surface | 14.视神经管 optic canal |
| 5.圆孔 foramen rotundum | 15.前床突 anterior clinoid process |
| 6.翼管 pterygoid canal | 16.垂体窝 hypophysial fossa |
| 7.蝶棘 spine of sphenoid bone | 17.交叉前沟 sulcus prechiasmaticus |
| 8.翼突内侧板 medial pterygoid plate | 18.卵圆孔 foramen ovale |
| 9.翼突外侧板 lateral pterygoid plate | 19.棘孔 foramen spinosum |
| 10.体 body | |



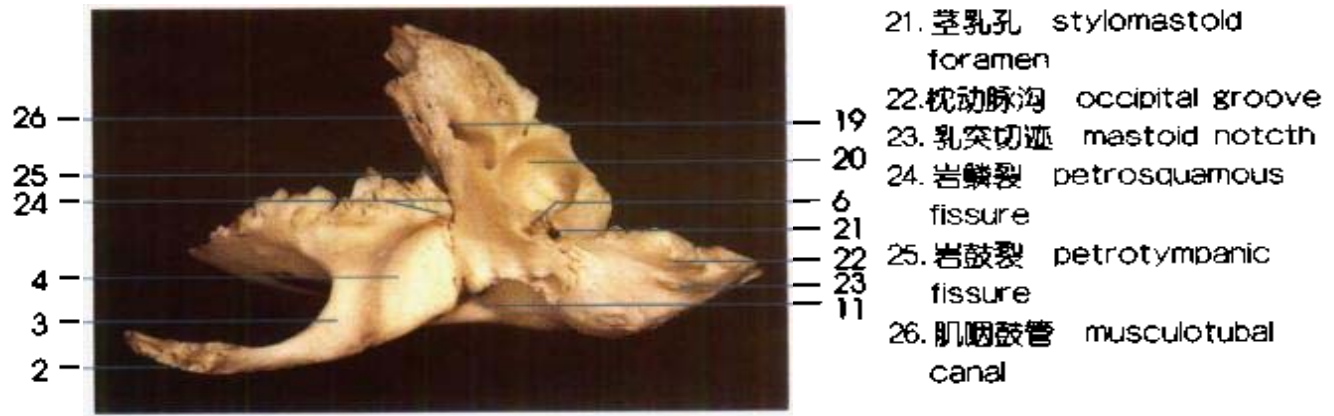
外面观

- 1. 鳞部 squamous part
- 2. 颧突 zygomatic process
- 3. 关节结节 articular tubercle
- 4. 下颌窝 mandibular fossa
- 5. 鼓部 tympanic part
- 6. 茎突 styloid process
- 7. 鼓乳裂 tympanomastoid fissure
- 8. 乳突 mastoid process
- 9. 道上嵴 superameatal spine
- 10. 道上小凹 superameatal foveola
- 11. 外耳门 external acoustic pore



内面观

- 12. 鼓室盖 tegmen tympani
- 13. 弓状隆起 arcuate eminence
- 14. 三叉神经压迹 trigeminal impression
- 15. 内耳门 internal acoustic pore
- 16. 前庭水管外口 external aperture of aqueduct of vestibule
- 17. 岩上窦沟 sulcus for superior petrosal sinus
- 18. 乙状窦沟 sulcus for sigmoid sinus
- 19. 颈动脉管 carotid canal
- 20. 颈静脉窝 jugular fossa
- 21. 茎乳孔 stylomastoid foramen



下面观

- 22. 枕动脉沟 occipital groove
- 23. 乳突切迹 mastoid notch
- 24. 岩鳞裂 petrosquamous fissure
- 25. 岩鼓裂 petrotympanic fissure
- 26. 肌咽鼓管 musculotubal canal

图 23 颞骨(外、内和下面观)
The temporal bone(external,internal and inferior aspect)

1. 垂直板 perpendicular plate
2. 筛骨迷路 ethmoidal labyrinth
3. 中鼻甲 middle nasal concha
4. 上鼻甲 superior nasal concha
5. 眶板 orbital plate
6. 筛孔 cribriform foramina
7. 筛板 cribriform plate
8. 鸡冠 crista galli

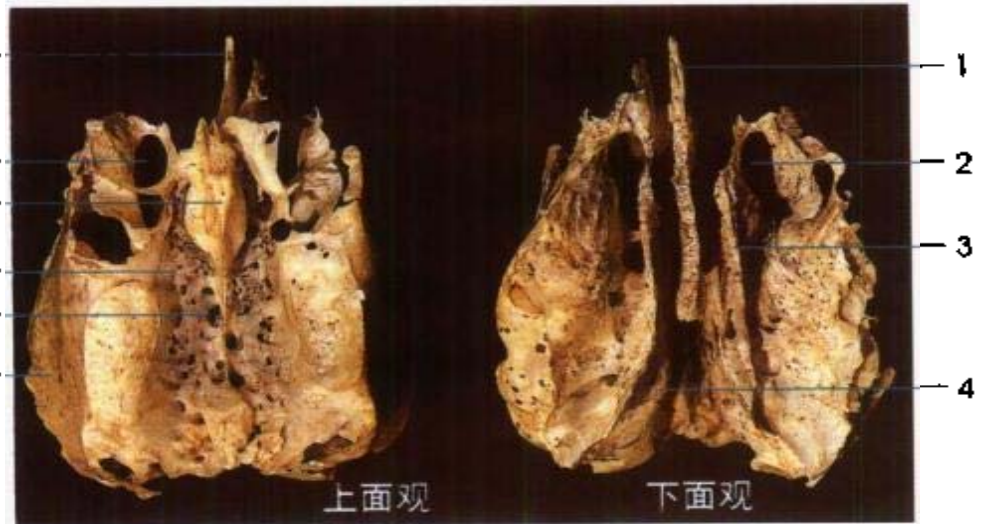

图 24 筛骨(上和下面观)
The ethmoid bone (superior and inferior aspect)

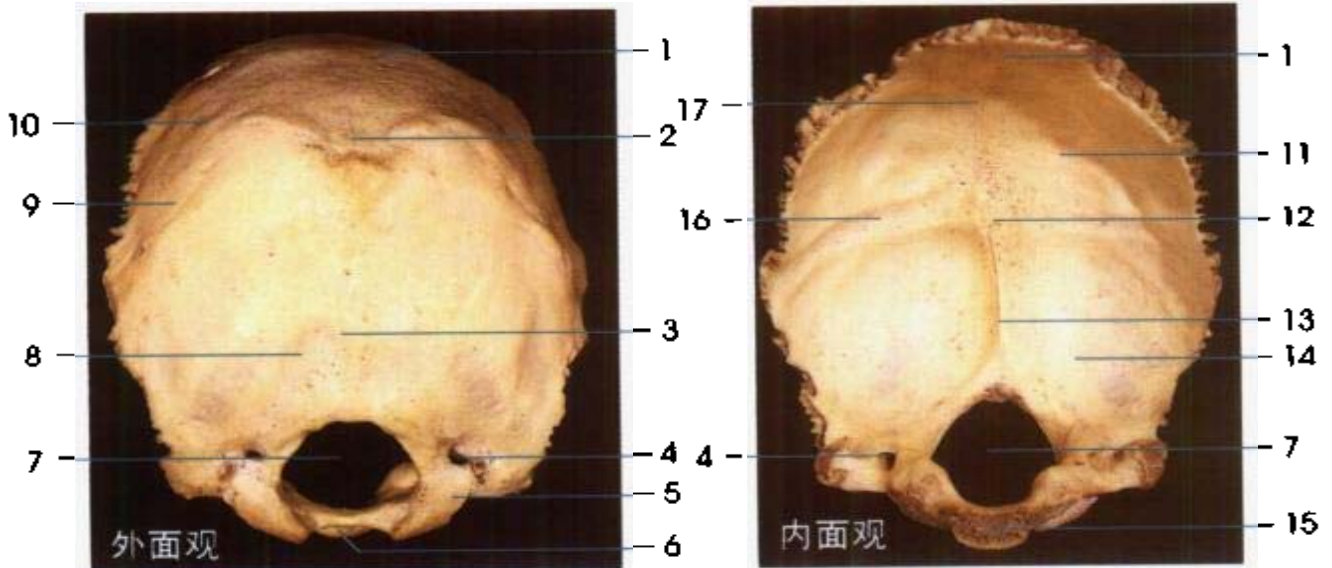


图 25 枕骨(外和内面观)
The occipital bone (external and internal aspect)

1. 枕鳞 occipital squama
2. 枕外隆凸 external occipital protuberance
3. 枕外嵴 external occipital crest
4. 髁管 condylar canal
5. 枕髁 occipital condyle
6. 咽结节 pharyngeal tubercle
7. 大孔 foramen magnum
8. 下项线 inferior nuchal line
9. 上项线 superior nuchal line
10. 最上项线 highest nuchal line

11. 大脑窝 cerebral fossa
12. 枕内隆凸 internal occipital protuberance
13. 枕内嵴 internal occipital crest
14. 小脑窝 cerebellar fossa
15. 基底部 basilar part
16. 横窦沟 sulcus for transverse sinus
17. 上矢状窦沟 sulcus for superior sagittal sinus

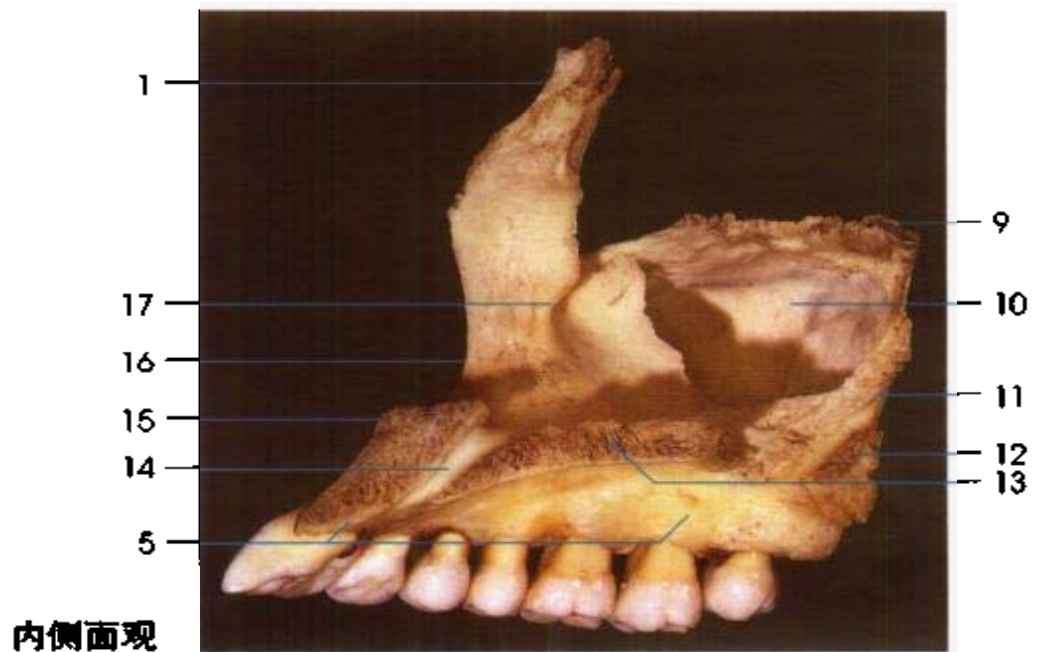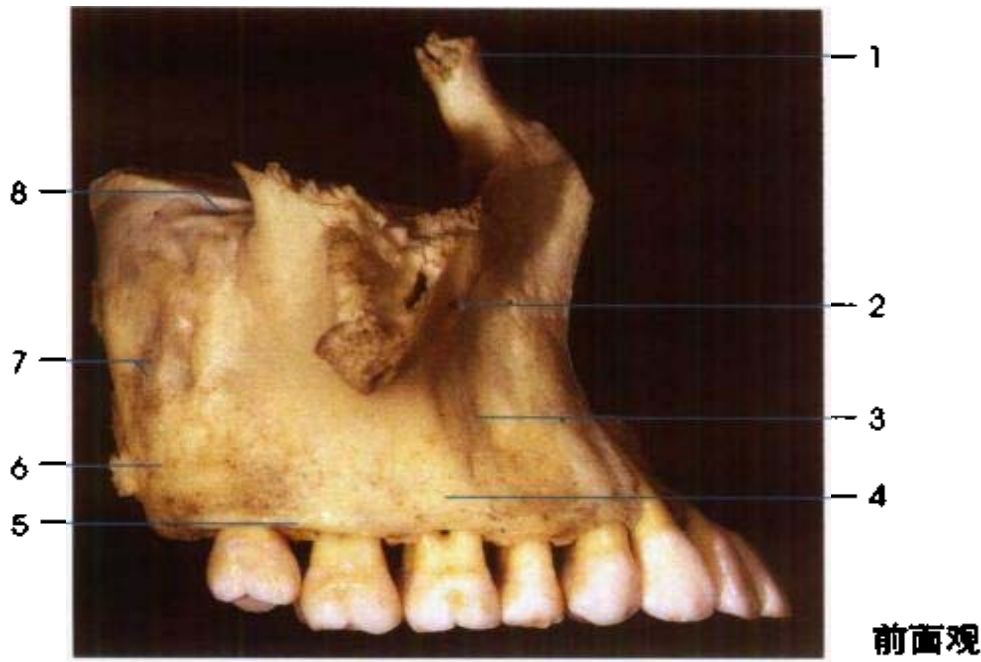


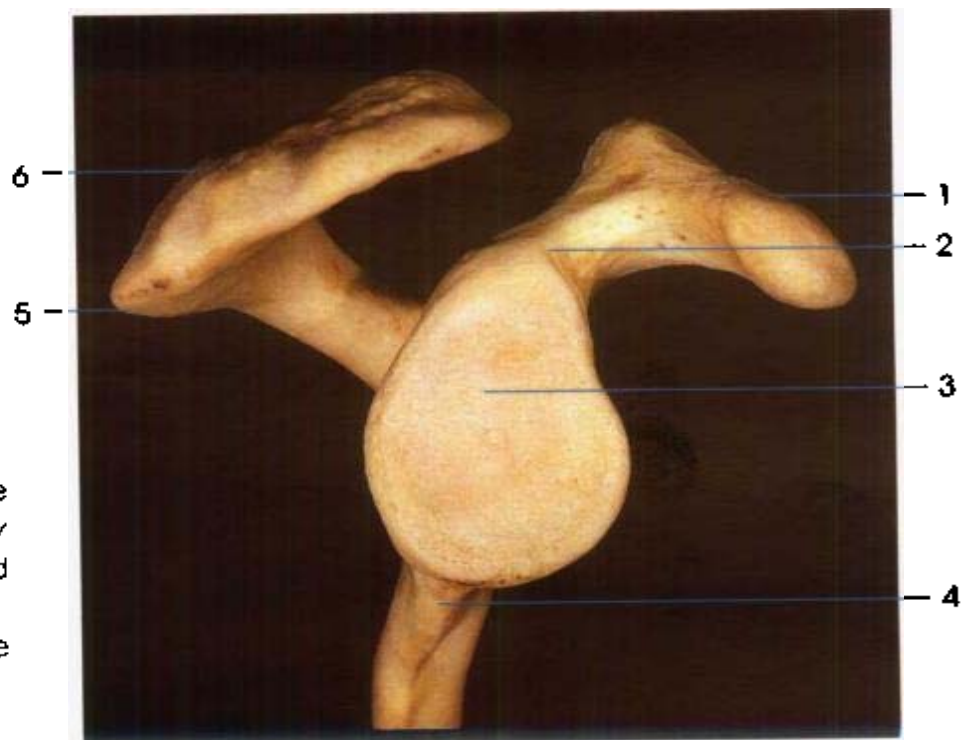
图 26 上颌骨(前和内侧面观)
The maxilla bone (anterior and medial aspect)

- | | |
|------------------------------|---------------------------------|
| 1. 额突 frontal process | 10. 上颌窝裂孔 maxillary hiatus |
| 2. 眶下孔 infraorbital foramen | 11. 腭大沟 greater palatine sulcus |
| 3. 尖牙窝 canine fossa | 12. 腭小沟 lesser palatine sulcus |
| 4. 牙槽嵴 juga alveolaria | 13. 腭突 palatine process |
| 5. 牙槽突 alveolar process | 14. 切牙管 incisive canal |
| 6. 上颌结节 maxillary tuberosity | 15. 鼻前棘 anterior nasal spine |
| 7. 牙槽孔 alveolar foramina | 16. 鼻切迹 nasal notch |
| 8. 眶下沟 infraorbital groove | 17. 泪沟 lacrimal groove |
| 9. 颧突 zygomatic process | |

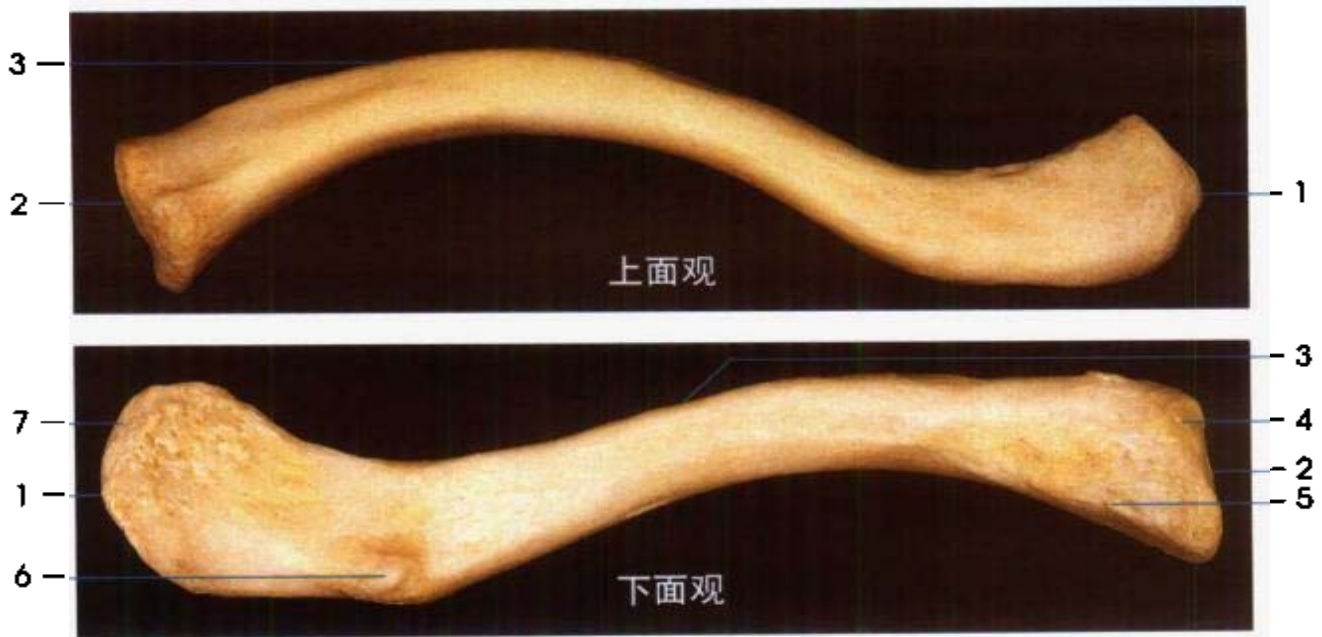

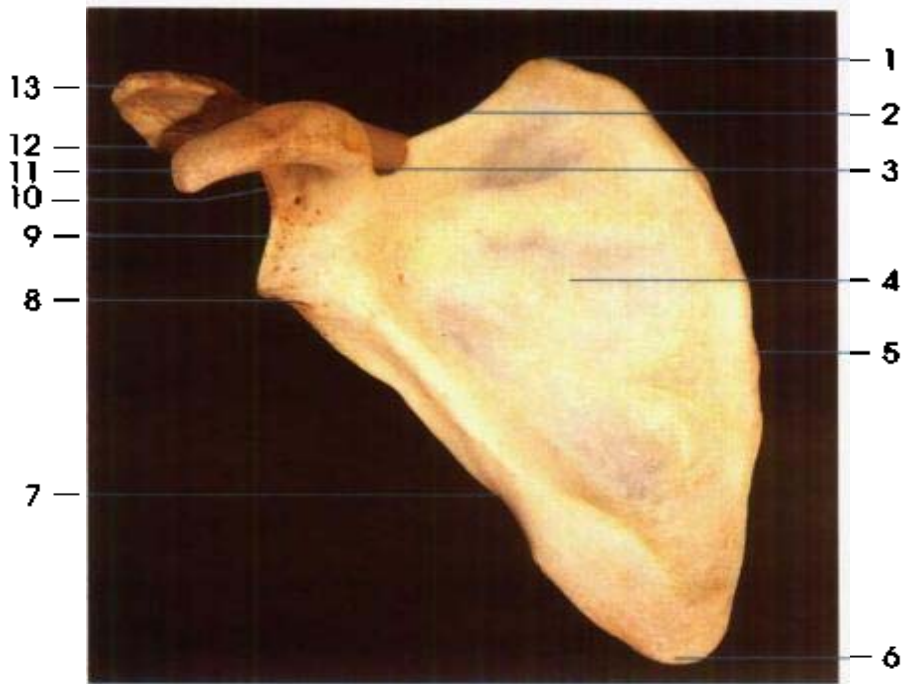
图 27 锁骨(上和下面观)
The clavicle(superior and inferior aspect)

- | | |
|--|---|
| 1. 肩峰端 acromial end | 5. 肋锁韧带压迹 impression for costoclavicular lig. |
| 2. 胸骨端 sternal end | 6. 锥状结节 conoid tubercle |
| 3. 锁骨体 shaft of clavicle | 7. 肩峰关节面 acromial articular surface |
| 4. 胸骨关节面 articular surface for sternum | |



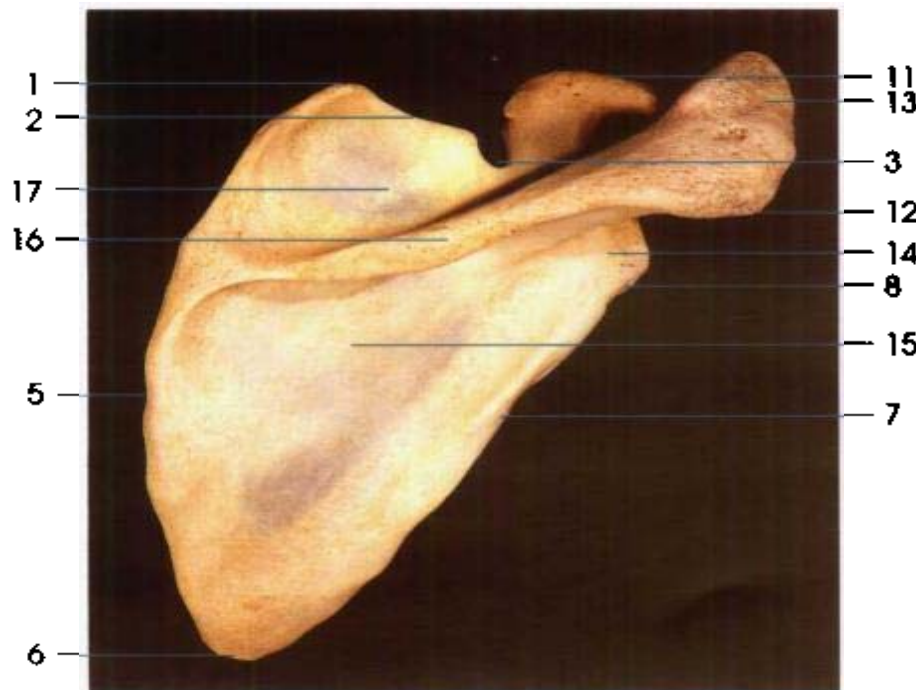
- | |
|-------------------------------|
| 1. 喙突 coracoid process |
| 2. 孟上结节 supraglenoid tubercle |
| 3. 关节盂 glenoid cavity |
| 4. 孟下结节 infraglenoid tubercle |
| 5. 肩峰角 acromial angle |
| 6. 肩峰 acromion |

图 28 肩胛骨(外侧角)
The scapula(lateral angle)



前面观

- 1. 上角 superior angle
- 2. 上缘 superior border
- 3. 肩胛切迹 notch of scapula
- 4. 肩胛下窝 subscapular fossa
- 5. 内侧缘 medial border
- 6. 下角 inferior angle
- 7. 外侧缘 lateral border



后面观

- 8. 盂下结节 infraglenoid tubercle
- 9. 关节盂 glenoid cavity
- 10. 盂上结节 supraglenoid tubercle
- 11. 喙突 coracoid process
- 12. 肩峰角 acromial angle
- 13. 肩峰 acromion
- 14. 肩胛颈 neck of scapula
- 15. 冈下窝 infraspinous fossa
- 16. 肩胛冈 spine of scapula
- 17. 冈上窝 supraspinous fossa

图 29 肩胛骨(前和后面观)
The scapula(anterior and posterior aspect)

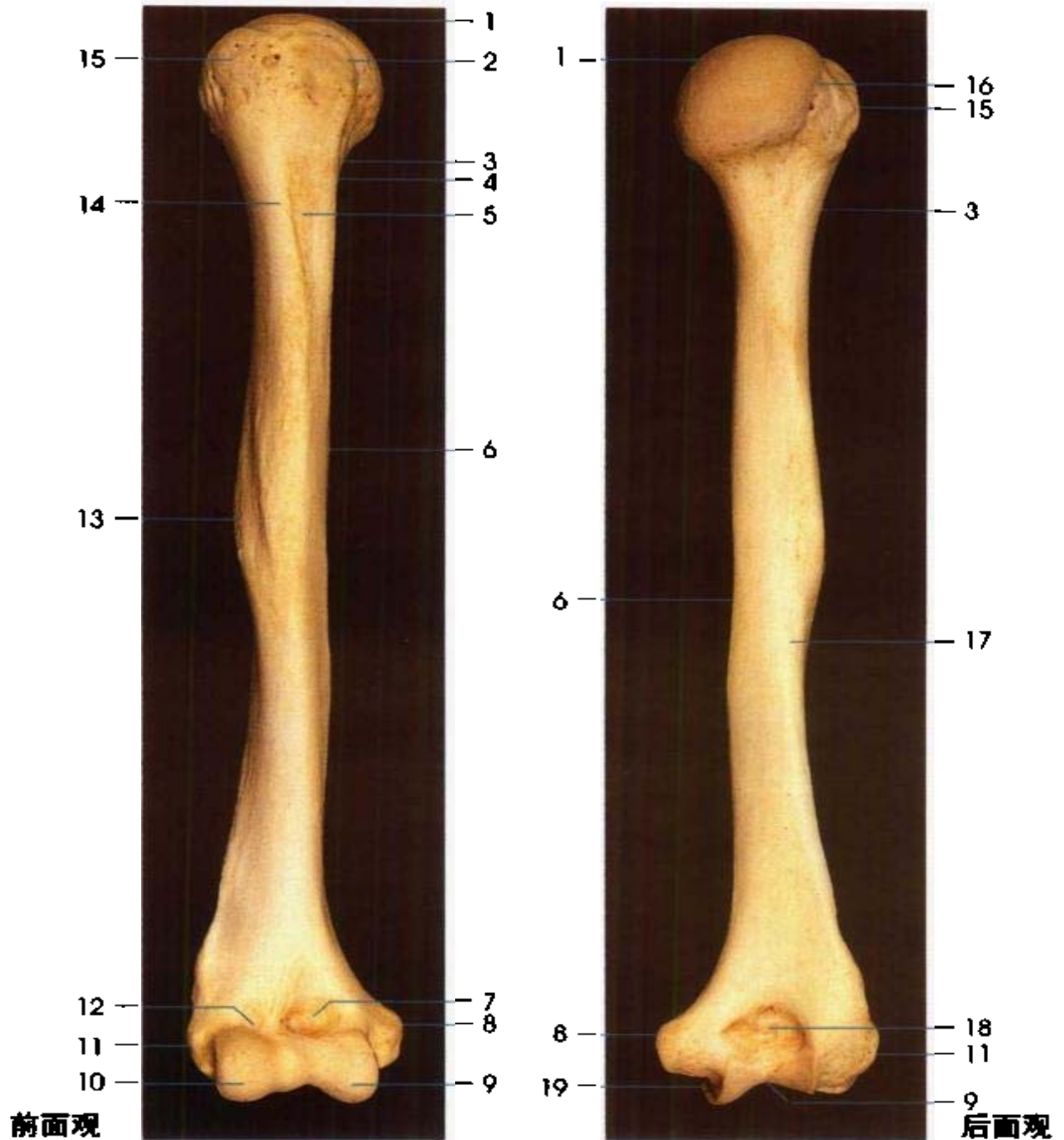
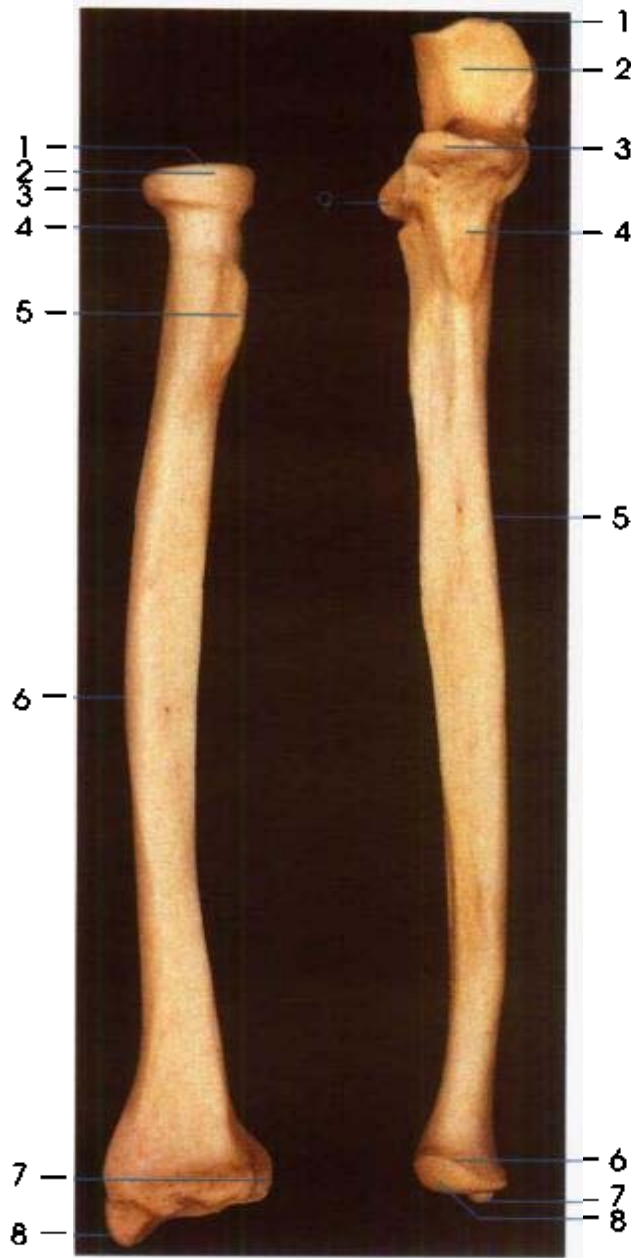


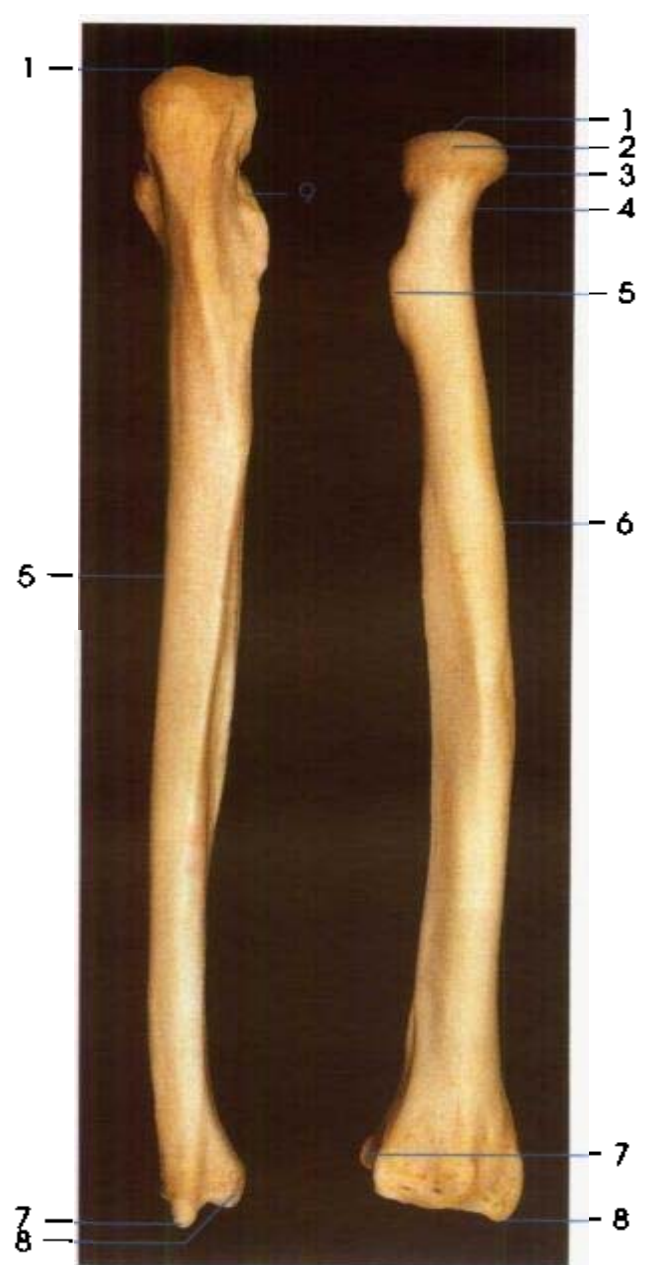
图 30 肱骨(前和后面观)
The humerus(anterior and posterior aspect)

- | | |
|----------------------------------|------------------------------------|
| 1. 肱骨头 head of humerus | 11. 外上髁 lateral epicondyle |
| 2. 小结节 lesser tubercle | 12. 桡窝 radial fossa |
| 3. 外科颈 Surgical neck | 13. 三角肌粗隆 deltoid tuberosity |
| 4. 小结节嵴 crest of lesser tubercle | 14. 大结节嵴 crest of greater tubercle |
| 5. 结节间沟 intertubercular sulcus | 15. 大结节 greater tubercle |
| 6. 肱骨体 shaft of humerus | 16. 解剖颈 anatomical neck |
| 7. 冠突窝 coronoid fossa | 17. 桡神经沟 sulcus for radial n. |
| 8. 内上髁 medial epicondyle | 18. 鹰嘴窝 olecranon fossa |
| 9. 肱骨滑车 trochlea of humerus | 19. 尺神经沟 sulcus for ulnar n. |
| 10. 肱骨小头 capitulum of humerus | |



A. 前面观

图 31 尺骨(A.右图, B.左图)
The ulna(A.the right figure,
B.the left figure)



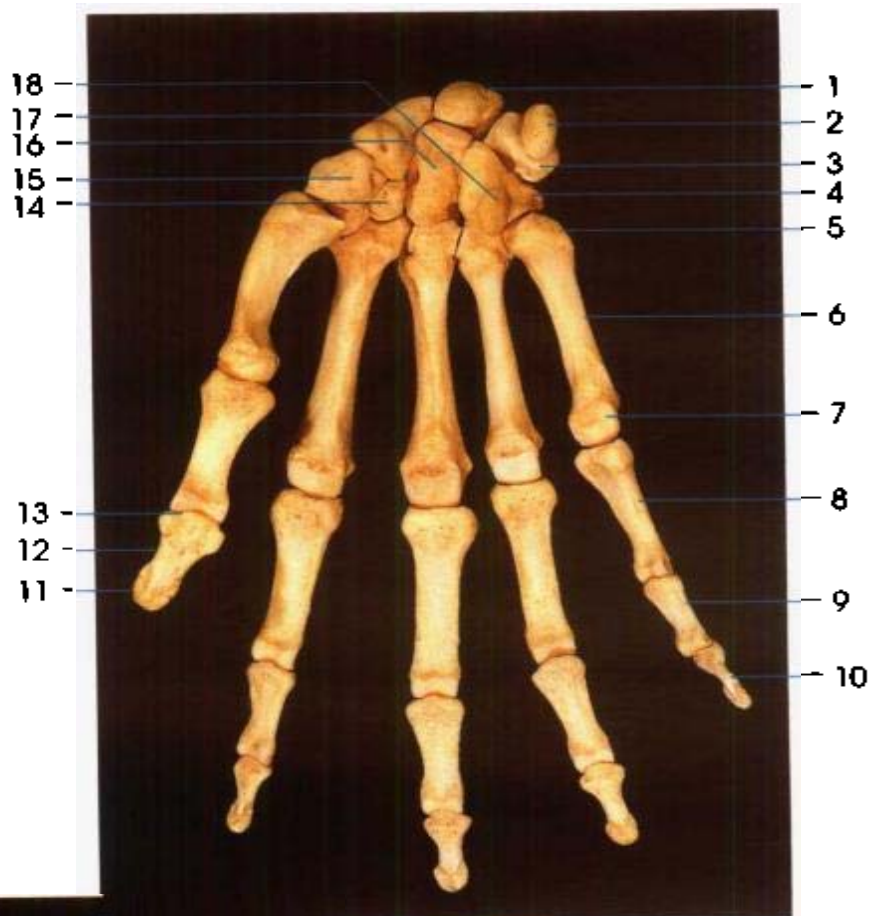
B. 后面观

图 32 桡骨(A.左图, B.右图)
The radius(A.the left figure,
B.the right figure)

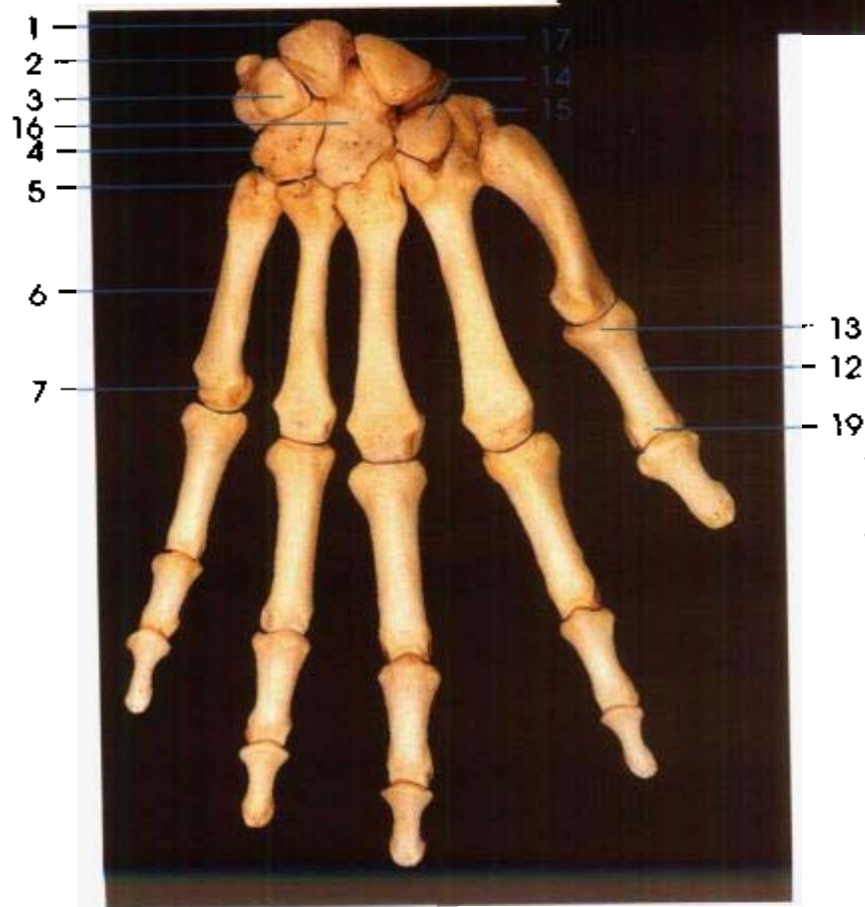
1. 鹰嘴 olecranon
2. 滑车切迹 trochlear notch
3. 冠突 coronoid process
4. 尺骨粗隆 ulnar tuberosity
5. 尺骨体 shaft of ulna
6. 尺骨头 head of ulna
7. 茎突 styloid process
8. 环状关节面 articular circumference
9. 桡切迹 radius notch

1. 关节凹 articular fovea
2. 环状关节面 articular circumference
3. 桡骨头 head of radius
4. 桡骨颈 neck of radius
5. 桡骨粗隆 radius tuberosity
6. 桡骨体 shaft of radius
7. 尺切迹 ulnar notch
8. 茎突 styloid process

1. 月骨 lunate bone
2. 豌豆骨 pisiform bone
3. 三角骨 triquetral bone
4. 钩骨 hamate bone
5. 掌骨底 base of metacarpal bone
6. 掌骨体 shaft of metacarpal bone
7. 掌骨头 head of metacarpal bone
8. 近节指骨 proximal phalanx
9. 中节指骨 middle phalanx
10. 远节指骨 distal phalanx
11. 指骨粗隆 tuberosity of phalanx
12. 指骨体 shaft of phalanx



前面观



后面观

13. 指骨底 base of phalanx
14. 小多角骨 trapezoid bone
15. 大多角骨 trapezium bone
16. 头状骨 capitate bone
17. 手舟骨 scaphoid bone
18. 钩骨钩 hamulus of hamate bone
19. 指骨滑车 trochlea of phalanx

图 33 手骨(前和后面观)
The bones of the hand (anterior and posterior aspect)

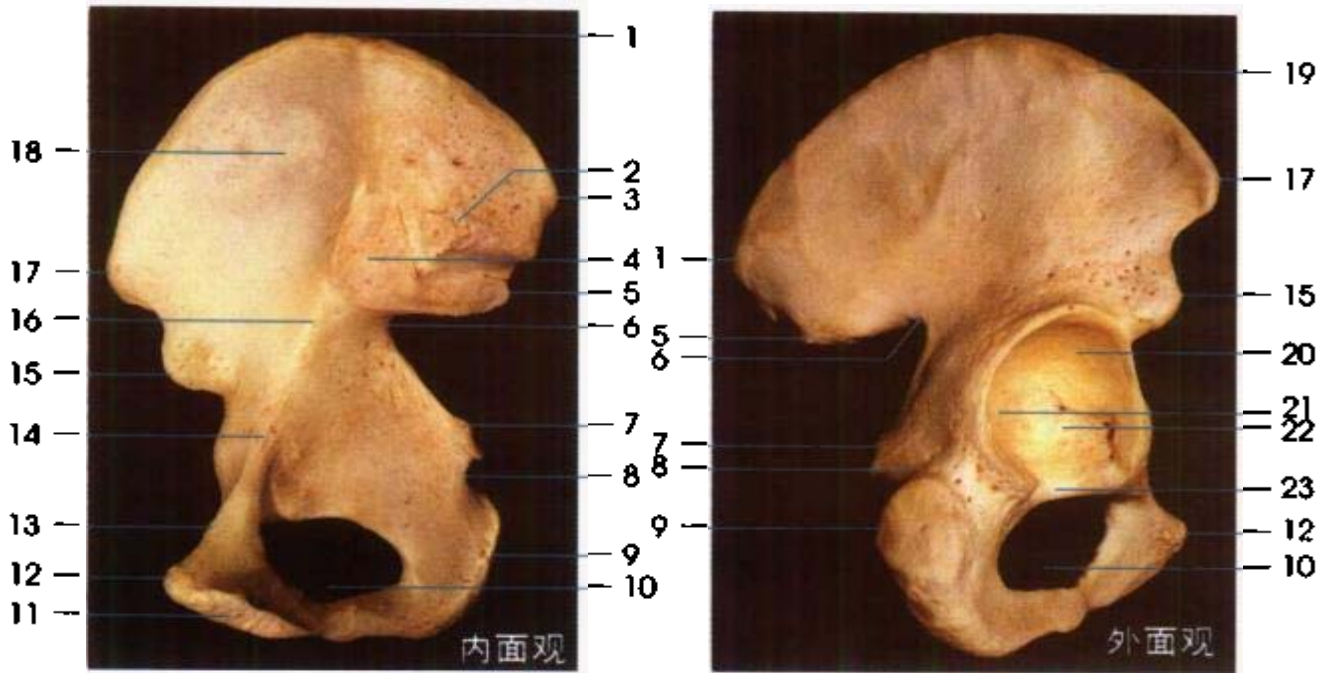


图 34 髌骨(内和外面观)
The hip bone(internal and external aspect)

- 1. 髌嵴 iliac crest
- 2. 髌粗隆 iliac tuberosity
- 3. 髌后上棘 posterior superior iliac spine
- 4. 耳状面 auricular surface
- 5. 髌后下棘 posterior inferior iliac spine
- 6. 坐骨大切迹 greater sciatic notch
- 7. 坐骨棘 ischial spine
- 8. 坐骨小切迹 lesser sciatic notch
- 9. 坐骨结节 ischial tuberosity

- 10. 闭孔 obturator foramen
- 11. 耻骨联合面 symphyseal surface
- 12. 耻骨结节 pubic tubercle
- 13. 耻骨梳 pecten of pubis
- 14. 髌耻隆起 iliopectic eminence
- 15. 髌前下棘 anterior inferior iliac spine
- 16. 弓状线 arcuate line
- 17. 髌前上棘 anterior superior iliac spine
- 18. 髌窝 iliac fossa
- 19. 髌结节 iliac tubercle
- 20. 髌臼 acetabulum
- 21. 月状面 lunate surface
- 22. 髌臼窝 acetabular fossa
- 23. 髌臼切迹 acetabular notch

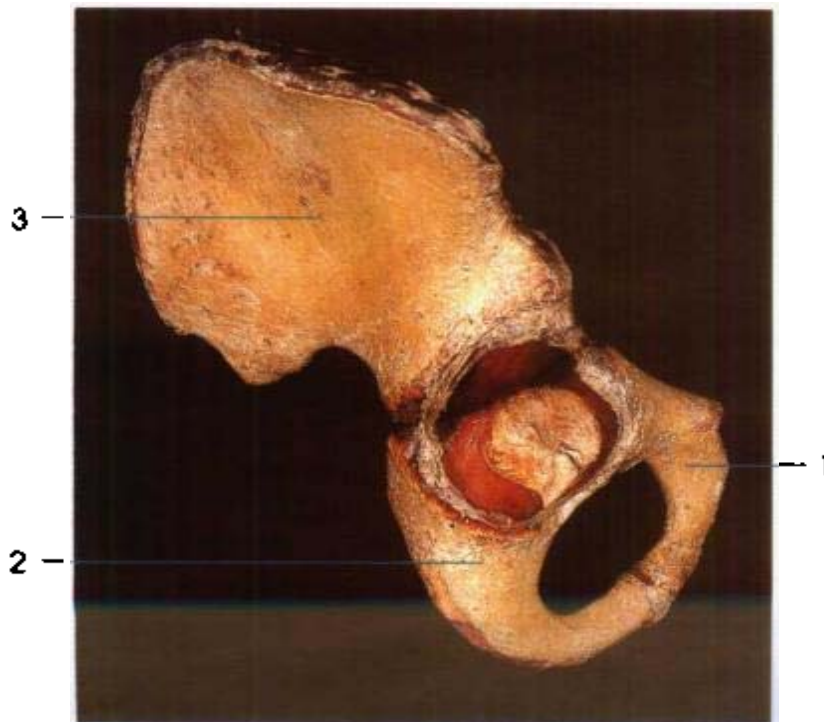


图 35 婴儿髌骨(外面观)
The hip bone of the infant(external aspect)

- 1. 耻骨 pubis
- 2. 坐骨 ischium
- 3. 髌骨 ilium

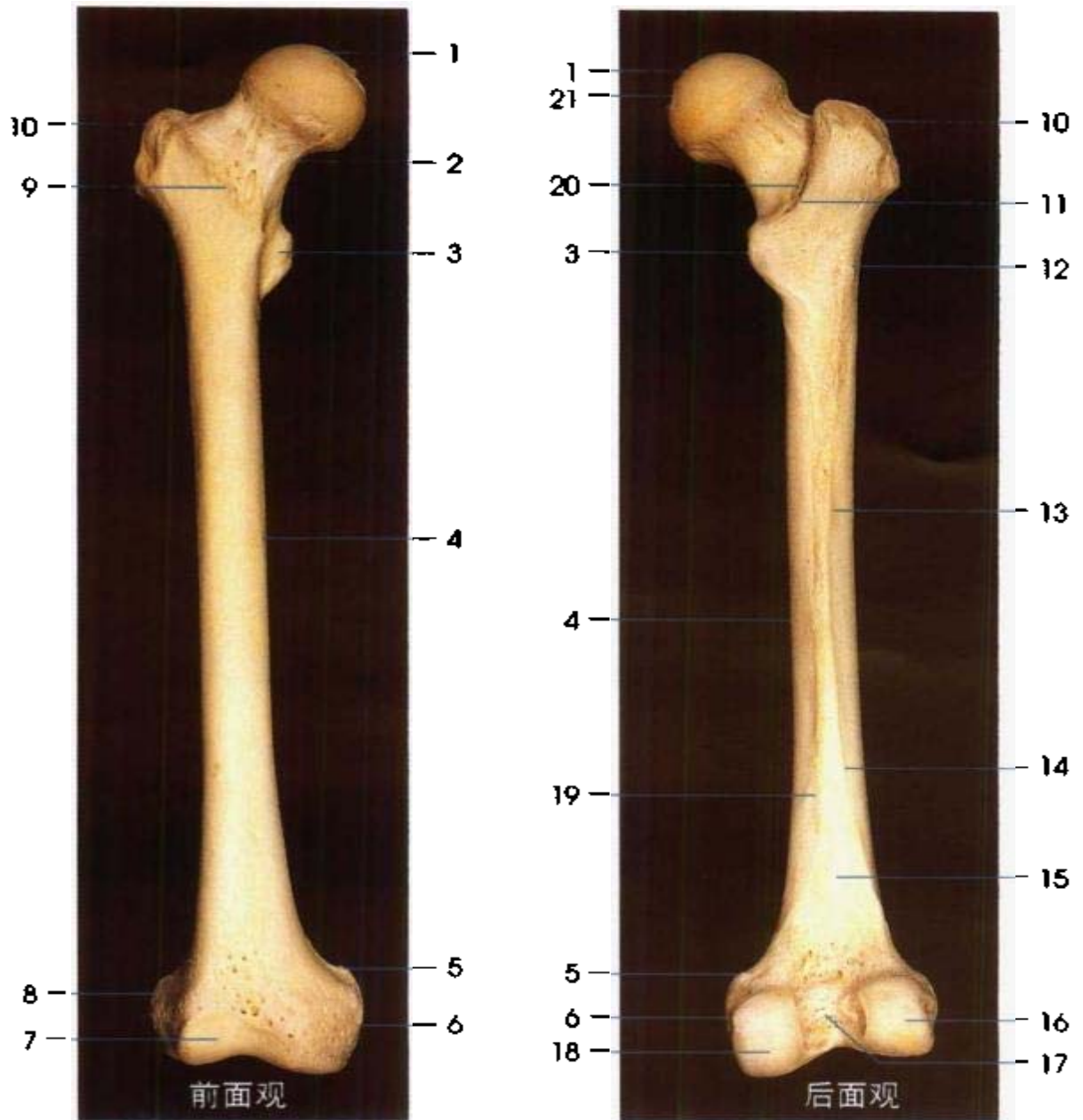


图 36 股骨(前和后面观)
The femur(anterior and posterior aspect)

- 1. 股骨头 femoral head
- 2. 股骨颈 neck of femur
- 3. 小转子 lesser trochanter
- 4. 股骨体 shaft of femur
- 5. 收肌结节 adductor tubercle
- 6. 内上髁 medial epicondyle
- 7. 髌面 patellar surface
- 8. 外上髁 lateral epicondyle
- 9. 转子间线 intertrochanteric line
- 10. 大转子 greater trochanter
- 11. 转子间嵴 intertrochanteric crest

- 12. 髁肌粗隆 gluteal tuberosity
- 13. 粗线 linea aspera
- 14. 外侧唇 lateral lip
- 15. 腓面 popliteal surface
- 16. 外侧髁 lateral condyle
- 17. 髁间窝 intercondylar fossa
- 18. 内侧髁 medial condyle
- 19. 内侧唇 medial lip
- 20. 转子窝 trochanteric fossa
- 21. 股骨头凹 fovea of femoral head



图 37 髌骨(前和后面观)
The patella(anterior and posterior aspect)

- 1. 髌底 base of patella
- 2. 关节面 articular surface
- 3. 髌尖 apex of patella

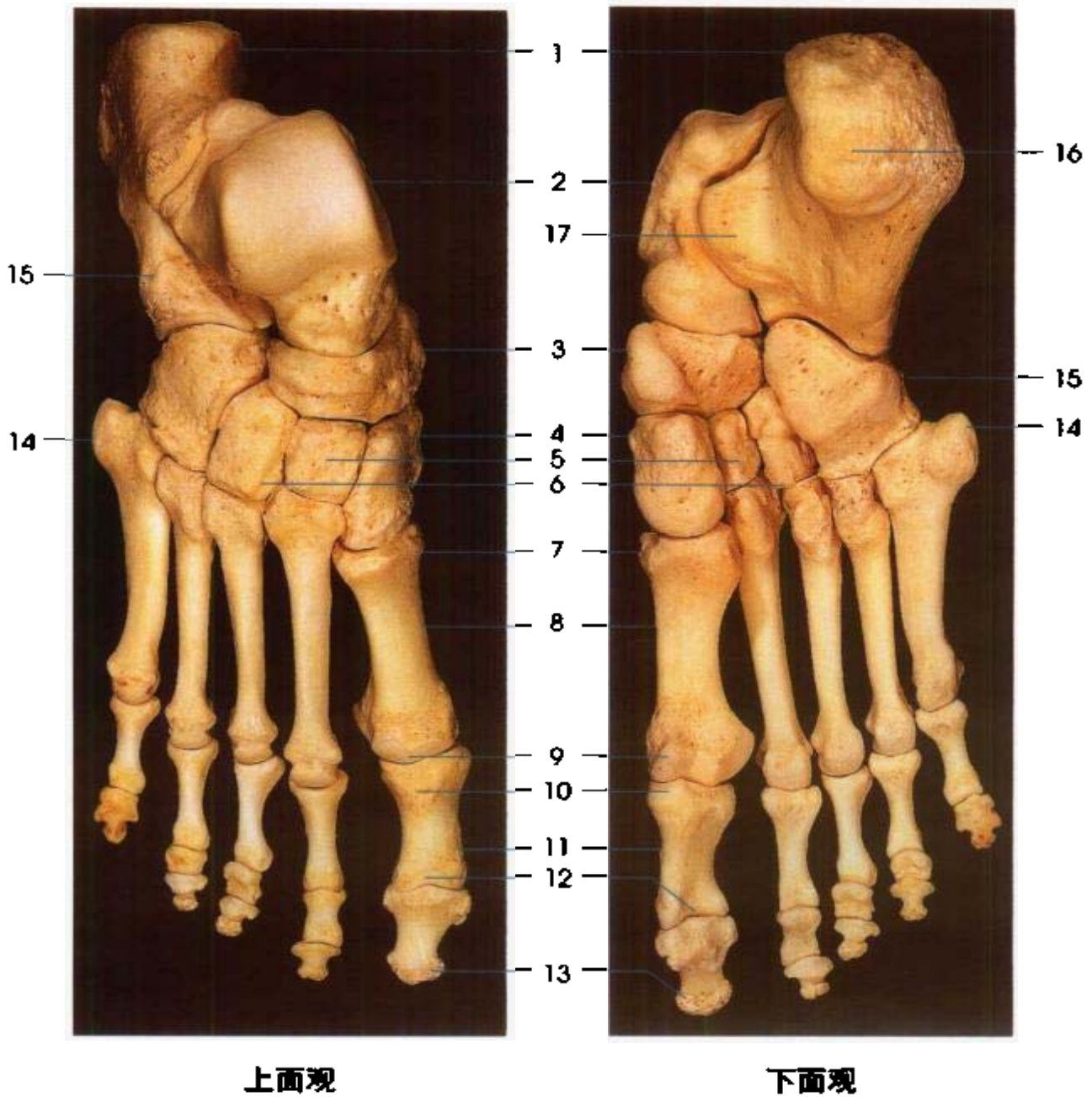


图 39 足骨(上和下面观)
The bones of the foot(superior and inferior aspect)

- | | |
|-------------------------------------|--|
| 1. 跟骨 calcaneus | 10. 趾骨底 base of phalanx |
| 2. 距骨 talus | 11. 趾骨体 shaft of phalanx |
| 3. 足舟骨 navicular bone | 12. 趾骨滑车 trochlea of phalanx |
| 4. 内侧楔骨 medial cuneiform bone | 13. 趾骨粗隆 tuberosity of phalanx |
| 5. 中间楔骨 intermediate cuneiform bone | 14. 第五跖骨粗隆 tuberosity of fifth metatarsal bone |
| 6. 外侧楔骨 lateral cuneiform bone | 15. 骰骨 cuboid bone |
| 7. 跖骨底 base of metatarsal bone | 16. 跟骨结节 calcaneal tuberosity |
| 8. 跖骨体 shaft of metatarsal bone | 17. 载距突 sustentaculum tali |
| 9. 跖骨头 head of metatarsal bone | |

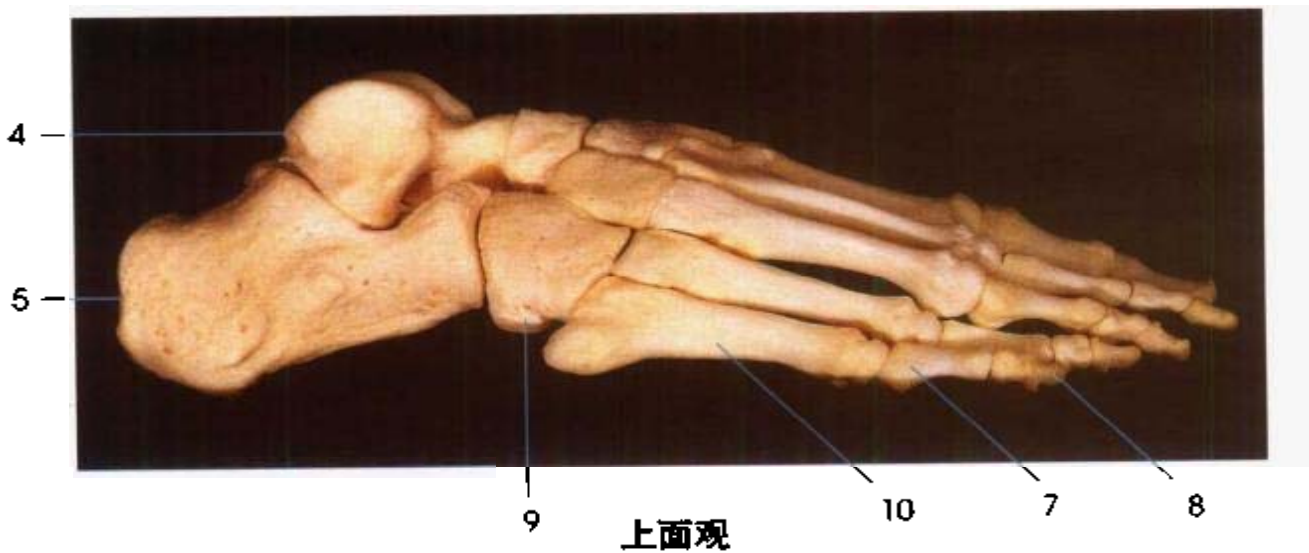
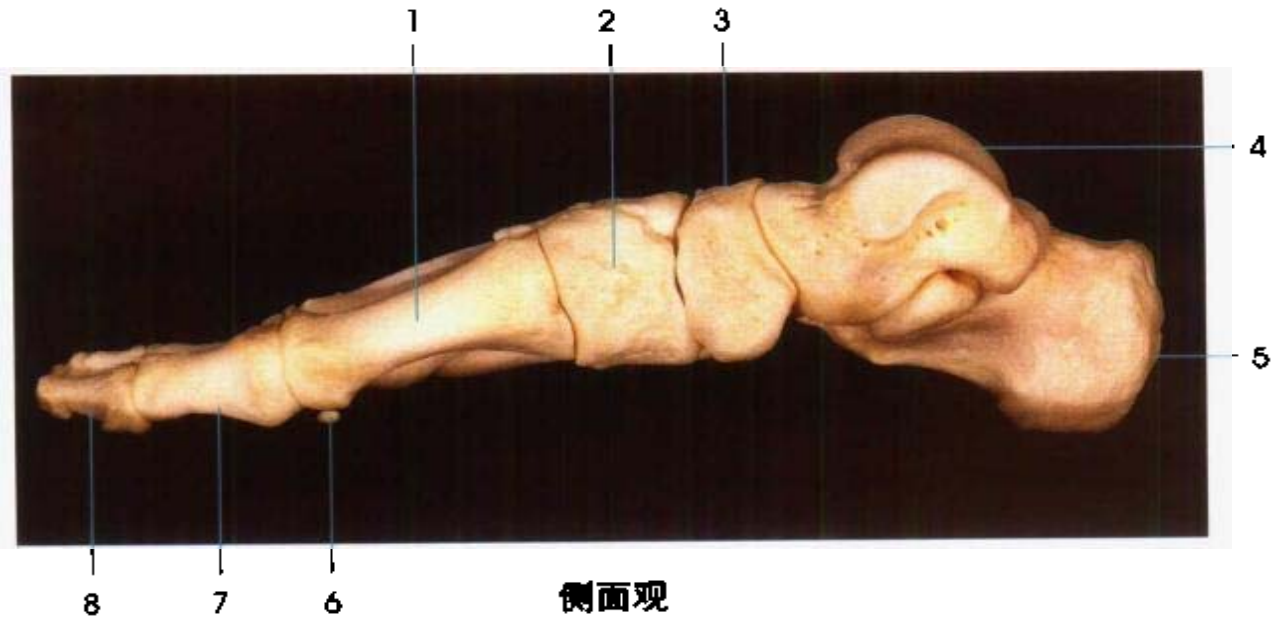


图 40 足纵弓(侧面及上面观)
The longitudinal arches of the foot(lateral and superior aspect)

- 1. 第一跖骨 1st metatarsal bone
- 2. 内侧楔骨 medial cuneiform bone
- 3. 足舟骨 navicular bone
- 4. 距骨 talus
- 5. 跟骨 calcaneus

- 6. 籽骨 sesamoid bone
- 7. 近节趾骨 proximal phalanx
- 8. 远节趾骨 distal phalanx
- 9. 骰骨 cuboid bone
- 10. 第五跖骨 5th metatarsal bone

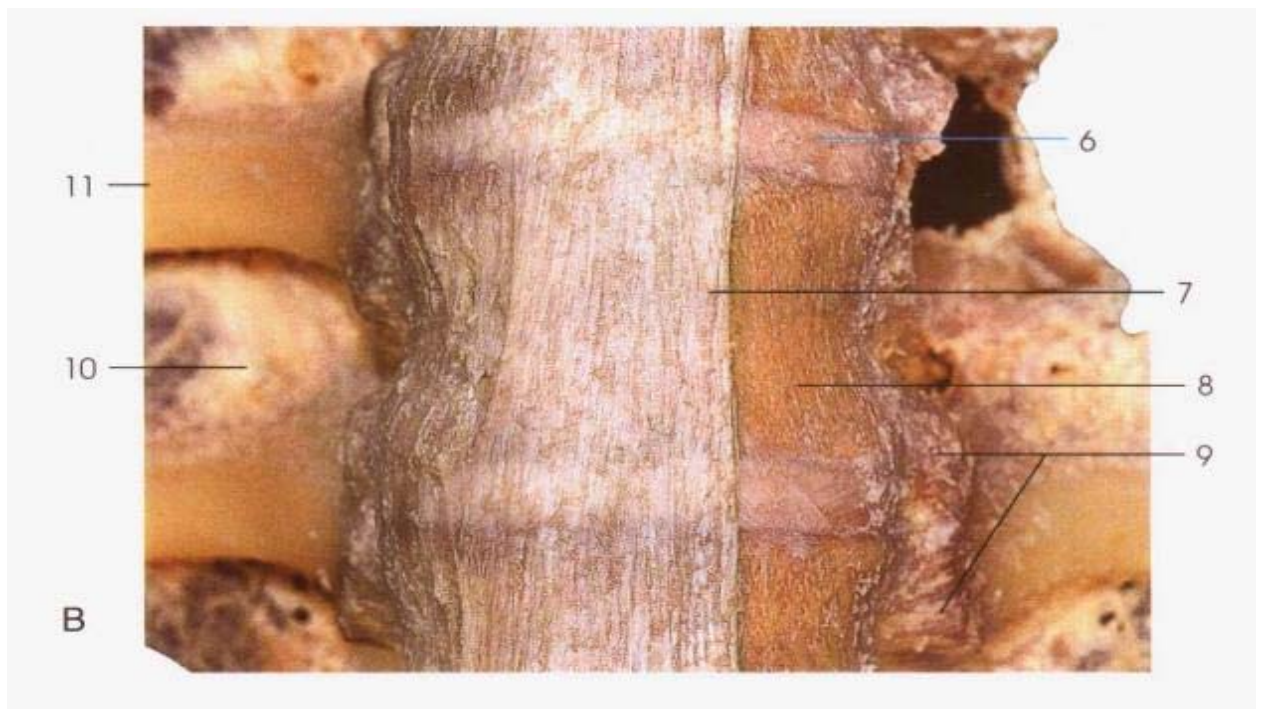
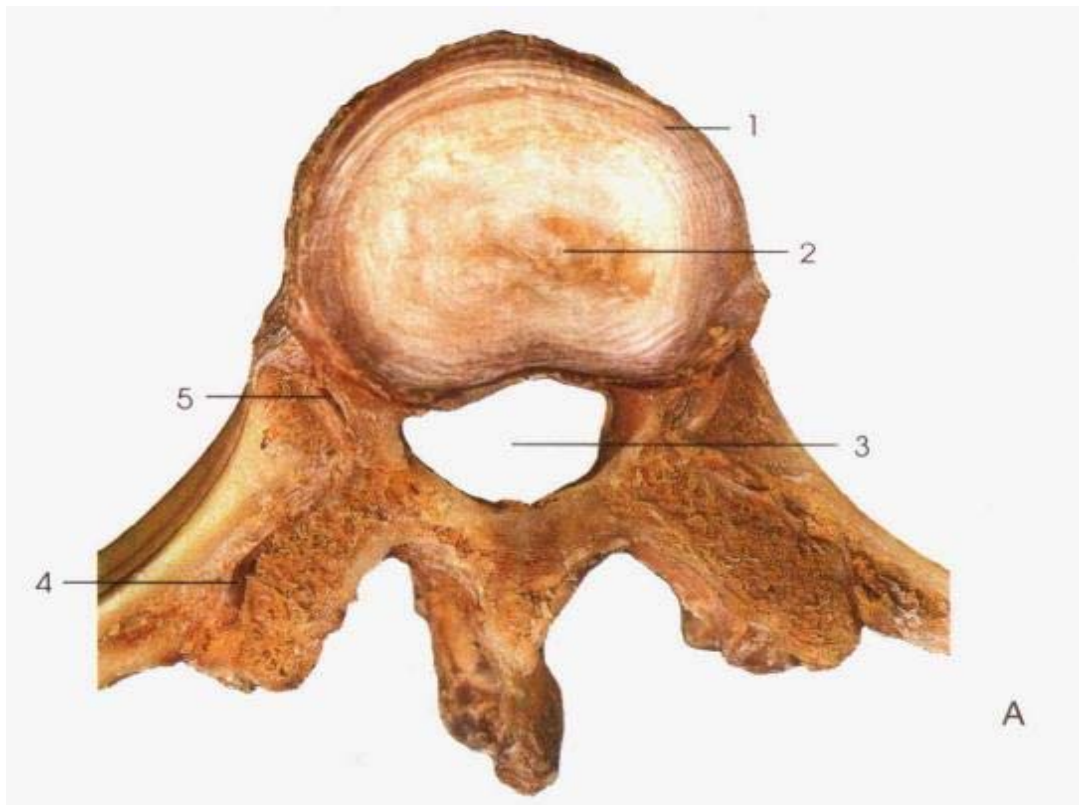


图 A、B

1. 纤维环 anulus fibrosus
2. 髓核 nucleus pulposus
3. 椎孔 vertebral foramen
4. 肋横突关节 costotransverse joint
5. 肋头关节 joint of costal head
6. 椎间盘 intervertebral discs

7. 前纵韧带 anterior longitudinal lig.
8. 椎体 vertebral body
9. 肋头辐状韧带 radiate lig. of costal head
10. 肋横突上韧带 superior costotransverse lig.
11. 肋骨 costal bone

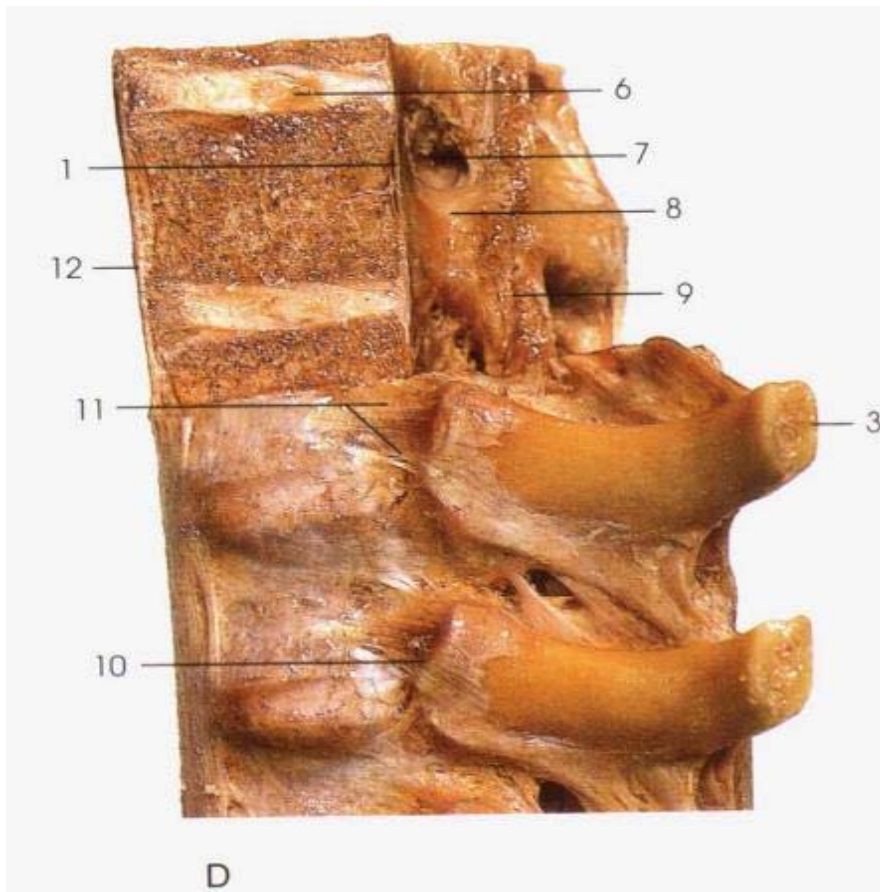
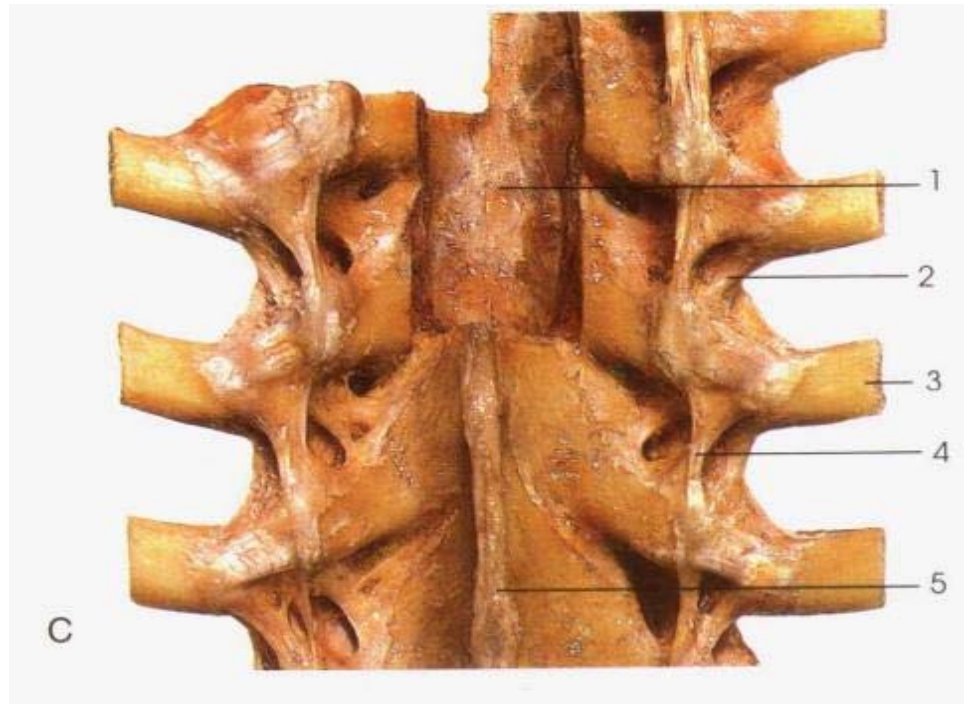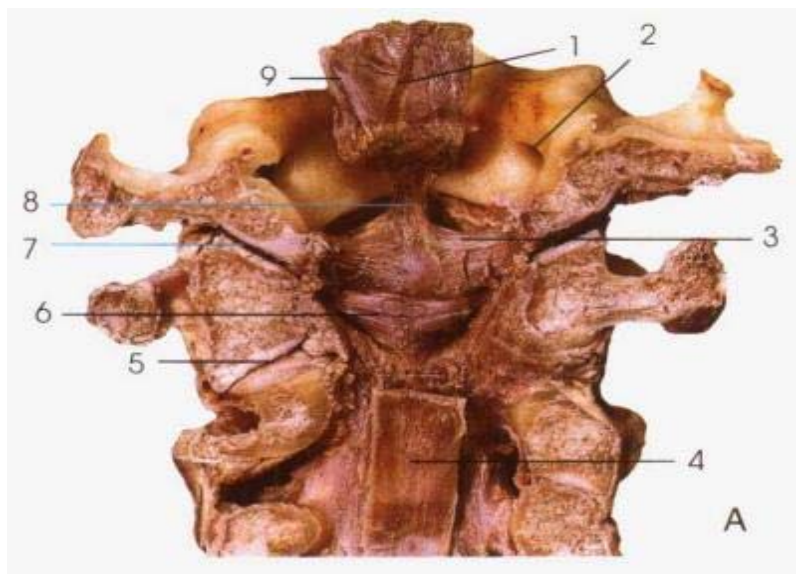


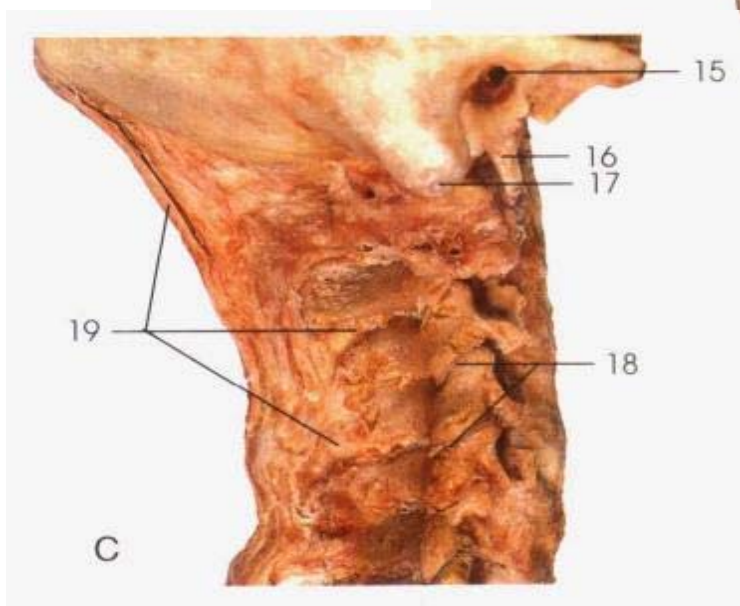
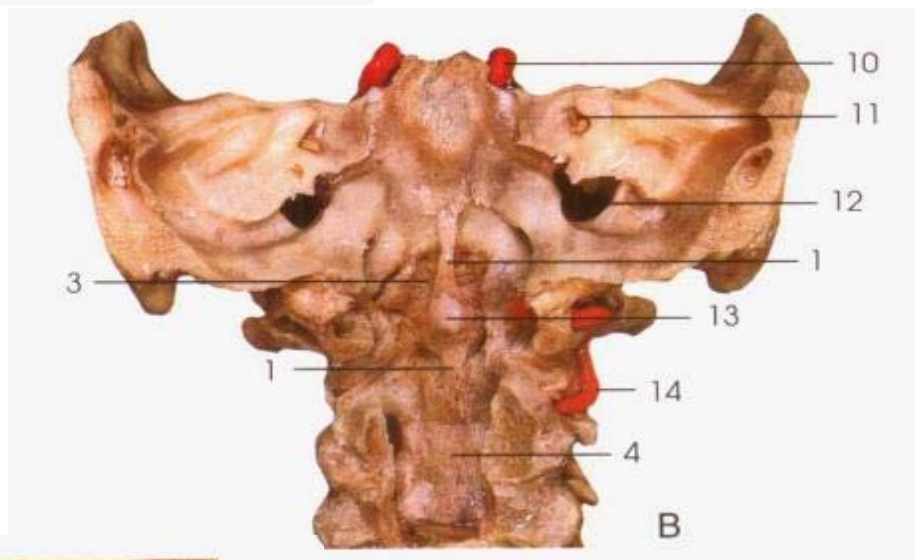
图 C、D

1. 后纵韧带 posterior longitudinal lig.
2. 肋横突上韧带 superior costotransverse lig.
3. 肋骨 costal bone
4. 横突间韧带 intertransverse lig.
5. 棘上韧带 supraspinal lig.
6. 椎间盘 intervertebral disc
7. 椎间孔 intervertebral foramen
8. 椎弓板 lamina of vertebral arch
9. 黄韧带 ligamenta flava
10. 肋头关节 joint of costal head
11. 肋头辐状韧带 radiate lig. of costal head
12. 前纵韧带 anterior longitudinal lig.

图 41 椎骨间连结(A、B、C、D)
Intervertebral joints(A,B,C,D)

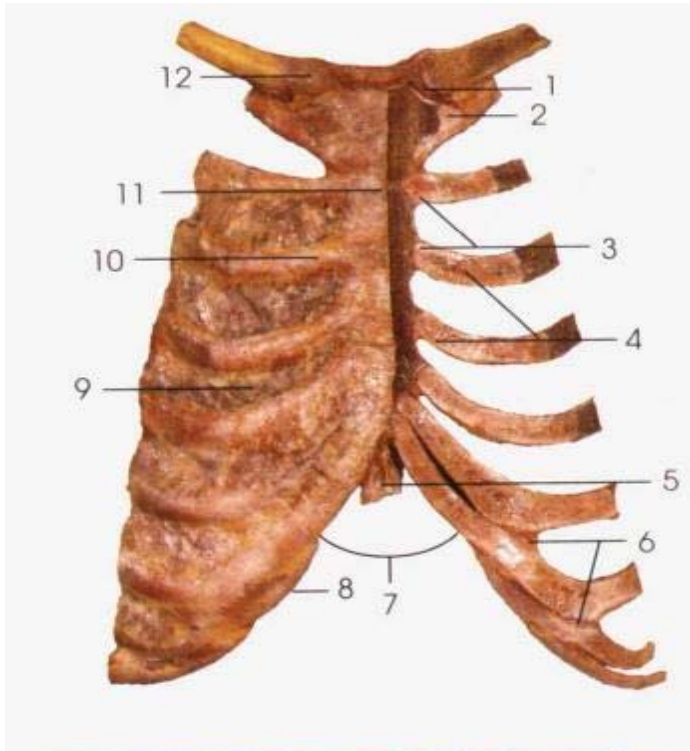


1. 纵束 longitudinal bands
2. 舌下神经管 hypoglossal canal
3. 翼状韧带 alar lig.of dens
4. 后纵韧带 posterior longitudinal lig.
5. 寰枢外侧关节 lateral atlantoaxial joint
6. 寰椎横韧带 transverse lig.of atlas
7. 寰枕关节 atlantooccipital joint
8. 齿突尖韧带 apical lig.of dens
9. 覆膜 tectorial membrane



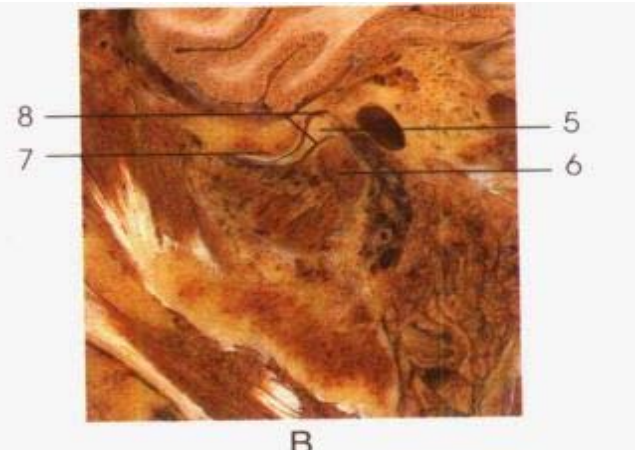
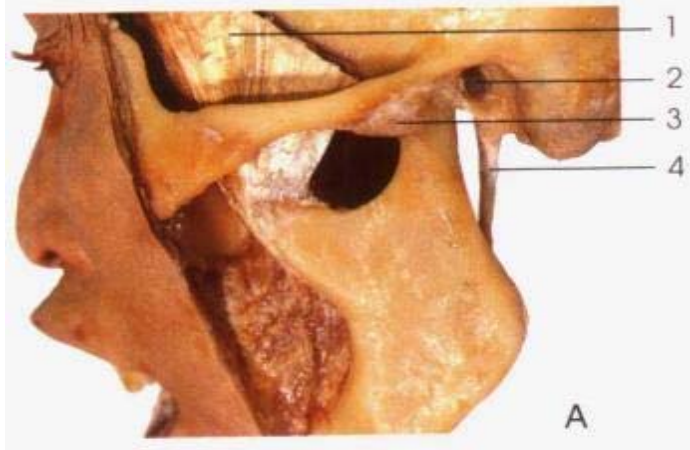
10. 颈内动脉 internal carotid a.
11. 内耳门 internal acoustic pore
12. 颈静脉孔 jugular foramen
13. 寰椎十字韧带 cruciform lig.of atlas
14. 椎动脉 vertebral a.
15. 外耳门 external acoustic pore
16. 茎突 styloid process
17. 乳突 mastoid process
18. 关节突关节 zygapophysial joints
19. 顶韧带 ligamentum nuchae

图 42 颅骨与椎骨连结(A、B、C)
The joints of the skull and vertebra(A,B,C)



1. 关节盘 articular disc
2. 第一胸肋结合 sternocostal synchondrosis of first rib
3. 胸肋关节 sternocostal joints
4. 肋软骨 costochondral joints
5. 剑突 xiphoid process
6. 软骨间关节 interchondral joints
7. 胸骨下角 infrasternal angle
8. 肋弓 costal arch
9. 肋间隙 intercostal space
10. 胸肋辐状韧带 radiate sternocostal lig.
11. 胸骨角 sternal angle
12. 胸锁关节 sternoclavicular joint

图 43 肋与胸骨连结
The joints of ribs and the sternum



A. 外面观 Lateral aspect

1. 颞肌 temporalis
2. 外耳道 external acoustic meatus
3. 关节囊 articular capsule
4. 茎突 styloid process

B. 矢状剖面 Sagittal section

5. 关节盘 articular disc
6. 髁突 condylar process
7. 关节结节 articular tubercle
8. 关节腔 articular cavity

C. 内面观 medial aspect

9. 蝶下颌韧带 sphenomandibular lig.
10. 茎突下颌韧带 tylomandibular lig.

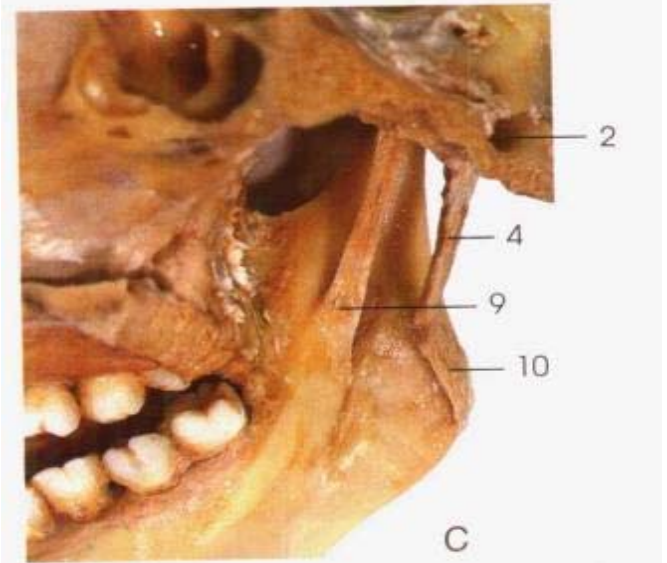
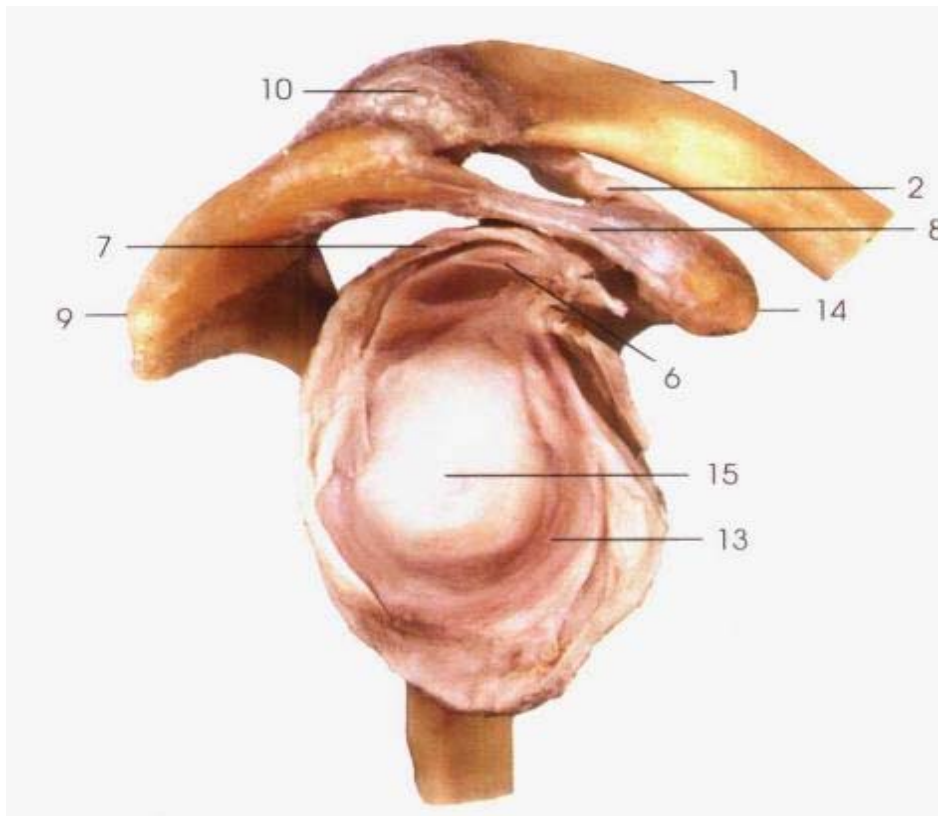
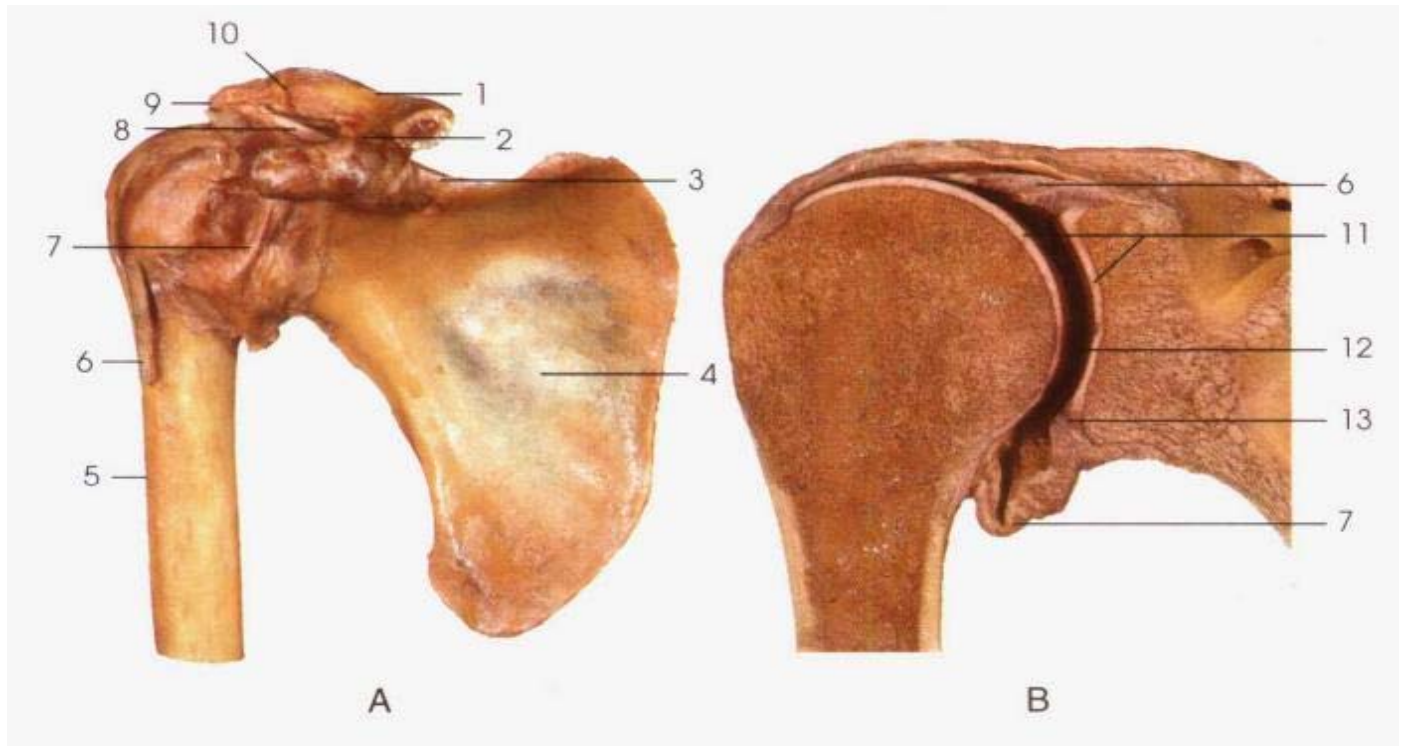


图 44 颞下颌关节(A、B、C)
The temporomandibular joint(A,B,C)



A. 前面观 Anterior aspect

1. 锁骨 clavicle
2. 喙锁韧带 coracoclavicular lig.
3. 肩胛上横韧带 superior transverse scapular lig.
4. 肩胛骨 scapula
5. 肱骨 humerus
6. 肱二头肌长头腱 long head tendon of biceps brachii
7. 关节囊 articular capsule
8. 喙肩韧带 coracoacromial lig.
9. 肩峰 acromion
10. 肩锁关节 acromioclavicular joint

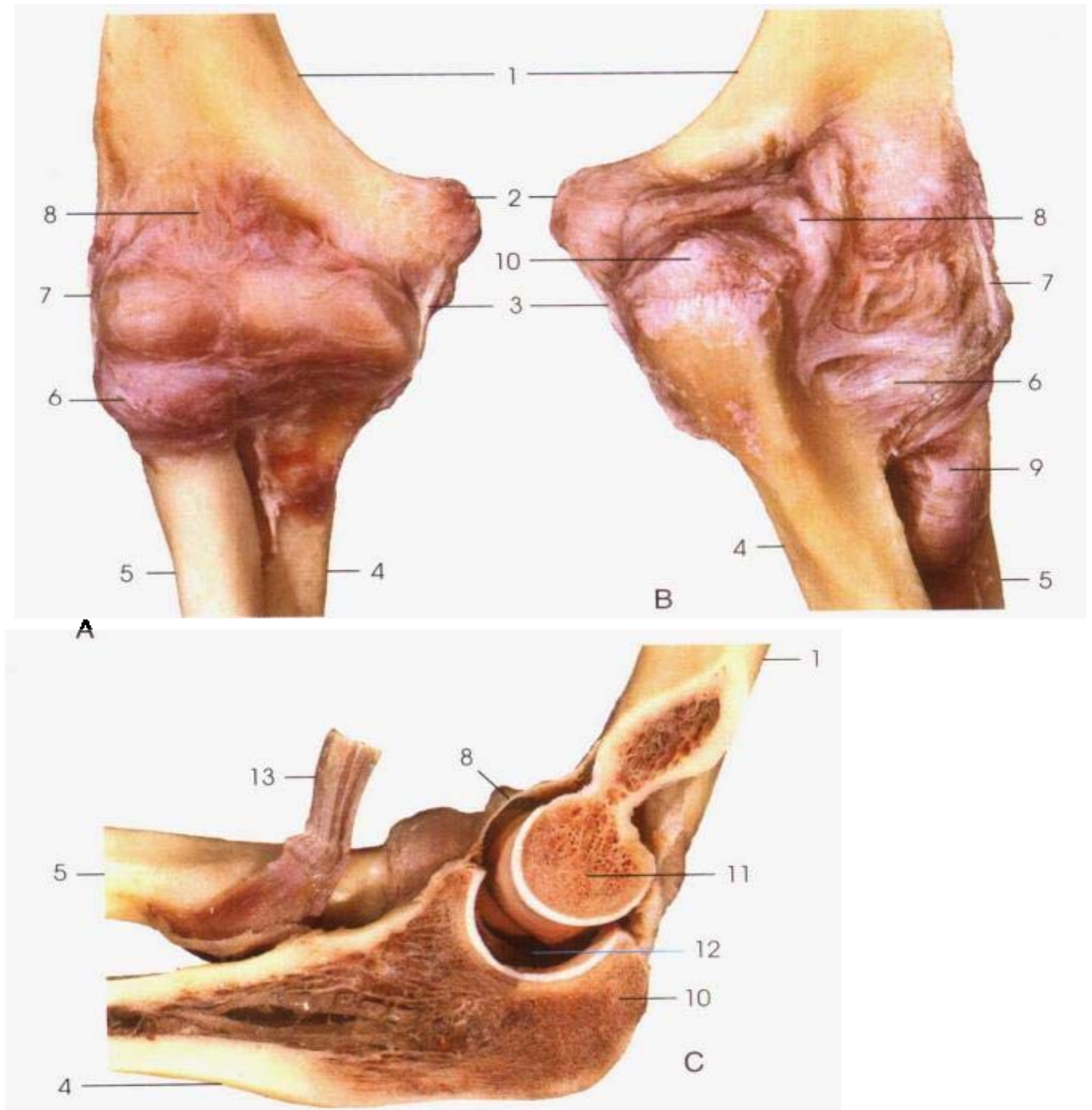
B. 剖面观 Section

11. 关节软骨 articular cartilage
12. 关节腔 articular cavity
13. 孟唇 glenoid labrum

C. 内面观 medial aspect

14. 喙突 coracoid process
15. 关节盂 glenoid cavity

图 45 肩关节(A、B、C)
The shoulder joint(A,B,C)



A. 前面观 Anterior aspect

- 1. 肱骨 humerus
- 2. 内上髁 medial epicondyle
- 3. 尺侧副韧带 ulnar collateral lig.
- 4. 尺骨 ulna
- 5. 桡骨 radius
- 6. 桡骨环状韧带 annular lig.of radius
- 7. 桡侧副韧带 radial collateral lig.

8. 关节囊 articular capsule

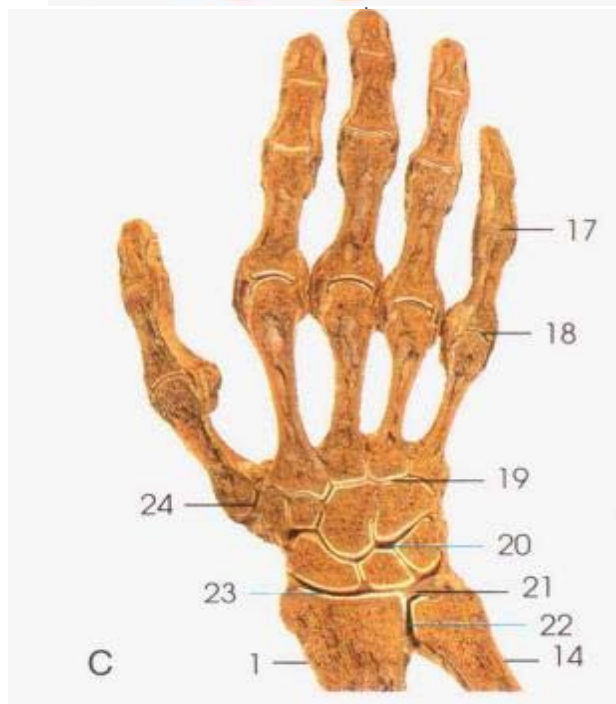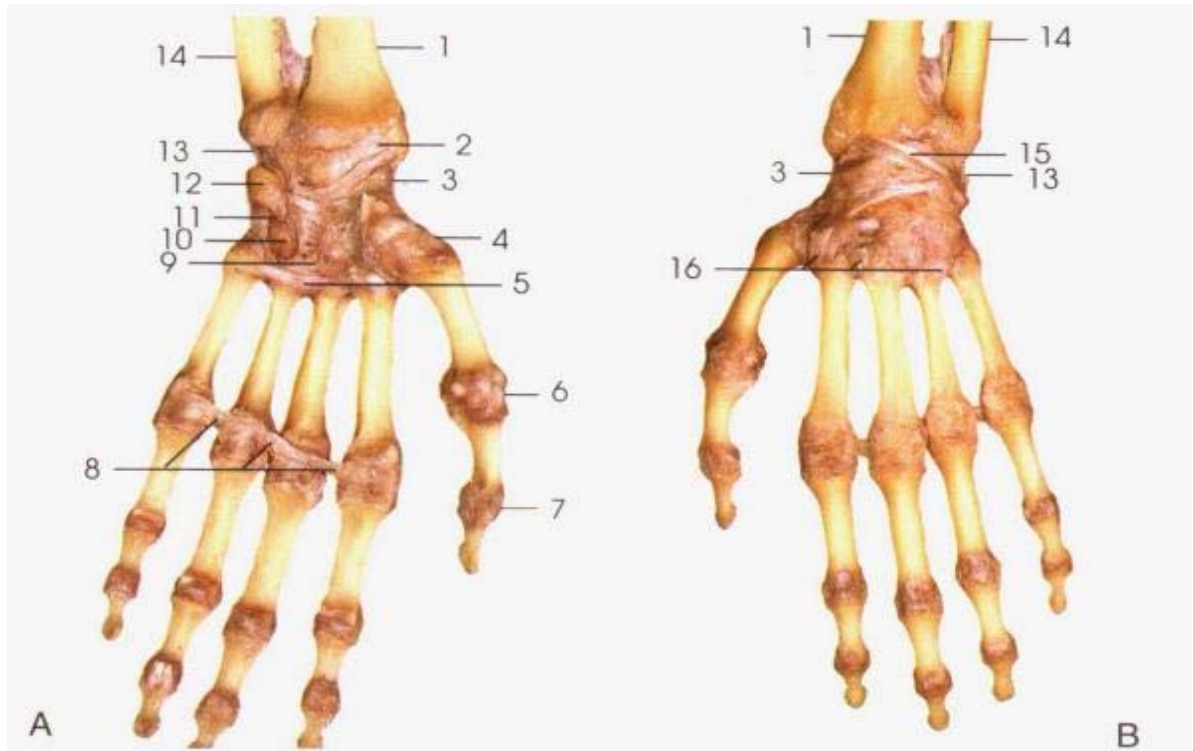
B. 后面观 Posterior aspect

- 9. 桡骨粗隆 radial tuberosity
- 10. 鹰嘴 olecranon

C. 剖面观 Section

- 11. 肱骨滑车 trochlea of humerus
- 12. 关节腔 articular cavity
- 13. 肱二头肌腱 bicipital tendon

图 46 肘关节(A, B, C)
The elbow joint(A,B,C)

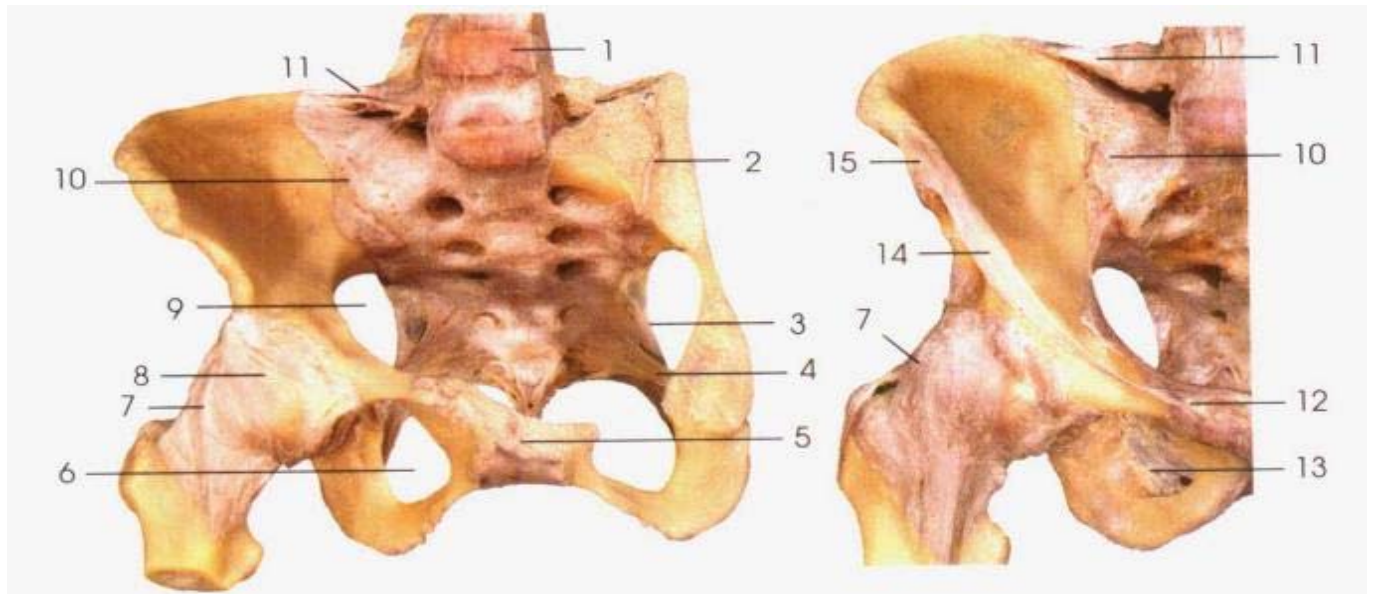


A. 前面观 Anterior aspect

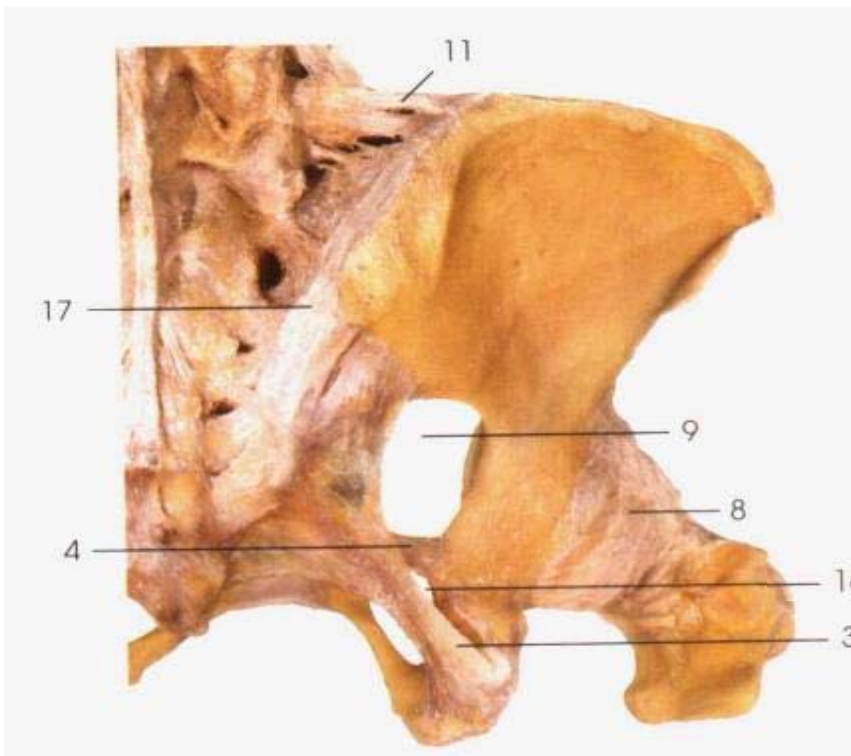
- 1. 桡骨 radius
- 2. 桡腕掌侧韧带 palmar radiocarpal lig.
- 3. 腕桡侧副韧带 collateral carporadial lig.
- 4. 拇指腕掌关节 carpometacarpal joint of thumb
- 5. 掌骨间韧带 interosseous metacarpal lig.
- 6. 第一掌指关节 first metacarpophalangeal joint
- 7. 指间关节 interphalangeal joint of hand

- 8. 掌骨深横韧带 deep transverse metacarpal lig.
 - 9. 腕掌掌侧韧带 palmar carpometacarpal lig.
 - 10. 钩骨钩 hamulus of hamate bone
 - 11. 豆钩韧带 pisohamate lig.
 - 12. 豌豆骨 pisiform bone
 - 13. 腕尺侧副韧带 ulnar carpal collateral lig.
 - 14. 尺骨 ulna
- B. 后面观 Posterior aspect**
- 15. 桡腕背侧韧带 dorsal radiocarpal lig.
 - 16. 腕掌背侧韧带 dorsal carpometacarpal lig.
- C. 剖面观 Section**
- 17. 指间关节腔 interphalangeal joint cavity
 - 18. 掌指关节腔 metacarpophalangeal joint cavity
 - 19. 腕掌关节腔 carpometacarpal joint cavity
 - 20. 腕骨间关节腔 intercarpal joint cavity
 - 21. 关节盘 articular disc
 - 22. 桡尺远侧关节腔 distal radioulnar joint cavity
 - 23. 桡腕关节腔 radiocarpal joint cavity
 - 24. 拇指腕掌关节腔 carpometacarpal joint cavity of thumb

**图 47 手骨连结(A、B、C)
The joints of the hand(A,B,C)**



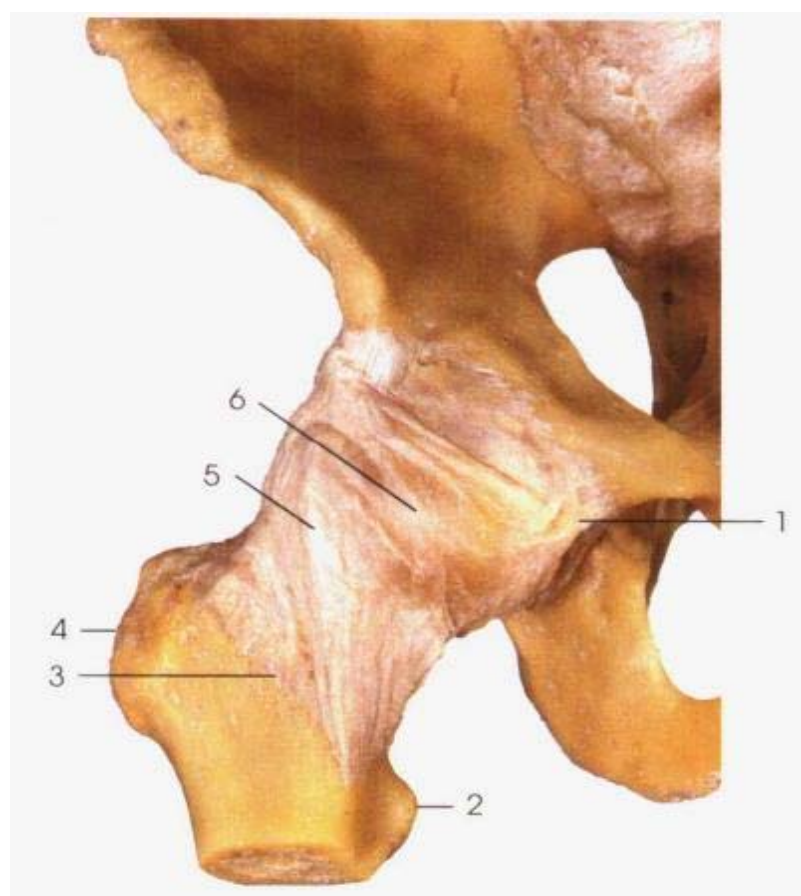
前面观



后面观

1. 椎间盘 intervertebral discs
2. 骶髂关节 sacroiliac joint
3. 骶结节韧带 sacrotuberous lig.
4. 骶棘韧带 sacrospinous lig.
5. 耻骨联合腔 pubic symphysis cavity
6. 闭孔 obturator foramen
7. 髂股韧带 iliofemoral lig.
8. 髋关节囊 hip articular capsule
9. 坐骨大孔 greater sciatic foramen
10. 骶髂腹侧韧带 ventral sacroiliac lig.
11. 髂腰韧带 iliolumbar lig.
12. 耻骨结节 pubic tubercle
13. 闭孔膜 obturator membrane
14. 腹股沟韧带 inguinal lig.
15. 髂前上棘 anterior superior iliac spine
16. 坐骨小孔 lesser sciatic foramen
17. 骶髂背侧韧带 dorsal sacroiliac lig.

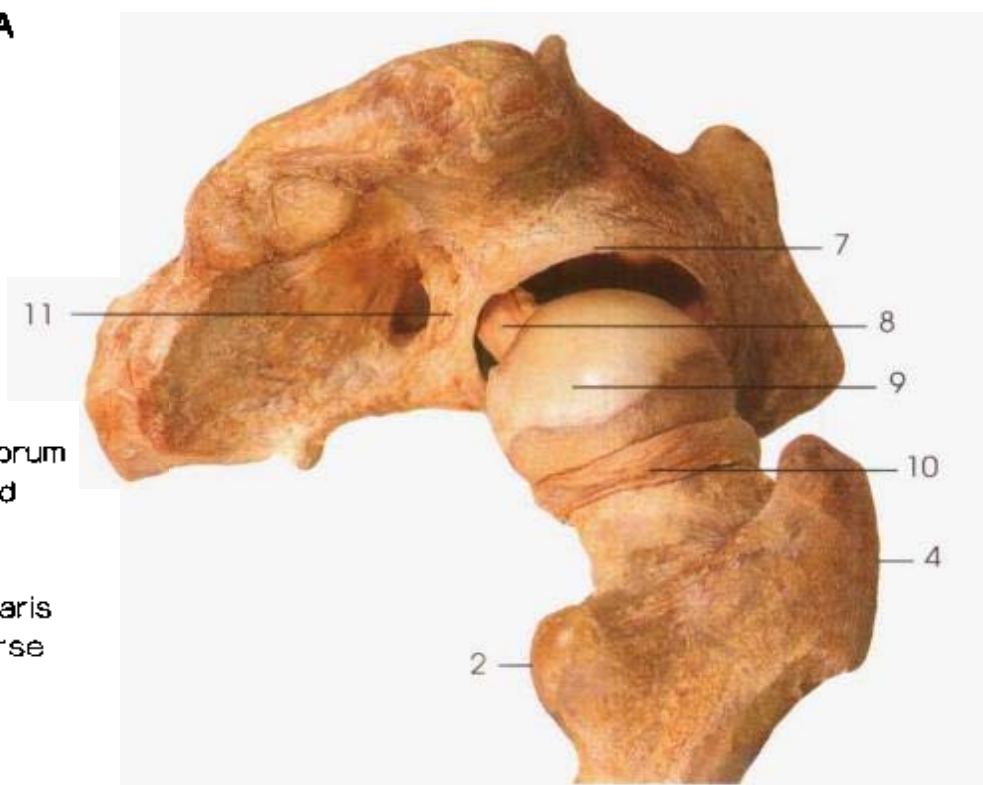
图 48 骨盆的连结(前和后面观)
The joints of the pelvis(anterior and posterior aspect)



A. 前面观 Anterior aspect

- 1. 耻股韧带 pubofemoral lig.
- 2. 小转子 lesser trochanter
- 3. 转子间线 intertrochanteric line
- 4. 大转子 greater trochanter
- 5. 髂股韧带 iliofemoral lig.
- 6. 关节囊 articular capsule

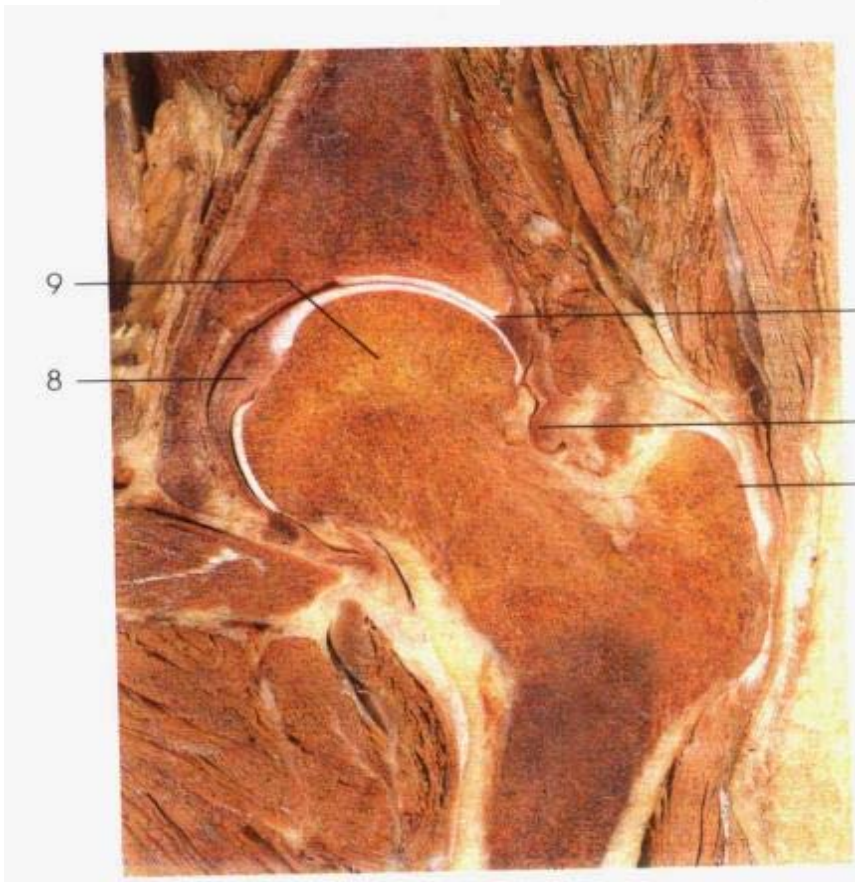
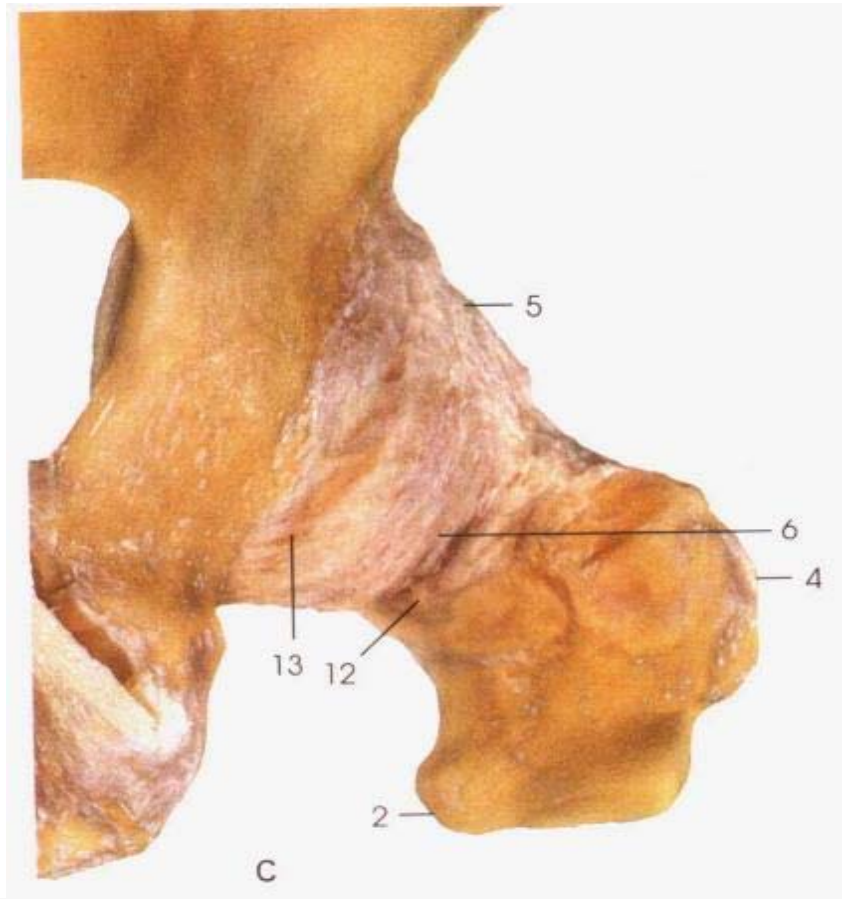
A



B. 切开 Incision

- 7. 髋臼唇 acetabular labrum
- 8. 股骨头韧带 lig. of head of femur
- 9. 股骨头 femoral head
- 10. 轮匝带 zona orbicularis
- 11. 髋臼横韧带 transverse acetabular lig.

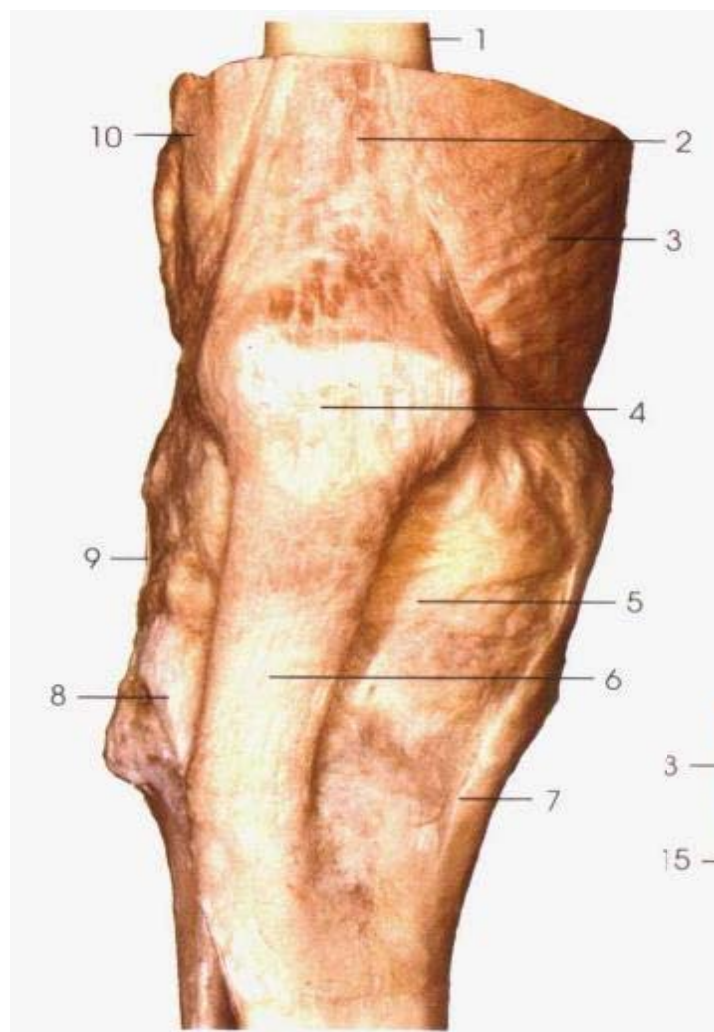
B



C. 后面观 Posterior aspect
12. 股骨颈 neck of femur
13. 坐股韧带 ischiofemoral lig.

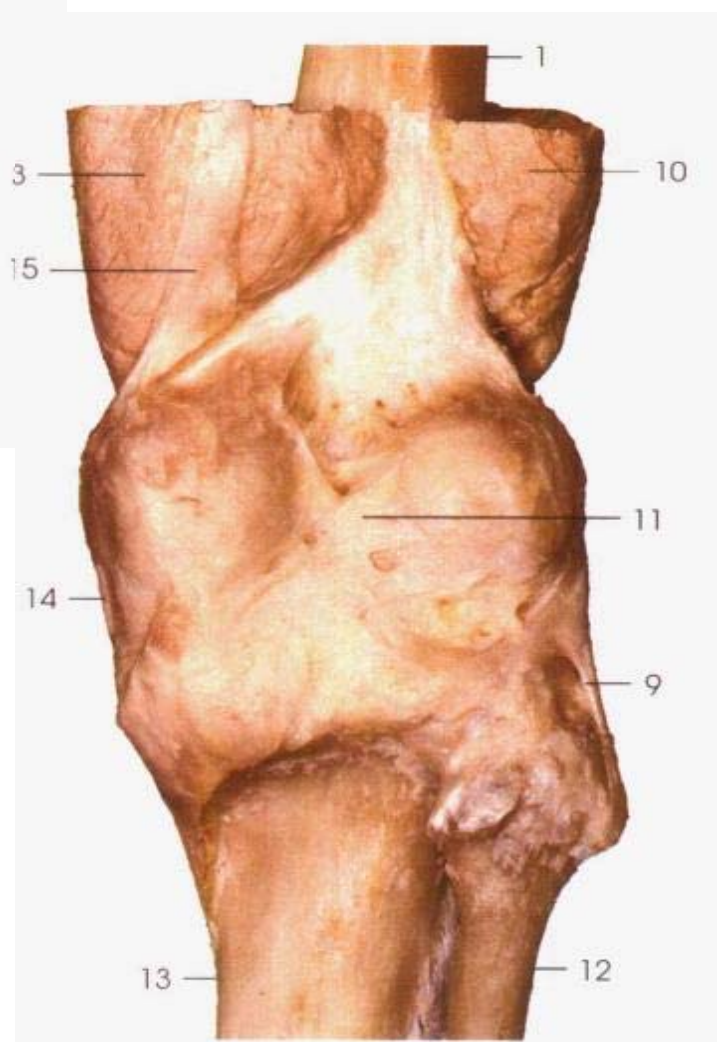
D

图 49 髋关节(A, B, C, D)
The hip joint(A, B, C, D)



前面观

1. 股骨 femur
2. 股直肌 rectus femoris
3. 股内侧肌 vastus medialis
4. 髌骨 patella
5. 髌内侧支持带 medial patellar retinaculum
6. 髌韧带 patellar lig.
7. 缝匠肌腱 sartorius tendon
8. 髌外侧支持带 lateral patellar retinaculum



后面观

9. 腓侧副韧带 fibular collateral lig.
10. 股外侧肌 vastus lateralis
11. 腓斜韧带 oblique popliteal lig.
12. 腓骨 fibula
13. 胫骨 tibia
14. 胫侧副韧带 tibial collateral lig.
15. 大收肌腱 adductor magnus tendon

图 50 膝关节(前和后面观)
The knee joint(anterior and posterior aspect)

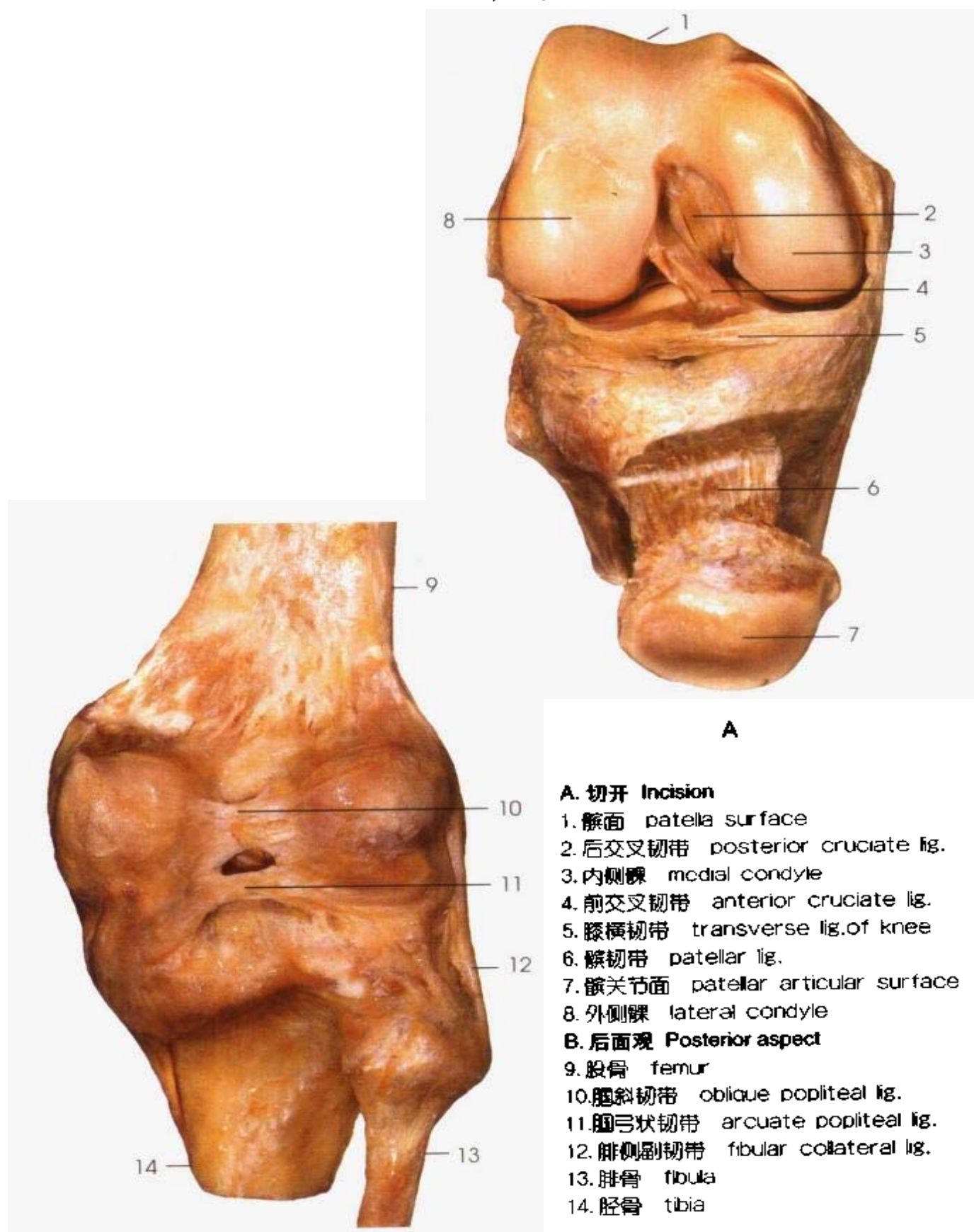
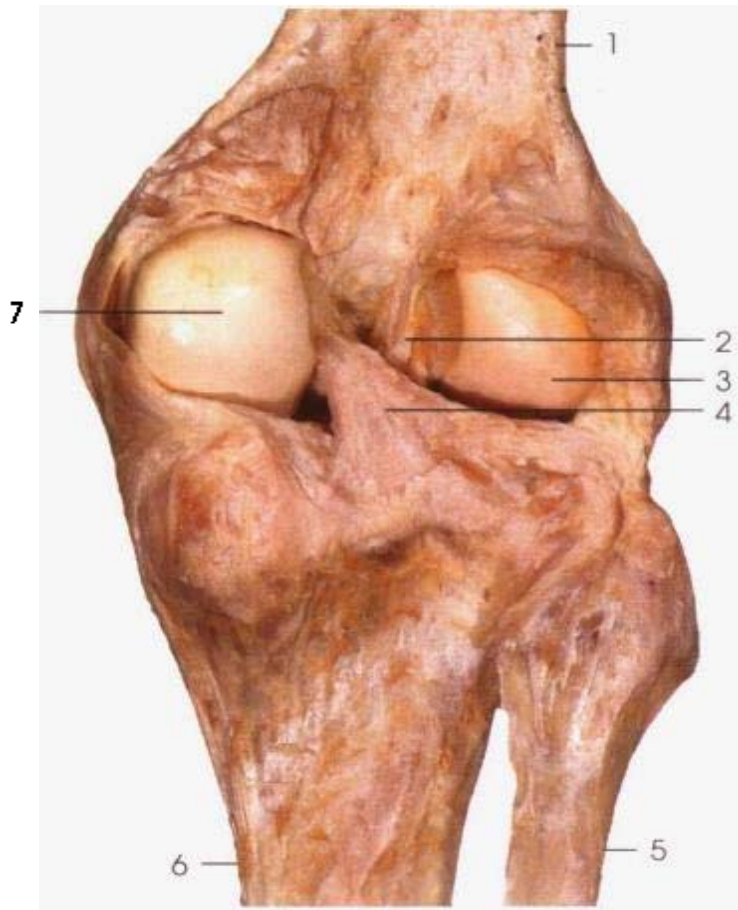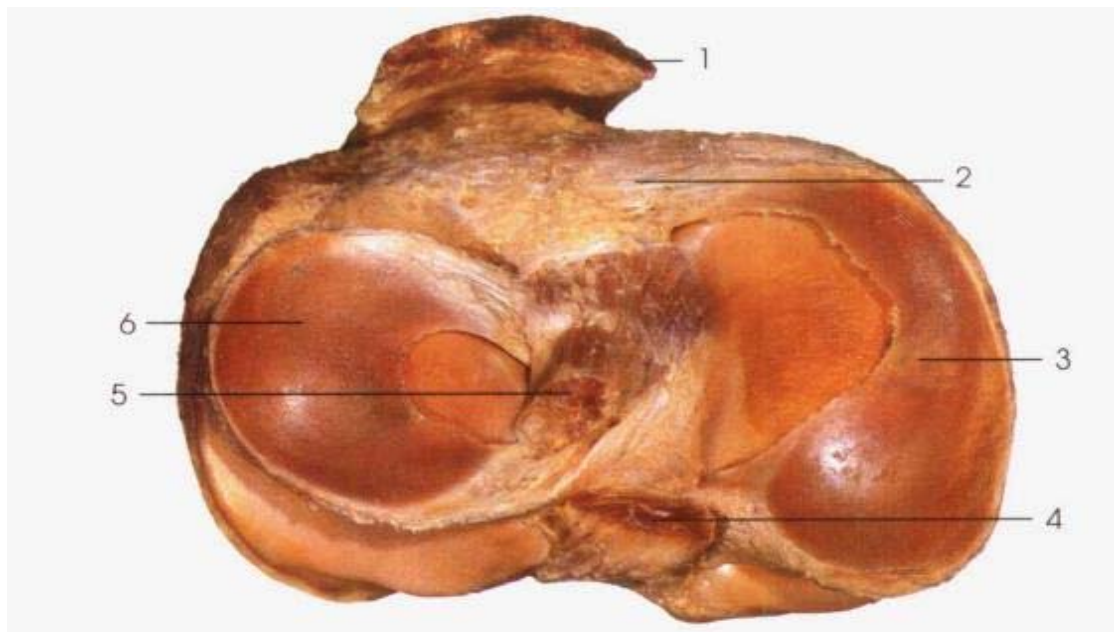


图 51 膝关节(A、B)
The knee joint (A,B)



- 1. 股骨 femur
- 2. 前交叉韧带 anterior cruciate lig.
- 3. 外侧髁 lateral condyle
- 4. 后交叉韧带 posterior cruciate lig.
- 5. 腓骨 fibula
- 6. 胫骨 tibia
- 7. 内侧髁 medial condyle

图 52 膝关节(切开)
The knee joint(incision)



- 1. 髌韧带 patellar lig.
- 2. 膝横韧带 transverse lig.of knee
- 3. 内侧半月板 medial meniscus
- 4. 后交叉韧带 posterior cruciate lig.
- 5. 前交叉韧带 anterior cruciate lig.
- 6. 外侧半月板 lateral meniscus

图 53 膝关节(半月板)
The knee joint(meniscuses)

1. 股骨 femur
2. 髌上囊 suprapatellar capsule
3. 股四头肌腱 quadriceps femoris tendon
4. 髌骨 patella
5. 翼状襞 alar folds
6. 髌韧带 patellar lig.
7. 胫骨 tibia

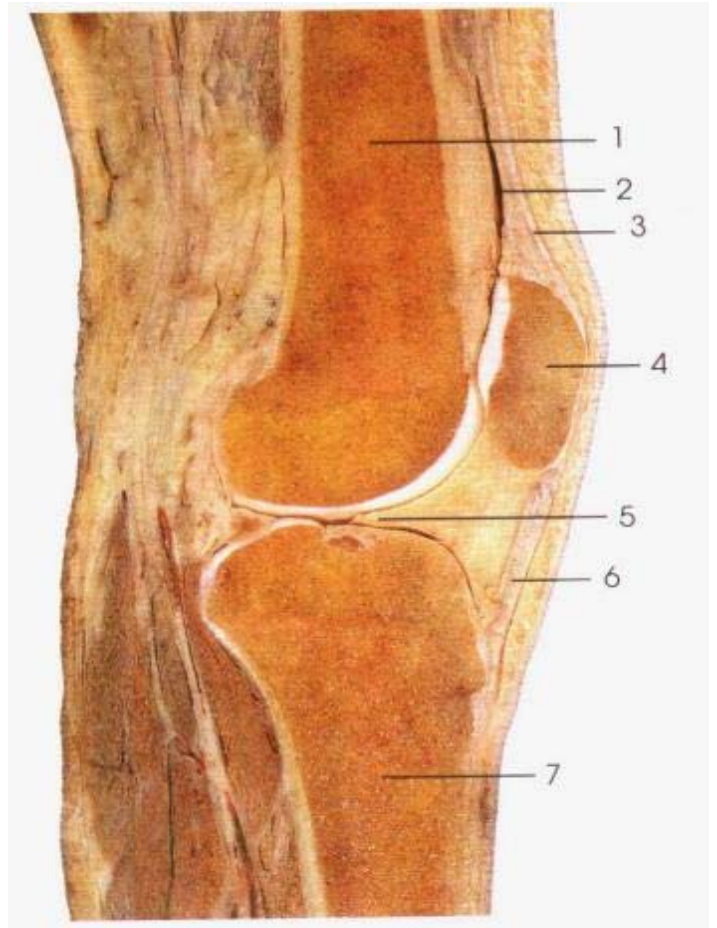


图 54 膝关节(矢状切面)
The knee joint(sagittal section)


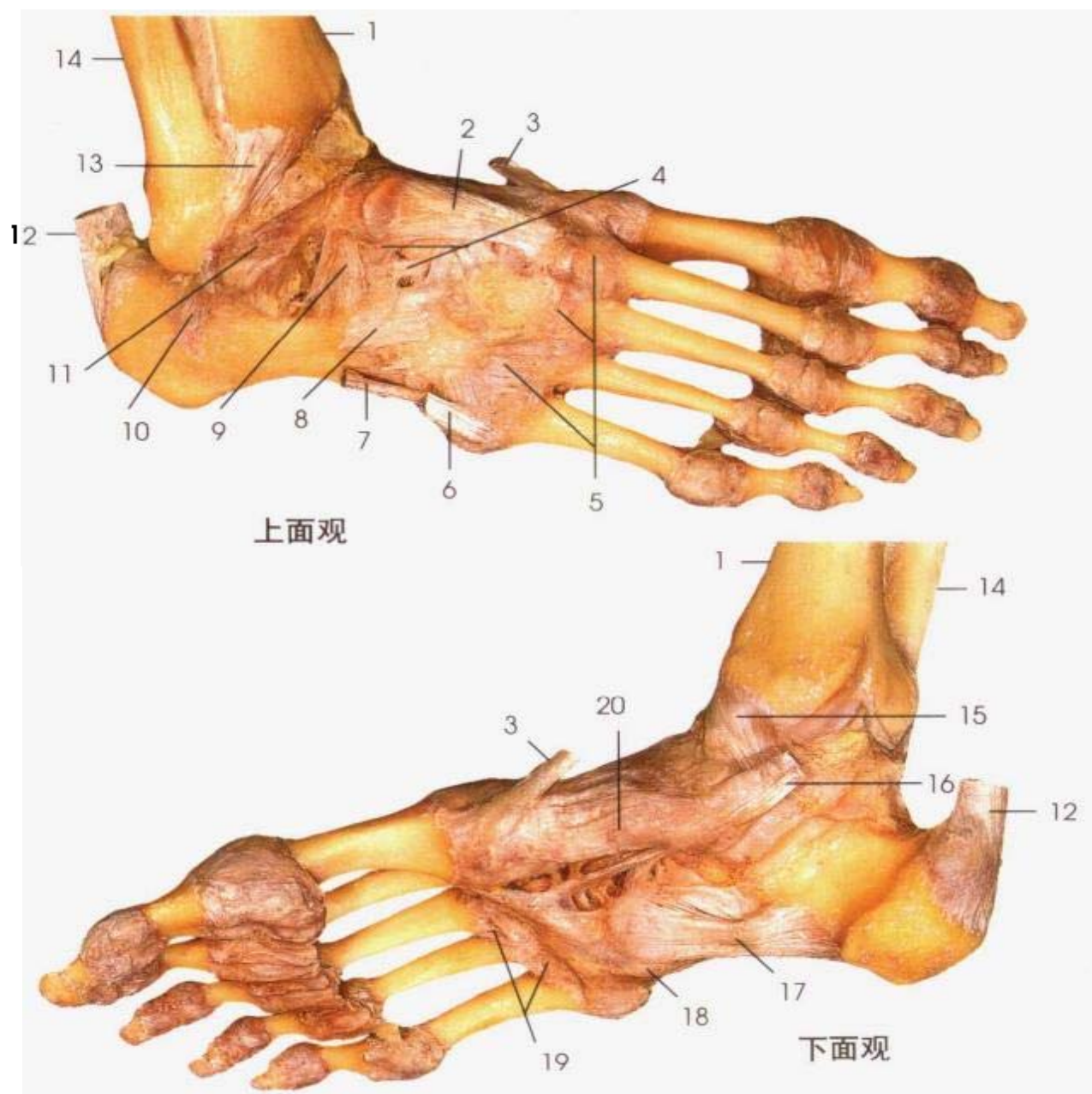


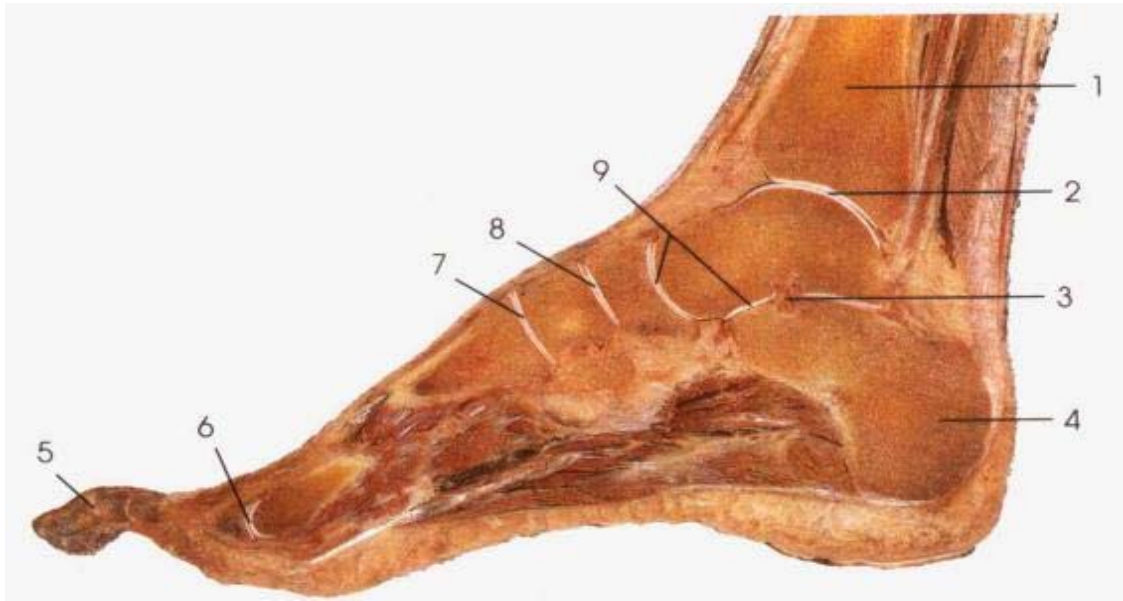
图 55 小腿骨的连结
The joints of the leg

1. 胫骨 tibia
2. 小腿骨间膜 crural interosseous membrane
3. 胫腓前韧带 anterior tibiofibular lig.
4. 腓骨 fibula
5. 胫腓关节 tibiofibular joint

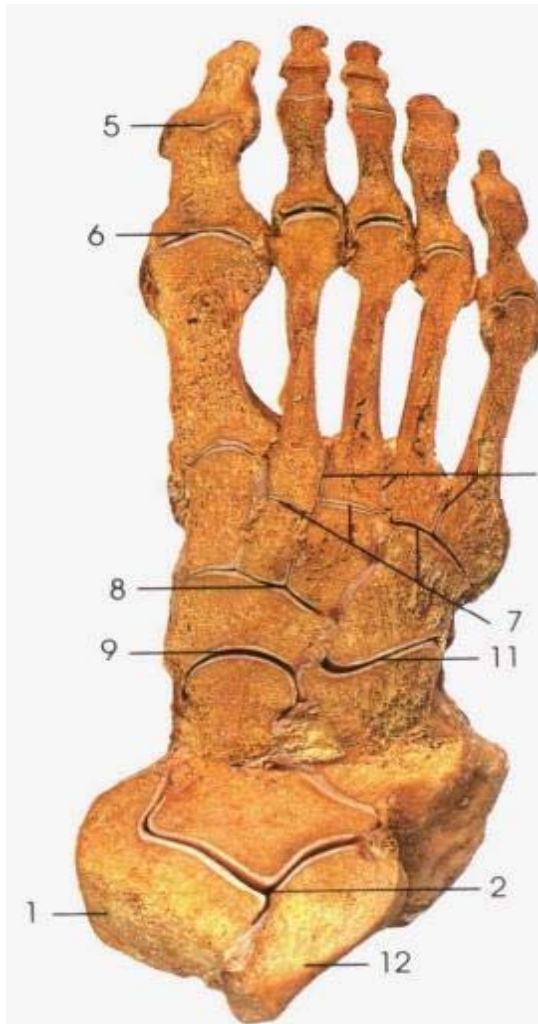

- | | |
|---|---|
| 1. 胫骨 tibia | 11. 距腓前韧带 anterior talofibular lig. |
| 2. 楔舟背侧韧带 dorsal cuneonavicular lig. | 12. 跟腱 tendo calcaneus |
| 3. 胫骨前肌腱 tibialis anterior tendon | 13. 胫腓前韧带 anterior tibiofibular lig. |
| 4. 分枝韧带 bifurcated lig. | 14. 腓骨 fibula |
| 5. 跗跖背侧韧带 dorsal tarsometatarsal lig. | 15. 内侧(三角)韧带 medial (deltoid) lig. |
| 6. 腓骨短肌腱 peroneus brevis tendon | 16. 胫骨后肌腱 tibialis posterior tendon |
| 7. 腓骨长肌腱 peroneus longus tendon | 17. 足底长韧带 long plantar lig. |
| 8. 跟骰背侧韧带 dorsal calcaneocuboid lig. | 18. 腓骨长肌腱 peroneus longus tendon |
| 9. 距跟骨间韧带 interosseous talocalcaneal lig. | 19. 跗骨足底韧带 plantar metatarsal lig. |
| 10. 跟腓韧带 calcaneofibular lig. | 20. 跗跖足底韧带 plantar tarsometatarsal lig. |

图 56 足骨的连结(上和下面观)
The joints of the foot(superior and inferior aspect)




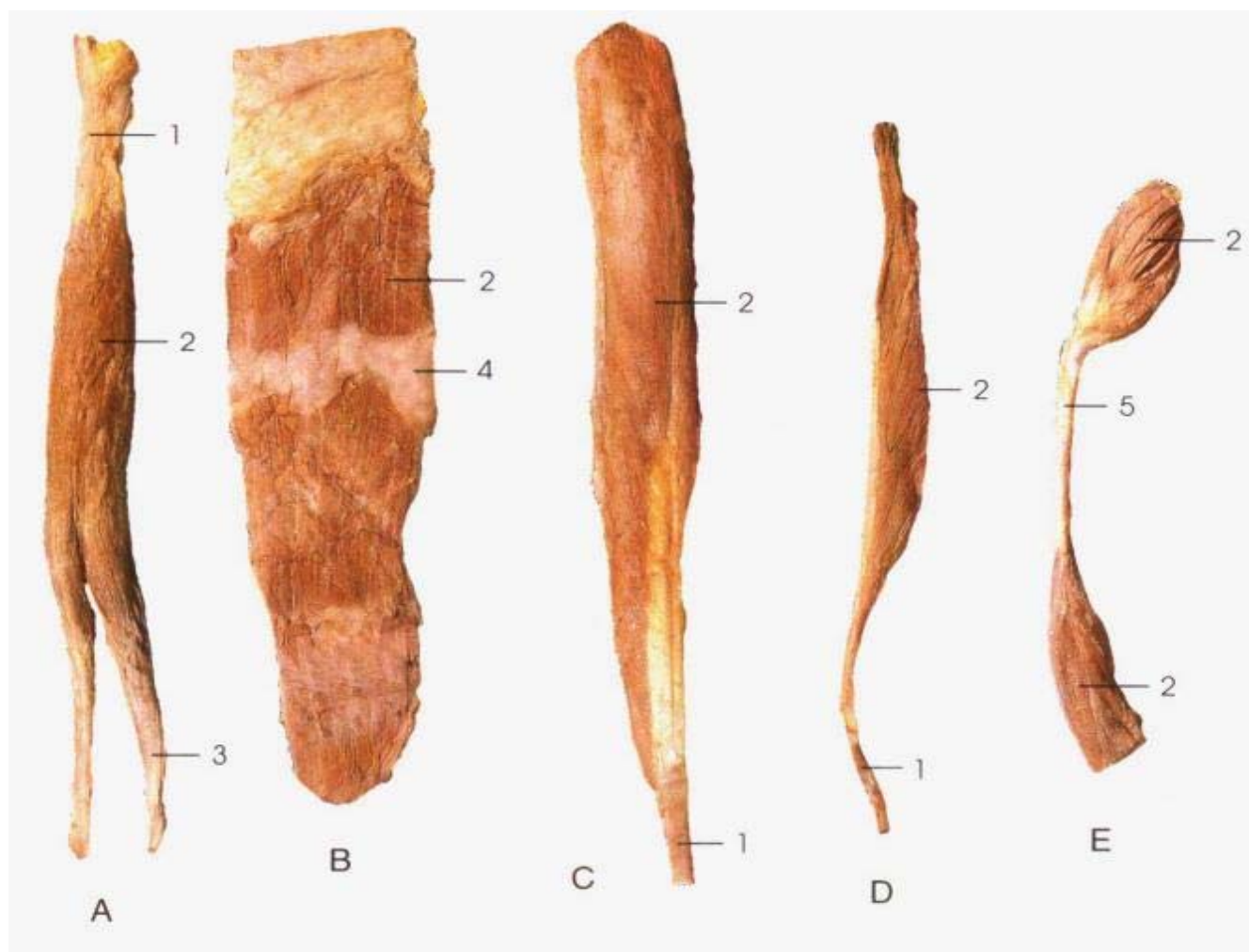
A. 矢状剖面观



B. 冠状剖面观

1. 胫骨 tibia
2. 距小腿关节(踝关节) talocrural (ankle) joint
3. 距跟骨间韧带 interosseous talocalcaneal lig.
4. 跟骨 calcaneus
5. 趾骨间关节 interphalangeal joint
6. 跖趾关节 metatarsophalangeal joint
7. 跗跖关节 tarsometatarsal joints
8. 楔舟关节 cuneonavicular joint
9. 距跟舟关节 talocalcaneonavicular joint
10. 跖骨间关节 intermetatarsal joints
11. 跟骰关节 calcaneocuboid joint
12. 腓骨 fibula

图 57 足骨的连结(A, B)
The joints of the foot(A, B)



- A. 二头肌 biceps
 B. 多腹肌 polyvent m.
 C. 羽状肌 bipennate m.
 D. 半羽状肌 unipennate m.
 E. 二腹肌 digastric
 F. 多羽肌 multipennate m.
 G. 扁肌 flat muscle
 H. 轮匝肌 orbicular m.
 1. 肌腱 tendon
 2. 肌腹 muscle belly
 3. 肌头 head of m.
 4. 腱划 tendinous intersection
 5. 中间腱 intermediate tendon
 6. 腱膜 aponeurosis

图 58 肌的形态(A ~ H)
 Forms of muscles(A ~ H)

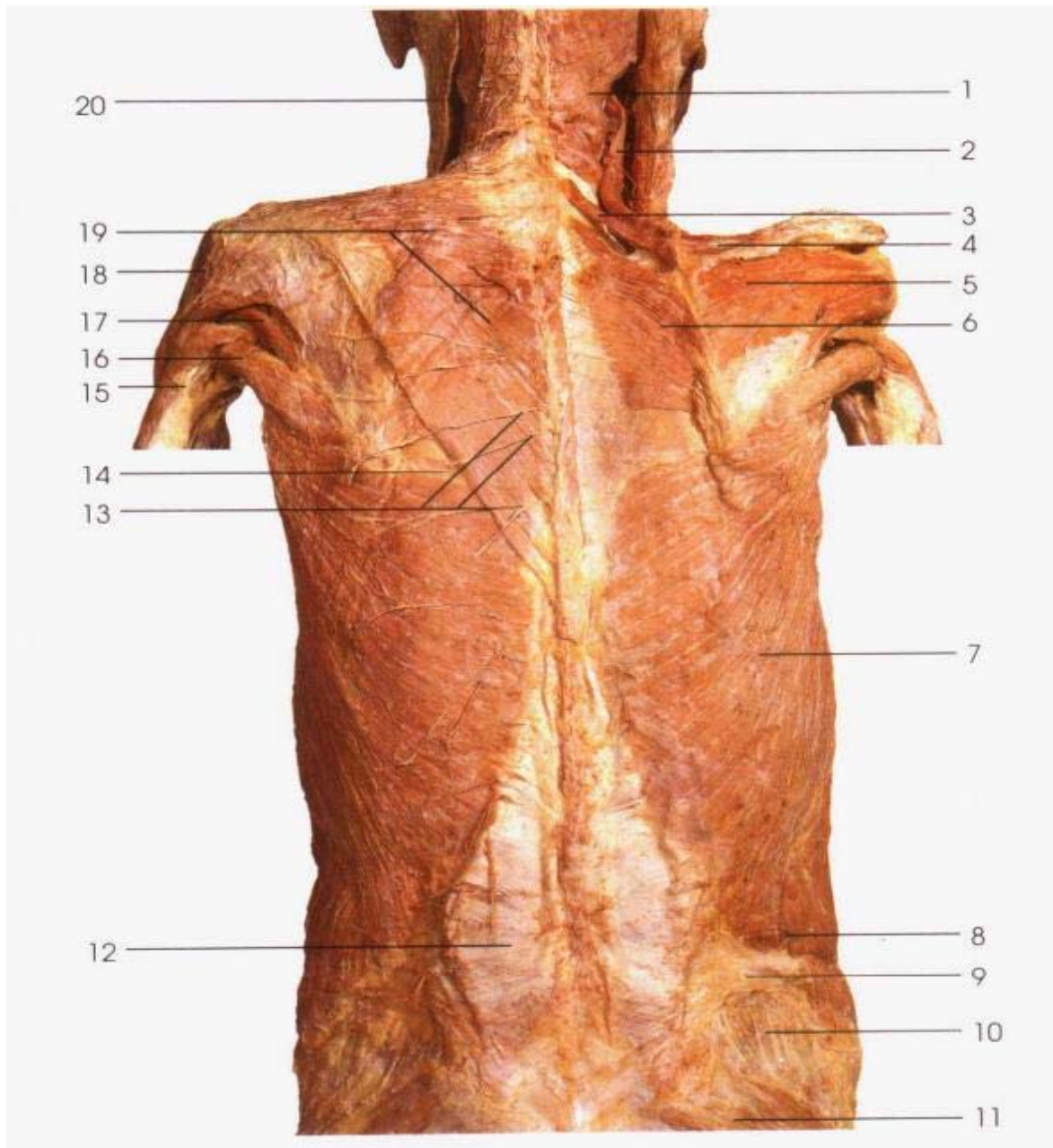
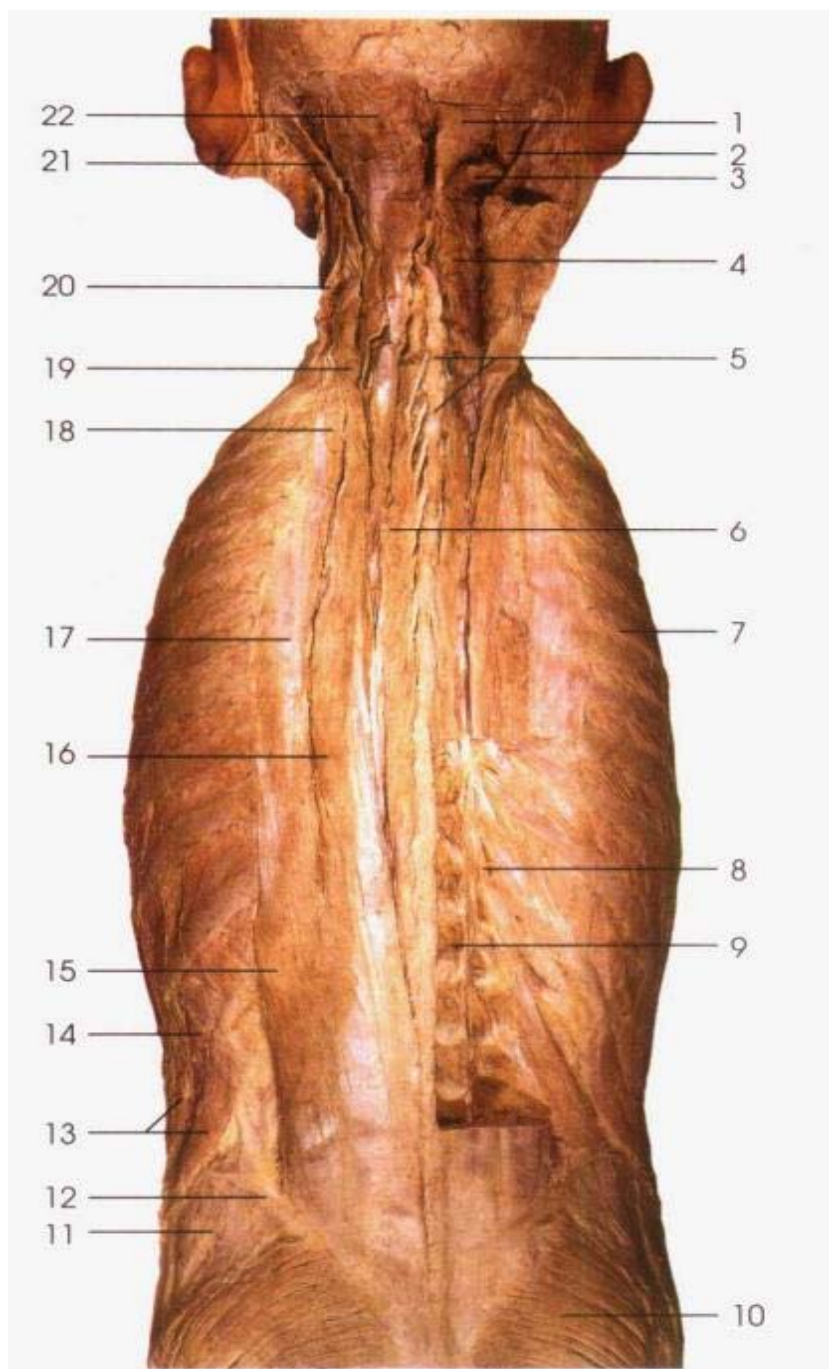


图 59 背部的肌(1)
Muscles of the back(1)

- | | | | |
|---------|------------------|-----------|-----------------------------------|
| 1. 头夹肌 | splenius capitis | 12. 胸腰筋膜 | thoracolumbar fascia |
| 2. 肩胛提肌 | levator scapulae | 13. 胸神经后支 | posterior branches of thoracic n. |
| 3. 小菱形肌 | rhomboides minor | 14. 听诊三角 | triangle of auscultation |
| 4. 冈上肌 | supraspinatus | 15. 肱三头肌 | triceps brachii |
| 5. 冈下肌 | infraspinatus | 16. 大圆肌 | teres major |
| 6. 大菱形肌 | rhomboides major | 17. 小圆肌 | teres minor |
| 7. 背阔肌 | latissimus dorsi | 18. 三角肌 | deltoid |
| 8. 腰三角 | lumbar triangle | 19. 斜方肌 | trapezius |
| 9. 髂嵴 | ilac crest | 20. 胸锁乳突肌 | sternocleidomastoid |
| 10. 臀中肌 | gluteus medius | | |
| 11. 臀大肌 | gluteus maximus | | |

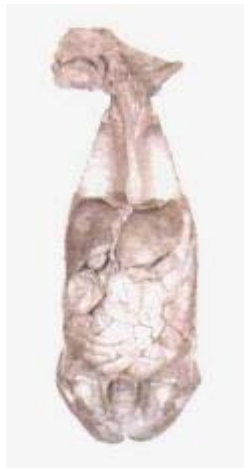

- | | |
|---|--|
| 1. 头后大直肌, <i>rectus capitis posterior major</i> | 12. 髂嵴 <i>iliac crest</i> |
| 2. 头上斜肌, <i>obliquus capitis superior</i> | 13. 腰外斜肌, <i>obliquus externus abdominis</i> |
| 3. 头下斜肌, <i>obliquus capitis inferior</i> | 14. 腰内斜肌, <i>obliquus internus abdominis</i> |
| 4. 颈半棘肌, <i>semispinalis cervicis</i> | 15. 腰肋助肌, <i>iliocostalis lumborum</i> |
| 5. 棘间肌, <i>interspinales</i> | 16. 胸最长肌, <i>longissimus thoracis</i> |
| 6. 棘肌, <i>spinalis</i> | 17. 胸肋助肌, <i>iliocostalis thoracis</i> |
| 7. 肋间外肌, <i>intercostales externi</i> | 18. 颈肋助肌, <i>iliocostalis cervicis</i> |
| 8. 肋提肌, <i>levatores costarum</i> | 19. 颈最长肌, <i>longissimus cervicis</i> |
| 9. 横突间肌, <i>intertransversarii</i> | 20. 后斜角肌, <i>scalenus posterior</i> |
| 10. 臀大肌, <i>gluteus maximus</i> | 21. 头最长肌, <i>longissimus capitis</i> |
| 11. 臀中肌, <i>gluteus medius</i> | 22. 头半棘肌, <i>semispinalis capitis</i> |

图 60 背部的肌(Ⅱ)
Muscles of the back(Ⅱ)

2

DIGESTIVE SYSTEM



第2章

消

化

系

统

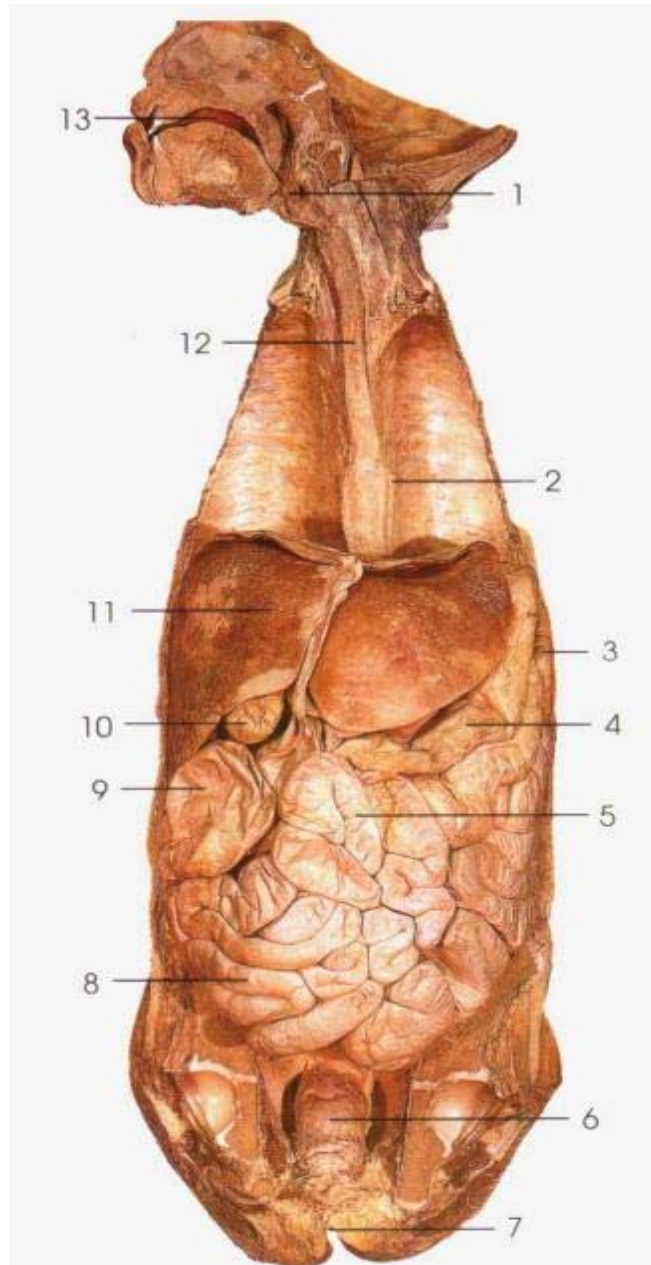


图 61 消化系统概观
General arrangement of the digestive apparatus

- | | |
|------------------------|-----------------------------|
| 1. 咽 pharynx | 8. 回肠 ileum |
| 2. 胸主动脉 thoracic aorta | 9. 结肠右曲 right colic flexure |
| 3. 脾 spleen | 10. 胆囊 gall bladder |
| 4. 胃 stomach | 11. 肝 liver |
| 5. 空肠 jejunum | 12. 食管 esophagus |
| 6. 直肠 rectum | 13. 口腔 oral cavity |
| 7. 肛门 anus | |

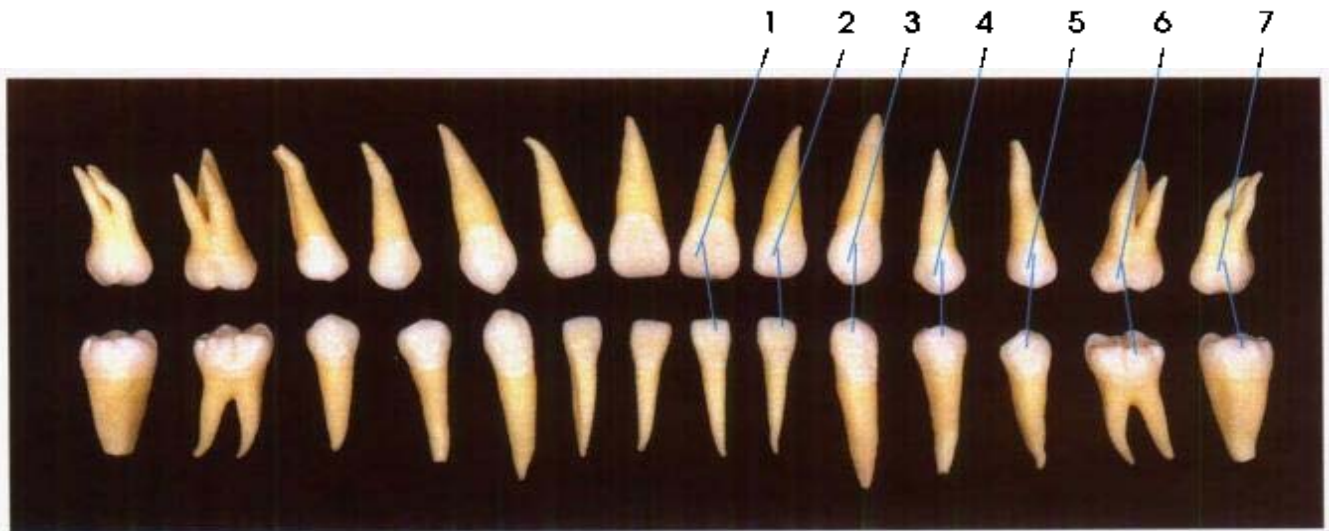


图 62 恒牙 Permanent teeth

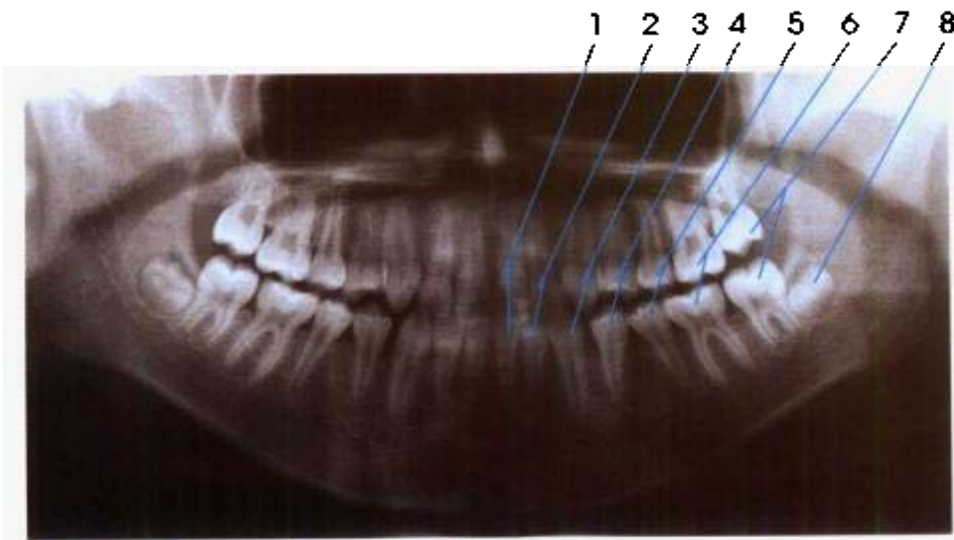


图 63 曲面断层 X 线片
Panoramic

1. 中切牙 medial incisor
2. 侧切牙 lateral incisor
3. 尖牙 canine teeth
4. 第一前磨牙 premolars I
5. 第二前磨牙 premolars II
6. 第一磨牙 molars I
7. 第二磨牙 molars II
8. 第三磨牙 molars III
9. 釉质 enamel
10. 牙本质 dentine
11. 牙髓 dental pulp
12. 牙骨质 cement
13. 牙根管 root canal
14. 牙周膜 periodontal membrane
15. 牙根尖孔 apical fora
16. 牙槽骨 alveolar bone
17. 牙龈 gum
18. 牙腔 dental cavity

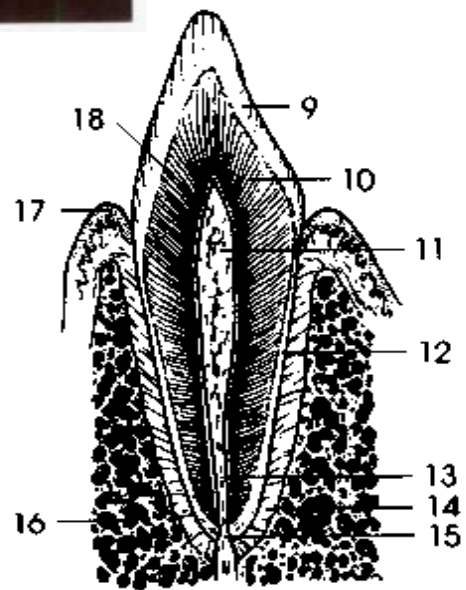
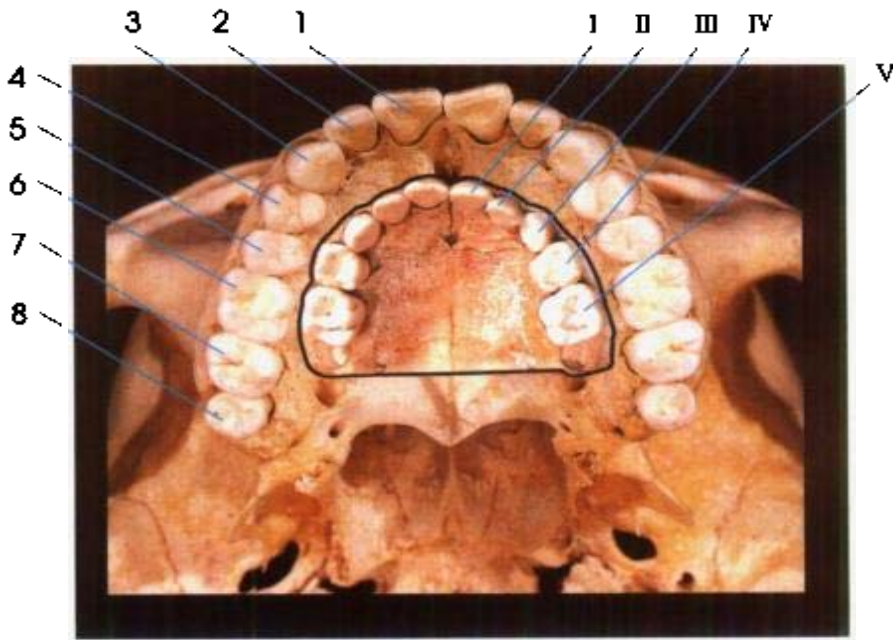


图 64 牙的构造模式图(纵切)
Diagram of the structure of a
tooth(sagittal section)



- 1. 中切牙 central incisor
- 2. 侧切牙 lateral incisor
- 3. 尖牙 canine
- 4. 第一前磨牙 premolars I
- 5. 第二前磨牙 premolars II
- 6. 第一磨牙 molars I
- 7. 第二磨牙 molars II
- 8. 第三磨牙 molars III

图 65 上颌恒、乳牙(下面观)
Upper permanent and deciduous teeth
(inferior aspect)

- I. 乳中切牙 deciduous central incisor
- II. 乳侧切牙 deciduous lateral incisor
- III. 乳尖牙 deciduous canine
- IV. 第一乳磨牙 deciduous molars I
- V. 第二乳磨牙 deciduous molars II

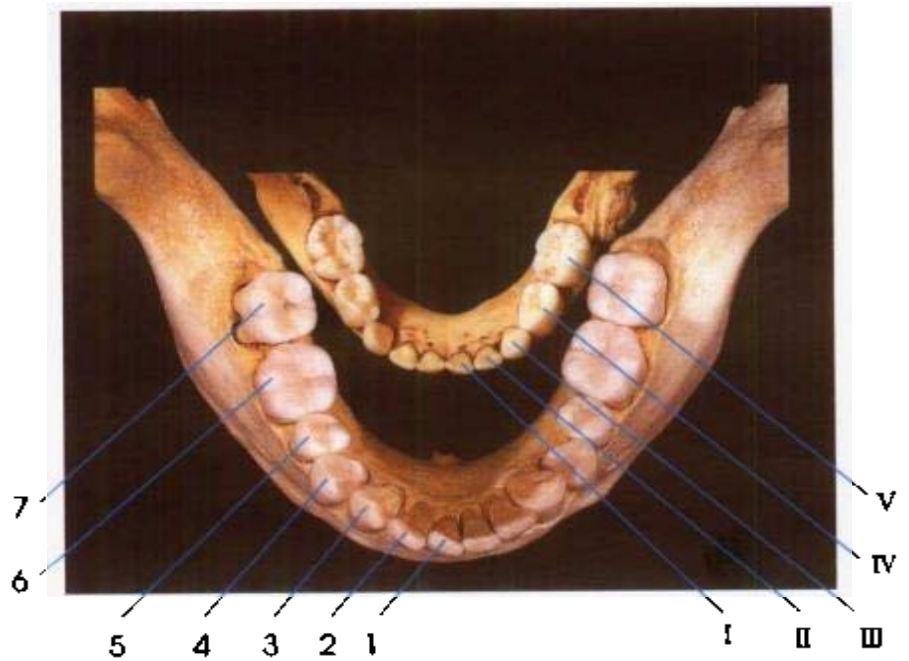
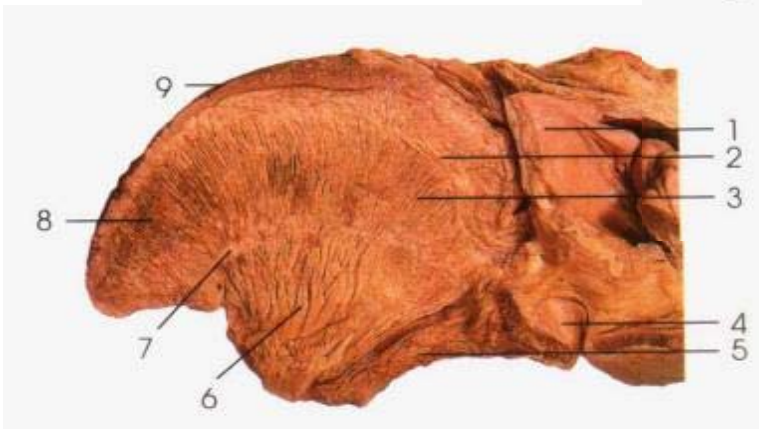
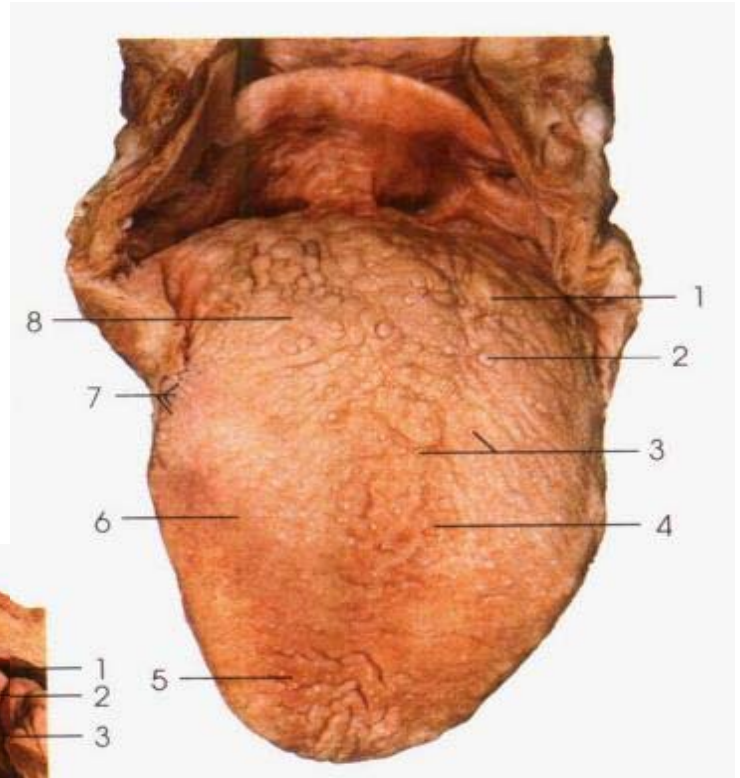


图 66 下颌恒、乳牙(上面观)
Lower permanent and deciduous teeth
(superior aspect)

A. 舌背面 The dorsum of the tongue

1. 舌扁桃体 lingual tonsil
2. 轮廓乳头 vallate papillae
3. 菌状乳头 fungiform papillae
4. 丝状乳头 filiform papillae
5. 舌尖 apex of tongue
6. 舌体 body of tongue
7. 叶状乳头 foliate papillae
8. 舌根 root of tongue



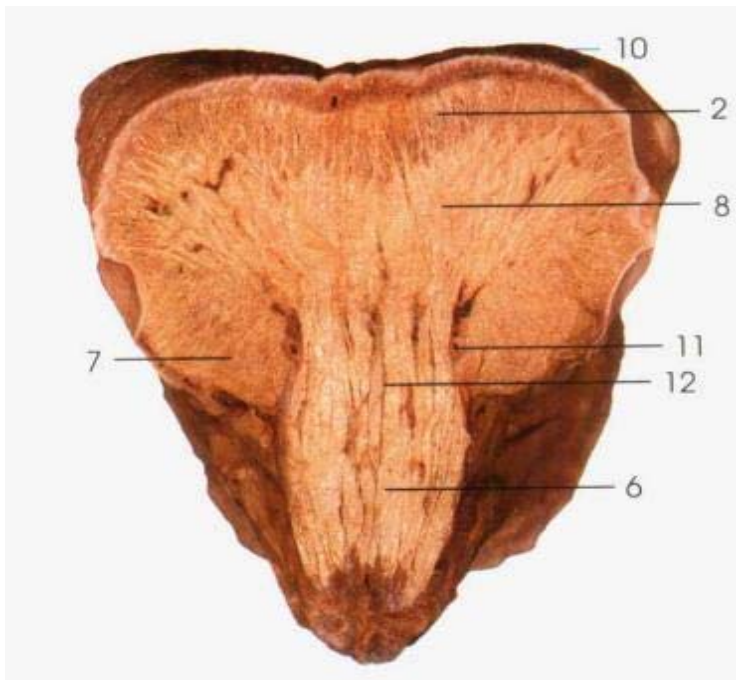
**B. 舌矢状切面
(Sagittal section)**

**A. 舌背面
(Dorsal aspect)**

B. 舌矢状切面 Sagittal section through tongue

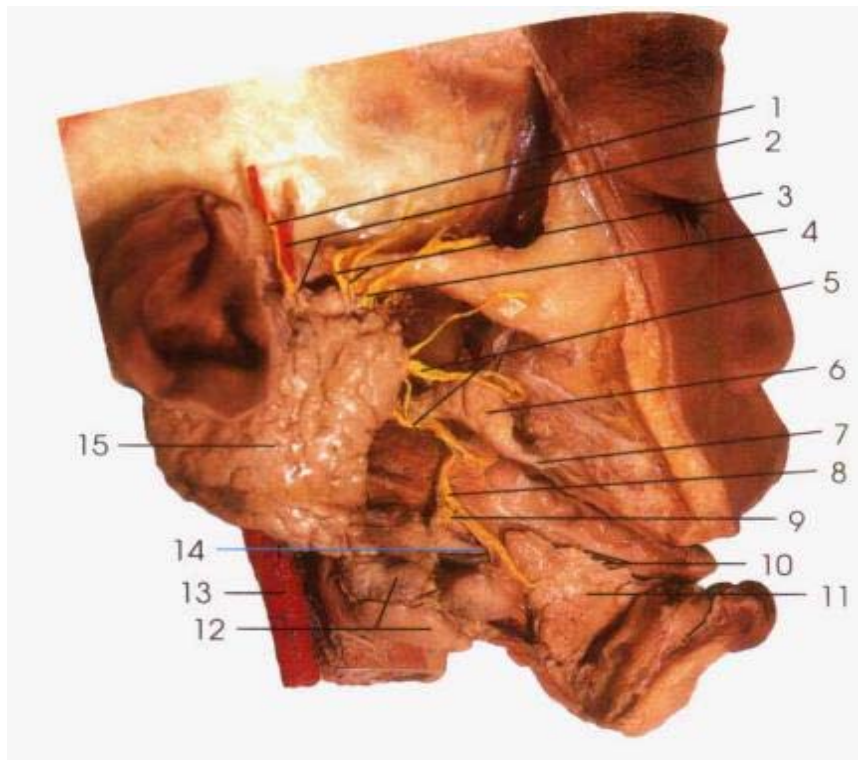
C. 舌冠状切面 Coronal section through tongue

1. 会厌 epiglottis
2. 上纵肌 superior longitudinal muscle
3. 舌垂直肌 vertical muscle of tongue
4. 舌骨 hyoid bone
5. 颏舌骨肌 geniohyoid
6. 颏舌肌 genioglossus
7. 下纵肌 inferior longitudinal muscle
8. 舌横肌 transverse muscle of tongue
9. 舌背 dorsum of tongue
10. 舌粘膜 lingual mucous membrane
11. 舌动脉 lingual artery
12. 舌中隔 septum of tongue



**C. 舌冠状切面
(Coronal section)**

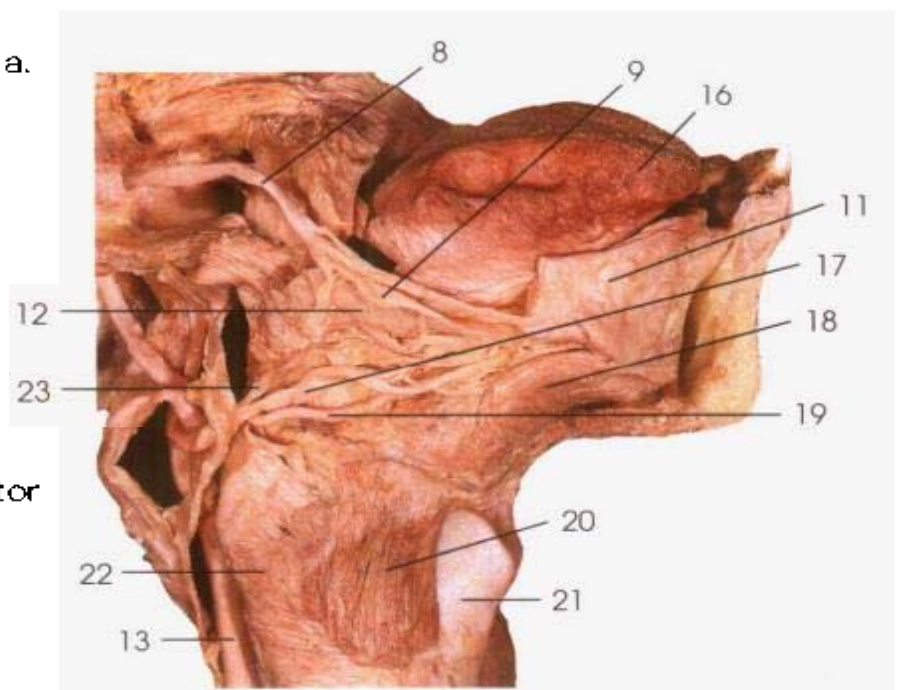
**图67 舌(A, B, C)
Tongue(A, B, C)**



1. 耳颞神经 auriculotemporal n.
2. 颞浅动脉和静脉 superficial temporal a. & v.
3. 颞支 temporal branches
4. 颧支 zygomatic branches
5. 颊支 buccal branches
6. 副腮腺 accessory parotid gland
7. 腮腺管 parotid duct
8. 舌神经 lingual n.
9. 下颌下神经节 submandibular ganglion
10. 舌下腺管 sublingual duct
11. 舌下腺 sublingual gland
12. 下颌下腺 submandibular gland

A. 外侧面观
Lateral aspect

13. 颈总动脉 common carotid a.
14. 下颌下腺管 submandibular duct
15. 腮腺 parotid gland
16. 舌 tongue
17. 舌下神经 hypoglossal n.(XII)
18. 颌舌骨肌 geniohyoid
19. 舌动脉 lingual a.
20. 甲状舌骨肌 thyrohyoid
21. 甲状软骨 thyroid cartilage
22. 咽下缩肌 inferior constrictor of pharynx
23. 舌静脉 lingual v.



B. 内侧面观
Medial aspect

图 68 大唾液腺(A、B)
The large salivary glands(A,B)

1. 腭大孔 greater palatine foramen
2. 腭帆张肌 tensor veli palatini
3. 软腭 soft palate
4. 腭垂 uvula
5. 舌根 root of tongue
6. 舌正中沟 median sulcus of tongue
7. 舌尖 apex of tongue
8. 舌体 body of tongue
9. 腭舌弓 palatoglossal arch
10. 腭咽弓 palatopharyngeal arch
11. 腭骨水平板 horizontal palate of palatine bone

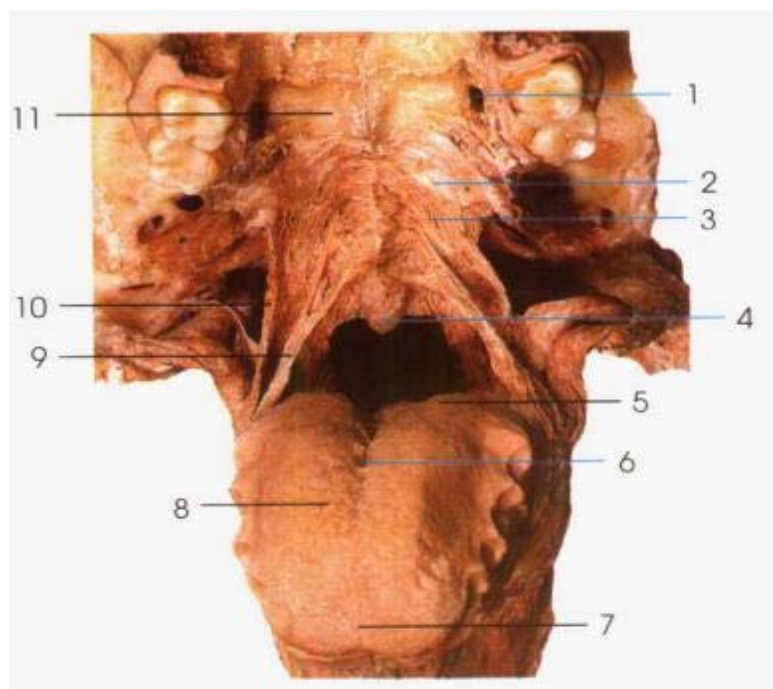


图 69 咽腔(前面观)
The pharyngeal cavity(anterior aspect)

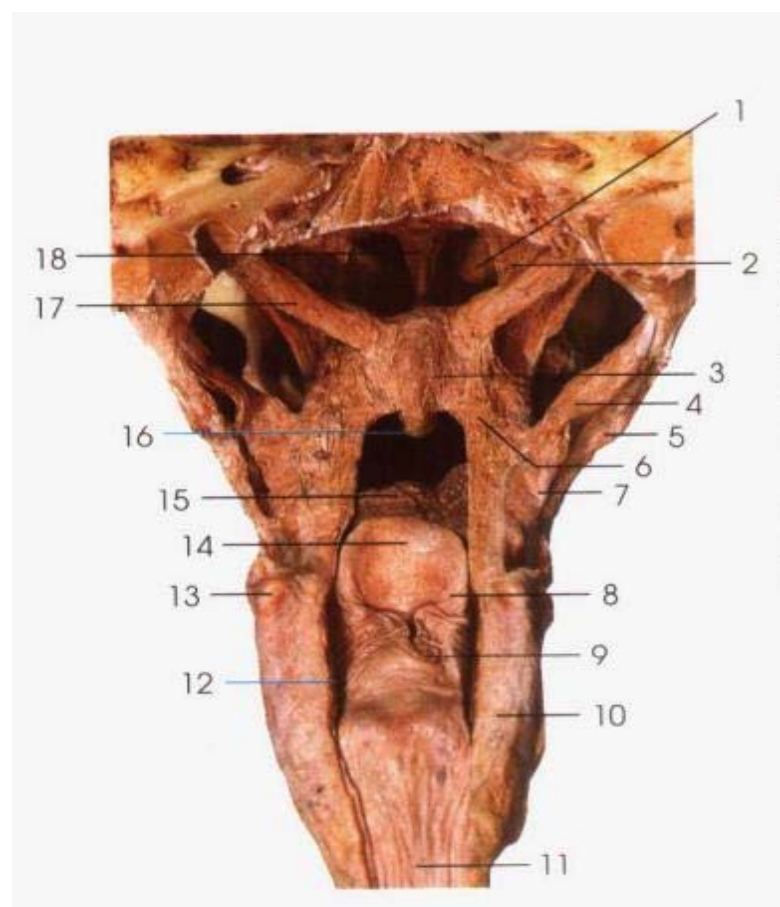
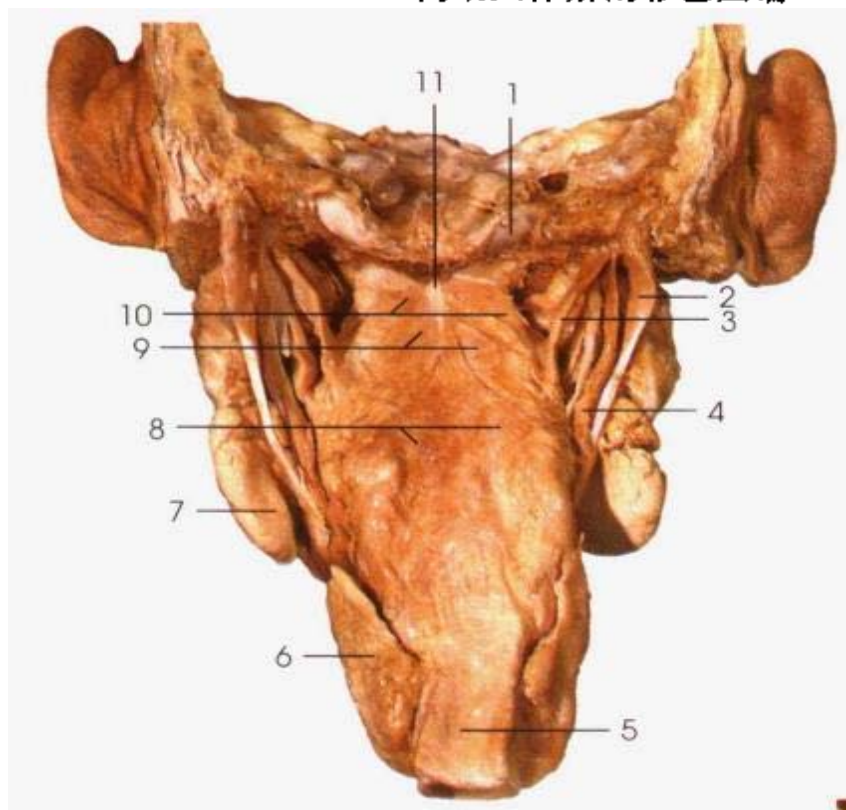


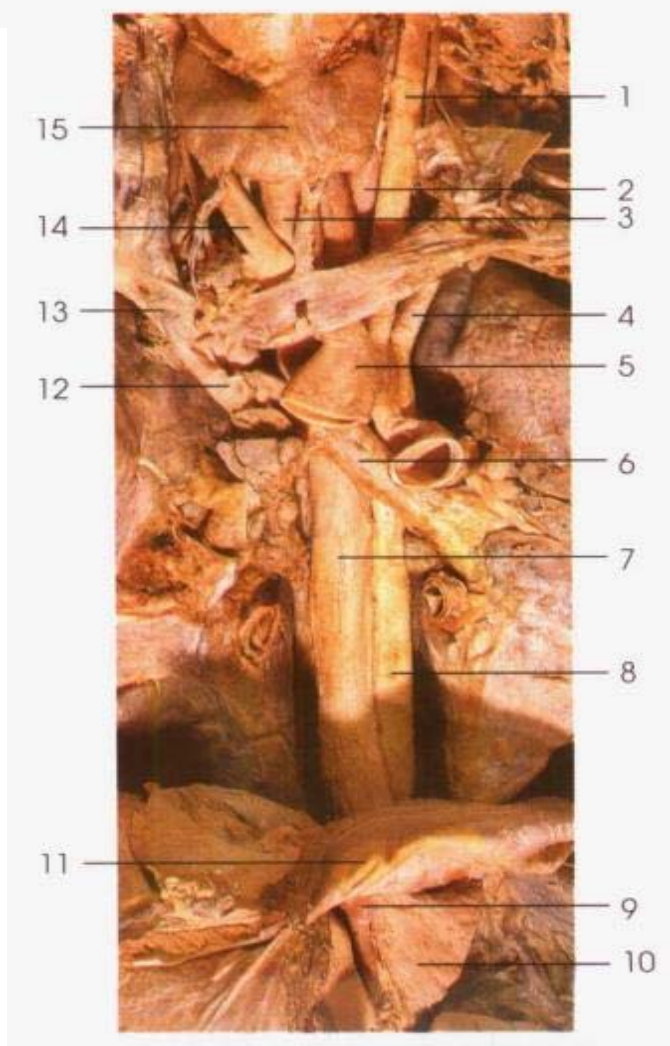
图 70 咽腔(后面观)
The pharyngeal cavity(posterior aspect)

1. 下鼻甲 inferior nasal concha
2. 腭帆张肌 tensor veli palatini
3. 软腭 soft palate
4. 茎突咽肌 stylopharyngeus
5. 茎突舌骨肌 stylohyoid
6. 腭咽肌 palatopharyngeus
7. 咽上缩肌 superior constrictor of pharynx
8. 杓状会厌襞 aryepiglottic fold
9. 杓间切迹 interarytenoid notch
10. 咽下缩肌 inferior constrictor of pharynx
11. 食管 esophagus
12. 梨状隐窝 piriform recess
13. 甲状软骨上角 superior horn of thyroid cartilage
14. 会厌 epiglottis
15. 舌 tongue
16. 腭垂肌 musculus uvulae
17. 腭帆提肌 levator veli palatini
18. 鼻中隔 nasal septum



1. 枕骨髁 Occipital condyle
2. 二腹肌后腹 Digastric muscle (posterior belly)
3. 茎突咽肌 Stylopharyngeus muscle
4. 茎突舌骨肌 Stylohyoid muscle
5. 食管 esophagus
6. 甲状腺左侧叶 Thyroid gland (Left lobe)
7. 下颌下腺 submandibular gland
8. 咽下缩肌 inferior constrictor of pharynx
9. 咽中缩肌 middle constrictor of pharynx
10. 咽上缩肌 superior constrictor of pharynx
11. 咽结节 pharyngeal tubercle

图 71 咽肌(后面观)
Muscles of pharynx
(posterior aspect)



1. 左颈总动脉 left common carotid a.
2. 食管颈部 esophagus(cervical part)
3. 气管 trachea
4. 左锁骨下动脉 left subclavian a.
5. 主动脉弓 arch of aorta
6. 左主支气管 left main bronchus
7. 食管胸部 esophagus(Thoracic part)
8. 胸主动脉 thoracic aorta
9. 食管腹部 esophagus(abdominal part)
10. 胃 stomach
11. 膈 diaphragm
12. 上腔静脉 superior Vena cava
13. 右无名静脉 right brachiocephalic V.
14. 右颈总动脉 right common carotid a.
15. 甲状腺 thyroid gland

图 72 食管 Esophagus

1. 胃底 fundus of stomach
2. 贲门切迹 cardiac incisure
3. 胃体 body of stomach
4. 胃大弯 greater curvature of stomach
5. 胃肌层 musculature of stomach
6. 幽门窦 pyloric antrum
7. 幽门管 pyloric canal
8. 幽门 pylorus
9. 十二指肠上部 superior part of duodenum
10. 角切迹 angular incisure
11. 胃小弯 lesser curvature
12. 贲门 cardia
13. 食管腹部 abdominal part of esophagus

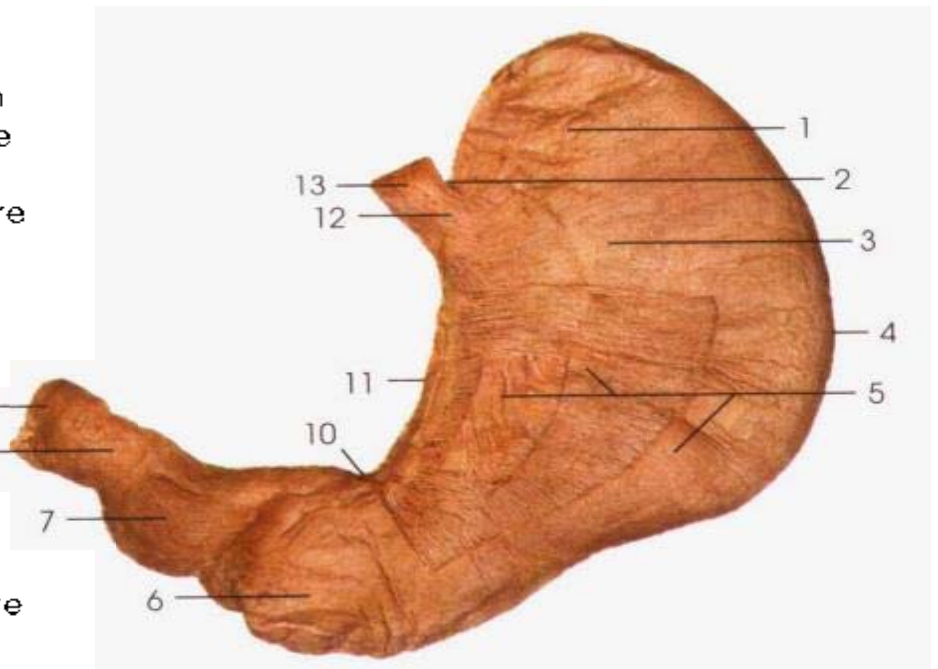
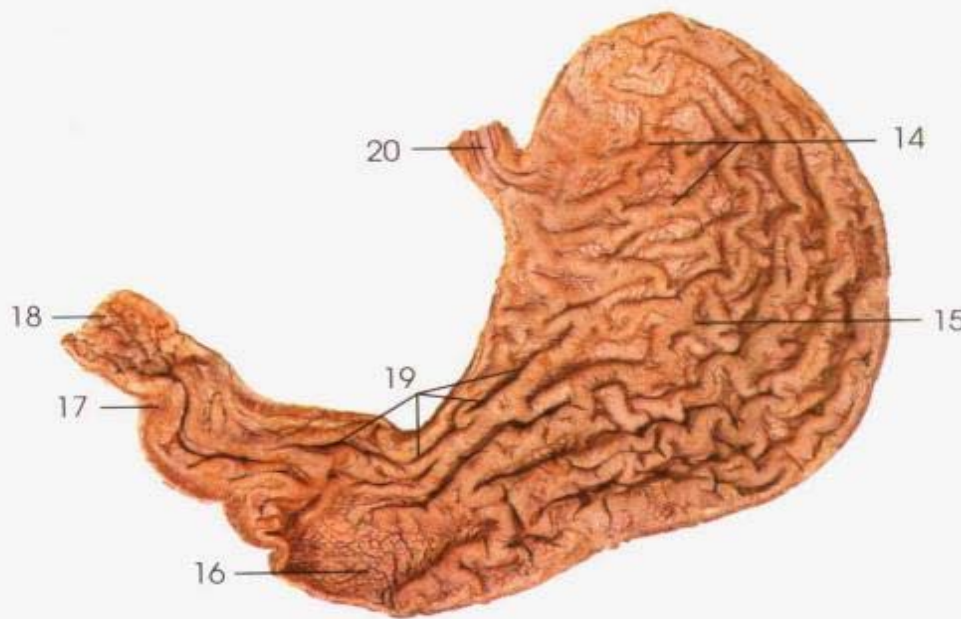


图73 胃(I)
Stomach(I)



14. 胃粘膜皱襞 gastric folds
15. 16. 胃小凹 gastric pit
17. 幽门括约肌 pyloric sphincter
18. 十二指肠皱襞 folds of duodenum
19. 胃路 gastric canal
20. 食管纵皱襞 longitudinal folds of esophagus

图74 胃(II)
Stomach(II)

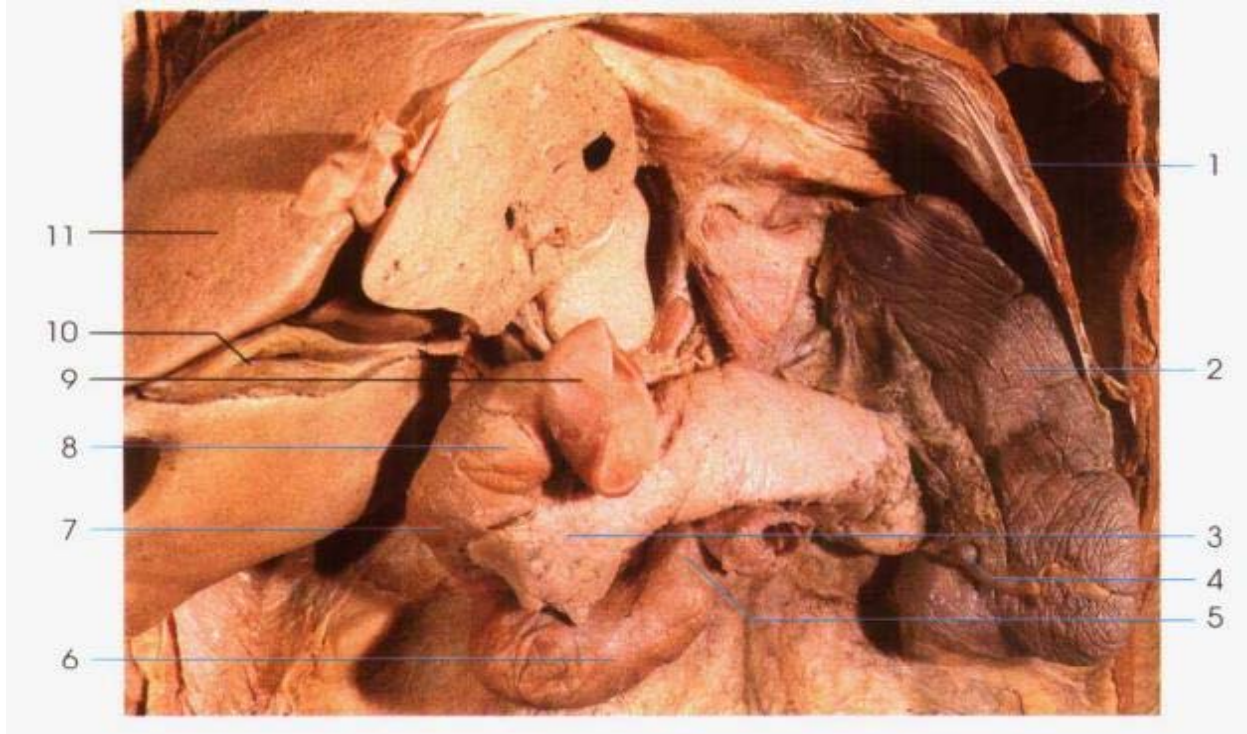

图 75 十二指肠
Duodenum

- | | |
|------------------------------------|-------------------------------------|
| 1. 膈 diaphragm | 7. 十二指肠降部 duodenum(descending part) |
| 2. 脾 spleen | 8. 十二指肠上部 duodenum(superior part) |
| 3. 胰头 head of pancreas | 9. 胃幽门部 pyloric part of stomach |
| 4. 付脾 accessory spleen | 10. 胆囊 gall bladder |
| 5. 十二指肠升部 duodenum(ascending part) | 11. 肝右叶 right lobe of liver |
| 6. 十二指肠下部 duodenum(inferior part) | |

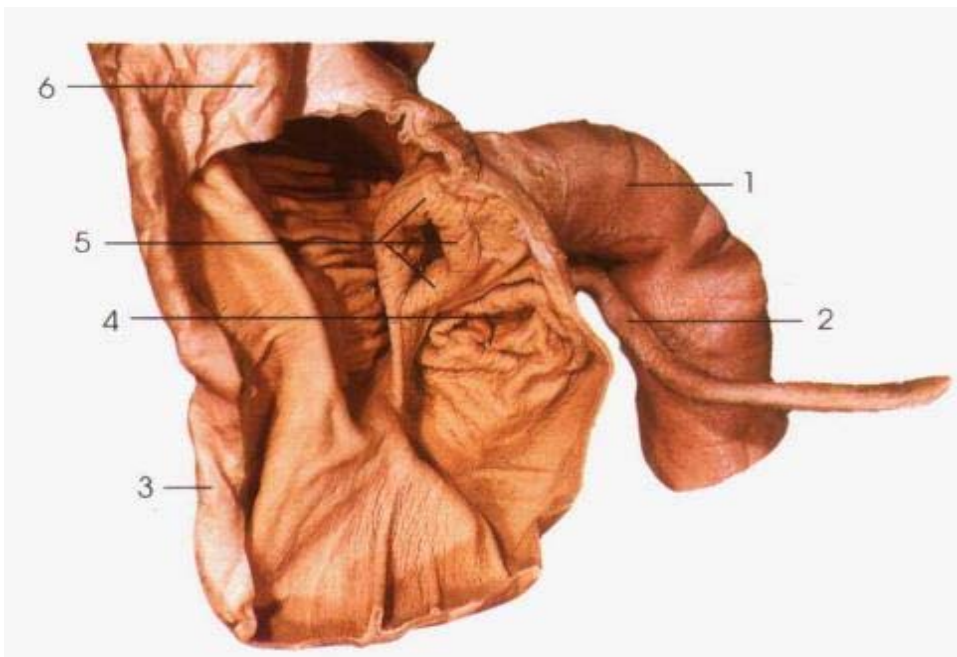


图 76 回盲部结构
Caecal region

- | |
|--------------------------------------|
| 1. 回肠 ileum |
| 2. 阑尾 vermiform appendix |
| 3. 盲肠 cecum |
| 4. 阑尾口 orifice of vermiform appendix |
| 5. 回盲瓣 lips of ileocecal valve |
| 6. 升结肠 ascending colon |

- 7. 粘膜 mucosa
- 8. 粘膜下层 submucosa
- 9. 环肌层 stratum circularis of muscularis
- 10. 纵肌层 stratum longitudinalis of muscularis
- 11. 浆膜层 serosa

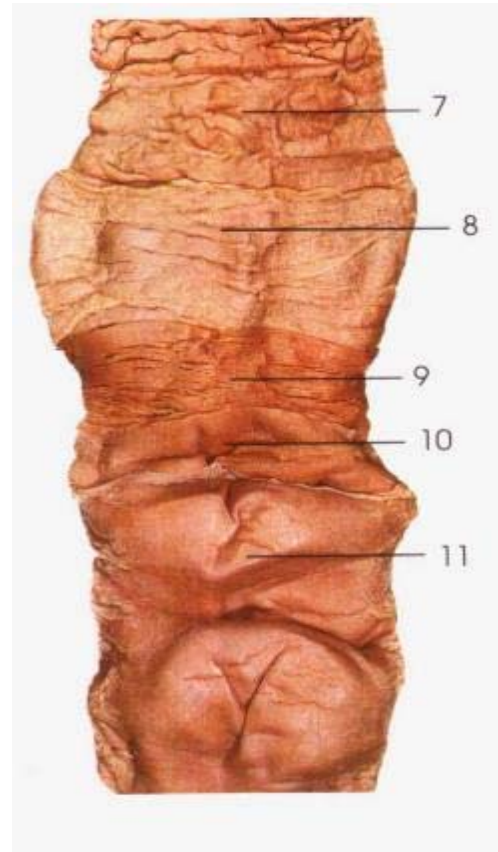
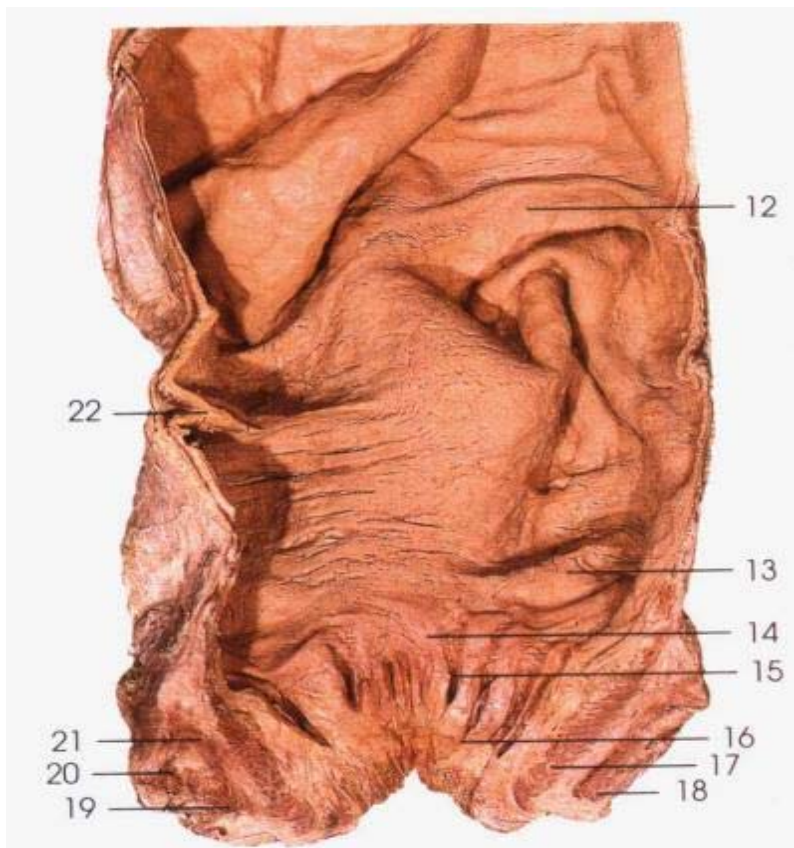


图 77 消化管的一般结构
Layers of alimentary canal



- 12. 上直肠横襞 superior transverse folds of rectum
- 13. 下直肠横襞 inferior transverse folds of rectum
- 14. 肛柱 anal column
- 15. 肛窦 anal sinuses
- 16. 肛瓣 anal valves
- 17. 肛门内括约肌 sphincter ani internus
- 18. 肛门外括约肌 sphincter ani externus
- 19. 皮下部 subcutaneous part
- 20. 浅部 superficial part
- 21. 深部 deep part
- 22. 中直肠横襞 middle transverse folds of rectum

图 78 直肠(内面观)
The rectum(internal aspect)

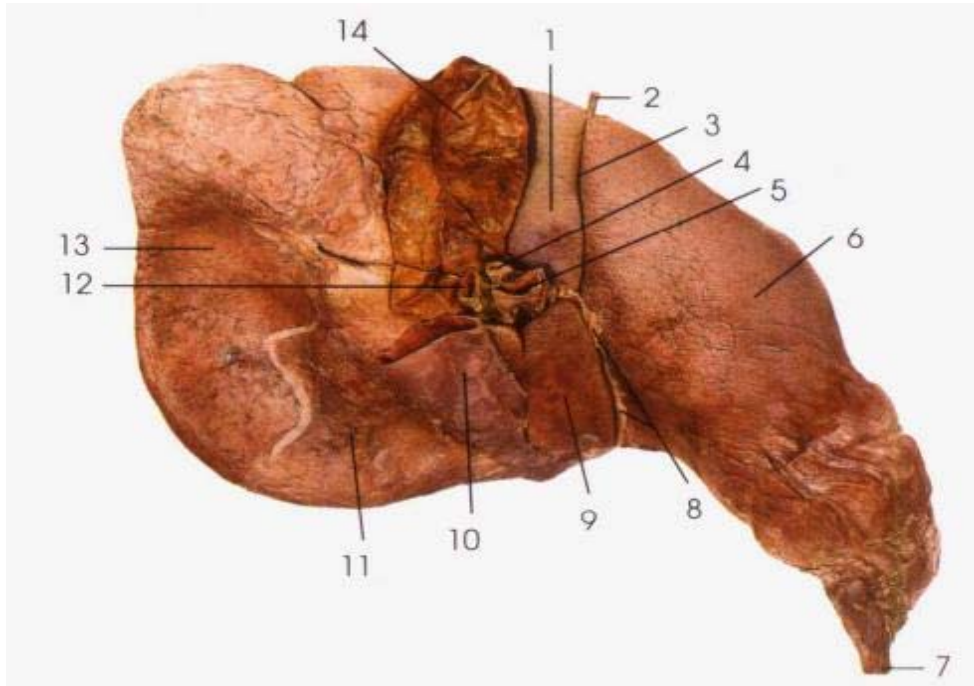


图 79 肝(脏面)
Liver(visceral surface)

- | | |
|---|---------------------------------|
| 1. 方叶 quadrate lobe | 8. 肝胃韧带 hepatogastric ligament |
| 2. 肝圆韧带 ligamentum teres hepatis | 9. 尾状叶 caudate lobe |
| 3. 肝圆韧带裂 fissure for ligamentum teres hepatis | 10. 29. 下腔静脉 inferior vena cava |
| 4. 肝固有动脉 proper hepatic a. | 11. 22. 肝裸区 bare area of liver |
| 5. (肝)门静脉 portal v. | 12. 胆总管 common bile duct |
| 6. 18. 肝左叶 left lobe of liver | 13. 24. 肝右叶 right lobe of liver |
| 7. 19. 左三角韧带 left triangular ligament | |

- | |
|---|
| 14. 胆囊 gall bladder |
| 15. 主动脉 aorta |
| 16. 食管 esophagus |
| 17. 脾 spleen |
| 20. 左冠状韧带后层 posterior layer of left coronary ligament |
| 21. 左冠状韧带前层 anterior layer of left coronary ligament |
| 23. 镰状韧带 falciform ligament of liver |
| 25. 右冠状韧带上层 superior layer of right coronary ligament |
| 26. 右三角韧带 right triangular ligament |
| 27. 膈 diaphragm |
| 28. 肋膈隐窝 costodiaphragmatic recess |

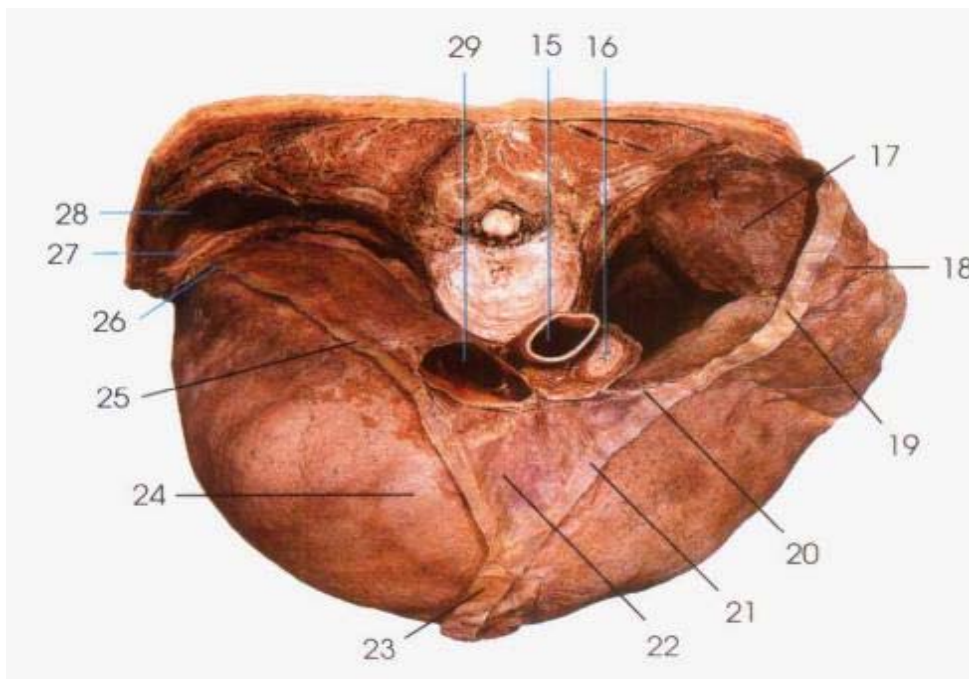


图 80 肝(上面观)
Liver(superior aspect)

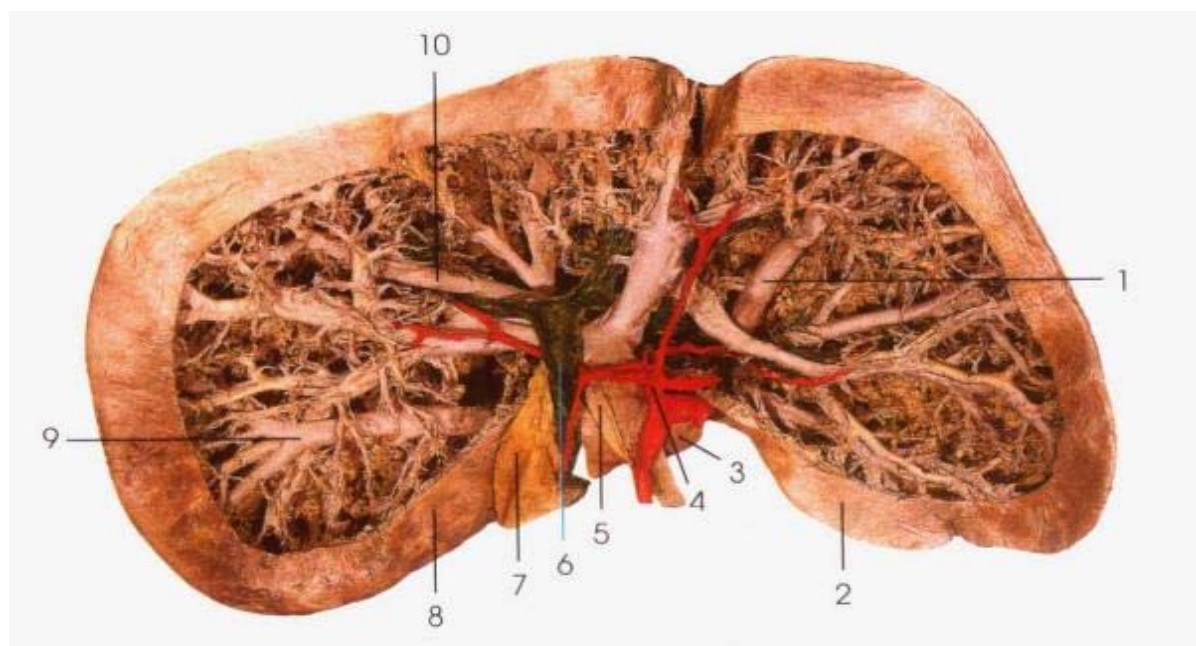
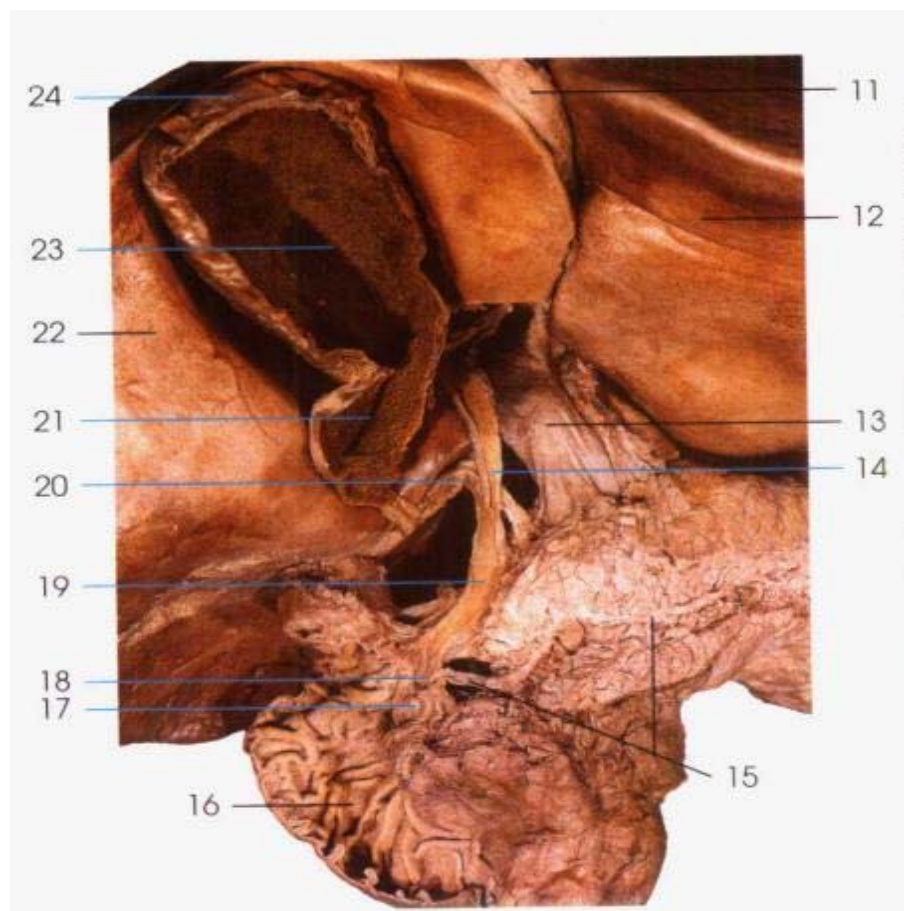


图 81 肝内的血管和胆管
The blood vessels and bile ducts in the liver



- 1.9.10. 肝静脉 hepatic v.
- 2.12. 肝左叶 left lobe of liver
- 3. 尾状叶 caudate lobe of liver
- 4. 肝固有动脉 proper hepatic a.
- 5.13. 门静脉 portal v.
- 6.14. 肝总管 common hepatic duct
- 7. 胆囊 gall bladder
- 8.22. 肝右叶 right lobe of liver
- 11. 肝圆韧带 ligamentum teres hepatis
- 15. 胰管 pancreatic duct
- 16. 十二指肠降部 descending part of duodenum
- 17. 十二指肠大乳头 maior duodenal papilla
- 18. 肝胰壶腹 hepatopancreatic ampulla
- 19. 胆总管 common bile duct
- 20. 胆囊管 cystic duct
- 21. 胆囊颈 neck of gallbladder
- 23. 胆囊体 body of gallbladder
- 24. 胆囊底 fundus of gallbladder

图 82 肝外胆道
Extrahepatic bile ducts

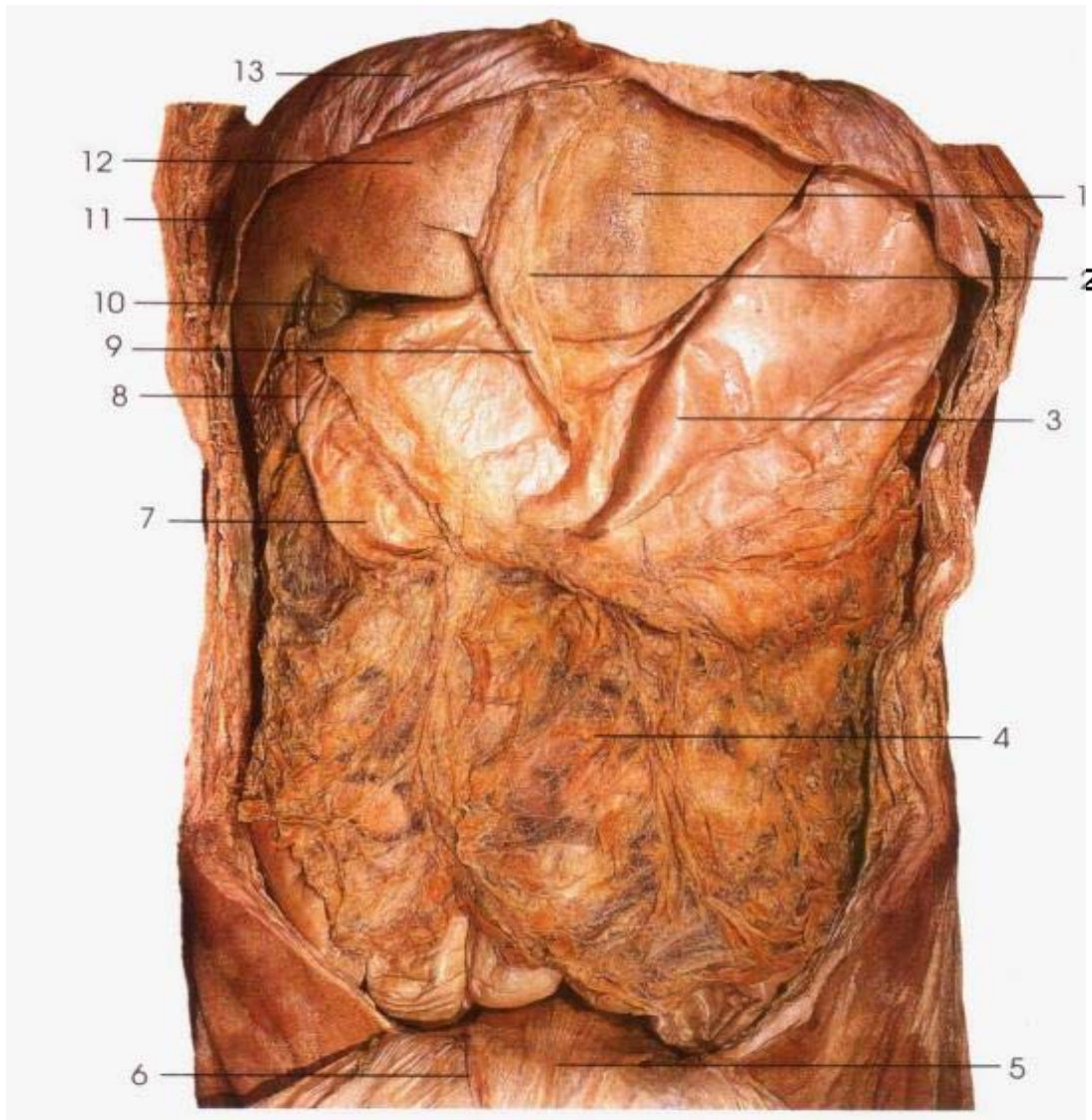


图 83 腹膜的配布(I)
Arrangement of the peritoneum(I)

- | | |
|-------------------------------------|------------------------------------|
| 1. 肝左叶 left lobe of liver | 8. 结肠右曲 right colic flexure |
| 2. 镰状韧带 falciform ligament of liver | 9. 肝圆韧带 ligament teres hepatis |
| 3. 胃 stomach | 10. 胆囊 gall bladder |
| 4. 大网膜 greater omentum | 11. 肋膈隐窝 costodiaphragmatic recess |
| 5. 脐正中襞 median umbilical fold | 12. 肝右叶 right lobe of liver |
| 6. 左脐内侧襞 left medial umbilical fold | 13. 膈 diaphragm |
| 7. 横结肠 transverse colon | |

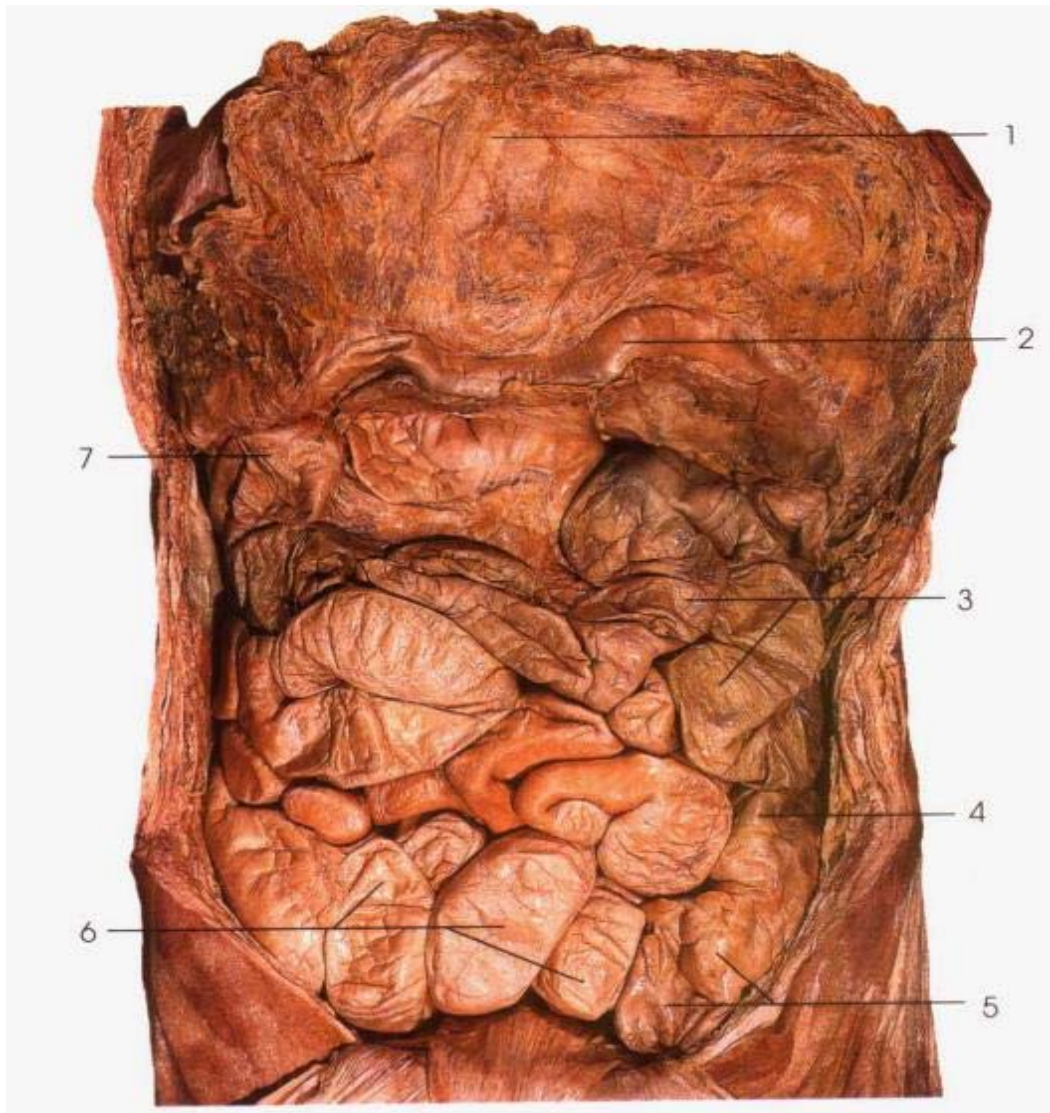
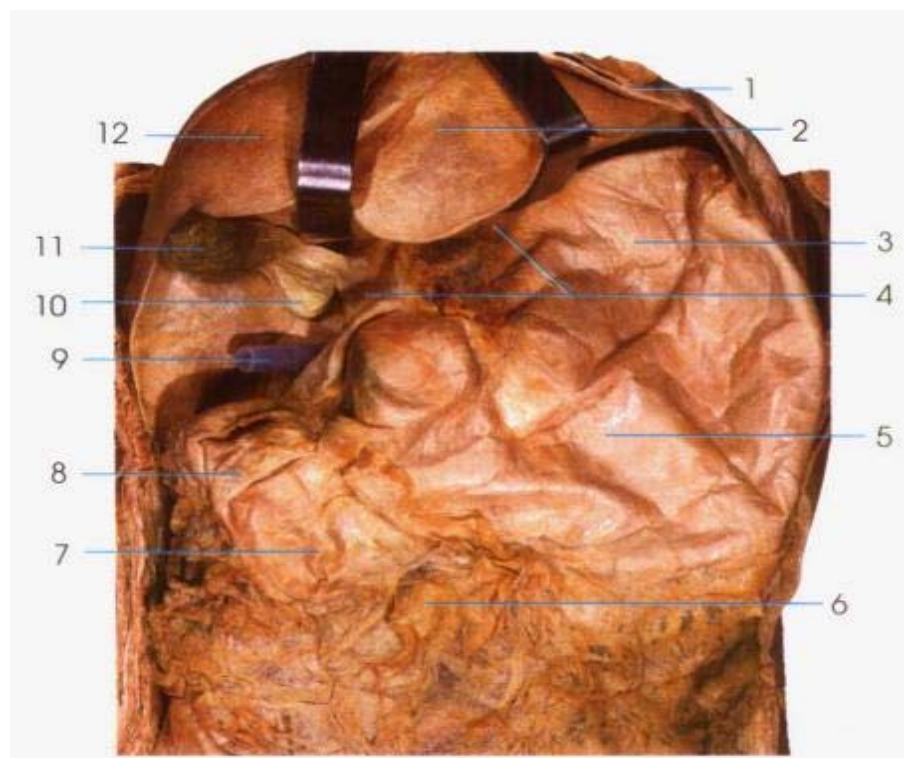


图 84 腹膜的配布(Ⅱ)
Arrangement of the peritoneum(Ⅱ)

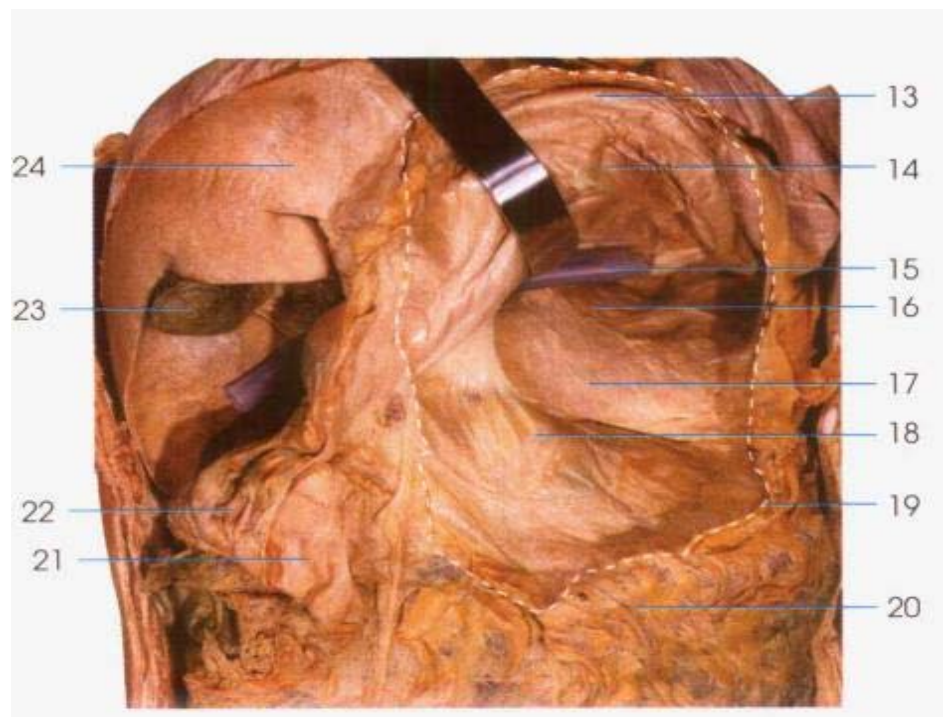1. 大网膜 greater omentum
2. 横结肠 transverse colon
3. 空肠 jejunum
4. 降结肠 descending colon

5. 乙状结肠 sigmoid colon
6. 回肠 ileum
7. 结肠右曲 right colic flexure



- 1. 膈 diaphragm
- 2. 肝左叶 left lobe of liver
- 3.5. 胃 stomach
- 4. 小网膜 lesser omentum
- 6.20. 大网膜 greater omentum
- 7.21. 横结肠 transverse colon
- 8.22. 结肠右曲 right colic flexure
- 9.15. 导管(通过网膜孔) catheter (through the omental foramen)
- 10. 哈特曼囊 (Hartmann's pouch)
- 11.23. 胆囊底 (fundus of gallbladder)
- 12.24. 肝右叶 right lobe of liver

图 85 网膜
Omenta

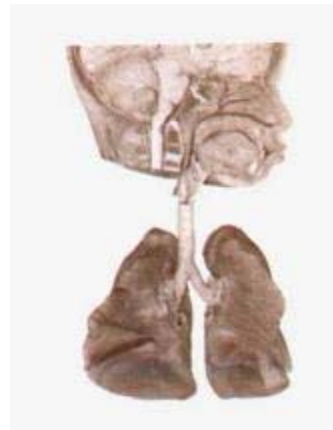


- 13. 胃大弯 greater curvature of stomach
- 14. 胃后壁 posterior wall of stomach
- 16.18. 网膜囊 omental bursa
- 17. 胰体 the body of pancreas
- 19. 切缘 cut edge

图 86 网膜囊
Omental bursa

3

RESPIRATORY SYSTEM



第3章

呼

吸

系

统

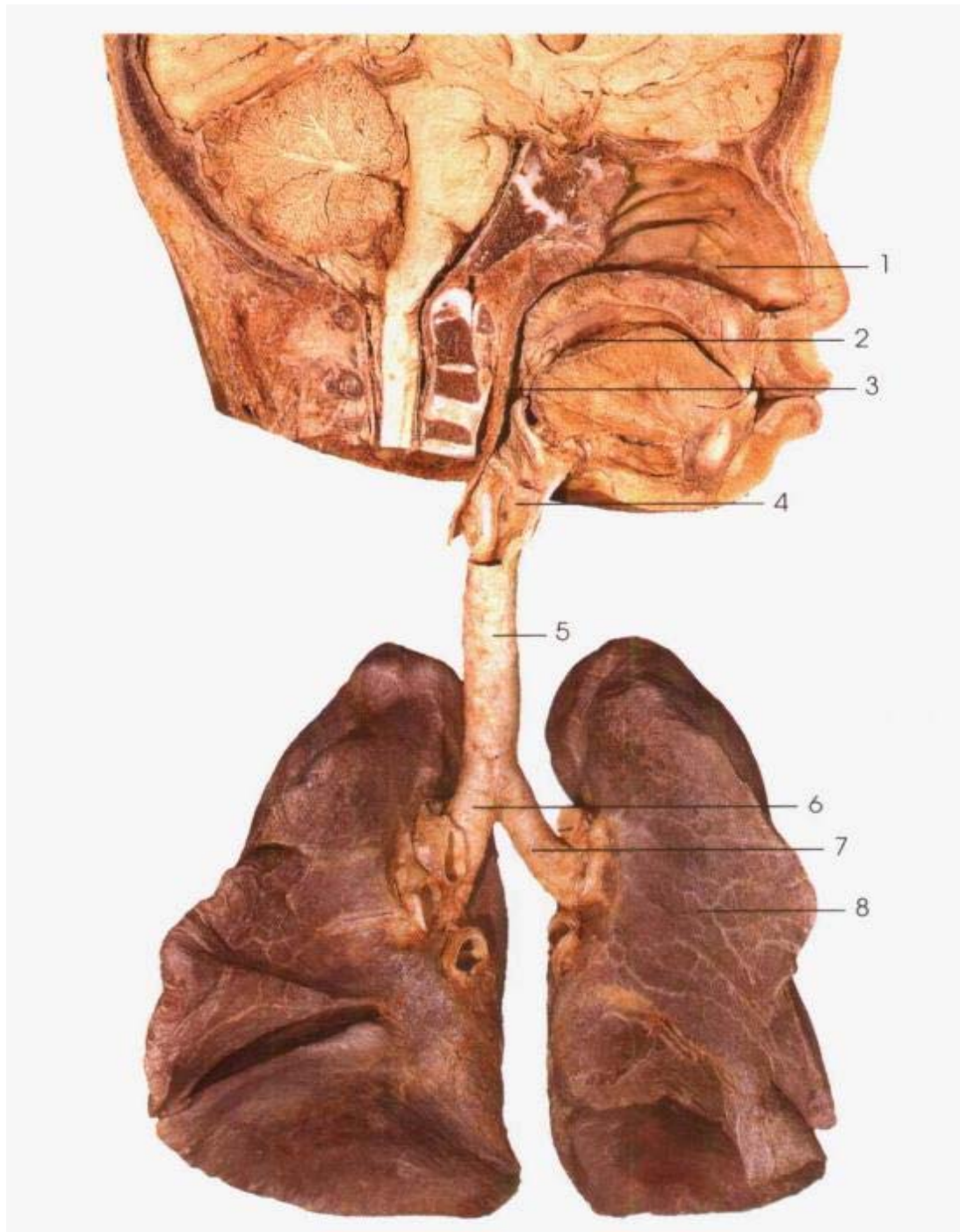
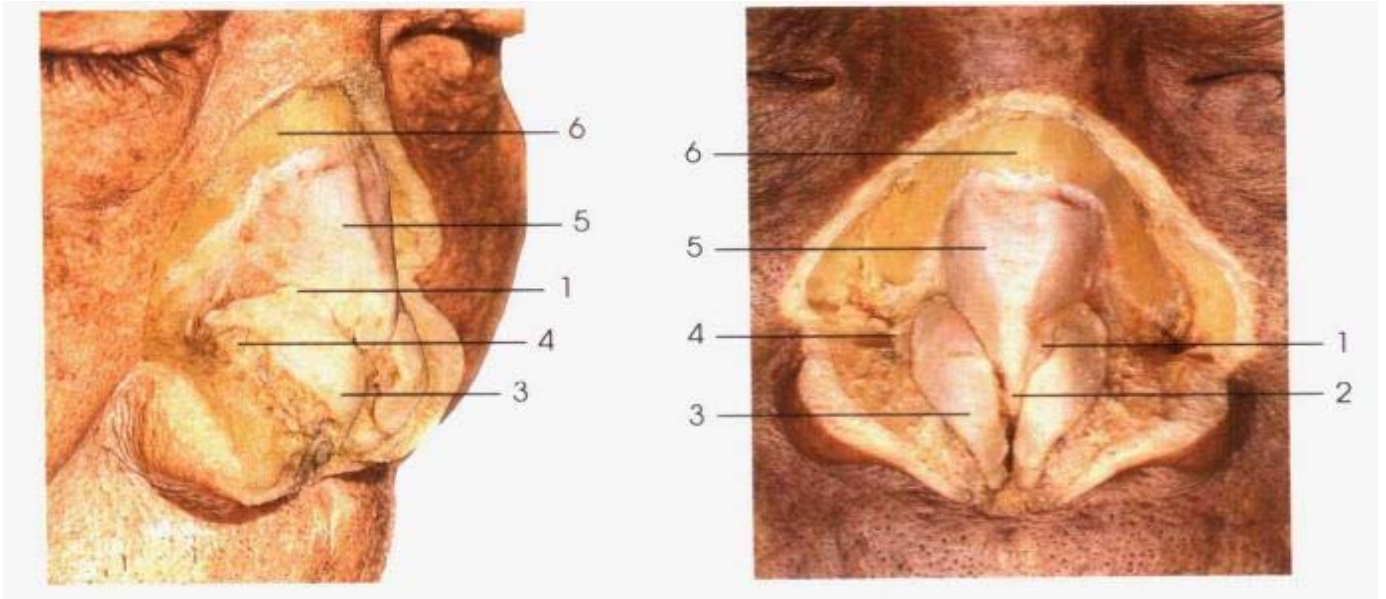


图 87 呼吸系統概观
General arrangement of respiratory system

- 1. 鼻腔 nasal cavity
- 2. 口腔 oral cavity
- 3. 咽 pharynx
- 4. 喉腔 laryngeal cavity
- 5. 气管 trachea

- 6. 右主支气管 right principal bronchus
- 7. 左主支气管 left principal bronchus
- 8. 肺 lung



A

图 88 鼻软骨(A、B)
Nasal cartilages(A,B)

B

- | | | | |
|----------|---------------------------|----------|-------------------------|
| 1. 鼻副软骨 | accessory nasal cartilage | 4. 鼻翼小软骨 | minor alar cartilage |
| 2. 鼻中隔软骨 | septal cartilage of nose | 5. 鼻外侧软骨 | lateral nasal cartilage |
| 3. 鼻翼大软骨 | major alar cartilage | 6. 鼻骨 | nasal bone |

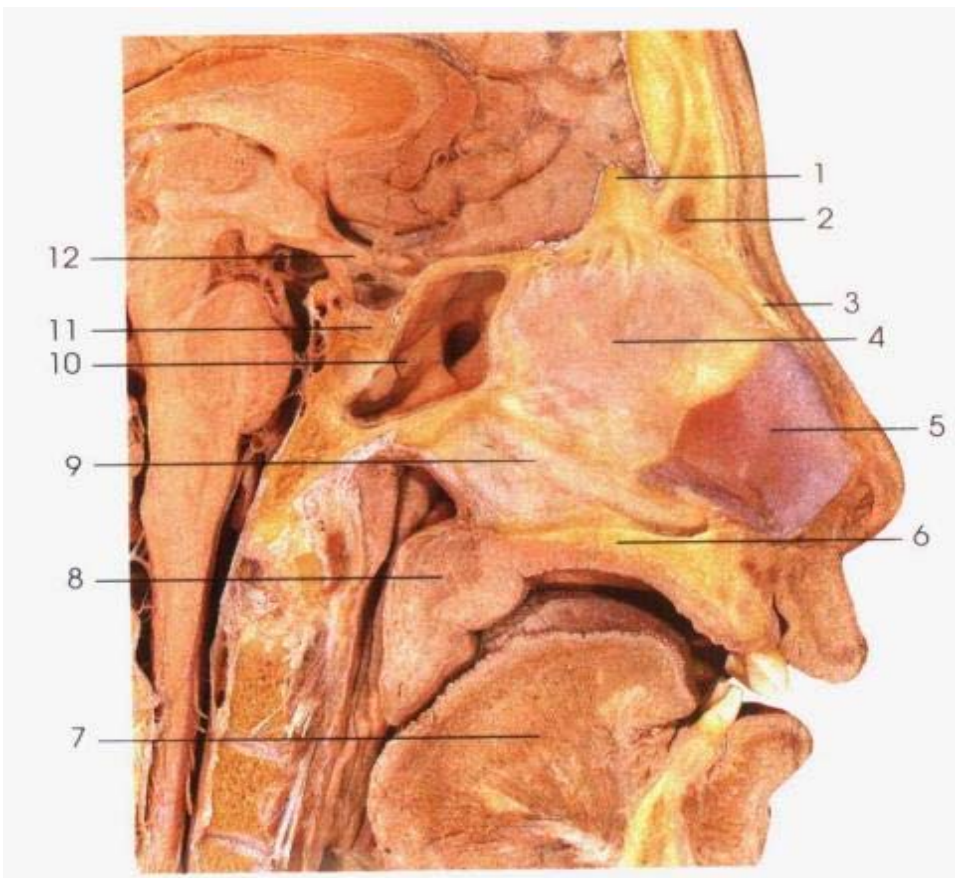
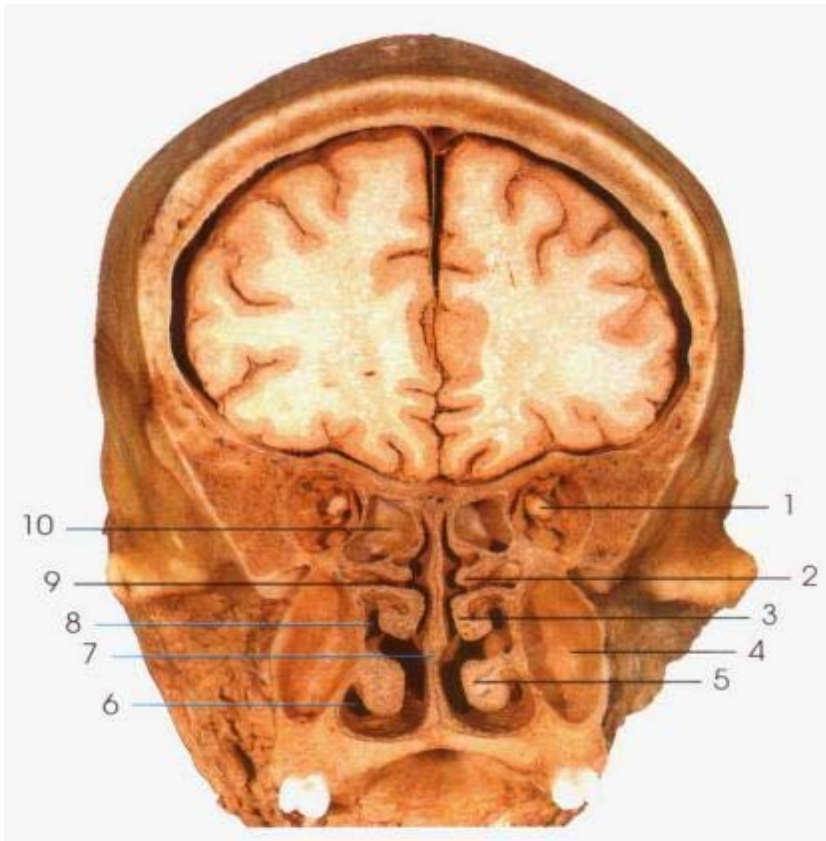


图 89 鼻中隔
Nasal septum

- | | |
|----------|-------------------------------------|
| 1. 筛骨鸡冠 | crista galli of ethmoid bone |
| 2. 额窦 | frontal sinus |
| 3. 鼻骨 | nasal bone |
| 4. 筛骨垂直板 | perpendicular plate of ethmoid bone |
| 5. 鼻中隔软骨 | septal cartilage of nose |
| 6. 硬腭 | hard palate |
| 7. 舌 | tongue |
| 8. 软腭 | soft palate |
| 9. 犁骨 | vomer |
| 10. 蝶窦 | sphenoidal sinus |
| 11. 垂体 | hypophysis |
| 12. 视交叉 | optic chiasma |



- 1. 视神经 optic n.
- 2. 上鼻甲 superior nasal concha
- 3. 中鼻甲 middle nasal concha
- 4. 上颌窦 maxillary sinus
- 5. 下鼻甲 inferior nasal concha
- 6. 下鼻道 inferior nasal meatus
- 7. 鼻中隔 nasal septum
- 8. 中鼻道 middle nasal meatus
- 9. 上鼻道 superior nasal meatus
- 10. 蝶窦 sphenoidal sinus

图 90 鼻甲和鼻道
Nasal conchae and meatuses

- 1. 额窦 frontal sinus
- 2. 中鼻甲 middle nasal concha
- 3. 中鼻道 middle nasal meatus
- 4. 鼻咽 limen nasi
- 5. 鼻前庭 nasal vestibule
- 6. 下鼻甲 inferior nasal concha
- 7. 下鼻道 inferior nasal meatus
- 8. 硬腭 hard palate
- 9. 颊舌肌 genioglossus
- 10. 会厌 epiglottis
- 11. 腭咽弓 palatopharyngeal arch
- 12. 软腭 soft palate
- 13. 咽鼓管咽口 pharyngeal opening of auditory tube
- 14. 咽鼓管圆枕 tubal torus
- 15. 咽隐窝 pharyngeal recess
- 16. 上鼻道 superior nasal meatus
- 17. 上鼻甲 superior nasal concha
- 18. 蝶窦 sphenoidal sinus
- 19. 垂体 hypophysis

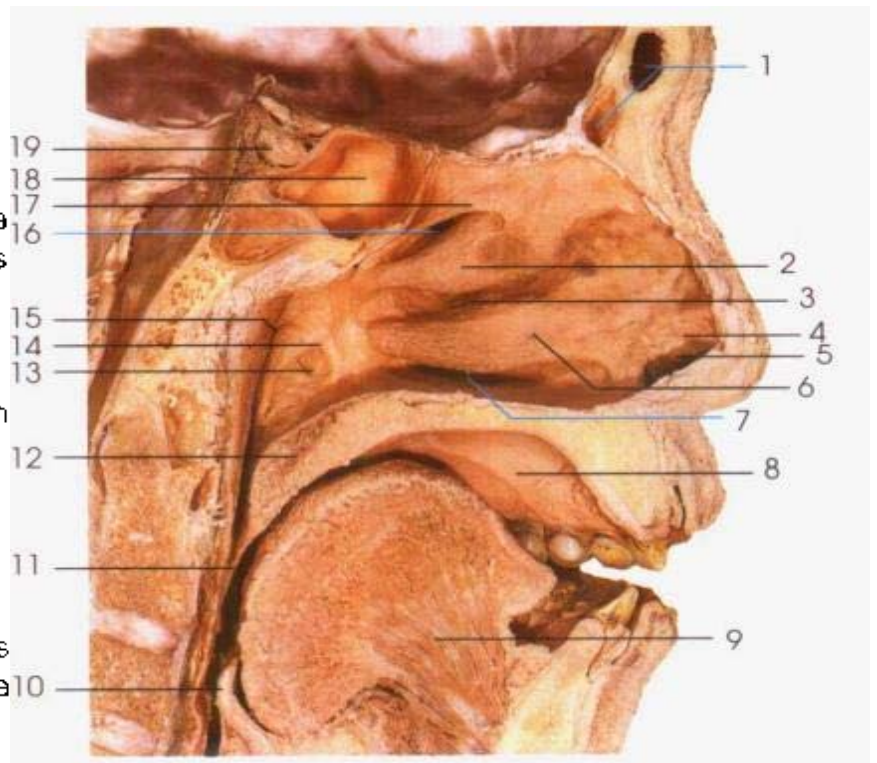


图 91 鼻腔外侧壁
Lateral wall of nasal cavity

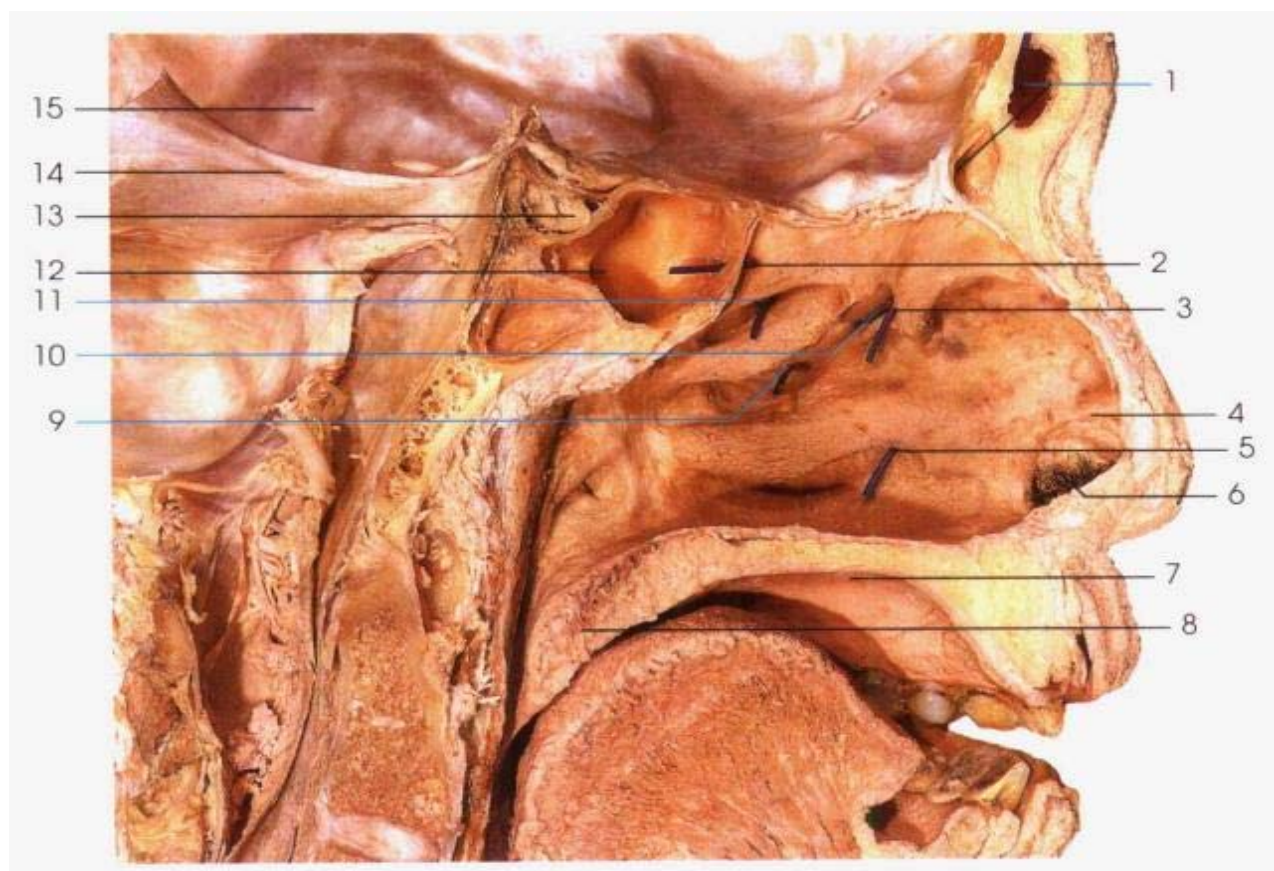


图 92 鼻旁窦的开口
Orifices of paranasal sinuses

- | | |
|---------------------------------------|--|
| 1. 额窦 frontal sinuses | 10. 筛窦前群开口 orifices of anterior ethmoidal sinuses |
| 2. 蝶窦开口 orifice of sphenoidal sinus | 11. 筛窦后群开口 orifices of posterior ethmoidal sinuses |
| 3. 额窦开口 orifice of frontal sinus | 12. 蝶窦 sphenoidal sinus |
| 4. 鼻咽 limen nasi | 13. 垂体 hypophysis |
| 5. 鼻泪管开口 orifice of nasolacrimal duct | 14. 小脑幕 tentorium of cerebellum |
| 6. 鼻前庭 nasal vestibule | 15. 硬脑膜 cerebral dura mater |
| 7. 硬腭 hard palate | |
| 8. 软腭 soft palate | |
| 9. 上颌窦开口 orifice of maxillary sinus | |

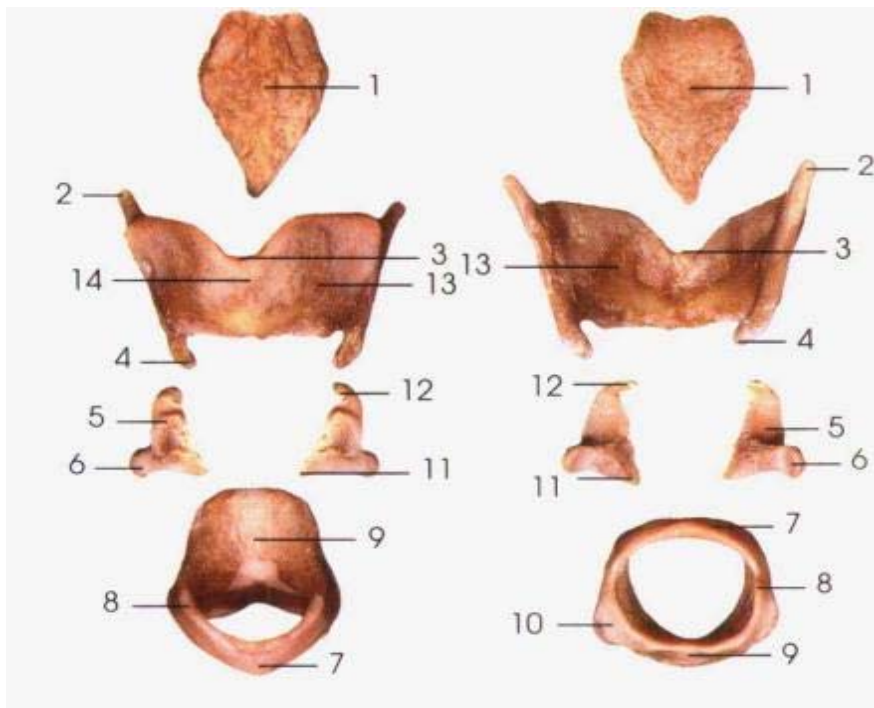


图 93 喉软骨前、后面观
Anterior and posterior aspect of
the cartilages of larynx

1. 会厌软骨 epiglottic cartilage
2. 甲状软骨上角 superior cornu of thyroid cartilage
3. 甲状软骨上切迹 superior thyroid notch
4. 甲状软骨下角 inferior cornu of thyroid cartilage
5. 杓状软骨 arytenoid cartilage
6. 杓状软骨肌突 muscular process of arytenoid cartilage
7. 环状软骨弓 arch of cricoid cartilage
8. 环状软骨 cricoid cartilage
9. 环状软骨板 lamina of cricoid cartilage
10. 甲关节面 thyroid articular surface
11. 声带突 vocal process of arytenoid cartilage
12. 小角软骨 corniculate cartilage
13. 甲状软骨板 lamina of thyroid cartilage
14. 喉结 laryngeal prominence

1. 会厌软骨 epiglottic cartilage
2. 舌骨大角 greater horn of hyoid
3. 甲状舌骨膜 thyrohyoid membrane
4. 甲状会厌韧带 thyroepiglottic lig.
5. 杓状软骨 arytenoid cartilage
6. 甲状软骨 thyroid cartilage
7. 环状软骨板 lamina of cricoid cartilage
8. 气管 trachea
9. 环状软骨 cricoid cartilage
10. 环甲韧带 cricothyroid lig.
11. 甲状舌骨正中韧带 median thyrohyoid lig.
12. 舌骨体 body of hyoid bone

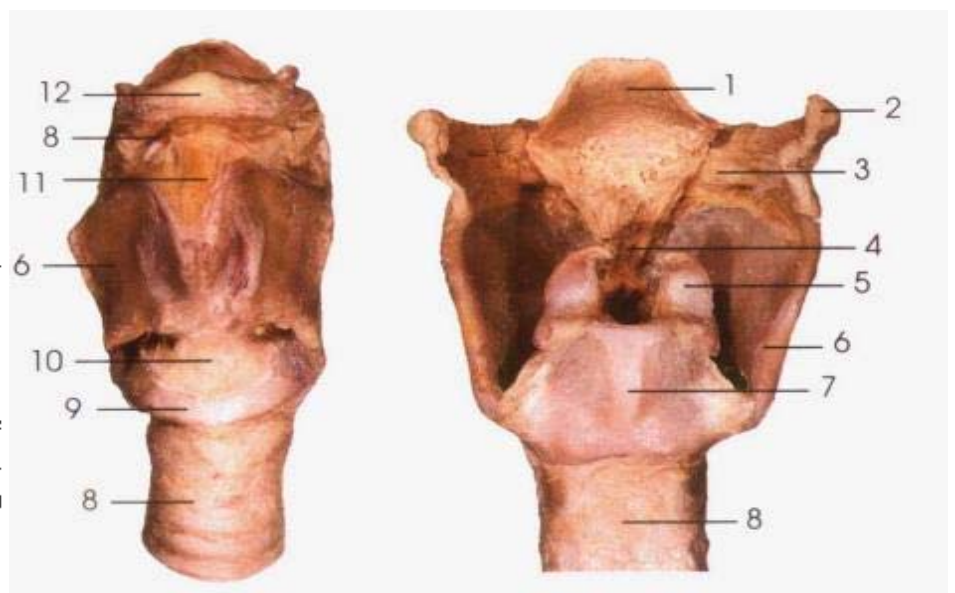


图 94 喉的软骨和韧带(I)
Cartilages and ligaments of larynx(I)

1. 舌骨大角 greater horn of hyoid
2. 会厌 epiglottis
3. 方形膜 quadrangular membrane
4. 杓状软骨尖 apex of arytenoid cartilage
5. 声带突 vocal process
6. 肌突 muscular process
7. 弹性圆锥 conus elasticus
8. 环状软骨板 lamina of cricoid cartilage
9. 气管软骨 tracheal cartilages
10. 环状软骨弓 arch of cricoid cartilage
11. 环甲韧带 cricothyroid lig.
12. 甲状软骨 thyroid cartilage
13. 声韧带 vocal lig.
14. 前庭韧带 vestibular lig.
15. 喉结 laryngeal prominence
16. 甲状舌骨膜 thyrohyoid membrane
17. 舌骨体 body of hyoid bone

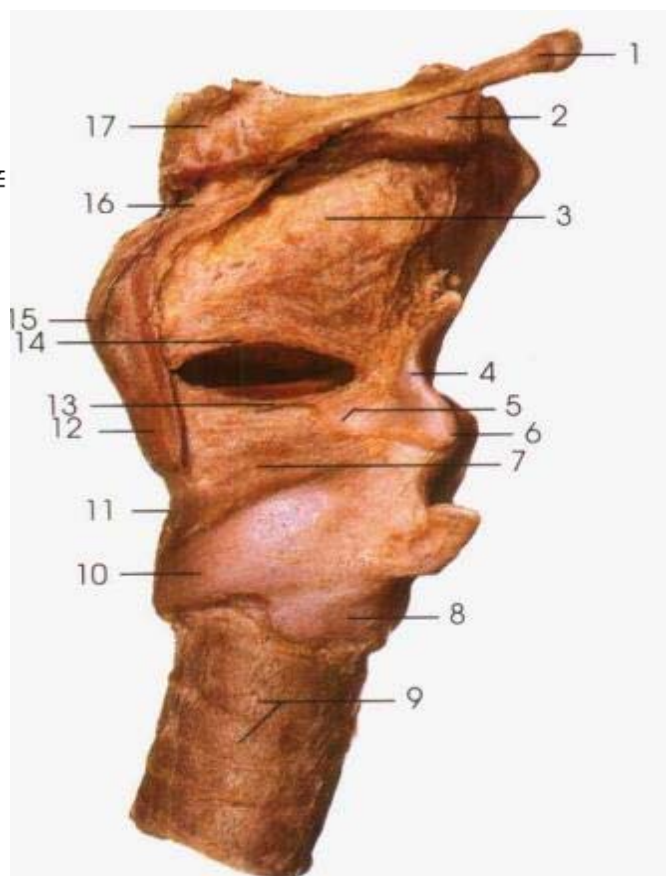


图 95 喉的软骨和韧带(Ⅱ)
Cartilages and ligaments of larynx(Ⅱ)

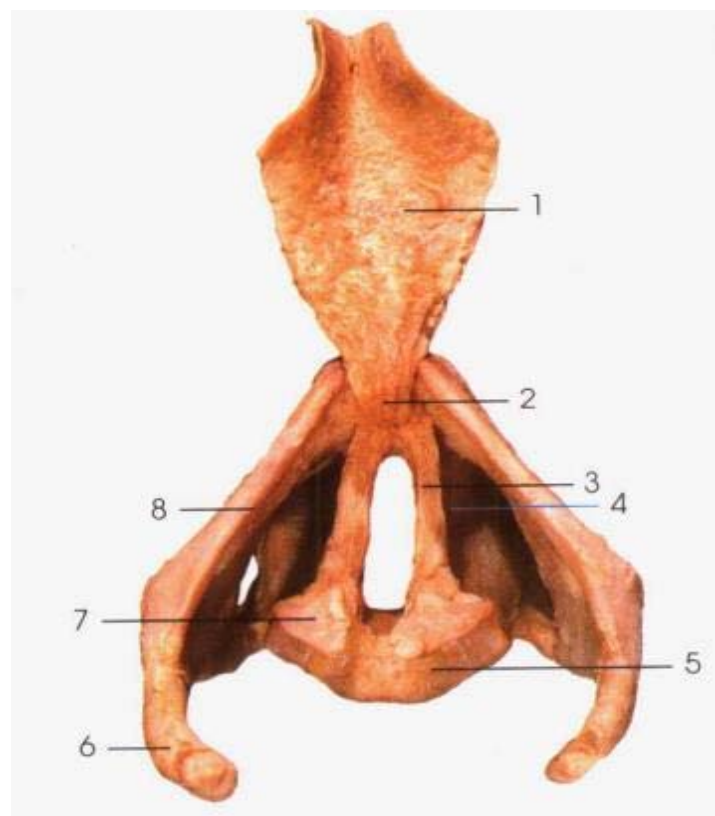
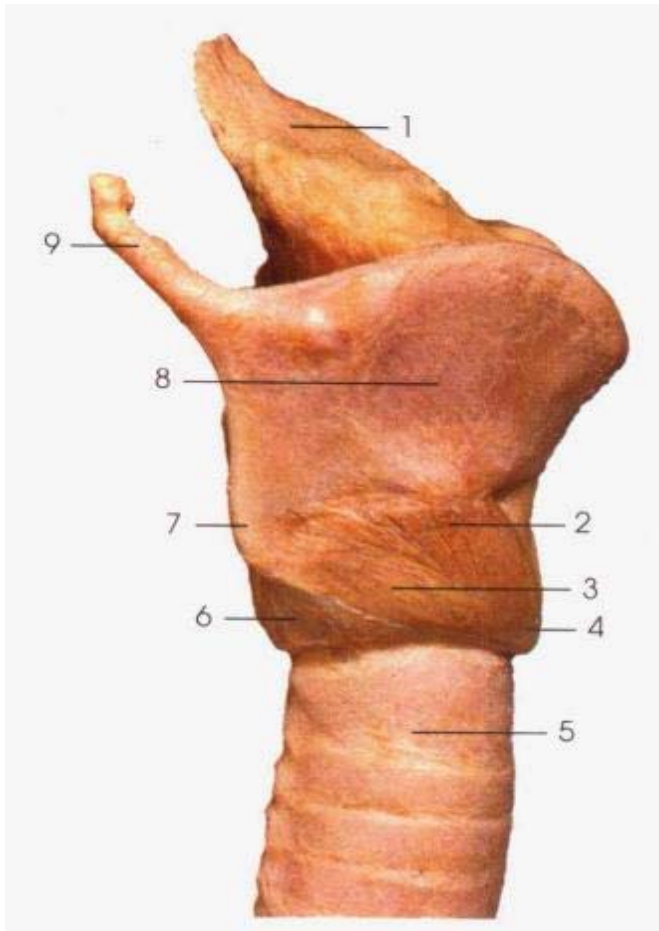


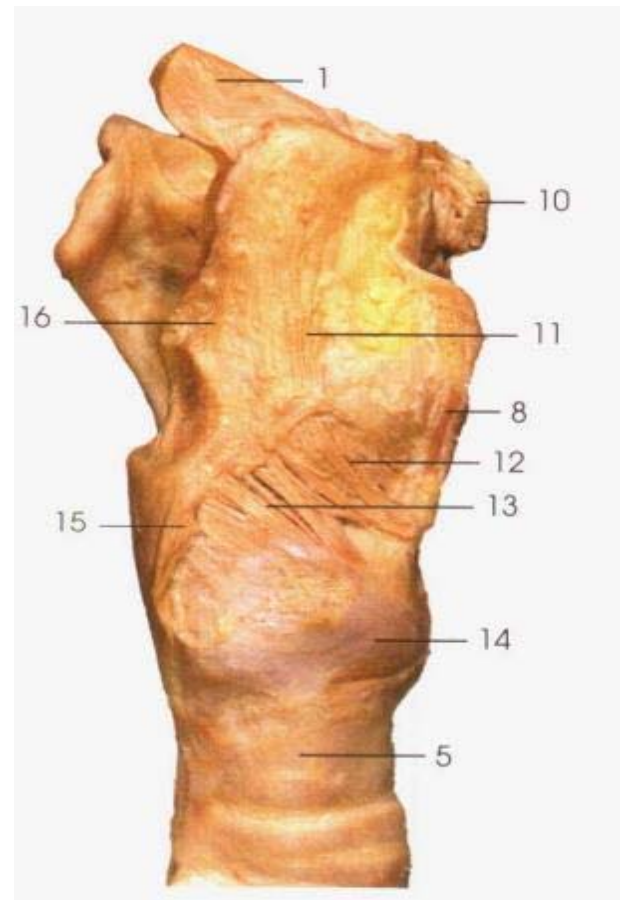
图 96 喉的软骨和韧带(Ⅲ)
Cartilages and ligaments of larynx(Ⅲ)

1. 会厌软骨 epiglottic cartilage
2. 甲状会厌韧带 thyroepiglottic lig.
3. 声韧带 vocal lig.
4. 弹性圆锥 conus elasticus
5. 环状软骨板 lamina of cricoid cartilage
6. 甲状软骨上角 superior cornu of thyroid cartilage
7. 杓状软骨 arytenoid cartilage
8. 甲状软骨 thyroid cartilage



A

1. 会厌 epiglottis
2. 环甲肌直部 straight part of cricothyroid m.
3. 环甲肌斜部 oblique part of cricothyroid m.
4. 环状软骨弓 arch of cricoid cartilage
5. 气管 trachea
6. 环状软骨板 lamina of cricoid cartilage
7. 甲状软骨下角 inferior cornu of thyroid cartilage
8. 甲状软骨右板 right lamina of thyroid cartilage
9. 甲状软骨上角 superior cornu of thyroid cartilage



B

10. 舌骨 hyoid bone
11. 甲杓肌甲状会厌部 thyroepiglottic part of thyroarytenoid m.
12. 甲杓肌 thyroarytenoid m.
13. 环杓侧肌 lateral cricoarytenoid m.
14. 环状软骨 cricoid cartilage
15. 环杓后肌 posterior cricoarytenoid
16. 杓斜肌杓会厌部 aryepiglottic part of oblique arytenoid m.

图 97 喉肌右侧观(A、B 甲状软骨右板被切除)
Right aspect of muscles of larynx(A,B Right lamina of thyroid cartilage is removed)

1. 会厌 epiglottis
2. 杓斜肌杓会厌部 aryepiglottic part of oblique arytenoid m.
3. 杓横肌 transeverse arytenoid m.
4. 杓斜肌 oblique arytenoid m.
5. 环杓后肌 posterior cricoarytenoid m.
6. 环状软骨 cricoid cartilage
7. 气管软骨 tracheal cartilage
8. 甲状软骨板 lamina of thyroid cartilage
9. 甲状舌骨膜 thyrohyoid membrane
10. 舌骨大角 greater horn of hyoid bone

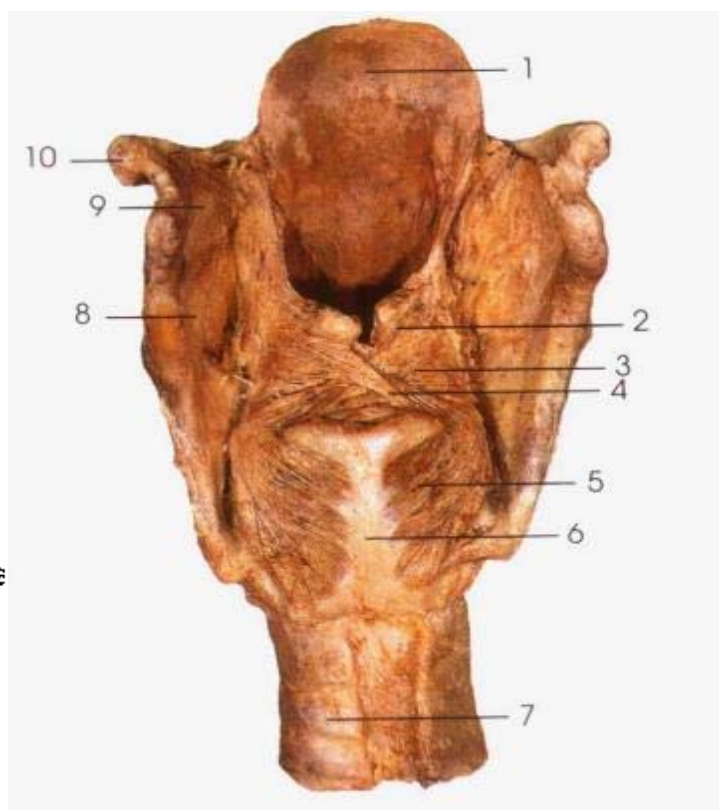
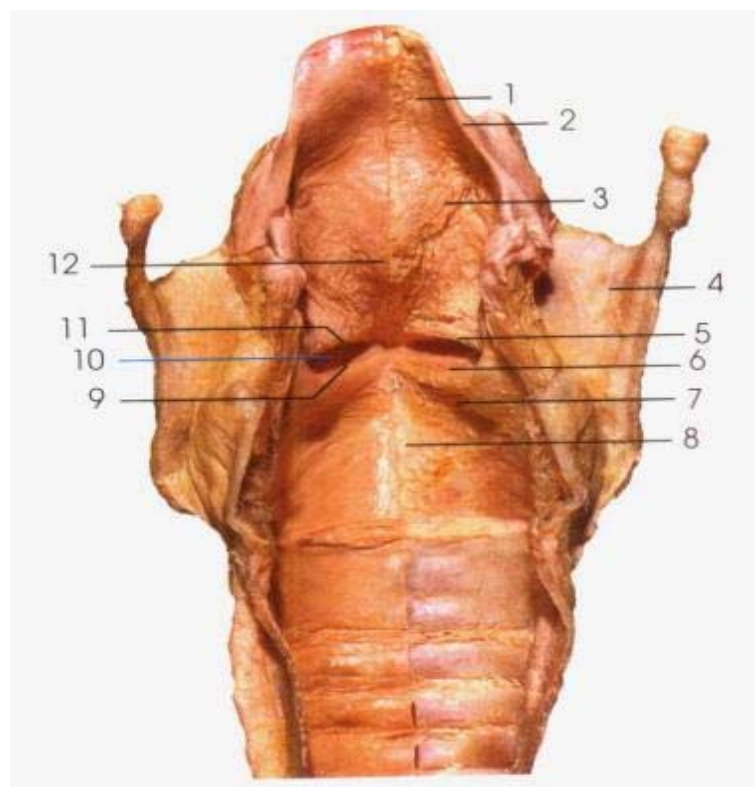


图 98 喉肌后面观
Posterior aspect of muscles of larynx



1. 会厌软骨 epiglottic cartilage
2. 杓会厌襞 aryepiglottic fold
3. 方形膜 quadrangular membrane
4. 甲状软骨 thyroid cartilage
5. 前庭韧带 vestibular lig.
6. 声韧带 vocal lig.
7. 弹性圆锥 conus elasticus
8. 声门下腔 infraglottic cavity
9. 声襞 vocal fold
10. 喉中间腔 intermedial cavity of larynx
11. 前庭襞 vestibular fold
12. 喉前庭 laryngeal vestibule

图 99 喉腔后面观
Posterior aspect of cavity of larynx(right half of membrane is removed)

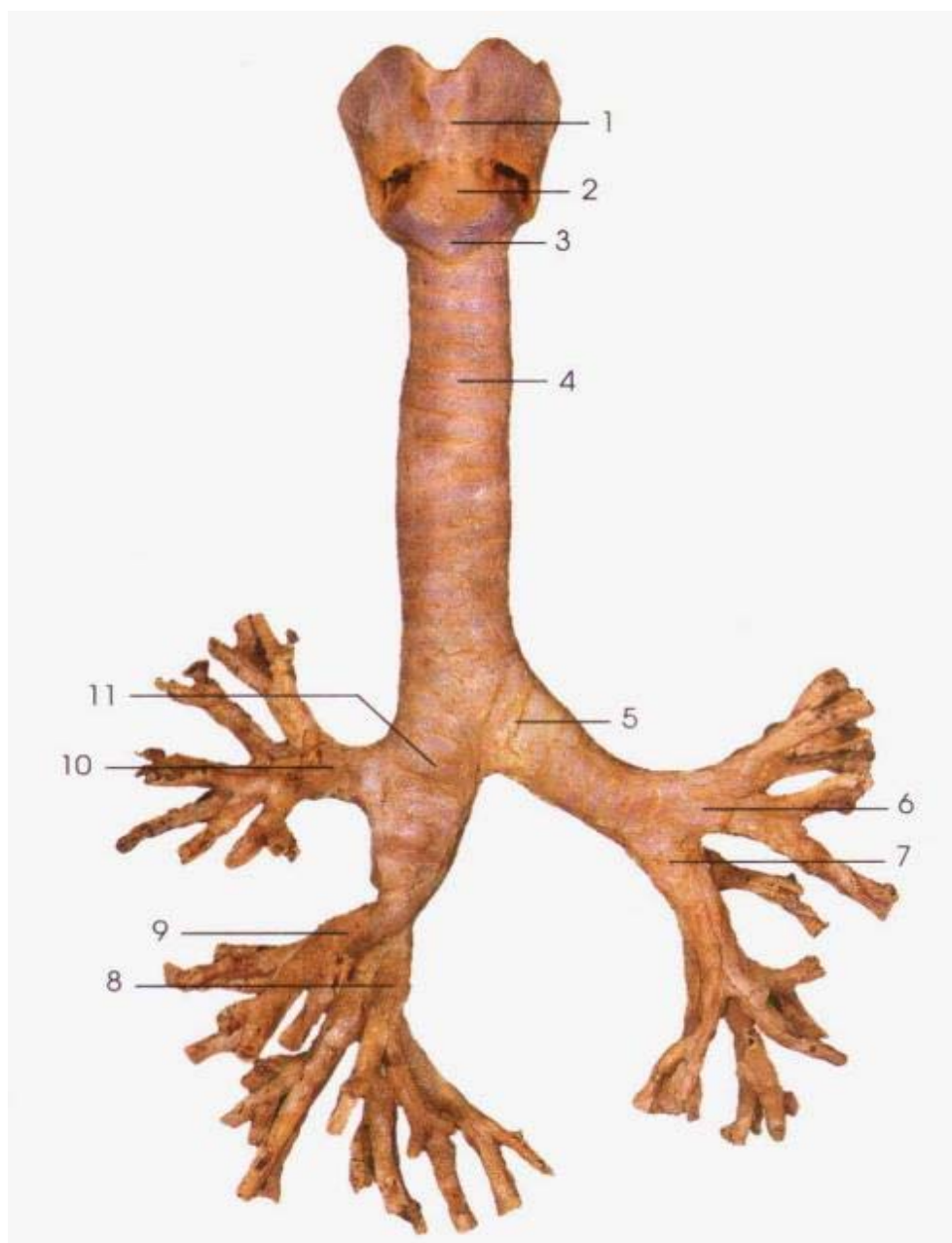


图 100 喉、气管和支气管
Larynx, trachea and bronchi

- | | |
|---|---|
| 1. 甲状软骨 thyroid cartilage | bronchus |
| 2. 环甲正中韧带 median cricothyroid lig. | 8. 右肺下叶支气管 right inferior lobar bronchus |
| 3. 环状软骨 cricoid cartilage | 9. 右肺中叶支气管 right middle lobar bronchus |
| 4. 气管 trachea | 10. 右肺上叶支气管 right superior lobar bronchus |
| 5. 左主支气管 left principal bronchus | 11. 右主支气管 right principal bronchus |
| 6. 左肺上叶支气管 left superior lobar bronchus | |
| 7. 左肺下叶支气管 left inferior lobar | |

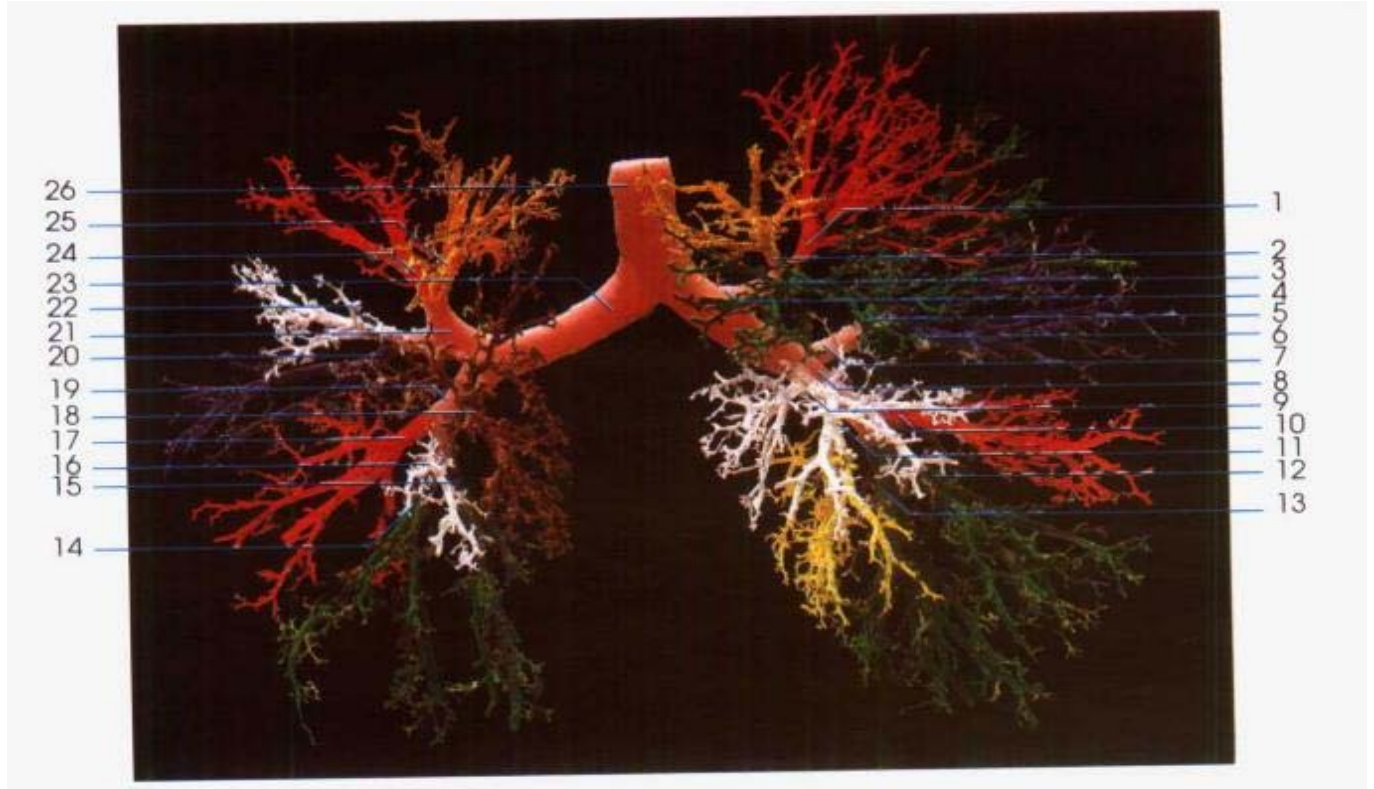
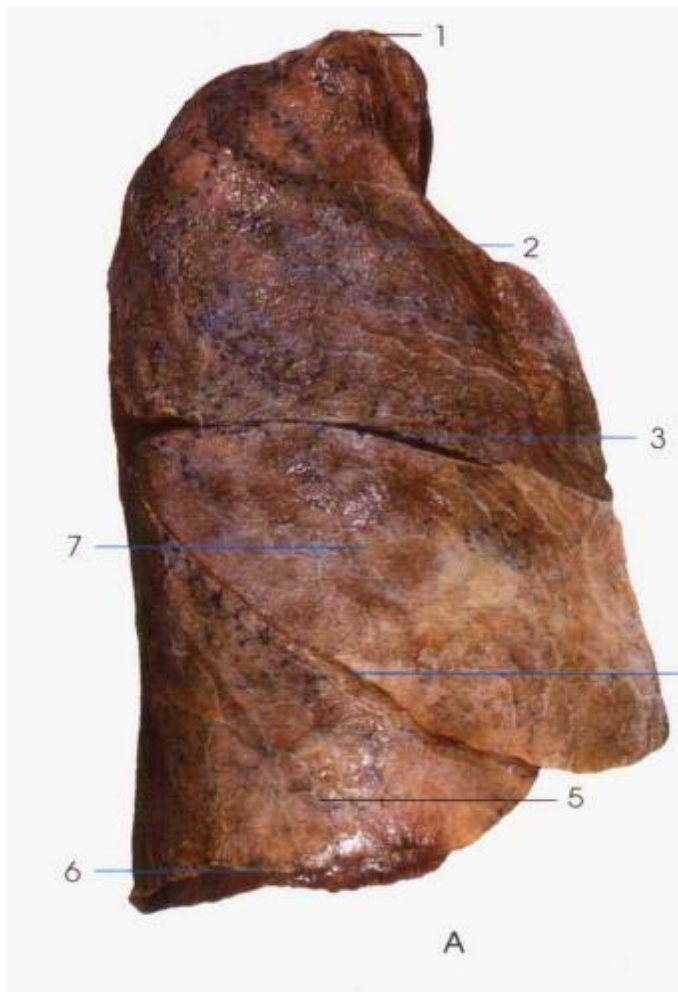
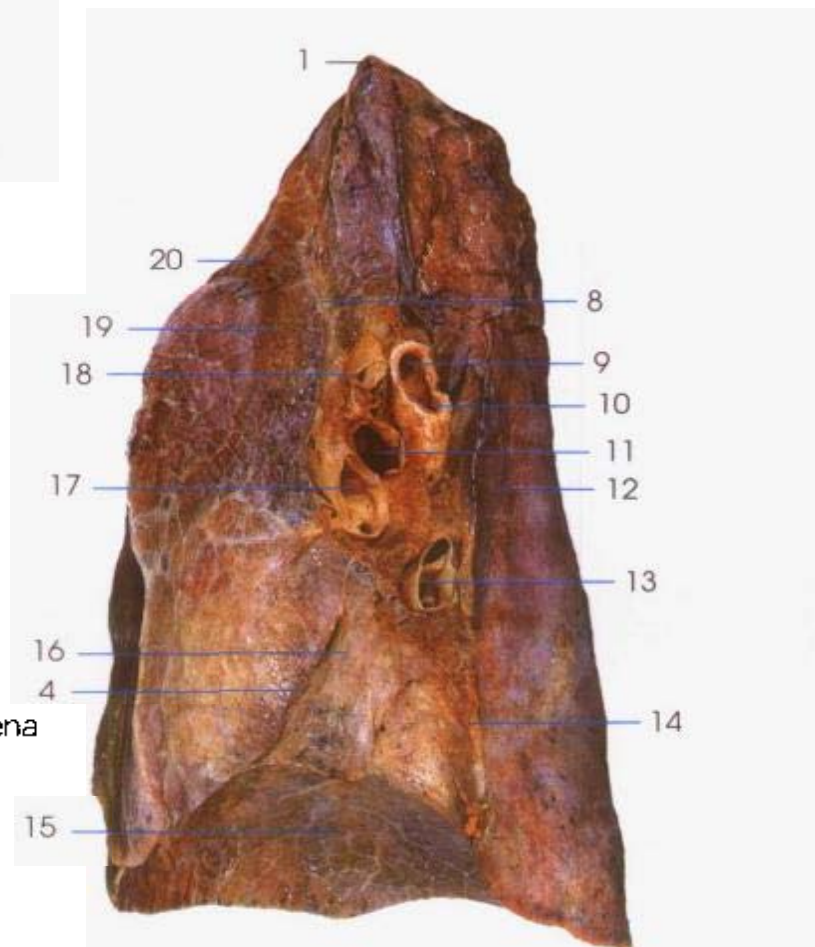


图 101 肺叶和肺段支气管(后面观)
Lobar and segmental bronchi (posterior aspect)

- | | |
|---|--|
| <p>1. 右肺前段支气管(B III) anterior segmental bronchus of right lung (B III)</p> <p>2. 右肺尖段支气管(B I) apical segmental bronchus of right lung (B I)</p> <p>3. 右肺后段支气管(B II) posterior segmental bronchus of right lung (B II)</p> <p>4. 右肺上叶支气管 right superior lobar bronchus</p> <p>5. 右肺内侧段支气管(B V) medial segmental bronchus of right lung (B V)</p> <p>6. 右肺外侧段支气管(B IV) lateral segmental bronchus of right lung (B IV)</p> <p>7. 右肺中叶支气管 right middle lobar bronchus</p> <p>8. 右肺下叶支气管 right inferior lobar bronchus</p> <p>9. 右肺上段支气管(B VI) superior segmental bronchus of right lung (B VI)</p> <p>10. 右肺外侧底段支气管(B IX) lateral basal segmental bronchus of right lung (B IX)</p> <p>11. 右肺内侧底段支气管(B VII) medial basal segmental bronchus of right lung (B VII)</p> <p>12. 右肺前底段支气管(B VIII) anterior basal segmental bronchus of right lung (B VIII)</p> <p>13. 右肺后底段支气管(B X) posterior basal segmental bronchus of right lung (B X)</p> | <p>14. 左肺前底段支气管(B VIII) anterior basal segmental bronchus of left lung (B VIII)</p> <p>15. 左肺后底段支气管(B X) posterior basal segmental bronchus of left lung (B X)</p> <p>16. 左肺内侧底段支气管(B VII) medial basal segmental bronchus of left lung (B VII)</p> <p>17. 左肺外侧底段支气管(B IX) lateral basal segmental bronchus of left lung (B IX)</p> <p>18. 左肺上段支气管(B VI) superior segmental bronchus of left lung (B VI)</p> <p>19. 左肺下叶支气管 left inferior lobar bronchus</p> <p>20. 左肺下舌段支气管(B V) inferior lingular segmental bronchus of left lung (B V)</p> <p>21. 左肺上叶支气管 left superior lobar bronchus</p> <p>22. 左肺上舌段支气管(B IV) superior lingular segmental bronchus of left lung (B IV)</p> <p>23. 左主支气管 left principal bronchus</p> <p>24. 左肺前段支气管(B III) anterior segmental bronchus of left lung (B III)</p> <p>25. 左肺尖后段支气管(B I + II) apicoposterior segmental bronchus of left lung (B I + II)</p> <p>26. 气管 trachea</p> |
|---|--|



1. 肺尖 apex
2. 上叶 upper lobe
3. 水平裂 horizontal fissure
4. 斜裂 oblique fissure
5. 下叶 lower lobe
6. 下缘 inferior margin
7. 中叶 middle lobe
8. 奇静脉沟 groove for azygos v.
9. 上叶支气管 superior lobar bronchus
10. 中间支气管 Intermediate bronchus
11. 肺动脉叶间部 interlobular part of pulmonary a.




12. 食管沟 groove for esophagus
13. 下肺静脉 inferior pulmonary v.
14. 肺韧带 pulmonary ligament
15. 膈面 diaphragmatic surface
16. 心压迹 cardiac impression
17. 上肺静脉 superior pulmonary v.
18. 上叶支 superior lobar branch of pulmonary a.
19. 上腔静脉沟 groove for superior vena cava
20. 第一肋沟 groove for the first rib

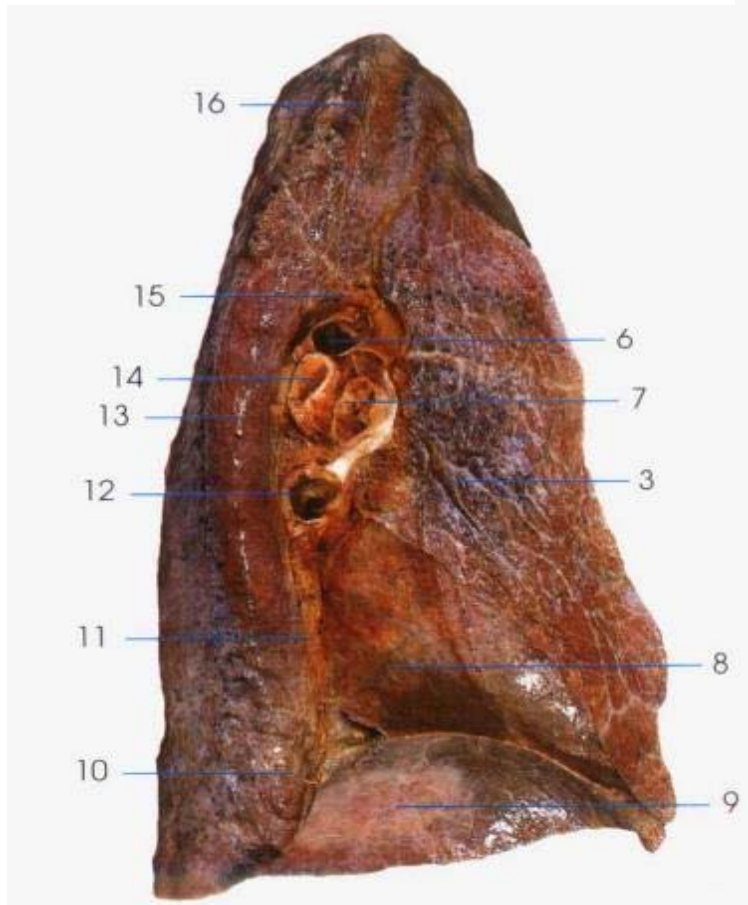
图 102 右肺(A. 外侧面观, B. 内侧面观)
Right lung(A.lateral aspect,B.medial aspect)

B

1. 肺尖 apex
2. 上叶 upper lobe
3. 斜裂 oblique fissure
4. 下叶 lower lobe
5. 下缘 inferior margin
6. 左肺动脉 left pulmonary a.
7. 上肺静脉 superior pulmonary v.
8. 心压迹 cardiac impression
9. 膈面 diaphragmatic surface
10. 食管沟 groove for esophagus



A



B

11. 肺韧带 pulmonary ligament
12. 下肺静脉 inferior pulmonary vein
13. 降主动脉沟 groove for descending aorta
14. 左主支气管 left principal bronchus
15. 主动脉弓沟 groove for arch of aorta
16. 左锁骨下动脉沟 groove for left subclavian a.

图 103 左肺(A. 外侧面观, B. 内侧面观)
Left lung(A.lateral aspect,B.medial aspect)

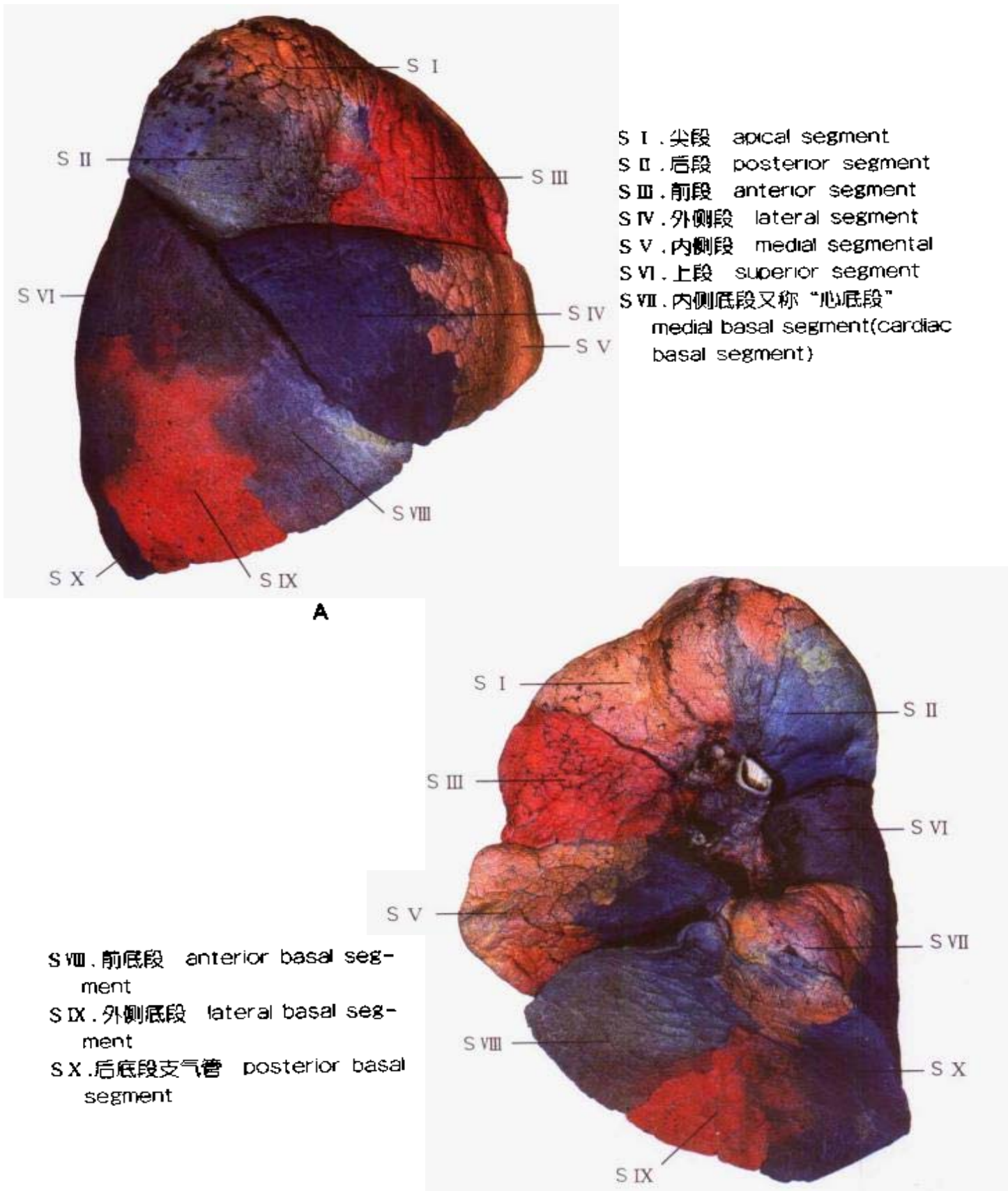
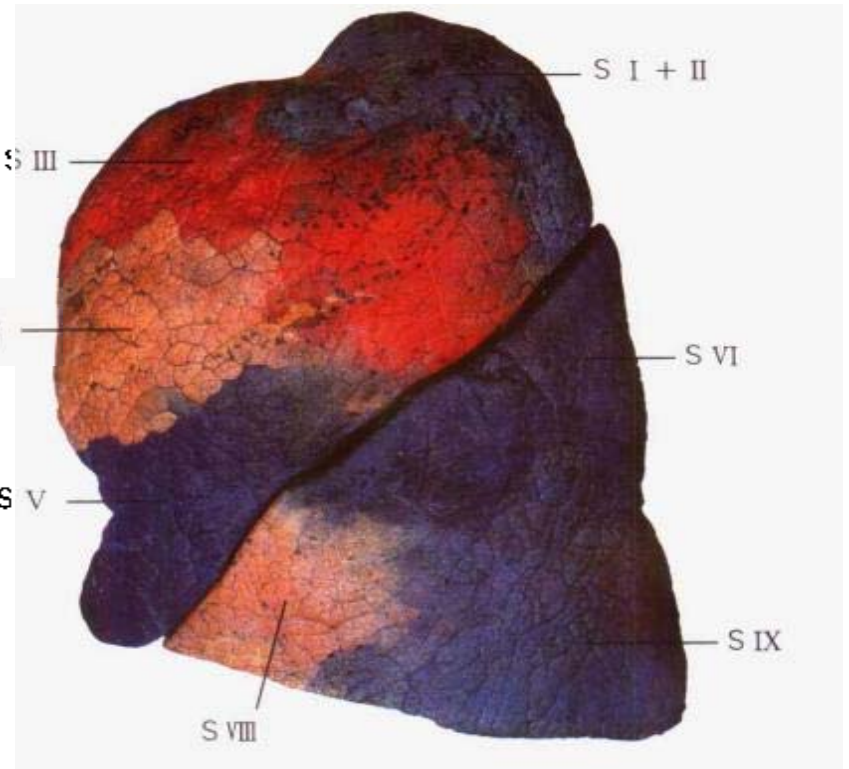
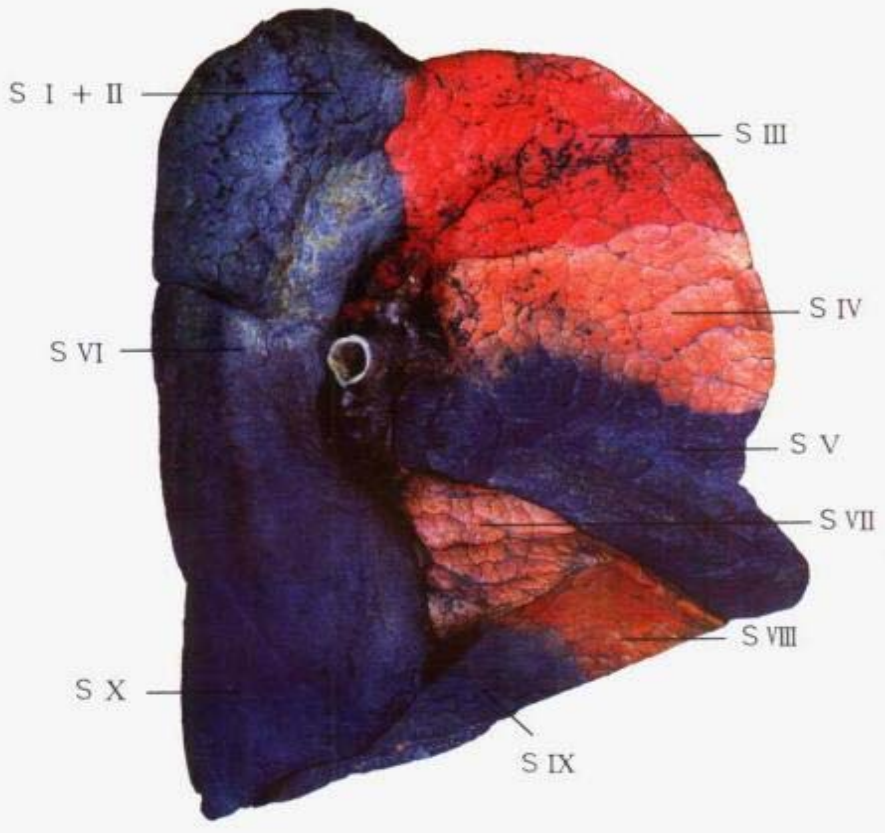


图 104 右肺支气管肺段(A. 外侧面观, B. 内侧面观)
Bronchopulmonary segments of right lung
(A. lateral aspect, B. medial aspect)

- S I + II . 尖后段 apicoposterior segment
- S III . 前段 anterior segment
- S IV . 上舌段 superior lingular segment
- S V . 下舌段 inferior lingular segment
- S VI . 上段 superior segment



A



B

- S VII . 内侧底段又称“心底段”
medial basal segment (cardiac basal segment)
- S VIII . 前底段. anterior basal segment
- S IX . 外侧底段 lateral basal segment
- S X . 后底段 posterior basal segment

图 105 左肺支气管肺段(A. 外侧面观, B. 内侧面观)
Bronchopulmonary segments of left lung
(A.lateral aspect,B.medial aspect)

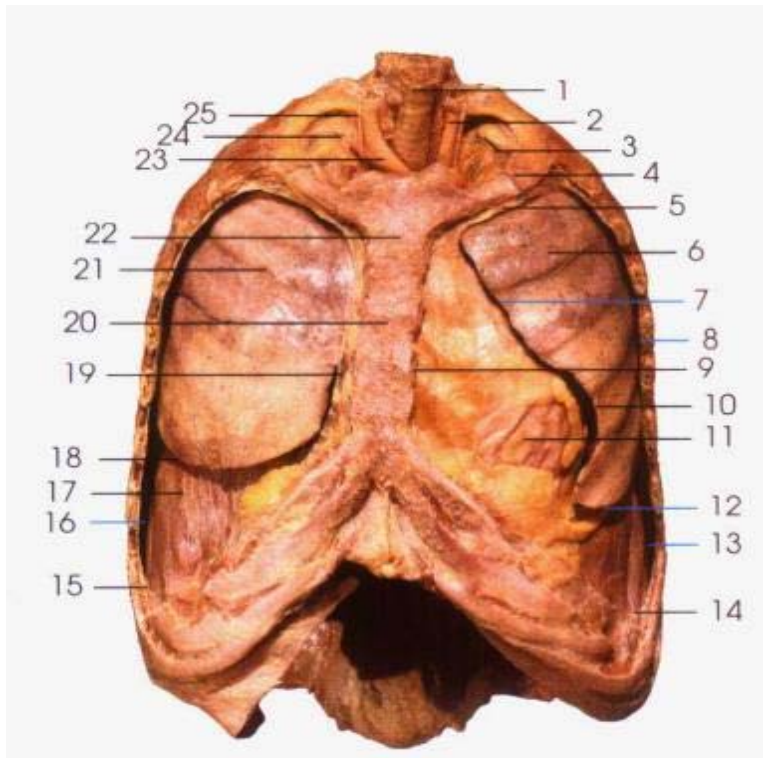
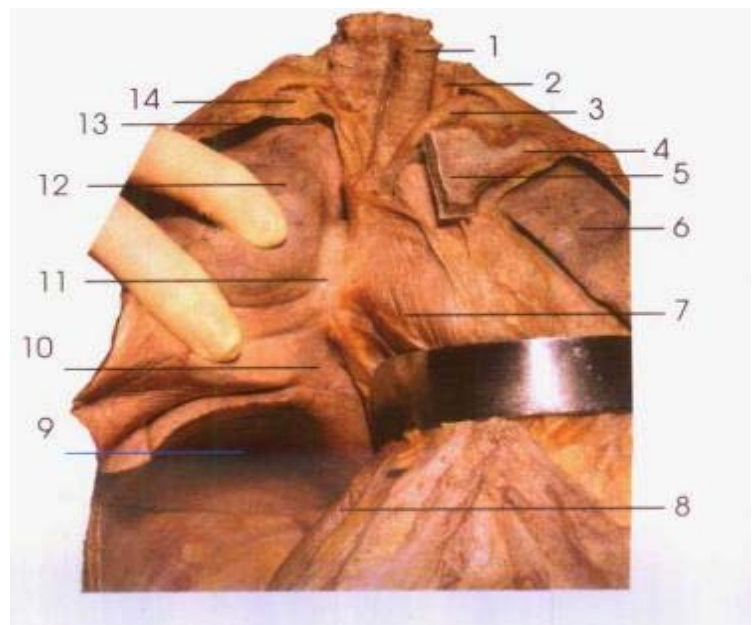


图 106 胸膜和胸膜腔
Pleura and pleural cavity

1. 气管 trachea
2. 左颈总动脉 left common carotid a.
3. 头臂干 brachiocephalic trunk
4. 第一肋 the first rib
5. 胸骨柄 manubrium sterni
6. 左肺 left lung
7. 纵隔右侧面和纵隔胸膜 right aspect of mediastinum and mediastinal pleura
8. 膈和膈胸膜 diaphragm and diaphragmatic pleura
9. 右肺膈面 diaphragmatic surface of right lung
10. 肺韧带 pulmonary lig.
11. 右肺根 root of right lung
12. 右肺 right lung
13. 右肺尖 apex of right lung
14. 胸膜顶 cupula of pleura

图 107 肺根和肺韧带(右侧)
Root of lung and pulmonary ligament(Right side)

1. 气管 trachea
2. 左颈总动脉 left common carotid a.
3. 左肺尖 apex of left lung.
4. 第一肋 the first rib
5. 肋胸膜 costal pleura
6. 左肺及肺胸膜 left lung and pulmonary pleura
7. 左肺前缘 anterior margin of left lung
8. 胸膜腔 pleural cavity
9. 左肋纵隔胸膜返折线 left costomedias-tinal line of reflection.
10. 心切迹 cardiac notch
11. 心包及纵隔胸膜 pericardium and med-iaistinal pleura
12. 左肺下缘 inferior margin of left lung
13. 左肋膈隐窝 left costodiaphragmatic recess
14. 左肋膈胸膜返折线 left costodia-phragmatic line of reflection.
15. 右肋膈胸膜返折线 right costodia-phragmatic line of reflection
16. 右肋膈隐窝 right costodiaphragmatic recess
17. 膈及膈胸膜 diaphragm and diaphr-agmaic pleura
18. 右肺下缘 inferior margin of right lung
19. 肋胸膜 costal pleura
20. 胸骨体 body of sternum
21. 右肺 right lung
22. 胸骨柄 manubrium sterni
23. 头臂干 brachiocephalic trunk
24. 胸膜顶 cupula of pleura
25. 迷走神经 vagus n.

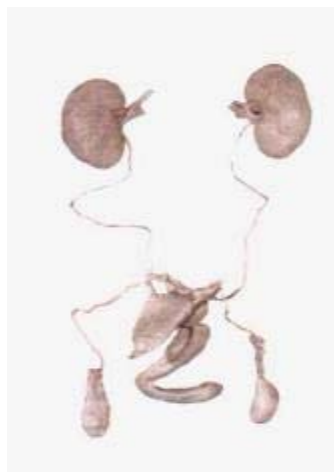


4

第4章

UROGENITAL SYSTEM

泌尿生殖系统



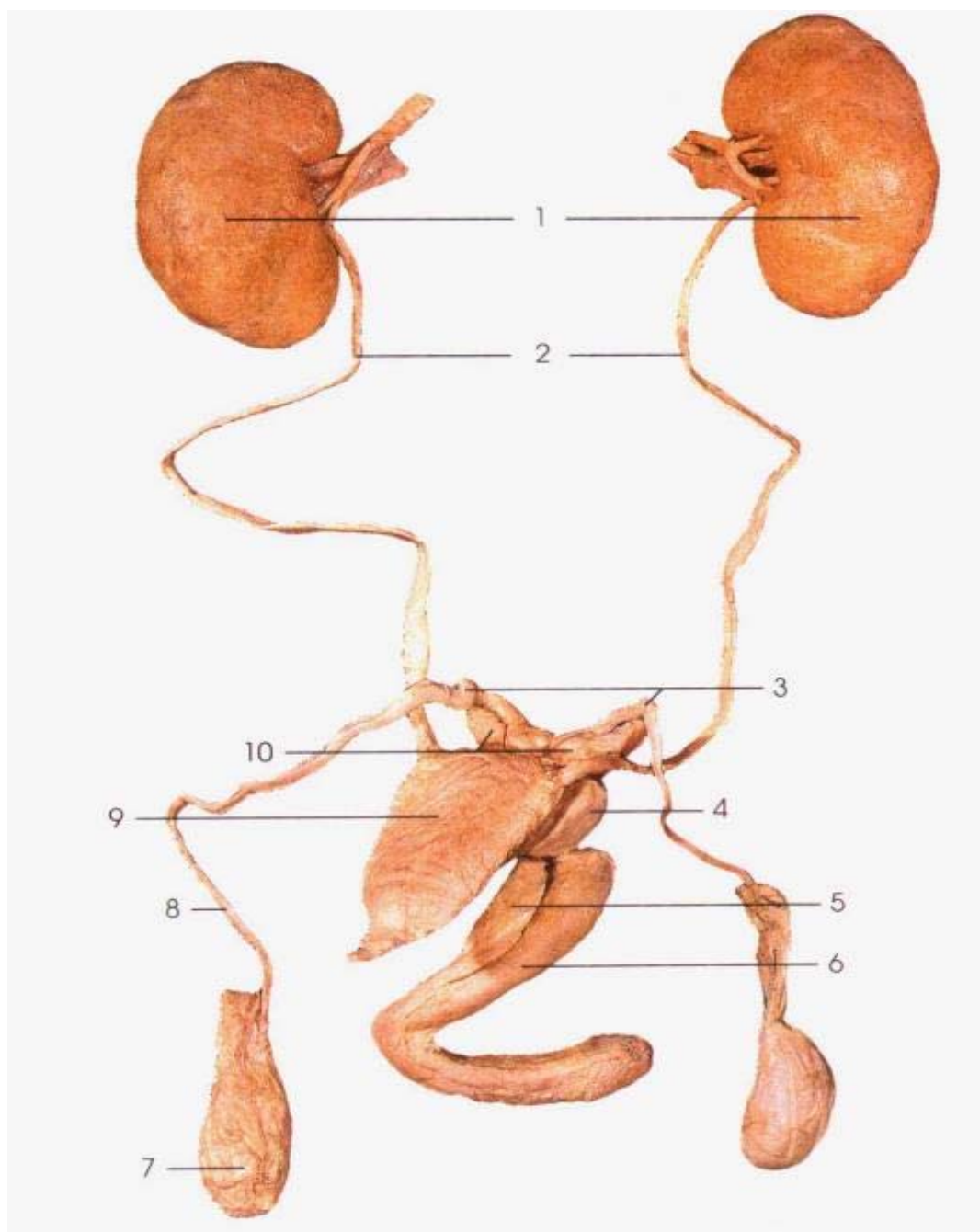


图 108 男性泌尿生殖系统概观
General arrangement of the urogenital system of male

- | | |
|--------------------------------------|-----------------------------------|
| 1. 肾 kidneys | urethra |
| 2. 输尿管 ureters | 7. 睾丸及其被膜 testis and its covering |
| 3. 输精管壶腹 ampulla of deferent ducts | 8. 输精管 deferent duct |
| 4. 前列腺 prostate | 9. 膀胱 urinary bladder |
| 5. 阴茎海绵体 cavernous body of the penis | 10. 精囊腺 seminal vesicle |
| 6. 尿道海绵体 spongy body of the | |

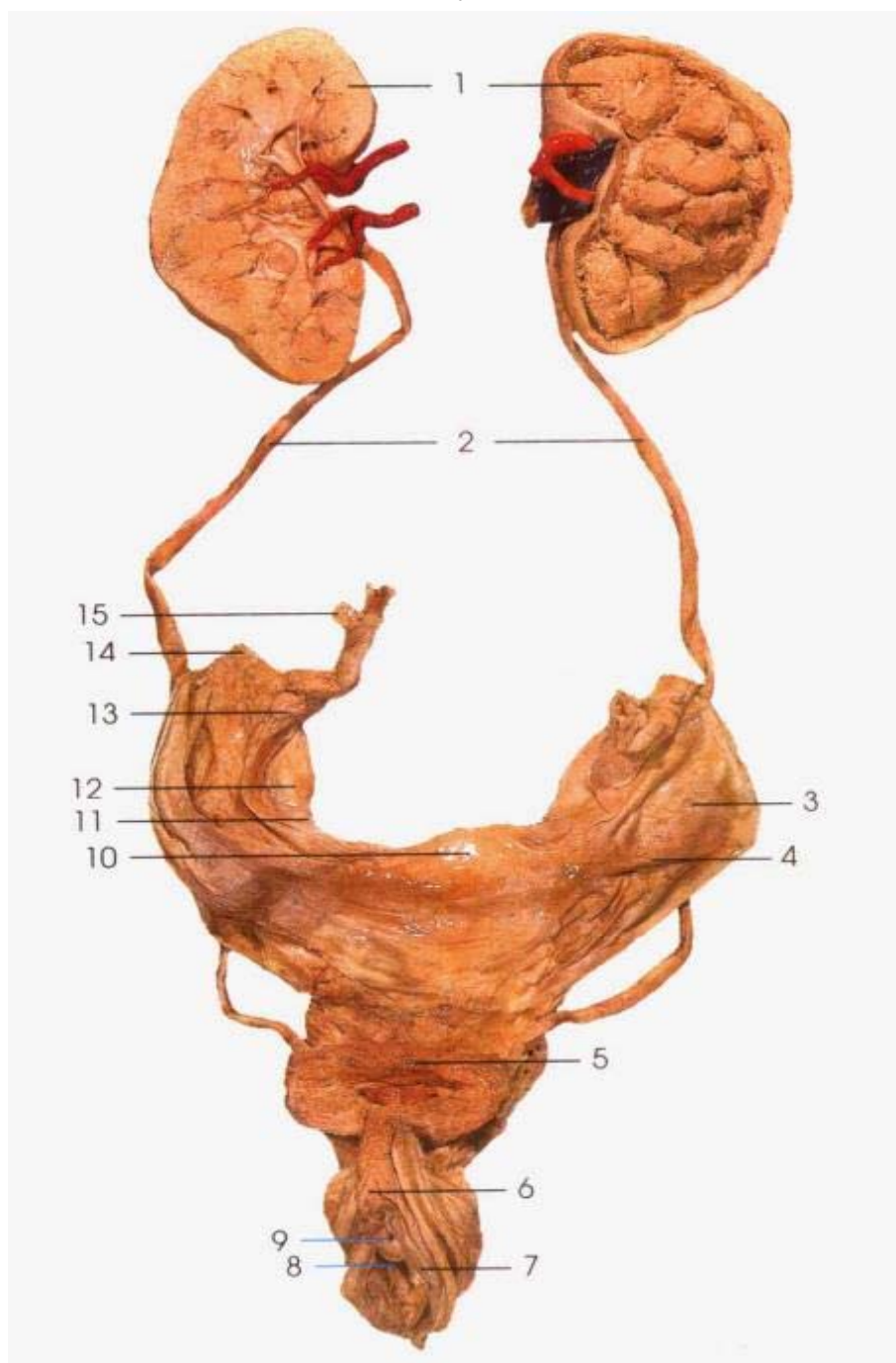
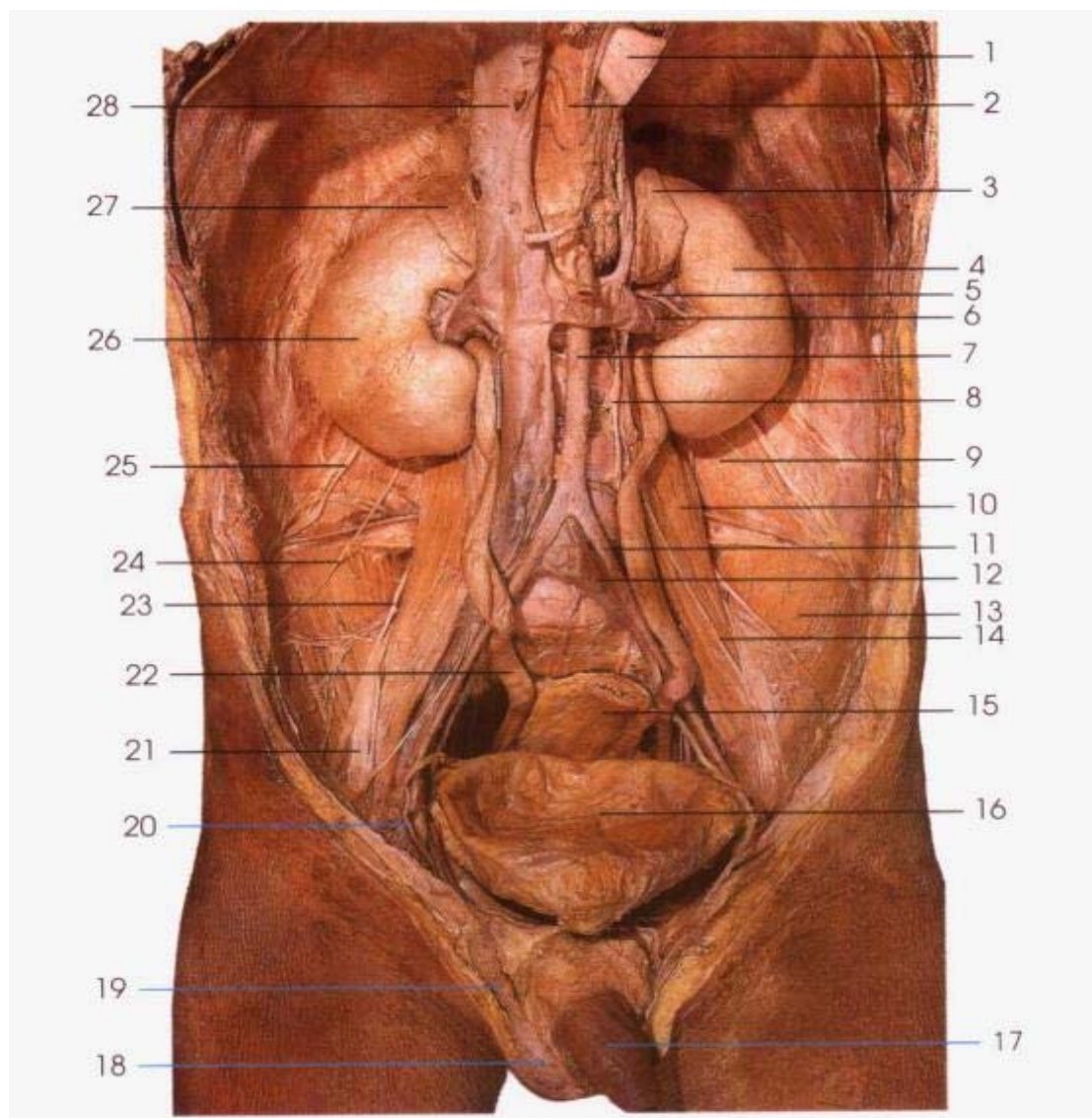


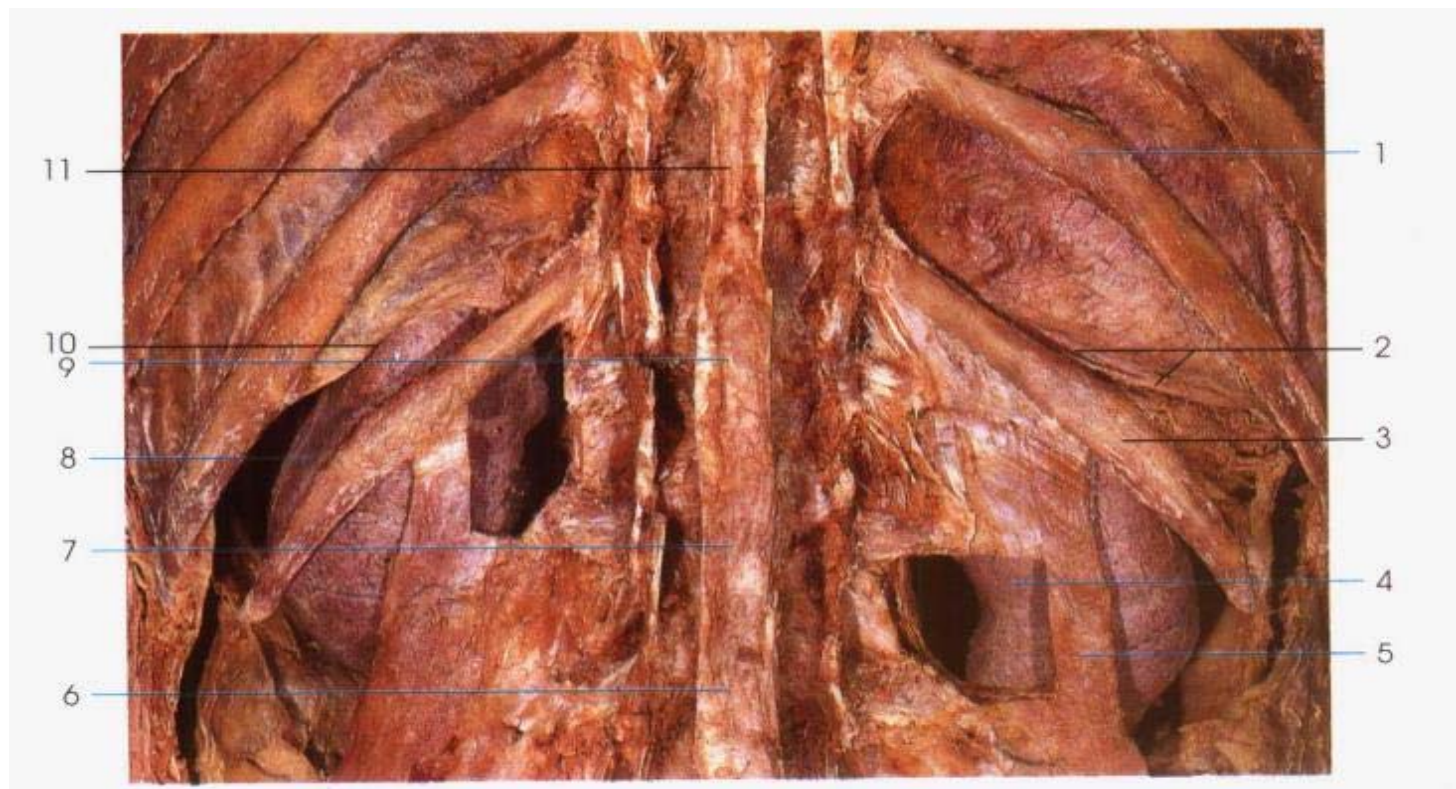图 109 女性泌尿生殖系统概观
General arrangement of the urogenital system of female

- | | |
|-----------------------------------|--|
| 1. 肾 kidneys | 9. 尿道外口 external orifice of urethra |
| 2. 输尿管 ureters | 10. 子宫 uterus |
| 3. 子宫阔韧带 broad ligament of uterus | 11. 卵巢固有韧带 proper ligament of ovary |
| 4. 子宫圆韧带 round ligament of uterus | 12. 卵巢 ovary |
| 5. 膀胱 urinary bladder | 13. 输卵管 uterine tube |
| 6. 阴蒂 clitoris | 14. 卵巢悬韧带 suspensory ligament of ovary |
| 7. 小阴唇 lesser lip of pudendum | 15. 输卵管伞 fimbriae of uterine tube |
| 8. 阴道口 vaginal orifice | |



A. 前面观
Anterior aspect

- | | |
|-------------------------------------|---|
| 1. 食管腹段 abdominal part of esophagus | 16. 膀胱 urinary bladder |
| 2. 膈 diaphragm | 17. 阴茎 penis |
| 3. 左肾上腺 left suprarenal gland | 18. 睾丸 testis |
| 4. 左肾 left kidney | 19. 精索 spermatic cord |
| 5. 左肾动脉 left renal a. | 20. 输精管 deferent duct |
| 6. 左肾静脉 left renal v. | 21. 股神经 femoral n. |
| 7. 腹主动脉 abdominal aorta | 22. 输尿管 ureter |
| 8. 腰交感神经节 lumbar ganglion | 23. 股外侧皮神经 lateral femoral cutaneous n. |
| 9. 腰方肌 quadratus lumborum | 24. 髂腹股沟神经 ilioinguinal n. |
| 10. 腰大肌 psoas major | 25. 髂腹下神经 iliohypogastric n. |
| 11. 左髂总动脉 left common iliac a. | 26. 右肾 right kidney |
| 12. 左髂总静脉 left common iliac v. | 27. 右肾上腺 right suprarenal gland |
| 13. 髂肌 iliacus | 28. 下腔静脉 inferior vena cava |
| 14. 生殖股神经 genitofemoral n. | |
| 15. 直肠 rectum | |



B. 后面观 (肾后毗邻)
Posterior aspect (posterior relationship of kidneys)

- | | |
|--------------------------------------|---|
| 1. 第十一肋 11th rib | 6,7. 棘突(L2, L1) spinous process(L2,L1) |
| 2,10. 胸膜下缘 inferior margin of pleura | 8. 左肾 left kidney |
| 3. 第十二肋 12th rib | 9,11 棘突(T12, T11) spinous process (T12,T11) |
| 4. 右肾 right kidney | |
| 5. 腰方肌 quadratus lumborum | |

图 110 肾和输尿管位置(A, B)
Location of kidneys and uretersem(A,B)

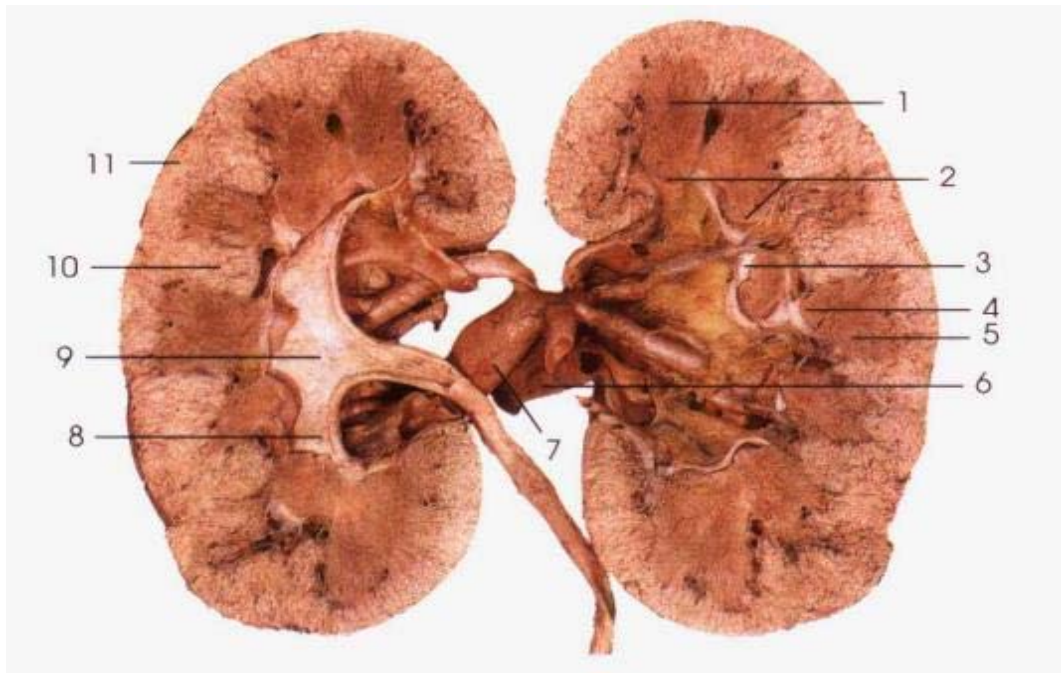


图 111 肾(冠状切面)
Kidney(coronal section)

- 1.5.16. 肾锥体 renal pyramids
 2.4.23. 肾乳头 renal papillae
 3.12.19.21. 肾小盏 minor renal calices
 6. 肾静脉 renal v.
 7. 肾动脉 renal a.
 8.13.20. 肾大盏 major renal calices
 9.14.17. 肾盂 renal pelvis
 10. 肾柱 renal columns
 11.22. 肾皮质 renal cortex
 15.18. 输尿管 ureter

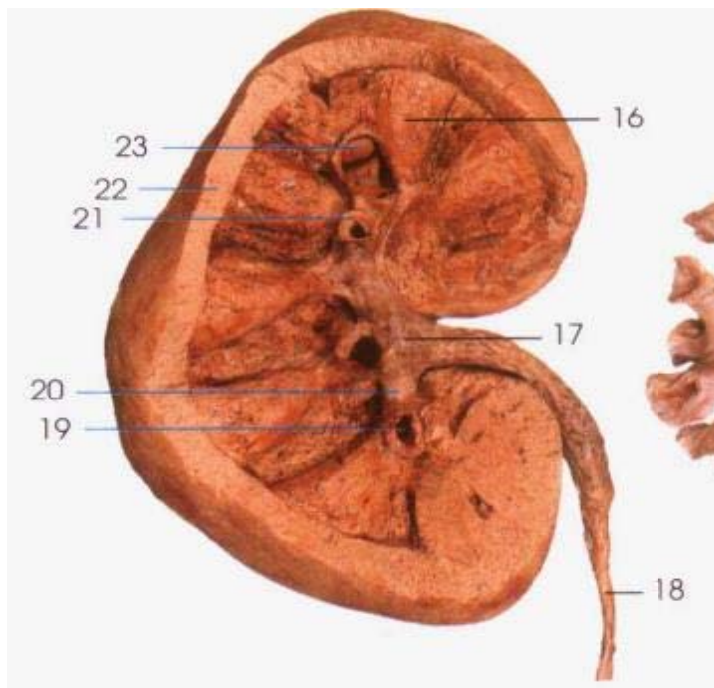


图 112 肾(小叶)
Kidney(renal lobes)

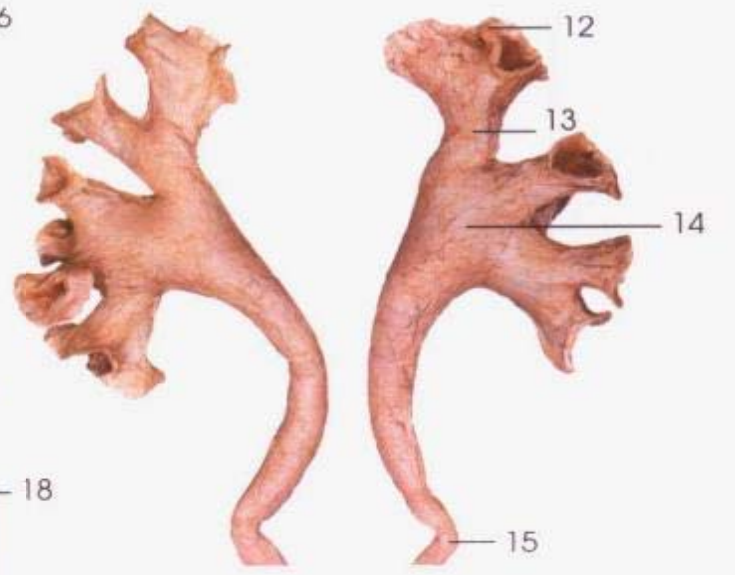


图 113 肾盏及肾盂
Renal calices and pelvis

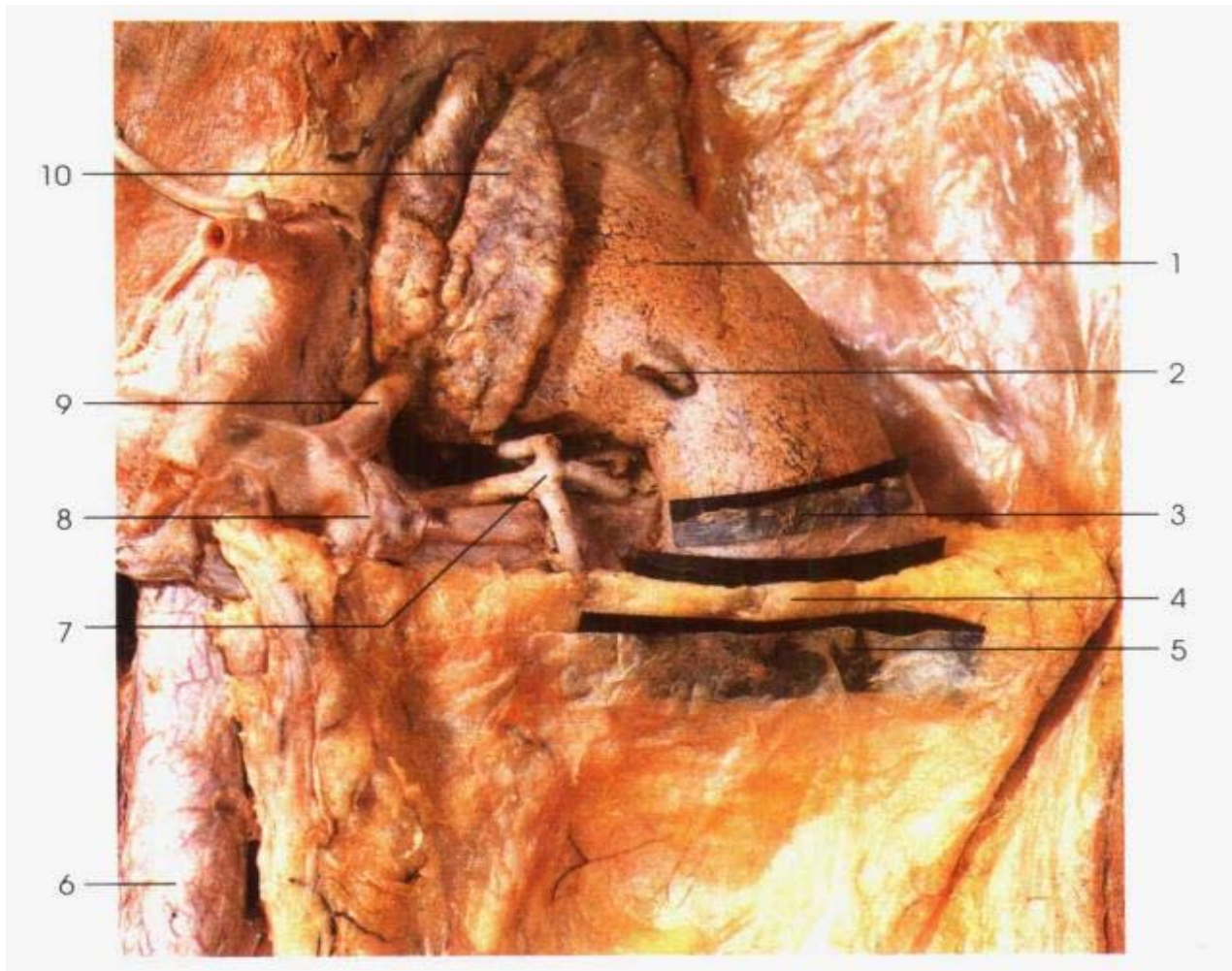

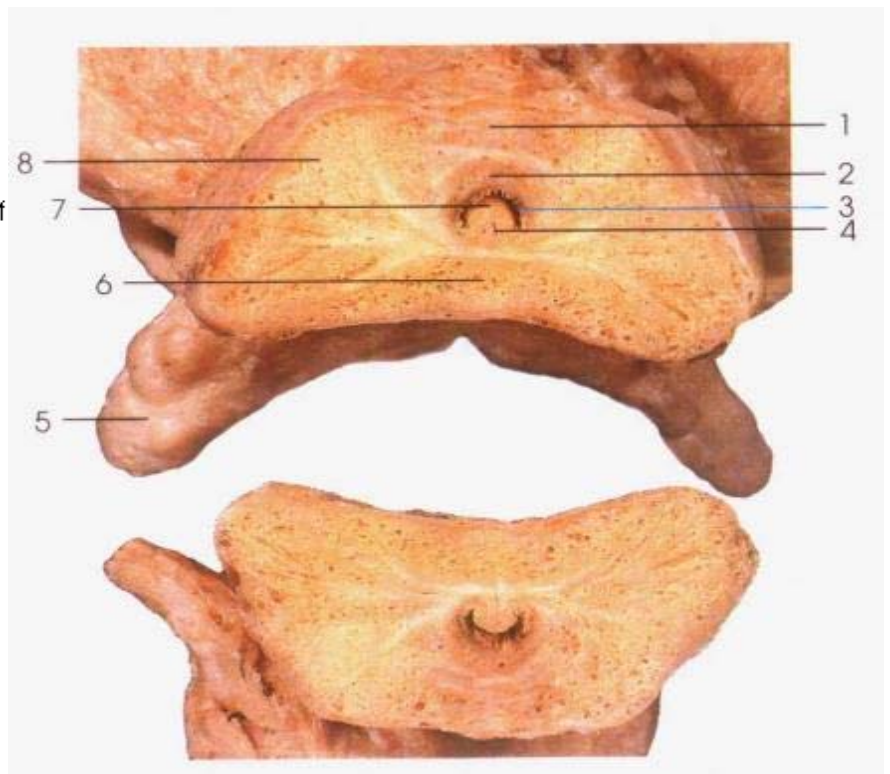


图 114 (左)肾的被膜
The coverings of (left) kidney

- | | |
|-----------------------------------|--------------------------------|
| 1. 肾 kidney | 5. 肾筋膜 renal fascia |
| 2. 副肾动脉 accessory renal a. | 6. 腹主动脉 abdominal aorta |
| 3. 肾纤维囊 fibrous capsule of kidney | 7. 肾动脉 renal a. |
| 4. 脂肪囊 adipose capsule | 8. 肾静脉 renal v. |
| | 9. 左肾上腺静脉 left suprarenal v. |
| | 10. 左肾上腺 left suprarenal gland |

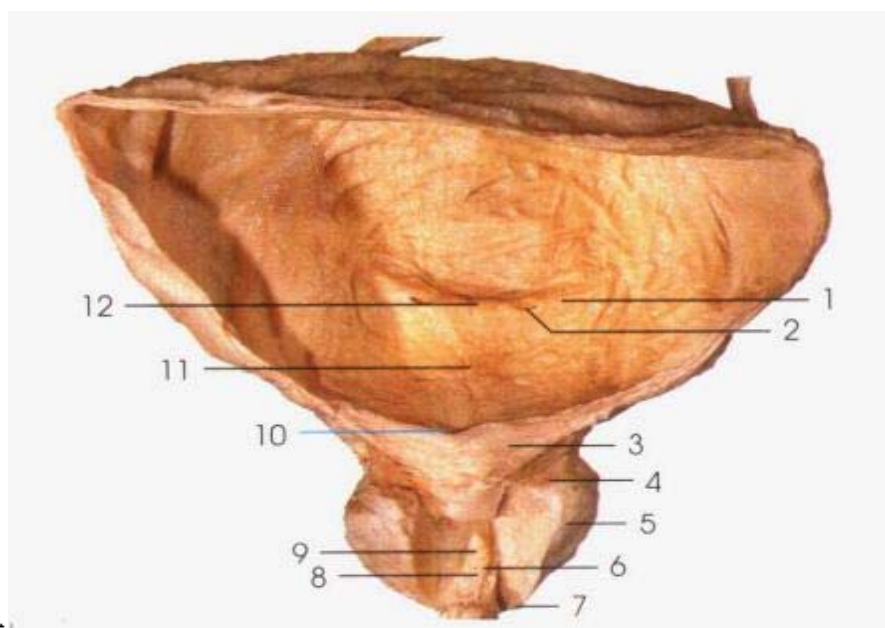


- | | |
|------------------------|--|
| 1. 输尿管 ureter | 6. 膀胱底 base of bladder |
| 2. 输精管 deferent ducts | 7. 膀胱体 body of bladder |
| 3. 精囊腺 seminal vesicle | 8. 膀胱尖 apex of bladder |
| 4. 前列腺 prostate | 9. 脐正中韧带 median umbilical ligament
(obliterated allantoic duct) |
| 5. 膀胱颈 neck of bladder | |

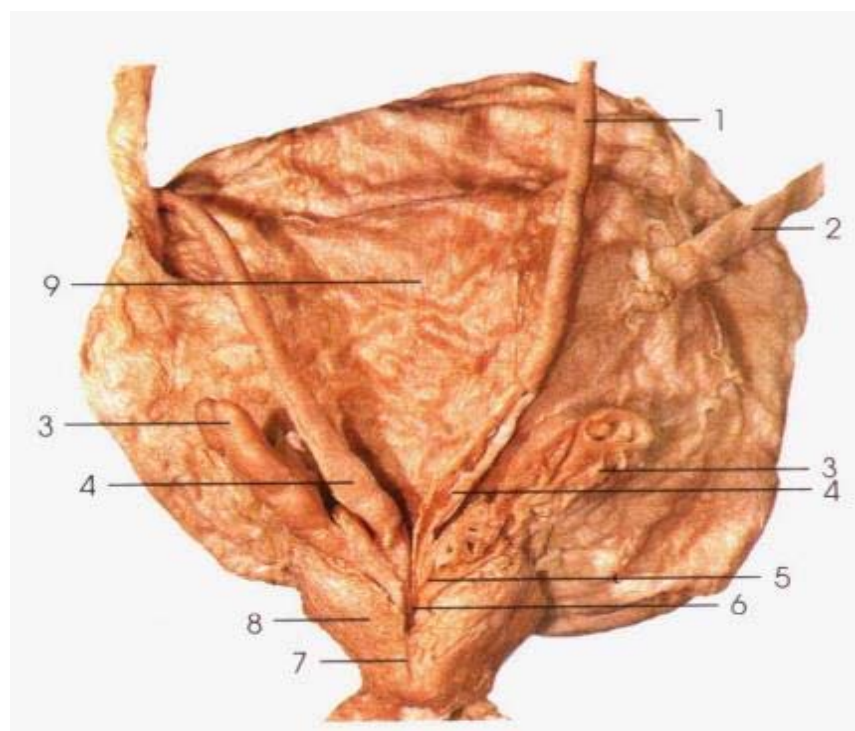


- | |
|--|
| 1. 前列腺前叶 anterior lobe of prostate |
| 2. 前列腺中叶 median lobe of prostate |
| 3. 尿道前列腺部 prostatic portion of the urethra |
| 4. 射精管 ejaculatory duct |
| 5. 精囊腺 seminal vesicle |
| 6. 前列腺后叶 posterior lobe of prostate |
| 7. 尿道嵴 urethral crest |
| 8. 前列腺侧叶 lateral lobe of prostate |

1. 输尿管襞 ureteric fold
2. 输尿管口 ureteric orifice
3. 膀胱颈 neck of urinary bladder
4. 前列腺底 base of the prostate
5. 前列腺体 body of the prostate
6. 射精管开口 opening of ejaculatory duct
7. 前列腺尖 apex of the prostate
8. 尿道嵴 urethral crest
9. 精阜 seminal colliculus
10. 尿道内口 internal urethral orifice
11. 膀胱三角 trigone of bladder
12. 输尿管间襞 interureteric fold



C. 前面观
Anterior aspect



D. 后面观
Posterior aspect

1. 输精管 deferent duct
2. 输尿管 ureter
3. 精囊腺 seminal vesicle
4. 输精管壶腹 ampulla of deferent duct
5. 精囊腺排泄管 excretory duct of seminal vesicle
6. 射精管 ejaculatory duct
7. 前列腺沟 groove of prostate
8. 前列腺 prostate
9. 膀胱底 base of urinary bladder

图 115 膀胱、前列腺和精囊(A, B, C, D)
The urinary bladder, prostate and seminal vesicle(A,B,C,D)

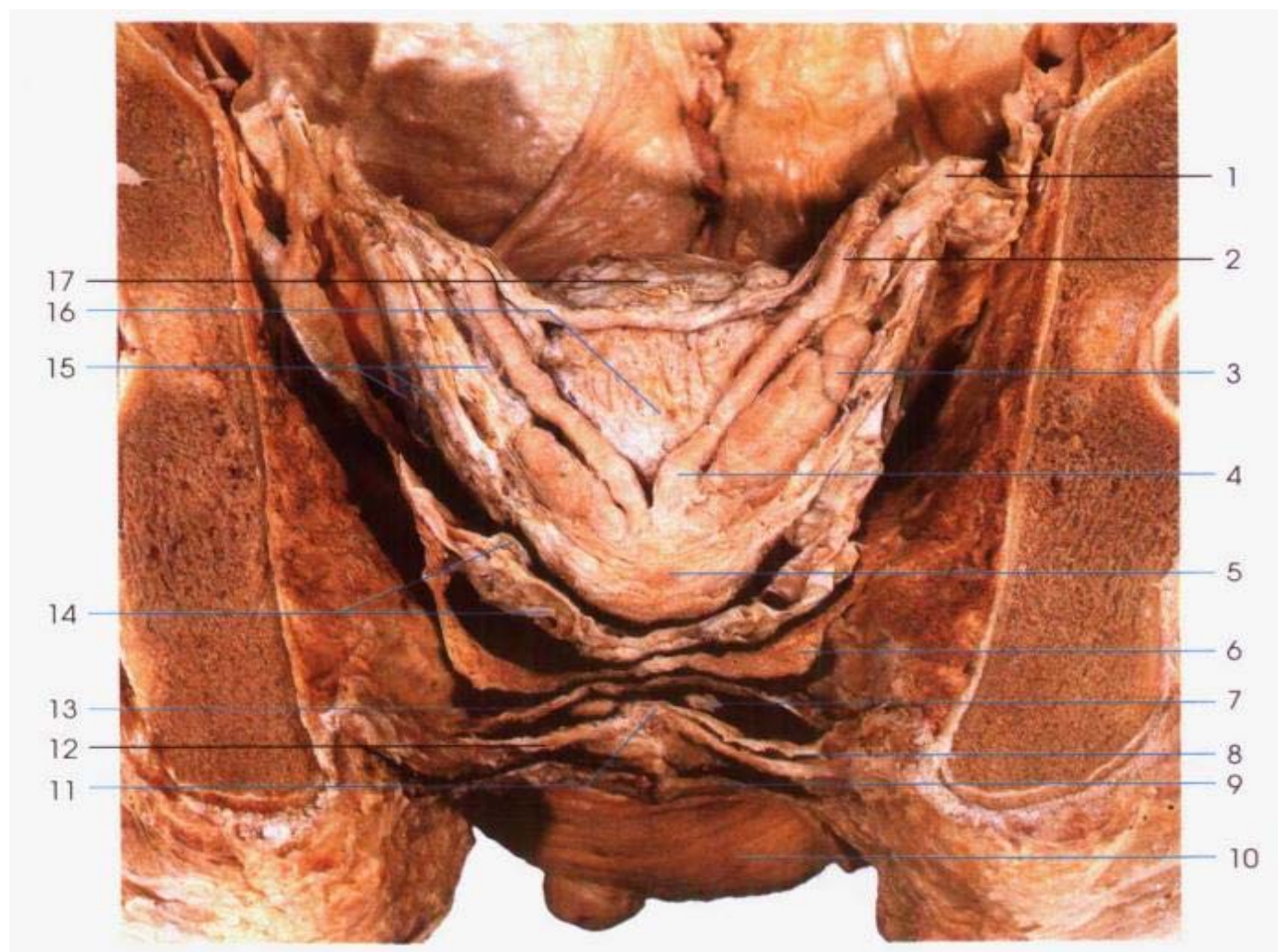


图 116 男性膀胱底(后面观)
Fundus of the male urinary bladder (posterior aspect)

- | | |
|---|--|
| 1. 输尿管 ureter | 11. 会阴体 (会阴中心腱) perineal body (perineal central tendon) |
| 2. 输精管 deferent duct | 12. 会阴浅横肌 superficial transverse muscle of perineum |
| 3. 精囊 seminal vesicle | 13. 会阴深横肌和尿生殖膈上筋膜 deep transverse muscle of perineum and superior fascia of urogenital diaphragm |
| 4. 输精管壶腹 ampulla of deferent duct | 14. 前列腺静脉丛 prostatic venous plexus |
| 5. 前列腺 prostate | 15. 膀胱静脉丛 vesical venous plexus |
| 6. 肛提肌(盆膈) levator ani (pelvic diaphragm) | 16. 膀胱 urinary bladder |
| 7. 尿道球腺 bulbourethral gland | 17. 脏腹膜 visceral peritoneum |
| 8. 尿生殖膈下筋膜 inferior fascia of urogenital | |
| 9. 会阴浅筋膜 superficial fascia of perineum | |
| 10. 阴囊 scrotum | |

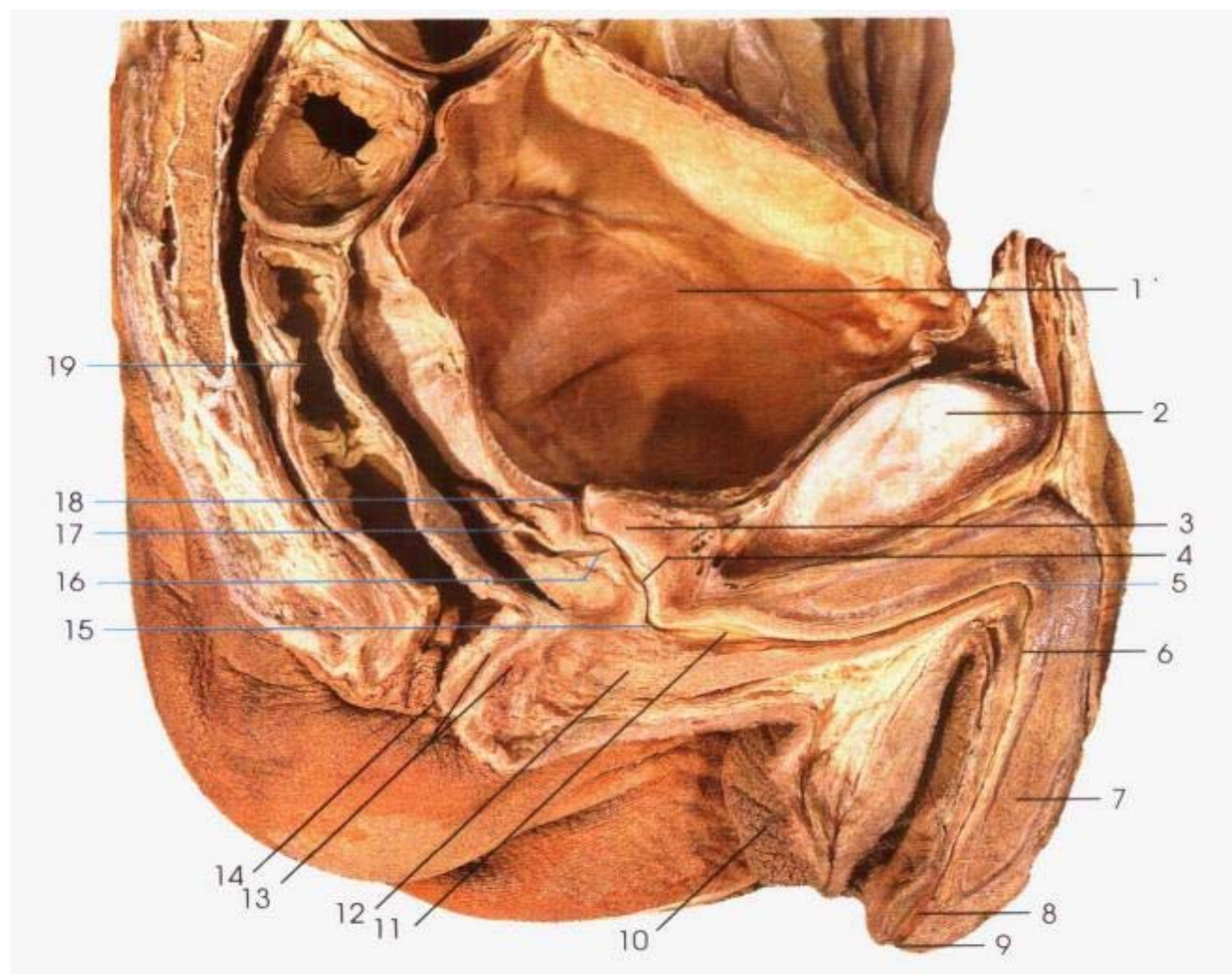
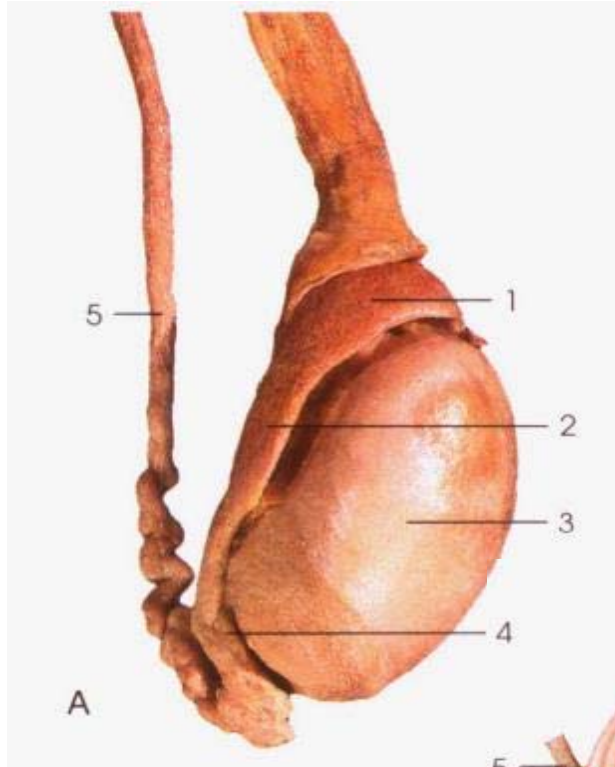
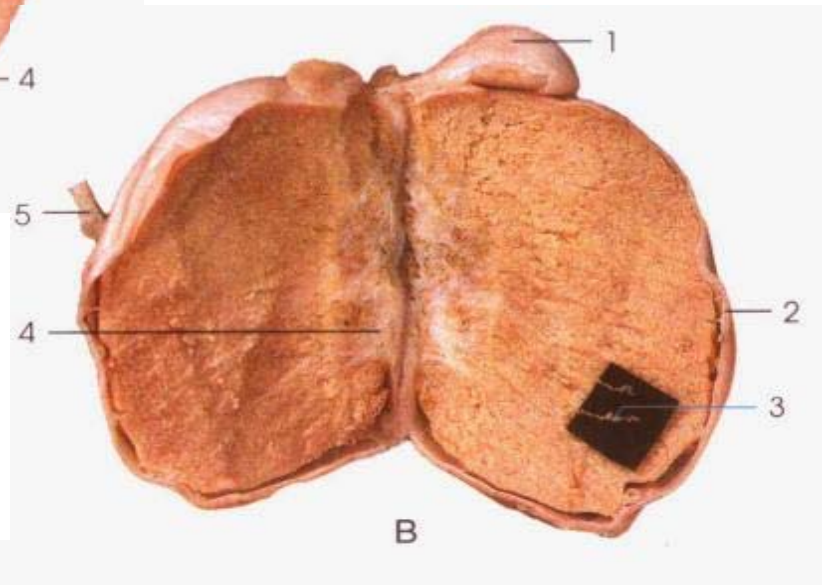


图 117 男性盆部(正中矢状剖面)
The pelvis of the male(median sagittal section)

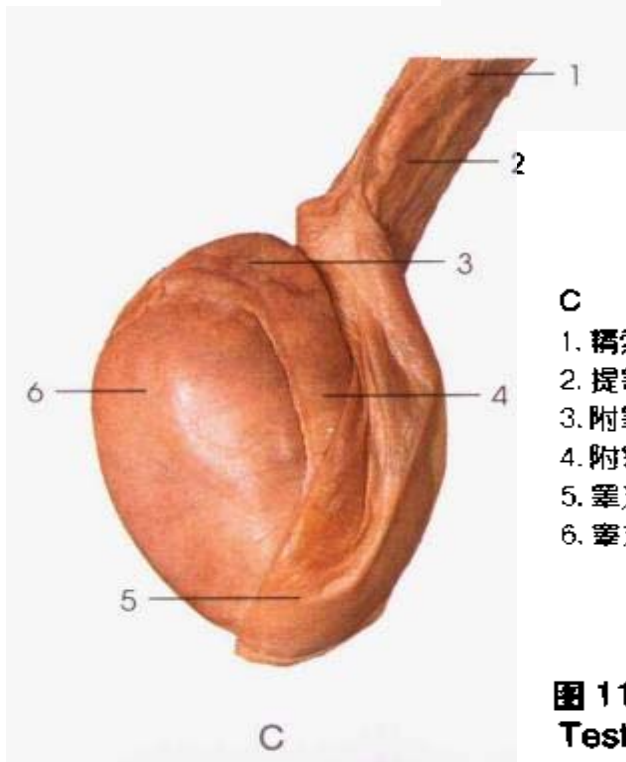
- | | |
|--|---|
| 1.膀胱 urinary bladder | 11.尿道球部 bulbo part of the urethra |
| 2.耻骨联合 symphysis pubis | 12.尿道球 bulb of urethra |
| 3.前列腺 prostate | 13.肛门括约肌 sphincter muscles of the anus |
| 4.尿道前列腺部 prostatic portion of the urethra | 14.肛门 anus |
| 5.耻骨前弯 prepubis curvature | 15.尿道膜部 membranous portion of the urethra |
| 6.尿道海绵体部 The spongy portion of the urethra | 16.射精管 ejaculatory duct |
| 7.阴茎海绵体 cavernous body of penis | 17.精囊腺 seminal vesicle |
| 8.舟状窝 navicular fossa | 18.尿道内口 internal urethral orifice |
| 9.尿道外口 external urethral orifice | 19.直肠 rectum |
| 10.阴囊 scrotum | |



- A**
1. 附睾头 head of epididymis
 2. 附睾体 body of epididymis
 3. 睾丸 testis
 4. 附睾尾 tail of epididymis
 5. 输精管 deferent duct



- B**
1. 附睾 epididymis
 2. 睾丸白膜 tunica albuginea of testis
 3. 精曲小管 seminiferous tubules
 4. 睾丸纵隔 mediastinum testis
 5. 输精管 deferent duct



- C**
1. 精索 spermatic cord
 2. 提睾肌 cremasteric m.
 3. 附睾头 head of epididymis
 4. 附睾体 body of epididymis
 5. 睾丸鞘膜壁层 parietal tunica vaginalis
 6. 睾丸 testis

图 118 睾丸与附睾(A、B、C)
Testis and epididymis(A,B,C)

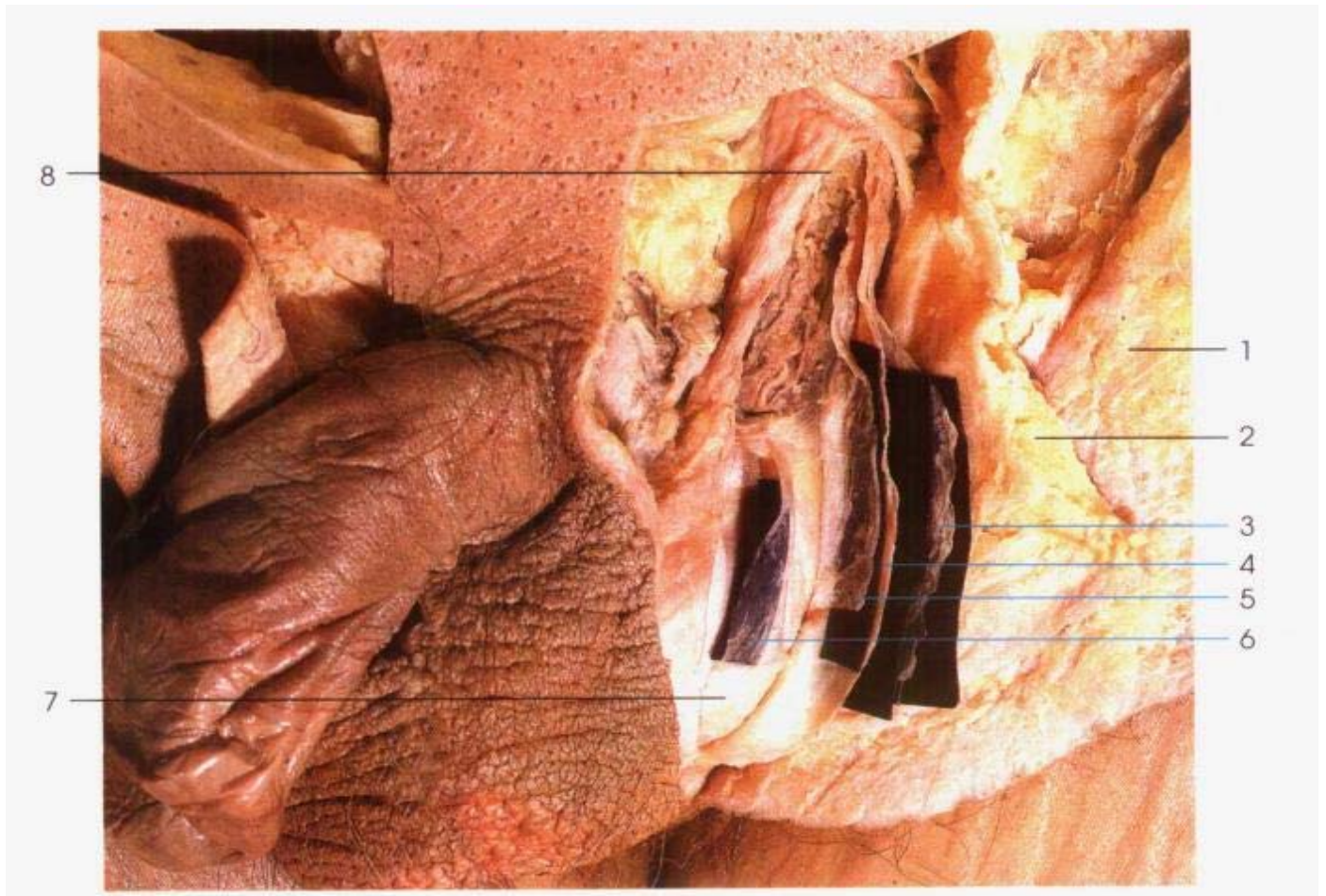
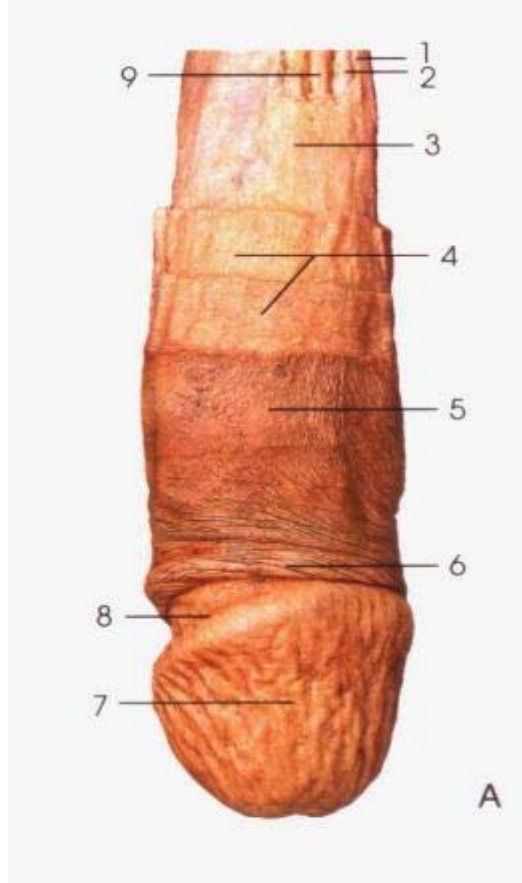


图 119 阴囊的层次
The coverings of scrotum

- 1. 皮肤 skin
- 2. 阴囊肉膜 dartos m. and fascia
- 3. 精索外筋膜 external spermatic fascia
- 4. 睾提肌 cremasteric m.

- 5. 精索内筋膜 internal spermatic fascia
- 6. 睾丸鞘膜壁层 parietal tunica vaginalis
- 7. 睾丸 testis
- 8. 精索 spermatic cord



A

1. 阴茎背神经 dorsal n. of penis
2. 阴茎背动脉 dorsal a. of penis
3. 阴茎深筋膜 deep fascia of penis
4. 阴茎浅筋膜 superficial fascia of penis
5. 皮肤 skin
6. 阴茎包皮 prepuce of penis
7. 阴茎头 glans penis
8. 阴茎颈 neck of penis
9. 阴茎背深静脉 deep dorsal v. of penis

B

1. 尿道球 bulb of urethra
2. 阴茎脚 crus penis
3. 尿道海绵体 cavernous body of urethra
4. 阴茎头 glans penis
5. 阴茎海绵体 cavernous body of penis
6. 阴茎背深静脉 deep dorsal vein of penis
7. 阴茎深动脉 deep a. of penis
8. 男尿道 male urethra
9. 阴茎海绵体白膜 albuginea of cavernous body of penis

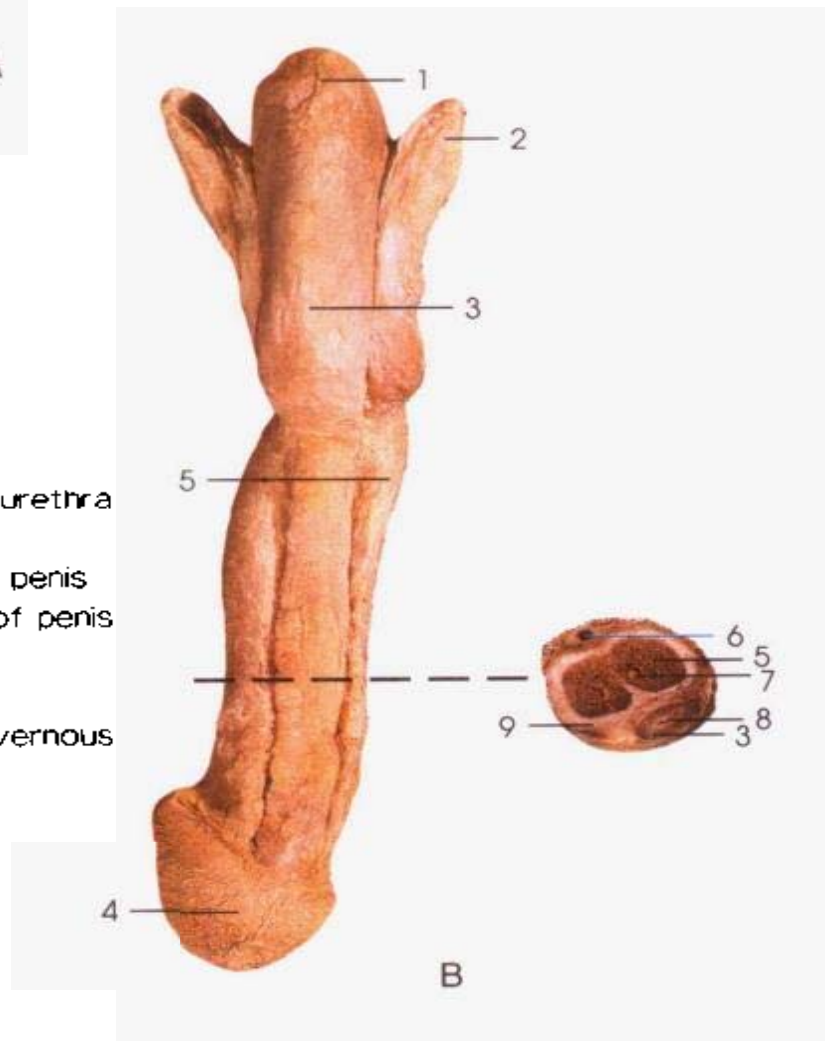


图 120 阴茎(A、B)
Penis(A,B)

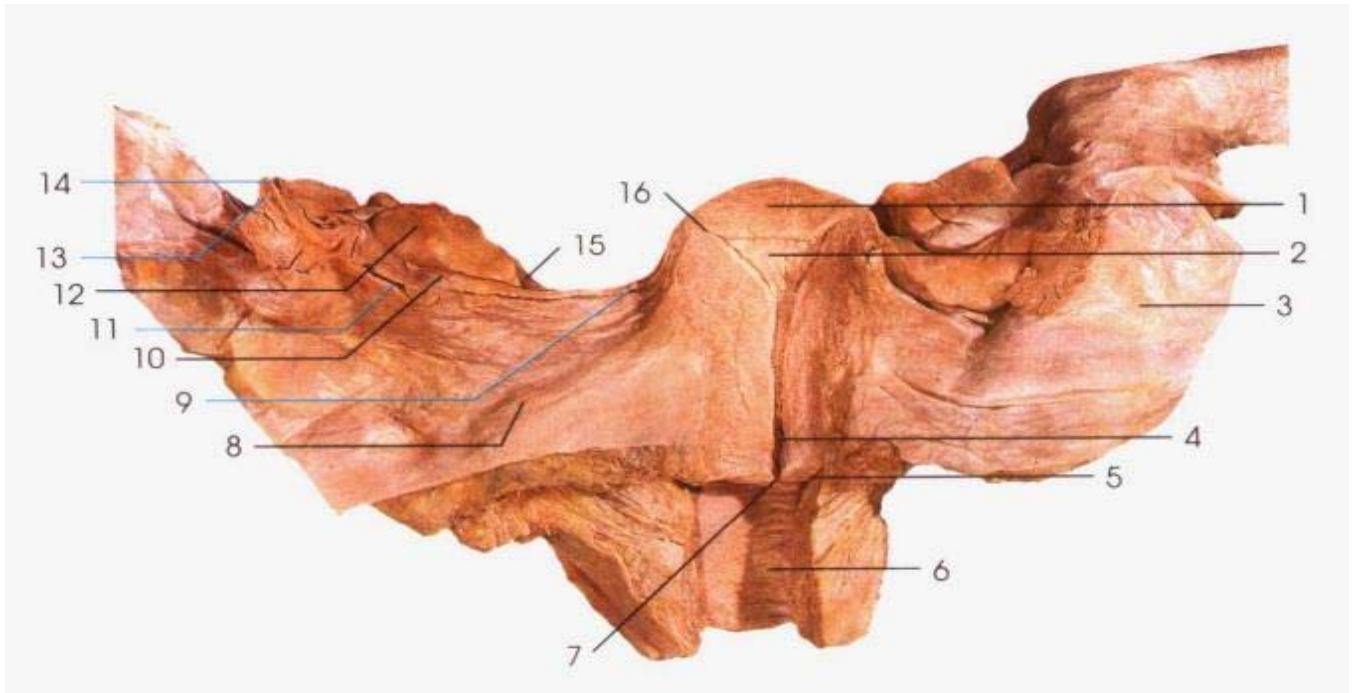


图 121 女性内生殖器
The female internal genital organs

- | | |
|----------------------------------|---|
| 1. 子宫底 fundus of uterus | 10. 输卵管壶腹 ampulla of uterine tube |
| 2. 子宫腔 cavity of uterus | 11. 输卵管腔 cavity of uterine tube |
| 3. 子宫阔韧带 broad lig.of uterus | 12. 卵巢 ovary |
| 4. 子宫颈管 cervical canal of uterus | 13. 输卵管漏斗部 infundibulum of uterine tube |
| 5. 阴道侧穹 lateral fornix of vagina | 14. 输卵管腹腔口 abdominal ostium |
| 6. 阴道褶 rugae of vagina | 15. 卵巢固有韧带 proper lig.of ovary |
| 7. 子宫口 ostium of uterus | 16. 输卵管子宫部 uterine part of uterine tube |
| 8. 子宫圆韧带 round lig.of uterus | |
| 9. 输卵管峡部 isthmus of uterine tube | |

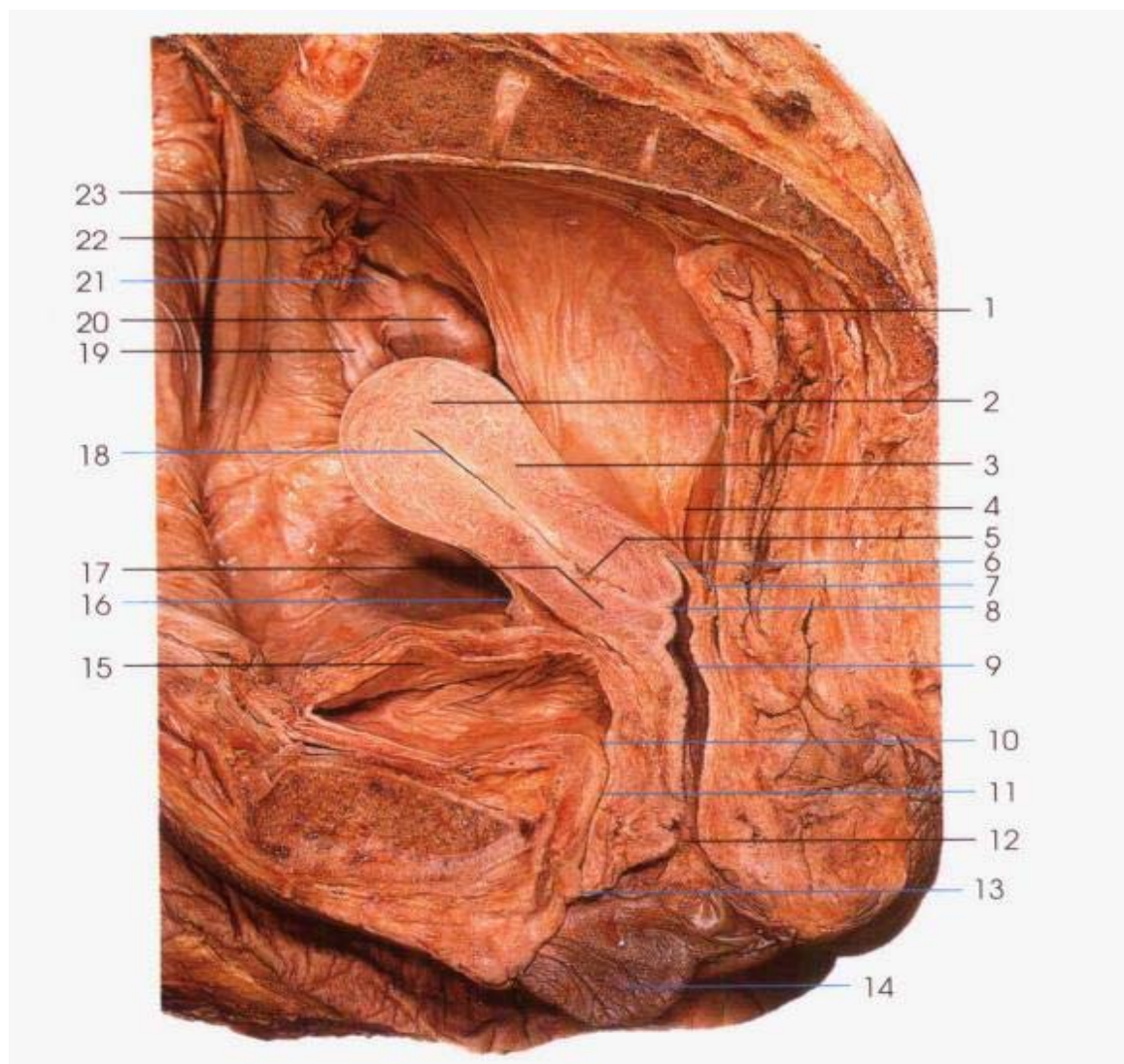


图 122 女性盆部(正中矢状剖面)
The pelvis of the female
(median sagittal section)

- | | |
|---|--------------------------------------|
| 1. 直肠 rectum | 12. 阴道口 vaginal orifice |
| 2. 子宫底 fundus of uterus | 13. 尿道外口 external orifice of urethra |
| 3. 子宫体 body of uterus | 14. 小阴唇 lesser lip of pudendum |
| 4. 直肠子宫襞 rectouterine fold | 15. 膀胱 urinary bladder |
| 5. 子宫颈管 canal of cervix of uterus | 16. 膀胱子宫陷凹 vesicouterine pouch |
| 6. 阴道穹(后部) fornix of vagina
(posterior part) | 17. 子宫颈 neck of uterus |
| 7. 直肠子宫陷凹 rectouterine pouch | 18. 子宫腔 cavity of uterus |
| 8. 子宫口 orifice of uterus | 19. 输卵管 uterine tube |
| 9. 阴道 vagina | 20. 卵巢 ovary |
| 10. 尿道内口 internal orifice of urethra | 21. 卵巢系膜 mesovarium |
| 11. 女尿道 female urethra | 22. 输卵管伞 fimbriae of uterine tube |
| | 23. 卵巢悬韧带 suspensory lig. of ovary |

1. 阴阜 mons pubis
2. 阴蒂 clitoris
3. 尿道外口 external orifice of urethra
4. 阴道口 vaginal orifice
5. 肛门 anus
6. 会阴 perineum
7. 小阴唇 lesser lip of pudendum
8. 大阴唇 greater lip of pudendum

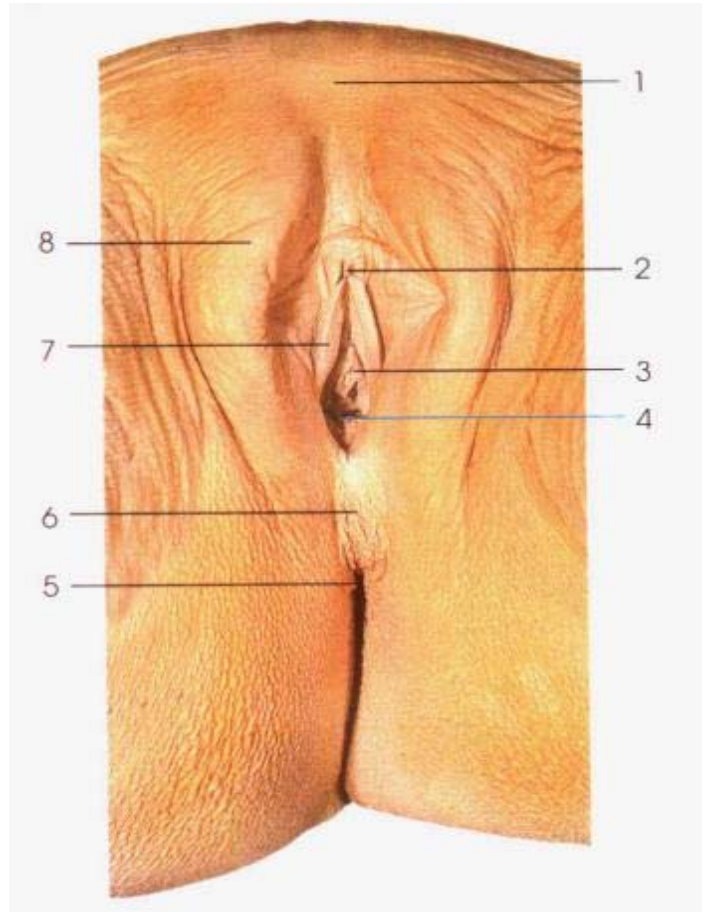


图 123 女性外生殖器
The female external organs

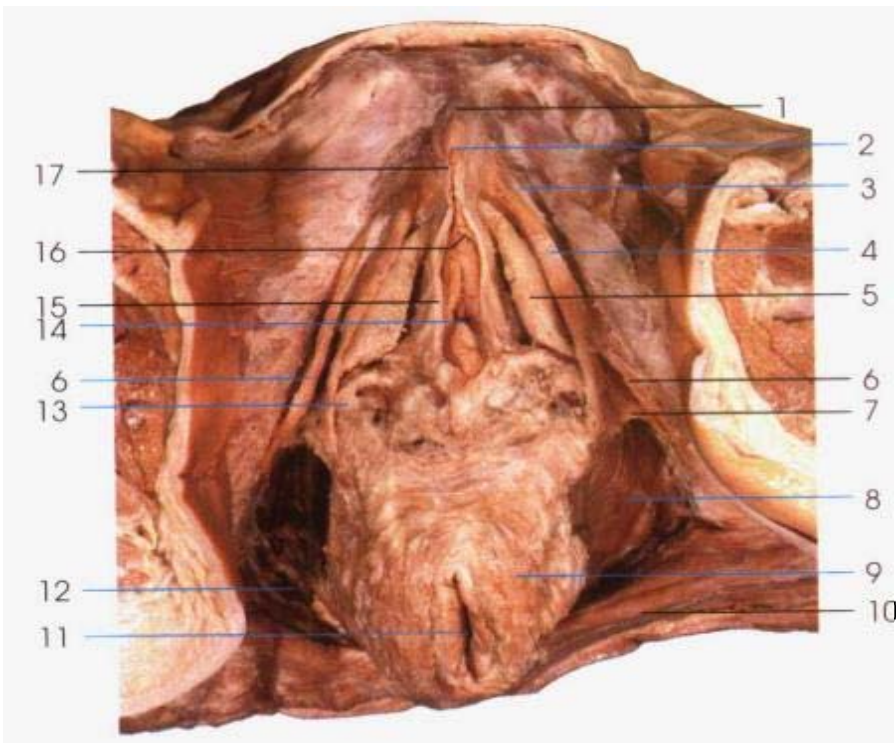
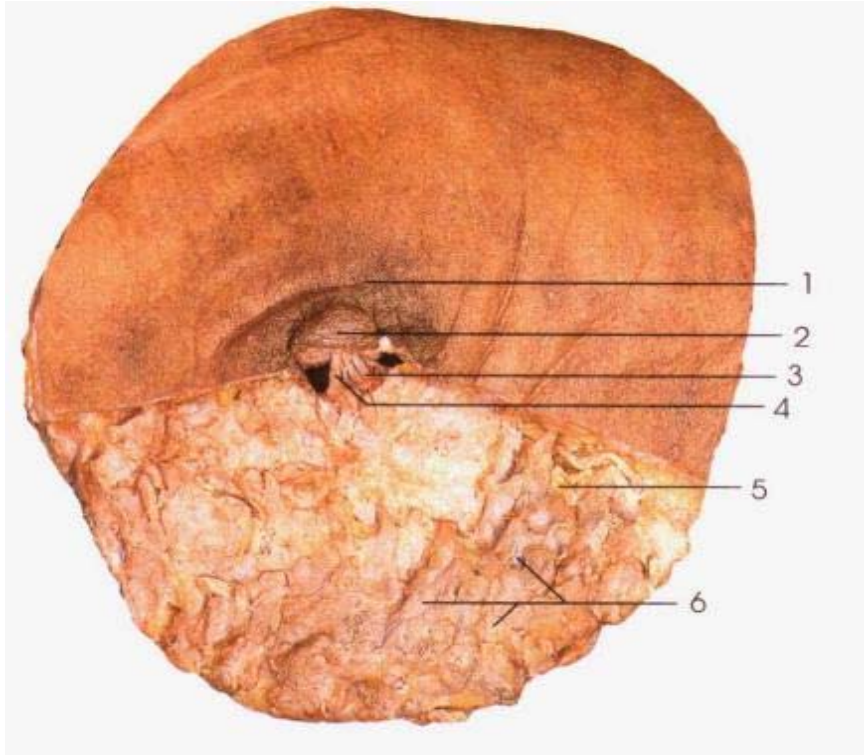


图 124 女性会阴浅隙及坐骨肛门窝
Superficial perineal space and
ischioanal fossa of the female

1. 阴蒂海绵体 cavernous body of clitoris
2. 阴蒂及阴蒂包皮 clitoris and prepuce of clitoris
3. 阴蒂脚 crus of clitoris
4. 球海绵体肌 bulbocavernosus
5. 前庭球 bulb of vestibule
6. 坐骨海绵体肌 ischiocavernosus
7. 会阴浅横肌 superficial transverse muscle of perineum
8. 肛提肌 levator ani
9. 肛门外括约肌 sphincter ani externus
10. 臀大肌 gluteus maximus
11. 肛门 anus
12. 坐骨肛门窝 ischioanal fossa
13. 前庭大腺 greater vestibular gland
14. 阴道口 vaginal orifice
15. 小阴唇 lesser lip of pudendum
16. 尿道外口 external orifice of urethra
17. 阴蒂系带 frenulum of clitoris



1. 乳晕 areola
2. 乳头 nipple
3. 输乳管 lactiferous ducts
4. 输乳管窦 ampulla
5. 脂肪 fat
6. 乳腺小叶 gland lobules

图 125 女性乳房
Female breast

1. 阴茎头 glans of penis
2. 深阴茎筋膜 deep fascia of penis
3. 球海绵体肌 bulbocavernosus
4. 会阴深横肌 deep transverse perineal m.
5. 会阴体 perineal body
6. 尿生殖膈上筋膜 superior fascia of urogenital diaphragm
7. 坐骨肛门窝 ischioanal fossa
8. 肛提肌 levator ani
9. 尾骨尖 the apex of coccyx
10. 臀大肌 gluteus maximus
11. 肛门 anus
12. 肛门外括约肌 external anal sphincter
13. 会阴浅横肌 transversus perineal superficialis
14. 尿生殖膈下筋膜 inferior fascia of urogenital diaphragm
15. 坐骨海绵体肌 ischiocavernosus

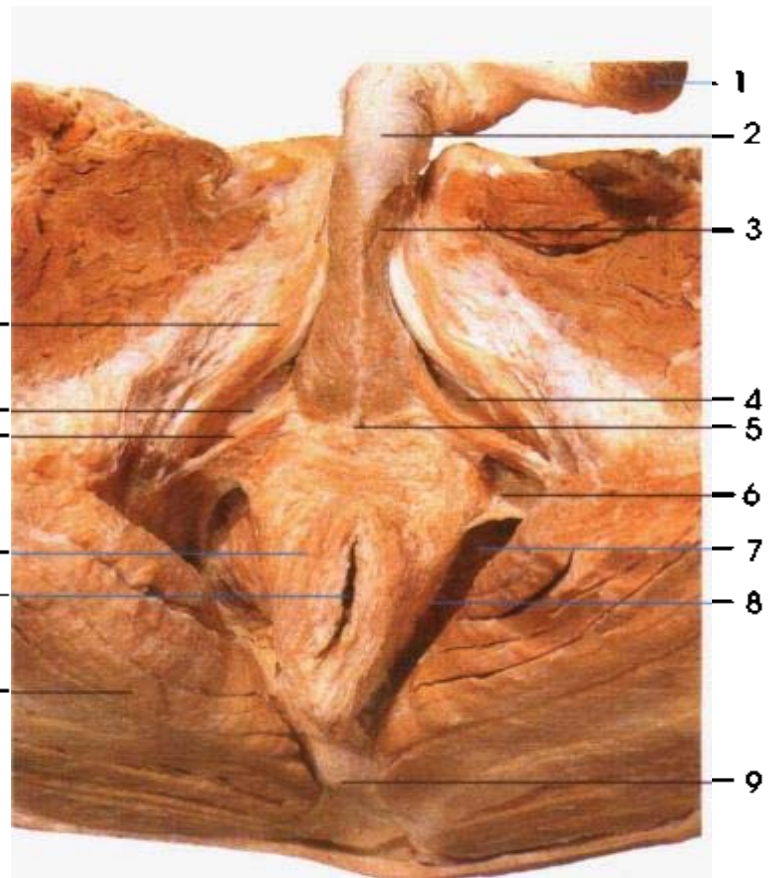


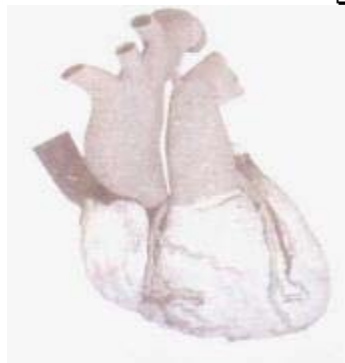图 126 男性会阴肌
The male perineum

第5章

心
血
管
系
统

5

CARDIOVASCULAR SYSTEM



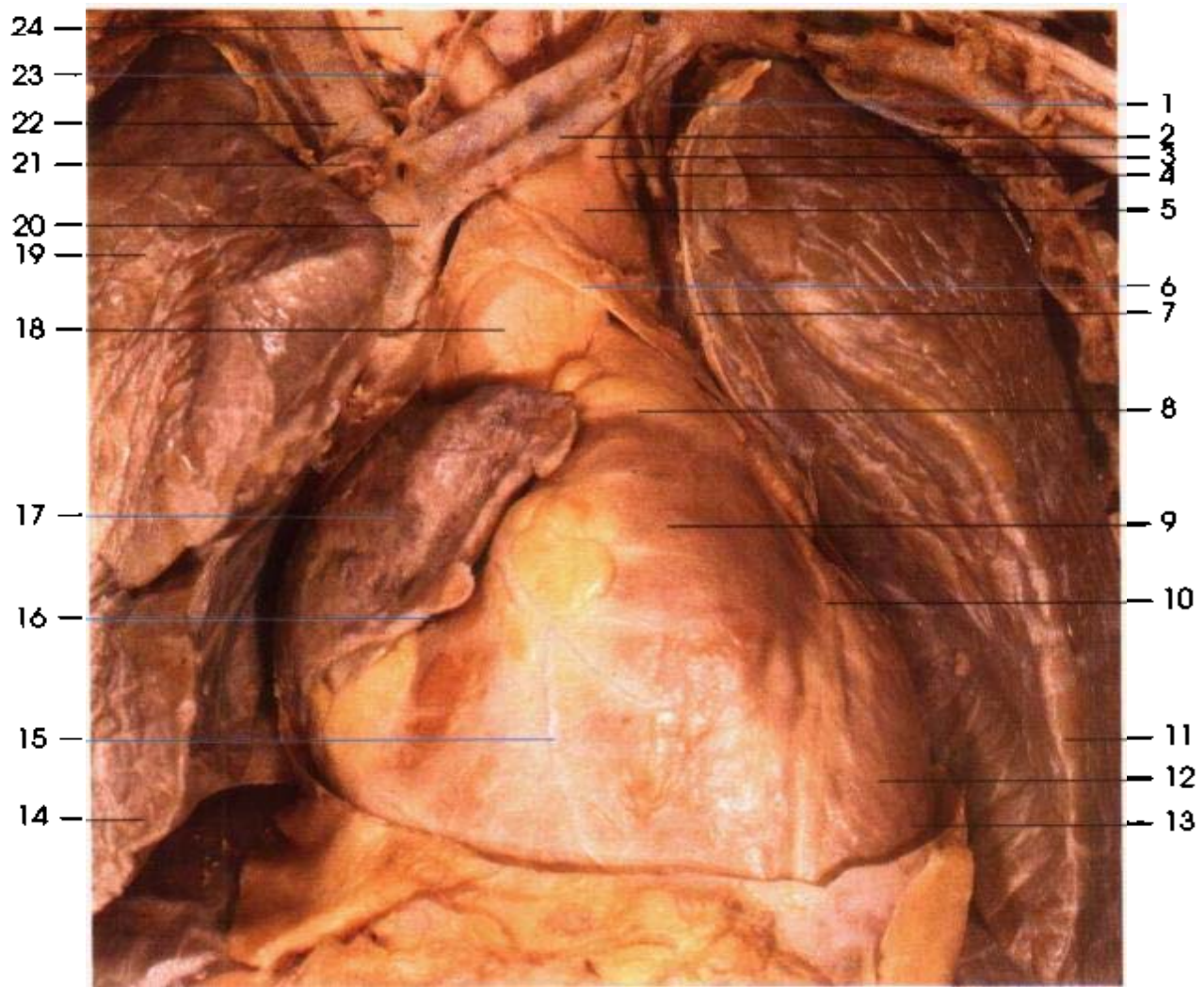


图 127 心前面观
Heart anterior aspect

- | | |
|---|---|
| 1. 左迷走神经 left vagus n. | 13. 心尖 apex of heart |
| 2. 左头臂静脉 left brachiocephalic v. | 14. 右肺中叶 middle lobe of right lung |
| 3. 左颈总动脉 left common carotid a. | 15. 右室前壁 anterior wall of right ventricle |
| 4. 左锁骨下动脉 left subclavian a. | 16. 右冠状沟 right coronary sulcus |
| 5. 主动脉弓 arch of aorta | 17. 右心耳 right auricle |
| 6. 纤维心包 fibrous pericardium | 18. 升主动脉 ascending aorta |
| 7. 左膈神经 left phrenic n. | 19. 右肺上叶 superior lobe of right lung |
| 8. 肺动脉干 pulmonary trunk | 20. 上腔静脉 superior vena cava |
| 9. 动脉圆锥 conus arteriosus | 21. 胸廓内静脉 internal thoracic v. |
| 10. 前室间沟 anterior interventricular sulcus | 22. 右头臂静脉 right brachiocephalic v. |
| 11. 左肺下叶 inferior lobe of left lung | 23. 甲状腺下静脉 inferior thyroid v. |
| 12. 左室前壁 anterior wall of left ventricle | 24. 头臂干 brachiocephalic trunk |

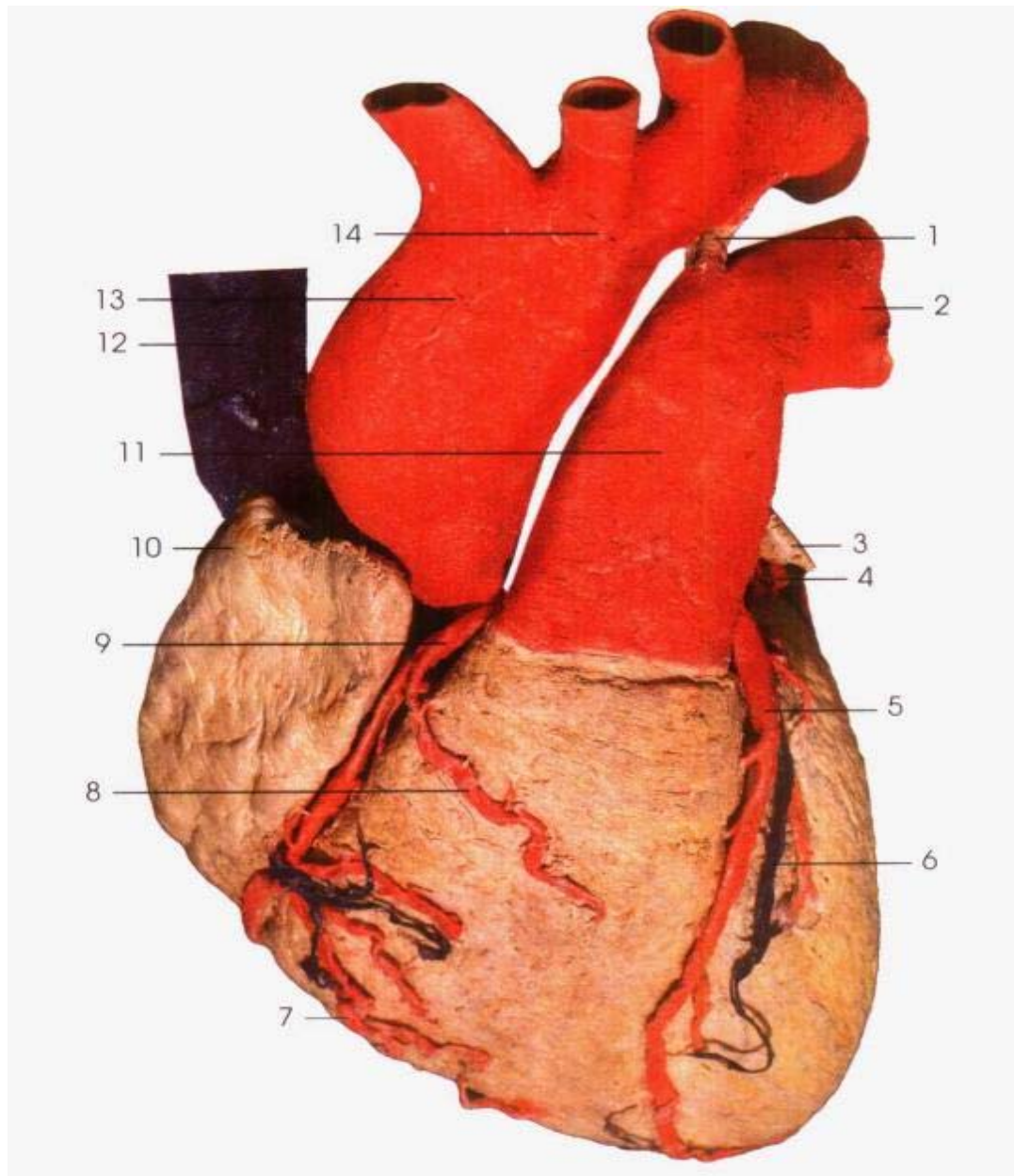
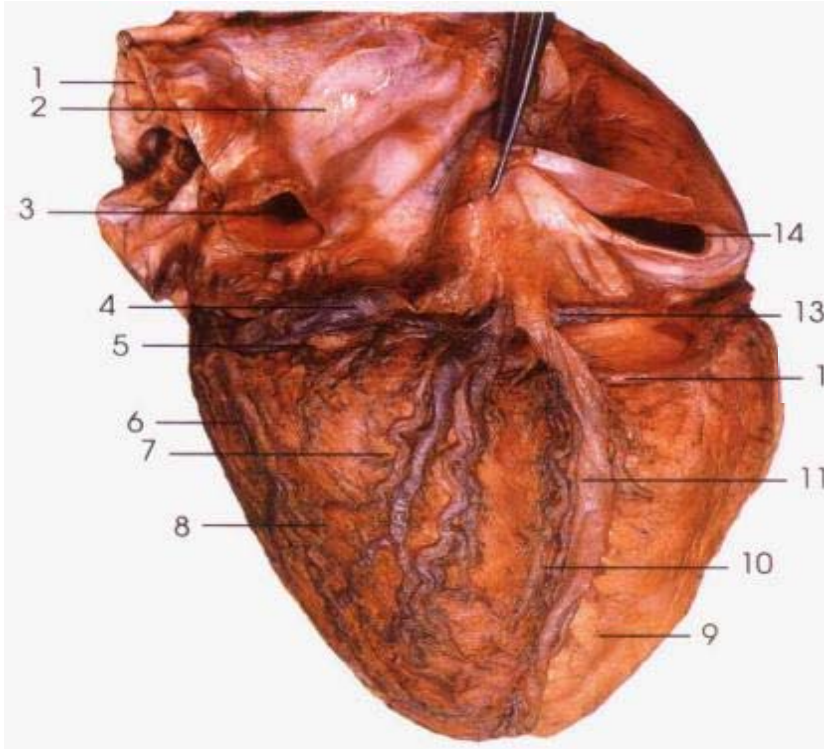


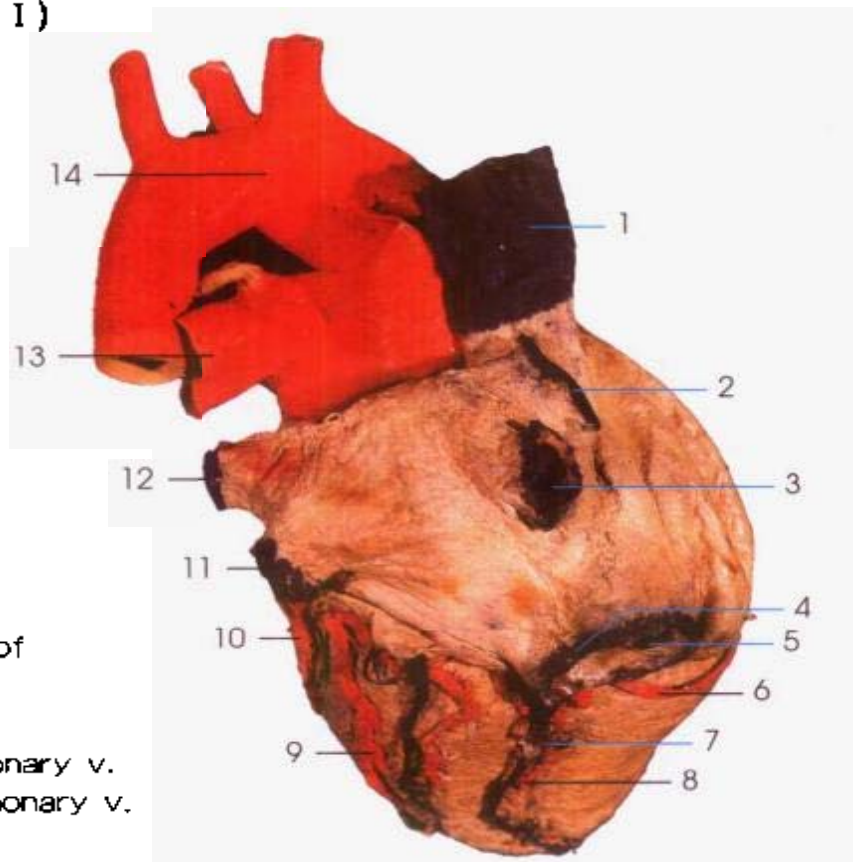
图 128 心的前面或胸肋面
The anterior or sternocostal
surface of the heart

- | | |
|---|---|
| 1. 动脉韧带 arteriosus lig. | 8. 右室前支 anterior branch of right ven-
tricle |
| 2. 左肺动脉 left pulmonary a. | 9. 右冠状动脉 right coronary a. |
| 3. 左心房 left atrium | 10. 右心耳 right atrium |
| 4. 左冠状动脉旋支 circumflex branch of the
left coronary a. | 11. 肺动脉干 pulmonary trunk |
| 5. 前室间支 anterior interventricular branch | 12. 上腔静脉 superior vena cava |
| 6. 心大静脉 great cardiac v. | 13. 升主动脉 ascending aorta |
| 7. 右缘支 right marginal branch | 14. 主动脉弓 arch of aorta |



1. 左上肺静脉 left superior pulmonary v.
2. 左心房 left atrium
3. 左下肺静脉 left inferior pulmonary v.
4. 冠状窦 coronary sinus
5. 旋支 circumflex branch
6. 左缘支 left marginal branch
7. 旋支后支 posterior branch of circumflex branch
8. 左心室后壁 posterior wall of left ventricle
9. 右心室后壁 posterior wall of right ventricle
10. 后室间支 posterior interventricular branch
11. 心中静脉 middle cardiac v.
12. 右冠状动脉 right coronary a.
13. 心小静脉 small cardiac v.
14. 下腔静脉 inferior vena cava

图 129 心底和膈面(I)
The base and diaphragmatic surface of the heart(I)



1. 上腔静脉 superior vena cava
2. 右肺上静脉 right superior pulmonary v.
3. 右下肺静脉 right inferior pulmonary vein
4. 冠状窦 coronary sinus
5. 下腔静脉 inferior vena cava
6. 右冠状动脉 right coronary a.
7. 心中静脉 middle cardiac v.
8. 后室间动脉 posterior interventricular a.
9. 左室后动脉 posterior branch of the left ventricle
10. 左缘支 left marginal branch
11. 左下肺静脉 left inferior pulmonary v.
12. 左上肺静脉 left superior pulmonary v.
13. 左肺动脉 left pulmonary a.
14. 主动脉弓 arch of aorta

图 130 心底和膈面(II)
The base and diaphragmatic surface of the heart(II)

1. 升主动脉 ascending aorta
2. 上腔静脉 superior vena cava
3. 卵圆窝 fossa ovalis
4. 三尖瓣隔瓣 septal leaflet of the tricuspid valve
5. 冠状窦瓣 valve of coronary sinus
6. 冠状窦口 orifice of coronary sinus
7. 下腔静脉瓣 valve of inferior vena cava
8. 下腔静脉口 orifice of inferior vena cava
9. 界嵴 crista terminalis
10. 梳状肌 pectinate m.
11. 右心耳 right auricle

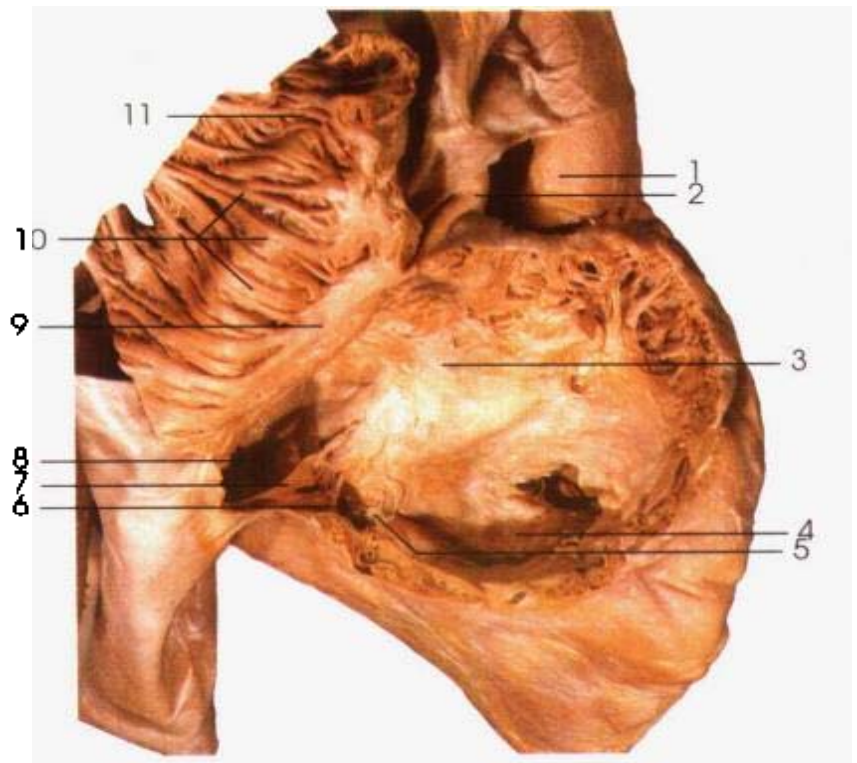


图 131 右心房内部结构(前面观)
Internal structures of the right atrium
(viewed from front)

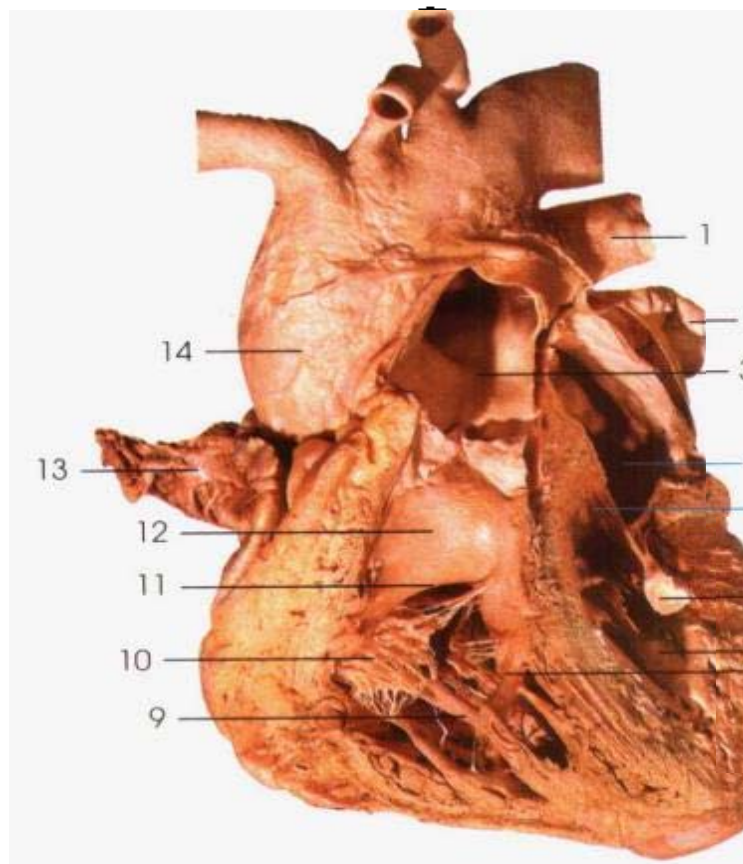
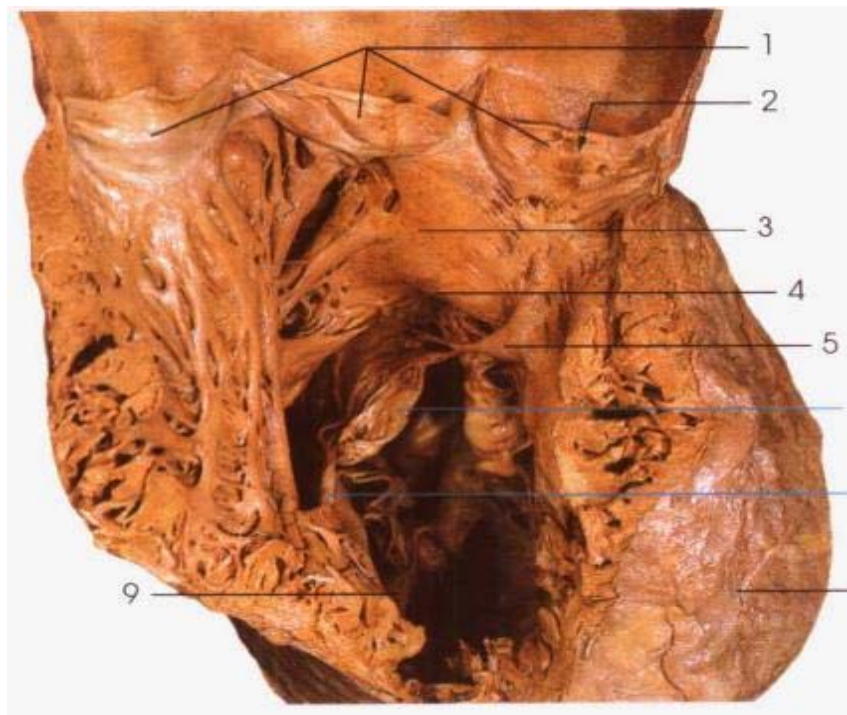


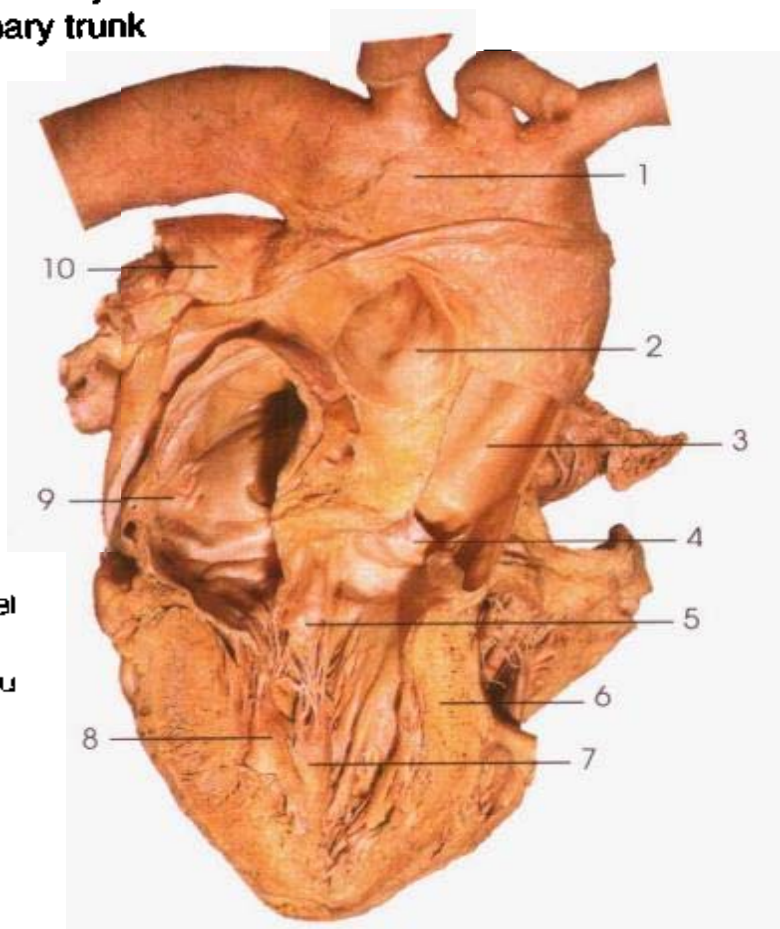
图 132 右心室内结构(前面观)
Internal structures of the right
ventricle(viewed from front)

1. 左肺动脉 left pulmonary a.
2. 左上肺静脉 left superior pulmonary v.
3. 肺动脉干 pulmonary trunk
4. 左心房 left atrium
5. 二尖瓣前瓣 anterior cusp of mitral valve
6. 左心室前乳头肌 anterior papillary m.
7. 左室后乳头肌 posterior papillary m.
8. 隔缘肉柱 septomarginal trabeculae
9. 右室前乳头肌 anterior papillary muscle of right ventricle
10. 三尖瓣前瓣 anterior cusp of tricuspid valve
11. 室上嵴 supraventricular crest
12. 动脉圆锥 conus arteriosus
13. 右心耳 right auricle
14. 升主动脉 ascending aorta



- 1. 肺动脉半月瓣 pulmonary valve
- 2. 肺动脉窦 sinus of pulmonary trunk
- 3. 动脉圆锥 conus arteriosus
- 4. 室上嵴 supraventricular crest
- 5. 隔侧乳头肌 septal papillary m.
- 6. 三尖瓣前瓣 anterior cusp of tricuspid valve
- 7. 前乳头肌 anterior papillary m.
- 8. 前室间动脉 anterior interventricular branch
- 9. 后乳头肌 posterior papillary m.

图 133 肺动脉半月瓣和肺动脉窦
Semilunar cusps of pulmonary valve
and sinus of pulmonary trunk



- 1. 主动脉弓 arch of aorta
- 2. 肺动脉干 pulmonary trunk
- 3. 升主动脉 ascending aorta
- 4. 主动脉瓣 aortic valve
- 5. 二尖瓣前瓣 anterior cusp of mitral valve.
- 6. 室间隔肌性部 muscular interventricular septum
- 7. 前乳头肌 anterior papillary m.
- 8. 后乳头肌 posterior papillary m.
- 9. 左心房 left atrium
- 10. 左肺动脉 left pulmonary a.

图 134 左心室内部结构(前面观)
Internal structures of left ventricle
(viewed from front)

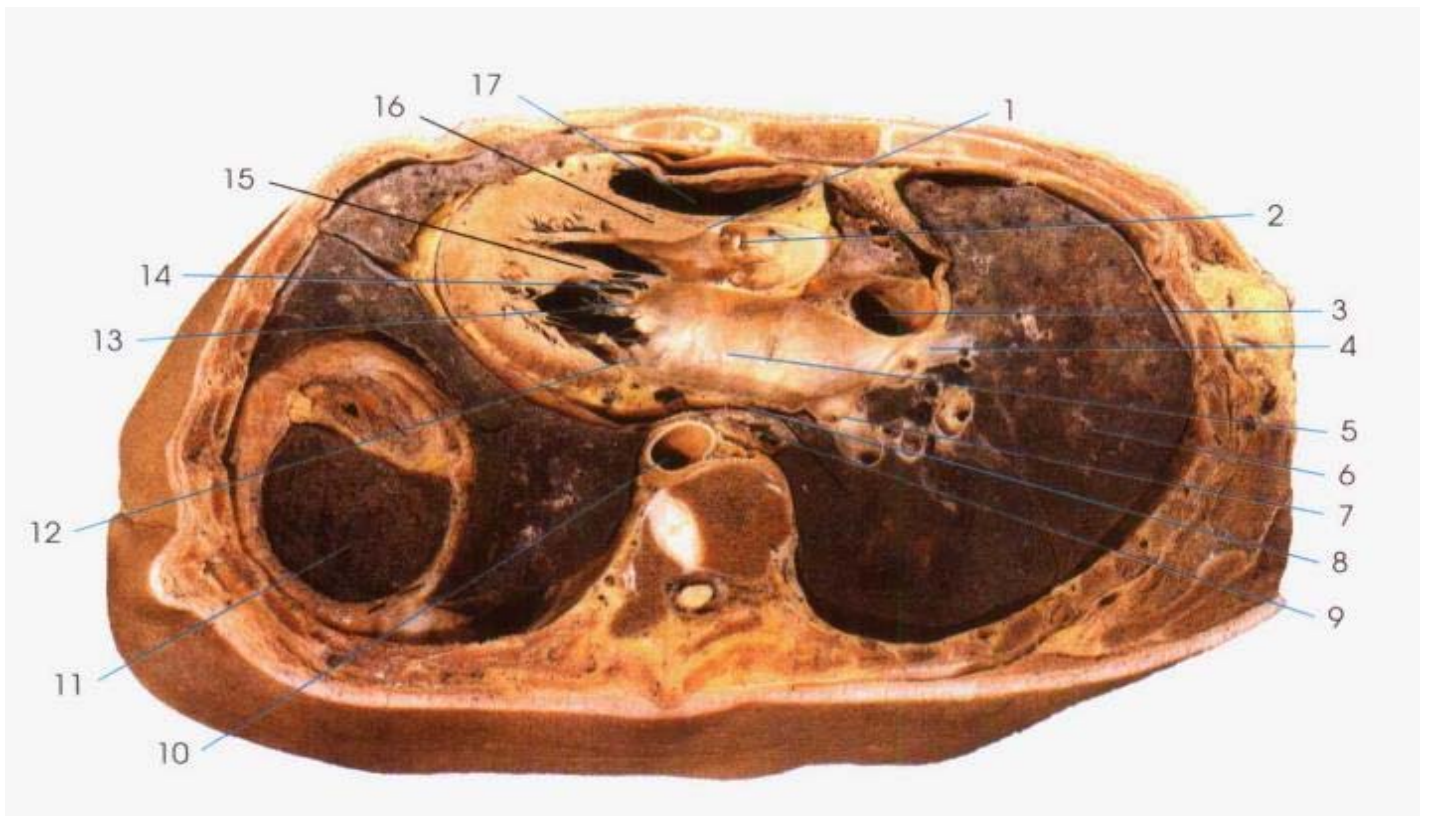

图 135 经心长轴斜切面
The section at the long axis of the heart on oblique

- | | | | |
|------------------|---|------------|--------------------------------|
| 1. 室间隔膜部 | interventricular membranous part | 9. 食管 | esophagus |
| 2. 主动脉右前窦、右冠状动脉口 | right aortic sinus of (valsalva) and orifice of right coronary a. | 10. 胸主动脉 | thoracic aorta |
| 3. 上腔静脉 | superior vena cava | 11. 脾 | spleen |
| 4. 右上肺静脉 | right superior pulmonary v. | 12. 二尖瓣后瓣 | posterior cusp of mitral valve |
| 5. 左心房 | left atrium | 13. 二尖瓣前瓣 | anterior cusp of mitral valve |
| 6. 右肺上叶 | superior lobar of right lung | 14. 腱索 | chordae tendineae |
| 7. 右肺下静脉 | right inferior pulmonary v. | 15. 前乳头肌 | anterior papillary m. |
| 8. 心包斜窦 | oblique pericardial sinus | 16. 室间隔肌性部 | interventricular muscular part |
| | | 17. 右心室 | right ventricle |

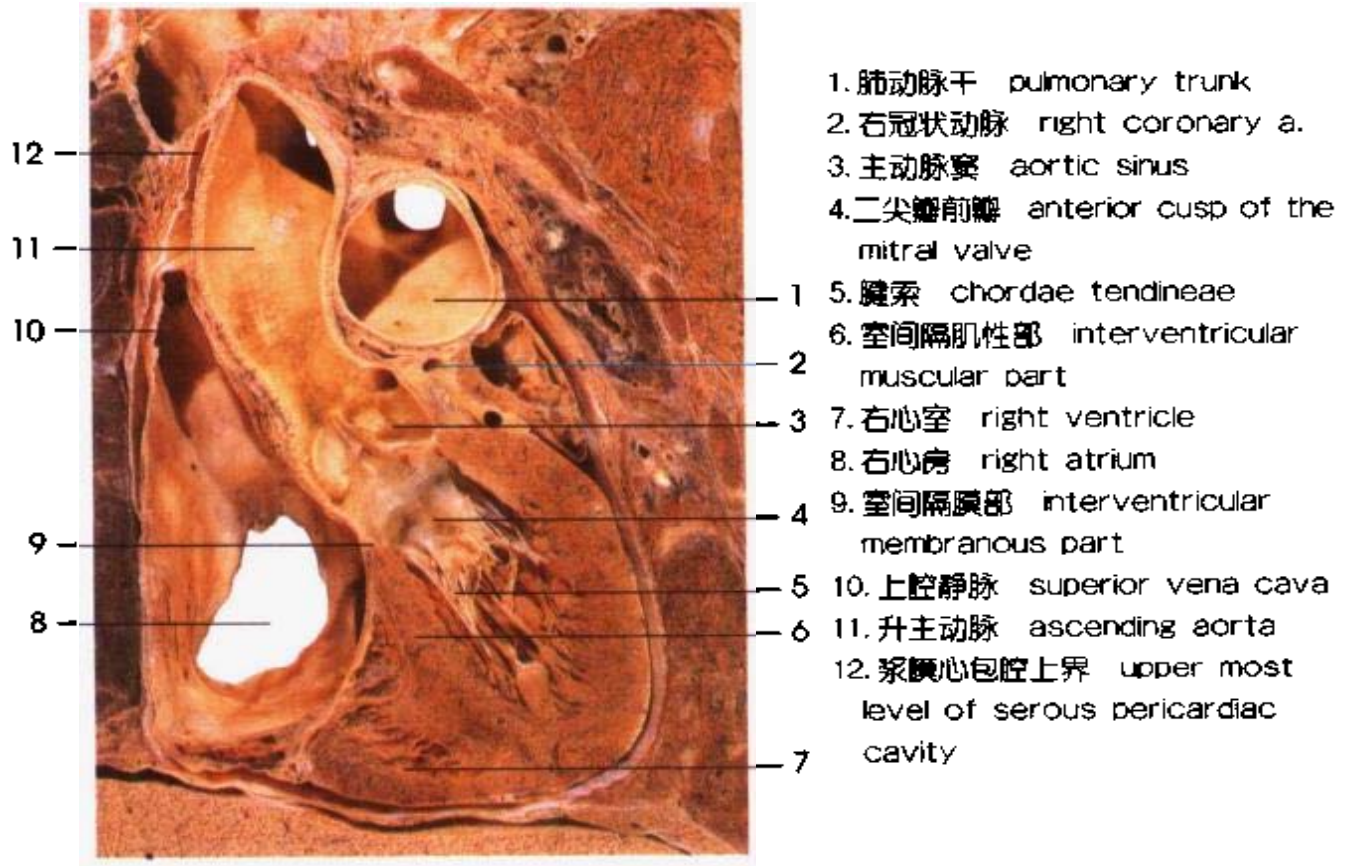


图 136 经左心室冠状切面
The coronary section through
the left ventricle

1. 左冠状动脉口 orifice of left coronary a.
2. 右冠状动脉口 orifice of right coronary a.
3. 主动脉窦 aortic sinuses (of valsalva)
4. 半月瓣小结 nodule of semilunar valve
5. 室间隔膜部 membranous part of interventricular septum
6. 二尖瓣前瓣 anterior cusp of mitral valve
7. 腱索 chordae tendineae
8. 室间隔肌性部 muscular part of interventricular septum
9. 前乳头肌 anterior papillary m.
10. 后乳头肌 posterior papillary m.

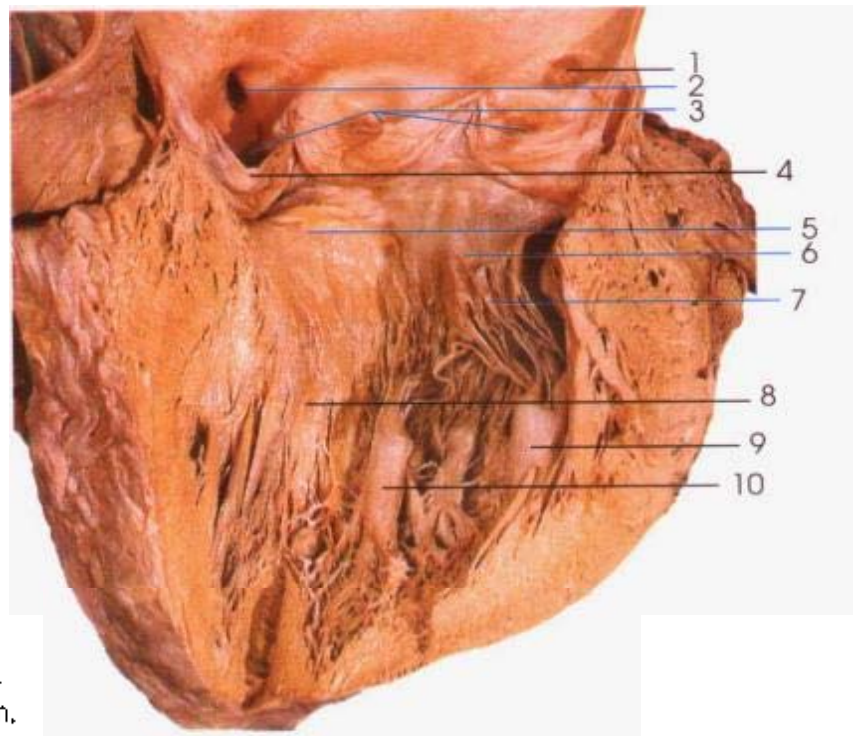


图 137 主动脉瓣和主动脉窦
Mitral valve and aortic sinuses

- 1.肺动脉窦 sinus of pulmonary trunk
- 2.肺动脉半月瓣 semilunar cusp of pulmonary valve
- 3.纤维环 annulus fibrosus
- 4.主动脉半月瓣 semilunar cusp of aortic valve
- 5.二尖瓣后瓣 posterior cusp of mitral valve
- 6.主动脉窦 sinus of aorta
- 7.右心耳 right auricle
- 8.三尖瓣前瓣 anterior cusp of tricuspid valve
- 9.三尖瓣隔侧瓣 septal cusp of tricuspid valve
- 10.三尖瓣后瓣 posterior cusp of tricuspid valve

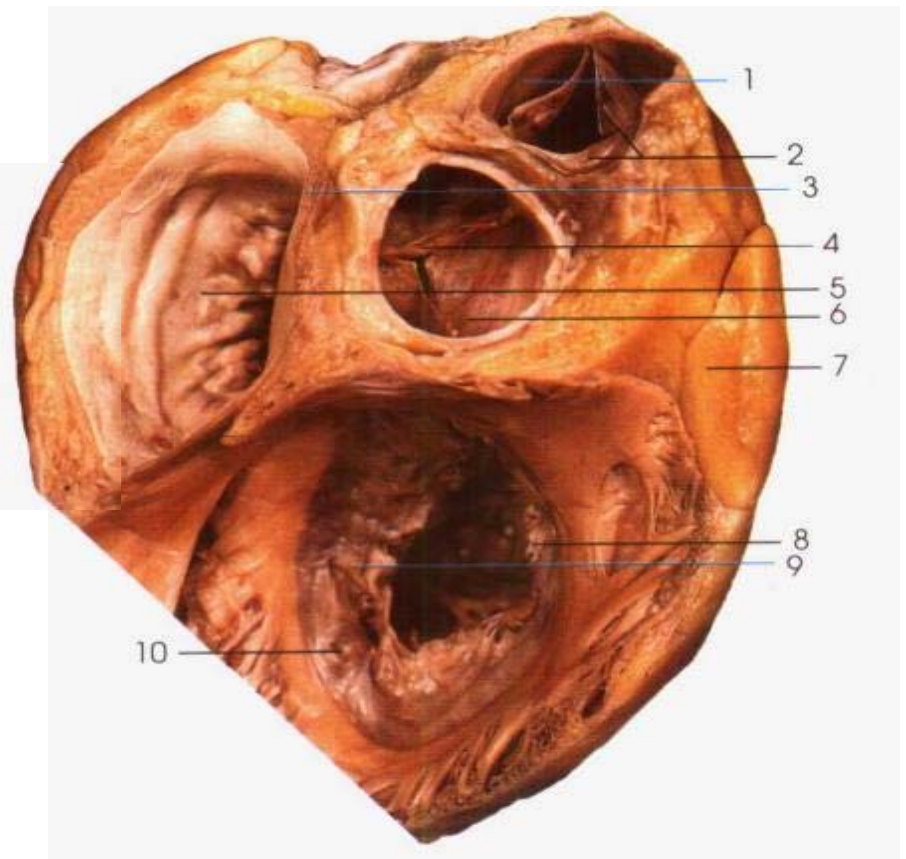
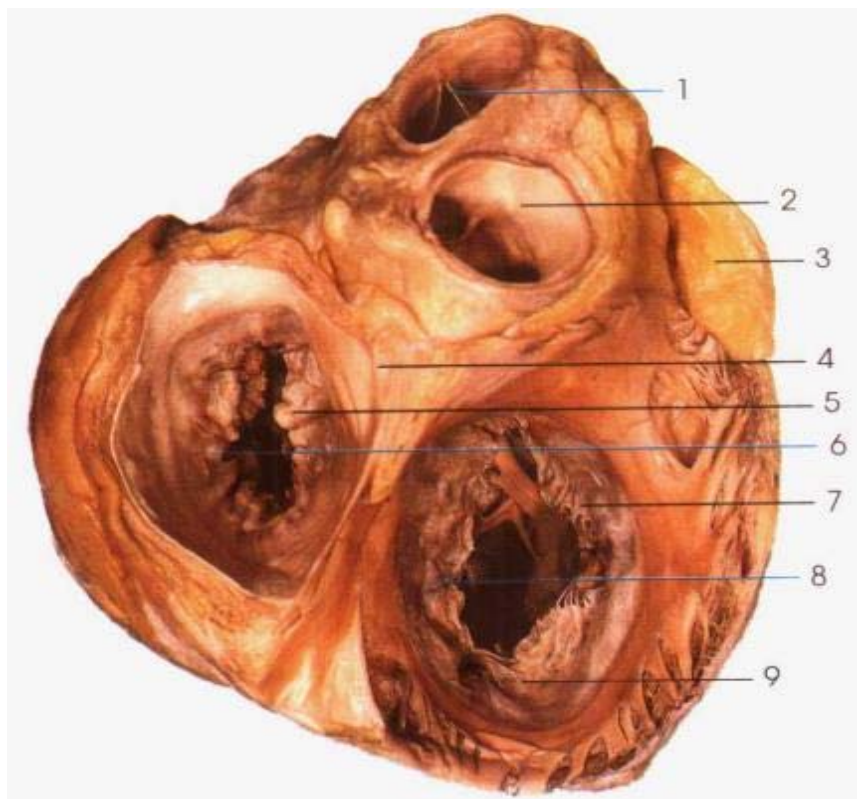


图 138 心的瓣膜(I)
Valves of heart(I)



- 1.肺动脉半月瓣 semilunar cusp of pulmonary trunk
- 2.升主动脉 ascending aorta
- 3.右心耳 right auricle
- 4.右纤维三角 right fibrous trigone
- 5.二尖瓣前瓣 anterior cusp of mitral valve
- 6.二尖瓣后瓣 posterior cusp of mitral valve
- 7.三尖瓣前瓣 posterior cusp of tricuspid valve
- 8.三尖瓣隔瓣 anterior cusp of tricuspid valve
- 9.三尖瓣后瓣 posterior cusp of tricuspid valve

图 139 心的瓣膜(II)
Valves of heart(II)

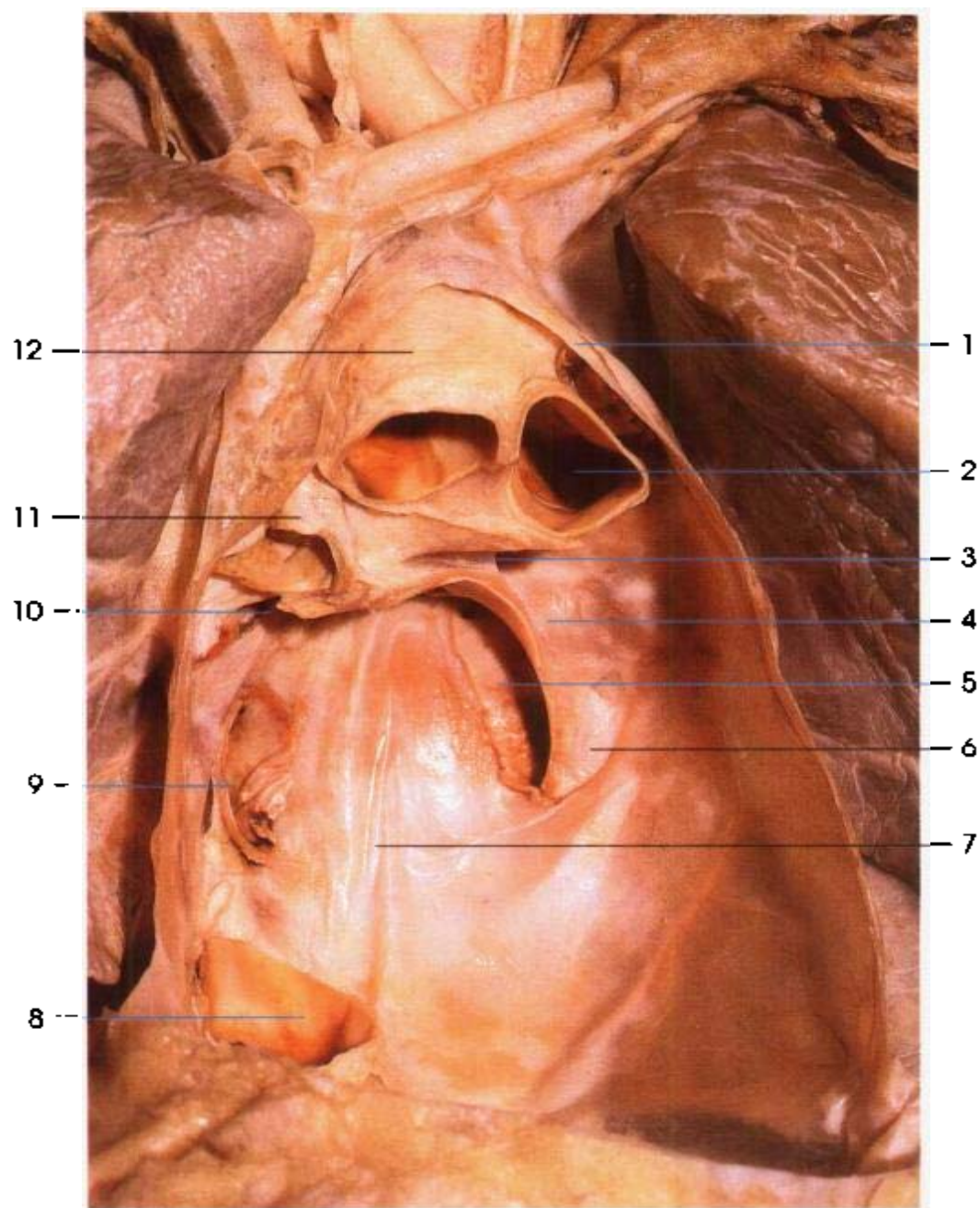


图 140 心包
The pericardium

- | | |
|-------------------------------------|---------------------------------------|
| 1. 纤维心包 fibrous pericardium | 7. 心包斜窦 oblique sinus of pericardium |
| 2. 肺动脉干 pulmonary trunk | 8. 下腔静脉 inferior vena cava |
| 3. 右肺动脉隐窝 right pulmonary recess | 9. 右下肺静脉 right inferior pulmonary v. |
| 4. 左上肺静脉 left superior pulmonary v. | 10. 右上肺静脉 right superior pulmonary v. |
| 5. 左肺静脉总干 left common pulmonary v. | 11. 上腔静脉 superior vena cava |
| 6. 左下肺静脉 left inferior pulmonary v. | 12. 升主动脉 ascending aorta |

1. 胸腺 thymus
2. 肺动脉干 pulmonary trunk
3. 左腔静脉襞 fold of left vena cava
4. 心包横窦 transverse pericardial sinus
5. 左肺静脉 left pulmonary vv.
6. 心包斜窦 oblique sinus of pericardium
7. 下腔静脉 inferior vena cava
8. 后室间沟 posterior interventricular sulcus
9. 左房斜静脉 oblique vein of left atrium
10. 左心房 left atrium
11. 左心耳 left auricle
12. 心包横窦 transverse pericardial sinus
13. 上腔静脉 superior vena cava
14. 升主动脉 ascending aorta

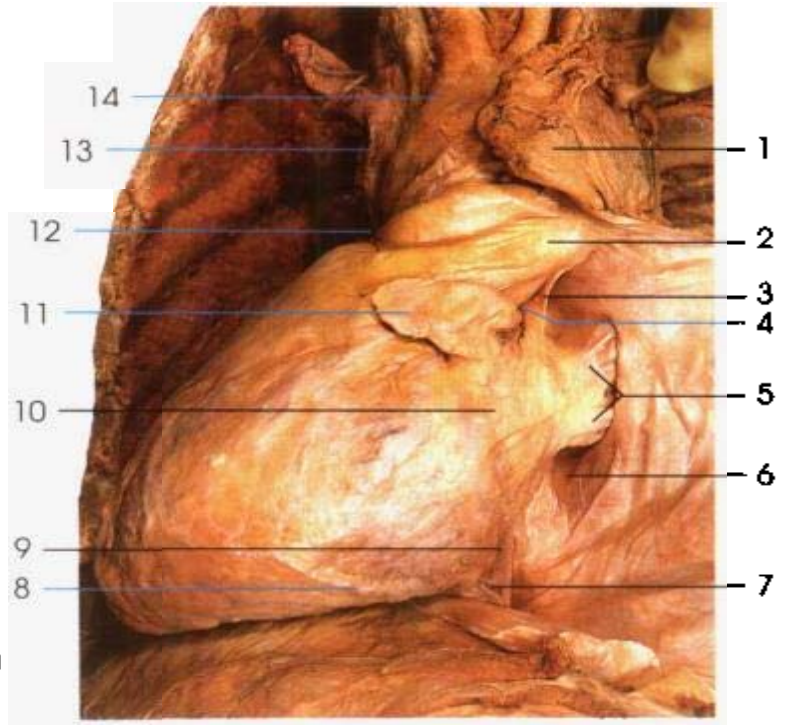
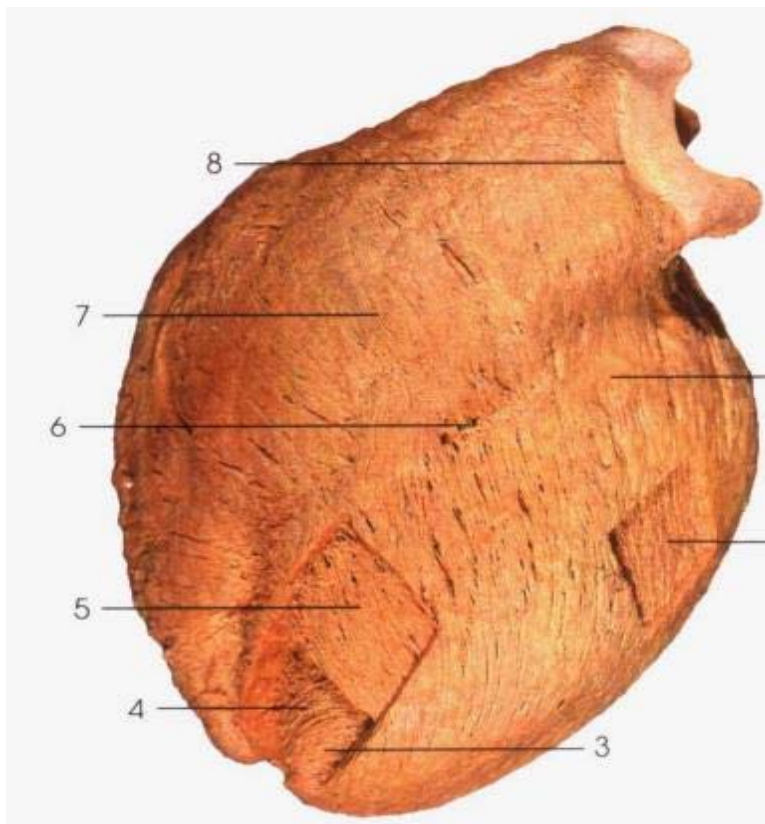
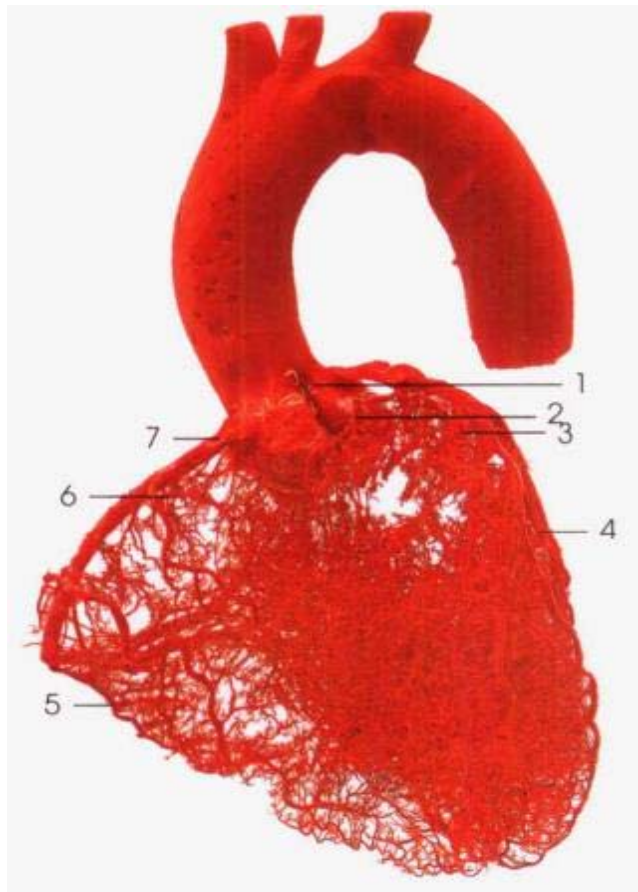


图 141 浆膜心包
Serous pericardium



1. 左心室浅层肌 superficial layer of left ventricle
2. 左心室中层肌 middle layer muscle of left ventricle
3. 心窝 vortex of apex of heart
4. 左心室深层肌 deep layer muscle of the left ventricle
5. 前室间沟 anterior interventricular groove
6. 右心室浅层肌 superficial layer muscle of right ventricle
7. 肺动脉干 pulmonary trunk
8. 肺动脉干 pulmonary trunk

图 142 心肌构筑
The myocardiac architecture



1. 左冠状动脉 left coronary a.
2. 左动脉圆锥支 left branch of the arterial conus
3. 前室间支 anterior interventricular branch
4. 左缘支 left marginal branch
5. 右缘支 right marginal branch
6. 右动脉圆锥支 right branch of arterial conus
7. 右冠状动脉 right coronary a.

图 143 心冠状动脉红色铸型
The color red resin of the coronary arteries of the heart

1. 左冠状动脉 left coronary a.
2. 卵圆窝 foramen valis
3. 左心房 left atrium
4. 房室结 atrioventricular node
5. 室间隔膜部 membranous interventricular septum
6. 房室束 atrioventricular bundle
7. 左束支 left bundle branch
8. 左室前乳头肌 anterior papillary muscle of the left ventricle
9. 隔缘肉柱 septomarginal trabeculae
10. 右室前乳头肌 anterior papillary muscle of the right ventricle
11. 右束支 right bundle branch
12. 后结间束 posterior internodal tract
13. 中结间束 middle internodal tract
14. 前结间束 anterior internodal tract
15. 窦房结 sinoatrial node
16. 上腔静脉口 orifice of superior vena cava

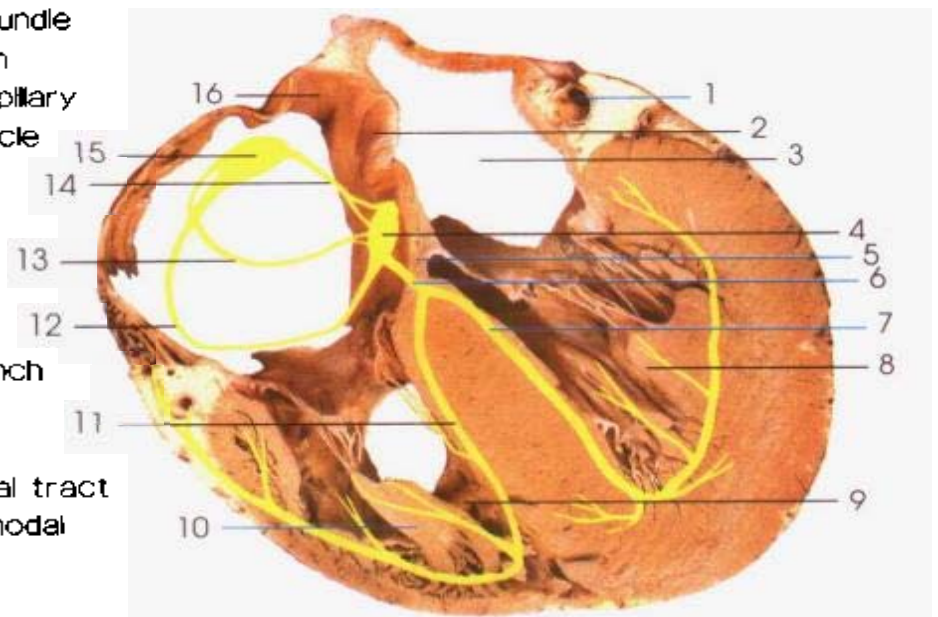
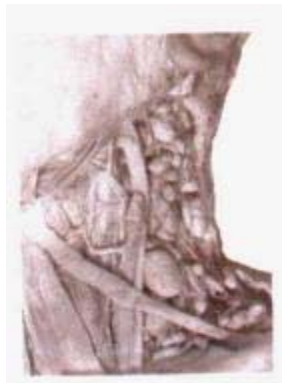

图 144 心传导系统
The cardiac conducting system

6

LYMPHATIC SYSTEM



第6章

淋

巴

系

统

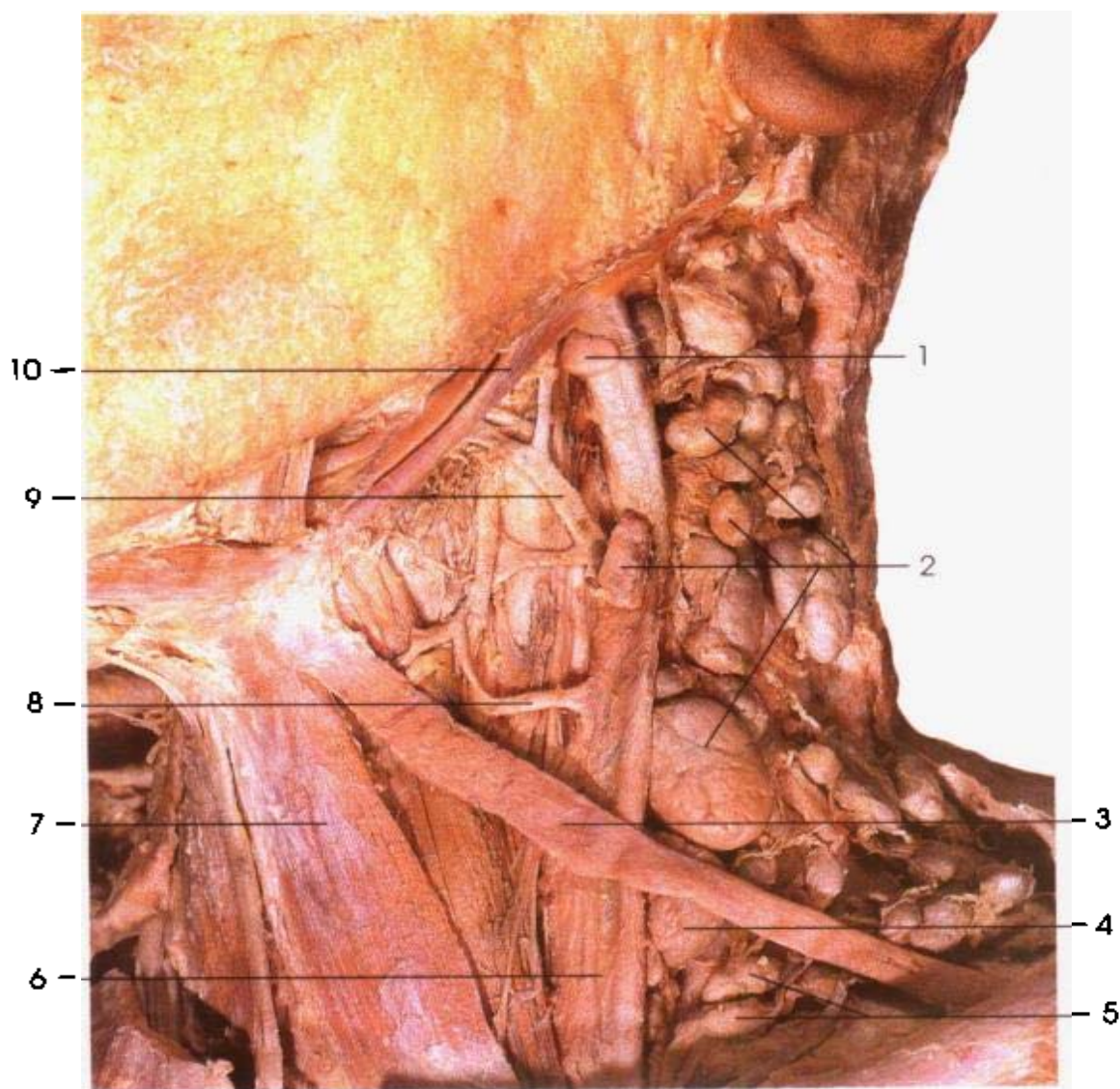


图 145 颈部深淋巴结
Deep lymph nodes of the neck

- | | |
|--|--|
| 1. 颈内静脉二腹肌淋巴结 jugulodigastric lymph node | 5. 锁骨上淋巴结 supraclavicular lymph nodes |
| 2. 颈外侧深淋巴结 deep lateral cervical lymph nodes | 6. 颈内静脉 internal jugular v. |
| 3. 肩胛舌骨肌 omohyoid | 7. 胸骨舌骨肌 sternohyoid |
| 4. 颈内静脉肩胛舌骨肌淋巴结 juguloomohyoid lymph node | 8. 甲状腺上静脉 superior thyroid v. |
| | 9. 面总静脉 common facial v. |
| | 10. 二腹肌后腹 posterior belly of the digastric |

1. 左头臂静脉 left brachiocephalic v.
2. 主动脉弓 aortic arch
3. 气管支气管上淋巴结 superior tracheobronchial lymph node
4. 左主支气管 left principal bronchus
5. 支气管肺门淋巴结 bronchopulmonary hilar lymph nodes
6. 食管 esophagus
7. 肺门淋巴结 pulmonary hilar lymph nodes
8. 气管支气管下淋巴结 inferior tracheobronchial lymph nodes
9. 上腔静脉 superior vena cava
10. 纵隔前淋巴结 anterior mediastinal lymph nodes

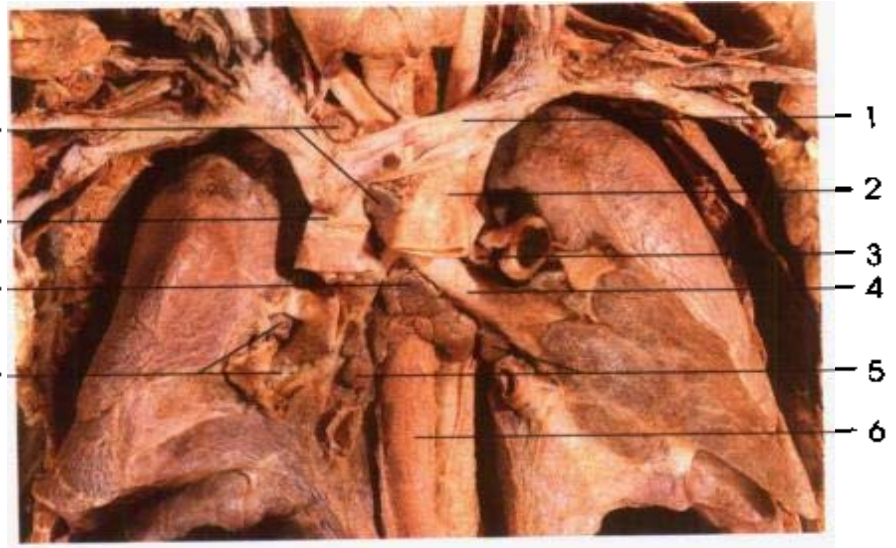
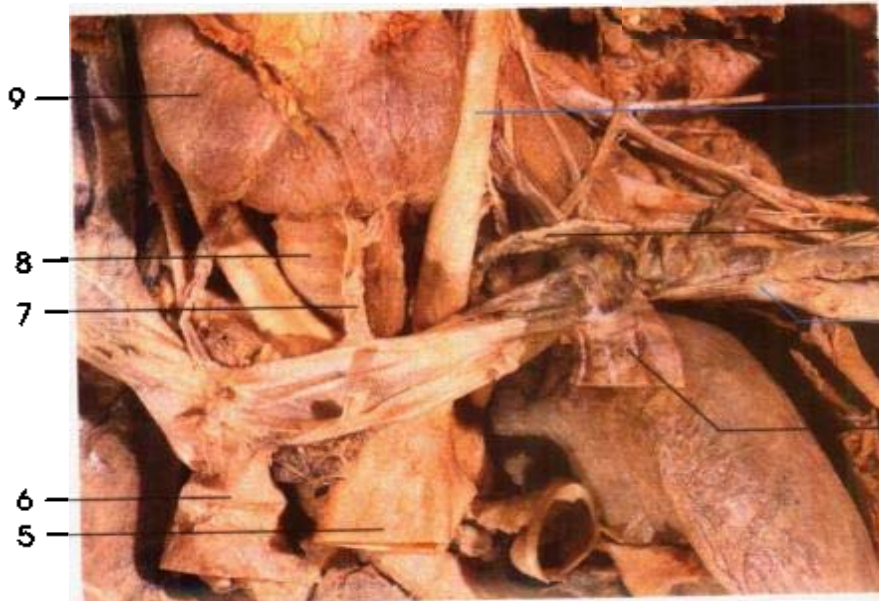

图 146 胸腔脏器淋巴结
Lymph nodes of the thoracic viscera



1. 左颈总动脉 common carotid a. left
2. 胸导管 thoracic duct
3. 左锁骨下静脉 left subclavian v.
4. 左颈内静脉 left internal jugular v.
5. 升主动脉 ascending aorta
6. 上腔静脉 superior vena cava
7. 甲状腺下静脉 inferior thyroid v.
8. 气管 trachea
9. 甲状腺 thyroid gland

图 147 胸导管颈段
Cervical part of the thoracic duct

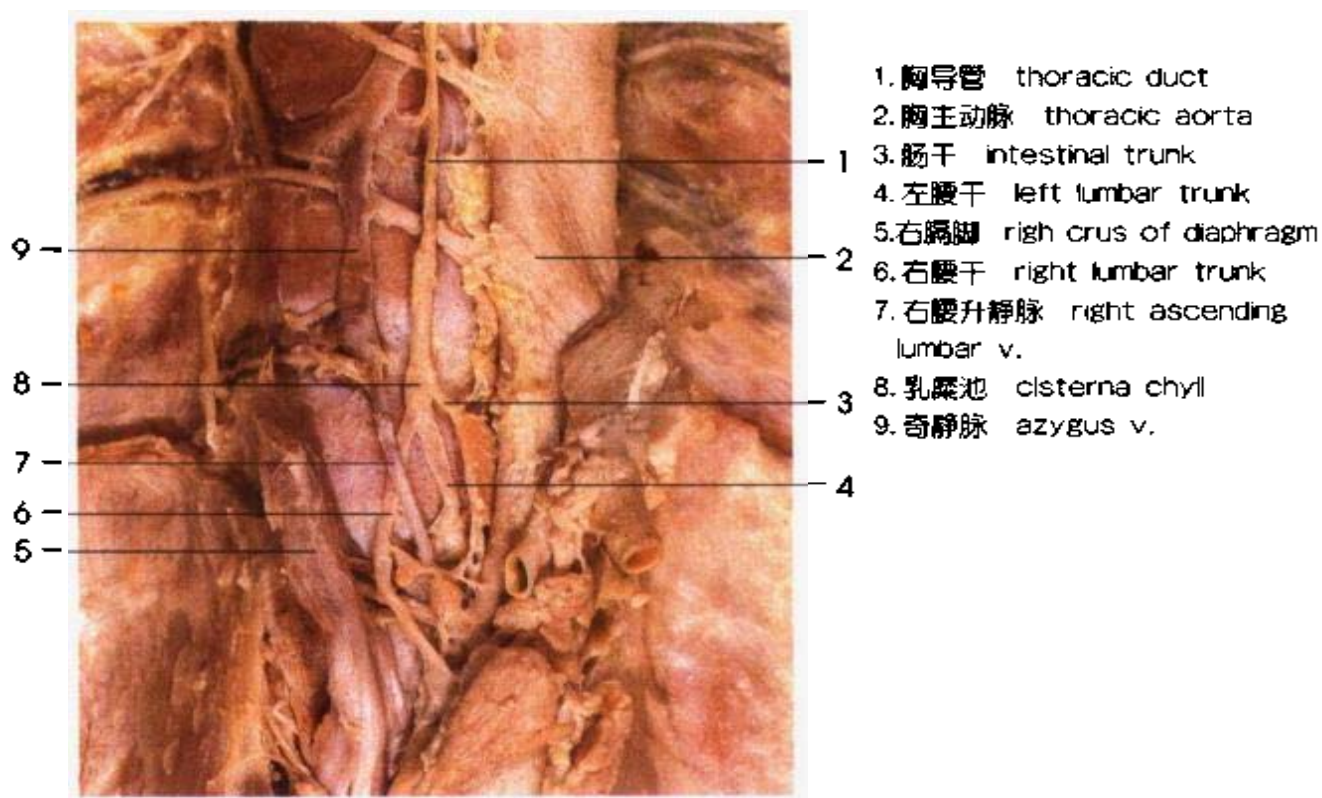


图 148 乳糜池
Cisterna chyli

1. 胃左静脉 left gastric v.
 2. 胃左淋巴结 left gastric lymph nodes
 3. 腹腔淋巴结 celiac lymph nodes
 4. 胃 stomach
 5. 大网膜 greater omentum
 6. 胃网膜右淋巴结 right gastroepiploic lymph nodes
 7. 胃网膜右动脉 right gastroepiploic a.
 8. 幽门淋巴结 pyloric lymph node
 9. 胆囊 gallbladder
 10. 胆囊淋巴结 cystic lymph node
 11. 肝淋巴结 hepatic lymph nodes

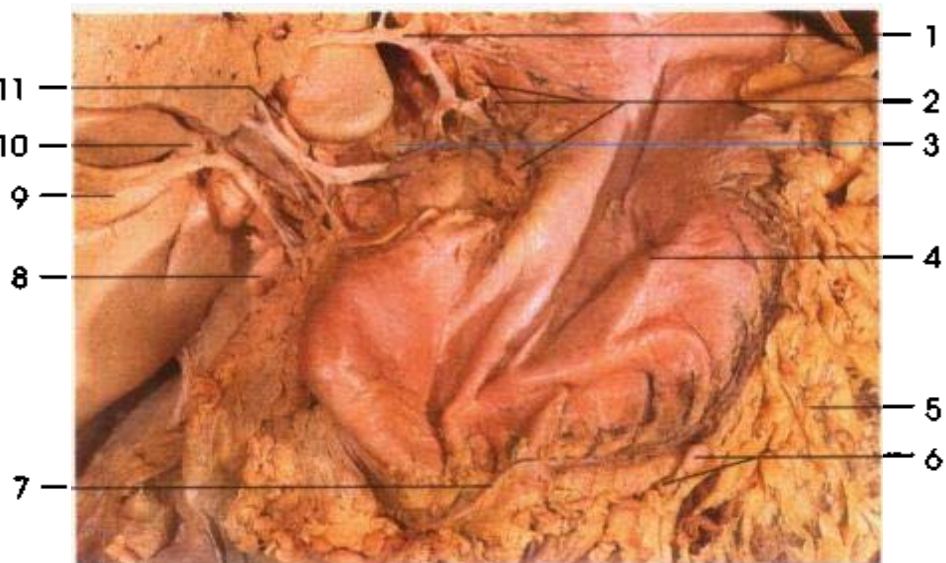


图 149 肝和胃的淋巴结
Lymph nodes around liver and stomach

- 1. 骶淋巴结 sacral lymph node
- 2. 髂内动脉 internal iliac a.
- 3. 髂内淋巴结 internal iliac lymph nodes
- 4. 膀胱 urinary bladder
- 5. 髂外淋巴结 external iliac lymph nodes
- 6. 髂外动脉 external iliac a.
- 7. 髂总动脉 common iliac a.

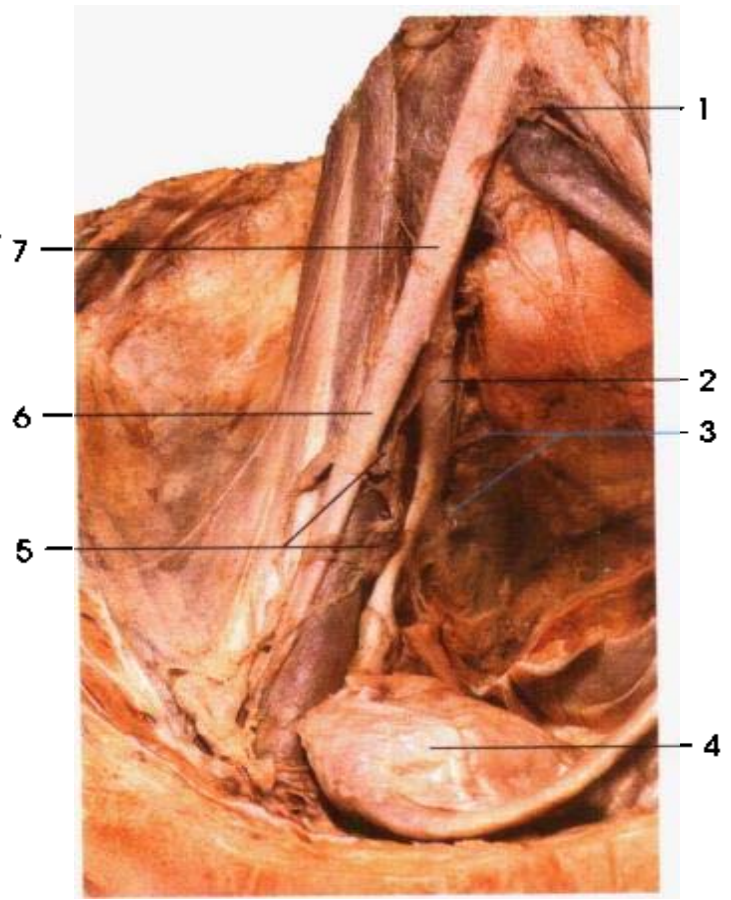


图 150 髂内、外淋巴结
External and internal iliac lymph nodes

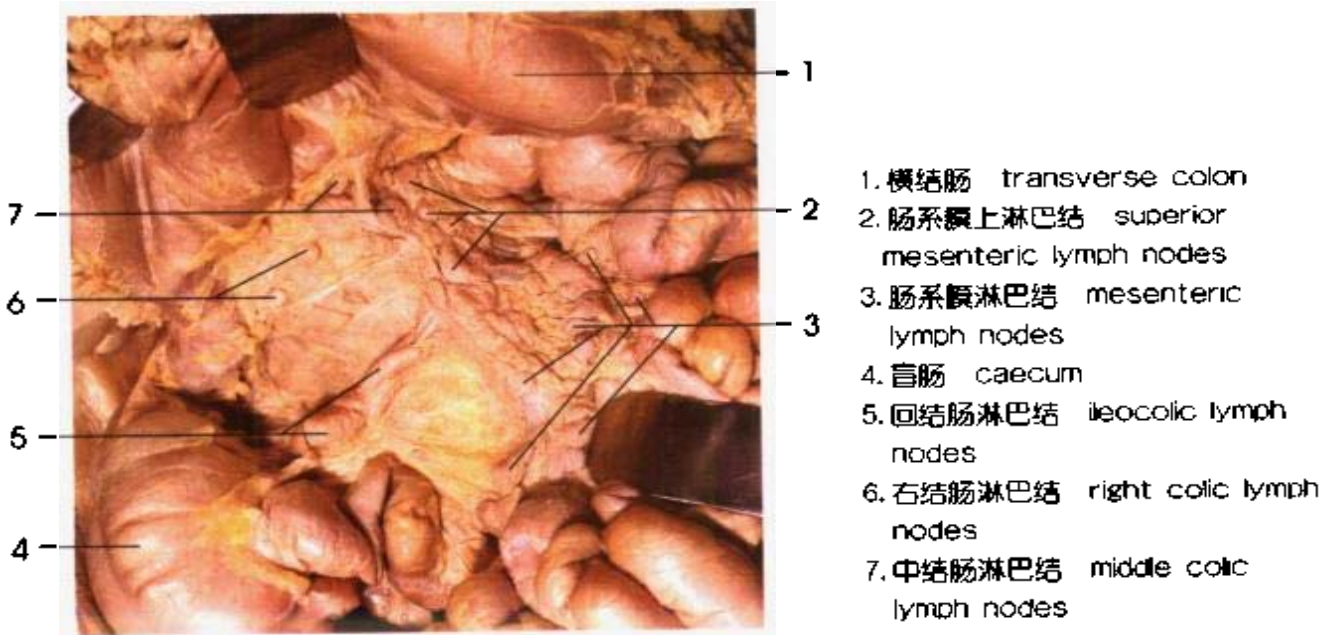
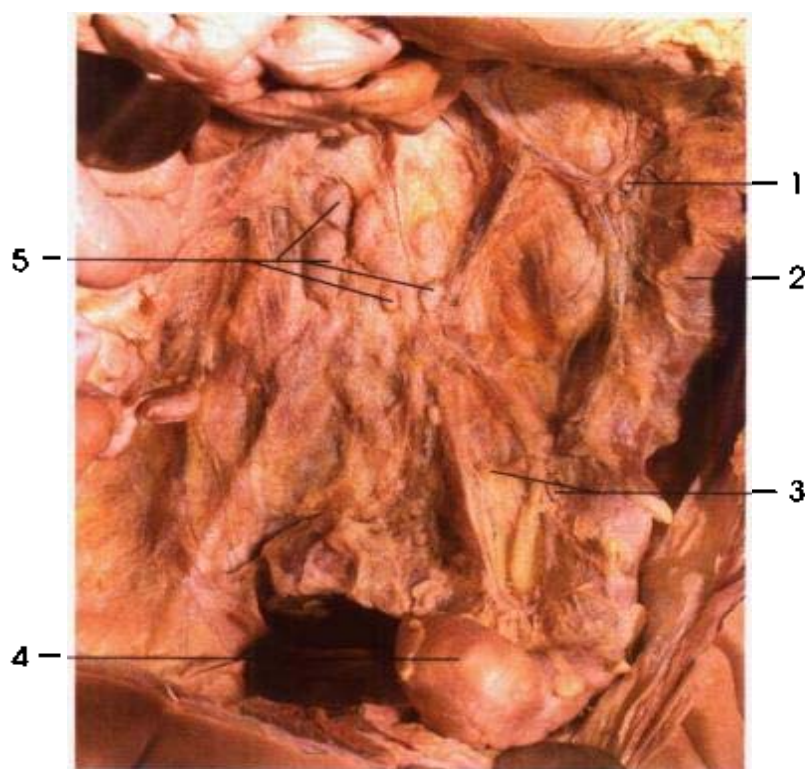


图 151 肠系膜上淋巴结
Superior mesenteric lymph nodes



1. 左结肠淋巴结 left colic lymph nodes
2. 降结肠 descending colon
3. 乙状结肠淋巴结 sigmoid lymph nodes
4. 乙状结肠 sigmoid colon
5. 肠系膜下淋巴结 inferior mesenteric lymph nodes

图 152 肠系膜下淋巴结
Inferior mesenteric lymph nodes

1. 肠系膜上淋巴结 superior mesenteric lymph nodes
2. 腹主动脉 abdominal aorta
3. 左腰淋巴结 left lumbar lymph nodes
4. 左髂总淋巴结 left common iliac lymph node
5. 右髂总动脉 right common iliac a.
6. 右髂总淋巴结 right common iliac lymph nodes
7. 下腔静脉 inferior vena cava
8. 右腰淋巴结 right lumbar lymph nodes
9. 肠系膜上动脉 superior mesenteric a.

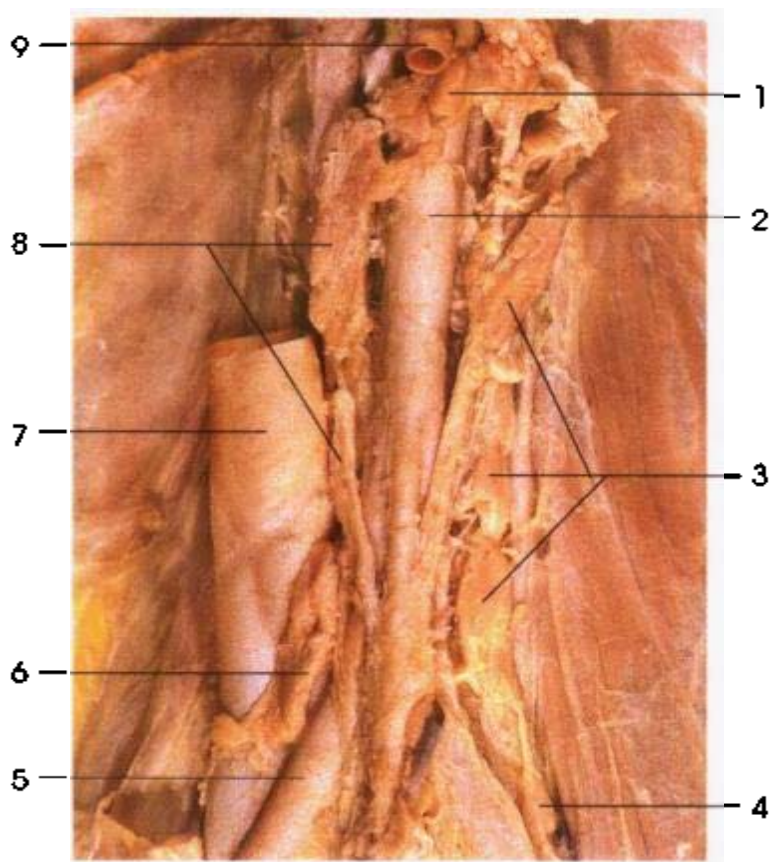


图 153 腹后壁淋巴结
Lymph nodes of the posterior abdominal wall

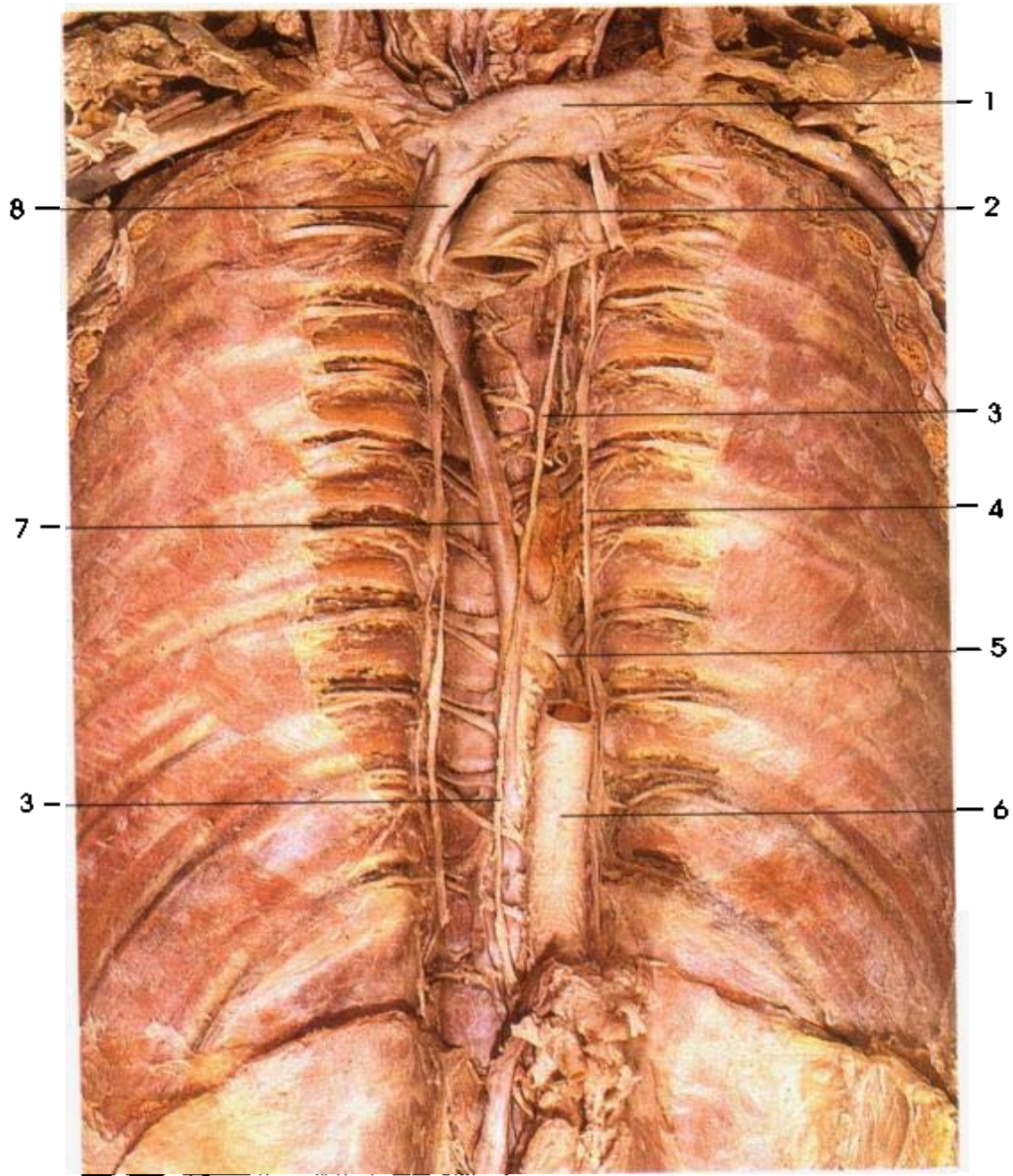
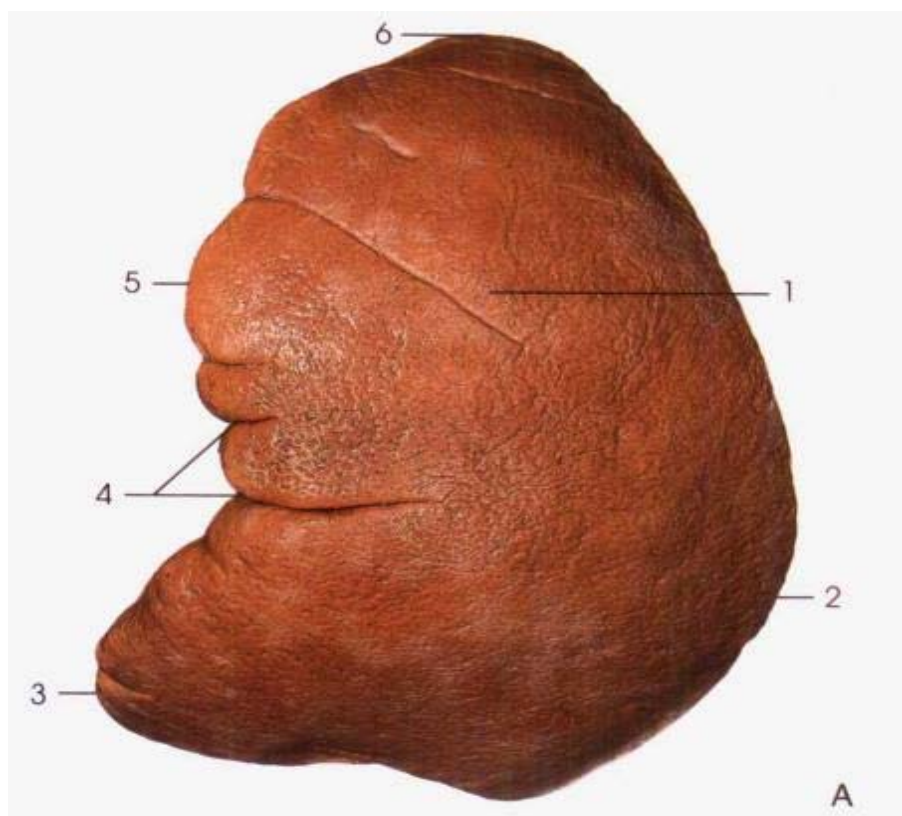


图 154 胸导管胸段
Thoracic part of the thoracic duct

1. 左头臂静脉 left brachiocephalic v.
2. 主动脉弓 aortic arch
3. 胸导管 thoracic duct
4. 左交感干 left sympathetic trunk

5. 半奇静脉 hemiazygos v.
6. 胸主动脉 thoracic aorta
7. 奇静脉 azygos v.
8. 上腔静脉 superior vena cava



- 1. 膈面 diaphragmatic surface
- 2. 下缘 inferior border
- 3. 前端 anterior extremity
- 4. 脾切迹 splenic notch
- 5. 上缘 superior border
- 6. 后端 posterior extremity
- 7. 脏面 visceral surface
- 8. 脾门 hilum of spleen

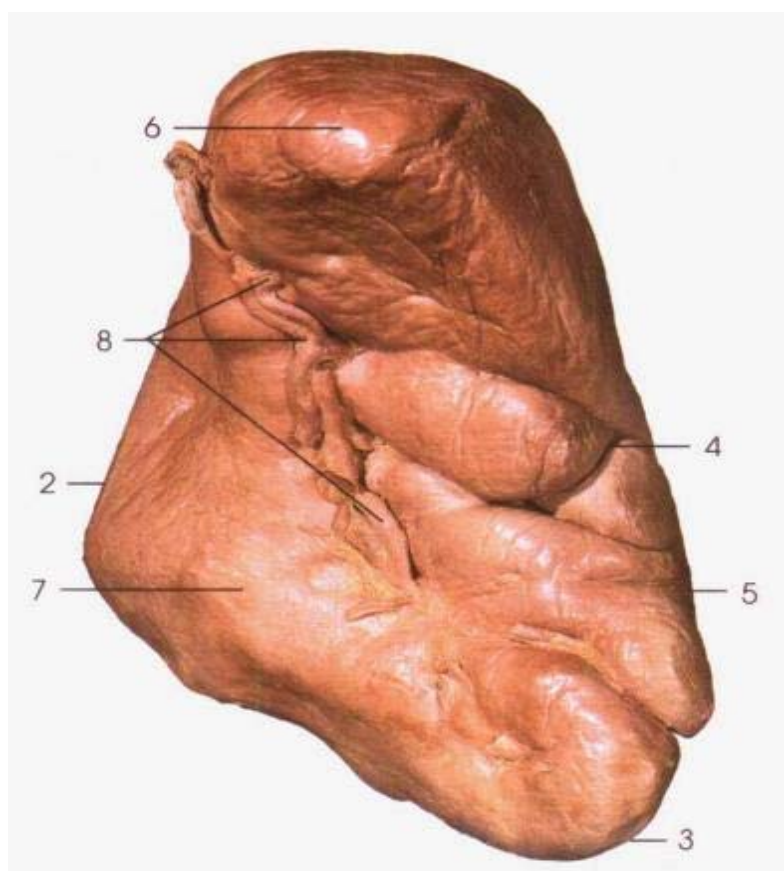


图 155 脾(A.膈面, B.脏面)
Spleen(A.diaphragmatic
surface,B.visceral surface)

B

1. 尖淋巴结 apical lymph nodes
2. 胸肌淋巴结 pectoral lymph nodes
3. 胸外侧动脉 lateral thoracic a.
4. 胸背动脉和神经 thoracodorsal a. and n.
5. 肩胛下淋巴结 subscapular lymph nodes
6. 中央淋巴结 central lymph nodes
7. 外侧淋巴结 lateral lymph nodes
8. 胸小肌 pectoralis minor
9. 胸大肌 pectoralis major

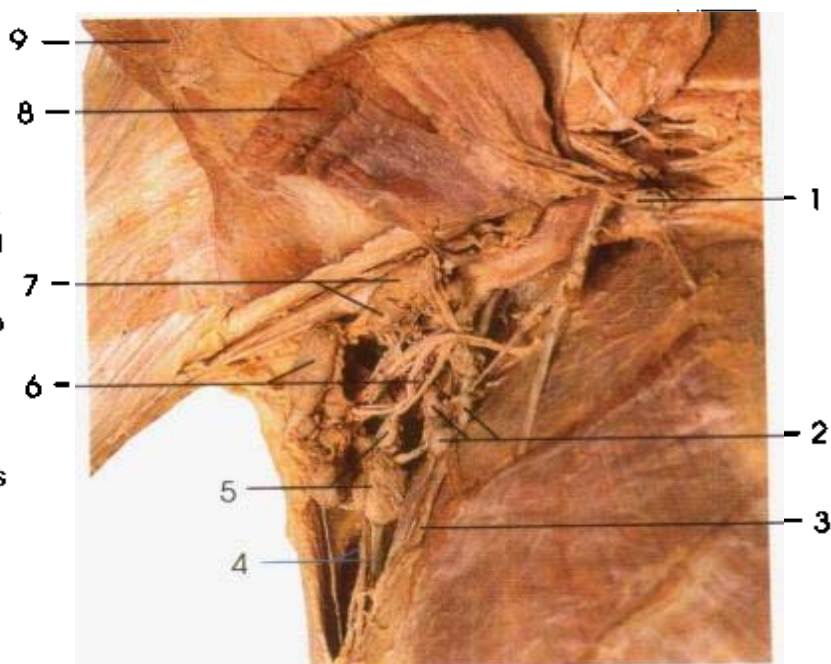
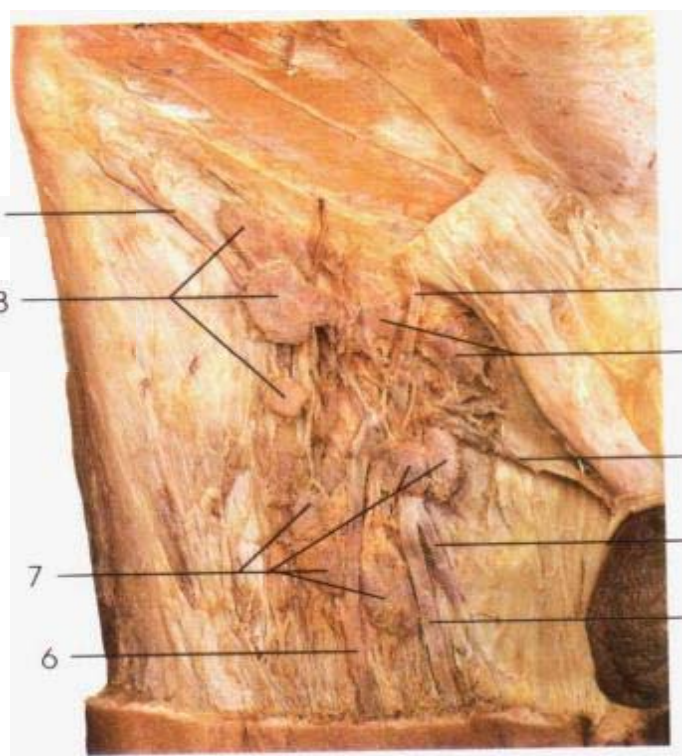


图 156 腋淋巴结
Axillary lymph nodes



1. 腹壁浅静脉 superficial epigastric v.
2. 腹股沟上内侧浅淋巴结 superomedial superficial inguinal lymph nodes
3. 阴部外静脉 external pudendal v.
4. 股内侧浅静脉 medial superficial femoral v.
5. 大隐静脉 great saphenous v.
6. 股外侧浅静脉 lateral superficial femoral v.
7. 腹股沟下浅淋巴结 inferior superficial inguinal lymph nodes
8. 腹股沟上外侧浅淋巴结 superolateral superficial inguinal lymph nodes
9. 旋髂浅静脉 superficial iliac circumflex v.

图 157 腹股沟浅淋巴结
Superficial inguinal lymph nodes

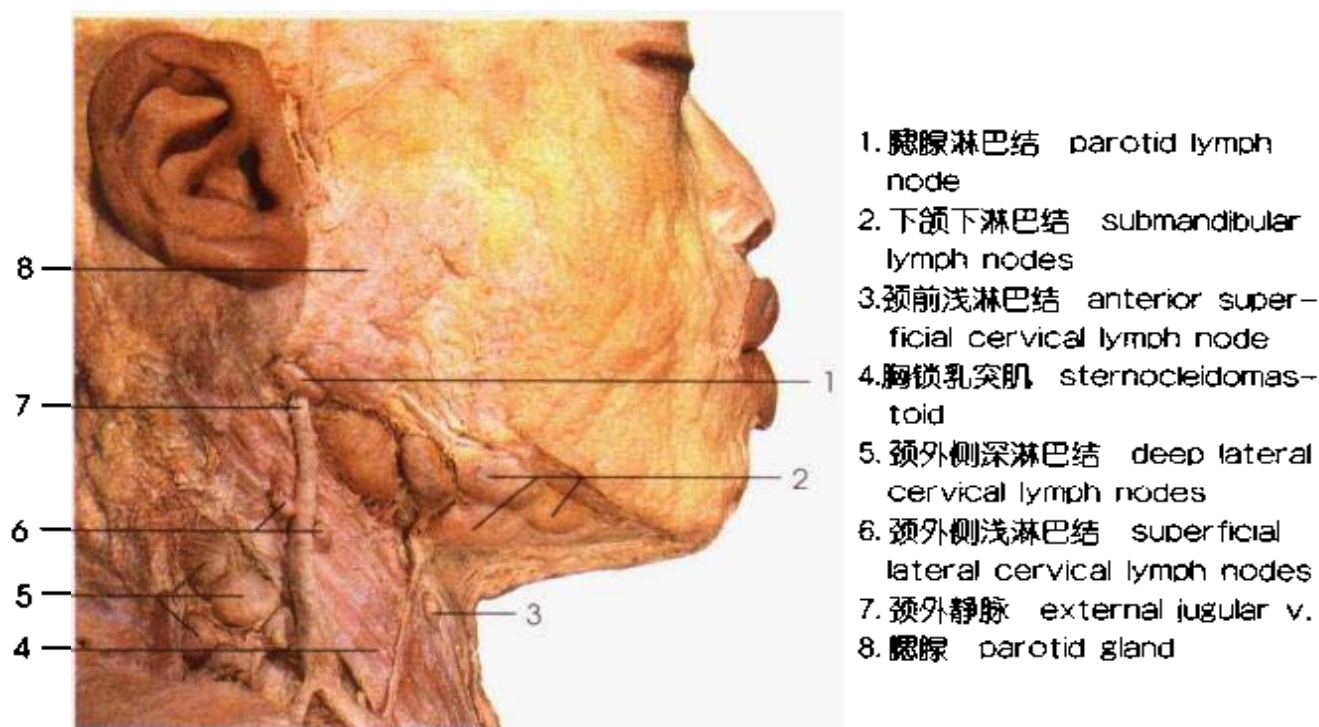


图 158 头颈部浅淋巴结(前分)
 Superficial lymph nodes of the head and neck(anterior part)

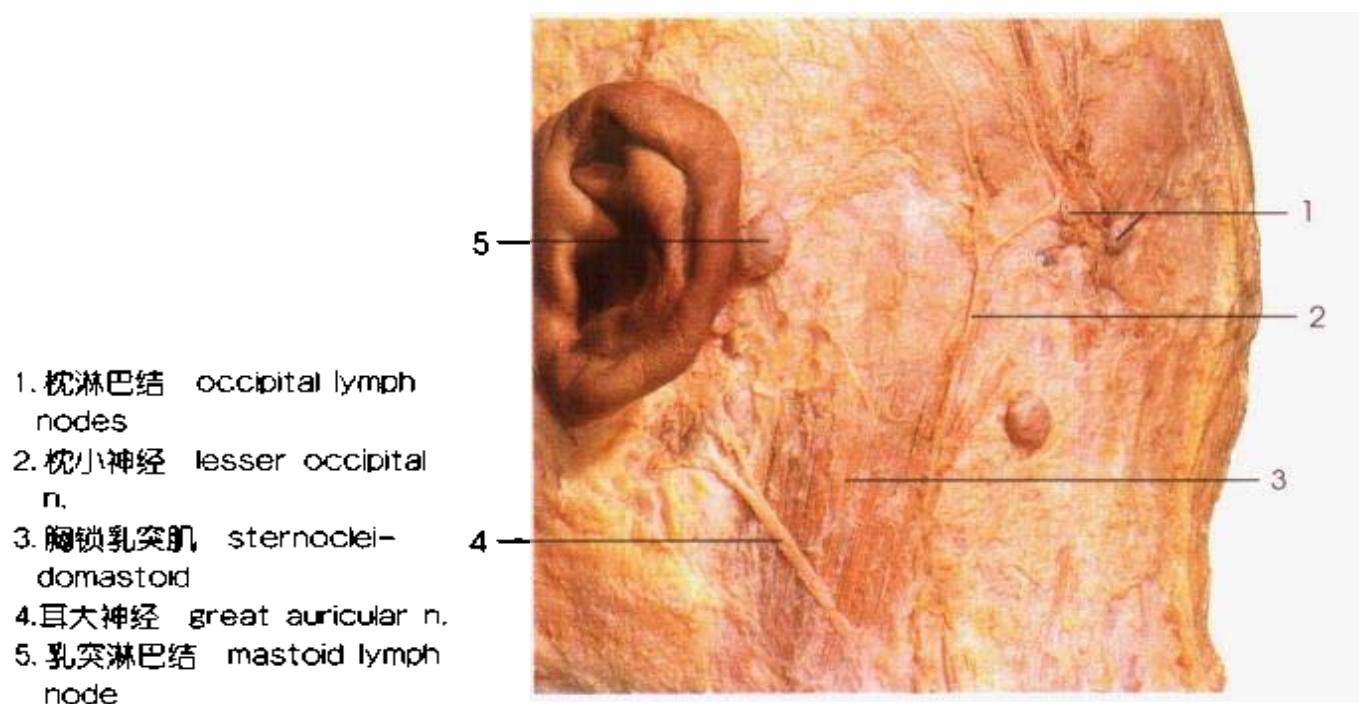


图 159 头颈部浅淋巴结(后分)
 Superficial lymph nodes of the head and neck(posterior part)

7

第7章

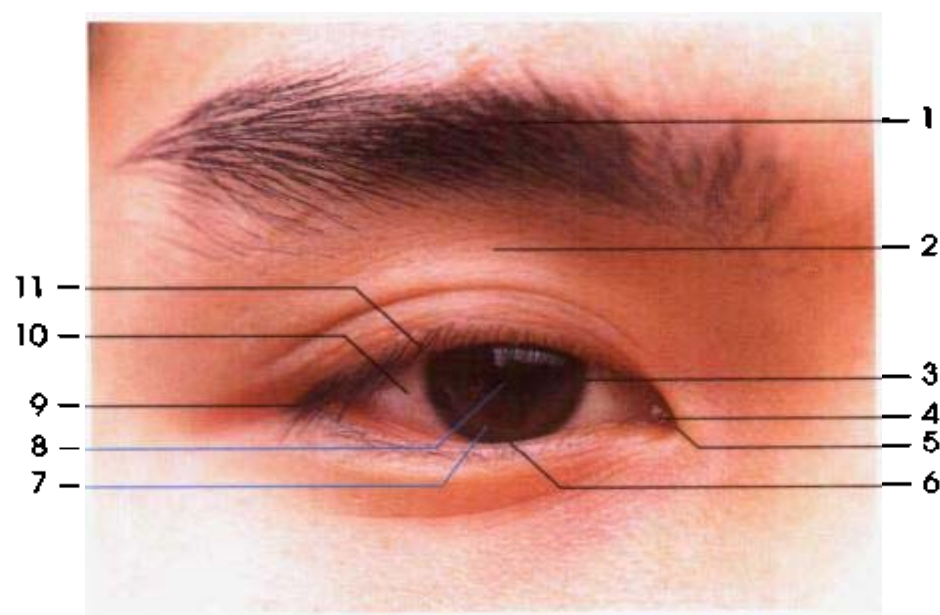
SENSE ORGANS

感

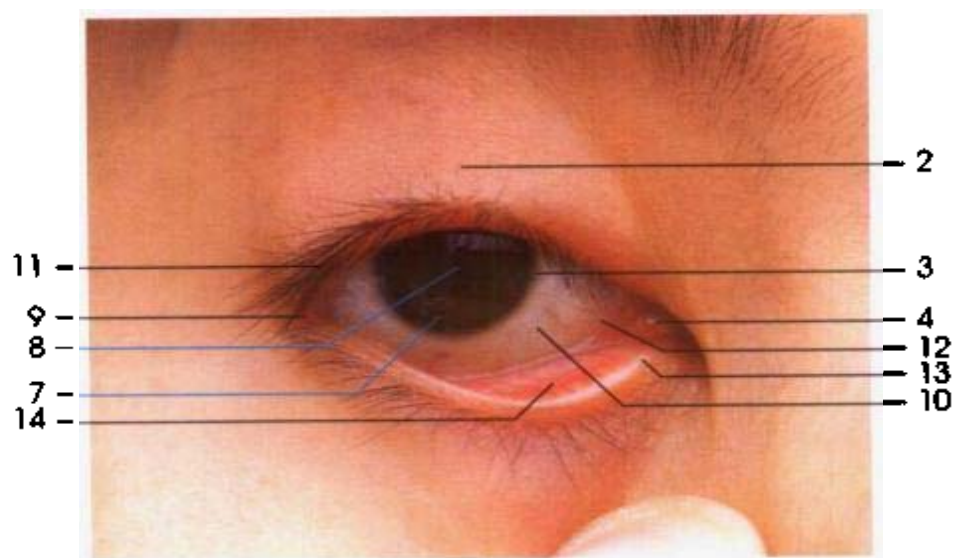
觉

器





A



B

- | | |
|---------------------------|---------------------------------------|
| 1. 眉 eyebrows | 8. 瞳孔 pupil |
| 2. 上睑 upper eyelid | 9. 外眦 lateral angle of eye |
| 3. 角膜缘 limbus corneae | 10. 球结膜 bulbar conjunctiva |
| 4. 泪阜 lacrimal caruncle | 11. 睫 ciliary |
| 5. 内眦 medial angle of eye | 12. 结膜半月襞 conjunctival semilunar fold |
| 6. 睑缘 palpebral edge | 13. 下泪点 lower lacrimal punctum |
| 7. 角膜 cornea | 14. 睑结膜 palpebral conjunctiva |

图 160 眼(右侧)的前面观(A、B)
Anterior aspect of the eye(right side)(A,B)

1. 皮下组织 subcutaneous tissue
2. 眼轮匝肌 orbicularis oculi
3. 皮肤 skin
4. 毛囊 hair follicle
5. 下动脉弓 inferior arterial arch
6. 睑板腺 tarsal glands
7. 睑板腺管 tarsal glands duct
8. 睑板 tarsus
9. 睑结膜 palpebral conjunctiva
10. 米勒肌 müller m.
11. 上动脉弓 superior arterial arch

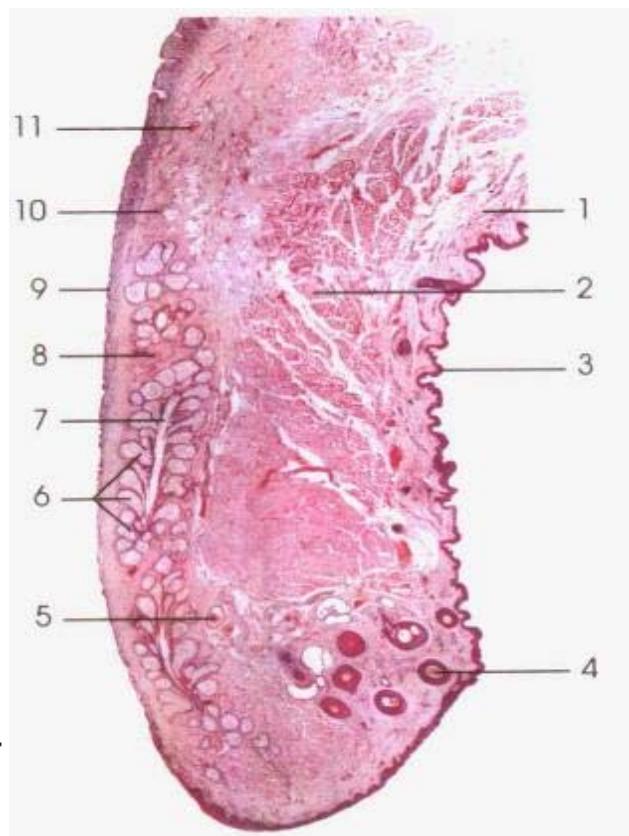


图 161 睑(矢状切面)
The eyelid(sagittal section)

1. 眶上切迹 supraorbital notch
2. 筛后孔 posterior ethmoidal foramen
3. 视神经管 optic canal
4. 筛骨眶板 orbital plate for ethmoid bone
5. 泪囊窝 fossa for lacrimal sac
6. 泪后嵴 posterior lacrimal crest
7. 上颌骨眶面 orbital surface for maxilla bone
8. 上颌骨 maxilla bone
9. 眶下孔 infraorbital foramen
10. 颧骨 zygomatic bone
11. 眶下沟 infraorbital groove
12. 眶下裂 inferior orbital fissure
13. 蝶骨眶面 orbital surface for sphenoid bone
14. 眶上裂 superior orbital fissure
15. 泪腺窝 fossa for lacrimal gland
16. 眶上缘 supraorbital margin

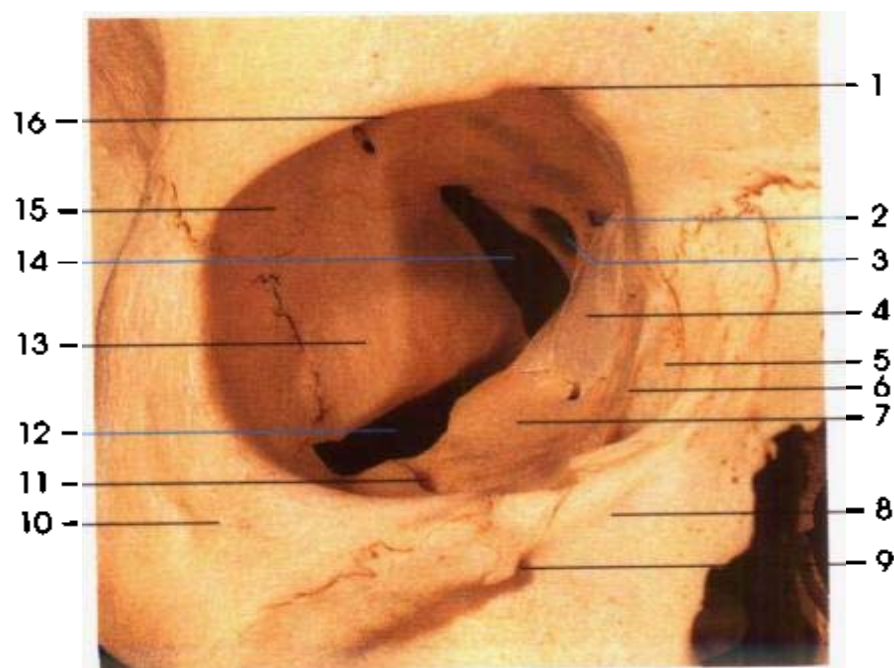
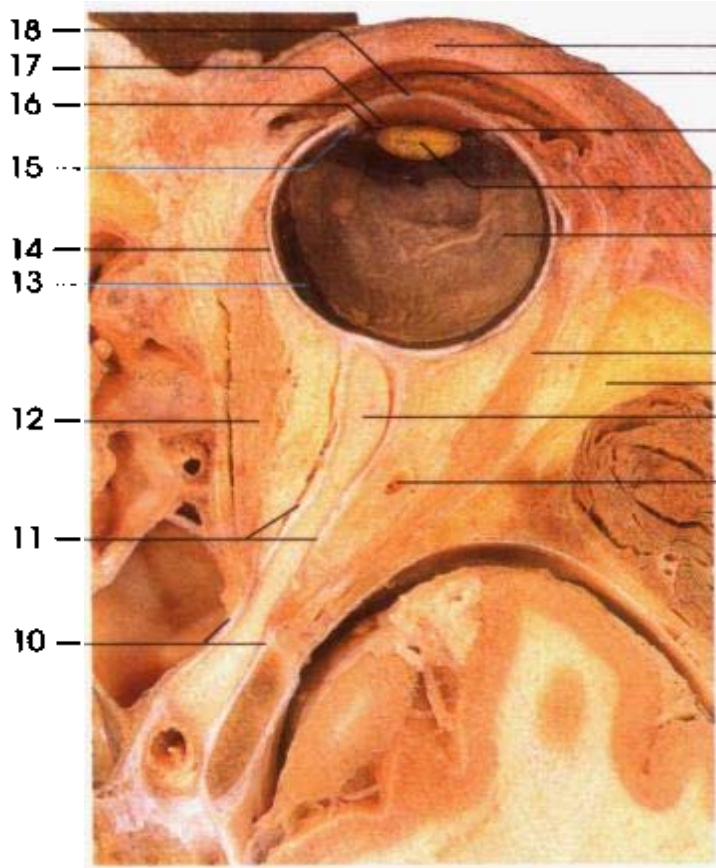


图 162 眶(前面观)
The orbit(anterior aspect)

1. 眶上切迹 supraorbital notch
2. 筛后孔 posterior ethmoidal foramen
3. 视神经管 optic canal
4. 筛骨眶板 orbital plate for ethmoid bone
5. 泪囊窝 fossa for lacrimal sac
6. 泪后嵴 posterior lacrimal crest
7. 上颌骨眶面 orbital surface for maxilla bone
8. 上颌骨 maxilla bone
9. 眶下孔 infraorbital foramen
10. 颧骨 zygomatic bone
11. 眶下沟 infraorbital groove
12. 眶下裂 inferior orbital fissure
13. 蝶骨眶面 orbital surface for sphenoid bone
14. 眶上裂 superior orbital fissure
15. 泪腺窝 fossa for lacrimal gland
16. 眶上缘 supraorbital margin



1. 下睑 lower eyelid
2. 结膜囊 conjunctival sac
3. 虹膜 iris
4. 晶状体 lens
5. 视网膜 retina
6. 外直肌 lateral rectus
7. 眶脂体 adipose body of orbit
8. 视神经(Ⅱ) optic n.(Ⅱ)
9. 眼动脉 ophthalmic a.
10. 总腱环 common tendinous ring
11. 视神经外鞘 outer sheath of optic n.
12. 内直肌 medial rectus
13. 脉络膜 choroid
14. 巩膜 sclera
15. 睫状体 ciliary body
16. 后房 posterior chamber
17. 前房 anterior chamber
18. 角膜 cornea

图 163 右侧眼眶水平断面(上面观)
Horizontal section through orbit(superior aspect)

1. 上睑提肌 levator palpebrae superioris
2. 上直肌 superior rectus
3. 上斜肌腱 tendon of superior obliquus
4. 巩膜 sclera
5. 内直肌 medial recutus
6. 脉络膜 choroid
7. 视网膜 retina
8. 睫状缘 ciliary margin
9. 睫状襞 ciliary folds
10. 晶状体 lens
11. 瞳孔 pupil
12. 泪腺 lacrimal gland
13. 虹膜 iris
14. 睫状突 ciliary processes




图 164 眼球前半(后面观)
Anterior half of the eyeball(postiror aspect)

1. 视网膜颞侧上小静脉 superior temporal venule of retina
2. 视网膜颞侧上小动脉 superior temporal arteriole of retina
3. 视网膜鼻侧上小动脉 superior nasal arteriole of retina
4. 视网膜鼻侧上小静脉 superior nasal venule of retina
5. 视神经盘 optic disc
6. 视网膜鼻侧下小静脉 inferior nasal venule of retina
7. 视网膜鼻侧下小动脉 inferior nasal arteriole of retina
8. 视网膜颞侧下小动脉 inferior temporal arteriole of retina
9. 视网膜颞侧下小静脉 inferior temporal venule of retina
10. 黄斑下小静脉 inferior macular venule
11. 黄斑下小动脉 inferior macular arteriole
12. 黄斑 macula lutea
13. 黄斑上小静脉 superior macular venule
14. 黄斑上小动脉 superior macula arteriole




图 165 眼底的血管
Blood vessel of the eyeball fundus

1. 结膜上穹 superior conjunctival fornix
2. 虹膜 iris
3. 睑结膜 palpebral conjunctiva
4. 角膜 cornea
5. 晶状体 lens
6. 结膜下穹 inferior conjunctival fornix
7. 下斜肌 inferior obliquus
8. 下直肌 inferior rectus
9. 眶脂体 adipose body of orbit
10. 总腱环 common tendinous ring
11. 视神经(Ⅱ) optic n. (Ⅱ)
12. 视网膜 retina
13. 脉络膜 choroid
14. 巩膜 sclera
15. 上直肌 superior rectus
16. 上睑提肌 levator palpebrae superioris




图 166 眼球及眶矢状切面
Sagittal section through eyeball and orbital cavity

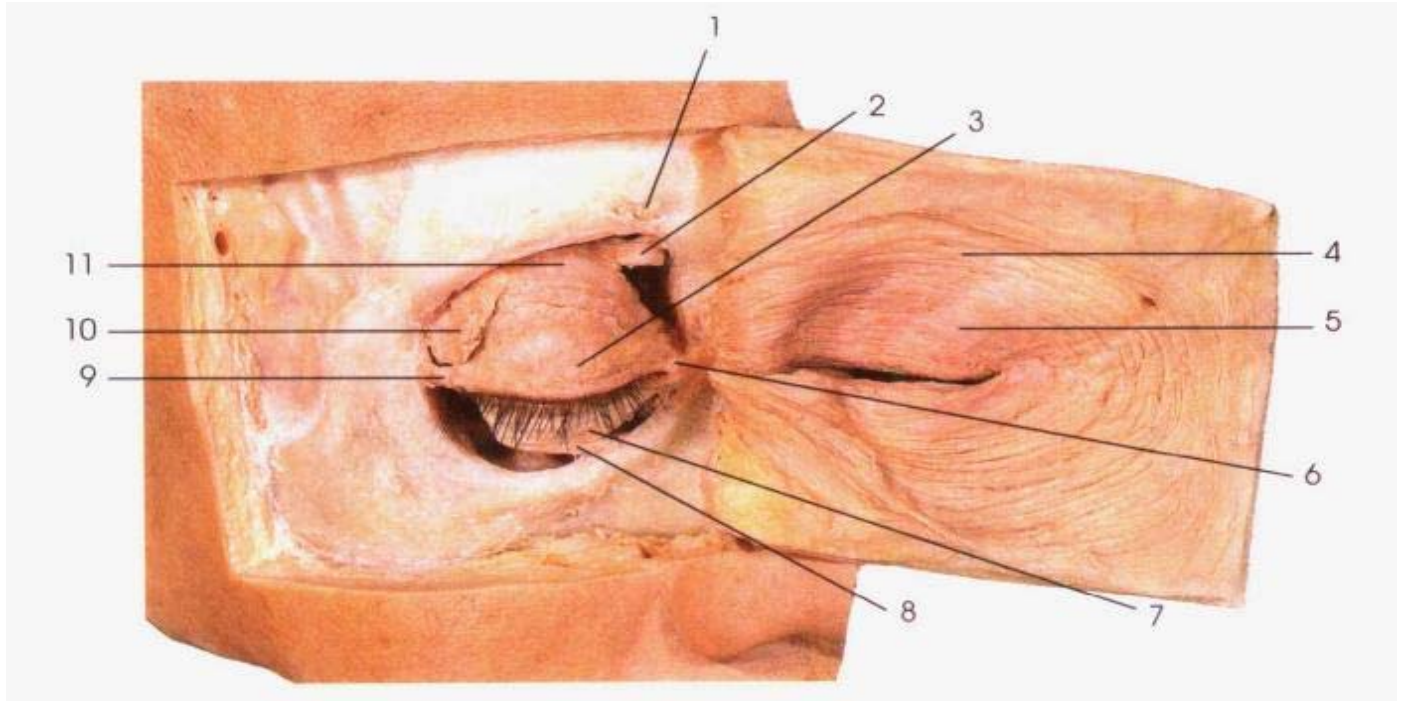


图 167 眼外肌
The extraocular muscles

- | | |
|--|---------------------------------------|
| 1. 眶上神经和血管 supraorbital n. and blood vessels | 6. 睑内侧韧带 medial palpebral lig. |
| 2. 上斜肌 superior obliquus | 7. 下睑板 inferior tarsus |
| 3. 上睑板 superior tarsus | 8. 下斜肌 inferior obliquus |
| 4. 眼轮匝肌眶部 orbital part of orbicularis oculi | 9. 睑外侧韧带 lateral palpebral lig. |
| 5. 眼轮匝肌睑部 palpebral of orbicularis oculi | 10. 泪腺 lacrimal gland |
| | 11. 上睑提肌 levator palpebrae superioris |

1. 眶上神经和血管 supraorbital n. and blood vessels
2. 滑车上神经 supratrochlear n.
3. 上睑板 superior tarsus
4. 滑车下神经 infratrochlear n.
5. 睑内侧韧带 medial palpebral lig.
6. 睑内侧连合 medial palpebral commissure
7. 下睑板 inferior tarsus
8. 眶隔 orbital septum
9. 睑外侧连合 lateral palpebral commissure
10. 睑外侧韧带 lateral palpebral lig.

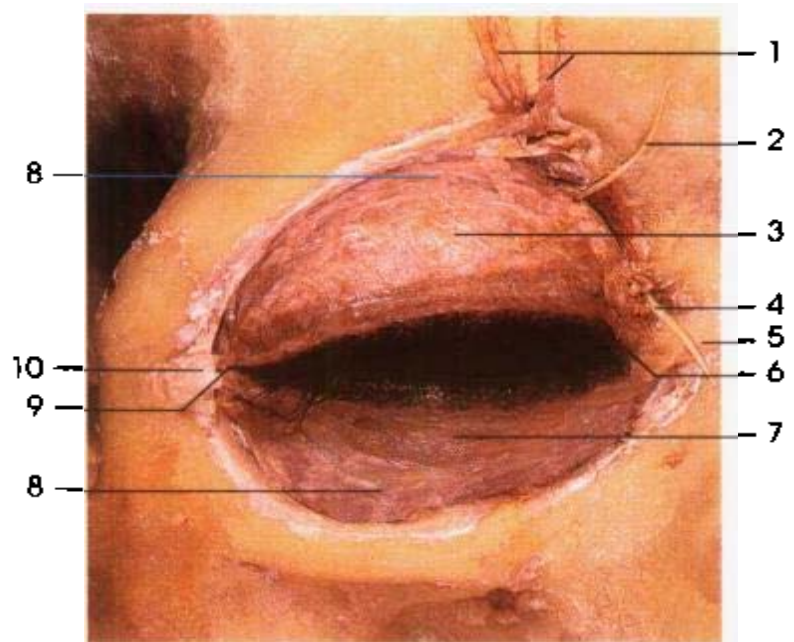
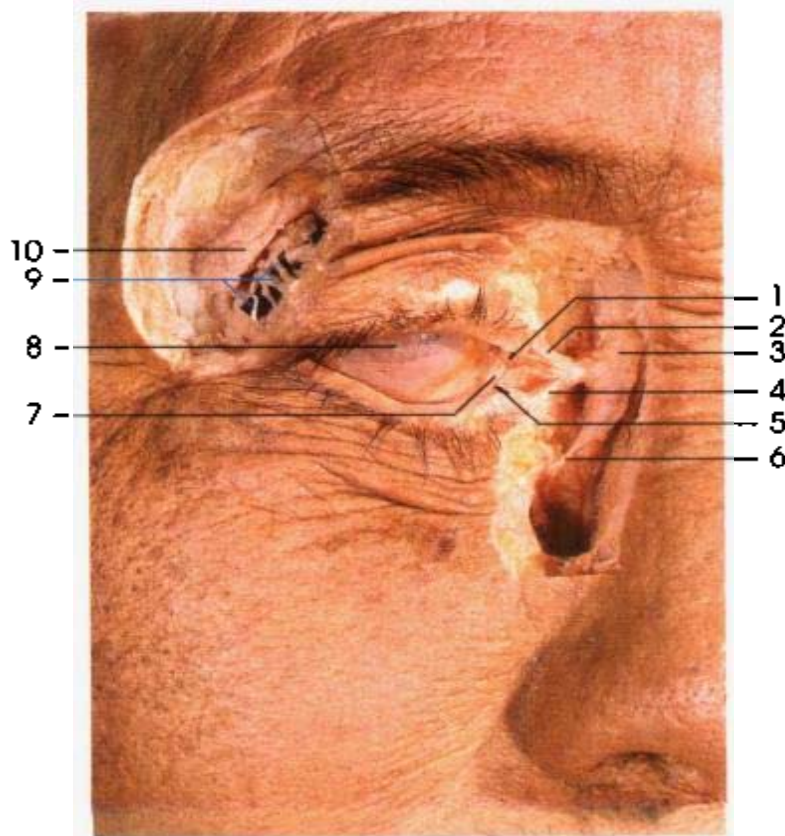
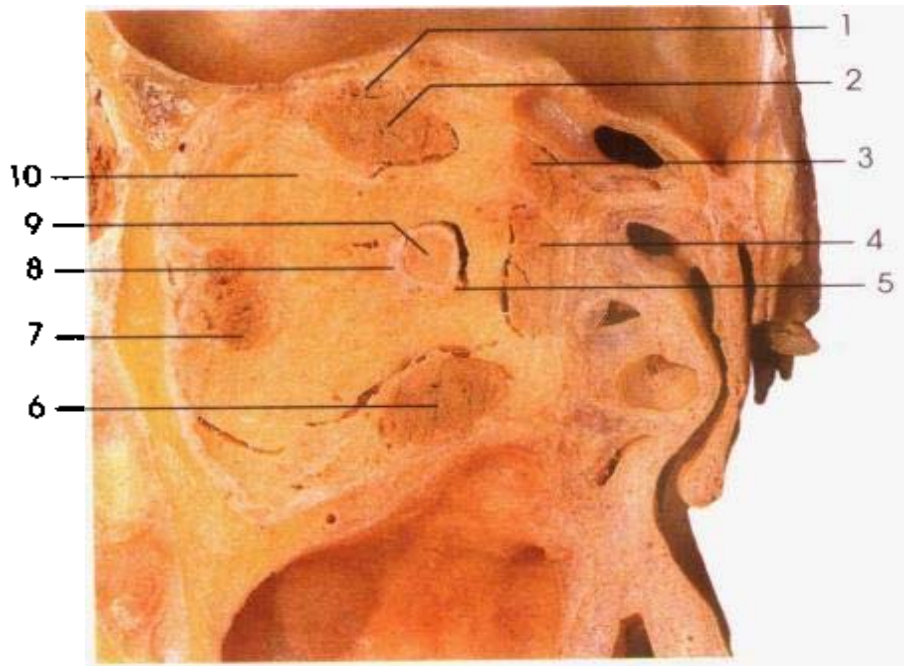


图 168 右眼眶隔
Orbital septum of the right eye



1. 上泪点 upper lacrimal punctum
2. 上泪小管 upper lacrimal ductule
3. 泪囊 lacrimal sac
4. 下泪小管 lower lacrimal punctum
5. 下泪点 lower lacrimal punctum
6. 鼻泪管 nasolacrimal duct
7. 结膜半月襞 conjunctival semilunar
8. 角膜 cornea
9. 泪腺排泄小管 excretory ductules of lacrimal
10. 泪腺 lacrimal gland

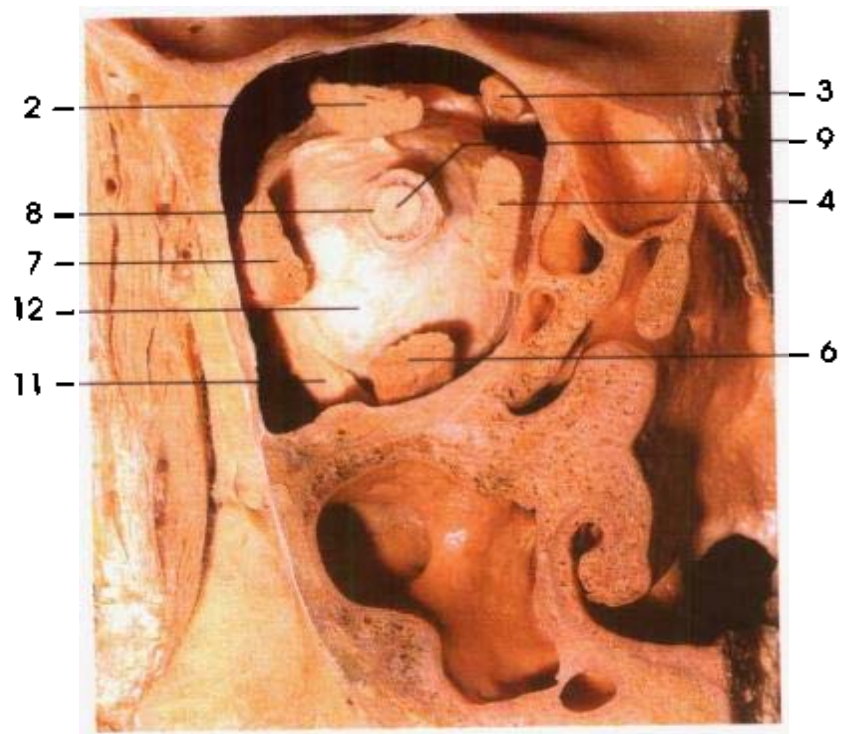
图 169 泪器(右侧)
The lacrimal apparatus(right side)



- 1. 上睑提肌 levator palpebrae superioris
- 2. 上直肌 superior rectus
- 3. 上斜肌 superior obliquus
- 4. 内直肌 medial rectus
- 5. 眼动脉 ophthalmic a.
- 6. 下直肌 inferior rectus
- 7. 外直肌 lateral rectus

A

- 8. 视神经外鞘 outer sheath of optic n.
- 9. 视神经(Ⅱ) optic n.(Ⅱ)
- 10. 眶脂体 adipose body of orbit
- 11. 下斜肌 inferior obliquus
- 12. 眼球 eyeball



B

图 170 眼球后的结构(后面观 A、B)
Posterior structural of eyeball(A,B)

1. 上睑提肌 levator palpebrae superioris
2. 上直肌 superior rectus
3. 角膜 cornea
4. 外直肌 lateral rectus
5. 眼球 eyeball
6. 下斜肌 inferior obliquus
7. 下直肌 inferior rectus
8. 颈内动脉 internal carotid a.
9. 内直肌 medial rectus
10. 上斜肌 superior obliquus

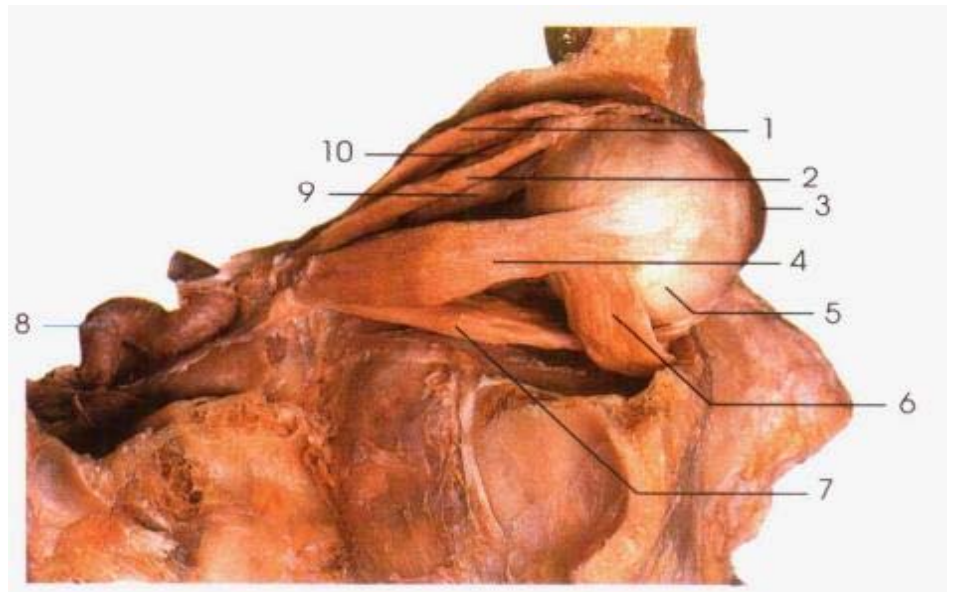
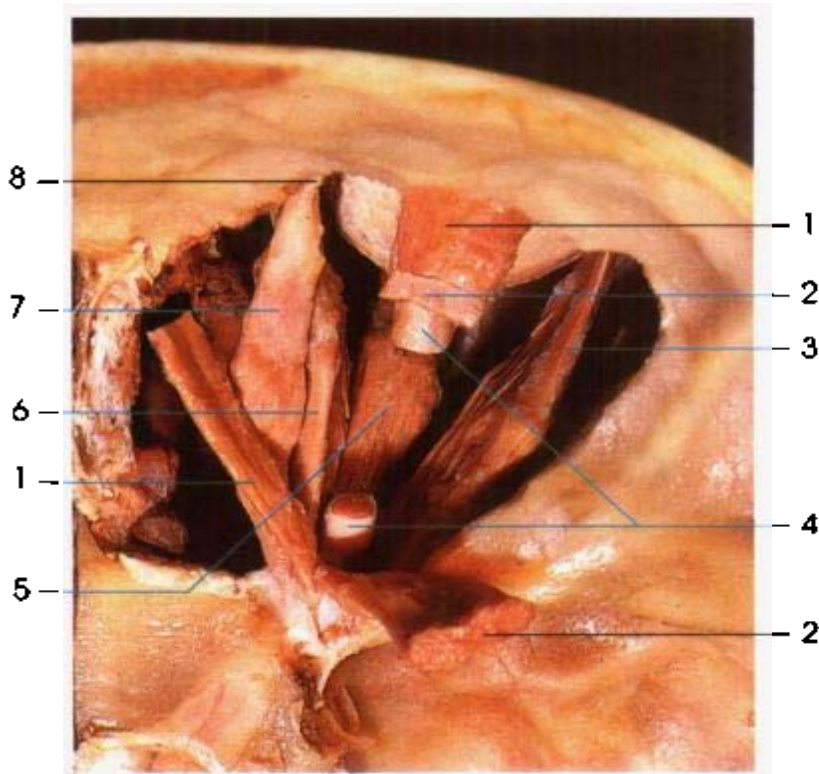
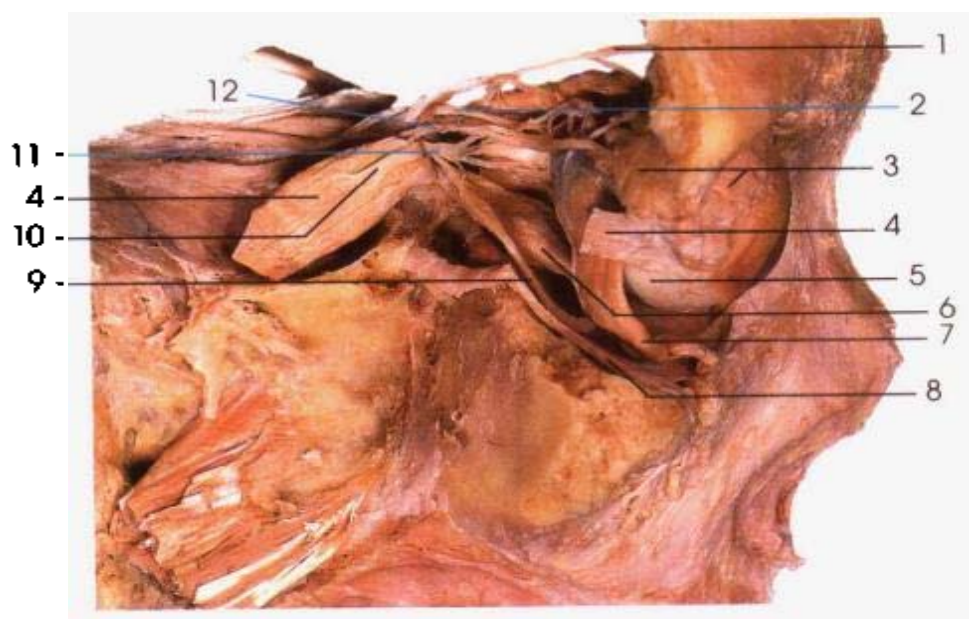


图 171 眼球外肌(外侧观)
The ocular muscles(lateral aspect)



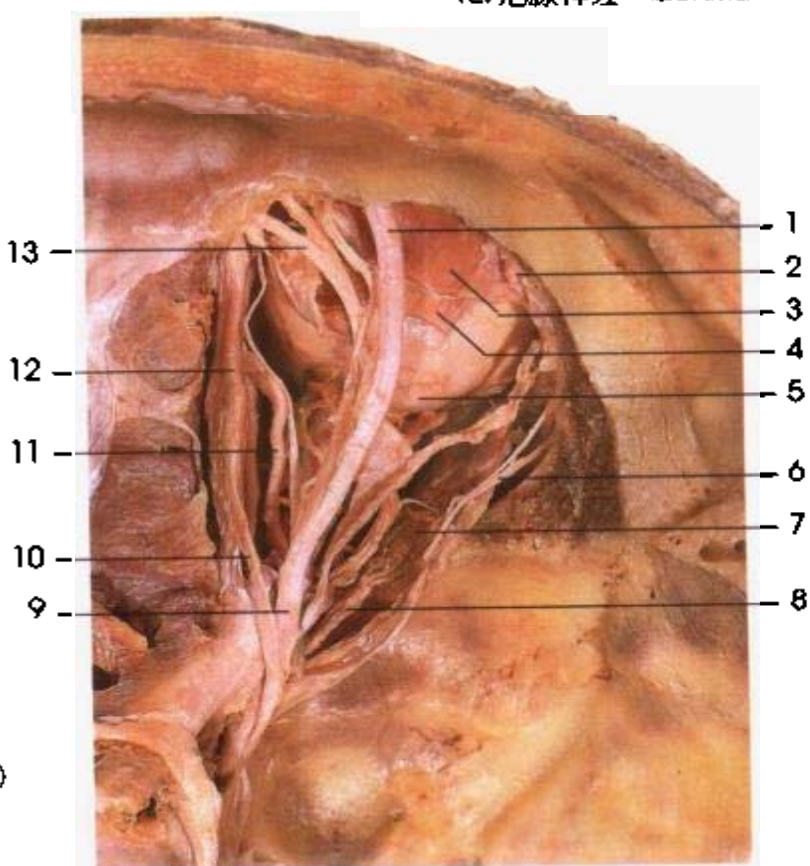
1. 上睑提肌 levator palpebrae superioris
2. 上直肌 superior rectus
3. 外直肌 lateral rectus
4. 视神经(II) optic n.(II)
5. 下直肌 inferior rectus
6. 内直肌 medial rectus
7. 上斜肌 superior obliquus
8. 滑车 trochlea

图 172 眼球外肌(上面观)
The ocular muscles(supeior aspect)



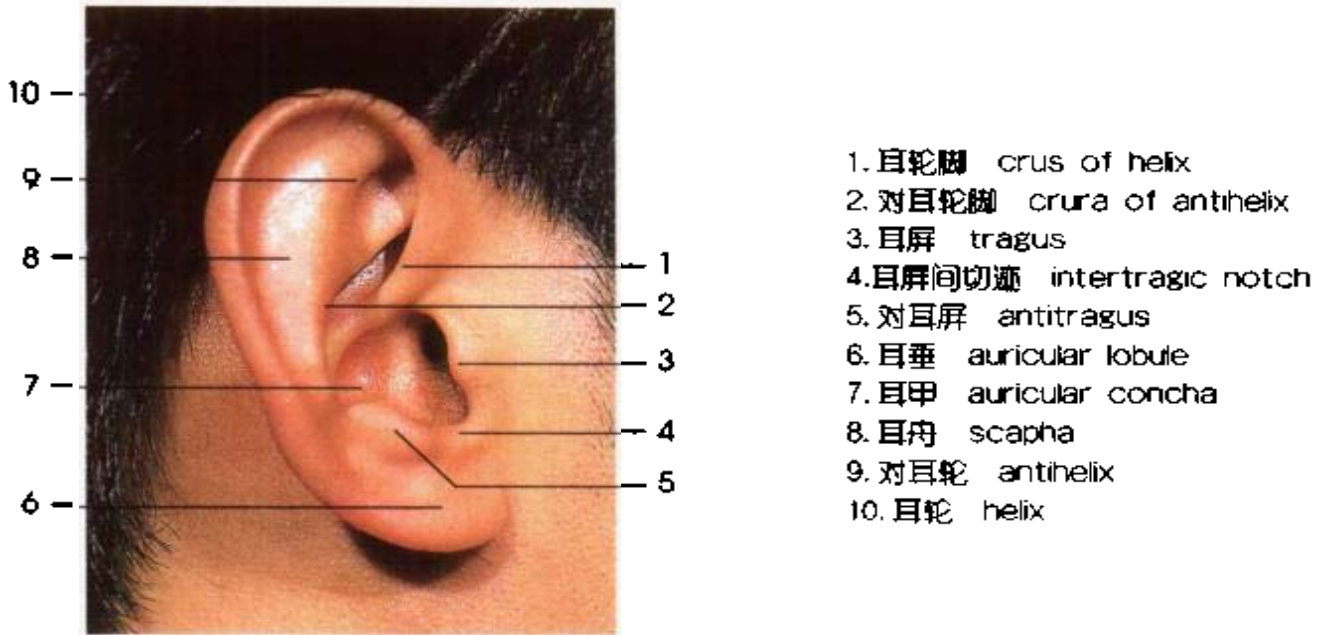
1. 额神经 frontal n.
2. 动眼神经上支 superior branch of oculomotor n.
3. 泪腺 lacrimal gland
4. 外直肌 lateral recus
5. 眼球 eyeball
6. 下直肌 inferior recu-tsu
7. 下斜肌 inferior oblig-uus
8. 眶下神经 infraorbital n.
9. 动眼神经下支 Inferior branch of oculomotor n.
10. 展神经(VI) abducent n.(VI)
11. 睫状神经节 ciliary ganglion
12. 泪腺神经 lacrima n.

图 173 右眼眶内容(外侧面)
Right orbital contents(lateral aspect)



1. 额神经 frontal n.
2. 泪腺 lacrimal gland
3. 上睑提肌 levator palpebrae superioris
4. 上直肌 superior rectus
5. 眼球 eyeball
6. 泪腺神经 lacrimal n.
7. 外直肌 lateral rectus
8. 展神经(VI) abducent n.(VI)
9. 眼神经 ophthalmic n.
10. 动眼神经(III) Oculomotor n.(III)
11. 眼动脉 ophthalmic a.
12. 内直肌 medial rectus
13. 滑车上神经 supratrochlear n.

图 174 右眼眶内容(上面观)
Right orbital contents(superior aspect)



1. 耳轮脚 crus of helix
2. 对耳轮脚 crura of antihelix
3. 耳屏 tragus
4. 耳屏间切迹 intertragic notch
5. 对耳屏 antitragus
6. 耳垂 auricular lobule
7. 耳甲 auricular concha
8. 耳舟 scapha
9. 对耳轮 antihelix
10. 耳轮 helix

图 175 耳廓
Auricle

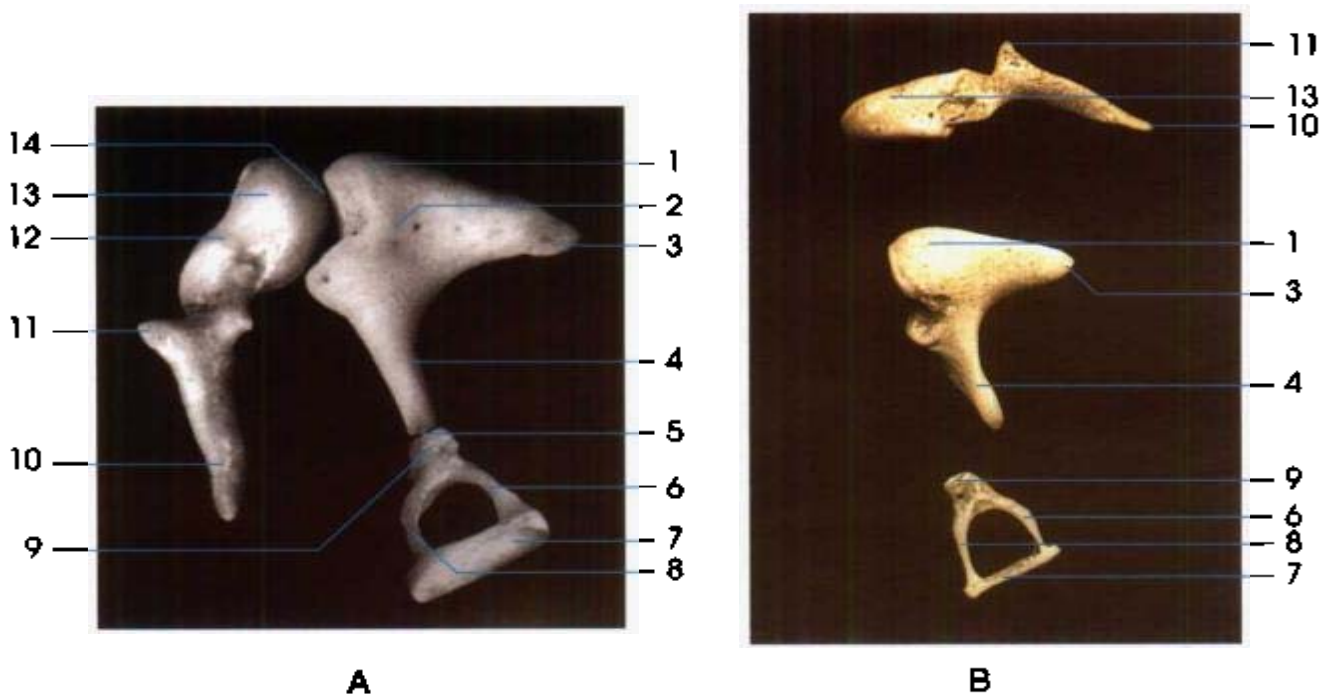


图 176 听小骨(A、B)
Auditory ossicles(A,B)

1. 砧骨 incus
2. 砧骨体 body of incus
3. 短脚 short crus
4. 长脚 long crus
5. 砧镫关节 incudostapedial joint
6. 后脚 posterior crus
7. 镫骨底 base of stapes

8. 前脚 anterior crus
9. 镫骨 stapes
10. 锤骨柄 manubrium of malleus
11. 前突 anterior process
12. 锤骨颈 neck of malleus
13. 锤骨头 head of malleus
14. 砧锤关节 incudomalleolar joint

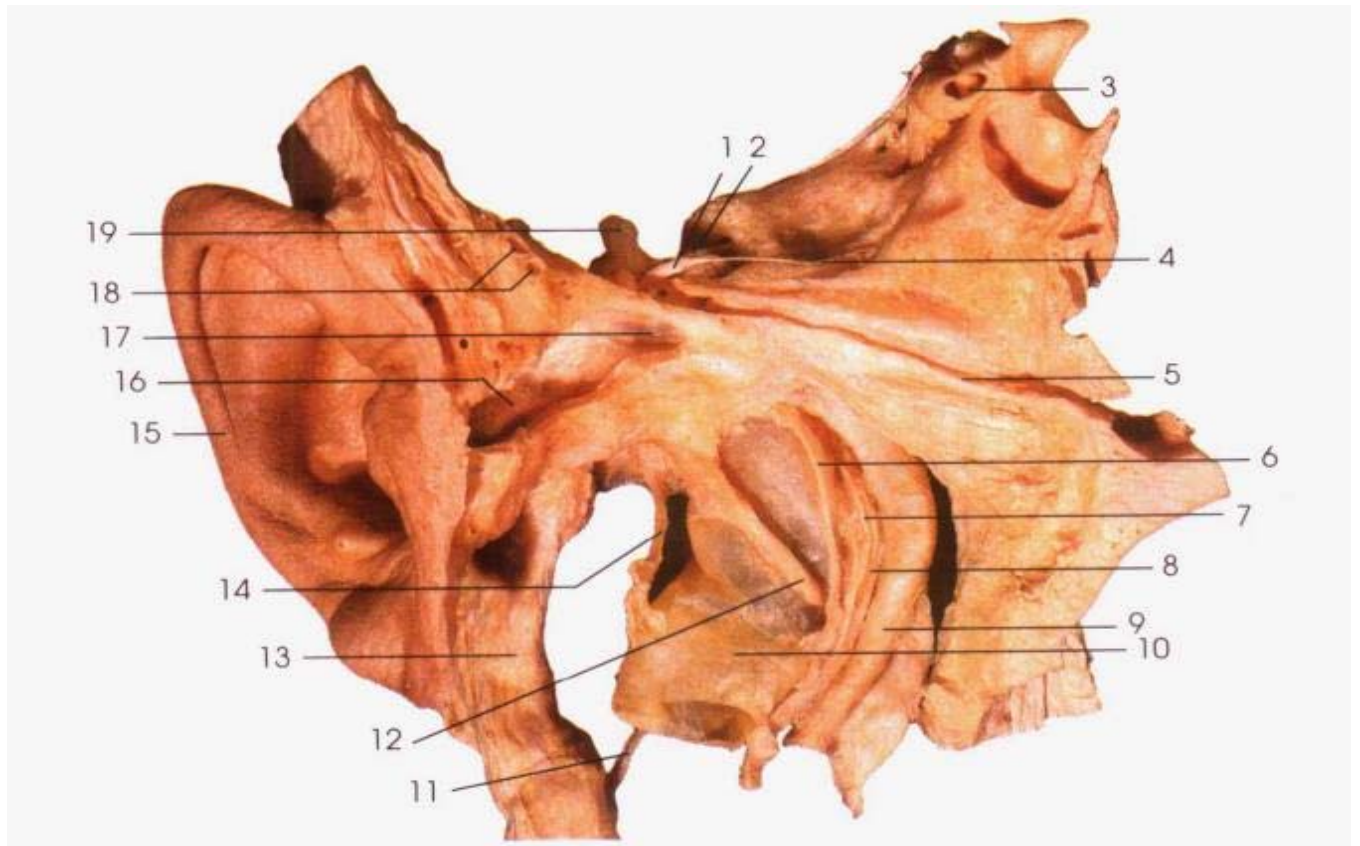


图 177 外、中、内耳(冠状切面)
External middle internal of the
ear(coronal section)

- | | |
|--|----------------------------------|
| 1.膝神经节 geniculum ganglion of facial n. | 10.颈内静脉 internal carotid v. |
| 2,14.面神经(VII) facial n.(VII) | 12.茎突 styloid process |
| 3,9.颈内动脉 internal carotid a. | 13.胸锁乳突肌 sternocleidomastoid |
| 4.岩大神经 greater petrosal n. | 15.耳廓 auricle |
| 5.咽鼓管 auditory tube | 16.外耳道 external acoustic meatus |
| 6.迷走神经(X) vagus n.(X) | 17.鼓膜 tympanic membrane |
| 7,11.副神经(XI) accesory n.(XI) | 18.乳突小房 mastoid cells |
| 8.舌咽神经(IX) glossopharyngeal n.(IX) | 19.骨半规管 bony semicircular canals |

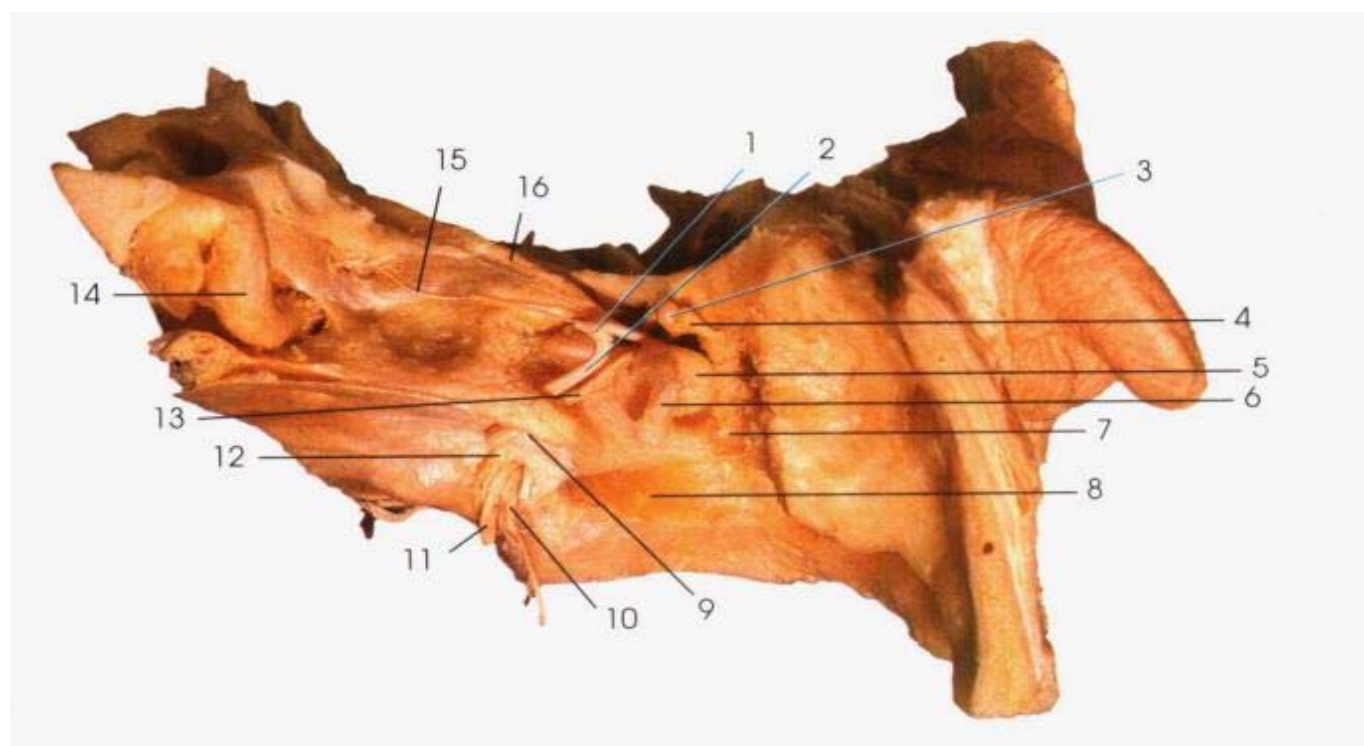


图 178 耳上后面观
Superior posterior aspect of the ear

- | | |
|--|---|
| 1.膝神经节 geniculum ganglion of facial n. | 9.内耳门 internal acoustic pore |
| 2.面神经 facial n. | 10.副神经(XI) accessory n.(XI) |
| 3.砧骨 incus | 11.迷走神经(X) vagus n.(X) |
| 4.锤骨 malleus | 12.舌咽神经(IX) glossopharyngeal n.(IX) |
| 5.外半规管 lateral semicircular canal | 13.前庭蜗神经(VIII) vestibulocochlear n.(VIII) |
| 6.前半规管 anterior semicircular canal | 14.颈内动脉 interior carotid a. |
| 7.后半规管 posterior semicircular canal | 15.岩大神经 greater petrosal n. |
| 8.乙状窦沟 sulcus for sigmoid sinus | 16.鼓膜张肌 tensor tympani |

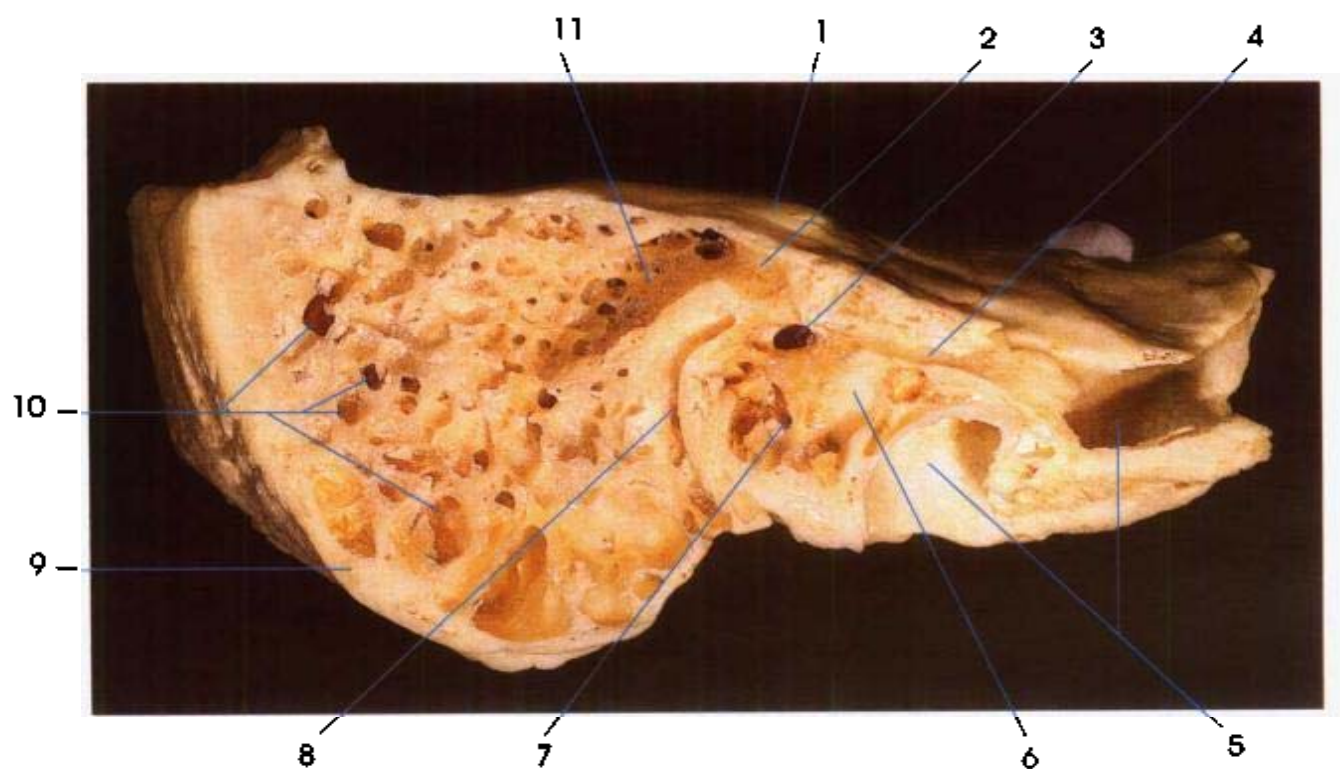


图 179 鼓室内侧壁(右侧)
Medial wall of the tympanic cavity(right side)

- | | |
|---|-----------------------------|
| 1. 弓状隆起 arcuate eminence | 6. 岬 promontory |
| 2. 乳突窦入口 entrance to mastoid antrum | 7. 蜗窗 fenestra cochleae |
| 3. 前庭窗 fenestra vestibuli | 8. 面神经管 canal for facial n. |
| 4. 咽鼓管半管 semicircular for auditory tube | 9. 乳突 mastoid process |
| 5. 颈动脉管 carotid canal | 10. 乳突小房 mastoid cells |
| | 11. 乳突窦 mastoid antrum |

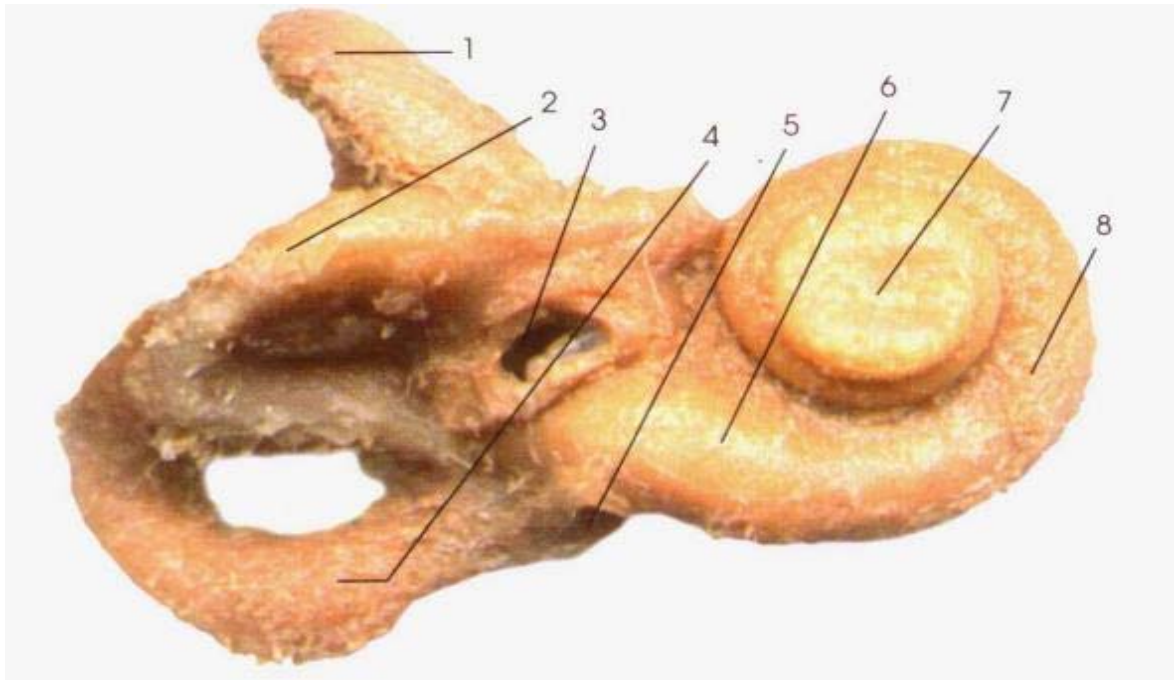


图 180 骨迷路
Bony labyrinth

- | | | | |
|----------|------------------------------|-------|-------------------|
| 1. 前骨半规管 | anterior semicircular canal | 5. 蜗窗 | fenestra cochleae |
| 2. 外骨半规管 | lateral semicircular canal | 6. 前庭 | vestibule |
| 3. 前庭窗 | fenestra vestibuli | 7. 蜗顶 | cupula of cochlea |
| 4. 后骨半规管 | posterior semicircular canal | 8. 耳蜗 | cochlea |

1. 前庭膜 vestibule membranous
2. 蜗管 cochlear duct
3. 血管纹 stria vascularis
4. 外毛细胞 outer hair cells
5. 螺旋嵴 spiral crest
6. 鼓阶 scala tympani
7. 螺旋膜 spiral membranous
8. 内毛细胞 inner hair cells
9. 骨螺旋板 osseous spiral lamina
10. 盖膜 tectorial membrane
11. 前庭阶 scala vestibuli

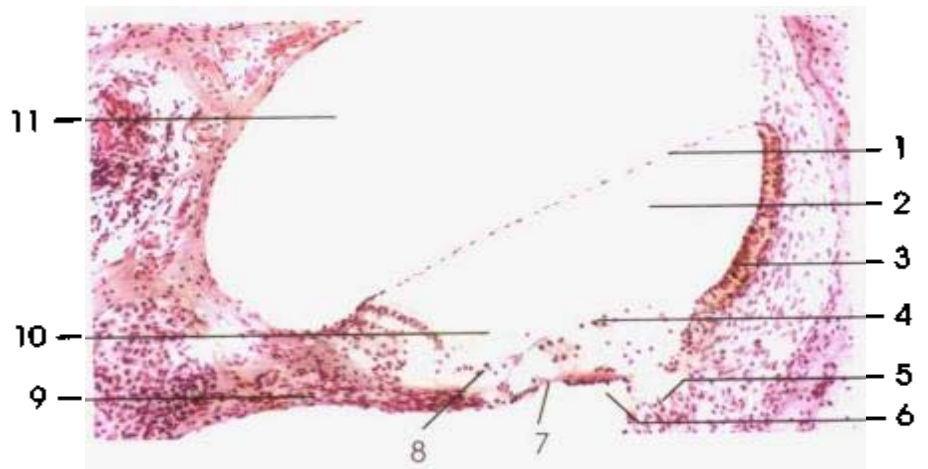
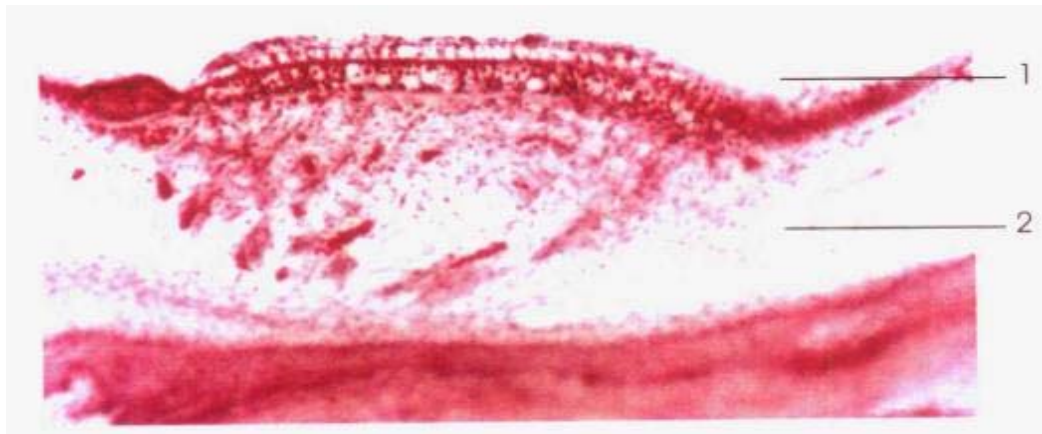
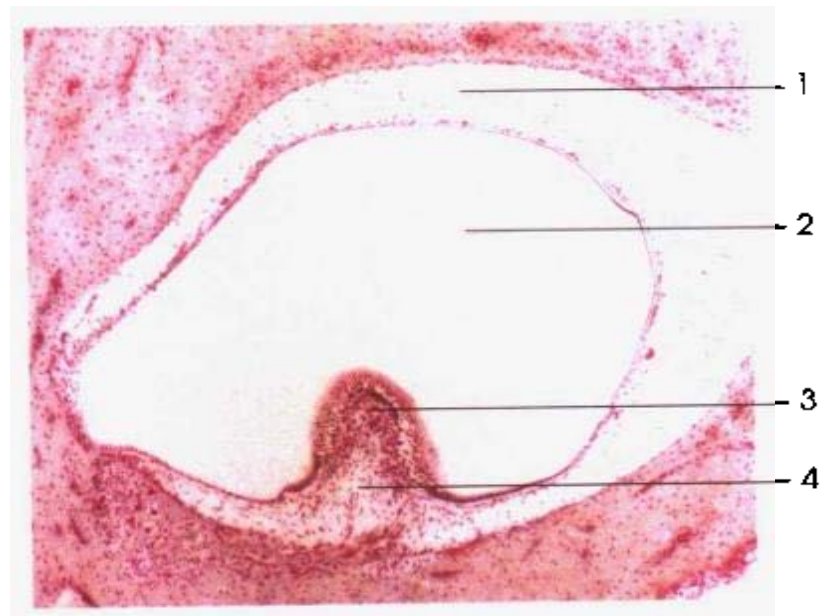


图 181 螺旋器
The spiral organ



- 1. 球囊 saccule
- 2. 骨迷路 bony labyrinth

图 182 位觉斑
The macula of utricle and macula of saccule



- 1. 骨迷路 bony labyrinth
- 2. 膜半规管壶腹 semicircular duct for ampullae
- 3. 壶腹帽 cupula
- 4. 神经纤维 nerve fiber

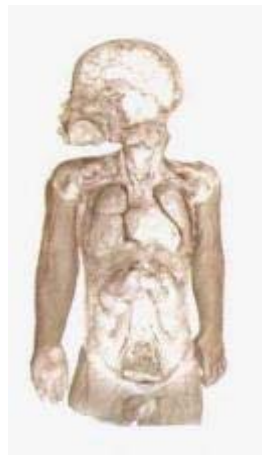图 183 壶腹嵴
The ampullary crest

第8章

内
分
泌
系
统

8

ENDOCRINE SYSTEM



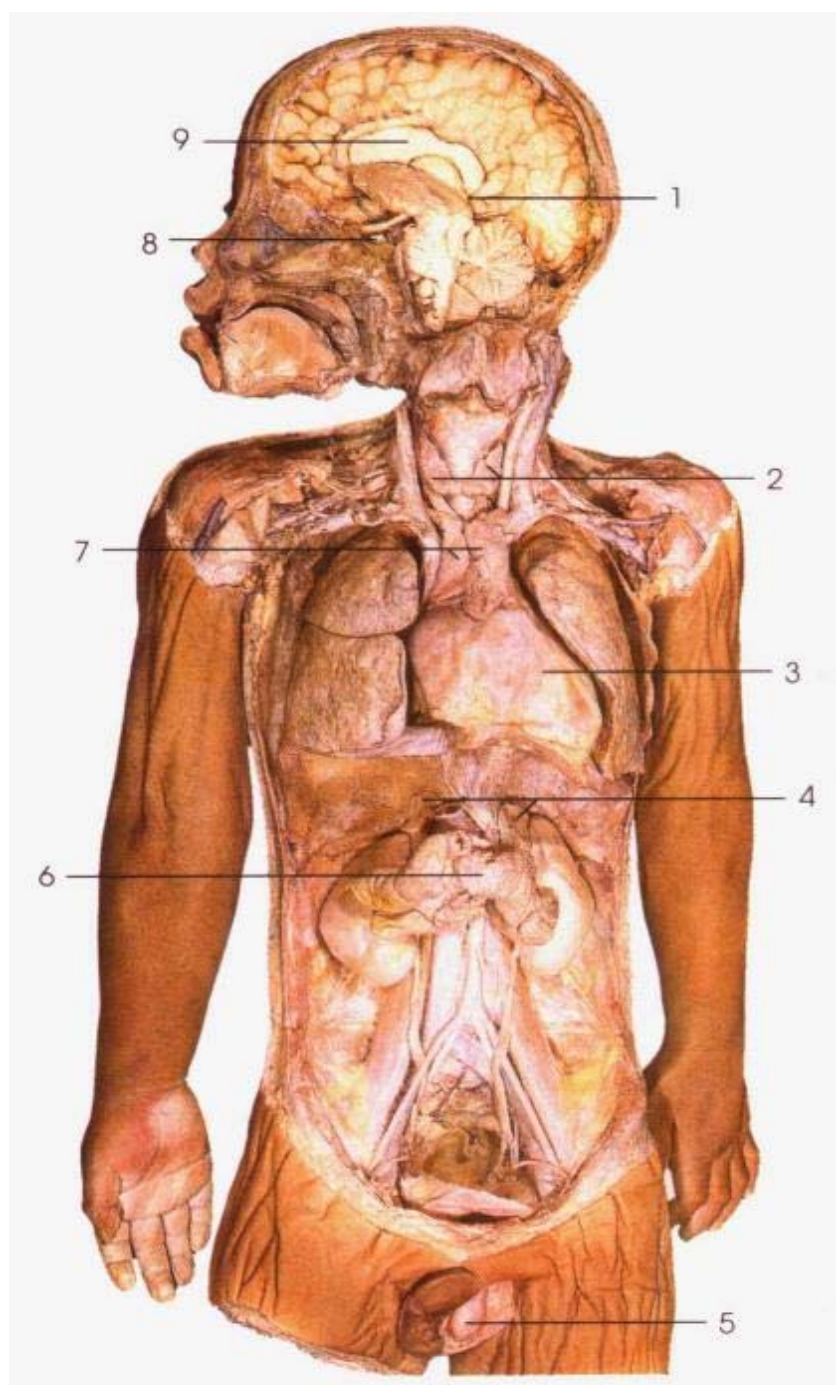


图 184 全身主要内分泌器官
The endocrine organs of body

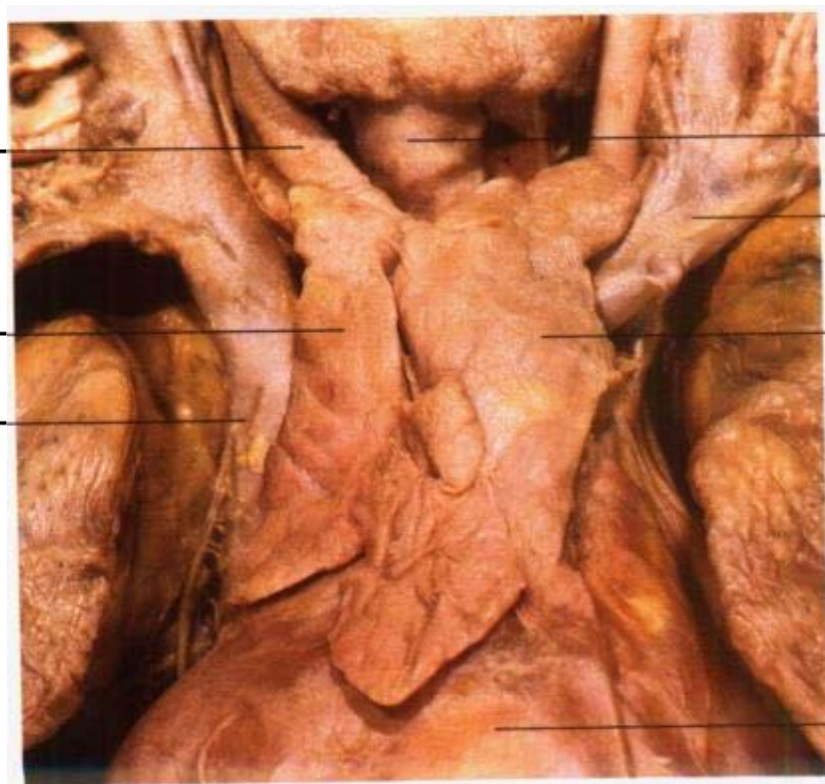
- | | |
|-------------------------|------------------------|
| 1. 松果体 pineal body | 6. 胰 pancreas |
| 2. 甲状腺 thyroid gland | 7. 胸腺 thymus |
| 3. 心包 pericardium | 8. 垂体 hypophysis |
| 4. 肾上腺 suprarenal gland | 9. 胼胝体 corpus callosum |
| 5. 睾丸 testis | |

1. 胼胝体 corpus callosum
2. 松果体 pineal body
3. 上丘 superior colliculus
4. 下丘 inferior colliculus
5. 垂体 hypophysis
6. 视交叉 optic chiasma
7. 动眼神经 oculomotor n.

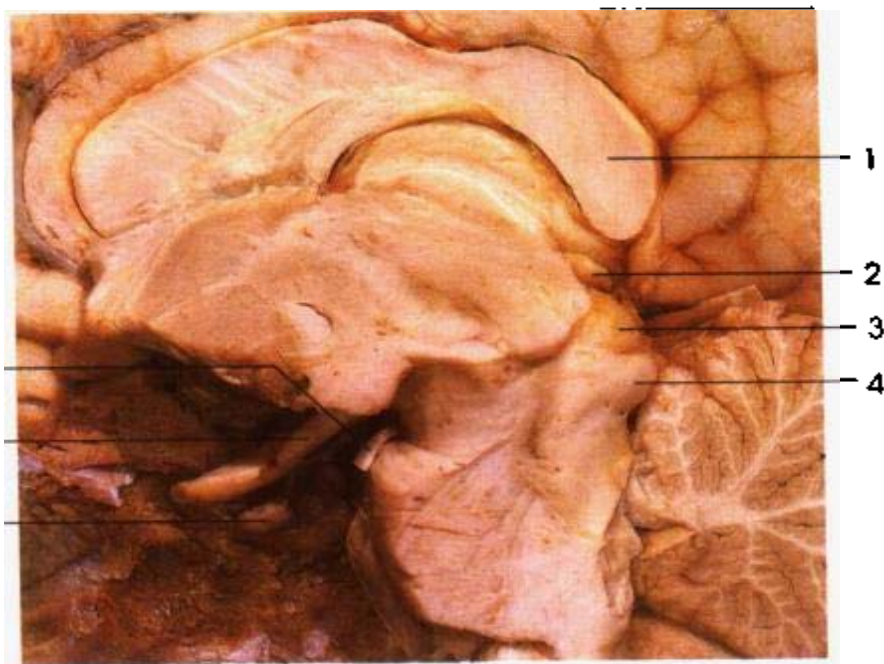

图 185 垂体与松果体
Hypophysis and pineal body

- 7
- 6
- 5



1. 气管 trachea
2. 左头臂静脉 left brachiocephalic v.
3. 胸腺左叶 left lobe of thymus
4. 心包 pericardium
5. 上腔静脉 superior vena cava
6. 胸腺右叶 right lobe of thymus
7. 右颈总动脉 right common carotid a.

图 186 胸腺
Thymus

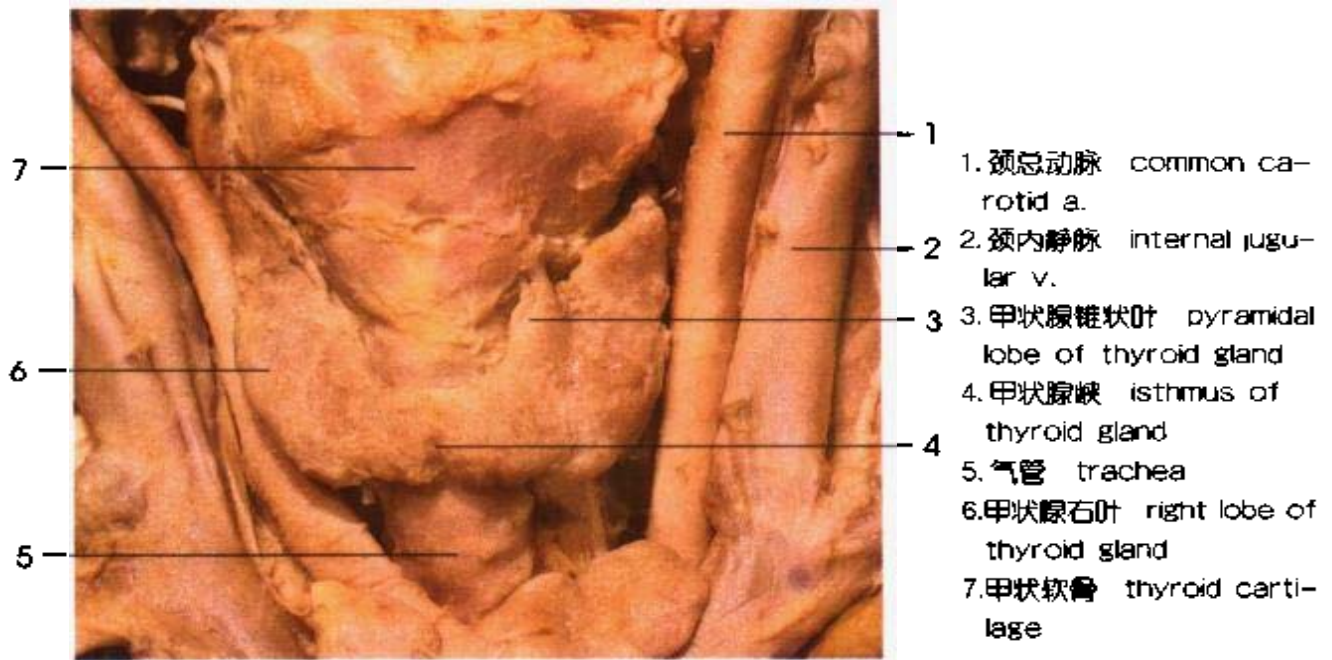


图 187 甲状腺(前面观)
Thyroid gland(anterior aspect)

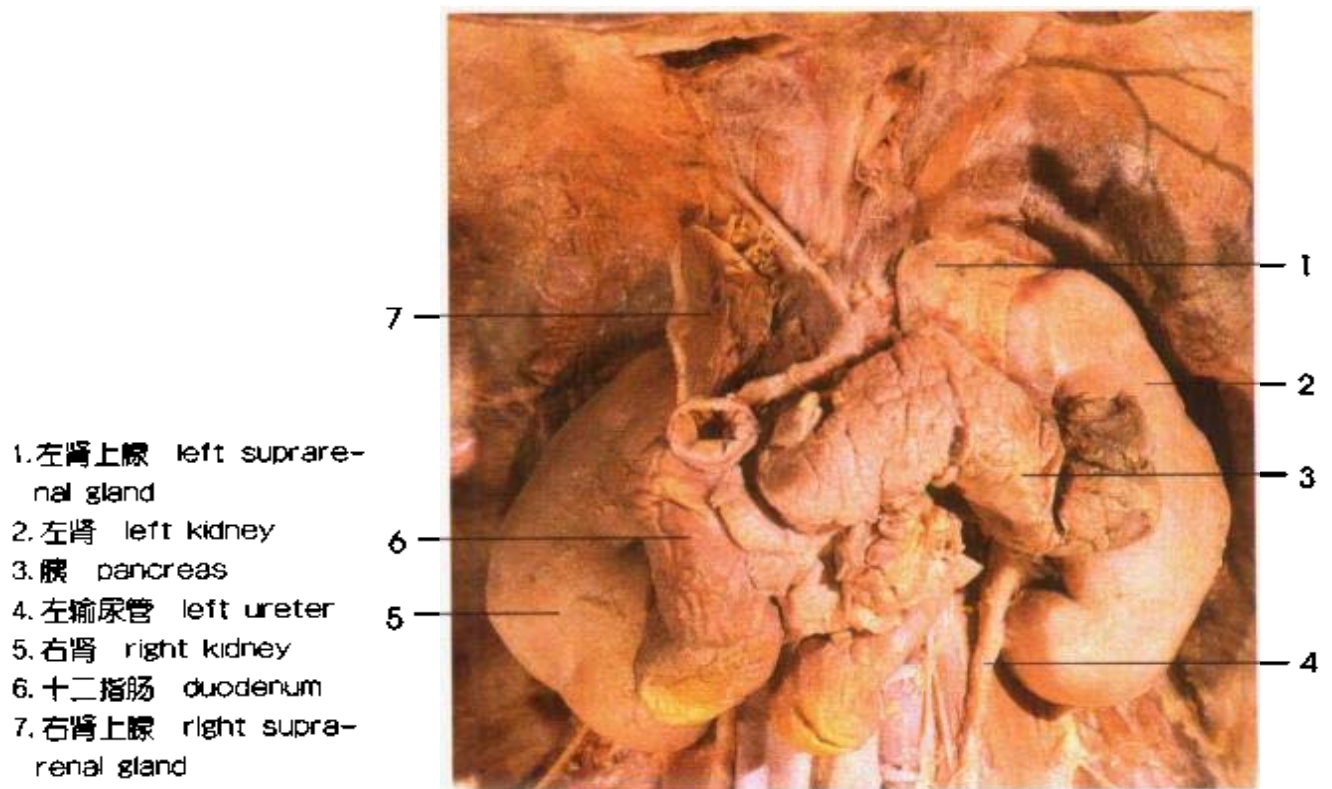


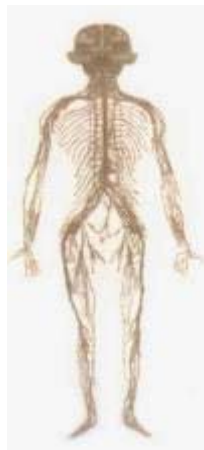
图 188 肾上腺
Suprarenal gland

第9章

中
枢
神
经
系
统

9

CENTRAL NERVOUS SYSTEM



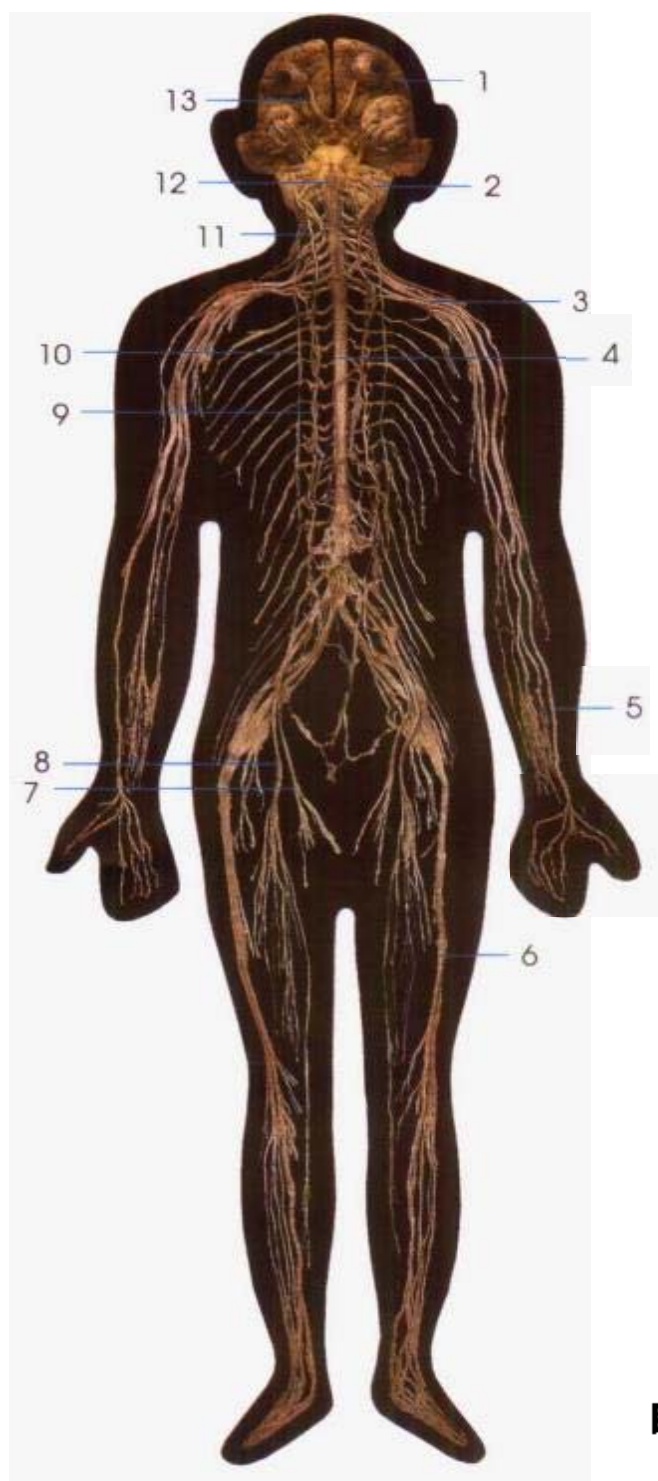


图 189 神经系统
Nervous system

- 1. 大脑半球 cerebral hemisphere
- 2. 小脑 cerebellum
- 3. 臂丛 brachial plexus
- 4. 脊髓 spinal cord
- 5. 正中神经 median n.
- 6. 坐骨神经 sciatic n.
- 7. 闭孔神经 obturator n.

- 8. 股神经 femoral n.
- 9. 交感干 sympathetic trunk
- 10. 膈神经 phrenic n.
- 11. 迷走神经(X) vagus n.(X)
- 12. 脑干 brain stem
- 13. 视神经(II) optic n.(II)

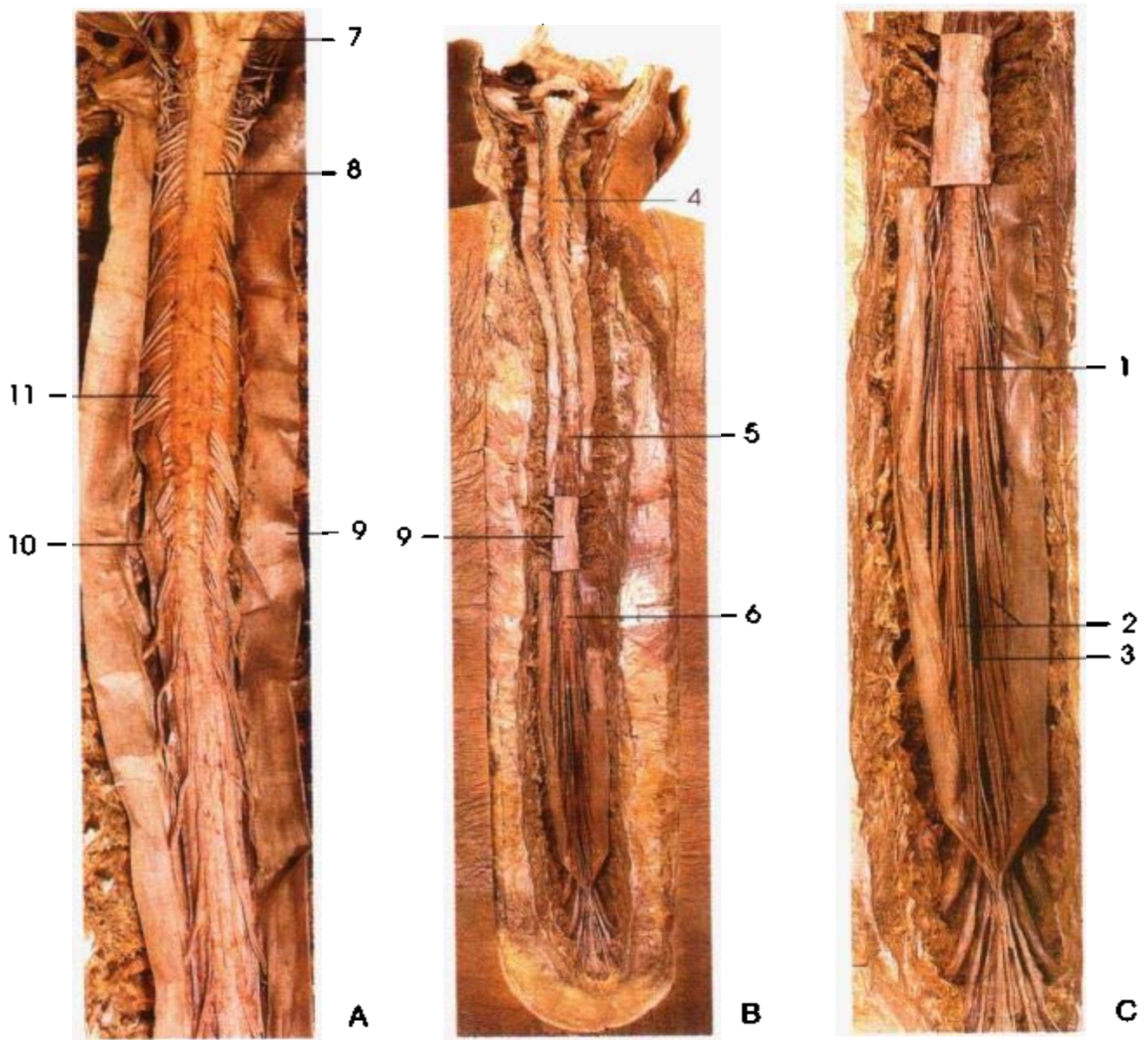
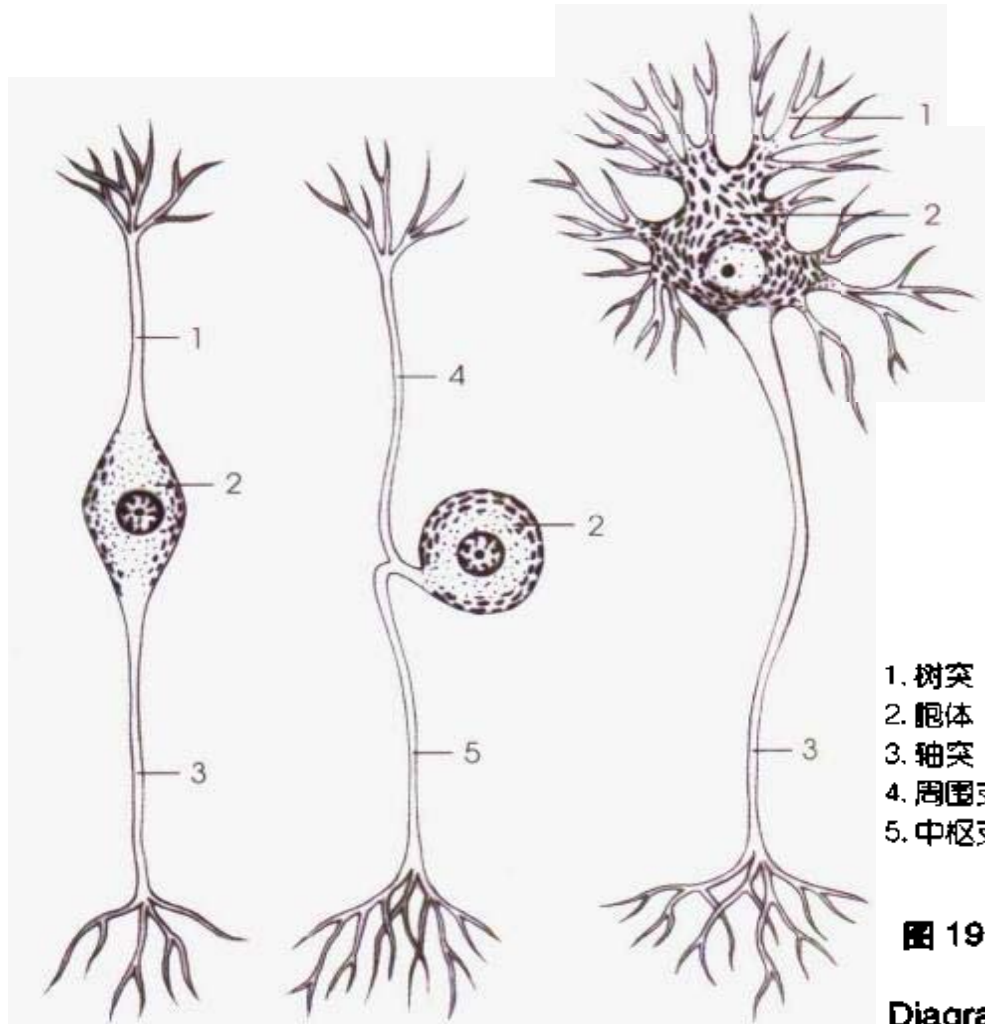


图 190 脊髓的外形和被膜(A、B、C)
External features and meninges of the spinal cord(A,B,C)

- 1. 脊髓圆锥 conus medullaris
- 2. 马尾 cauda equina
- 3. 终丝 filum terminale
- 4. 颈膨大 cervical enlargement
- 5. 脊髓蛛网膜 spinal arachnoid mater
- 6. 腰骶膨大 lumbosacral enlargement

- 7. 延髓 medulla oblongata
- 8. 后正中沟 posterior median sulcus
- 9. 硬脊膜 spinal dura mater
- 10. 齿状韧带 denticulate ligament
- 11. 后根 posterior root



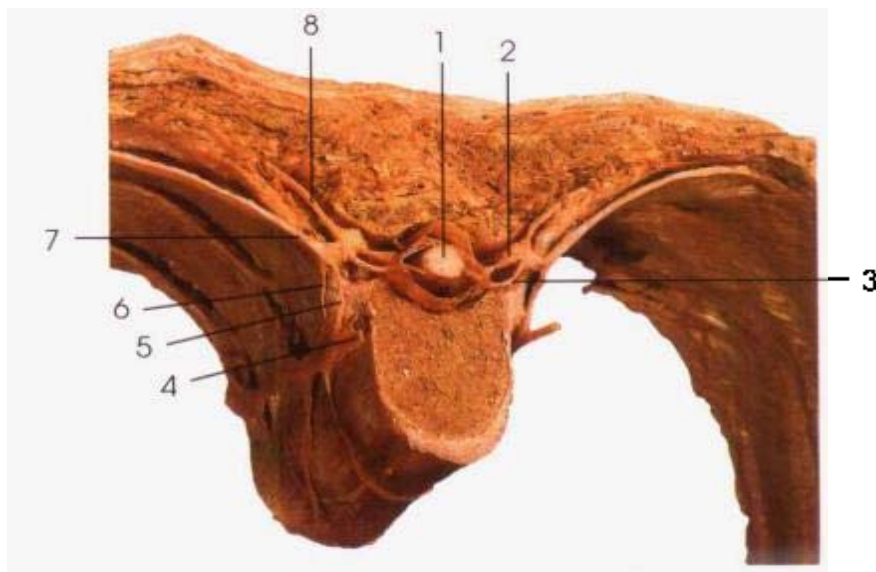
- 1. 树突 dendrite
- 2. 胞体 cell body
- 3. 轴突 axon
- 4. 周围支 peripheral branch
- 5. 中枢支 central branch

图 191 神经元模式图
(A, B, C)
Diagram of the neurons
(A,B,C)

A. 双极神经元
bipolar neuron

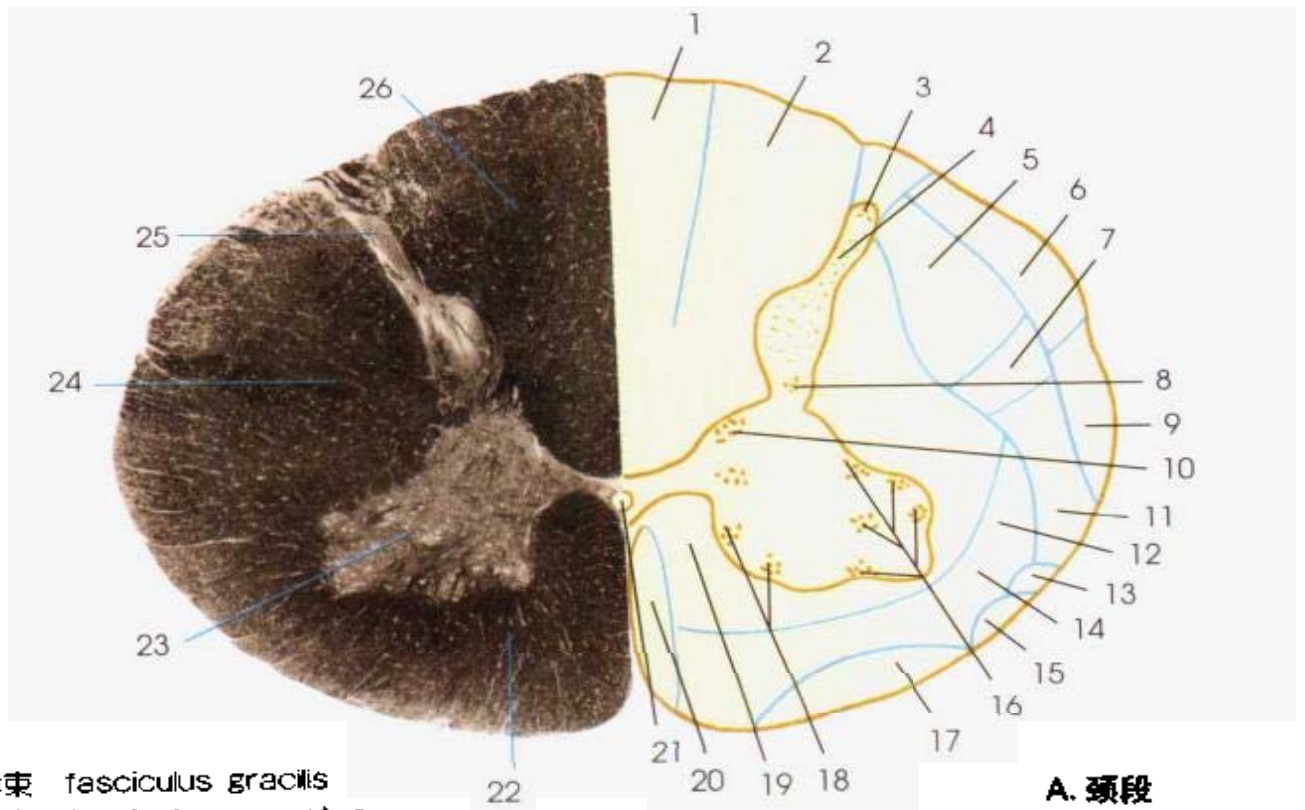
B. 假单极神经元
pseudounipolar
neuron

C. 多极神经元
multipolar
neuron



- 1. 脊髓 spinal cord
- 2. 脊神经节 spinal ganglion
- 3. 前根 anterior root
- 4. 交感干 sympathetic trunk
- 5. 白交通支 white communi-
cating branch
- 6. 灰交通支 gray communi-
cating branch
- 7. 前支 anterior branch
- 8. 后支 posterior branch

图 192 脊神经的组成
The constitution of spinal nerve



1. 薄束 fasciculus gracilis
2. 楔束 fasciculus cuneatus
3. 缘层 marginal layer
4. 胶状质 substantia gelatinosa
5. 皮质脊髓侧束 lateral corticospinal tract
6. 脊髓小脑后束 posterior spinocerebellar tract
7. 红核脊髓束 rubrospinal tract
8. 后角固有核 nucleus proprius
9. 脊髓小脑前束 anterior spinocerebellar tract
10. 胸核 nucleus thoracicus
11. 脊髓丘脑束 spinothalamic tract
12. 网状脊髓束 reticulospinal tract
13. 脊髓顶盖束 spinotectal tract
14. 顶盖脊髓束 tectospinal tract
15. 橄榄脊髓束 olivospinal tract
16. 外侧核 lateral nucleus
17. 前庭脊髓束 vestibulospinal tract
18. 内侧核 medial nucleus
19. 内侧纵束 medial longitudinal fasciculus
20. 皮质脊髓前束 anterior corticospinal tract
21. 中央管 central canal
22. 前索 anterior funiculus
23. 前角 anterior horn
24. 外侧索 lateral funiculus
25. 后角 posterior horn
26. 后索 posterior funiculus

A. 颈段
Cervical segment



B. 颈段
Cervical segment

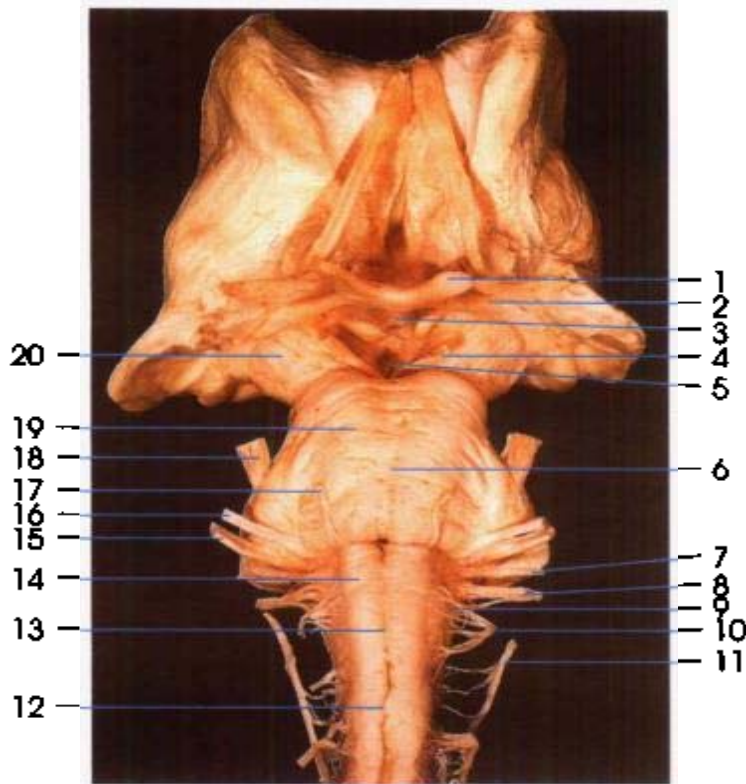
C. 胸段
Thoracic segment



D. 腰段
Lumbar segment

E. 骶段
Sacral segment

图 193 脊髓横切面(A, B, C, D, E)
Transverse section of spinal cord(A,B,C,D,E)



1. 视神经(Ⅱ) optic n.(Ⅱ)
2. 视束 optic tract
3. 漏斗 infundibulum
4. 动眼神经(Ⅲ) oculomotor n.(Ⅲ)
5. 脚间窝 interpeduncular fossa
6. 基底沟 basilar sulcus
7. 舌咽神经(Ⅸ) glossopharyngeal n.(Ⅸ)
8. 迷走神经(X) vagus n.(X)
9. 橄榄 olive
10. 舌下神经(Ⅻ) hypoglossal n.(Ⅻ)
11. 副神经(XⅠ) accessory n.(XⅠ)
12. 锥体交叉 decussation of pyramid
13. 前正中裂 anterior median fissure
14. 锥体 pyramid
15. 前庭蜗(位听)神经(Ⅷ) vestibulocochlear n.(Ⅷ)
16. 面神经(VⅦ) facial n.(VⅦ)
17. 展神经(VⅠ) abducent n.(VⅠ)
18. 三叉神经(V) trigeminal n.(V)
19. 脑桥 pons
20. 大脑脚 cerebral peduncle

图 194 脑干腹面观
Ventral aspect of brain stem

1. 背侧丘脑 dorsal thalamus
2. 下丘 inferior colliculus
3. 滑车神经(Ⅳ) trochlear n.(Ⅳ)
4. 内侧隆起 medial eminence
5. 正中沟 median sulcus
6. 界沟 sulcus limitans
7. 前庭区 vestibular area
8. 髓纹 striae medullares
9. 舌下神经三角 hypoglossal triangle
10. 迷走神经三角 vagal triangle
11. 楔束结节 cuneate tubercle
12. 后正中沟 posterior median sulcus
13. 薄束结节 gracile tubercle
14. 副神经(XⅠ) accessory n.(XⅠ)
15. 舌下神经(Ⅻ) hypoglossal n.(Ⅻ)
16. 迷走神经(X) vagus n.(X)
17. 面神经丘 facial colliculus
18. 上丘 superior colliculus
19. 内侧膝状体 medial geniculate body
20. 松果体 pineal body
21. 丘脑髓纹 thalamic medulary stria

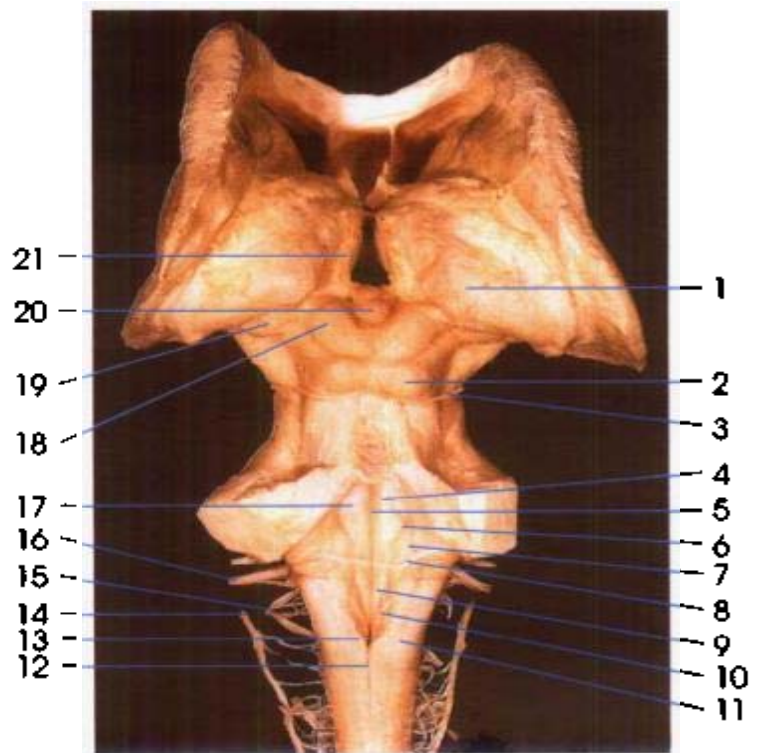


图 195 脑干背面观
Dorsal aspect of brain stem

1. 外侧膝状体 lateral geniculate body
2. 内侧膝状体 medial geniculate body
3. 上丘 superior colliculus
4. 下丘 inferior colliculus
5. 滑车神经(IV) trochlear n.(IV)
6. 小脑中脚 middle cerebellar peduncle
7. 小脑下脚 inferior cerebellar peduncle
8. 橄榄 olive
9. 锥体 pyramid
10. 脑桥 pons
11. 三叉神经(V) trigeminal n.(V)
12. 动眼神经(III) oculomotor n.(III)
13. 大脑脚 cerebral peduncle
14. 视束 optic tract
15. 杏仁体 amygdaloid body
16. 豆状核 lentiform nucleus
17. 辐射冠 corona radiata

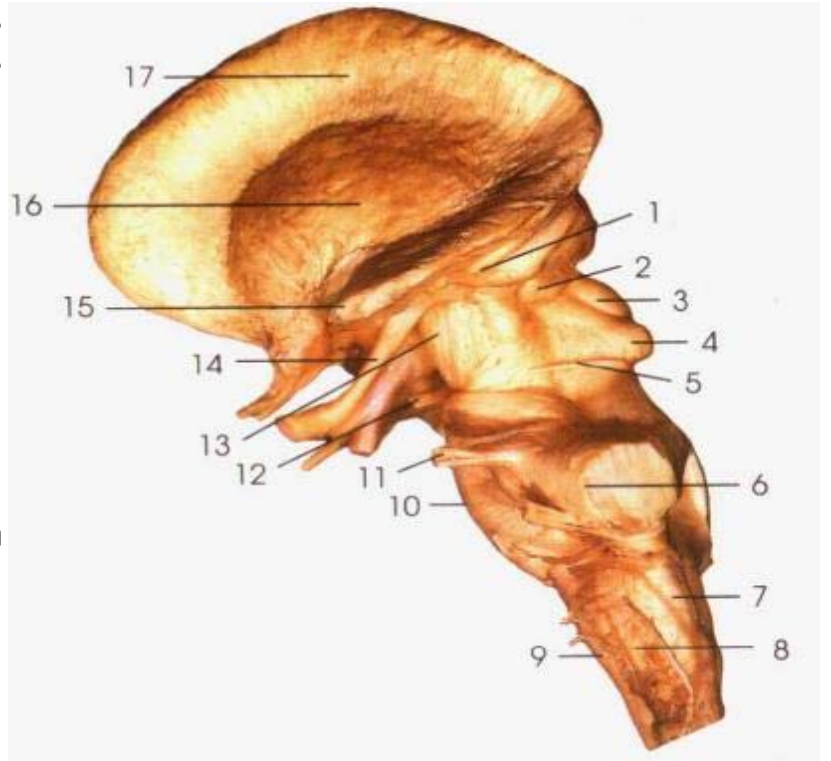


图 196 脑干侧面观
Lateral aspect of the brain stem

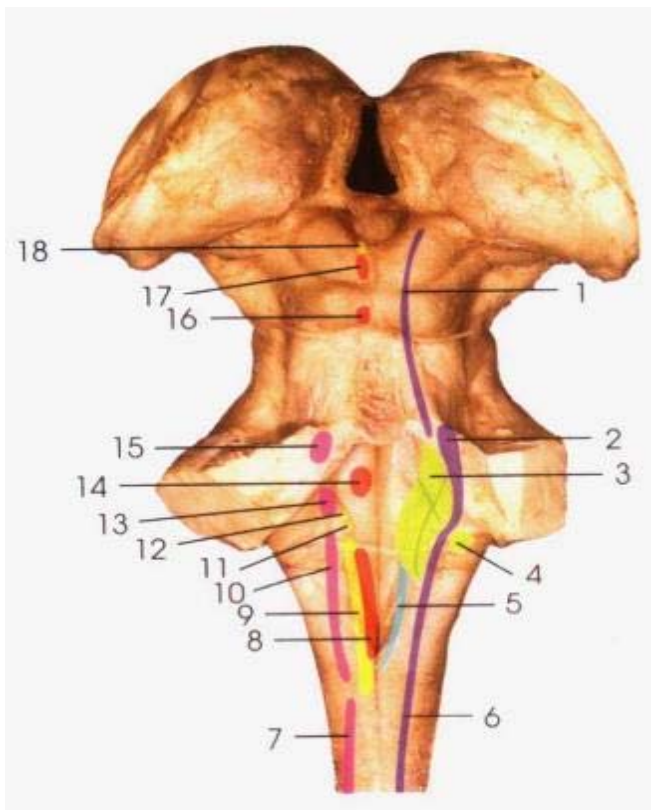


图 197 脑神经核模式图(背面观)
Diagram of the nuclei of the cranial nerves(dorsal aspect)

1. 三叉神经中脑核 mesencephalic nucleus of trigeminal n.
2. 三叉神经脑桥核 pontine nucleus of trigeminal n.
3. 前庭神经核 vestibular nuclei
4. 蜗神经核 cochlear nuclei
5. 孤束核 nucleus of solitary tract
6. 三叉神经脊核 spinal nucleus of trigeminal n.
7. 副神经核 accessory nucleus
8. 舌下神经核 nucleus of hypoglossal n.
9. 迷走神经背核 dorsal nucleus of vagus n.
10. 疑核 nucleus ambiguus
11. 下涎涎核 inferior salivatory nucleus
12. 上涎涎核 superior salivatory nucleus
13. 面神经核 nucleus of facial n.
14. 展神经核 nucleus of abducent n.
15. 三叉神经运动核 motor nucleus of trigeminal n.
16. 滑车神经核 nucleus of trochlear n.
17. 动眼神经核 nucleus of oculomotor n.
18. 动眼神经副核 accessory nucleus of oculomotor n.

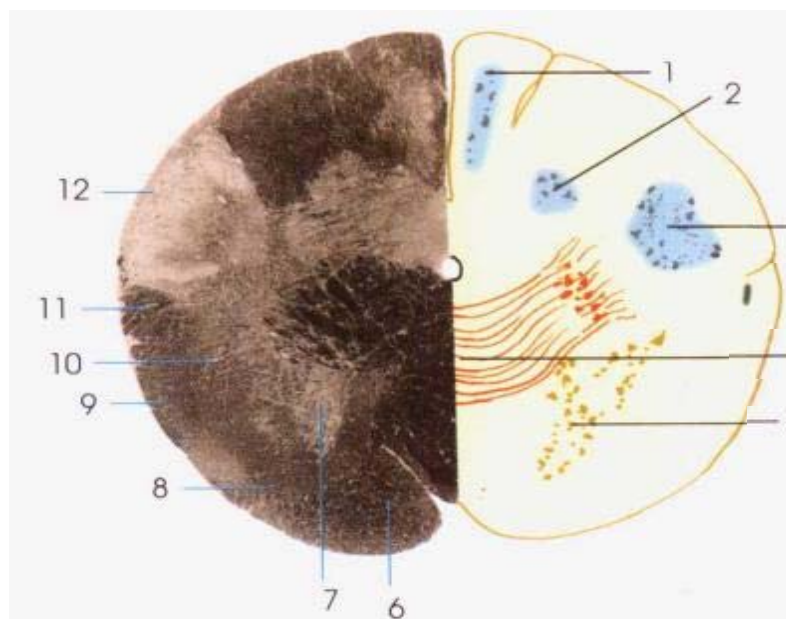


图 198 延髓横切面(经锥体交叉)
Transverse section of the medulla oblongata (through the pyramidal decussation)

1. 薄束核 gracile nucleus
2. 楔束核 cuneate nucleus
3. 三叉神经脊束核 spinal nucleus of trigeminal n.
4. 锥体交叉 decussation of pyramid
5. 副神经核 accessory nucleus
6. 锥体束 pyramidal tract
7. 前角 anterior horn
8. 前庭脊髓束 vestibulospinal tract
9. 脊髓小脑前束 anterior spinocerebellar tract
10. 脊髓丘脑束 spinothalamic tract
11. 脊髓小脑后束 posterior spinocerebellar tract
12. 三叉神经脊束 spinal tract of trigeminal n.

1. 薄束核 gracile nucleus
2. 楔束核 cuneate nucleus
3. 三叉神经脊束核 spinal nucleus of trigeminal n.
4. 疑核 nucleus ambiguus
5. 舌下神经核 nucleus of hypoglossal n.
6. 内侧丘系交叉 decussation of medial lemniscus
7. 锥体束 pyramidal tract
8. 脊髓小脑前束 anterior spinocerebellar tract
9. 脊髓丘脑束 spinothalamic tract
10. 脊髓小脑后束 posterior spinocerebellar tract
11. 内弓状纤维 internal arcuate fibers
12. 三叉神经脊束 spinal tract of trigeminal n.

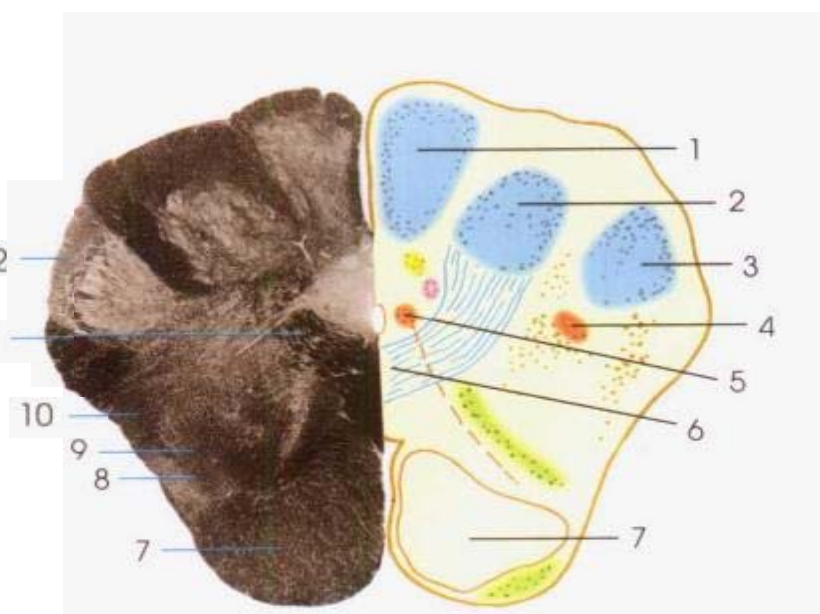


图 199 延髓横切面(经内侧丘系交叉)
Transverse section of the medulla oblongata (through the decussation of the medial lemniscus)

1. 舌下神经核 nucleus of hypoglossal n.
2. 迷走神经背核 dorsal nucleus of vagus n.
3. 孤束核 nucleus of solitary tract
4. 前庭神经下核 inferior vestibular nucleus
5. 三叉神经脊束核 spinal nucleus of trigeminal n.
6. 疑核 nucleus ambiguus
7. 内侧丘系 medial lemniscus
8. 下橄榄核 inferior olivary nucleus
9. 锥体束 pyramidal tract
10. 脊髓丘脑束 spinothalamic tract
11. 网状结构 reticular formation
12. 三叉神经脊束 spinal tract of trigeminal n.
13. 小脑下脚 inferior cerebellar peduncle
14. 孤束 solitary tract

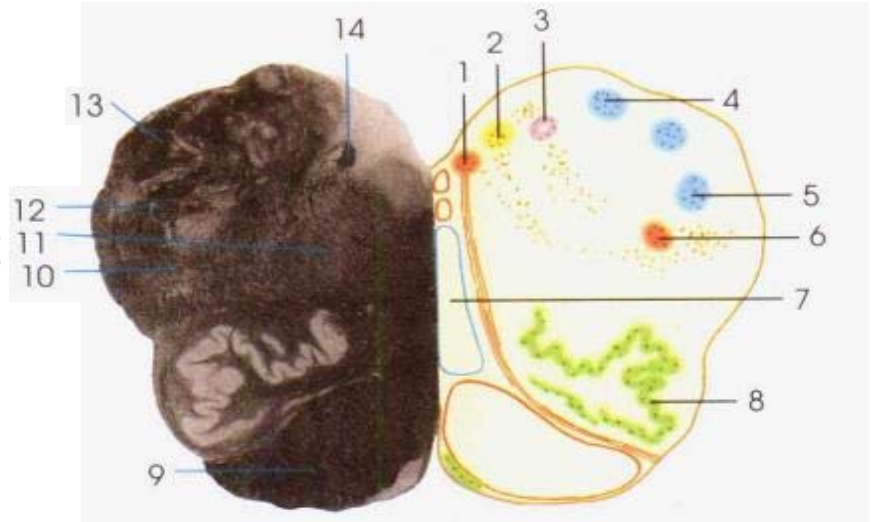


图 200 延髓横切面(经过下橄榄核中部)
Transverse section of the medulla oblongata(through the middle part of the inferior olive)

1. 舌下神经核 nucleus of hypoglossal n.
2. 孤束核 nucleus of solitary tract
3. 前庭神经下核 inferior vestibular nucleus
4. 蜗背侧核 dorsal cochlear nucleus
5. 蜗腹侧核 ventral cochlear nucleus
6. 三叉神经脊束核 spinal nucleus of trigeminal n.
7. 疑核 nucleus ambiguus
8. 内侧丘系 medial lemniscus
9. 下橄榄核 inferior olivary nucleus
10. 锥体束 pyramidal tract
11. 脊髓丘脑束 spinothalamic tract
12. 三叉神经脊束 spinal tract of trigeminal n.
13. 小脑下脚 inferior cerebellar peduncle
14. 网状结构 reticular formation

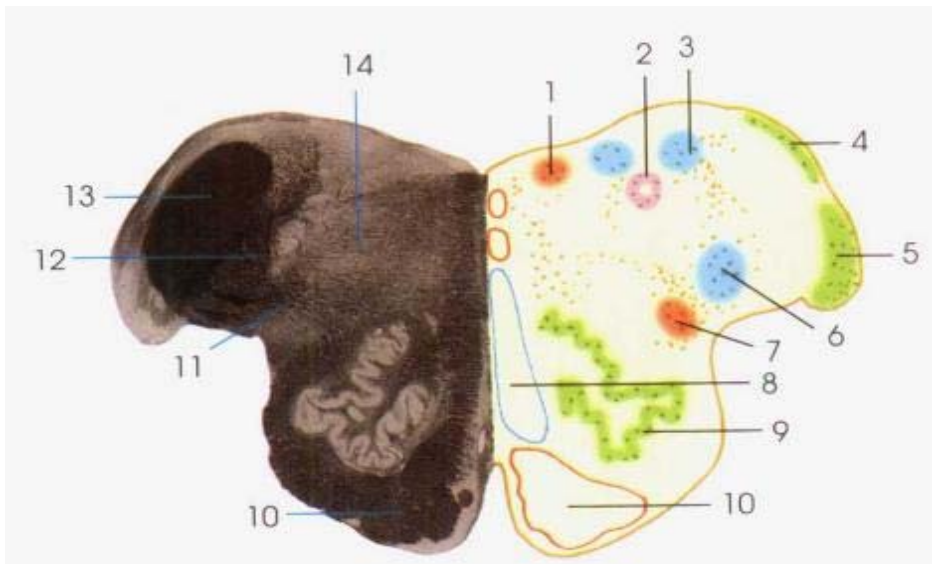


图 201 延髓横切面(经过蜗神经核)
Transverse section of the medulla oblongata(through the cochlear nuclei)

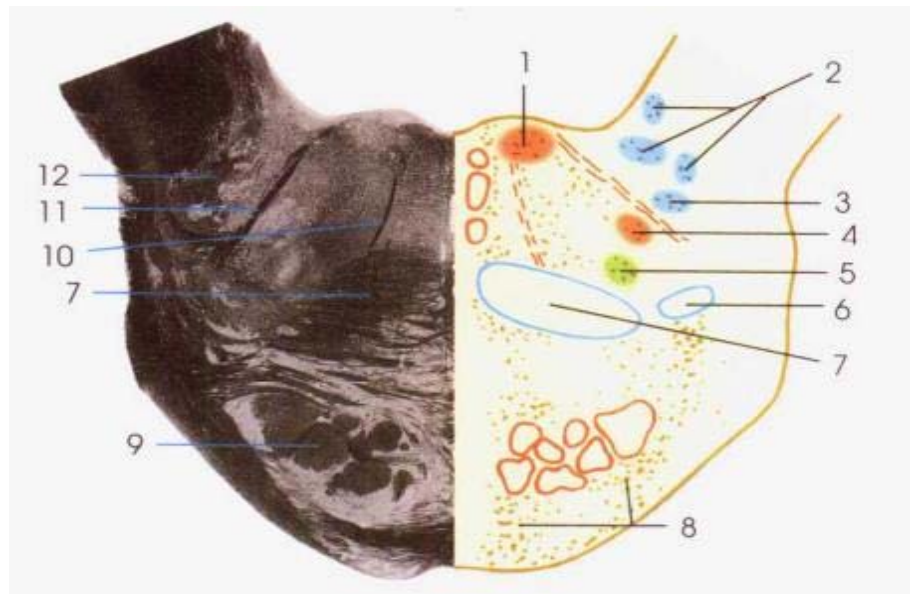


图 202 脑桥横切面(经面丘)
Transverse section of the
pons(through the facial colliculus)

- | | |
|--|---|
| 1. 展神经核 nucleus of abducent n. | 7. 内侧丘系和斜方体 medial lemniscus and trapezoid body |
| 2. 前庭神经核 vestibular nucleus | 8. 脑桥核 pontine nucleus |
| 3. 三叉神经脊束核 spinal nucleus of trigeminal n. | 9. 锥体束 pyramidal tract |
| 4. 面神经核 nucleus of facial n. | 10. 展神经(VI) abducent n.(VI) |
| 5. 上橄榄核 superior olivary nucleus | 11. 面神经(VII) facial n.(VII) |
| 6. 外侧丘系 lateral lemniscus | 12. 三叉神经脊束 spinal tract of trigeminal n. |

- | |
|---|
| 1. 网状结构 reticular formation |
| 2. 三叉神经中脑核 mesencephalic nucleus of trigeminal n. |
| 3. 三叉神经脑桥核 pontine nucleus of trigeminal n. |
| 4. 三叉神经运动核 motor nucleus of trigeminal n. |
| 5. 外侧丘系 lateral lemniscus |
| 6. 内侧丘系 medial lemniscus |
| 7. 脑桥核 pontine nucleus |
| 8. 锥体束 pyramidal tract |
| 9. 小脑中脚 middle cerebellar peduncle |
| 10. 小脑上脚 superior cerebellar peduncle |

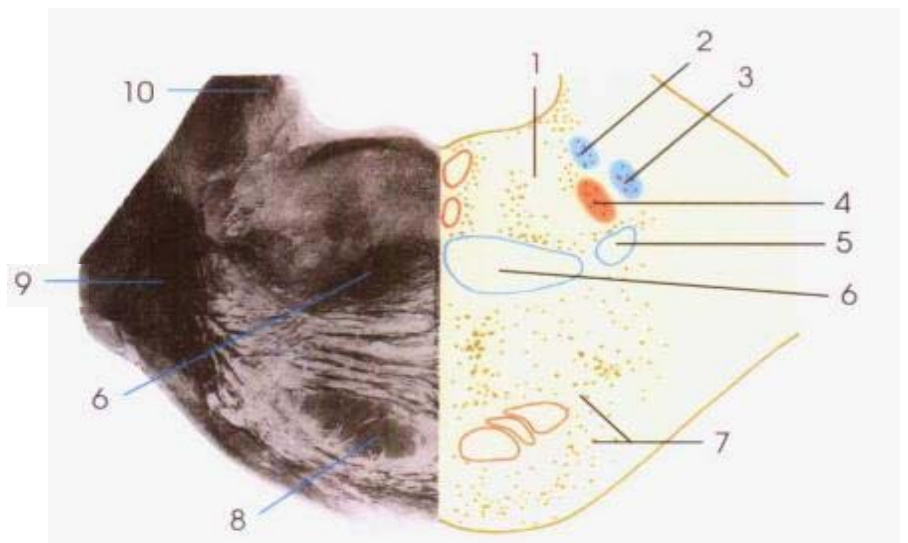


图 203 脑桥横切面(经三叉运动核)
Transverse section of the pons(through the
motor nucleus of the trigeminal nerve)

1. 三叉神经中脑核 mesencephalic nucleus of trigeminal n.
2. 滑车神经核 nucleus of trochlear n.
3. 内侧纵束 medial longitudinal fasciculus
4. 内侧丘系 medial lemniscus
5. 大脑脚底 crus cerebri
6. 黑质 substantia nigra
7. 小脑上脚交叉 decussation of superior cerebellar peduncle
8. 顶盖脊髓束 tectospinal tract
9. 中央灰质 central gray matter
10. 外侧丘系 lateral lemniscus
11. 中脑水管 mesencephalic aqueduct
12. 下丘核 nucleus of inferior colliculus

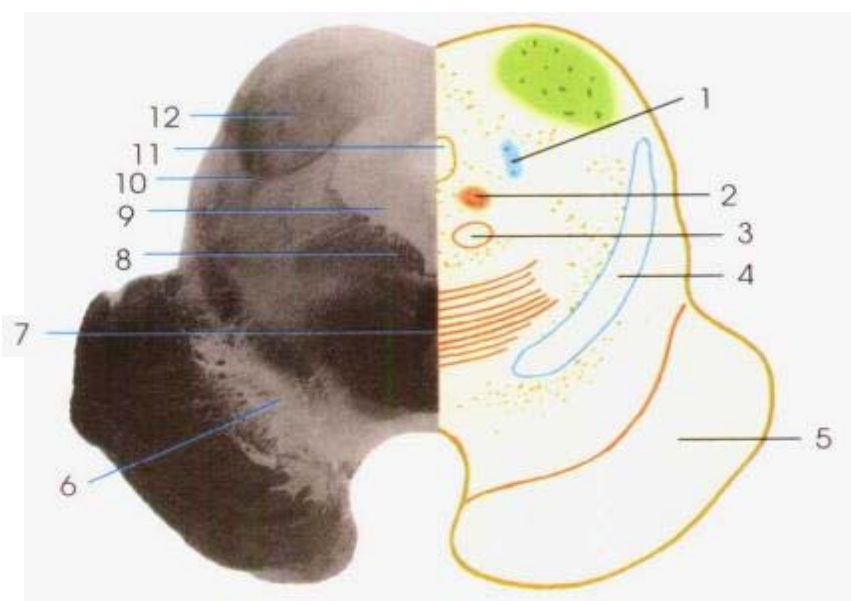


图 204 中脑横切面(经下丘)
Transverse section of the midbrain(through the inferior colliculus)

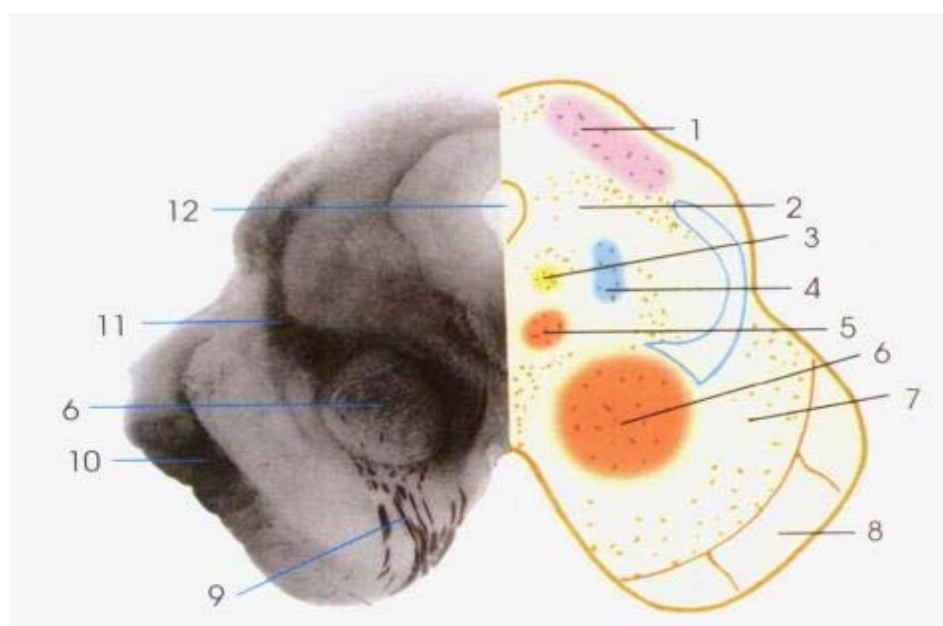


图 205 中脑横切面(经上丘)
Transverse section of the midbrain(through the superior colliculus)

1. 上丘层 gray matter layer of superior colliculus
2. 中央灰质 central gray matter
3. 动眼神经副核 accessory nucleus of oculomotor n.
4. 三叉神经中脑核 mesencephalic nucleus of trigeminal n.
5. 动眼神经核 nucleus of oculomotor n.
6. 红核 red nucleus
7. 黑质 substantia nigra
8. 锥体束 pyramidal tract
9. 动眼神经(Ⅲ) oculomotor n. (Ⅲ)
10. 大脑脚底 crus cerebri
11. 内侧丘系 medial lemniscus
12. 中脑水管 mesencephalic aqueduct




图 206 小脑(上面观)
The cerebellum(superior aspect)

- | | |
|------------------------------------|---|
| 1. 中央小叶 central lobule | 7. 上半月小叶 superior semilunar lobule |
| 2. 山顶 culmen | 8. 方形小叶(后部) posterior quadrangular lobule |
| 3. 山坡 declive | 9. 原裂 primary fissure |
| 4. 蚓叶 folium of vermis | 10. 方形小叶(前部) anterior quadrangular lobule |
| 5. 下半月小叶 inferior semilunar lobule | |
| 6. 水平裂 horizontal fissure | |

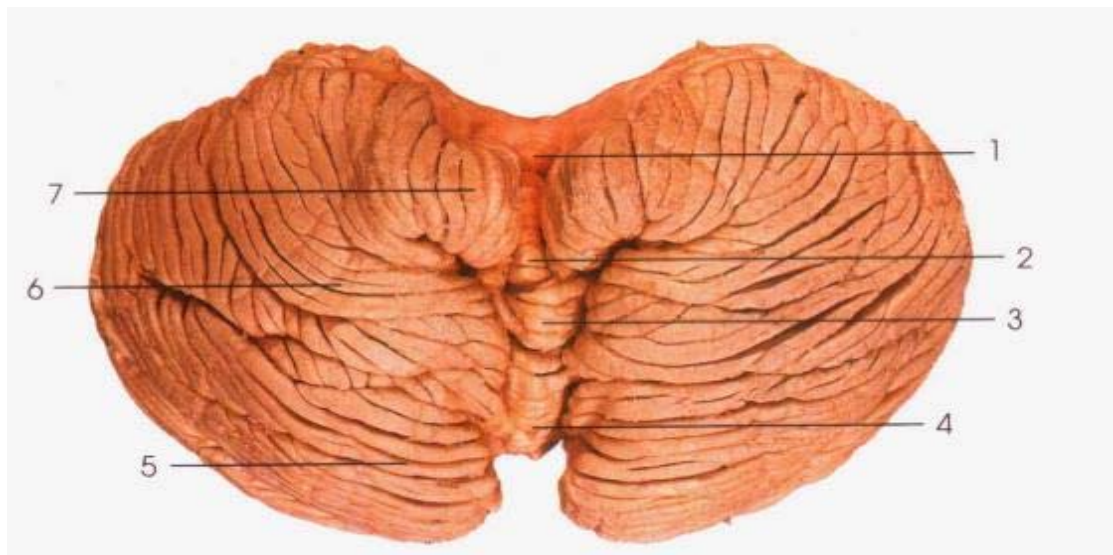


图 207 小脑(下面观)
The cerebellum(inferior aspect)

- | | |
|--------------------------|------------------------------------|
| 1. 小结 nodule | 5. 下半月小叶 inferior semilunar lobule |
| 2. 蚓垂 uvula of vermis | 6. 二腹小叶 biventral lobule |
| 3. 蚓锥体 pyramid of vermis | 7. 小脑扁桃体 tonsil of cerebellum |
| 4. 蚓结节 tuber of vermis | |

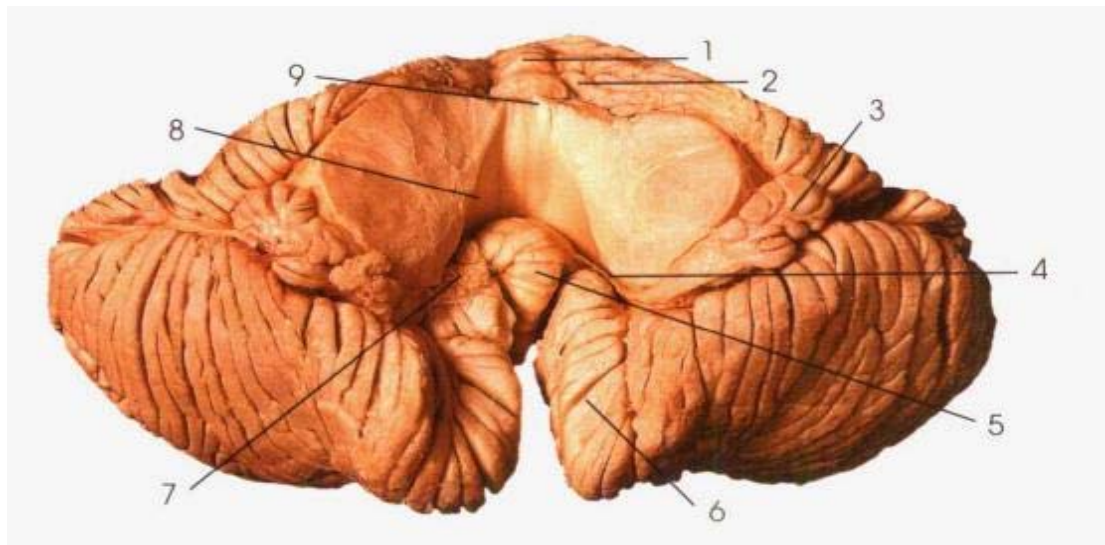


图 208 小脑(前面观)
The cerebellum(anterior aspect)

- | | |
|--------------------------------|---|
| 1. 中央小叶 central lobule | 6. 小脑扁桃体 tonsil of cerebellum |
| 2. 中央小叶翼 ala of central lobule | 7. 第四脑室脉络丛 choroid plexus of fourth ventricle |
| 3. 绒球 flocculus | 8. 第四脑室 fourth ventricle |
| 4. 绒球脚 peduncle of flocculus | 9. 前髓帆 anterior medullary velum |
| 5. 小结 nodule | |

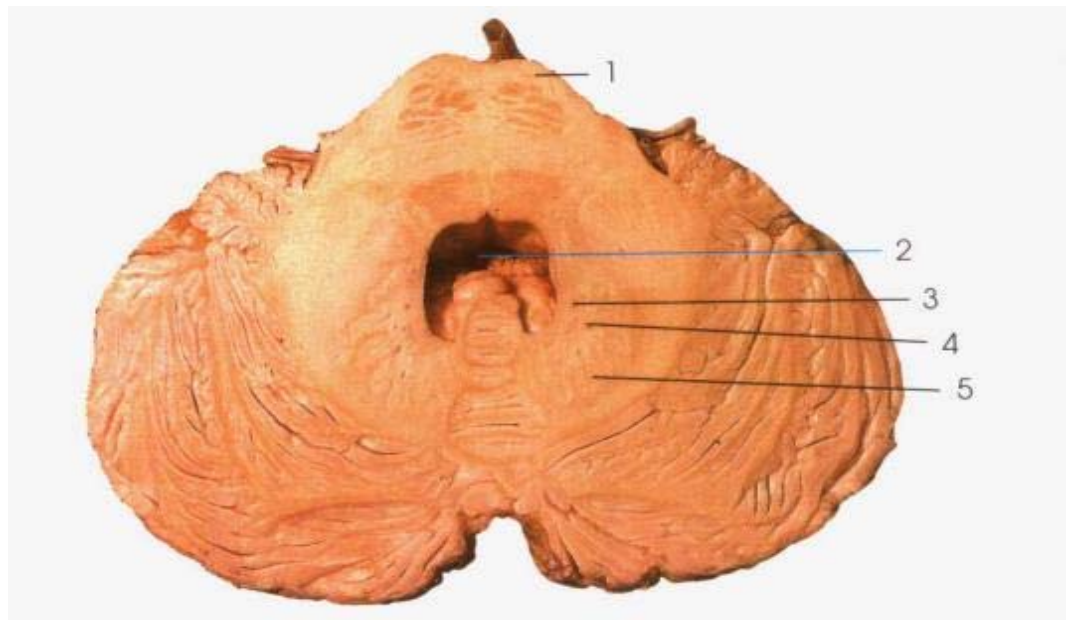
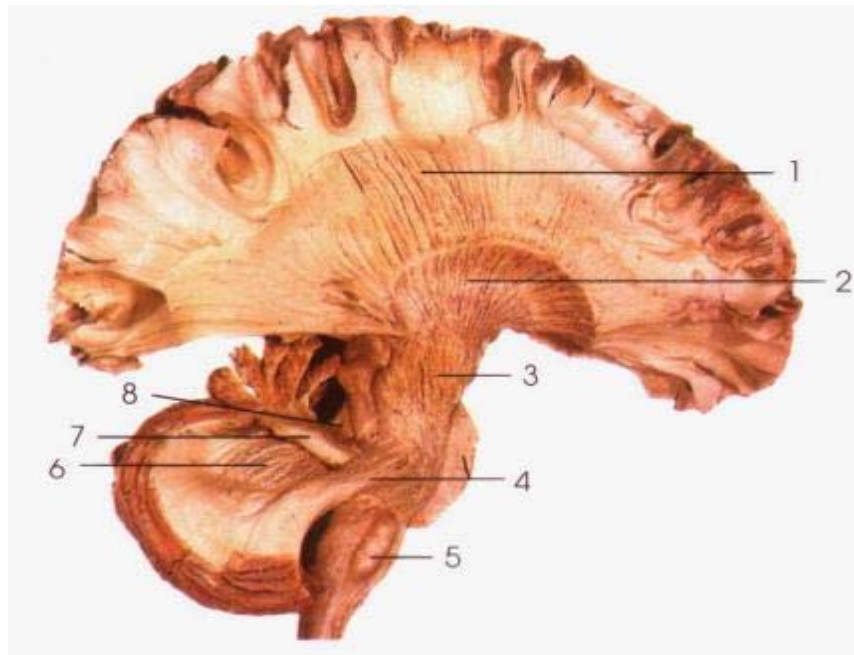


图 209 小脑横断面
Transverse section of the cerebellum

- | | |
|--------------------------|---------------------------|
| 1. 脑桥 pons | 4. 栓状核 emboliform nucleus |
| 2. 第四脑室 fourth ventricle | 5. 齿状核 dentate nucleus |
| 3. 球状核 globose nucleus | |



1. 辐射冠 corona radiata
2. 内囊 internal capsule
3. 锥体束 pyramidal tract
4. 小脑中脚 middle cerebellar peduncle
5. 橄榄 olive
6. 齿状核 dentate nucleus
7. 小脑下脚 inferior cerebellar peduncle
8. 小脑上脚 superior cerebellar peduncle

图 210 小脑脚及锥体束
The peduncles of cerebellum and the pyramidal tract

1. 尾状核 caudate nucleus
2. 豆状核 lentiform nucleus
3. 杏仁体 amygdaloid body
4. 视束 optic tract
5. 视神经(Ⅱ) optic n.(Ⅱ)
6. 漏斗 infundibulum
7. 大脑脚 cerebral peduncle
8. 脑桥 pons
9. 三叉神经(V) trigeminal n.(V)
10. 前庭蜗神经(XII) vestibulocochlear n.(XII)
11. 小脑中脚 middle cerebellar peduncle
12. 齿状核 dentate nucleus
13. 小脑上脚 superior cerebellar peduncle
14. 下丘 inferior colliculus
15. 内侧膝状体 medial geniculate body
16. 上丘 superior colliculus
17. 外侧膝状体 lateral geniculate body

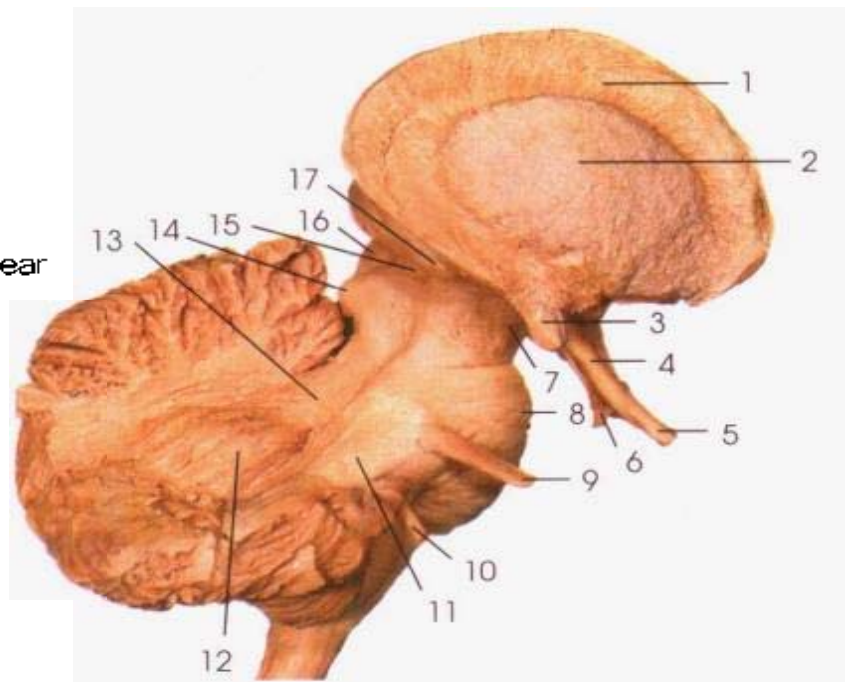


图 211 基底核和脑干
The basal nuclei and the brain stem

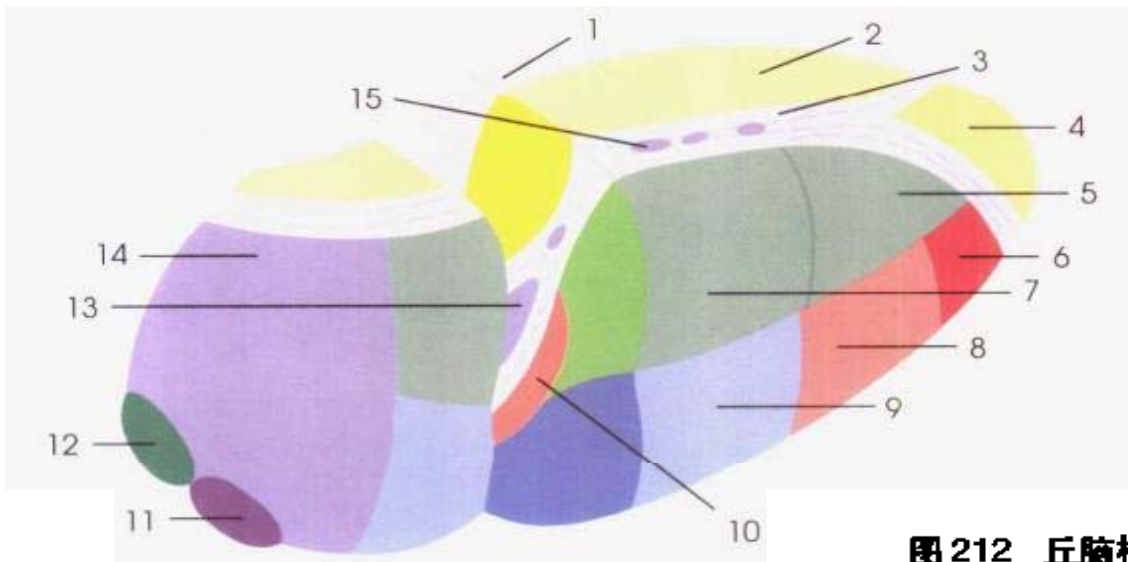


图 212 丘脑核团模式图
Diagram of the thalamic nuclei

- | | |
|--------------------------------------|---|
| 1. 中线核群 midline nuclear group | 9. 腹后外侧核 ventral posterolateral nucleus |
| 2. 内侧背核 mediodorsal nucleus | 10. 腹后内侧核 ventral posteromedial nucleus |
| 3. 内髓板 internal medullary lamina | 11. 外侧膝状体 lateral geniculate body |
| 4. 前核 anterior nucleus | 12. 内侧膝状体 medial geniculate body |
| 5. 外侧背核 lateral dorsal nucleus | 13. 中央中核 centromedian nucleus |
| 6. 腹前核 ventral anterior nucleus | 14. 枕核 nuclei pulvinare |
| 7. 外侧后核 lateral posterior nucleus | 15. 板内核群 intralaminar nuclear group |
| 8. 腹中间核 ventral intermediate nucleus | |

- | | |
|------------------------------------|----|
| 1. 室间孔 interventricular foramen | |
| 2. 丘脑间粘合 interthalamic adhesion | |
| 3. 背内侧核 dorsomedial nucleus | |
| 4. 下丘脑沟 hypothalamic sulcus | |
| 5. 后核 posterior nucleus | 14 |
| 6. 腹内侧核 ventromedial nucleus | 13 |
| 7. 乳头体 mamilary body | 12 |
| 8. 弓状核 arcuate nucleus | 11 |
| 9. 视上核 supraoptic nucleus | |
| 10. 视交叉 optic chiasma | |
| 11. 视前外侧核 lateral preoptic nucleus | |
| 12. 视前内侧核 medial preoptic nucleus | |
| 13. 前核 anterior nucleus | |
| 14. 室旁核 paraventricular nucleus | |

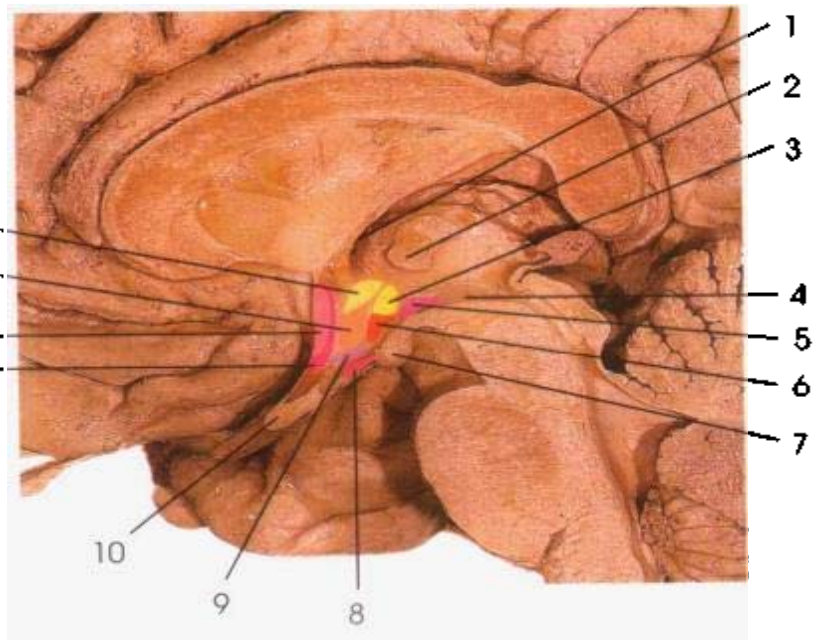


图 213 下丘脑核团模式图
Diagram of the hypothalamic nuclei

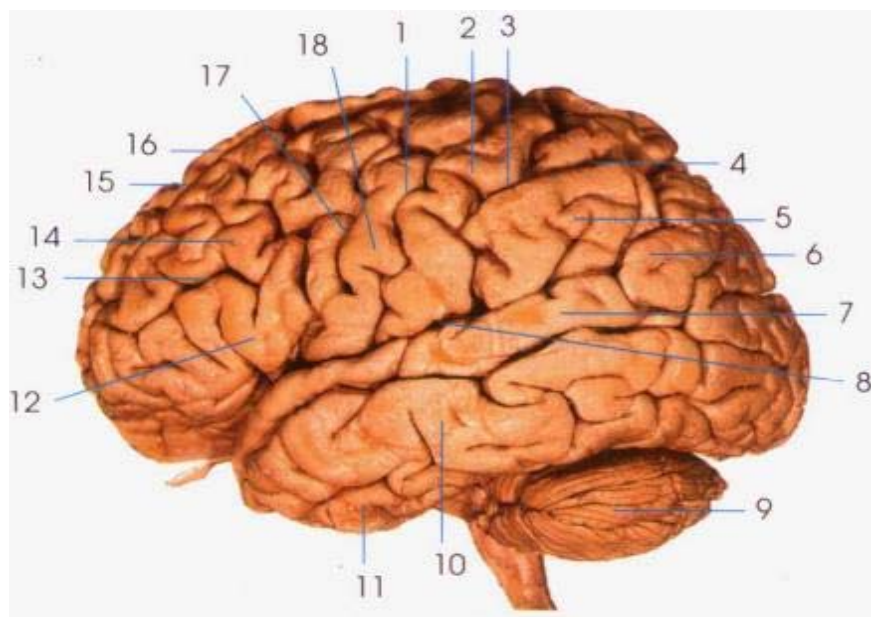


图 214 脑的外侧面
Lateral surface of the brain

1. 中央沟 central sulcus
2. 中央前回 postcentral gyrus
3. 中央后沟 postcentral sulcus
4. 顶内沟 intraparietal sulcus
5. 缘上回 supramarginal gyrus
6. 角回 angular gyrus
7. 颞上回 superior temporal gyrus
8. 外侧沟 lateral sulcus
9. 小脑 cerebellum
10. 颞中回 middle temporal gyrus
11. 颞下回 inferior temporal gyrus
12. 额下回 inferior frontal gyrus
13. 额下沟 inferior frontal sulcus
14. 额中回 middle frontal gyrus
15. 额上沟 superior frontal sulcus
16. 额上回 superior frontal gyrus
17. 中央前沟 precentral sulcus
18. 中央前回 precentral gyrus

1. 中央旁小叶 paracentral lobule
2. 中央旁沟 paracentral sulcus
3. 扣带回 cingulate gyrus
4. 胼胝体 corpus callosum
5. 额上回 superior frontal gyrus
6. 透明隔 septum pellucidum
7. 扣带沟 cingulate sulcus
8. 室间孔 interventricular foramen
9. 下丘脑沟 hypothalamic sulcus
10. 视交叉 optic chiasma
11. 中脑水管 mesencephalic aqueduct
12. 脑桥 pons
13. 小脑 cerebellum
14. 第四脑室 fourth ventricle
15. 松果体 pineal body
16. 舌回 lingual gyrus
17. 距状沟 calcarine sulcus
18. 楔叶 cuneus
19. 顶枕沟 parietooccipital sulcus
20. 缘支 marginal ramus

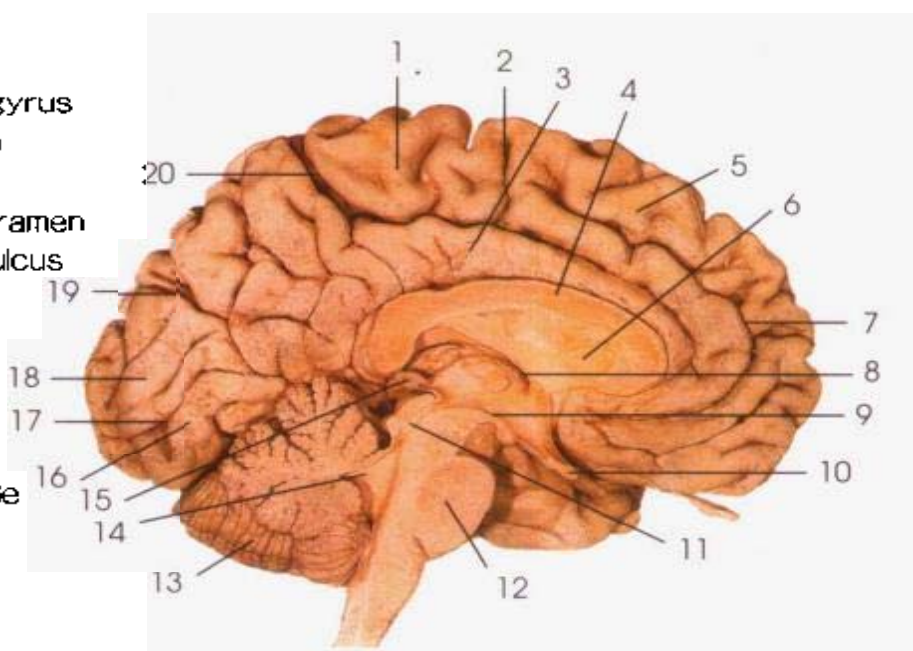


图 215 脑的正中矢状切面
Median sagittal section of the brain

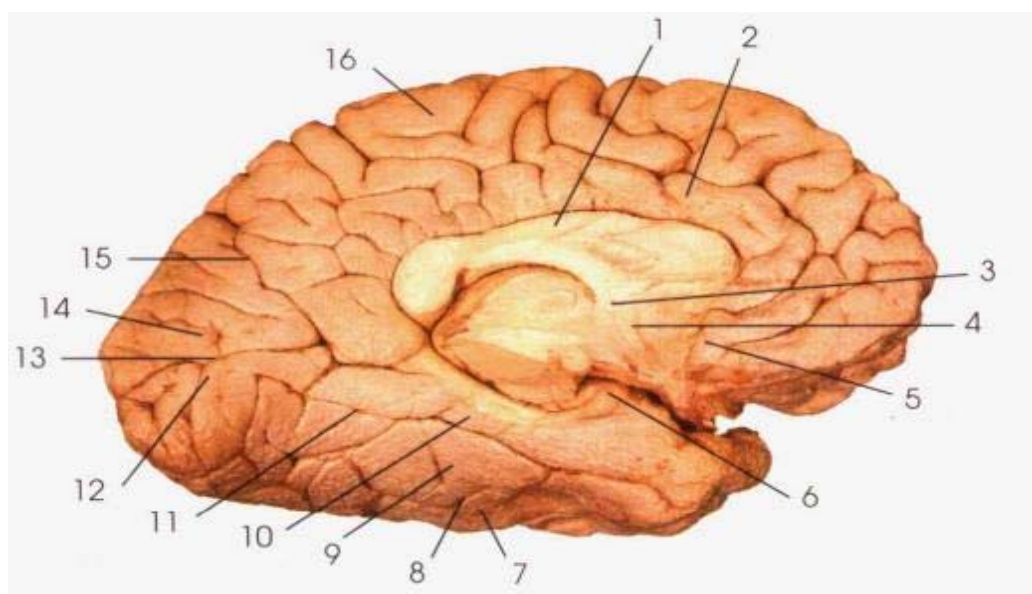


图 216 大脑半球内侧面
Medial surface of the cerebral hemisphere

- | | |
|---|--|
| 1. 胼胝体 corpus callosum | 9. 枕颞内侧回 medial occipitotemporal gyrus |
| 2. 扣带回 cingulate gyrus | 10. 海马旁回 parahippocampal gyrus |
| 3. 前连合 anterior commissure | 11. 侧副沟 collateral sulcus |
| 4. 终板旁回 paraterminal gyrus | 12. 舌回 lingual gyrus |
| 5. 胼胝体下区 subcallosal area | 13. 距状沟 calcarine sulcus |
| 6. 钩 uncus | 14. 楔叶 cuneus |
| 7. 枕颞外侧回 lateral occipitotemporal gyrus | 15. 顶枕沟 parietooccipital sulcus |
| 8. 枕颞沟 occipitotemporal sulcus | 16. 中央旁小叶 paracentral lobule |

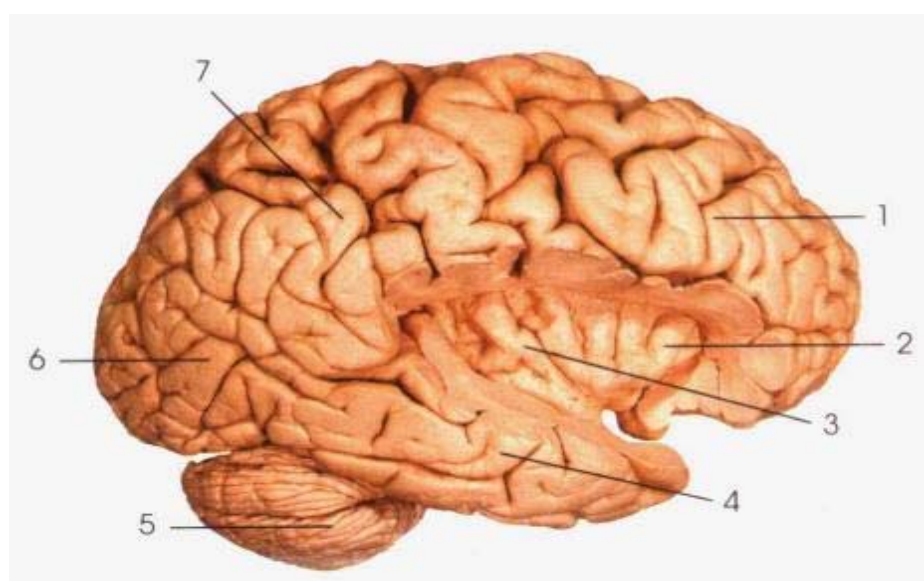
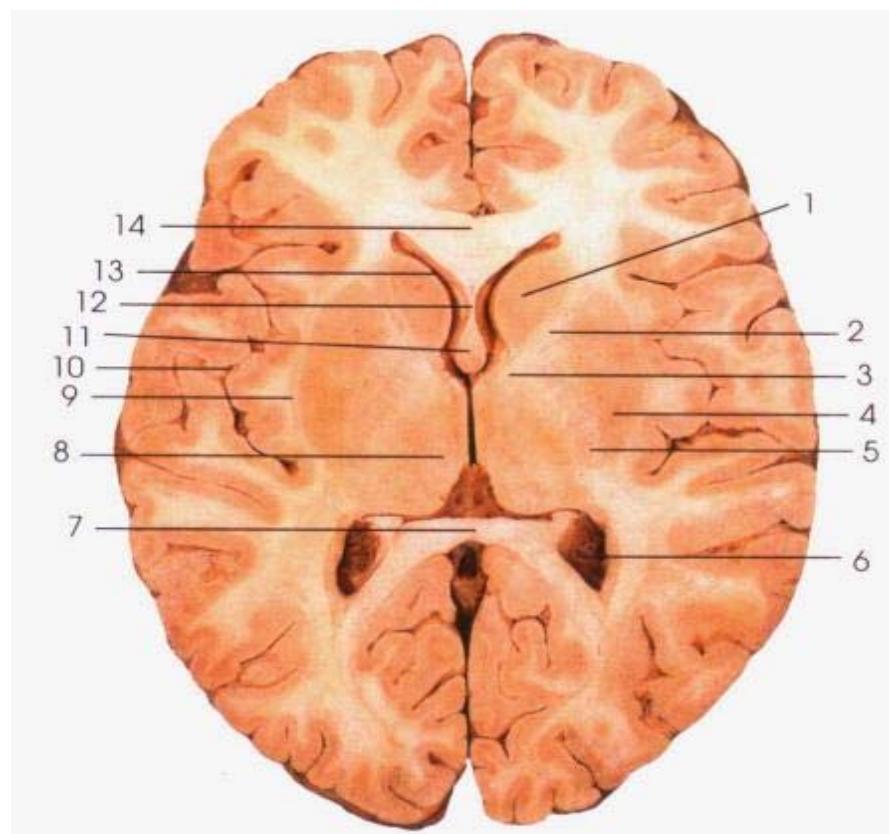


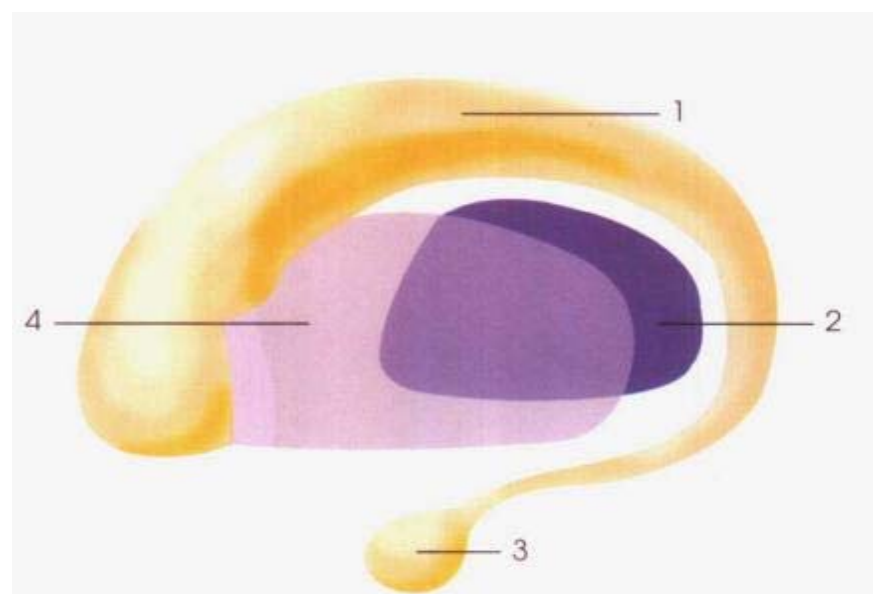
图 217 脑岛
The insula

- | |
|------------------------------|
| 1. 额叶 frontal lobe |
| 2. 岛短回 short gyrus of insula |
| 3. 岛长回 long gyrus of insula |
| 4. 颞叶 temporal lobe |
| 5. 小脑 cerebellum |
| 6. 枕叶 occipital lobe |
| 7. 顶叶 parietal lobe |



1. 尾状核头 Head of caudate nucleus
2. 内囊前肢 anterior limb of internal capsule
3. 内囊膝 genu of internal capsule
4. 豆状核 lentiform nucleus
5. 内囊后肢 posterior limb of internal capsule
6. 后角 posterior horn
7. 胼胝体压部 splenium of corpus callosum
8. 丘脑 thalamus
9. 屏状核 claustrum
10. 脑岛 insula
11. 穹窿柱 column of fornix
12. 透明隔 septum pellucidum
13. 前角 anterior horn
14. 胼胝体膝 genu of corpus callosum

图 218 脑的水平切面
Horizontal section of the brain



1. 尾状核 caudate nucleus
2. 背侧丘脑 dorsal thalamus
3. 杏仁体 amygdaloid body
4. 豆状核 lentiform nucleus

图 219 基底神经核
The basal nuclei

1. 尾状核 caudate nucleus
2. 内囊 internal capsule
3. 豆状核 lentiform nucleus
4. 脑岛 insula
5. 第三脑室 third ventricle
6. 背侧丘脑 dorsal thalamus
7. 苍白球 globus pallidus
8. 壳 putamen
9. 屏状核 claustrum
10. 穹窿 fornix
11. 透明隔 septum pellucidum
12. 侧脑室 lateral ventricle
13. 胼胝体 corpus callosum

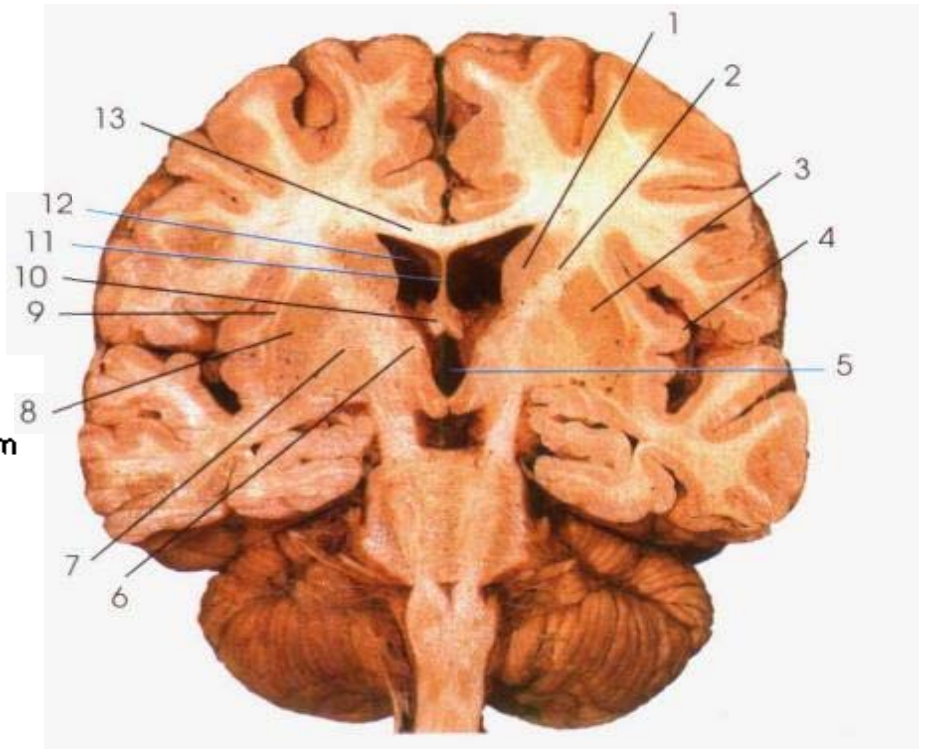
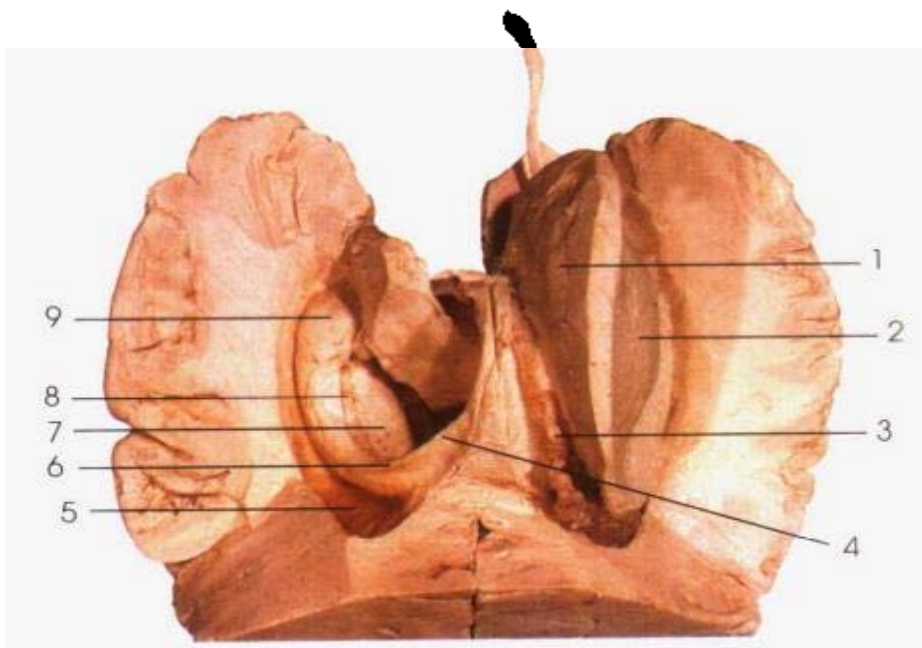


图 220 脑的冠状切面
Coronal section of the brain



1. 尾状核 caudate nucleus
2. 豆状核 lentiform nucleus
3. 侧脑室脉络丛 choroid plexus of lateral ventricle
4. 穹窿脚 crus of fornix
5. 侧副三角 collateral trigone
6. 海马伞 fimbria of hippocampus
7. 海马旁回 parahippocampal gyrus
8. 齿状回 dentate gyrus
9. 海马 hippocampus

图 221 侧脑室下角
Inferior horn of lateral ventricle

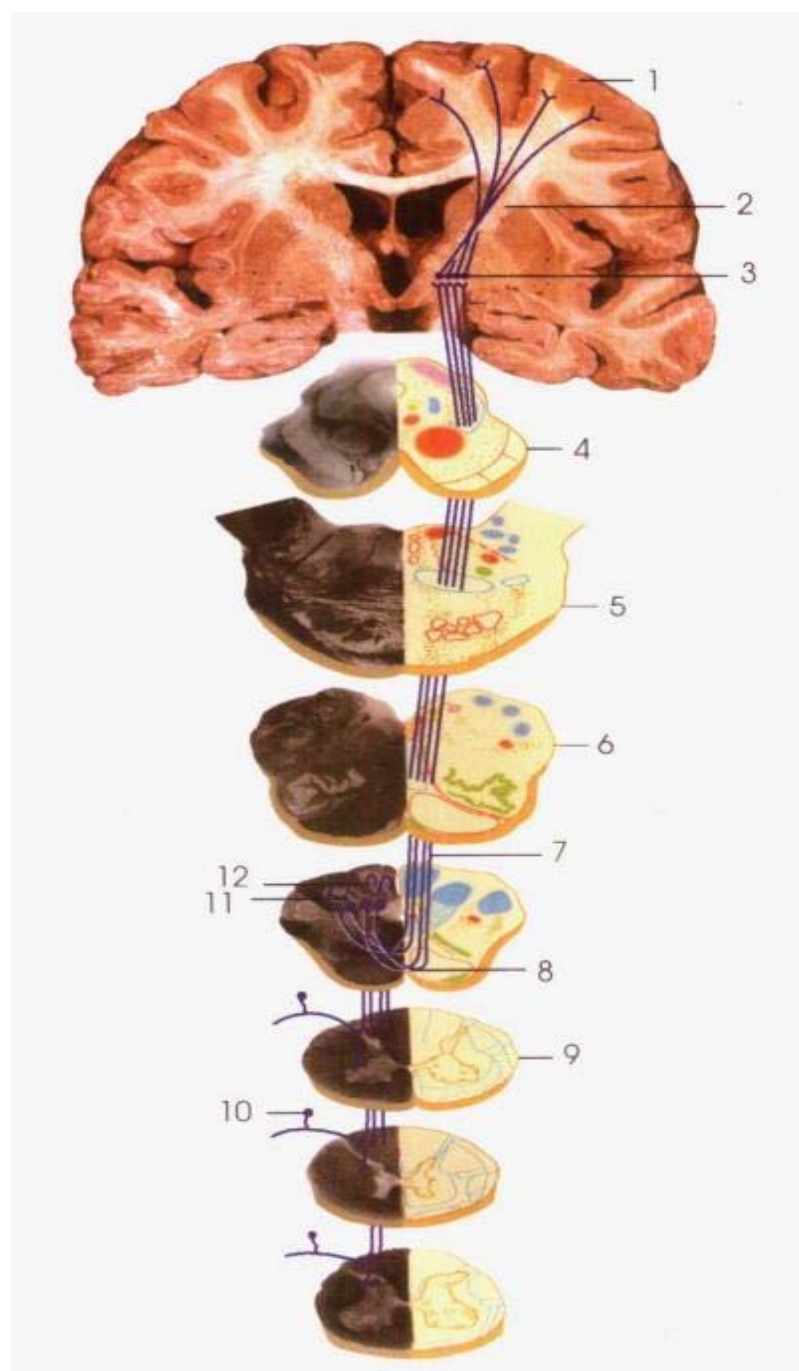
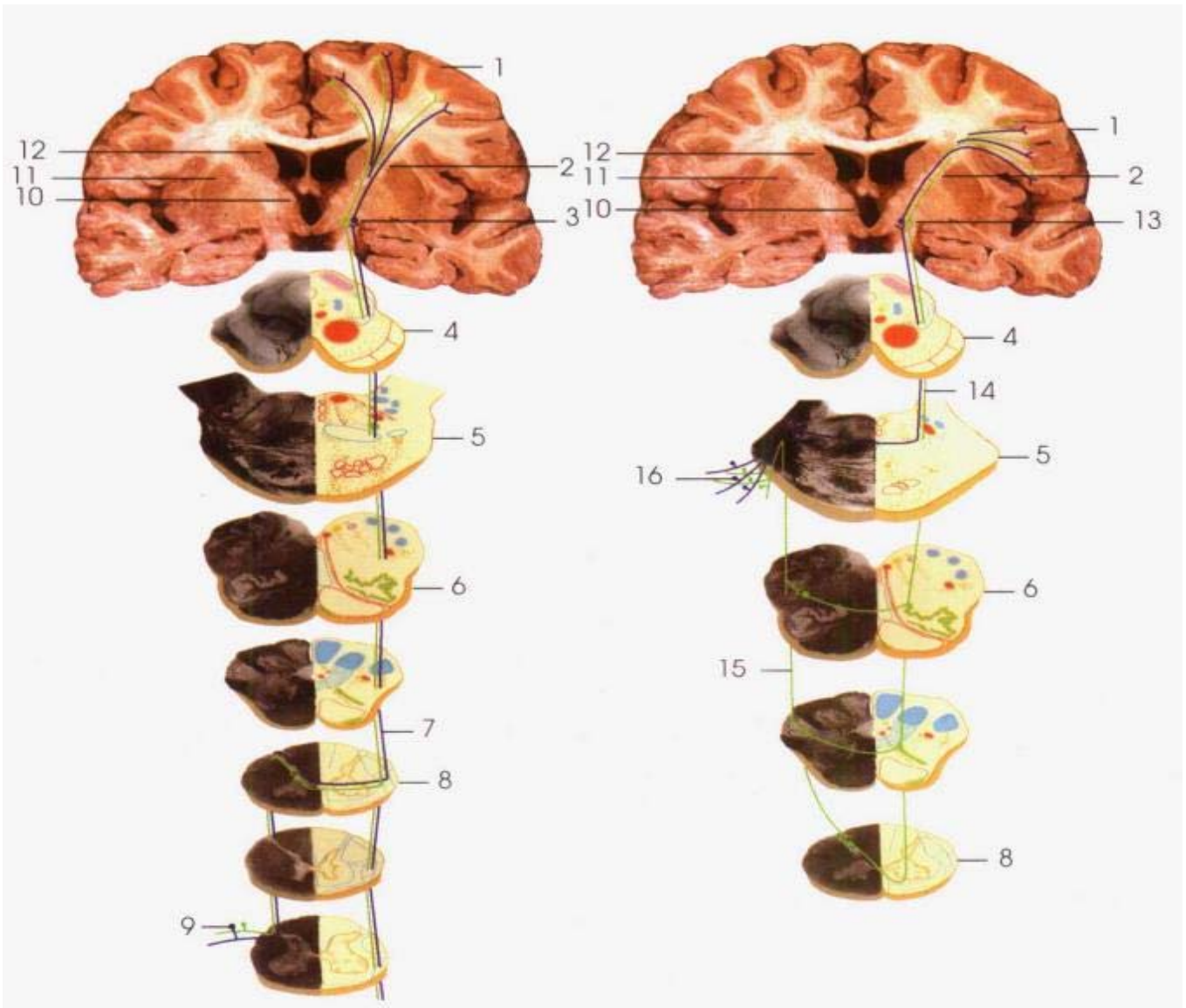


图 222 本体感觉传导道
Pathway of the proprioceptive sensibility

- | | |
|---|---|
| 1. 中央后回 postcentral gyrus | 7. 内侧丘系 medial lemniscus |
| 2. 内囊 internal capsule | 8. 内侧丘系交叉 decussation of medial lemniscus |
| 3. 腹后外侧核 ventral posterolateral nucleus | 9. 脊髓 spinal cord |
| 4. 中脑 midbrain | 10. 脊神经节 spinal ganglion |
| 5. 脑桥 pons | 11. 楔束核 cuneate nucleus |
| 6. 延髓 medulla oblongata | 12. 薄束核 gracile nucleus |



A. 脊髓丘系
Spinal lemniscus

B. 三叉丘系
Trigeminal lemniscus

图 223 浅感觉传导道(A、B)
Pathway of the exteroceptive sensibility(A,B)

- 1. 中央后回 postcentral gyrus
- 2. 内囊 internal capsule
- 3. 腹后外侧核 ventral posterolateral nucleus
- 4. 中脑 midbrain
- 5. 脑桥 pons
- 6. 延髓 medulla oblongata
- 7. 脊髓丘脑束 spinothalamic tract
- 8. 脊髓 spinal cord

- 9. 脊神经节 spinal ganglion
- 10. 背侧丘脑 dorsal thalamus
- 11. 豆状核 lentiform nucleus
- 12. 尾状核 caudate nucleus
- 13. 腹后内侧核 ventral posteromedial nucleus
- 14. 三叉丘系 trigeminal lemniscus
- 15. 三叉神经脊束 spinal tract of trigeminal n.
- 16. 三叉神经节 trigeminal ganglion

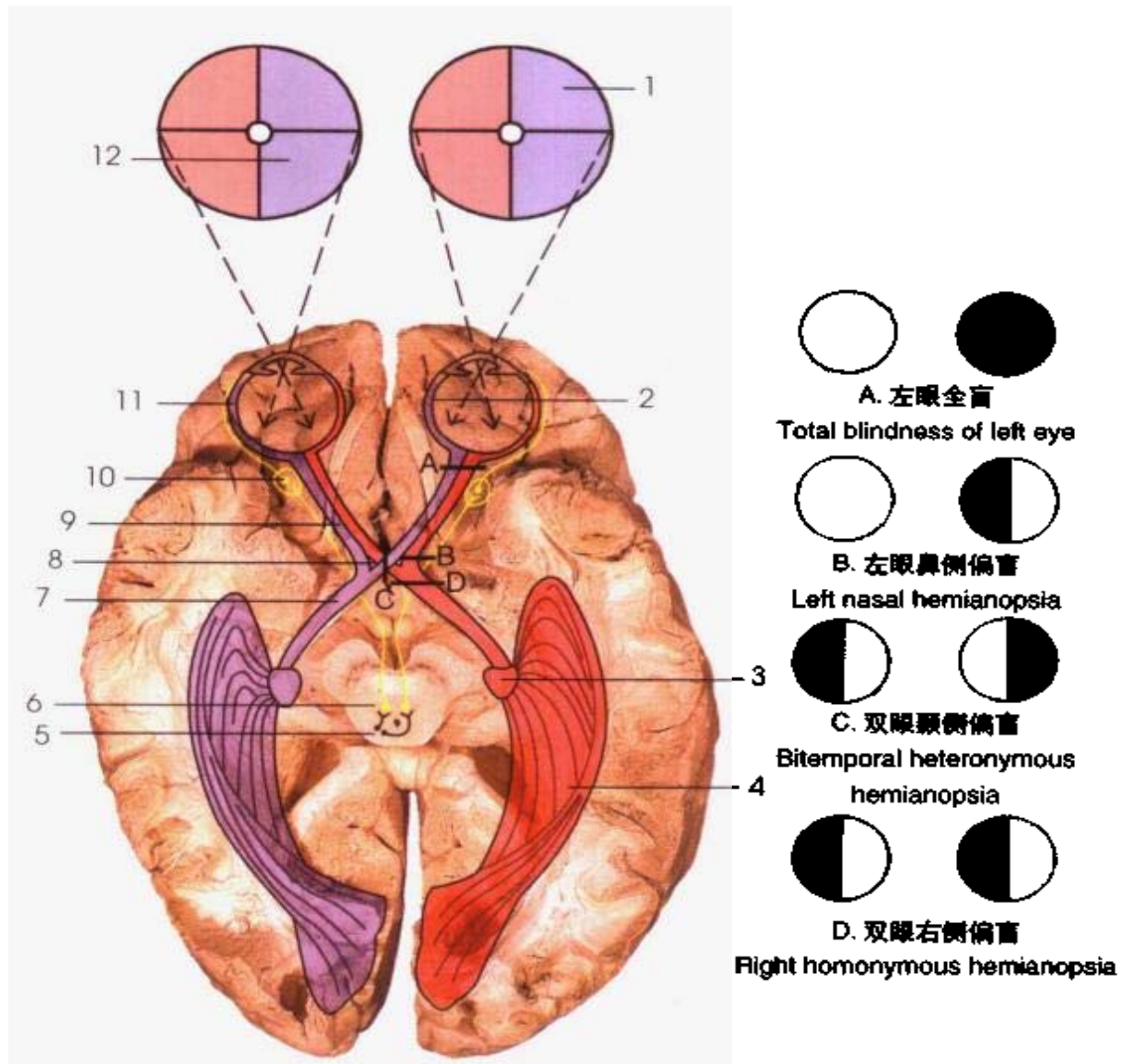


图 224 视觉传导道(下面观)
The visual pathway(inferior aspect)

- | | |
|--|-----------------------------|
| 1. 颞侧视野 temporal visual field | 7. 视束 optic tract |
| 2. 鼻侧视网膜 nasal retina | 8. 视交叉 optic chiasma |
| 3. 外侧膝状体 lateral geniculate body | 9. 视神经(Ⅱ) optic n.(Ⅱ) |
| 4. 视辐射 optic radiation | 10. 睫状神经节 ciliary ganglion |
| 5. 顶盖前区 pretectal area | 11. 颞侧视网膜 temporal retina |
| 6. 动眼神经副核 accessory nucleus of oculomotor n. | 12. 鼻侧视野 nasal visual field |

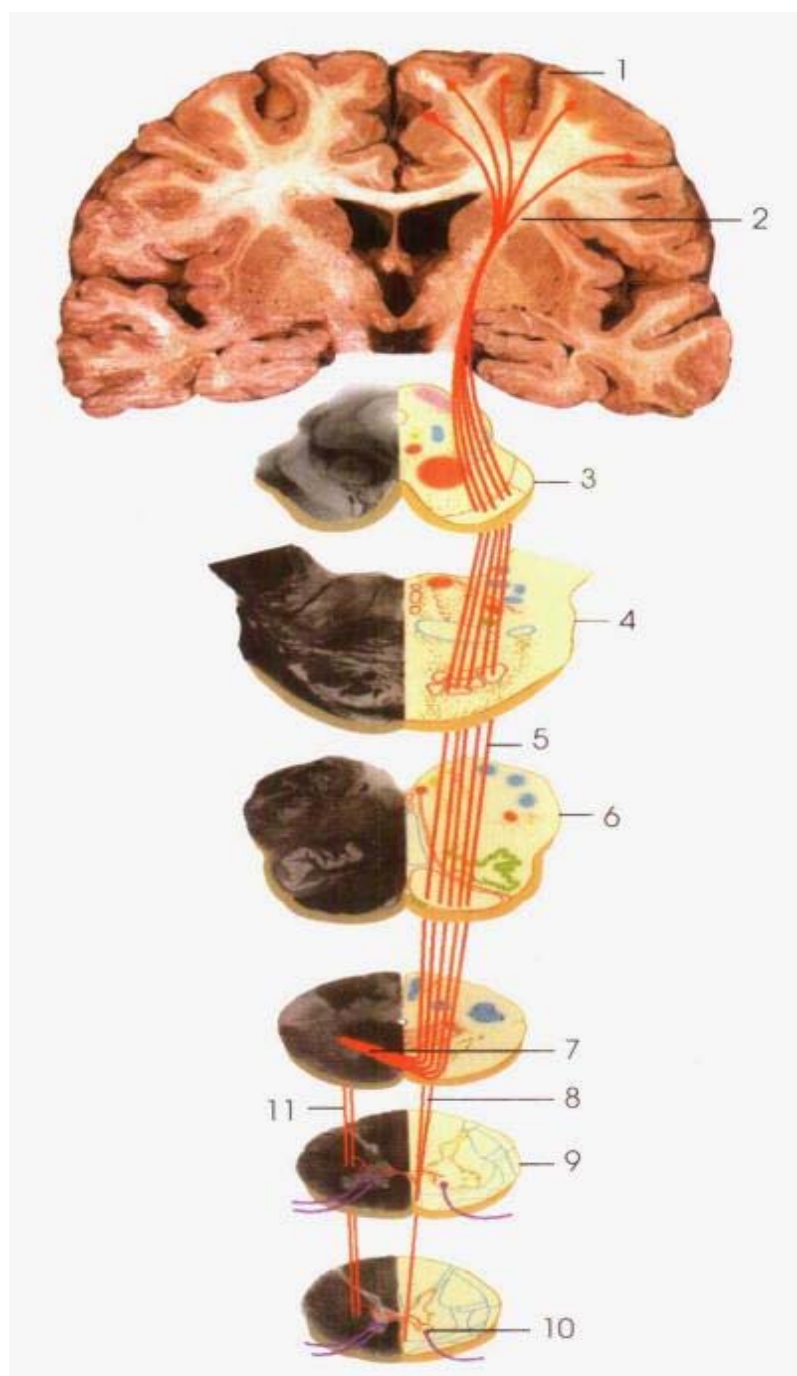


图 225 锥体系(皮质脊髓束)
Pyramidal system(corticospinal tract)

- | | |
|-------------------------------|--|
| 1. 中央前回 precentral gyrus | 7. 锥体交叉 decussation of pyramid |
| 2. 内囊 internal capsule | 8. 皮质脊髓前束 anterior corticospinal tract |
| 3. 中脑 midbrain | 9. 脊髓 spinal cord |
| 4. 脑桥 pons | 10. 前角 anterior horn |
| 5. 皮质脊髓束 corticospinal tracts | 11. 皮质脊髓侧束 lateral corticospinal tract |
| 6. 延髓 medulla oblongata | |

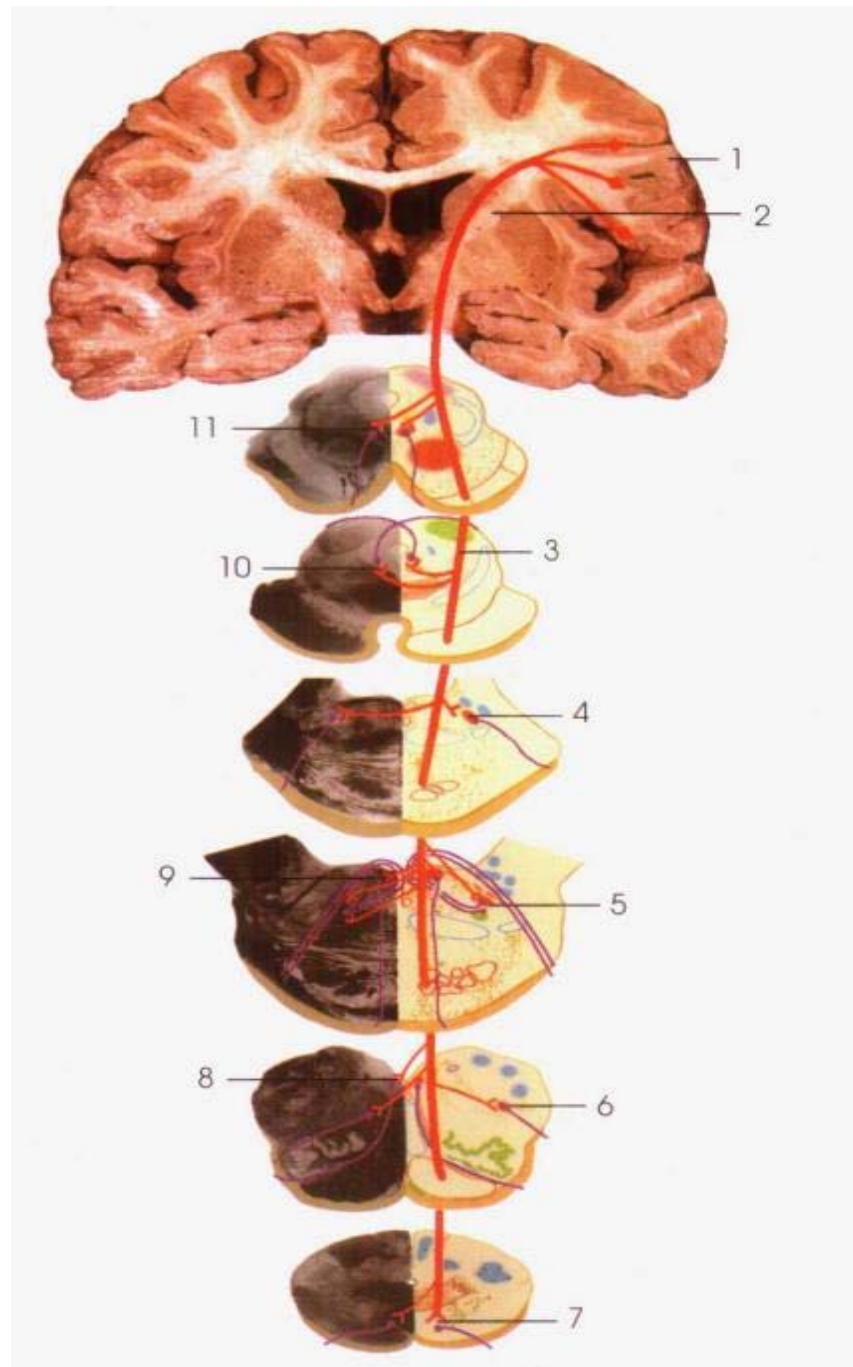


图 226 锥体系(皮质核束)
Pyramidal system(corticospinal tract)

- | | |
|--|------------------------------------|
| 1. 中央前回 precentral gyrus | 6. 疑核 nucleus ambiguus |
| 2. 内囊 internal capsule | 7. 副神经核 nucleus of accessory n. |
| 3. 皮质核束 corticospinal tract | 8. 舌下神经核 nucleus of hypoglossal n. |
| 4. 三叉神经运动核 motor nucleus of tri-
geminal n. | 9. 展神经核 nucleus of abducent n. |
| 5. 面神经核 nucleus of facial n. | 10. 滑车神经核 nucleus of trochlear n. |
| | 11. 动眼神经核 nucleus of oculomotor n. |

1. 面神经核 nucleus of facial n.
2. 面神经核下瘫 infranuclear paralysis
3. 面神经核上瘫 supranuclear paralysis

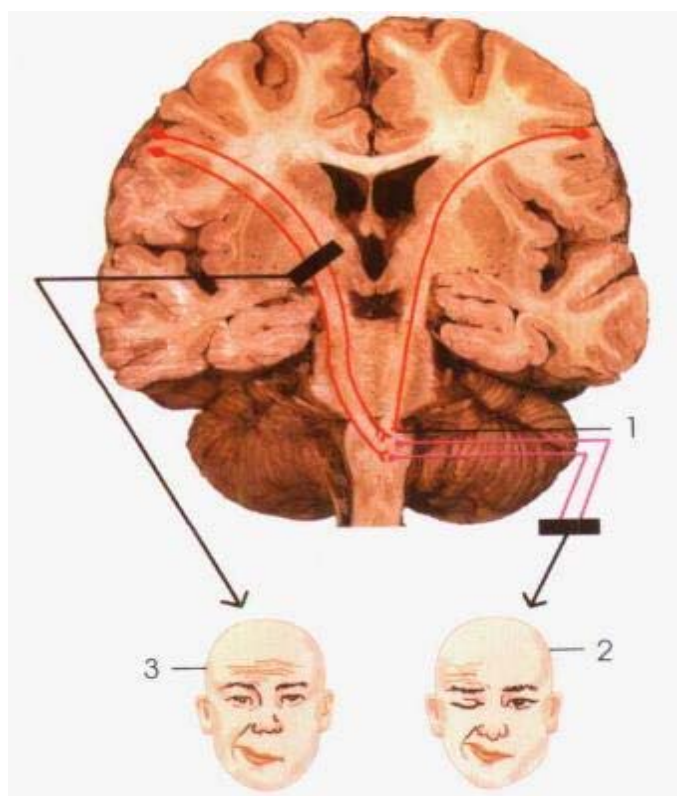
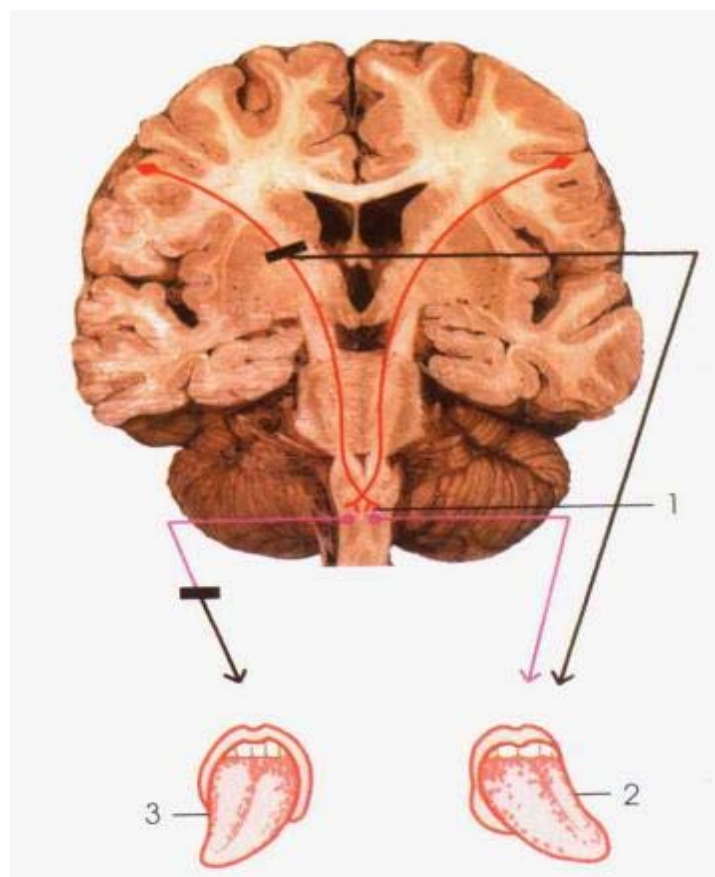
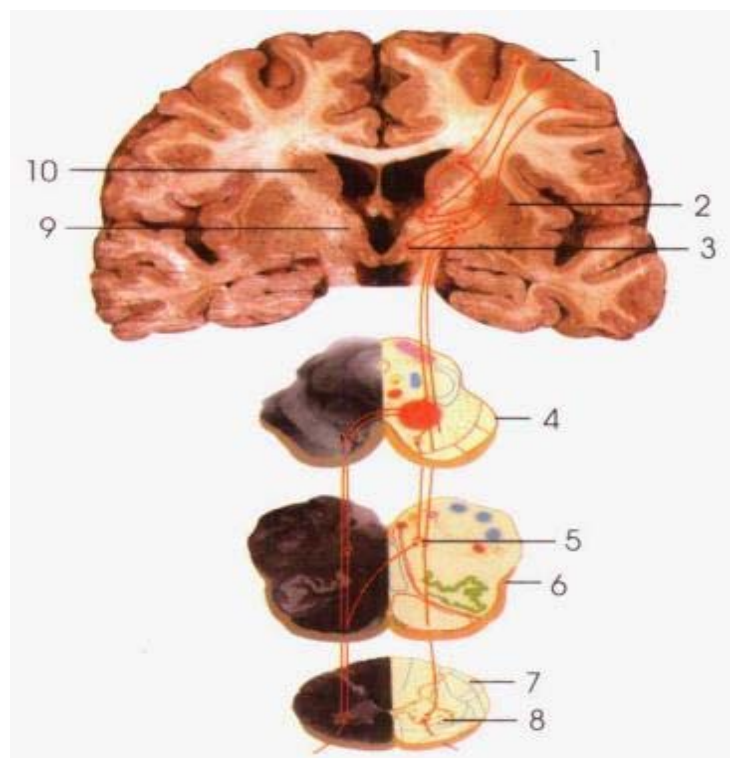


图 227 面神经瘫
Paralysis of the facial nerve



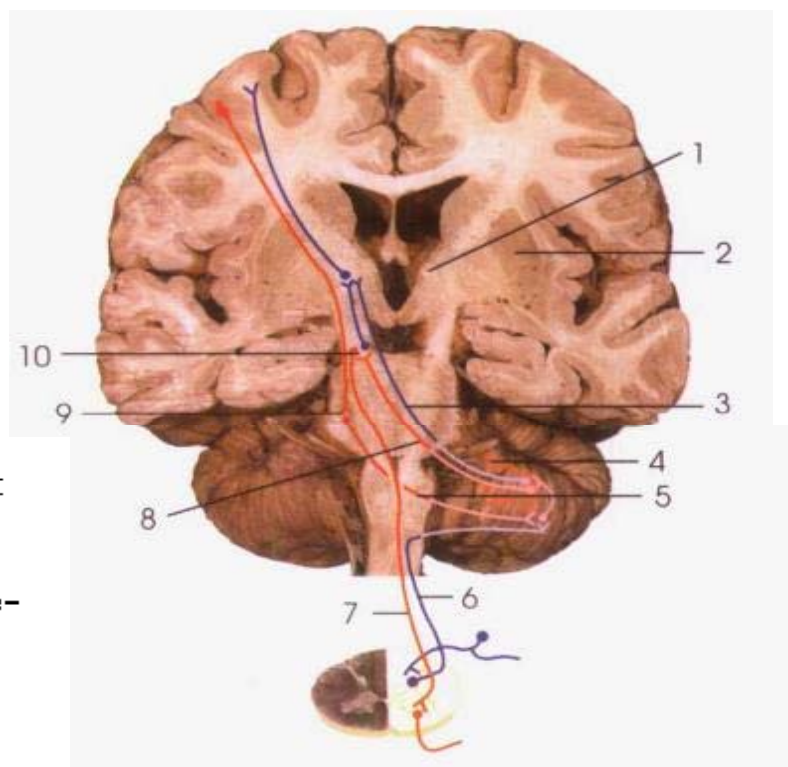
1. 舌下神经核 nucleus of hypoglossal n.
2. 舌下神经核上瘫 supranuclear paralysis
3. 舌下神经核下瘫 infranuclear paralysis

图 228 舌下神经瘫
Paralysis of the hypoglossal nerve



1. 大脑皮质 cerebral cortex
2. 豆状核 lentiform nucleus
3. 底丘脑核 subthalamic nucleus
4. 中脑 midbrain
5. 网状结构 reticular formation
6. 延髓 medulla oblongata
7. 脊髓 spinal cord
8. 前角 anterior horn
9. 背侧丘脑 dorsal thalamus
10. 尾状核 caudate nucleus

图 229 锥体外系(纹状体苍白球系)
Extrapyramidal system
(striopallidal system)



1. 背侧丘脑 dorsal thalamus
2. 豆状核 lentiform nucleus
3. 齿状丘脑束 dentatothalamic tract
4. 齿状核 dentate nucleus
5. 脑桥小脑束 pontocerebellar tract
6. 脊髓小脑后束 posterior spinocerebellar tract
7. 红核脊髓束 rubrospinal tract
8. 齿状红核束 dentatorubral tract
9. 脑桥核 pontine nuclei
10. 红核 red nucleus

图 230 锥体外系(皮质脑桥小脑系)
Extrapyramidal system(corticopontocerebellar system)

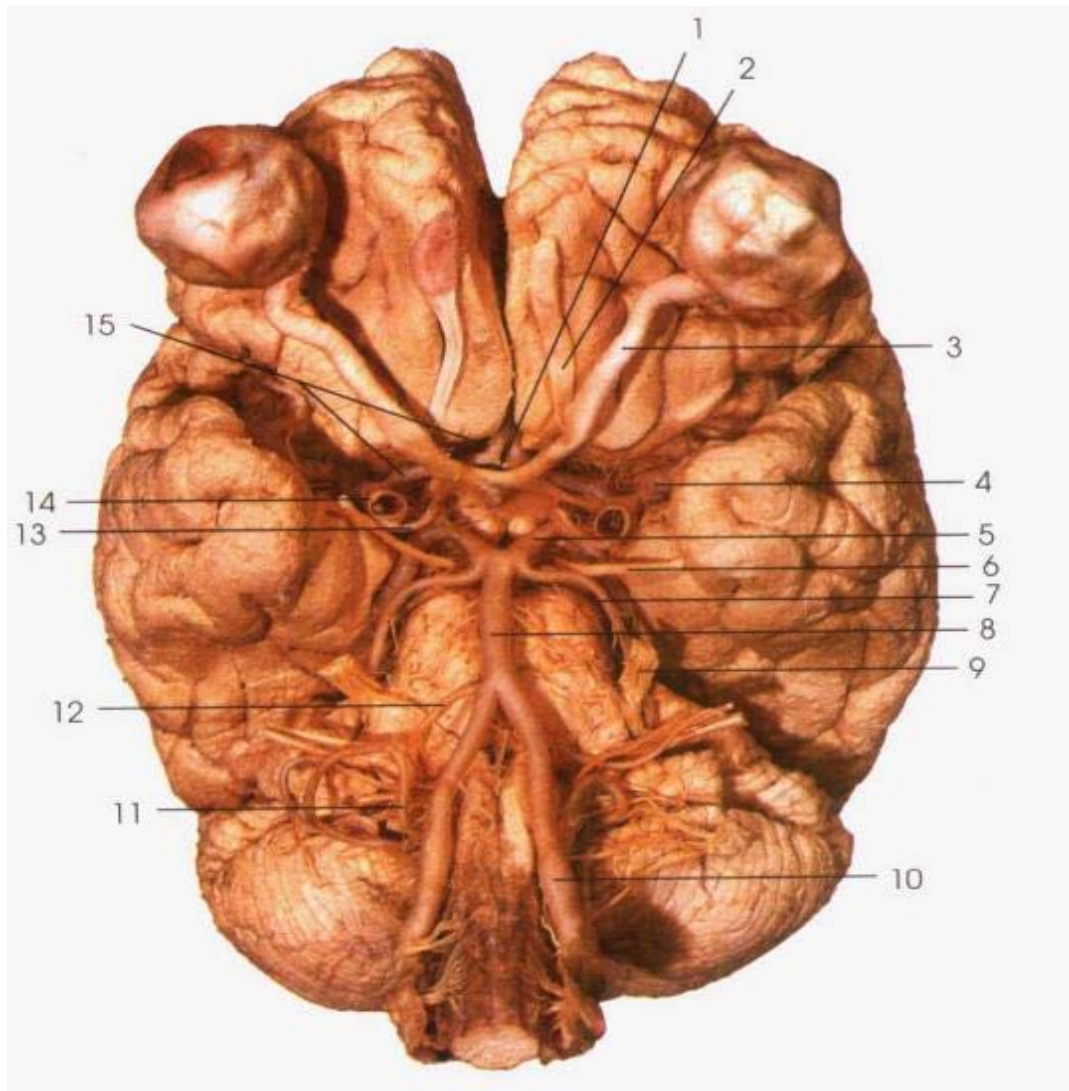


图 231 脑底的动脉
Arteries at the base of the brain

- | | |
|------------------------------------|---|
| 1. 前交通动脉 anterior communicating a. | 10. 椎动脉 vertebral a. |
| 2. 嗅束 olfactory tract | 11. 小脑后下动脉 posterior inferior cerebellar a. |
| 3. 视神经(Ⅱ) optic n.(Ⅱ) | 12. 小脑前下动脉 anterior inferior cerebellar a. |
| 4. 大脑中动脉 middle cerebral a. | 13. 后交通动脉 posterior communicating a. |
| 5. 大脑后动脉 posterior cerebral a. | 14. 颈内动脉 internal carotid a. |
| 6. 动眼神经(Ⅲ) oculomotor n.(Ⅲ) | 15. 大脑前动脉 anterior cerebral a. |
| 7. 小脑上动脉 superior cerebellar a. | |
| 8. 基底动脉 basilar a. | |
| 9. 三叉神经(V) trigeminal n.(V) | |

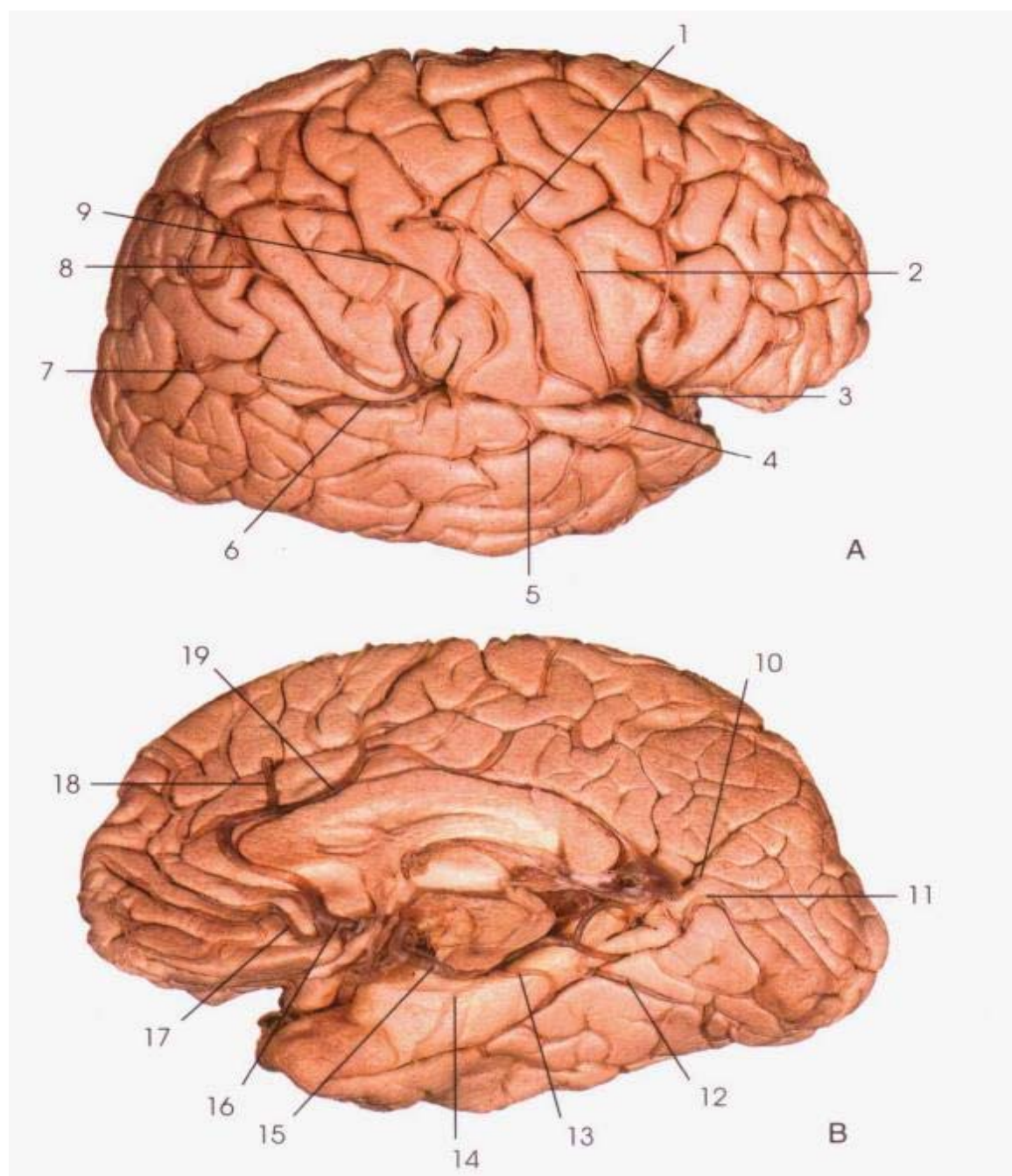


图 232 大脑半球的动脉(A. 外侧面, B. 内侧面)
Arteries of the cerebral hemisphere(A.lateral surface,B.medial surface)

- | | |
|------------------------------------|---|
| 1. 中央沟动脉 a. of central sulcus | 11. 距状沟支 calcarine branch |
| 2. 中央前沟动脉 a. of precentral sulcus | 12. 颞后支 posterior temporal branches |
| 3. 大脑中动脉 middle cerebral a. | 13. 颞中间支 intermediate temporal branches |
| 4. 颞前动脉 anterior temporal a. | 14. 颞前支 anterior temporal branches |
| 5. 颞中动脉 middle temporal a. | 15. 大脑后动脉 posterior cerebral a. |
| 6. 颞后动脉 posterior temporal a. | 16. 大脑前动脉 anterior cerebral a. |
| 7. 角回动脉 a. of angular gyrus | 17. 额极动脉 frontopolar a. |
| 8. 顶后动脉 posterior parietal artery | 18. 胼缘动脉 calcosomarginal a. |
| 9. 中央后沟动脉 a. of postcentral sulcus | 19. 胼胝体周动脉 pericallosal a. |
| 10. 顶枕支 parietooccipital branch | |

1. 上吻合静脉 superior anastomotic v.
2. 下吻合静脉 inferior anastomotic v.
3. 大脑中浅静脉 superficial middle cerebral v.
4. 大脑上静脉 superior cerebral v.

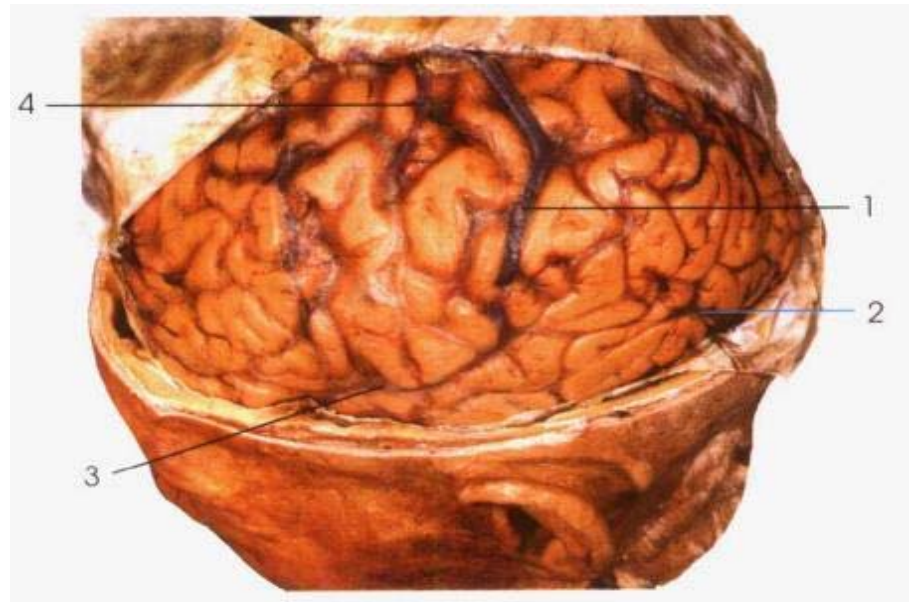
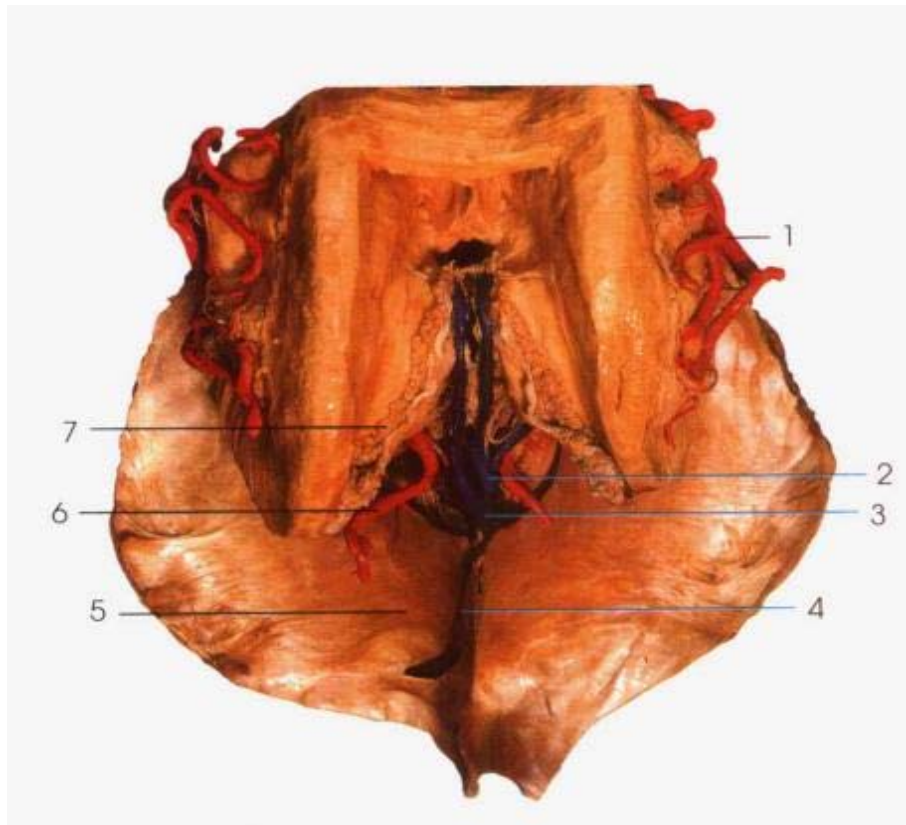
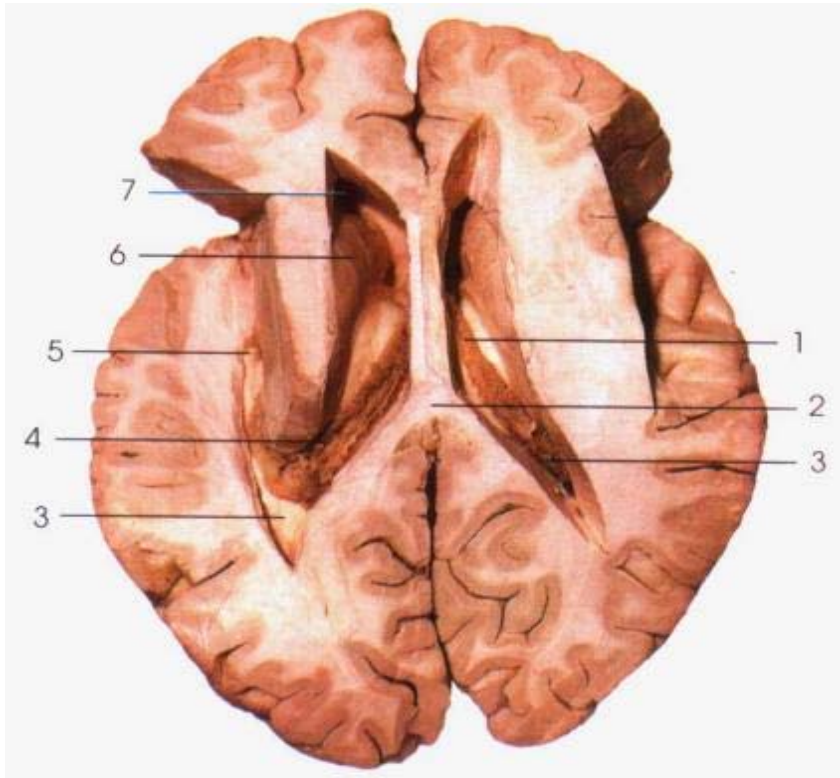


图 233 大脑半球外侧面的静脉
Veins of the lateral surface of cerebral hemisphere



1. 大脑中动脉 middle cerebral a.
2. 大脑内静脉 internal cerebral v.
3. 大脑大静脉 great cerebral v.
4. 直窦 rectus sinuss
5. 小脑幕 tentorium of cerebellum
6. 大脑后动脉 posterior cerebral a.
7. 侧脑室脉络丛 choroid plexus of lateral ventricle

图 234 大脑深静脉
The deep cerebral veins



- 1.侧脑室中央部 central part of lateral ventricle
- 2.胼胝体压部 splenium of corpus callosum
- 3.侧脑室后角 posterior horn of lateral ventricle
- 4.侧脑室脉络丛 choroid plexus of lateral ventricle
- 5.海马 hippocampus
- 6.尾状核头 head of caudate nucleus
- 7.侧脑室前角 anterior horn of lateral ventricle

图 235 侧脑室(上面观)
Lateral ventricle(superior aspect)

- 1.视神经(Ⅱ) optic n.(Ⅱ)
- 2.视交叉 optic chiasma
- 3.颈内动脉 internal carotid a.
- 4.动眼神经(Ⅲ) oculomotor n. (Ⅲ)
- 5.幕切迹 tentorial incisure
- 6.小脑幕 tentorium of cerebellum
- 7.横窦 transverse sinus
- 8.窦汇 confluence of sinuses
- 9.直窦 straight sinus
- 10.上矢状窦 superior sagittal sinus
- 11.大脑镰 cerebral falx

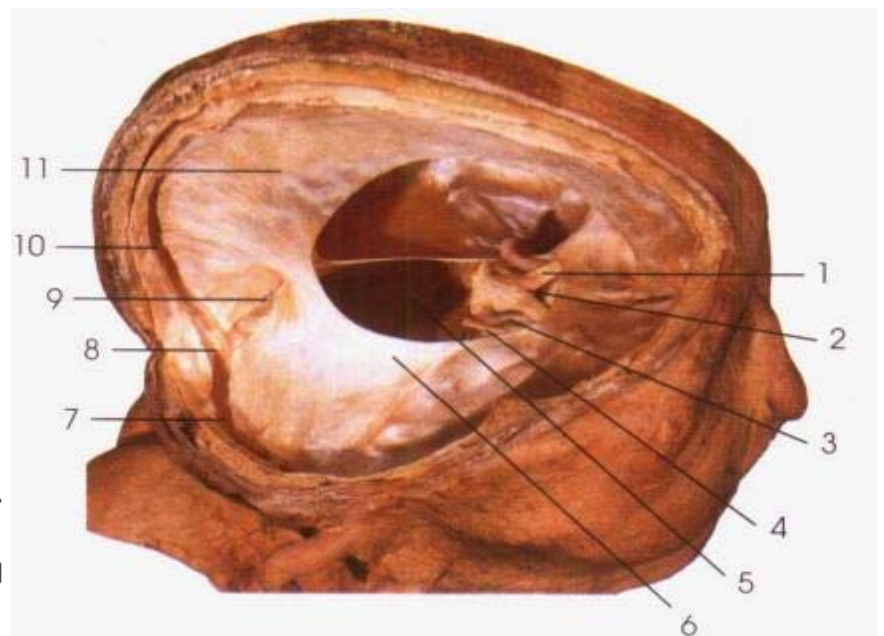


图 236 硬脑膜及硬脑膜窦
Cerebral dura mater and sinuses
of the dura mater

1. 第三脑室 third ventricle
2. 视交叉 optic chiasma
3. 漏斗 infundibulum
4. 动眼神经(III) oculomotor n.(III)
5. 滑车神经(IV) trochlear n.(IV)
6. 眼神经 ophthalmic n.
7. 上颌神经 maxillary n.
8. 展神经(VI) abducent n.(VI)
9. 海绵窦 cavernous sinus
10. 颈内动脉 internal carotid a.
11. 垂体 hypophysis
12. 大脑中动脉 middle cerebral a.

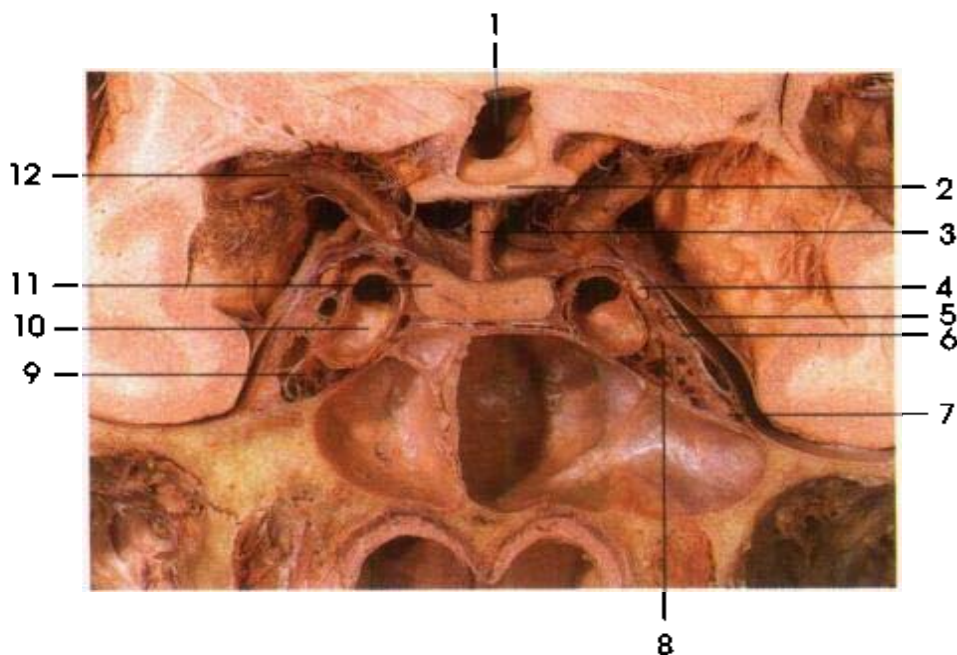
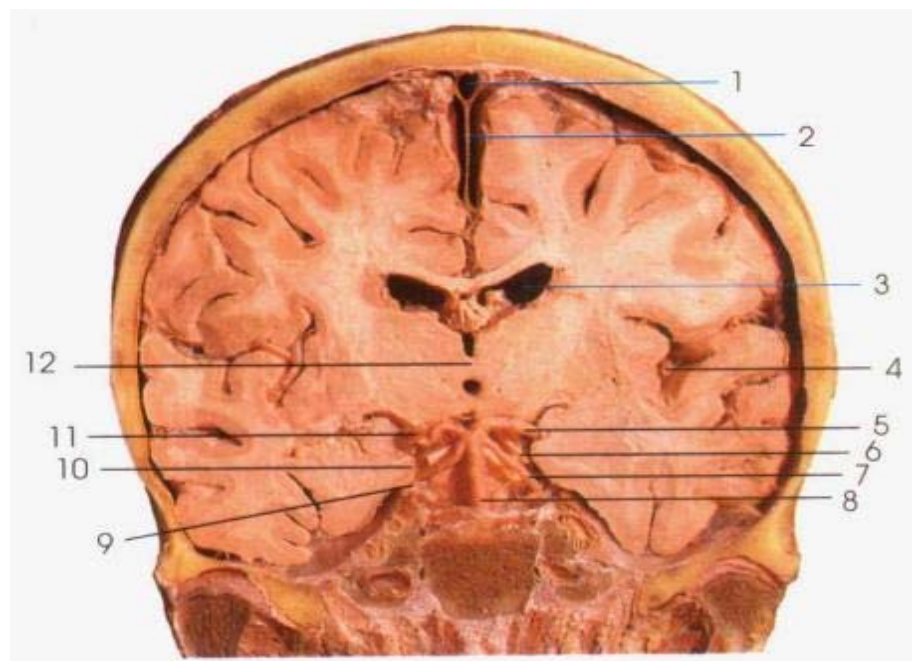


图 237 海绵窦的冠状切面
Coronal section of the cavernous sinus



1. 上矢状窦 superior sagittal sinus
2. 大脑镰 cerebral falx
3. 侧脑室 lateral ventricle
4. 大脑中动脉 middle cerebral a.
5. 大脑后动脉 posterior cerebral a.
6. 动眼神经(III) oculomotor N. (III)
7. 小脑上动脉 superior cerebellar a.
8. 基底动脉 basilar a.
9. 小脑幕 tentorium of cerebellum
10. 钩 uncus
11. 后交通动脉 posterior communicating a.
12. 丘脑间粘合 interthalamic adhesion

图 238 脑的冠状切面(经过小脑幕切迹)
Coronal section of the brain(through the tentorial incisure of cerebellum)

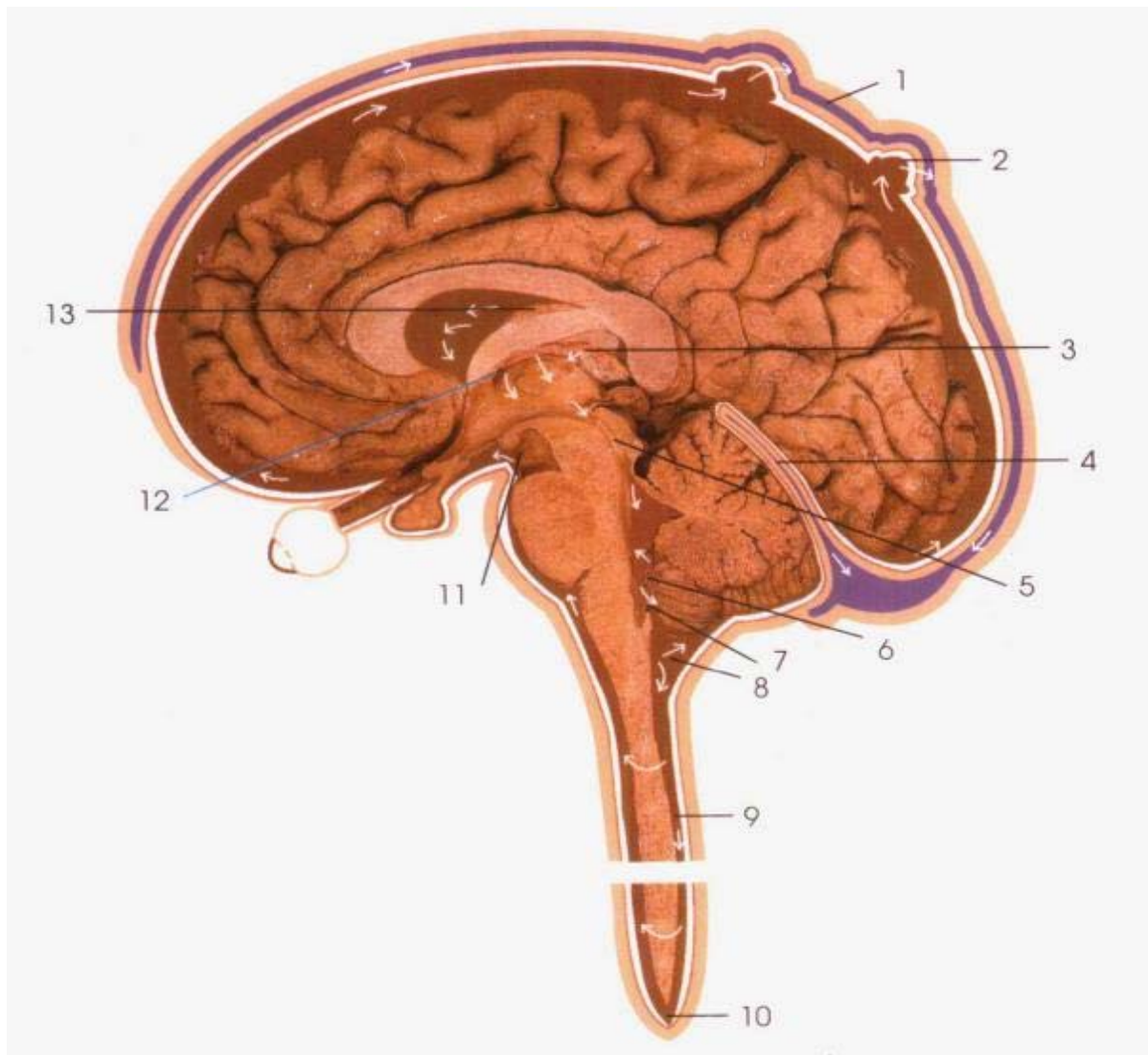


图 239 脑脊液循环模式图
Diagram of the cerebrospinal fluid circulation

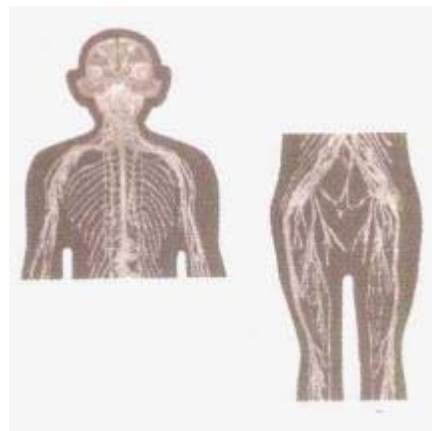
- 1. 上矢状窦 superior sagittal sinus
- 2. 蛛网膜粒 arachnoid granulations
- 3. 第三脑室脉络丛 choroid plexus of third ventricle
- 4. 直窦 straight sinus
- 5. 中脑导水管 mesencephalic aqueduct
- 6. 第四脑室脉络丛 choroid plexus of fourth ventricle

- 7. 第四脑室正中孔 median aperture of fourth ventricle
- 8. 小脑延髓池 cerebellomedullary cistern
- 9. 蛛网膜下腔 subarachnoid space
- 10. 终池 terminal cistern
- 11. 脚间池 interpeduncular cistern
- 12. 室间孔 interventricular foramen
- 13. 侧脑室脉络丛 choroid plexus of lateral ventricle

10

第 10 章

TOPOGRAPHY



局

部

解

剖

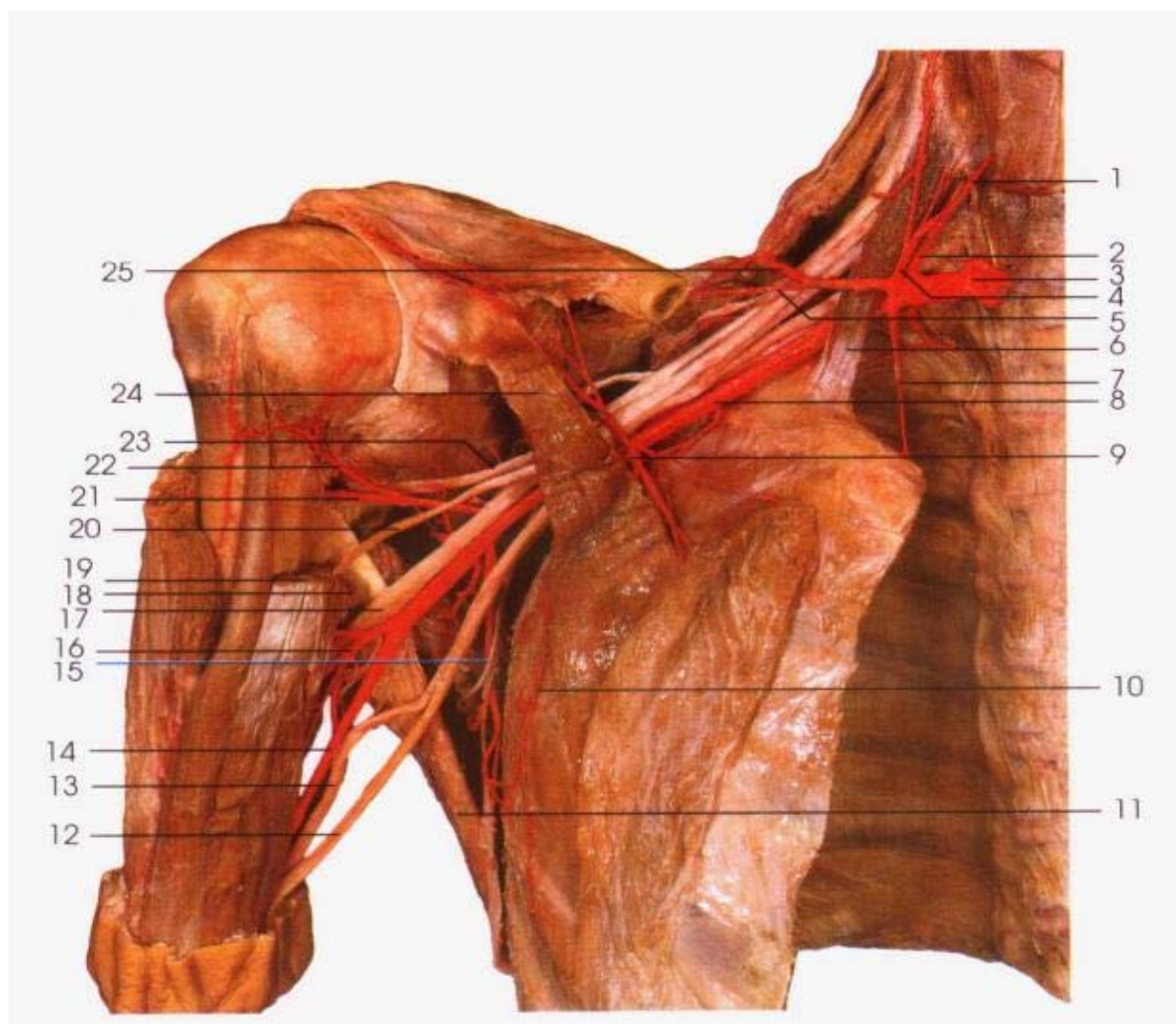


图 240 腋窝的血管和神经
Blood vessels and nerves of the axillary fossa

- | | |
|-------------------------------|---|
| 1. 甲状腺下动脉 inferior thyroid a. | a. and n. |
| 2. 椎动脉 vertebral a. | 16. 肱深动脉 deep brachial a. |
| 3. 锁骨下动脉 subclavian a. | 17. 桡神经 radial n. |
| 4. 甲状腺颈干 thyrocervical trunk | 18. 喙肱肌 coracobrachialis |
| 5. 肩胛上动脉 suprascapular a. | 19. 肱二头肌 biceps brachii |
| 6. 前斜角肌 scalenus anterior | 20. 肌皮神经 musculocutaneous n. |
| 7. 胸廓内动脉 internal thoracic a. | 21. 旋肱后动脉 posterior humeral circumflex a. |
| 8. 腋动脉 axillary a. | 22. 旋肱前动脉 anterior humeral circumflex a. |
| 9. 胸肩峰动脉 thoracoacromial a. | 23. 腋神经 axillary n. |
| 10. 胸外侧动脉 lateral thoracic a. | 24. 胸小肌 pectoralis minor |
| 11. 背阔肌 latissimus dorsi | 25. 颈浅动脉 superficial cervical a. |
| 12. 正中神经 median n. | |
| 13. 尺神经 ulnar n. | |
| 14. 肱动脉 brachial a. | |
| 15. 胸背动脉和胸背神经 thoracodorsal | |

1. 锁骨 clavicle
2. 胸大肌 pectoralis major
3. 前锯肌 serratus anterior
4. 前臂外侧皮神经 lateral antebrachial cutaneous n.
5. 肘正中静脉 median cubital v.
6. 贵要静脉 basilic v.
7. 前臂内侧皮神经 medial antebrachial cutaneous n.
8. 头静脉 cephalic v.
9. 肱二头肌 biceps brachii
10. 三角肌 deltoid

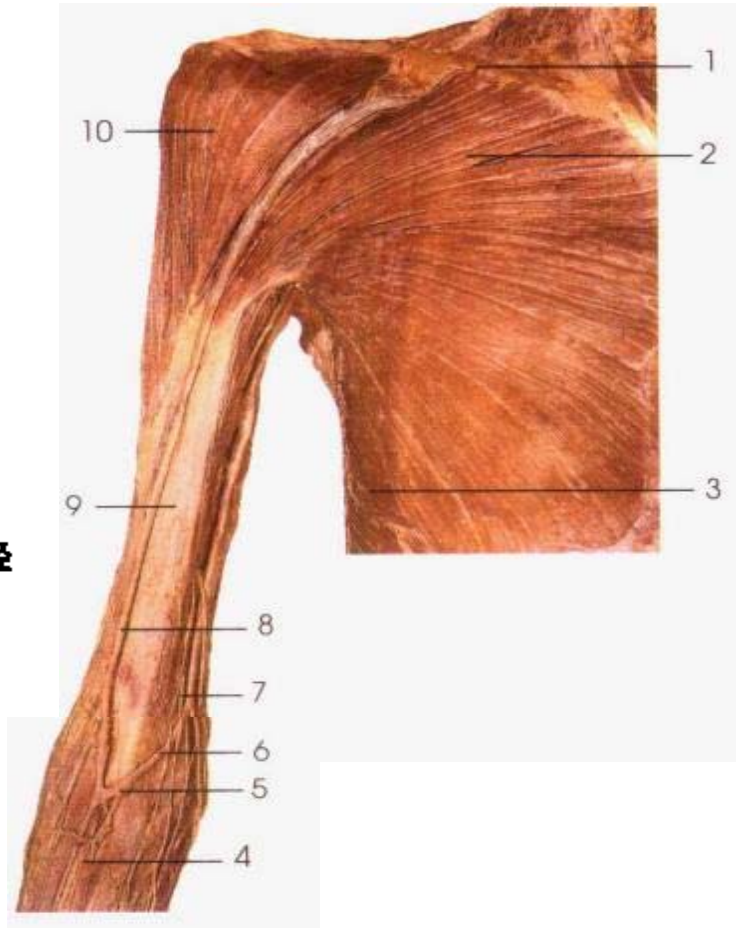
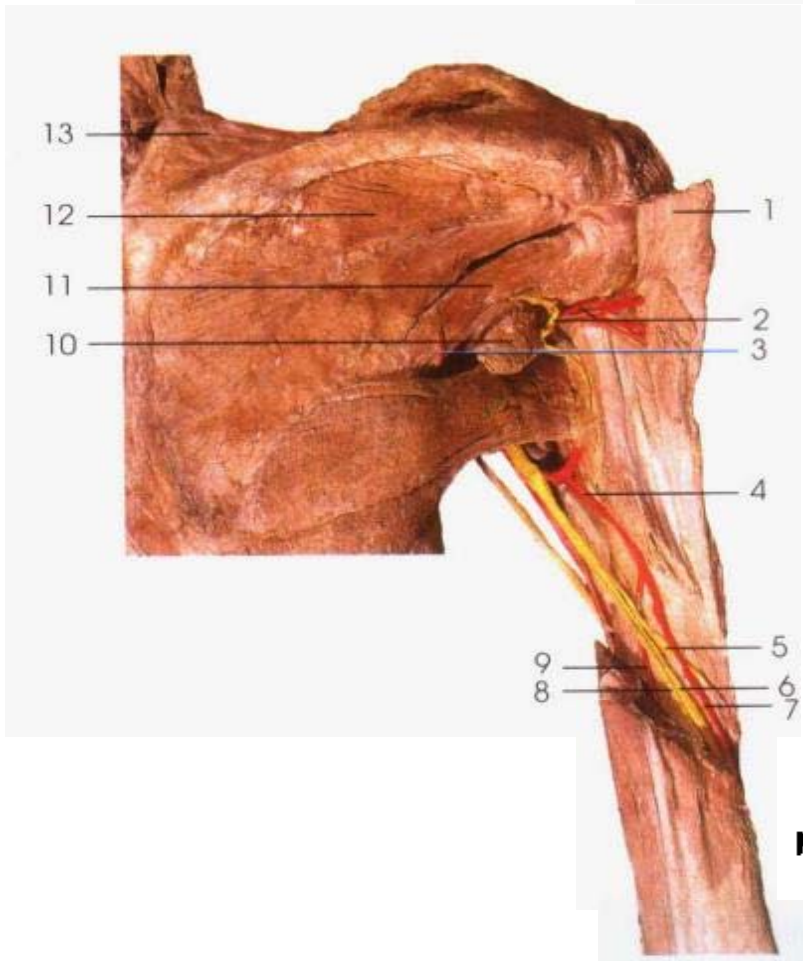


图 241 肩和臂前面的肌、血管和神经
Muscles, blood vessels and nerves
of the anterior aspect of the
shoulder and upper arm



1. 三角肌 deltoid
2. 腋神经和旋肱后动脉 axillary n. and posterior humeral circumflex a.
3. 旋肩胛动脉 circumflex scapular a.
4. 肱深动脉 deep brachii a.
5. 前臂后皮神经 posterior cutaneous nerve of the forearm
6. 桡神经 radial n.
7. 桡侧副动脉 radial collateral a.
8. 桡神经后肌支 posterior muscular branch of radial n.
9. 中副动脉 middle collateral a.
10. 肱三头肌长头 long head of triceps brachii
11. 小圆肌 teres minor
12. 冈下肌 infraspinatus
13. 冈上肌 supraspinatus

图 242 肩胛区和臂后区的肌、血管和神经
Muscles, blood vessels and nerves
of the scapular and posterior
brachial region

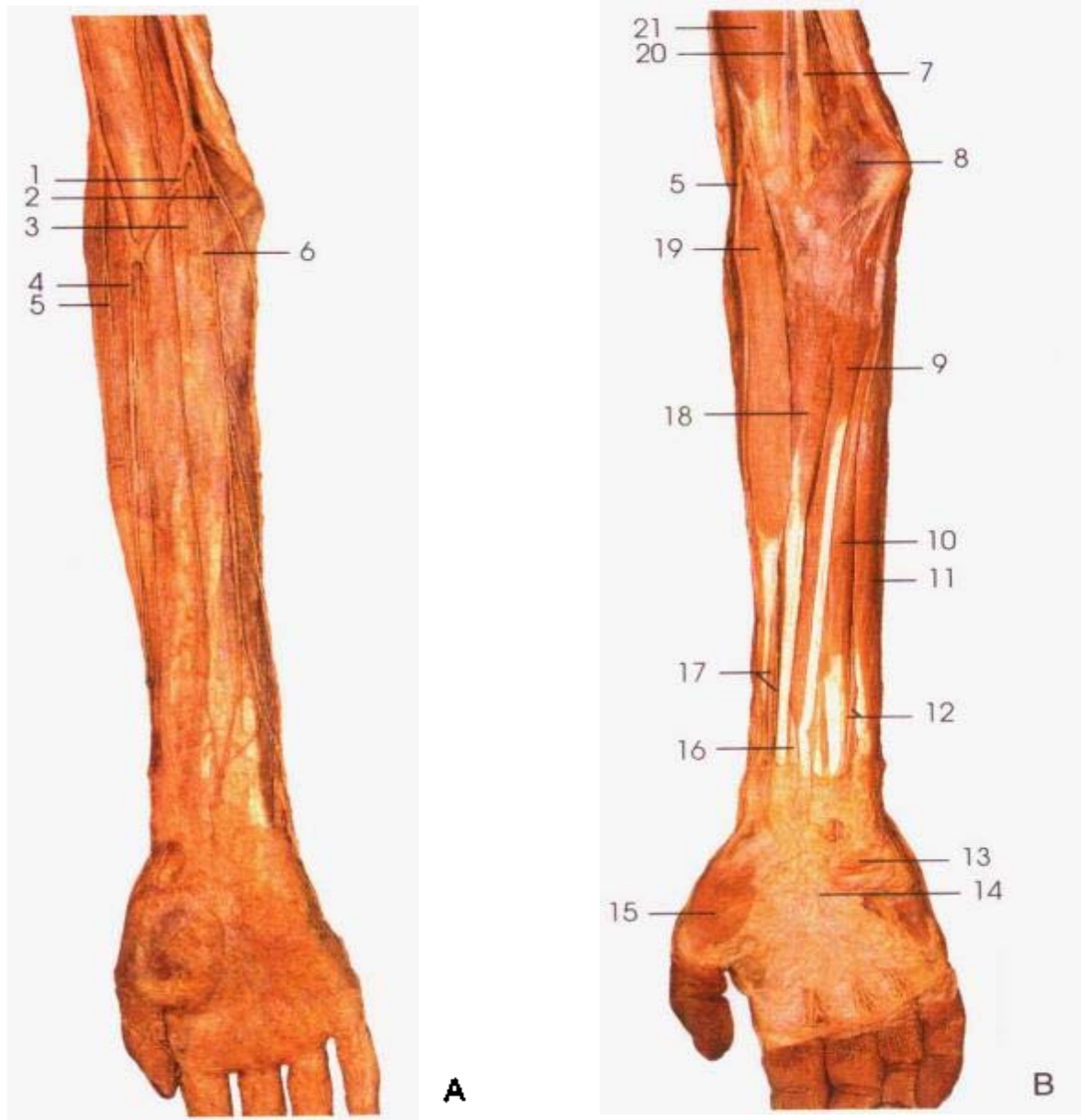


图 243 肘前区和前臂前区的肌、血管及神经(I)(A、B)
Muscles, blood vessels and nerves of the anterior cubital region and anterior anterbrachial region (I)(A,B)

1. 肘正中静脉 median cubital v.
2. 贵要静脉 basilic v.
3. 前臂正中静脉 median antebrachial v.
4. 头静脉 cephalic v.
5. 前臂外侧皮神经 lateral antebrachial cutaneous n.
6. 前臂内侧皮神经 medial antebrachial cutaneous n.
7. 正中神经 median n.
8. 旋前圆肌 pronator teres
9. 掌长肌 palmaris longus
10. 指浅屈肌 flexor digitorum superficial

11. 尺侧腕屈肌 flexor carpi ulnaris
12. 尺动脉和尺静脉 ulnar a. and v.
13. 掌短肌 palmaris brevis
14. 掌腱膜 palmar aponeurosis
15. 拇短展肌 abductor pollicis brevis
16. 正中神经 median n.
17. 桡动脉和静脉 radial a. and v.
18. 桡侧腕屈肌 flexor carpi radialis
19. 肱桡肌 brachioradialis
20. 肱动脉 brachial a.
21. 肱二头肌 biceps brachii

1. 尺神经 ulnar n.
2. 肱动脉 brachial a.
3. 正中神经 median n.
4. 肱二头肌腱膜 bicipital aponeurosis
5. 尺动脉 ulnar a.
6. 尺侧腕屈肌 flexor carpi ulnaris
7. 指深屈肌 flexor digitorum profundus
8. 指浅屈肌腱 tendon of the flexor digitorum superficialis
9. 尺神经浅支 superficial branch of ulnar n.
10. 掌浅弓 superficial palmar arch
11. 指掌侧总动脉及神经 common palmar digital a. and n.
12. 拇短展肌 abductor pollicis brevis
13. 屈肌支持带 flexor retinaculum
14. 桡动脉掌浅支 superficial palmar branch of radial a.
15. 桡侧腕屈肌腱 tendon of flexor carpi radialis
16. 拇长屈肌腱 tendon of flexor pollicis longus
17. 旋前方肌 pronator quadratus
18. 骨间前动脉和神经 interosseus anterior a. and n.
19. 桡动脉 radial a.
20. 桡神经浅支 superficial branch of radial n.
21. 旋前圆肌 pronator teres
22. 桡侧返动脉 radial recurrent a.
23. 肱二头肌腱 tendon of biceps brachii
24. 肱桡肌 brachioradialis
25. 肱二头肌 biceps brachii

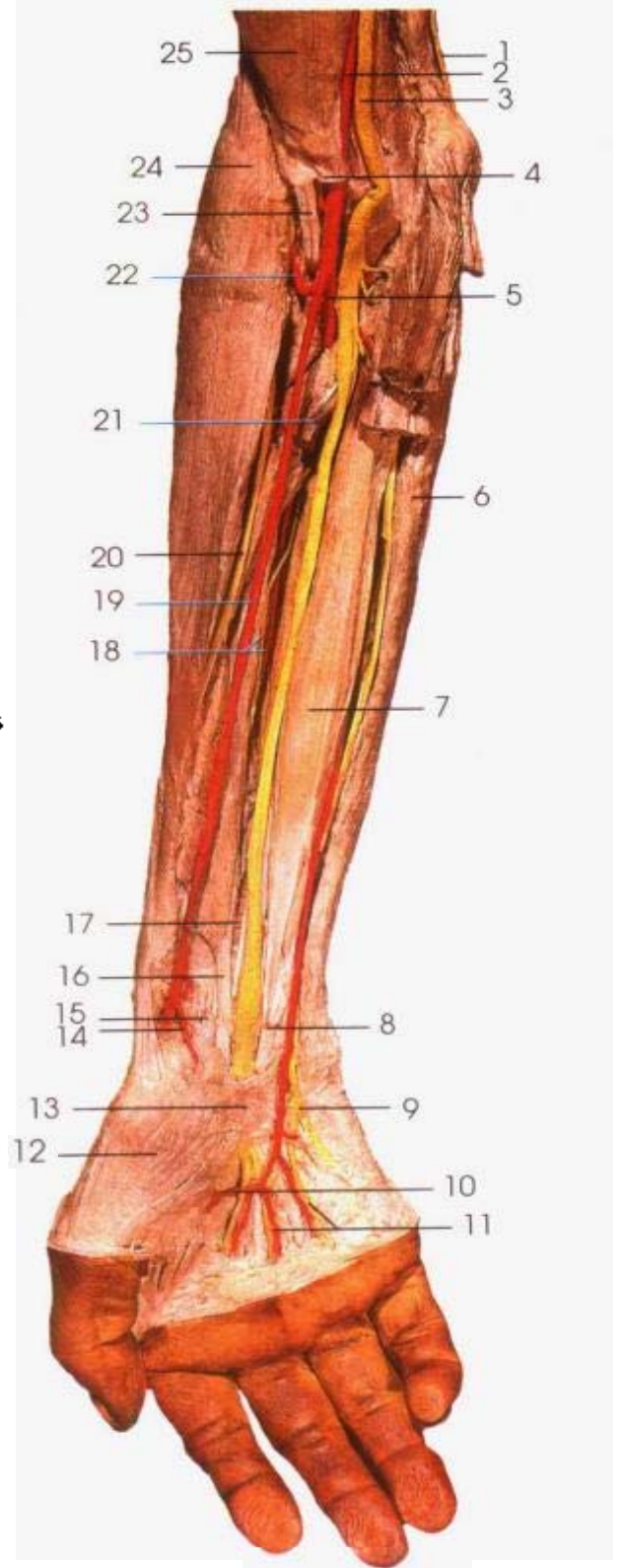


图 244 肘前区和前臂前区的肌、血管及神经(Ⅱ)
Muscles, blood vessels and nerves of the
anterior cubital region and anterior
antebrachial region(Ⅱ)

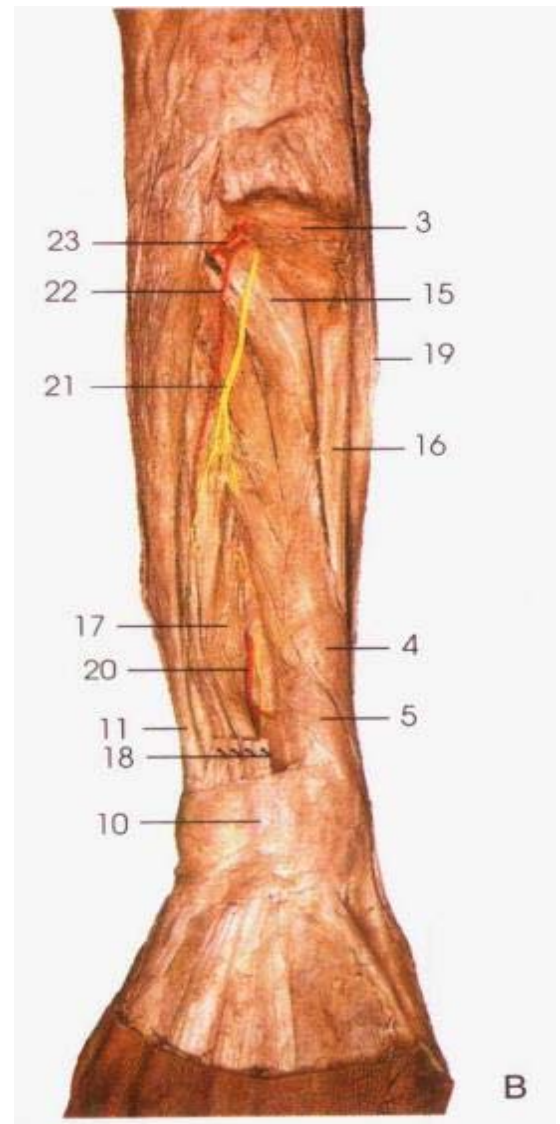
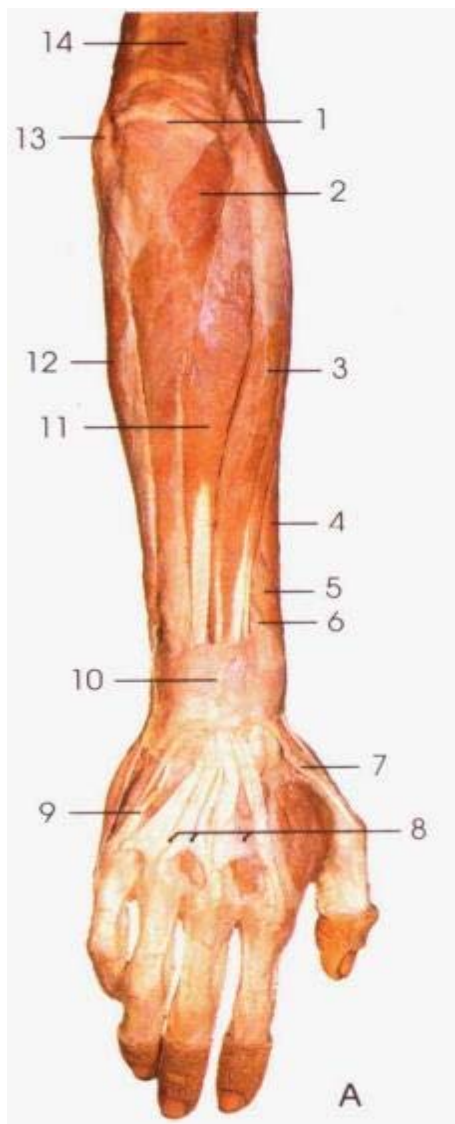


图 245 前臂后区的肌、血管和神经(A、B)
Muscles, blood vessels and nerves of the
posterior antebrachial region (A,B)

- 1. 鹰咀 olecranon
- 2. 肘肌 anconeus
- 3. 指伸肌 extensor digitorum
- 4. 拇长展肌 abductor pollicis longus
- 5. 拇短伸肌 extensor pollicis brevis
- 6. 桡侧腕短伸肌腱 tendon of extensor carpi radialis brevis
- 7. 拇长伸肌腱 tendon of extensor pollicis longus
- 8. 腱间结合 intertendinous connections
- 9. 小指伸肌 extensor digiti minimi
- 10. 伸肌支持带 extensor retinaculum
- 11. 尺侧腕伸肌 extensor carpi ulnaris
- 12. 尺侧腕屈肌 flexor carpi ulnaris
- 13. 尺神经 ulnar n.

- 14. 肱三头肌 triceps brachii
- 15. 旋后肌 supinator
- 16. 桡侧腕短伸肌 extensor carpi radialis brevis
- 17. 拇长伸肌 extensor pollicis longus
- 18. 指伸肌腱 tendon of extensor digitorum
- 19. 桡侧腕长伸肌 extensor carpi radialis longus
- 20. 骨间前动脉后支 posterior branch of anterior interosseous a.
- 21. 骨间后神经 posterior interosseous n.
- 22. 骨间后动脉 posterior interosseous a.
- 23. 骨间返动脉 recurrent interosseous a.

1. 头静脉 cephalic v.
2. 桡神经浅支 superficial branch of radial n.
3. 伸肌支持带 extensor retinaculum
4. 尺神经手背支 dorsal branch of ulnar n.
5. 第一掌背动脉 first dorsal metacarpal a.
6. 尺神经交通支 communicating branch with ulnar n.
7. 指背静脉网 dorsal venous rete of fingers
8. 手背静脉网 dorsal venous rete of hand
9. 指伸肌腱 tendons of extensor digitorum
10. 贵要静脉 basilic v.

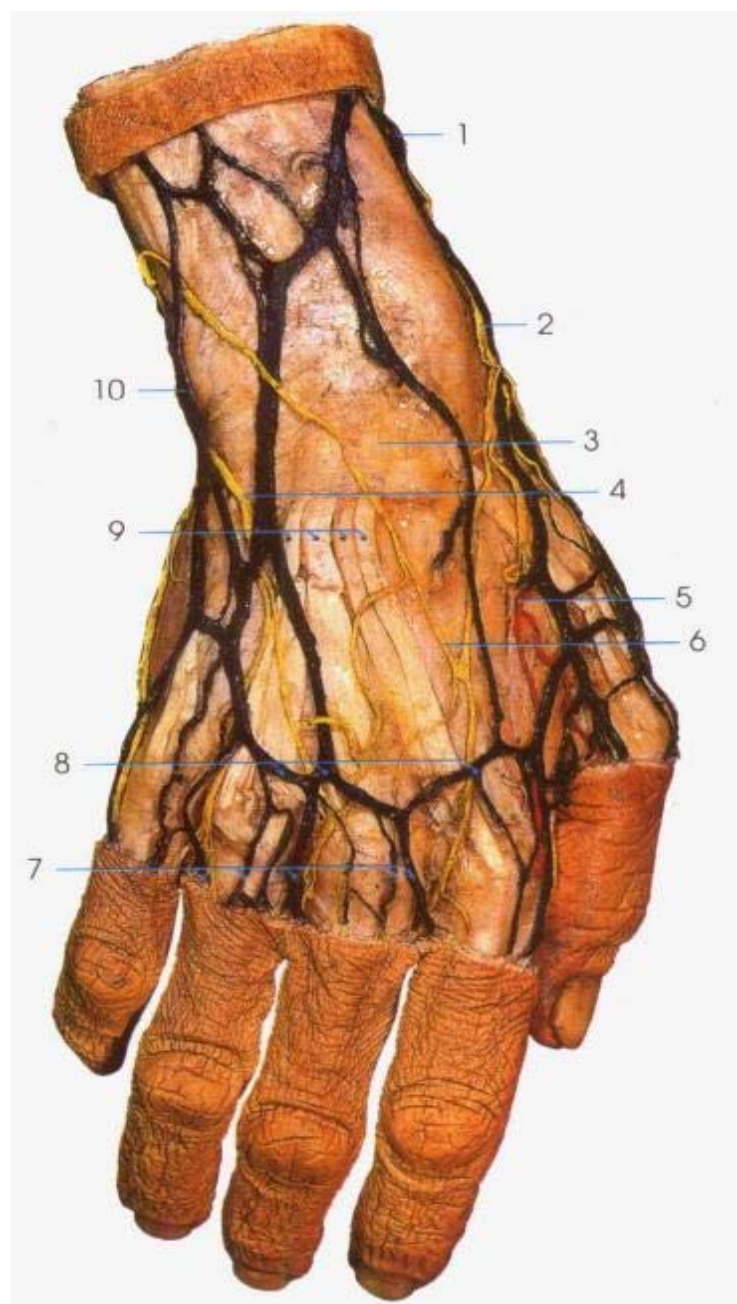
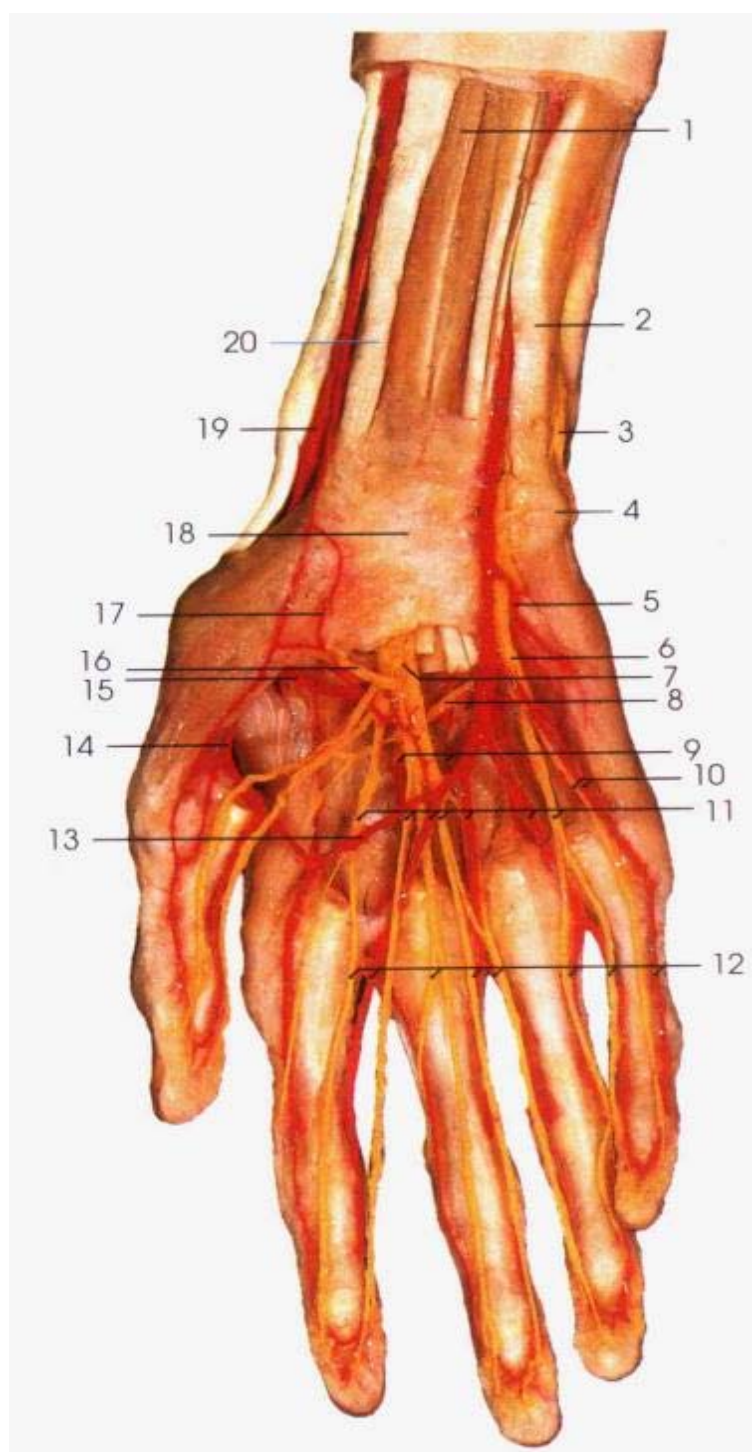
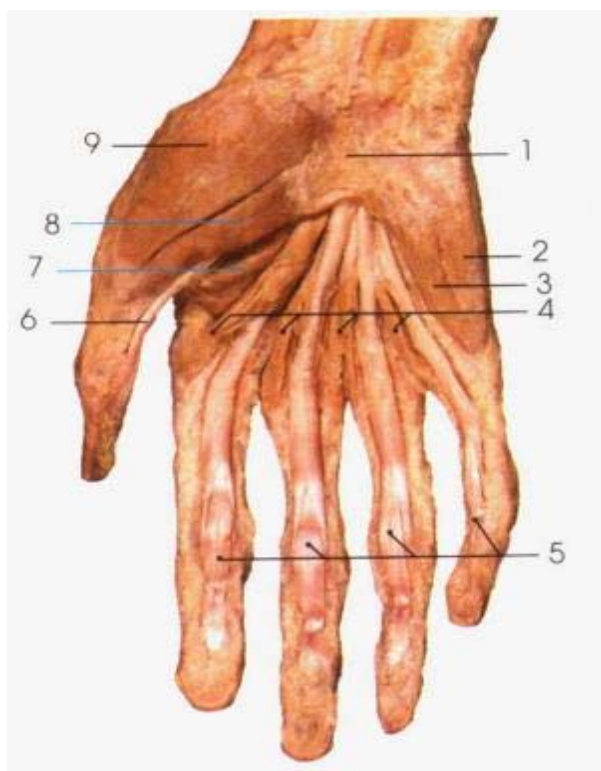


图 246 手背的血管和神经
Blood vessels and nerves of the
dorsum of hand

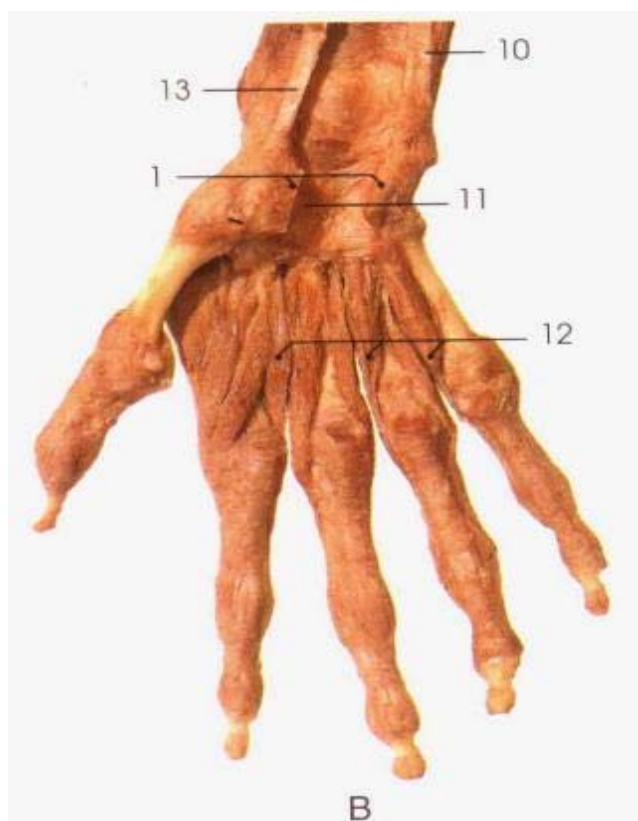


1. 指浅屈肌腱 tendons of flexor digitorum superficialis
2. 尺侧腕屈肌腱 tendon of flexor carpi ulnaris
3. 尺神经手背支 dorsal branch of ulnar n.
4. 豌豆骨 pisiform
5. 尺动脉掌深支及尺神经深支 deep palmar branch of ulnar a. and deep branch of ulnar n.
6. 尺神经浅支 superficial branch of ulnar n.
7. 正中神经 median n.
8. 尺神经深支 deep branch of ulnar n.
9. 掌心动脉 palmar metacarpal a.
10. 小指尺掌侧动脉及神经 ulnar palmar a. and n. of little finger
11. 指掌侧总动脉及神经 common palmar digital a. & n.
12. 指掌侧固有动脉和神经 proper palmar digital a. & n.
13. 掌浅弓 superficial palmar arch
14. 拇主要动脉 principal artery of thumb
15. 掌深弓 deep palmar arch
16. 正中神经返支 recurrent branch of median n.
17. 桡动脉掌浅支 superficial palmar branch of radial a.
18. 屈肌支持带 flexor retinaculum
19. 桡动脉 radial a.
20. 桡侧腕屈肌腱 tendon of flexor carpi radialis

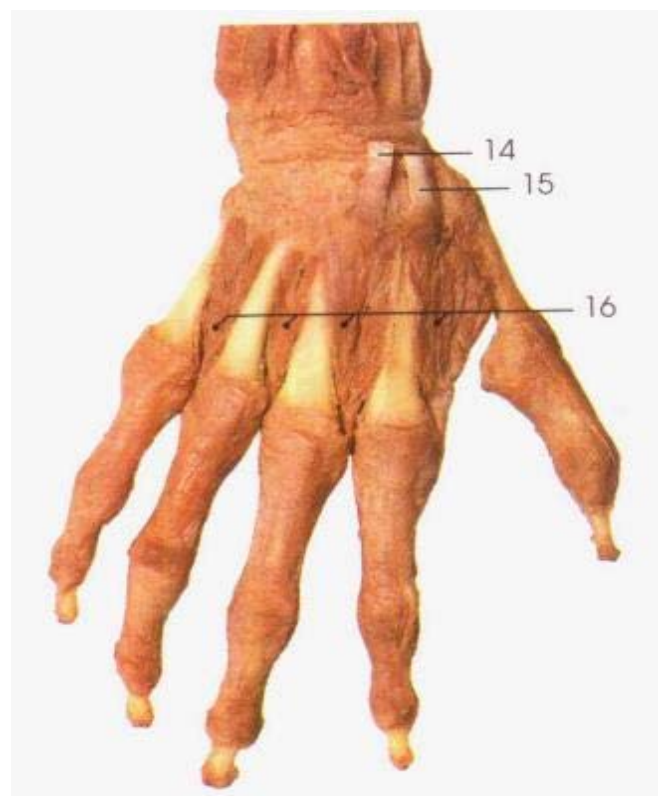
图 247 手掌深部
Deep layer of the palm of hand



A



B



C

1. 屈肌支持带 flexor retinaculum
2. 小指展肌 abductor digiti minimi
3. 小指短屈肌 flexor digiti minimi brevis
4. 蚓状肌 lumbricales
5. 指深屈肌腱 tendons of flexor digitorum profundus
6. 拇长屈肌腱 tendon of flexor pollicis longus
7. 拇收肌 adductor pollicis
8. 拇短屈肌 flexor pollicis brevis
9. 拇短展肌 abductor pollicis brevis
10. 尺侧腕屈肌腱 tendon of flexor carpi ulnaris
11. 腕管 canalis carpalis (carpal canal)
12. 骨间掌侧肌 palmar interossei
13. 桡侧腕屈肌 tendon of flexor carpi radialis
14. 桡侧腕短伸肌腱 tendon of extensor carpi radialis brevis
15. 桡侧腕长伸肌腱 tendon of extensor carpi radialis longus
16. 骨间背侧肌 dorsal interossei

图 248 手肌(A、B、C)
Muscles of hand (A,B,C)

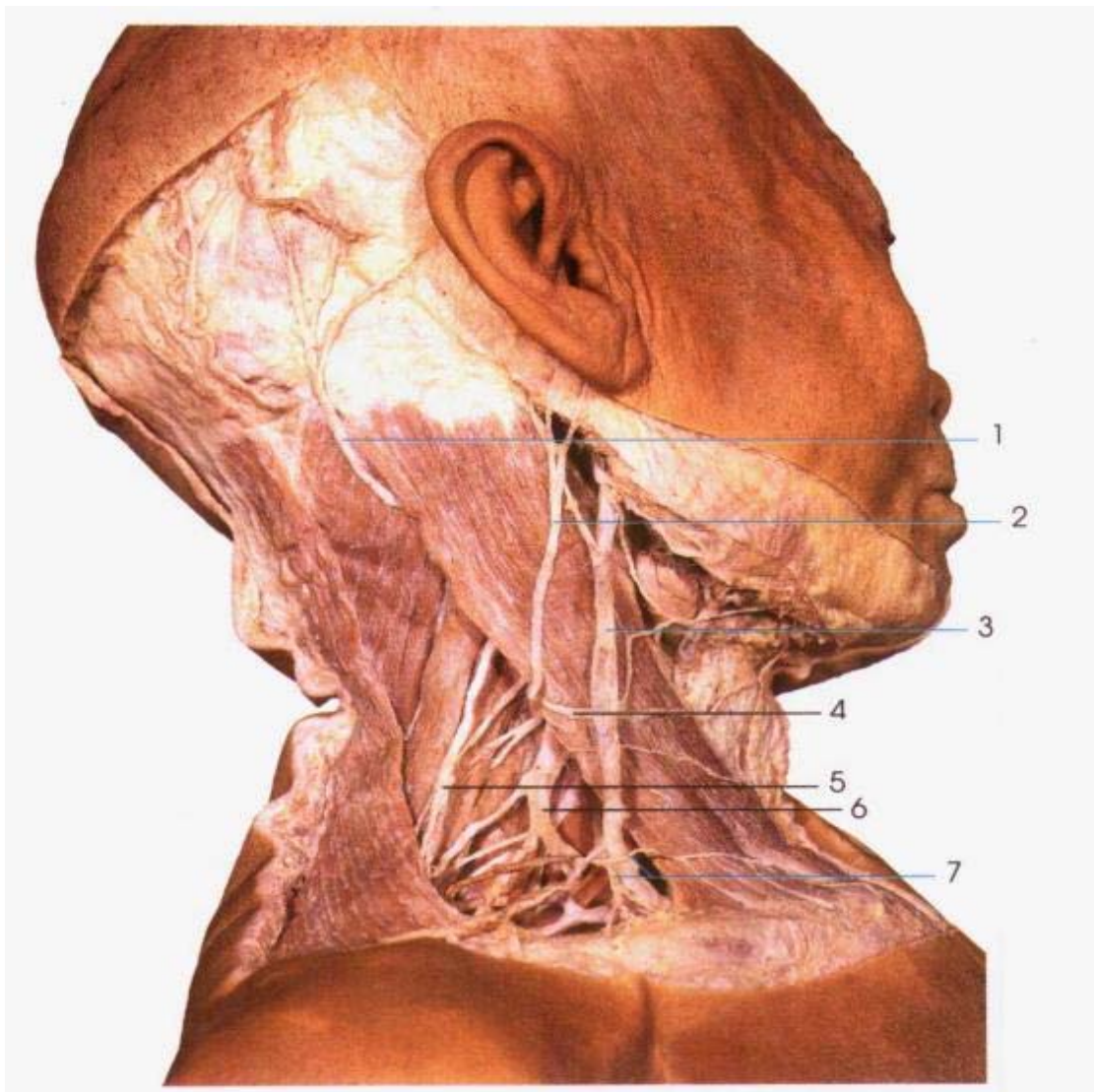


图 249 颈丛及其分支
Cervical plexus and its branches

- | | | | |
|---------|--------------------------|----------|--------------------|
| 1. 枕小神经 | lesser occipital n. | 5. 副神经 | accessory n. |
| 2. 耳大神经 | great auricular n. | 6. 颈丛 | cervical plexus |
| 3. 颈外静脉 | external jugular v. | 7. 锁骨上神经 | supraclavicular n. |
| 4. 颈横神经 | transverse nerve of neck | | |

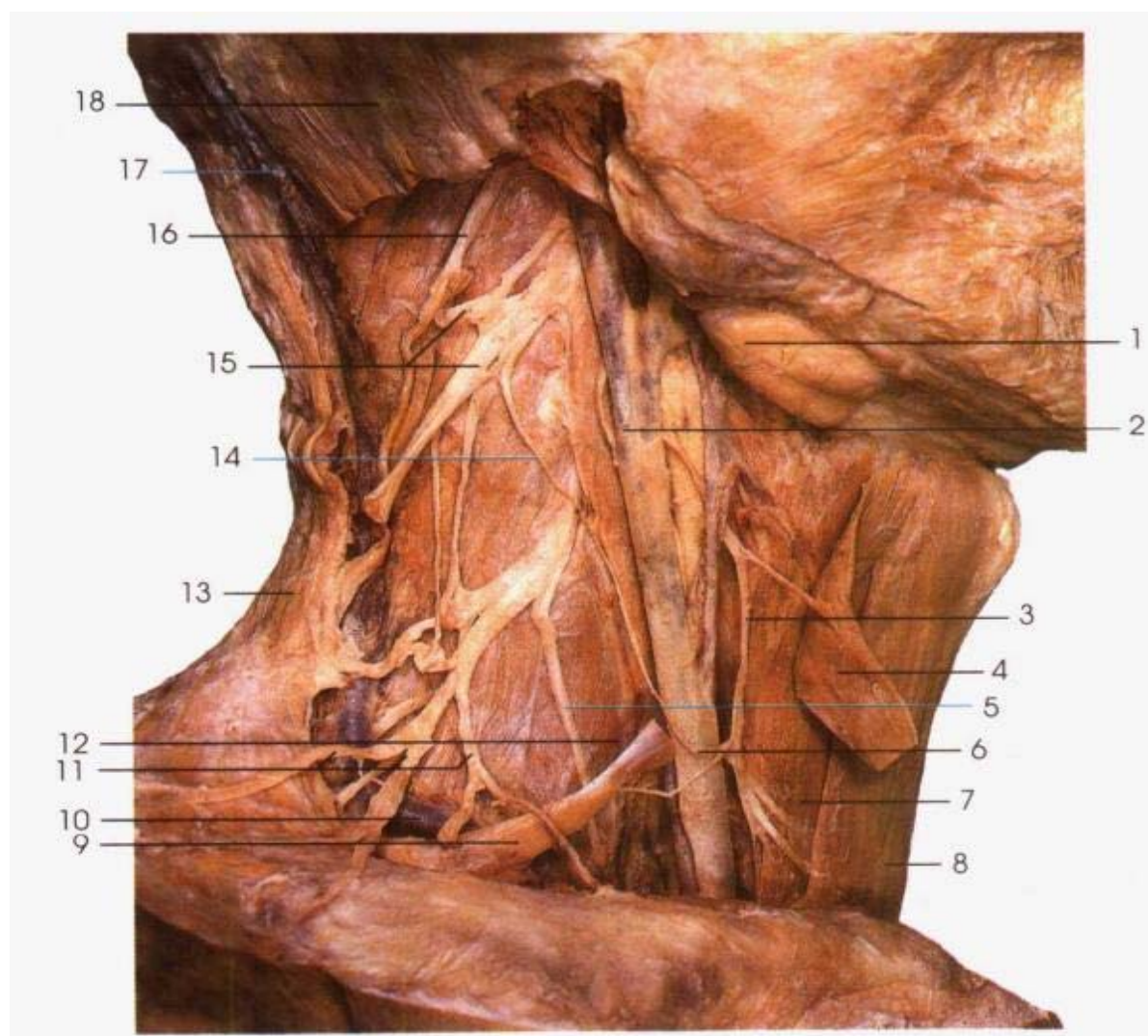


图 250 颈部右侧面的肌、血管和神经(I)
Muscles, blood vessels and nerves of the
right lateral aspect of the neck(I)

- | | |
|--|-------------------------------|
| 1. 下颌下腺 submandibular gland | omohyoid |
| 2. 颈内静脉 internal jugular v. | 10. 锁骨下静脉 subclavian v. |
| 3. 上根 superior root | 11. 锁骨上神经 supraclavicular n. |
| 4. 肩胛舌骨肌上腹 superior belly
of omohyoid | 12. 前斜角肌 scalenus anterior |
| 5. 膈神经 phrenic n. | 13. 斜方肌 trapezius |
| 6. 颈襻 ansa cervicalis | 14. 下根 inferior root |
| 7. 胸骨甲状肌 sternothyroid | 15. 颈丛 cervical plexus |
| 8. 胸骨舌骨肌 sternohyoid | 16. 副神经 accessory n. |
| 9. 肩胛舌骨肌下腹 inferior belly of | 17. 枕静脉 occipital v. |
| | 18. 胸锁乳突肌 sternocleidomastoid |

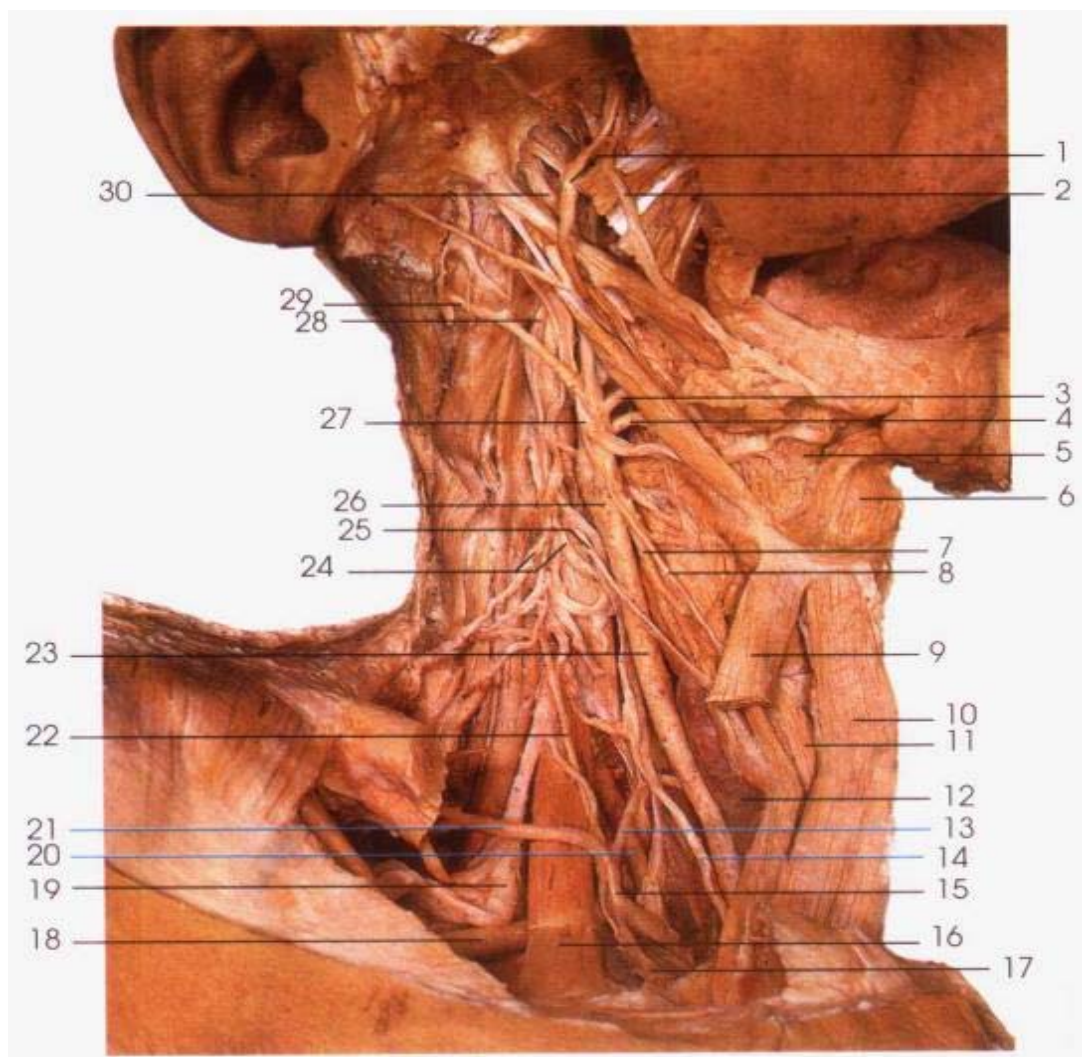


图 251 颈部右侧面的肌、血管和神经(Ⅱ)
Muscles, blood vessels and nerves of the
right lateral aspect of the neck(Ⅱ)

- | | |
|--------------------------------|---------------------------------|
| 1. 下牙槽神经 inferior alveolar n. | 16. 前斜角肌 scalenus anterior |
| 2. 舌神经 lingual n. | 17. 胸廓内动脉 internal thoracic a. |
| 3. 面动脉 facial a. | 18. 锁骨下动脉 subclavian a. |
| 4. 舌动脉 lingual a. | 19. 臂丛 brachial plexus |
| 5. 舌骨舌肌 hyoglossus | 20. 椎动脉 vertebral a. |
| 6. 下颌舌骨肌 mylohyoid | 21. 颈横动脉 transverse cervical a. |
| 7. 甲状腺上动脉 superior thyroid a. | 22. 膈神经 phrenic n. |
| 8. 上根 superior root | 23. 颈总动脉 common carotid a. |
| 9. 肩胛舌骨肌 omohyoid | 24. 颈丛 cervical plexus |
| 10. 胸骨舌骨肌 sternohyoid | 25. 下根 inferior root |
| 11. 胸骨甲状腺肌 sternothyroid | 26. 颈动脉窦 carotid sinus |
| 12. 甲状腺 thyroid gland | 27. 舌下神经 hypoglossal n. |
| 13. 甲状腺下动脉 inferior thyroid a. | 28. 副神经 accessory n. |
| 14. 迷走神经 vagus n. | 29. 枕动脉 occipital a. |
| 15. 甲状腺颈干 thyrocervical trunk | 30. 舌咽神经 glossopharyngeal n. |

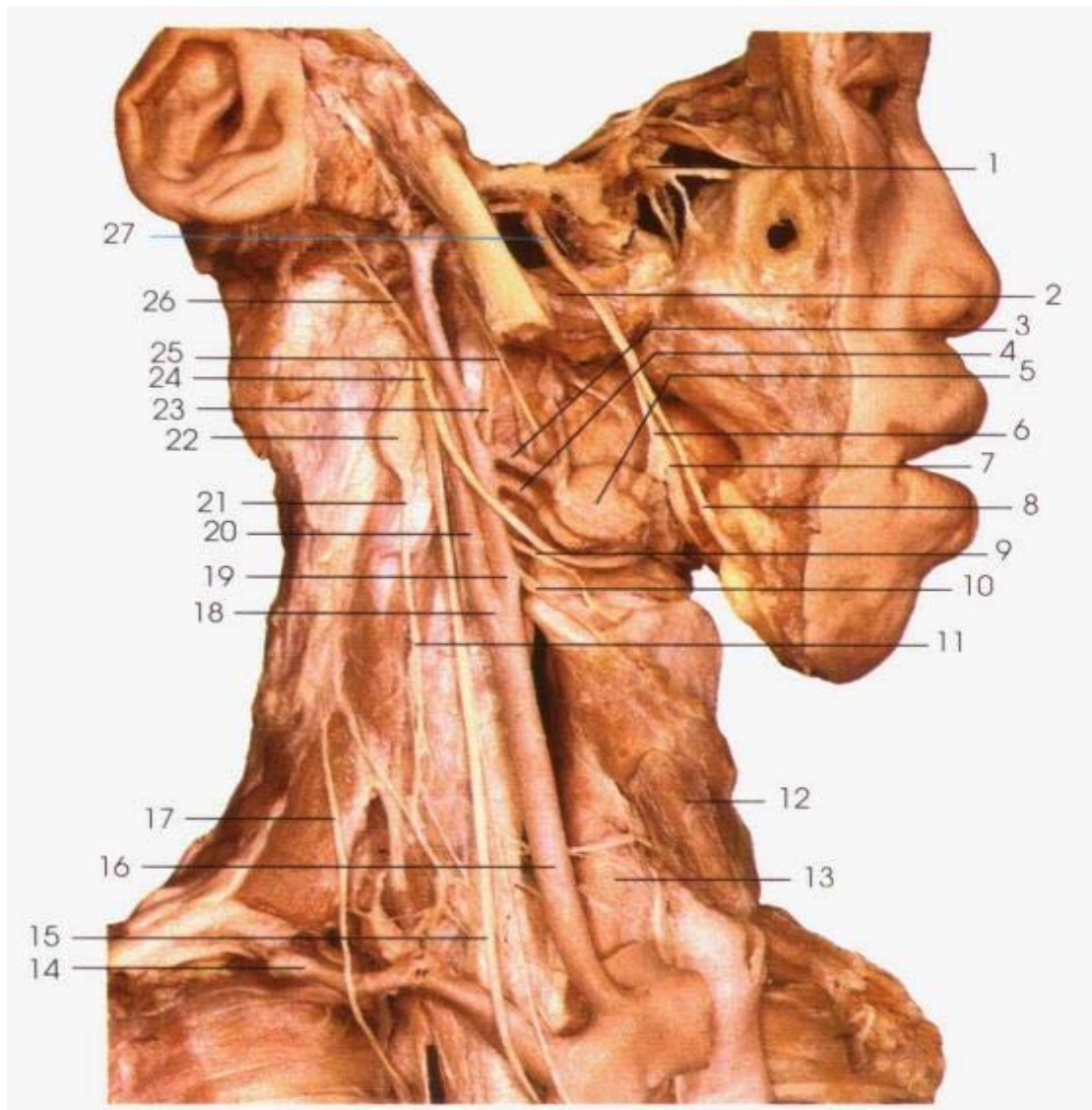


图 252 颈深部血管和神经
Deep blood vessels and nerves of the neck

- | | |
|------------------------------------|--------------------------------------|
| 1. 上颌神经 maxillary n. | 15. 迷走神经 vagus n. |
| 2. 翼外肌 lateral pterygoid | 16. 颈总动脉 common carotid a. |
| 3. 面动脉 facial a. | 17. 膈神经 phrenic n. |
| 4. 舌动脉 lingual a. | 18. 颈动脉窦 carotid sinus |
| 5. 下颌下腺 submandibular gland | 19. 颈外动脉 external carotid a. |
| 6. 舌神经 facial n. | 20. 颈内动脉 internal carotid a. |
| 7. 下颌下节 submandibular ganglion | 21. 交感干 sympathetic trunk |
| 8. 下牙槽神经 inferior alveolar n. | 22. 交感颈上节 superior cervical ganglion |
| 9. 喉上神经 superior laryngeal n. | 23. 咽升动脉 ascending pharyngeal a. |
| 10. 甲状腺上动脉 superior thyroid a. | 24. 舌下神经 sublingual n. |
| 11. 交感颈中节 middle cervical ganglion | 25. 舌咽神经 glossopharyngeal n. |
| 12. 甲状腺 thyroid gland | 26. 枕动脉 occipital a. |
| 13. 咽 pharynx | 27. 下颌神经 submandibular n. |
| 14. 锁骨下动脉 subclavian a. | |

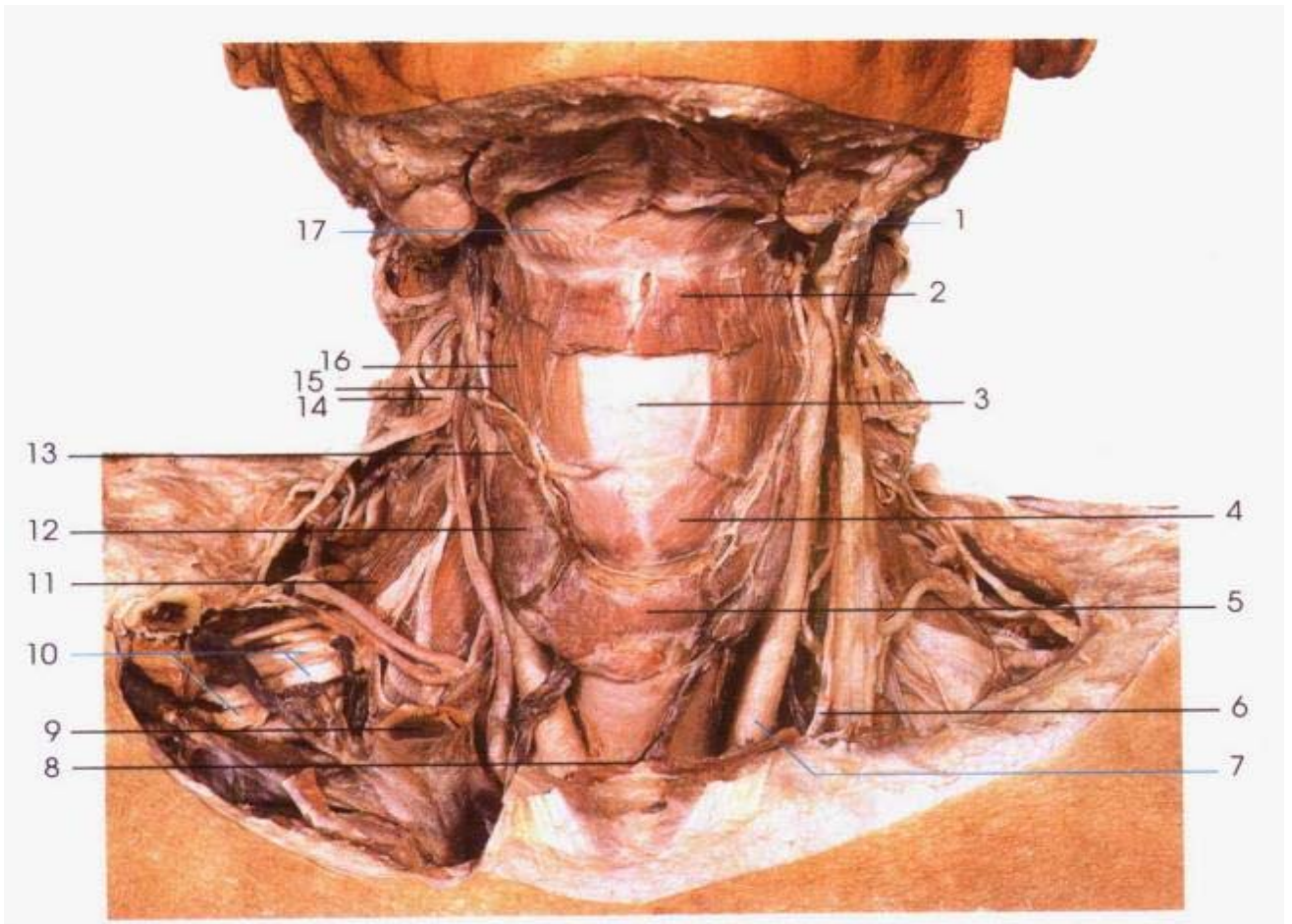


图 253 甲状腺区前面观
Anterior aspect of the region of thyroid

- | | |
|-----------------------------------|---|
| 1. 下颌下腺 submandibular gland | 10. 臂丛 brachial plexus |
| 2. 胸骨舌骨肌 sternohyoid | 11. 中斜角肌 scalenus medius |
| 3. 甲状软骨 thyroid cartilage | 12. 甲状腺侧叶 lateral lobe of thyroid gland |
| 4. 环甲肌 cricothyroid | 13. 喉上神经 superior laryngeal n. |
| 5. 甲状腺峡部 isthmus of thyroid gland | 14. 颈丛 cervical plexus |
| 6. 迷走神经 vagus v. | 15. 甲状腺上动脉 superior thyroid a. |
| 7. 颈总动脉 common carotid a. | 16. 甲状舌骨肌 thyrohyoid |
| 8. 甲状腺下静脉 inferior thyroid v. | 17. 下颌舌骨肌 mylohyoid |
| 9. 颈内静脉 internal jugular v. | |

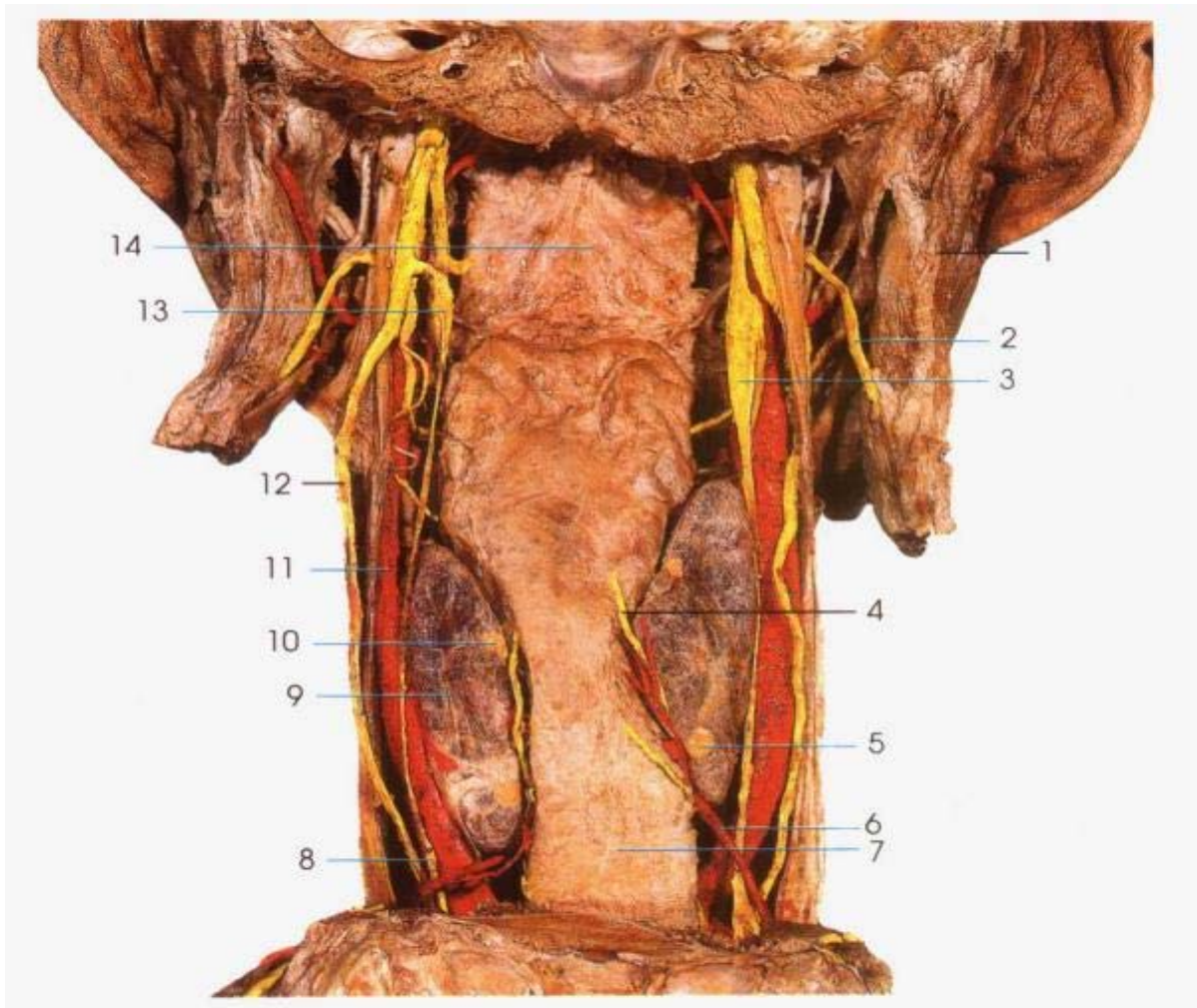


图 254 甲状腺区后面观
Posterior aspect of the region of thyroid gland

- | | |
|--|--------------------------------------|
| 1. 胸锁乳突肌 sternocleidomastoid | 9. 甲状腺 thyroid gland |
| 2. 副神经 accessory n. | 10. 上甲状旁腺 superior parathyroid gland |
| 3. 交感颈上节 superior cervical ganglion | 11. 颈总动脉 common carotid a. |
| 4. 右喉返神经 right recurrent laryngeal n. | 12. 迷走神经 vagus n. |
| 5. 下甲状旁腺 inferior parathyroid gland | 13. 喉上神经 superior laryngeal n. |
| 6. 甲状腺下动脉 inferior thyroid a. | 14. 咽 pharynx |
| 7. 食管颈部 cervical part of the esophagus | |
| 8. 颈交感干 cervical sympathetic trunk | |

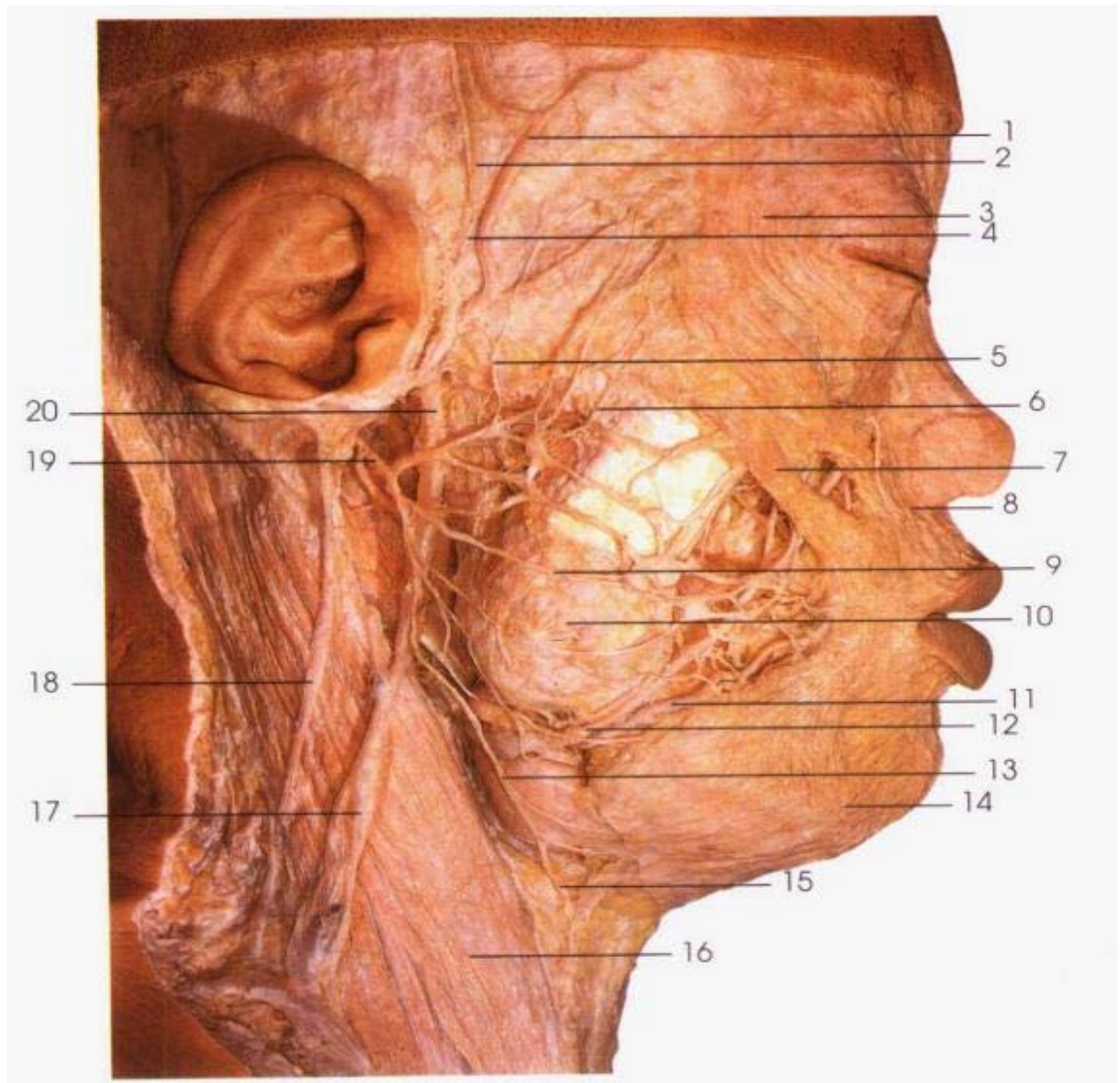


图 255 头颈的肌、血管和神经
Muscles, blood vessels and nerves of the head and neck

1. 颞浅动脉 superficial temporal a.
2. 颞浅静脉 superficial temporal v.
3. 眼轮匝肌 orbicularis oculi
4. 耳颞神经 auriculotemporal n.
5. 颞支 temporal branches
6. 颧支 zygomatic branches
7. 颧大肌 zygomaticus major
8. 提上唇肌 levator labii superioris
9. 颊支 buccal branches
10. 咬肌 masseter

11. 面动脉 facial a.
12. 面静脉 facial v.
13. 下颌缘支 marginal mandibular branch
14. 降口角肌 depressor anguli oris
15. 颈支 cervical branch
16. 胸锁乳突肌 sternocleidomastoid
17. 颈外静脉 external jugular v.
18. 耳大神经 great auricular n.
19. 面神经 facial n.
20. 下颌后静脉 ratromandibular v.

1. 顶支 parietal branch
2. 额支 frontal branch
3. 颞深前、后动脉 anterior posterior deep temporal a.
4. 上牙槽后动脉 posterior superior alveolar a.
5. 颊动脉 buccal a.
6. 翼肌支 pterygoid branches
7. 下牙槽动脉 inferior alveolar a.
8. 面动脉 facial a.
9. 舌动脉 lingual a.
10. 喉上动脉 superior laryngeal a.
11. 甲状腺上动脉 superior thyroid a.
12. 颈总动脉 common carotid a.
13. 颈内动脉 internal carotid a.
14. 颈外动脉 external carotid a.
15. 上颌动脉 maxillary a.
16. 耳后动脉 posterior auricular a.
17. 枕动脉 occipital a.
18. 脑膜中动脉 middle meningeal a.
19. 颞浅动脉 superficial temporal a.

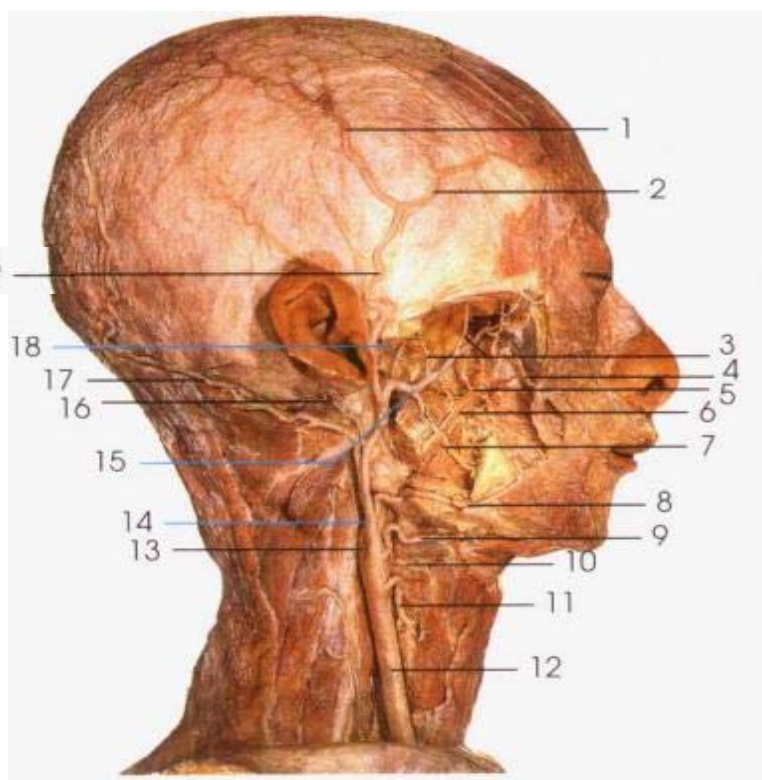


图 256 颈外动脉分支(右侧)
The branches of external carotid artery (right side)

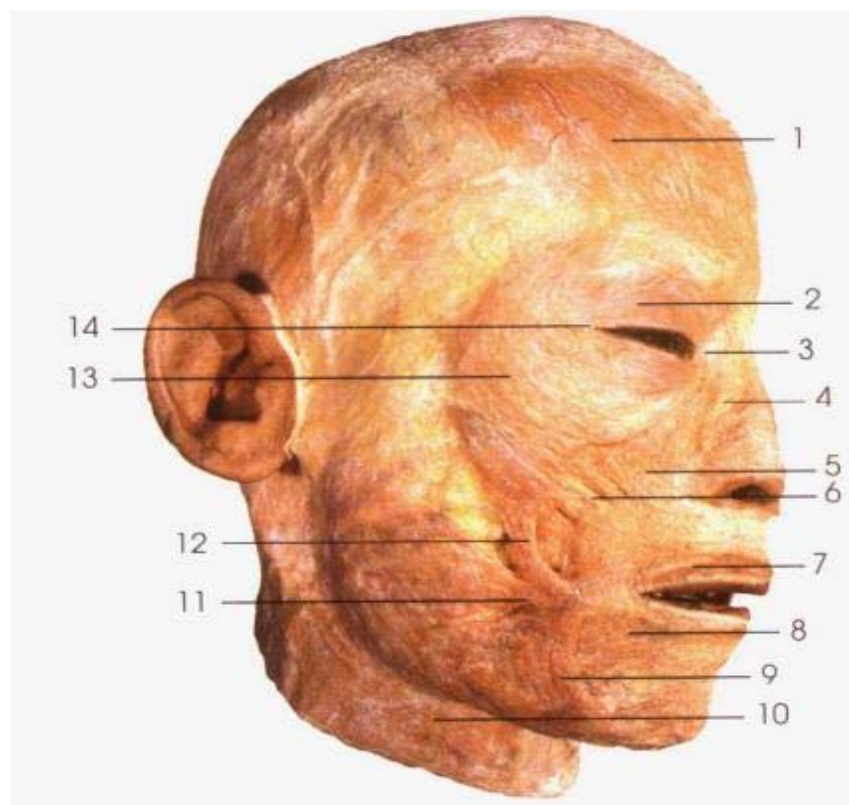
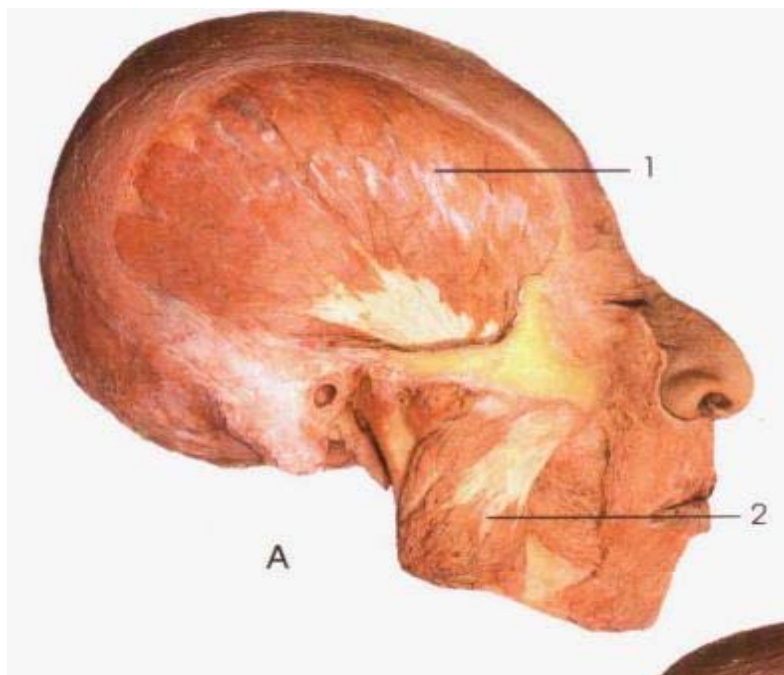


图 257 表情肌
Muscles of facial expression

1. 枕额肌额腹 frontal belly of occipitofrontalis
2. 眼轮匝肌睑部 palpebral part of orbicularis oculi
3. 睑内侧韧带 medial palpebral ligament
4. 提上唇鼻翼肌 levator labii superioris alaeque nasi
5. 提上唇肌 levator labii superioris
6. 颧小肌 zygomaticus minor
7. 口轮匝肌 orbicularis oris
8. 降下唇肌 depressor labii inferioris
9. 降口角肌 depressor anguli oris
10. 颈阔肌 platysma
11. 笑肌 risorius
12. 颧大肌 zygomaticus major
13. 眼轮匝肌眶部 orbital part of orbicularis oculi
14. 睑外侧韧带 lateral palpebral ligament



- 1. 颞肌 temporalis
- 2. 咬肌 masseter
- 3. 翼内肌 medial pterygoid
- 4. 翼外肌 lateral pterygoid

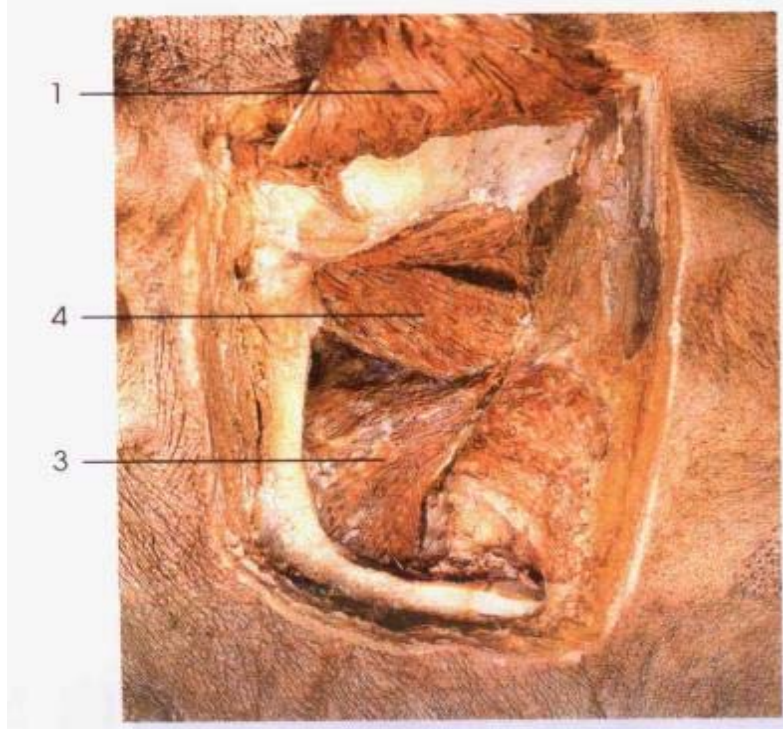
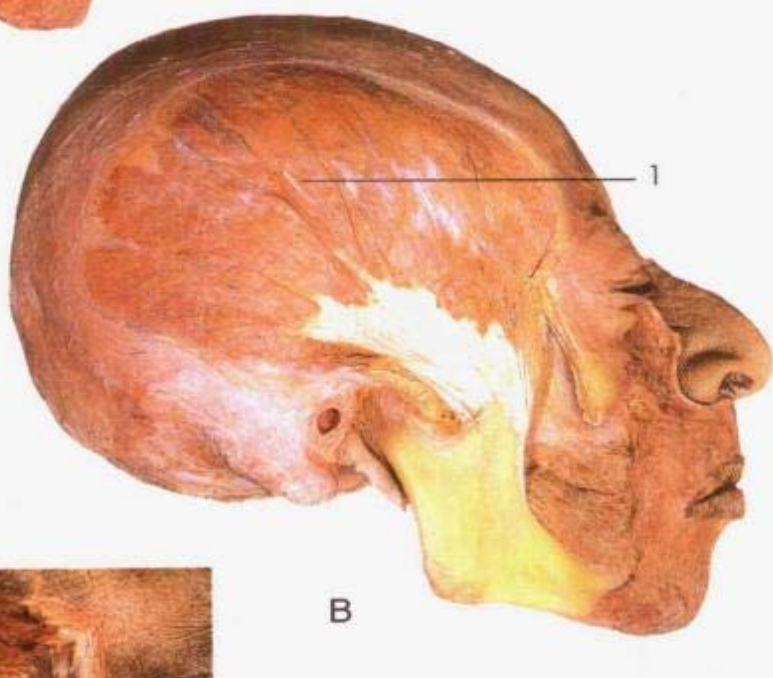


图 258 右侧咀嚼肌(A、B、C)
Masseter of right side(A,B,C)

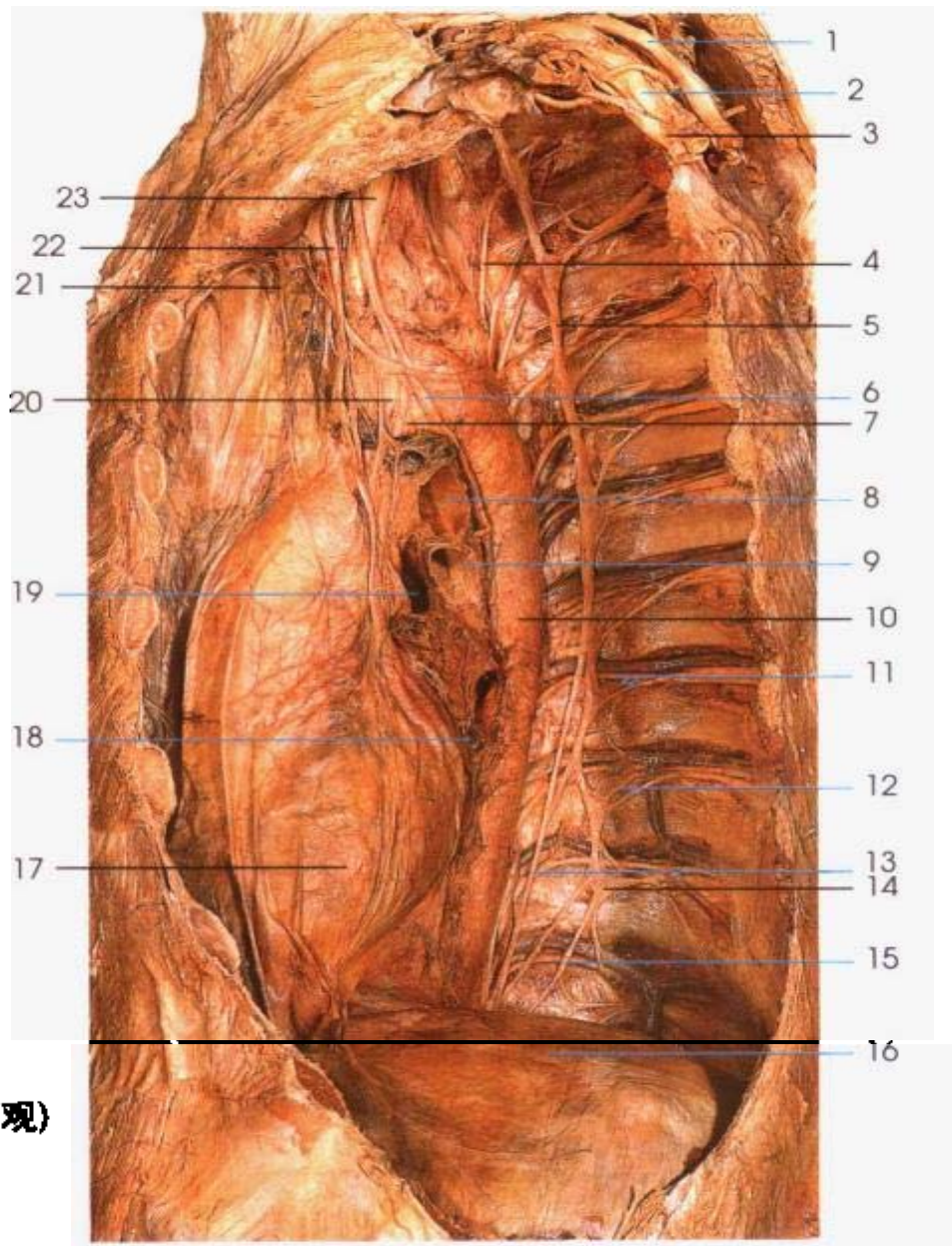


图 259 纵隔(左侧面观)
Mediastinum(left lateral aspect)

- | | |
|--|--|
| <ul style="list-style-type: none"> 1. 臂丛外侧束 lateral cord of brachial plexus 2. 腋动脉 axillary a. 3. 臂丛内侧束 medial cord of brachial plexus 4. 肋间动脉 intercostal a. 5. 交感干 sympathetic trunk 6. 迷走神经 vagus n. 7. 左喉返神经 left recurrent laryngeal n. 8. 左肺动脉 left pulmonary trunk 9. 左主支气管 left principal bronchus 10. 胸主动脉 thoracic aorta 11. 肋间静脉、动脉和神经 intercostal v., a. & n. | <ul style="list-style-type: none"> 12. 灰白交通支 gray and white rami communicantes 13. 内脏大神经 greater splanchnic n. 14. 交感神经节 sympathetic ganglion 15. 内脏小神经 lesser splanchnic n. 16. 膈 diaphragm 17. 心包 fibrous pericardium 18. 肺韧带 pulmonary ligament 19. 左肺静脉 left pulmonary v. 20. 动脉韧带 ligamentum arteriosum 21. 心包膈动脉 pericardiophrenic a. 22. 膈神经 phrenic n. 23. 左锁骨下动脉 left subclavian a. |
|--|--|

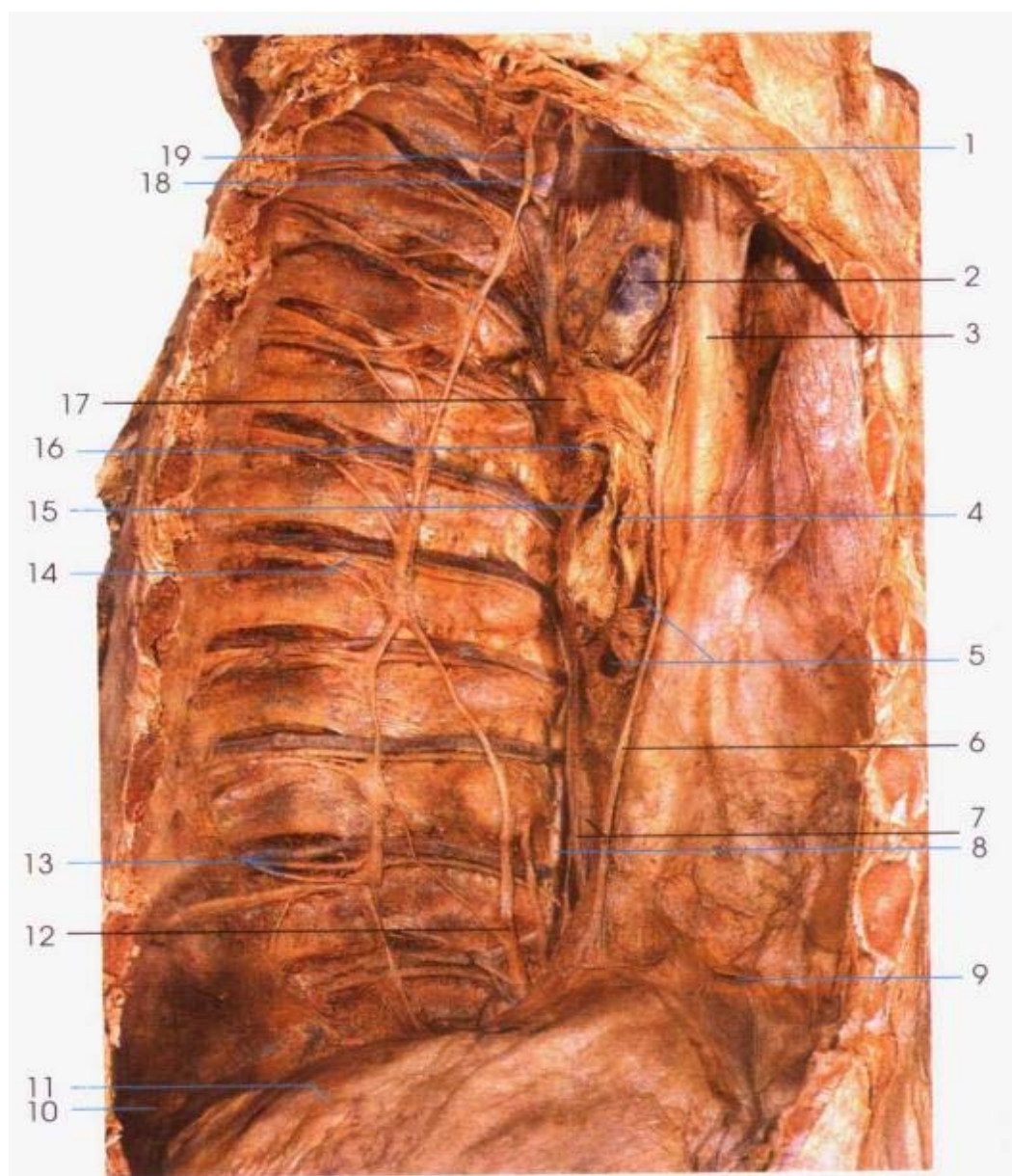


图 260 纵隔(右侧面观)
Mediastinum(right lateral aspect)

- | | |
|---|--|
| 1. 右迷走神经 right vagus n. | 12. 内脏大神经 greater splanchnic n. |
| 2. 奇静脉弓淋巴结 lymph nodes of azygos arch | 13. 肋间神经、血管 intercostal nerve and vessels |
| 3. 上腔静脉 superior vena cava | 14. 灰白交通支 gray and white rami communicantes |
| 4. 右肺动脉 right pulmonary a. | 15. 中间支气管 intermediate bronchus |
| 5. 右肺静脉 right pulmonary v. | 16. 右肺上叶支气管 superior lobar bronchi of right lung |
| 6. 右膈神经 right phrenic n. | 17. 奇静脉弓 arch of azygos v. |
| 7. 食管及神经丛 esophagus and plexus | 18. 右肋间最上静脉 right highest intercostal v. |
| 8. 奇静脉 azygos v. | 19. 胸交感干 sympathetic trunk |
| 9. 下腔静脉 inferior vena cava | |
| 10. 右肋膈隐窝 right costodiaphragmatic recess of pleura | |
| 11. 膈(覆盖胸膜) diaphragm(covered by pleural) | |

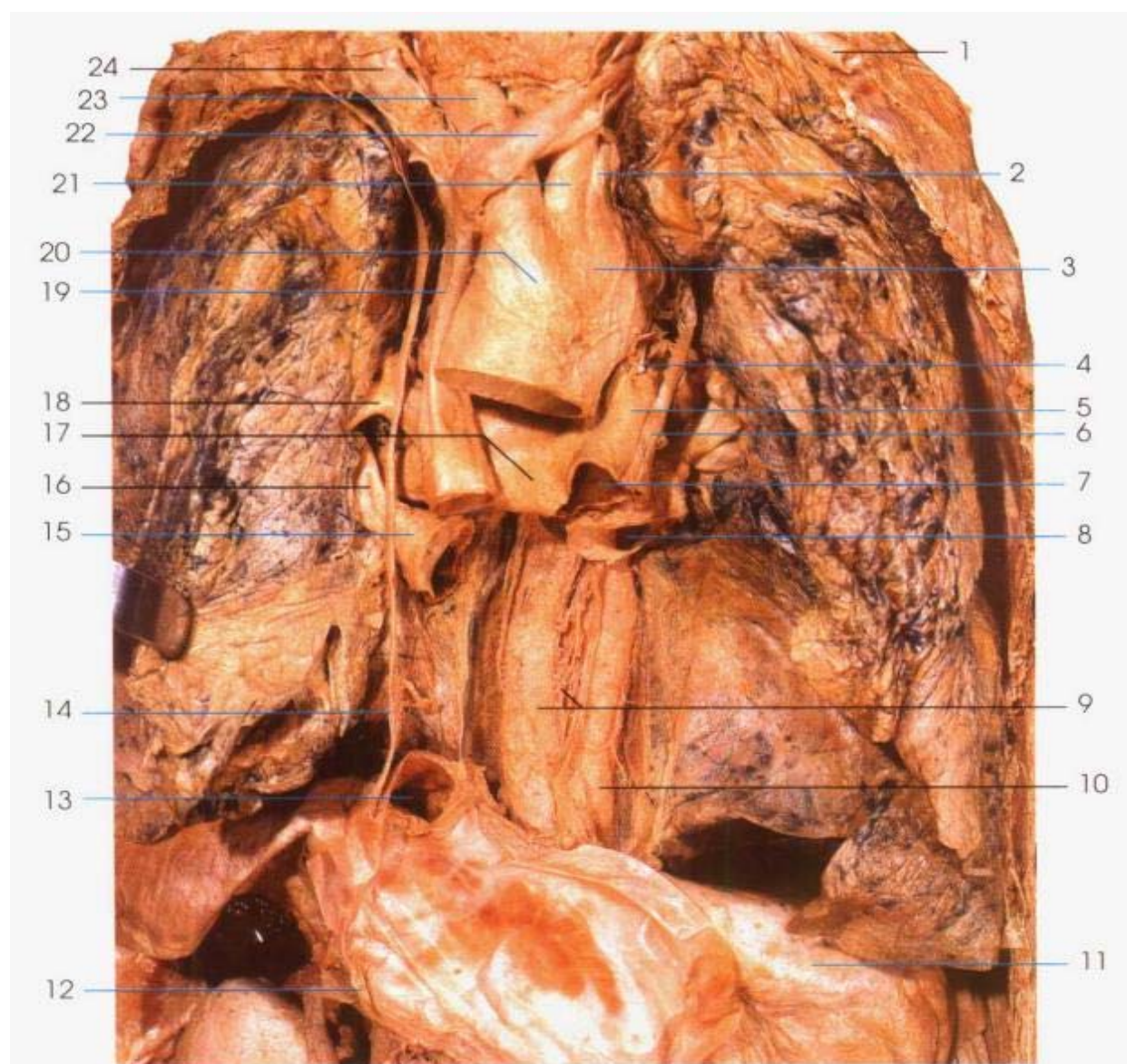

图 261 上纵隔和后纵隔
Superior mediastenum and posterior mediastenum

- | | |
|--|---|
| 1. 腋动脉 axillary a. | 14. 右膈神经 right phrenic n. |
| 2. 左锁骨下动脉 left subclavian a. | 15. 右肺静脉 right pulmonary v. |
| 3. 主动脉弓 arch of aorta | 16. 右肺下叶支 inferior lobar branches of right lung |
| 4. 动脉韧带 ligamentum arteriosum | 17. 右肺动脉 right pulmonary a. |
| 5. 左肺动脉 left pulmonary a. | 18. 右肺上叶支 superior lobar branches of right lung |
| 6. 左迷走神经 left vagus n. | 19. 上腔静脉 superior vena cava |
| 7. 肺动脉干 pulmonary trunk | 20. 升主动脉 ascending aorta |
| 8. 左肺静脉 left pulmonary v. | 21. 左颈总动脉 left carotid a. |
| 9. 食管及其神经丛 esophagus and esophageal plexus | 22. 左头臂静脉 left brachiocephalic v. |
| 10. 胸主动脉 thoracic aorta | 23. 头臂干 brachiocephalic trunk |
| 11. 膈胸膜 diaphragmatic pleura | 24. 右头臂静脉 right brachiocephalic v. |
| 12. 纤维心包(切断处)fibrous pericardium(cut) | |
| 13. 下腔静脉 inferior vena cava | |

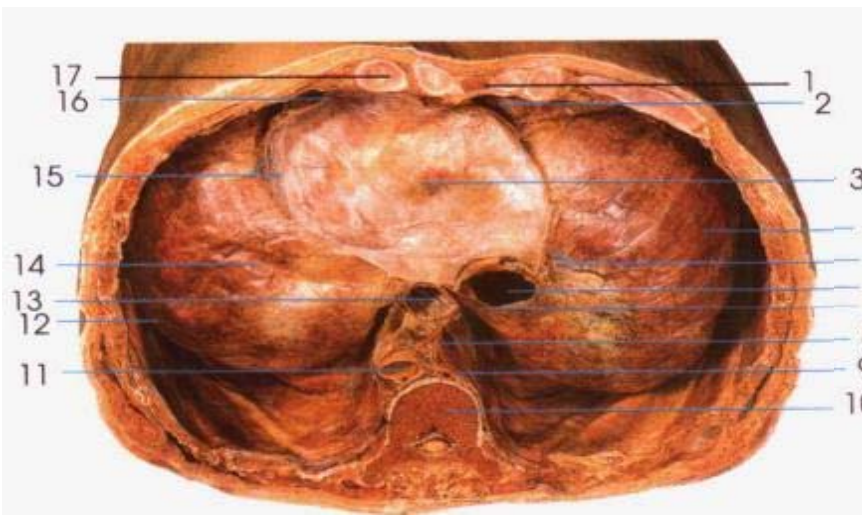


图 262 膈(胸腔面)
Diaphragm(thoracic surface)

1. 胸骨 sternum
2. 右肋膈隐窝 right costodiaphragmatic recess
3. 膈中心腱中叶(被纤维心包覆盖) middle leaflet of central tendon covered by pericardium
4. 膈 diaphragm
5. 右膈神经和心包膈动脉、静脉 right phrenic n. and pericardiophrenic a. & v.
6. 下腔静脉 inferior vena cava
7. 食管隐窝 esophageal recess
8. 胸导管 thoracic duct
9. 奇静脉 azygos v.
10. 胸椎椎体 thoracic vertebral body
11. 胸主动脉 thoracic aorta
12. 左肋膈隐窝 left costodiaphragmatic recess
13. 食管 esophagus
14. 纤维心包(切断处)fibrous pericardium(cut)
15. 左膈神经和心包膈动脉、静脉 left phrenic n. and pericardiophrenic a. & v.
16. 左肋纵隔窝 left costomedastinal recess
17. 肋软骨 costal cartilage

1. 竖脊肌 erector spinae
2. 后纵隔淋巴结 posterior mediasternal lymph nodes
3. 奇静脉 azygos v.
4. 胸主动脉 thoracic a.
5. 肋 rib
6. 肋间最内肌 innermost intercostales intimi
7. 肋间内肌 internal intercostales interni
8. 肋间外肌 external intercostales externi
9. 胸廓内动脉 internal thoracic a.
10. 腹直肌 rectus abdominis
11. 胸骨 sternum
12. 胸导管 thoracic duct
13. 内脏大神经 greater splanchnic n.
14. 交感干 sympathetic trunk
15. 肋间后动脉 posterior intercostal a.
16. 肋间后静脉 posterior intercostal v.
17. 脊神经前支 anterior branch of spinal n.



图 263 肋间神经和血管
Intercostal nerves and blood vessels

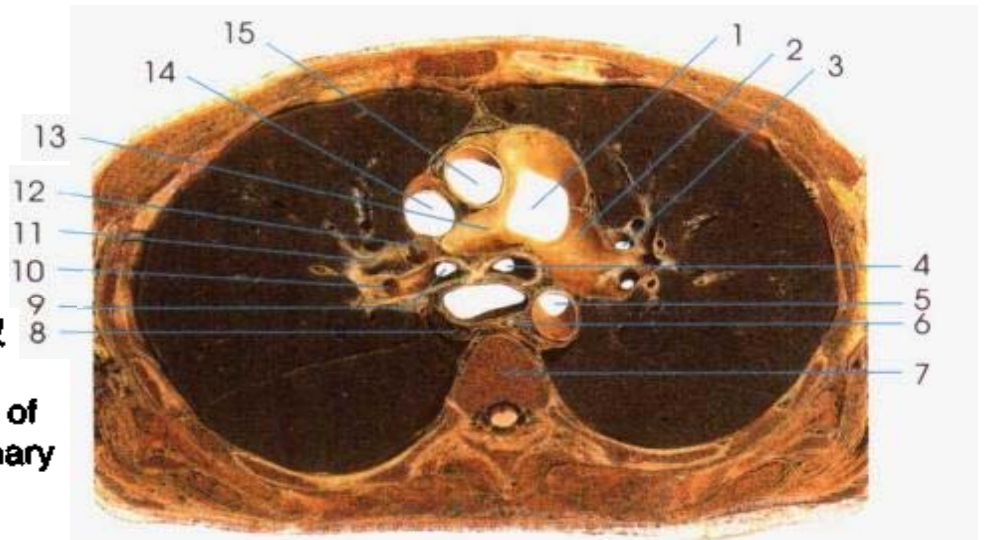


图 264 经肺动脉分叉
平面横断面

The section at the level of
the bifurcation of pulmonary
trunk on transverse

- | | |
|-----------------------------------|---|
| 1. 肺动脉干 pulmonary trunk | 10. 右肺上叶支气管 right superior lobar bronchus |
| 2. 左肺动脉 left pulmonary a. | 11. 右上肺静脉 right superior pulmonary v. |
| 3. 左肺上静脉 left pulmonary v. | 12. 右肺上叶动脉 right superior pulmonary a. |
| 4. 左主支气管 left principal bronchus | 13. 右肺动脉 right pulmonary a. |
| 5. 胸主动脉 thoracic aorta | 14. 上腔静脉 superior vena cava |
| 6. 胸导管 thoracic duct | 15. 升主动脉 ascending aorta |
| 7. 胸椎椎体 vertebral body | |
| 8. 奇静脉 azygos v. | |
| 9. 右主支气管 right principal bronchus | |

1. 关节囊 articular capsule
2. 喙突 coracoid process
3. 冈上肌 supraspinatus
4. 肱二头肌短头 short head of biceps brachii
5. 肱二头肌长头 long head of biceps brachii
6. 肩胛下肌 subscapularis
7. 四边孔 foramen quadrilaterum
8. 肱三头肌长头 long head of triceps brachii
9. 三边孔 foramen triaterum
10. 大圆肌 teres major

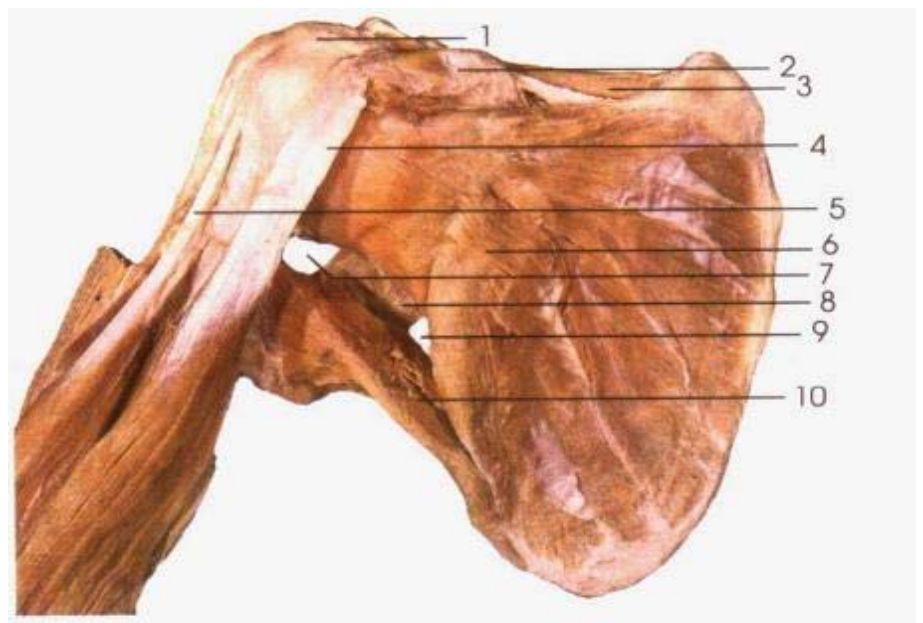


图 265 肩袖肌前面观
Anterior aspect of rotator cuff muscles

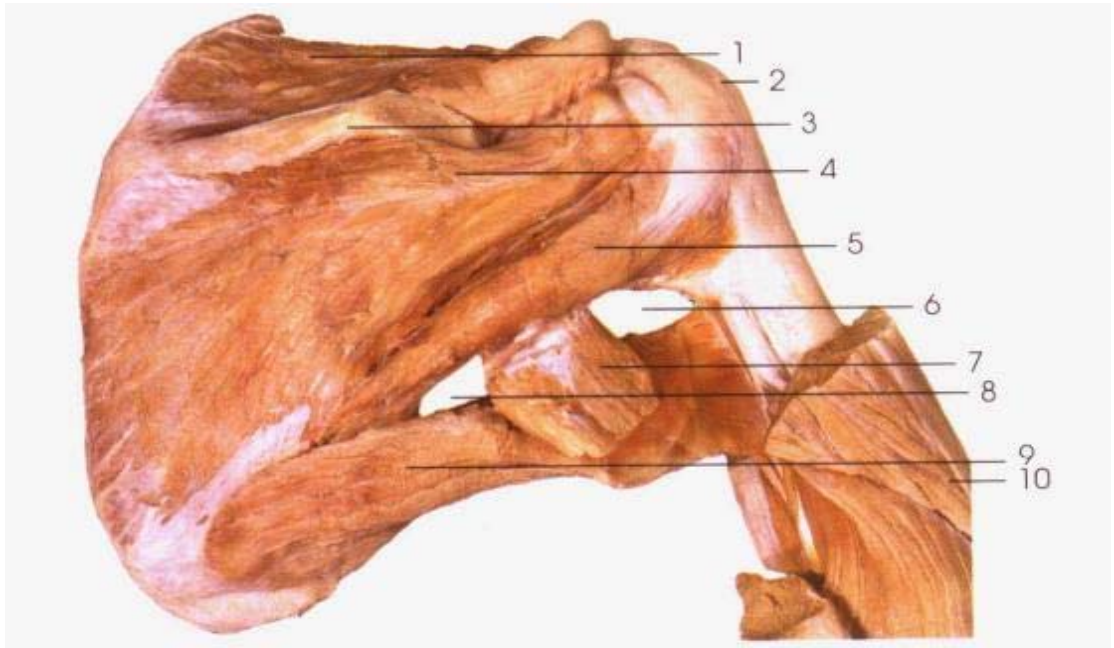


图 266 肩袖肌后面观
Posterior aspect of rotator cuff muscles

- | | | | |
|--------|-----------------------|-----------|------------------------------|
| 1. 冈上肌 | supraspinatus | 7. 肱三头肌长头 | long head of triceps brachii |
| 2. 关节囊 | articular capsule | 8. 三边孔 | foramen trilaterum |
| 3. 肩胛冈 | spine of scapula | 9. 大圆肌 | teres major |
| 4. 冈下肌 | infraspinatus | 10. 三角肌 | deltoid |
| 5. 小圆肌 | teres minor | | |
| 6. 四边孔 | foramen quadrilaterum | | |

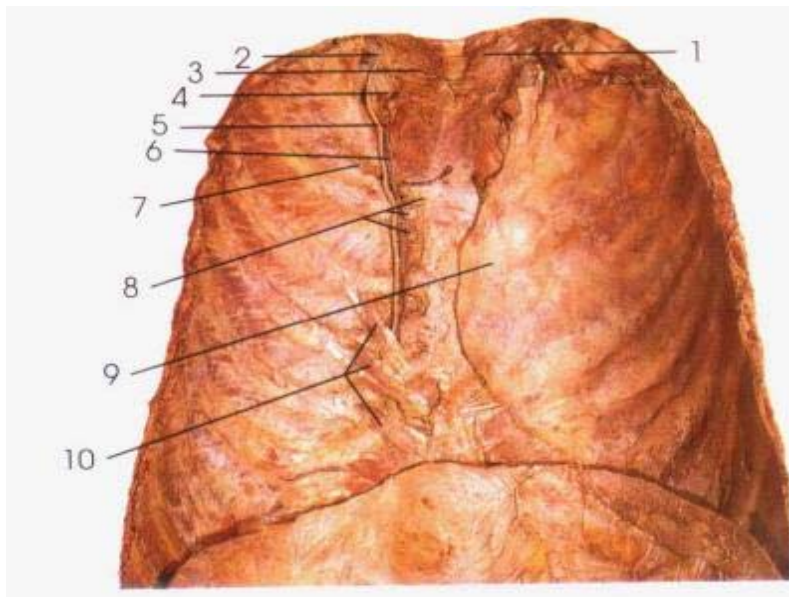


图 267 胸前壁(内面观)
Anterior thoracic wall(internal aspect)

- | | |
|-----------|---|
| 1. 胸骨舌骨肌 | sternohyoid |
| 2. 右锁骨下动脉 | right subclavian a. |
| 3. 胸骨甲状肌 | sternothyroid |
| 4. 右头臂静脉 | right brachiocephalic v. |
| 5. 胸廓内动脉 | internal thoracic a. |
| 6. 胸廓内静脉 | internal thoracic v. |
| 7. 穿支 | perforating branch of internal thoracic arterg. |
| 8. 胸骨旁淋巴结 | parasternal lymphatic nodes |
| 9. 胸膜前反折线 | anterior pleural reflex |
| 10. 胸横肌 | transversus |

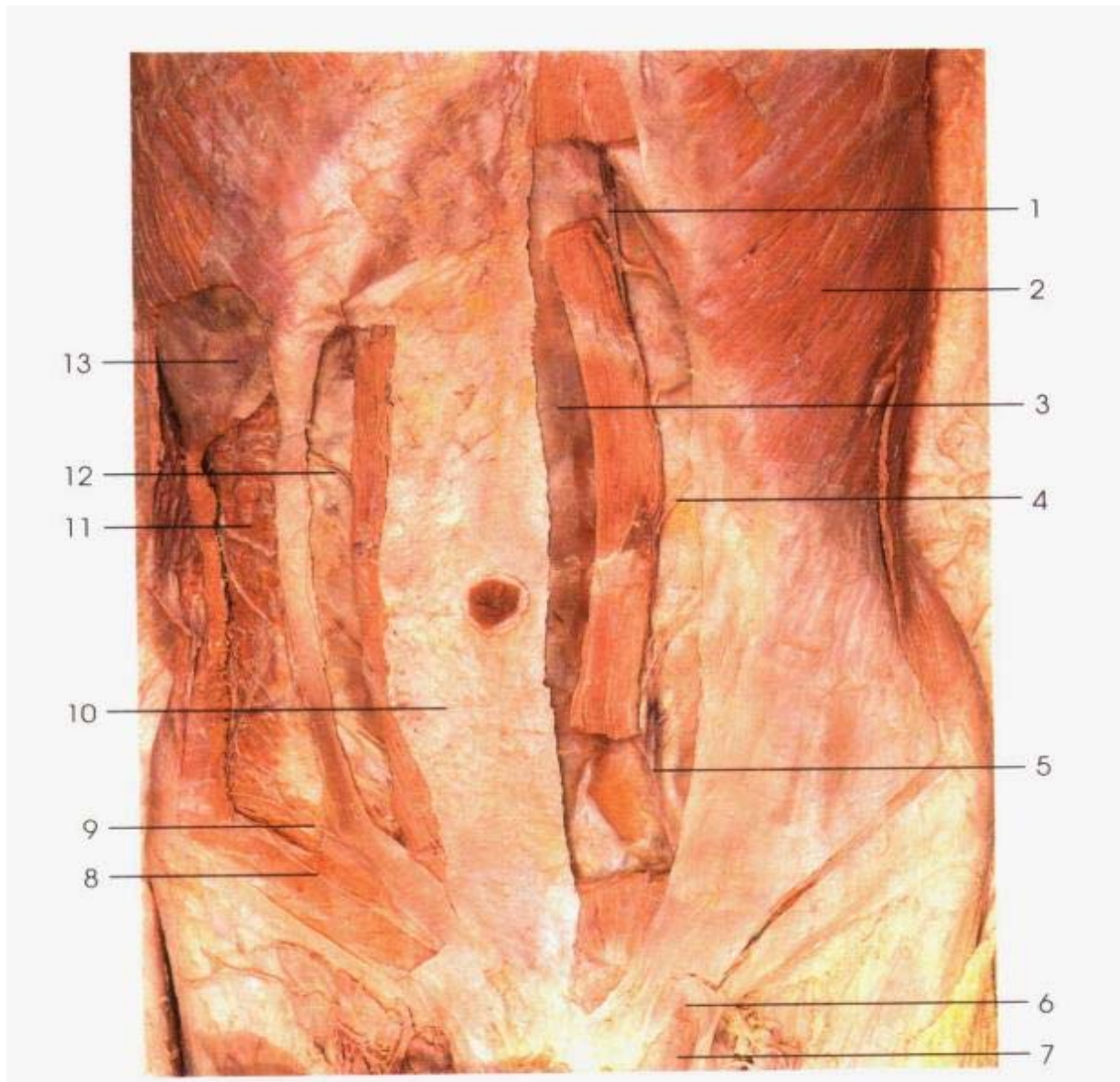
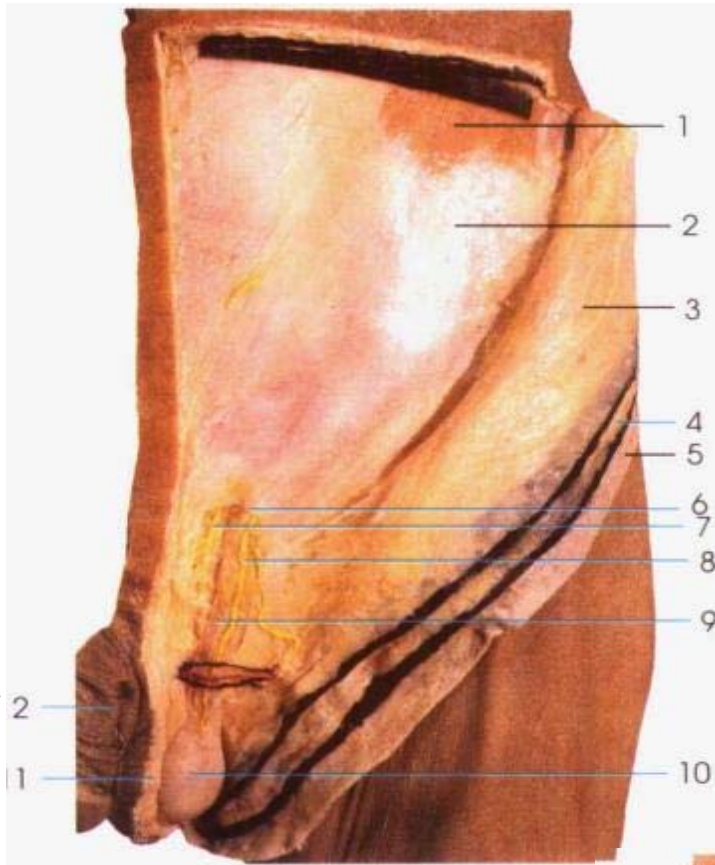


图 268 腹前外侧壁的肌、神经和血管
Muscles, nerves and blood vessels of
anterolateral wall of abdomen

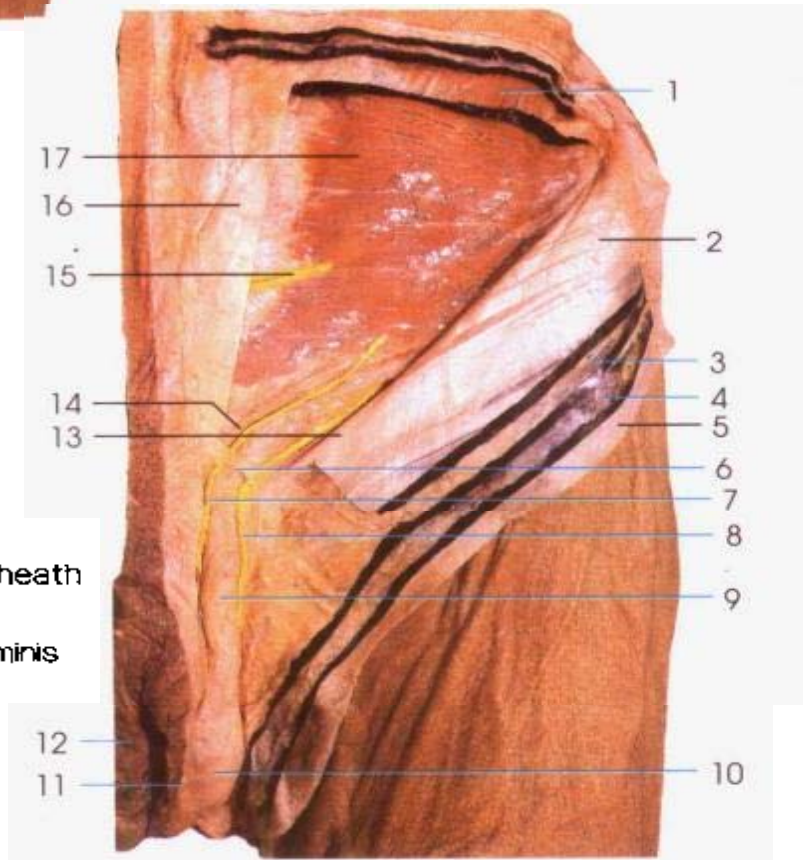
- | | |
|---|---|
| 1. 腹壁上动脉、静脉 superior epigastric a. & v. | 7. 精索 spermatic cord |
| 2. 腹外斜肌 obliquus externus abdominis | 8. 髂腹股沟神经 ilioinguinal n. |
| 3. 腹直肌鞘后层 posterior layer of sheath of rectus abdominis | 9. 髂腹下神经 iliohypogastric n. |
| 4. 第10胸神经 thoracic n.(T.10) | 10. 腹直肌鞘前层 anterior layer of sheath of rectus abdominis |
| 5. 腹壁下动脉、静脉 inferior epigastric a. & v. | 11. 腹横肌 transversus abdominis |
| 6. 腹股沟管浅环 superficial inguinal ring | 12. 第十胸神经及血管 10th thoracic n. and blood vessels |
| | 13. 腹内斜肌 obliquus internus abdominis |



- 1. 腹外斜肌 obliquus externus abdominis
- 2. 腹外斜肌(腱膜) obliquus externus abdominis(aponeurosis)
- 3. 浅筋膜(膜性层) superficial(Scarpa) fascia
- 4. 浅筋膜(脂性层) superficial(Camper) fascia
- 5. 皮肤 skin
- 6. 腹股沟管浅环 superficial inguinal ring
- 7. 髂腹股沟神经 ilioinguinal n.

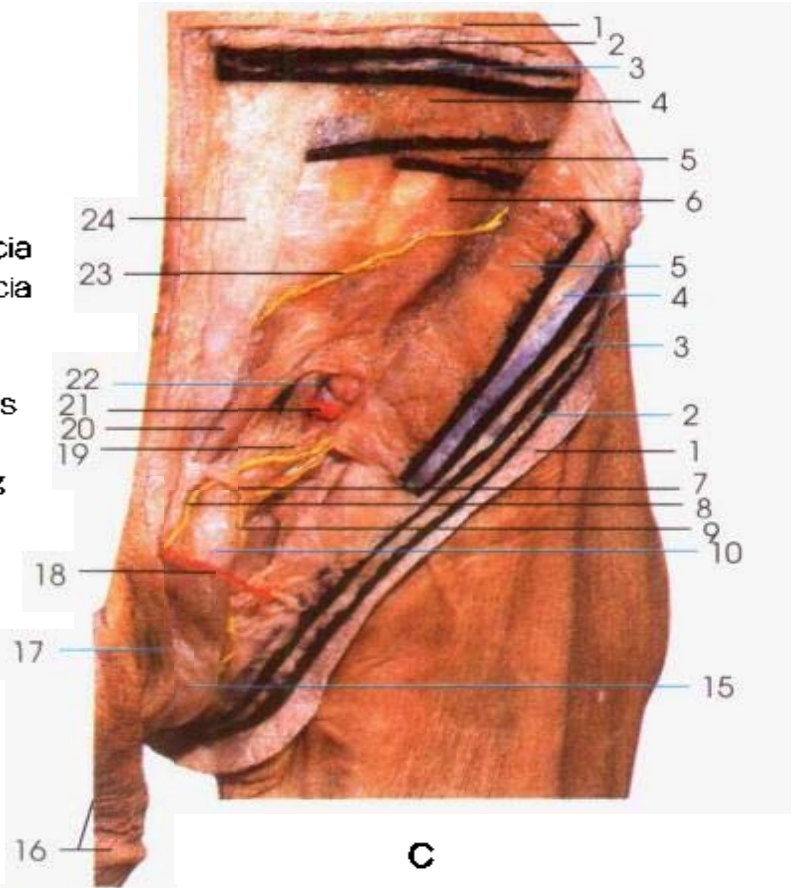
A

- 8. 生殖股神经(生殖支) genitofemoral n.(genital branch)
- 9. 精索 spermatic cord
- 10. 睾丸 testis
- 11. 阴囊 scrotum
- 12. 阴茎 penis
- 13. 腹股沟韧带 inguinal lig.
- 14. 腹股沟镰 inguinal falx
- 15. 髂腹下神经 iliohypogastric n.
- 16. 腹直肌鞘前层 anterior layer of sheath of rectus abdominis
- 17. 腹内斜肌 obliquus internus abdominis

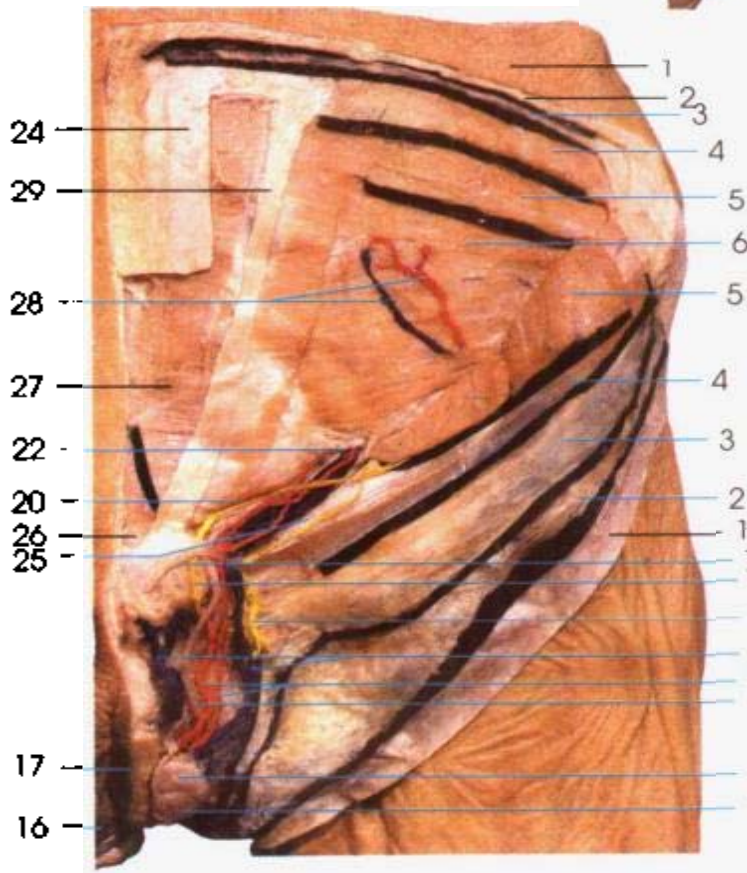

B

1. 皮肤 skin
2. 浅筋膜(脂性层) superficial(Camper) fascia
3. 浅筋膜(膜性层) superficial(Scarpa) fascia
4. 腹外斜肌(腱膜) obliquus externus abdominis (aponeurosis)
5. 腹内斜肌 obliquus internus abdominis
6. 腹横肌 transversus abdominis
7. 腹股沟管浅环 superficial inguinal ring
8. 髂腰股沟神经 ilioinguinal n.
9. 生殖股神经(生殖支) genitofemoral n. (genital branch)
10. 精索 spermatic cord
11. 睾丸静脉 testicular v.
12. 睾丸动脉 testicular a.
13. 输精管 ductus deferens
14. 副睾头 head of epididymis



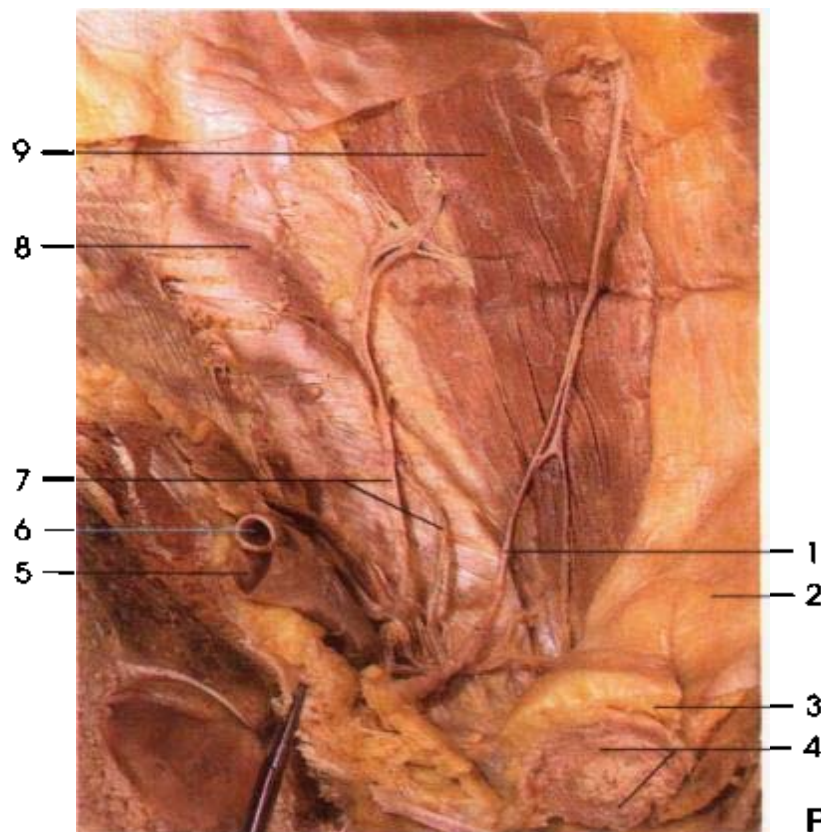
C



D

15. 睾丸 testis
16. 阴茎 penis
17. 阴囊 scrotum
18. 阴部外动脉 external pudendal a.
19. 提睾肌 cremaster
20. 腹股沟镰 inguinal falx
21. 腹壁下动脉 inferior epigastric a.
22. 腹股沟管深环 deep inguinal ring
23. 髂腹下神经 iliohypogastric n.
24. 腹直肌鞘前层 anterior layer of sheath of rectus abdominis
25. 腹股沟韧带 inguinal lig.
26. 链状肌 pyramidalis
27. 腹直肌 rectus abdominis
28. 旋髂深动脉、静脉 deep iliac circumflex a. & v.
29. 半月线 linea semilunaris

图 269 腹股沟管(A、B、C、D)
Inguinal canal(A,B,C,D)



1. 脐内侧韧带 medial umbilical lig.
2. 腹膜 peritoneum
3. 腹膜外脂 extraperitoneal fat
4. 膀胱尖 apex of urinary bladder
5. 髂外静脉 external iliac v.
6. 髂外动脉 external iliac a.
7. 腹壁下动、静脉 inferior epigastric a. & v.
8. 腹横肌 transversus abdominis
9. 腹直肌 rectus abdominis

图 270 腹前壁后面观(左)
Posterior aspect of the anterior abdominal wall(left)

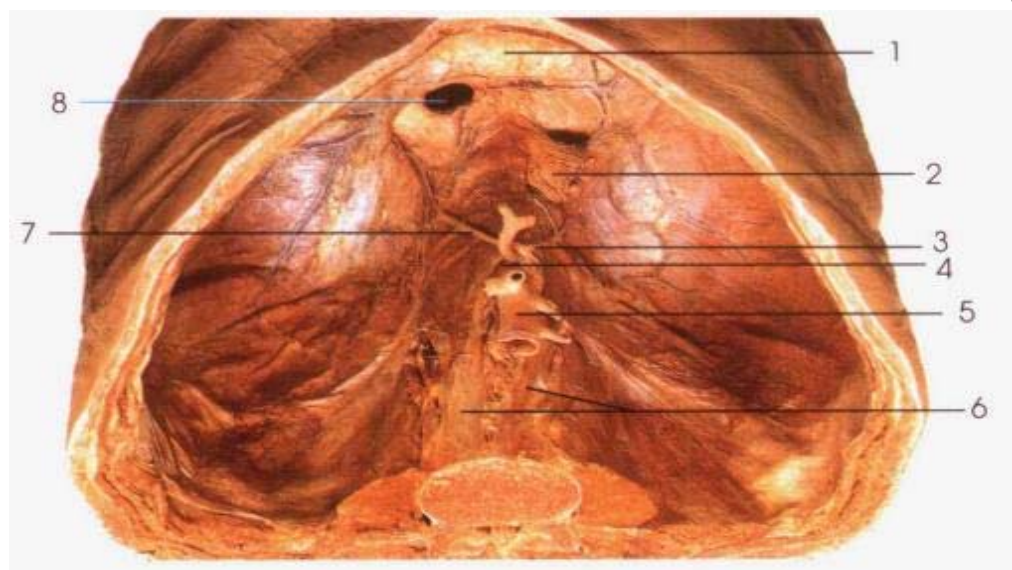


图 271 膈(下面观)
Diaphragm(inferior aspect)

- | | |
|-------------------------------------|------------------------------------|
| 1. 中心腱 central tendon | 6. 左、右膈脚 left and right crus |
| 2. 食管腹段 abdominal part of esophagus | 7. 右膈下动脉 right inferior phrenic a. |
| 3. 左膈下动脉 left inferior phrenic a. | 8. 下腔静脉 inferior vena cava |
| 4. 主动脉裂孔 aortic hiatus | |
| 5. 腹主动脉 abdominal aorta | |

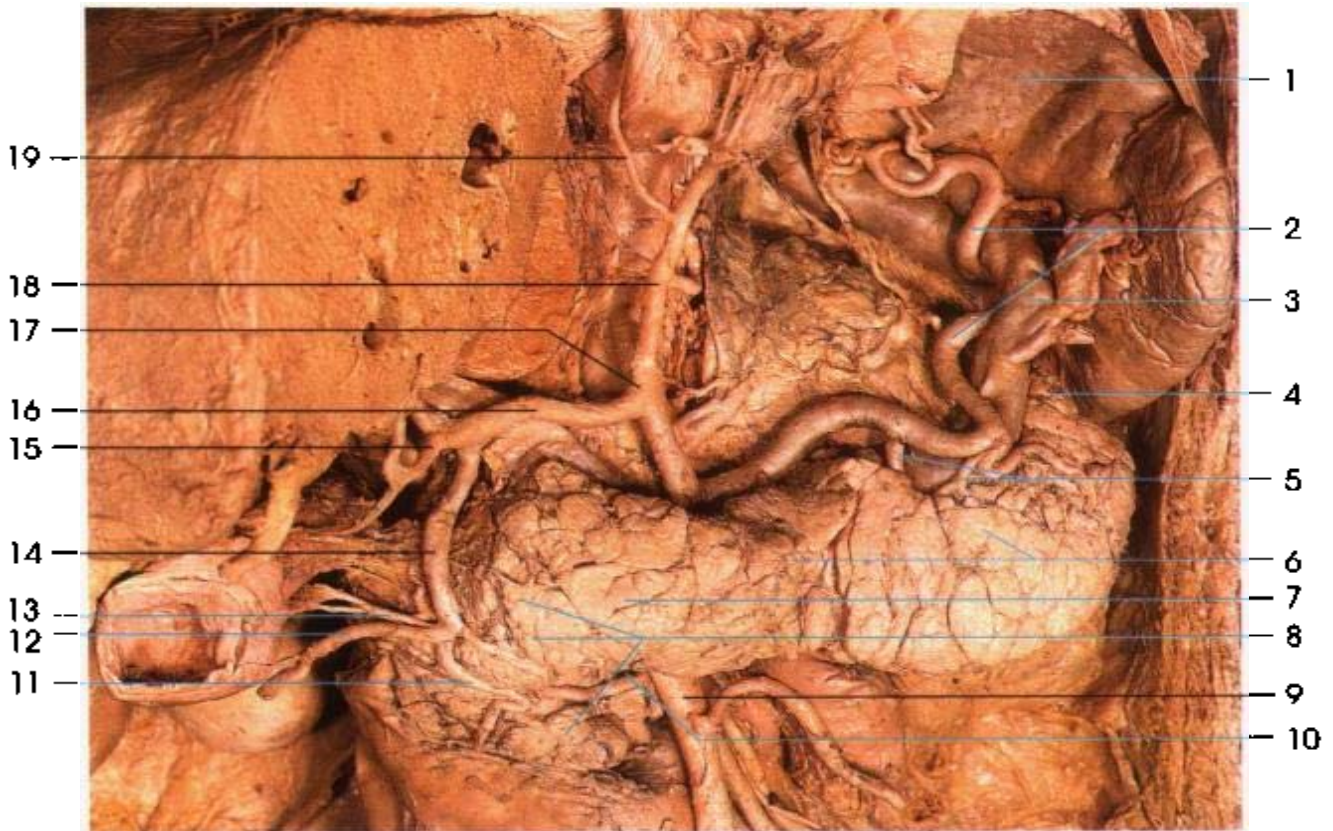


图 272 腹腔干
Celiac trunk

- | | |
|-----------------------------------|---|
| 1. 脾 spleen | 11. 胰十二指肠前上动脉 anterior superior pancreaticoduodenal a. |
| 2. 脾动脉 splenic a. | 12. 胃网膜右动脉 right gastroepiploic a. |
| 3. 脾静脉 splenic v. | 13. 胰十二指肠后上动脉 posterior superior pancreaticoduodenal a. |
| 4. 胰尾 tail of pancreas | 14. 胃十二指肠动脉 gastroduodenal a. |
| 5. 胰支 pancreatic branches | 15. 肝固有动脉 proper hepatic a. |
| 6. 胰体 body of pancreas | 16. 肝总动脉 common hepatic a. |
| 7. 胰颈 neck of pancreas | 17. 腹腔干 celiac trunk |
| 8. 胰头 head of pancreas | 18. 胃左动脉 left gastric a. |
| 9. 肠系膜上动脉 superior mesenteric a. | 19. 食管支 esophageal branches |
| 10. 肠系膜上静脉 superior mesenteric v. | |

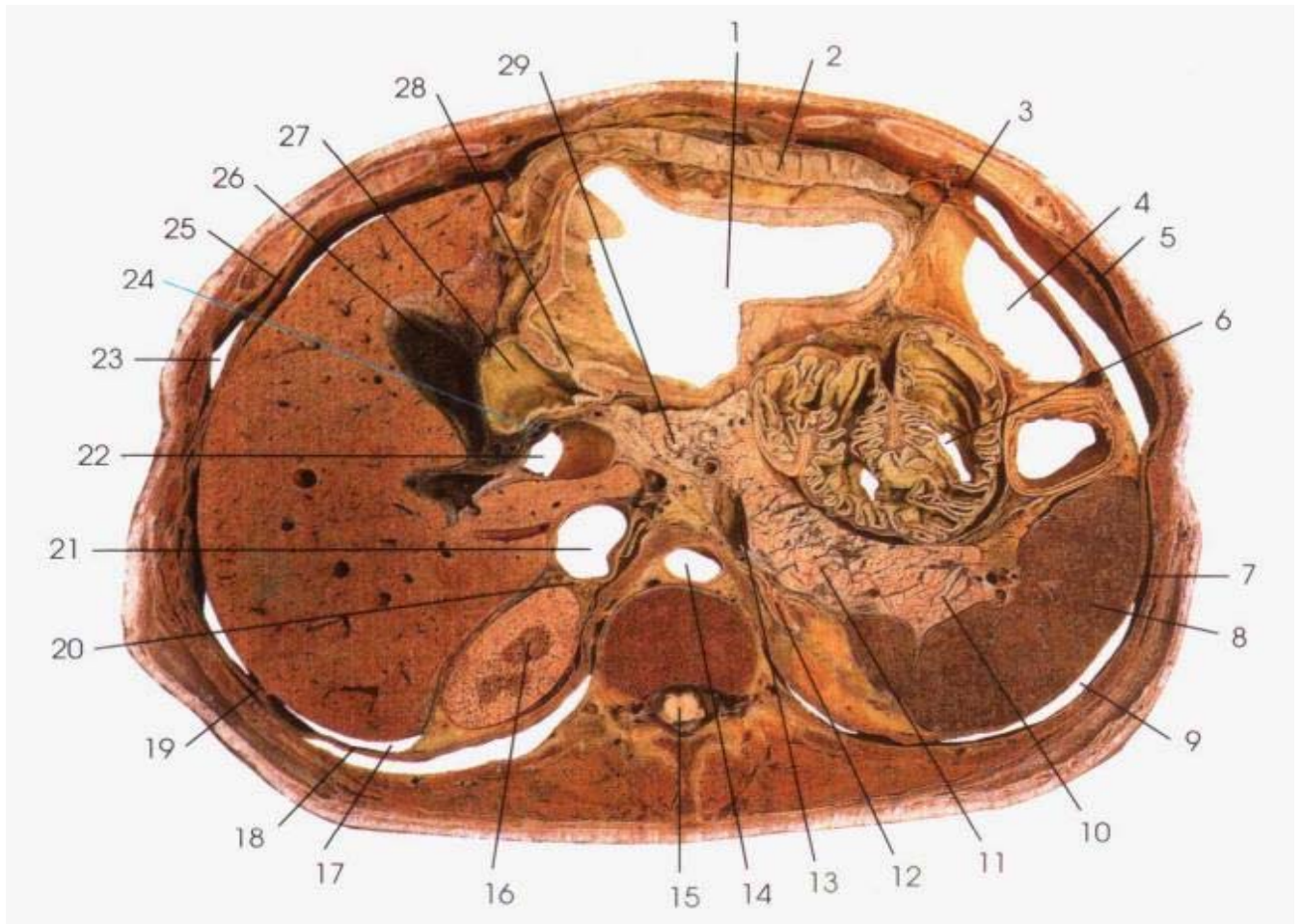


图 273 幽门平面横断面
Transverse section at level of pylorus

- | | |
|---------------------------------------|---------------------------------------|
| 1. 胃 stomach | 14. 腹主动脉 abdominal aorta |
| 2. 回肠 ileum | 15. 脊髓 spinal cord |
| 3. 膈结肠韧带 phrenicocolic lig. | 16. 右肾 right kidney |
| 4. 结肠左曲 left colic flexure | 17. 肝肾隐窝(囊) hepatorenal recess(pouch) |
| 5. 7. 18. 25. 膈 diaphragm | 19. 右三角韧带 right triangular lig. |
| 6. 空肠 jejunum | 20. 右肾上腺 right suprarenal gland |
| 8. 脾 spleen | 21. 下腔静脉 inferior vena cava |
| 9. 23. 肋膈隐窝 costodiaphragmatic recess | 22. (肝)门静脉 portal v. |
| 10. 胰尾 tail of pancreas | 24. 胆总管 common bile duct |
| 11. 胰体 body of pancreas | 26. 胆囊 gall bladder |
| 12. 左肾上腺 left suprarenal gland | 27. 十二指肠上部 superior part of duodenum |
| 13. 脾静脉 splenic v. | 28. 幽门口 pyloric orifice |
| | 29. 胰头 head of pancreas |

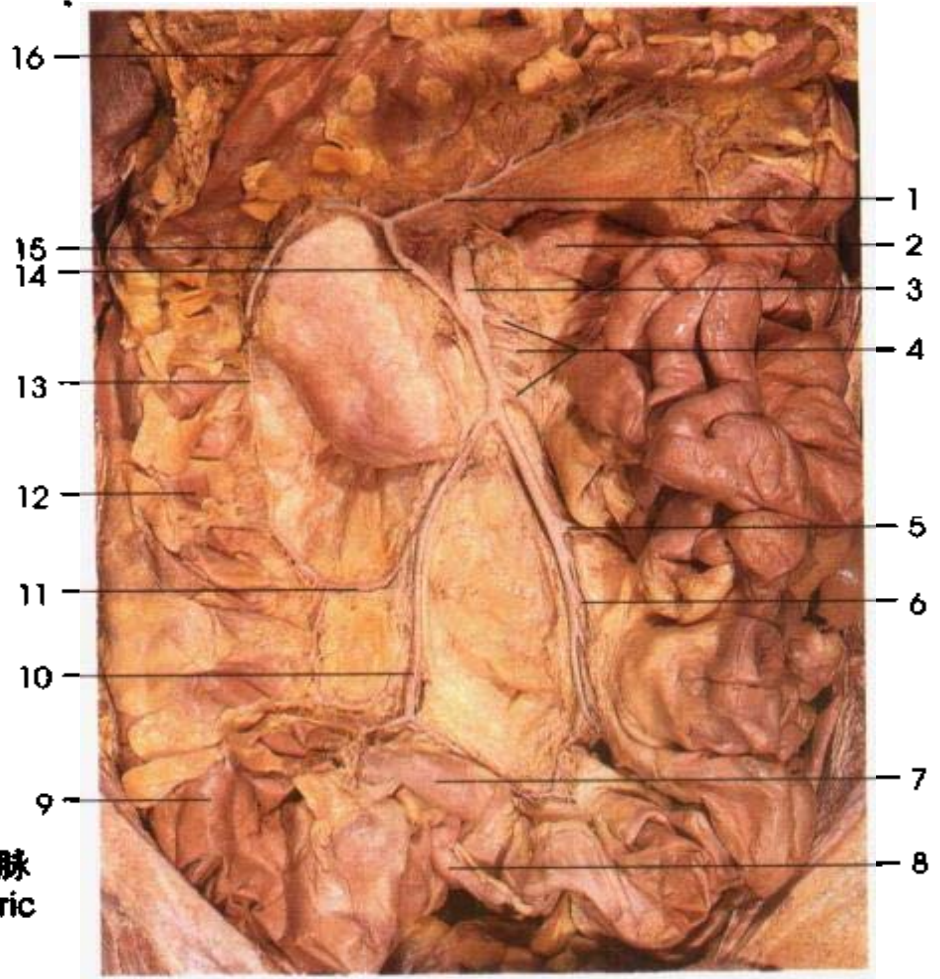


图 274 肠系膜上动脉
Superior mesenteric
artery

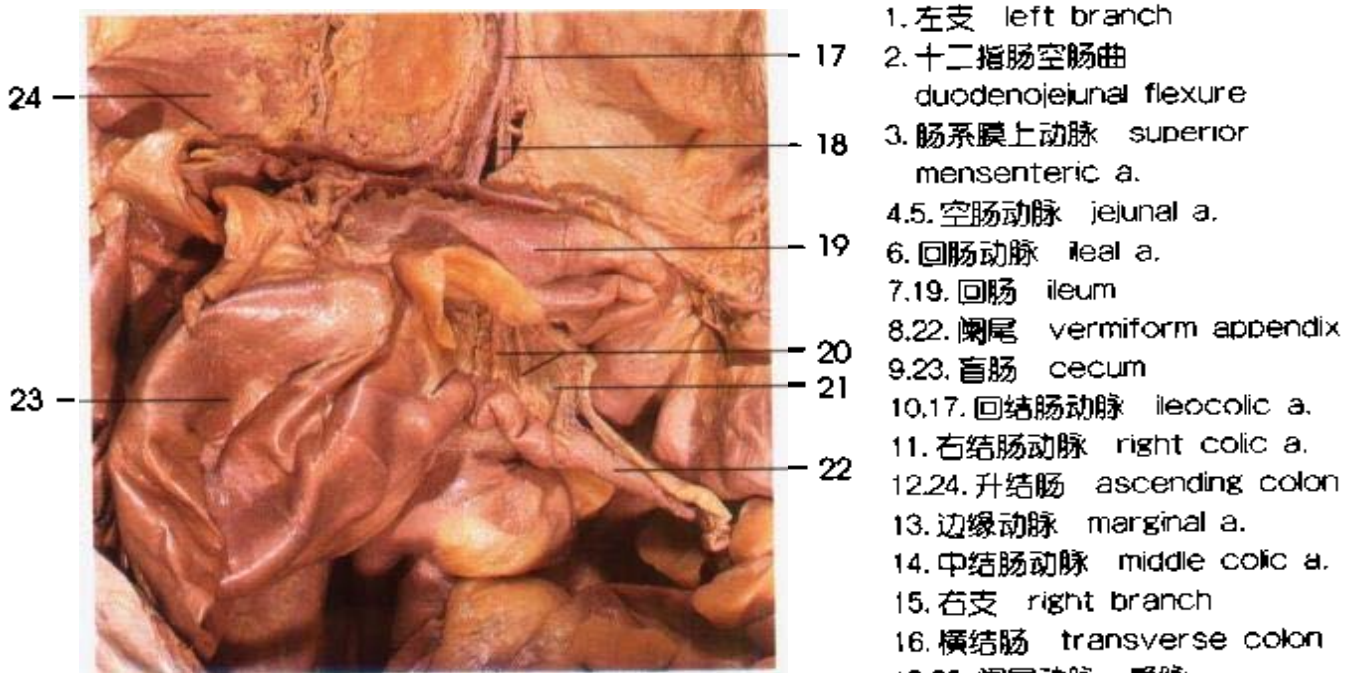

图 275 回结肠动脉
Ileocolic artery

1. 左支 left branch
2. 十二指肠空肠曲 duodenojejunal flexure
3. 肠系膜上动脉 superior mesenteric a.
- 4.5. 空肠动脉 jejunal a.
6. 回肠动脉 ileal a.
- 7.19. 回肠 ileum
- 8.22. 阑尾 vermiform appendix
- 9.23. 盲肠 cecum
- 10.17. 回结肠动脉 ileocolic a.
11. 右结肠动脉 right colic a.
- 12.24. 升结肠 ascending colon
13. 边缘动脉 marginal a.
14. 中结肠动脉 middle colic a.
15. 右支 right branch
16. 横结肠 transverse colon
- 18.20. 阑尾动脉、静脉 appendicular a. & v.
21. 阑尾系膜 mesoappendix

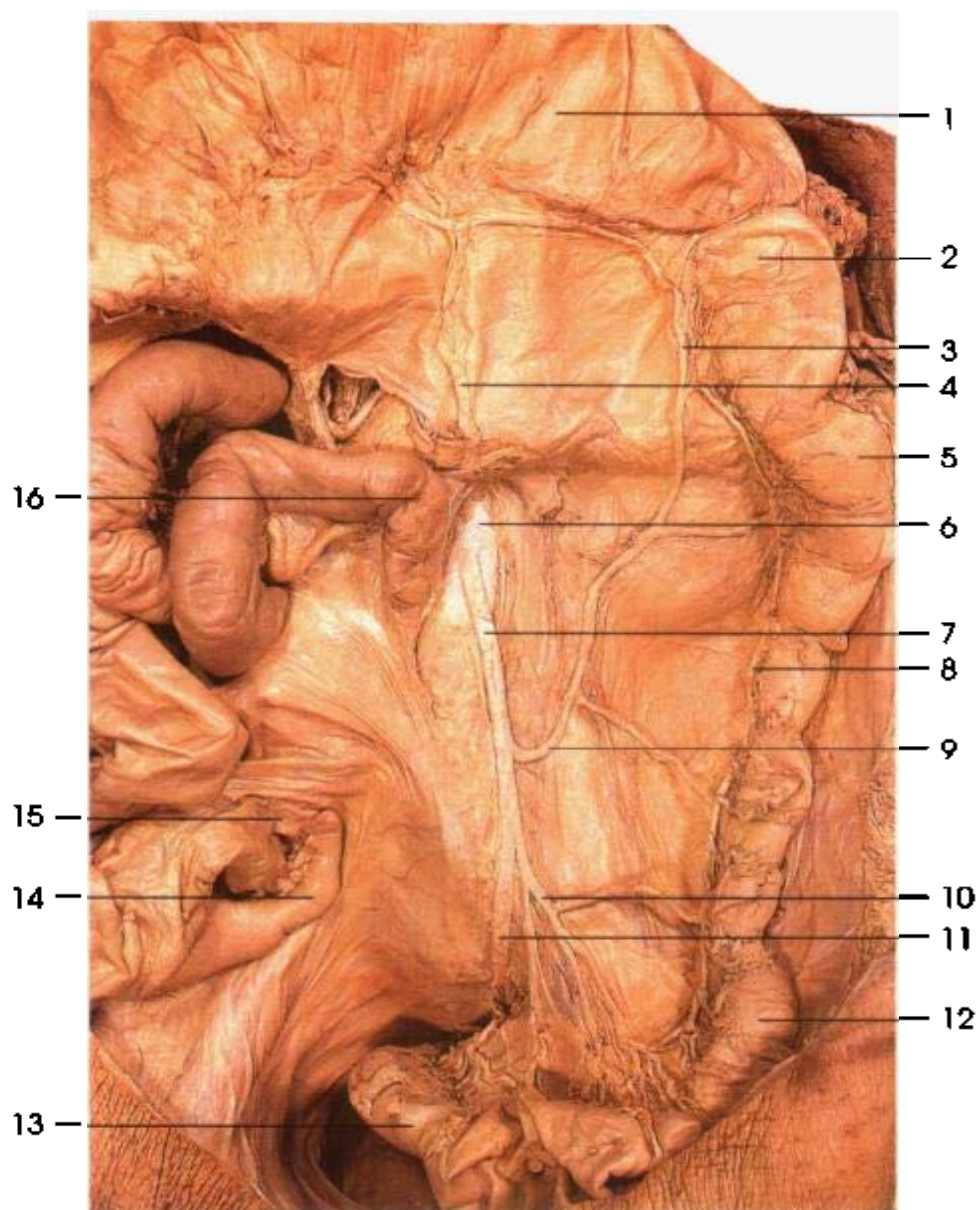


图 276 肠系膜下动脉
Inferior mesenteric artery

- | | |
|----------------------------------|------------------------------------|
| 1. 横结肠 transverse colon | 10. 乙状结肠动脉 sigmoid a. |
| 2. 结肠左曲 left colic flexure | 11. 直肠上动脉 superior rectal a. |
| 3. 边缘动脉 marginal a. | 12. 乙状结肠 sigmoid colon |
| 4. 中结肠动脉 middle colic a. | 13. 直肠 rectum |
| 5. 降结肠 descending colon | 14. 阑尾 vermiform appendix |
| 6. 腹主动脉 abdominal aorta | 15. 阑尾系膜 mesoappendix |
| 7. 肠系膜下动脉 inferior mesenteric a. | 16. 十二指肠空肠曲 duodenojejunal flexure |
| 9. 左结肠动脉 left colic a. | |

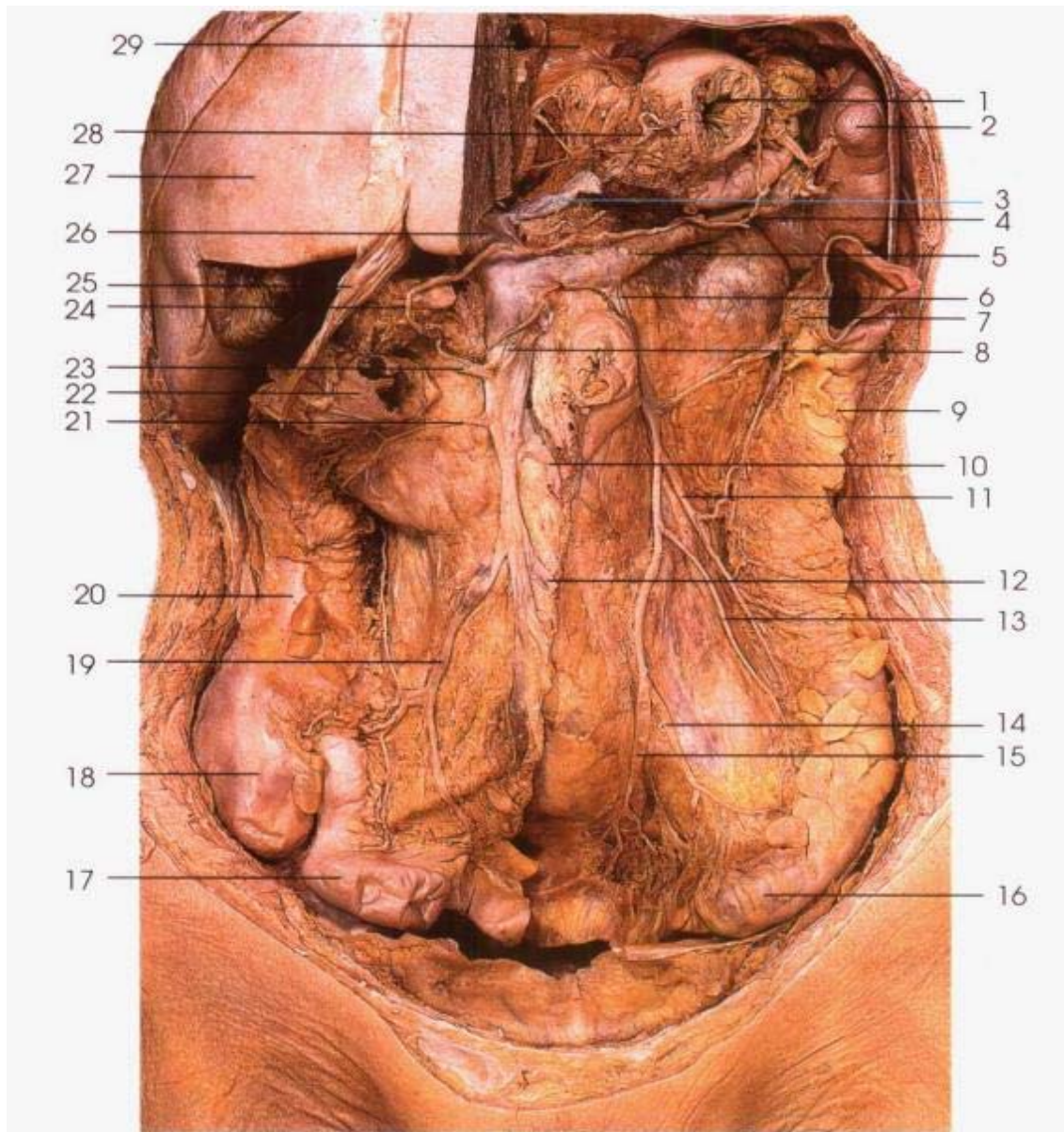


图 277 肝门静脉
Hepatic portal vein

- | | | |
|----------------------------------|------------------------------|--------------------------------------|
| 1. 胃底 fundas of stomach | 10,12. 空肠静脉 jejunal v. | 24. 胃网膜右静脉 right gastroepiploic v. |
| 2. 脾 spleen | 11. 左结肠静脉 left colic v. | 25. 肝圆韧带 ligamentum teres hepatis |
| 3. 胃左静脉 left gastric v. | 13,14. 乙状结肠静脉 sigmoid v. | 26. 肝门静脉 hepatic portal v. |
| 4. 胃网膜左静脉 left gastroepiploic v. | 15. 直肠上静脉 superior rectal v. | 27. 肝右叶 right lobe of liver |
| 5. 脾静脉 splenic v. | 16. 乙状结肠 sigmoid colon | 28. 胃底部静脉 viens of fundas of stomach |
| 6. 肠系膜下静脉 inferior mesenteric v. | 17. 回肠 ileum | 29. 食管腹段 abdominal part of esophagus |
| 7. 结肠左曲 left colic flexure | 18. 盲肠 cecum | |
| 8. 肠系膜上静脉 superior mesenteric v. | 19. 回结肠静脉 ileocolic v. | |
| 9. 降结肠 descending colon | 20. 升结肠 ascending colon | |
| | 21. 右结肠静脉 right colic v. | |
| | 22. 结肠右曲 right colic flexure | |
| | 23. 中结肠静脉 middle colic v. | |

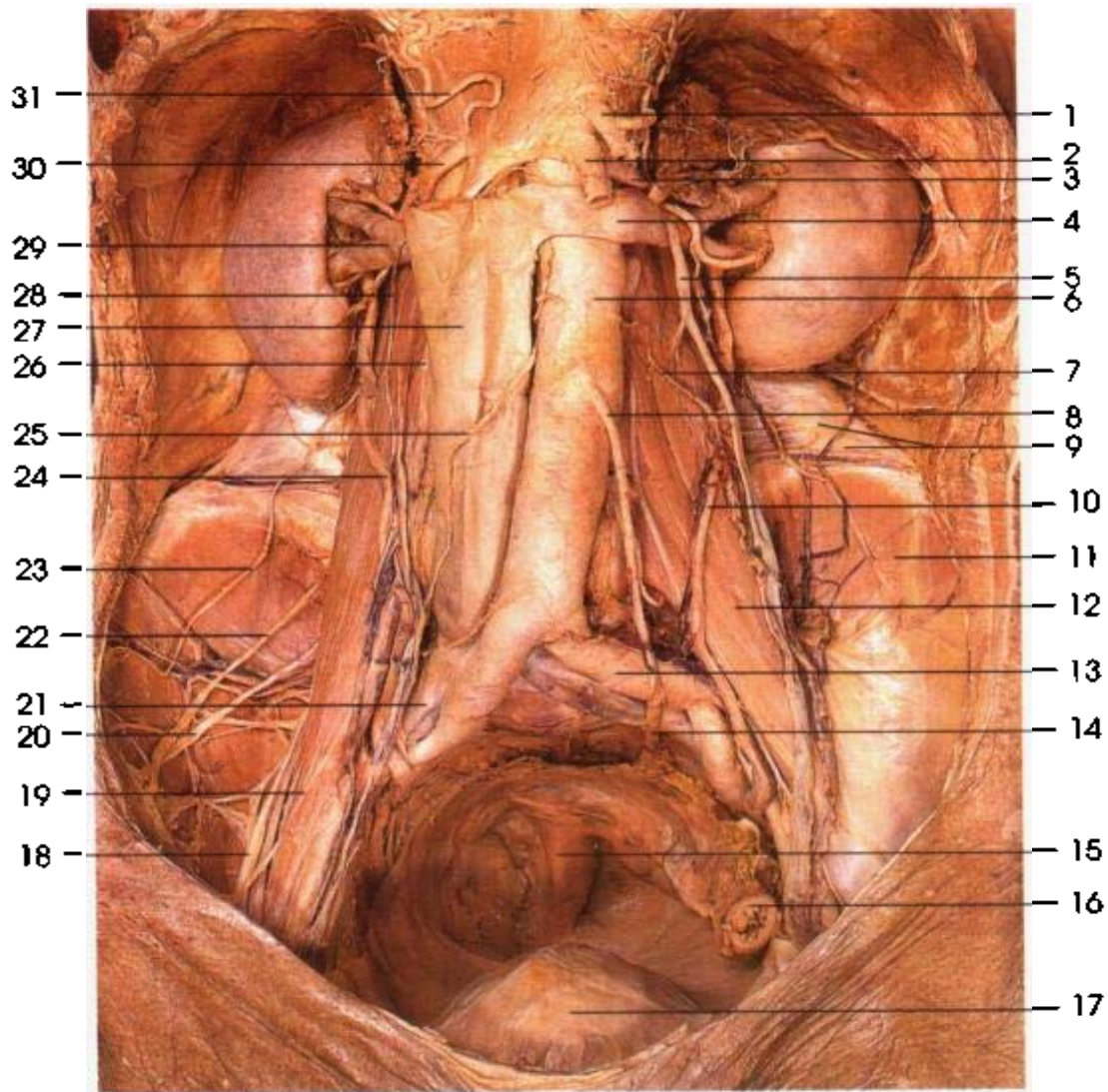


图 278 腹后隙的肌、血管和神经
Muscles, blood vessels and nerves in the retroperitoneal space

- | | |
|----------------------------------|---|
| 1. 腹腔干 celiac trunk | 17. 膀胱 urinary bladder |
| 2. 肠系膜上动脉 superior mesenteric a. | 18. 股神经 femoral n. |
| 3. 左肾动脉 left renal a. | 19. 生殖股神经 genitofemoral n. |
| 4. 左肾静脉 left renal v. | 20. 股外侧皮神经 lateral femoral cutaneous n. |
| 5. 左睾丸静脉 left testicular v. | 21. 右髂总静脉 right common iliac v. |
| 6. 腹主动脉 abdominal aorta | 22. 髂腹股沟神经 ilioinguinal n. |
| 7. 左睾丸动脉 left testicular a. | 23. 髂腹下神经 iliohypogastric n. |
| 8. 肠系膜下动脉 inferior mesenteric a. | 25. 右睾丸动脉 right testicular a. |
| 9. 腰方肌 quadratus lumborum | 26. 右睾丸静脉 right testicular v. |
| 10. 24. 输尿管 ureter | 27. 下腔静脉 inferior vena cava |
| 11. 髂肌 iliacus | 28. 副睾丸动脉 accessory testicular a. |
| 12. 腰大肌 psoas major | 29. 右肾静脉 right renal v. |
| 13. 左髂总动脉 left common iliac a. | 30. 右肾动脉 right renal a. |
| 14. 直肠上动脉 superior rectal a. | 31. 右膈下动脉 right inferior phrenic a. |
| 15. 直肠 rectum | |
| 16. 乙状结肠 sigmoid colon | |

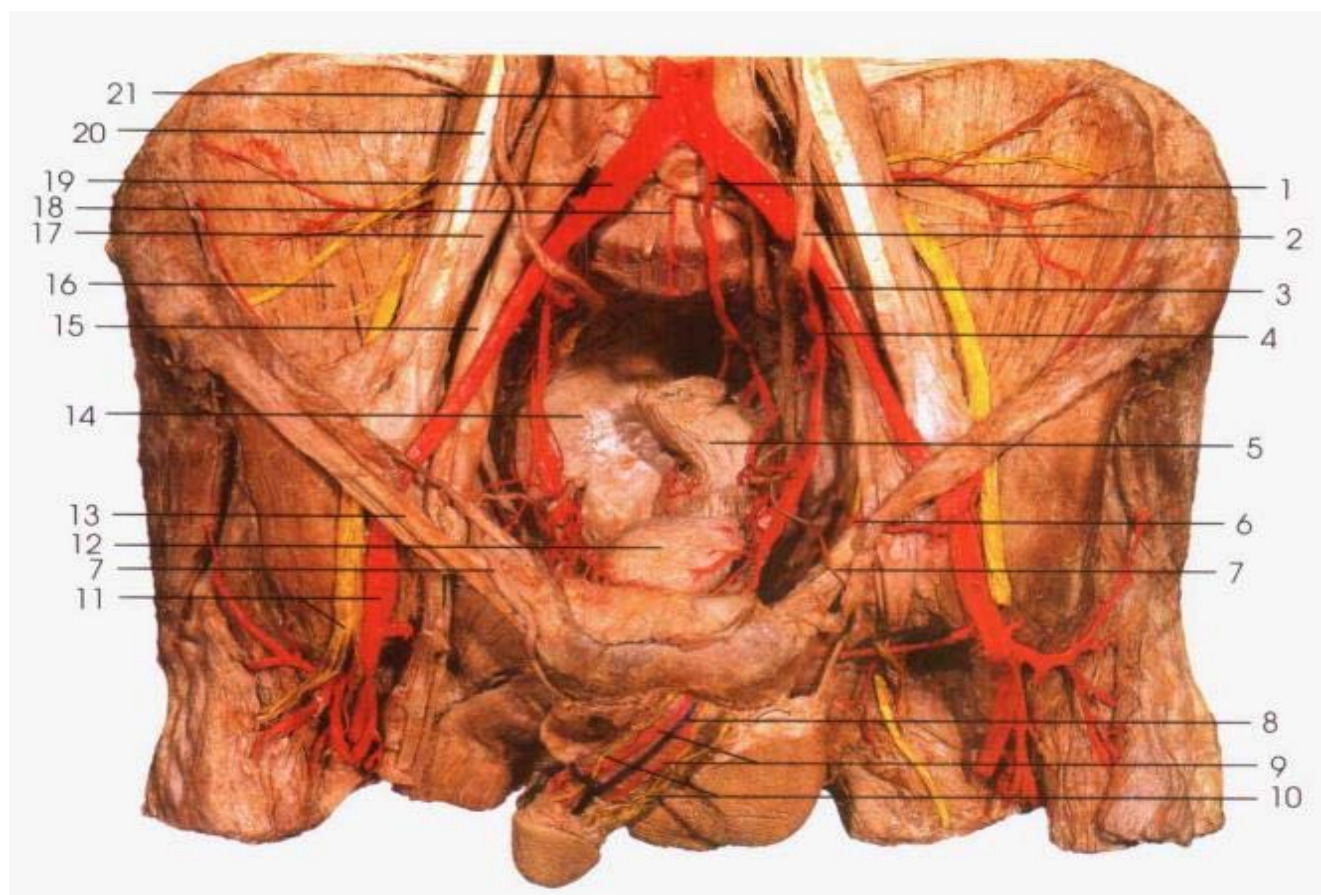


图 279 男性盆部的动脉(上面观)
Arteries of the pelvis of the male(superior aspect)

- | | |
|---|----------------------------|
| 1. 直肠上动脉 superior rectal a. | 11. 股神经、动脉 femoral n. & a. |
| 2. 输尿管 ureter | 12. 膀胱 urinary bladder |
| 3. 髂外动脉 external iliac a. | 13. 腹股沟韧带 inguinal lig. |
| 4. 脐动脉 umbilical a. | 14. 直肠 rectum |
| 5. 乙状结肠 sigmoid colon | 15. 髂外静脉 external iliac v. |
| 6. 腹壁下动脉闭孔支(副闭孔动脉) obturator
branch of inferior epigastric
a.(accessory obturator a.) | 16. 髂肌 iliacus |
| 7. 输精管 ductus deferens | 17. 腰大肌 psoas major |
| 8. 阴茎背深静脉 deep dorsal v.of penis | 18. 骶正中动脉 median sacral a. |
| 9. 阴茎背动脉 dorsal a.of penis | 19. 髂总动脉 common iliac a. |
| 10. 阴茎背神经 dorsal n.of penis | 20. 腰小肌 psoas minor |
| | 21. 腹主动脉 abdominal aorta |

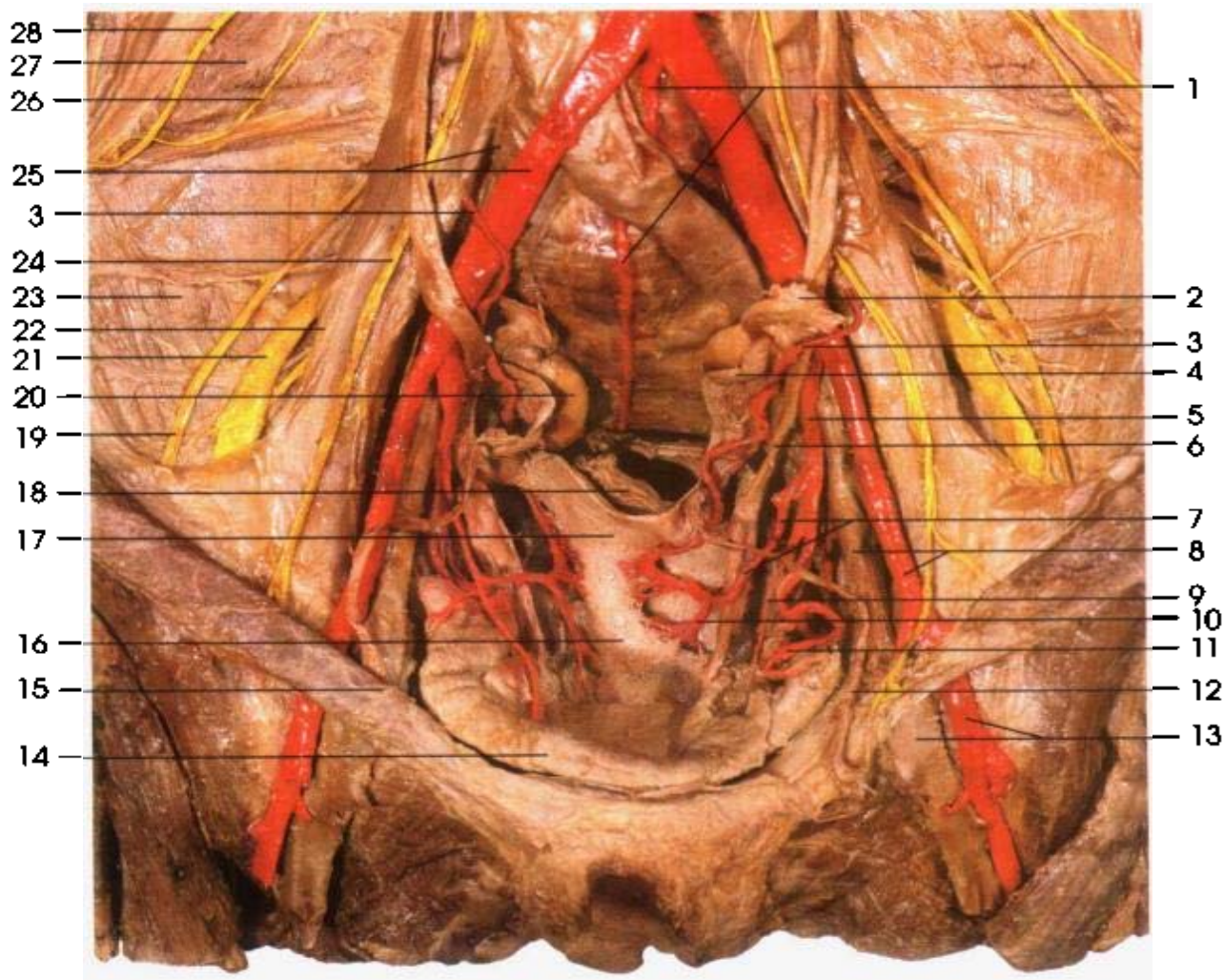


图 280 女性盆部的动脉(上面观)
Arteries of the female pelvis(superior aspect)

- | | |
|--|---|
| 1. 骶正中动脉 median sacral a. | 15. 腹股沟韧带 inguinal lig. |
| 2. 输卵管伞 fimbriae of uterine tube | 16. 子宫颈 neck of uterus |
| 3. 卵巢动脉 ovarian a. | 17. 子宫体 body of uterus |
| 4. 输卵管 uterine tube | 18. 直肠 rectum |
| 5. 髂内动脉 internal iliac a. | 19. 股外侧皮神经 lateral femoral cutaneous n. |
| 6. 输尿管 ureter | 20. 卵巢 ovary |
| 7. 子宫动脉 uterine a. | 21. 股神经 femoral n. |
| 8. 髂外静脉和动脉 external iliac v. & a. | 22. 腰大肌 psoas major |
| 9. 膀胱下动脉 inferior vesical a. | 23. 髂肌 iliacus |
| 10. 子宫动脉(阴道支) uterine a.(vaginal branches) | 24. 生殖股神经 genitofemoral n. |
| 11. 脐动脉 umbilical a. | 25. 髂总动脉、静脉 common iliac a. & v. |
| 12. 子宫圆韧带 round ligament of uterus | 26. 髂腹股沟神经 ilioinguinal n. |
| 13. 股静脉和股动脉 femoral v. & a. | 27. 腰方肌 quadratus lumborum |
| 14. 膀胱 urinary bladder | 28. 髂腹下神经 iliohypogastric n. |

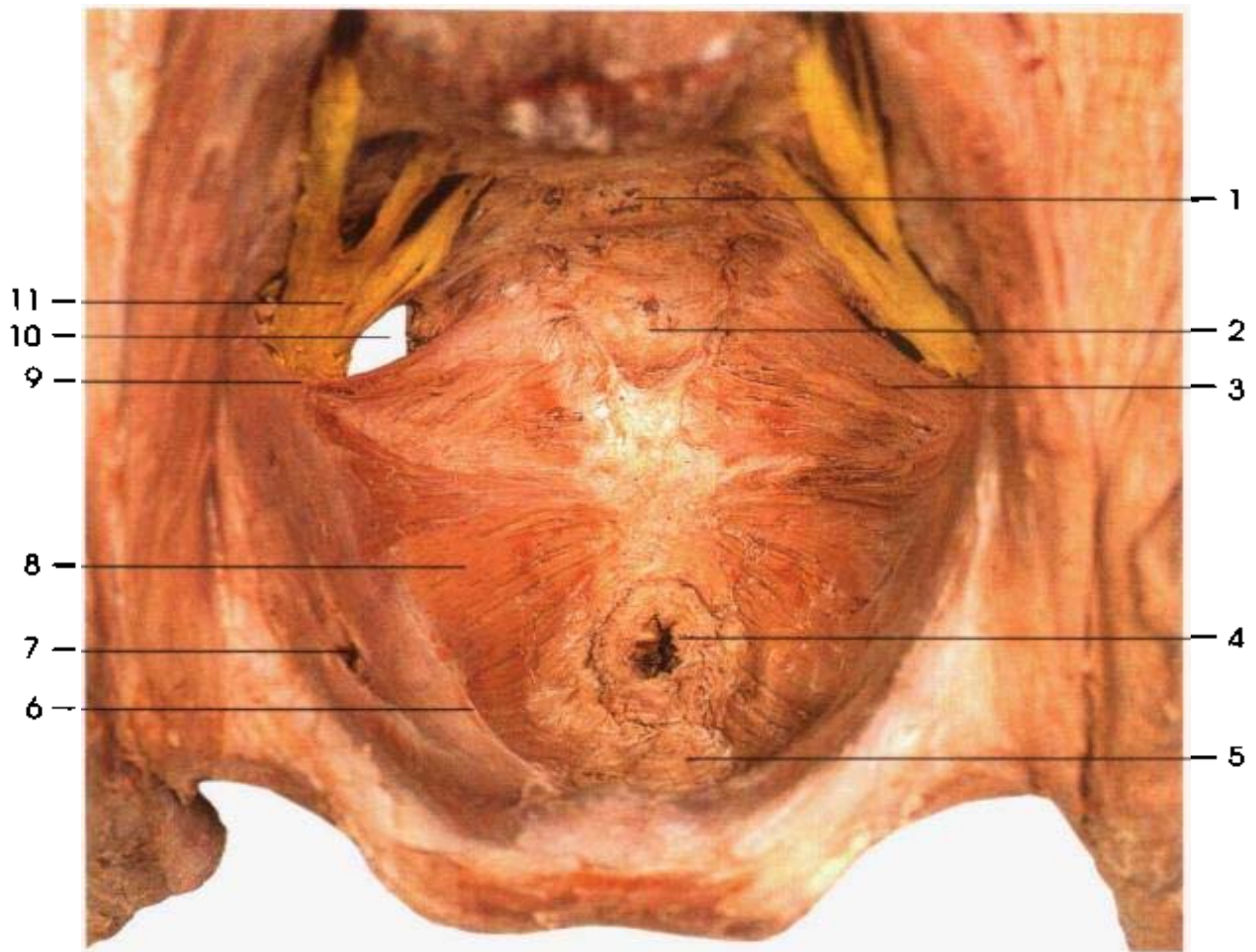


图 281 肛提肌(上面观)
Levator ani(superior aspect)

- | | |
|--|----------------------------------|
| 1. 骶骨 sacrum | levator ani |
| 2. 尾骨 coccyx | 7. 闭孔 obturator foramen |
| 3. 尾骨肌 coccygeus | 8. 肛提肌 levator ani |
| 4. 直肠 rectum | 9. 坐骨棘 ischial spine |
| 5. 男尿道(膜部) male urethra
(membranous part) | 10. 坐骨大孔 greater sciatic foramen |
| 6. 肛提肌腱弓 tendinous arch of | 11. 骶丛 sacral plexus |

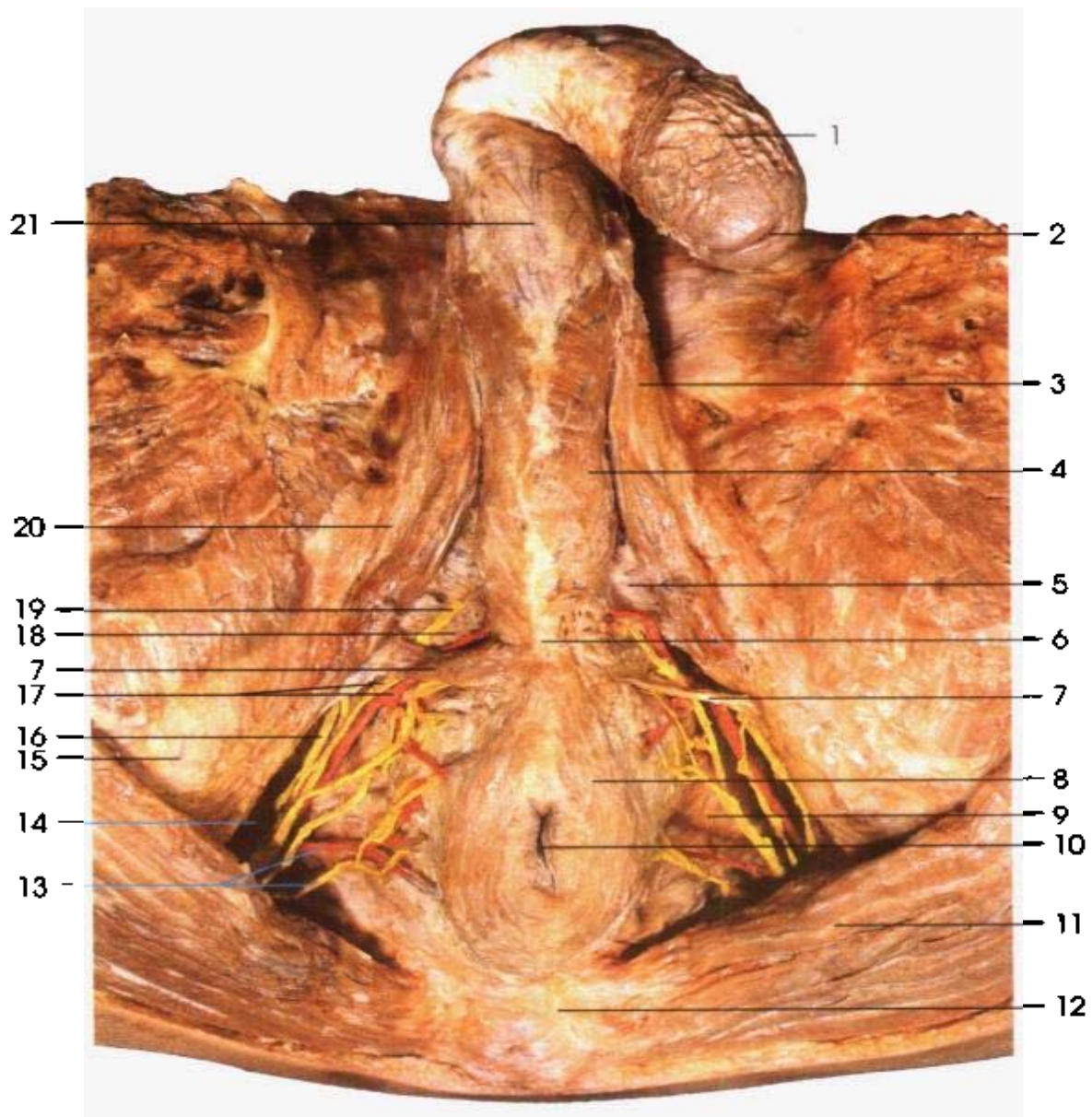


图 282 男性会阴浅隙和坐骨肛门窝
Superficial perineal space and ischioanal fossa of the male

- | | |
|--|--|
| 1. 阴茎头 glans penis | 11. 臀大肌 gluteus maximus |
| 2. 尿道外口 external orifice of urethra | 12. 尾骨 coccyx |
| 3. 坐骨海绵体肌 ischiocavernosus | 13. 肛神经、动脉 anal n. & a. |
| 4. 球海绵体肌 bulbocavernosus | 14. 坐骨肛门窝 ischioanal fossa |
| 5. 尿生殖膈下筋膜 inferior fascia of urogenital diaphragm | 15. 坐骨结节 ischial tuberosity |
| 6. 会阴体 perineal body | 16. 阴茎背神经 dorsal nerve of penis |
| 7. 会阴浅横肌 superficial transverse muscle of perineum | 17. 会阴神经、动脉 perineal n. & a. |
| 8. 肛门外括约肌 sphincter ani externus | 18. 会阴深横肌 deep transverse muscle of perineum |
| 9. 肛提肌 levator ani | 19. 阴囊后神经 posterior scrotal n. |
| 10. 肛门 anus | 20. 耻骨弓 pubic arch |
| | 21. 尿道海绵体 spongy body of penis |

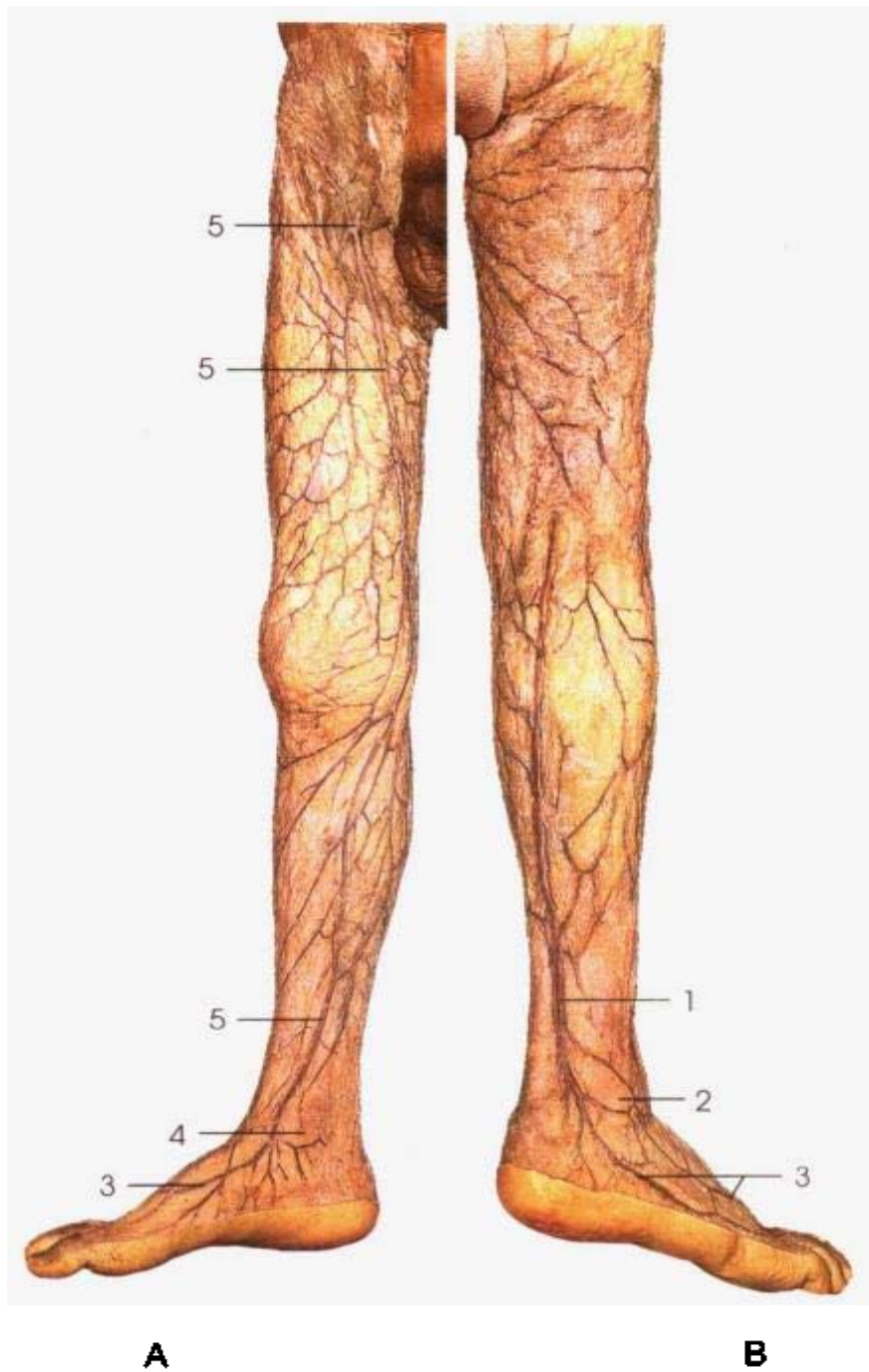
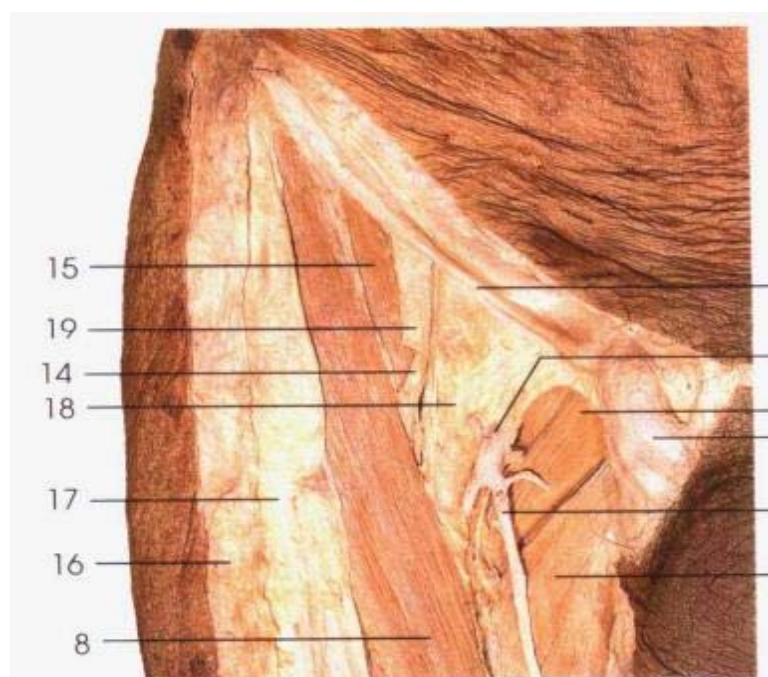


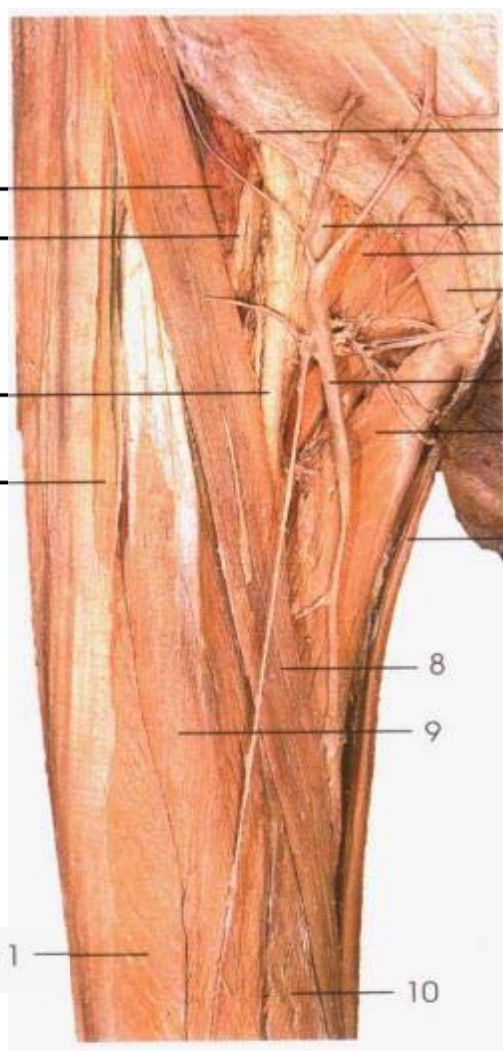
图 283 下肢的浅静脉(A、B)
Superficial veins of the lower limb(A、B)

- | | |
|----------------------------|----------------------------|
| 1. 小隐静脉 small saphenous v. | arch of foot |
| 2. 外踝 lateral malleolus | 4. 内踝 medial malleolus |
| 3. 足背静脉弓 dorsal venous | 5. 大隐静脉 great saphenous v. |



1. 腹股沟韧带 inguinal lig.
2. 股静脉 femoral v.
3. 耻骨肌 pectineus
4. 精索 spermatic cord
5. 大隐静脉 great saphenous v.
6. 长收肌 adductor longus
7. 股薄肌 gracilis
8. 缝匠肌 sartorius
9. 股直肌 rectus femoris

图 284 股鞘
Femoral sheath



10. 股内侧肌 vastus medialis
11. 股外侧肌 vastus lateralis
12. 阔筋膜张肌 tensor fasciae latae
13. 股动脉 femoral a.
14. 股神经 femoral n.
15. 髂腰肌 iliopsoas
16. 浅筋膜 superficial fascia
17. 阔筋膜 fascia lata
18. 股鞘 femoral sheath
19. 髂筋膜 iliac fascia

图 285 股前内侧区的肌、神经和血管(I)
Muscles, nerves and blood vessels
of anterior medial region
of the thigh(I)

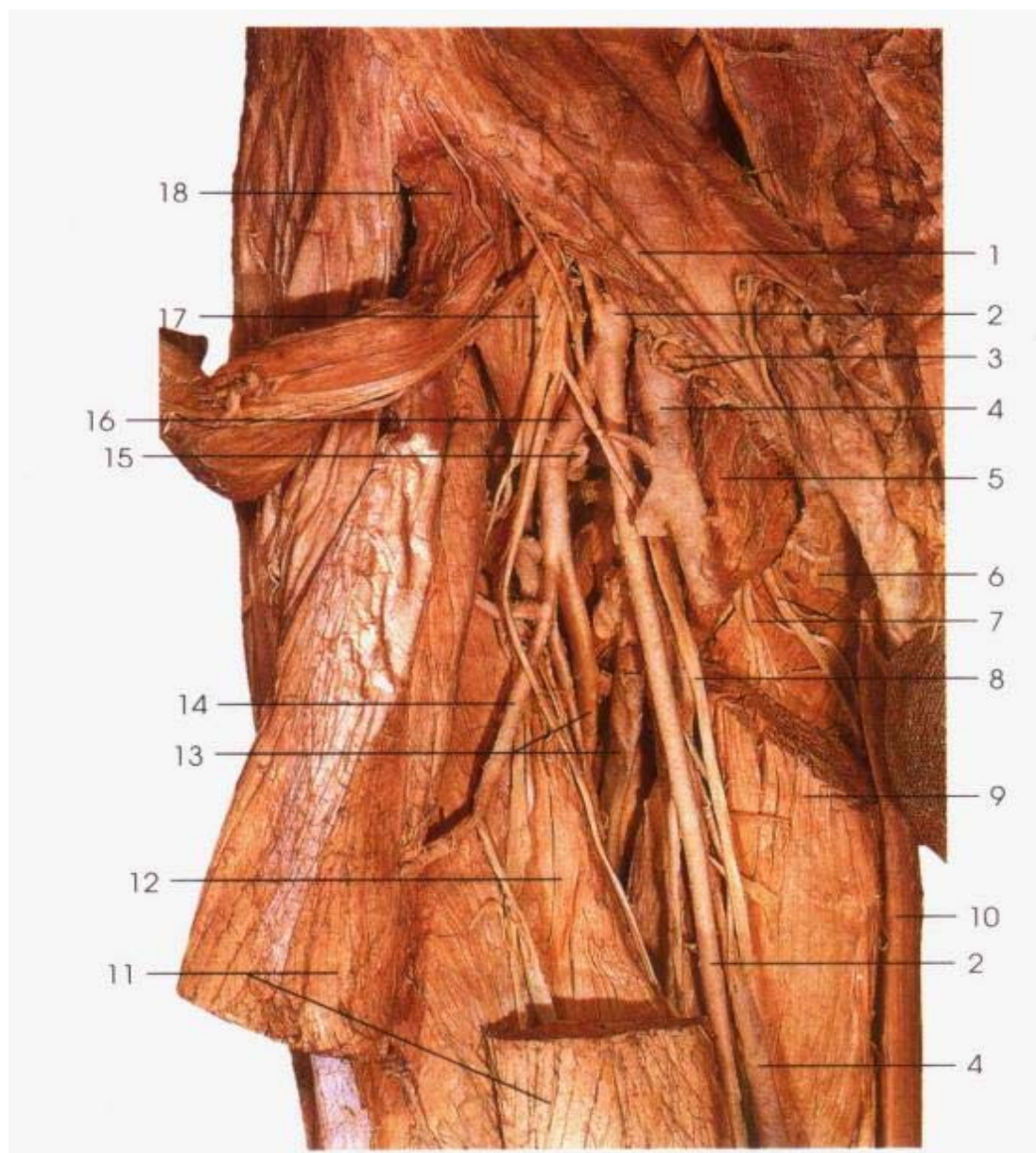


图 286 股前内侧区的肌、神经和血管(Ⅱ)
Muscles, nerves and blood vessels of anterior and medial region of the thigh(Ⅱ)

- | | |
|---|--|
| 1. 腹股沟韧带 inguinal lig. | 10. 股薄肌 gracilis |
| 2. 股动脉 femoral a. | 11. 股直肌 rectus femoris |
| 3. 股管及腹股沟深淋巴结 femoral canal and deep inguinal lymph nodes | 12. 股内侧肌 vastus medialis |
| 4. 股静脉 femoral v. | 13. 股深静脉、动脉 deep femoral v. & a. |
| 5. 耻骨肌 pectineus | 14. 旋股外侧动脉 lateral femoral circumflex a. |
| 6. 短收肌 adductor brevis | 15. 旋股内侧动脉 medial femoral circumflex a. |
| 7. 闭孔神经(前支) obturator n. (anterior branch) | 16. 股深动脉 deep femoral a. |
| 8. 隐神经 saphenous n. | 17. 股神经 femoral n. |
| 9. 长收肌 adductor longus | 18. 缝匠肌 sartorius |

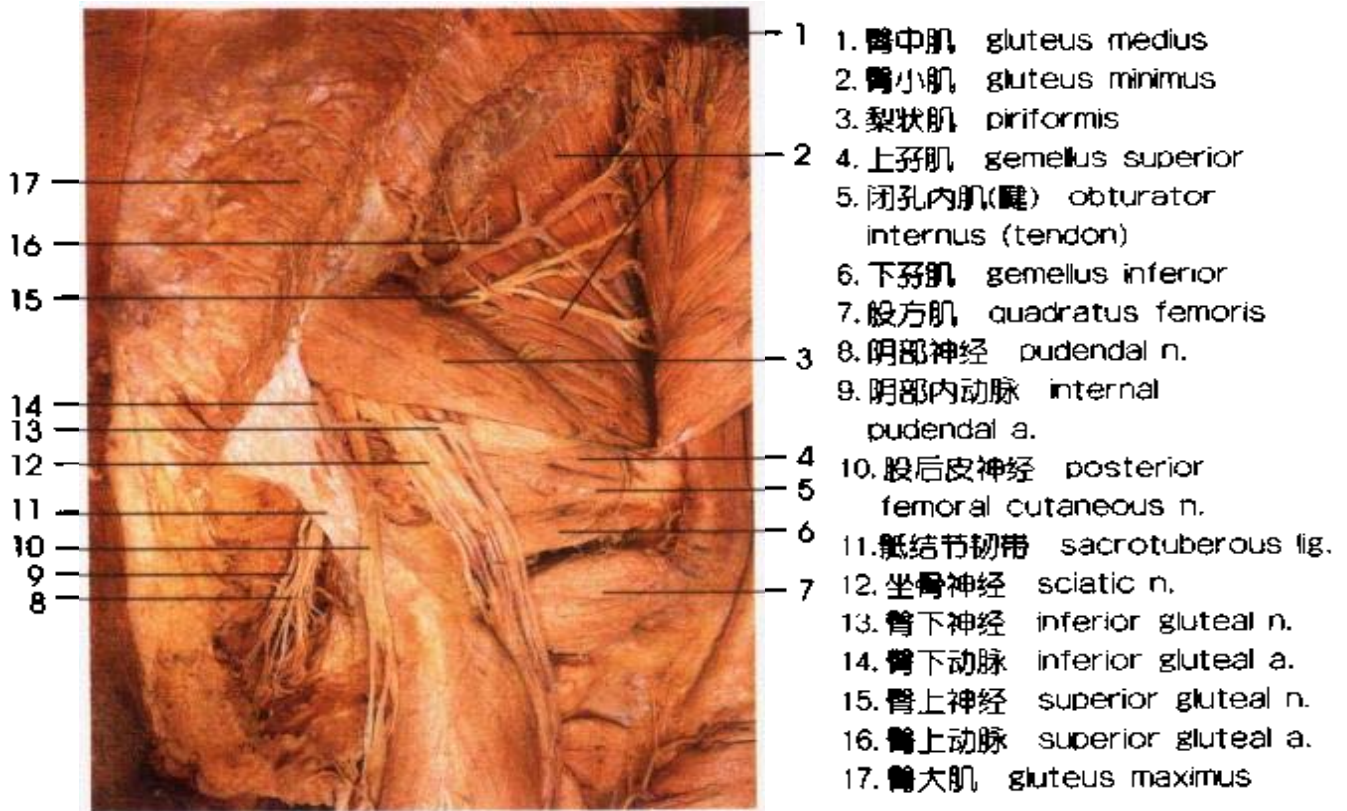
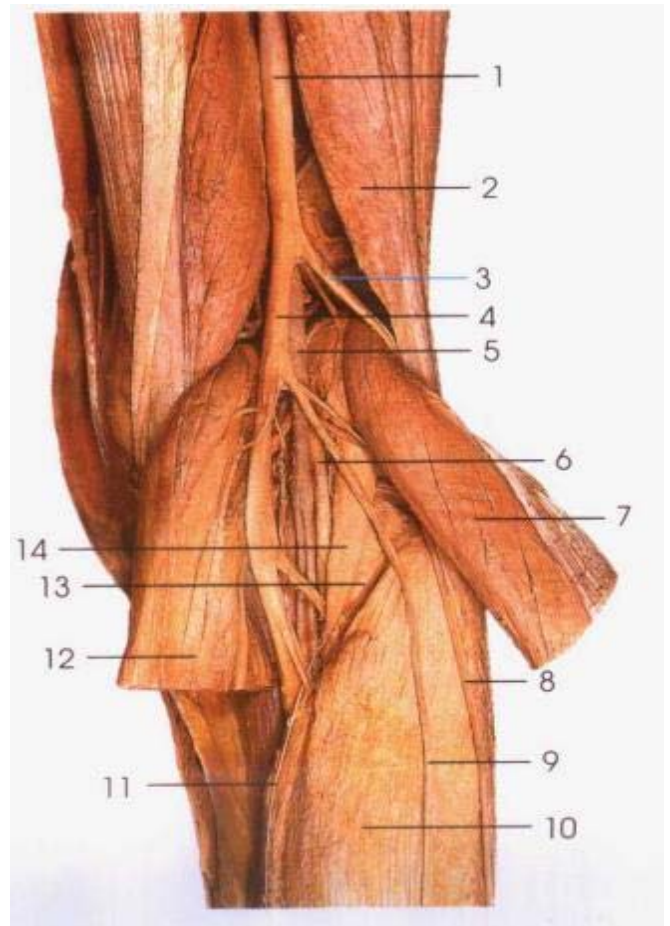


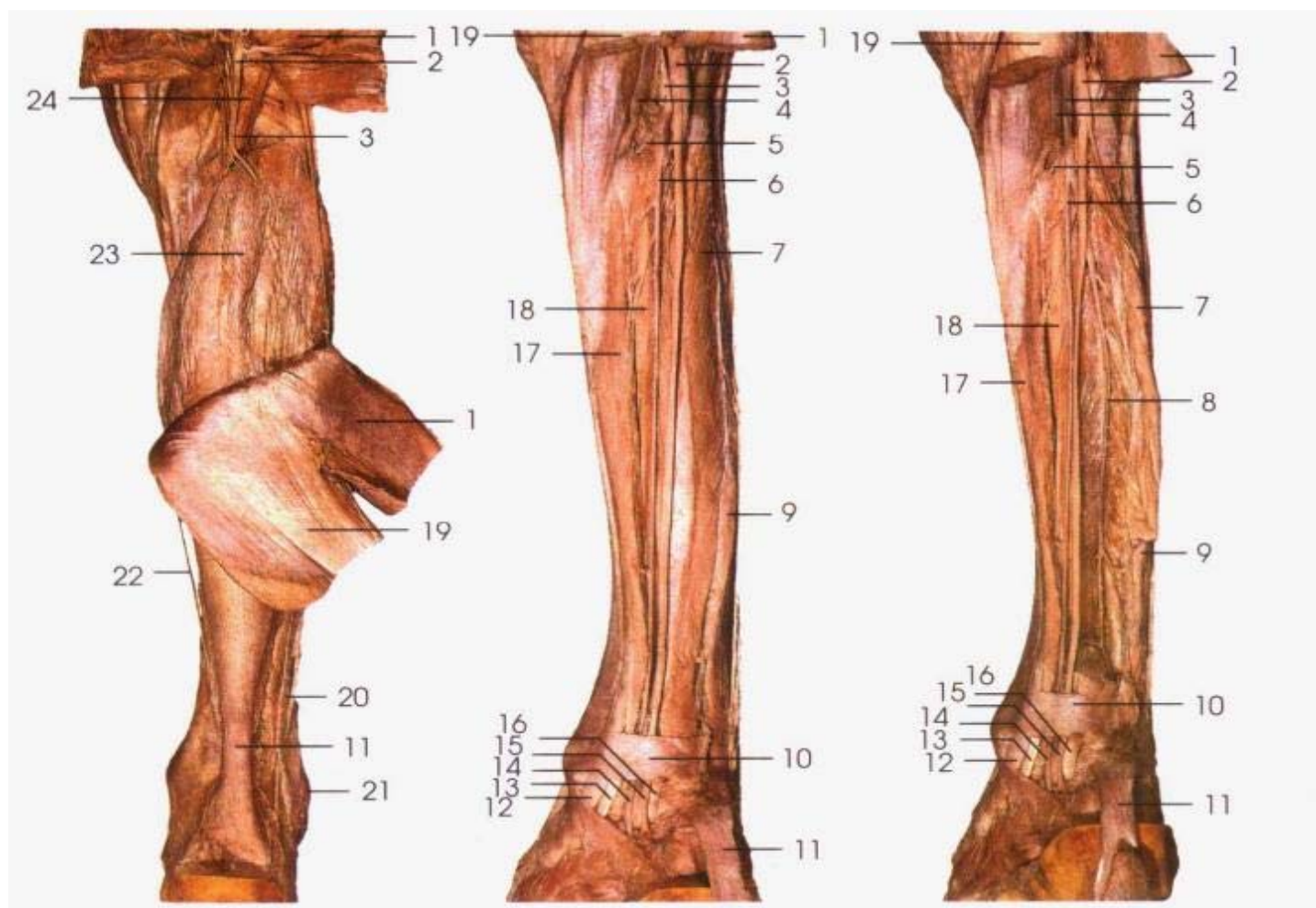图 287 臀区的肌、神经和血管
Muscles, nerves and blood vessels
of the gluteal region

- 1. 臀中肌 gluteus medius
- 2. 臀小肌 gluteus minimus
- 3. 梨状肌 piriformis
- 4. 上孖肌 gemellus superior
- 5. 闭孔内肌(腱) obturator internus (tendon)
- 6. 下孖肌 gemellus inferior
- 7. 股方肌 quadratus femoris
- 8. 阴部神经 pudendal n.
- 9. 阴部内动脉 internal pudendal a.
- 10. 股后皮神经 posterior femoral cutaneous n.
- 11. 骶结节韧带 sacrotuberous lig.
- 12. 坐骨神经 sciatic n.
- 13. 臀下神经 inferior gluteal n.
- 14. 臀下动脉 inferior gluteal a.
- 15. 臀上神经 superior gluteal n.
- 16. 臀上动脉 superior gluteal a.
- 17. 臀大肌 gluteus maximus

- 1. 坐骨神经 sciatic n.
- 2. 股二头肌 biceps femoris
- 3. 腓总神经 common peroneal n.
- 4. 胫神经 tibial n.
- 5. 腓静脉 popliteal v.
- 6. 腓动脉 popliteal a.
- 7. 腓肠肌(外侧头) gastrocnemius (lateral head)
- 8. 腓肠外侧皮神经 lateral sural cutaneous n.
- 9. 腓肠内侧皮神经 medial sural cutaneous n.
- 10. 比目鱼肌 soleus
- 11. 跖肌(腱) plantaris (tendon)
- 12. 腓肠肌(内侧头) gastrocnemius (medial head)
- 13. 腓肌 popliteus
- 14. 跖肌 plantaris

图 288 腓窝的神经和血管
Nerves and blood vessels of
the popliteal fossa





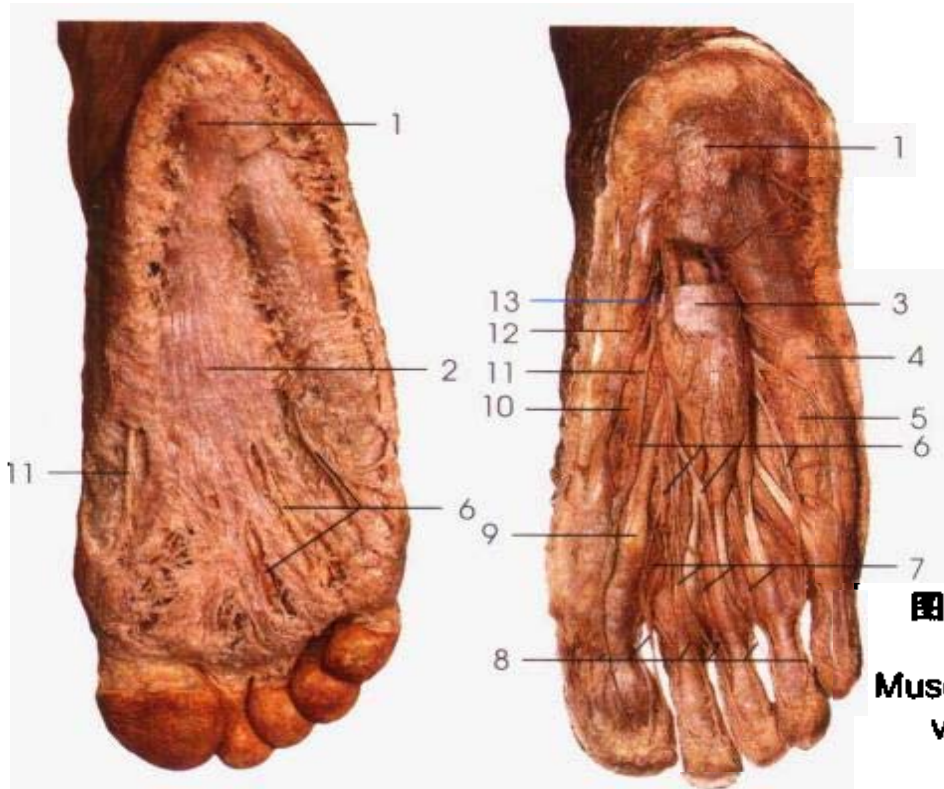
A

B

C

图 289 小腿后区的肌、神经和血管(A、B、C)
Muscles, nerves and blood vessels of the
posterior crural region(A,B,C)

- | | |
|--|---|
| 1. 腓肠肌(外侧头) gastrocnemius (lateral head) | longus (tendon) |
| 2. 胫神经 tibial n. | 14. 胫后动脉 posterior tibial a. |
| 3. 腘动脉 popliteal a. | 15. 胫神经 tibial n. |
| 4. 腘静脉 popliteal v. | 16. 拇长屈肌(腱) flexor hallucis longus (tendon) |
| 5. 胫前动脉 anterior tibial a. | 17. 趾长屈肌 flexor digitorum longus |
| 6. 胫后动脉 posterior tibial a. | 18. 胫骨后肌 tibialis posterior |
| 7. 拇长屈肌 flexor hallucis longus | 19. 腓肠肌(内侧头) gastrocnemius (medial head) |
| 8. 腓动脉 peroneal a. | 20. 小隐静脉 small saphenous v. |
| 9. 腓骨长肌 peroneus longus | 21. 外踝 lateral malleolus |
| 10. 屈肌支持带 flexor retinaculum | 22. 跖肌(腱) plantaris (tendon) |
| 11. 跟腱 tendo calcaneus | 23. 比目鱼肌 soleus |
| 12. 胫骨后肌(腱) tibialis posterior (tendon) | 24. 跖肌 plantaris |
| 13. 趾长屈肌(腱) flexor digitorum | |



1. 跟骨 calcaneus
2. 足底腱膜 plantar aponeurosis
3. 趾短屈肌 flexor digitorum brevis
4. 小趾展肌 abductor digiti minimi
5. 小趾短屈肌 flexor digiti minimi brevis

图 291 足底肌、神经和血管(I)
Muscles, nerves and blood vessels of the sole of foot(I)

图 290 足底腱膜
Plantar aponeurosis

6. 趾足底总神经 common plantar digital n.
7. 趾足底总动脉 common plantar digital a.
8. 趾足底固有动脉、神经 proper plantar digital a. & n.
9. 拇长屈肌(腱) flexor hallucis longus (tendon)
10. 拇短屈肌 flexor hallucis brevis
11. 足底内侧神经 medial plantar n.
12. 拇展肌 abductor hallucis
13. 足底内侧动脉 medial plantar a.
14. 足底外侧神经 lateral plantar n.
15. 足底方肌 quadratus plantae
16. 蚓状肌 lumbricales
17. 趾长屈肌(腱) flexor digitorum longus (tendon)
18. 胫后动脉 posterior tibial a.
19. 胫骨后肌(腱) tibialis posterior(tendon)

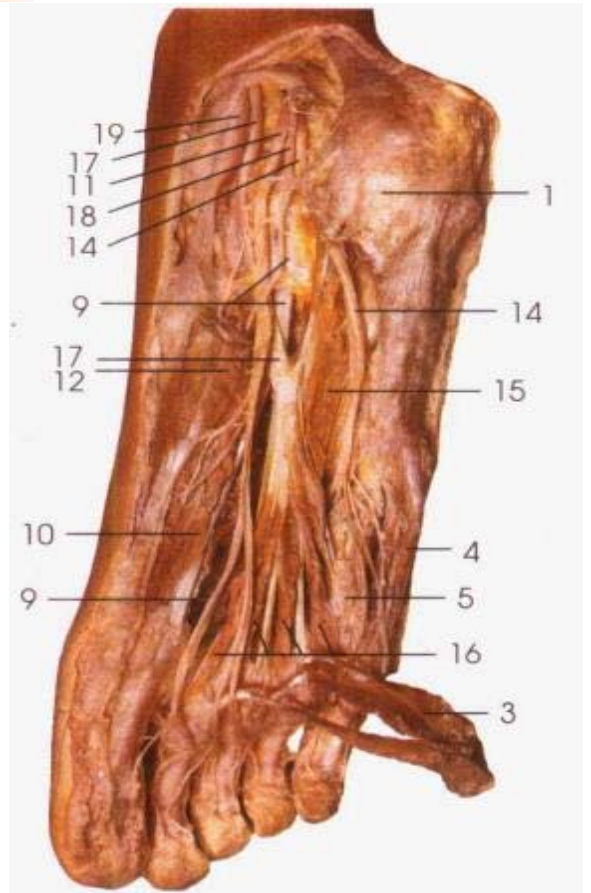


图 292 足底肌、神经和血管(II)
Muscles, nerves and blood vessels of the sole of foot(II)

1. 腓深神经 deep peroneal n.
2. 胫前动脉 anterior tibial a.
3. 胫骨前肌 tibialis anterior
4. 踇长伸肌 extensor hallucis longus
5. 趾长伸肌 extensor digitorum longus
6. 伸肌上支持带 superior extensor retinaculum
7. 腓浅神经 superficial peroneal n.
8. 伸肌下支持带 inferior extensor retinaculum
9. 趾短伸肌 extensor digitorum brevis

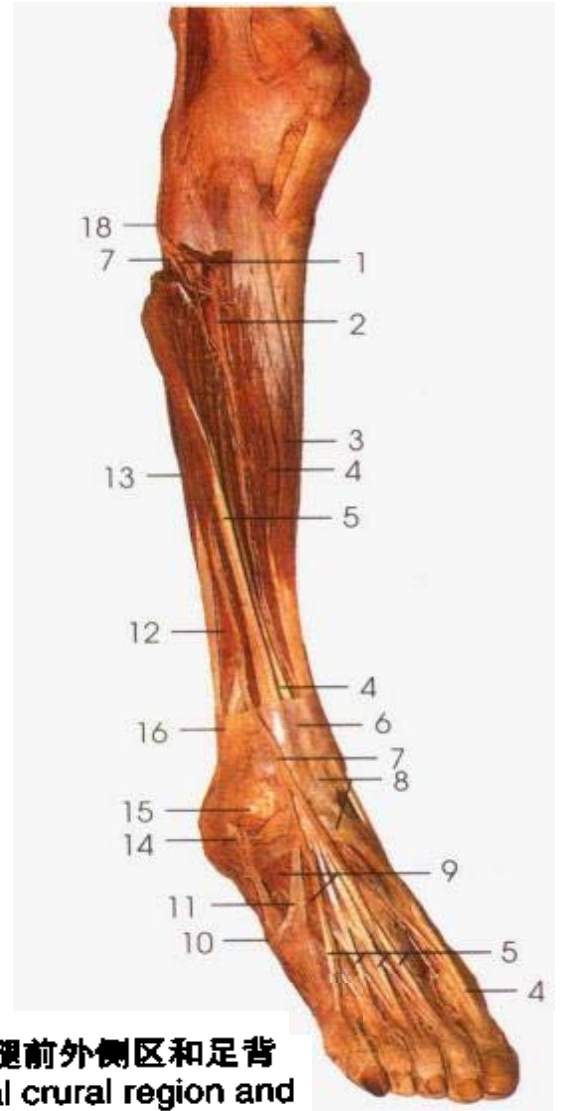

图 293 小腿前外侧区和足背
Anteriolateral crural region and
dorsum of foot

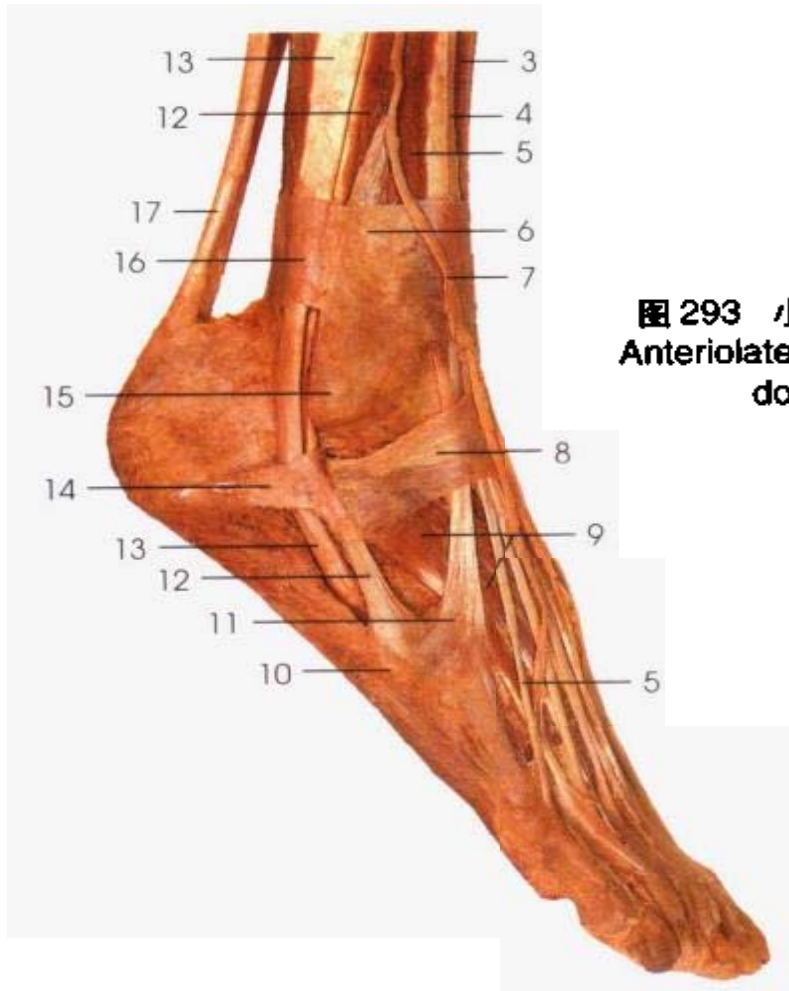


图 294 小腿伸肌支持带和腓骨肌支持带
Extensor retinaculum and peroneal
retinaculum of the leg.

10. 第五跖骨粗隆 tuberosity of fifth metatarsal bone
11. 第三腓骨肌(腱) peroneus tertius (tendon)
12. 腓骨短肌(腱) peroneus brevis (tendon)
13. 腓骨长肌(腱) peroneus longus (tendon)
14. 腓骨肌下支持带 inferior peroneal retinaculum
15. 外踝 lateral malleolus
16. 腓骨肌上支持带 superior peroneal retinaculum
17. 跟腱 tendo calcaneus
18. 腓总神经 common peroneal n.

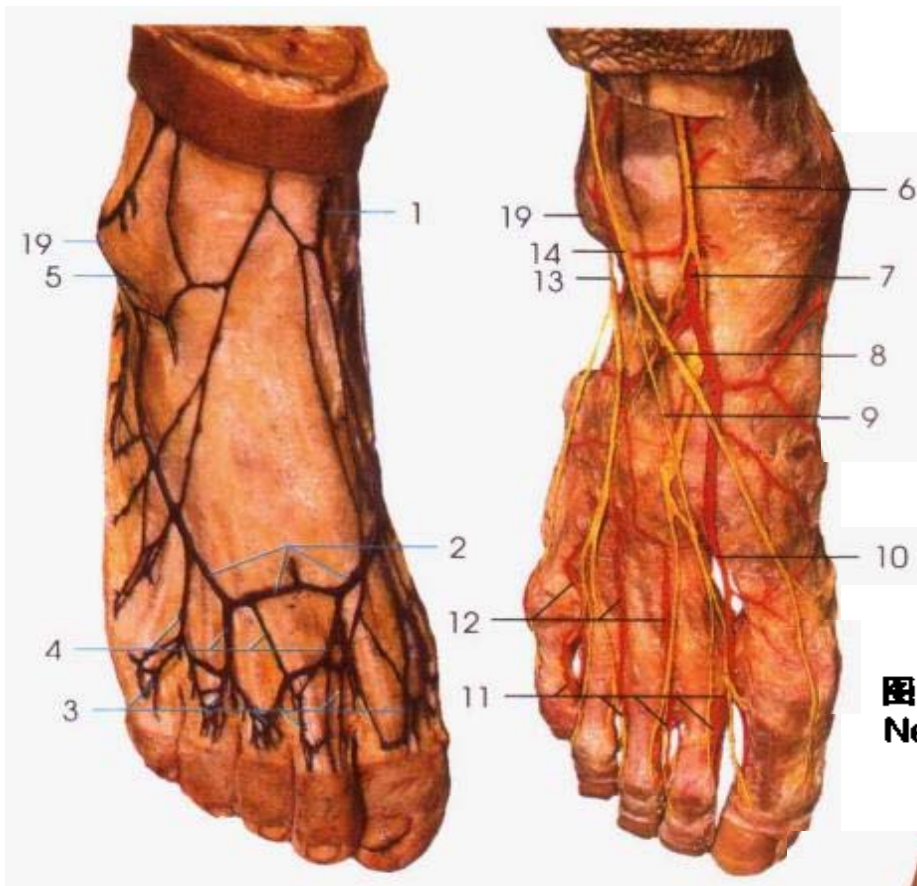


图 295 足背的浅静脉(上面观)
Superficial veins of the dorsum of foot (superior aspect)

6. 腓深神经 deep peroneal n.
7. 足背动脉 dorsal a. of foot
8. 足背内侧皮神经 medial dorsal cutaneous n. of foot
9. 足背中间皮神经 intermediate dorsal cutaneous n. of foot
10. 第一跖背动脉 first dorsal metatarsal a.
11. 趾背神经和动脉 dorsal digital n. and a. of foot
12. 跖背动脉 dorsal metatarsal a.
13. 足背外侧皮神经 lateral dorsal cutaneous n. of foot
14. 腓浅神经 superficial peroneal n.
15. 趾短伸肌 extensor digitorum brevis
16. 骨间背侧肌 dorsal interossei
17. 腓骨短肌(腱) peroneus brevis (tendon)
18. 腓骨长肌(腱) peroneus longus (tendon)
19. 外踝 lateral malleolus

1. 大隐静脉 great saphenous v.
2. 足背静脉弓 dorsal venous arch of foot
3. 趾背静脉 dorsal digital v. of foot
4. 跖背静脉 dorsal metatarsal v.
5. 小隐静脉 small saphenous v.

图 296 足背的神经和动脉
Nerves and arteries of the dorsum of foot

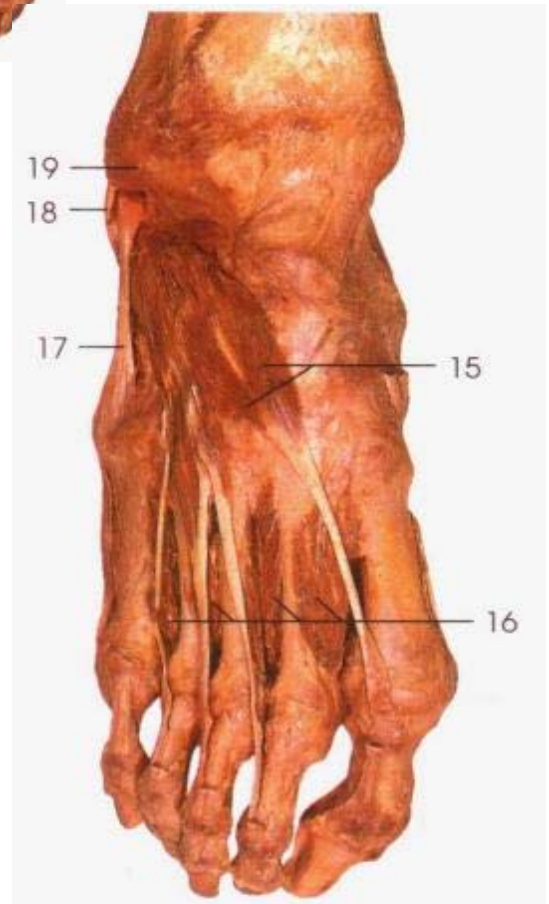


图 297 足肌(上面观)
Muscles of the foot (superior aspect)

索引

A

鞍背 dorsum sellae 12

B

白交通支 white communicating branch 144
板内核群 intralaminar nuclear group 155
板障 diploe 3
半奇静脉 hemiazygos v. 117
半羽状肌 unipennate muscle 46
半月瓣小结 nodule of semilunar valve 106
膀胱 urinary bladder 82,83,84,206,208
膀胱尖 apex of urinary bladder 88
膀胱静脉丛 vesical venous plexus 90
膀胱三角 trigone of bladder 89
膀胱下动脉 inferior vesical a. 208
背侧丘脑 dorsal thalamus 146,158,159,161,166
背内侧核 dorsomedial nucleus 155
贲门 cardia 57
贲门切迹 cardiac incisure 57
鼻骨 nasal bone 10,13,67
鼻后孔 posterior nasal aperture 11
鼻泪管 nasolacrimal duct 127
鼻泪管开口 orifice of nasolacrimal duct 69
鼻窦窦的开口 Orifices of paranasal sinuses 69
鼻前棘 anterior nasal spine 18
鼻前庭 nasal vestibule 68,69
鼻腔 nasal cavity 66
鼻切迹 nasal notch 18
鼻阈 limen nasi 68,69
鼻中隔 nasal septum 10,55,68
鼻中隔软骨 septal cartilage of nose 67
比目鱼肌 soleus 214,215
比目鱼肌线 soleal line 27
闭孔 obturator foramen 24,37,209
闭孔膜 obturator membrane 37
闭孔内肌(腱) obturator internus (tendon) 214
闭孔神经 obturator n. 142,213
臂丛 brachial plexus 142,184,185
臂丛内侧束 medial cord of brachial plexus 191
边缘动脉 marginal a. 203,204

扁骨 flat bone 3

扁肌 flat muscle 45

杓横肌 transeverse arytenoid m. 73

杓会厌襞 aryepiglottic fold 73

杓斜肌 oblique arytenoid m. 72,73

杓状软骨 arytenoid cartilage 70,71

髌底 base of patella 26

髌骨 patella 2,40,43

髌尖 apex of patella 26

髌面 patella surface 25,41

髌内侧支持带 medial patellar retinaculum 40

髌韧带 patellar lig. 40,41,42,43

髌上囊 suprapatellar capsule 43

髌外侧支持带 lateral patellar retinaculum 40

薄束核 gracile nucleus 148,160

薄束结节 gracile tubercle 146

不规则骨 irregular bone 3

C

苍白球 globus pallidus 159

侧副沟 collateral sulcus 157

侧副三角 collateral trigone 159

侧块 lateral mass 5

侧脑脉络丛 choroid plexus of lateral ventricle 159,169,170,172

侧脑室 lateral ventricle 159,171

侧脑室后角 posterior horn of lateral ventricle 170

侧脑室前角 anterior horn of lateral ventricle 170

侧脑室中央部 central part of lateral ventricle 170

侧切牙 lateral incisor

长脚 long crus 131

长收肌 adductor longus 212,213

肠干 intestinal trunk 114

肠系膜淋巴结 mesenteric lymph nodes 115

肠系膜上动脉 superior mesenteric a. 116,201,203

肠系膜上静脉 superior mesenteric v. 201,205

肠系膜上淋巴结 superior mesenteric lymph nodes 115,116

- 肠系膜下动脉 inferior mesenteric a. 204,206
肠系膜下静脉 inferior mesenteric v. 205
肠系膜下淋巴结 inferior mesenteric lymph nodes 116
尺侧副韧带 ulnar collateral lig. 35
尺侧腕屈肌 flexor carpi ulnaris 176,177,178
尺侧腕伸肌 extensor carpi ulnaris 178
尺动脉 ulnar a. 176,177
尺静脉 ulnar v. 176
尺骨 ulna 2,35
尺骨粗隆 ulnar tuberosity 22
尺骨茎突 styloid process of ulnar 22
尺骨体 shaft of ulna 22
尺切迹 ulnar notch 22
尺神经 ulnar n. 174,177,178
尺神经沟 sulcus for ulnar n. 21
尺神经浅支 superficial branch of ulnar n. 177,180
尺神经深支 deep branch of ulnar n. 180
尺神经手背支 dorsal branch of ulnar n. 179,180
齿突 dens 5
齿突凹 dental fovea 5
齿状核 dentate nucleus 153,154,166
齿状红核束 dentatorubral tract 166
齿状回 dentate gyrus 159
齿状丘脑束 dentatohalamic tract 166
齿状韧带 denticulate lig. 143
耻骨 pubis 24
耻骨弓 pubic arch 210
耻骨肌 pectineus 213
耻骨结节 pubic tubercle 24,37
耻骨联合面 symphyseal surface 24
耻骨联合腔 pubic symphysis cavity 37
耻股韧带 pubofemoral lig. 38
耻骨梳 pecten of pubis 24
垂体 hypophysis 67,69,138,139,171
垂体窝 hypophysial fossa 12,15
垂直板 perpendicular plate 17
锤骨 malleus 133
锤骨柄 manubrium of malleus 131
锤骨颈 neck of malleus 131
锤骨头 head of malleus 131
粗线 linea aspera 25
- D**
- 大多角骨 trapezium bone 23
大结节 greater tubercle 21
大结节嵴 crest of greater tubercle 21
大菱形肌 rhomboideus major 47
大脑半球 cerebral hemisphere 142
大脑大静脉 great cerebral v. 169
大脑后动脉 posterior cerebral a. 167,168,169,171
大脑脚 cerebral peduncle 146,147,154
大脑脚底 crus cerebri 151
大脑镰 cerebral falx 170,171
大脑内静脉 internal cerebral v. 169
大脑皮质 cerebral cortex 166
大脑上静脉 superior cerebral v. 169
大脑窝 cerebral fossa 17
大脑中动脉 middle cerebral a. 167,168,169,171
大脑中浅静脉 superficial middle cerebral v. 169
大收肌腱 adductor magnus tendon 40
大网膜 greater omentum 62,63,64,114
大翼 greater wing 12,15
大阴唇 greater lip of pudendum 97
大隐静脉 great saphenous v. 211,212,218
大圆肌 teres major 47,195,196
大转子 greater trochanter 25,38
胆囊 gallbladder 50,58,60,61,62,114,202
胆囊底 fundus of gallbladder 61,64
胆囊管 cystic duct 61
胆囊颈 neck of gallbladder 61
胆囊淋巴结 cystic lymph node 114
胆囊体 body of gallbladder 61
胆总管 common bile duct 60,61,202
弹性圆锥 conus elasticus
岛长回 long gyrus of insula 157
岛短回 short gyrus of insula 157
道上嵴 suprameatal spine 16
道上小凹 suprameatal foveola 16
镫骨 stapes 131
底丘脑核 subthalamic nucleus 166
骶丛 sacral plexus 209
骶粗隆 sacral tuberosity 8
骶骨 sacrum 2,4,209
骶骨尖 apex of sacrum 8
骶管 sacral canal 8
骶管裂孔 sacral hiatus 8
骶后孔 posterior sacral foramen 8
骶棘韧带 sacrospinous lig. 37
骶岬淋巴结 lymph node of promontory 115

- 骶角 sacral cornu 8
 骶结节韧带 sacrotuberous lig. 37,214
 骶髂背侧韧带 dorsal sacroiliac lig. 37
 骶髂腹侧韧带 ventral sacroiliac lig. 37
 骶髂关节 sacroiliac joint 37
 骶前孔 anterior sacrum foramen 8
 骶外侧嵴 lateral sacral crest 8
 骶翼 alar of sacrum 8
 骶正中动脉 median sacral a. 207,208
 骶正中嵴 median sacral crest 8
 骶中间嵴 intermediate sacral crest 8
 第11肋 11th rib 85
 第12肋 12th rib 85
 第二肋切迹 2nd costal notch 9
 第二磨牙 molars II 51,52
 第二前磨牙 premolars II 51,52
 第二乳磨牙 deciduous molars II 52
 第六、七肋切迹 6,7th costal notches 9
 第三腓骨肌(腱) peroneus tertius(tendon) 217
 第三肋切迹 3rd costal notch 9
 第三脑室 third ventricle 159,171
 第三脑室脉络丛 choroid plexus of third ventricle 172
 第四肋切迹 4th costal notch 9
 第四脑室 fourth ventricle 153,156
 第四脑室脉络丛 choroid plexus of fourth ventricle 153,172
 第四脑室正中孔 median aperture of fourth ventricle 172
 第五肋切迹 5th costal notch 9
 第五跖骨 5th metatarsal bone 29
 第五跖骨粗隆 tuberosity of fifth metatarsal bone 28,217
 第一肋 first rib 80
 第一肋沟 groove for first rib 76
 第一肋切迹 1st costal notch 9
 第一磨牙 1st molars 51,52
 第一前磨牙 1st premolars 51,52
 第一乳磨牙 1st deciduous molars 52
 第一胸肋结合 sternocostal synchondrosis of first rib 33
 第一掌背动脉 first dorsal metacarpal a. 179
 第一掌指关节 first metacarpophalangeal joint 36
 第一跖背动脉 first dorsal metatarsal a. 218
 第一跖骨 1st metatarsal bone 29
 蝶窦 sphenoidal sinus 67,68,69
 蝶窦口 aperture of sphenoidal sinus 15,69
 蝶骨眶面 orbital surface for sphenoid bone 123
 蝶骨大翼 greater wing of sphenoid bone 13
 蝶嵴 sphenoid crest 15
 蝶甲 sphenoidal concha 15
 蝶下颌韧带 sphenomandibular lig. 33
 顶盖脊髓束 tectospinal tract 151
 顶盖前区 pretectal area 162
 顶骨 parietal bone 10
 顶后动脉 posterior parietal a. 168
 顶孔 parietal foramen 10
 顶内沟 intraparietal sulcus 156
 顶叶 parietal lobe 157
 顶枕沟 parietooccipital sulcus 156,157
 顶枕支 parietooccipital branch 168
 顶支 parietal branch 189
 动脉韧带 arteriosus lig. 101,191,193
 动脉圆锥 conus arteriosus 103,104
 动眼神经(Ⅲ) oculomotor n.(Ⅲ) 130,139,146,147,151,167,170
 动眼神经副核 accessory nucleus of oculomotor n. 147,151,162
 动眼神经核 nucleus of oculomotor n. 147,151,164
 豆钩韧带 pisohamate lig. 36
 豆状核 lentiform nucleus 147,154,158,159,161,166
 窦房结 sinuatrial node 110
 短骨 short bone 3
 短脚 short crus 131
 短收肌 adductor brevis 213
 对耳轮 antihelix 131
 对耳轮脚 crura of antihelix 131
 对耳屏 antitragus 131
 多腹肌 polyvent muscle 45
 多羽肌 multipennate muscle 45
- E**
- 额窦 frontal sinus 67,68,69
 额窦开口 orifice of frontal sinus 69
 额骨 frontal bone 10,13
 额极动脉 frontopolar a. 168
 额嵴 frontal crest 12
 额结节 frontal tuberosity
 额上沟 superior frontal sulcus 156
 额上回 superior frontal gyrus 156

- 额神经 frontal n. 130
额突 frontal process 18
额下沟 inferior frontal sulcus 156
额下回 inferior frontal gyrus 156
额叶 frontal lobe 157
额支 frontal branch 189
额中回 middle frontal gyrus 156
腭垂 uvula 55
腭垂肌 musculus uvulae 55
腭大沟 greater palatine sulcus 18
腭大孔 greater palatine foramen 11
腭帆提肌 levator veli palatini 55
腭帆张肌 tensor veli palatini 55
腭骨水平板 horizontal palate of palatine bone 55
腭横缝 transverse palatine suture 11
腭舌弓 palatoglossal arch 55
腭突 palatine process 11,18
腭小沟 lesser palatine sulcus 18
腭小孔 lesser palatine foramen 11,55
腭咽弓 palatopharyngeal arch 55,68
腭咽肌 palatopharyngeus 55
腭正中缝 median palatine suture 11
耳垂 auricular lobule 131
耳大神经 great auricular n. 120,182,188
耳后动脉 posterior auricular a. 189
耳甲 auricular concha 131
耳廓 auricle 132
耳轮 helix 131
耳轮脚 crus of helix 131
耳颞神经 auriculotemporal n. 54,188
耳屏 tragus 131
耳屏间切迹 intertragic notch 131
耳状面 auricular surface 8,24
二腹肌 digastric 45
二腹肌后腹 posterior belly of digastric 56,112
二腹肌窝 digastric fossa 14
二腹小叶 biventral lobule 152
二尖瓣后瓣 posterior cusp of mitral valve 105,107
二尖瓣前瓣 anterior cusp of mitral valve 103,104,105,106,107
- F**
方形膜 quadrangular membrane 73
方叶 quadrate lobe 60
房室结 atrioventricular node 110
房室束 atrioventricular bundle 110
腓侧副韧带 fibular collateral lig. 40,41
腓肠肌(内侧头) gastrocnemius (medial head) 214,215
腓肠肌(外侧头) gastrocnemius (lateral head) 214,215
腓肠外侧皮神经 lateral sural cutaneous n. 214
腓动脉 peroneal a. 215
腓骨长肌 peroneus longus 215,217,218
腓骨 fibula 2,40,41,42,43,44,45
腓骨短肌 peroneus brevis 217,218
腓骨颈 neck of fibula 27
腓骨体 shaft of fibula 27
腓骨头 head of fibula 27
腓骨头尖 apex of fibular head 27
腓关节面 fibular articular facet 27
腓浅神经 superficial peroneal n. 217,218
腓切迹 fibular notch 27
腓深神经 deep peroneal n. 217,218
腓总神经 common peroneal n. 214,217
肺 lung 66
肺动脉半月瓣 semilunar cusp of pulmonary trunk 104,107
肺动脉窦 sinus of pulmonary trunk 104,107
肺动脉干 pulmonary trunk 100,101,103,104,106,108,109,193,195
肺动脉叶间部 interlobular part of pulmonary a. 76
肺尖 apex of lung 76,77
肺门淋巴结 pulmonary lymph nodes 113
肺韧带 pulmonary lig. 76,80,191
分岐韧带 bifurcated lig. 44
缝匠肌 sartorius 212
跗跖背侧韧带 dorsal tarsometatarsal lig. 44
跗跖关节 tarsometatarsal joints 45
跗跖足底韧带 plantar tarsometatarsal lig. 44
辐射冠 corona radiata 147,154
附睾 epididymis 92
附睾头 head of epididymis 92,199
副睾丸动脉 accessory testicular a. 206
副腮腺 accessory parotid gland 54
副神经(XI) accessory n.(XI) 132,133,146,182,183,184,187
副神经核 nucleus of accessory n. 147,148,164
副肾动脉 accessory renal a. 87

- 腹壁浅静脉 superficial epigastric v. 119
 腹壁上动脉、静脉 superior epigastric a.v. 197
 腹壁下动、静脉 inferior epigastric a.& v. 197,200
 腹壁下动脉闭孔支(副闭孔动脉) obturator branch of inferior epigastric a. (accessory obturator a.) 207
 腹股沟管浅环 superficial inguinal ring 197,198,199
 腹股沟镰 inguinal falx 37,198,199
 腹壁下动脉 inferior epigastric a. 199
 腹股沟韧带 inguinal lig. 198,199,207,208,211,213
 腹股沟上内侧浅淋巴结 superomedial superficial inguinal lymph nodes 119
 腹股沟上外侧浅淋巴结 superolateral superficial inguinal lymph nodes 119
 腹股沟下浅淋巴结 inferior superficial inguinal lymph nodes 119
 腹横肌 transversus abdominis 197,199,200
 腹后内侧核 ventral posteromedial nucleus 155,161
 腹后外侧核 ventral posterolateral nucleus 155,160,161
 腹膜 peritoneum 200
 腹膜外脂 extraperitoneal fat 200
 腹内侧核 ventromedial nucleus 155
 腹内斜肌 obliquus internus abdominis 48,197,198,199
 腹前核 ventral anterior nucleus 155
 腹腔干 celiac trunk 201,206
 腹外斜肌 abliquus externus abdominis m. 48,197,198
 腹外斜肌(腱膜) obliquus externus abdominis (aponeurosis) 198,199
 腹直肌 rectus abdominis m. 194,199,200
 腹直肌鞘后层 posterior layer of sheath of rectus abdominis 197
 腹直肌鞘前层 anterior layer of sheath of rectus abdominis 197,198,199
 腹中间核 ventral intermediate nucleus 155
 腹主动脉 abdominal aorta 84,87,116,200,202,204,207
- G**
 盖膜 tectorial membrane 135
 肝 liver 50,58
 肝固有动脉 proper hepatic a. 201
 肝圆韧带 ligamentum teres hepatis 60,61,62,205
 肝固有动脉 proper hepatic a. 60,61
 肝静脉 hepatic v. 61
 肝淋巴结 hepatic lymph nodes 114
 肝裸区 bare area of liver 60
 肝门静脉 hepatic portal v. 60,205
 肝肾隐窝(囊) hepatorenal recess(pouch) 202
 肝圆韧带裂 fissure for ligamentum teres hepatis 60
 肝胃韧带 hepatogastric ligament 60
 肝胰腹壶 hepatopancreatic ampulla 61
 肝右叶 right lobe of liver 60,61,62,64,205
 肝总动脉 common hepatic a. 201
 肝总管 common hepatic duct 61
 肝左叶 left lobe of liver 60,61,62,64
 橄榄 olive 146,147,154
 橄榄脊髓束 olivospinal tract 145
 冈上肌 supraspinatus 47,175,195,196
 冈上窝 supraspinous fossa 20
 冈下肌 infraspinatus 47,175,196
 冈下窝 infraspinous fossa 20
 肛瓣 anal valves 59
 肛窦 anal sinuses 59
 肛门 anus 50,91,97,98,210
 肛门括约肌 sphincter muscles of the anus 91
 肛门内括约肌 sphincter ani internus 59
 肛门外括约肌 external anal sphincter 59,97,98,210
 肛神经、动脉 anal n. & a. 210
 肛提肌 levator ani 90,97,98,209,210
 肛提肌腱弓 tendinous arch of levator ani 209
 肛柱 anal column 59
 睾丸 testis 82,84,92,93,138,198,199
 睾丸动脉 testicular a. 199
 睾丸静脉 testicular v. 199
 隔膜肉柱 septomarginal trabeculae 103,110
 膈 diaphragm 56,58,60,62,64,84,191,192,194,202
 膈侧乳头肌 septal papillary m. 104
 膈和膈胸膜 diaphragm and diaphragmatic pleura 80
 膈结肠韧带 phrenicocolic ligament 202
 膈面 diaphragmatic surface 76,77,118
 膈神经 phrenic n. 142,183,184,185,191
 膈胸膜 diaphragmatic pleura 193
 跟腓韧带 calcaneofibular lig. 44

- 跟骨 calcaneus 28,45,216
跟骨结节 calcaneal tuberosity 28
跟腱 tendo calcaneus 44,215,217
跟骰背侧韧带 dorsal calcaneocuboid lig. 44
跟骰关节 calcaneocuboid joint 45
弓状核 arcuate nucleus 155
弓状隆起 arcuate eminence 12,16,134
弓状线 arcuate line 24
腓动脉 popliteal a. 214,215
腓静脉 popliteal v. 214,215
肱动脉 brachial a. 174,176,177
肱二头肌 biceps brachii 176,177
肱二头肌长头腱 long head tendon of biceps brachii 34
肱二头肌腱 bicipital tendon 35,177
肱二头肌腱膜 bicipital aponeurosis 177
肱骨 humerus 2,34,35
肱骨滑车 trochlea of humerus 21,35
肱骨内上髁 medial epicondyle of humerus 21
肱骨体 shaft of humerus 21
肱骨头 head of humerus 21
肱骨外上髁 lateral epicondyle of humerus 21
肱骨小头 capitulum of humerus 21
肱桡肌 brachioradialis 176,177
肱三头肌 triceps brachii 47,178
肱三头肌长头 long head of triceps brachii 175,195,196
肱深动脉 deep brachial a. 174,175
巩膜 sclera 124,125
钩骨 hamate bone 23
钩骨钩 hamulus of hamate bone 23,36
孤束 solitary tract 149
孤束核 nucleus of solitary tract 147,149
股薄肌 gracilis 212,213
股动脉 femoral a. 213
股二头肌 biceps femoris 174,175,214
股二头肌(长头) biceps femoris(long head) 195
股二头肌(短头) biceps femoris(short head) 195
股方肌 quadratus femoris 214
股骨 femur 2,40,41,42,43
股骨大转子 greater trochanter
股骨颈 neck of femur 25,39
股骨体 shaft of femur 25
股骨头 femur head 25
股骨头凹 fovea of femoral head 25
股管及腹股沟深淋巴结 femoral canal and deep inguinal lymph nodes 213
股后皮神经 posterior femoral cutaneous n. 214
股静脉 femoral v. 207,208,211,213
股动脉 femoral a. 207,208,212,213
股内侧肌 vastus medialis 40,212,213
股内侧浅静脉 medial superficial femoral v. 119
股鞘 femoral sheath 212
股深动脉 deep femoral a. 213
股深静脉 deep femoral v. 213
股神经 femoral n. 84,142,206,207,208,212,213
股四头肌腱 quadriceps femoris tendon 43
股外侧肌 vastus lateralis 40,212
股外侧皮神经 lateral femoral cutaneous n. 84,206,208
股外侧浅静脉 lateral superficial femoral v. 119
股直肌 rectus femoris 40,212,213
骨半规管 bony semicircular canals 132
骨间背侧肌 dorsal interossei 181,218
骨间返动脉 recurrent interosseous a. 178
骨间后动脉 posterior interosseous a. 178
骨间前动脉和神经 interosseus anterior a. and n. 177
骨间前动脉后支 posterior branch of anterior interosseous a. 178
骨间掌侧肌 palmar interossei 181
骨螺旋板 osseous spiral lamina 135
骨迷路 bony labyrinth 136
骨膜 periosteum 3,132
骨髓 bone marrow 3
鼓部 tympanic part 16
鼓阶 scala tympani 135
鼓膜 tympanic membrane 132
鼓膜张肌 tensor tympani 133
鼓室盖 tegmen tympani 12,16
关节凹 articular fovea 22
关节结节 articular tubercle 11,13,16,33
关节面 articular surface 26
关节囊 articular capsule 33,34,35,38,195,196
关节盘 articular disc 33
关节腔 articular cavity 33,34,35
关节软骨 articular cartilage 3,34
关节突关节 zygapophysial joints 32
关节盂 glenoid cavity 19,20,34,36
冠突 coronoid process 13,14,22
冠突窝 coronoid fossa 21
冠状窦 coronary sinus 102

- 冠状窦瓣 valve of coronary sinus 103
 冠状窦口 orifice of coronary sinus 103
 冠状缝 coronal suture 10,13
 贵要静脉 basilic v. 175,176,179
- H**
- 哈特曼囊 hartmann's pouch 64
 海马 hippocampus 159,170
 海马旁回 parahippocampal gyrus 157,159
 海马伞 fimbria of hippocampus 159
 海绵窦 cavernous sinus 171
 黑质 substantia nigra 151
 横窦 transverse sinus 170
 横窦沟 sulcus for transverse sinus 12
 横结肠 transverse colon 62,63,64,115,203,204
 横突 transverse process 5,6,7
 横突间肌 intertransversarii 48
 横突间韧带 intertransverse lig. 31
 横突孔 transverse foramen 5,6
 横突肋凹 transverse costal fovea 6
 红核 red nucleus 151,166
 红核脊髓束 rubrospinal tract 145,166
 虹膜 iris 124,125
 喉结 laryngeal prominence 70,71
 喉前庭 laryngeal vestibule 73
 喉腔 laryngeal cavity 66
 喉上动脉 superior laryngeal a. 185,189
 喉上神经 superior laryngeal n. 186,187
 喉中间腔 intermedial cavity of larynx 73
 后半规管 posterior semicircular canal 133
 后端 posterior extremity 118
 后房 posterior chamber 124
 后根 posterior root 143
 后弓 posterior arch 5
 后骨半规管 posterior semicircular canal 135
 后核 posterior nucleus 155
 后交叉韧带 posterior cruciate lig. 41,42
 后交通动脉 posterior communicating a. 167,171
 后角 posterior horn 158
 后脚 posterior crus 131,145
 后结节束 posterior internodal tract 110
 后结节 posterior tubercle 5,6
 后乳头肌 posterior papillary m. 104
 后室间动脉 posterior interventricular a. 102
 后室间沟 posterior interventricular sulcus 109
 后脚固有核 nucleus proprius 145
 后室间支 posterior interventricular branch 102
 后索 posterior funiculus 145
 后外侧窝 posterolateral fontanelle 13
 后斜角肌 scalenus posterior 48
 后囟 posterior fontanelle 13
 后正中沟 posterior median sulcus 143,146
 后支 posterior branch 144
 后纵隔淋巴结 posterior mediasternal lymph nodes 194
 后纵韧带 posterior longitudinal lig. 31,32
 壶腹帽 cupua 136
 滑车切迹 trochlear notch 22
 滑车上神经 supratrochlear n. 127,130
 滑车神经(IV) trochlear n.(IV) 146,147,171
 滑车神经核 nucleus of trochlear n. 147,151,164
 滑车下神经 infratrochlear n. 127
 环杓侧肌 lateral cricoarytenoid m. 72
 环杓后肌 posterior cricoarytenoid m. 72,73
 环肌层 stratum circularis of muscularis 59
 环甲肌 cricothyroid 186
 环甲肌斜部 oblique part of cricothyroid m. 72
 环甲肌直部 straight part of cricothyroid m. 72
 环甲韧带 cricothyroid lig. 70,71
 环甲正中韧带 median cricothyroid lig. 74
 环状关节面 articular circumference 22
 环状软骨 Cricoid cartilage 70,72,73,74
 环状软骨板 lamina of cricoid cartilage 70,71,72
 环状软骨弓 arch of cricoid cartilage 70,71,72
 寰枢外侧关节 lateral atlantoaxial joint 32
 寰椎横韧带 transverse lig. of atlas 32
 寰椎十字韧带 cruciform lig. of atlas 32
 黄斑 macula lutea 125
 黄斑上小动脉 superior macula arteriole 125
 黄斑上小静脉 superior macular venule 125
 黄斑下小动脉 inferior macular arteriole 125
 黄斑下小静脉 inferior macular venule 125
 黄韧带 ligamenta flava 31
 灰白交通支 gray and white rami communicantes 191,192
 灰交通支 gray communicating branch 144
 回肠 ileum 50,58,63,203,205
 回肠动脉 ileal a. 203
 回结肠动脉 ileocolic a. 203
 回结肠静脉 ileocolic v. 205
 回结肠淋巴结 ileocolic lymph nodes 115
 回盲瓣 lips of ileocecal valve 58

会厌 epiglottis 53,55,68,71,72,73
会厌软骨 epiglottic cartilage 70,71,73
会阴浅横肌 superficial transverse muscle of perineum 90,97,210
会阴浅筋膜 superficial fascia of perineum 90
会阴深横肌 deep transverse muscle of perineum 90,98,210
会阴神经. 动脉 perineal n.& a. 210
会阴体 perineal body 90,98
喙肱肌 coracobrachialis 174
喙锁韧带 coracoclavicular lig. 34
喙突 coracoid process 19,20,34,195

J

肌腹 muscle belly 46
肌腱 tendon 46
肌皮神经 musculocutaneous n. 174
肌头 head of muscle 46
肌突 muscular process of arytenoid cartilage 71
肌咽鼓管 musculotubal canal 16
鸡冠 crista galli 12,17
基底部 basilar part 17
基底动脉 basilar a. 167,171
基底沟 basilar sulcus 146
棘肌 spinalis 48
棘间肌 interspinales 48
棘孔 foramen spinosum 11,12,15
棘上韧带 supraspinal lig. 31
棘突 spinous process 5,6,7,85
脊神经节 spinal ganglion 144,160,161
脊神经前支 anterior branch of spinal n. 194
脊髓 spinal cord 142,144,160,161,163,166,202
脊髓顶盖束 spinotectal tract 145
脊髓丘脑束 spinothalamic tract 145,148,149,161
脊髓小脑后束 posterior spinocerebellar tract 145,148,166
脊髓小脑前束 anterior spinocerebellar tract 145,148
脊髓圆锥 conus medullaris 143
脊髓蛛网膜 spinal arachnoid mater 143
岬 promontory 8,134
颊动脉 buccal a. 189
颊支 buccal branches 54,188
甲杓肌 thyroarytenoid m. 72
甲关节面 thyroid articular surface 70
甲状会厌韧带 thyroepiglottic lig. 70,71

甲状颈干 thyrocervical trunk 174,184
甲状软骨 thyroid cartilage 54,70,71,73,140,186
甲状软骨板 lamina of thyroid cartilage 70,73,74
甲状软骨上角 superior cornu of thyroid cartilage 55,70,71,72
甲状软骨上切迹 superior thyroid notch 70
甲状软骨下角 inferior cornu of thyroid cartilage 70,72
甲状软骨右板 right lamina of thyroid cartilage 72
甲状舌骨肌 thyrohyoid 54,186
甲状舌骨膜 thyrohyoid membrane 70,71,73
甲状腺 thyroid gland 56,113,138,184,185,187
甲状腺侧叶 lateral lobe of thyroid gland 186
甲状腺上动脉 superior thyroid a. 184,185,186,189
甲状腺上静脉 superior thyroid v. 112
甲状腺峡 isthmus of thyroid gland 186
甲状腺下动脉 inferior thyroid a. 174,184,187
甲状腺下静脉 inferior thyroid v. 100,112,186
甲状腺右叶 right lobe of thyroid gland 140
甲状腺左侧叶 Thyroid gland(Left lobe) 56
尖淋巴结 apical lymph nodes 119
尖牙 canine teeth 51,52
尖牙窝 canine fossa 18
肩峰 acromion 19,20,34
肩峰端 acromial end 19
肩峰关节面 acromial articular surface 19
肩峰角 acromial angle 19,20
肩胛冈 spine of scapula 20
肩胛骨 scapula 2,34
肩胛颈 neck of scapula 20
肩胛切迹 notch of scapula 20
肩胛上动脉 suprascapular a. 174
肩胛上横韧带 superior transverse scapular lig. 34
肩胛舌骨肌 omohyoid m. 112,184
肩胛舌骨肌上腹 omohyoid superior belly 183
肩胛舌骨肌下腹 inferior belly of omohyoid 183
肩胛提肌 levator scapulae 47
肩胛下肌 subscapularis 195
肩胛下淋巴结 subscapular lymph nodes 119
肩胛下窝 subscapular fossa 20
肩锁关节 acromioclavicular joint 34
睑板腺 tarsal glands 123
睑板腺管 tarsal gland duct 123
睑结膜 palpebral conjunctival 122,123,125

- 睑内侧连合 medial palpebral commissure 127
 睑内侧韧带 medial palpebral lig. 126,127,189
 睑外侧连合 lateral palpebral commissure 126,127
 睑外侧韧带 lateral palpebral lig. 127,189
 睑缘 palpebral edge 122
 剑突 xiphoid process 9,33
 腱划 tendinous intersections 46
 腱间结合 intertendinous connections 178
 腱膜 aponeurosis 46
 腱索 chordae tendineae 105,106
 浆膜层 serosa 57
 降结肠 descending colon 63,116,204,205
 降口角肌 depressor anguli oris 188,189
 降下唇肌 depressor labii inferioris 189
 降主动脉沟 groove for descending aorta 77
 交叉前沟 sulcus prechiasmaticus 12,15
 交感干 sympathetic trunk 142,144,185,191,194.
 交感颈上节 superior cervical ganglion 185,187
 交感颈中节 middle cervical ganglion 185
 交感神经节 sympathetic ganglion 191
 胶状质 substantia gelatinosa 145
 角回 angular gyrus 156
 角回动脉 a. of angular gyrus 168
 角膜 cornea 122,124,125,127,129
 角膜缘 limbus corneae 122
 角切迹 angular incisure 57
 脚间池 interpeduncular cistern 172
 脚间窝 interpeduncular fossa 146
 结肠右曲 right colic flexure 50,62,63,64,205
 结肠左曲 left colic flexure 202,204,205
 结节间沟 intertubercular sulcus 21
 结膜半月襞 conjunctival semilunar fold 122,127
 结膜囊 conjunctival sac 124
 结膜上穹 superior conjunctival fornix 125
 结膜下穹 inferior conjunctival fornix 125
 睫 ciliary 122
 睫状襞 ciliary folds 124
 睫状神经节 ciliary ganglion 130,162
 睫状体 ciliary body 124
 睫状突 ciliary processes 124
 睫状缘 ciliary margin 124
 解剖颈 anatomical neck 21
 界沟 sulcus limitans 146
 界嵴 crista terminalis 103
 近节趾骨 proximal phalanx 23,29
 茎乳孔 stylomastoid foramen 11,16
 茎突 styloid process 11,13,16,22,32,33,132
 茎突舌骨肌 stylohyoid m. 55,56
 茎突下颌韧带 tylomandibular lig. 33
 茎突咽肌 Stylopharyngeus m. 55,56
 晶状体 lens 124,125
 精囊腺 seminal vesicle 82,88,89,91
 精索 spermatic cord 84,92,93,197,198,199,211
 颈半棘肌 semispinalis cervicis 48
 颈丛 cervical plexus 182,183,184,186
 颈动脉窦 carotid sinus 184,185
 颈动脉沟 carotid sulcus 12
 颈动脉管 carotid canal 16,134
 颈横动脉 tranverse cervical a. 184
 颈横神经 tranverse nerve of neck 182
 颈交感干 cervical sympathetic trunk 187
 颈静脉孔 jugular foramen 12,32
 颈静脉切迹 jugular notch 9
 颈静脉窝 jugular fossa 11,16
 颈阔肌 platysma 189
 颈内动脉 interior carotid a. 32,129,132,133, 167,170,171,185,189
 颈内静脉 internal carotid v. 112,132,140,183,186
 颈内静脉二腹肌淋巴结 jugulodigastric lymph node 112
 颈内静脉肩脾舌骨肌淋巴结 juguloomohyoid lymph node 112
 颈襻 ansa cervicalis 183
 颈膨大 cervical enlargement 143
 颈肋肋肌 iliocostalis cervicis 48
 颈前浅淋巴结 anterior superficial cervical lymph node 120
 颈外侧浅淋巴结 superficial lateral cervical lymph nodes 120
 颈外侧深淋巴结 deep lateral cervical lymph nodes 112,120
 颈外动脉 external carotid a. 185,189
 颈外静脉 external jugular v. 120,182,188
 颈支 cervical branch 188
 颈椎 cervical vertebrae 2,4
 颈总动脉 common carotid a. 54,170,184,185,186, 187,189
 颈最长肌 longissimus cervicis 48
 胫侧副韧带 tibial collateral lig. 40
 胫腓关节 tibiofibular joint 43
 胫腓前韧带 anterior tibiofibular lig. 43,44

胫骨 tibia 2,40,41,42,43,44,45
胫骨粗隆 tuberosity of tibia 27
胫骨后肌 tibialis posterior 215
胫骨前肌 tibialis anterior 217
胫骨体 shaft of tibia 27
胫后动脉 posterior tibial a. 215,216
胫神经 tibial n. 214,215
胫神经及胫后动脉 tibial n. and posterior tibial a. 215
距腓前韧带 anterior talofibular lig. 44
距跟骨间韧带 interosseous talocalcaneal lig. 44,45
距跟舟关节 talocalcaneonavicular joint 45
距骨 talus 28,29
距小腿关节(踝关节) talocrural (ankle) joint 45
距状沟 calcarine sulcus 156,157
距状沟支 calcarine branch 167
菌状乳头 fungiform papillae 53

K

颈棘 mental spine 14
颈孔 mental foramen 10,13,14
颈隆凸 mental protuberance 14
颈舌骨肌 geniohyoid 53,54
颈舌肌 genioglossus m. 53,68
颌下静脉 submental v.
髁管 condylar canal 11,17
髁间隆起 intercondylar eminence 27
髁突 condylar process 13,14,33
壳 putamen 159
空肠 jejunum 50,63,203
空肠动脉 jejunal a. 203
空肠静脉 jejunal v. 205
口轮匝肌 orbicularis oris 189
口腔 oral cavity 50,66
扣带沟 cingulate sulcus 156
扣带回 cingulate gyrus 156,157
髌骨 hip bone 2
髌关节囊 hip articular capsule 37
髌臼 acetabulum 24
髌臼横韧带 transverse acetabular lig. 38
髌臼切迹 acetabular notch 24
髌臼窝 acetabular fossa 24
眶板 orbital plate 17
眶面 orbital surface 15
眶上孔 supraorbital foramen 10

眶上切迹 superior orbital notch 10,123
眶上缘 supraorbital margin 123
眶下沟 infraorbital groove 18
眶下孔 infraorbital foramen 10,18,123
眶下裂 inferior orbital fissure 10,123
眶下神经 infraorbital n. 130
眶脂体 adipose body of orbit 124,125,128
阔筋膜 fascia lata 212
阔筋膜张肌 tensor fasciae latae 212

L

阑尾 vermiform appendix 58,203,204
阑尾动脉、静脉 appendicular a.v. 203
阑尾系膜 mesoappendix 203,204
肋 rib 2,194
肋膈隐窝 costodiaphragmatic recess. 60,62,202
肋骨 costal bone 10,30,31,33
肋横突关节 costotransverse joint 30
肋横突上韧带 superior costotransverse lig. 30,31
肋间动脉 intercostal a. 191
肋间后动脉 posterior intercostal a. 194
肋间后静脉 posterior intercostal v. 194
肋间内肌 intercostales interni 194
肋间外肌 intercostales externi 48,194
肋间隙 intercostal space 33
肋间最内肌 innercostales intimi 194
肋角 costal angle 9
肋结节 costal tubercle 9
肋颈 costal neck 9
肋软骨 costal cartilage 33,194
肋锁韧带压迹 impression for costoclavicular lig 19
肋体 shaft of rib 9
肋头 costal head 9
肋头辐状韧带 radiate lig. of costal head 30,31
肋头关节 joint of costal head 30,31
肋胸膜 costal pleura 80
泪阜 lacrimal caruncle 122
泪沟 lacrimal groove 18
泪后嵴 posterior lacrimal crest
泪囊 lacrimal sac 127
泪囊窝 fossa for lacrimal sac 123
泪器(右侧) the lacrimal apparatus (right side) 127
泪腺 lacrimal gland 124,126,127,130
泪腺排泄小管 excretory ductules of

lacrimal 127
 泪腺神经 lacrimal n. 130
 泪腺窝 fossa for lacrimal gland 123
 梨状肌 piriformis 214
 梨状孔 piriform aperture 10
 梨状隐窝 piriform recess 55
 犁骨 vomer 11,67
 镰状韧带 falciform ligament of liver 60,62
 鳞部 squamous part 16
 漏斗 infundibulum 146,154,171
 颅骨 cranial bones 2
 卵巢 ovary 95,96,208
 卵巢动脉 ovarian a. 208
 卵巢固有韧带 proper lig. of ovary 83,95
 卵巢系膜 mesovarium 96
 卵巢悬韧带 suspensory lig. of ovary 83,96
 卵圆孔 foramen ovale 11,12,15
 卵圆窝 foramen valis 103,110
 镰状韧带 falciform ligament of liver 62
 轮廓乳头 vallate papillae 53
 轮匝带 zona orbicularis 38
 轮匝肌 orbicular muscle 46
 螺旋嵴 spiral crest 135

M

马尾 cauda equina 143
 脉络膜 choroid 124
 盲肠 caecum 58,115,203,205
 盲孔 foramen caecum 12
 眉 eyebrows 122
 眉弓 Superciliary arch 10
 眉间 glabella 10
 门静脉 portal v. 60,61,202
 迷走神经(X) vagus n.(X) 132,133,142,146,
 184,187,191
 迷走神经背核 dorsal nucleus of vagus n.
 147,149
 迷走神经三角 vagal triangle 146
 米勒肌 muller m. 123
 密质 compact 3
 面动脉 facial a. 184,185,188,189
 面静脉 facial v. 188
 面神经(VII) facial n.(VII) 132,133,146,150,188
 面神经核 nucleus of facial n. 147,150,164,165
 面神经丘 facial colliculus 146
 面总静脉 common facial v. 112

膜半规管壶腹 The semicircular canal for
 ampullae 136
 拇长屈肌腱 tendon of flexor pollicis longus 181
 拇长屈肌腱鞘 synovial sheath of flexor
 pollicis longus 177
 拇长伸肌 extensor pollicis longus 178
 拇长伸肌腱 tendon of extensor pollicis
 longus 178
 拇短屈肌 flexor pollicis brevis 178,181
 拇收肌 adductor pollicis 181
 拇指腕掌关节 carpometacarpal joint of
 thumb 36
 拇主要动脉 principal artery of thumb 180
 幕切迹 tentorial incisure 170

N

内侧(三角)韧带 medial(deltoid) lig. 44
 内侧半月板 medial meniscus 42
 内侧背核 mediodorsal nucleus 155
 内侧唇 internal lip 25
 内侧核 medial nucleus 145
 内侧髁 medial condyle 25,27,41,42
 内侧隆起 medial eminence 146
 内侧丘系 medial lemniscus 149,150,151,160
 内侧丘系交叉 decussation of medial
 lemniscus 148,160
 内侧膝状体 medial geniculate body
 146,147,154,155
 内侧楔骨 medial cuneiform bone 28,29
 内侧缘 medial border 20
 内侧纵束 medial longitudinal fasciculus 145,151
 内耳门 internal acoustic pore 16,32,133
 内弓状纤维 internal arcuate fibers 148
 内踝 medial malleolus 27,211
 内踝关节面 medial malleolar articular
 surface 27
 内囊 internal capsule 154,159,160,161,163,164
 内囊后肢 posterior limb of internal capsule 158
 内囊前肢 anterior limb of internal capsule 158
 内囊膝 genu of internal capsule 158
 内上髁 medial epicondyle 21,25,35
 内髓板 internal medullary lamina 155
 内脏大神经 greater splanchnic n. 191,192,194
 内脏小神经 lesser splanchnic n. 191
 内直肌 medial rectus 124,128,129,130
 内眦 medial angle of eye 122

脑岛 insula 158,159
脑干 brain stem 142
脑膜中动脉 middle meningeal a. 189
脑桥 pons 146,147,153,154,156,160,161,163
脑桥核 pontine nuclei 150,166
脑桥小脑束 pontocerebellar tract 166
尿道膜部 membranous portion of the urethra 91
尿道内口 internal urethral orifice 89,91,96
尿道球 bulb of urethra 91,94
尿道球部 bulbo part of the urethra 91
尿道球腺 bulbourethral gland 90
尿道外口 external orifice of urathra 83,91,96,97,210
尿生殖膈下筋膜 inferior fascia of urogenital diaphragm 90,98,210
颞侧视网膜 temporal retina 162
颞侧视野 temporal visual field 162
颞骨 temporal bone 10
颞后动脉 posterior temporal a. 168
颞后支 posterior temporal branches 168
颞肌 temporalis 33,190
颞前动脉 anterior temporal a. 168
颞前支 anterior temporal branches 168
颞浅动脉 superficial temporal a. 188,189
颞浅静脉 superficial temporal v. 188
颞上回 superior temporal gyrus 156
颞深前、后动脉 anterior posterior deep temporal a. 189
颞下回 inferior temporal gyrus 156
颞叶 temporal lobe 157
颞支 temporal branches 188
颞中动脉 middle temporal a. 168
颞中间 middle temporal gyrus 156
颞中间支 intermediate temporal branches 168
女尿道 female urethra 96

P

皮质核束 corticonuclear tract 164
皮质脊髓侧束 lateral corticospinal tract 145,163
皮质脊髓前束 anterior corticospinal tract 145,163
皮质脊髓束 corticospinal tracts 145,163
脾 spleen 50,58,60,105,201,202,204
脾动脉 splenic a. 201
脾静脉 splenic v. 201,202,204
脾门 hilus of the spleen 118

脾切迹 splenic notches 118
胼缘动脉 callosomarginal a. 168
胼胝体 corpus callosum 138,139,156,157,159
胼胝体膝 genu of corpus callosum 158
胼胝体下区 subcallosal area 157
胼胝体压部 splenium of corpus callosum 157,170
胼胝体周动脉 pericallosal a. 168
屏状核 claustrum 158,159
破裂孔 foramen lacerum 11,12

Q

奇静脉 agygos v. 114,117,192,194,195
奇静脉弓 arch of axygos v. 192
奇静脉弓淋巴结 lymph nodes of azygos arch 192
奇静脉沟 groove for azygos v. 76
脐动脉 umbilical a. 207,208
脐内侧韧带 medial umbilical ligament
脐正中襞 median umbilical fold
气管 trachea 56,66,70,72,74,75,80,113,139,140
气管软骨 tracheal cartilage 71,73
气管支气管下淋巴结 inferior tracheobronchial lymph nodes 113
髂耻隆起 iliopubic eminence 24
髂相隆 iliac trberosity 24
髂腹股沟神经 ilioinguinal n. 84,197,198,199,206,208
髂腹下神经 iliohypogastric n. 84,197,198,199,206,208
髂股韧带 iliofemoral lig. 37,38
髌骨 ilium 24
髌后上棘 posterior superior iliac spine 24
髌后下棘 posterior inferior iliac spine 24
髌肌 iliacus m. 84,206,207,208
髌嵴 iliac crest 24,47,48
髌结节 iliac tubercle 24
髌筋膜 iliac fascia 212
髌内动脉 internal iliac a. 115,208
髌内淋巴结 internal iliac lymph nodes 115
髌前上棘 anterior superior iliac spine 37
髌前下棘 anterior inferior iliac spine 24
髌外动脉 external iliac a. 115,207,208
髌外静脉 external iliac v. 115,207,208
髌外淋巴结 external ilial lymph nodes 115
髌窝 iliac fossa 24
髌腰肌 iliopsoas 212
髌腰韧带 iliolumbar lig. 37

- 髂总动脉 common iliac a. 115,207,208
 髂总静脉 common iliac v. 208
 前半规管 anterior semicircular canal 133
 前臂后皮神经 posterior cutaneous nerve
 of the forearm 175
 前臂内侧皮神经 medial antebrachial
 cutaneous n. 175
 前臂正中静脉 median antebrachial v. 175
 前床突 anterior clinoid process 12,15
 前端 anterior extremity 118
 前房 anterior chamber 124
 前根 anterior root 144
 前弓 anterior arch 5
 前骨半规管 anterior semicircular canal 133,135
 前核 anterior nucleus 155
 前交叉韧带 anterior cruciate lig. 41,42
 前交通动脉 anterior communicating a. 167
 前角 anterior horn 145,148,158,163,166
 前结间束 anterior internodal tract 110
 前结节 anterior tubercle 5,6
 前锯肌 serratus anterior m. 175
 前锯肌粗隆 tuberosity for serratus anterior 9
 前连合 anterior commissure 157
 前列腺 prostate 82,88,89,90,91
 前列腺静脉丛 prostatic venous plexus 90
 前列腺前叶 anterior lobe of prostate 88
 前乳头肌 anterior papillary m. 104,105,106
 前室间动脉 anterior interventricular branch 104
 前室间沟 anterior interventricular groove 109,100
 前室间支 anterior interventricular
 branch 101,110
 前髓帆 anterior medullary velum 153
 前索 anterior funiculus 145
 前庭 vestibule 135
 前庭袋 vestibular fold 73
 前庭窗 fenestra vestibuli 134,135
 前庭脊髓束 vestibulospinal tract 145,148
 前庭阶 scala vestibuli 135
 前庭膜 vestibule membranous 135
 前庭区 vestibular area 146
 前庭韧带 vestibular lig. 70,73
 前庭神经核 vestibular nuclei 148,150
 前庭神经下核 inferior vestibular nucleus 149
 前庭水管外口 external aperture of aqueduct
 of vestibule 16
 前庭蜗(位听)神经(Ⅷ) vestibulocochlear
 n.(Ⅷ) 133,146,154
 前外侧肉 anterolateral fontanelle 13
 前斜角肌 scalenus anterior 174,183,184
 前斜角肌结节 tubercle for scalenus anterior 9
 前囟 anterior fontanelle 13
 前正中裂 anterior median fissure 146
 前纵韧带 anterior longitudinal lig. 30,31
 浅部 superficial part 59
 浅筋膜 superficial fascia 212
 浅筋膜膜层 scarpa fascia 198,199
 浅筋膜脂层 camper fascia 198,199
 腔静脉孔 vena caval foramen
 切牙管 incisive canal 18
 切牙孔 incisive foramina 11
 切缘 cut edge 64
 穹隆 fornix 159
 穹隆脚 crus of fornix 159
 穹隆柱 column of fornix 158
 丘脑 thalamus 158
 丘脑间粘合 interthalamic adhesion 155,171
 丘脑髓纹 thalamic medulary stria 146
 球海绵体肌 bulbocavernosus 97,98,210
 球结膜 bulbar conjunctiva 122
 球囊 sacculle 136
 球状核 globose nucleus 153
 屈肌支持带 flexor retinaculum 180,181,215
 颧大肌 zygomaticus major 188,189
 颧弓 zygomatic arch 11,13
 颧骨 zygomatic bone 10,13,123
 颧突 zygomatic process 15,18
 颧小肌 zygomaticus minor 189
 颧支 zygomatic branches 54,188
- ## R
- 桡侧返动脉 radial recurrent a. 177
 桡侧副动脉 radial collateral a. 175
 桡侧副韧带 radial collateral lig. 35
 桡侧腕长伸肌 extensor carpi radialis
 longus 178,181
 桡侧腕短伸肌 extensor carpi radialis
 brevis 178,181
 桡侧腕屈肌 flexor carpi radialis 176
 桡侧腕屈肌腱 tendon of flexor carpi
 radialis 177,180,181
 桡尺远侧关节腔 distal radoulnar joint
 cavity 36

- 桡动脉 radial a. 176,177,180
桡静脉 radial v. 176
桡动脉掌浅支 superficial palmar branch of radial a. 177,180
桡骨 radius 2,35,36
桡骨粗隆 radial taberosity 22,35
桡骨环状韧带 annular lig. of radius 35
桡骨茎突 styloid process of radius 22
桡骨颈 neck of radius 22
桡骨体 shaft of radius 22
桡骨头 head of radius 22
桡切迹 radius notch 22
桡神经 radial n. 174,175
桡神经沟 sulcus for radial n. 21
桡神经后肌支 posterior muscular branch of radial n. 175
桡神经浅支 superficial branch of radial n. 177,189
桡腕背侧韧带 dorsal radiocarpal lig. 36
桡腕关节腔 radiocarpal joint cavity 36
桡腕掌侧韧带 palmar radiocarpal lig. 36
桡窝 radial fossa 21
人字缝 lambdiod suture 10,13
绒球 flocculus 153
绒球脚 peduncle of flocculus 153
乳侧切牙 deciduous lateral incisor 51
乳尖牙 deciduous canine 51
乳糜池 cisterna chyli 114
乳头体 mamillary body 155
乳突 mamillary process 7,11,13,16,32,134
乳突窦 mastoid antrum 134
乳突孔 mastoid foramen 11
乳突淋巴结 mastoid lymph node 120
乳突切迹 mastoid notch 16
乳突窦入口 entrance to mastoid antrum 134
乳突小房 mastoid cells 132,134
乳晕 areola 98
乳中切牙 deciduous central incisor 52
软腭 soft palate 55,67,68,69
软骨间关节 interchondral joints 33
- S**
腮腺 parotid gland 54,120
腮腺淋巴结 parotid lymph node 120
三边孔 foramen trilaterum 195,196
三叉丘系 trigeminal lemniscus 161
三叉神经(V) A trigeminal n.(V) 146,147,154,167
三叉神经脊束 spinal tract of trigeminal n. 148,149,150,161
三叉神经脊束核 spinal nucleus of trigeminal n. 147,148,149,150
三叉神经节 trigeminal ganglion 161
三叉神经脑桥核 pontine nucleus of trigeminal n. 147,150
三叉神经压迹 trigeminal impression 12,16
三叉神经运动核 motor nucleus of trigeminal n. 147,150,164
三叉神经中脑核 mesencephalic nucleus of trigeminal n. 147,150,151
三尖瓣隔侧瓣 septal cusp of tricuspid valve 107
三尖瓣后瓣 posterior cusp of tricuspid valve 107
三尖瓣前瓣 anterior cusp of tricuspid valve 103,104,107
三角骨 triquetral bone 23
三角肌 deltoid 47,175,196
三角肌粗隆 deltoid tuberosity 21
筛板 cribriform plate 12,17
筛窦后群开口 orifices of posterior ethmoidal sinuses 69
筛骨垂直板 perpendicular plate of ethmoid bone 17
筛骨鸡冠 crista galli of ethmoid bone 67
筛骨眶板 orbital plate for ethmoid bone 123
筛骨迷路 ethmoidal labyrinth 17
筛后孔 posterior ethmoidal foramen 123
筛孔 ethmoidal foramen 17
山顶 culmen 152
山坡 declive 152
上籽肌 gemellus superior 214
上半月小叶 superior semilunar lobule 152
上鼻道 superior nasal meatus 68
上鼻甲 superior nasal concha 17,68
上肺静脉 superior pulmonary v. 76,77
上橄榄核 superior olivary nucleus 150
上根 superior root 183,184
上关节凹 superior articular fovea 5
上关节面 superior articular surface 5,27
上关节突 superior articular process 6,7,8
上颌动脉 maxillary a. 189
上颌窦 maxillary sinus 68

- 上颌窦开口 orifice of maxillary sinus 69
 上颌窦裂孔 maxillary hiatus 18
 上颌骨 maxilla 10,13,123
 上颌骨眶面 orbital surface for maxilla bone 123
 上颌结节 maxillary tubercle 18
 上颌神经 maxillary n. 185,171
 上睑 upper eyelid 122
 上睑板 superior tarsus 126,127
 上睑提肌 levator palpebrae superioris 124,125,126,128,129,130
 上角 superior angle 20
 上泪点 upper lacrimal punctum 127
 上泪小管 upper lacrimal ductule 127
 上涎核 superior salivatory nucleus 147
 上颞线 superior temporal line 13
 上腔静脉 superior vena cava 56,101,102,103,104,106,108,109,113,117,139,192,193,195
 上腔静脉沟 groove for superior vena cava 76
 上腔静脉口 orifice of superior vena cava 110
 上丘 superior colliculus 139,146,147,154
 上矢状窦 superior sagittal sinus 171
 上矢状窦沟 sulcus for superior sagittal sinus 17
 上吻合静脉 superior anastomotic v. 169
 上矢状窦 superior sagittal sinus 170,171,172
 上项线 superior nuchal line 11
 上斜肌 superior obliquus 126,128,129
 上牙槽后动脉 posterior superior alveolar a. 189
 上叶 upper lobe 76,77
 上缘 superior border 20,118
 上直肠横襞 superior transverse fold of rectum 59
 上直肌 superior rectus 124,125,128,129,130
 上纵肌 superior longitudinal muscle 56
 舌背 dorsum of tongue 53
 舌扁桃体 lingual tonsil 53
 舌垂直肌 vertical muscle of tongue 53
 舌动脉 lingual a. 53,54,184,185,189
 舌根 root of tongue 53,55
 舌骨 hyoid bone 53,72
 舌骨大角 greater horn of hyoid bone 70,71,73
 舌骨舌肌 hyoglossus 184
 舌骨体 body of hyoid bone 14,70,71
 舌回 lingual gyrus 156,157
 舌尖 apex of tongue 53
 舌静脉 lingual v. 54
 舌神经 lingual n. 54,184,185
 舌体 body of tongue 53,55
 舌下神经(XII) hypoglossal n.(XII) 54,146,184,185
 舌下神经管 hypoglossal canal 32
 舌下神经核 nucleus of hypoglossal n. 54,147,148,149,164,165
 舌下神经三角 hypoglossal triangle 146
 舌下腺 sublingual gland 54
 舌下腺凹 sublingual fovea 14,54
 舌下腺管 sublingual duct 54
 舌咽神经(IX) glossopharyngeal n.(IX) 132,133,146,184,185
 舌粘膜 lingual mucous membrane 53
 舌正中沟 median sulcus of tongue 55
 舌中隔 septum of tongue 53
 射精管 ejaculatory duct 88,89,91
 射精管开口 opening of ejaculatory duct 89
 伸肌上支持带 superior extensor retinaculum 217
 伸肌下支持带 inferior extensor retinaculum 217
 肾 kidneys 82,86,87
 肾大盏 major renal calices 86
 肾动脉 renal a. 86,87
 肾静脉 renal v. 86,87
 肾皮质 renal cortex 86
 肾上腺 suprarenal gland 138
 肾小盏 minor renal calices 86
 肾盂 renal pelvis 86
 肾柱 renal column 86
 肾锥体 renal pyramids 86
 升结肠 ascending colon 203,205
 升主动脉 ascending aorta 100,101,103,104,106,107,108,109,113,193
 生殖股神经 genitofemoral n. 84,206,208
 声襞 vocal fold 73
 声带突 vocal process of arytenoid cartilage 70,71
 声门下腔 infraglottic cavity 73
 声韧带 vocal lig. 71,73
 十二指肠 duodenum 140
 十二指肠大乳头 major duodenal papilla 61
 十二指肠降部 descending part of duodenum 58,61
 十二指肠升部 ascending part of duodenum 58
 十二指肠空肠曲 duodenoejejunal flexure 203,204

- 十二指肠上部 superior part of duodenum 57,58,202
十二指肠下部 inferior part 58
十二指肠皱襞 folds of duodenum 57
食管 esophagus 50,55,56,60,105,113,192,194
食管沟 groove for esophagus 76,77
食管颈段 cervical part of the esophagus 187
食管隐窝 esophageal recess 194
食管支 esophageal branches 201
食管纵皱襞 longitudinal folds of esophagus 57
矢状缝 sagittal suture 10,13
视辐射 optic radiation 162
视交叉 optic chiasma 67,139,155,156,162,170,171
视前内侧核 medial preoptic nucleus 155
视前外侧核 lateral preoptic nucleus 155
视上核 supraoptic nucleus 155
视神经(Ⅱ) optic n.(Ⅱ) 68,124,125,128,129,142,146,154,162,167,170
视神经管 optic canal 10,12,15,123
视束 optic tract 146,147,154,162
视网膜 retina 124,125
视网膜鼻侧上小动脉 superior nasol arteriole of retina 125
视网膜鼻侧上小静脉 superior nasal venule of retina 125
视网膜鼻侧下小动脉 inferior nasal arteriole of retina 125
视网膜鼻侧下小静脉 inferior nasal infnasal venule of retina 125
视网膜颞侧上小动脉 superior temporal arteriole of retina 125
视网膜颞侧上小静脉 superior temporal venule of retina 125
视网膜颞侧下小静脉 inferior temporal venule of retina 125
室间隔肌性部 interventricular muscular part 104,105,106
室间隔膜部 interventricular membranous part 104,106,110
室间孔 interventricular foramen 155,156,172
室旁核 paraventricular nucleus 155
室上嵴 supraventricular crest 103,104
收肌结节 adductor tubercle 25
手背静脉网 dorsal venous rete of hand 179
手骨 bones of hand 2
手舟骨 scaphoid bone 23
梳状肌 muscoli pectinati 103
输精管 deferent duct 82,84,88,89,90,92,199,207
输精管壶腹 ampulla ductus deferentis 82,89,90
输卵管 uterine tube 83,96,208
输卵管腹腔口 abdominal ostium 95
输卵管壶腹 ampulla of uterine tube 95
输卵管漏斗部 infundibulum of uterine tube 95
输卵管伞 fimbriae of uterine tube 83,96,207
输卵管子宫部 uterine part of uterine tube 95
输尿管襞 ureteric fold 89
输尿管间襞 interureteric fold 89
输尿管 ureter 83,84,86,88,89,90,206,207,208
树突 dendrite 144
竖脊肌 erector spinae 194
栓状核 emboliform nucleus 153
水平板 horizontal plate 11
水平裂 horizontal fissure 76,152
四边孔 foramen quadrilaterum 195,196
松果体 pineal body 139,146,156
松质 spongy 3
髓核 nucleus pulposus 30
髓纹 striae medullares 146
锁骨 clavicle 2,34,175
锁骨上淋巴结 supraclavicular lymph nodes 112
锁骨上神经 supraclavicular n. 182,183
锁骨体 shaft of clavicle 19
锁骨下动脉 subclavian a. 174,184,185
锁骨下动脉沟 sulcus for subclavian a. 9
锁骨下静脉 subclavian v. 183
锁骨下静脉沟 sulcus for subclavian v. 9
锁切迹 clavicular notch 9
- 丁
- 提睾肌 cremaster 92,199
提上唇鼻翼肌 levator labii superioris alaegue nasi 189
提上唇肌 levator labii superioris 188,189
听小骨 auditory ossicles 131
听诊三角 triangle of auscultation 47
瞳孔 pupil 122,124
头半棘肌 semispinalis capitis 48
头臂干 brachiocephalic trunk 80,100,193
头后大直肌 rectus capitis posterior major 48
头夹肌 splenirs capitis 47
头静脉 cephalic v. 179
头上斜肌 obliquus capitis superior 48

头下斜肌 obliquus capitis inferior 48
 头状骨 capitate bone 23
 头最长肌 longissimus capitis 48
 骰骨 cuboid bone 28,29
 透明隔 septum pellucidum 156,158,159
 臀大肌 gluteus maximus 47,48,97,98,210,214
 臀肌粗隆 gluteal tuberosity 25
 臀上动脉 superior gluteal a. 214
 臀上神经 superior gluteal n. 214
 臀下动脉 inferior gluteal a. 214
 臀下神经 inferior gluteal n. 214
 臀小肌 gluteus minimus 47,214
 臀中肌 gluteus medius 47,48,214

W

外半规管 lateral semicircular canal 133
 外侧半月板 lateral meniscus 42
 外侧背核 lateral dorsal nucleus 155
 外侧核 lateral nucleus 145
 外侧后核 lateral posterior nucleus 155
 外侧髁 lateral condyle 25,41,42
 外侧丘系 lateral lemniscus 150,151
 外侧索 lateral funiculus 145
 外侧膝状体 lateral geniculate body
 147,154,155,162
 外侧楔骨 lateral cuneiform bone 28
 外耳道 external acoustic meatus 33,132
 外耳门 external acoustic pore 11,13,16,32
 外骨半规管 lateral semicircular canal 135
 外踝 lateral malleolus 27,211,215,217,218
 外踝窝 lateral malleolar fossa 27
 外科颈 Surgical neck 21
 外毛细胞 outer hair cells 135
 外上髁 lateral epicondyle 21,25
 外直肌 lateral rectus 124,128,129,130
 外眦 lateral angle of eye 122
 豌豆骨 pisiform bone 23,36,180
 腕尺侧副韧带 carpal collateral lig. 36
 腕骨间关节腔 intercarpal joint cavity 36
 腕管 canalis carpalis(carpal canal) 181
 腕桡侧副韧带 collateral carporadial lig. 36
 腕掌背侧韧带 dorsal carpometacarpal lig. 36
 腕掌关节腔 carpometacarpal joint cavity 36
 腕掌掌侧韧带 palmar carpometacarpal lig. 36
 网膜囊 omental bursa 64
 网状脊髓束 reticulospinal tract 145

网状结构 reticular formation 149,150,166
 尾骨 coccyx 2,4,209,210
 尾骨肌 coccygeus 209
 尾骨角 coccygeal cornu 8
 尾状核 caudate nucleus 154,158,159,161,166
 尾状核头 head of caudate nucleus 158,170
 尾状叶 caudal lobe of liver 60,61
 位觉斑 the macula of utricle and macula
 of saccule 136
 胃大弯 greater curvature of stomach 57,64
 胃底 fundus of stomach 57,205
 胃底部静脉 veins of fundus of stomach 205
 胃管(路) pyloric canal 57
 胃后壁 posterior wall of stomach 64
 胃肌层 musculature of stomach 57
 胃十二指肠动脉 gastroduodenal a. 201
 胃体 body of stomach 57
 胃网膜右动脉 right gastroepiploic a. 201
 胃网膜右静脉 right gastroepiploic v. 205
 胃网膜左静脉 left gastroepiploic v. 205
 胃小凹 gastric pit 57
 胃小弯 lesser curvature 57
 胃粘膜皱襞 gastric folds 57
 胃左动脉 left gastric a. 201
 胃左静脉 left gastric v. 205
 蜗背侧核 dorsal cochlear nucleus 149
 蜗窗 fenestra cochleae 134,135
 蜗腹侧核 ventral cochlear nucleus 149
 蜗管 cochlear canal 135
 蜗神经核 cochlear nuclei 147

X

膝横韧带 transverse lig. of knee 41,42
 膝神经节 geniculum ganglion of facial n. 132,133
 下半月小叶 inferior semilunar lobule 152
 下鼻道 inferior nasal meatus 68
 下动脉弓 inferior arterial arch 123
 下肺静脉 inferior pulmonary v. 76,77
 下橄榄核 inferior olivary nucleus 149
 下颌后静脉 ratromandibular v. 188
 下颌角 angle of mandible 13,14
 下颌颈 neck of mandible 14
 下颌孔 mandibular foramen 14
 下颌切迹 mandibular notch 14
 下颌舌骨肌 mylohyoid 184,186
 下颌舌骨肌神经 mylohyoid n. 14

- 下颌舌骨肌线 mylohyoid line 14
下颌神经 mandibular n. 185
下颌体 body of mandible 13,14
下颌头 head of mandible 14
下颌窝 mandibular fossa 11,16
下颌下节 submandibular ganglion 185
下颌下淋巴结 submandibular lymph nodes 120
下颌下神经节 submandibular ganglion 54
下颌下腺 submandibular gland 183,185,186
下颌下腺凹 submandibular fovea 14
下颌下腺管 submandibular duct 54
下颌小舌 mandibular lingula 14
下颌缘支 marginal mandibular branch 188
下颌支 ramus of mandible 10,13,14
下甲状旁腺 inferior parathyroid gland 187
下睑 lower eyelid 124
下睑板 inferior tarsus 126,127
下角 inferior angle 20
下肋凹 inferior costal fovea 6
下泪点 lower lacrimal punctum 122,127
下泪小管 lower lacrimal punctum 127
下涎核 inferior salivatory nucleus 147
下颞线 inferior temporal line 13
下腔静脉 inferior vena cava 102,116,192,200,202
下腔静脉瓣 valve of inferior vena cava 103
下腔静脉 inferior vena cava 84,103,108,109, 116,193,194,206
下丘 inferior colliculus 139,146,147,154
下丘核 nucleus of inferior colliculus 151
下丘脑沟 hypothalamic sulcus 155,156
下吻合静脉 inferior anastomotic v. 169
下项线 inferior nucha line 11
下斜肌 inferior obliquus 125,126,128,129,130
下牙槽动脉 inferior alveolar a. 189
下牙槽神经 inferior alveolar n. 184,185
下叶 lower lobe 76,77
下缘 inferior border 76,77
下直肌 inferior rectus 125,128,129,130
纤维心包 fibrous pericardium 100,108,193,194
项韧带 ligamentum nuchae 32
小多角骨 trapezoid bone 23
小角 lesser horn 14
小角软骨 corniculate cartilage 70
小结 nodule 152,153
小结节 lesser tubercle 21
小结节嵴 crest of lesser tubercle 21
小菱形肌 rhomboideus minor 47
小脑 cerebellum 142,156,157
小脑扁桃体 tonsil of cerebellum 152,153
小脑后下动脉 posterior inferior cerebellar a. 167
小脑幕 tentorium of cerebellum 69,169,170,171
小脑前下动脉 anterior inferior cerebellar a. 167
小脑上动脉 superior cerebellar a. 167,171
小脑上脚 superior cerebellar peduncle 150,154
小脑上脚交叉 decussation of superior cerebellar peduncle 151
小脑窝 cerebellar fossa 17
小脑下脚 inferior cerebellar peduncle 147,149,154
小脑延髓池 cerebellomedullary cistern 172
小脑中脚 middle cerebellar peduncle 147,150,154
小腿骨间膜 crural interosseous membrane 43
小网膜 lesser omentum 64
小翼 lesser wing 12,15
小阴唇 lesser lip of pudendum 83,96,97
小隐静脉 small saphenous v. 211,215,218
小指尺掌侧动脉及神经 ulnar palmar a. and n. of little finger 180
小圆肌 teres minor 47,175,196
小指短屈肌 flexor digiti minimi brevis 181
小指伸肌 extensor digiti minimi 178
小指展肌 abductor digiti minimi 181
小趾短屈肌 flexor digiti minimi brevis 216
小趾展肌 abductor digiti minimi 216
小转子 lesser trochanter 25,38
笑肌 risorius 189
楔束 fasciculus cuneatus 145
楔束核 cuneate nucleus 148,160
楔束结节 cuneate tubercle 146
楔叶 cuneus 156,157
楔舟背侧韧带 dorsal cuneonavicular lig. 44
斜方肌 trapezius 47,183
斜裂 oblique fissure 14,76,77
心包 pericardium 80,138,139,191
心包膈动脉 pericardiophrenic a. 191
心包横窦 transverse pericardial sinus 109
心包斜窦 oblique pericardial sinus 105,108,109
心大静脉 great cardiac v. 101
心尖 apex of heart 100
心切迹 cardiac notch 80
心窝 vortex of apex of heart 109
心小静脉 small cardiac v. 102
心压迹 cardiac impression 76,77

- 心中静脉 middle cardiac v. 102
 杏仁体 amygdaloid body 147,154,158
 胸背动脉 thoracodorsal a. 174
 胸背神经 thoracodorsal n. 174
 胸大肌 pectoralis major 175
 胸导管 thoracic duct 114,194
 胸骨柄 manubrium sterni 9
 胸骨关节面 articular surface for sternum 19
 胸骨甲状肌 Sternothyoid 183,184,196
 胸骨角 sternal angle 9
 胸骨旁淋巴结 parasternal lymphatic nodes 196
 胸骨舌骨肌 sternohyoid m. 112,183,184,186,196
 胸骨体 sternal body 9,80
 胸骨下角 infrasternal angle 33
 胸核 nucleus thoracicus 145
 胸横肌 transversus thoracis 196
 胸肌淋巴结 pectoral lymph nodes 119
 胸交感干 sympathetic trunk 192
 胸廓内动脉 internal thoracic a. 174,184,194,196
 胸廓内静脉 internal thoracic v. 100,196
 胸肋辐状韧带 radiate sternocostal lig. 33
 胸肋关节 sternocostal joints 33
 胸膜顶 cupula of pleura 80
 胸膜腔 pleural cavity 80
 胸膜下缘 inferior margin of pleura 85
 胸髂肋肌 iliocostalis thoracis 48
 胸锁关节 sternoclavicular joint 33
 胸锁乳突肌 sternocleidomastoid 47,120,132, 183,187,188
 胸外侧动脉 lateral thoracic a. 119,174
 胸腺 thymus 109,138
 胸腺右叶 right lobe of thymus 139
 胸腺左叶 left lobe of thymus 139
 胸小肌 pectoralis minor 119,174
 胸腰筋膜 thoracolumbar fascia 47
 胸主动脉 thoracic aorta 50,56,105,114,117, 191,193,194,195
 胸椎 thoracic vertebrae 2,4
 胸椎椎体 thoracic vertebral body 194,195
 胸最长肌 longissimus thoracis 48
 嗅束 olfactory tract 167
 旋肱后动脉 posterior humeral circumflex a. 174
 旋肱前动脉 anterior humeral circumflex a. 174
 旋股内侧动脉 medial femoral circumflex a. 213
 旋股外侧动脉 lateral femoral circumflex a. 213
 旋后肌 supinator 178
 旋肩胛动脉 circumflex scapular a. 175
 旋髂浅静脉 superficial iliac circumflex v. 119
 旋前方肌 pronator quadratus 177
 旋前圆肌 pronator teres 176,177
 旋支 circumflex branch 102
 旋支后支 posterior branch of circumflex branch 102
 血管纹 stria vascularis 135
- Y**
 牙本质 dentine 51
 牙槽韧带 juga alveolaria 18
 牙槽骨 alveolar bone 51
 牙槽孔 alveolar foramen 18
 牙槽突 alveolar process 18
 牙根管 root canal 51
 牙根尖孔 apical foramen 51
 牙骨质 cement 51
 牙腔 dental cavity 51
 牙髓 dental pulp 51
 牙龈 gum 51
 牙周膜 periodontal membrane 51
 咽 pharynx 50,66,185,187
 咽鼓管 auditory tube 68,132
 咽鼓管半管 semicanal for auditory tube 134
 咽鼓管咽口 pharyngeal opening of auditory tube 68
 咽结节 pharyngeal tubercle 11,17,56
 咽上缩肌 superior constrictor of pharynx 55,56
 咽升动脉 ascending pharyngeal a. 185
 咽下缩肌 inferior constrictor of pharynx 54,55,56
 咽隐窝 pharyngeal recess 68
 咽中缩肌 middle constrictor of pharynx 56
 延髓 medulla oblongata 143,160,161,163,166
 岩大神经 greater petrosal n. 132,133
 岩鼓裂 petrotympanic fissure 16
 岩鳞裂 petrosquamous fissure 16
 岩上窦沟 sulcus for superior petrosal sinus 16
 眼动脉 ophthalmic a. 124,128,130
 眼轮匝肌 orbicularis oculi 123,126,188
 眼球 eyeball 128,129,130
 眼神经 ophthalmic n. 130,171
 腰大肌 psoas major m. 84,206,207,208
 腰骶膨大 lumbosacral enlargement 143
 腰方肌 quadratus lumborum m. 84,85,206,208
 腰交感神经节 lumbar ganglia 84

- 腰髂肋肌 iliocostalis lumborum 48
腰三角 lumbar triangle 47
腰小肌 psoas minor 207
腰椎 lumbar vertebrae 2,4
咬肌 masseter 188,190
咬肌粗隆 masseteric tuberosity 13,14
叶状乳头 filiate papillae 53
腋动脉 axillary a. 174,191,193
腋神经 axillary n. 174,175
胰 pancreas 138
胰管 pancreatic duct 61
胰颈 neck of pancreas 201
胰十二指肠后上动脉 posterior superior pancreaticoduodenal a. 201
胰体 body of pancreas 64,201,202
胰头 head of pancreas 58,201,202
胰尾 tail of pancreas 201,202
胰支 pancreatic branches 201
疑核 nucleus ambiguus 147,148,149,164
乙状窦沟 sulcus for sigmoid sinus 12,16,133
乙状结肠 sigmoid colon 63,116,204,205,206,207
乙状结肠动脉 sigmoid a. 204
乙状结肠静脉 sigmoid v. 205
乙状结肠淋巴结 sigmoid lymph nodes 116
翼点 pterion 13
翼管 pterygoid canal 15
翼肌粗隆 pterygoid tuberosity 14
翼肌支 pterygoid branches 189
翼内肌 medial pterygoid 190
翼突内侧板 medial pterygoid plate 11,15
翼突外侧板 lateral pterygoid plate 11,15
翼外肌 lateral pterygoid 185,190
翼窝 pterygoid fossa 11
翼状襞 alar folds 43
翼状韧带 alar lig. of dens 32
阴部内动脉 internal pudendal a. 214
阴部神经 pudendal n. 214
阴部外动脉 external pudendal a. 199
阴部外静脉 external pudendal v. 119
阴道口 vaginal orifice 83,96,97
阴蒂 clitoris 83,97
阴蒂海绵体 cavernous body of clitoris 82,97
阴蒂系带 frenulum of clitoris 97
阴阜 mons pubis 97
阴茎 penis 84,198,199
阴茎背动脉 dorsal a. of penis 94,207
阴茎背深静脉 deep dorsal v. of penis 94,207
阴茎背神经 dorsal n. of penis 94,207,210
阴茎头 glans penis 94,98,210
阴囊 scrotum 90,91,198,199
阴囊后神经 posterior scrotal n. 210
蚓垂 uvula of vermis 152
蚓结节 tuber of vermis 152
蚓叶 folium of vermis 152
蚓状肌 lunbricales 181,216
蚓锥体 pyramid of vermis 152
隐神经 saphenous n. 213
鹰嘴 olecranon 22,35,178
鹰嘴窝 olecranon fossa 21
硬腭 hard palate 67,68,69
硬脊膜 spinal dura mater 143
硬脑膜 cerebral dura mater 69
幽门 pyloric orifice 57
幽门窦 pyloric antrum 57
幽门管 pyloric canal 57
幽门口 pyloric orifice 202
幽门括约肌 pyloric sphincter 57
幽门淋巴结 pyloric lymph node 114
右动脉圆锥支 right branch of arterial conus 110
右肺上叶 superior lobar of right lung 100
右肺 right lung 80
右肺动脉 right pulmonary a. 192,193,195
右肺动脉隐窝 right pulmonary recess 108
右冠状动脉口 orifice of right coronary a. 106
右肺膈面 diaphragmatic surface of right lung 80
右肺根 root of right lung 80
右肺后底段支气管(B X) posterior basal segmental bronchus of right lung(B X) 75
右肺后段支气管(B II) posterior segmental bronchus of right lung(B II) 75
右肺尖 apex of right lung 80
右肺尖段支气管(B I) apical segmental bronchus of right lung(B I) 75
右肺静脉 right pulmonary v. 192,193
右肺内侧底段支气管(B VII) medial basal segmental bronchus of right lung(B VII) 75
右肺内侧段支气管(B V) medial segmental bronchus of right lung(B V) 75
右肺前底段支气管(B VIII) anterior basal segmental bronchus of right lung(B VIII) 75

- 右肺前段支(管)(B III) anterior segmental bronchus of right lung(B III) 75
 右肺上段支(管)(B VI) superior segmental bronchus of right lung(B VI) 75
 右肺上静脉 right superior pulmonary v. 102
 右肺上叶 superior lobe of right lung 100,105
 右肺上叶动脉 right superior pulmonary a. 195
 右肺上叶支(管) superior lobar branches of right lung 74,75,192,193,195
 右肺外侧底段支(管)(B IX) lateral basal segmental bronchus of right lung(B IX) 75
 右肺外侧段支(管)(B IV) lateral segmental bronchus of right lung(B IV) 75
 右肺下叶支(管) right inferior lobar bronchus 74,75,193
 右肺下缘 inferior margin of right lung 80
 右肺中叶 middle lobe of right lung 100
 右肺中叶支(管) right middle lobar bronchus 74,75
 右睾丸动脉 right testicular a. 206
 右睾丸静脉 right testicular v. 206
 右膈脚 right crus of diaphragm 114,200
 右膈神经 right phrenic n. 192,193,194
 右膈下动脉 right inferior phrenic a. 200,206
 右冠状动脉 right coronary a. 101,102,106,110
 右缘支 right marginal branch 101,110
 右冠状沟 right coronary sulcus 100
 右喉返神经 right recurrent laryngeal n. 187
 右结肠动脉 right colic a. 203
 右结肠静脉 right colic v. 205
 右结肠淋巴结 right colic lymph nodes 115
 右颈内静脉 right internal jugular v. 113
 右颈总动脉 right common carotid a. 56,139
 右肋膈隐窝 right costodiaphragmatic recess of pleura 80,192,194
 右迷走神经 right vagus n. 192
 右髂总动脉 right common iliac a. 116
 右髂总静脉 right common iliac v. 206
 右髂总淋巴结 right common iliac lymph nodes 116
 右三角韧带 right triangular ligament 202
 右上肺静脉 right superior pulmonary v. 105,108,195
 右肾 right kidney 84,85,140,202
 右肾动脉 right renal a. 206
 右肾静脉 right renal v. 206
 右肾上腺 right suprarenal gland 84,140,202
 右室前壁 anterior wall of right ventricle 100
 右室前支 anterior branch of right ventricle 101
 右束支 right bundle branch 110
 右锁骨下动脉 right subclavian a. 196
 右头臂静脉 right brachiocephalic v. 100,193,196
 右下肺静脉 right inferior pulmonary v. 102,108
 右室前乳头肌 anterior papillary muscle of right ventricle 103,110
 右纤维三角 right fibrous trigone 107
 右心耳 right auricle 100,101,103,107
 右心房 right atrium 106
 右心室 right ventricle 105,106
 右心室后壁 posterior wall of right ventricle 102
 右心室浅层肌 superficial layer of right ventricle 109
 右肺下静脉 right inferior pulmonary v. 105
 右腰干 right lumbar trunk 114
 右腰淋巴结 right lumbar lymph nodes 116
 右腰升静脉 right ascending lumbar v. 114
 右支 right branch 203
 右主支(管) right principal bronchus 66,74,195
 釉质 enamel 51
 盂唇 glenoid labrum 34
 孟上结节 supraglenoid tubercle 19,20
 孟下结节 infraglenoid tubercle 19,20
 羽状肌 bipennate muscle 46
 原裂 primary fissure 152
 圆孔 foramen rotundum 12,15
 缘层 marginal layer 145
 缘上回 supramarginal gyrus 156
 缘支 marginal ramus 156
 远节指骨 distal phalanx 23,29
 月骨 lunate bone 23
 月状面 lunate surface 24
- ## Z
- 载距突 sustentaculum tale 28
 脏腹膜 visceral peritoneum 90
 展神经(IV) abducent n.(IV) 130,146,150,171
 展神经核 nucleus of abducent n. 147,150,164
 掌长肌 palmaris longus 176
 掌短肌 palmaris brevis 176
 掌骨底 base of metacarpal bone 23

- 掌骨间韧带 interosseous metacarpal lig. 36
掌骨体 shaft of metacarpal bone 23
掌骨头 head of metacarpal bone 23
掌腱膜 palmar aponeurosis 176
掌浅弓 superficial palmar arch 177,180
掌深弓 deep palmar arch 180
掌心动脉 palmar metacarpal a. 180
掌指关节腔 metacarpophalangeal joint cavity 36
砧锤关节 incudomalleolar joint 131
砧骨 incus 131,133
砧骨体 body of incus 131
枕动脉 occipital a. 184,185,189
枕动脉沟 occipital groove 16
枕额肌额腹 frontal belly of occipitofrontalis 189
枕骨 occipital bone 10,13
枕骨大孔 foramen magnum 11,12
枕骨髁 Occipital condyle 56
枕核 nuclei pulvinares 155
枕静脉 occipital v. 183
枕髁 occipital condyle 11,17
枕淋巴结 occipital lymph nodes 120
枕鳞 occipital squama 17
枕内嵴 internal occipital crest 12,17
枕内隆凸 internal occipital protuberance 12,17
枕颞沟 occipitotemporal sulcus 157
枕颞内侧回 medial occipitotemporal gyrus 157
枕颞外侧回 lateral occipitotemporal gyrus 157
枕外嵴 external occipital crest 11,17
枕外隆凸 external occipital protuberance 11,17
枕小神经 lesser occipital n. 120,182
枕叶 occipital lobe 157
正中沟 median sulcus 146
正中神经 median n. 140,174,176,177,180
正中神经返支 recurrent branch of median n. 180
直肠 rectum 50,84,91,96,204,206,207,208,209
直肠上动脉 superior rectal a. 204,206,207
直肠上静脉 superior rectal v. 205
直肠子宫襞 rectouterine fold 96
直窦 rectus sinuss 169,170,172
跖背动脉 dorsal metatarsal a. 218
跖背静脉 dorsal metatarsal v. 218
跖骨底 base of metatarsal bone 28
跖骨间关节 intermetatarsal joints 45
跖骨头 head of metatarsal bone 28
跖骨足底韧带 plantar metatarsal lig. 44
跖肌 plantaris 214,215
跖趾关节 metatarsophalangeal joint 45
指背静脉网 dorsal venous rete of fingers 179
指骨粗隆 tuberosity of phalanx 23
指骨底 base of phalanx 23
指骨滑车 trochlea of phalanx 23
指骨体 shaft of phalanx 23
指间关节 interphalangeal joint of hand 36
指浅屈肌 flexor digitorum superficialis 176
指浅屈肌腱 tendon of the flexor digitorum superficialis 177,180
指深屈肌 flexor digitorum profundus 177
指掌侧固有动脉和神经 proper palmar digital a.& n. 180
指掌侧总动脉及神经 common palmar digital a.& n. 177,180
趾背静脉 dorsal digital v. of foot 218
趾背神经和动脉 dorsal digital n. and a. of foot 218
趾长屈肌 flexor digitorum longus 215,216
趾长伸肌 extensor digitorum longus 217
趾短屈肌 flexor digitorum brevis 216
趾短伸肌 extensor digitorum brevis 217,218
趾骨粗隆 tuberosity of phalanx 23,28
趾骨底 base of phalanx 23,28
趾骨滑车 trochlea of phalanx 28
趾骨间关节 interphalangeal joint 45
趾骨体 shaft of phalanx 23,28
趾足底固有动脉、神经 proper plantar digital a.& n. 216
趾足底总动脉 common plantar digital a. 216
趾足底总神经 common plantar digital n. 216
中鼻道 middle nasal meatus 68
中副动脉 middle collateral a. 175
中间腱 intermediate tendon 46
中间楔骨 intermediate cuneiform bone 28
中间支气管 intermediate bronchus 76,192
中节指骨 middle phalanx 23
中结肠动脉 middle colic a. 203,204
中结肠淋巴结 middle colic lymph nodes 115
中结间束 middle internodal tract 110
中脑 midbrain 160,161,163,166
中脑导水管 mesencephalic aqueduct 151,156,172
中切牙 central incisor 51

- 中根支 central branch 144
 中线核群 midline nuclear group 155
 中斜角肌 scalenus medius 186
 中心腱 central tendon 200
 中央沟 central sulcus 156
 中央沟动脉 a. of central sulcus 168
 中央管 central canal 145
 中央后沟 postcentral sulcus 156
 中央后沟动脉 a. of postcentral sulcus 168
 中央后回 postcentral gyrus 156,160,161
 中央灰质 central gray matter 151
 中央淋巴结 central lymph nodes 119
 中央旁沟 paracentral sulcus 156
 中央旁小叶 paracentral lobule 156,157
 中央前沟 precentral sulcus 156
 中央前沟动脉 a. of precentral sulcus 168
 中央前回 precentral gyrus 156,163,164
 中央小叶 central lobule 152,153
 中央小叶翼 ala of central lobule 153
 中央中核 centromedian nucleus 155
 中叶 middle lobe 76
 中直横襞 middle transverse fold of rectum 59
 终板旁回 paraterminal gyrus 157
 终池 terminal cistern 172
 终丝 filum terminale 143
 周围支 peripheral branch 144
 轴突 axon 144
 肘肌 anconeus 178
 肘正中静脉 median cubital v. 175,176
 蛛网膜粒 arachnoid granulations 172
 蛛网膜下腔 subarachnoid space 172
 主动脉半月瓣 semilunar cusp of aortic valve 107
 主动脉瓣 aortic valve 104
 主动脉窦 aortic sinus 106,107
 主动脉弓 aortic arch 56,100,101,102,104,117,193
 主动脉弓沟 groove for arch of aorta 77
 主动脉裂孔 aortic hiatus 200
 转子间嵴 intertrochanteric crest 25
 转子间线 intertrochanteric line 25,38
 转子窝 trochanteric fossa 25
 椎动脉 vertebral a. 32,167,174,184
 椎动脉沟 groove for vertebral a. 5
 椎弓 vertebral arch 5,6
 椎弓板 lamina of vertebral arch 6,31
 椎间孔 intervertebral foramen 31
 椎间盘 intervertebral discs 30,31,37
 椎孔 vertebral foramen 5,6,7,30
 椎上切迹 superior vertebral notch 6,7
 椎体 vertebral body 5,6,7,30
 椎体钩 uncus of vertebral body 6
 锥体 pyramid 146,147
 锥体交叉 decussation of pyramid 146,148,163
 锥体束 pyramidal tract 148,149,150,151,154
 锥状肌 pyramidalis m. 199
 锥状结节 conoid tubercle 19
 锥状叶 pyramidal lobe of thyroid gland 140
 籽骨 sesamoid bone 29
 子宫 uterus 83
 子宫底 fundus of uterus 95,96
 子宫动脉 uterine a. 208
 子宫颈 neck of uterus 96,208
 子宫腔 cavity of uterus 95,96
 子宫体 body of uterus 96,208
 子宫圆韧带 round ligament of uterus 83,95,208
 总腱环 common tendinous ring 124,125
 纵束 longitudinal bands 32
 足背动脉 dorsal a. of foot 218
 足背静脉弓 dorsal venous arch of foot 211,218
 足背内侧皮神经 medial dorsal cutaneous n. of foot 218
 足背外侧皮神经 lateral dorsal cutaneous n. of foot 218
 足背中间皮神经 intermediate dorsal cutaneous n. of foot 218
 足底长韧带 long plantar lig. 44
 足底方肌 quadratus plantae 216
 足底内侧动脉 medial plantar a. 216
 足底内侧神经 medial plantar n. 216
 足底外侧神经 lateral plantar n. 216
 足舟骨 navicular bone 28,29
 最上项线 highest nuchal line 17
 左、右膈脚 left and right crus 200
 左动脉圆锥支 left branch of the arterial conus 110
 左房斜静脉 oblique vein of left atrium 109
 左肺后底段支气管(B X) posterior basal segmental bronchus of left lung(B X) 75
 左肺尖 apex of left lung. 80
 左肺尖后段支气管(B I + II) apicoposterior segmental bronchus of left lung(B I + II) 75
 左肺静脉 left pulmonary v. 109,191,193

- 左肺动脉 left pulmonary a. 101,102,103,104, 191,193,195
- 左肺内侧底段支气管(B VII) medial basal segmental bronchus of left lung(B VII) 75
- 左肺前底段支气管(B VIII) anterior basal segmental bronchus of left lung(B VIII) 75
- 左肺前段支气管(B III) anterior segmental bronchus of left lung(B III) 75
- 左肺前缘 anterior margin of left lung 80
- 左肺上段支气管(B VI) superior segmental bronchus of left lung(B VI) 75
- 左肺上舌段支气管(B IV) superior lingular segmental bronchus of left lung(B IV) 75
- 左肺上叶支气管 left superior lobar bronchus 74,75
- 左肺下舌段支气管(B V) inferior lingular segmental bronchus of left lung(B V) 75
- 左肺下叶 inferior lobe of left lung 100
- 左肺下叶支气管 left inferior lobar bronchus 74,75
- 左肺下缘 inferior margin of left lung 80
- 左睾丸动脉 left testicular a. 206
- 左睾丸静脉 left testicular v. 206
- 左膈神经 left phrenic n. 100,194
- 左膈下动脉 left inferior phrenic a. 200
- 左冠状动脉 left coronary a. 110
- 左冠状动脉旋支 circumflex branch of the left coronary a. 101
- 左喉返神经 left recurrent laryngeal n. 191
- 左交感干 left sympathetic trunk 117
- 左结肠动脉 left colic a. 204
- 左结肠静脉 left colic v. 205
- 左结肠淋巴结 left colic lymph nodes 116
- 左颈内静脉 left internal jugular v. 113
- 左颈总动脉 left common carotid a. 56,80,100,193
- 左肋膈隐窝 left costodiaphragmatic recess 80,194
- 左肋纵隔窝 left costomediantinal recess 194
- 左肋纵隔胸膜返折线 left costomediastinal line of reflection. 80
- 左迷走神经 left vagus n. 100,193
- 左脐内侧襞 left medial umbilical fold 62
- 左髂总动脉 left common iliac a. 84,206
- 左髂总静脉 left common iliac v. 84
- 左髂总淋巴结 left common iliac lymph node 116
- 左腔静脉襞 fold of left vena cava 109
- 左锁骨下静脉 left subclavicular v. 56,100,113
- 左上肺静脉 left superior pulmonary v. 102,103,108
- 左肾动脉 left renal a. 84,206
- 左肾静脉 left renal v. 84,206
- 左肾上腺 left suprarenal gland 84,140,202
- 左室后动脉 posterior branch of the left ventricle 102
- 左室前壁 anterior wall of left ventricle 100
- 左室前乳头肌 anterior papillary muscle of the left ventricle. 103,110
- 左输尿管 left ureter 140
- 左束支 left bundle branch 110
- 左室后乳头肌 posterior papillary muscle 103
- 左锁骨下动脉 left subclavian a. 191
- 左头臂静脉 left brachiocephalic v. 100,117,139,193
- 左下肺静脉 left inferior pulmonary v. 102,108
- 左心室前乳头肌 anterior papillary m. 103
- 左心耳 left auricle 109
- 左心房 left atrium 101,102,103,104,105,109,110
- 左肺静脉 left pulmonary v. 195
- 左缘支 left marginal branch 102
- 左心室后壁 posterior wall of left ventricle 102
- 左心室浅层肌 superficial layer of the left ventricle 109
- 左腰干 left lumbar trunk 114
- 左腰淋巴结 left lumbar lymph nodes 116
- 左缘支 left marginal branch 110
- 左锁骨下动脉 left subclavian a. 100,193
- 左主支气管 left principal bronchus 56,66,74,75,113,191,195
- 坐股韧带 ischiofemoral lig. 39
- 坐骨 ischium 24
- 坐骨大孔 greater sciatic foramen 37,209
- 坐骨大切迹 greater sciatic notch 24
- 坐骨肛门窝 ischioanal fossa 97,98,210
- 坐骨海绵体肌 ischiocavernosus 97,98,209
- 坐骨棘 ischial spine 24,209
- 坐骨结节 ischial tuberosity 24,210
- 坐骨神经 sciatic n. 142,214
- 坐骨小孔 lesser sciatic foramen 37