

脊柱CT横断面解剖



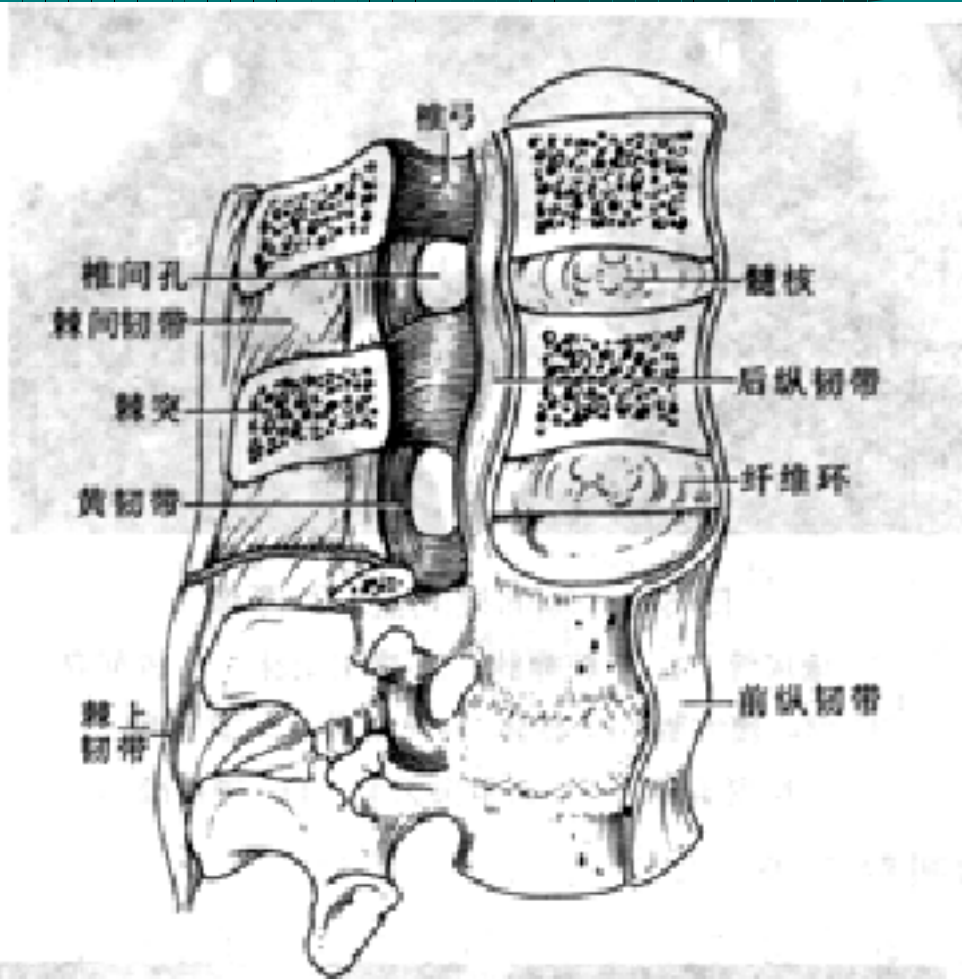


图 6-4 椎骨间的连结

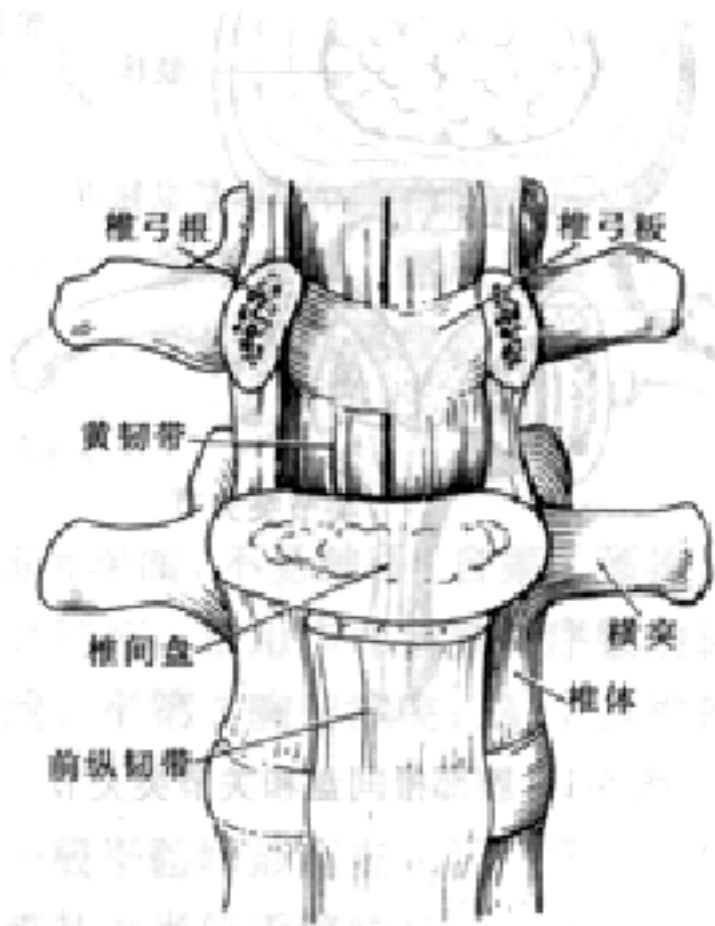


图 6-5 椎弓间连结

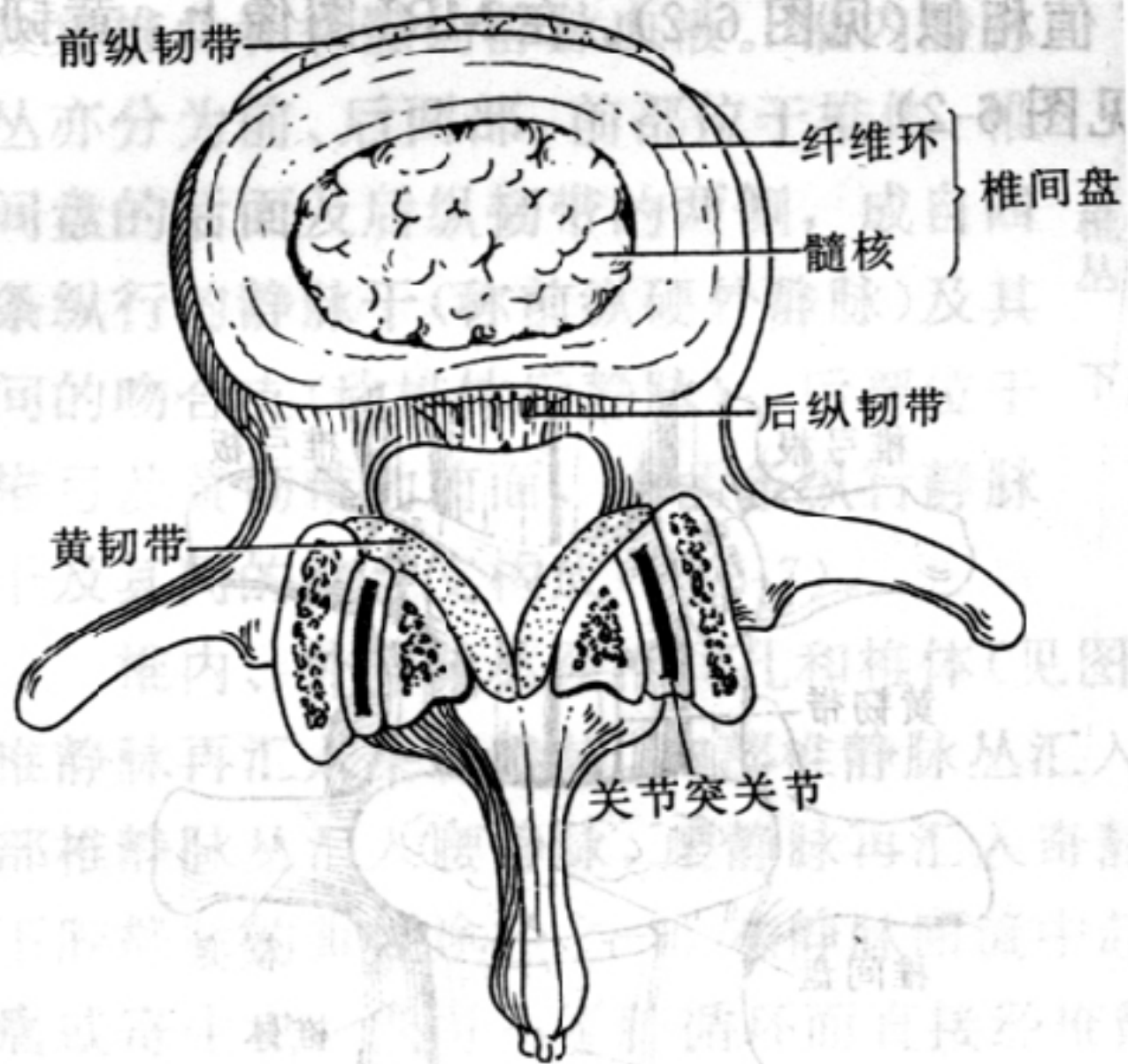



图 6-1 腰部椎间盘和关节突关节

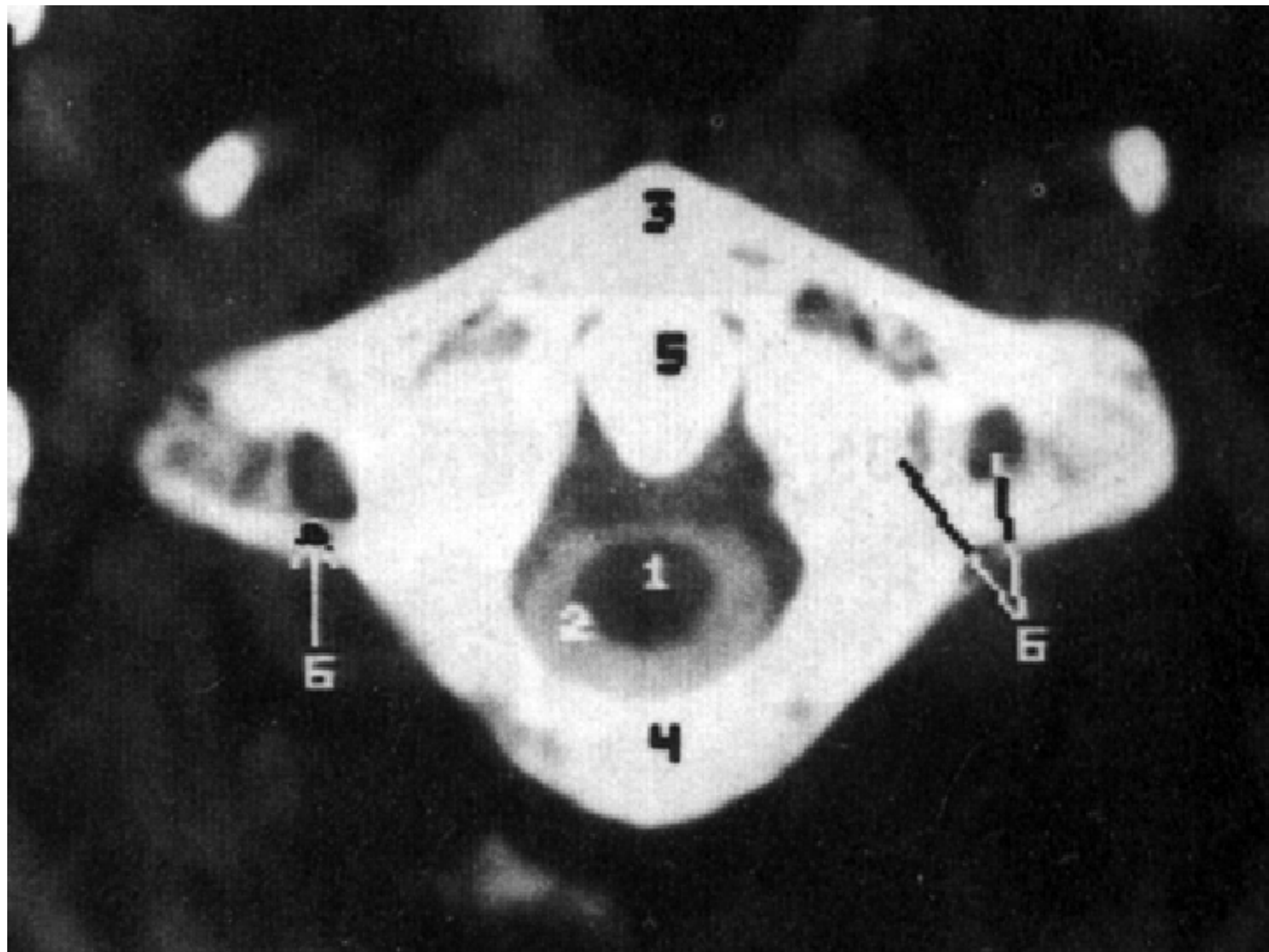
颈部CT横断面解剖



1第1颈椎 平面:


- 颈1椎前结节、颈1椎前弓、齿凹、颈2椎齿突、寰齿关节、颈1侧块、横突、横突孔、颈1椎后结节、颈1椎后弓、椎孔、脊髓、蛛网膜下腔。

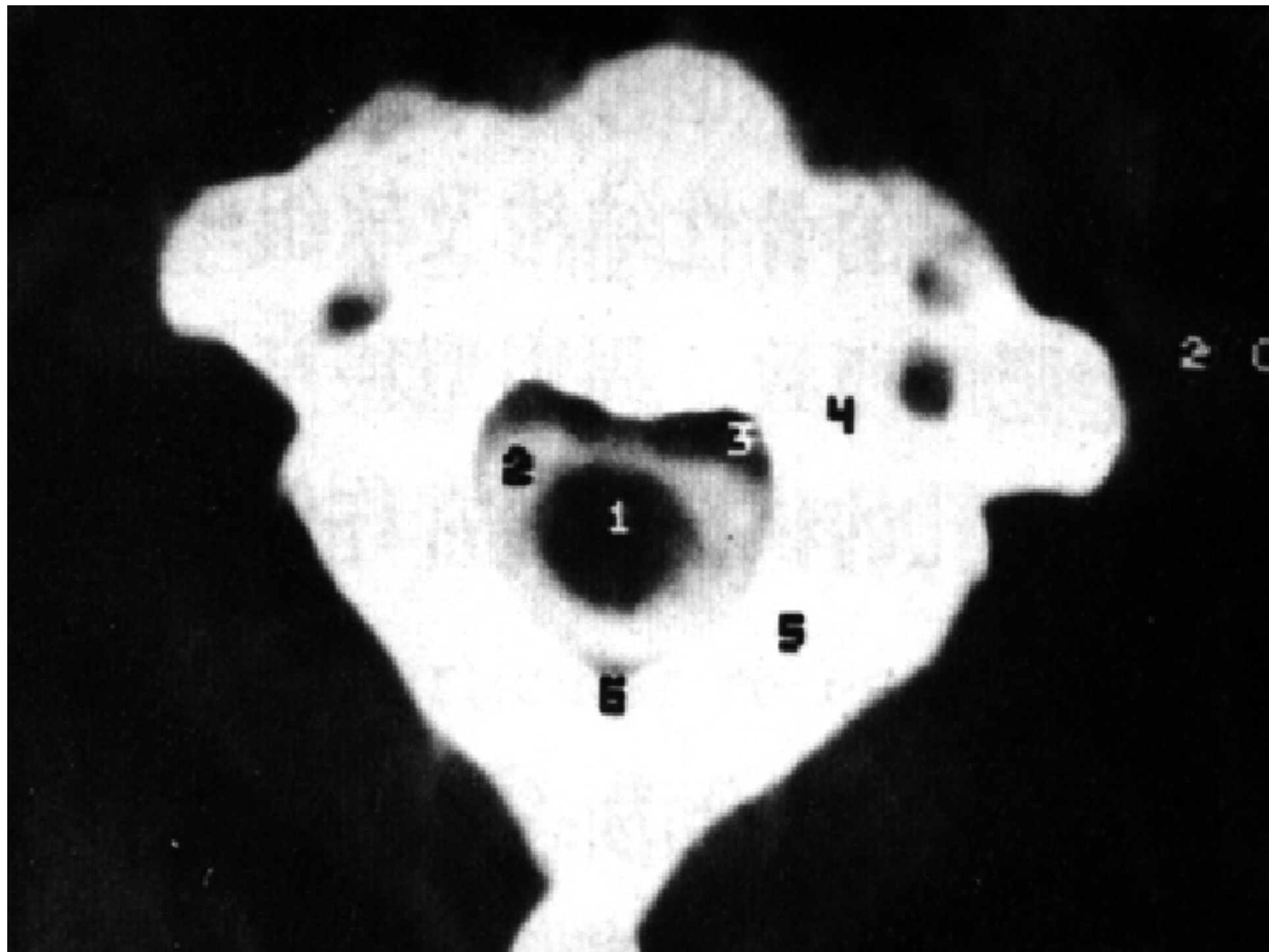




2 颈椎椎弓根平面:


- 颈椎椎体、椎基静脉、骨帽、横突、横突孔、关节突、椎弓根、椎板、棘突、椎孔、脊髓、蛛网膜下腔。

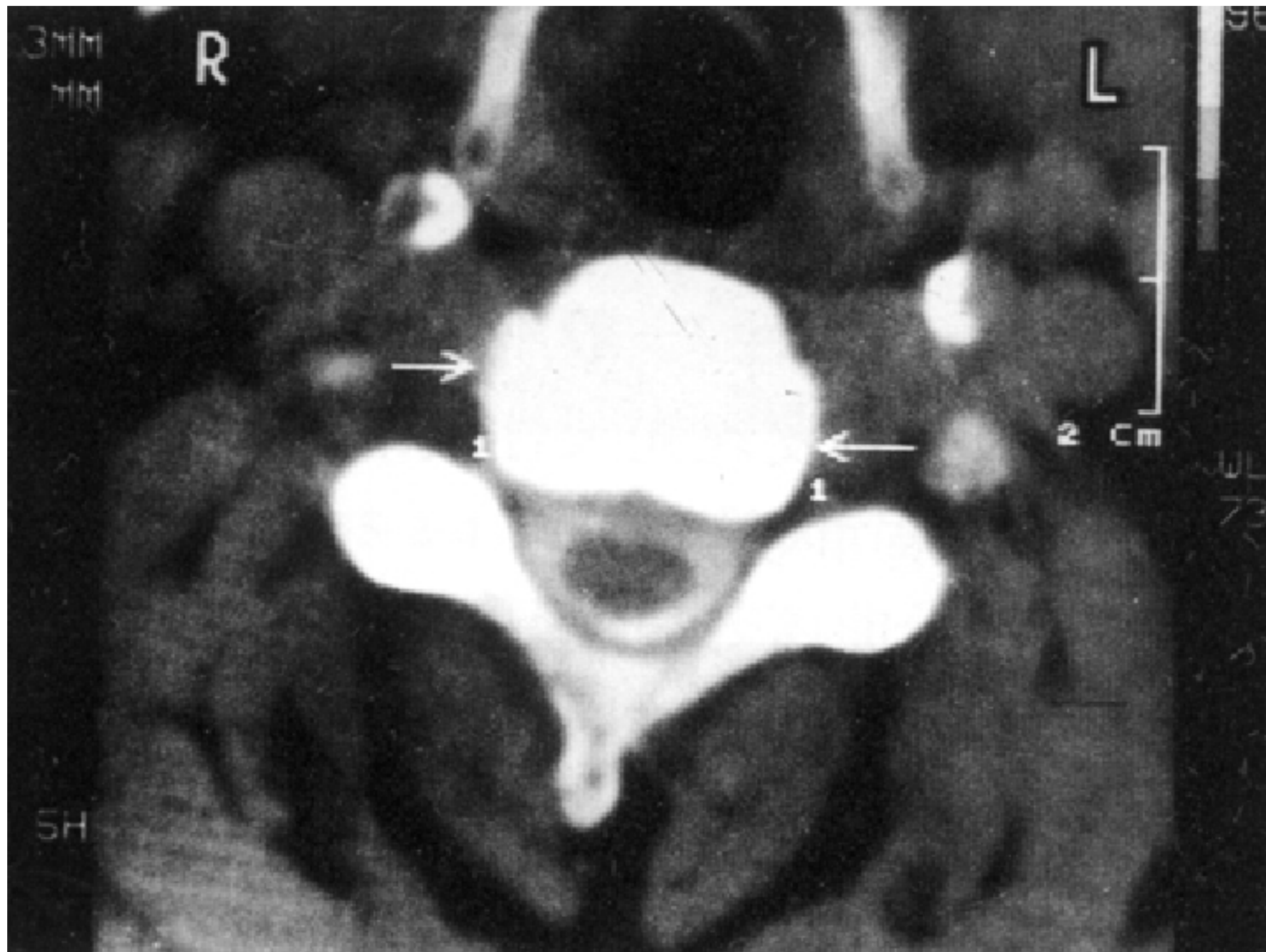




3 颈椎椎间孔平面:


- 颈椎椎体、椎体钩(钩突)、椎间孔、关节突、椎弓、椎板、棘突、椎孔、脊髓、蛛网膜下腔。





颈椎椎体 平面:

- 颈椎椎体、横突、横突孔内椎动脉、椎弓根、椎板、棘突、脊髓



05697 9307514 NECK LI DE MING
01.01:01 NO C
SN -50.0mm
+100.0mm
+00.0°
AZ 90°

53: M
1993/11/09 14:51:49

A

40

H

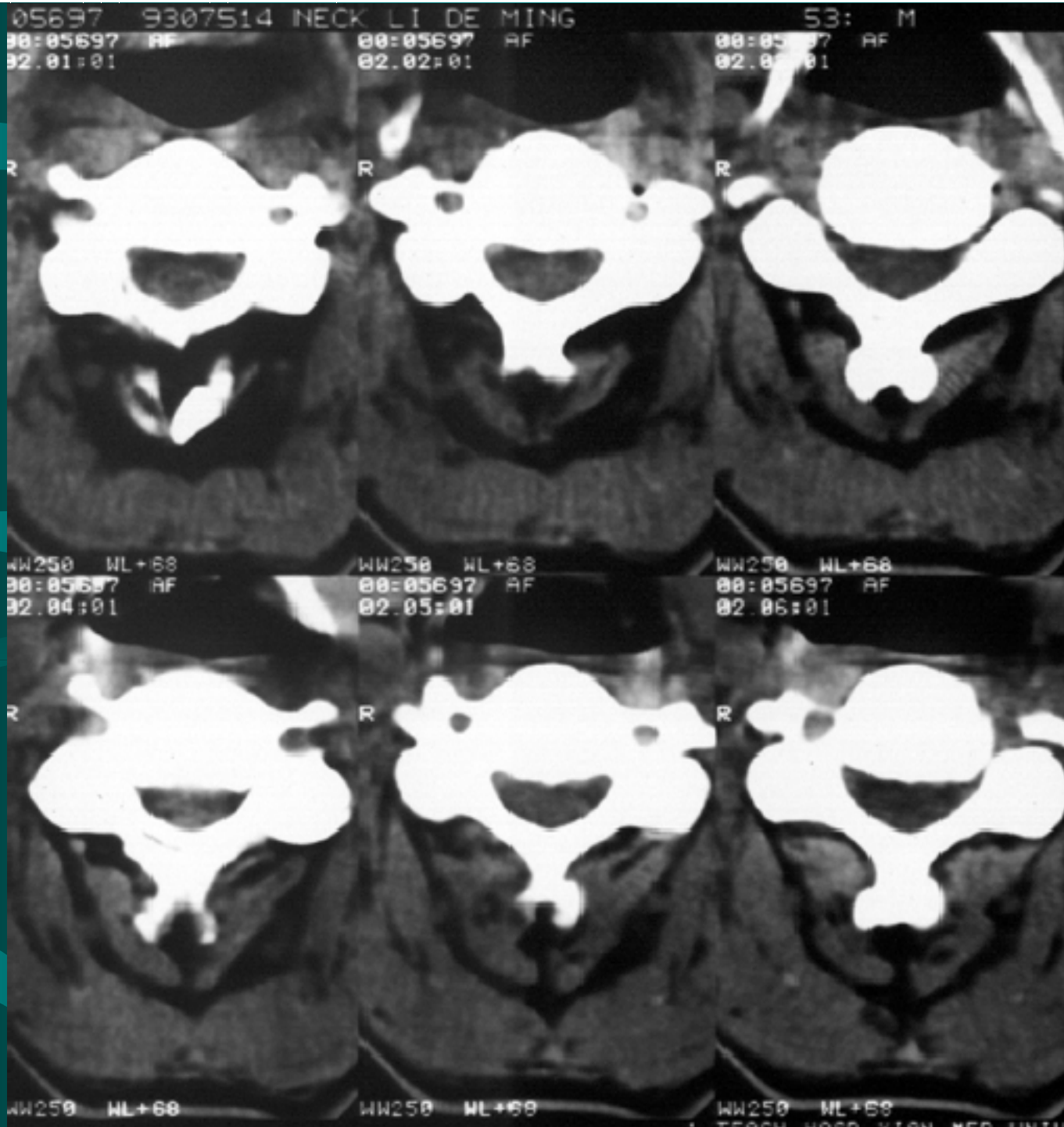
0202 0204 0206 0208 0210 0212 0214
0201 0203 0205 0207 0209 0211 0213

120 kV
30 mA

120 100 80 60 40

MAG:1.5 x= -1.17cm y= +0.22cm P
WW250 WL+68

: TEACH HOSP XIAN MED UNIV



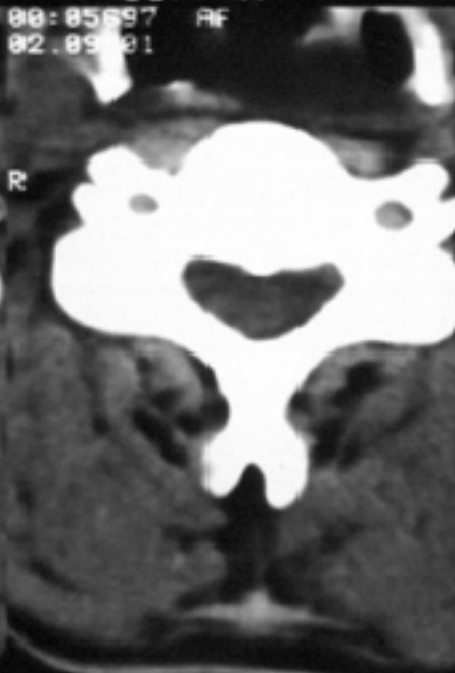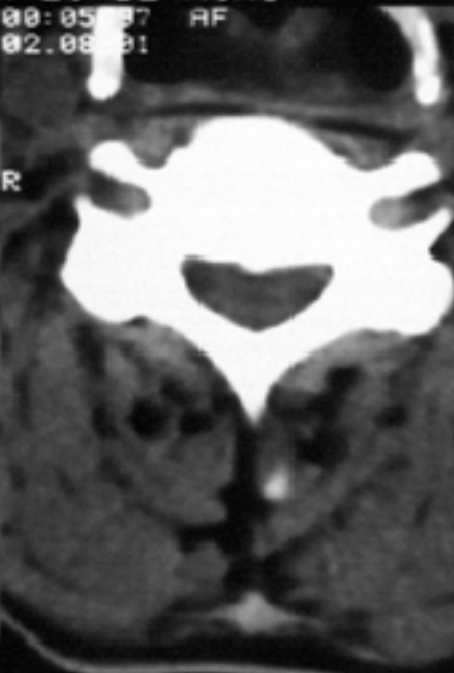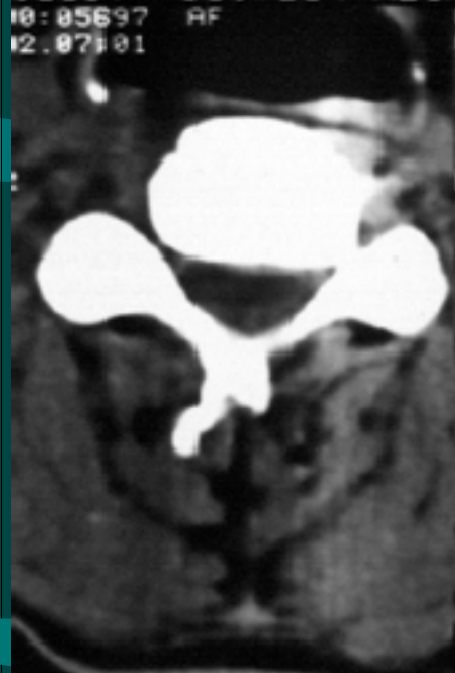
05697 9307514 NECK LI DE MING

53: M

00:05:37 AF
02.07:01

00:05:37 AF
02.08:01

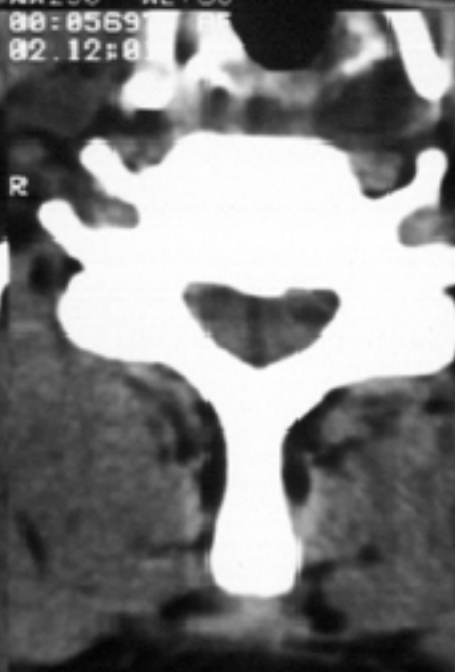
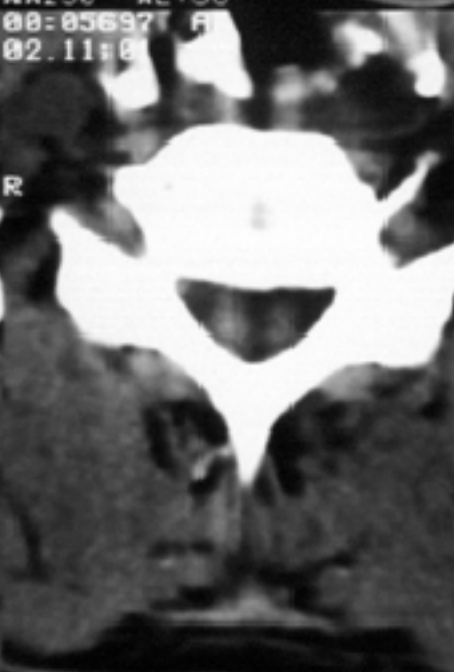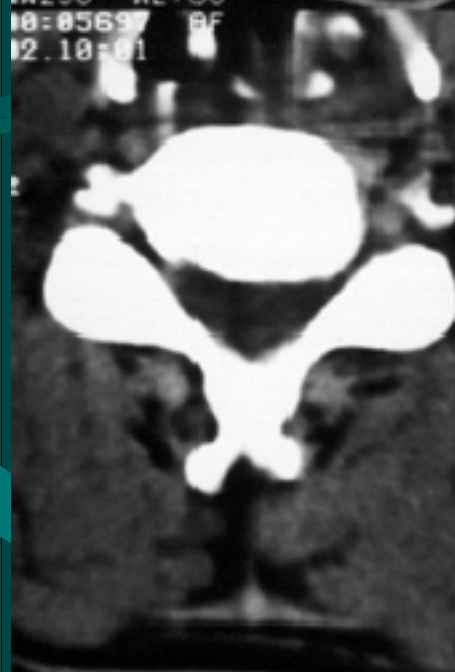
00:05:37 AF
02.09:01



WW250 WL+68
00:05:37 AF
02.10:01

WW250 WL+68
00:05:37 AF
02.11:01

WW250 WL+68
00:05:37 AF
02.12:01



WW250 WL+68

WW250 WL+68

WW250 WL+68

05697 9307514 NECK LI DE MING
00:05697 AF 00:05697 AF
02.07:01 02.08:01

53: M
00:05697 AF
02.09:01

R

R

R

MM2000 NL+226
00:05697 AF
02.10:01

MM2000 NL+226
00:05697 AF
02.11:01

MM2000 NL+226
00:05697 AF
02.12:01

R

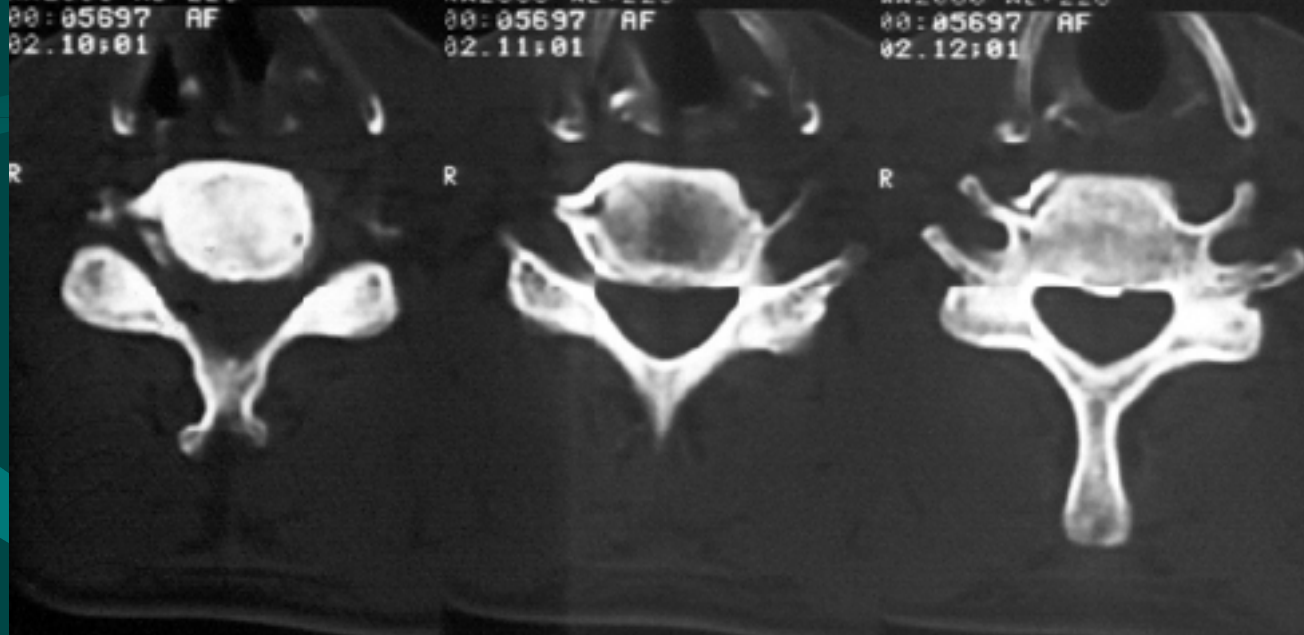
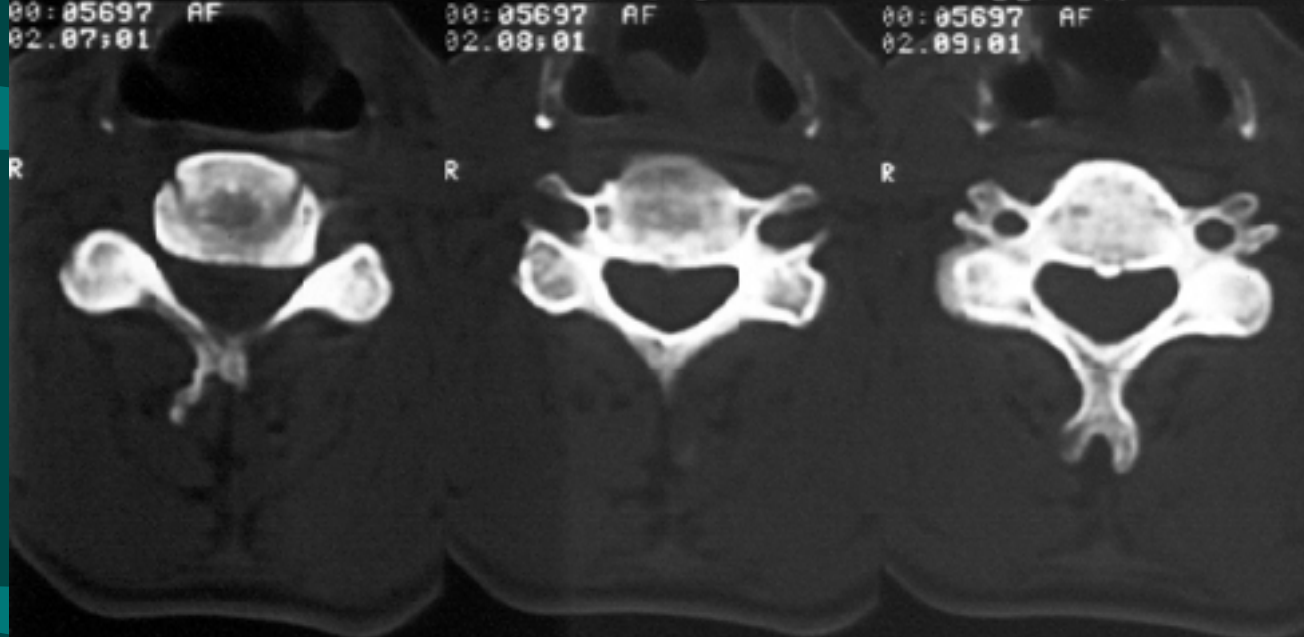
R

R

MM2000 NL+226

MM2000 NL+226

MM2000 NL+226
: TEACH HOSP XIAN MED UNIV



颈椎椎间盘 平面:

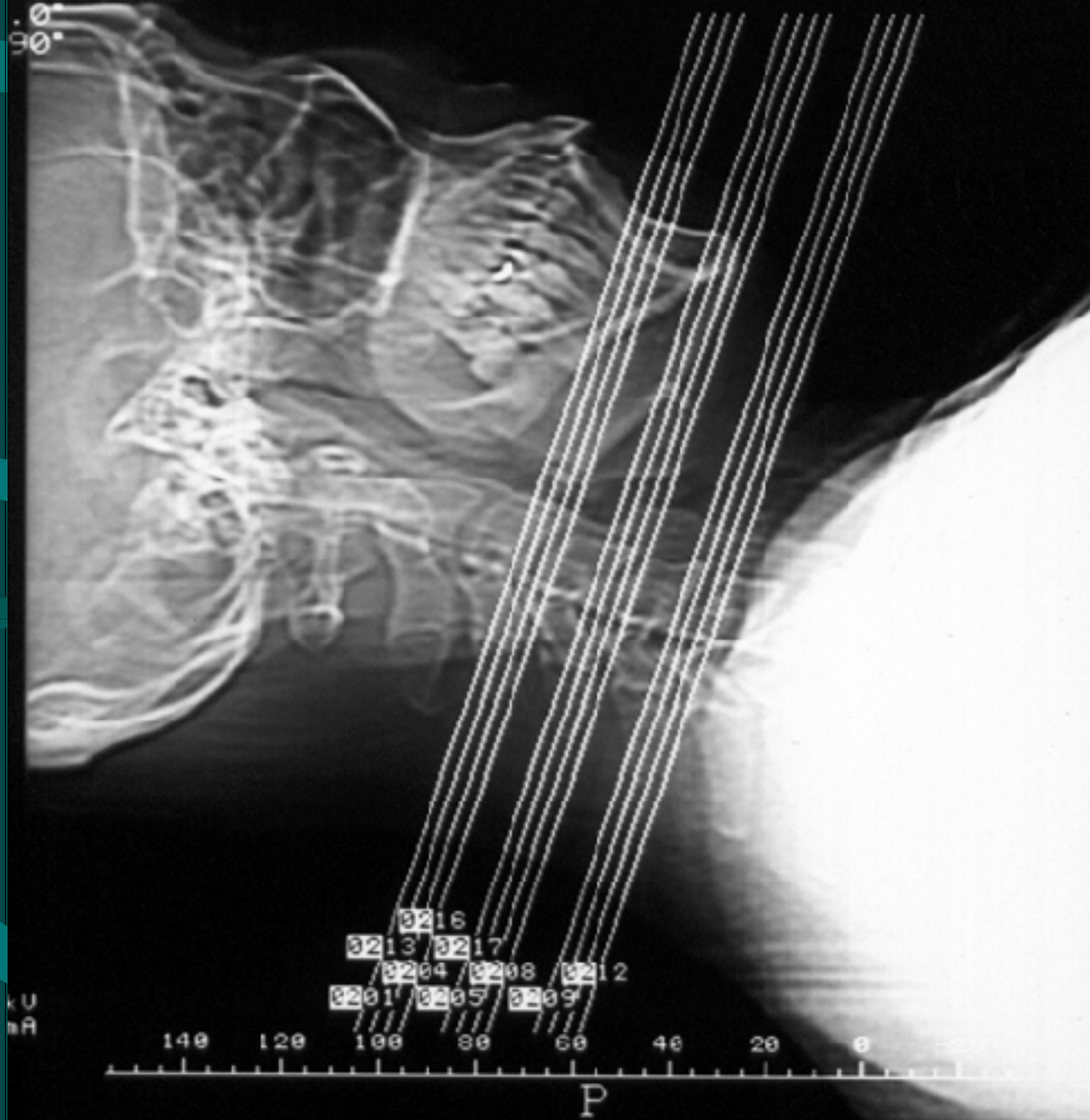
- 颈椎椎间盘、椎体钩(钩突)、后纵韧带、外侧隐窝、椎间孔内脊神经、黄韧带、脊髓



01:01 NO C
-50.0mm
+180.0mm
.0
90°

A

1993/12/16 14:35

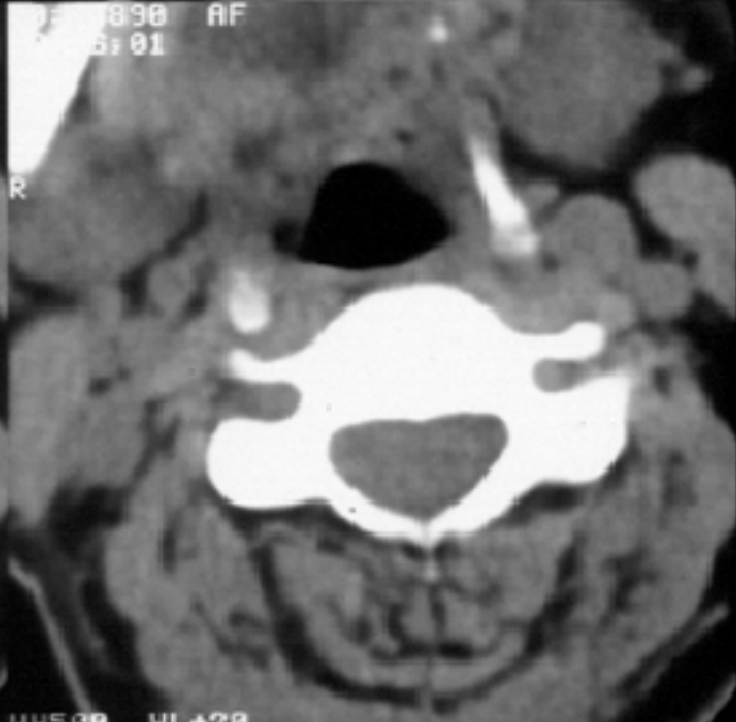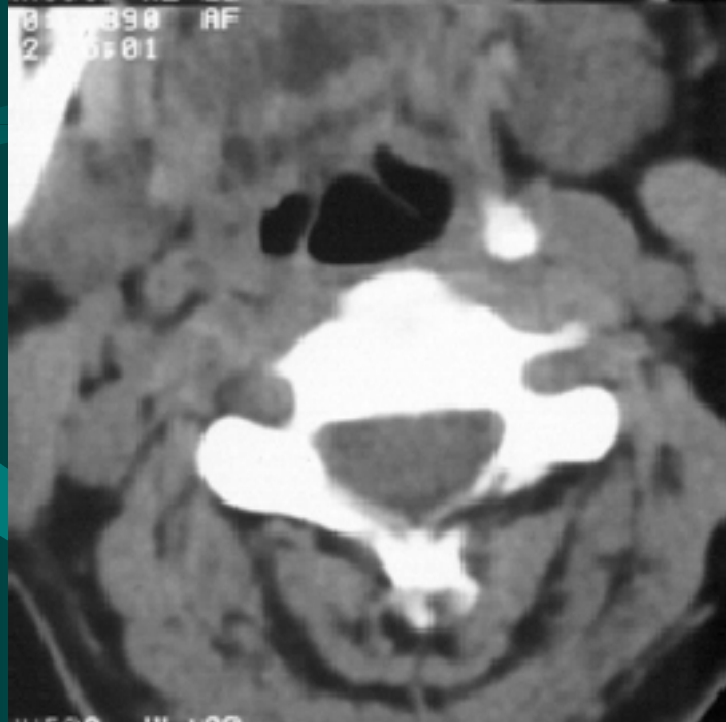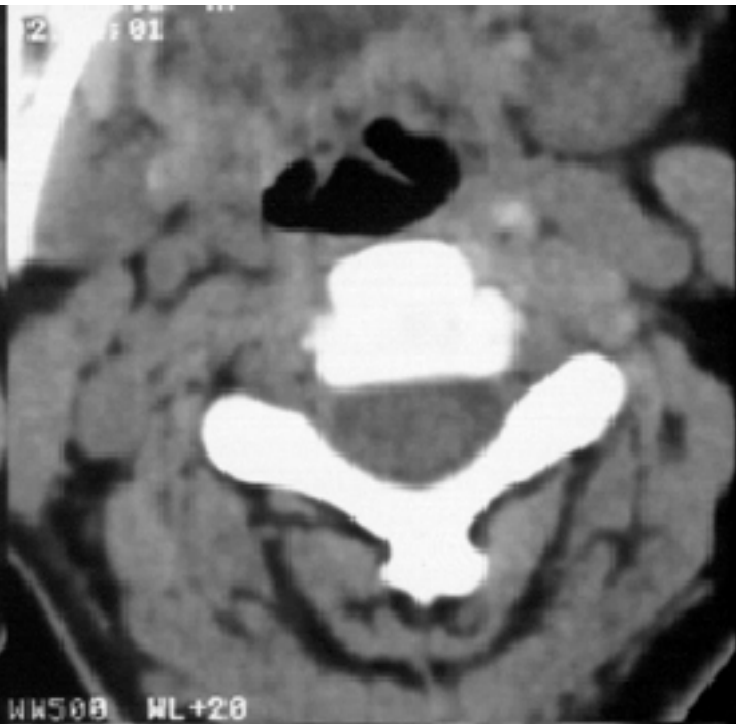


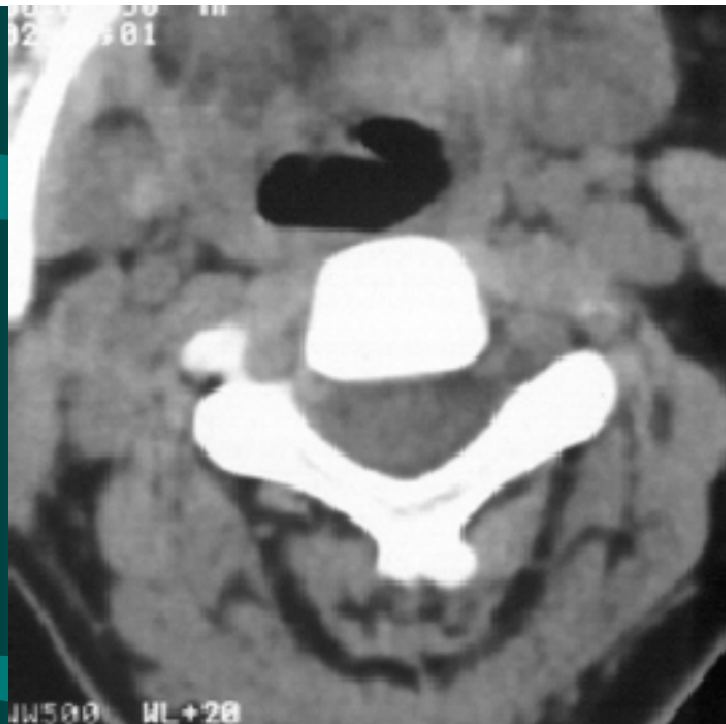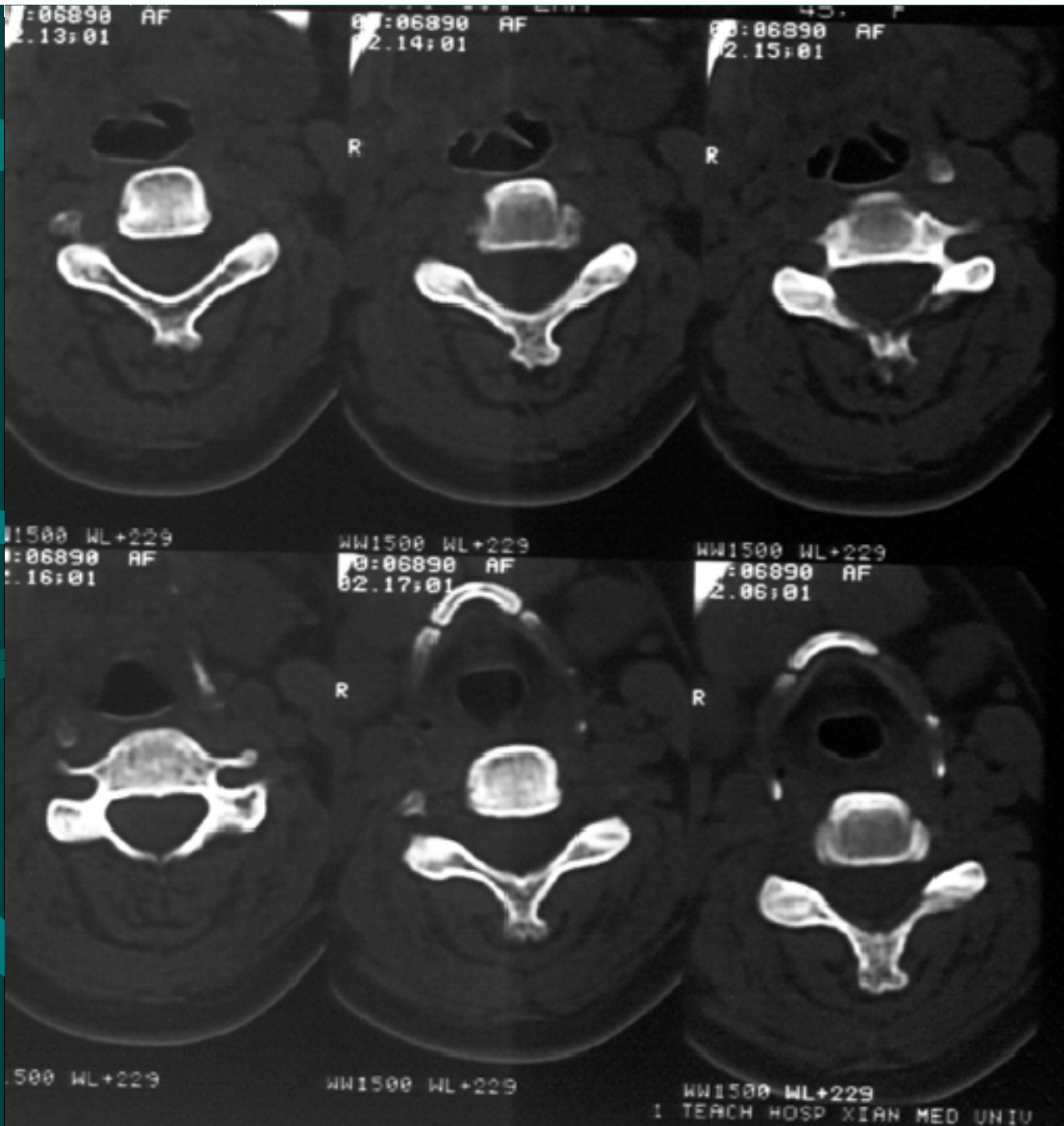
0216
0213 0217
0204 0208 0212
0201 0205 0209

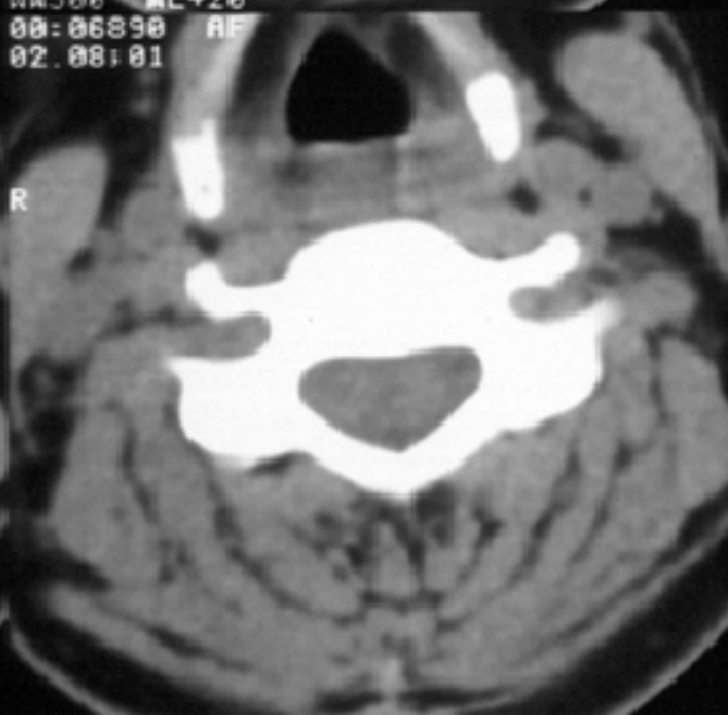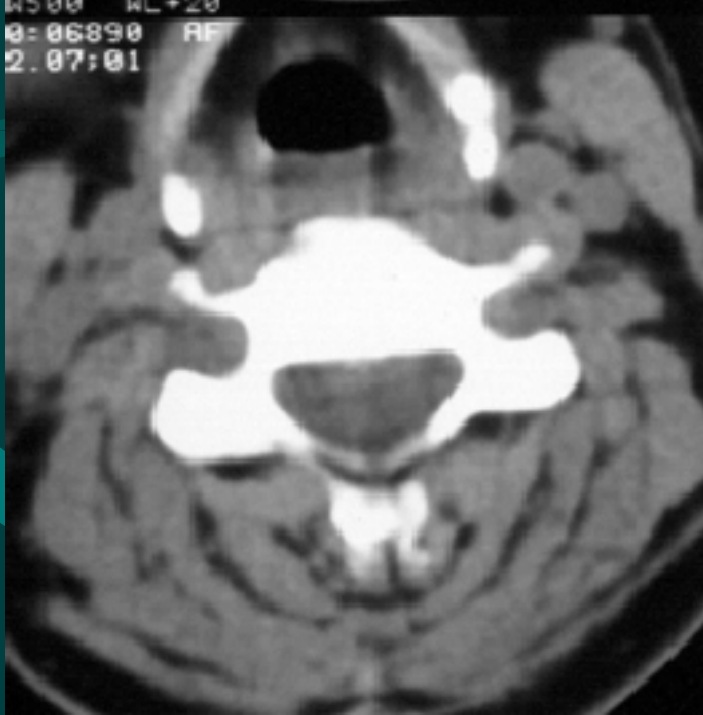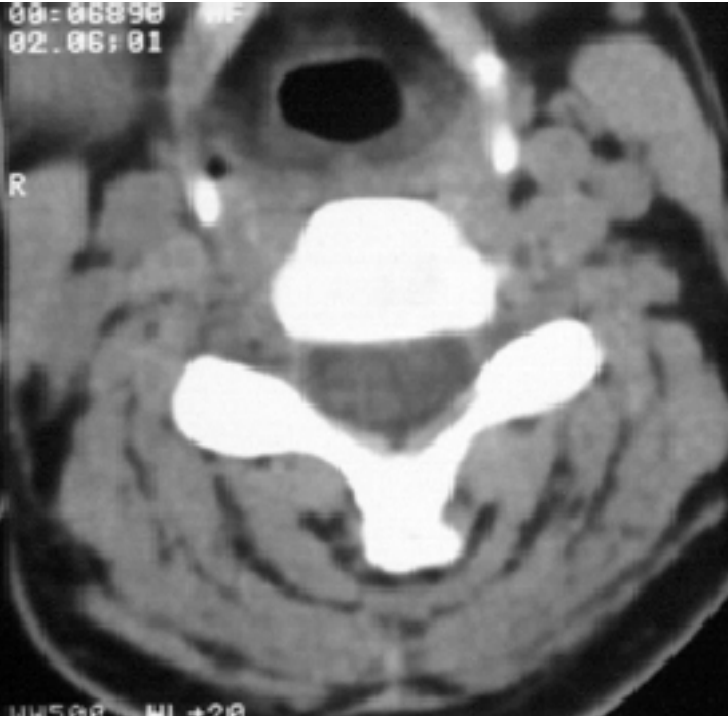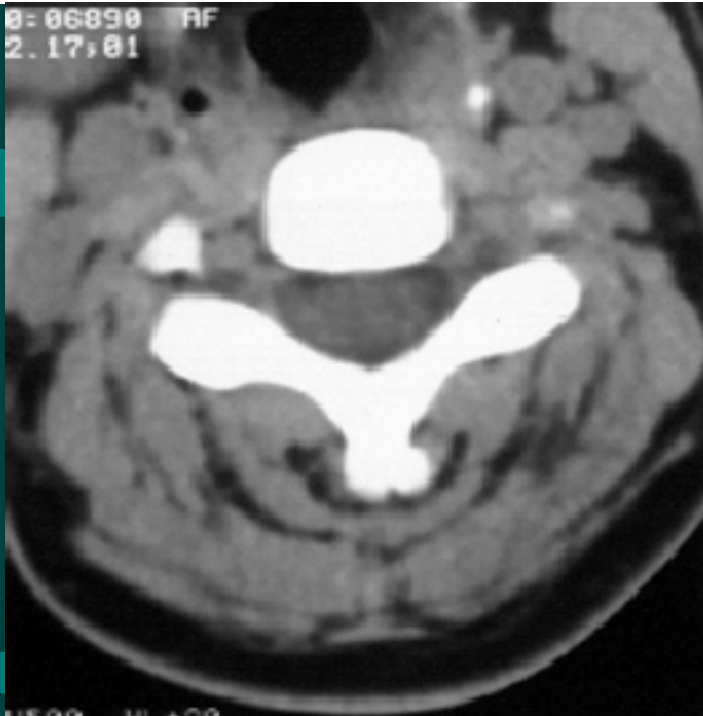kU
mA

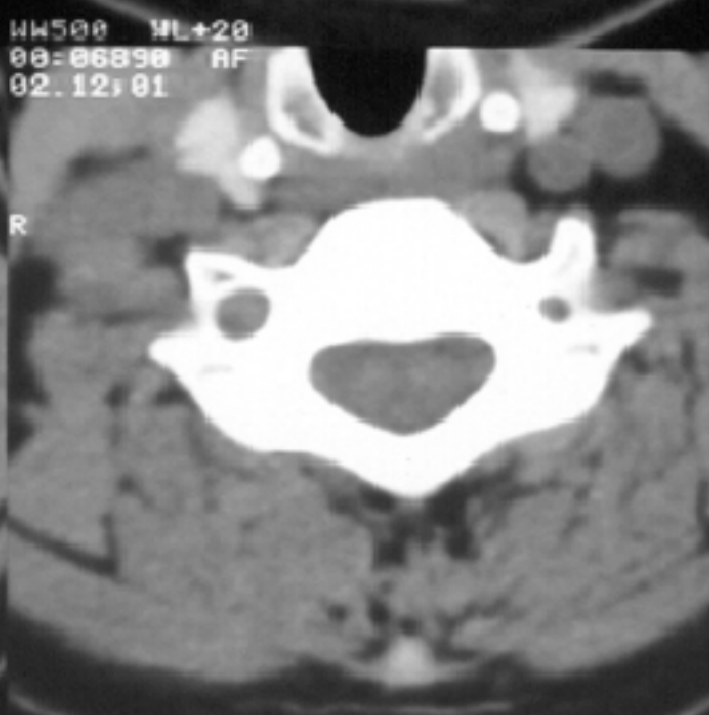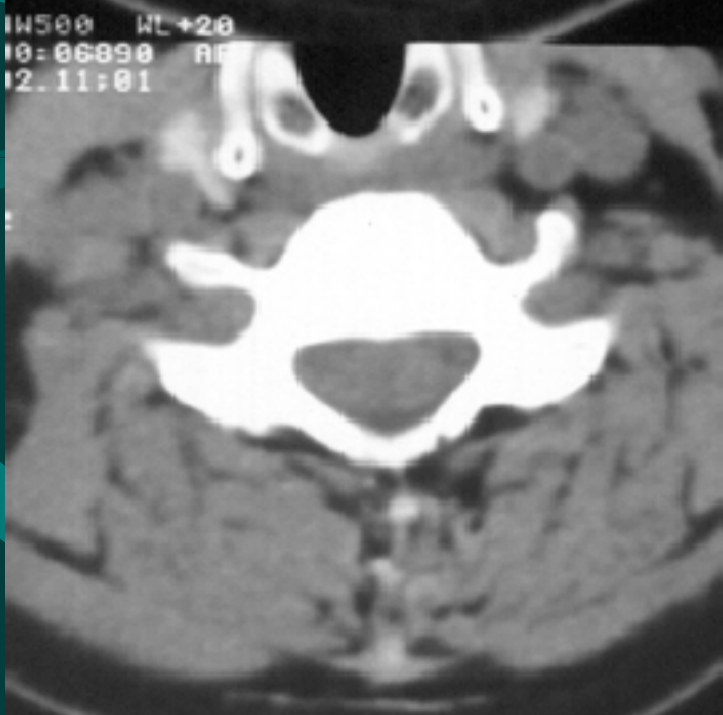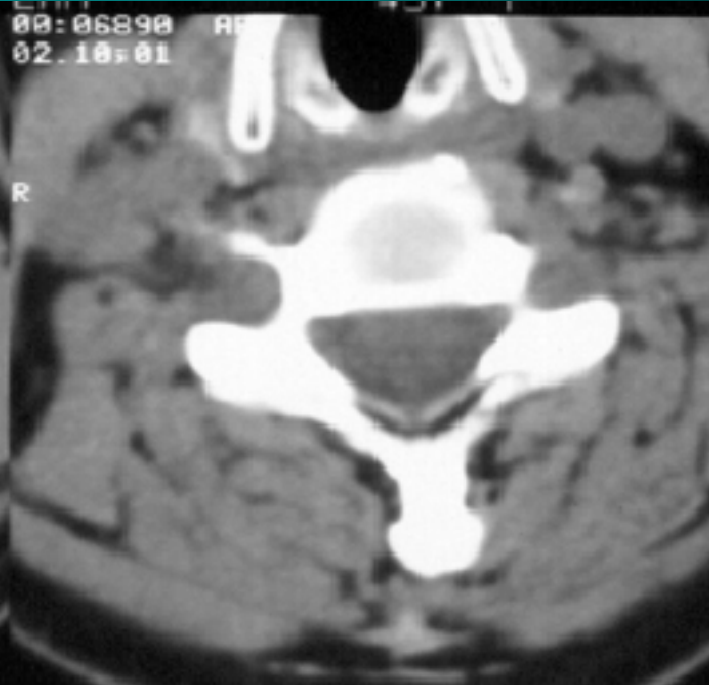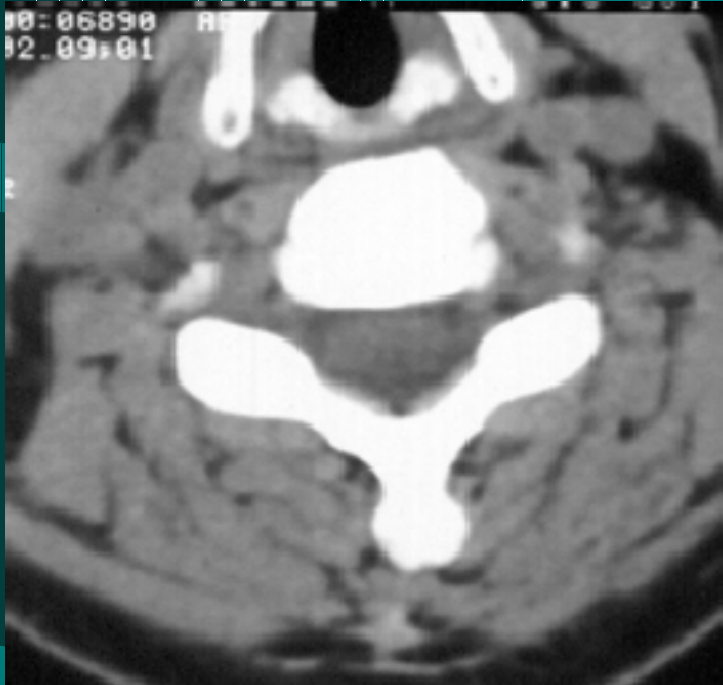140 120 100 80 60 40 20 0

P









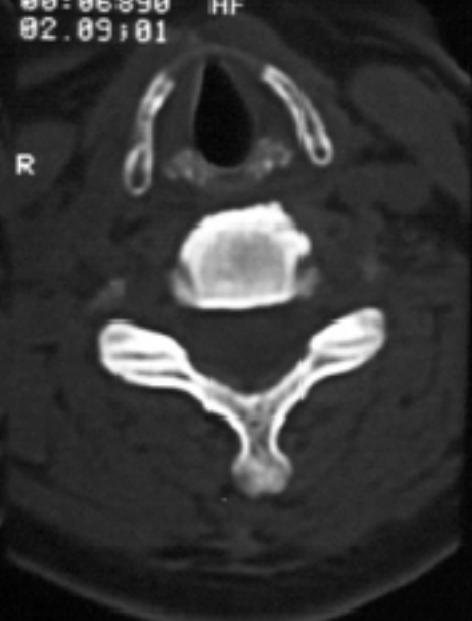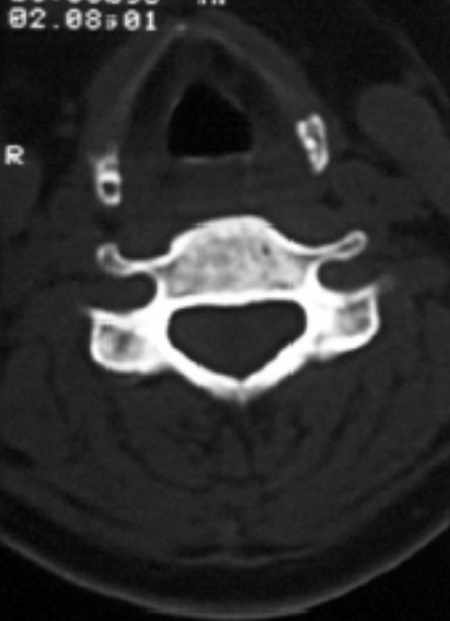
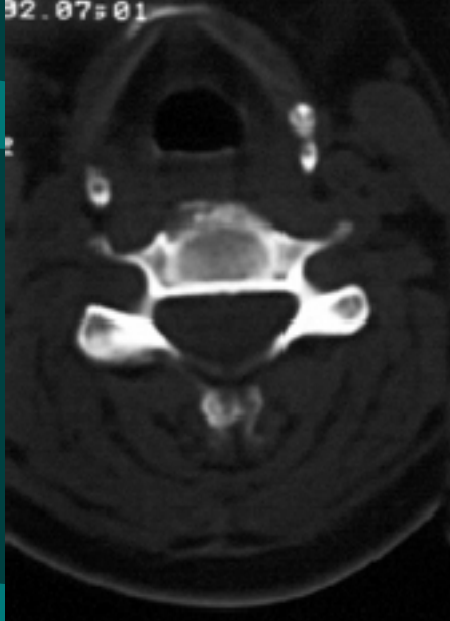
WW500 WL+20

WW500 WL+20

06890 930853 N
00:06890 AF
02.07:01

QIU GUI LAN
00:06890 AF
02.08:01

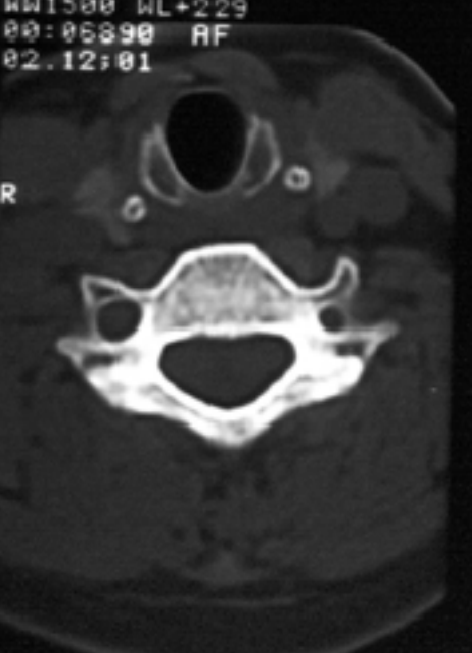
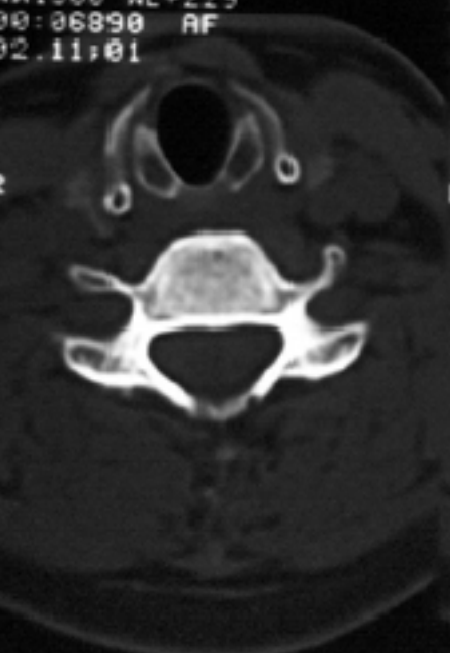
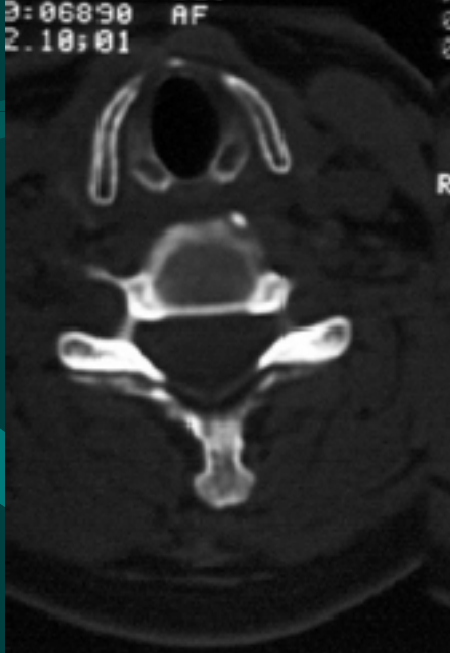
45: F
00:06890 AF
02.09:01



WW1500 WL+229
00:06890 AF
02.10:01

WW1500 WL+229
00:06890 AF
02.11:01

WW1500 WL+229
00:06890 AF
02.12:01



1500 WL+229

WW1500 WL+229


WW1500 WL+229

胸部CT横断面解剖



1胸椎椎弓根平面:

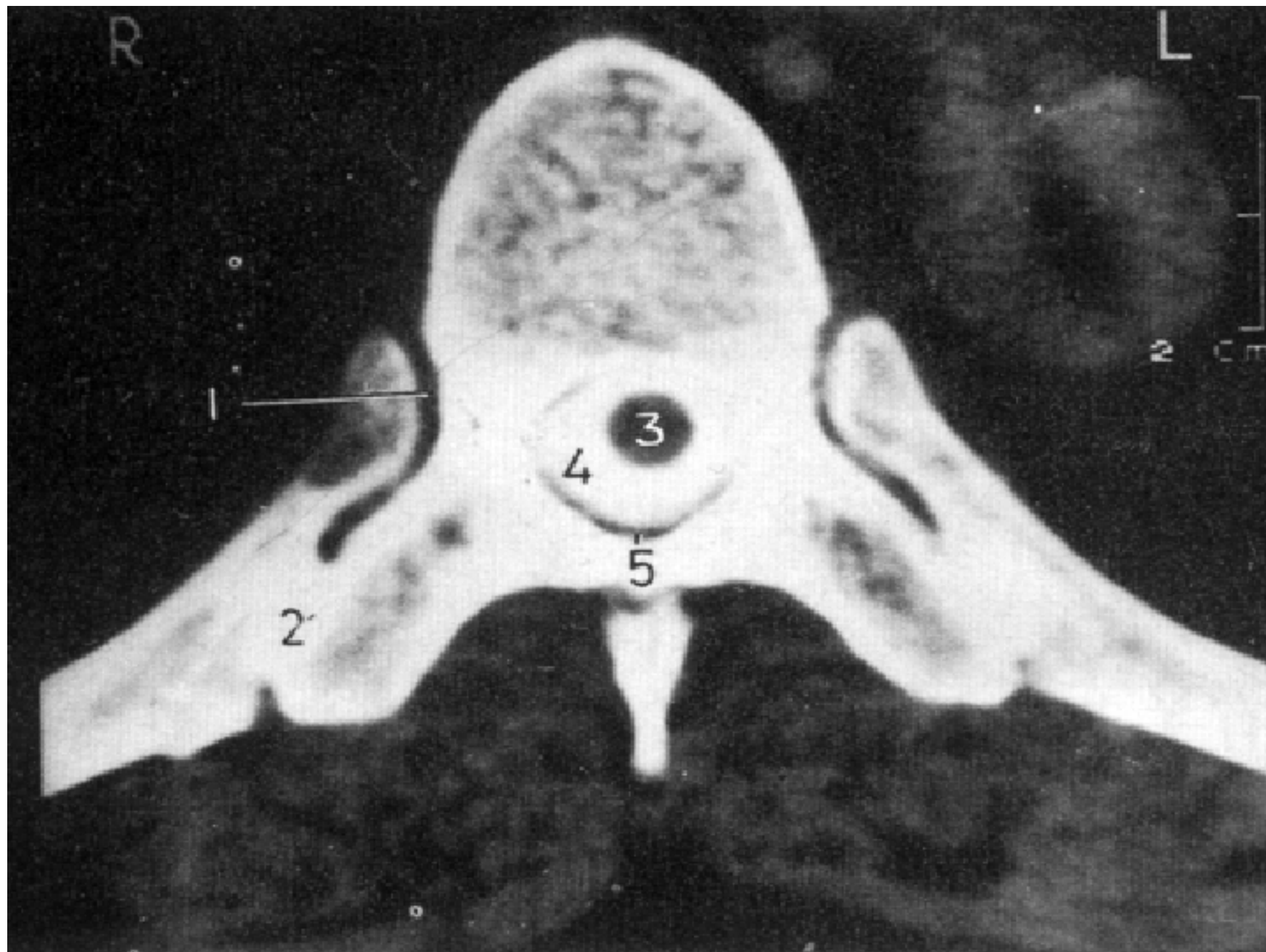
- 胸椎椎体、椎基静脉、骨帽、椎弓根、关节突、椎板、棘突、椎孔、横突、肋-胸椎体关节、肋-横突关节



胸椎椎体 平面:

- 胸椎椎体、椎弓根、椎板、棘突、椎孔、横突、肋-胸椎体关节、肋-横突关节、脊髓

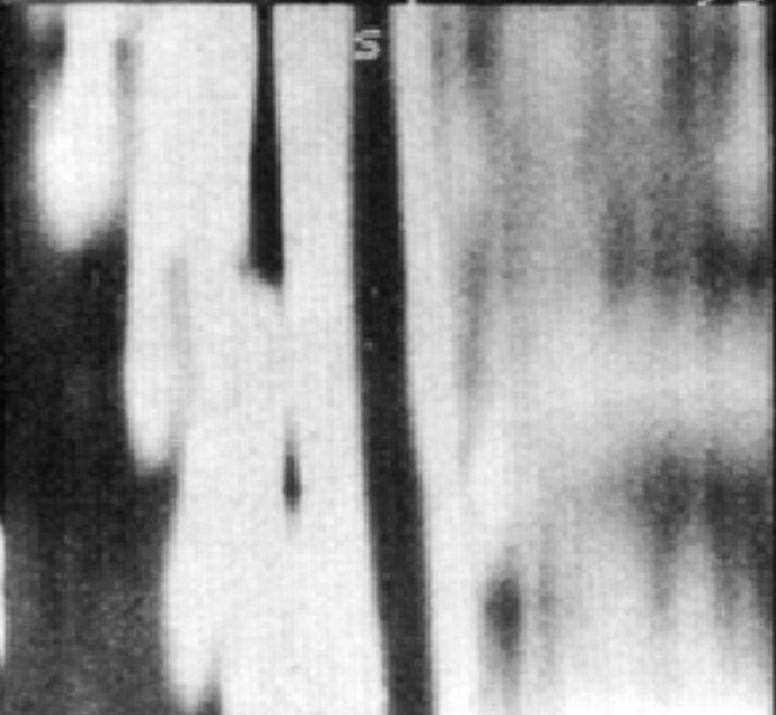
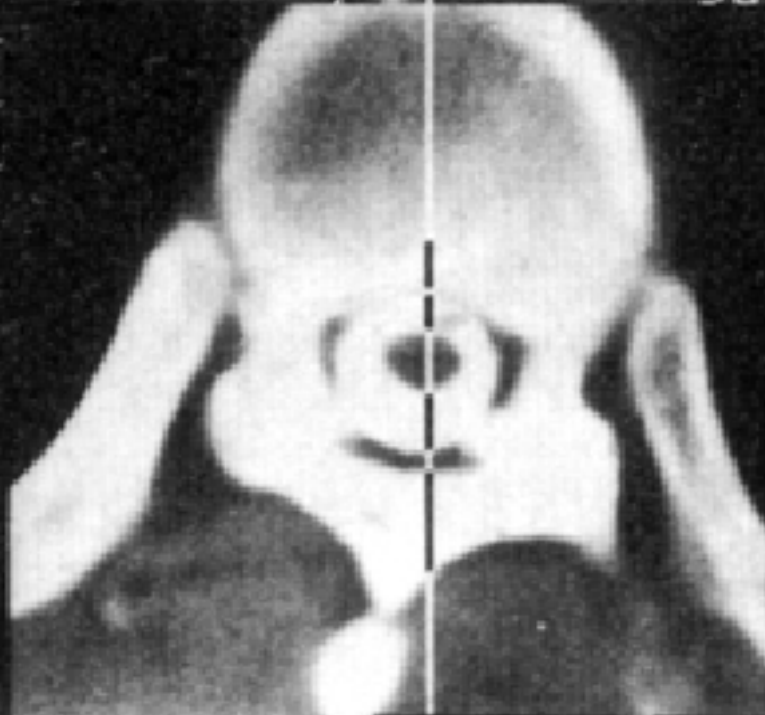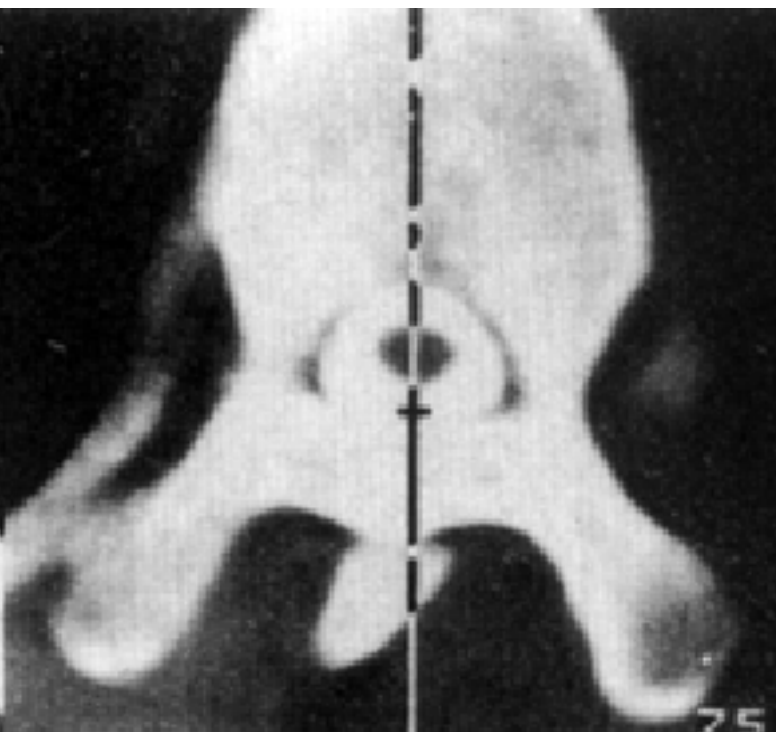
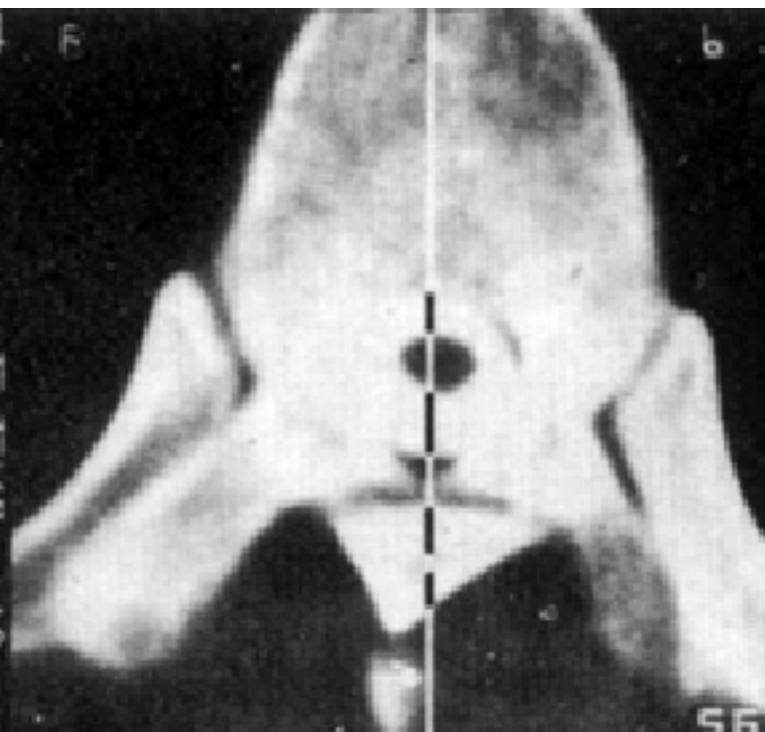


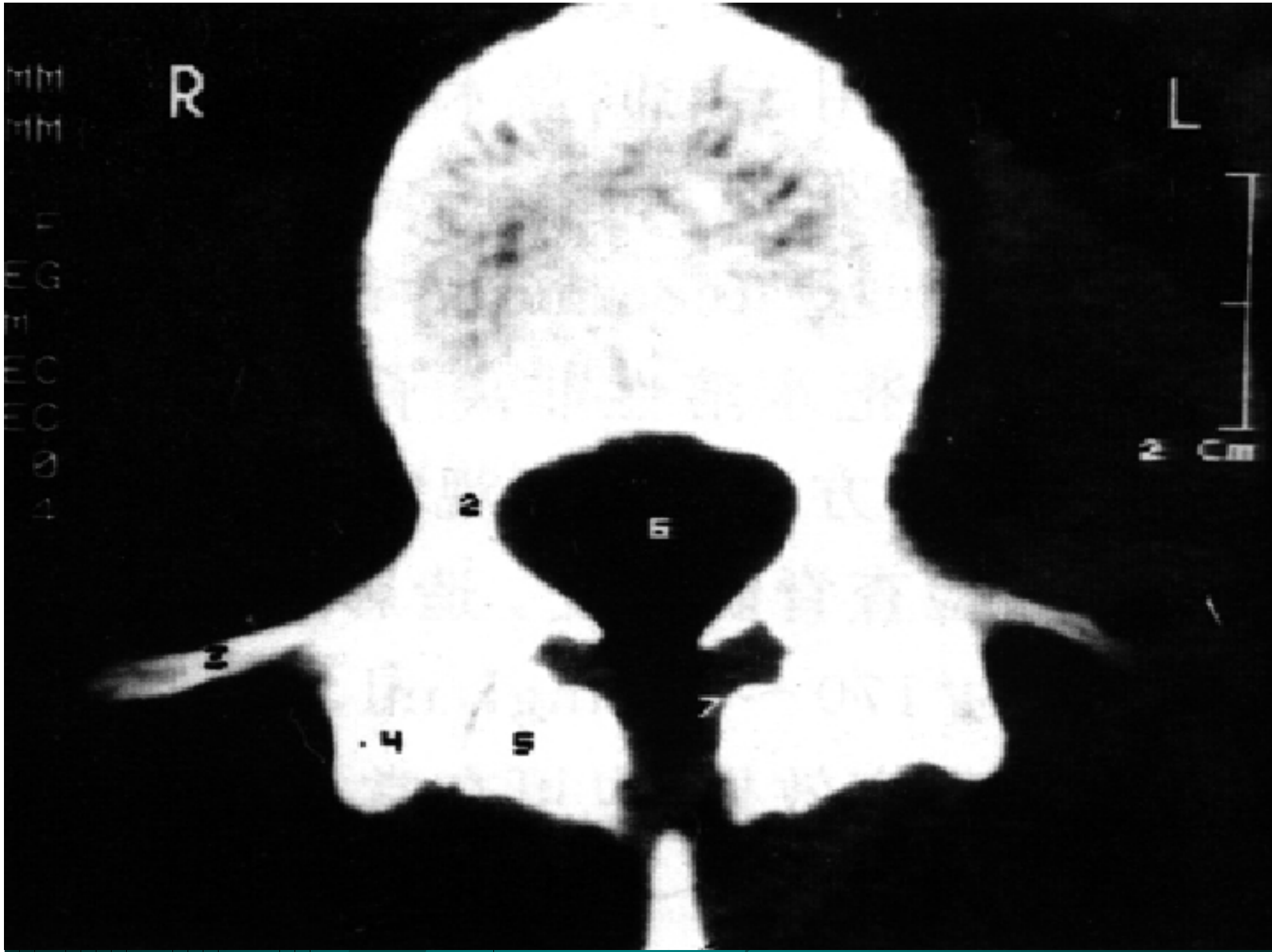


- 1154 R
1101 TA

Ø 496MM
Ø 0MM
Ø 0DEG

X2 N 15
19 128
128 PXL
128 PXL
62 5PXL
15





78
54

STANDING HIGH

M 22

PP
PP

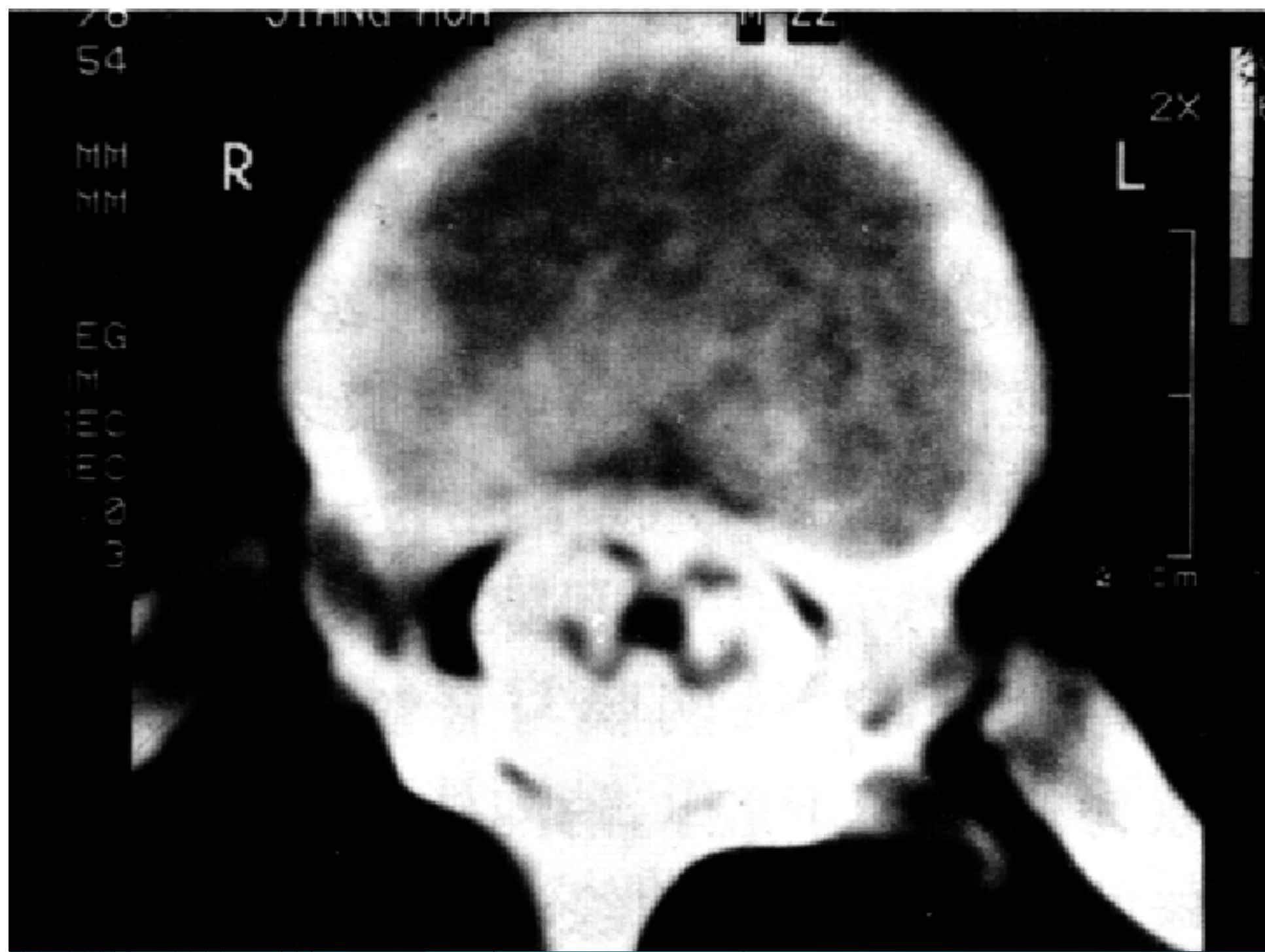
R

000000
000000
000000

2X

L

1E



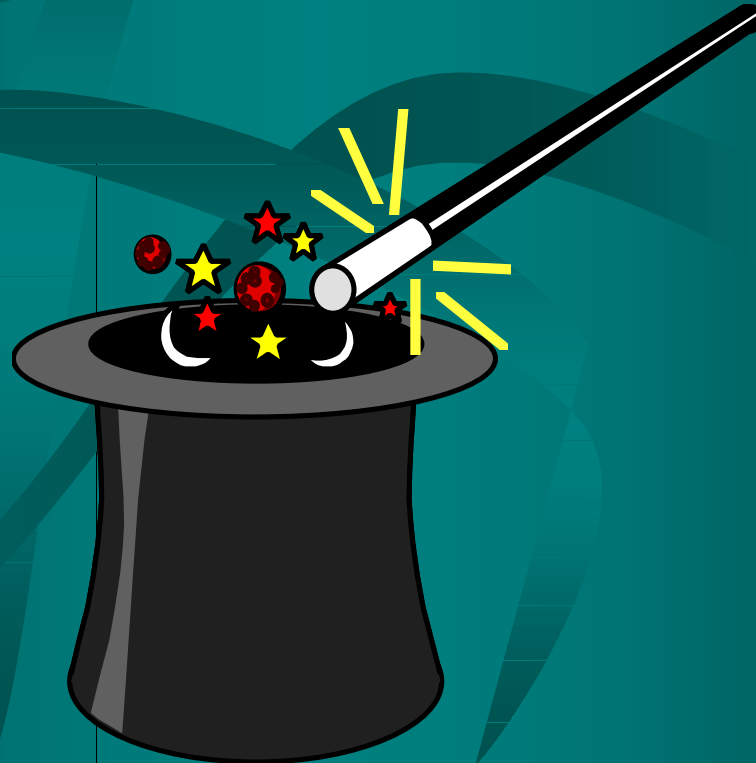
胸椎椎间孔平面:

- 胸椎椎体、椎间孔、关节突、椎板、棘突、椎孔

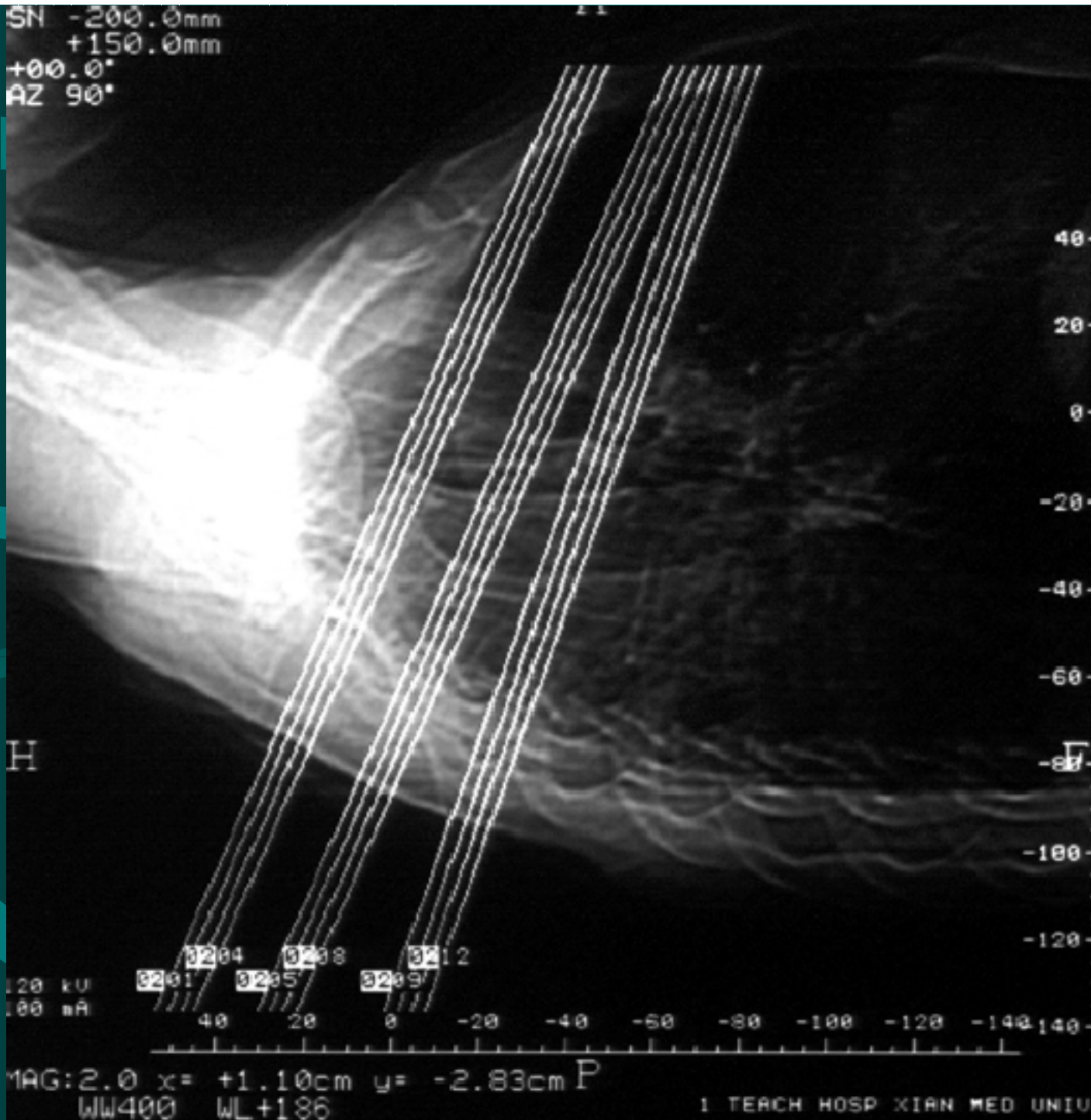


胸椎椎间盘平面:

- 胸椎椎间盘、后纵韧带、外侧隐窝内脊神经、椎间孔内脊神经、黄韧带、脊髓



SN -200.0mm
+150.0mm
+00.0°
AZ 90°



40
20
0
-20
-40
-60
-80
-100
-120

02:09:01 NO C
SN -46.5mm
-19.5°
3.0mm
32.0cm
x= +0.00cm
y= -5.54cm
DETL

AF 1993/11/27 09:28:07

QMC

1.5
0
cm

R

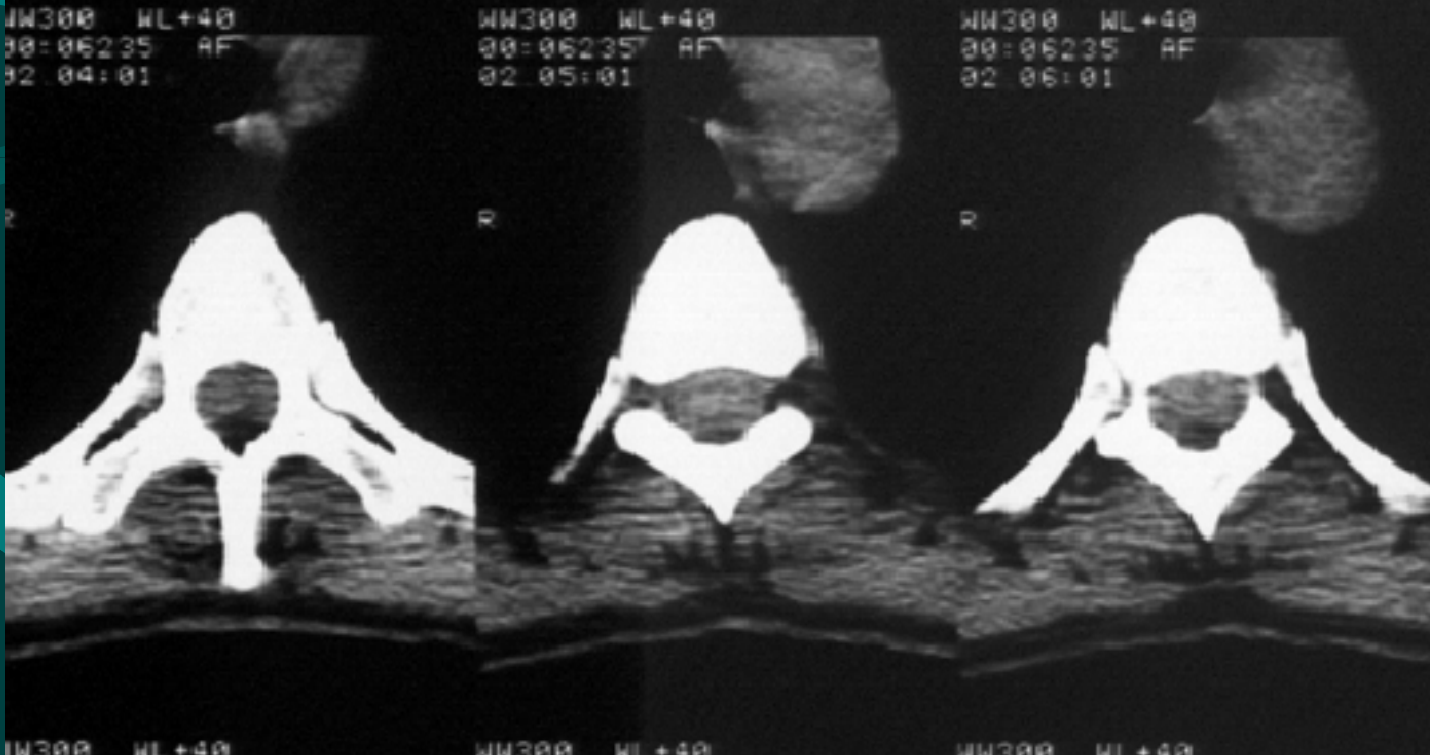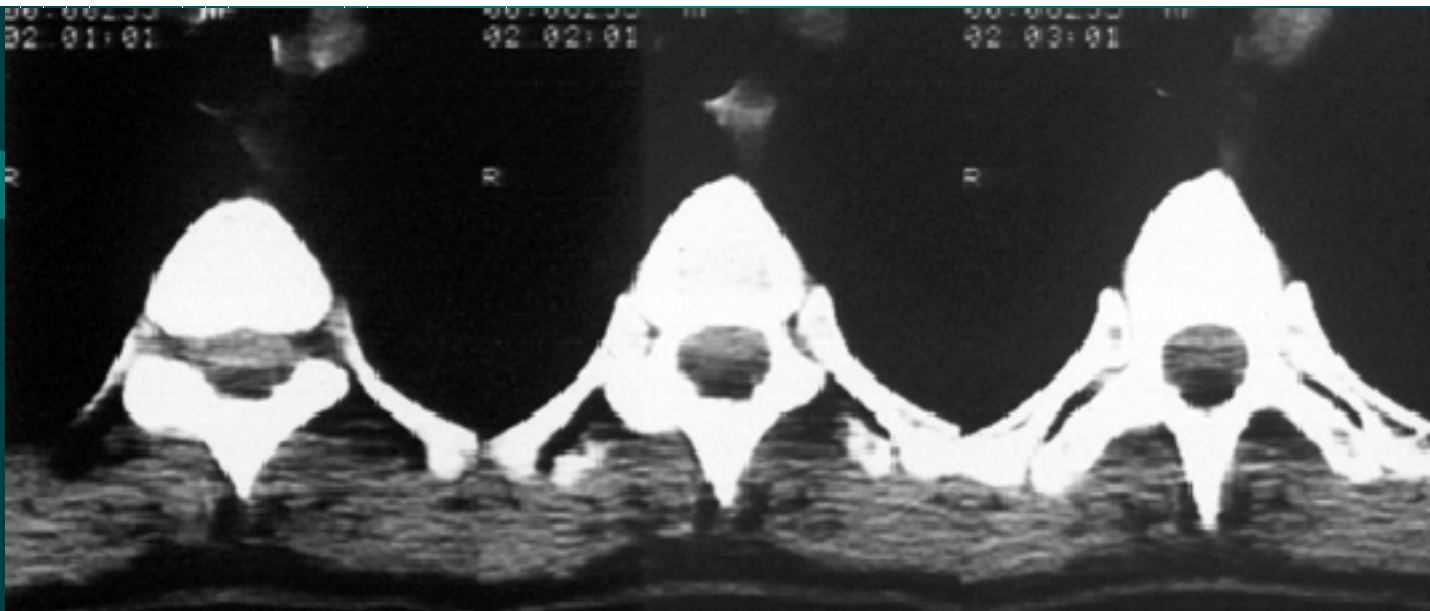L

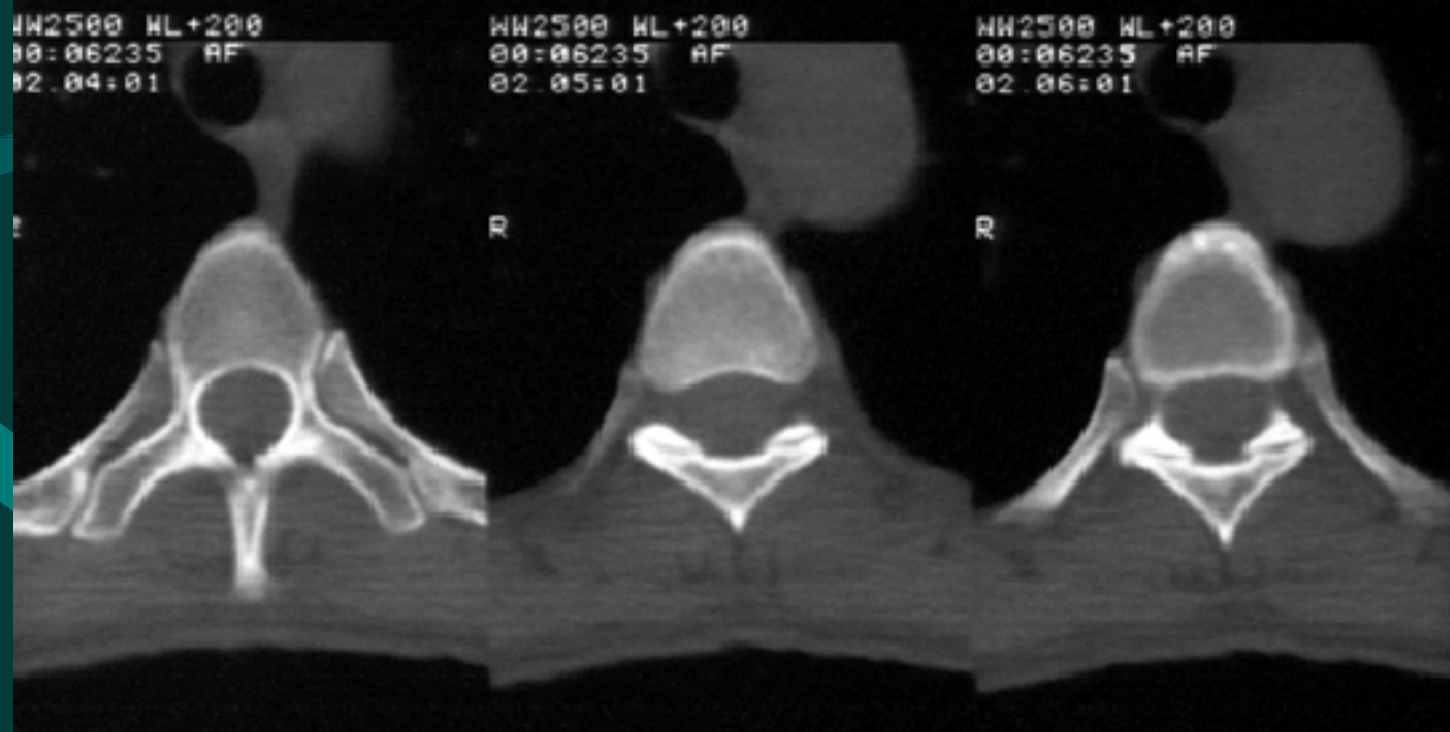
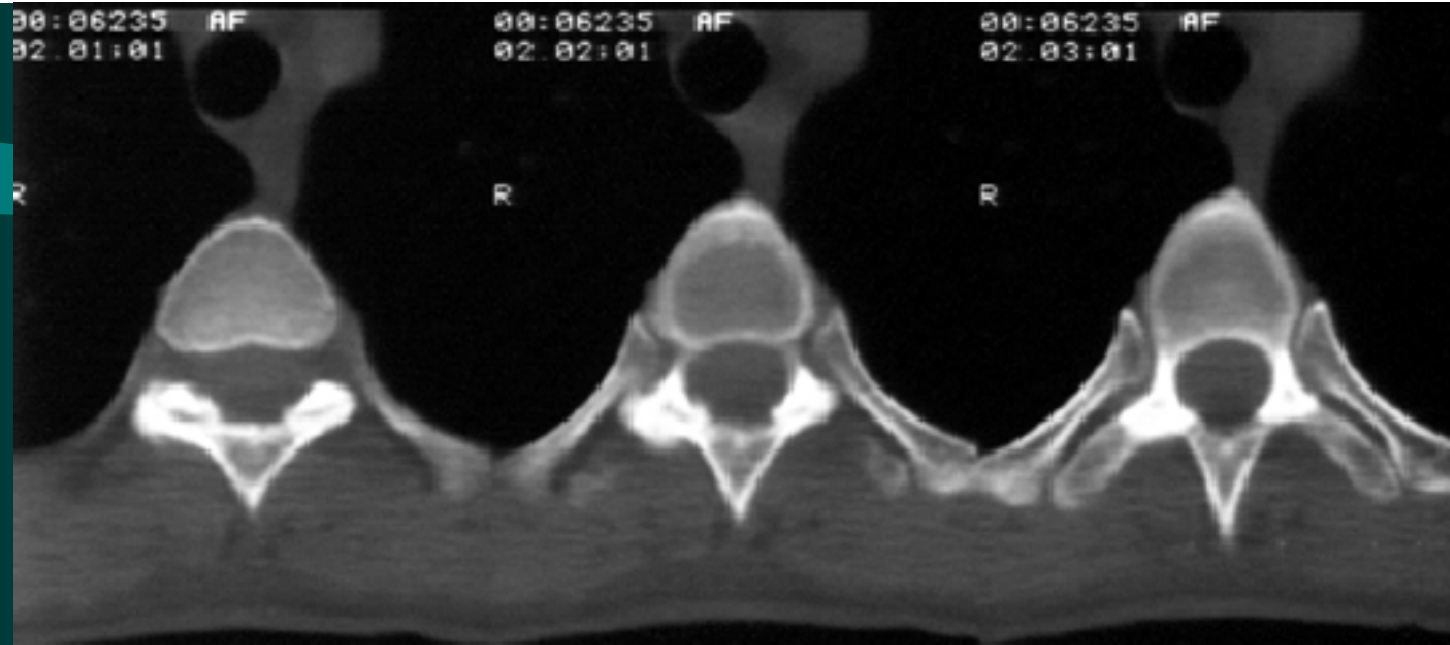
120 kV
100 mA
2.0 sec
35-CAL

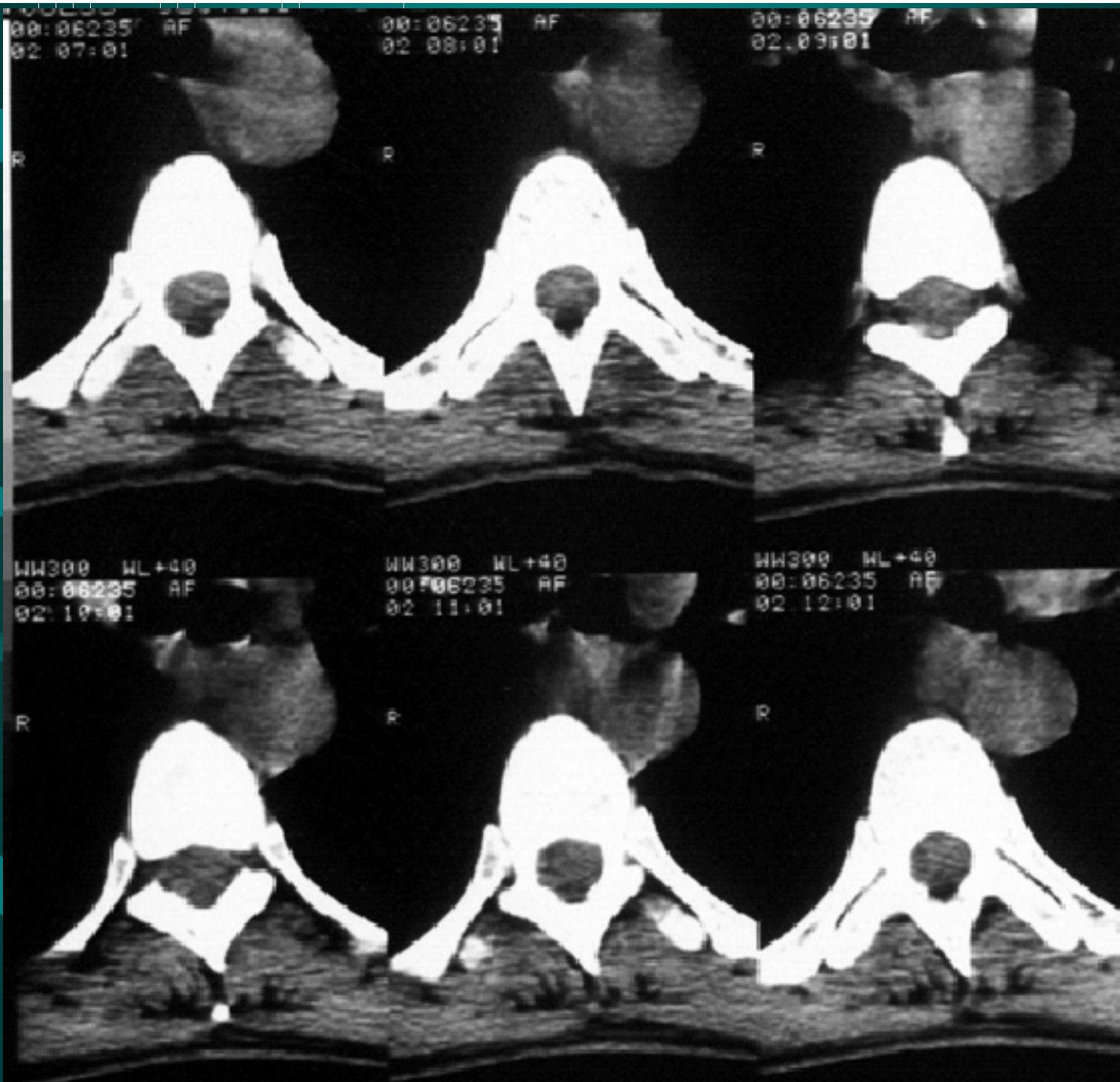
MAG:4.1 x= -0.22cm y= -0.22cm PH

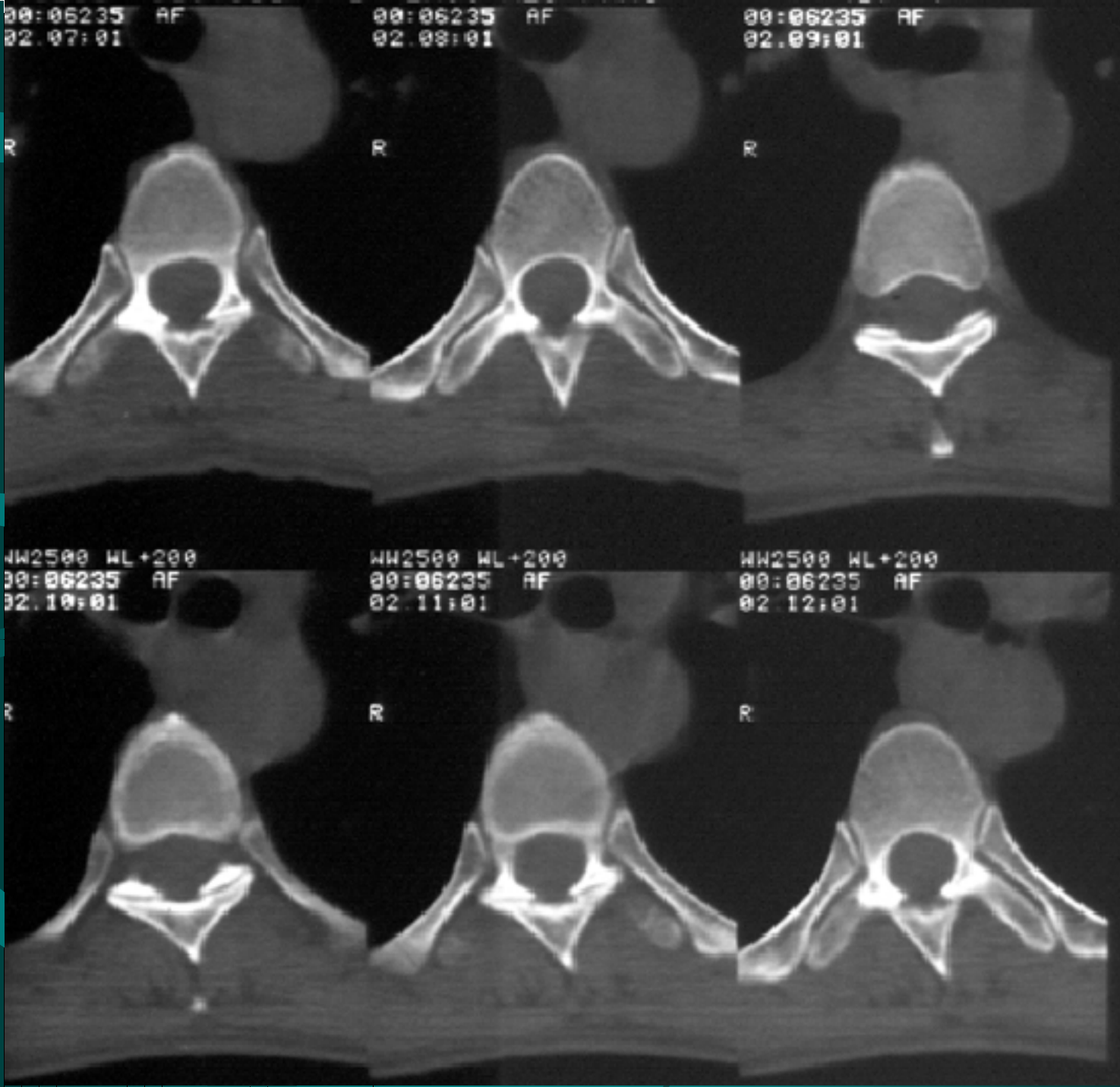
1 TEACH HOSP XI'AN MED UNIV

LN300 WL +40











腰部CT横断面解剖



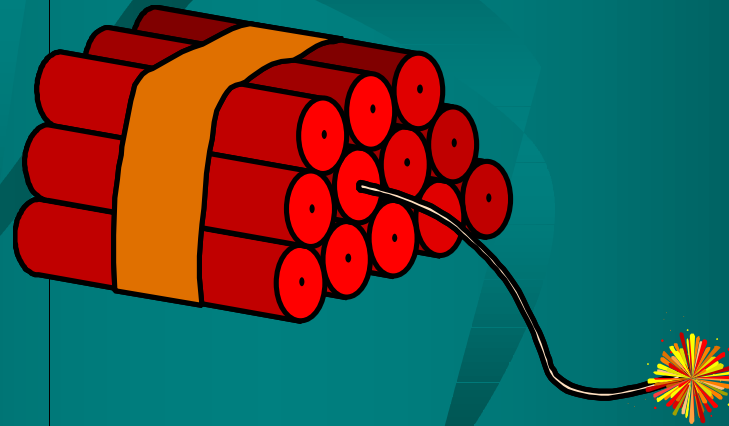
腰椎椎弓根平面:

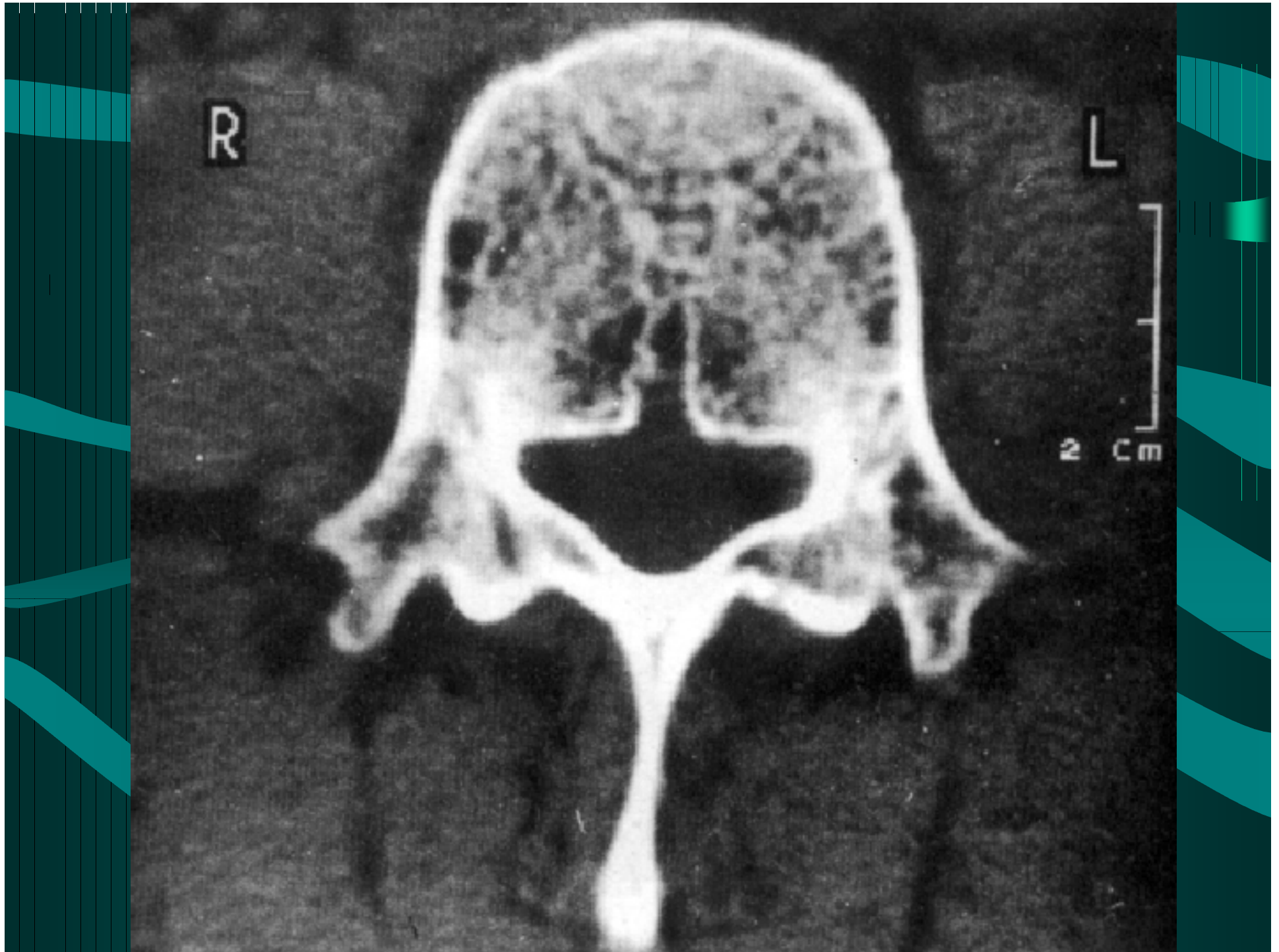
- 腰椎椎体、椎基静脉、骨帽、椎弓根、椎板、关节突、棘突、椎孔、横突

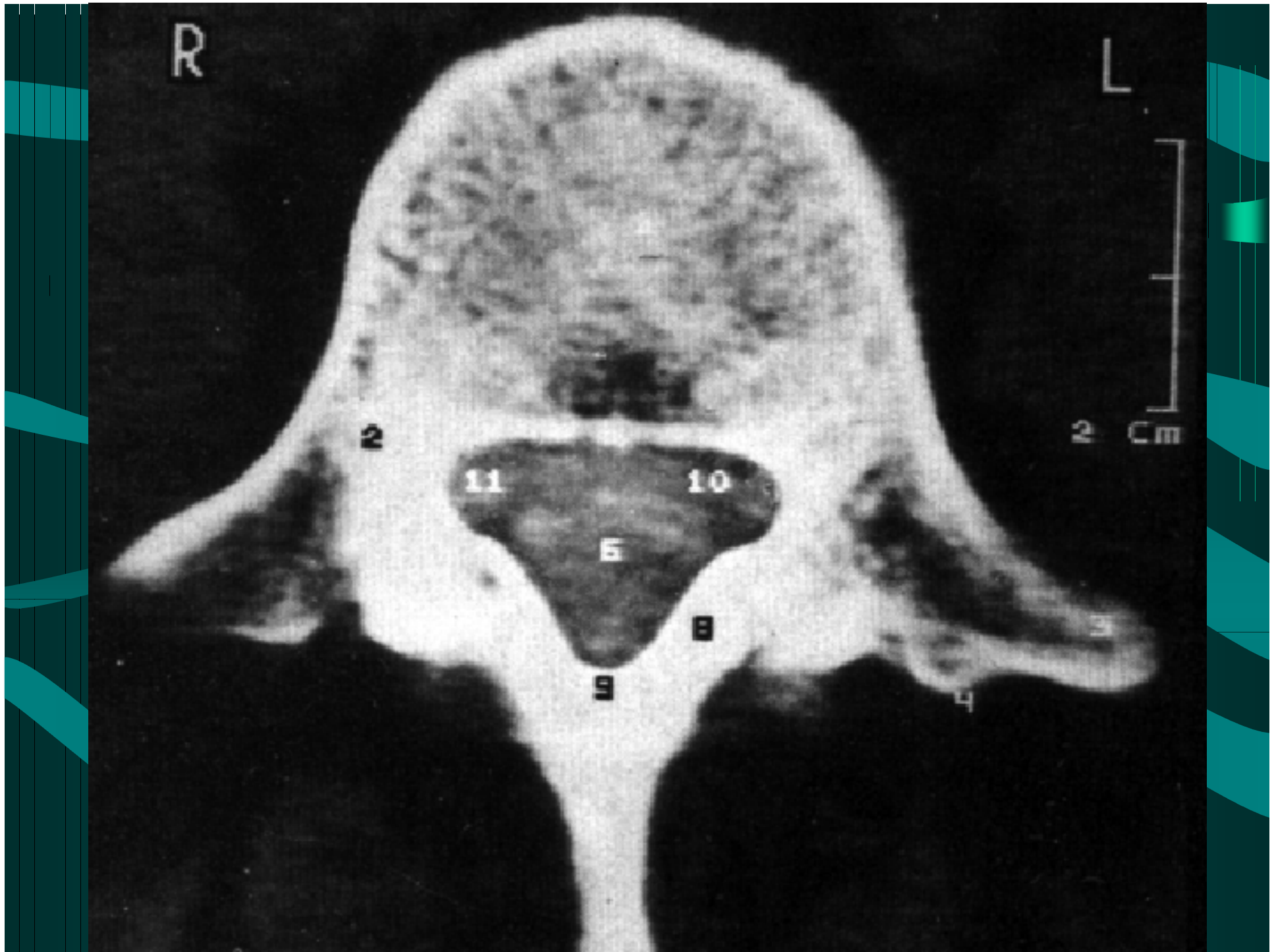


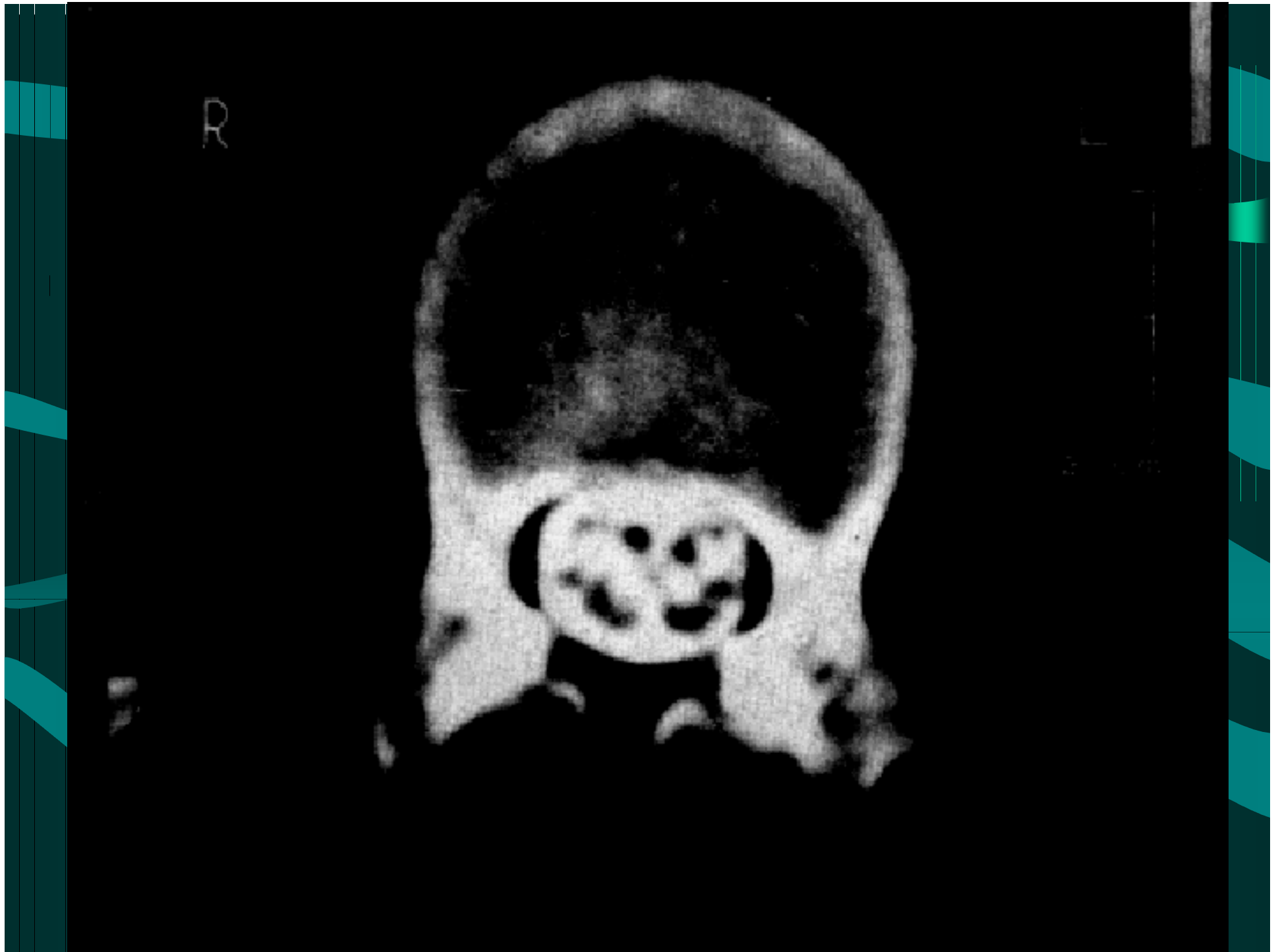
腰椎椎体 平面:

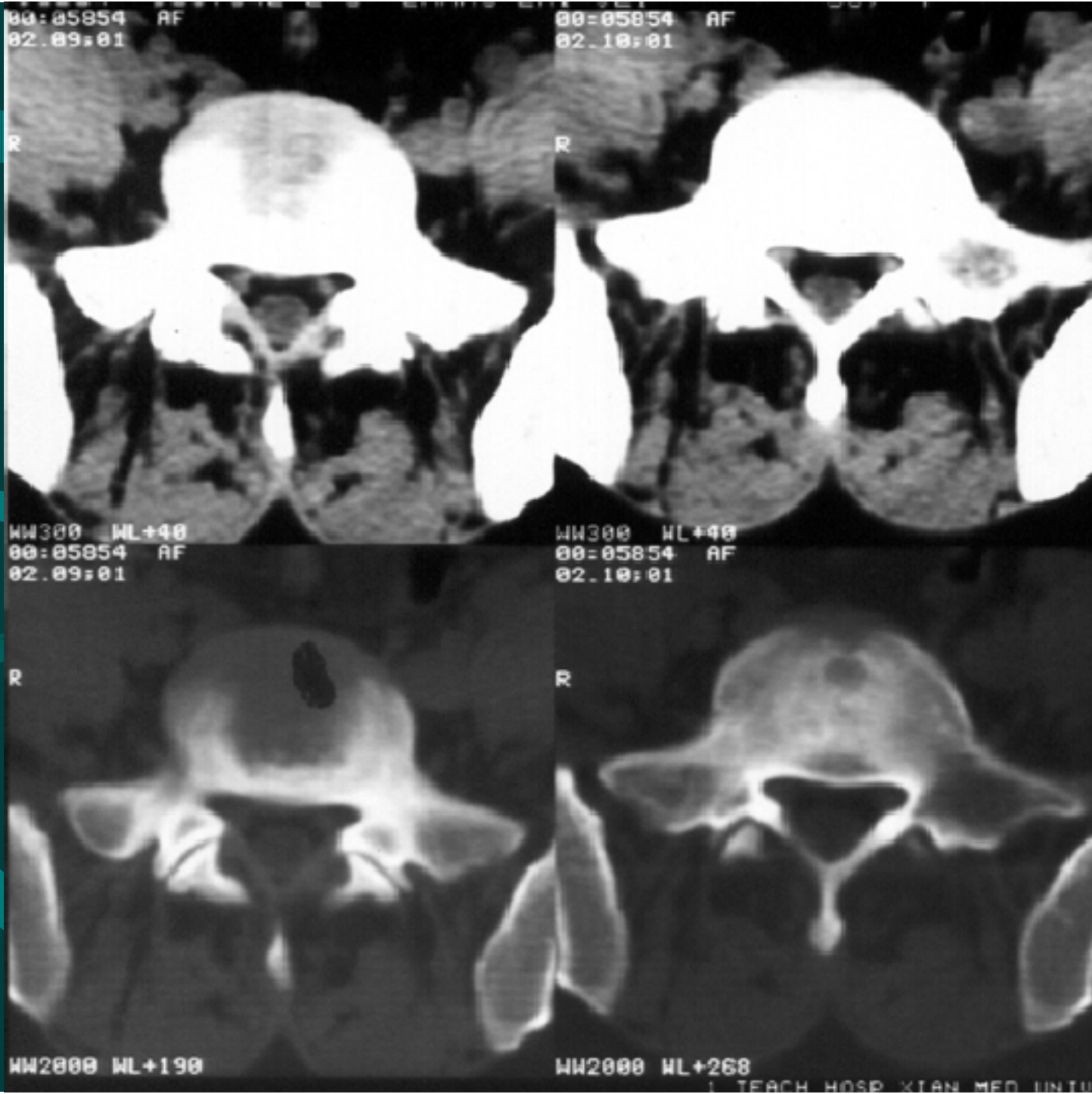
- 腰椎椎体、后纵韧带、硬膜囊、外侧隐窝内脊神经、黄韧带












腰椎椎间孔平面:

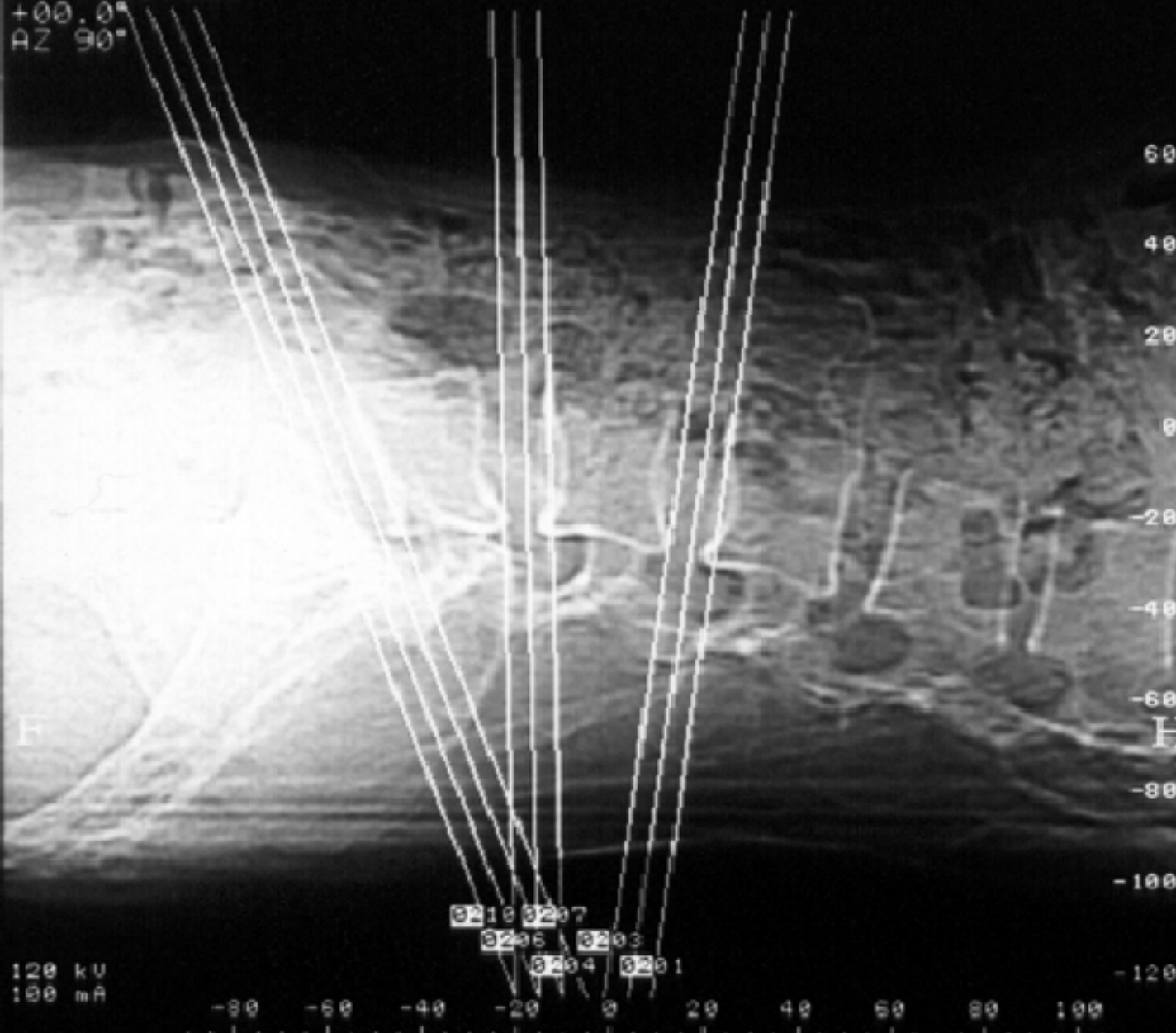- 腰椎椎体、椎基静脉、骨帽、椎间孔、椎板、关节突、棘突、椎孔、横突



01.01:01 NO C
IC +150.0mm
-150.0mm
+00.0
AZ 90°

A

1993/11/13 11:56:46



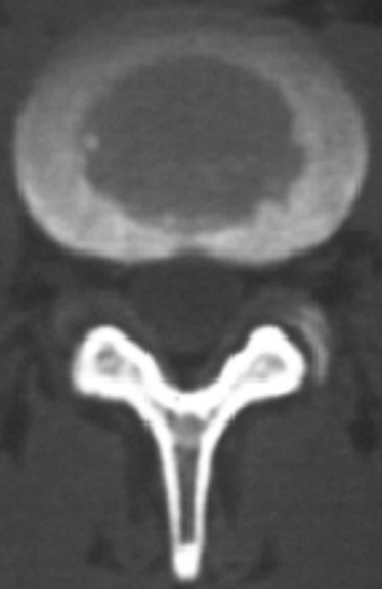120 kV
100 mA

MAG: 2.0 x= -0.15cm y= -1.65cm P
WL250 WL+153

TEACH HOSP XIAN MED UNIV

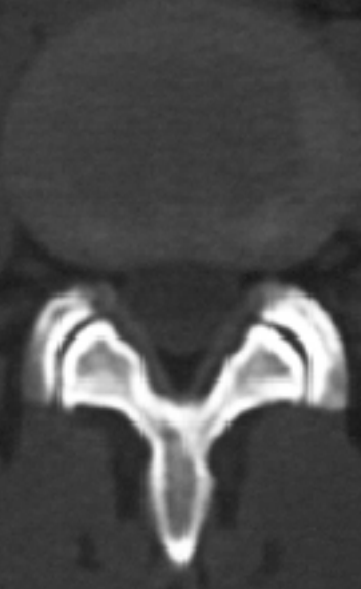00:05744 A
02.01:01

R



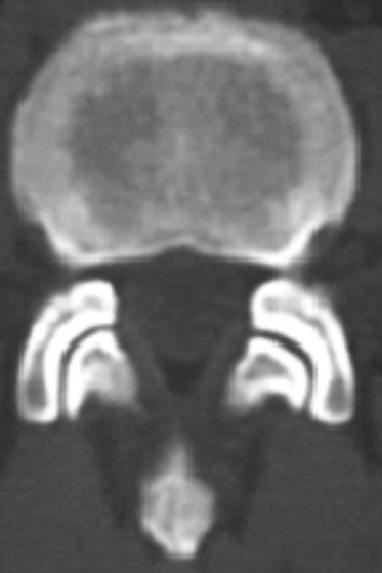00:05744 A
02.02:01

R



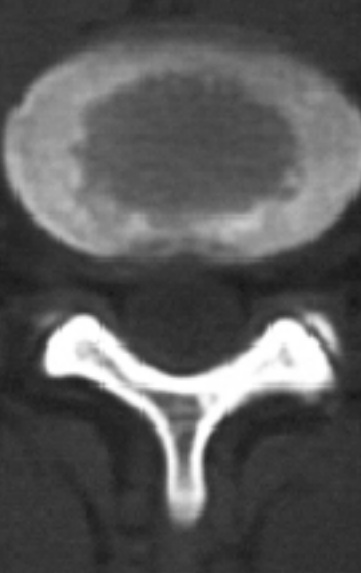
HW2000 ML+150
00:05744 A
02.03:01

R



HW2000 ML+150
00:05744 AF
02.04:01

R



HW2000 ML+150

HW2000 ML+150

00:85744 AF
02.05:01

00:85744 AF
02.06:01

R

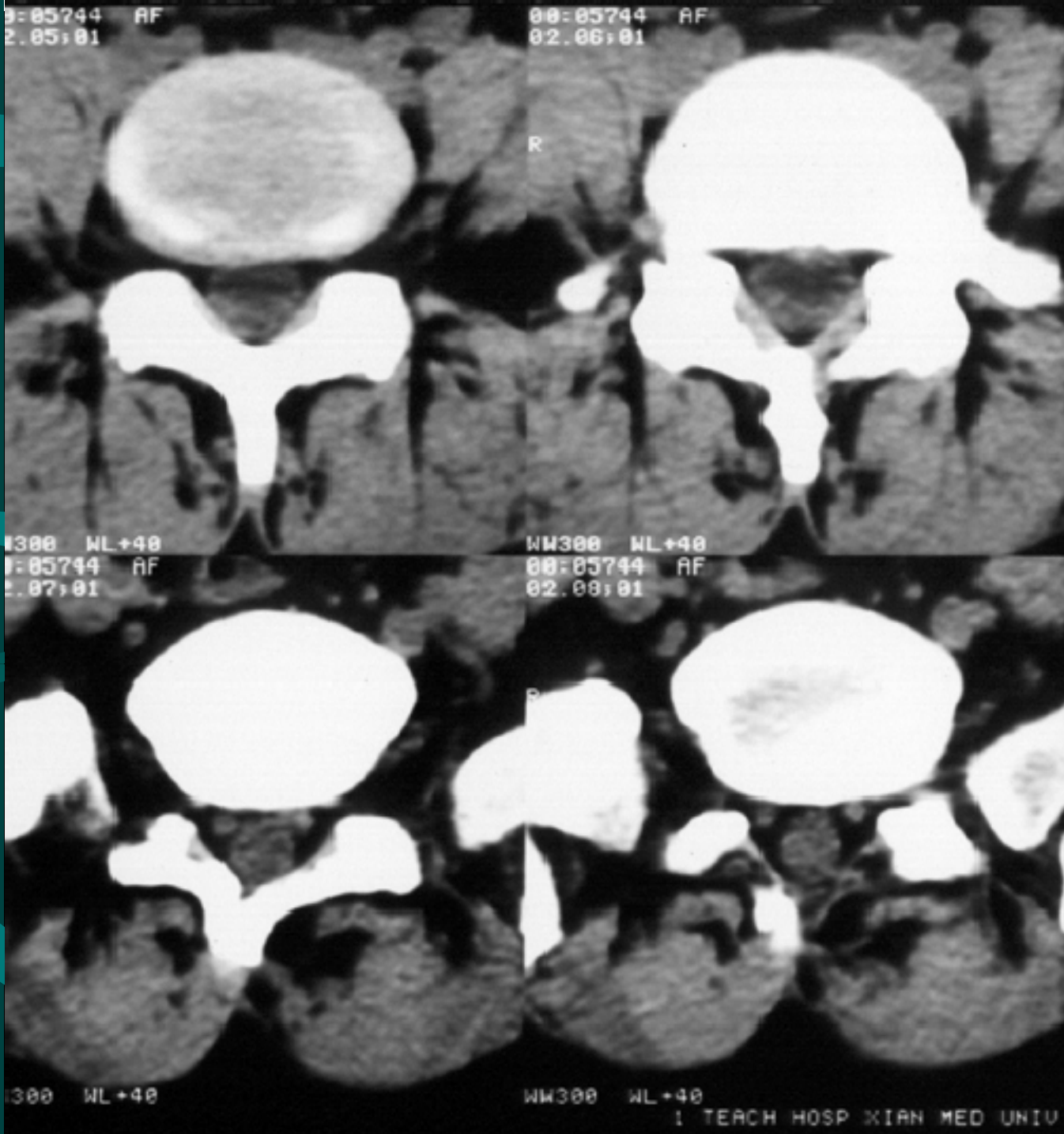
W300 ML+40
00:85744 AF
02.07:01

WM300 ML+40
00:85744 AF
02.08:01

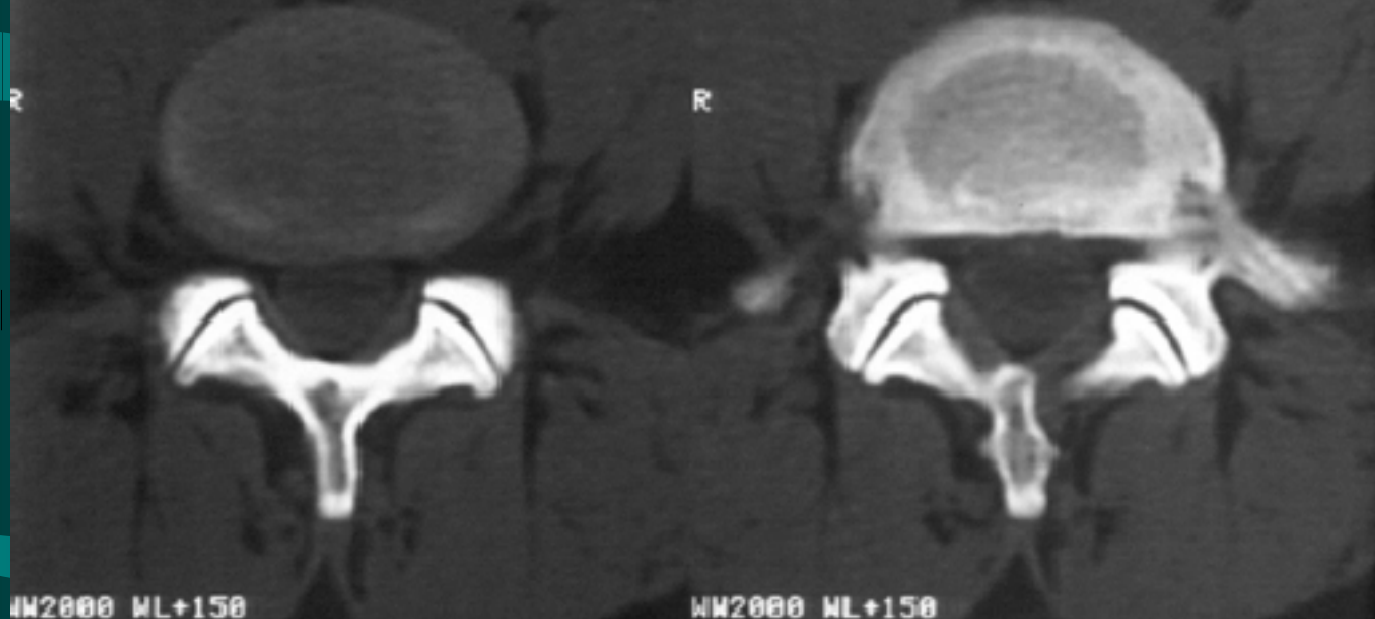W300 ML+40

WM300 ML+40

! TEACH HOSP XIAN MED UNIV

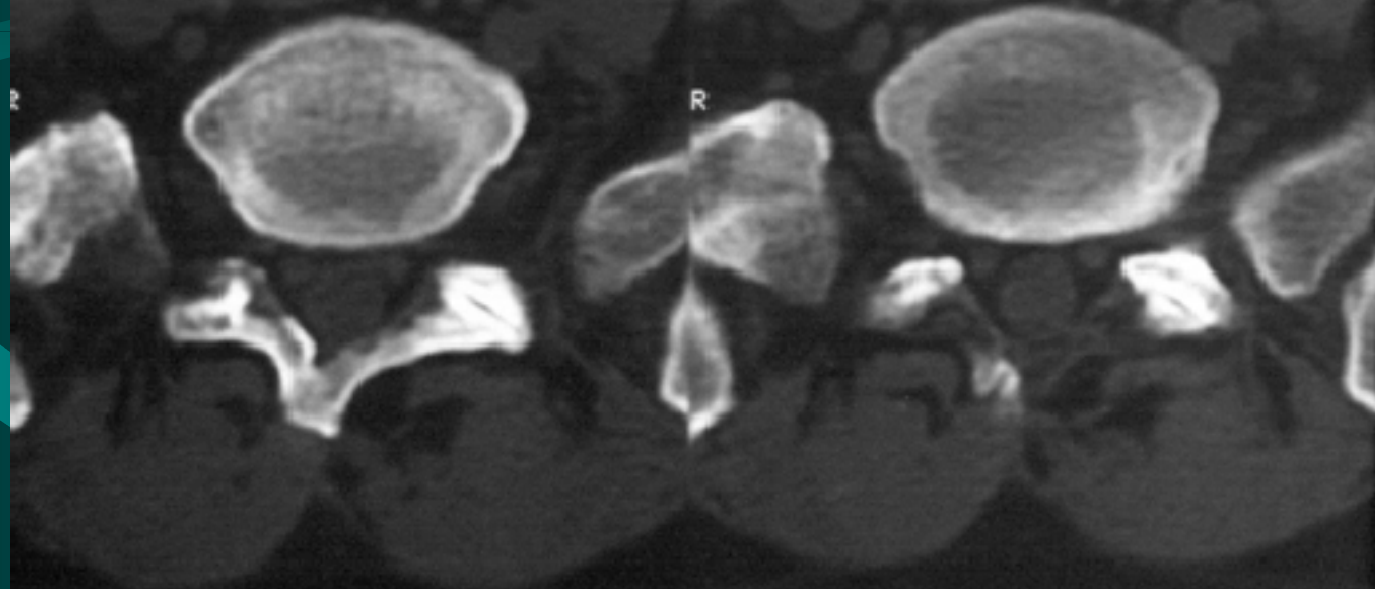


05744 9307522 L-S LIU ZHONG 32: M
00:05744 AF 00:05744 AF
02.05:01 02.06:01



WW2000 WL+150
00:05744 AF
02.07:01

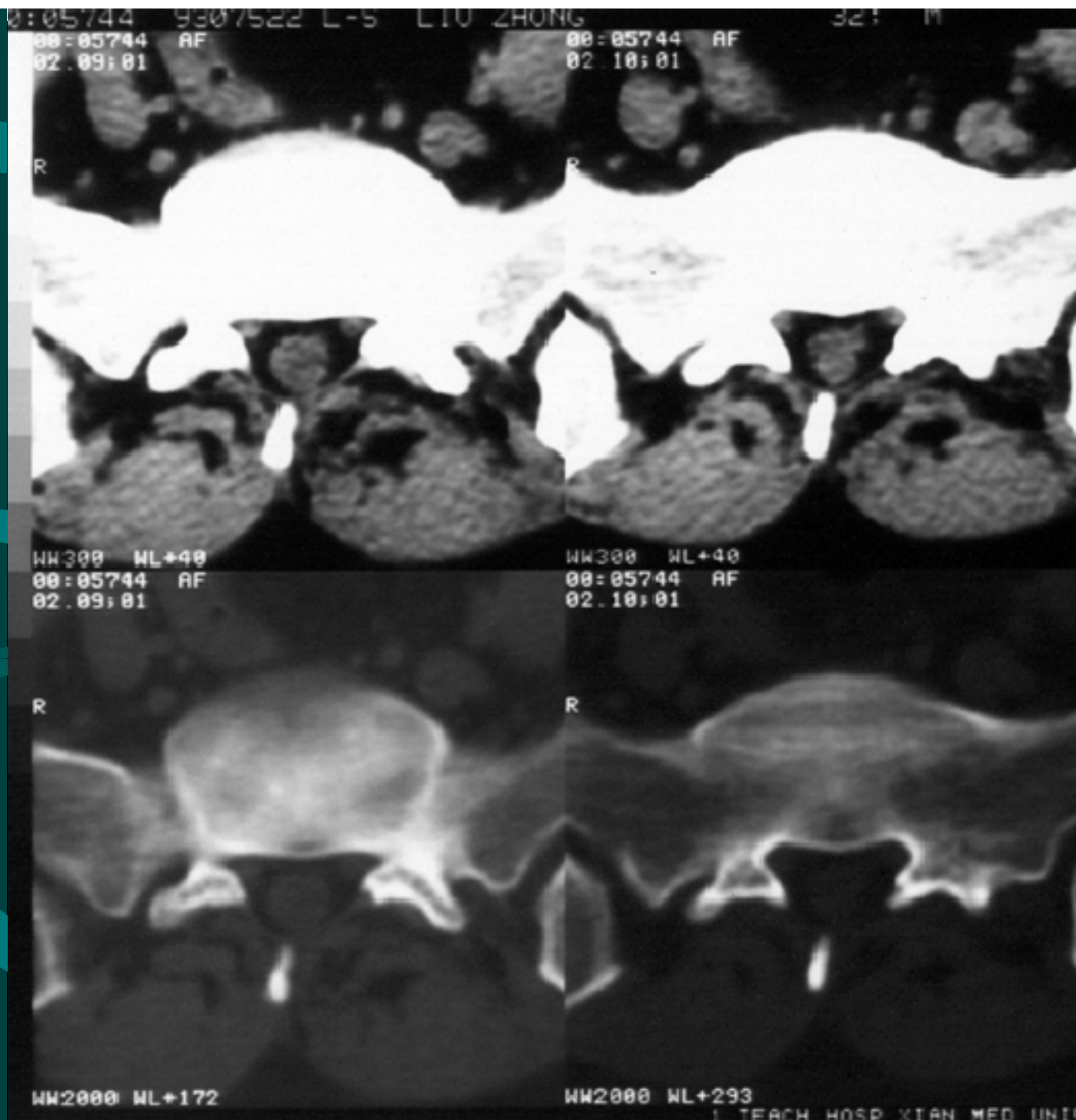
WW2000 WL+150
00:05744 AF
02.08:01

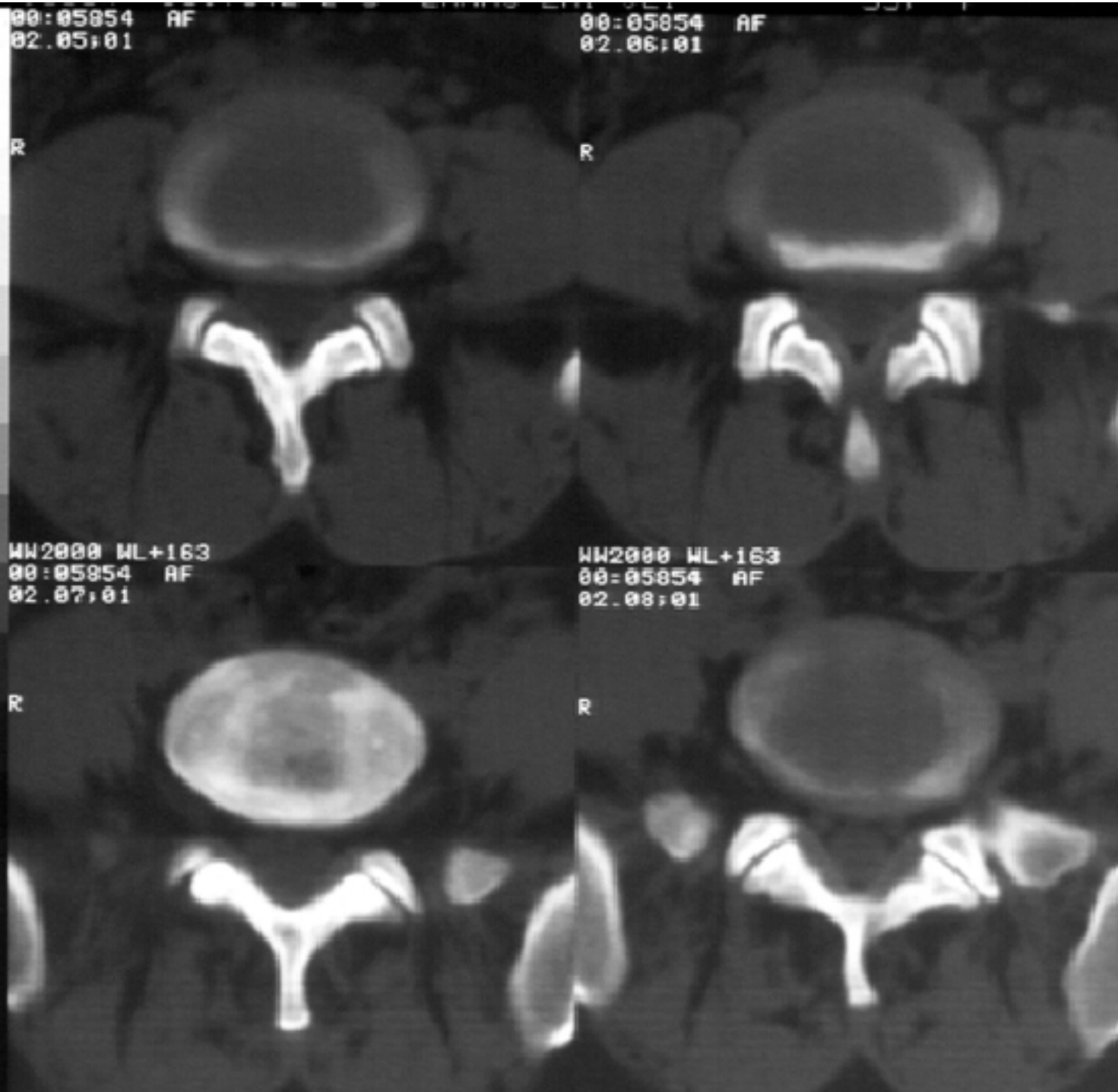


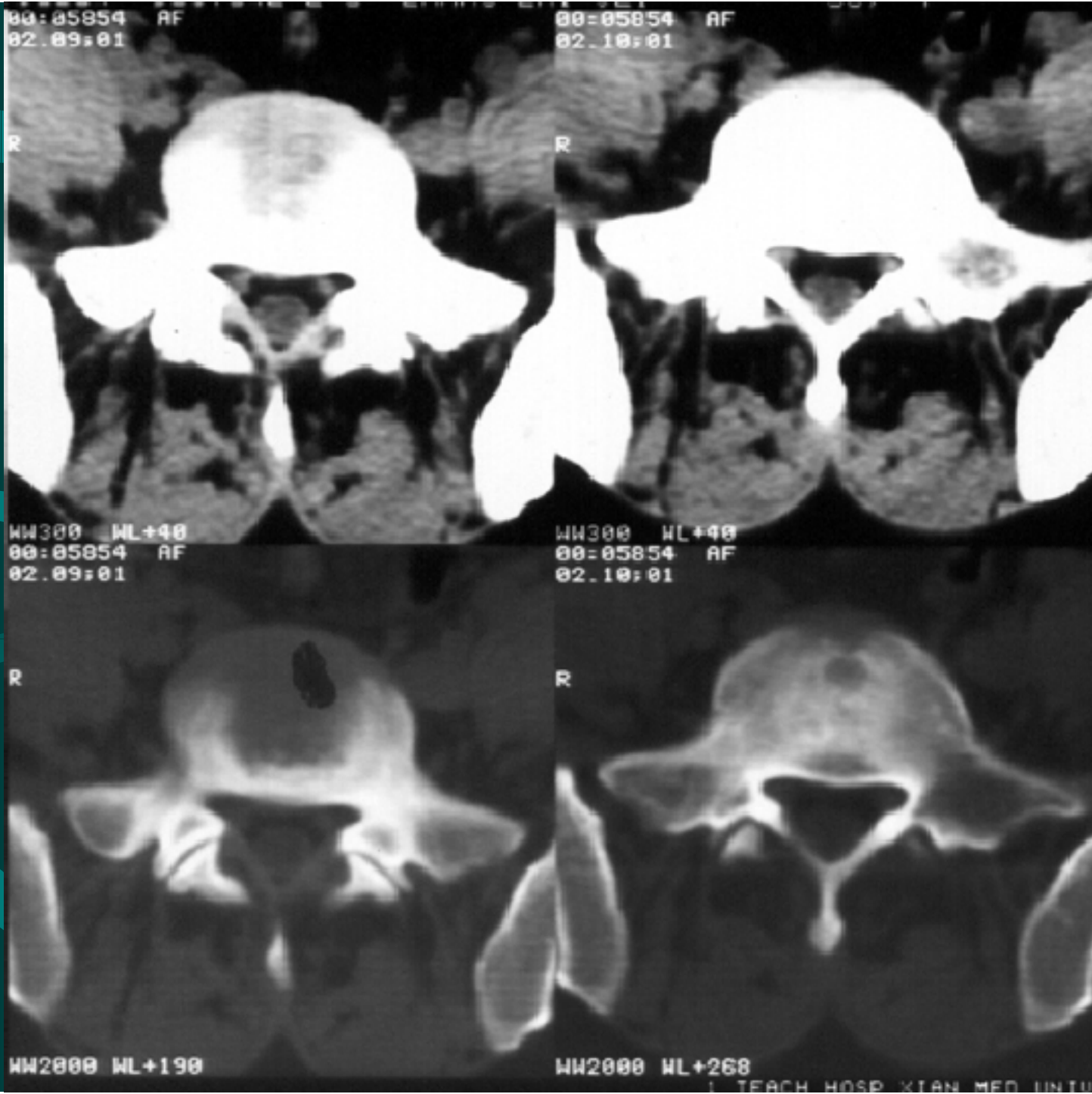
WW2000 WL+150

WW2000 WL+150

1. TECH. HOSP. XISHI MED. UNIV.

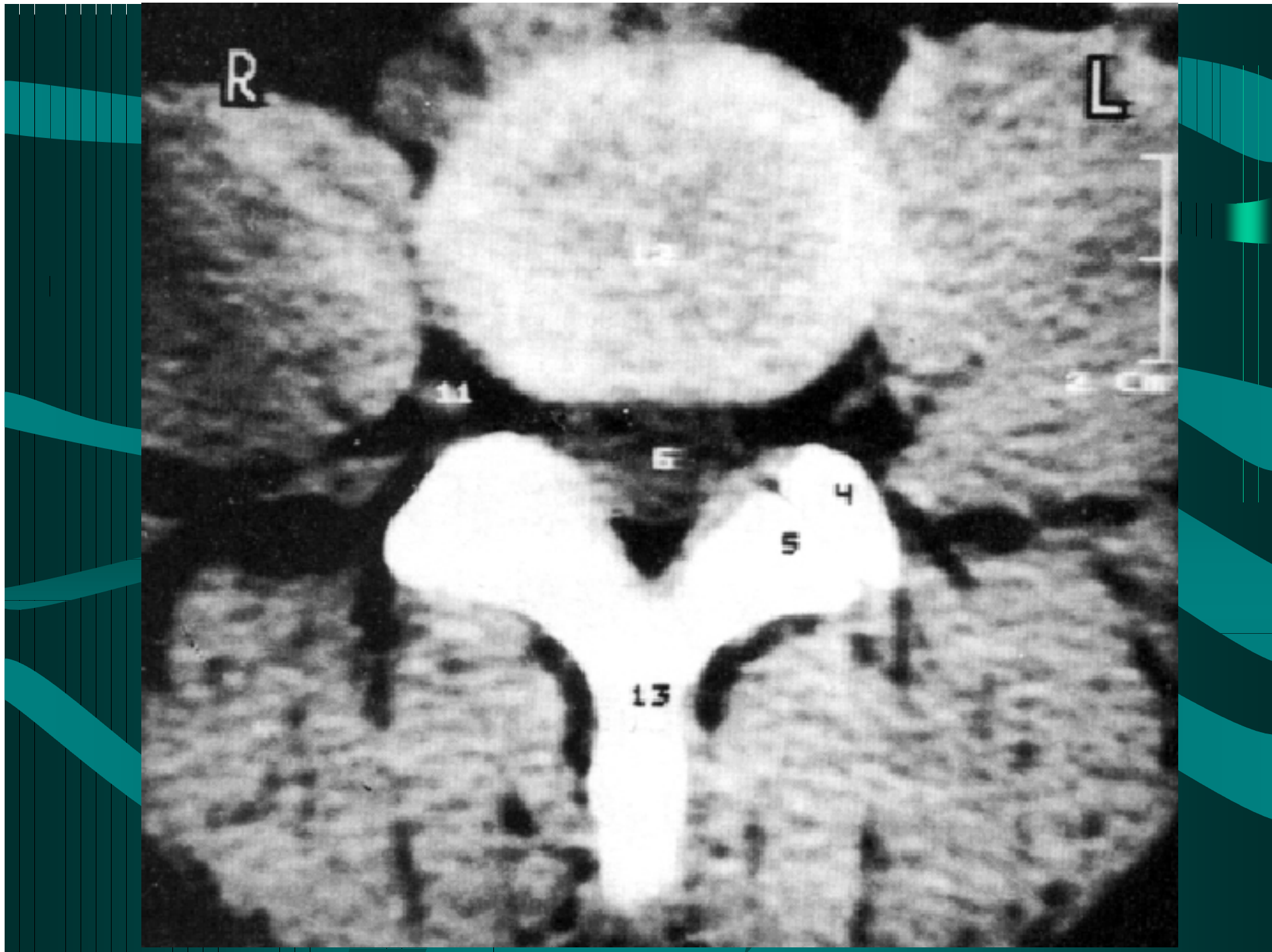






腰椎椎间盘平面:

- 腰椎椎间盘、后纵韧带、硬膜囊、外侧隐窝内脊神经、黄韧带



谢 谢

