



CT

与

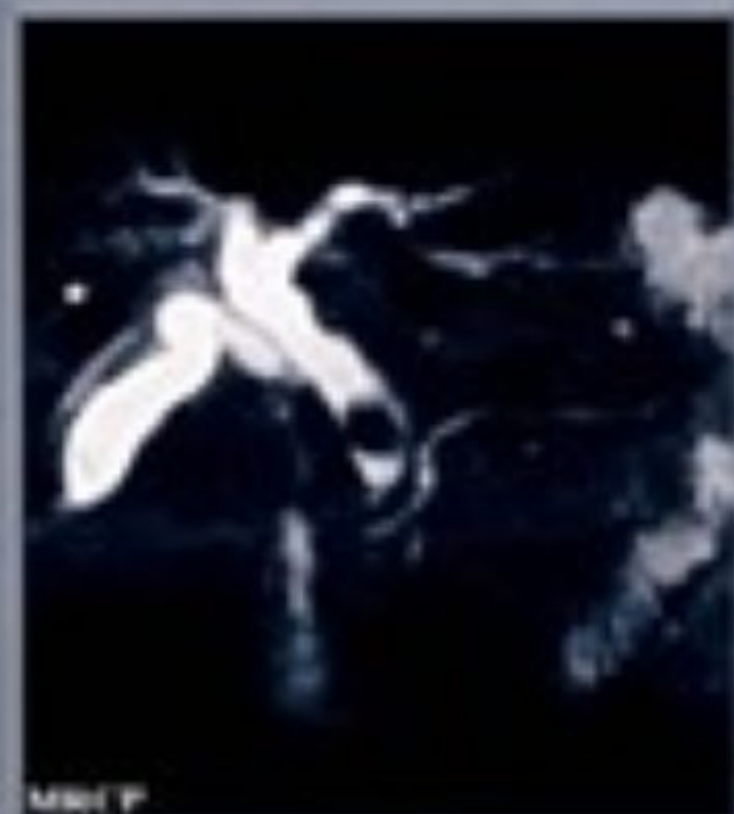MRI

影像解剖学 图谱

ANATOMIC ATLAS OF CT
AND MRI IMAGING



● 主编 / 姜树学 马述盛



辽宁科学技术出版社

目 录

头颈部

水平断面图 HC	2
额状断面图 FC	44
矢状断面图 SC	74
磁共振血管成像 MRA	100

五官部

耳的水平断面图 HE	102
耳的额状断面图 FE	140
喉的水平断面图 HL	176
视器的水平断面图 HV	186
视器的额状断面图 FV	192

胸部

水平断面图 HT	204
额状断面图 FT	238
矢状断面图 ST	254
磁共振成像(气管、心脏) MRI	276

腹部

水平断面图 HA	278
额状断面图 FA	308
矢状断面图 SA	324
磁共振成像(胆、胰管及输尿管) MRI	346

盆部

女盆水平断面图 HPf	348
男盆水平断面图 HPm	376
女盆额状断面图 FPf	394
男盆矢状断面图 SPm	406
磁共振成像(前列腺) MRI	418

脊柱区

第 2 颈椎水平断面图 HC ₂	420
第 3 颈椎水平断面图 HC ₃	422
第 4、5 颈椎间盘水平断面图 HC ₄₋₅	424
第 5 颈椎水平断面图 HC ₅	426
颈椎正中矢状断面图 MSC	428
颈椎旁正中矢状断面图 PSC	429
第 5 胸椎水平断面图 HT ₅	430
第 8 胸椎水平断面图 HT ₈	432
第 9、10 胸椎间盘水平断面图 HT ₉₋₁₀	434
第 10 胸椎水平断面图 HT ₁₀	436
胸椎正中矢状断面图 MST	438
胸椎旁正中矢状断面图 PST	439
第 3 腰椎水平断面图 HL ₃	440
第 4、5 腰椎间盘水平断面图 HL ₄₋₅	442
第 5 腰椎水平断面 HL ₅	444
第 1 骶椎水平断面图 HS ₁	446
腰骶部正中矢状断面图 MSL	448
腰骶部旁正中矢状断面图 PSL	449
脊柱额状断面图 FVR	450

四肢部

左上肢水平断面图 HUL	452
左下肢水平断面图 HLL	464
左膝关节额状断面图 FK(L)	476
右膝关节矢状断面图 SK(R)	490

CONTENTS

HEAD AND NECK (CEPHALIC AND CERVICAL REGIONS)

Horizontal Sections HC	2
Frontal Sections FC	44
Sagittal Sections SC	74
MR Angiography MRA	100

FIVE SENSE ORGANS

Horizontal Sections of the Ear HE	102
Frontal Sections of the Ear FE	140
Horizontal Sections of the Larynx HL	176
Horizontal Sections of the Visual Organ HV	186
Frontal Sections of the Visual Organ FV	192

THORAX

Horizontal Sections HT	204
Frontal Sections FT	238
Sagittal Sections ST	254
MRI (trachea, heart)	276

ABDOMEN (ABDOMEN AND PELVIS)

Horizontal Sections HA	278
Frontal Sections FA	308
Sagittal Sections SA	324
MRI (cystic, pancreatic duct and ureter)	346

PELVIS

Horizontal Sections, female HPf	348
Horizontal Sections, male HPm	376
Frontal Sections, female FPf	394
Sagittal Sections, male SPM	406
MRI (prostate)	418

VERTEBRAL REGION

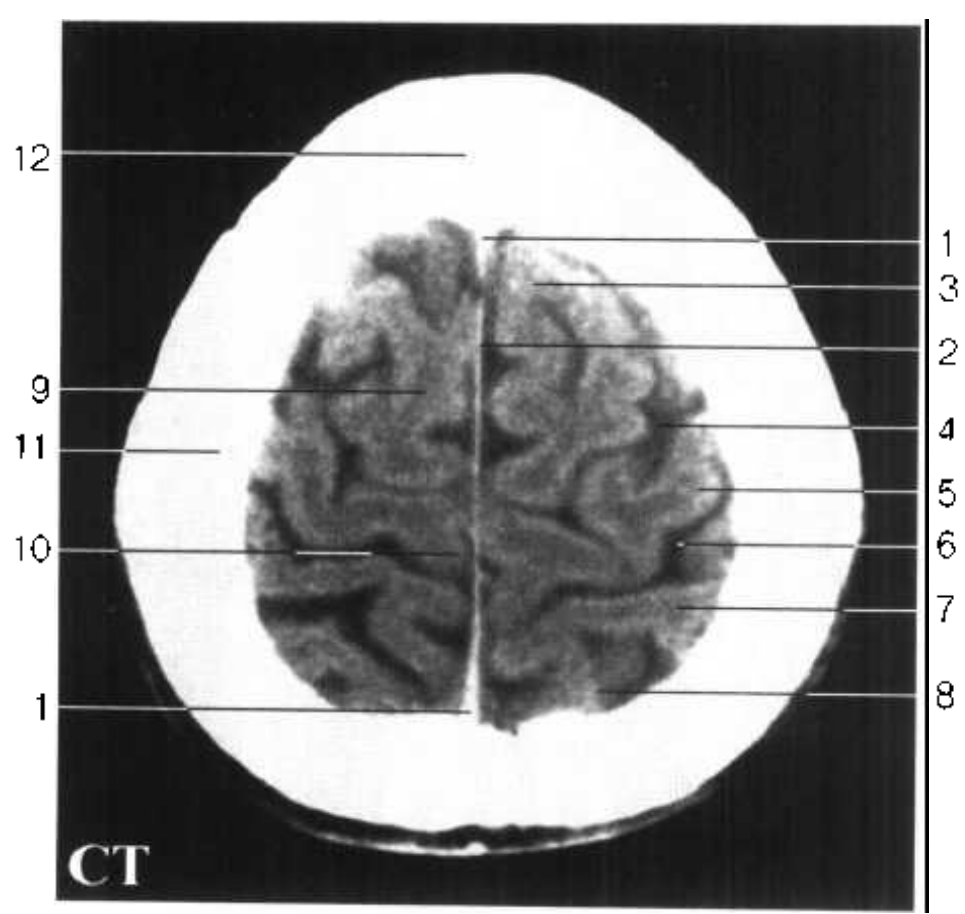
Horizontal Section of 2nd Cervical Vertebrae HC ₂	420
Horizontal Section of 3rd Cervical Vertebrae HC ₃	422
Horizontal Section of 4, 5th Cervical Intervertebral Disc HC ₄₋₅	424
Horizontal Section of 5th Cervical Vertebrae HC ₅	426
Median Sagittal Section of Cervical Vertebrae MSC	428
Paramedian Sagittal Section of Cervical Vertebrae PSC	429
Horizontal Section of 5th Thoracic Vertebrae HT ₅	430
Horizontal Section of 8th Thoracic Vertebrae HT ₈	432
Horizontal Section of 9, 10th Thoracic Intervertebral Disc HT ₉₋₁₀	434
Horizontal Section of 10th Thoracic Vertebrae HT ₁₀	436
Median Sagittal Section of Thoracic Vertebrae MST	438
Paramedian Sagittal Section of Thoracic Vertebrae PST	439
Horizontal Section of 3rd Lumbar Vertebrae HL ₃	440
Horizontal Section of 4, 5th Lumbar Intervertebral Disc HL ₄₋₅	442
Horizontal Section of 5th Lumbar Vertebrae HL ₅	444
Horizontal Section of 1st Sacral Vertebrae HS ₁	446
Median Sagittal Section of Lumbosacral Vertebrae MSL	448
Paramedian Sagittal Section of Lumbosacral Vertebrae PSL	449
Frontal Section of the Vertebral Region FVR	450

LIMBS

Horizontal Sections of the Left Upper Limb HUL	452
Horizontal Sections of the Left Lower Limb HLL	464
Frontal Sections of the Left Knee FK(L)	476
Sagittal Sections of the Right Knee SK(R)	490

头颈部

**HEAD AND
NECK**



水平断面图 HC

Fig. HC 1

- 1. 上矢状窦 superior sagittal sinus
- 2. 大脑镰 cerebral falx
- 3. 额上回 superior frontal gyrus
- 4. 中央前沟 precentral sulcus
- 5. 中央前回 precentral gyrus
- 6. 中央沟 central sulcus
- 7. 中央后回 postcentral gyrus
- 8. 顶上小叶 superior parietal lobule
- 9. 辐射冠 corona radiata

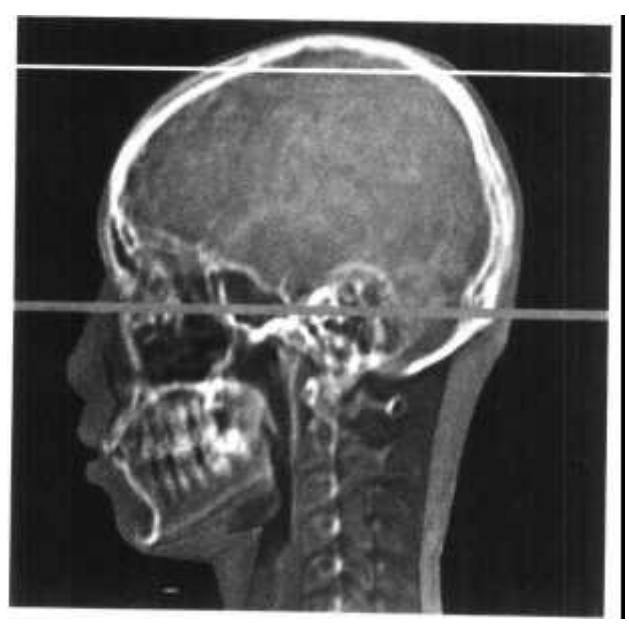
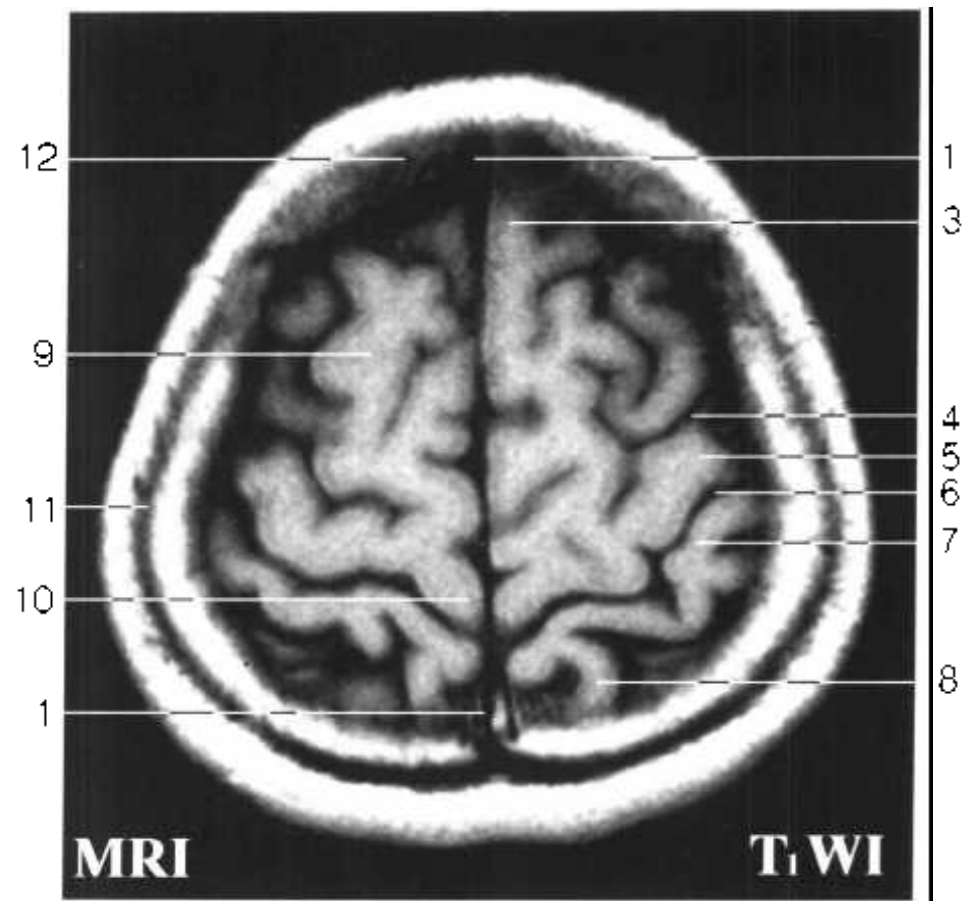
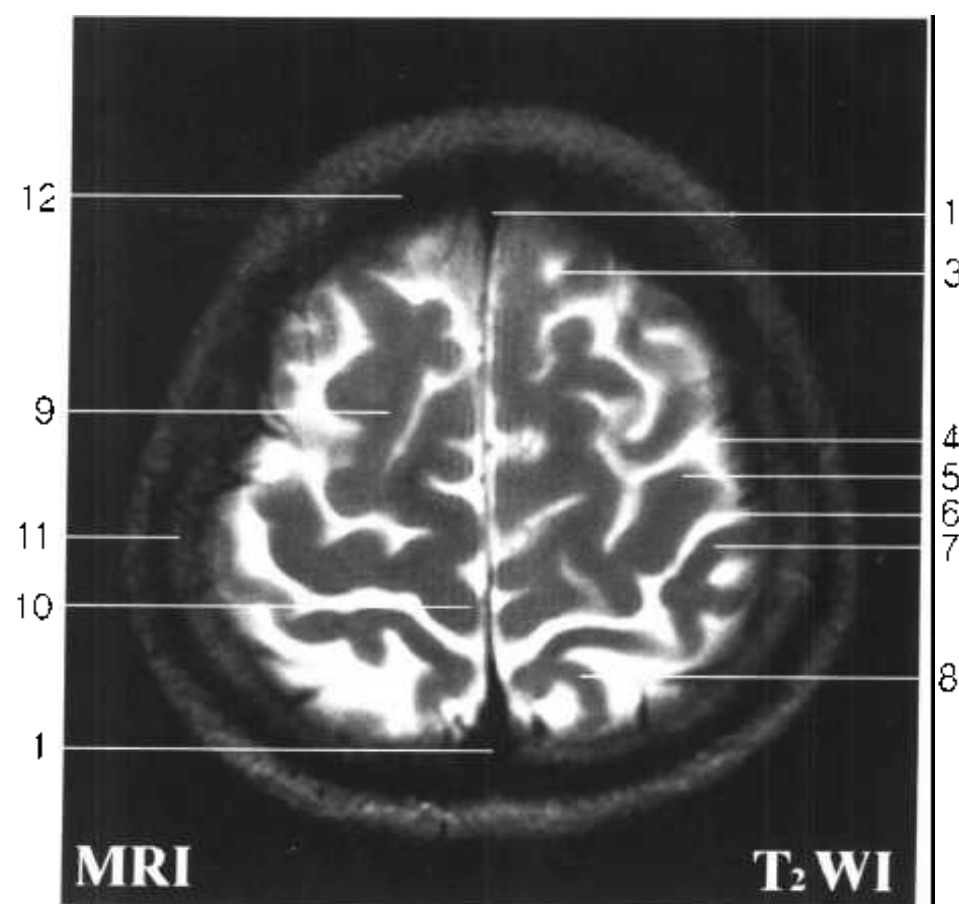


Fig. HC 1



- 10. 中央旁小叶 paracentral lobule
- 11. 顶骨 parietal bone
- 12. 额骨 frontal bone



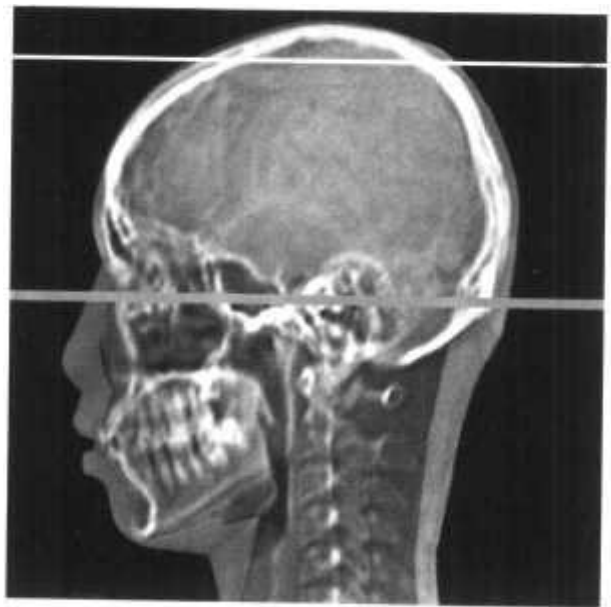
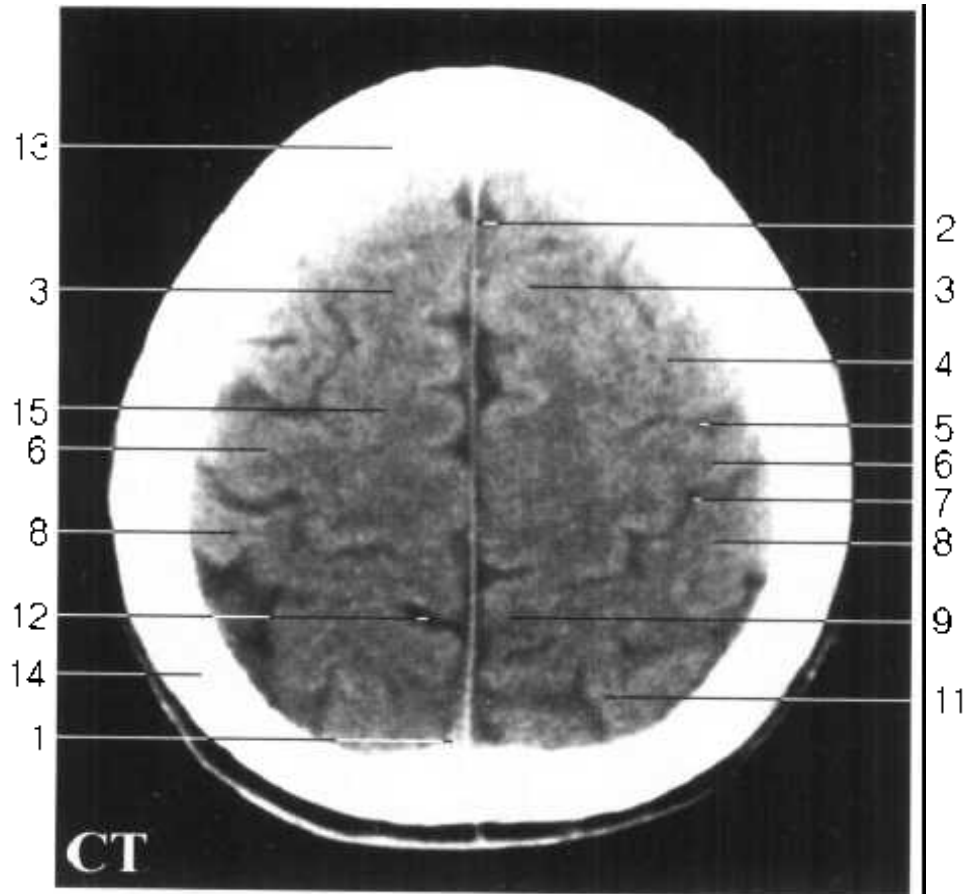
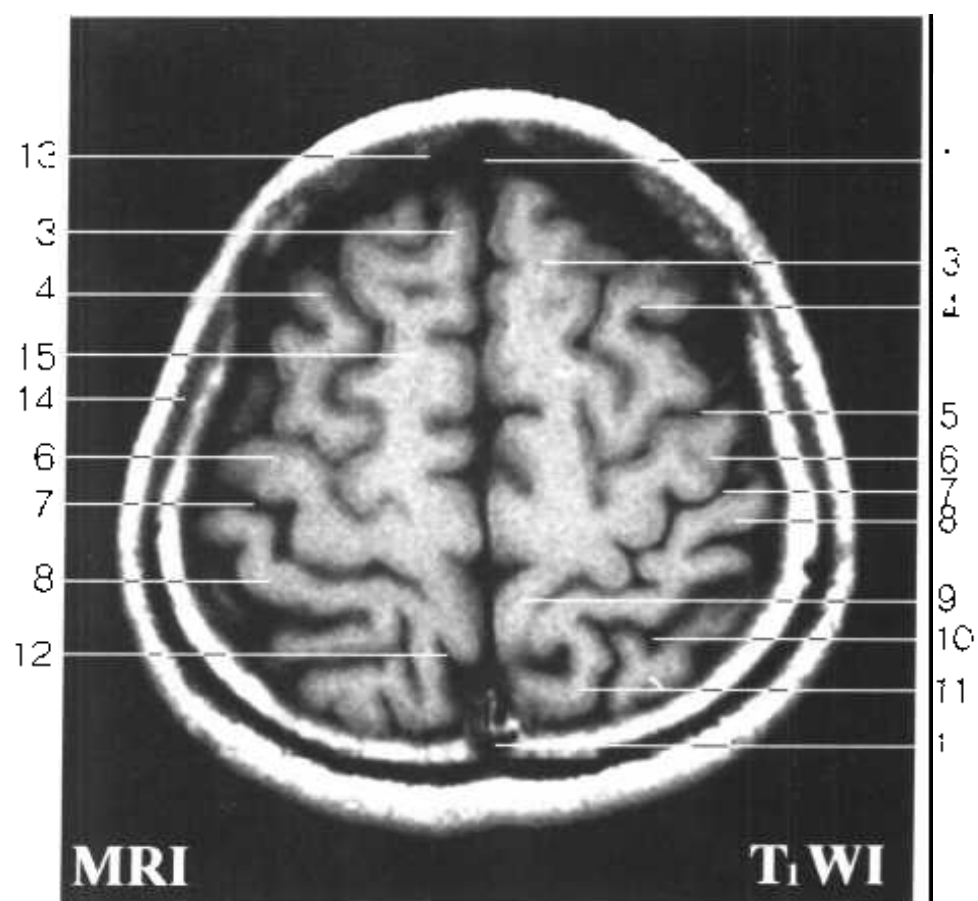


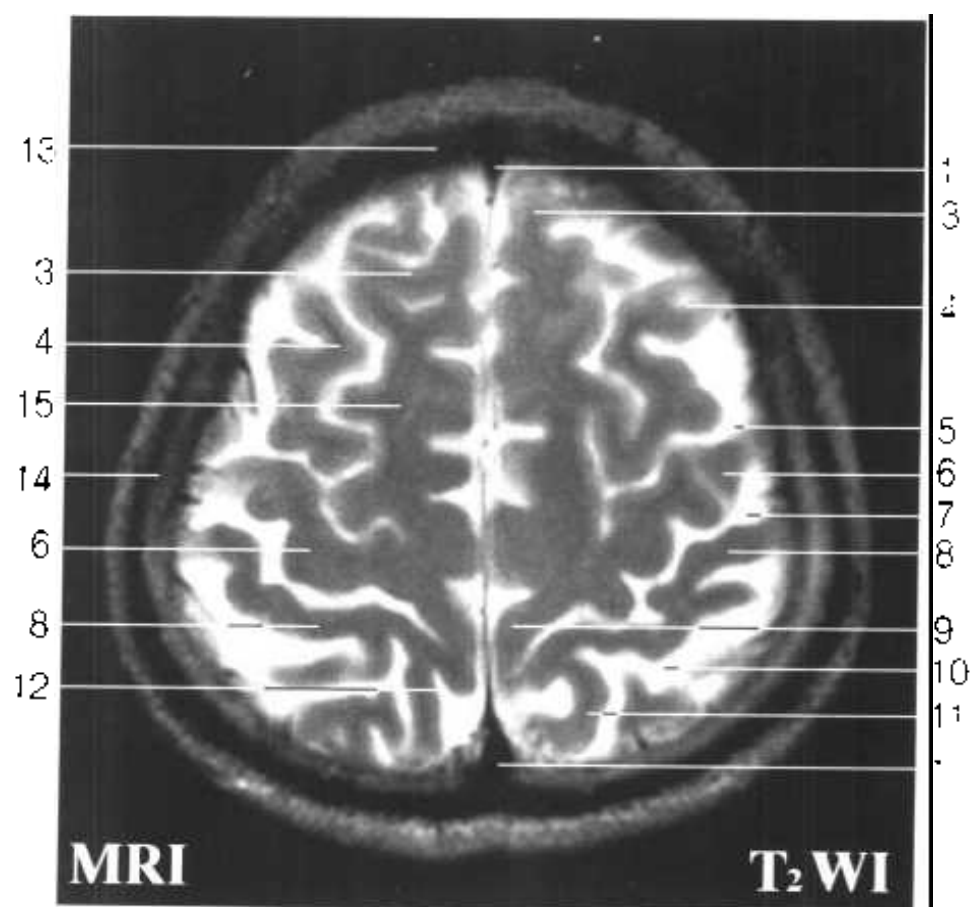
Fig. HC 2

- 1. 上矢状窦 superior sagittal sinus
- 2. 大脑镰 cerebral falx
- 3. 额上回 superior frontal gyrus
- 4. 额中回 middle frontal gyrus
- 5. 中央前沟 precentral sulcus
- 6. 中央前回 precentral gyrus
- 7. 中央沟 central sulcus
- 8. 中央后回 postcentral gyrus
- 9. 中央旁小叶 paracentral lobule
- 10. 中央后沟 postcentral sulcus

Fig. HC 2



- 11. 顶上小叶 superior parietal lobule
- 12. 扣带沟缘支 marginal ramus of cingulate sulcus
- 13. 额骨 frontal bone
- 14. 顶骨 parietal bone
- 15. 放射冠 corona radiata



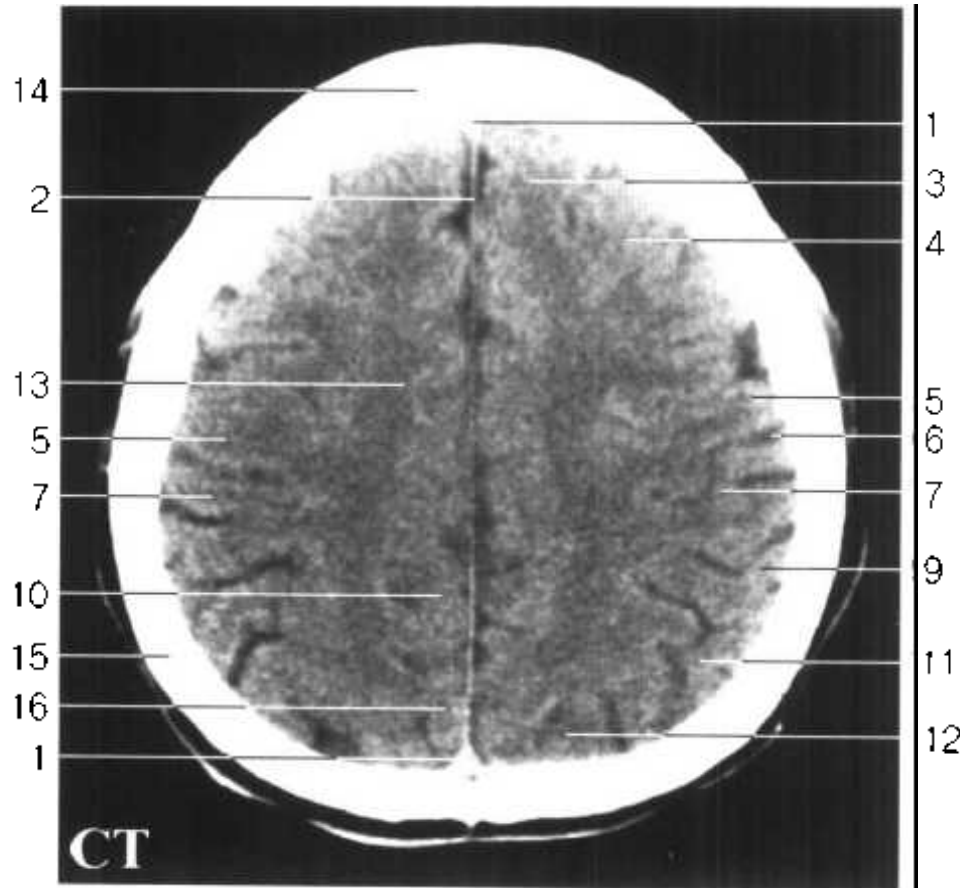


Fig. HC 3

1. 上矢状窦 superior sagittal sinus
2. 大脑镰 cerebral falx
3. 额上回 superior frontal gyrus
4. 额中回 middle frontal gyrus
5. 中央前回 precentral gyrus
6. 中央沟 central sulcus
7. 中央后回 postcentral gyrus
8. 中央后沟 postcentral sulcus
9. 缘上回 supramarginal gyrus
10. 中央旁小叶 paracentral lobule
11. 角回 angular gyrus
12. 顶上小叶 superior parietal lobule

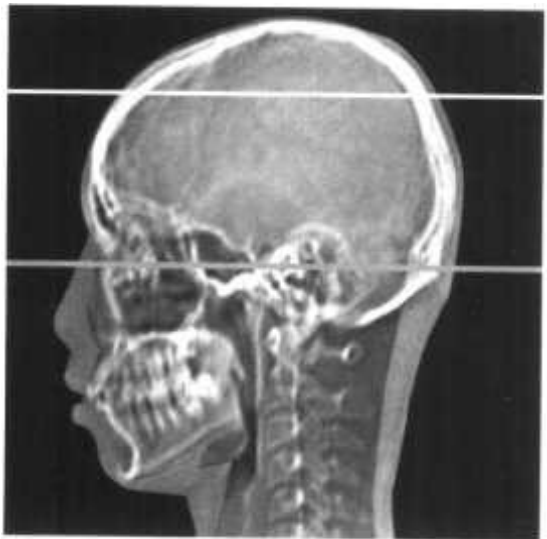
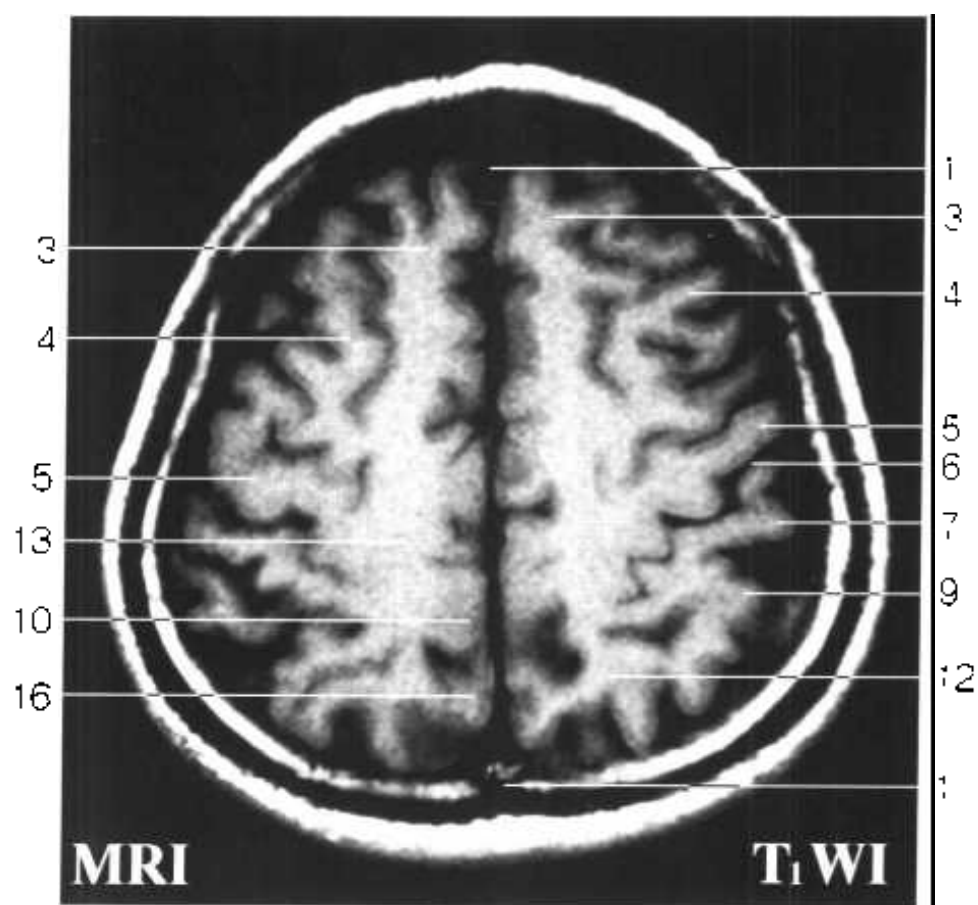
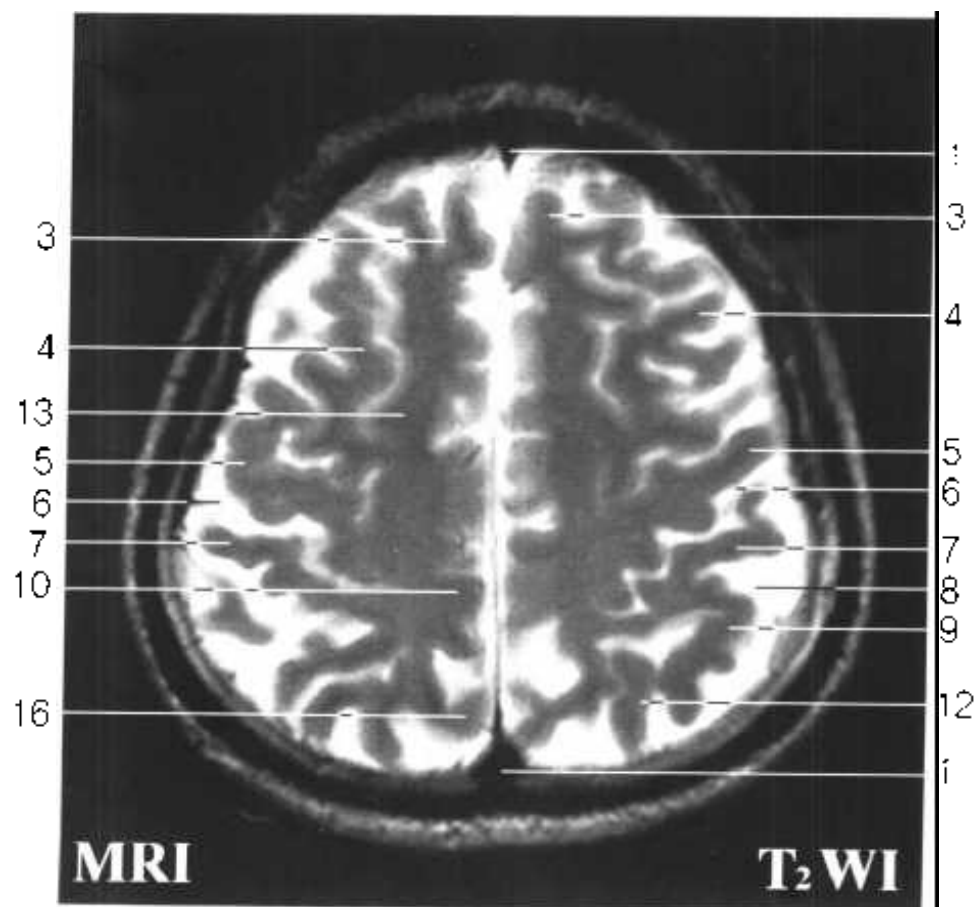


Fig. HC 3



- 13. 辐射冠(半卵圆中心) corona radiata (centrum semiovale)
- 14. 额骨 frontal bone
- 15. 顶骨 parietal bone
- 16. 楔前叶 precuneus



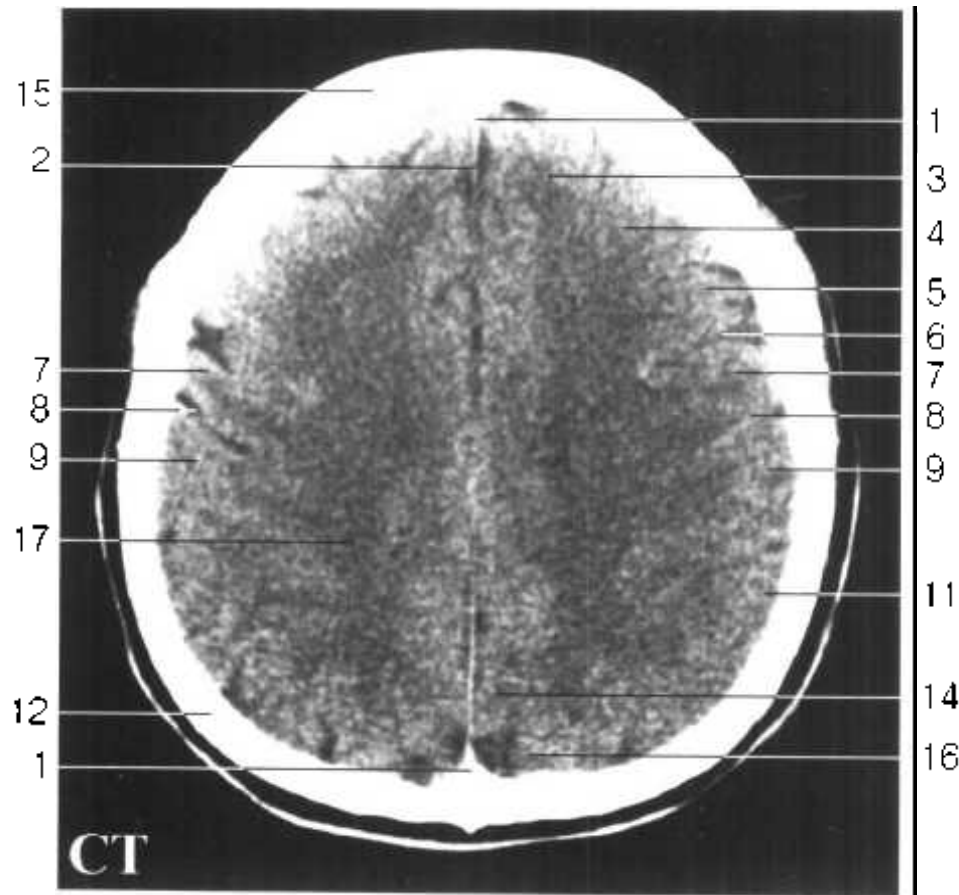


Fig. HC 4

1. 上矢状窦 superior sagittal sinus
2. 大脑镰 cerebral falx
3. 额上回 superior frontal gyrus
4. 额中回 middle frontal gyrus
5. 额下回 inferior frontal gyrus
6. 中央前沟 precentral sulcus
7. 中央前回 precentral gyrus
8. 中央沟 central sulcus
9. 中央后回 postcentral gyrus
10. 中央后沟 postcentral sulcus
11. 缘上回 supramarginal gyrus
12. 顶骨 parietal bone

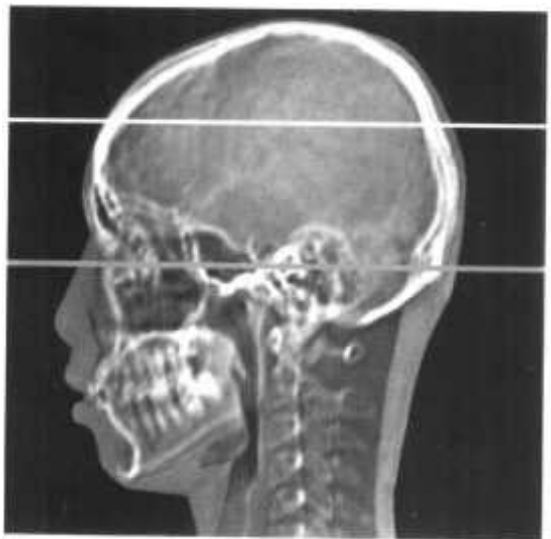
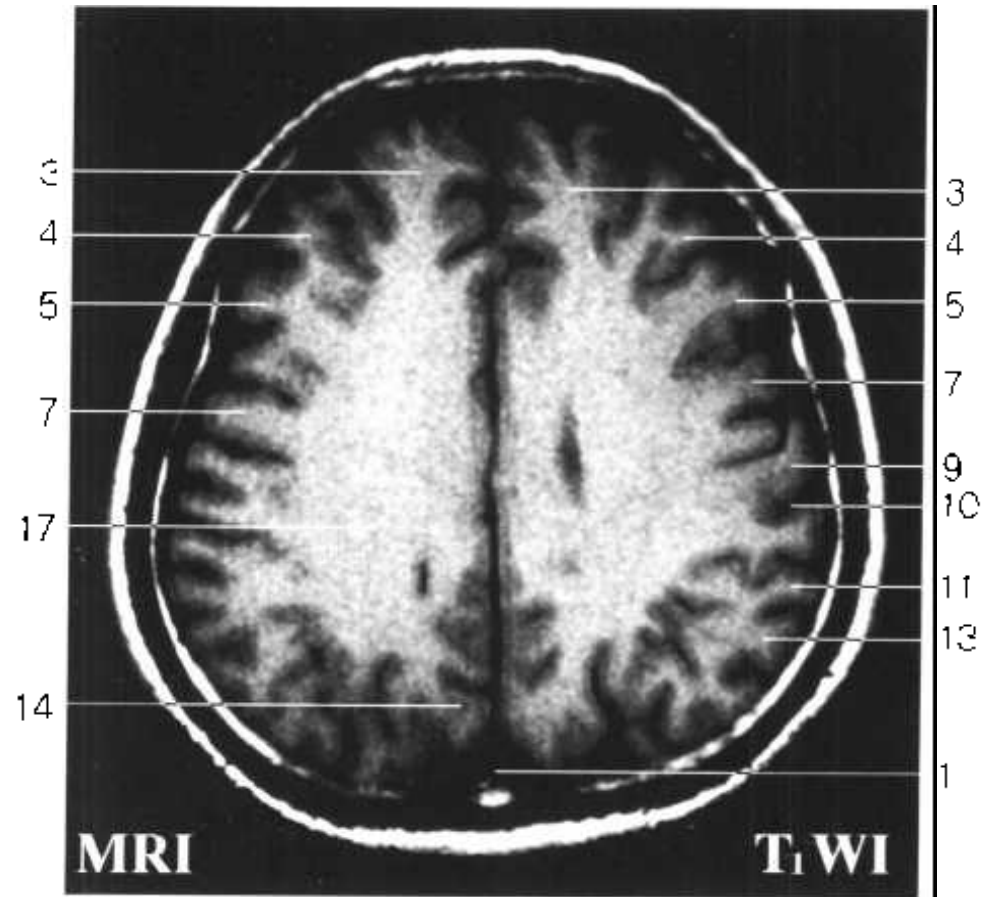
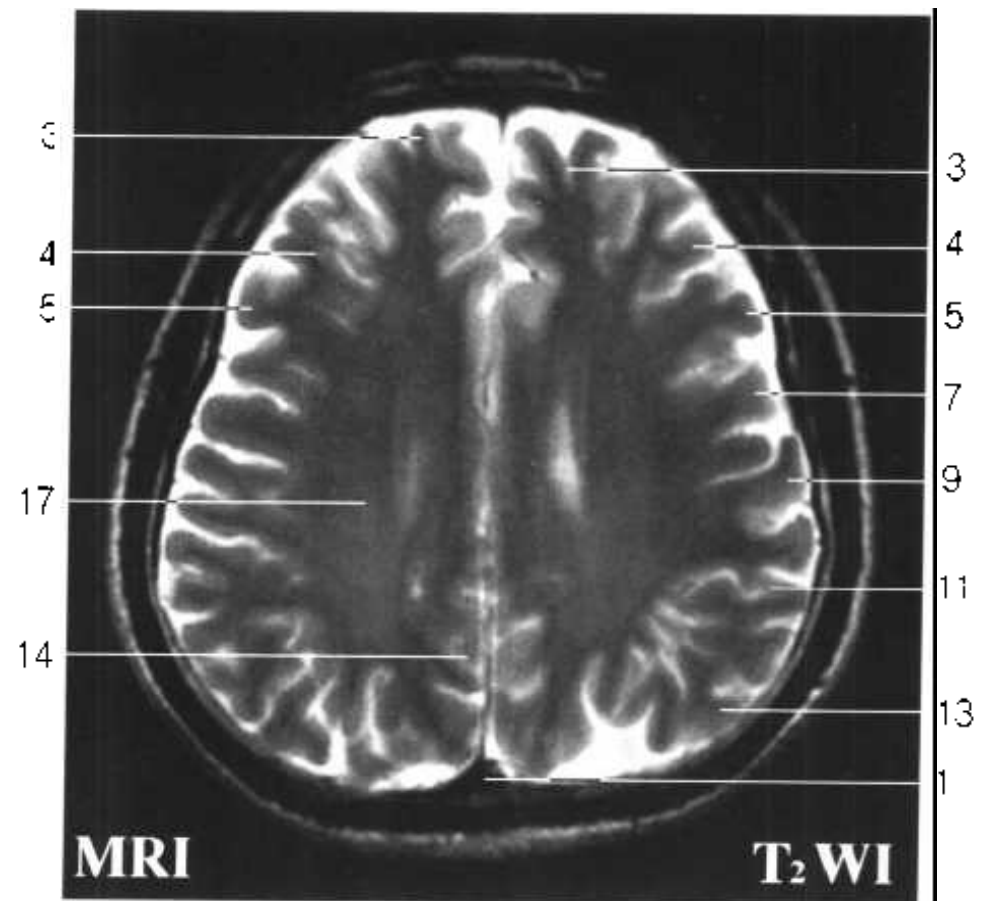


Fig. HC 4



- 13. 角回 angular gyrus
- 14. 楔前叶 precuneus
- 15. 额骨 frontal bone
- 16. 楔叶 cuneus
- 17. 辐射冠(半卵圆中心) corona radiata (centrum semiovale)



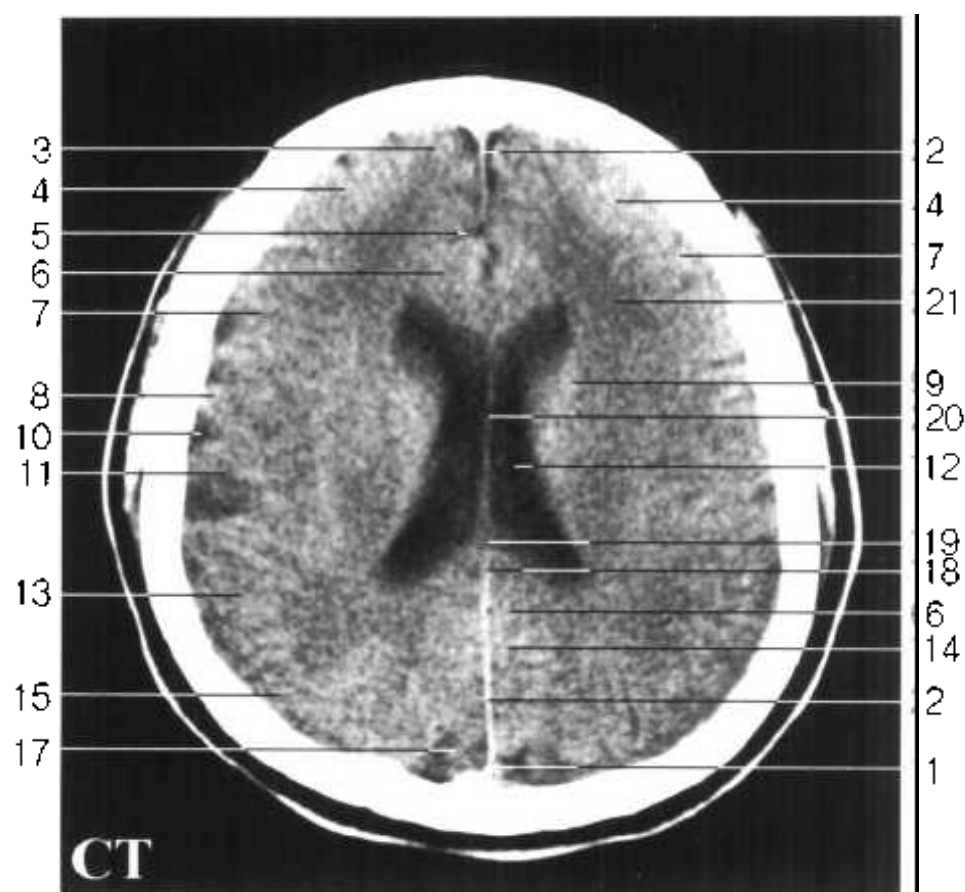


Fig. HC 5

1. 上矢状窦 superior sagittal sinus
2. 大脑镰 cerebral falx
3. 额上回 superior frontal gyrus
4. 额中回 middle frontal gyrus
5. 扣带沟 cingulate sulcus
6. 扣带回 cingulate gyrus
7. 额下回 inferior frontal gyrus
8. 中央前回 precentral gyrus
9. 尾状核体 body of caudate nucleus
10. 中央沟 central sulcus
11. 中央后回 postcentral gyrus
12. 侧脑室中央部 central part of lateral ventricle

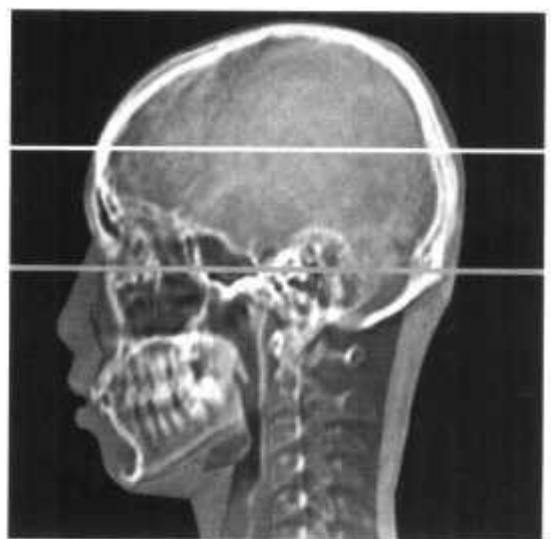
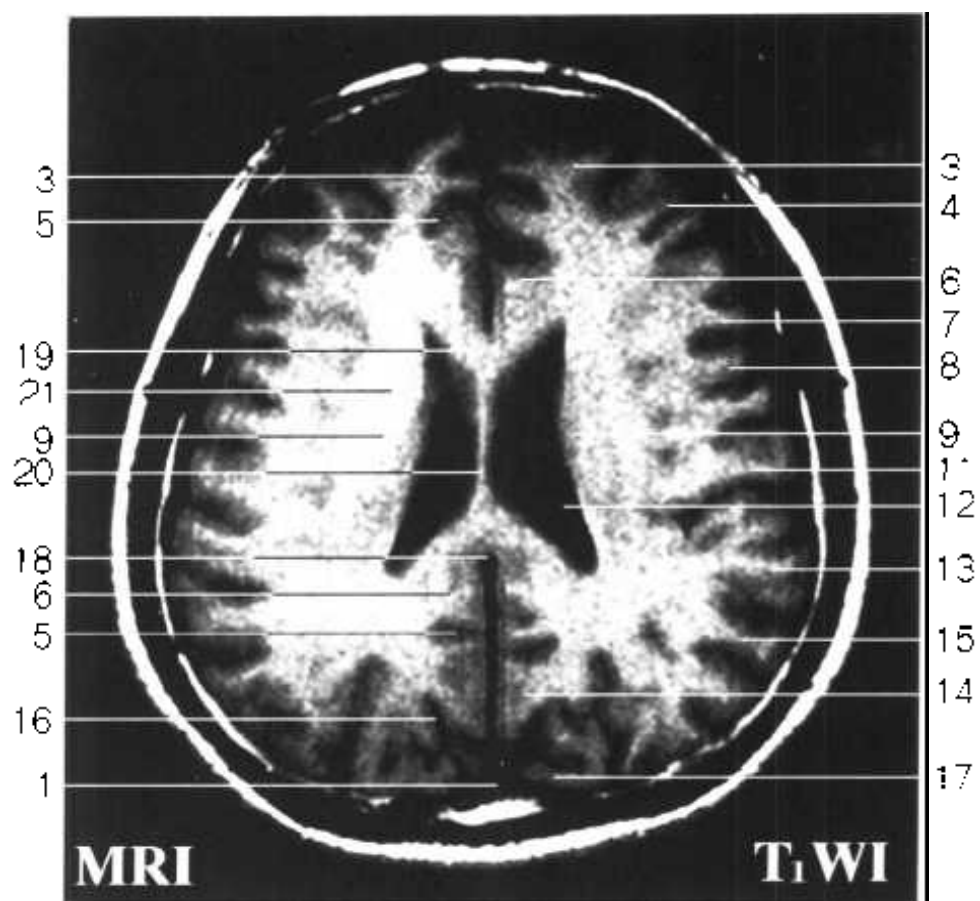
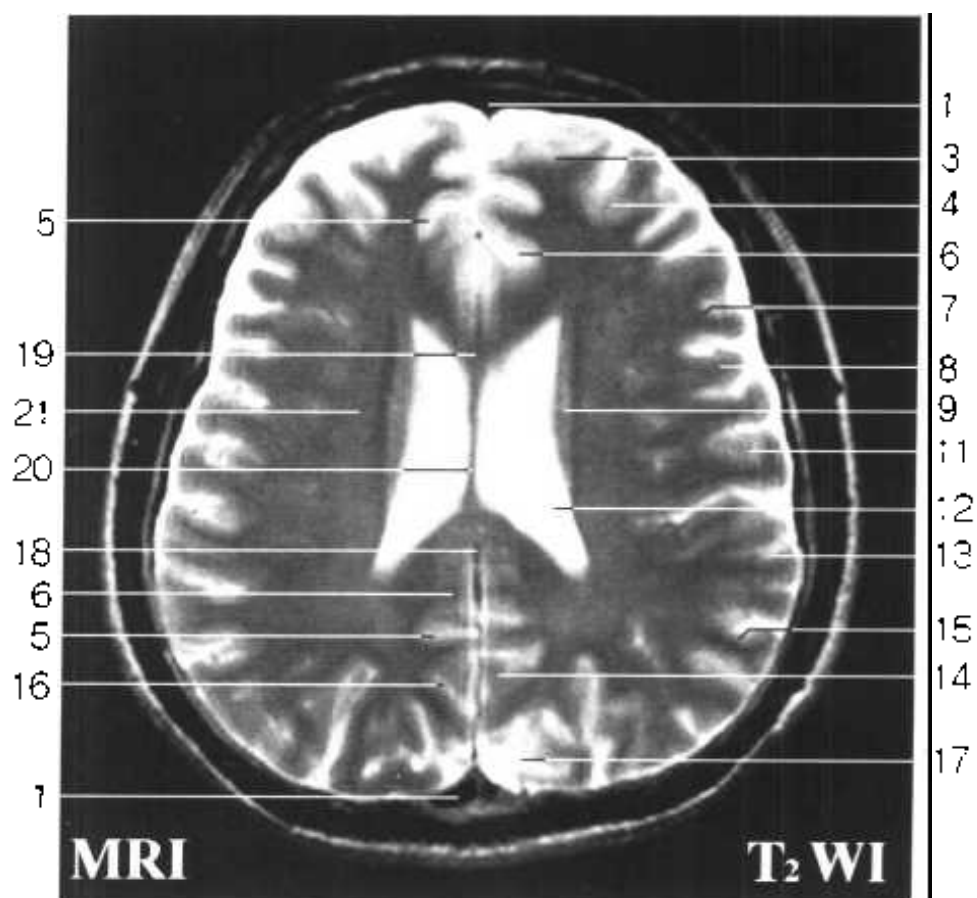


Fig. HC 5



- 13. 缘上回 supramarginal gyrus
- 14. 楔前叶 precuneus
- 15. 角回 angular gyrus
- 16. 顶枕沟 parietooccipital sulcus
- 17. 楔叶 cuneus
- 18. 下矢状窦 inferior sagittal sinus
- 19. 胼胝体 corpus callosum
- 20. 透明隔 septum pellucidum
- 21. 辐射冠(半卵圆中心) corona radiata (centrum semiovale)



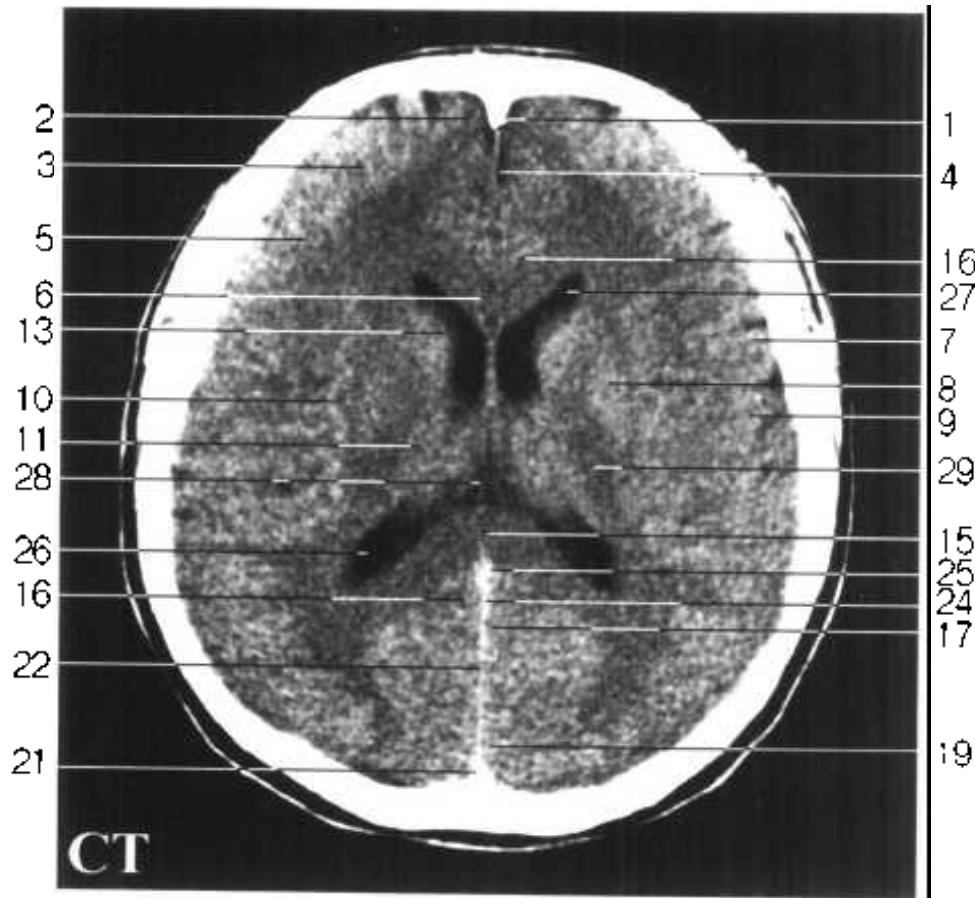
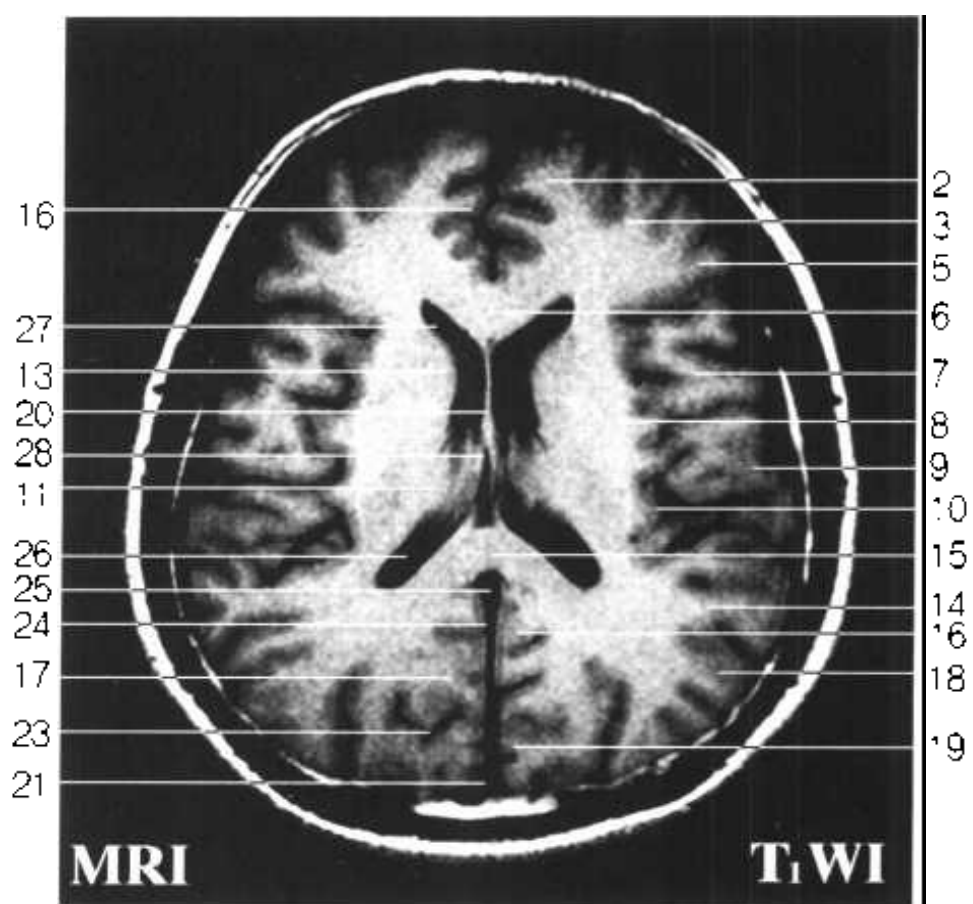


Fig. HC 6

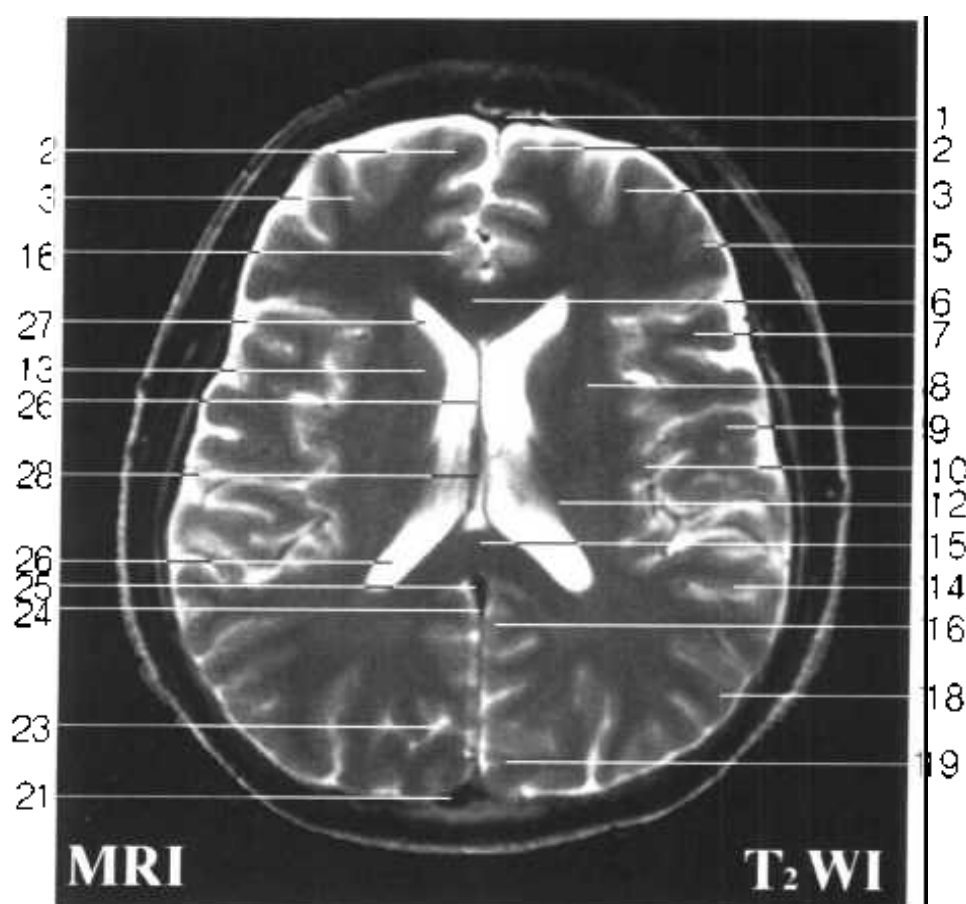
1. 上矢状窦 superior sagittal sinus
2. 额上回 superior frontal gyrus
3. 额中回 middle frontal gyrus
4. 大脑镰 cerebral falx
5. 额下回 inferior frontal gyrus
6. 胼胝体膝 genu of corpus callosum
7. 中央前回 precentral gyrus
8. 壳 putamen
9. 中央后回 postcentral gyrus
10. 岛叶 insular lobe
11. 背侧丘脑 dorsal thalamus
12. 丘脑内侧核群 medial nuclear group of thalamus
13. 尾状核头 head of caudate nucleus
14. 缘上回 supramarginal gyrus
15. 胼胝体压部 splenium of corpus callosum

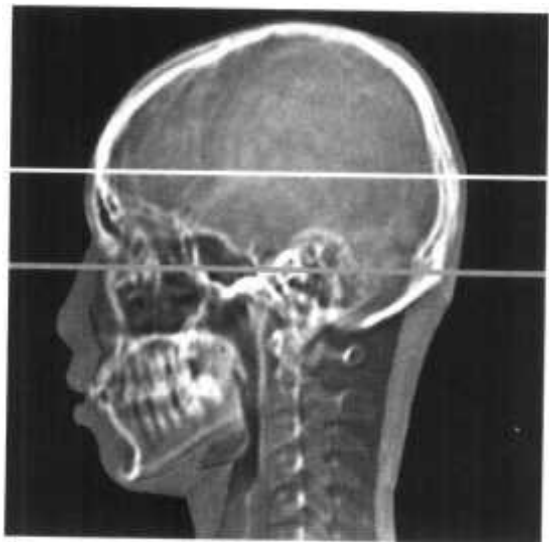

Fig. HC 6



- 16. 扣带回 cingulate gyrus
- 17. 楔前叶 precuneus
- 18. 角回 angular gyrus
- 19. 楔叶 cuneus
- 20. 透明隔 septum pellucidum
- 21. 上矢状窦 superior sagittal sinus
- 22. 大脑镰 cerebral falx
- 23. 顶枕沟 parietooccipital sulcus
- 24. 直窦 straight sinus
- 25. 大脑大静脉 great cerebral v.
- 26. 侧脑室后角 posterior horn of lateral ventricle
- 27. 侧脑室前角 anterior horn of lateral ventricle
- 28. 穹窿体 body of fornix
- 29. 内囊后肢 posterior limb of internal capsule



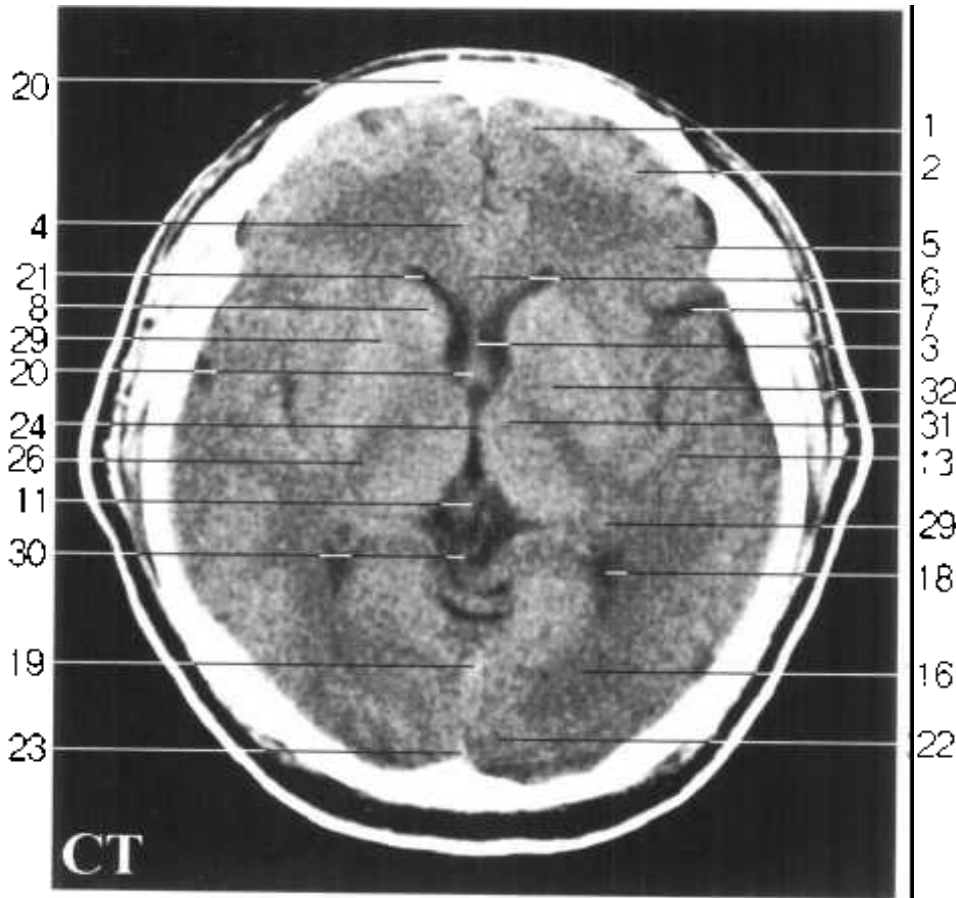
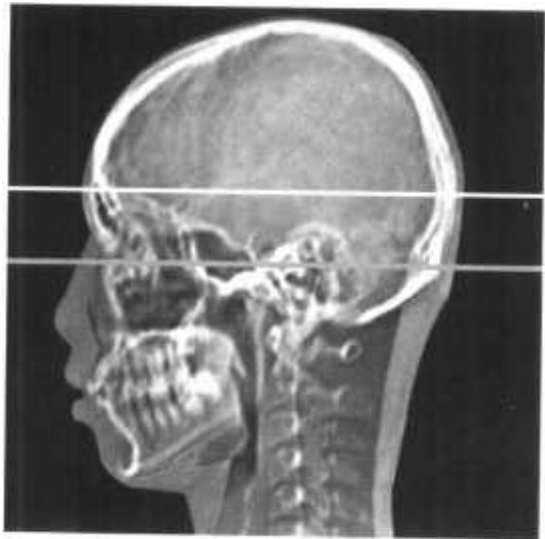
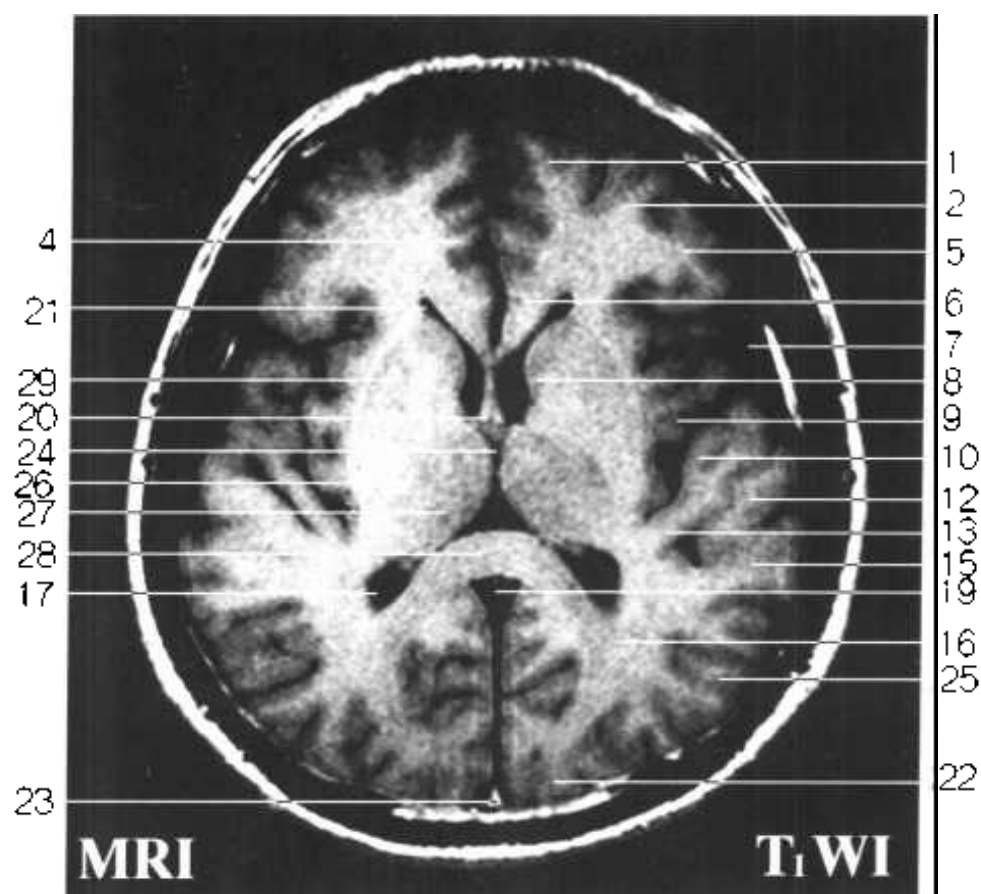


Fig. HC 7

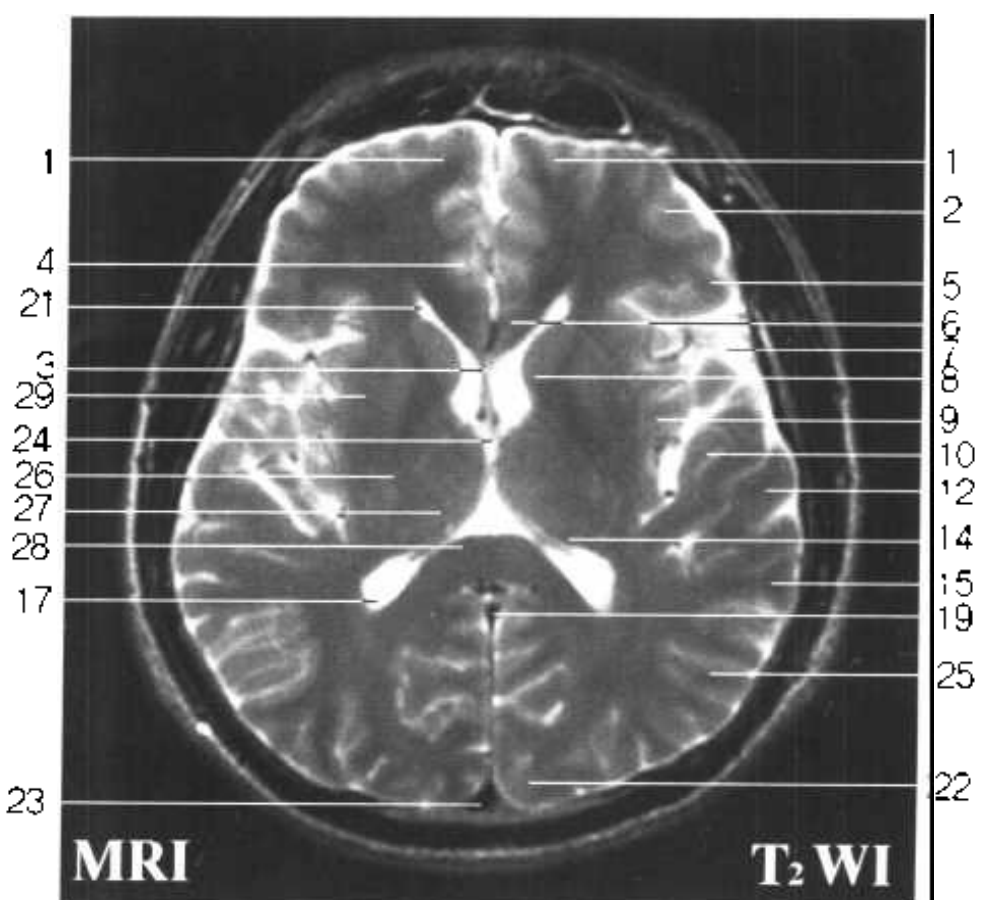


1. 额上回 superior frontal gyrus
2. 额中回 middle frontal gyrus
3. 透明隔 septum pellucidum
4. 扣带回 cingulate gyrus
5. 额下回 inferior frontal gyrus
6. 胼胝体膝 genu of corpus callosum
7. 大脑外侧窝池 cistern of lateral fossa of cerebrum
8. 尾状核头 head of caudate nucleus
9. 岛叶 insular lobe
10. 颞横回 transverse temporal gyri
11. 松果体 pineal body
12. 颞上回 superior temporal gyrus
13. 听辐射 acoustic radiation
14. 尾状核尾 tail of caudate nucleus
15. 颞中回 middle temporal gyrus
16. 视辐射 optic radiation
17. 侧脑室后角 posterior horn of lateral ventricle

Fig. HC 7



- 18. 侧脑室三角 trigone of lateral ventricle
- 19. 直窦 straight sinus
- 20. 穹窿柱 column of fornix
- 21. 侧脑室前角 anterior horn of lateral ventricle
- 22. 楔叶 cuneus
- 23. 上矢状窦 superior sagittal sinus
- 24. 第三脑室 third ventricle
- 25. 颞下回 inferior temporal gyrus
- 26. 内囊后肢 posterior limb of internal capsule
- 27. 背侧丘脑 dorsal thalamus
- 28. 胼胝体压部 splenium of corpus callosum
- 29. 壳 putamen
- 30. 大脑内静脉 internal cerebral v.
- 31. 背侧丘脑 dorsal thalamus
- 32. 苍白球 globus pallidus



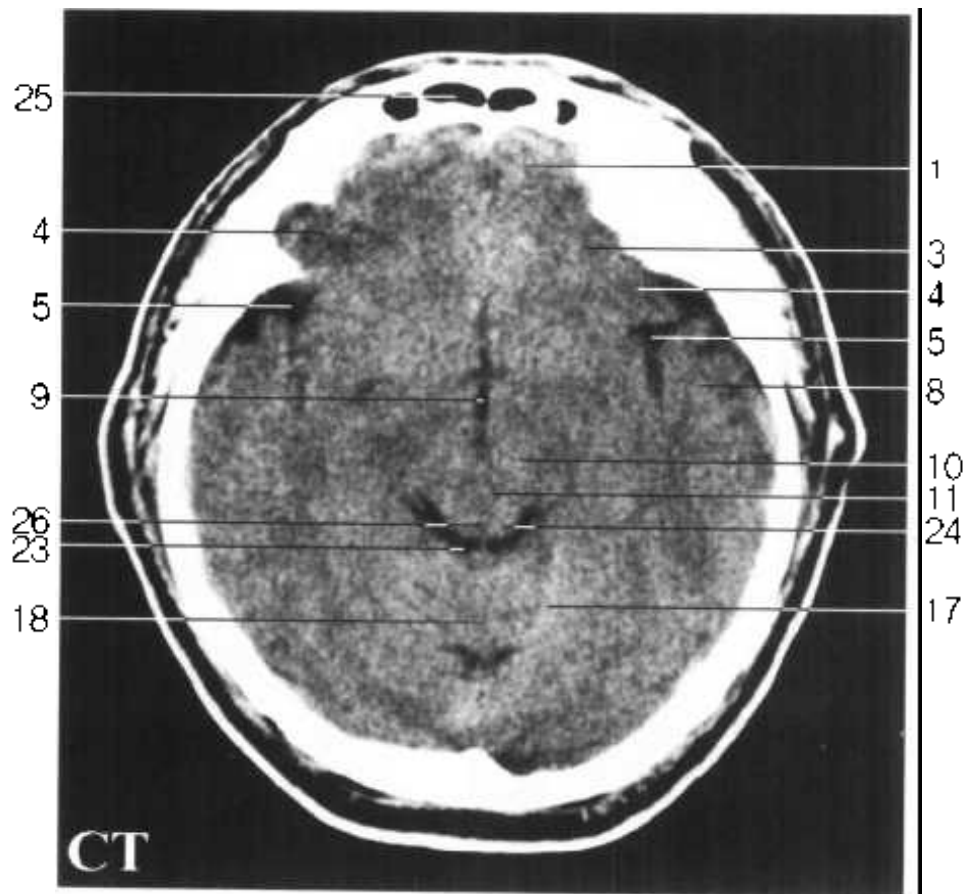


Fig. HC 8

1. 额上回 superior frontal gyrus
2. 隔区 septal area
3. 额中回 middle frontal gyrus
4. 额下回 inferior frontal gyrus
5. 大脑外侧窝池 cistern of lateral fossa of cerebrum
6. 壳 putamen
7. 颞肌 temporalis
8. 颞上回 superior temporal gyrus
9. 第三脑室 third ventricle
10. 大脑脚底 crus cerebri
11. 红核 red nucleus
12. 海马 hippocampus
13. 颞中回 middle temporal gyrus
14. 侧脑室下角 inferior horn of lateral ventricle
15. 海马旁回 parahippocampal gyrus
16. 四叠体池 quadrigeminal cistern
17. 小脑幕 tentorium of cerebellum

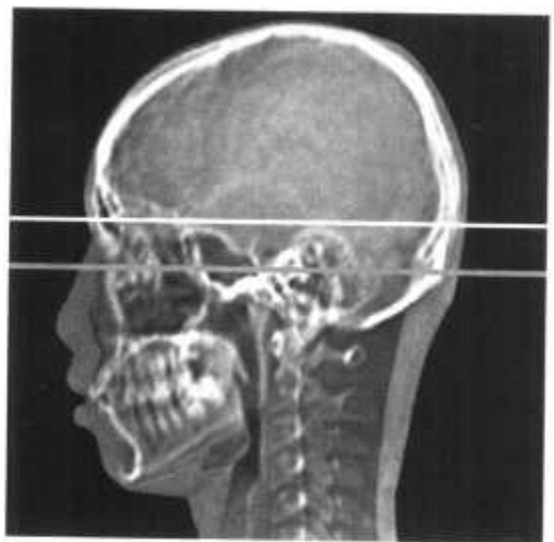
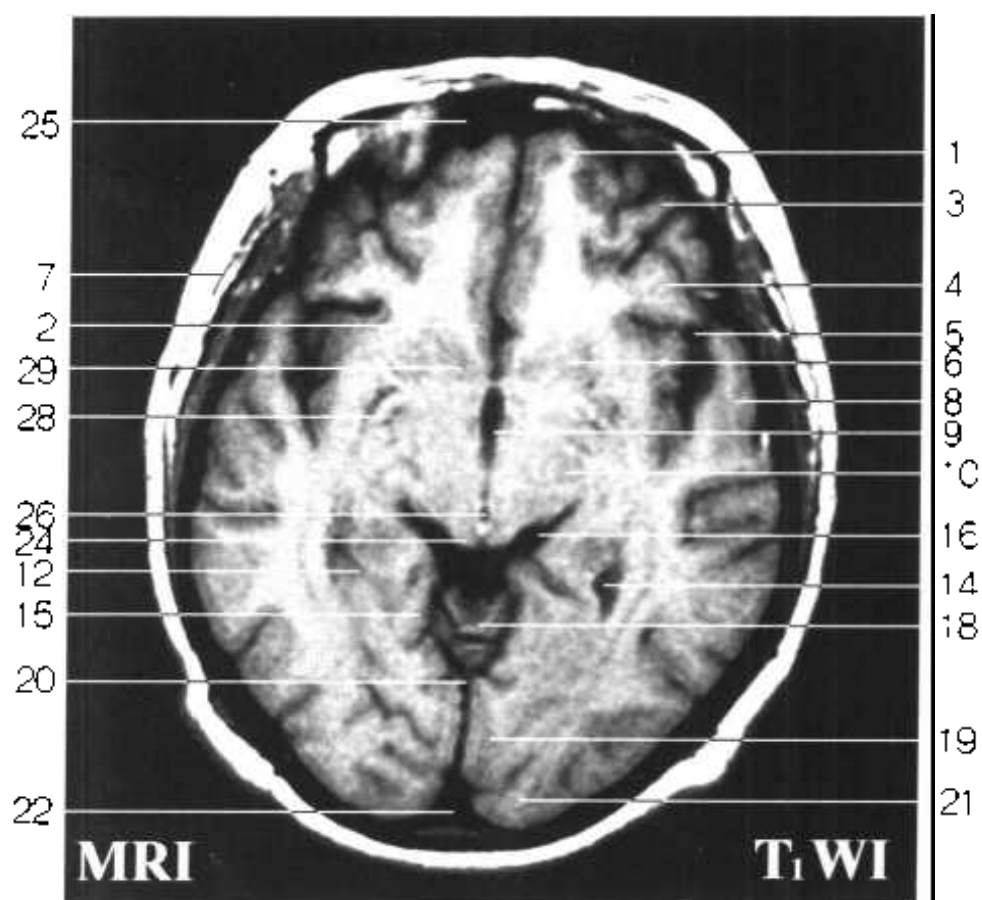
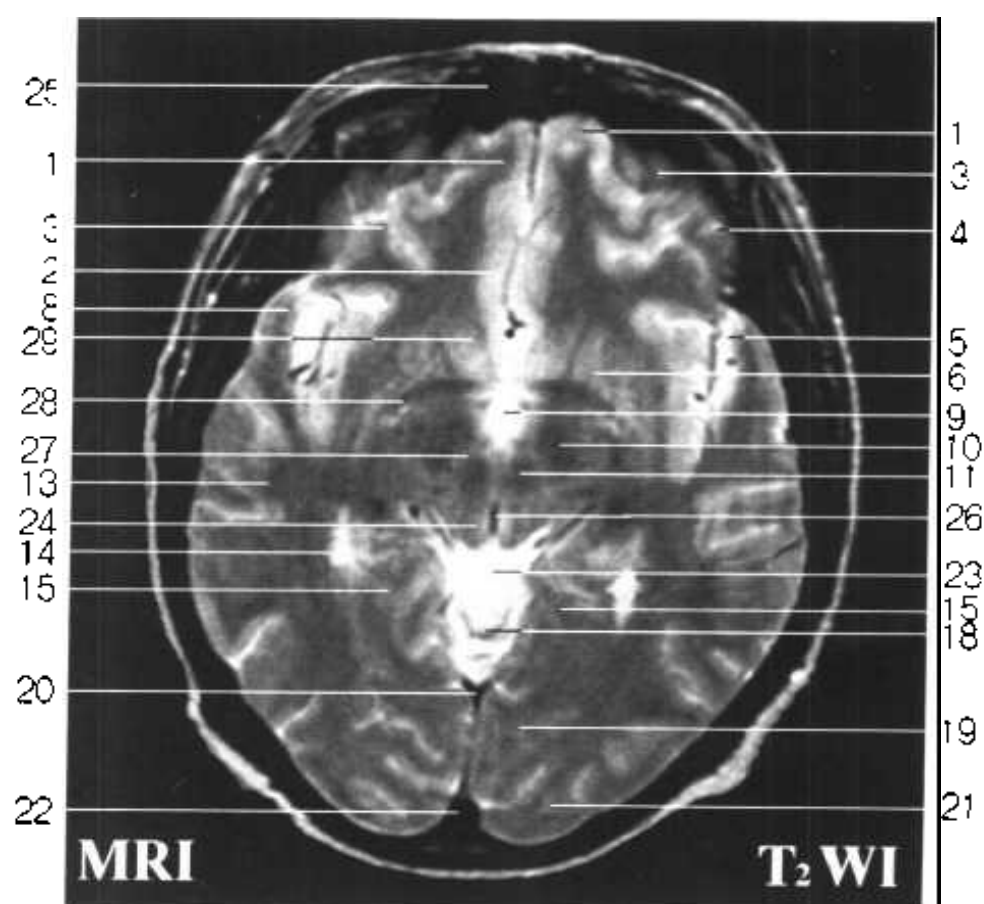


Fig. HC 8



- 18. 小脑蚓 vermis
- 19. 舌回 lingual gyrus
- 20. 直窦 straight sinus
- 21. 楔叶 cuneus
- 22. 上矢状窦 superior sagittal sinus
- 23. 四叠体池 quadrigeminal cistern
- 24. 下丘 inferior colliculus
- 25. 额窦 frontal sinus
- 26. 中脑水管 mesencephalic aqueduct
- 27. 黑质 substantia nigra
- 28. 前连合 anterior commissure
- 29. 尾状核头 head of caudate nucleus



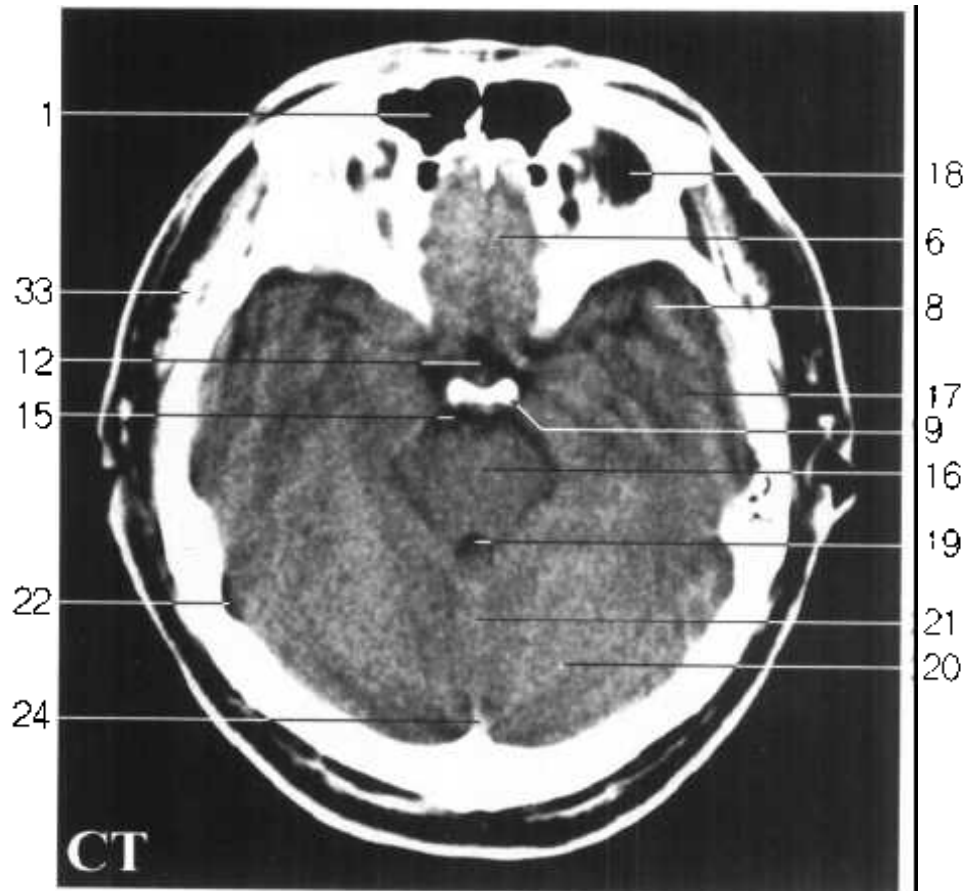


Fig. HC 9

1. 额窦 frontal sinus
2. 眼球 eyeball
3. 鸡冠 crista galli
4. 眶脂体 adipose body of orbit
5. 视神经 optic n.
6. 直回 gyrus rectus
7. 眶回 orbital gyrus
8. 颞上回 superior temporal gyrus
9. 后床突 posterior clinoid process
10. 视交叉 optic chiasma
11. 漏斗 infundibulum
12. 鞍上池 suprasellar cistern
13. 侧脑室下角 inferior horn of lateral ventricle
14. 泪腺 lacrimal gland
15. 桥池 pontine cistern
16. 脑桥基部 basilar part of pons
17. 颞中回 middle temporal gyrus

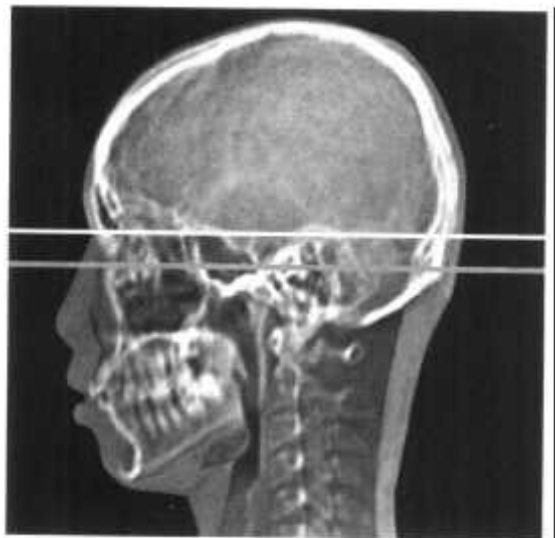
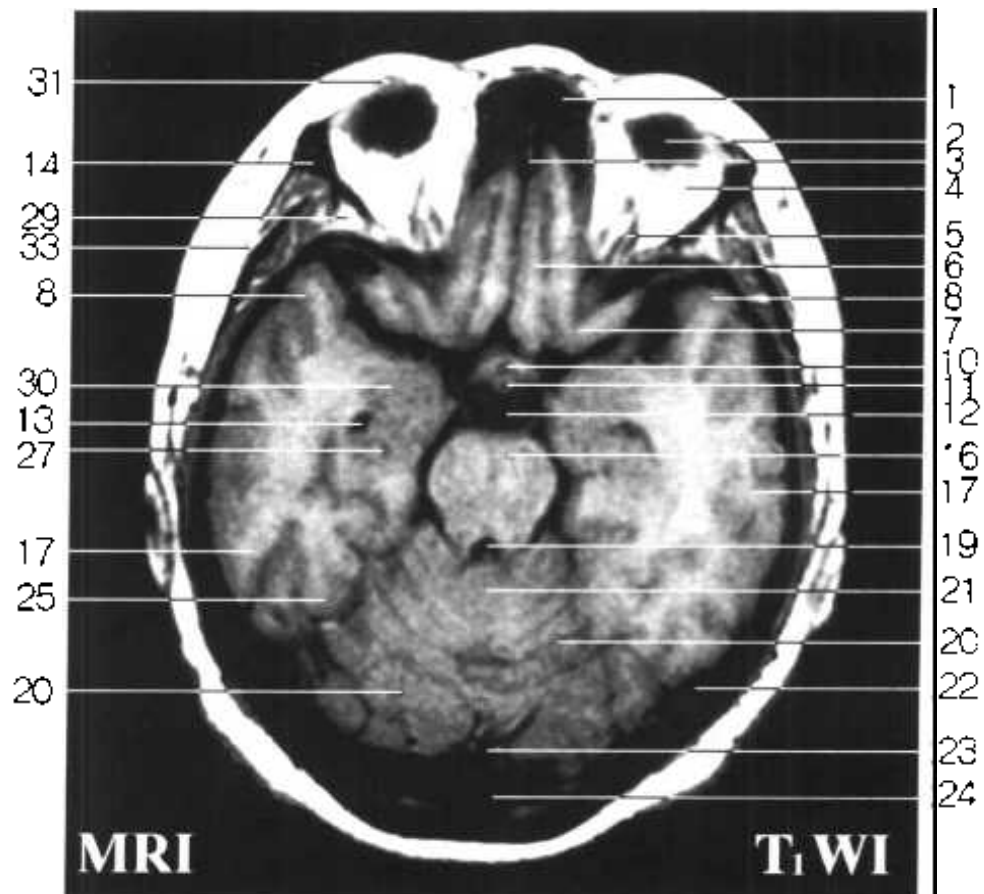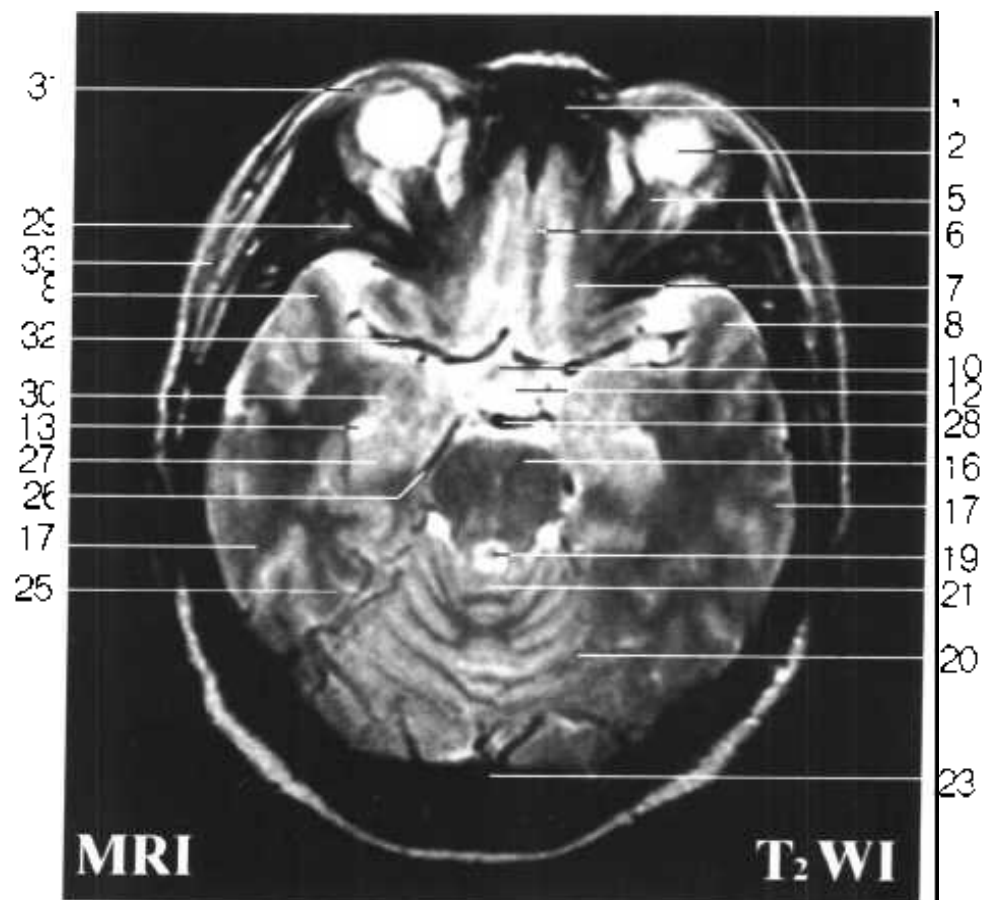


Fig. HC 9



- 18. 眶腔 orbital cavity
- 19. 第四脑室 fourth ventricle
- 20. 小脑半球 cerebellar hemisphere
- 21. 小脑蚓 vermis
- 22. 横窦 transverse sinus
- 23. 直窦 straight sinus
- 24. 窦汇 confluence of sinuses
- 25. 舌回 lingual gyrus
- 26. 小脑上动脉 superior cerebellar a.
- 27. 海马 hippocampus
- 28. 基底动脉 basilar a.
- 29. 蝶骨大翼 greater wing of sphenoid bone
- 30. 杏仁体 amygdaloid body
- 31. 上睑板 superior tarsus
- 32. 大脑中动脉 middle cerebral a.
- 33. 颞肌 temporalis



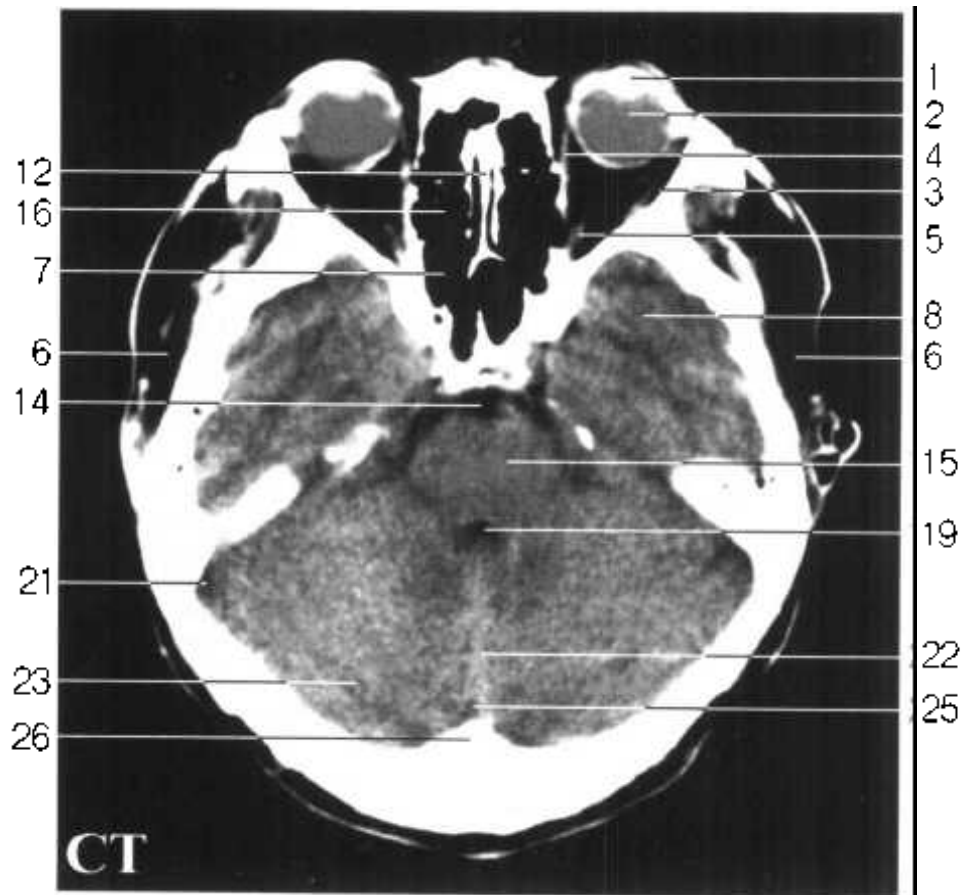
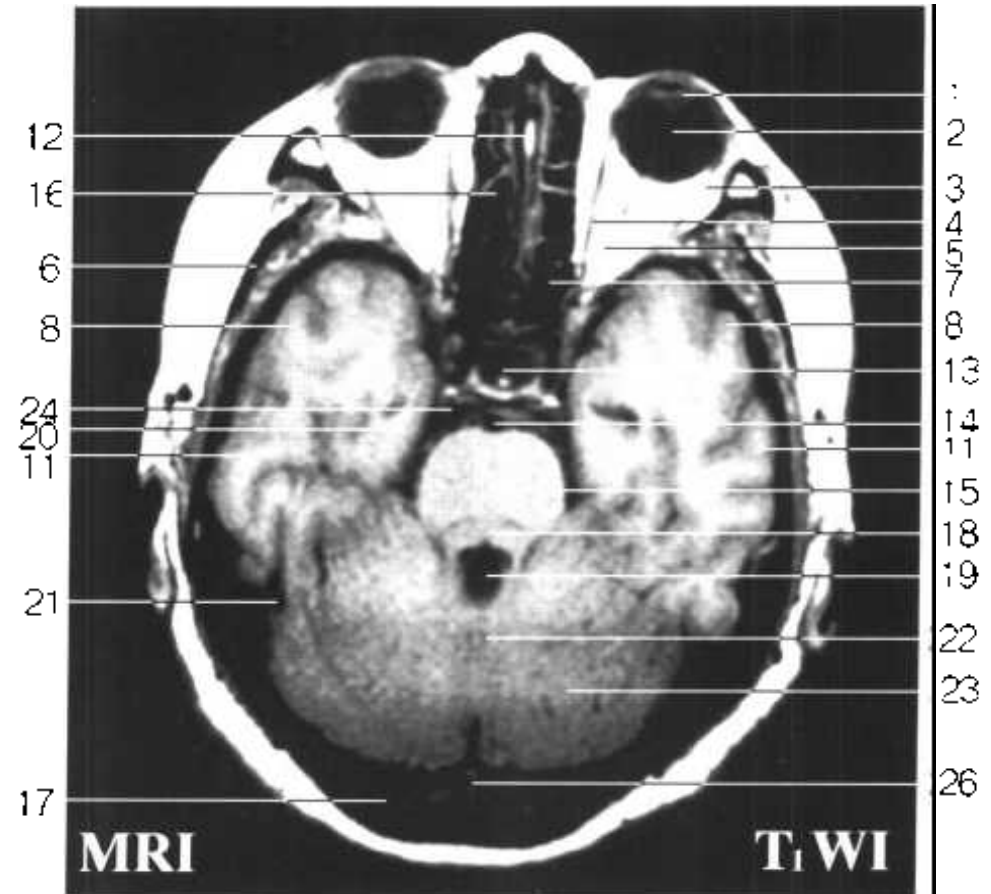


Fig. HC 10

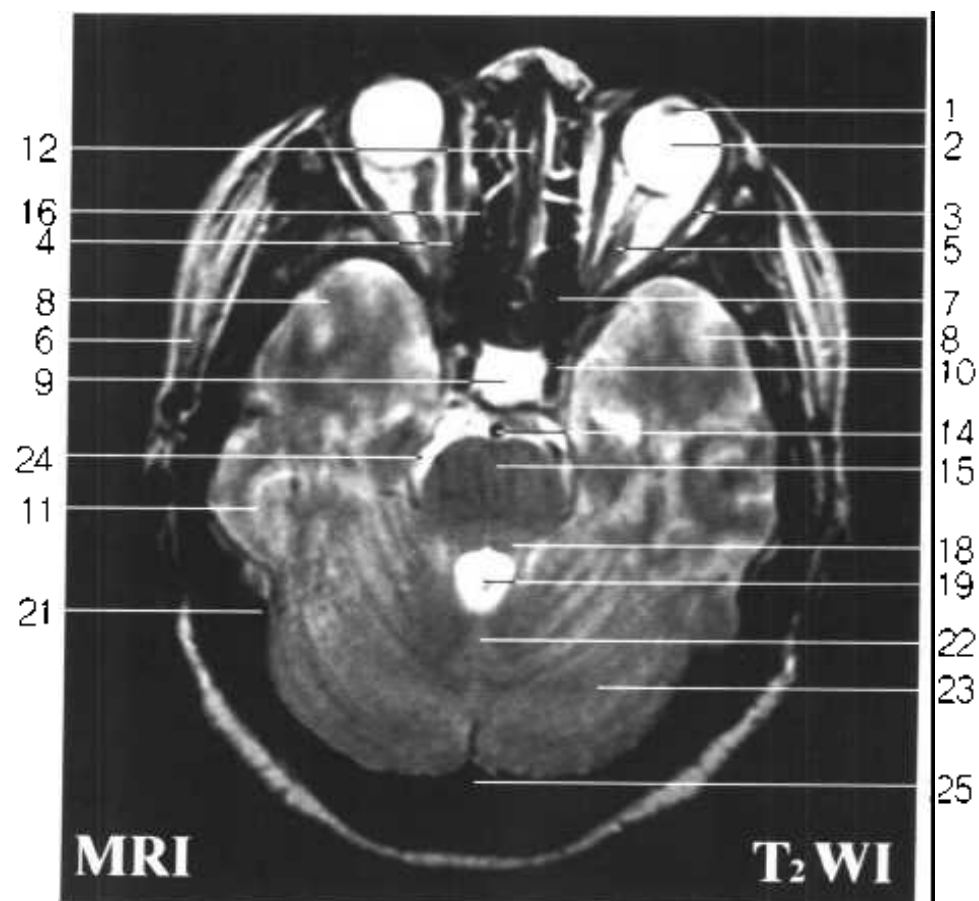
1. 晶状体 lens
2. 眼球 eyeball
3. 外直肌 lateral rectus
4. 内直肌 medial rectus
5. 视神经 optic n.
6. 颞肌 temporalis
7. 后筛窦 posterior ethmoidal sinuses
8. 颞中回 middle temporal gyrus
9. 鞍上池 suprasellar cistern
10. 颈内动脉 internal carotid a.
11. 颞下回 inferior temporal gyrus
12. 鼻中隔 nasal septum
13. 垂体 hypophysis

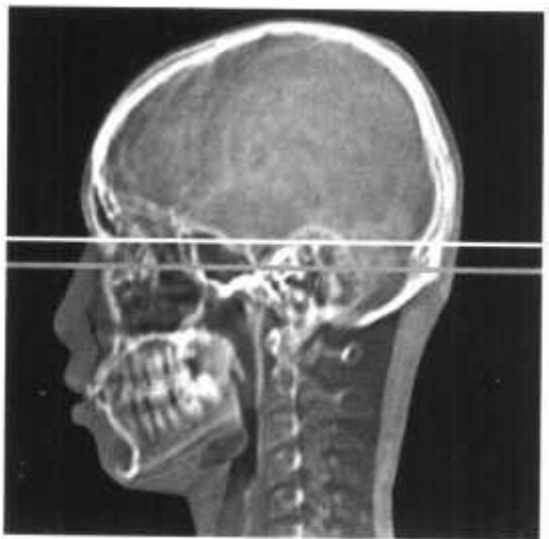

Fig. HC 10



- 14. 基底动脉 basilar a.
- 15. 脑桥基部 basilar part of pons
- 16. 中筛窦 middle ethmoidal sinuses
- 17. 枕骨 occipital bone
- 18. 脑桥被盖部 tegmentum of pons
- 19. 第四脑室 fourth ventricle
- 20. 海马旁回 parahippocampal gyrus
- 21. 横窦 transverse sinus
- 22. 小脑蚓 vermis
- 23. 小脑半球 cerebellar hemisphere
- 24. 桥池 pontine cistern
- 25. 枕窦 occipital sinus
- 26. 枕内隆凸 internal occipital protuberance



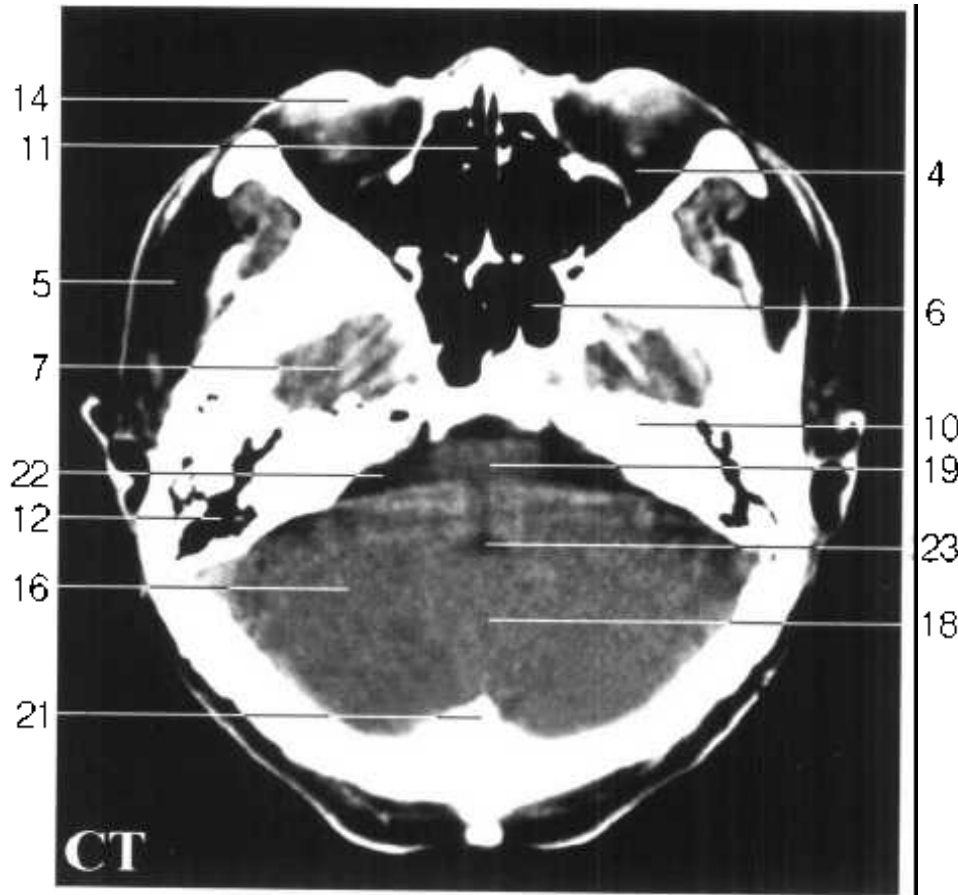
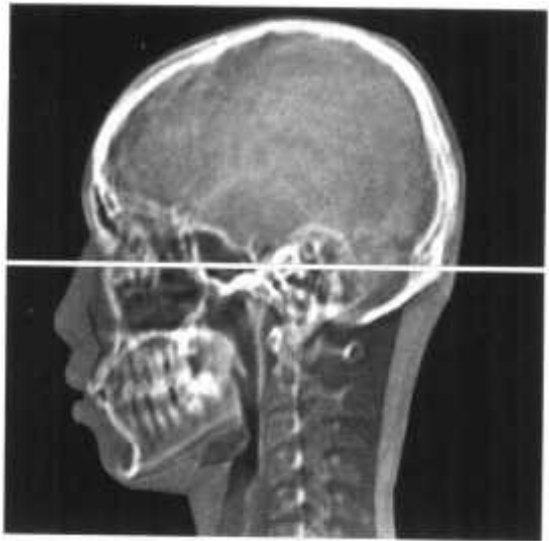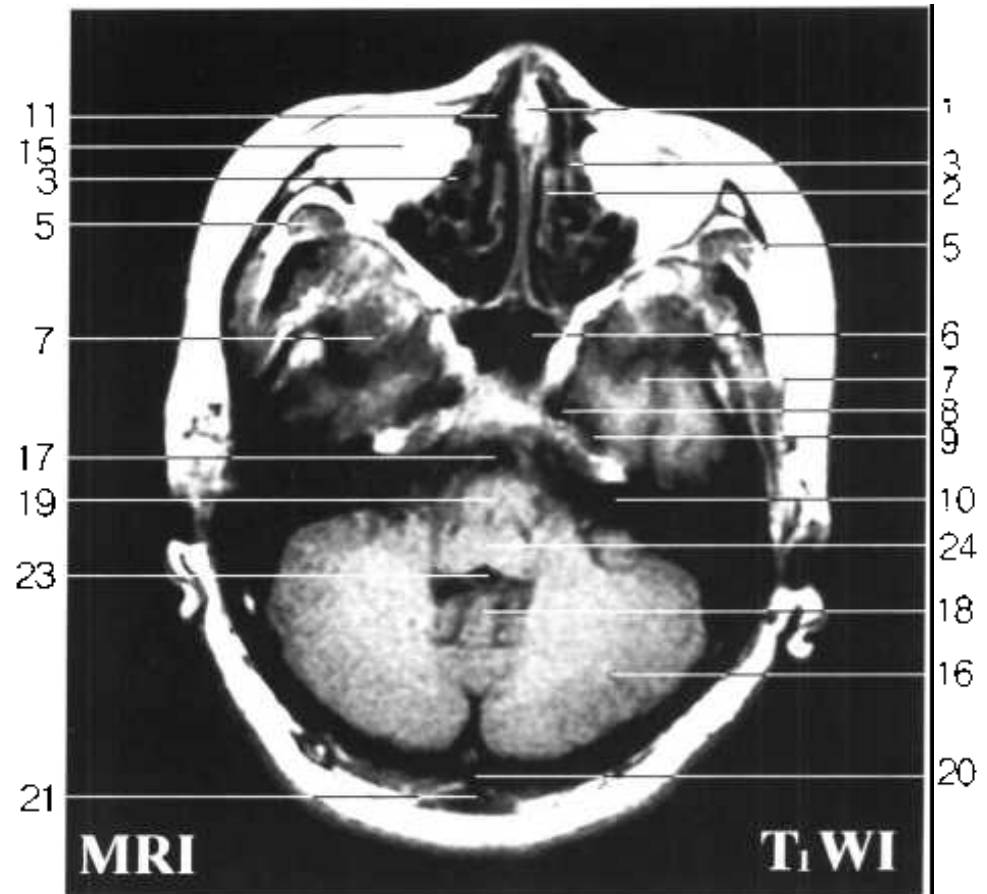


Fig.HC 11

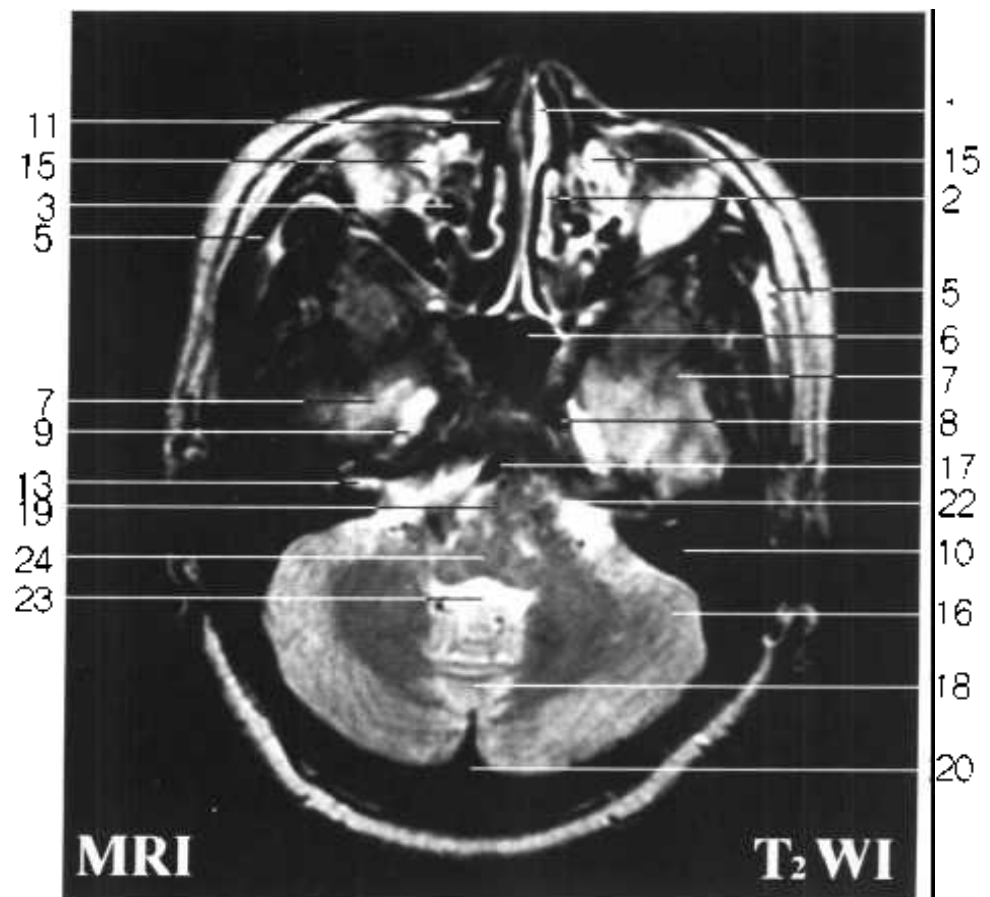


1. 鼻中隔 nasal septum
2. 中鼻甲 middle nasal concha
3. 筛泡 ethmoidal bulla
4. 眶腔 orbital cavity
5. 颞肌 temporalis
6. 蝶窦 sphenoidal sinus
7. 颞下回 inferior temporal gyrus
8. 颈内动脉 internal carotid a.
9. 三叉神经节 trigeminal ganglion
10. 颞骨岩部 petrous part of temporal bone
11. 鼻腔 nasal cavity
12. 鼓室 tympanic cavity
13. 面神经及前庭蜗神经 facial n.and vestibulocochlear n.

Fig.HC 11



- 14. 眼球 eyeball
- 15. 眶脂体 adipose body of orbit
- 16. 小脑半球 cerebellar hemisphere
- 17. 基底动脉 basilar a.
- 18. 小脑蚓 vermis
- 19. 脑桥 pons
- 20. 枕窦 occipital sinus
- 21. 枕内隆凸 internal occipital protuberance
- 22. 脑桥小脑三角池 cistern of pontocerebellar trigone
- 23. 第四脑室 fourth ventricle
- 24. 延髓 medulla oblongata



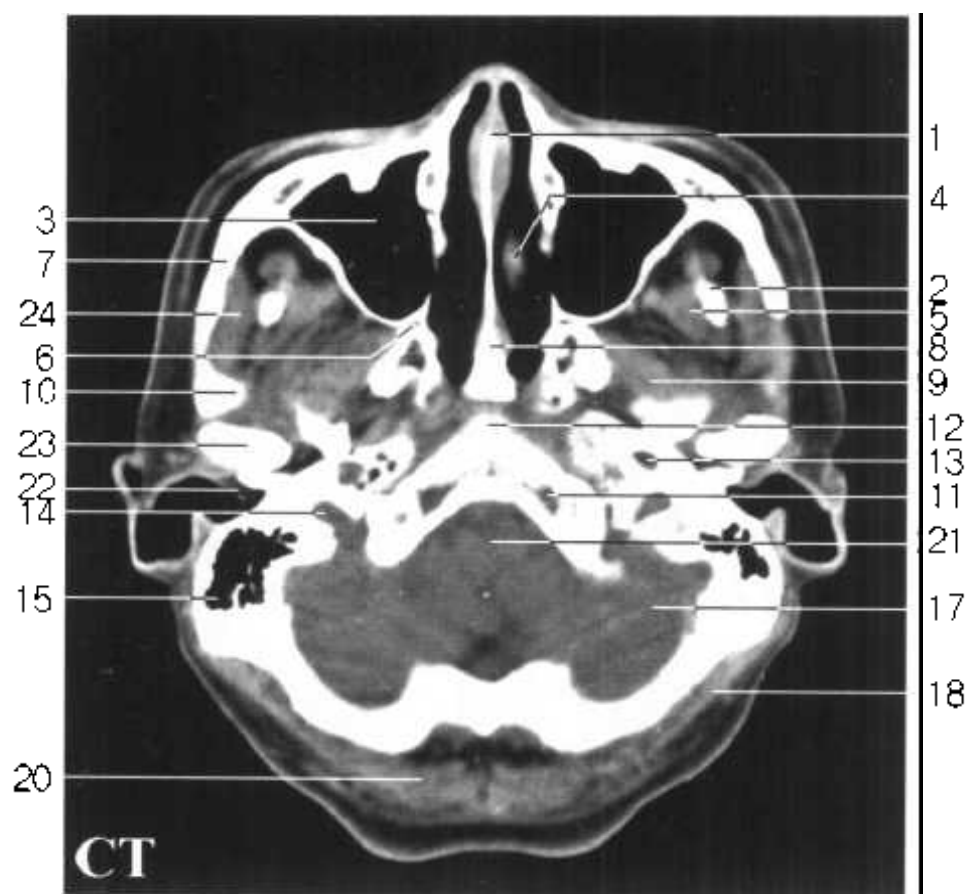


Fig. HC 12

1. 鼻中隔 nasal septum
2. 冠突 coronoid process
3. 上颌窦 maxillary sinus
4. 下鼻甲 inferior nasal concha
5. 颞肌 temporalis
6. 翼腭窝 pterygopalatine fossa
7. 颧弓 zygomatic arch
8. 犁骨 vomer
9. 翼外肌 lateral pterygoid
10. 关节结节 articular tubercle
11. 舌下神经管 hypoglossal canal
12. 枕骨基部 basilar part of occipital bone
13. 颈内动脉 internal carotid a.

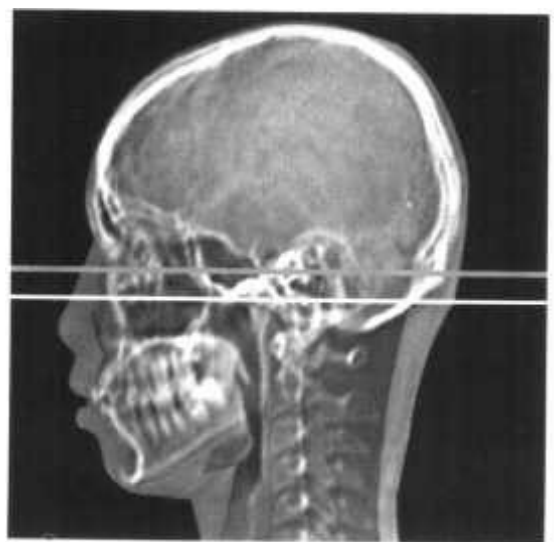
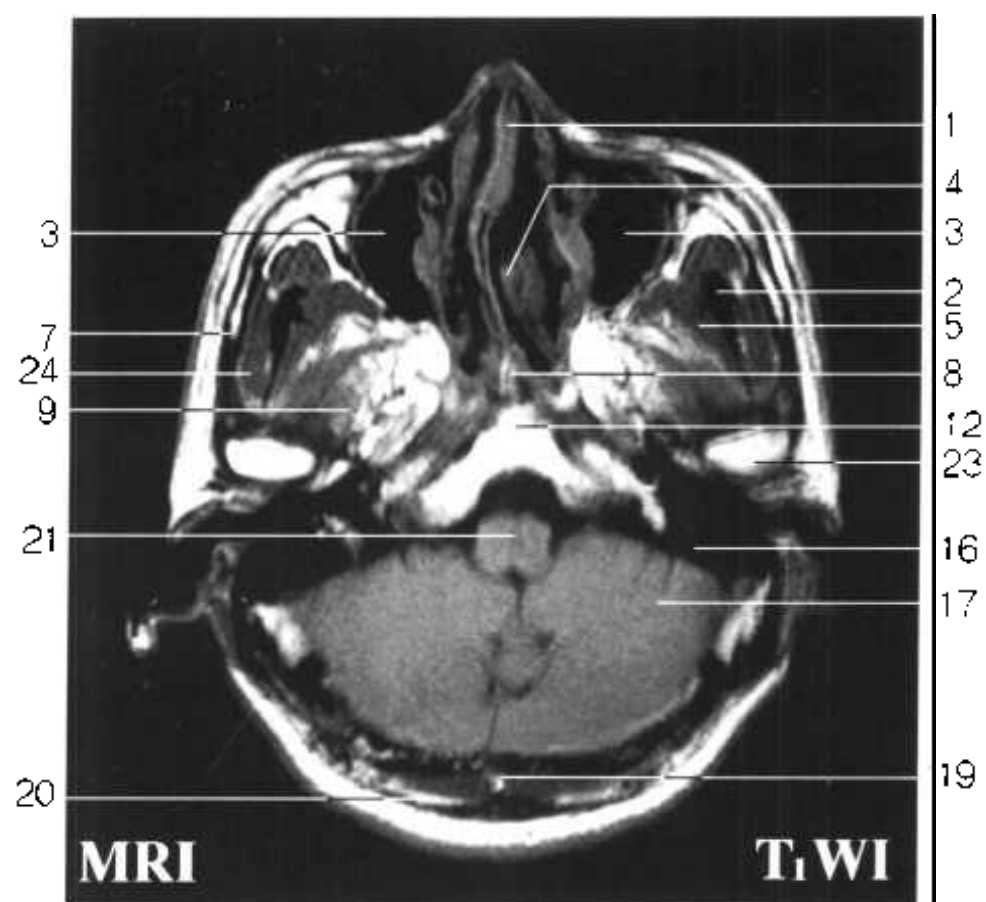


Fig. HC 12



- 14. 颈内静脉 internal jugular v.
- 15. 乳突小房 mastoid cells
- 16. 乙状窦 sigmoid sinus
- 17. 小脑半球 cerebellar hemisphere
- 18. 头夹肌 splenius capitis
- 19. 枕内隆凸 internal occipital protuberance
- 20. 头半棘肌 semispinalis capitis
- 21. 延髓 medulla oblongata
- 22. 外耳道 external acoustic meatus
- 23. 下颌头 head of mandible
- 24. 咬肌 masseter

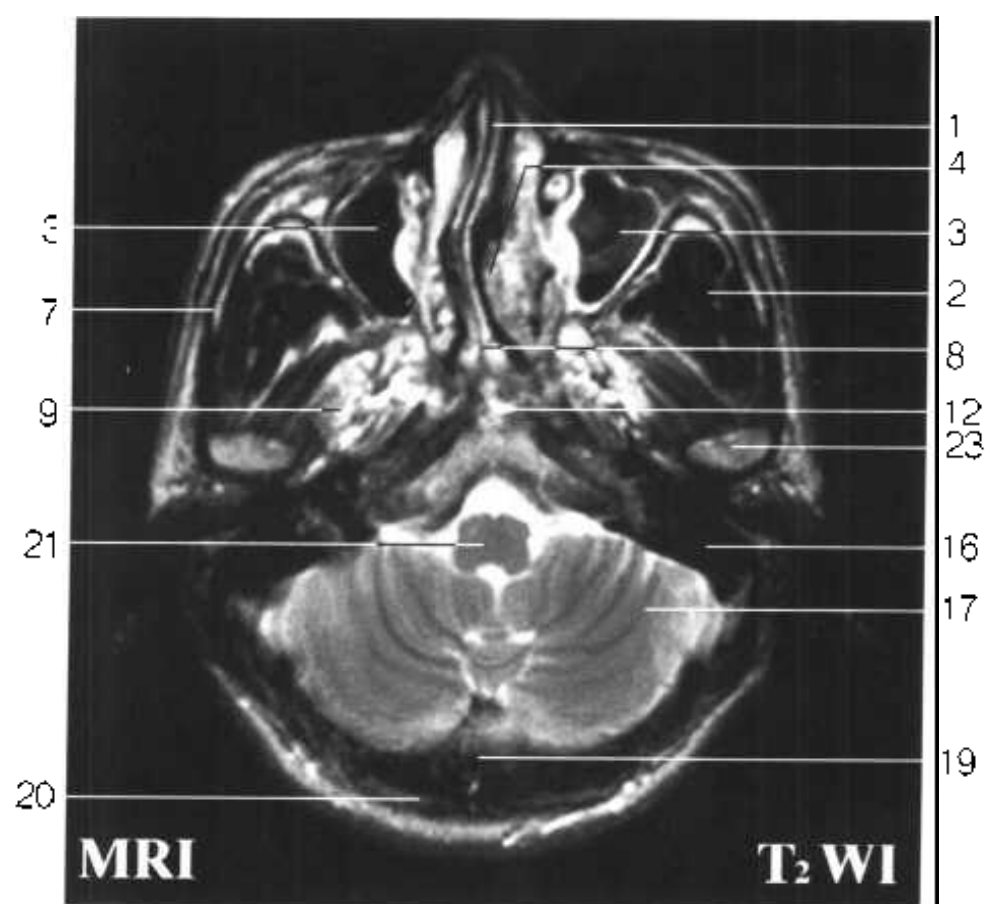

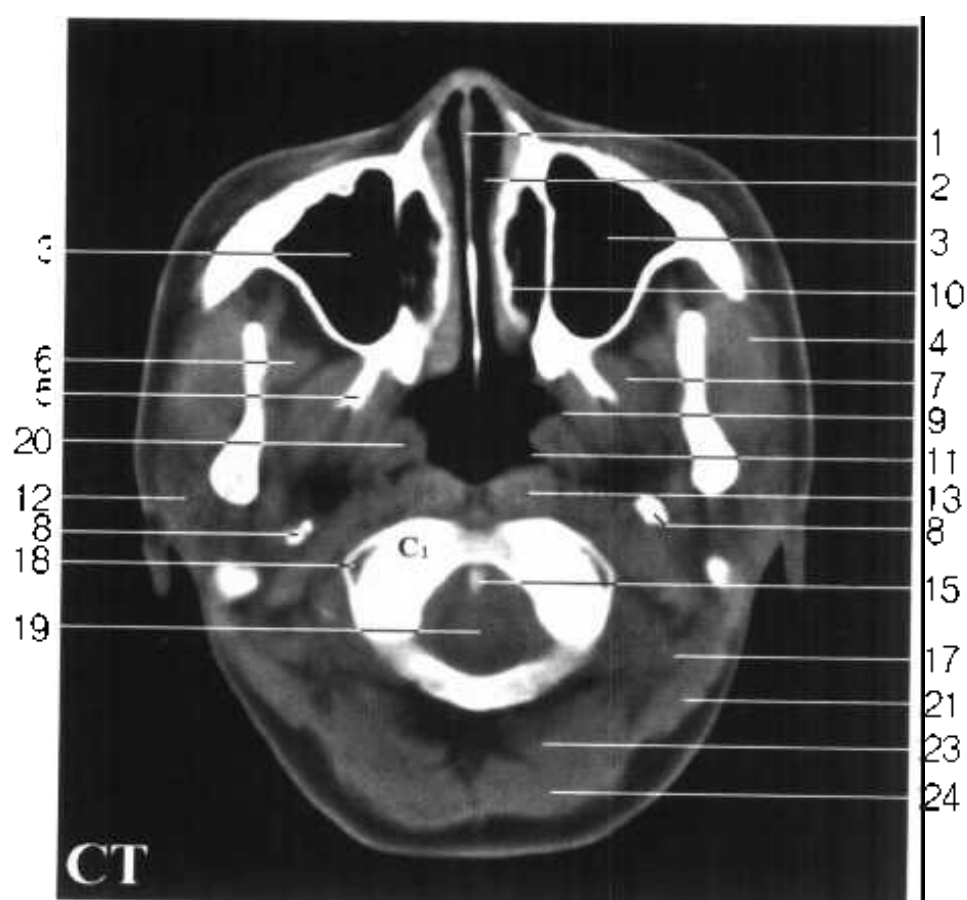
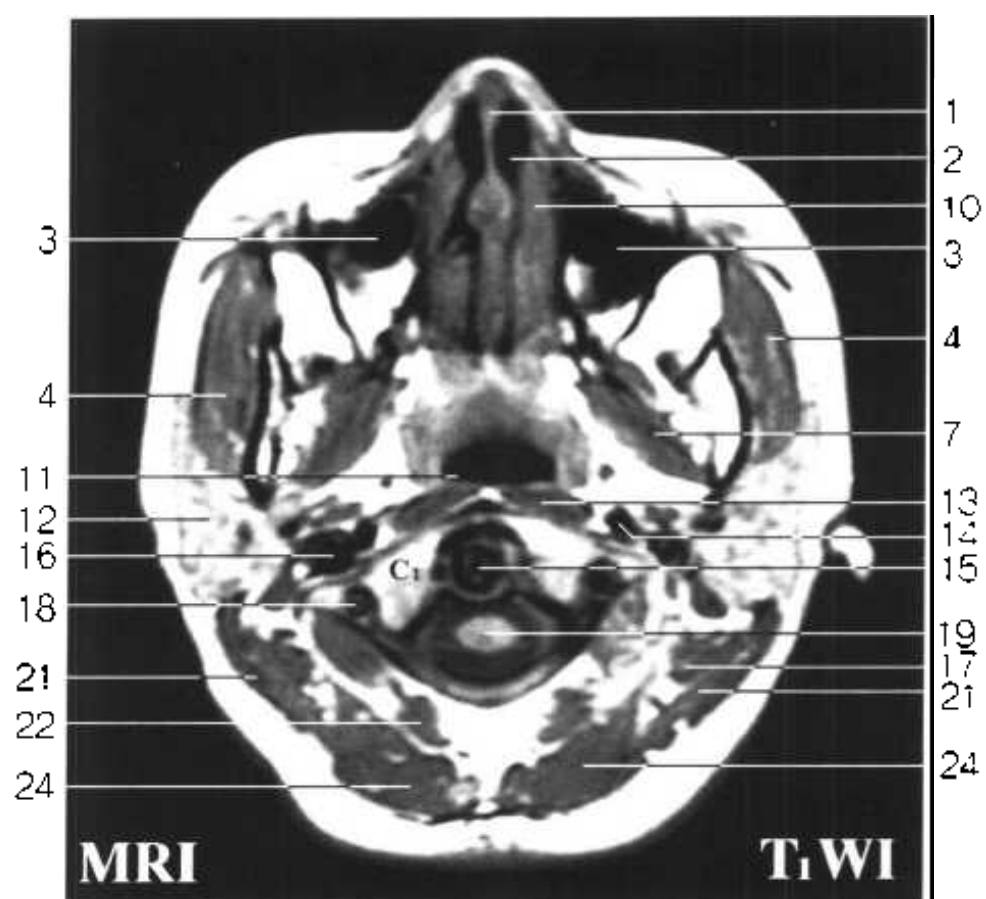


Fig.HC 13

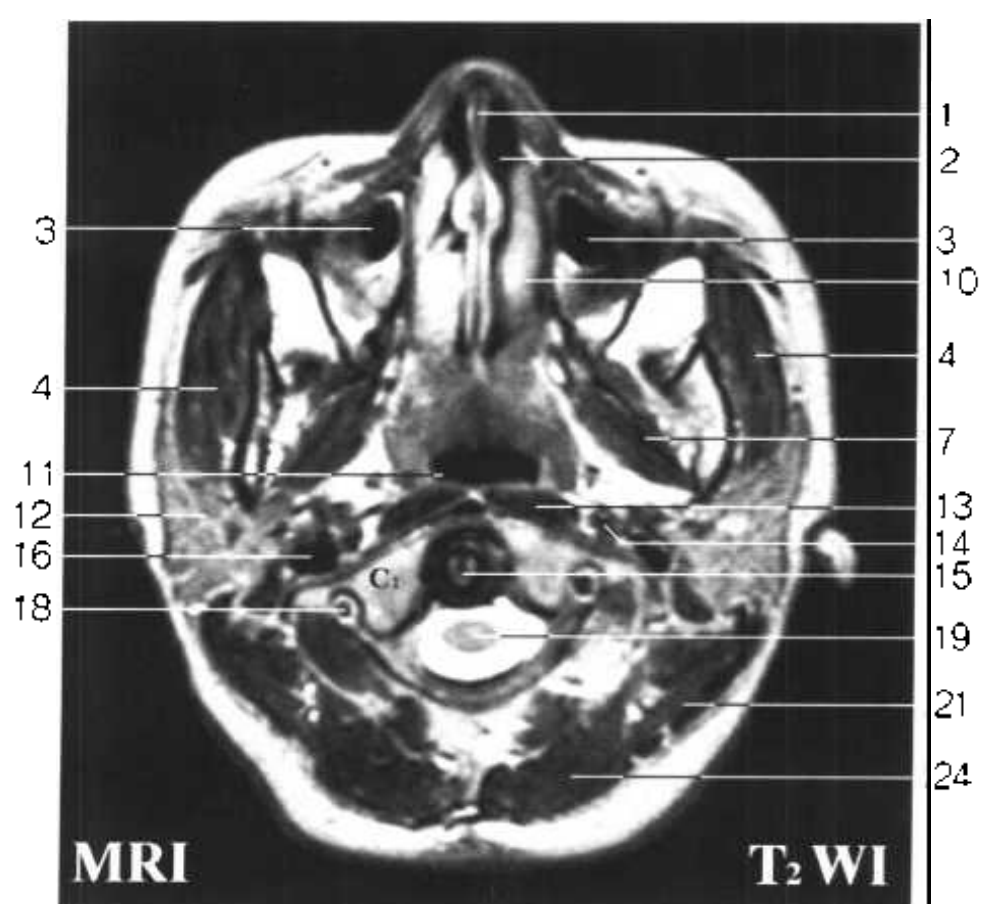
1. 鼻中隔软骨 septal cartilage of nose
2. 下鼻道 inferior nasal meatus
3. 上颌窦 maxillary sinus
4. 咬肌 masseter
5. 翼突外侧板 lateral pterygoid plate
6. 颞肌 temporalis
7. 翼外肌 lateral pterygoid
8. 茎突 styloid process
9. 咽鼓管咽口 pharyngeal opening of auditory tube
10. 下鼻甲 inferior nasal concha
11. 咽隐窝 pharyngeal recess
12. 腮腺 parotid gland
13. 头长肌 longus capitis

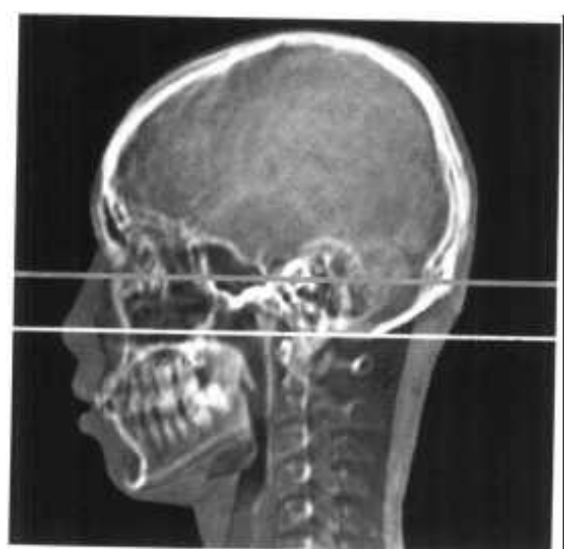

Fig. HC 13



- 14. 颈内动脉 internal carotid a.
- 15. 齿突 dens
- 16. 颈内静脉 internal jugular v.
- 17. 头最长肌 longissimus capitis
- 18. 椎动、静脉 vertebral a.and v.
- 19. 脊髓 spinal cord
- 20. 咽鼓管软骨 cartilage of auditory tube
- 21. 头夹肌 splenius capitis
- 22. 头后小直肌 rectus capitis posterior minor
- 23. 头后大直肌 rectus capitis posterior major
- 24. 头半棘肌 semispinalis capitis



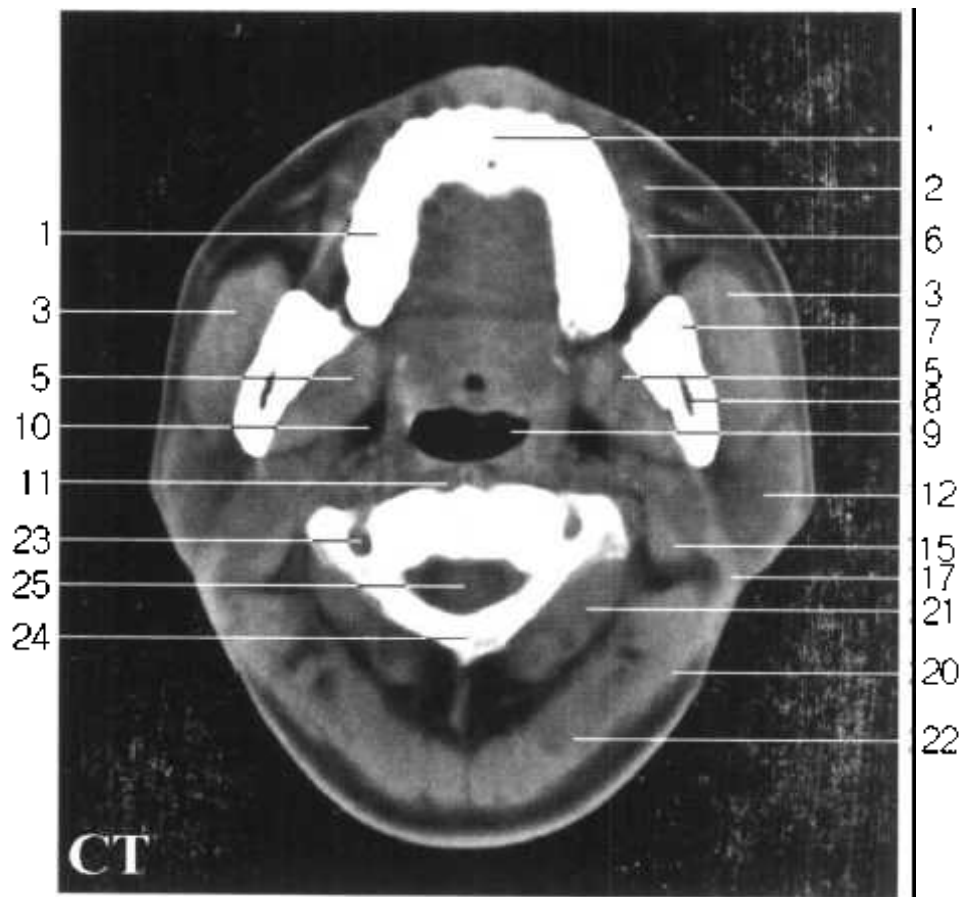
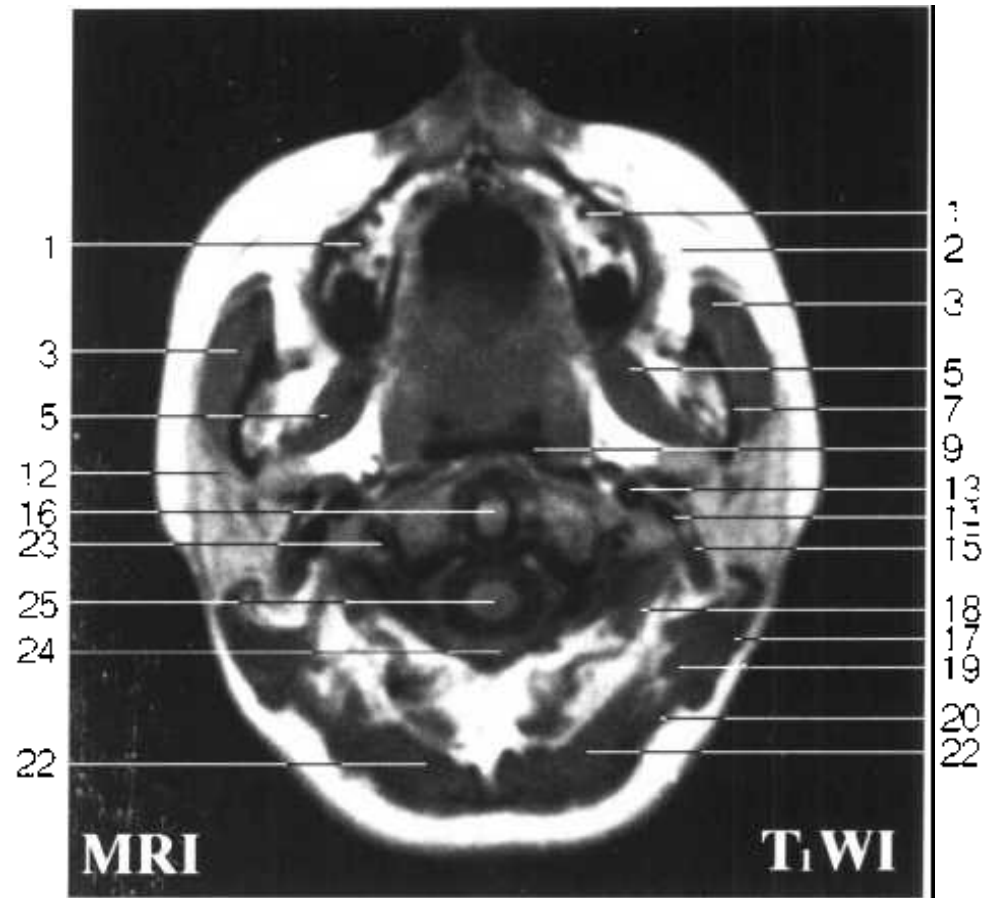


Fig. HC 14

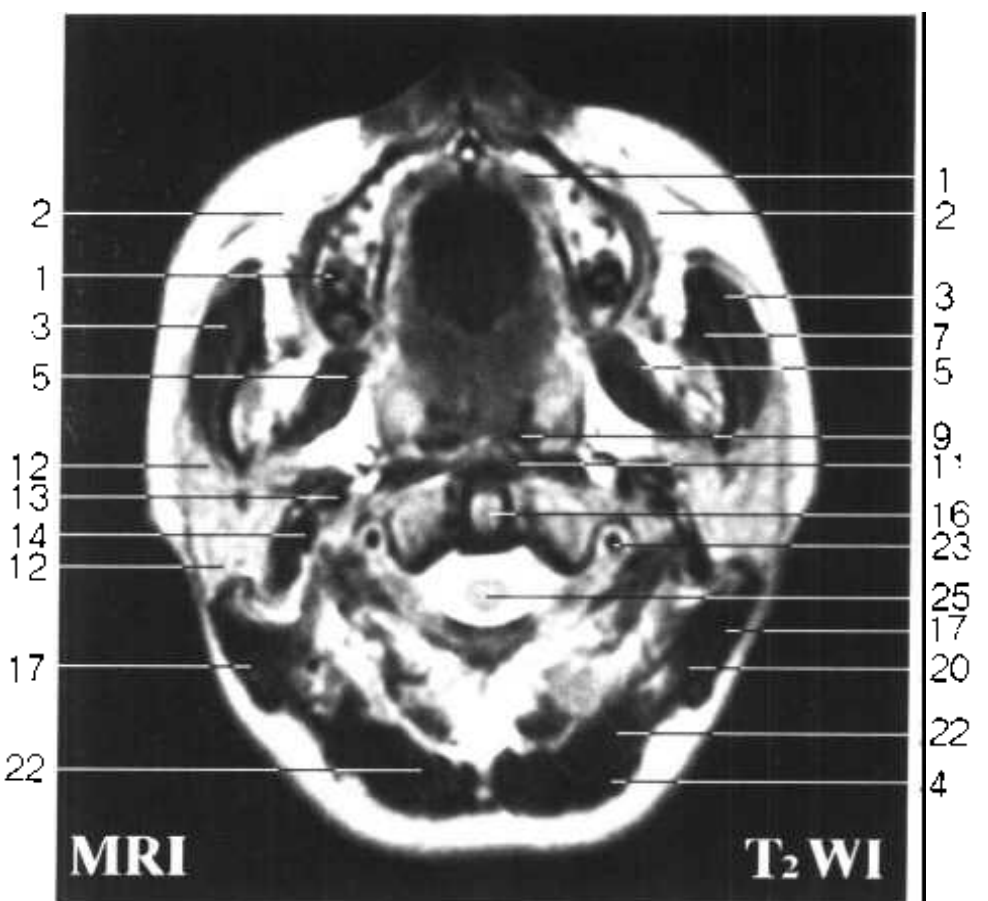
1. 上颌牙根 root of maxillary tooth
2. 颊脂体 buccal fat pad
3. 咬肌 masseter
4. 斜方肌 trapezius
5. 翼内肌 medial pterygoid
6. 颊肌 buccinator
7. 下颌支 ramus of mandible
8. 下牙槽神经 inferior alveolar n.
9. 咽腔 cavity of pharynx
10. 咽外侧间隙 lateropharyngeal space
11. 头长肌 longus capitis
12. 腮腺 parotid gland
13. 颈内动脉 internal carotid a.
14. 颈内静脉 internal jugular v.

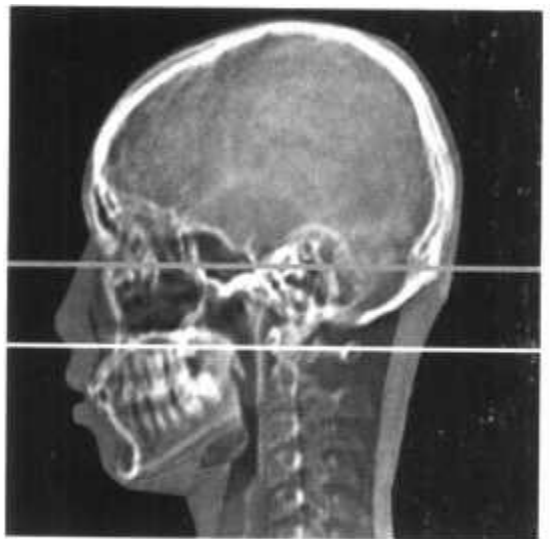

Fig. HC 14



- 15. 二腹肌后腹 posterior belly of digastric
- 16. 齿突 dens
- 17. 胸锁乳突肌 sternocleidomastoid
- 18. 头下斜肌 obliquus capitis inferior
- 19. 头最长肌 longissimus capitis
- 20. 头夹肌 splenius capitis
- 21. 头后大直肌 rectus capitis posterior major
- 22. 头半棘肌 semispinalis capitis
- 23. 椎动、静脉 vertebral a.and v.
- 24. 寰椎后弓 posterior arch of atlas
- 25. 脊髓 spinal cord



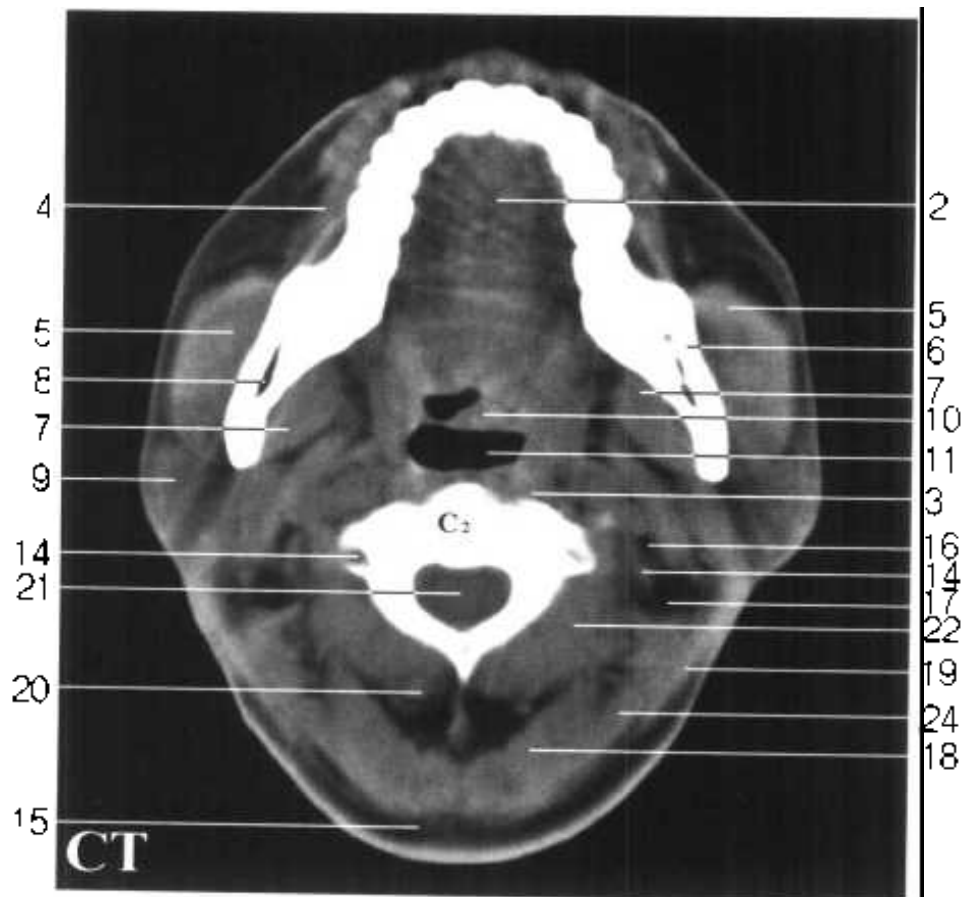


Fig. HC 15

1. 口轮匝肌 orbicularis oris
2. 硬腭 hard palate
3. 头长肌 longus capitis
4. 颊肌 buccinator
5. 咬肌 masseter
6. 下颌支 ramus of mandible
7. 翼内肌 medial pterygoid
8. 下牙槽动脉与神经 inferior alveolar a. and n.
9. 腮腺 parotid gland
10. 软腭 soft palate
11. 咽腔 cavity of pharynx
12. 茎突舌肌 styloglossus
13. 颈长肌 longus colli

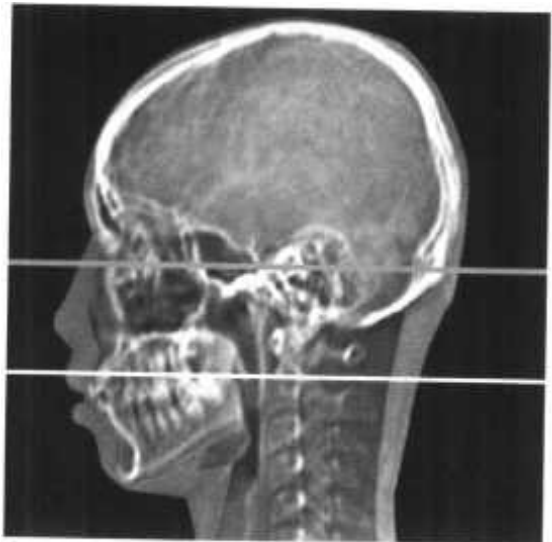
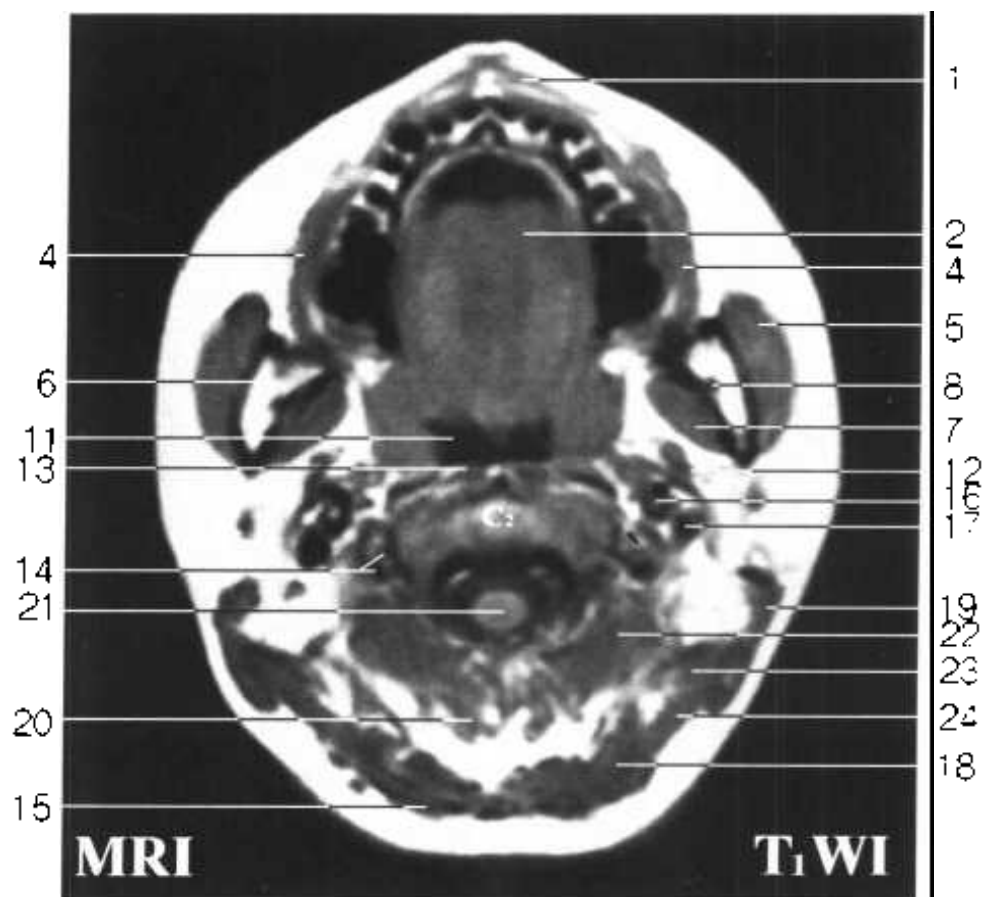
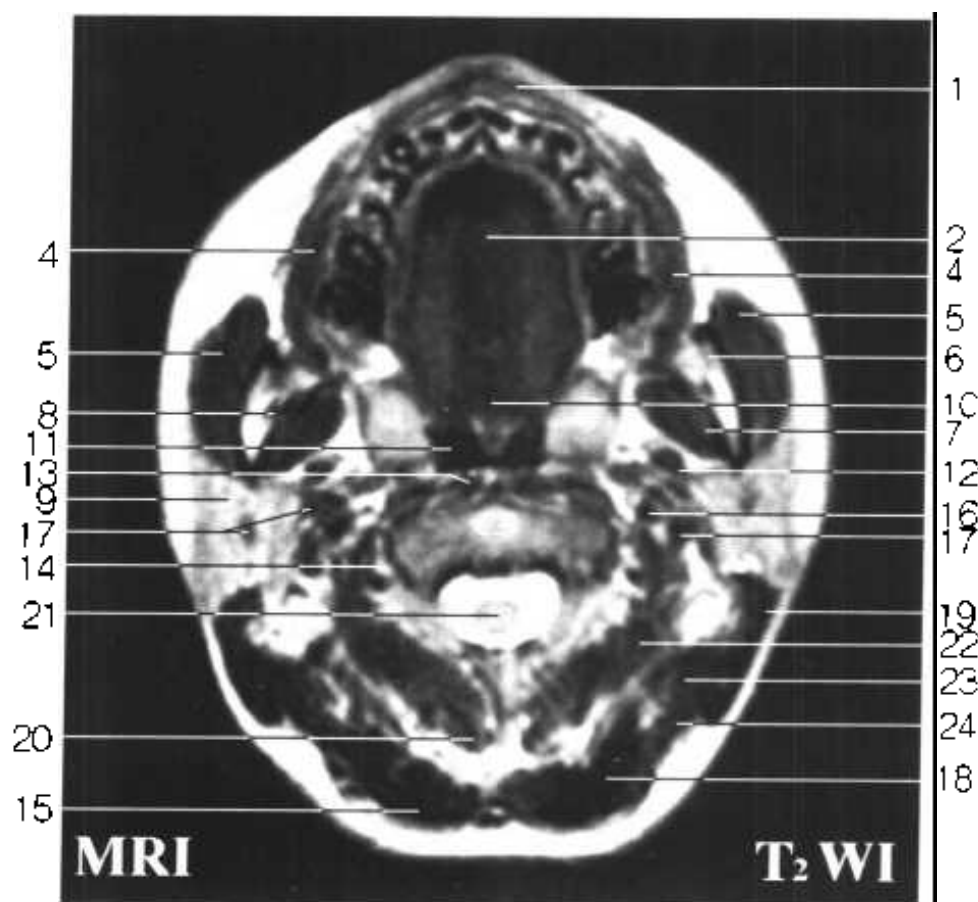


Fig. HC 15



- 14. 椎动、静脉 vertebral a.and v.
- 15. 斜方肌 trapezius
- 16. 颈内动脉 internal carotid a.
- 17. 颈内静脉 internal jugular v.
- 18. 头半棘肌 semispinalis capitis
- 19. 胸锁乳突肌 sternocleidomastoid
- 20. 头后大直肌 rectus capitis posterior major
- 21. 脊髓 spinal cord
- 22. 头下斜肌 obliquus capitis inferior
- 23. 头最长肌 longissimus capitis
- 24. 头夹肌 splenius capitis



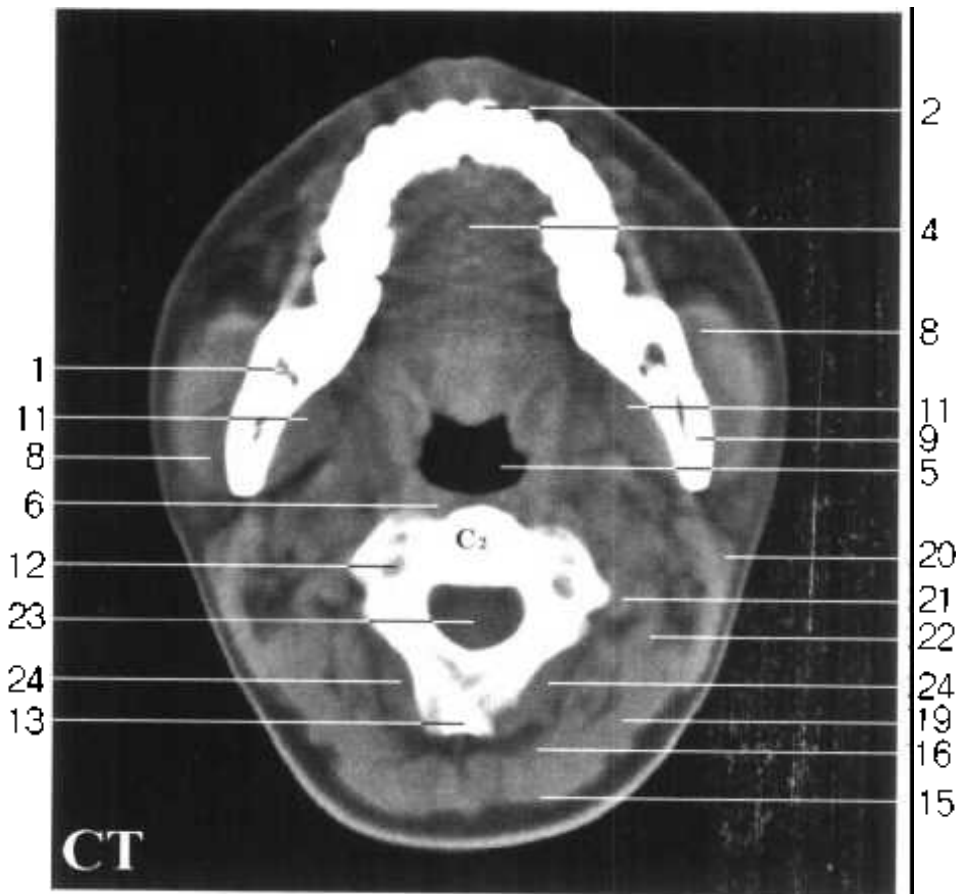


Fig. HC 16

1. 下牙槽动脉与神经 inferior alveolar a. and n.
2. 切牙 incisor
3. 降口角肌 depressor anguli oris
4. 舌中隔 septum of tongue
5. 咽腔 cavity of pharynx
6. 头长肌与颈长肌 longus capitis and longus colli
7. 颈外静脉 external jugular v.
8. 咬肌 masseter
9. 下颌支 ramus of mandible
10. 舌咽神经、迷走神经和副神经 glossopharyngeal n. vagus n. and accessory n.

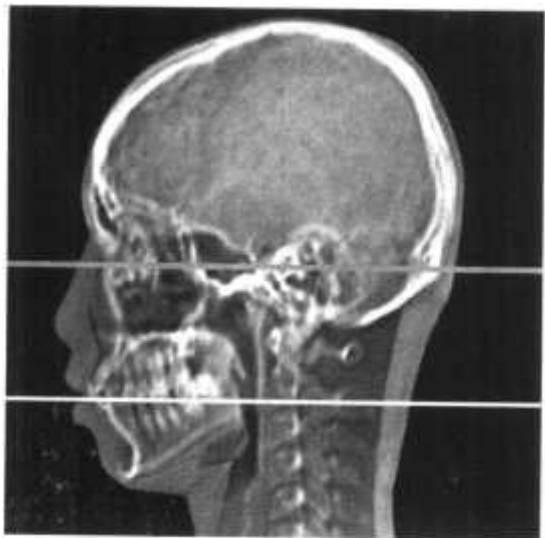
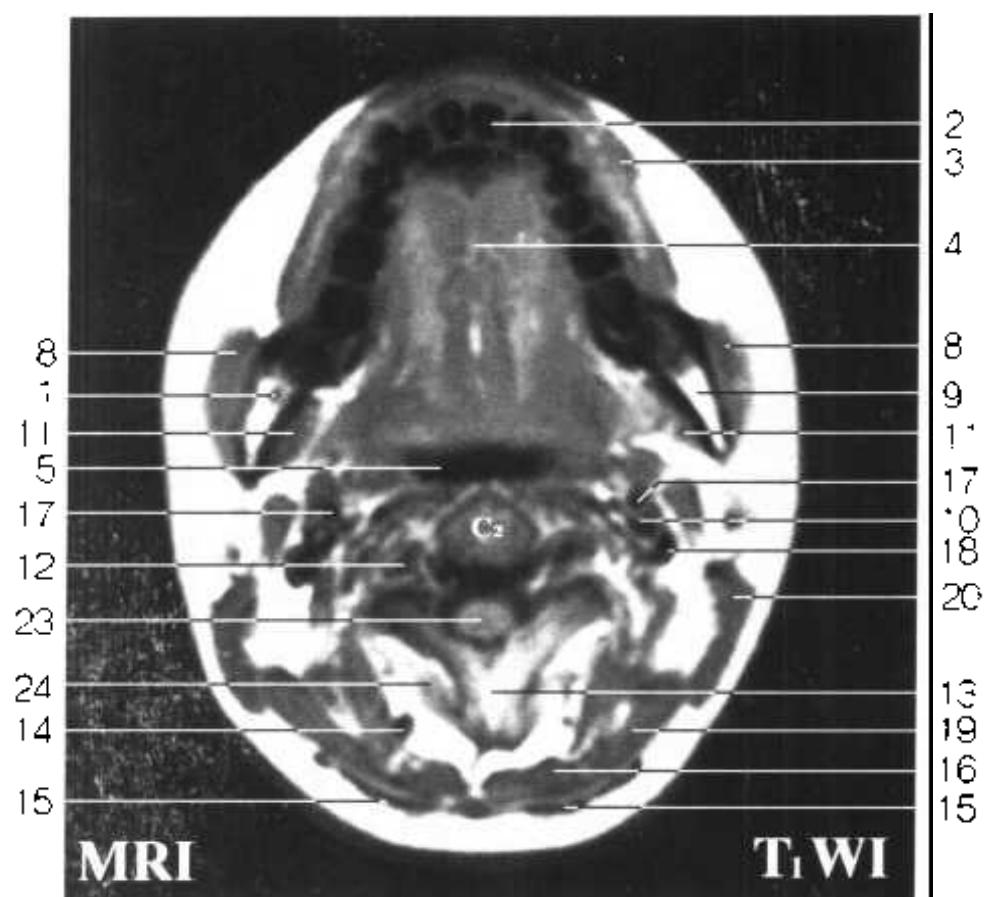
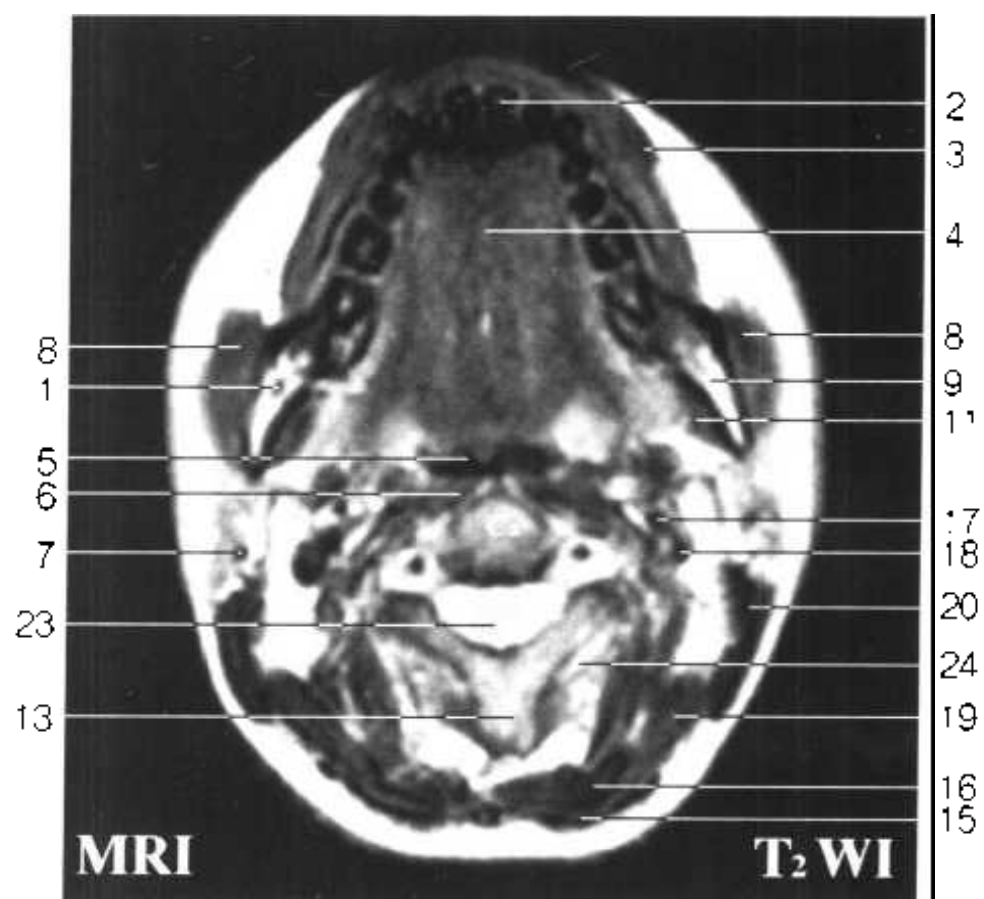


Fig. HC 16



- 11. 翼内肌 medial pterygoid
- 12. 椎动、静脉 vertebral a.and v.
- 13. 枢椎棘突 spinous process of axis
- 14. 颈深动脉 deep cervical a.
- 15. 斜方肌 trapezius
- 16. 头半棘肌 semispinalis capitis
- 17. 颈内动脉 internal carotid a.
- 18. 颈内静脉 internal jugular v.
- 19. 头夹肌 splenius capitis
- 20. 胸锁乳突肌 sternocleidomastoid
- 21. 中斜角肌 scalenus medius
- 22. 肩胛提肌 levator scapulae
- 23. 脊髓 spinal cord
- 24. 头下斜肌 obliquus capitis inferior



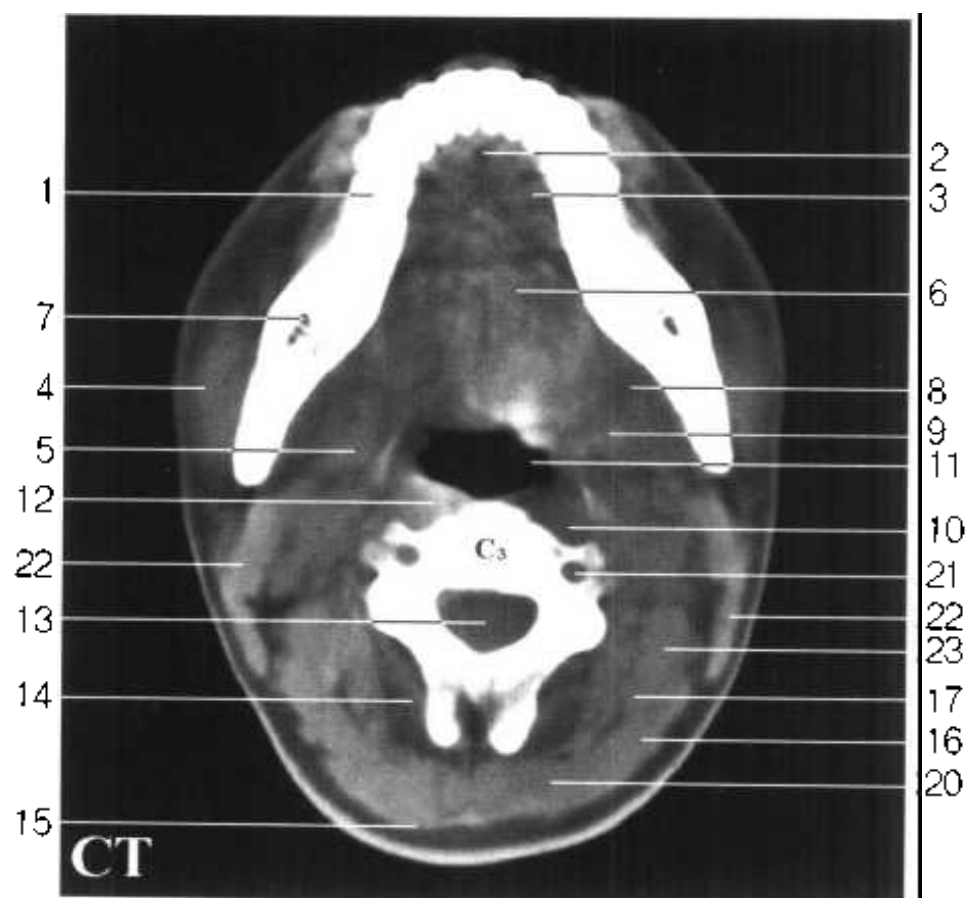


Fig. HC 17

1. 下颌骨 mandible
2. 舌下动脉 sublingual a.
3. 舌下腺 sublingual gland
4. 咬肌 masseter
5. 下颌下腺 submandibular gland
6. 颏舌肌 genioglossus
7. 下牙槽神经 inferior alveolar n.
8. 下颌舌骨肌 mylohyoid
9. 茎突舌肌 styloglossus
10. 头长肌 longus capitis
11. 咽腔 cavity of pharynx
12. 颈长肌 longus colli

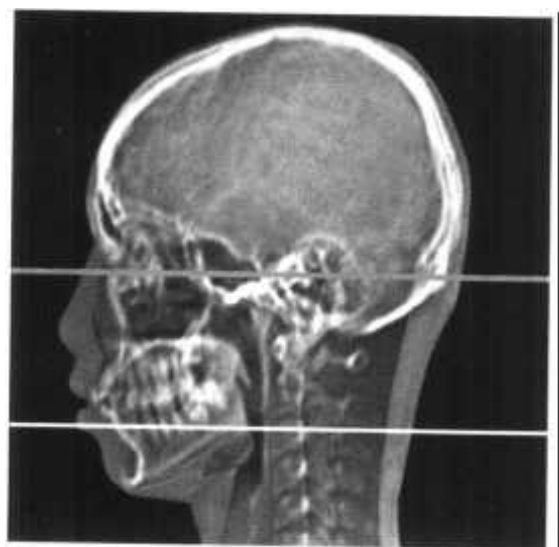
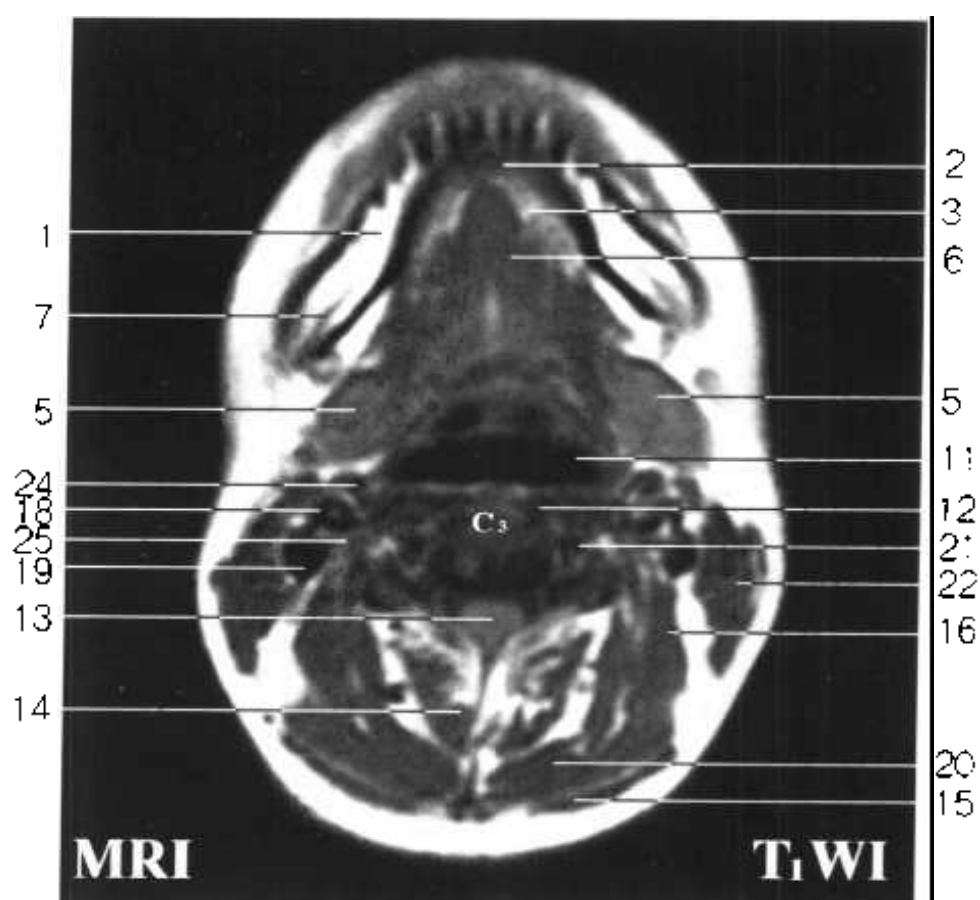
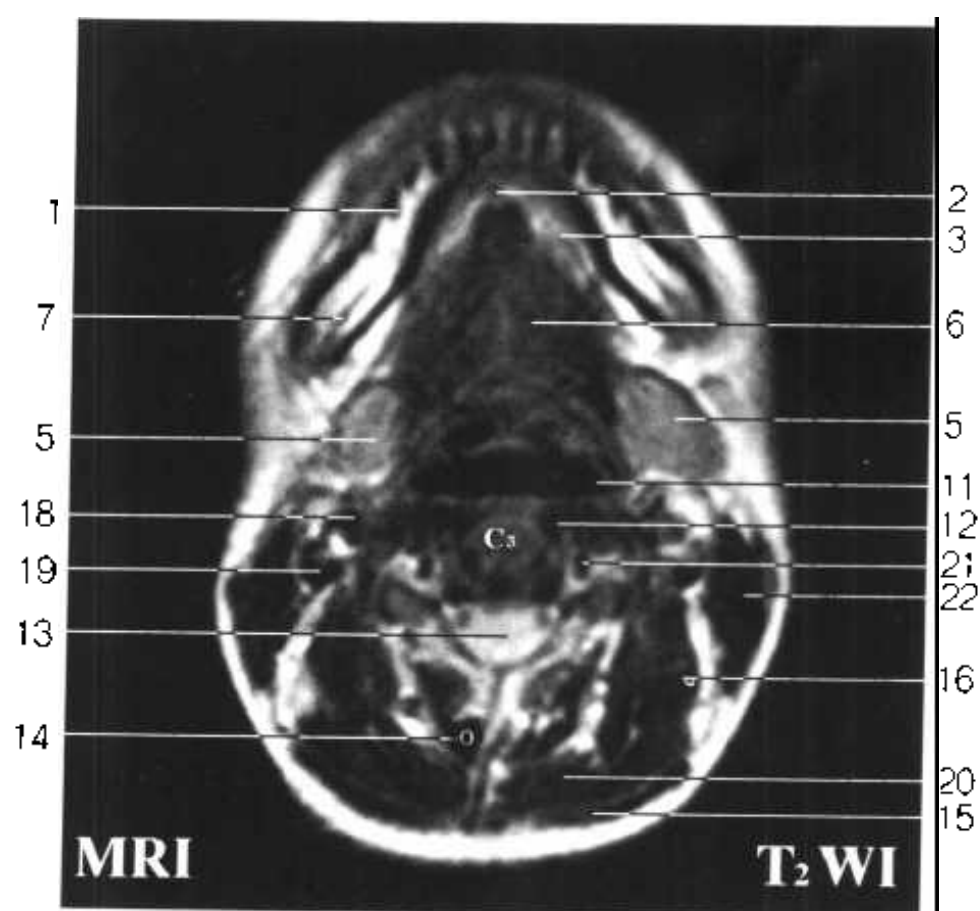


Fig. HC 17



- 13. 脊髓 spinal cord
- 14. 颈半棘肌 semispinalis cervicis
- 15. 斜方肌 trapezius
- 16. 头夹肌 splenius capitis
- 17. 头最长肌 longissimus capitis
- 18. 颈内动脉 internal carotid a.
- 19. 颈内静脉 internal jugular v.
- 20. 头半棘肌 semispinalis capitis
- 21. 椎动脉 vertebral a.
- 22. 胸锁乳突肌 sternocleidomastoid
- 23. 肩胛提肌 levator scapulae
- 24. 颈外动脉 external carotid a.
- 25. 迷走神经 vagus n.



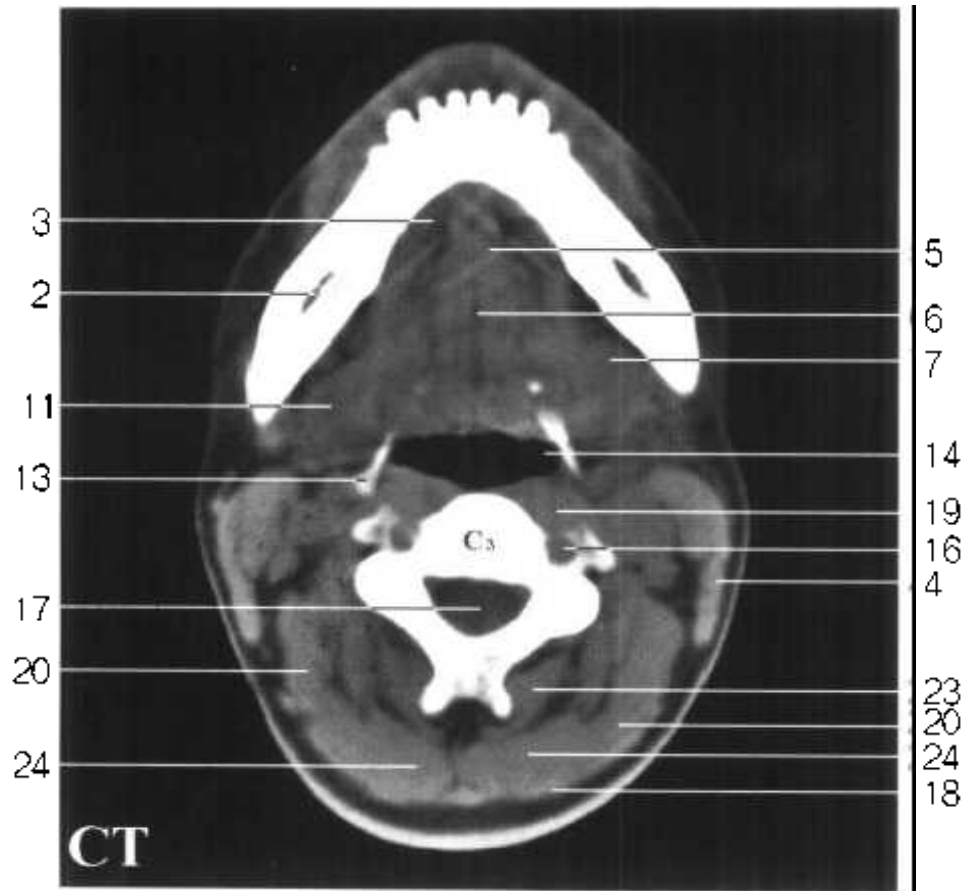
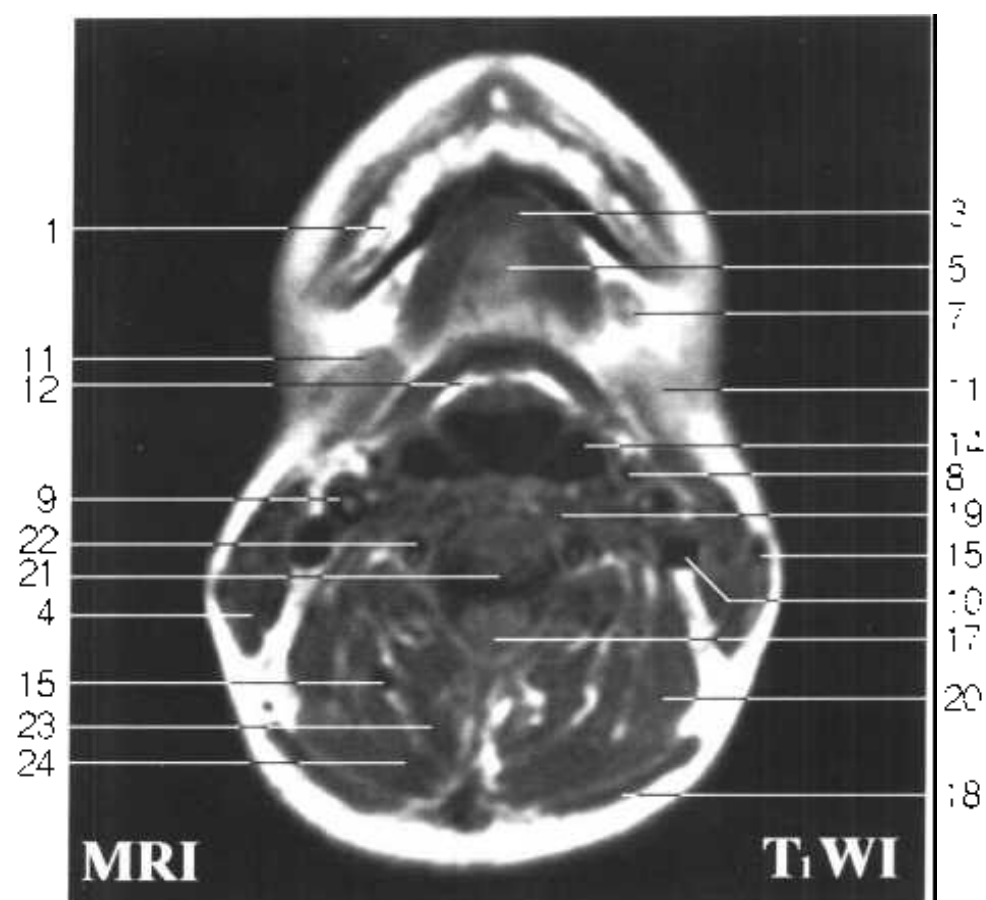


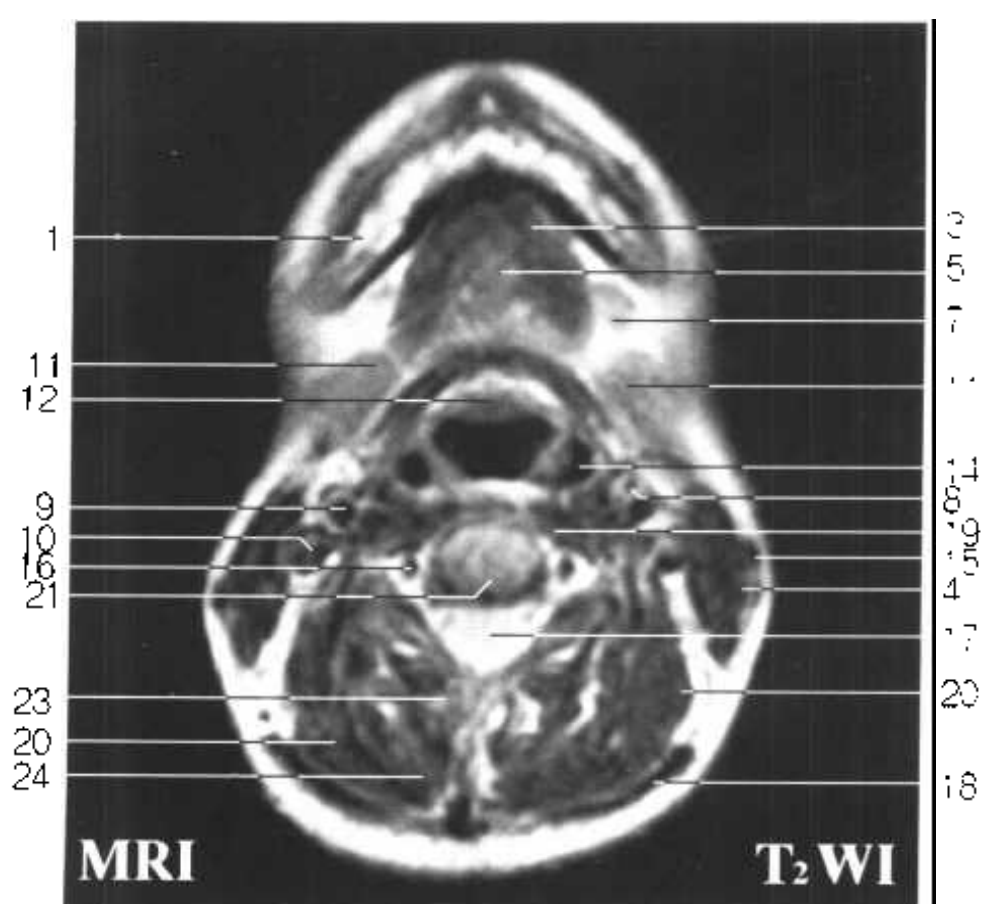
Fig. HC 18

1. 下颌骨 mandible
2. 下牙槽神经 inferior alveolar n.
3. 舌下腺 sublingual gland
4. 胸锁乳突肌 sternocleidomastoid
5. 颏舌肌 genioglossus
6. 舌中隔 septum of tongue
7. 下颌舌骨肌 mylohyoid
8. 颈外动脉 external carotid a.
9. 颈内动脉 internal carotid a.
10. 颈内静脉 internal jugular v.
11. 下颌下腺 submandibular gland
12. 会厌 epiglottis
13. 舌骨大角 greater horn of hyoid bone

Fig. HC 18



- 14. 咽腔 cavity of pharynx
- 15. 颈深动脉 deep cervical a.
- 16. 椎动脉 vertebral a.
- 17. 脊髓 spinal cord
- 18. 斜方肌 trapezius
- 19. 头长肌与颈长肌 longus capitis and longus colli
- 20. 头夹肌 splenius capitis
- 21. 3、4 颈椎间盘 intervertebral disc (C₃~C₄)
- 22. 椎静脉 vertebral v.
- 23. 颈半棘肌 semispinalis cervicis
- 24. 头半棘肌 semispinalis capitis



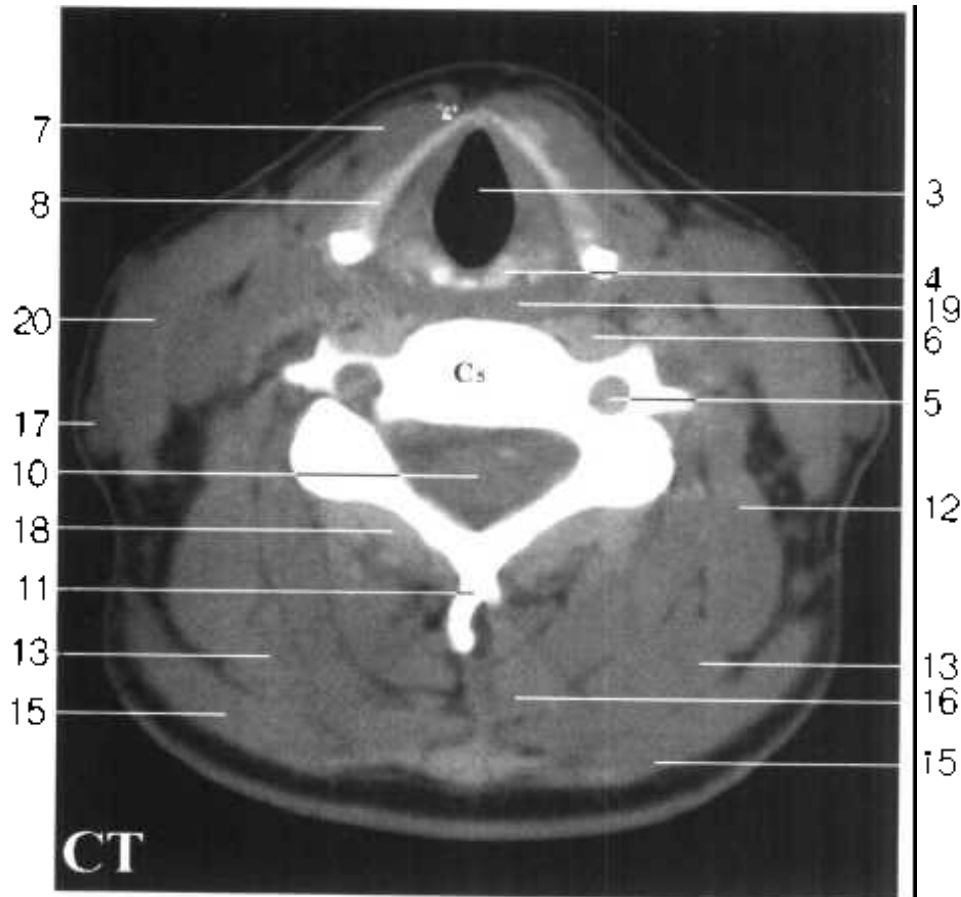


Fig. HC 19

1. 杓状软骨 arytenoid cartilage

2. 声襞 vocal fold

3. 喉腔 laryngeal cavity

4. 环状软骨 cricoid cartilage

5. 椎动脉 vertebral a.

6. 颈长肌 longus colli

7. 胸骨舌骨肌 sternohyoid

8. 甲状软骨右板 right lamina of thyroid cartilage

9. 中、后斜角肌 scalenus medius and posterior

10. 脊髓 spinal cord

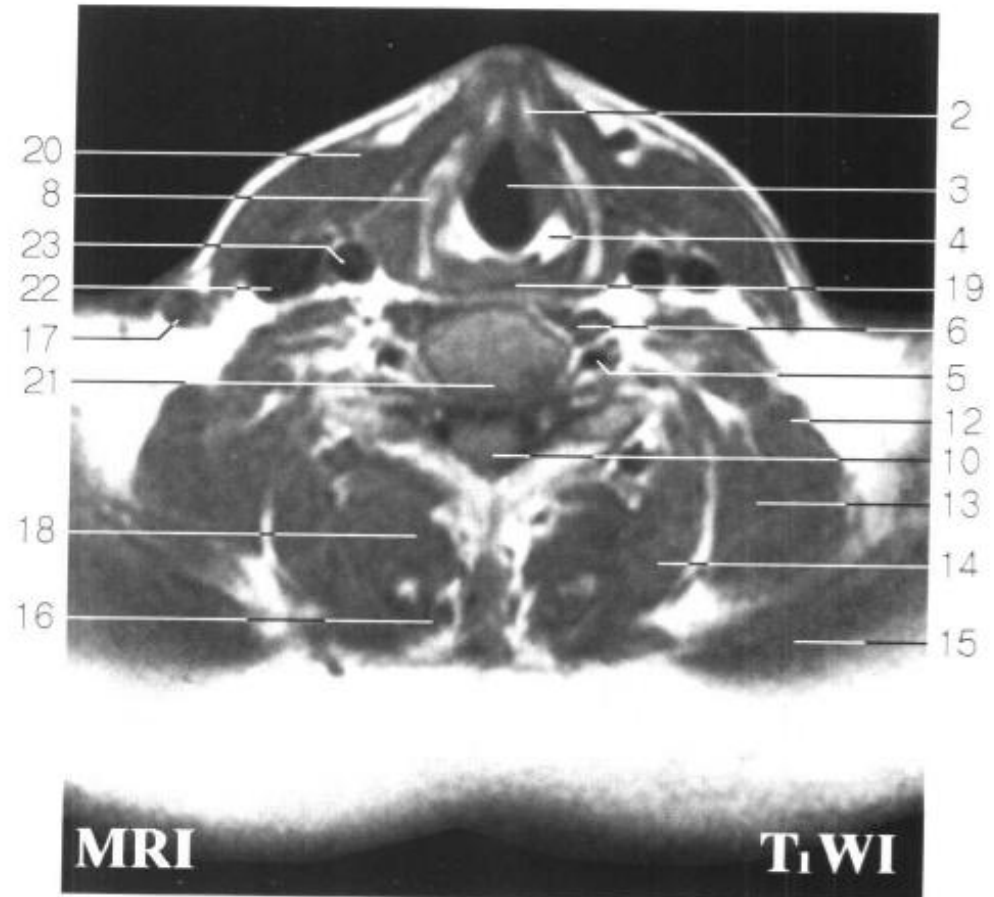
11. 第5颈椎棘突 spinous process(C5)

12. 肩胛提肌 levator scapulae

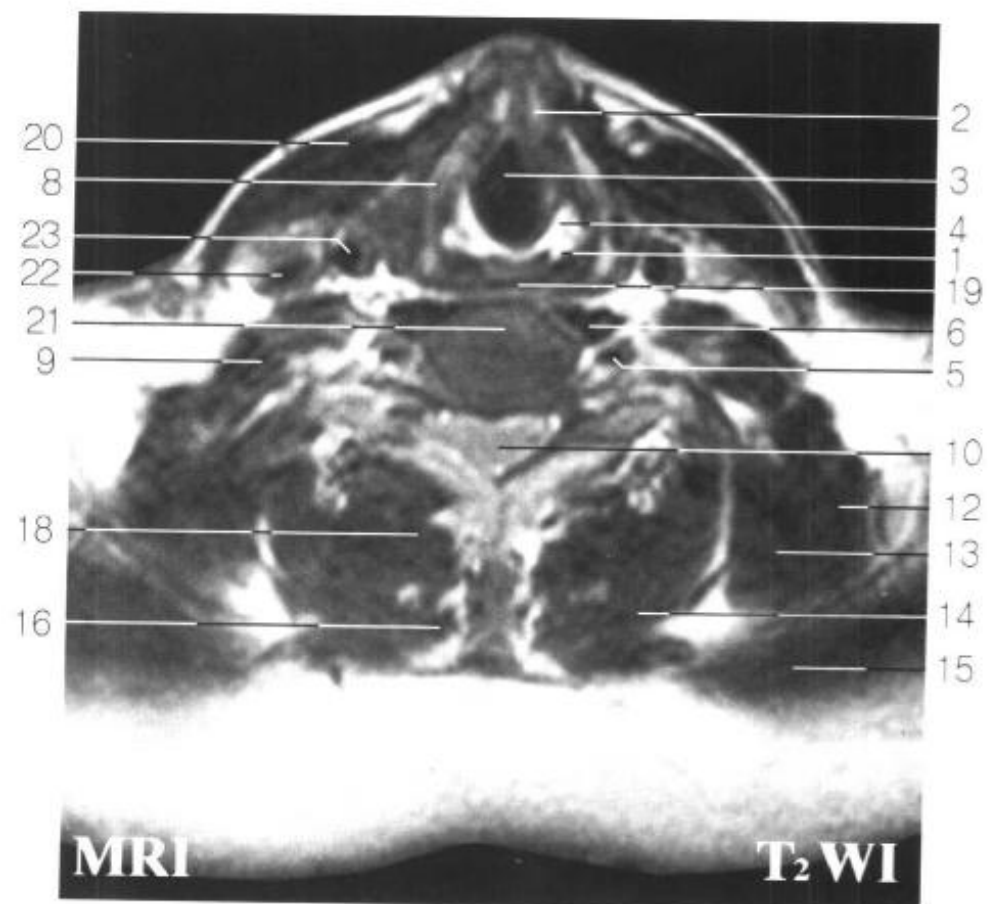
13. 夹肌 splenius

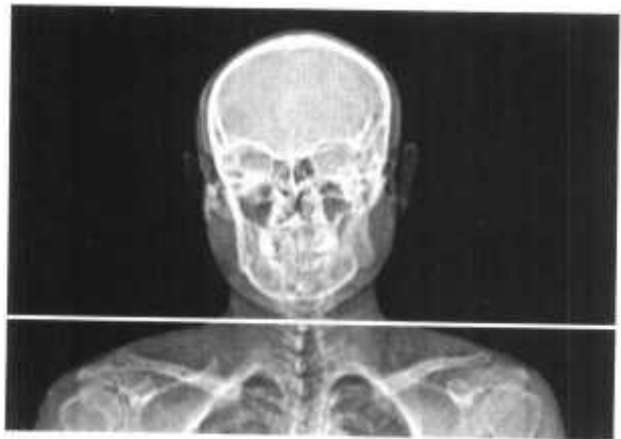

Fig. HC 19



- 14. 头半棘肌 semispinalis capitis
- 15. 斜方肌 trapezius
- 16. 颈半棘肌 semispinalis colli
- 17. 右颈外静脉 right external jugular v.
- 18. 多裂肌 multifidi
- 19. 咽喉 laryngopharynx
- 20. 胸锁乳突肌 sternocleidomastoid
- 21. 4、5 颈椎间盘 intervertebral disc (C₄~C₅)
- 22. 右颈内静脉 right internal jugular v.
- 23. 右颈总动脉 right common carotid a.



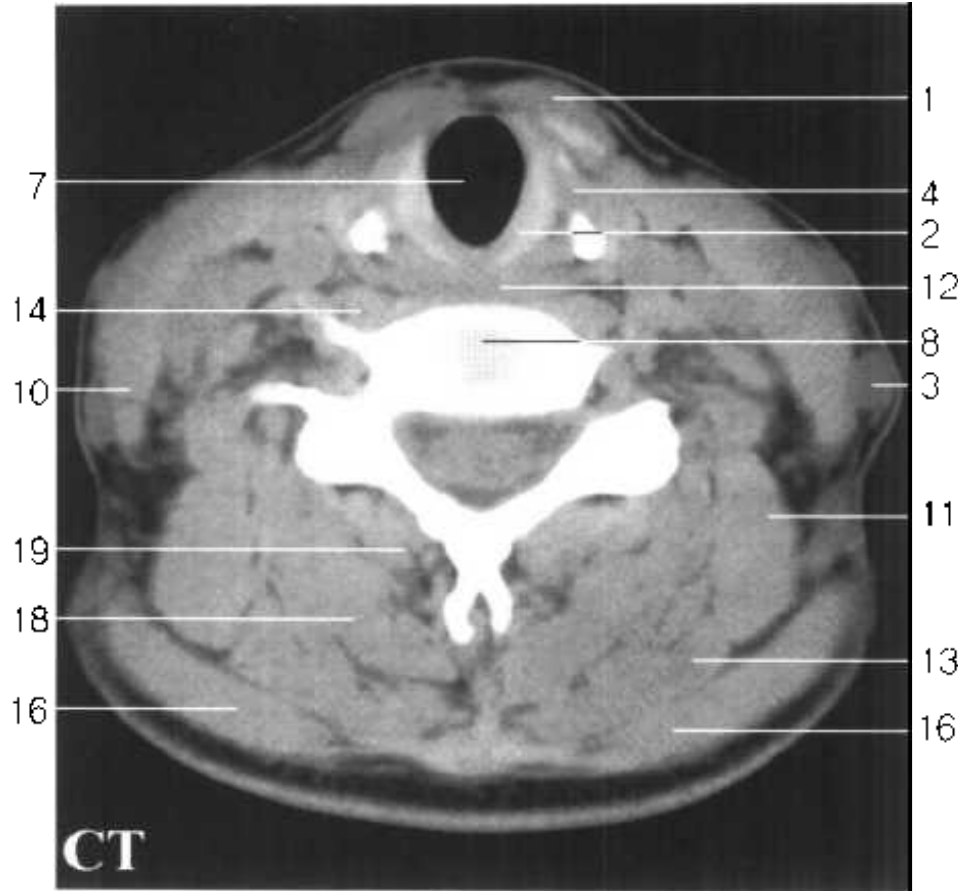
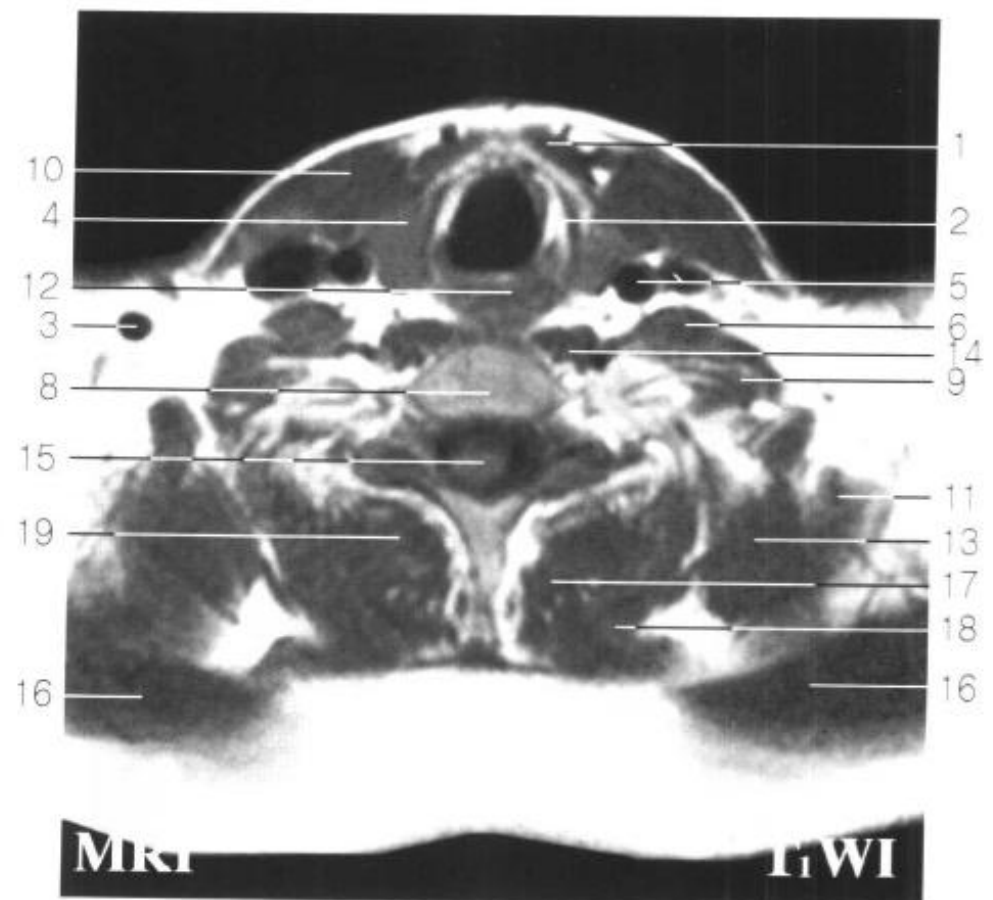


Fig. HC 20

1. 胸骨舌骨肌 sternohyoid
2. 环状软骨 cricoid cartilage
3. 颈外静脉 external jugular v.
4. 甲状腺 thyroid gland
5. 左颈总动脉与颈内静脉 left common carotid
a. and internal jugular v.
6. 前斜角肌 scalenus anterior
7. 声门下腔 infraglottic cavity
8. 5、6 颈椎间盘 intervertebral disc(C₅~C₆)
9. 中、后斜角肌 scalenus medius and posterior

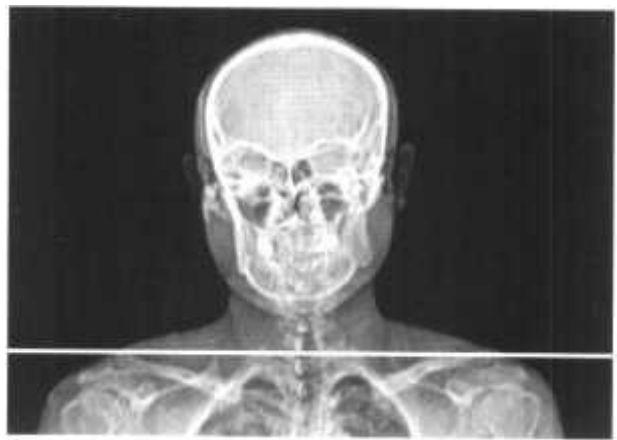

Fig. HC 20



10. 胸锁乳突肌 sternocleidomastoid

11. 肩胛提肌 levator scapulae

12. 喉咽 laryngopharynx

13. 夹肌 splenius

14. 颈长肌 longus colli

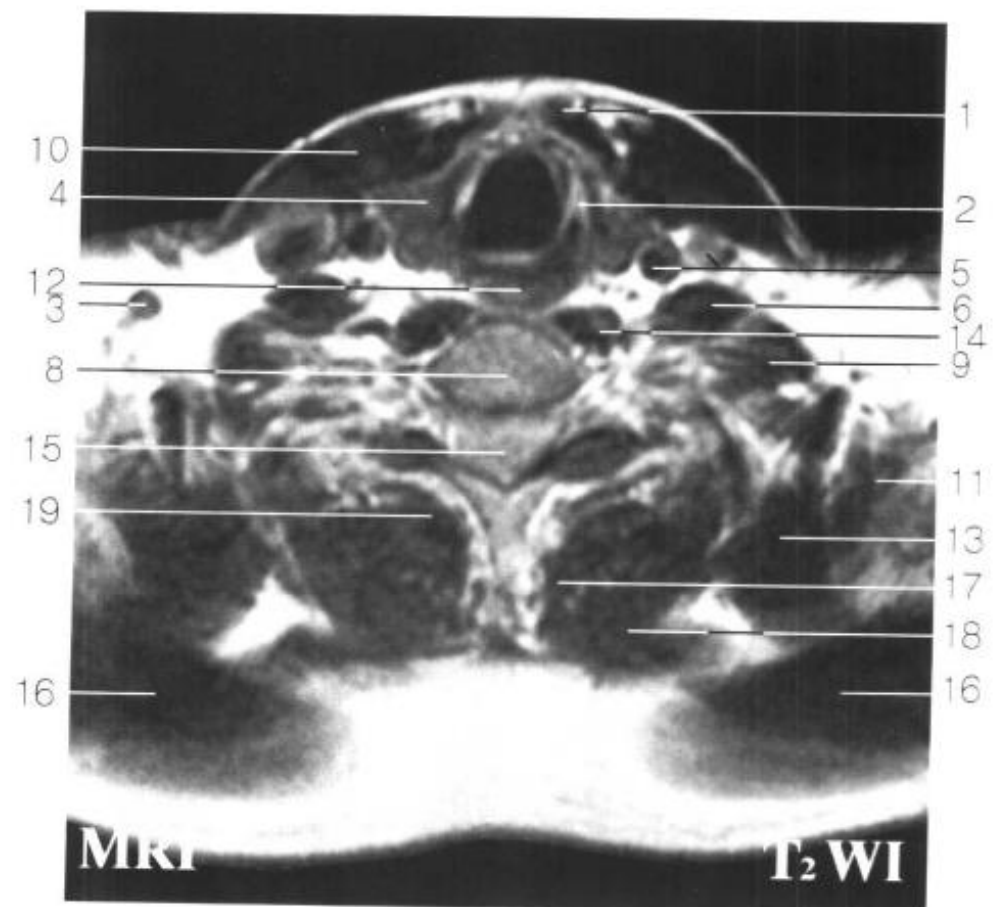
15. 脊髓 spinal cord

16. 斜方肌 trapezius

17. 颈半棘肌 semispinalis colli

18. 头半棘肌 semispinalis capitis

19. 多裂肌 multifidi



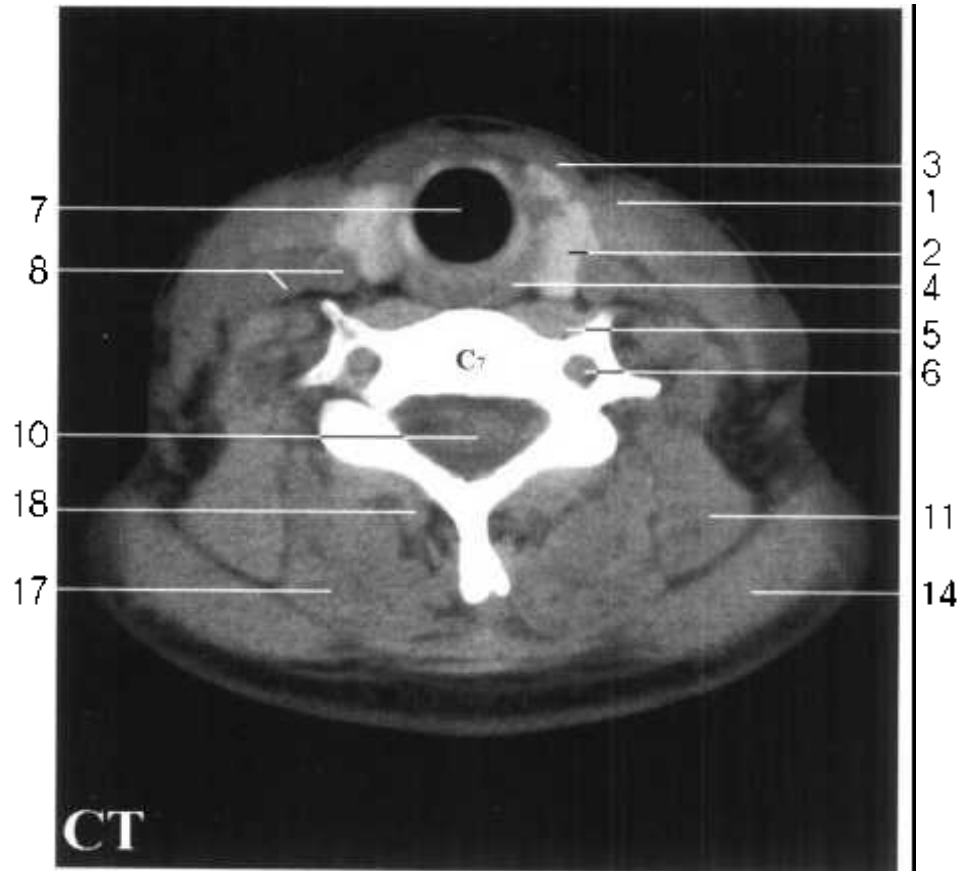
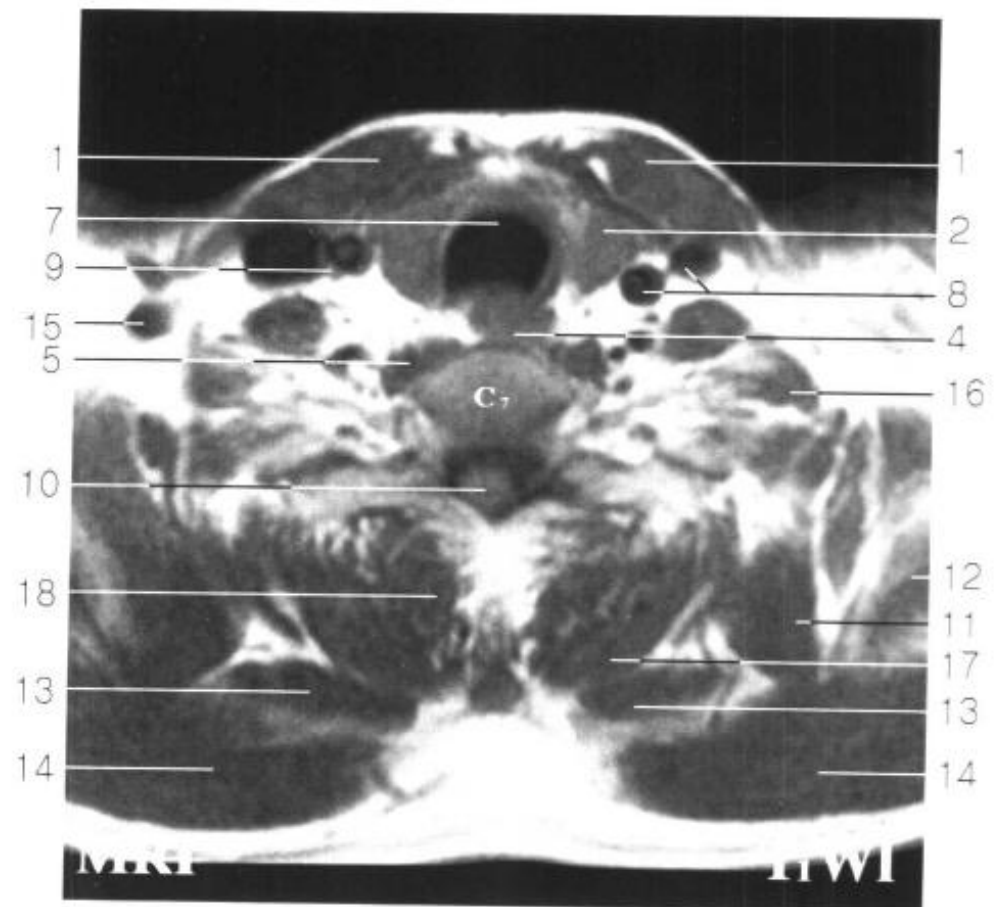


Fig. HC 21

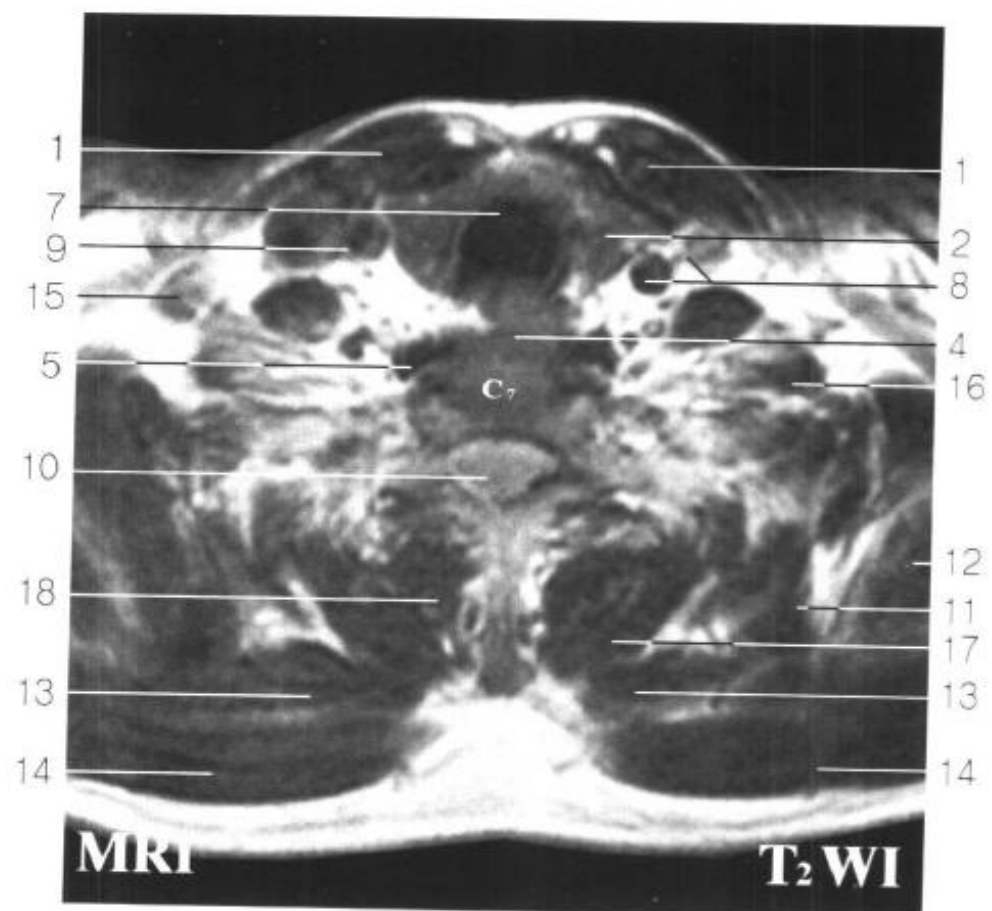
1. 胸锁乳突肌 sternocleidomastoid
2. 甲状腺 thyroid gland
3. 胸骨舌骨肌 sternohyoid
4. 食管 esophagus
5. 颈长肌 longus colli
6. 椎动脉 vertebral a.
7. 气管 trachea
8. 颈总动脉与颈内静脉 common carotid a. and internal jugular v.
9. 迷走神经 vagus n.
10. 脊髓 spinal cord
11. 肩胛提肌 levator scapulae
12. 冈上肌 supraspinatus

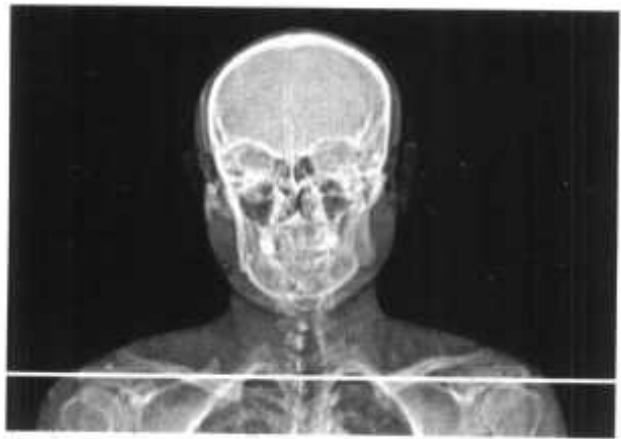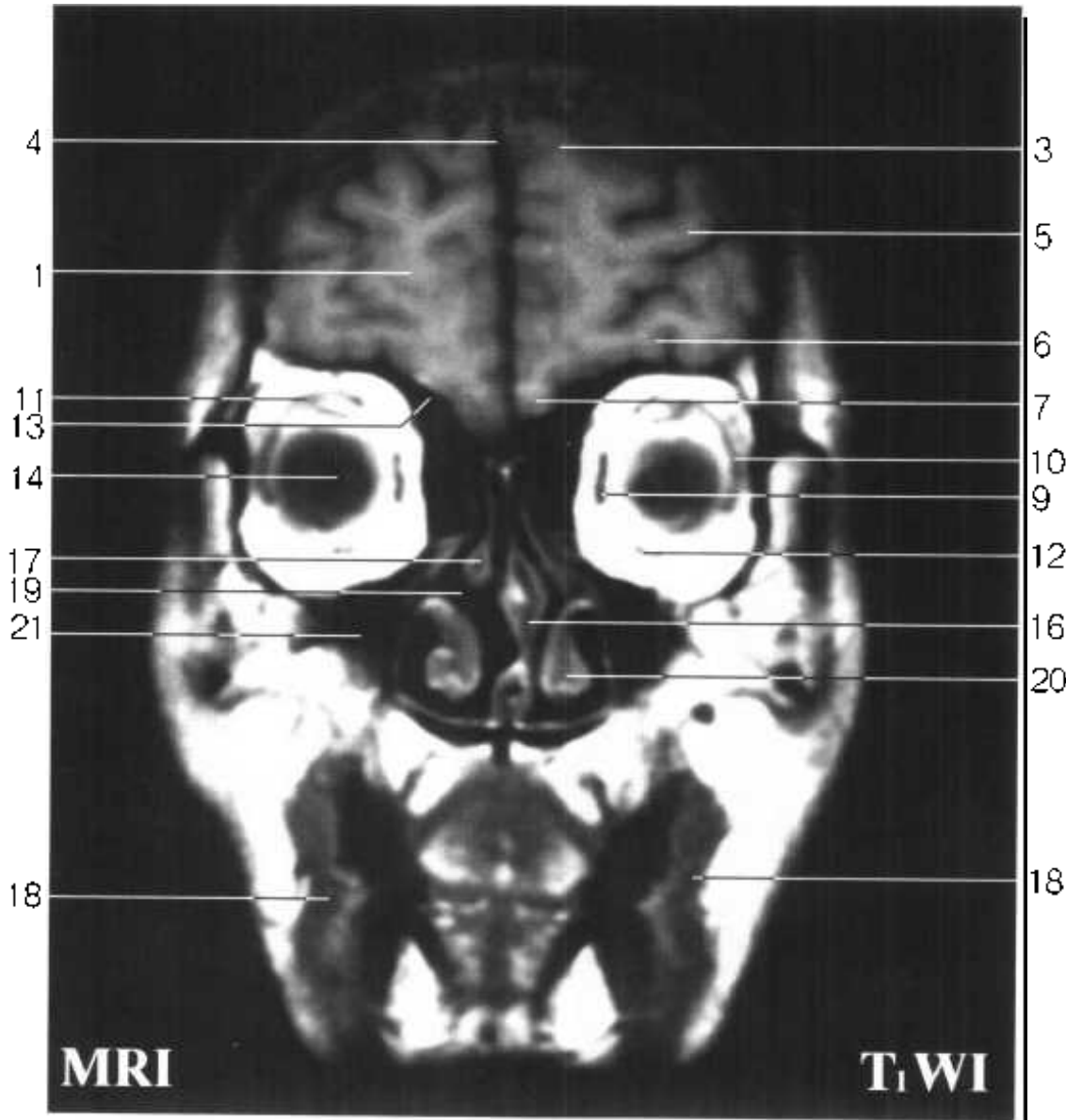


Fig. HC 21



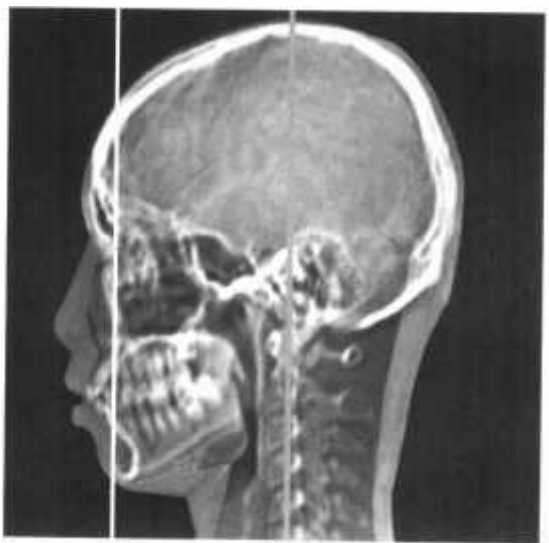
- 13. 小菱形肌 rhomboideus minor
- 14. 斜方肌 trapezius
- 15. 颈外静脉 external jugular v.
- 16. 中、后斜角肌 scalenus medius
- 17. 夹肌 splenius
- 18. 颈半棘肌 semispinalis cervicis





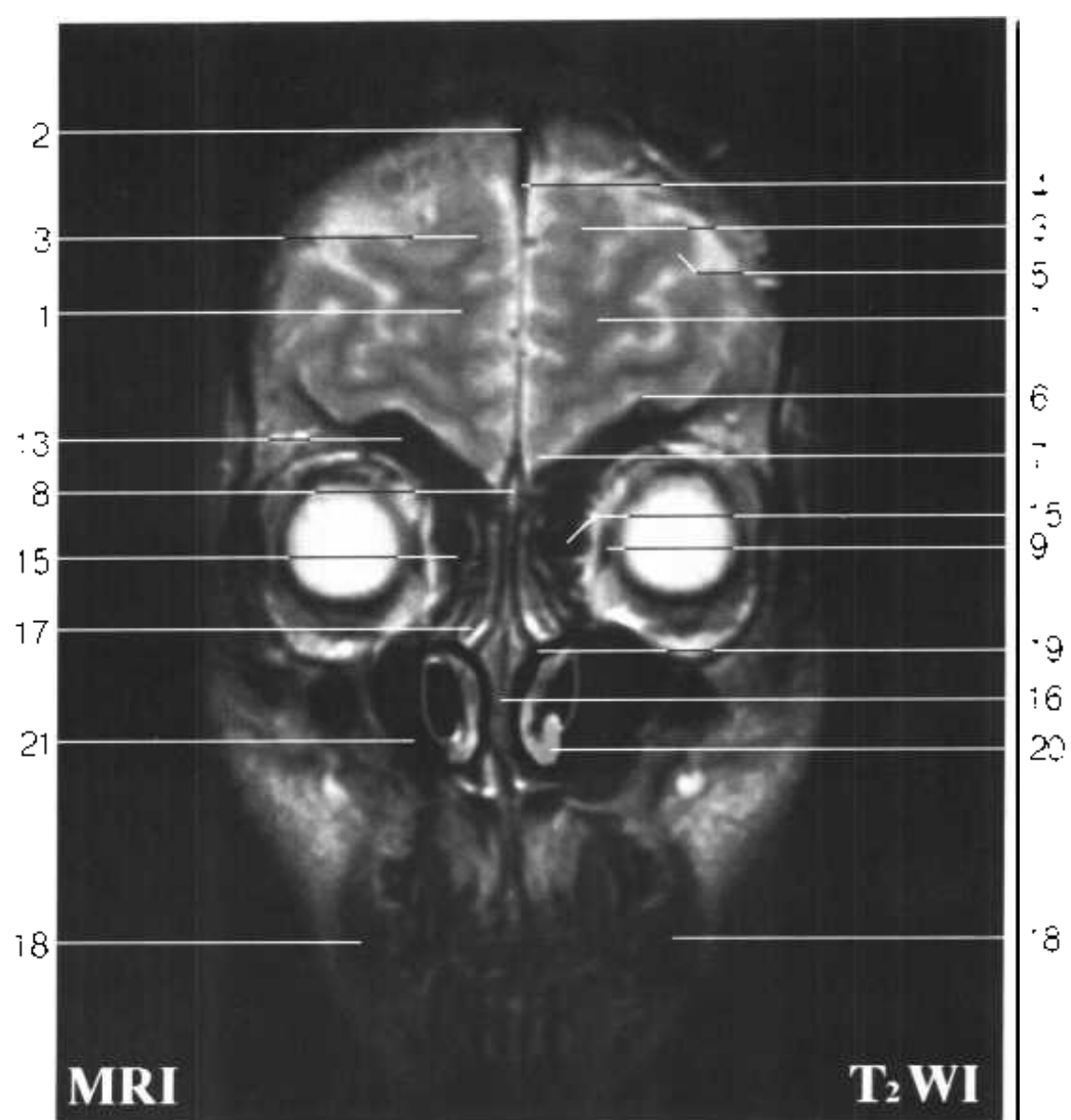
额状断面图 FC

Fig. FC 1



- 1. 辐射冠 corona radiata
- 2. 上矢状窦 superior sagittal sinus
- 3. 额上回 superior frontal gyrus
- 4. 大脑镰 cerebral falx
- 5. 额中回 middle frontal gyrus
- 6. 眶回 orbital gyrus
- 7. 直回 gyrus rectus
- 8. 鸡冠 crista galli
- 9. 内直肌 medial rectus
- 10. 外直肌 lateral rectus

Fig. FC 1



- 11. 上睑提肌及上直肌 levator palpebrae superioris and superior rectus
- 12. 下直肌 inferior rectus
- 13. 额窦 frontal sinus
- 14. 眼球 eyeball
- 15. 筛窦 ethmoidal sinuses
- 16. 鼻中隔 nasal septum
- 17. 中鼻甲 middle nasal concha
- 18. 颊肌 buccinator
- 19. 中鼻道 middle nasal meatus
- 20. 下鼻甲 inferior nasal concha
- 21. 上颌窦 maxillary sinus

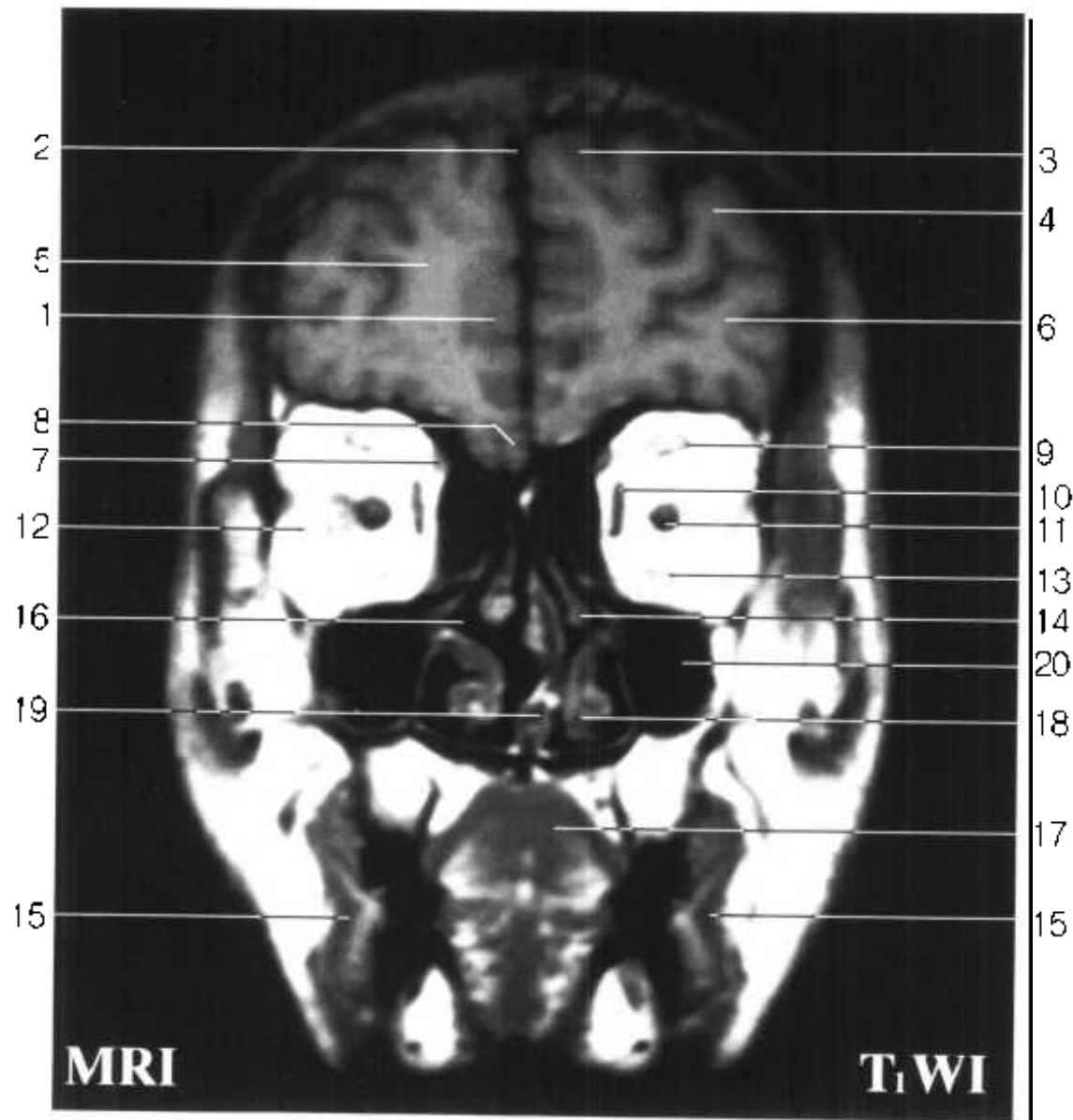
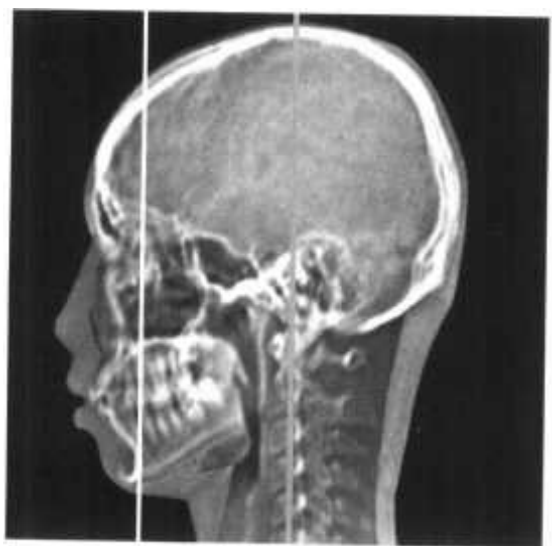
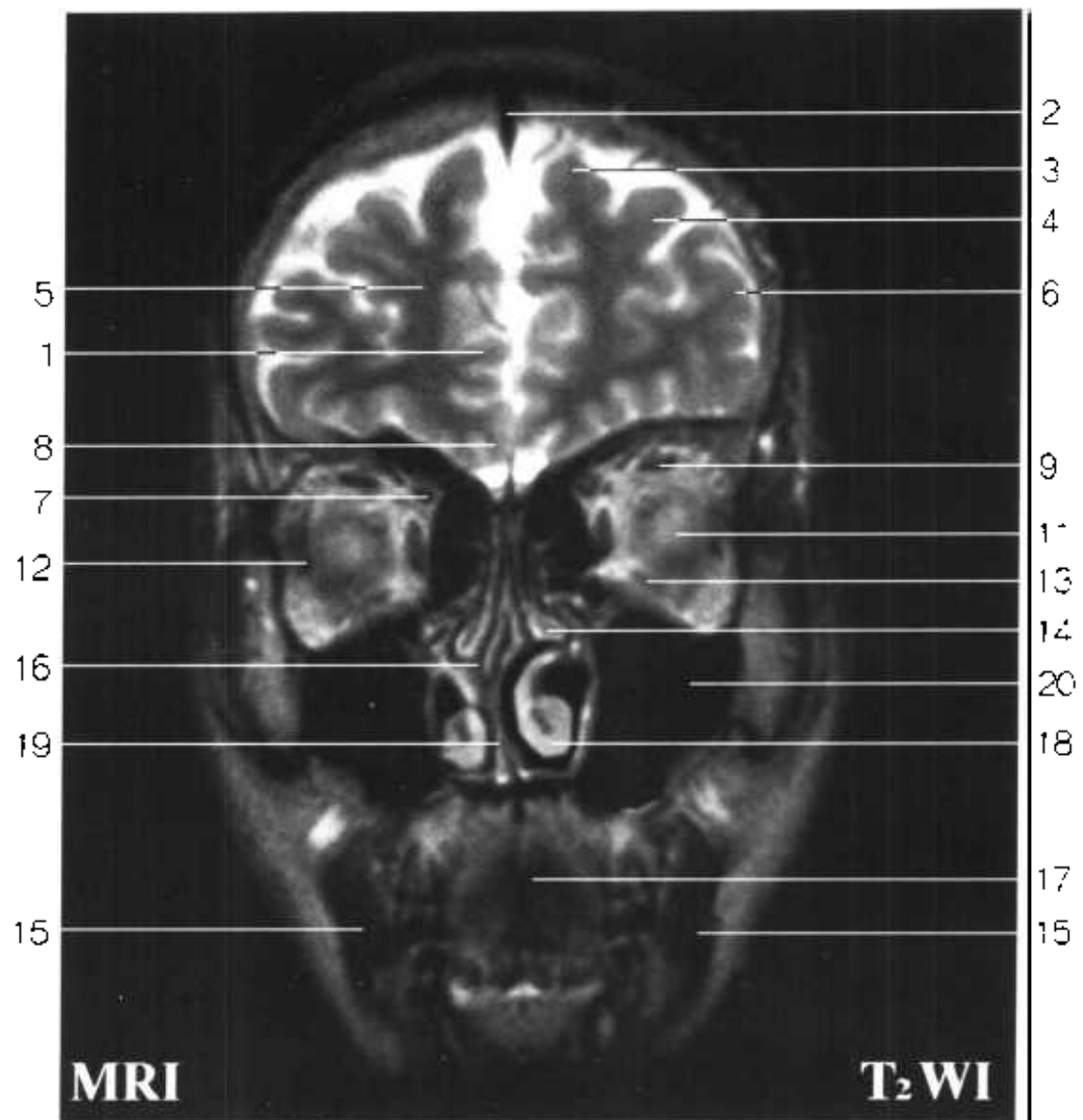


Fig. FC 2



- 1. 扣带回 cingulate gyrus
- 2. 上矢状窦 superior sagittal sinus
- 3. 额上回 superior frontal gyrus
- 4. 额中回 middle frontal gyrus
- 5. 辐射冠 corona radiata
- 6. 额下回 inferior frontal gyrus
- 7. 上斜肌 superior obliquus
- 8. 直回 gyrus rectus
- 9. 上睑提肌及上直肌 levator palpebrae superioris and superior rectus

Fig. FC 2



- 10. 内直肌 medial rectus
- 11. 视神经 optic n.
- 12. 外直肌 lateral rectus
- 13. 下直肌 inferior rectus
- 14. 中鼻甲 middle nasal concha
- 15. 颊肌 buccinator
- 16. 中鼻道 middle nasal meatus
- 17. 舌 tongue
- 18. 下鼻甲 inferior nasal concha
- 19. 鼻中隔 nasal septum
- 20. 上颌窦 maxillary sinus

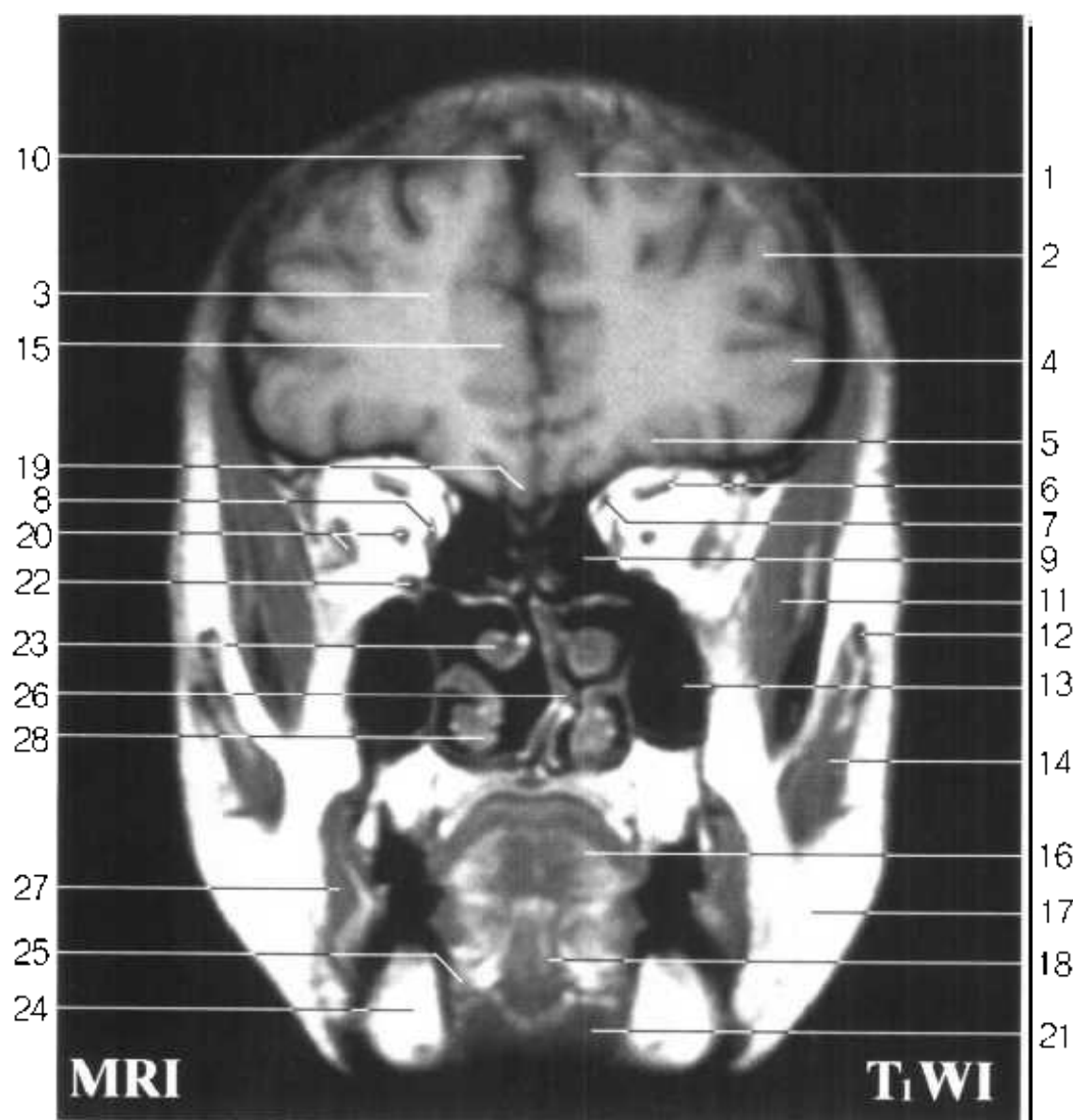
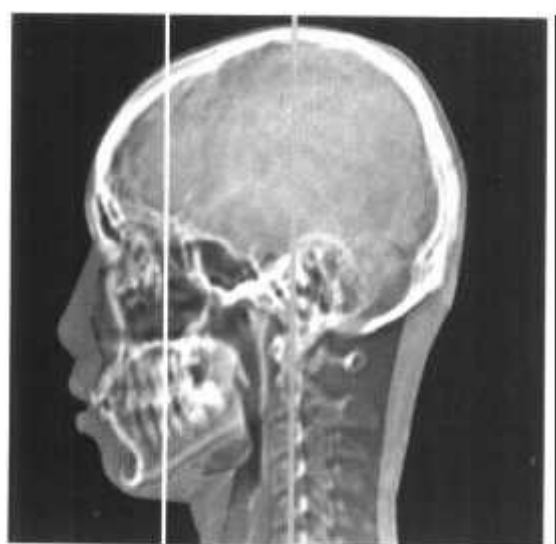
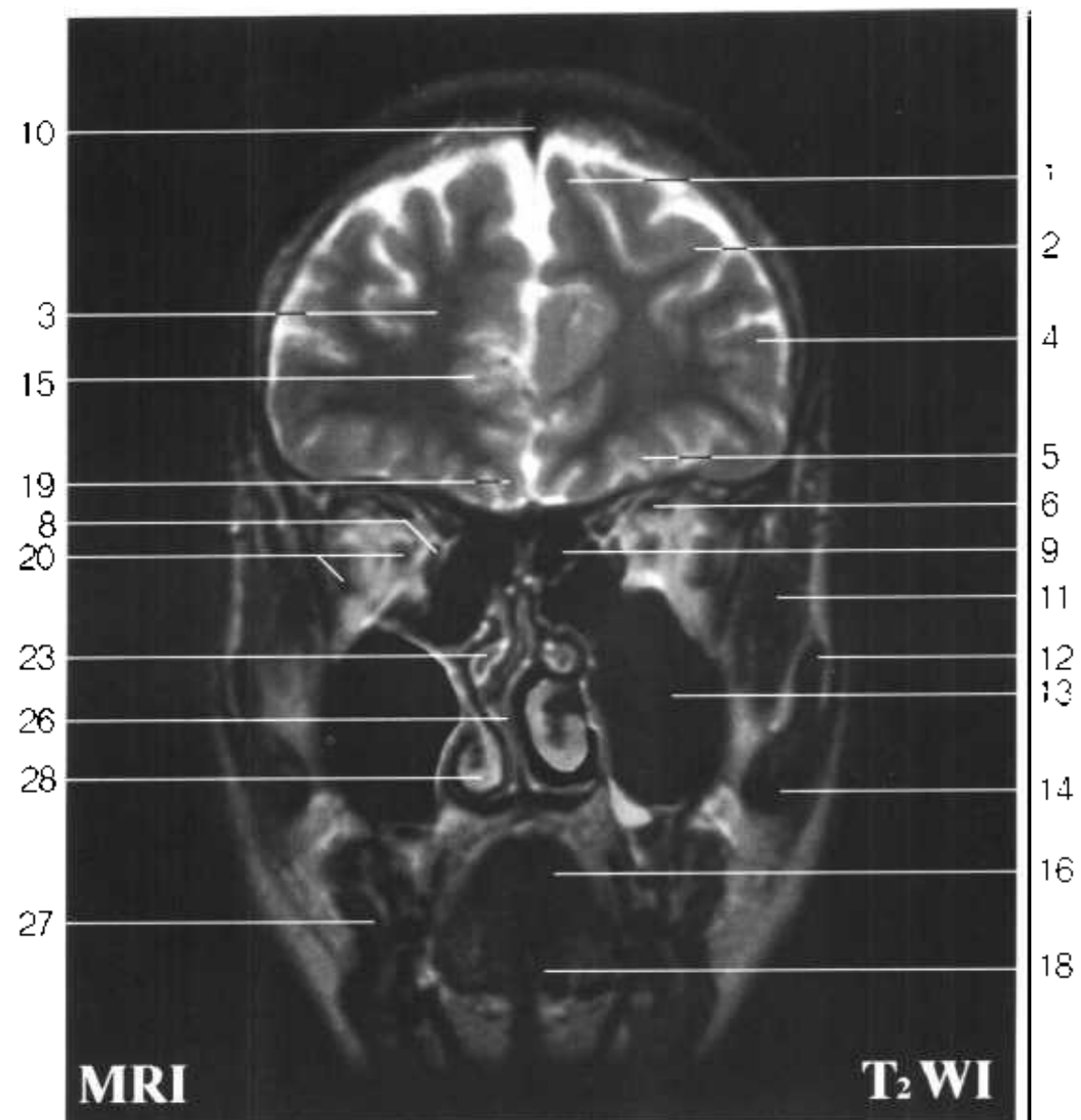


Fig. FC 3



1. 额上回 superior frontal gyrus
2. 额中回 middle frontal gyrus
3. 辐射冠 corona radiata
4. 额下回 inferior frontal gyrus
5. 眶回 orbital gyrus
6. 上睑提肌及上直肌 levator palpebrae superioris and superior rectus
7. 上斜肌 superior obliquus
8. 内直肌 medial rectus
9. 筛窦 ethmoidal sinuses
10. 上矢状窦 superior sagittal sinus
11. 颞肌 temporalis

Fig. FC 3



- 12. 颧弓 zygomatic arch
- 13. 上颌窦 maxillary sinus
- 14. 咬肌 masseter
- 15. 扣带回 cingulate gyrus
- 16. 舌 tongue
- 17. 颊脂体 buccal fat pad
- 18. 颏舌肌 genioglossus
- 19. 直回 gyrus rectus
- 20. 视神经与外直肌 optic n.and lateral rectus
- 21. 颏舌骨肌 geniohyoid
- 22. 下直肌 inferior rectus

- 23. 中鼻甲 middle nasal concha
- 24. 下颌骨 mandible
- 25. 舌下腺 sublingual gland
- 26. 鼻中隔 nasal septum
- 27. 颊肌 buccinator
- 28. 下鼻甲 inferior nasal concha

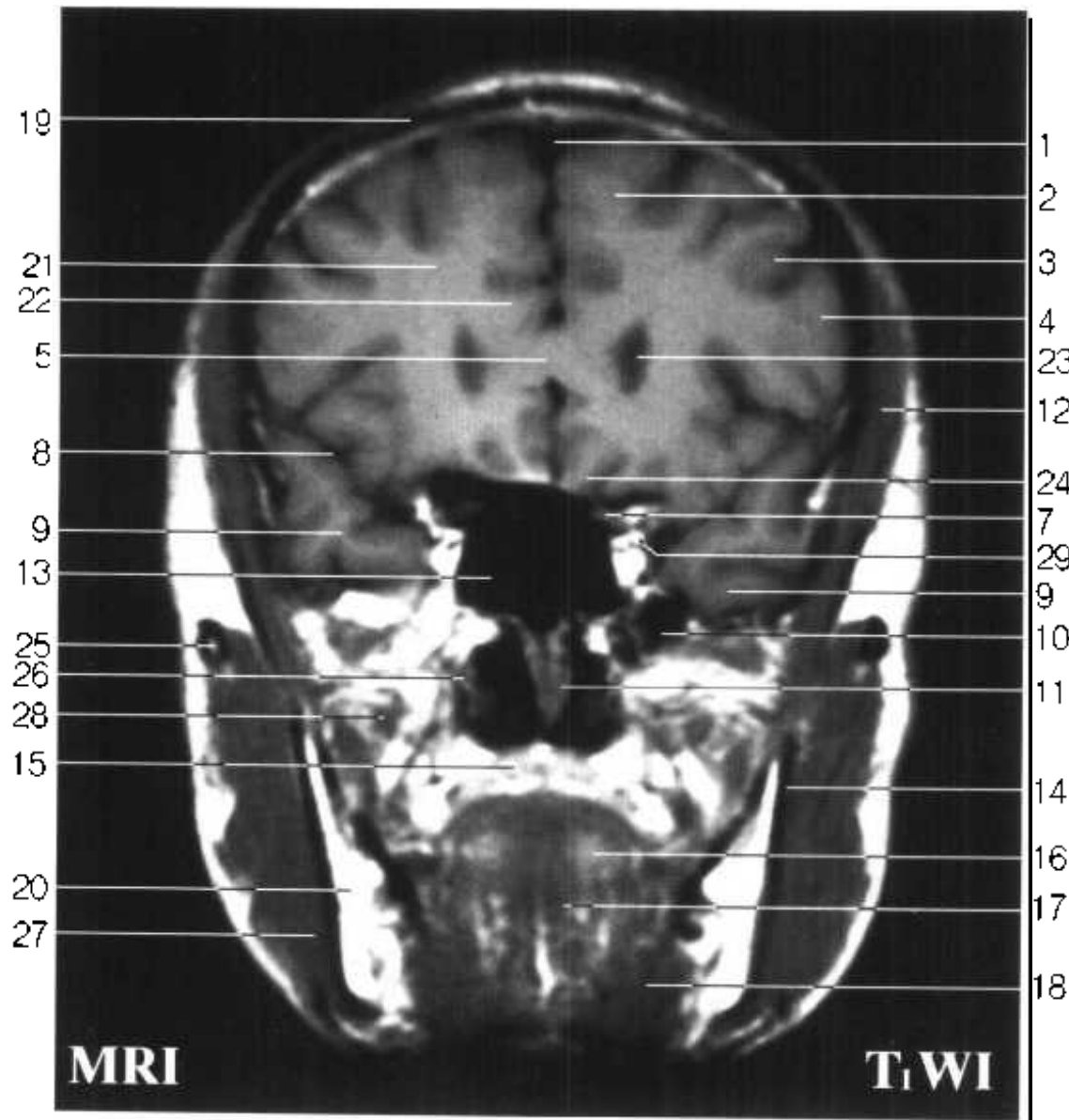
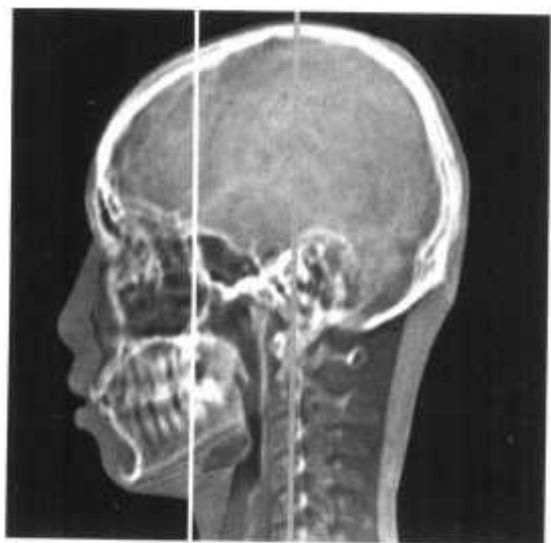
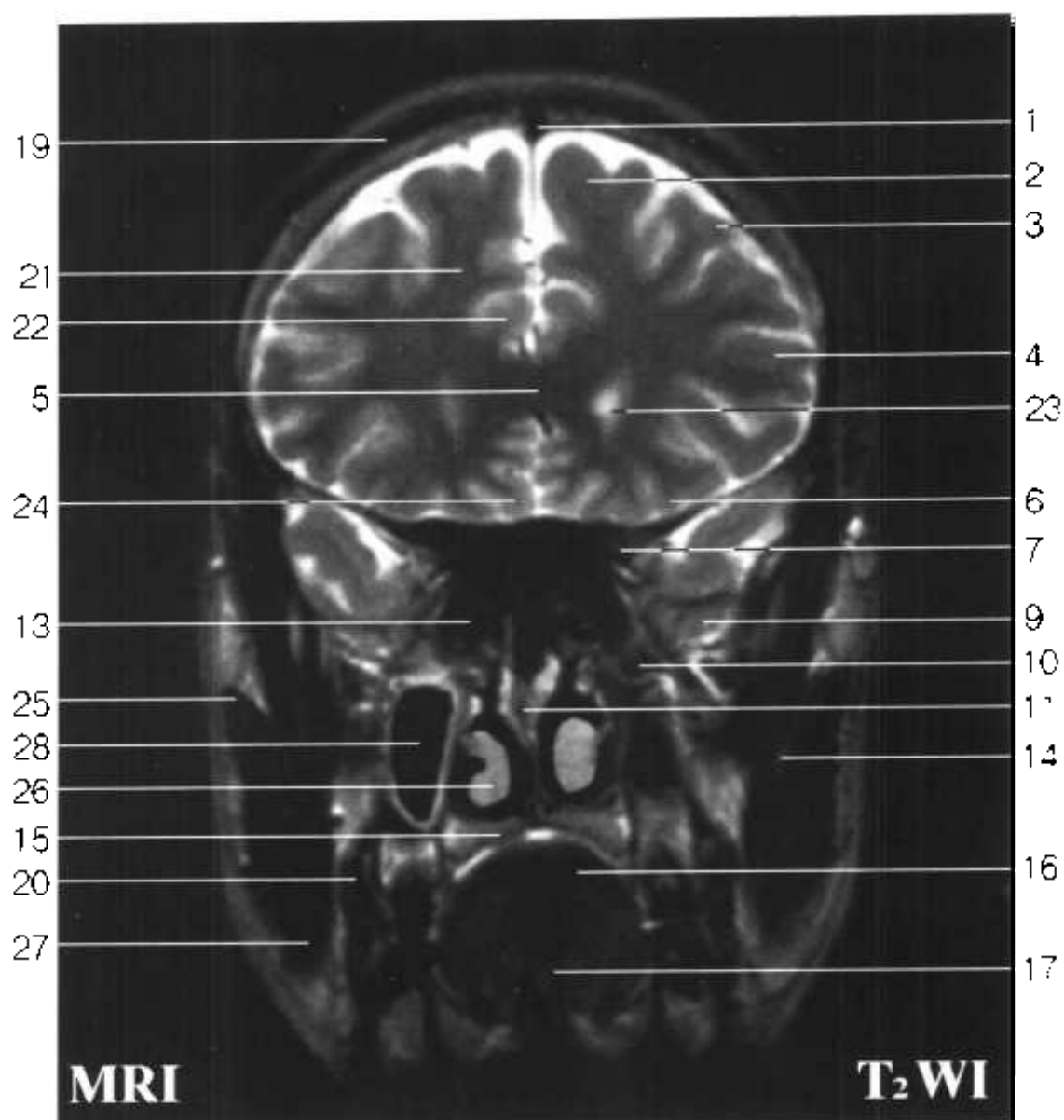


Fig. FC 4



1. 上矢状窦 superior sagittal sinus
2. 额上回 superior frontal gyrus
3. 额中回 middle frontal gyrus
4. 额下回 inferior frontal gyrus
5. 胼胝体膝 genu of corpus callosum
6. 眶回 orbital gyrus
7. 视神经 optic n.
8. 外侧沟 lateral sulcus
9. 颞极 temporal pole
10. 筛窦 ethmoidal sinuses
11. 鼻中隔 nasal septum
12. 颞肌 temporalis

Fig. FC 4



- | | |
|--|--|
| 13. 蝶窦 sphenoidal sinus | 22. 扣带回 cingulate gyrus |
| 14. 下颌骨冠突 coronoid process of mandible | 23. 侧脑室前角 anterior horn of lateral ventricle |
| 15. 硬腭及腭腺 hard palate and palatine glands | 24. 直回 gyrus rectus |
| 16. 舌 tongue | 25. 颧弓 zygomatic arch |
| 17. 颏舌肌 genioglossus | 26. 下鼻甲 inferior nasal concha |
| 18. 舌下腺 sublingual gland | 27. 咬肌 masseter |
| 19. 额骨 frontal bone | 28. 上颌窦 maxillary sinus |
| 20. 下颌骨 mandible | 29. 眼动、静脉 ophthalmic a.and v. |
| 21. 辐射冠(圆中心) corona radiata (centrum semivale) | |

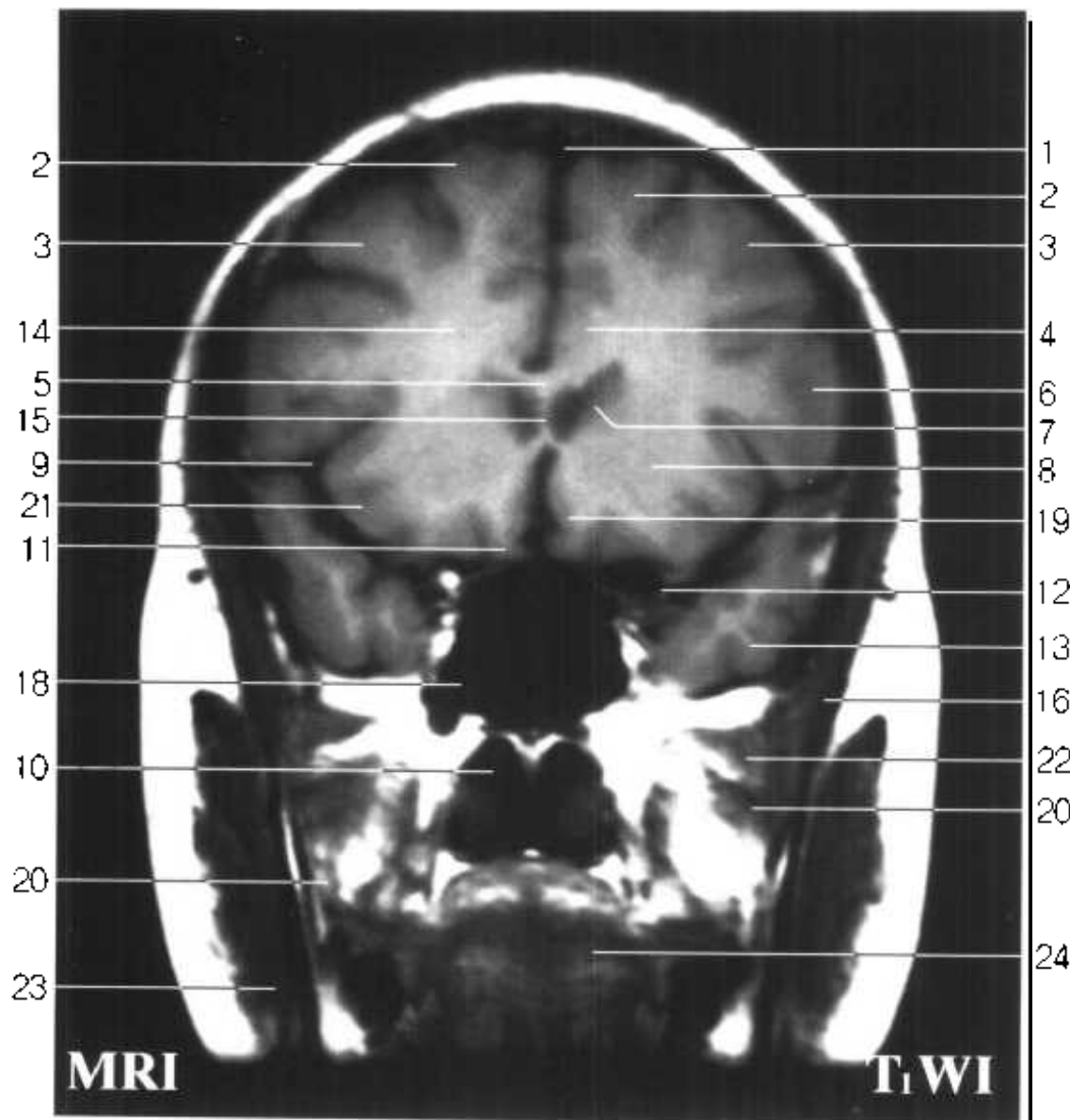
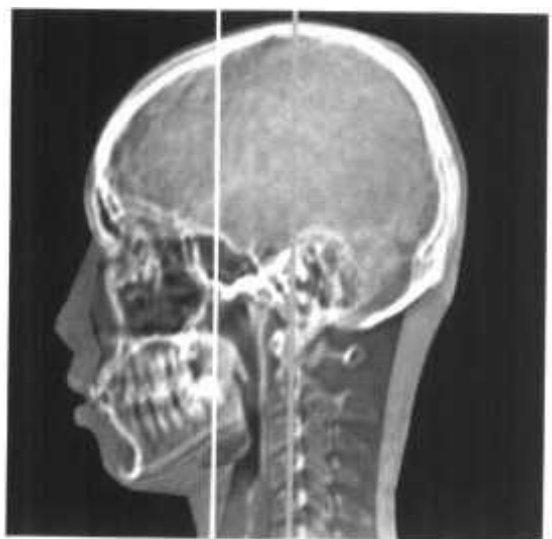
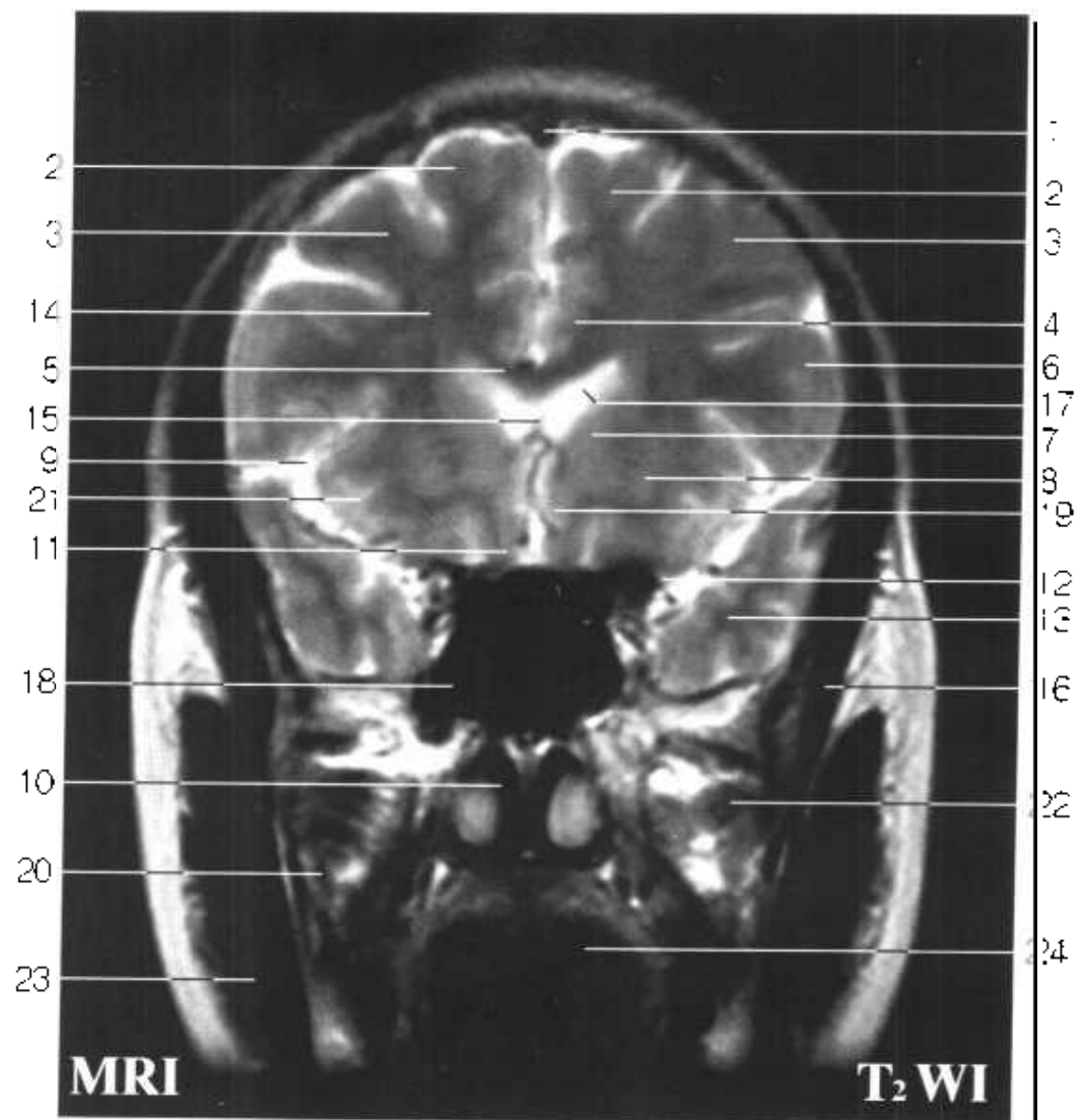


Fig. FC 5



1. 上矢状窦 superior sagittal sinus
2. 额上回 superior frontal gyrus
3. 额中回 middle frontal gyrus
4. 扣带回 cingulate gyrus
5. 胼胝体 corpus callosum
6. 额下回 inferior frontal gyrus
7. 尾状核头 head of caudate nucleus
8. 壳 putamen
9. 大脑外侧窝池 cistern of lateral fossa of cerebrum
10. 鼻腔 nasal cavity
11. 直回 gyrus rectus
12. 动眼神经 oculomotor n.
13. 颞叶 temporal lobe

Fig. FC 5



- 14. 辐射冠(半卵圆中心) corona radiata
(centrum semiovale)
- 15. 透明隔 septum pellucidum
- 16. 颞肌 temporalis
- 17. 侧脑室前角 anterior horn of lateral
ventricle
- 18. 蝶窦 sphenoidal sinus
- 19. 终板旁回 paraterminal gyrus
- 20. 翼内肌 medial pterygoid
- 21. 岛叶 insular lobe
- 22. 翼外肌 lateral pterygoid
- 23. 咬肌 masseter
- 24. 舌内肌 intrinsic muscles of tongue

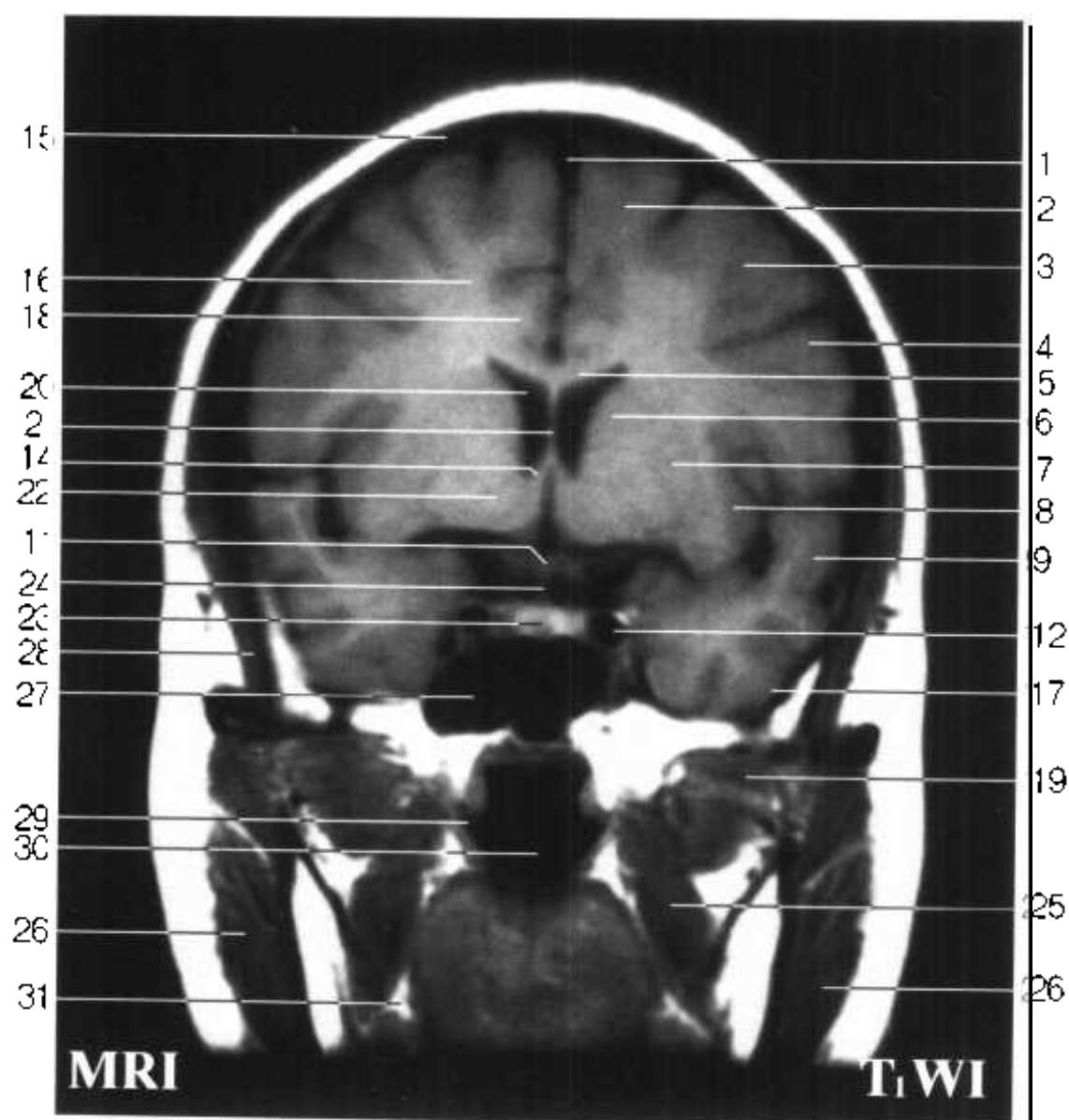
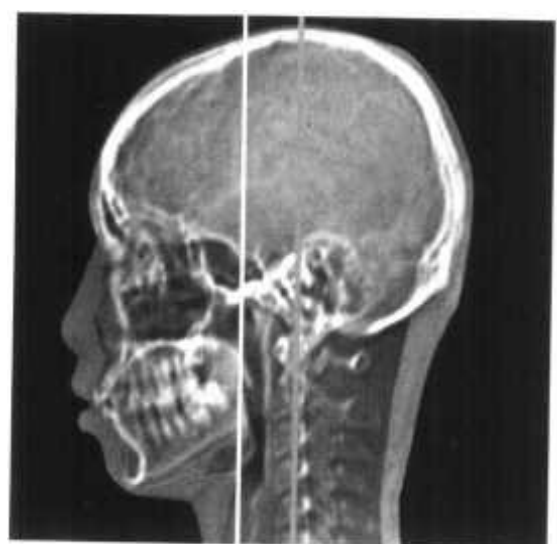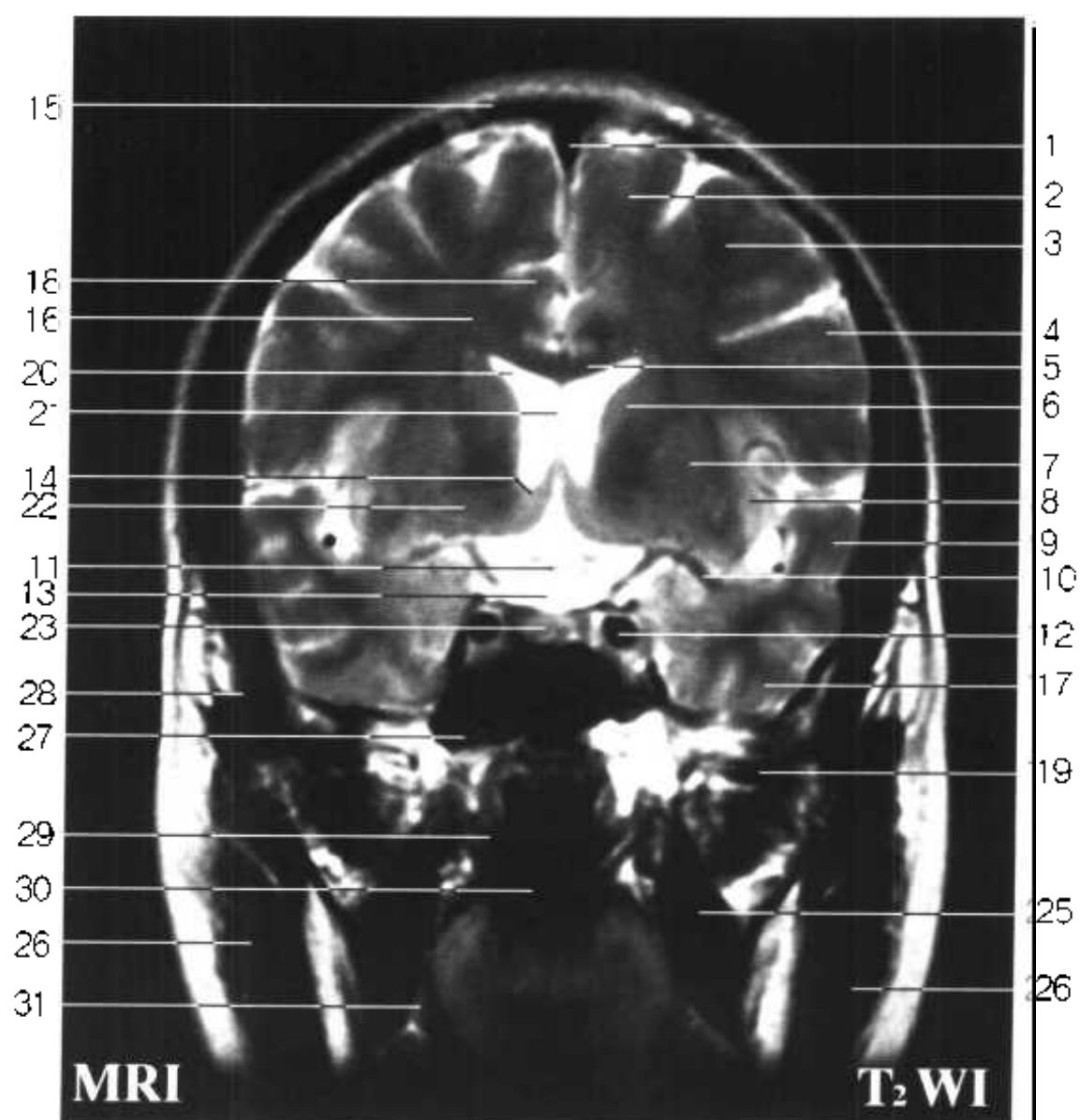


Fig. FC 6



1. 上矢状窦 superior sagittal sinus
2. 额上回 superior frontal gyrus
3. 额中回 middle frontal gyrus
4. 中央前回 precentral gyrus
5. 胼胝体 corpus callosum
6. 尾状核头 head of caudate nucleus
7. 壳 putamen
8. 岛叶 insular lobe
9. 颞上回 superior temporal gyrus
10. 大脑中动脉 middle cerebral a.
11. 视交叉 optic chiasma
12. 颈内动脉 internal carotid a.

Fig. FC 6



- 13. 鞍上池 suprasellar cistern
- 14. 隔核 nuclei septi
- 15. 额骨 frontal bone
- 16. 辐射冠 corona radiata
- 17. 颞下回 inferior temporal gyrus
- 18. 扣带回 cingulate gyrus
- 19. 翼外肌 lateral pterygoid
- 20. 侧脑室中央部 central part of lateral ventricle
- 21. 透明隔 septum pellucidum
- 22. 伏隔核 nucleus accumbens septi
- 23. 垂体 hypophysis

- 24. 漏斗 infundibulum
- 25. 翼内肌 medial pterygoid
- 26. 咬肌 masseter
- 27. 蝶窦 sphenoidal sinus
- 28. 颞肌 temporalis
- 29. 咽鼓管咽口 pharyngeal opening of auditory tube
- 30. 咽腔 cavity of pharynx
- 31. 舌神经 lingual n.

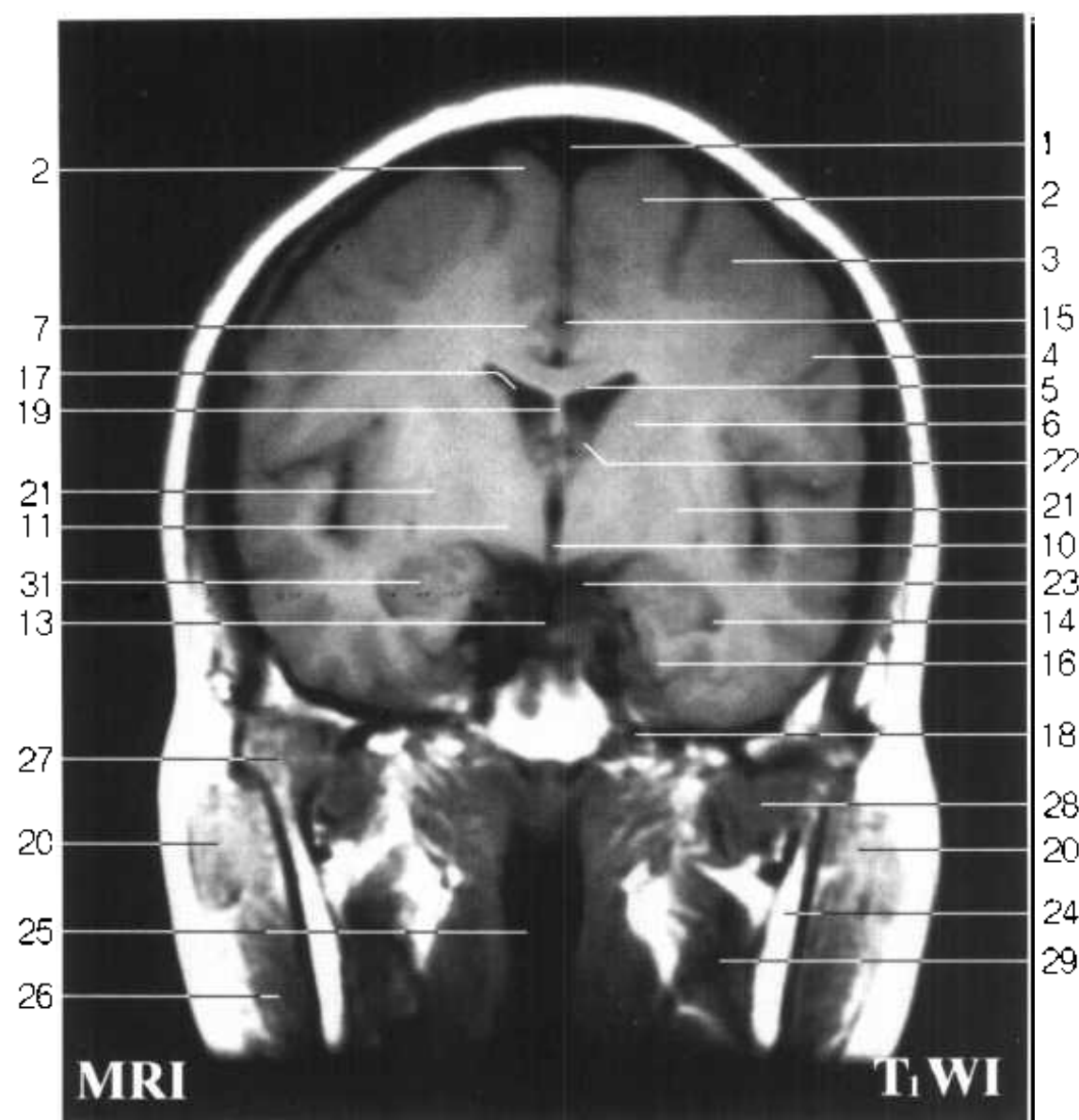
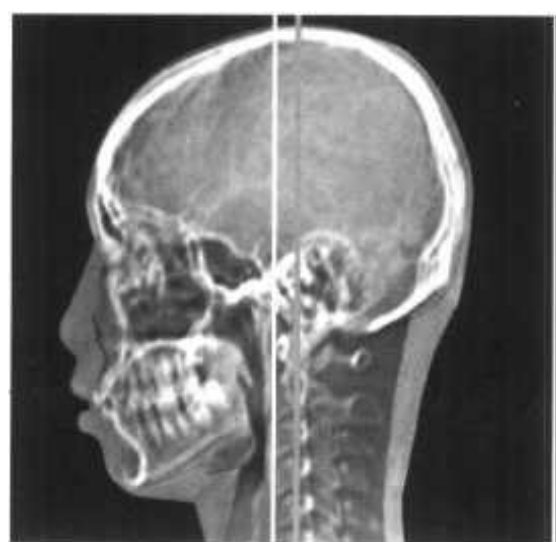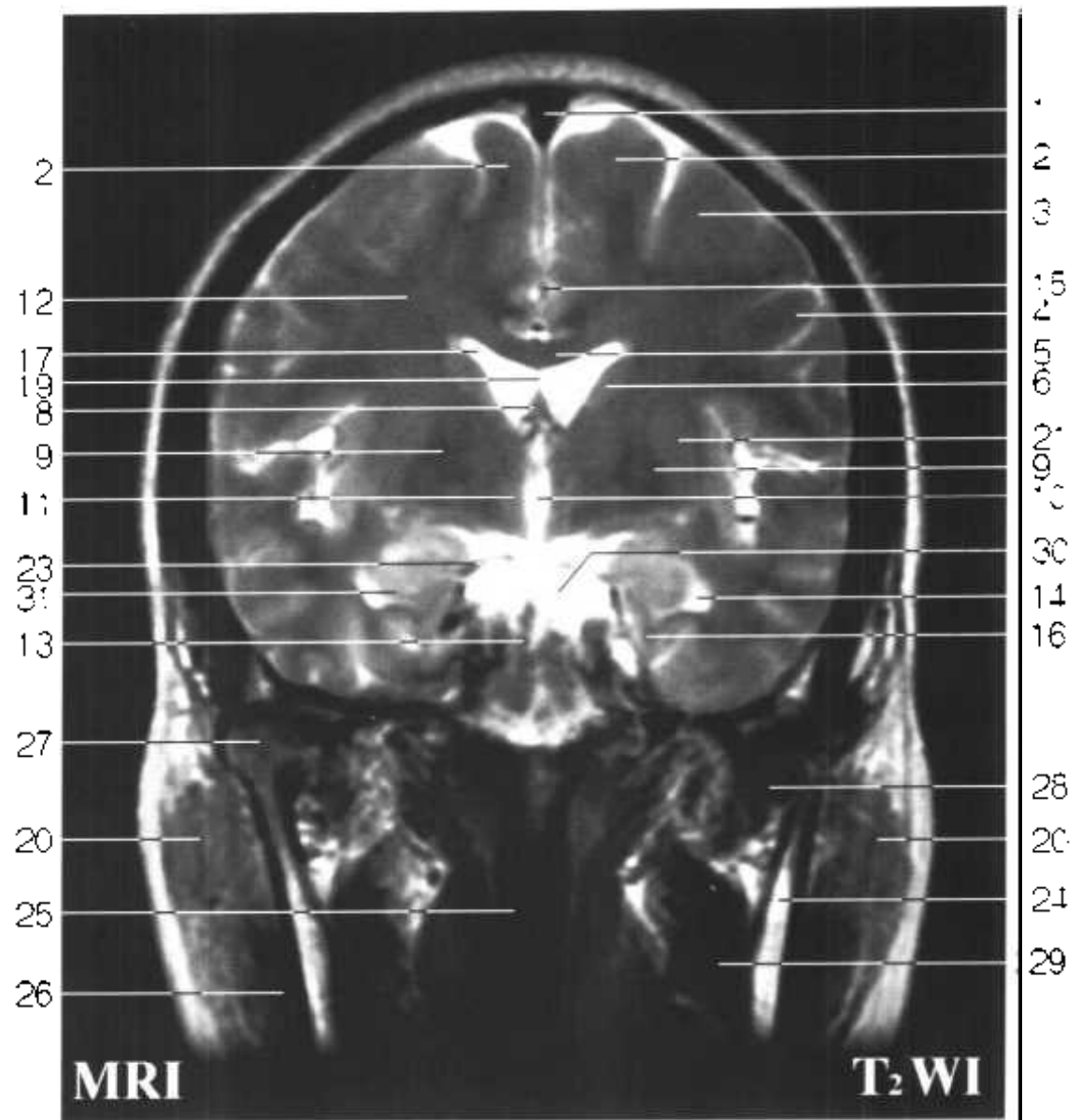


Fig. FC 7



1. 上矢状窦 superior sagittal sinus
2. 额上回 superior frontal gyrus
3. 中央前回 precentral gyrus
4. 中央后回 postcentral gyrus
5. 胼胝体干 trunk of corpus callosum
6. 尾状核体 body of caudate nucleus
7. 扣带回 cingulate gyrus
8. 穹窿柱 column of fornix
9. 苍白球 globus pallidus
10. 第三脑室 third ventricle
11. 背侧丘脑 dorsal thalamus

Fig. FC 7



- | | |
|--|----------------------------------|
| 12. 辐射冠(半卵圆中心) corona radiata
(centrum semiovale) | 21. 壳 putamen |
| 13. 基底动脉 basilar a. | 22. 室间孔 interventricular foramen |
| 14. 侧脑室下角 inferior horn of lateral
ventricle | 23. 大脑后动脉 posterior cerebral a. |
| 15. 大脑前动脉 anterior cerebral a. | 24. 下颌骨 mandible |
| 16. 海马旁回 parahippocampal gyrus | 25. 咽腔 cavity of pharynx |
| 17. 侧脑室中央部 central part of lateral
ventricle | 26. 咬肌 masseter |
| 18. 颈内动脉 internal carotid a. | 27. 下颌头 head of mandible |
| 19. 透明隔 septum pellucidum | 28. 翼外肌 lateral pterygoid |
| 20. 腮腺 parotid gland | 29. 翼内肌 medial pterygoid |
| | 30. 桥池 pontine cistern |
| | 31. 海马 hippocampus |

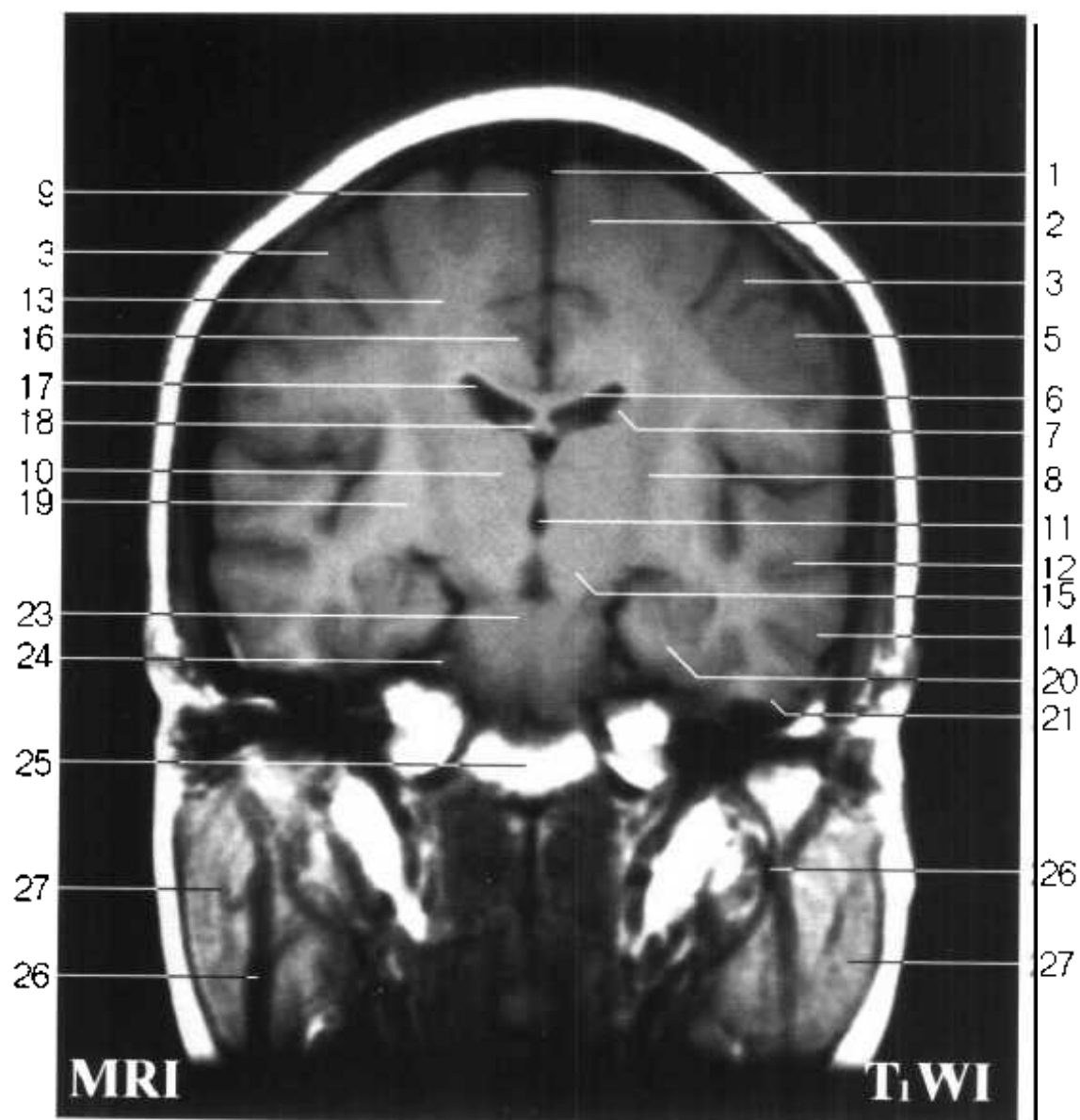
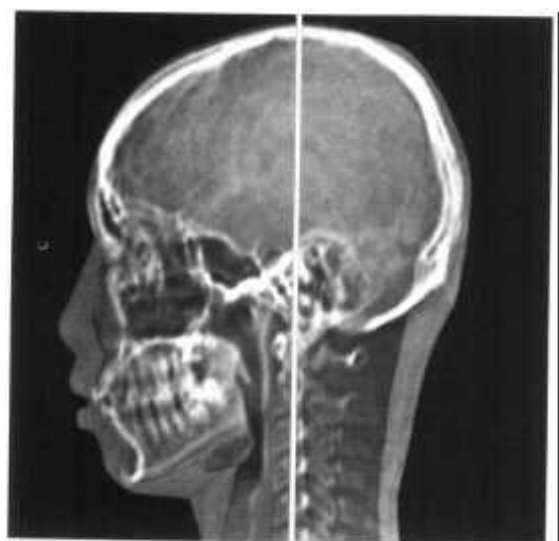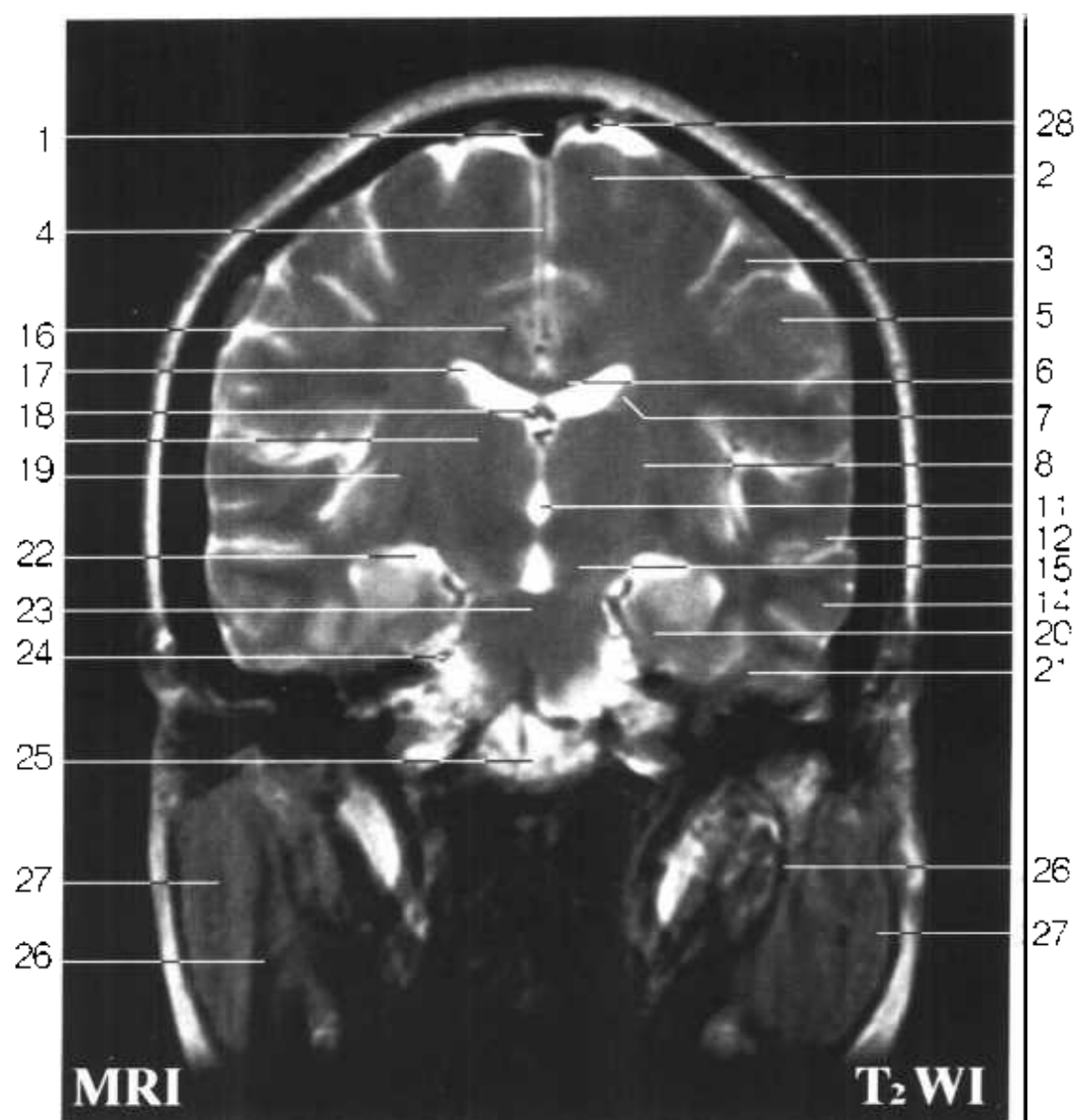


Fig. FC 8



1. 上矢状窦 superior sagittal sinus
2. 中央前回 precentral gyrus
3. 中央后回 postcentral gyrus
4. 大脑镰 cerebral falx
5. 顶上小叶 superior parietal lobule
6. 胼胝体干 trunk of corpus callosum
7. 尾状核体 body of caudate nucleus
8. 内囊后肢 posterior limb of internal capsule
9. 中央旁小叶 paracentral lobule
10. 背侧丘脑 dorsal thalamus
11. 第三脑室 third ventricle

Fig. FC 8



- | | |
|--|--|
| 12. 颞上回 superior temporal gyrus | 22. 侧脑室下角 inferior horn of lateral ventricle |
| 13. 辐射冠 corona radiata | 23. 脑桥 pons |
| 14. 颞中回 middle temporal gyrus | 24. 三叉神经根 root of trigeminal n. |
| 15. 中脑 midbrain | 25. 枕骨基底部 basilar part of occipital bone |
| 16. 扣带回 cingulate gyrus | 26. 颈内静脉 internal jugular v. |
| 17. 侧脑室中央部 central part of lateral ventricle | 27. 腮腺 parotid gland |
| 18. 穹窿体 body of fornix | 28. 外侧陷窝 lateral lacunae |
| 19. 壳 putamen | |
| 20. 海马旁回 parahippocampal gyrus | |
| 21. 枕颞外侧回 lateral occipitotemporal gyrus | |

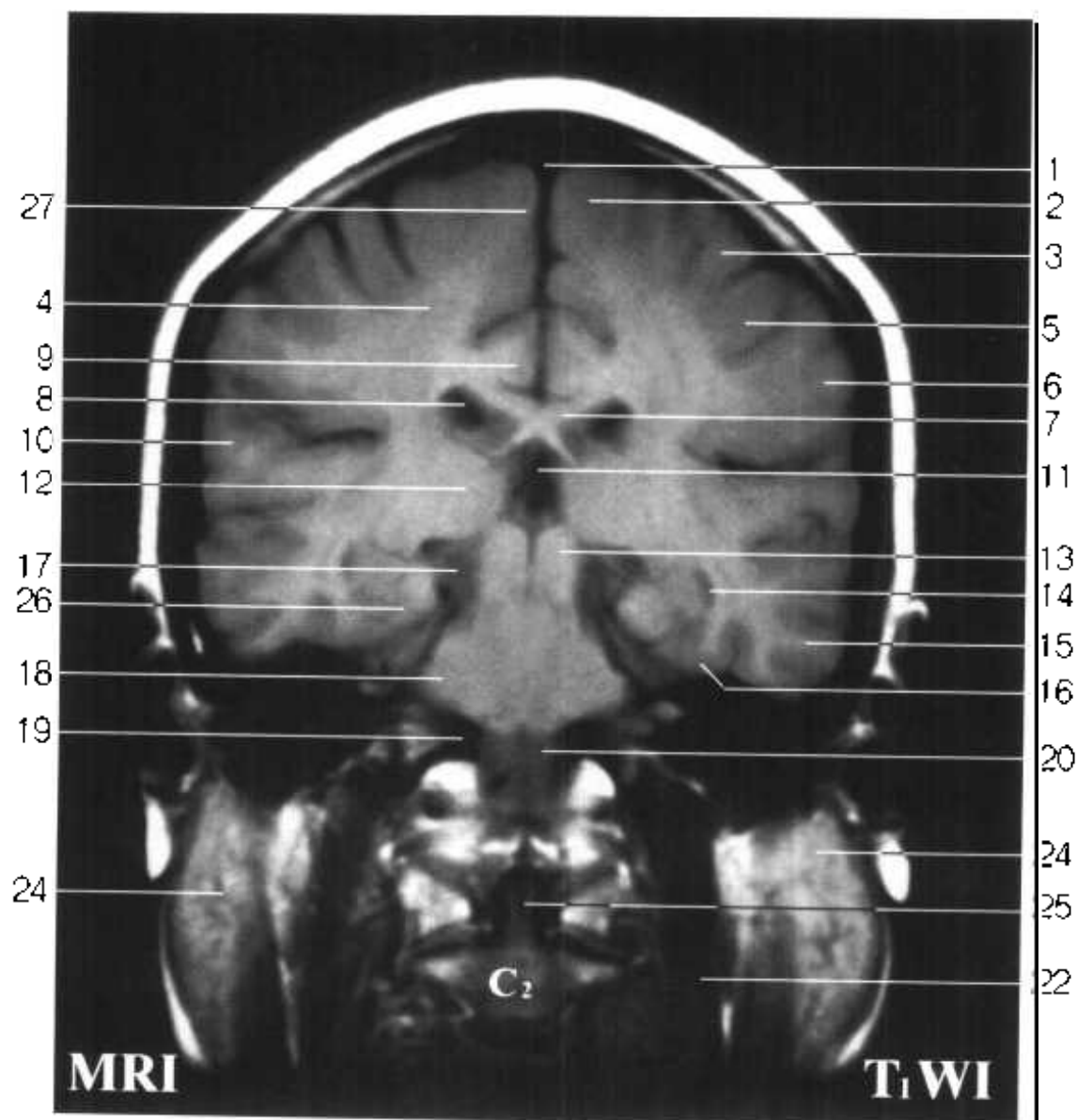
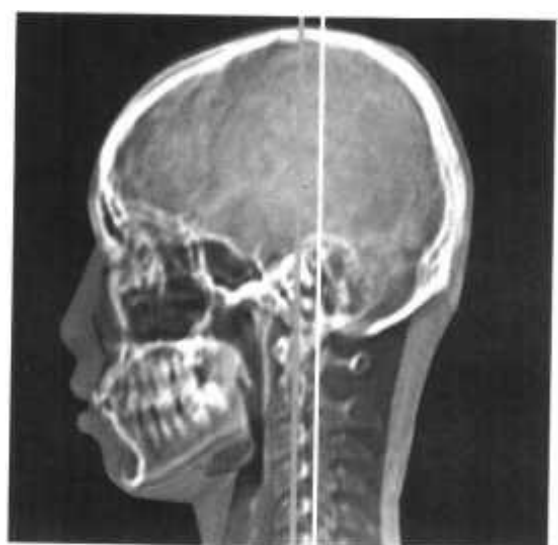
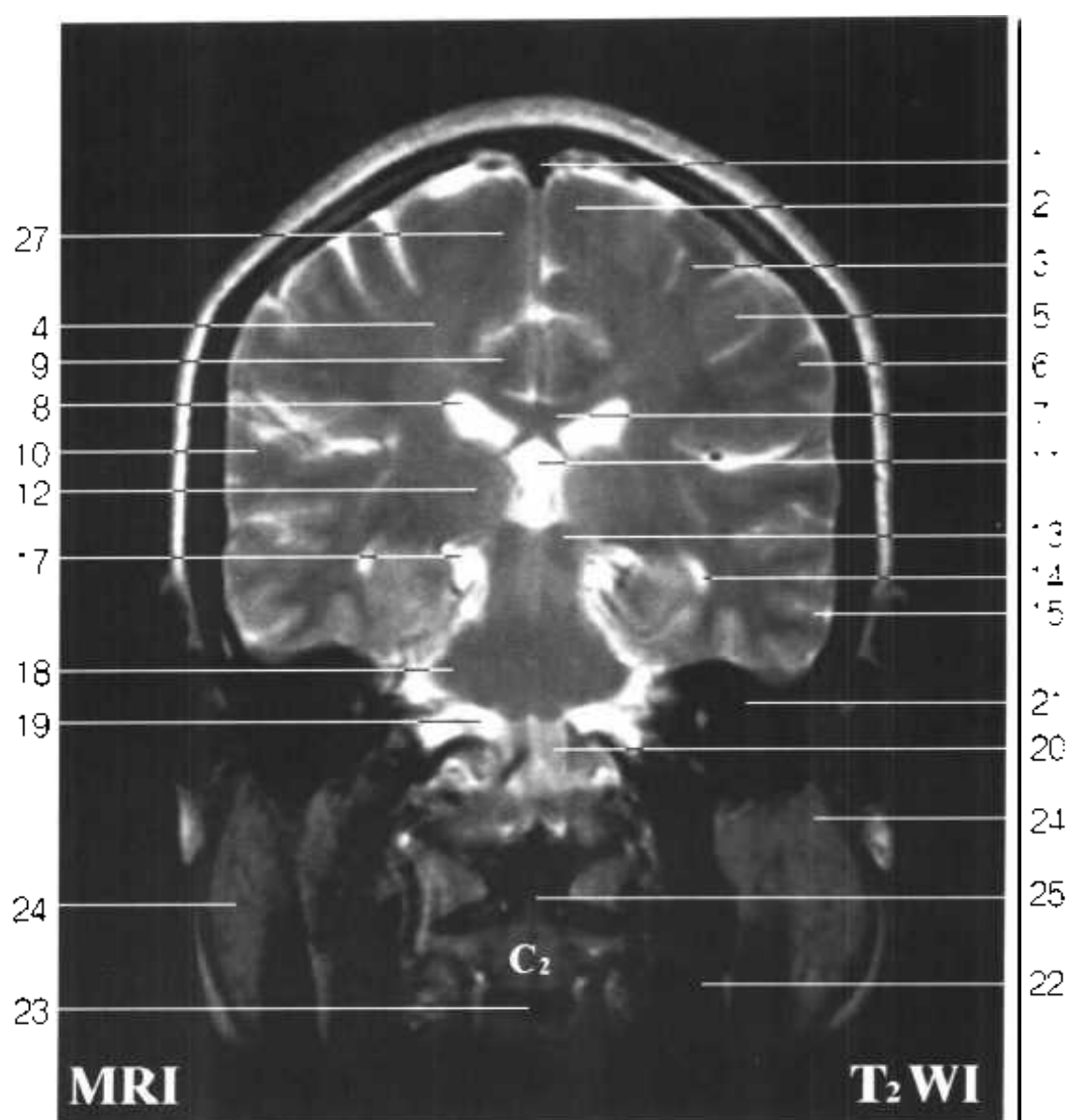


Fig. FC 9

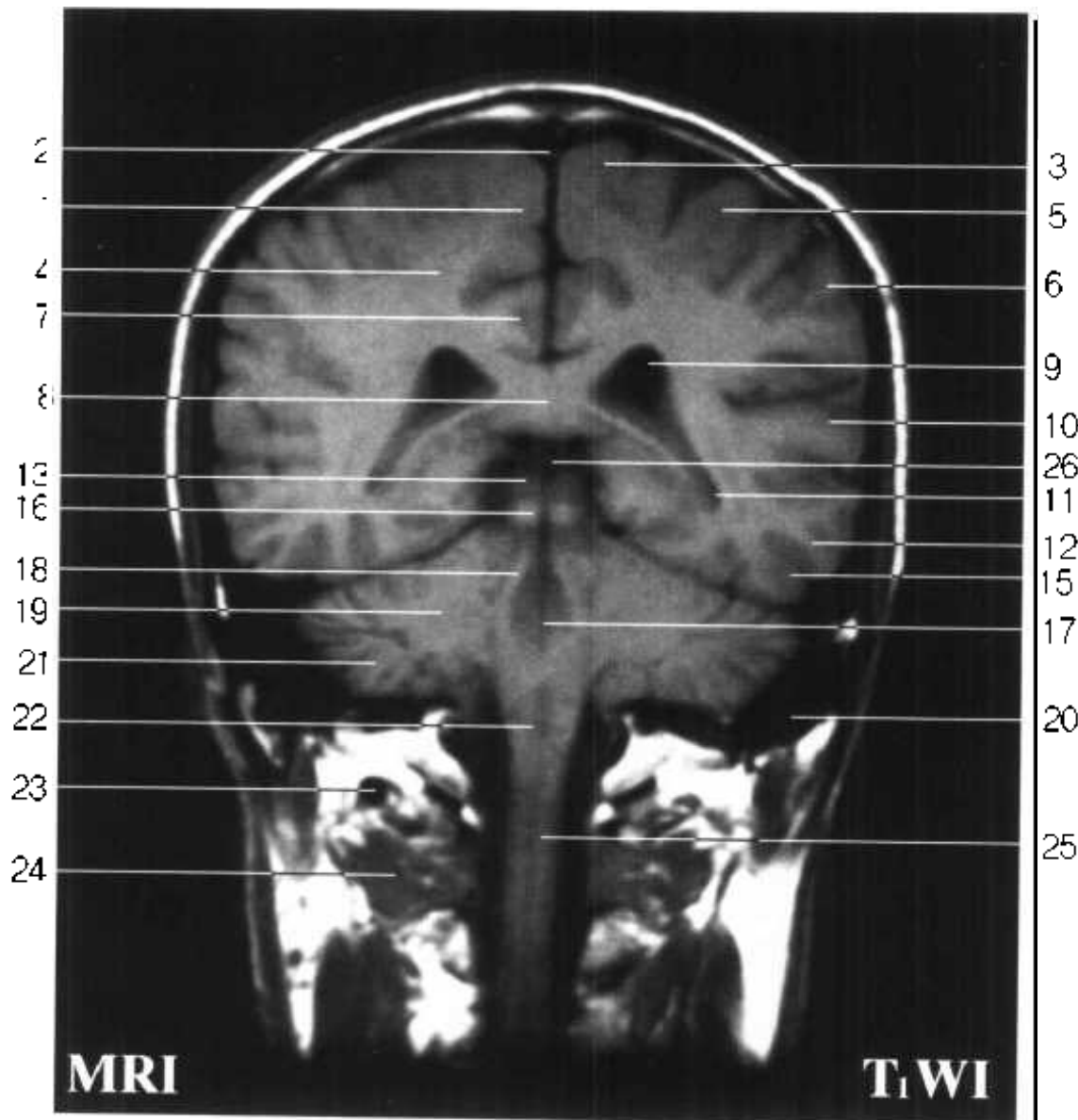


1. 上矢状窦 superior sagittal sinus
2. 中央前回 precentral gyrus
3. 中央后回 postcentral gyrus
4. 辐射冠 corona radiata
5. 顶上小叶 superior parietal lobule
6. 缘上回 supramarginal gyrus
7. 胼胝体干 trunk of corpus callosum
8. 侧脑室中央部 central part of lateral ventricle
9. 扣带回 cingulate gyrus
10. 颞上回 superior temporal gyrus
11. 第三脑室 third ventricle

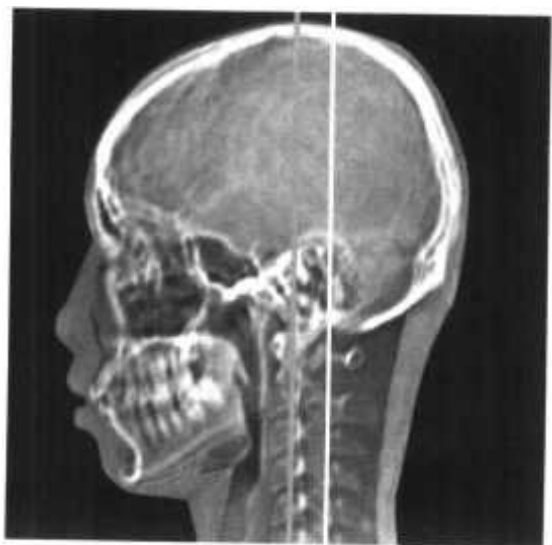
Fig. FC 9



- | | |
|--|---|
| 12. 背侧丘脑 dorsal thalamus | 20. 延髓 medulla oblongata |
| 13. 大脑脚 cerebral peduncle | 21. 颞骨岩部 petrous part of temporal bone |
| 14. 侧脑室下角 inferior horn of lateral ventricle | 22. 颈内静脉 internal jugular v. |
| 15. 颞下回 inferior temporal gyrus | 23. 2、3 颈椎间盘 intervertebral disc(C ₂ ~C ₃) |
| 16. 枕颞内侧回 medial occipitotemporal gyrus | 24. 腮腺 parotid gland |
| 17. 环池 cisterna ambiens | 25. 齿突 dens |
| 18. 小脑中脚 middle cerebellar peduncle | 26. 海马旁回 parahippocampal gyrus |
| 19. 脑桥小脑三角池 cistern of pontocerebellar trigone | 27. 中央旁小叶 paracentral lobule |

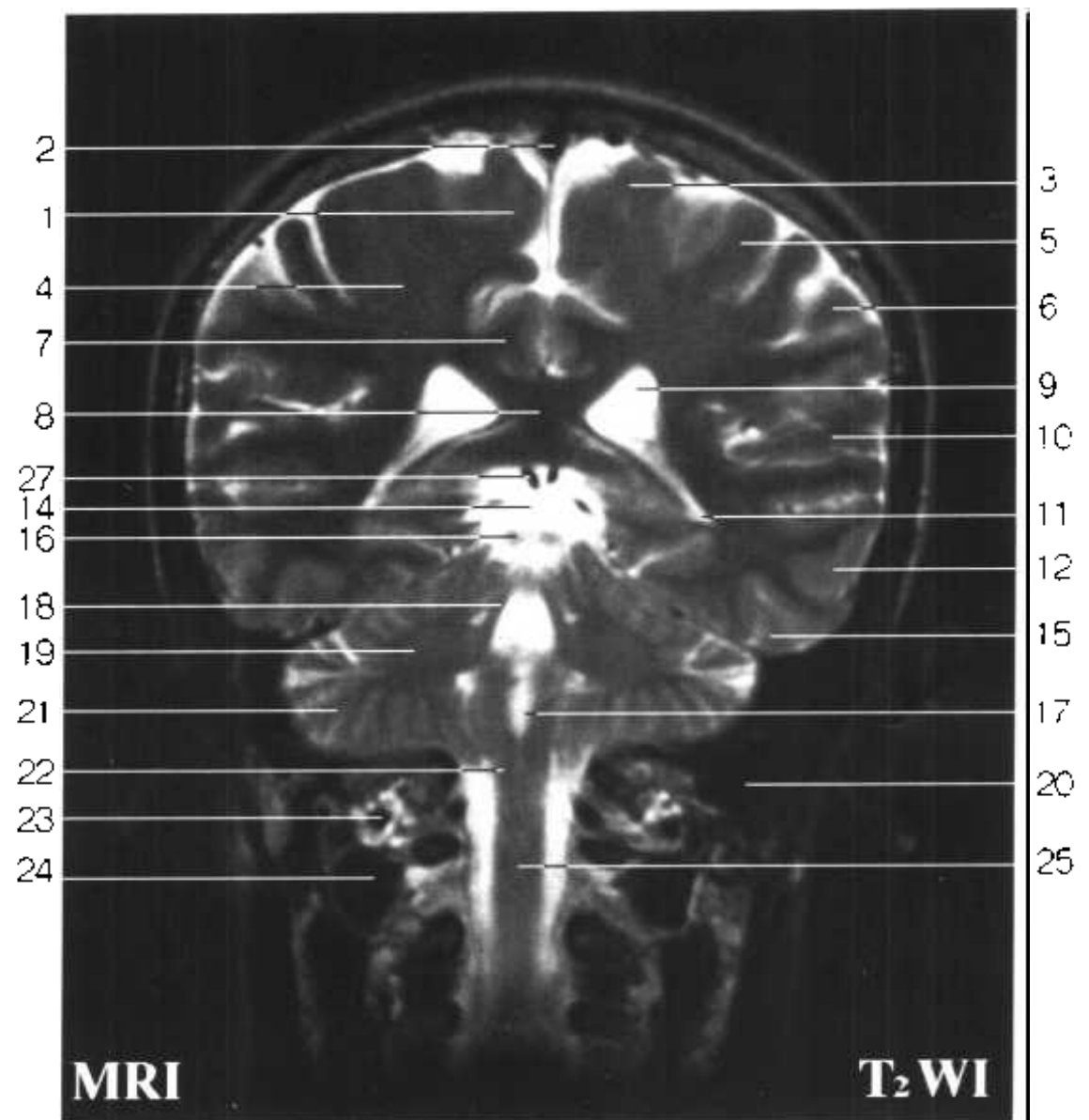


Hig. FC 10



- 1. 中央旁小叶 paracentral lobule
- 2. 上矢状窦 superior sagittal sinus
- 3. 中央后回 postcentral gyrus
- 4. 辐射冠 corona radiata
- 5. 顶上小叶 superior parietal lobule
- 6. 缘上回 supramarginal gyrus
- 7. 扣带回 cingulate gyrus
- 8. 胼胝体压部 splenium of corpus callosum
- 9. 侧脑室三角 trigone of lateral ventricle
- 10. 颞上回 superior temporal gyrus
- 11. 侧脑室下角 inferior horn of lateral ventricle
- 12. 颞中回 middle temporal gyrus
- 13. 上丘 superior colliculus
- 14. 四叠体池 gaudrigeminal cistern
- 15. 颞下回 inferior temporal gyrus

Fig. FC 10



- 16. 下丘 inferior colliculus
- 17. 第四脑室 fourth ventricle
- 18. 小脑上脚 superior cerebellar peduncle
- 19. 小脑中脚 middle cerebellar peduncle
- 20. 乙状窦 sigmoid sinus
- 21. 小脑半球 cerebellar hemisphere
- 22. 延髓 medulla oblongata
- 23. 椎动脉 vertebral a.
- 24. 头下斜肌 obliquus capitis inferior
- 25. 脊髓 spinal cord
- 26. 松果体 pineal body
- 27. 大脑内静脉 internal cerebral v.

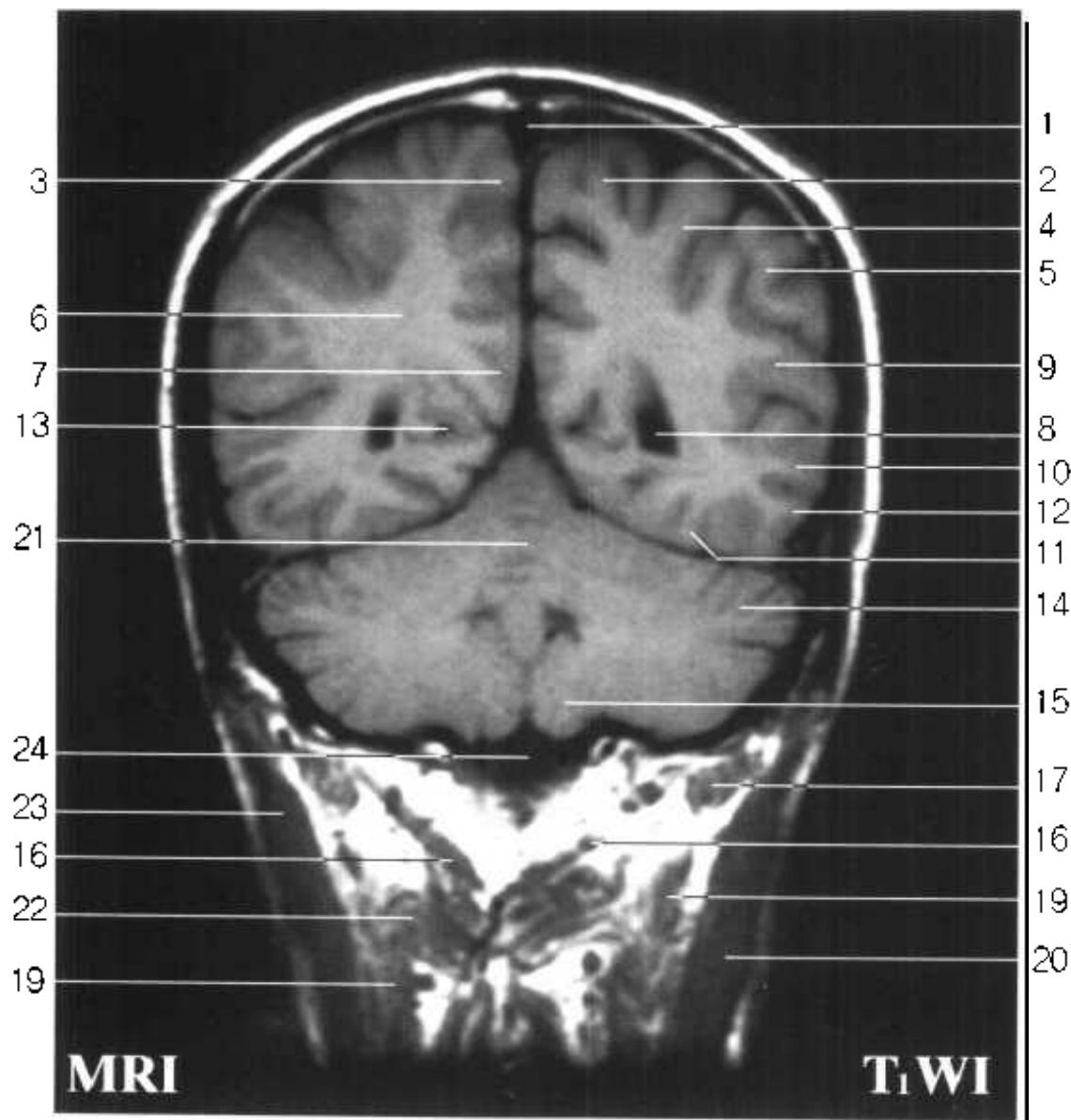
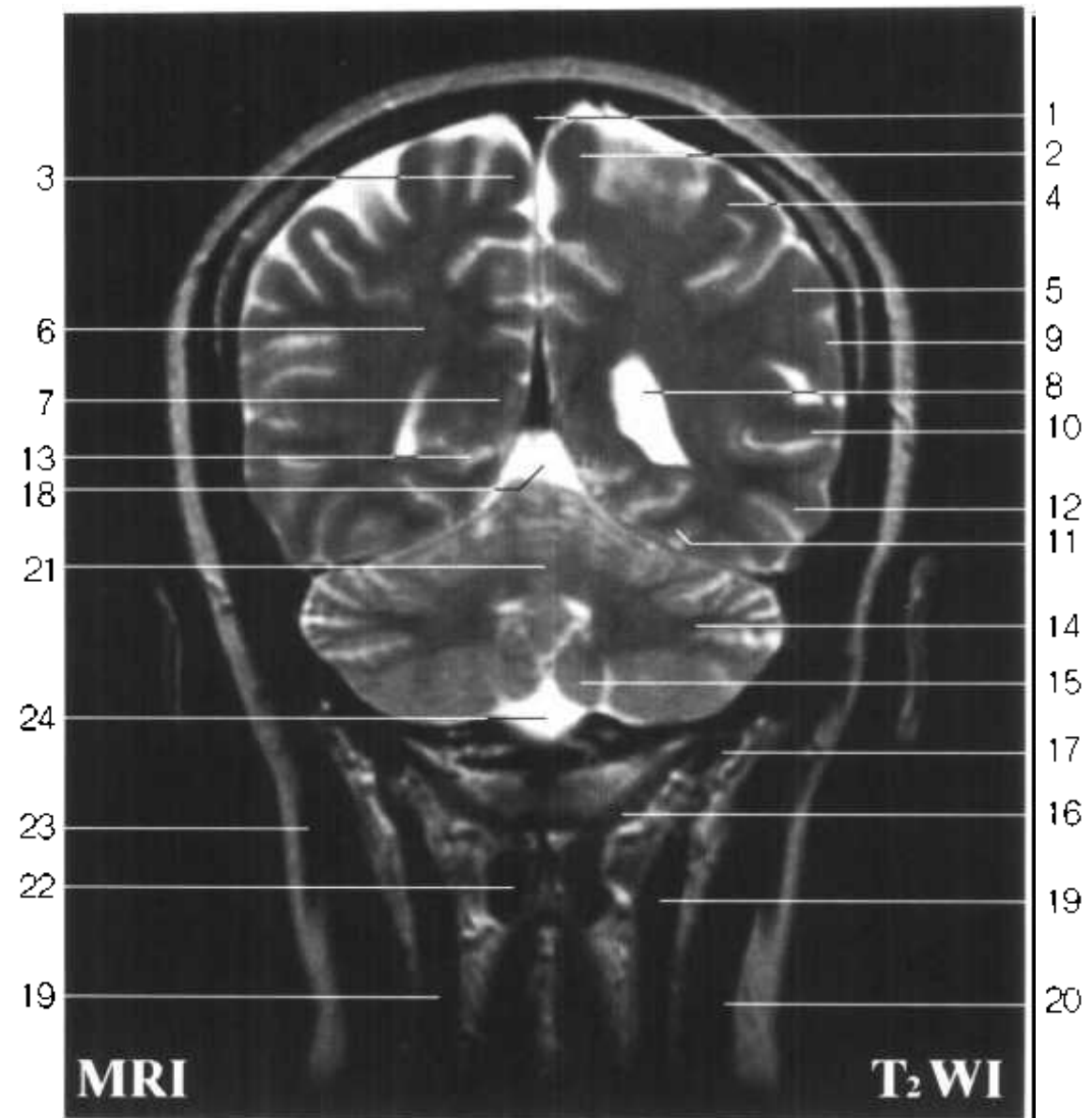


Fig. FC 11

1. 上矢状窦 superior sagittal sinus
2. 中央后回 postcentral gyrus
3. 中央旁小叶 paracentral lobule
4. 顶上小叶 superior parietal lobule
5. 缘上回 supramarginal gyrus
6. 辐射冠 corona radiata
7. 扣带回 cingulate gyrus
8. 侧脑室后角 posterior horn of lateral ventricle
9. 颞上回 superior temporal gyrus
10. 颞中回 middle temporal gyrus
11. 枕颞内侧回 medial occipitotemporal gyrus
12. 颞下回 inferior temporal gyrus
13. 距状沟 calcarine sulcus
14. 小脑半球 cerebellar hemisphere

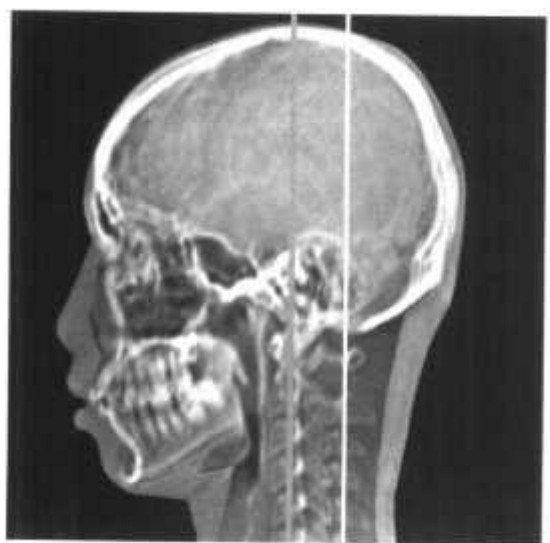

Fig. FC 11



- 15. 小脑扁桃体 tonsil of cerebellum
- 16. 头后大直肌 rectus capitis posterior major
- 17. 头上斜肌 obliquus capitis superior
- 18. 小脑上池 supracerebellar cistern
- 19. 头半棘肌 semispinalis capitis
- 20. 头夹肌 splenius capitis
- 21. 小脑蚓 vermis
- 22. 头下斜肌 obliquus capitis inferior
- 23. 胸锁乳突肌 sternocleidomastoid
- 24. 小脑延髓池 cerebellomedullary cistern

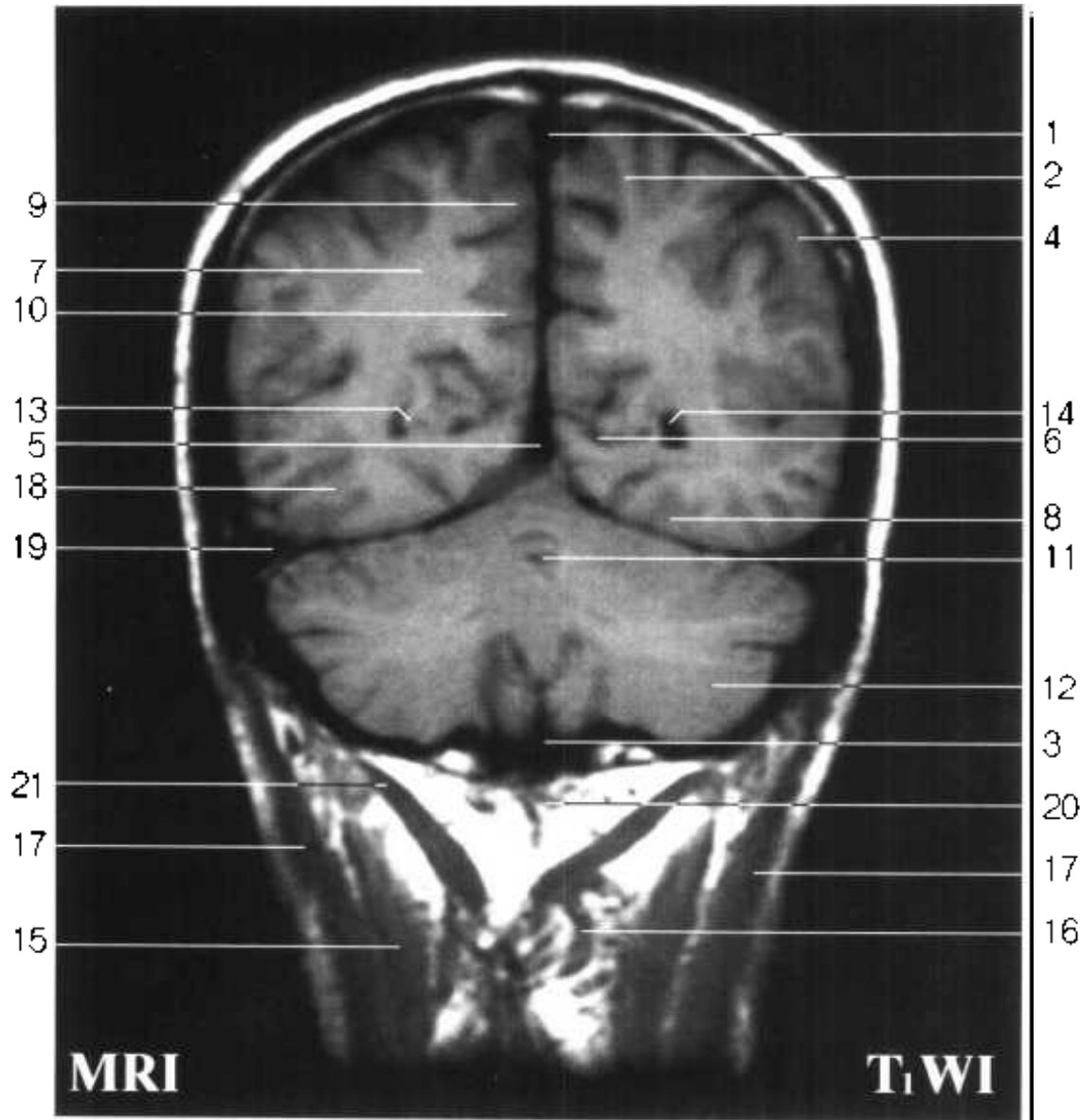


Fig. FC 12

1. 上矢状窦 superior sagittal sinus
2. 顶上小叶 superior parietal lobule
3. 小脑延髓池 cerebellomedullary cistern
4. 角回 angular gyrus
5. 直窦 straight sinus
6. 距状沟 calcarine sulcus
7. 辐射冠 corona radiata
8. 枕颞内侧回 medial occipitotemporal gyrus
9. 楔前叶 precuneus
10. 楔叶 cuneus
11. 小脑蚓 vermis
12. 小脑半球 cerebellar hemisphere

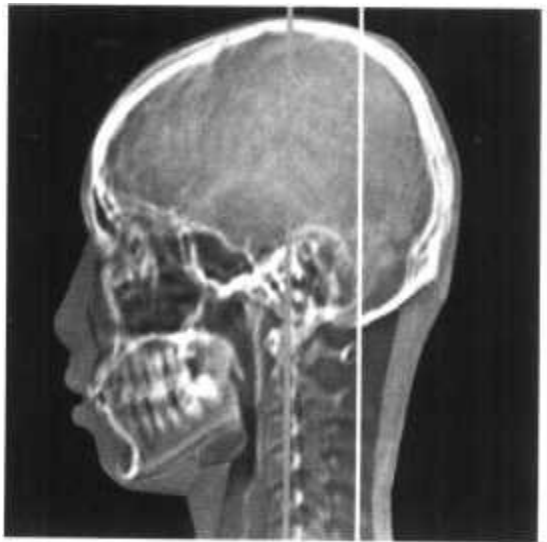

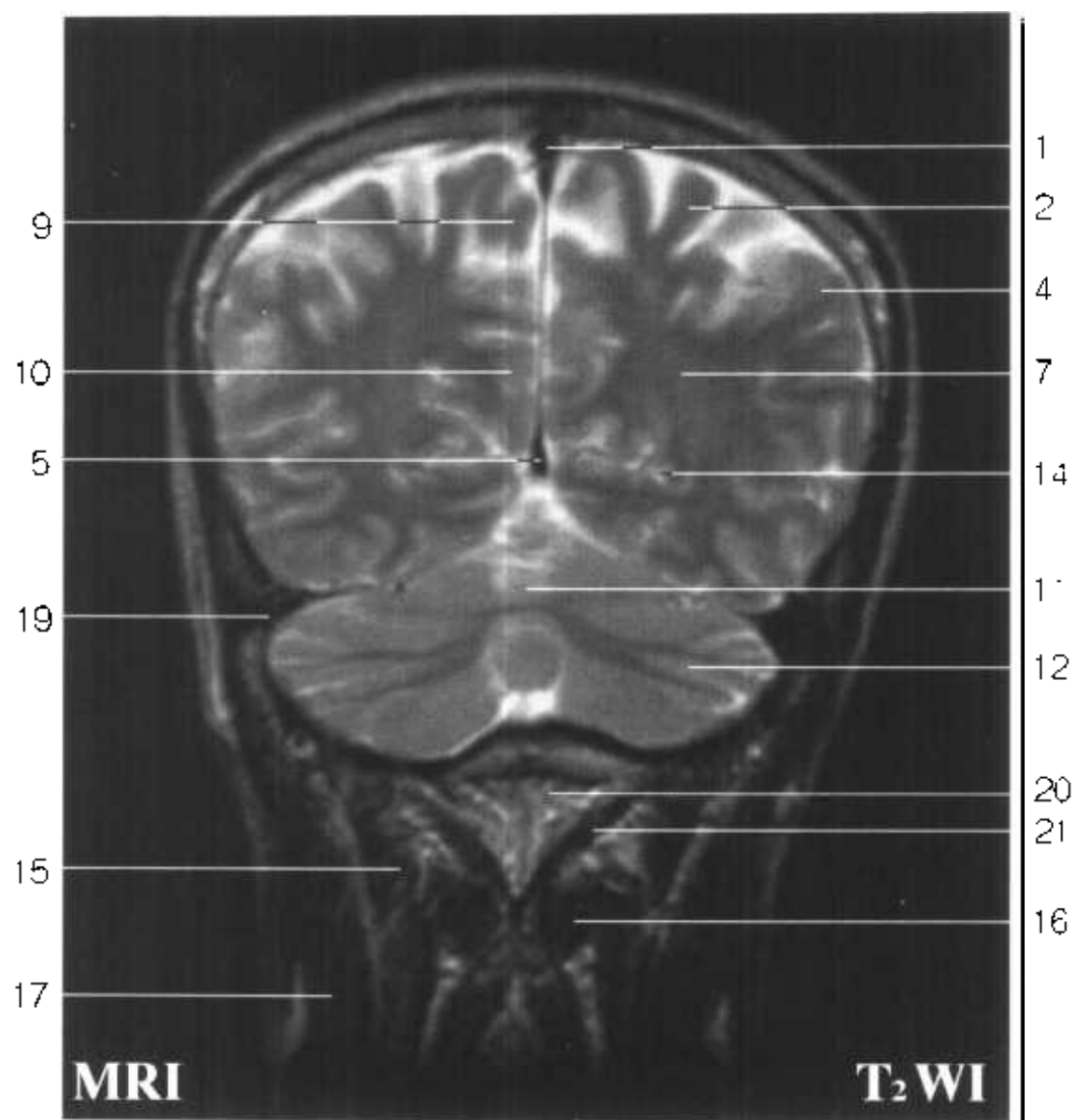


Fig. FC 12





- 13. 禽距 calcar avis
- 14. 侧脑室后角 posterior horn of lateral ventricle
- 15. 头半棘肌 semispinalis capitis
- 16. 头下斜肌 obliquus capitis inferior
- 17. 头夹肌 splenius capitis
- 18. 枕颞外侧回 lateral occipitotemporal gyrus
- 19. 横窦 transverse sinus
- 20. 头后小直肌 rectus capitis posterior minor
- 21. 头后大直肌 rectus capitis posterior major

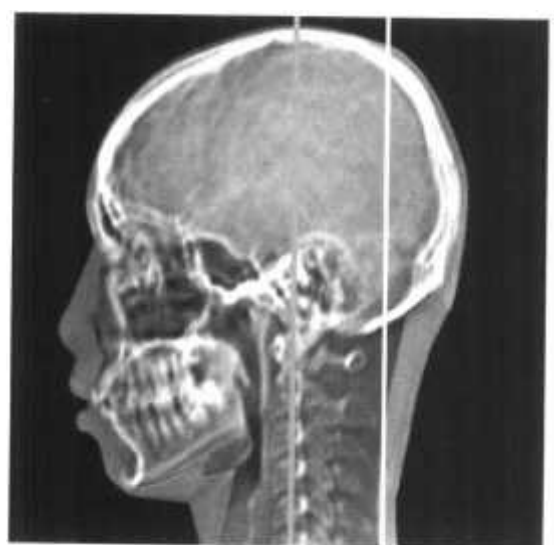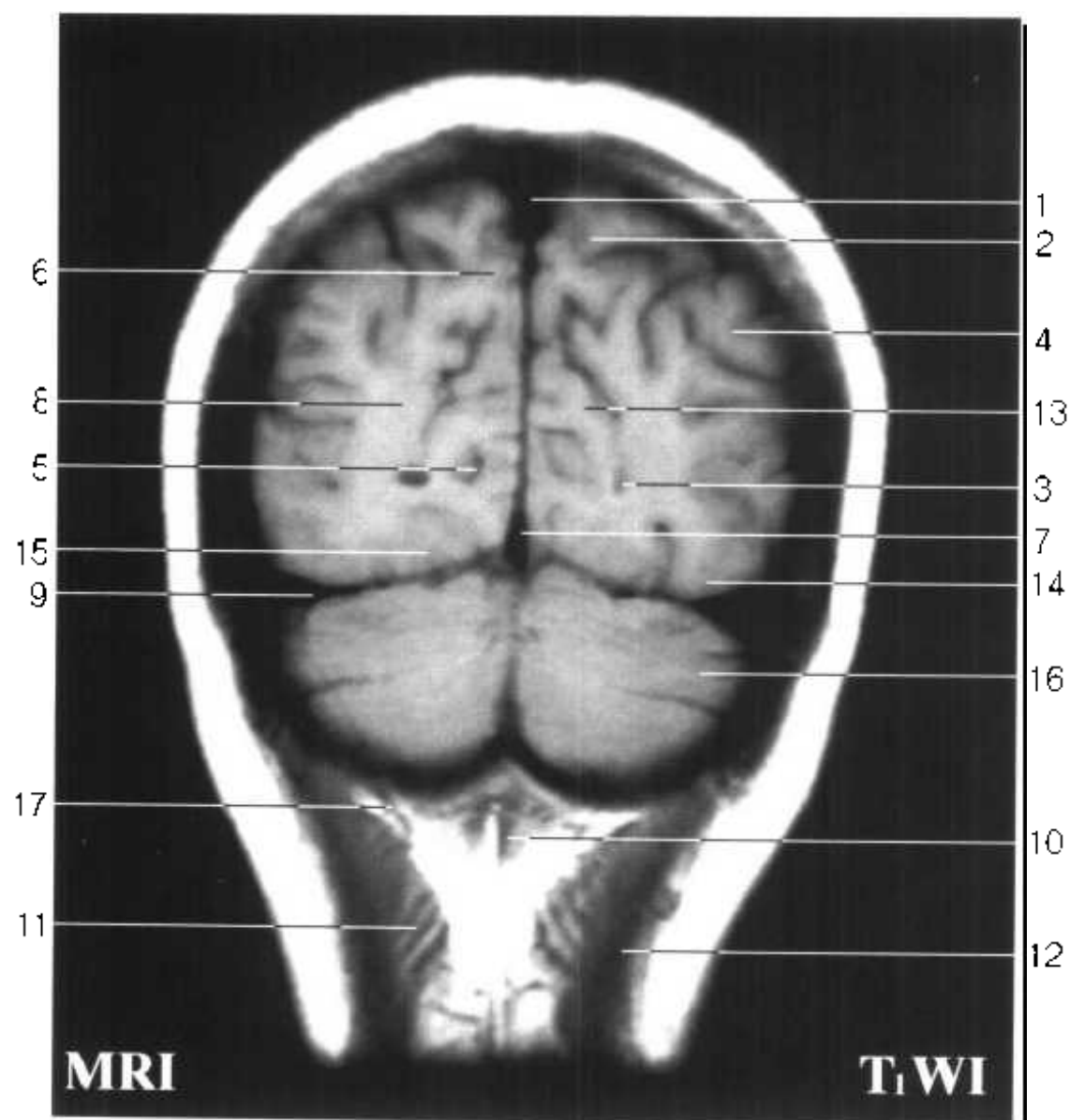
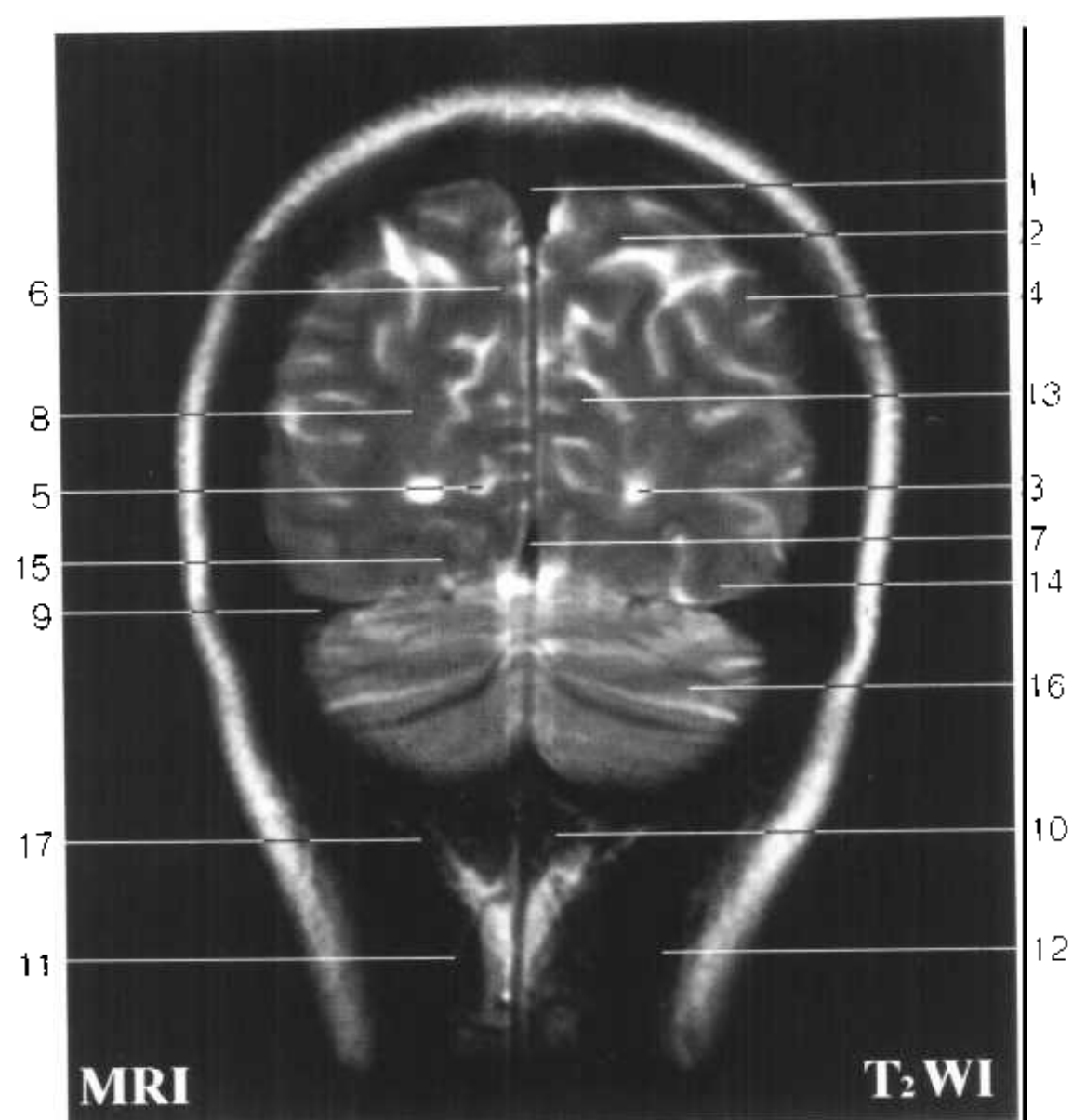


Fig. FC 13

1. 上矢状窦 superior sagittal sinus
2. 顶上小叶 superior parietal lobule
3. 侧脑室后角 posterior horn of lateral ventricle
4. 角回 angular gyrus
5. 距状沟 calcarine sulcus
6. 楔前叶 precuneus
7. 直窦 straight sinus
8. 辐射冠 corona radiata
9. 横窦 transverse sinus
10. 头后小直肌 rectus capitis posterior minor

Fig. FC 13



- 11. 头半棘肌 semispinalis capitis
- 12. 头夹肌 splenius capitis
- 13. 楔叶 cuneus
- 14. 枕颞外侧回 lateral occipitotemporal gyrus
- 15. 枕颞内侧回 medial occipitotemporal gyrus
- 16. 小脑半球 cerebellar hemisphere
- 17. 头后大直肌 rectus capitis posterior major

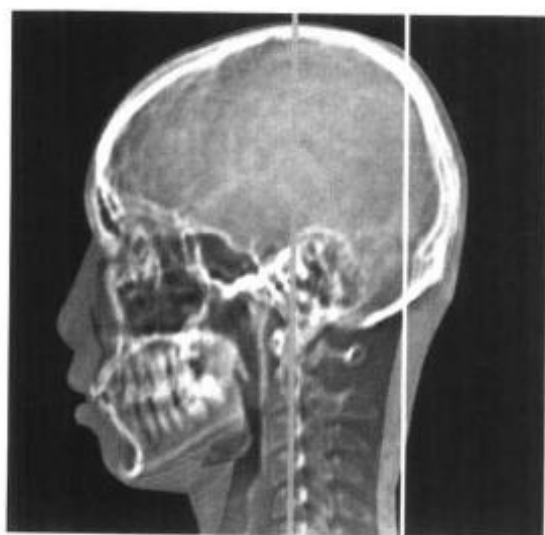
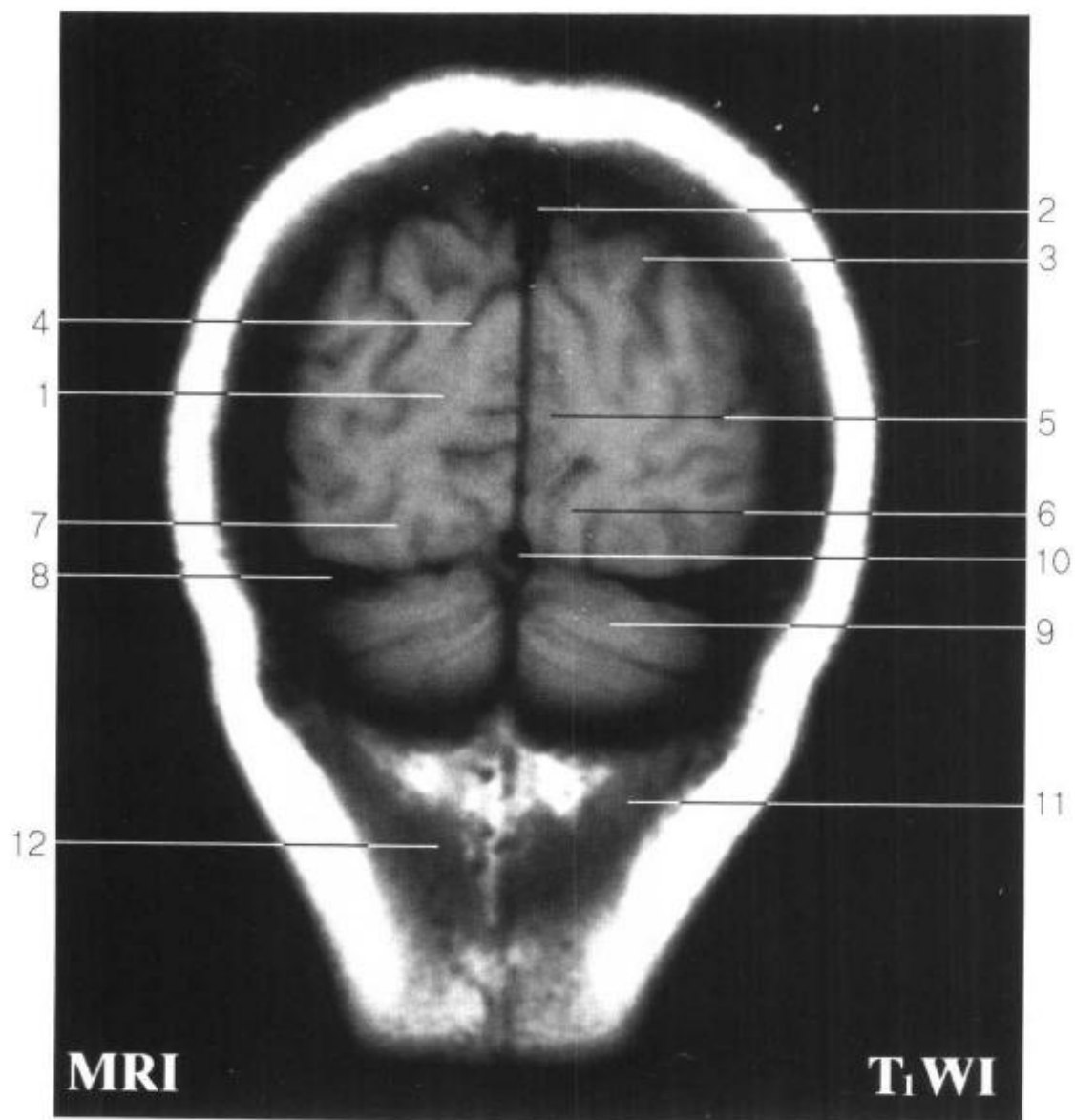
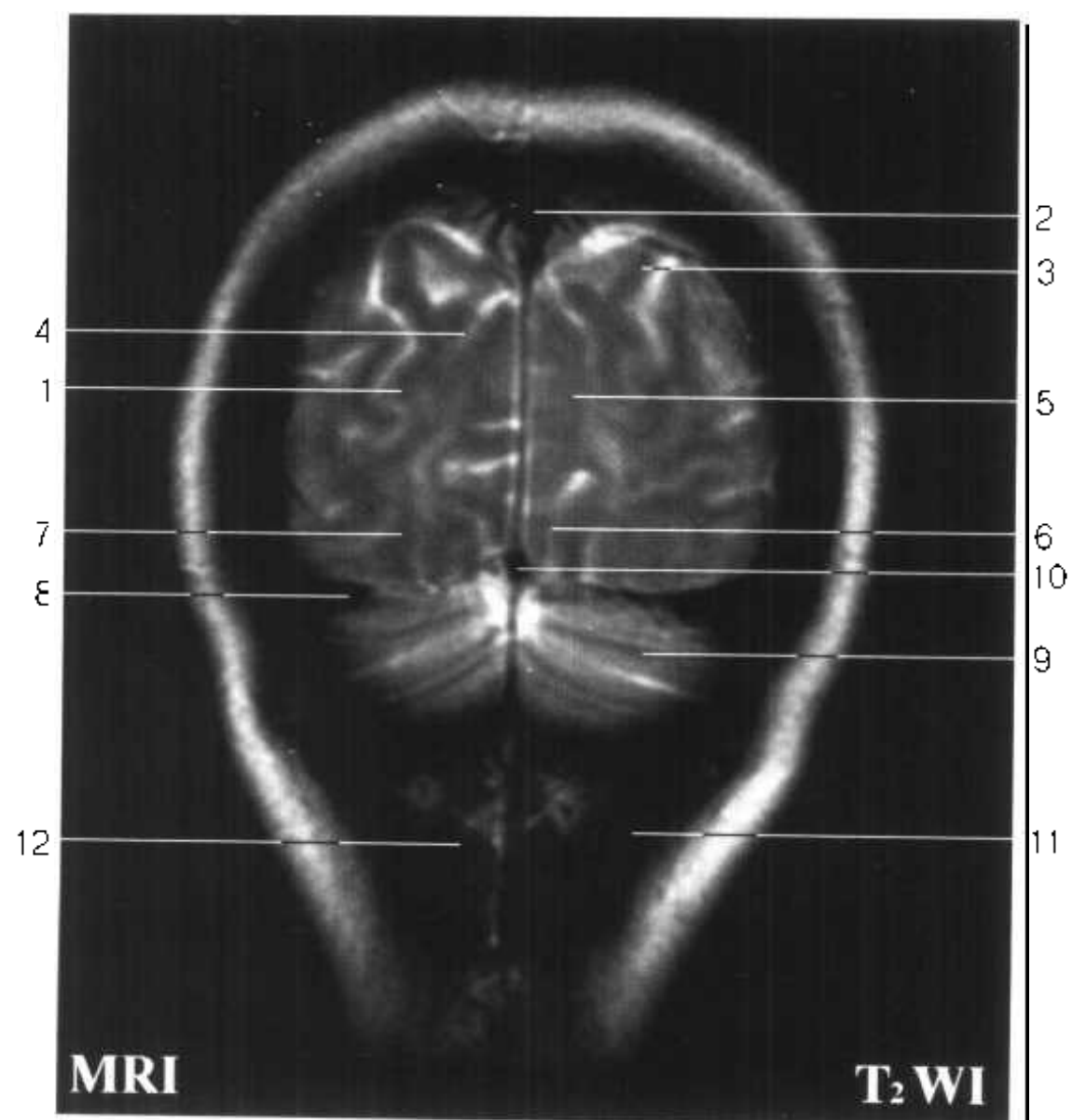


Fig. FC 14

1. 辐射冠 corona radiata
2. 上矢状窦 superior sagittal sinus
3. 楔叶 cuneus
4. 距状沟 calcarine sulcus
5. 舌回 lingual gyrus
6. 枕颞内侧回 medial occipitotemporal gyrus
7. 枕外侧回 lateral occipital gyrus
8. 横窦 transverse sinus

Fig. FC 14



- 9. 小脑半球 cerebellar hemisphere
- 10. 直窦 straight sinus
- 11. 头夹肌 splenius capitis
- 12. 头半棘肌 semispinalis capitis

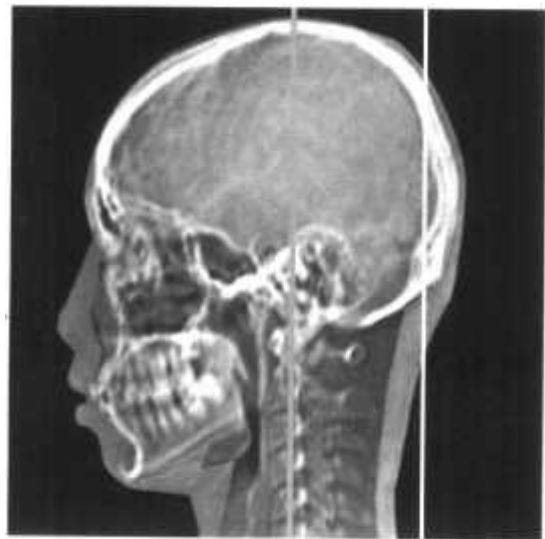
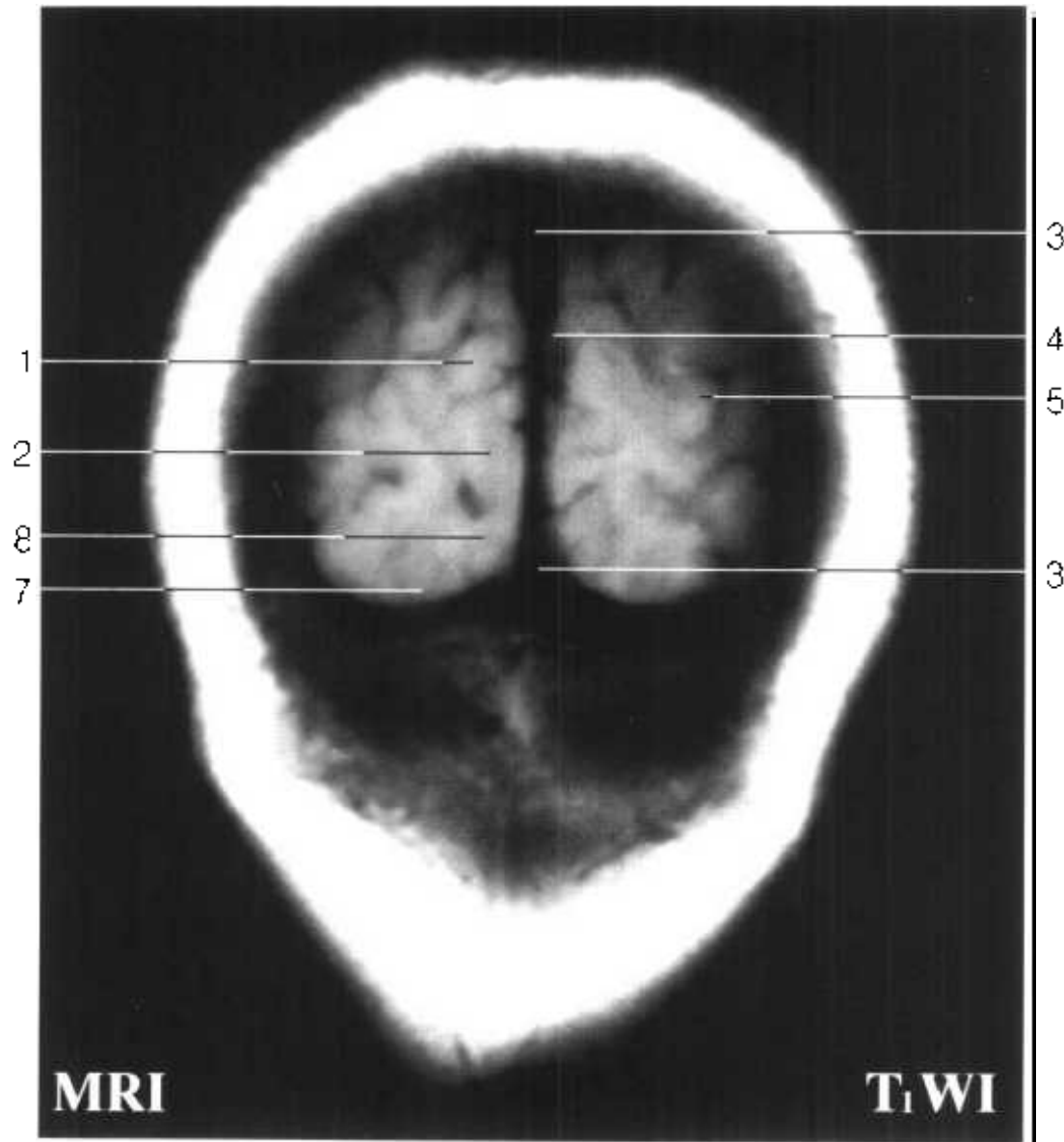
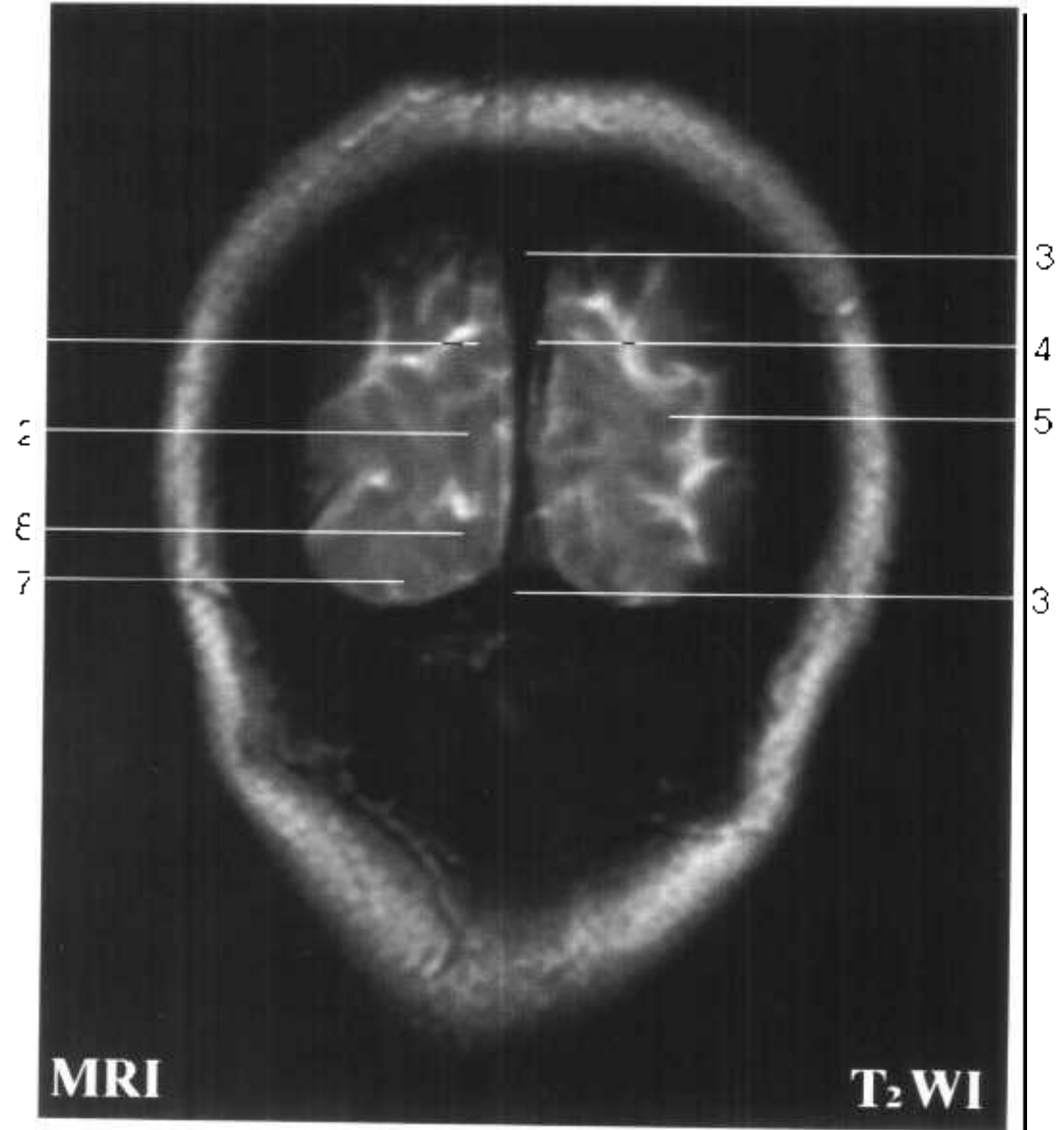


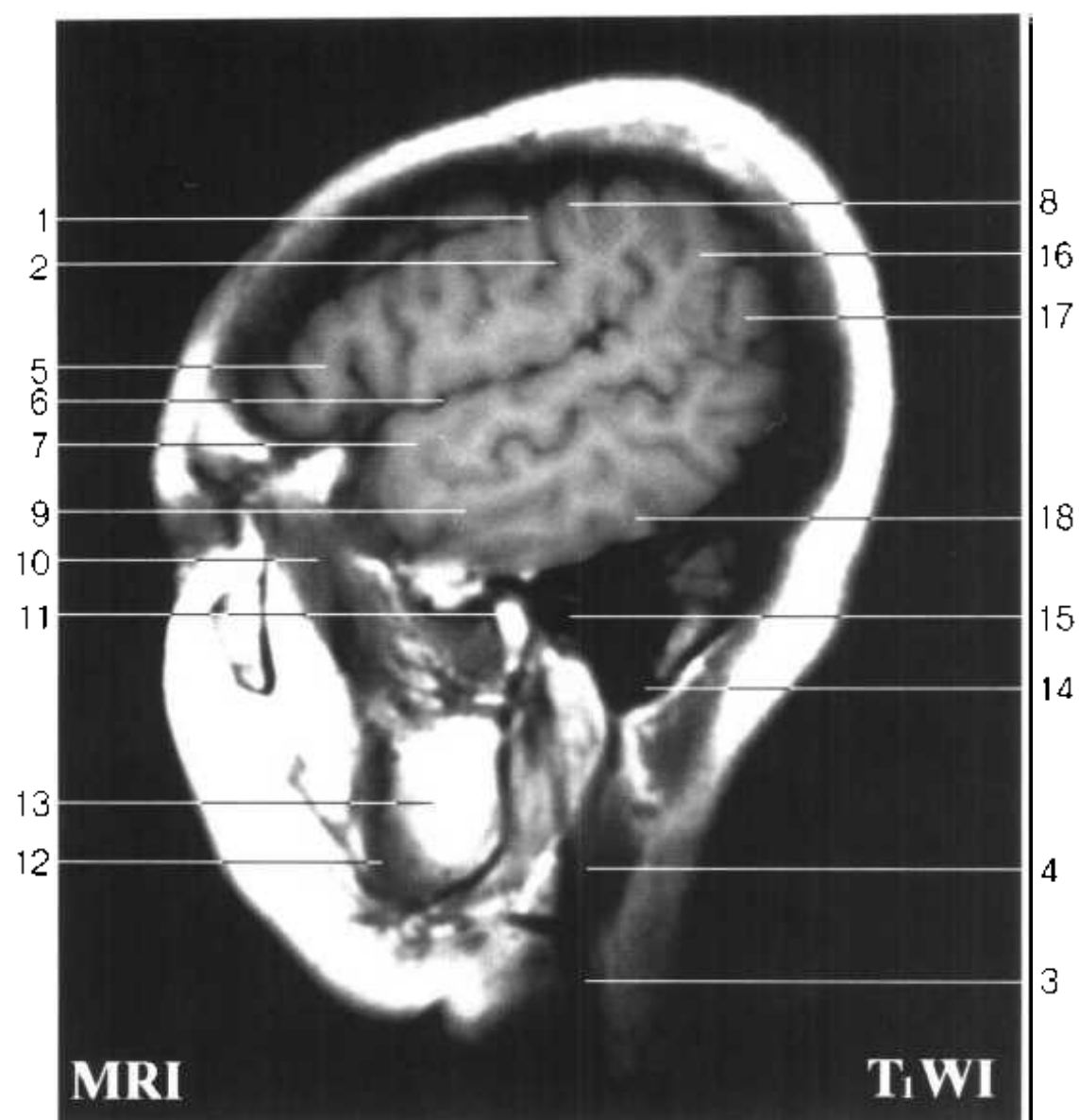
Fig. FC 15

- 1. 楔叶 cuneus
- 2. 舌回 lingual gyrus
- 3. 上矢状窦 superior sagittal sinus
- 4. 大脑镰 cerebral falx
- 5. 枕外侧回 lateral occipital gyrus
- 6. 上矢状窦 superior sagittal sinus

Fig. FC 15



- 7. 枕颞外侧回 lateral occipitotemporal gyrus
- 8. 枕颞内侧回 medial occipitotemporal gyrus



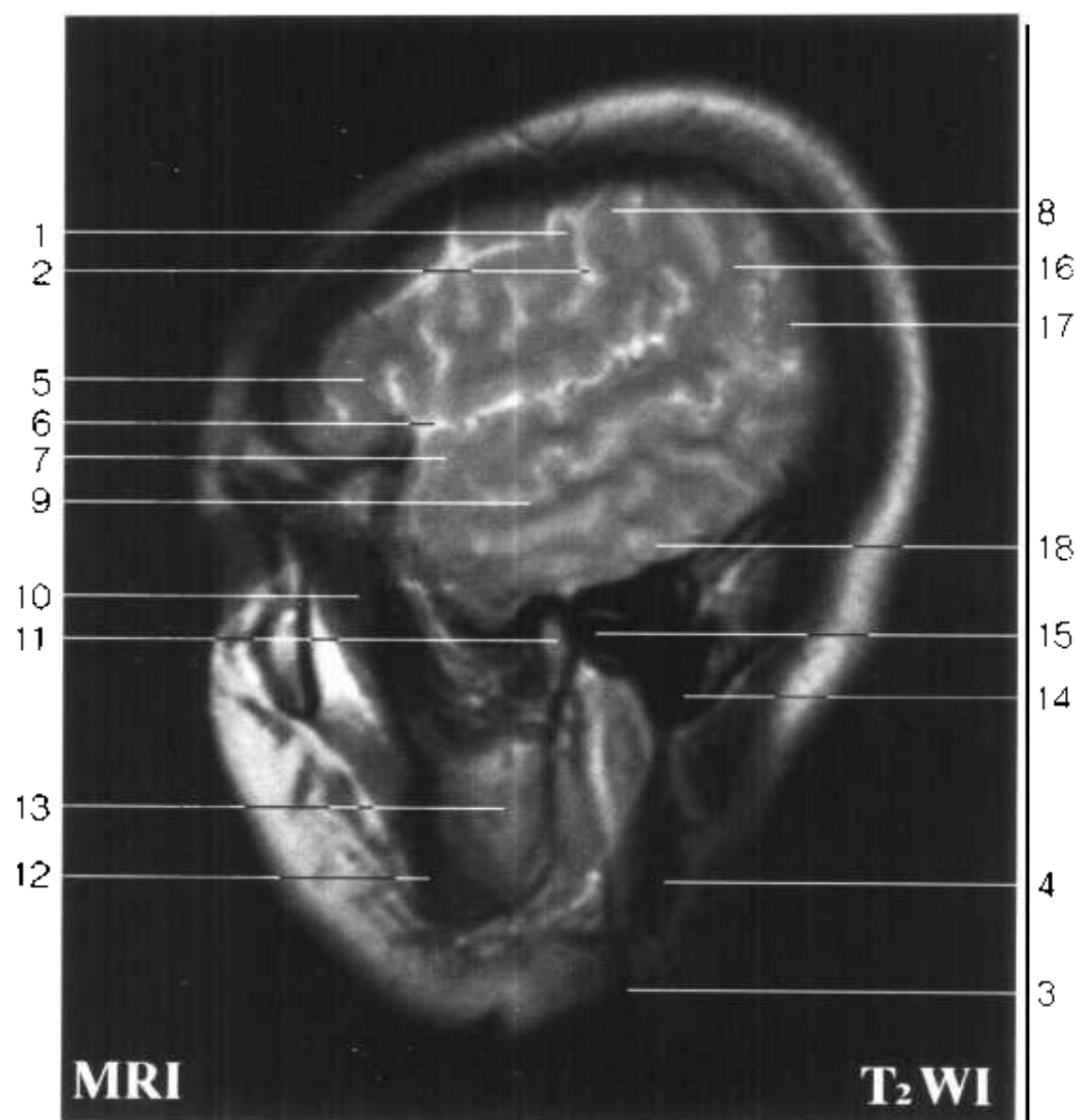
矢状断面图 SC

Fig SC 1

1. 中央前回 precentral gyrus
2. 中央沟 central sulcus
3. 颈外静脉 external jugular v.
4. 胸锁乳突肌 sternocleidomastoid
5. 额下回 inferior frontal gyrus
6. 外侧沟 lateral sulcus
7. 颞上回 superior temporal gyrus
8. 中央后回 postcentral gyrus
9. 颞中回 middle temporal gyrus

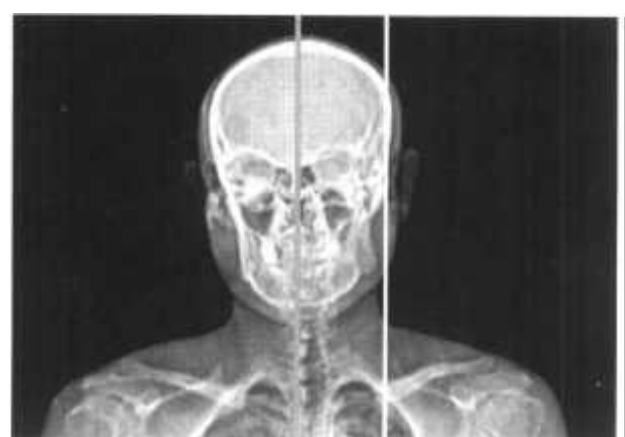

Fig. SC 1



- 10. 颞肌 temporalis
- 11. 髁突 condylar process
- 12. 咬肌 masseter
- 13. 腮腺 parotid gland
- 14. 乳突小房 mastoid cells
- 15. 外耳道 external acoustic meatus
- 16. 缘上回 supramarginal gyrus
- 17. 角回 angular gyrus
- 18. 颞下回 inferior temporal gyrus

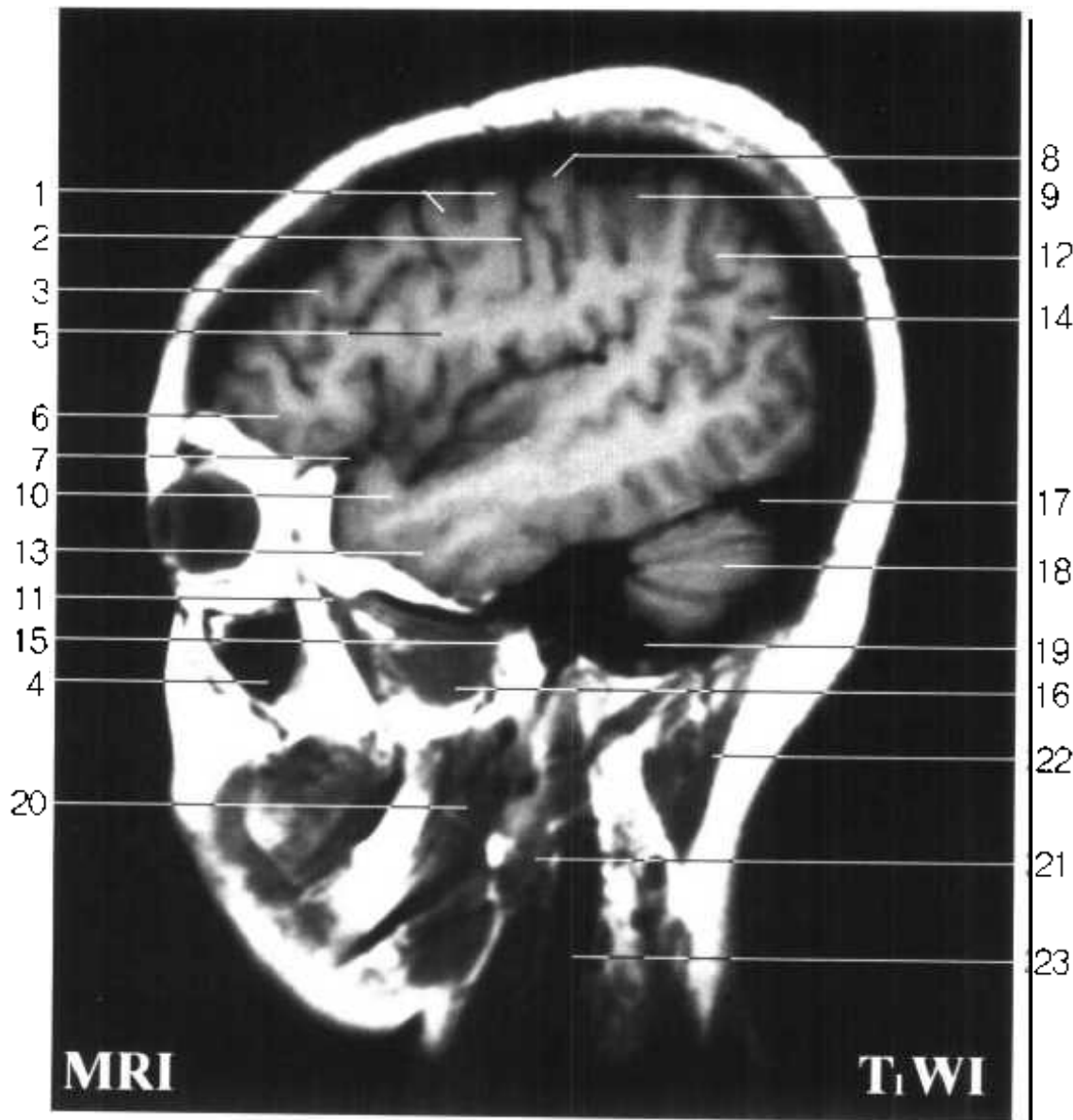
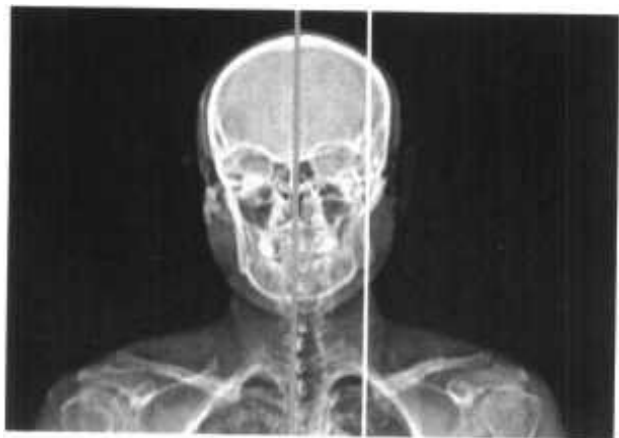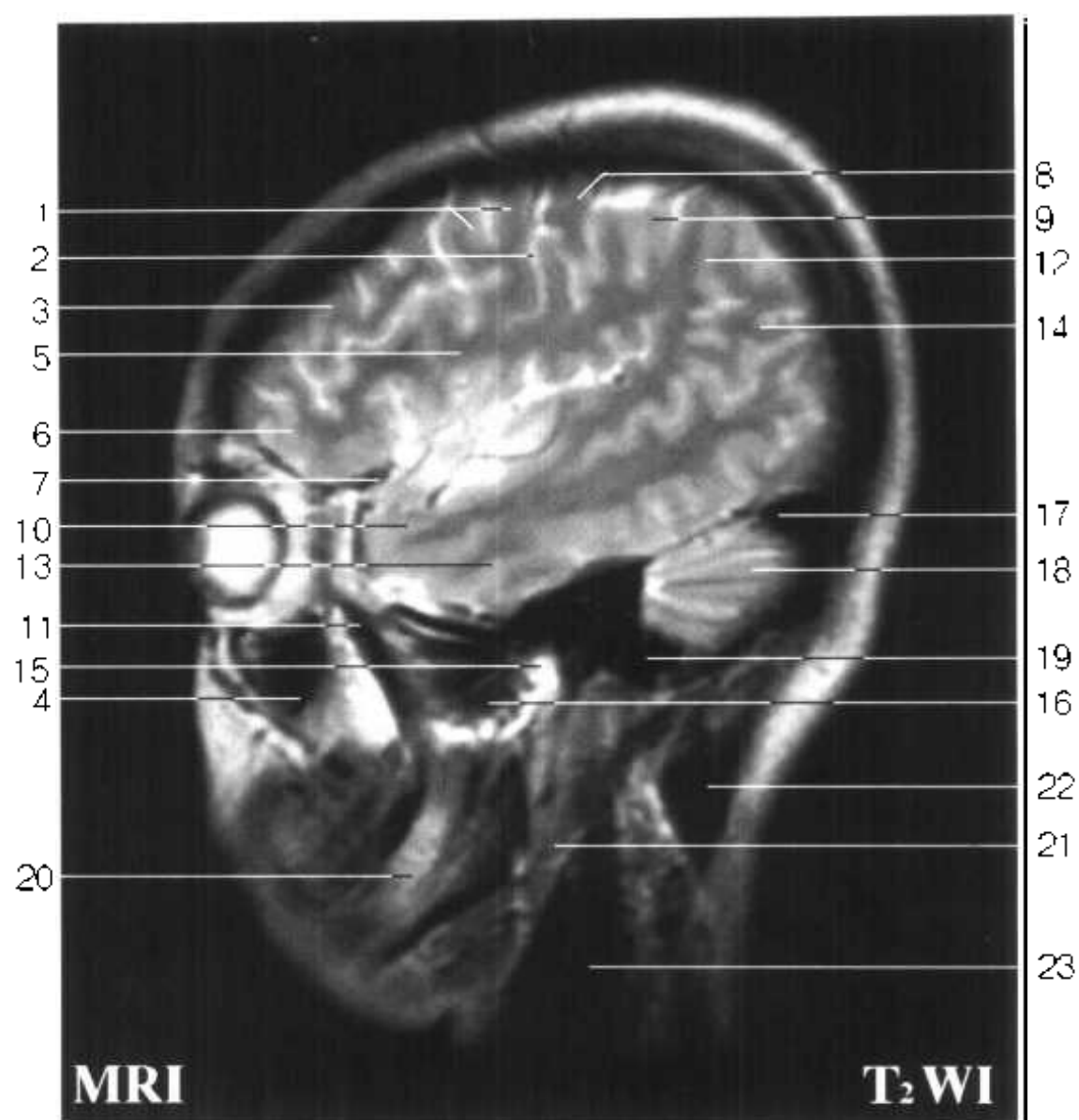


Fig SC 2



1. 中央前回 precentral gyrus
2. 中央沟 central sulcus
3. 额中回 middle frontal gyrus
4. 上颌窦 maxillary sinus
5. 辐射冠 corona radiata
6. 额下回 inferior frontal gyrus
7. 外侧沟 lateral sulcus
8. 中央后回 postcentral gyrus
9. 顶上小叶 superior parietal lobule
10. 颞上回 superior temporal gyrus
11. 颞肌 temporalis
12. 缘上回 supramarginal gyrus
13. 颞中回 middle temporal gyrus

Fig. SC 2



- 14. 角回 angular gyrus
- 15. 髁突 condylar process
- 16. 翼外肌 lateral pterygoid
- 17. 横窦 transverse sinus
- 18. 小脑半球 cerebellar hemisphere
- 19. 乙状窦 sigmoid sinus
- 20. 翼内肌 medial pterygoid
- 21. 腮腺 parotid gland
- 22. 头夹肌 splenius capitis
- 23. 胸锁乳突肌 sternocleidomastoid

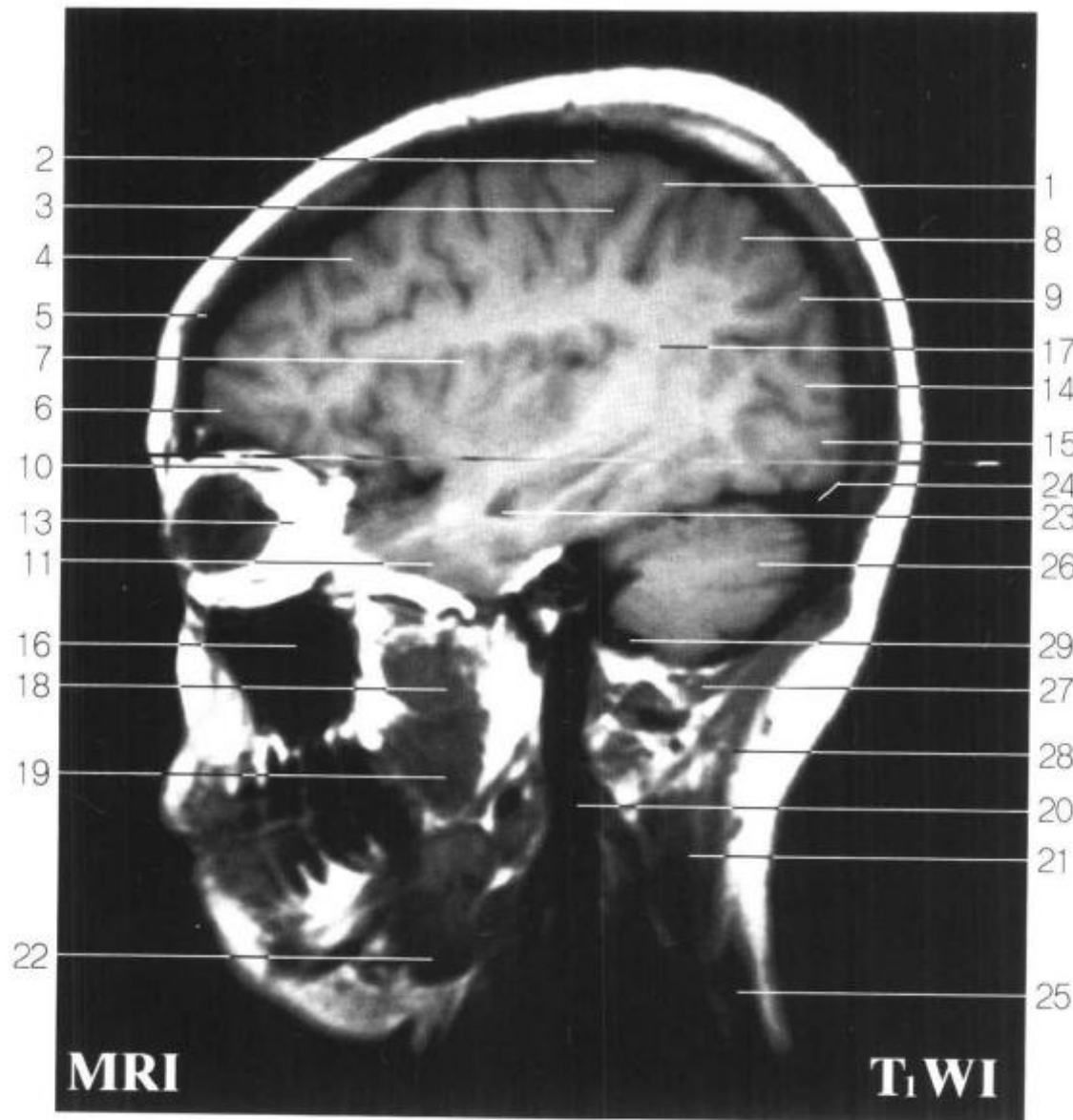
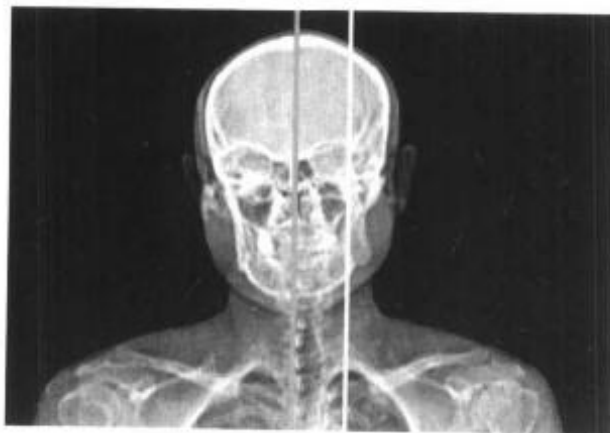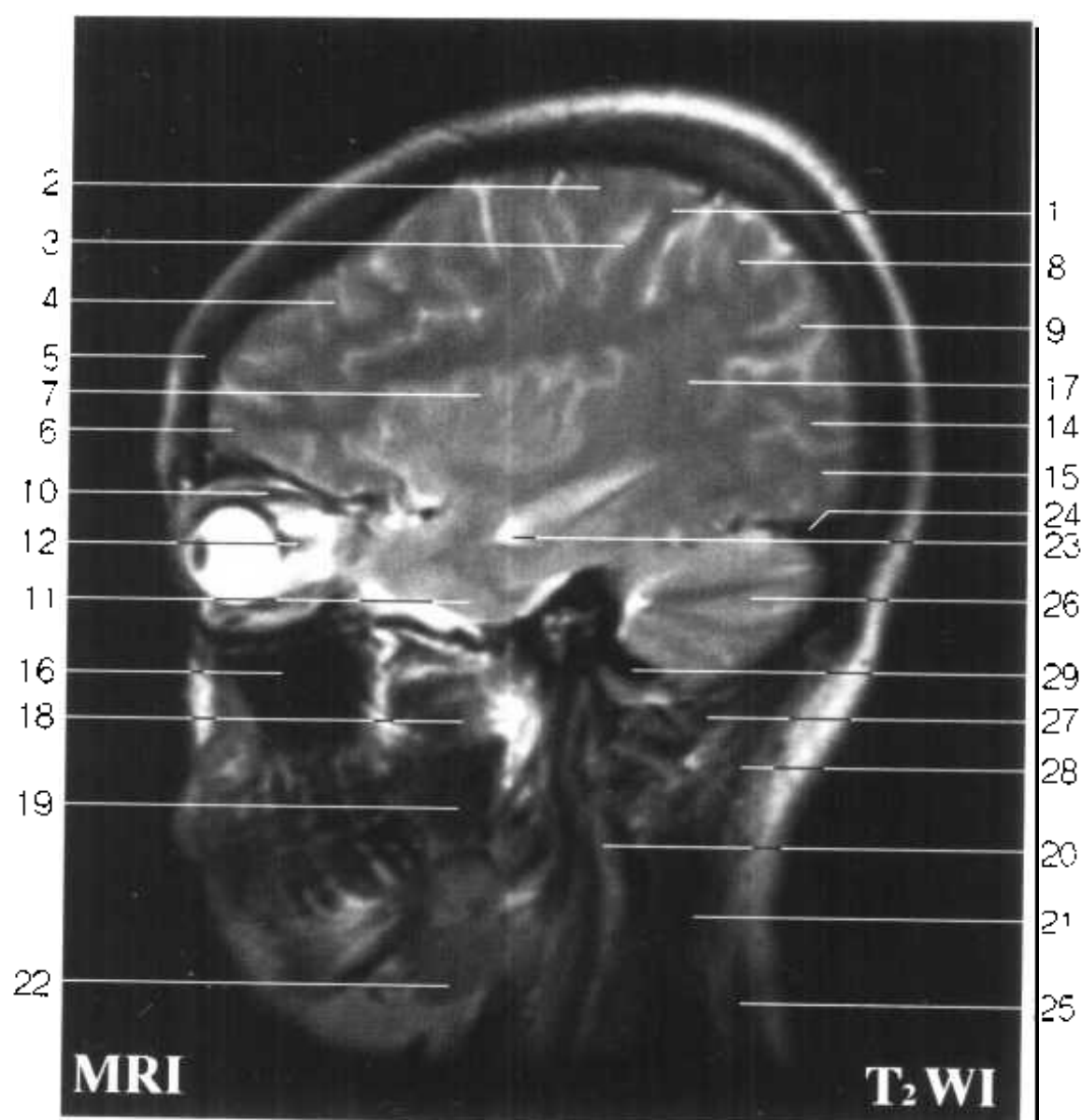


Fig SC 3



1. 中央后回 postcentral gyrus
2. 中央前回 precentral gyrus
3. 中央沟 central sulcus
4. 额中回 middle frontal gyrus
5. 额骨 frontal bone
6. 额极 frontal pole
7. 岛叶 insular lobe
8. 顶[上]小叶 superior parietal lobule
9. 缘[上]回 supramarginal gyrus
10. 上睑提肌及上[直]肌 levator palpebrae superioris and superior rectus

Fig. SC 3



- | | |
|-------------------------------|--|
| 11. 颞极 temporal pole | 23. 侧脑室下角 inferior horn of lateral ventricle |
| 12. 视神经 optic n. | 24. 横窦 transverse sinus |
| 13. 眶脂体 adipose body of orbit | 25. 斜方肌 trapezius |
| 14. 角回 angular gyrus | 26. 小脑半球 cerebellar hemisphere |
| 15. 枕叶 occipital lobe | 27. 头上斜肌 obliquus capitis superior |
| 16. 上颌窦 maxillary sinus | 28. 头夹肌 splenius capitis |
| 17. 辐射冠 corona radiata | 29. 乙状窦 sigmoid sinus |
| 18. 翼外肌 lateral pterygoid | |
| 19. 翼内肌 medial pterygoid | |
| 20. 颈内静脉 internal jugular v. | |
| 21. 头半棘肌 semispinalis capitis | |
| 22. 下颌下腺 submandibular gland | |

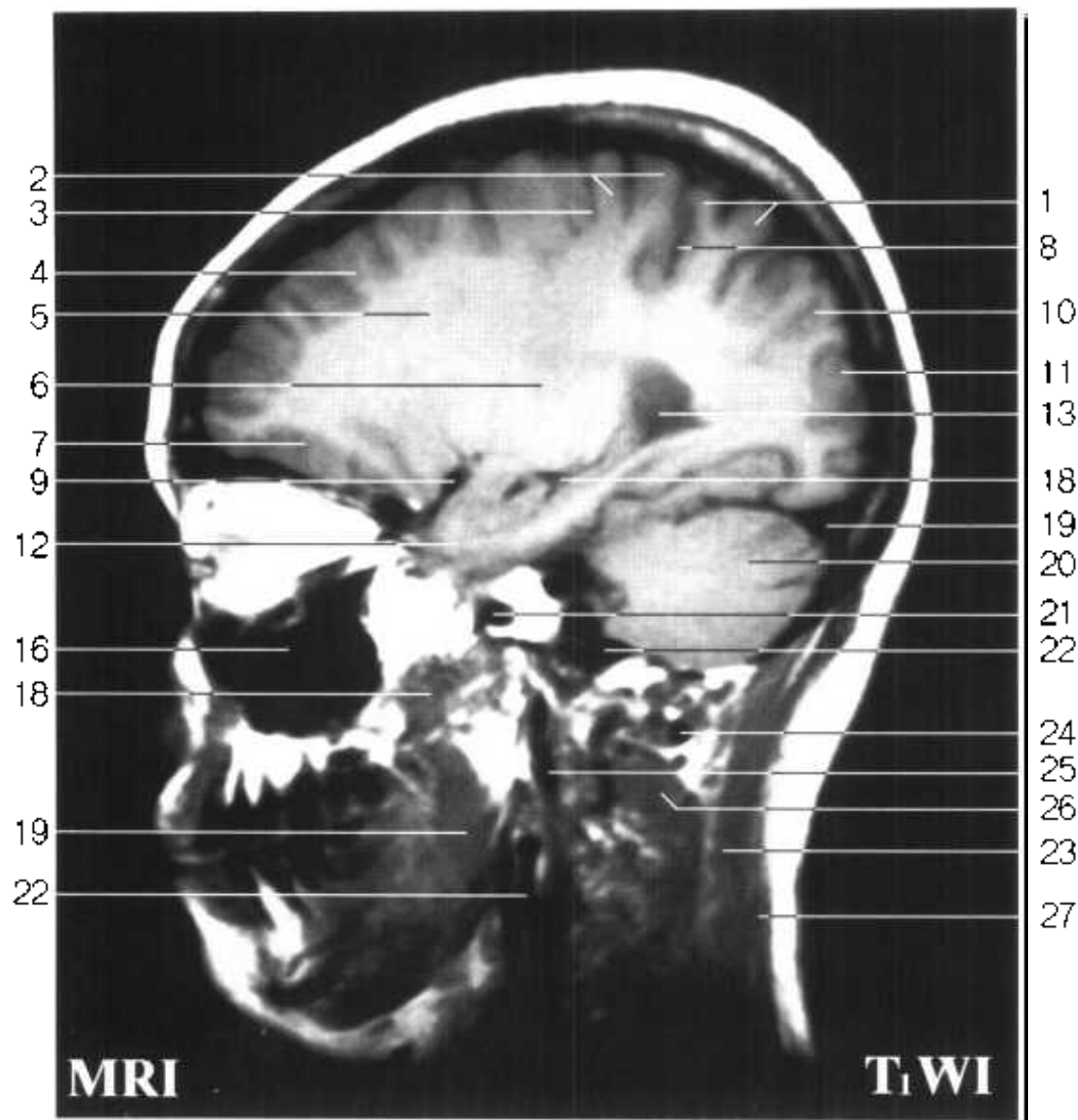
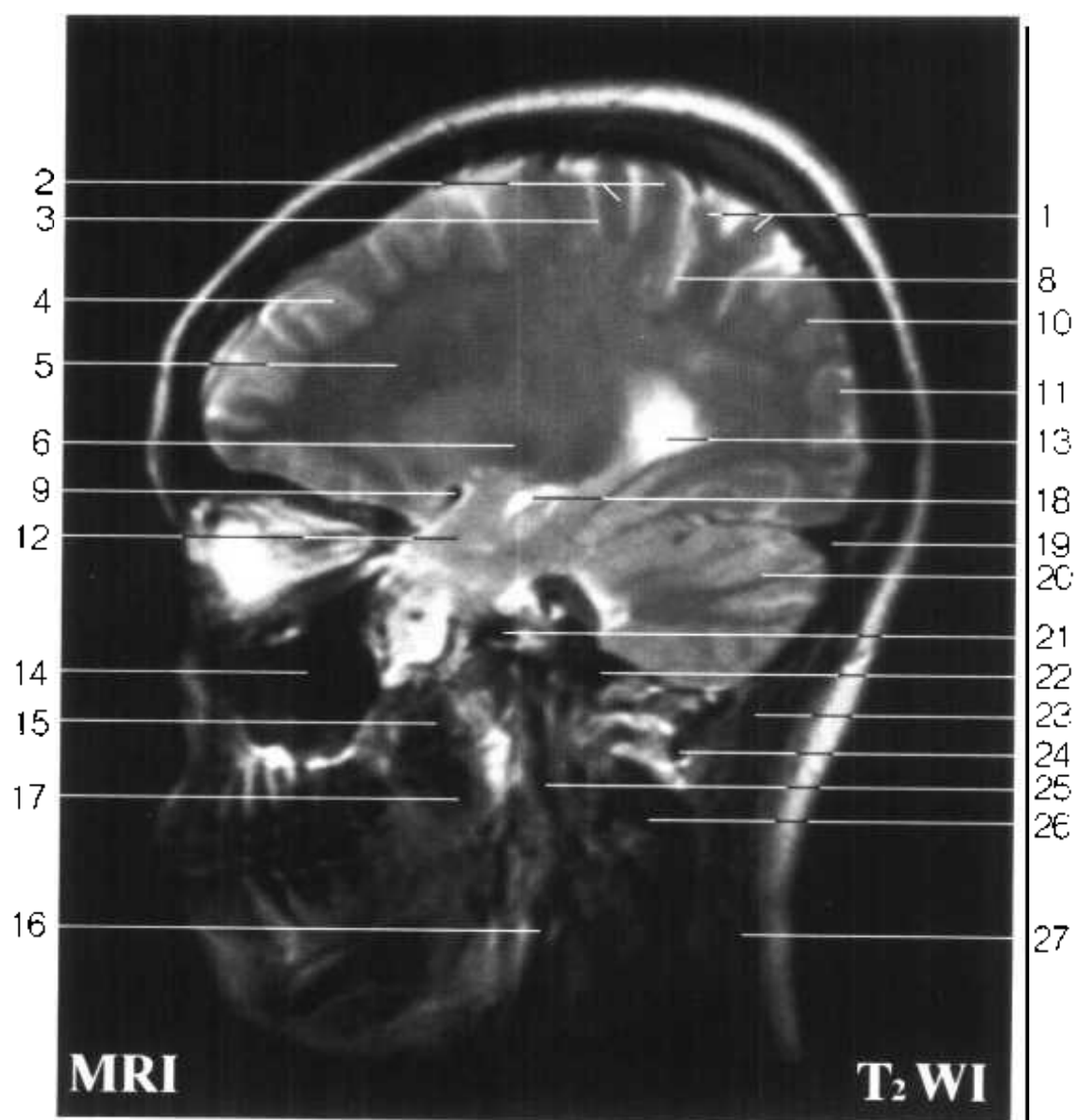


Fig SC 4

1. 中央后回 postcentral gyrus
2. 中央前回 precentral gyrus
3. 中央前沟 precentral sulcus
4. 额中回 middle frontal gyrus
5. 辐射冠(半卵圆中心) corona radiata (centrum semiovale)
6. 壳 putamen
7. 眶回 orbital gyrus
8. 中央沟 central sulcus
9. 外侧沟与大脑中动脉 lateral sulcus and middle cerebral a.

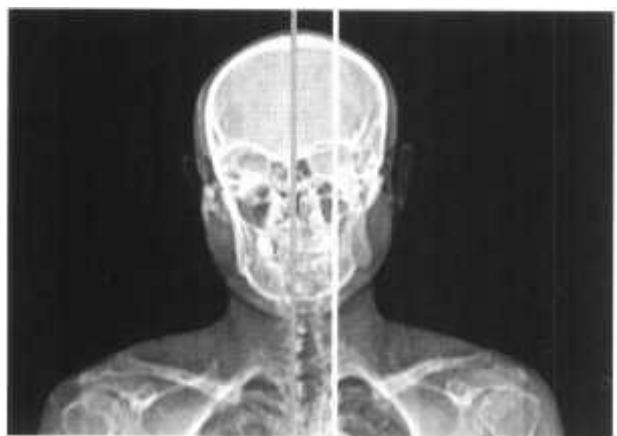

Fig. SC 4



- | | |
|--|------------------------------------|
| 10. 顶上小叶 superior parietal lobule | 21. 颈内动脉 internal carotid a. |
| 11. 楔叶 cuneus | 22. 乙状窦 sigmoid sinus |
| 12. 颞极 temporal pole | 23. 头半棘肌 semispinalis capitis |
| 13. 侧脑室三角 trigone of lateral ventricle | 24. 椎动、静脉 vertebral a.and v. |
| 14. 上颌窦 maxillary sinus | 25. 颈内静脉 internal jugular v. |
| 15. 翼外肌 lateral pterygoid | 26. 头下斜肌 obliquus capitis inferior |
| 16. 颈内动脉 internal carotid a. | 27. 头夹肌 splenius capitis |
| 17. 翼内肌 medial pterygoid | |
| 18. 侧脑室下角 inferior horn of lateral ventricle | |
| 19. 横窦 transverse sinus | |
| 20. 小脑半球 cerebellar hemisphere | |

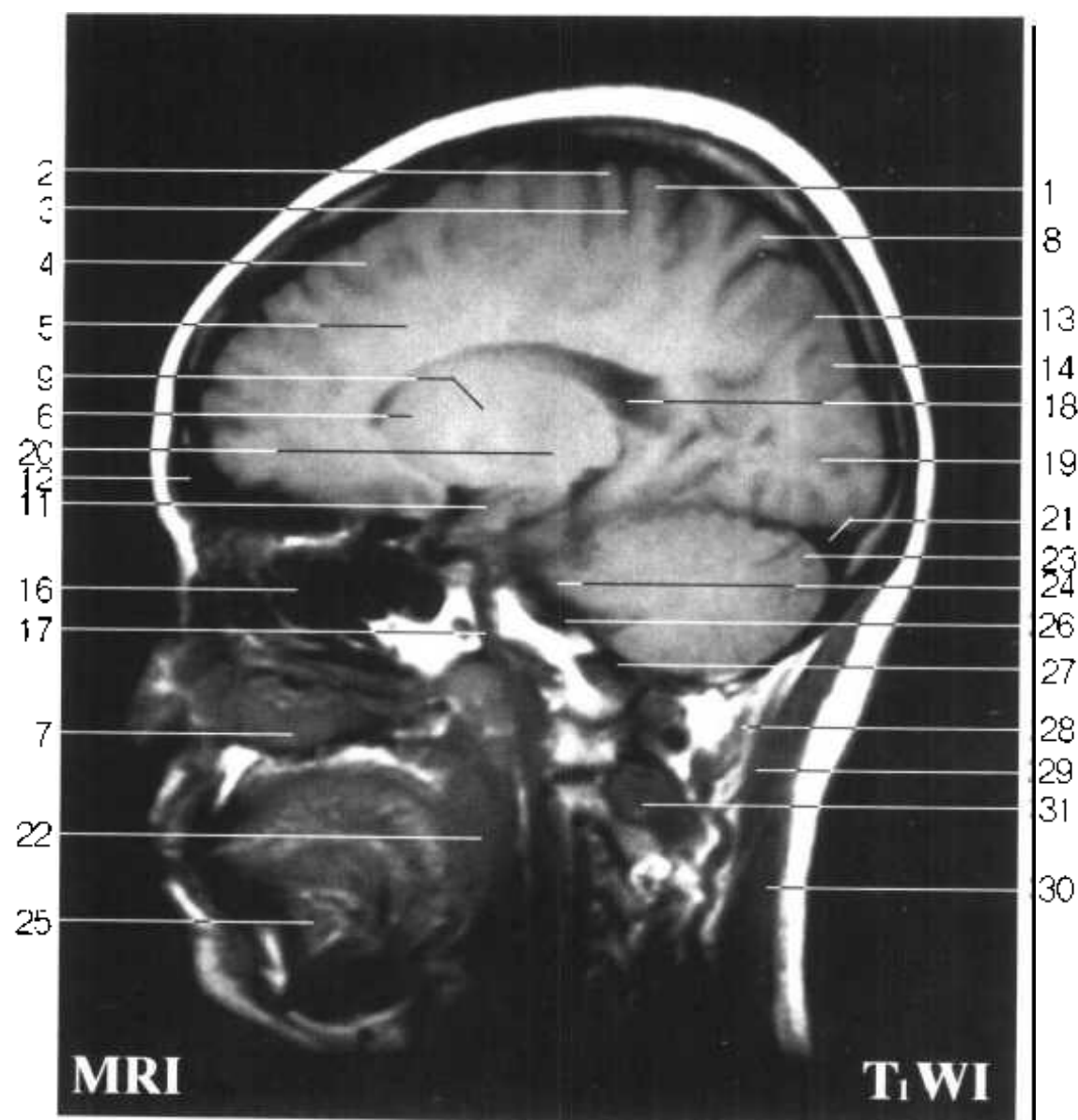
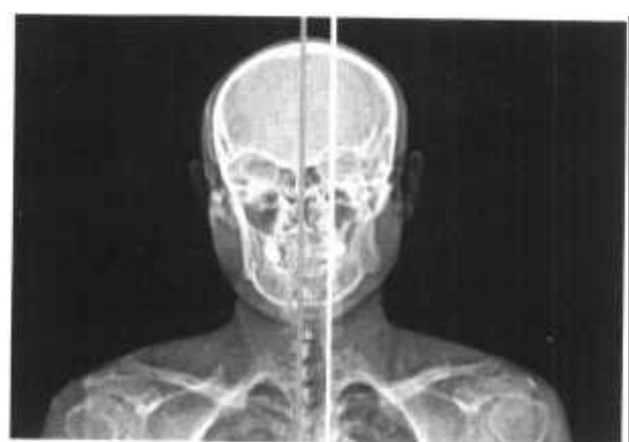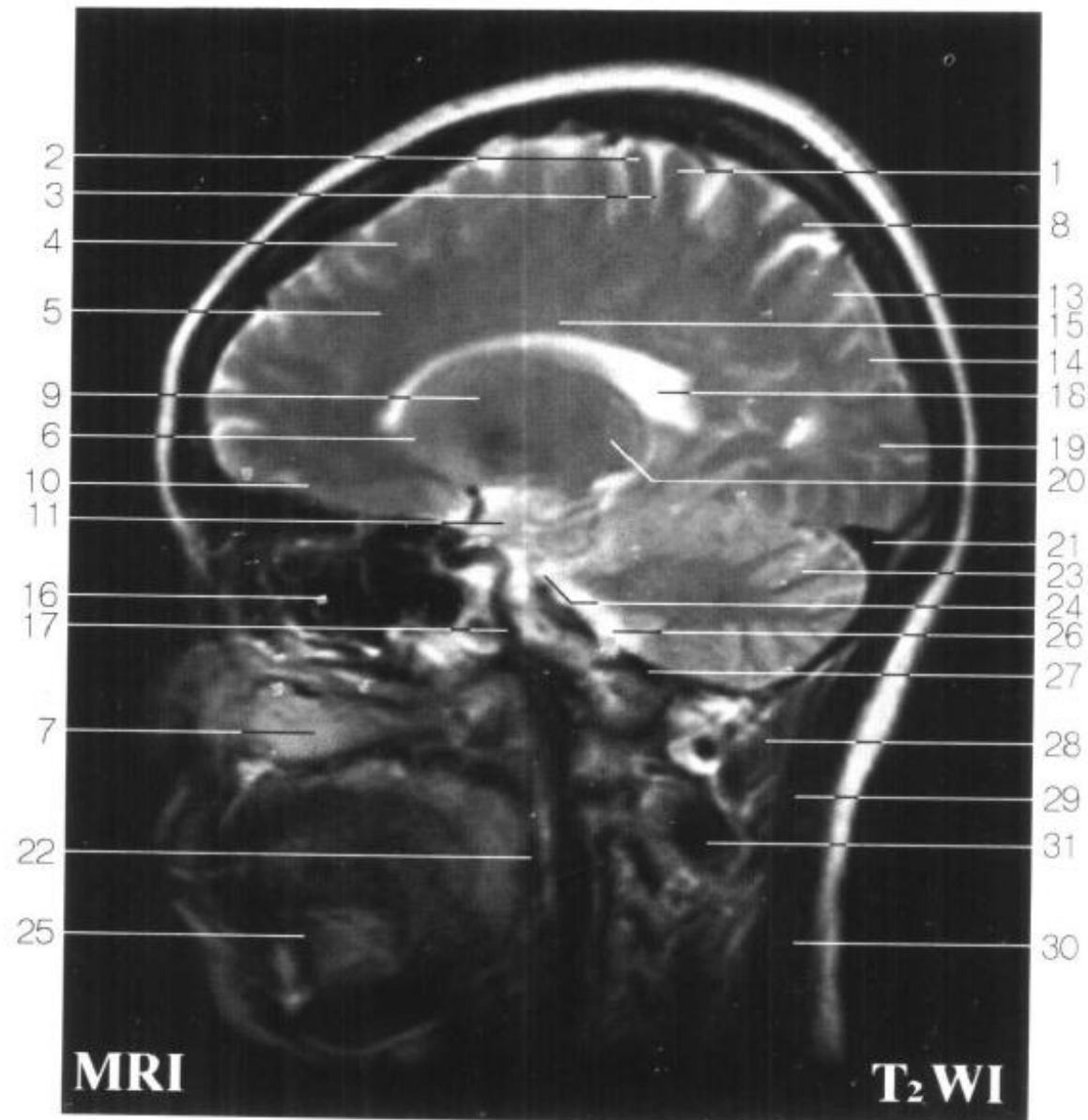


Fig SC 5



1. 中央后回 postcentral gyrus
2. 中央前回 precentral gyrus
3. 中央沟 central sulcus
4. 额上回 superior frontal gyrus
5. 辐射冠(半卵圆中心) corona radiata (centrum semiovale)
6. 尾状核头 head of caudate nucleus
7. 下鼻甲 inferior nasal concha
8. 楔前叶 precuneus
9. 内囊后肢 posterior limb of internal capsule
10. 眶回 orbital gyrus

Fig. SC 5



- | | |
|---------------------------------|--|
| 11. 杏仁体 amygdaloid body | 23. 小脑半球 cerebellar hemisphere |
| 12. 额窦 frontal sinus | 24. 三叉神经根 root of trigeminal n. |
| 13. 顶枕沟 parietooccipital sulcus | 25. 舌下腺 sublingual gland |
| 14. 楔叶 cuneus | 26. 脑桥小脑三角池 cistern of pontocerebellar trigene |
| 15. 胼胝体 corpus callosum | 27. 乙状窦 sigmoid sinus |
| 16. 筛窦 ethmoidal sinuses | 28. 头后大直肌 rectus capitis posterior major |
| 17. 颈内动脉 internal carotid a. | 29. 头半棘肌 semispinalis capitis |
| 18. 侧脑室 lateral ventricle | 30. 头夹肌 splenius capitis |
| 19. 距状沟 calcarine sulcus | 31. 头下斜肌 obliquus capitis inferior |
| 20. 背侧丘脑 dorsal thalamus | |
| 21. 横窦 transverse sinus | |
| 22. 口咽 oropharynx | |

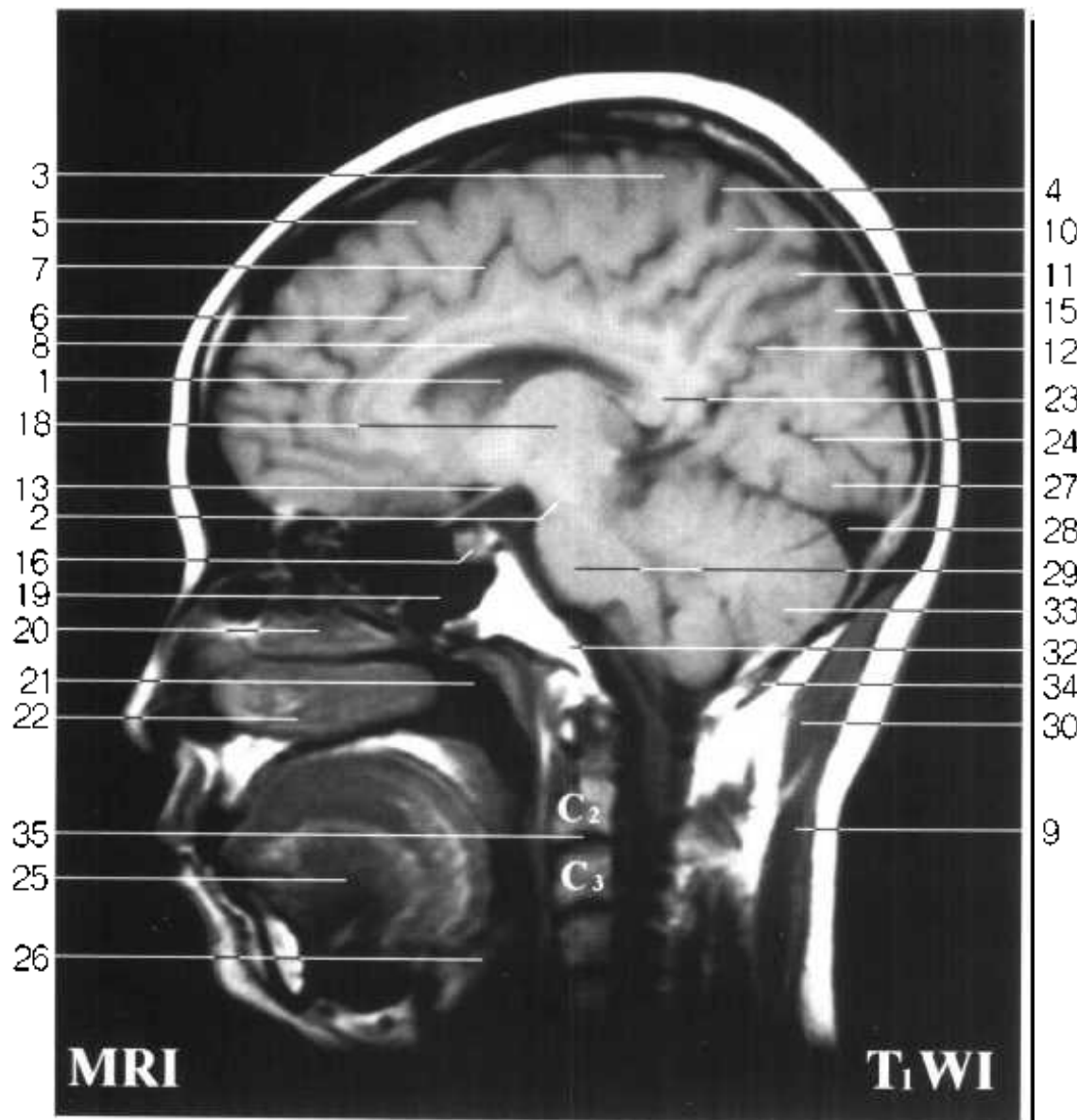
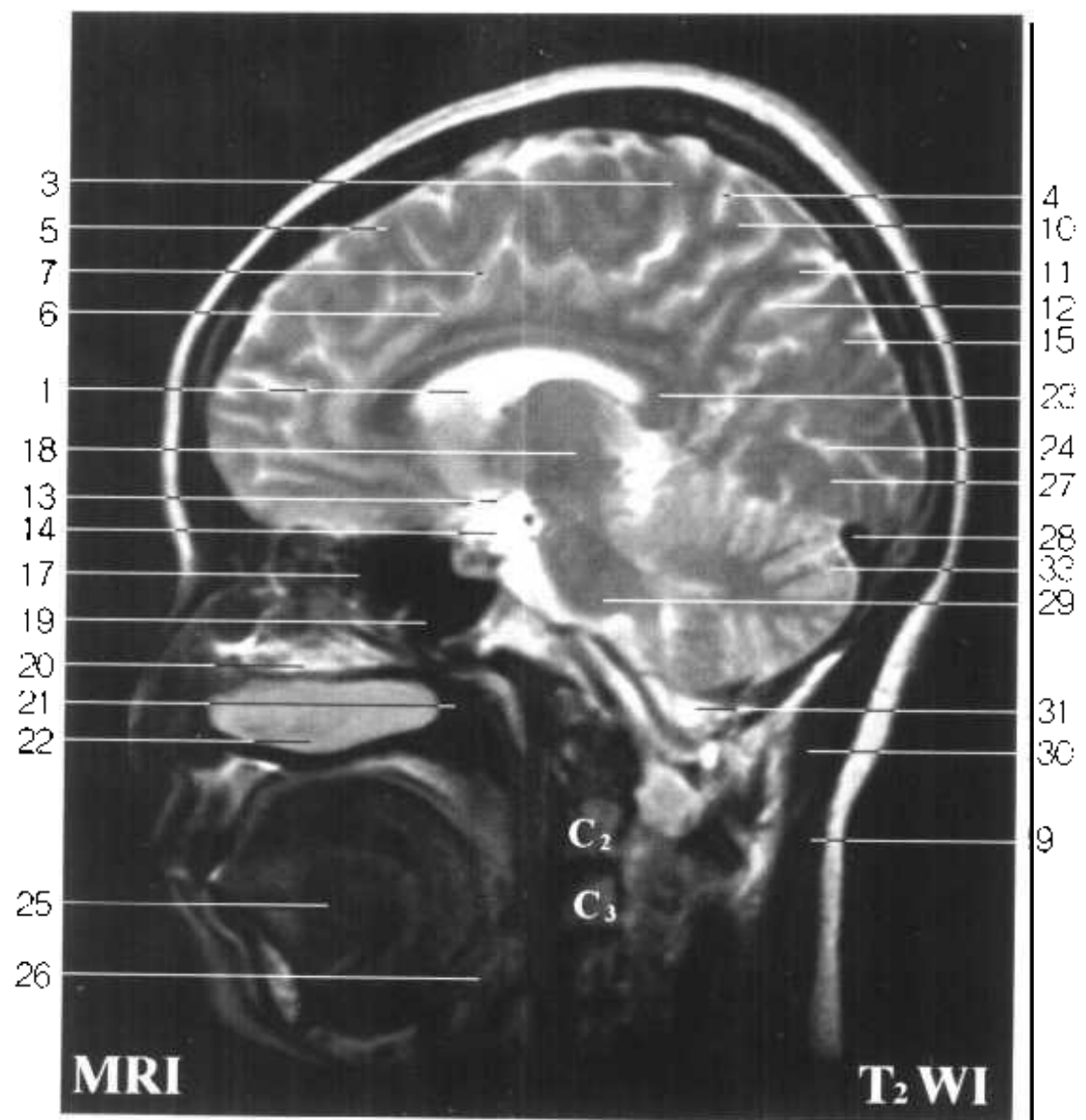


Fig SC 6

1. 侧脑室 lateral ventricle
2. 大脑脚 cerebral peduncle
3. 中央前回 precentral gyrus
4. 中央沟 central sulcus
5. 额上回 superior frontal gyrus
6. 扣带回 cingulate gyrus
7. 扣带沟 cingulate sulcus
8. 胼胝体干 trunk of corpus callosum
9. 头夹肌 splenius capitis
10. 中央后回 postcentral gyrus
11. 楔前叶 precuneus
12. 顶枕沟 parietooccipital sulcus

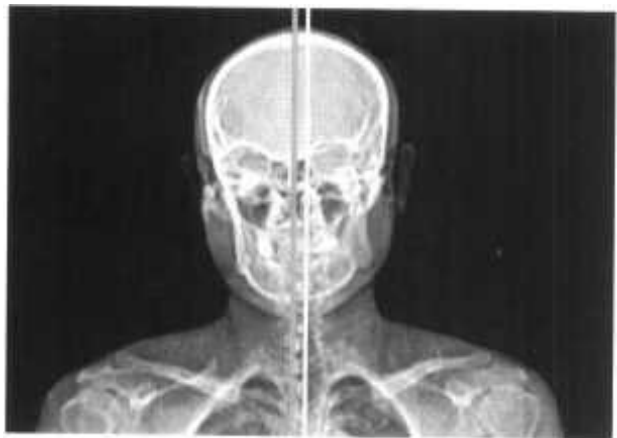

Fig . SC 6



- | | |
|---------------------------------------|--|
| 13. 视束 optic tract | 25. 颌舌肌 genioglossus |
| 14. 脚间池 interpeduncular cistern | 26. 会厌 epiglottis |
| 15. 楔叶 cuneus | 27. 舌回 lingual gyrus |
| 16. 垂体 hypophysis | 28. 横窦 transverse sinus |
| 17. 筛窦 ethmoidal sinuses | 29. 脑桥 pons |
| 18. 背侧丘脑 dorsal thalamus | 30. 头半棘肌 semispinalis capitis |
| 19. 蝶窦 sphenoidal sinus | 31. 小脑延髓池 cerebellomedullary cistern |
| 20. 中鼻甲 middle nasal concha | 32. 斜坡 clivus |
| 21. 鼻咽 nasopharynx | 33. 小脑半球 cerebellar hemisphere |
| 22. 下鼻甲 inferior nasal concha | 34. 头后大直肌 rectus capitis posterior major |
| 23. 胼胝体压部 splenium of corpus callosum | 35. 2、3 颈椎间盘 intervertebral disc (C ₂ ~C ₃) |
| 24. 距状沟 calcarine sulcus | |

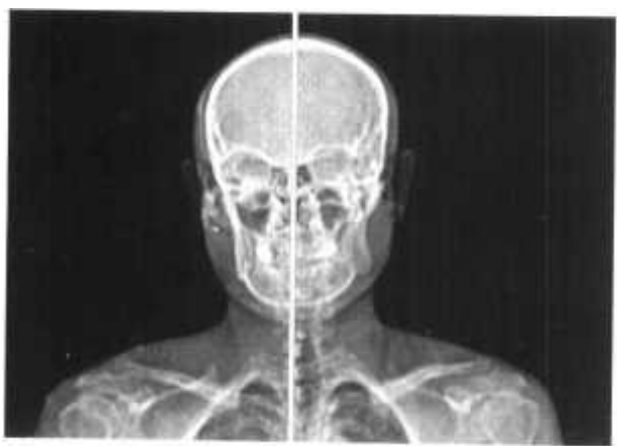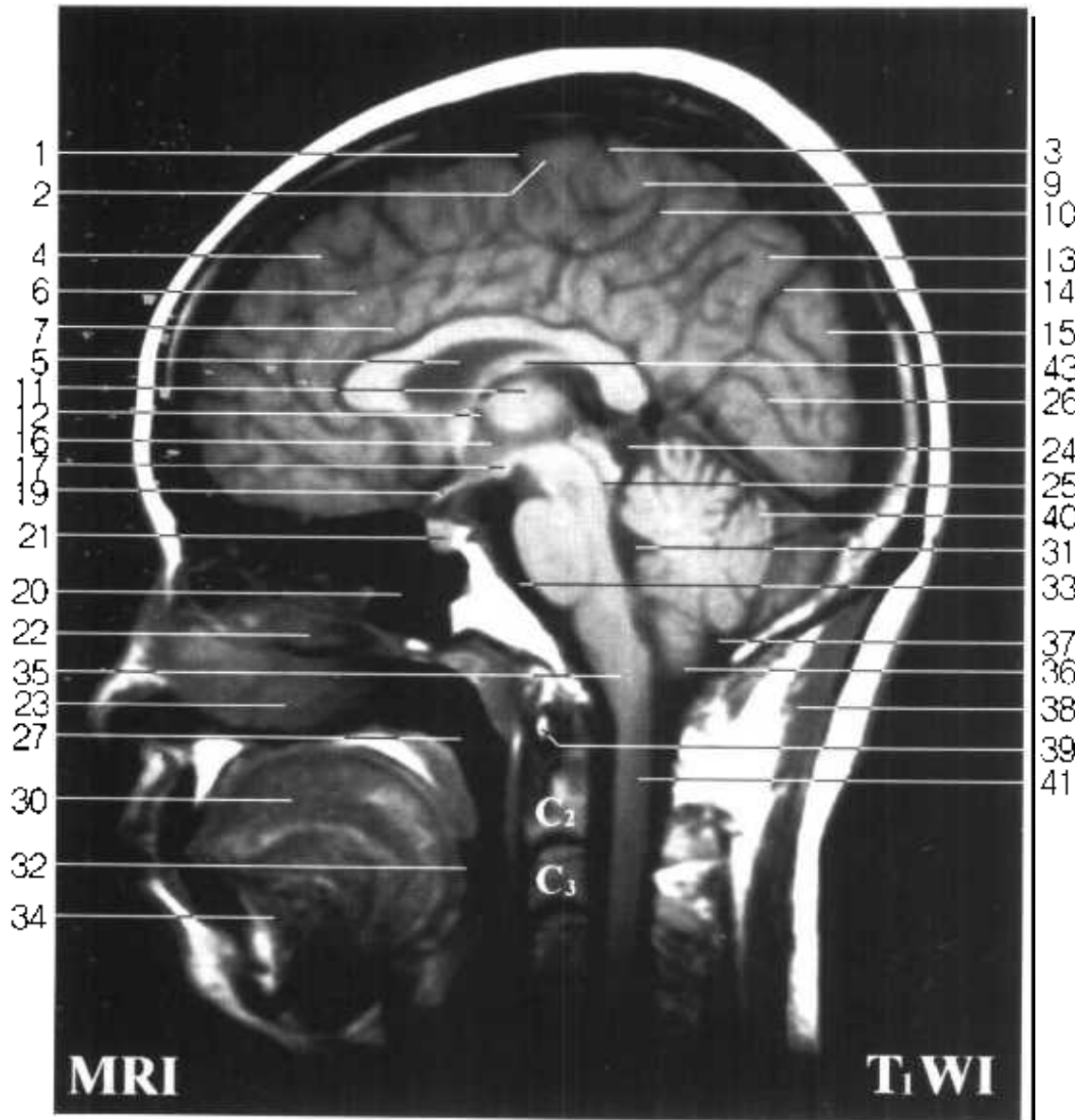
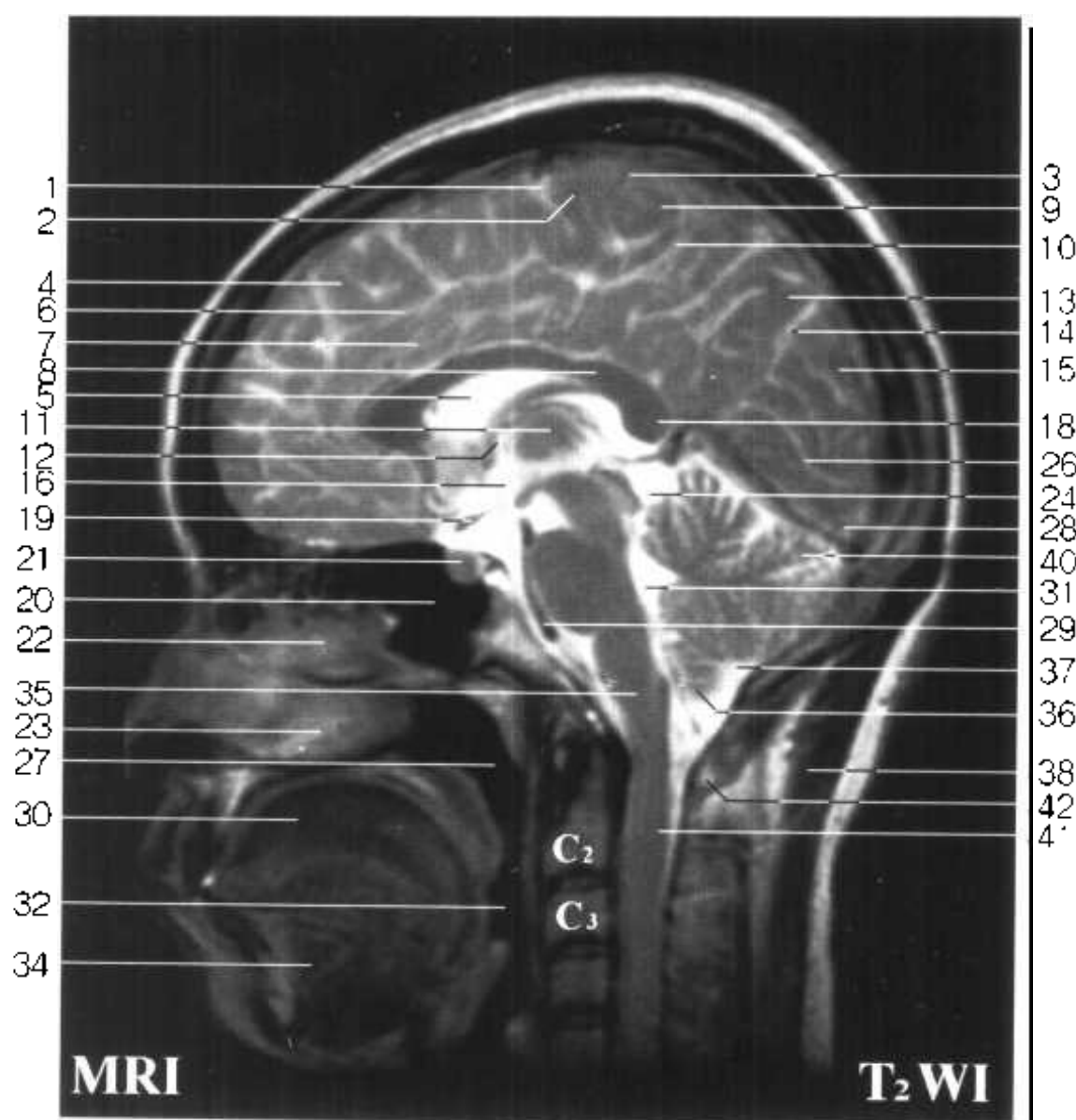


Fig SC 7

1. 中央前沟 precentral sulcus
2. 中央前回 precentral gyrus
3. 中央沟 central sulcus
4. 额上回 superior frontal gyrus
5. 侧脑室 lateral ventricle
6. 扣带沟 cingulate sulcus
7. 扣带回 cingulate gyrus
8. 胼胝体干 trunk of corpus callosum
9. 中央后回 postcentral gyrus
10. 扣带沟缘支 marginal ramus of cingulate sulcus
11. 背侧丘脑 dorsal thalamus
12. 室间孔 interventricular foramen
13. 楔前叶 precuneus

Fig. SC 7



- | | |
|---------------------------------------|--------------------------------------|
| 14. 顶枕沟 parietooccipital sulcus | 29. 基底动脉 basilar a. |
| 15. 楔叶 cuneus | 30. 舌 tongue |
| 16. 第三脑室 third ventricle | 31. 第四脑室 fourth ventricle |
| 17. 乳头体 mamillary body | 32. 口咽 oropharynx |
| 18. 胼胝体压部 splenium of corpus callosum | 33. 桥池 pontine cistern |
| 19. 视交叉 optic chiasma | 34. 舌下腺 sublingual gland |
| 20. 蝶窦 sphenoidal sinus | 35. 延髓 medulla oblongata |
| 21. 垂体 hypophysis | 36. 小脑扁桃体 tonsil of cerebellum |
| 22. 中鼻甲 middle nasal concha | 37. 小脑延髓池 cerebellomedullary cistern |
| 23. 下鼻甲 inferior nasal concha | 38. 头半棘肌 semispinalis capitis |
| 24. 四叠体池 quadrigeminal cistern | 39. 寰椎前弓 anterior arch of atlas |
| 25. 中脑水管 mesencephalic aqueduct | 40. 小脑 cerebellum |
| 26. 距状沟 calcarine sulcus | 41. 脊髓 spinal cord |
| 27. 鼻咽 nasopharynx | 42. 寰椎后弓 posterior arch of atlas |
| 28. 舌回 lingual gyrus | 43. 穹隆体 body of fornix |

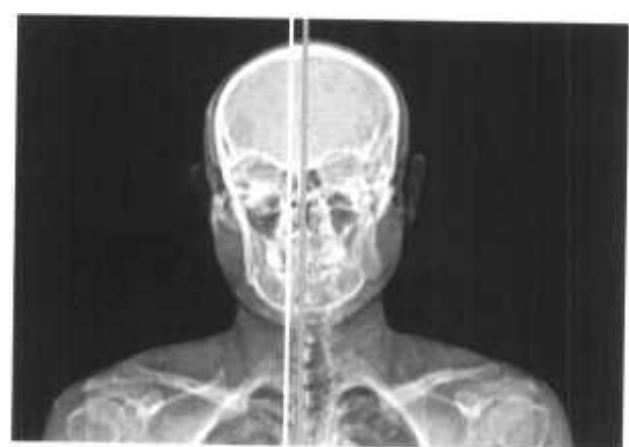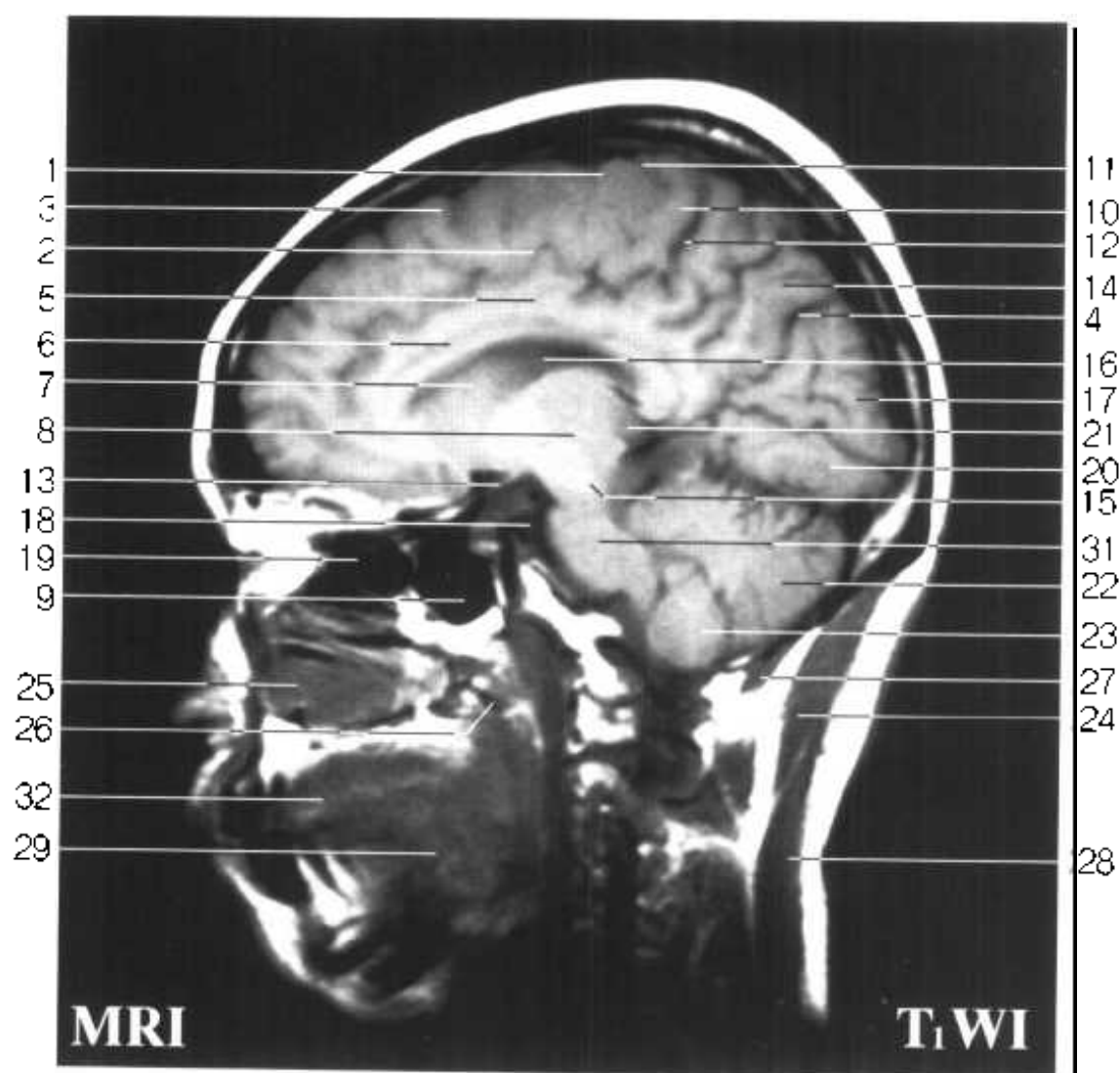
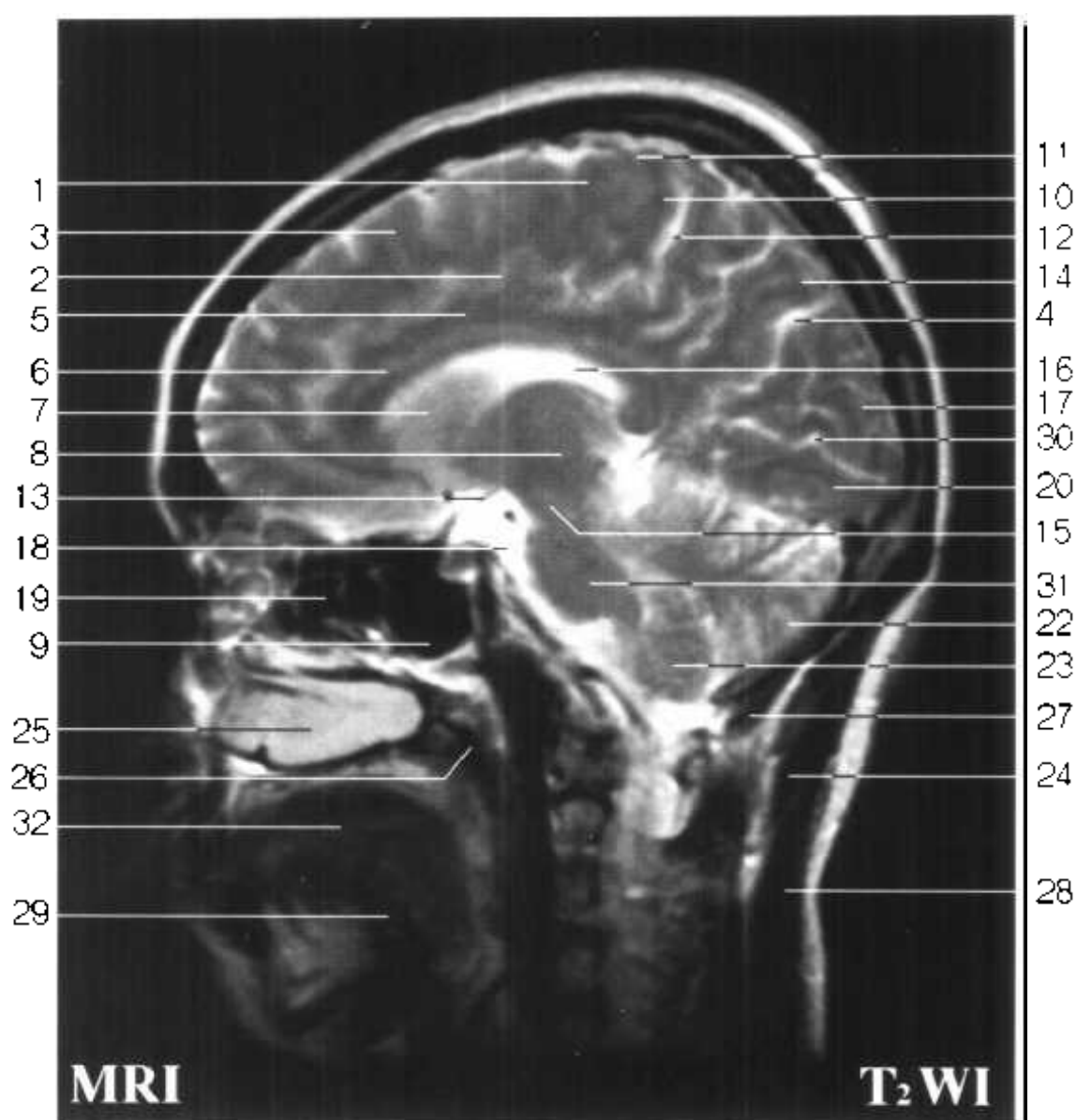


Fig SC 8

1. 中央前回 precentral gyrus
2. 扣带沟 cingulate sulcus
3. 额上回 superior frontal gyrus
4. 顶枕沟 frontal bone
5. 扣带回 cingulate gyrus
6. 胼胝体 corpus callosum
7. 尾状核体 body of caudate nucleus
8. 背侧丘脑 dorsal thalamus
9. 蝶窦 sphenoidal sinus
10. 中央后回 postcentral gyrus
11. 中央沟 central sulcus
12. 扣带沟缘支 marginal ramus of cingulate sulcus

Fig. SC 8



- | | |
|--------------------------------|---|
| 13. 视束 optic tract | 25. 下鼻甲 inferior nasal concha |
| 14. 楔前叶 precuneus lobe | 26. 咽鼓管咽口 pharyngeal opening of auditory tube |
| 15. 大脑脚 cerebral peduncle | 27. 头后大直肌 rectus capitis posterior major |
| 16. 侧脑室 lateral ventricle | 28. 头夹肌 splenius capitis |
| 17. 楔叶 cuneus | 29. 舌下腺 sublingual gland |
| 18. 桥池 pontine cistern | 30. 距状沟 calcarine sulcus |
| 19. 筛窦 ethmoidal sinuses | 31. 脑桥 pons |
| 20. 舌回 lingual gyrus | 32. 舌 tongue |
| 21. 丘脑枕 pulvinar | |
| 22. 小脑半球 cerebellar hemisphere | |
| 23. 小脑扁桃体 tonsil of cerebellum | |
| 24. 头半棘肌 semispinalis capitis | |

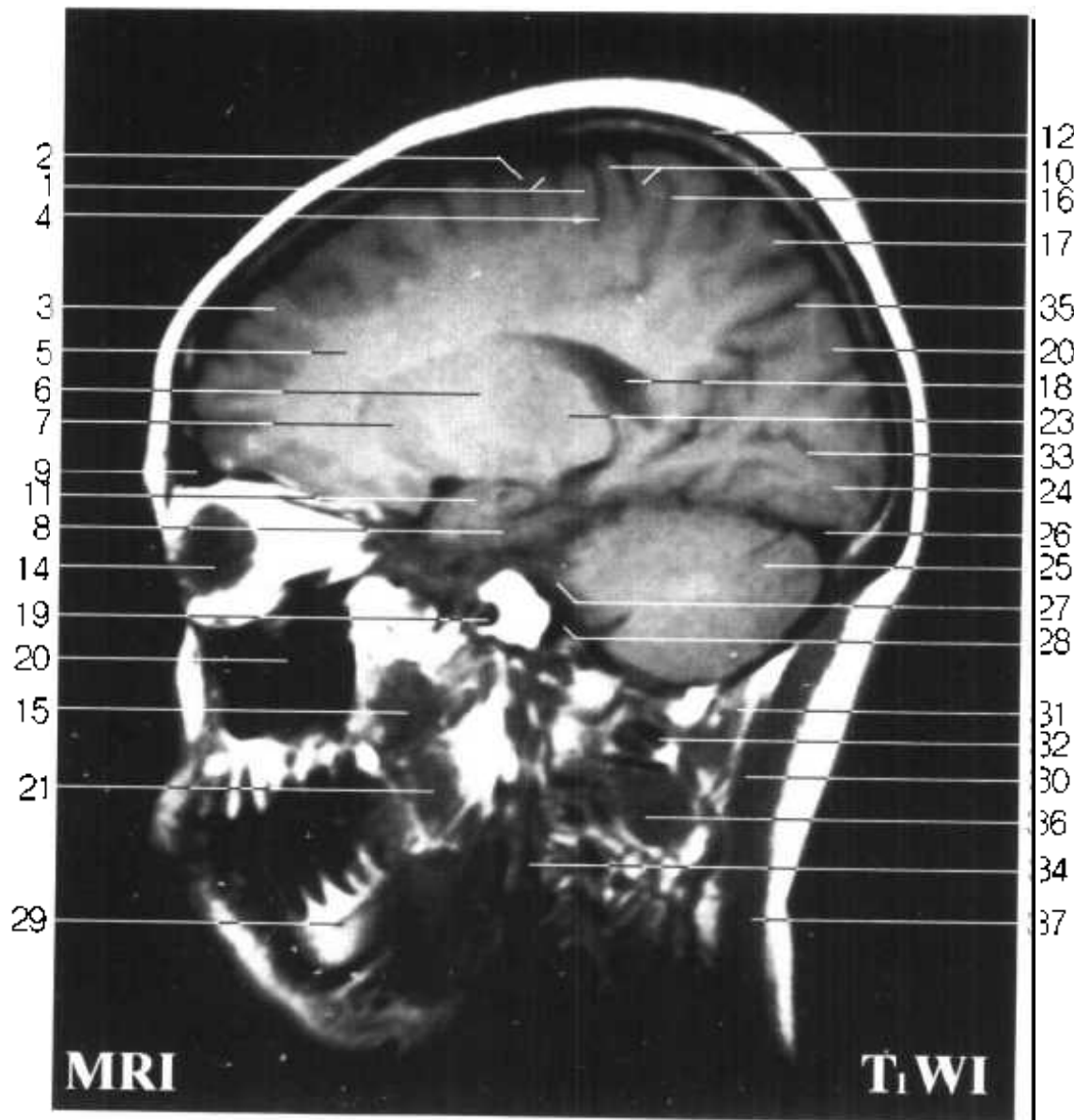
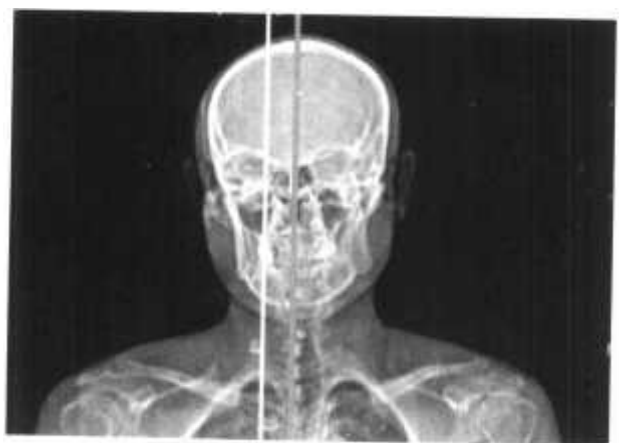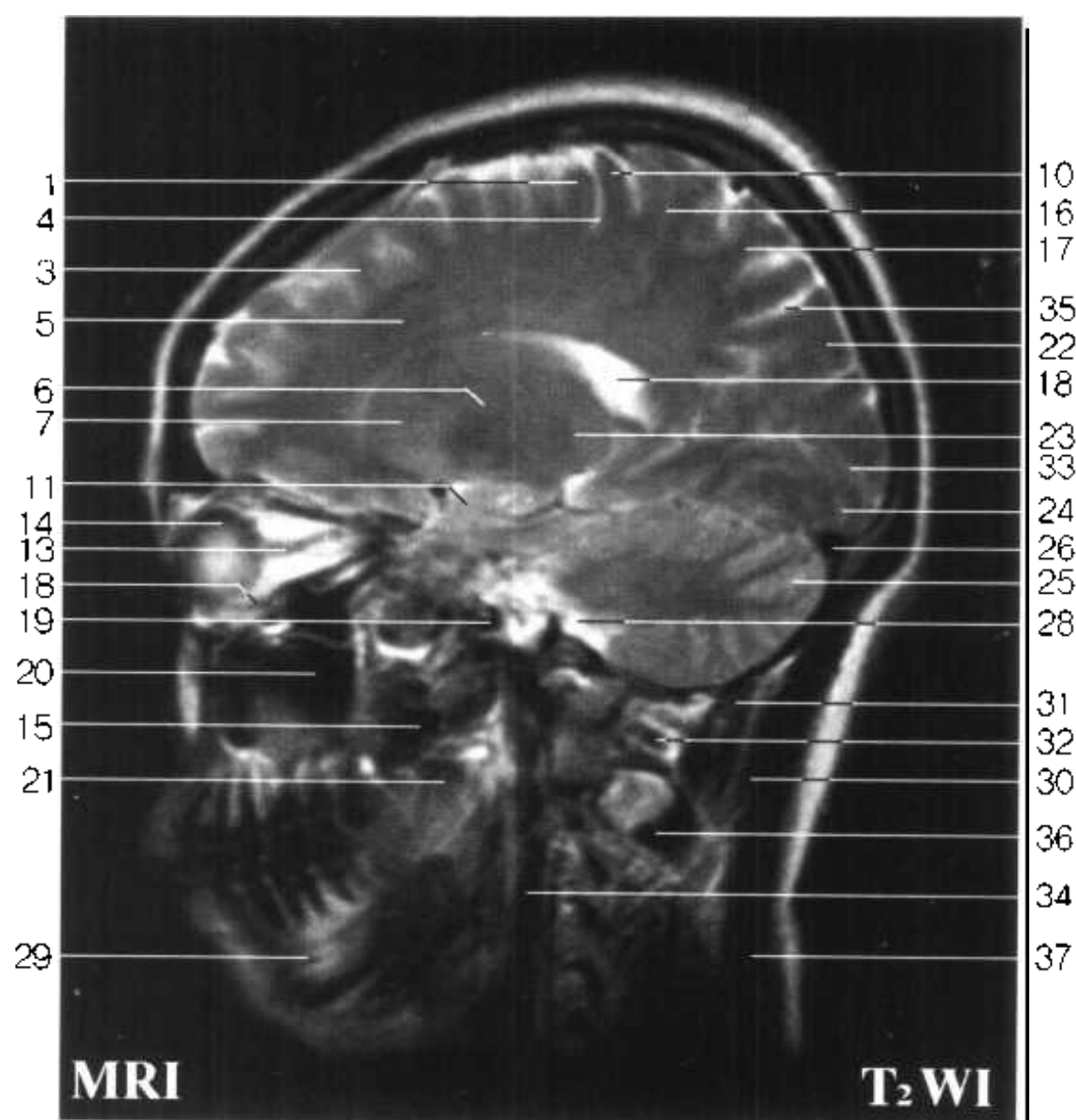


Fig SC 9



1. 中央前回 precentral gyrus
2. 中央前沟 precentral sulcus
3. 额上回 superior frontal gyrus
4. 中央沟 central sulcus
5. 辐射冠(半卵圆中心) corona radiata (centrum semiovale)
6. 内囊后肢 posterior limb of internal capsule
7. 壳 putamen
8. 海马旁回 parahippocampal gyrus
9. 额窦 frontal sinus
10. 中央后回 postcentral gyrus
11. 杏仁体 amygdaloid body
12. 顶骨 parietal bone
13. 视神经 optic n.

Fig. SC 9



- | | |
|--|---|
| 14. 眼球 eyeball | 27. 三叉神经根 root of trigeminal n. |
| 15. 翼外肌 lateral pterygoid | 28. 脑桥小脑三角池 cistern of pontocerebellar trigone |
| 16. 中央后沟 postcentral sulcus | 29. 下牙槽神经 inferior alveolar n. |
| 17. 顶上小叶 superior parietal lobule | 30. 头半棘肌 semispinalis capitis |
| 18. 侧脑室三角 trigone of lateral ventricle | 31. 头后大直肌 rectus capitis posterior major |
| 19. 颈内动脉 internal carotid a. | 32. 横突孔与椎动脉 transverse foramen and vertebral a. |
| 20. 上颌窦 maxillary sinus | 33. 距状沟 calcarine sulcus |
| 21. 翼内肌 medial pterygoid | 34. 颈长肌 longus colli |
| 22. 楔叶 cuneus | 35. 顶枕沟 parietooccipital sulcus |
| 23. 背侧丘脑 dorsal thalamus | 36. 头下斜肌 obliquus capitis inferior |
| 24. 舌回 lingual gyrus | 37. 头夹肌 splenius capitis |
| 25. 小脑半球 cerebellar hemisphere | |
| 26. 横窦 transverse sinus | |

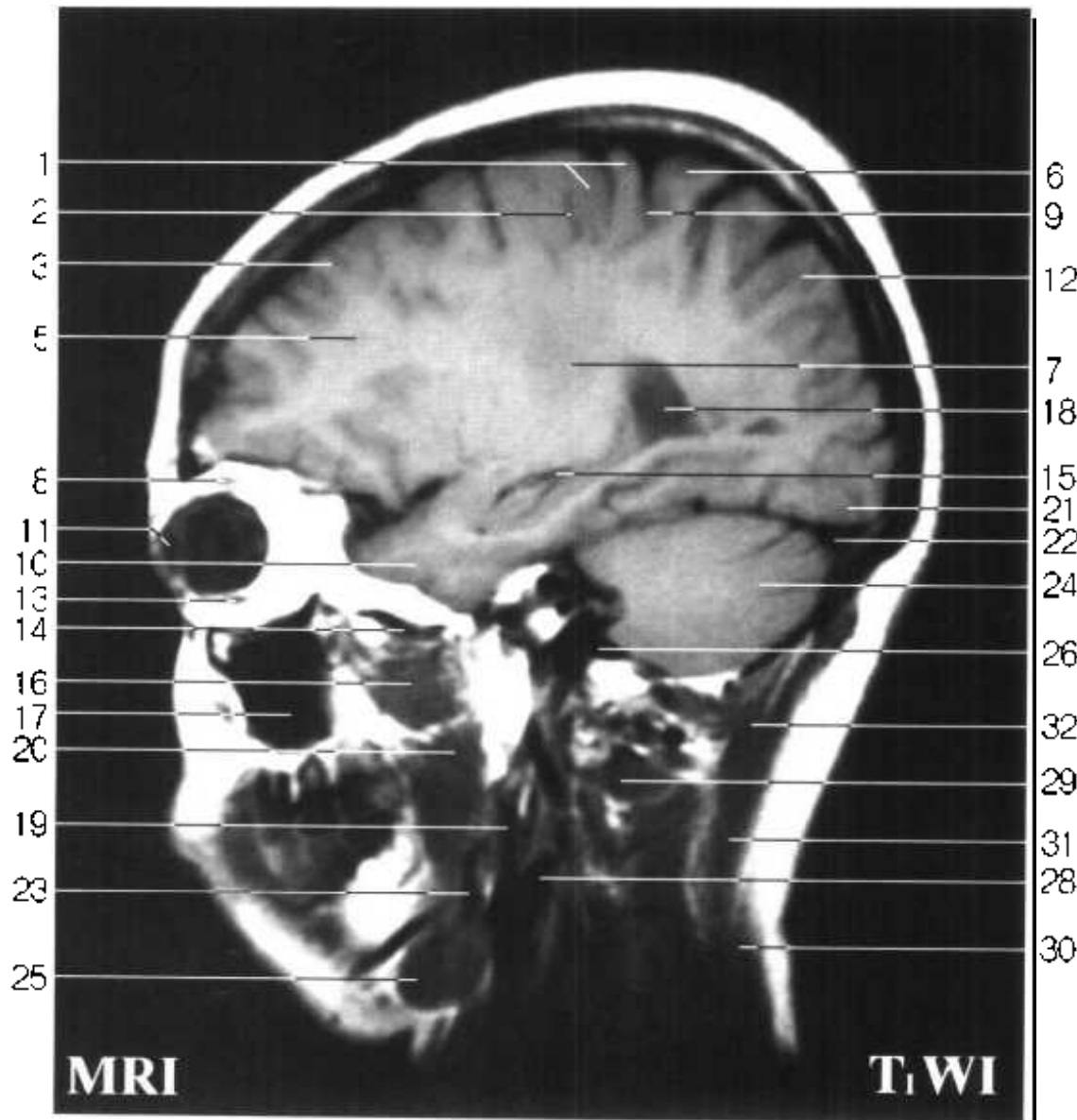
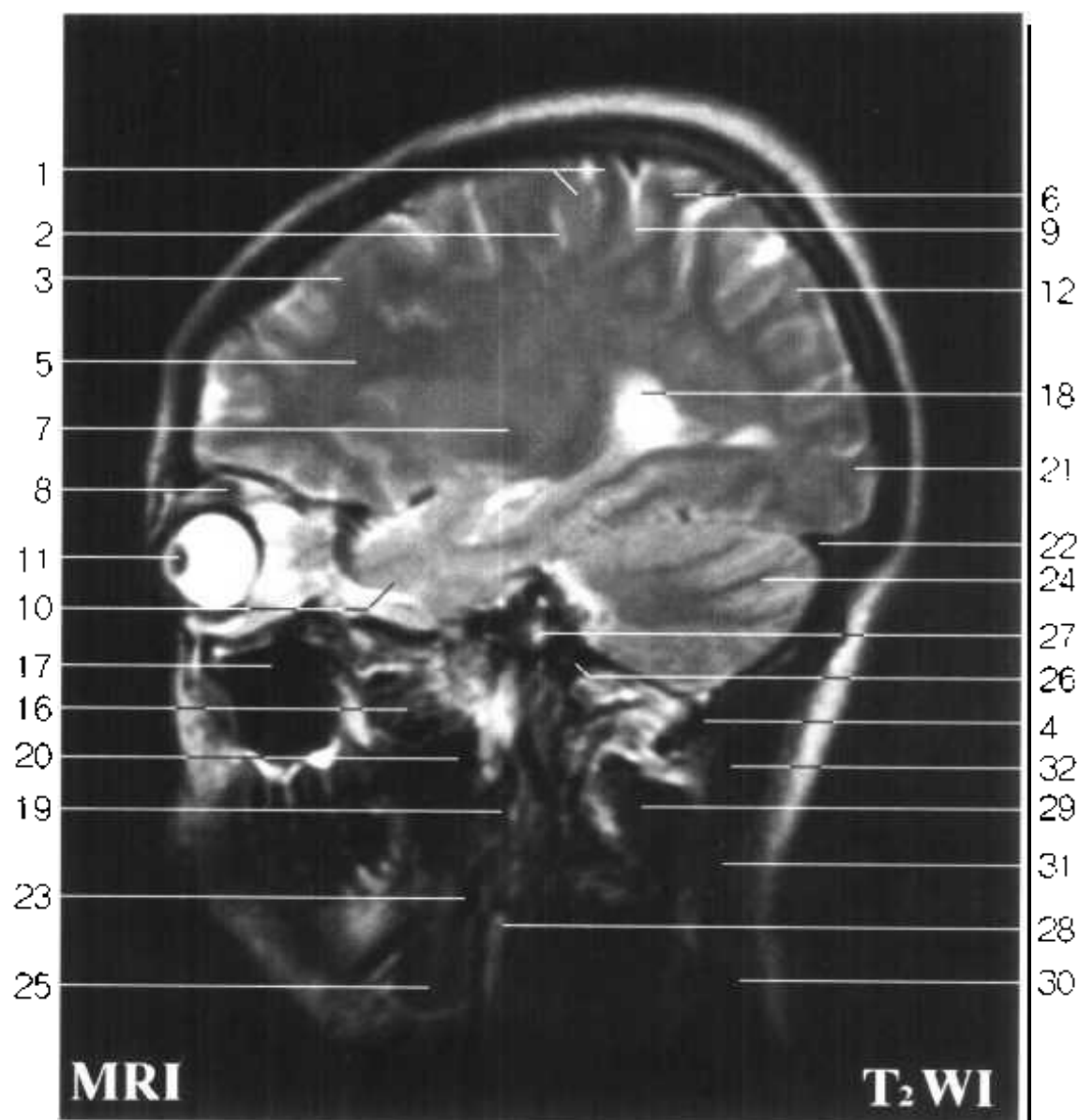


Fig SC 10

1. 中央前回 precentral gyrus
2. 中央前沟 precentral sulcus
3. 额中回 middle frontal gyrus
4. 头后大直肌 rectus capitis posterior major
5. 辐射冠(半卵圆中心) corona radiata (centrum semiovale)
6. 中央后回 postcentral gyrus
7. 壳 putamen
8. 上睑提肌与上直肌 levator palpebrae superioris and superior rectus
9. 中央沟 central sulcus
10. 颞极 temporal pole

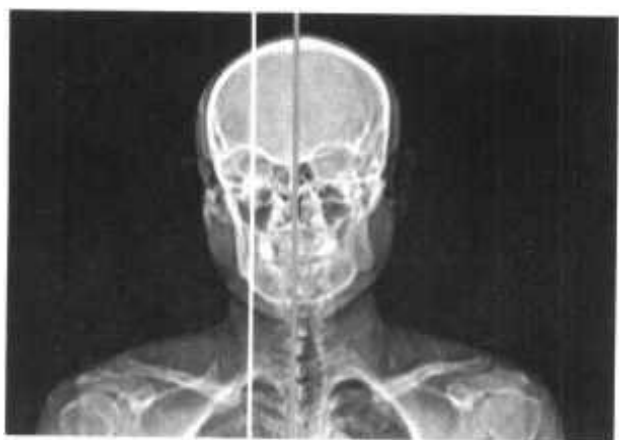

Fig. SC 10



- | | |
|--|--|
| 11. 角膜 cornea | 22. 横窦 transverse sinus |
| 12. 顶上小叶 superior parietal lobule | 23. 二腹肌与茎突舌骨肌 digastric and stylohyoid |
| 13. 下直肌 inferior rectus | 24. 小脑半球 cerebellar hemisphere |
| 14. 蝶骨大翼 greater wing of sphenoid bone | 25. 下颌下腺 submandibular gland |
| 15. 侧脑室下角 inferior horn of lateral ventricle | 26. 乙状窦 sigmoid sinus |
| 16. 翼外肌 lateral pterygoid | 27. 面神经与前庭蜗神经 facial n. and vestibulocochlear n. |
| 17. 上颌窦 maxillary sinus | 28. 颈内动脉 internal carotid a. |
| 18. 侧脑室三角 trigone of lateral ventricle | 29. 头下斜肌 obliquus capitis inferior |
| 19. 茎突咽肌 stylopharyngeus | 30. 斜方肌 trapezius |
| 20. 翼内肌 medial pterygoid | 31. 头夹肌 splenius capitis |
| 21. 枕叶 occipital lobe | 32. 头半棘肌 semispinalis capitis |

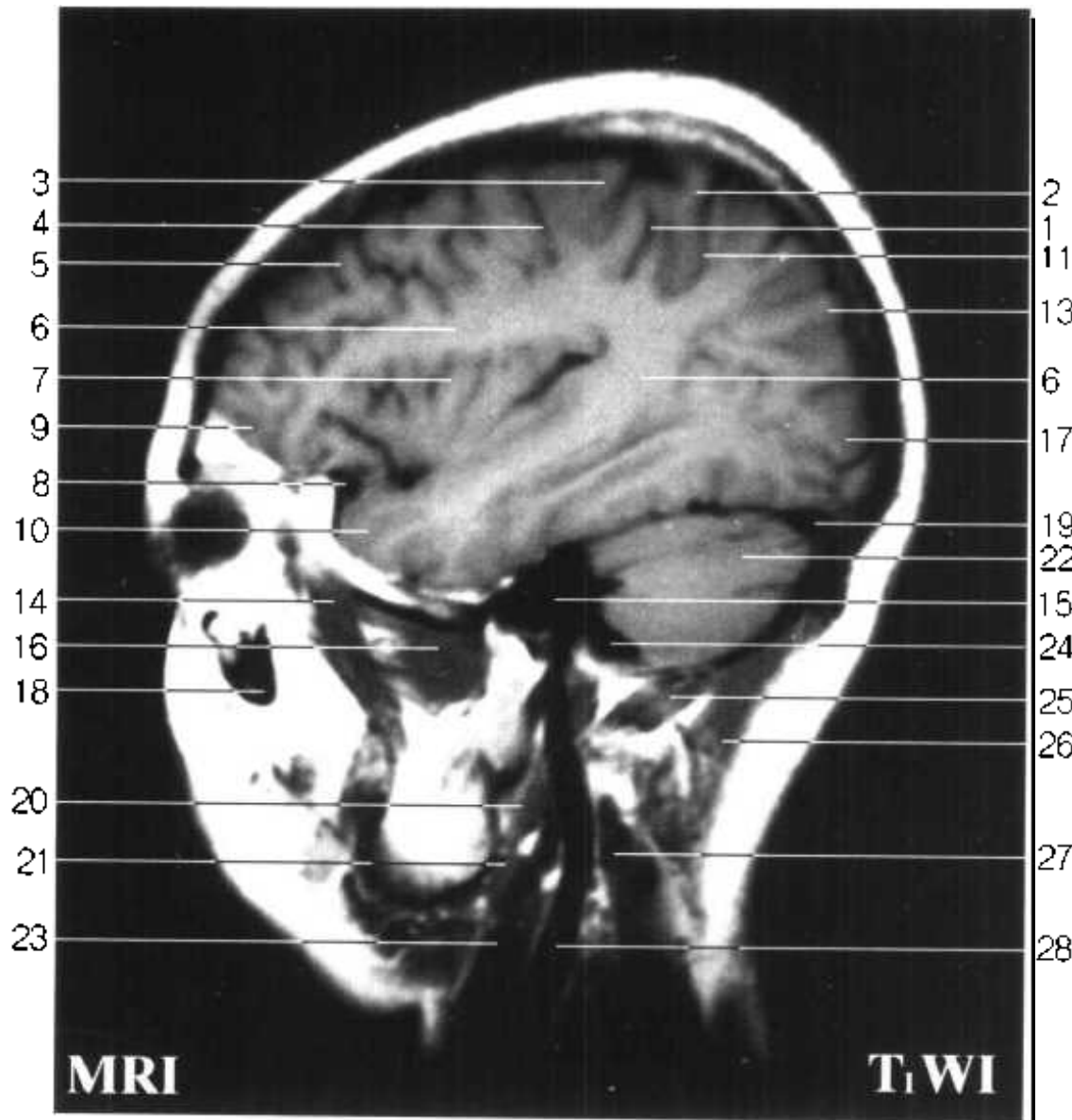
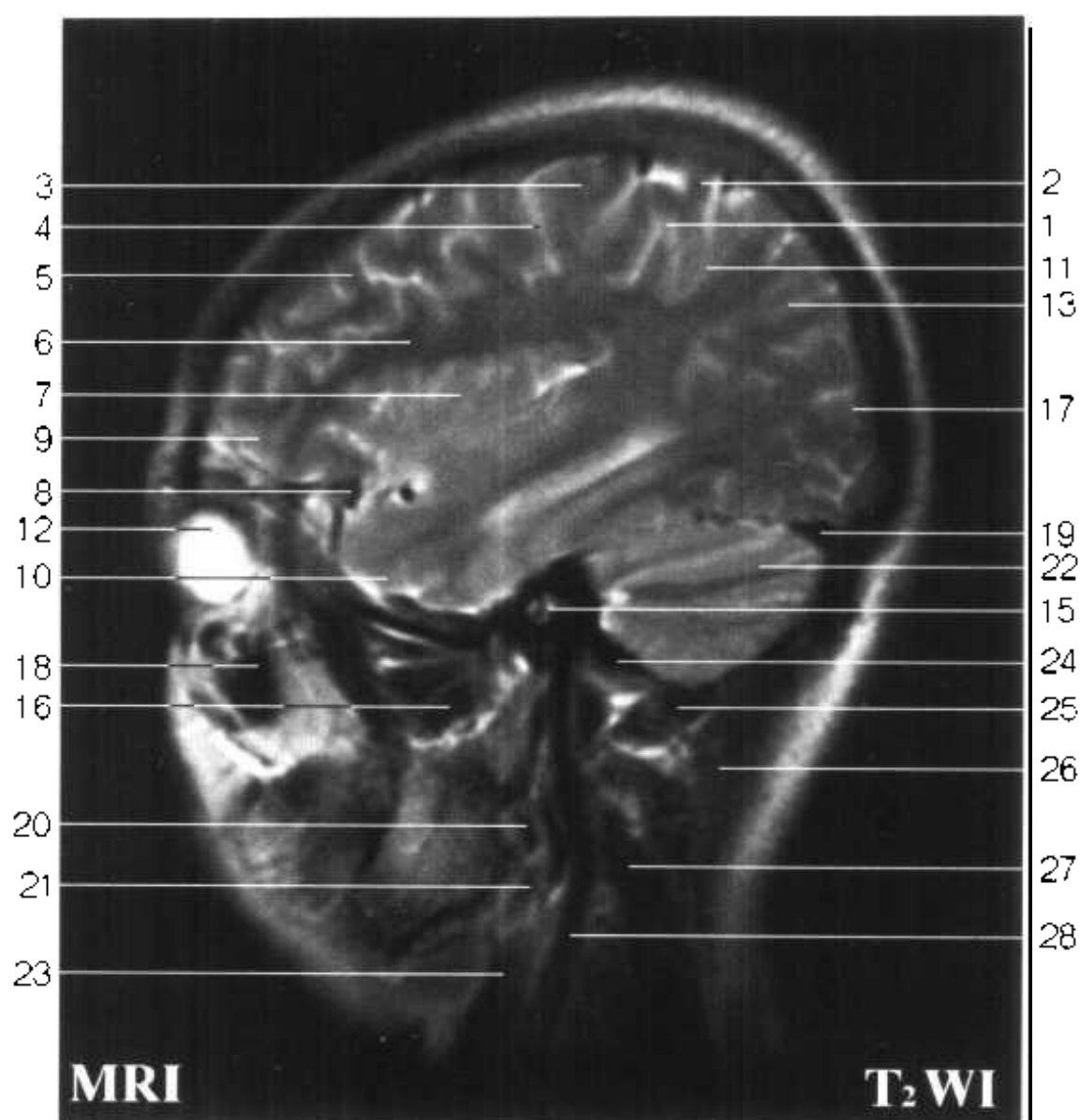


Fig SC 11

- 1. 中央沟 central sulcus
- 2. 中央后回 postcentral gyrus
- 3. 中央前回 precentral gyrus
- 4. 中央前沟 precentral sulcus
- 5. 额中回 middle frontal gyrus
- 6. 辐射冠 corona radiata
- 7. 岛叶 insular lobe
- 8. 外侧沟 lateral sulcus
- 9. 额下回 inferior frontal gyrus
- 10. 颞叶 temporal gyrus
- 11. 中央后沟 postcentral sulcus

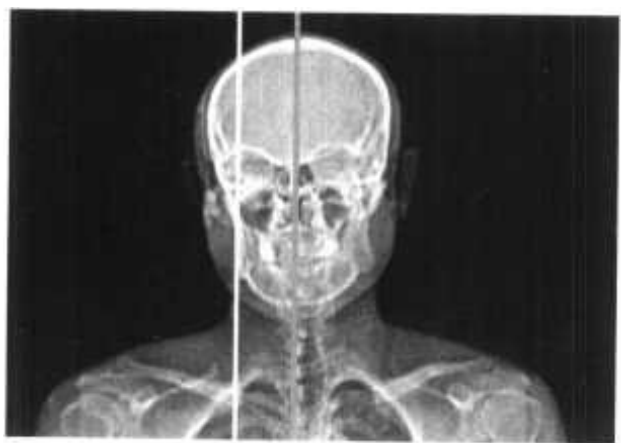

Fig. SC 11



- | | |
|---|------------------------------------|
| 12. 眼球 eyeball | 23. 茎突舌骨肌 stylohyoid |
| 13. 角回 angular gyrus | 24. 乙状窦 sigmoid sinus |
| 14. 颞肌 temporalis | 25. 头上斜肌 obliquus capitis superior |
| 15. 鼓室 tympanic cavity | 26. 头夹肌 splenius capitis |
| 16. 翼外肌 lateral pterygoid | 27. 头半棘肌 semispinalis capitis |
| 17. 枕叶 occipital lobe | 28. 颈内静脉 internal jugular v. |
| 18. 上颌窦 maxillary sinus | |
| 19. 横窦 transverse sinus | |
| 20. 茎突与茎突舌骨肌 styloid process and styloglossus | |
| 21. 茎突咽肌 stylopharyngeus | |
| 22. 小脑半球 cerebellar hemisphere | |

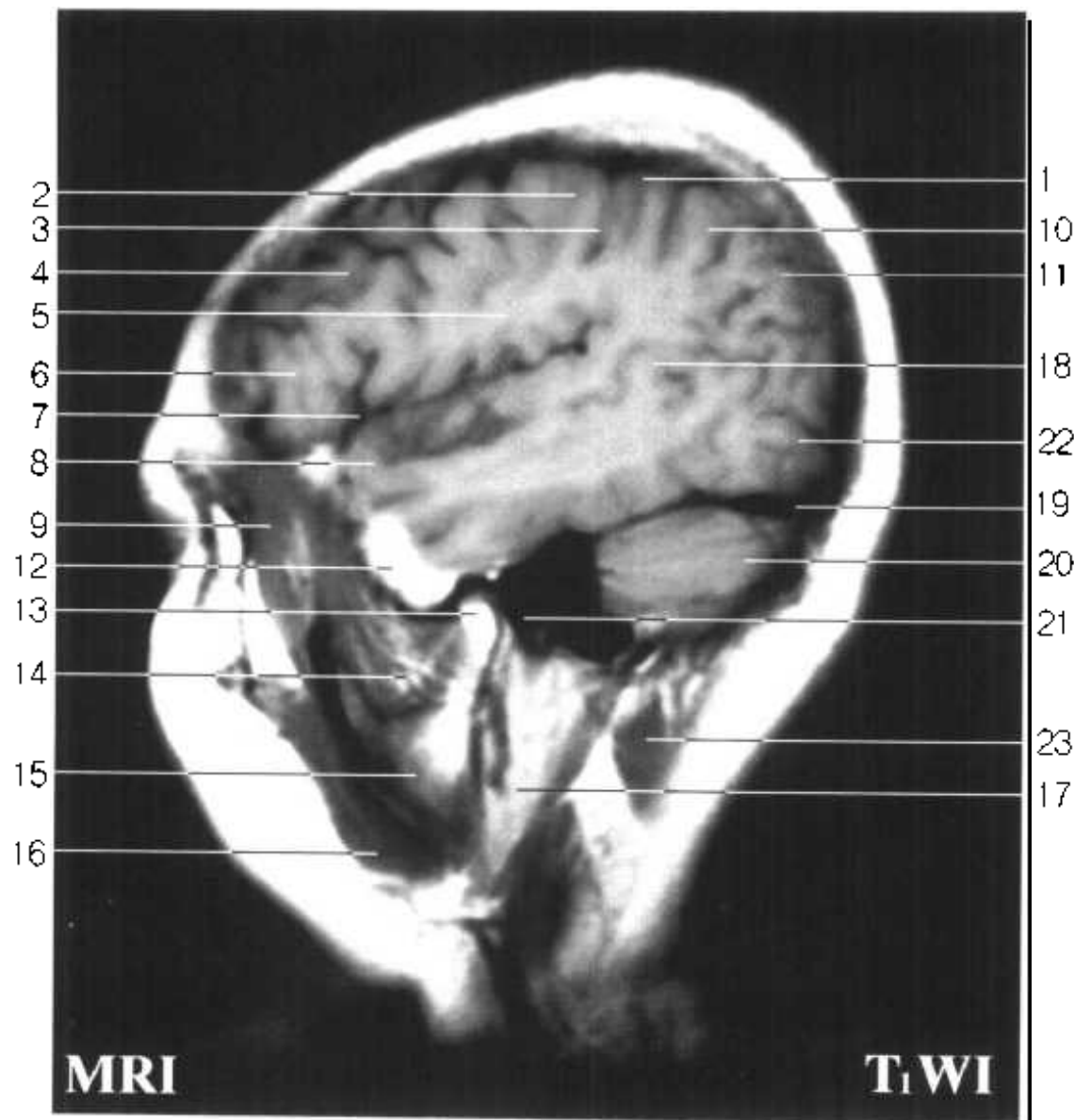
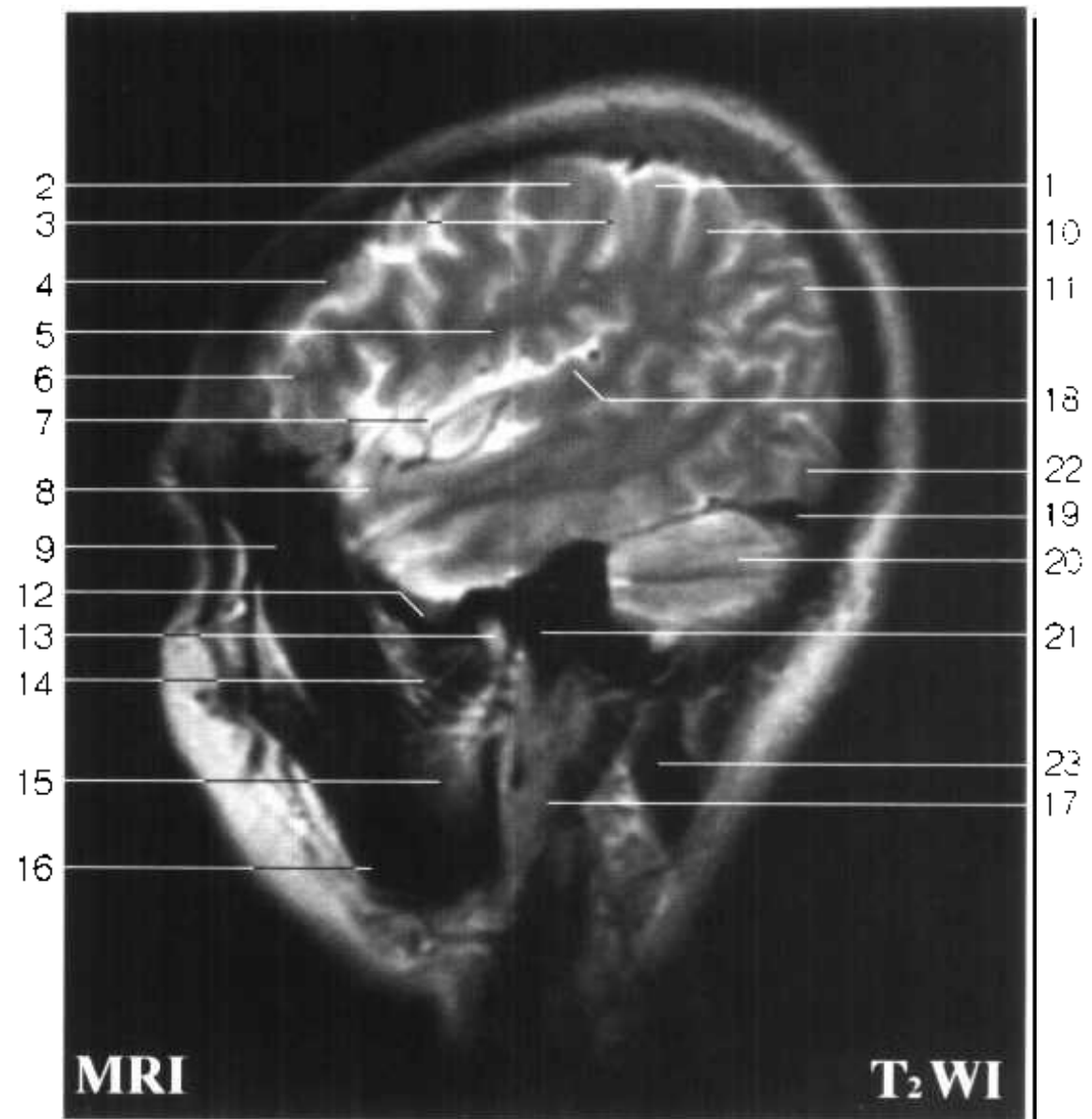


Fig SC 12

1. 中央后回 postcentral gyrus
2. 中央前回 precentral gyrus
3. 中央沟 central sulcus
4. 额中回 middle frontal gyrus
5. 辐射冠 corona radiata
6. 额下回 inferior frontal gyrus
7. 外侧沟 lateral sulcus
8. 颞上回 superior temporal gyrus
9. 颞肌 temporalis

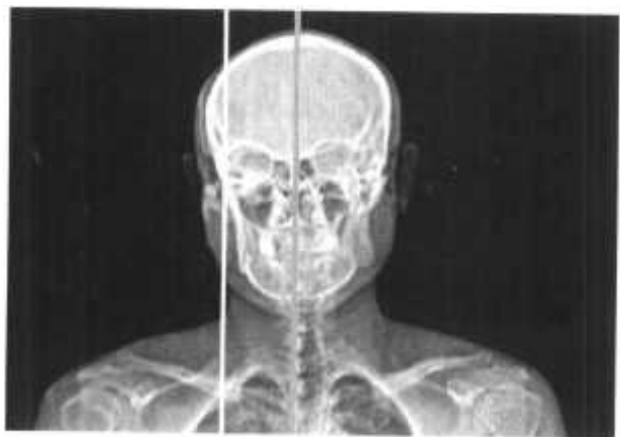

Fig. SC 12



- | | |
|--|-----------------------------------|
| 10. 缘上回 supramarginal gyrus | 17. 腮腺 parotid gland |
| 11. 角回 angular gyrus | 18. 颞横回 transverse temporal gyrus |
| 12. 关节结节 articular tubercle | 19. 横窦 transverse sinus |
| 13. 下颌骨髁突 condylar process of mandible | 20. 小脑半球 cerebellar hemisphere |
| 14. 翼外肌 lateral pterygoid | 21. 外耳道 external acoustic meatus |
| 15. 下颌骨 mandible | 22. 枕叶 occipital lobe |
| 16. 咬肌 masseter | 23. 头夹肌 splenius capitis |

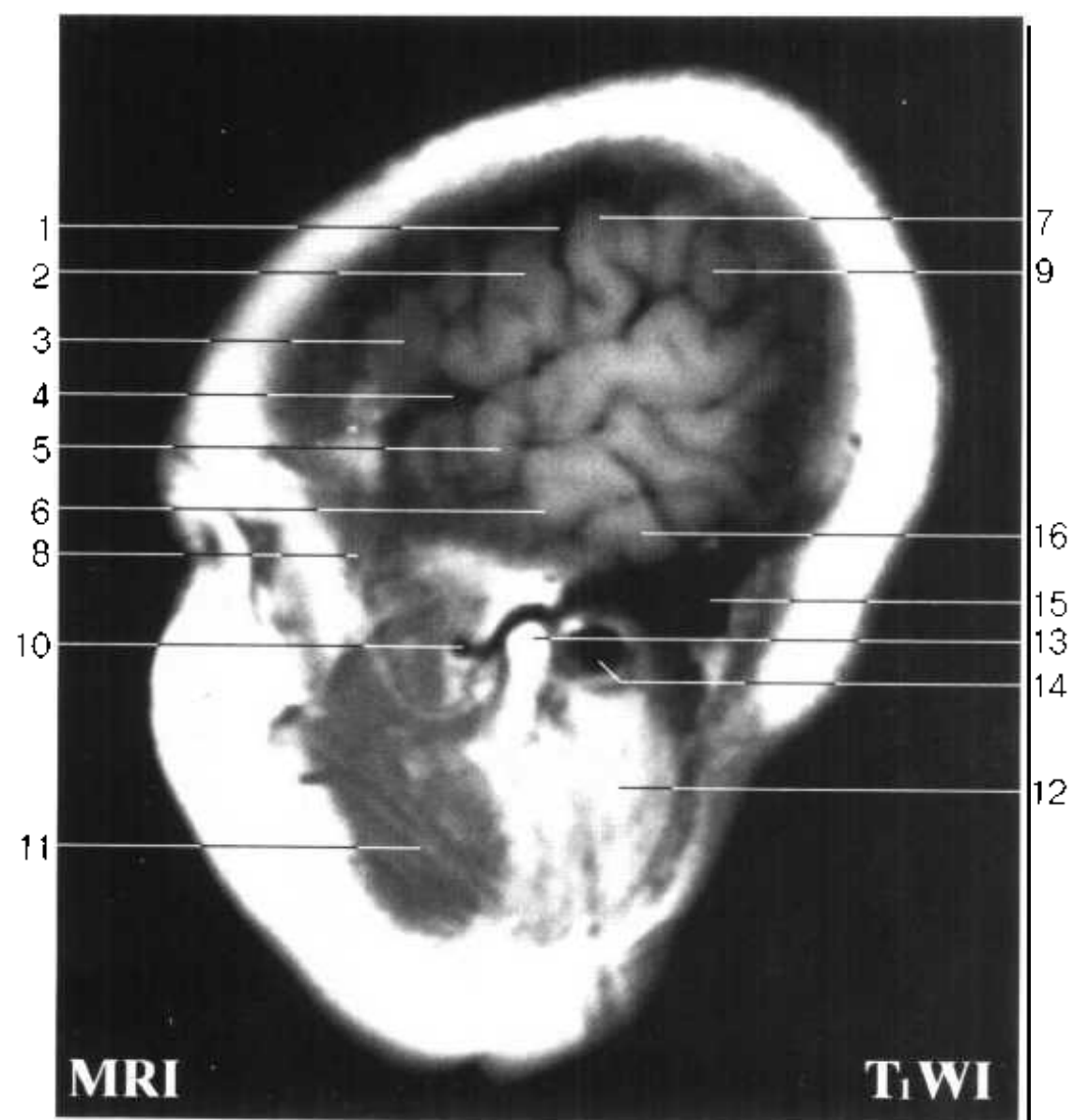
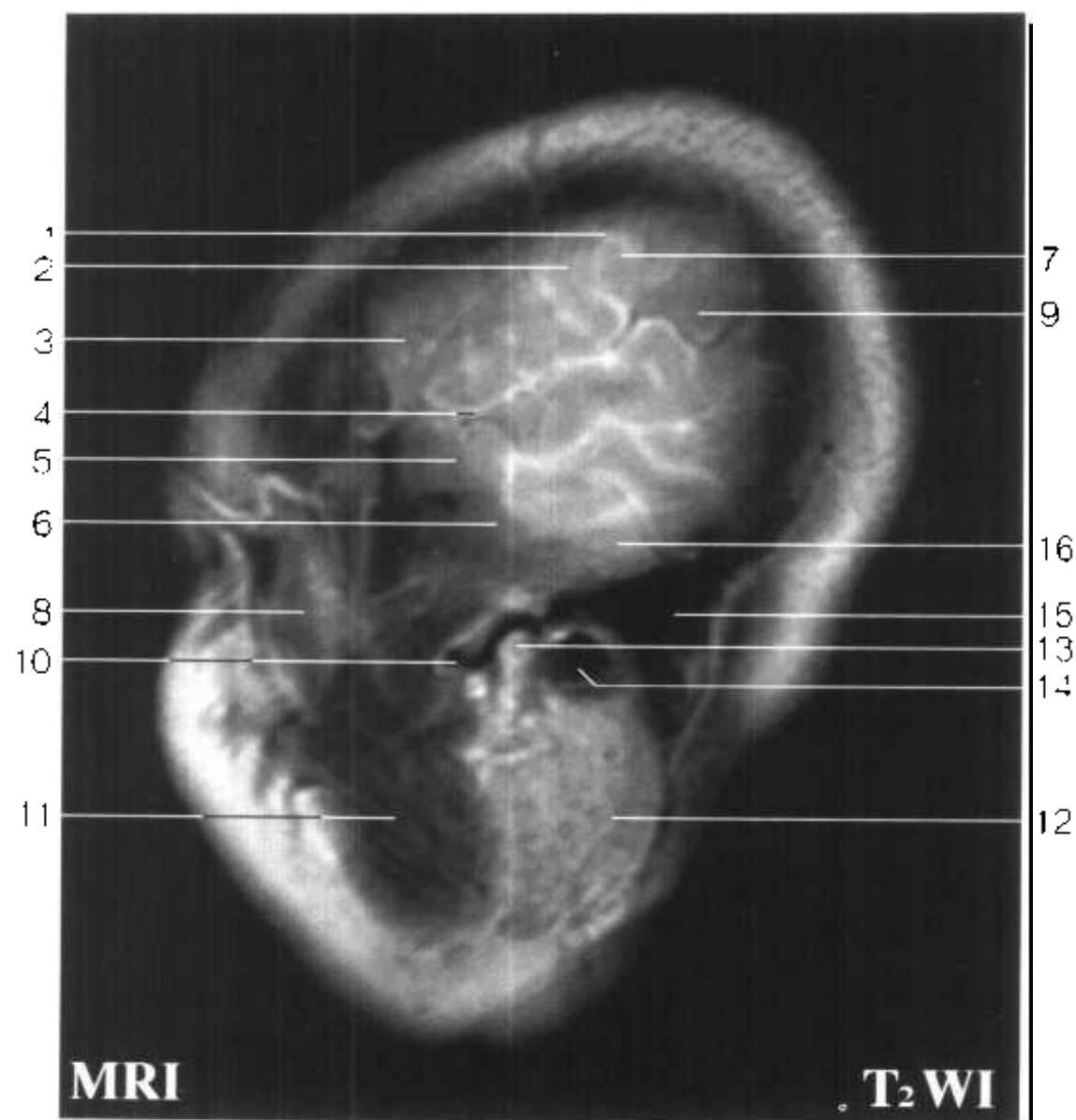


Fig SC 13

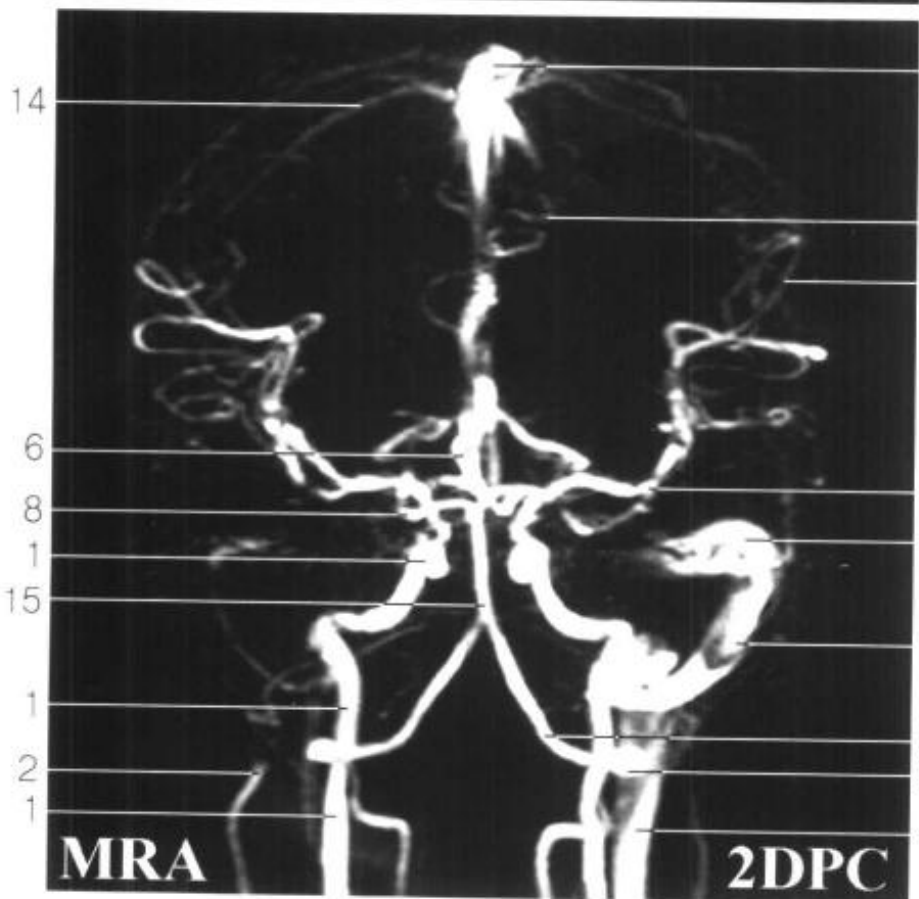
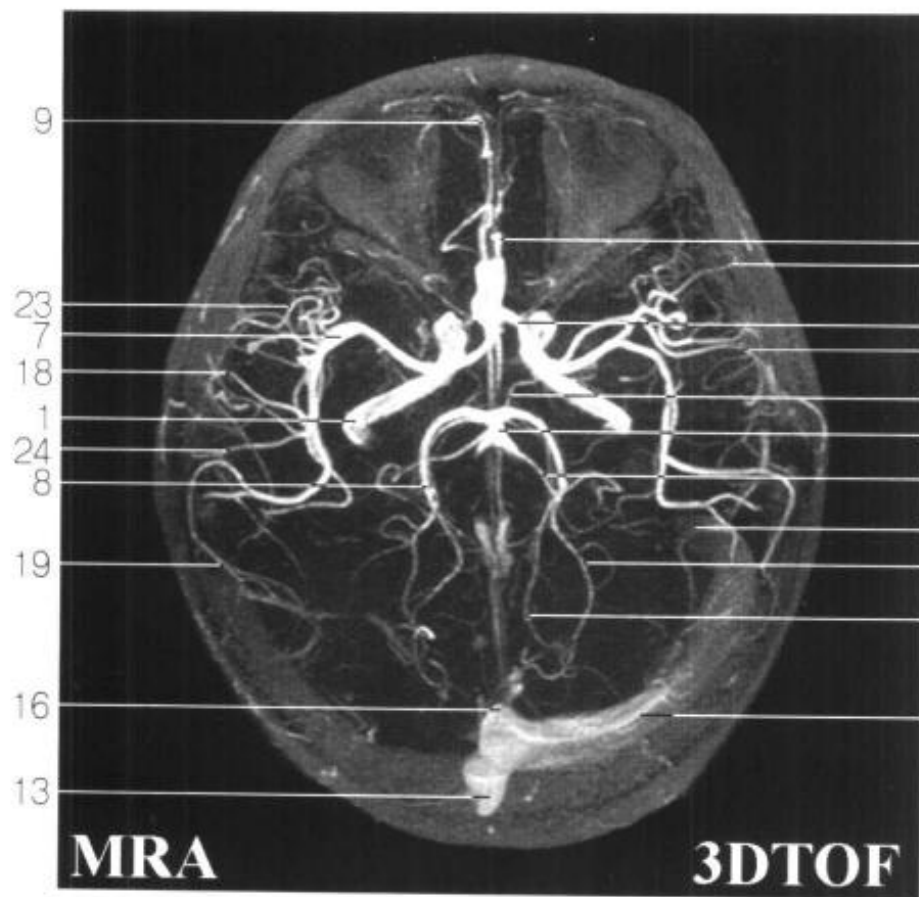
1. 中央沟 central sulcus
2. 中央前回 precentral gyrus
3. 额下回 inferior frontal gyrus
4. 外侧沟 lateral sulcus
5. 颞上回 superior temporal gyrus
6. 颞中回 middle temporal gyrus
7. 中央后回 postcentral gyrus
8. 颞肌 temporalis
9. 缘上回 supramarginal gyrus

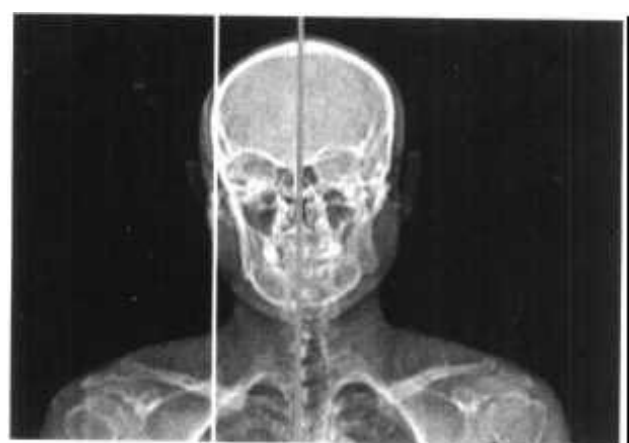

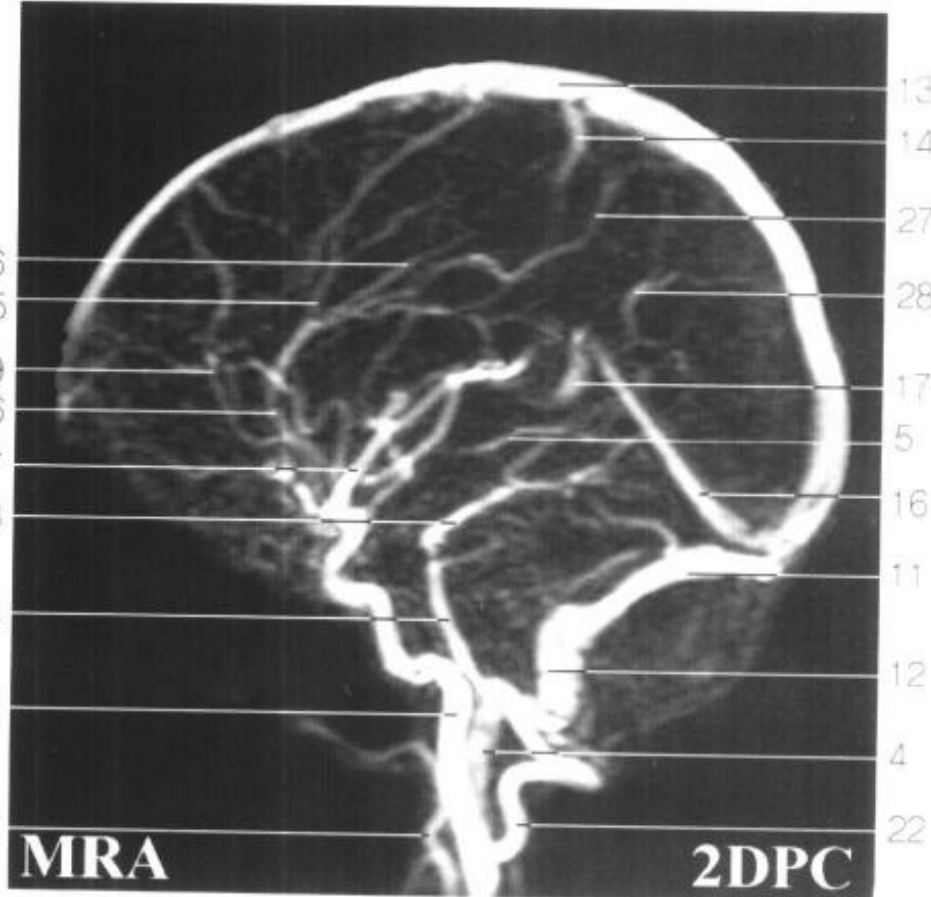
Fig. SC 13



- 10. 颧弓 zygomatic arch
- 11. 咬肌 masseter
- 12. 腮腺 parotid gland
- 13. 下颌骨髁突 condylar process of mandible
- 14. 外耳道 external acoustic meatus
- 15. 乳突小房 mastoid cells
- 16. 颞下回 inferior temporal gyrus



6. 大脑前动脉 anterior cerebral a.
7. 大脑中动脉 middle cerebral a.
8. 大脑后动脉 posterior cerebral a.
9. 额叶前内侧支 anteromedial frontal branch
10. 小脑上动脉 superior cerebellar a.
11. 横窦 transverse sinus
12. 乙状窦 sigmoid sinus
13. 上矢状窦 superior sagittal sinus
14. 大脑上静脉 superior cerebral v.
15. 基底动脉 basilar a.
16. 直窦 straight sinus
17. 大脑大静脉 great cerebral v.
18. 中央沟动脉 artery of central sulcus
19. 角回动脉 artery of angular gyrus
20. 顶枕动脉 parietooccipital a.
21. 距状沟动脉 calcarine a.
22. 椎动脉 vertebral a.
23. 中央前沟动脉 artery of precentral sulcus
24. 中央后沟动脉 artery of postcentral sulcus
25. 额叶中内侧支 mediomedial frontal branch
26. 额叶后内侧支 posteromedial frontal branch
27. 旁中央动脉 paracentral a.
28. 楔前动脉 precuneal a.



磁共振血管成像 MRA

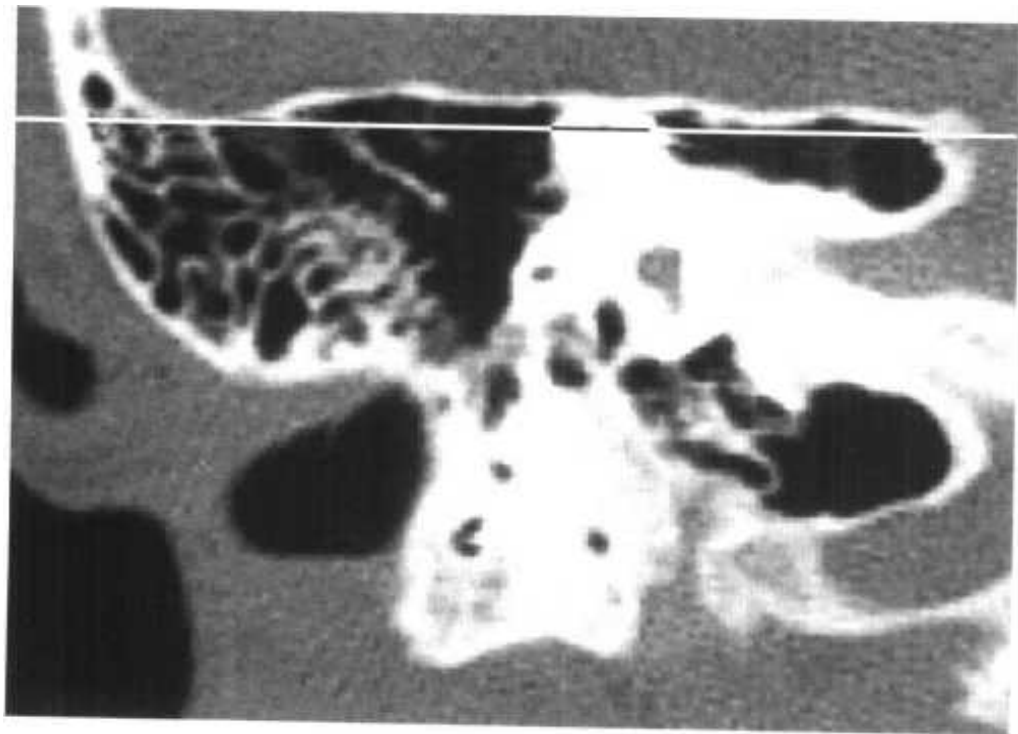
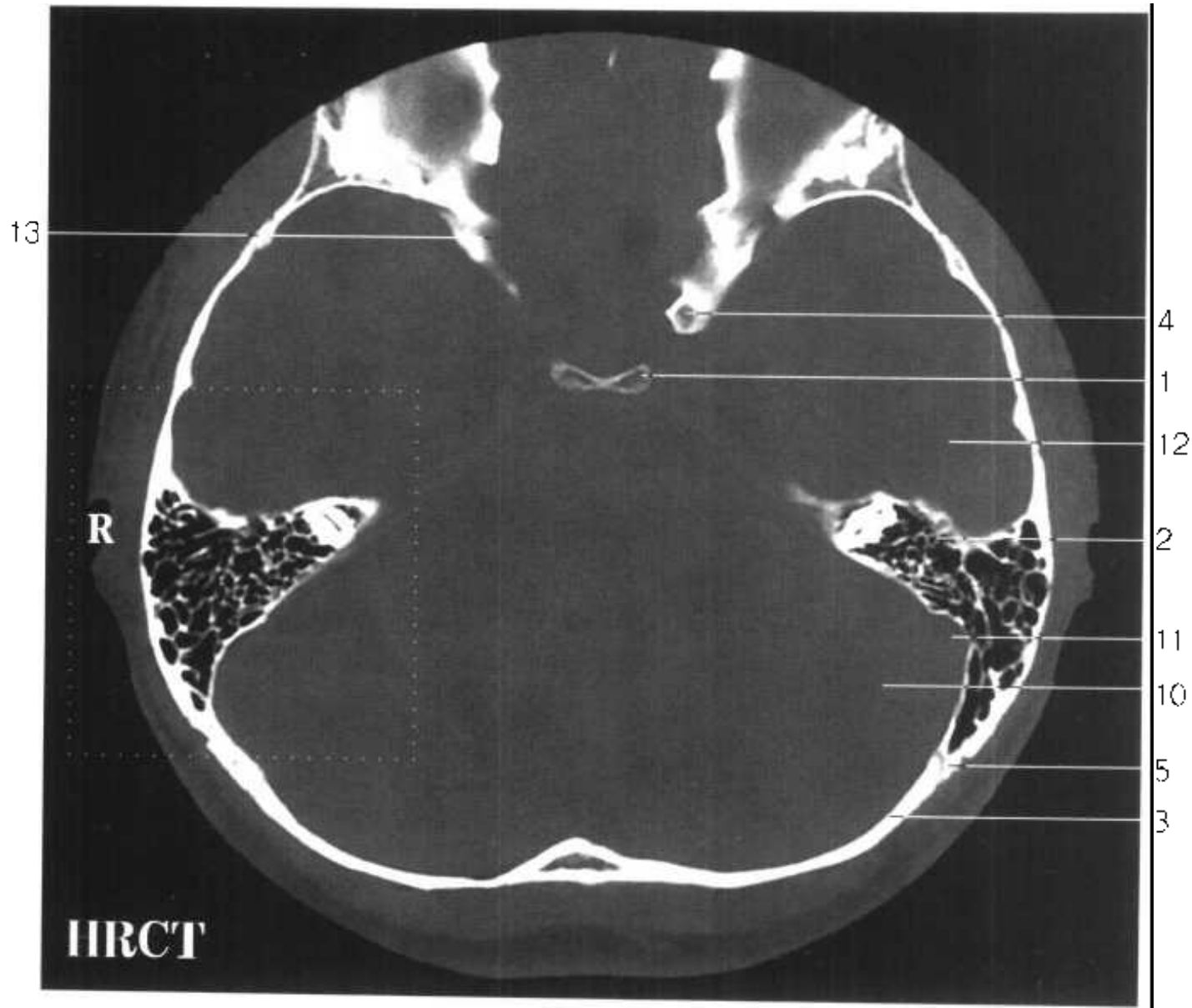
Fig. MRA

1. 颈内动脉 internal carotid a.
2. 颈外动脉 external carotid a.
3. 后交通动脉 posterior communicating a.
4. 颈内静脉 internal jugular v.
5. 脉络丛前动脉 anterior choroidal a.

Fig. MRA

五官部

FIVE SENSE
ORGANS



耳的水平断面图 HE

Fig. HE 1

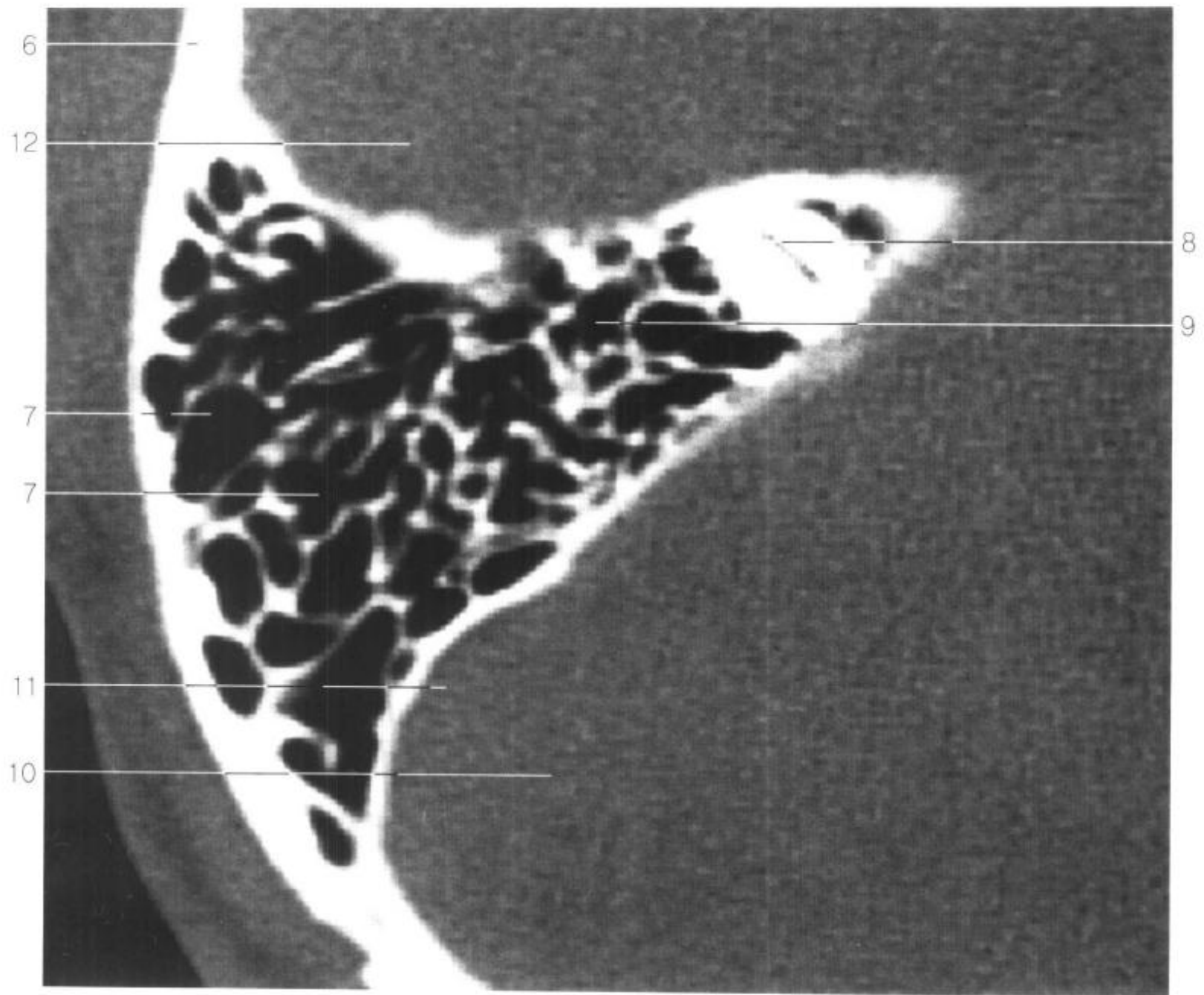


Fig.HE 1

- | | |
|--|---------------------------------------|
| 1. 鞍背 dorsum sellae | 8. 前骨半规管 anterior semicircular canal |
| 2. 颞骨岩部 petrous part of temporal bone | 9. 鼓室上隐窝 epitympanic recess |
| 3. 枕骨 occipital bone | 10. 小脑半球 cerebellar hemisphere |
| 4. 前床突 anterior clinoid process | 11. 乙状窦 sigmoid sinus |
| 5. 枕乳突缝 occipitomastoid suture | 12. 颞叶 temporal lobe |
| 6. 颞骨鳞部 squamous part of temporal bone | 13. 蝶骨小翼 lesser wing of sphenoid bone |
| 7. 乳突小房 mastoid cells | |

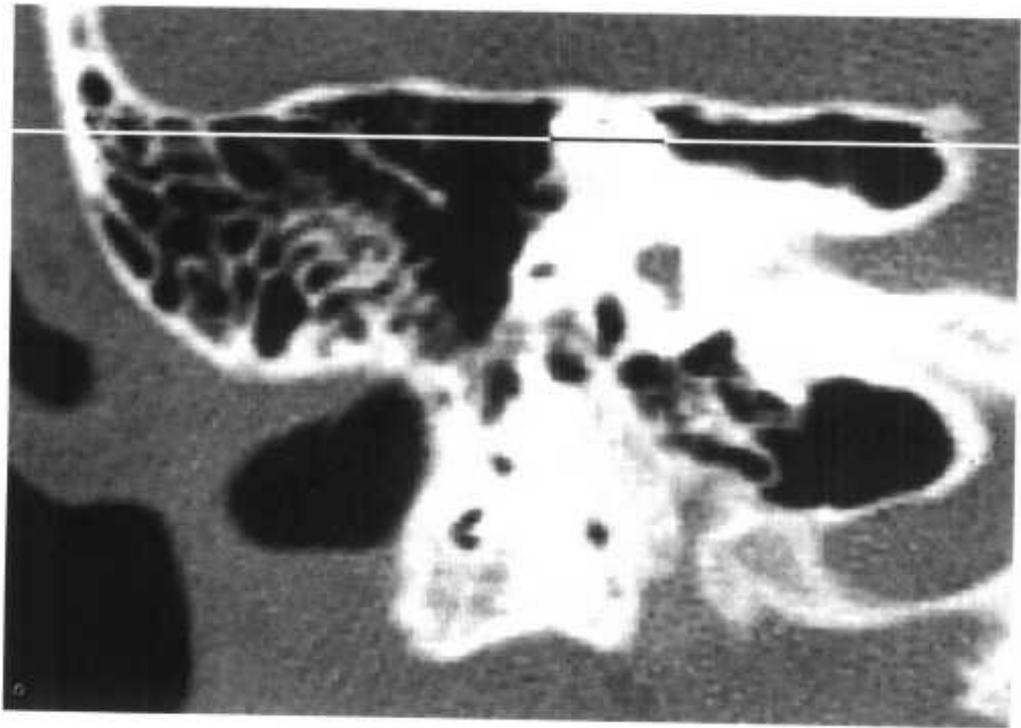
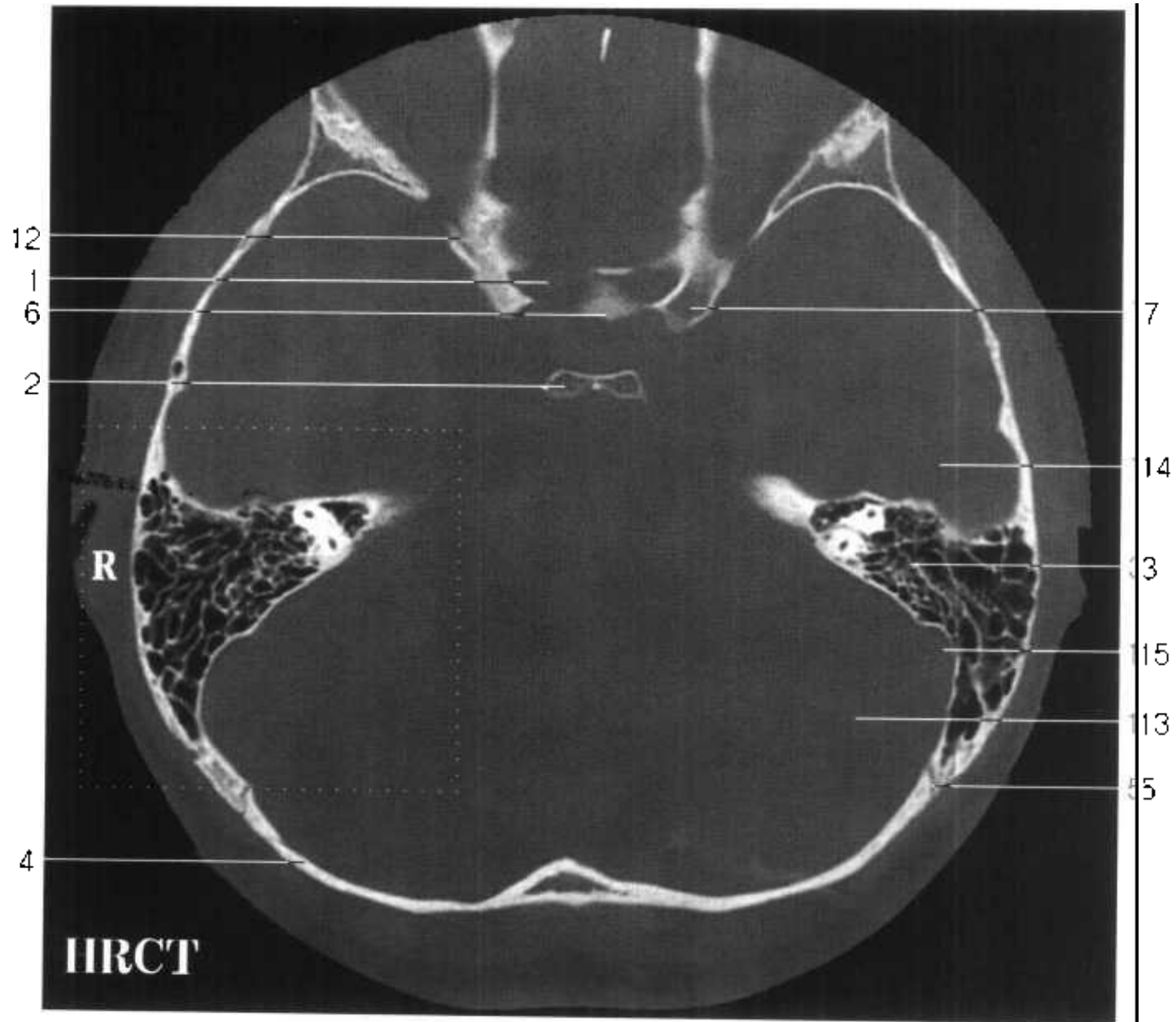


Fig. HE 2

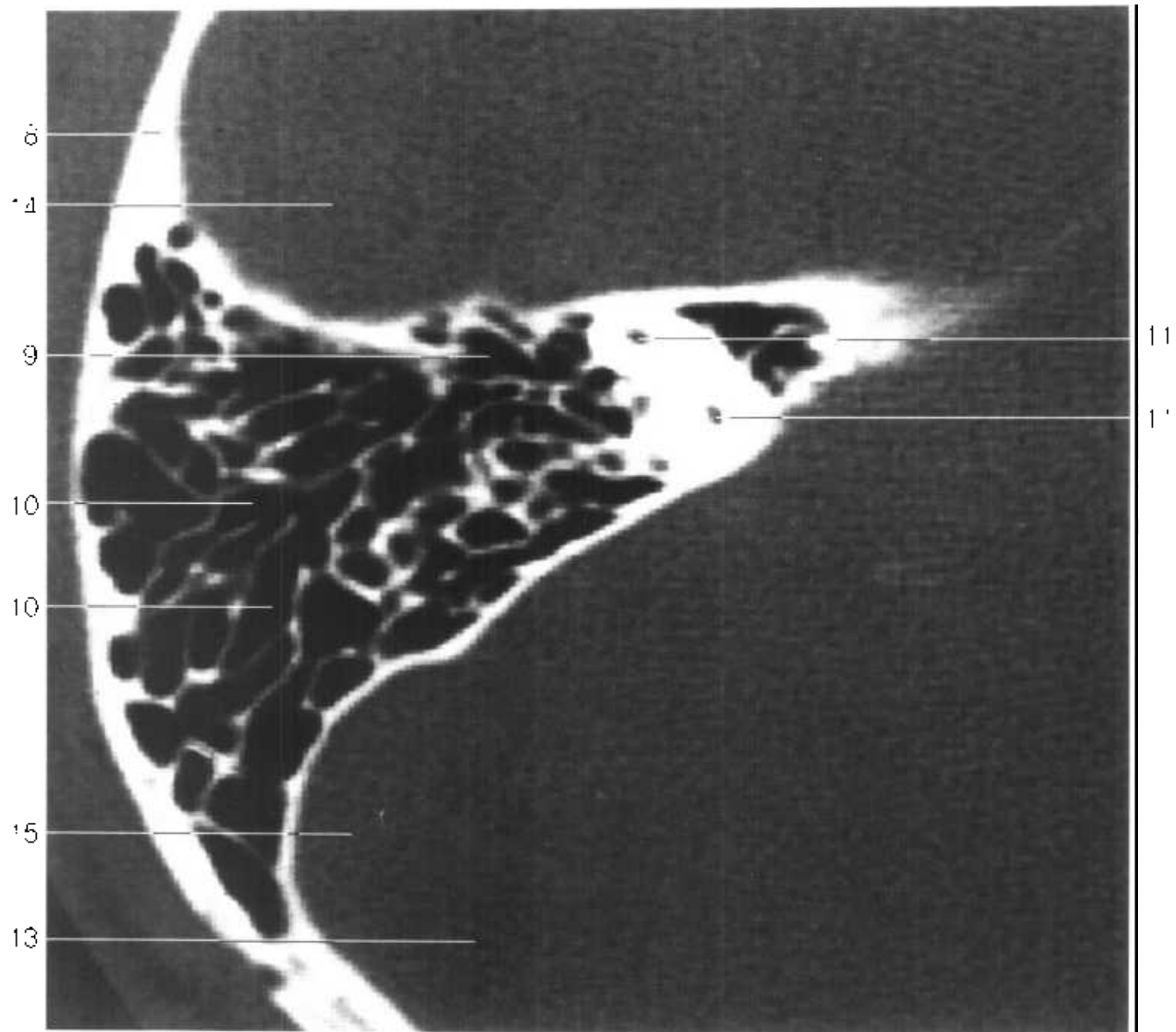


Fig.HE 2

- | | |
|--|---------------------------------------|
| 1. 视神经管 optic canal | 9. 鼓室上隐窝 epitympanic recess |
| 2. 鞍背 dorsum sellae | 10. 乳突小房 mastoid cells |
| 3. 颞骨岩部 petrous part of temporal bone | 11. 前骨半规管 anterior semicircular canal |
| 4. 枕骨 occipital bone | 12. 蝶骨小翼 lesser wing of sphenoid bone |
| 5. 枕乳突缝 occipitomastoid suture | 13. 小脑半球 cerebellar hemisphere |
| 6. 鞍结节 tuberculum sellae | 14. 颞叶 temporal lobe |
| 7. 前床突 anterior clinoid process | 15. 乙状窦 sigmoid sinus |
| 8. 颞骨鳞部 squamous part of temporal bone | |

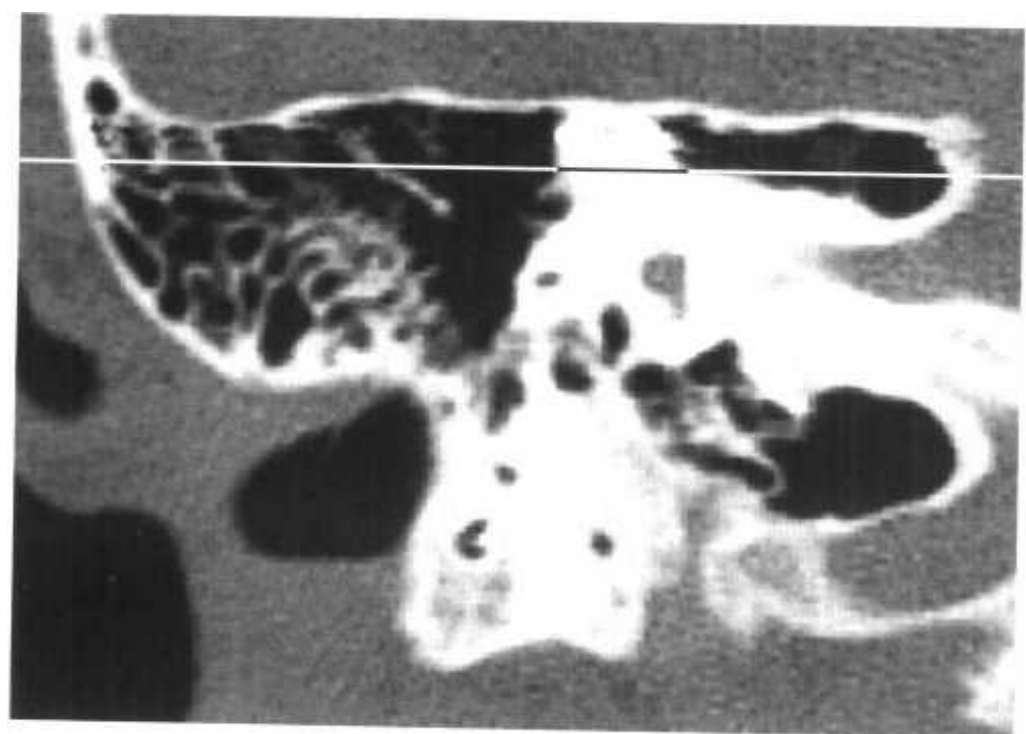
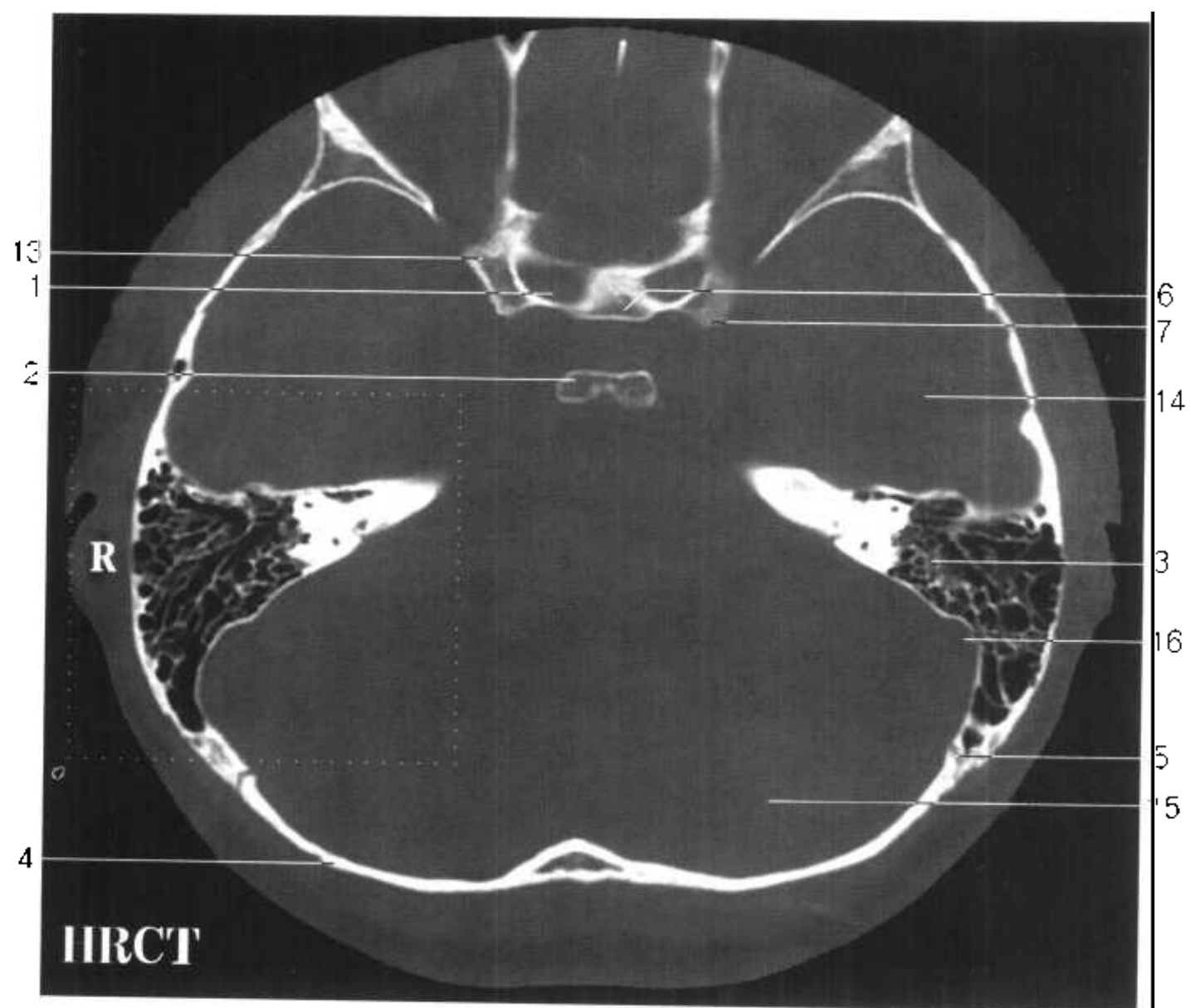


Fig. HE 3

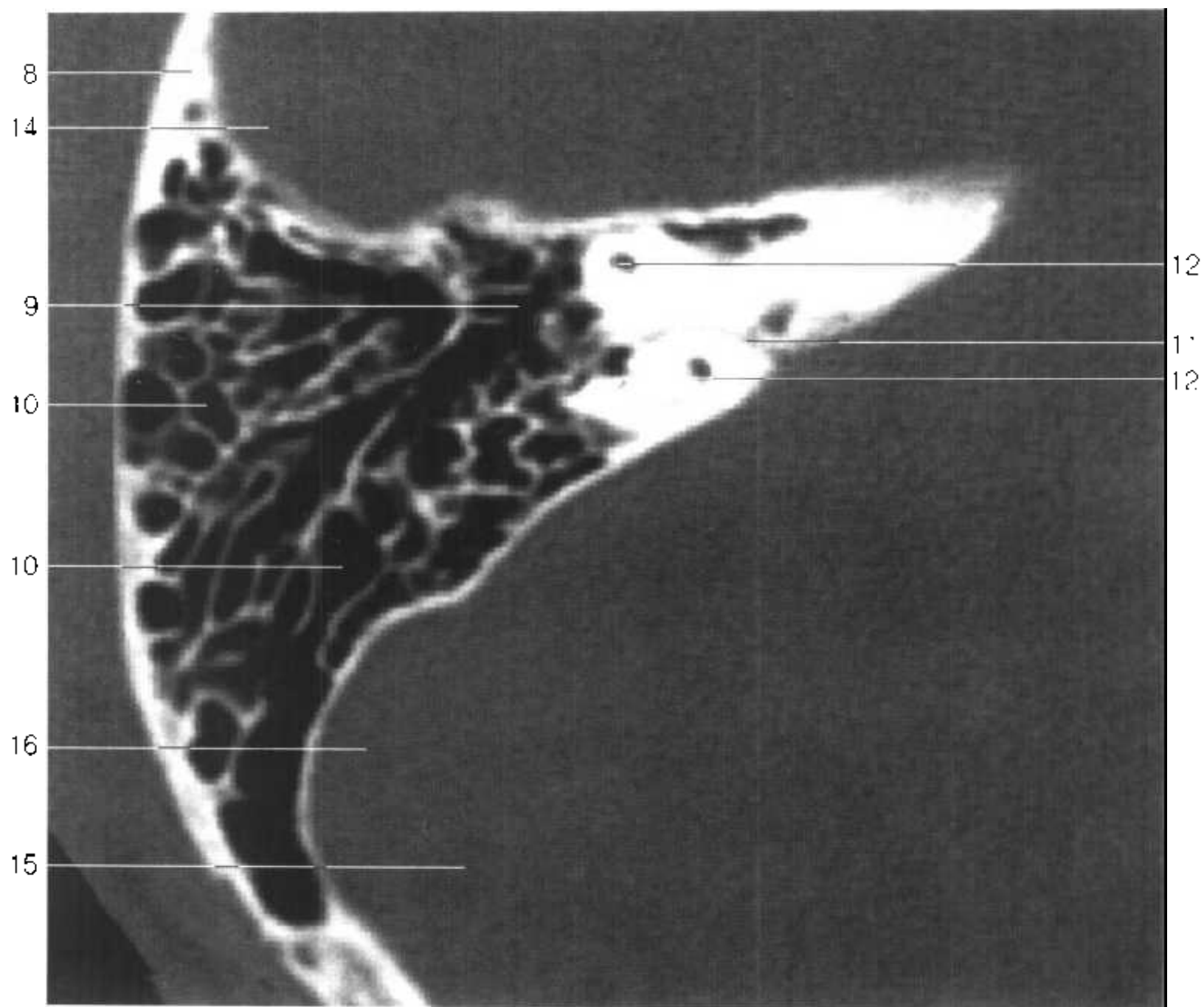


Fig.HE 3

- | | |
|--|---------------------------------------|
| 1. 视神经管 optic canal | 9. 鼓室上隐窝 epitympanic recess |
| 2. 鞍背 dorsum sellae | 10. 乳突小房 mastoid cells |
| 3. 颞骨岩部 petrous part of temporal bone | 11. 弓形下窝 subarcuate fossa |
| 4. 枕骨 occipital bone | 12. 前骨半规管 anterior semicircular canal |
| 5. 枕乳突缝 occipitomastoid suture | 13. 蝶骨小翼 lesser wing of sphenoid bone |
| 6. 鞍结节 tuberculum sellae | 14. 颞叶 temporal lobe |
| 7. 前床突 anterior clinoid process | 15. 小脑半球 cerebellar hemisphere |
| 8. 颞骨鳞部 squamous part of temporal bone | 16. 乙状窦 sigmoid sinus |

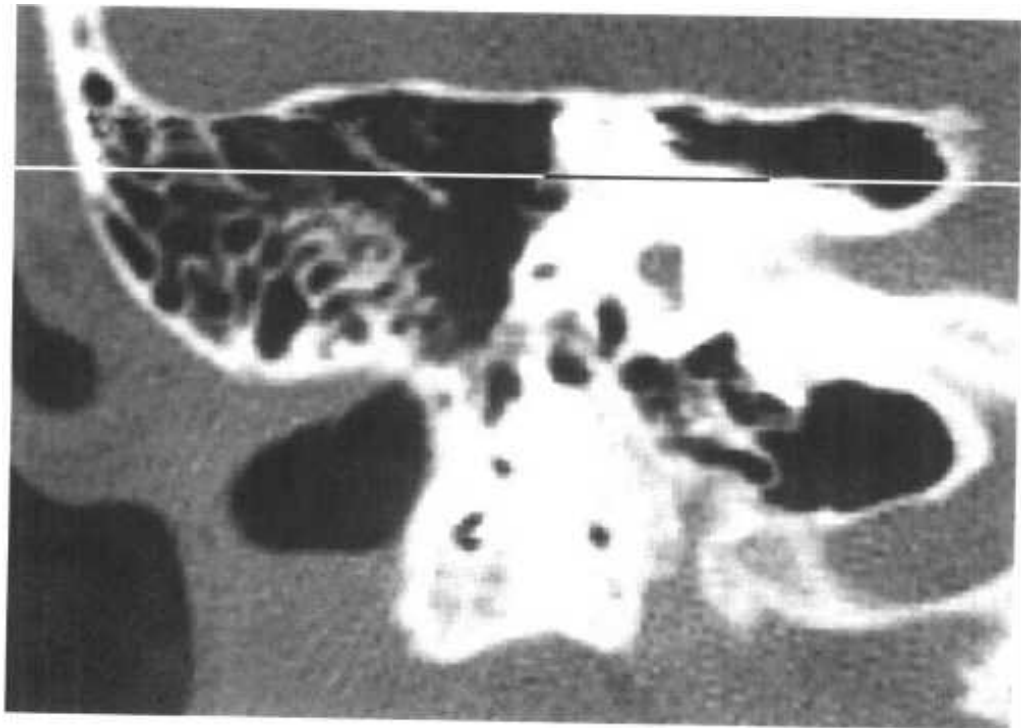
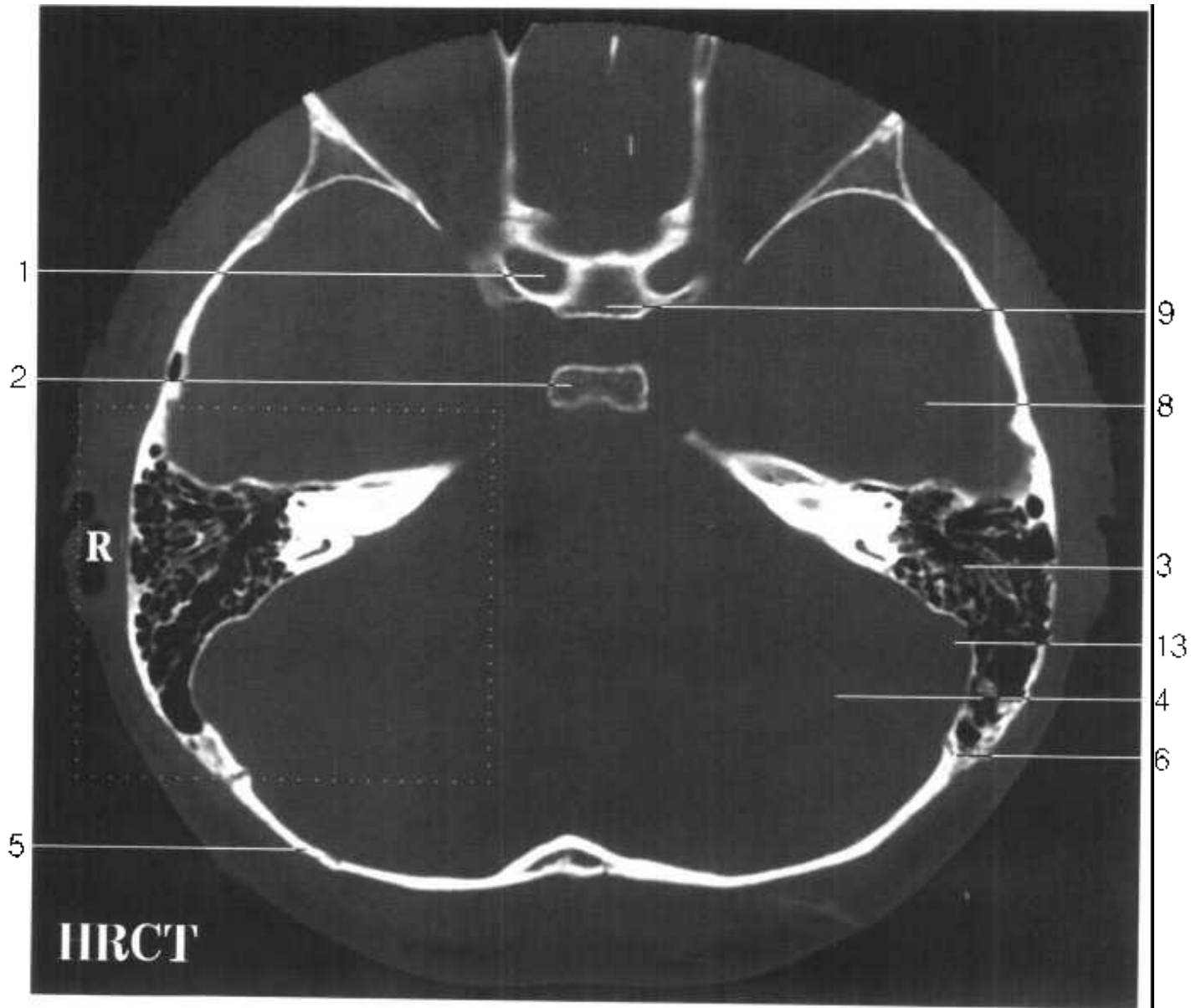


Fig. HE 4




Fig.HE 4

- | | |
|---------------------------------------|---|
| 1. 视神经管 optic canal | 10. 颞骨鳞部 squamous part of temporal bone |
| 2. 鞍背 dorsum sellae | 11. 鼓室上隐窝 epitympanic recess |
| 3. 颞骨岩部 petrous part of temporal bone | 12. 乳突小房 mastoid cells |
| 4. 小脑半球 cerebellar hemisphere | 13. 乙状窦 sigmoid sinus |
| 5. 枕骨 occipital bone | 14. 后骨半规管 posterior semicircular canal |
| 6. 枕乳突缝 occipitomastoid suture | 15. 总骨脚 common bony crus |
| 7. 前骨半规管 anterior semicircular canal | 16. 弓形下窝 subarcuate fossa |
| 8. 颞叶 temporal lobe | 17. 内耳道 internal acoustic meatus |
| 9. 鞍结节 tuberculum sellae | |

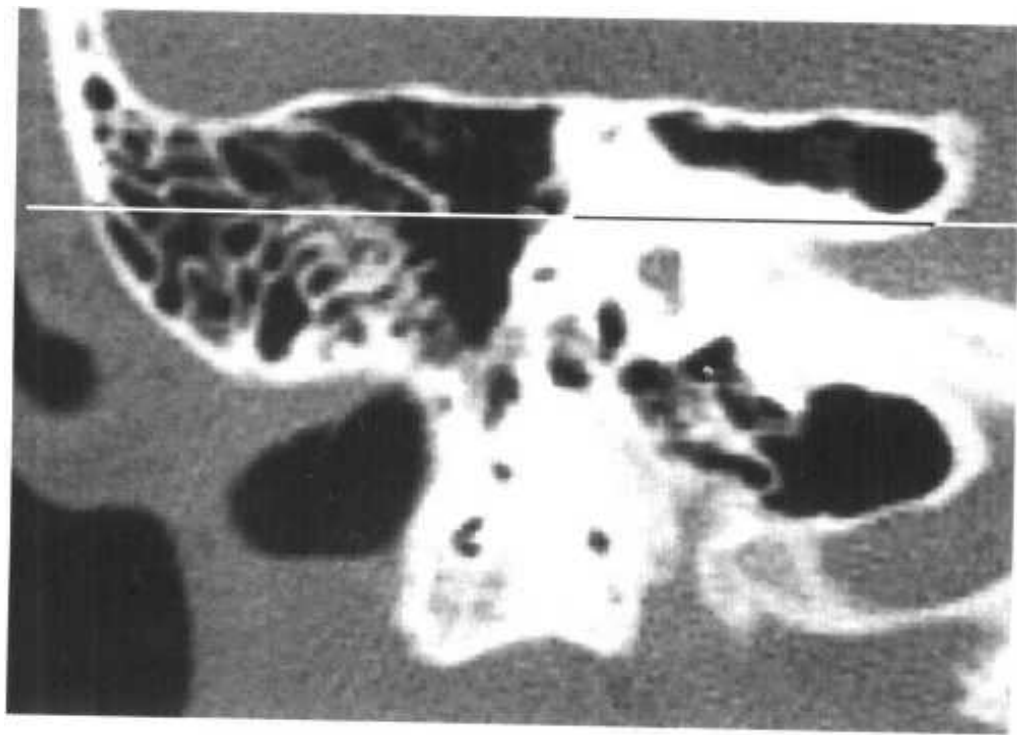
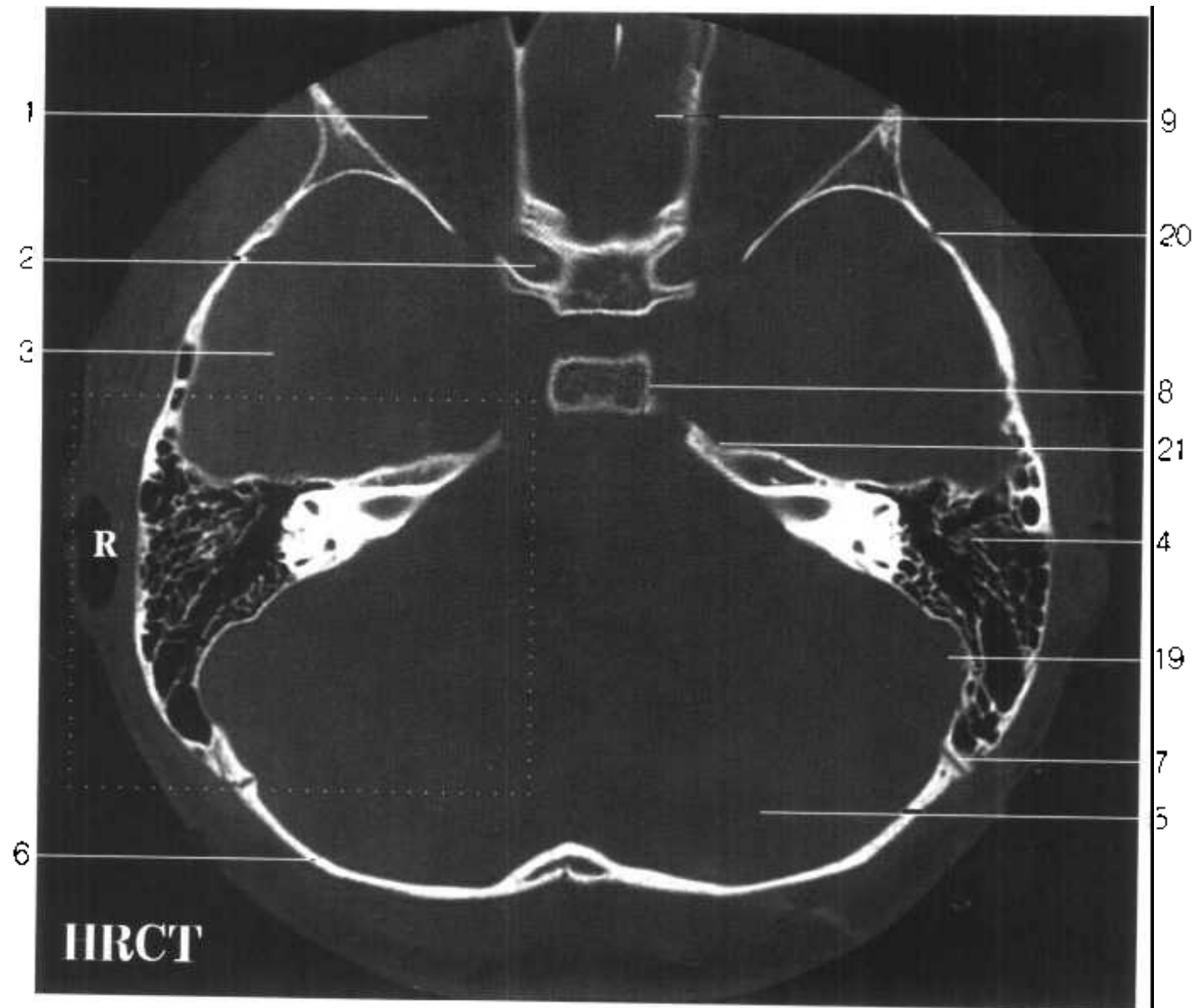


Fig. HE 5

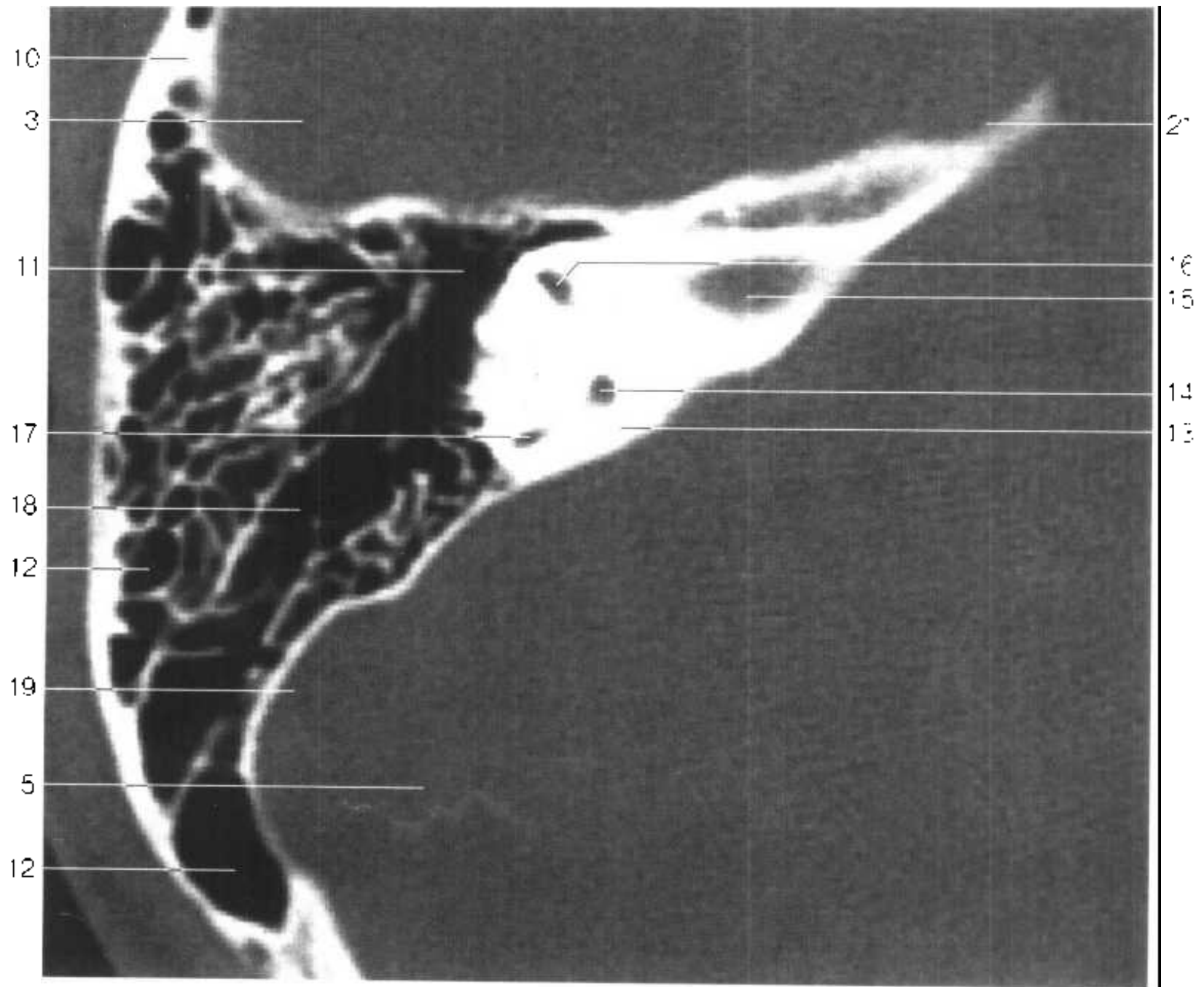


Fig.HE 5

- | | |
|---|--|
| 1. 眼眶 orbit | 12. 乳突小房 mastoid cells |
| 2. 视神经管 optic canal | 13. 前庭水管 vestibular aqueduct |
| 3. 颞叶 temporal lobe | 14. 总骨脚 common bony crus |
| 4. 颞骨岩部 petrous part of temporal bone | 15. 内耳道 internal acoustic meatus |
| 5. 小脑半球 cerebellar hemisphere | 16. 前骨壶腹 anterior bony ampulla |
| 6. 枕骨 occipital bone | 17. 后骨半规管 posterior semicircular canal |
| 7. 枕乳突缝 occipitomastoid suture | 18. 乳突窦 mastoid antrum |
| 8. 鞍背 dorsum sellae | 19. 乙状窦 sigmoid sinus |
| 9. 直回 gyrus rectus | 20. 蝶鳞缝 sphenosquamosal suture |
| 10. 颞骨鳞部 squamous part of temporal bone | 21. 三叉神经压迹 trigeminal impression |
| 11. 鼓室上隐窝 epitympanic recess | |

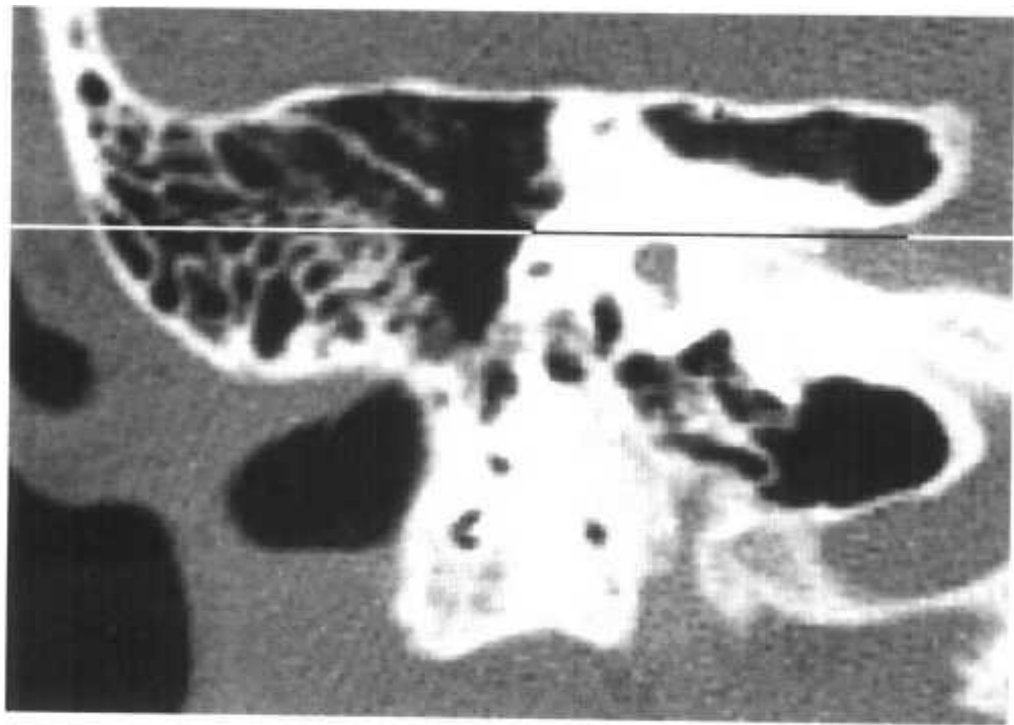
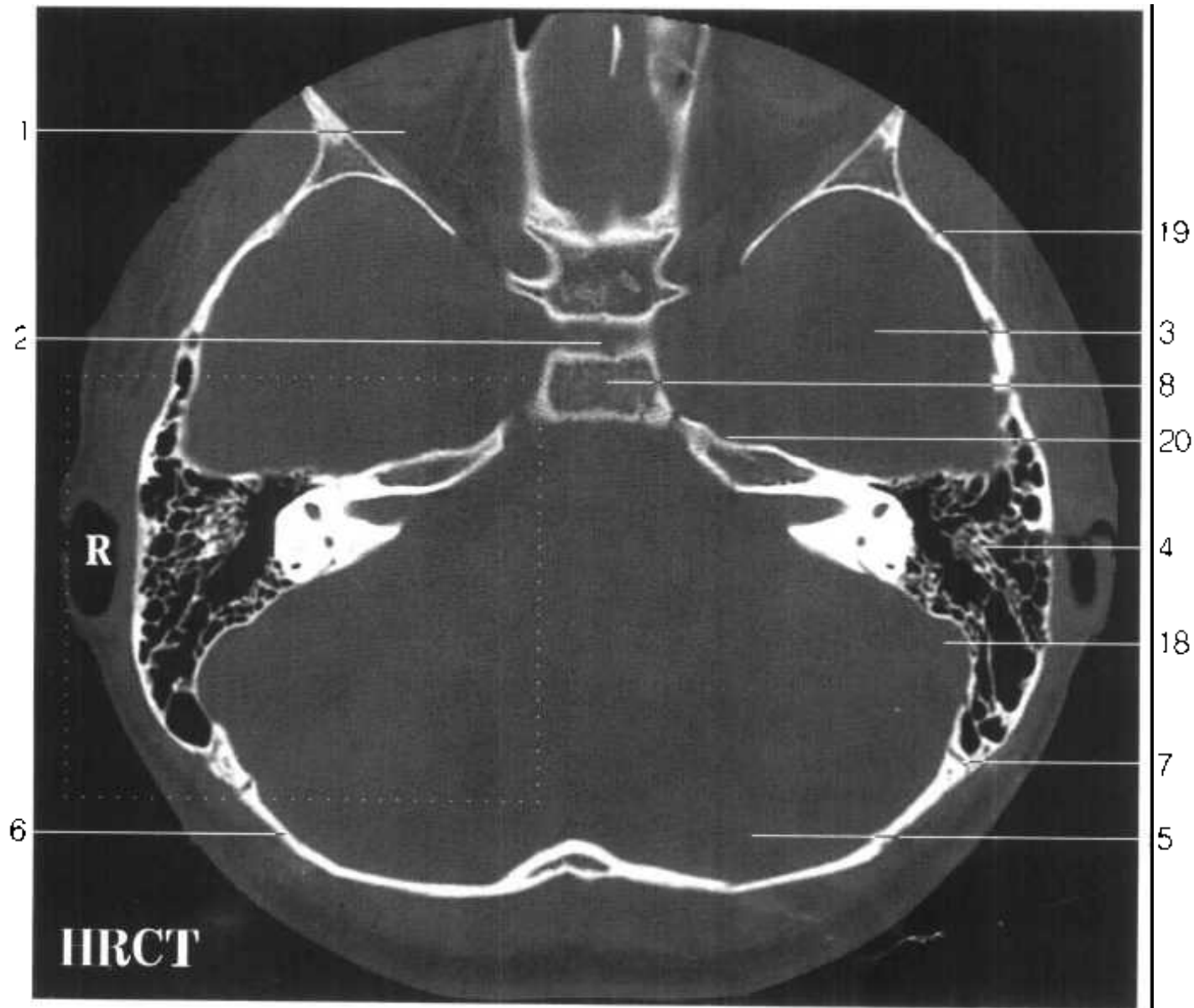


Fig. HE 6

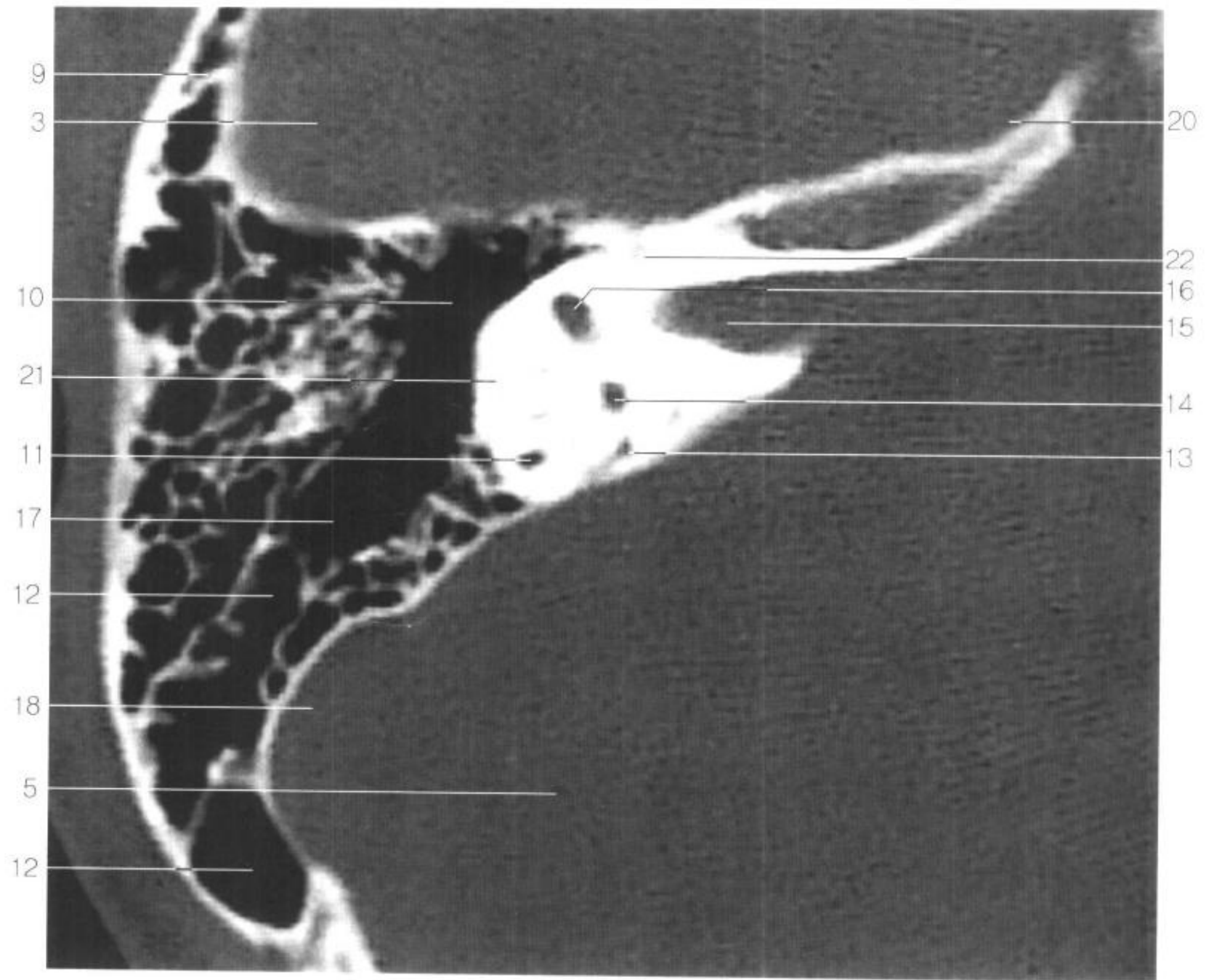


Fig.HE 6

- | | |
|--|--------------------------------------|
| 1. 眼眶 orbit | 12. 乳突小房 mastoid cells |
| 2. 垂体窝 hypophysial fossa | 13. 前庭水管 vestibular aqueduct |
| 3. 颞叶 temporal lobe | 14. 总骨脚 common bony crus |
| 4. 颞骨岩部 petrous part of temporal bone | 15. 内耳道 internal acoustic meatus |
| 5. 小脑半球 cerebellar hemisphere | 16. 前骨壶腹 anterior bony ampulla |
| 6. 枕骨 occipital bone | 17. 乳突窦 mastoid antrum |
| 7. 枕乳突缝 occipitomastoid suture | 18. 乙状窦 sigmoid sinus |
| 8. 鞍背 dorsum sellae | 19. 蝶鳞缝 sphenosquamosal suture |
| 9. 颞骨鳞部 squamous part of temporal bone | 20. 三叉神经压迹 trigeminal impression |
| 10. 鼓室上隐窝 epitympanic recess | 21. 外骨半规管 lateral semicircular canal |
| 11. 后骨半规管 posterior semicircular canal | 22. 面神经管 canal for facial n. |

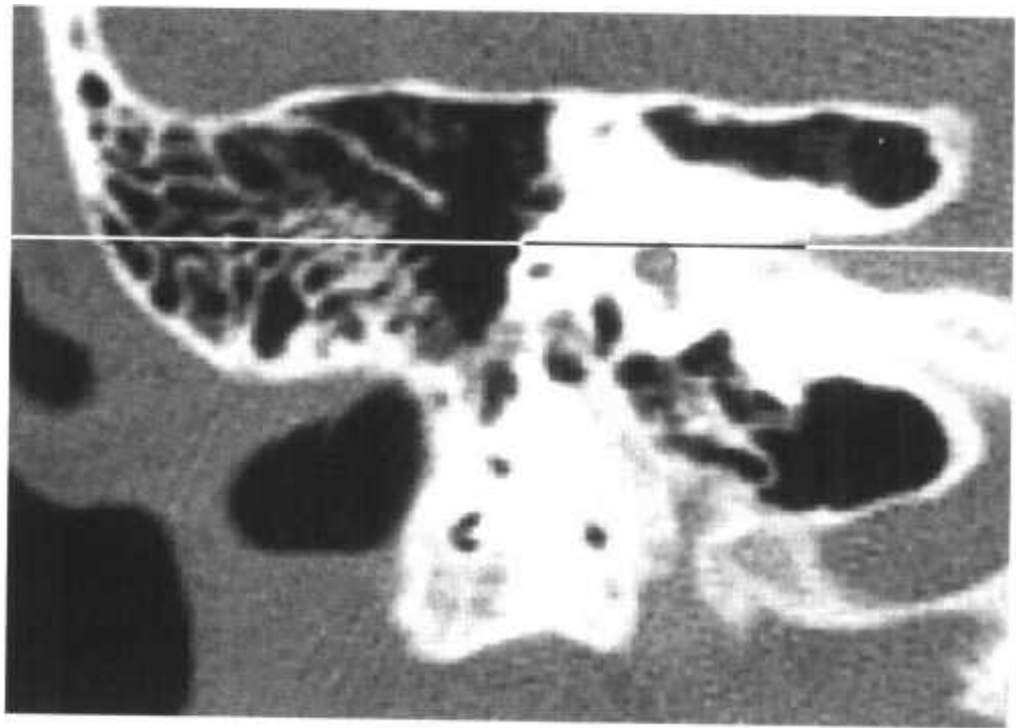
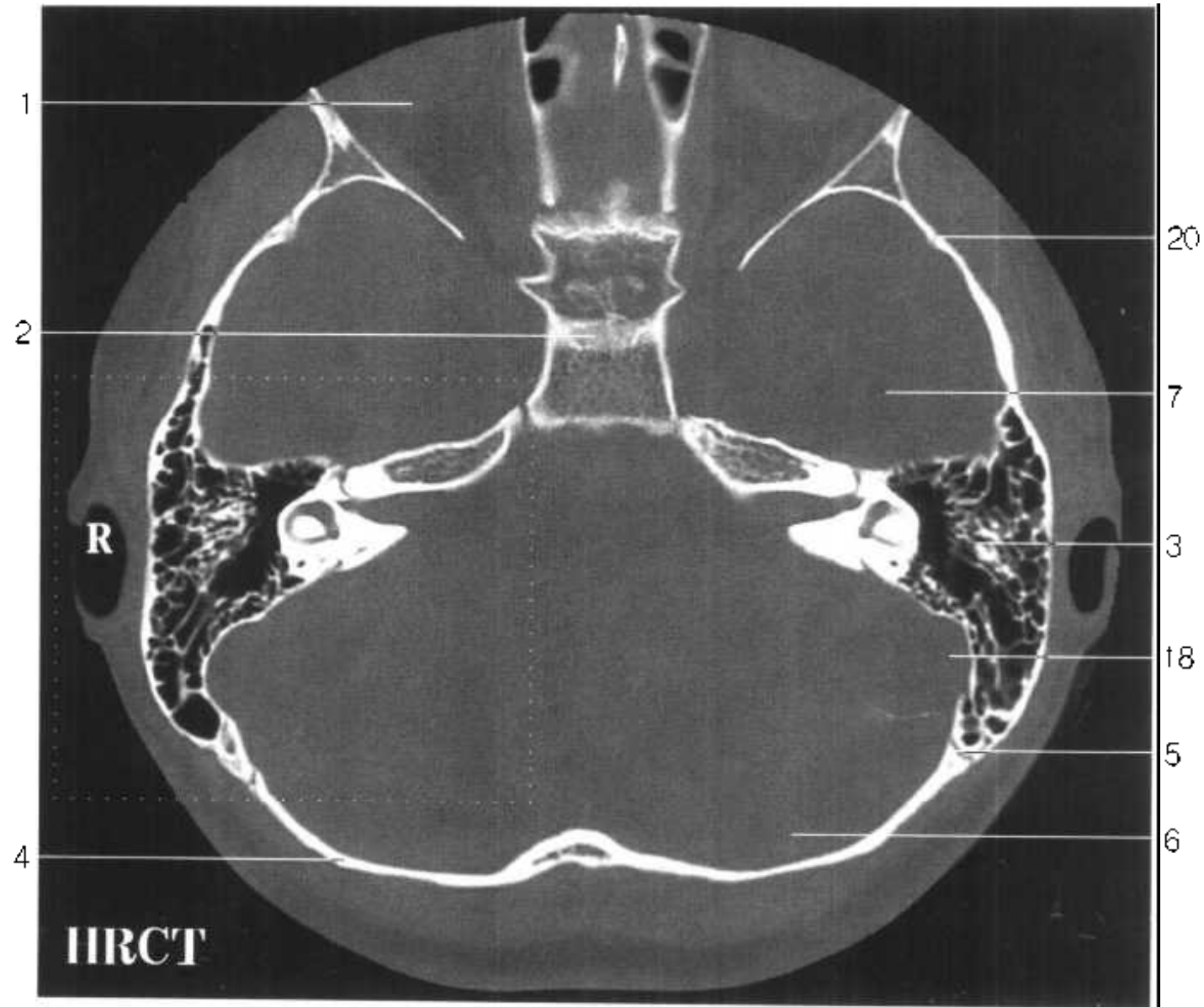


Fig. HE 7

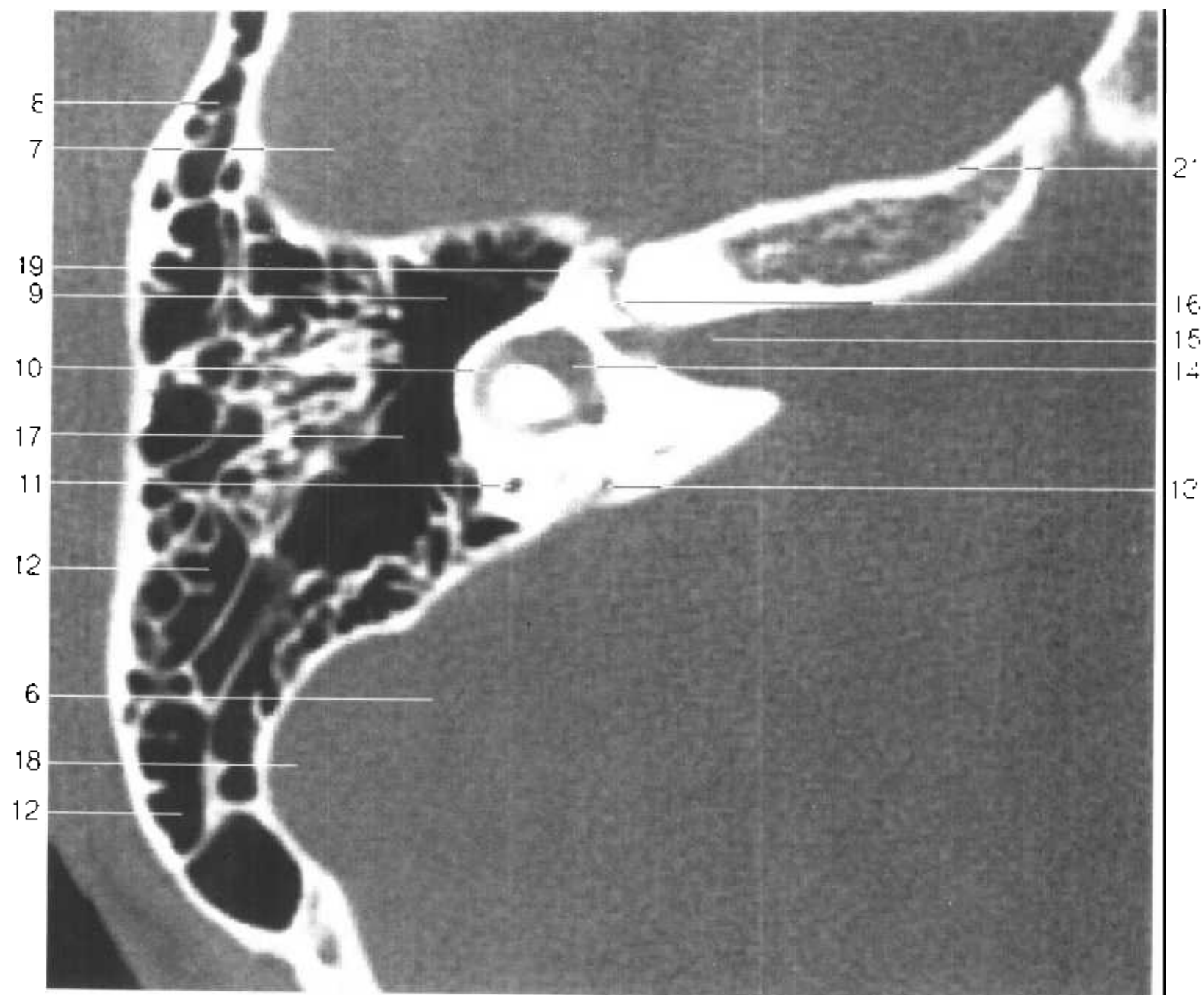


Fig.HE 7

- | | |
|---|---|
| <ul style="list-style-type: none"> 1. 眼眶 orbit 2. 垂体窝 hypophysial fossa 3. 颞骨岩部 petrous part of temporal bone 4. 枕骨 occipital bone 5. 枕乳突缝 occipitomastoid suture 6. 小脑半球 cerebellar hemisphere 7. 颞叶 temporal lobe 8. 颞骨鳞部 squamous part of temporal bone 9. 鼓室上隐窝 epitympanic recess 10. 外骨半规管 lateral semicircular canal | <ul style="list-style-type: none"> 11. 后骨半规管 posterior semicircular canal 12. 乳突小房 mastoid cells 13. 前庭水管 vestibular aqueduct 14. 前庭 vestibule 15. 内耳道 internal acoustic meatus 16. 面神经管迷路段 canal for facial nerve : labyrinthic segment 17. 乳突窦 mastoid antrum 18. 乙状窦 sigmoid sinus 19. 膝神经节 geniculate ganglion 20. 蝶鳞缝 sphenosquamosal suture 21. 三叉神经压迹 trigeminal impression |
|---|---|

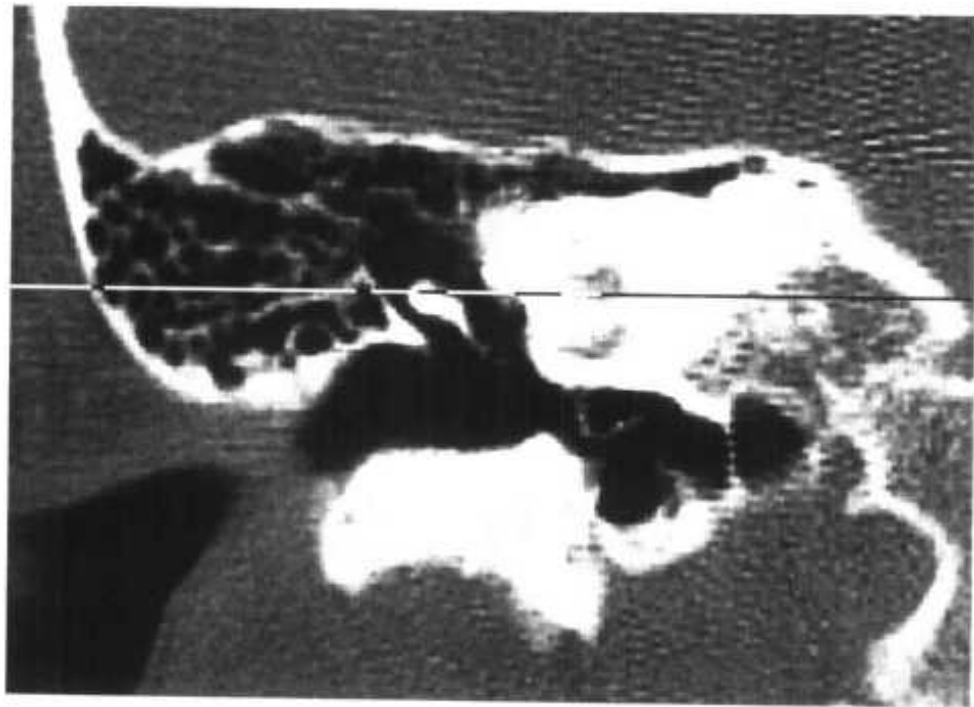
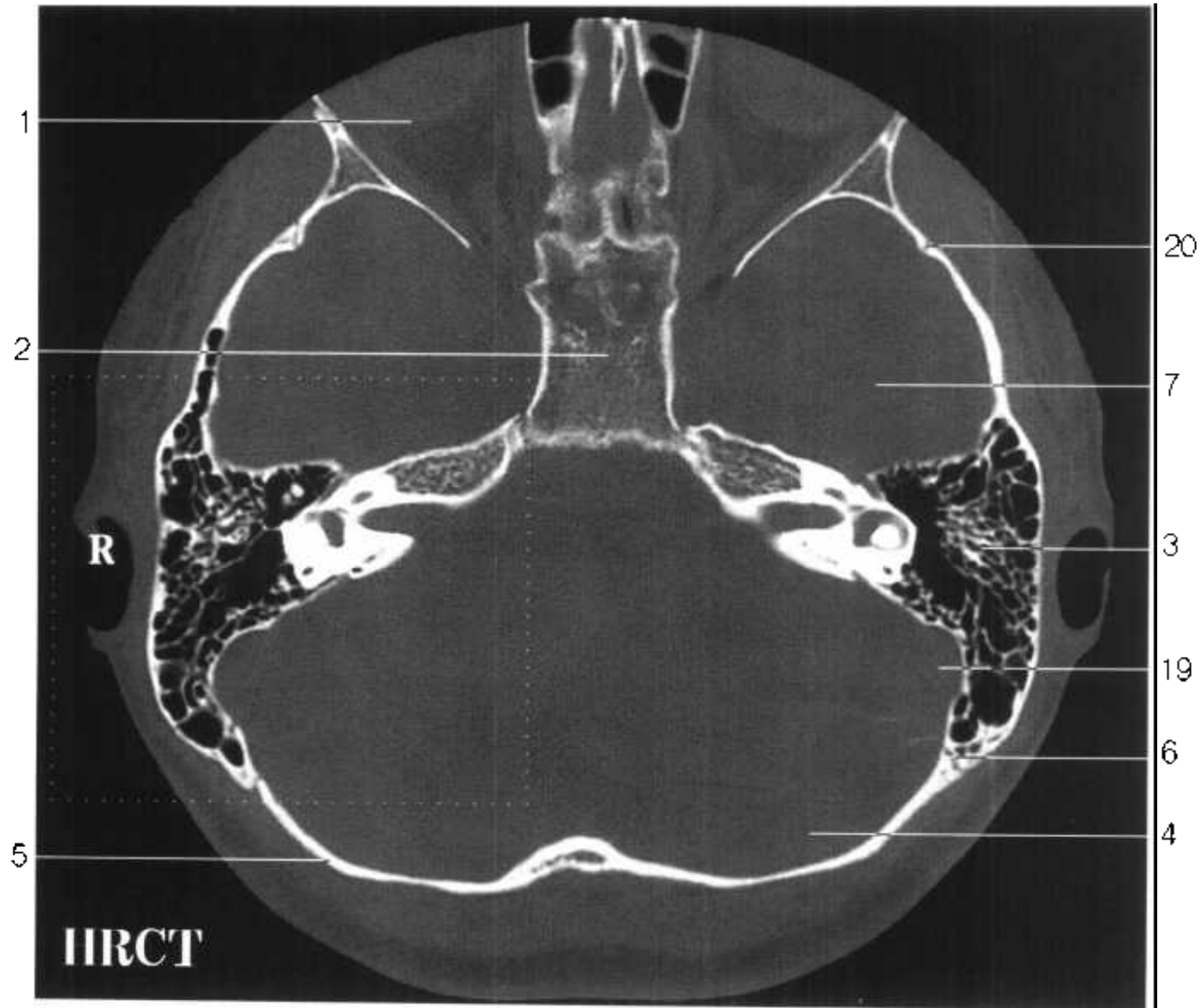


Fig. HE 8

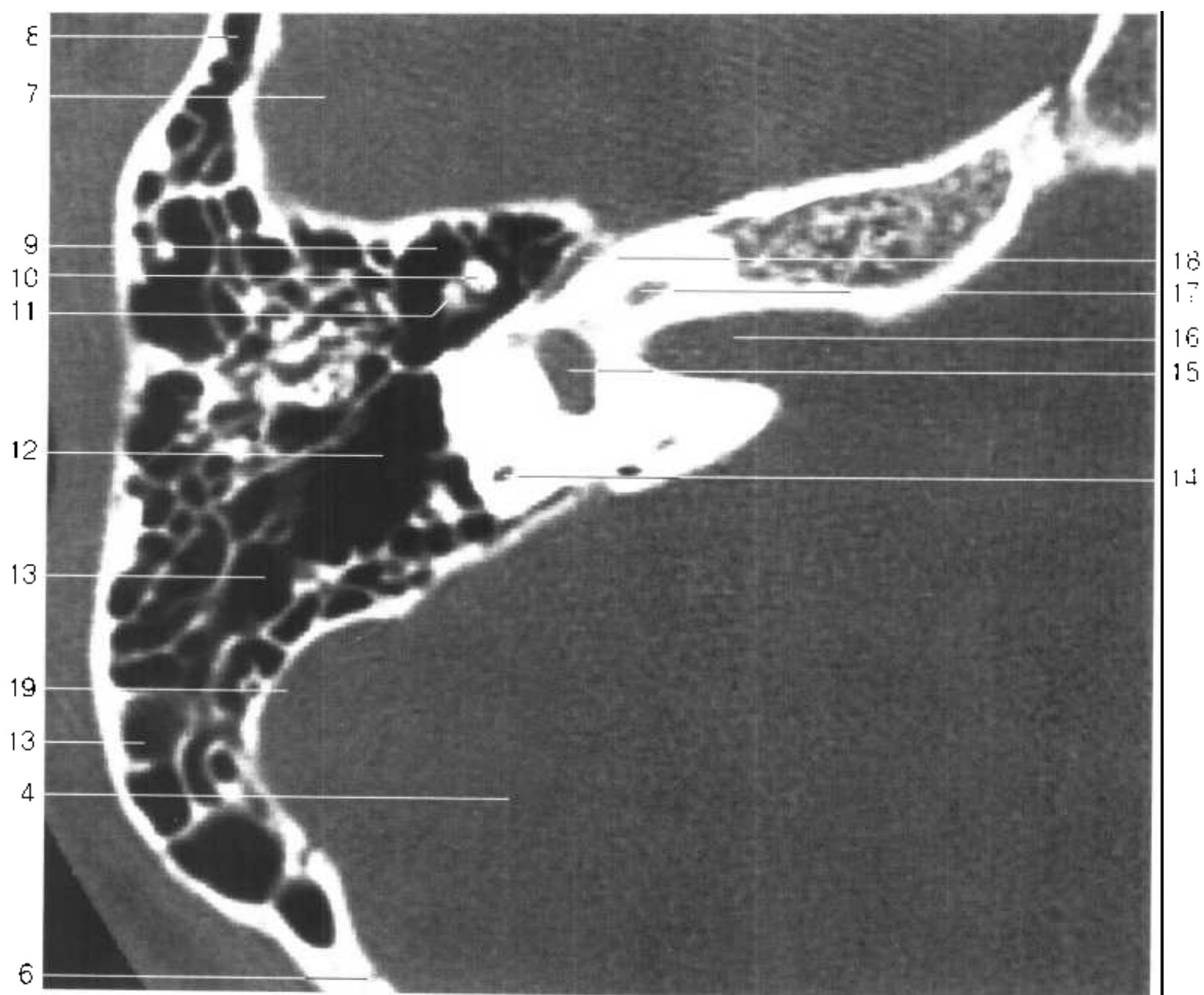


Fig.HE 8

- | | |
|---------------------------------------|--|
| 1. 眼眶 orbit | 11. 砧骨体 body of incus |
| 2. 蝶骨 sphenoid bone | 12. 乳突突 mastoid antrum |
| 3. 颞骨岩部 petrous part of temporal bone | 13. 乳突小房 mastoid cells |
| 4. 小脑半球 cerebellar hemisphere | 14. 后骨半规管 posterior semicircular canal |
| 5. 枕骨 occipital bone | 15. 前庭 vestibule |
| 6. 枕乳突缝 occipitomastoid suture | 16. 内耳道 internal acoustic meatus |
| 7. 颞叶 temporal lobe | 17. 耳蜗 cochlea |
| 8. 颞骨鳞部 squamous part of tempoal bone | 18. 岩大神经管裂孔 hiatus of canal for greater petrosal nerve |
| 9. 鼓室上隐窝 epitympanic recess | 19. 乙状窦 sigmoid sinus |
| 10. 锤骨头 head of malleus | 20. 蝶鳞缝 sphenosquamosal suture |

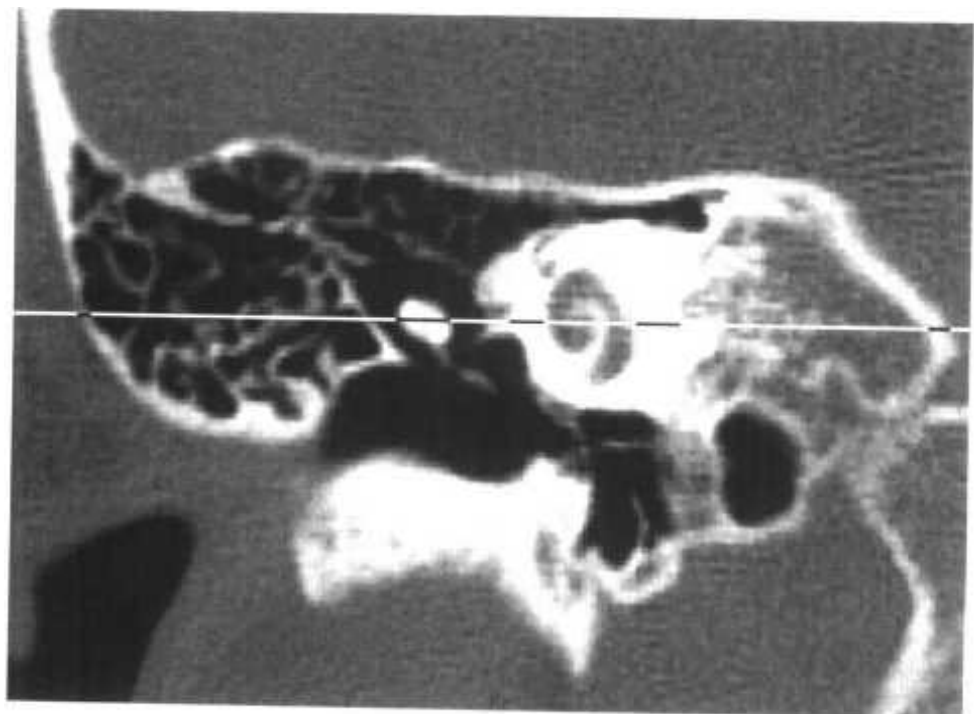
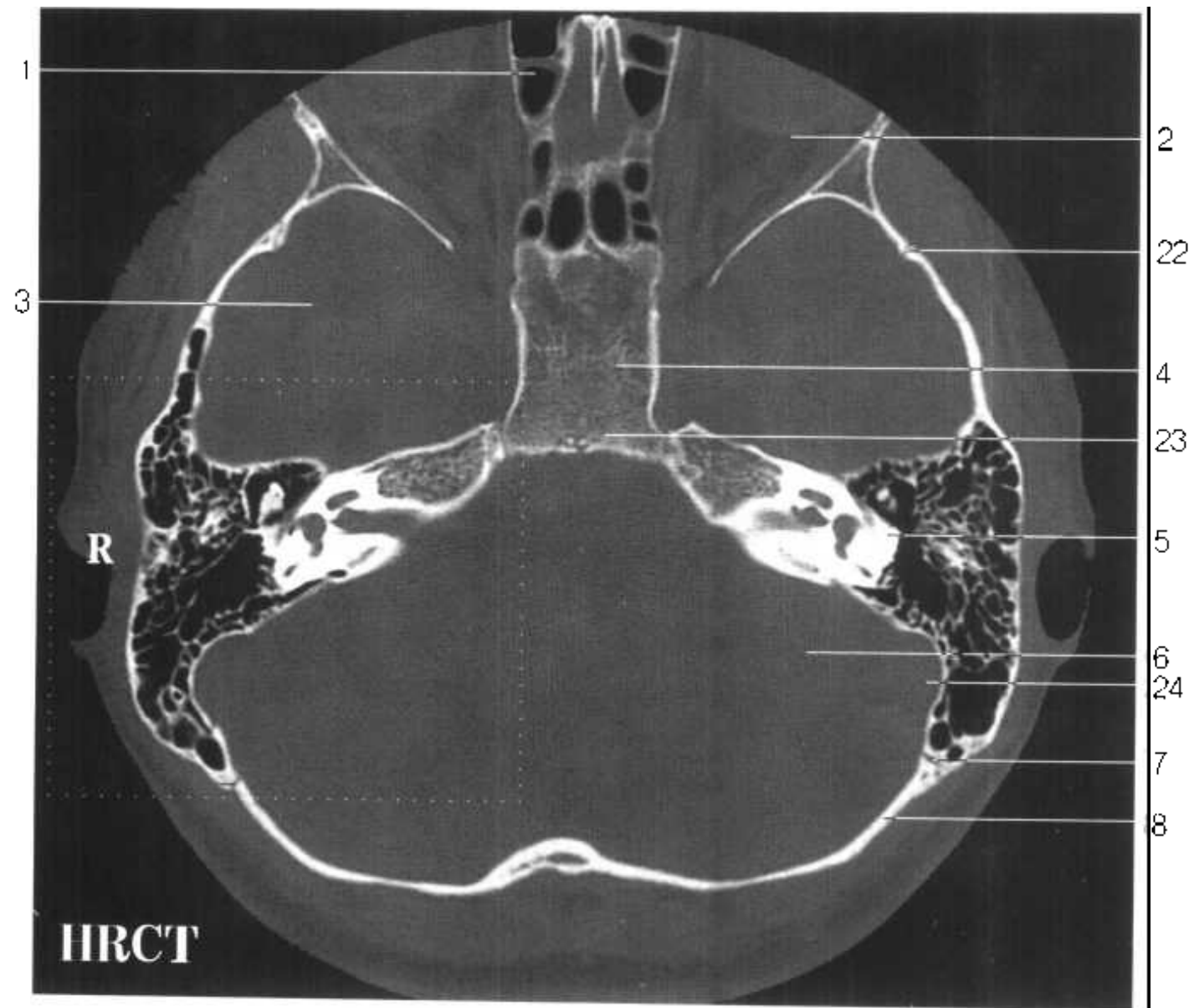


Fig. HE 9

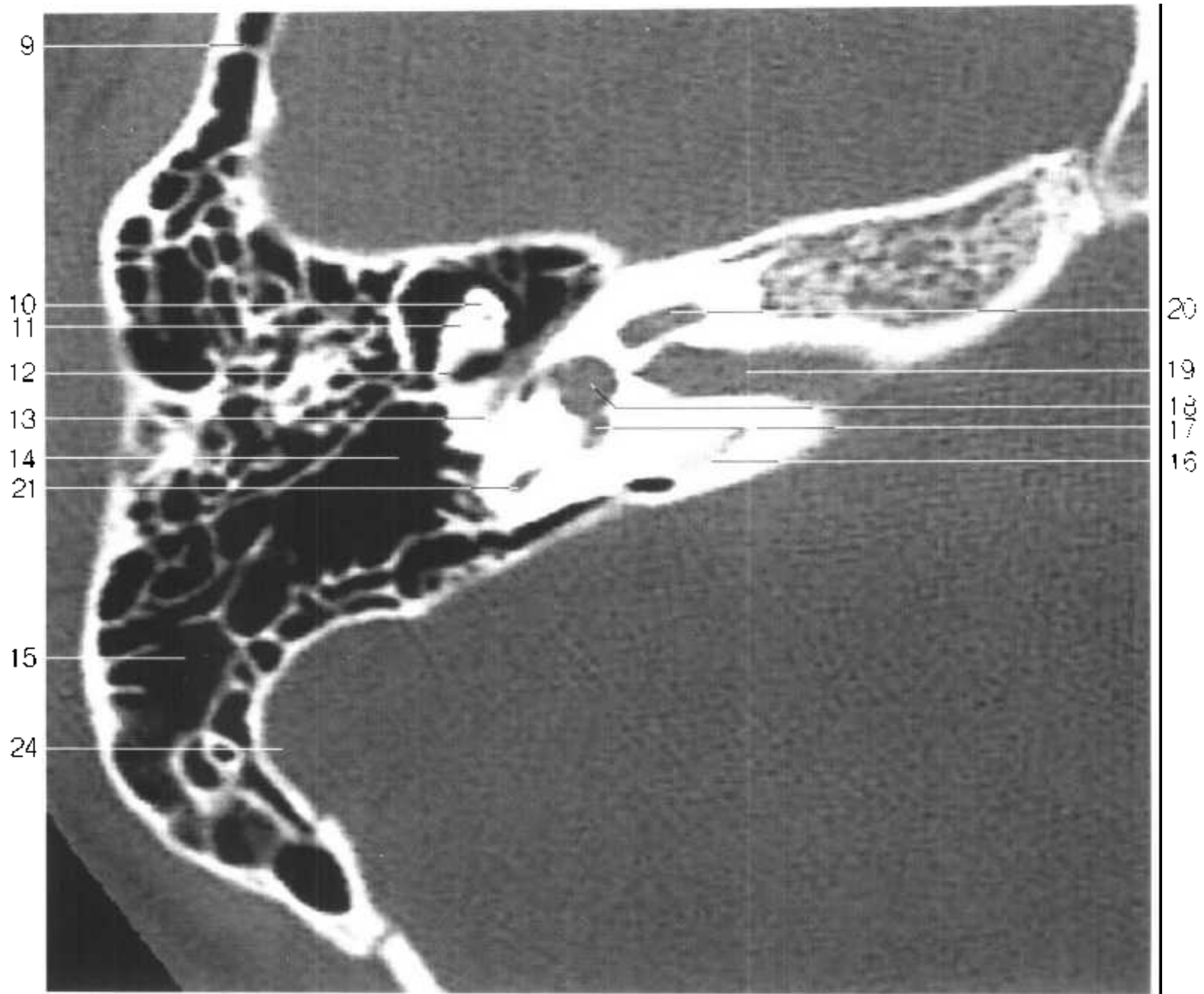


Fig.HE 9

- | | |
|--|--|
| 1. 筛窦 ethmoidal sinuses | 14. 乳突窦 mastoid antrum |
| 2. 眶腔 orbit | 15. 乳突小房 mastoid cells |
| 3. 颞叶 temporal lobe | 16. 前庭水管 vestibular aqueduct |
| 4. 蝶骨 sphenoid bone | 17. 后骨半规管 posterior semicircular canal |
| 5. 颞骨岩部 petrous part of temporal bone | 18. 前庭 vestibule |
| 6. 小脑半球 cerebellar hemisphere | 19. 内耳道 internal acoustic meatus |
| 7. 枕乳突缝 occipitomastoid suture | 20. 耳蜗 cochlea |
| 8. 枕骨 occipital bone | 21. 后骨半规管 posterior semicircular canal |
| 9. 颞骨鳞部 squamous part of temporal bone | 22. 蝶鳞缝 sphenosquamosal suture |
| 10. 锤骨头 head of malleus | 23. 枕骨斜坡 clivus of occipital bone |
| 11. 砧骨体 body of incus | 24. 乙状窦 sigmoid sinus |
| 12. 砧骨短脚 short crus of incus | |
| 13. 面神经管鼓室段 canal for facial nerve :tympanic segment | |

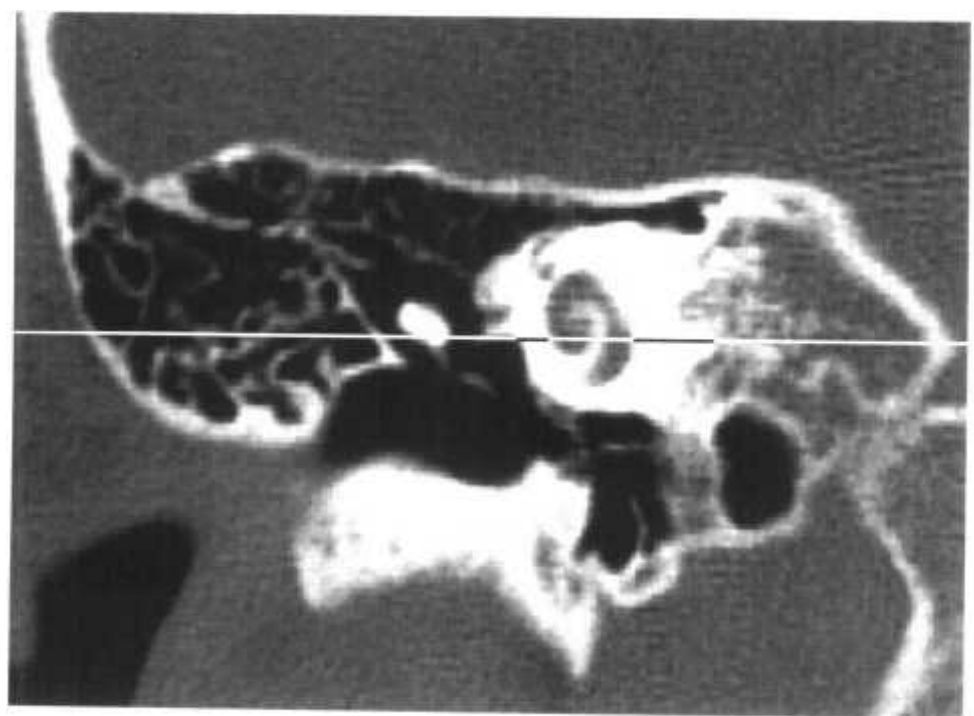
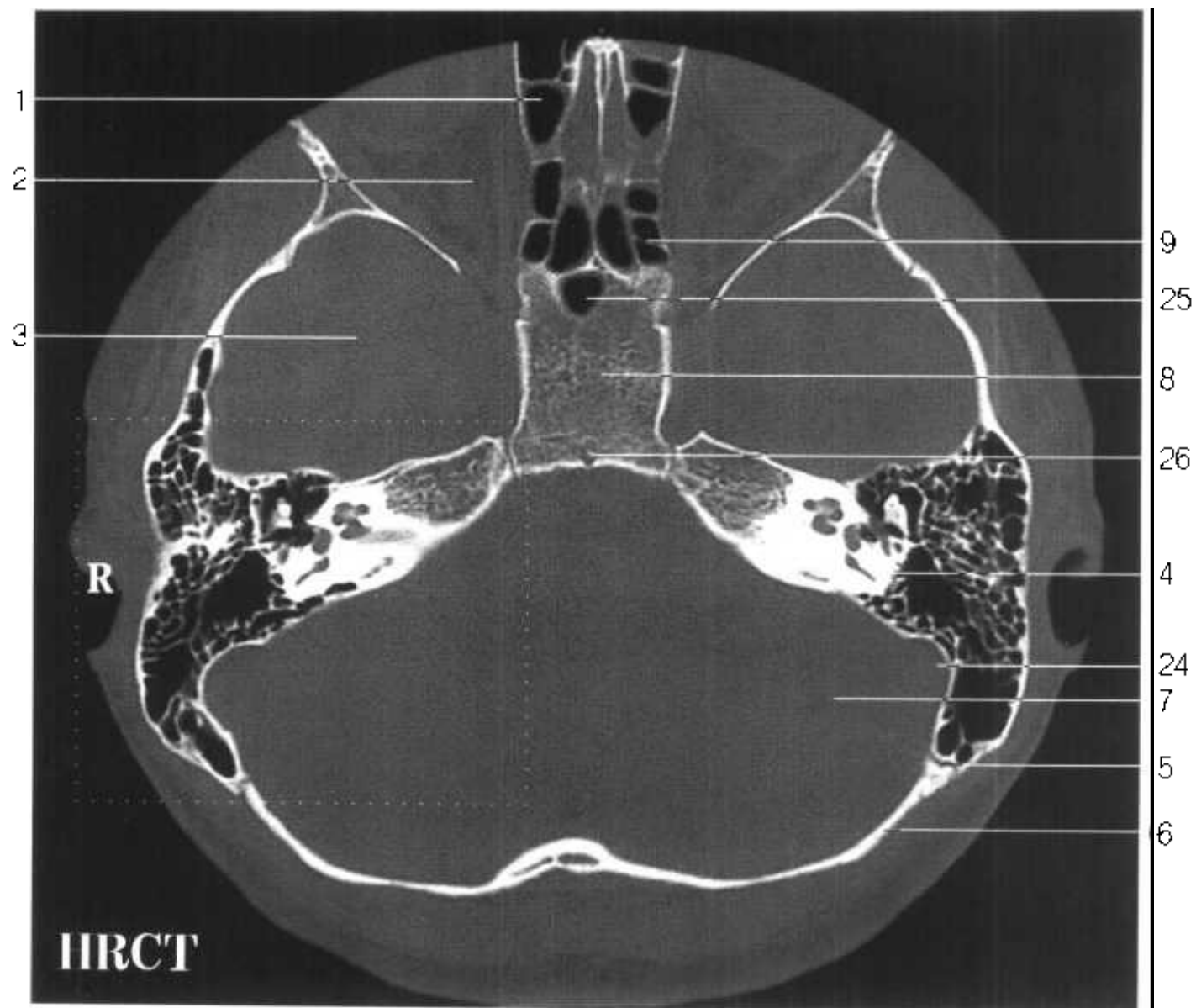


Fig. HE 10

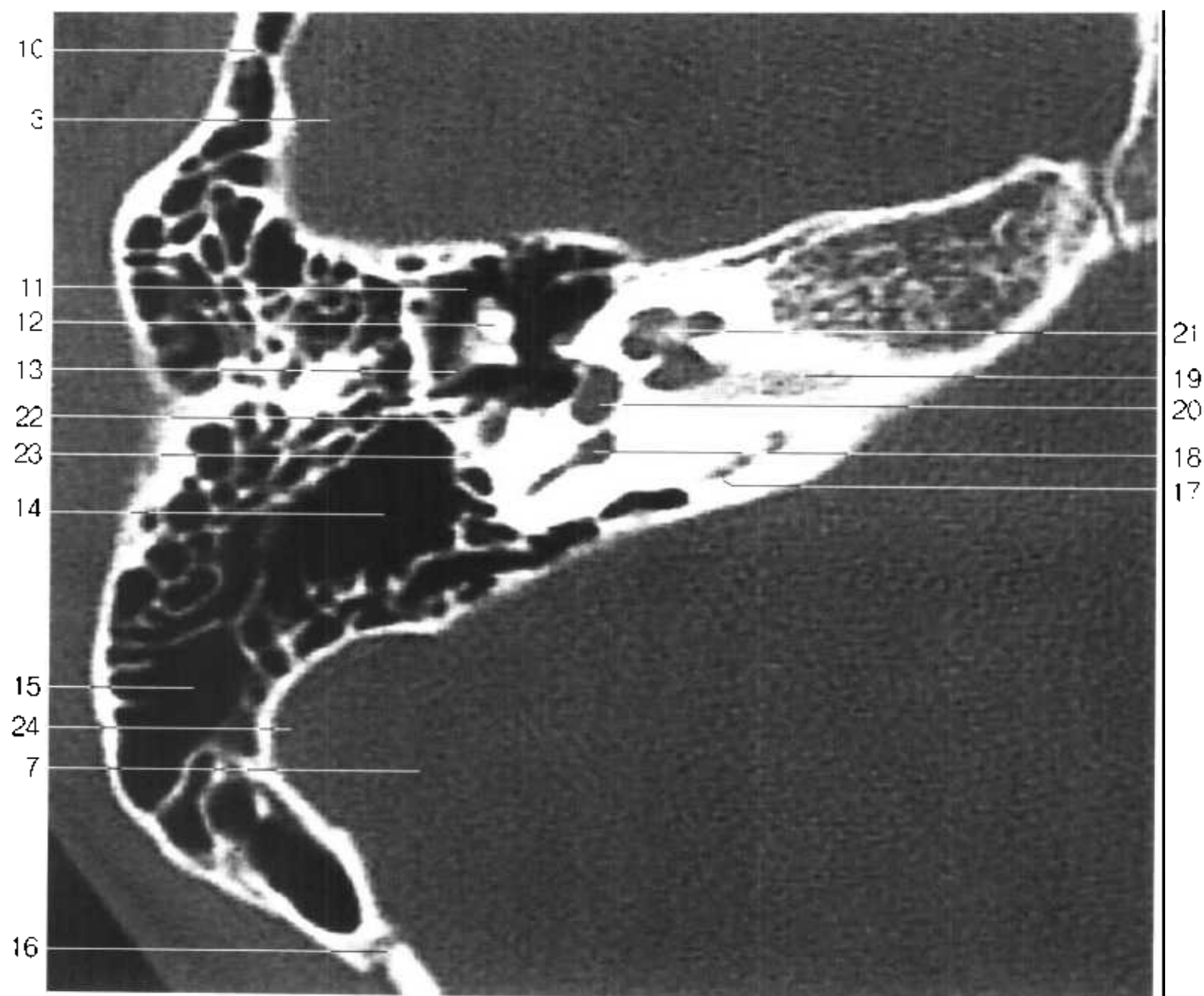


Fig.HE 10

- | | |
|---|--|
| 1. 筛窦 ethmoidal sinus | 14. 乳突突 mastoid antrum |
| 2. 眶腔 orbit | 15. 乳突小房 mastoid cells |
| 3. 颞叶 temporal lobe | 16. 枕乳突缝 occipitomastoid suture |
| 4. 颞骨岩部 petrous part of temporal bone | 17. 前庭水管 vestibular aqueduct |
| 5. 枕乳突缝 occipitomastoid suture | 18. 后骨半规管 posterior semicircular canal |
| 6. 枕骨 occipital bone | 19. 内耳道 internal acoustic meatus |
| 7. 小脑半球 cerebellar hemisphere | 20. 前庭 vestibule |
| 8. 蝶骨 sphenoid bone | 21. 蜗螺旋管 cochlear spiral canal |
| 9. 筛窦 ethmoidal sinus | 22. 锥隆起 pyramidal eminence |
| 10. 颞骨鳞部 squamous part of temporal bone | 23. 面神经管 facial canal |
| 11. 鼓室上隐窝 epitympanic recess | 24. 乙状窦 sigmoid sinus |
| 12. 锤骨头 head of malleus | 25. 蝶窦 sphenoidal sinus |
| 13. 砧骨短脚 short crus of incus | 26. 枕骨斜坡 clivus of occipital bone |

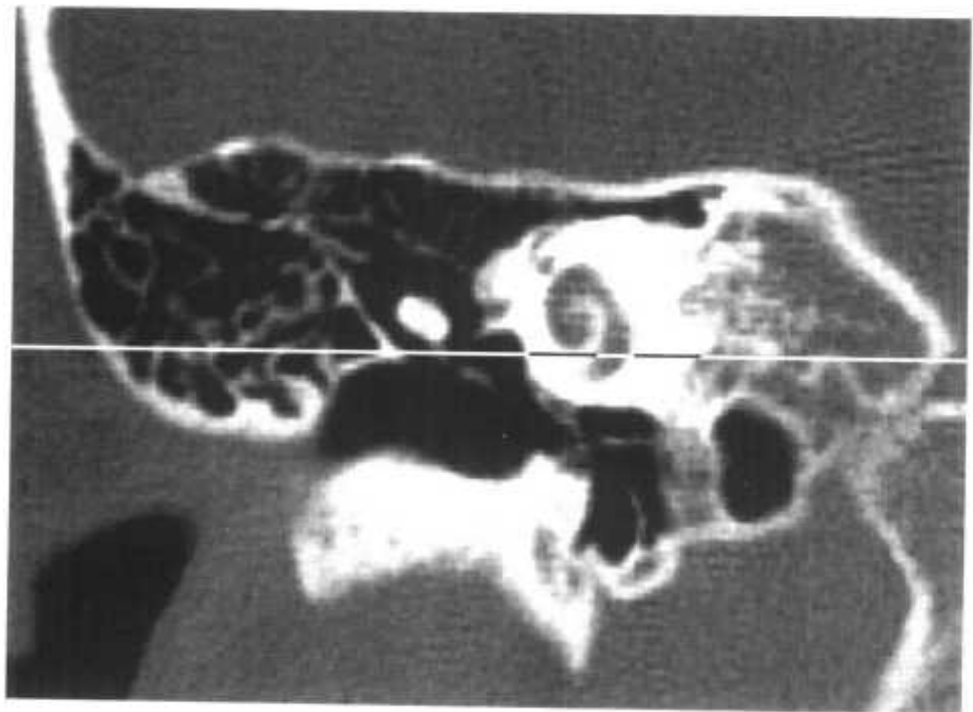
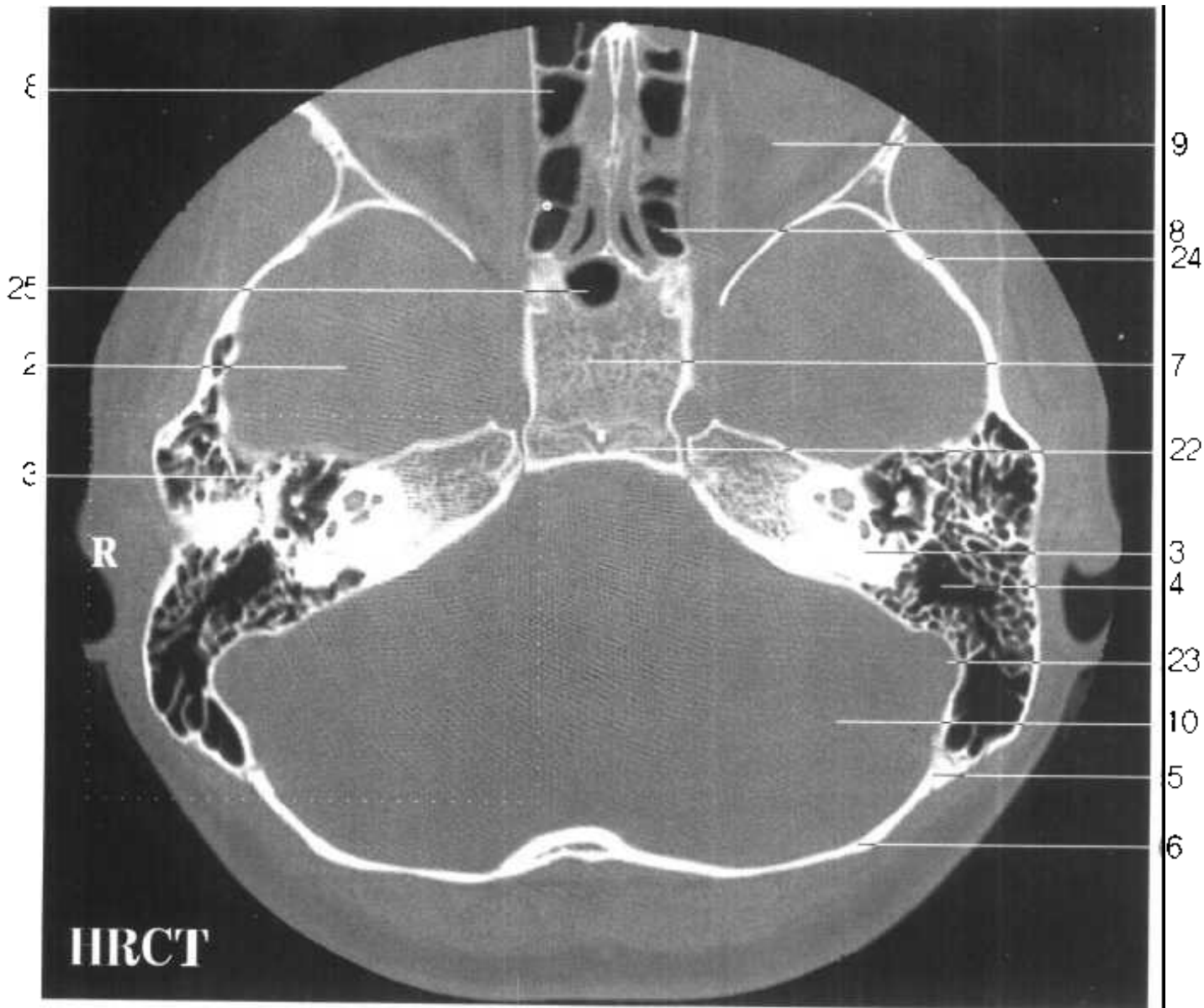


Fig. HE 11

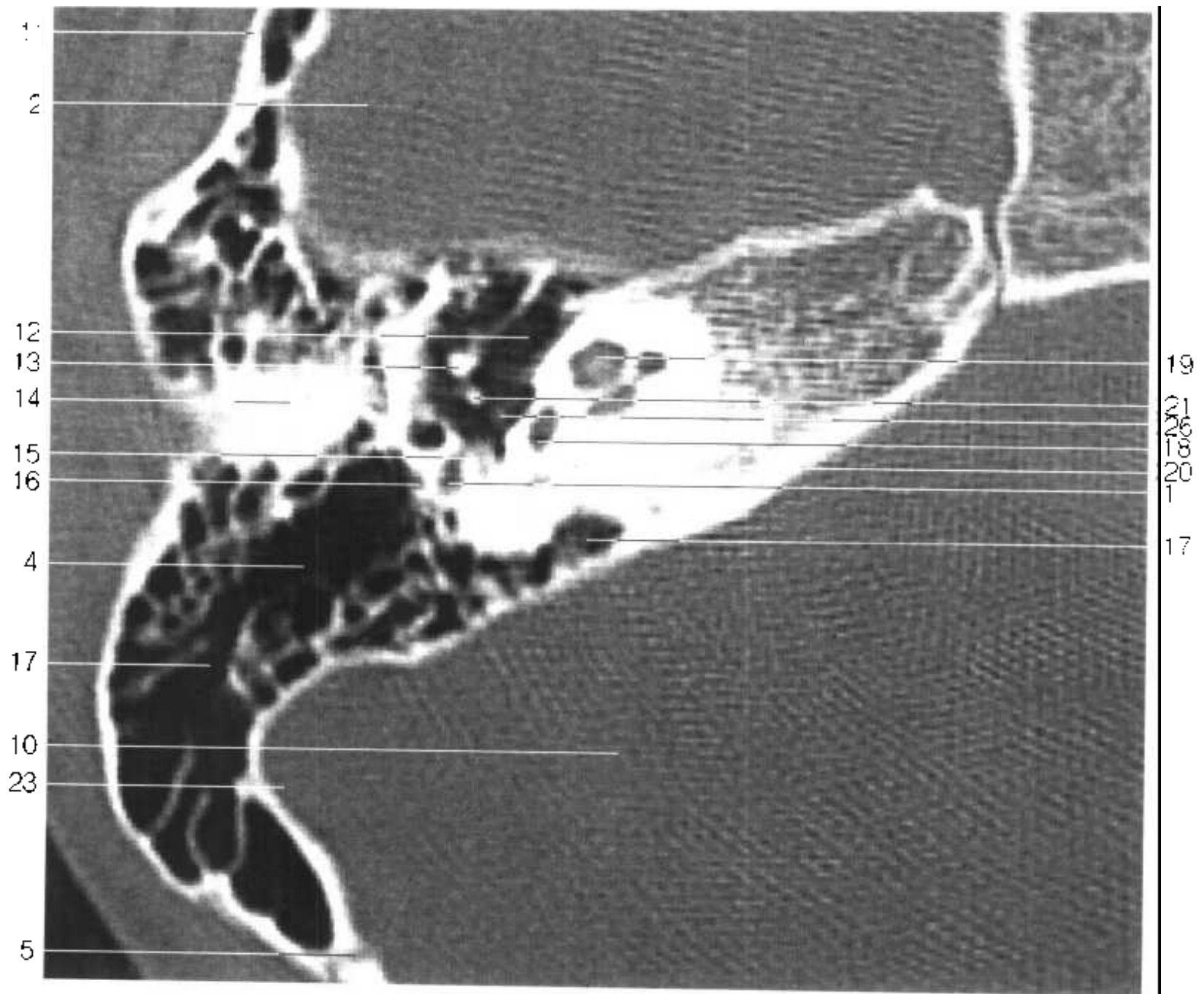


Fig.HE 11

- | | |
|---|-----------------------------------|
| 1. 镫骨肌窝 fossa of stapedius | 14. 外耳道 external acoustic meatus |
| 2. 颞叶 temporal lobe | 15. 锥隆起 pyramidal eminence |
| 3. 颞骨岩部 petrous part of temporal bone | 16. 面神经管 fascial canal |
| 4. 乳突窦 mastoid sinus | 17. 乳突小房 mastoid cells |
| 5. 枕乳突缝 occipitomastoid suture | 18. 前庭 vestibule |
| 6. 枕骨 occipital bone | 19. 蜗螺旋管 cochlear spiral canal |
| 7. 蝶骨 sphenoid bone | 20. 内耳道 internal acoustic meatus |
| 8. 筛窦 ethmoidal sinus | 21. 砧骨长脚 long crus of incus |
| 9. 眼眶 orbit | 22. 枕骨斜坡 clivus of occipital bone |
| 10. 小脑半球 cerebellar hemisphere | 23. 乙状窦 sigmoid sinus |
| 11. 颞骨鳞部 squamous part of temporal bone | 24. 蝶鳞缝 sphenosquamosal suture |
| 12. 鼓室 tympanic cavity | 25. 蝶窦 sphenoidal sinus |
| 13. 锤骨柄 manubrium of malleus | 26. 镫骨 stapes |

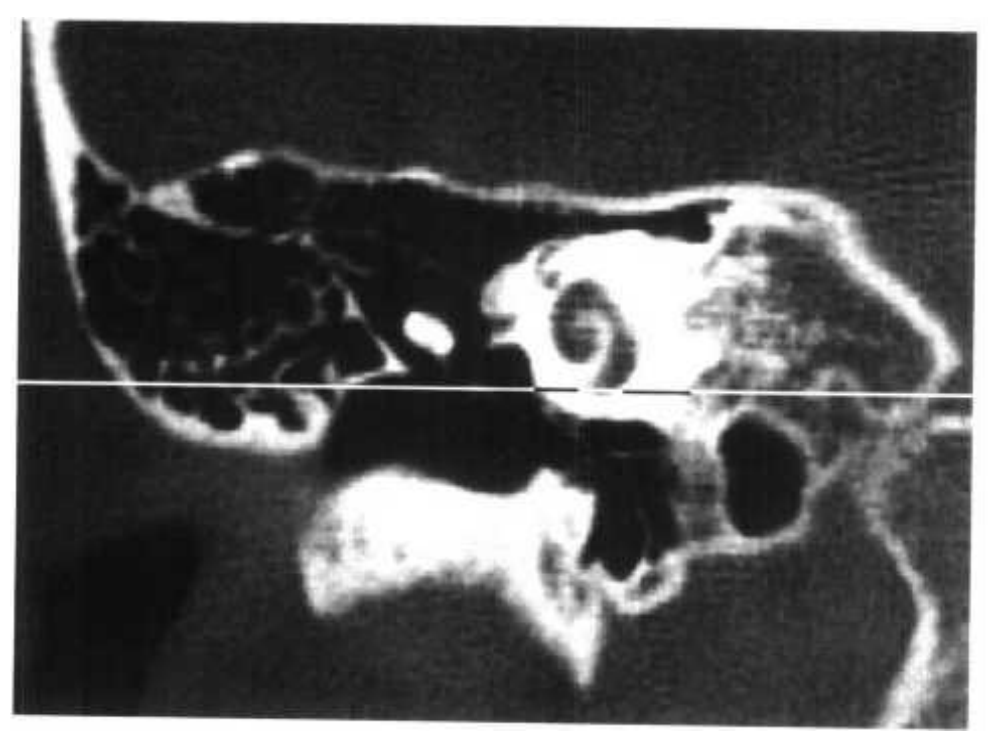
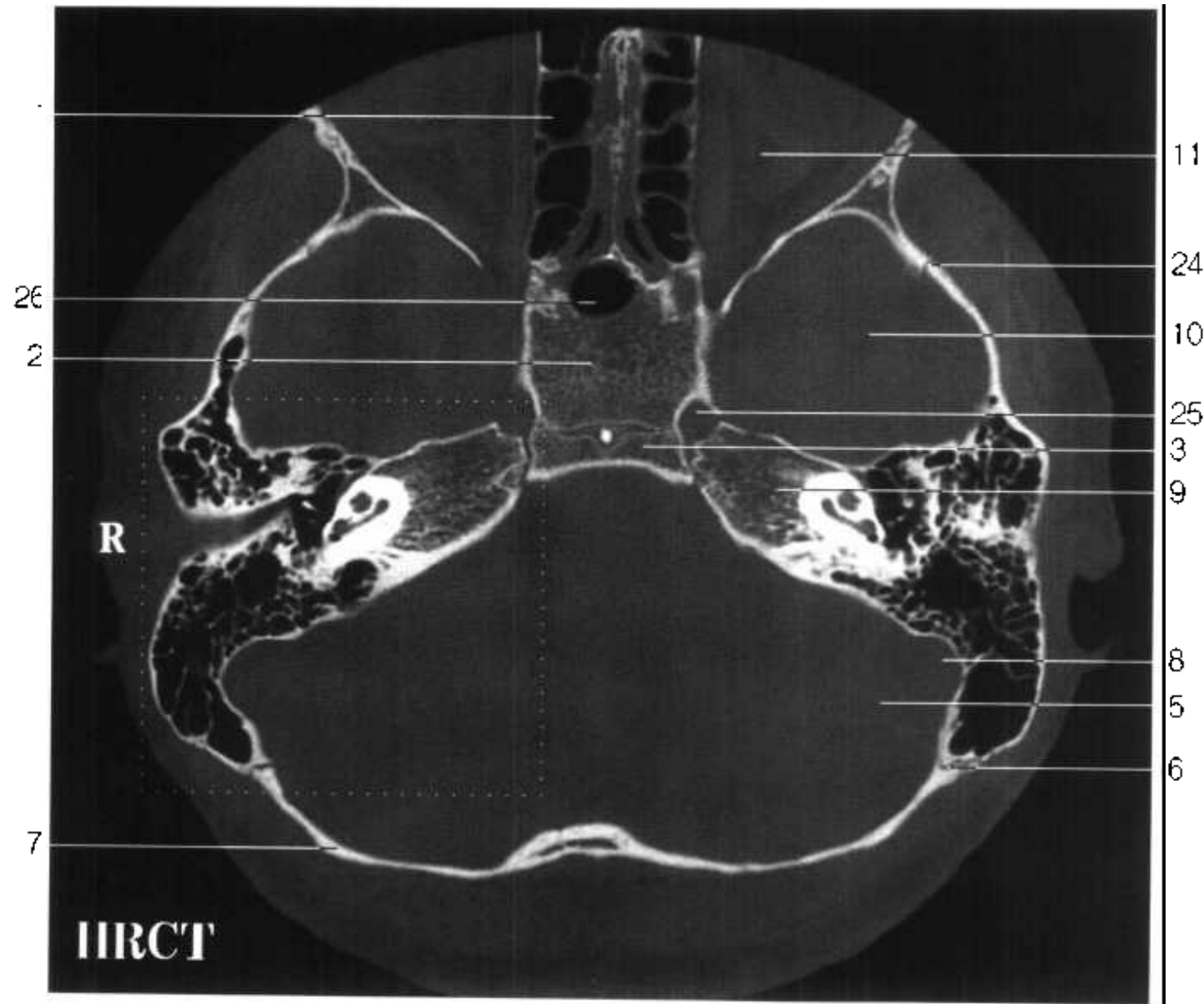


Fig. HE 12

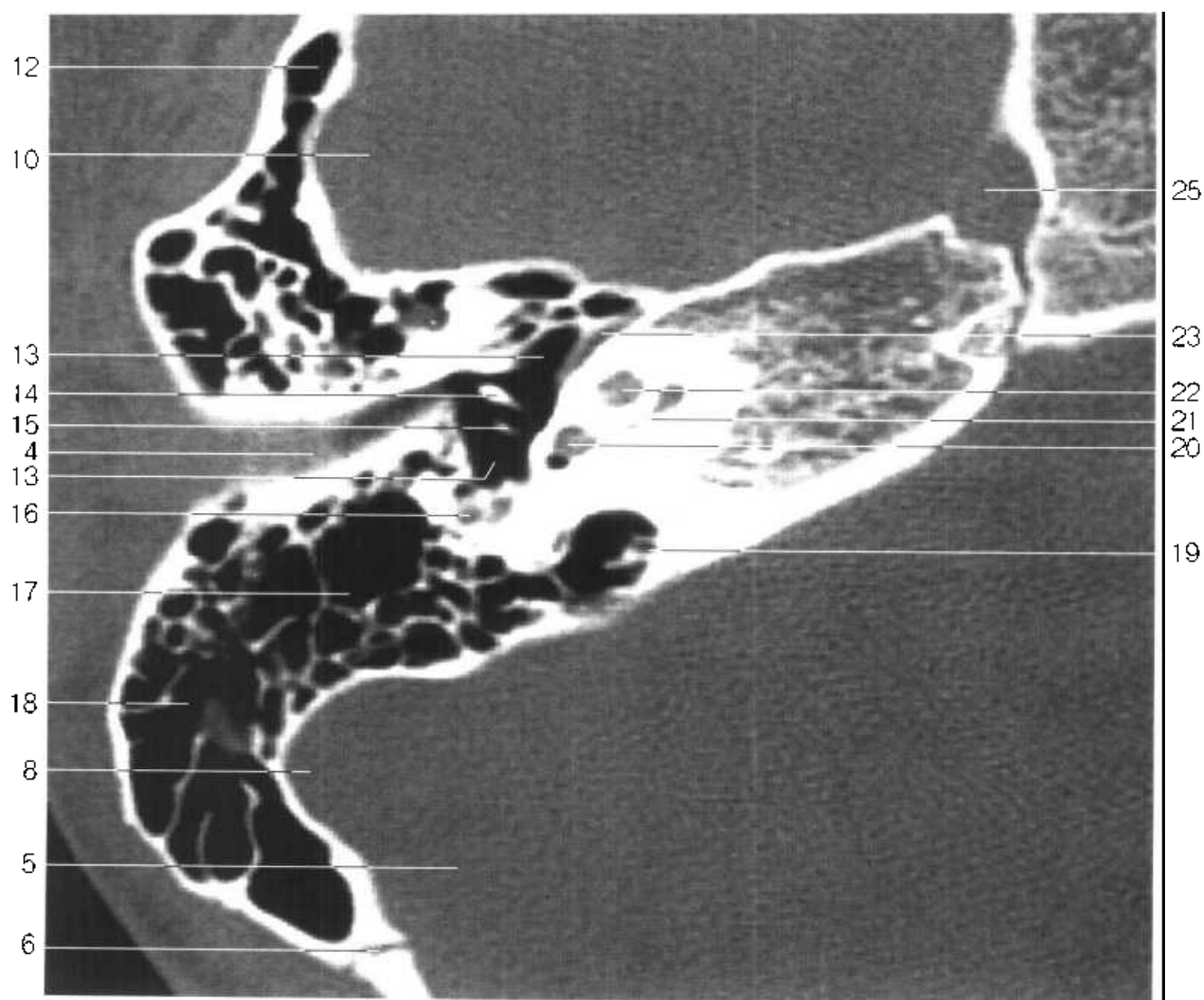


Fig.HE 12

- | | |
|---|---|
| 1. 筛窦 ethmoidal sinus | 15. 砧骨长脚 long crus of incus |
| 2. 蝶骨 sphenoid bone | 16. 面神经管鼓室段 canal for facial nerve : tympanic segment |
| 3. 枕骨斜坡 clivus of occipital bone | 17. 乳突窦 mastoid antrum |
| 4. 外耳道 external acoustic meatus | 18. 乳突小房 mastoid cells |
| 5. 小脑半球 cerebellar hemisphere | 19. 颈内静脉 internal jugular v. |
| 6. 枕乳突缝 occipitomastoid suture | 20. 前庭 vestibule |
| 7. 枕骨 occipital bone | 21. 蜗螺旋管第一周 first whorl of cochlear spiral canal |
| 8. 乙状窦 sigmoid sinus | 22. 耳蜗 cochlea |
| 9. 颞骨岩部 petrous part bone of temporal | 23. 鼓膜张肌 tensor tympani : tendon |
| 10. 颞叶 temporal lobe | 24. 蝶鳞缝 sphenosquamosal suture |
| 11. 眶腔 orbit | 25. 颈内动脉岩内段 petrous segment of internal carotid a. |
| 12. 颞骨鳞部 squamous part of temporal bone | 26. 蝶窦 sphenoidal sinus |
| 13. 鼓室 tympanic cavity | |
| 14. 锤骨柄 manubrium of malleus | |

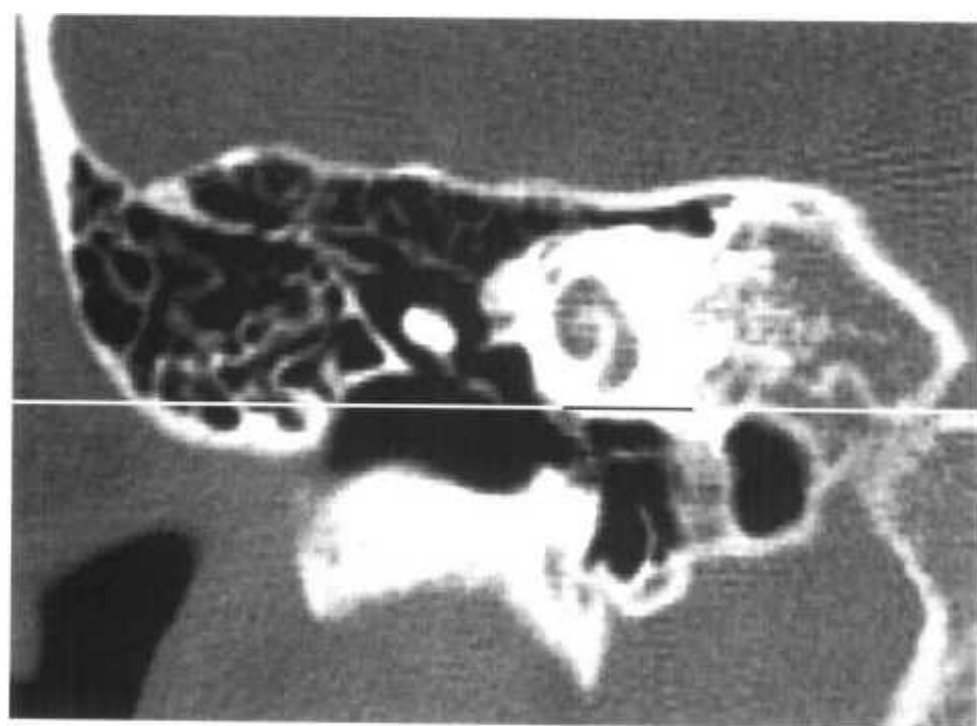
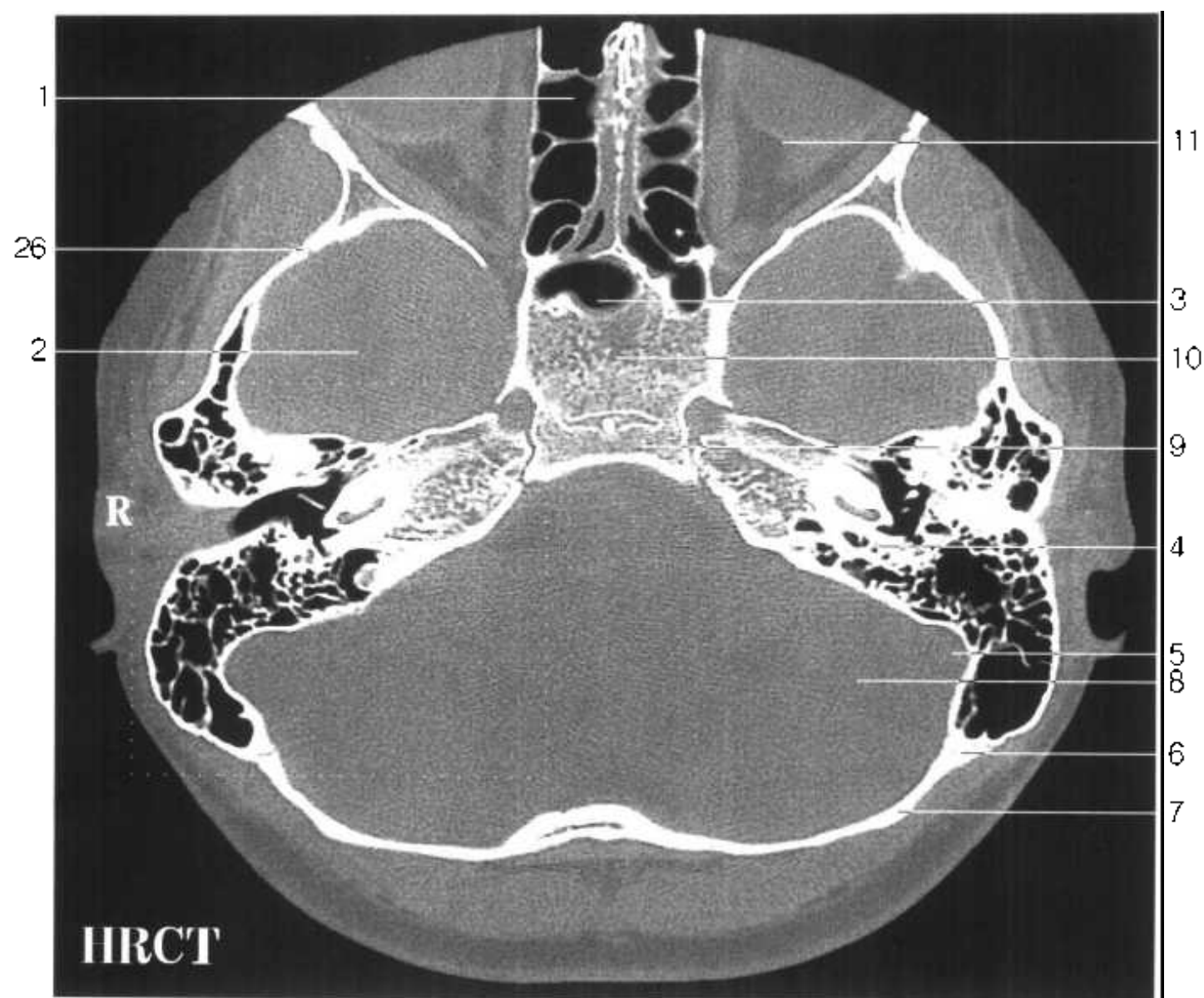


Fig. HE 13

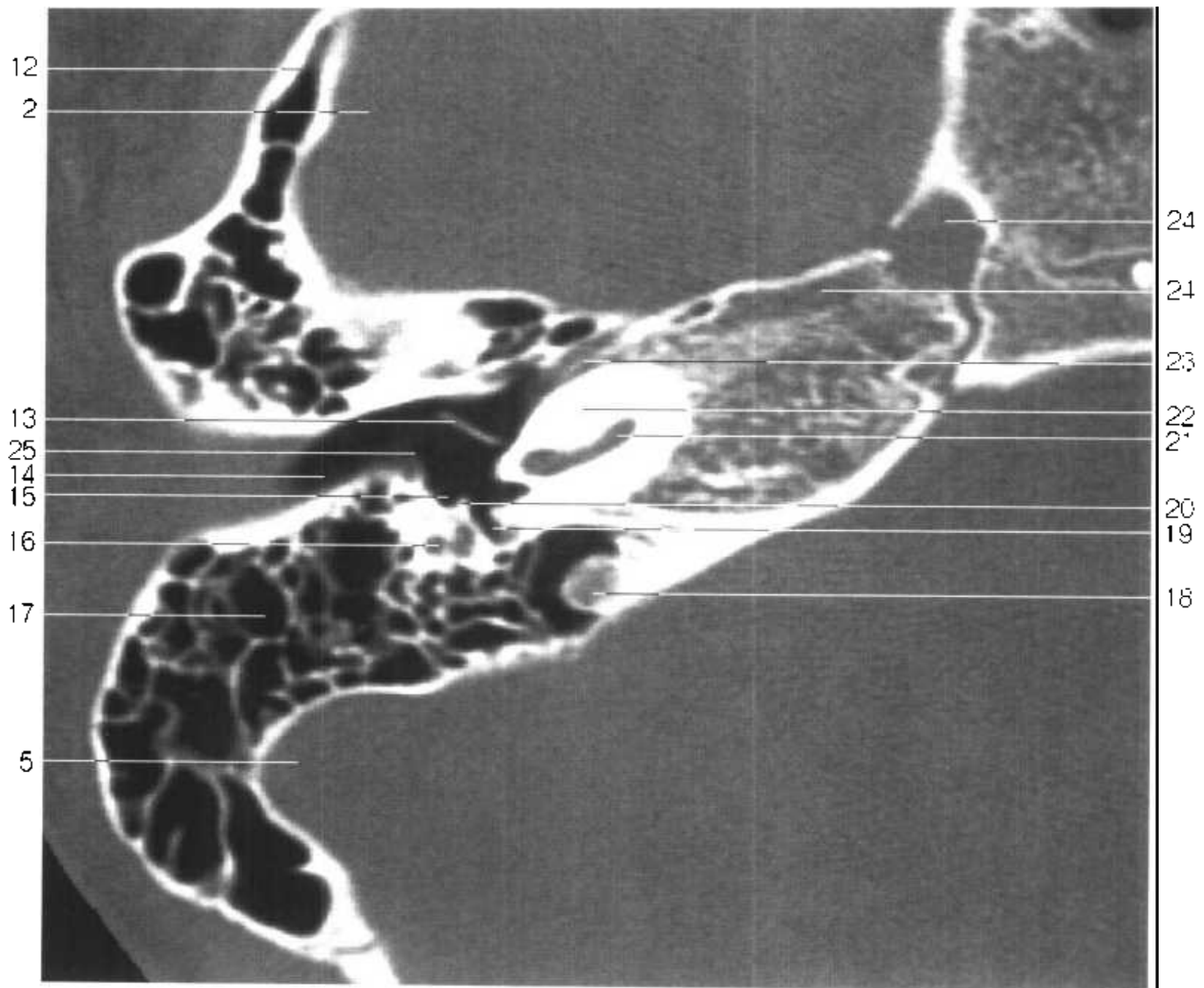


Fig.HE 13

- | | |
|---|--|
| 1. 筛窦 ethmoidal sinus | 15. 鼓室 tympanic cavity |
| 2. 颞叶 temporal lobe | 16. 面神经管乳突部 canal for facial nerve : mastoid part |
| 3. 蝶窦 sphenoidal sinus | 17. 乳突小房 mastoid cells |
| 4. 颞骨岩部 petrous part of temporal bone | 18. 颈内静脉 internal jugular v. |
| 5. 乙状窦 sigmoid sinus | 19. 鼓窦 tympanic sinus |
| 6. 枕乳突缝 occipitomastoid suture | 20. 锥隆起 pyramidal eminence |
| 7. 枕骨 occipital bone | 21. 蜗螺旋管第一周 first whorl of cochlear spiral canal |
| 8. 小脑半球 cerebellar hemisphere | 22. 耳蜗 cochlea |
| 9. 枕骨斜坡 clivus of occipital bone | 23. 鼓膜张肌 tensor tympani |
| 10. 蝶骨体 body of sphenoid bone | 24. 颈内动脉岩内段 petrous segment of internal carotid a. |
| 11. 眶腔 orbit | 25. 鼓膜 tympanic membrane |
| 12. 颞骨鳞部 squamous part of temporal bone | 26. 蝶鳞缝 sphenosquamosal suture |
| 13. 锤骨柄 manubrium of malleus | |
| 14. 外耳道 external acoustic meatus | |

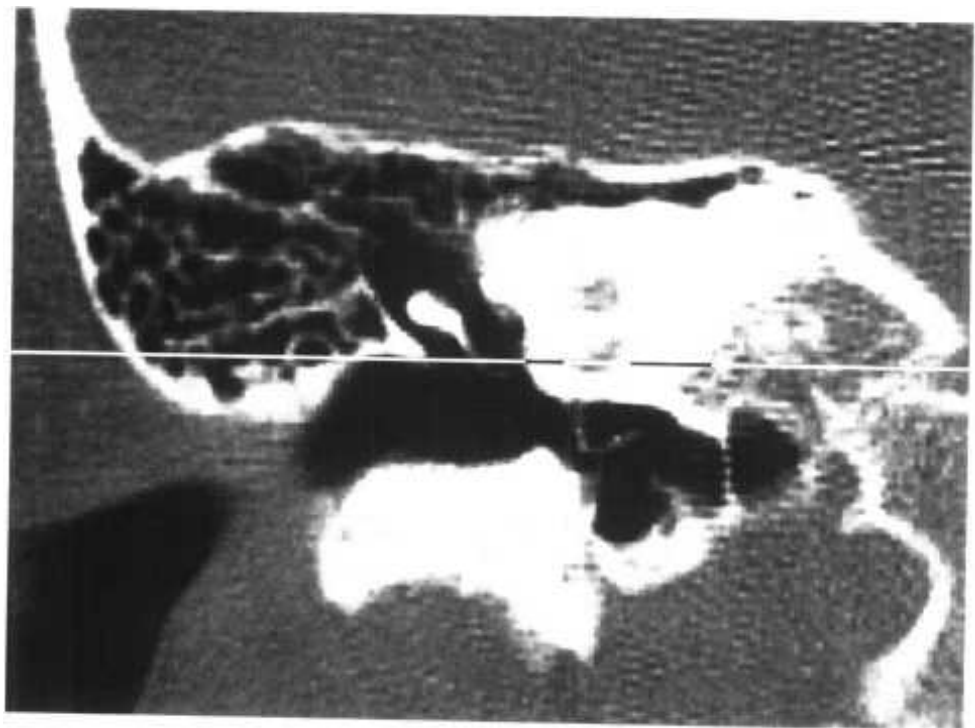
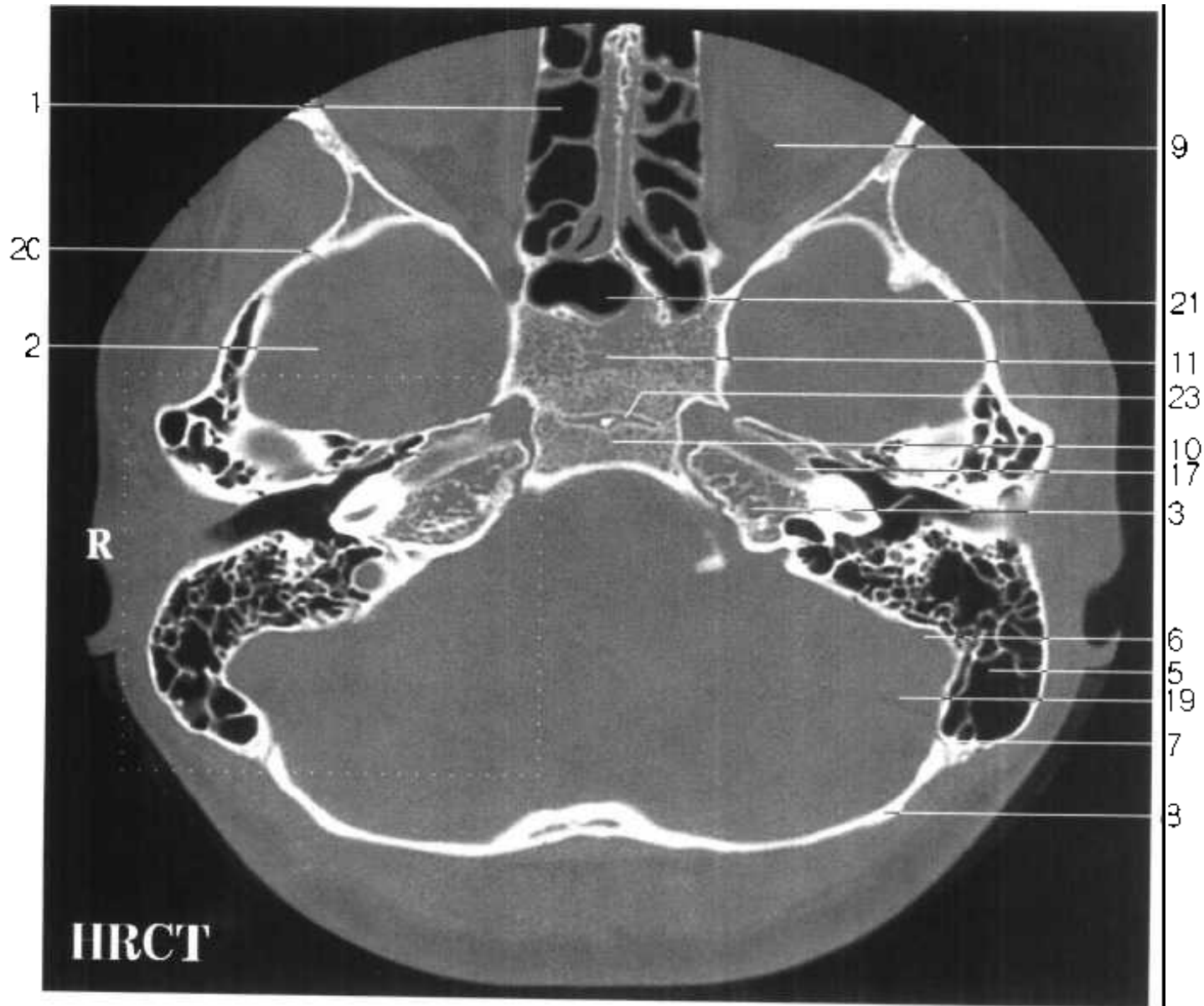


Fig. HE 14

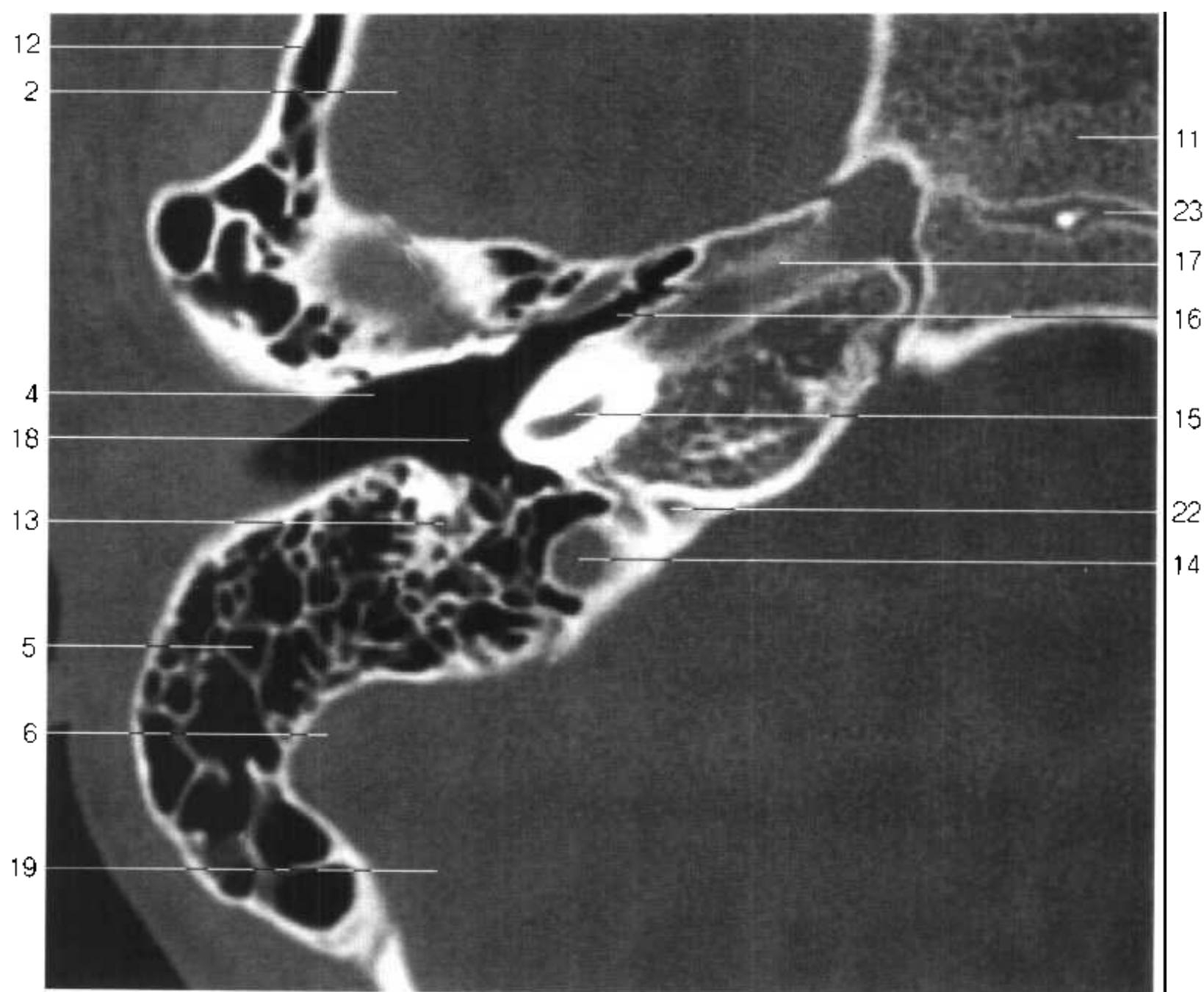


Fig.HE 14

- | | |
|---|--|
| 1. 筛窦 ethmoidal sinus | 13. 面神经管乳突部 canal for facial nerve: mastoid part |
| 2. 颞叶 temporal lobe | 14. 颈内静脉 internal jugular v. |
| 3. 颞骨岩部 petrous part of temporal bone | 15. 蜗螺旋管第一周 first whorl of cochlear spiral canal |
| 4. 外耳道 external acoustic meatus | 16. 咽鼓管 pharyngotympanic tube |
| 5. 乳突小房 mastoid cells | 17. 颈内动脉岩内段 petrous segment of internal carotid a. |
| 6. 乙状窦 sigmoid sinus | 18. 鼓室 tympanic cavity |
| 7. 枕乳突缝 occipitomastoid suture | 19. 小脑半球 cerebellar hemisphere |
| 8. 枕骨 occipital bone | 20. 蝶鳞缝 sphenosquamosal suture |
| 9. 眶腔 orbit | 21. 蝶窦 sphenoidal sinus |
| 10. 枕骨斜坡 clivus of occipital bone | 22. 蜗水管 cochlear aqueduct |
| 11. 蝶骨体 body of sphenoid bone | 23. 蝶枕结合 sphenoccipital synchondrosis |
| 12. 颞骨鳞部 squamous part of temporal bone | |

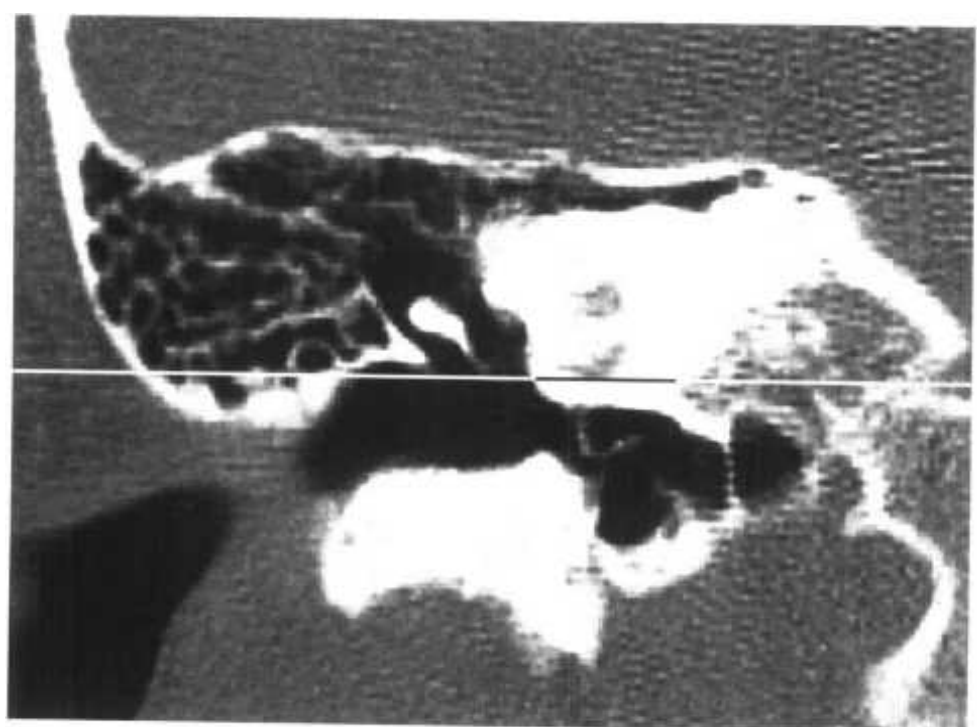
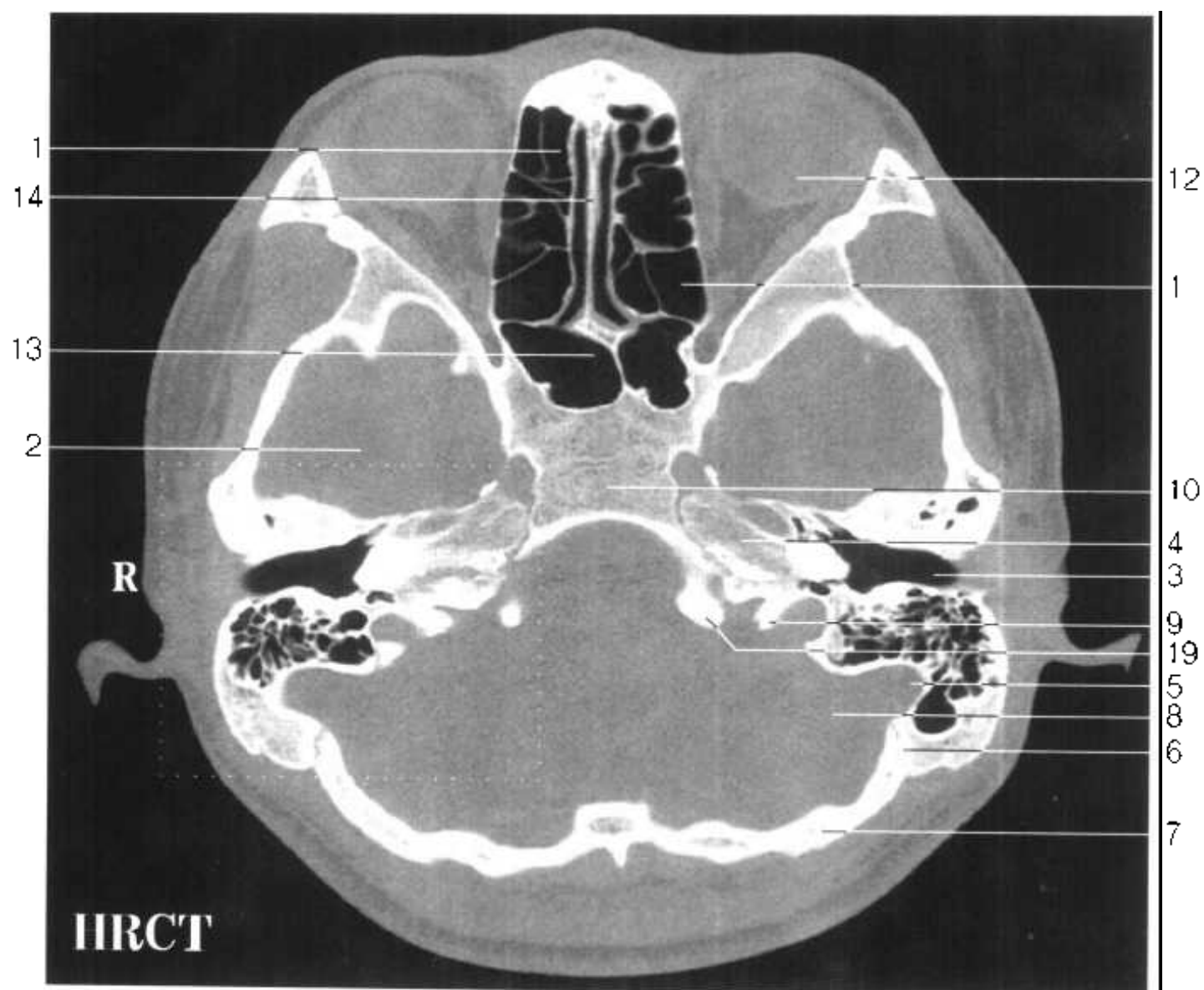


Fig. HE 15

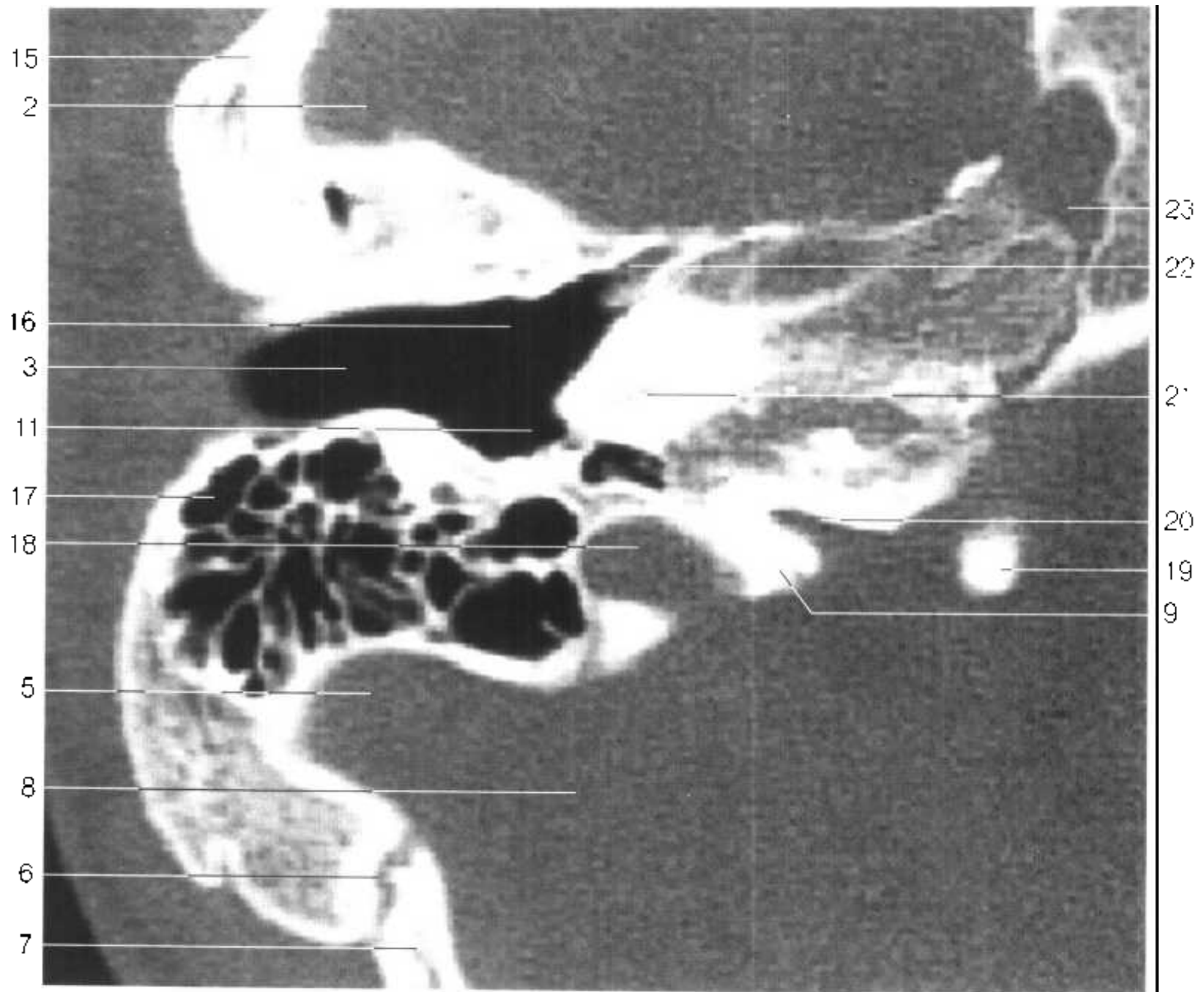


Fig. HE 15

- | | |
|---------------------------------------|--|
| 1. 筛窦 ethymoidal sinus | 14. 鼻中隔 nasal septum |
| 2. 颞叶 temporal lobe | 15. 颞骨鳞部 squamous part of temporal bone |
| 3. 外耳道 external acoustic meatus | 16. 鼓膜 tympanic membrane |
| 4. 颞骨岩部 petrous part of temporal bone | 17. 乳突小房 mastoid cells |
| 5. 乙状窦 sigmoid sinus | 18. 颈内静脉 internal jugular v. |
| 6. 枕乳突缝 occipitomastoid suture | 19. 颈静脉结节 jugular tubercle |
| 7. 枕骨 occipital bone | 20. 颈静脉孔神经部 nervous part of jugular foramen |
| 8. 小脑半球 cerebellar hemisphere | 21. 蜗螺旋管第一周 first whorl of cochlear spiral canal |
| 9. 颈静脉孔内突 intrajugular process | 22. 咽鼓管 pharyngotympanic tube |
| 10. 枕骨斜坡 clivus of occipital bone | 23. 颈内动脉岩内段 petrous segment of internal carotid a. |
| 11. 鼓室 tympanic cavity | |
| 12. 眼眶 orbit | |
| 13. 蝶窦 sphenoidal sinus | |

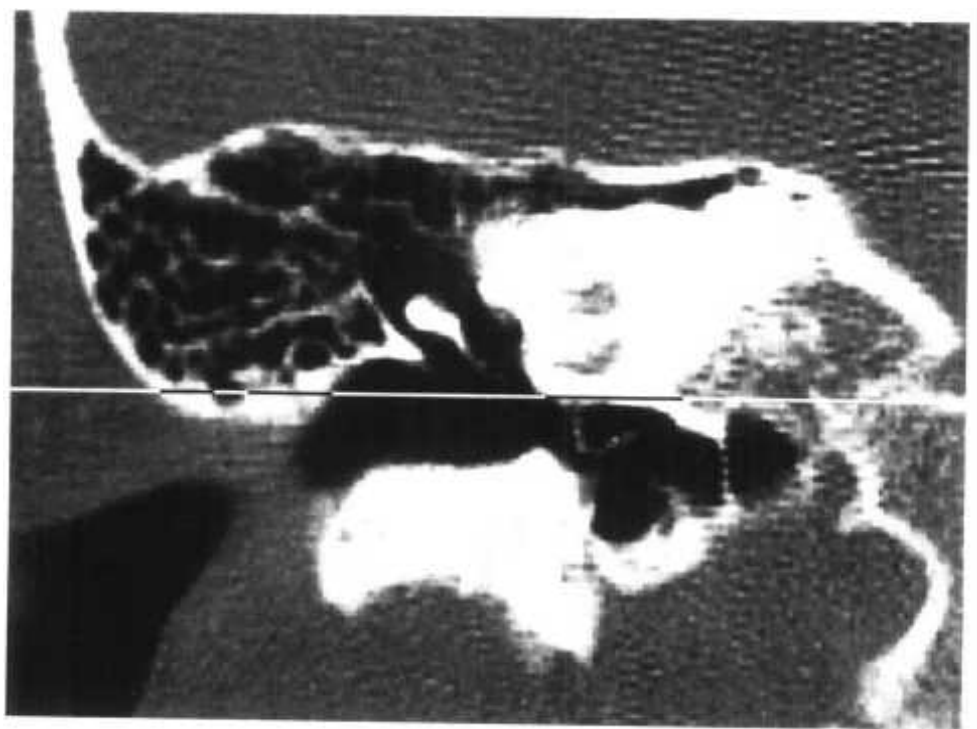
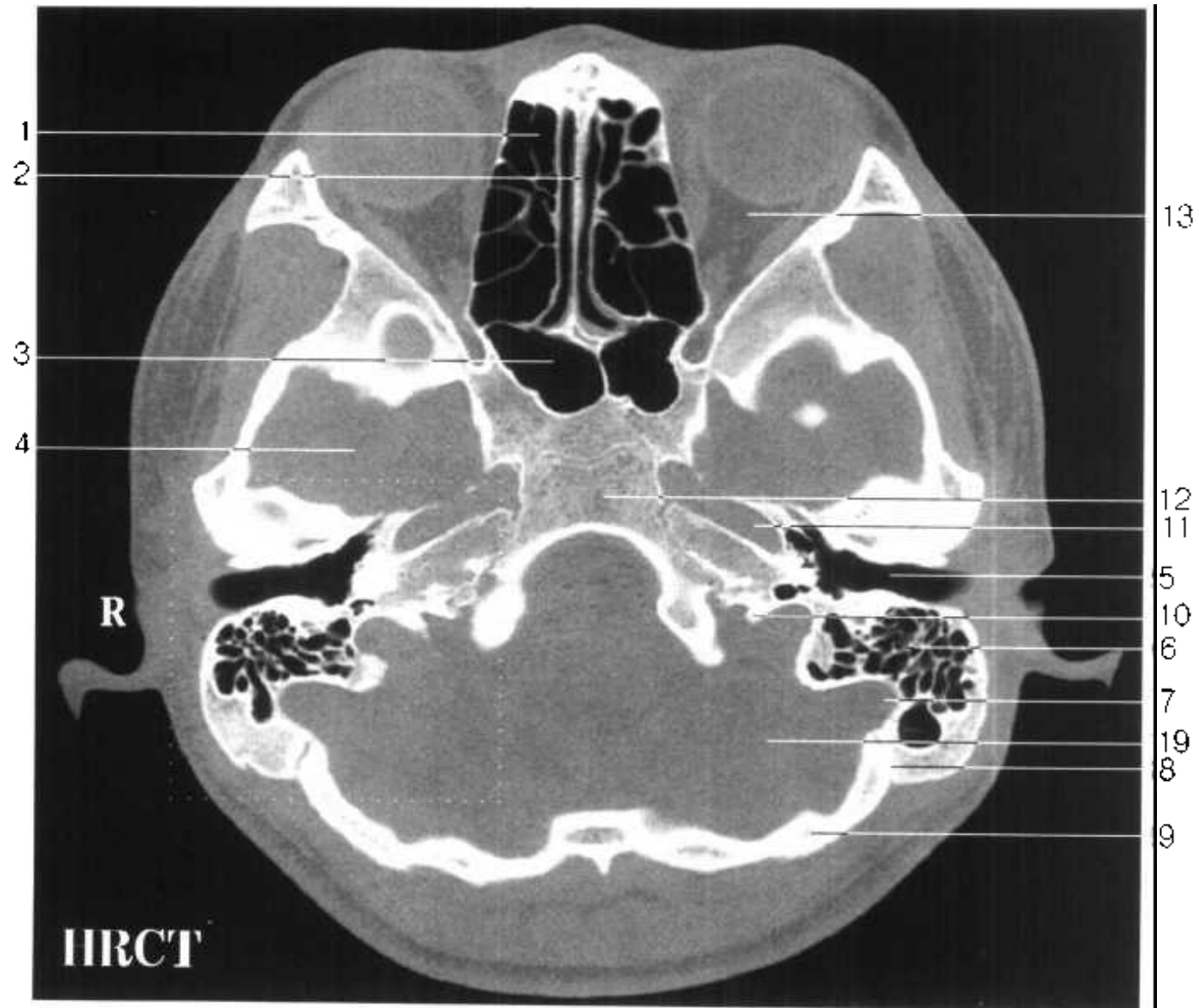


Fig. HE 16

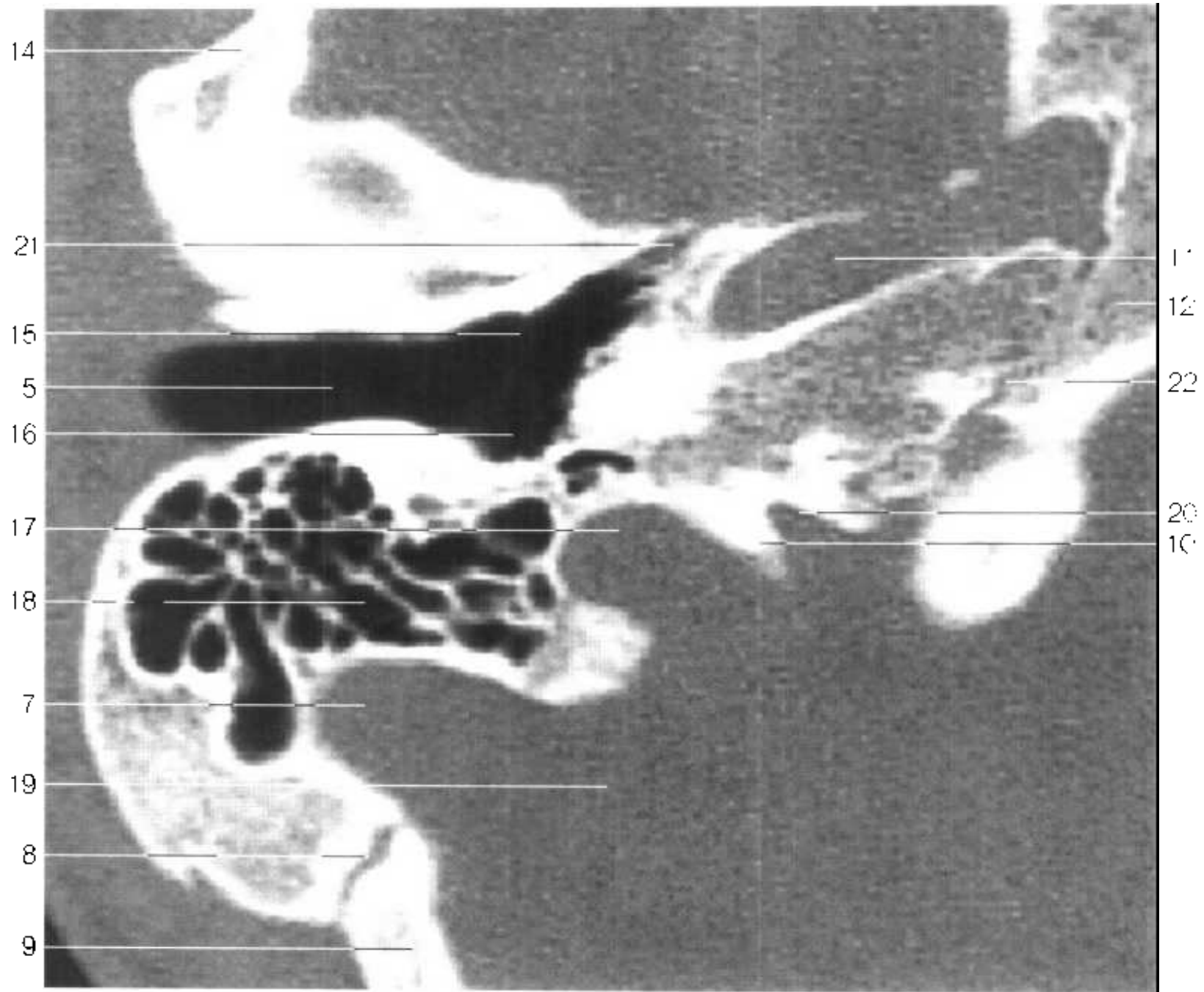


Fig.HE 16

- | | |
|--|---|
| 1. 筛窦 ethmoidal sinus | 12. 枕骨斜坡 clivus of occipital bone |
| 2. 鼻中隔 nasal septum | 13. 眶腔 orbit |
| 3. 蝶窦 sphenoidal sinus | 14. 颞骨鳞部 squamous part of temporal bone |
| 4. 颞叶 temporal lobe | 15. 鼓膜 tympanic membrane |
| 5. 外耳道 external acoustic meatus | 16. 鼓室 tympanic cavity |
| 6. 颞骨岩部 petrous part of temporal bone | 17. 颈内静脉 internal jugular v. |
| 7. 乙状窦 sigmoid sinus | 18. 乳突小房 mastoid cells |
| 8. 枕乳突缝 occipitomastoid suture | 19. 小脑半球 cerebellar hemisphere |
| 9. 枕骨 occipital bone | 20. 颈静脉孔神经部 nervous part of jugular foramen |
| 10. 颈静脉孔内突 intrajugular process | 21. 咽鼓管 pharyngotympanic tube |
| 11. 颈内动脉岩内段 petrous segment of internal carotid a. | 22. 岩枕结合 petrooccipital synchondrosis |

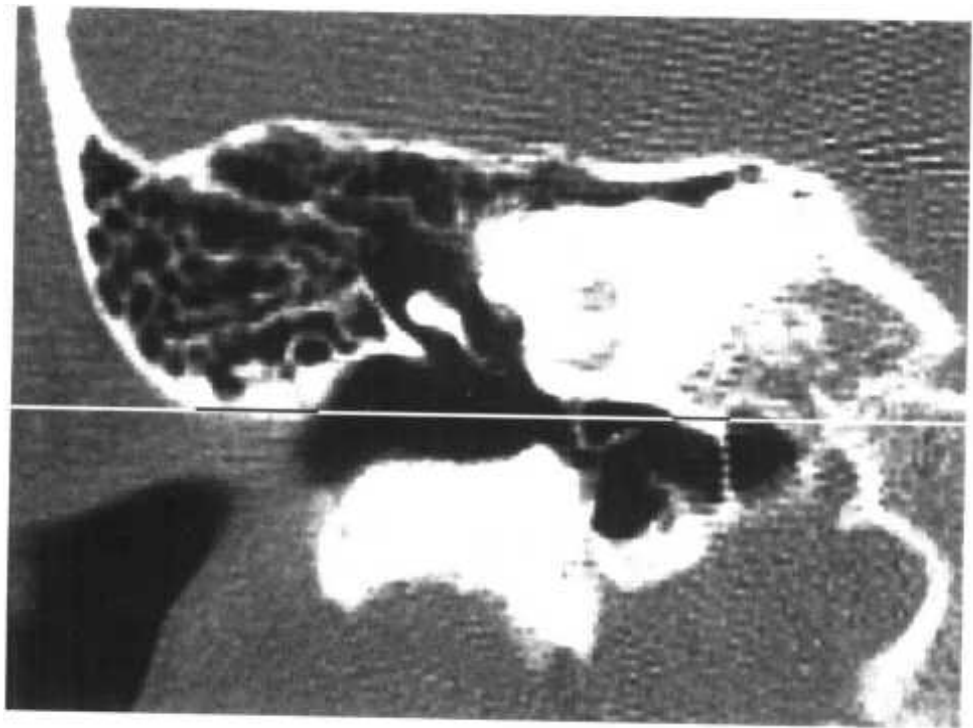
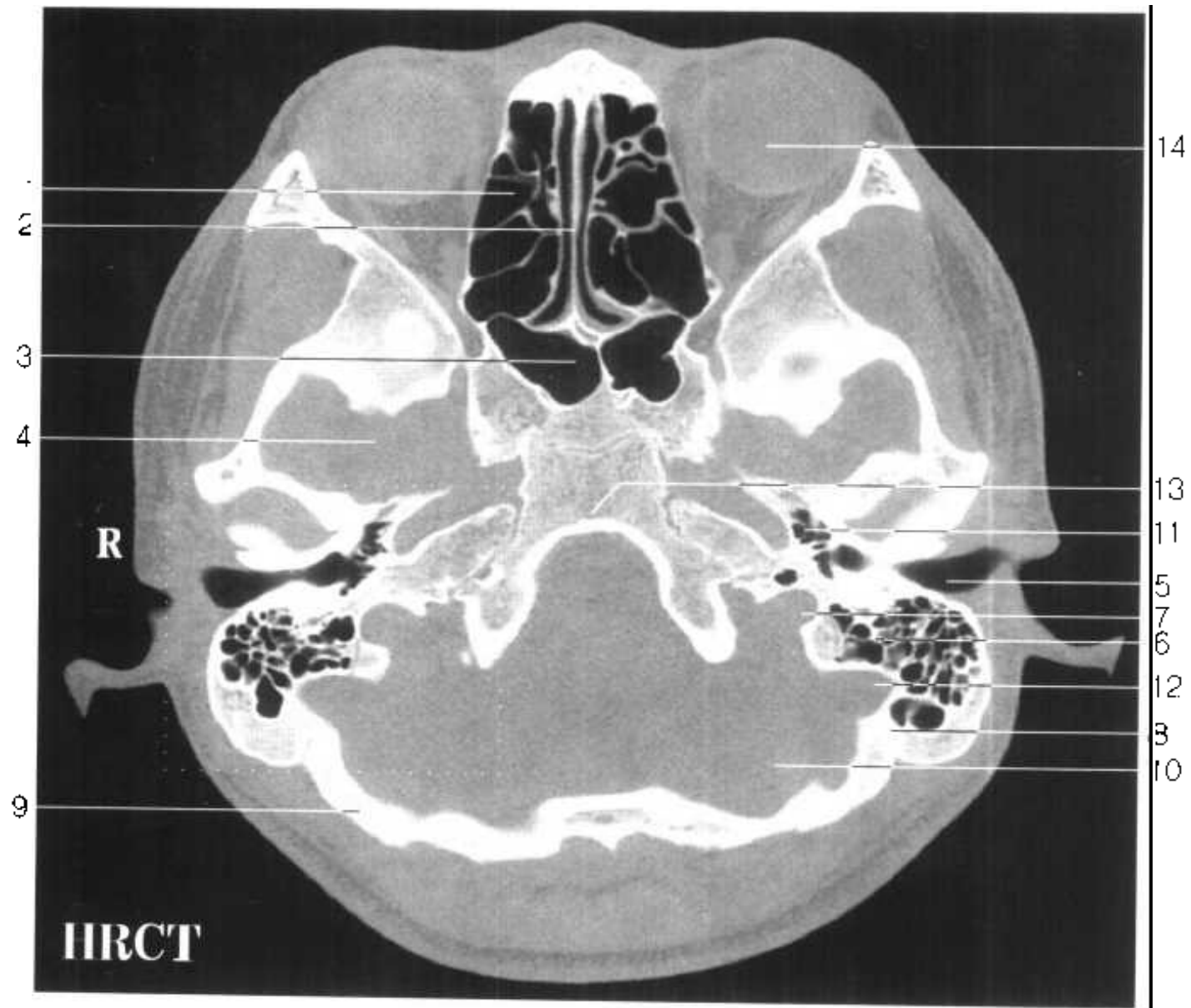


Fig. HE 17

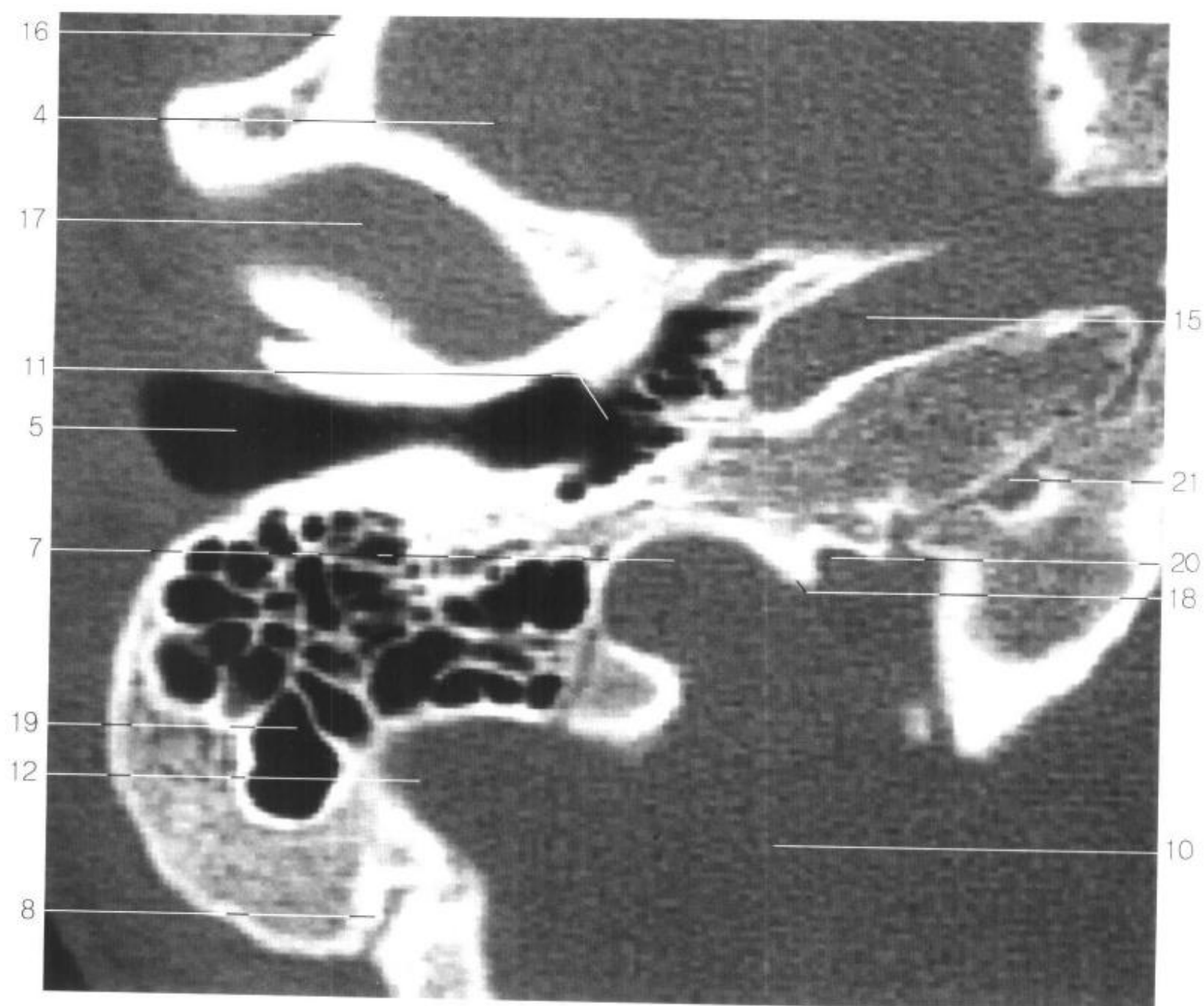


Fig.HE 17

- | | |
|---------------------------------------|--|
| 1. 筛窦 ethmoidal sinus | 13. 枕骨斜坡 clivus of occipital bone |
| 2. 鼻中隔 nasal septum | 14. 眼眶 orbit |
| 3. 蝶窦 sphenoidal sinus | 15. 颈内动脉岩内段 petrous segment of internal carotid a. |
| 4. 颞叶 temporal lobe | 16. 颞骨鳞部 squamous part of temporal bone |
| 5. 外耳道 external acoustic meatus | 17. 下颌窝 mandibular fossa |
| 6. 颞骨岩部 petrous part of temporal bone | 18. 颈静脉孔内突 intrajugular process |
| 7. 颈内静脉 internal jugular v. | 19. 乳突小房 mastoid cells |
| 8. 枕乳突缝 occipitomastoid suture | 20. 颈静脉孔神经部 nervous part of jugular foramen |
| 9. 枕骨 occipital bone | 21. 岩枕结合 petrooccipital synchondrosis |
| 10. 小脑半球 cerebellar hemisphere | |
| 11. 鼓室下隐窝 hypotympanic recess | |
| 12. 乙状窦 sigmoid sinus | |

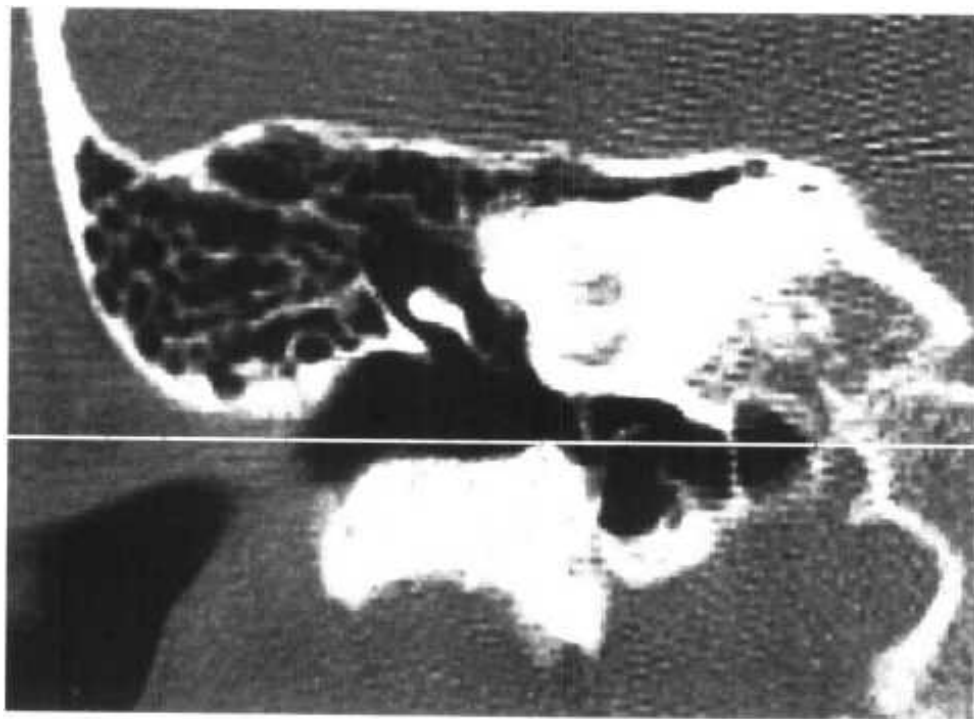
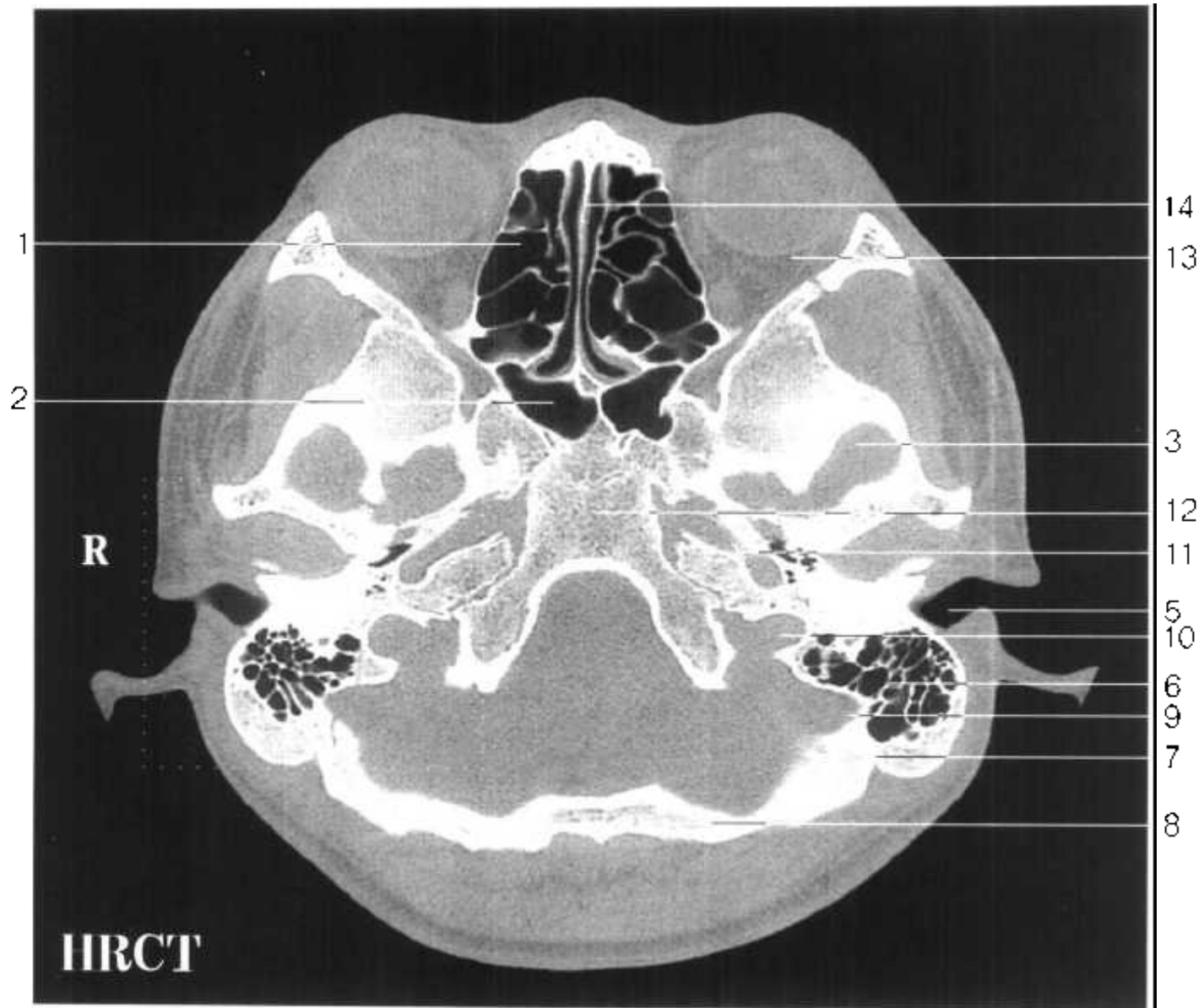


Fig. HE 18

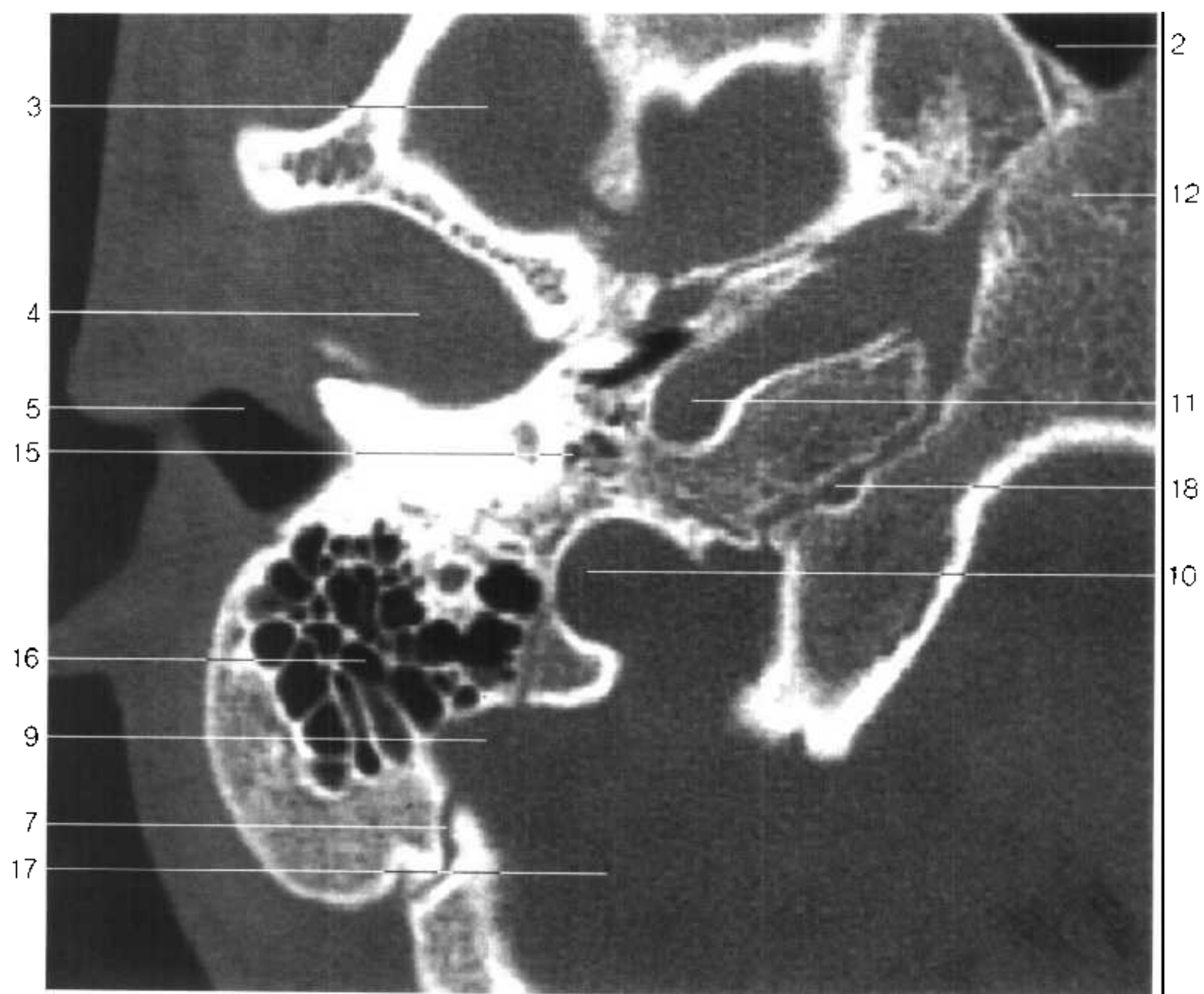

Fig.HE 18

- | | |
|---------------------------------|--|
| 1. 筛窦 ethmoidal sinus | 11. 颈内动脉岩内段 petrous segment of internal carotid a. |
| 2. 蝶窦 sphenoidal sinus | 12. 枕骨基部 basilar part of occipital bone |
| 3. 颞叶 temporal lobe | 13. 眶腔 orbit |
| 4. 下颌窝 mandibular fossa | 14. 鼻中隔 nasal septum |
| 5. 外耳道 external acoustic meatus | 15. 鼓室下隐窝 hypotympanic recess |
| 6. 乳突 mandibular process | 16. 乳突小房 mastoid cells |
| 7. 枕乳突缝 occipitomastoid suture | 17. 小脑半球 cerebellar hemisphere |
| 8. 枕骨 occipital bone | 18. 岩枕结合 petrooccipital synchondrosis |
| 9. 乙状窦 sigmoid sinus | |
| 10. 颈内静脉 internal jugular v. | |

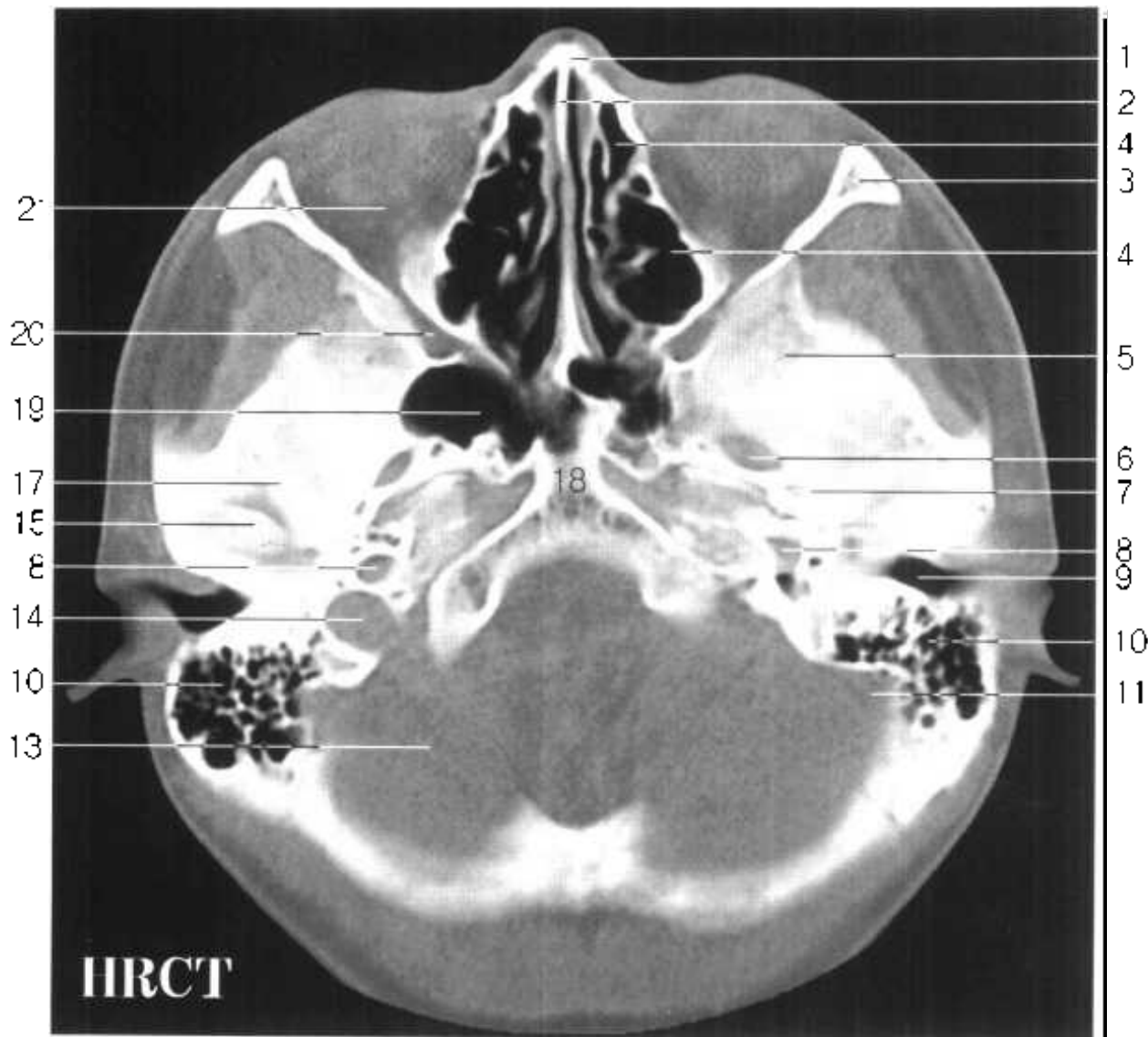
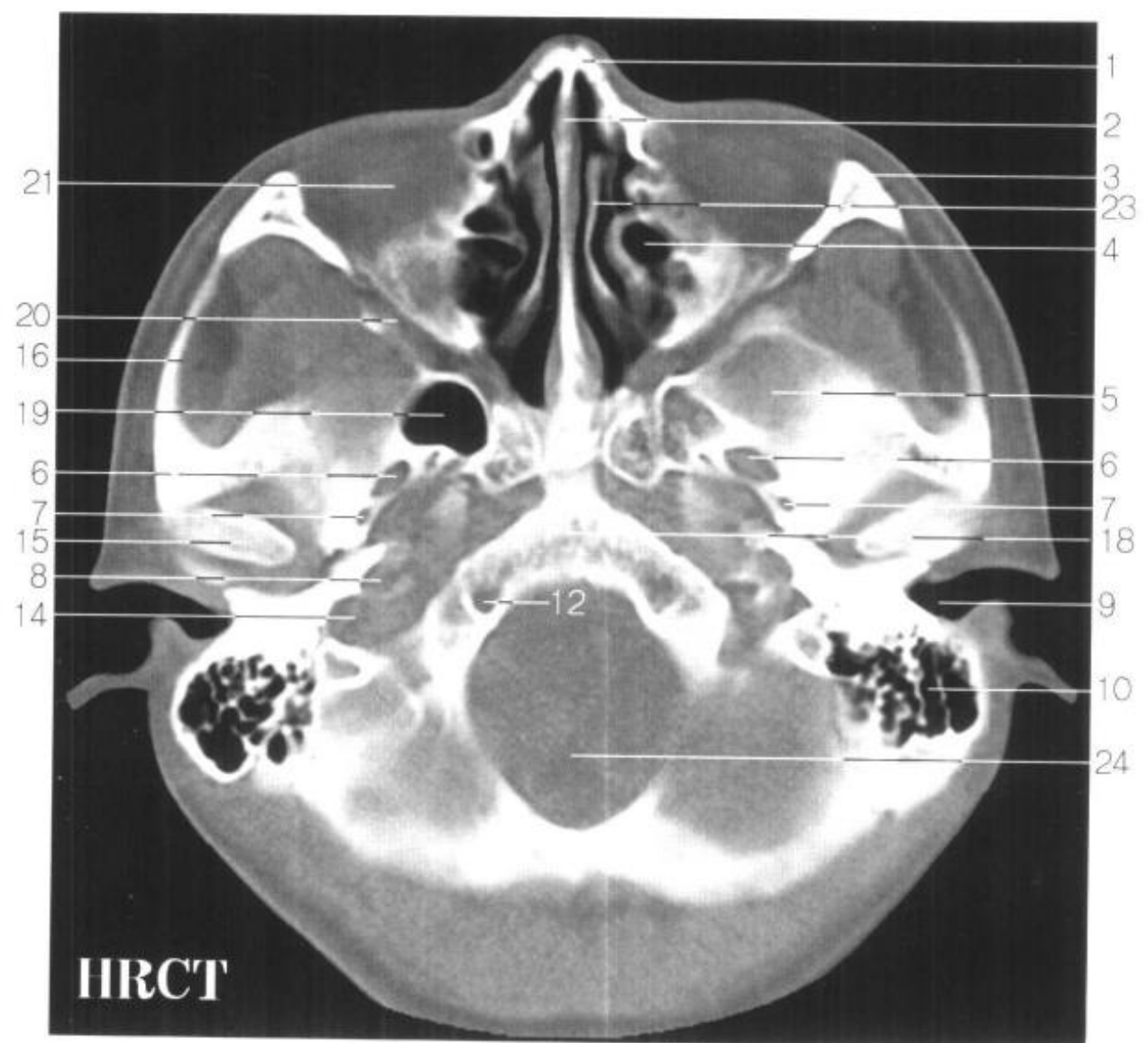
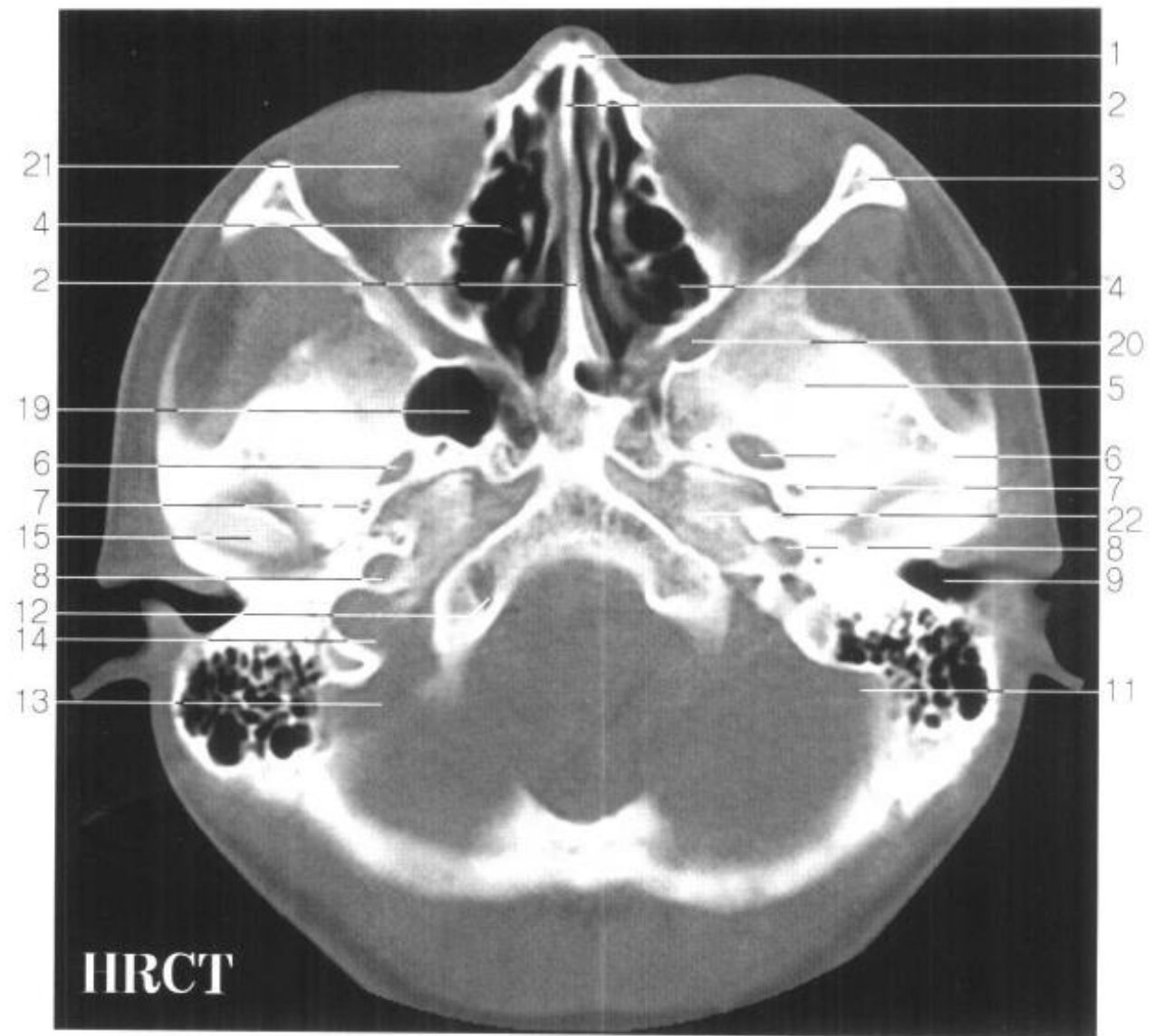
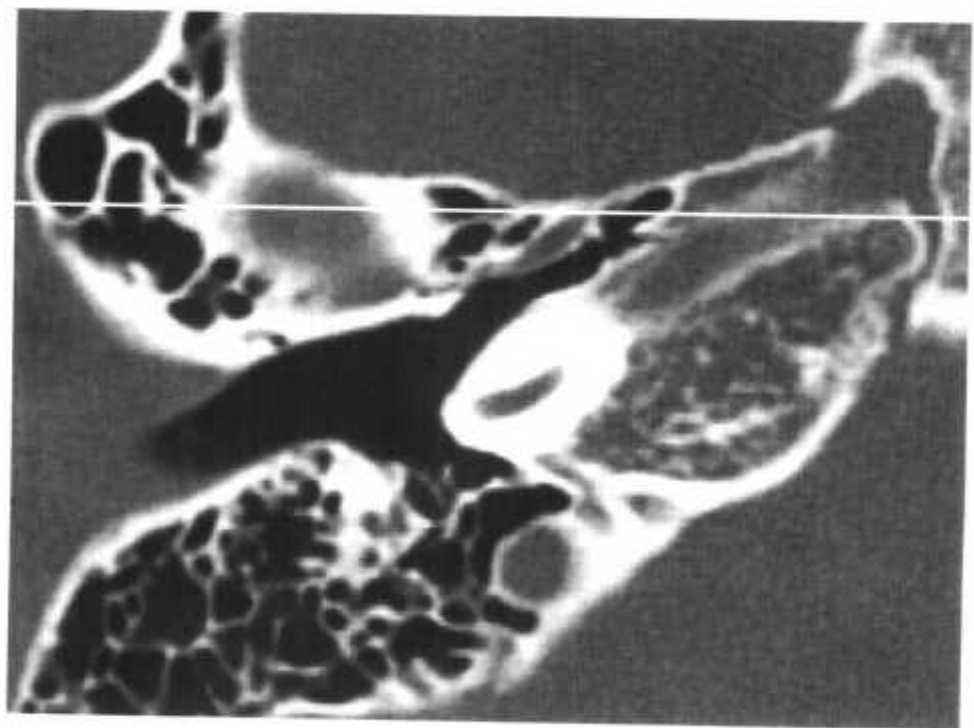
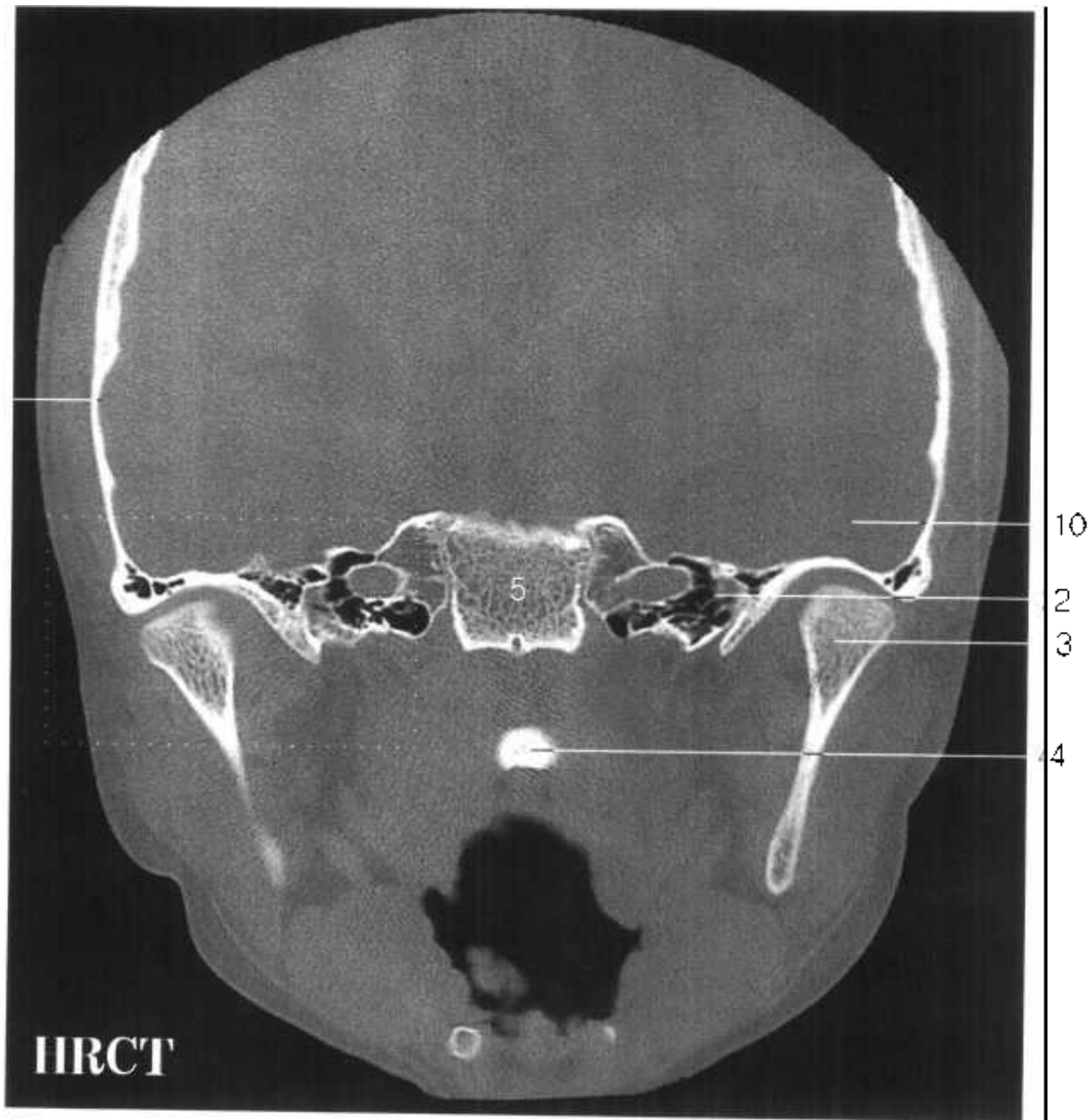


Fig.HE 19

- | | |
|--|---|
| 1. 鼻骨 nasal bone | 14. 颈静脉孔 jugular foramen |
| 2. 鼻中隔 nasal septum | 15. 下颌头 head of mandible |
| 3. 颧骨 zygomatic bone | 16. 颧弓 zygomatic arch |
| 4. 筛窦 ethmoidal sinus | 17. 关节结节 articular tubercle |
| 5. 颞下窝 infratemporal fossa | 18. 枕骨基部 basilar part of occipital bone |
| 6. 卵圆孔 foramen ovale | 19. 蝶窦 sphenoidal sinus |
| 7. 棘孔 foramen spinosum | 20. 眶下裂 inferior orbital fissure |
| 8. 颈动脉管外口 external aperture of carotid canal | 21. 眼眶 orbit |
| 9. 外耳道 external acoustic meatus | 22. 颈动脉管 carotid canal |
| 10. 乳突小房 mastoid cells | 23. 上鼻甲 superior nasal concha |
| 11. 乙状窦 sigmoid sinus | 24. 枕骨大孔 foramen magnum of occipital bone |
| 12. 舌下神经管 hypoglossal canal | |
| 13. 小脑半球 cerebellar hemisphere | |

Fig.HE 19





耳的额状断面图 FE

Fig. FE 1

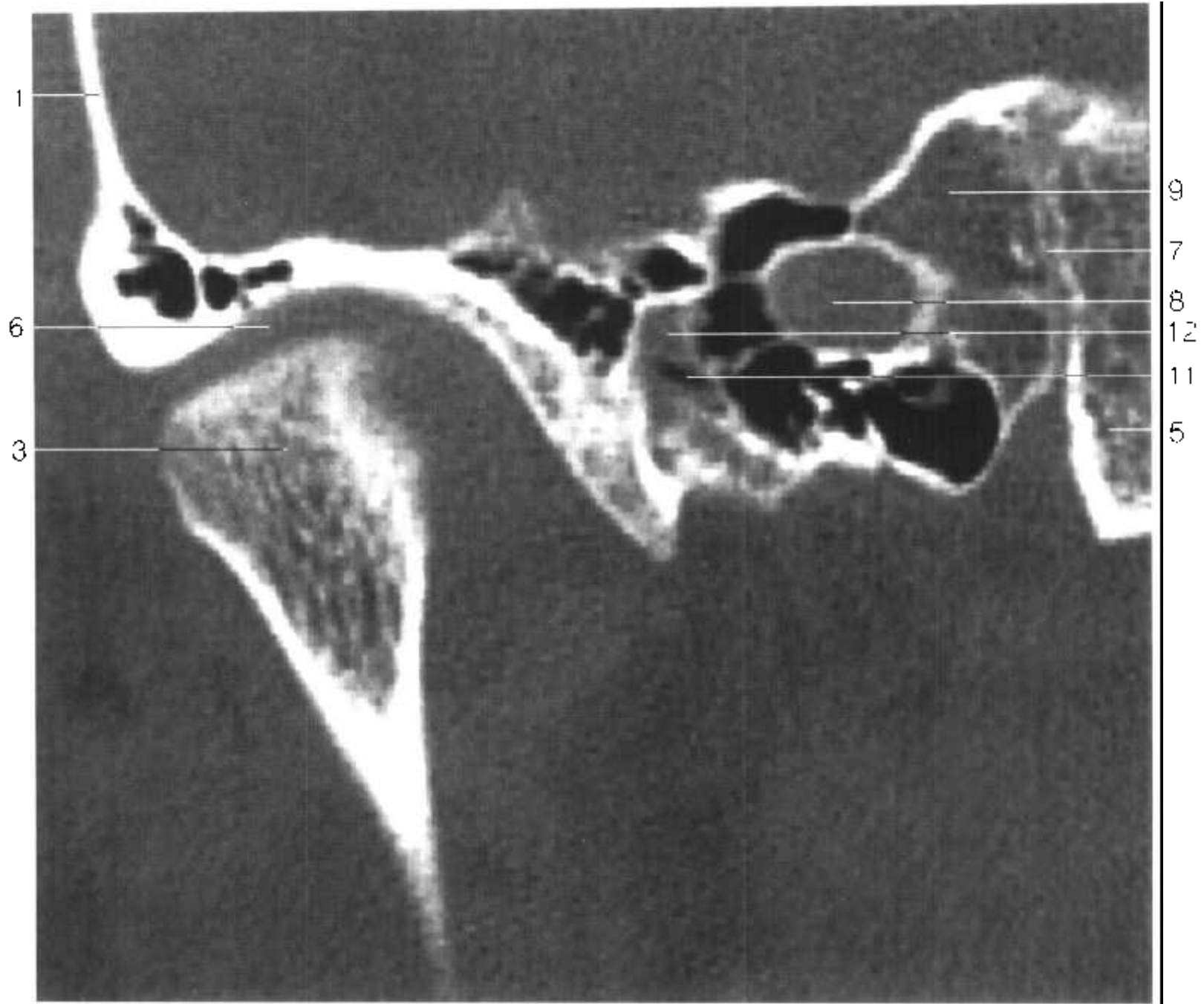


Fig.FE 1

- | | |
|--|---|
| 1. 颞骨鳞部 squamous part of temporal bone | 7. 岩枕结合 petrooccipital synchondrosis |
| 2. 颞骨岩部 petrous part of temporal bone | 8. 颈内动脉岩内段 petrous segment of internal carotid a. |
| 3. 下颌头 head of mandible | 9. 颞骨岩部 petrous part of temporal bone |
| 4. 寰椎前结节 anterior tubercle of atlas | 10. 颞叶 temporal lobe |
| 5. 枕骨基部 basilar part of occipital bone | 11. 咽鼓管 pharyngotympanic tube |
| 6. 颞下颌关节 temporomandibular joint | 12. 鼓膜张肌 tensor tympani |

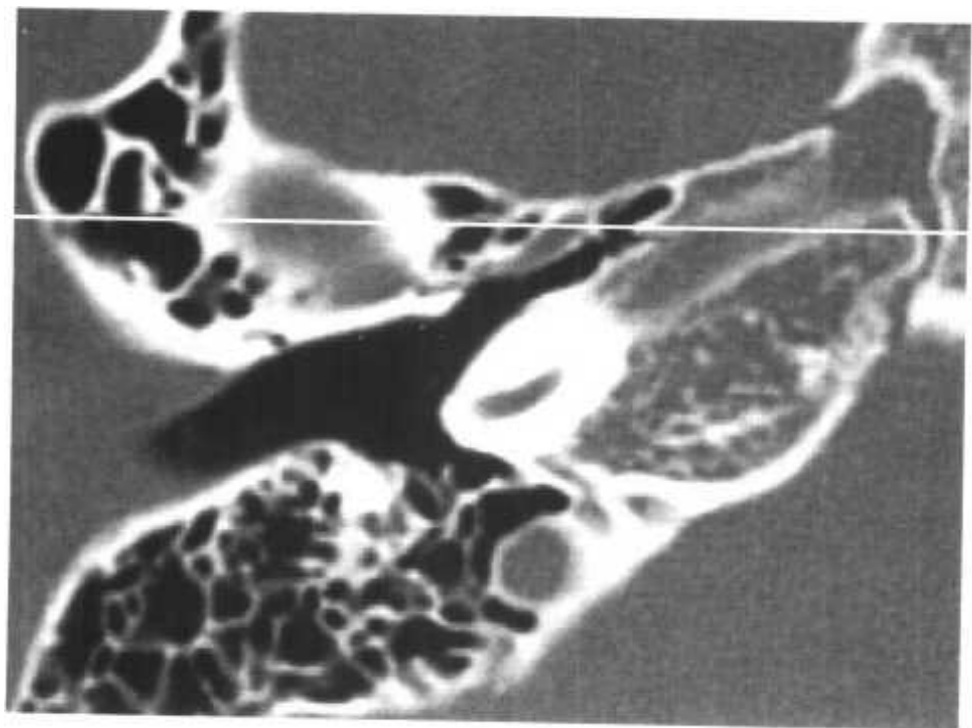
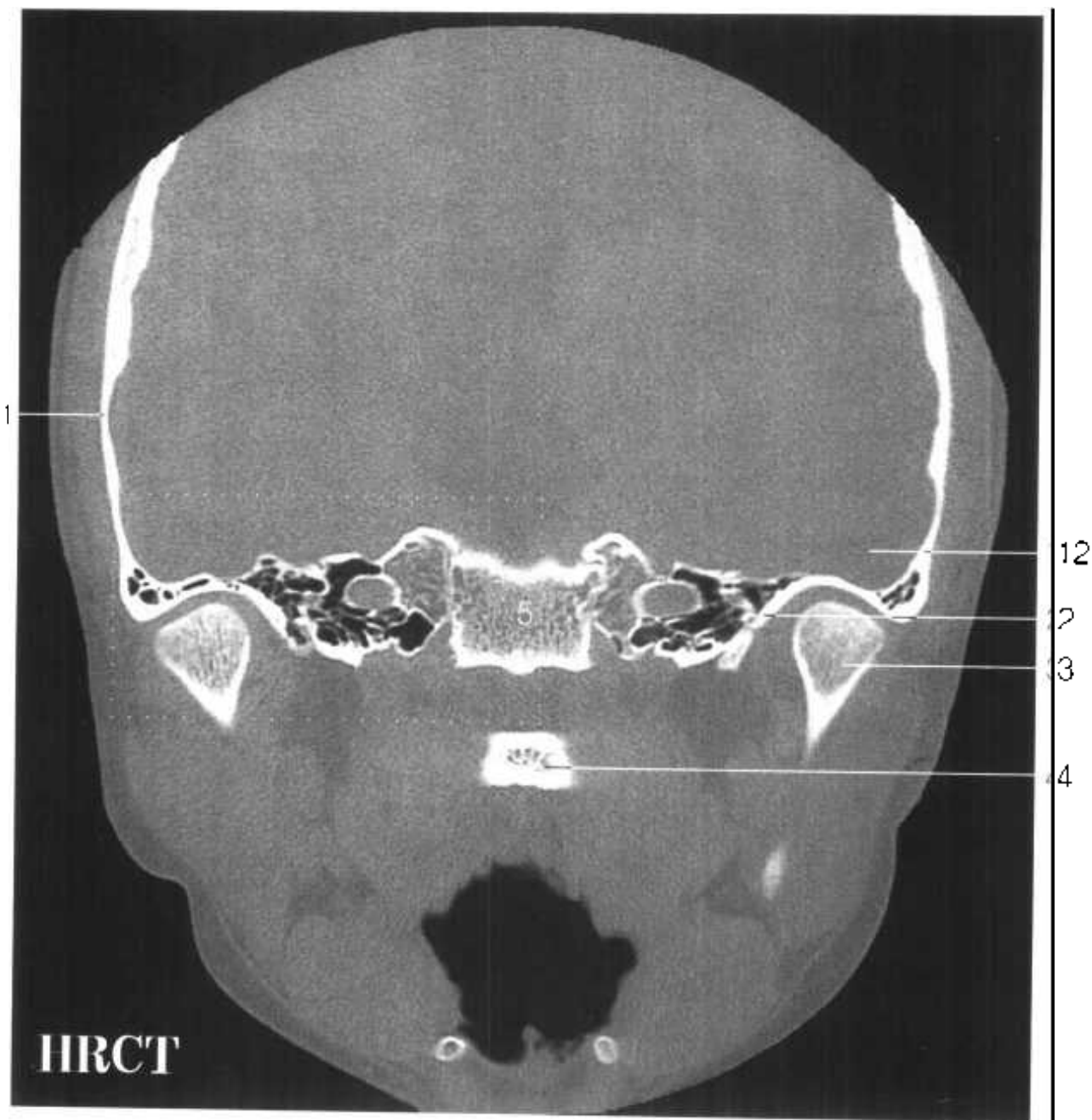


Fig. FE 2

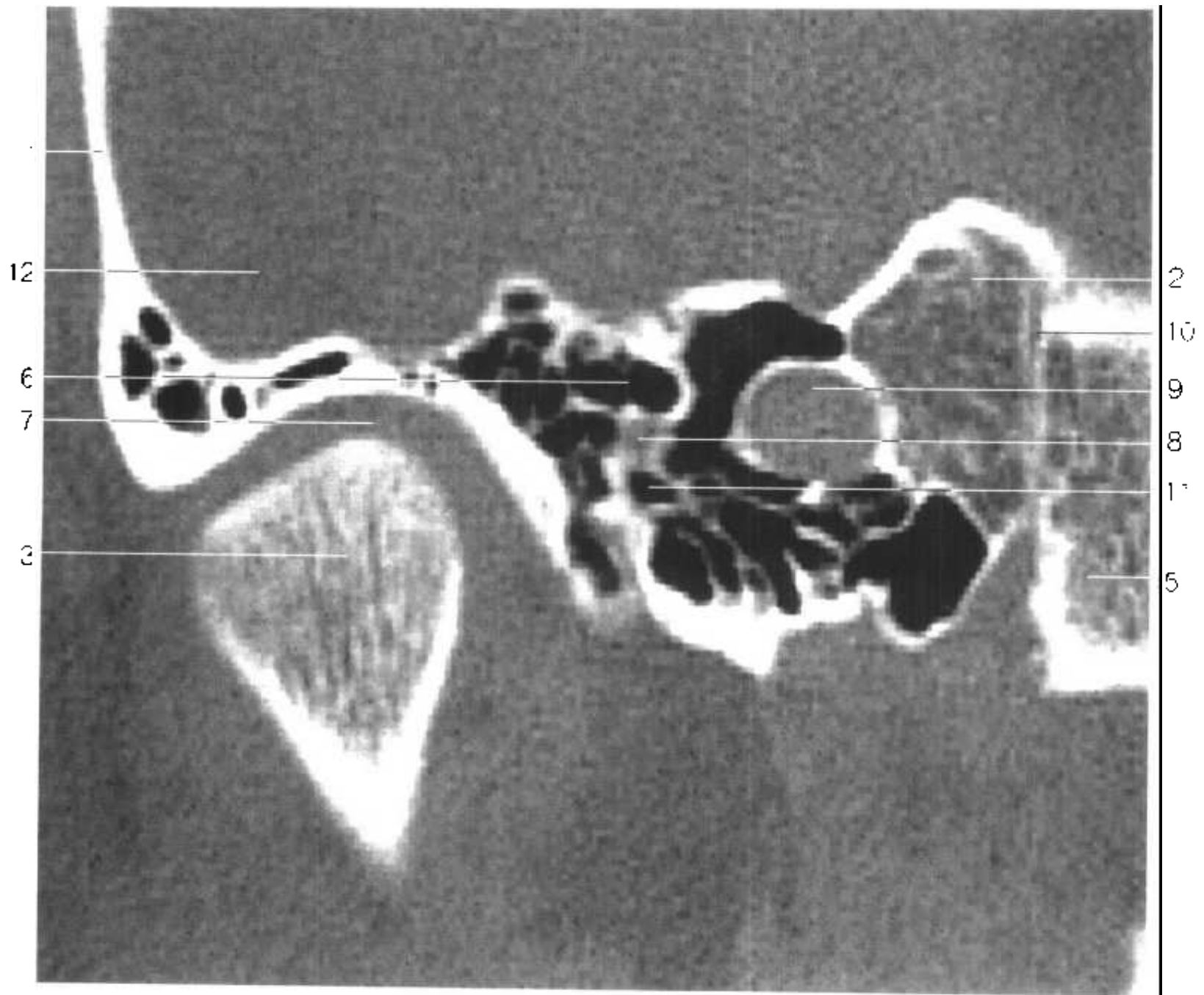


Fig.FE 2

- | | |
|---|---|
| 1. 颞骨鳞部 squamous part of temporal bone | 8. 鼓膜张肌 tensor tympani |
| 2. 颞骨岩部 petrous part of temporal bone | 9. 颈内动脉岩内段 petrous segment of internal carotid a. |
| 3. 下颌头 head of mandible | 10. 岩枕结合 petrooccipital synchondrosis |
| 4. 寰椎前结节 anterior tubercle of atlas | 11. 咽鼓管 pharyngotympanic tube |
| 5. 枕骨基底部 basilar part of occipital bone | 12. 颞叶 temporal lobe |
| 6. 鼓室 tympanic cavity | |
| 7. 颞下颌关节 temporomandibular joint | |

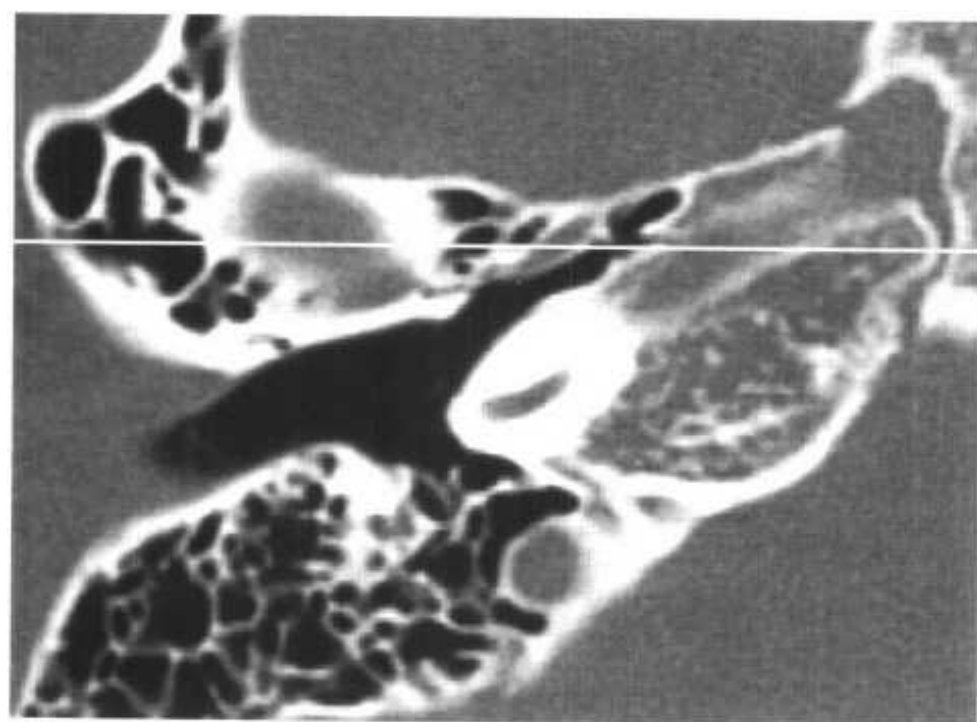
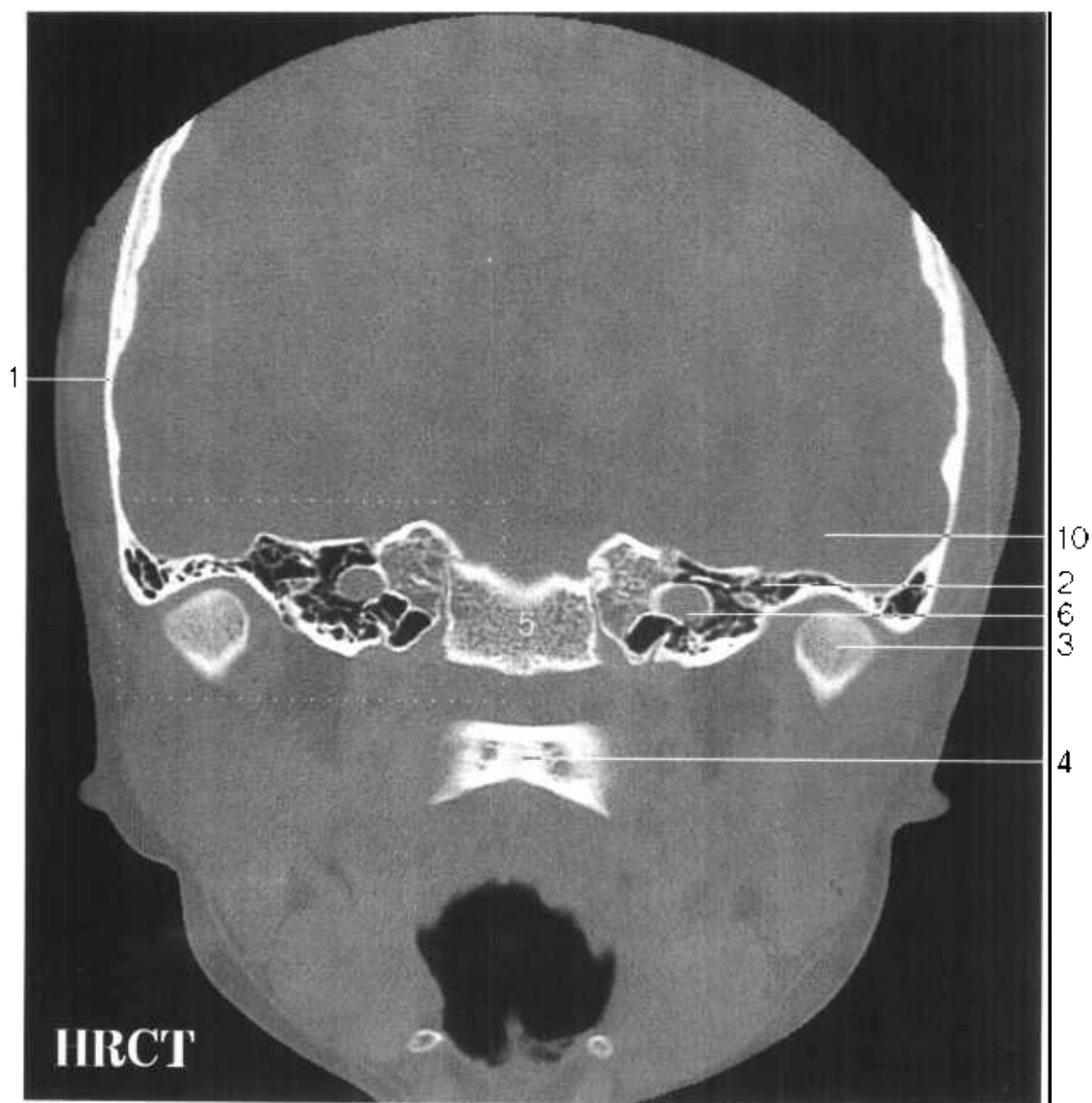


Fig. FE 3

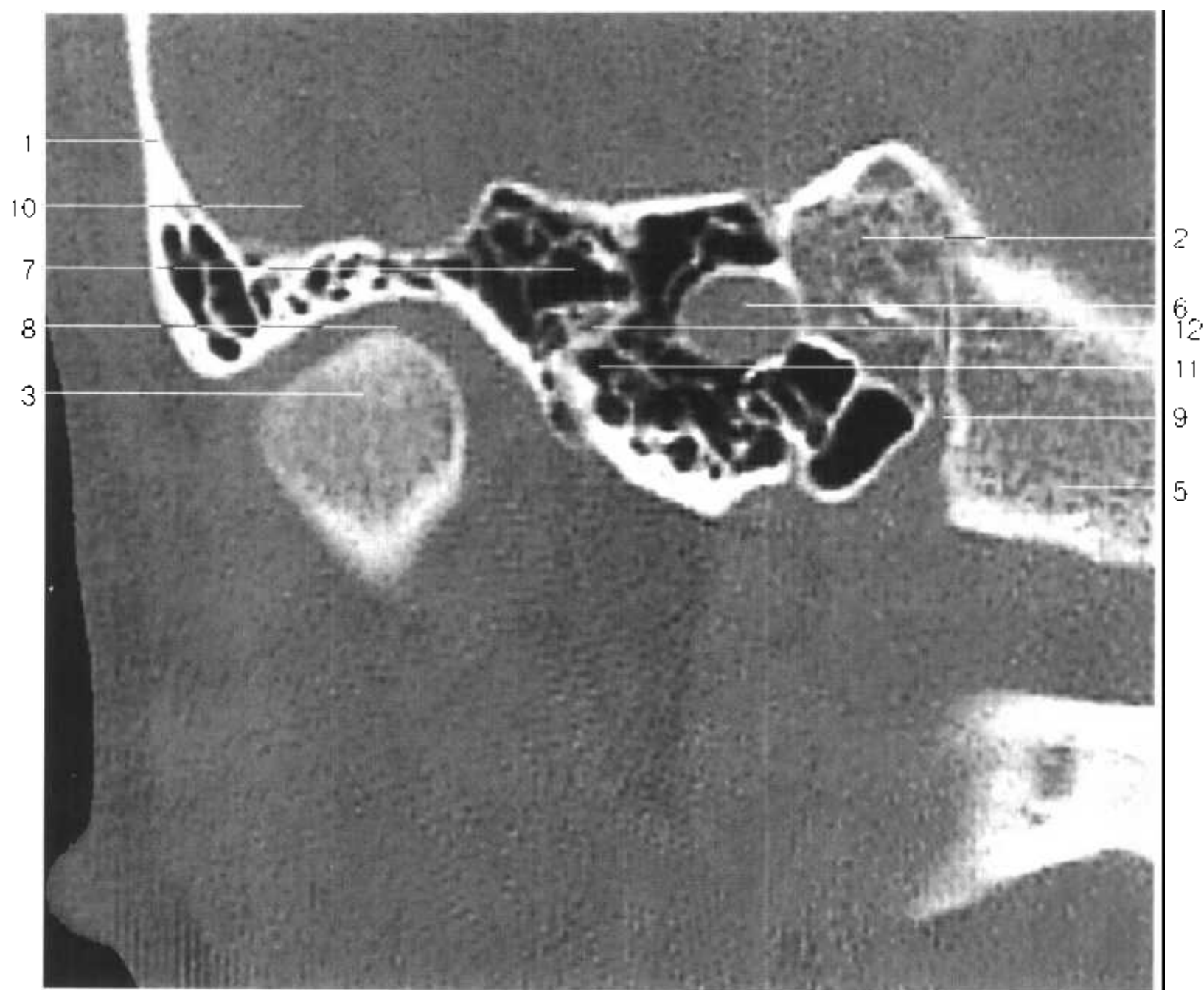


Fig.FE 3

- | | |
|---|---|
| 1. 颞骨鳞部 squamous part of temporal bone | 6. 颈内动脉岩内段 petrous segment of internal carotid a. |
| 2. 颞骨岩部 petrous part of temporal bone | 7. 鼓室 tympanic cavity |
| 3. 下颌头 head of mandible | 8. 颞下颌关节 temporomandibular joint |
| 4. 寰椎前结节 anterior tubercle of atlas | 9. 岩枕结合 petrooccipital synchondrosis |
| 5. 枕骨基底部 basilar part of occipital bone | 10. 颞叶 temporal lobe |
| | 11. 咽鼓管 pharyngotympanic tube |
| | 12. 鼓膜张肌 tensor tympani |

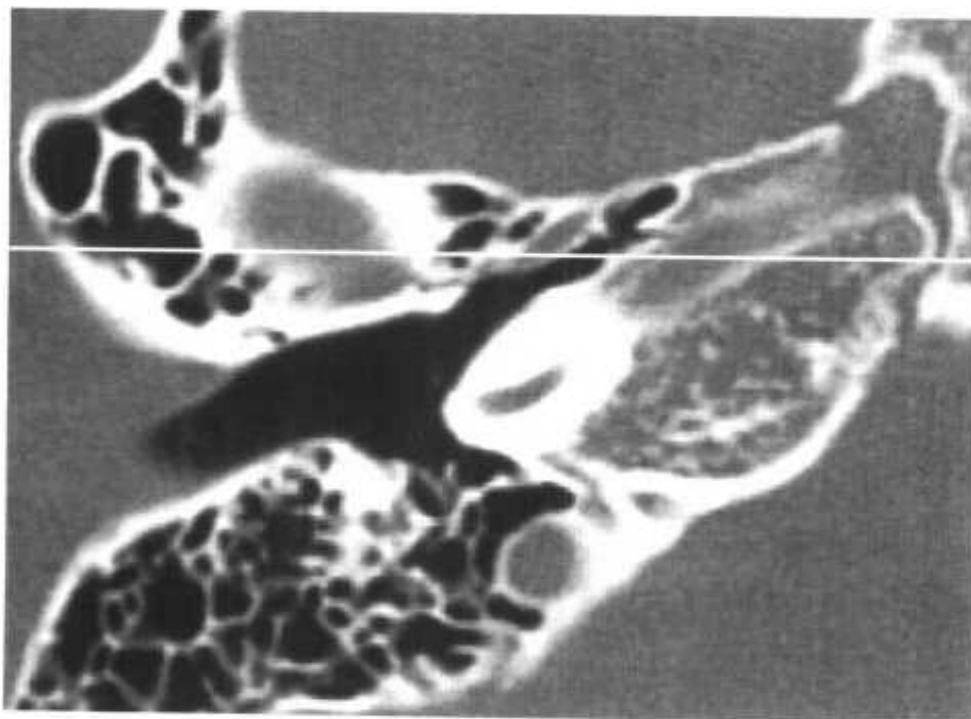
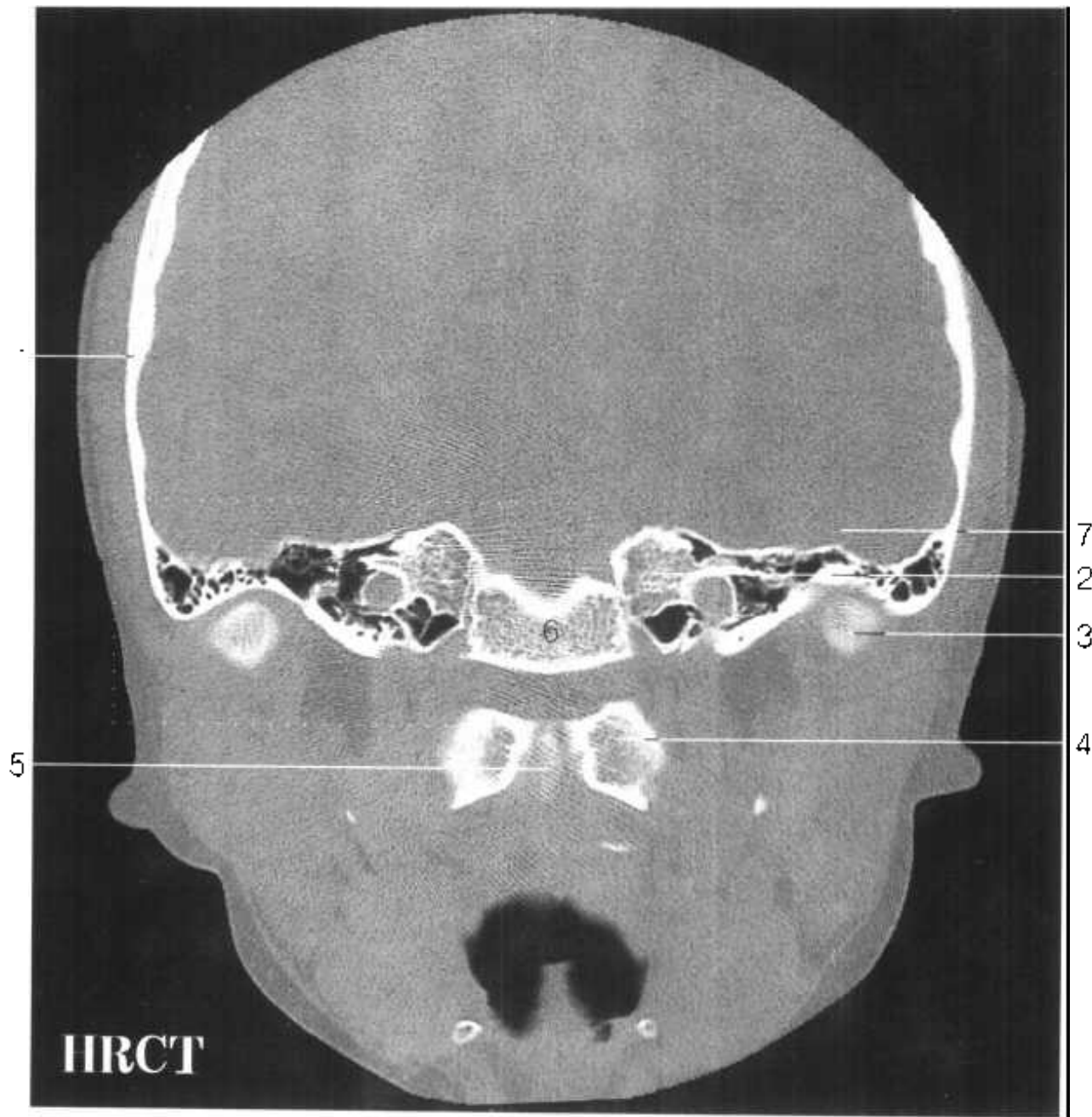


Fig. FE 4

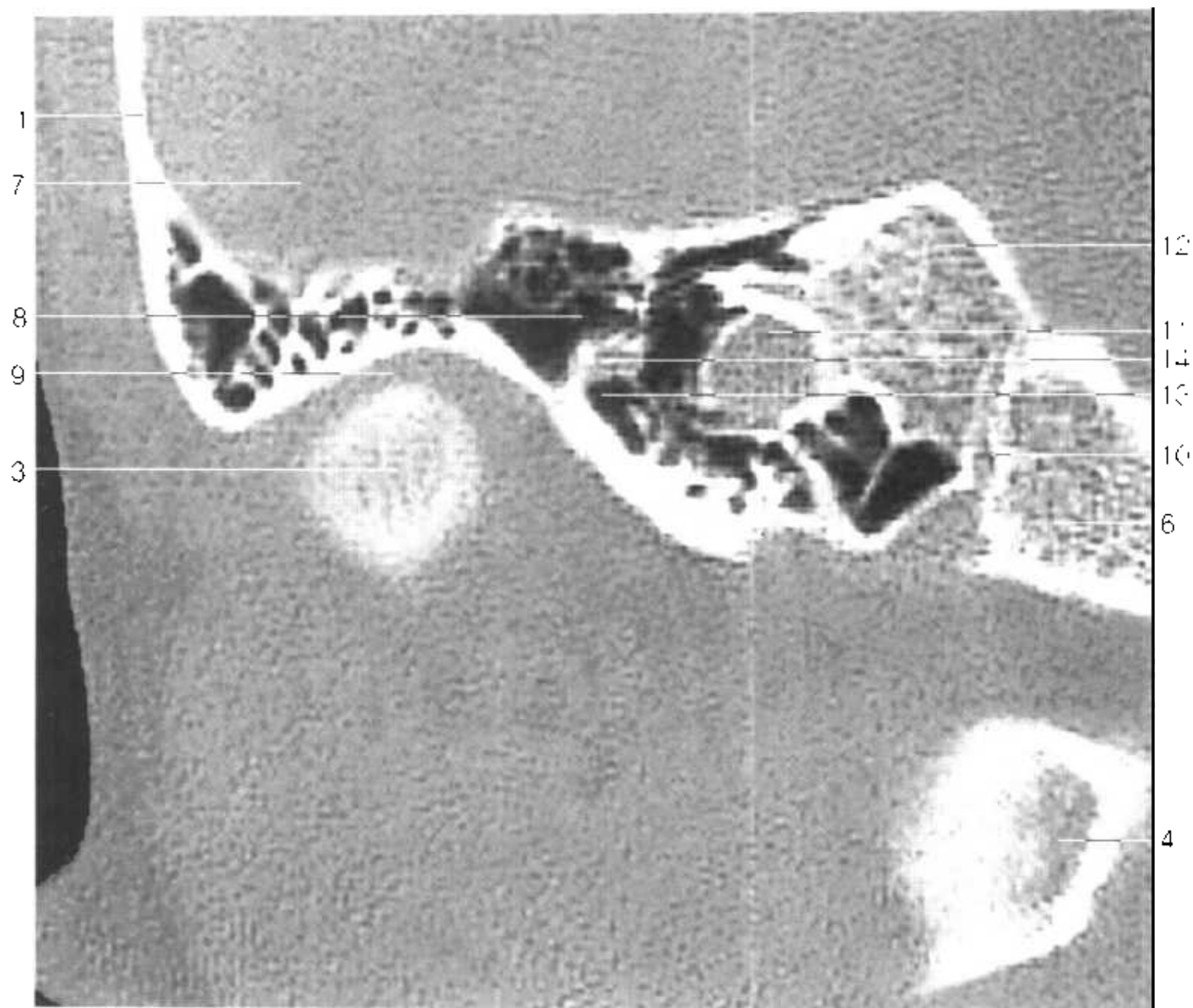


Fig.FE 4

- | | |
|--|--|
| <ul style="list-style-type: none"> 1. 颞骨鳞部 squamous part of temporal bone 2. 颞骨岩部 petrous part of temporal bone 3. 下颌头 head of mandible 4. 寰椎前弓 anterior arch of atlas 5. 枢椎齿突 dens of axis 6. 枕骨基底部 basilar part of occipital bone 7. 颞叶 temporal lobe | <ul style="list-style-type: none"> 8. 鼓室 tympanic cavity 9. 颞下颌关节 temporomandibular joint 10. 岩枕结合 petrooccipital synchondrosis 11. 颈内动脉岩内段 petrous segment of internal carotid a. 12. 颞骨岩部 petrous part of temporal bone 13. 咽鼓管 pharyngotympanic tube 14. 鼓膜张肌 tensor tympani |
|--|--|

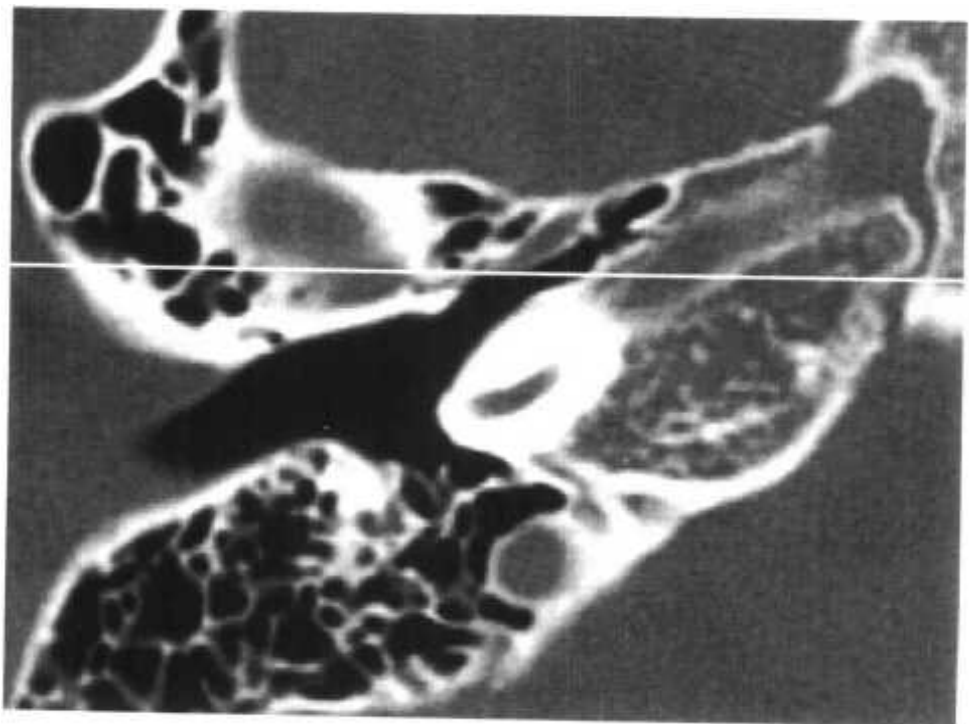
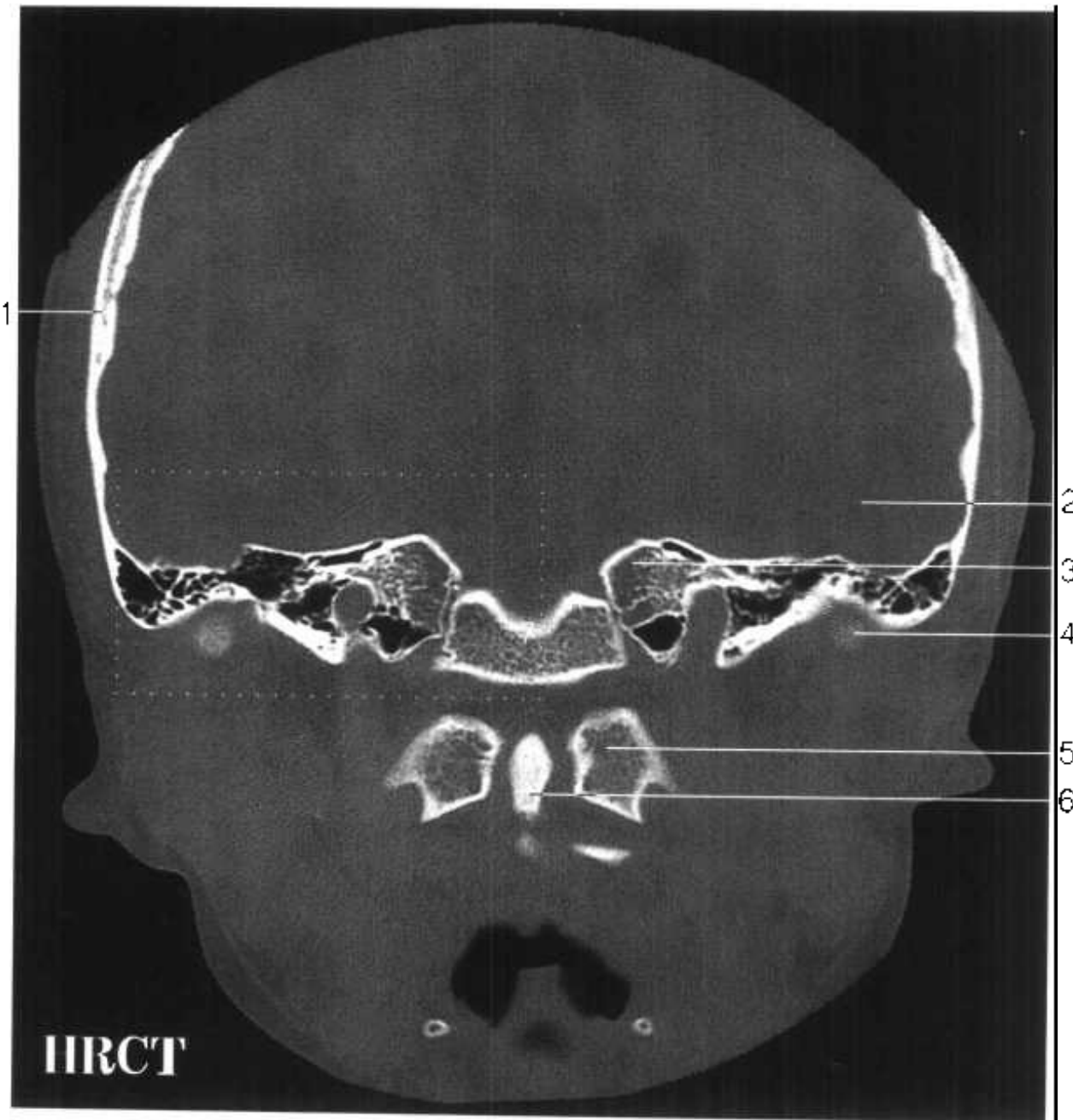


Fig. FE 5

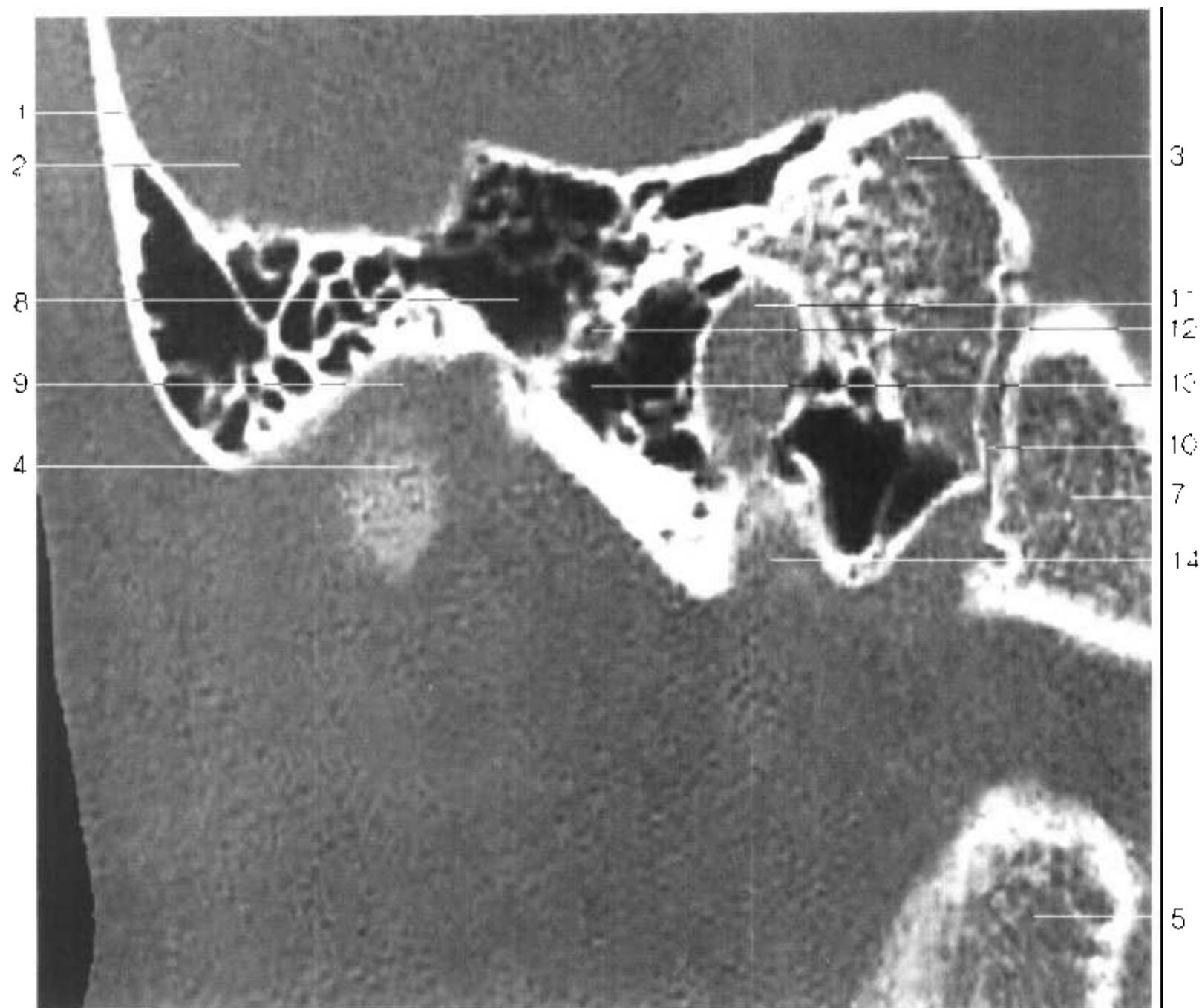


Fig.FE 5

- | | |
|---|--|
| <p>1. 颞骨鳞部 squamous part of temporal bone</p> <p>2. 颞叶 temporal lobe</p> <p>3. 颞骨岩部 petrous part of temporal bone</p> <p>4. 下颌头 head of mandible</p> <p>5. 寰椎前弓 anterior arch of atlas</p> <p>6. 枢椎齿突 dens of axis</p> <p>7. 枕骨基底部 basilar part of occipital bone</p> | <p>8. 鼓室 tympanic cavity</p> <p>9. 颞下颌关节 temporomandibular joint</p> <p>10. 岩枕结合 petrooccipital synchondrosis</p> <p>11. 颈内动脉岩内段 petrous segment of internal carotid a.</p> <p>12. 鼓膜张肌 tensor tympani</p> <p>13. 咽鼓管 pharyngotympanic tube</p> <p>14. 颈动脉管外口 external aperture of carotid canal</p> |
|---|--|

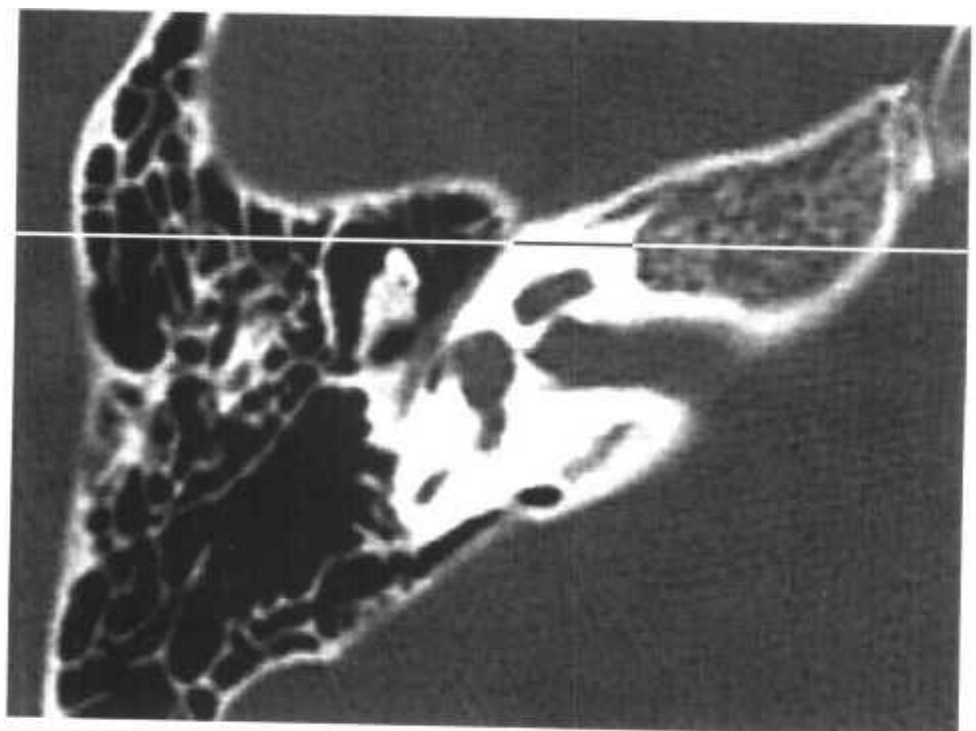
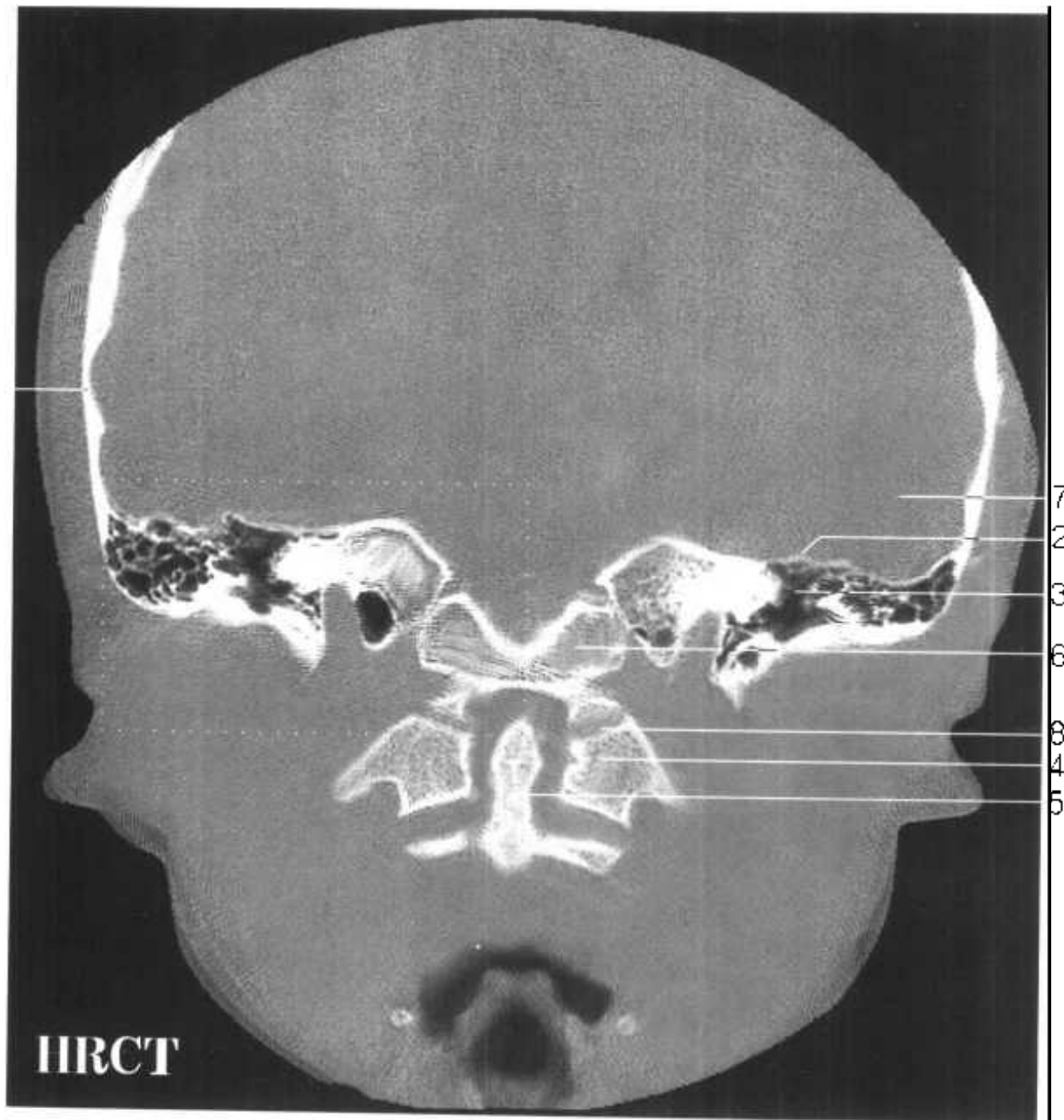


Fig. FE 6

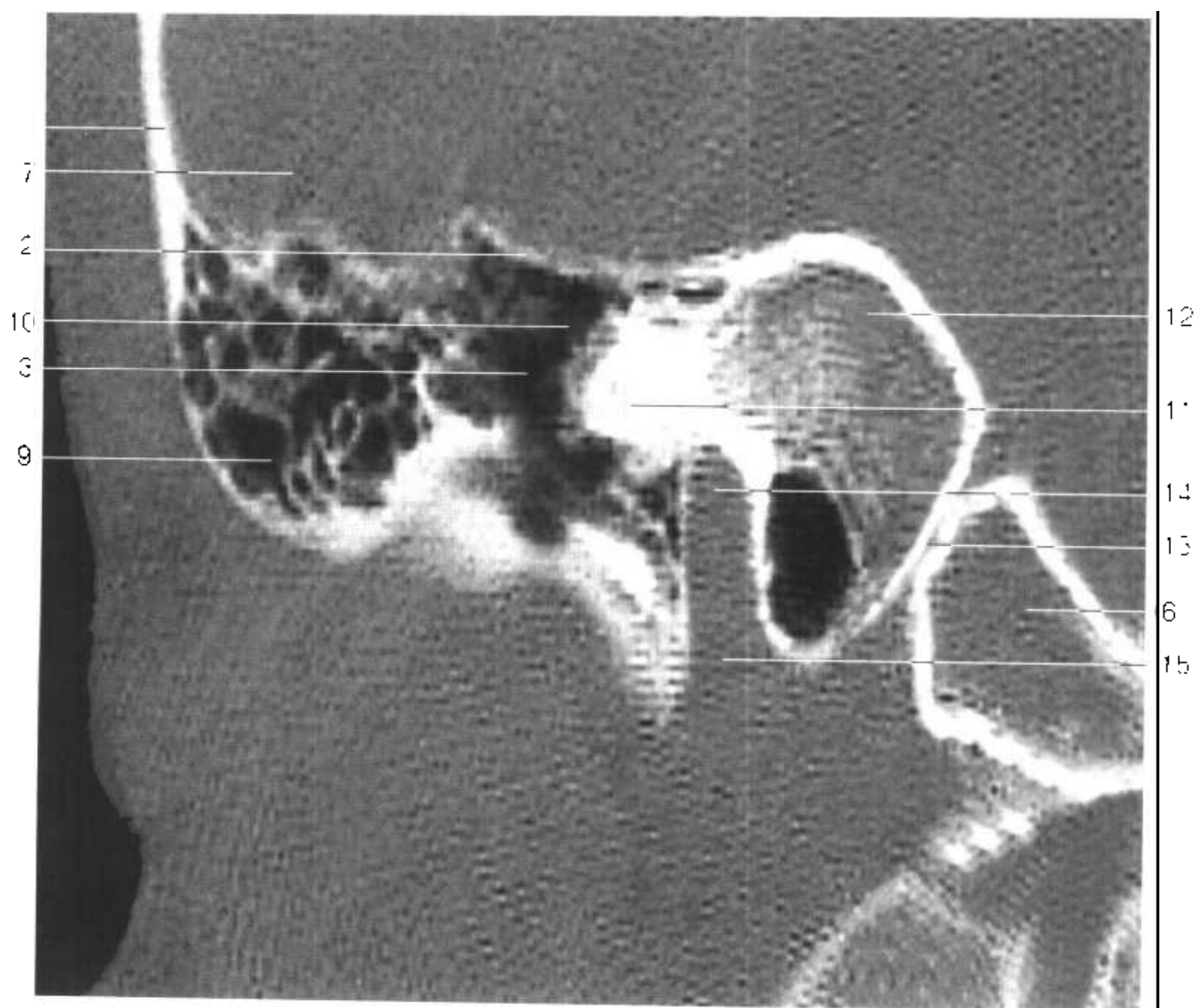

Fig.FE 6

- | | |
|---|---|
| 1. 颞骨鳞部 squamous part of temporal bone | 8 寰枕关节 atlantooccipital joint |
| 2. 鼓室盖壁 tegmental wall of tympanic cavity | 9. 乳突小房 mastoid cells |
| 3. 鼓室 tympanic cavity | 10. 鼓室上隐窝 epitympanic recess |
| 4. 寰椎前弓 anterior arch of atlas | 11. 耳蜗 cochlea |
| 5. 枢椎齿突 dens of axis | 12. 颞骨岩部 petrous part of temporal bone |
| 6. 枕骨基部 basilar part of occipital bone | 13. 岩枕结合 petrooccipital synchondrosis |
| 7. 颞叶 temporal lobe | 14. 颈内动脉 internal carotid a. |
| | 15. 颈动脉管外口 external aperture of carotid canal |

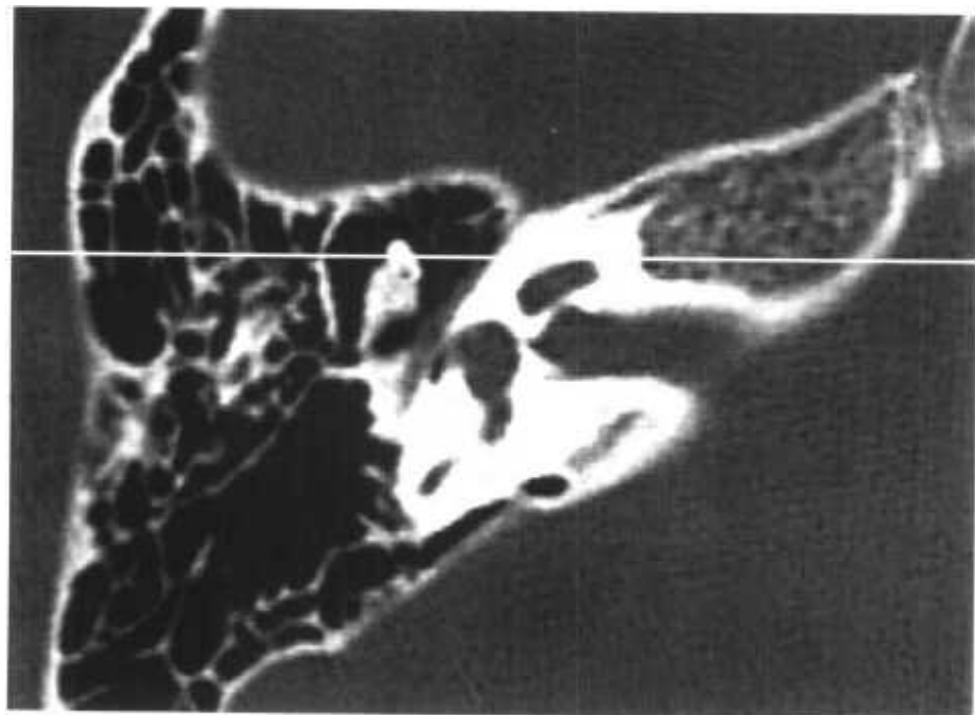
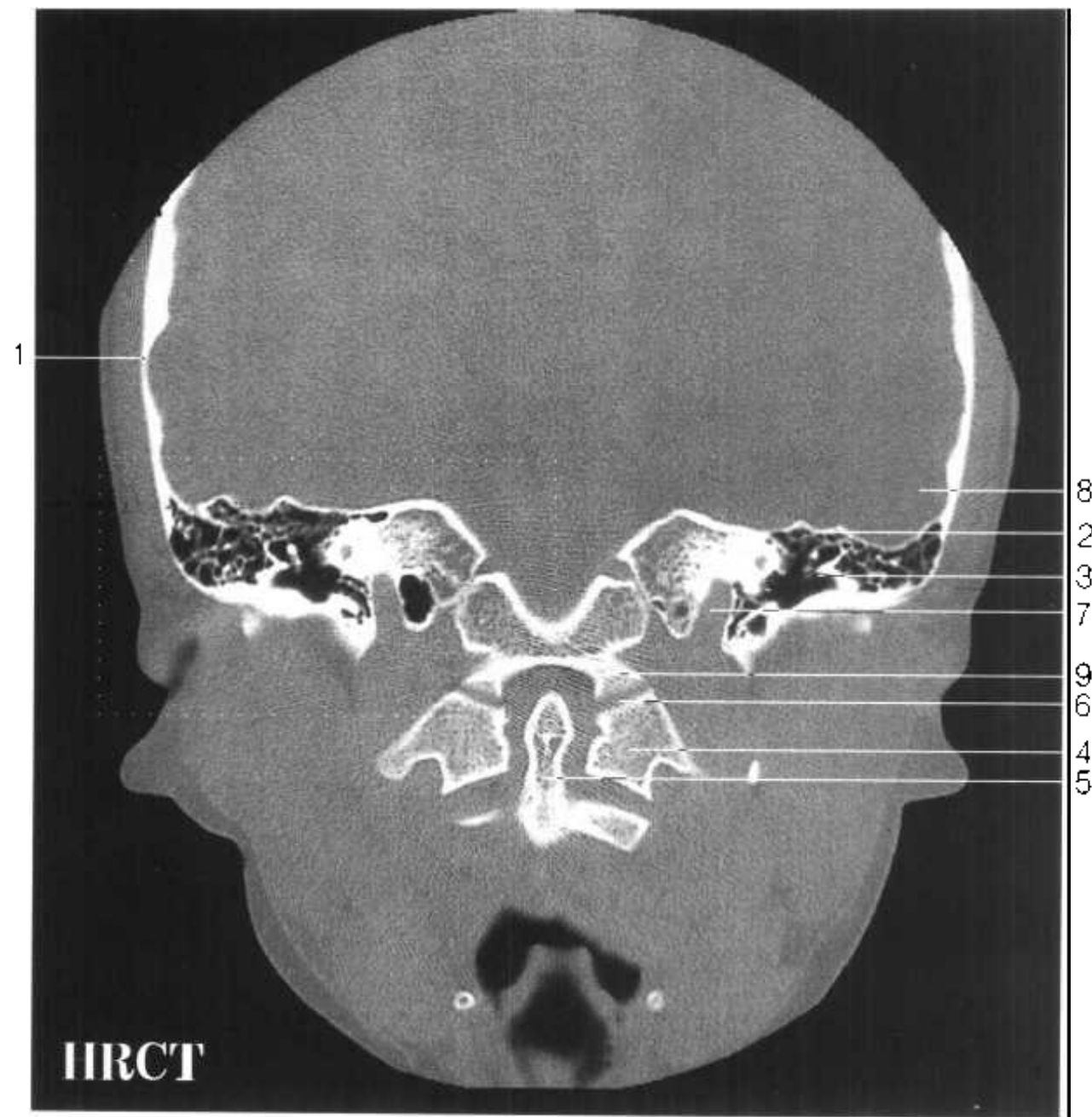


Fig. FE 7

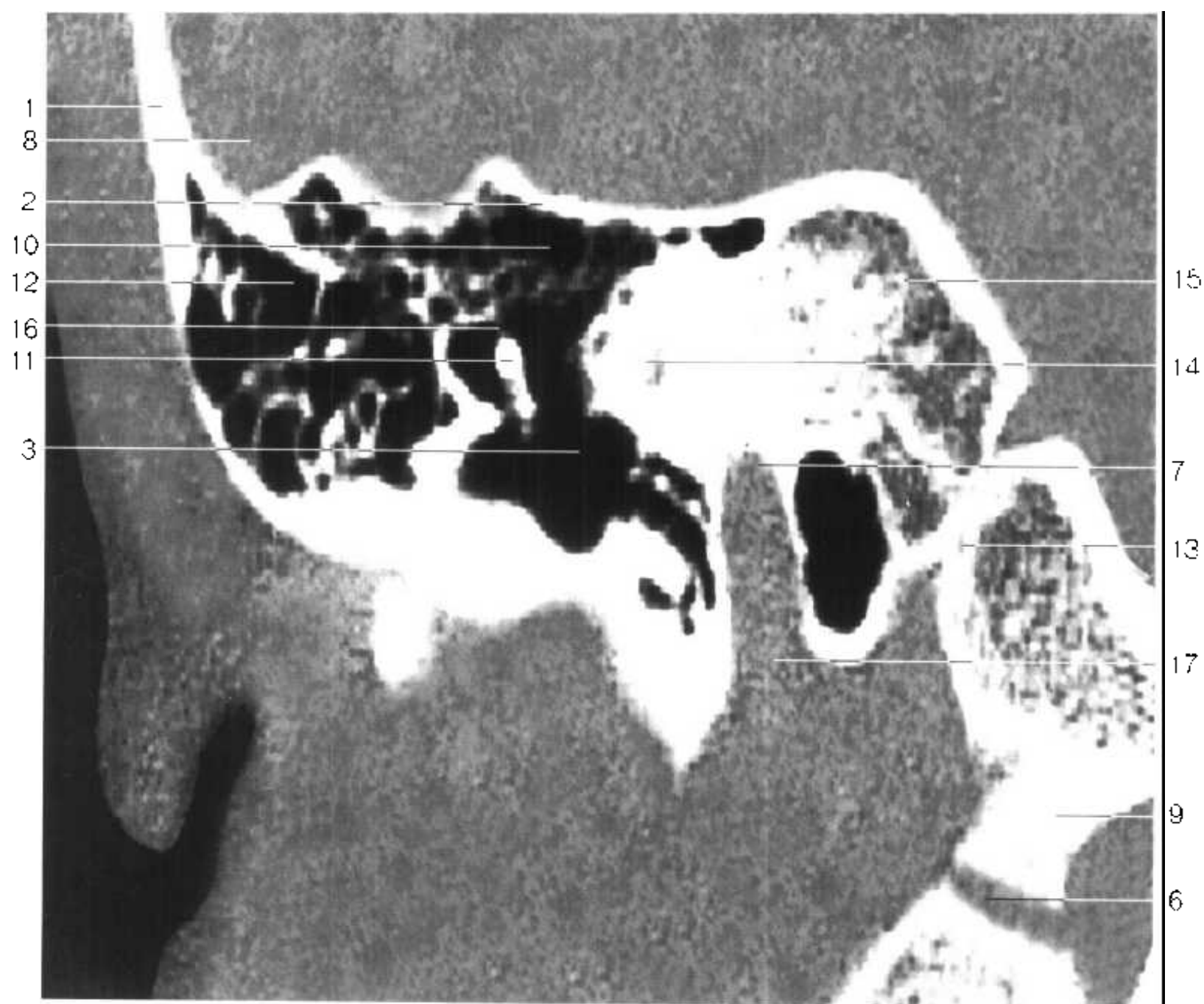


Fig.FE 7

- | | |
|---|---|
| 1. 颞骨鳞部 squamous part of temporal bone | 10. 鼓室上隐窝 epitympanic recess |
| 2. 鼓室盖壁 tegmental wall of tympanic cavity | 11. 锤骨头 head of malleus |
| 3. 鼓室 tympanic cavity | 12. 乳突小房 mastoid cells |
| 4. 寰椎侧块 lateral mass of atlas | 13. 岩枕结合 petrooccipital synchondrosis |
| 5. 枢椎齿突 dens of axis | 14. 耳蜗 cochlea |
| 6. 寰枕关节 atlantooccipital joint | 15. 颞骨岩部 petrous part of temporal bone |
| 7. 颈内动脉 internal carotid a. | 16. 锤骨上韧带 superior ligament of malleus |
| 8. 颞叶 temporal lobe | 17. 颈动脉管外口 external aperture of carotid canal |
| 9. 枕髁 occipital condyle | |

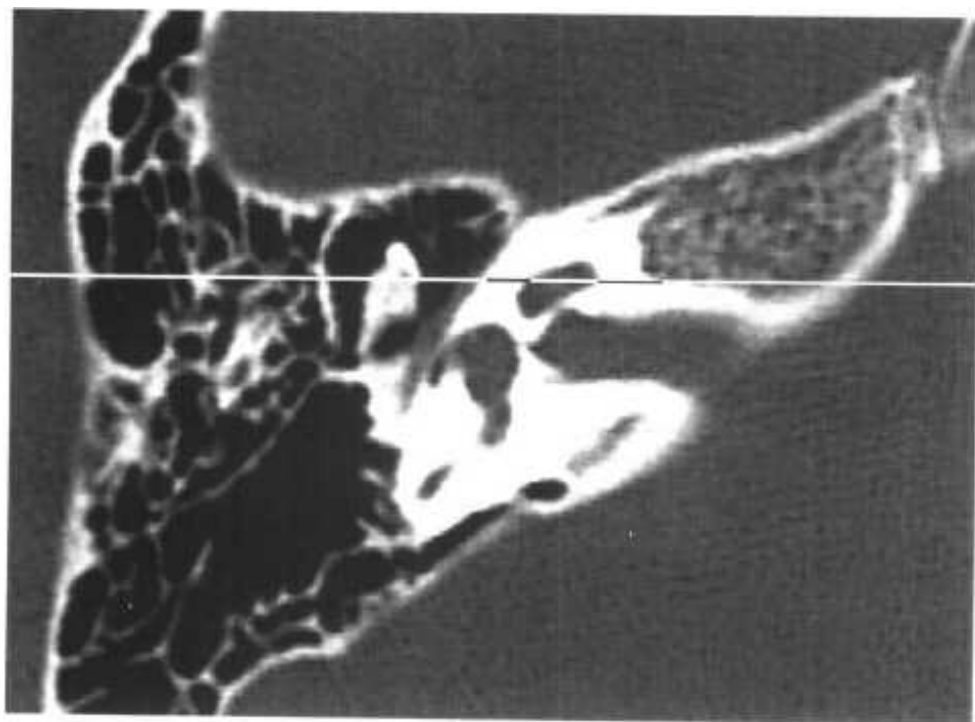
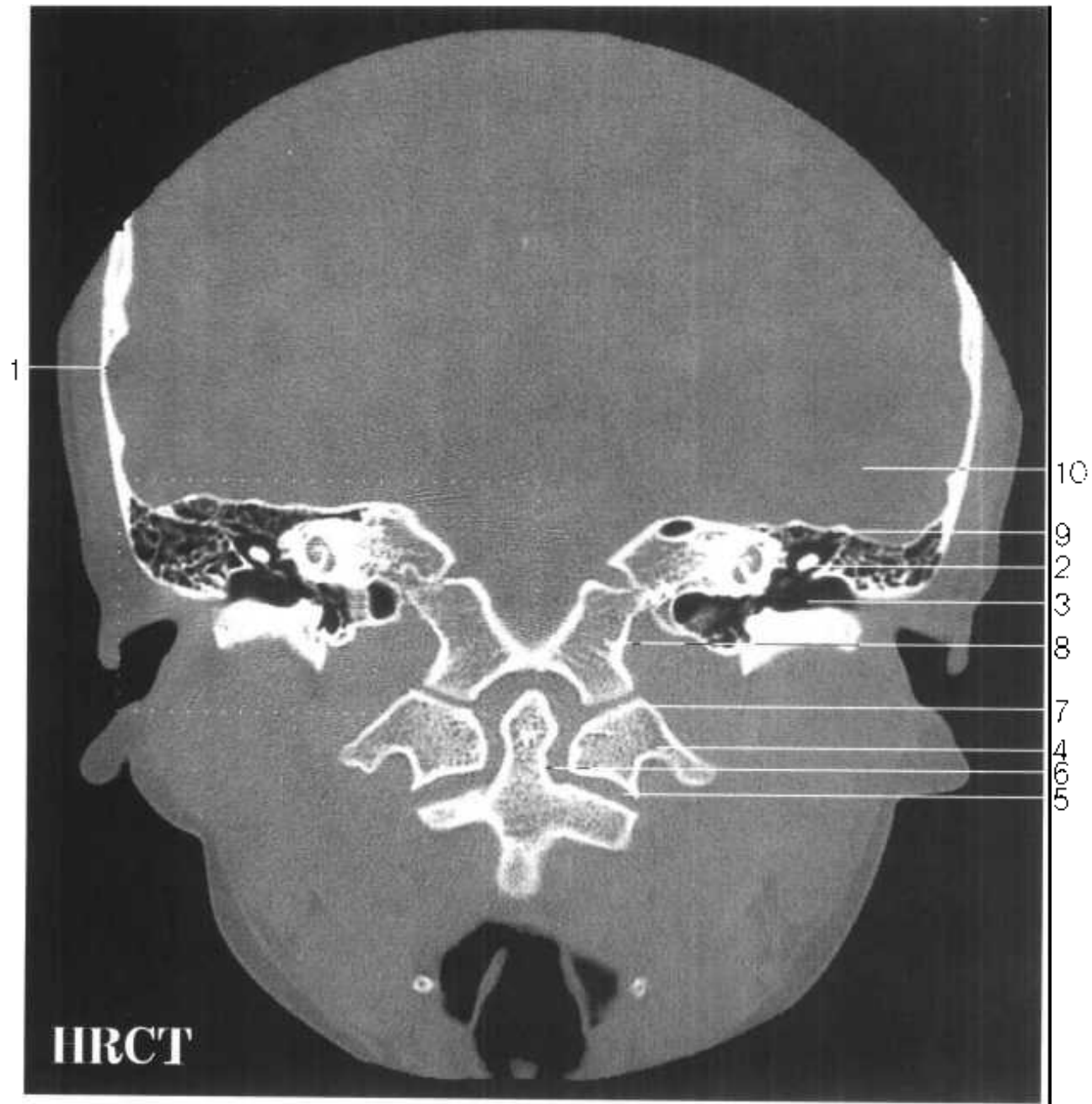


Fig. FE 8

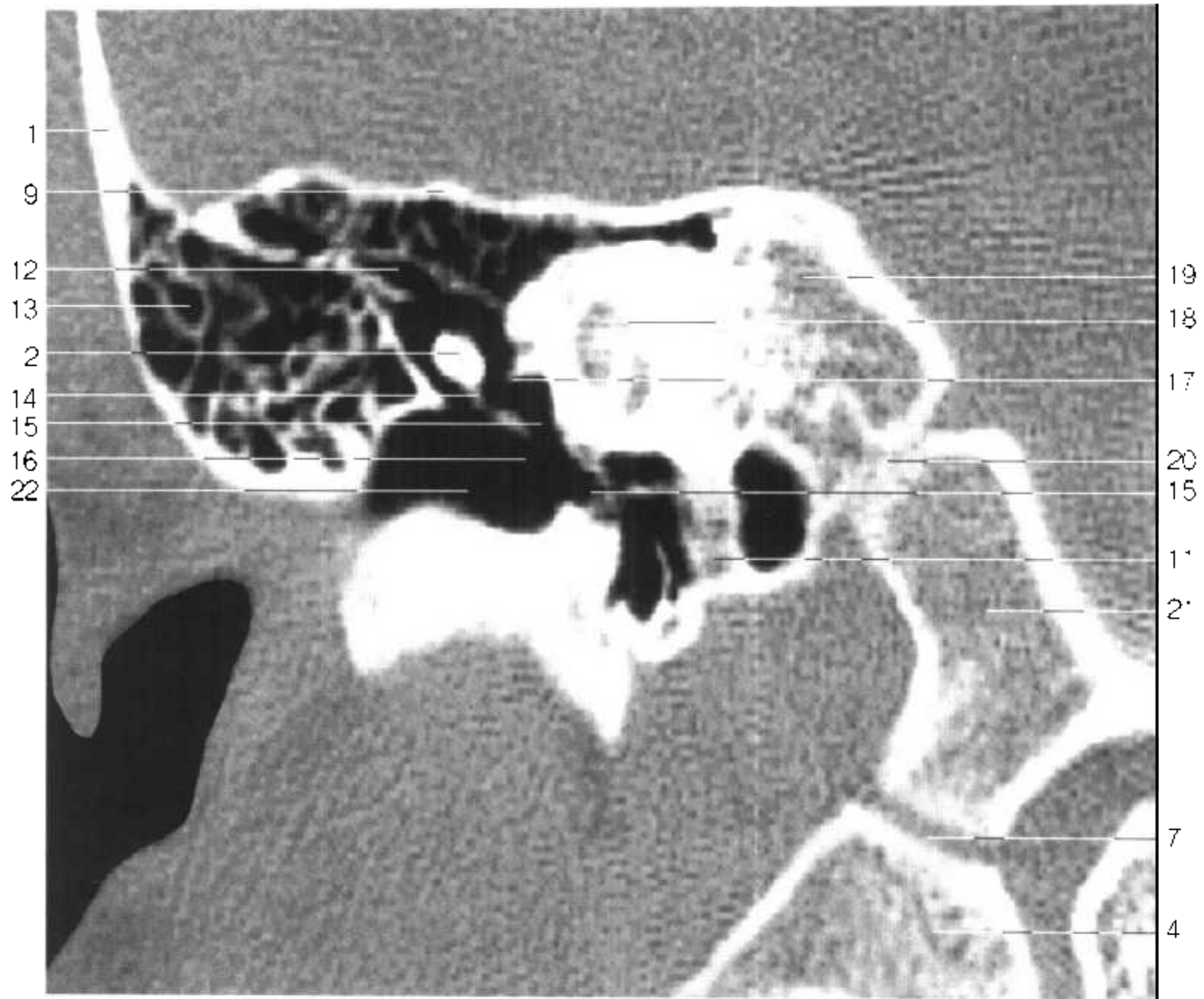


Fig.HE 8

- | | |
|---|--|
| 1. 颞骨鳞部 squamous part of temporal bone | 12. 鼓室上隐窝 epitympanic recess |
| 2. 锤骨头 head of malleus | 13. 乳突小房 mastoid cells |
| 3. 外耳道 external acoustic meatus | 14. 锤骨柄 manubrium of malleus |
| 4. 寰椎侧块 lateral mass of atlas | 15. 鼓室 tympanic cavity |
| 5. 寰枢外侧关节 lateral atlantoaxial joint | 16. 鼓膜 tympanic membrane |
| 6. 枢椎齿突 dens of axis | 17. 匙突 cochleariform process |
| 7. 寰枕关节 atlantooccipital joint | 18. 蜗螺旋管 cochlear spiral canal |
| 8. 枕骨基底部 basilar part of occipital bone | 19. 颞骨岩部 petrous part of temporal bone |
| 9. 鼓室盖壁 tegmental wall of tympanic cavity | 20. 岩枕结合 petrooccipital synchondrosis |
| 10. 颞叶 temporal lobe | 21. 枕骨基底部 basilar part of occipital bone |
| 11. 颈动脉管外口 external aperture of carotid canal | 22. 外耳道 external acoustic meatus |

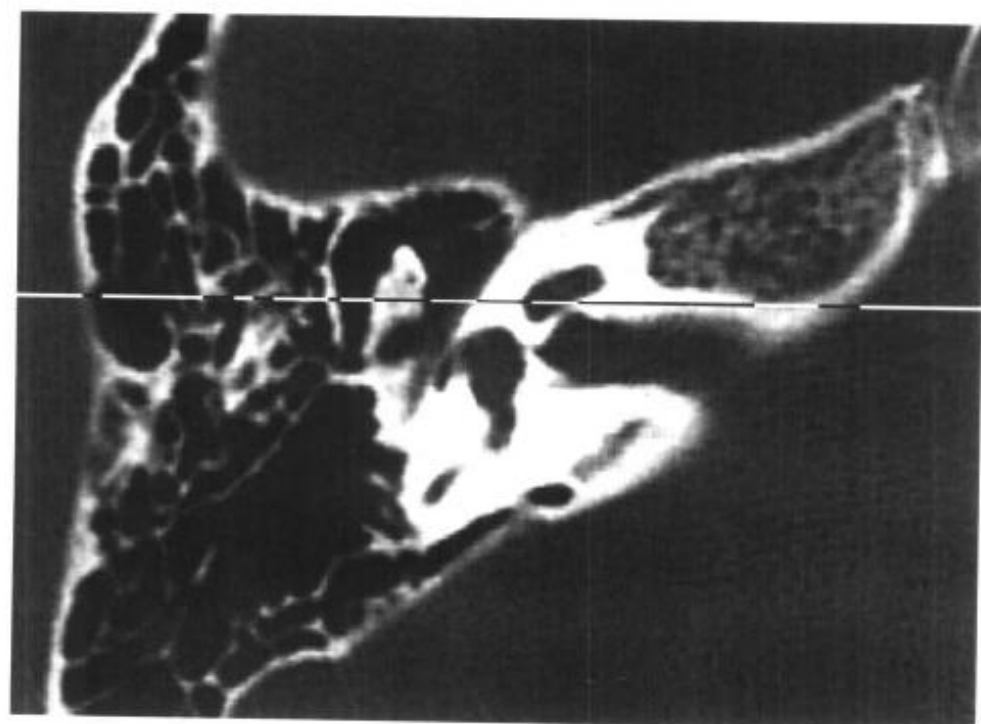
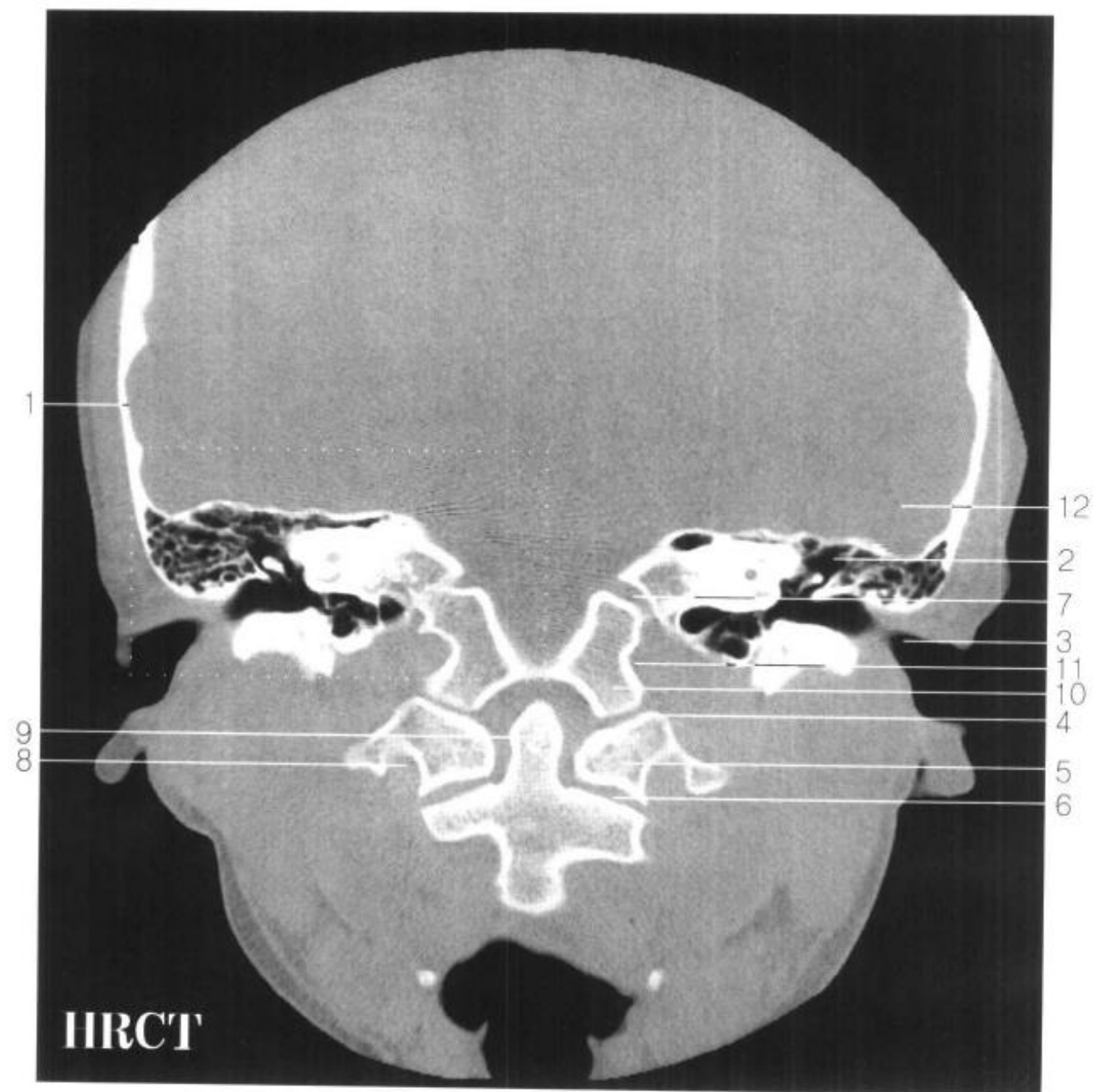


Fig. FE 9

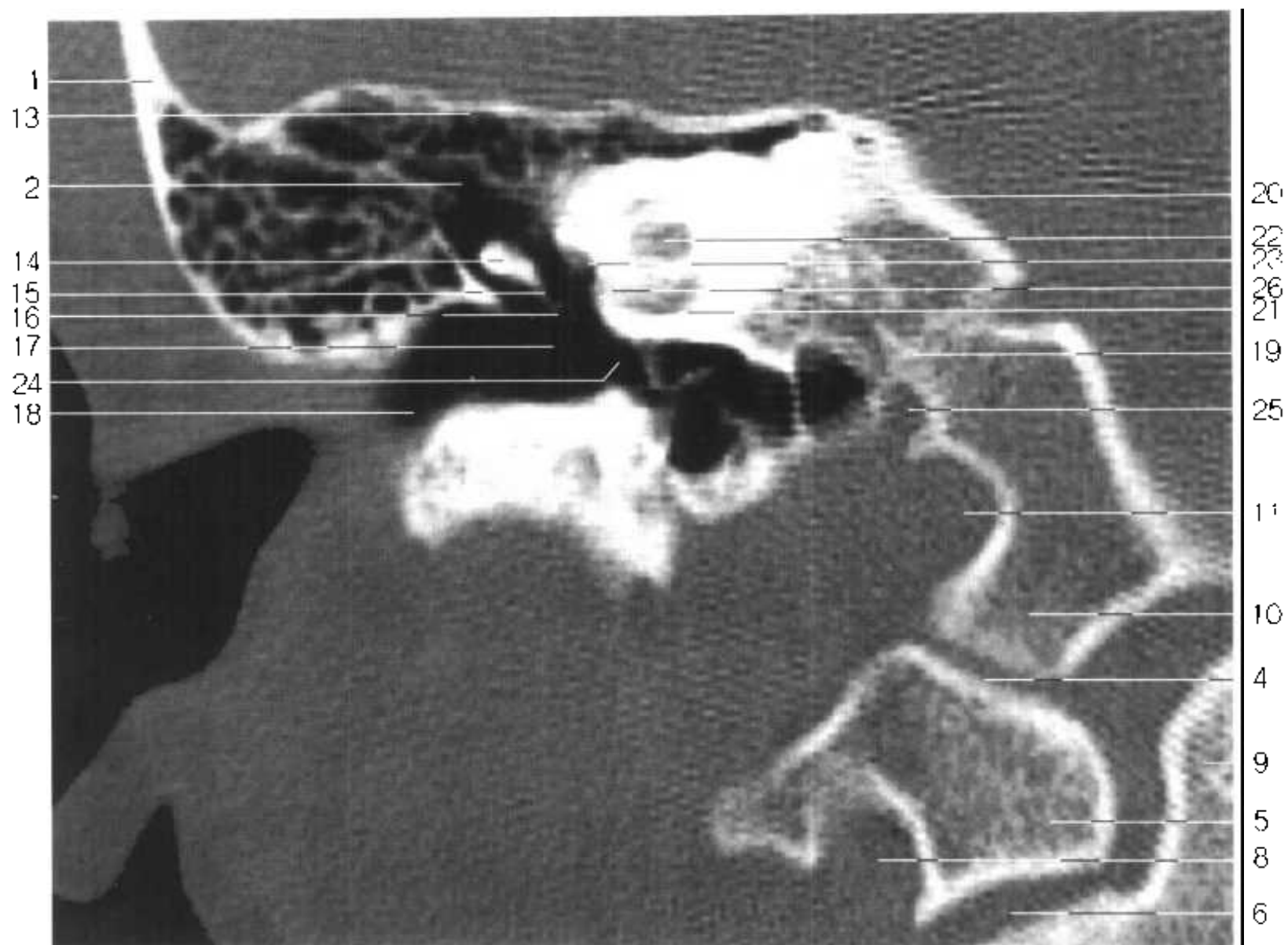


Fig.FE 9

- | | |
|--|---|
| <p>1. 颞骨鳞部 squamous part of temporal bone</p> <p>2. 鼓室上隐窝 epitympanic recess</p> <p>3. 外耳道 external acoustic meatus</p> <p>4. 寰枕关节 atlantooccipital joint</p> <p>5. 寰椎侧块 lateral mass of atlas</p> <p>6. 寰椎外侧关节 lateral atlantoaxial joint</p> <p>7. 颈静脉孔 jugular foramen</p> <p>8. 寰椎横突孔 transverse foramen of atlas</p> <p>9. 枢椎齿突 dens of axis</p> <p>10. 枕髁 occipital condyle</p> <p>11. 舌下神经管 hypoglossal canal</p> <p>12. 颞叶 temporal lobe</p> <p>13. 鼓室盖壁 tegmental wall of tympanic cavity</p> | <p>14. 砧骨体 body of incus</p> <p>15. 砧骨长脚 long crus of incus</p> <p>16. 镫骨 stapes</p> <p>17. 鼓膜 tympanic membrane</p> <p>18. 外耳道 external acoustic meatus</p> <p>19. 岩枕结合 petrooccipital synchondrosis</p> <p>20. 颞骨岩部 petrous part of temporal bone</p> <p>21. 蜗螺旋管 cochlear spiral canal</p> <p>22. 耳蜗 cochlea</p> <p>23. 前庭窗 fenestra vestibuli</p> <p>24. 鼓室 tympanic cavity</p> <p>25. 颈静脉孔 jugular foramen</p> <p>26. 蜗窗 fenestra cochleae</p> |
|--|---|

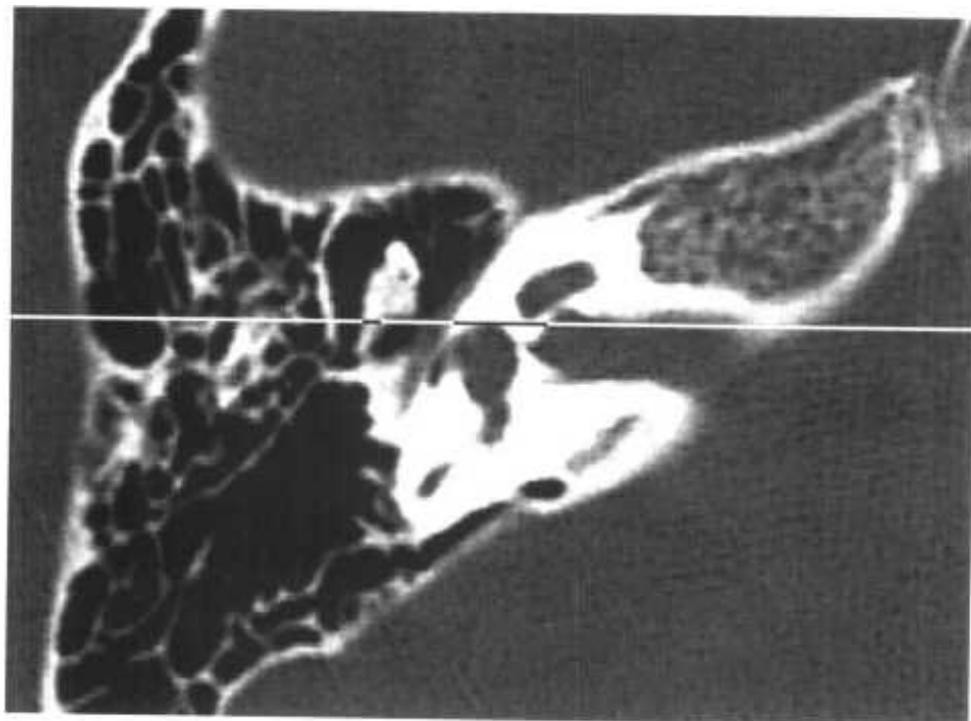
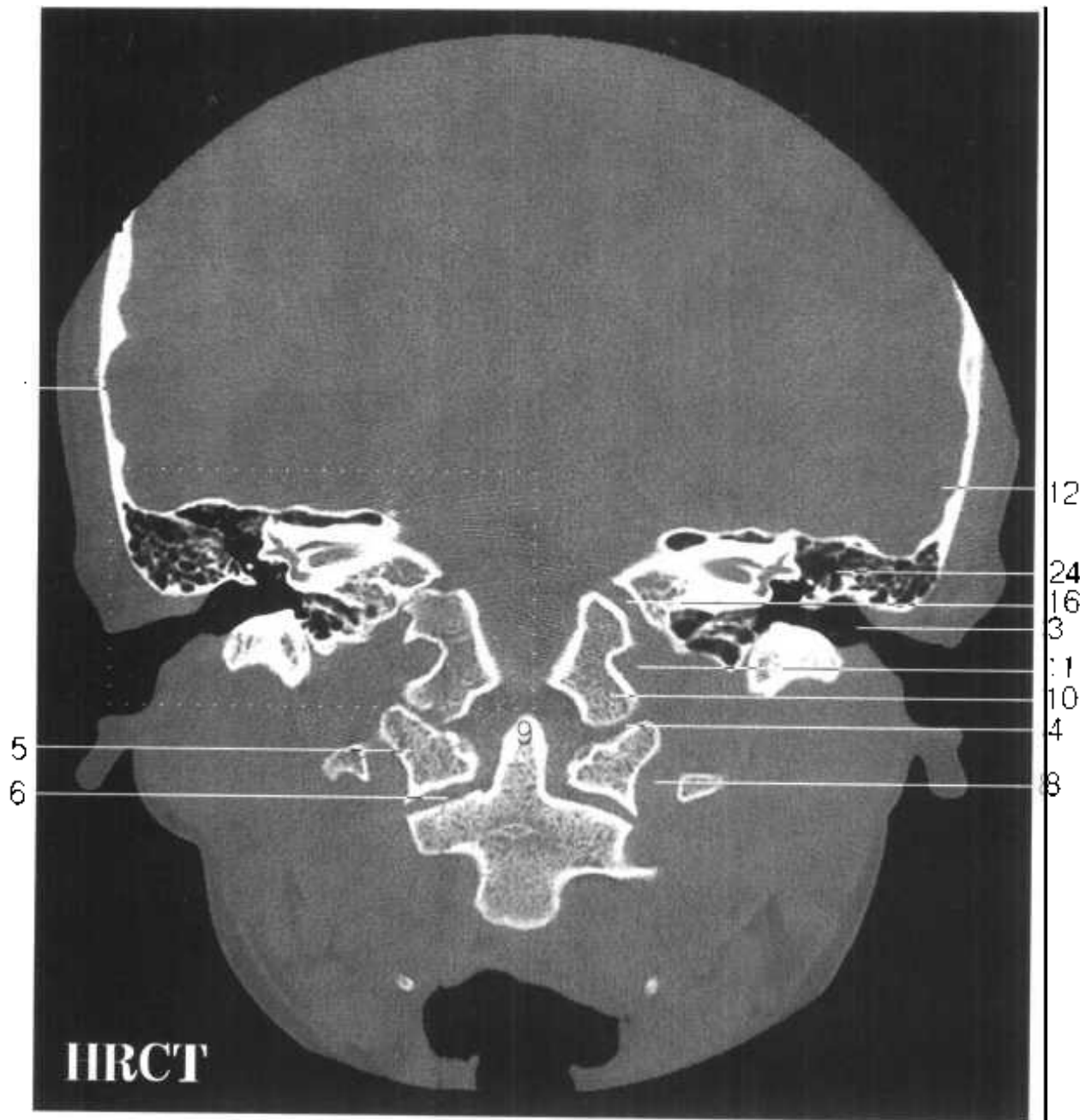


Fig. FE 10

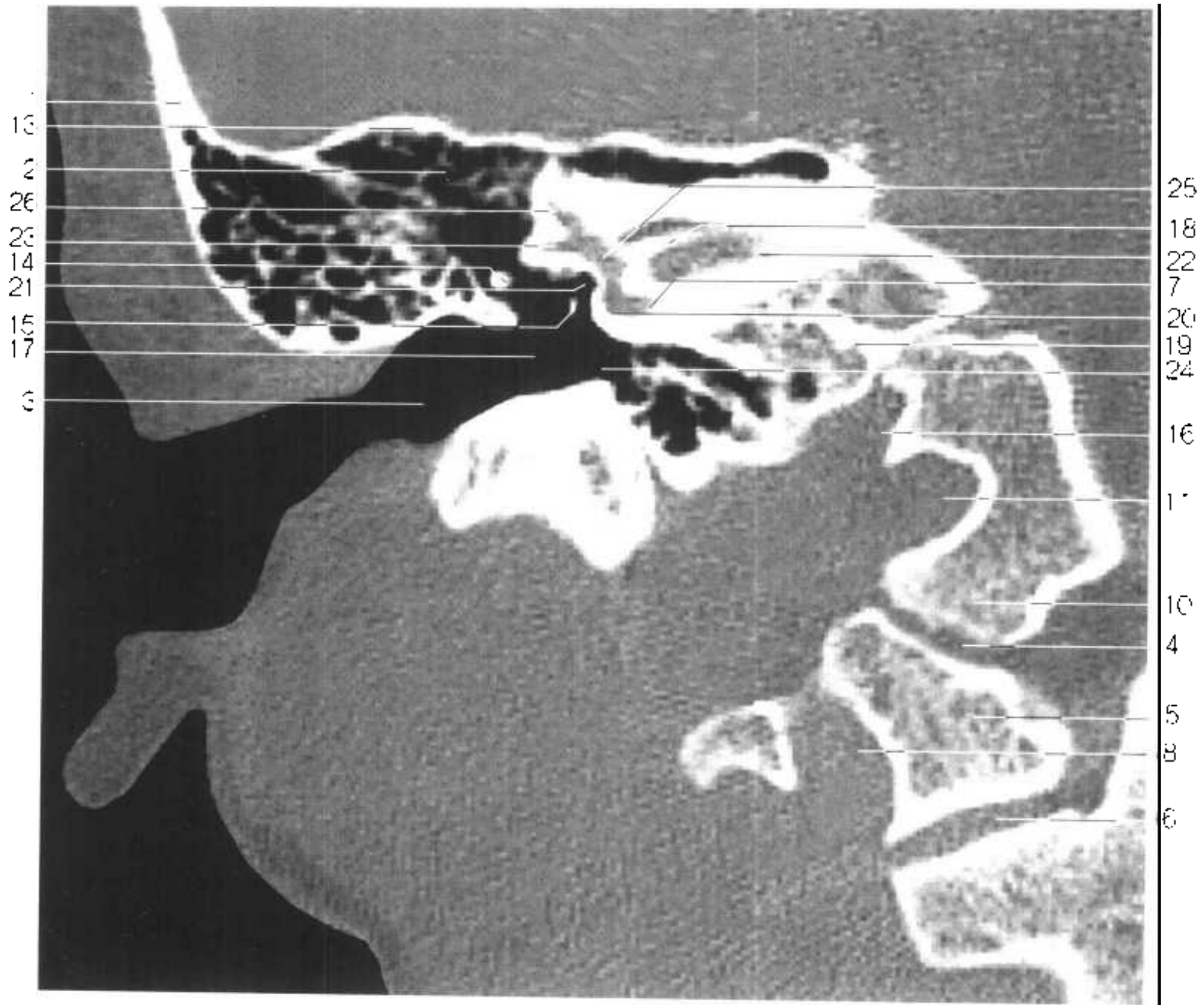


Fig.FE 10

- | | |
|--|--|
| 1. 颞骨鳞部 squamous part of temporal bone | 14. 砧骨 incus |
| 2. 鼓室上隐窝 epitympanic recess | 15. 镫骨 stapes |
| 3. 外耳道 external acoustic meatus | 16. 颈静脉孔 jugular foramen |
| 4. 寰枕关节 atlantooccipital joint | 17. 鼓膜 tympanic membrane |
| 5. 寰椎侧块 lateral mass of atlas | 18. 横嵴 transverse crest |
| 6. 寰枢外侧关节 lateral atlantoaxial joint | 19. 颞骨岩部 petrous part of temporal bone |
| 7. 蜗螺旋管 cochlear spiral canal | 20. 蜗窗 fenestra cochleae |
| 8. 寰椎横突孔 transverse foramen of atlas | 21. 前庭窗 fenestra vestibuli |
| 9. 枢椎齿突 dens of axis | 22. 内耳道 internal acoustic meatus |
| 10. 枕髁 occipital condyle | 23. 外骨半规管 lateral semicircular canal |
| 11. 舌下神经管 hypoglossal canal | 24. 鼓室 tympanic cavity |
| 12. 颞叶 temporal lobe | 25. 前庭 vestibule |
| 13. 鼓室盖壁 tegmental wall of tympanic cavity | 26. 前骨半规管 anterior semicircular canal |

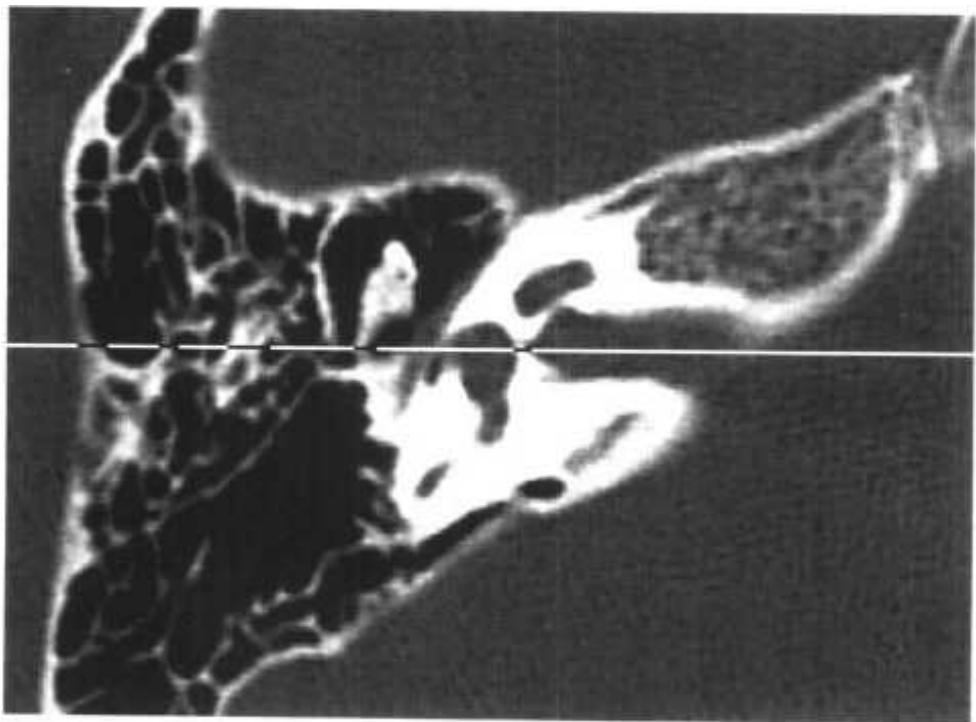
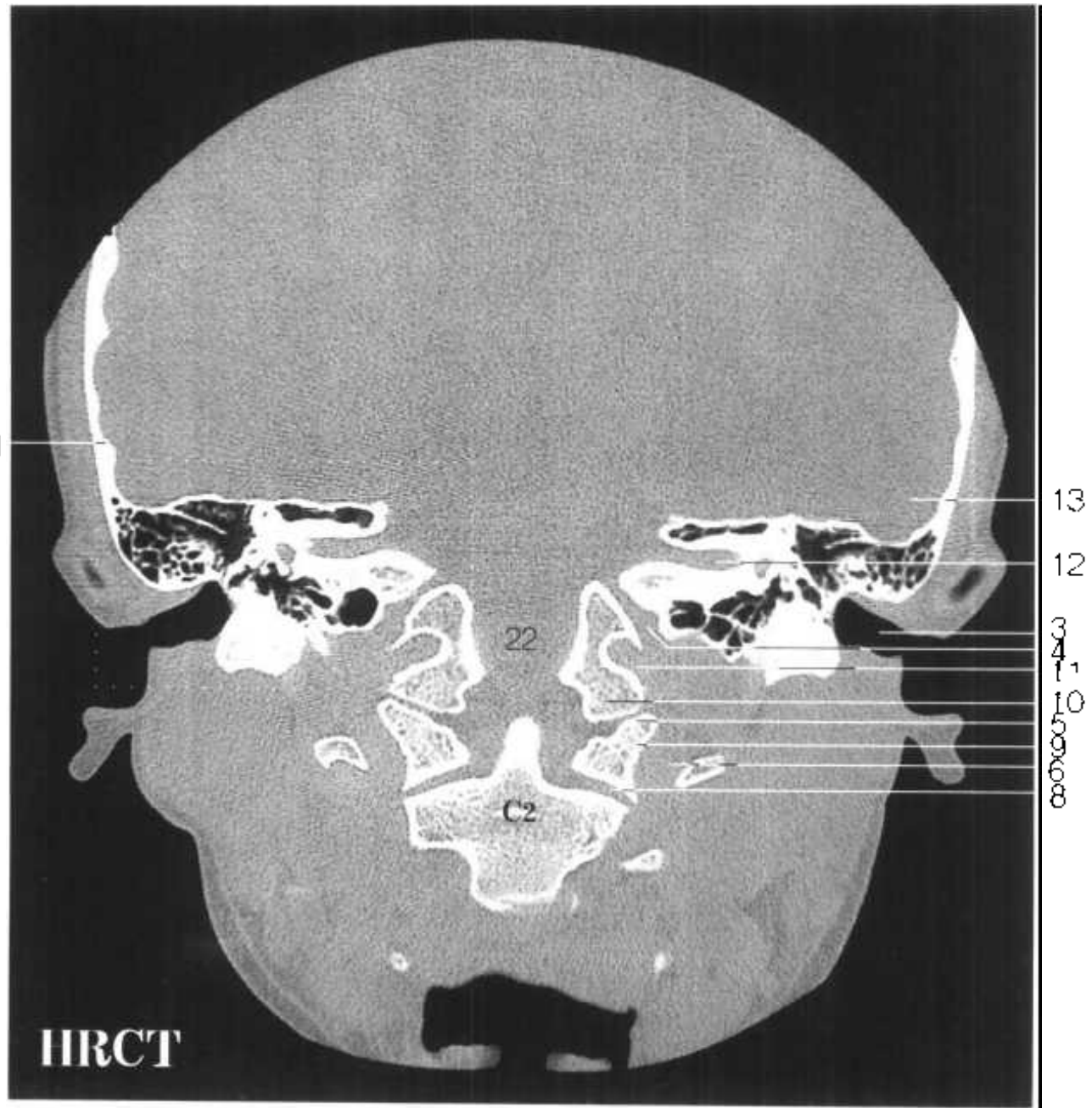


Fig. FE 11

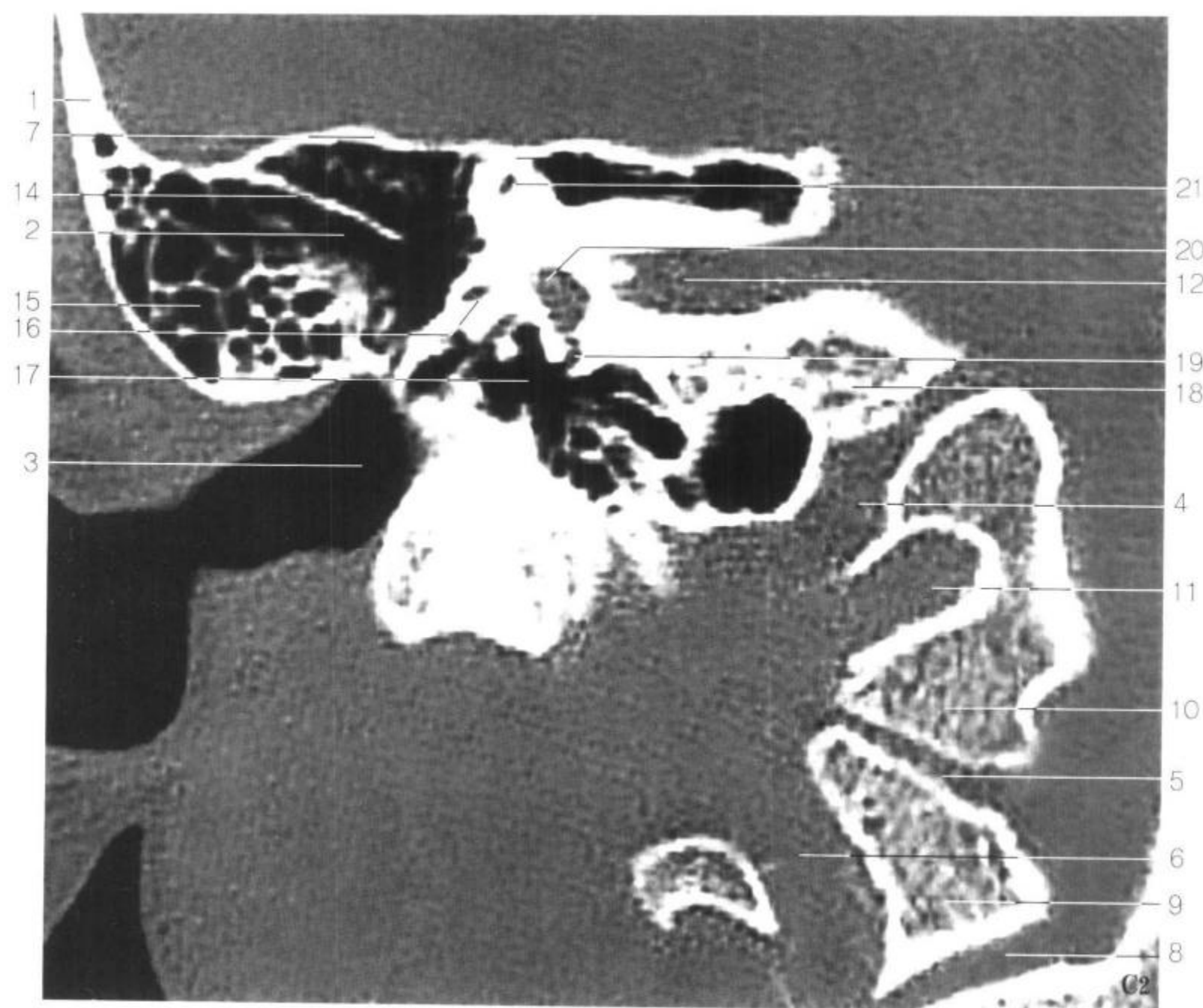


Fig.FE 11

- | | |
|--|--|
| <ul style="list-style-type: none"> 1. 颞骨鳞部 squamous part of temporal bone 2. 乳突窦 mastoid antrum 3. 外耳道 external acoustic meatus 4. 颈静脉孔 jugular foramen 5. 寰枕关节 atlantooccipital joint 6. 寰椎横突孔 transverse foramen of atlas 7. 鼓室盖壁 tegmental wall of tympanic cavity 8. 寰枢外侧关节 lateral atlantoaxial joint 9. 寰椎侧块 lateral mass of atlas 10. 枕髁 occipital condyle 11. 舌下神经管 hypoglossal canal | <ul style="list-style-type: none"> 12. 内耳道 internal acoustic meatus 13. 颞叶 temporal lobe 14. 乳突窦间隔 septum of mastoid antrum 15. 乳突小房 mastoid cells 16. 外骨半规管 lateral semicircular canal 17. 鼓室 tympanic cavity 18. 颞骨岩部 petrous part of temporal bone 19. 蜗窗 fenestra cochleae 20. 前庭 vestibule 21. 前骨半规管 anterior semicircular canal 22. 枕骨大孔 foramen magnum of occipital bone |
|--|--|

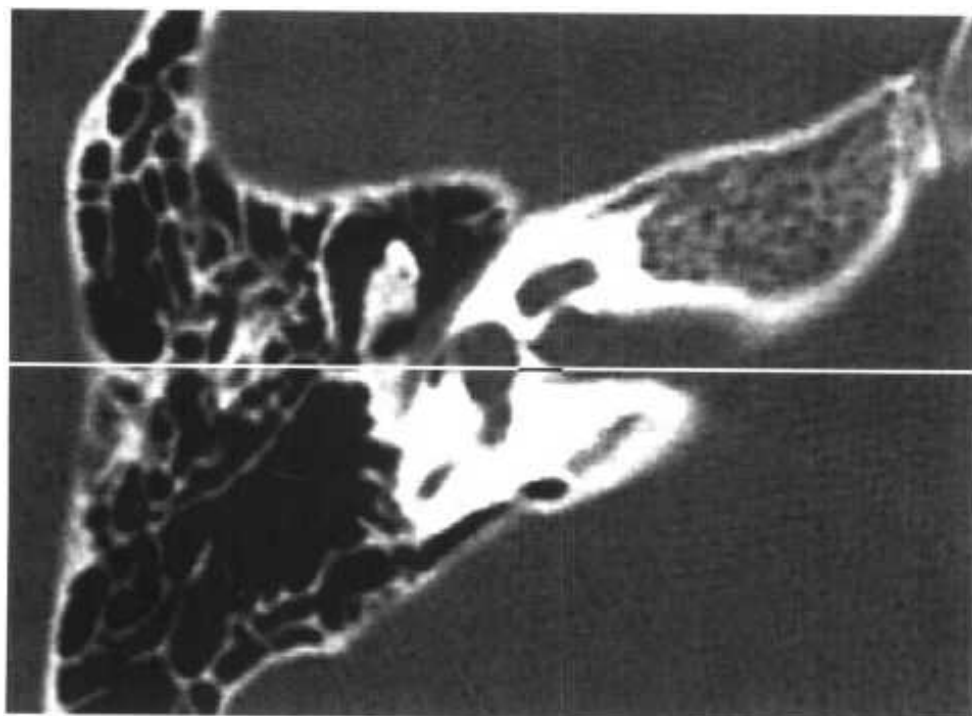
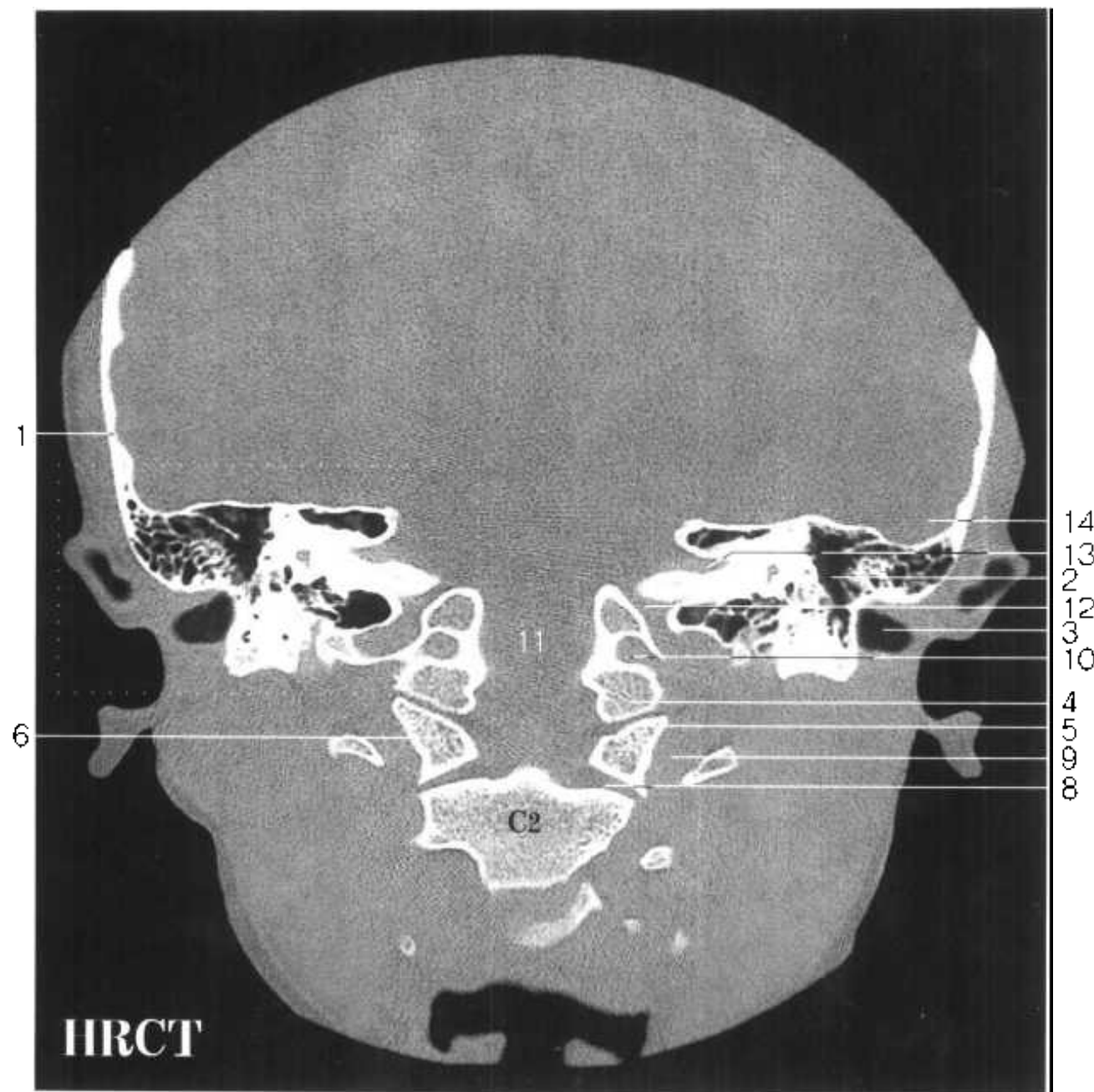


Fig. FE 12

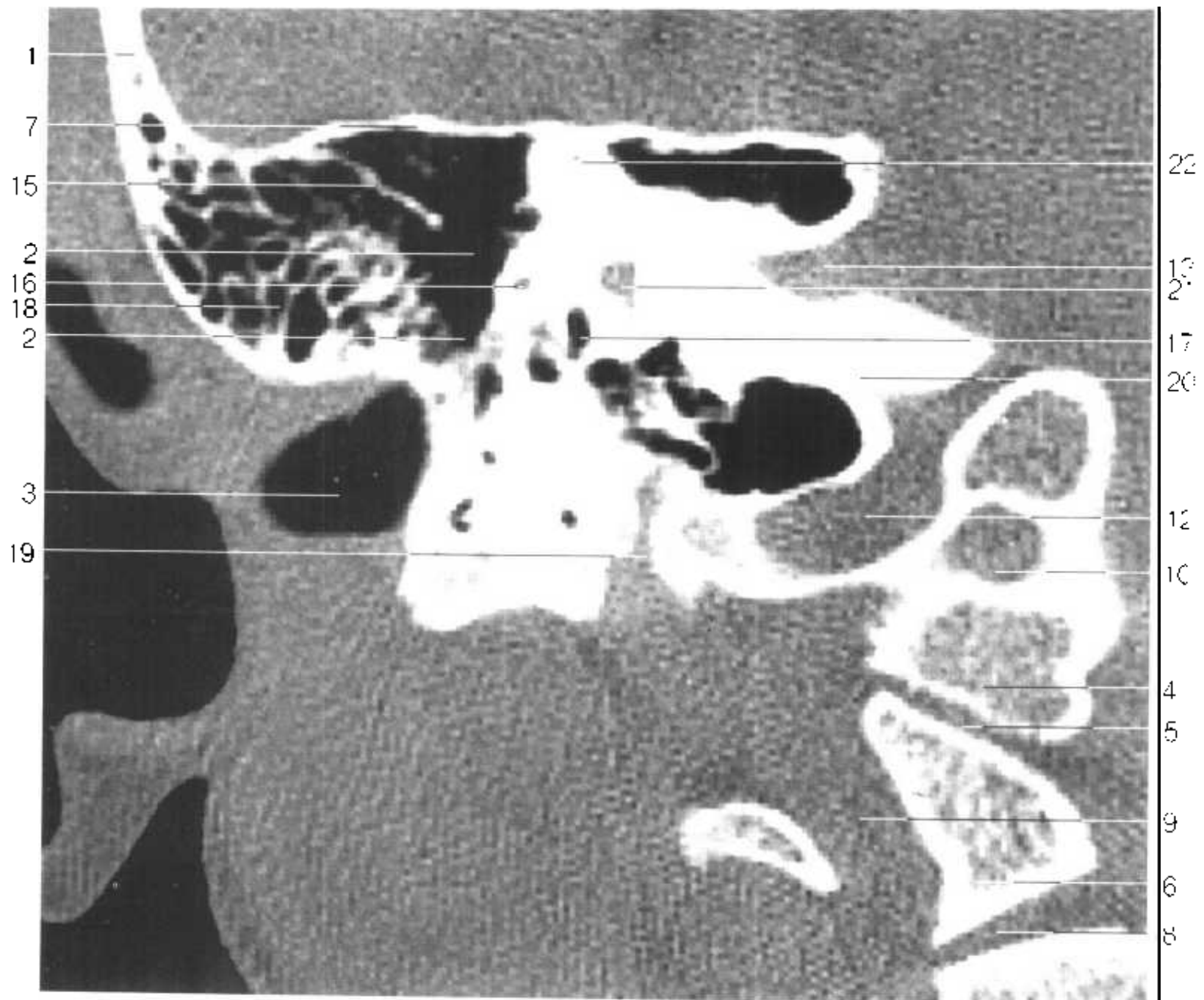


Fig.FE 12

- | | |
|--|--|
| <ol style="list-style-type: none"> 1. 颞骨鳞部 squamous part of temporal bone 2. 乳突窦 mastoid antrum 3. 外耳道 external acoustic meatus 4. 枕髁 occipital condyle 5. 寰枕关节 atlantooccipital joint 6. 寰椎侧块 lateral mass of atlas 7. 鼓室盖壁 tegmental wall of tympanic cavity 8. 寰椎外侧关节 lateral atlantoaxial joint 9. 寰椎横突孔 transverse foramen of atlas 10. 舌下神经管 hypoglossal canal | <ol style="list-style-type: none"> 11. 枕骨大孔 foramen magnum of occipital bone 12. 颈静脉孔 jugular foramen 13. 内耳道 internal acoustic meatus 14. 颞叶 temporal lobe 15. 乳突窦间隔 septum of mastoid antrum 16. 外骨半规管 lateral semicircular canal 17. 鼓室 tympanic cavity 18. 乳突小房 mastoid cells 19. 茎乳孔 stylomastoid foramen 20. 前庭水管 vestibular aqueduct 21. 前庭 vestibule 22. 前骨半规管 anterior semicircular canal |
|--|--|

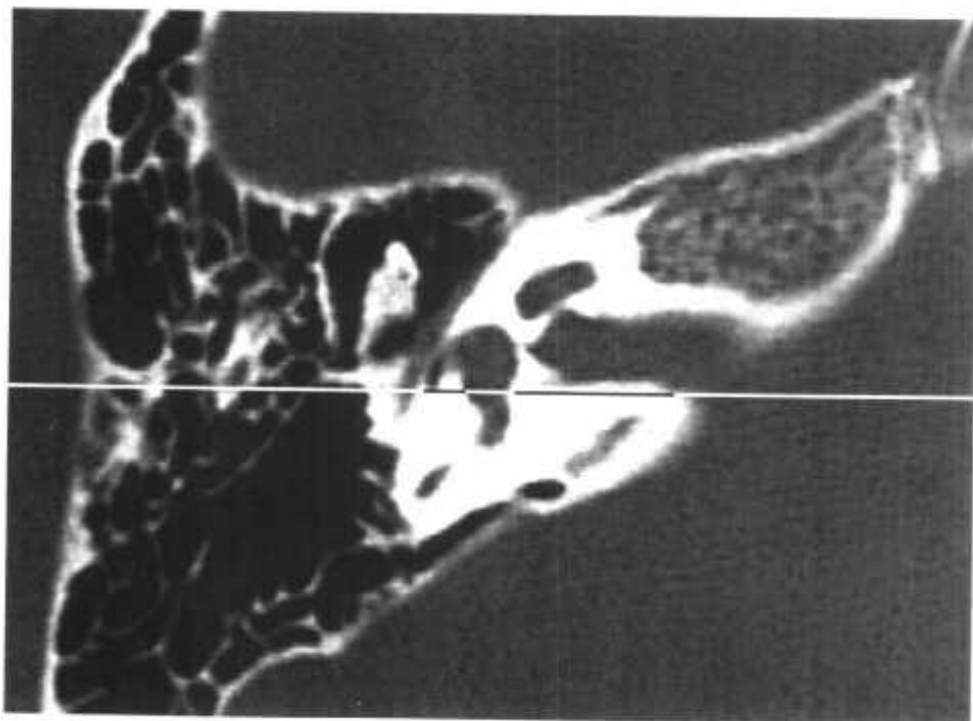
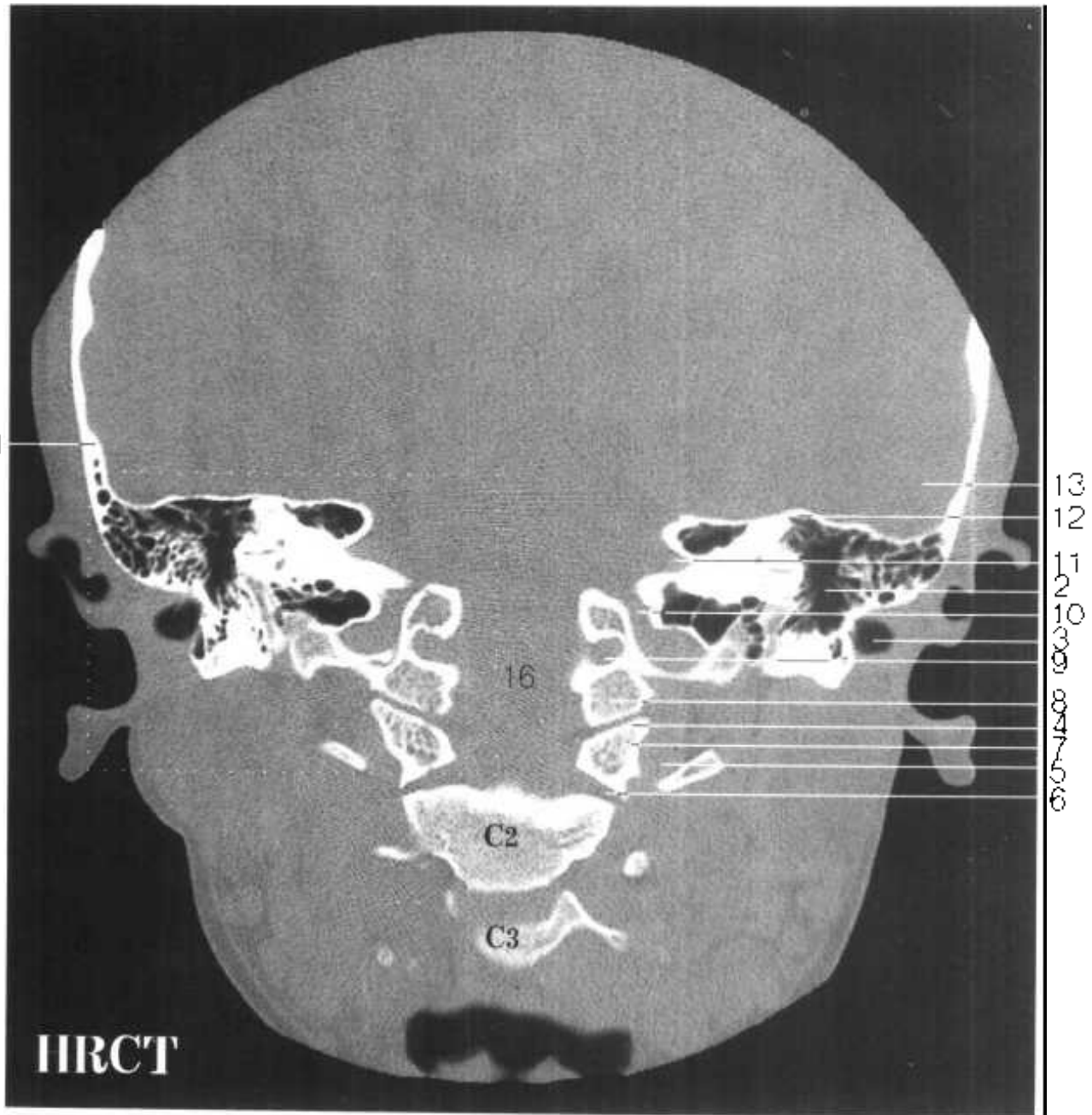


Fig. FE 13

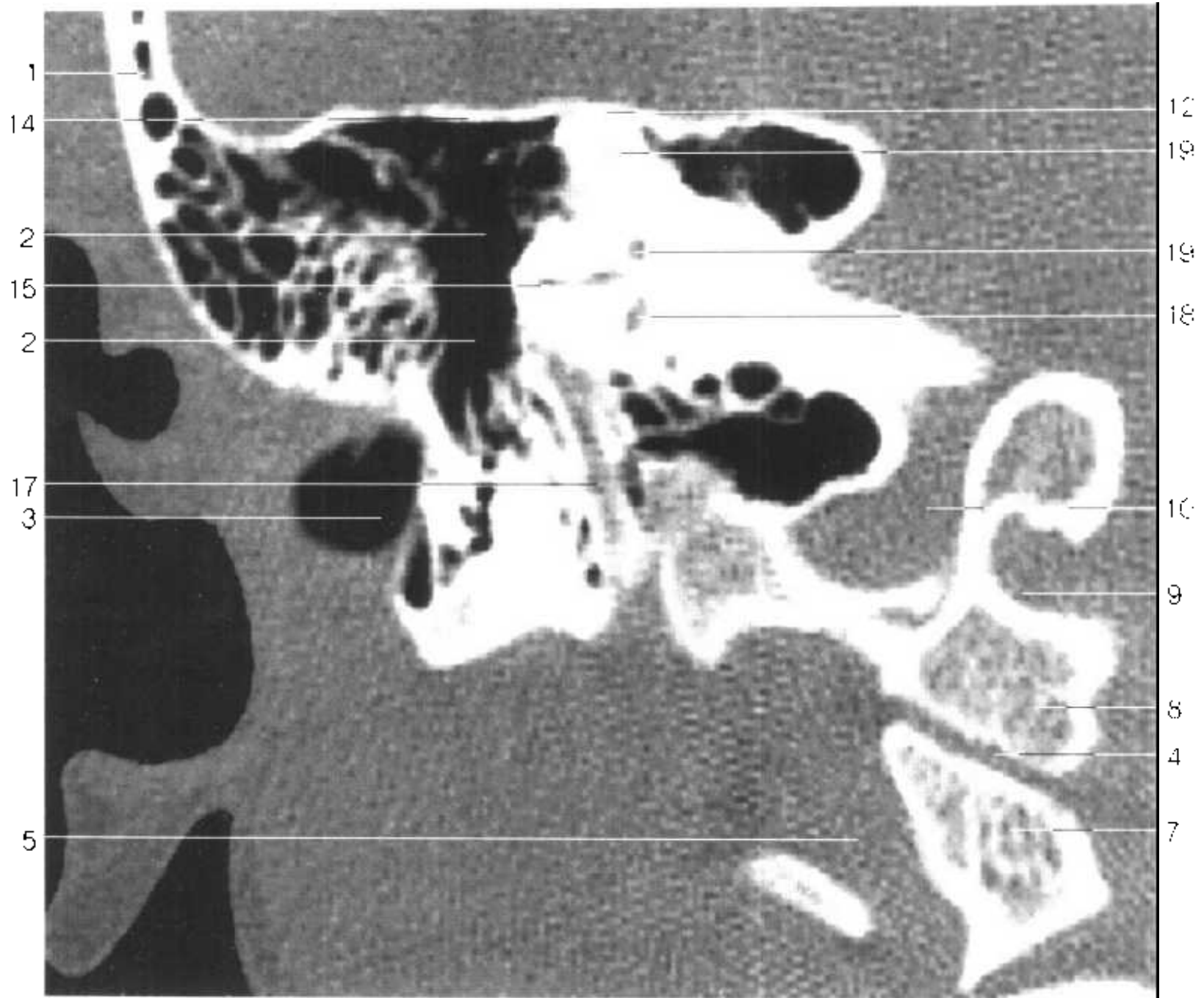


Fig.FE 13

- | | |
|--|---|
| <ul style="list-style-type: none"> 1. 颞骨鳞部 squamous part of temporal bone 2. 乳突窦 mastoid antrum 3. 外耳道 external acoustic meatus 4. 寰枕关节 atlantooccipital joint 5. 寰椎横突孔 transverse foramen of atlas 6. 寰枢外侧关节 lateral atlantoaxial joint 7. 寰椎侧块 lateral mass of atlas 8. 枕髁 occipital condyle 9. 舌下神经管 hypoglossal canal 10. 颈静脉孔 jugular foramen 11. 内耳道 internal acoustic meatus | <ul style="list-style-type: none"> 12. 弓状隆起 arcuate eminence 13. 颞叶 temporal lobe 14. 鼓室盖壁 tegmental wall of tympanic cavity 15. 外骨半规管 lateral semicircular canal 16. 枕骨大孔 foramen magnum of occipital bone 17. 面神经管乳突段 canal for facial nerve : mastoid segment 18. 前庭 vestibule 19. 前骨半规管 anterior semicircular canal |
|--|---|

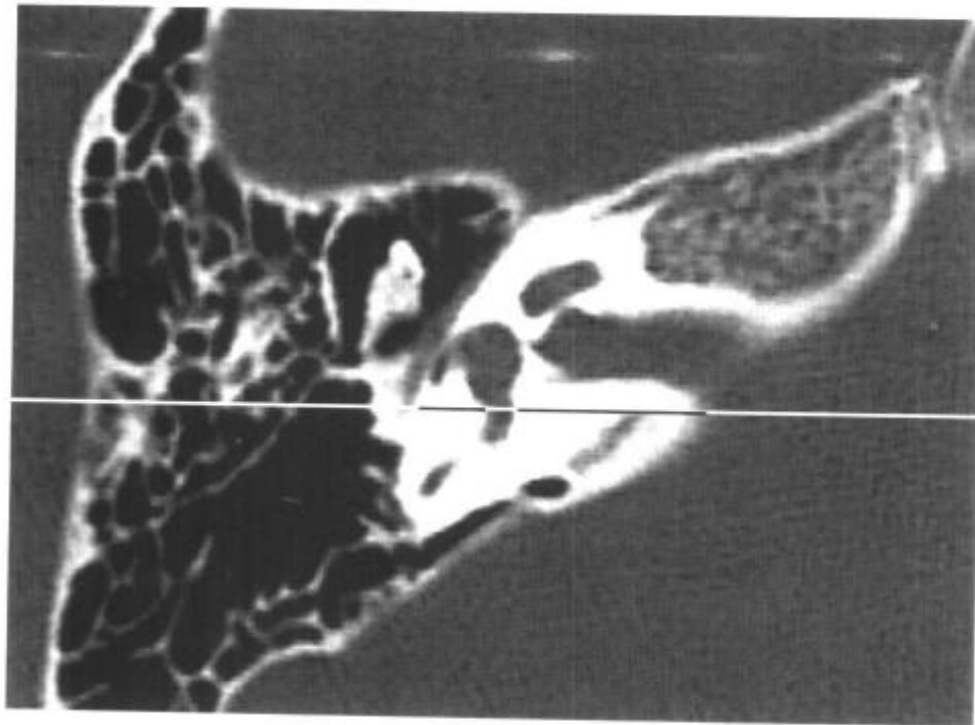
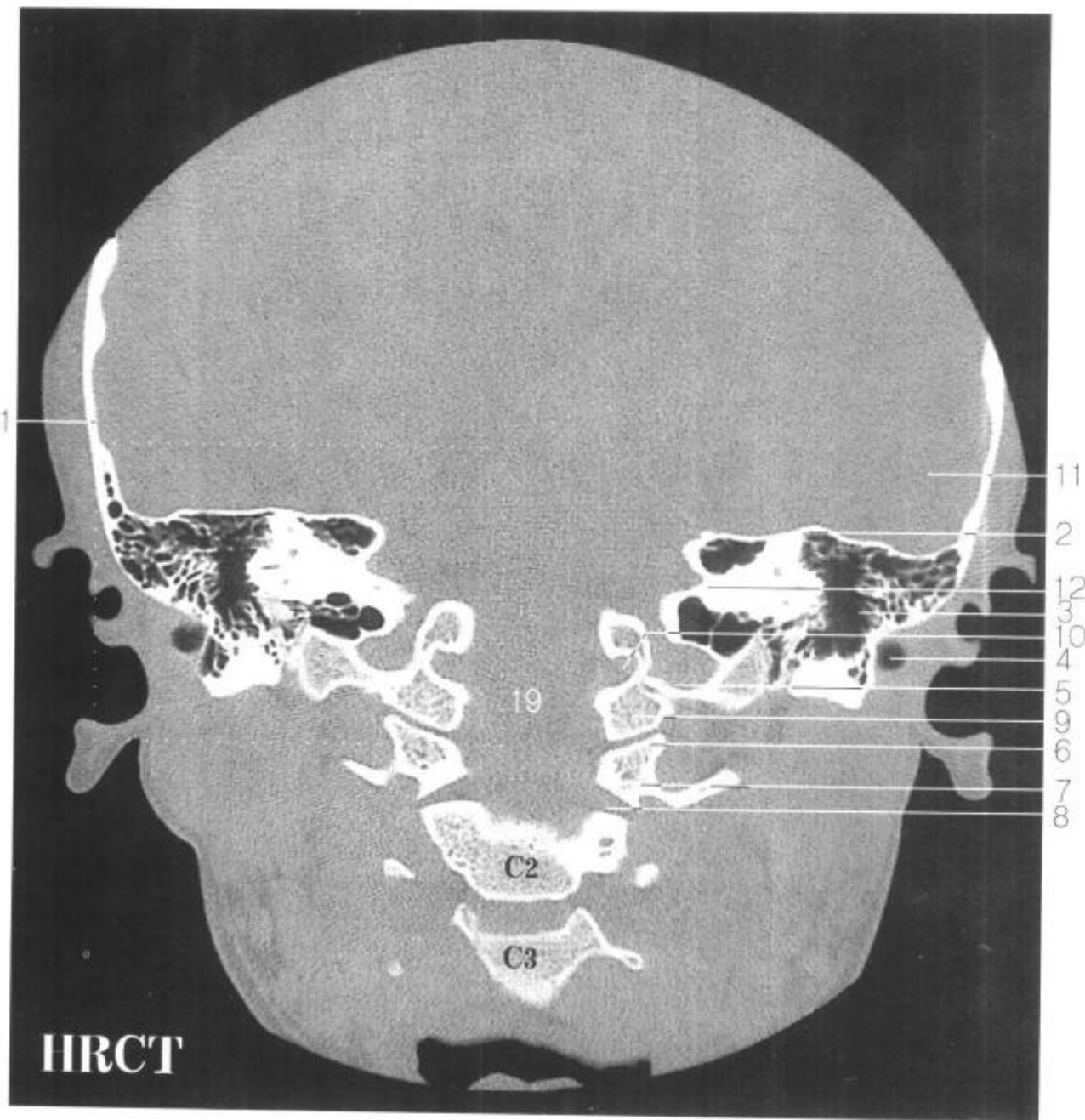


Fig. FE 14

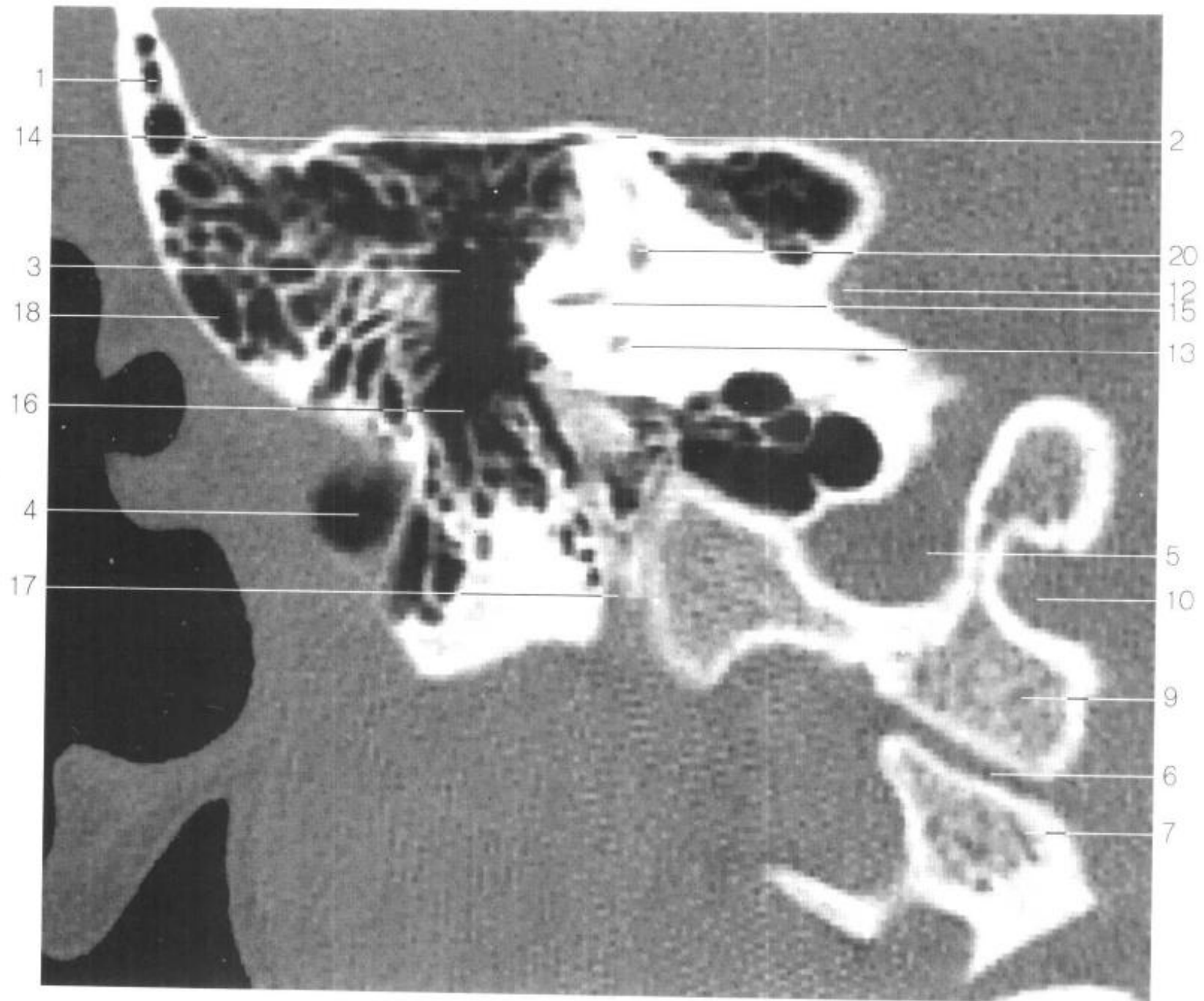


Fig.FE 14

- | | |
|--|--|
| 1. 颞骨鳞部 squamous part of temporal bone | 12. 内耳道 internal acoustic meatus |
| 2. 弓状隆起 arcuate eminence | 13. 前庭 vestibule |
| 3. 乳突窦 mastoid antrum | 14. 鼓室盖壁 tegmental wall of tympanic cavity |
| 4. 外耳道 external acoustic meatus | 15. 外骨半规管 lateral semicircular canal |
| 5. 乙状窦 sigmoid sinus | 16. 前骨半规管 anterior semicircular canal |
| 6. 寰枕关节 atlantooccipital joint | 17. 茎乳孔 stylomastoid foramen |
| 7. 寰椎侧块 lateral mass of atlas | 18. 乳突小房 mastoid cells |
| 8. 寰枢外侧关节 lateral atlantoaxial joint | 19. 枕骨大孔 foramen magnum of occipital bone |
| 9. 枕髁 occipital condyle | 20. 前骨半规管 anterior semicircular canal |
| 10. 舌下神经管 hypoglossal canal | |
| 11. 颞叶 temporal lobe | |

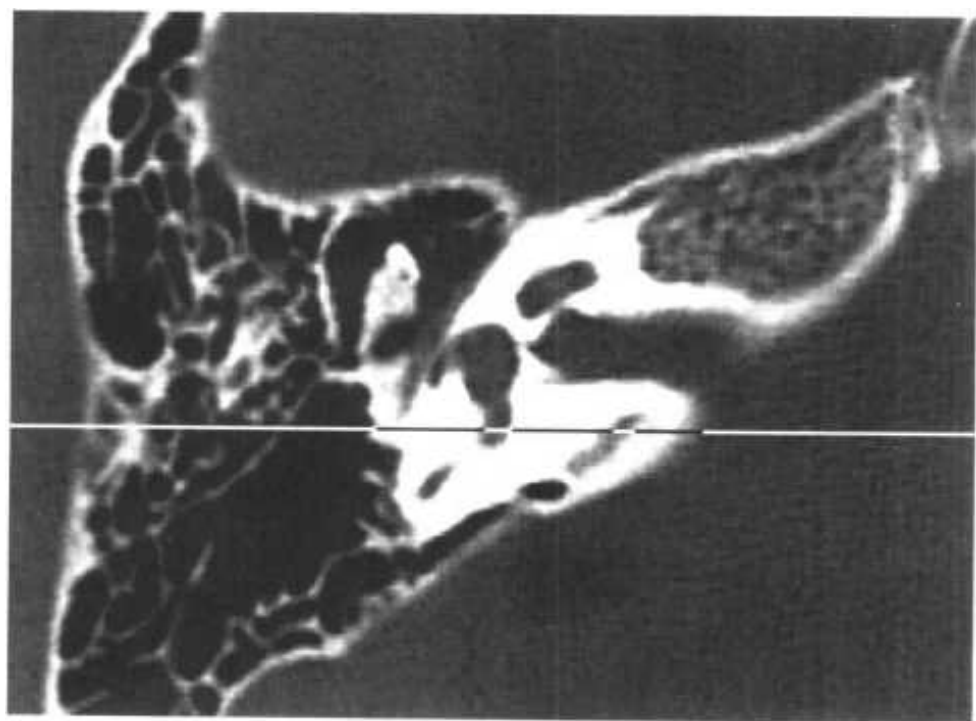
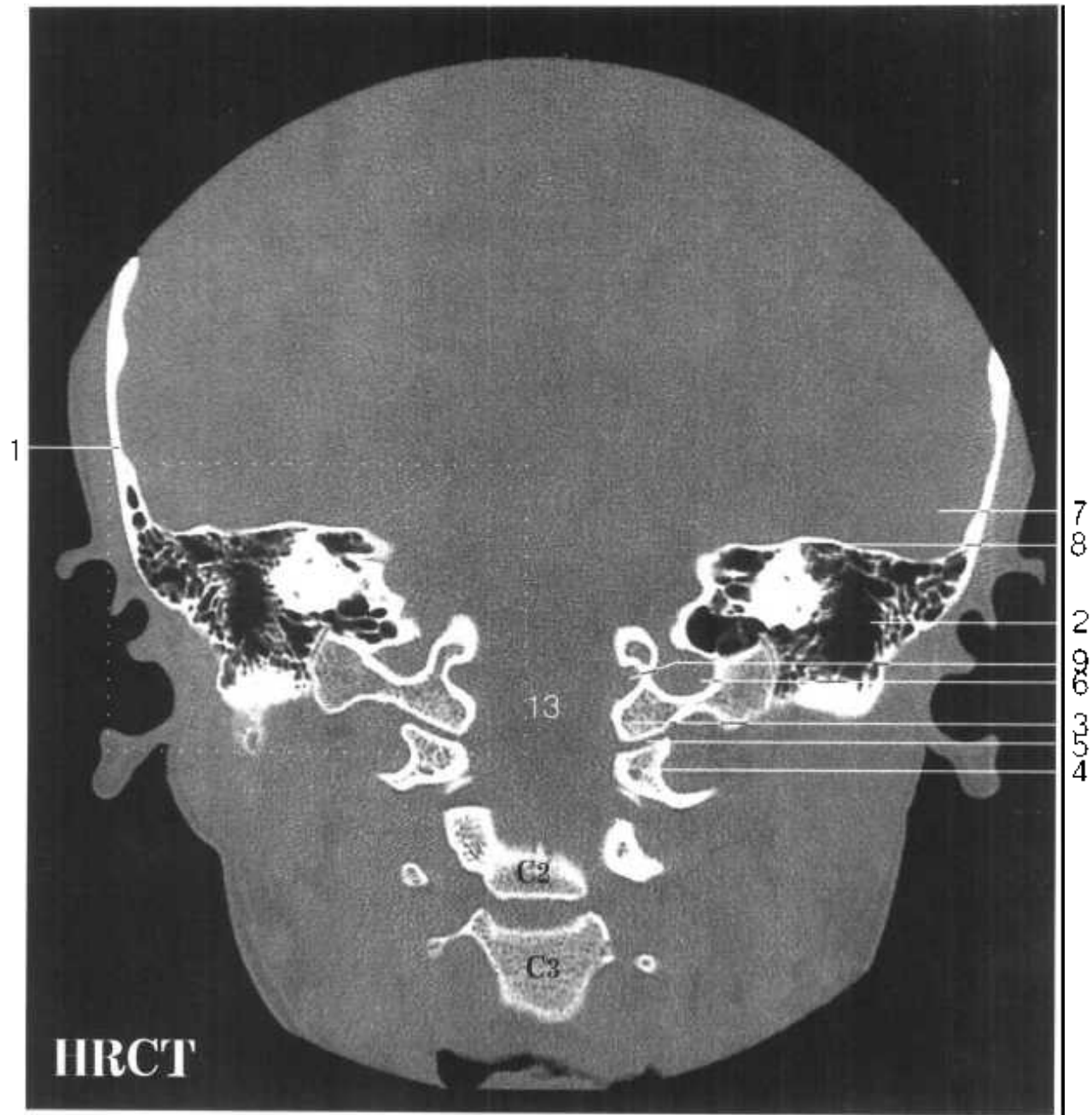


Fig. FE 15

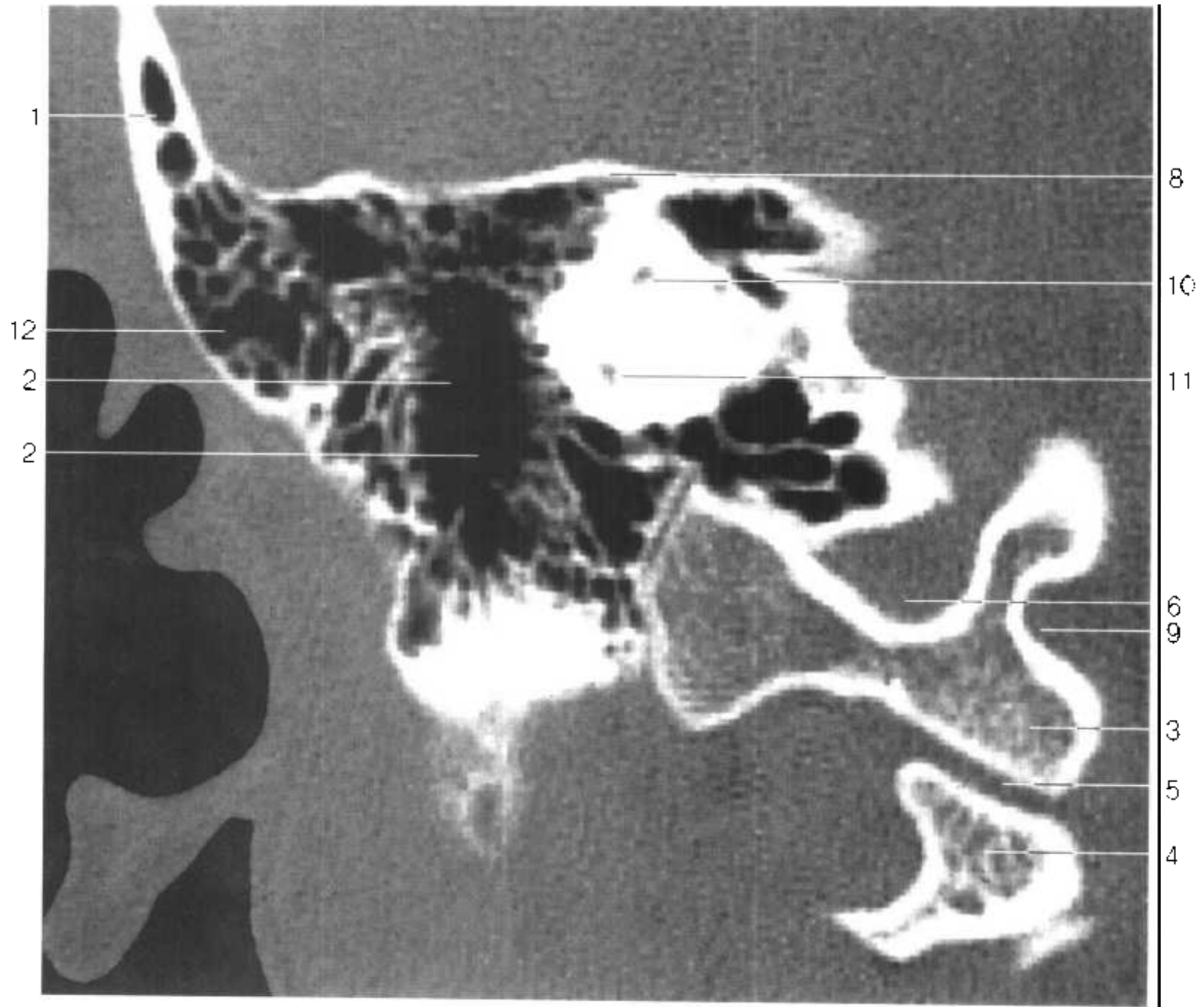


Fig.FE 15

- | | |
|---|---|
| <p>1. 颞骨鳞部 squamous part of temporal bone</p> <p>2. 乳突窦 mastoid antrum</p> <p>3. 枕髁 occipital condyle</p> <p>4. 寰椎侧块 lateral mass of atlas</p> <p>5. 寰枕关节 atlantooccipital joint</p> <p>6. 乙状窦 sigmoid sinus</p> <p>7. 颞叶 temporal lobe</p> | <p>8. 弓状隆起 arcuate eminence</p> <p>9. 舌下神经管 hypoglossal canal</p> <p>10. 前骨半规管 anterior semicircular canal</p> <p>11. 外骨半规管 lateral semicircular canal</p> <p>12. 乳突小房 mastoid cells</p> <p>13. 枕骨大孔 foramen magnum of occipital bone</p> |
|---|---|

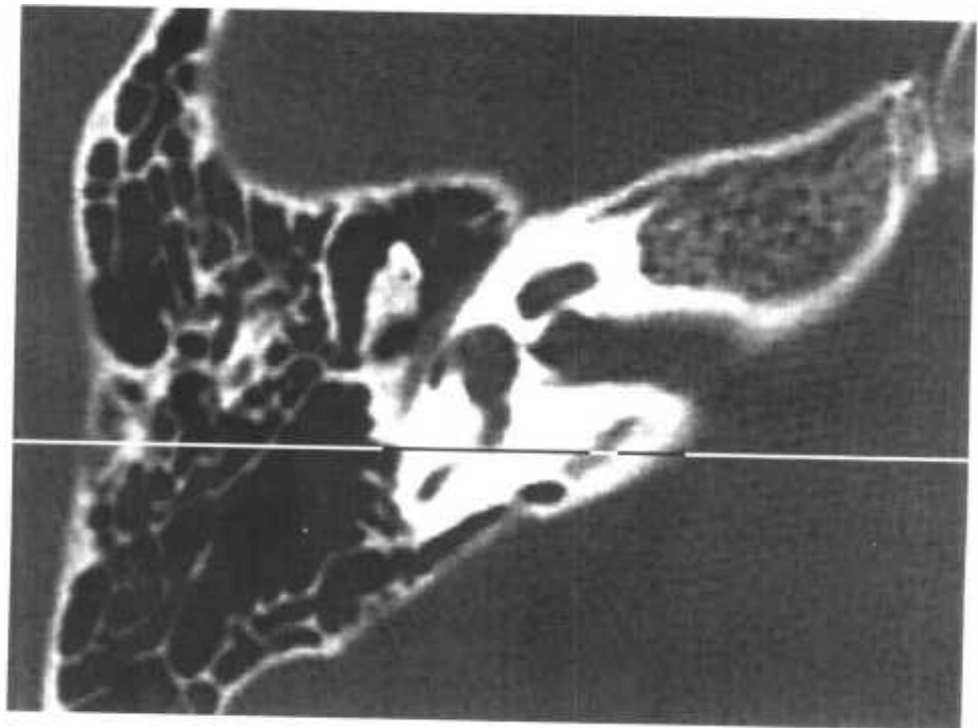
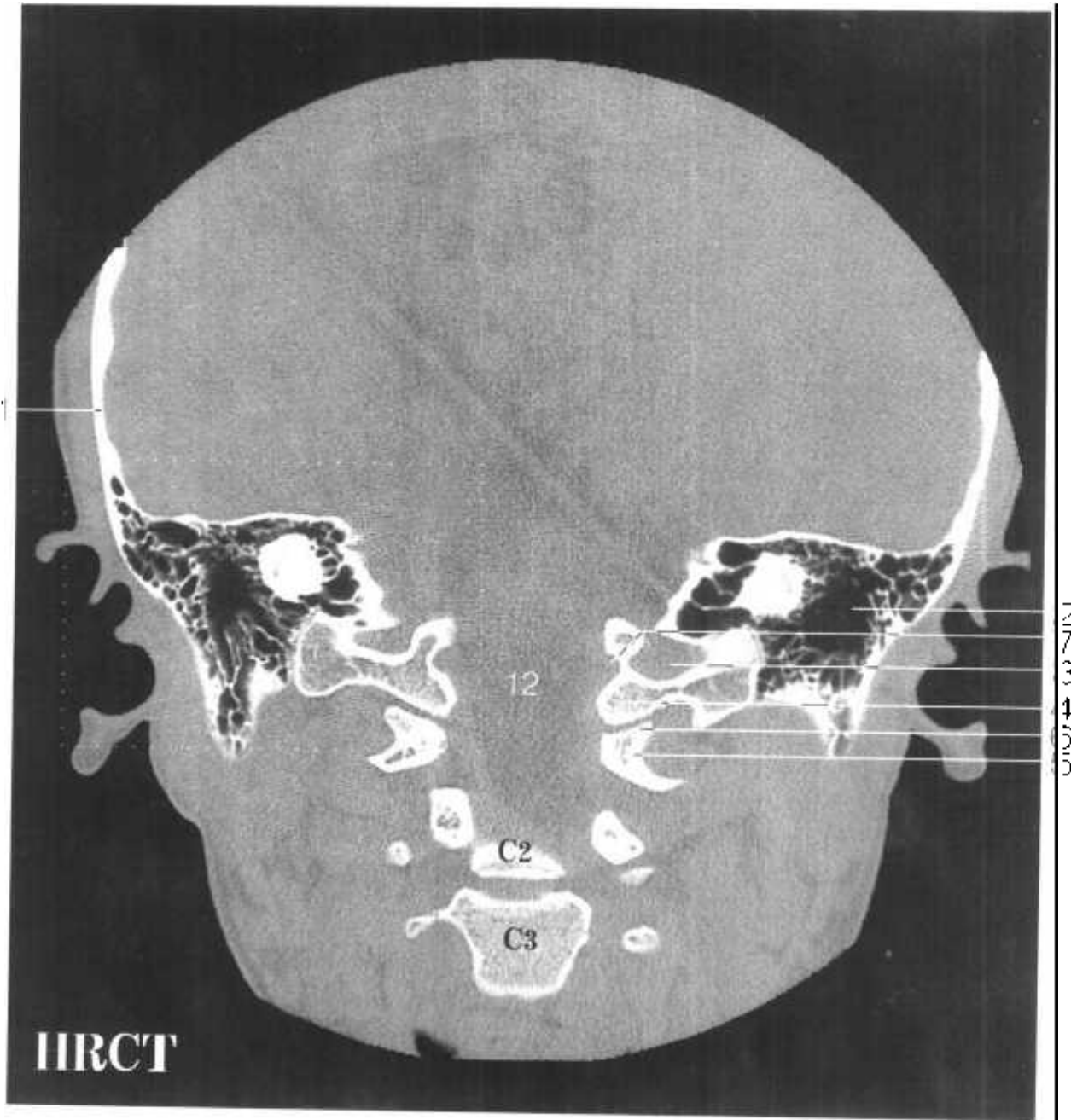


Fig. FE 16

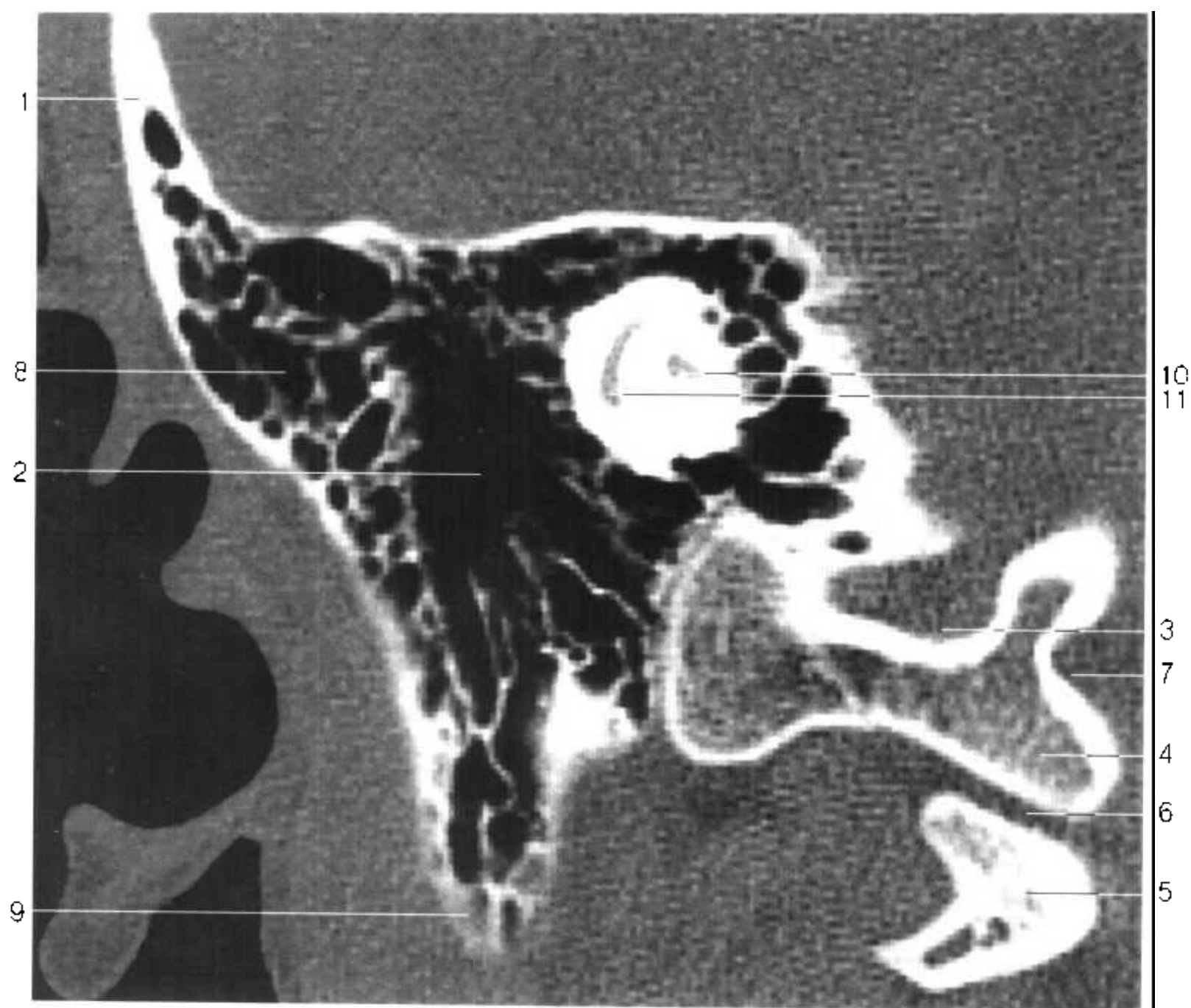

Fig.FE 16

- | | |
|--|--|
| <p>1. 颞骨鳞部 squamous part of temporal bone</p> <p>2. 乳突窦 mastoid antrum</p> <p>3. 乙状窦 sigmoid sinus</p> <p>4. 枕髁 occipital condyle</p> <p>5. 寰椎侧块 lateral mass of atlas</p> <p>6. 寰枕关节 atlantooccipital joint</p> | <p>7. 舌下神经管 hypoglossal canal</p> <p>8. 乳突小房 mastoid cells</p> <p>9. 乳突 mastoid process</p> <p>10. 外骨半规管 lateral semicircular canal</p> <p>11. 后骨半规管 posterior semicircular canal</p> <p>12. 枕骨大孔 foramen magnum of occipital bone</p> |
|--|--|

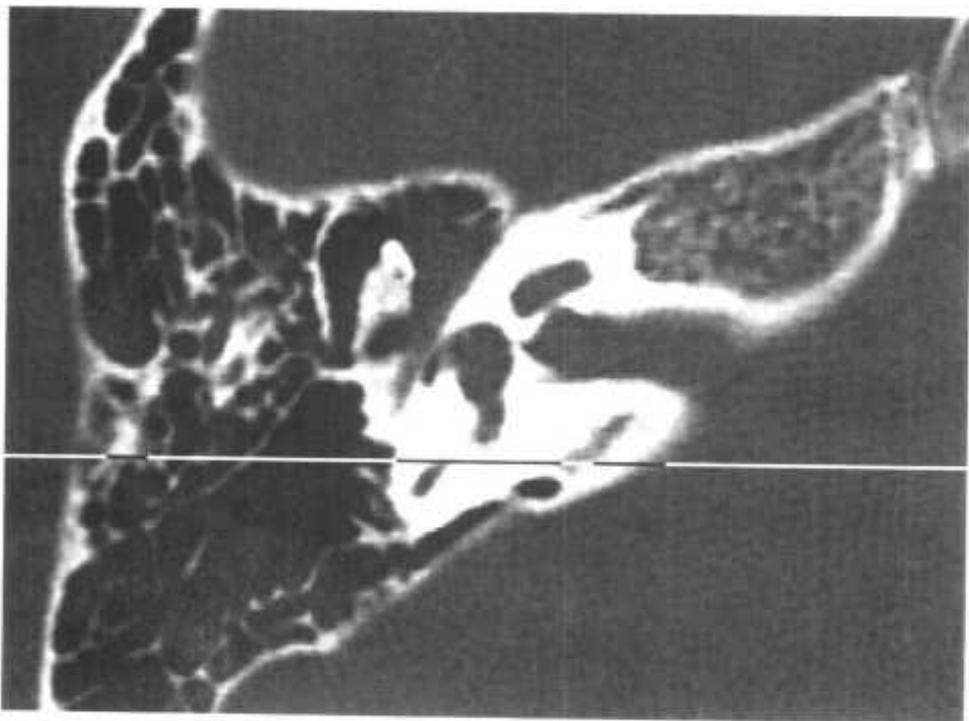
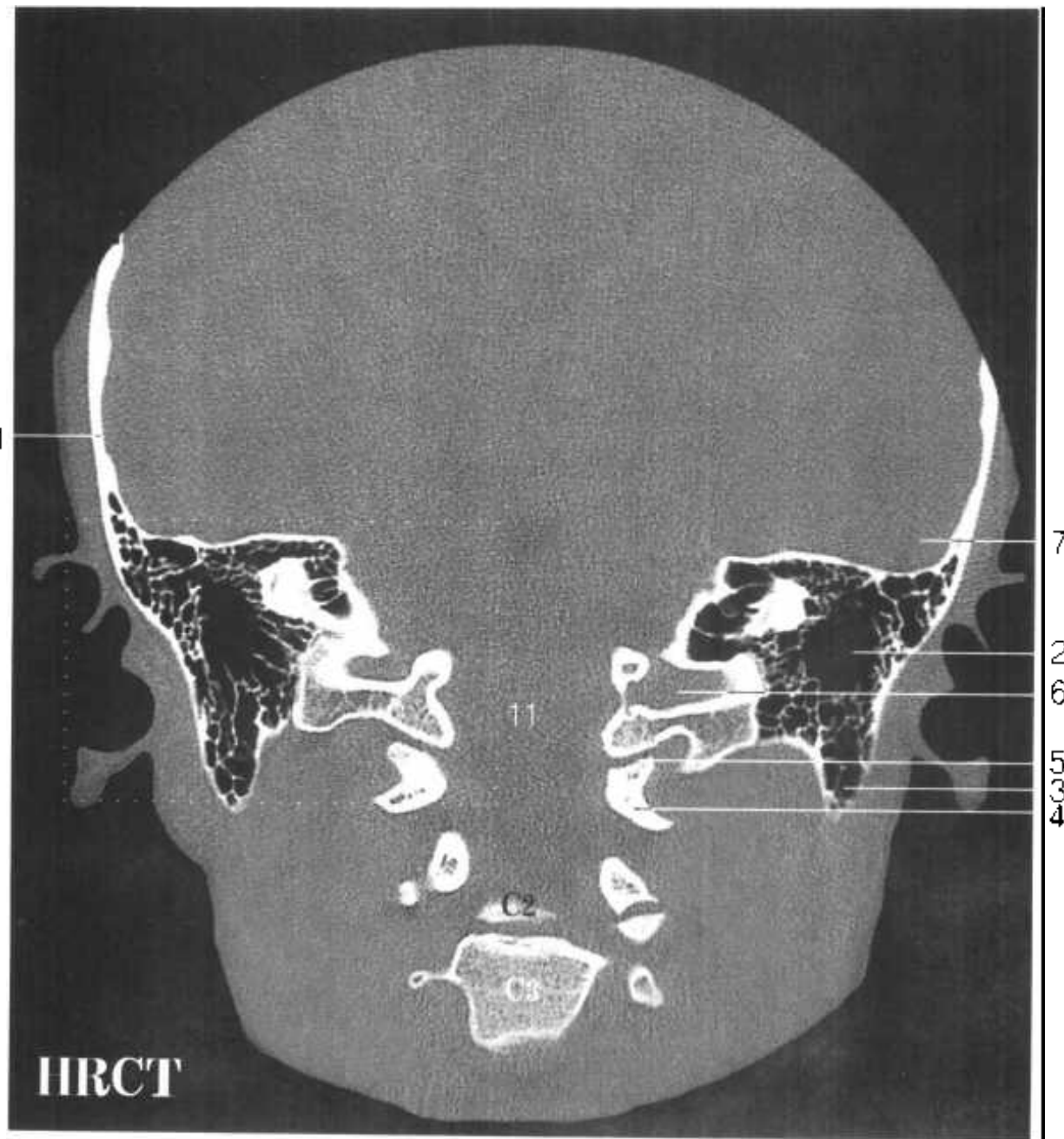


Fig. FE 17

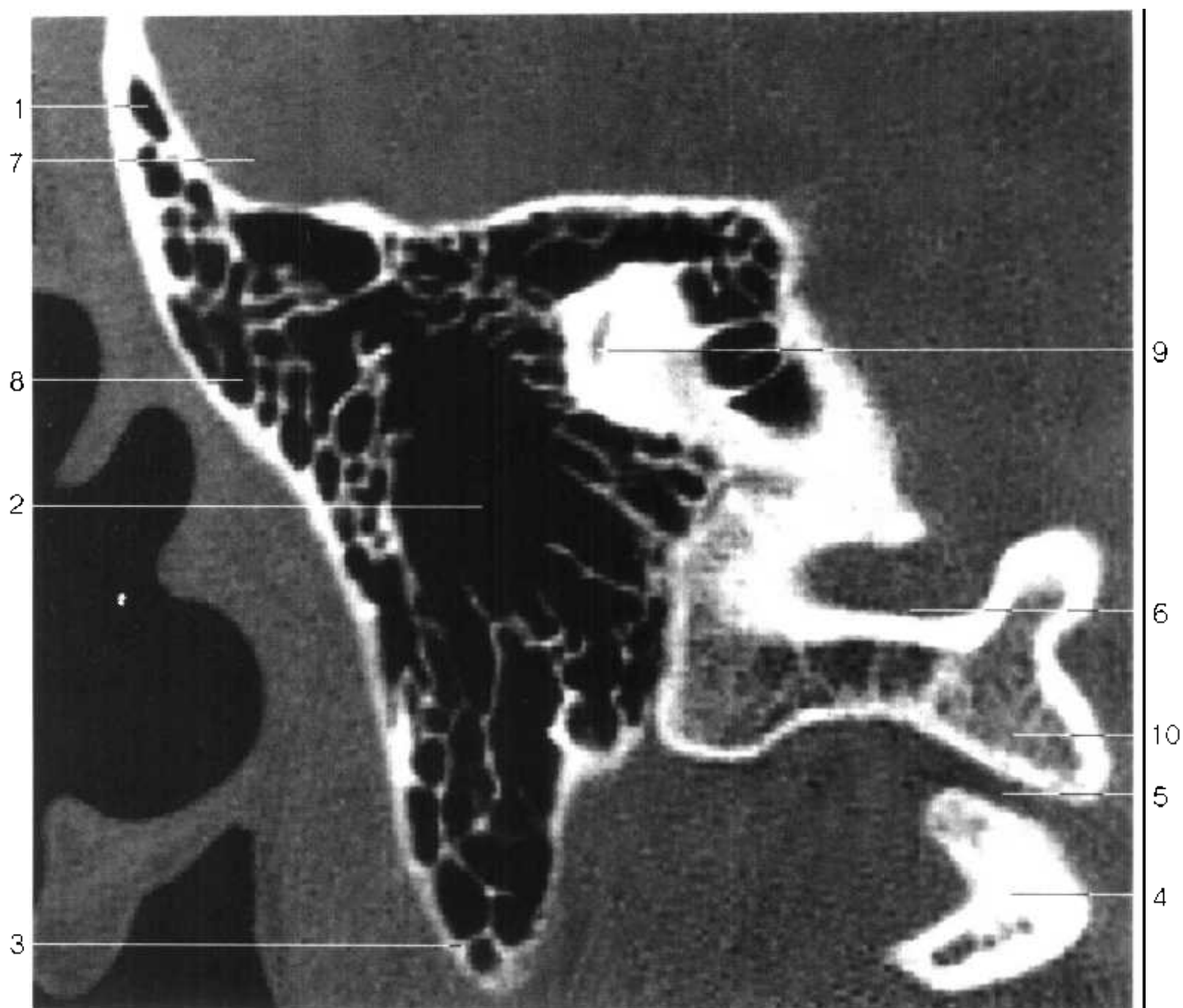

Fig.FE 17

- | | |
|--|---|
| 1. 颞骨鳞部 squamous part of temporal bone | 7. 颞叶 temporal lobe |
| 2. 乳突窦 mastoid antrum | 8. 乳突小房 mastoid cells |
| 3. 乳突 mastoid process | 9. 后骨半规管 posterior semicircular canal |
| 4. 寰椎侧块 lateral mass of atlas | 10. 枕髁 occipital condyle |
| 5. 寰枕关节 atlantooccipital joint | 11. 枕骨大孔 foramen magnum of occipital bone |
| 6. 乙状窦 sigmoid sinus | |

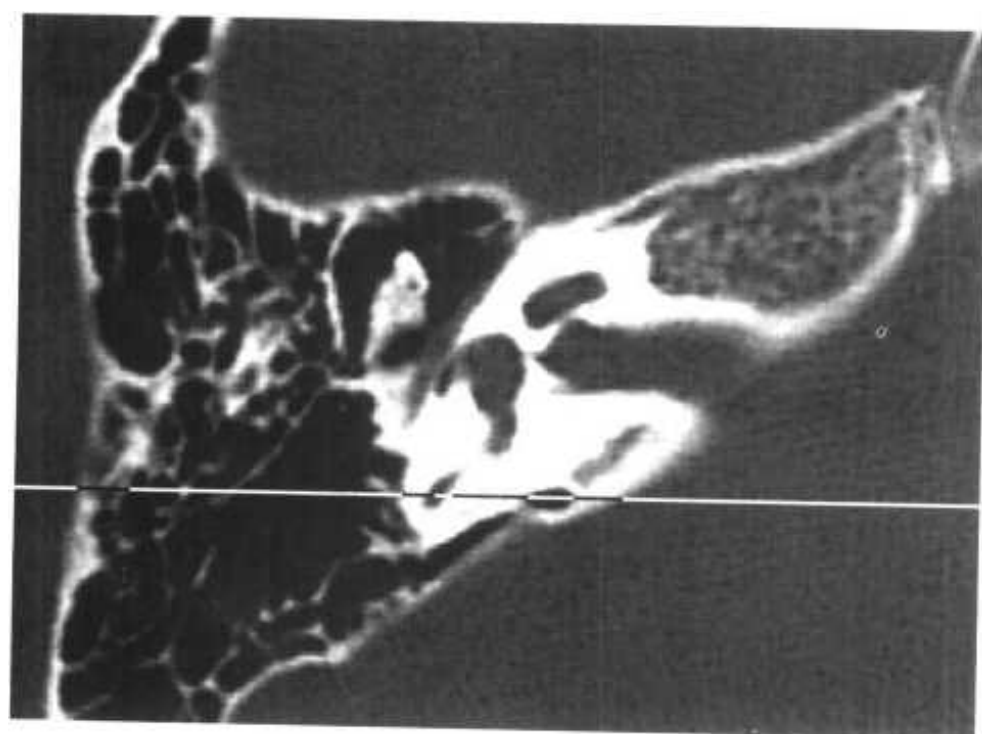
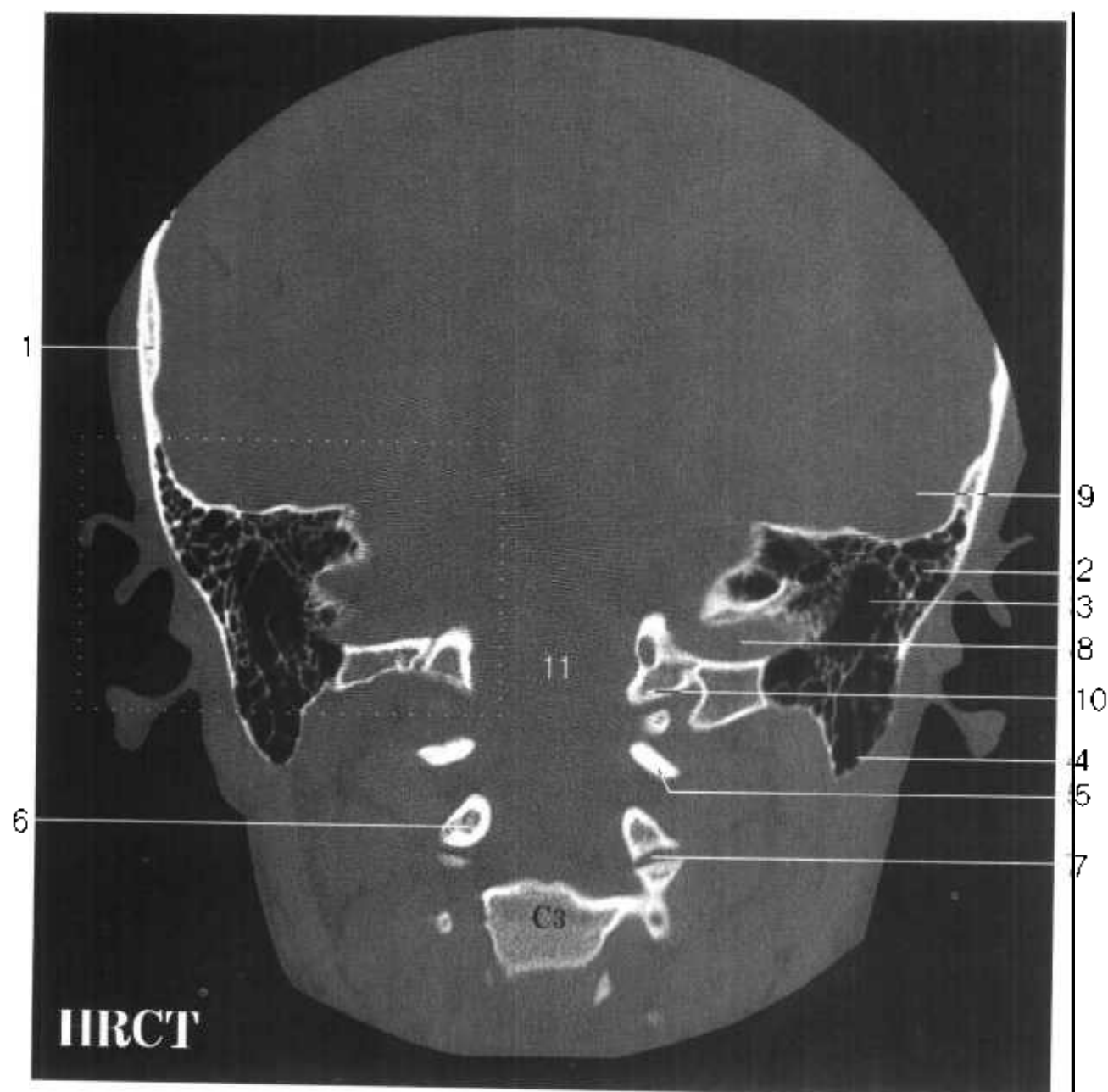


Fig. FE 18

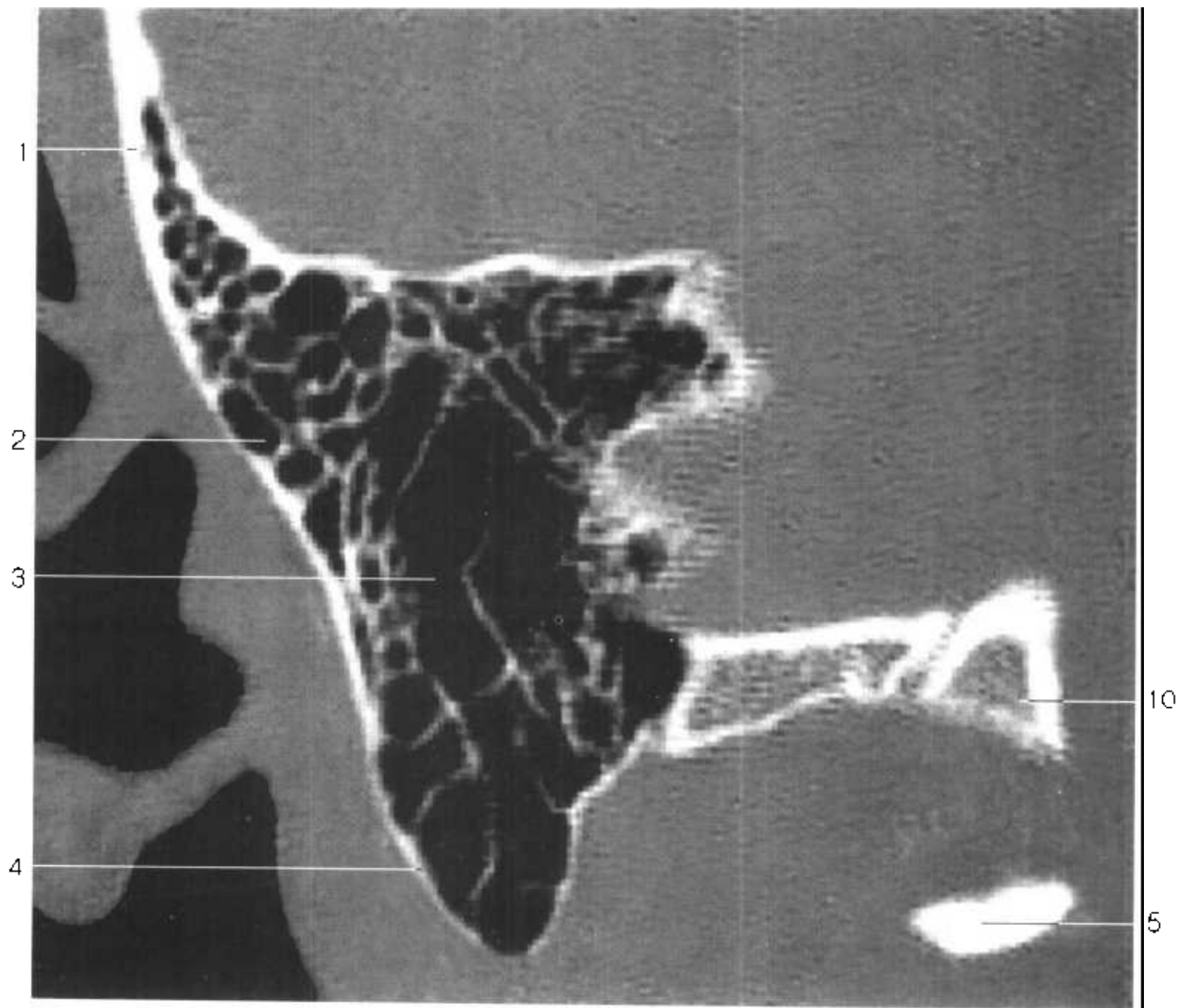
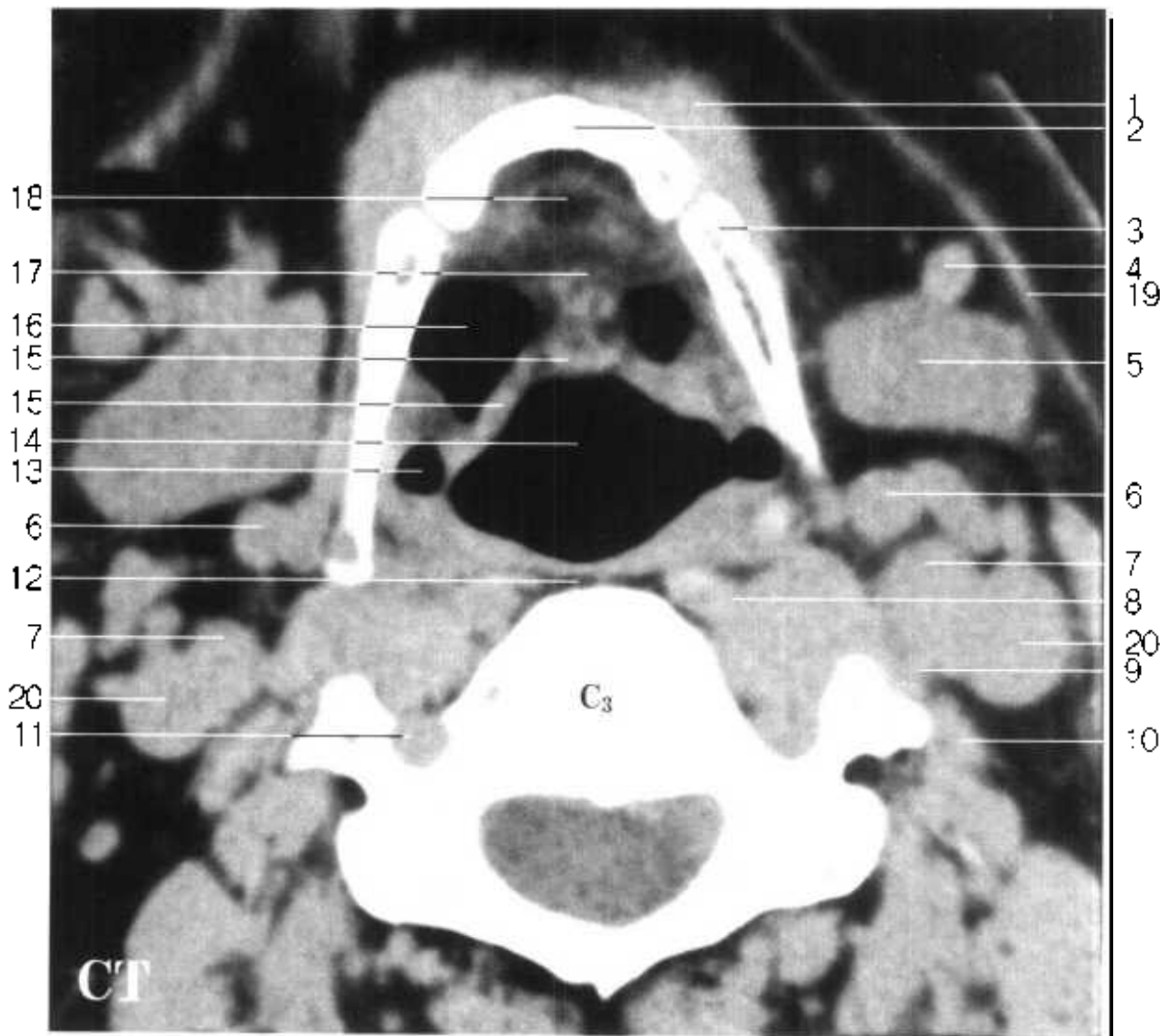


Fig.FE 18

- | | |
|---|--|
| <p>1. 颞骨鳞部 squamous part of temporal bone</p> <p>2. 乳突小房 mastoid cells</p> <p>3. 乳突窦 mastoid antrum</p> <p>4. 乳突 mastoid process</p> <p>5. 寰椎后弓 posterior arch of atlas</p> <p>6. 枢椎下关节突 inferior articular process of axis</p> | <p>7. 2,3颈椎关节突关节 zygapophysial joint (C₂ - C₃)</p> <p>8. 乙状窦 sigmoid sinus</p> <p>9. 颞叶 temporal lobe</p> <p>10. 枕髁 occipital condyle</p> <p>11. 枕骨大孔 foramen magnum of occipital bone</p> |
|---|--|



喉的水平断面图 HL

Fig.HL 1-3

- | | |
|---|---|
| <ul style="list-style-type: none"> 1. 舌骨下肌 infrahyoid muscles 2. 舌骨体 body of hyoid bone 3. 舌骨大角 greater horn of hyoid bone 4. 颈前静脉 anterior jugular v. 5. 下颌下腺 submandibular gland 6. 颈外动脉 external carotid a. 7. 颈内动脉 internal carotid a. 8. 颈长肌 longus colli 9. 前斜角肌 scalenus anterior 10. 中斜角肌 scalenus medius 11. 横突孔 transverse foramen 12. 咽后间隙 retropharyngeal space 13. 梨状隐窝 piriform recess | <ul style="list-style-type: none"> 14. 咽腔 cavity of pharynx 15. 会厌 epiglottis 16. 会厌谷 epiglottic vallecula 17. 舌会厌正中襞 median glossoepiglottic fold 18. 会厌前间隙(会厌软骨前脂体) preepiglottic space(preepiglottic adipose body) 19. 颈阔肌 platysma 20. 颈内静脉 internal jugular v. 21. 3、4 颈椎间盘 intervertebral disc (C₃ - C₄) 22. 椎间孔 intervertebral foramina 23. 3、4 颈椎关节突关节 zygapophysial joint(C₃ - C₄) 24. 迷走神经 vagus n. 25. 甲状舌骨膜 thyrohyoid membrane |
|---|---|

Fig.HL 1-3

喉的水平断面图 HL

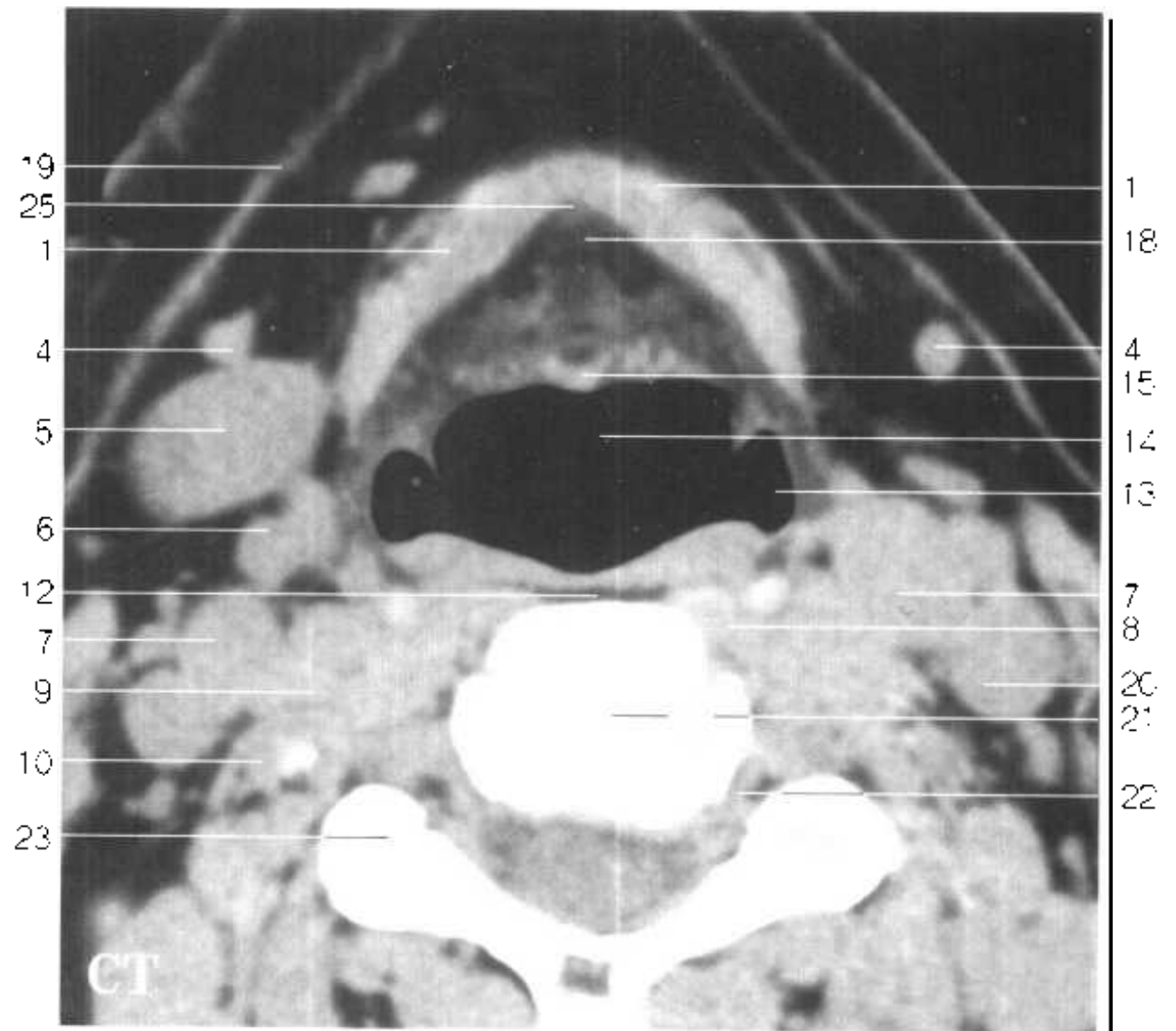
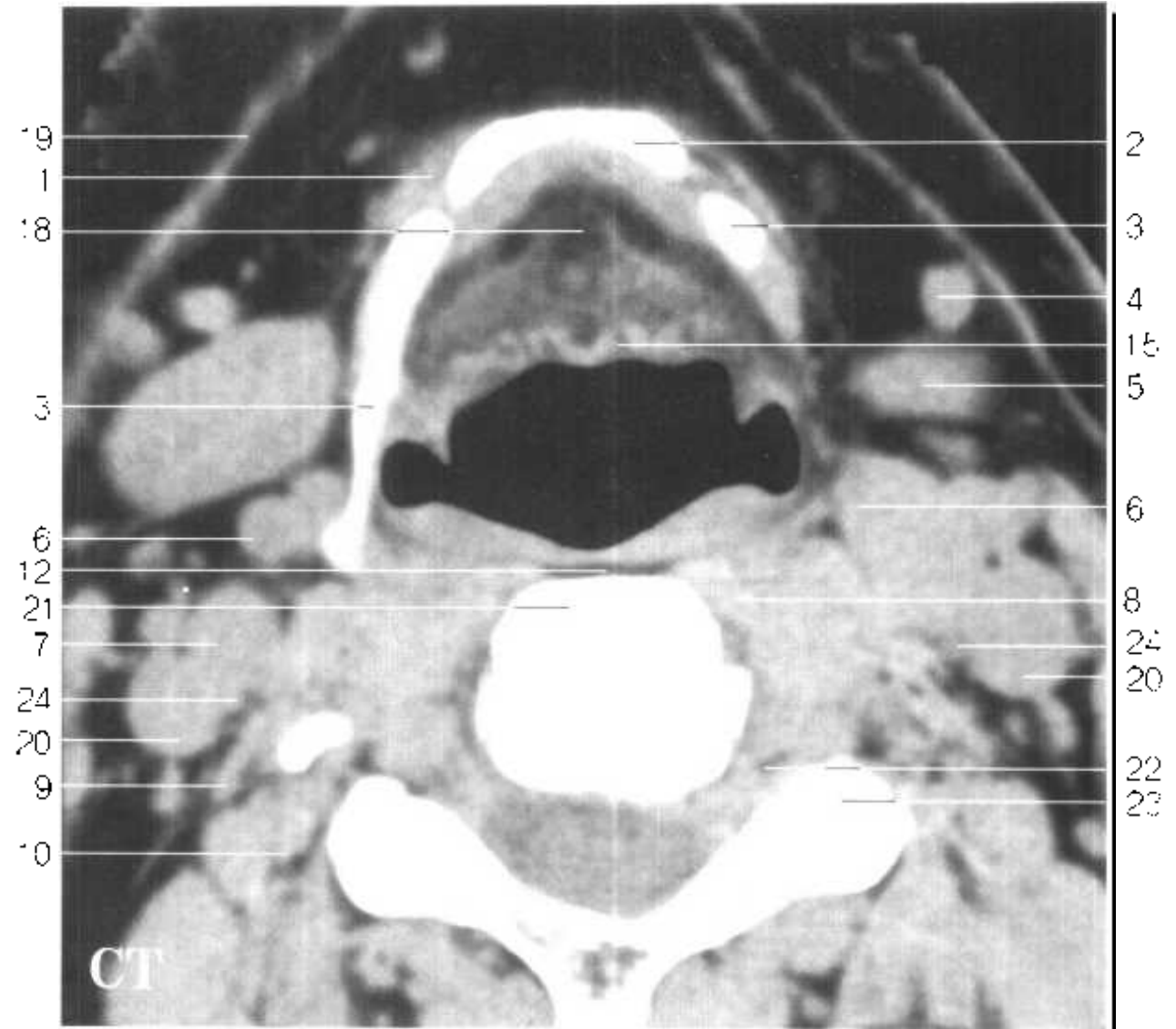
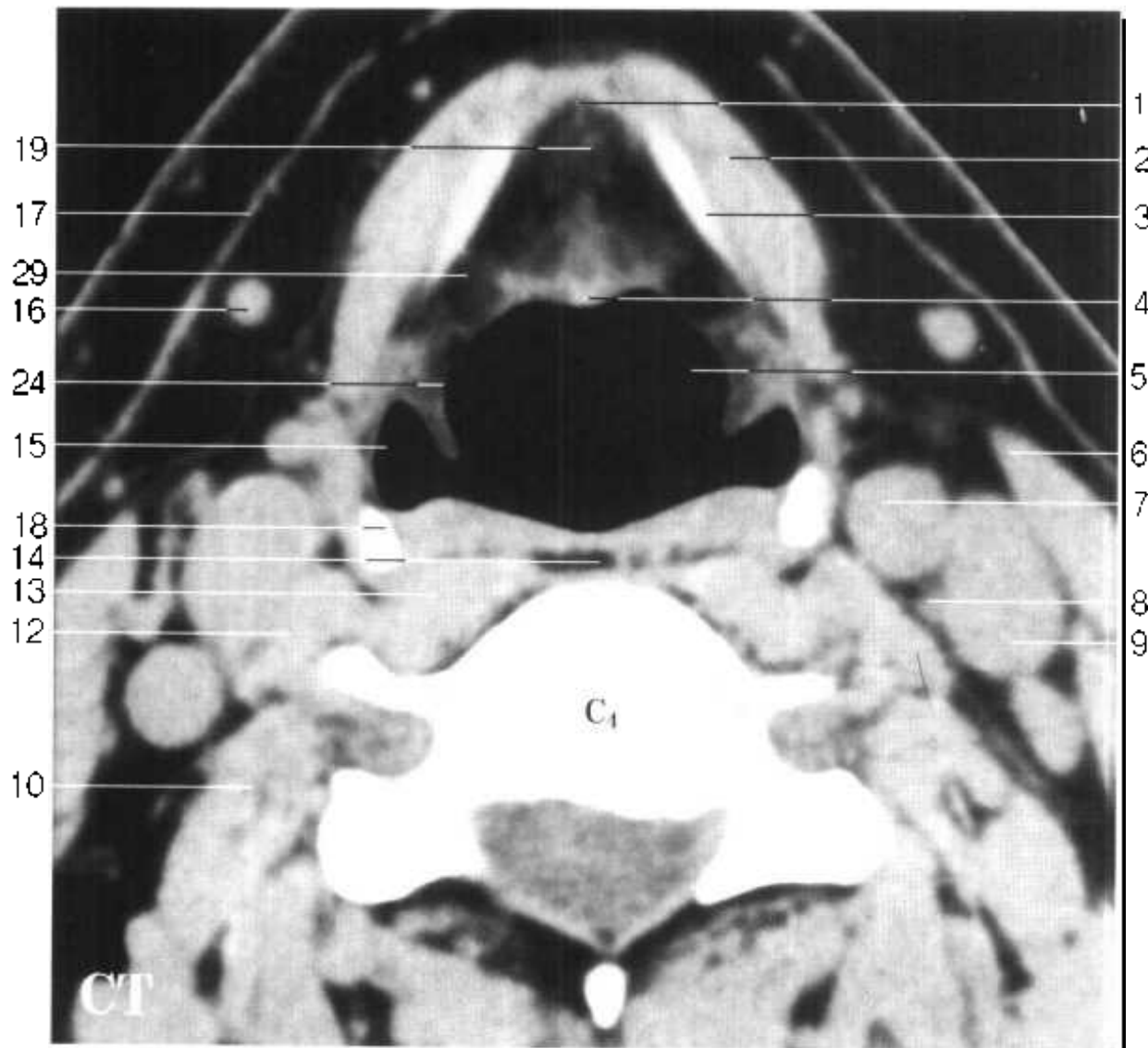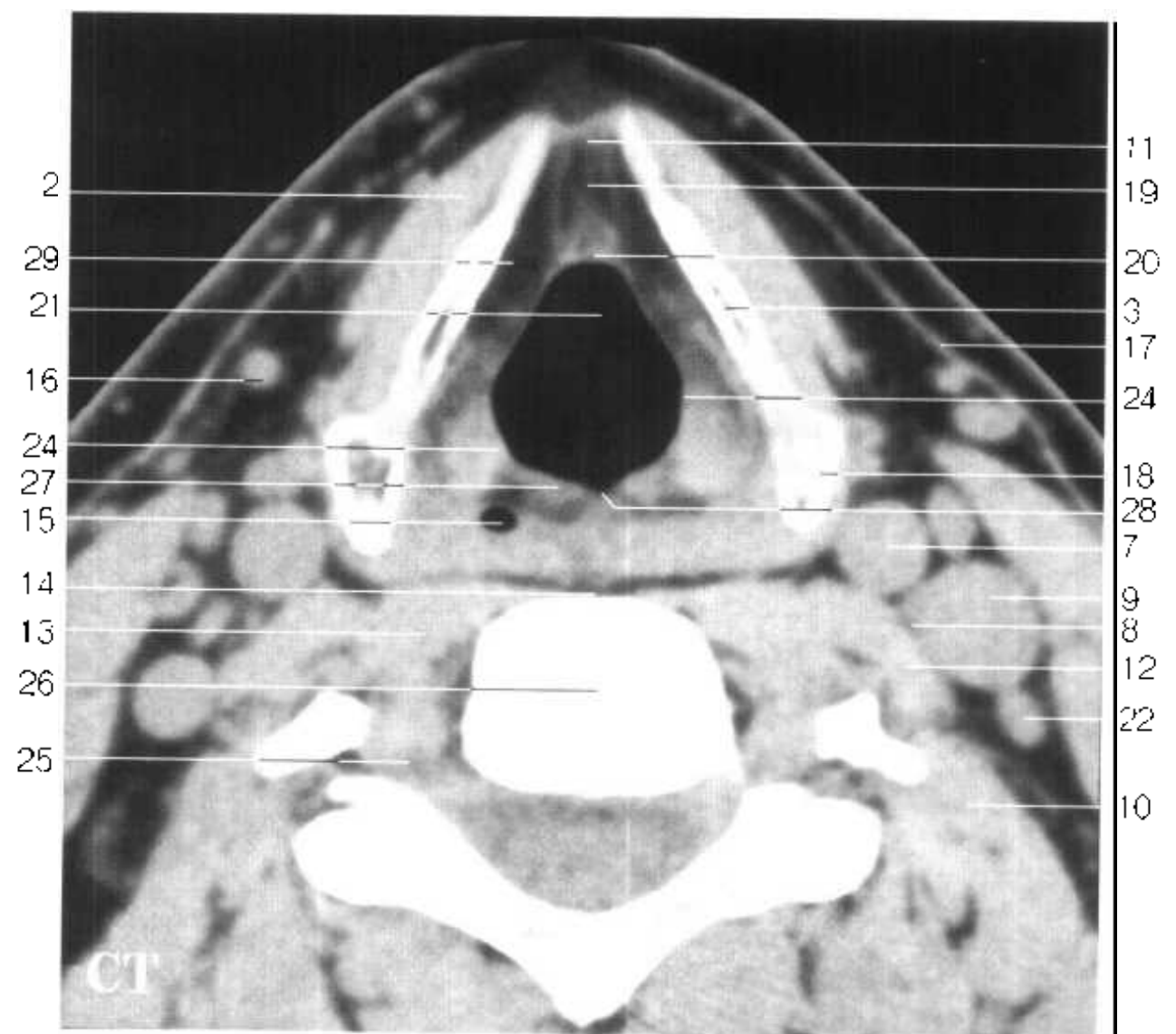
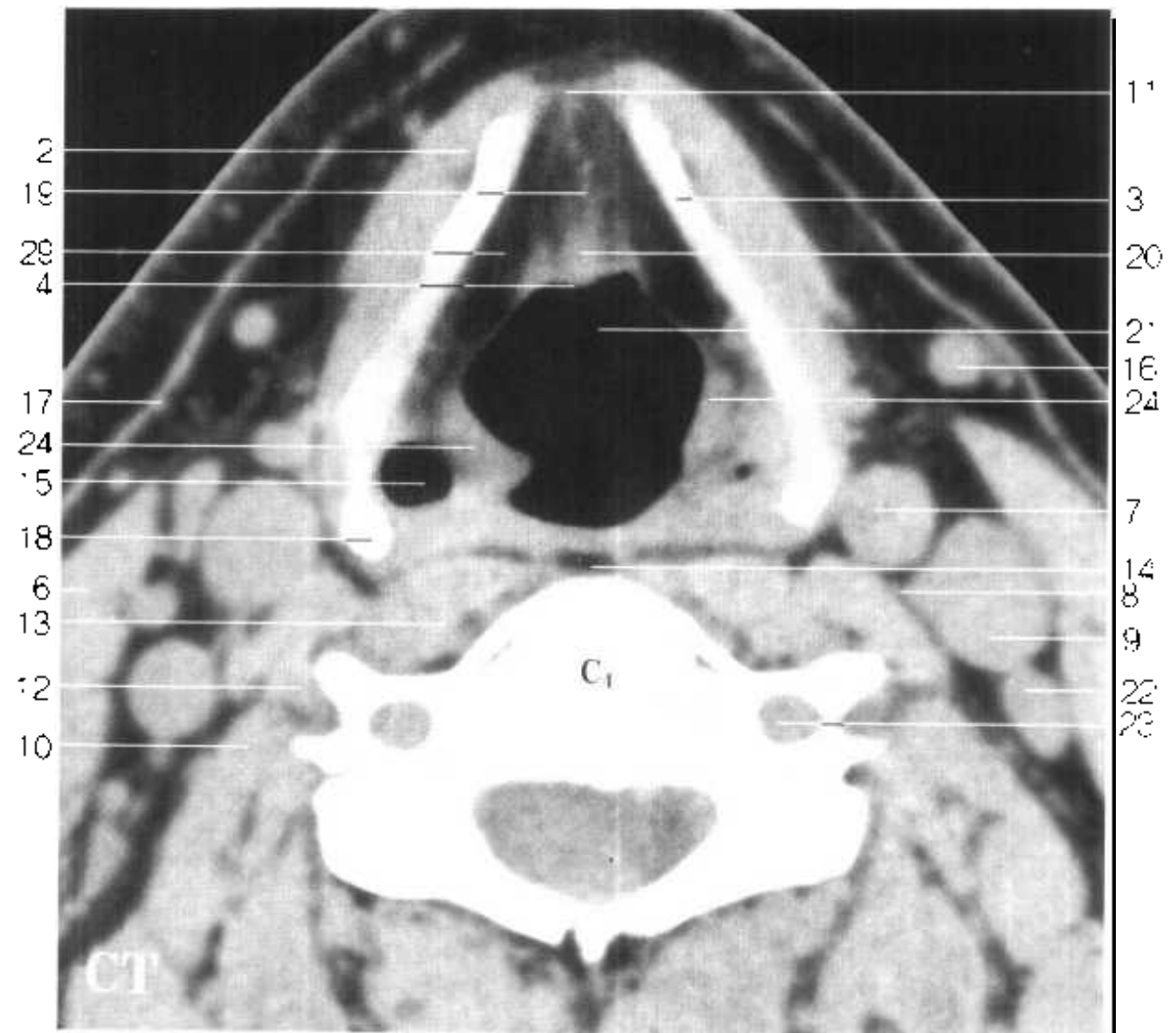




Fig.HL 4-6

- | | |
|---|---|
| 1. 甲状舌骨膜 thyrohyoid membrane | 17. 颈阔肌 platysma |
| 2. 舌骨下肌 infrahyoid muscles | 18. 甲状软骨上角 superior cornu of thyroid cartilage |
| 3. 甲状软骨左板 left lamina of thyroid cartilage | 19. 会厌前间隙(会厌软骨前脂体) preepiglottic space (preepiglottic adipose body) |
| 4. 会厌 epiglottis | 20. 甲状会厌韧带 thyroepiglottic ligament |
| 5. 咽腔 cavity of pharynx | 21. 喉口 aperture of larynx |
| 6. 胸锁乳突肌 sternocleidomastoid | 22. 颈外侧深淋巴结 deep lateral cervical lymph nodes |
| 7. 颈总动脉 common carotid a. | 23. 第4颈椎横突孔 transverse foramen(C ₄) |
| 8. 迷走神经 vagus n. | 24. 杓状会厌襞 aryepiglottic fold |
| 9. 颈内静脉 internal jugular v. | 25. 椎间孔 intervertebral foramina |
| 10. 中斜角肌 scalenus medius | 26. 4、5颈椎间盘 intervertebral disc(C ₄ ~C ₅) |
| 11. 甲状软骨上切迹 superior thyroid notch of thyroid cartilage | 27. 小角结节 corniculate tubercle |
| 12. 前斜角肌 scalenus anterior | 28. 杓间切迹 interarytenoid notch |
| 13. 颈长肌 longus colli | 29. 会厌周围间隙 periepiglottic space |
| 14. 咽后间隙 retropharyngeal space | |
| 15. 梨状隐窝 piriform recess | |
| 16. 颈前静脉 anterior jugular v. | |

Fig.HL 4-6



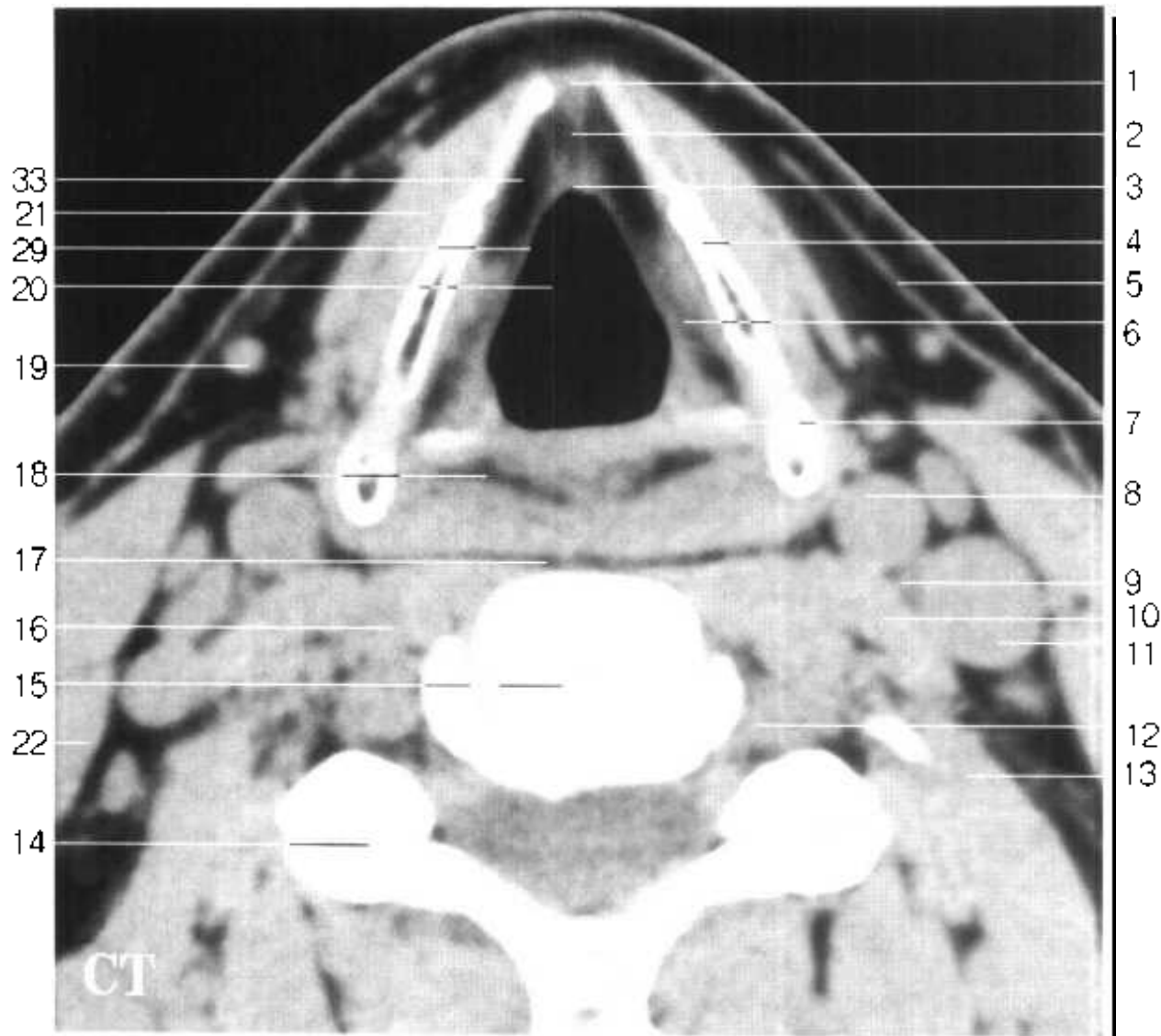
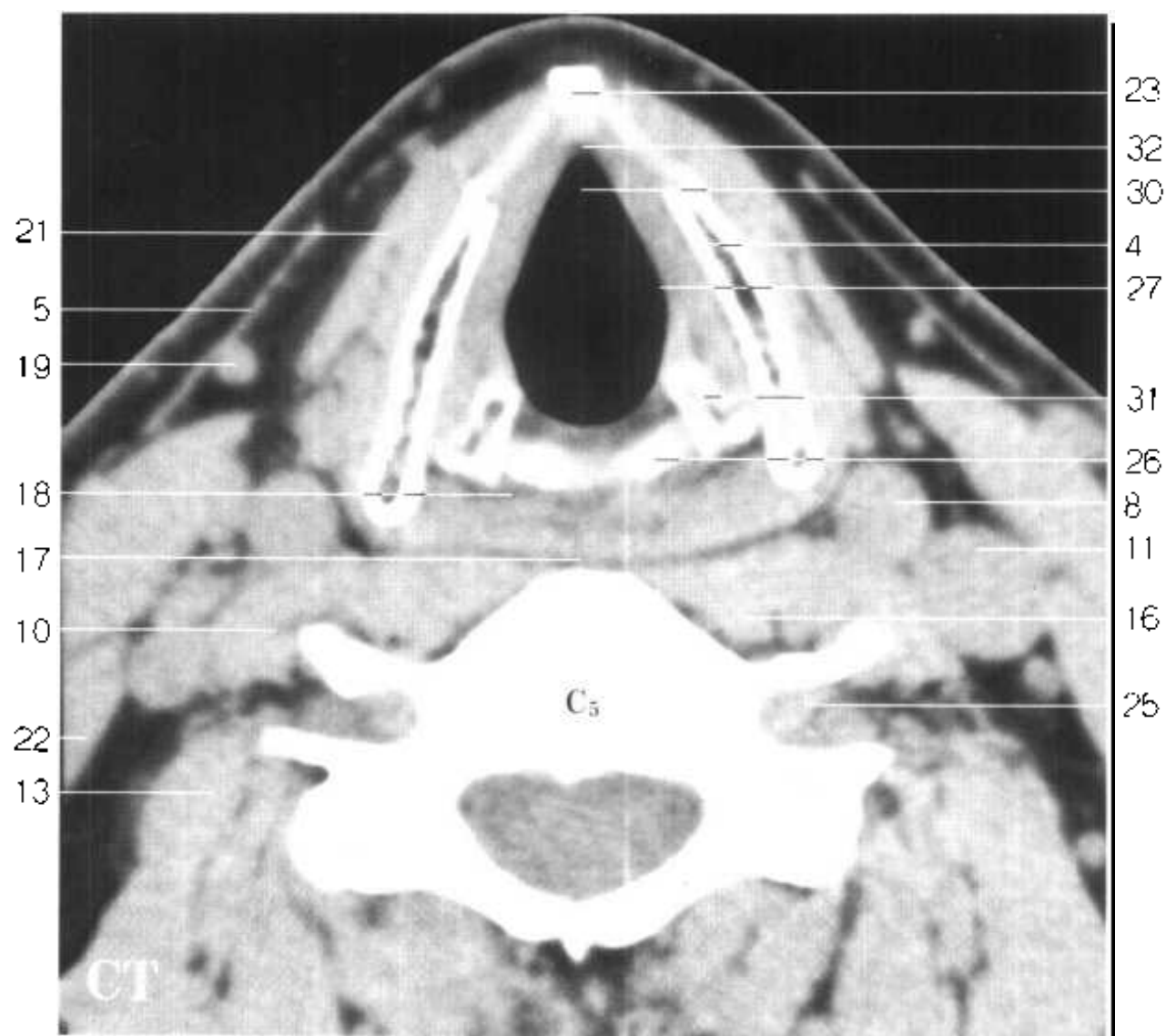
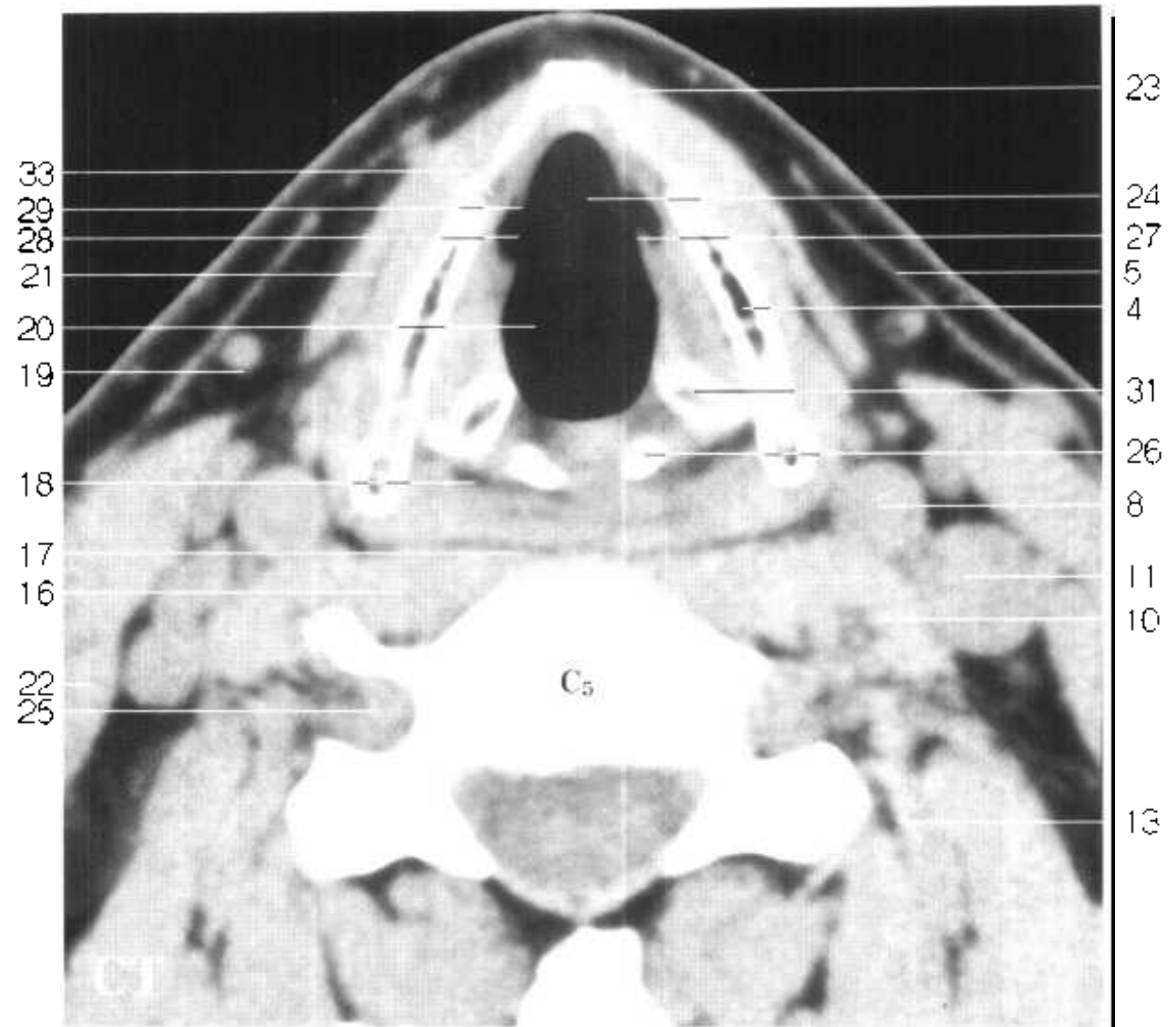


Fig.HL 7-9

- | | |
|--|---|
| 1. 甲状软骨上切迹 superior thyroid notch of thyroid cartilage | 15. 4、5 颈椎间盘 intervertebral disc (C ₄ ~ C ₅) |
| 2. 会厌前间隙(会厌软骨前脂体) preepiglottic space (preepiglottic adipose body) | 16. 颈长肌 longus colli |
| 3. 甲状会厌韧带 thyroepiglottic ligament | 17. 咽后间隙 retropharyngeal space |
| 4. 甲状软骨左板 left lamina of thyroid cartilage | 18. 梨状隐窝 piriform recess |
| 5. 颈阔肌 platysma | 19. 颈前静脉 anterior jugular v. |
| 6. 杓状会厌襞 aryepiglottic fold | 20. 喉口 aperture of larynx |
| 7. 杓状软骨尖 apex of arytenoid cartilage | 21. 舌骨下肌 infrahyoid muscles |
| 8. 颈总动脉 common carotid a. | 22. 胸锁乳突肌 sternocleidomastoid |
| 9. 迷走神经 vagus n. | 23. 甲状软骨 thyroid cartilage |
| 10. 前斜角肌 scalenus anterior | 24. 喉前庭 laryngeal vestibule |
| 11. 颈内静脉 internal jugular v. | 25. 横突孔 transverse foramen |
| 12. 椎间孔 intervertebral foramina | 26. 环状软骨板 lamina of cricoid cartilage |
| 13. 中斜角肌 scalenus medius | 27. 声襞 vocal fold |
| 14. 4、5 颈椎关节突关节 zygapophysial joint (C ₄ ~ C ₅) | 28. 喉室 ventricle of larynx |
| | 29. 前庭襞 vestibular fold |
| | 30. 声门裂 fissure of glottis |
| | 31. 杓状软骨 arytenoid cartilage |
| | 32. 前连合 anterior commissure |
| | 33. 声门旁间隙 paraglottic space |

Fig.HL 7-9



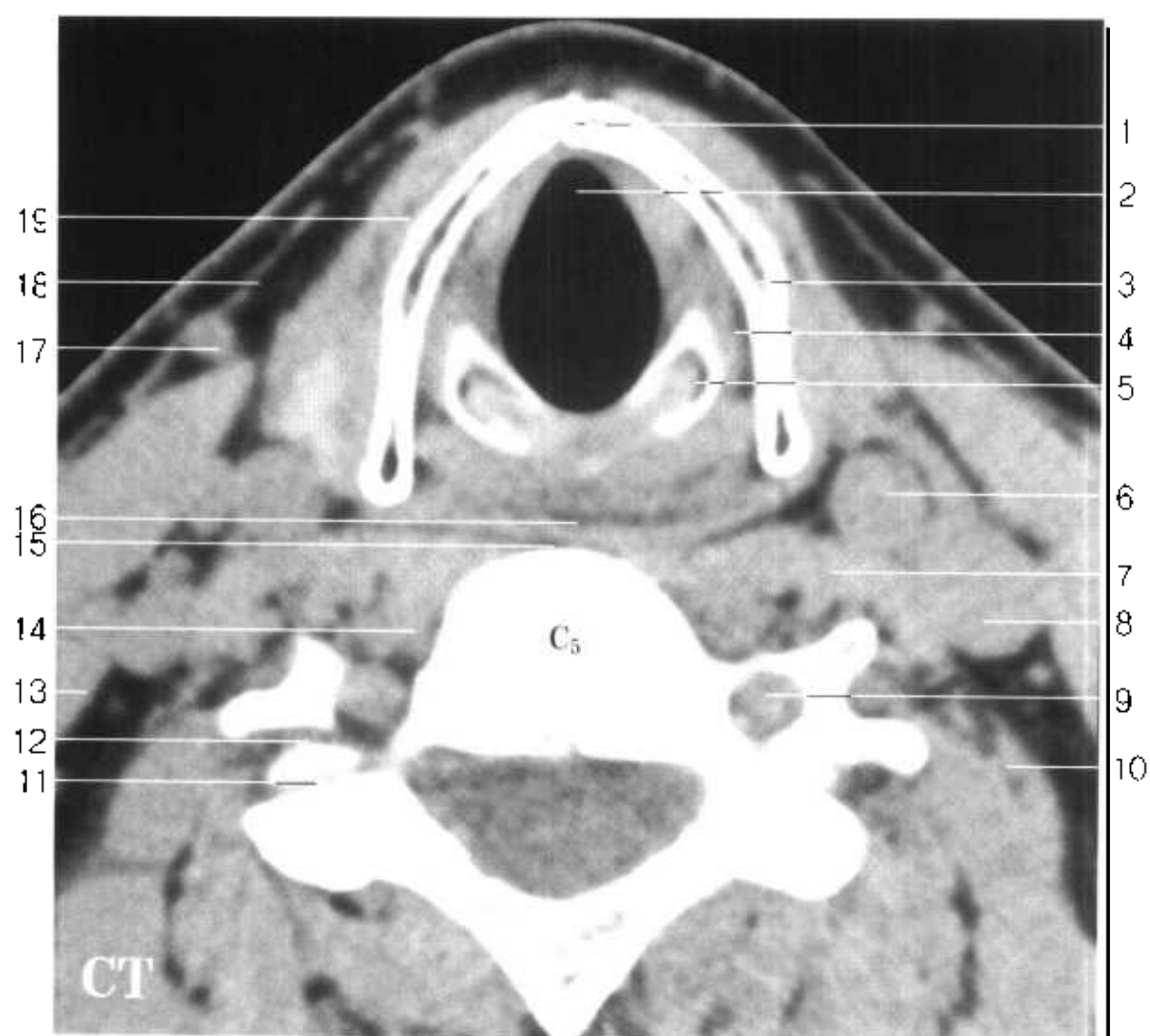
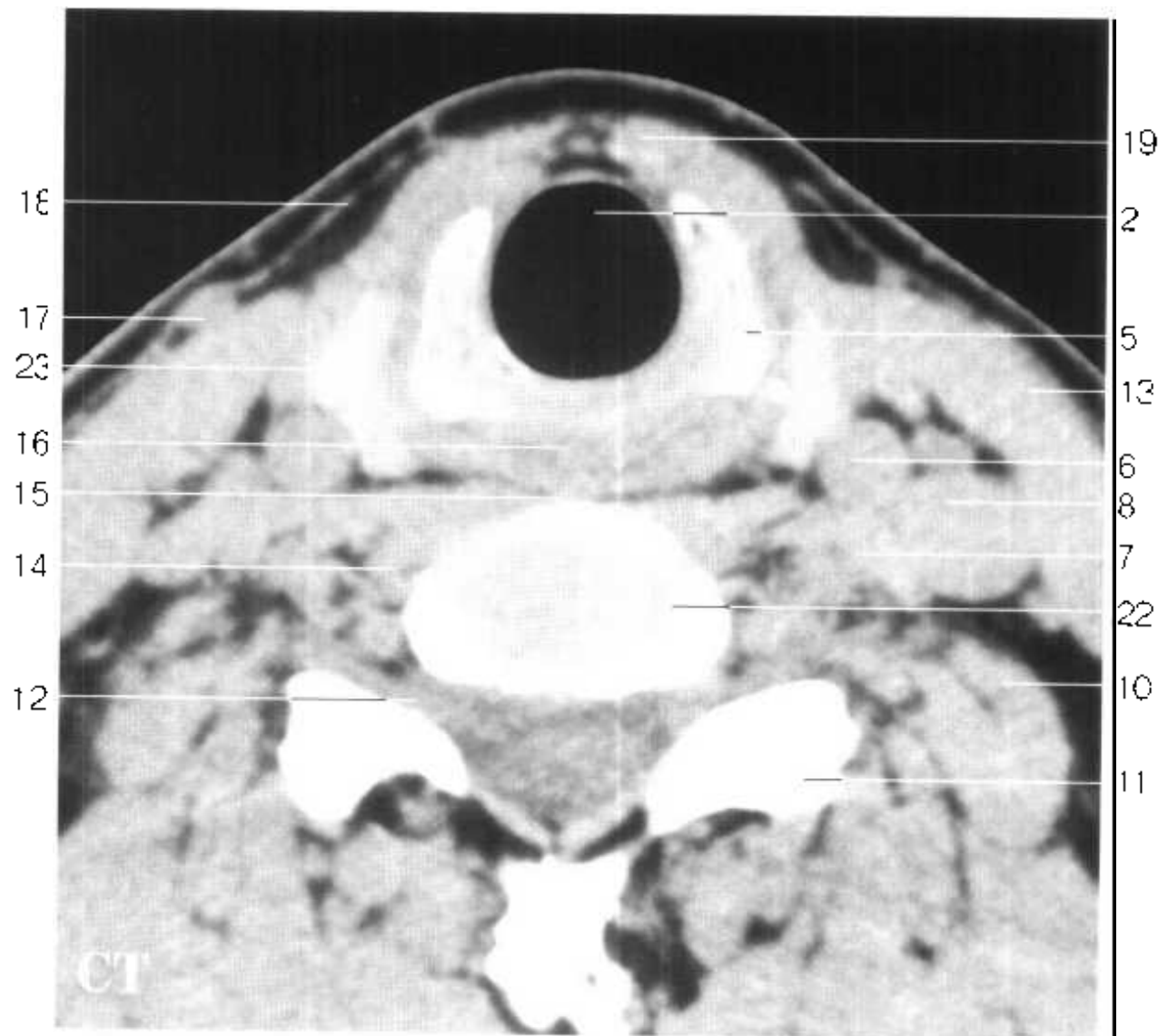
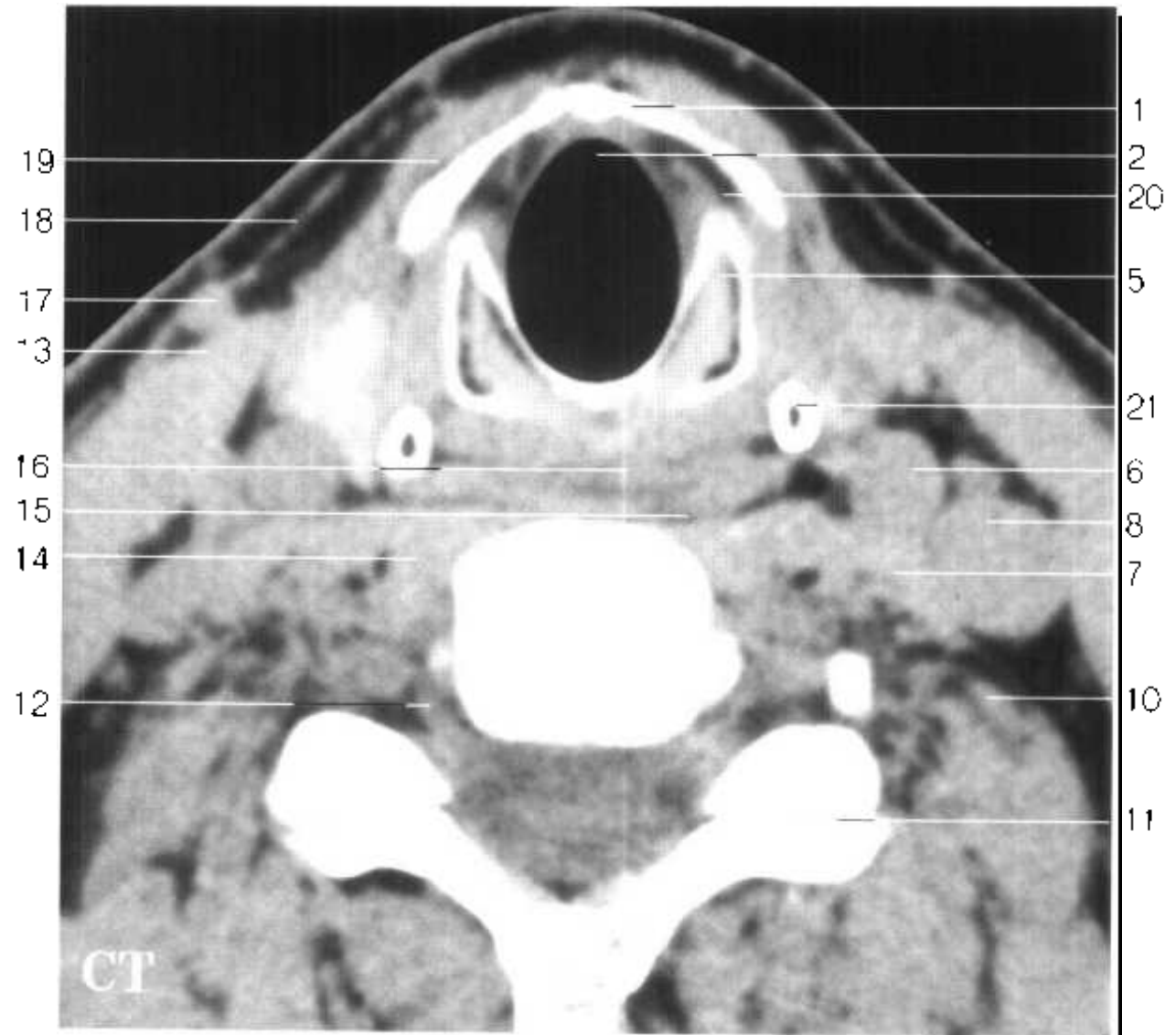


Fig.HL 10-12

- | | |
|--|---|
| 1. 甲状软骨 thyroid cartilage | 13. 胸锁乳突肌 sternocleidomastoid |
| 2. 声门下腔 infraglottic cavity | 14. 颈长肌 longus colli |
| 3. 甲状软骨左板 left lamina of thyroid cartilage | 15. 咽后间隙 retropharyngeal space |
| 4. 环甲间隙 cricothyroid space | 16. 咽腔 cavity of pharynx |
| 5. 环状软骨板 lamina of cricoid cartilage | 17. 颈前静脉 anterior jugular v. |
| 6. 颈总动脉 common carotid a. | 18. 颈阔肌 platysma |
| 7. 前斜角肌 scalenus anterior | 19. 舌骨下肌 infrahyoid muscles |
| 8. 颈内静脉 internal jugular v. | 20. 环甲间隙 cricothyroid space |
| 9. 横突孔 transverse foramen | 21. 甲状软骨下角 inferior cornu of thyroid cartilage |
| 10. 中斜角肌 scalenus medius | 22. 5、6 颈椎间盘 intervertebral disc (C ₅ - C ₆) |
| 11. 5、6 颈椎关节突关节 zygapophysial joint (C ₅ - C ₆) | 23. 甲状腺 thyroid gland |
| 12. 椎间孔 intervertebral foramen | |

Fig. HL 10-12



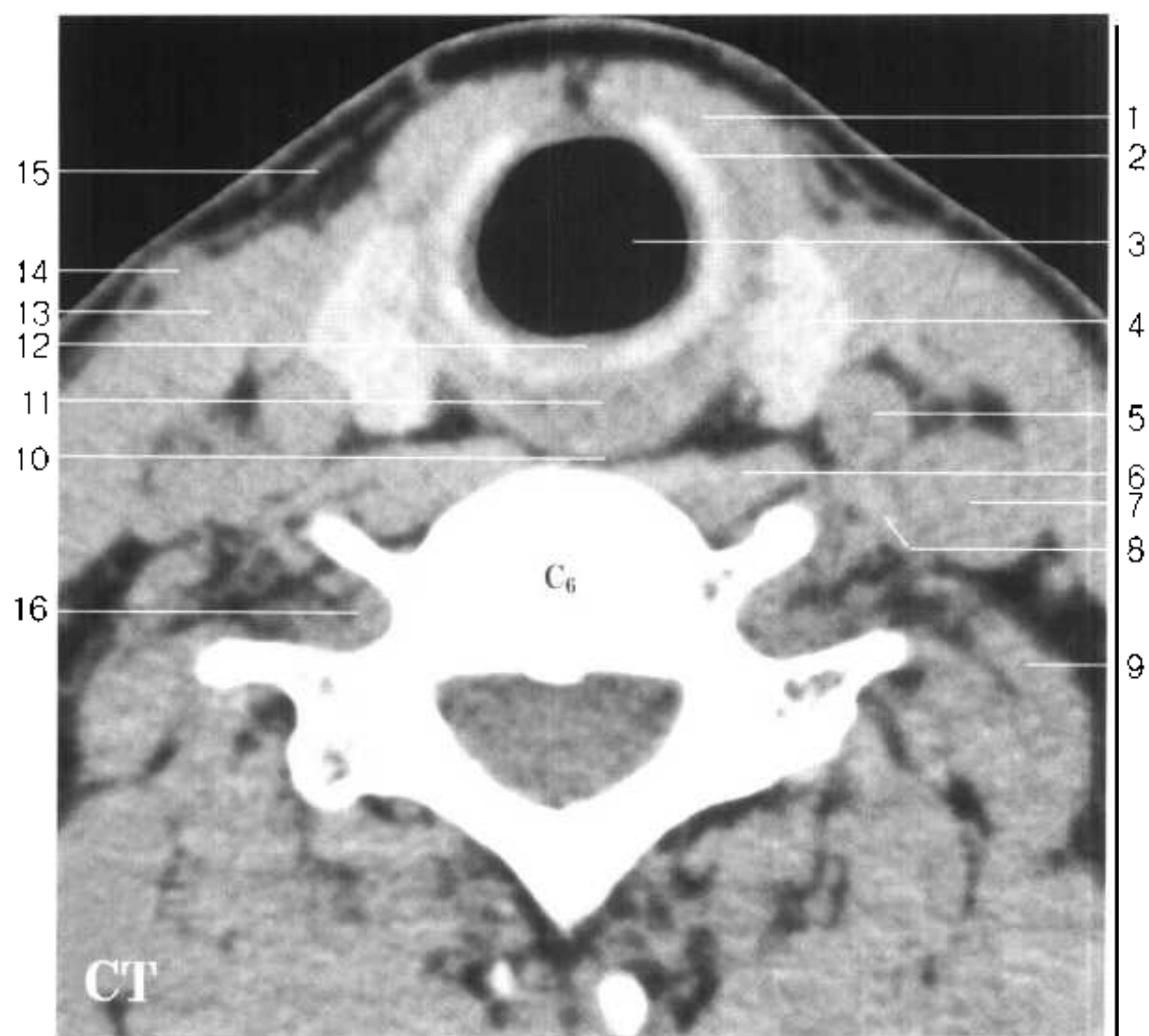
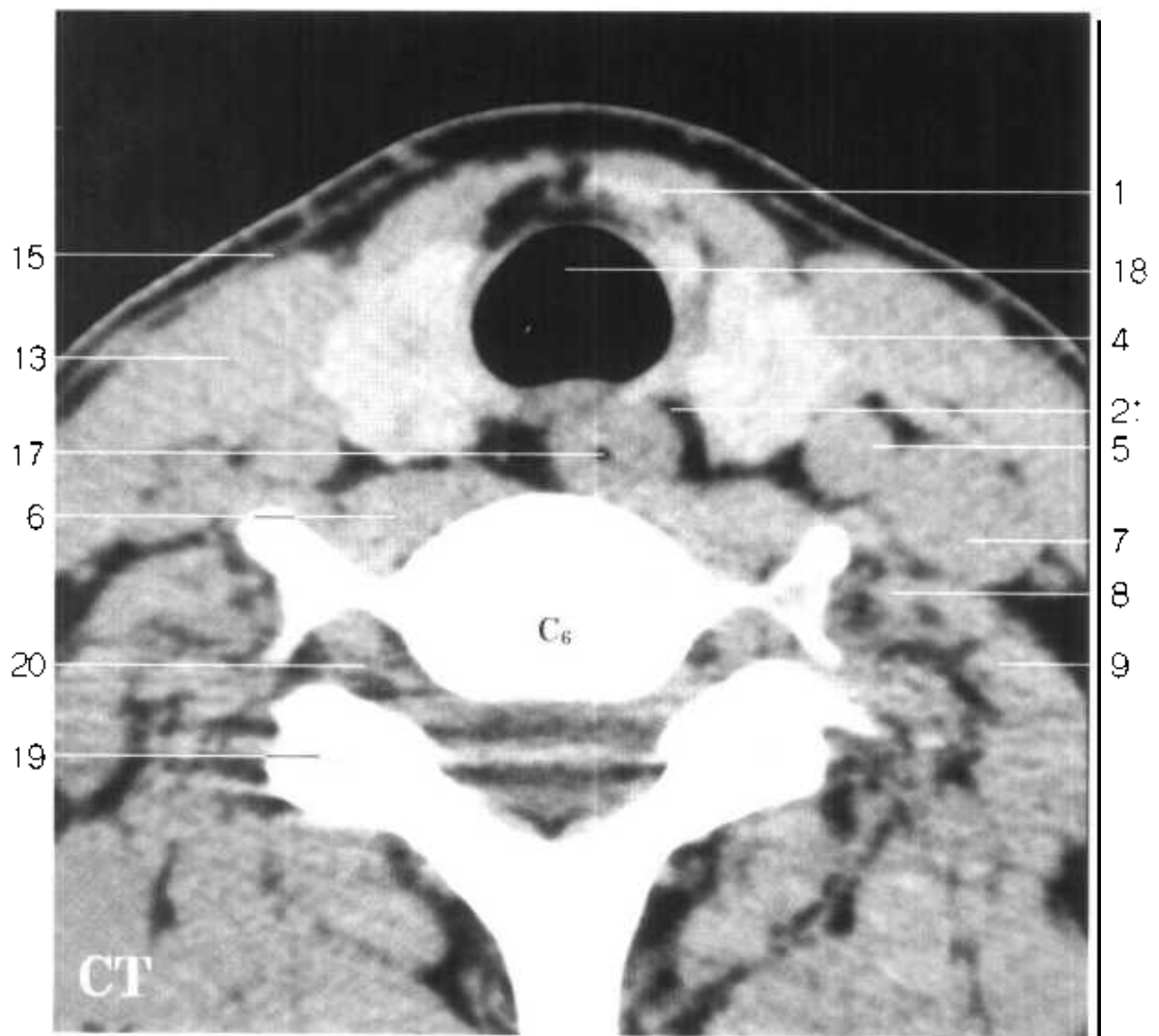
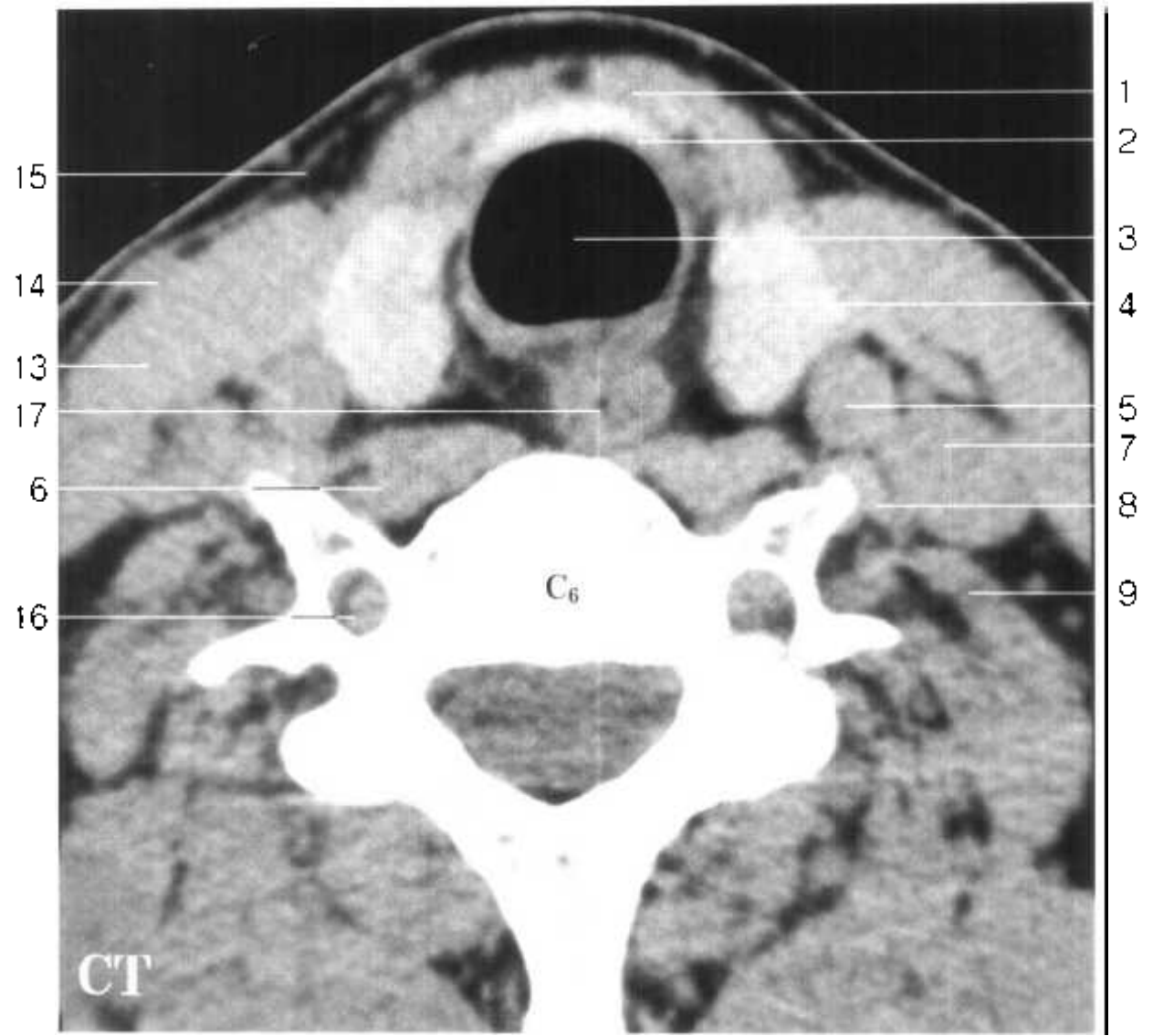
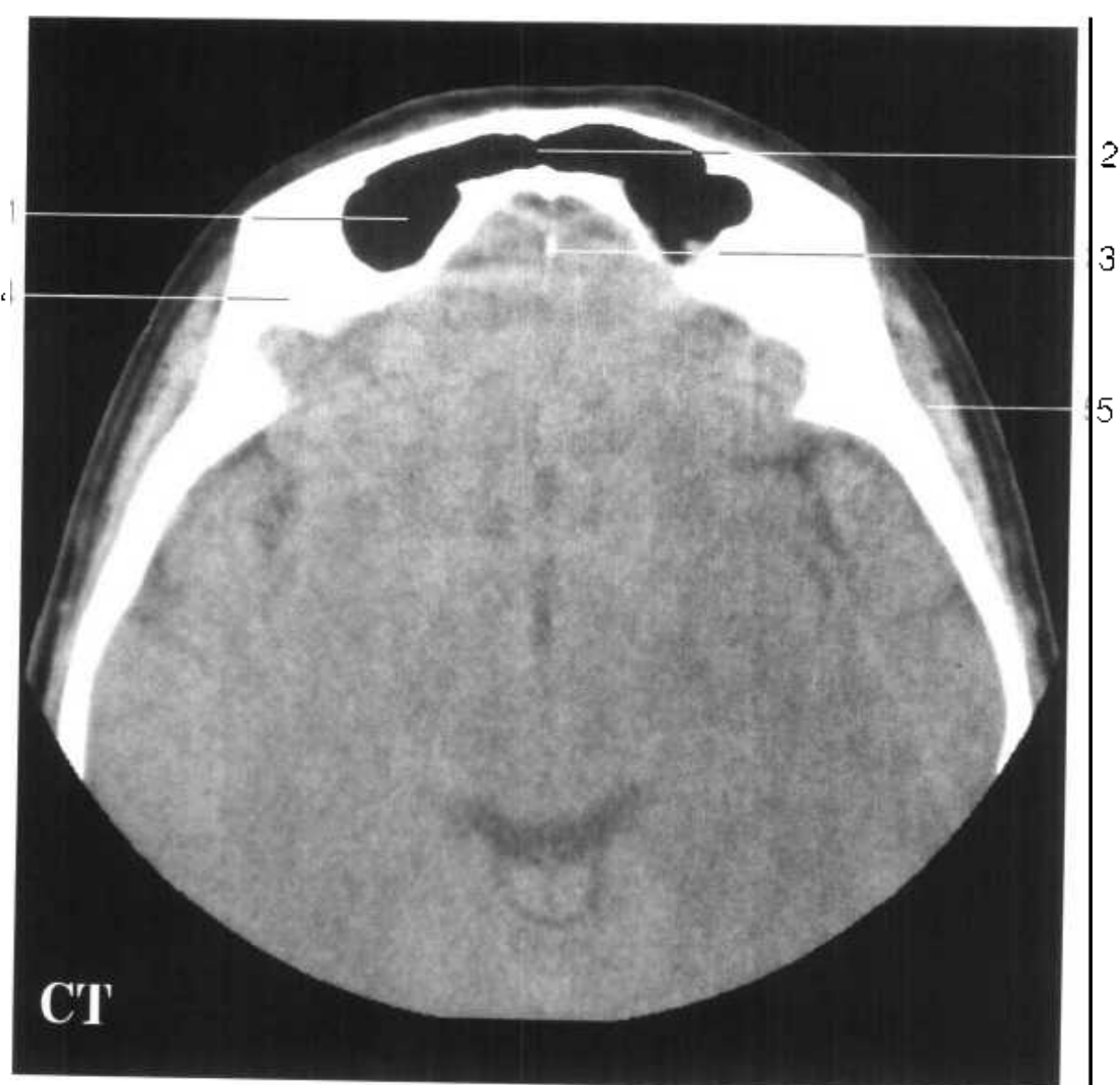


Fig.HL 13-15

- | | |
|------------------------------------|--|
| 1. 舌骨下肌 infrahyoid muscles | 12. 环状软骨板 lamina of cricoid cartilage |
| 2. 环状软骨弓 arch of cricoid cartilage | 13. 胸锁乳突肌 sternocleidomastoid |
| 3. 声门下腔 infraglottic cavity | 14. 颈前静脉 anterior jugular v. |
| 4. 甲状腺 thyroid gland | 15. 颈阔肌 platysma |
| 5. 颈总动脉 common carotid a. | 16. 横突孔 transverse foramen |
| 6. 颈长肌 longus colli | 17. 食管 esophagus |
| 7. 颈内静脉 internal jugular v. | 18. 气管 trachea |
| 8. 前斜角肌 scalenus anterior | 19. 6、7 颈椎关节突关节 zygapophysial joint (C ₆ - C ₇) |
| 9. 中斜角肌 scalenus medius | 20. 椎间孔 intervertebral foramen |
| 10. 咽后间隙 retropharyngeal space | 21. 气管食管沟 tracheoesophageal sulcus |
| 11. 咽腔 cavity of pharynx | |

Fig.HL 13-15



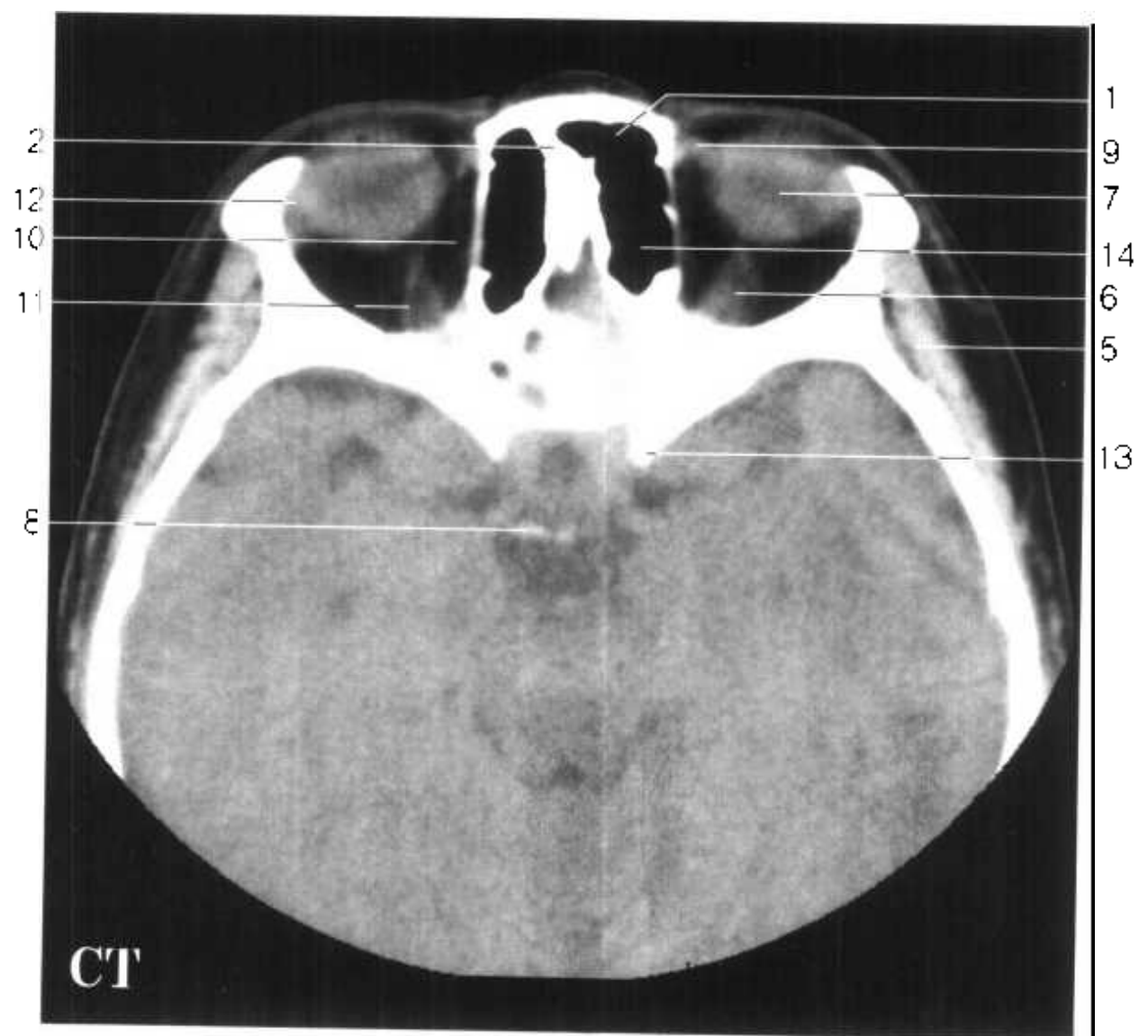
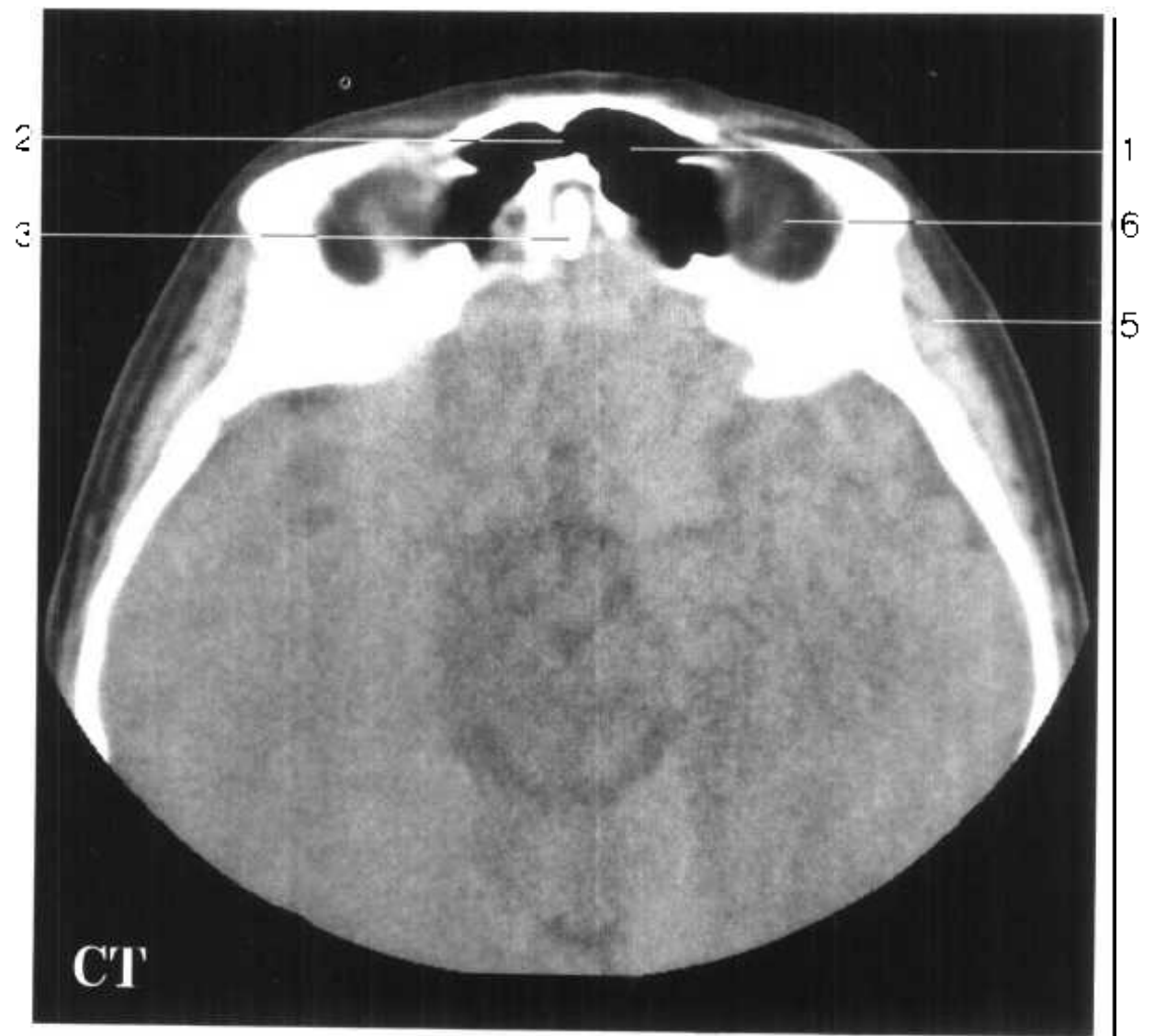


视器的水平断面图 HV

Fig.HV 1-3

- | | |
|--|--|
| <ol style="list-style-type: none"> 1. 额窦 frontal sinus 2. 额窦中隔 septum of frontal sinus 3. 鸡冠 crista galli 4. 眶顶壁 orbital parietal wall 5. 颞肌 temporalis 6. 上睑提肌及上直肌 levator palpebrae superioris and superior rectus | <ol style="list-style-type: none"> 7. 眼球 eyeball 8. 后床突 posterior clinoid process 9. 滑车 trochlea 10. 上斜肌 superior obliquus 11. 眼上静脉 superior ophthalmic v. 12. 泪腺 lacrimal gland 13. 前床突 anterior clinoid process 14. 筛窦 ethmoidal sinus |
|--|--|

Fig.HV 1-3



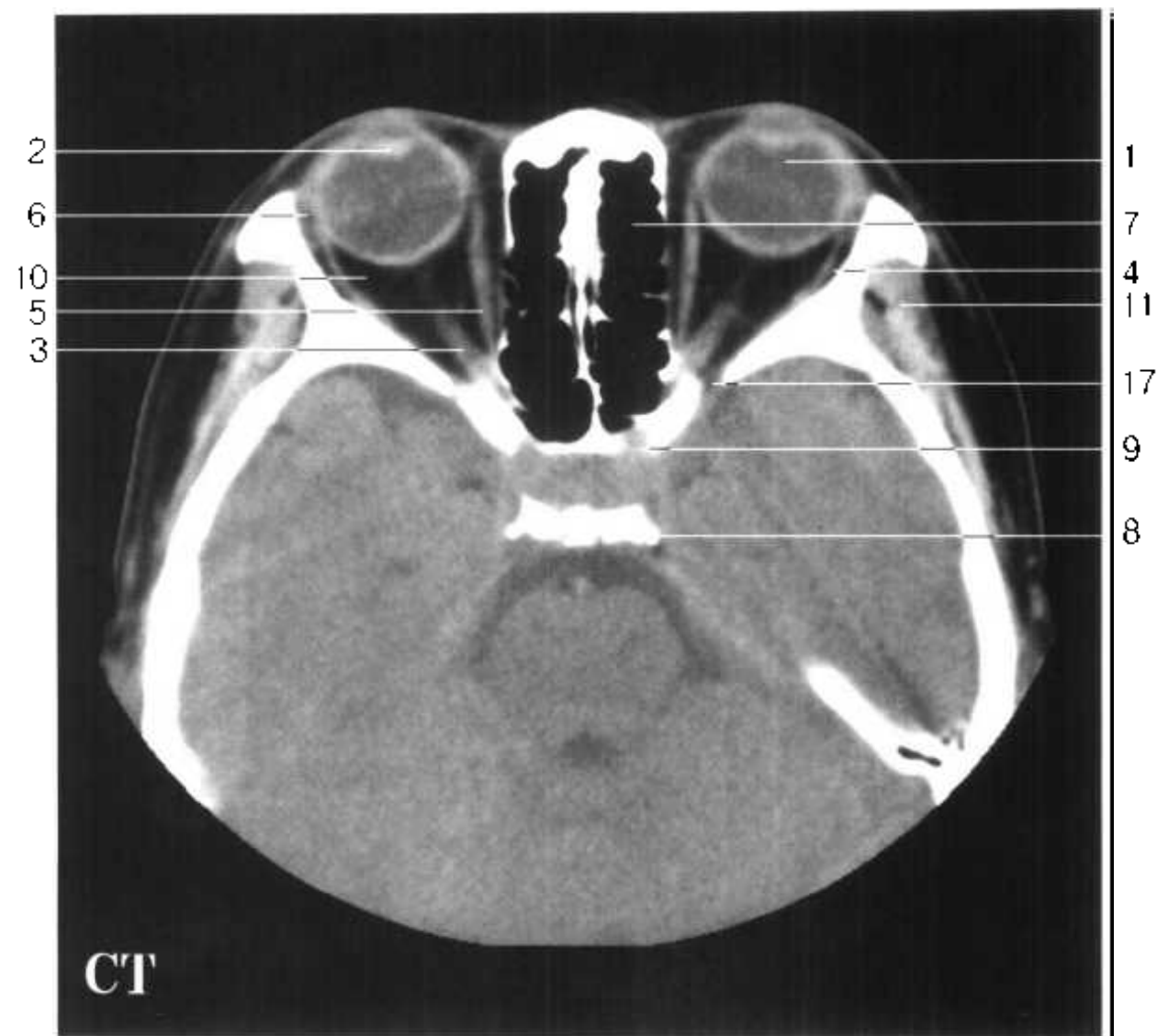
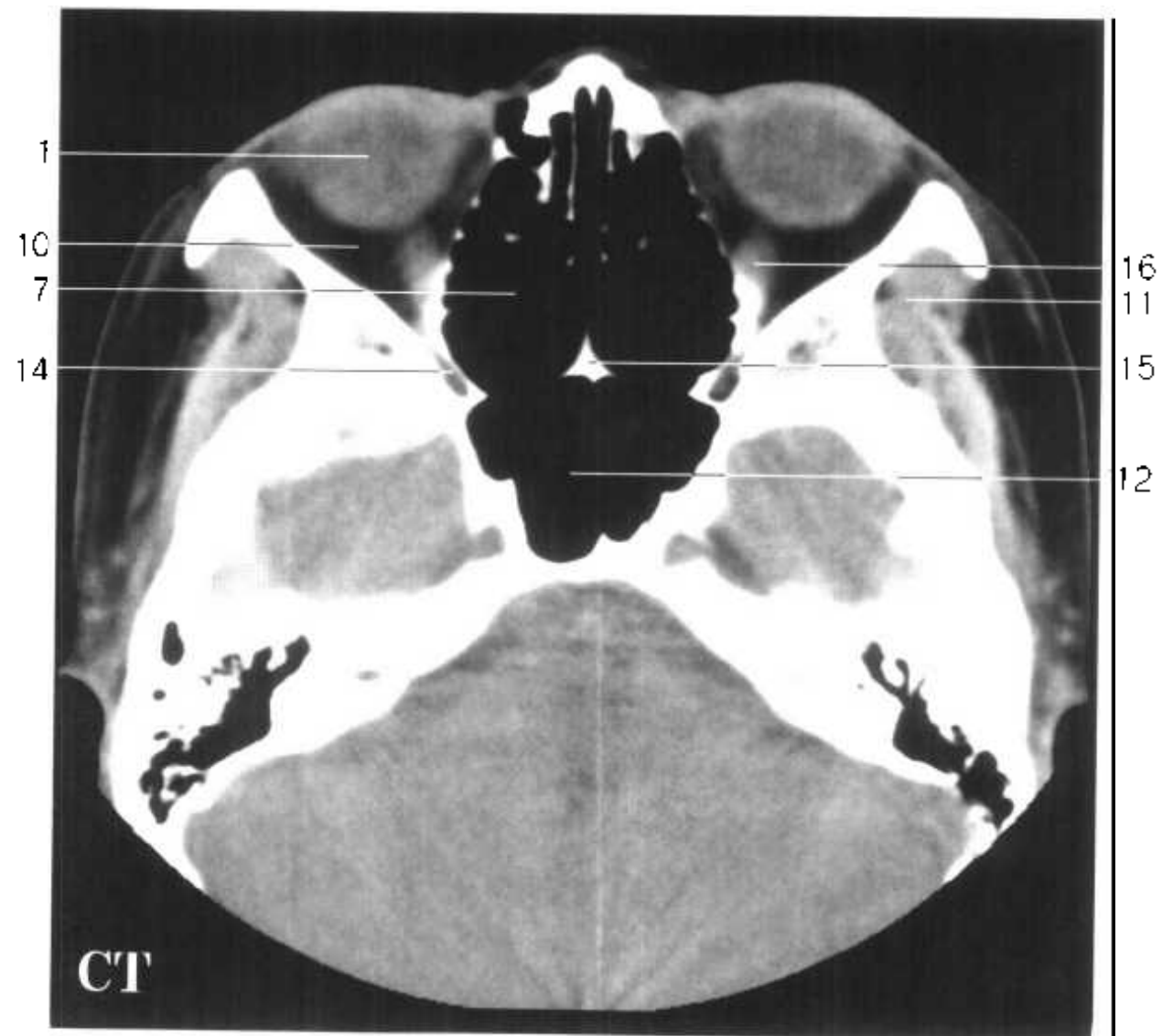
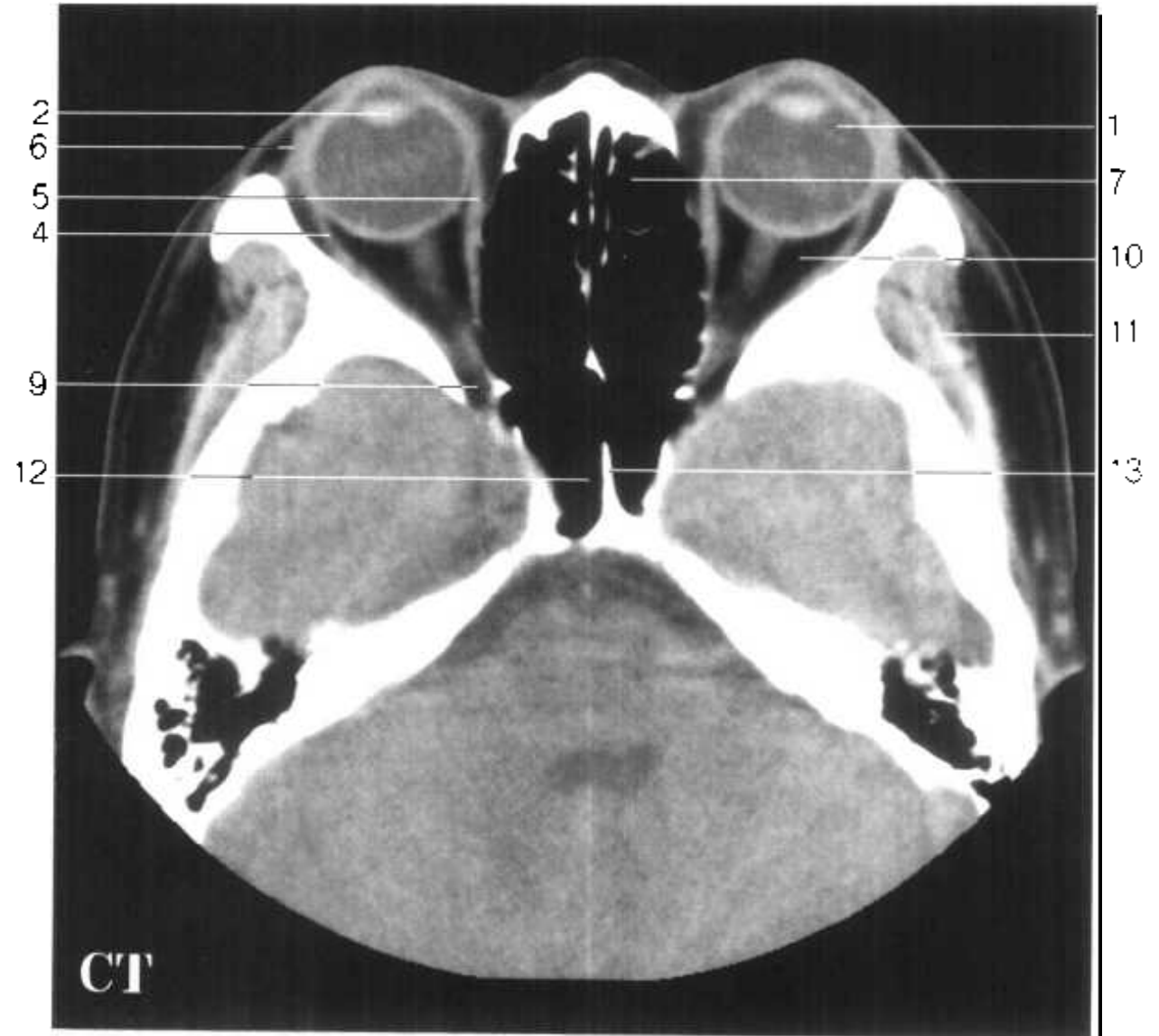


Fig.HV 4-6

- | | |
|----------------------------------|-------------------------------------|
| 1. 眼球 eyeball | 9. 视神经管 optic canal |
| 2. 晶状体 lens | 10. 眶脂体 adipose body of orbit |
| 3. 视神经 optic n. | 11. 颞肌 temporalis |
| 4. 外直肌 lateral rectus | 12. 蝶窦 sphenoidal sinus |
| 5. 内直肌 medial rectus | 13. 蝶窦中隔 septum of sphenoidal sinus |
| 6. 泪腺 lacrimal gland | 14. 眶下裂 inferior orbital fissure |
| 7. 筛窦 ethmoidal sinus | 15. 犁骨 vomer |
| 8. 后床突 posterior clinoid process | 16. 下直肌 inferior rectus |
| | 17. 眶上裂 superior orbital fissure |

Fig.HV 4-6



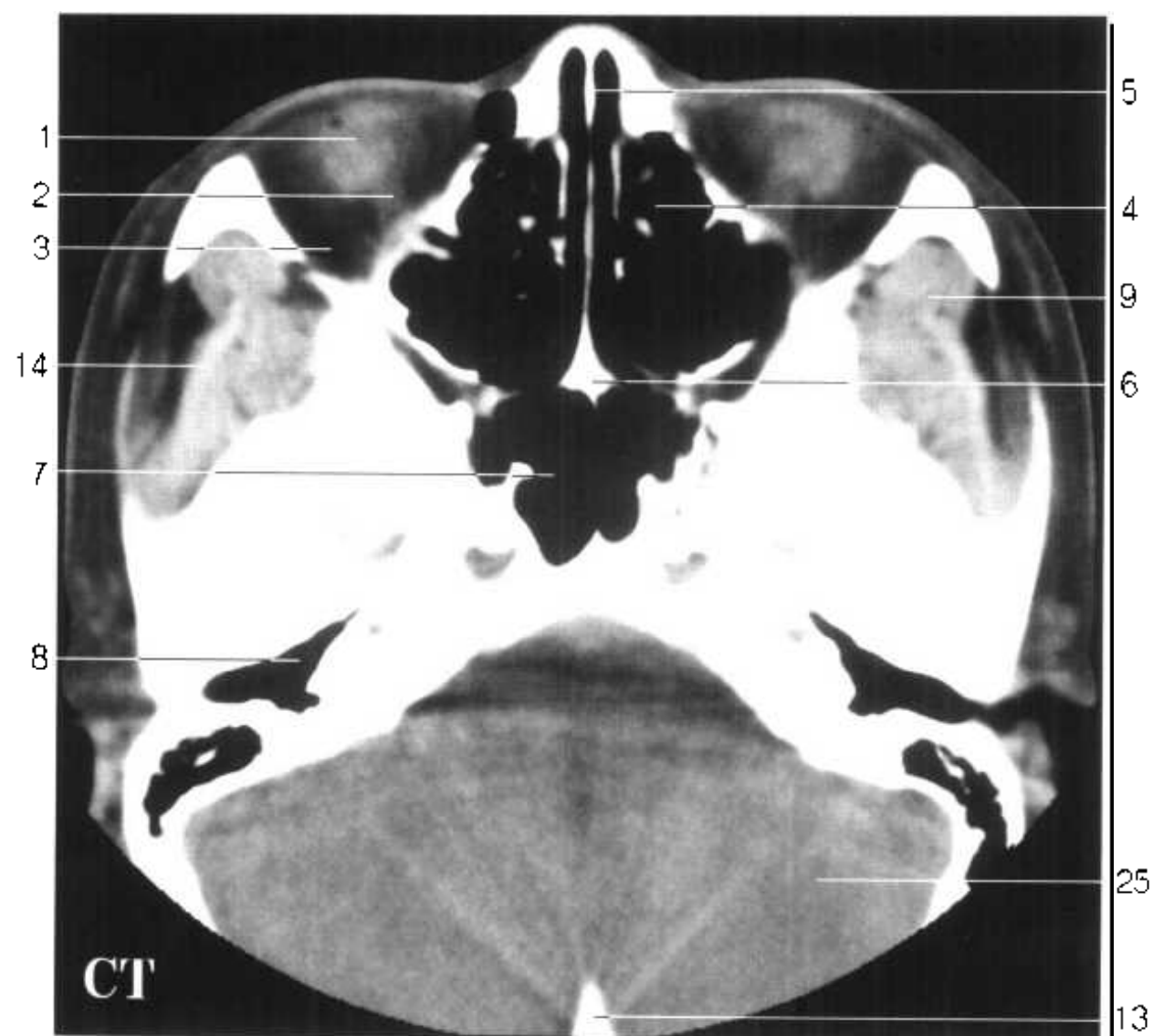
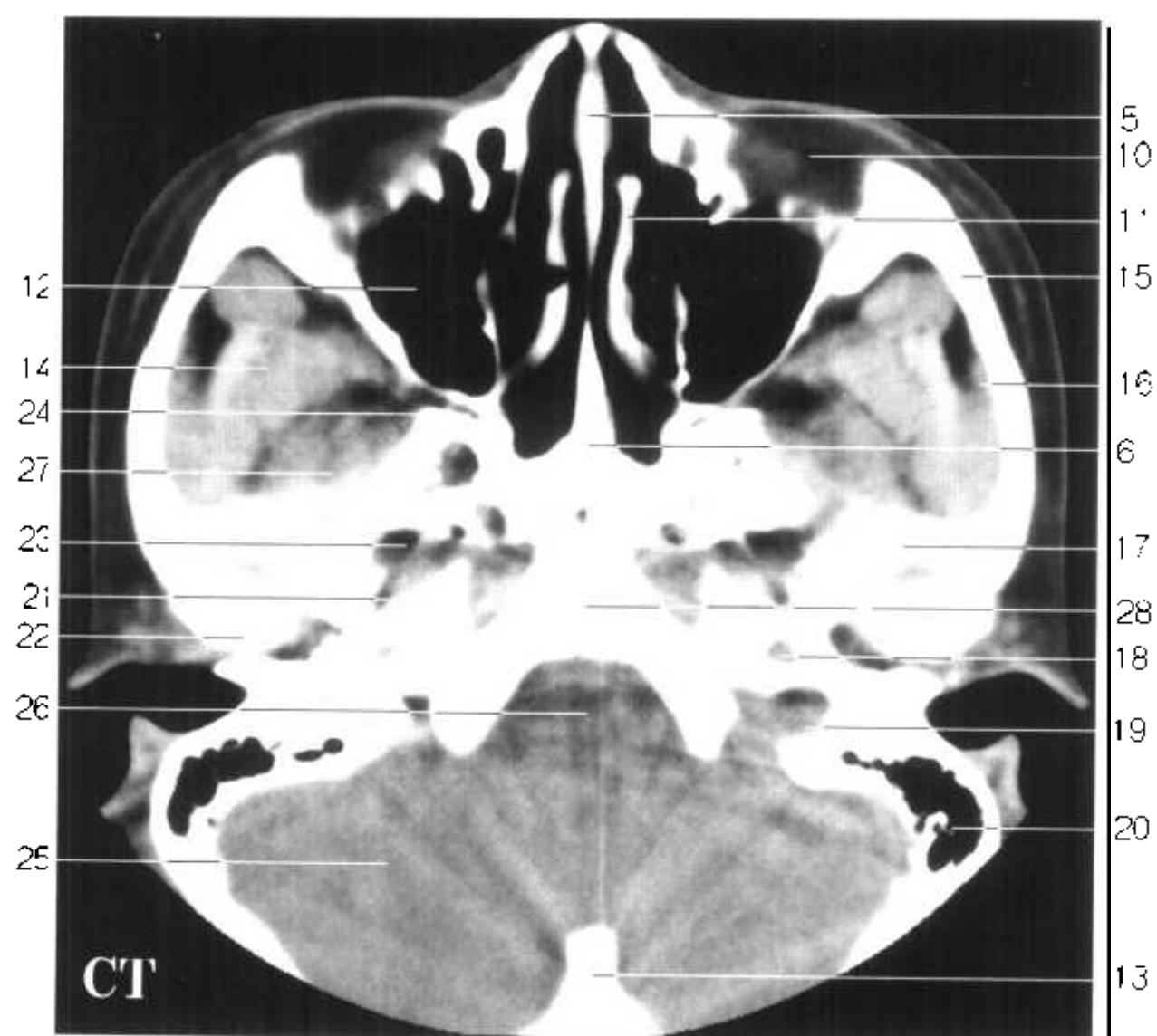


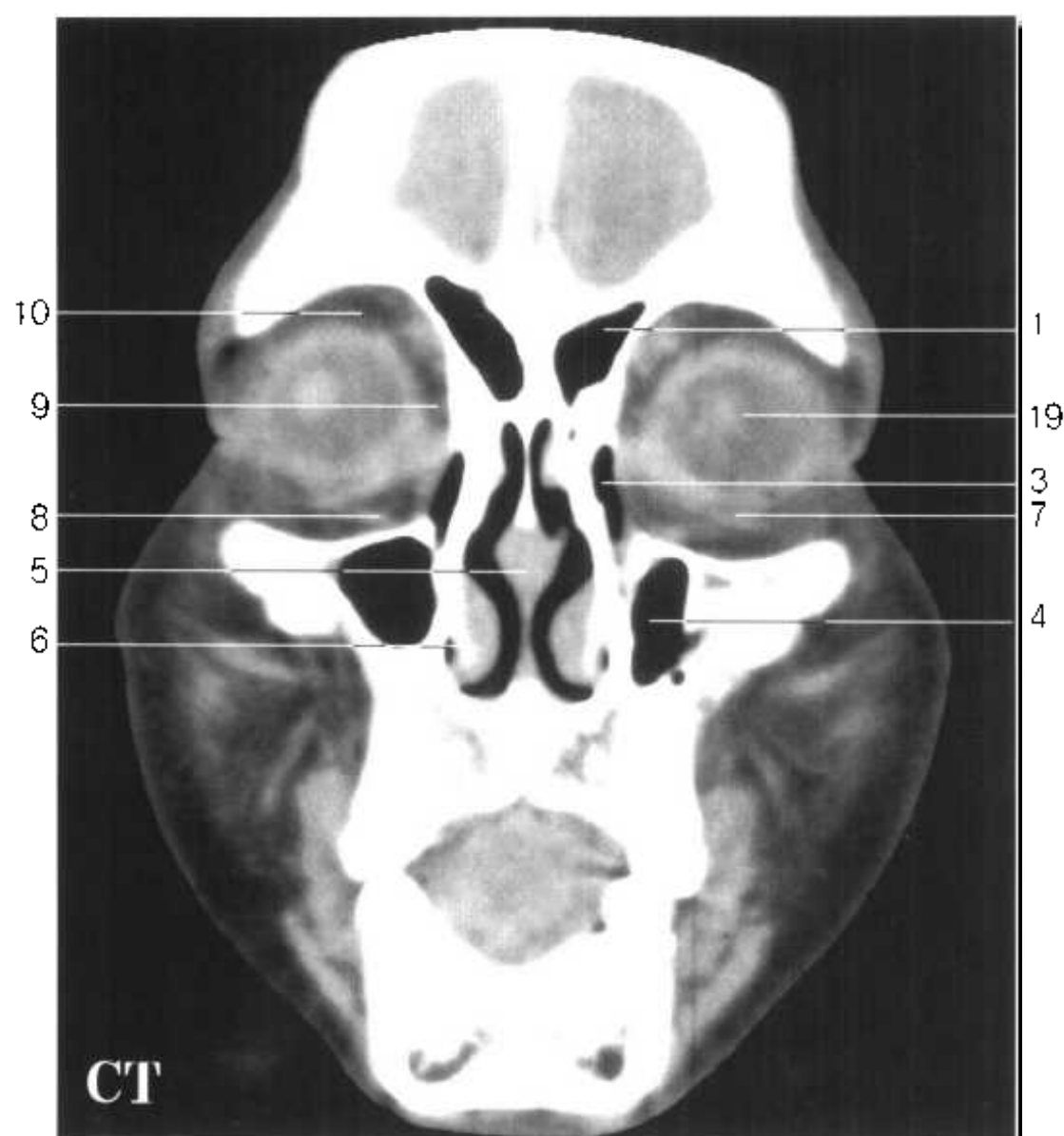
Fig.HV 7-8

- | | |
|------------------------------|--|
| 1. 眼球 eyeball | 9. 颞肌 temporalis |
| 2. 下直肌 inferior rectus | 10. 眶下壁 inferior wall of orbit |
| 3. 眶脂体 adipose body of orbit | 11. 中鼻甲 middle nasal concha |
| 4. 筛窦 ethmoidal sinus | 12. 上颌窦 maxillary sinus |
| 5. 鼻中隔 nasal septum | 13. 枕内隆凸 internal occipital protuberance |
| 6. 犁骨 vomer | 14. 颞肌 temporalis |
| 7. 蝶窦 sphenoidal sinus | 15. 颧弓 zygomatic arch |
| 8. 鼓室 tympanic cavity | |

Fig. HV 7-8



- | | |
|---|--|
| 16. 咬肌 masseter | 23. 卵圓孔 foramen ovale |
| 17. 关节结节 articular tubercle | 24. 翼腭窩 pterygopalatine fossa |
| 18. 颈动脉管外口 external aperture of carotid canal | 25. 小脑半球 cerebellar hemisphere |
| 19. 颈静脉孔 jugular foramen | 26. 延髓 medulla oblongata |
| 20. 乳突 mastoid process | 27. 翼外肌 lateral pterygoid |
| 21. 棘孔 foramen spinosum | 28. 枕骨基底部 basilar part of occipital bone |
| 22. 下颌头 head of mandible | |

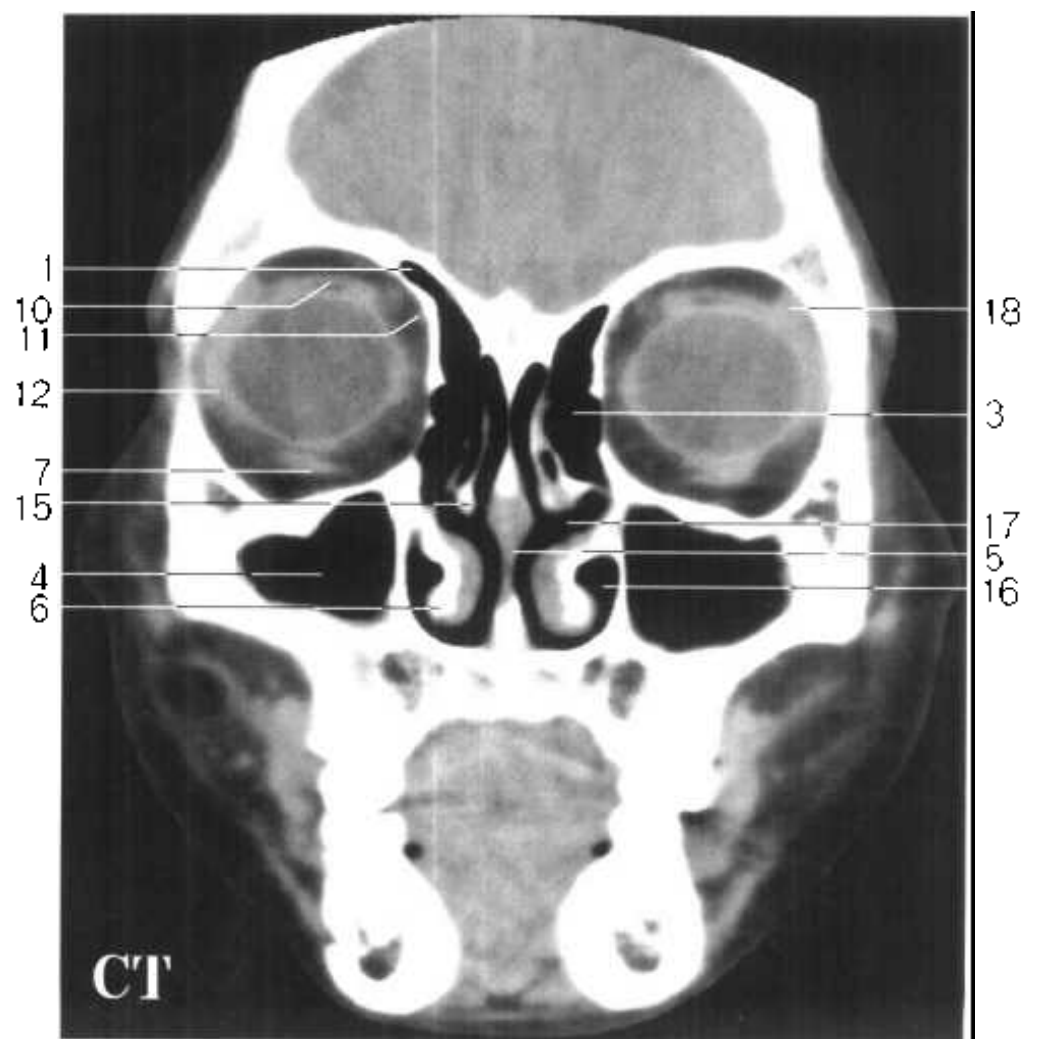
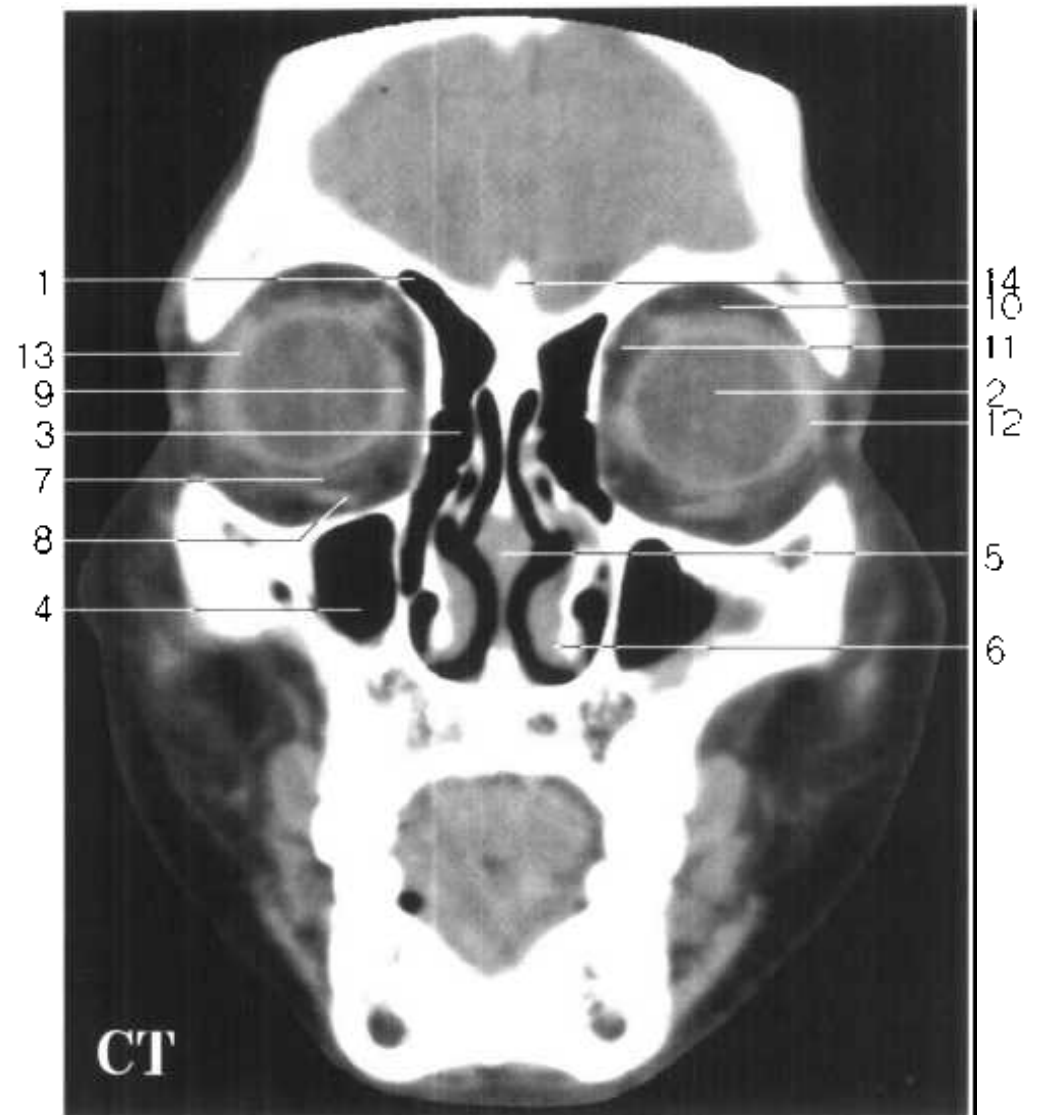


视器的额状断面图 FV

Fig.FV 1-3

- | | |
|---|---|
| <ul style="list-style-type: none"> 1. 额窦 frontal sinus 2. 眼球 eyeball 3. 筛窦 ethmoidal sinuses 4. 上颌窦 maxillary sinus 5. 鼻中隔 nasal septum 6. 下鼻甲 inferior nasal concha 7. 下直肌 inferior rectus 8. 下斜肌 inferior oblique 9. 内直肌 medial rectus | <ul style="list-style-type: none"> 10. 上睑提肌及上直肌 levator palpebrae superioris and superior rectus 11. 上斜肌 superior oblique 12. 外直肌 lateral rectus 13. 眼球壁 wall of eyeball 14. 鸡冠 crista galli 15. 中鼻甲 middle nasal concha 16. 下鼻道 inferior nasal meatus 17. 中鼻道 middle nasal meatus 18. 泪腺 lacrimal gland 19. 晶状体 lens |
|---|---|

Fig.FV 1-3



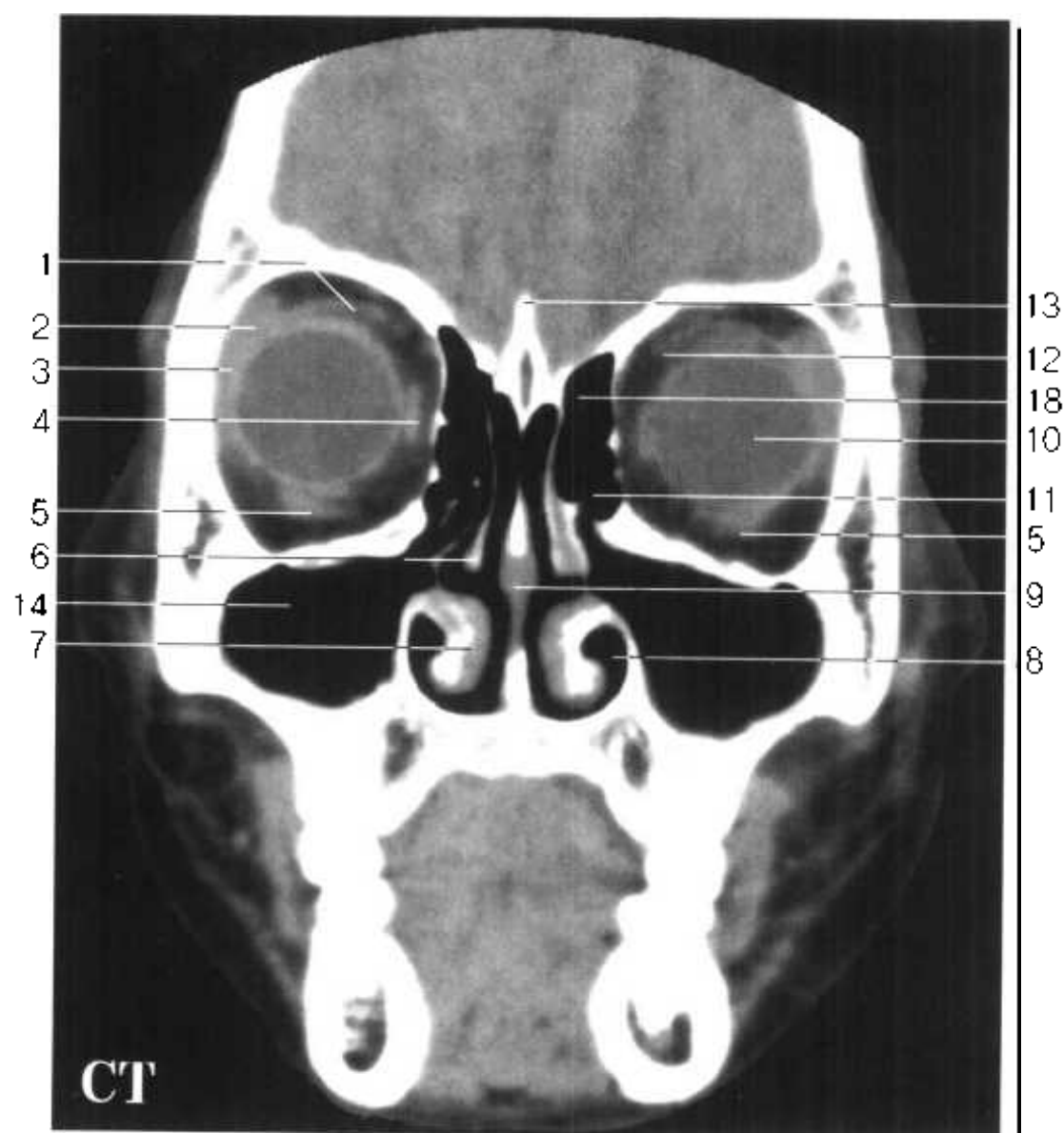
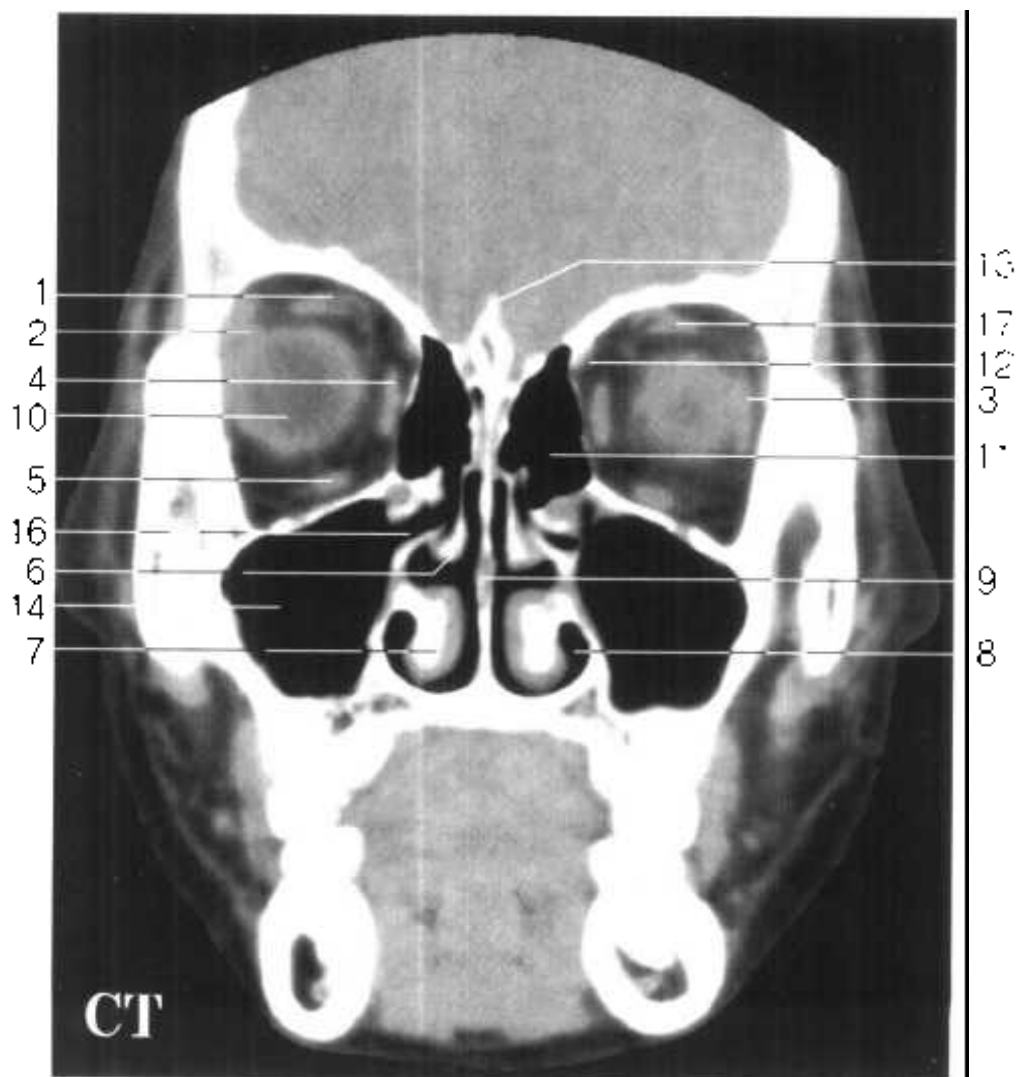
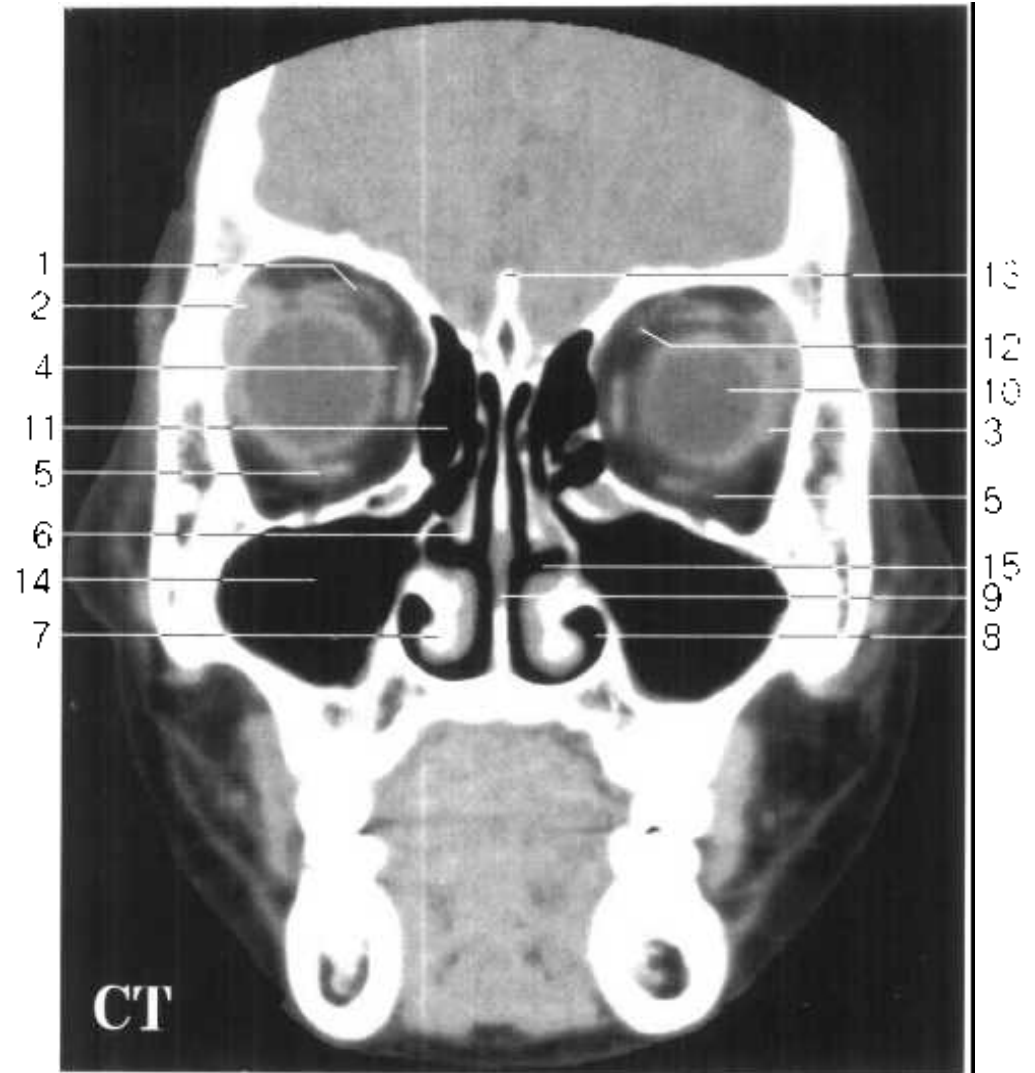


Fig.FV 4-6

- | | |
|--|-------------------------------------|
| 1. 上睑提肌及上直肌 levator palpebrae superioris and superior rectus | 10. 眼球 eyeball |
| 2. 泪腺 lacrimal gland | 11. 筛窦 ethmoidal sinus |
| 3. 外直肌 lateral rectus | 12. 上斜肌 superior obliquus |
| 4. 内直肌 medial rectus | 13. 鸡冠 crista galli |
| 5. 下直肌 inferior rectus | 14. 上颌窦 maxillary sinus |
| 6. 中鼻甲 middle nasal concha | 15. 中鼻道 middle nasal meatus |
| 7. 下鼻甲 inferior nasal concha | 16. 上颌窦口 orifice of maxillary sinus |
| 8. 下鼻道 inferior nasal meatus | 17. 上直肌 superior rectus |
| 9. 鼻中隔 nasal septum | 18. 额窦 frontal sinus |

Fig.FV 4-6



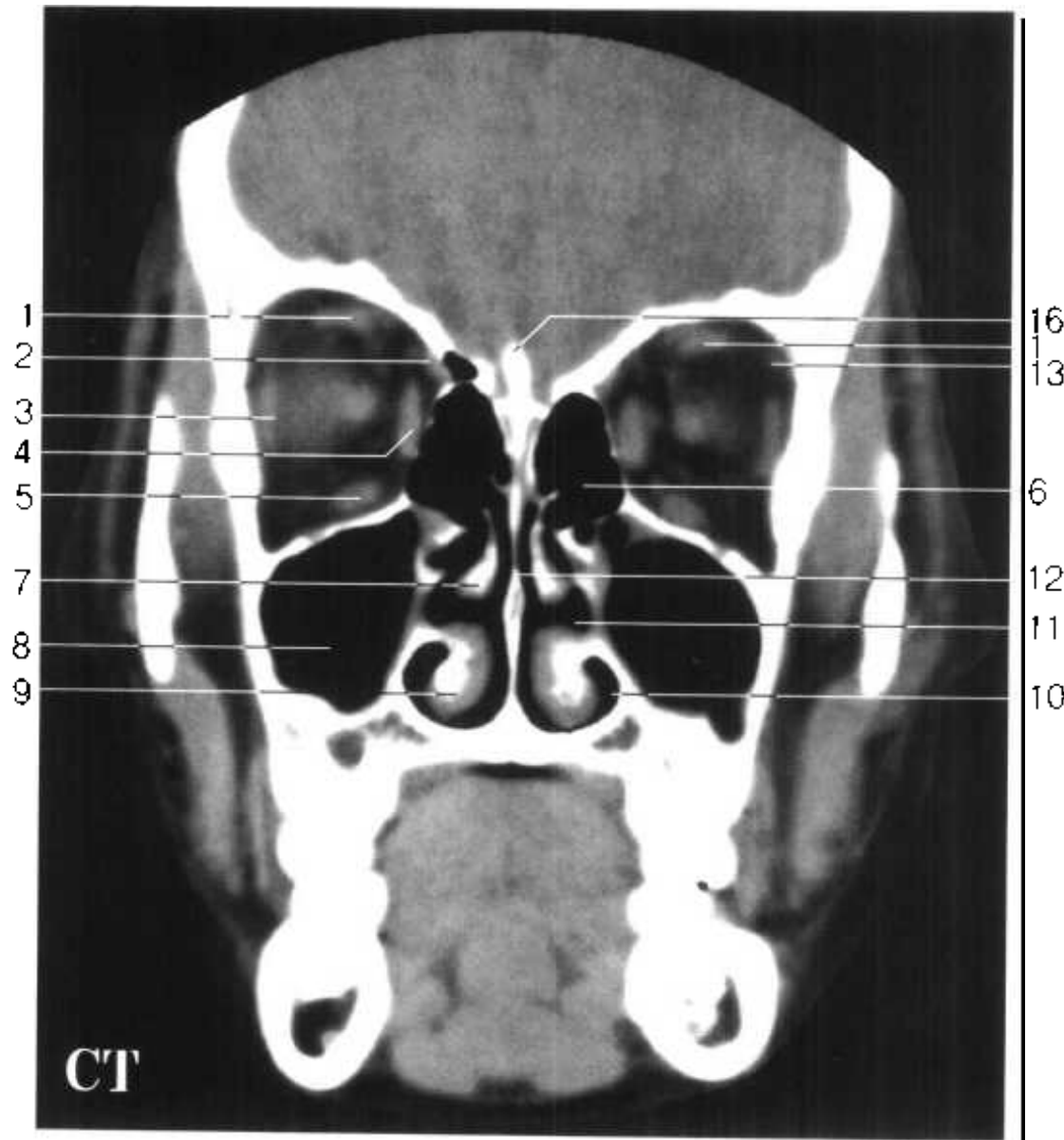
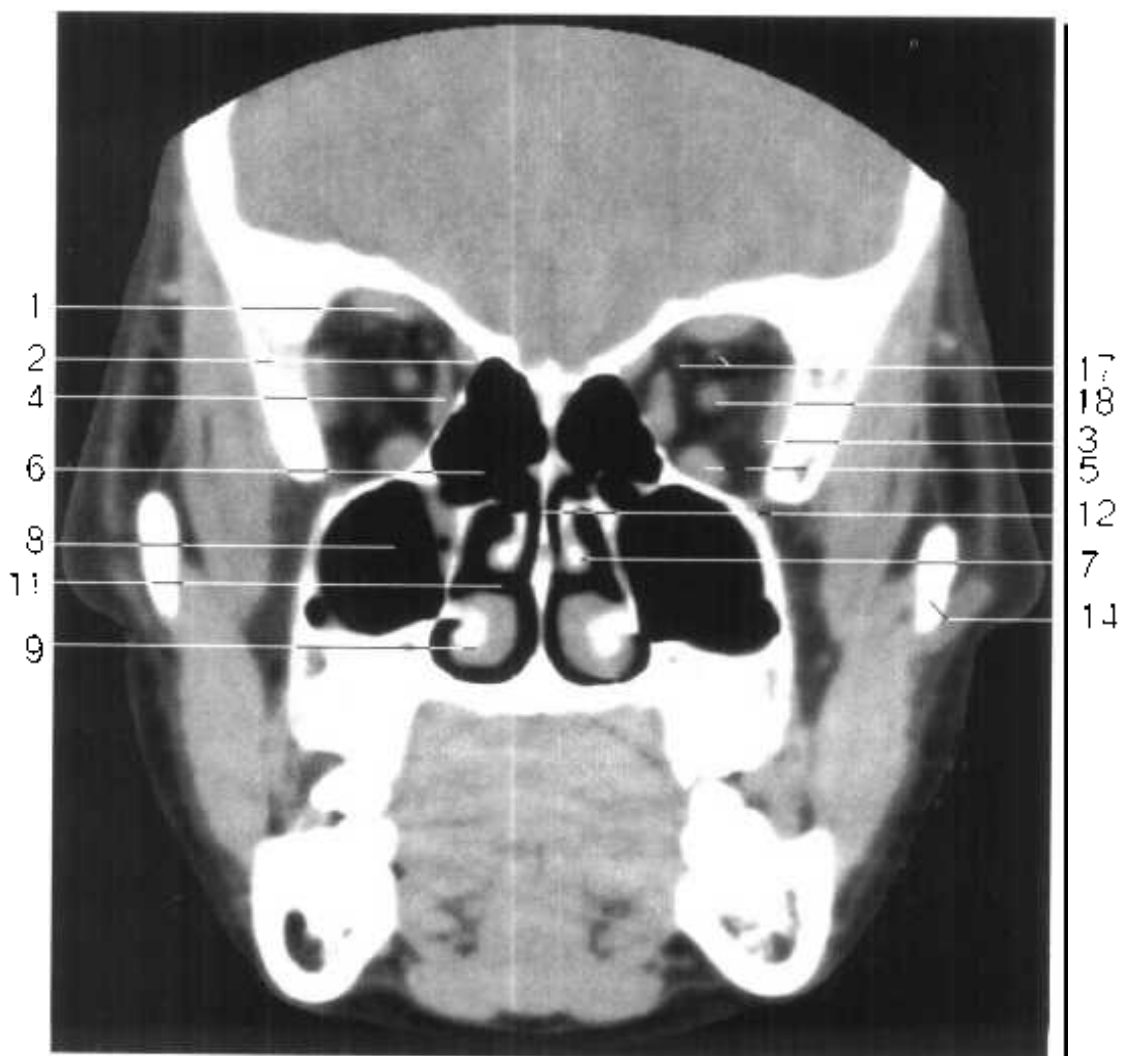
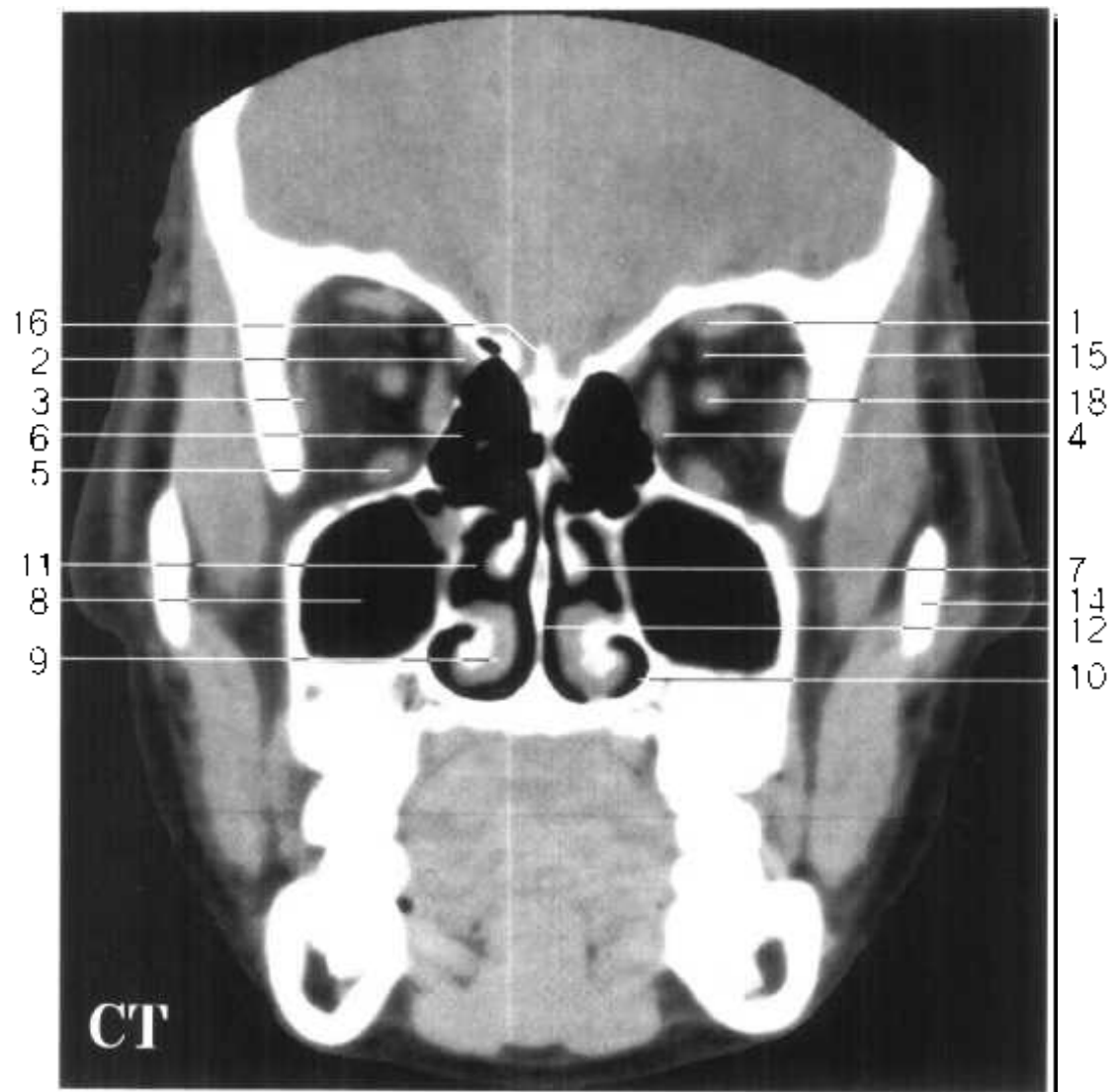


Fig.FV 7-9

- | | |
|--|---|
| <ol style="list-style-type: none"> 1. 上睑提肌及上直肌 levator palpebrae superioris and superior rectus 2. 上斜肌 superior obliquus 3. 外直肌 lateral rectus 4. 内直肌 medial rectus 5. 下直肌 inferior rectus 6. 筛窦 ethmoidal sinus 7. 中鼻甲 middle nasal concha 8. 上颌窦 maxillary sinus 9. 下鼻甲 inferior nasal concha | <ol style="list-style-type: none"> 10. 下鼻道 inferior nasal meatus 11. 中鼻道 middle nasal meatus 12. 鼻中隔 nasal septum 13. 泪腺 lacrimal gland 14. 颧弓 zygomatic arch 15. 眼上动脉 superior ophthalmic a. 16. 鸡冠 crista galli 17. 眼上动脉和眼上静脉 superior ophthalmic a. and superior ophthalmic v. 18. 视神经 optic n. |
|--|---|

Fig.FV 7-9



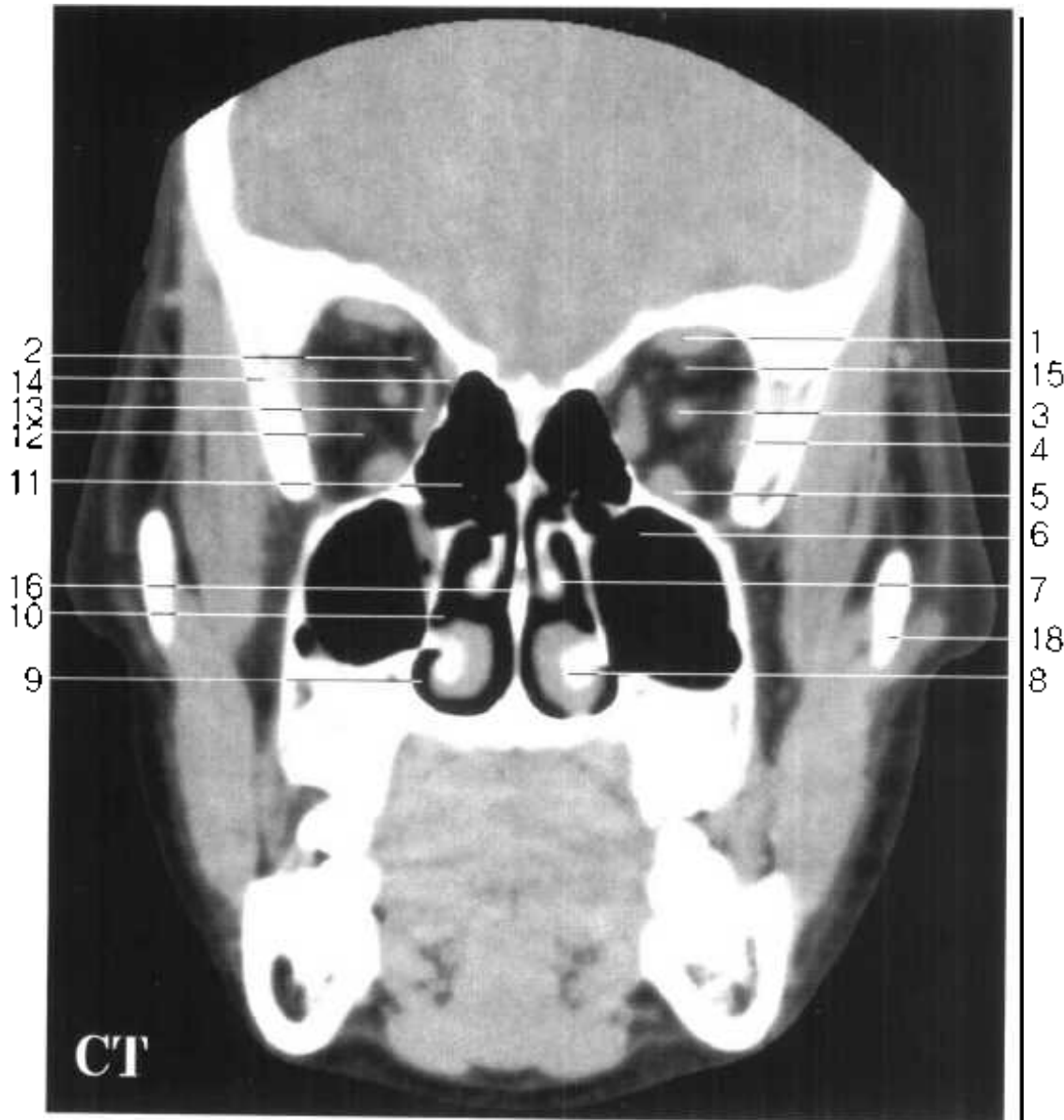
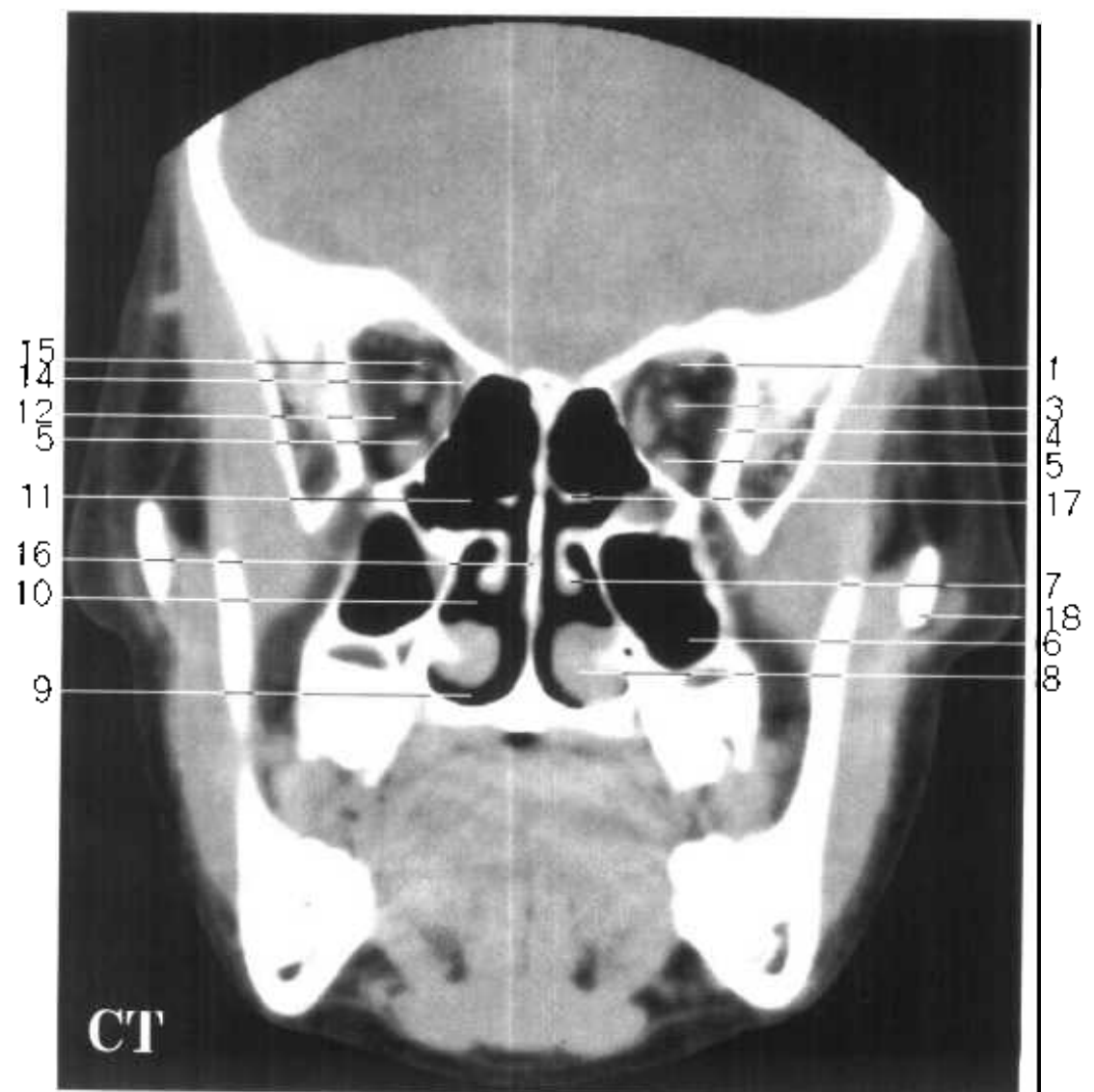
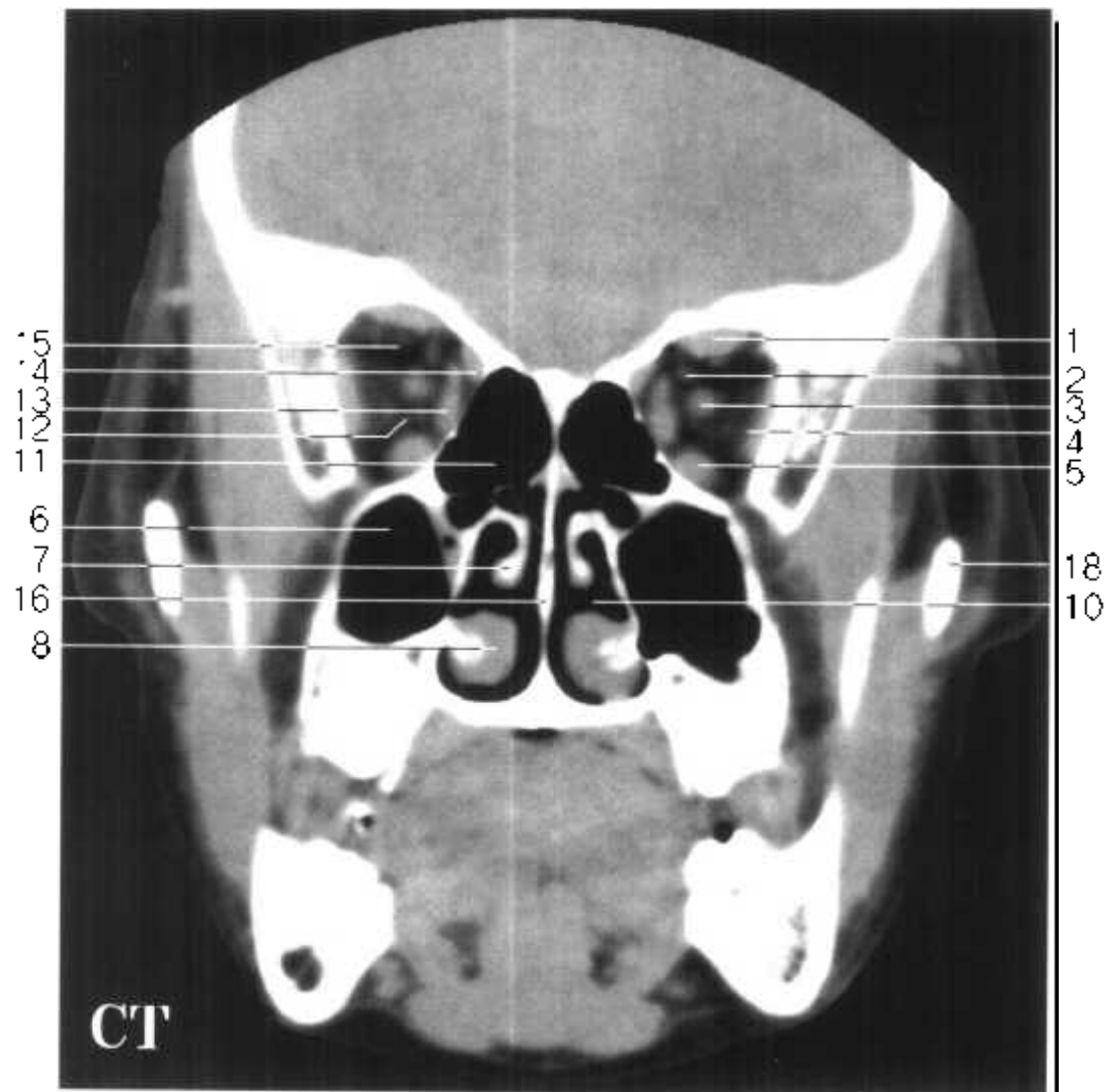


Fig.FV 10-12

- | | |
|---|--|
| <p>1. 上睑提肌及上直肌 levator palpebrae superioris and superior rectus</p> <p>2. 眼上静脉 superior ophthalmic v.</p> <p>3. 视神经 optic n.</p> <p>4. 外直肌 lateral rectus</p> <p>5. 下直肌 inferior rectus</p> <p>6. 上颌窦 maxillary sinus</p> <p>7. 中鼻甲 middle nasal concha</p> <p>8. 下鼻甲 inferior nasal concha</p> <p>9. 下鼻道 inferior nasal meatus</p> | <p>10. 中鼻道 middle nasal meatus</p> <p>11. 筛窦 ethmoidal sinus</p> <p>12. 眼下静脉 inferior ophthalmic v.</p> <p>13. 内直肌 medial rectus</p> <p>14. 上斜肌 superior obliquus</p> <p>15. 眼动脉 ophthalmic a.</p> <p>16. 鼻中隔 nasal septum</p> <p>17. 上鼻甲 superior nasal concha</p> <p>18. 颧弓 zygomatic arch</p> |
|---|--|

Fig.FV 10-12



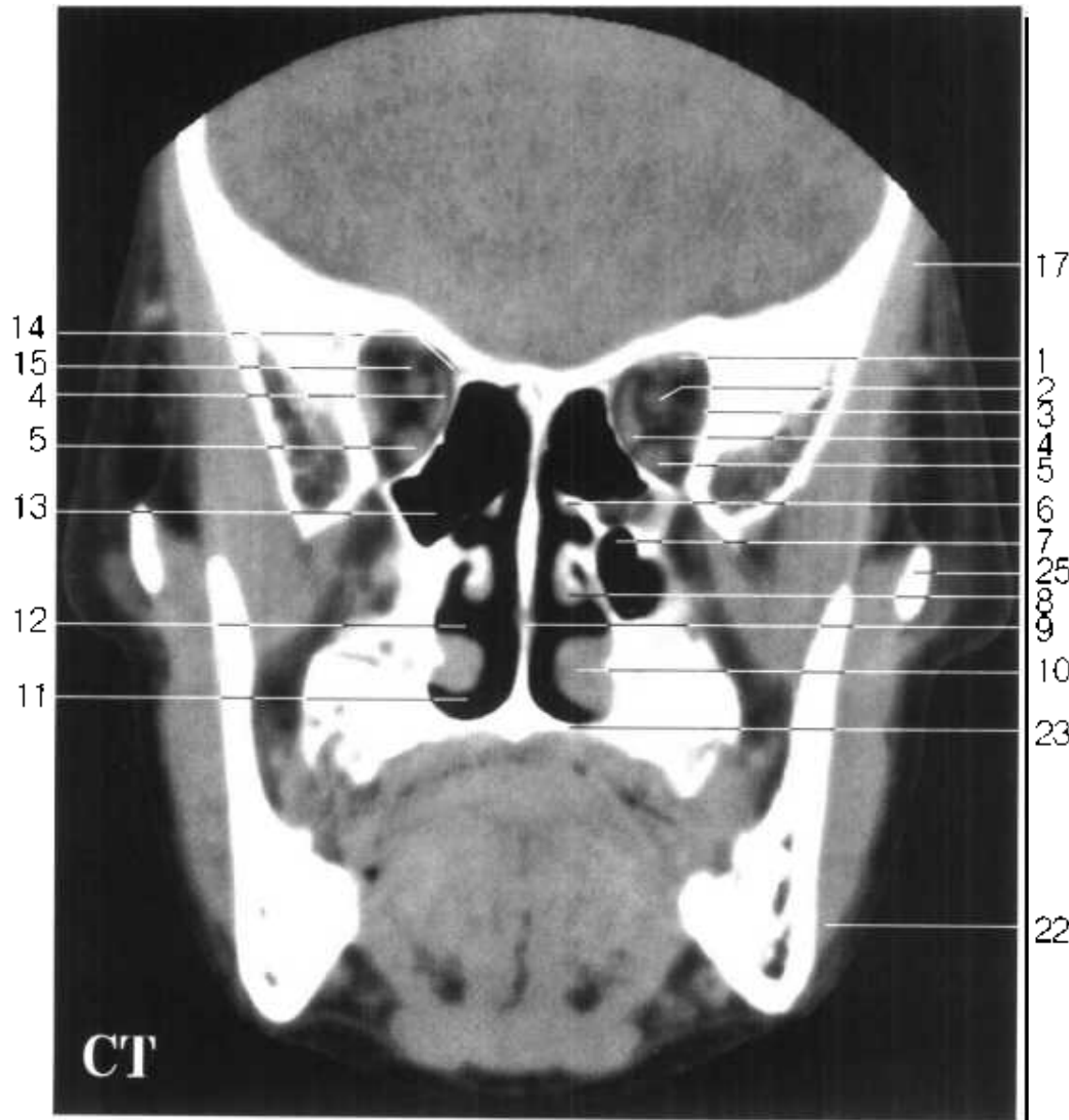
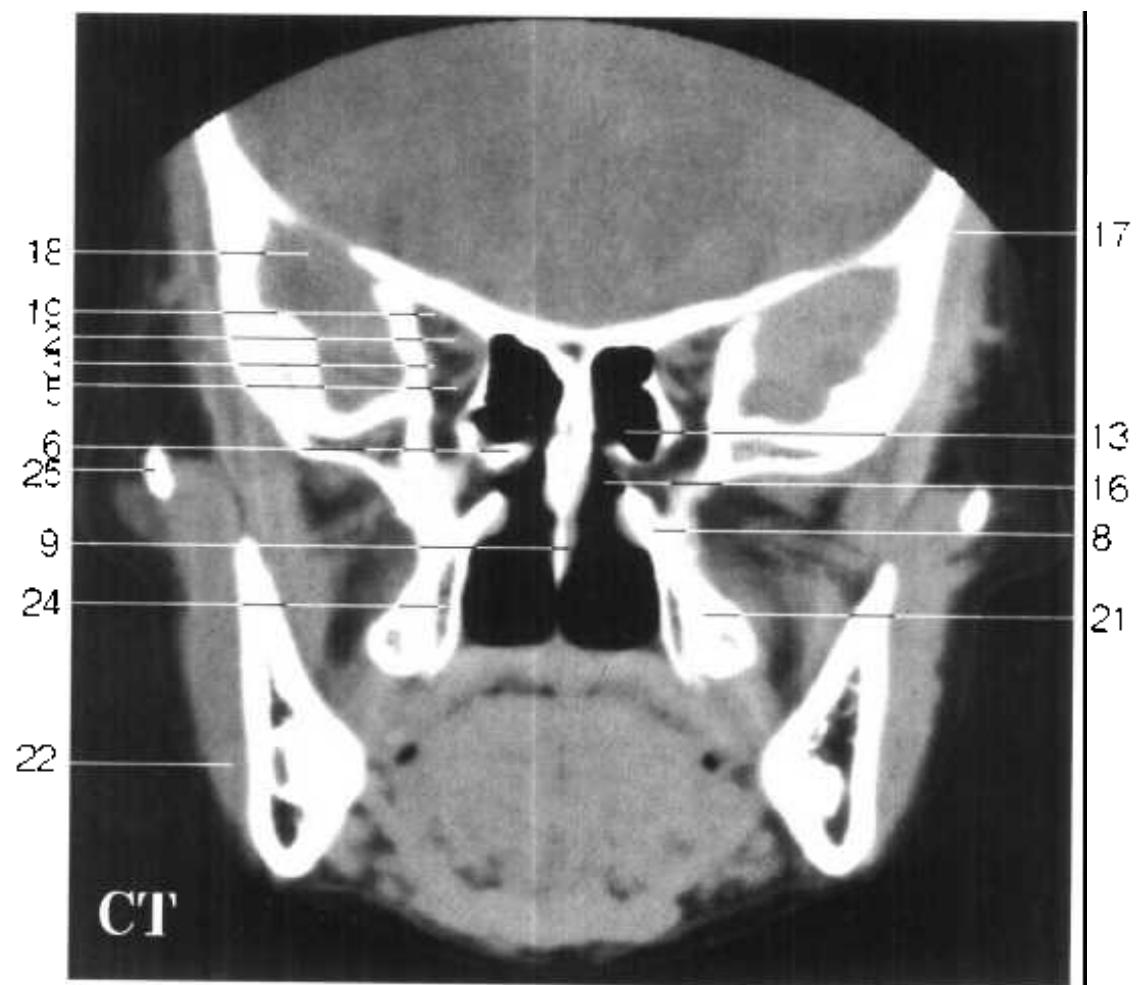
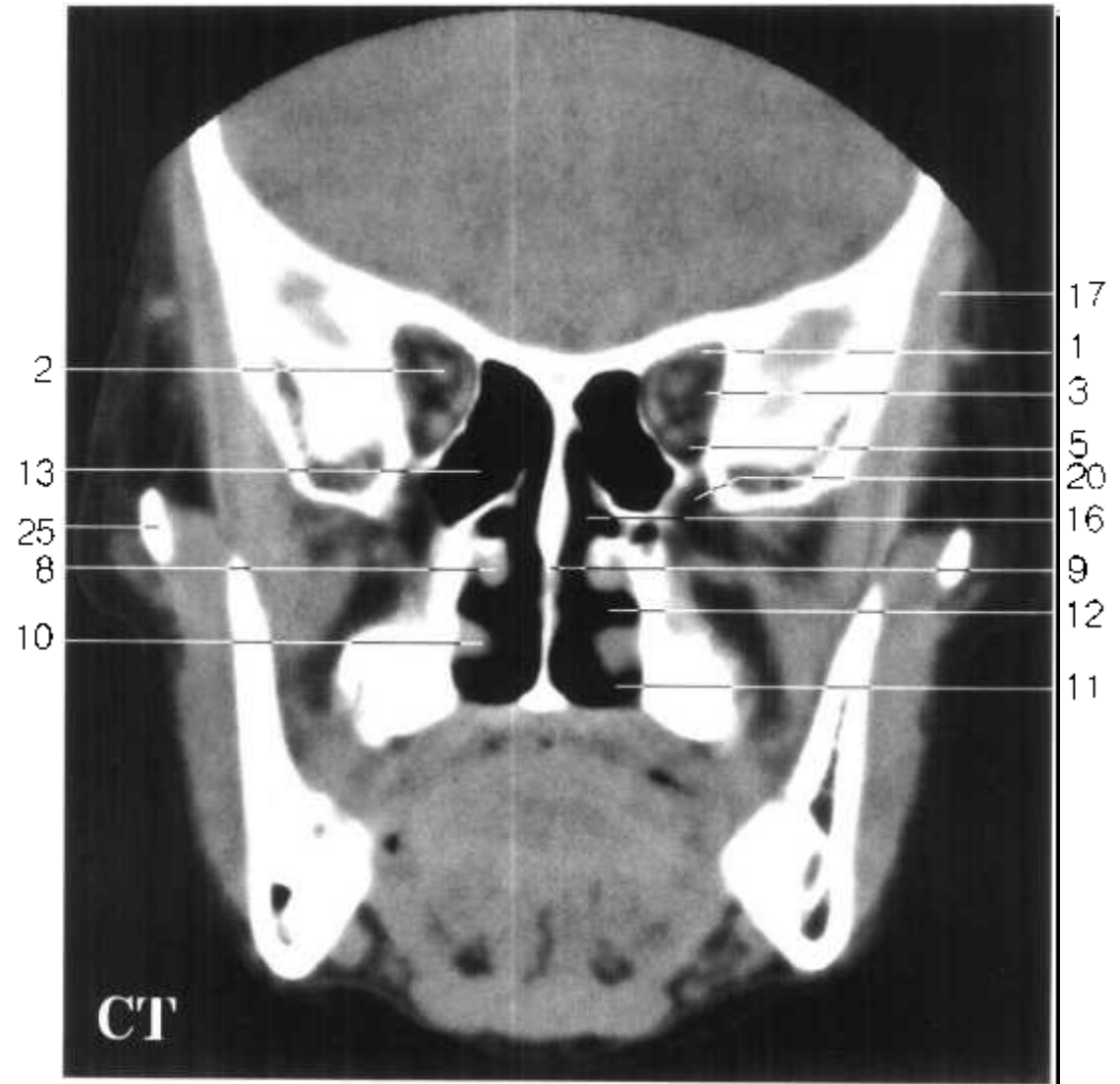


Fig.FV 13-15

- | | |
|--|---|
| 1. 上睑提肌及上直肌 levator palpebrae superioris and superior rectus | 13. 筛窦 ethmoidal sinus |
| 2. 视神经 optic n. | 14. 上斜肌 superior obliquus |
| 3. 外直肌 lateral rectus | 15. 眼动脉 ophthalmic a. |
| 4. 内直肌 medial rectus | 16. 上鼻道 superior nasal meatus |
| 5. 下直肌 inferior rectus | 17. 颞肌 temporalis |
| 6. 上鼻甲 superior nasal concha | 18. 颞叶 temporal lobe |
| 7. 上颌窦 maxillary sinus | 19. 上直肌 superior rectus |
| 8. 中鼻甲 middle nasal concha | 20. 翼腭窝 pterygopalatine fossa |
| 9. 鼻中隔 nasal septum | 21. 翼突 pterygoid process |
| 10. 下鼻甲 inferior nasal concha | 22. 咬肌 masseter |
| 11. 下鼻道 inferior nasal meatus | 23. 腭骨水平板 horizontal plate of palatine bone |
| 12. 中鼻道 middle nasal meatus | 24. 腭大管 greater palatine canal |
| | 25. 颧弓 zygomatic arch |

Fig.FV 13-15



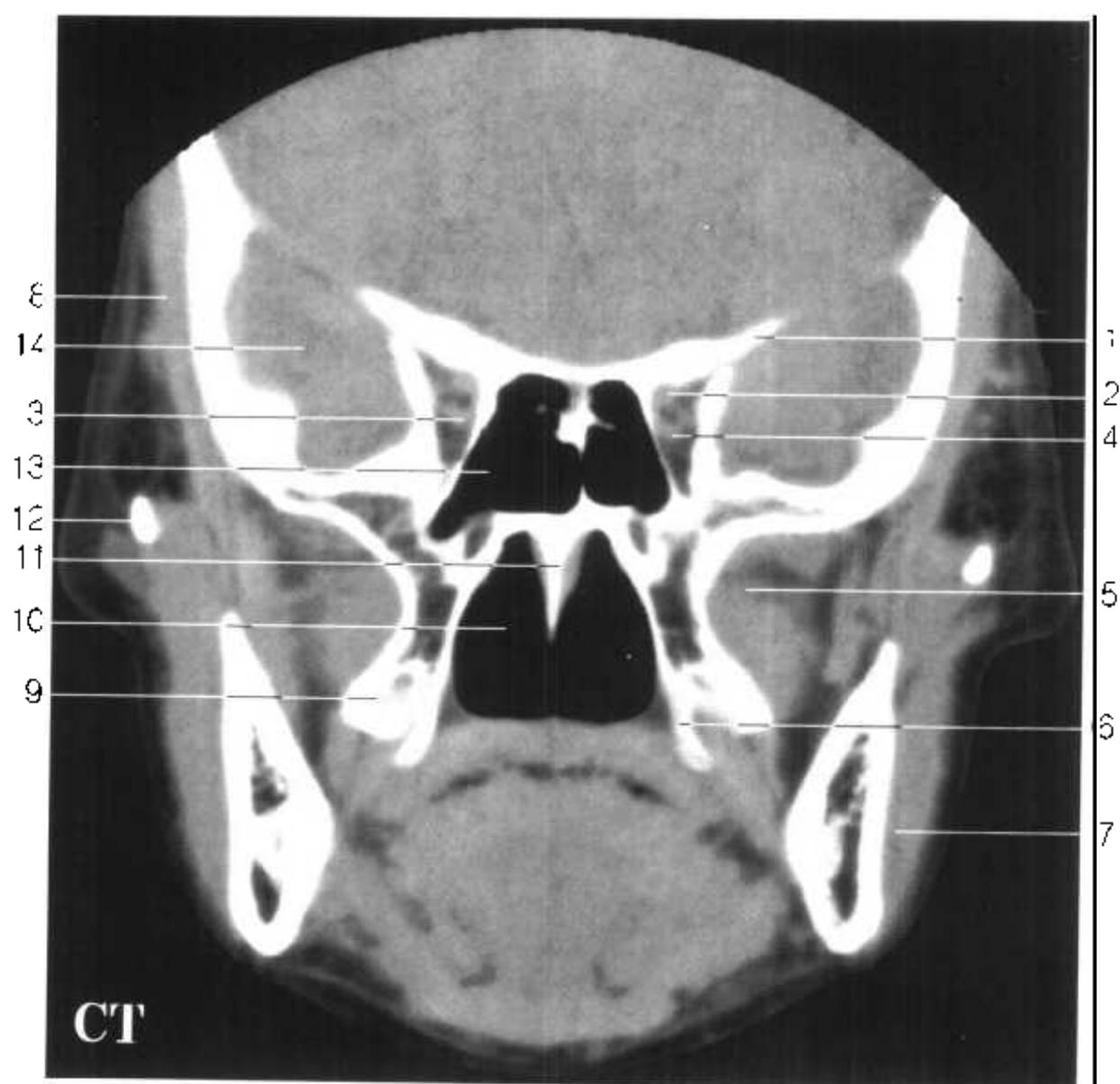


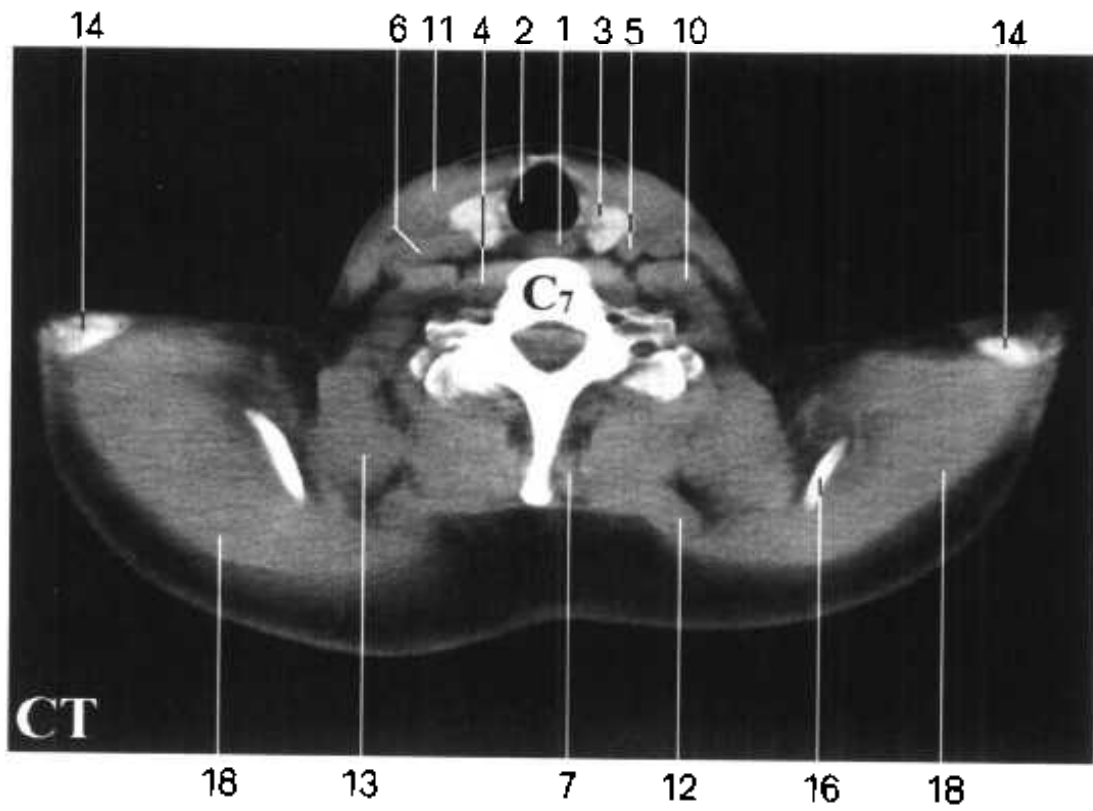
Fig.FV 16

- | | |
|--------------------------------------|-----------------------------------|
| 1. 蝶骨小翼 lesser wing of sphenoid bone | 8. 颞肌 temporalis |
| 2. 上斜肌 superior obliquus | 9. 翼突外侧板 lateral pterygoid plate |
| 3. 视神经 optic n. | 10. 鼻后孔 posterior nasal apertures |
| 4. 内直肌 medial rectus | 11. 犁骨 vomer |
| 5. 颞下窝 infratemporal fossa | 12. 颧弓 zygomatic arch |
| 6. 翼突内侧板 medial pterygoid plate | 13. 蝶窦 sphenoidal sinus |
| 7. 咬肌 masseter | 14. 颞叶 temporal lobe |

Fig.FV 16

胸部

THORAX



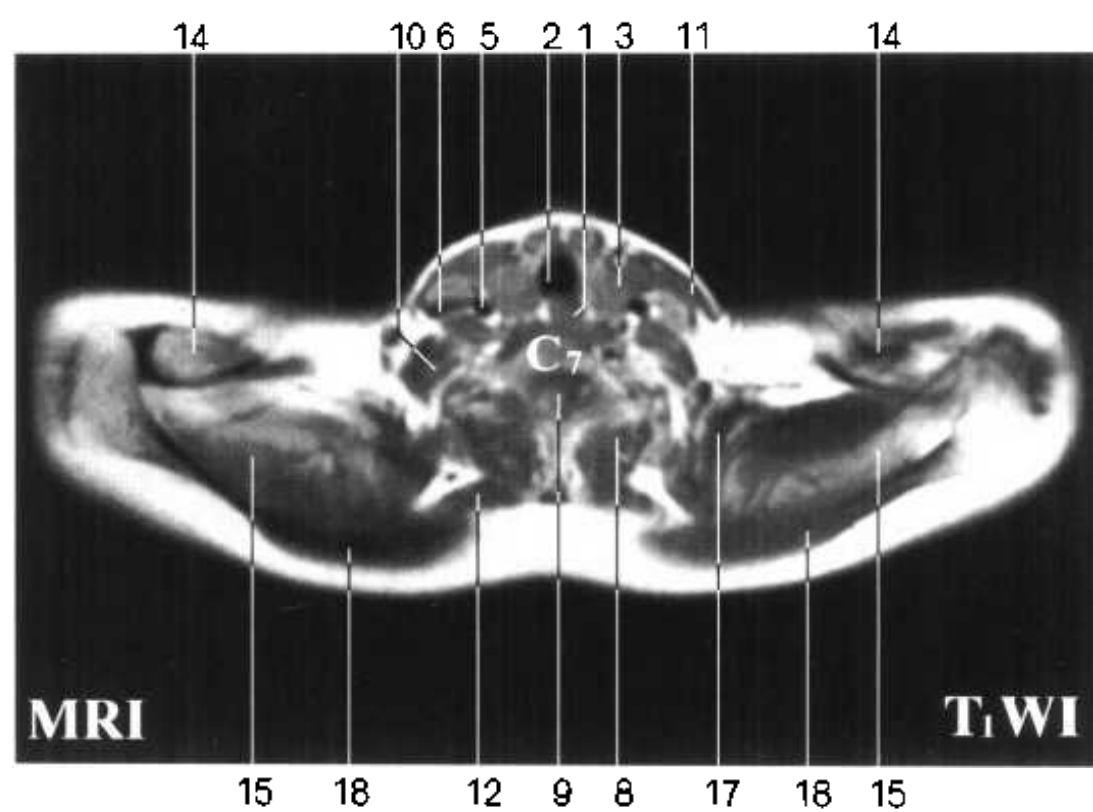
水平断面图 HT

Fig. HT 1

1. 食道 esophagus
2. 气管 trachea
3. 甲状腺 thyroid gland
4. 颈长肌 longus colli
5. 颈内动脉 internal carotid a.
6. 颈内静脉 internal jugular v.
7. 颈半棘肌 semispinalis cervicis
8. 多裂肌与回旋肌 multifidi and rotatores
9. 脊髓 spinal cord

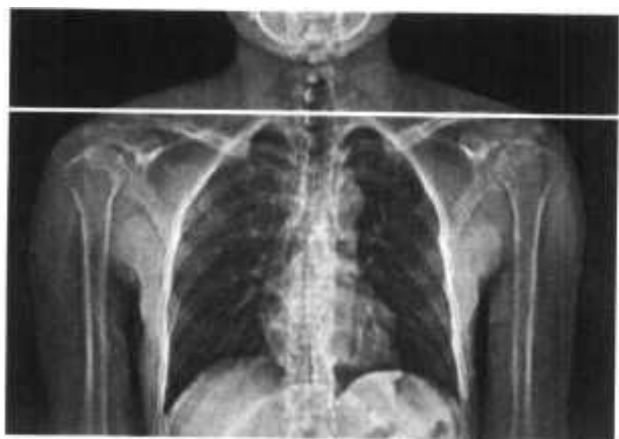

Fig. HT 1



- 10. 前斜角肌 *scalenus anterior*
- 11. 胸锁乳突肌 *sternocleidomastoid*
- 12. 小菱形肌 *rhomboideus minor*
- 13. 前锯肌 *serratus anterior*
- 14. 锁骨 *clavicle*
- 15. 冈上肌 *supraspinatus*
- 16. 肩胛骨 *scapula*
- 17. 肩胛提肌 *levator scapulae*
- 18. 斜方肌 *trapezies*

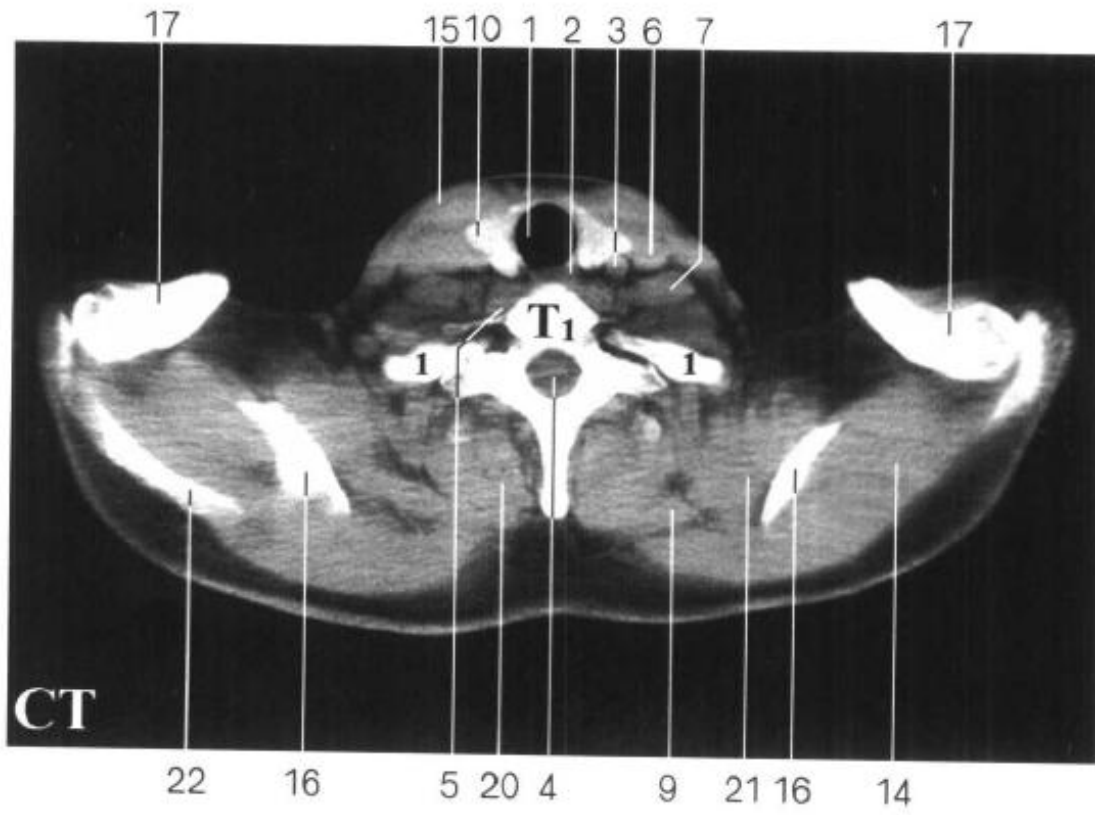
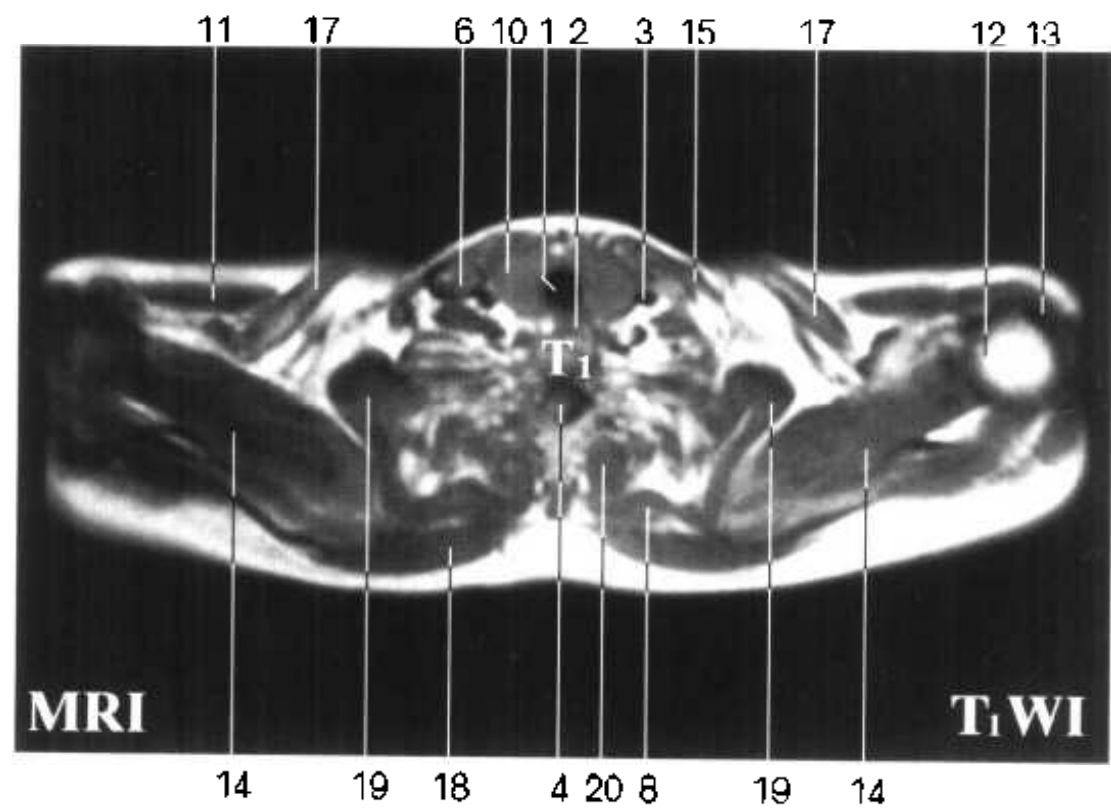


Fig. HT 2

1. 气管 trachea
2. 食道 esophagus
3. 颈总动脉 common carotid a.
4. 脊髓 spinal cord
5. 颈长肌 longus colli
6. 颈内静脉 internal jugular v.
7. 前斜角肌 scalenus anterior
8. 大菱形肌 rhomboideus major
9. 小菱形肌 rhomboideus minor
10. 甲状腺 thyroid gland
11. 胸大肌 pectoralis major
12. 肱骨头 head of humerus
13. 三角肌 deltoid

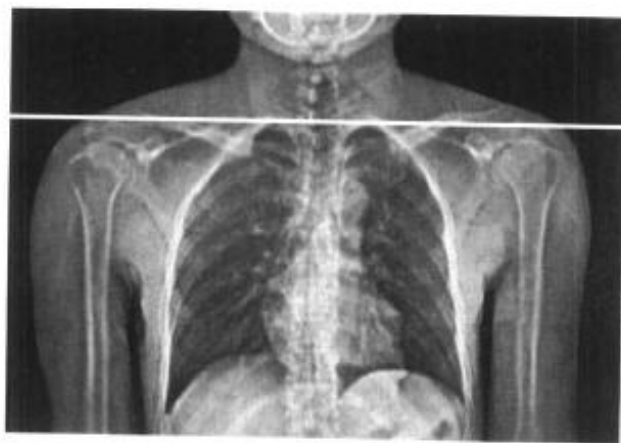

Fig. HT 2



- 14. 冈上肌 supraspinatus
- 15. 胸锁乳突肌 sternocleidomastoid
- 16. 肩胛骨 scapula
- 17. 锁骨 clavicle
- 18. 斜方肌 trapezius
- 19. 前锯肌 serratus anterior
- 20. 竖脊肌 erector spinae
- 21. 肩胛下肌 subscapularis
- 22. 肩胛冈 spine of scapula

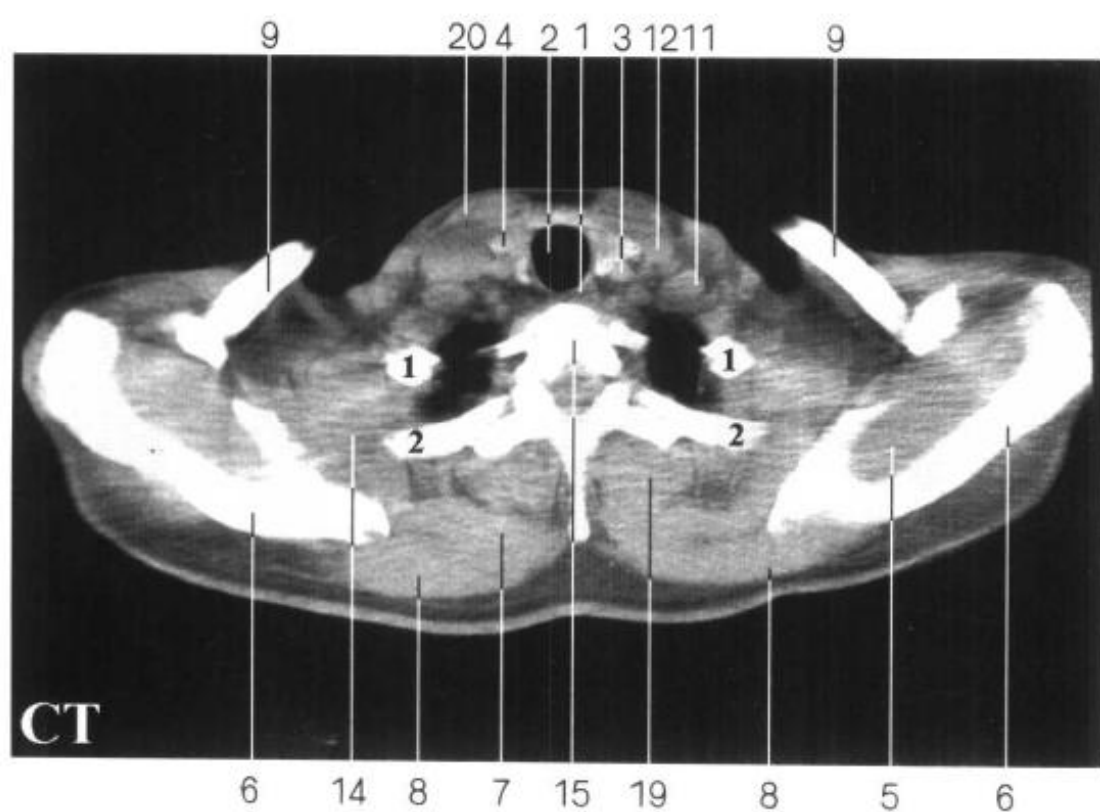
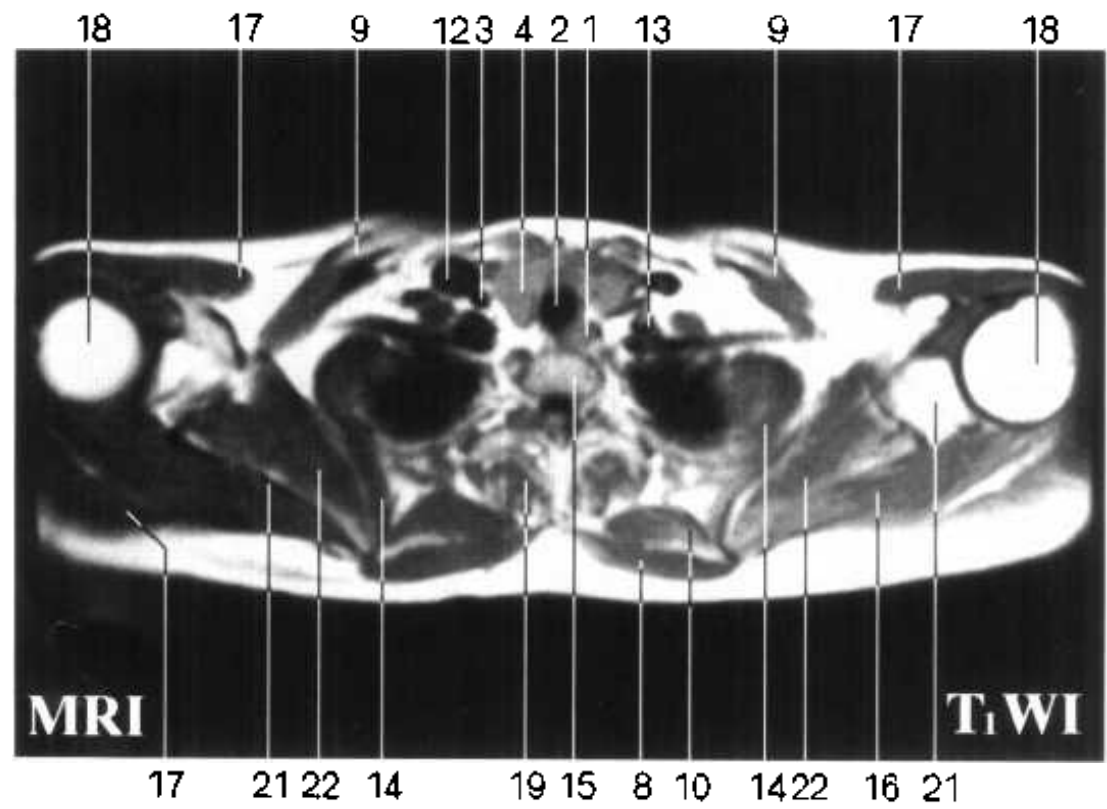


Fig. HT 3

1. 食道 esophagus
2. 气管 trachea
3. 颈总动脉 common carotid a.
4. 甲状腺 thyroid gland
5. 冈上肌 supraspinatus
6. 肩胛冈 spine of scapula
7. 大菱形肌 rhomboideus major
8. 斜方肌 trapezius
9. 锁骨 clavicle
10. 小菱形肌 rhomboideus minor
11. 前斜角肌 scalenus anterior
12. 颈内静脉 internal jugular v.
13. 椎动、静脉 vertebral a.and v.
14. 前锯肌 serratus anterior

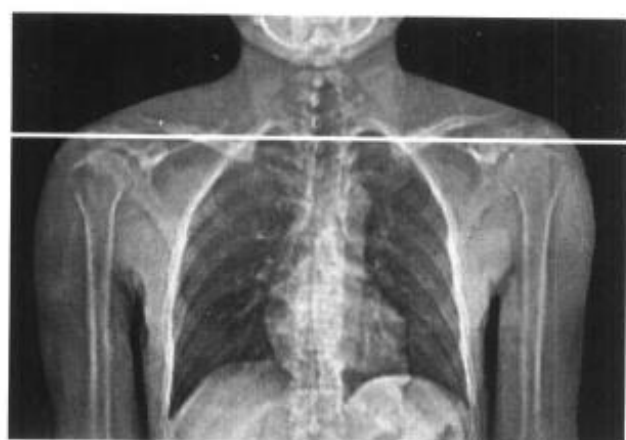

Fig. HT 3



- 15. 1、2胸椎间盘 intervertebral disc(T₁-T₂)
- 16. 冈下肌 infraspinatus
- 17. 三角肌 deltoid
- 18. 肱骨头 head of thumerus
- 19. 竖脊肌 erector spinae
- 20. 胸锁乳突肌 sternocleidomastoid
- 21. 肩胛骨 scapula
- 22. 肩胛下肌 subscapularis

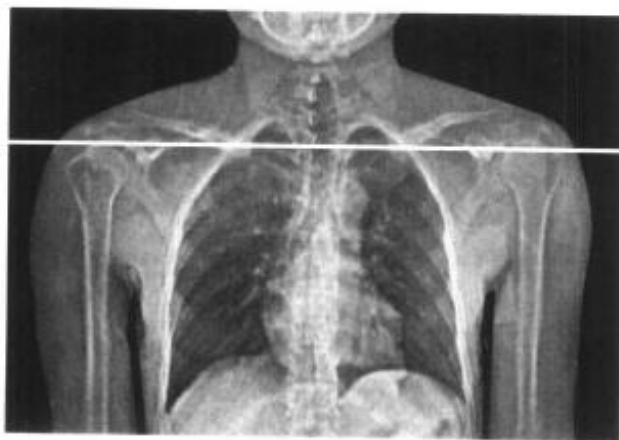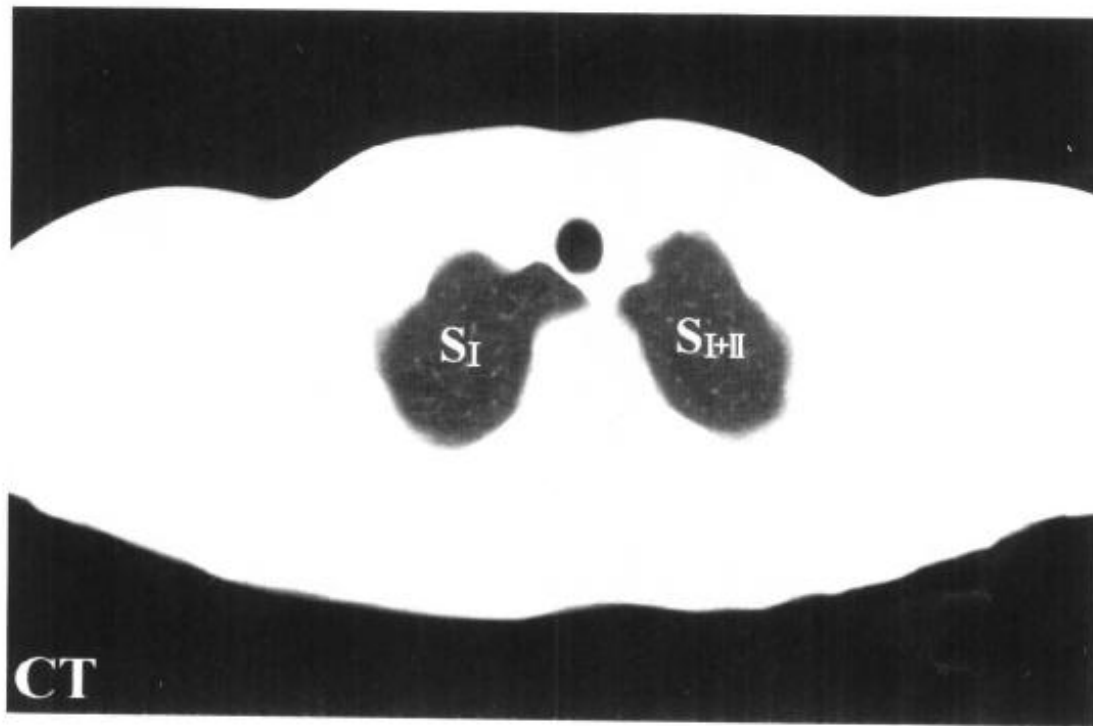
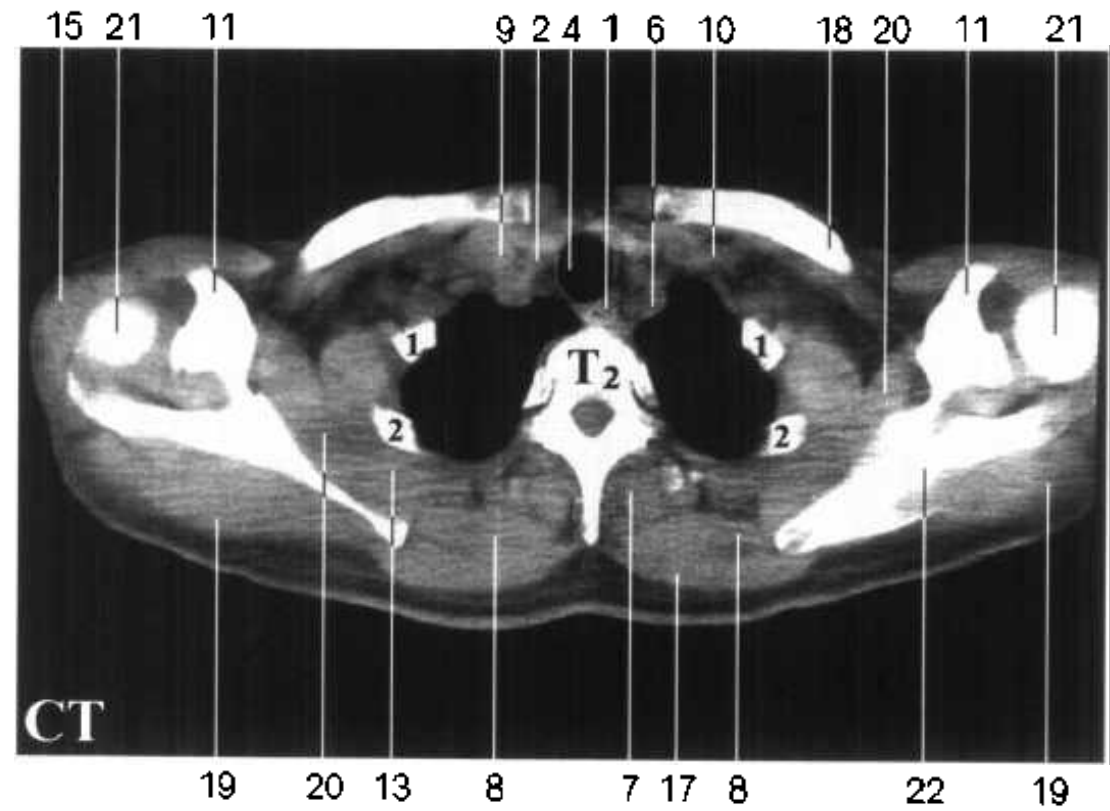


Fig. HT 4

1. 食管 esophagus
2. 头臂干 brachiocephalic trunk
3. 左锁骨下动静脉 left subclavian a.and v.
4. 气管 trachea
5. 左颈总动脉 left common carotid a.
6. 左锁骨下动、静脉 left subclavian a.and v.
7. 竖脊肌 erector spinae
8. 大菱形肌 rhomboideus major
9. 右头臂静脉 right brachiocephalic v.
10. 左头臂静脉 left brachiocephalic v.
11. 喙突 coraciod process
12. 胸大肌 pectoralis major
13. 前锯肌 serratus anterior

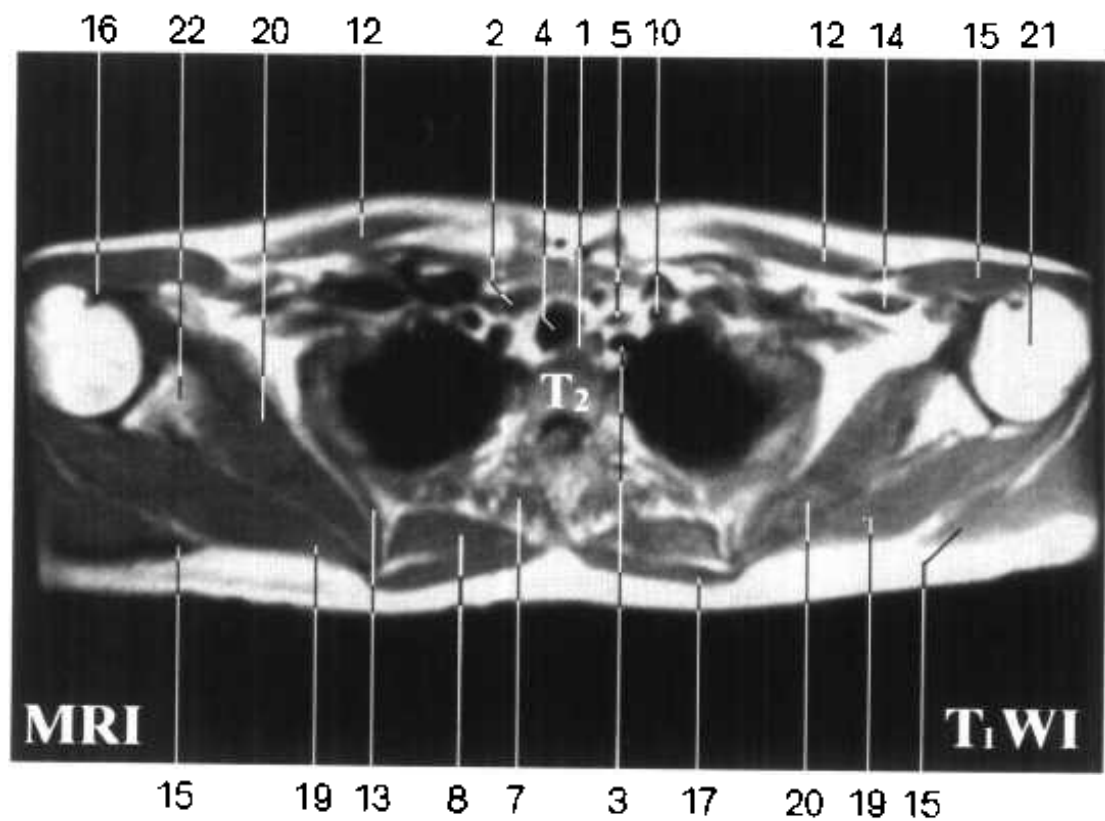
Fig. HT 4



- 14. 胸小肌 pectoralis minor
- 15. 三角肌 deltoid
- 16. 肱二头肌长头 long head of biceps brachii
- 17. 斜方肌 trapezius
- 18. 锁骨 clavicle
- 19. 冈下肌 infraspinatus
- 20. 肩胛下肌 subscapularis
- 21. 肱骨头 head of humerus
- 22. 肩胛骨 scapula

S₁: 尖段(S₁) apical segment(S₁)

S_{1+II}: 尖后段(S_{1+II}) apicoposterior segment(S_{1+II})



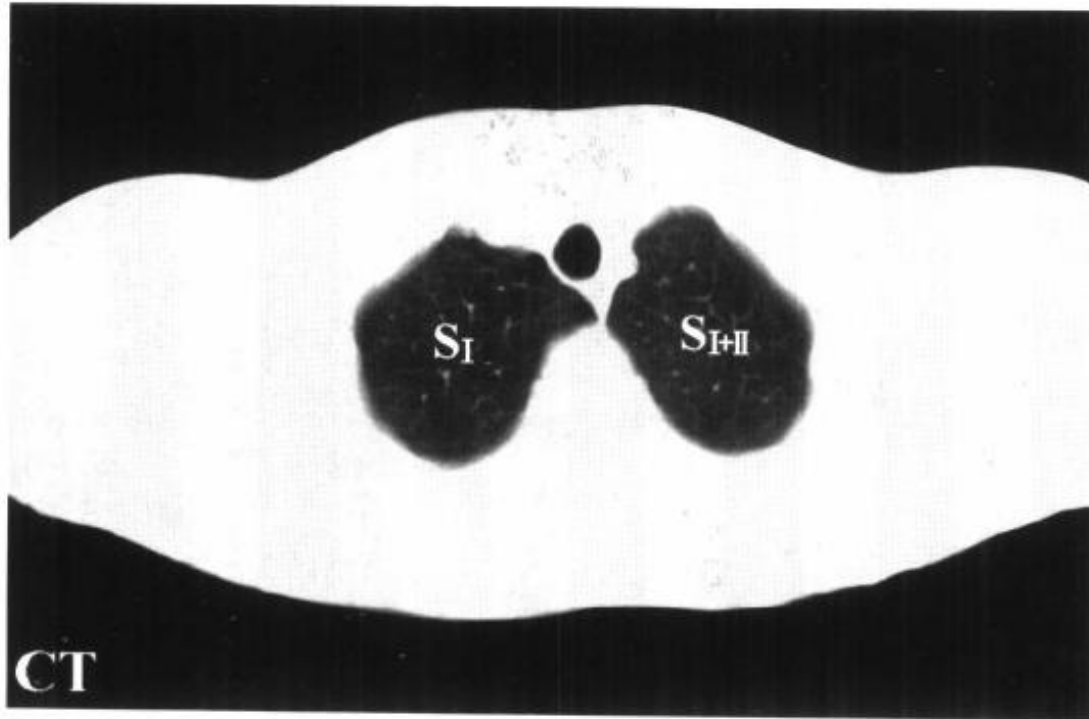
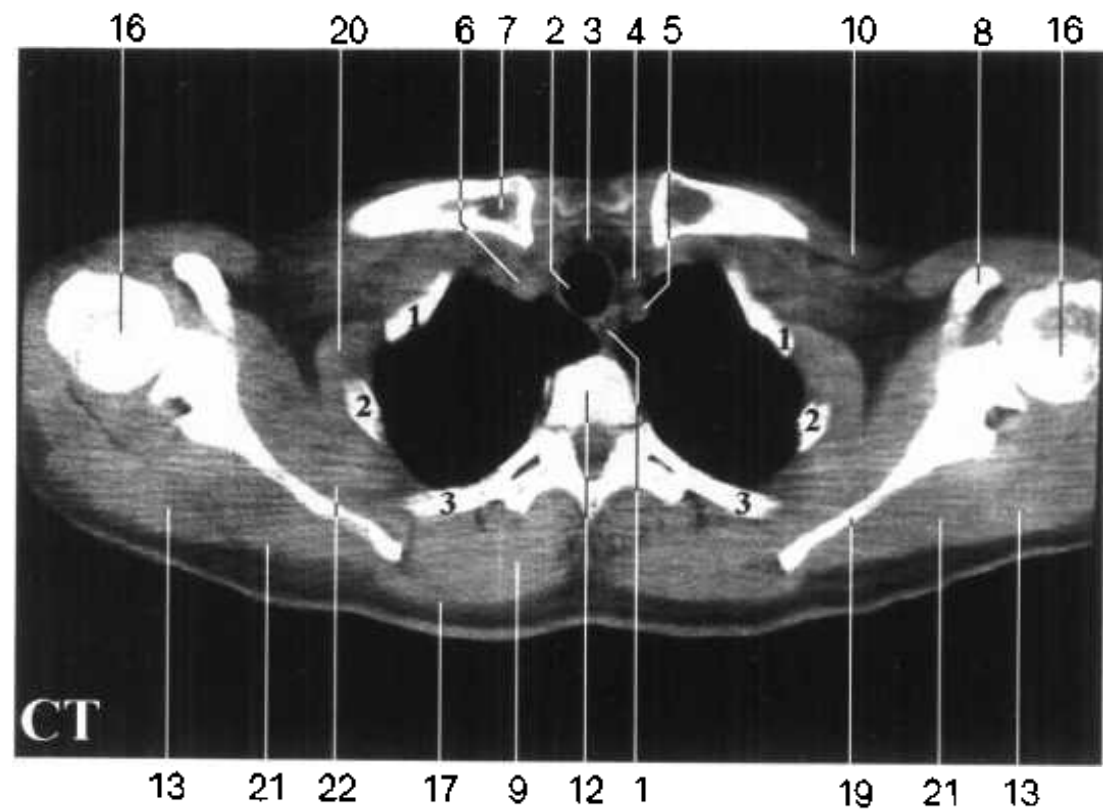


Fig. HT 5

1. 食管 esophagus
2. 气管 trachea
3. 头臂干 brachiocephalic trunk
4. 左颈总动脉 left common carotid a.
5. 左锁骨下动脉 left subclavian
6. 头臂静脉 brachiocephalic v.
7. 锁骨胸骨端 sternal end of clavicle
8. 喙突 coracoid process
9. 大菱形肌 rhomboideus major
10. 胸大肌 pectoralis major
11. 肱二头肌短头与喙肱肌 short head of biceps brachii and coracobrachialis
12. 2、3胸椎间盘 intervertebral disc(T₂-T₃)
13. 三角肌 deltoid

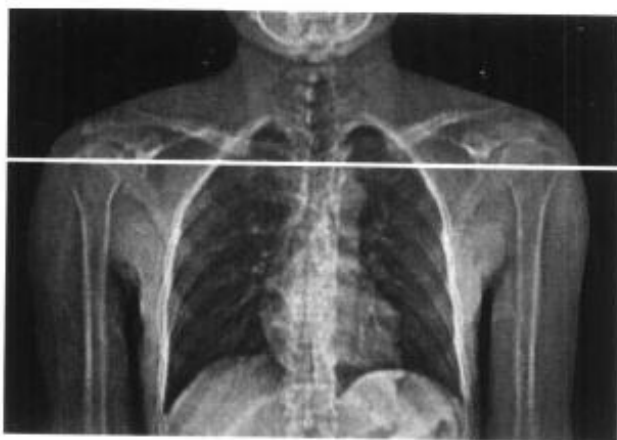

Fig. HT 5



- 14. 肱二头肌长头 long head of biceps brachii
- 15. 竖脊肌 erector spinae
- 16. 肱骨头 head of humerus
- 17. 斜方肌 trapezius
- 18. 胸小肌 pectoralis minor
- 19. 肩胛骨 scapula
- 20. 前锯肌 serratus anterior
- 21. 冈下肌 infraspinatus
- 22. 肩胛下肌 subscapularis
- S_{I+II} : 尖后段(S_{I+II})
apicoposterior segment(S_{I+II})
- S_I : 尖段(S_I) apical segment(S_I)

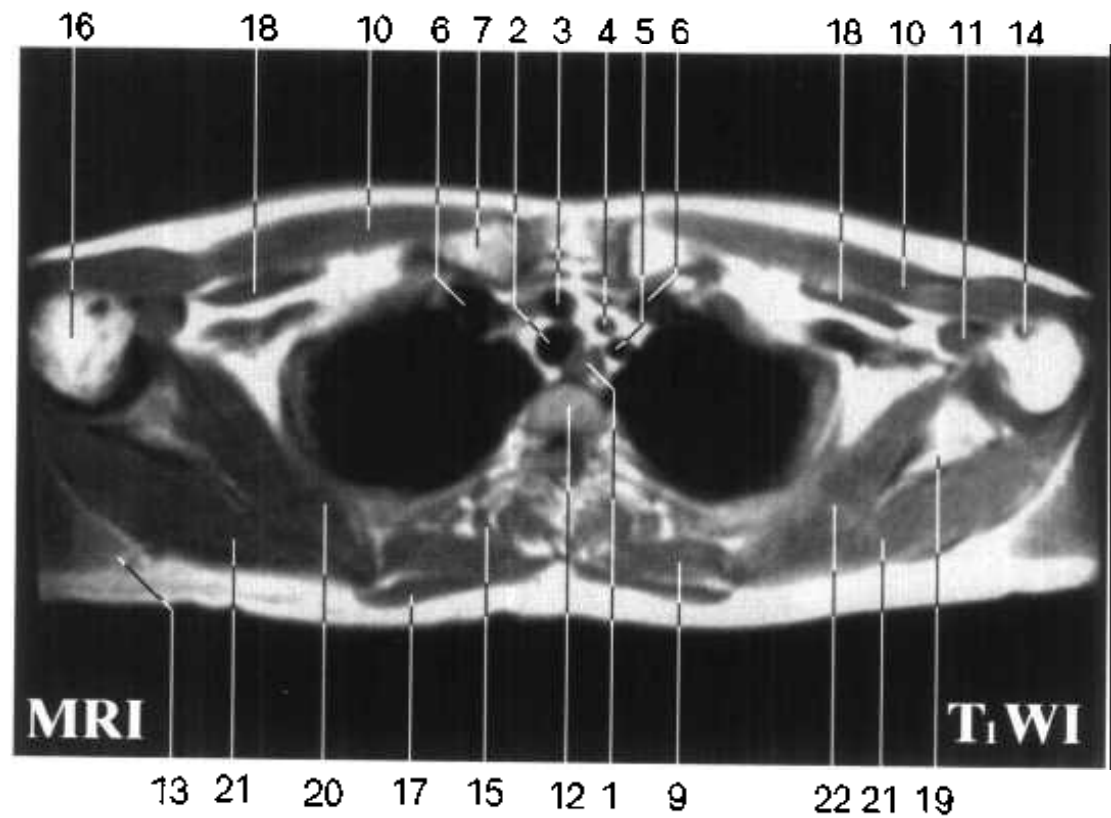
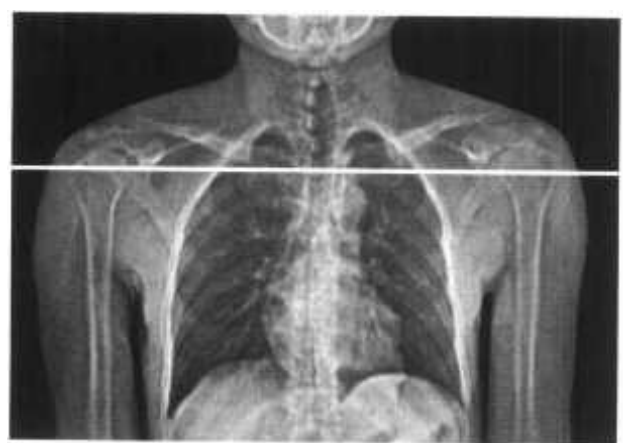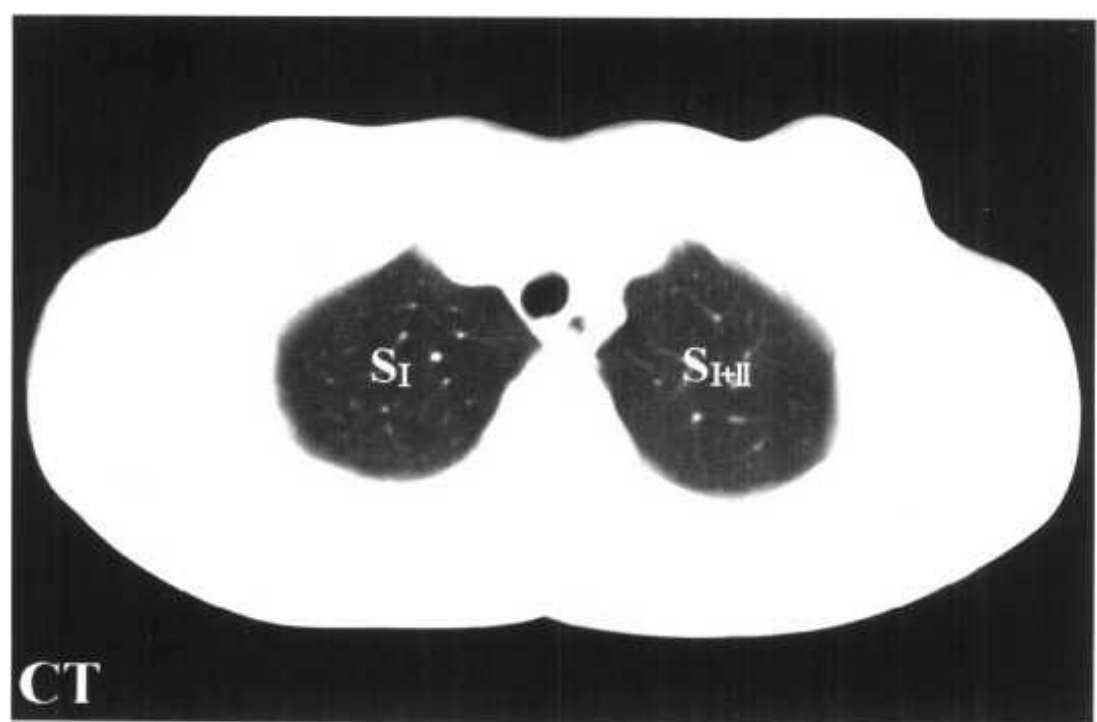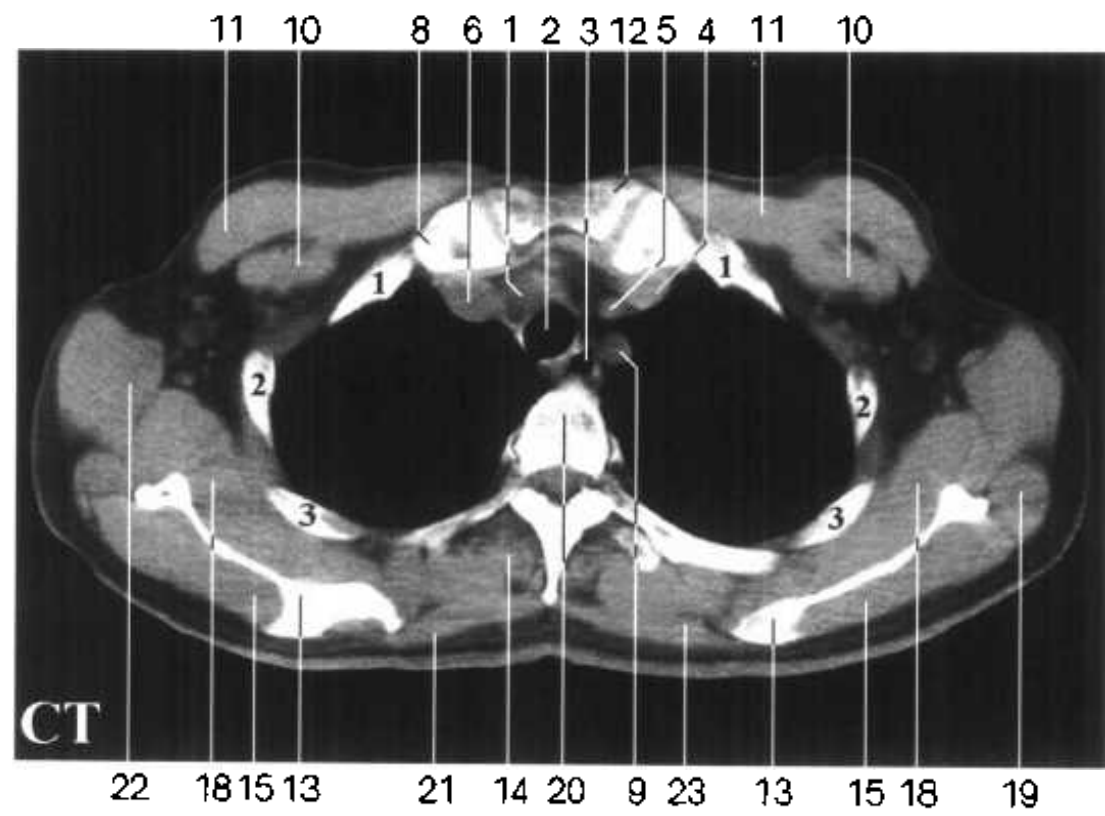




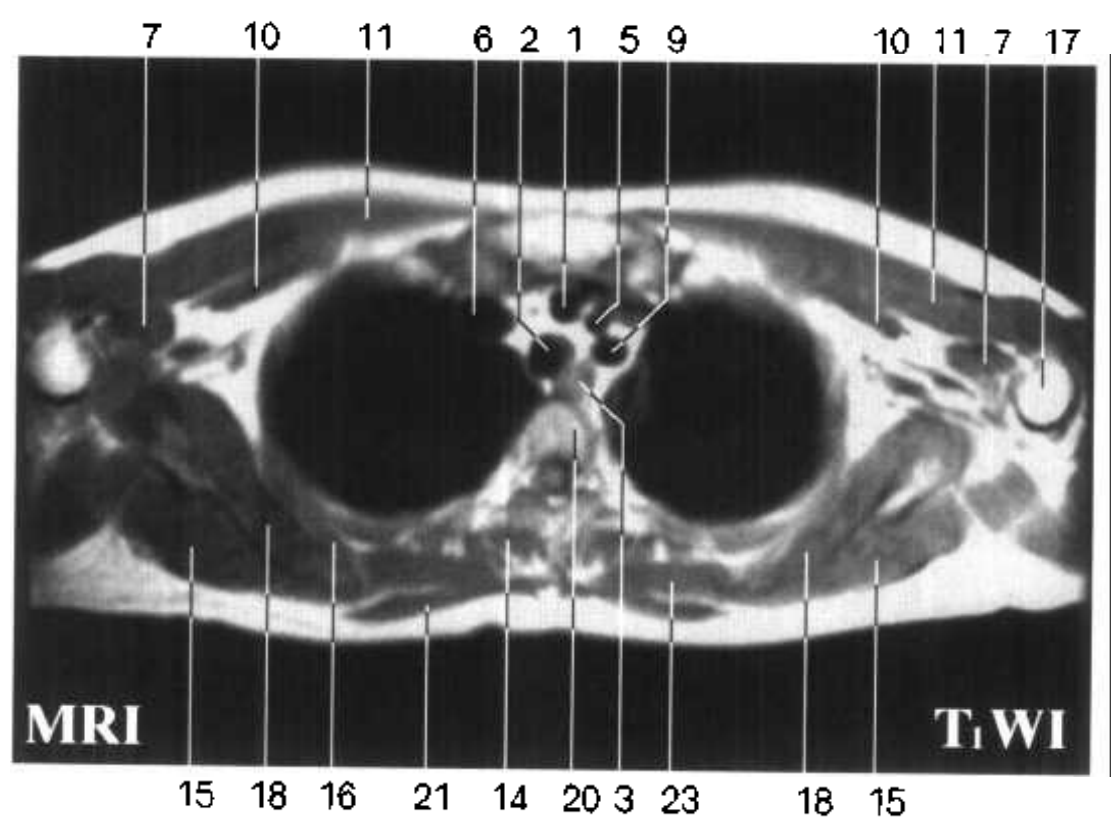
Fig. HT 6

1. 头臂干 brachiocephalic trunk
2. 气管 trachea
3. 食管 exophagus
4. 左头臂静脉 left brachiocephalic v.
5. 左颈总动脉 left common carotid a.
6. 右头臂静脉 right brachiocephalic v.
7. 肱二头肌 biceps brachii
8. 锁骨 clavicle
9. 锁骨下动脉 subclavian v.
10. 胸小肌 pectoralis minor
11. 胸大肌 pectoralis major
12. 胸骨柄 manubrium sterni
13. 肩胛骨 scapula
14. 竖脊肌 erector spinae

Fig. HT 6



- 15. 冈下肌 infraspinatus
- 16. 前锯肌 serratus anterior
- 17. 肱骨 humerus
- 18. 肩胛下肌 subscapularis
- 19. 小圆肌 teres minor
- 20. 3、4胸椎间盘 intervertebral disc(T₃~T₄)
- 21. 斜方肌 trapezius
- 22. 大圆肌 teres major
- 23. 大菱形肌 rhomboideus major
- S_I:尖段(S_I) apical segment(S_I)
- S_{I+II}:尖后段(S_{I+II}) apicoposterior segment(S_{I+II})



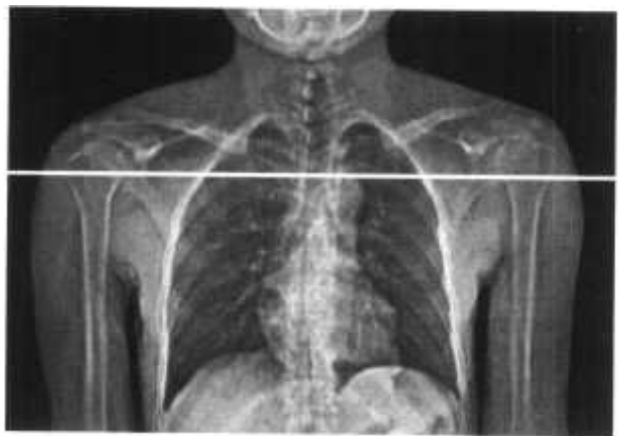
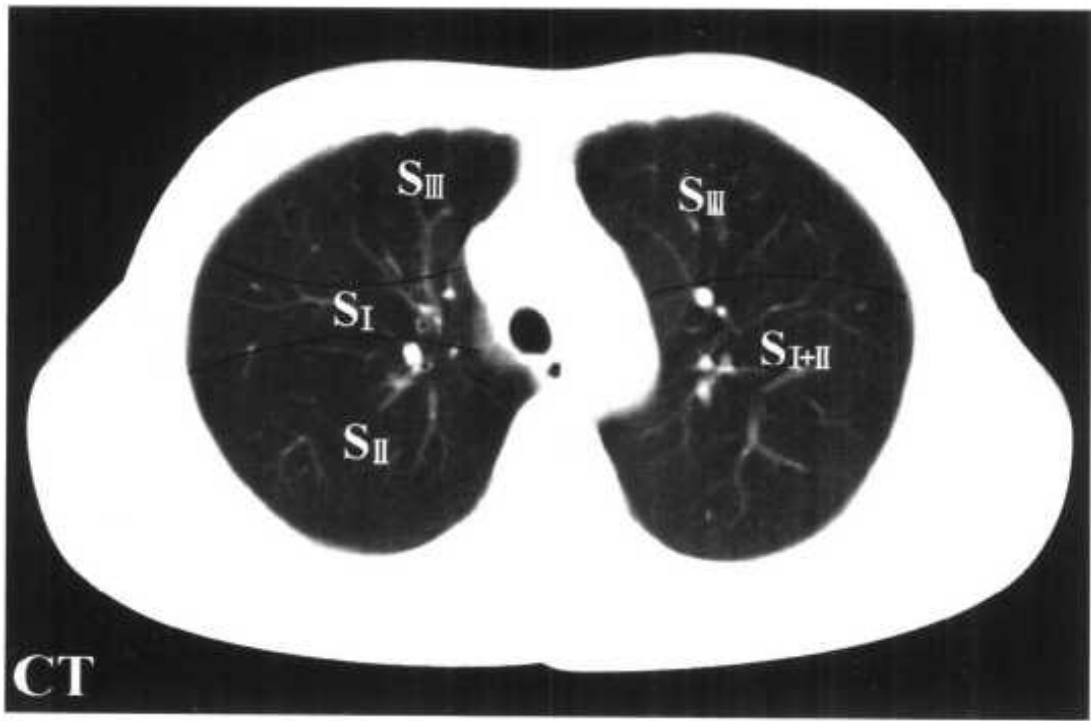
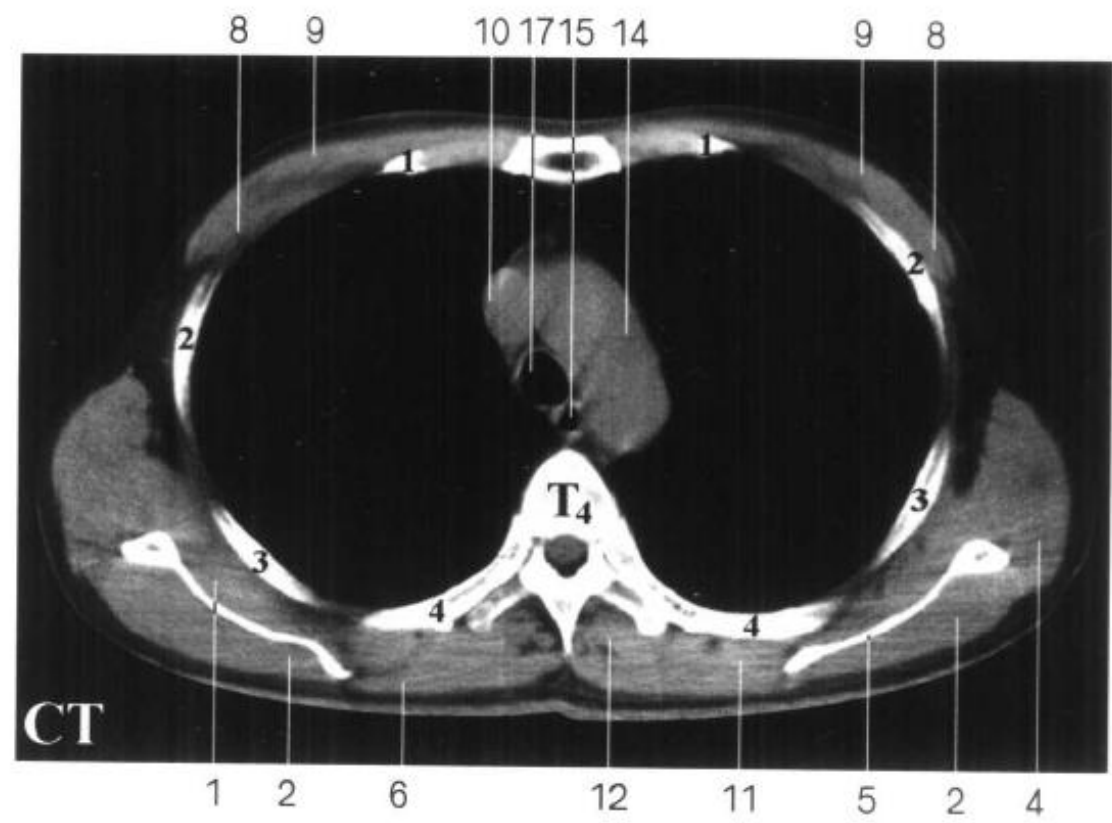


Fig. HT 7

1. 肩胛下肌 subscapularis
2. 冈下肌 infraspinatus
3. 小圆肌 teres minor
4. 大圆肌 teres major
5. 肩胛骨 scapula
6. 斜方肌 trapezius
7. 肱骨 humerus
8. 胸小肌 pectoralis minor
9. 胸大肌 pectoralis major
10. 上腔静脉 superior vena cava
11. 大菱形肌 rhomboideus major
12. 竖脊肌 erector spinae
13. 胸骨柄 manubrium sterni

Fig. HT 7



14. 主动脉弓 aortic arch

15. 食管 esophagus

16. 脊髓 spinal cord

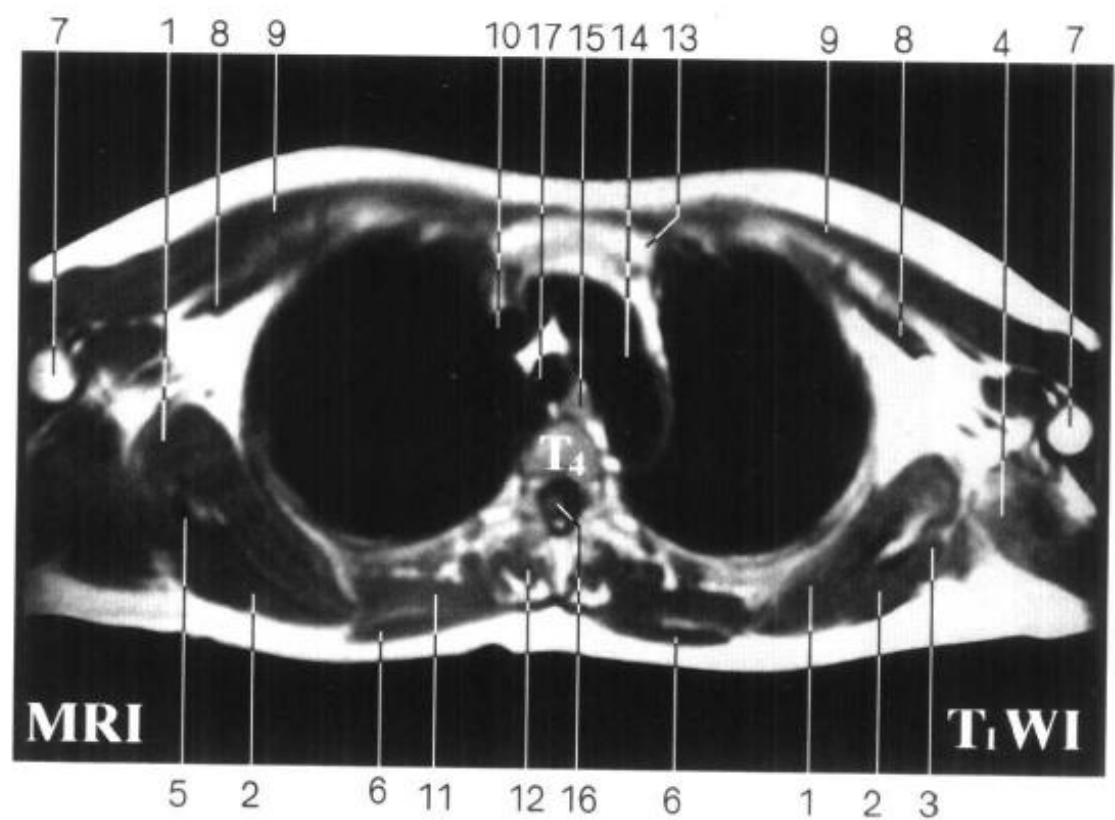
17. 气管 trachea

S_I: 尖段(S_I) apical segment(S_I)

S_{I+II}: 尖后段(S_{I+II}) apicoposterior segment(S_{I+II})

S_{II}: 后段(S_{II}) anterior segment(S_{II})

S_{III}: 前段(S_{III}) anterior segment(S_{III})



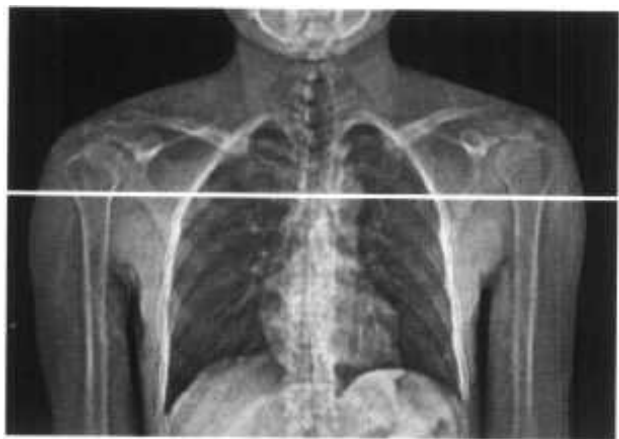
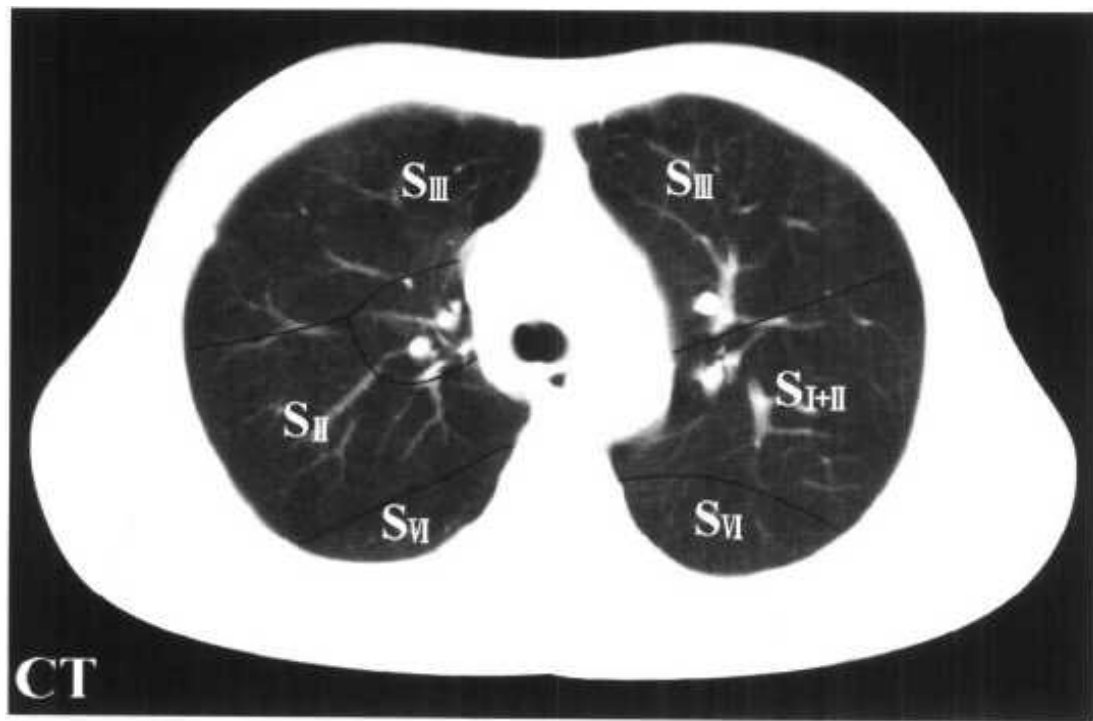
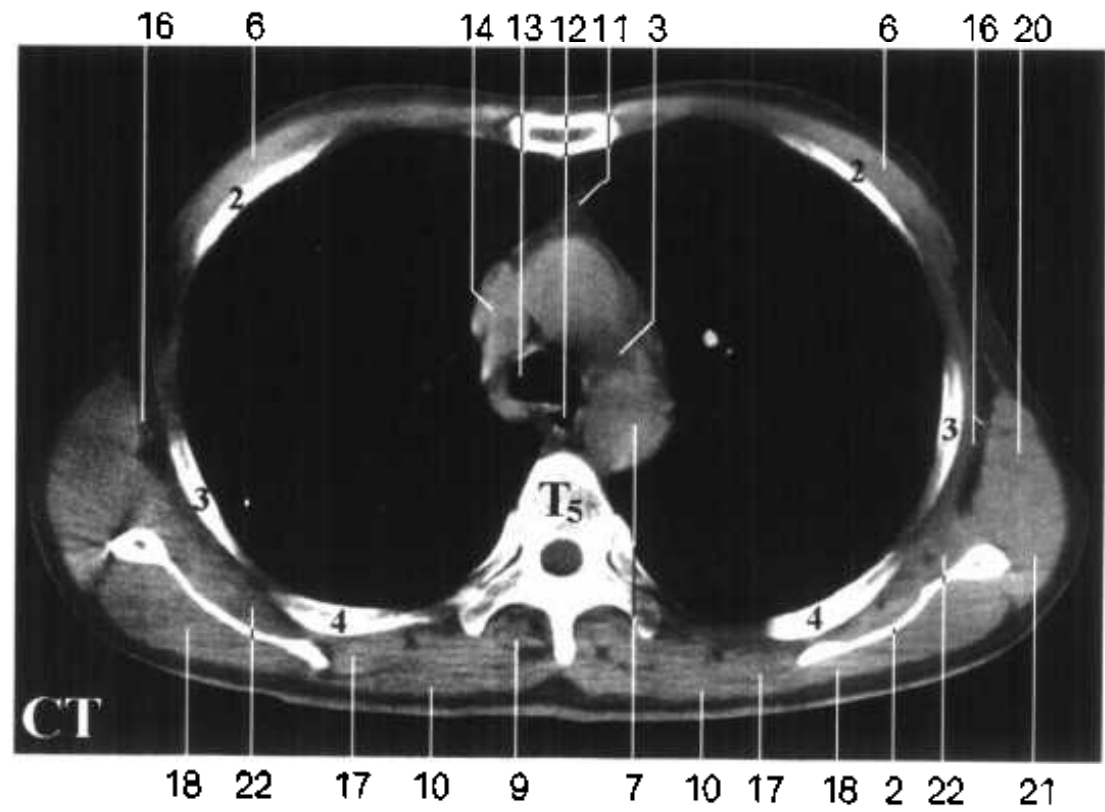



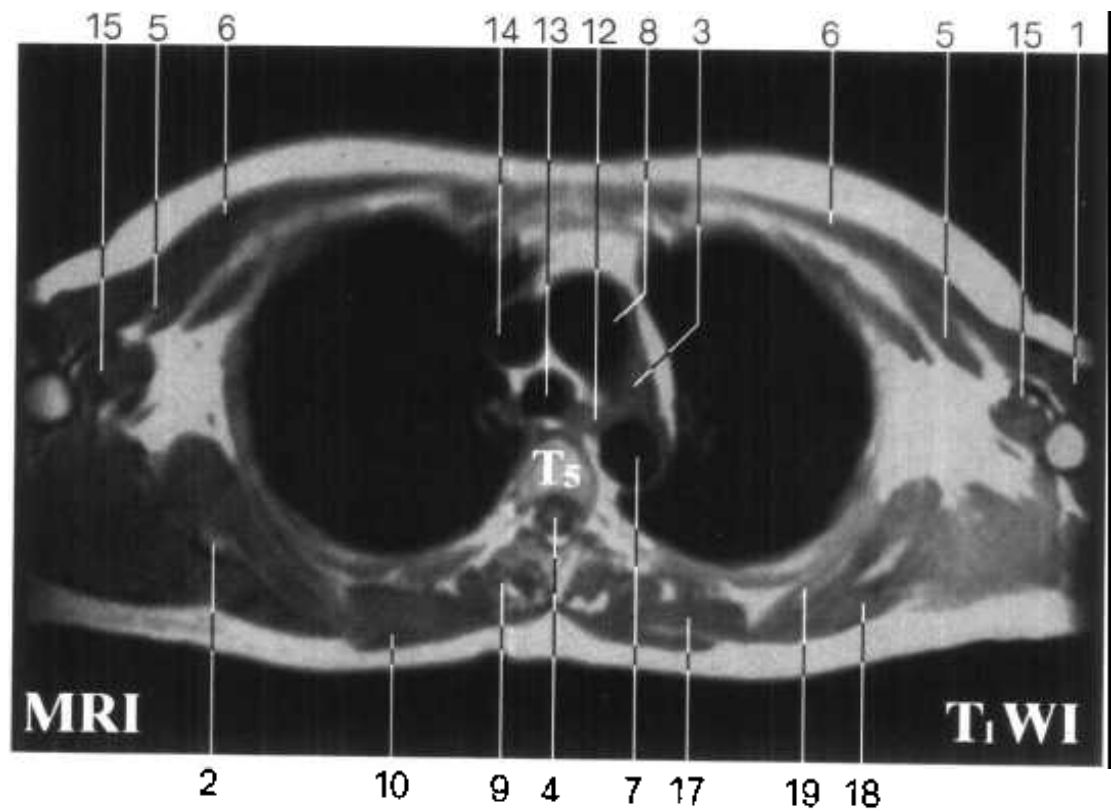
Fig. HT 8

1. 三角肌 deltoid
2. 肩胛骨 scapula
3. 主动脉肺动脉窗 aorto-pulmonary window
4. 脊髓 spinal cord
5. 胸小肌 pectoralis minor
6. 胸大肌 pectoralis major
7. 胸主动脉 thoracic aorta
8. 升主动脉 ascending aorta
9. 竖脊肌 erector spinae
10. 斜方肌 trapezius
11. 胸腺 thymus
12. 食管 esophagus
13. 气管 trachea
14. 上腔静脉 superior vena cava
15. 肱二头肌 biceps brachii
16. 胸背动、静脉与胸背神经 thoracodorsal a., v. and thoracodorsal n.

Fig. HT 8



- 17. 大菱形肌 rhomboideus major
- 18. 冈下肌 infraspinatus
- 19. 前锯肌 serratus anterior
- 20. 背阔肌 latissimus dorsi
- 21. 大圆肌 teres major
- 22. 肩胛下肌 subscapularis
- S_{I+II}: 尖后段(S_{I+II})
apicoposterior
segment(S_{I+II})
- S_{II}: 后段(S_{II}) posterior
segment(S_{II})
- S_{III}: 前段(S_{III}) anterior
segment(S_{III})
- S_{VI}: 上段(S_{VI}) superior
segment(S_{VI})



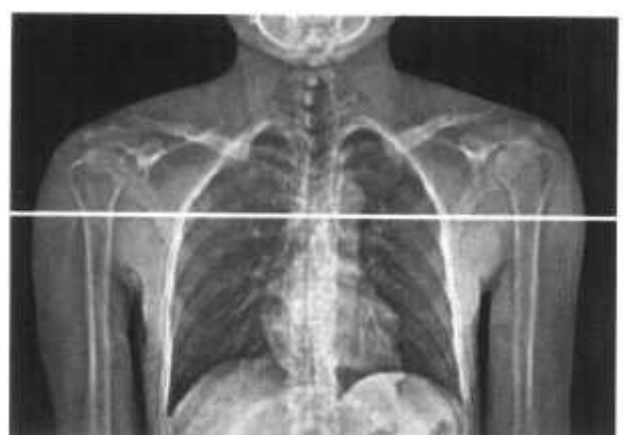
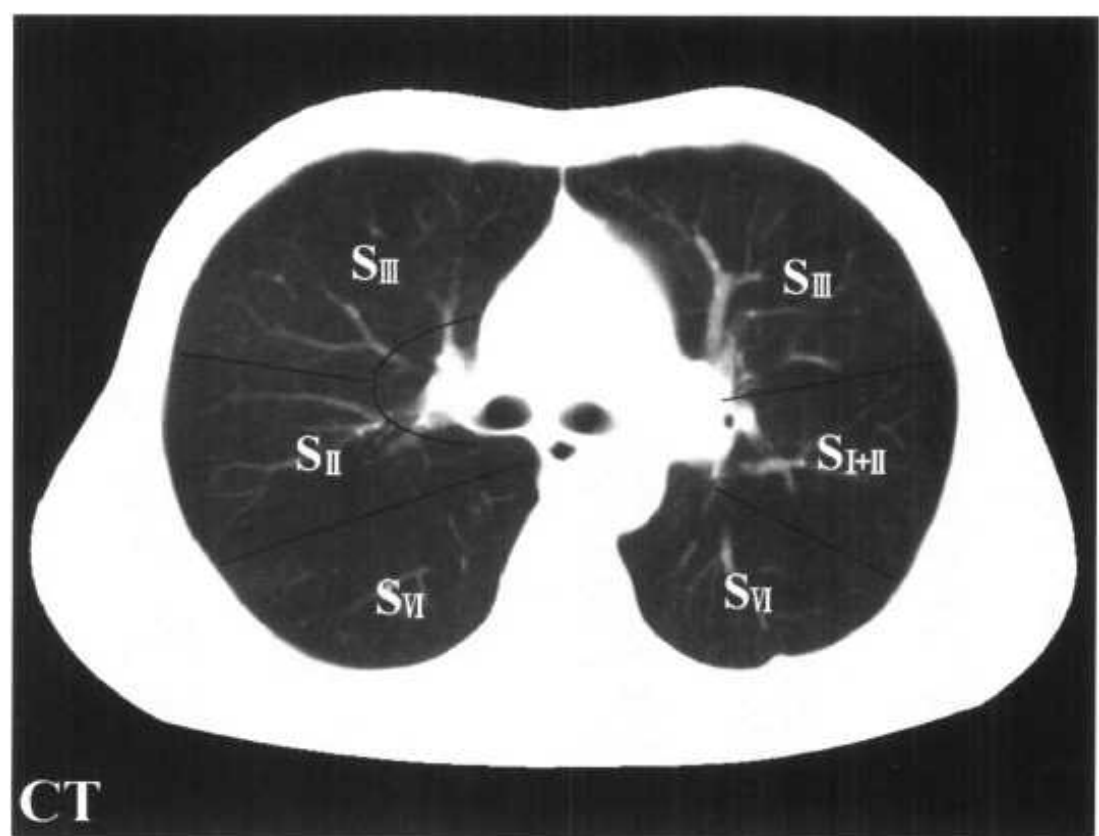
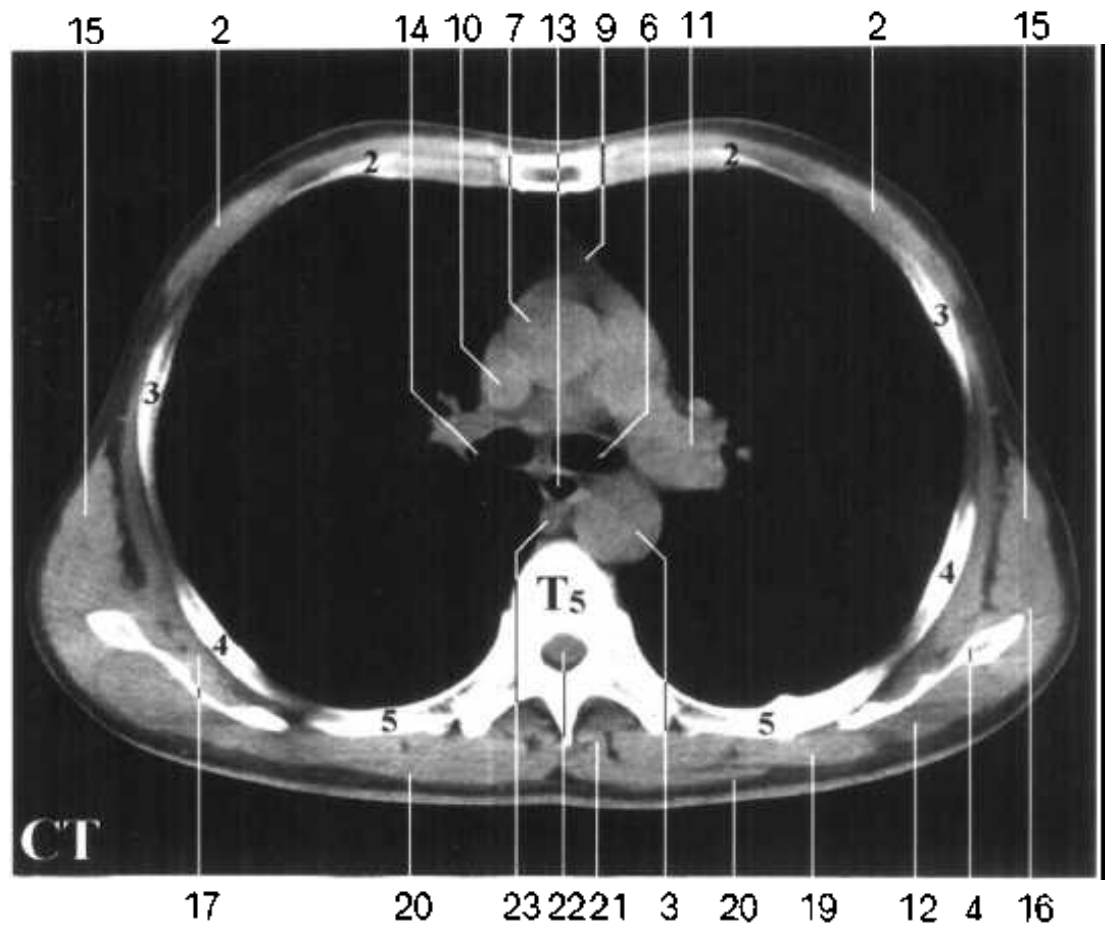


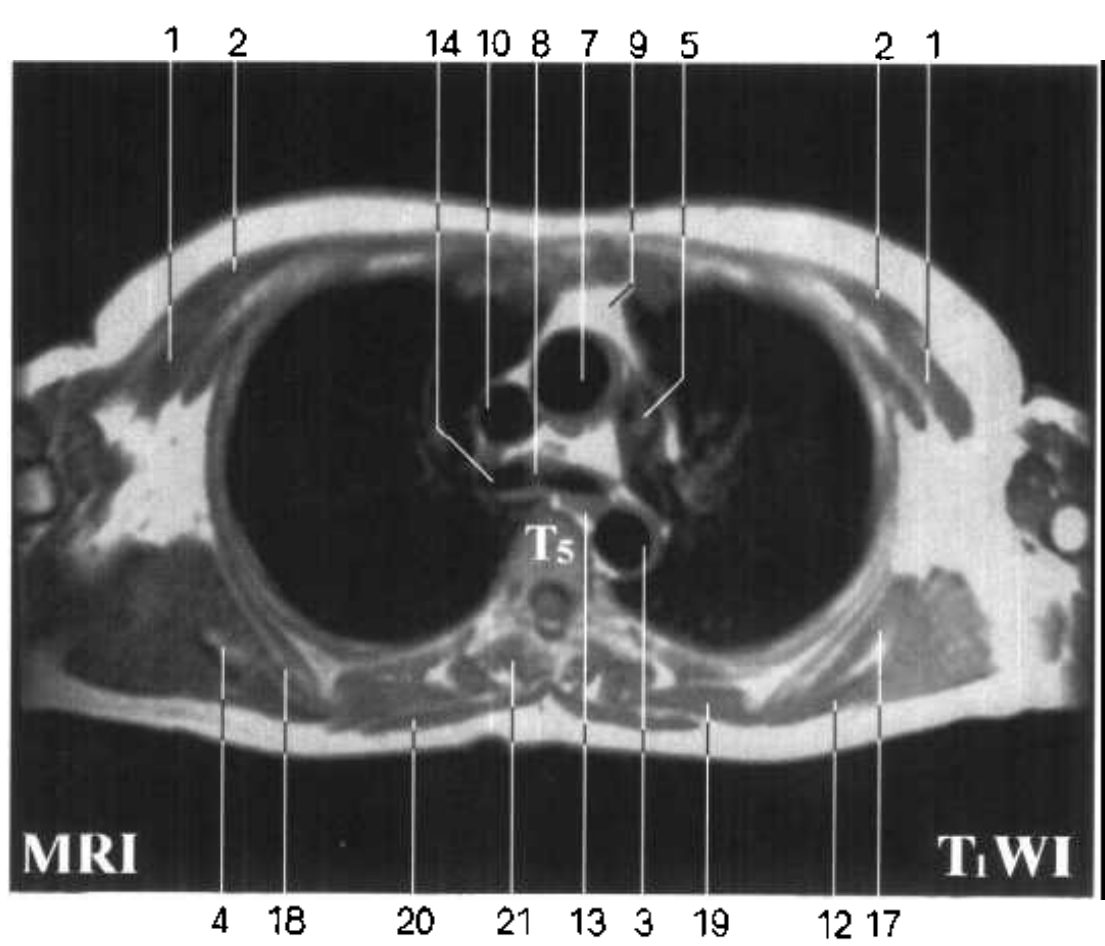
Fig. HT 9

1. 胸小肌 pectoralis minor
2. 胸大肌 pectoralis major
3. 胸主动脉 thoracic aorta
4. 肩胛骨 scapula
5. 肺动脉 pulmonar a.
6. 左主支气管 left principal bronchus
7. 升主动脉 ascending aorta
8. 气管隆嵴 carina of trachea
9. 胸腺 thymus
10. 上腔静脉 superior vena cava
11. 左肺动脉 left pulmonary a.
12. 冈下肌 infraspinatus
13. 食管 esophagus
14. 右主支气管 right principe branchus
15. 背阔肌 latissimus dorsi
16. 大圆肌 teres major
17. 肩胛下肌 subscapularis

Fig. HT 9



- 18. 前锯肌 serratus anterior
- 19. 大菱形肌 rhomboideus major
- 20. 斜方肌 trapezius
- 21. 竖脊肌 erector spinae
- 22. 脊髓 spinal cord
- 23. 奇静脉 azygos v.
- S_{I+II}: 尖后段(S_{I+II})
apicoposterior segment(S_{I+II})
- S_{II}: 后段(S_{II}) posterior segment(S_{II})
- S_{III}: 前段(S_{III}) anterior segment(S_{III})
- S_{VI}: 上段(S_{VI}) superior segment(S_{VI})



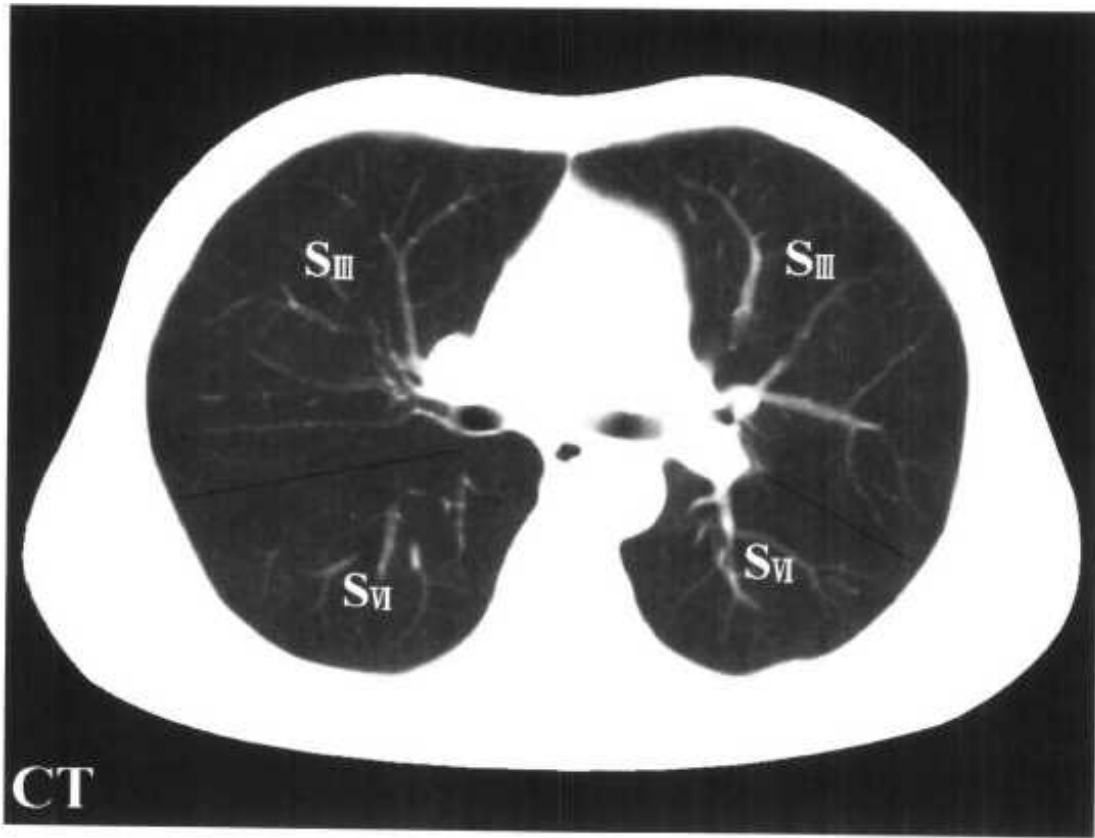
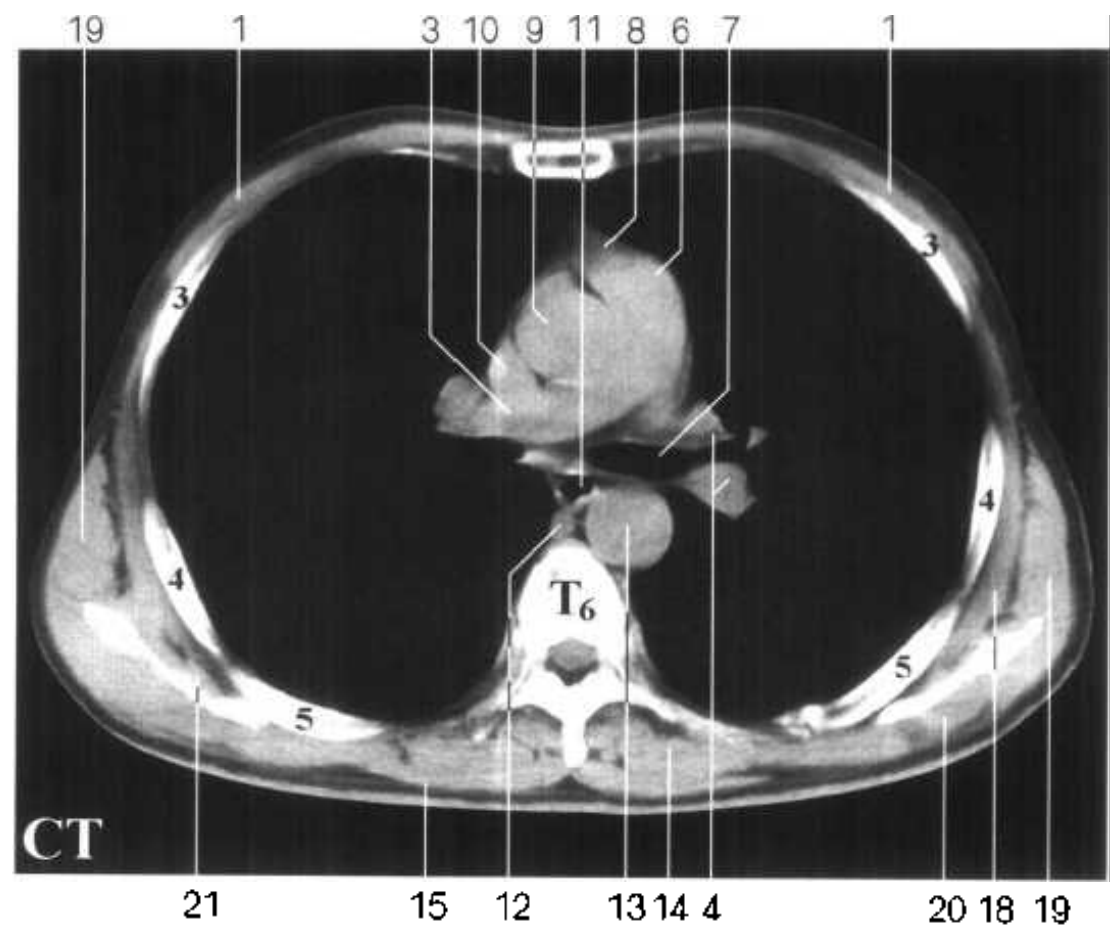


Fig. HT 10

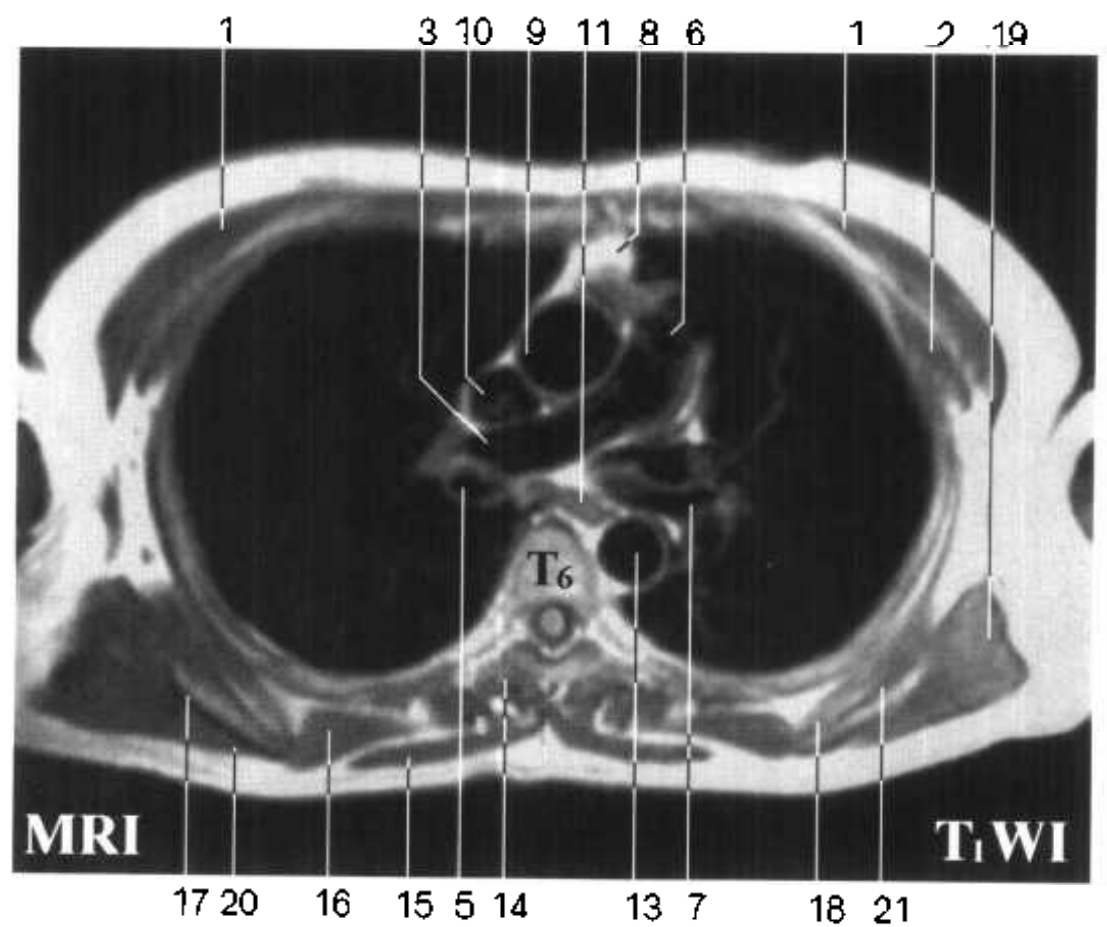
1. 胸大肌 pectoralis major
2. 胸小肌 pectoralis minor
3. 右肺动脉 right pulmonary a.
4. 左肺动脉及左肺上静脉 left pulmonary a. and left superior pulmonary v.
5. 右主支气管 right principal bronchus
6. 肺动脉干 pulmonary trunk
7. 左主支气管 left principal bronchus
8. 胸腺 thymus
9. 升主动脉 ascending aorta
10. 上腔静脉 superior vena cava
11. 食管 esophagus
12. 奇静脉 azygos v.
13. 胸主动脉 thoracic aorta
14. 竖脊肌 erector spinae

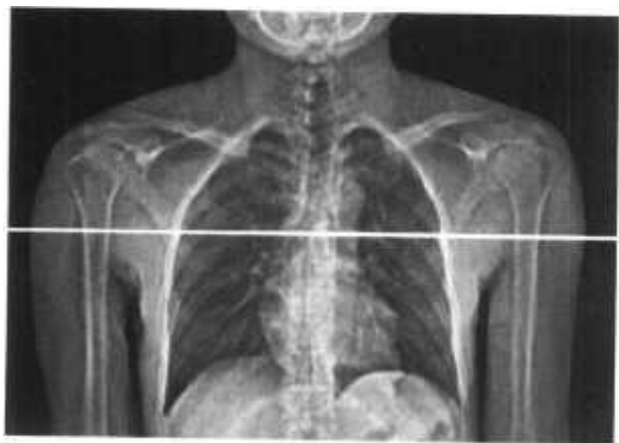

Fig. HT 10



- 15. 斜方肌 trapezius
- 16. 大菱形肌 rhomboideus major
- 17. 肩胛骨 scapula
- 18. 前锯肌 serratus anterior
- 19. 背阔肌 latissimus dorsi
- 20. 冈下肌 infraspinatus
- 21. 肩胛下肌 subscapularis
- S_{III}: 前段(S_{III}) anterior segment(S_{III})
- S_{VI}: 上段(S_{VI}) superior segment(S_{VI})



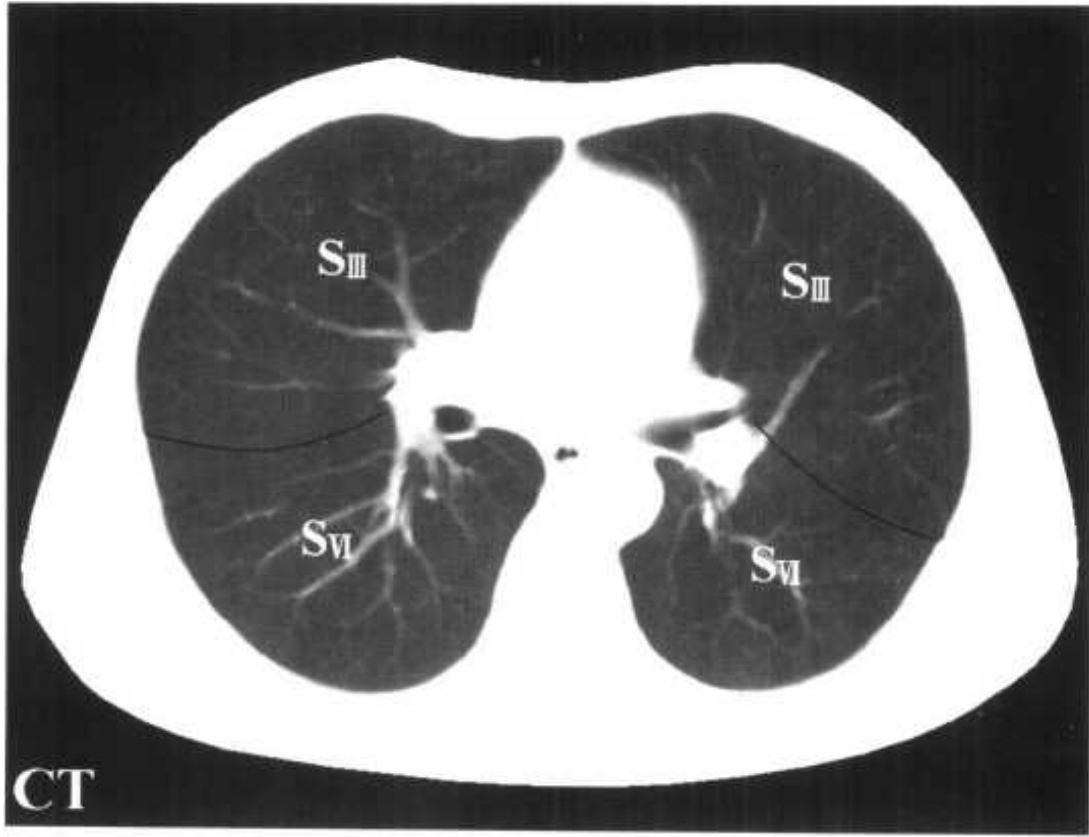
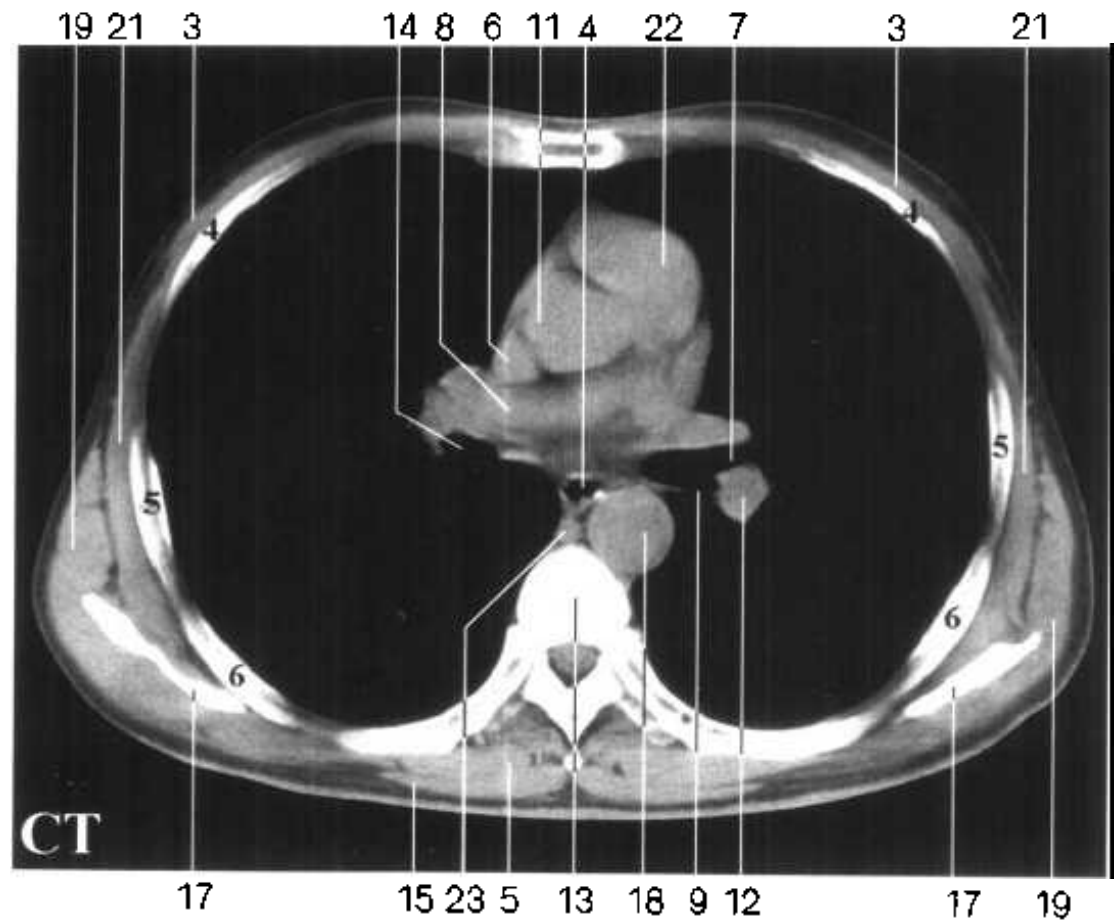


Fig. HT 11

1. 乳腺 mammary gland
2. 胸小肌 pectoralis minor
3. 胸大肌 pectoralis major
4. 食管 esophagus
5. 竖脊肌 erector spinae
6. 上腔静脉 superior vena cava
7. 左肺上叶支气管 left superior lobar bronchus
8. 右肺动脉 right pulmonary a.
9. 左肺下叶支气管 left inferior lobar bronchus
10. 胸腺 thymus
11. 升主动脉 ascending aorta
12. 左肺动脉 left pulmonary a.
13. 6、7 胸椎间盘 intervertebral disc(T₆-T₇)

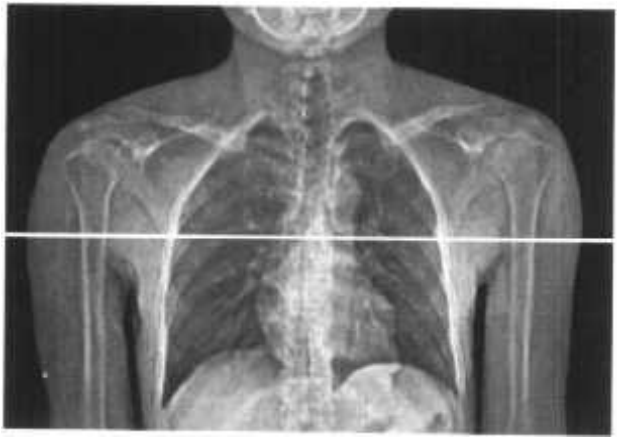

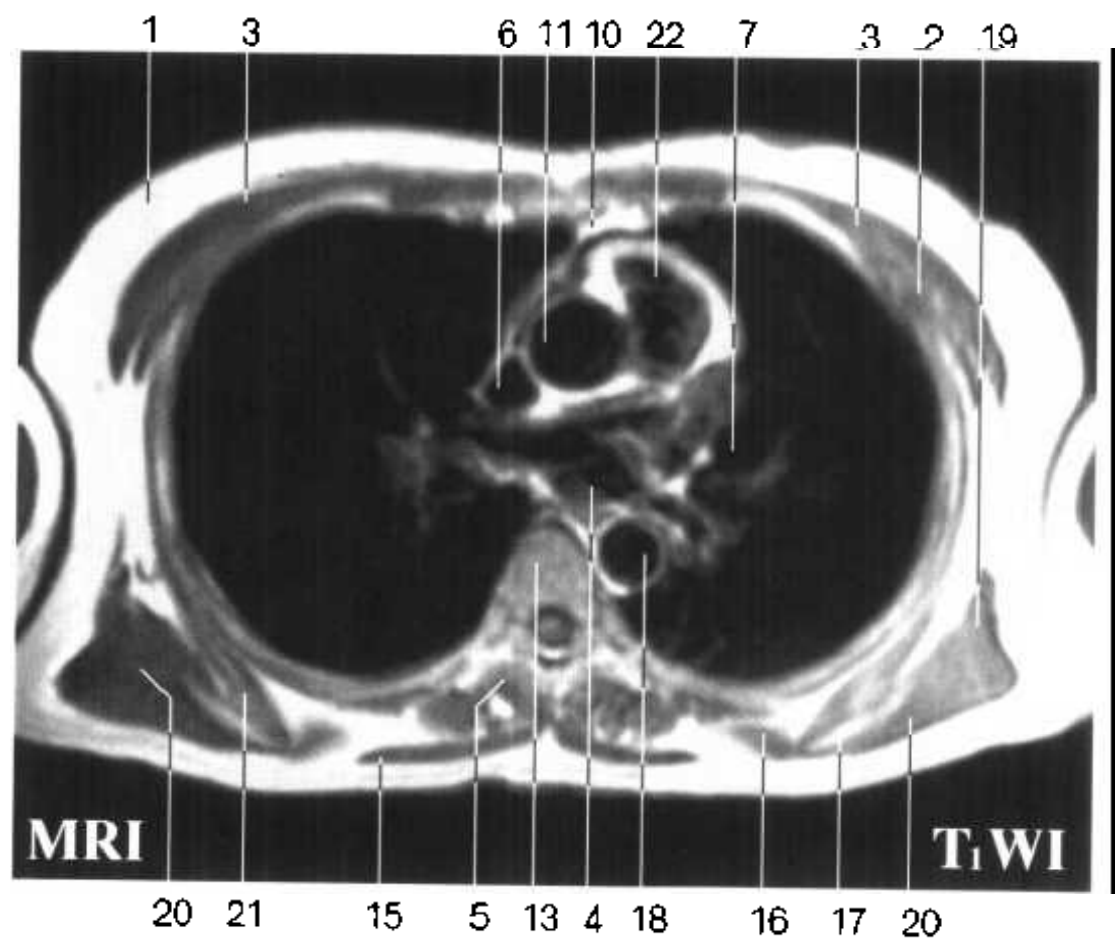
Fig. HT 11



- 14. 右主支气管 right principal bronchus
- 15. 斜方肌 trapezius
- 16. 大菱形肌 rhomboideus major
- 17. 肩胛骨 scapula
- 18. 胸主动脉 thoracic aorta
- 19. 背阔肌 latissimus dorsi
- 20. 大圆肌 teres major
- 21. 前锯肌 serratus anterior
- 22. 肺动脉干 pulmonary trunk
- 23. 奇静脉 azygos v.

S_m: 前段(S_m) anterior segment(S_m)

S_v: 上段(S_v) superior segment(S_v)



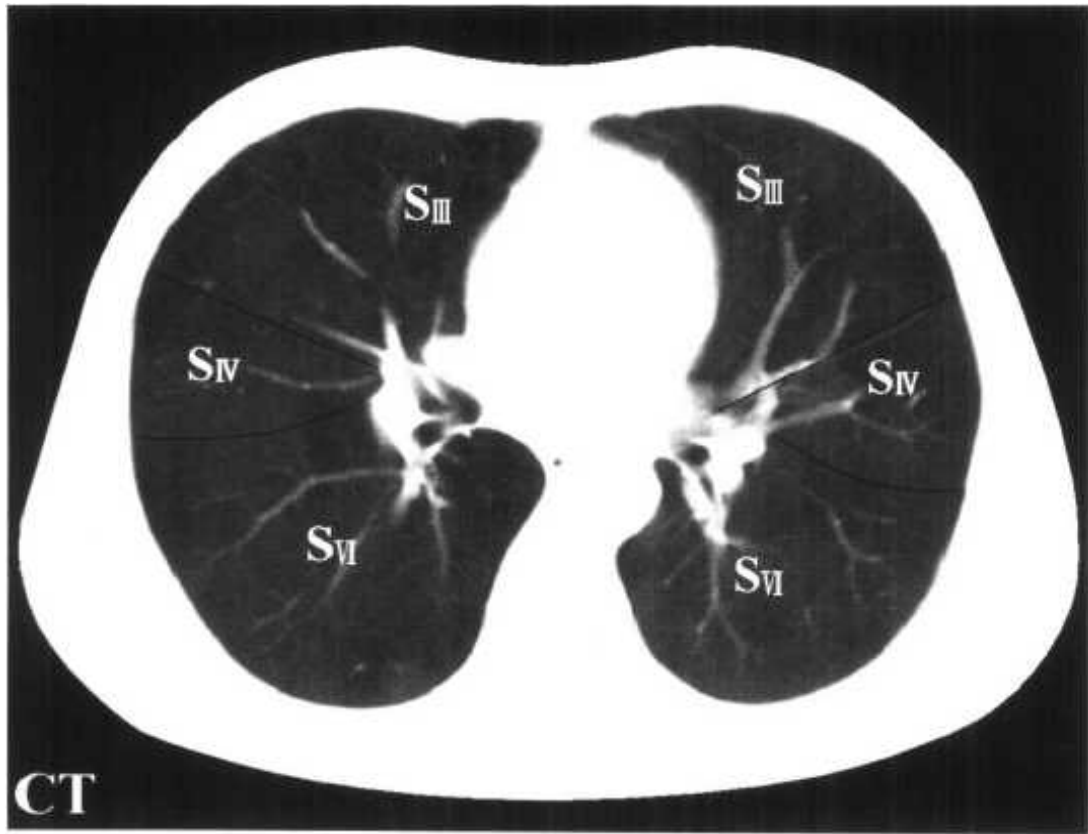
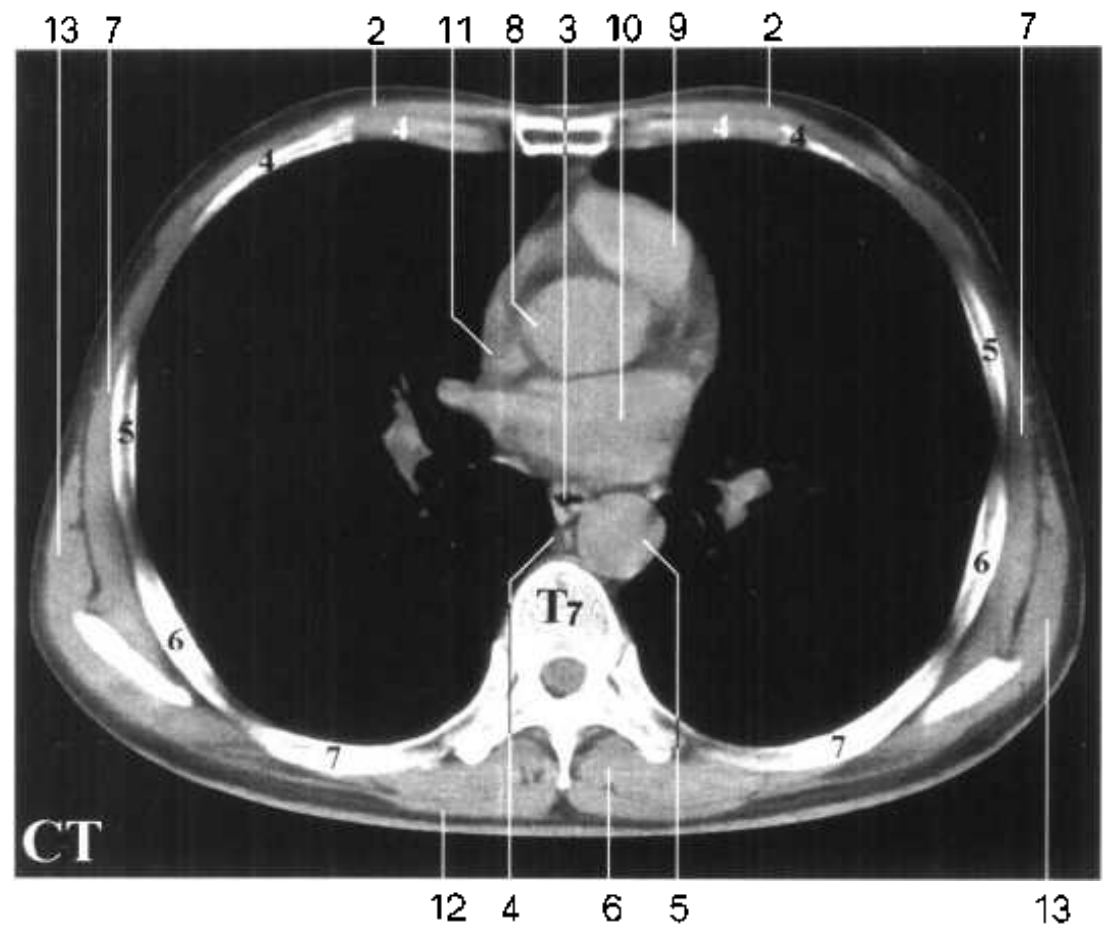


Fig. HT 12

1. 乳腺 mammary gland
2. 胸大肌 pectoralis major
3. 食管 esophagus
4. 奇静脉 azygos v.
5. 胸主动脉 thoracic aorta
6. 竖脊肌 erector spinae
7. 前锯肌 serratus anterior
8. 升主动脉 ascending aorta
9. 右心室 right ventricle
10. 左心房 left atrium

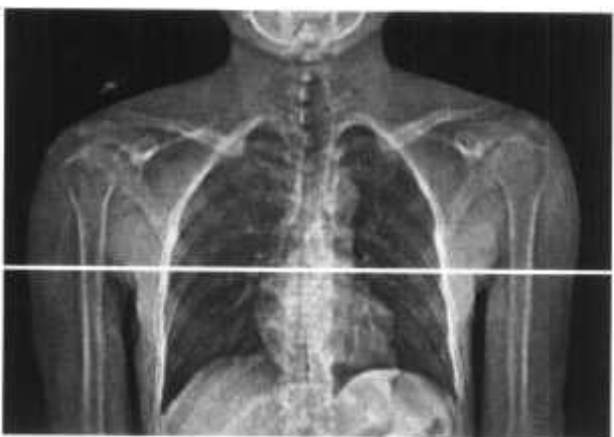

Fig. HT 12



11. 右心房 right atrium

12. 斜方肌 trapezius

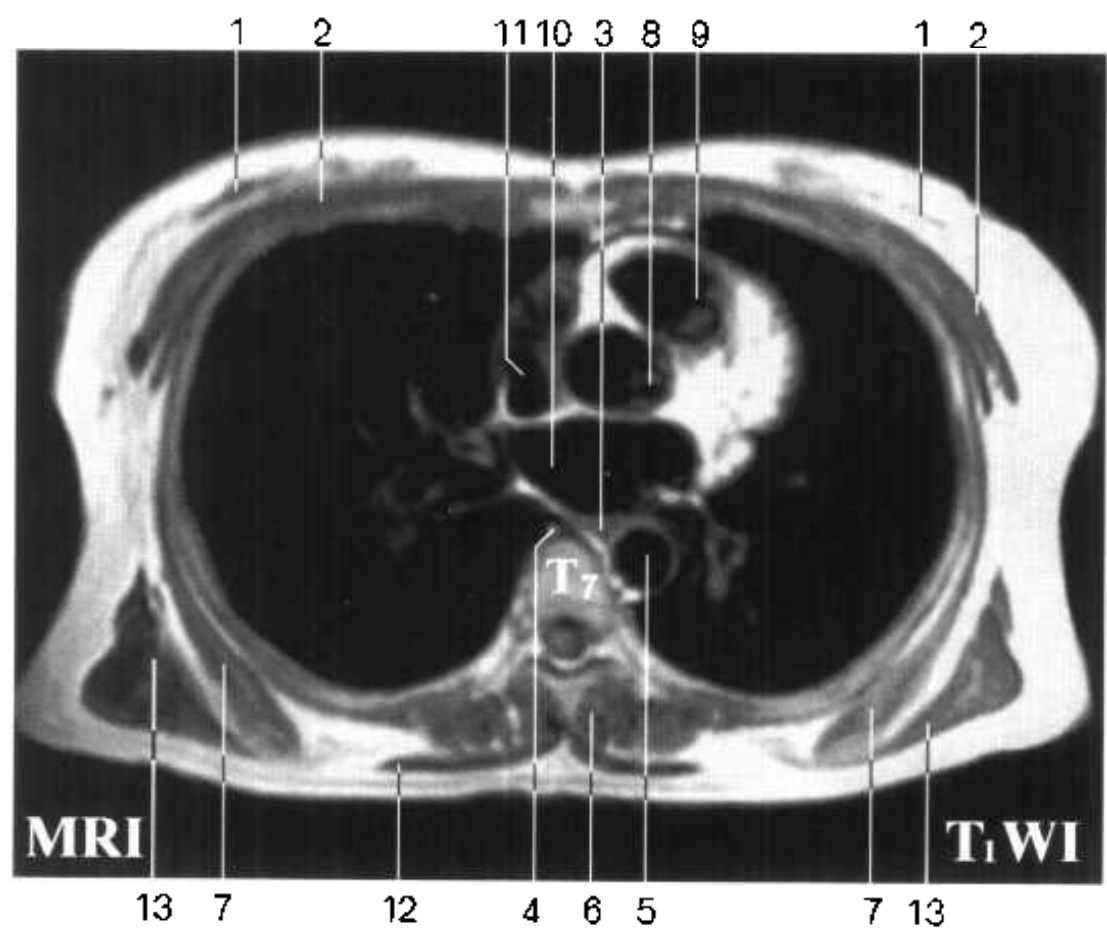
13. 背阔肌 latissimus dorsi

S_{III}: 前段(S_{III}) anterior
segment (S_{III})

S_{IV}: 上舌段(S_{IV}) superior lingual
segment(S_{IV})

S_{IV}: 外侧段(S_{IV}) lateral
segment(S_{IV})

S_{VI}: 上段(S_{VI}) superior
segment(S_{VI})



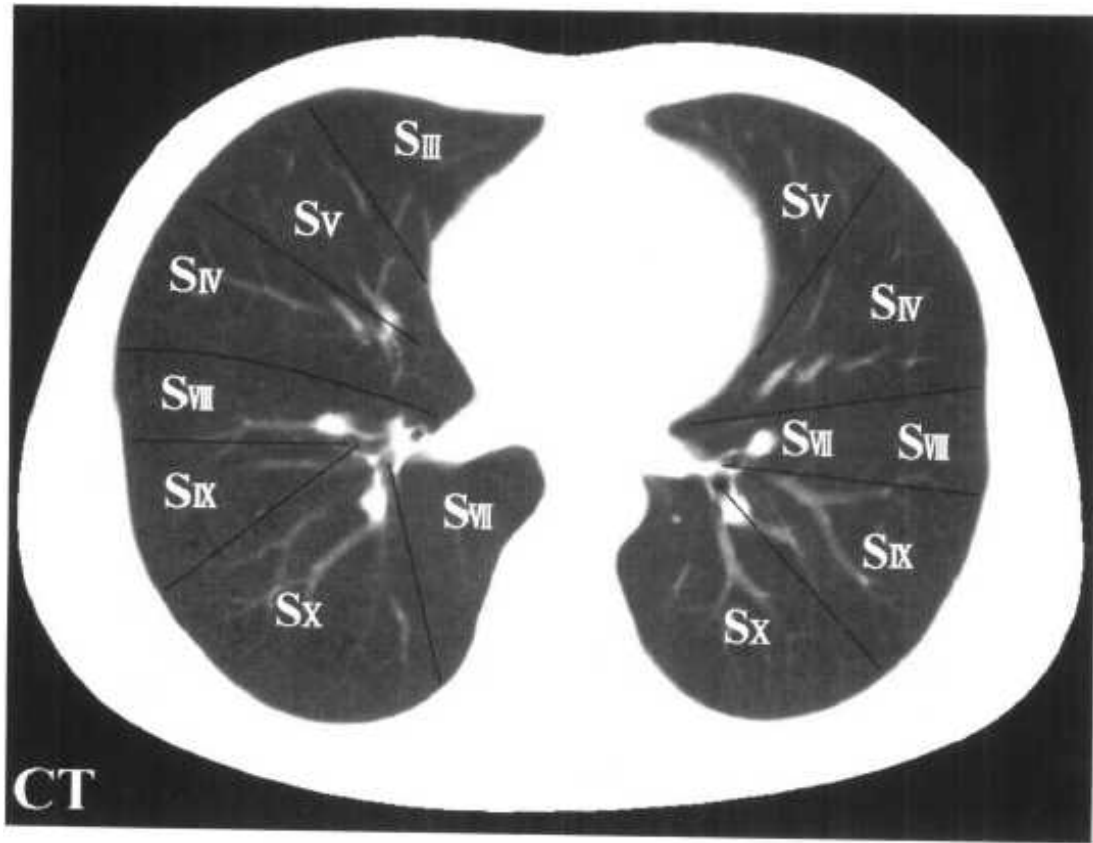
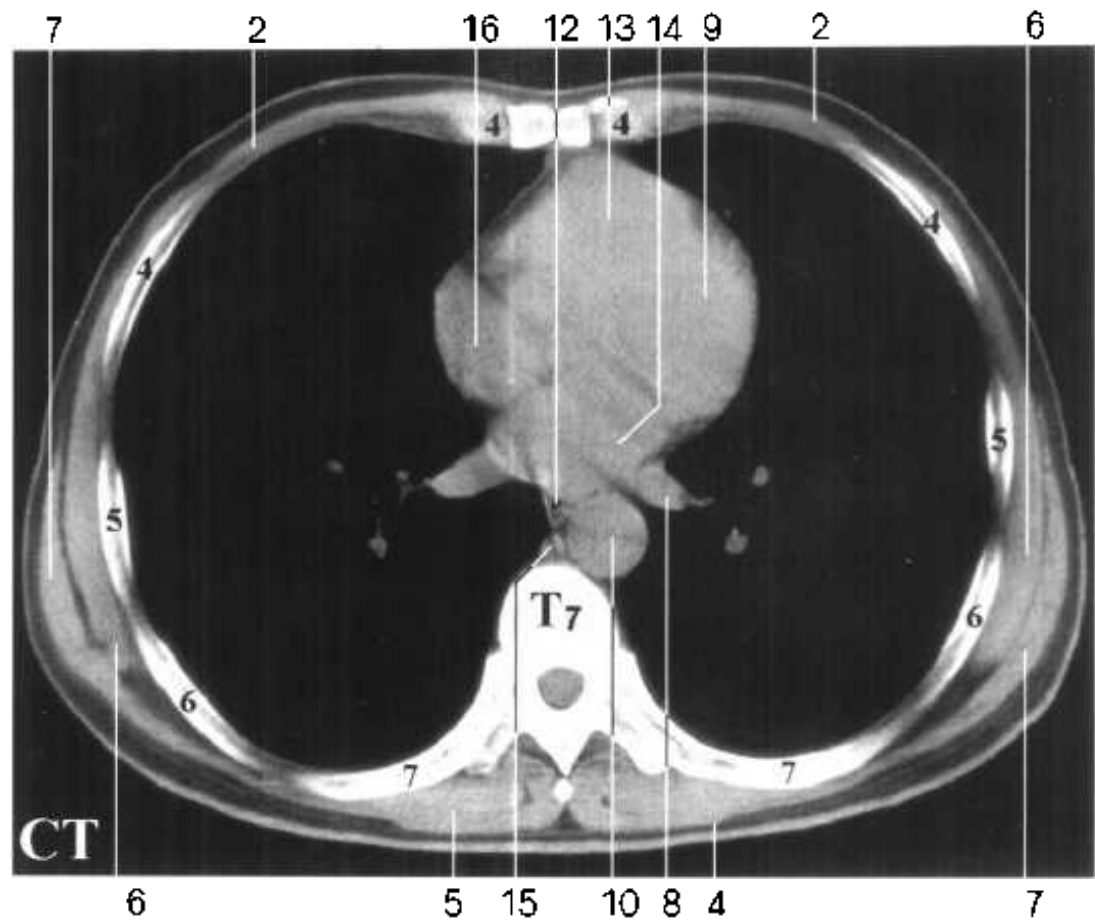


Fig. HT 13

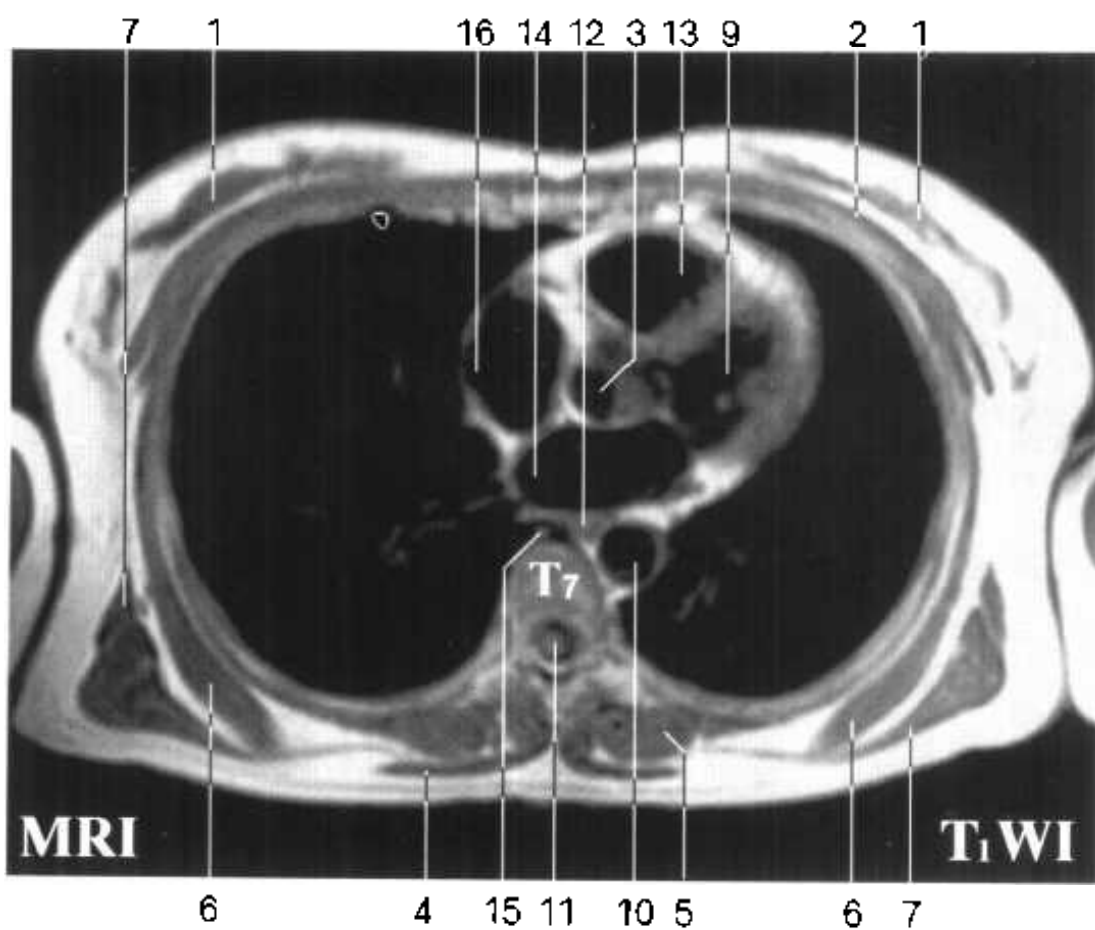
1. 乳腺 mammary gland
2. 胸大肌 pectoralis major
3. 升主动脉 ascending aorta
4. 斜方肌 trapezius
5. 竖脊肌 erector spinae
6. 前锯肌 serratus anterior
7. 背阔肌 latissimus dorsi
8. 左下肺静脉 left inferior pulmonary v.
9. 左心室 left ventricle
10. 胸主动脉 thoracic aorta
11. 脊髓 spinal cord
12. 食管 esophagus
13. 右心室 right ventricle
14. 左心房 left atrium
15. 奇静脉 azygos v.
16. 右心房 right atrium

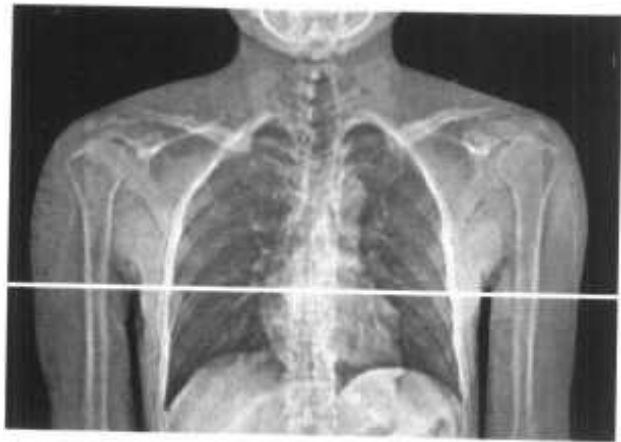

Fig. HT 13



- S_{III}: 前段(S_{III}) anterior segment(S_{III})
- S_{IV}: 上舌段(S_{IV}) superior lingual segment(S_{IV})
- S_{IV}: 外侧段(S_{IV}) lateral segment(S_{IV})
- S_{IV}: 外侧段(S_{IV}) lateral segment(S_{IV})
- S_V: 内侧段(S_V) medial segment(S_V)
- S_X: 后底段(S_X) posterior basal segment(S_X)
- S_{IX}: 外侧底段(S_{IX}) lateral basal segment(S_{IX})
- S_{VII}: 内侧底段(S_{VII}) medial basal segment(S_{VII})
- S_{VIII}: 前底段(S_{VIII}) anterior basal segment(S_{VIII})



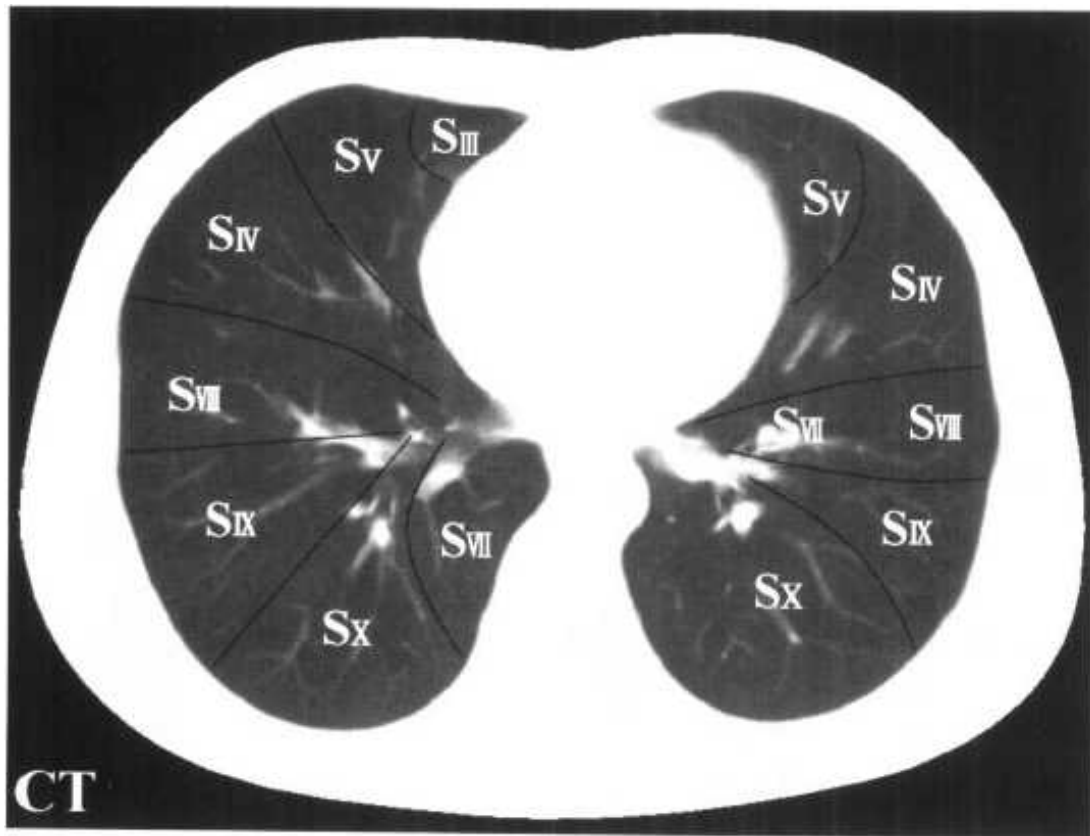
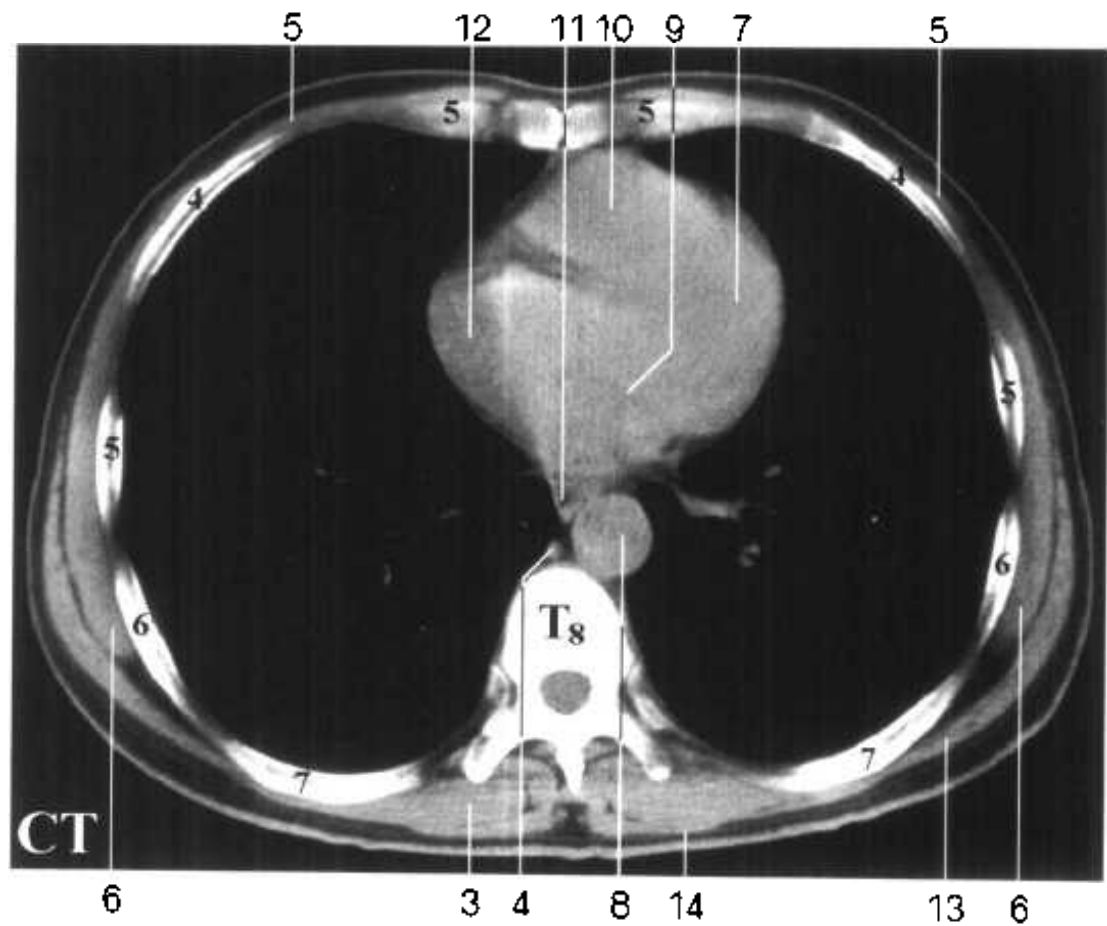


Fig. HT 14

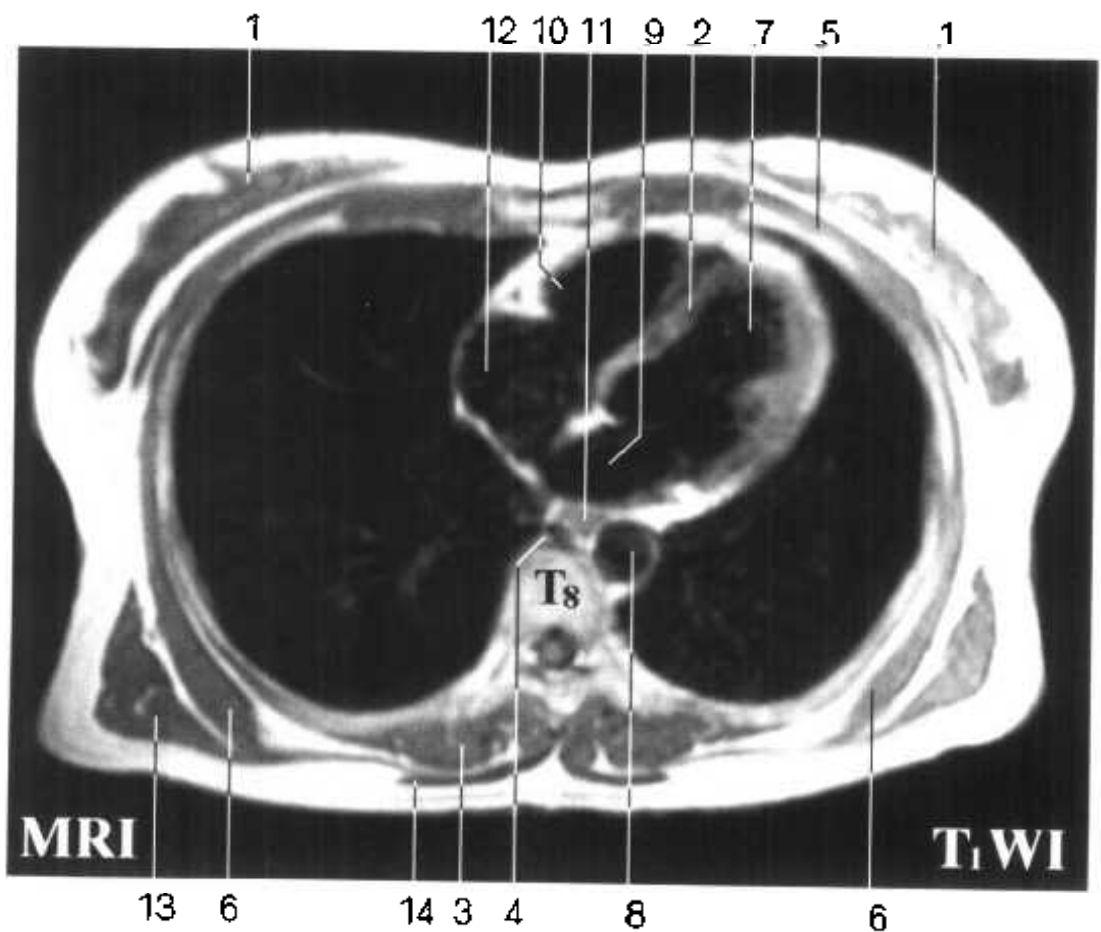
1. 乳腺 mammary gland
 2. 室间隔 interventricular septum
 3. 竖脊肌 erector spinae
 4. 奇静脉 azygos v.
 5. 胸大肌 pectoralis major
 6. 前锯肌 serratus anterior
 7. 左心室 left ventricle
 8. 胸主动脉 thoracic aorta
 9. 左心房 left atrium
 10. 右心室 right ventricle
 11. 食管 esophagus
 12. 右心房 right atrium
 13. 背阔肌 latissimus dorsi
 14. 斜方肌 trapezius
- S_{III}: 前段(S_{III}) anterior segment(S)

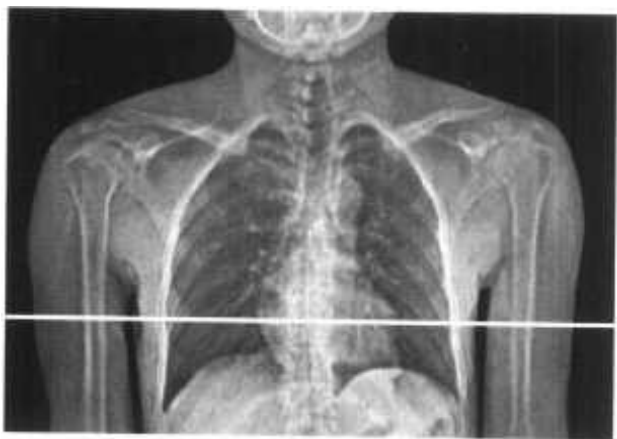

Fig. HT 14



- S_{IV}: 外侧段(S_{IV}) lateral segment (S_{IV})
- S_V: 上舌段(S_V) superior lingual segment
- S_{VI}: 下舌段(S_{VI}) inferior lingual segment(S_{VI})
- S_{VII}: 内侧段(S_{VII}) medial segment(S_{VII})
- S_{VIII}: 内侧底段(S_{VIII}) medial basal segment(S_{VIII})
- S_{IX}: 前底段(S_{IX}) anterior basal segment(S_{IX})
- S_X: 外侧底段(S_X) lateral basal segment(S_X)
- S_{XI}: 后底段(S_{XI}) posterior basal segment(S_{XI})



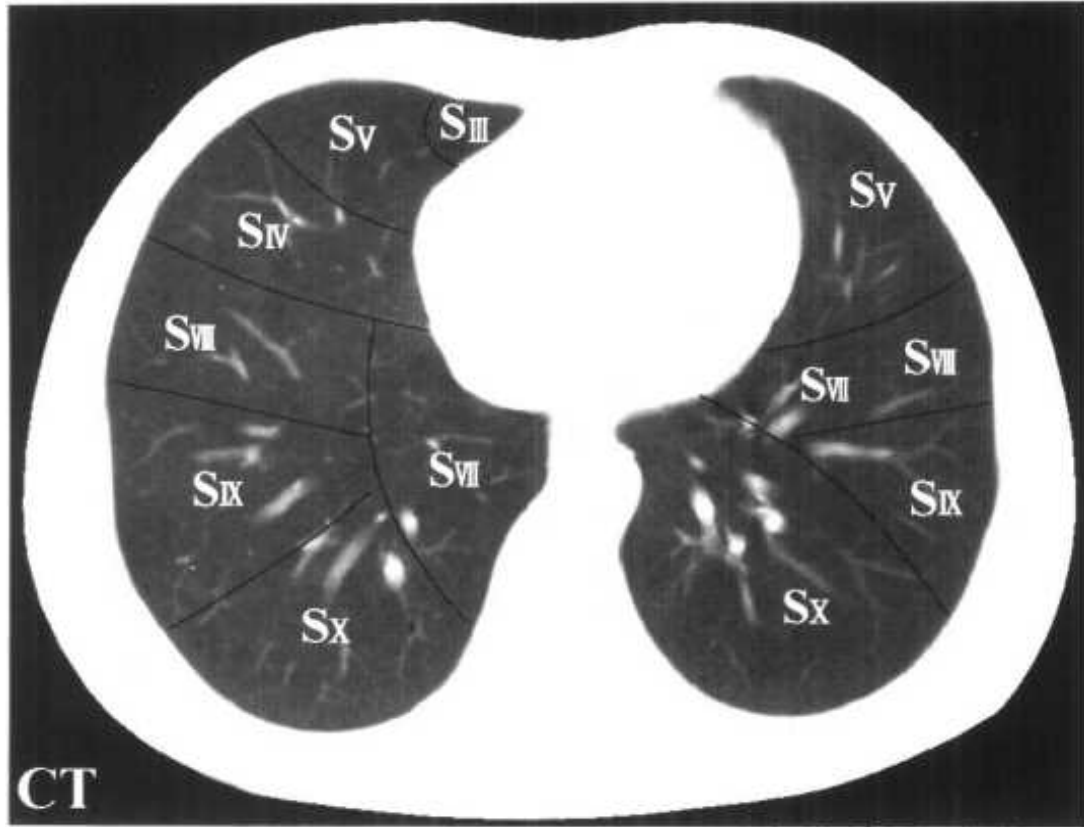
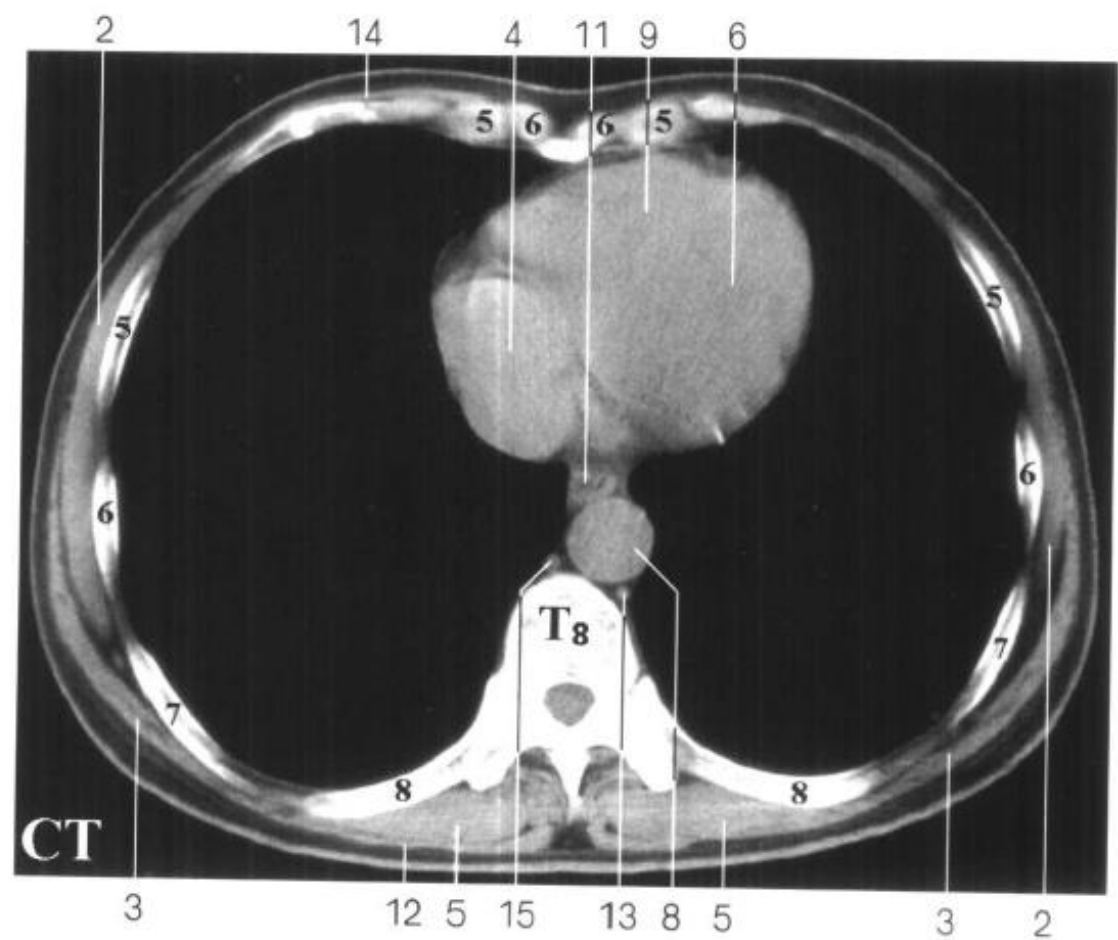


Fig. HT 15

1. 乳腺 mammary gland
2. 前锯肌 serratus anterior
3. 背阔肌 latissimus dorsi
4. 右心房 right atrium
5. 竖脊肌 erector spinae
6. 左心室 left ventricle
7. 室间隔 interventricular septum
8. 胸主动脉 thoracic aorta
9. 右心室 right ventricle
10. 脊髓 spinal cord
11. 食管 esophagus
12. 斜方肌 trapezius
13. 半奇静脉 hemiazygos v.
14. 胸大肌 pectoralis major
15. 奇静脉 azygos v.

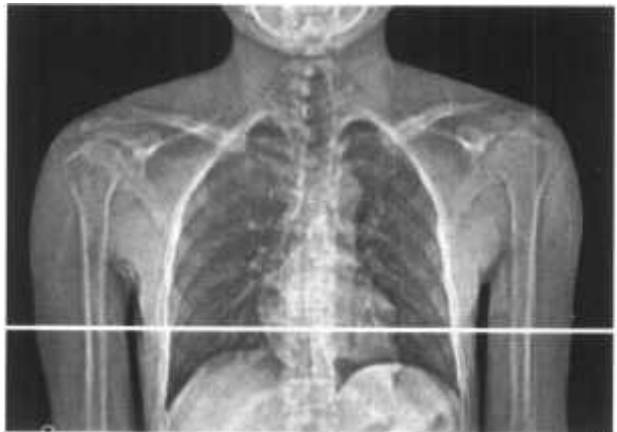

Fig. HT 15



- S : 前段(S_{III}) anterior segment(S_{III})
- S_{IV}: 外侧段(S_{IV}) lateral segment(S_{IV})
- S_V: 下舌段(S_V) inferior lingual segment(S_V)
- S_V: 内侧段(S_V) medial segment(S_V)
- S_{VII}: 内侧底段(S_{VII}) medial basal segment(S_{VII})
- S_{VIII}: 前底段(S_{VIII}) anterior basal segment(S_{VIII})
- S_{IX}: 外侧底段(S_{IX}) lateral basal segment(S_{IX})
- S_X: 后底段(S_X) posterior basal segment(S_X)

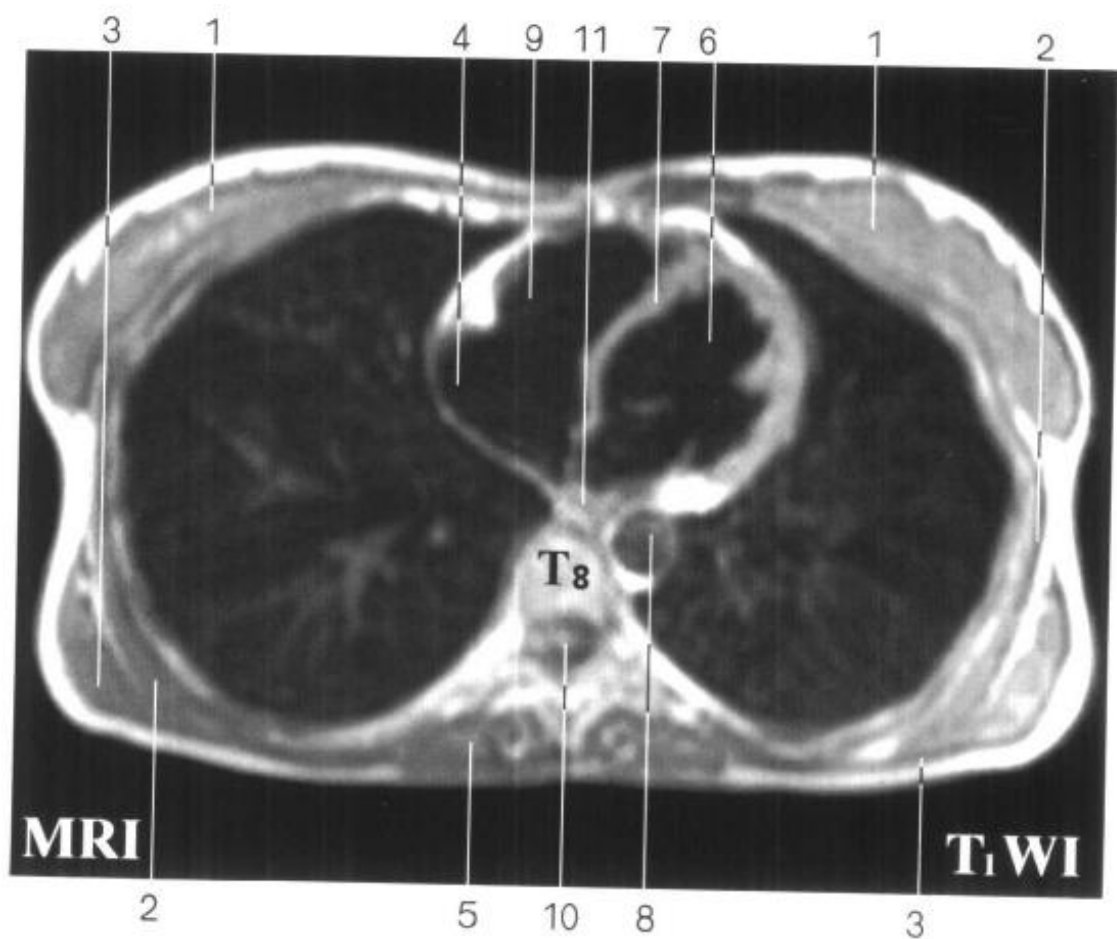

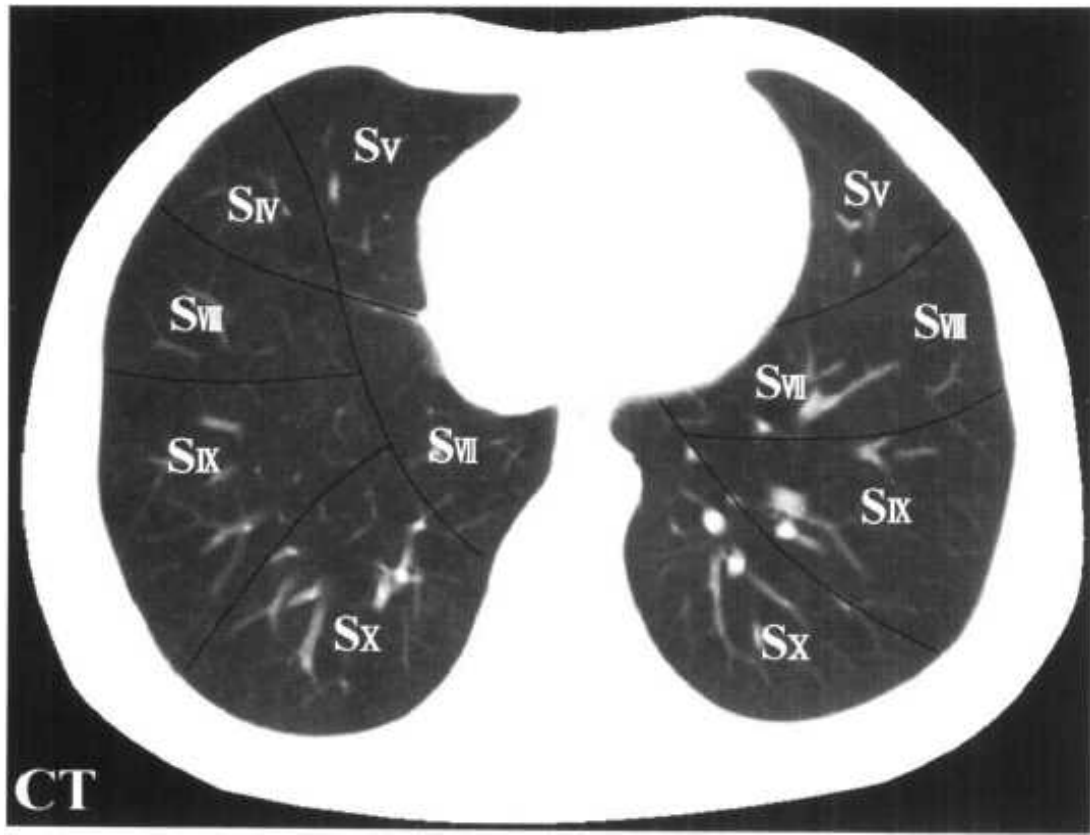
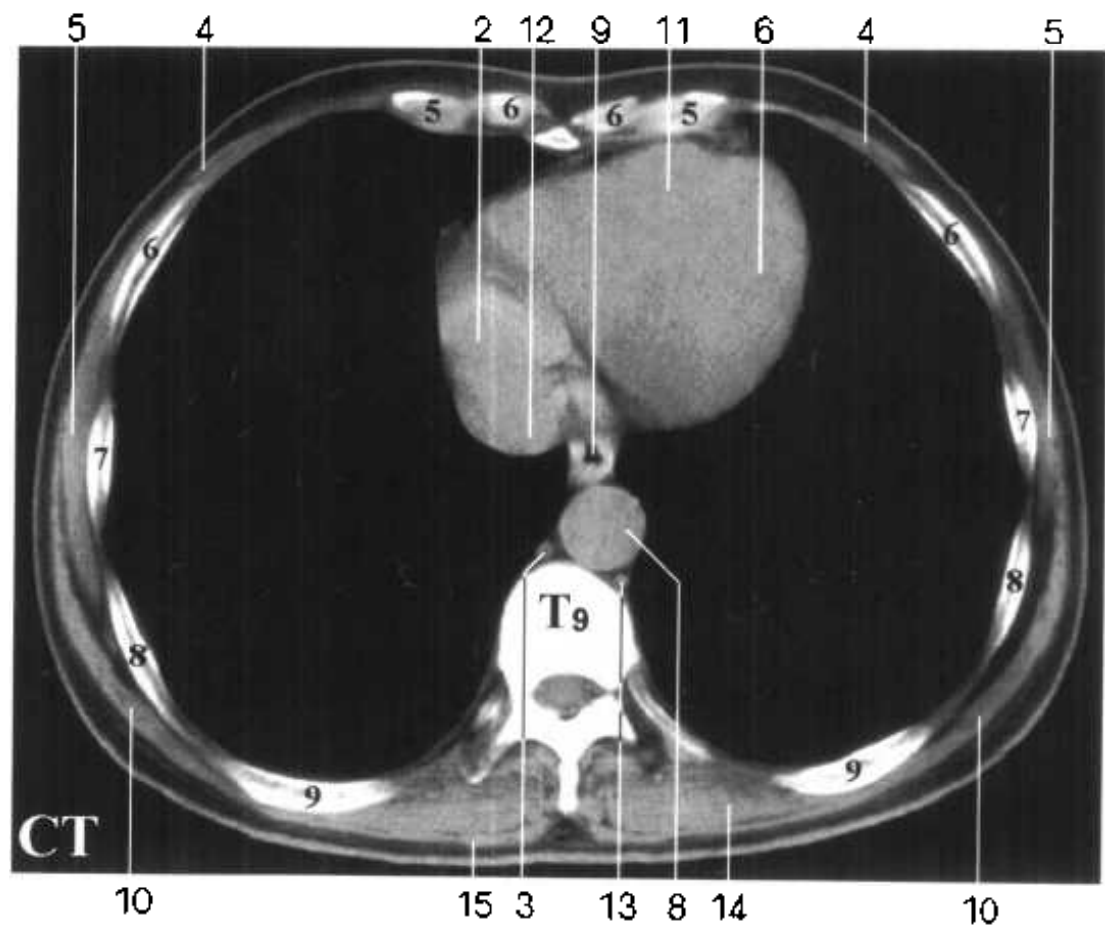


Fig. HT 16

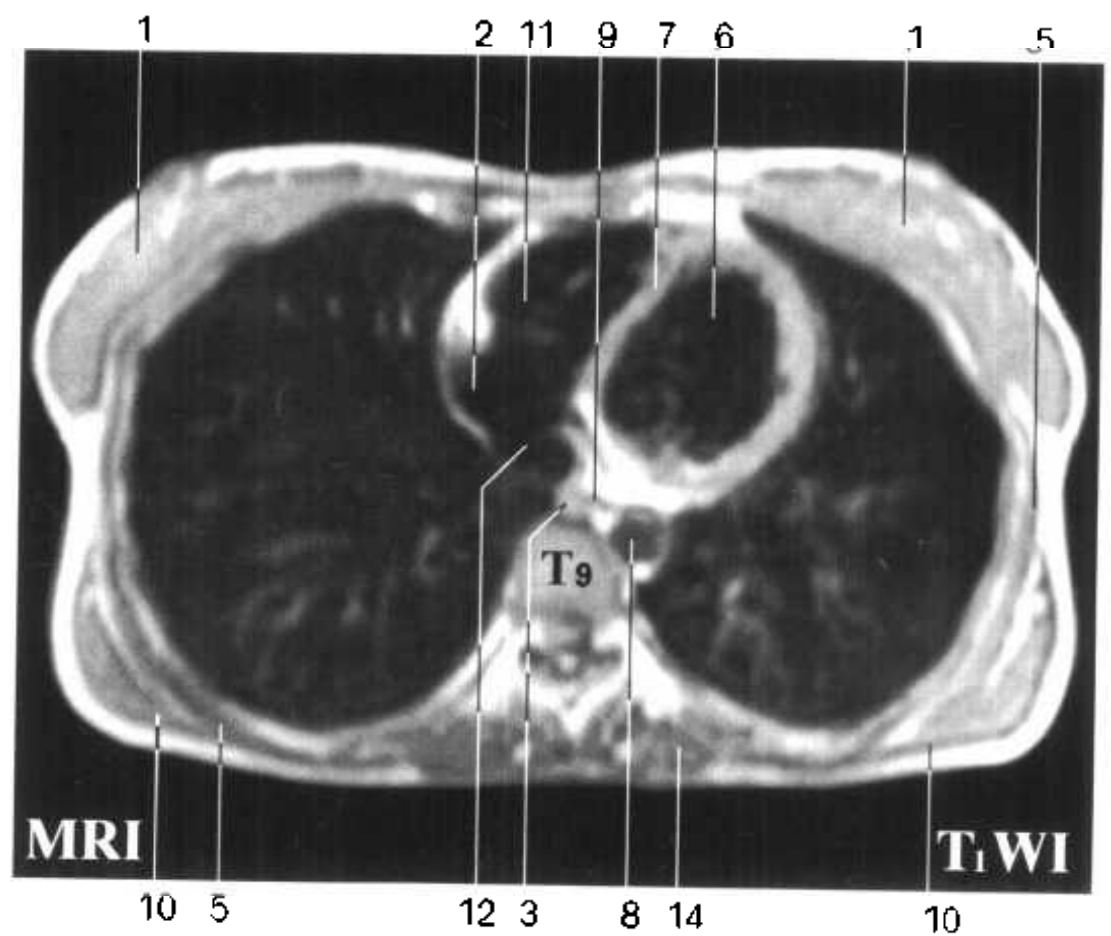
1. 乳腺 mammary gland
2. 右心房 right atrium
3. 奇静脉 azygos v.
4. 胸大肌 pectoralis major
5. 前锯肌 serratus anterior
6. 左心室 left ventricle
7. 室间隔 interventricular septum
8. 胸主动脉 thoracic aorta
9. 食管 esophagus
10. 背阔肌 latissimus dorsi
11. 右心室 right ventricle
12. 下腔静脉 inferior vena cava
13. 半奇静脉 hemiazygos v.
14. 竖脊肌 erector spinae
15. 斜方肌 trapezius

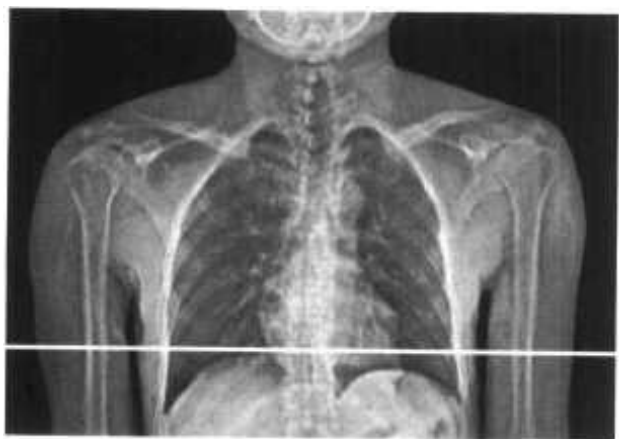

Fig. HT 16



- S_{IV}: 外側段(S_{IV}) lateral segment(S_{IV})
- S_V: 下舌段(S_V) inferior lingual segment(S_V)
- S_{VI}: 內側段(S_{VI}) medial segment(S_{VI})
- S_{VII}: 內側底段(S_{VII}) medial basal segment(S_{VII})
- S_{VIII}: 前底段(S_{VIII}) anterior basal segment(S_{VIII})
- S_{IX}: (S_{IX}) lateral basal segment(S_{IX})
- S_X: 后底段(S_X) posterior basal segment(S_X)



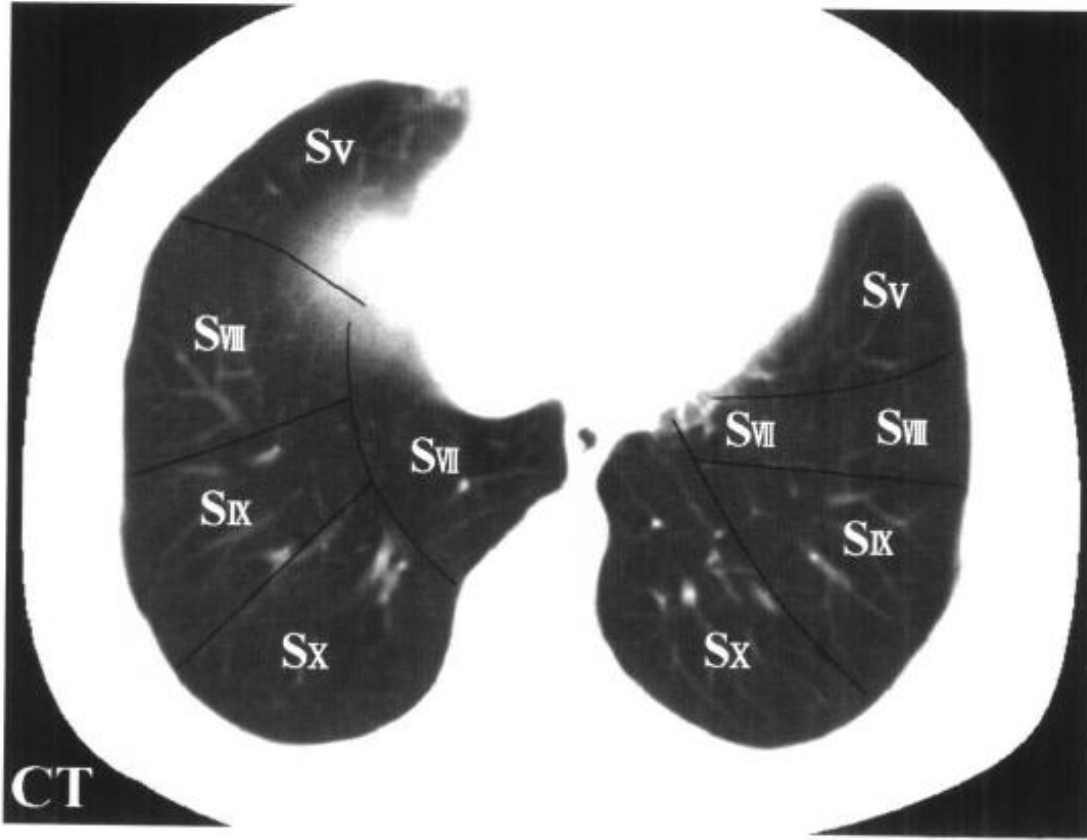
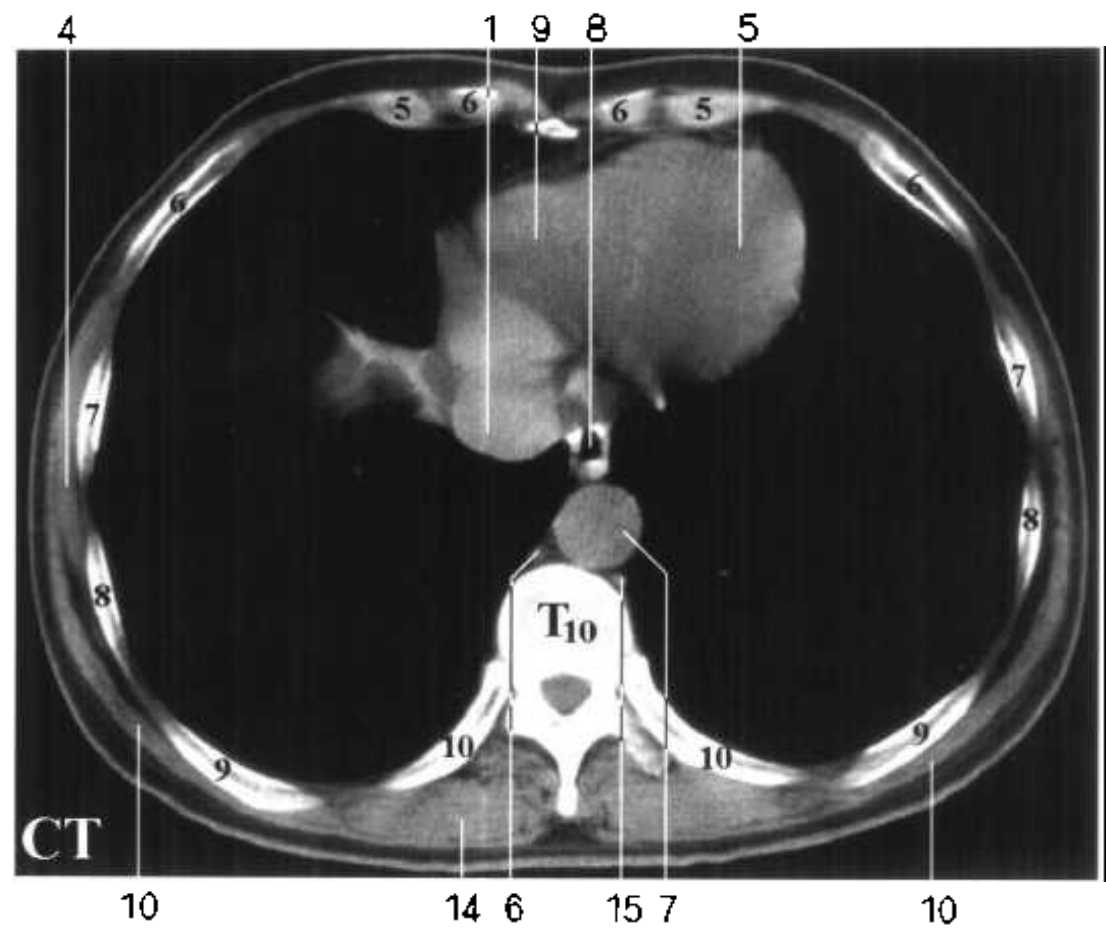


Fig. HT 17

1. 下腔静脉 inferior vena cava
2. 胸大肌 pectoralis major
3. 乳腺 mammary gland
4. 前锯肌 serratus anterior
5. 左心室 left ventricle
6. 奇静脉 azygos v.
7. 胸主动脉 thoracic aorta
8. 食管 esophagus
9. 右心室 right ventricle
10. 背阔肌 latissimas dorsi
11. 室间隔 interventricular septum
12. 斜方肌 trapezius
13. 肝 liver
14. 竖脊肌 erector spinae

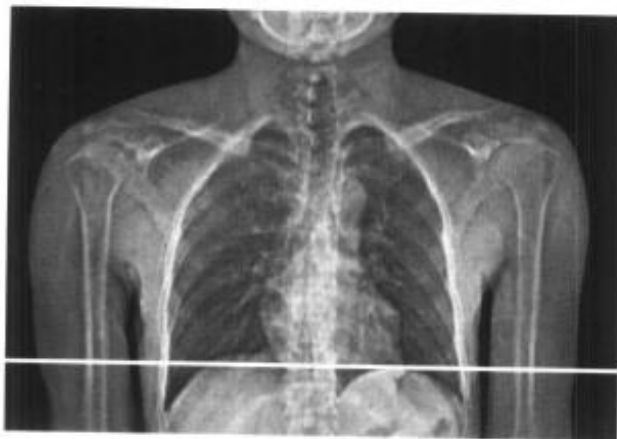

Fig. HT 17



15. 半奇静脉 hemiazygos v.

S_v: 内侧段(S_v) medial segment(S_v)

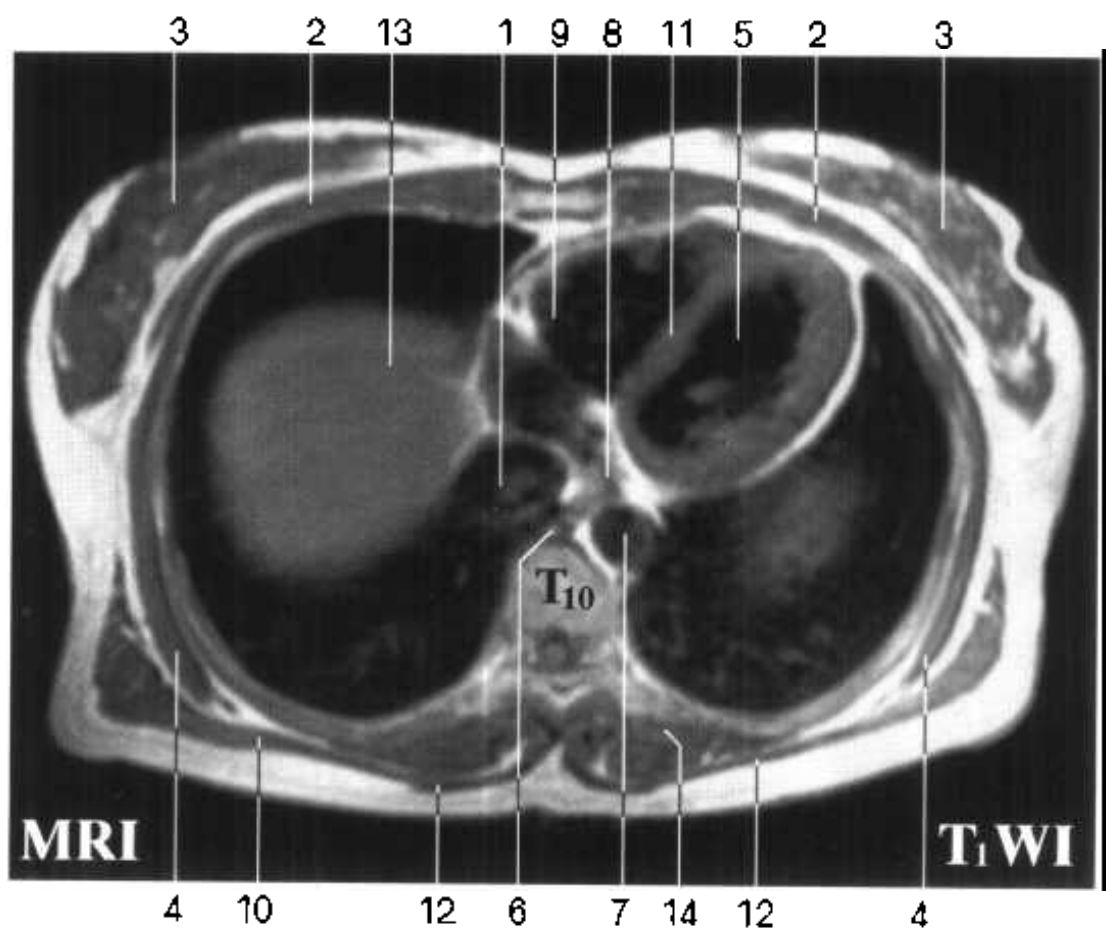
S_v: 下舌段(S_v) inferior lingual segment(S_v)

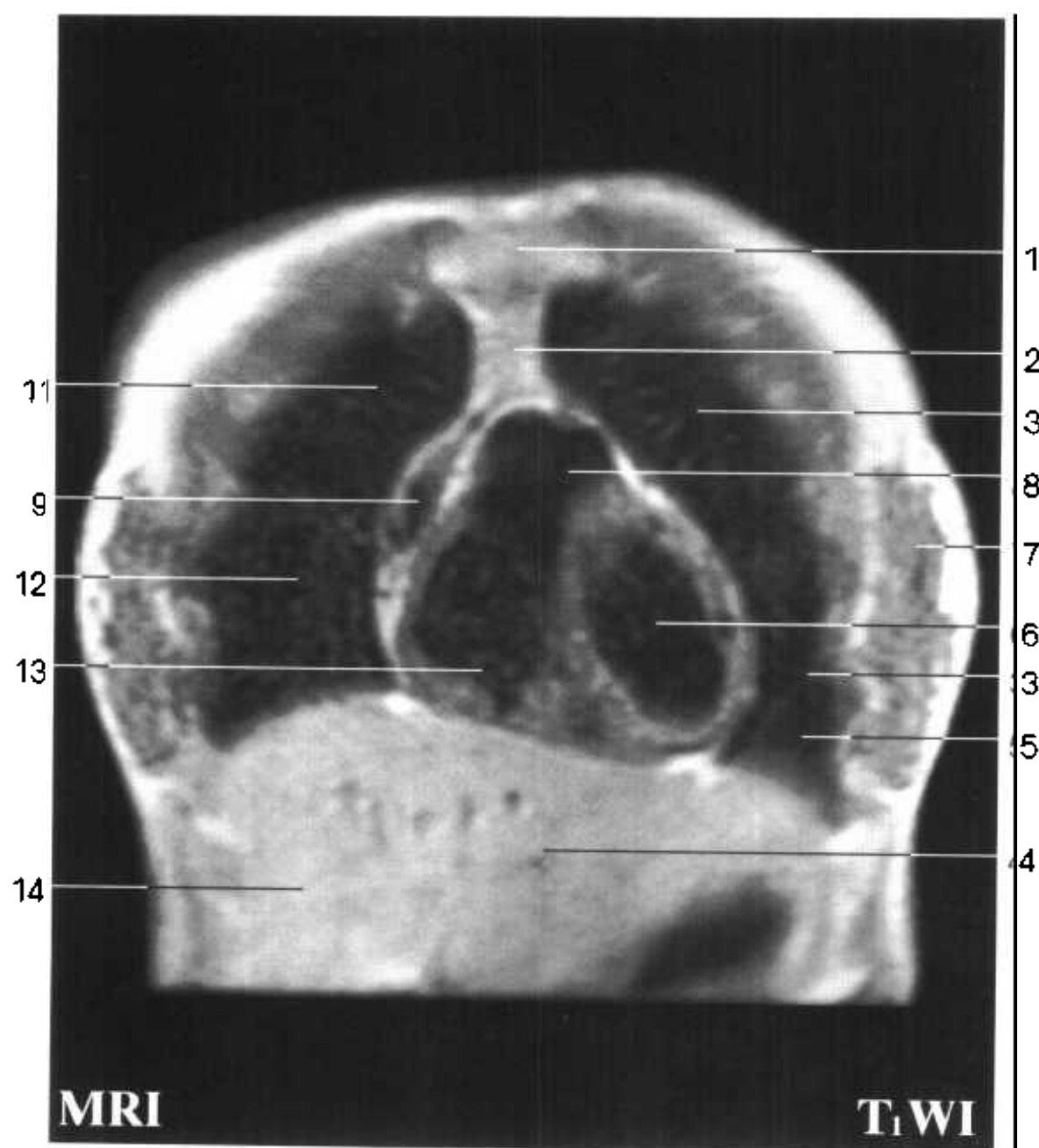
S_{vii}: 内侧底段(S_{vii}) medial basal segment(S_{vii})

S_{viii}: 前底段(S_{viii}) anterior basal segment(S_{viii})

S_{ix}: 外侧底段(S_{ix}) lateral basal segment(S_{ix})

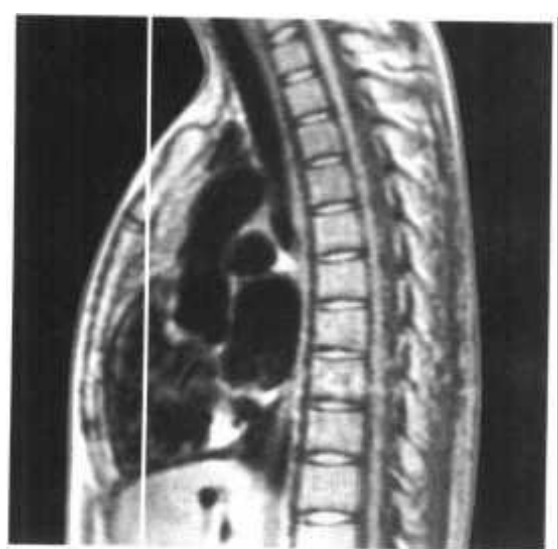S_x: 后底段(S_x) posterior basal segment(S_x)





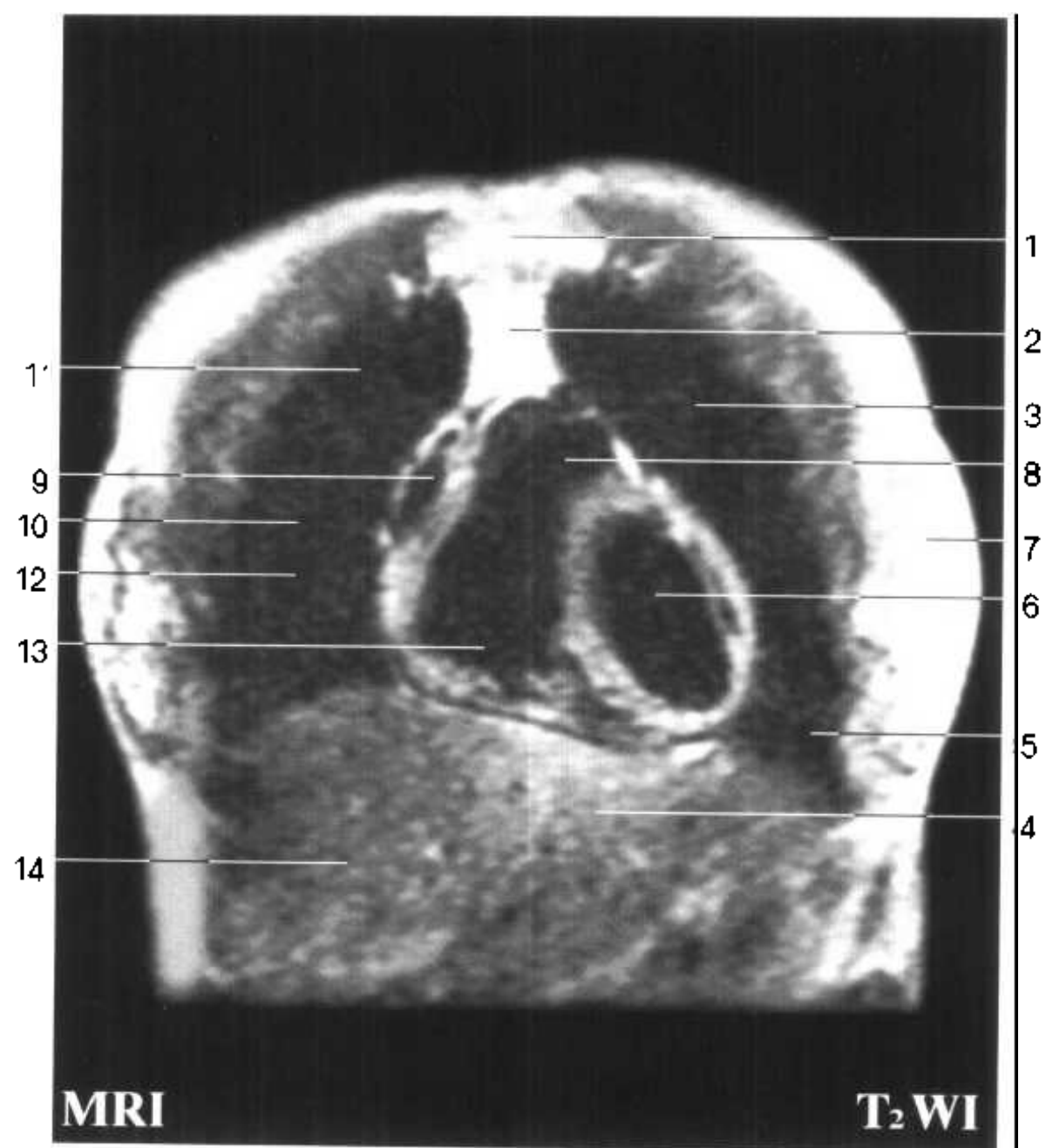
额状断面图 FT

Fig. FT 1



1. 胸骨柄 manubrium sterni
2. 胸骨心包韧带 sternopericardial ligament
3. 左肺上叶 superior lobe of left lung
4. 左外叶 left lateral lobe
5. 左肺下叶 inferior lobe of left lung
6. 左心室 left ventricle
7. 乳腺 mammary gland
8. 肺动脉干 pulmonary trunk

Fig. FT 1



- 9. 右心耳 right auricle
- 10. 右肺水平裂 horizontal fissure of right lung
- 11. 右肺上叶 superior lobe of right lung
- 12. 右肺中叶 middle lobe of right lung
- 13. 右心室 right ventricle
- 14. 左内叶 left medial lobe

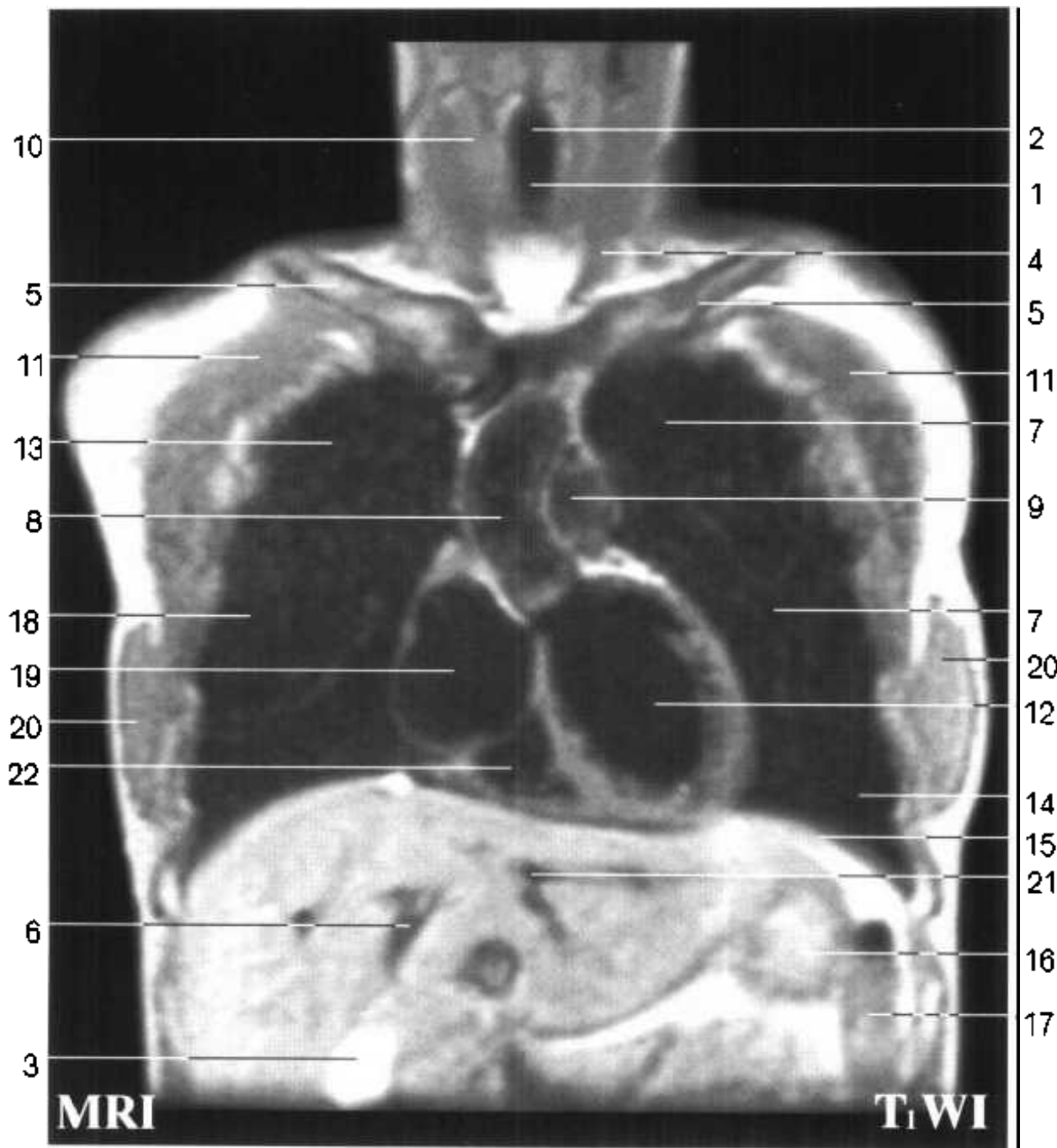
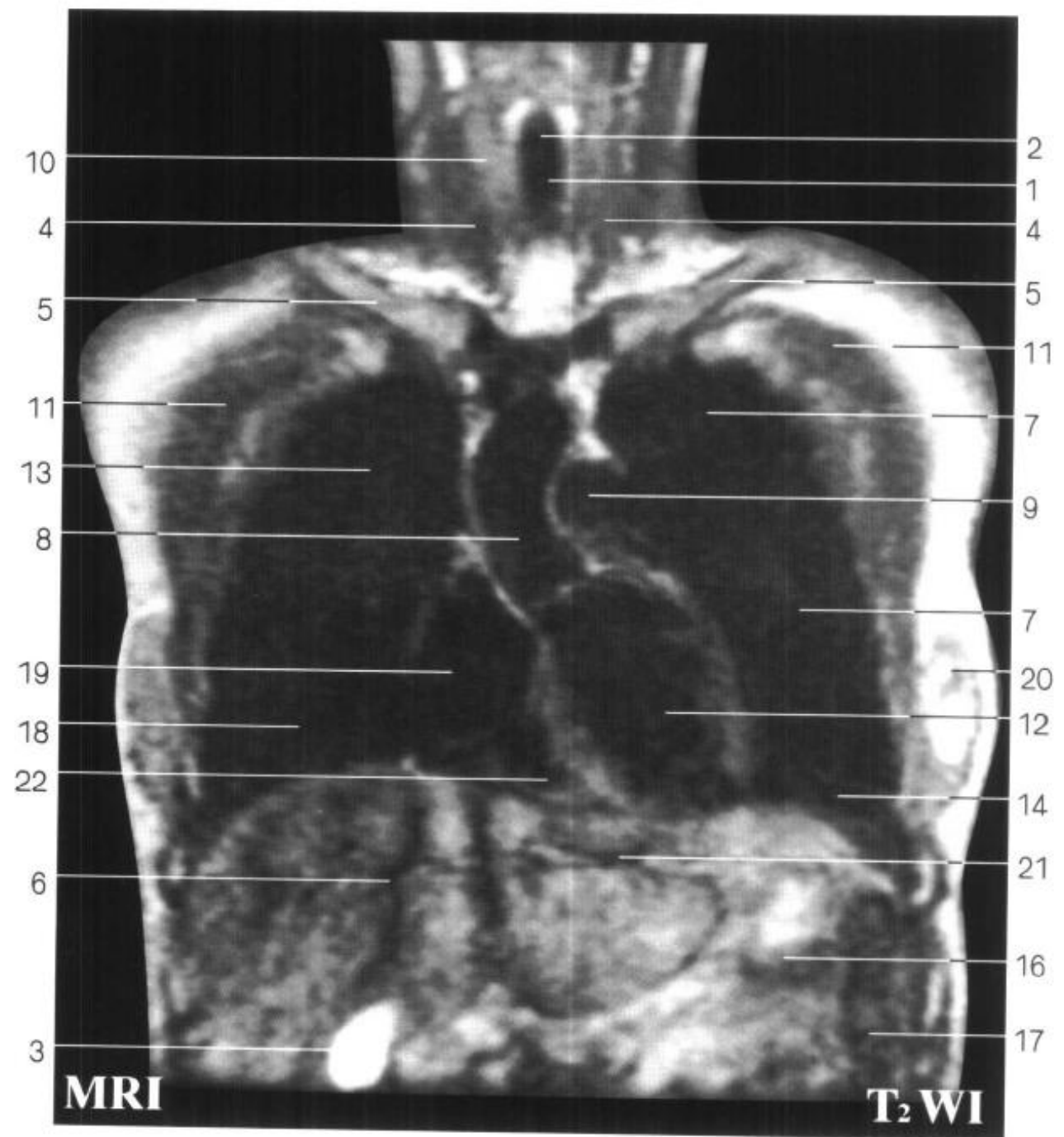


Fig. FT 2

1. 气管 trachea
2. 声门下腔 infeaglottic cavity
3. 胆囊 gallbladder
4. 胸锁乳突肌 sternocleidomastoid
5. 锁骨 clavicle
6. 肝中间静脉 intermediate hepatic v.
7. 左肺上叶 superior lobe of left lung
8. 升主动脉 ascending aorta
9. 肺动脉干 pulmonary trunk
10. 甲状腺 thyroid gland
11. 胸大肌 pectoralis major

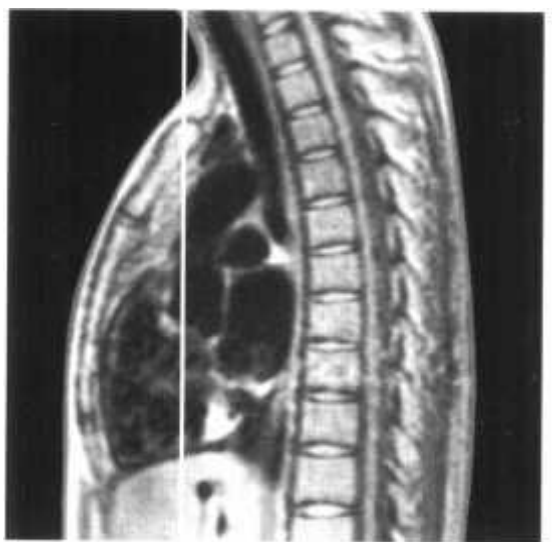

Fig. FT 2



- 12. 左心室 left ventricle
- 13. 右肺上叶 superior lobe of right lung
- 14. 左肺下叶 inferior lobe of left lung
- 15. 膈 diaphragm
- 16. 胃底 fundus of stomach
- 17. 脾 spleen
- 18. 右肺中叶 middle lobe of right lung
- 19. 右心房 right atrium
- 20. 乳腺 mammary gland
- 21. 肝左静脉 left hepatic v.
- 22. 右心室 right ventricle

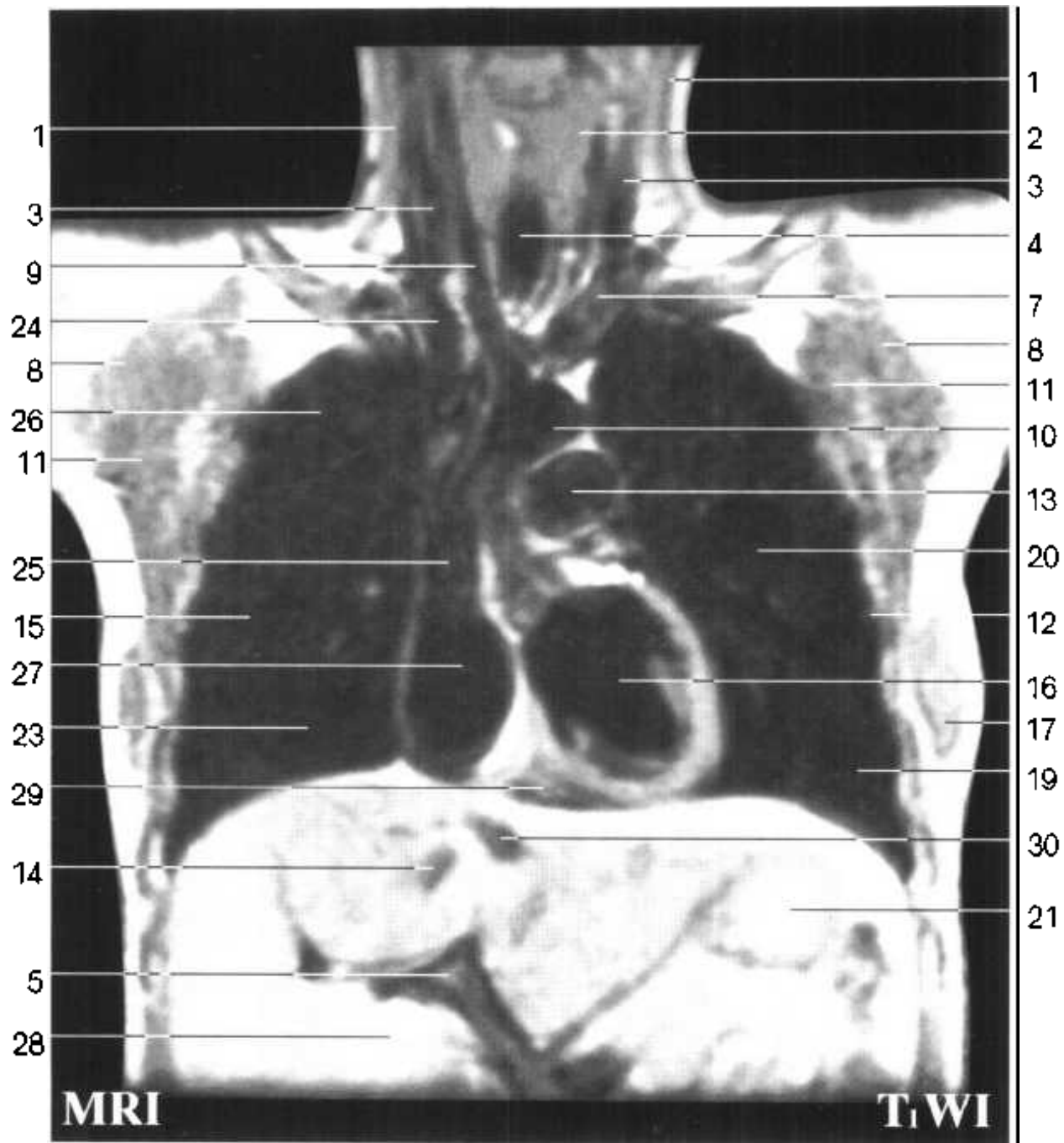

Fig. FT 3

1. 胸锁乳突肌 sternocleidomastoid
2. 甲状腺 thyroid gland
3. 颈内静脉 internal jugular v.
4. 气管 trachea
5. 肝门 porta hepatis
6. 左颈总动脉 left common carotid a.
7. 左头臂静脉 left brachiocephalic v.
8. 胸大肌 pectoralis major
9. 右颈总动脉 right common carotid a.
10. 主动脉弓 arch of aorta

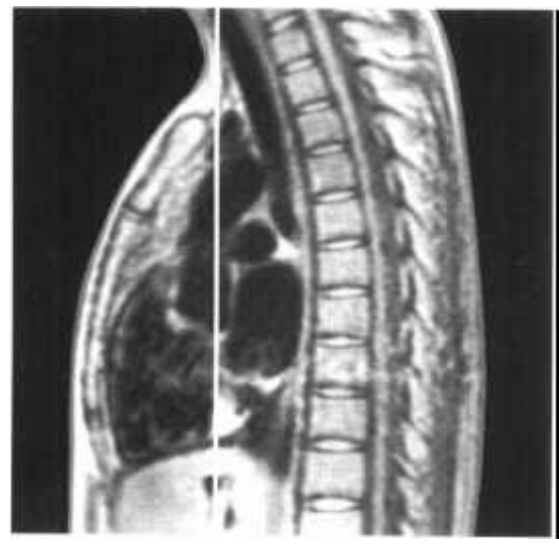
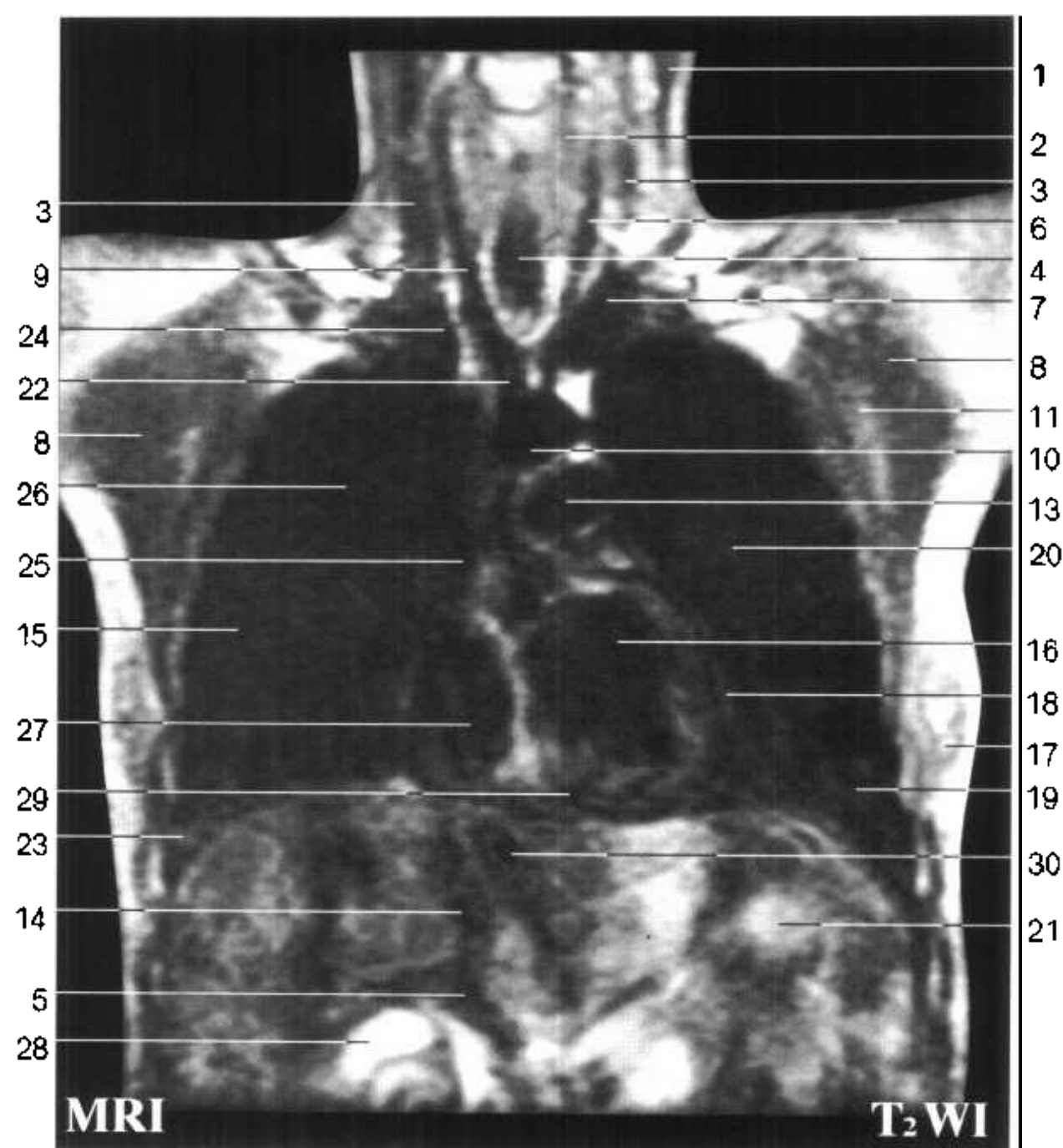

Fig. FT 3



- | | |
|-------------------------------------|--------------------------------------|
| 11. 胸小肌 pectoralis minor | 21. 胃底 fundus of stomach |
| 12. 斜裂 oblique fissure | 22. 头臂干 brachiocephalic trunk |
| 13. 肺动脉干 pulmonary trunk | 23. 右肺下叶 inferior lobe of right lung |
| 14. 肝中间静脉 intermediate hepatic v. | 24. 右头臂静脉 right brachiocephalic v. |
| 15. 右肺中叶 middle lobe of right lung | 25. 上腔静脉 superior vena cava |
| 16. 左心室 left ventricle | 26. 右肺上叶 superior lobe of right lung |
| 17. 乳腺 mammary gland | 27. 右心房 right atrium |
| 18. 心包 pericardium | 28. 胆囊 gallbladder |
| 19. 左肺下叶 inferior lobe of left lung | 29. 右心室 right ventricle |
| 20. 左肺上叶 superior lobe of left lung | 30. 肝左静脉 left hepatic v. |

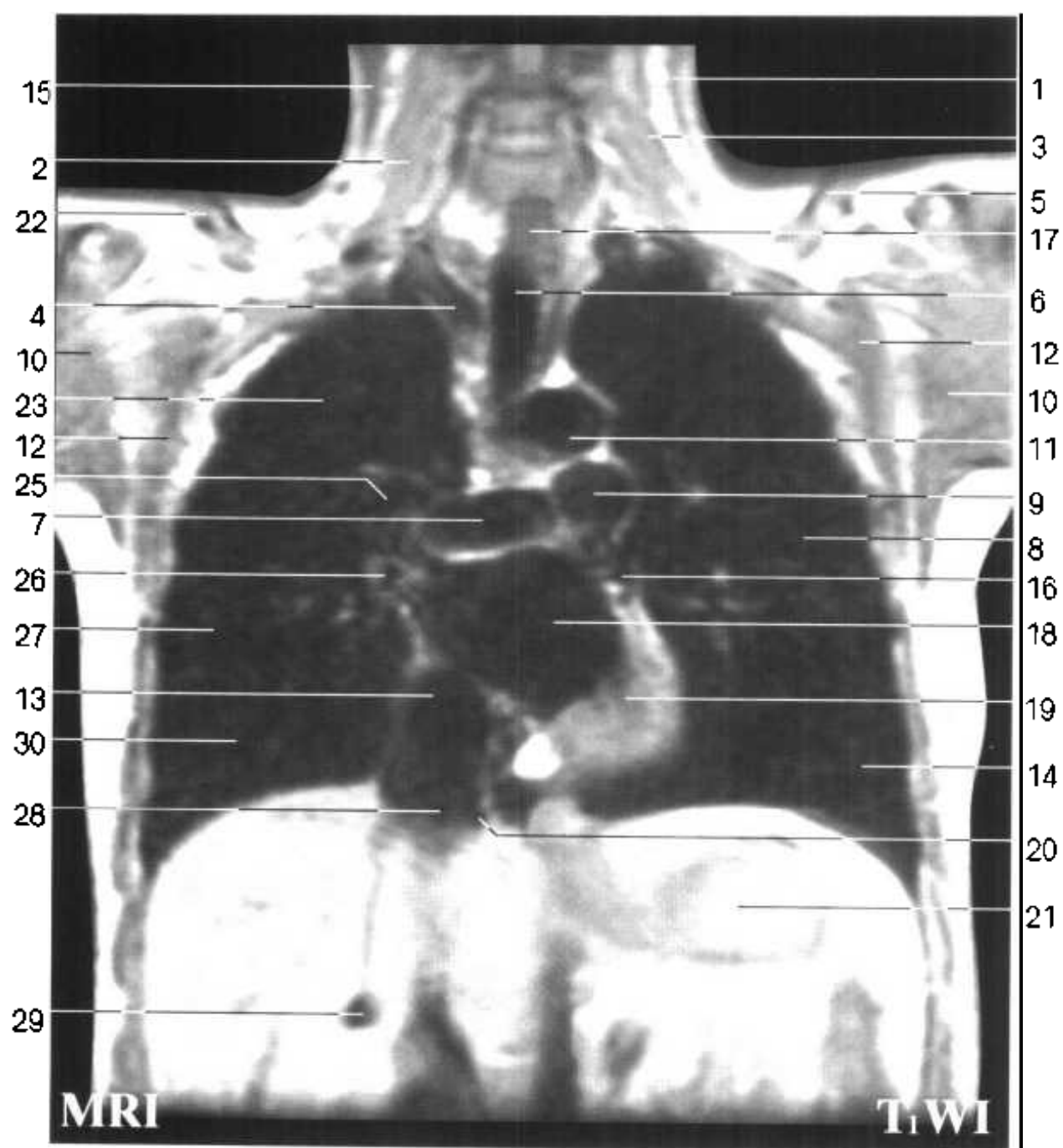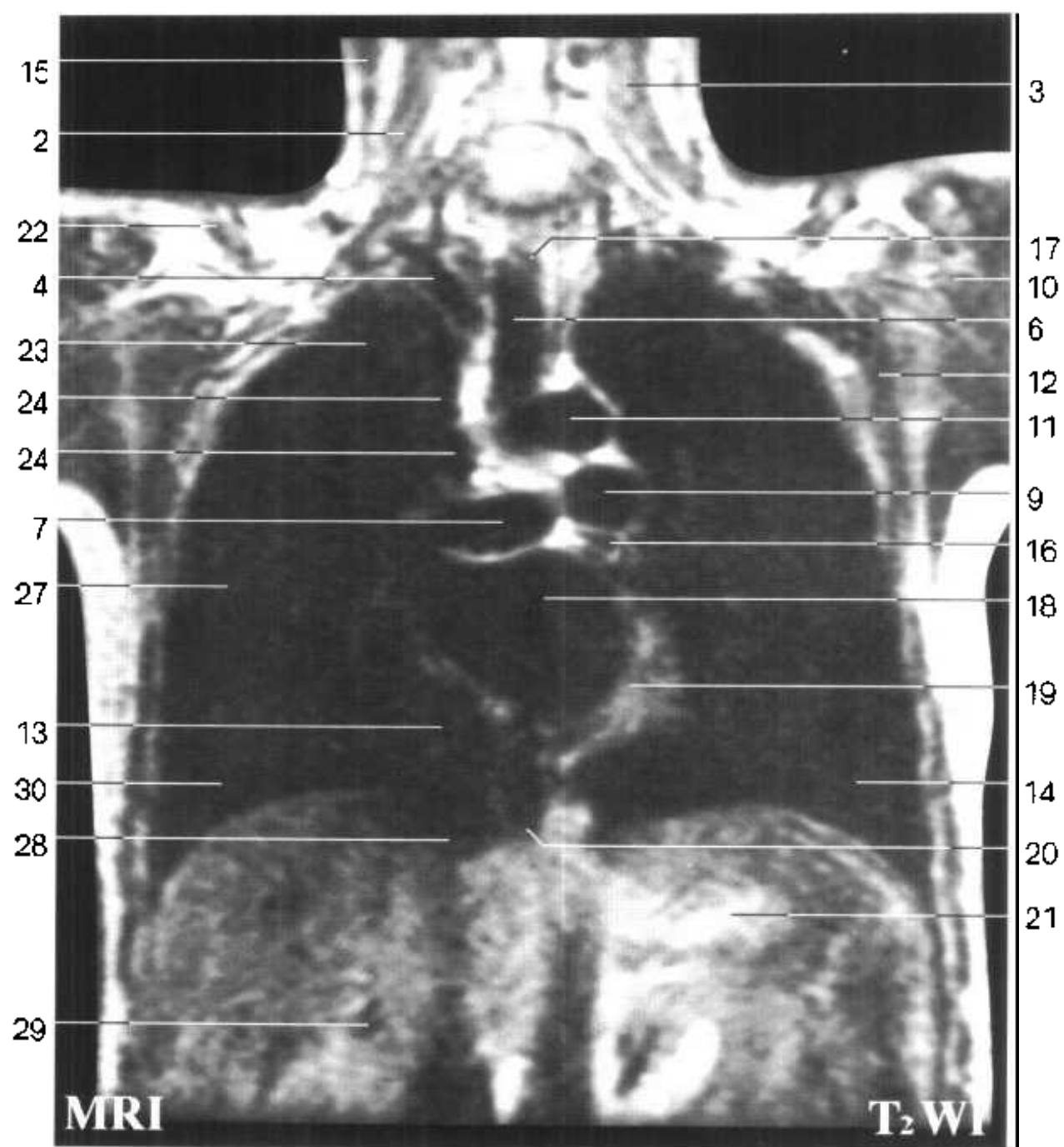


Fig. FT 4

1. 胸锁乳突肌 sternocleidomastoid
2. 中斜角肌 scalenus medius
3. 前斜角肌 scalenus anterior
4. 右头臂静脉 right brachiocephalic v.
5. 锁骨 clavicle
6. 气管 trachea
7. 右肺动脉 right pulmonary a.
8. 左肺上叶 superior lobe of left lung
9. 左肺动脉 left pulmonary a.
10. 胸大肌 pectoralis major
11. 主动脉弓 aortic arch

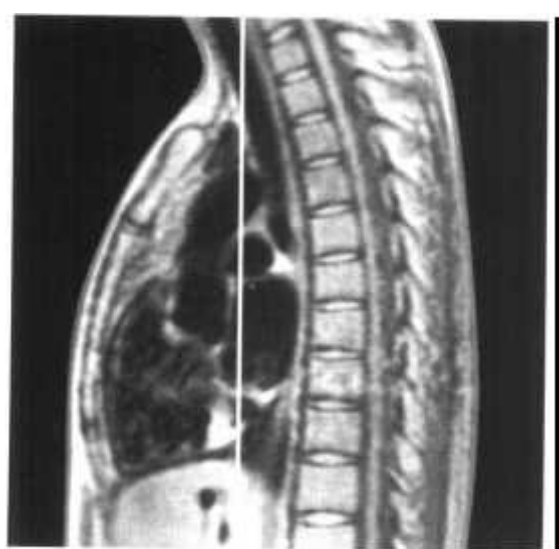

Fig. FT 4



- | | |
|-------------------------------------|---|
| 12. 胸小肌 pectoralis minor | 23. 右肺上叶 superior lobe of right lung |
| 13. 右心房 right atrium | 24. 上腔静脉 superior vena cava |
| 14. 左肺下叶 inferior lobe of left lung | 25. 右肺动脉支 br. right pulmonary a. |
| 15. 胸锁乳突肌 sternocleidomastoid | 26. 右肺中叶支气管 right middle lobar bronchus |
| 16. 左冠状动脉 left coronary a. | 27. 右肺中叶 middle lobe of right lung |
| 17. 食管 esophagus | 28. 下腔静脉 inferior vena cava |
| 18. 左心房 left atrium | 29. 肝门静脉左支脐部 umbilical part of left branch of hepatic portal v. |
| 19. 左心室 left ventricle | 30. 右肺下叶 inferior lobe of right lung |
| 20. 肝左静脉 left hepatic v. | |
| 21. 胃底 fundus of stomach | |
| 22. 锁骨 clavicle | |

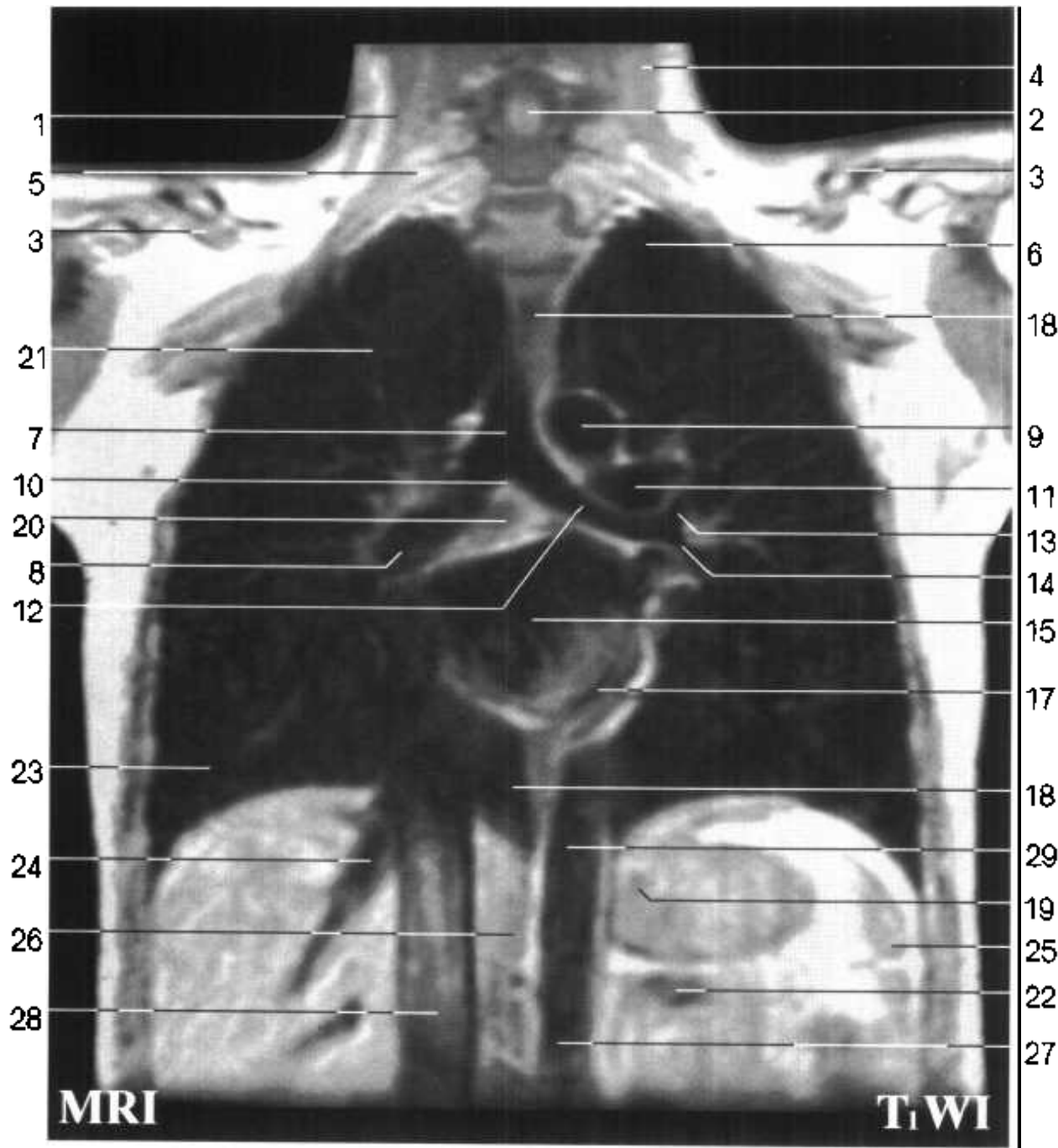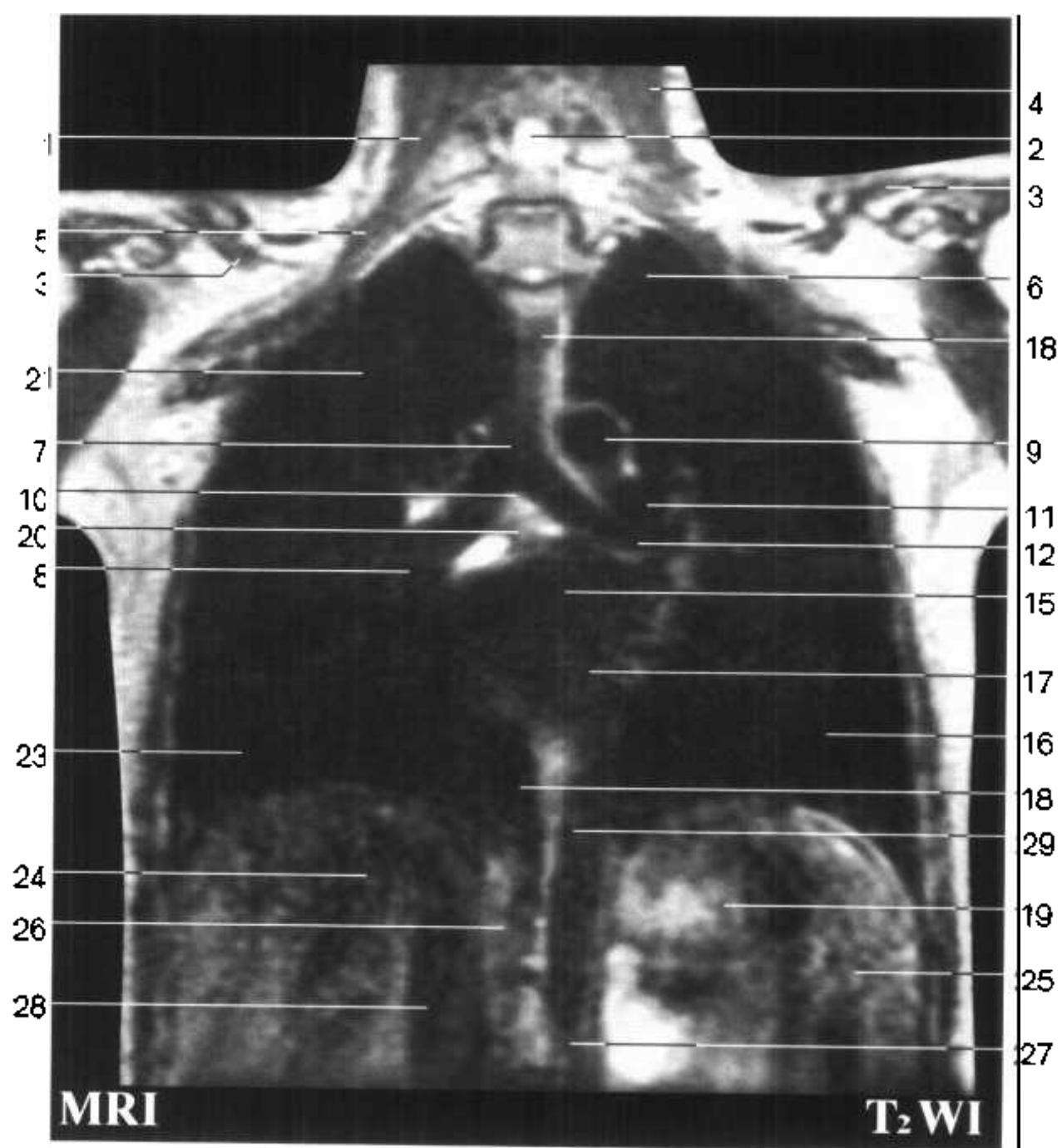


Fig. FT 5

1. 肩胛提肌 levator scapulae
2. 脊髓 spinal cord
3. 锁骨 clavicle
4. 胸锁乳突肌 sternocleidomastoid
5. 臂丛 brachial plexus
6. 左肺上叶 superior lobe of left lung
7. 气管 trachea
8. 右主支气管 right principal bronchus
9. 主动脉弓 aortic arch
10. 气管隆嵴 carina of trachea

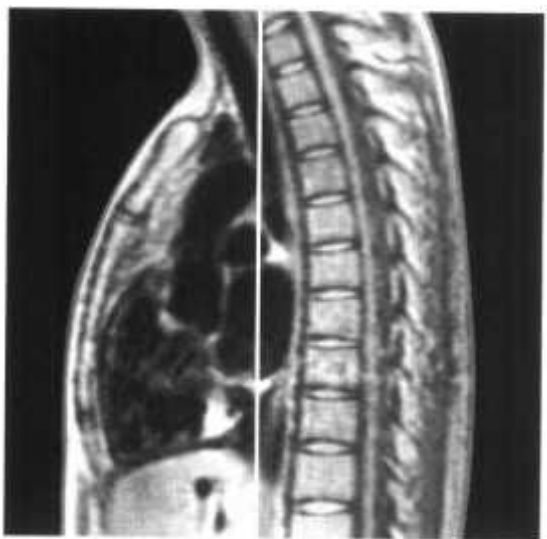

Fig. FT 5



- | | |
|--|---|
| 11. 左肺动脉 left pulmonary a. | 20. 气管支气管下淋巴结 inferior tracheobronchial lymph nodes |
| 12. 左主支气管 left principal bronchus | 21. 右肺上叶 superior lobe of right lung |
| 13. 左肺上叶支气管 left superior lobar bronchus | 22. 胰 pancreas |
| 14. 左肺下叶支气管 left inferior lobar bronchus | 23. 右肺下叶 inferior lobe of right lung |
| 15. 左心房 left atrium | 24. 肝右静脉 right hepatic v. |
| 16. 左肺下叶 inferior lobe of left lung | 25. 脾 spleen |
| 17. 冠状窦 coronary sinus | 26. 尾状叶 caudate lobe |
| 18. 食管 esophagus | 27. 腹主动脉 abdominal aorta |
| 19. 贲门 cardia | 28. 下腔静脉 inferior vena cava |
| | 29. 胸主动脉 thoracic aorta a. |

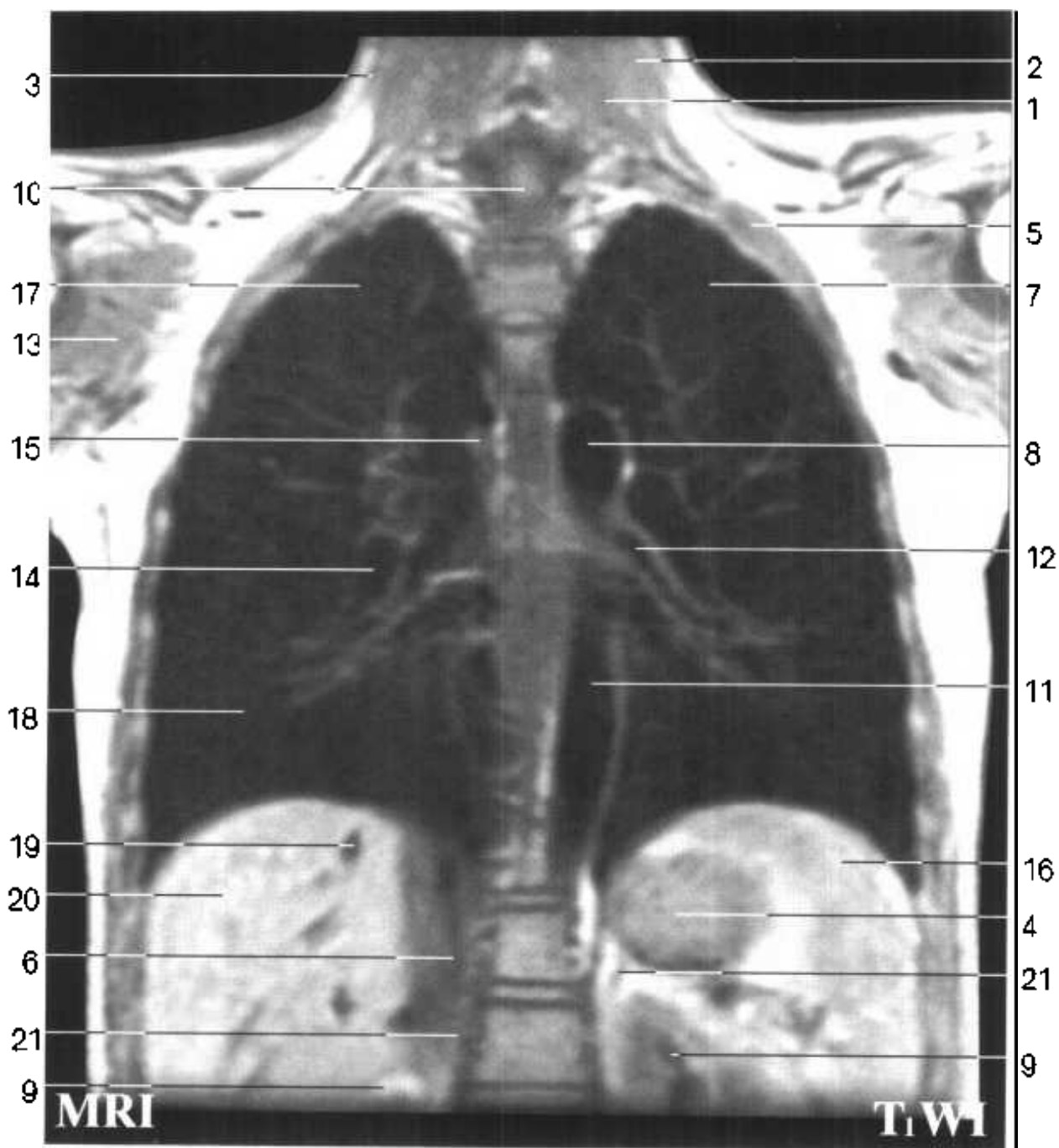
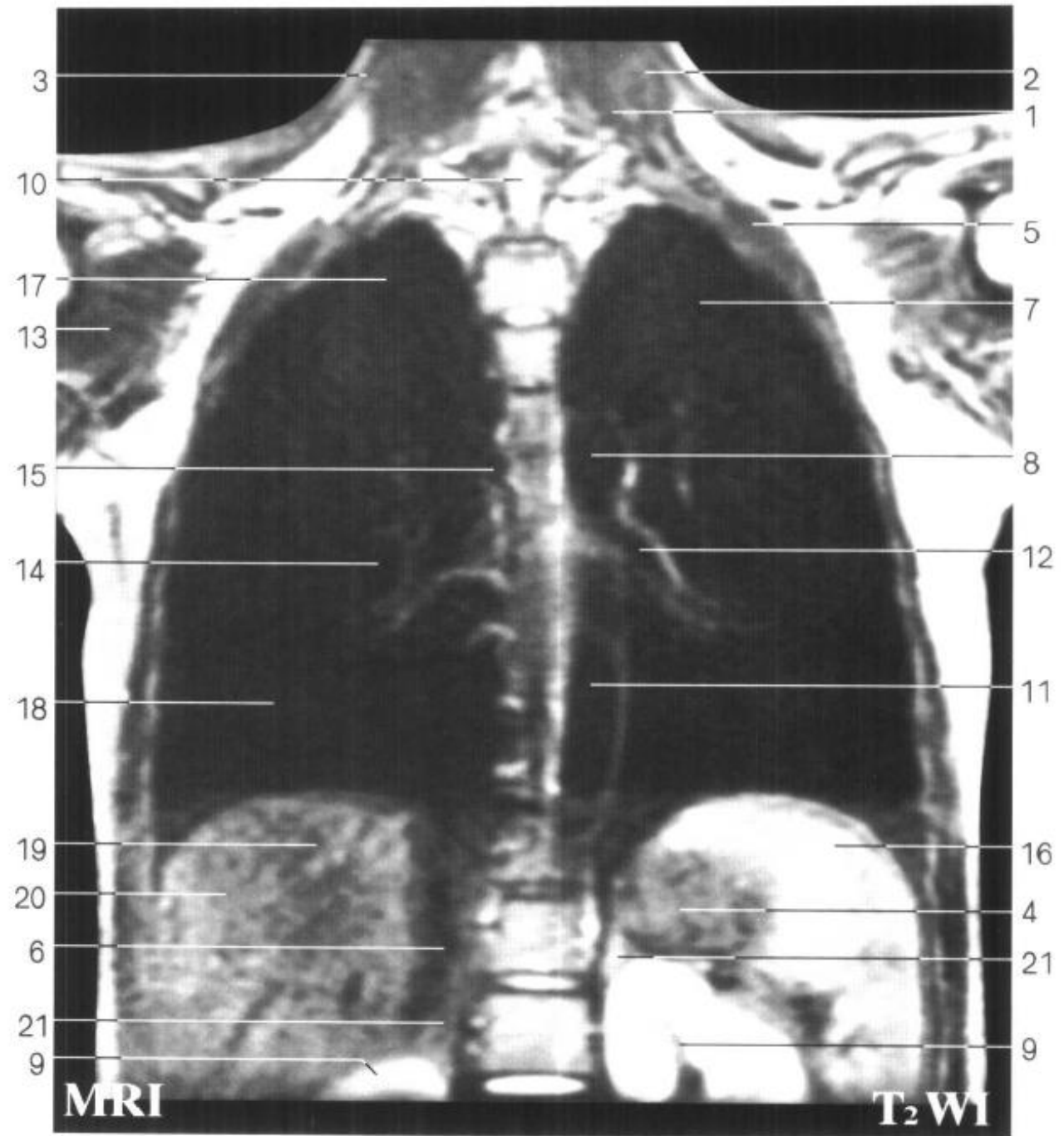


Fig. FT 6

1. 头半棘肌 semispinalis capitis
2. 头夹肌 splenius capitis
3. 斜方肌 trapezius
4. 胃 stomach
5. 前锯肌 serratus anterior
6. 下腔静脉 inferior vena cava
7. 左肺上叶 superior lobe of left lung

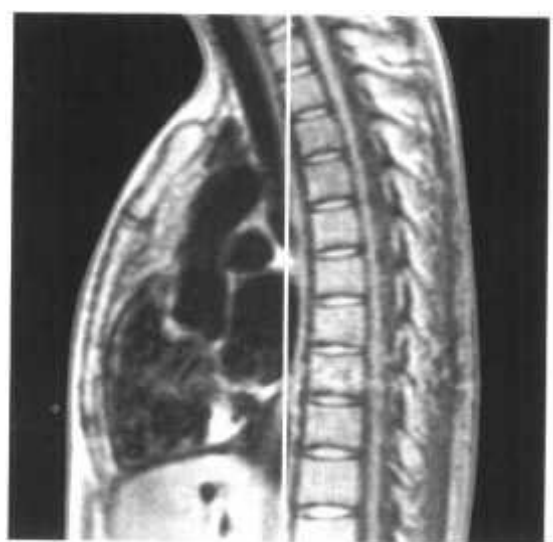

Fig. FT 6



- | | |
|--|--------------------------------------|
| 8. 主动脉弓 aortic arch | 15. 奇静脉 azygos v. |
| 9. 肾 kidney | 16. 脾 spleen |
| 10. 脊髓 spinal cord | 17. 右肺上叶 superior lobe of right lung |
| 11. 胸主动脉 thoracic aorta | 18. 右肺下叶 inferior lobe of right lung |
| 12. 后底段支气管(Bx) posterior basal
segmental bronchus(Bx) | 19. 肝右静脉 right hepatic v. |
| 13. 肩胛下肌 subscapularis | 20. 右后叶 right posterior lobe |
| 14. 右肺动脉支 br., right pulmonary a. | 21. 肾上腺 superarenal gland |

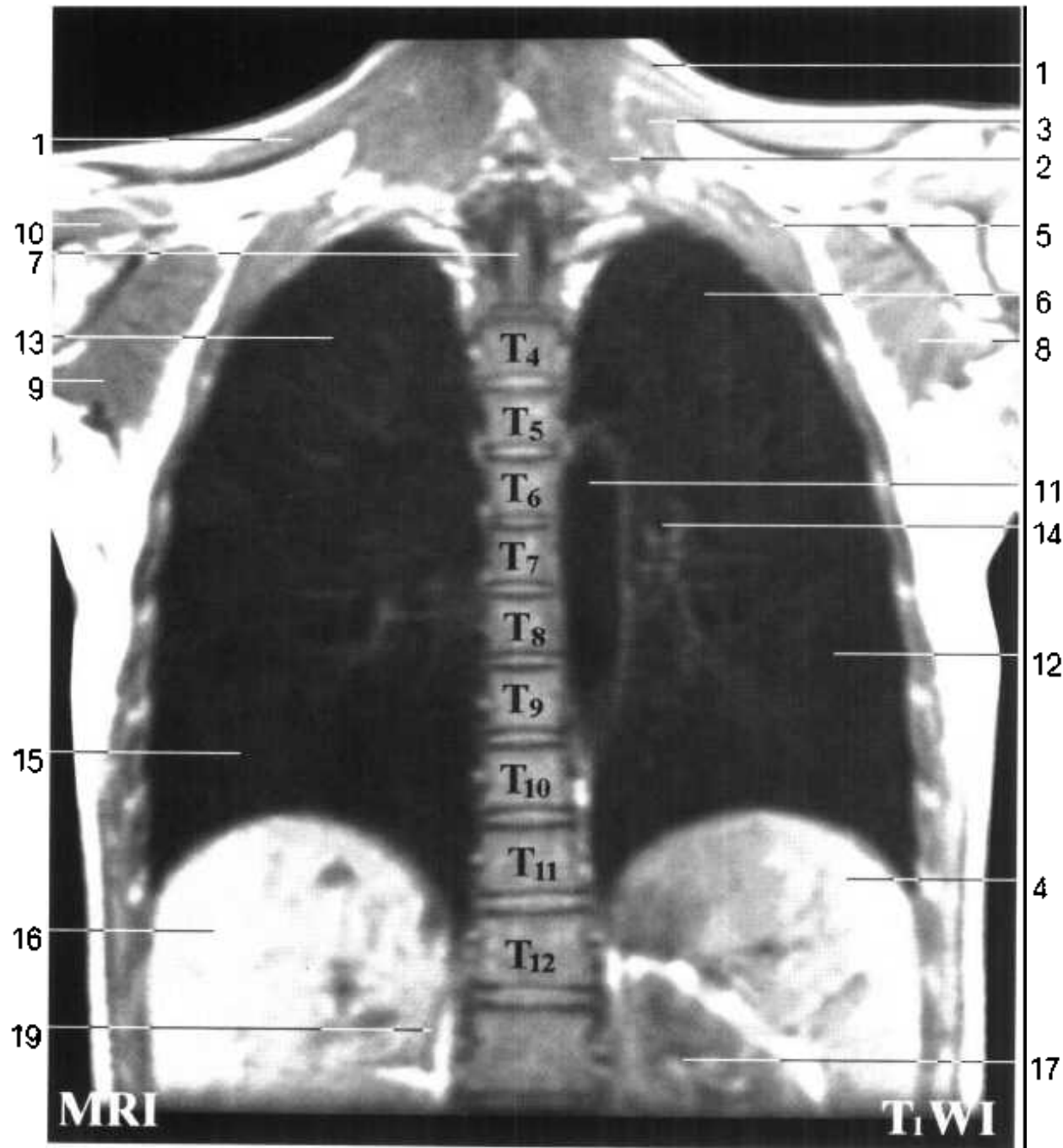
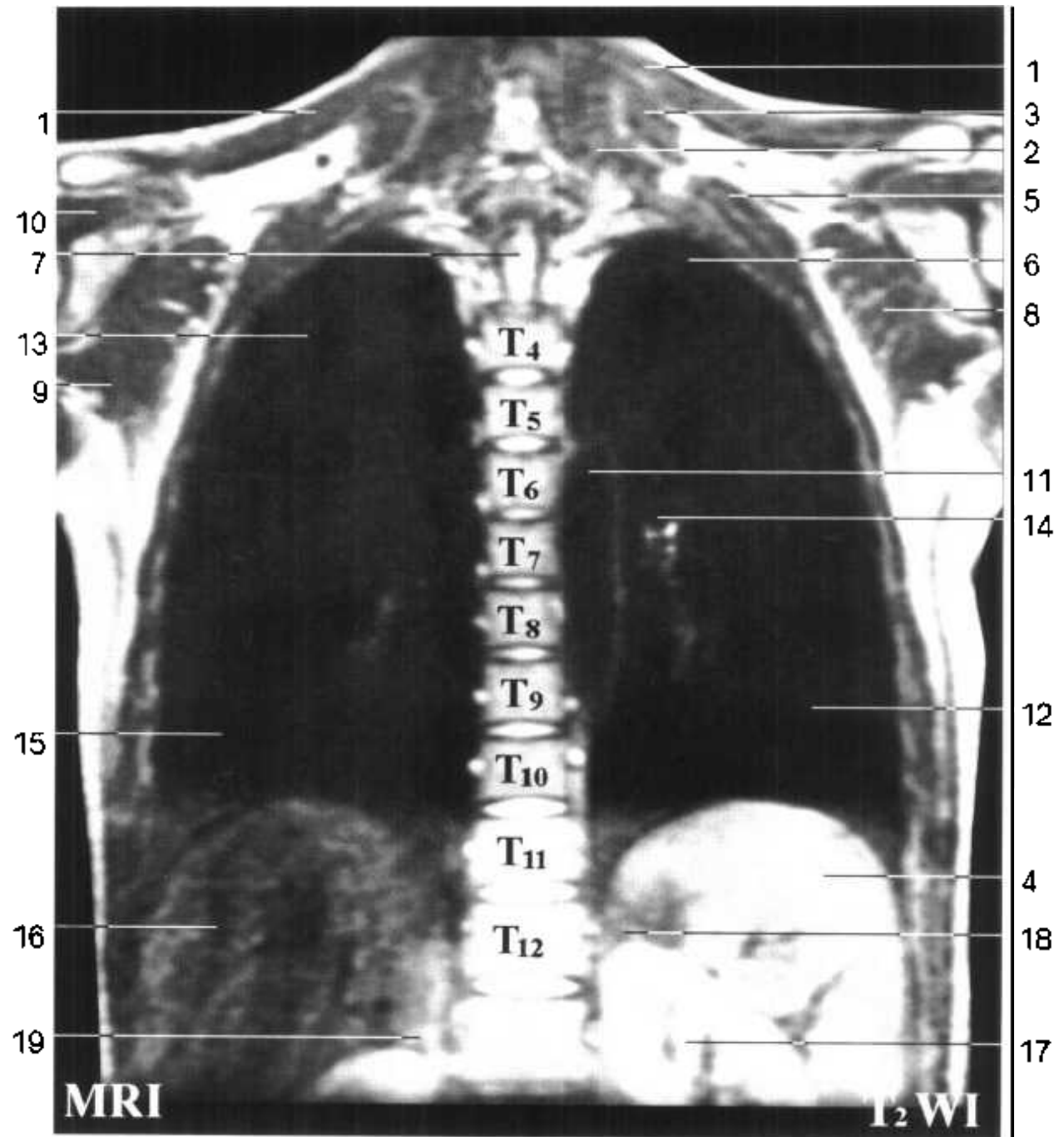


Fig. FT 7

1. 斜方肌 trapezius
2. 头夹肌 splenius capitis
3. 肩胛提肌 levator scapulae
4. 脾 spleen
5. 前锯肌 serratus anterior
6. 左肺上叶 superior lobe of left lung
7. 脊髓 spinal cord
8. 肩胛下肌 subscapularis
9. 大圆肌 teres major
10. 冈上肌 supraspinatus

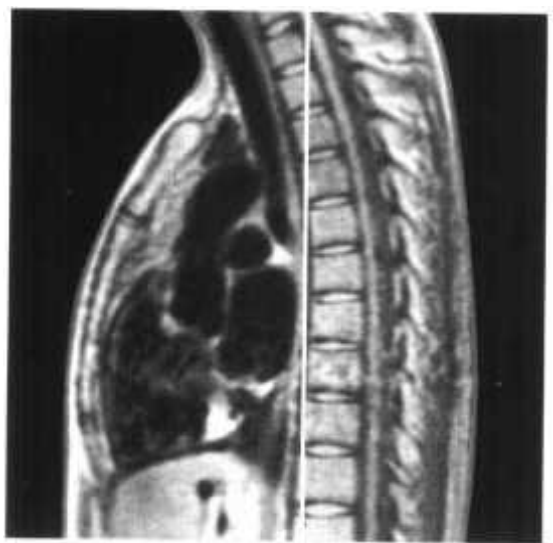

Fig. FT 7



- 11. 胸主动脉 thoracic aorta
- 12. 左肺下叶 inferior lobe of left lung
- 13. 右肺上叶 superior lobe of right lung
- 14. 后底段支气管(B_x) posterior basal segmental bronchus(B_x)
- 15. 右肺下叶 inferior lobe of right lung
- 16. 右后叶 right posterior lobe
- 17. 左肾 left kidney
- 18. 左肾上腺 left suprarenal gland
- 19. 右肾上腺 right suprarenal gland

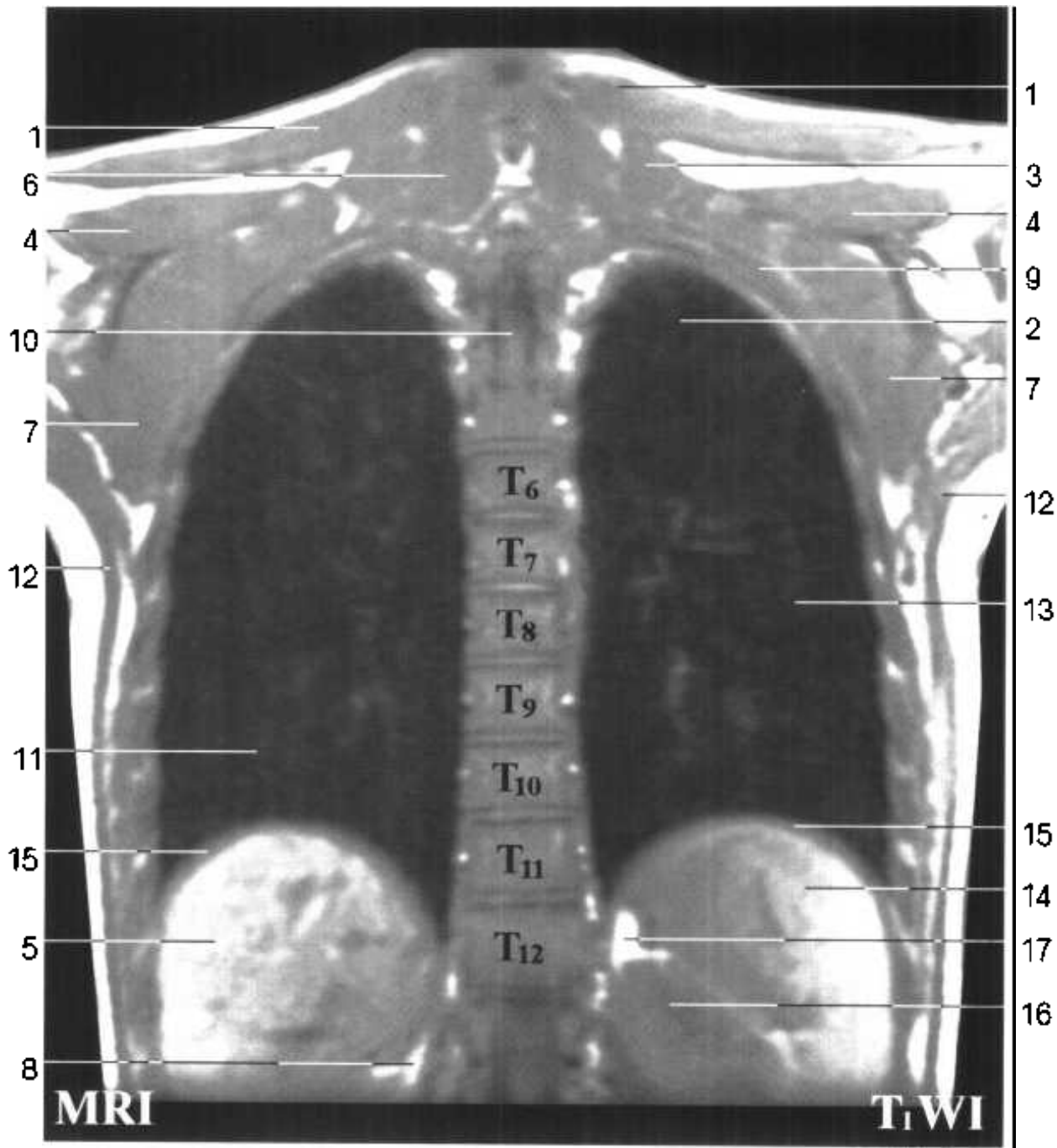
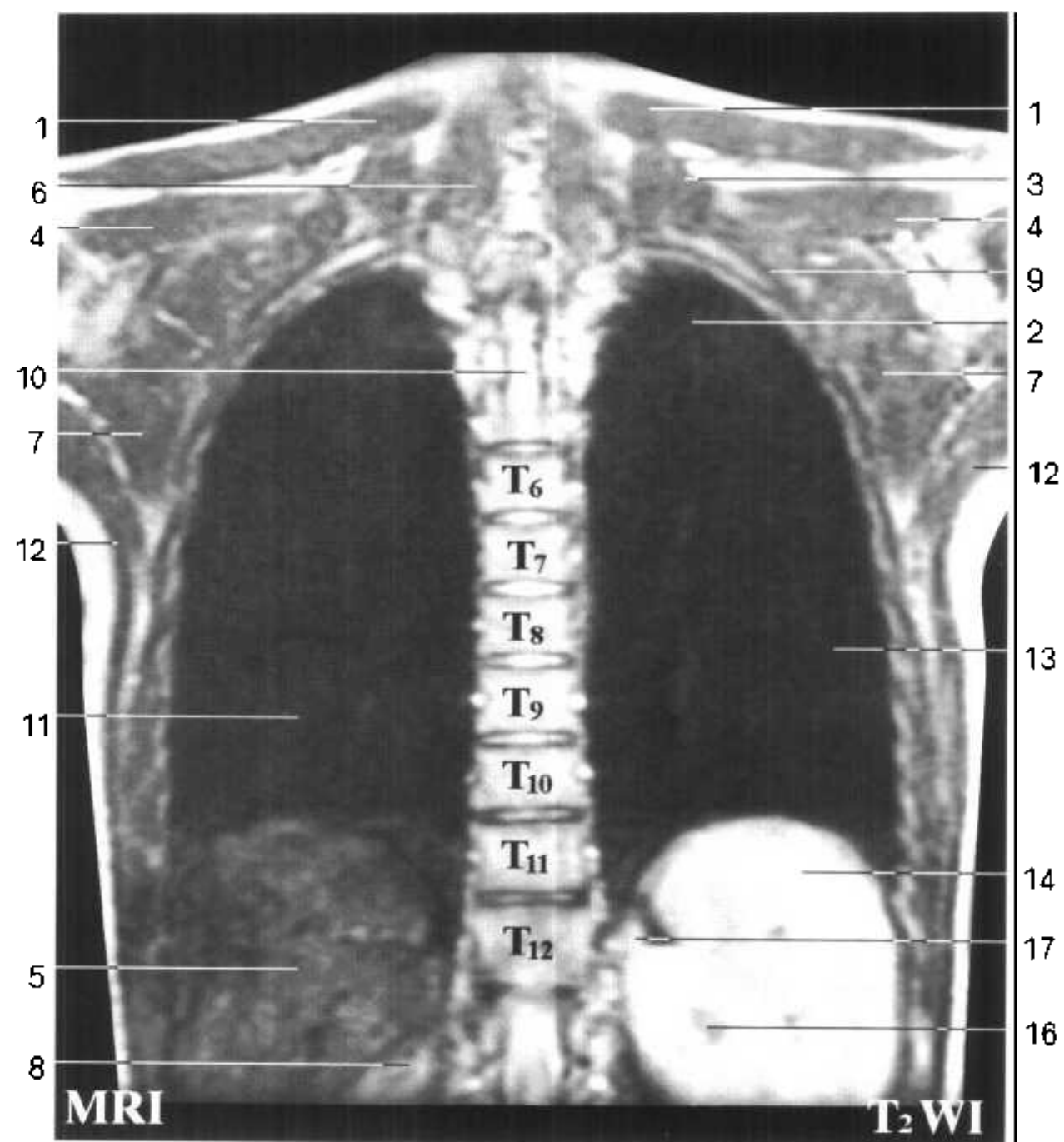


Fig. FT 8

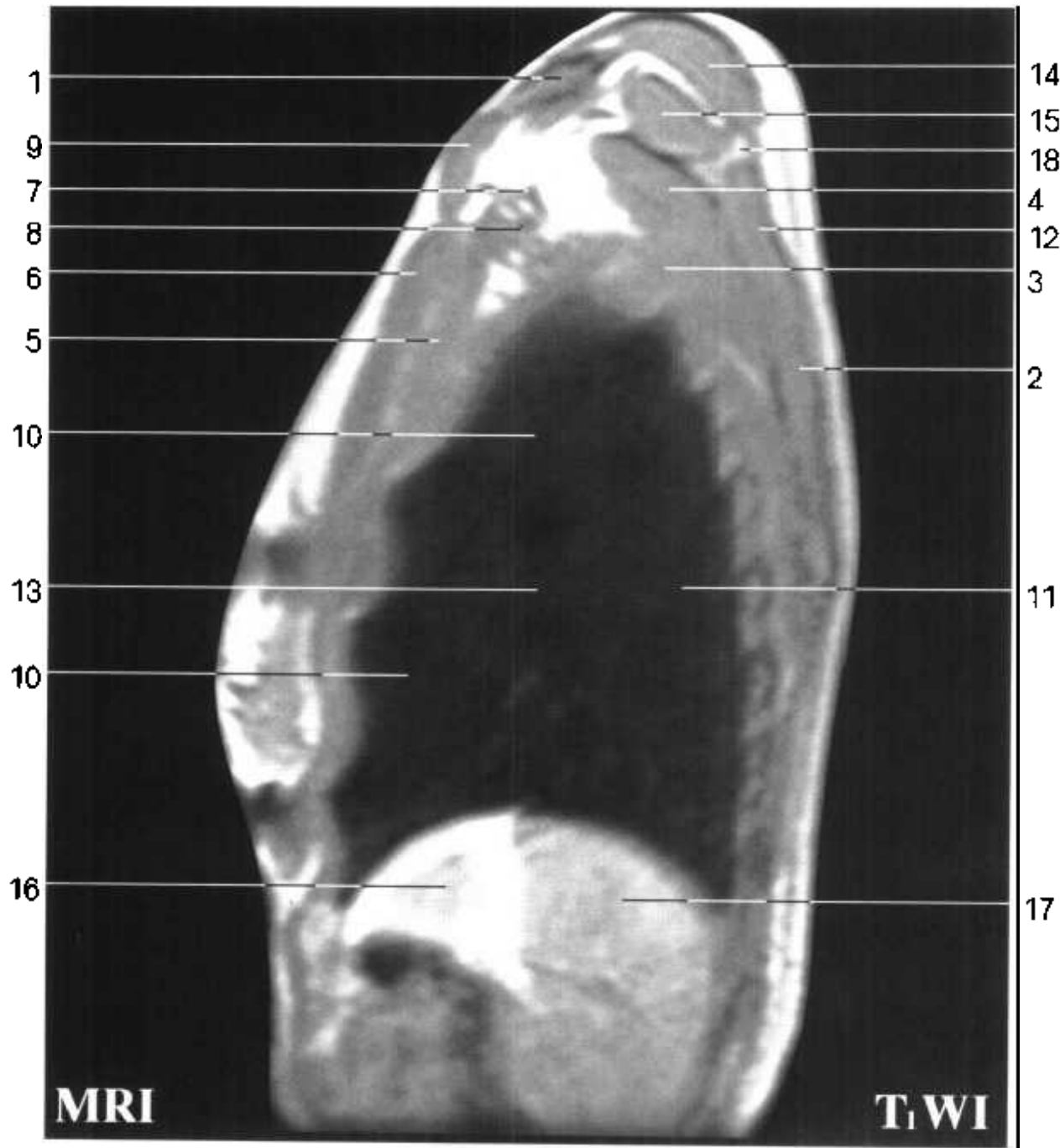
- 1. 斜方肌 trapezius
- 2. 左肺上叶 superior lobe of left lung
- 3. 肩胛提肌 levator scapulae
- 4. 冈上肌 supraspinatus
- 5. 右后叶 right posterior lobe
- 6. 竖脊肌 erector spinae
- 7. 肩胛下肌 subscapularis
- 8. 右肾上腺 right suprarenal gland
- 9. 前锯肌 serratus anterior
- 10. 脊髓 spinal cord

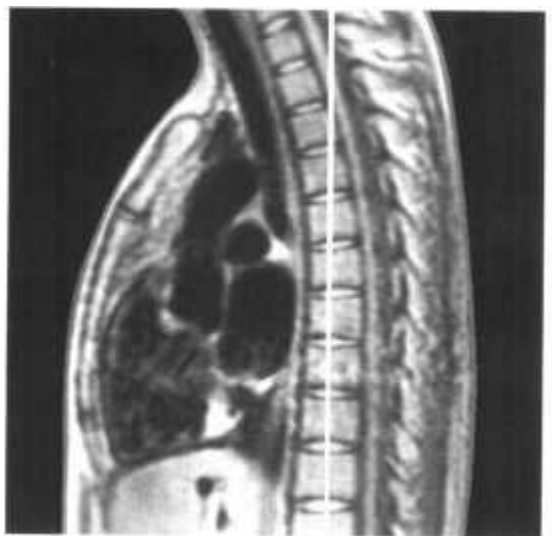

Fig. FT 8

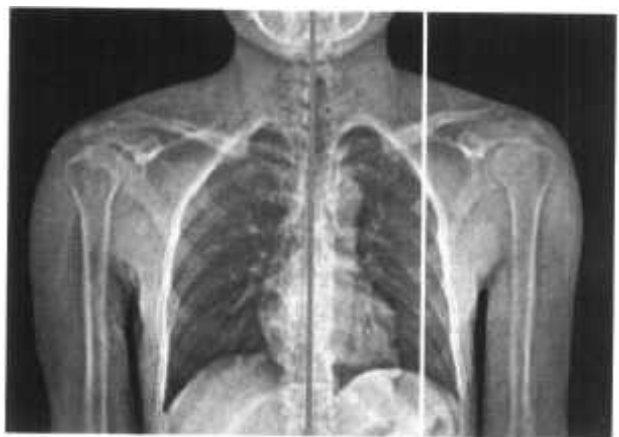

- 11. 右肺下叶 inferior lobe of right lung
- 12. 背阔肌 latissimus dorsi
- 13. 左肺下叶 inferior lobe of left lung
- 14. 脾 spleen
- 15. 膈 diaphragm
- 16. 左肾 left kidney
- 17. 左肾上腺 left suprarenal gland



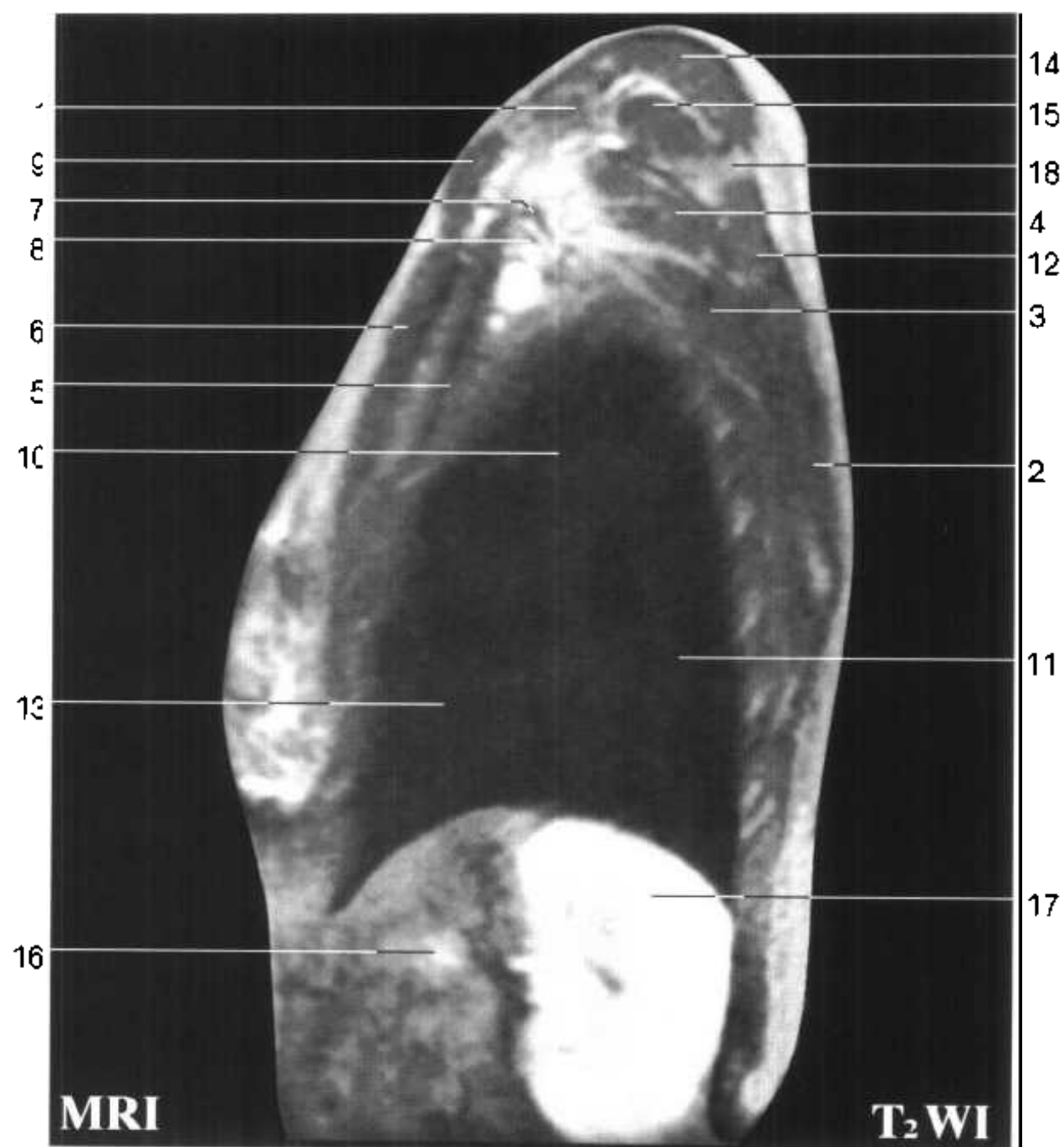
矢状断面图 ST

Fig. ST 1



- 1. 锁骨 clavicle
- 2. 背阔肌 latissimus dorsi
- 3. 前锯肌 serratus anterior
- 4. 肩胛下肌 subscapularis
- 5. 胸小肌 pectoralis minor
- 6. 胸大肌 pectoralis major
- 7. 腋动脉 axillary a.
- 8. 腋静脉 axillary v.
- 9. 三角肌 deltoid

Fig. ST 1



- 10. 左肺上叶 superior lobe of left lung
- 11. 左肺下叶 inferior lobe of left lung
- 12. 冈下肌 infraspinatus
- 13. 斜裂 oblique fissure
- 14. 斜方肌 trapezius
- 15. 冈上肌 supraspinatus
- 16. 胃底 fundus of stomach
- 17. 脾 spleen
- 18. 肩胛冈 spine of scapula

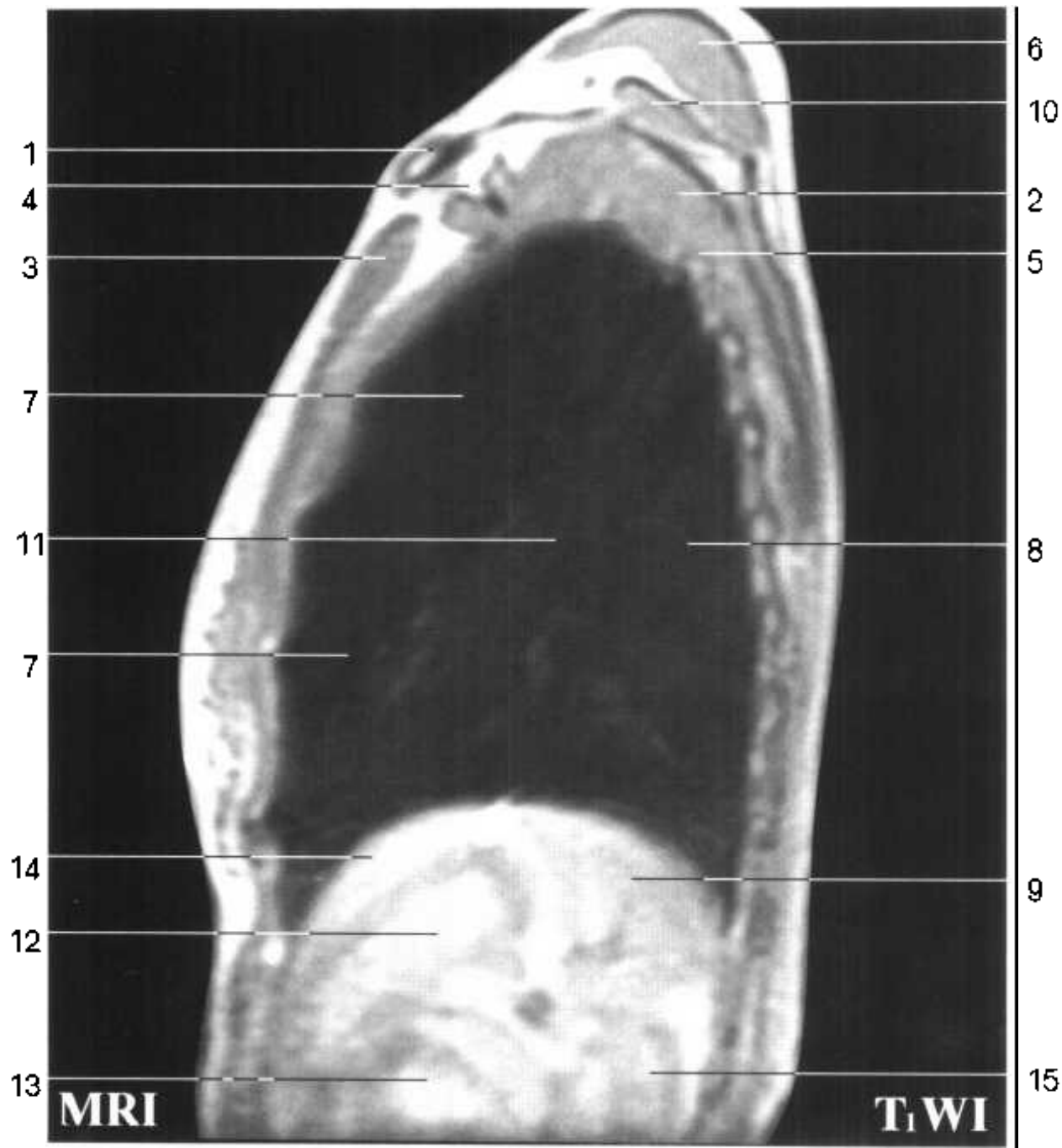
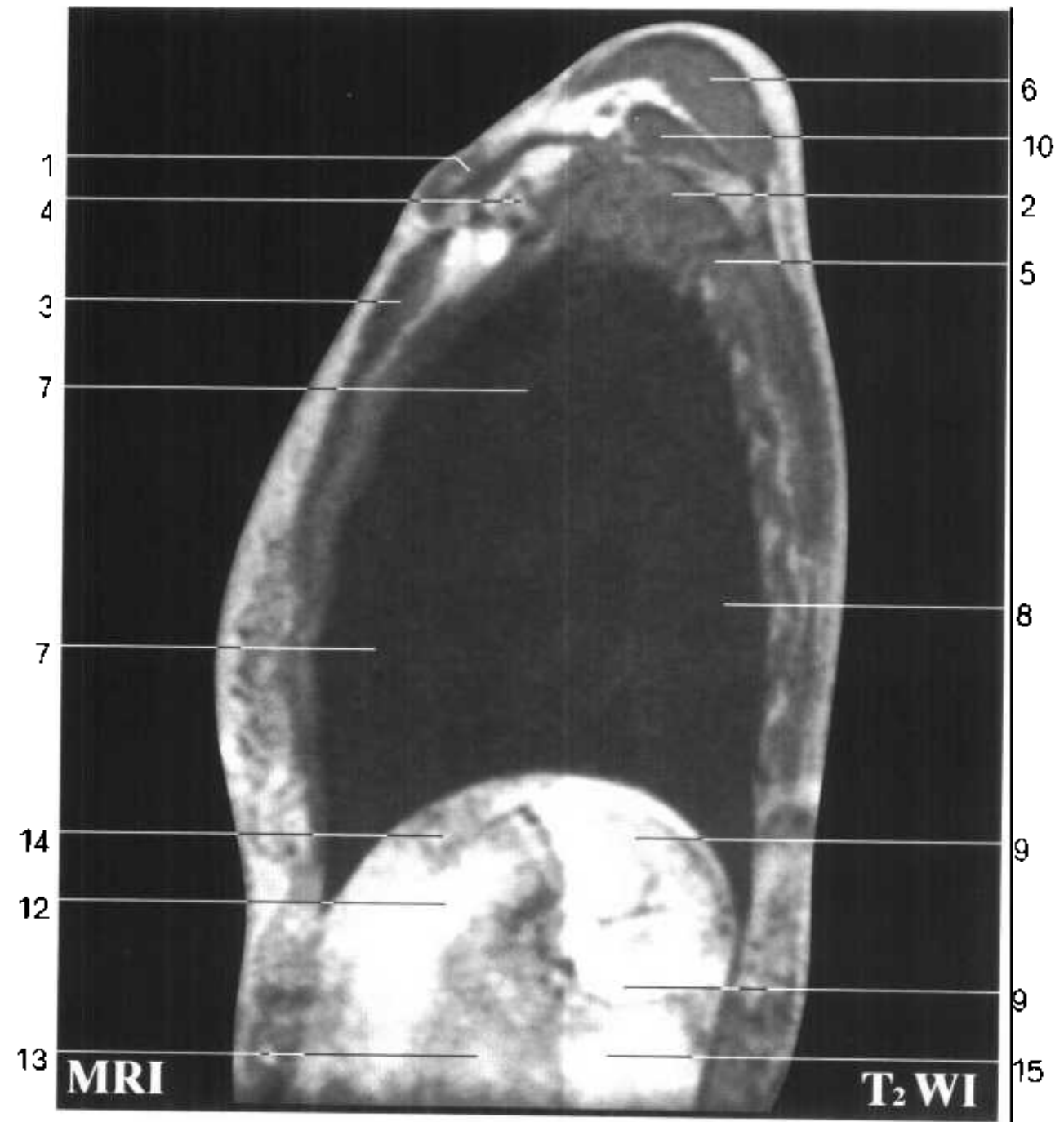


Fig. ST 2

- 1. 锁骨 clavicle
- 2. 肩胛下肌 subscapularis
- 3. 胸大肌 pectoralis major
- 4. 臂丛 brachial plexus
- 5. 前锯肌 serratus anterior
- 6. 斜方肌 trapezius
- 7. 左肺上叶 superior lobe of left lung
- 8. 左肺下叶 inferior lobe of left lung
- 9. 脾 spleen
- 10. 冈上肌 supraspinatus

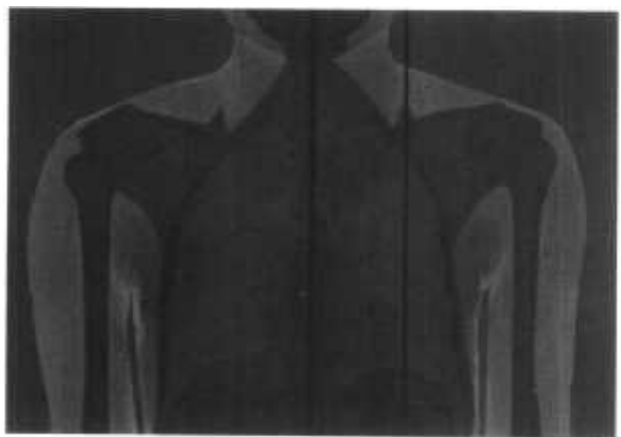

Fig. ST 2



- 11. 斜裂 oblique fissure
- 12. 胃底 fundus of stomach
- 13. 空肠 jejunum
- 14. 左外叶 left lateral lobe
- 15. 结肠左曲 left colic flexure

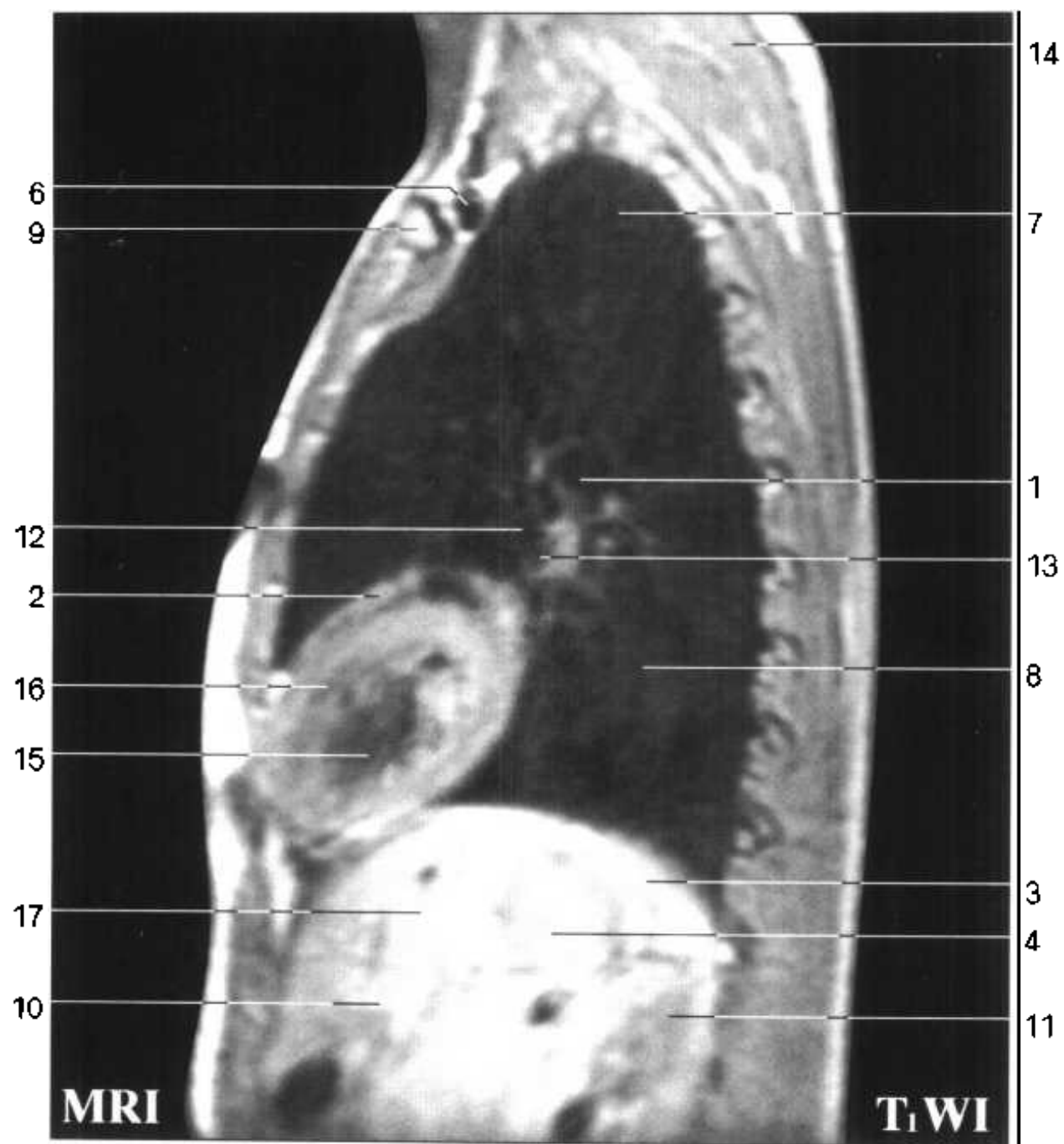

Fig. ST 3

1. 左肺动脉上叶支 superior lobar branches of left pulmonary a.
2. 心包 pericardium
3. 脾 spleen
4. 胃体 body of stomach
5. 左锁骨下动脉 left subclavian a.
6. 左锁骨下静脉 left subclavian v.
7. 左肺上叶 superior lobe of left lung
8. 左肺下叶 inferior lobe of left lung
9. 锁骨 clavicle

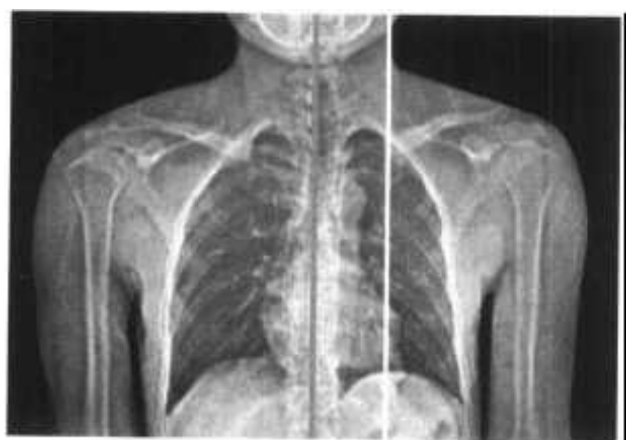
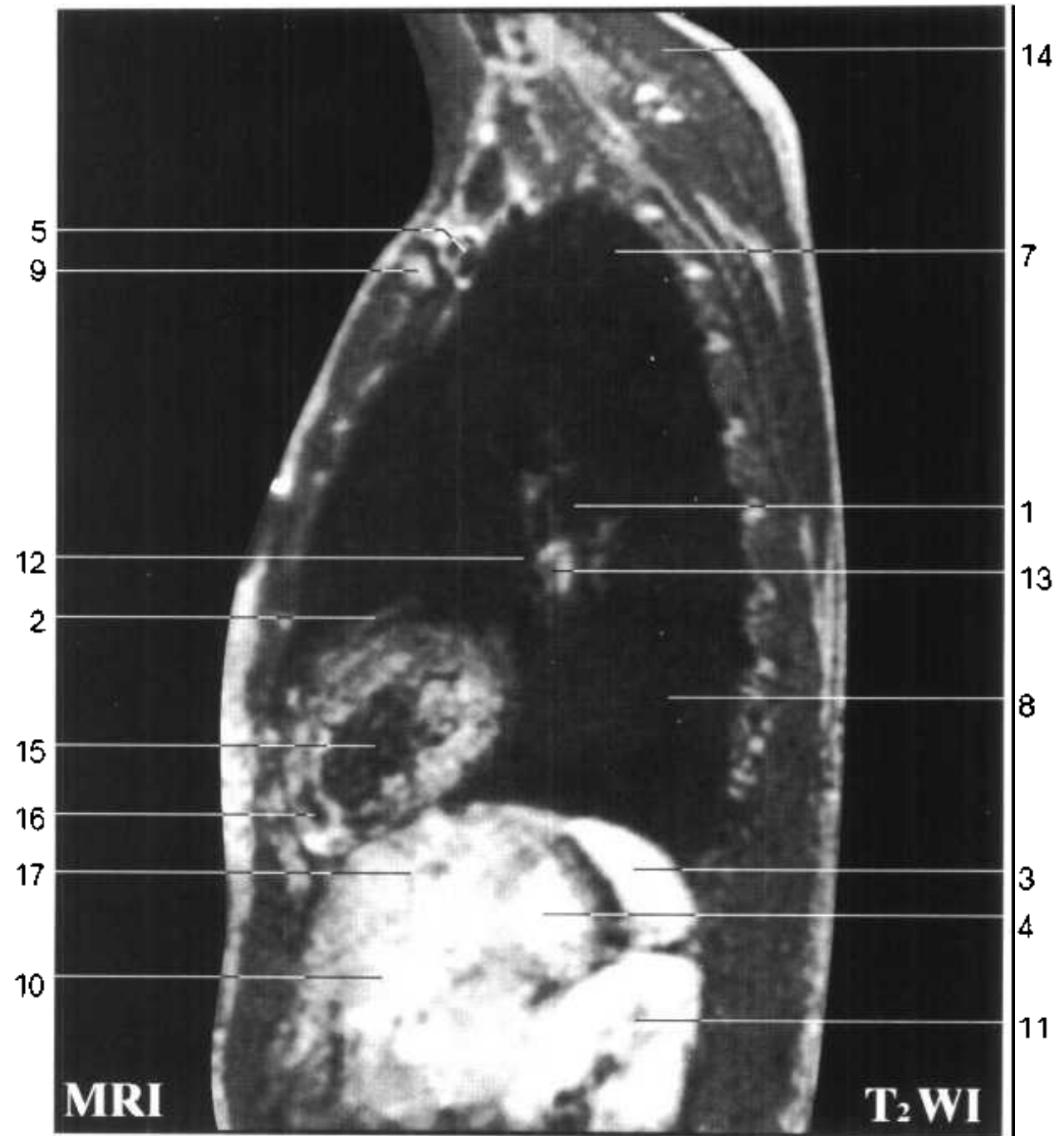


Fig. ST 3



- 10. 左外叶下段 inferior segment of left lateral lobe
- 11. 左肾 left kidney
- 12. 左上肺静脉 left superior pulmonary v.
- 13. 下舌段支气管(B_v) inferior lingual bronchus(B_v)
- 14. 斜方肌 trapezius
- 15. 左心室 left ventricle
- 16. 右心室 right ventricle
- 17. 左外叶上段 superior segment of left lateral lobe

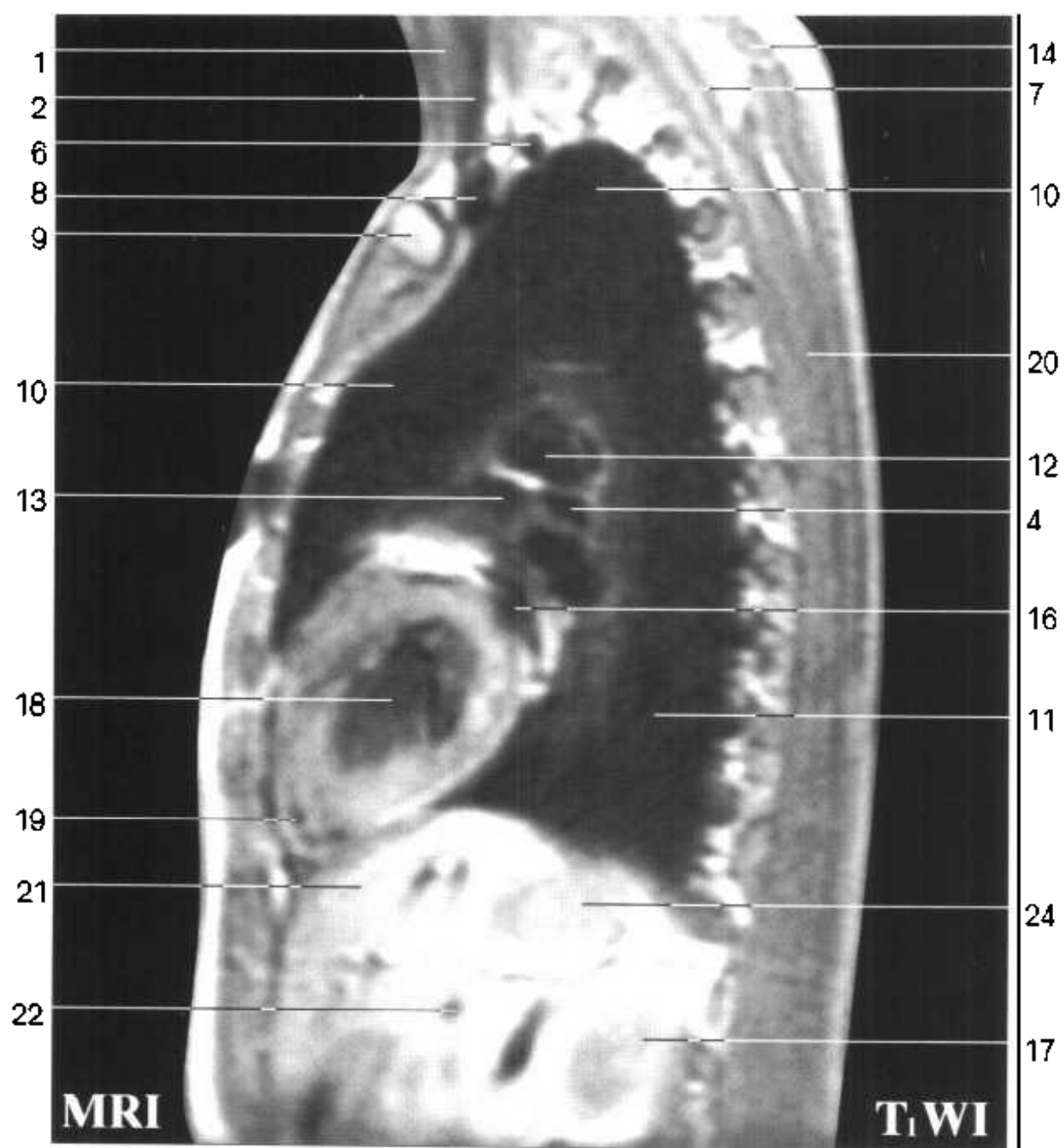

Fig. ST 4

1. 胸锁乳突肌 sternocleidomastoid
2. 颈内静脉 internal jugular v.
3. 中斜角肌 scalenus medius
4. 上段支气管(B_{VI}) superior segmental bronchus(B_{VI})
5. 臂丛(中干) brachial plexus(middle trunk)
6. 左锁骨下动脉 left subclavian a.
7. 肩胛提肌 levator scapulae
8. 左锁骨下静脉 left subclavian v.

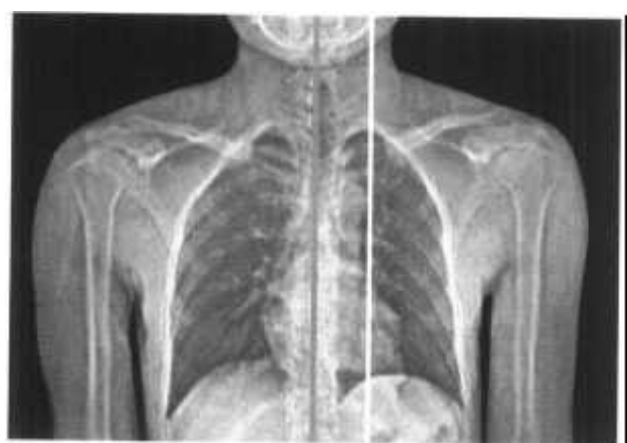
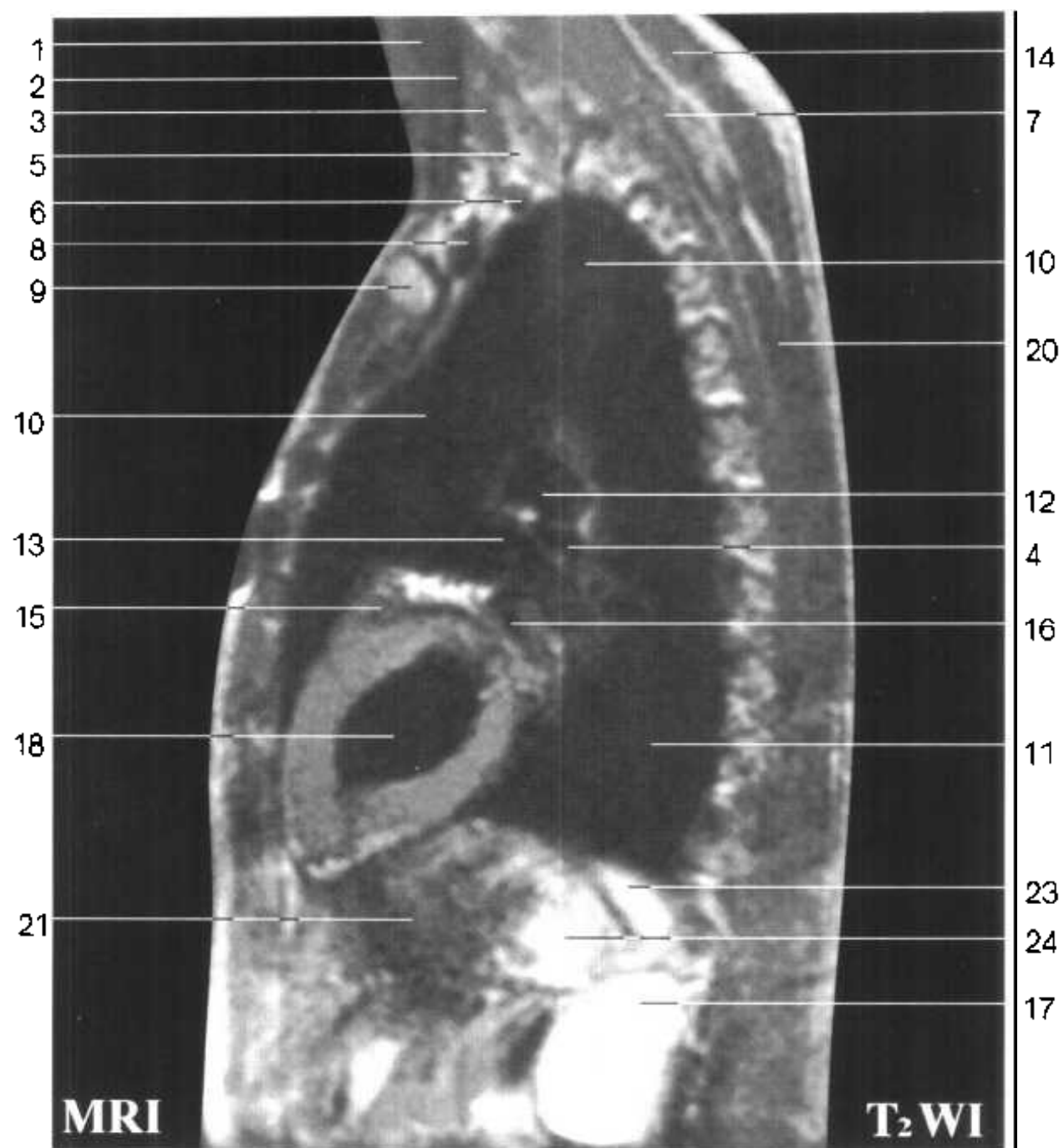

Fig. ST 4



- | | |
|---|---|
| 9. 锁骨 clavicle | 17. 左肾 left kidney |
| 10. 左肺上叶 superior lobe of left lung | 18. 左心室 left ventricle |
| 11. 左肺下叶 inferior lobe of left lung | 19. 右心室 right ventricle |
| 12. 左肺动脉 left pulmonary a. | 20. 菱形肌 rhomboideus |
| 13. 舌叶支气管 lingual lobar bronchus | 21. 左外叶上段 superior segment of left lateral lobe |
| 14. 斜方肌 trapezius | 22. 肝左静脉 left hepatic v. |
| 15. 左冠状动脉 left coronary a. | 23. 脾 spleen |
| 16. 后底段支气管(B _s) posterior basal segmental bronchus(B _s) | 24. 胃体 body of stomach |

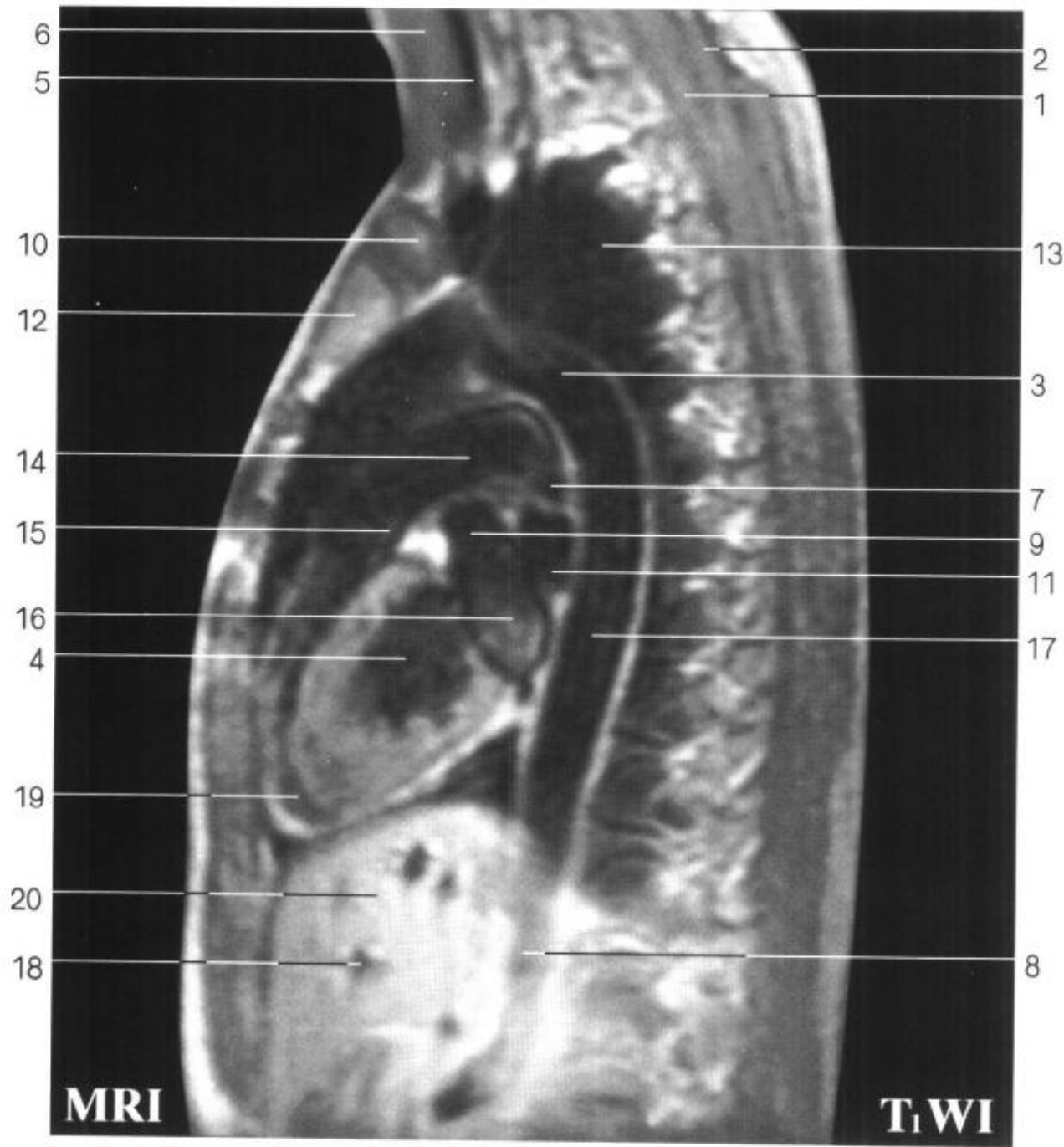


Fig. ST 5

1. 竖脊肌 erector spinae
2. 斜方肌 trapezius
3. 主动脉弓 aortic arch
4. 左心室 left ventricle
5. 左颈内静脉 left internal jugular v.
6. 胸锁乳突肌 sternocleidomastoid
7. 左主支气管 left principal bronchus
8. 腹主动脉 abdominal aorta
9. 左上肺静脉 left superior pulmonary v.
10. 锁骨 clavicle
11. 左下肺静脉 left inferior pulmonary v.

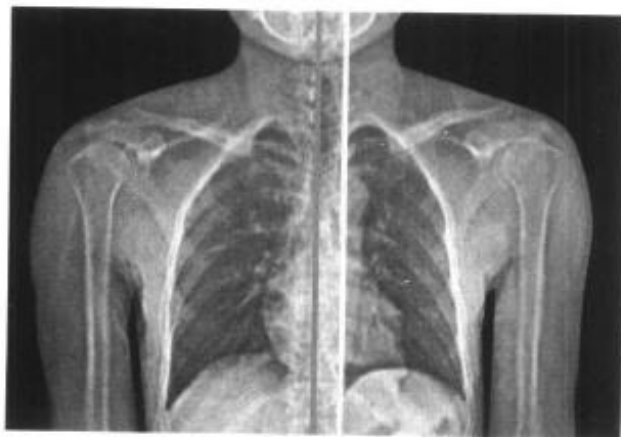
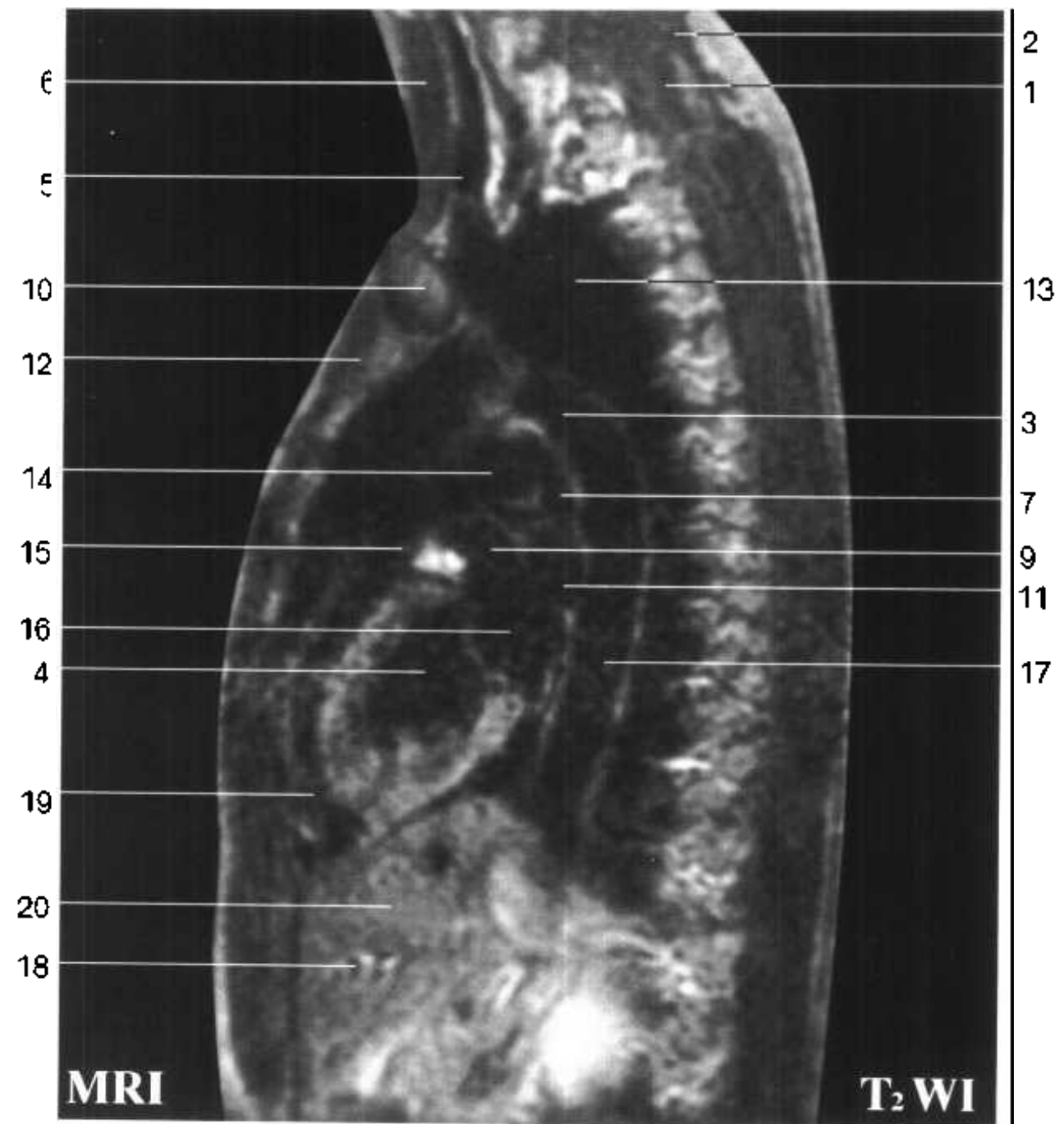

Fig. ST 5



- 12. 胸骨柄 manubrium sterni
- 13. 左肺上叶 superior lobe of left lung
- 14. 肺动脉干 pulmonary trunk
- 15. 肺动脉瓣 valve of pulmonary trunk
- 16. 左心房 left atrium
- 17. 胸主动脉 thoracic aorta
- 18. 肝左静脉 left hepatic v.
- 19. 右心室 right ventricle
- 20. 肝左叶 left lobe of liver

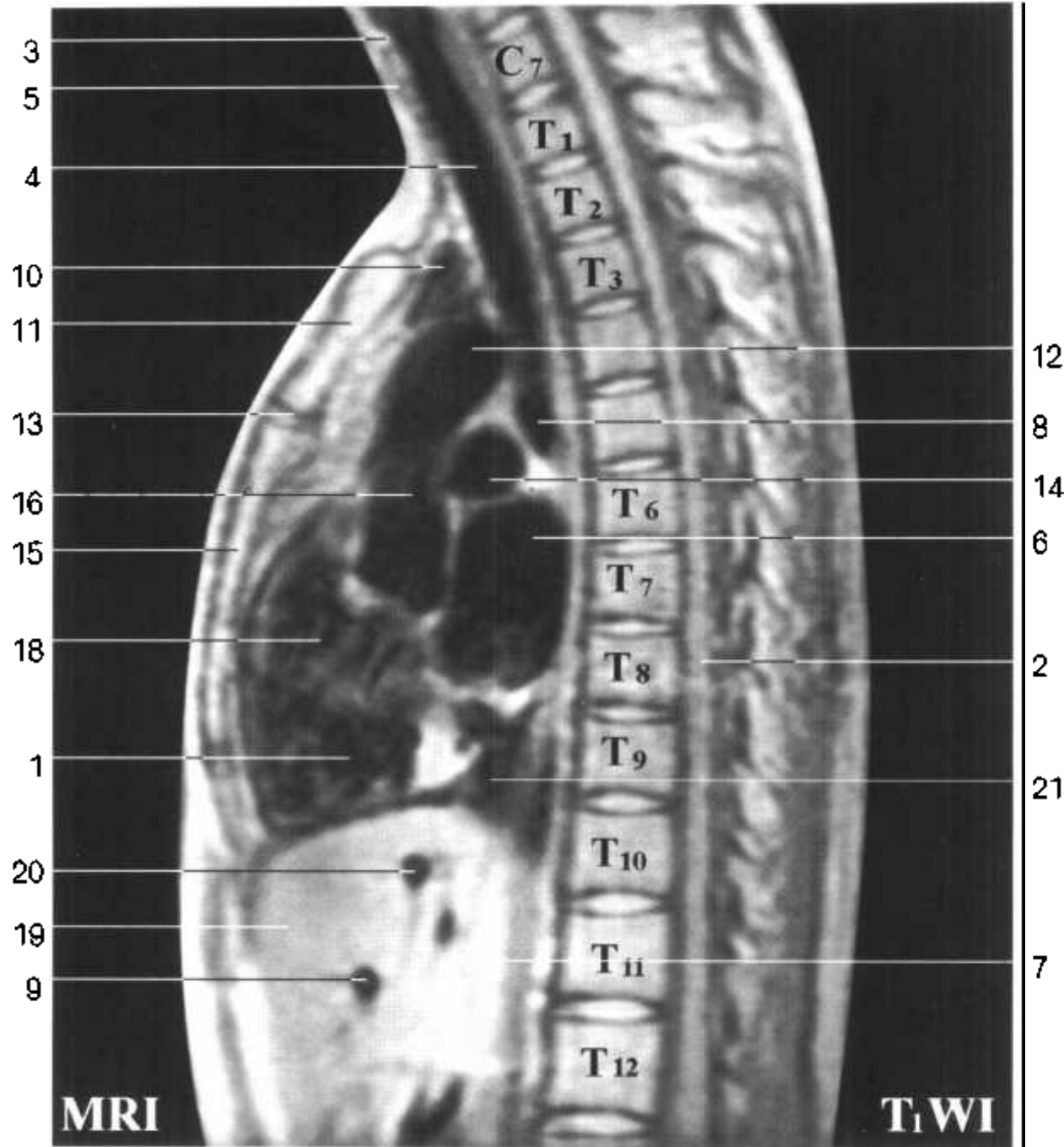


Fig. ST 6

1. 右心室 right ventricle
2. 脊髓 spinal cord
3. 环状软骨弓 arch of cricoid cartilage
4. 气管 trachea
5. 甲状腺峡 isthmus of thyroid gland
6. 左心房 left atrium
7. 尾状叶 caudate lobe
8. 右主支气管 right principal bronchus
9. 肝左静脉 left hepatic v.
10. 头臂干 brachiocephalic trunk
11. 胸骨柄 manubrium sterni

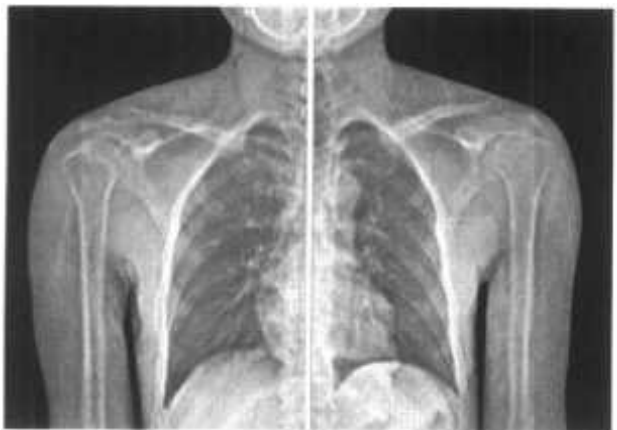
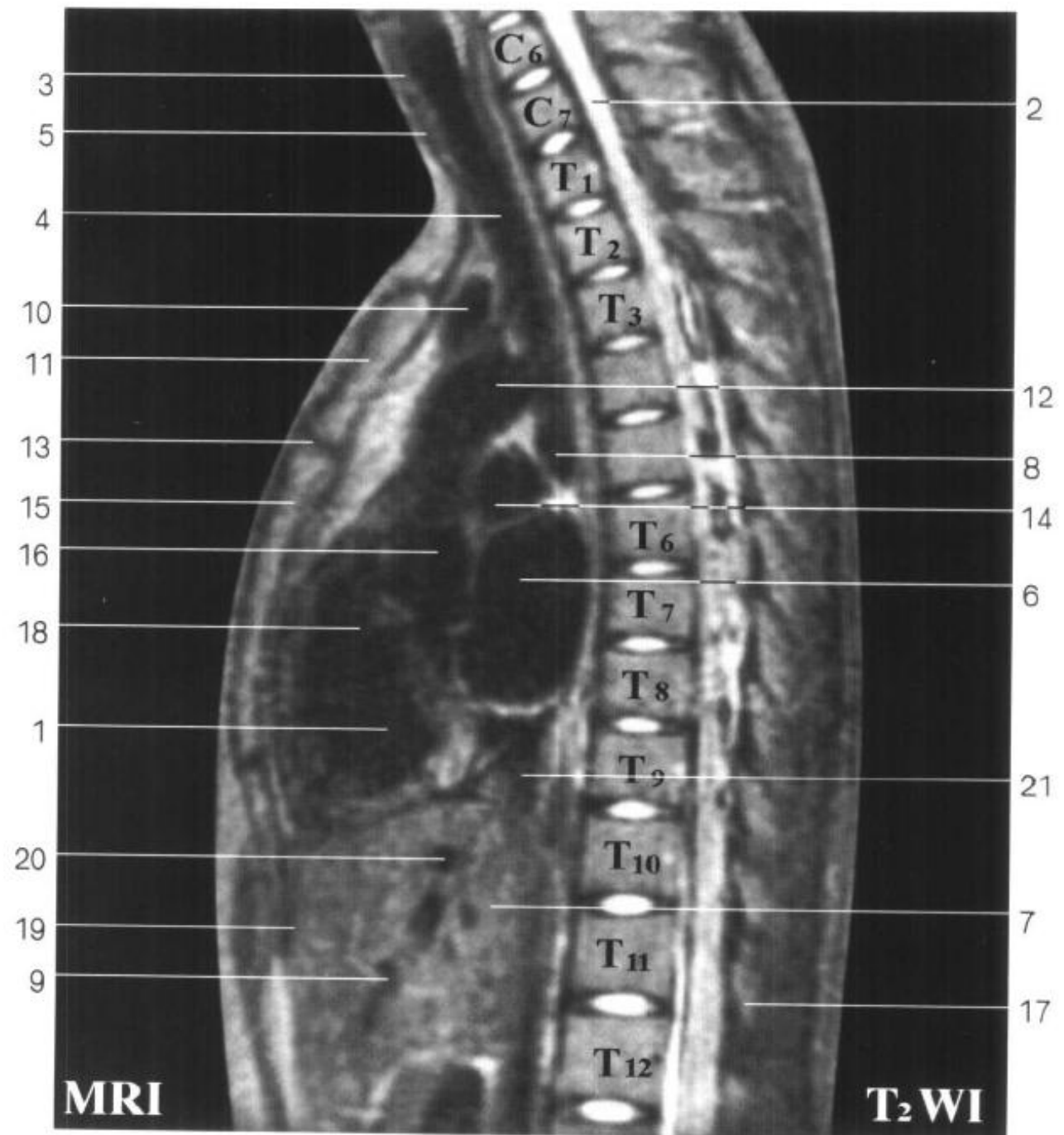
Fig. ST 6



- 12. 主动脉弓 aortic arch
- 13. 胸骨角 sternal angle
- 14. 右肺动脉 right pulmonary a.
- 15. 胸骨体 body of sternum
- 16. 升主动脉 ascending aorta
- 17. 第11胸椎棘突 spinous process(T₁₁)
- 18. 右心房 right atrium
- 19. 左外叶 left lateral lobe
- 20. 肝中间静脉 intermediate hepatic v.
- 21. 食管 esophagus

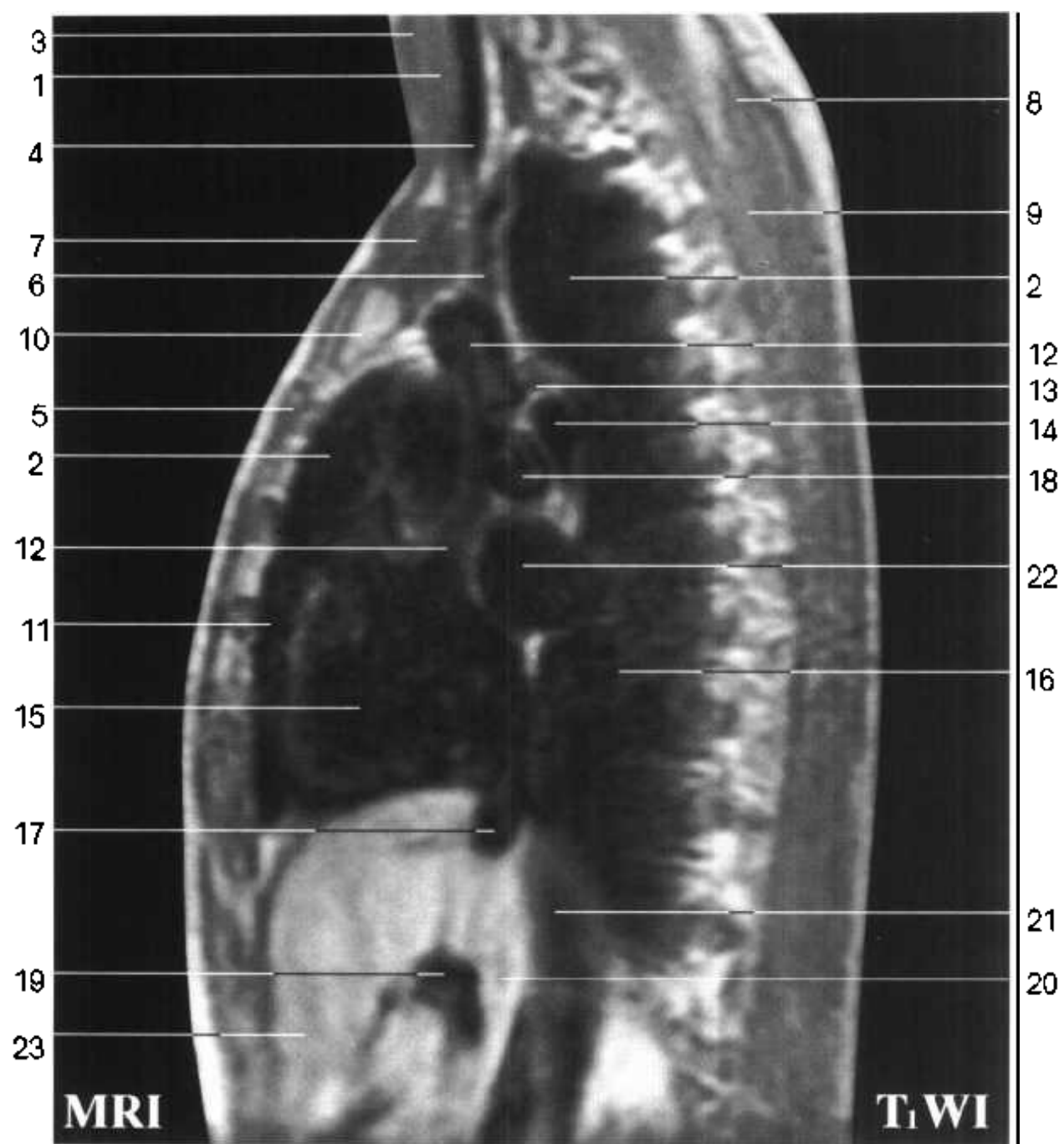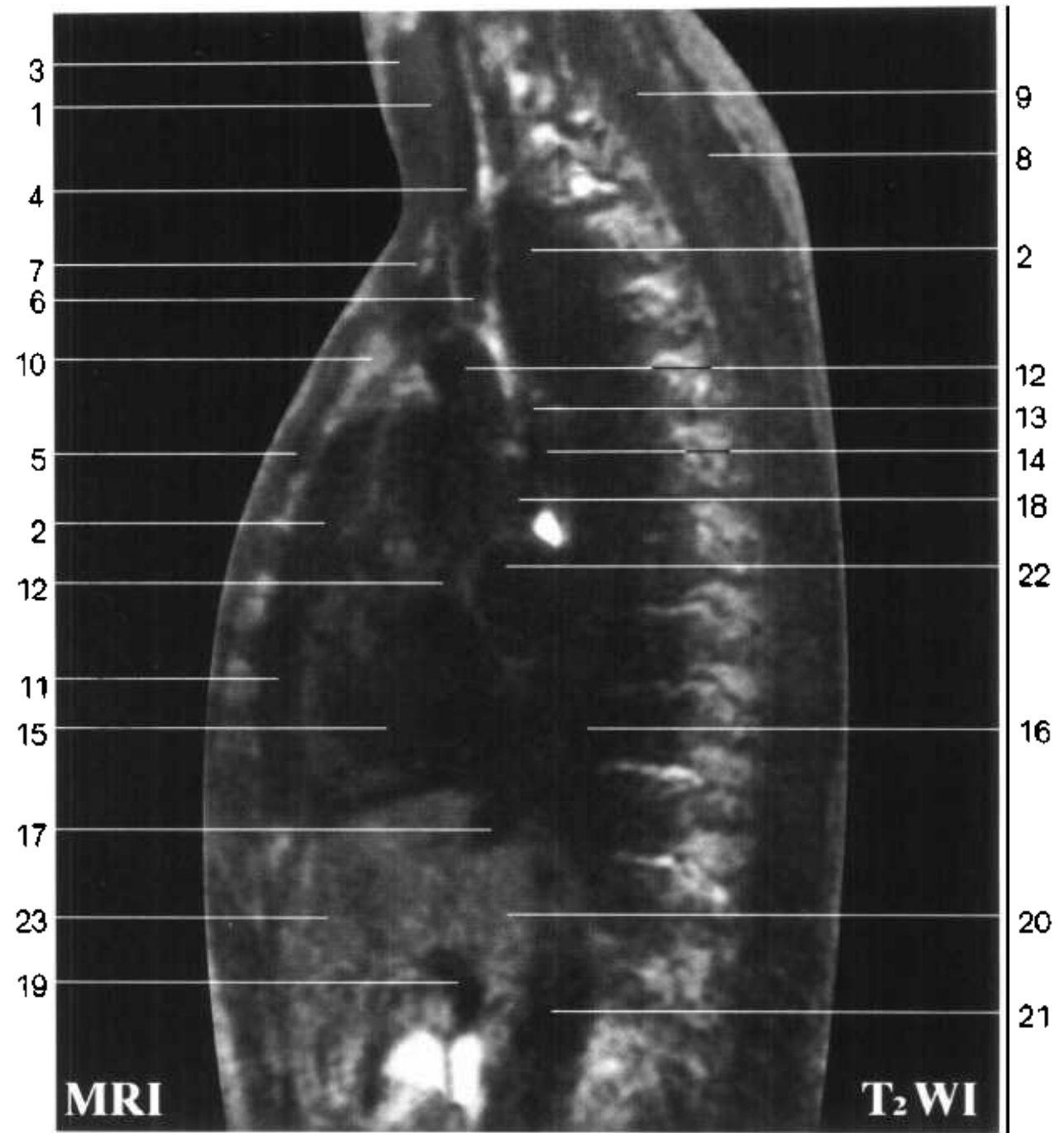


Fig. ST 7

1. 甲状腺 thyroid gland
2. 右肺上叶 superior lobe of right lung
3. 胸锁乳突肌 sternocleidomastoid
4. 颈内静脉 internal jugular v.
5. 胸大肌 pectoralis major
6. 右头臂静脉 right brachiocephalic v.
7. 锁骨 clavicle
8. 斜方肌 trapezius
9. 竖脊肌 erector spinae
10. 胸骨柄 manubrium sterni
11. 右肺中叶 middle lobe of right lung

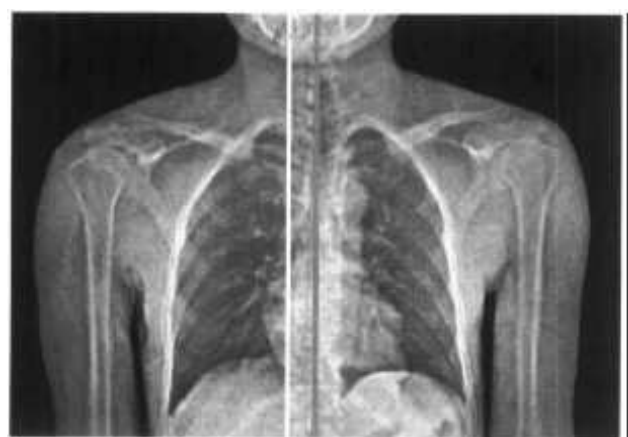

Fig. ST 7



- 12. 上腔静脉 superior vena cava
- 13. 奇静脉弓 arch of azygos v.
- 14. 右主支气管 right principal bronchus
- 15. 右心房 right atrium
- 16. 右肺下叶 inferior lobe of right lung
- 17. 肝中间静脉 intermediate hepatic v.
- 18. 右肺动脉 right pulmonary a.
- 19. 肝门静脉左支 left branch of hepatic portal v.
- 20. 尾状叶 caudate lobe
- 21. 下腔静脉 inferior vena cava

- 22. 左心房 left atrium
- 23. 左外叶 left lateral lobe

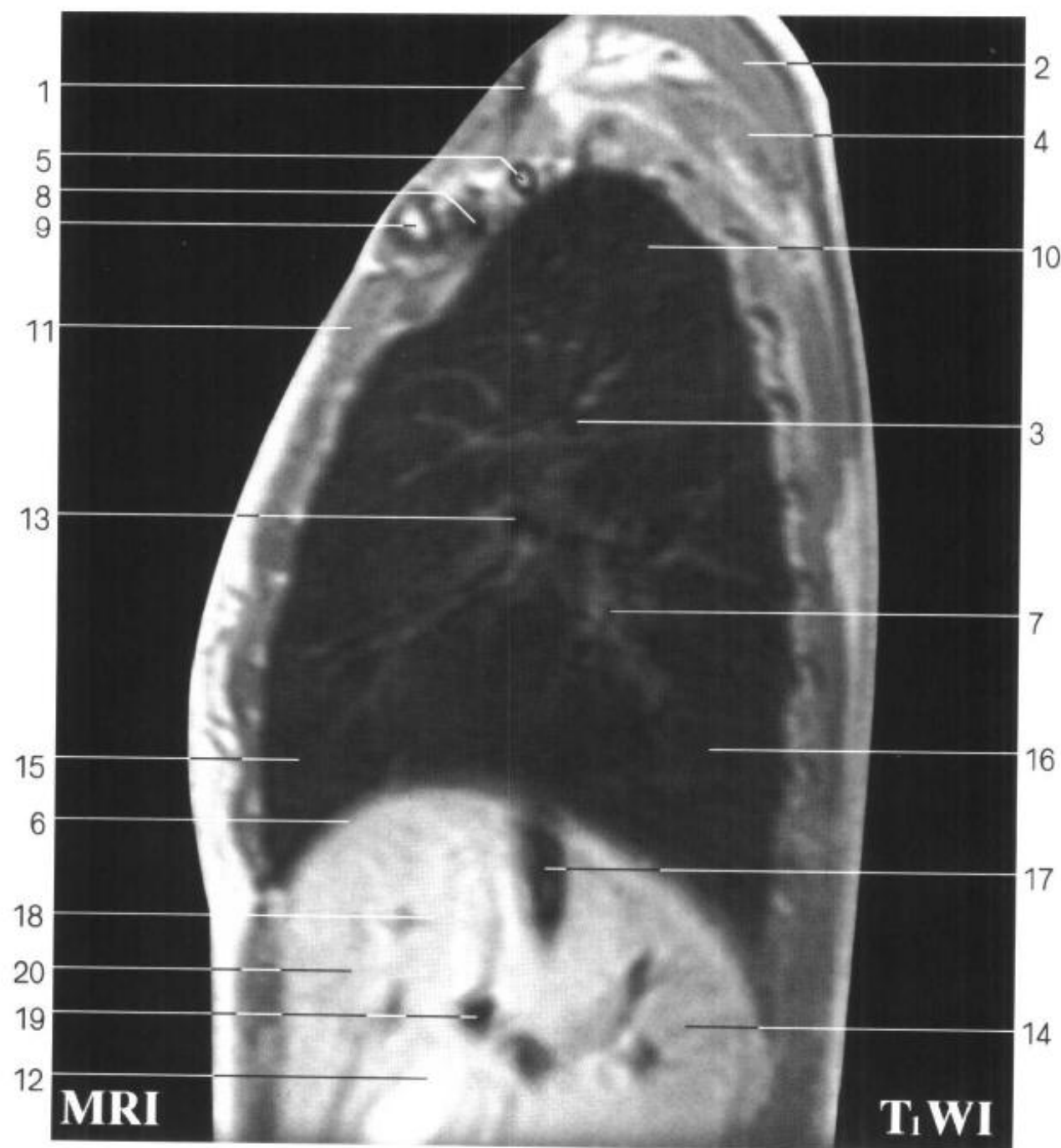

Fig. ST 8

1. 右颈内静脉 right internal jugular v.
2. 斜方肌 trapezius
3. 右肺上叶支气管 right superior lobar bronchus
4. 头夹肌 splenius capitis
5. 右锁骨下动脉 right subclavian a.
6. 膈 diaphragm
7. 右肺下叶支气管 right inferior lobar bronchus
8. 右锁骨下静脉 right subclavian v.
9. 锁骨 clavicle

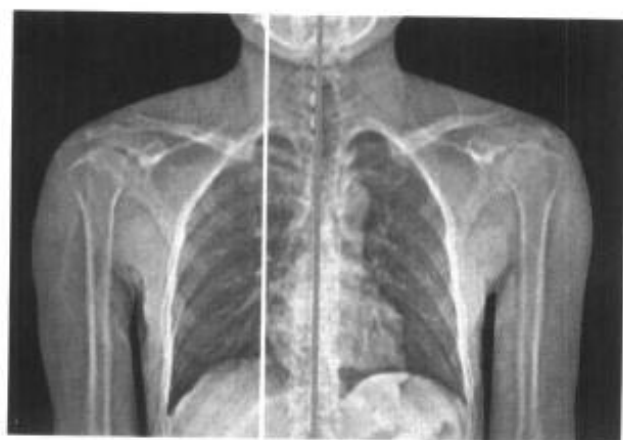
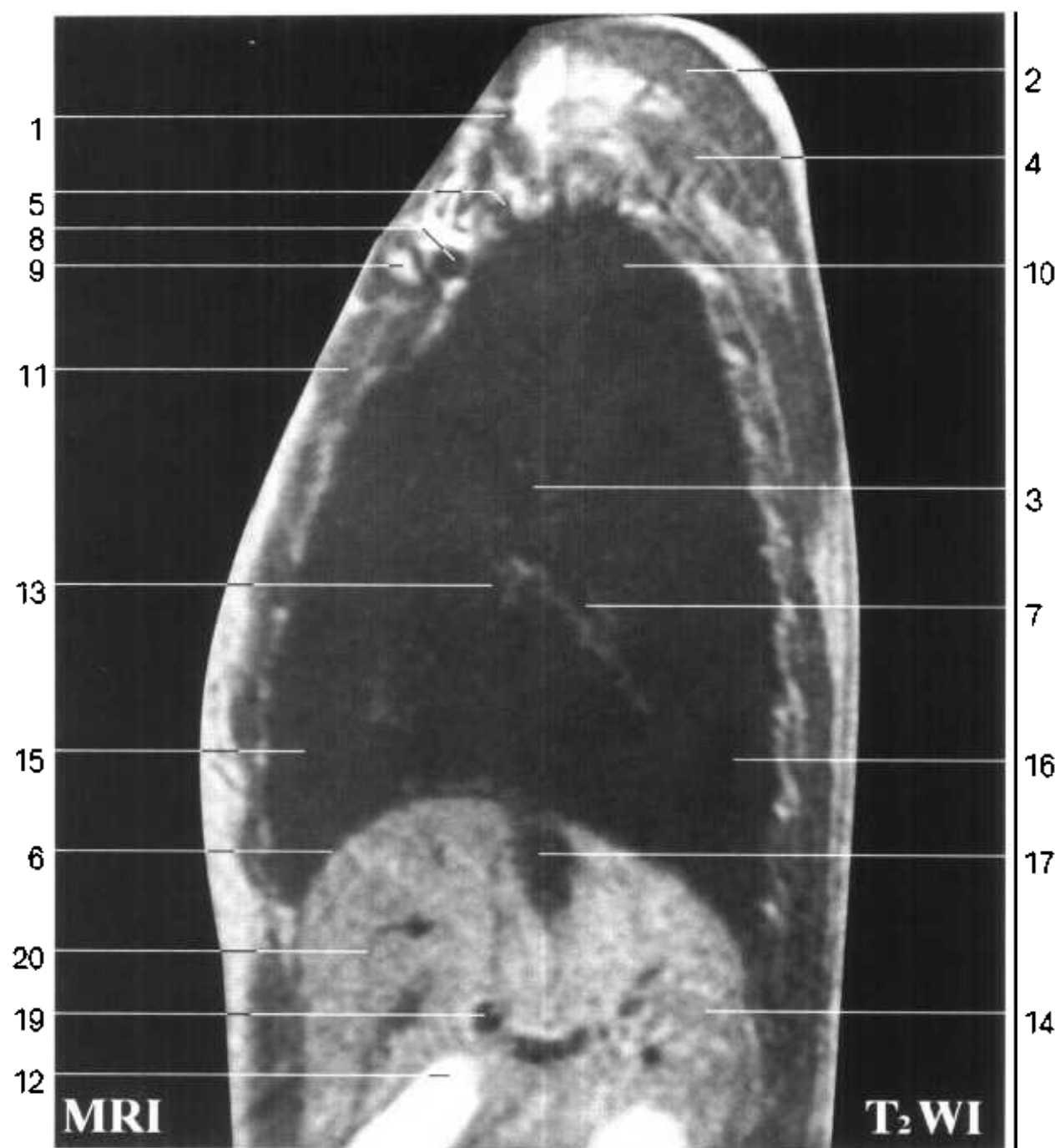

Fig. ST 8



- 10. 右肺上叶 superior lobe of right lung
- 11. 胸大肌 pectoralis major
- 12. 胆囊 gallbladder
- 13. 右肺中叶支气管 right middle lobar
bronchus
- 14. 右后叶 right posterior lobe
- 15. 右肺中叶 middle lobe of right lung
- 16. 右肺下叶 inferior lobe of right lung
- 17. 肝右静脉 right hepatic v.
- 18. 左内叶 left medial lobe
- 19. 肝中间静脉 intermediate hepatic v.
- 20. 左外叶 left lateral lobe

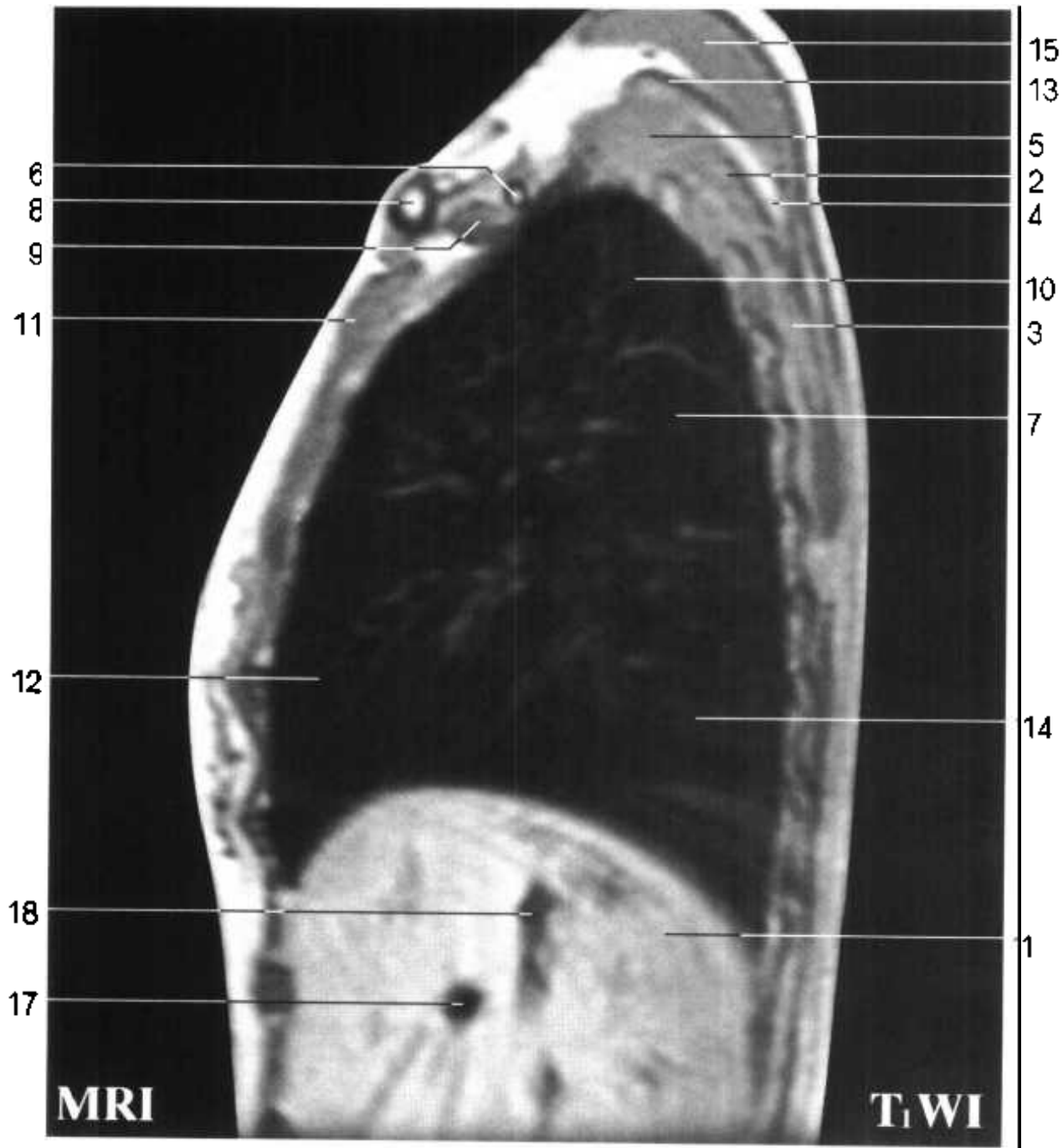

Fig. ST 9

1. 右后叶 right posterior lobe
2. 前锯肌 serratus anterior
3. 大菱形肌 rhomboideus major
4. 肩胛骨 scapula
5. 上后锯肌 serratus posterior superior
6. 锁骨下动脉 subclavian a.
7. 斜裂 oblique fissure
8. 锁骨 clavicle
9. 锁骨下静脉 subclavian v.
10. 右肺上叶 superior lobe of right lung

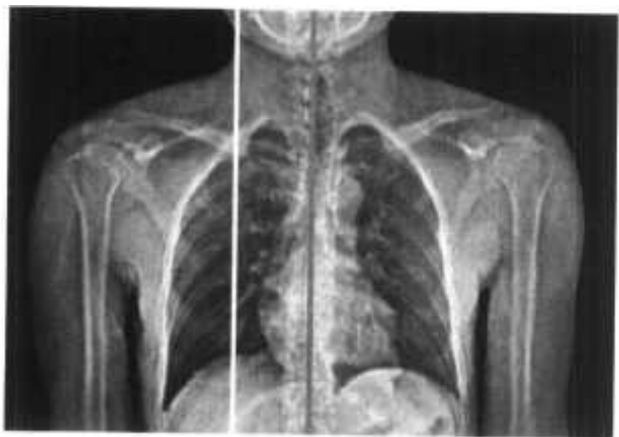
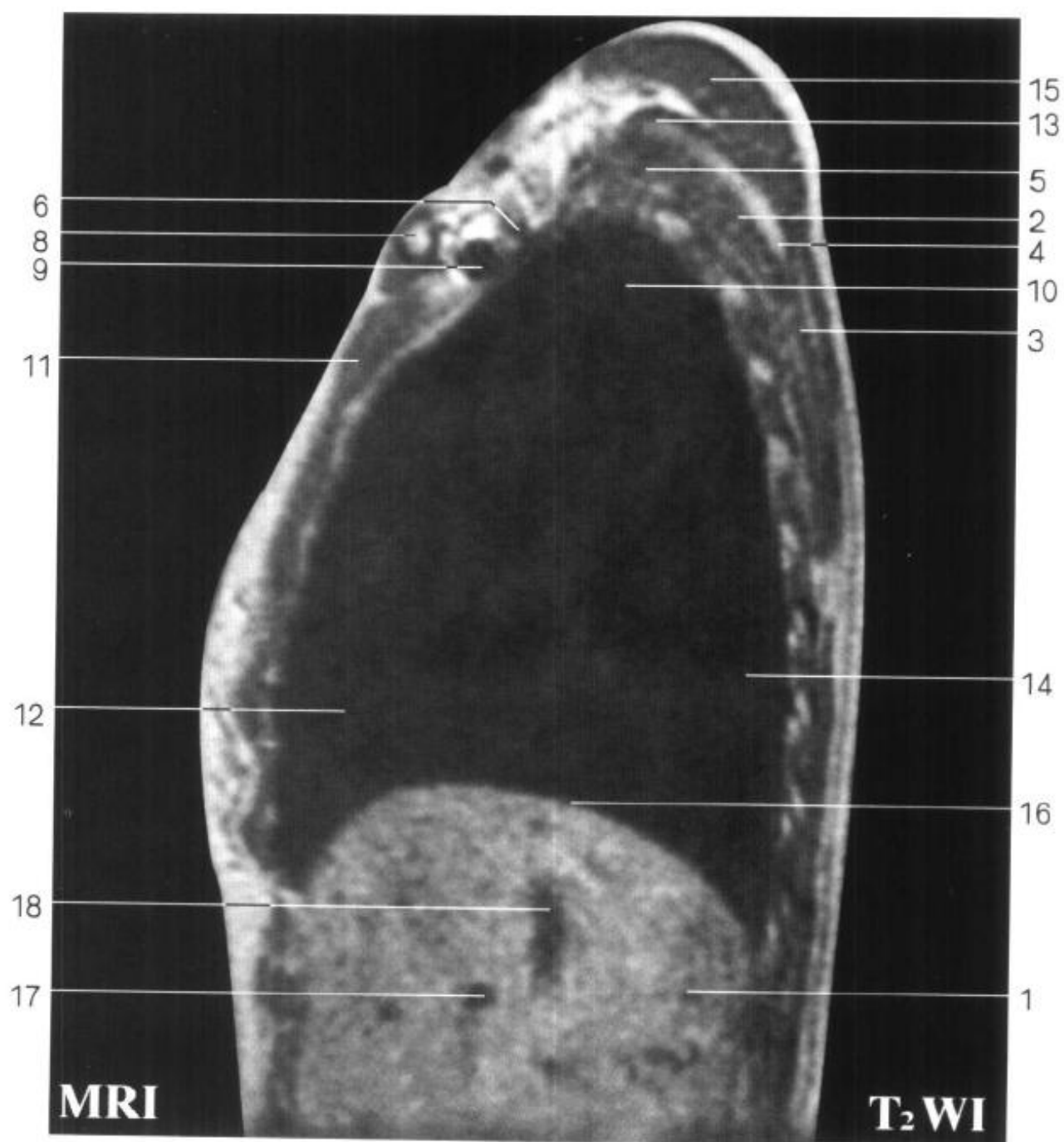


Fig. ST 9



- 11. 胸大肌 pectoralis major
- 12. 右肺中叶 middle lobe of right lung
- 13. 肩胛提肌 levator scapulae
- 14. 右肺下叶 inferior lobe of right lung
- 15. 斜方肌 trapezius
- 16. 膈 diaphragm
- 17. 肝中间静脉 intermediate hepatic v.
- 18. 肝右静脉 right hepatic v.

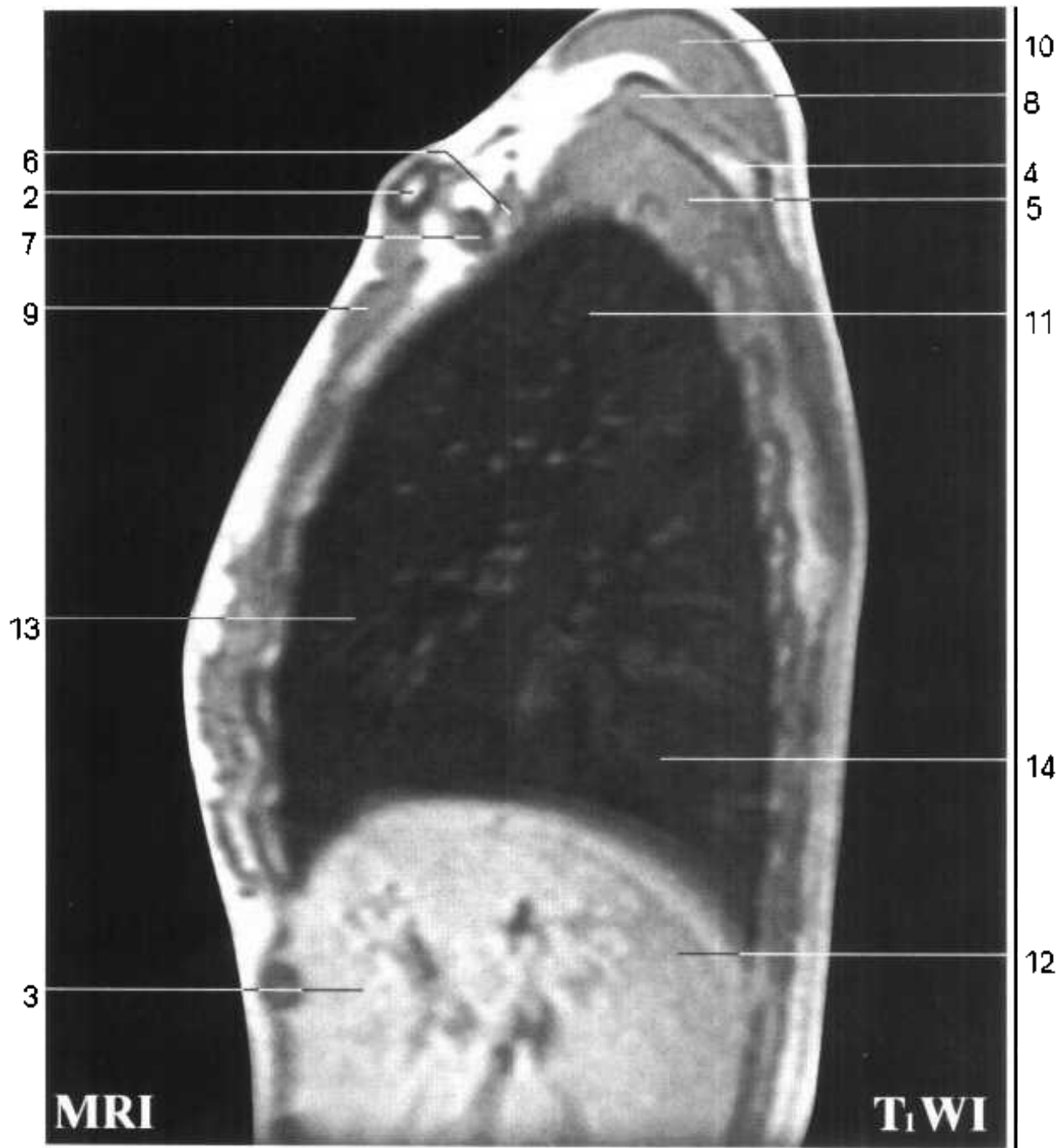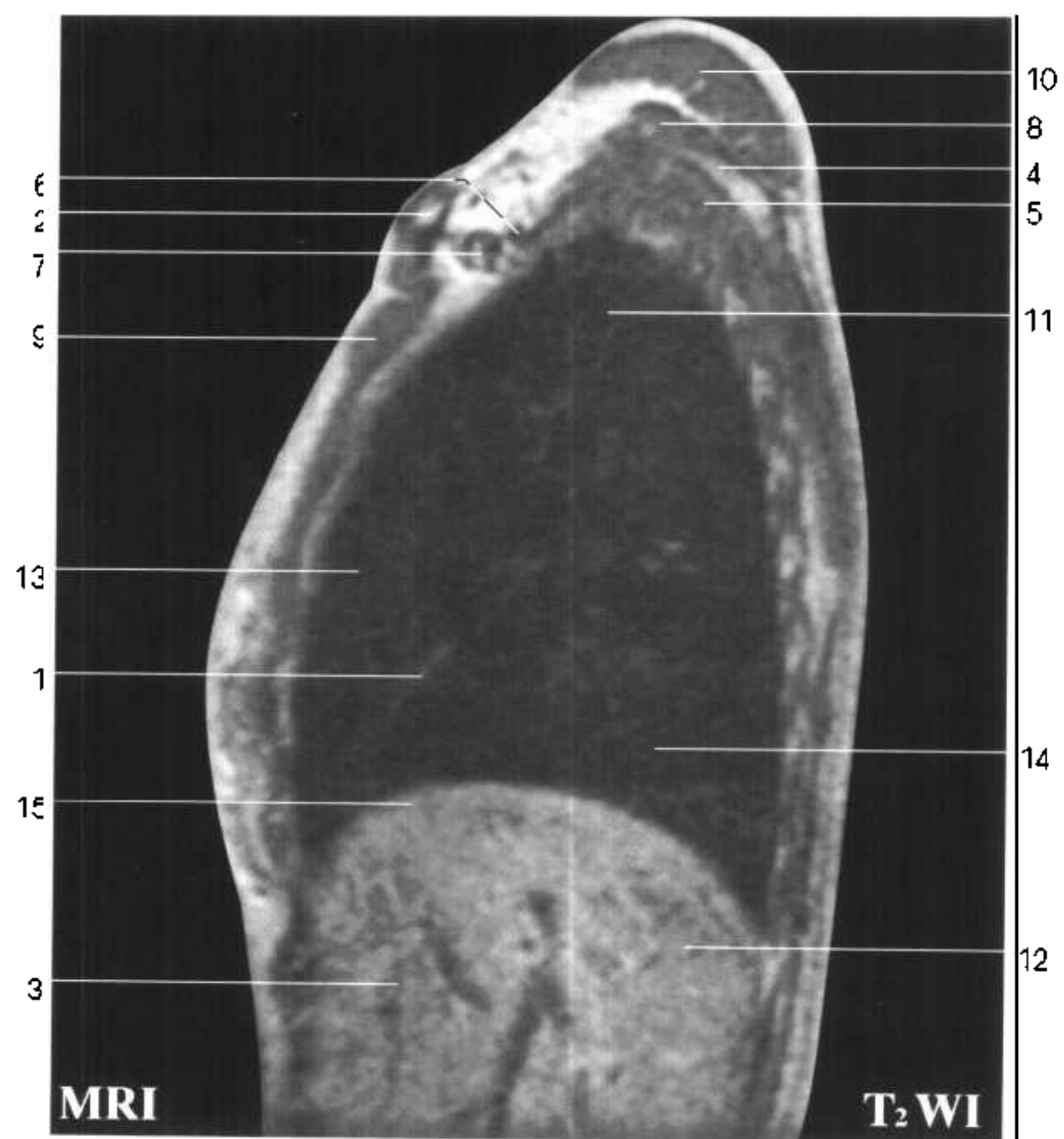


Fig. ST 10

- 1. 斜裂 loblique fissure
- 2. 锁骨 clavicle
- 3. 右前叶 right anterior lobe
- 4. 肩胛骨 scapula
- 5. 肩胛下肌 subscapularis
- 6. 腋动脉 axillary a.
- 7. 腋静脉 axillary v.
- 8. 冈上肌 supraspinatus
- 9. 胸大肌 pectoralis major
- 10. 斜方肌 trapezius

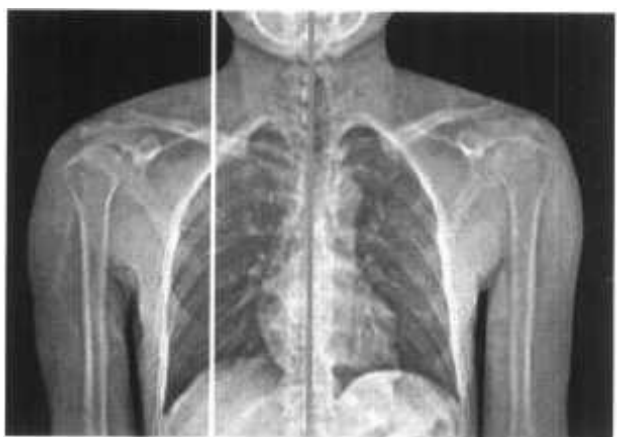

Fig. ST 10



- 11. 右肺上叶 superior lobe of right lung
- 12. 右后叶 right posterior lobe
- 13. 右肺中叶 middle lobe of right lung
- 14. 右肺下叶 inferior lobe of right lung
- 15. 膈 diaphragm

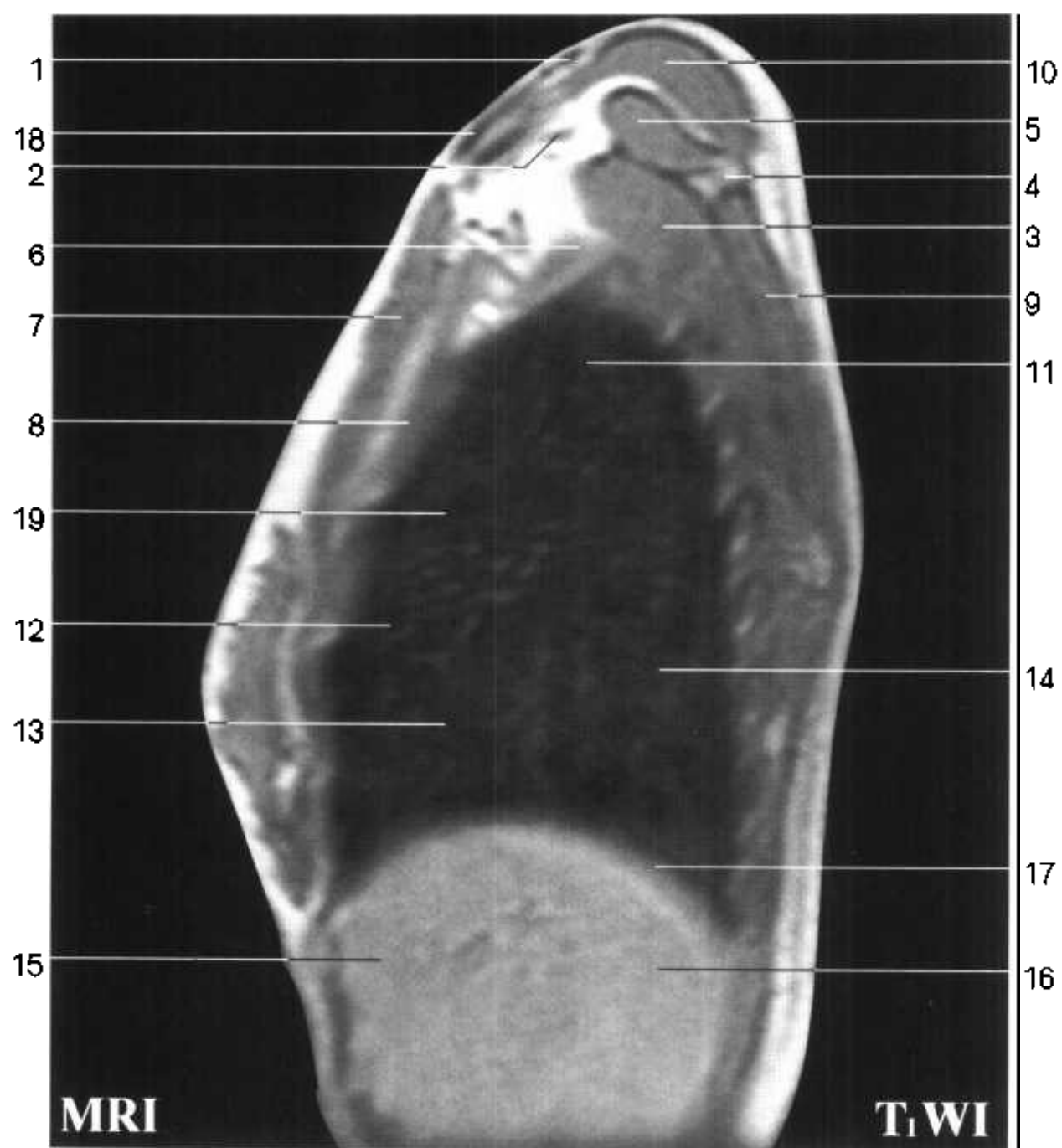

Fig. ST 11

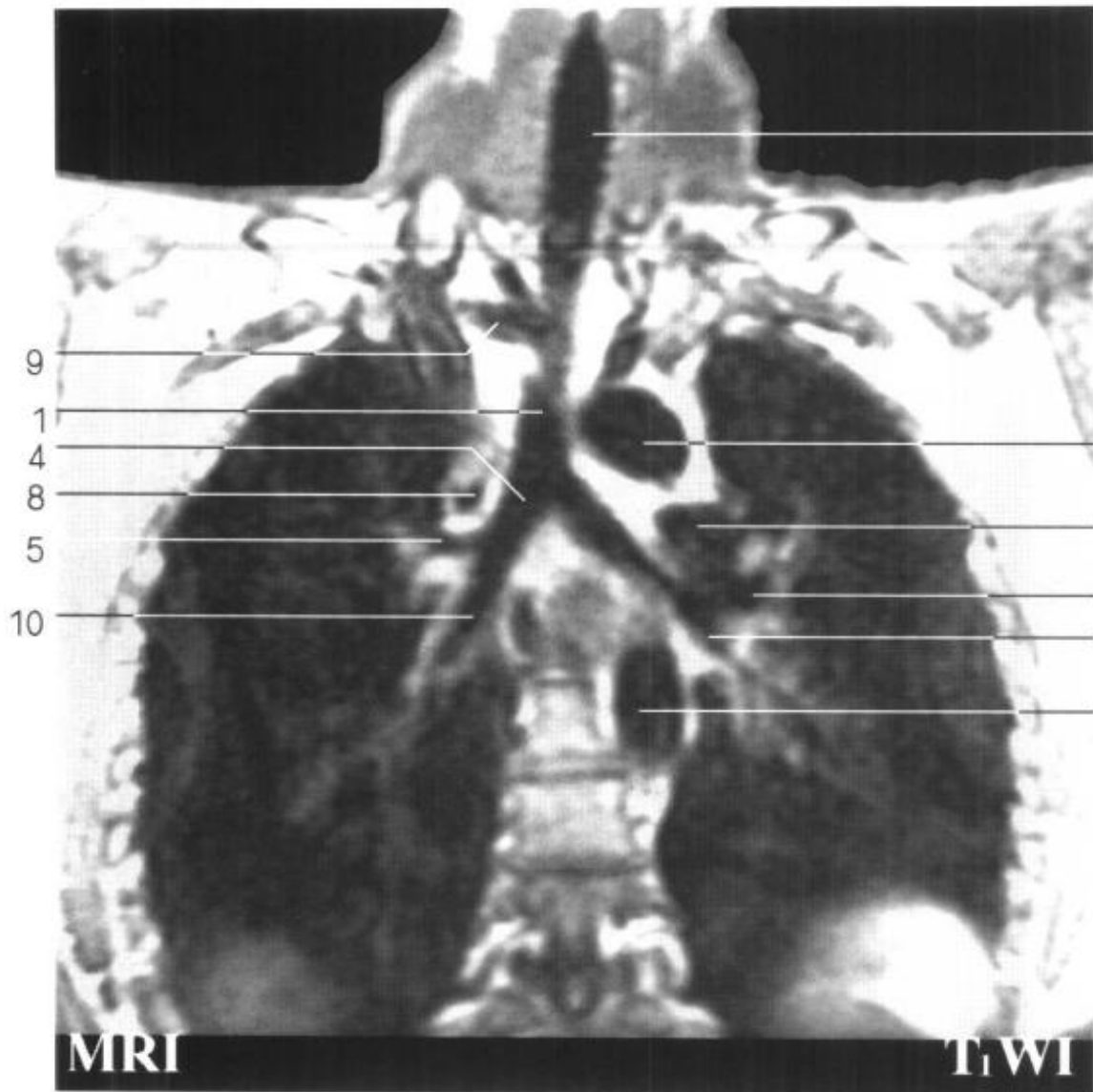
- 1. 锁骨 clavicle
- 2. 肩胛舌骨肌 omohyoid
- 3. 肩胛下肌 subscapularis
- 4. 肩胛冈 spine of scapula
- 5. 冈上肌 supraspinatus
- 6. 前锯肌 serratus anterior
- 7. 胸大肌 pectoralis major
- 8. 胸小肌 pectoralis minor
- 9. 冈下肌 infraspinatus
- 10. 斜方肌 trapezius
- 11. 右肺上叶 superior lobe of right lung

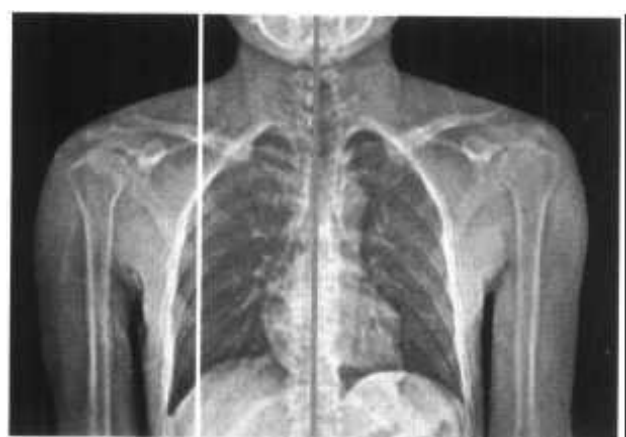
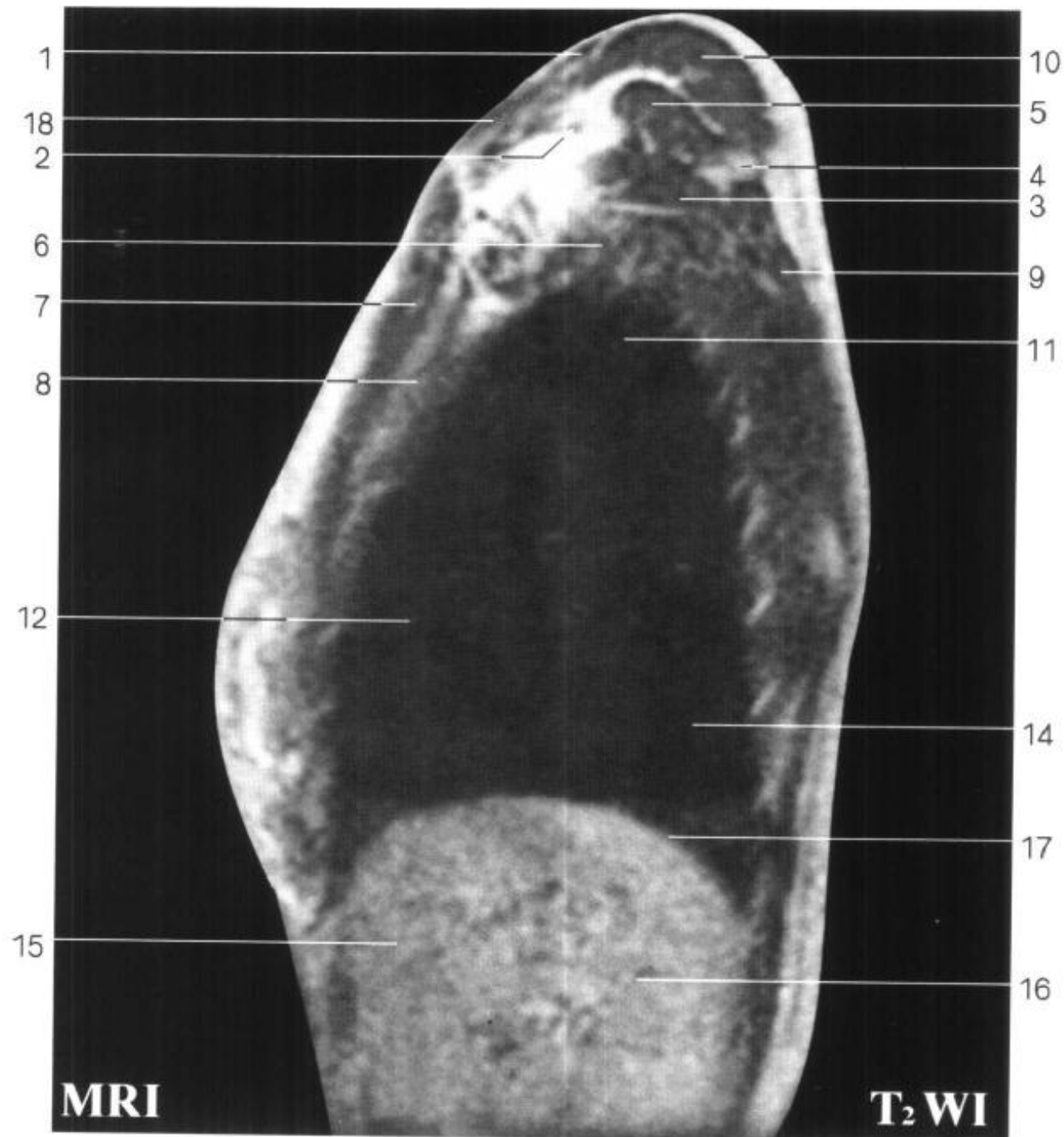
Fig. ST 11



- 12. 右肺中叶 middle lobe of right lung
- 13. 斜裂 oblique fissure
- 14. 右肺下叶 inferior lobe of right lung
- 15. 右前叶 right anterior lobe
- 16. 右后叶 right posterior lobe
- 17. 膈 diaphragm
- 18. 三角肌 deltoid
- 19. 右肺水平裂 horizontal fissure of right lung



- 10. 中间支气管 intermediate bronchus
- 11. 肺动脉干 pulmonary trunk
- 12. 升主动脉 ascending aorta
- 13. 左心室 left ventricle
- 14. 头臂干 brachiocephalic trunk
- 15. 上腔静脉 superior vena cava
- 16. 右心房 right atrium
- 17. 右心室 right ventricle
- 18. 膈 diaphragm
- 19. 心包 pericardium
- 20. 右颈总动脉 left common carotid a.
- 21. 肝右叶 right lobe of liver
- 22. 肝门静脉 hepatic portal v.
- 23. 肝左叶 left lobe of liver
- 24. 左冠状动脉 left coronary a.

磁共振成像 (气管、心脏) MRI

Fig.MRI

- 1. 气管 trachea
- 2. 主动脉弓 aortic arch
- 3. 右肺动脉 left pulmonary a.
- 4. 右主支气管 right principal bronchus
- 5. 上叶支气管 superior lobar bronchus
- 6. 左肺下叶支气管 left inferior lobar bronchus
- 7. 胸主动脉 thoracic aorta
- 8. 奇静脉弓 arch of azygos v.
- 9. 右锁骨下动脉 right subclavian a.

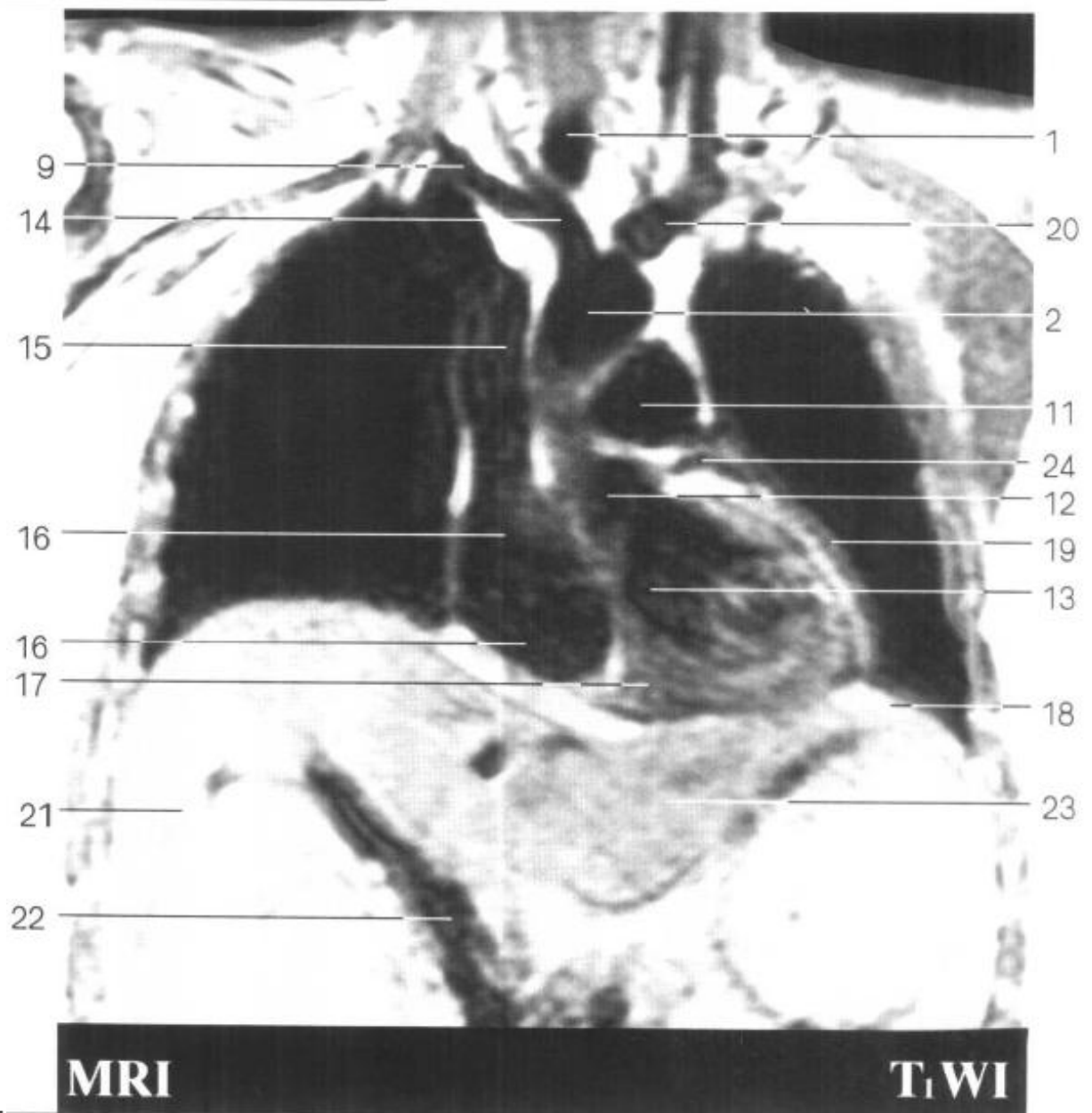
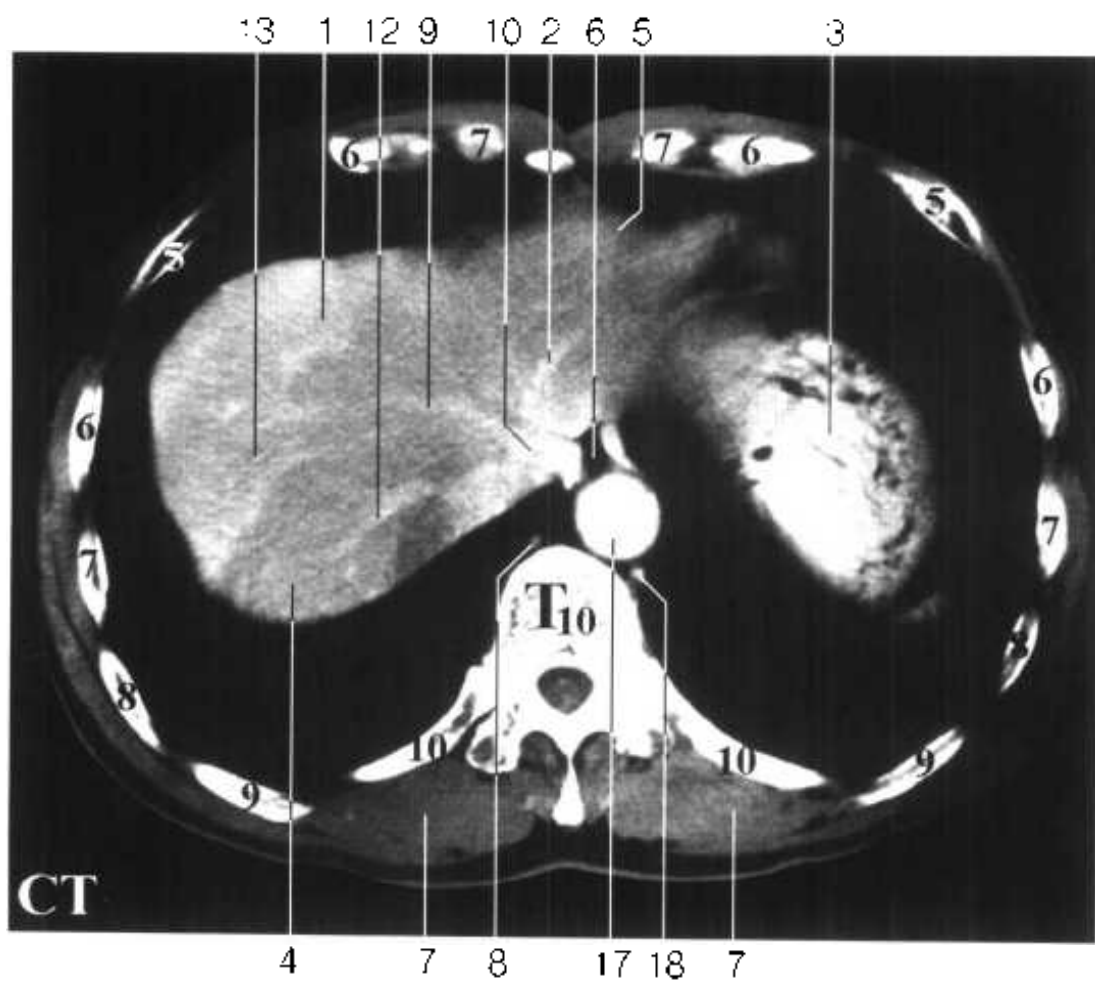


Fig. MRI

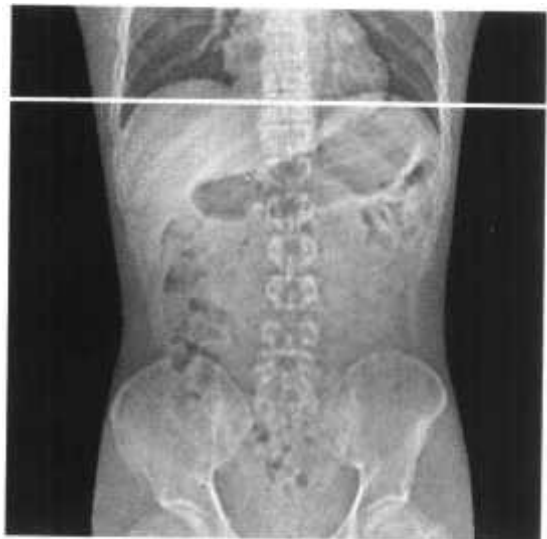

ABDOMEN



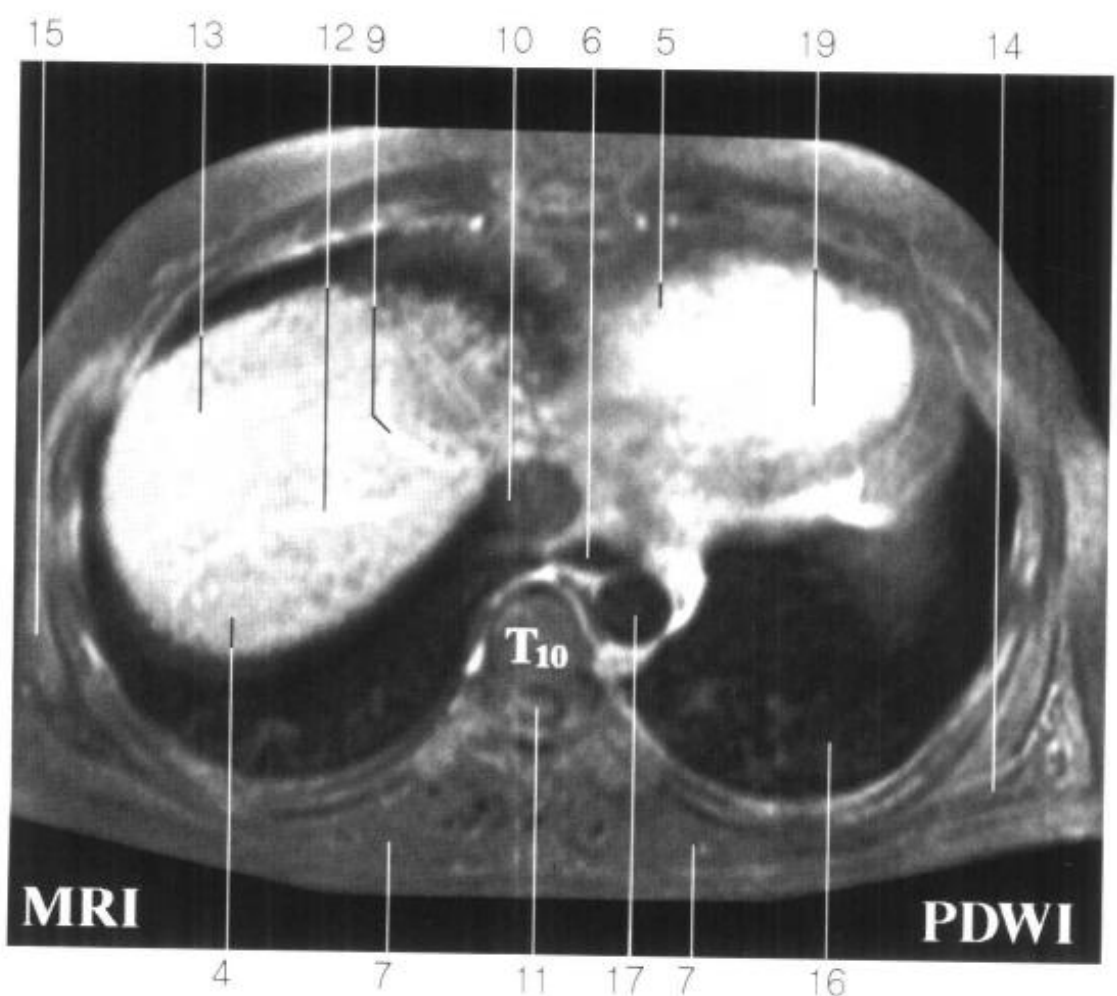
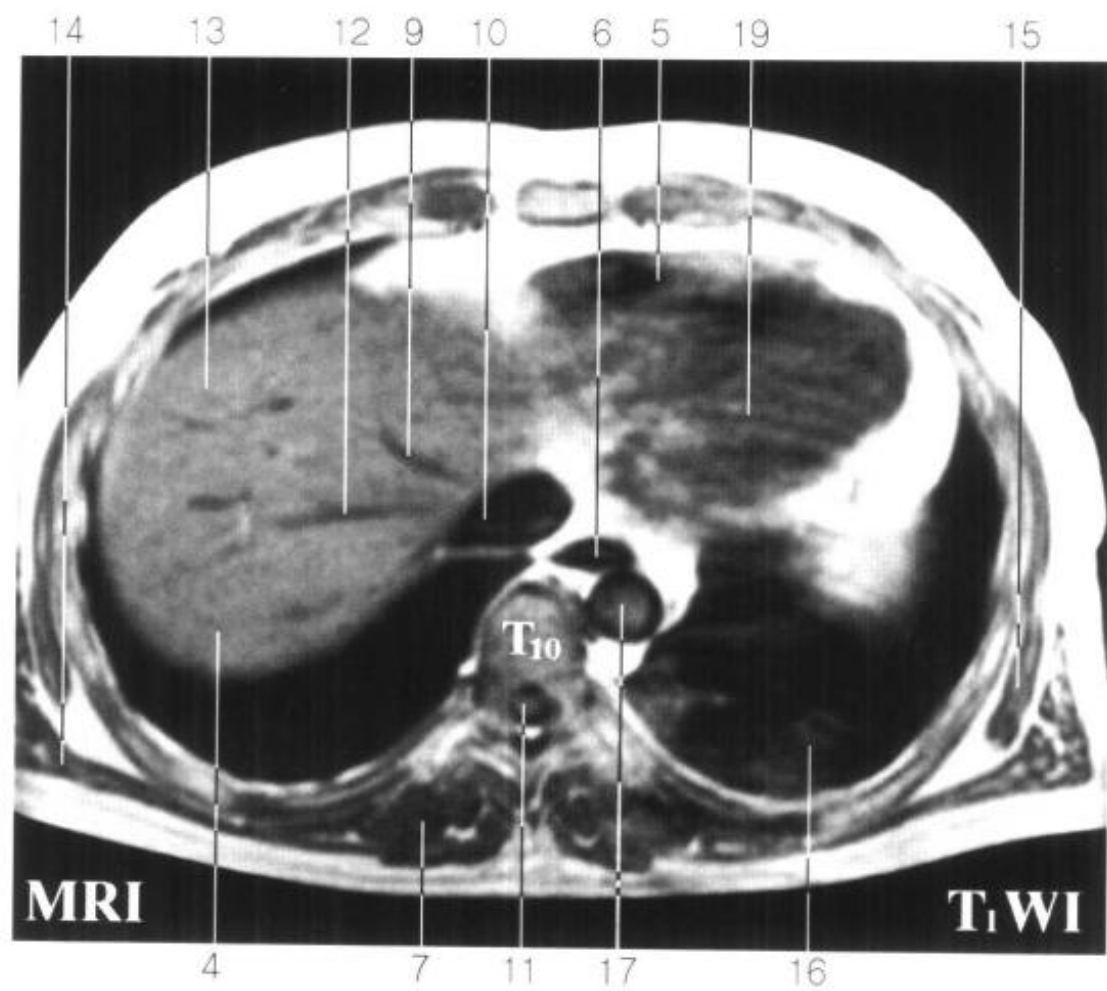
水平断面图 HA

Fig HA 1



1. 左内叶 left medial lobe
2. 肝左静脉 left hepatic v.
3. 胃底 fundus of stomach
4. 右后叶 right posterior lobe
5. 右心室 right ventricle
6. 食管 esophagus
7. 竖脊肌 erector spinae
8. 奇静脉 azygos v.
9. 肝中间静脉 intermediate hepatic v.
10. 下腔静脉 inferior vena cava

Fig. HA 1



- 11. 脊髓 spinal cord
- 12. 肝右静脉 right hepatic v.
- 13. 右前叶 right anterior lobe
- 14. 背阔肌 latissimus dorsi
- 15. 前锯肌 serratus anterior
- 16. 后底段(S_x) posterior basal segment(S_x)
- 17. 胸主动脉 thoracic aorta
- 18. 半奇静脉 semiazygos v.
- 19. 左心室 left ventricle

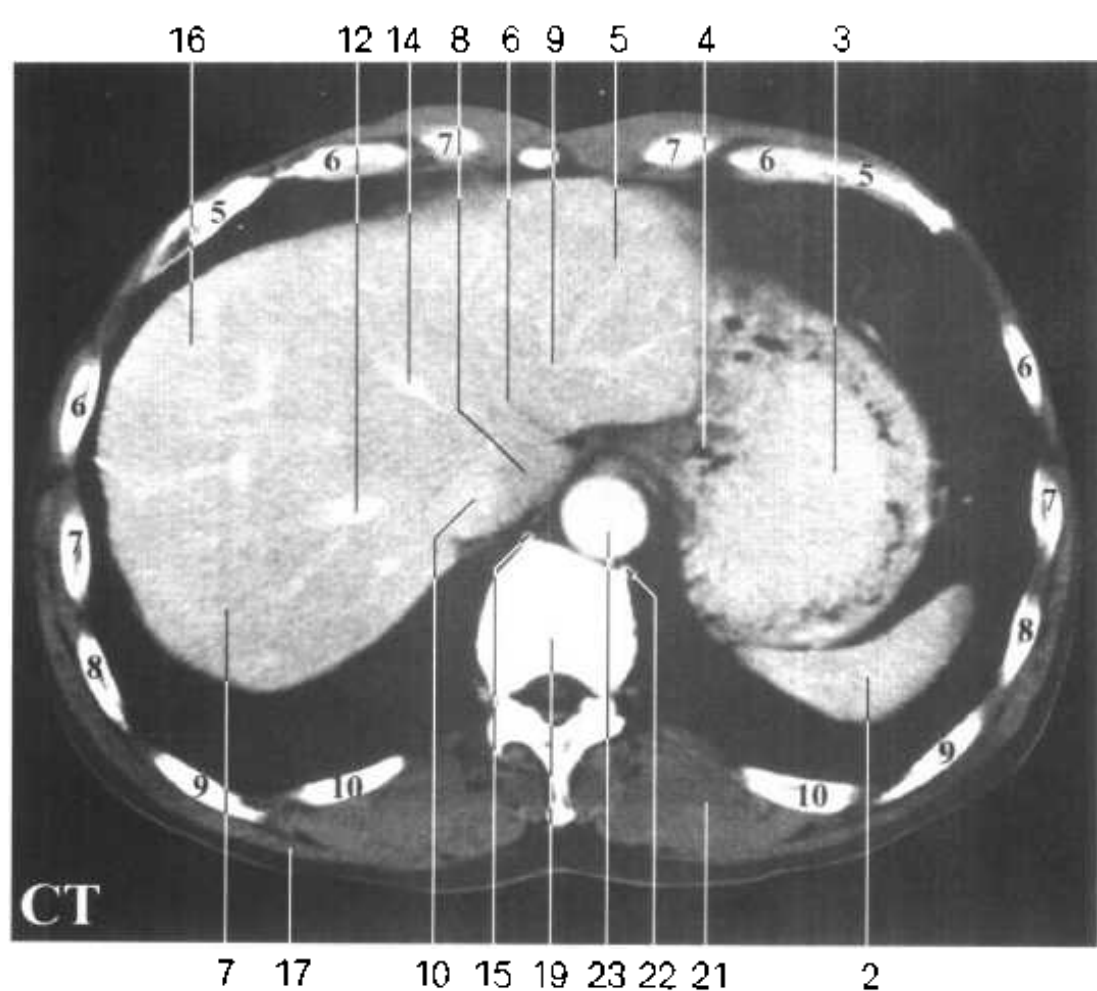
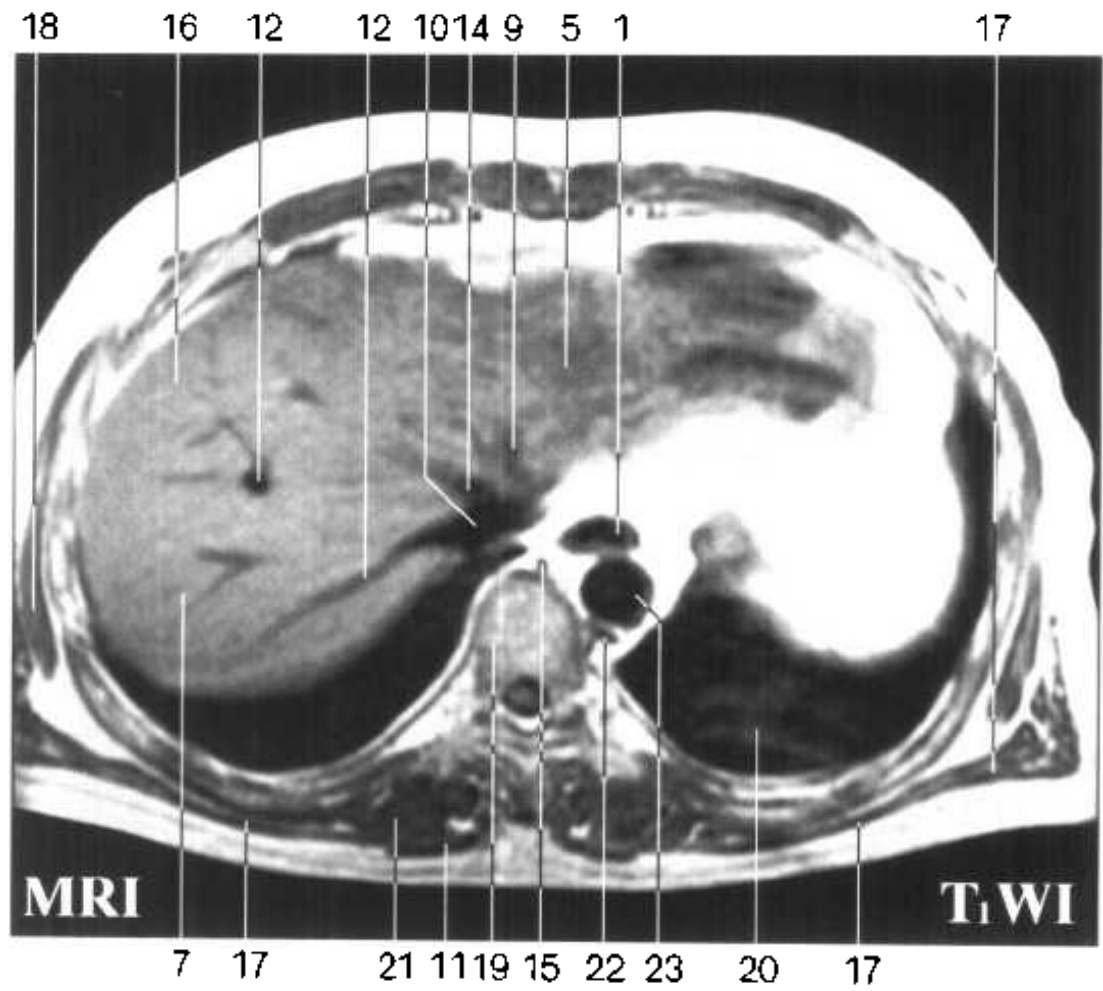


Fig HA 2

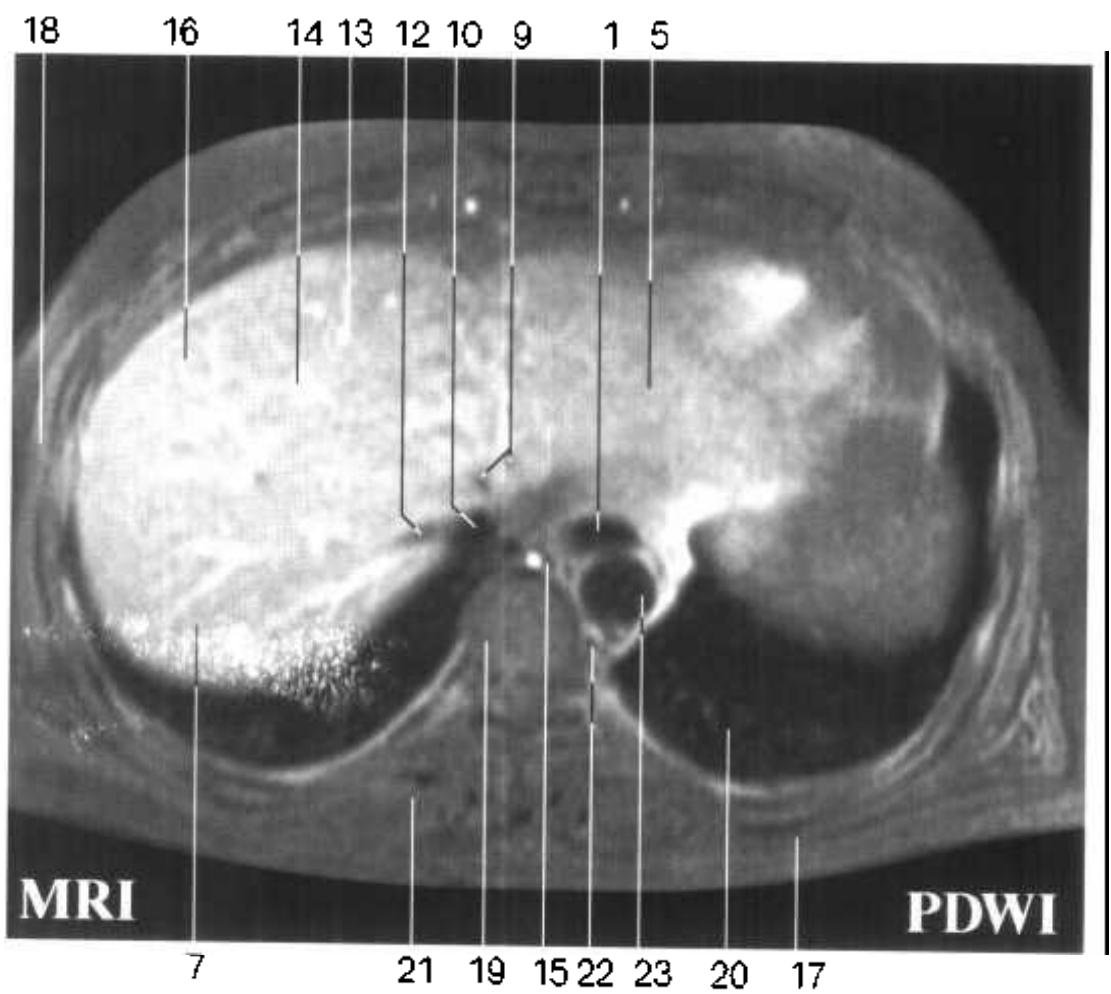
1. 食管 esophagus
2. 脾 spleen
3. 胃 stomach
4. 贲门 cardia
5. 左外叶 left lateral lobe
6. 静脉韧带裂 fissure for ligamentum venosum
7. 右后叶 right posterior lobe
8. 尾状叶 caudate lobe
9. 肝左静脉 left hepatic v.
10. 下腔静脉 inferior vena cava
11. 斜方肌 trapezius
12. 肝右静脉 right hepatic v.
13. 左内叶 left medial lobe

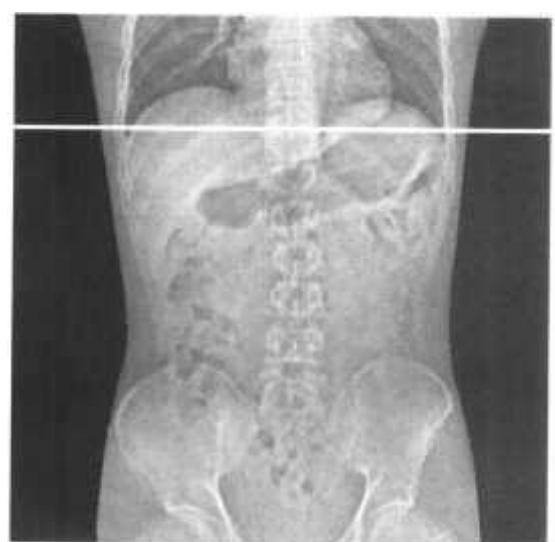

Fig. HA 2



- 14. 肝中间静脉 intermediate hepatic v.
- 15. 奇静脉 azygos v.
- 16. 右前叶 right anterior lobe
- 17. 背阔肌 latissimus dorsi
- 18. 前锯肌 serratus anterior
- 19. 10、11 胸椎间盘 intervertebral disc(T₁₀-T₁₁)
- 20. 后底段(S_x) posterior basal segment(S_x)
- 21. 竖脊肌 erector spinae
- 22. 半奇静脉 semiazygos v.
- 23. 胸主动脉 thoracic aorta



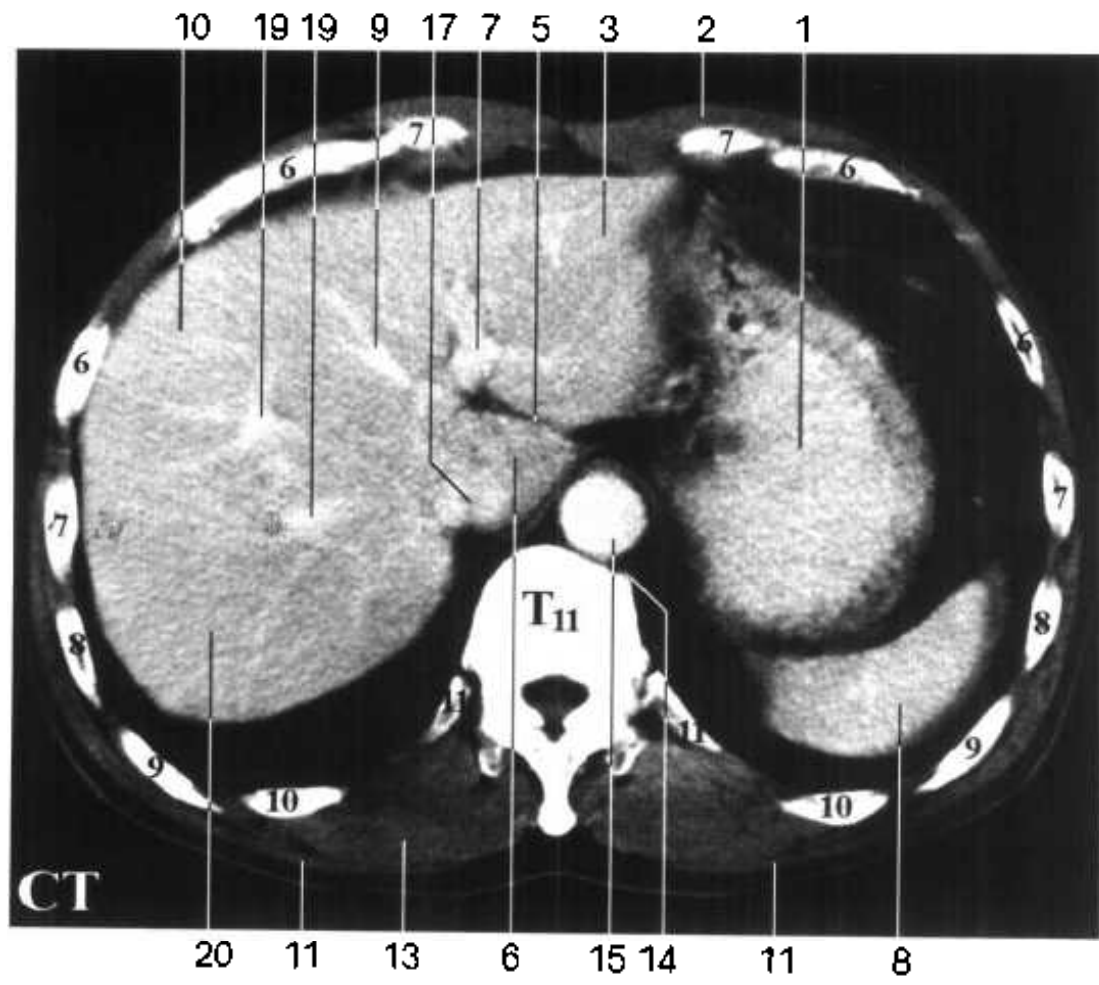
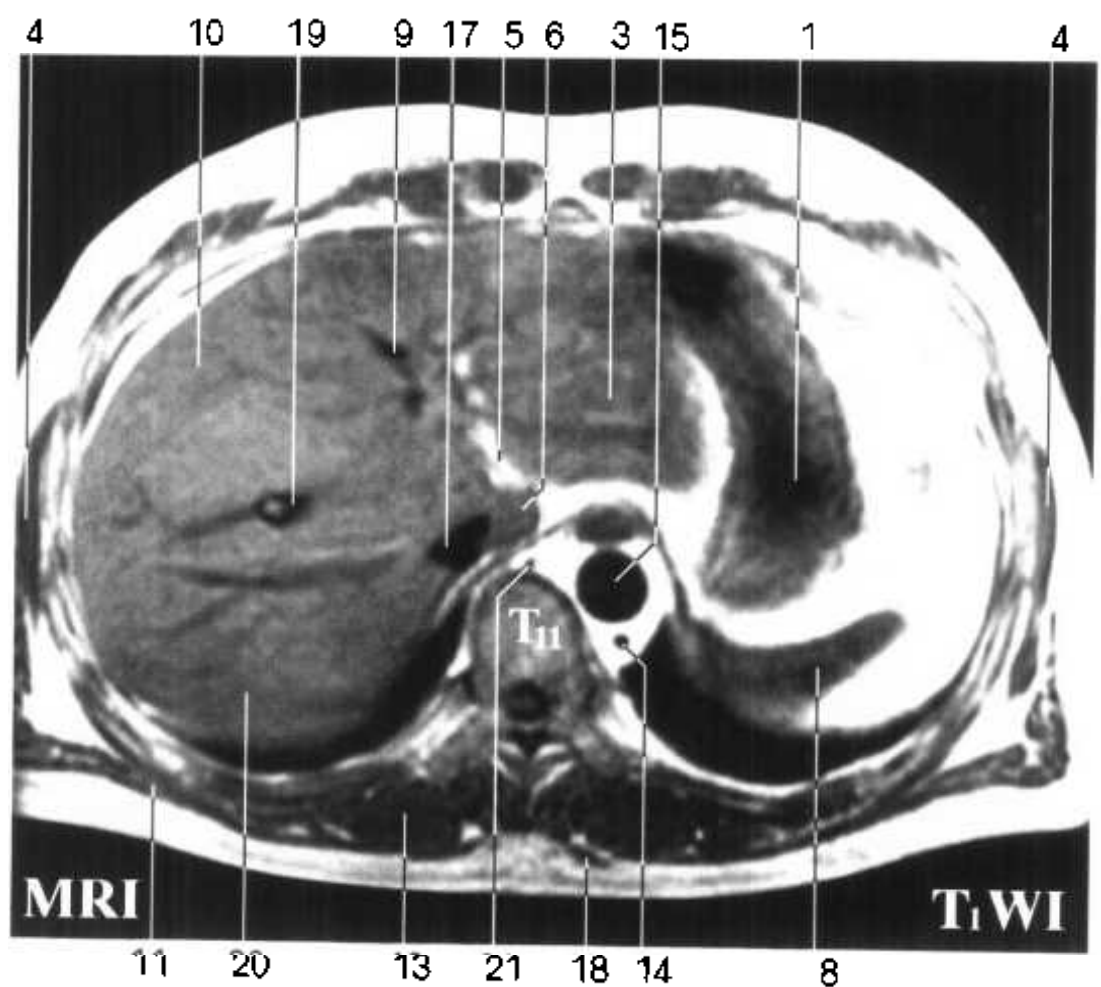


Fig HA 3

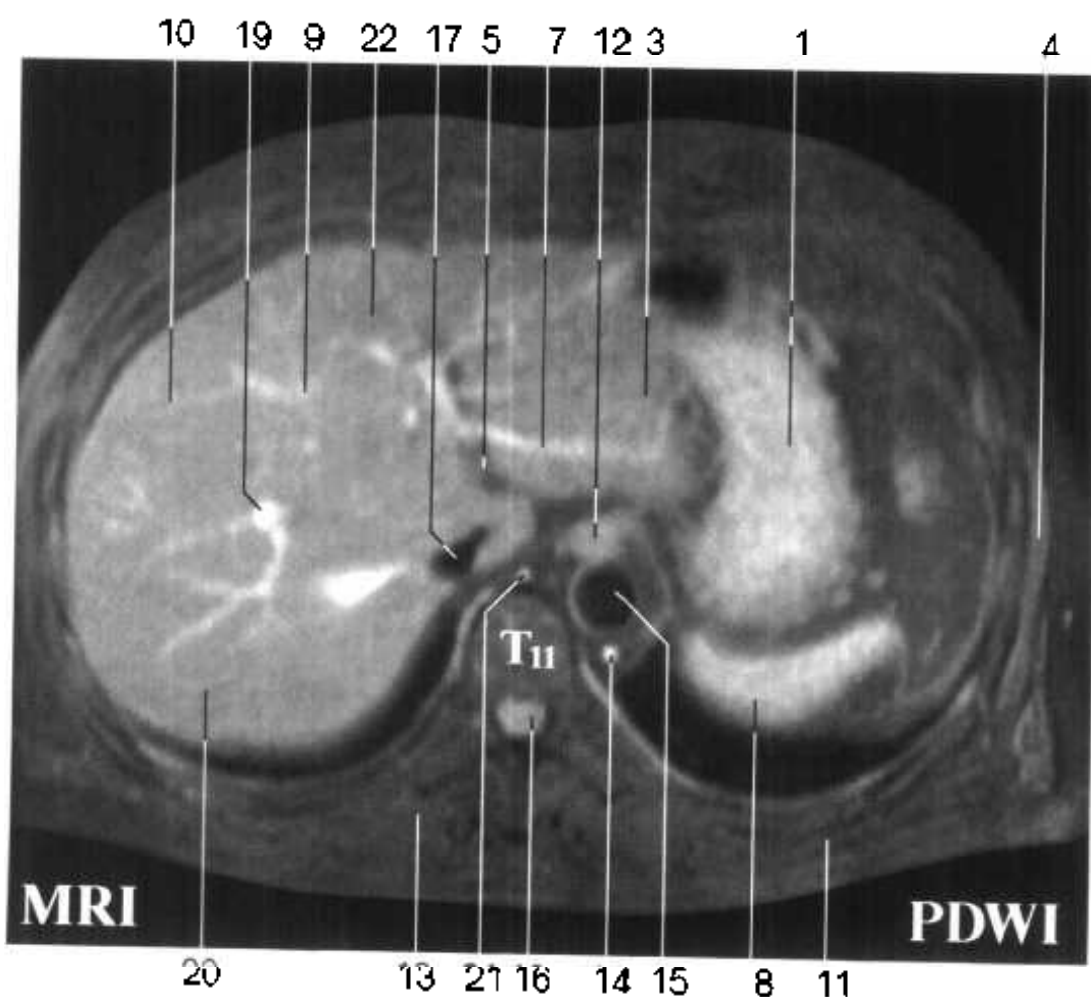
1. 胃 stomach
2. 腹直肌 rectus abdominis
3. 左外叶 left lateral lobe
4. 前锯肌 serratus anterior
5. 静脉韧带裂 fissure for ligamentum venosum
6. 尾状叶 caudate lobe
7. 肝门静脉左支 left branch of hepatic portal v.
8. 脾 spleen
9. 肝中间静脉 intermediate hepatic v.
10. 右前叶 right anterior lobe
11. 背阔肌 latissimus dorsi

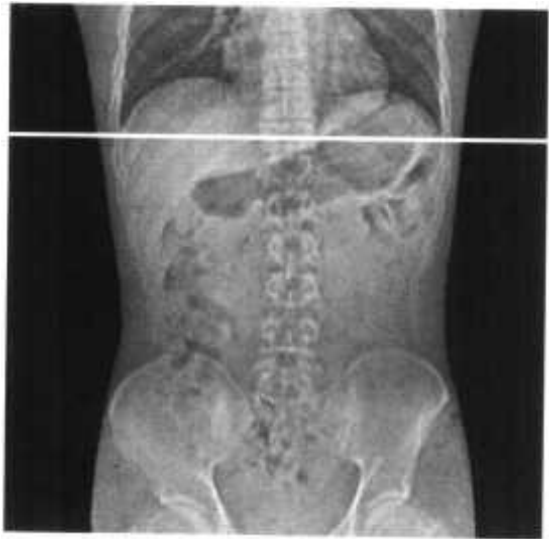

Fig. HA 3



- 12. 食管 esophagus
- 13. 竖脊肌 erector spinae
- 14. 半奇静脉 semiazygos v.
- 15. 胸主动脉 thoracic aorta
- 16. 脊髓 spinal cord
- 17. 下腔静脉 inferior vena cava
- 18. 斜方肌 trapezius
- 19. 肝右静脉 right hepatic v.
- 20. 右后叶 right posterior lobe
- 21. 奇静脉 azygos v.
- 22. 左内叶 left medial lobe



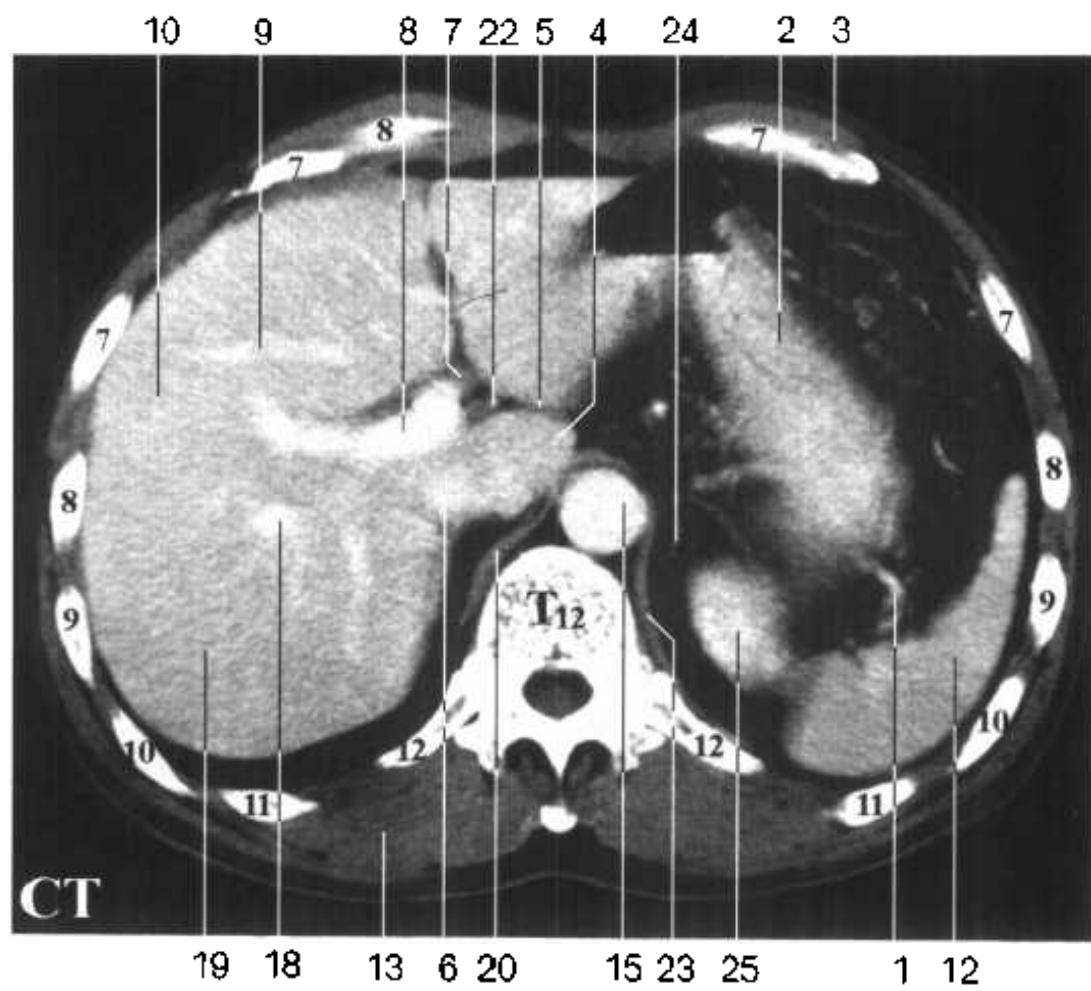
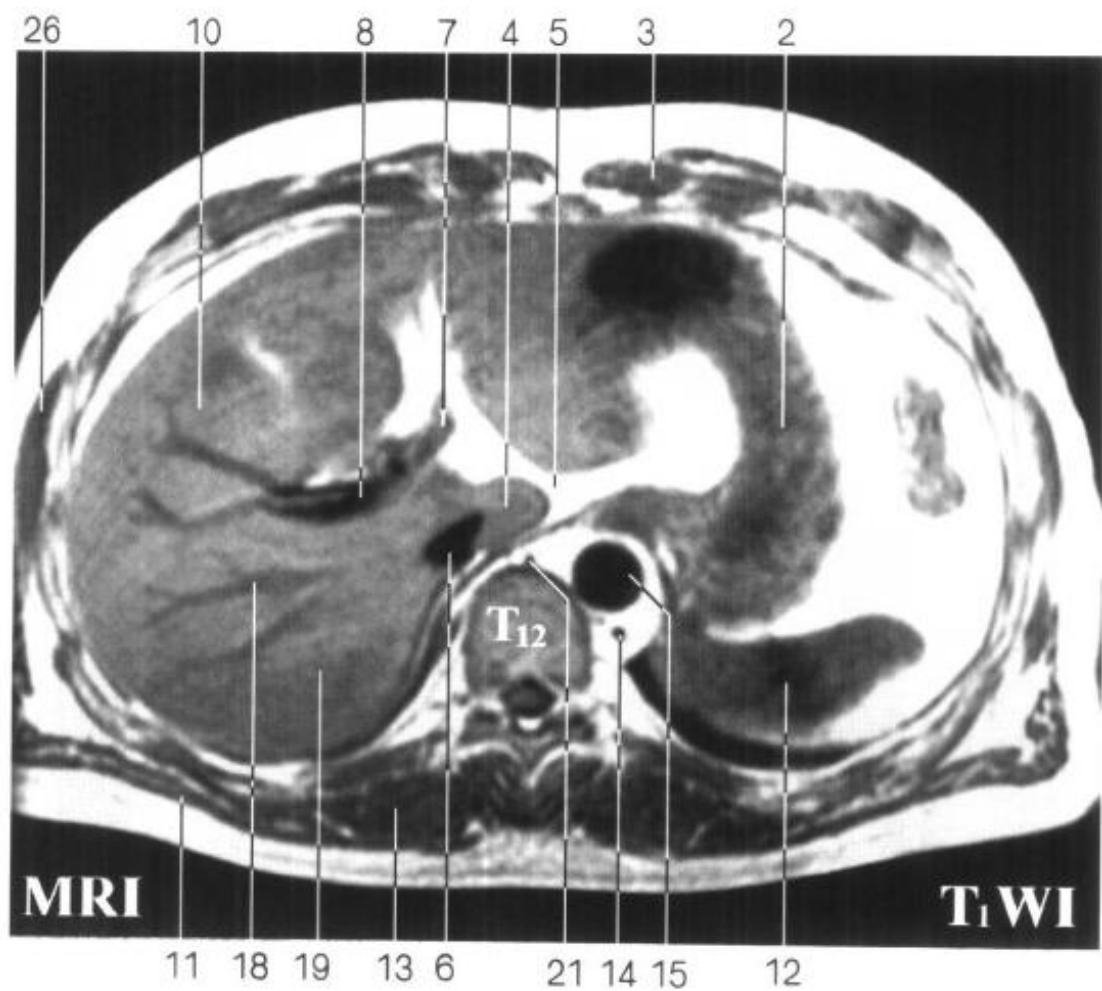


Fig. HA 4

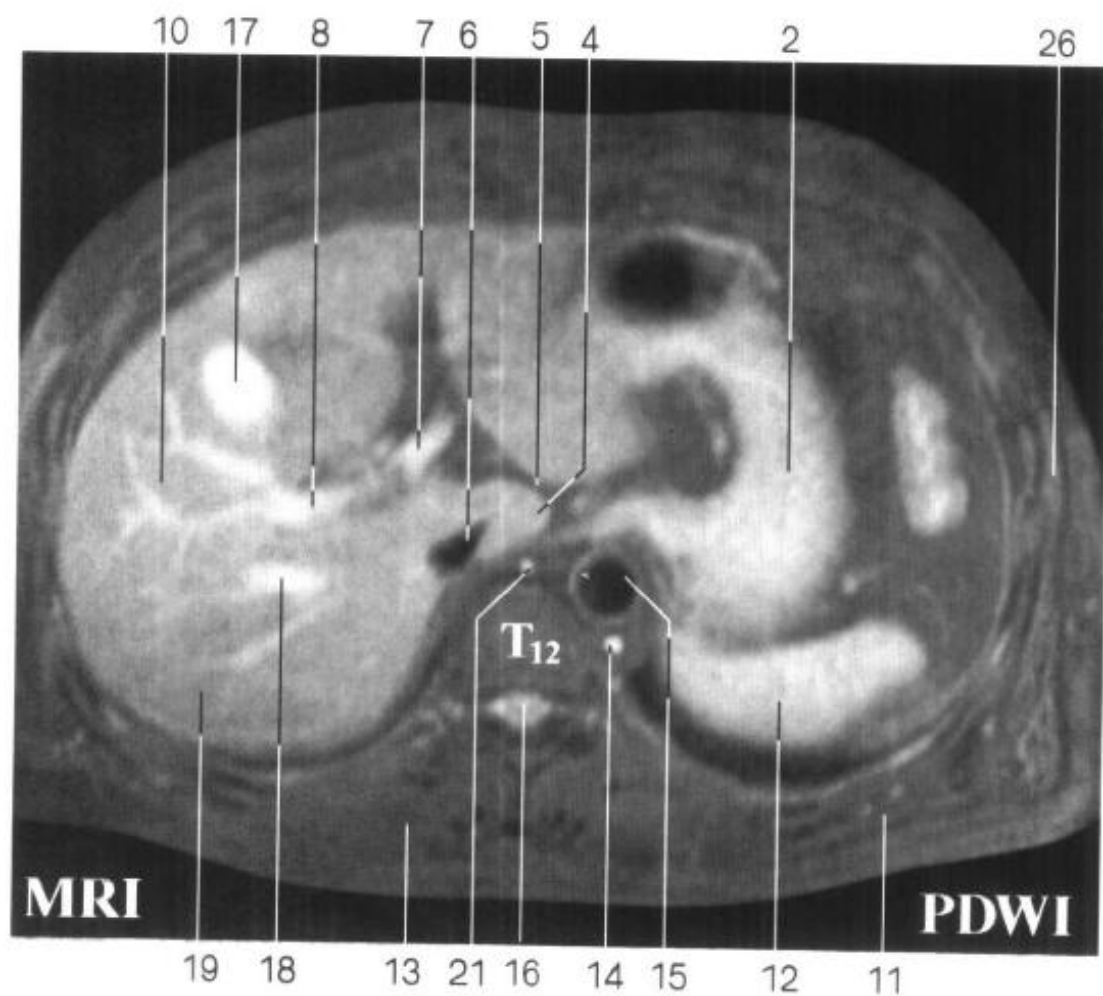
1. 脾动脉 splenic a.
2. 胃 stomach
3. 腹直肌 rectus abdominis
4. 尾状叶 caudate lobe
5. 静脉韧带裂 fissure for ligamentum venosum
6. 下腔静脉 inferior vena cava
7. 肝门静脉左支 left branch of hepatic portal v.
8. 肝门静脉右支 right branch of hepatic portal v.
9. 肝中间静脉 intermediate hepatic v.
10. 右前叶 right anterior lobe
11. 背阔肌 latissimus dorsi
12. 脾 spleen
13. 竖脊肌 erector spinae

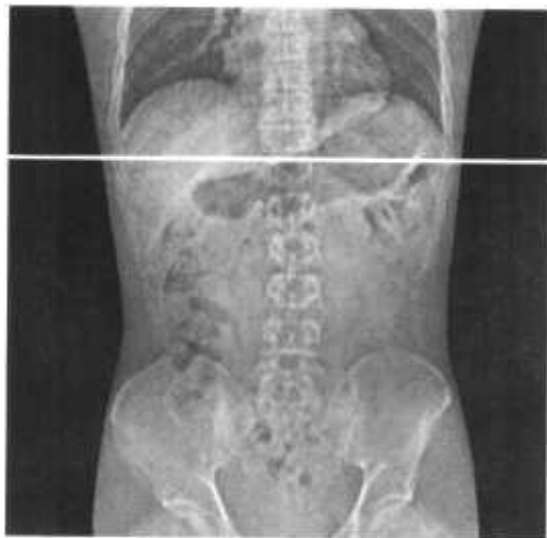

Fig. HA 4



- 14. 半奇静脉 semiazygos v.
- 15. 胸主动脉 thoracic aorta
- 16. 脊髓 spinal cord
- 17. 胆囊 gallbladder
- 18. 肝右静脉 right hepatic v.
- 19. 右后叶 right posterior lobe
- 20. 膈右脚 right crus of diaphragm
- 21. 奇静脉 azygos v.
- 22. 肝固有动脉 proper hepatic a.
- 23. 膈左脚 left crus of diaphragm
- 24. 左肾上腺 left suprarenal gland
- 25. 左肾 left kidney
- 26. 前锯肌 serratus anterior



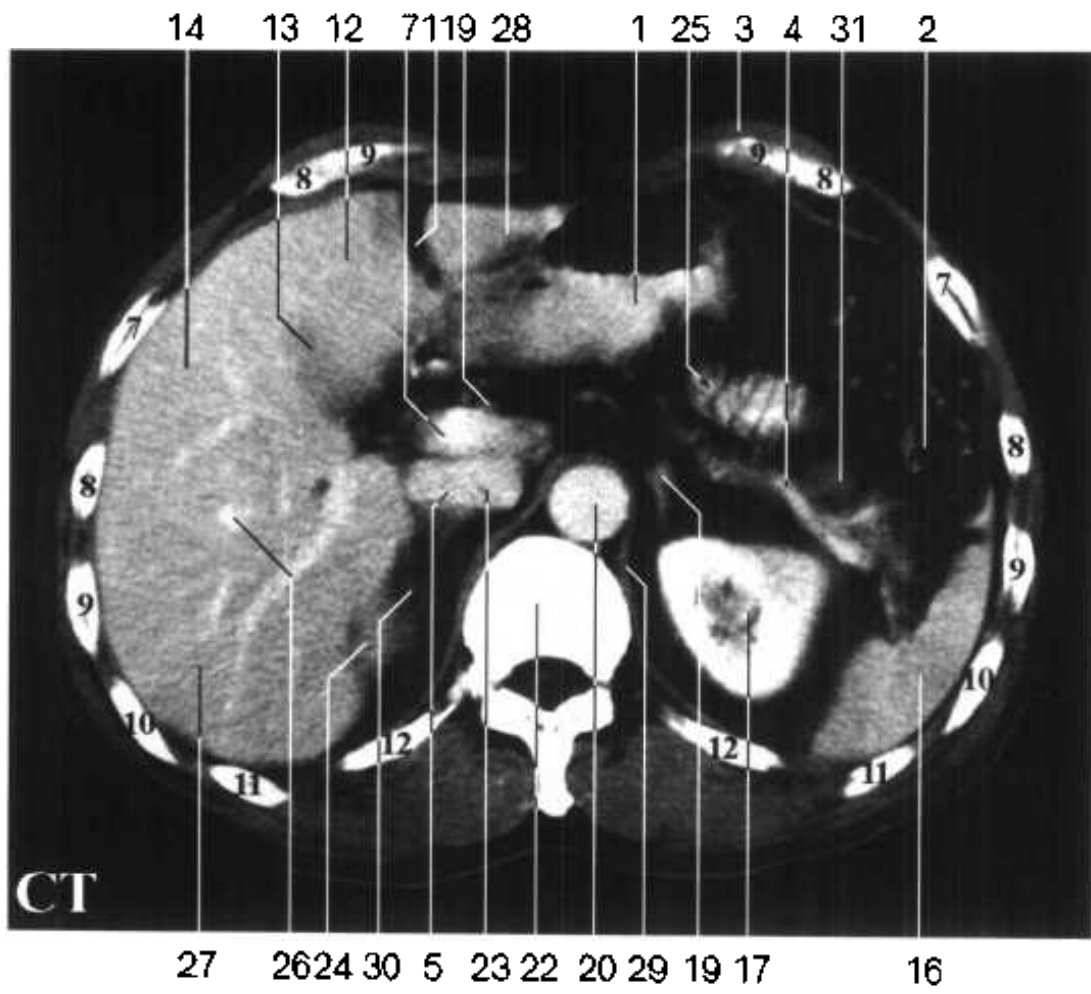
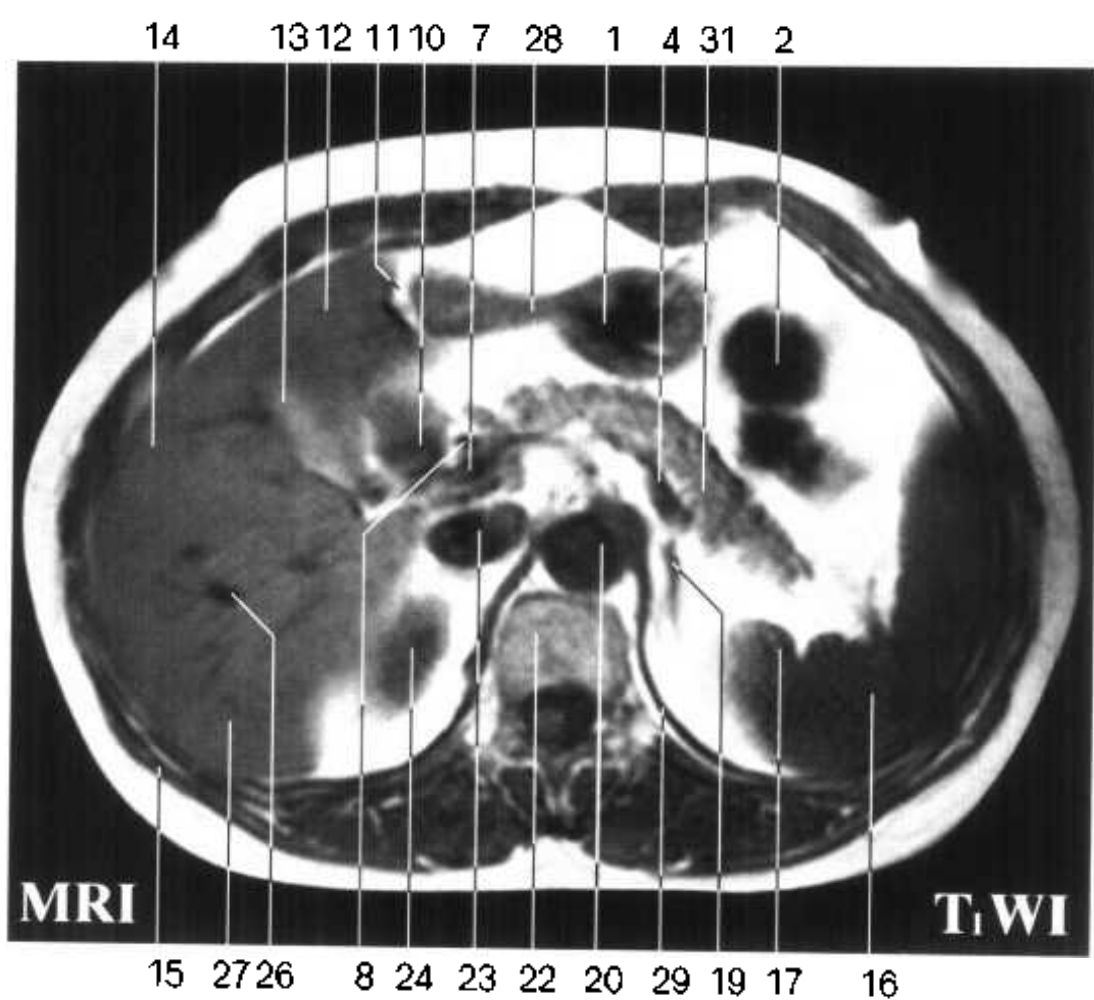


Fig HA 5

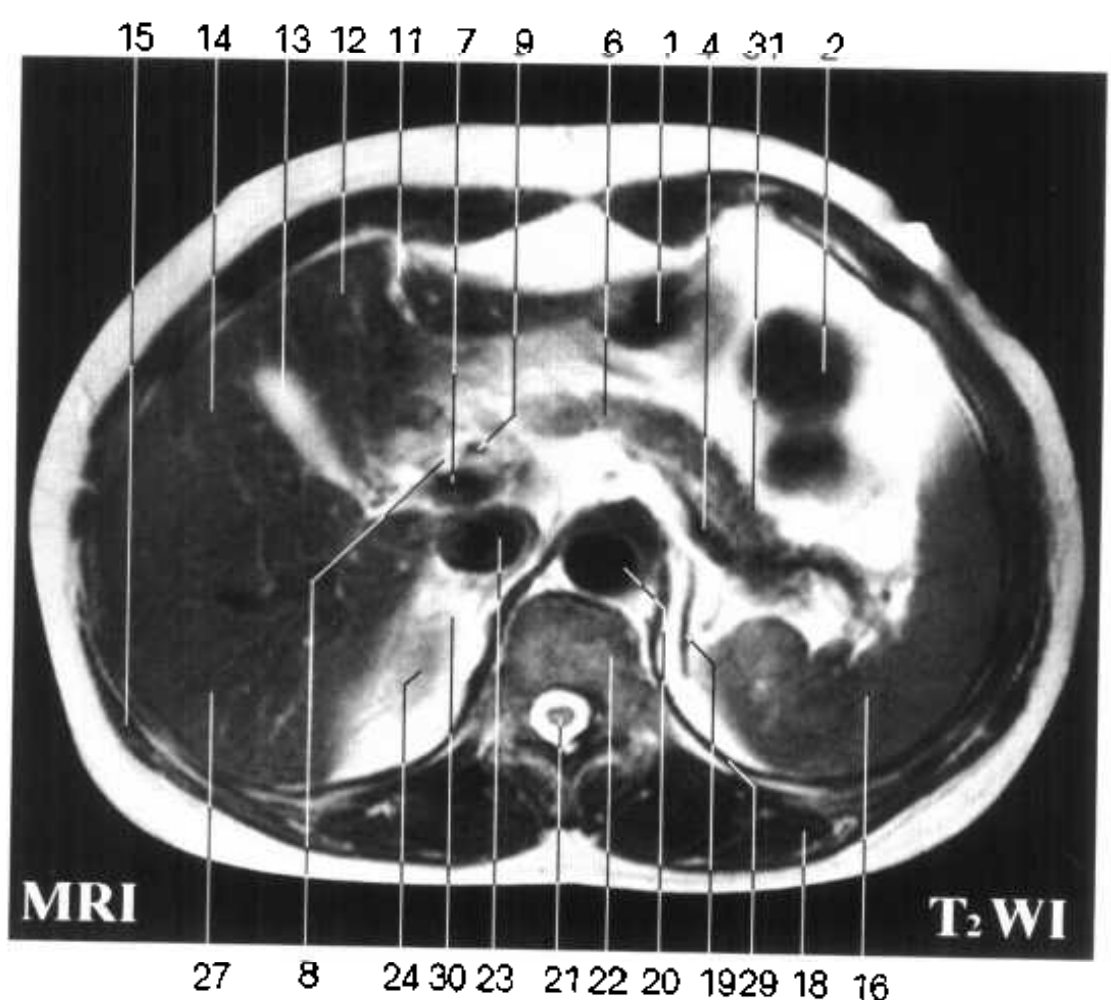
1. 胃 stomach
2. 降结肠 descending colon
3. 腹直肌 rectus abdominis
4. 脾静脉 splenic v.
5. 尾状叶 caudate lobe
6. 胰体 body of pancreas
7. 肝门静脉 hepatic portal v.
8. 胆总管 common bile duct
9. 肝固有动脉 proper hepatic a.
10. 幽门窦 pyloric antrum
11. 肝圆韧带裂 fissure for ligamentum teres hepatis
12. 左内叶 left medial lobe
13. 胆囊 gallbladder
14. 右前叶 right anterior lobe
15. 背阔肌 latissimus dorsi
16. 脾 spleen
17. 左肾 left kidney
18. 竖脊肌 erector spinae

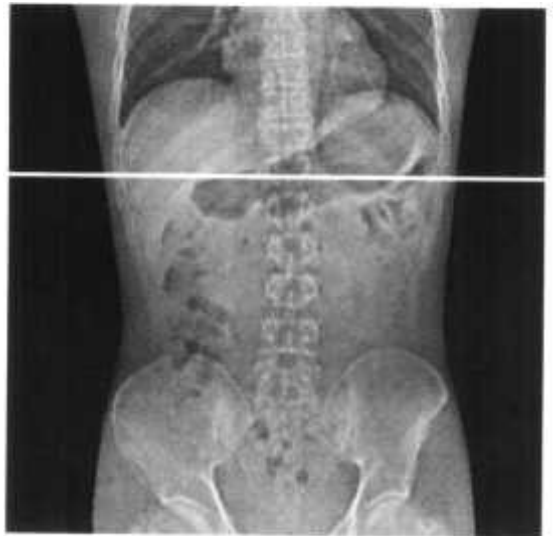

Fig. HA 5



- 19. 左肾上腺 left suprarenal gland
- 20. 腹主动脉 abdominal aorta
- 21. 脊髓 spinal cord
- 22. 第12胸椎与第1腰椎间盘
intervertebral disc (T₁₂~L₁)
- 23. 下腔静脉 inferior vena cava
- 24. 右肾 right kidney
- 25. 十二指肠空肠曲 duodenojejunal
flexure
- 26. 肝右静脉 right hepatic v.
- 27. 右后叶 right posterior lobe
- 28. 左外叶 left lateral lobe
- 29. 膈左脚 left crus of diaphragm
- 30. 右肾上腺 right suprarenal
gland
- 31. 胰尾 tail of pancreas



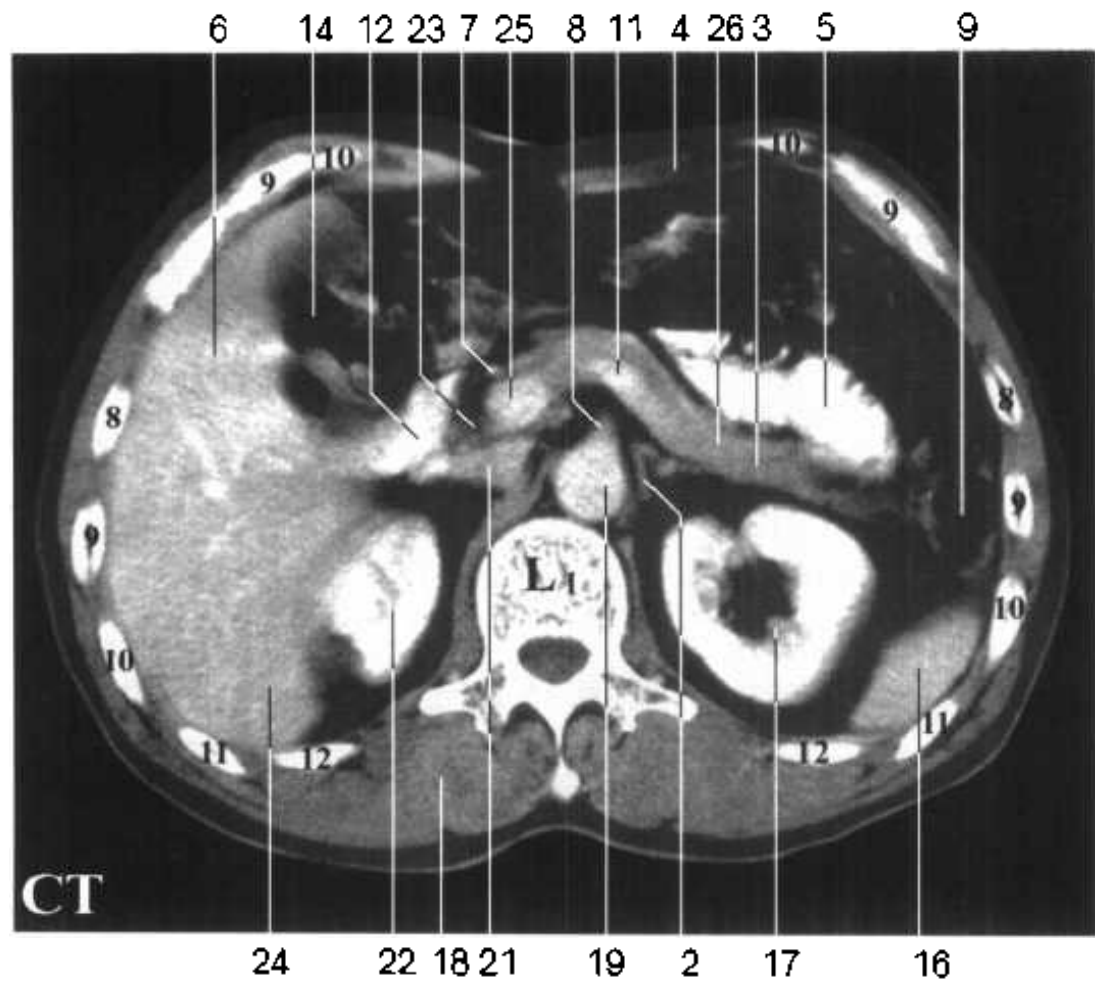
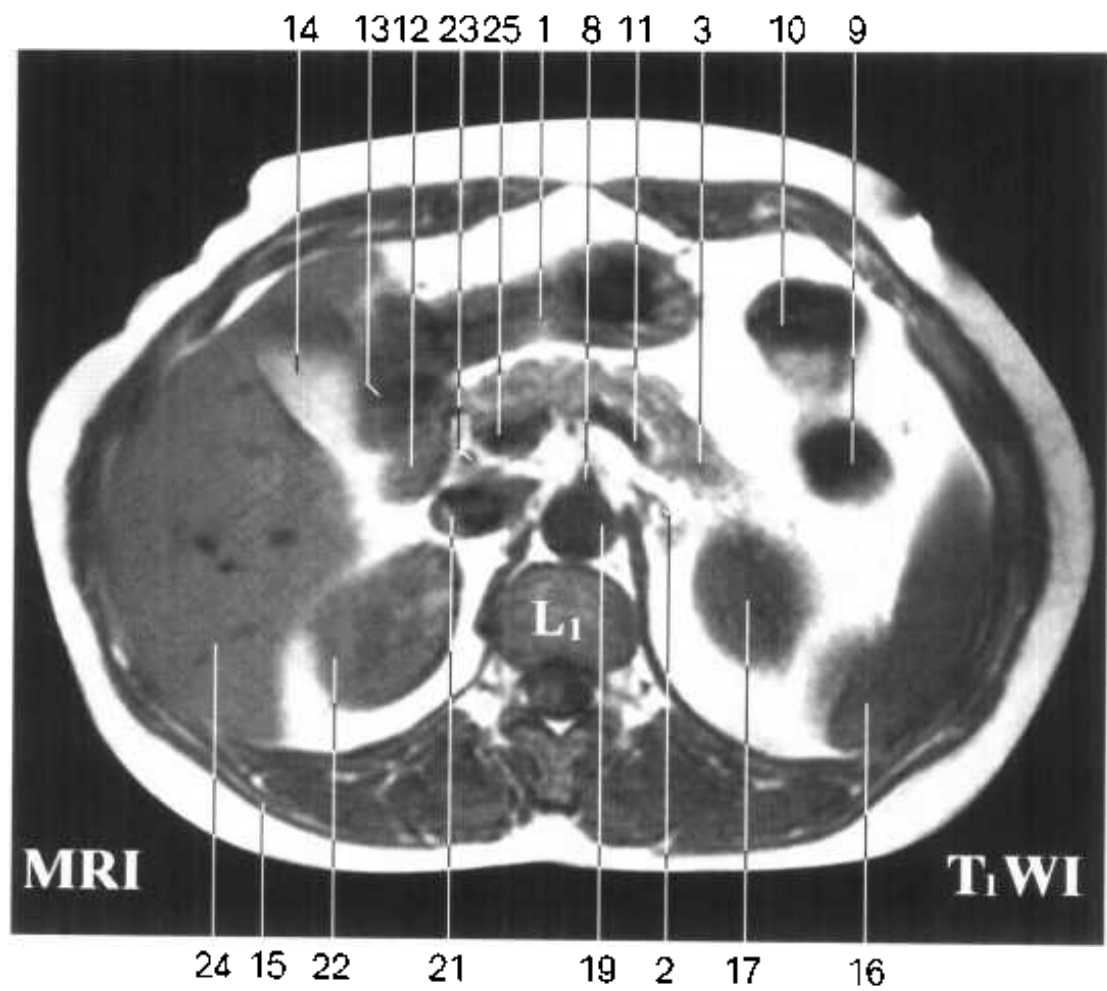


Fig HA 6

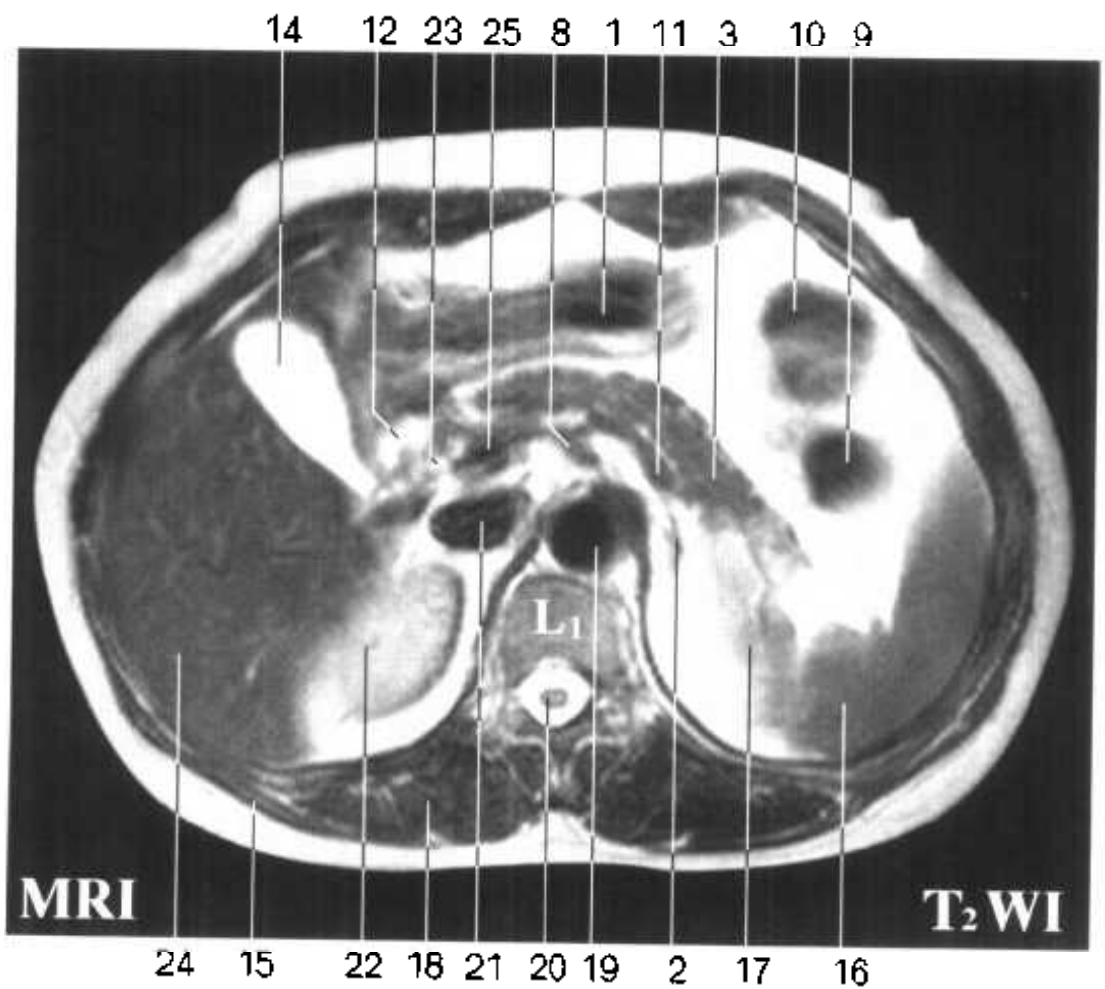
1. 胃 stomach
2. 左肾上腺 left suprarenal gland
3. 胰尾 tail of pancreas
4. 腹直肌 rectus abdominis
5. 空肠 jejunum
6. 右前叶 right anterior lobe
7. 肝固有动脉 proper hepatic a.
8. 肠系膜上动脉 superior mesenteric a.
9. 降结肠 descending colon
10. 横结肠 transverse colon
11. 脾静脉 splenic v.
12. 十二指肠降部 descending part of duodenum

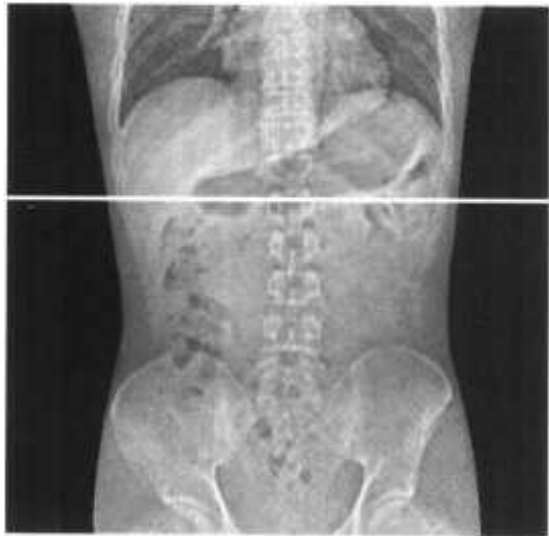

Fig. HA 6



- 13. 幽门 pylorus
- 14. 胆囊 gallbladder
- 15. 背阔肌 latissimus dorsi
- 16. 脾 spleen
- 17. 左肾 left kidney
- 18. 竖脊肌 erector spinae
- 19. 腹主动脉 abdominal aorta
- 20. 脊髓 spinal cord
- 21. 下腔静脉 inferior vena cava
- 22. 右肾 right kidney
- 23. 胆总管 common bile duct
- 24. 右后叶 right posterior lobe
- 25. 肝门静脉 hepatic portal v.
- 26. 胰体 body of pancreas



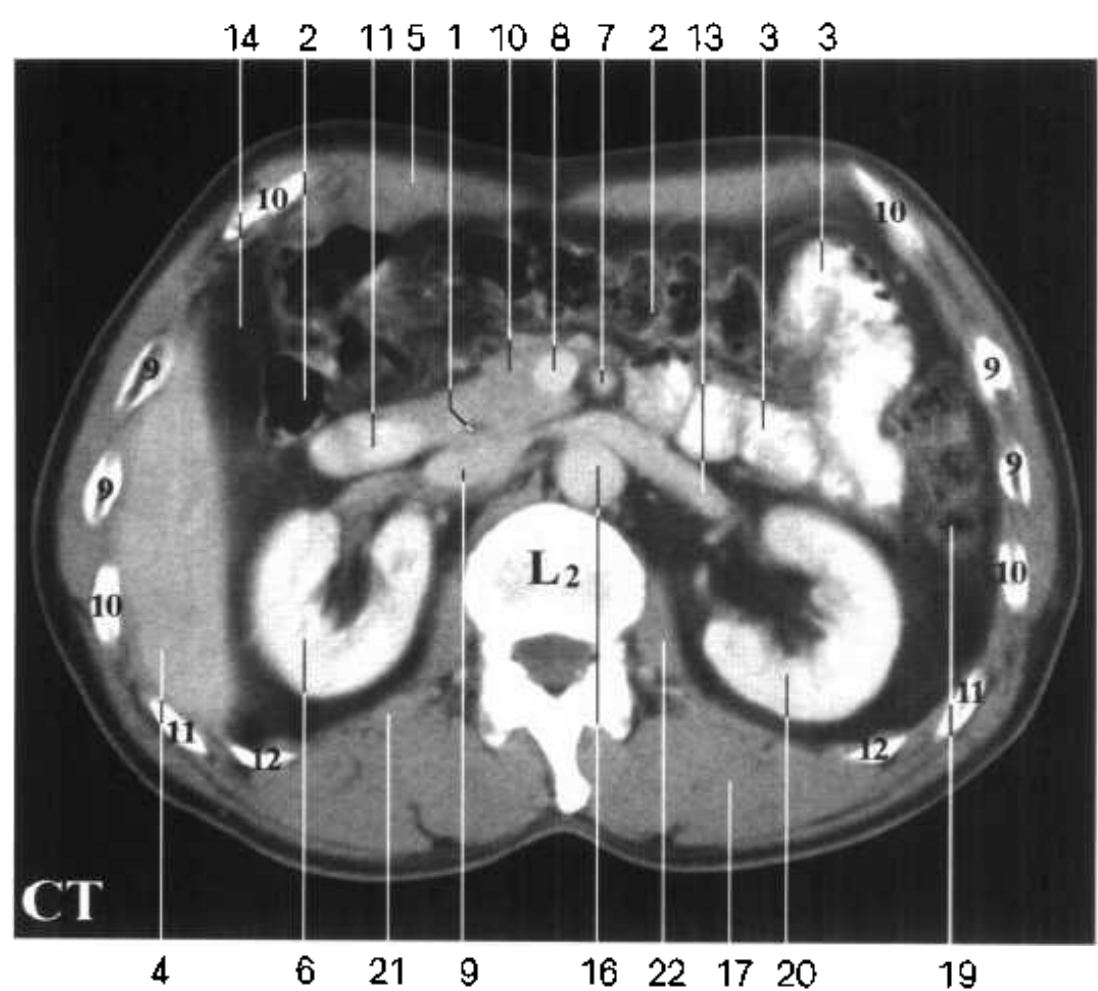
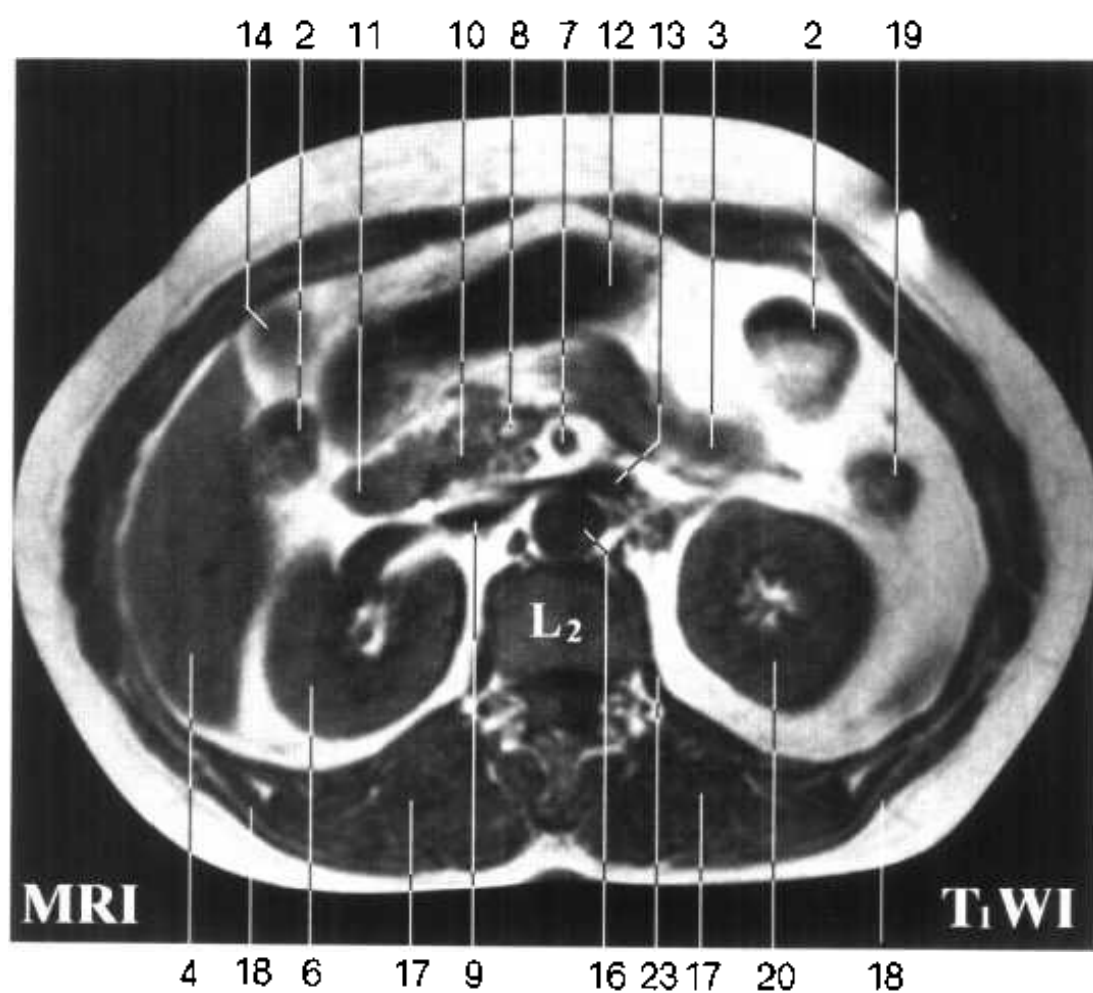


Fig HA 7

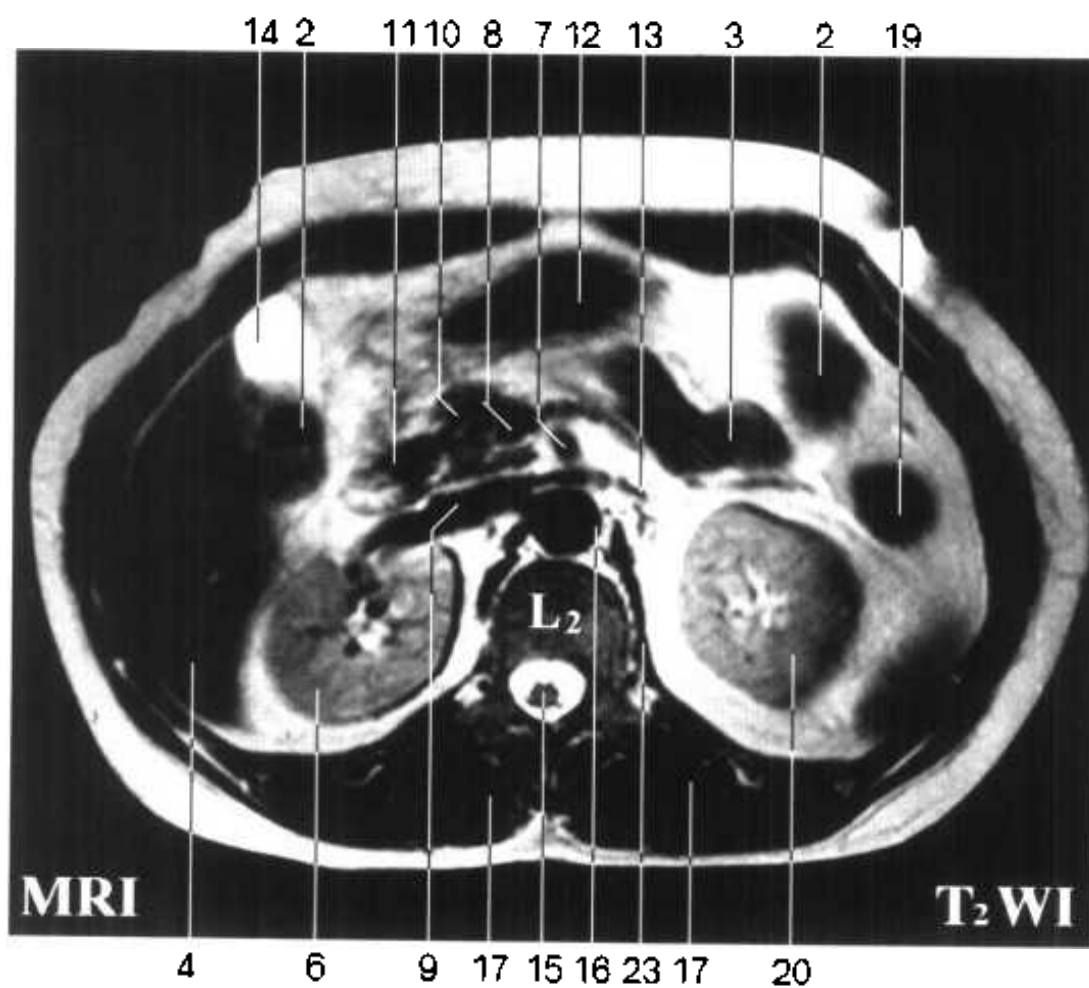
1. 胆总管 common bile duct
2. 横结肠 transverse colon
3. 空肠 jejunum
4. 右后叶 right posterior lobe
5. 腹直肌 rectus abdominis
6. 右肾 right kidney
7. 肠系膜上动脉 superior mesenteric a.
8. 肠系膜上静脉 superior mesenteric v.
9. 下腔静脉 inferior vena cava
10. 胰头 head of pancreas
11. 十二指肠降部 descending part of duodenum
12. 胃 stomach

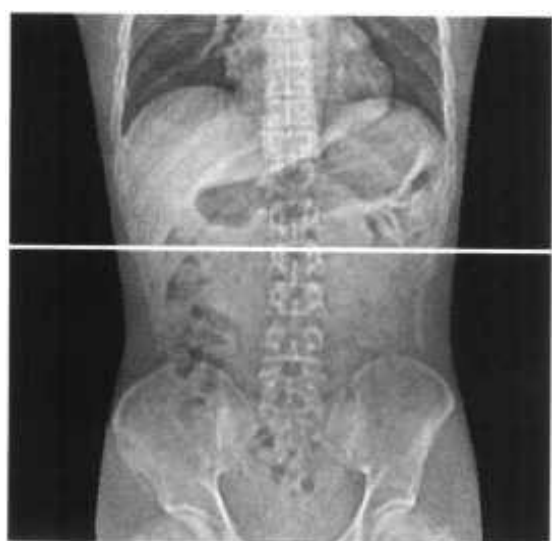

Fig. HA 7



- 13. 左肾静脉 left renal v.
- 14. 胆囊 gallbladder
- 15. 马尾 cauda equina
- 16. 腹主动脉 abdominal aorta
- 17. 竖脊肌 erector spinae
- 18. 背阔肌 latissimus dorsi
- 19. 降结肠 descending colon
- 20. 左肾 left kidney
- 21. 腰方肌 quadratus lumborum
- 22. 腰大肌 psoas major
- 23. 膈左脚 left crus of diaphragm



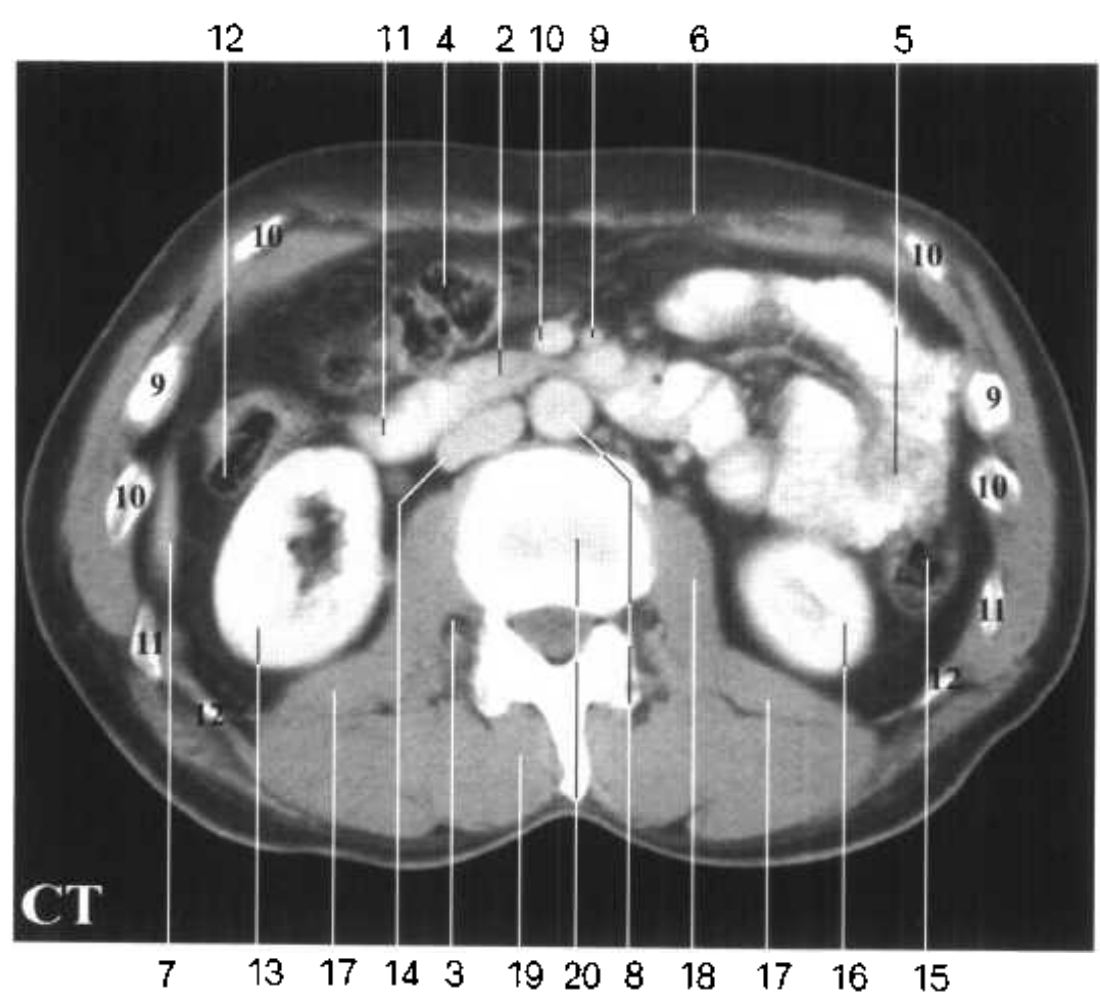
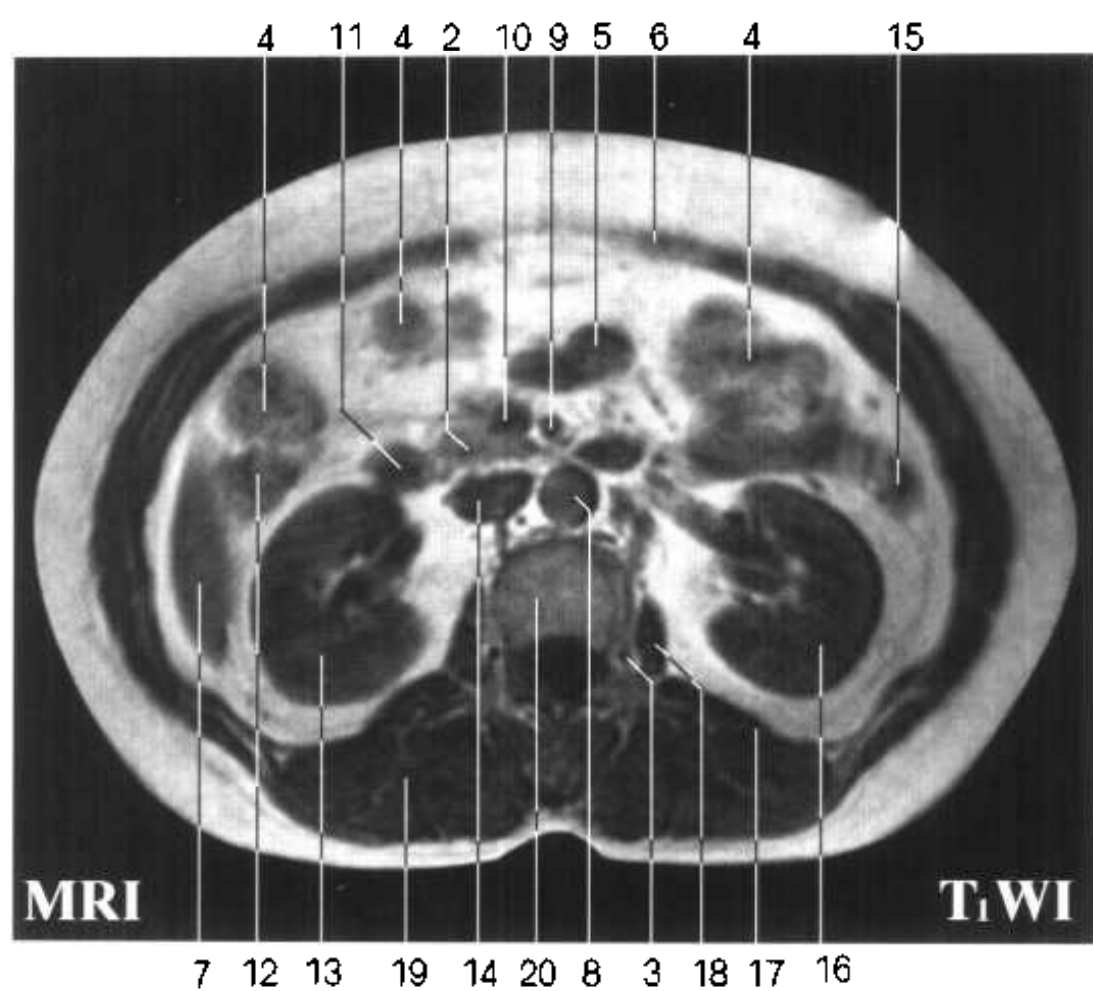


Fig HA 8

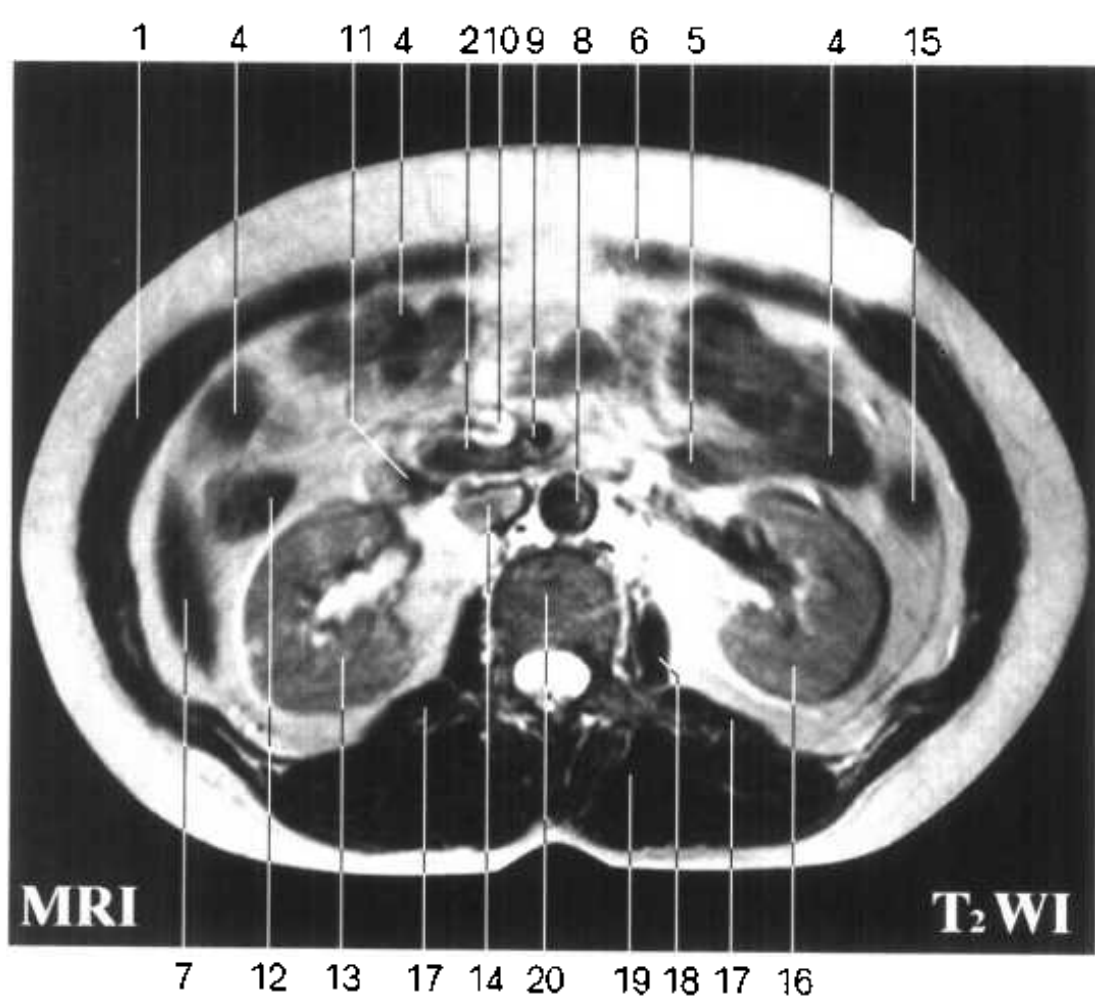
1. 腹外斜肌 obliquus externus abdominis
2. 钩突 uncinata process
3. 第2腰神经 2nd lumbar n.
4. 横结肠 transverse colon
5. 空肠 jejunum
6. 腹直肌 rectus abdominis
7. 右后叶 right posterior lobe
8. 腹主动脉 abdominal aorta
9. 肠系膜上动脉 superior mesenteric a.
10. 肠系膜上静脉 superior mesenteric v.
11. 十二指肠水平部 horizontal part of duodenum

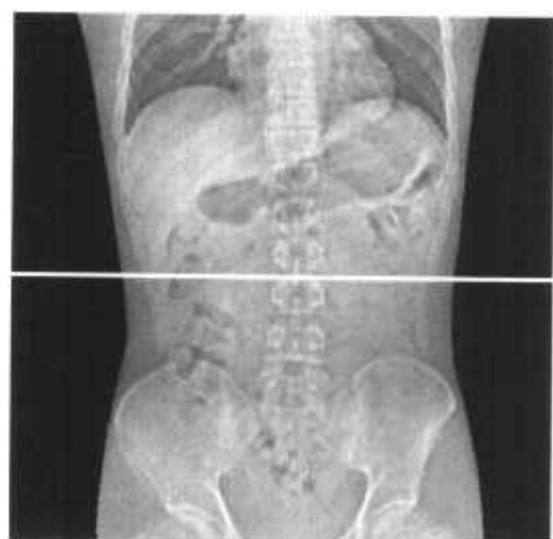

Fig. HA 8



- 12. 升结肠 ascending colon
- 13. 右肾 right kidney
- 14. 下腔静脉 inferior vena cava
- 15. 降结肠 descending colon
- 16. 左肾 left kidney
- 17. 腰方肌 quadratus lumborum
- 18. 腰大肌 psoas major
- 19. 竖脊肌 erector spinae
- 20. 2、3 腰椎间盘
intervertebral disc(L₂~L₃)



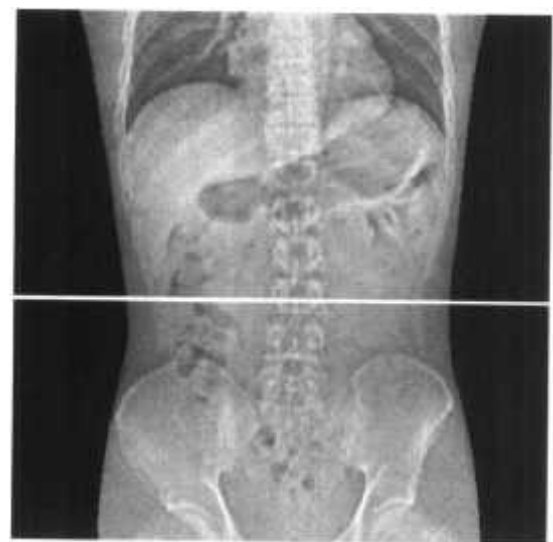
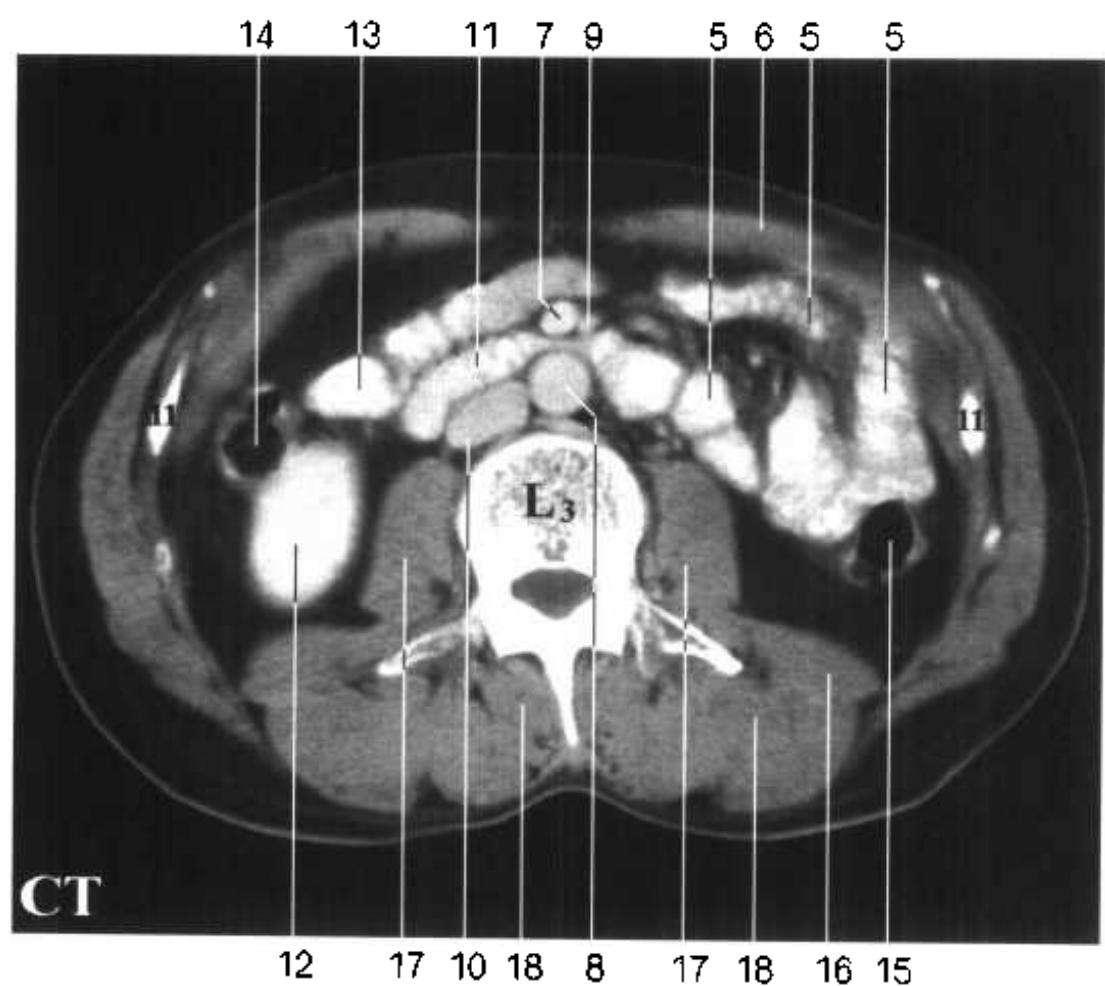
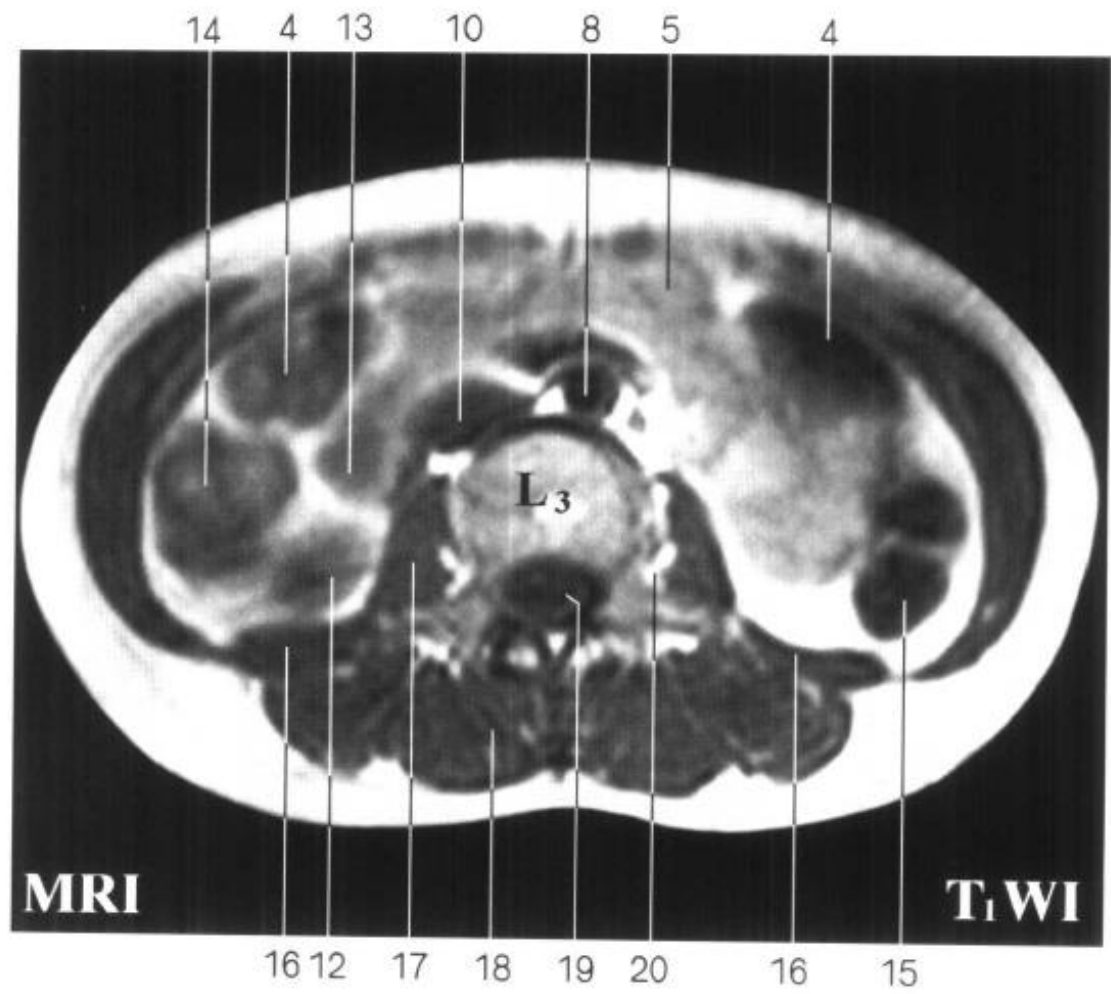


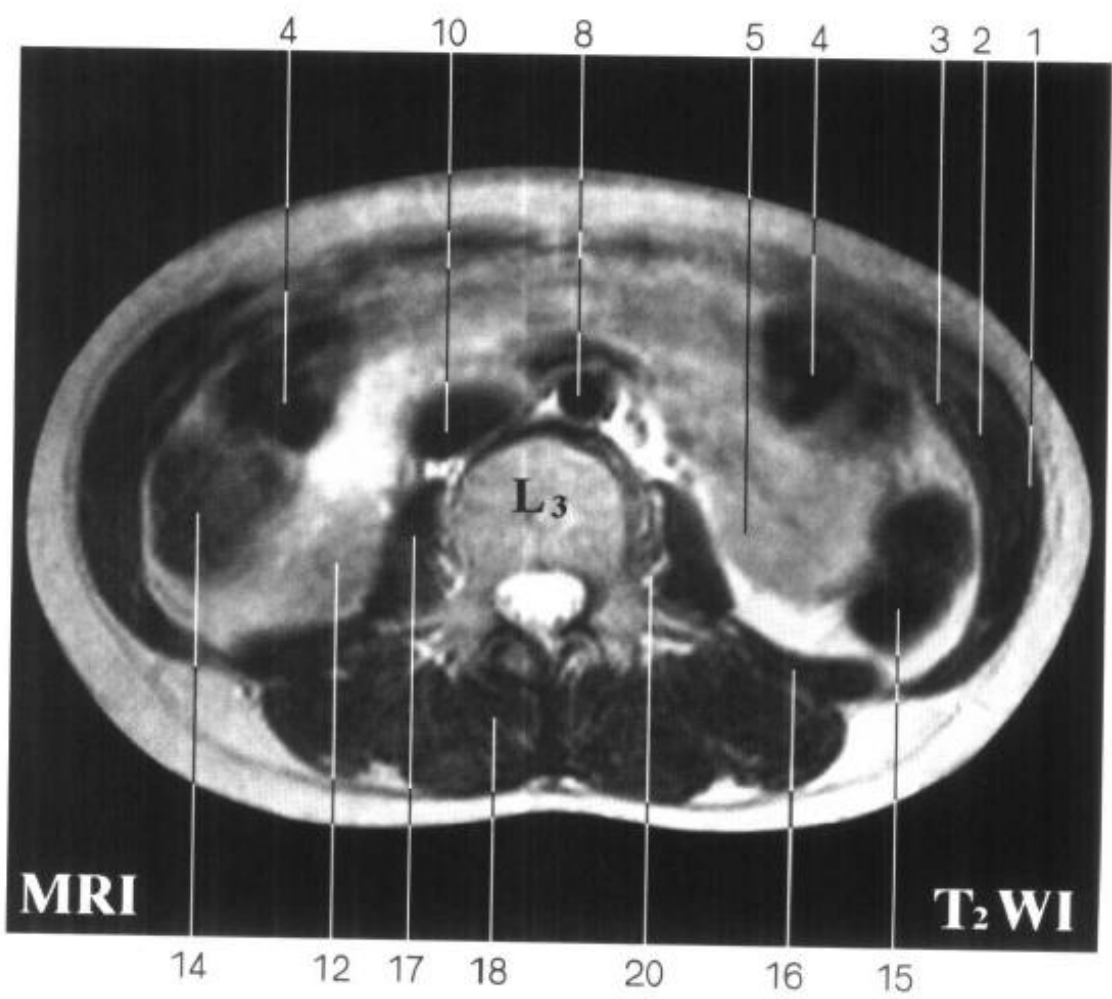
Fig HA 9

1. 腹外斜肌 obliquus externus abdominis
2. 腹内斜肌 obliquus internus abdominis
3. 腹横肌 transversus abdominis
4. 横结肠 transverse colon
5. 空肠 jejunum
6. 腹直肌 rectus abdominis
7. 肠系膜上静脉 superior mesenteric v.
8. 腹主动脉 abdominal aorta
9. 肠系膜上动脉 superior mesenteric a.
10. 下腔静脉 inferior vena cava
11. 十二指肠水平部 horizontal part of duodenum
12. 右肾 right kidney
13. 回肠 ileum
14. 升结肠 ascending colon
15. 降结肠 descending colon
16. 腰方肌 quadratus lumborum
17. 腰大肌 psoas major

Fig. HA 9



- 18. 竖脊肌 erector spinae
- 19. 马尾 cauda equina
- 20. 第3腰神经 3rd lumbar n.



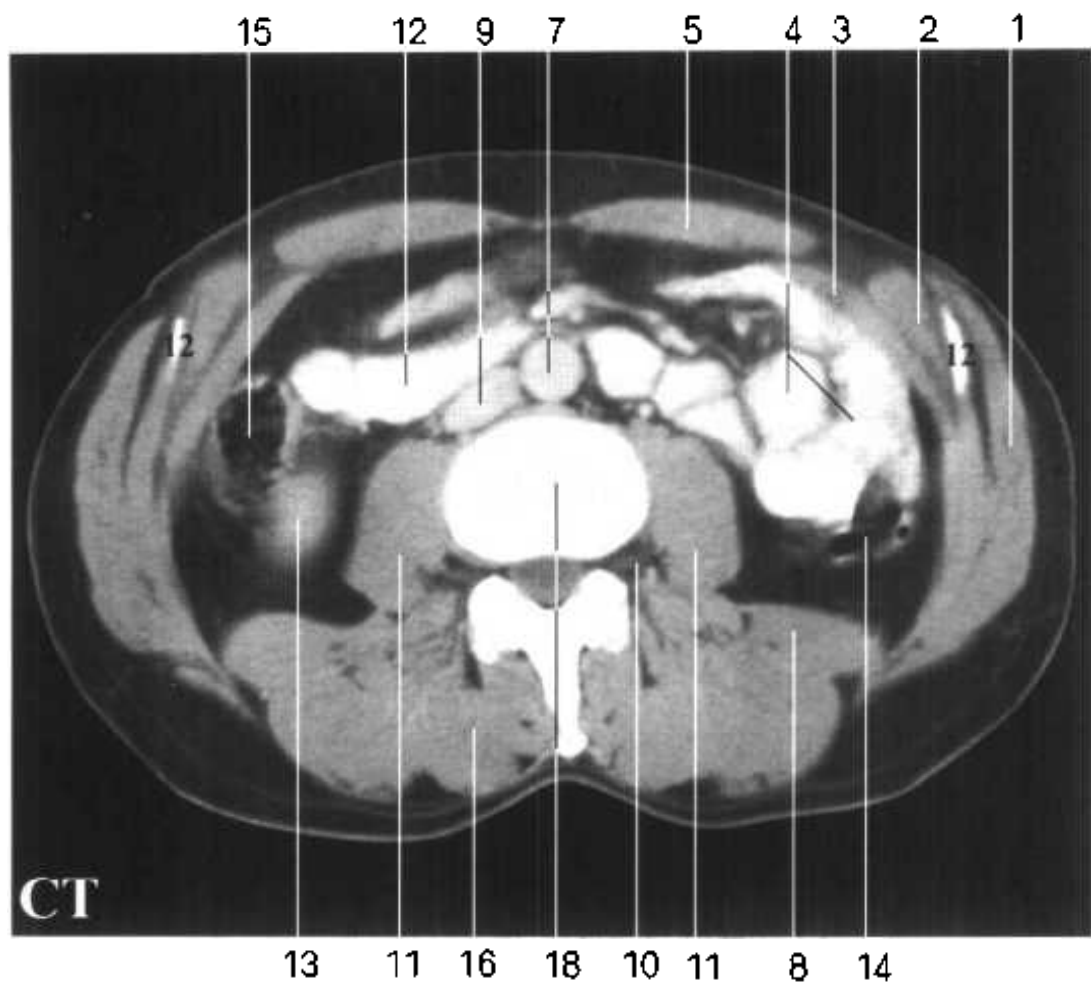


Fig HA 10

1. 腹外斜肌 obliquus externus abdominis
2. 腹内斜肌 obliquus internus abdominis
3. 腹横肌 transversus abdominis
4. 空肠 jejunum
5. 腹直肌 rectus abdominis
6. 横结肠 transverse colon
7. 腹主动脉 abdominal aorta
8. 腰方肌 quadratus lumborum
9. 下腔静脉 inferior vena cava
10. 第3腰神经 3rd lumbar n.
11. 腰大肌 psoas major

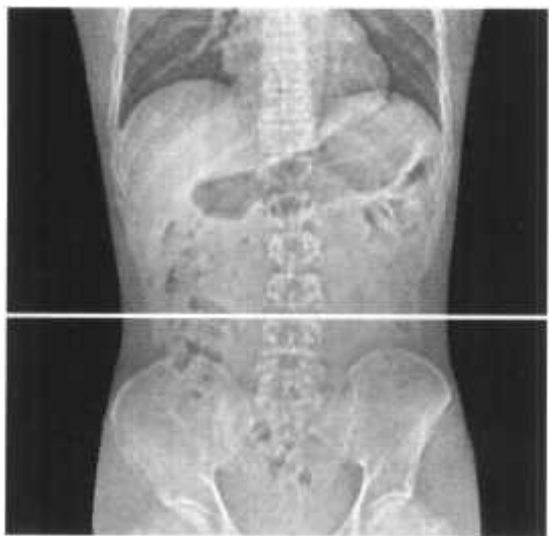
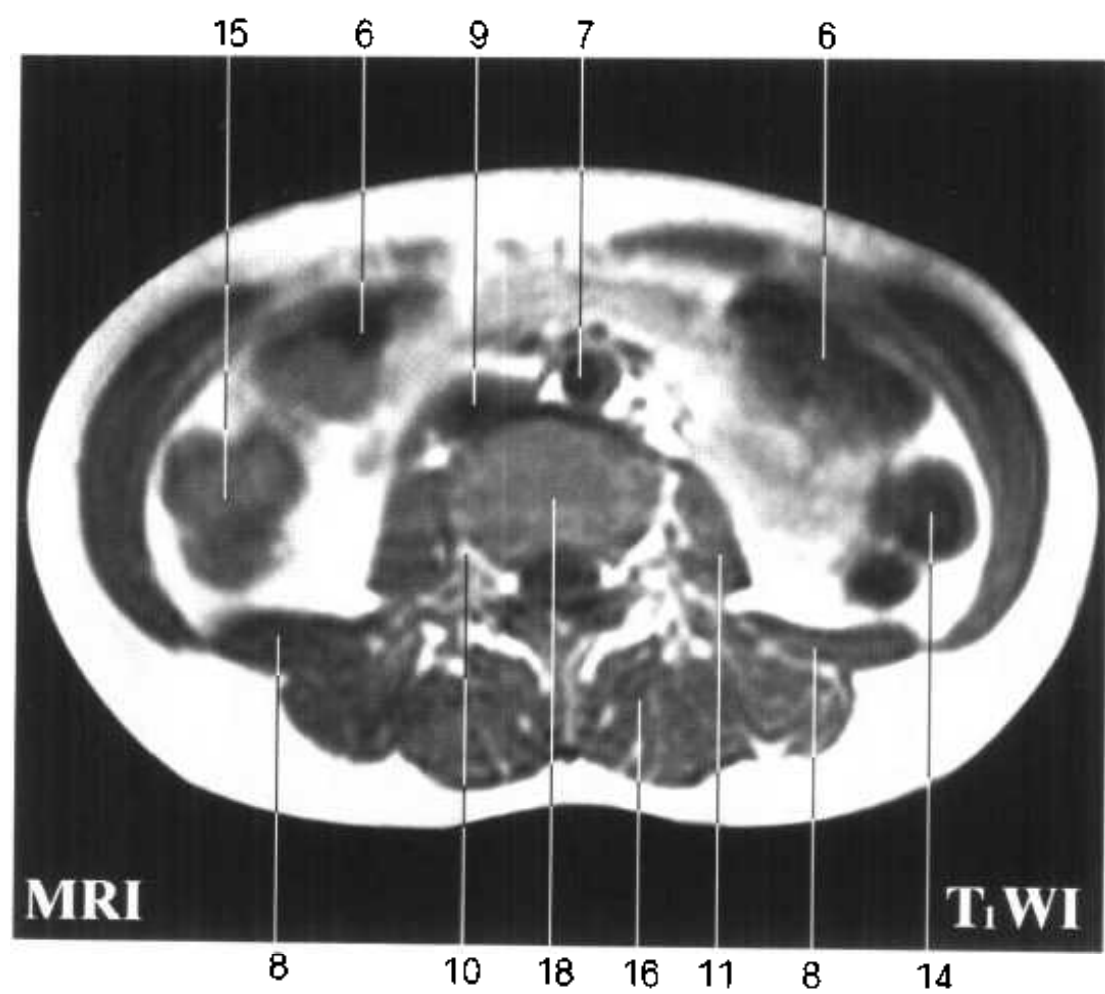
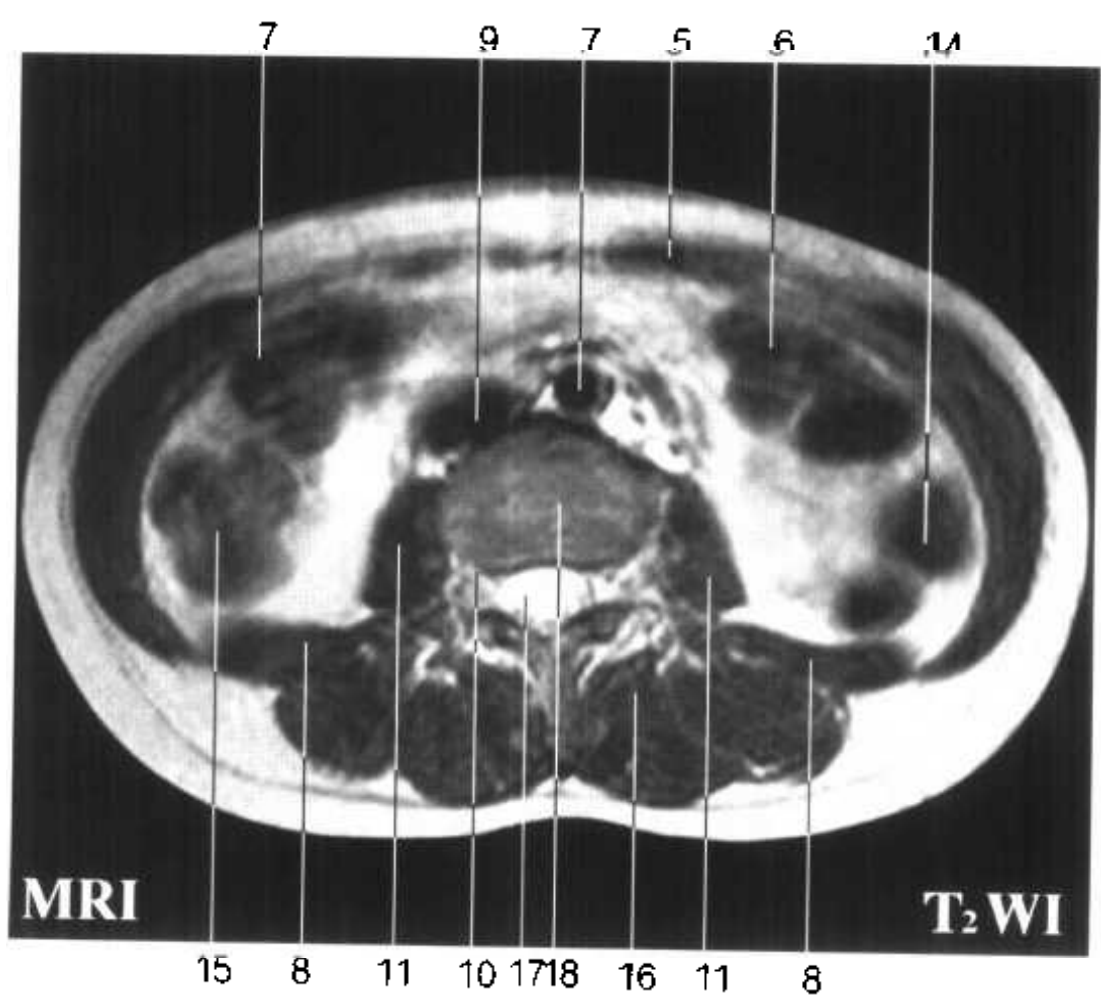


Fig. HA 10



- 12. 回肠 ileum
- 13. 右肾 right kidney
- 14. 降结肠 descending colon
- 15. 升结肠 ascending colon
- 16. 竖脊肌 erector spinae
- 17. 马尾 cauda equina
- 18. 3、4 腰椎间盘
intervertebral disc(L₃~L₄)



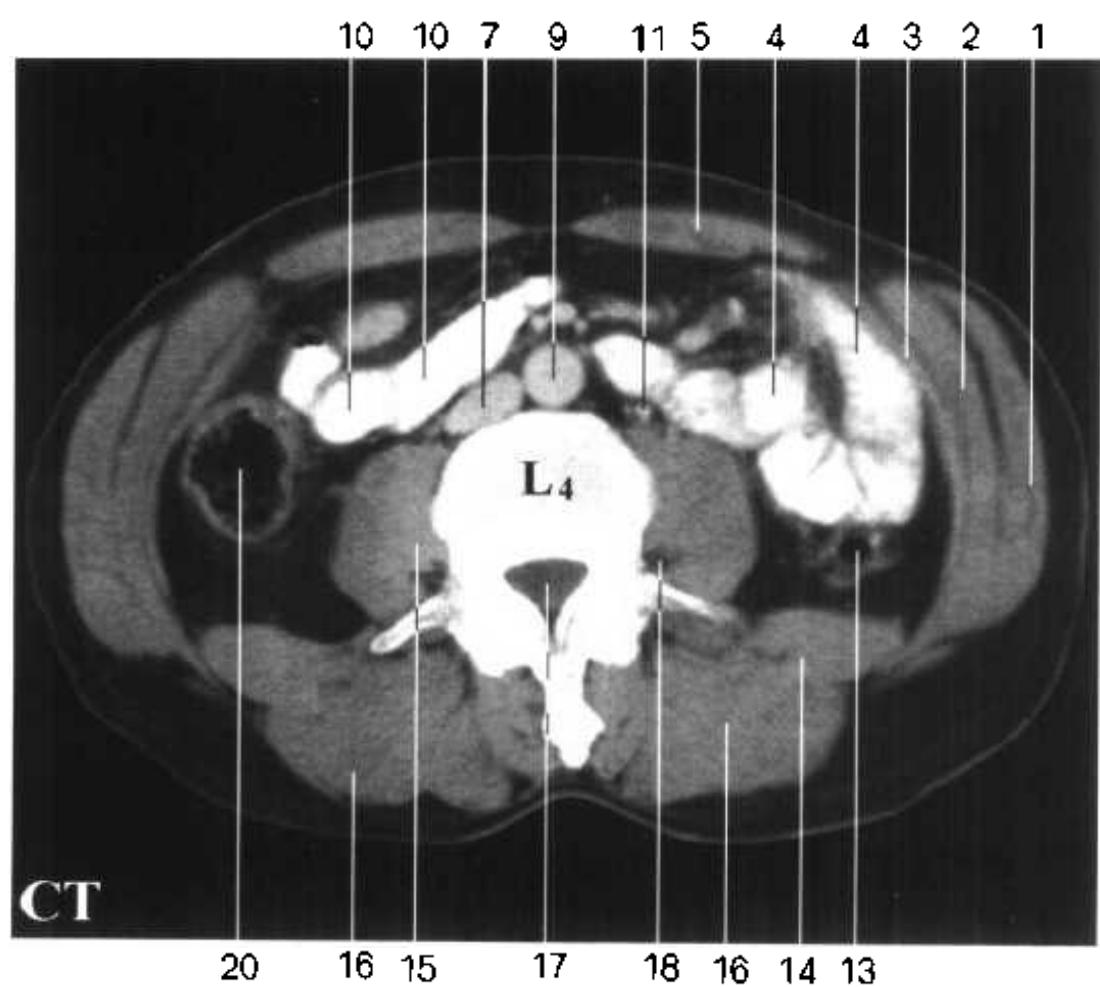
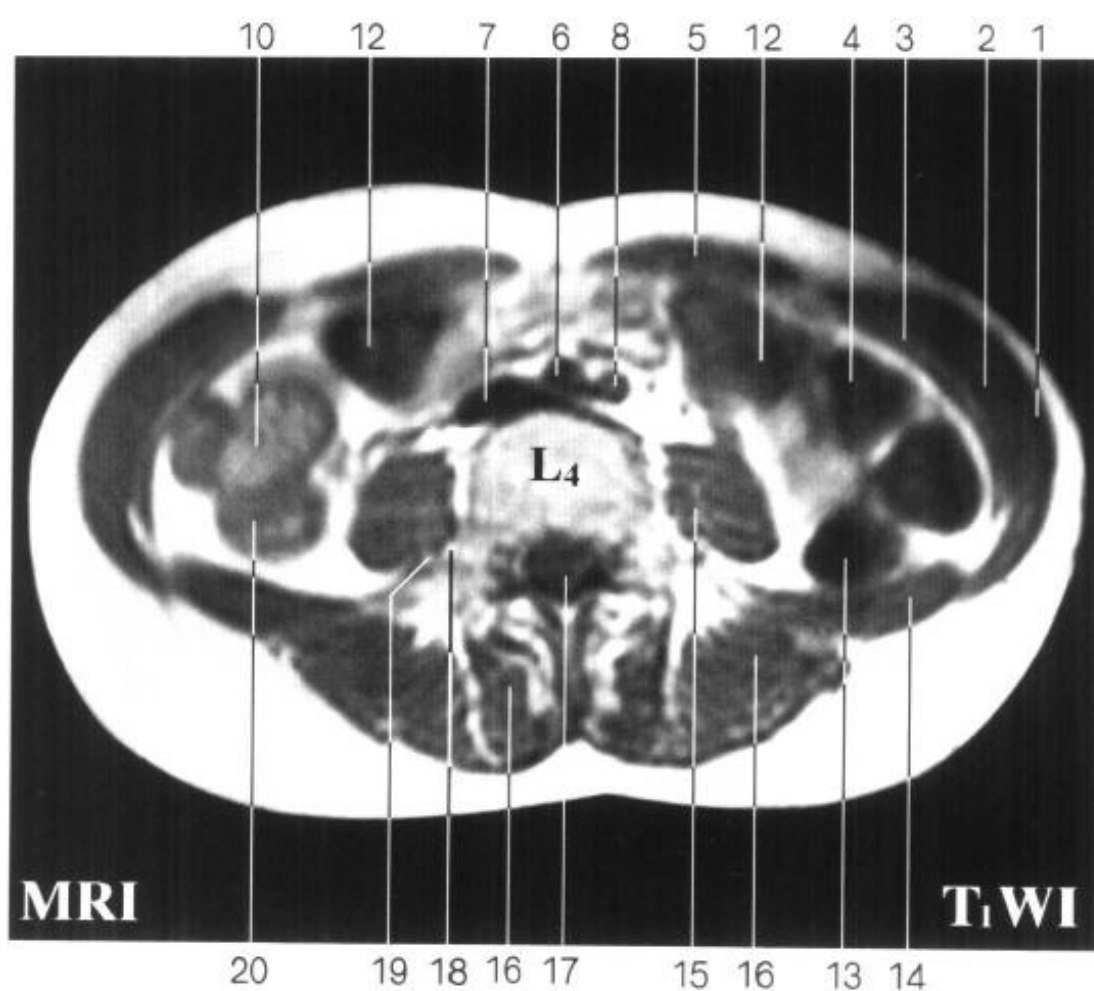


Fig HA 11

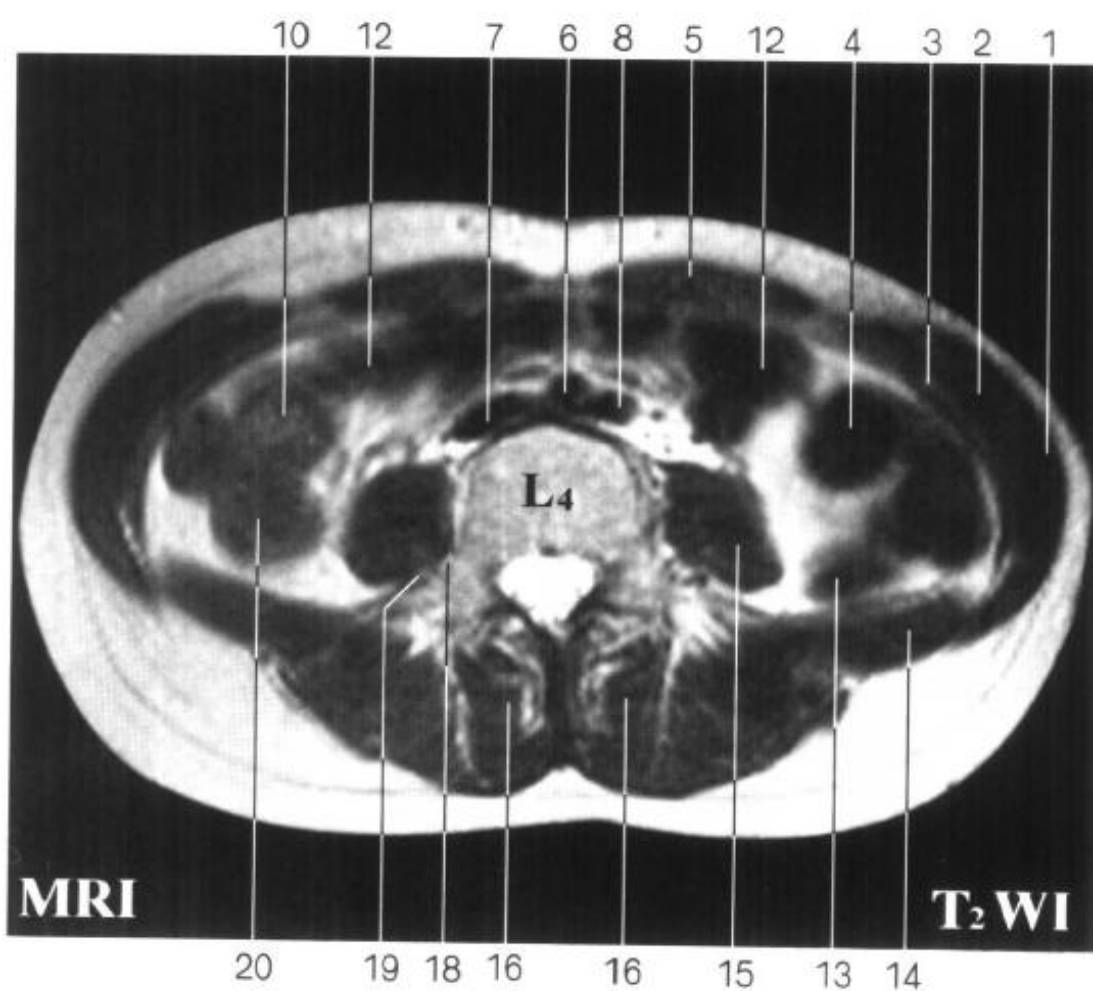
1. 腹外斜肌 obliquus externus abdominis
2. 腹内斜肌 obliquus internus abdominis
3. 腹横肌 transversus abdominis
4. 空肠 jejunum
5. 腹直肌 rectus abdominis
6. 右髂总动脉 right common iliac a.
7. 下腔静脉 inferior vena cava
8. 左髂总动脉 left common iliac a.
9. 腹主动脉 abdominal aorta
10. 回肠 ileum

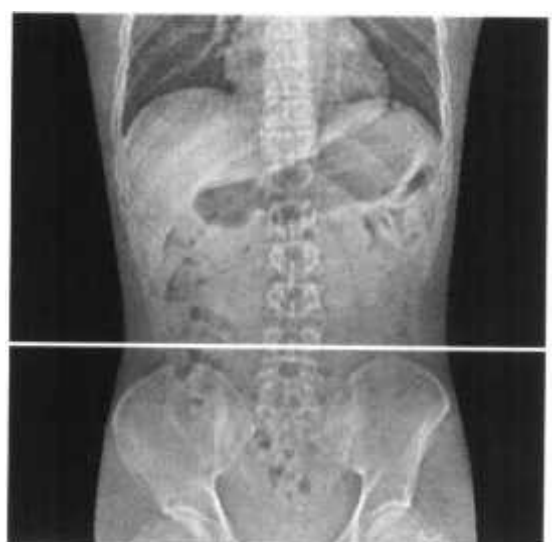

Fig.HA11



- 11. 输尿管 ureter
- 12. 横结肠 transverse colon
- 13. 降结肠 descending colon
- 14. 腰方肌 quadratus lumborum
- 15. 腰大肌 psoas major
- 16. 竖脊肌 erector spinae
- 17. 马尾 cauda equina
- 18. 第4腰神经 4th lumbar n.
- 19. 第3腰神经 3rd lumbar n.
- 20. 升结肠 ascending colon



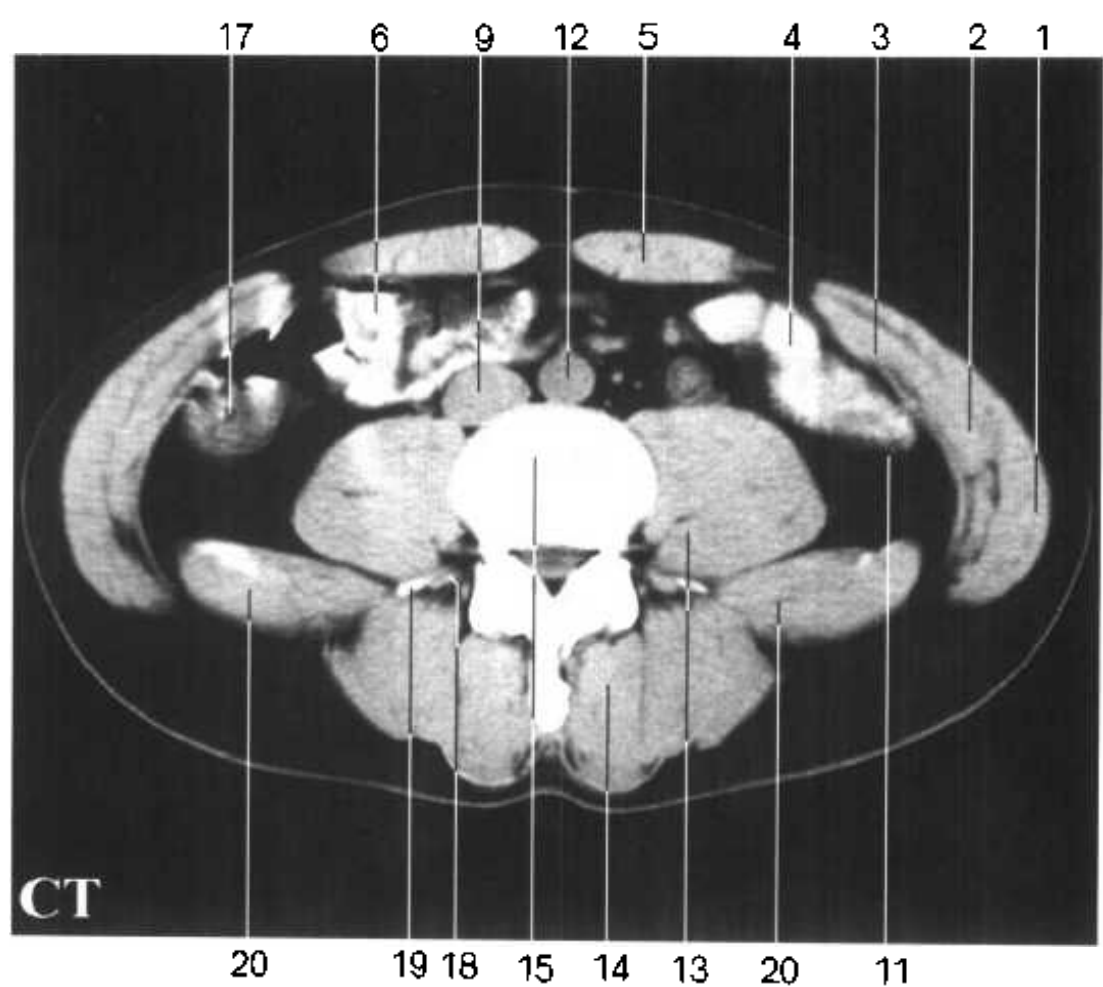


Fig HA 12

1. 腹外斜肌 obliquus externus abdominis
2. 腹内斜肌 obliquus internus abdominis
3. 腹横肌 transversus abdominis
4. 空肠 jejunum
5. 腹直肌 rectus abdominis
6. 回肠 ileum
7. 右髂总动脉 right common iliac a.
8. 左髂总静脉 left common iliac v.
9. 下腔静脉 inferior vena cava
10. 横结肠 transverse colon
11. 降结肠 descending colon

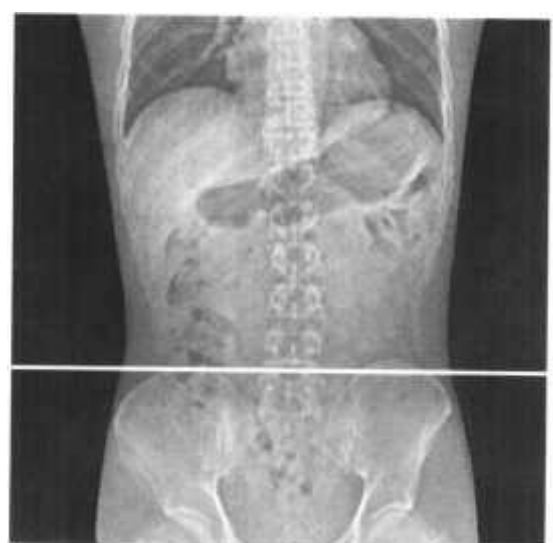
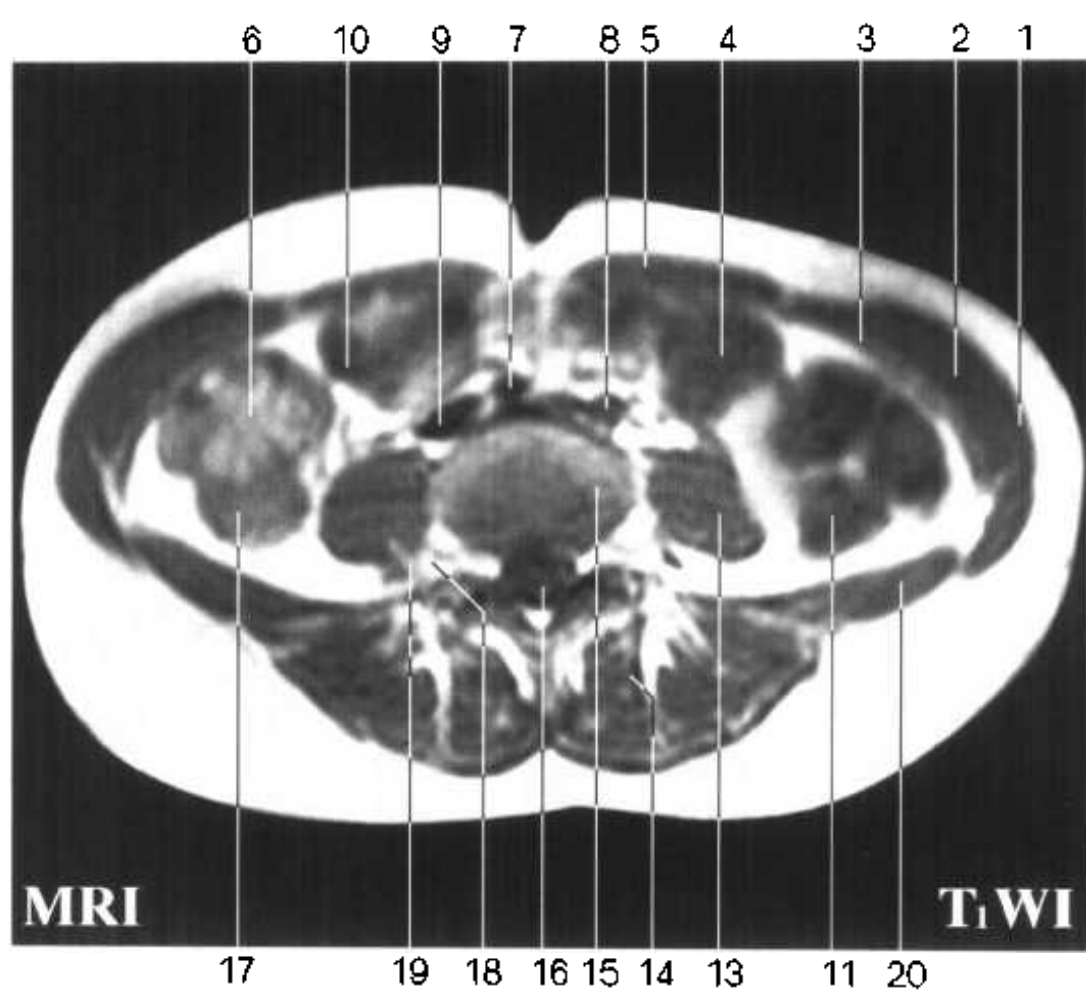
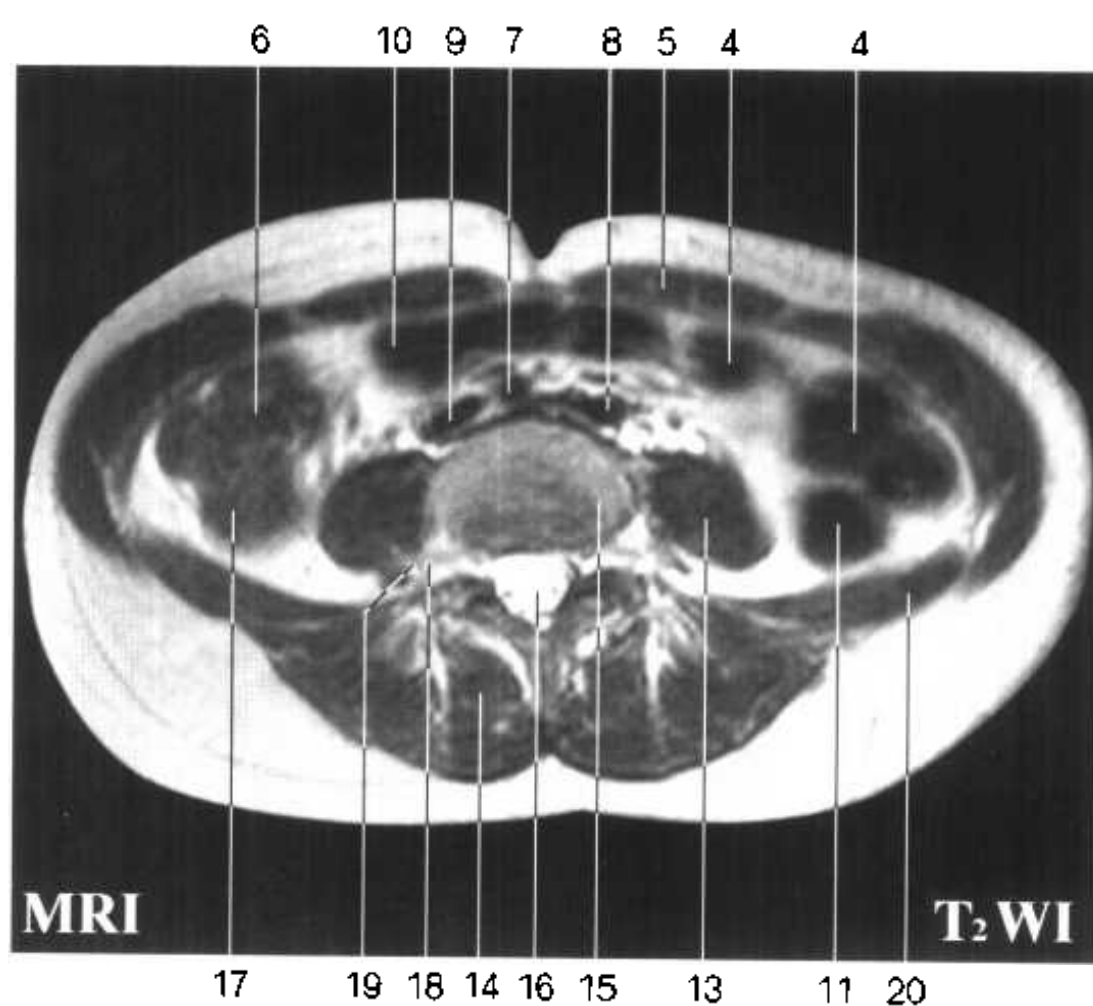


Fig. HA 12



- 12. 腹主动脉 abdominal aorta
- 13. 腰大肌 psoas major
- 14. 竖脊肌 erector spinae
- 15. 4、5 腰椎间盘
intervertebral disc(L₄ ~ L₅)
- 16. 马尾 cauda equina
- 17. 升结肠 ascending colon
- 18. 第4腰神经 4th lumbar n.
- 19. 第3腰神经 3rd lumbar n.
- 20. 腰方肌 quadratus lumborum



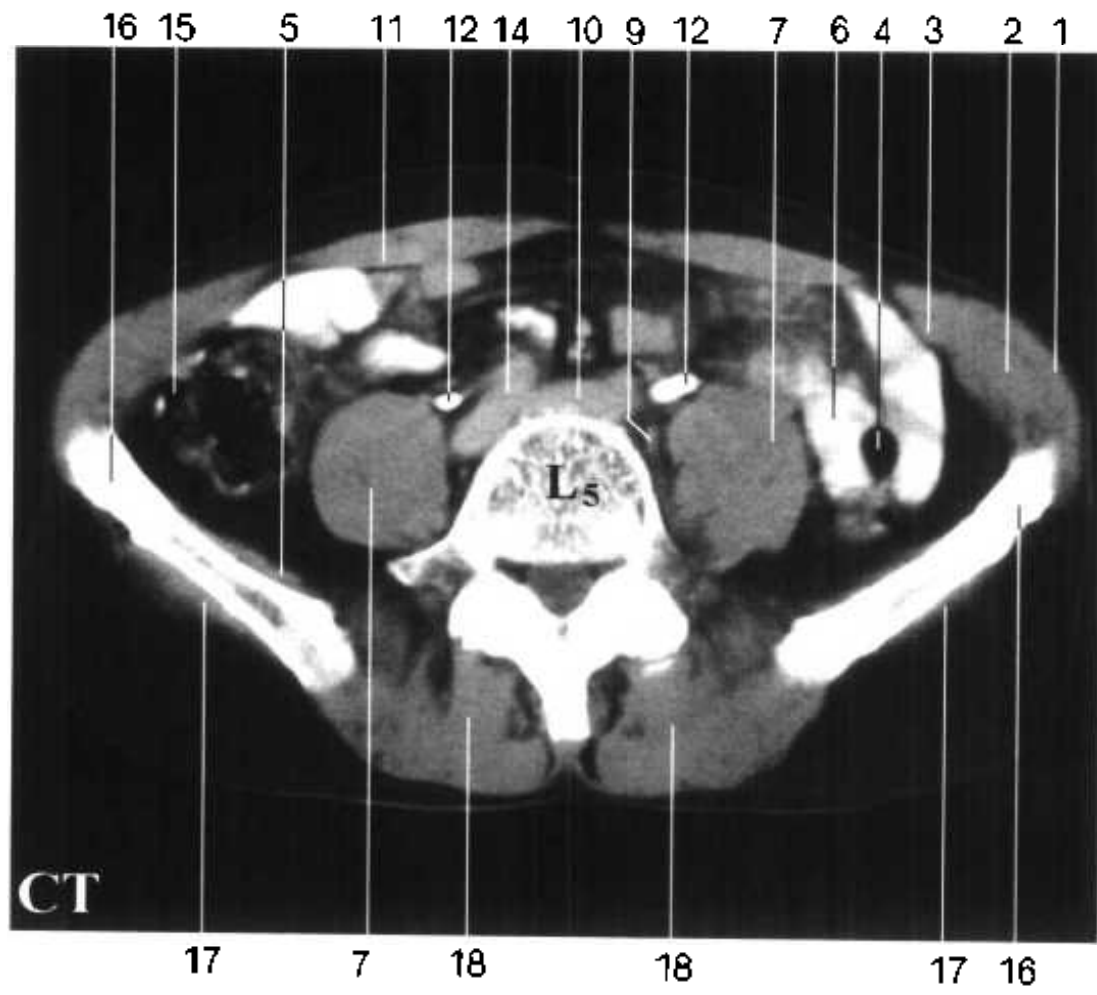
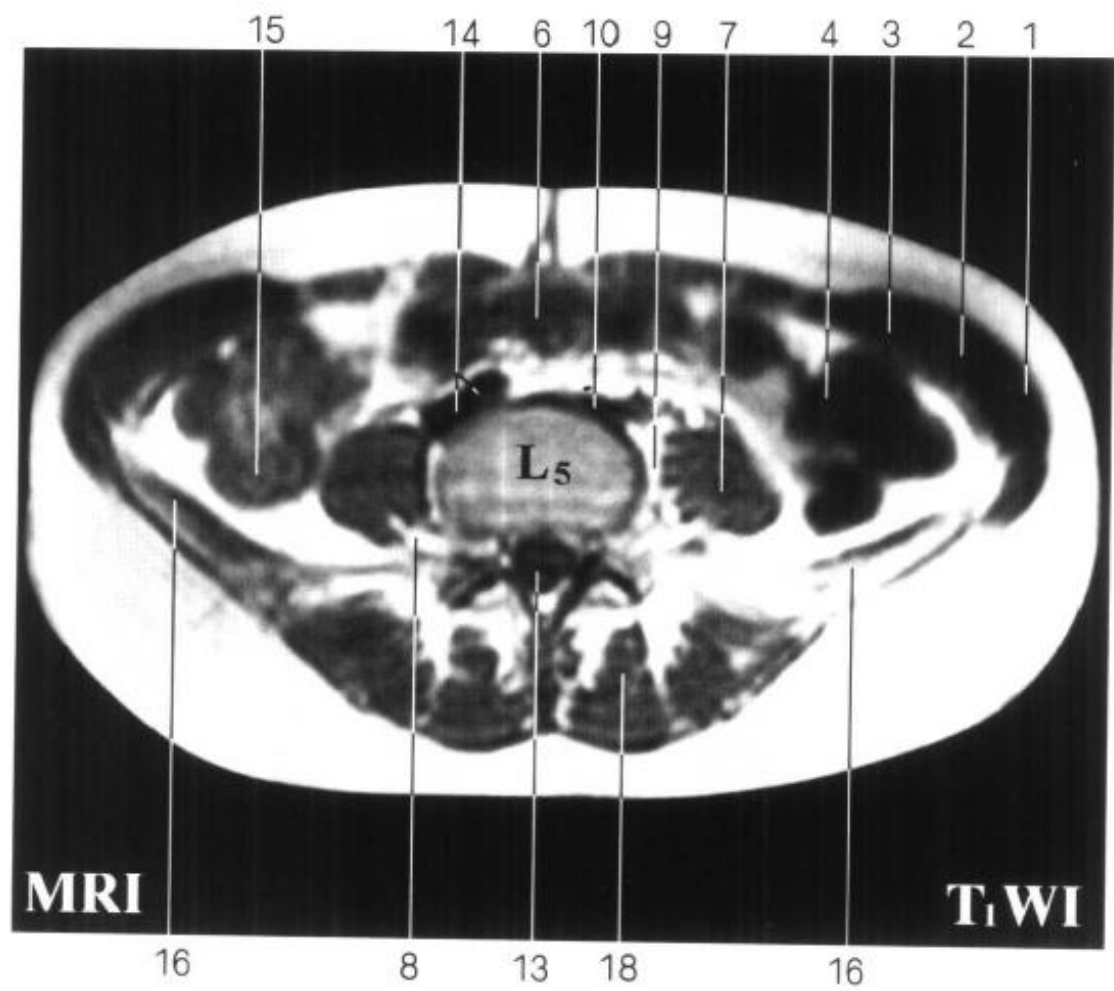


Fig HA 13

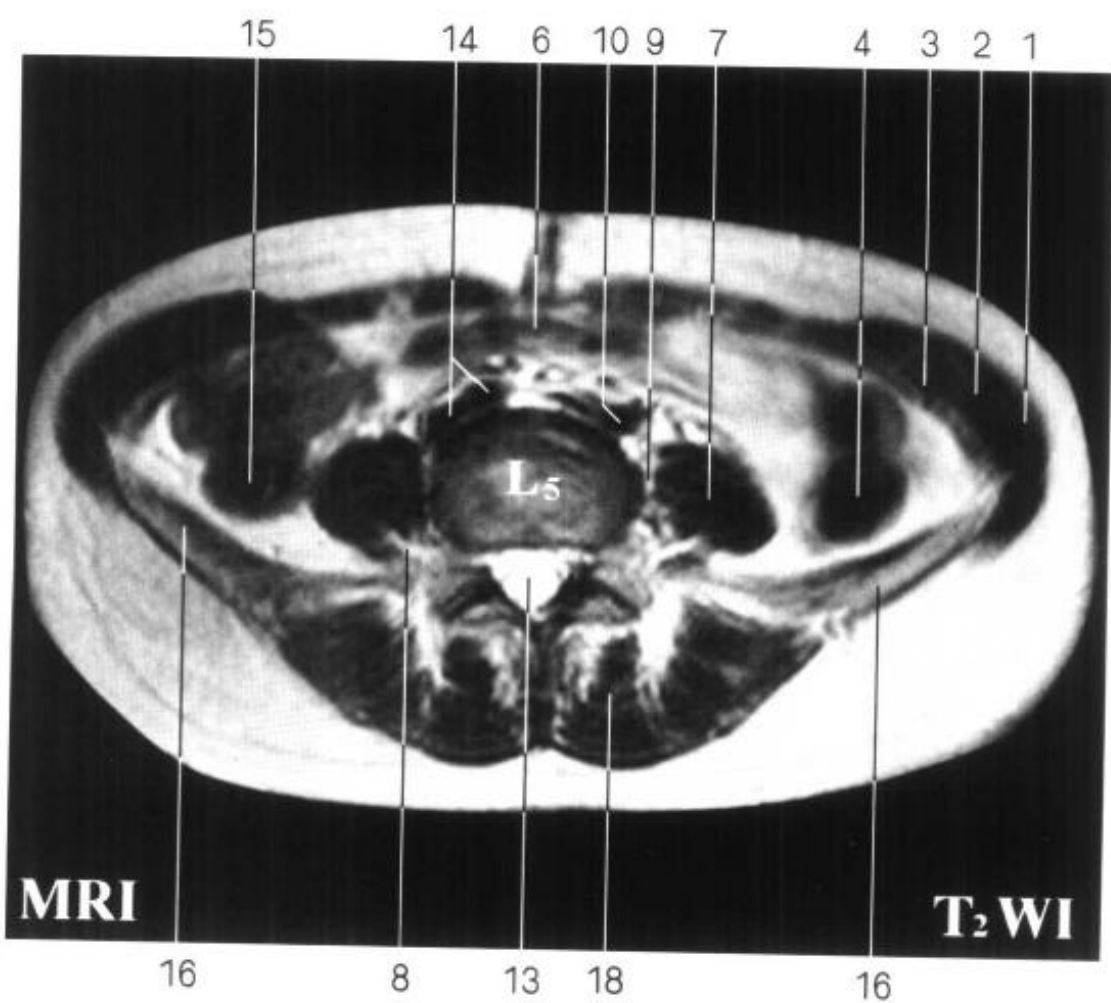
1. 腹外斜肌 obliquus externus abdominis
2. 腹内斜肌 obliquus internus abdominis
3. 腹横肌 transversus abdominis
4. 乙状结肠 sigmoid colon
5. 髂肌 iliacus
6. 回肠 ileum
7. 腰大肌 psoas major
8. 股神经 femoral n.
9. 闭孔神经 obturator n.
10. 左髂总动、静脉 left common iliac a.and v.

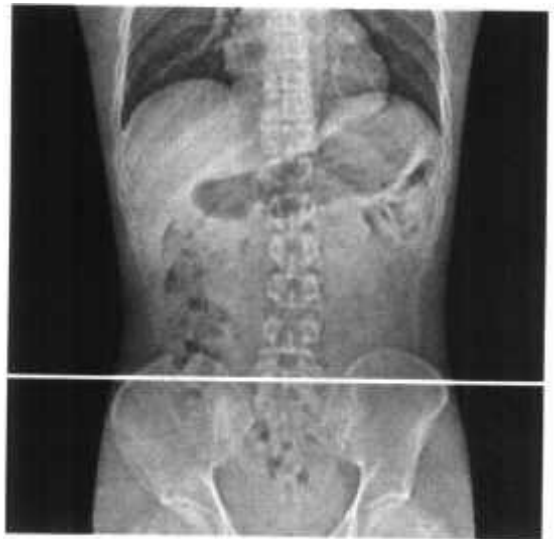

Fig. HA 13



- 11. 腹直肌 rectus abdominis
- 12. 输尿管 ureter
- 13. 马尾 cauda equina
- 14. 右髂总动、静脉 right common iliac a.and v.
- 15. 升结肠 ascending colon
- 16. 髂骨翼 ala of ilium
- 17. 臀中肌 gluteus medius
- 18. 竖脊肌 erector spinae



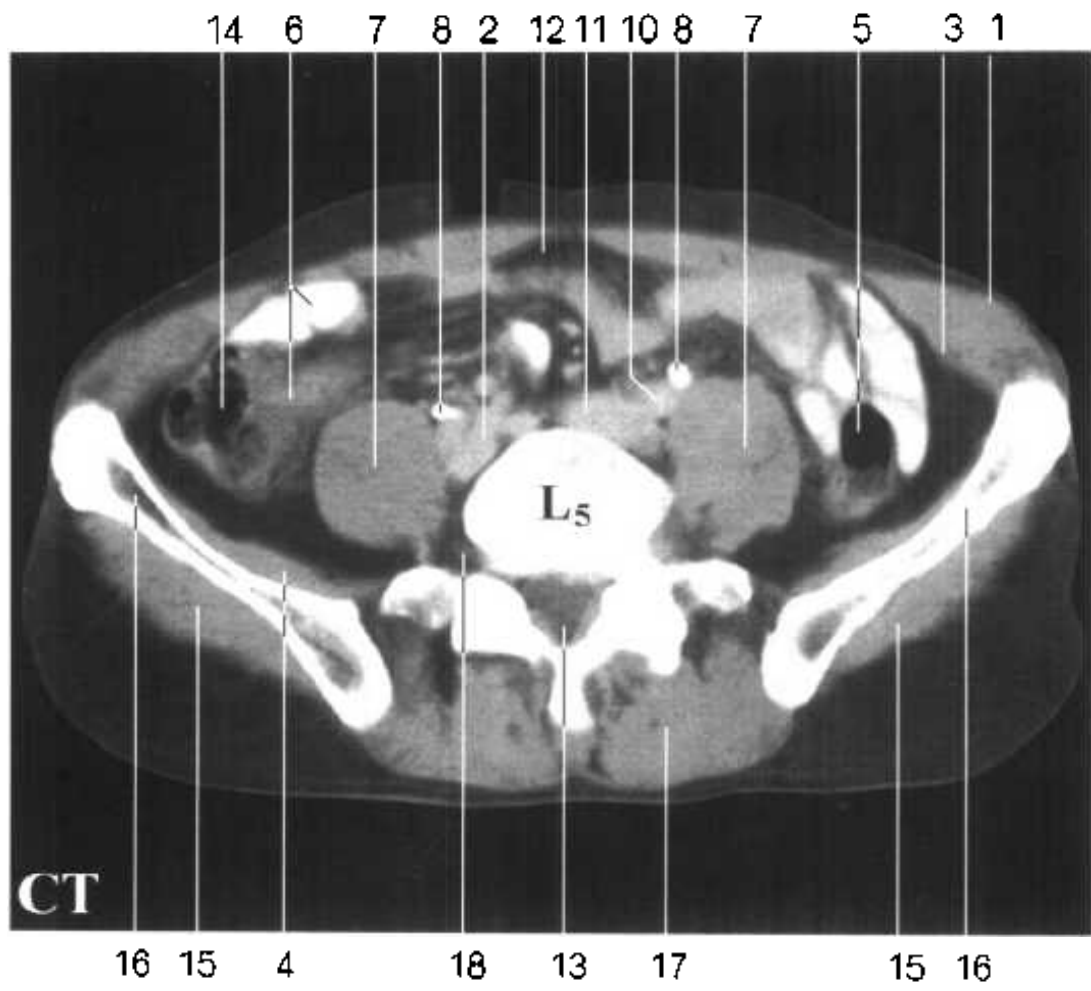
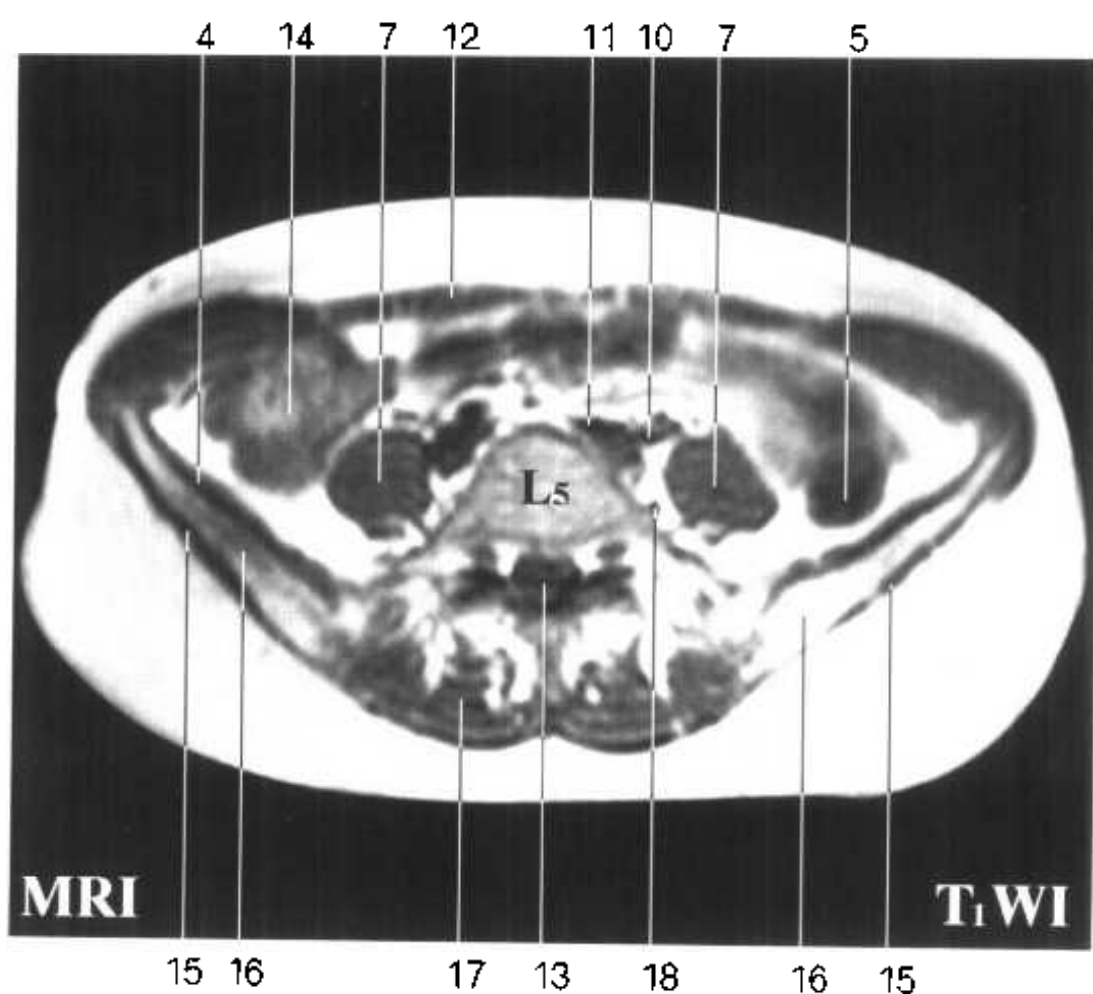


Fig HA 14

1. 腹外斜肌 obliquus externus abdominis
2. 右髂总静脉 right common ilial v.
3. 腹横肌 transversus abdominis
4. 髂肌 iliacus
5. 乙状结肠 sigmoid colon
6. 回肠 ileum
7. 腰大肌 psoas major
8. 输尿管 ureter
9. 左髂外动脉 left external iliac a.
10. 左髂内动脉 left internal iliac a.

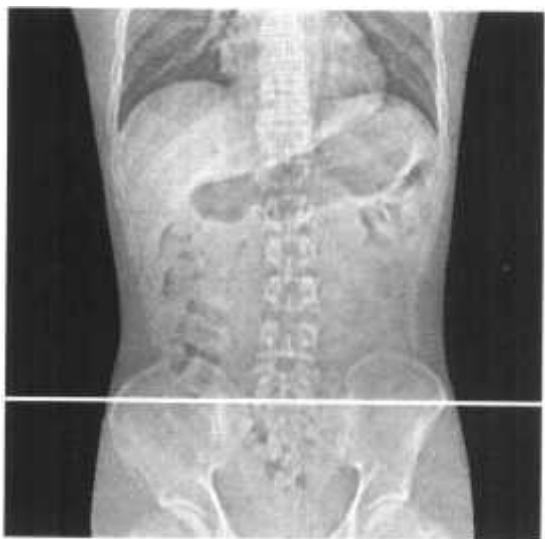

Fig. HA 14



11. 左髂总静脉 left common

iliac v.

12. 腹直肌 rectus abdominis

13. 马尾 cauda equina

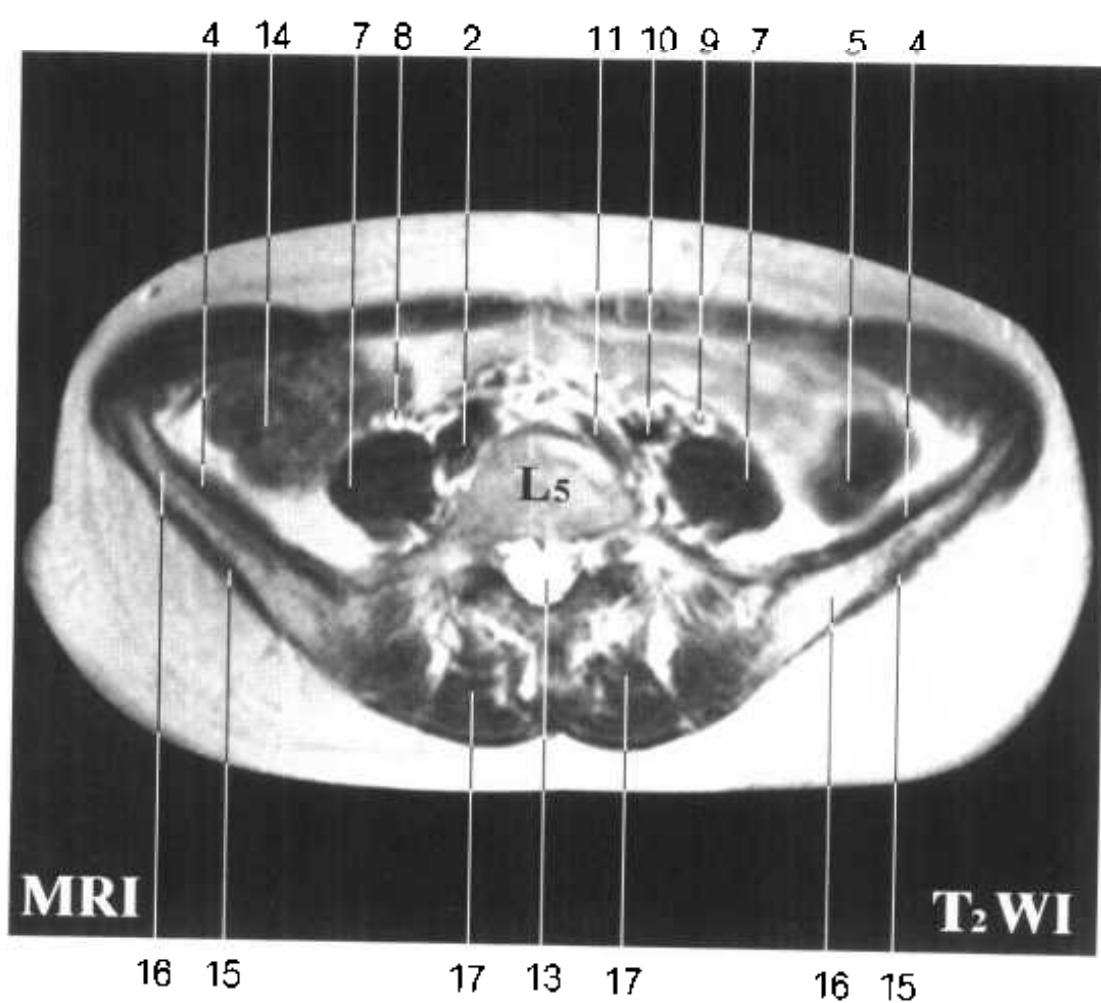
14. 升结肠 ascending colon

15. 臀中肌 gluteus medius

16. 髂骨翼 ala of ilium

17. 竖脊肌 erector spinae

18. 第5腰神经 5th lumbar n.



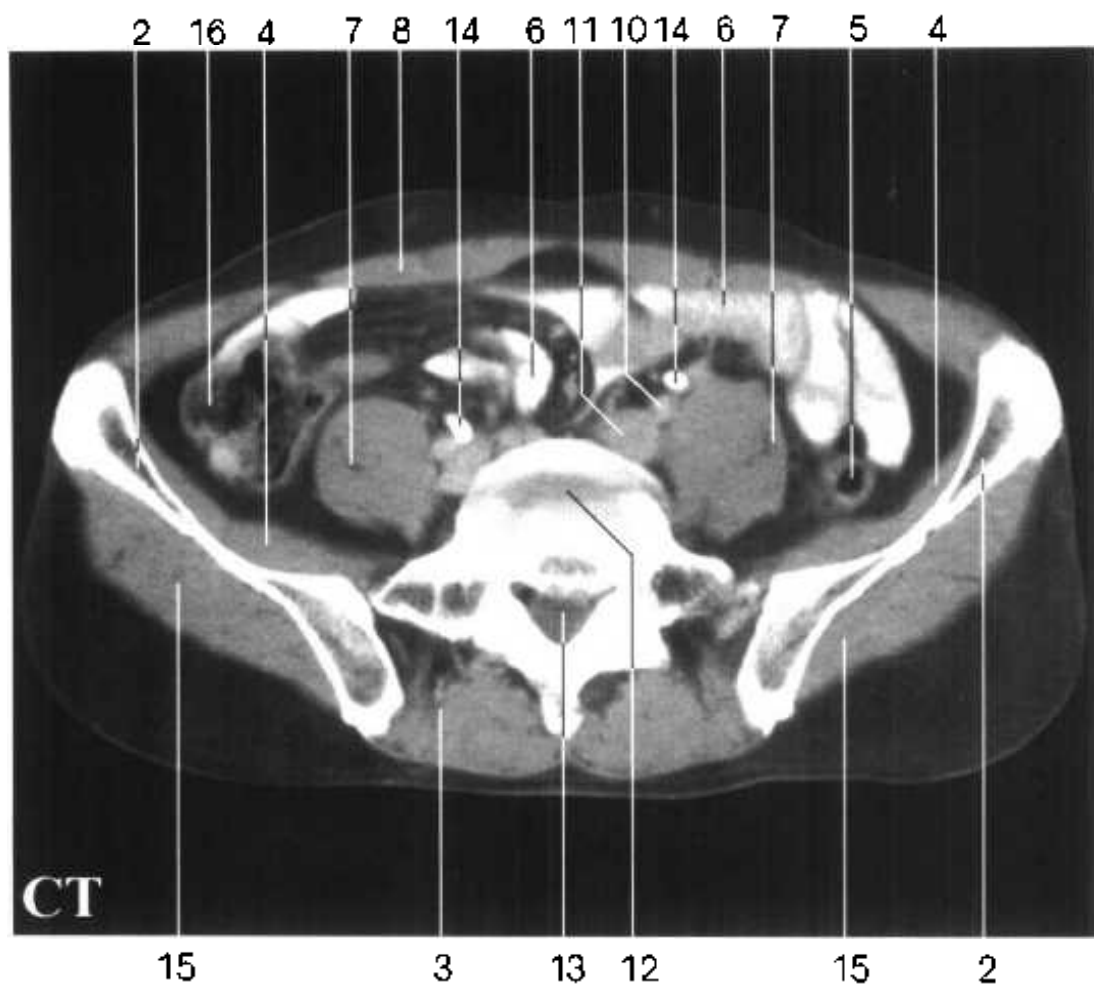
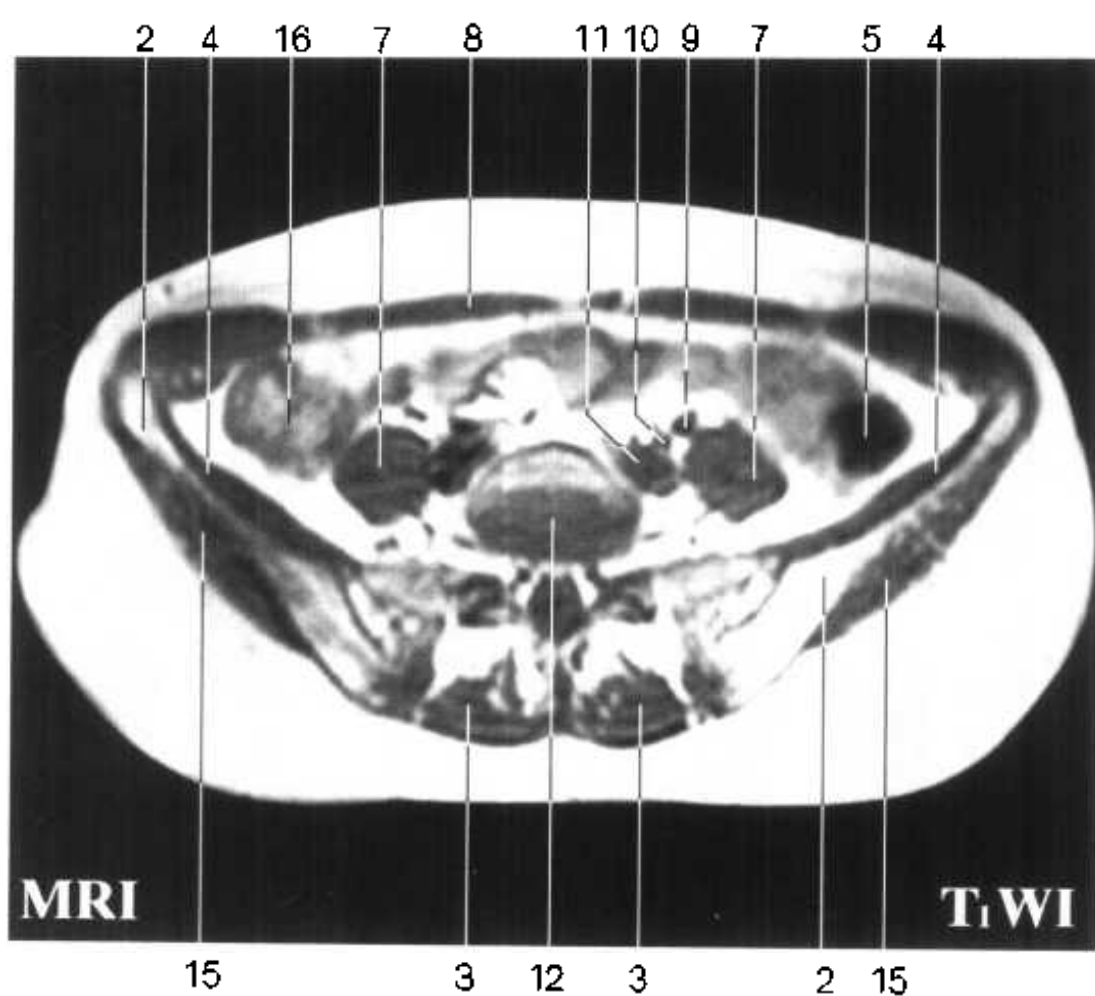


Fig HA 15

1. 右髂总静脉 right common iliac v.
2. 髂骨翼 ala of ilium
3. 竖脊肌 erector spinae
4. 髂肌 iliacus
5. 乙状结肠 sigmoid colon
6. 回肠 ileum
7. 腰大肌 psoas major
8. 腹直肌 rectus abdominis
9. 左髂外动脉 left external iliac a.
10. 左髂内动脉 left internal iliac a.

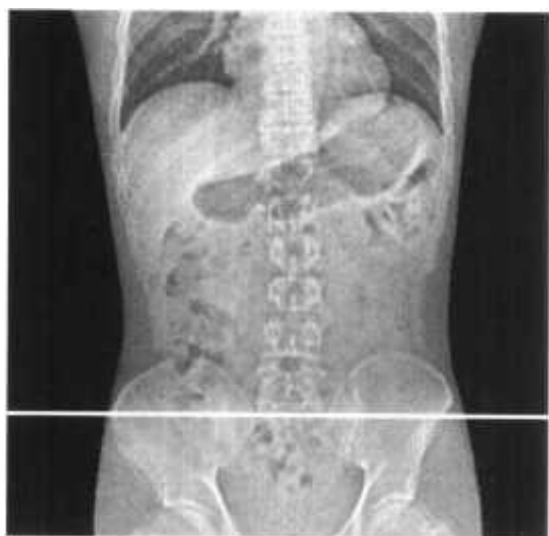

Fig. HA 15



11. 左髂总静脉 left common iliac v.

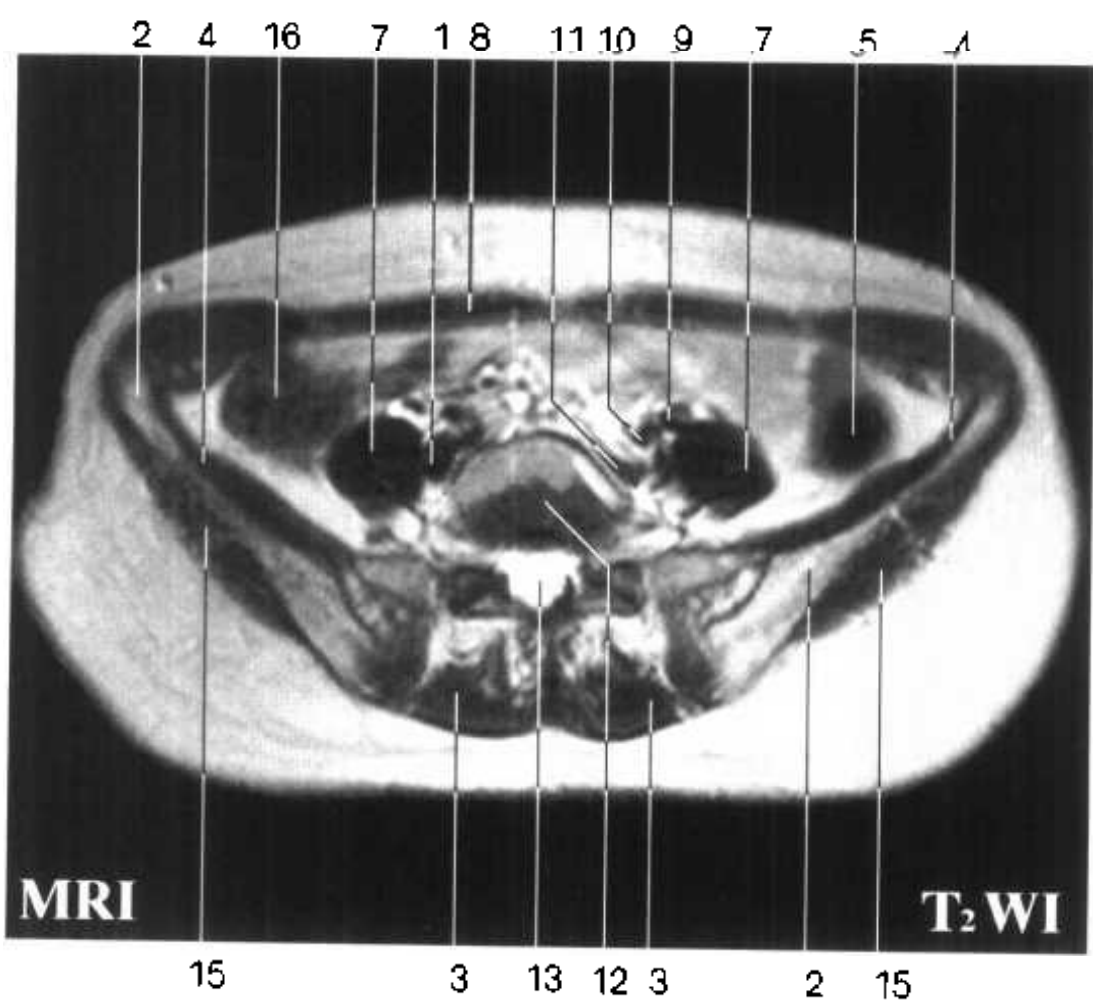
12. 第5腰椎与第1骶椎间盘 intervertebral disc(L₅-S₁)

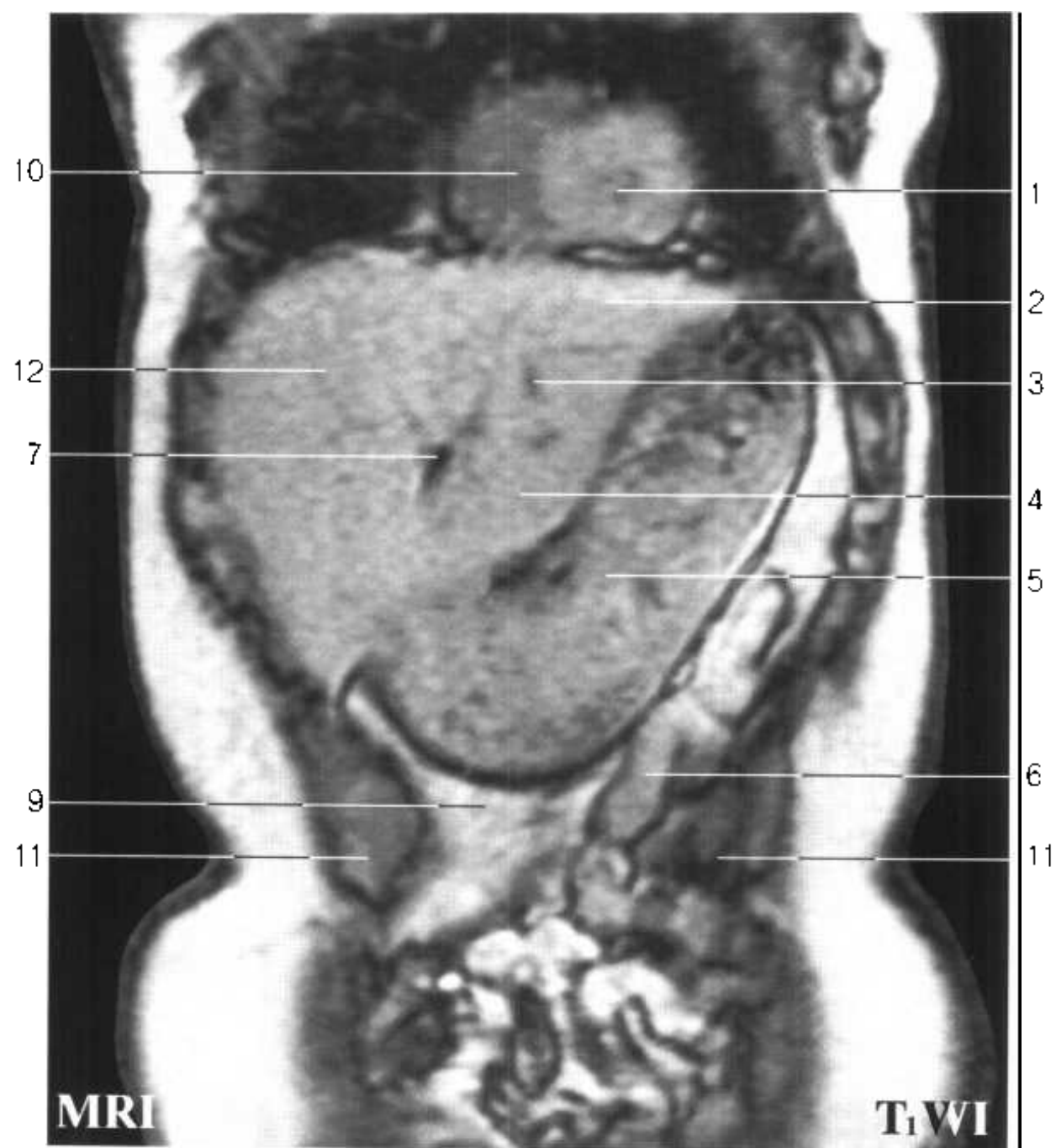13. 马尾 cauda equina

14. 输尿管 ureter

15. 臀中肌 gluteus medius

16. 升结肠 ascending colon





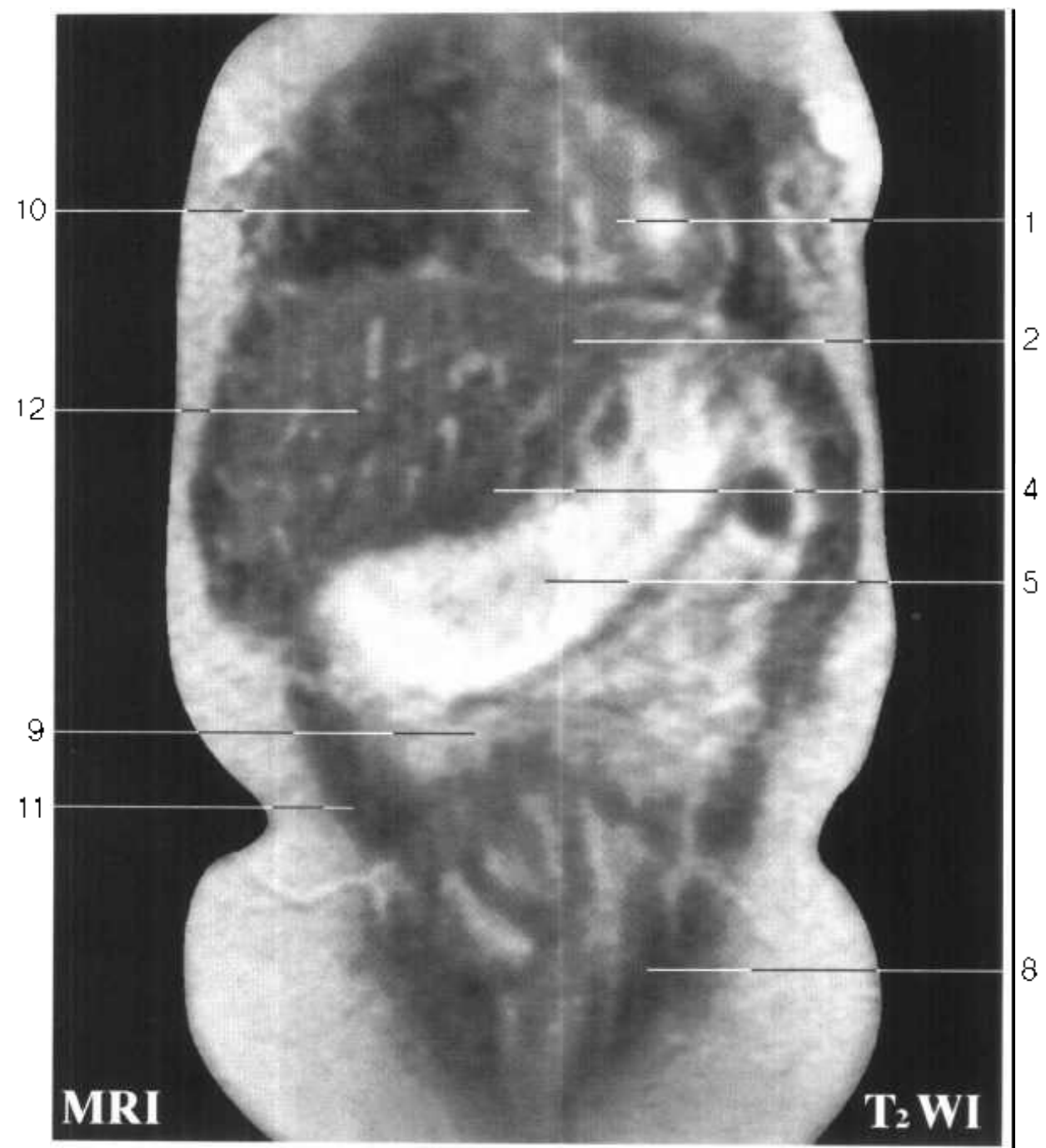
额状断面图 FA

Fig. FA 1

- 1. 左心室 left ventricle
- 2. 左外叶上段 superior segment of left lateral lobe
- 3. 肝左静脉 left hepatic v.
- 4. 左外叶下段 inferior segment of left lateral lobe
- 5. 胃 stomach

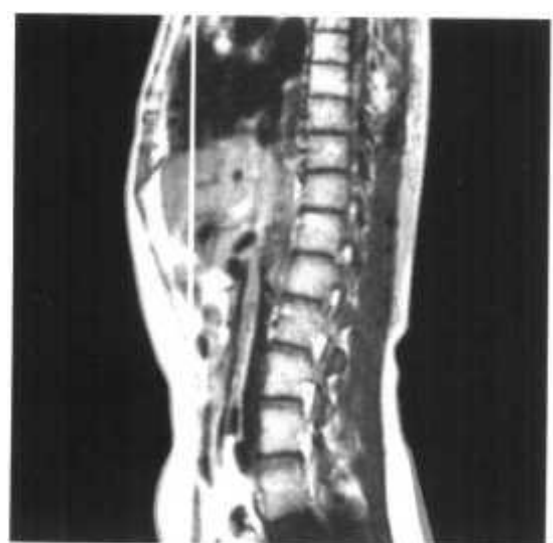

Fig. FA 1



- 6. 横结肠 transverse colon
- 7. 肝门静脉左支 left branch of hepatic portal v.
- 8. 腹直肌 rectus abdominis
- 9. 大网膜 greater omentum
- 10. 右心室 right ventricle
- 11. 腹横肌 transversus abdominis
- 12. 左内叶 left medial lobe

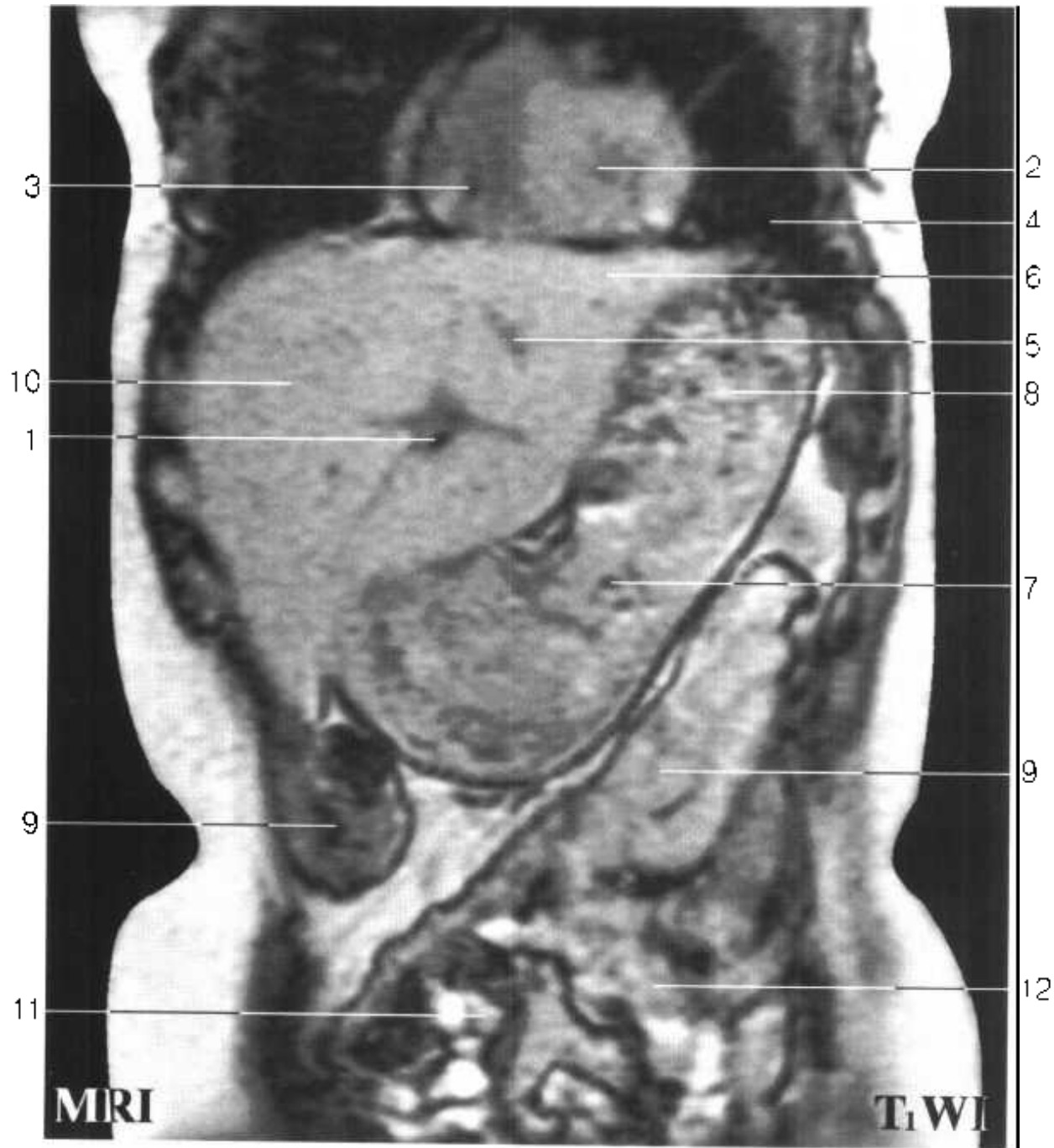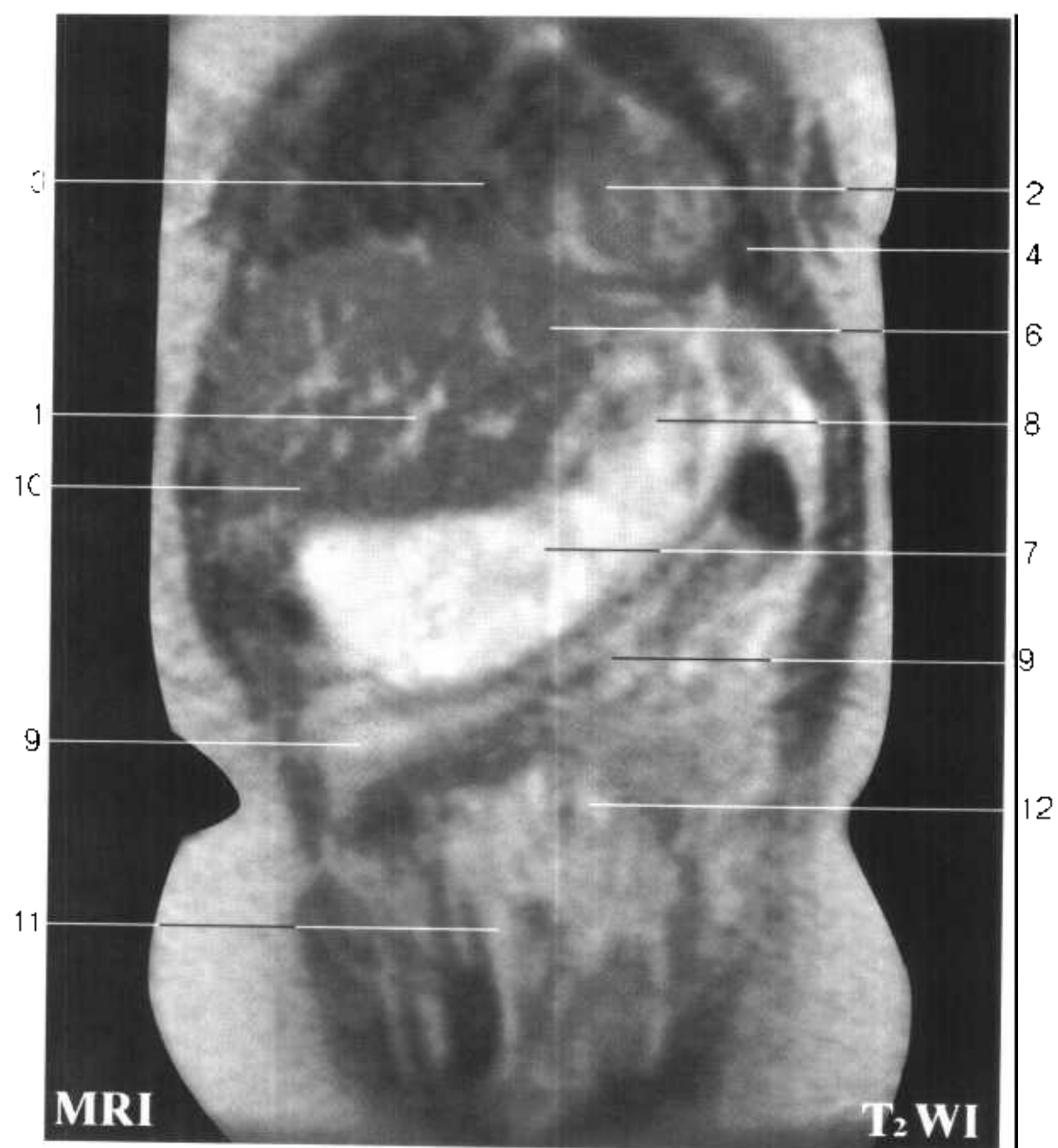


Fig. FA 2

- 1. 肝门静脉左支 left branch of hepatic portal v.
- 2. 左心室 left ventricle
- 3. 右心室 right ventricle
- 4. 左肺下叶 inferior lobe of left lung
- 5. 肝左静脉 left hepatic v.
- 6. 左外叶 left lateral lobe

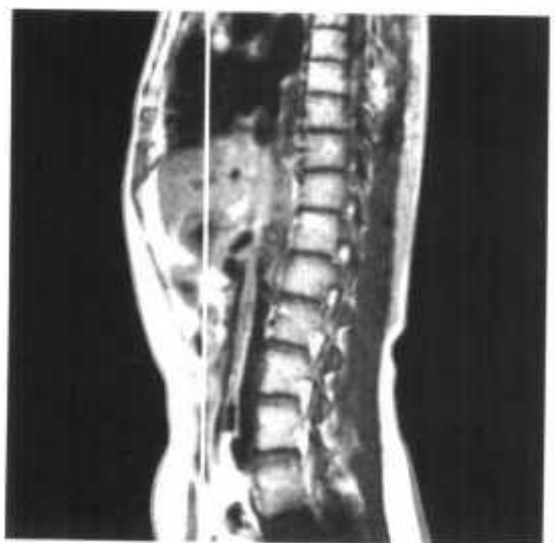

Fig. FA 2



- 7. 胃体 body of stomach
- 8. 胃底 fundus of stomach
- 9. 横结肠 transverse colon
- 10. 左内叶 left medial lobe
- 11. 空肠 jejunum
- 12. 空肠 jejunum

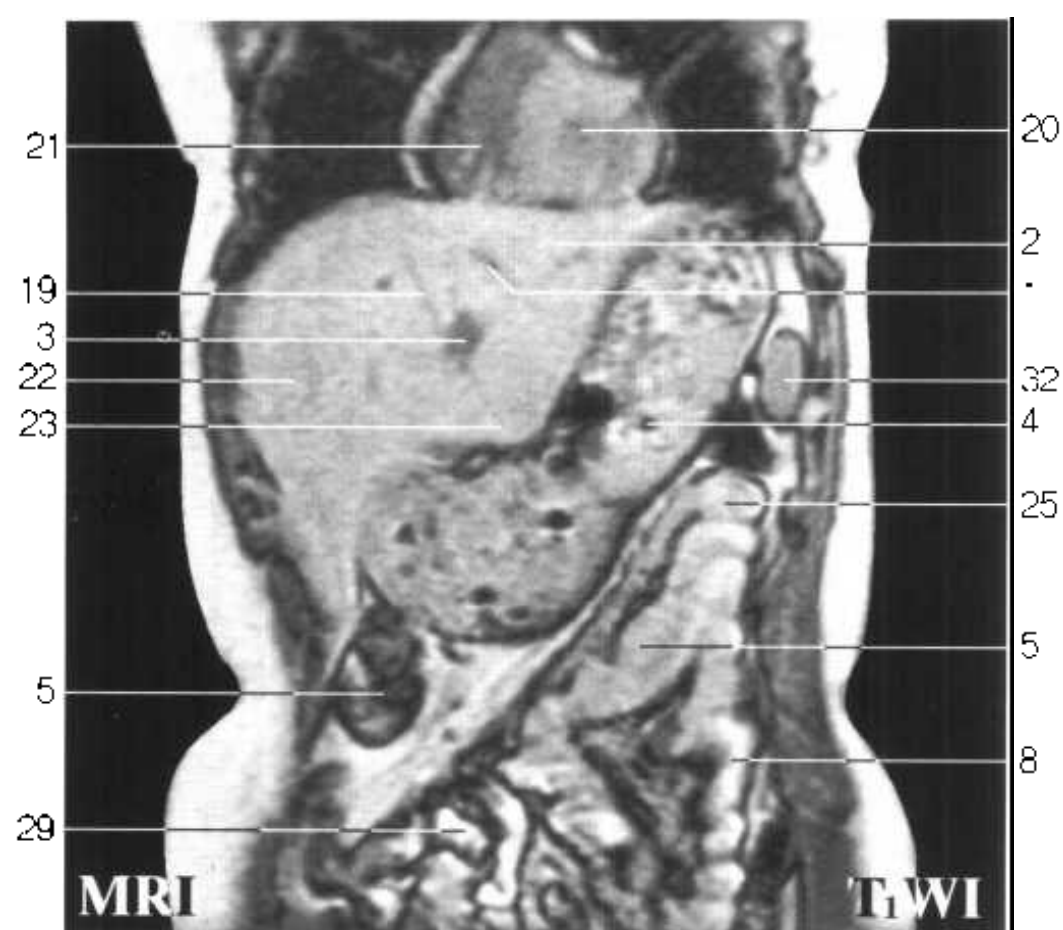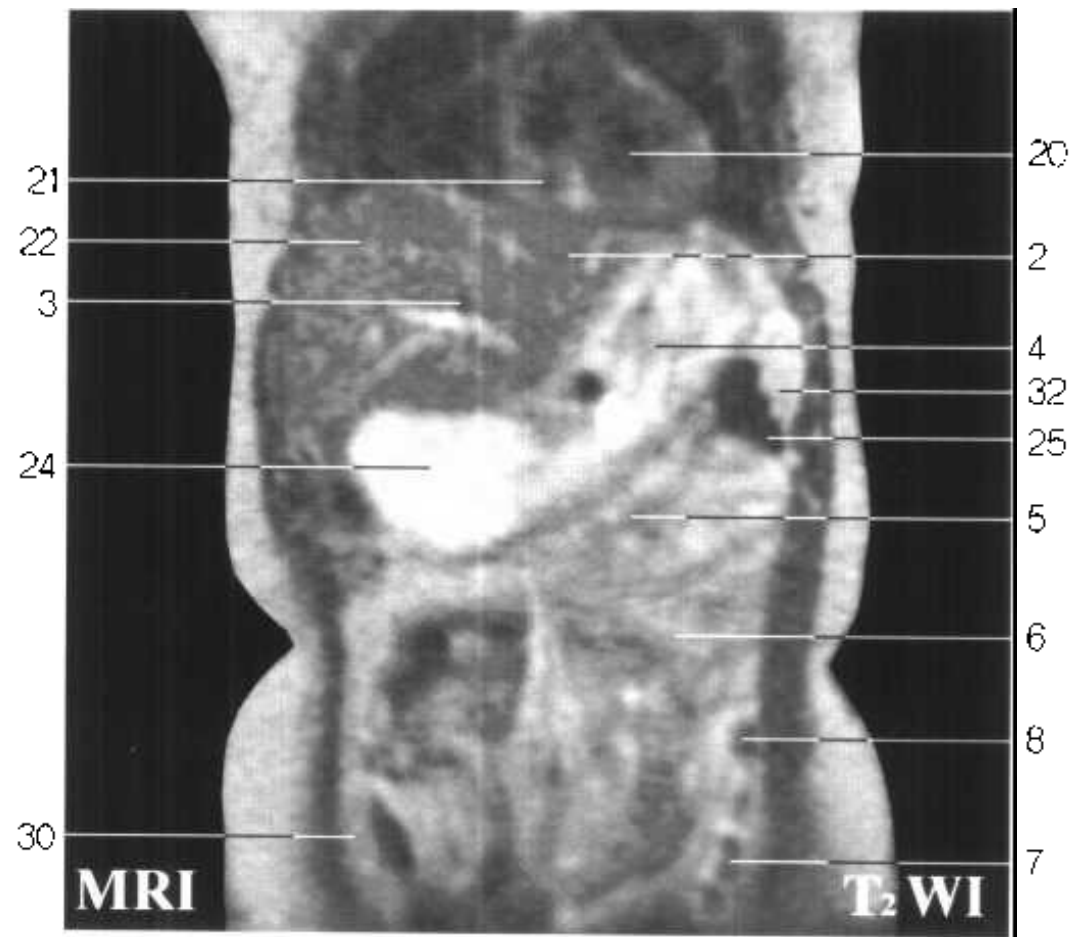


Fig. FA 3

1. 肝左静脉 left hepatic v.
2. 左外叶 left lateral lobe
3. 肝门静脉左支脐部 umbilical part of left branch of hepatic portal v.
4. 胃 stomach
5. 横结肠 transverse colon
6. 空肠 jejunum
7. 乙状结肠 sigmoid colon
8. 降结肠 descending colon
9. 阔筋膜张肌 tensor fasciae latae
10. 腰大肌 psoas major
11. 膀胱 urinary bladder
12. 耻骨 pubis
13. 耻骨肌 pectineus
14. 股直肌 rectus femoris
15. 阴茎脚 crus penis
16. 尿道海绵体 cavernous body of urethra
17. 股外侧肌 vastus lateralis

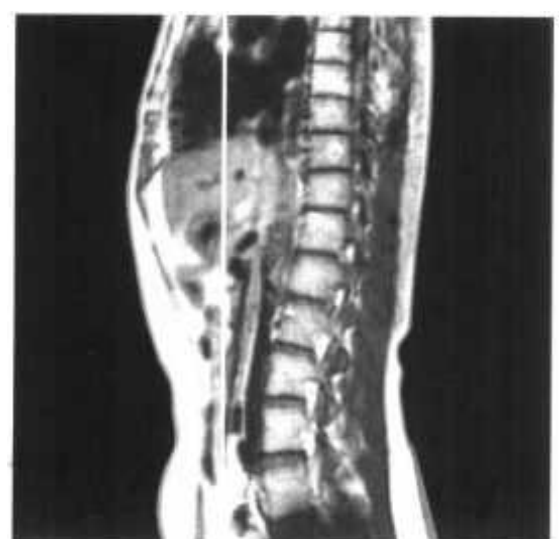

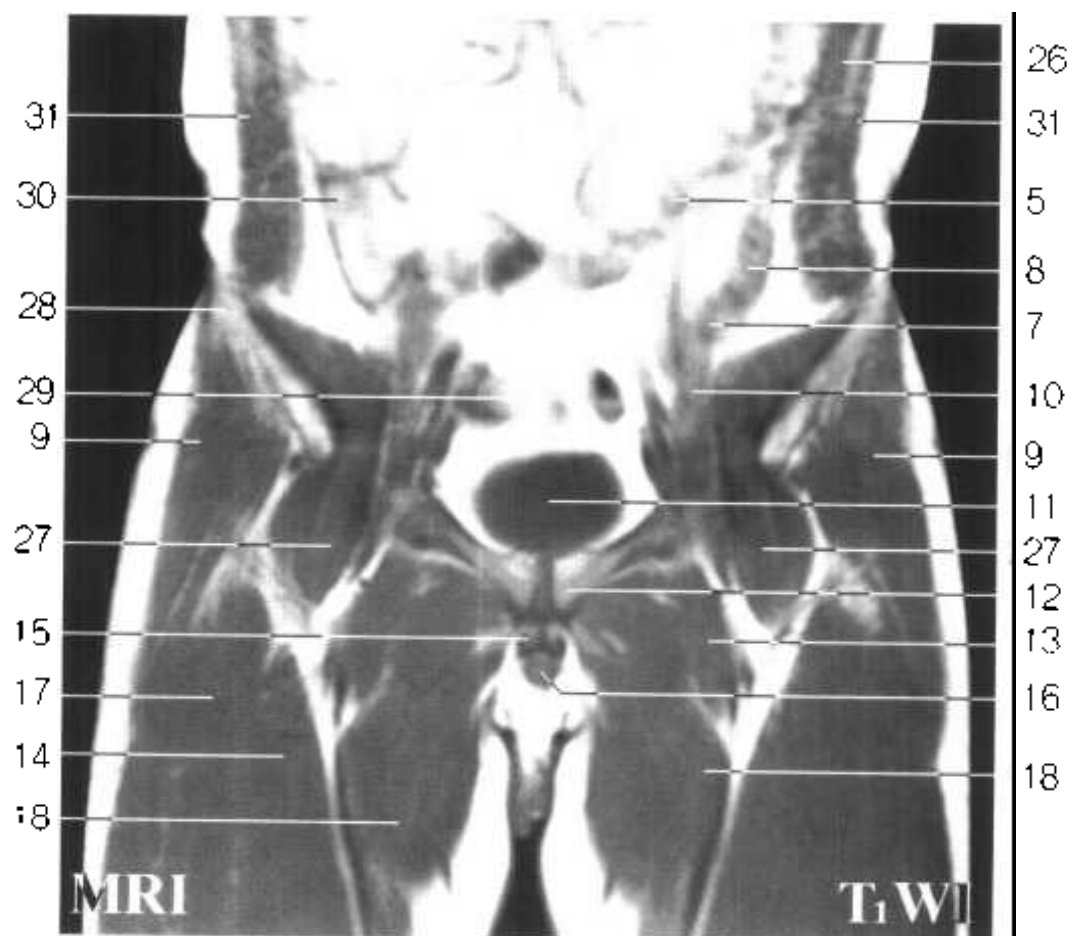Fig. FA 3



- 18. 长收肌 adductor longus
- 19. 左内叶 left medial lobe
- 20. 左心室 left ventricle
- 21. 右心房 right atrium
- 22. 右前叶 right anterior lobe
- 23. 肝圆韧带裂 fissure for ligamentum teres hepatis
- 24. 幽门窦 pyloric antrum
- 25. 结肠左曲 left colic flexure
- 26. 腹内斜肌 obliquus internus abdominis
- 27. 髂腰肌 iliopsoas
- 28. 髂前上棘 anterior superior iliac spine
- 29. 回肠 ileum
- 30. 升结肠 ascending colon
- 31. 腹外斜肌 obliquus externus abdominis
- 32. 脾 spleen



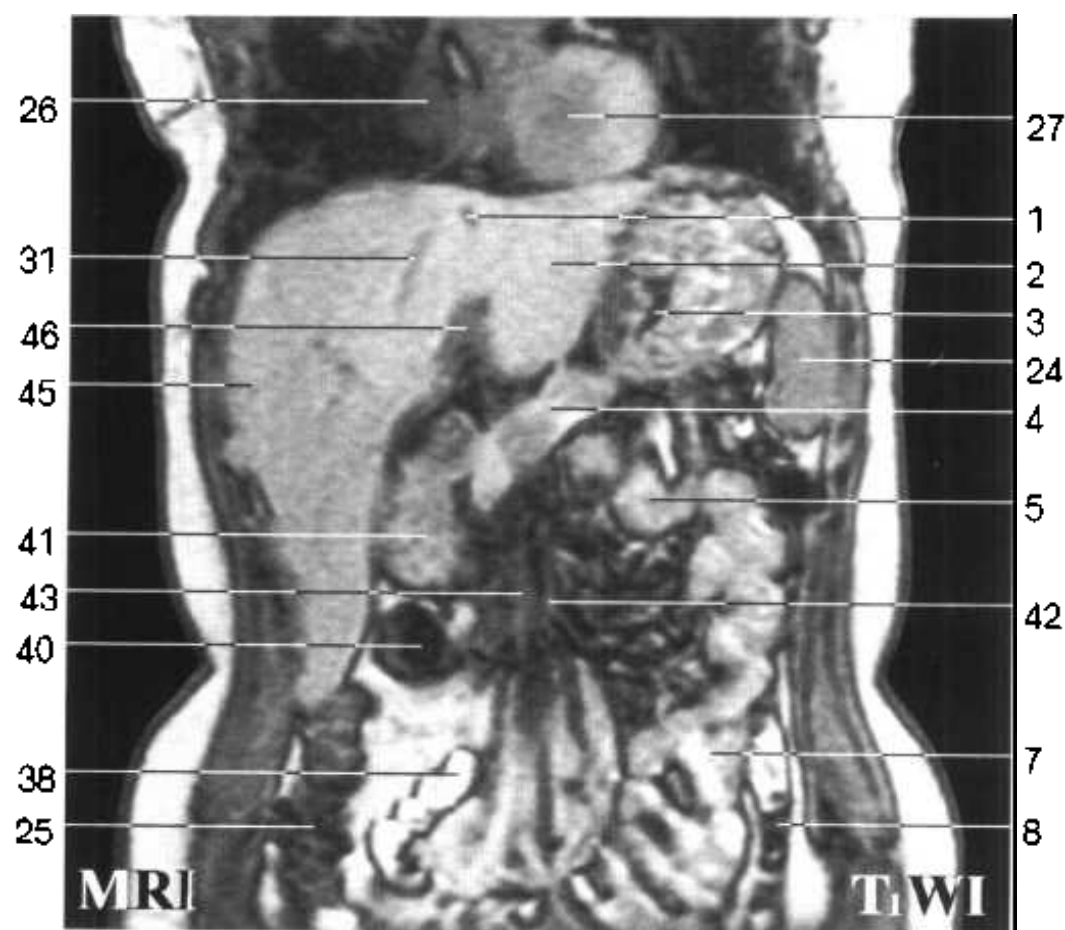
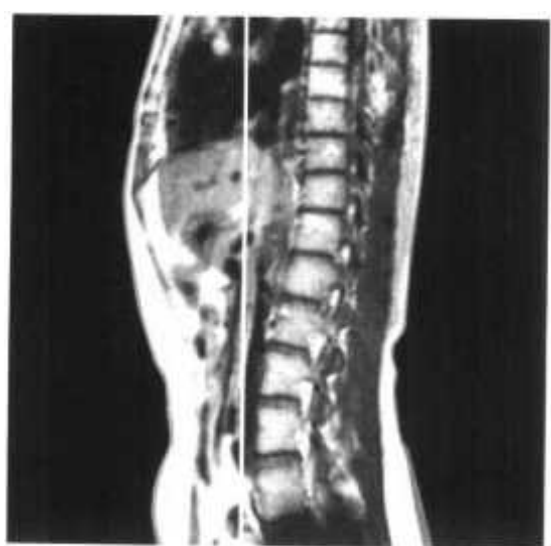

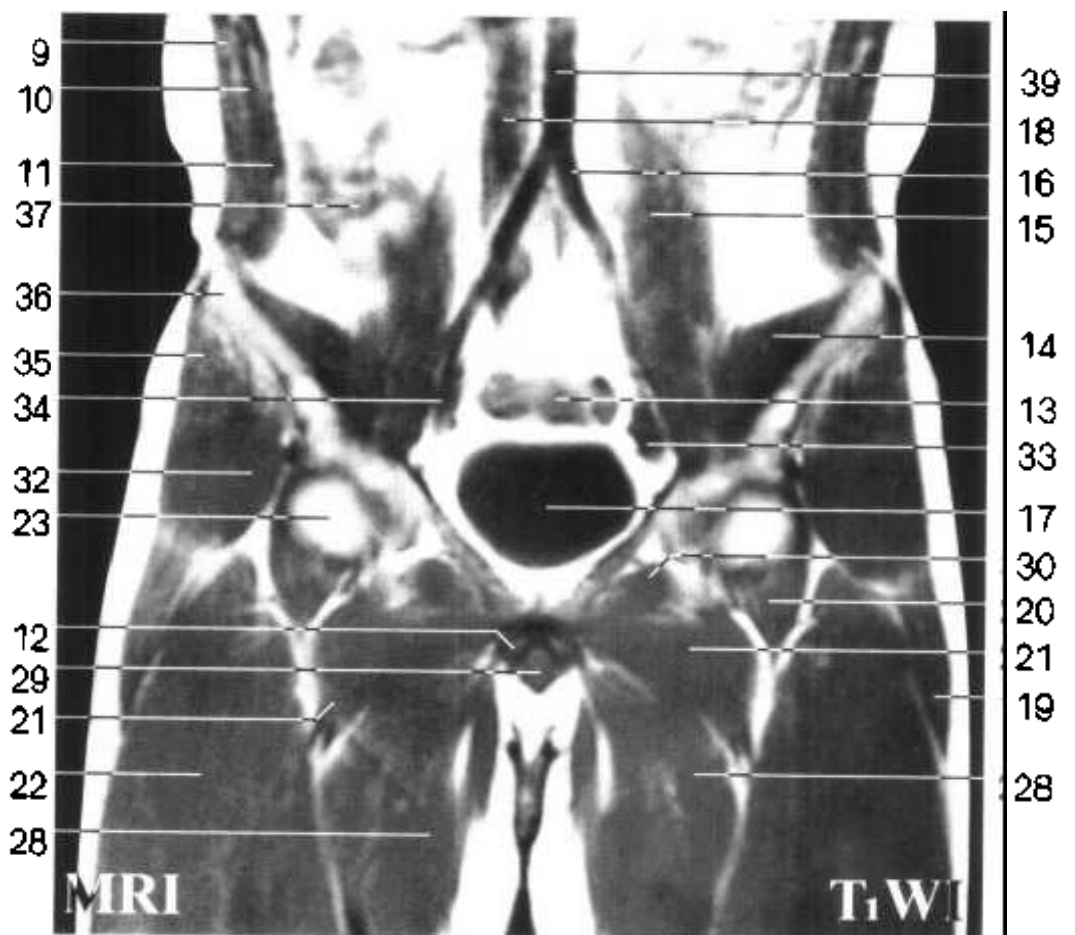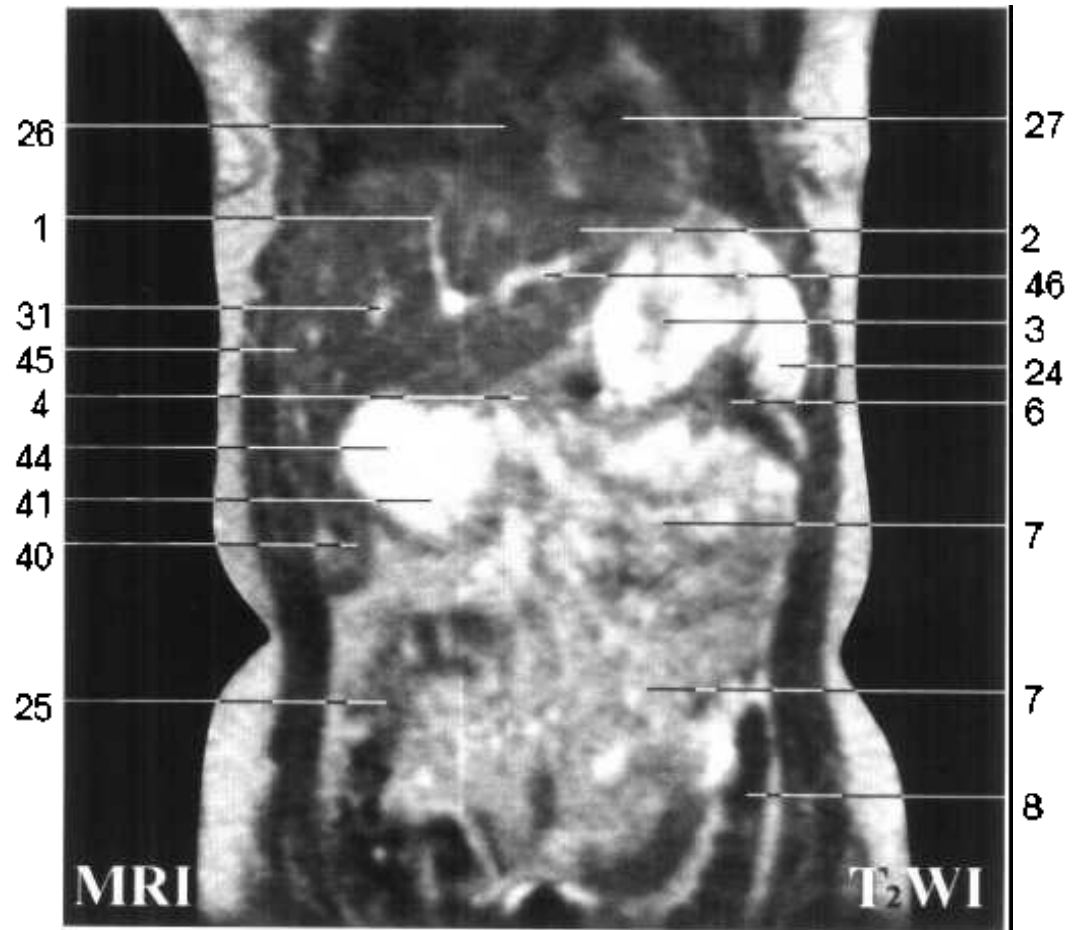
Fig. FA 4



1. 肝左静脉 left hepatic v.
2. 左外叶 left lateral lobe
3. 胃底 fundus of stomach
4. 胰 pancreas
5. 空肠 jejunum
6. 横结肠 transverse colon
7. 空肠 jejunum
8. 降结肠 descending colon
9. 腹外斜肌 obliquus externus abdominis
10. 腹内斜肌 obliquus internus abdominis
11. 腹横肌 transversus abdominis
12. 阴茎脚 crus penis
13. 乙状结肠 sigmoid colon
14. 髂肌 iliacus
15. 腰大肌 psoas major
16. 髂总动脉 common iliac a.
17. 膀胱 urinary bladder
18. 下腔静脉 inferior vena cava
19. 阔筋膜张肌 tensor fasciae latae
20. 髂腰肌 iliopsoas

Fig. FA 4

- 21. 耻骨肌 pectineus
- 22. 股直肌 rectus femoris
- 23. 股骨头 femoral head
- 24. 脾 spleen
- 25. 升结肠 ascending colon
- 26. 右心房 right atrium
- 27. 左心室 left ventricle
- 28. 长收肌 adductor longus
- 29. 尿道海绵体 cavernous body of urthra
- 30. 闭孔外肌 obturator externus
- 31. 肝中间静脉 intermediate hepatic v.
- 32. 臀小肌 gluteus minimus
- 33. 髂外静脉 external iliac v.
- 34. 髂外动脉 external iliac a.
- 35. 臀中肌 gluteus medius
- 36. 髂嵴 iliac crest
- 37. 盲肠 cecum
- 38. 回肠 ileum
- 39. 腹主动脉 abdominal aorta
- 40. 横结肠 transverse colon
- 41. 幽门窦 pyloric antrum
- 42. 肠系膜上动脉 superior mesenteric a.
- 43. 肠系膜上静脉 superior mesenteric v.
- 44. 胆囊 gallbladder
- 45. 右前叶 right anterior lobe
- 46. 肝门静脉左支脐部 umbilical part of left branch of hepatic portal v.



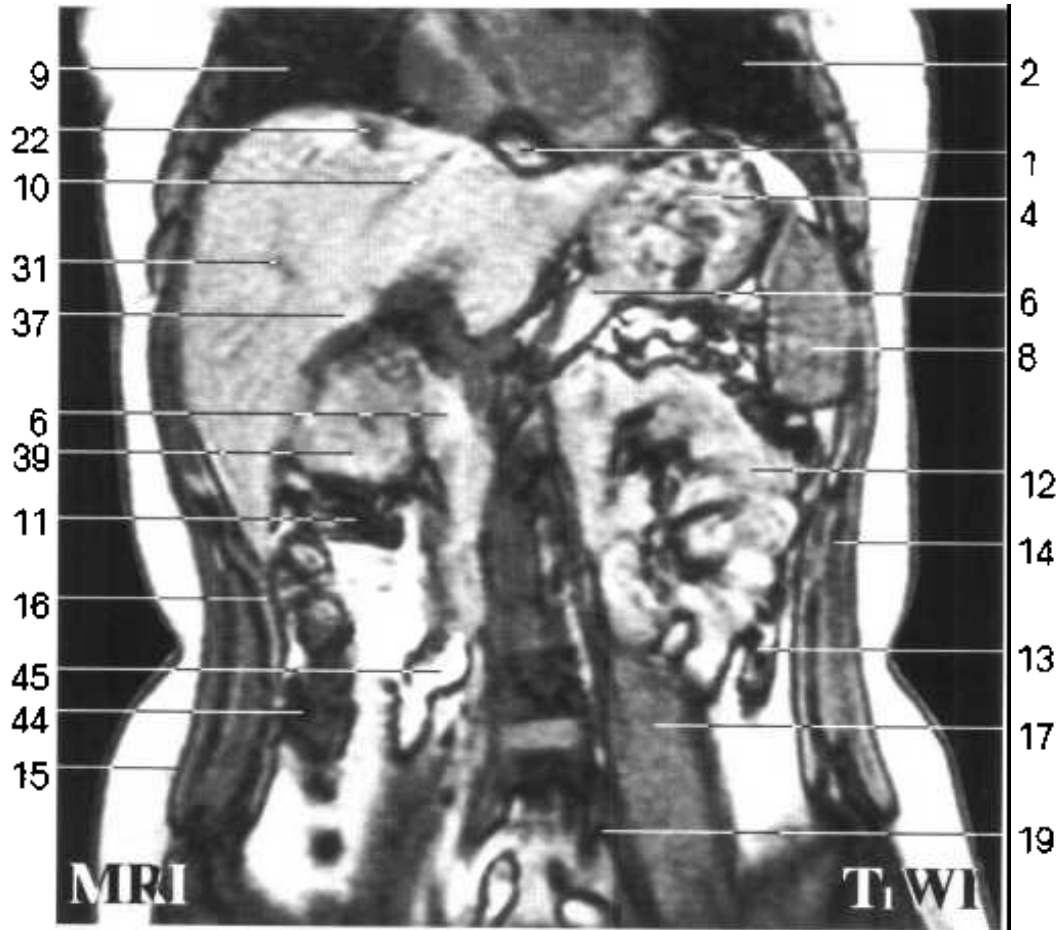
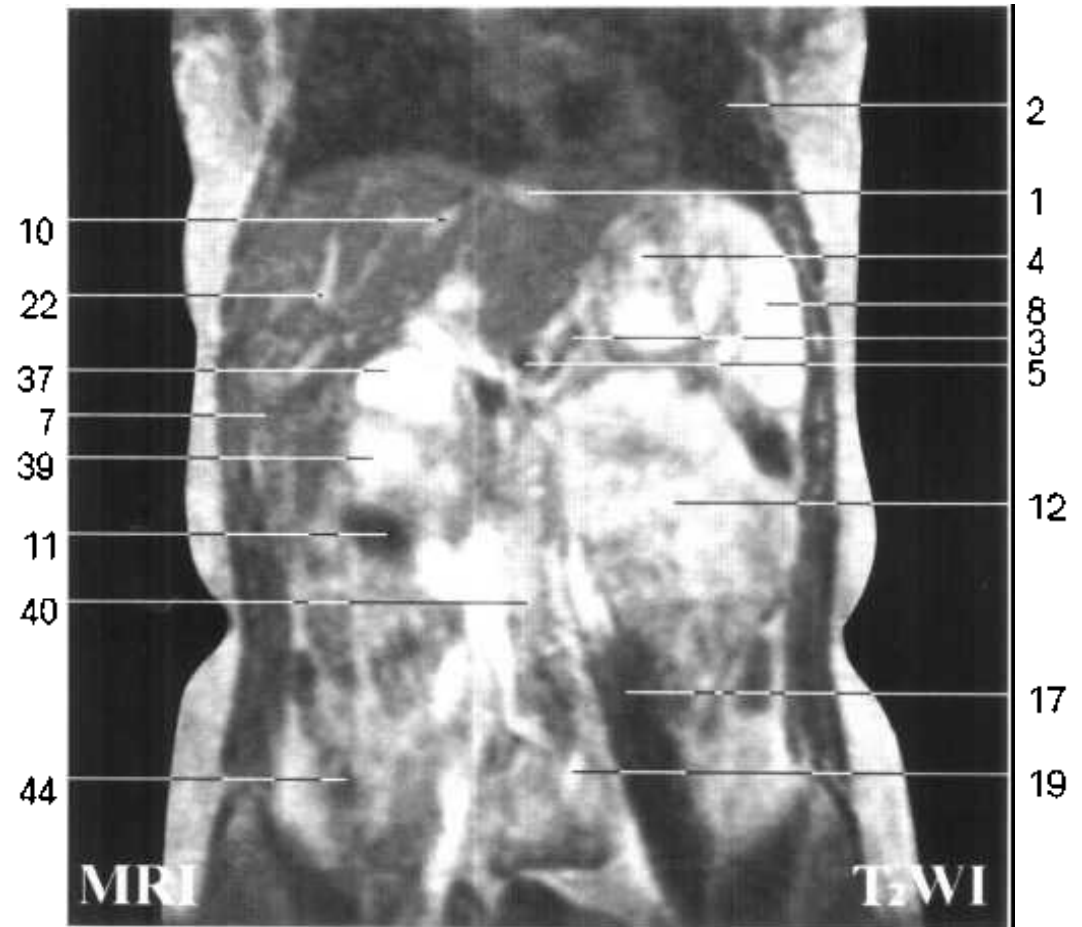


Fig. FA 5

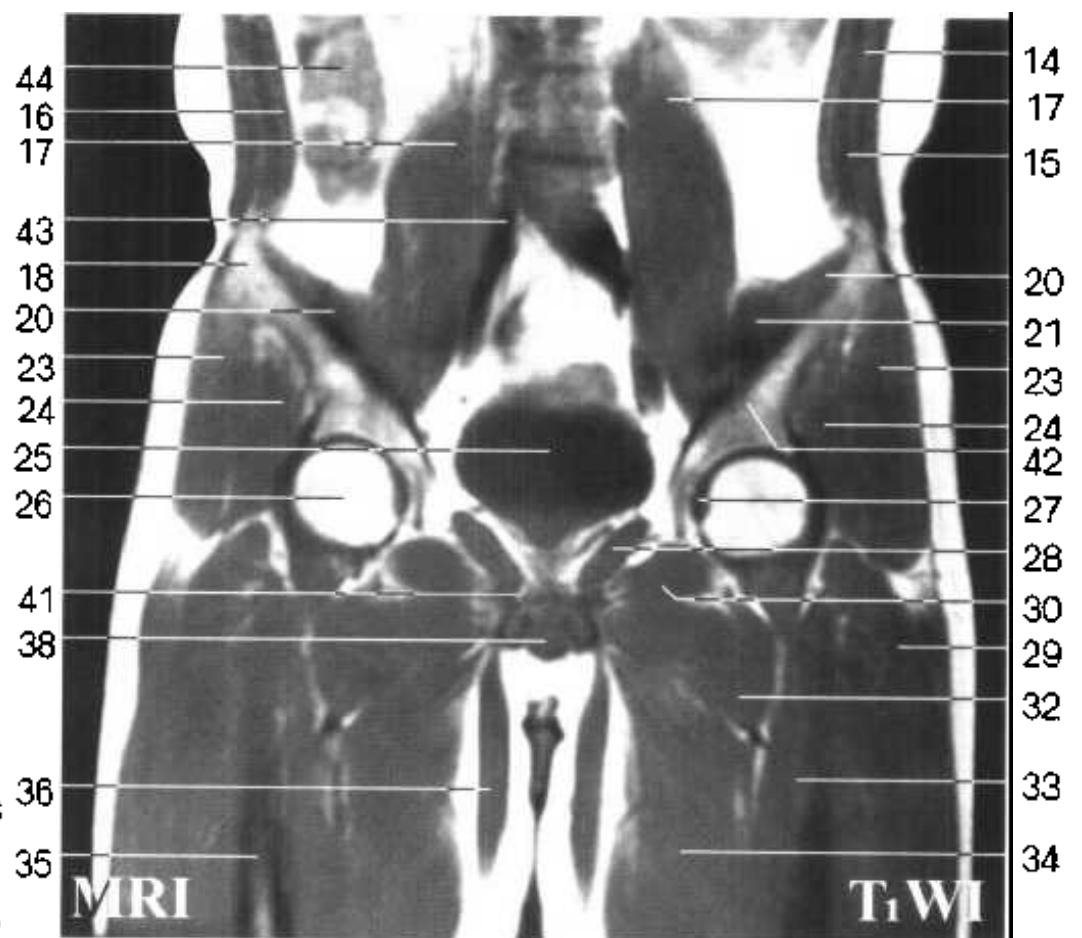
1. 食管 esophagus
2. 左肺下叶 inferior lobe of left lung
3. 腹腔干 celiac trunk
4. 贲门 cardia
5. 肠系膜上动脉 superior mesenteric a.
6. 胰 pancreas
7. 右后叶 right posterior lobe
8. 脾 spleen
9. 右肺下叶 inferior of right lung
10. 肝中间静脉 intermediate hepatic v.
11. 横结肠 transverse colon
12. 空肠 jejunum
13. 降结肠 descending colon
14. 腹外斜肌 obliquus externus abdominis
15. 腹内斜肌 obliquus internus abdominis
16. 腹横肌 transversus abdominis
17. 腰大肌 psoas major
18. 髂嵴 iliac crest
19. 左髂总动脉 left common iliac a.
20. 髂肌 iliacus
21. 乙状结肠 sigmoid colon

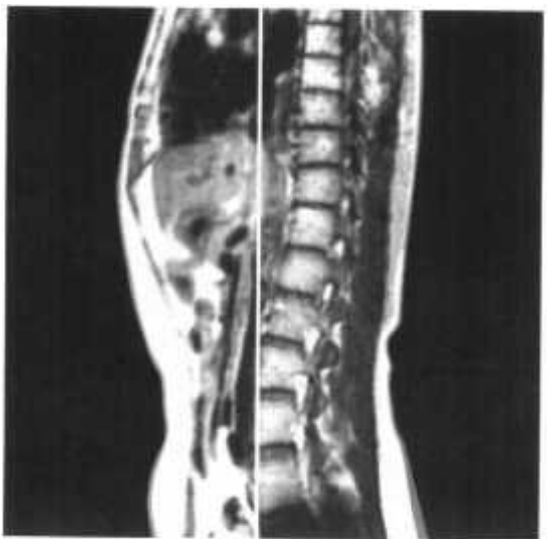

Fig. FA 5



- 22. 肝右静脉 right hepatic v.
- 23. 臀中肌 gluteus medius
- 24. 臀小肌 gluteus minimus
- 25. 膀胱 urinary bladder
- 26. 股骨头 femoral head
- 27. 股骨头韧带 ligament of head of femur
- 28. 闭孔内肌 obturator externus
- 29. 股外侧肌 vastus lateralis
- 30. 闭孔外肌 obturator externus
- 31. 肝门静脉右支 right branch of hepatic portal v.
- 32. 耻骨肌 pectineus
- 33. 股内侧肌 vastus medialis
- 34. 大收肌 adductor magnus
- 35. 股骨 femur
- 36. 股薄肌 gracilis
- 37. 胆囊 gallbladder
- 38. 尿道海绵体 cavernous body of urethra
- 39. 幽门管 pyloric canal
- 40. 腹主动脉 abdominal aorta
- 41. 耻骨下支 inferior ramus of pubis
- 42. 髂骨体 body of ilium
- 43. 右髂总静脉 right common iliac v.
- 44. 升结肠 ascending colon
- 45. 回肠 ileum



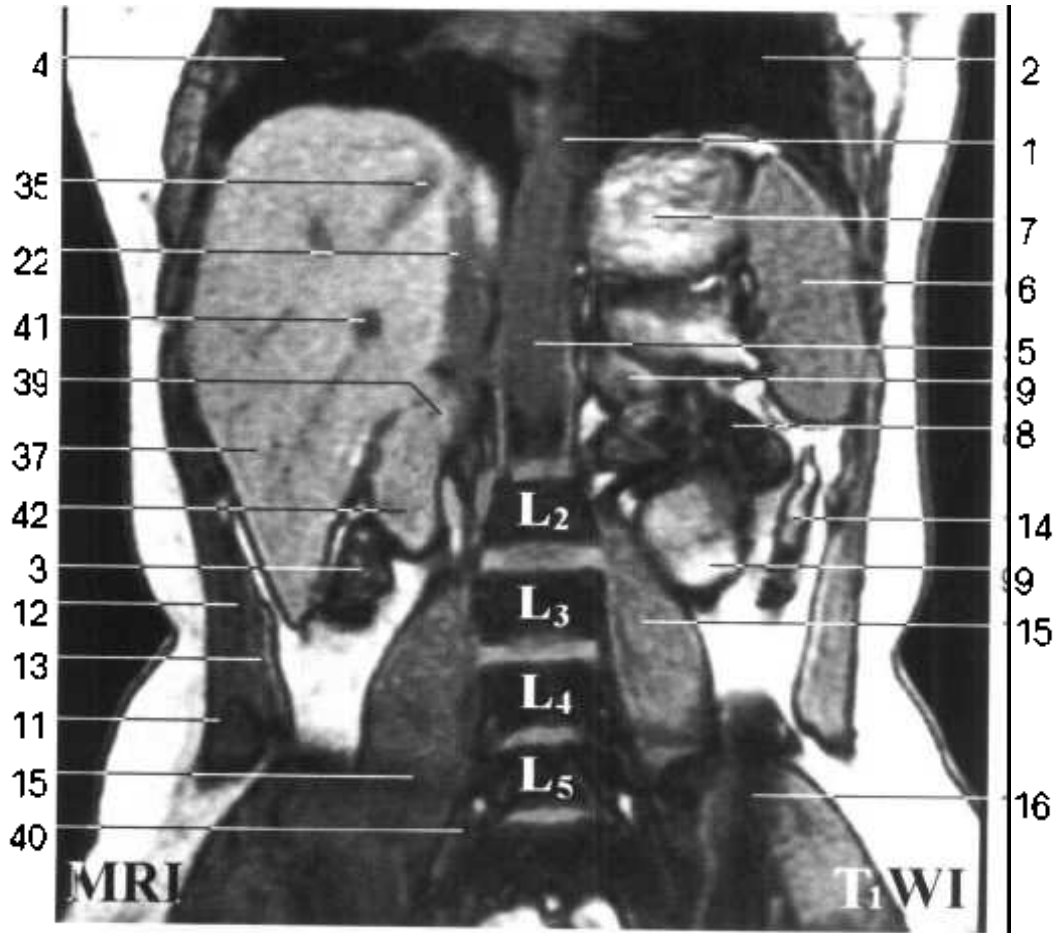


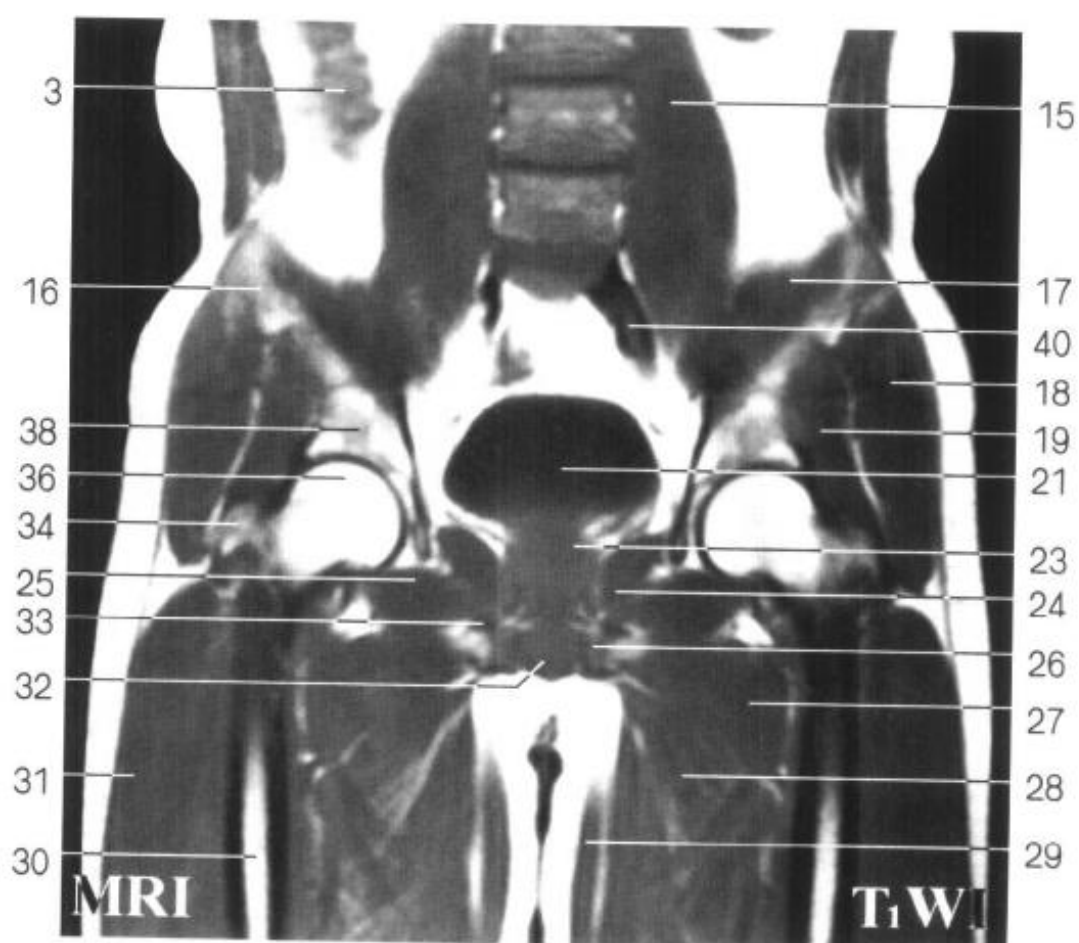
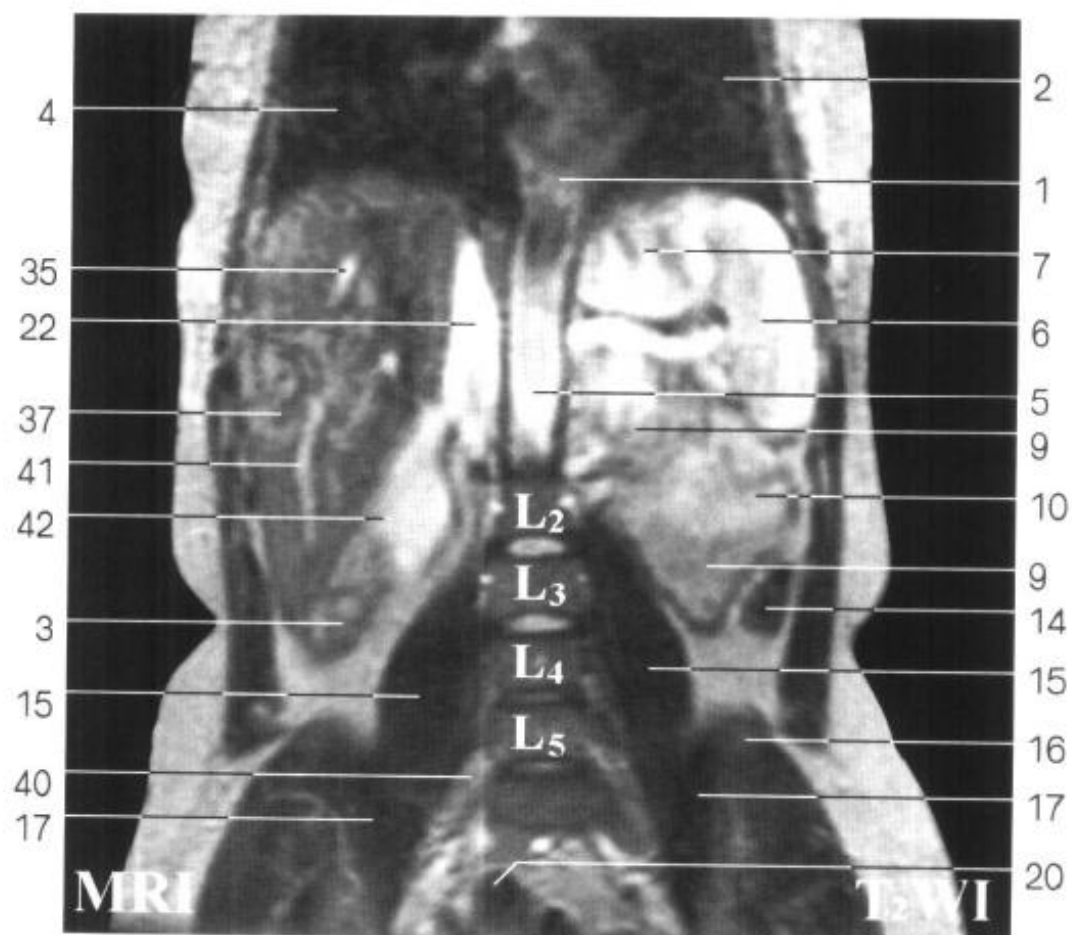
Fig. FA 6

1. 胸主动脉 thoracic aorta
2. 外侧底段(S IX) lateral basal segment(S IX)
3. 升结肠 ascending colon
4. 右肺下叶 inferior lobe of left lung
5. 腹主动脉 abdominal aorta
6. 脾 spleen
7. 胃底 fundus of stomach
8. 横结肠 transverse colon
9. 空肠 jejunum
10. 结肠左曲 left colic flexure
11. 腹外斜肌 obliquus externus abdominis
12. 腹内斜肌 obliquus internus abdominis
13. 腹横肌 transversus abdominis
14. 降结肠 descending colon
15. 腰大肌 psoas major
16. 髂嵴 iliac crest
17. 髂肌 iliacus
18. 臀中肌 gluteus medius
19. 臀小肌 gluteus minimus

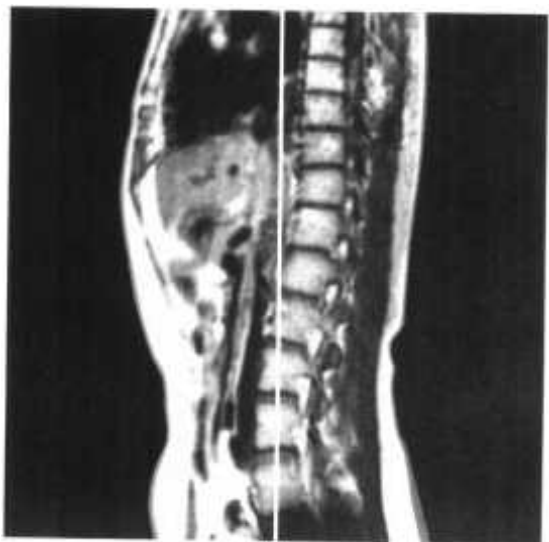

Fig. FA 6

- 20. 乙状结肠 sigmoid colon
- 21. 膀胱 urinary bladder
- 22. 下腔静脉 inferior vena cava
- 23. 前列腺 prostate gland
- 24. 闭孔内肌 obturator internus
- 25. 闭孔外肌 obturator externus
- 26. 阴茎脚 crus penis
- 27. 短收肌 adductor brevis
- 28. 大收肌 adductor magnus
- 29. 股薄肌 gracilis
- 30. 股骨 femur
- 31. 股外侧肌 vastus lateralis
- 32. 尿道球 bulb of urethra
- 33. 坐骨支 ramus of ischium
- 34. 大转子 greater trochanter
- 35. 肝右静脉 right hepatic v.
- 36. 股骨头 femoral head
- 37. 右后叶 right posterior lobe
- 38. 髌骨体 body of ilium
- 39. 右肾上腺 right suprarenal gland
- 40. 髂总动、静脉 common iliac a. and v.
- 41. 右前叶静脉 right anterior lobar v.
- 42. 右肾 right kidney



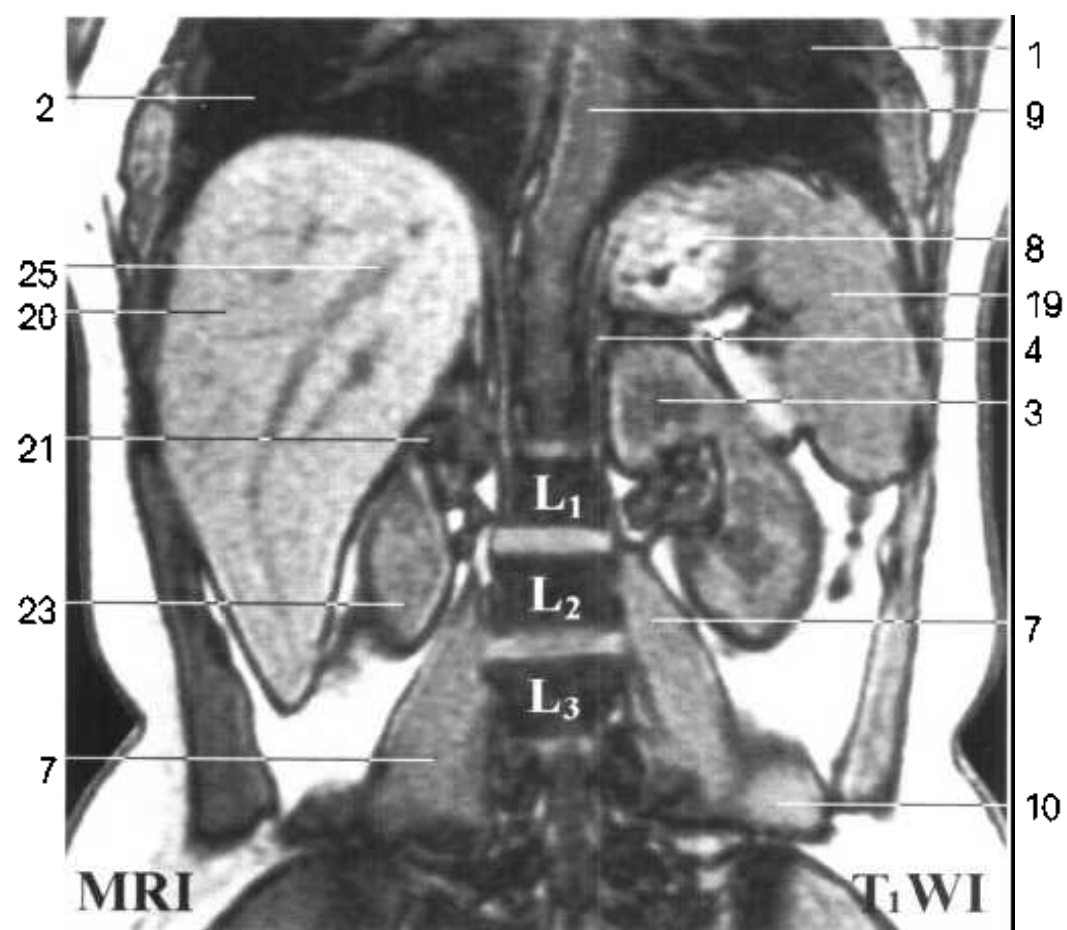
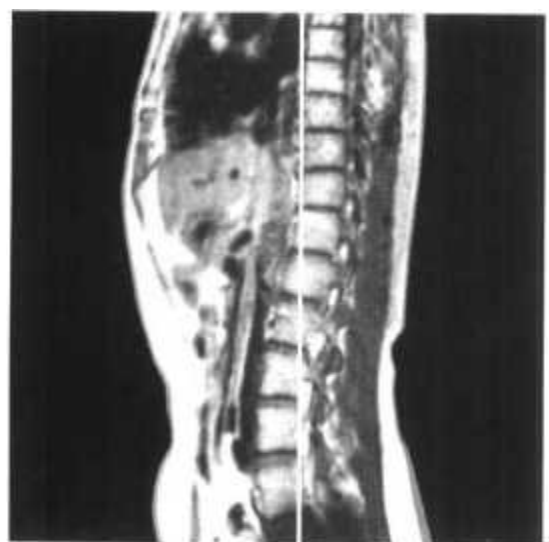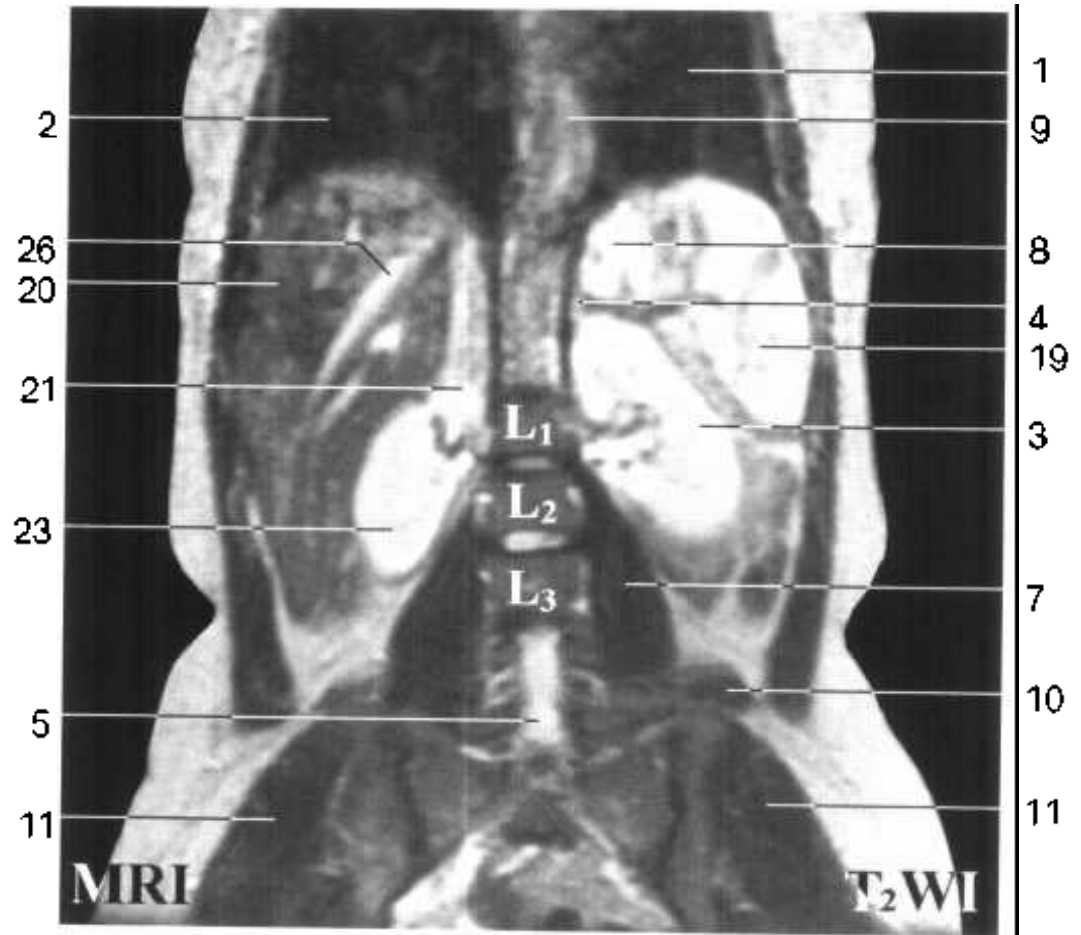


Fig. FA 7

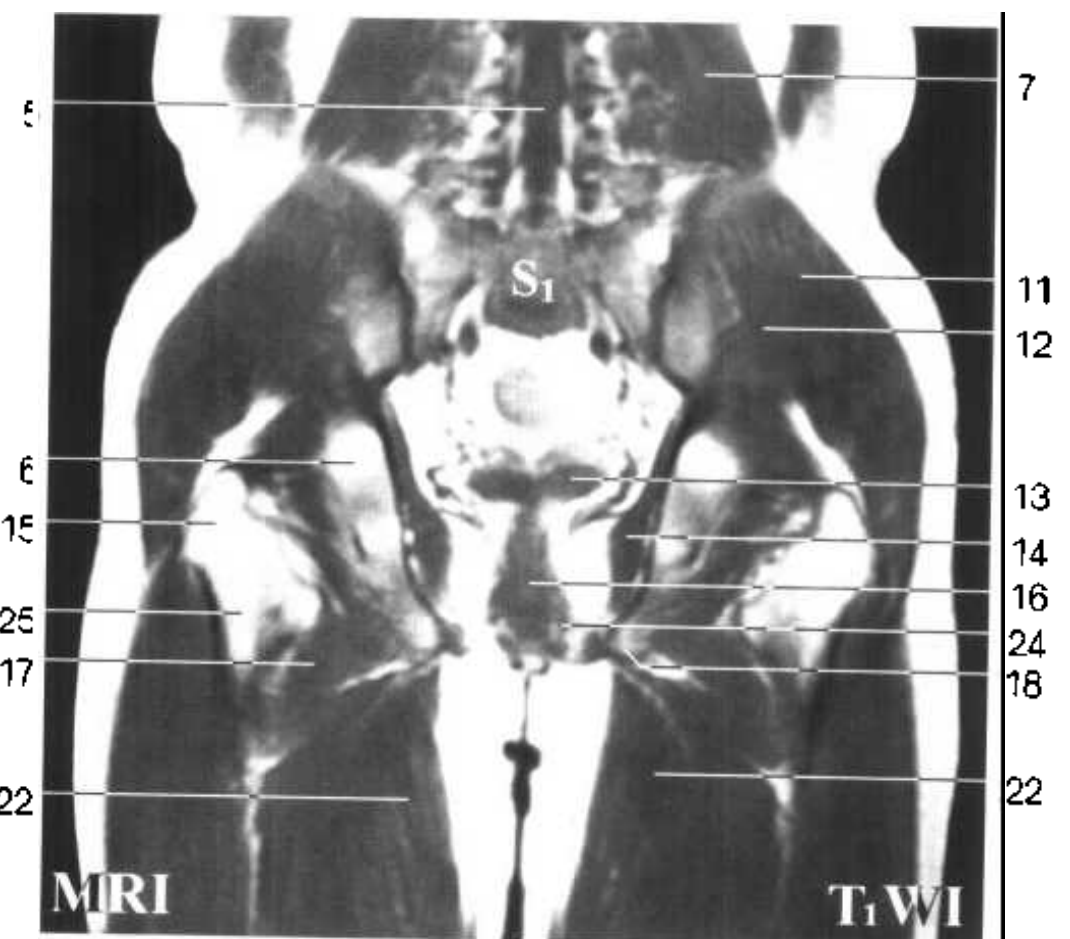


1. 左肺下叶 inferior lobe of left lung
2. 右肺下叶 inferior lobe of right lung
3. 左肾 left kidney
4. 左肾上腺 left suprarenal gland
5. 脊髓 spinal cord
6. 坐骨 ischium
7. 腰大肌 psoas major
8. 胃底 fundus of stomach
9. 胸主动脉 thoracic aorta
10. 髂肌 iliacus
11. 臀中肌 gluteus medius
12. 臀小肌 gluteus minimus
13. 乙状结肠 sigmoid colon

Fig. FA 7



- 14. 闭孔内肌 obturator internus
- 15. 大转子 greater trochanter
- 16. 直肠 rectum
- 17. 股方肌 quadratus femoris
- 18. 坐骨结节 ischial tuberosity
- 19. 脾 spleen
- 20. 右后叶 right posterior lobe
- 21. 右肾上腺 right suprarenal gland
- 22. 大收肌 adductor magnus
- 23. 右肾 right kidney
- 24. 肛提肌 levator ani
- 25. 股骨 femur
- 26. 肝右静脉 right hepatic v.



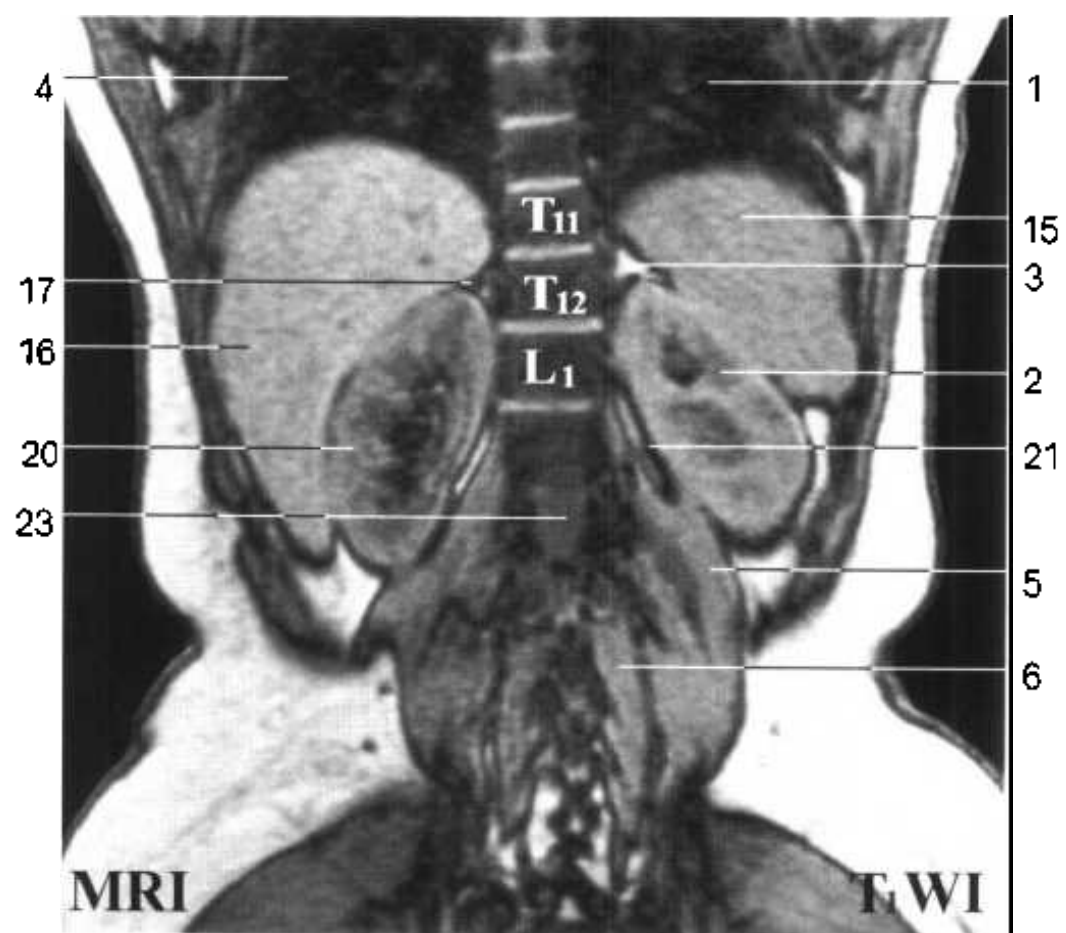
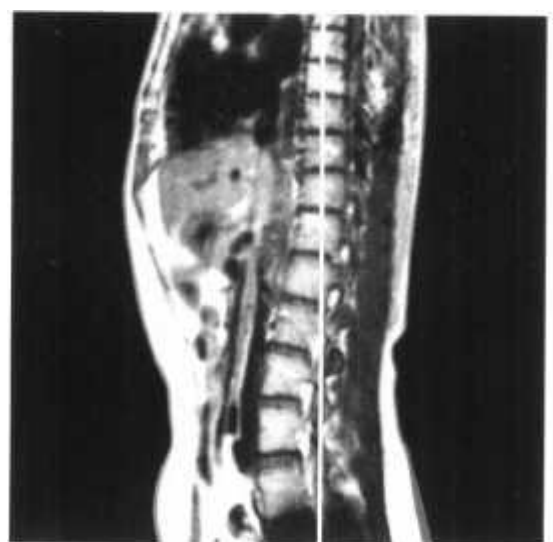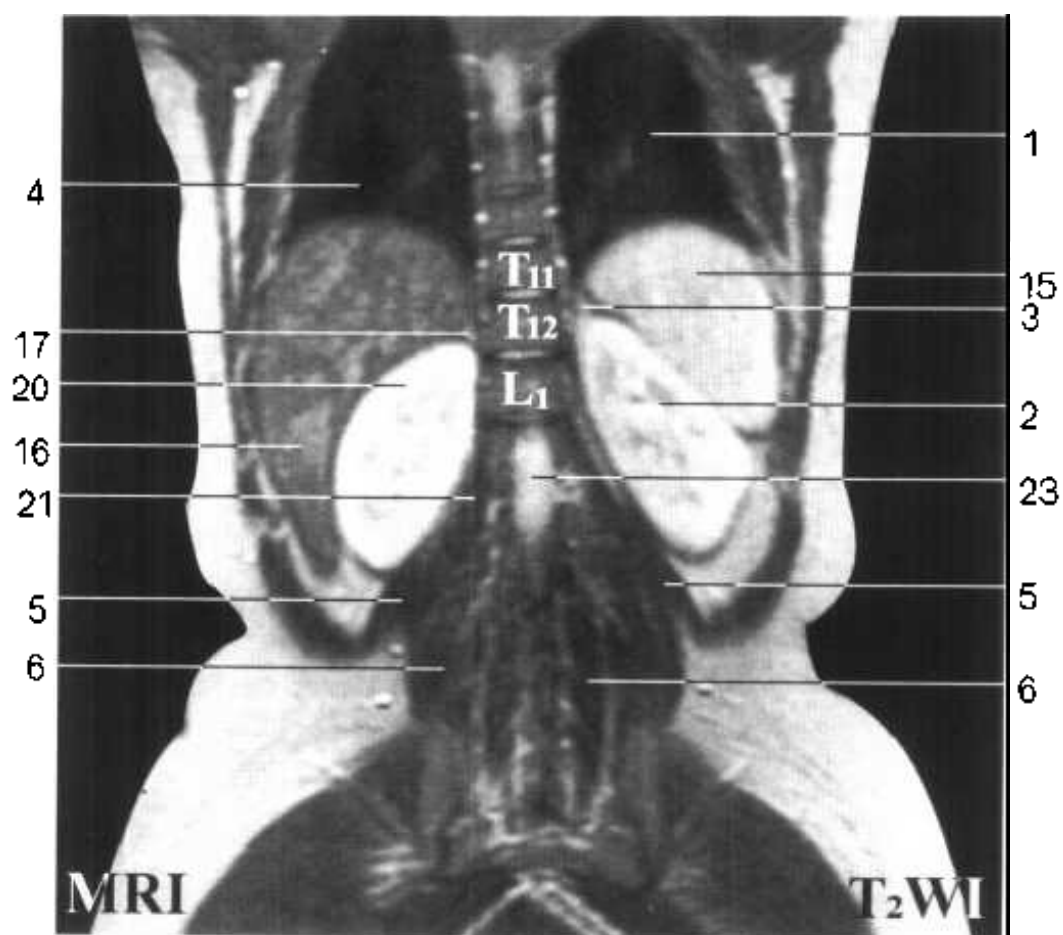


Fig. FA 8

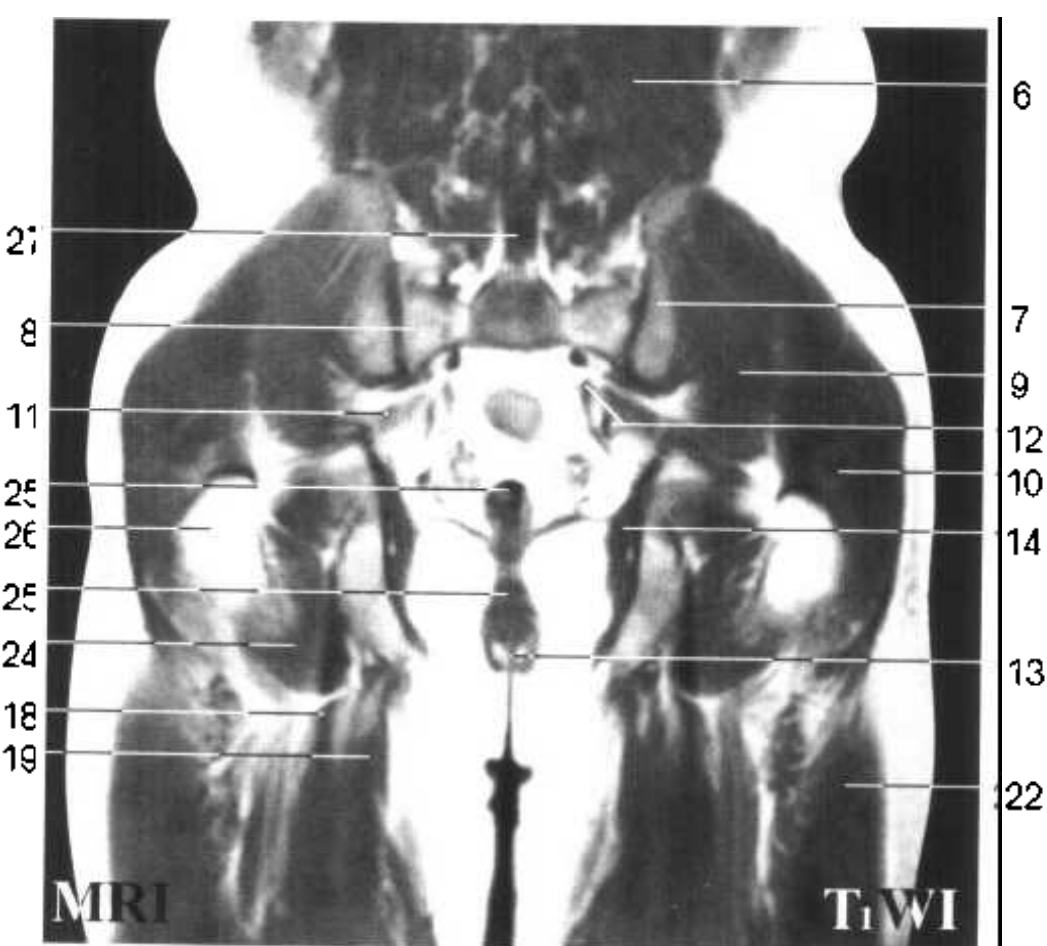


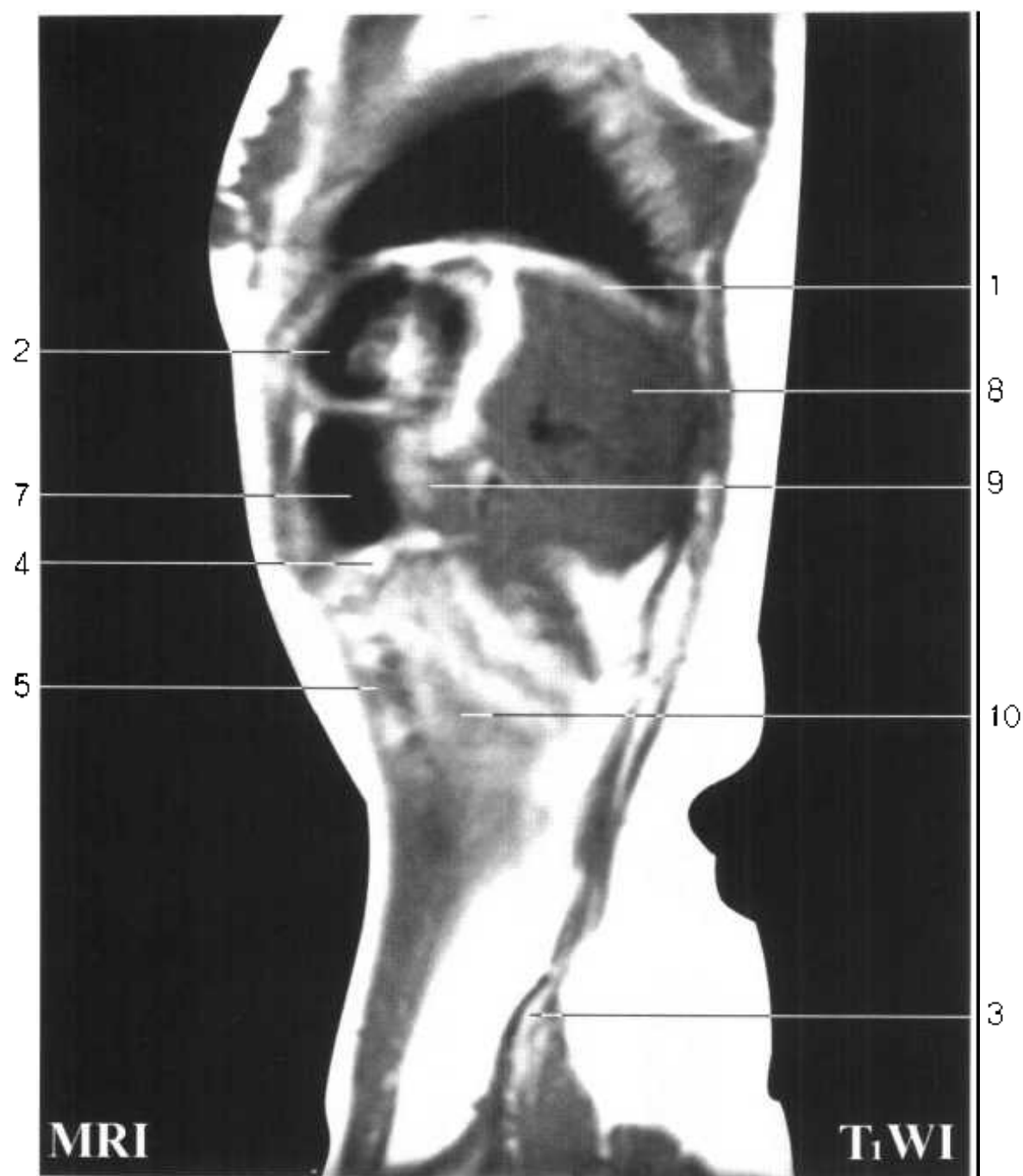
1. 左肺下叶 inferior lobe of left lung
2. 左肾 left kidney
3. 左肾上腺 left suprarenal gland
4. 右肺下叶 inferior lobe of right lung
5. 腰方肌 quadratus lumborum
6. 竖脊肌 erector spinae
7. 髂骨翼 ala of ilium
8. 骶翼 ala of sacrum
9. 臀中肌 gluteus medius
10. 臀大肌 gluteus maximus
11. 梨状肌 piriformis
12. 臀下动、静脉 inferior gluteal a.and v.
13. 肛门外括约肌 sphincter ani externus
14. 闭孔内肌 obturator internus
15. 脾 spleen

Fig. FA 8



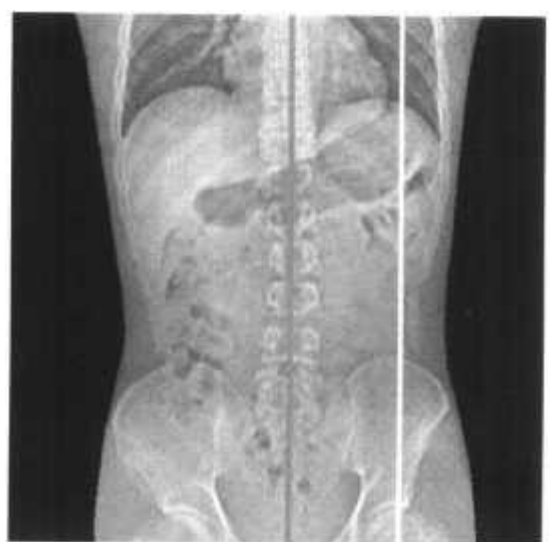- 16. 右后叶 right posterior lobe
- 17. 右肾上腺 right suprarenal gland
- 18. 股二头肌长头 long head of biceps femoris
- 19. 半腱肌 semitendinosus
- 20. 右肾 right kidney
- 21. 腰大肌 psoas major
- 22. 股外侧肌 vastus lateralis
- 23. 脊髓 spinal cord
- 24. 股方肌 quadratus femoris
- 25. 直肠 rectum
- 26. 大转子 greater trochanter
- 27. 骶管 sacral canal





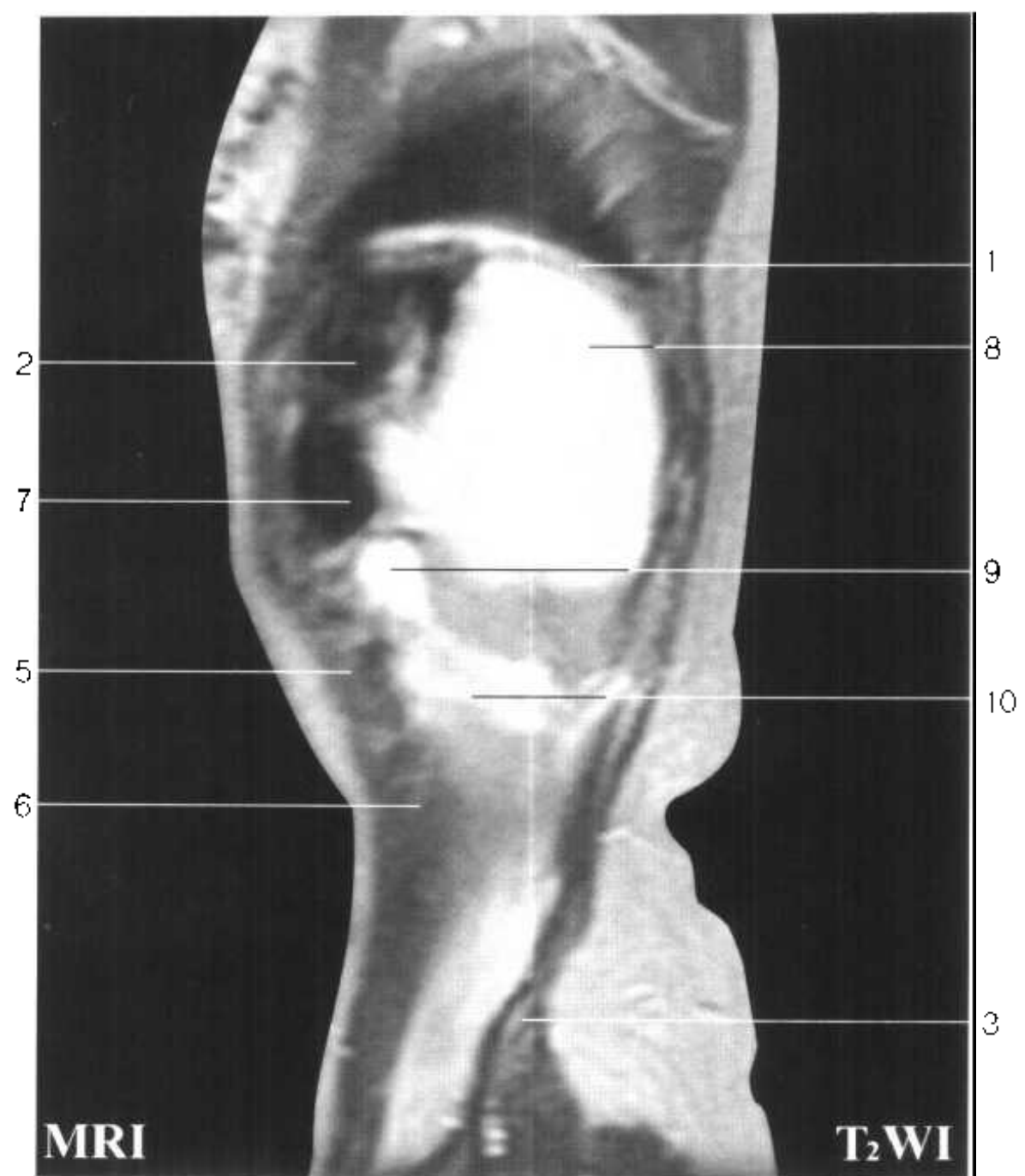矢状断面图 SA

Fig. SA 1



1. 膈 diaphragm
2. 胃底 fundus of stomach
3. 髂嵴 iliac crest
4. 大网膜 greater omentum
5. 腹外斜肌 obliquus externus abdominis
6. 腹内斜肌 obliquus internus abdominis
7. 胃体 body of stomach
8. 脾 spleen

Fig. SA 1



9. 结肠左曲 left colic flexure

10. 空肠 jejunum

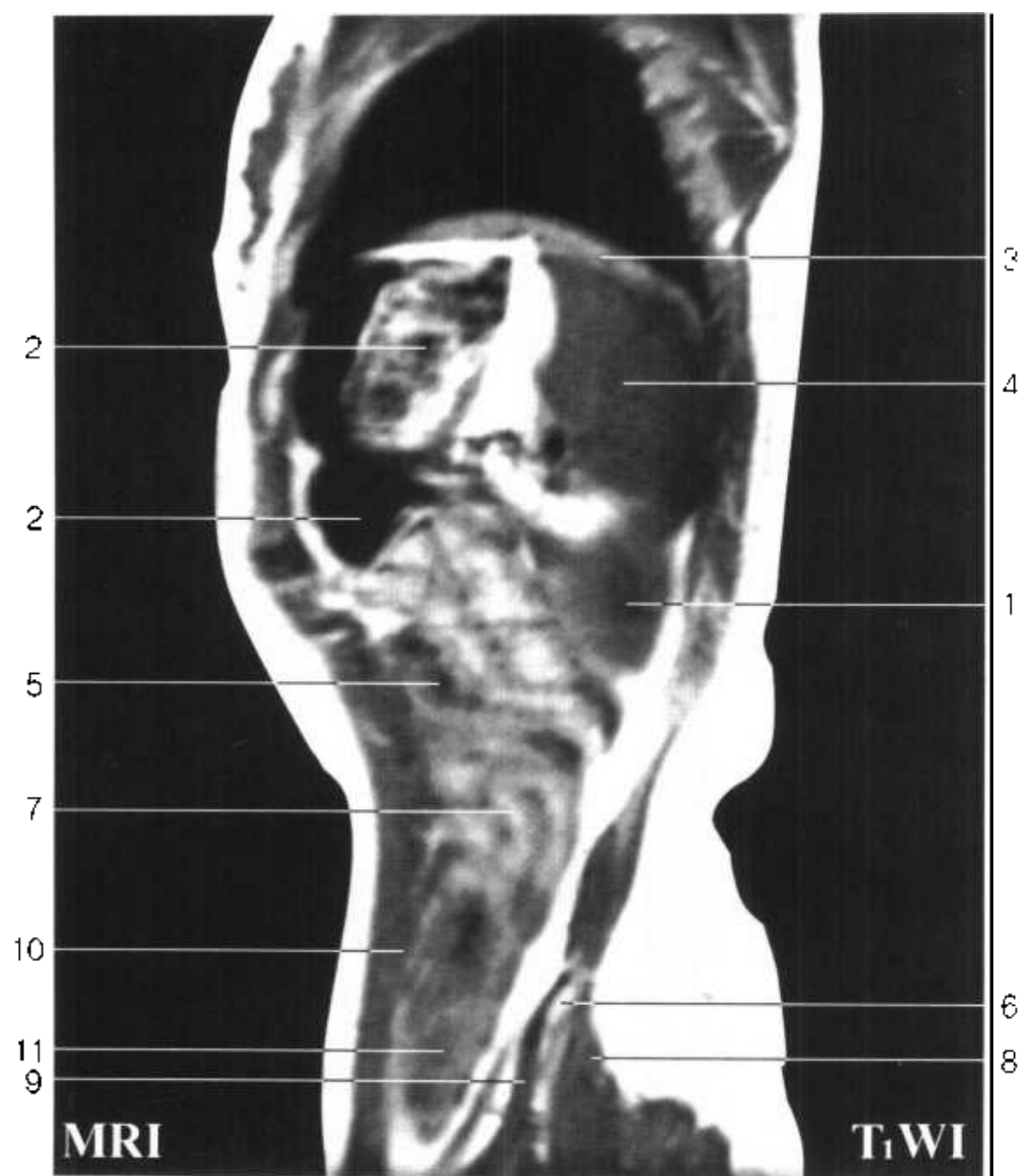


Fig. SA 2

- 1. 左肾 left kidney
- 2. 胃 stomach
- 3. 膈 diaphragm
- 4. 脾 spleen
- 5. 横结肠 transverse colon
- 6. 髂嵴 iliac crest
- 7. 空肠 jejunum

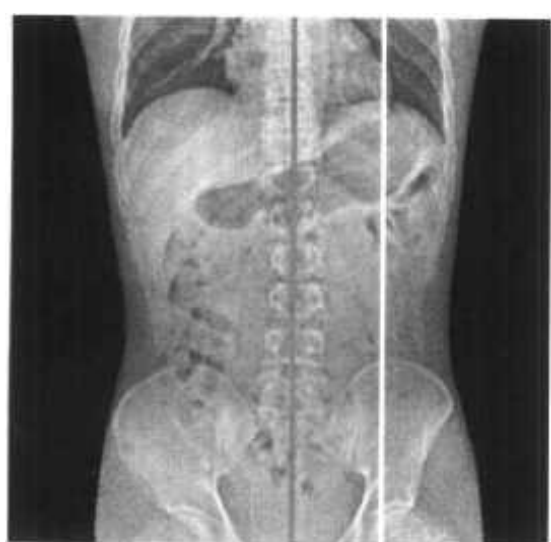
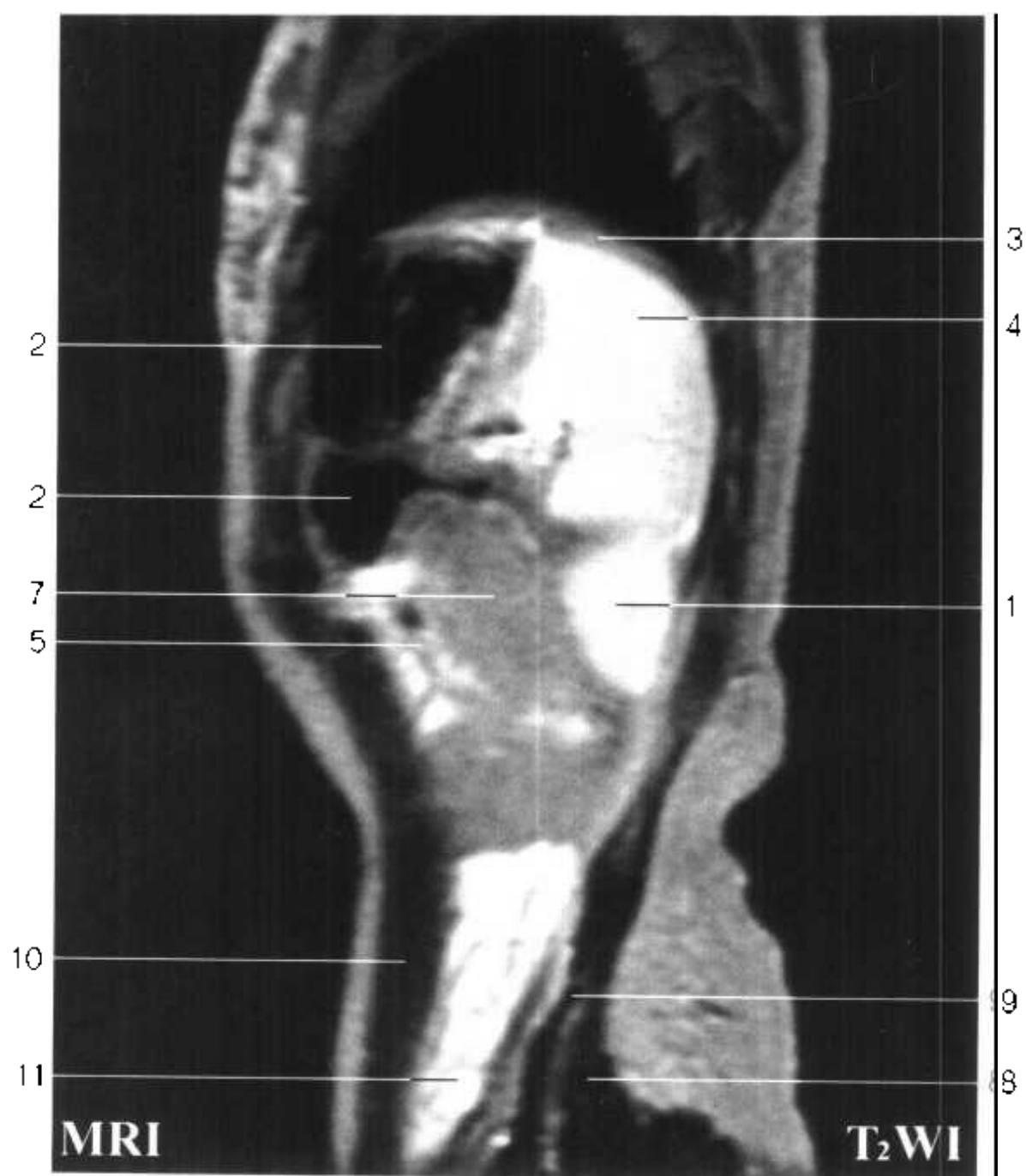
Fig. SA 2



- 8. 臀中肌 *gluteus medius*
- 9. 髂肌 *iliacus*
- 10. 腹外斜肌 *obliquus externus abdominis*
- 11. 乙状结肠 *sigmoid colon*

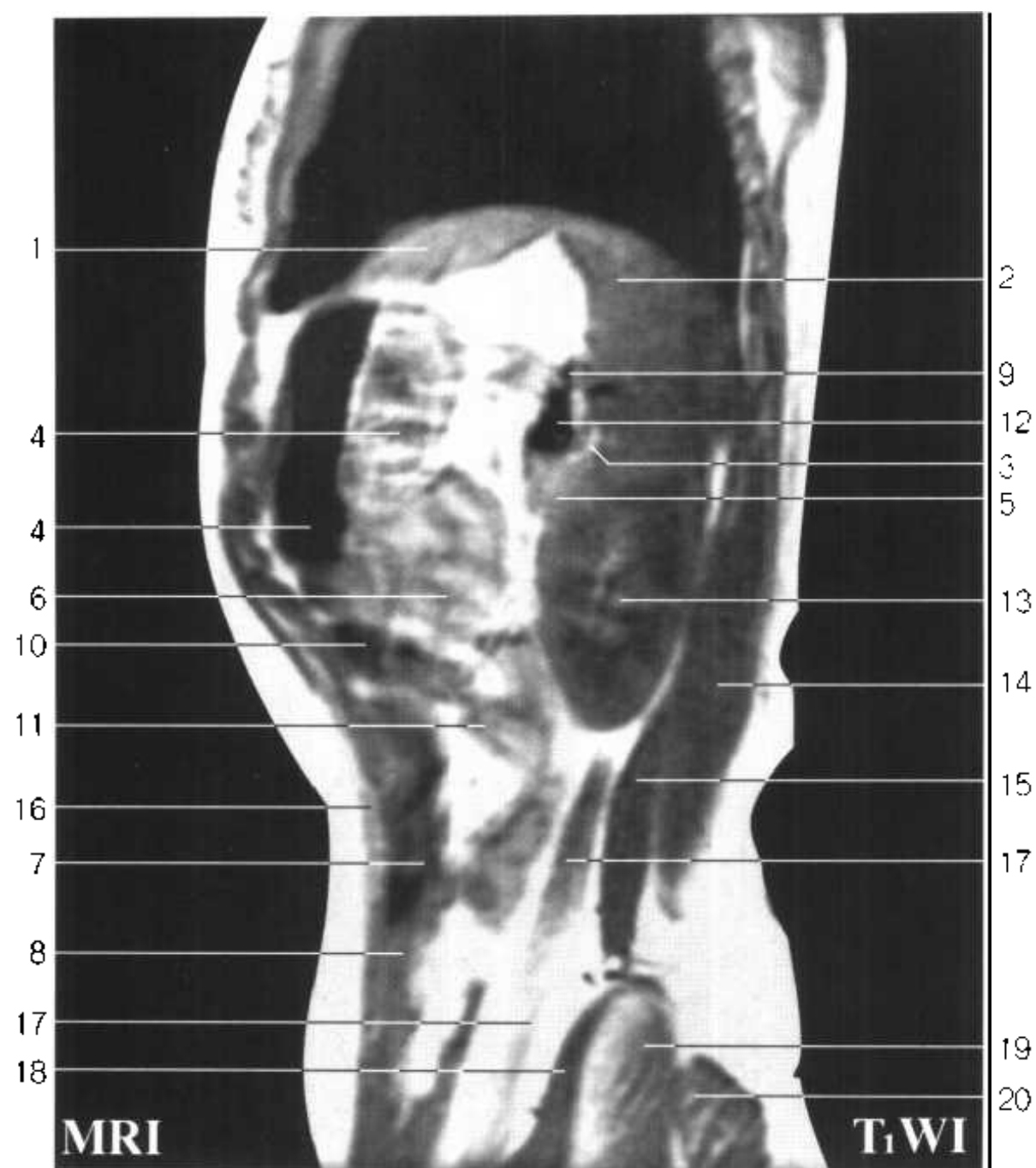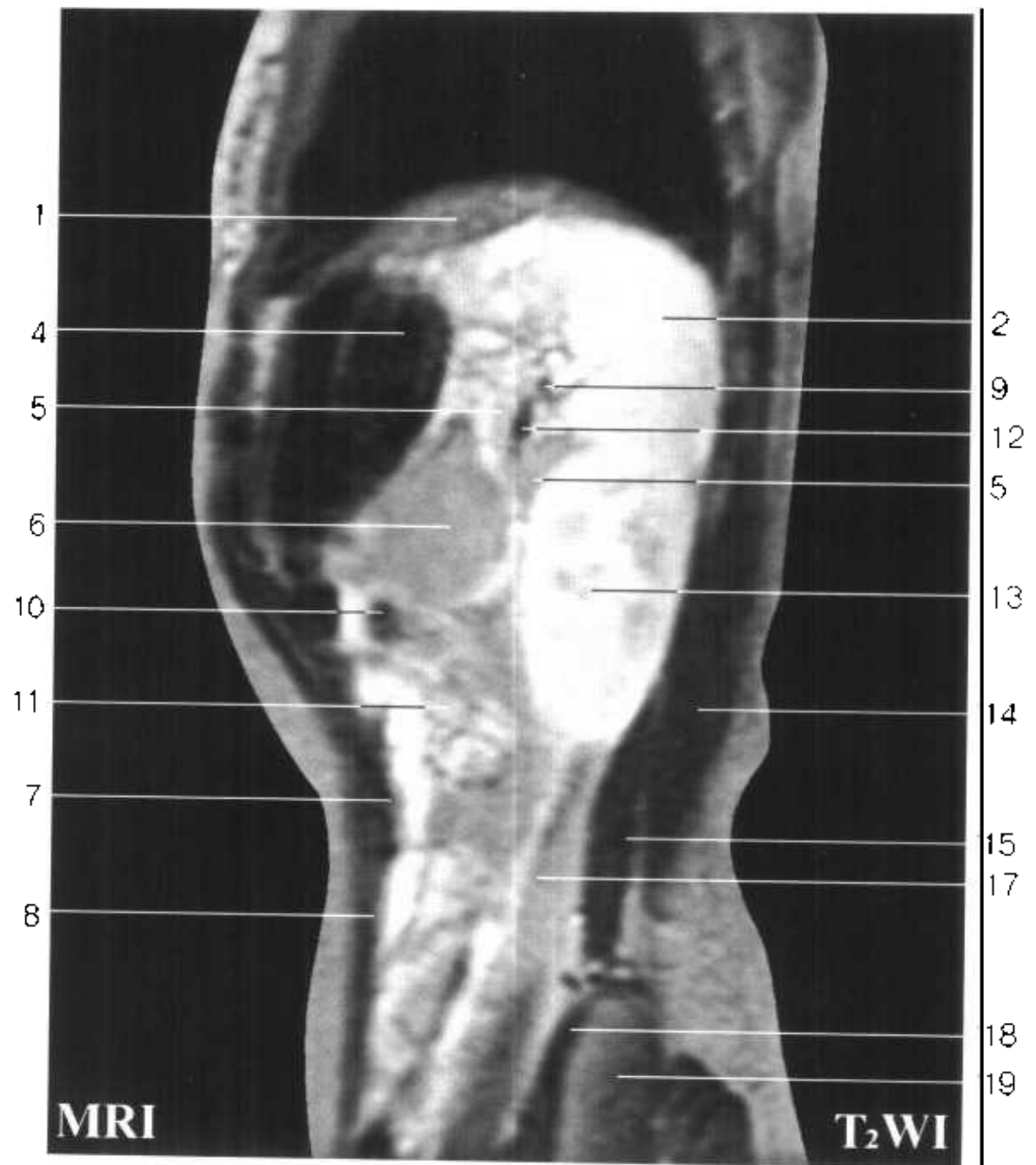


Fig. SA 3

1. 左外叶上段 superior segment of left lateral lobe
2. 脾 spleen
3. 左肾上腺 left suprarenal gland
4. 胃体 body of stomach
5. 胰 pancreas
6. 空肠 jejunum
7. 腹横肌 transversus abdominis
8. 腹内斜肌 obliquus internus abdominis
9. 脾动脉 splenic a.

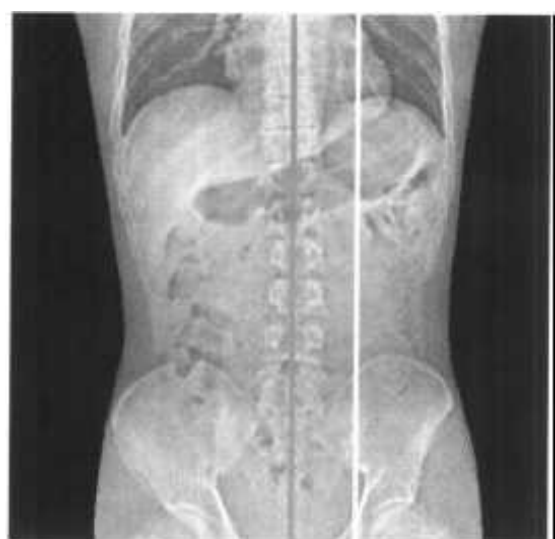

Fig. SA 3



- 10. 横结肠 transverse colon
- 11. 空肠 jejunum
- 12. 脾静脉 splenic v.
- 13. 左肾 left kidney
- 14. 竖脊肌 erector spinae
- 15. 腰方肌 quadratus lumborum
- 16. 腹外斜肌 obliquus externus abdominis
- 17. 腰大肌 psoas major
- 18. 髌骨 ilium
- 19. 臀中肌 gluteus medius
- 20. 臀大肌 gluteus maximus

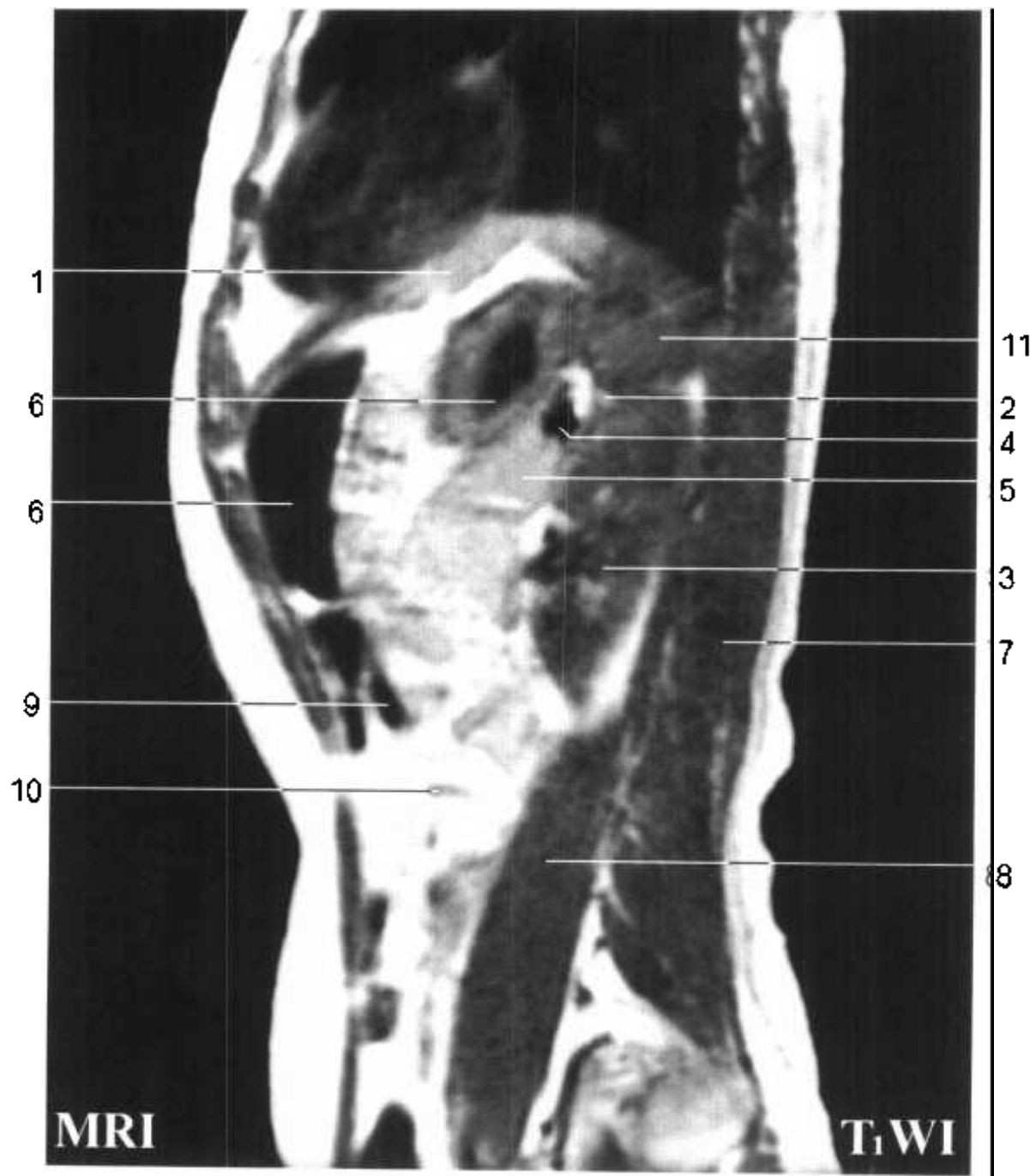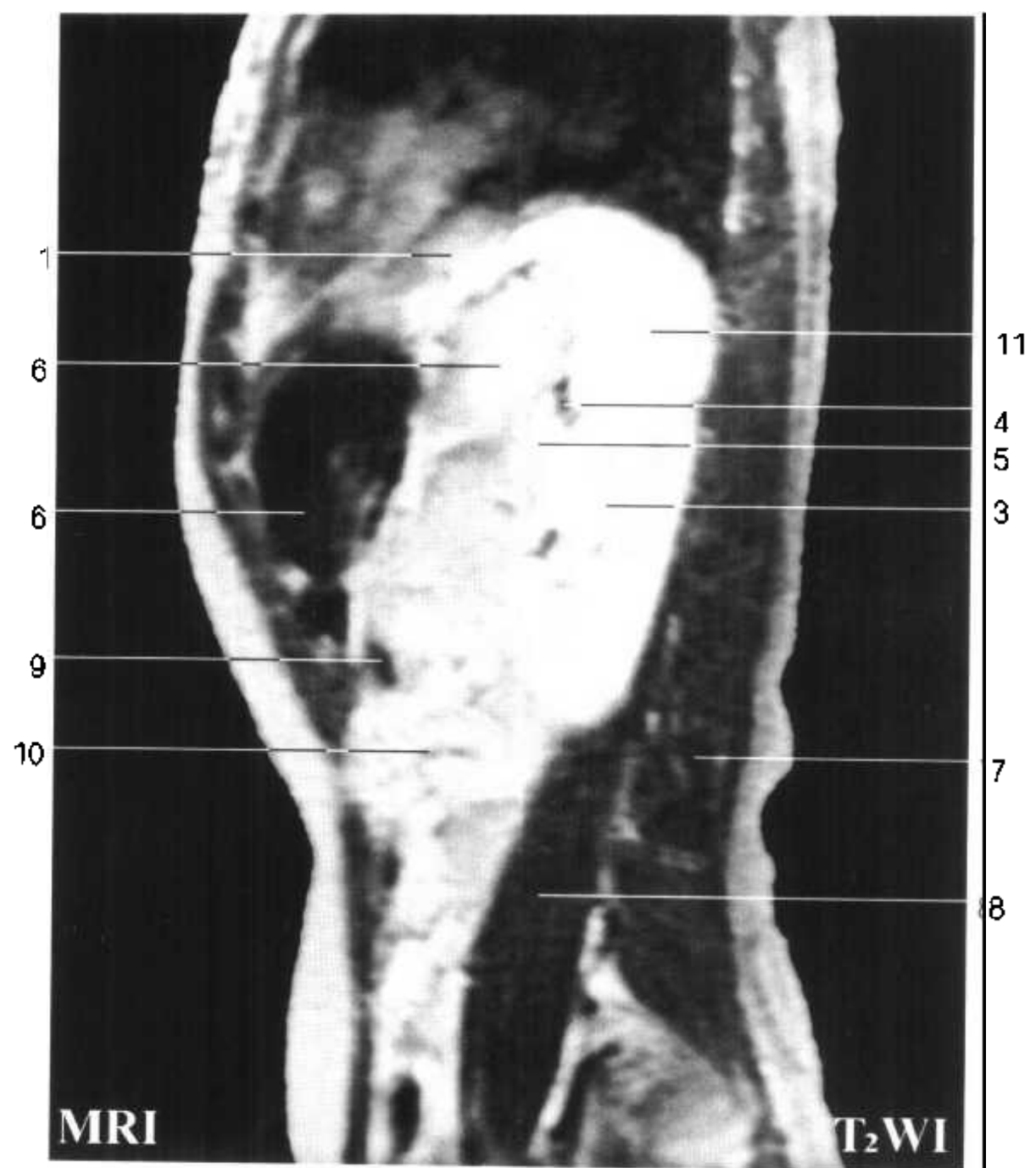


Fig. SA 4

- 1. 左外叶上段 superior segment of left lateral lobe
- 2. 左肾上腺 left suprarenal gland
- 3. 左肾 left kidney
- 4. 脾静脉 splenic v.
- 5. 胰 pancreas
- 6. 胃体 body of stomach

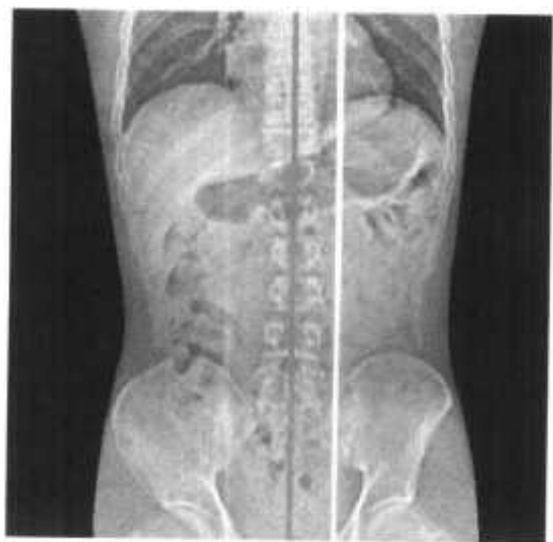

Fig.SA 4



- 7. 竖脊肌 erector spinae
- 8. 腰大肌 psoas major
- 9. 横结肠 transverse colon
- 10. 空肠 jejunum
- 11. 脾 spleen

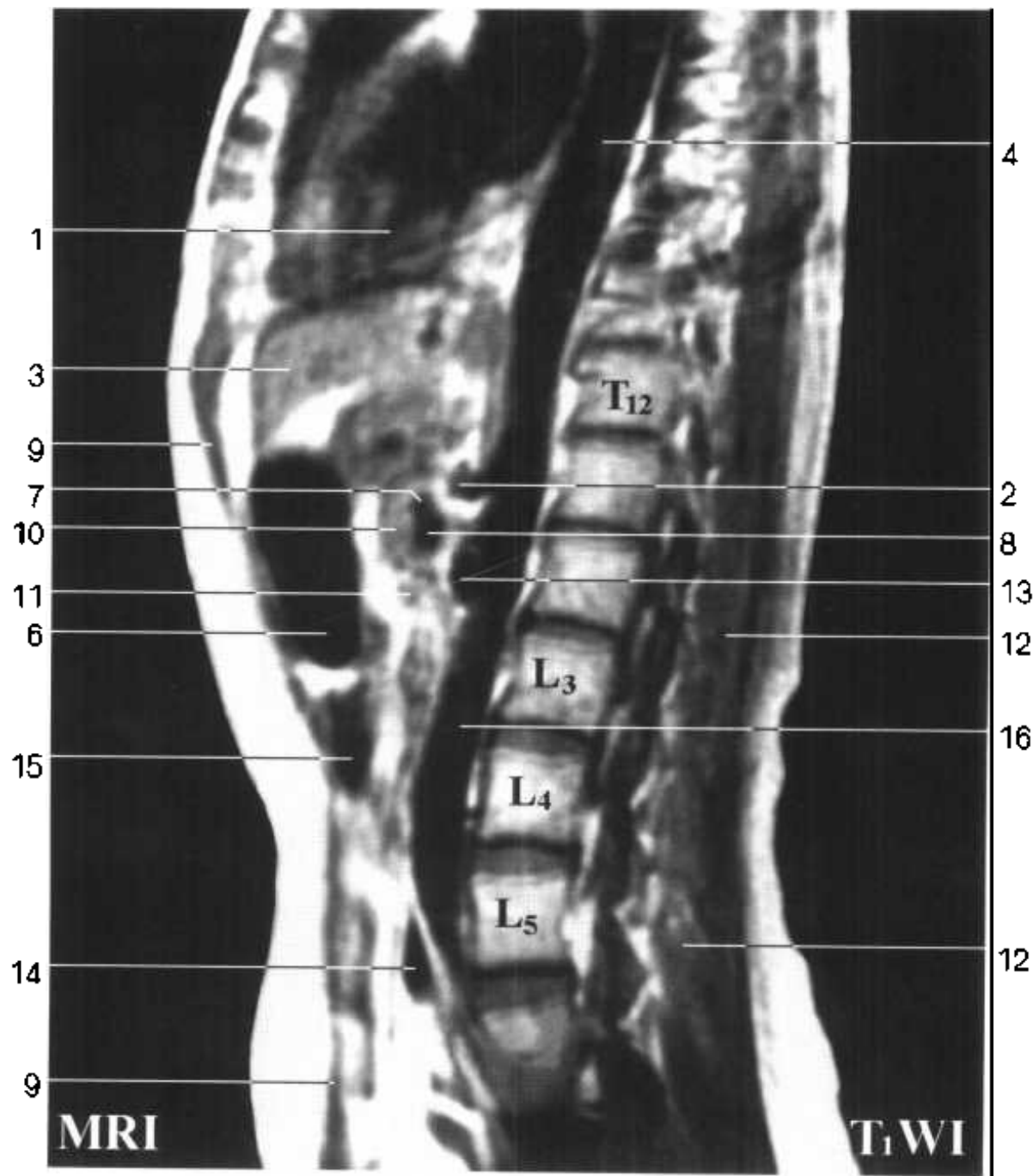
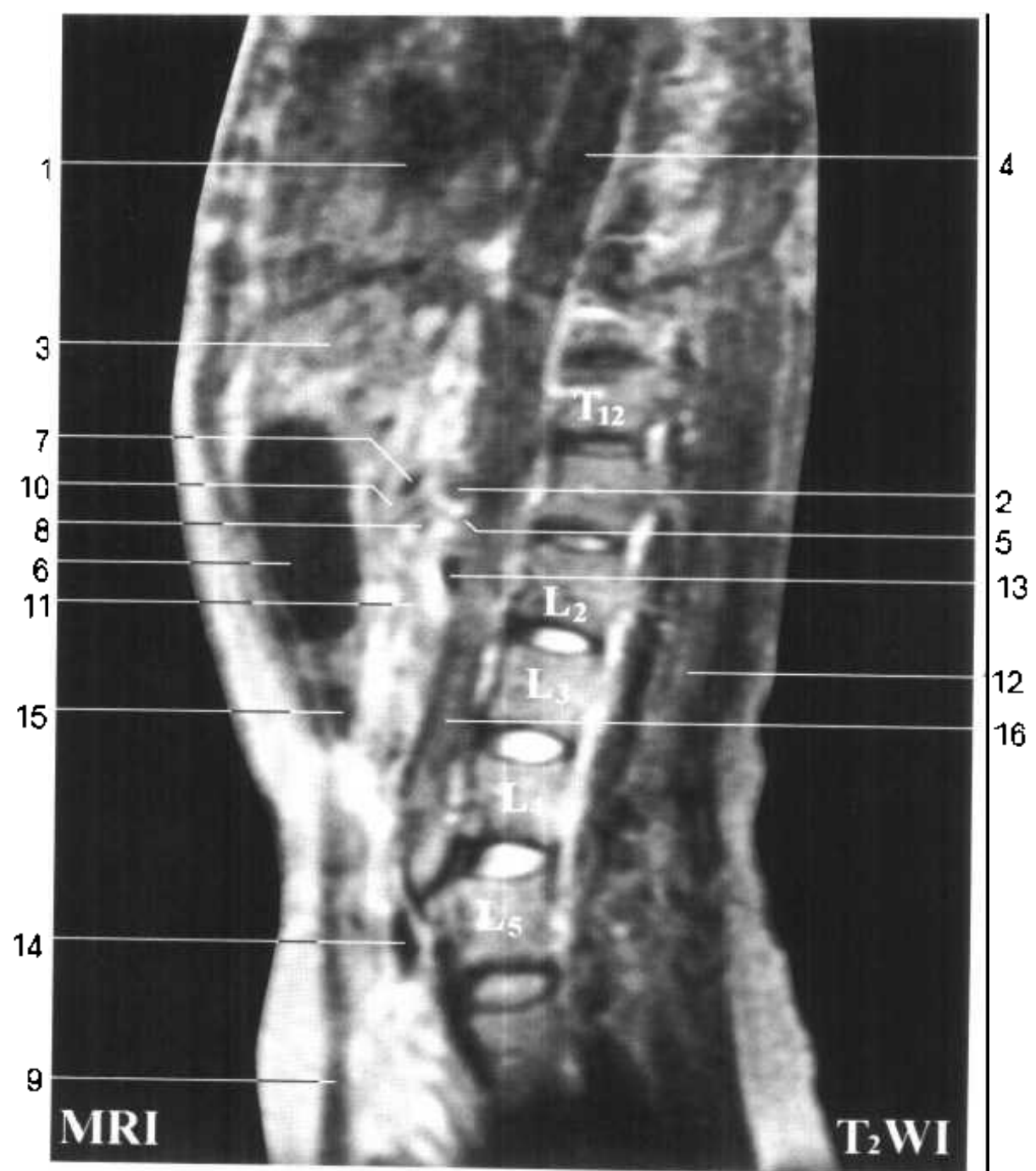


Fig. SA 5

- 1. 右心室 right ventricle
- 2. 腹腔干 celiac trunk
- 3. 左外叶 left lateral lobe
- 4. 胸主动脉 thoracic aorta
- 5. 肠系膜上动脉 superior mesenteric a.
- 6. 胃体 body of stomach
- 7. 脾动脉 splenic a.
- 8. 脾静脉 splenic v.

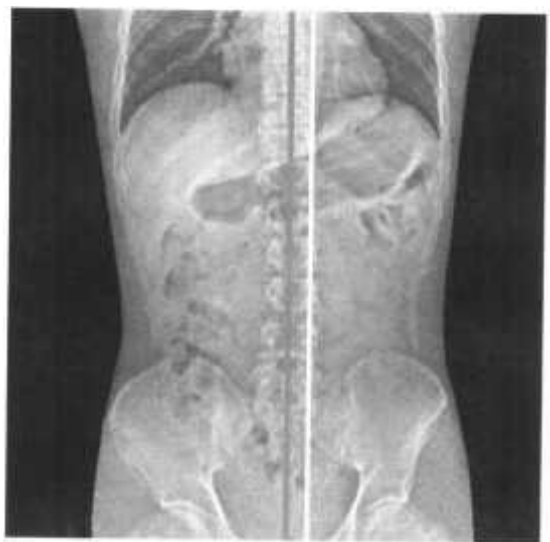

Fig. SA 5



- 9. 腹直肌 rectus abdominis
- 10. 胰 pancreas
- 11. 十二指肠水平部 horizontal part of duodenum
- 12. 竖脊肌 erector spinae
- 13. 左肾动脉 left renal a.
- 14. 左髂总静脉 left common iliac v.
- 15. 横结肠 transverse colon
- 16. 腹主动脉 abdominal aorta

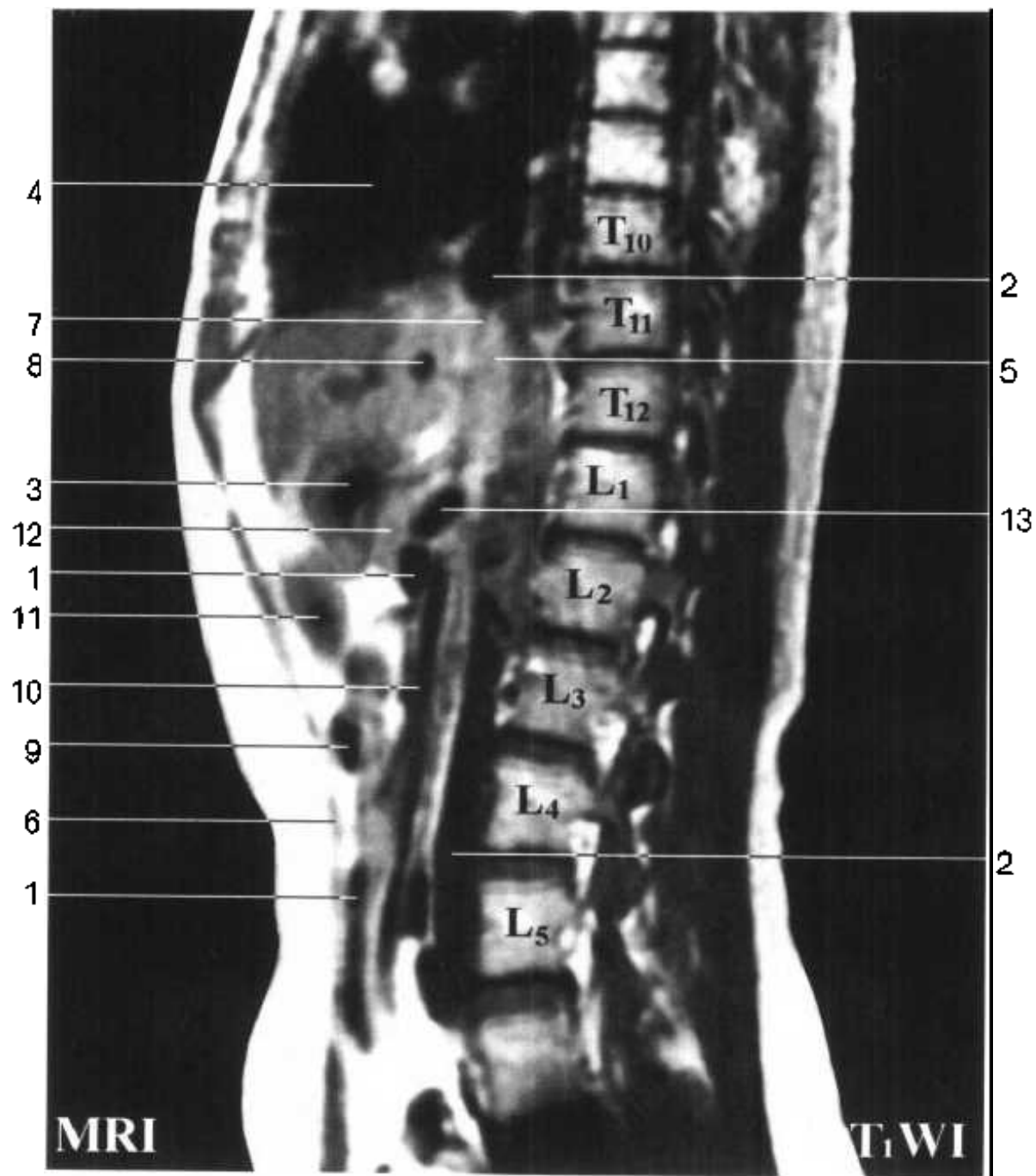
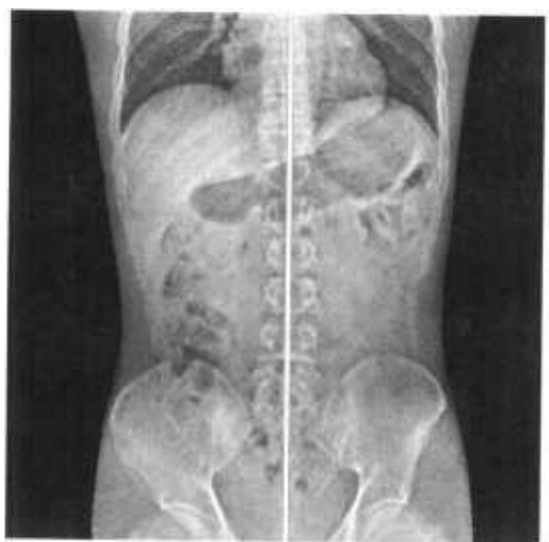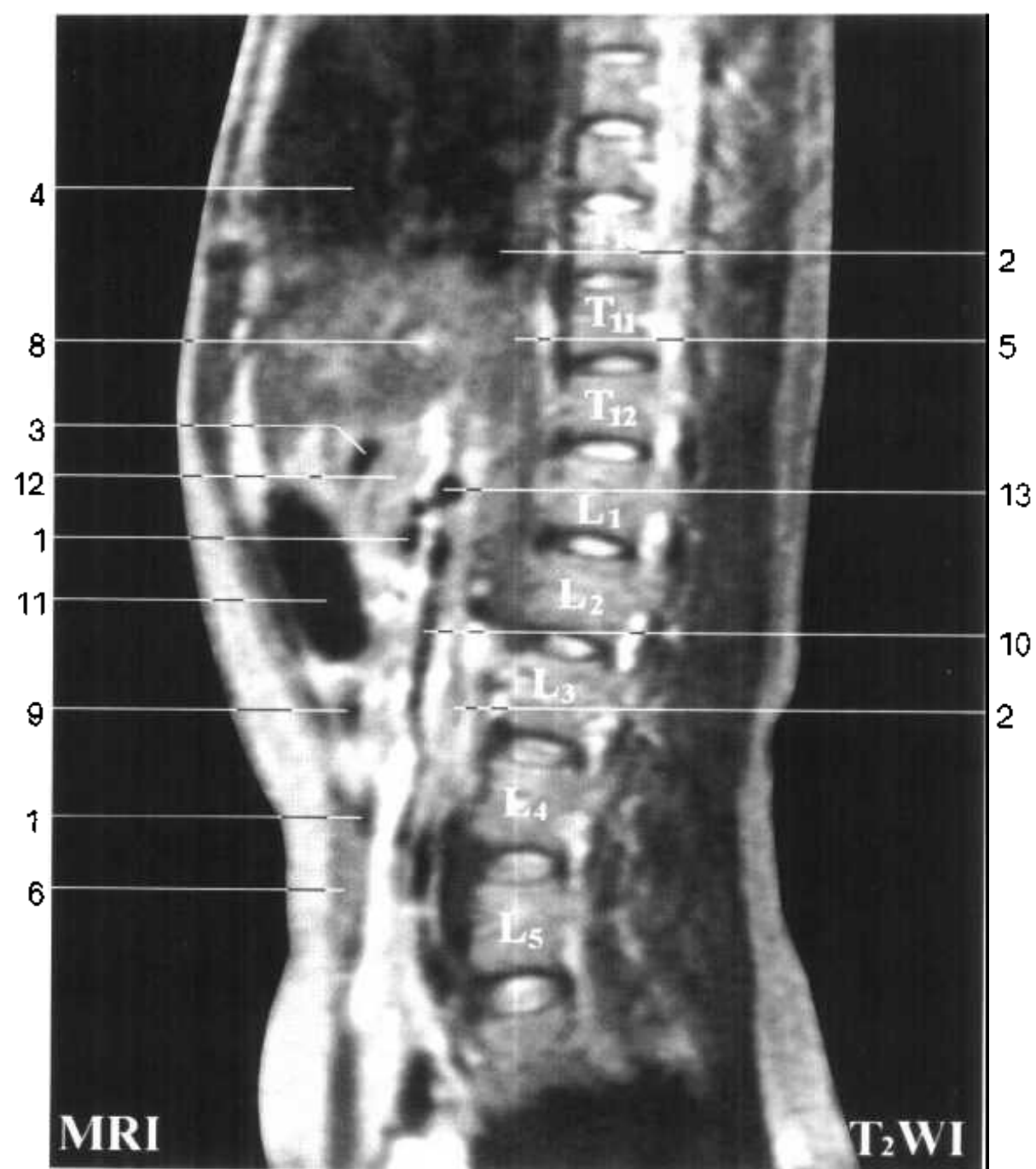


Fig. SA 6



1. 肠系膜上动脉 superior mesenteric a.
2. 下腔静脉 inferior vena cava
3. 胃 stomach
4. 右心房 right atrium
5. 尾状叶 caudate lobe
6. 腹直肌 rectus abdominis
7. 肝中间静脉 intermediate hepatic v.

Fig. SA 6



- 8. 肝左静脉 left hepatic v.
- 9. 横结肠 transverse colon
- 10. 肠系膜上静脉 superior mesenteric v.
- 11. 幽门管 pyloric canal
- 12. 胰 pancreas
- 13. 肝门静脉 hepatic portal v.

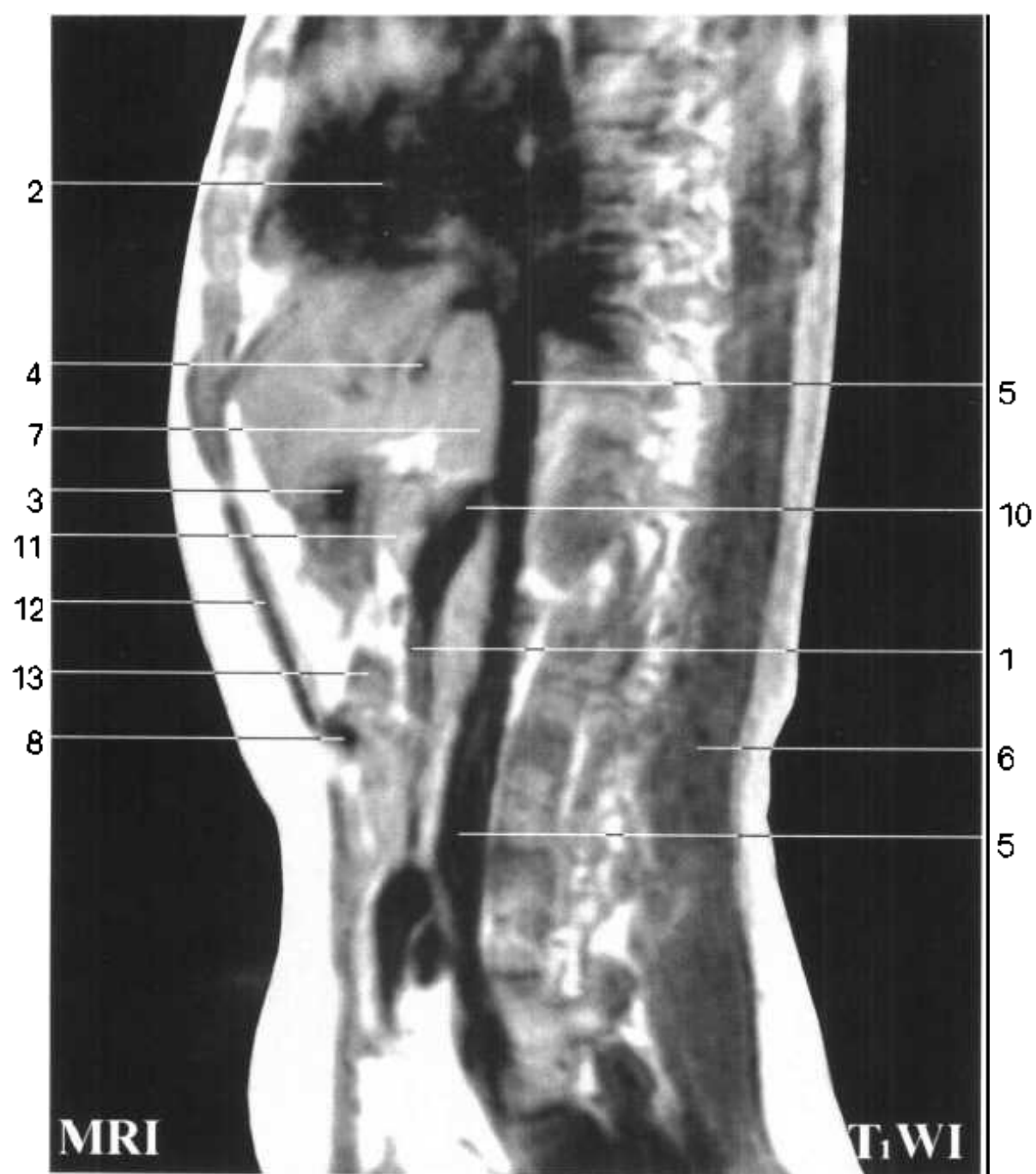
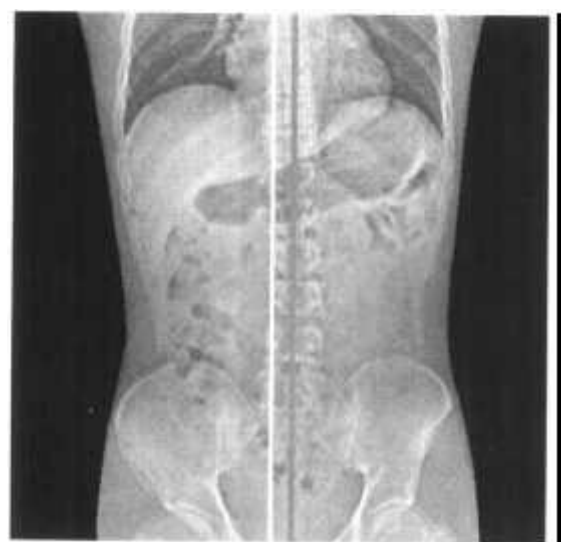
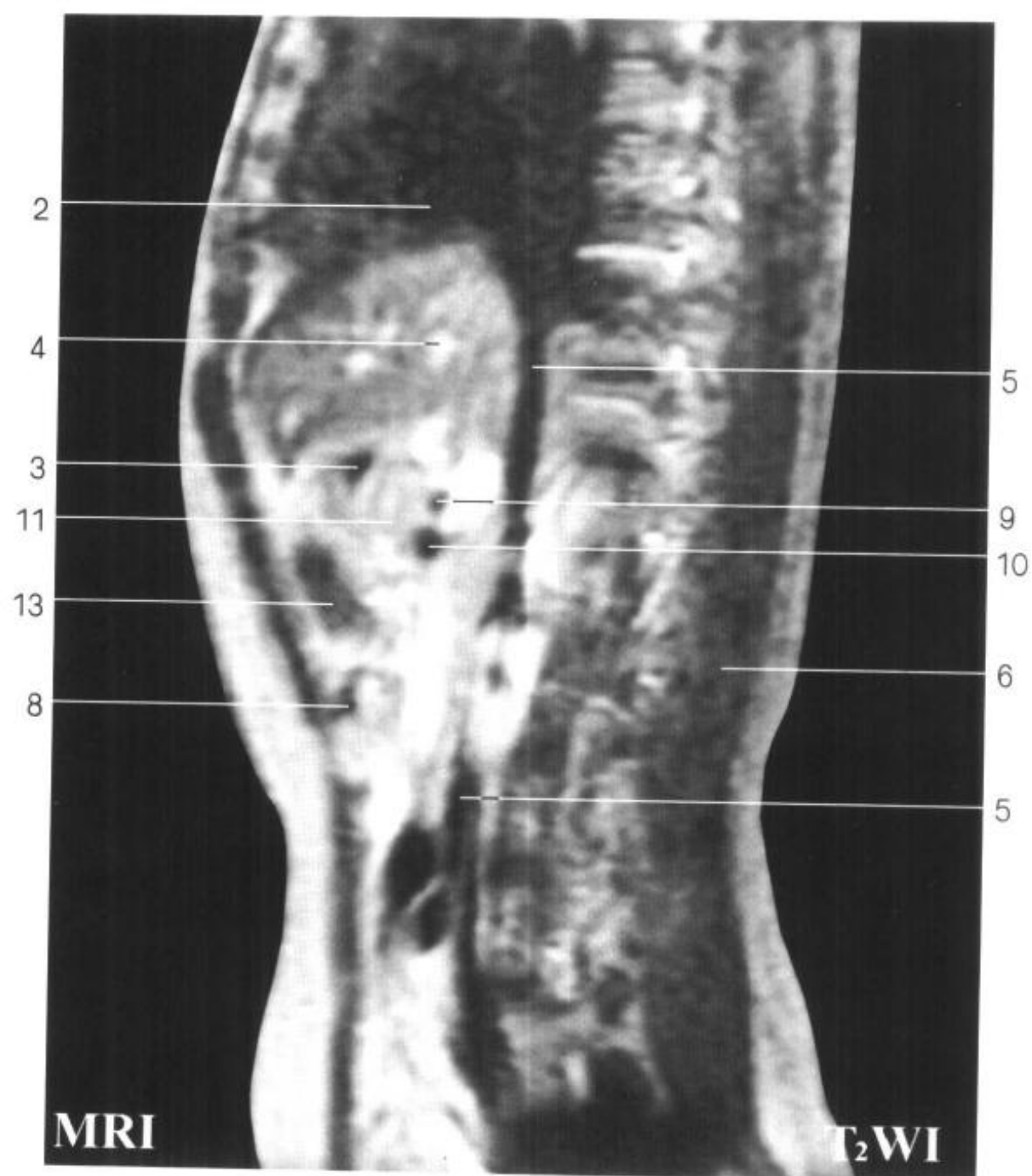Fig. SA 7



1. 肠系膜上静脉 superior mesenteric v.
2. 右心房 right atrium
3. 胃 stomach
4. 肝中间静脉 intermediate hepatic v.
5. 下腔静脉 inferior vena cava
6. 竖脊肌 erector spinae
7. 尾状叶 caudate lobe

Fig. SA 7



- 8. 横结肠 transverse colon
- 9. 肝固有动脉 proper hepatic a.
- 10. 肝门静脉 hepatic portal v.
- 11. 胰头 head of pancreas
- 12. 腹直肌 rectus abdominis
- 13. 幽门管 pyloric canal

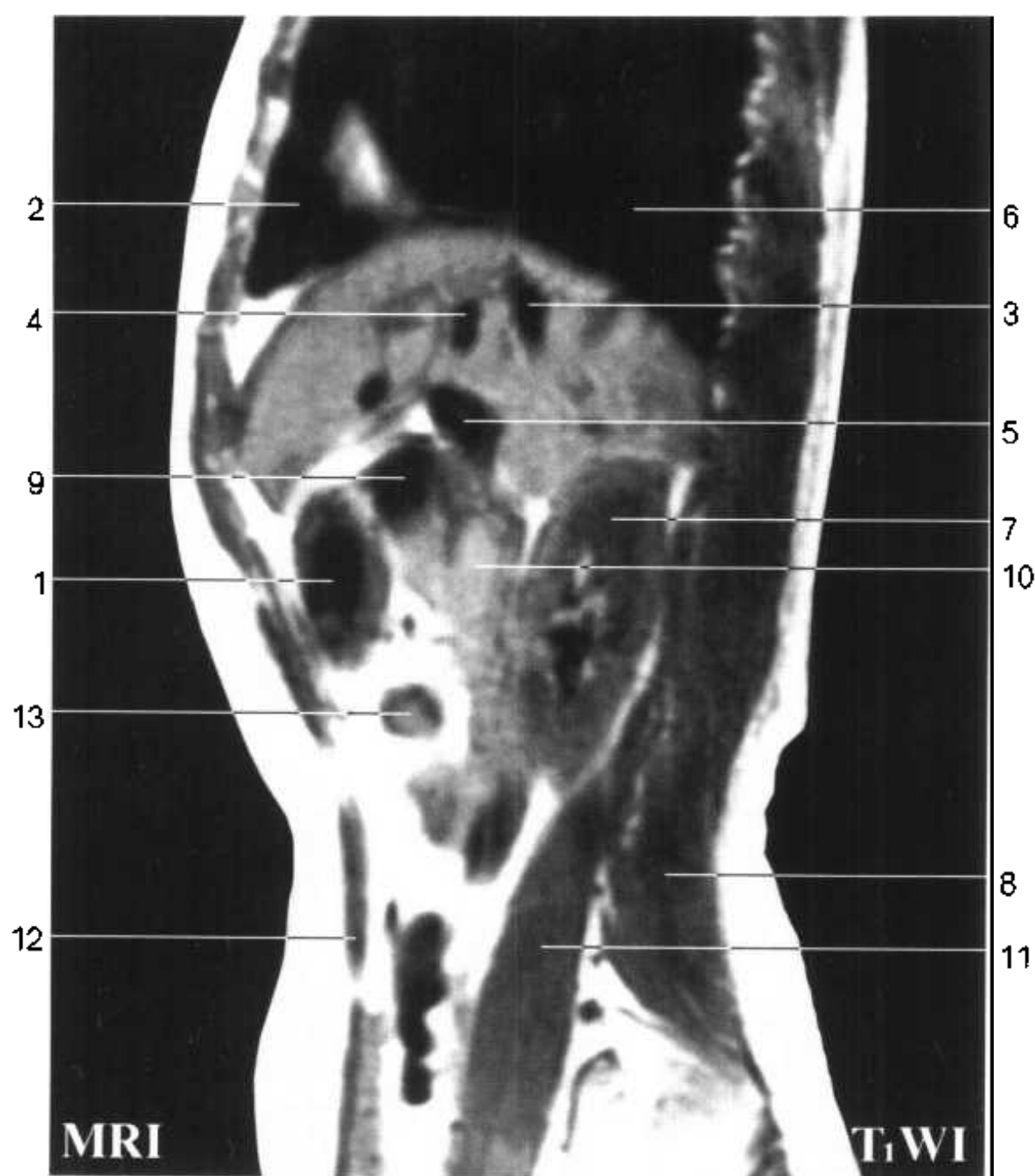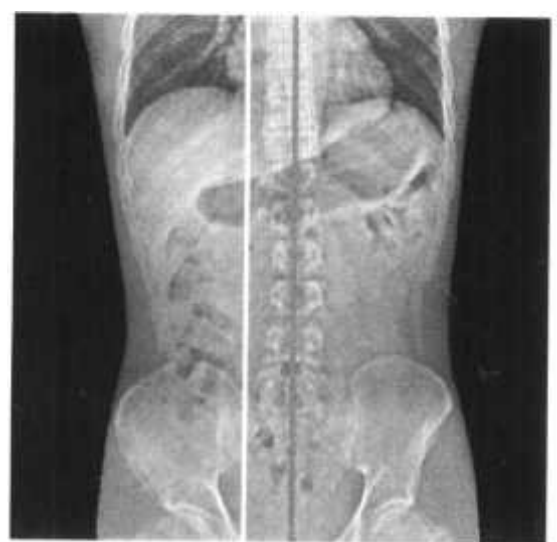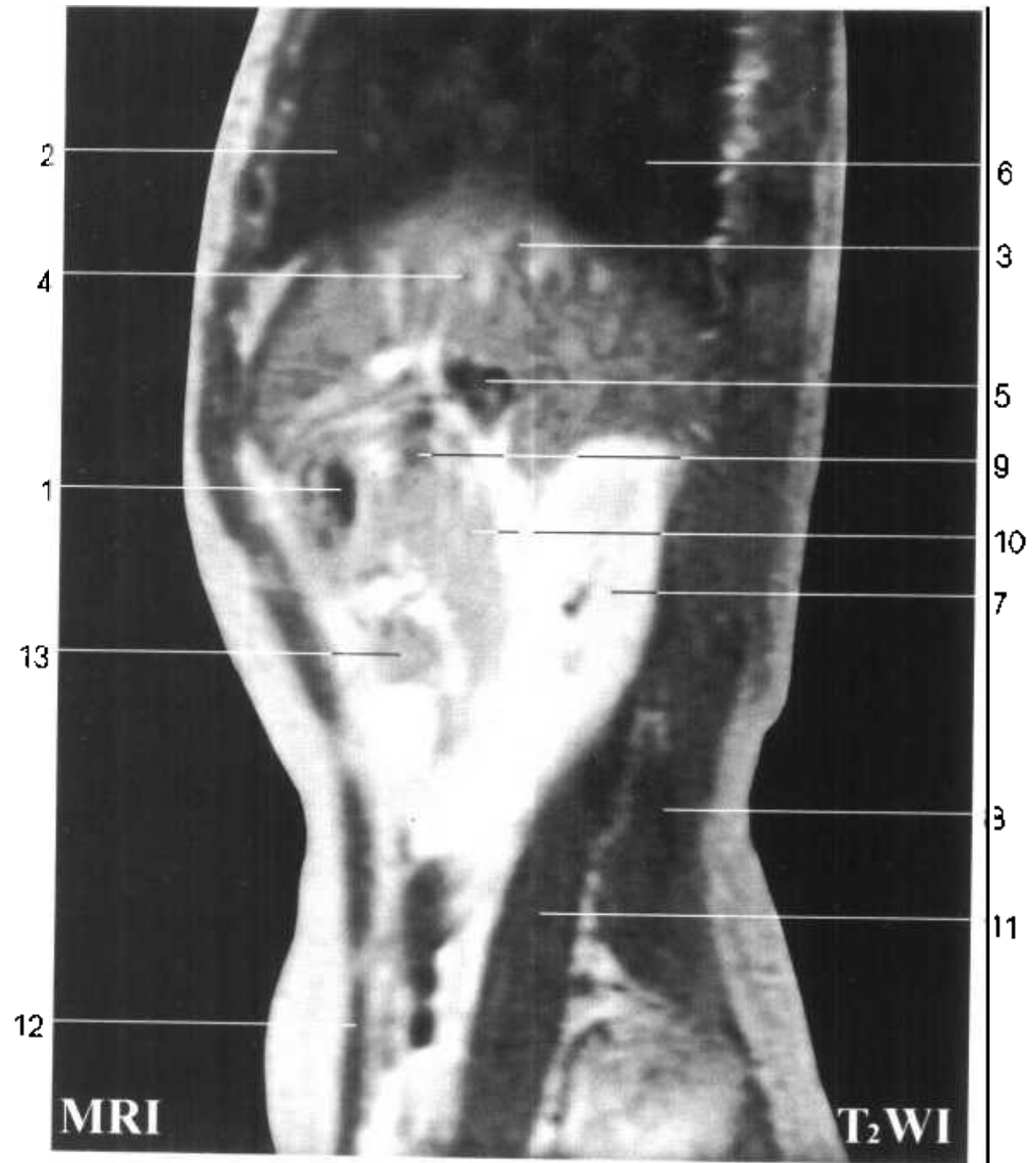


Fig. SA 8



1. 胃 stomach
2. 右肺中叶 middle lobe of right lung
3. 肝右静脉 right hepatic v.
4. 肝中间静脉 intermediate hepatic v.
5. 肝门静脉 hepatic portal v.
6. 右肺下叶 inferior lobe of right lung
7. 右肾 right kidney

Fig.SA 8



- 8. 竖脊肌 erector spinae
- 9. 十二指肠上部 superior part of duodenum
- 10. 胰头 head of pancreas
- 11. 腰大肌 psoas major
- 12. 腹直肌 rectus abdominis
- 13. 横结肠 transverse colon

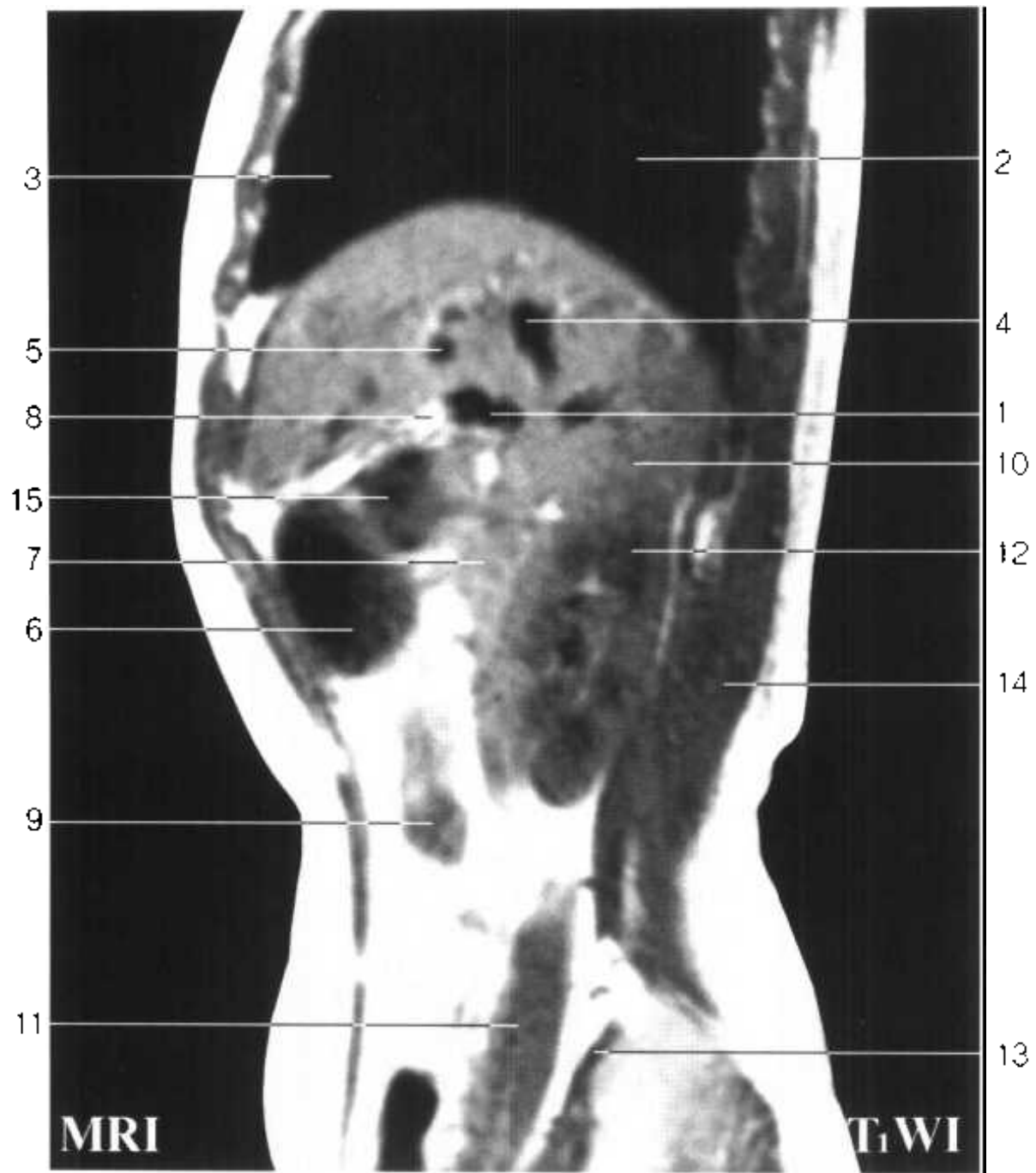
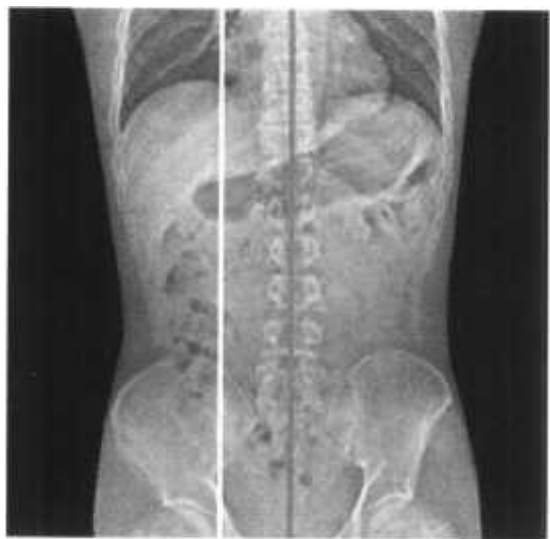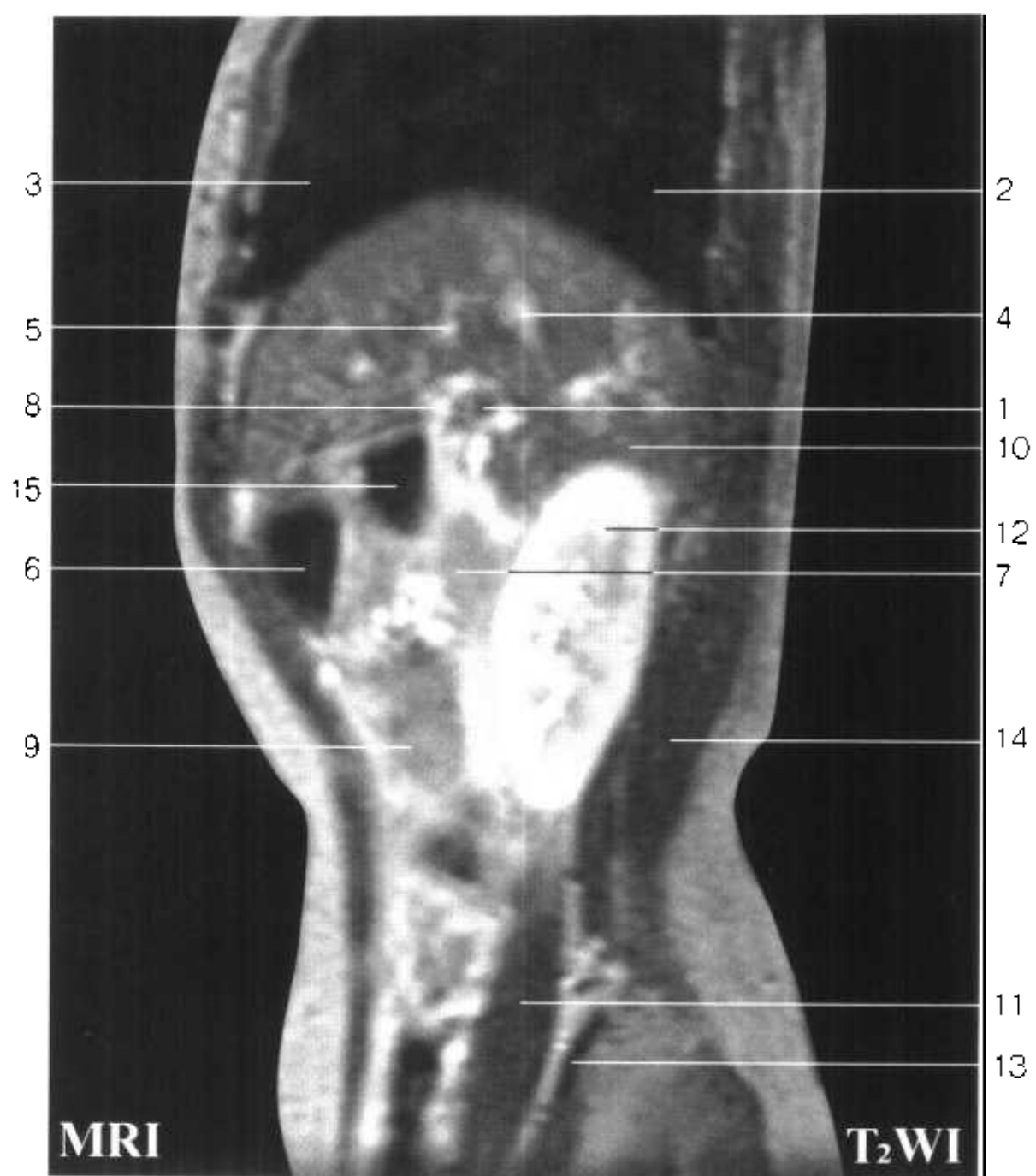


Fig. SA 9



1. 肝门静脉 hepatic portal v.
2. 右肺下叶 inferior lobe of right lung
3. 右肺中叶 middle lobe of right lung
4. 肝右静脉 right hepatic v.
5. 肝中间静脉 intermediate hepatic v.
6. 胃 stomach
7. 胰头 head of pancreas
8. 胆囊 gallbladder

Fig. SA 9



- 9. 横结肠 transverse colon
- 10. 右肾上腺 right suprarenal gland
- 11. 腰大肌 psoas major
- 12. 右肾 right kidney
- 13. 髂骨 ilium
- 14. 竖脊肌 erector spinae
- 15. 十二指肠降部 descending part of duodenum

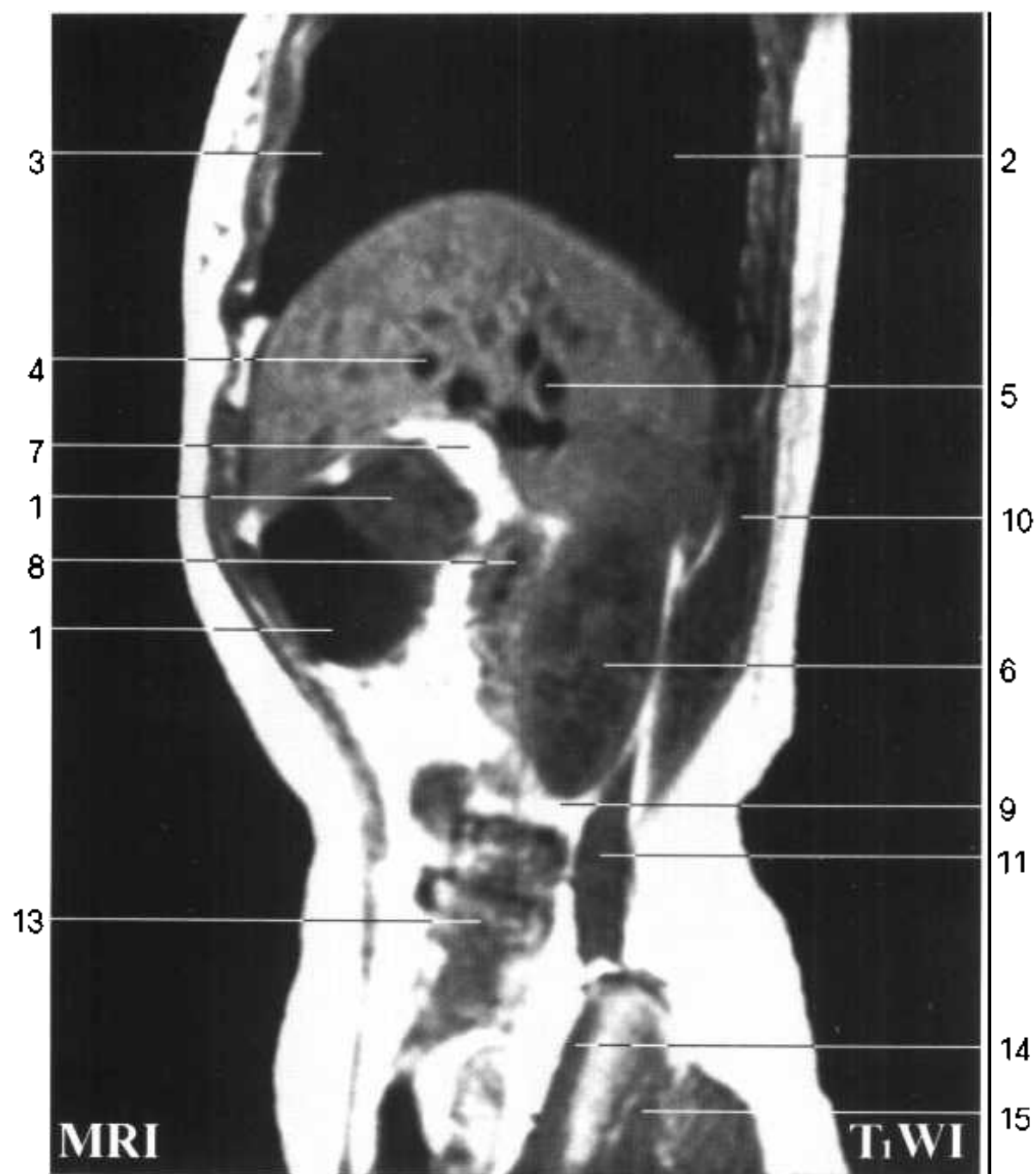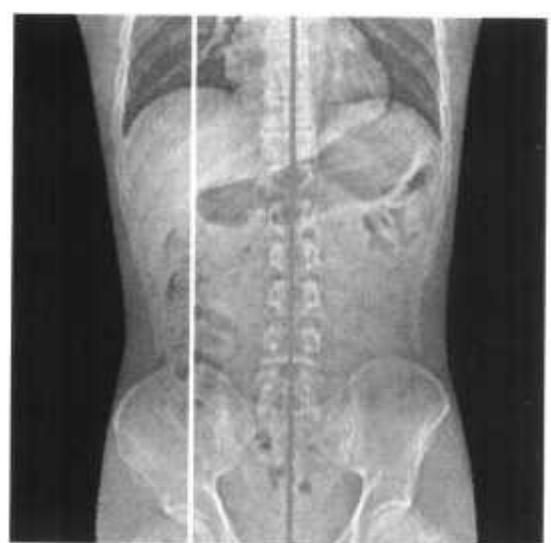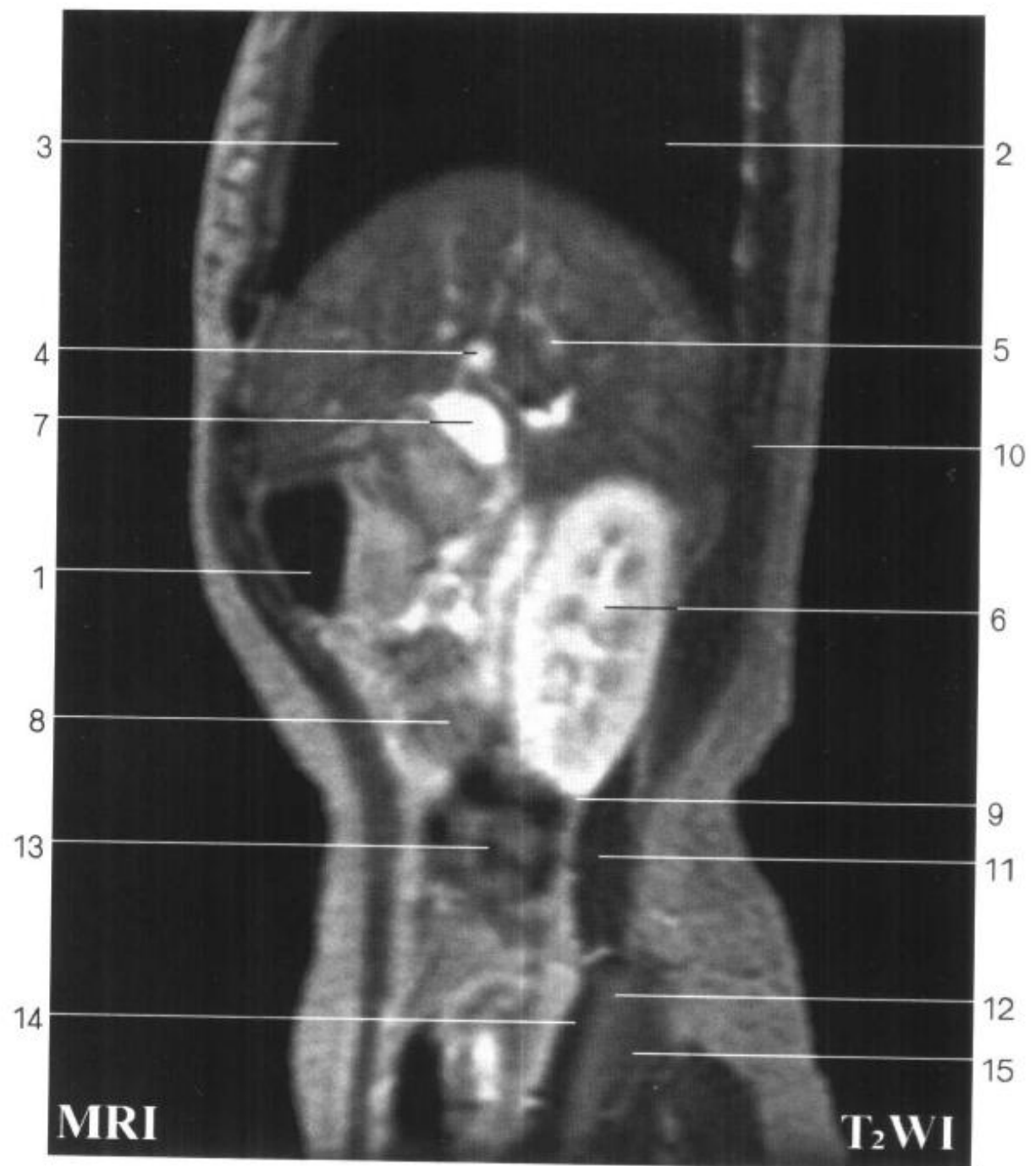


Fig. SA 10



- 1. 胃 stomach
- 2. 右肺下叶 inferior lobe of right lung
- 3. 右肺中叶 middle lobe of right lung
- 4. 肝中间静脉 intermediate hepatic v.
- 5. 肝右静脉 right hepatic v.
- 6. 右肾 right kidney
- 7. 胆囊 gallbladder

Fig.SA 10



8. 横结肠 transverse colon
9. 脂肪囊 fatty renal capsule
10. 竖脊肌 erector spinae
11. 腰方肌 quadratus lumborum
12. 髂嵴 iliac crest
13. 回肠 ileum
14. 髂肌 iliacus
15. 臀中肌 gluteus medius

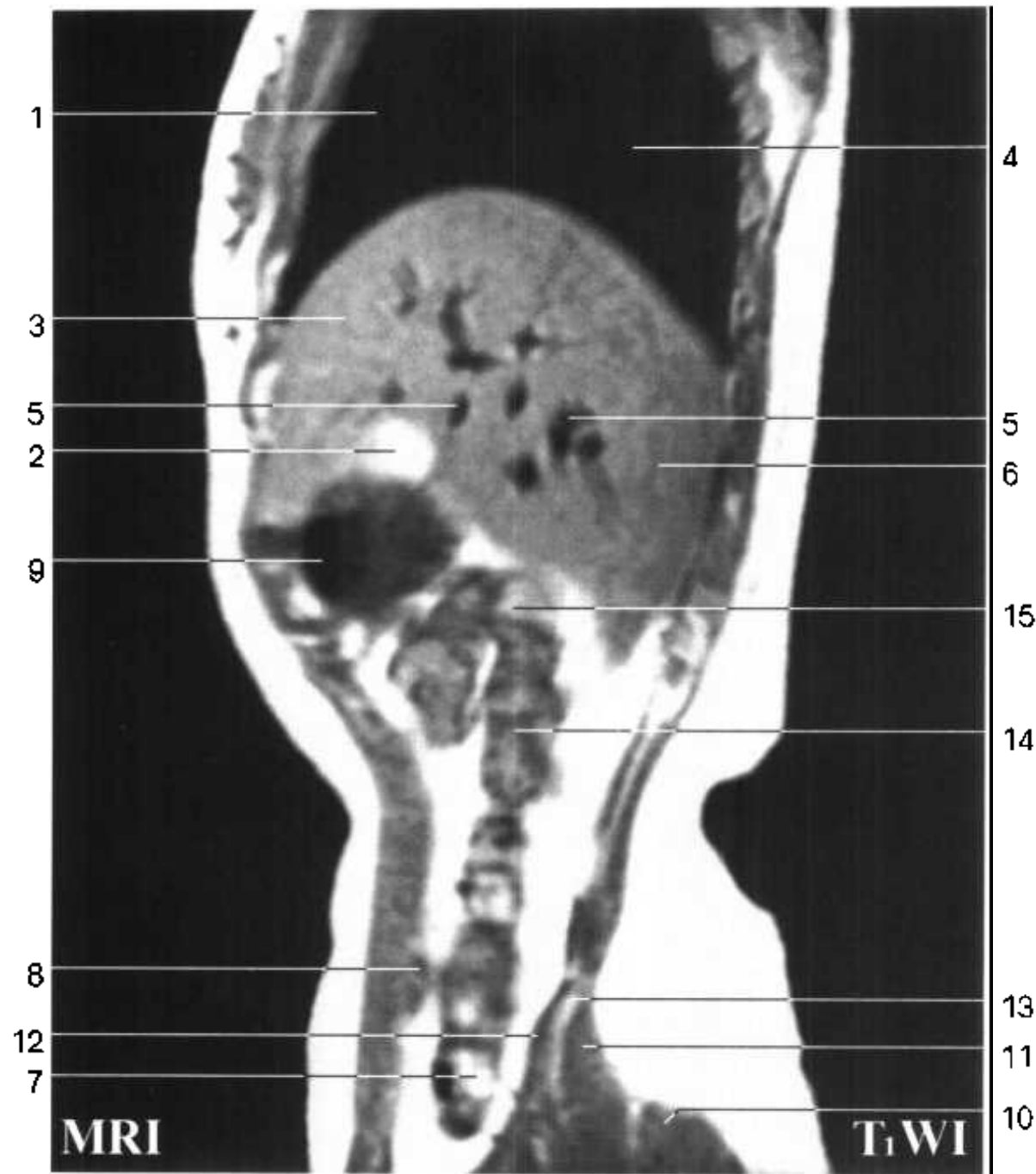
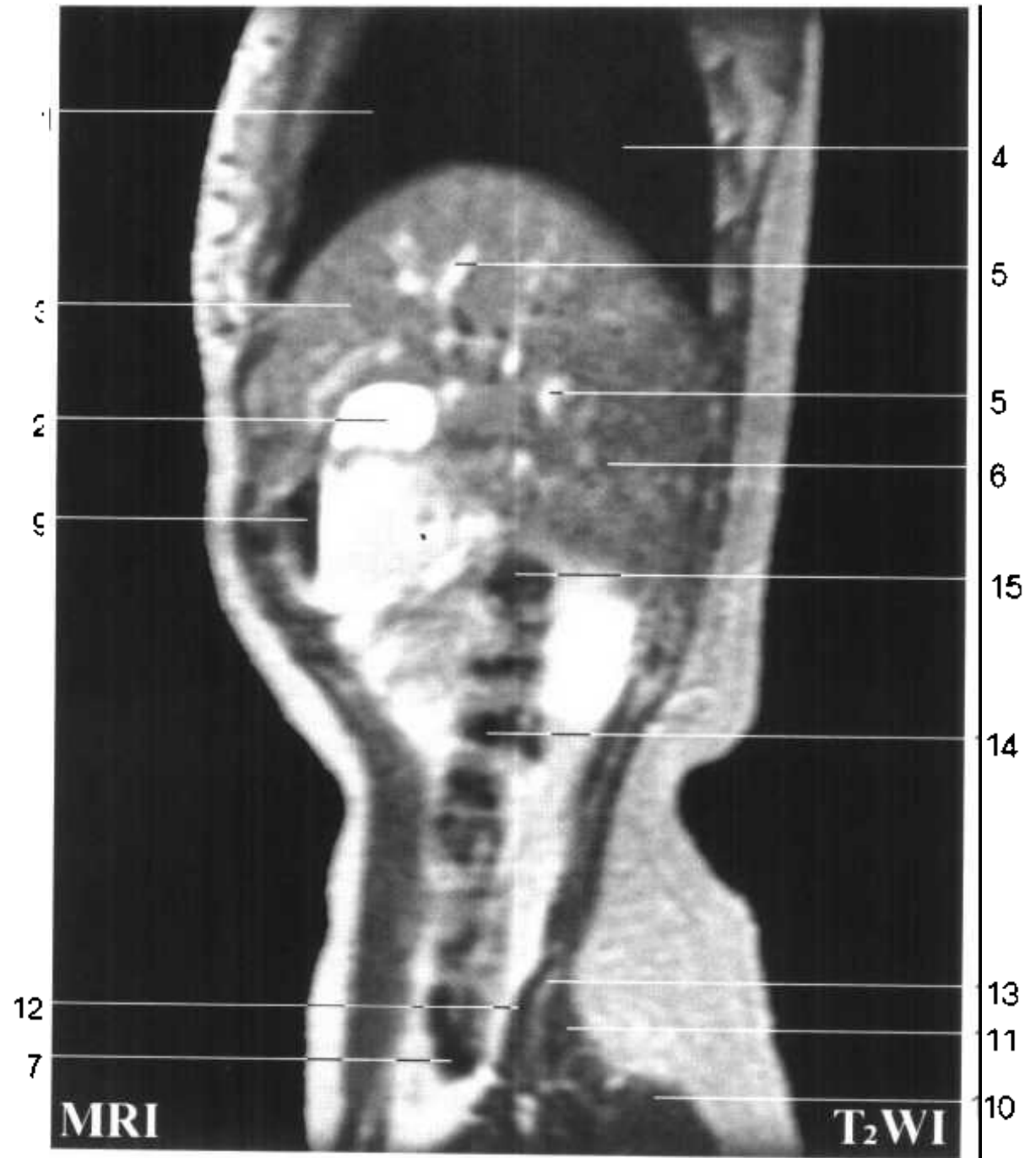


Fig. SA 11

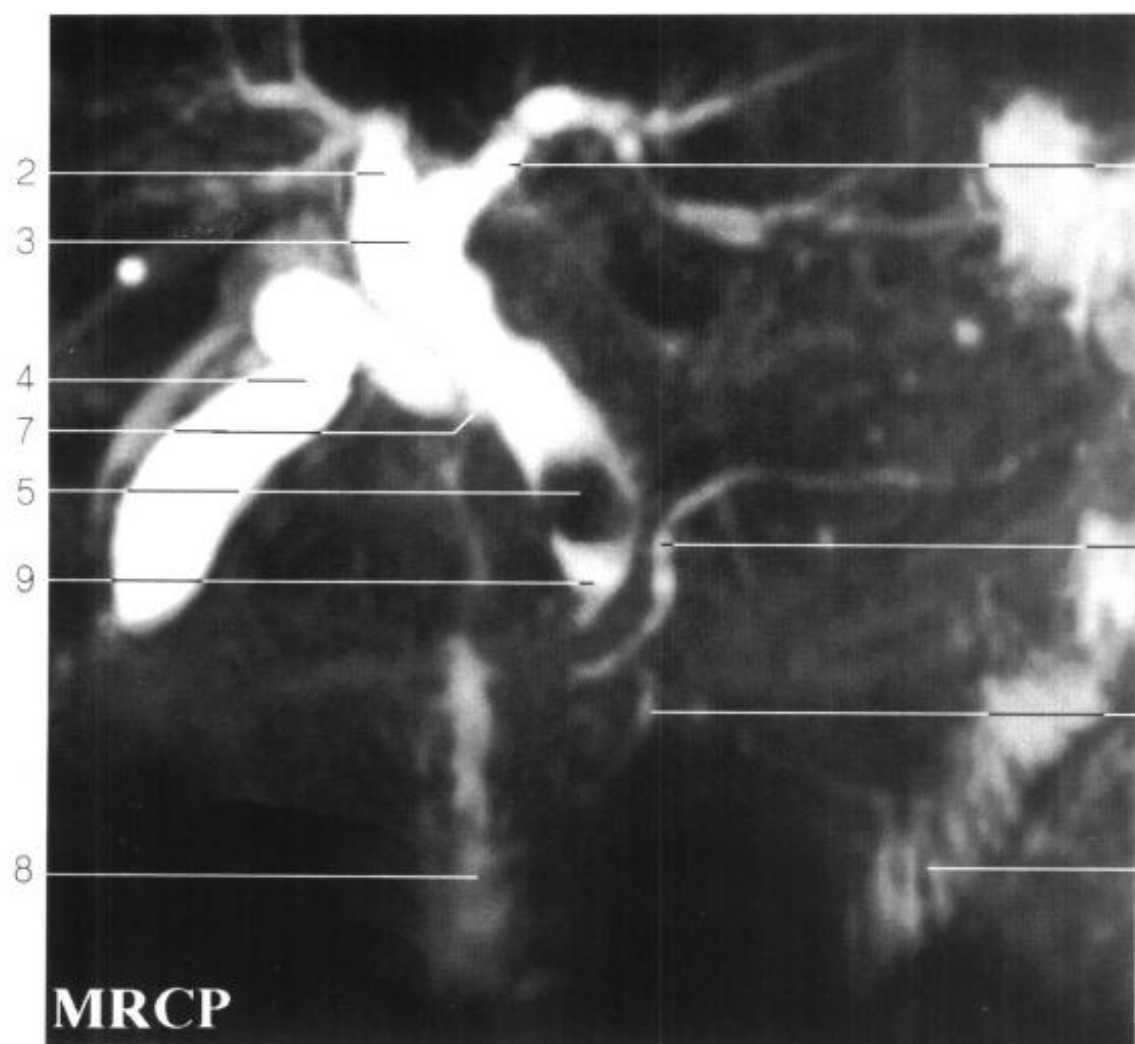
1. 右肺中叶 middle lobe of right lung
2. 胆囊 gallbladder
3. 右前叶 right anterior lobe
4. 右肺下叶 inferior lobe of right lung
5. 肝右静脉 right hepatic v.
6. 右后叶 right posterior lobe
7. 盲肠 cecum

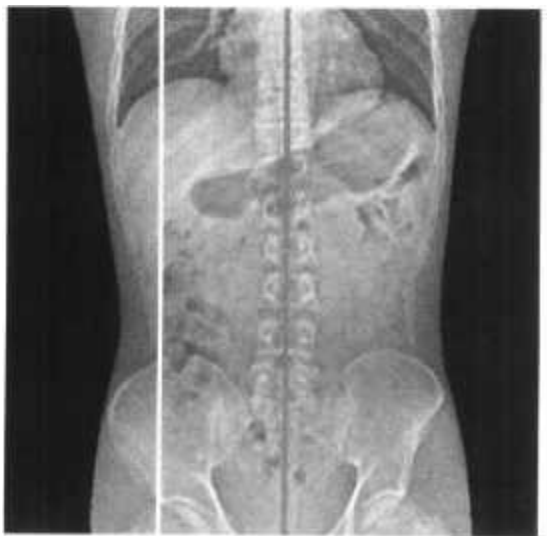

Fig. SA 11



- 8. 回肠 ileum
- 9. 胃 stomach
- 10. 臀大肌 gluteus maximus
- 11. 臀中肌 gluteus medius
- 12. 髂肌 iliacus
- 13. 髂嵴 iliac crest
- 14. 升结肠 ascending colon
- 15. 结肠右曲 right colic flexure



- 10. 肾 kidney
- 11. 肾盂 renal pelvis
- 12. 输尿管 ureter
- 13. 膀胱 urinary bladder
- 14. 精囊 seminal vesicle
- 15. 蛛网膜下隙 subarachnoid space
- 16. 横结肠 transverse colon
- 17. 坐骨支 ramus of ischium
- 18. 升结肠 ascending colon
- 19. 髌骨 ilium
- 20. 股骨头 femoral head
- 21. 肾大盏 major renal calices

磁共振成象(胆、胰管及输尿管)MRI

Fig.MRI

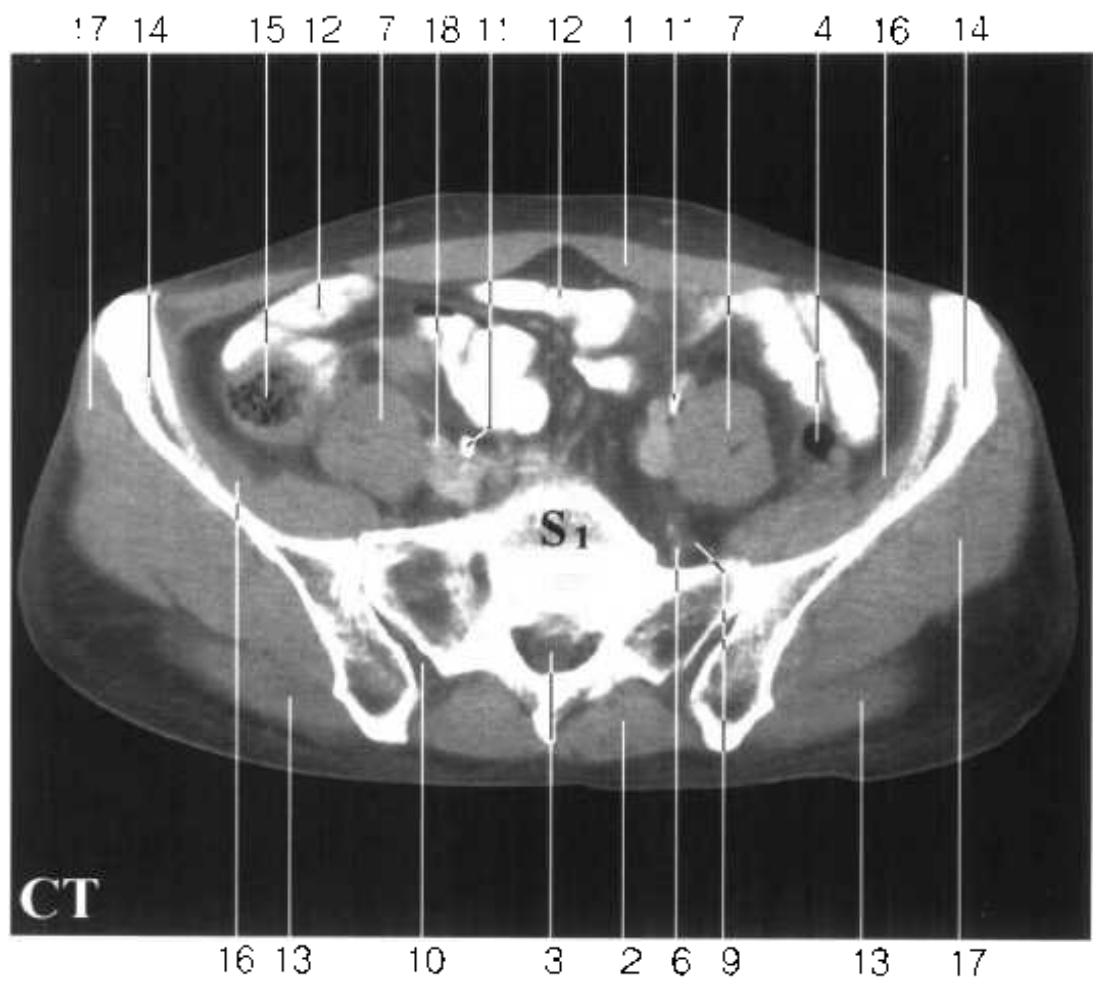
- 1. 肝左管 left hepatic duct
- 2. 肝右管 right hepatic duct
- 3. 肝总管 common hepatic duct
- 4. 胆囊 gallbladder
- 5. 胆结石 cholelith
- 6. 胰管 pancreatic duct
- 7. 胆囊管 cystic duct
- 8. 12指肠 duodenum
- 9. 胆总管 common bile duct

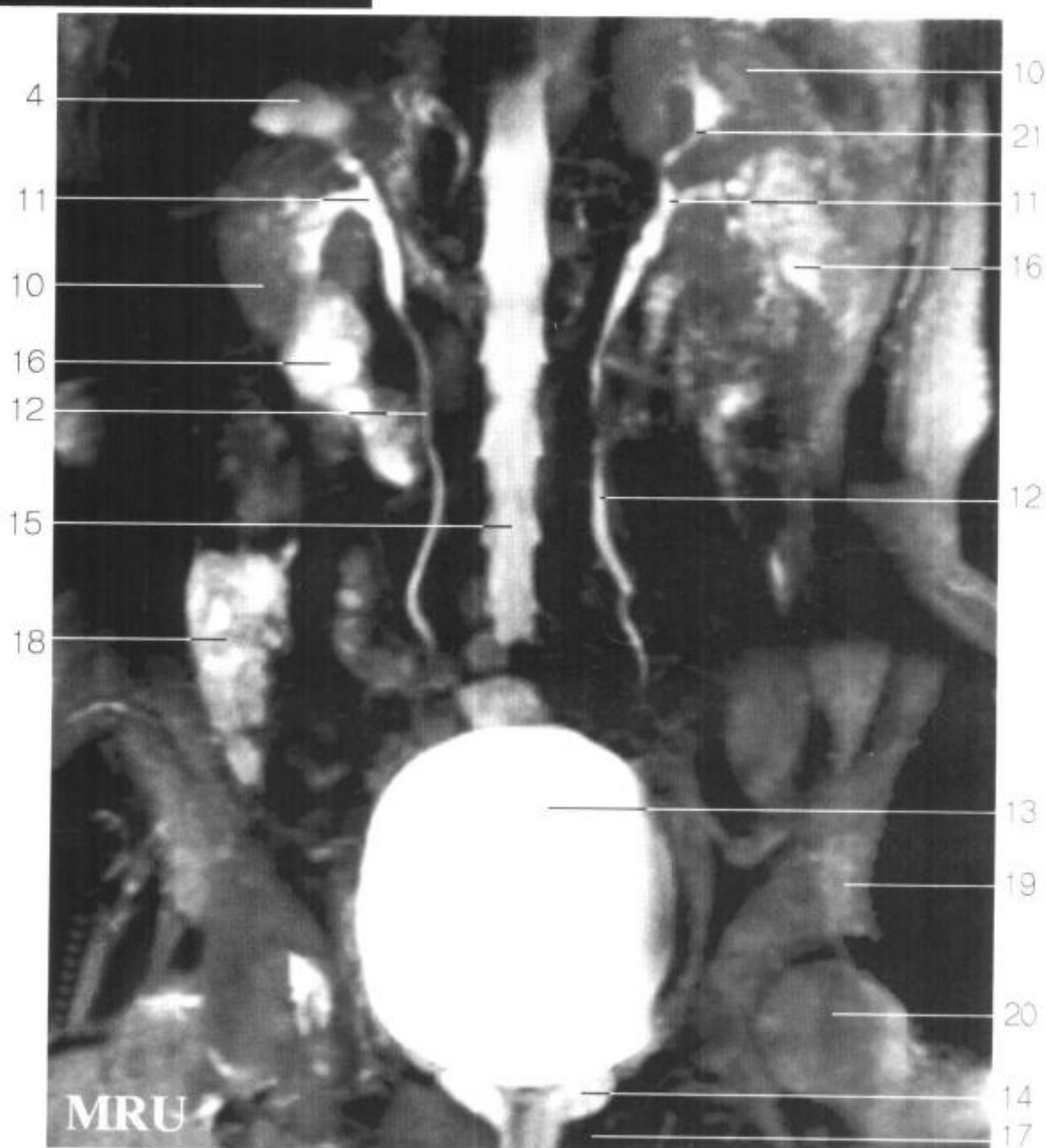

Fig. MRI

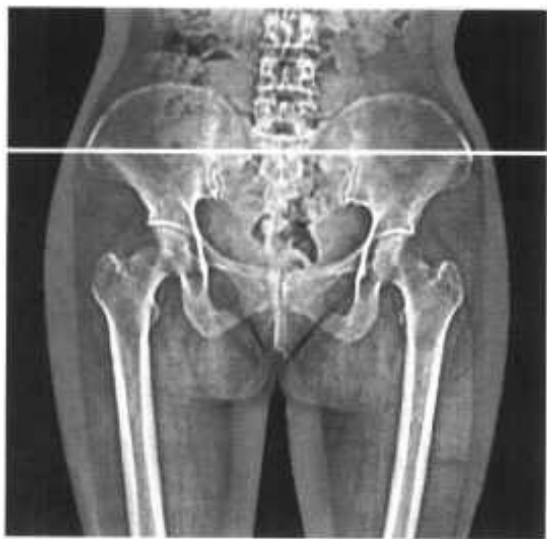盆 部

PELVIS



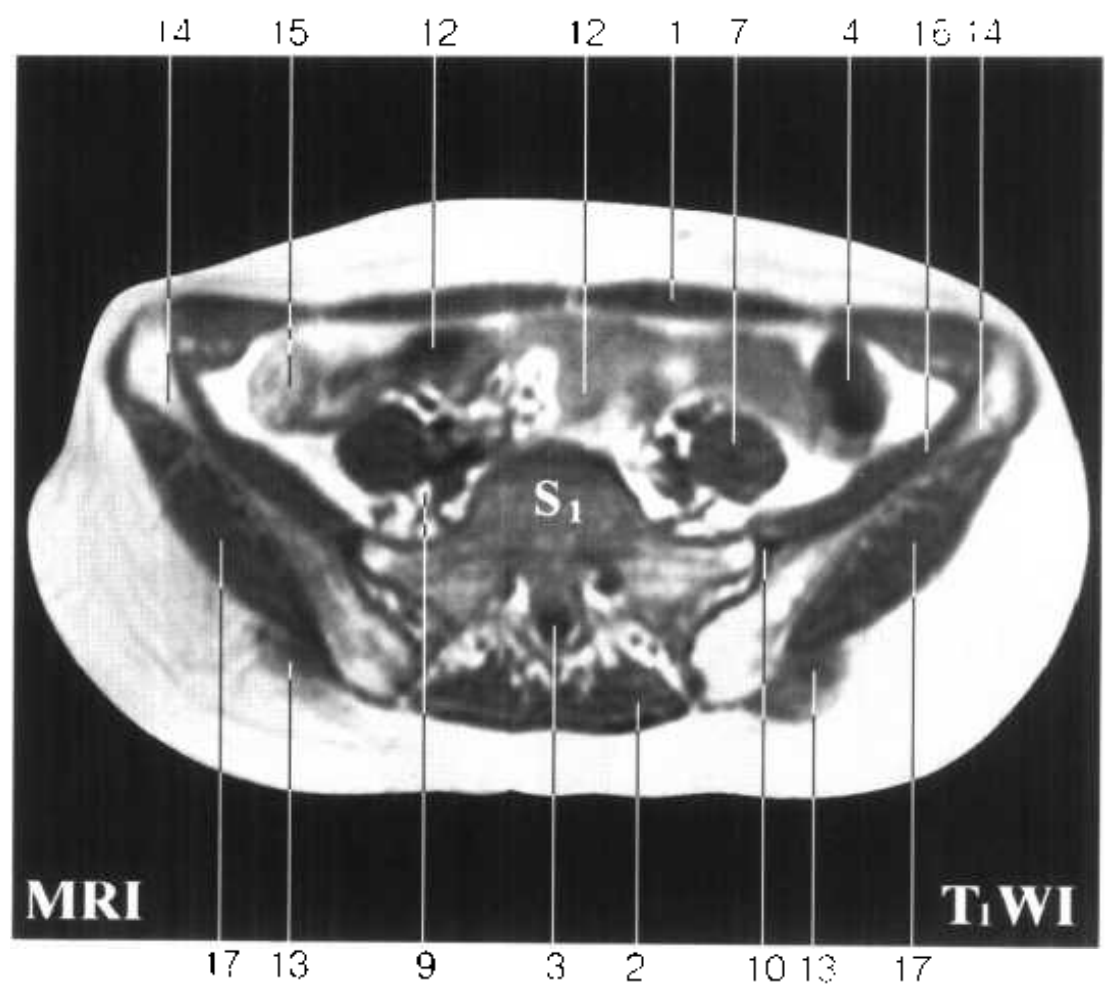
女盆水平断面图 HPf

Fig. HPf 1

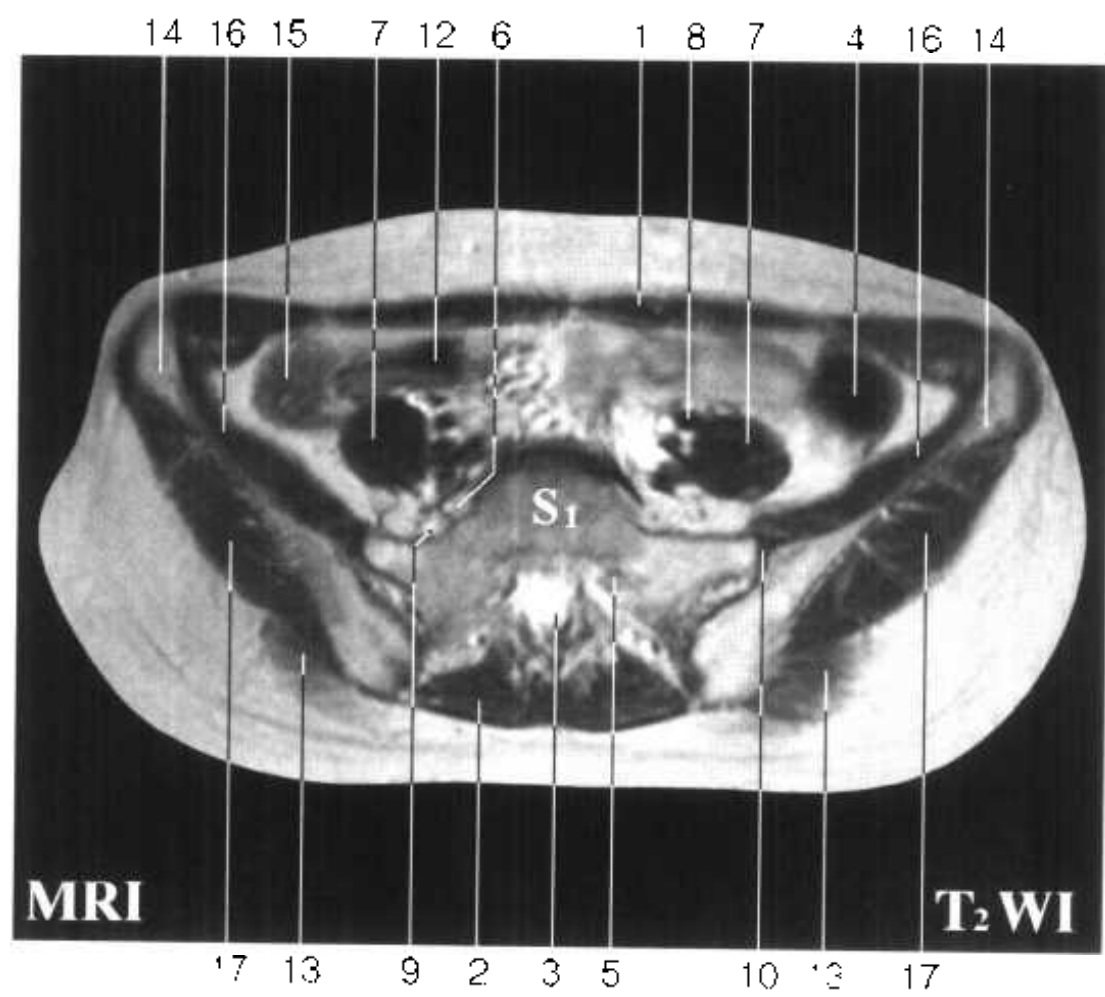


1. 腹直肌 rectus abdominis
2. 竖脊肌 erector spinae
3. 马尾 cauda equina
4. 乙状结肠 sigmoid colon
5. 第1骶神经 1st sacral n.
6. 腰骶干 lumbosacral trunk
7. 腰大肌 psoas major
8. 髂外动脉 external iliac a.

Fig. HPf 1



- 9. 闭孔神经 obturator n.
- 10. 骶髂关节 sacroiliac joint
- 11. 输尿管 ureter
- 12. 回肠 ileum
- 13. 臀大肌 gluteus maximus
- 14. 髂骨翼 ala of ilium
- 15. 盲肠 cecum
- 16. 髂肌 iliacus
- 17. 臀中肌 gluteus medius
- 18. 右髂外动脉 right external iliac a.



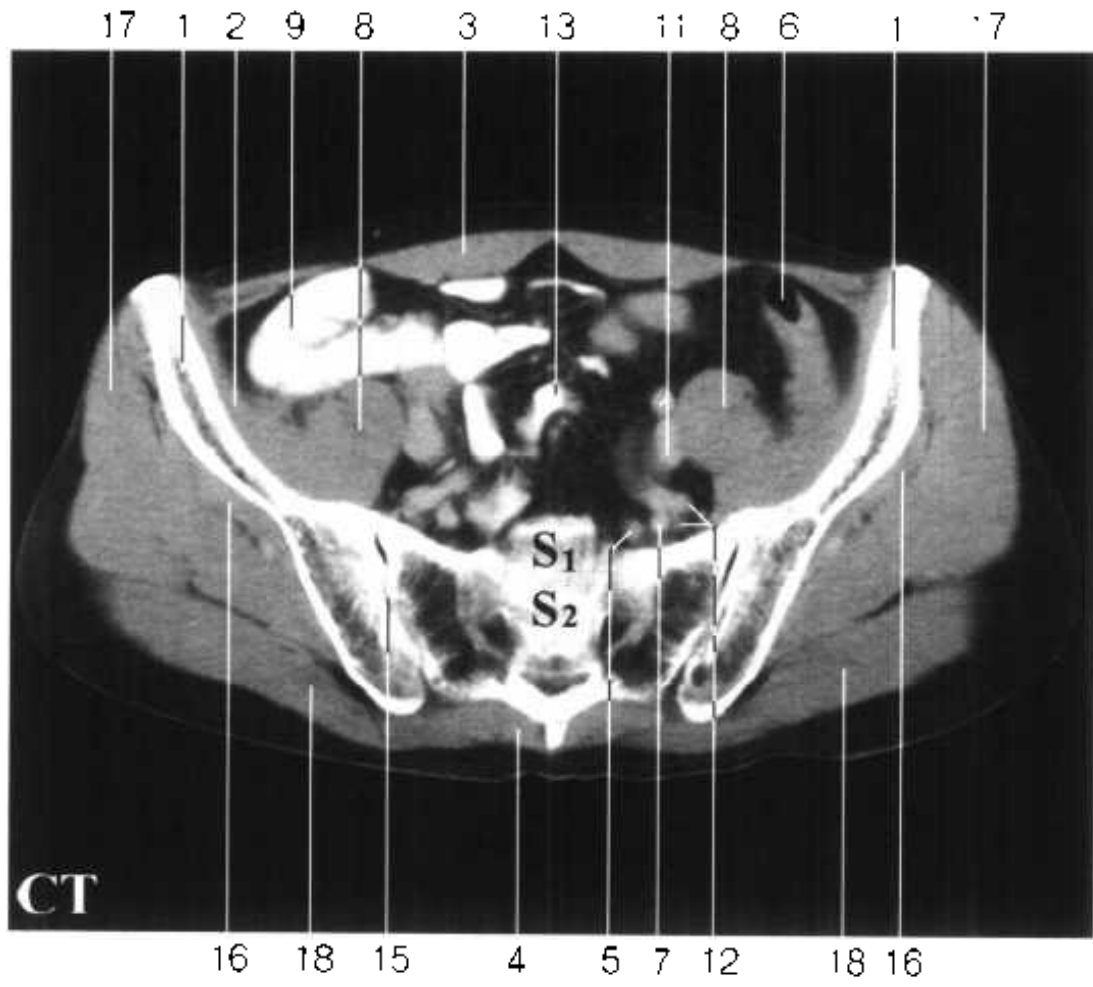
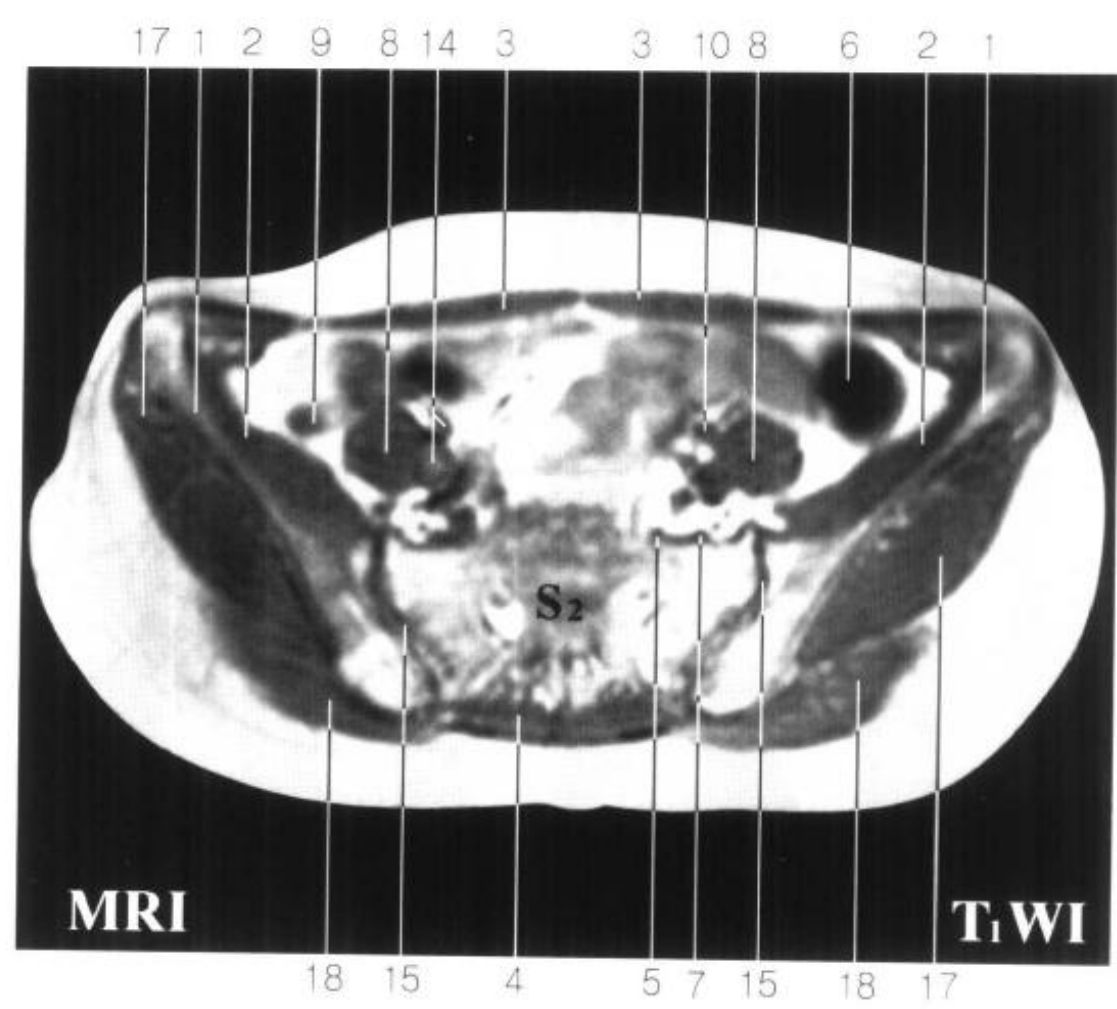


Fig. HPf 2

1. 髂骨翼 ala of ilium
2. 髂肌 iliacus
3. 腹直肌 rectus abdominis
4. 竖脊肌 erector spinae
5. 腰骶干 lumbosacral trunk
6. 乙状结肠 sigmoid colon
7. 闭孔神经 obturator n.
8. 腰大肌 psoas major
9. 回肠 ileum
10. 左髂外动脉 left external iliac a.

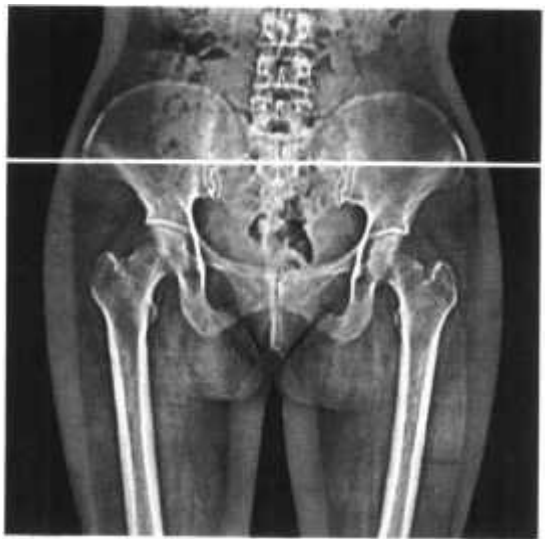

Fig. HPf 2



11. 左髂外静脉 left external iliac v.

12. 左髂内动脉 left internal iliac a.

13. 回肠 ileum

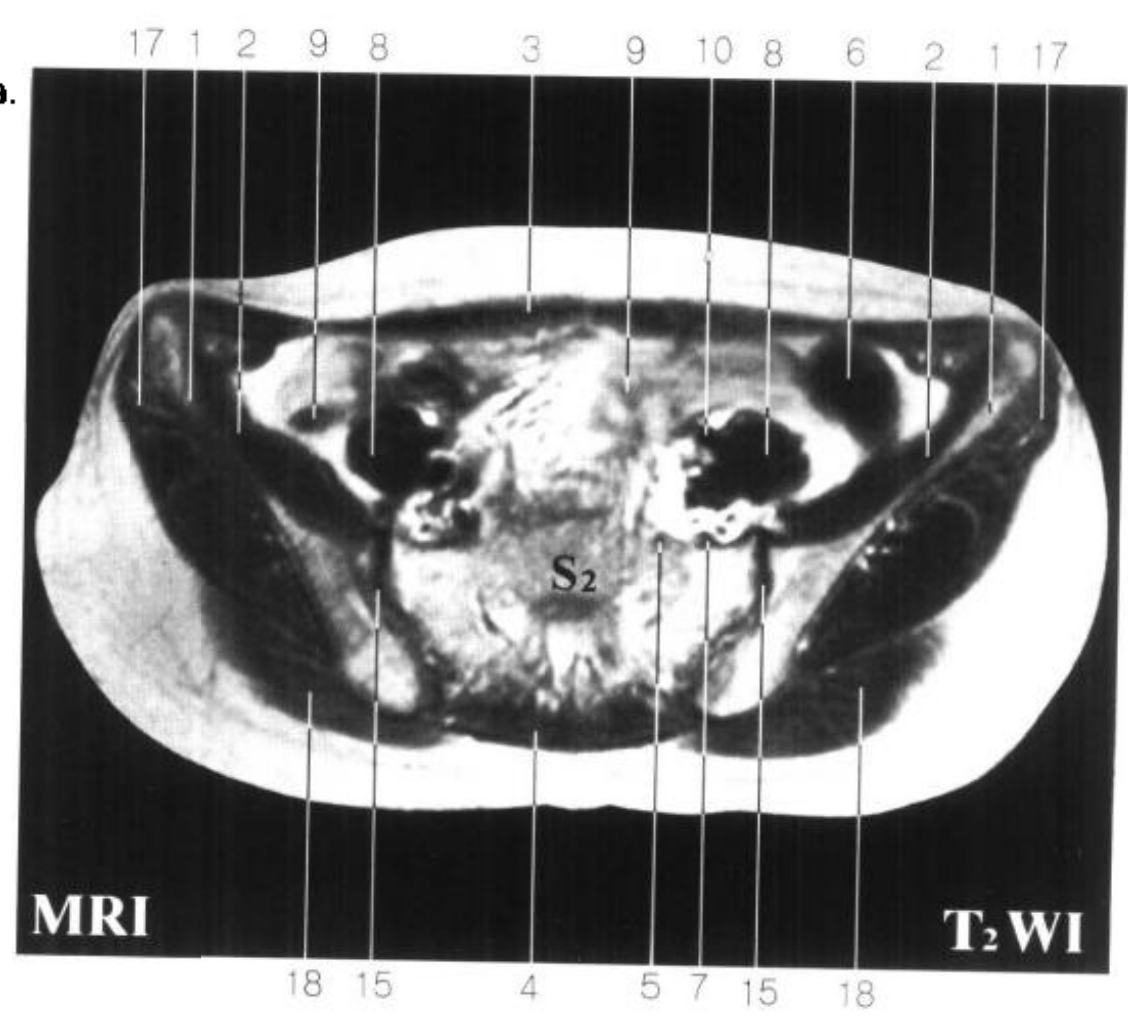
14. 右髂外动脉、静脉 right external iliac a.and v.

15. 骶髂关节 sacroiliac joint

16. 臀小肌 gluteus minimus

17. 臀中肌 gluteus medius

18. 臀大肌 gluteus maximus



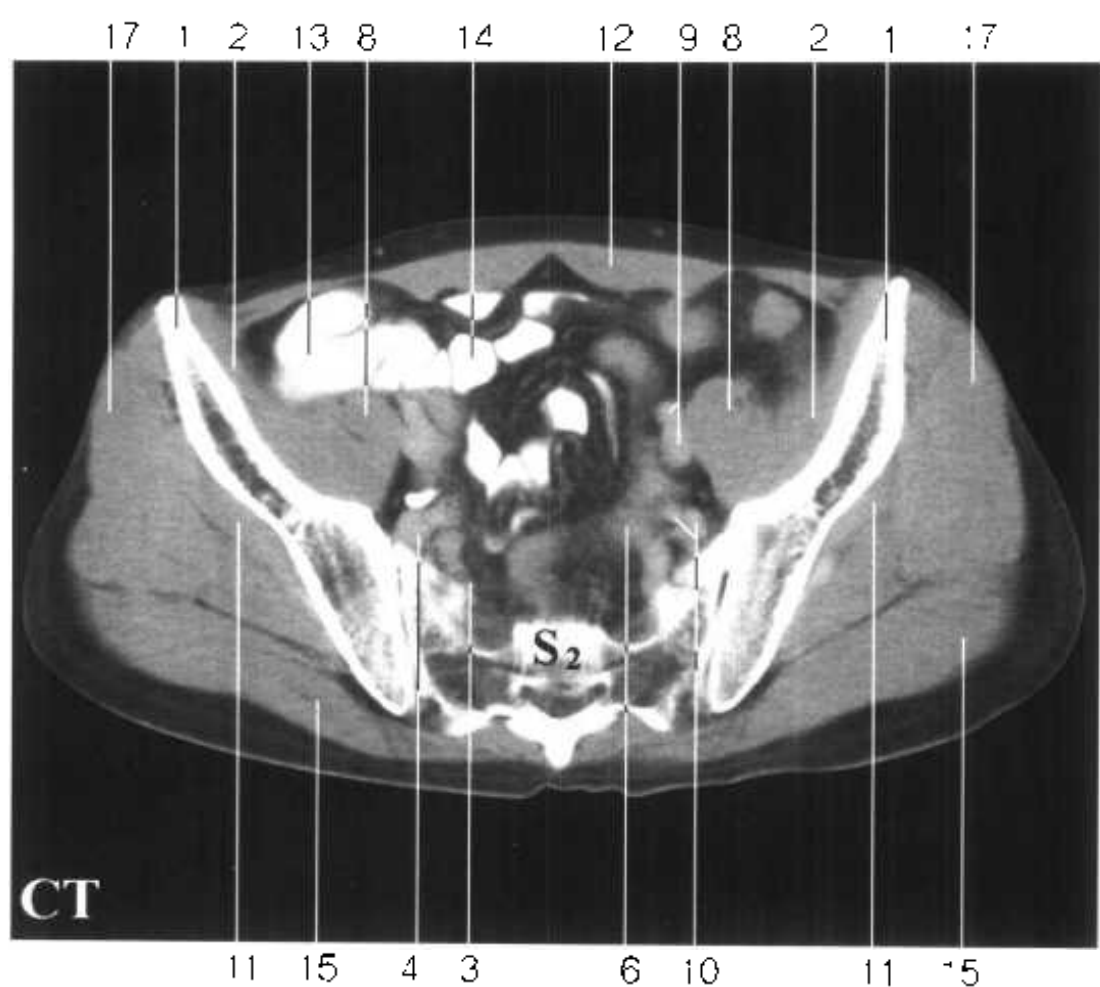
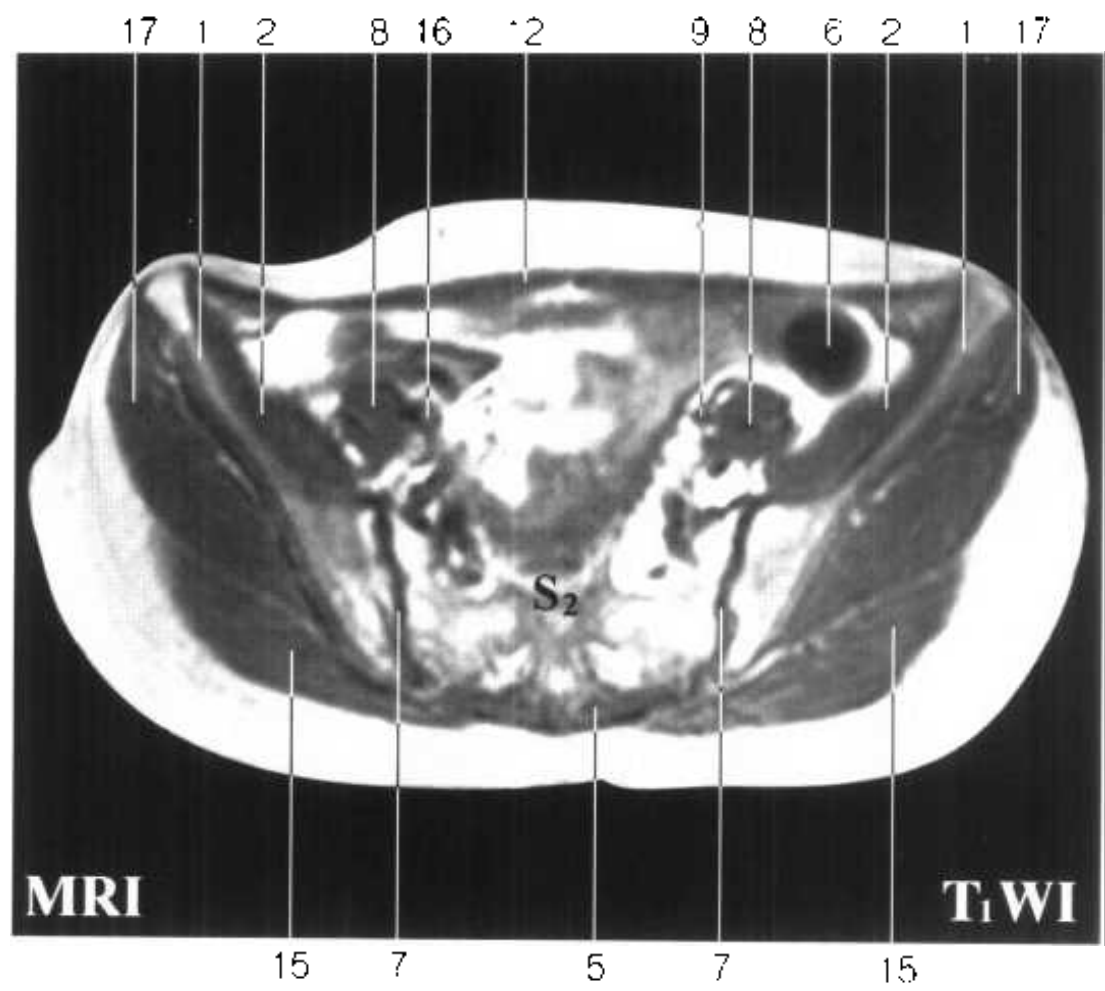


Fig. HPf 3

1. 髂骨翼 ala of ilium
2. 髂肌 iliacus
3. 第1骶神经 1st sacral n.
4. 腰骶干 lumbosacral trunk
5. 竖脊肌 erector spinae
6. 乙状结肠 sigmoid colon
7. 骶髂关节 sacroiliac joint
8. 腰大肌 psoas major
9. 左髂外动、静脉 left external iliac a.and v.

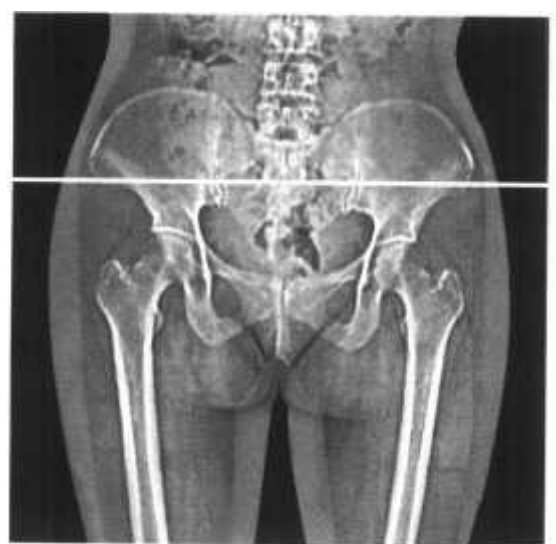

Fig. HPf 3



10. 左髂内动、静脉 left internal iliac a.and v.

11. 臀小肌 gluteus minimus

12. 腹直肌 rectus abdominis

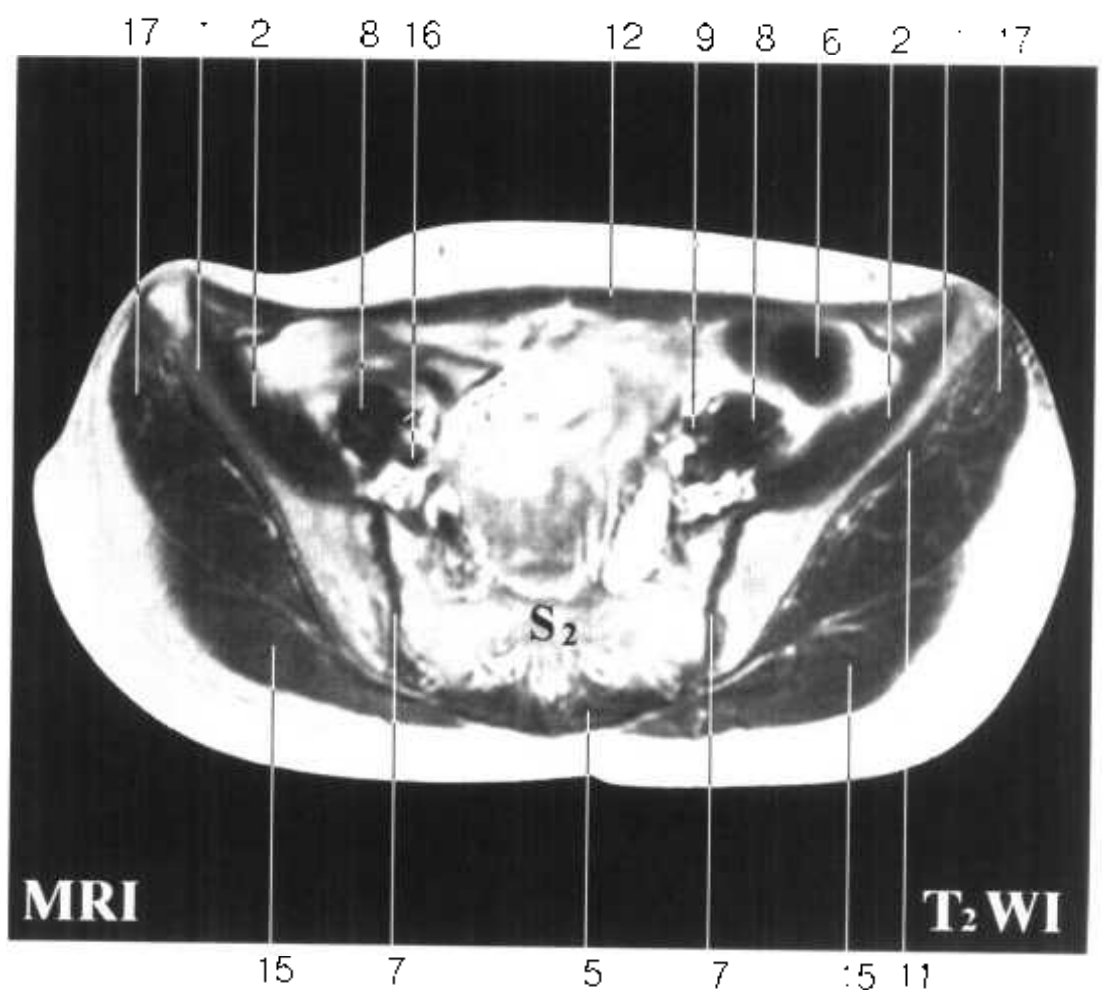
13. 回肠 ileum

14. 回肠 ileum

15. 臀大肌 gluteus maximus

16. 右髂外动、静脉 right external iliac a.and v.

17. 臀中肌 gluteus medius



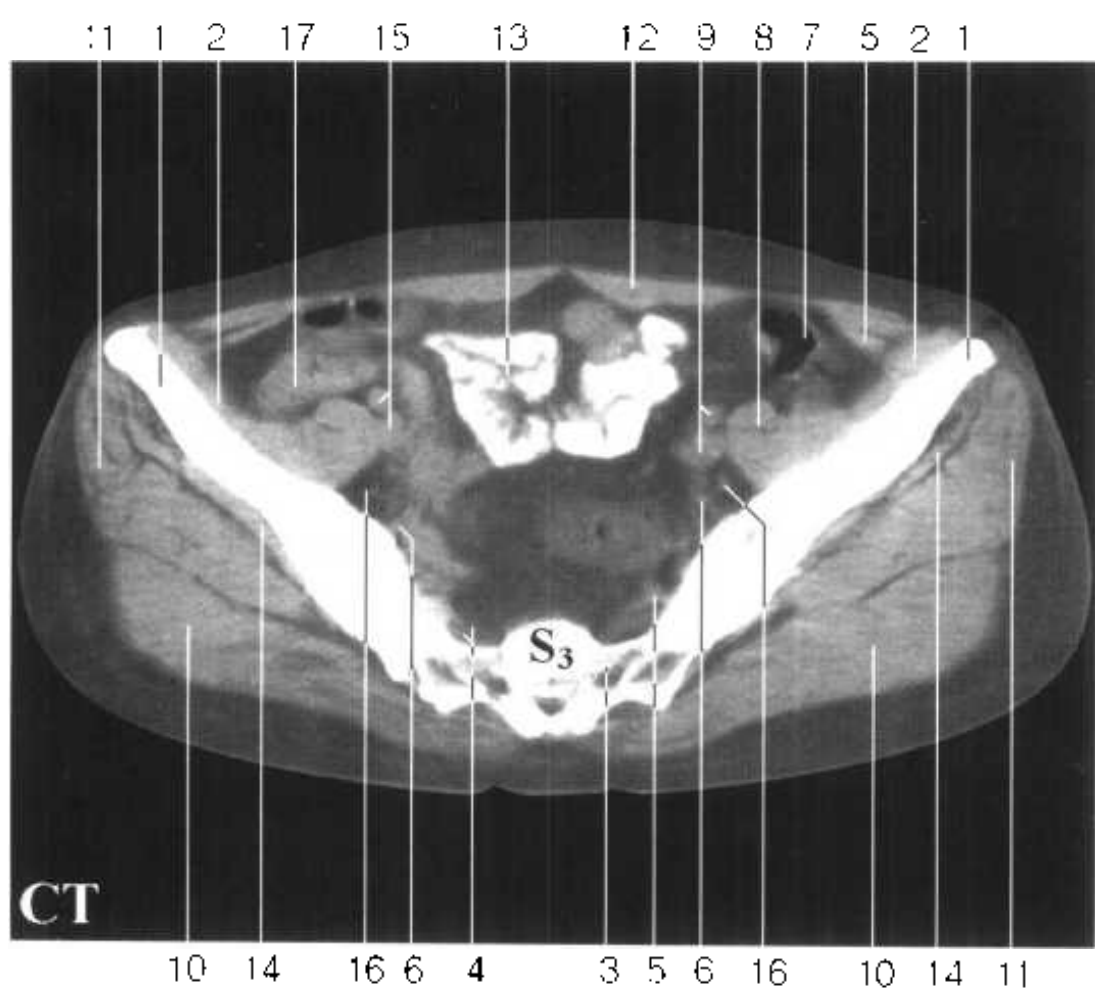
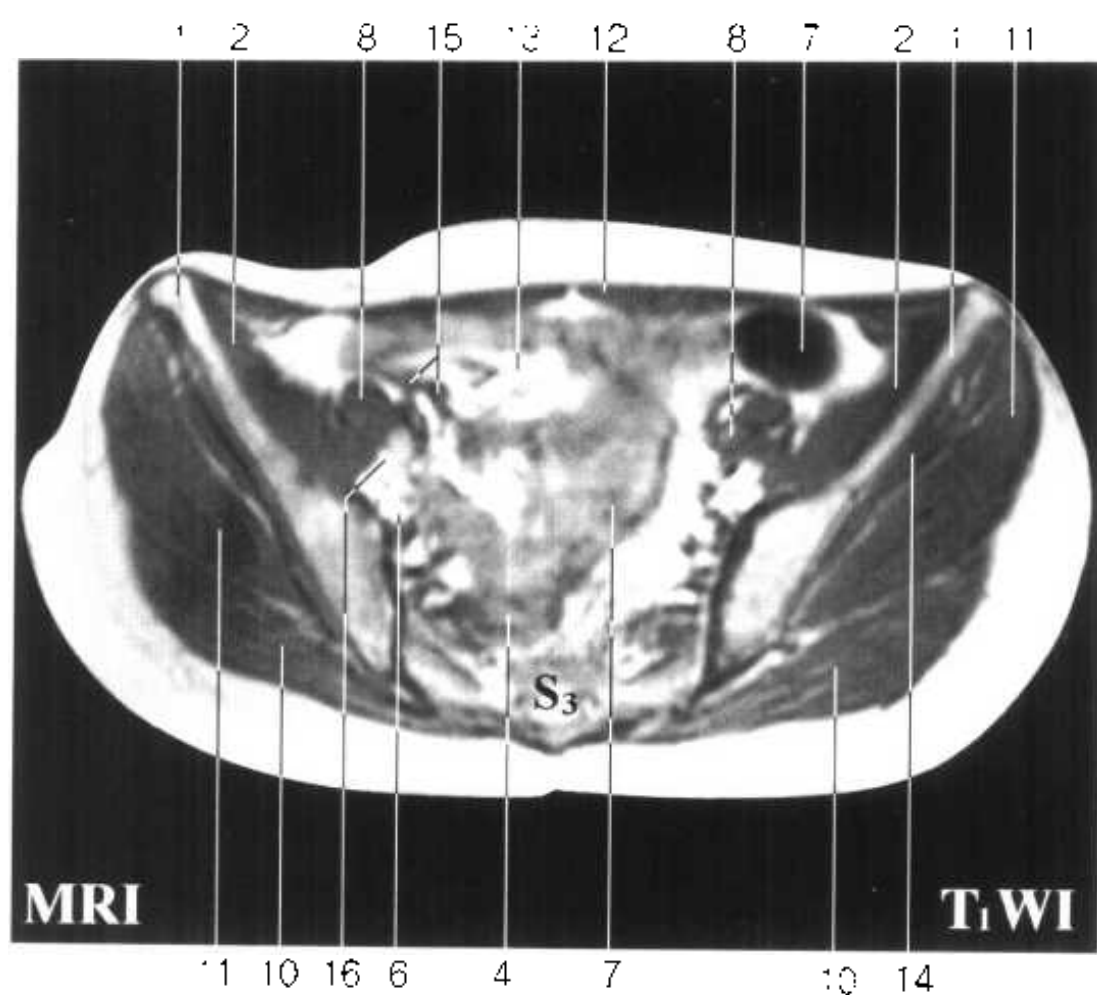


Fig. HPf 4

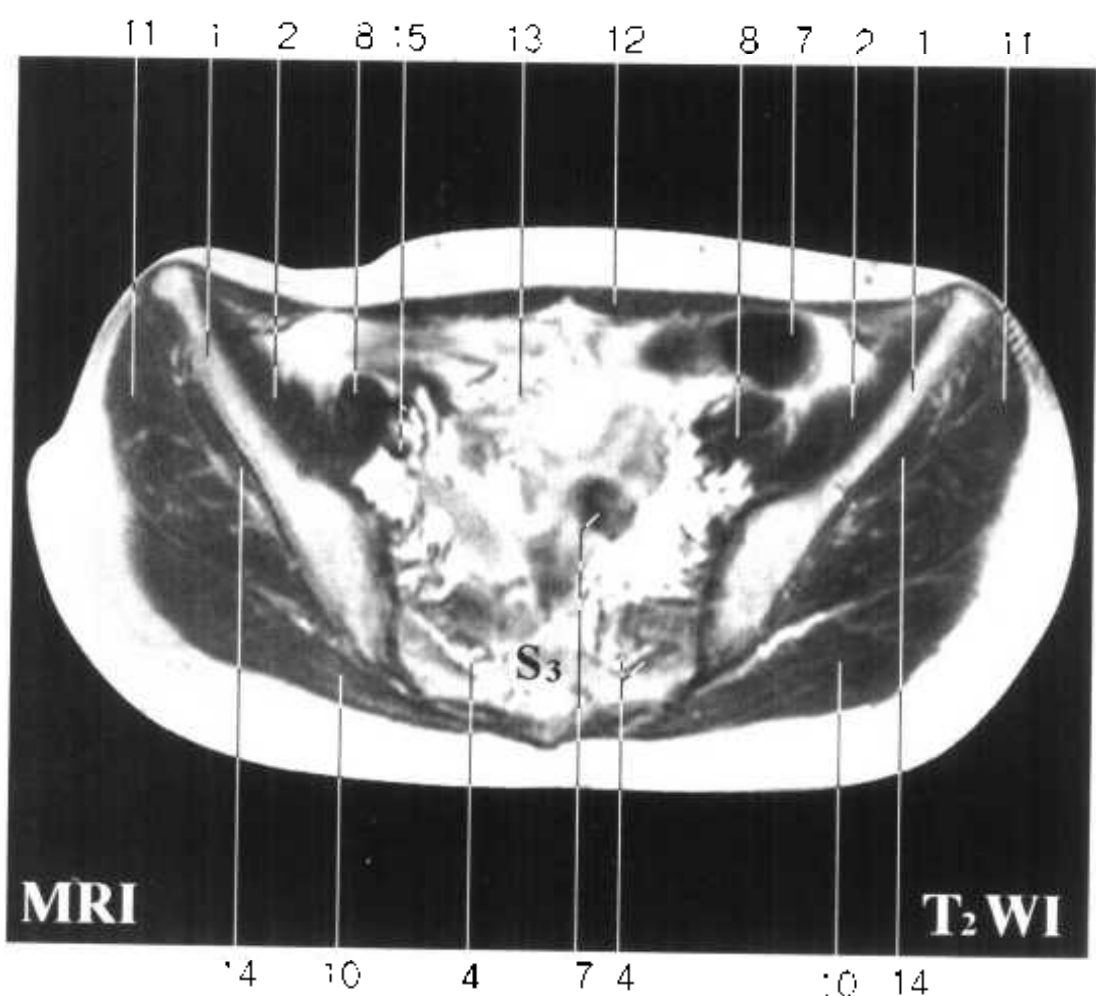
1. 髂骨翼 ala of ilium
2. 髂肌 iliacus
3. 第4骶神经 4th sacral n.
4. 第2骶神经与梨状肌 2nd sacral n.and piriformis
5. 第1骶神经 1st sacral n.
6. 腰骶干 lumbosacral trunk
7. 乙状结肠 sigmoid colon
8. 腰大肌 psoas major
9. 左髂外动、静脉 left external iliac a.and v.

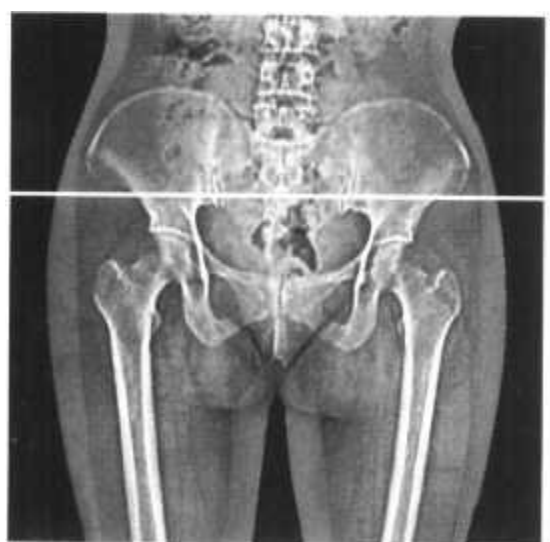

Fig. HPf 4



- 10. 臀大肌 gluteus maximus
- 11. 臀中肌 gluteus medius
- 12. 腹直肌 rectus abdominis
- 13. 回肠 ileum
- 14. 臀小肌 gluteus minimus
- 15. 右髂外动、静脉 right external iliac a.and v.
- 16. 闭孔神经 obturator n.
- 17. 盲肠 cecum



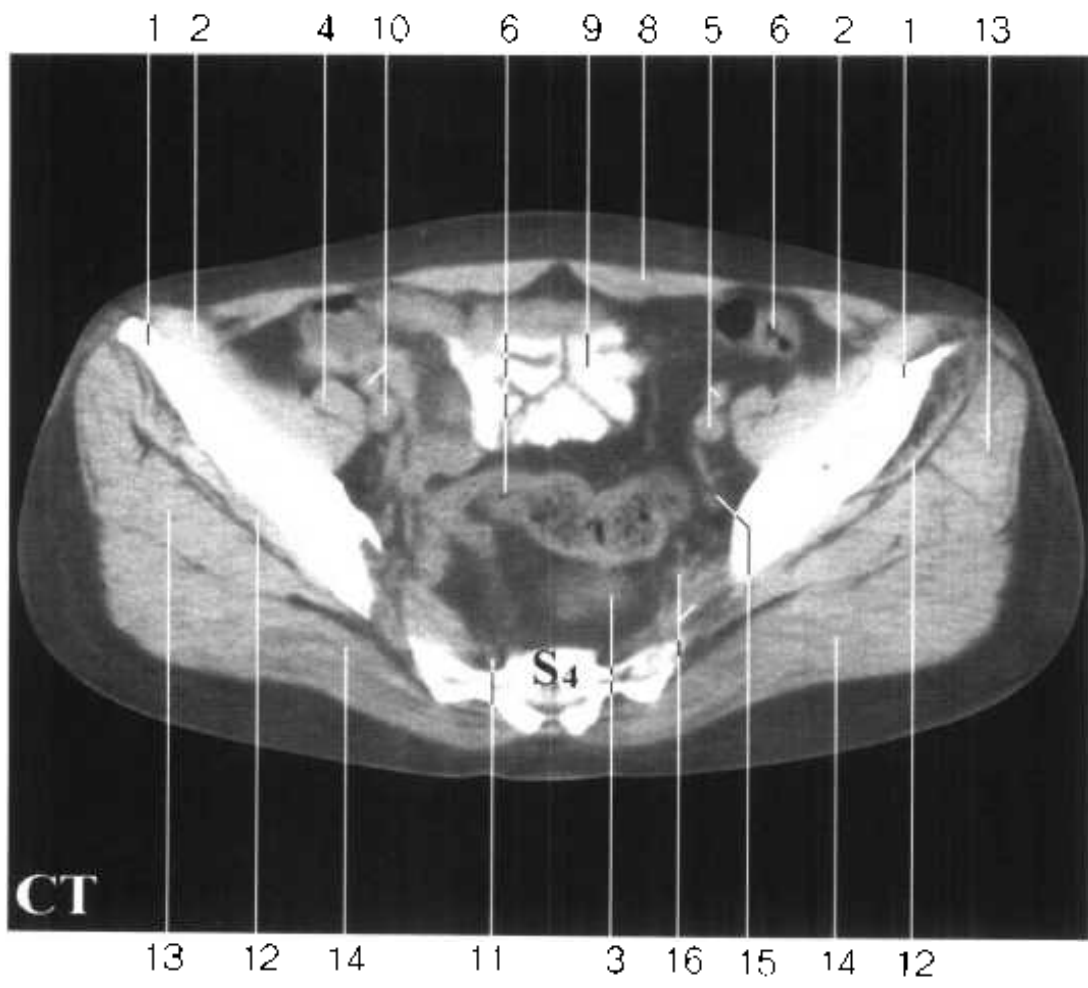
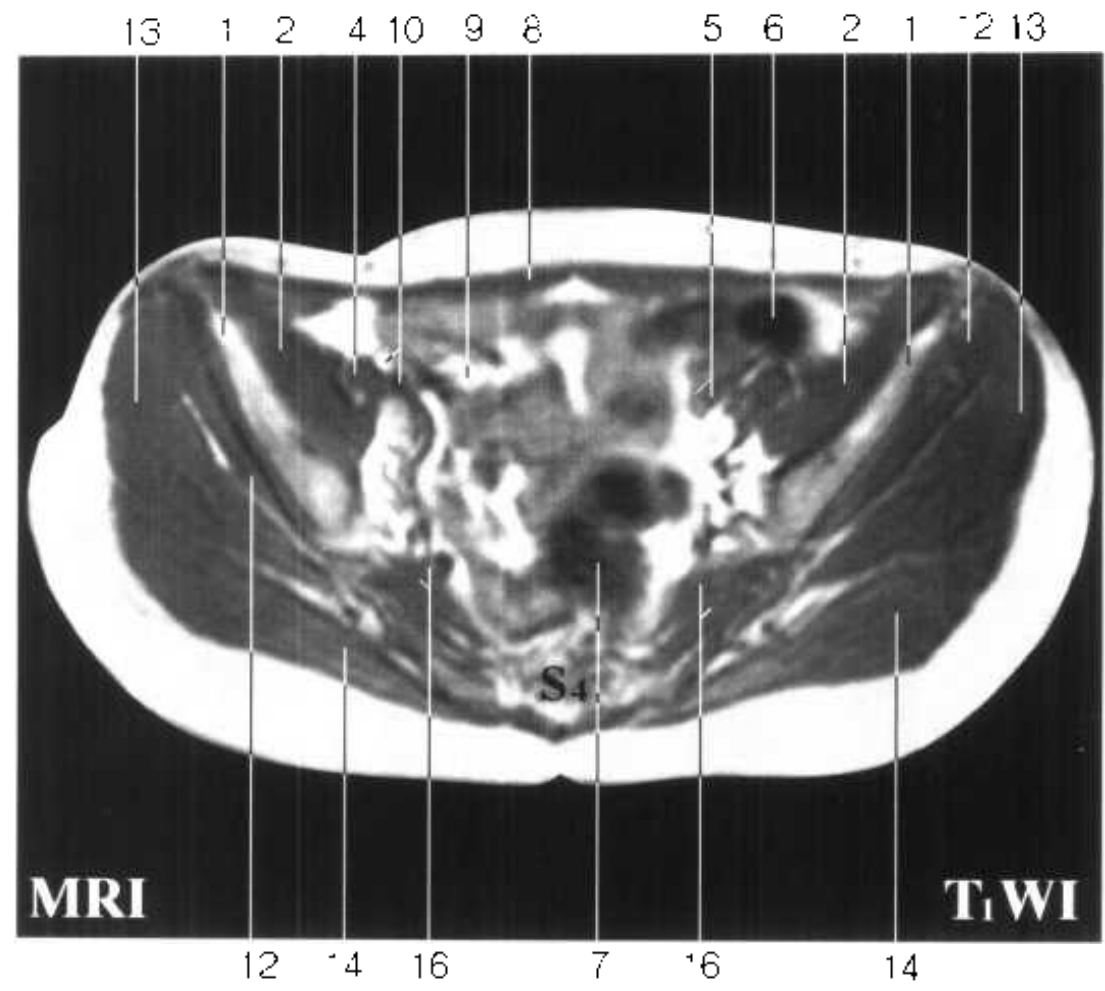


Fig. HPf 5

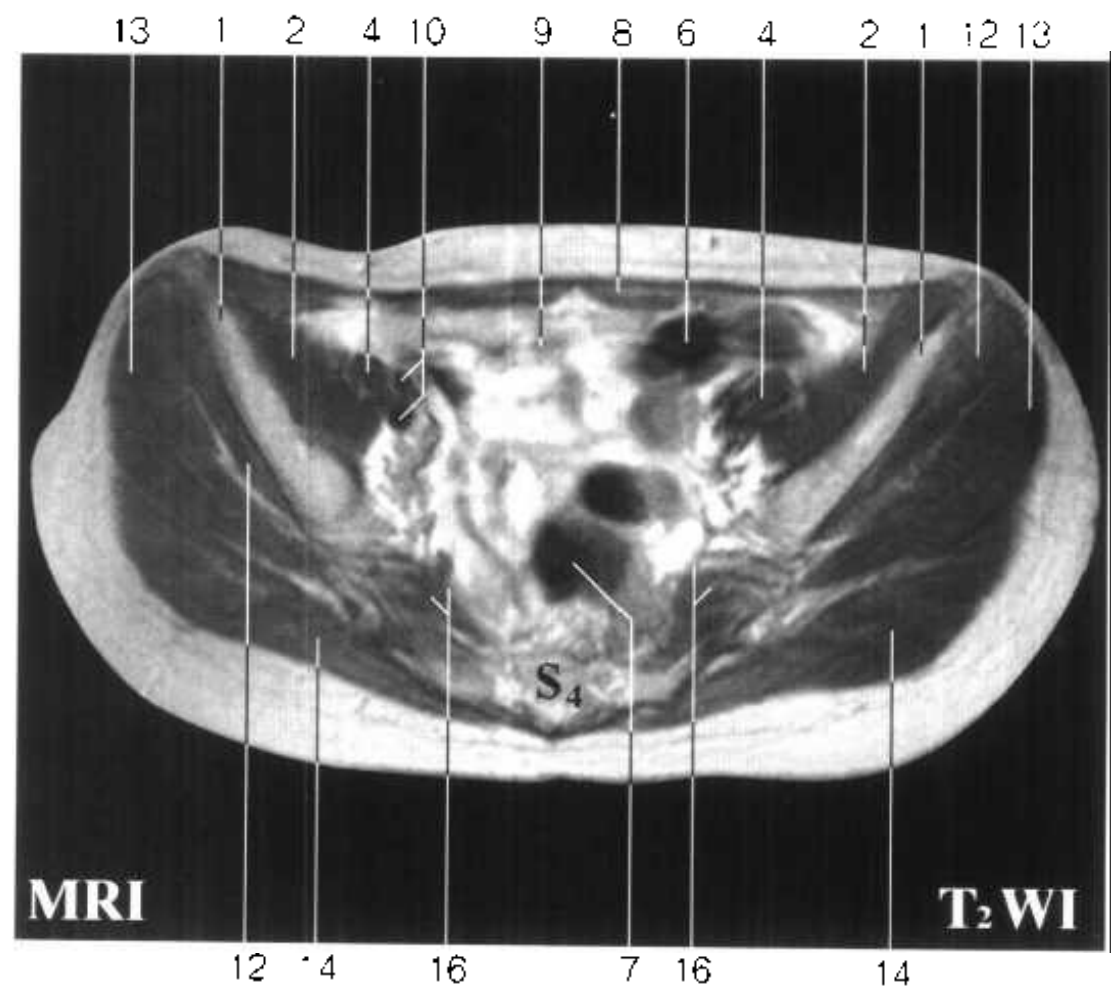
1. 髂骨翼 ala of ilium
2. 髂肌 iliacus
3. 子宫 uterus
4. 腰大肌 psoas major
5. 左髂外动、静脉 left external iliac a.and v.
6. 乙状结肠 sigmoid colon
7. 直肠 rectum
8. 腹直肌 rectus abdominis
9. 回肠 ileum
10. 右髂外动、静脉 right external iliac a.and v.

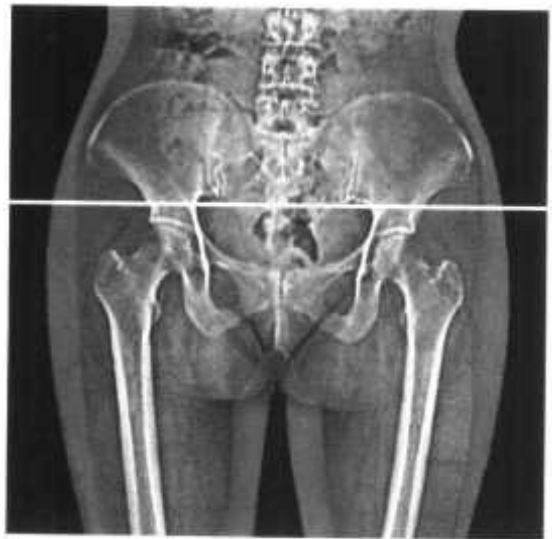

Fig. HPf 5



- 11. 第4骶神经 4th sacral n.
- 12. 臀小肌 gluteus minimus
- 13. 臀中肌 gluteus medius
- 14. 臀大肌 gluteus maximus
- 15. 腰骶干 lumbosacral trunk
- 16. 第2骶神经与梨状肌 2nd sacral n.and piriformis



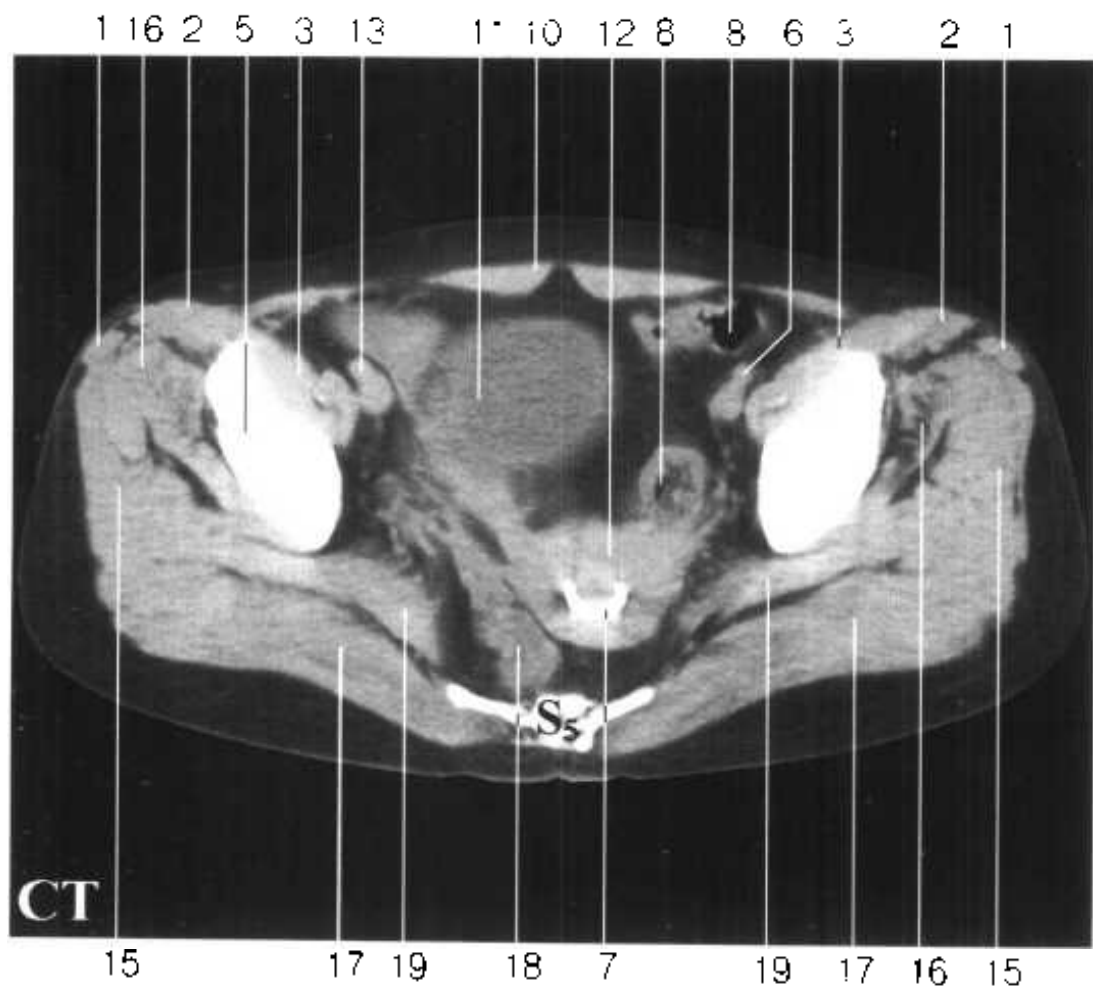
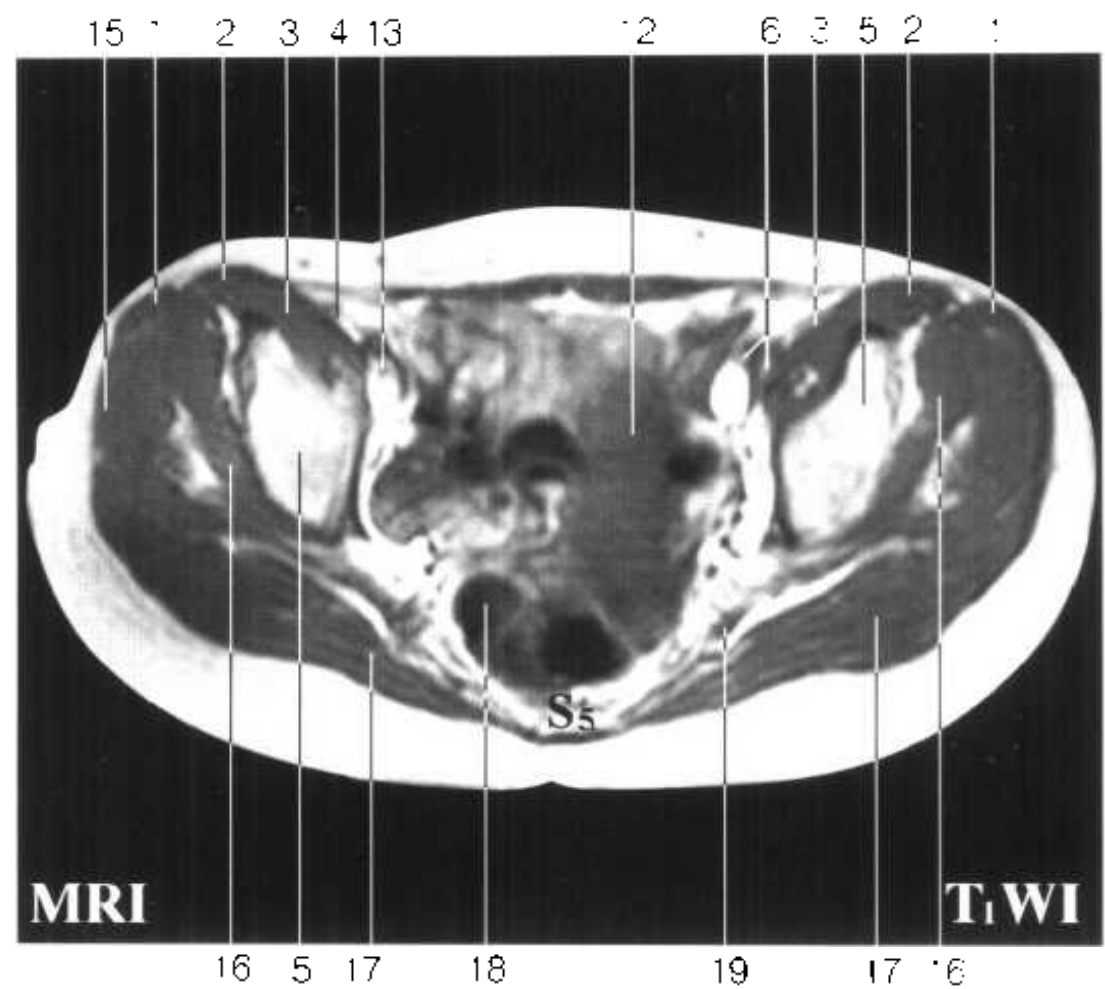


Fig. HPf 6

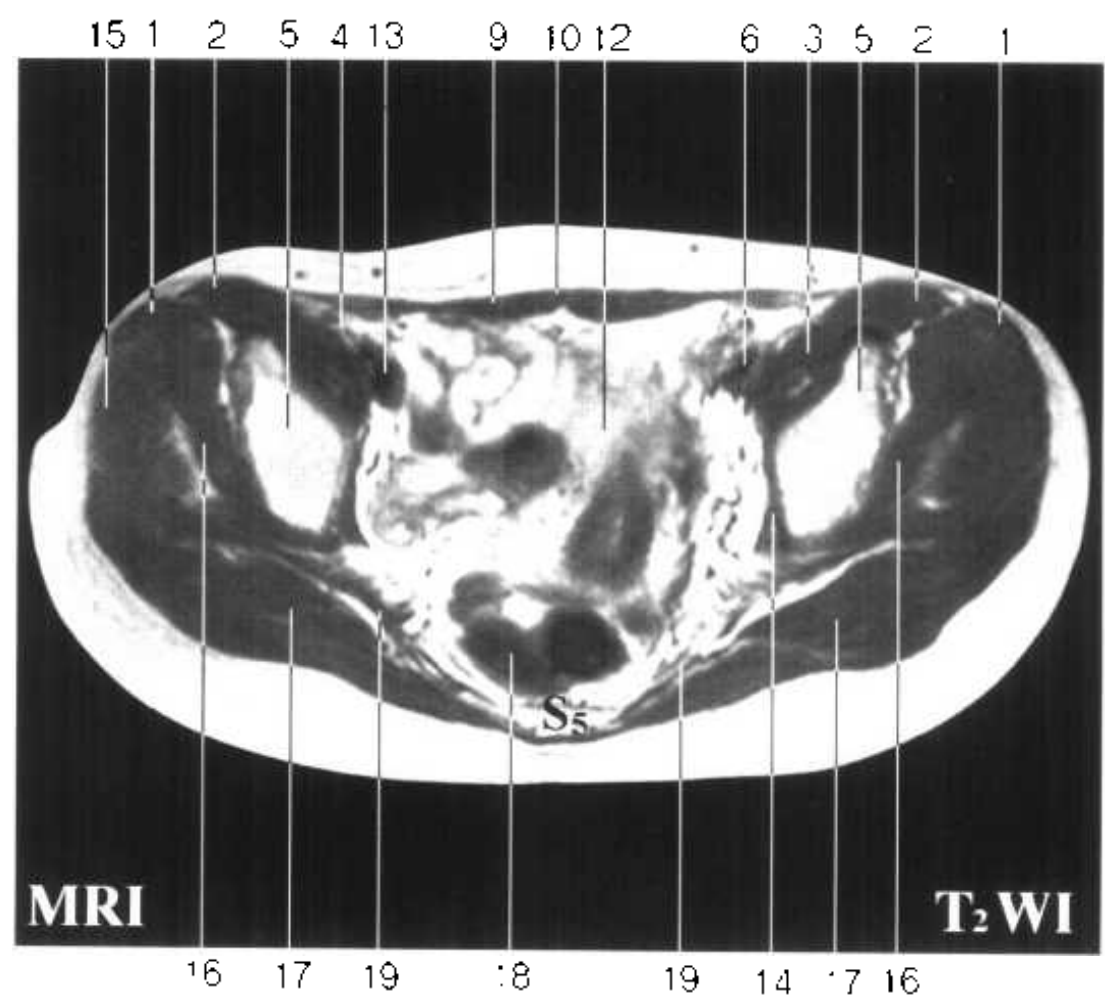
1. 阔筋膜张肌 tensor fasciae latae
2. 缝匠肌 sartorius
3. 髂腰肌 iliopsoas
4. 股神经 femoral n.
5. 髌骨体 body of ilium
6. 左髂外动、静脉 left external iliac a.and v.
7. 节育环 contraceptive ring
8. 乙状结肠 sigmoid colon
9. 腹直肌 rectus abdominis

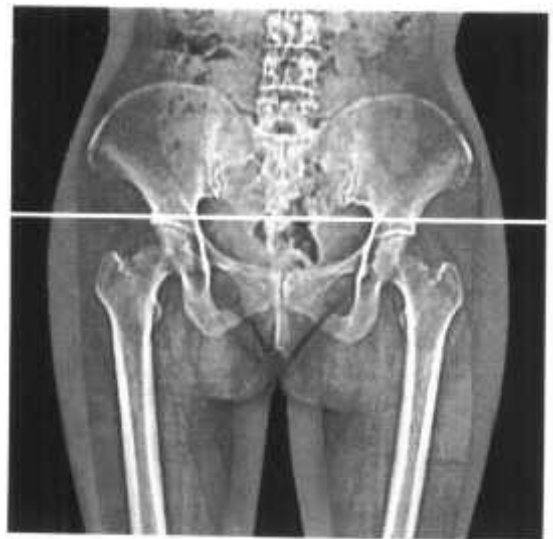

Fig. HPf 6



- 10. 锥状肌 pyramidalis
- 11. 膀胱尖 apex of bladder
- 12. 子宫底 fundus of uterus
- 13. 右髂外动脉 right external iliac a.
- 14. 闭孔内肌 obturator internus
- 15. 臀中肌 gluteus medius
- 16. 臀小肌 gluteus minimus
- 17. 臀大肌 gluteus maximus
- 18. 直肠 rectum
- 19. 梨状肌 piriformis



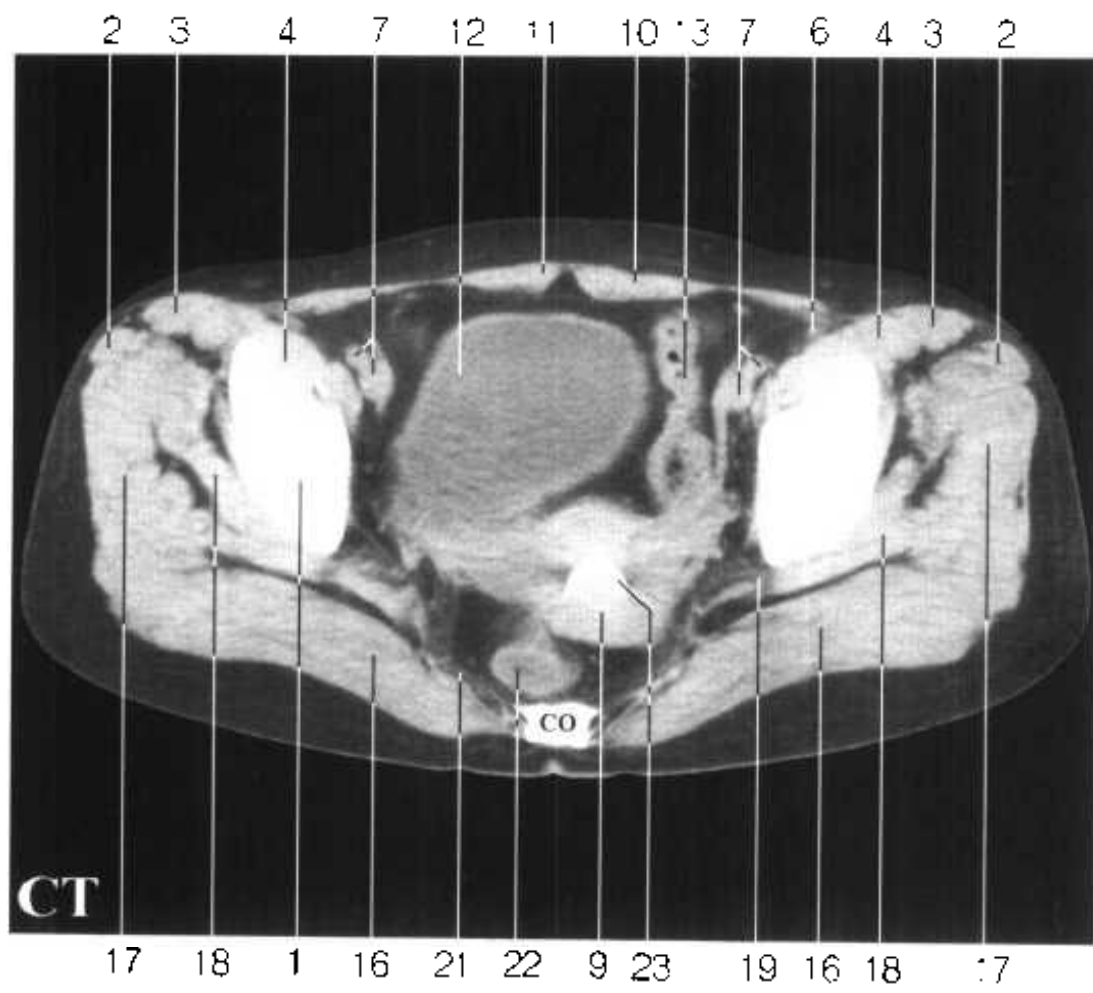
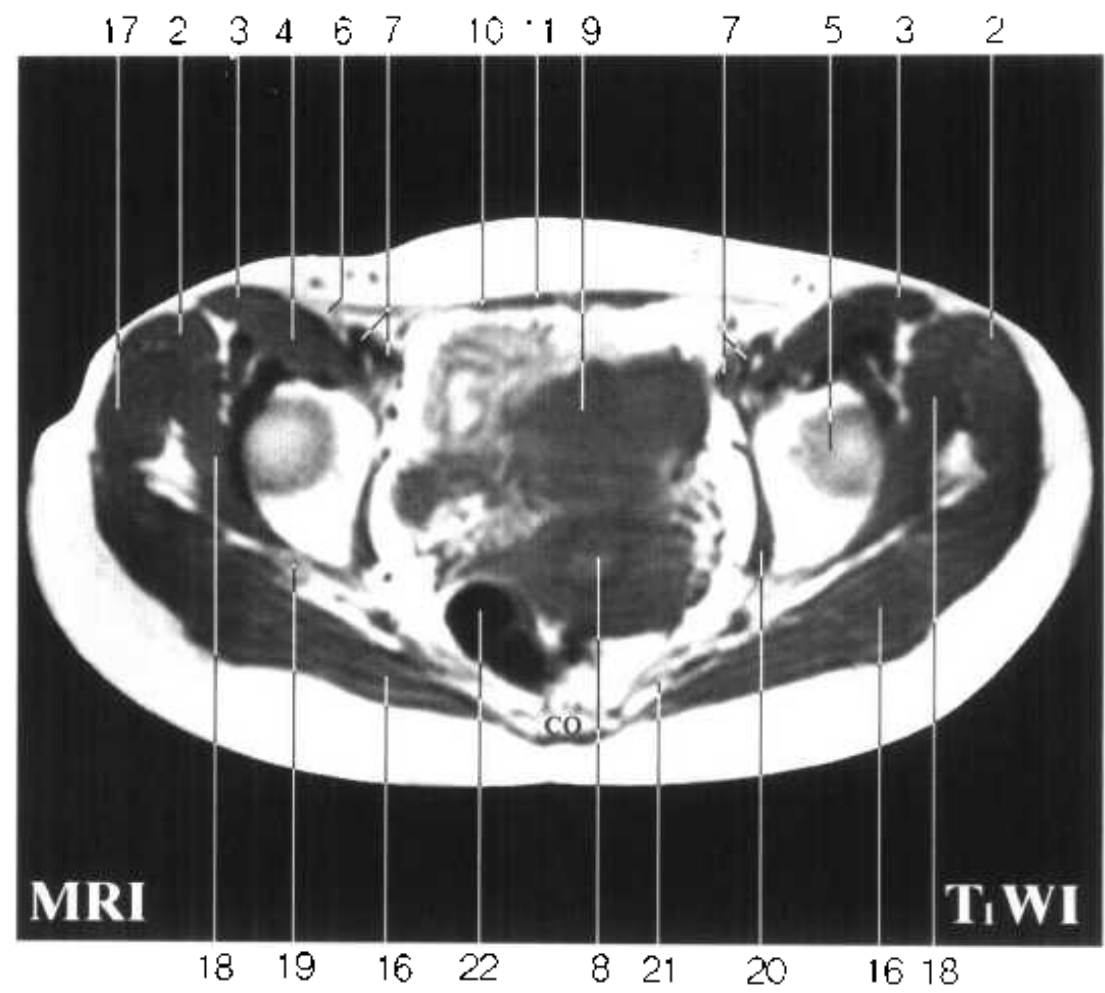


Fig. HPf 7

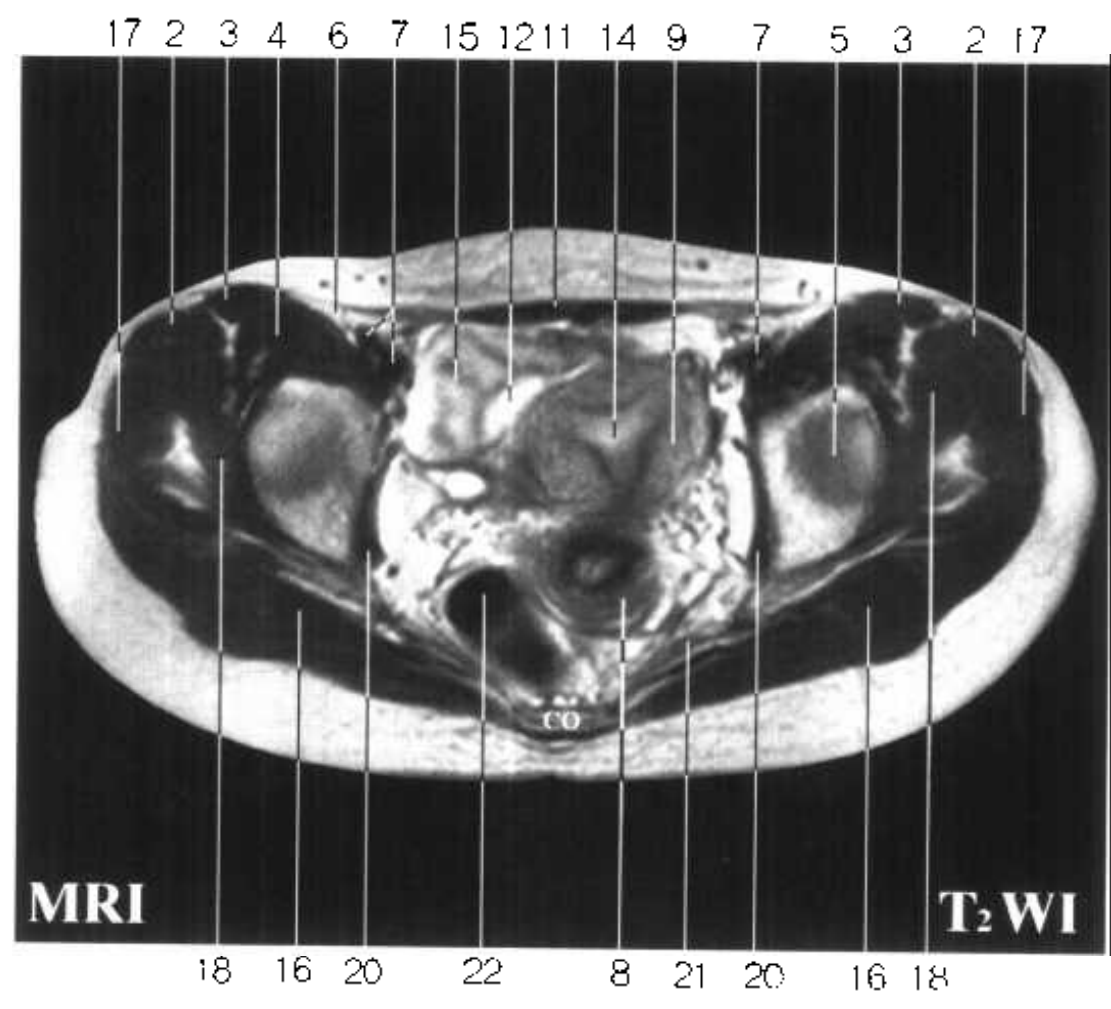
1. 髂骨体 body of ilium
2. 阔筋膜张肌 tensor fasciae latae
3. 缝匠肌 sartorius
4. 髂腰肌 iliopsoas
5. 股骨头 femoral head
6. 股神经 femoral n.
7. 左髂外动、静脉 left external iliac a.and v.
8. 子宫颈 neck of uterus
9. 子宫体 body of uterus
10. 腹直肌 rectus abdominis
11. 锥状肌 pyramidalis
12. 膀胱 urinary bladder

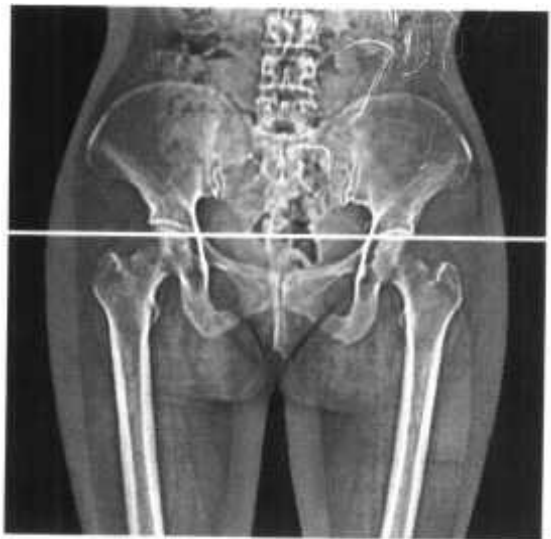

Fig. HPf 7



- 13. 乙状结肠 sigmoid colon
- 14. 子宫腔 cavity of uterus
- 15. 回肠 ileum
- 16. 臀大肌 gluteus maximus
- 17. 臀中肌 gluteus medius
- 18. 臀小肌 gluteus minimus
- 19. 坐骨神经 sciatic n.
- 20. 闭孔内肌 obturator internus
- 21. 尾骨肌 coccygeus
- 22. 直肠 rectum
- 23. 节育环 contraceptive ring



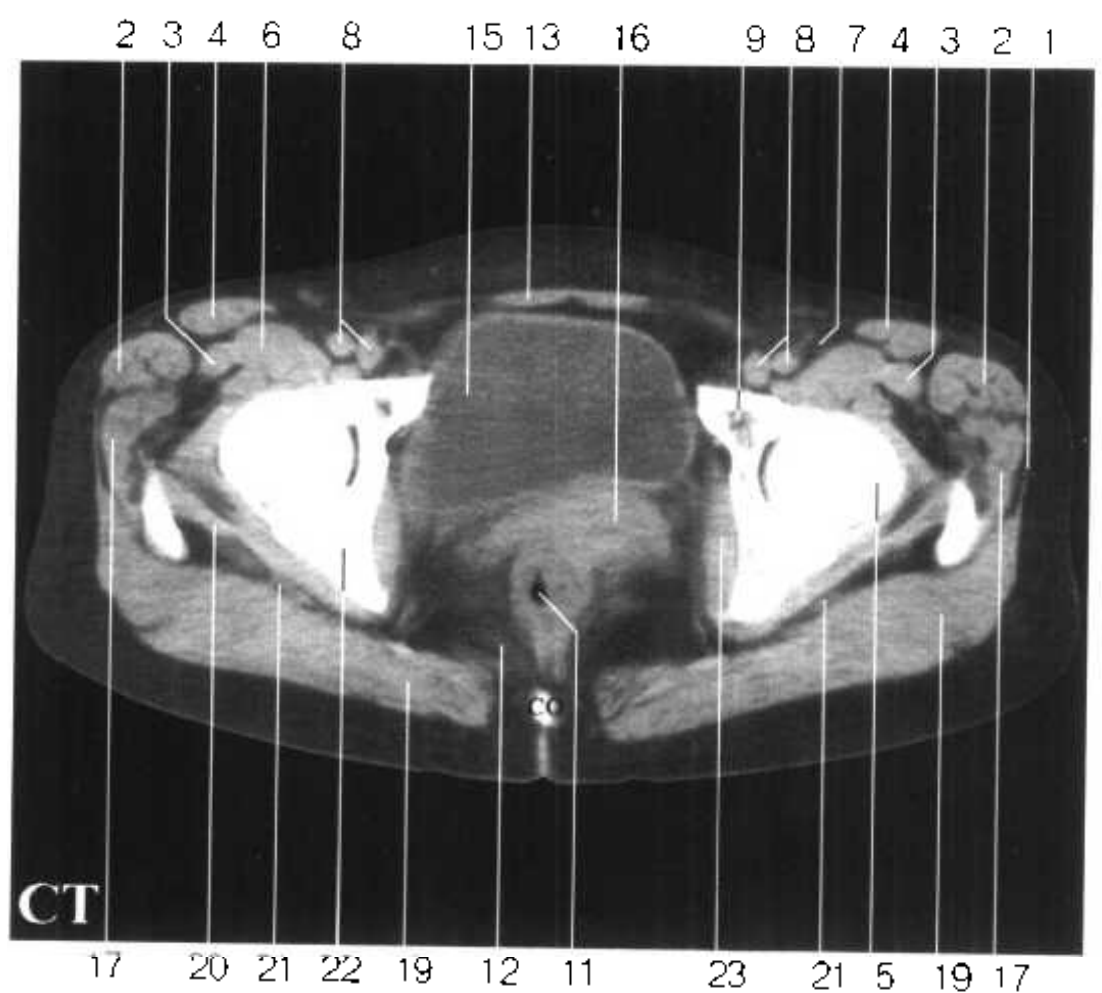
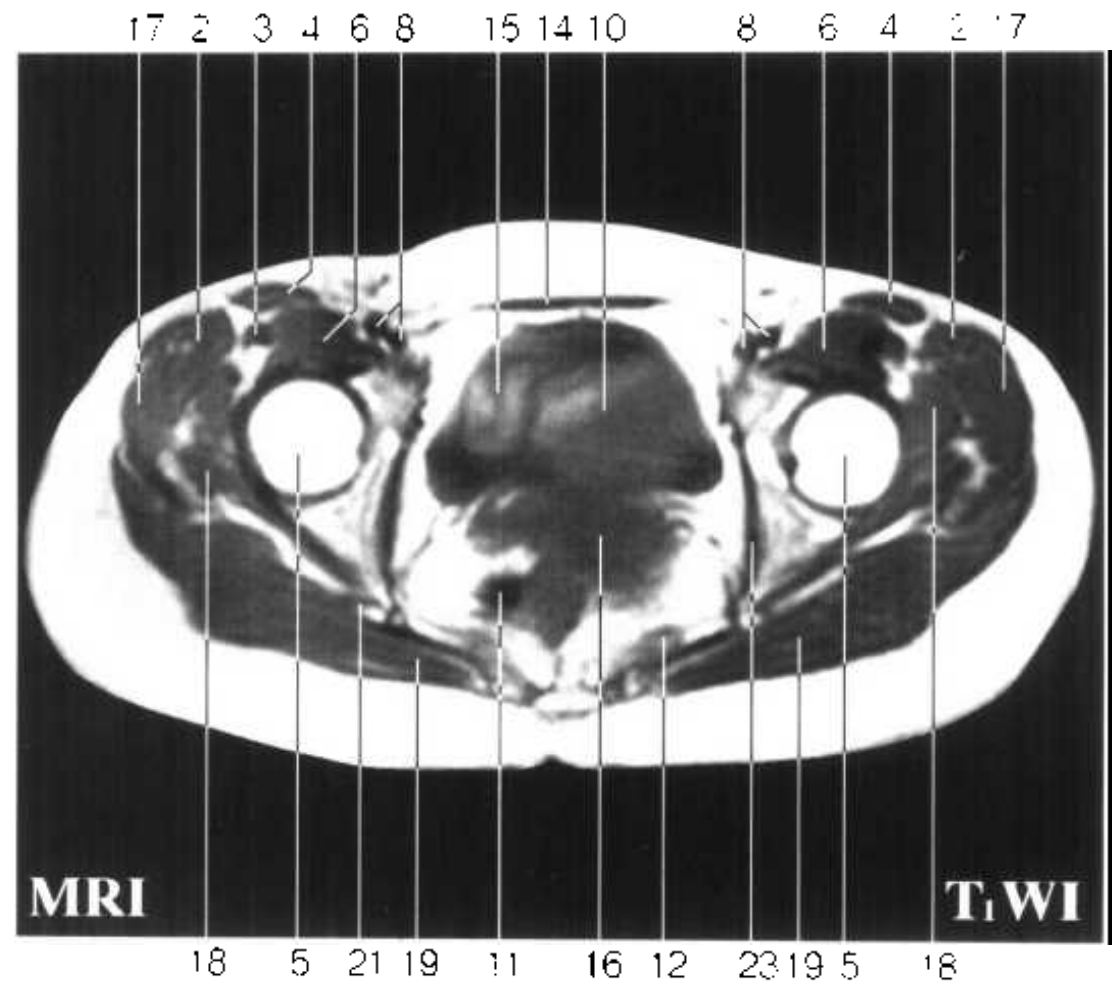


Fig. HPf 8

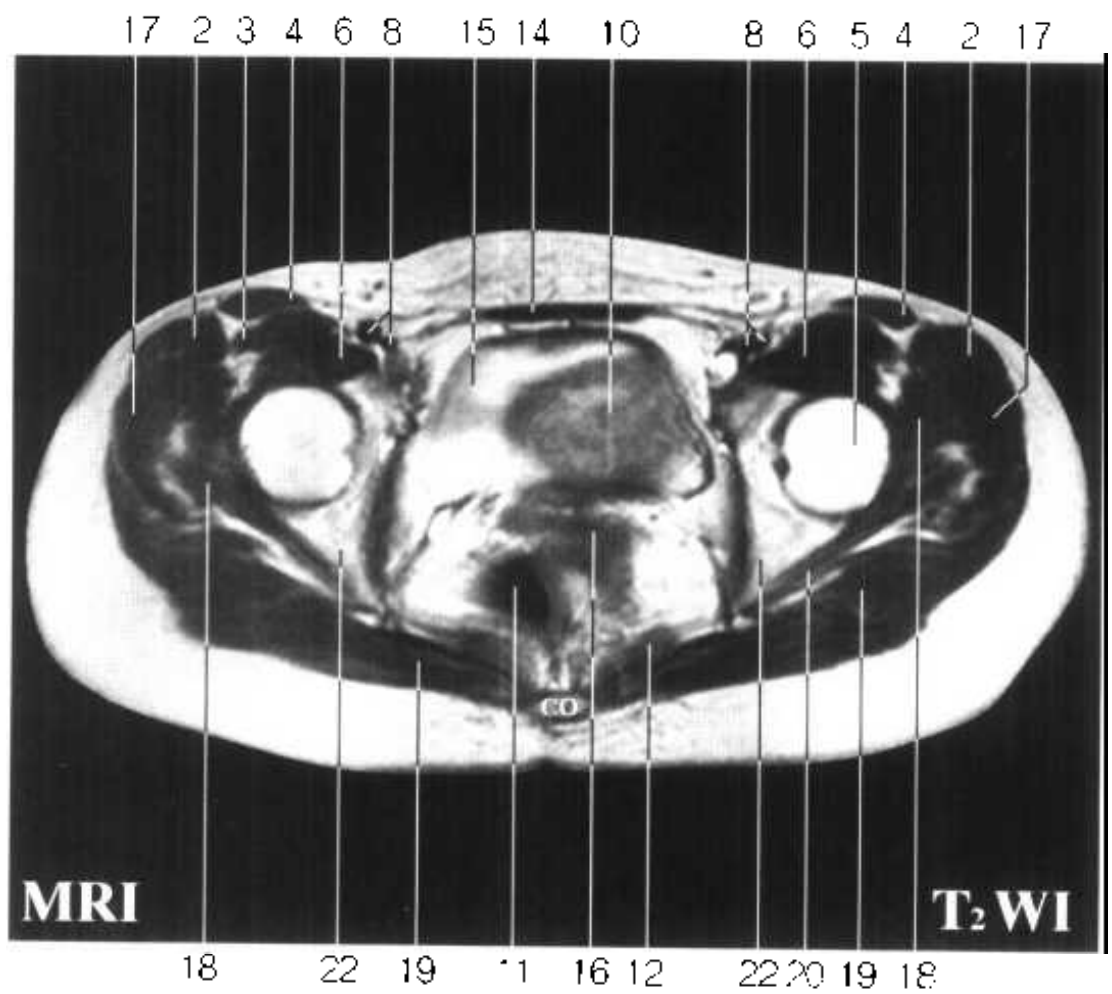
1. 髂胫束 iliotibial tract
2. 阔筋膜张肌 tensor fasciae latae
3. 股直肌 rectus femoris
4. 缝匠肌 sartorius
5. 股骨头 femoral head
6. 髂腰肌 iliopsoas
7. 股神经 femoral n.
8. 股动、静脉 femoral a.and v.
9. 耻骨体 body of pubis
10. 子宫体 body of uterus
11. 直肠 rectum
12. 尾骨肌 coccygeus

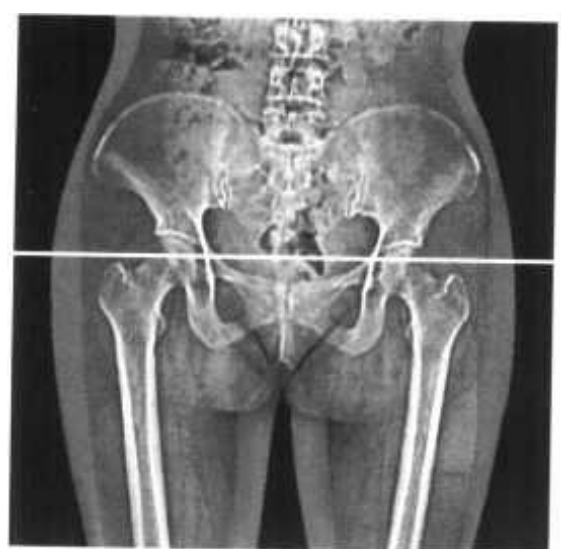

Fig. HPf 8



- 13. 腹直肌 rectus abdominis
- 14. 锥状肌 pyramidalis
- 15. 膀胱 urinary bladder
- 16. 子宫颈管 canal of cervix of uterus
- 17. 臀中肌 gluteus medius
- 18. 臀小肌 gluteus minimus
- 19. 臀大肌 gluteus maximus
- 20. 上孖肌 gemellus superior
- 21. 坐骨神经 sciatic n.
- 22. 坐骨体 body of ischium
- 23. 闭孔内肌 obturator internus



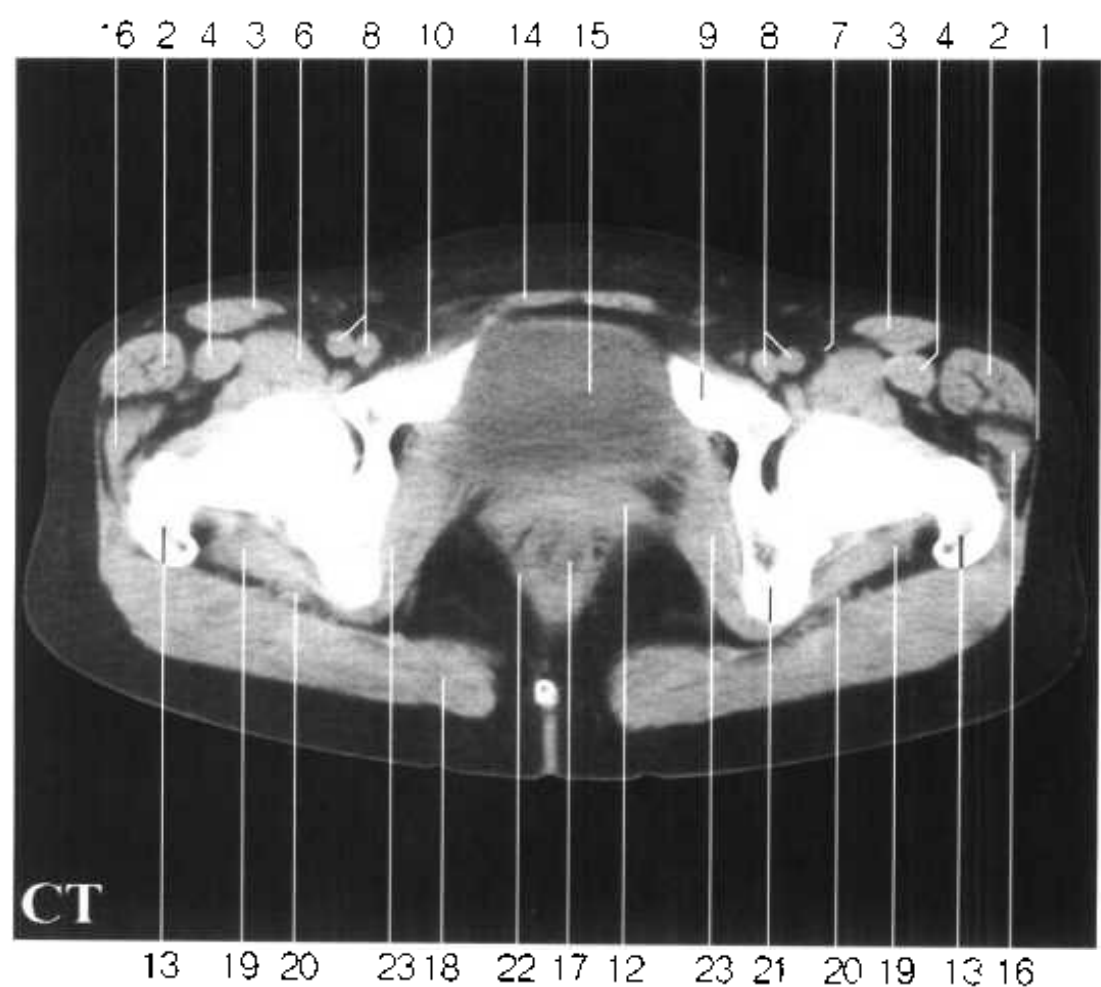
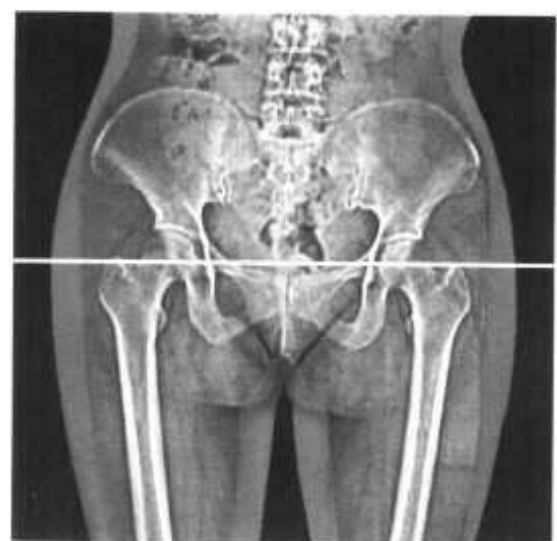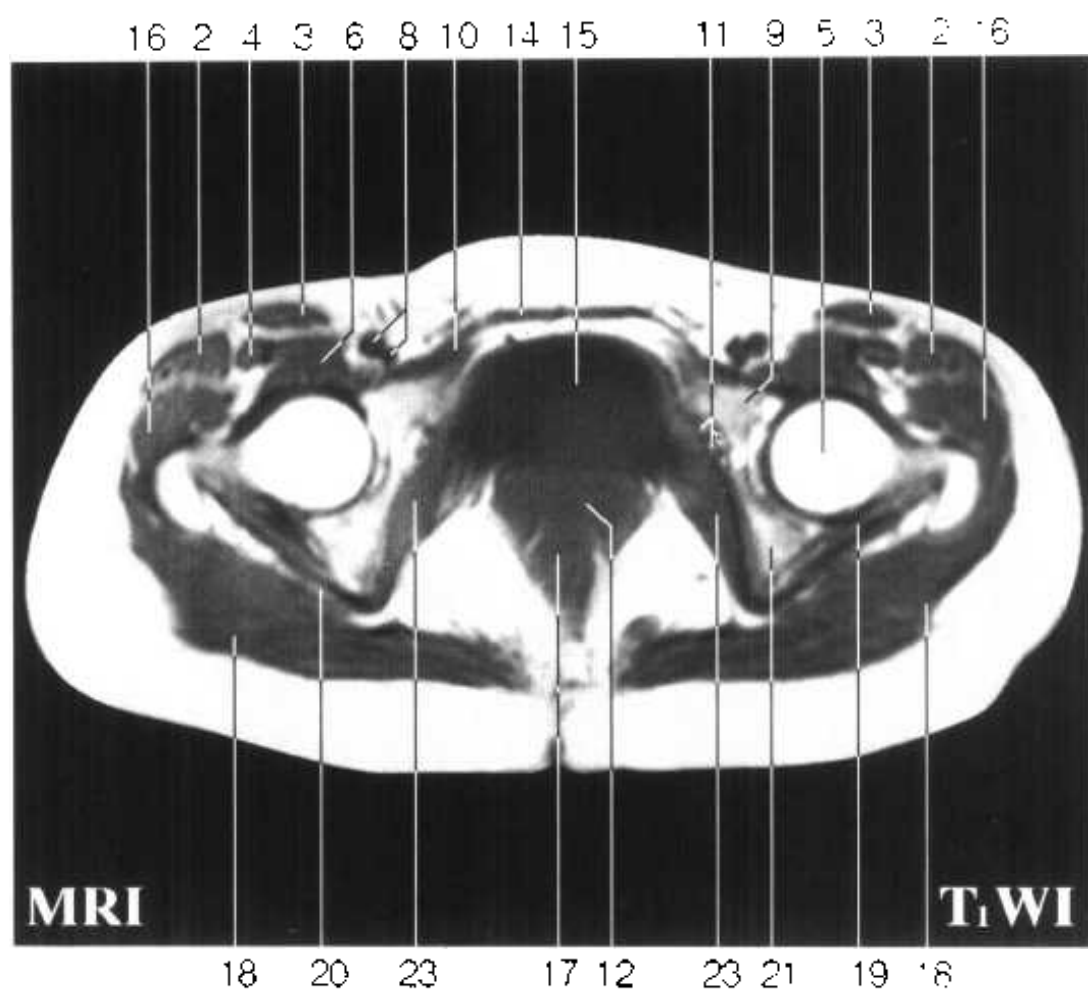


Fig. HPf 9

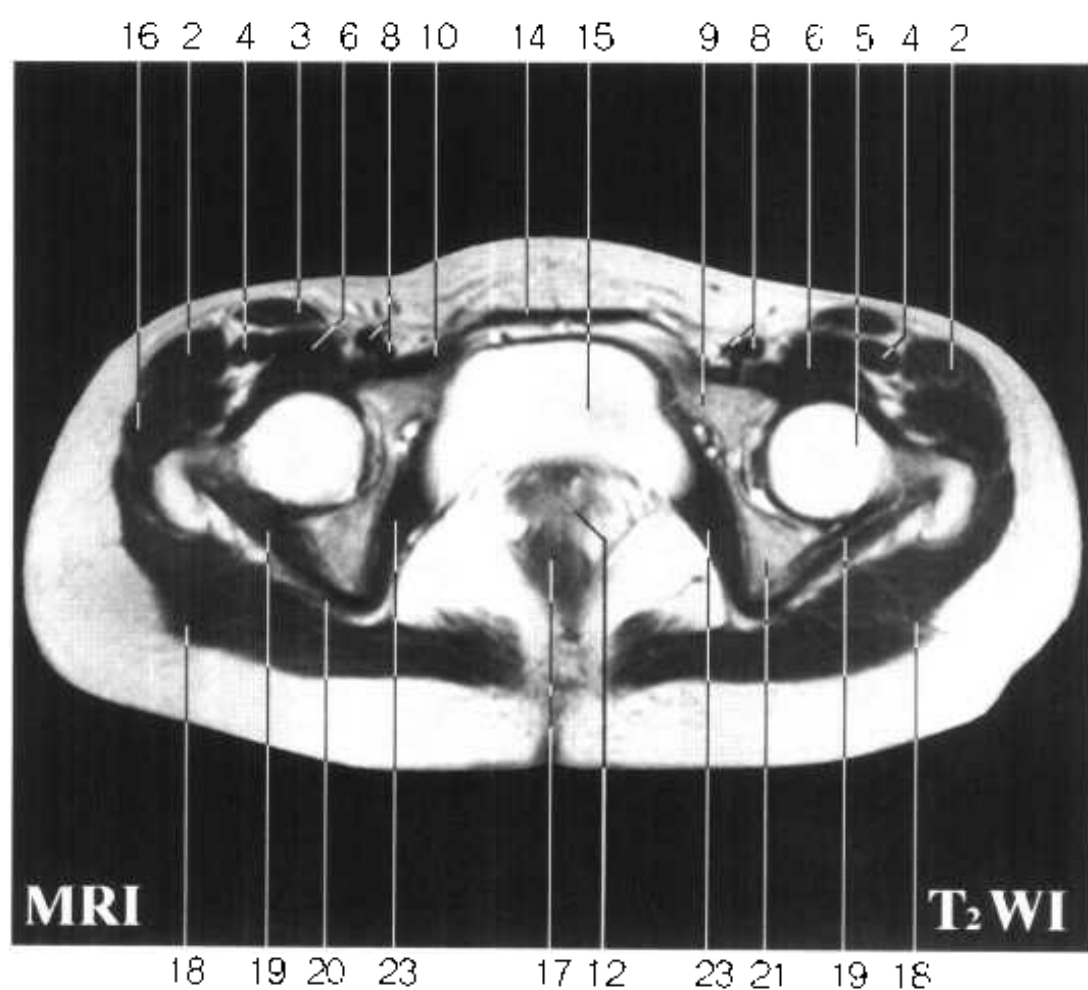


1. 髂胫束 iliotibial tract
2. 阔筋膜张肌 tensor fasciae latae
3. 缝匠肌 sartorius
4. 股直肌 rectus femoris
5. 股骨头 femoral head
6. 髂腰肌 iliopsoas
7. 股神经 femoral n.
8. 股动、静脉 femoral a.and v.
9. 耻骨体 body of pubis
10. 耻骨肌 pectineus
11. 闭孔动、静脉与闭孔神经 obturator a., v.and obturator n.

Fig. HPf 9



- 12. 阴道 vagina
- 13. 大转子 greater trochanter
- 14. 锥状肌 pyramidalis
- 15. 膀胱 urinary bladder
- 16. 臀中肌 gluteus medius
- 17. 直肠 rectum
- 18. 臀大肌 gluteus maximus
- 19. 下孖肌 gemellus inferior
- 20. 坐骨神经 sciatic n.
- 21. 坐骨体 body of ischium
- 22. 肛提肌 levator ani
- 23. 闭孔内肌 obturator internus



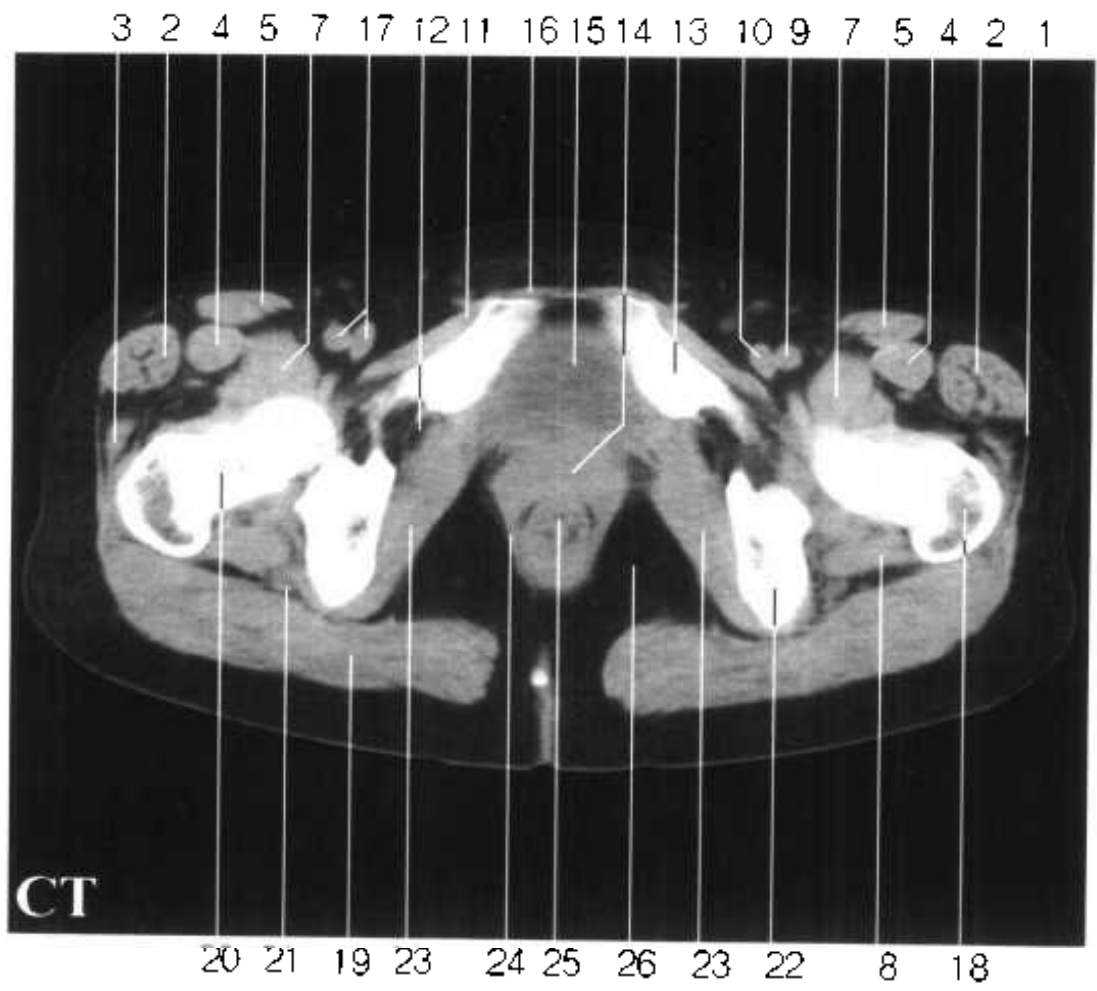
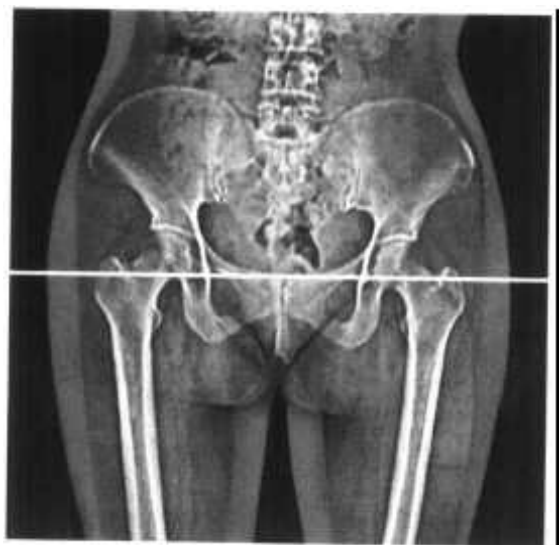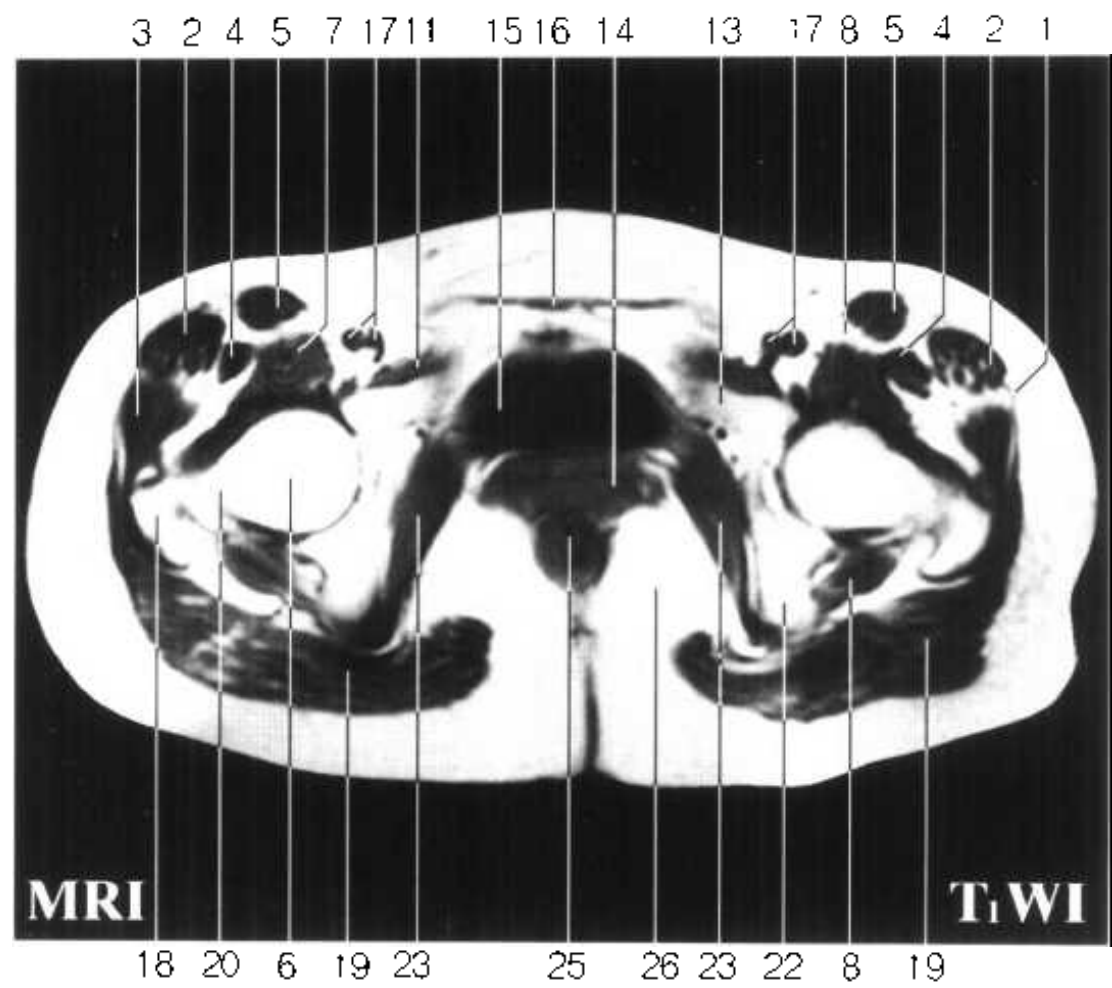


Fig. HPf 10

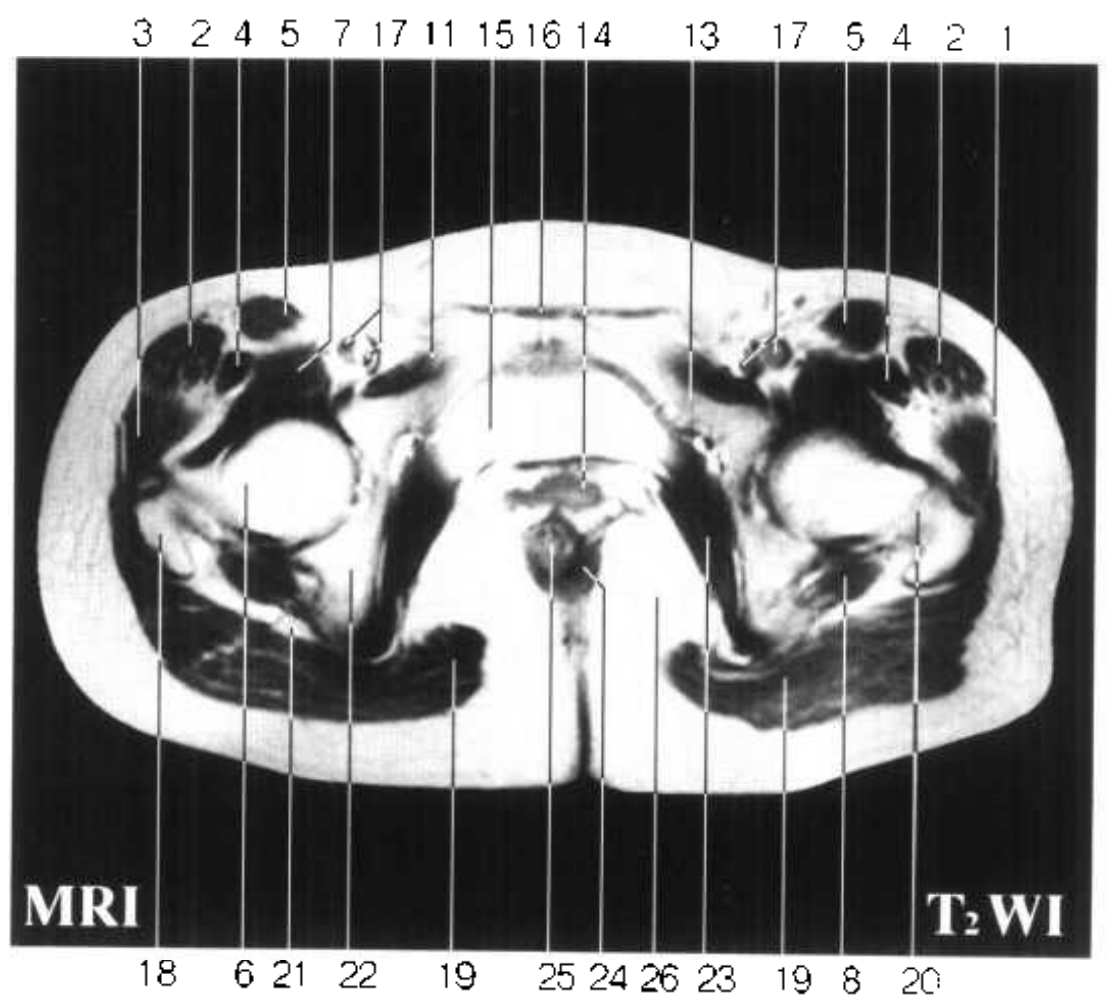


1. 髂胫束 iliotibial tract
2. 阔筋膜张肌 tensor fasciae latae
3. 臀中肌 gluteus medius
4. 股直肌 rectus femoris
5. 缝匠肌 sartorius
6. 股骨头 femoral head
7. 髂腰肌 iliopsoas
8. 股方肌 quadratus femoris
9. 股动脉 femoral a.
10. 股静脉 femoral v.
11. 耻骨肌 pectineus
12. 闭孔神经(闭膜管) obturator n.(obturator canal)
13. 耻骨上支 superior ramus of pubis
14. 阴道 vagina

Fig. HPf 10



- 15. 膀胱 urinary bladder
- 16. 锥状肌 pyramidalis
- 17. 股动、静脉 femoral a.and v.
- 18. 大转子 greater trochanter
- 19. 臀大肌 gluteus maximus
- 20. 股骨颈 neck of femur
- 21. 坐骨神经 sciatic n.
- 22. 坐骨体 body of ischium
- 23. 闭孔内肌 obturator internus
- 24. 肛提肌 levator ani
- 25. 直肠 rectum
- 26. 坐骨肛门窝脂体 adipose body of ischioanal fossa



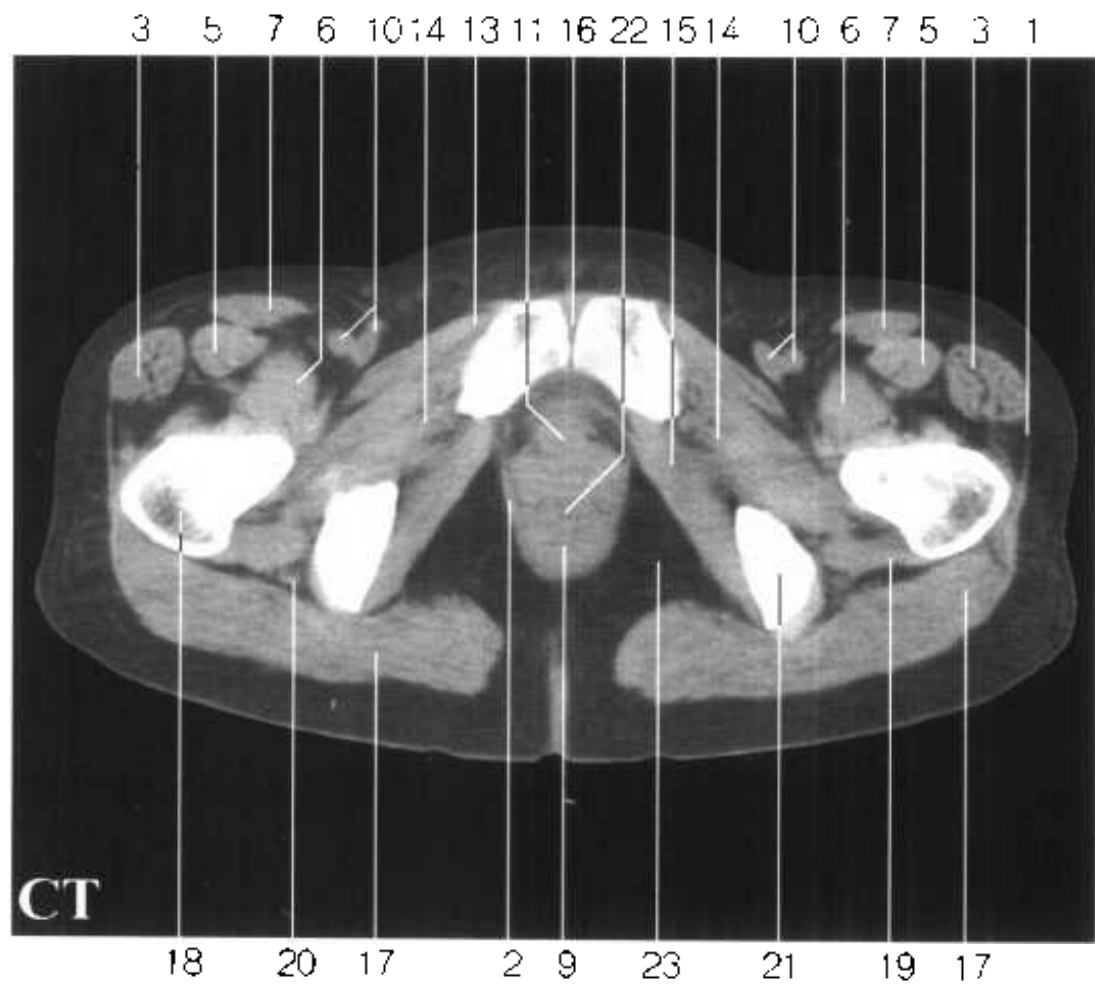
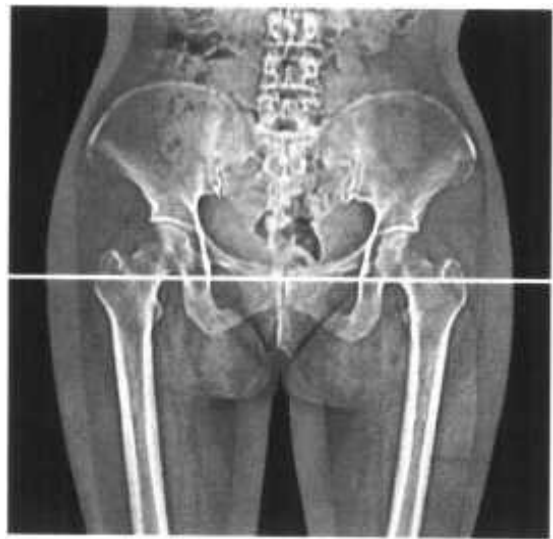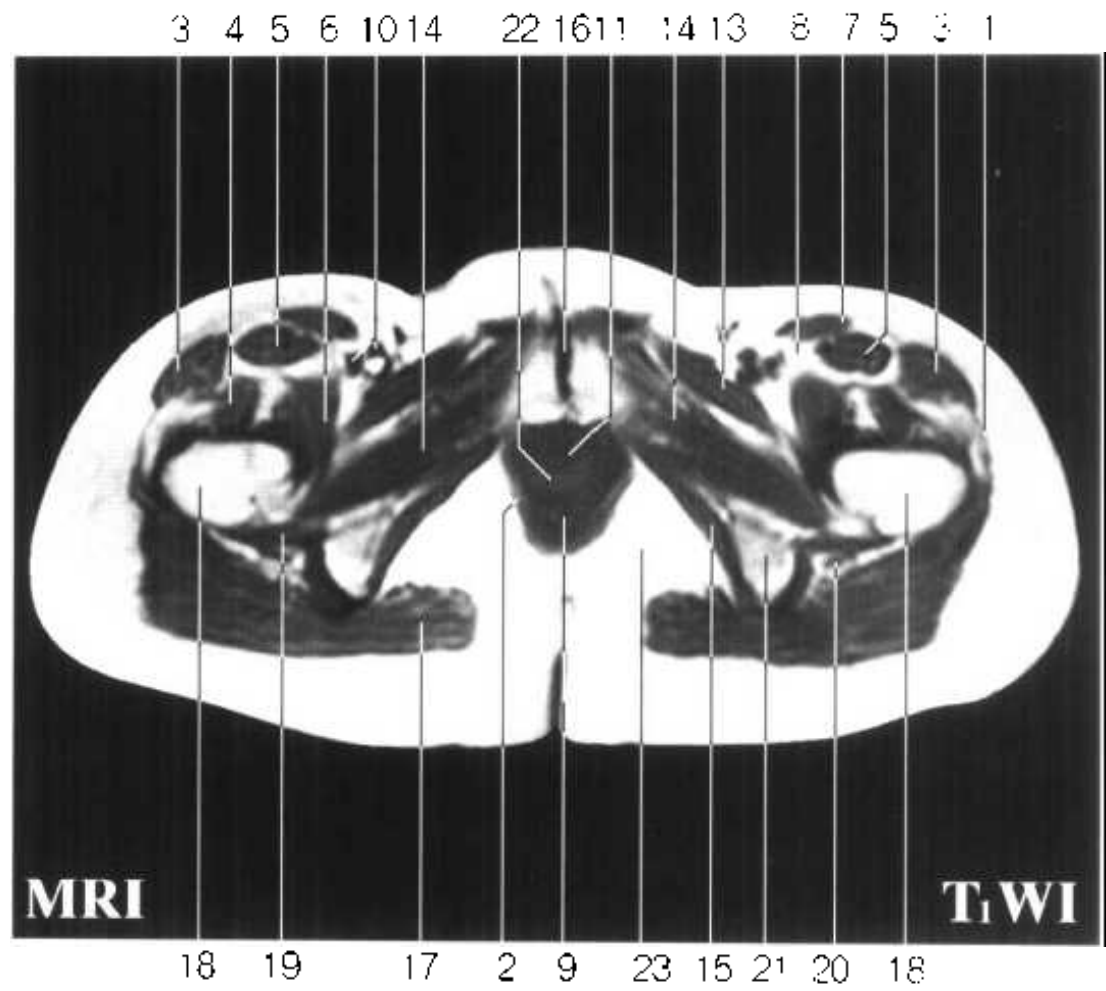


Fig. HPf 11

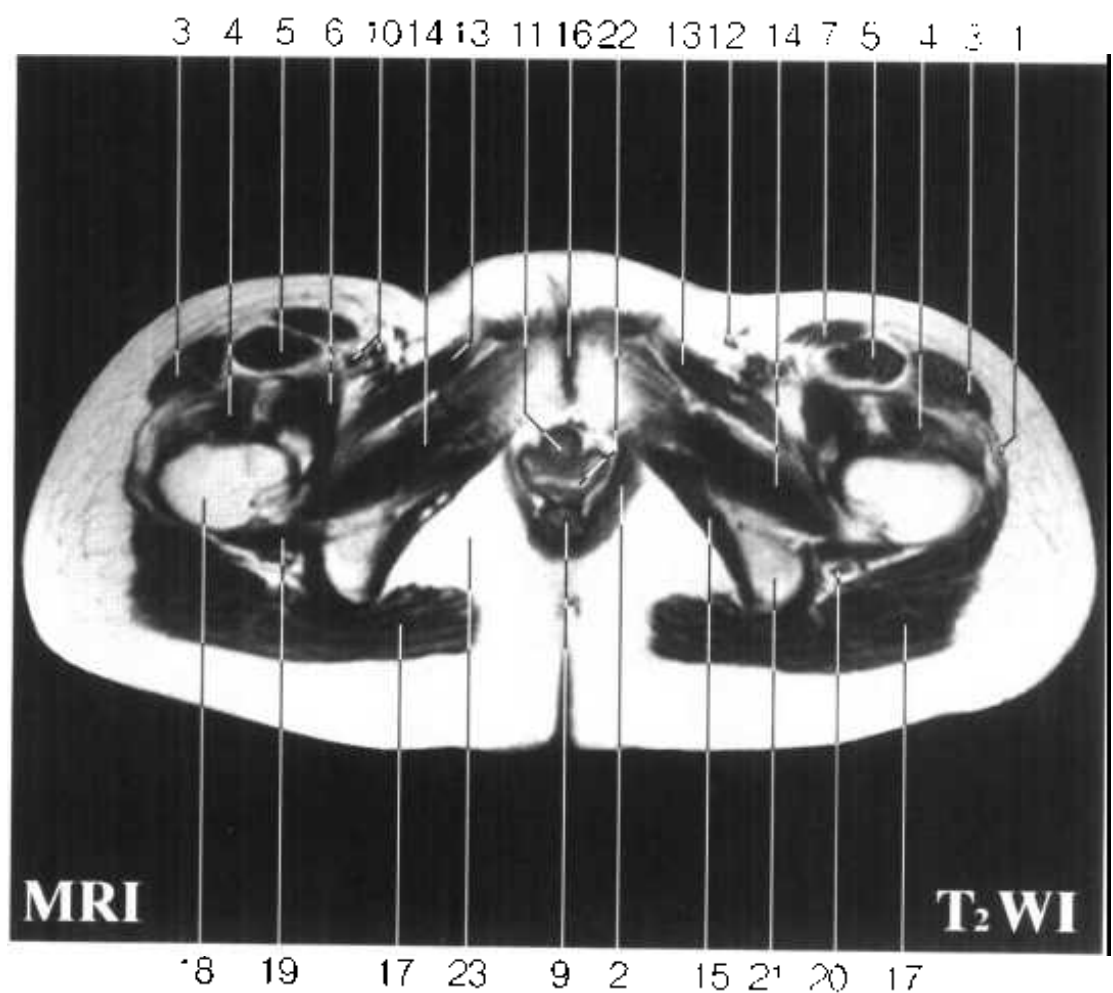


1. 髂胫束 iliotibial tract
2. 肛提肌 levator ani
3. 阔筋膜张肌 tensor fasciae latae
4. 股外侧肌 vastus lateralis
5. 股直肌 rectus femoris
6. 髂腰肌 iliopsoas
7. 缝匠肌 sartorius
8. 股神经 femoral n.
9. 直肠 rectum
10. 股动、静脉 femoral a. and v.
11. 女尿道 female urethra
12. 大隐静脉 great saphenous v.

Fig. HPf 11



- 13. 耻骨肌 pectineus
- 14. 闭孔外肌 obturator externus
- 15. 闭孔内肌 obturator internus
- 16. 耻骨联合 pubic symphysis
- 17. 臀大肌 gluteus maximus
- 18. 大转子 greater trochanter
- 19. 股方肌 quadratus femoris
- 20. 坐骨神经 sciatic n.
- 21. 坐骨结节 ischial tuberosity
- 22. 阴道 vagina
- 23. 坐骨肛门窝脂体 adipose body of ischioanal fossa



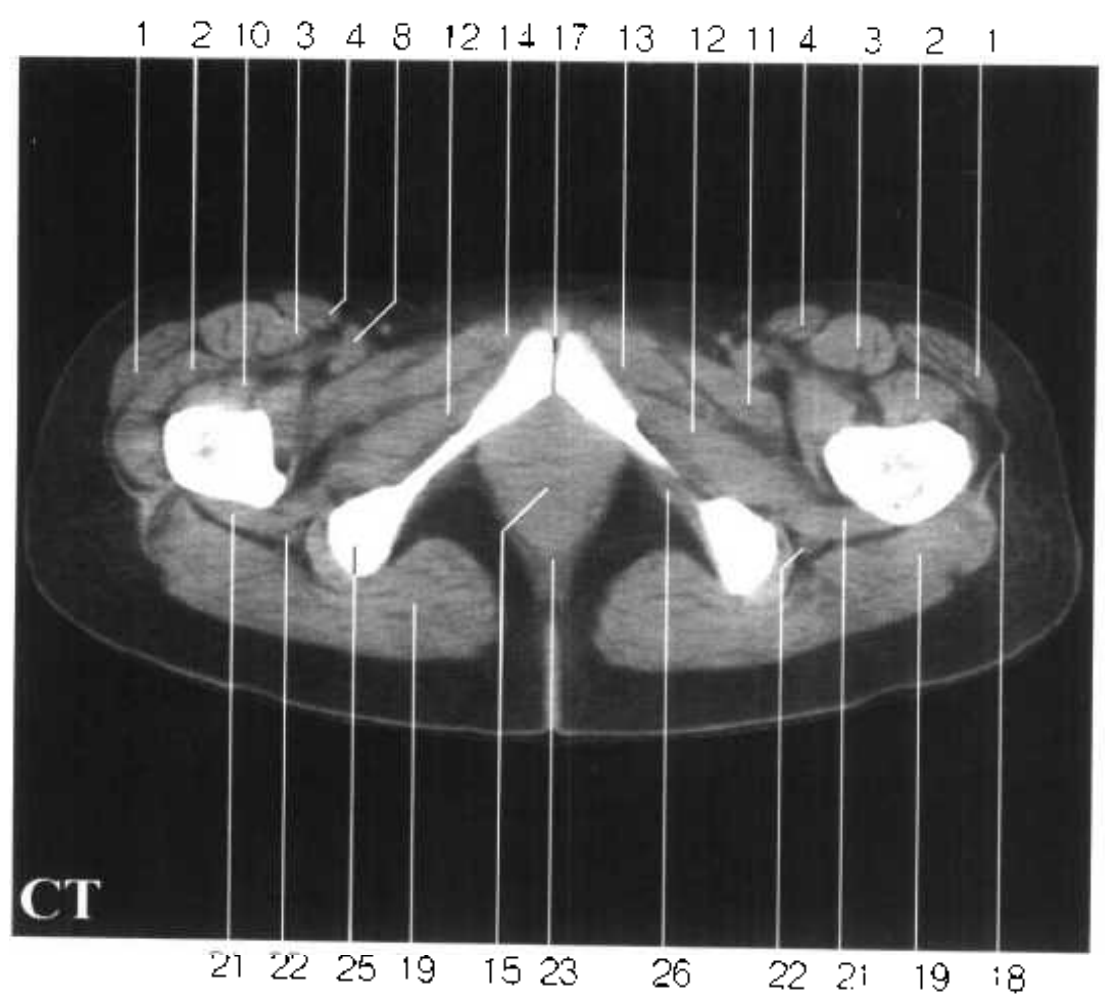
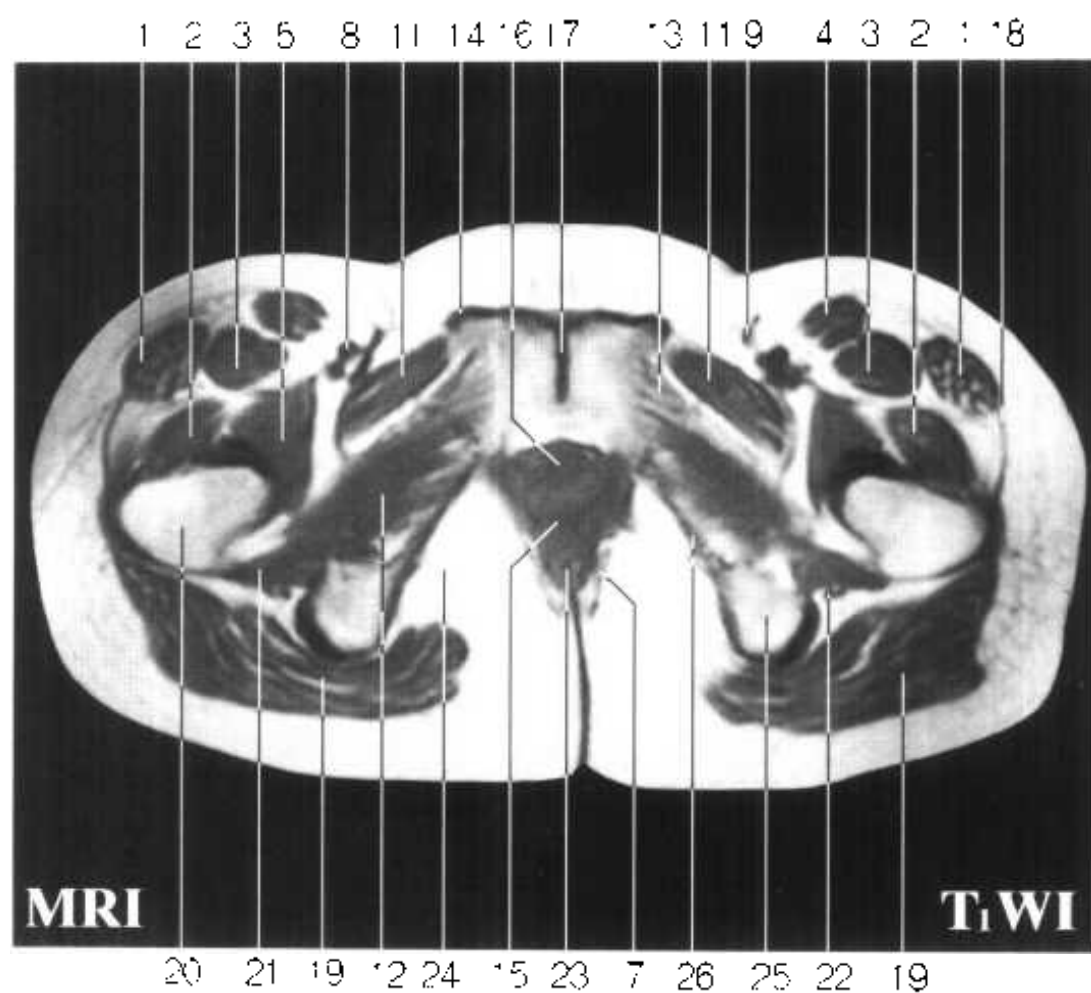


Fig. HPf 12

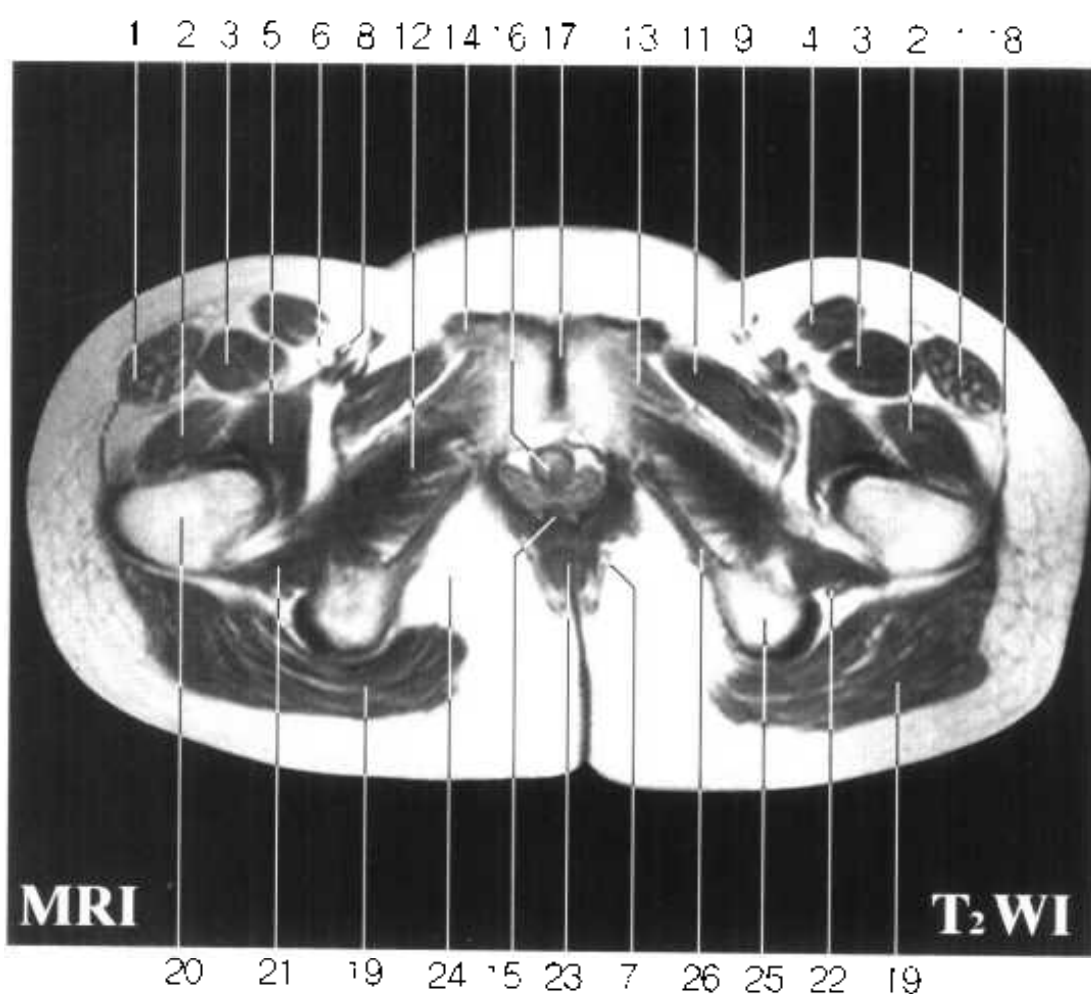
1. 阔筋膜张肌 tensor fasciae latae
2. 股外侧肌 vastus lateralis
3. 股直肌 rectus femoris
4. 缝匠肌 sartorius
5. 髂腰肌 iliopsoas
6. 股神经 femoral n.
7. 肛提肌 levator ani
8. 股动、静脉 femoral a. and v.
9. 大隐静脉 great saphenous v.
10. 股中间肌 vastus intermedius
11. 耻骨肌 pectineus
12. 大收肌 adductor magnus
13. 短收肌 adductor brevis
14. 长收肌 adductor longus

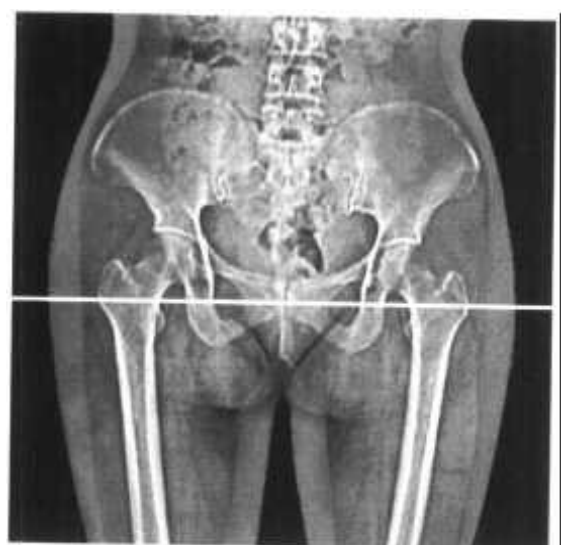

Fig. HPf 12



- 15. 阴道 vagina
- 16. 女尿道 female urethra
- 17. 耻骨联合 pubic symphysis
- 18. 髂胫束 iliotibial tract
- 19. 臀大肌 gluteus maximus
- 20. 大转子 greater trochanter
- 21. 股方肌 quadratus femoris
- 22. 坐骨神经 sciatic n.
- 23. 直肠 rectum
- 24. 坐骨肛门窝脂体 adipose body of ischioanal fossa
- 25. 坐骨结节 ischial tuberosity
- 26. 闭孔内肌 obturator internus



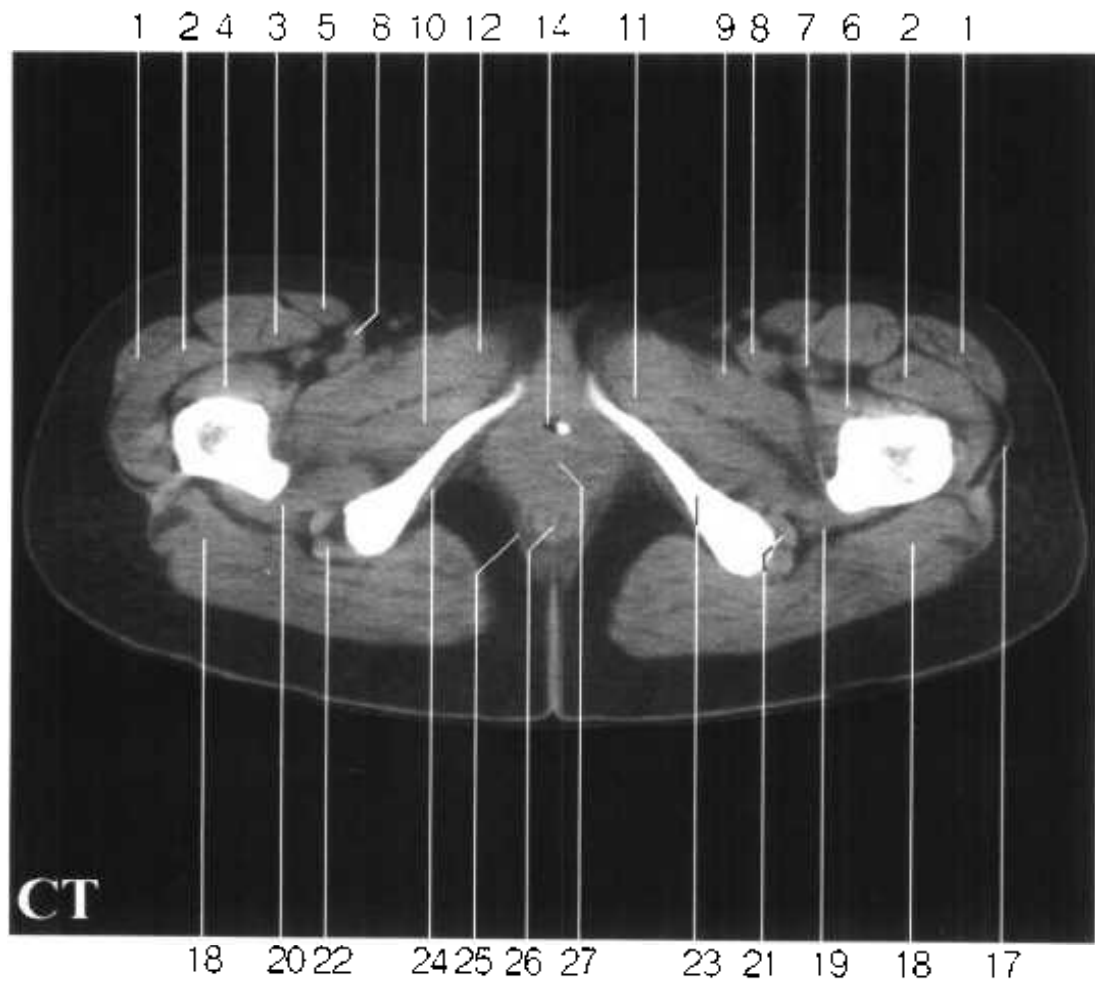
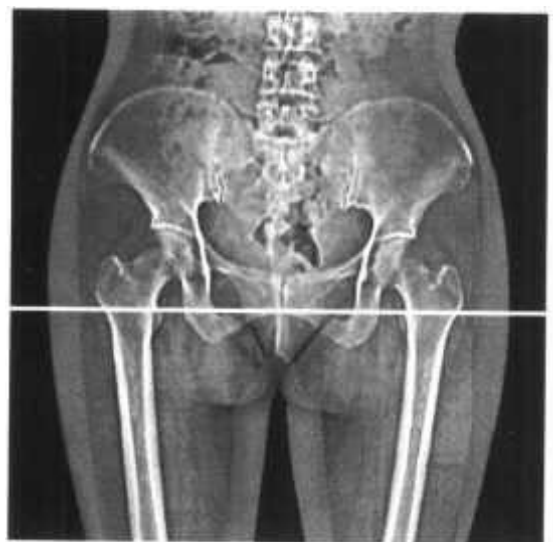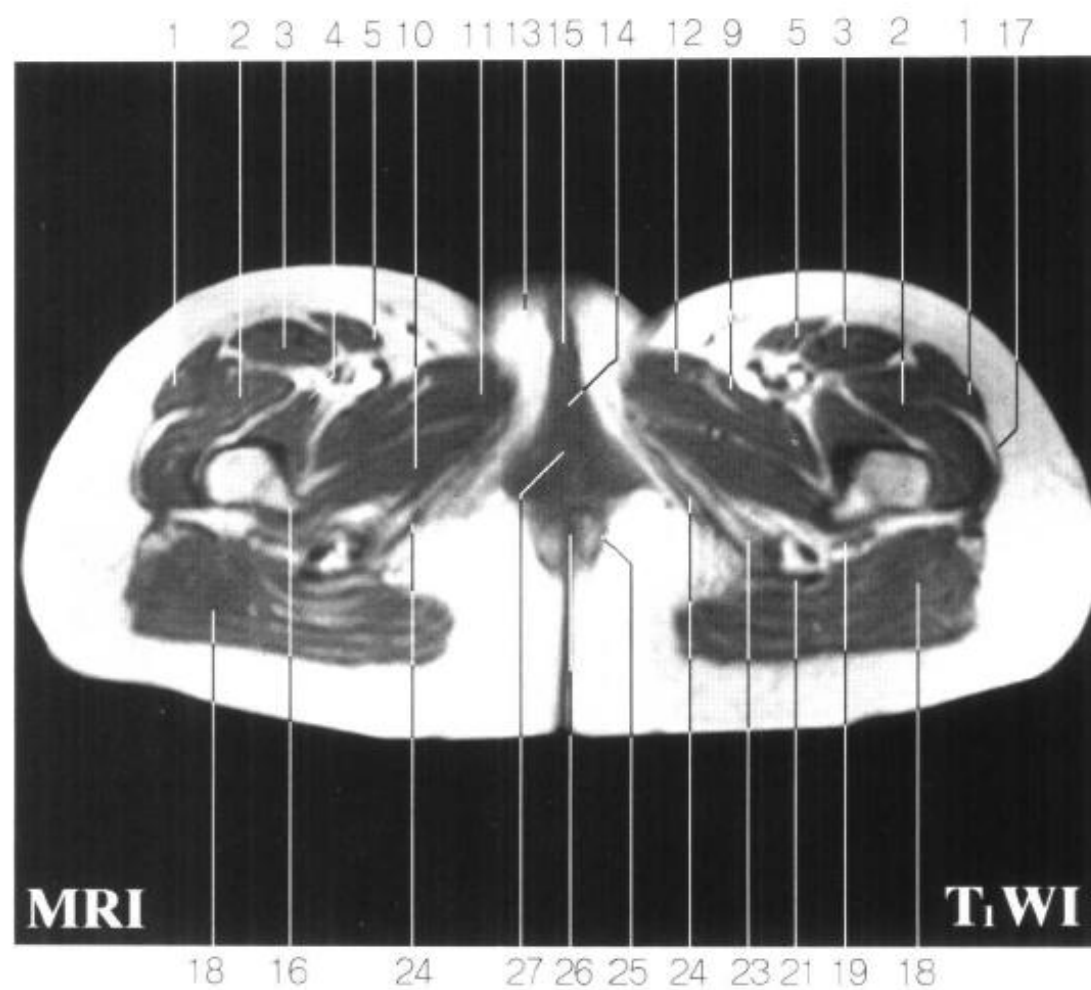


Fig. HPf 13



1. 阔筋膜张肌 tensor fasciae latae
2. 股外侧肌 vastus lateralis
3. 股直肌 rectus femoris
4. 股中间肌 vastus intermedius
5. 缝匠肌 sartorius
6. 髂腰肌 iliopsoas
7. 股深动脉 deep femoral a.
8. 股动、静脉 femoral a.and v.
9. 耻骨肌 pectineus
10. 大收肌 adductor magnus
11. 短收肌 adductor brevis
12. 长收肌 adductor longus
13. 大阴唇 greater lip of pudendum
14. 女尿道 female urethra
15. 阴蒂 clitoris
16. 小转子 lesser trochanter

Fig. HPf 13



- 17. 髂胫束 iliotibial tract
- 18. 臀大肌 gluteus maximus
- 19. 坐骨神经 sciatic n.
- 20. 股方肌 quadratus femoris
- 21. 半膜肌腱 tendon of semimembranosus
- 22. 半腱肌与股二头肌长头腱 semitendinosus and tendon of long head of biceps femoris
- 23. 坐骨支 ramus of ischium
- 24. 坐骨海绵体肌 ischiocavernosus
- 25. 肛门外括约肌 sphincter ani externus
- 26. 肛门 anus
- 27. 阴道 vagina
- 28. 大隐静脉 great saphenous v.

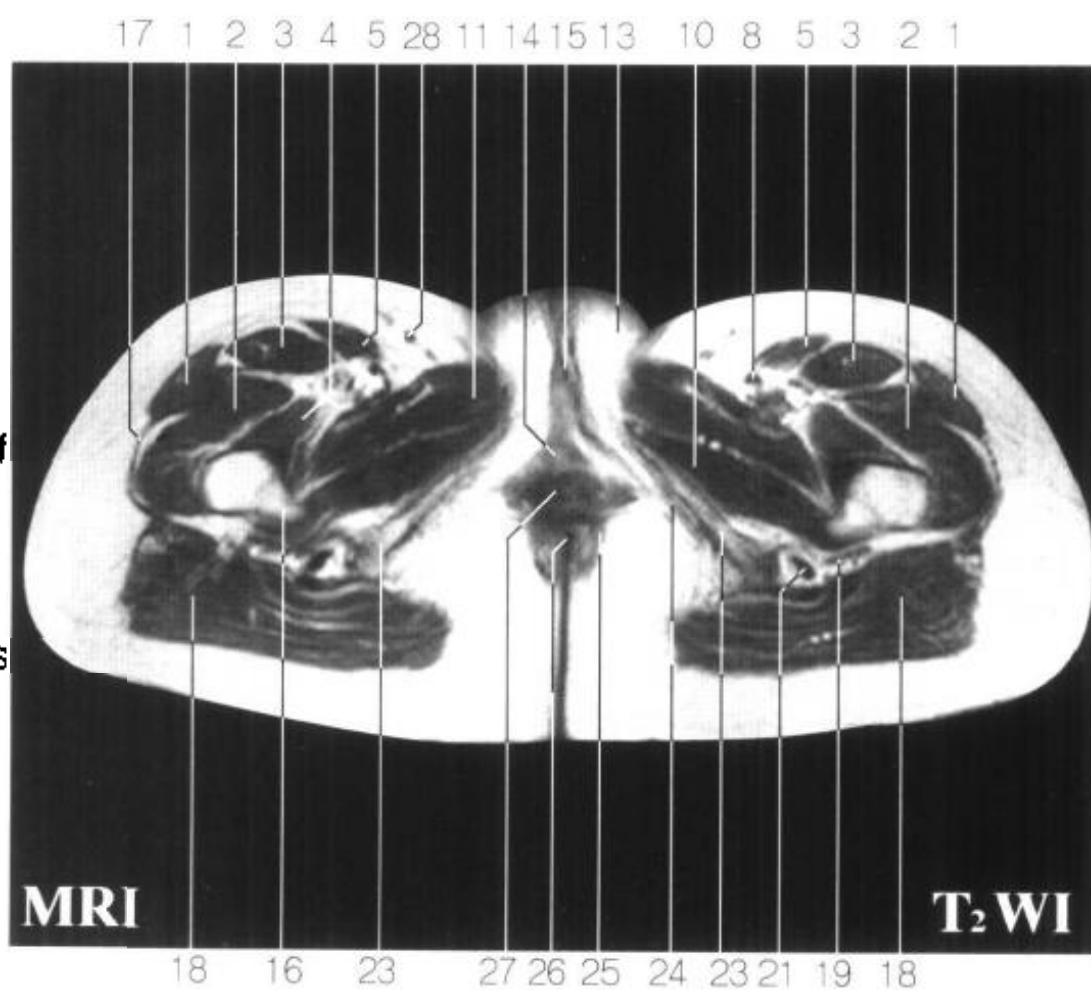

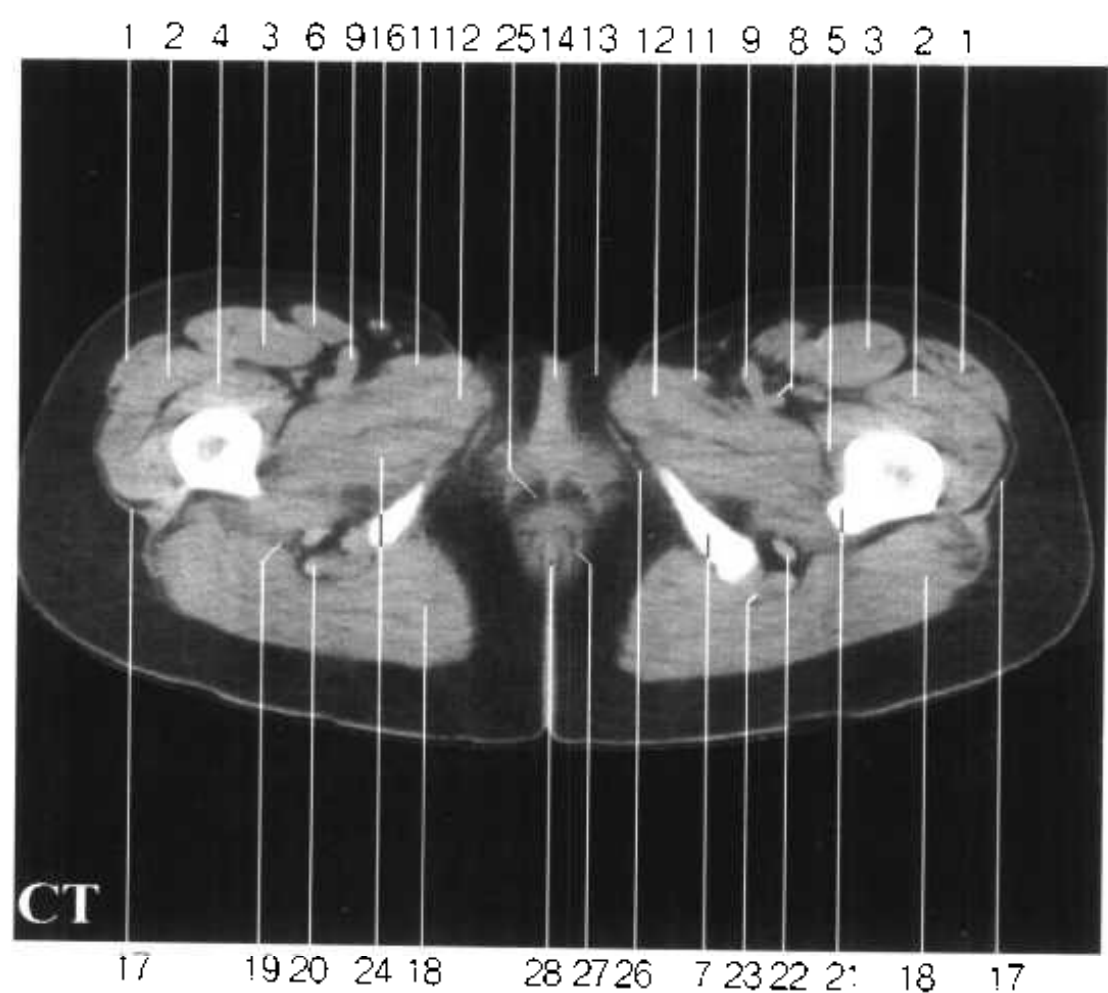
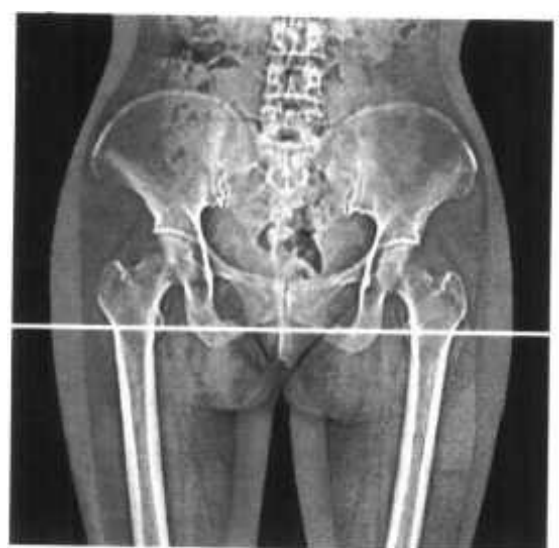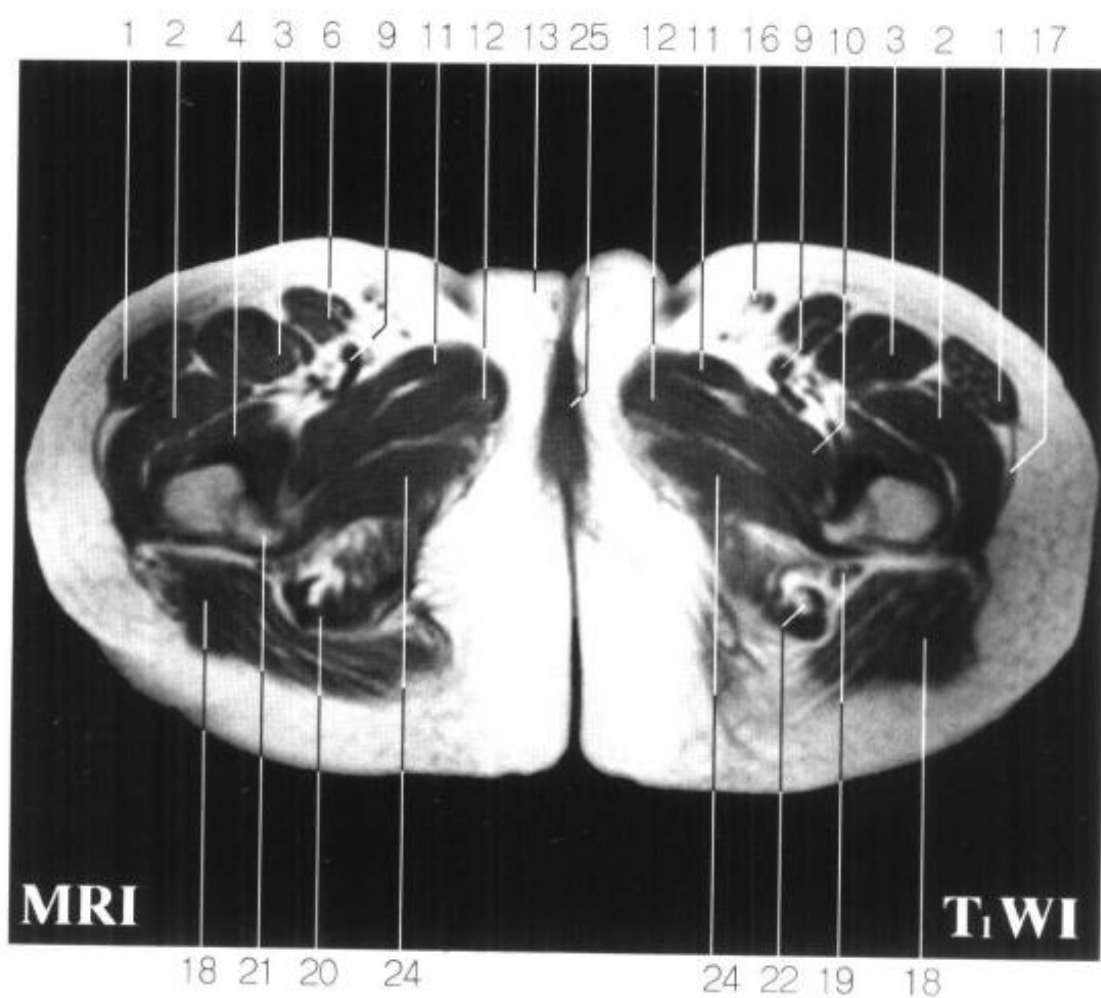


Fig. HPf 14



1. 阔筋膜张肌 tensor fasciae latae
2. 股外侧肌 vastus lateralis
3. 股直肌 rectus femoris
4. 股中间肌 vastus intermedius
5. 髂腰肌 iliopsoas
6. 缝匠肌 sartorius
7. 坐骨支 ramus of ischium
8. 股深动、静脉 deep femoral a.and v.
9. 股动、静脉 femoral a.and v.
10. 耻骨肌 pectineus
11. 长收肌 adductor longus
12. 短收肌 adductor brevis
13. 大阴唇 greater lip of pudendum
14. 阴蒂 clitoris
15. 小阴唇 lesser lip of pudendum

Fig. HPf 14



16. 大隐静脉 great saphenous v.

17. 髂胫束 iliotibial tract

18. 臀大肌 gluteus maximus

19. 坐骨神经 sciatic n.

20. 股二头肌长头腱 tendon of long head of biceps femoris

21. 小转子 lesser trochanter

22. 半膜肌腱 tendon of semimembranosus

23. 半腱肌 semitendinosus

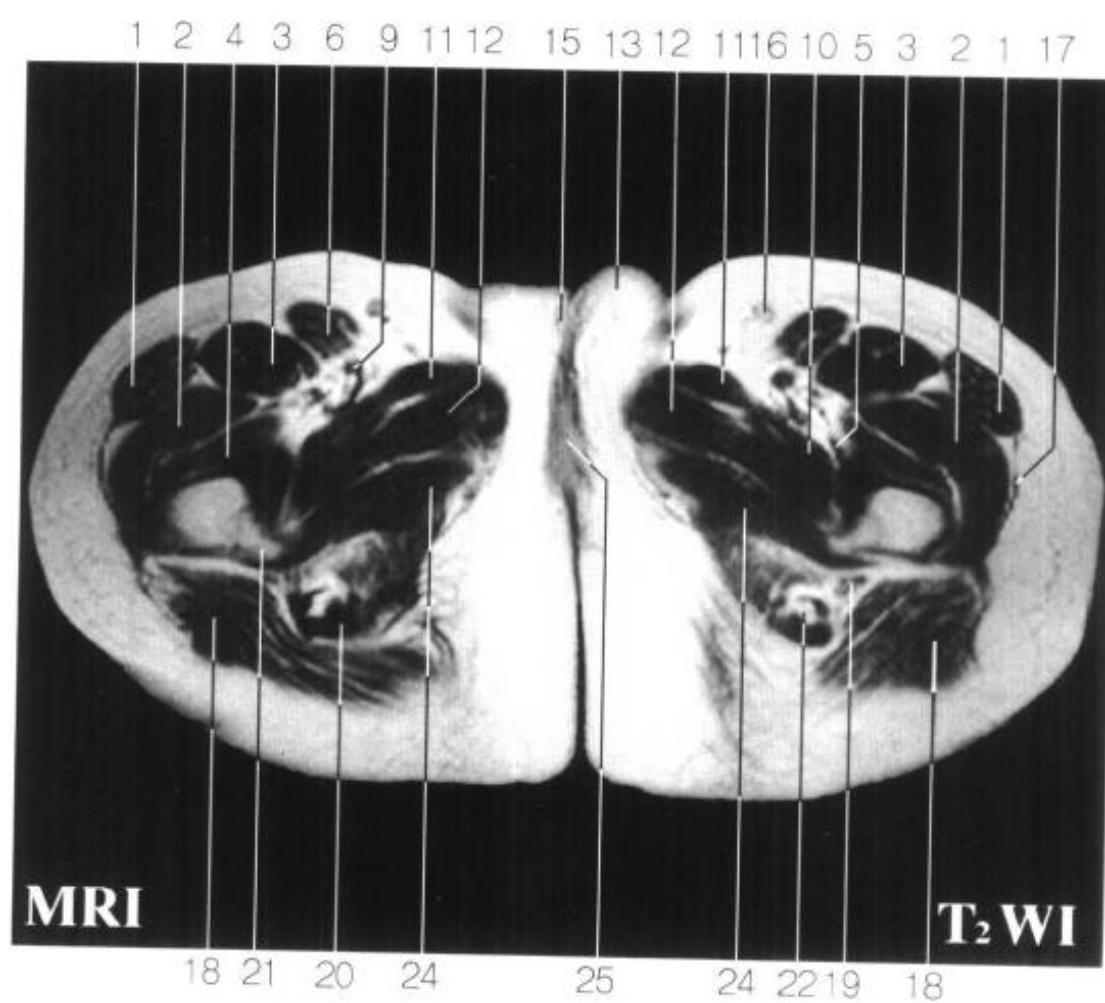24. 大收肌 adductor magnus

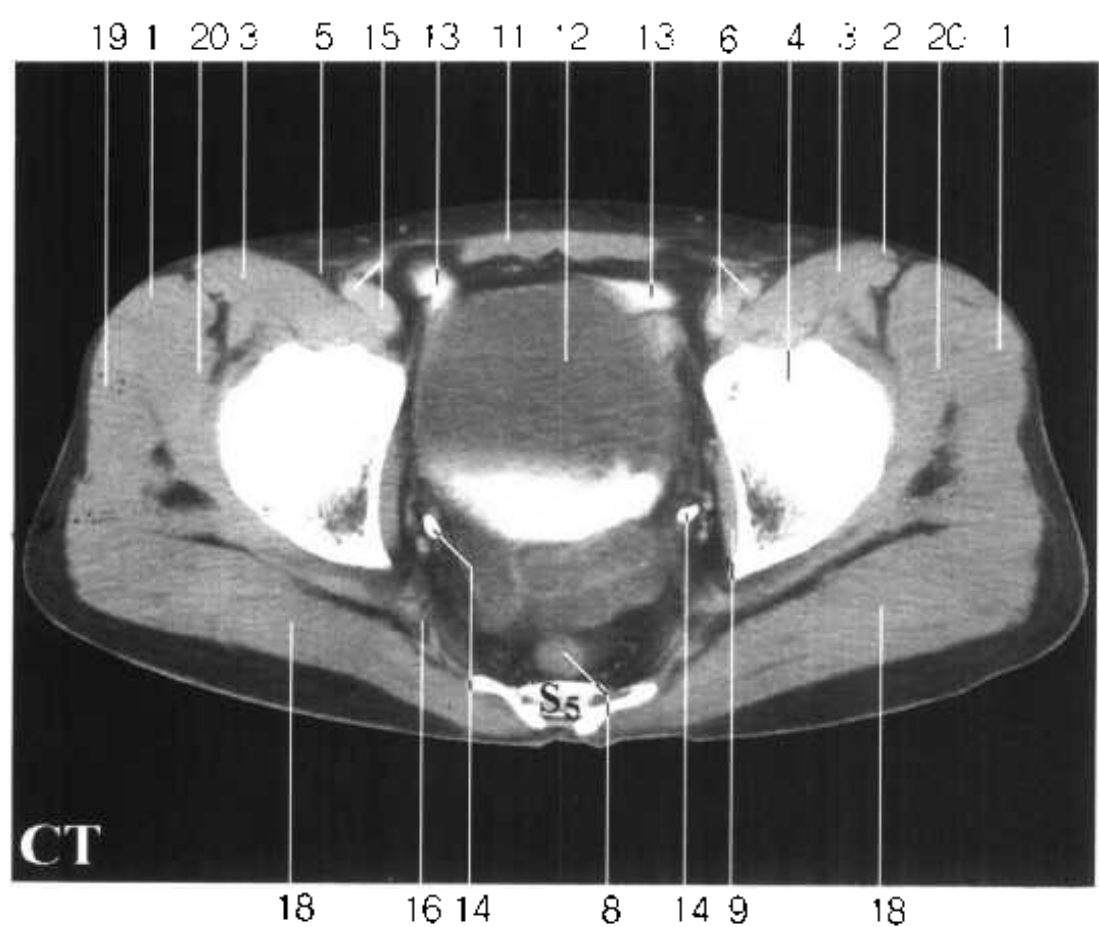
25. 阴道前庭 vaginal vestibule

26. 股薄肌 gracilis

27. 肛门外括约肌 sphincter ani externus

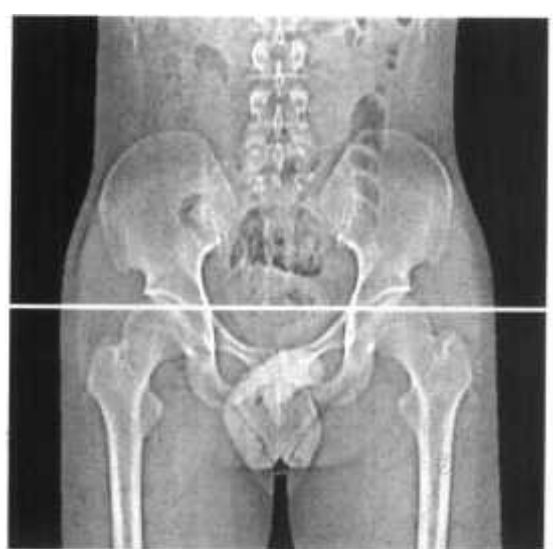28. 肛门 anus





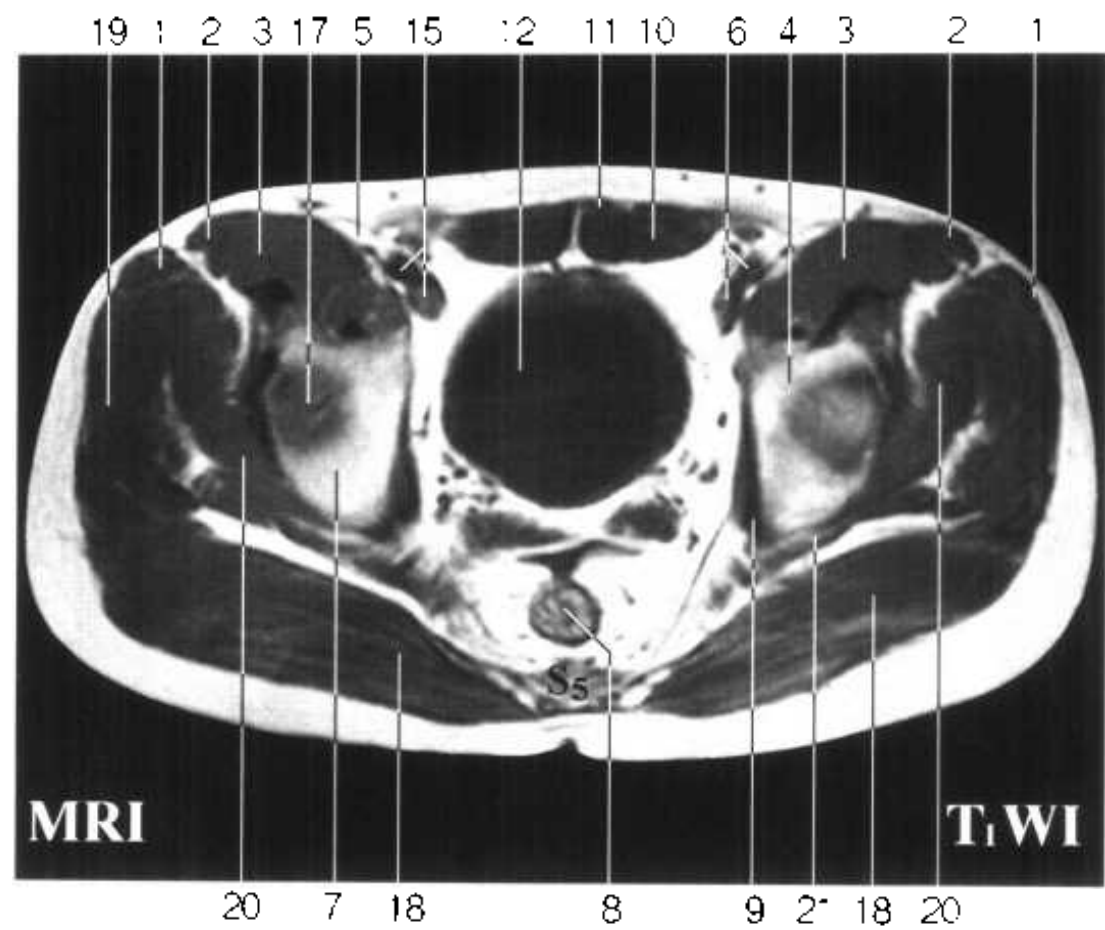
男盆水平断面图 HPm

Fig. HPm 1

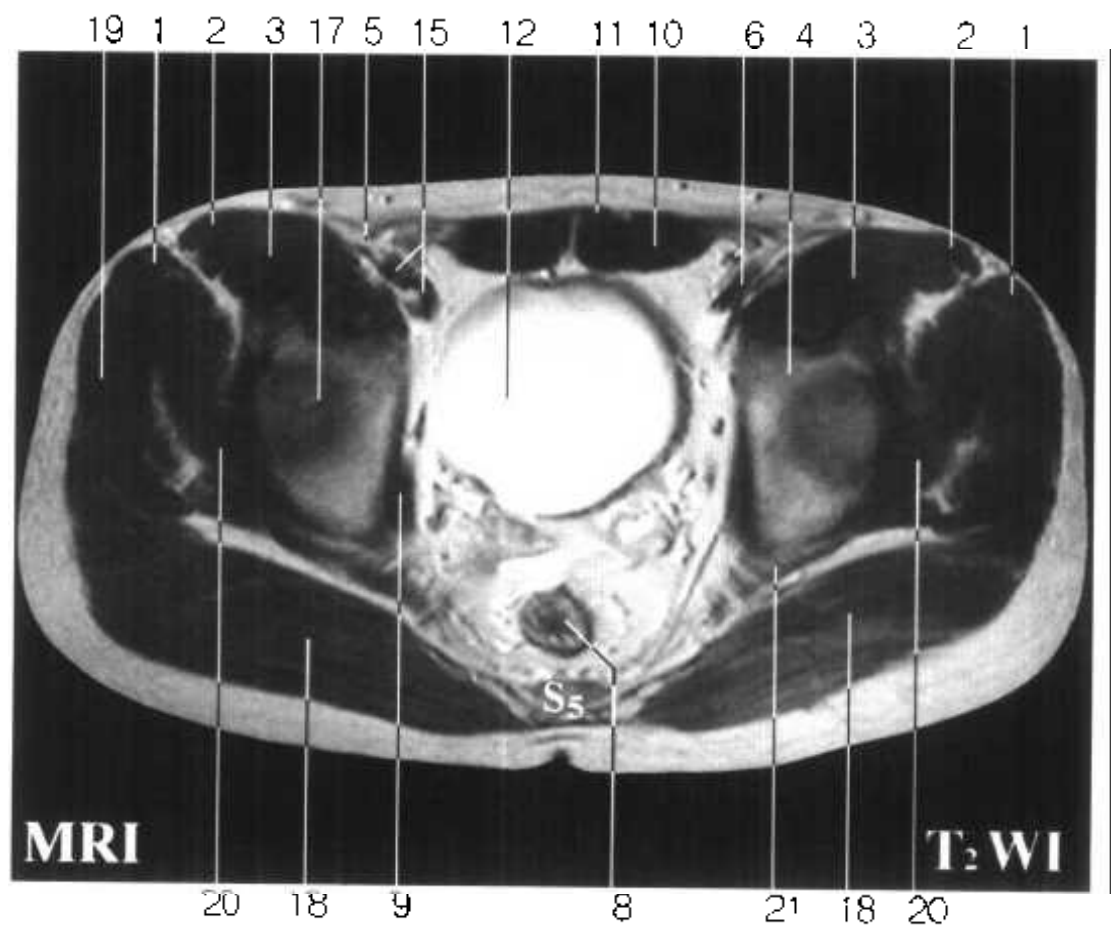


1. 阔筋膜张肌 tensor fasciae latae
2. 缝匠肌 sartorius
3. 髂腰肌 iliopsoas
4. 髂骨体 body of ilium
5. 股神经 femoral n.
6. 左髂外动、静脉 left external iliac a.and v.
7. 坐骨体 body of ischium
8. 直肠 rectum
9. 闭孔内肌 obturator internus
10. 腹直肌 rectus abdominis

Fig. HPm 1



- 11. 锥状肌 pyramidalis
- 12. 膀胱 urinary bladder
- 13. 回肠 ileum
- 14. 输尿管 ureter
- 15. 右骼外动、静脉 right external iliac a. and v.
- 16. 坐骨神经 sciatic n.
- 17. 股骨头 femoral head
- 18. 臀大肌 gluteus maximus
- 19. 臀中肌 gluteus medius
- 20. 臀小肌 gluteus minimus
- 21. 梨状肌 piriformis



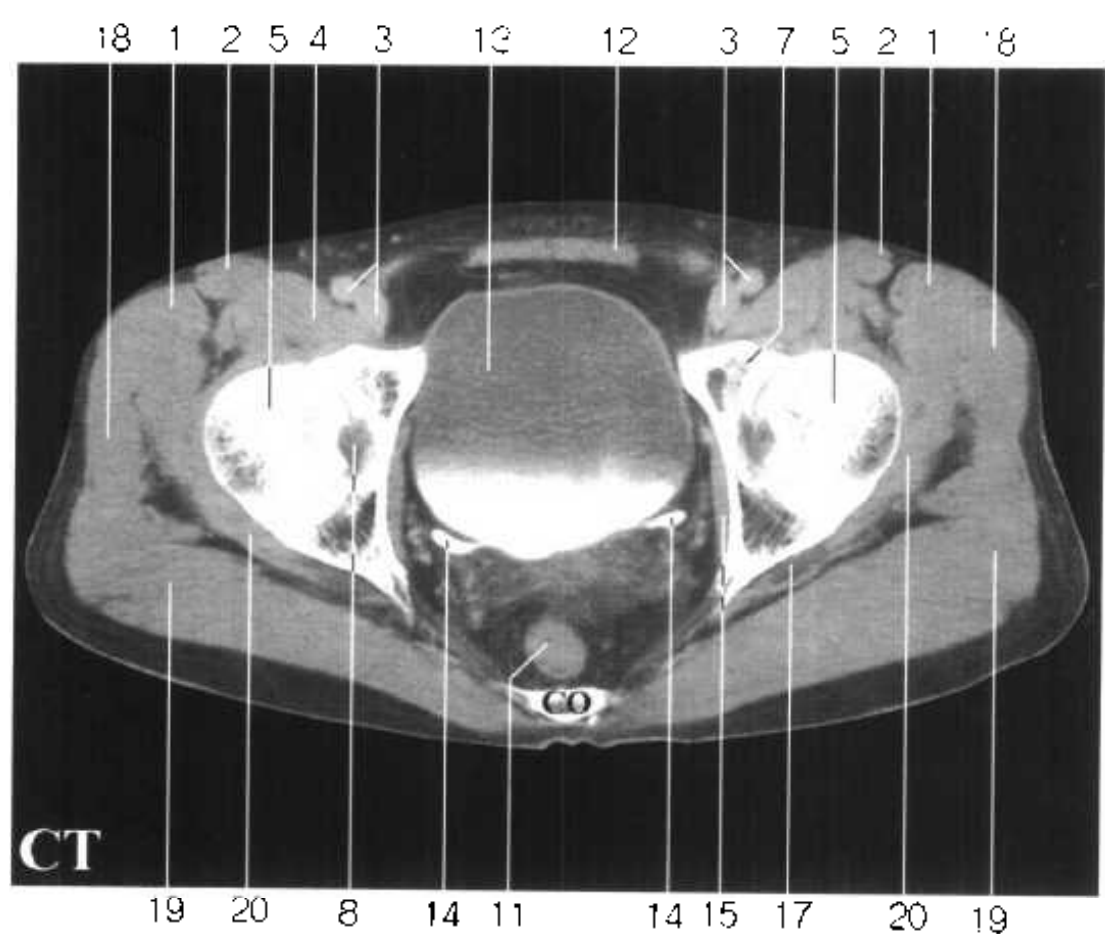
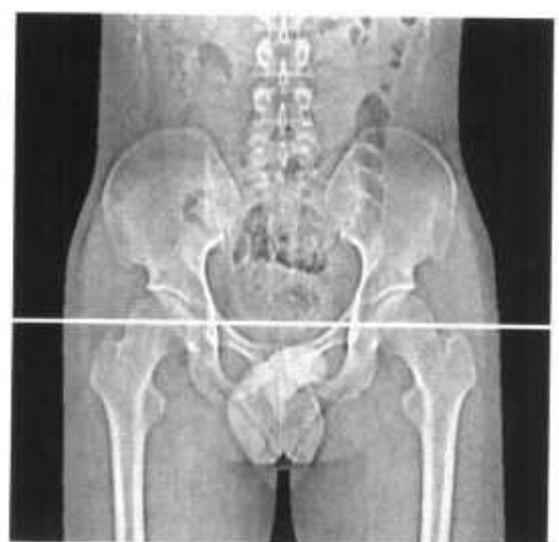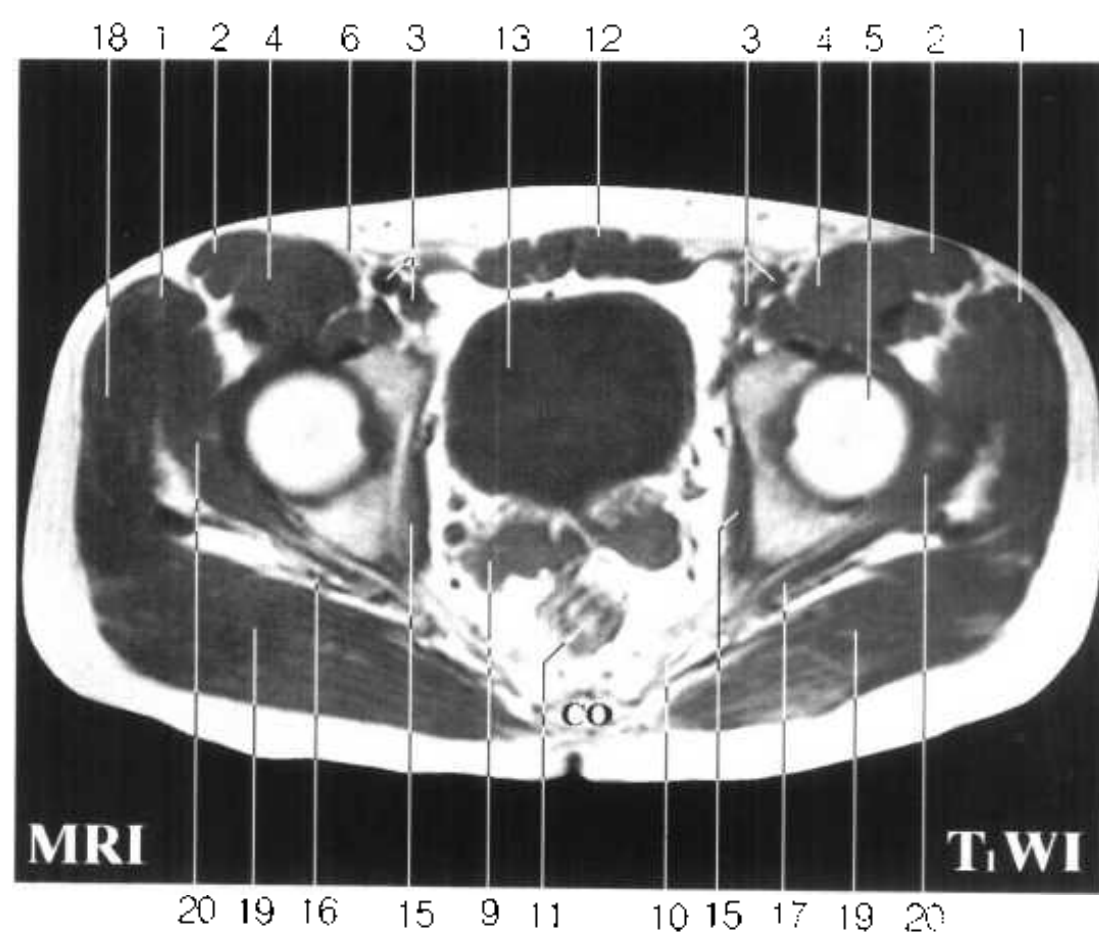


Fig. HPm 2

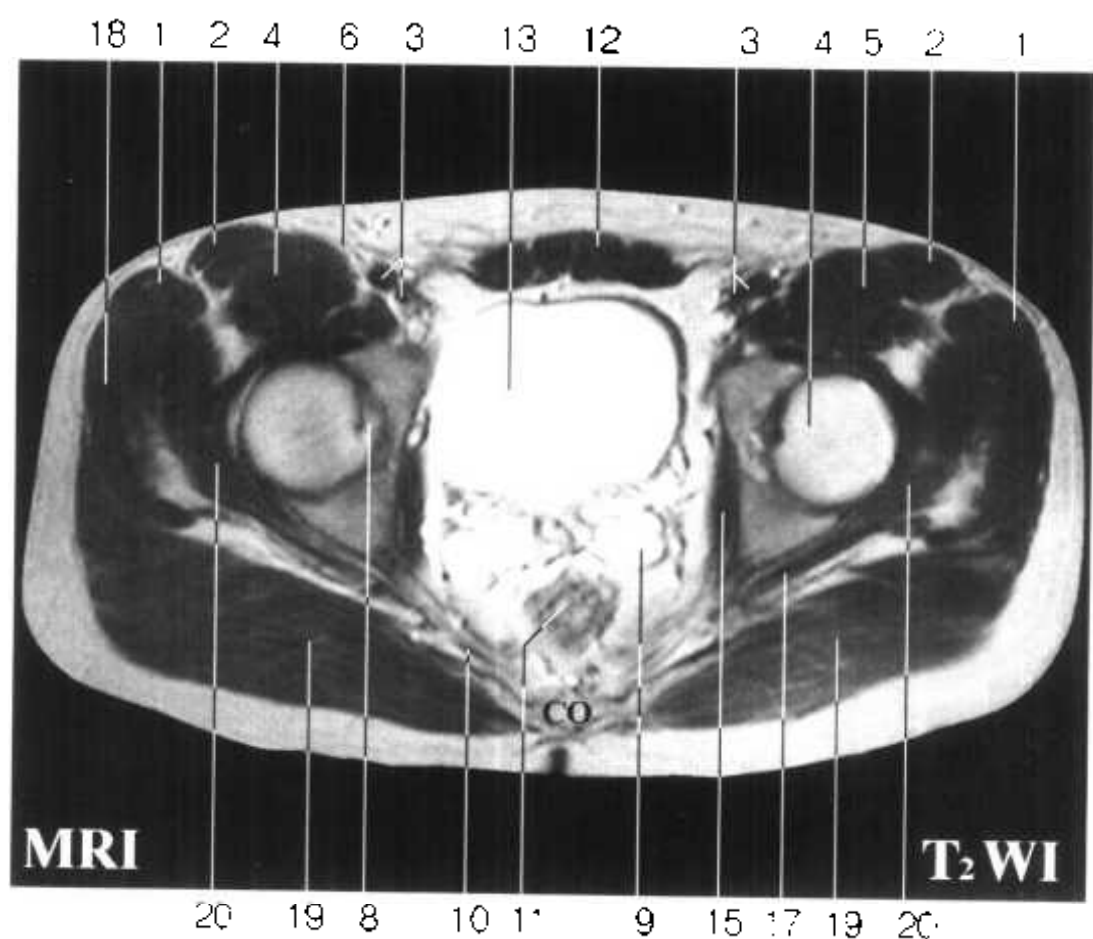


1. 阔筋膜张肌 tensor fasciae latae
2. 缝匠肌 sartorius
3. 股动、静脉 femoral a.and v.
4. 髂腰肌 iliopsoas
5. 股骨头 femoral head
6. 股神经 femoral n.
7. 耻骨体 body of pubis
8. 股骨头韧带 ligament of head of femur
9. 精囊 seminal vesicle
10. 尾骨肌 coccygeus
11. 直肠 rectum
12. 锥状肌 pyramidalis
13. 膀胱 urinary bladder

Fig. HPm 2



- 14. 输尿管 ureter
- 15. 闭孔内肌 obturator internus
- 16. 坐骨神经 sciatic n.
- 17. 上孖肌 gemellus superior
- 18. 臀中肌 gluteus medius
- 19. 臀大肌 gluteus maximus
- 20. 臀小肌 gluteus minimus



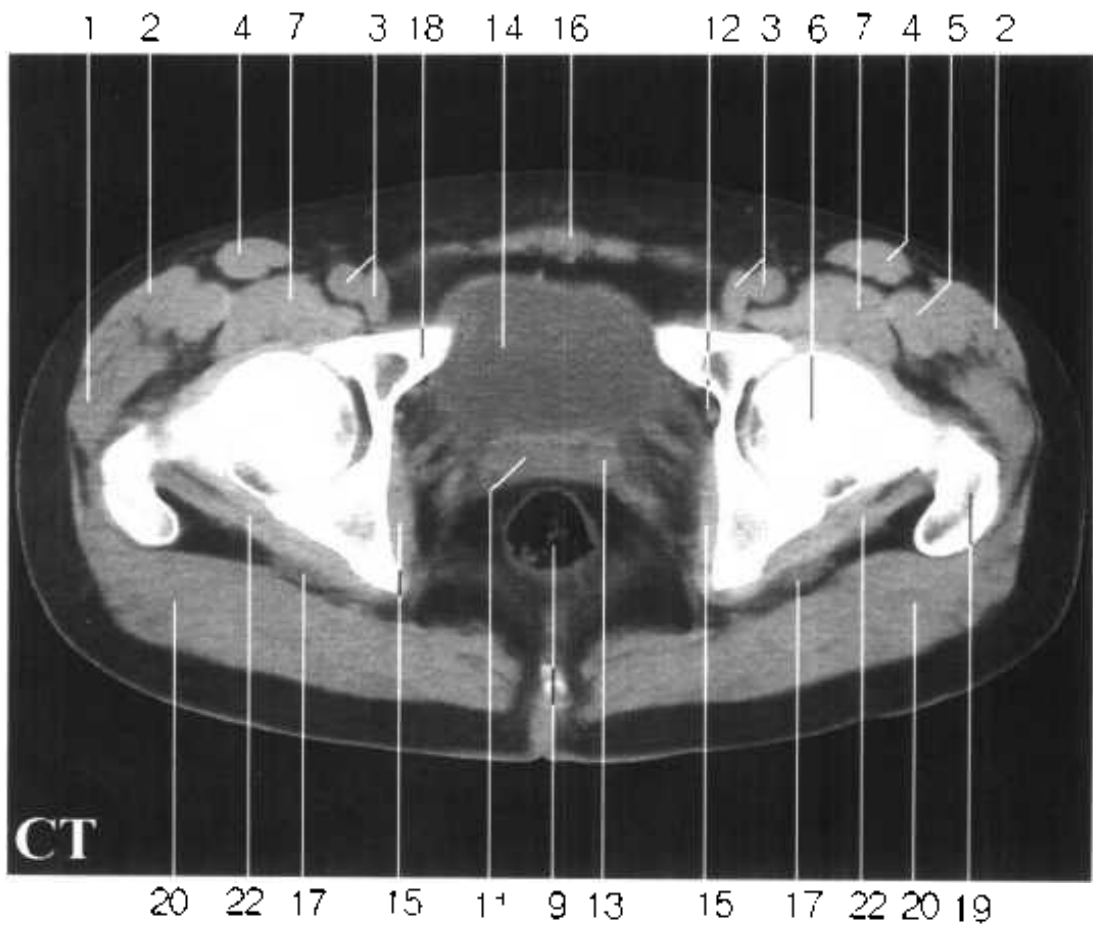
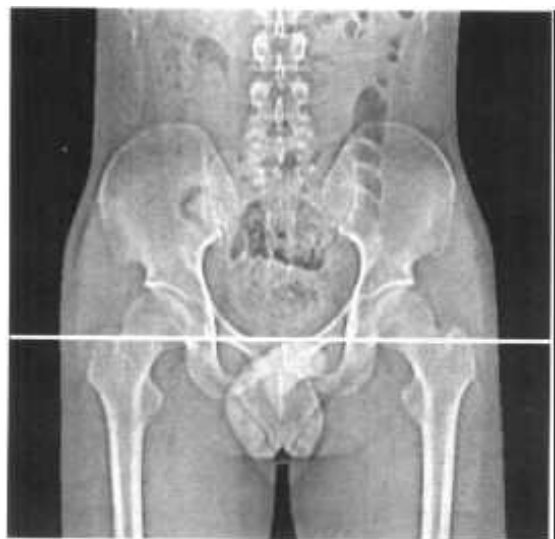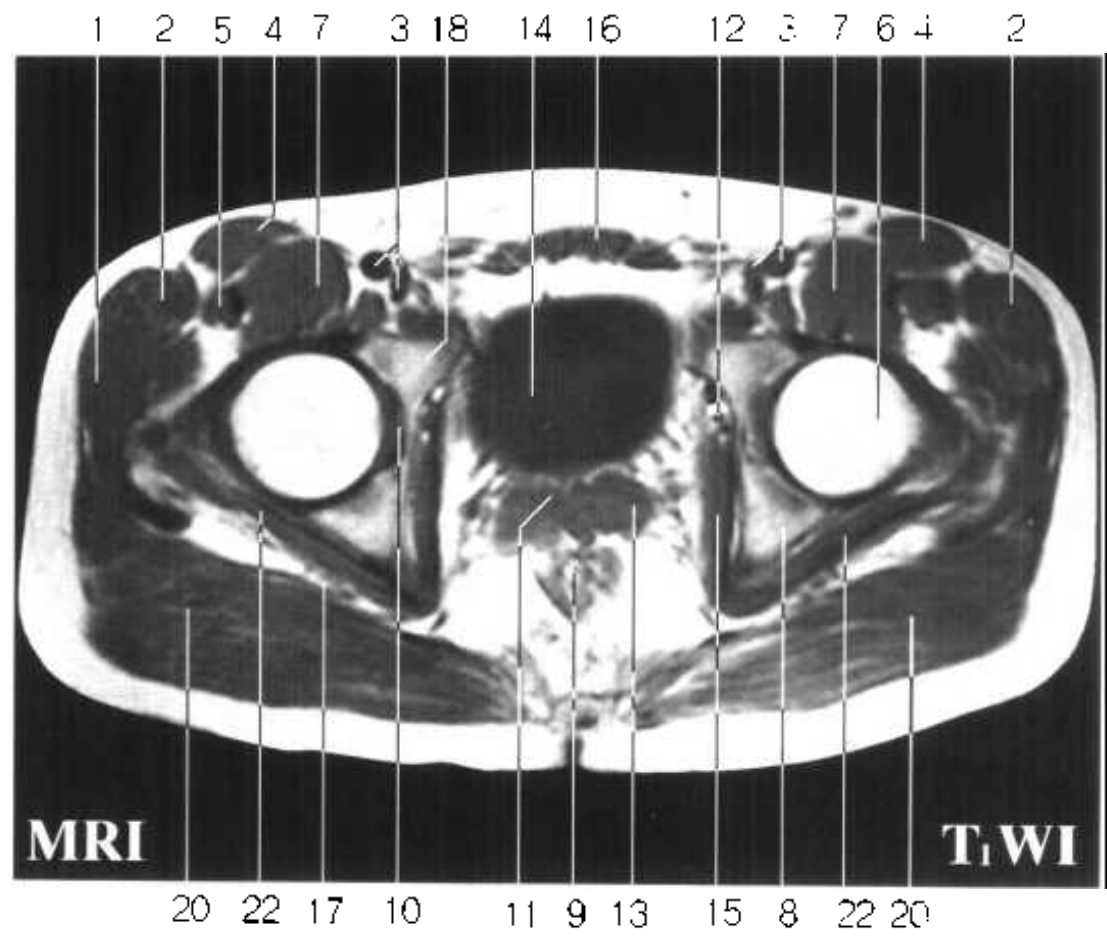


Fig. HPm 3

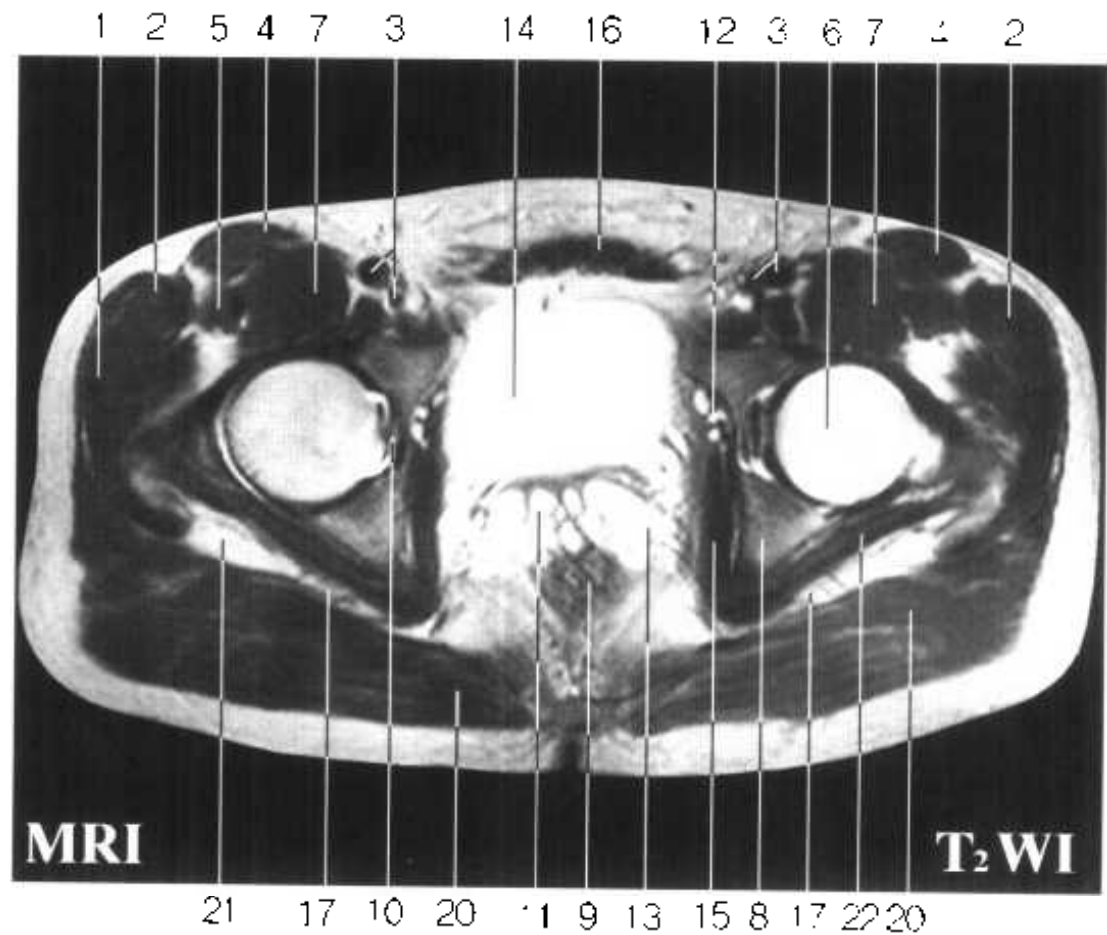


1. 臀中肌 gluteus medius
2. 阔筋膜张肌 tensor fasciae latae
3. 股动、静脉 femoral a. and v.
4. 缝匠肌 sartorius
5. 股直肌 rectus femoris
6. 股骨头 femoral head
7. 髂腰肌 iliopsoas
8. 坐骨体 body of ischium
9. 直肠 rectum
10. 股骨头韧带 ligament of head of femur
11. 输精管壶腹 ampulla ductus deferentis
12. 闭膜管 obturator canal
13. 精囊 seminal vesicle

Fig. HPm 3



- 14. 膀胱 urinary bladder
- 15. 闭孔内肌 obturator internus
- 16. 锥状肌 pyramidalis
- 17. 坐骨神经 sciatic n.
- 18. 耻骨体 body of pubis
- 19. 大转子 greater trochanter
- 20. 臀大肌 gluteus maximus
- 21. 闭孔内肌腱 tendon of obturator internus
- 22. 下孖肌 gemellus inferior



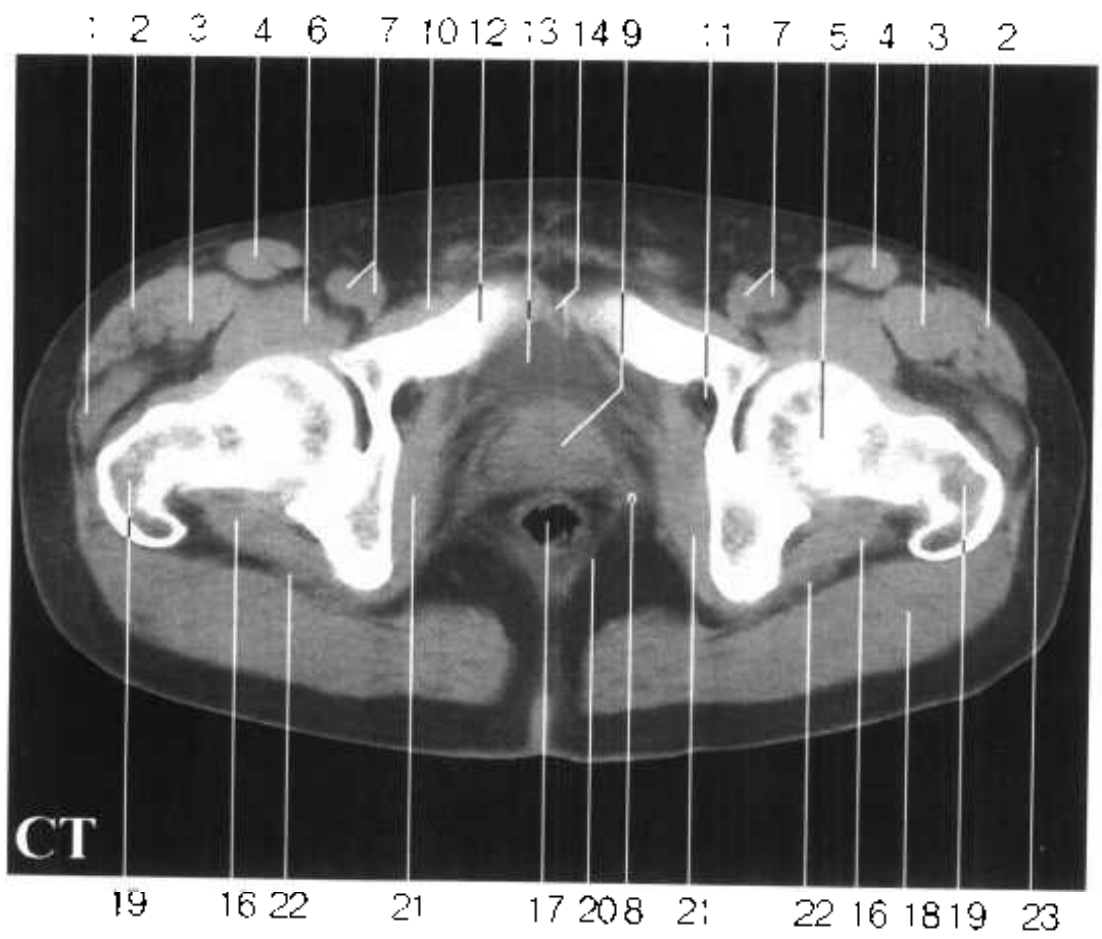
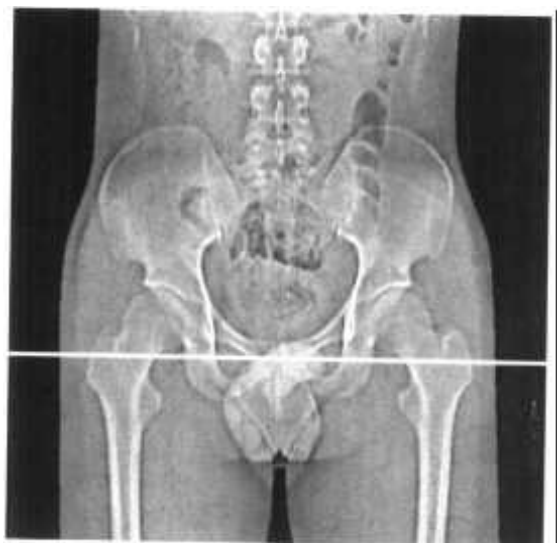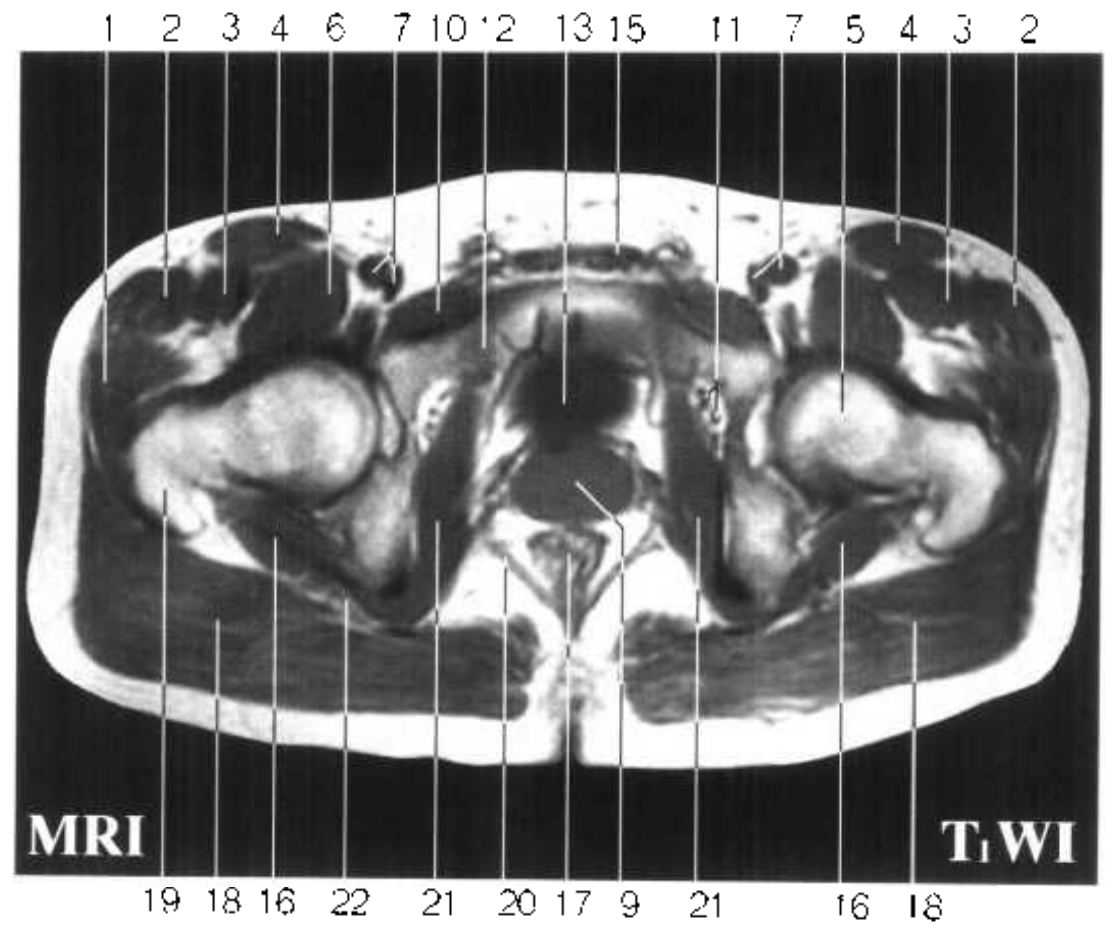


Fig. HPm 4

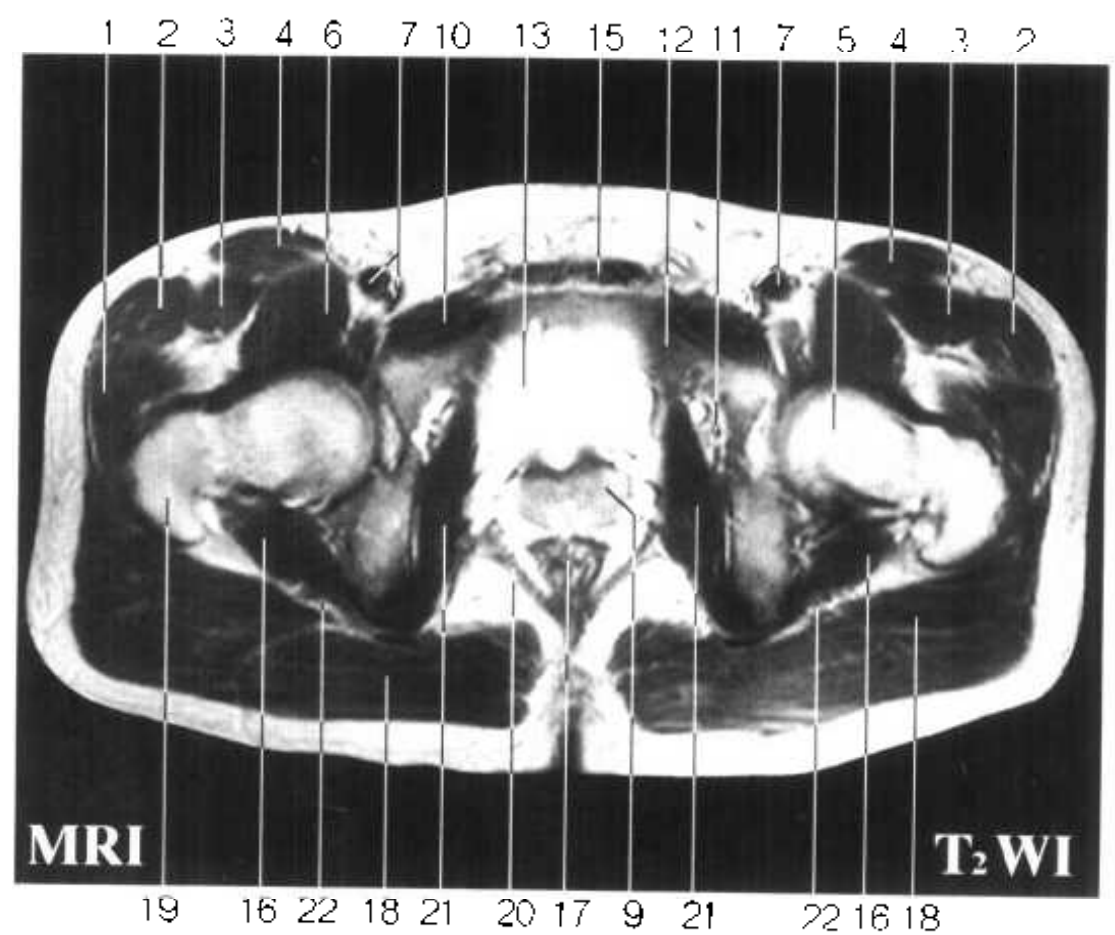


1. 臀中肌 *gluteus medius*
2. 阔筋膜张肌 *tensor fasciae latae*
3. 股直肌 *rectus femoris*
4. 缝匠肌 *sartorius*
5. 股骨头 *femoral head*
6. 髂腰肌 *iliopsoas*
7. 股动、静脉 *femoral a. and v.*
8. 静脉石 *phlebolith*
9. 前列腺 *prostate*
10. 耻骨肌 *pectineus*
11. 闭膜管 *obturator canal*
12. 耻骨上支 *superior ramus of pubis*

Fig. HPm 4



- 13. 膀胱 urinary bladder
- 14. 耻骨联合 pubic symphysis
- 15. 锥状肌 pyramidalis
- 16. 股方肌 quadratus femoris
- 17. 直肠 rectum
- 18. 臀大肌 gluteus maximus
- 19. 大转子 greater trochanter
- 20. 肛提肌 levator ani
- 21. 闭孔内肌 obturator internus
- 22. 坐骨神经 sciatic n.
- 23. 髂胫束 iliotibial tract



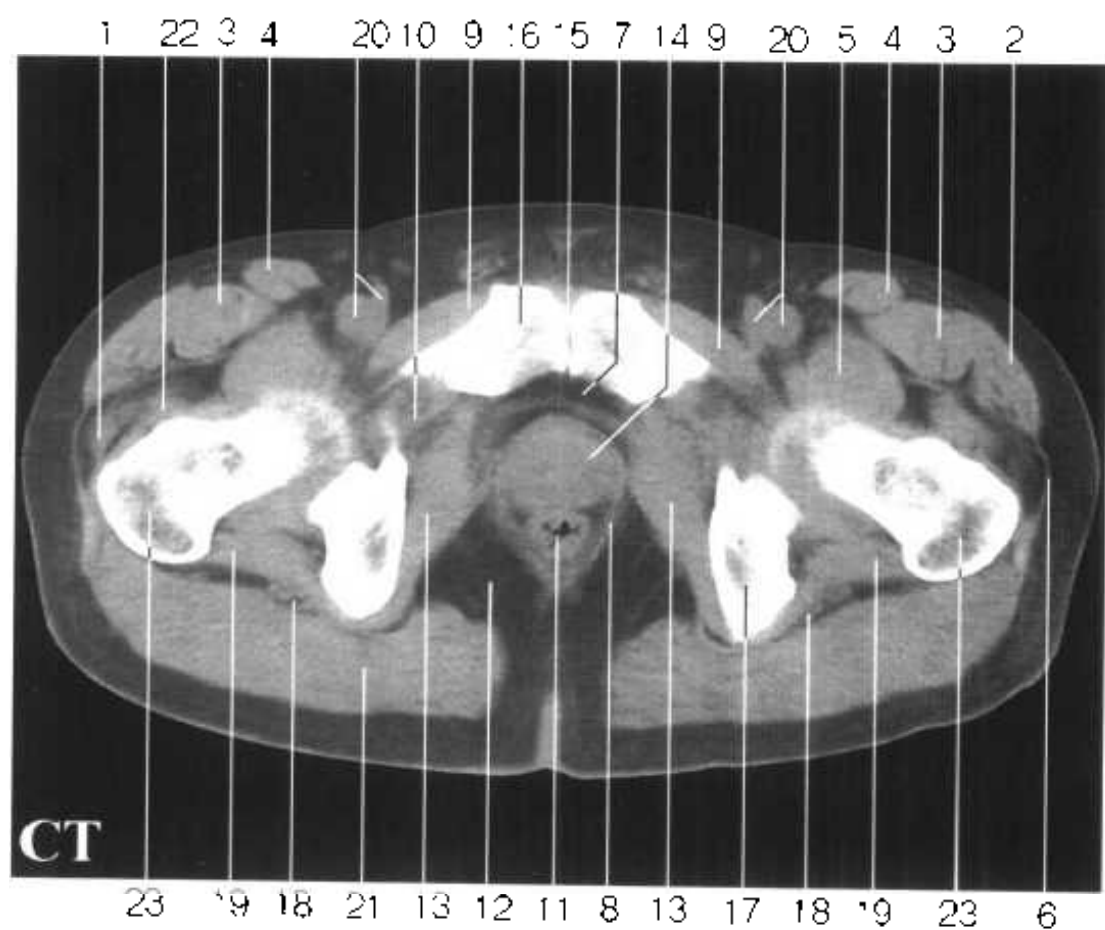
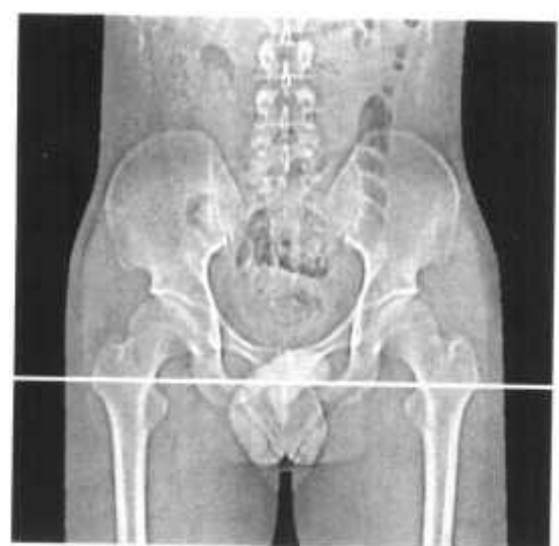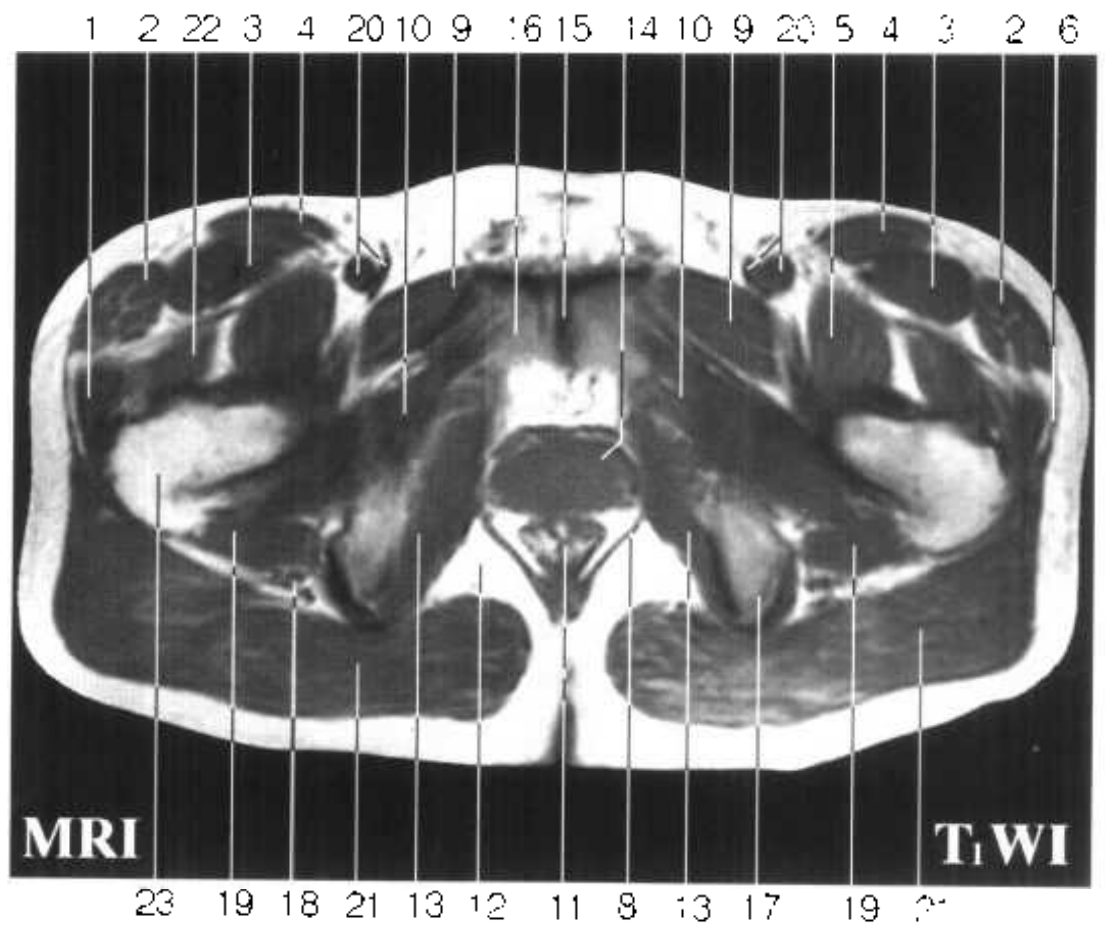


Fig. HPm 5



1. 股外侧肌 vastus lateralis
2. 阔筋膜张肌 tensor fasciae latae
3. 股直肌 rectus femoris
4. 缝匠肌 sartorius
5. 髂腰肌 iliopsoas
6. 髂胫束 iliotibial tract
7. 耻骨后〔间〕隙 retropubic space
8. 肛提肌 levator ani
9. 耻骨肌 pectineus
10. 闭孔外肌 obturator externus
11. 直肠 rectum
12. 坐骨肛门窝脂体 adipose body of ischioanal fossa
13. 闭孔内肌 obturator internus

Fig. HPm 5



14. 前列腺与尿道 prostate and urethra

15. 耻骨联合 pubic symphysis

16. 耻骨上支 superior ramus of pubis

17. 坐骨结节 ischial tuberosity

18. 坐骨神经 sciatic n.

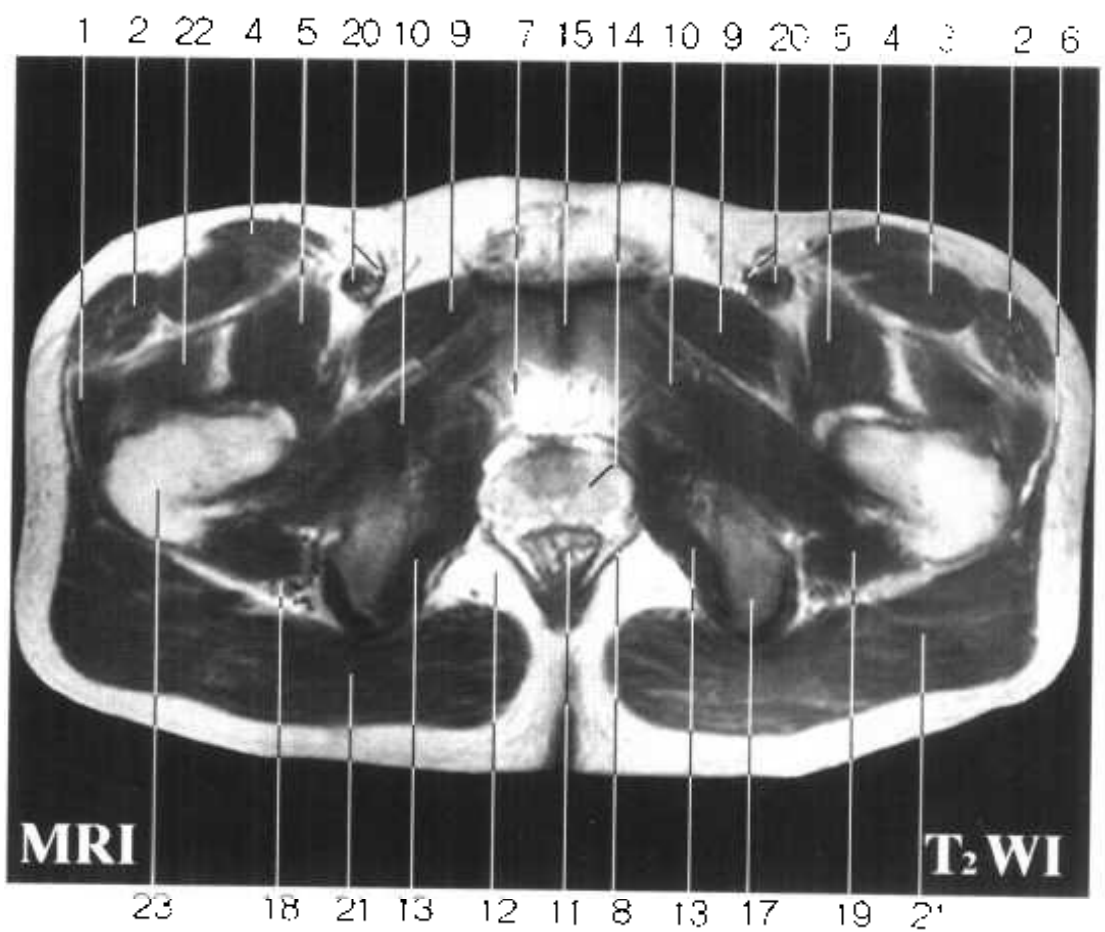
19. 股方肌 quadratus femoris

20. 股动、静脉 femoral a. and v.

21. 臀大肌 gluteus maximus

22. 股中间肌 vastus intermedius

23. 大转子 greater trochanter



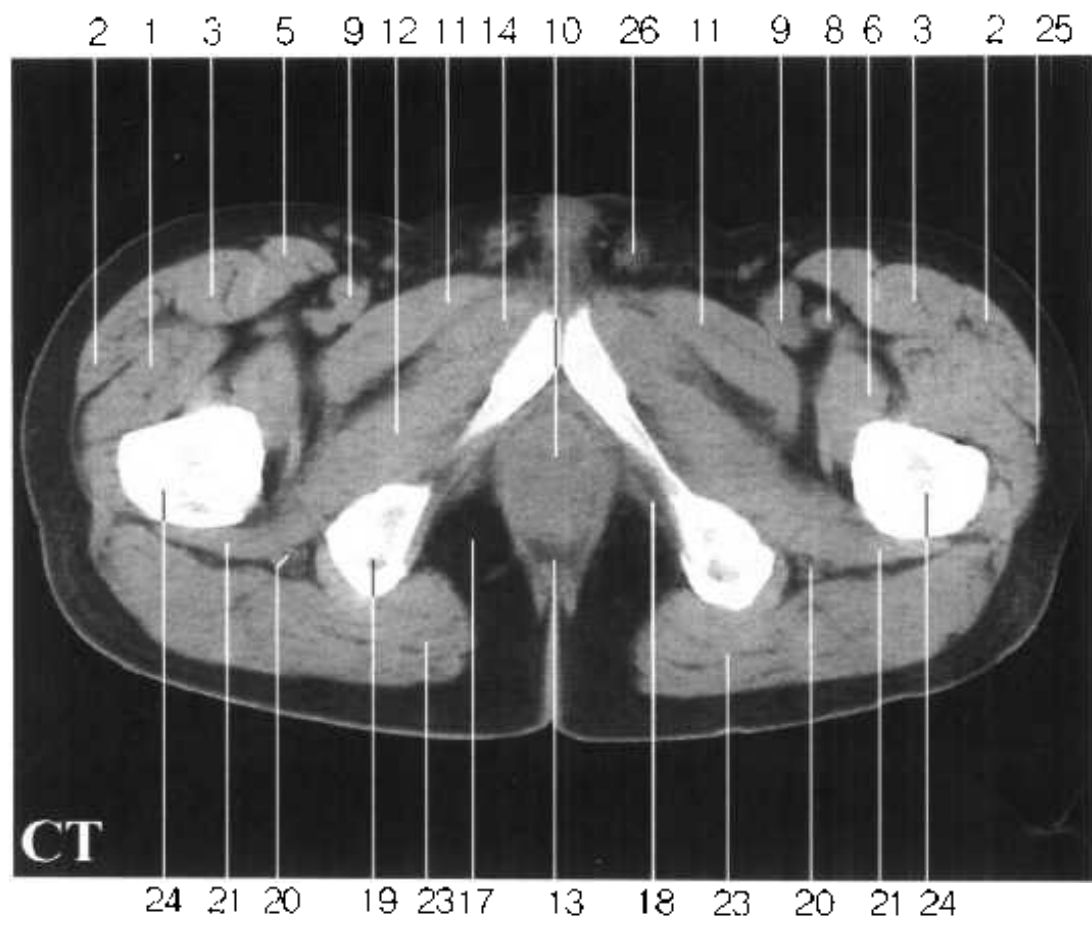
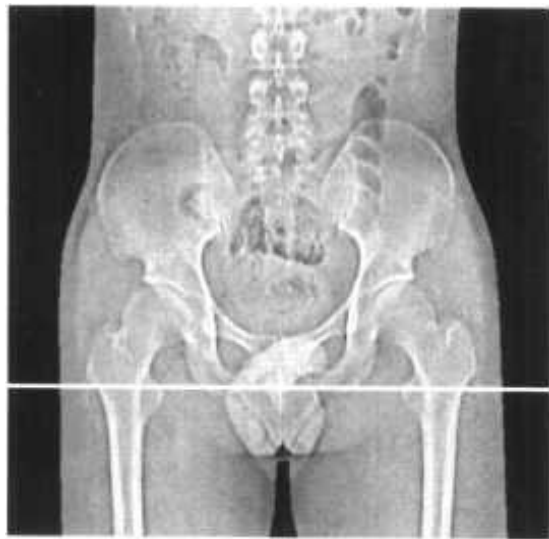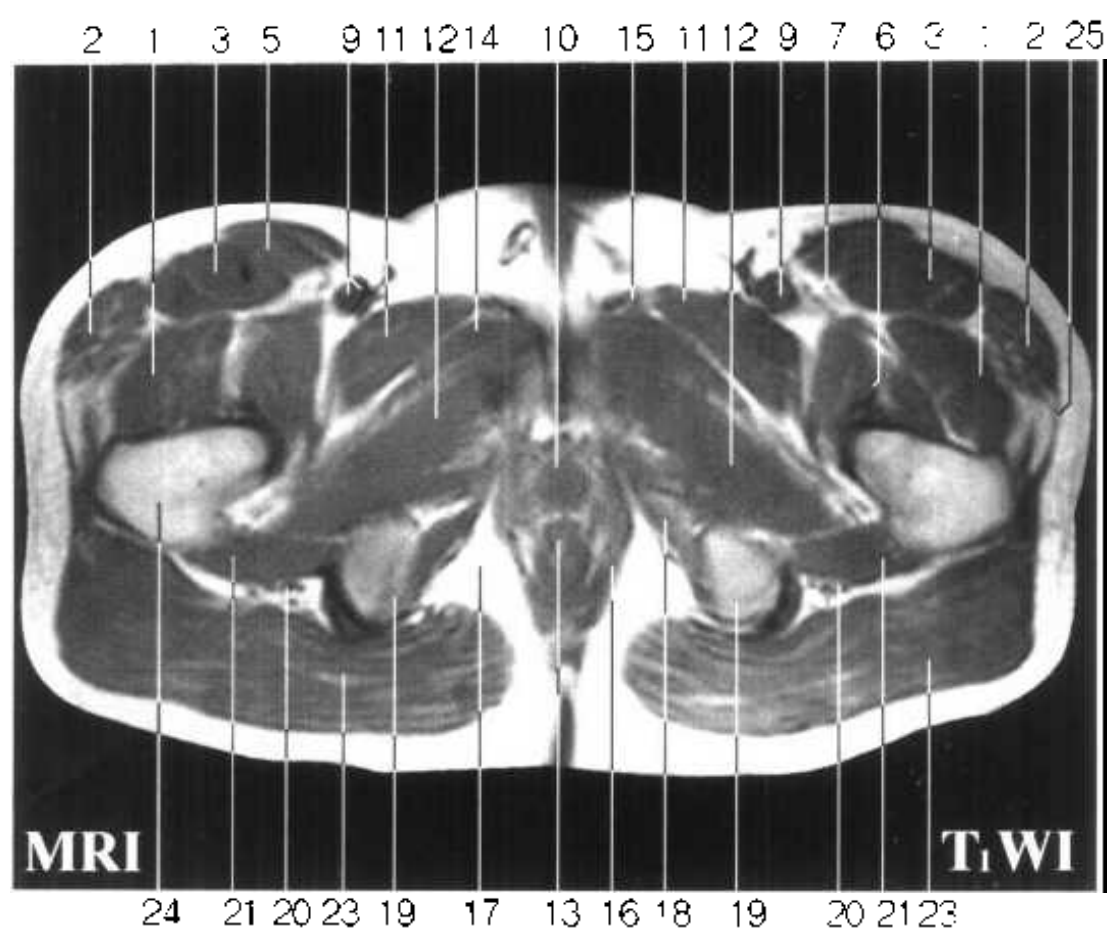


Fig. HPm 6

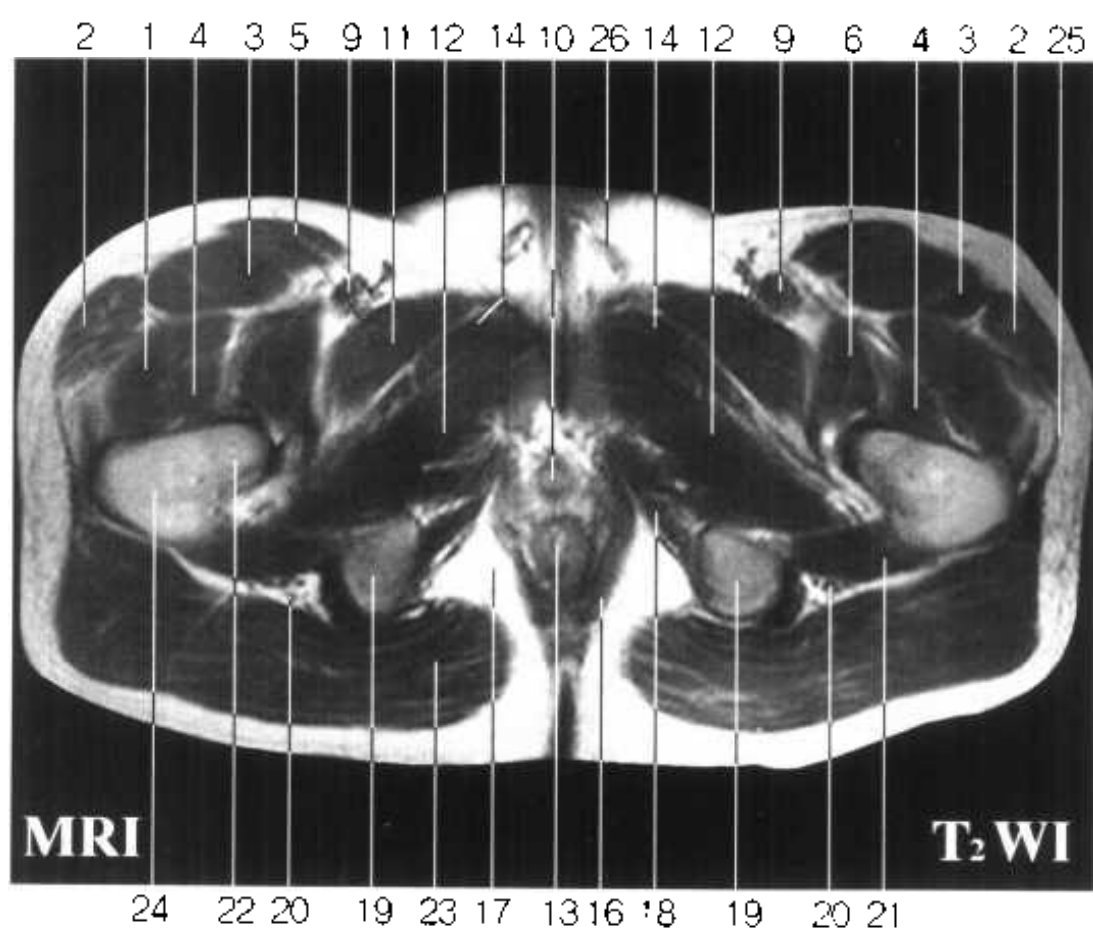


1. 股外侧肌 vastus lateralis
2. 阔筋膜张肌 tensor fasciae latae
3. 股直肌 rectus femoris
4. 股中间肌 vastus intermedius
5. 缝匠肌 sartorius
6. 髂腰肌 iliopsoas
7. 股神经 femoral n.
8. 股深动脉 deep femoral a.
9. 股动、静脉 femoral a.and v.
10. 前列腺与尿道 prostate and urethra
11. 耻骨肌 pectineus
12. 大收肌 adductor magnus
13. 直肠 rectum

Fig. HPm 6



- 14. 短收肌 adductor brevis
- 15. 长收肌 adductor longus
- 16. 肛提肌 levator ani
- 17. 坐骨肛门窝脂体 adipose body of ischioanal fossa
- 18. 闭孔内肌 obturator internus
- 19. 坐骨结节 ischial tuberosity
- 20. 坐骨神经 sciatic n.
- 21. 股方肌 quadratus femoris
- 22. 小转子 lesser trochanter
- 23. 臀大肌 gluteus maximus
- 24. 股骨 femur
- 25. 髂胫束 iliotibial tract
- 26. 精索 spermatic cord



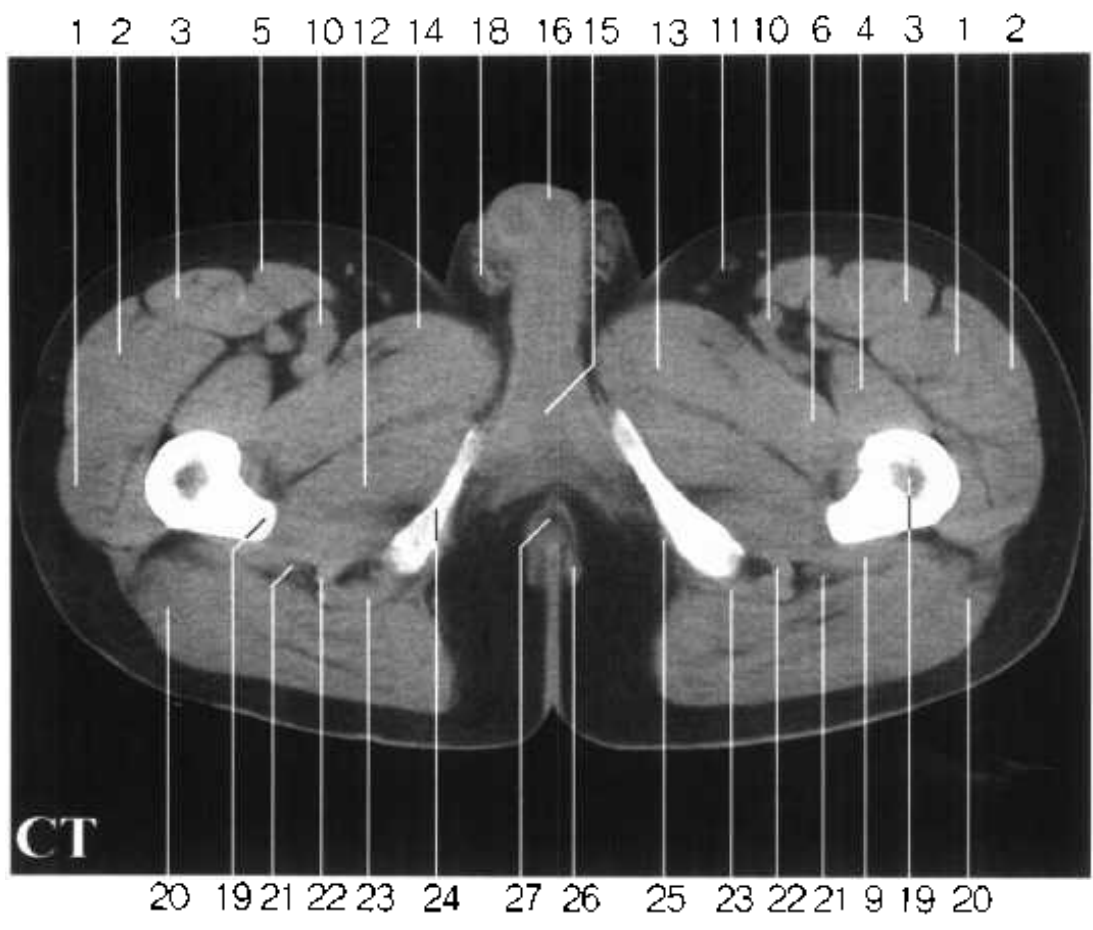
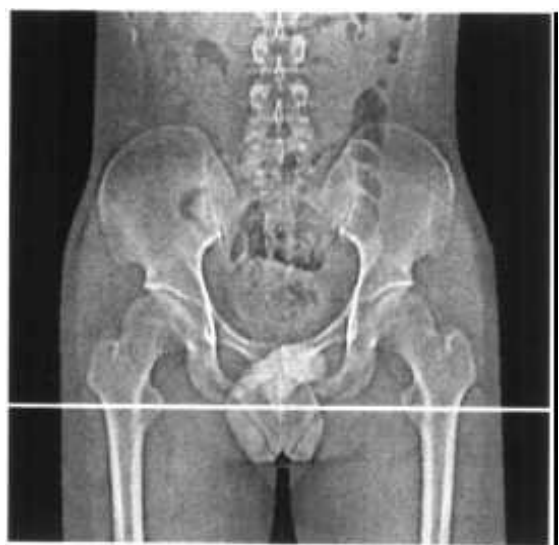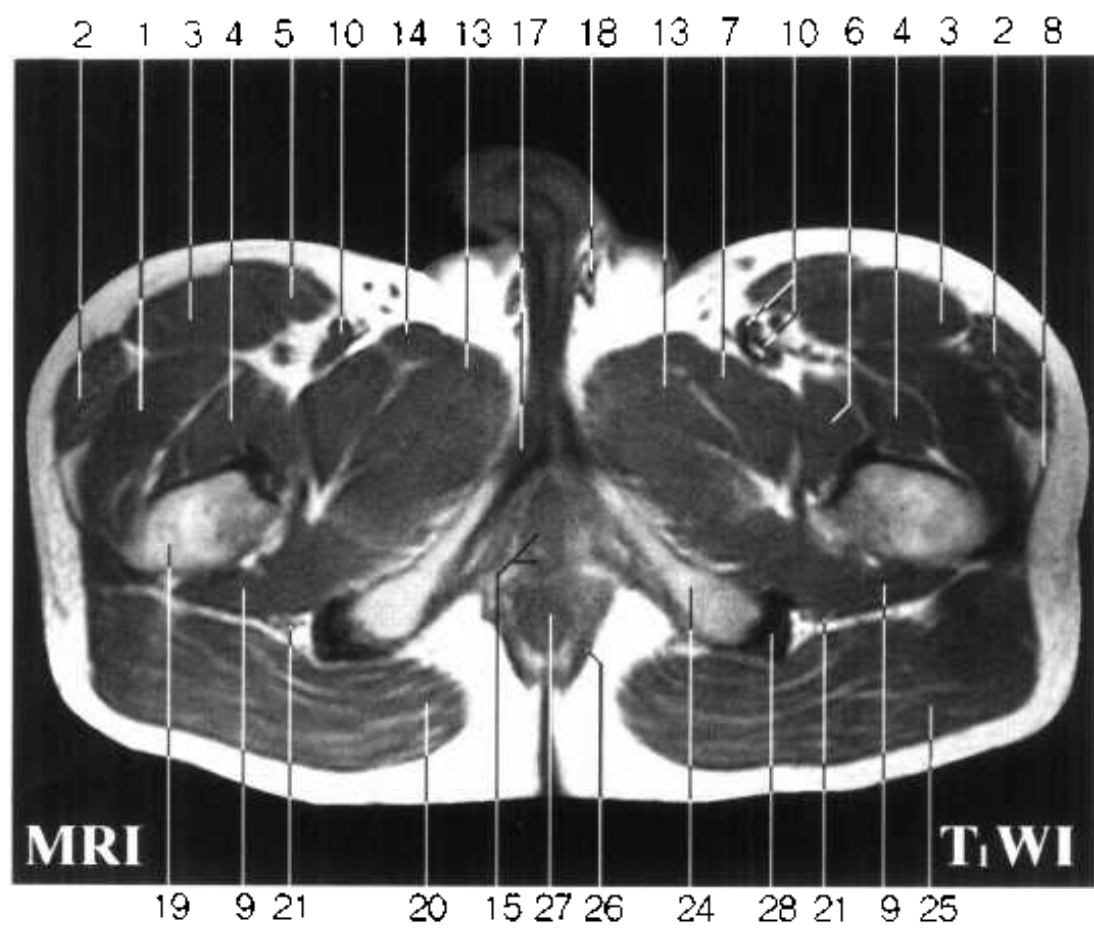


Fig. HPm 7



1. 股外侧肌 vastus lateralis
2. 阔筋膜张肌 tensor fasciae latae
3. 股直肌 rectus femoris
4. 股中间肌 vastus intermedius
5. 缝匠肌 sartorius
6. 髂腰肌 iliopsoas
7. 耻骨肌 pectineus
8. 髂胫束 iliotibial tract
9. 股方肌 quadratus femoris
10. 股动、静脉 femoral a.and v.
11. 大隐静脉 great saphenous v.
12. 大收肌 adductor magnus
13. 短收肌 adductor brevis
14. 长收肌 adductor longus
15. 尿道球 bulb of urethra
16. 睾丸 testis

Fig. HPm 7



17. 球海绵体肌 bulbocavernosus

18. 精索 spermatic cord

19. 股骨 femur

20. 臀大肌 gluteus maximus

21. 坐骨神经 sciatic n.

22. 半膜肌腱 tendon of semimembranosus

23. 股二头肌长头腱与半腱肌腱 tendon of long head of biceps femoris and semitendinosus

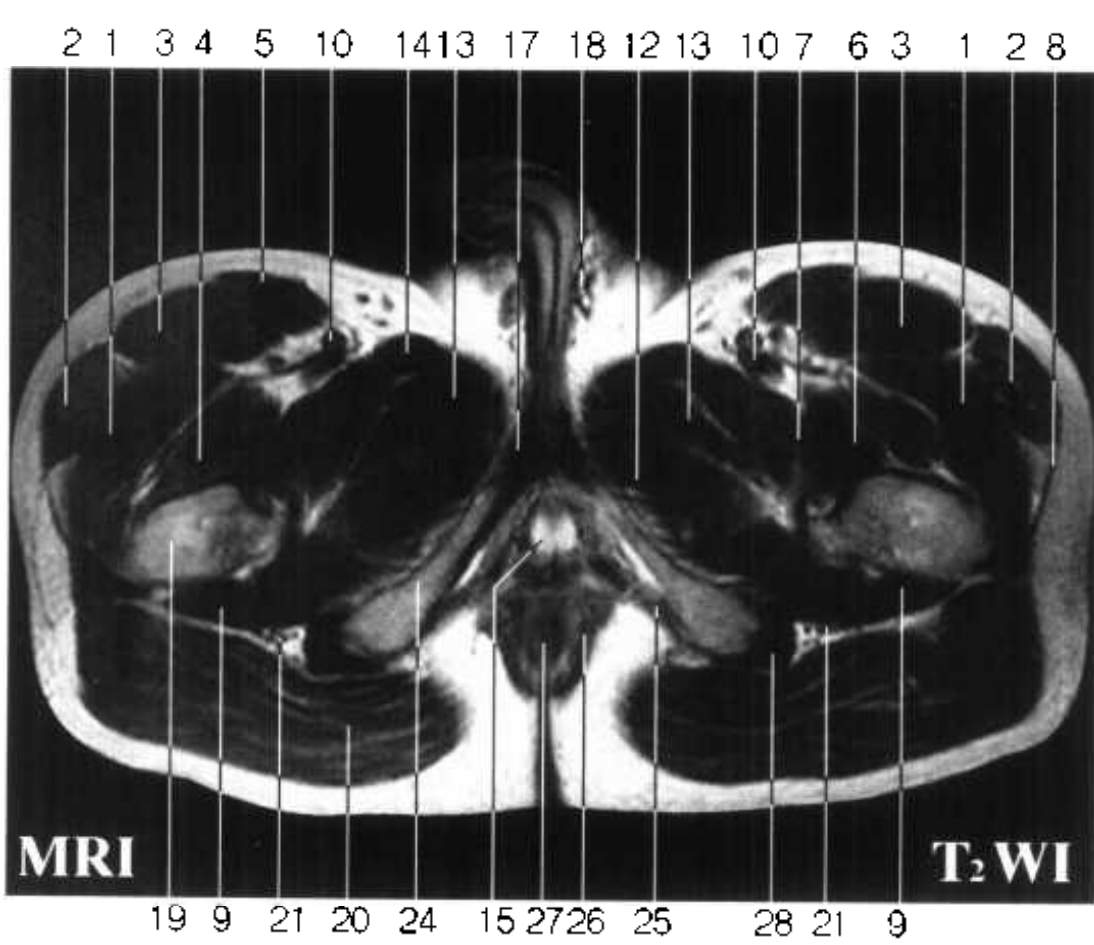
24. 坐骨支 ramus of ischium

25. 坐骨海绵体肌 ischiocavernosus

26. 肛门外括约肌 sphincter ani externus

27. 肛管 anal canal

28. 半腱肌 semitendinosus



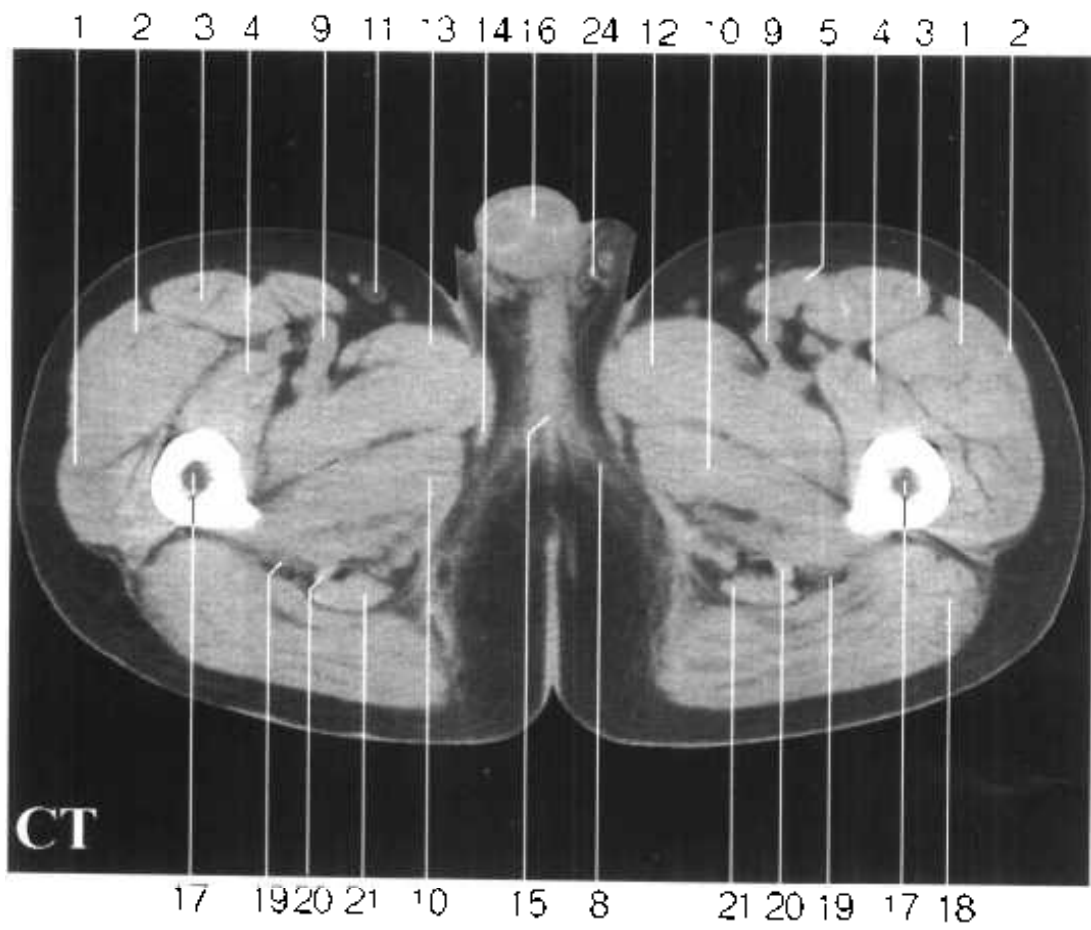
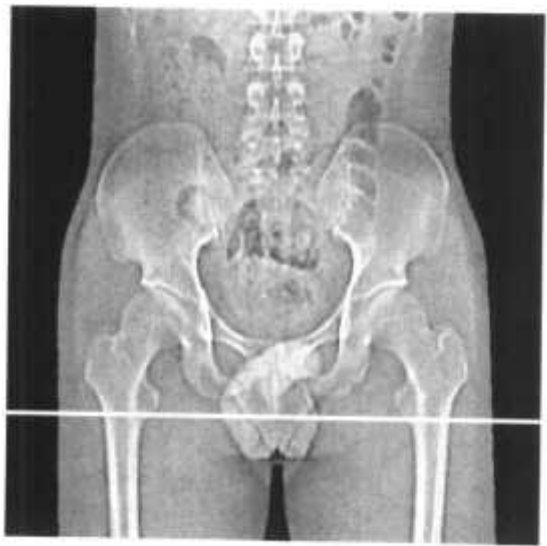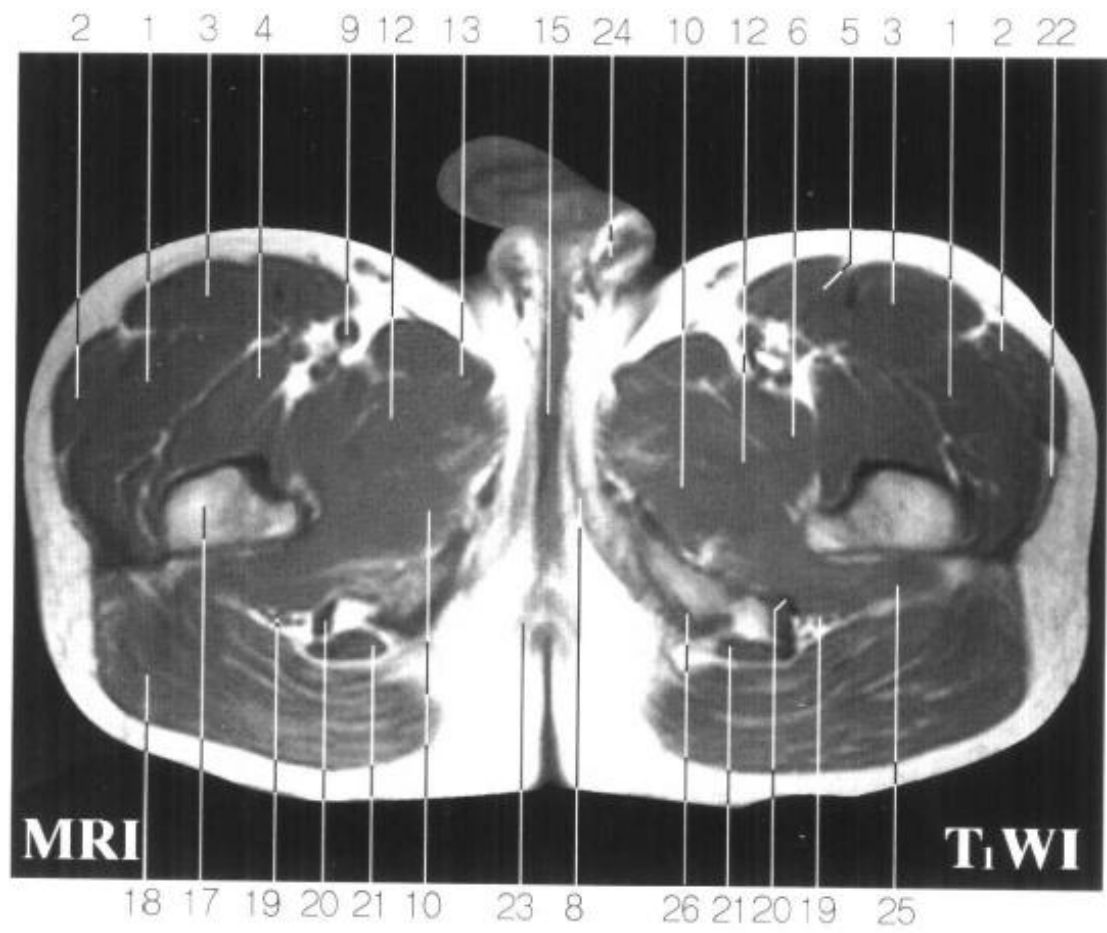


Fig. HPm 8

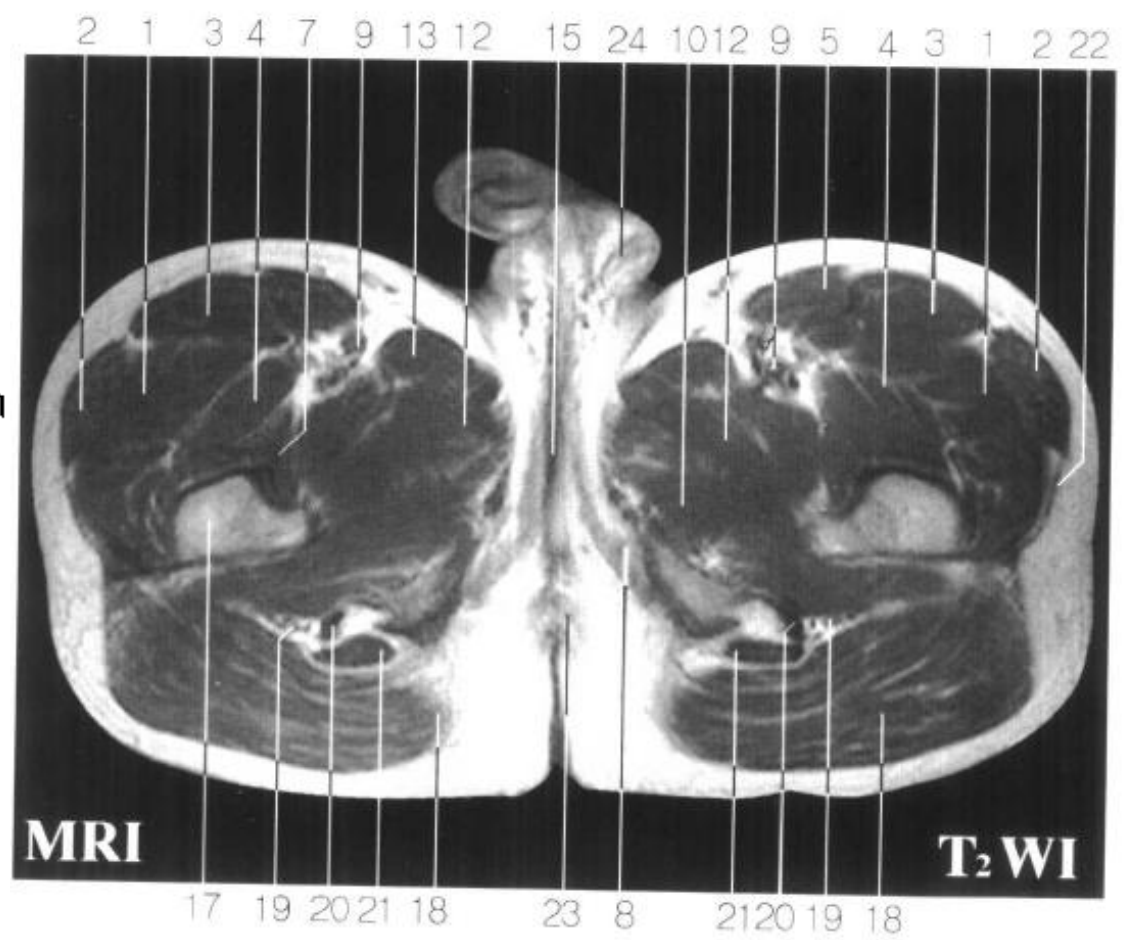


1. 股外侧肌 vastus lateralis
2. 阔筋膜张肌 tensor fasciae latae
3. 股直肌 rectus femoris
4. 股中间肌 vastus intermedius
5. 缝匠肌 sartorius
6. 耻骨肌 pectineus
7. 髂腰肌 iliopsoas
8. 坐骨海绵体肌 ischiocavernosus
9. 股动、静脉 femoral a. and v.
10. 大收肌 adductor magnus
11. 大隐静脉 great saphenous v.
12. 短收肌 adductor brevis
13. 长收肌 adductor longus
14. 股薄肌 gracilis
15. 尿道海绵体 cavernous body of urethra

Fig. HPm 8



- 16. 睾丸 testis
- 17. 股骨 femur
- 18. 臀大肌 gluteus maximus
- 19. 坐骨神经 sciatic n.
- 20. 半膜肌腱 tendon of semimembranosus
- 21. 股二头肌长头腱与半腱肌 tendon of long head of biceps femoris and semitendinosus
- 22. 髂胫束 iliotibial tract
- 23. 肛门外括约肌 sphincter ani externus
- 24. 精索 spermatic cord
- 25. 股方肌 quadratus femoris
- 26. 坐骨支 ramus of ischium



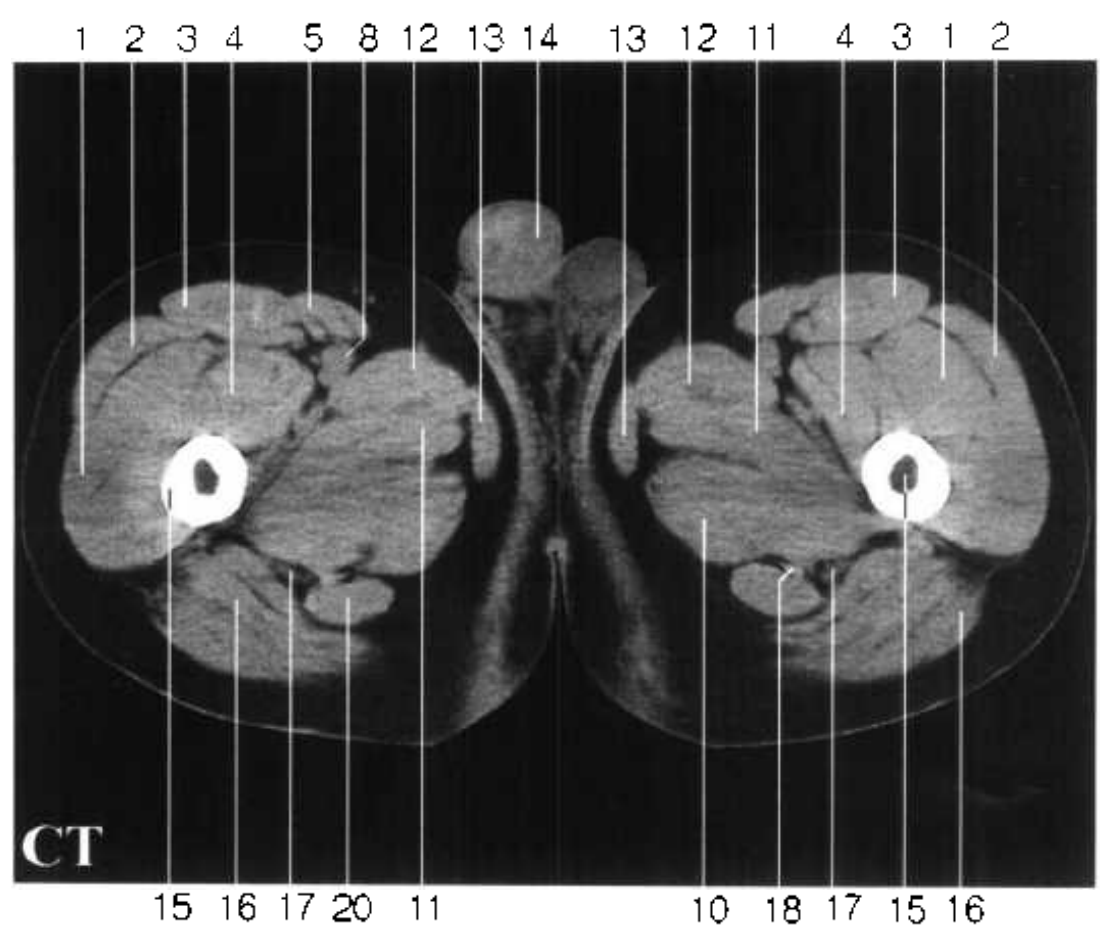
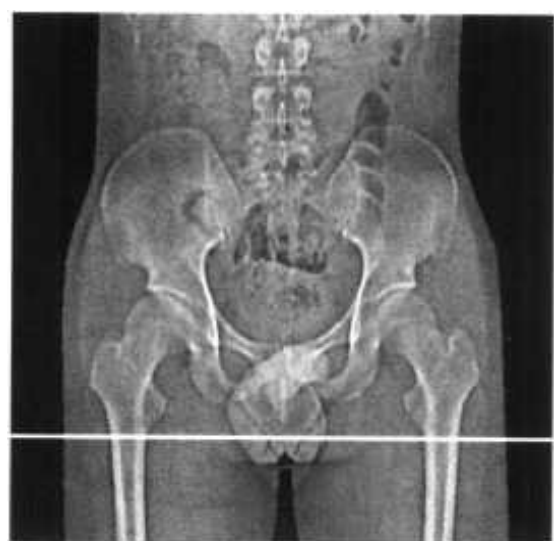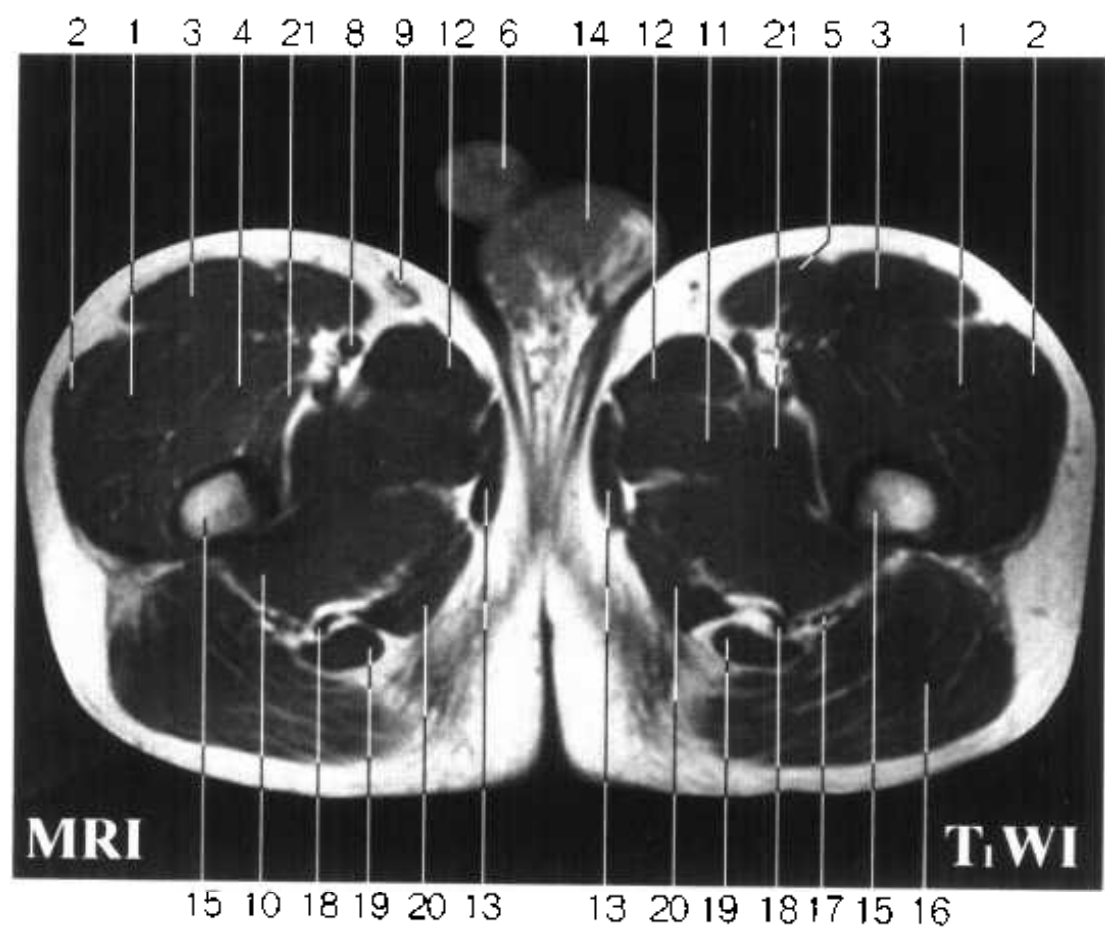


Fig. HPm 9

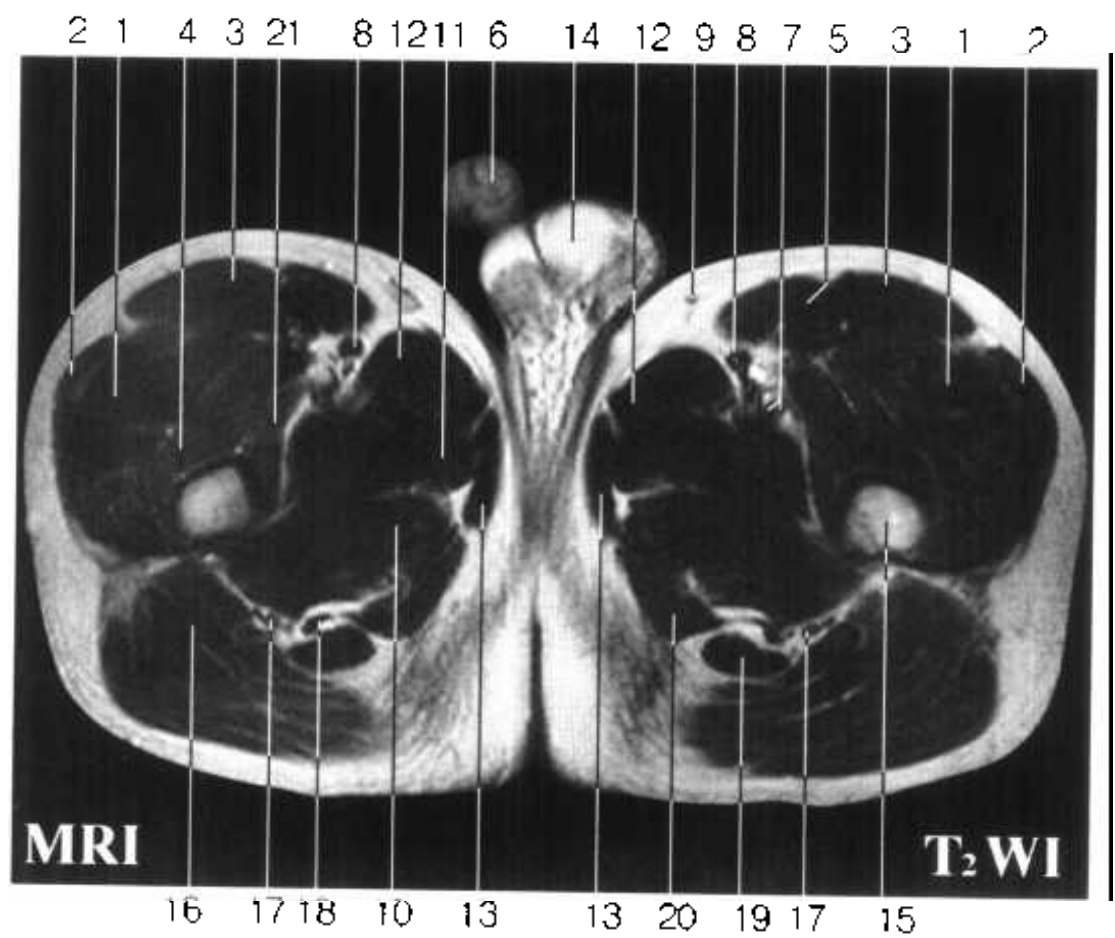


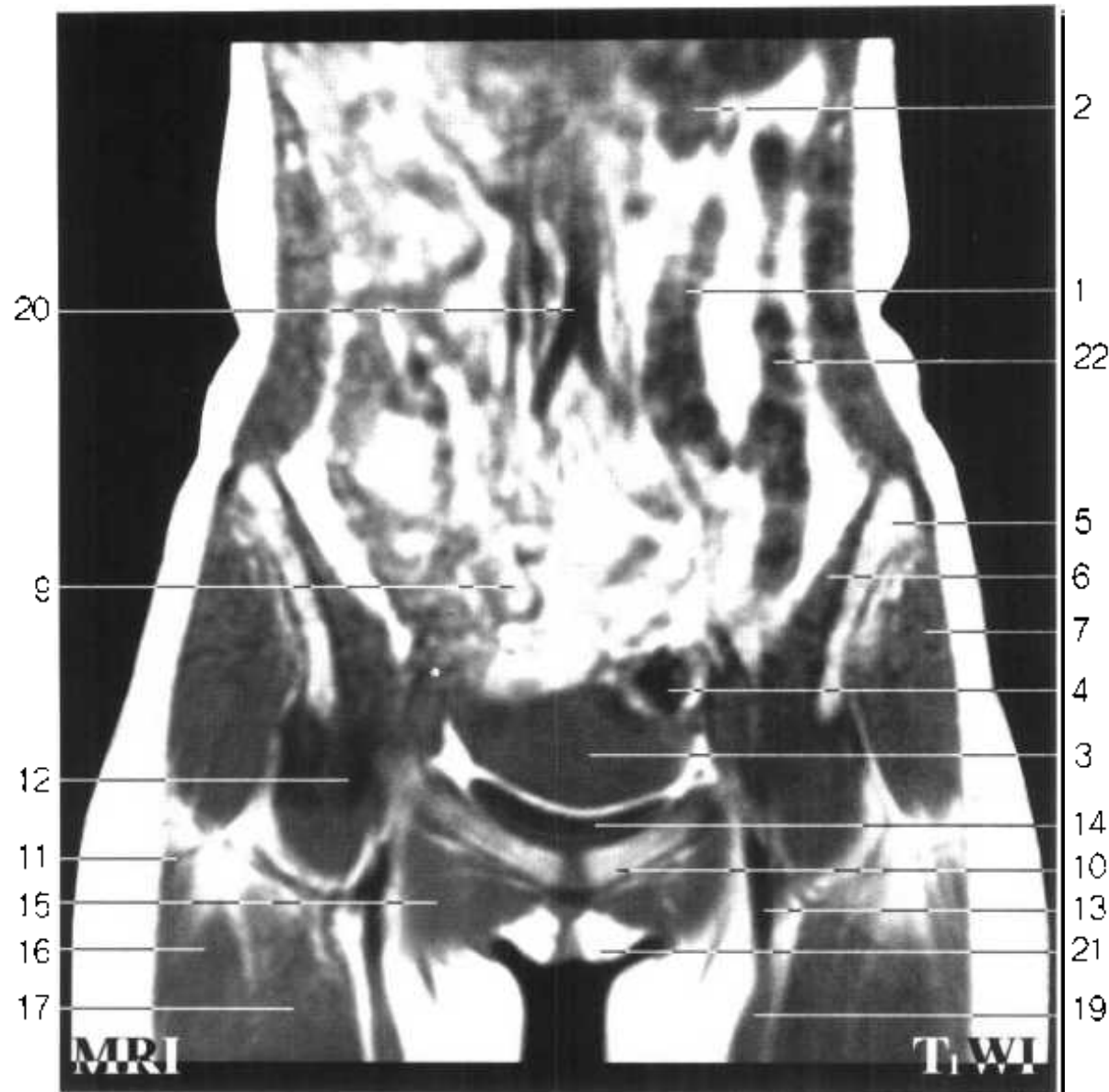1. 股外侧肌 vastus lateralis
2. 阔筋膜张肌 tensor fasciae latae
3. 股直肌 rectus femoris
4. 股中间肌 vastus intermedius
5. 缝匠肌 sartorius
6. 阴茎 penis
7. 股深动、静脉 deep femoral a.and v.
8. 股动、静脉 femoral a.and v.
9. 大隐静脉 great saphenous v.
10. 大收肌 adductor magnus
11. 短收肌 adductor brevis
12. 长收肌 adductor longus
13. 股薄肌 gracilis

Fig. HPm 9



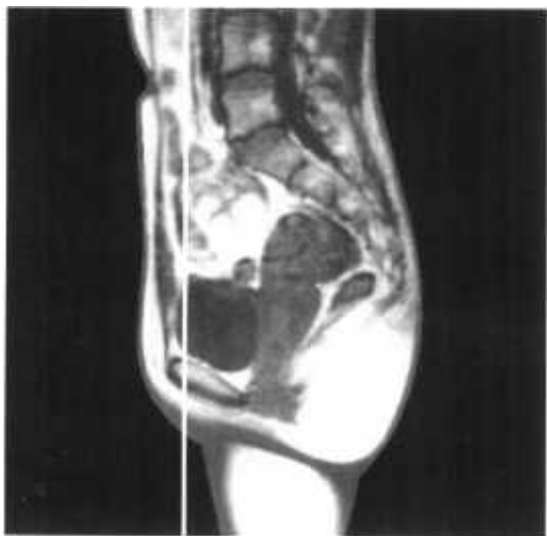- 14. 睾丸 testis
- 15. 股骨 femur
- 16. 臀大肌 gluteus maximus
- 17. 坐骨神经 sciatic n.
- 18. 半膜肌 semimembranosus
- 19. 股二头肌长头腱 tendon of long head of biceps femoris
- 20. 半腱肌 semitendinosus
- 21. 耻骨肌 pectineus





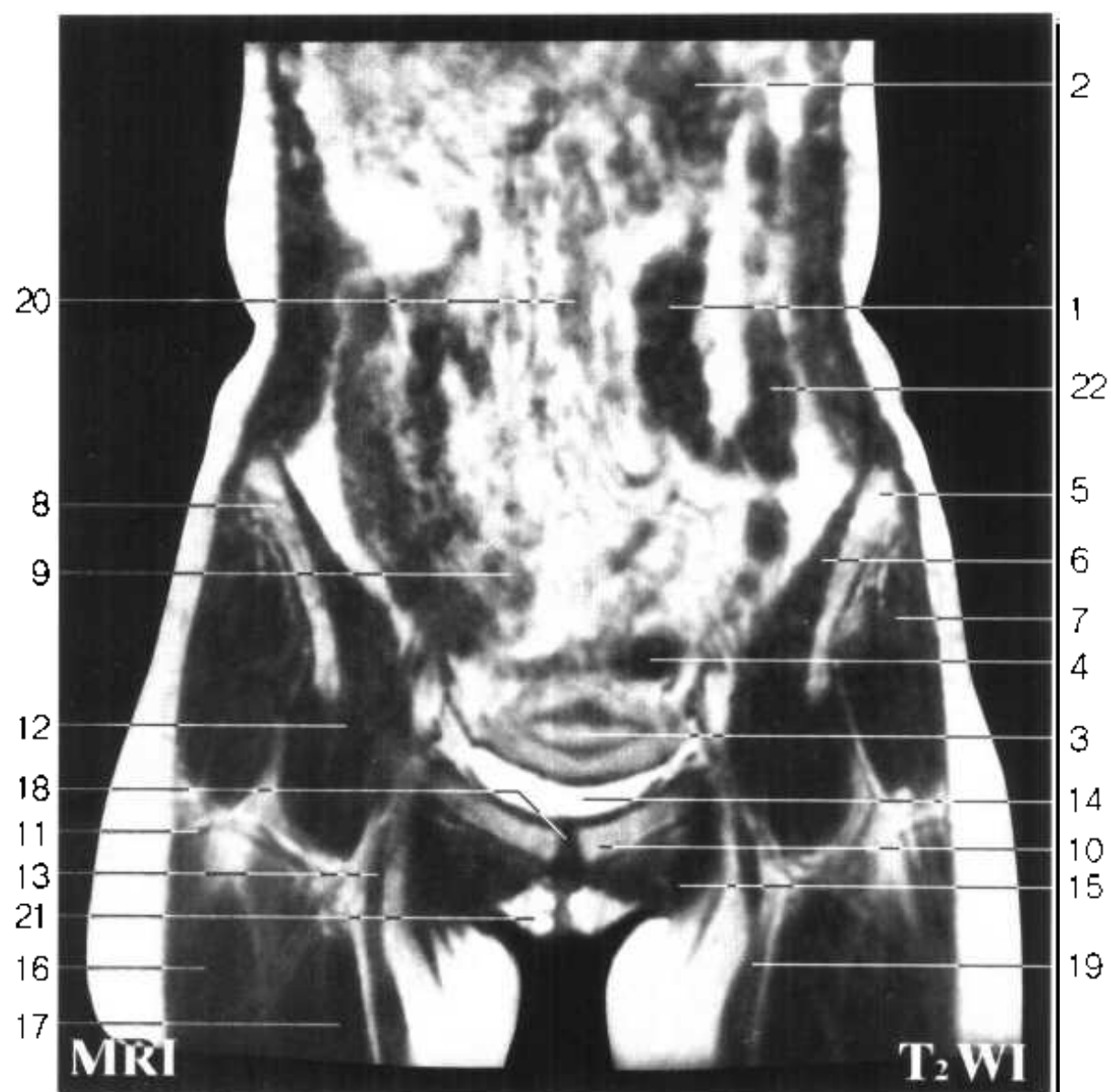
女盆额状断面图 FPf

Fig. FPf 1



1. 横结肠 transverse colon
2. 空肠 jejunum
3. 子宫 uterus
4. 乙状结肠 sigmoid colon
5. 髂骨翼 ala of ilium
6. 髂肌 iliacus
7. 臀中肌 gluteus medius
8. 髂嵴 iliac crest
9. 回肠 ileum
10. 耻骨上支 superior ramus of pubis
11. 阔筋膜张肌 tensor fasciae latae

Fig. FPf 1



- 12. 髂腰肌 iliopsoas
- 13. 股静脉 femoral v.
- 14. 膀胱 urinary bladder
- 15. 闭孔外肌 obturator externus
- 16. 股直肌 rectus femoris
- 17. 股内侧肌 vastus medialis
- 18. 耻骨联合 pubic symphysis
- 19. 缝匠肌 sartorius
- 20. 腹主动脉 abdominal aorta
- 21. 大阴唇 greater lip of pudendum
- 22. 降结肠 descending colon

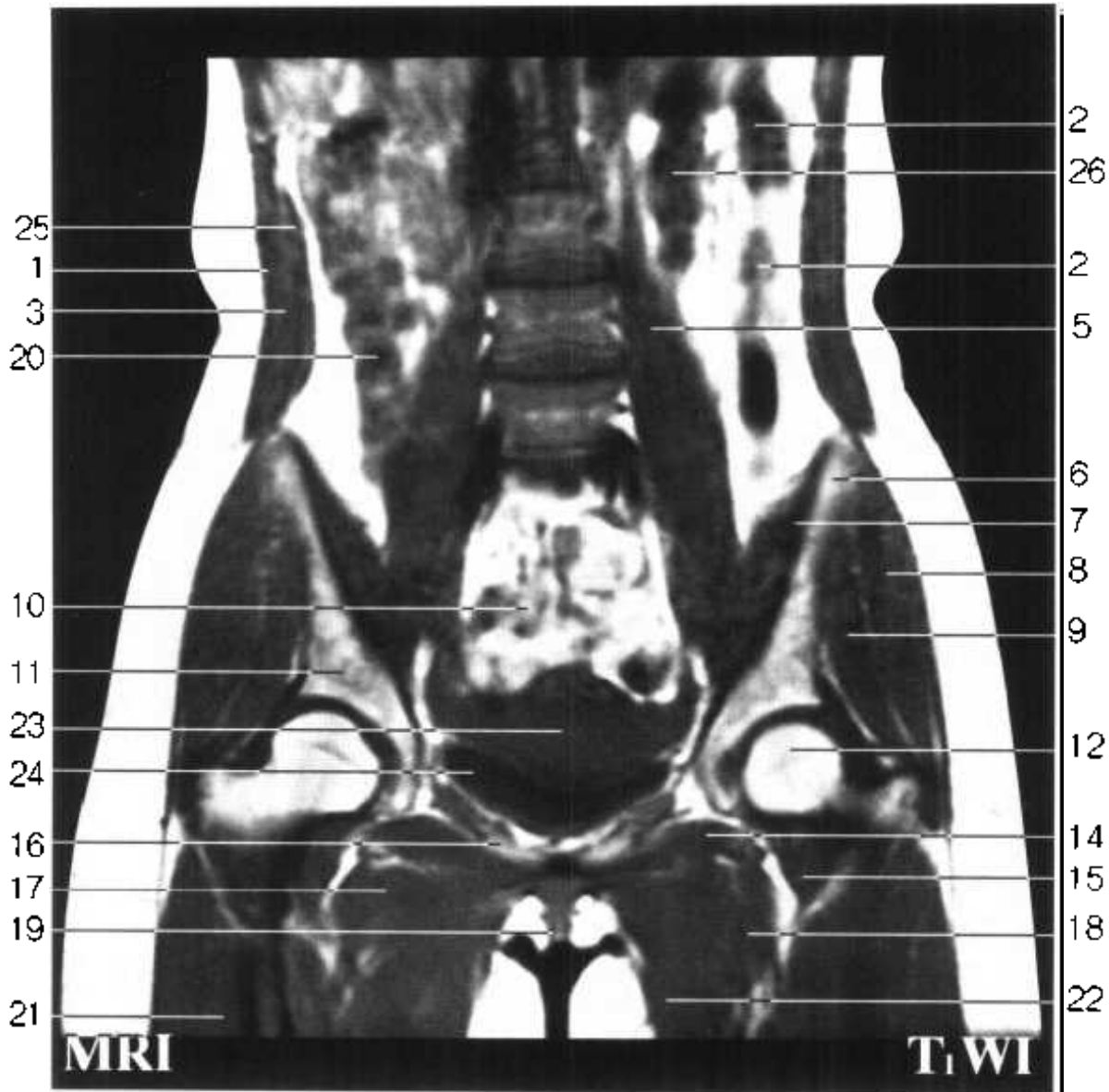
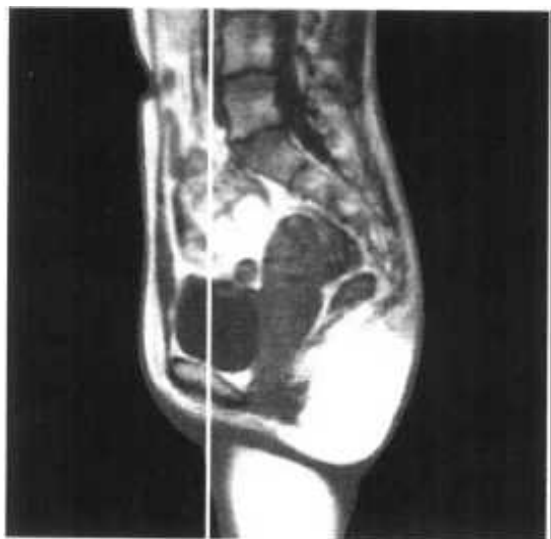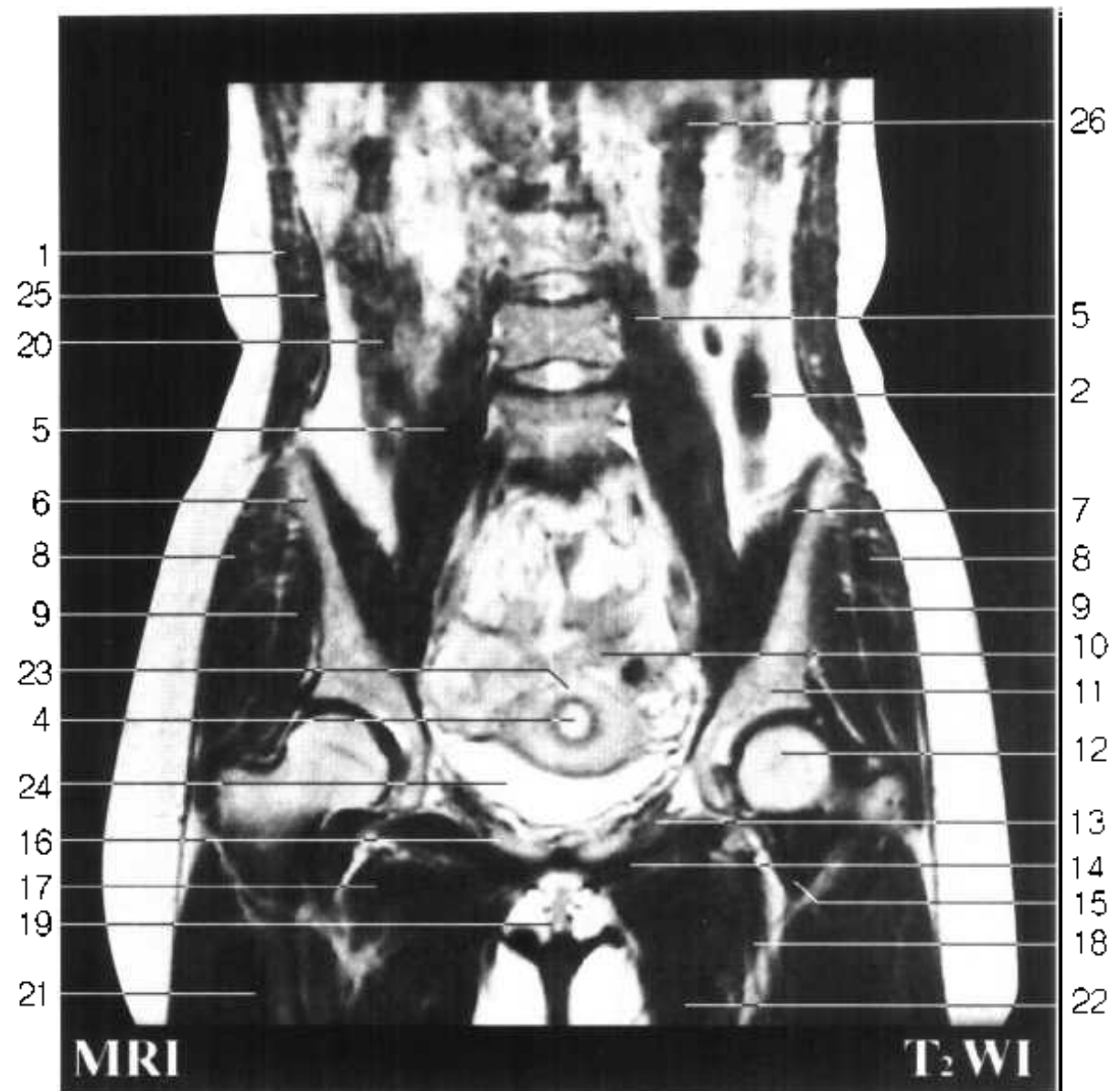


Fig. FPf 2



1. 腹外斜肌 obliquus externus abdominis
2. 降结肠 descending colon
3. 腹内斜肌 obliquus internus abdominis
4. 子宫腔 cavity of uterus
5. 腰大肌 psoas major
6. 髂骨翼 ala of ilium
7. 髂肌 iliacus
8. 臀中肌 gluteus medius
9. 臀小肌 gluteus minimus
10. 回肠 ileum
11. 髂骨体 body of ilium

Fig. FPf 2



- | | |
|----------------------------------|-------------------------------|
| 12. 股骨头 femoral head | 24. 膀胱 urinary bladder |
| 13. 闭孔内肌 obturator internus | 25. 腹横肌 transversus abdominis |
| 14. 闭孔外肌 obturator externus | 26. 横结肠 transverse colon |
| 15. 髂腰肌 iliopsoas | |
| 16. 耻骨下支 inferior ramus of pubis | |
| 17. 短收肌 adductor brevis | |
| 18. 耻骨肌 pectineus | |
| 19. 阴道前庭 vaginal vestibule | |
| 20. 升结肠 ascending colon | |
| 21. 股中间肌 vastus intermedius | |
| 22. 长收肌 adductor longus | |
| 23. 子宫 uterus | |

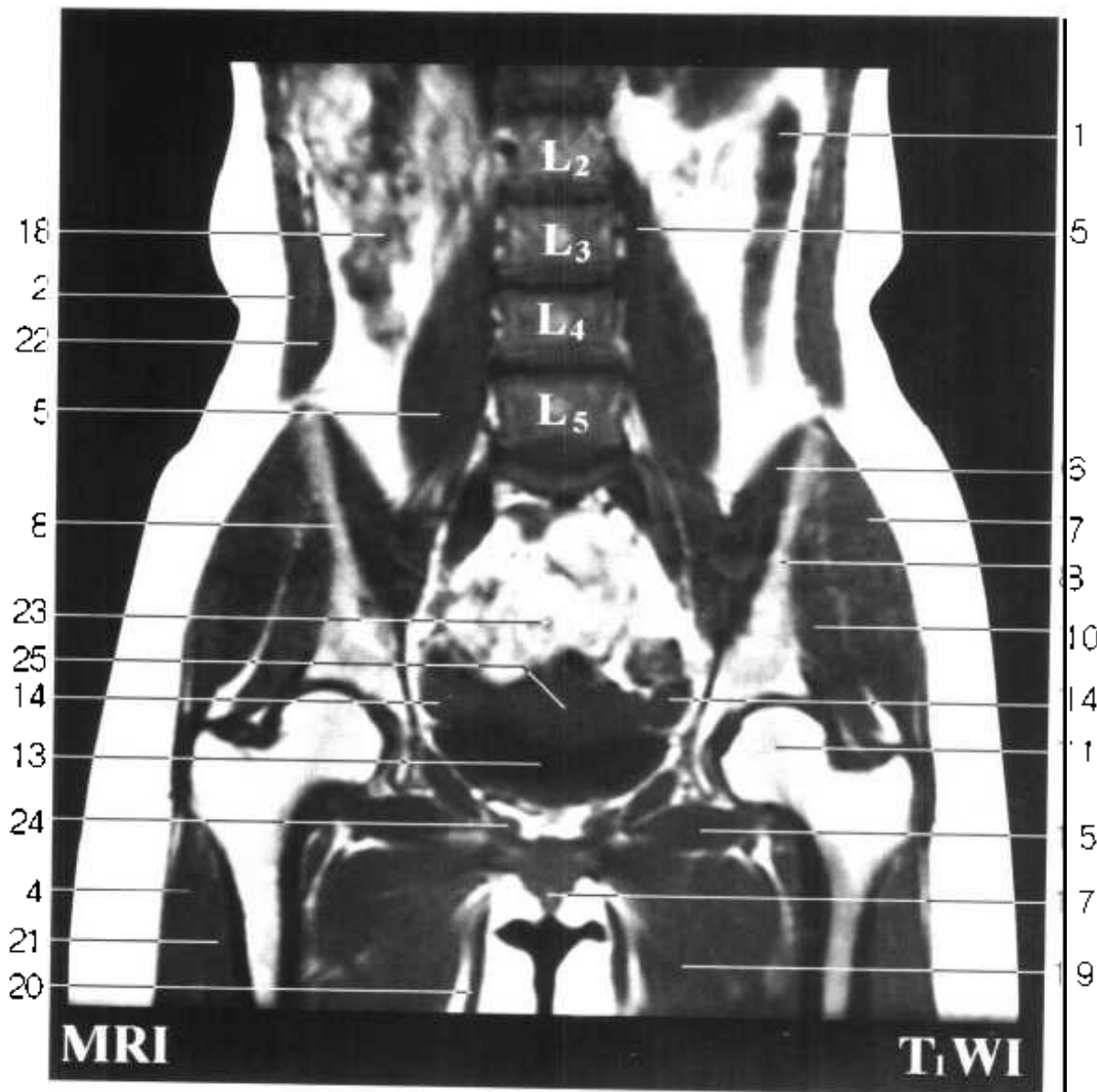
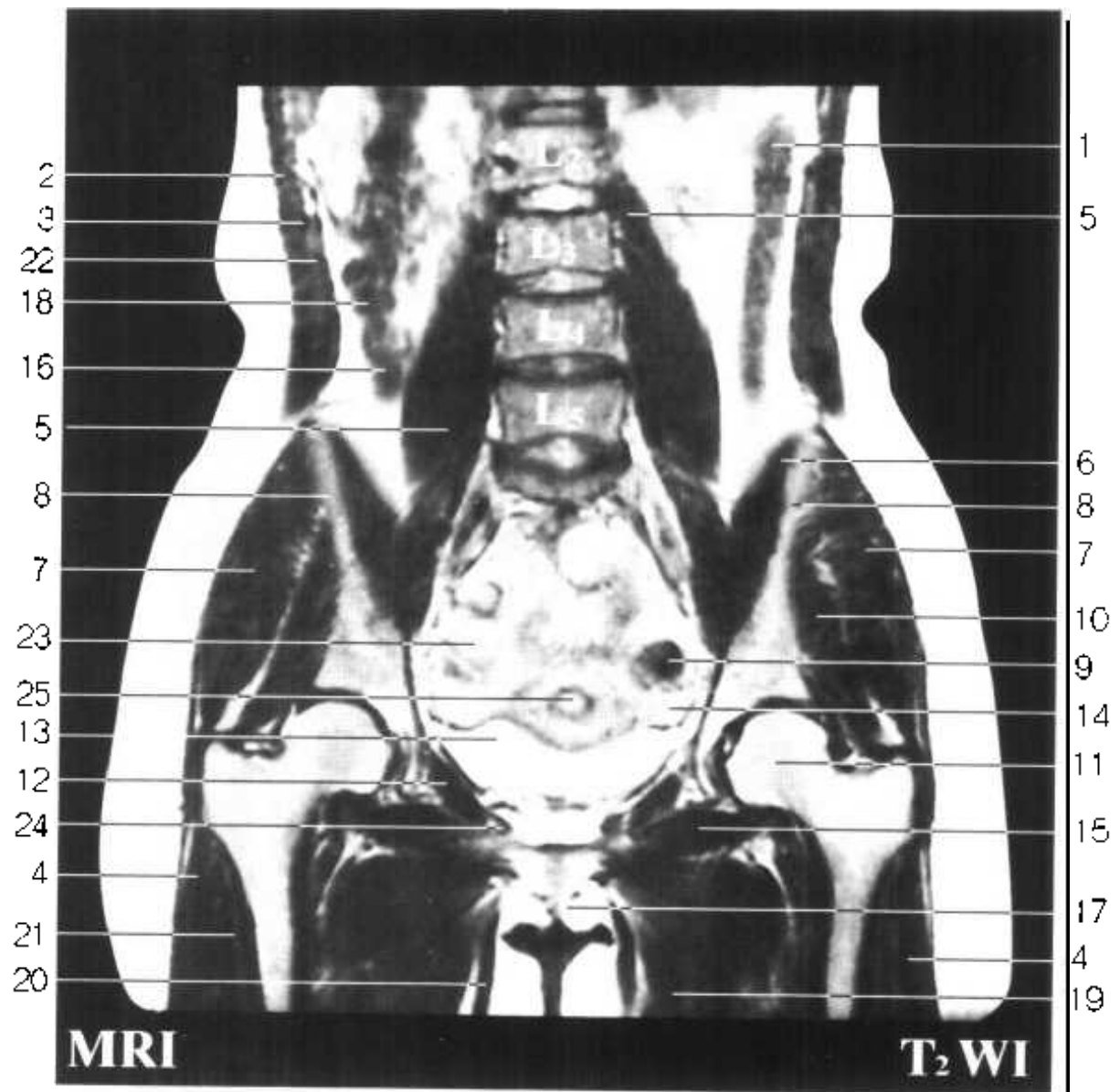


Fig. FPf 3

1. 降结肠 descending colon
2. 腹外斜肌 obliquus externus abdominis
3. 腹内斜肌 obliquus internus abdominis
4. 股外侧肌 vastus lateralis
5. 腰大肌 psoas major
6. 髂肌 iliacus
7. 臀中肌 gluteus medius
8. 髂骨翼 ala of ilium
9. 乙状结肠 sigmoid colon
10. 臀小肌 gluteus minimus
11. 股骨头 femoral head
12. 闭孔内肌 obturator internus

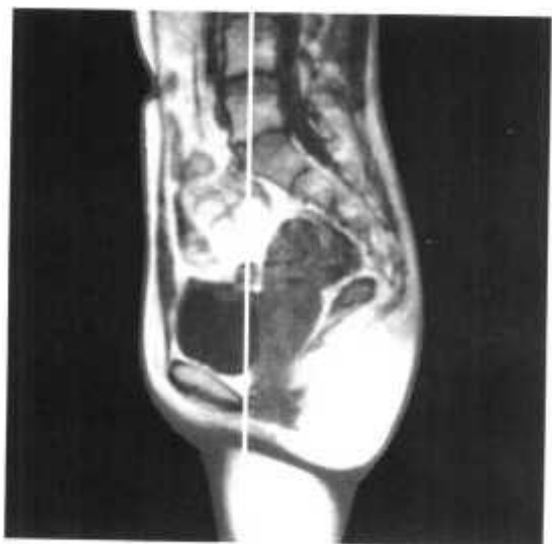

Fig. FPf 3



- 13. 膀胱 urinary bladder
- 14. 卵巢 ovary
- 15. 闭孔外肌 obturator externus
- 16. 盲肠 cecum
- 17. 阴道前庭 vaginal vestibule
- 18. 升结肠 ascending colon
- 19. 大收肌 adductor magnus
- 20. 股薄肌 gracilis
- 21. 股中间肌 vastus intermedius
- 22. 腹横肌 transversus abdominis
- 23. 回肠 ileum
- 24. 耻骨下支 inferior ramus of pubis
- 25. 子宫 uterus

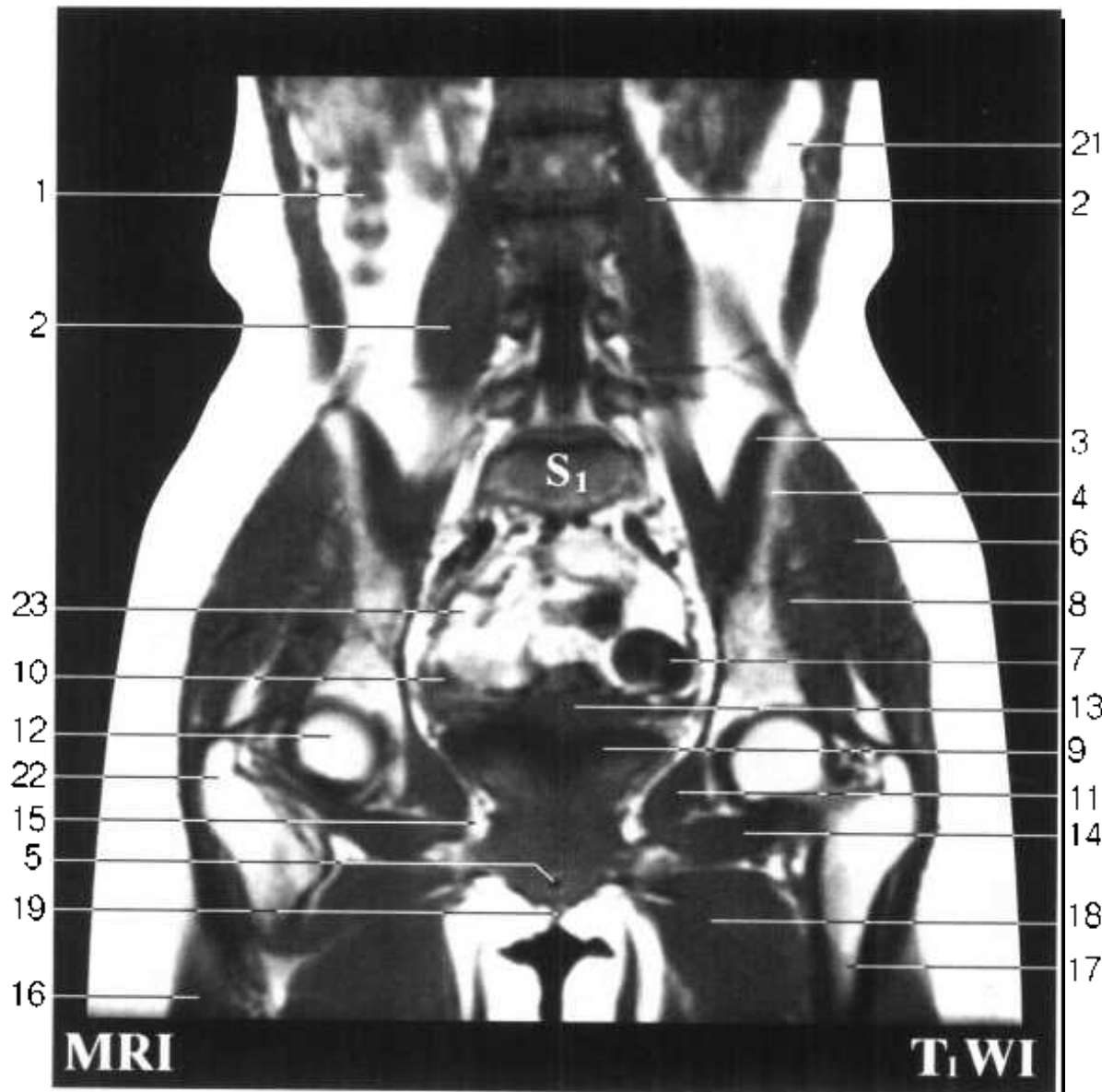
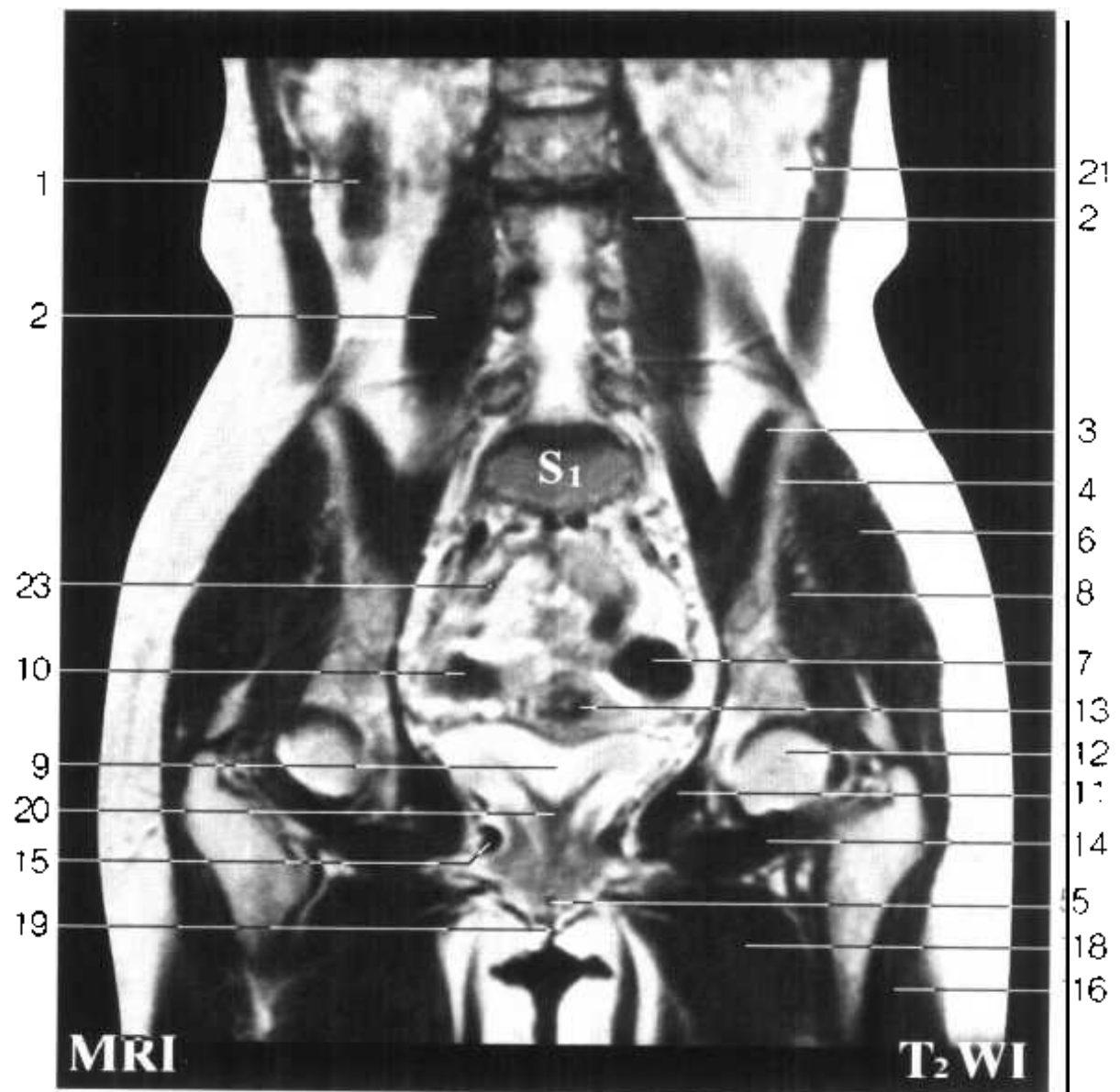


Fig. FPf 4

1. 升结肠 ascending colon
2. 腰大肌 psoas major
3. 髂肌 iliacus
4. 髂骨翼 ala of ilium
5. 尿道外口 external orifice of urethra
6. 臀中肌 gluteus medius
7. 乙状结肠 sigmoid colon
8. 臀小肌 gluteus minimus
9. 膀胱 urinary bladder
10. 回肠 ileum
11. 闭孔内肌 obturator internus

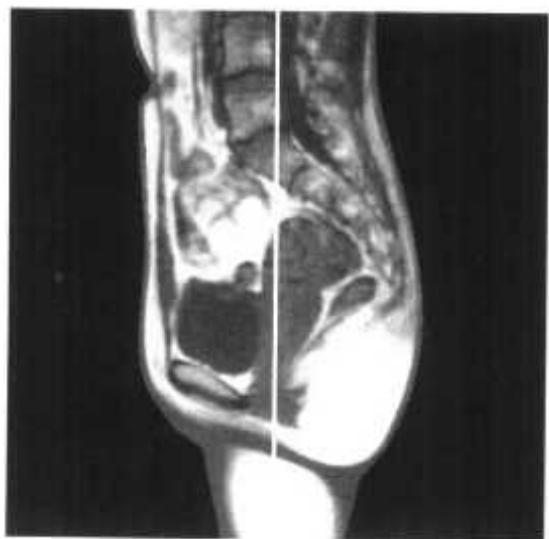

Fig. FPf 4



- 12. 股骨头 femoral head
- 13. 子宫 uterus
- 14. 闭孔外肌 obturator externus
- 15. 坐骨支 ramus of ischium
- 16. 股外侧肌 vastus lateralis
- 17. 股骨 femur
- 18. 大收肌 adductor magnus
- 19. 阴道前庭 vaginal vestibule
- 20. 阴道 vagina
- 21. 脂肪囊 fatty renal capsule
- 22. 大转子 greater trochanter
- 23. 回肠 ileum

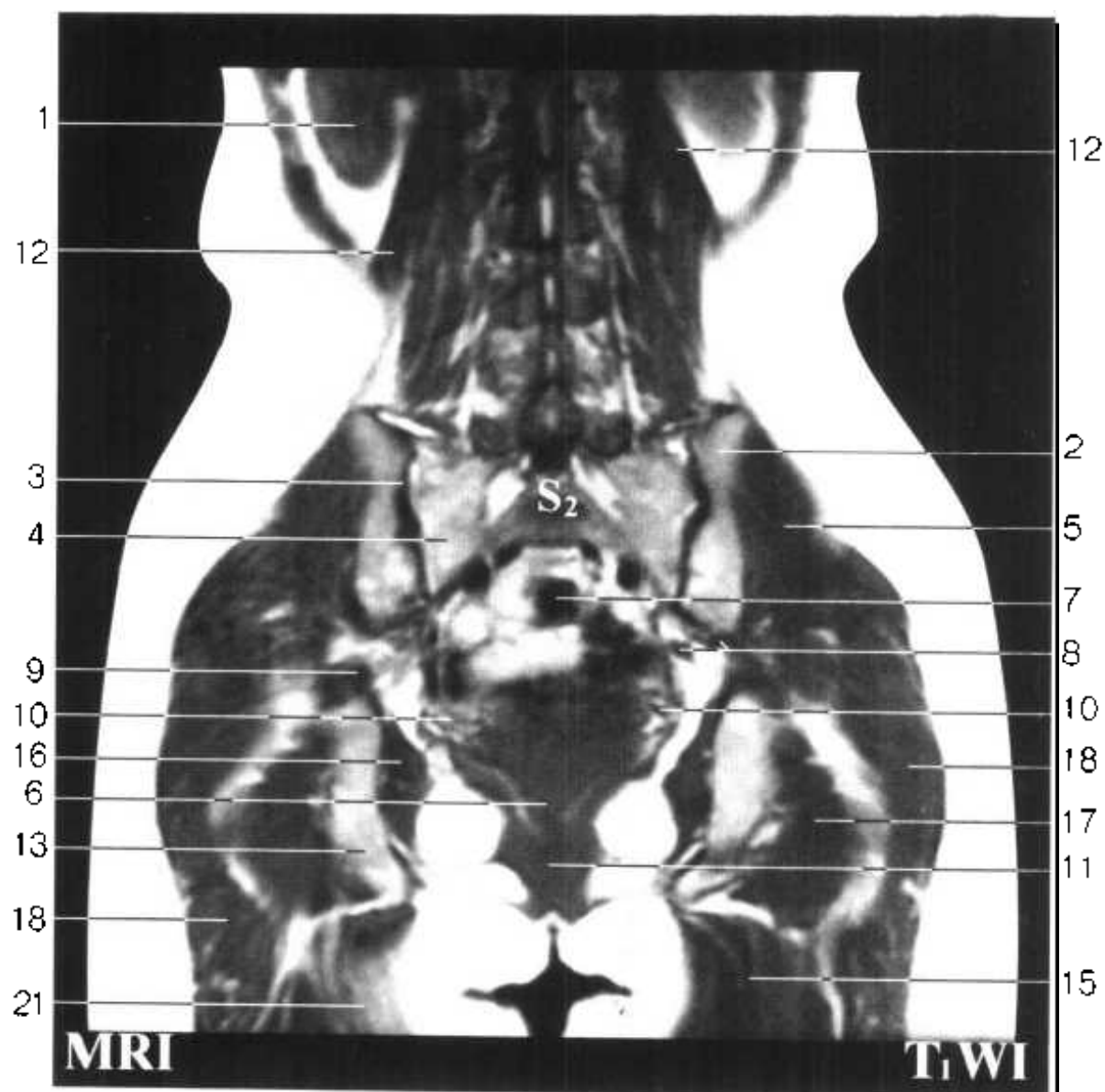


Fig. FPf 5

1. 肾 kidney
2. 髂骨翼 ala of ilium
3. 骶髂关节 sacroiliac joint
4. 骶粗隆 sacral tuberosity
5. 臀中肌 gluteus medius
6. 子宫颈 neck of uterus
7. 乙状结肠 sigmoid colon
8. 臀上动、静脉 superior gluteal a.and v.
9. 梨状肌 piriformis
10. 卵巢 ovary
11. 直肠 rectum

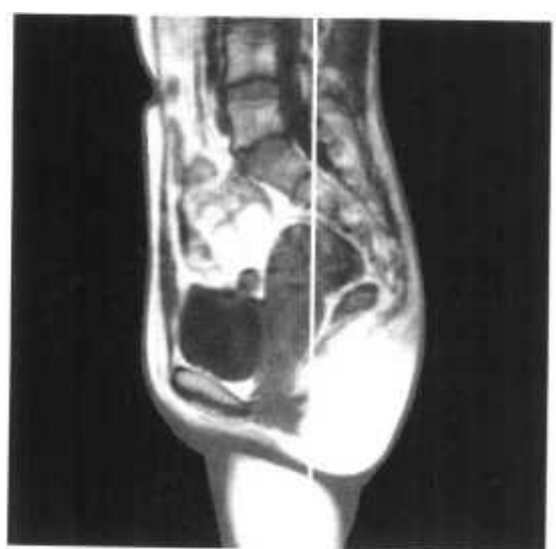
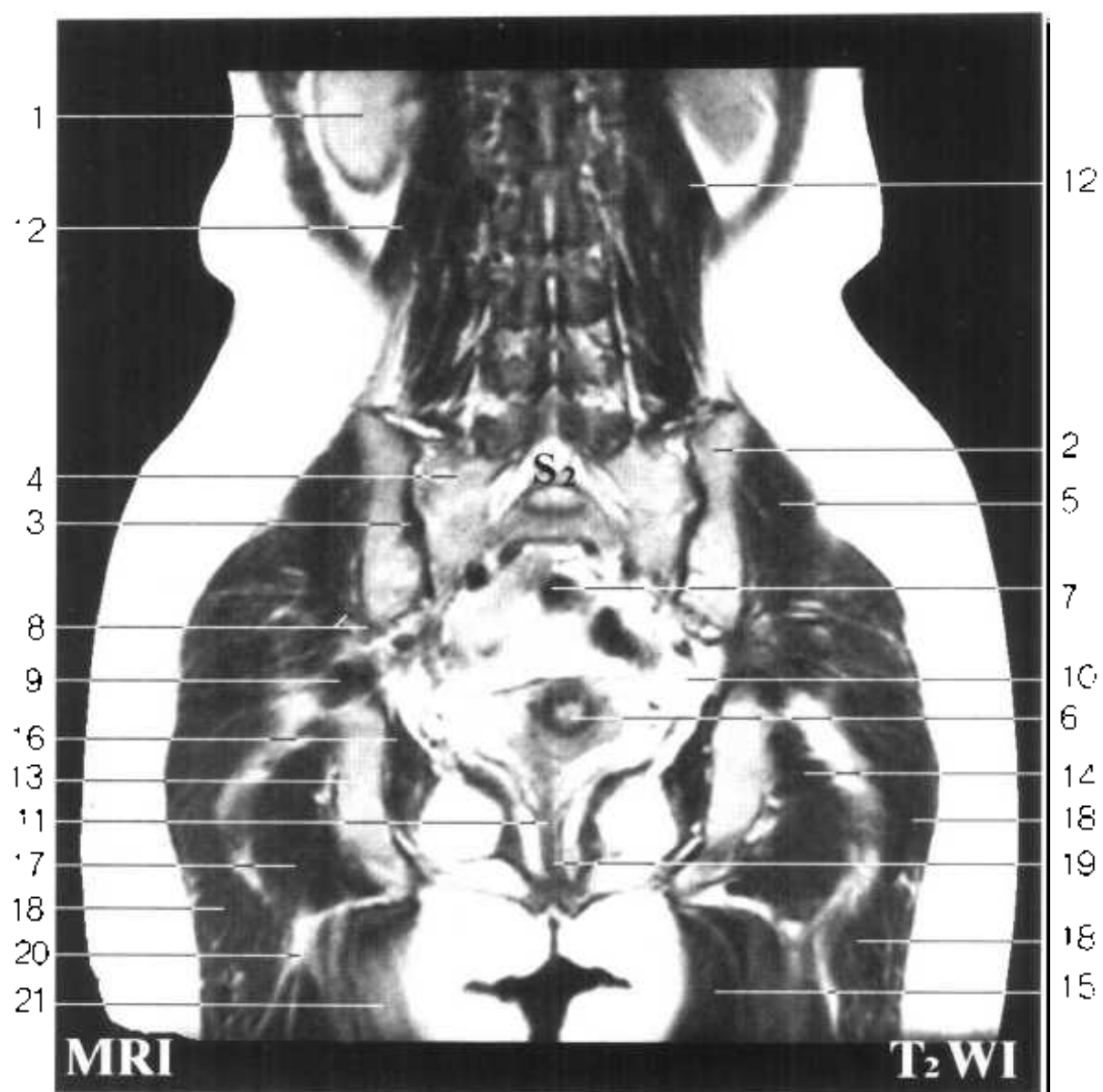
Fig. FPf 5



- 12. 腰方肌 quadratus lumborum
- 13. 坐骨 ischium
- 14. 闭孔内肌腱 tendon of obturator internus
- 15. 大收肌 adductor magnus
- 16. 闭孔内肌 obturator internus
- 17. 股方肌 quadratus femoris
- 18. 臀大肌 gluteus maximus
- 19. 肛管 anal canal
- 20. 坐骨神经 sciatic n.
- 21. 半腱肌 semitendinosus

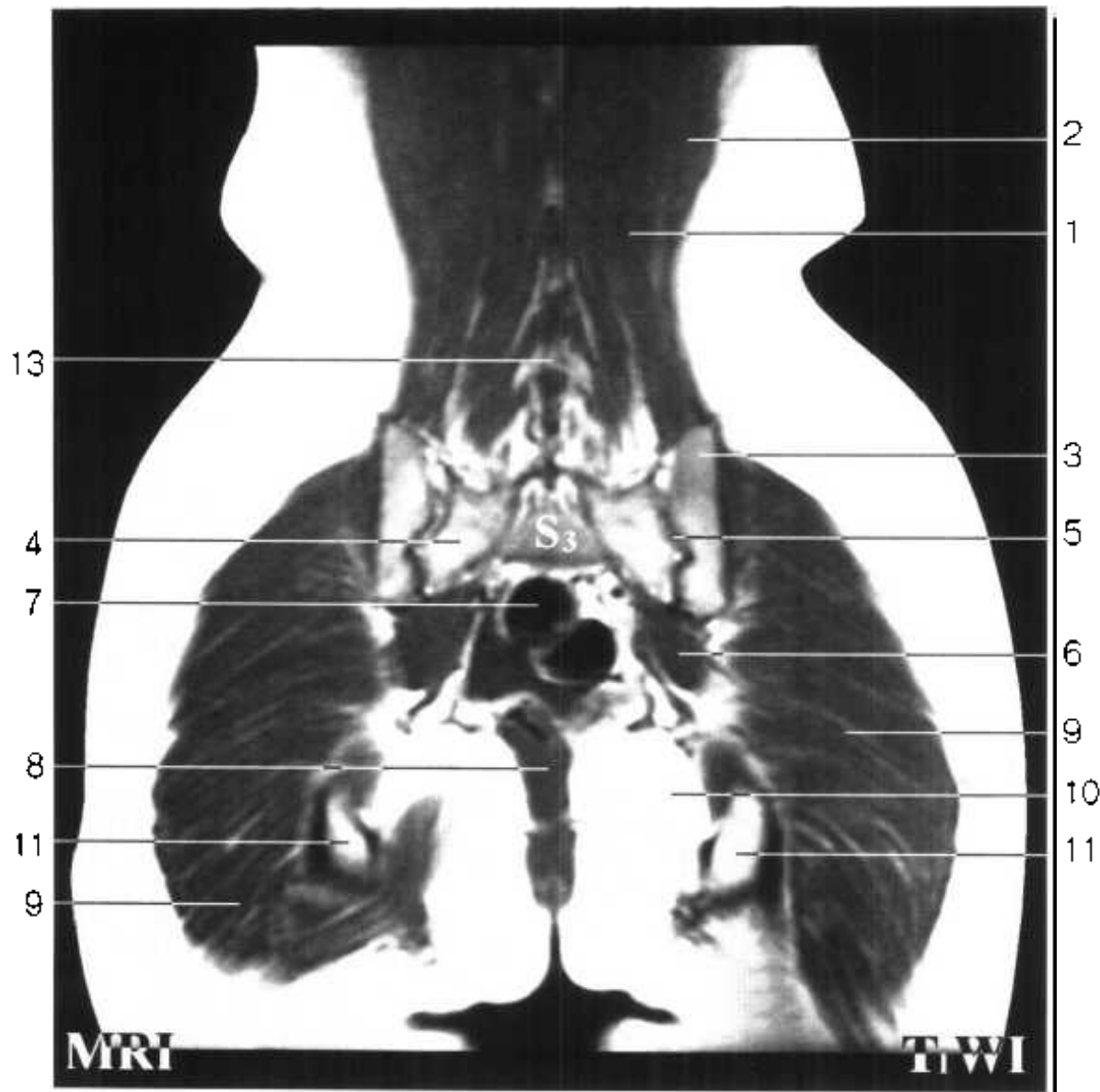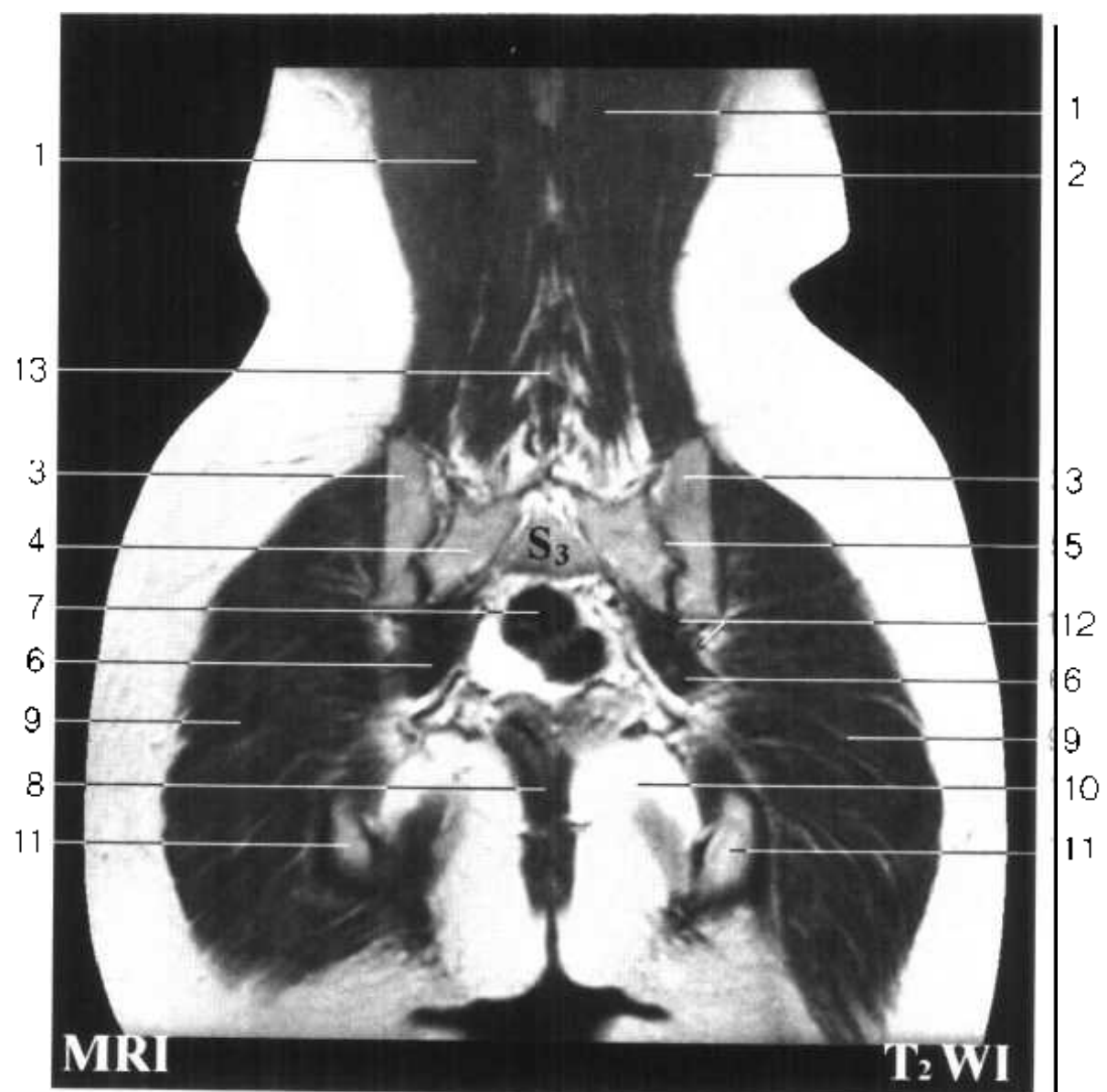


Fig. Fpf 6

1. 竖脊肌 erector spinae
2. 背阔肌 latissimus dorsi
3. 髂骨翼 ala of ilium
4. 骶翼 ala of sacrum
5. 骶髂关节 sacroiliac joint
6. 梨状肌 piriformis
7. 直肠壶腹 ampulla of rectum
8. 直肠 rectum

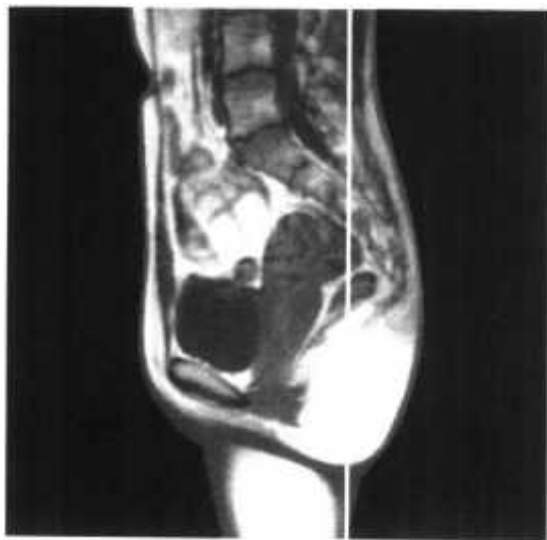

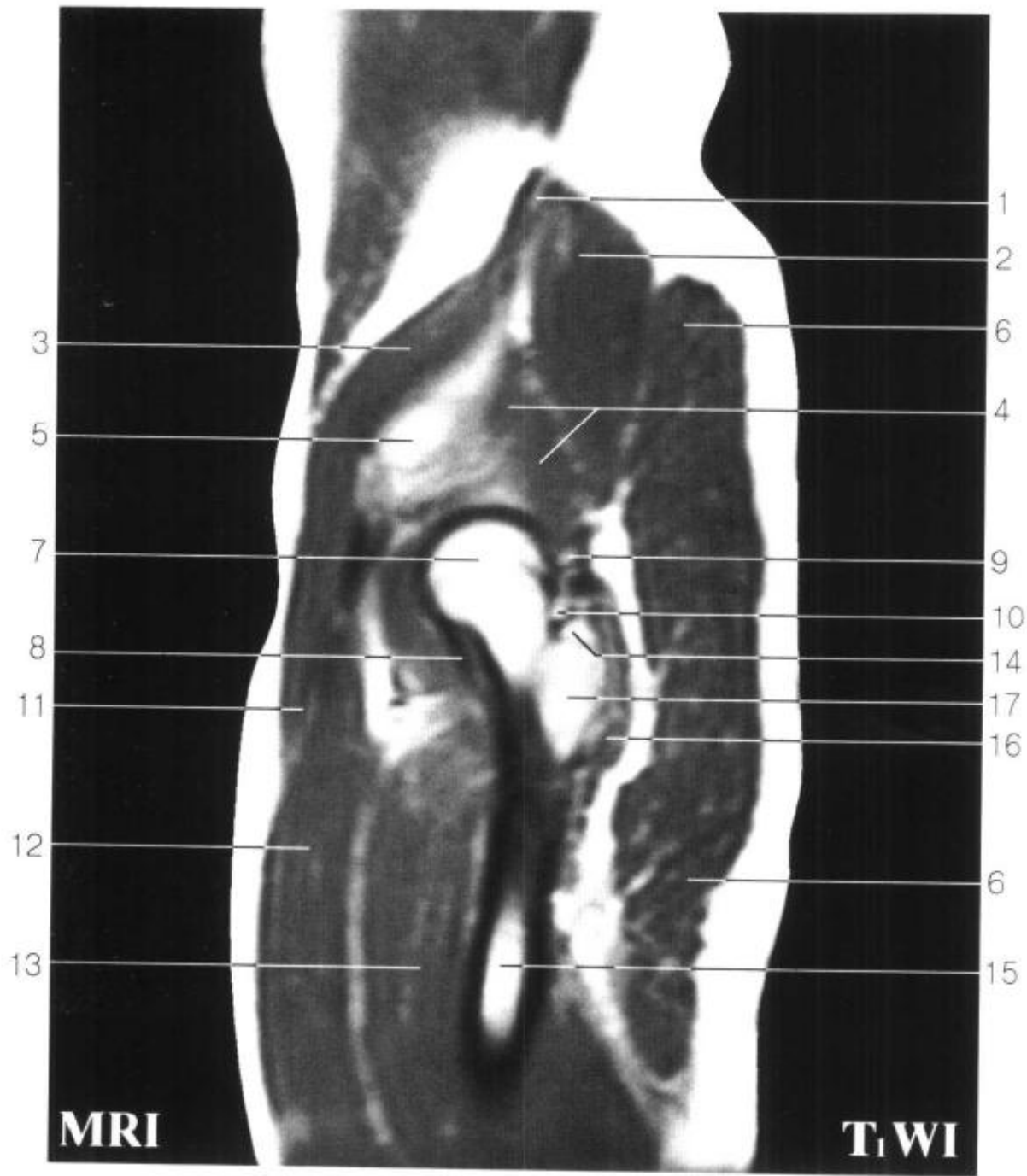Fig. Fpf 6



- 9. 臀大肌 gluteus maximus
- 10. 坐骨肛门窝 ischioanal fossa
- 11. 坐骨结节 ischial tuberosity
- 12. 臀上动脉 superior gluteal a.
- 13. 第5腰椎棘突 spinous process(L₅)



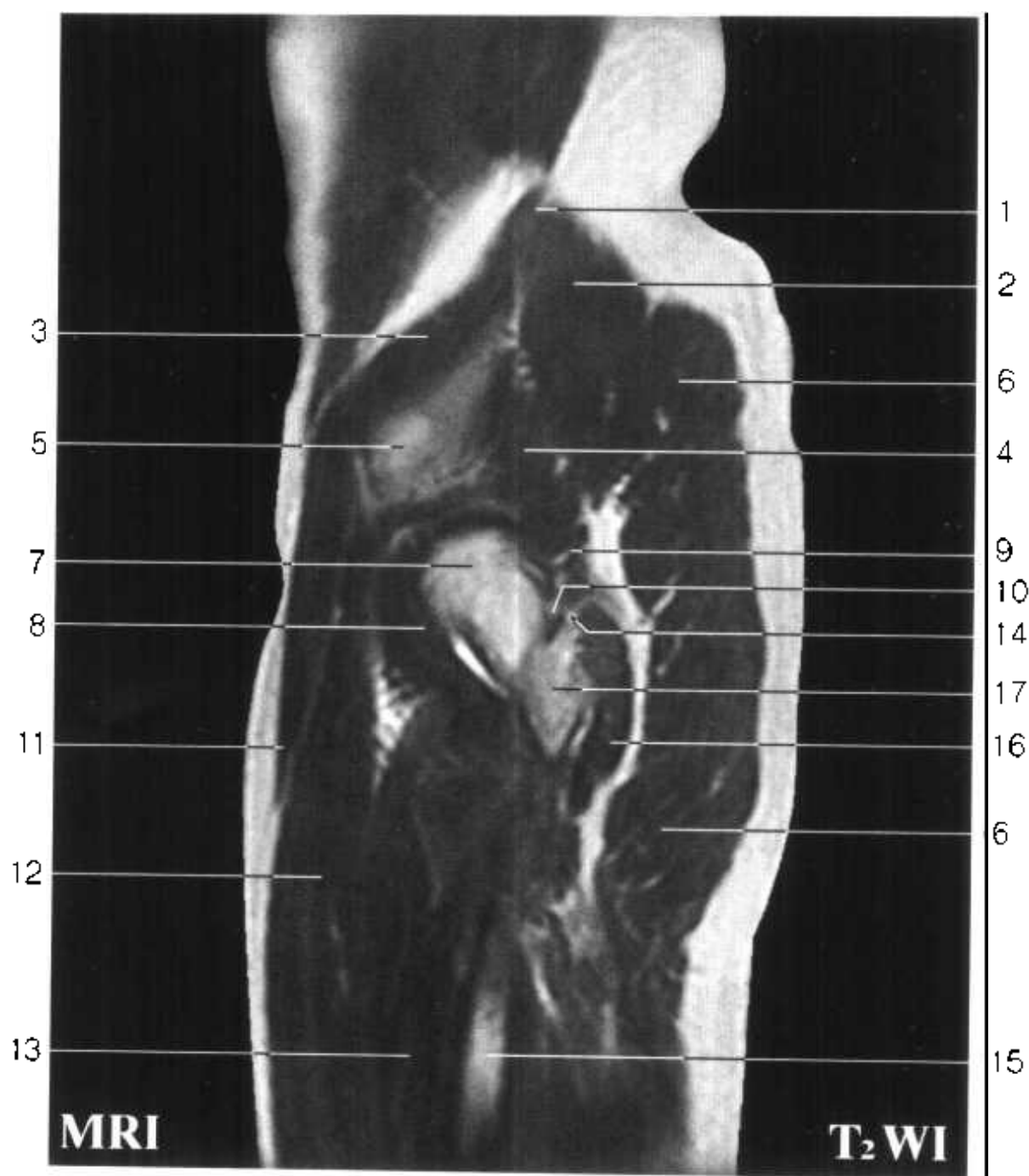
男盆矢状断面图 SPm

Fig. SPm 1

1. 髂嵴 iliac crest
2. 臀中肌 gluteus medius
3. 髂肌 iliacus
4. 臀小肌 gluteus minimus
5. 髌骨体 body of ilium
6. 臀大肌 gluteus maximus
7. 股骨头 femoral head
8. 关节囊 articular capsule

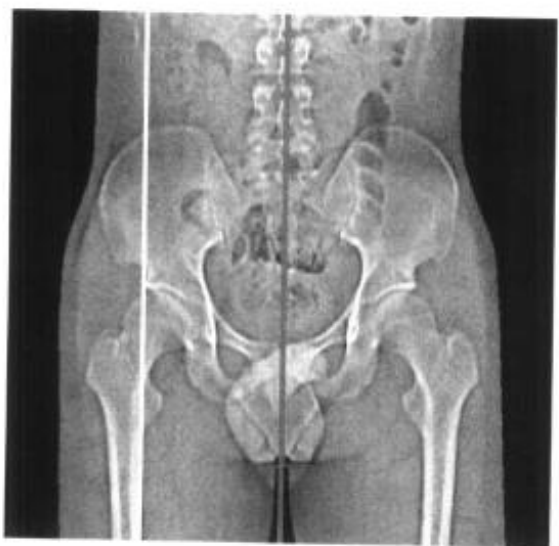

Fig. SPm 1



- 9. 梨状肌腱 tendon of piriformis
- 10. 闭孔内肌腱 tendon of obturator internus
- 11. 缝匠肌 sartorius
- 12. 股直肌 rectus femoris
- 13. 股中间肌 vastus intermedius
- 14. 闭孔外肌腱 tendon of obturator externus
- 15. 股骨体 shaft of femur
- 16. 股方肌 quadratus femoris
- 17. 大转子 greater trochanter

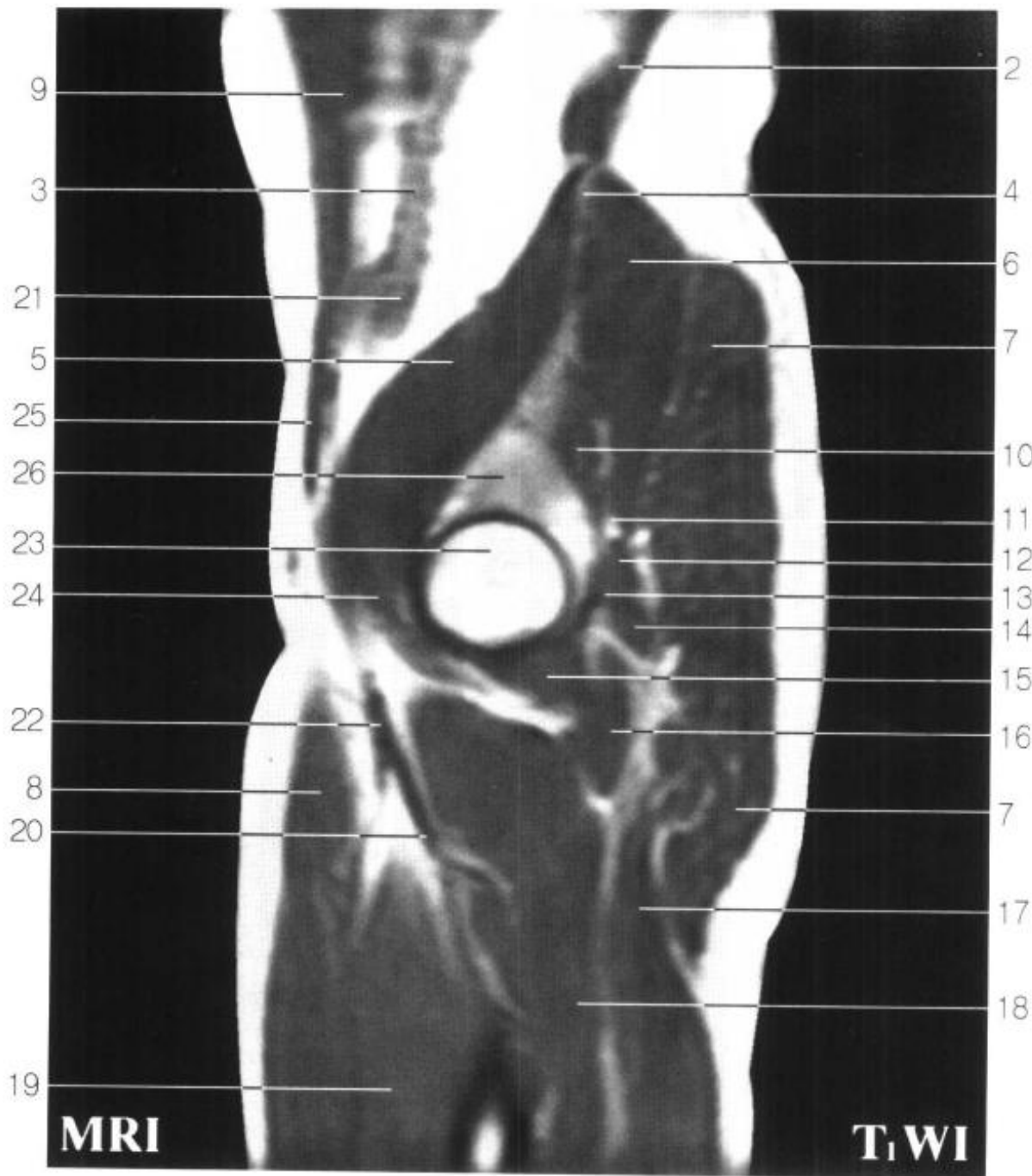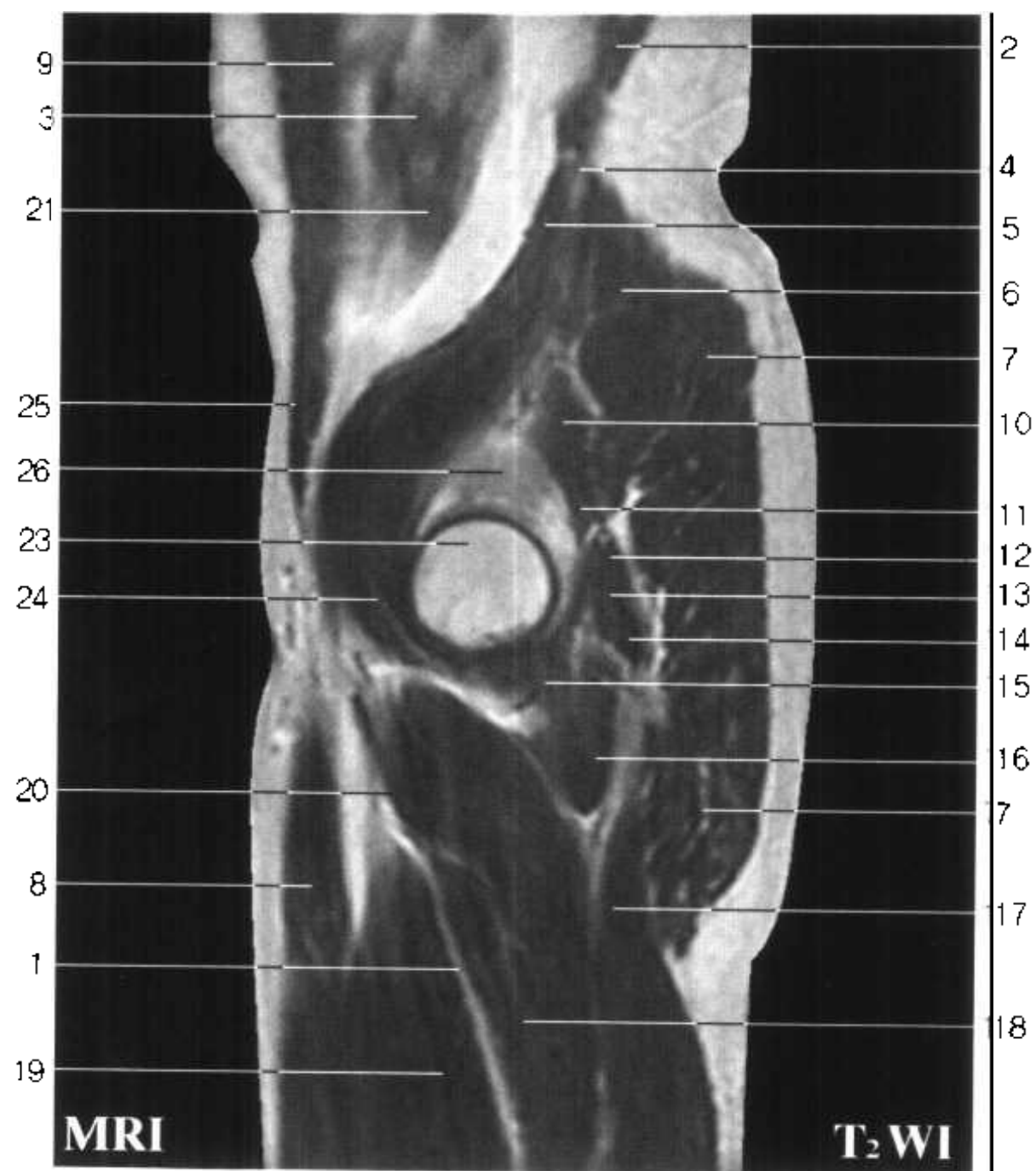


Fig. SPm 2

1. 肌间隔 intermuscular septum
2. 腰方肌 quadratus lumborum
3. 升结肠 ascending colon
4. 髂嵴 iliac crest
5. 髂肌 iliacus
6. 臀中肌 gluteus medius
7. 臀大肌 gluteus maximus
8. 缝匠肌 sartorius
9. 腹横肌 transversus abdominis
10. 臀小肌 gluteus minimus

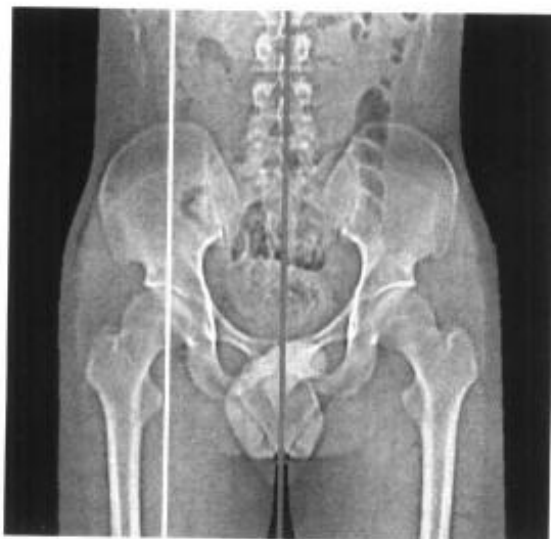

Fig. SPm 2



- | | |
|--|--------------------------------------|
| 11. 梨状肌 piriformis | 21. 盲肠 cecum |
| 12. 上孖肌 gemellus superior | 22. 股动脉 femoral a. |
| 13. 闭孔内肌腱 tendon of obturator internus | 23. 股骨头 femoral head |
| 14. 下孖肌 gemellus inferior | 24. 髂腰肌 iliopsoas |
| 15. 闭孔外肌 obturator externus | 25. 腹外斜肌 obliquus externus abdominis |
| 16. 股方肌 quadratus femoris | 26. 髌骨体 body of ilium |
| 17. 半腱肌 semitendinosus | |
| 18. 大收肌 adductor magnus | |
| 19. 长收肌 adductor longus | |
| 20. 股深动脉 deep femoral a. | |

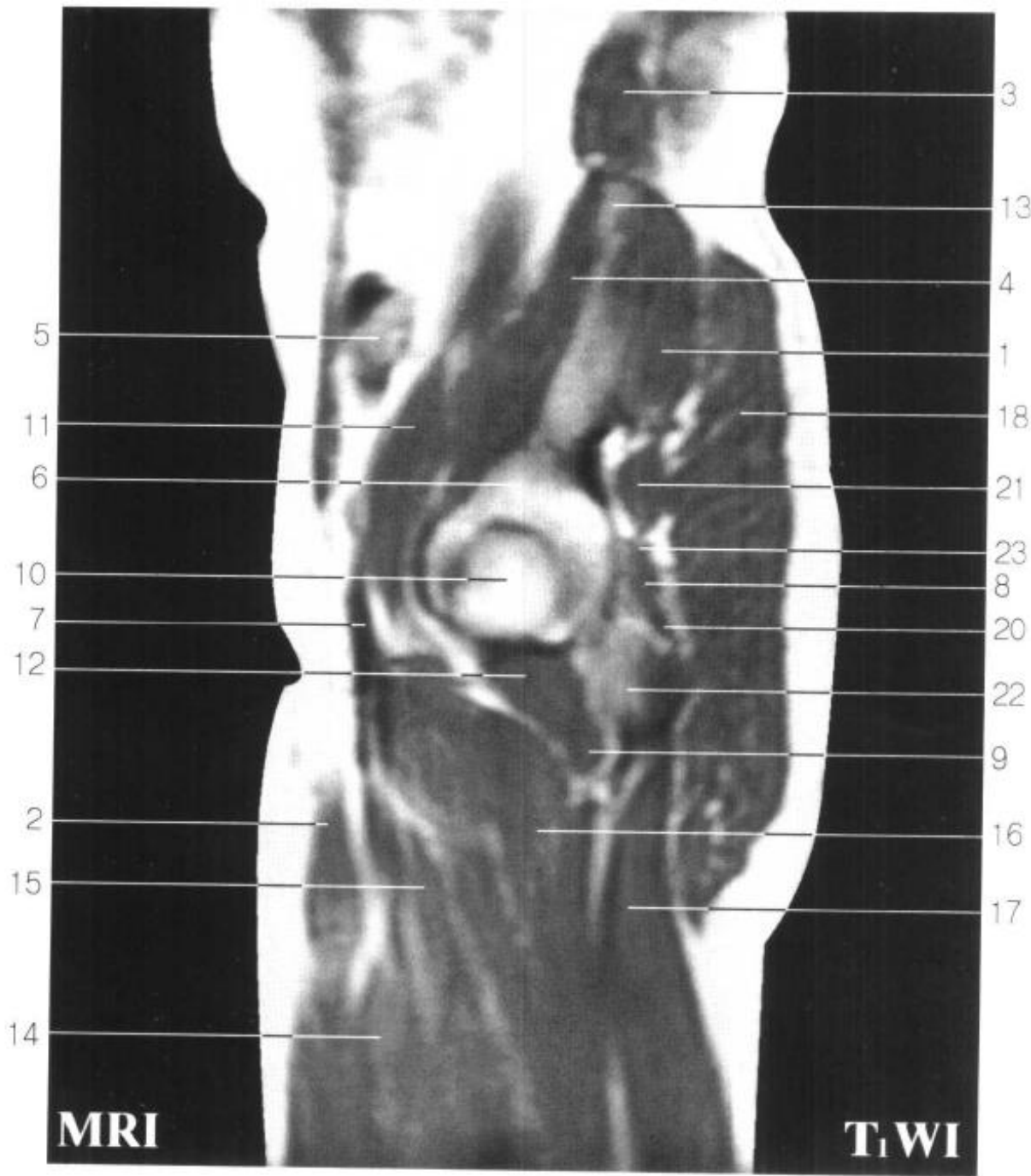
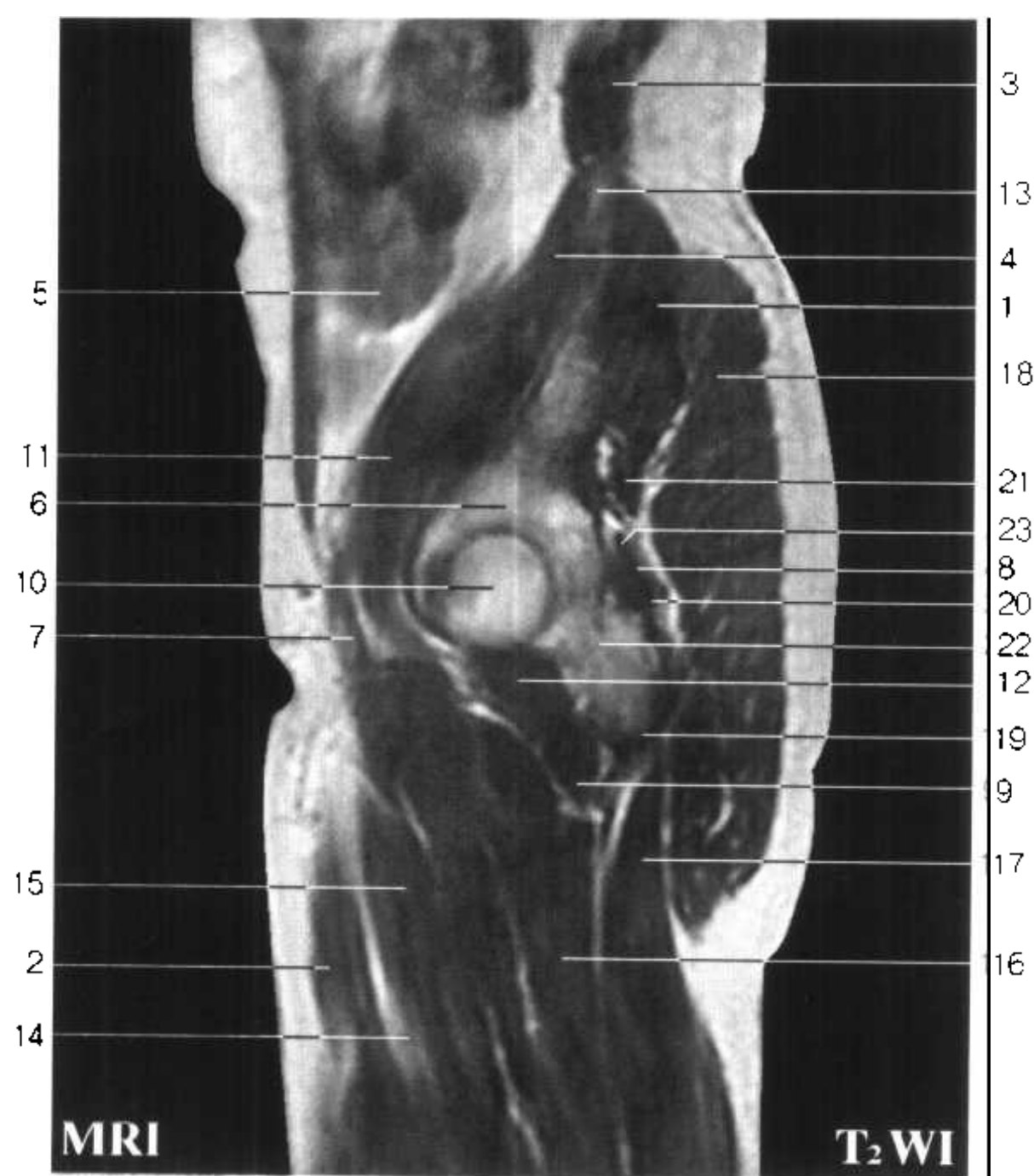


Fig. SPm 3

- 1. 臀中肌 gluteus medius
- 2. 缝匠肌 sartorius
- 3. 腰方肌 quadratus lumborum
- 4. 髂肌 iliacus
- 5. 回肠 ileum
- 6. 髌骨体 body of ilium
- 7. 右髂外静脉 right external iliac v.
- 8. 闭孔内肌 obturator internus
- 9. 股方肌 quadratus femoris

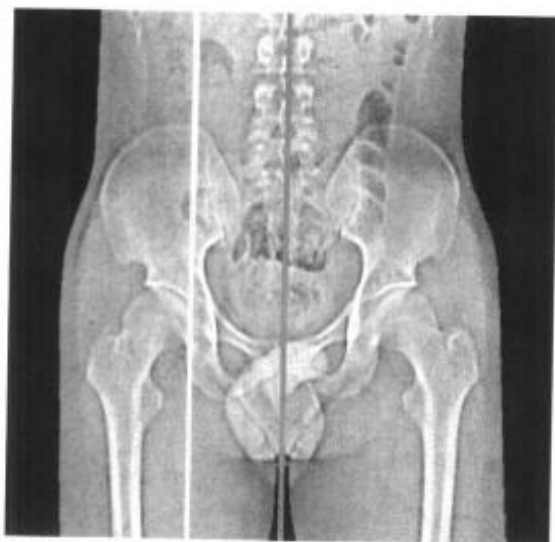

Fig. SPm 3



- | | |
|-----------------------------|---------------------------|
| 10. 股骨头 femoral head | 20. 下孖肌 gemellus inferior |
| 11. 腰大肌 psoas major | 21. 梨状肌 piriformis |
| 12. 闭孔外肌 obturator externus | 22. 坐骨体 body of ischium |
| 13. 髌骨 ilium | 23. 上孖肌 gemellus superior |
| 14. 长收肌 adductor longus | |
| 15. 短收肌 adductor brevis | |
| 16. 大收肌 adductor magnus | |
| 17. 半腱肌 semitendinosus | |
| 18. 臀大肌 gluteus maximus | |
| 19. 坐骨结节 ischial tuberosity | |

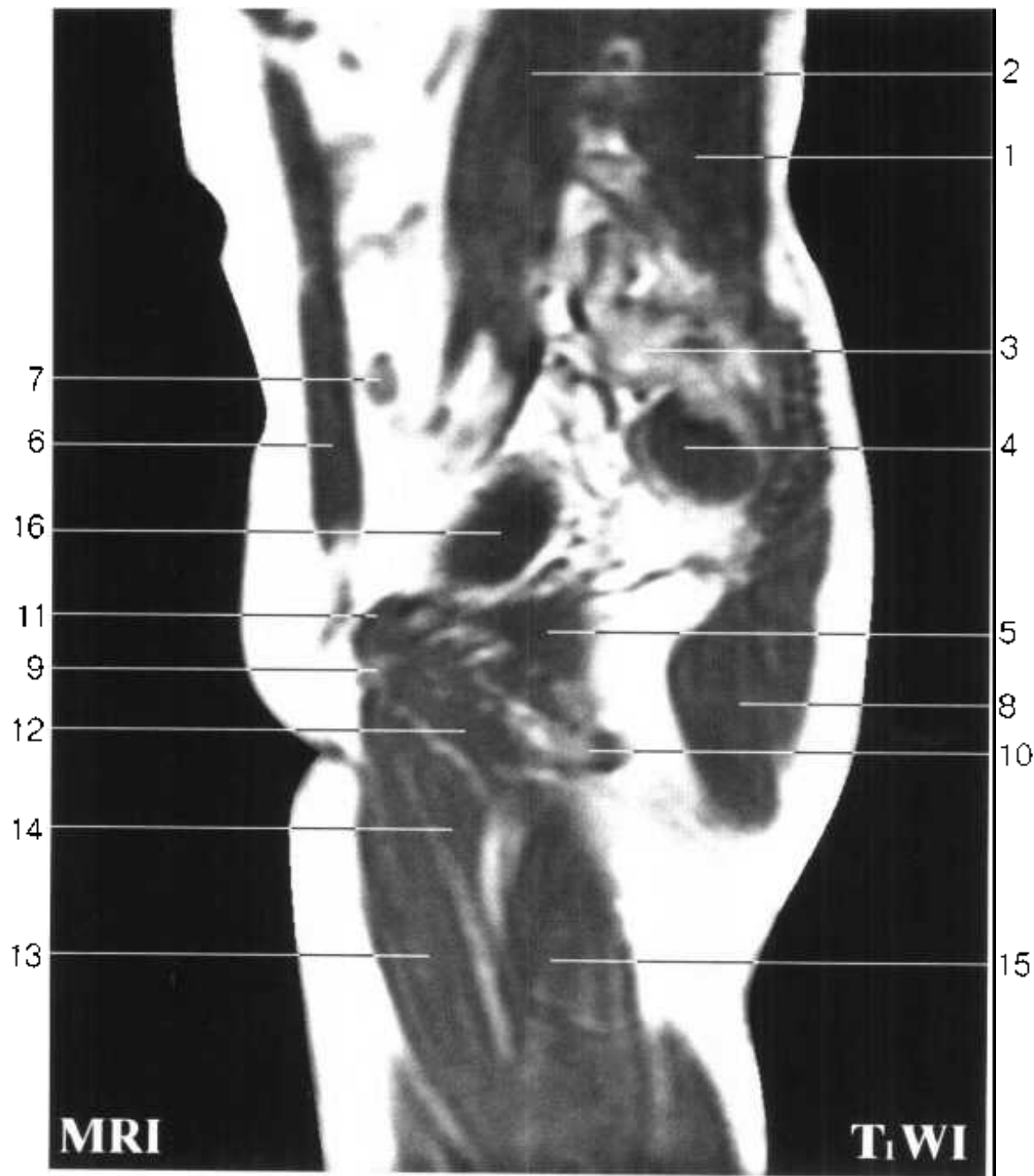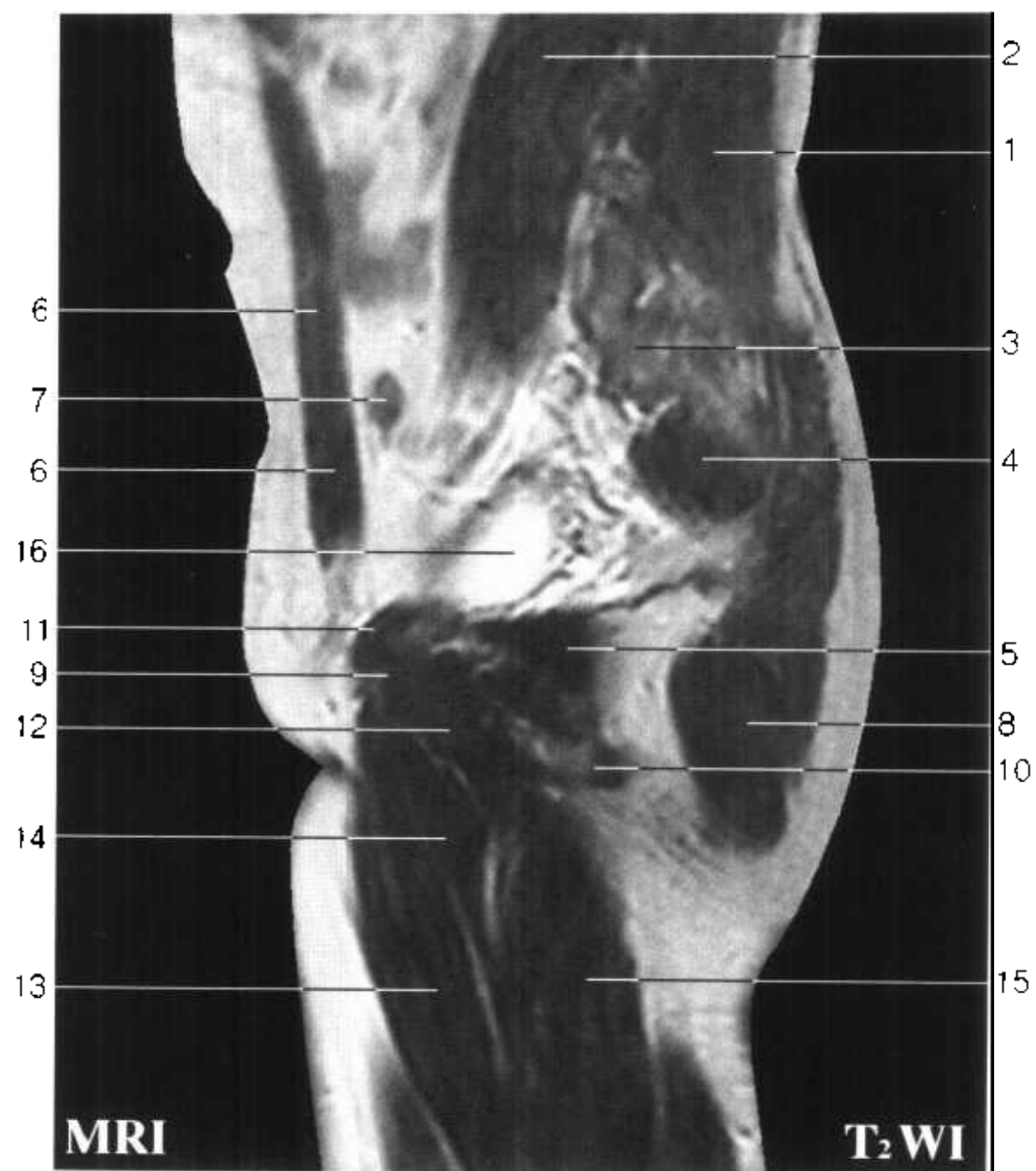


Fig. SPm 4

- 1. 竖脊肌 erector spinae
- 2. 腰大肌 psoas major
- 3. 骶骨 sacrum
- 4. 梨状肌 piriformis
- 5. 闭孔内肌 obturator internus
- 6. 腹直肌 rectus abdominis
- 7. 回肠 ileum
- 8. 臀大肌 gluteus maximus

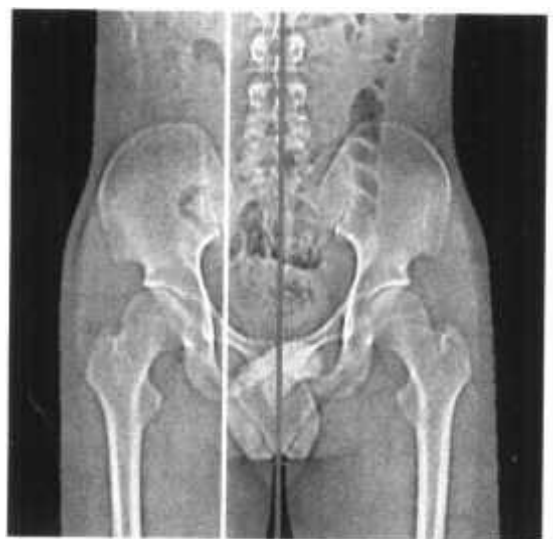

Fig. SPm 4



- 9. 耻骨上支 superior ramus of pubis
- 10. 坐骨支 ramus of ischium
- 11. 耻骨肌 pectineus
- 12. 闭孔外肌 obturator externus
- 13. 长收肌 adductor longus
- 14. 短收肌 adductor brevis
- 15. 大收肌 adductor magnus
- 16. 膀胱 urinary bladder

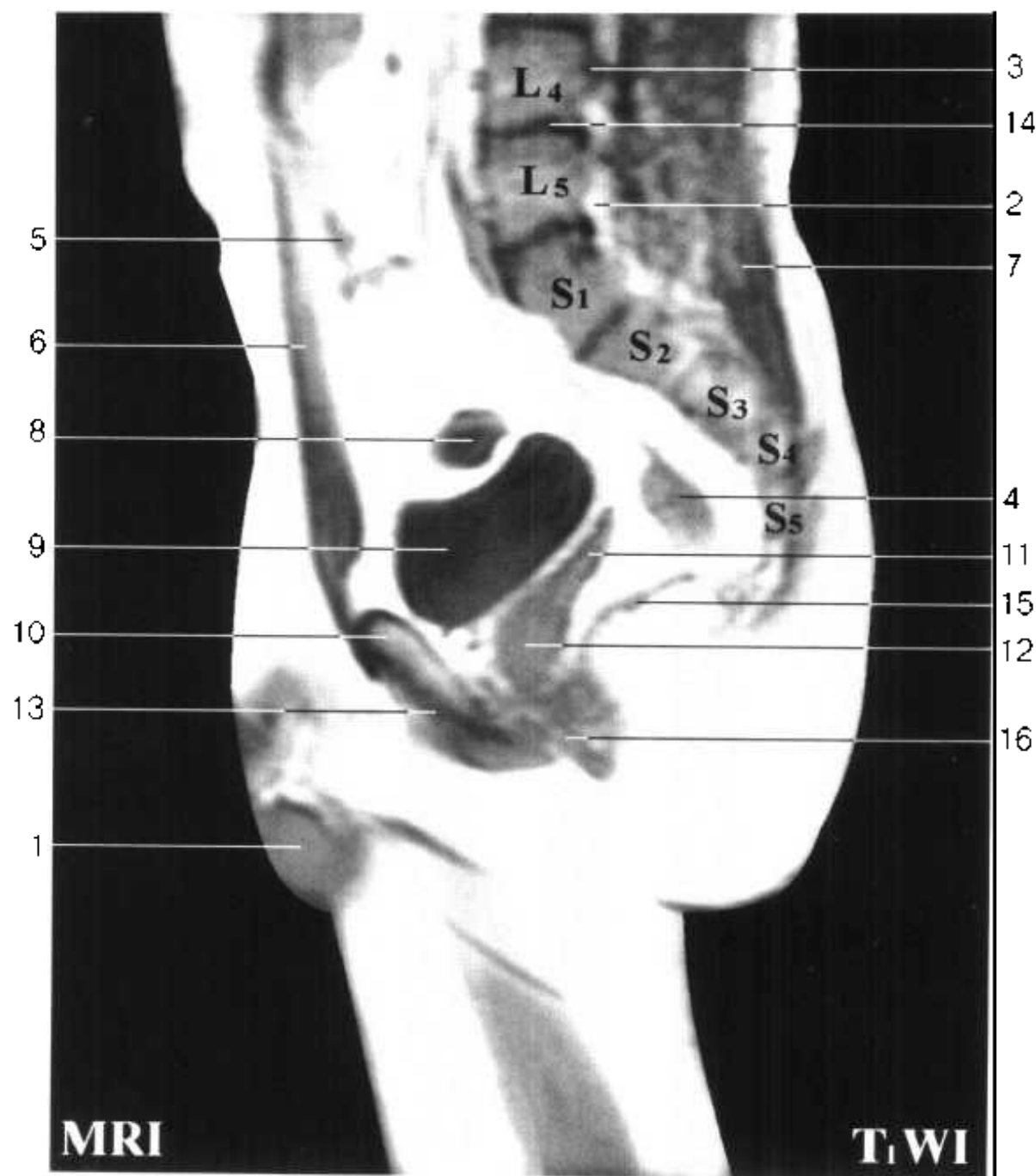
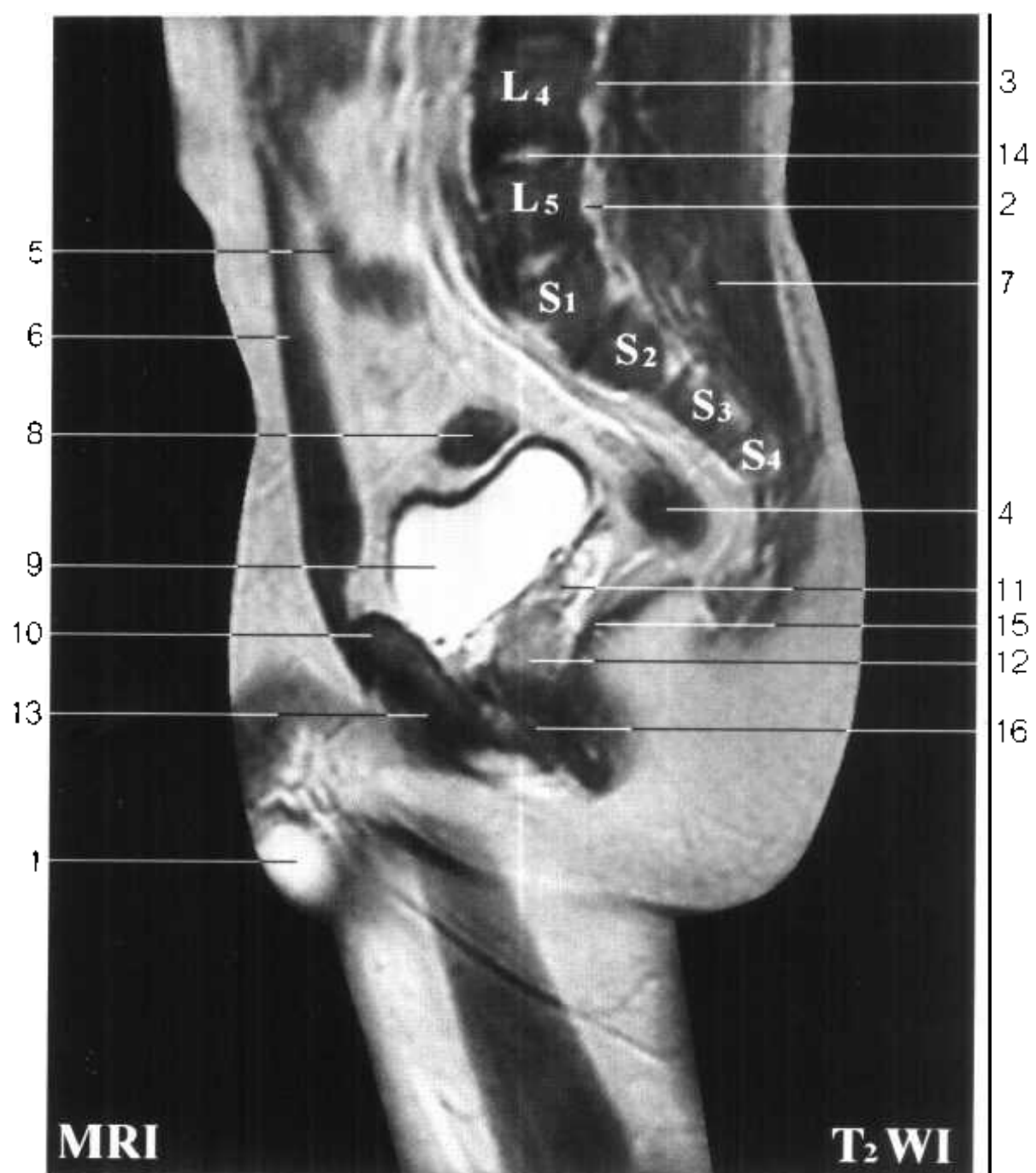


Fig. SPm 5

1. 睾丸 testis
2. 椎间孔 intervertebral foramen
3. 椎弓根 pedicle of vertebral arch
4. 直肠 rectum
5. 回肠 ileum
6. 腹直肌 rectus abdominis
7. 竖脊肌 erector spinae
8. 乙状结肠 sigmoid colon

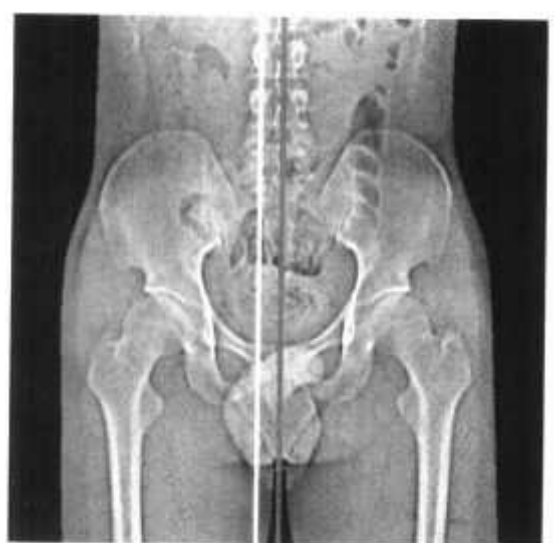

Fig. SPm 5



9. 膀胱 urinary bladder
10. 耻骨上支 superior ramus of pubis
11. 精囊 seminal vesicle
12. 前列腺 prostate
13. 闭孔外肌 obturator externus
14. 椎间盘 intervertebral disc
15. 肛提肌 levator ani
16. 球海绵体肌 bulbocavernosus

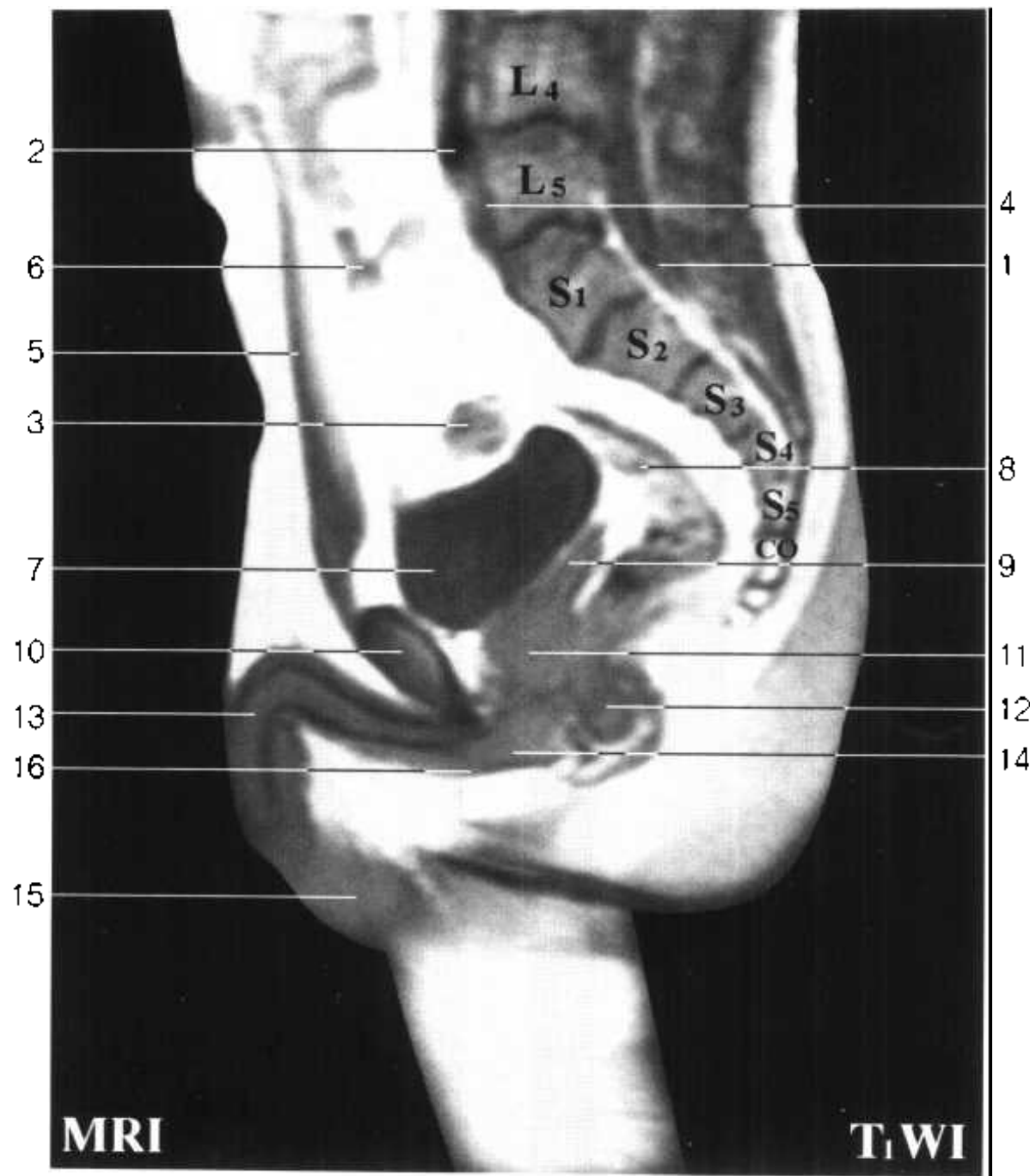
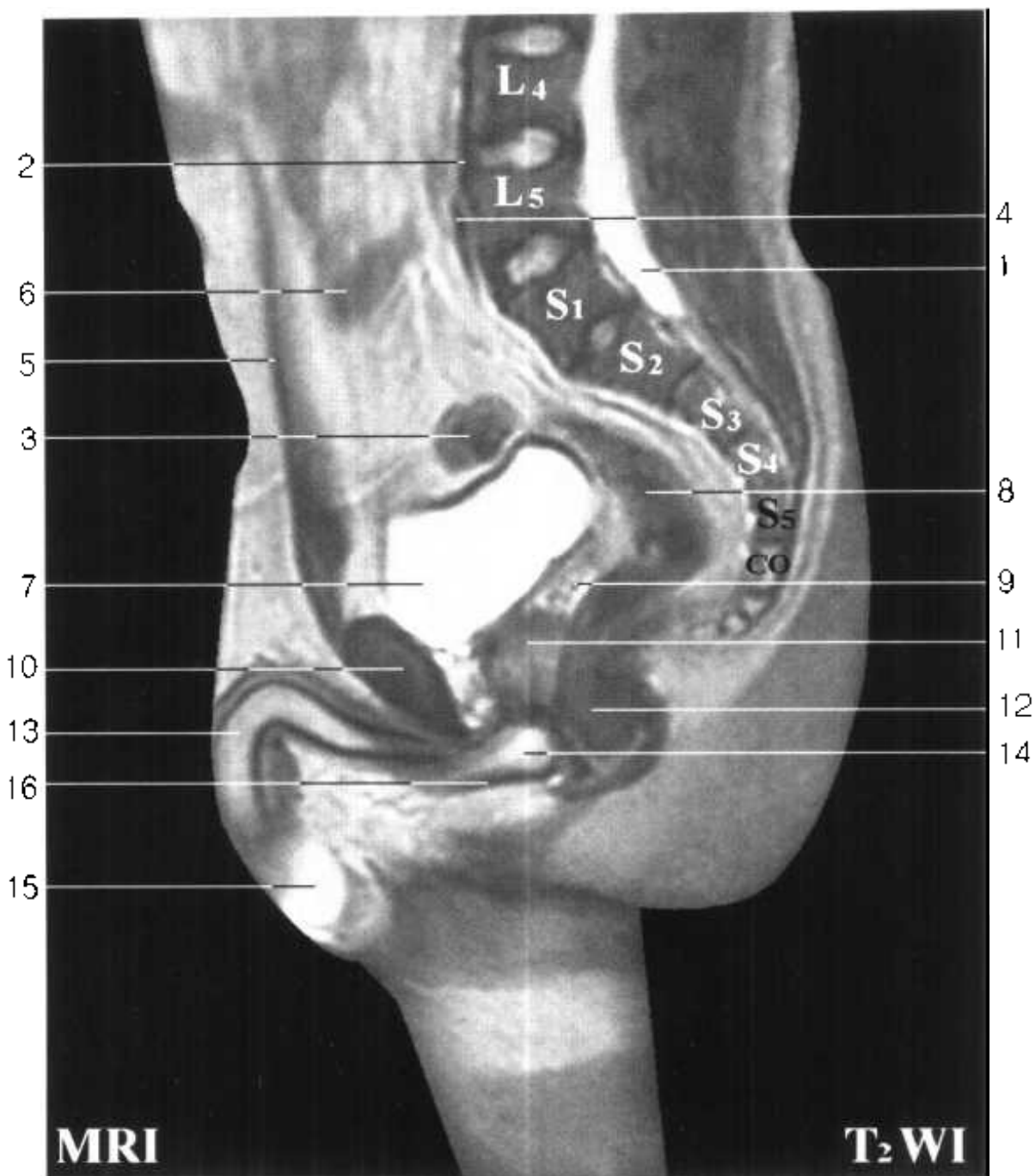


Fig. SPm 6

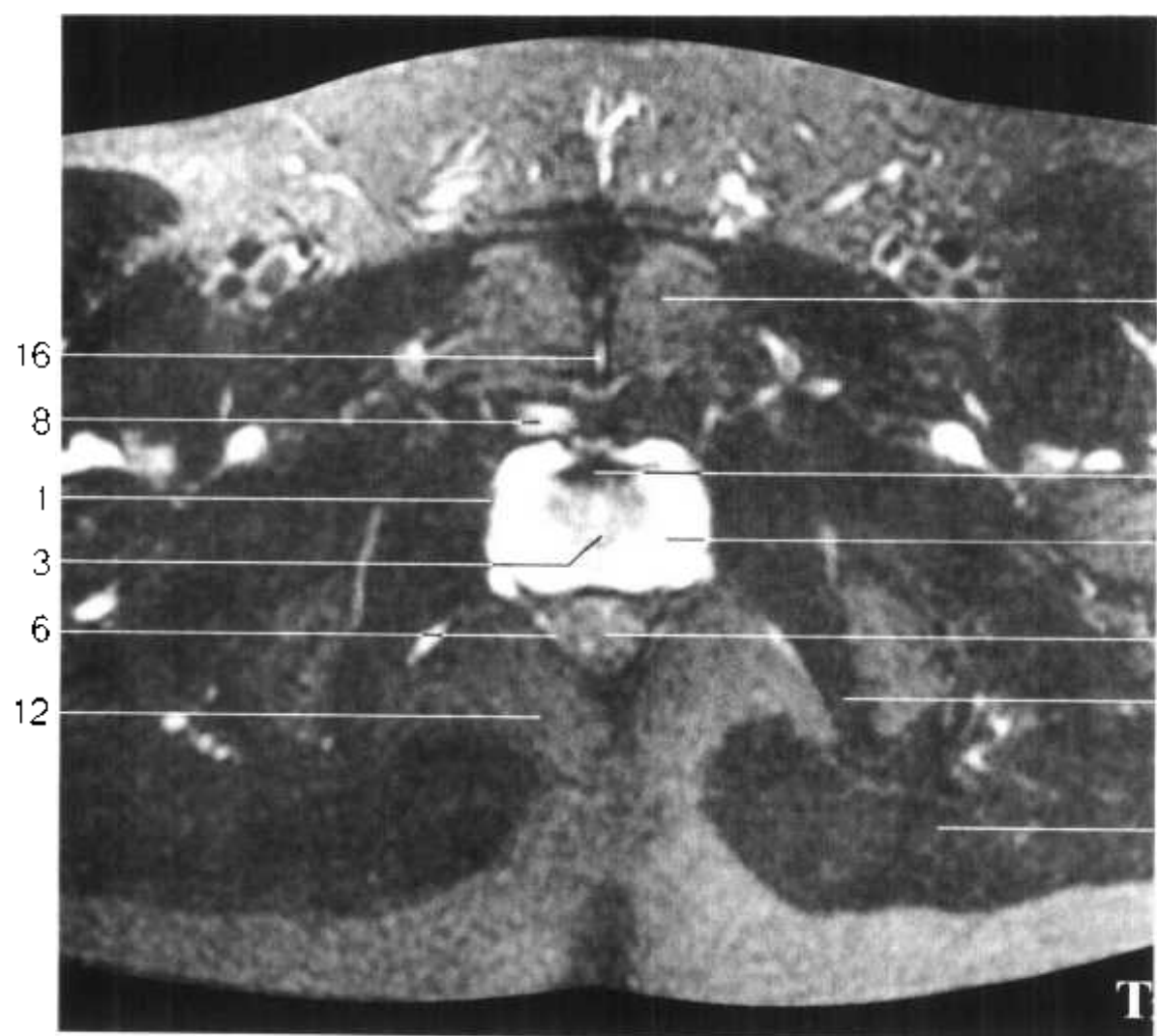
1. 骶管 sacral canal
2. 右髂总动脉 right common iliac a.
3. 乙状结肠 sigmoid colon
4. 右髂总静脉 right common iliac v.
5. 腹直肌 rectus abdominis
6. 回肠 ileum
7. 膀胱 urinary bladder
8. 直肠 rectum

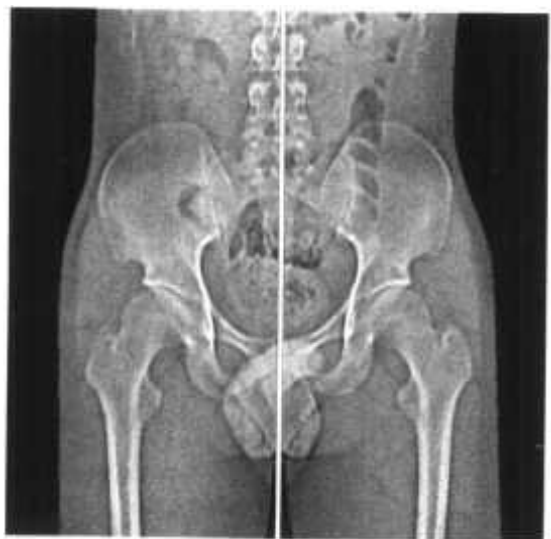

Fig. SPm 6



- 9. 精囊 seminal vesicle
- 10. 耻骨联合 pubic symphysis
- 11. 前列腺 prostate
- 12. 肛管 anal canal
- 13. 阴茎 penis
- 14. 尿道球 bulb of urethra
- 15. 睾丸 testis
- 16. 球海绵体肌 bulbocavernosus



- internus
- 10. 尿道海绵体 cavernous body of urethra
- 11. 臀大肌 gluteus maximus
- 12. 坐骨肛门窝脂体 adipose body of ischioanal fossa
- 13. 坐骨支 ramus of ischium
- 14. 髂骨体 body of ilium
- 15. 股骨头 femoral head
- 16. 耻骨联合 pubic symphysis
- 17. 阴茎脚 crus penis
- 18. 前列腺左叶 left lobe of prostate

磁共振成像(前列腺) MRI

Fig.MRI

- 1. 前列腺[纤维]囊 prostatic capsule
- 2. 前列腺右叶 right lobe of prostate
- 3. 前列腺中叶 middle lobe of prostate
- 4. 前列腺肌质 muscular substance of prostate
- 5. 直肠 rectum
- 6. 肛提肌 levator ani
- 7. 耻骨 pubis
- 8. 膀胱 urinary bladder
- 9. 闭孔内肌 obturator

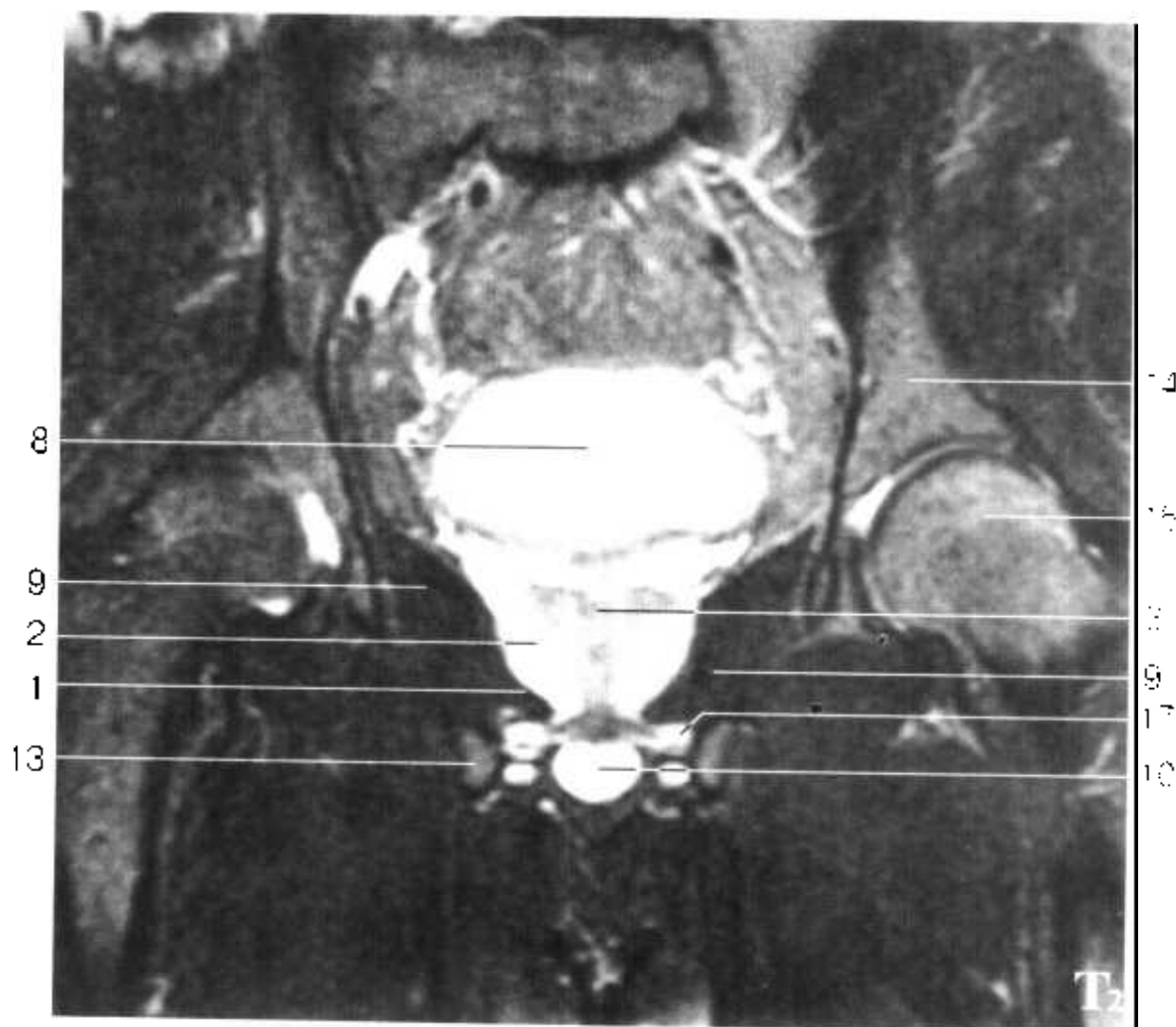
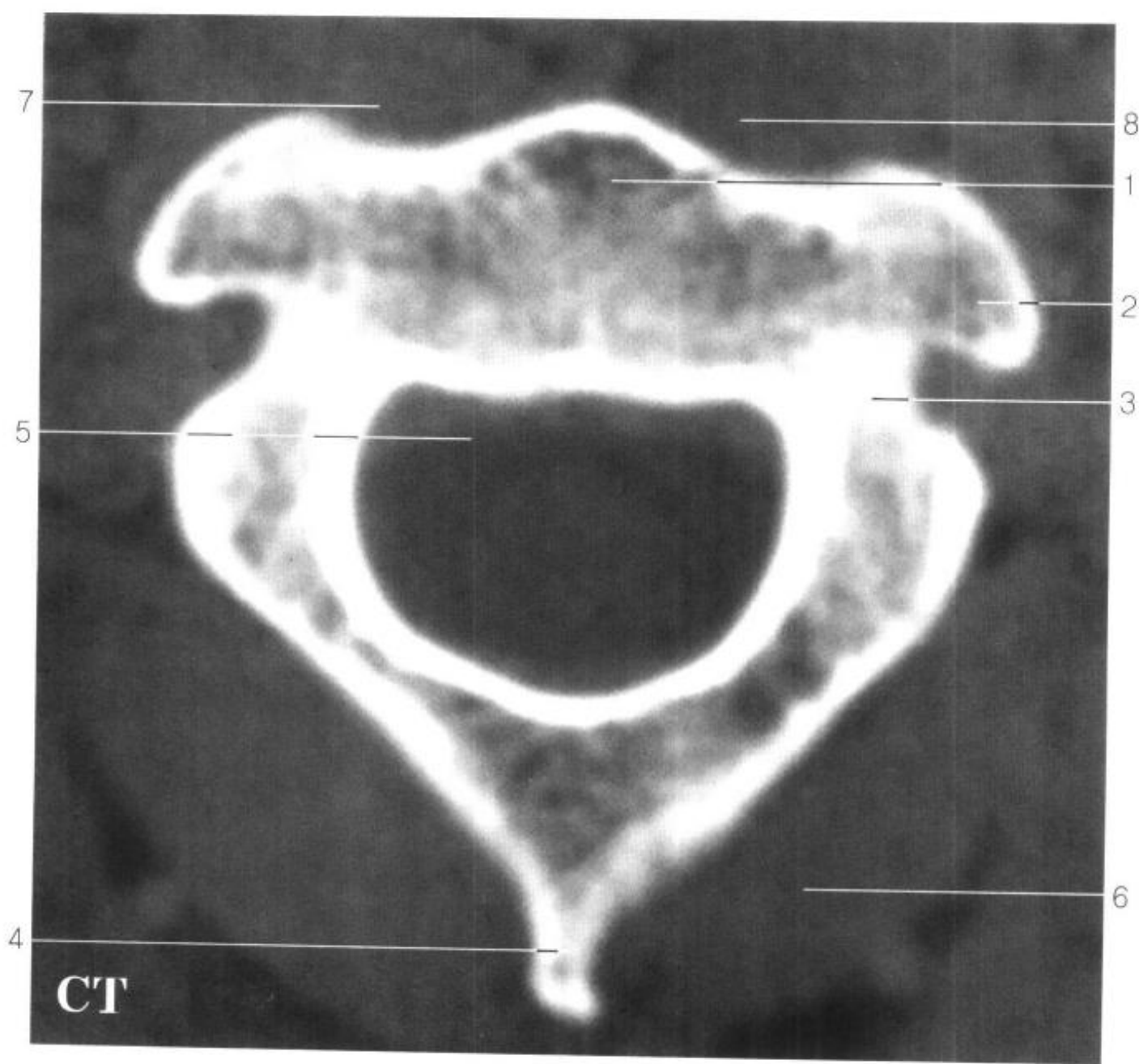


Fig . MRI

脊柱区

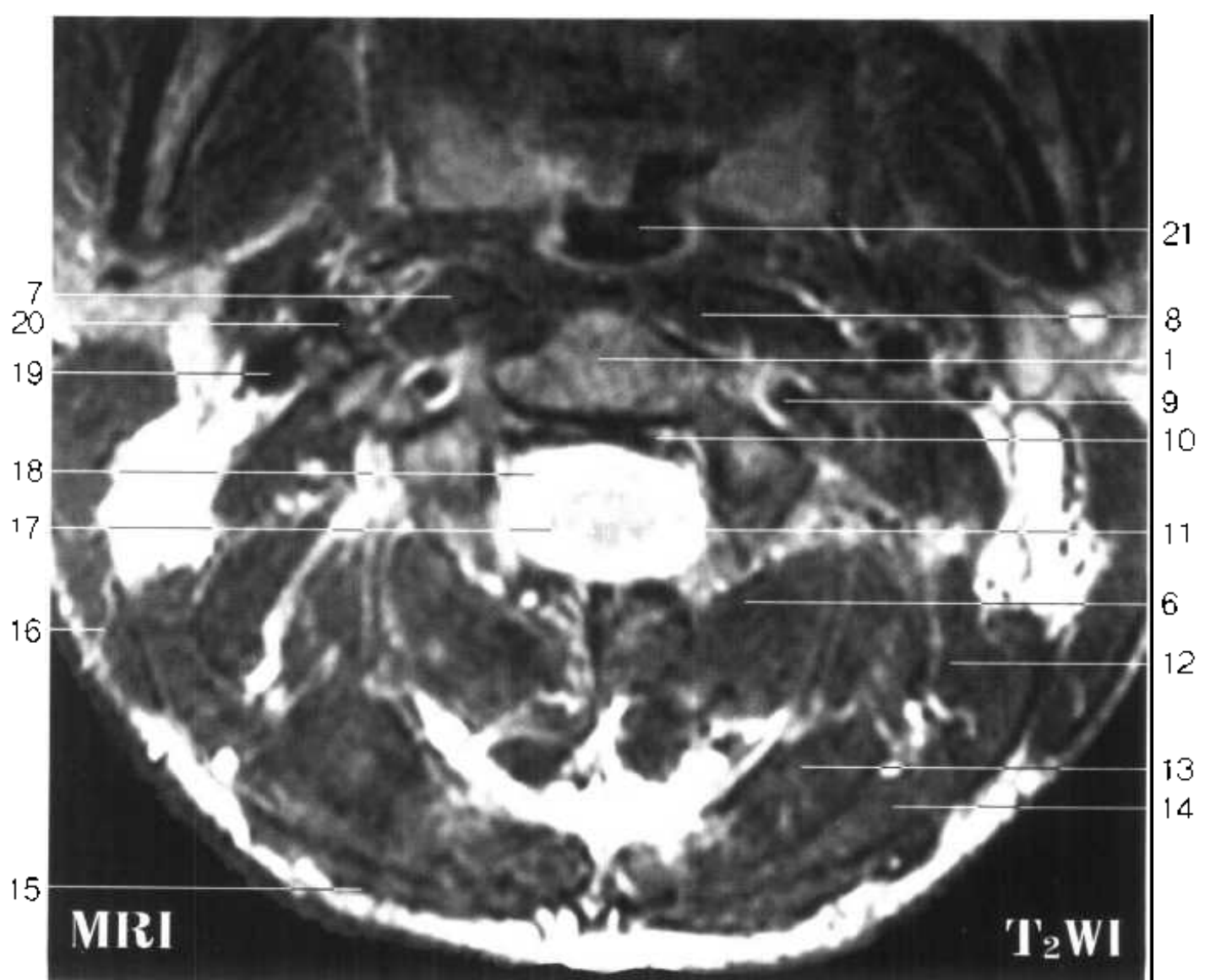
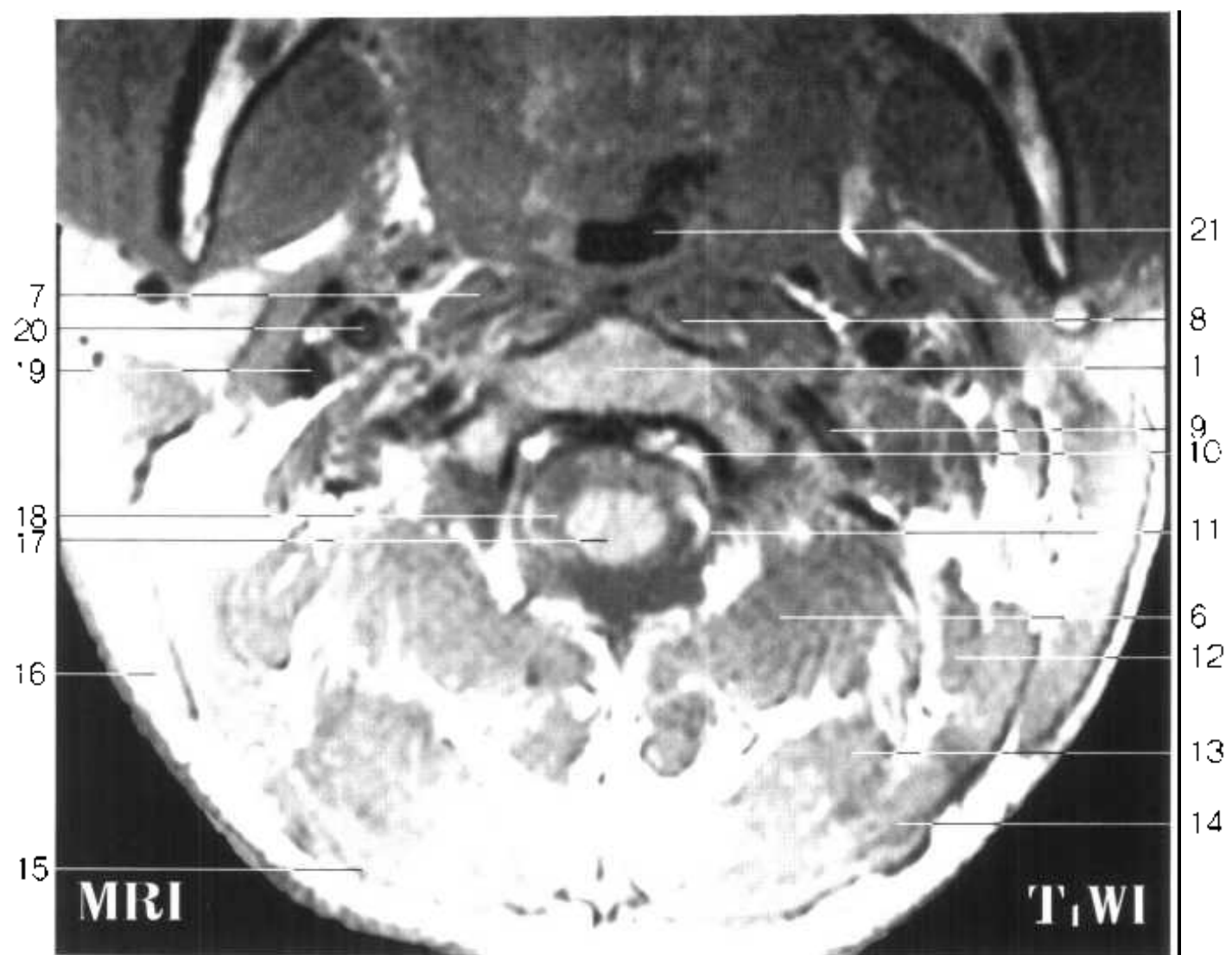
VERTEBRAL
REGION

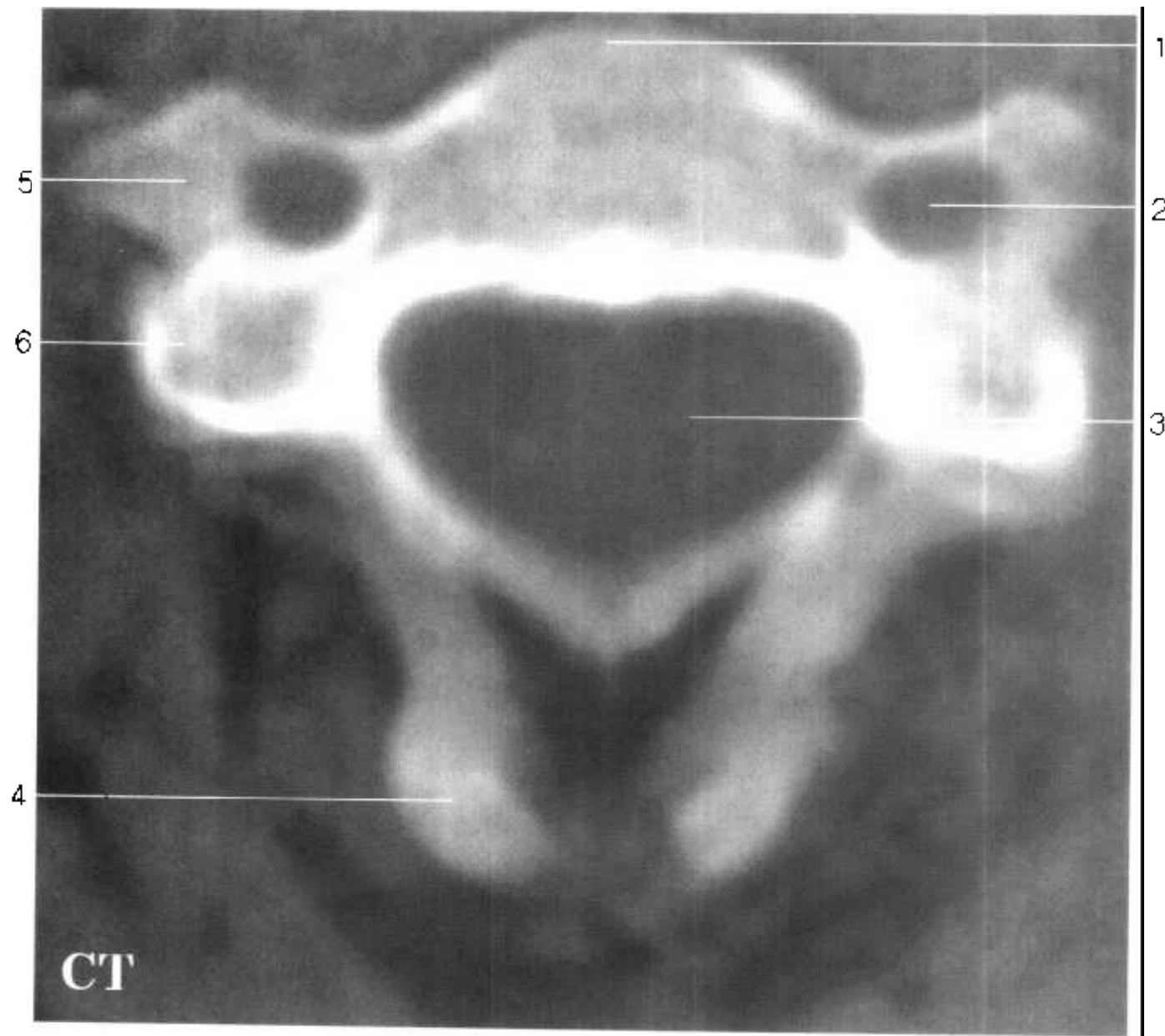


第2颈椎水平断面图 HC₂

- | | |
|--|-------------------------------|
| 1. 椎体 vertebral body | 11. 硬脊膜 spinal dura mater |
| 2. 横突 transverse process | 12. 头最长肌 longissimus capitis |
| 3. 椎弓根 pedicle of vertebral arch | 13. 头半棘肌 semispinalis capitis |
| 4. 棘突 spinous process | 14. 头夹肌 splenius capitis |
| 5. 椎管 vertebral canal | 15. 斜方肌 trapezius |
| 6. 头下斜肌 obliquus capitis inferior | 16. 胸锁乳突肌 sternocleidomastoid |
| 7. 头长肌 longus capitis | 17. 脊髓 spinal cord |
| 8. 颈长肌 longus colli | 18. 蛛网膜下隙 subarachnoid space |
| 9. 椎动脉 vertebral a. | 19. 颈内静脉 internal jugular v. |
| 10. 椎内前静脉丛 anterior internal vertebral venous plexus | 20. 颈内动脉 internal carotid a. |
| | 21. 咽腔 cavity of pharynx |

Fig. HC₂

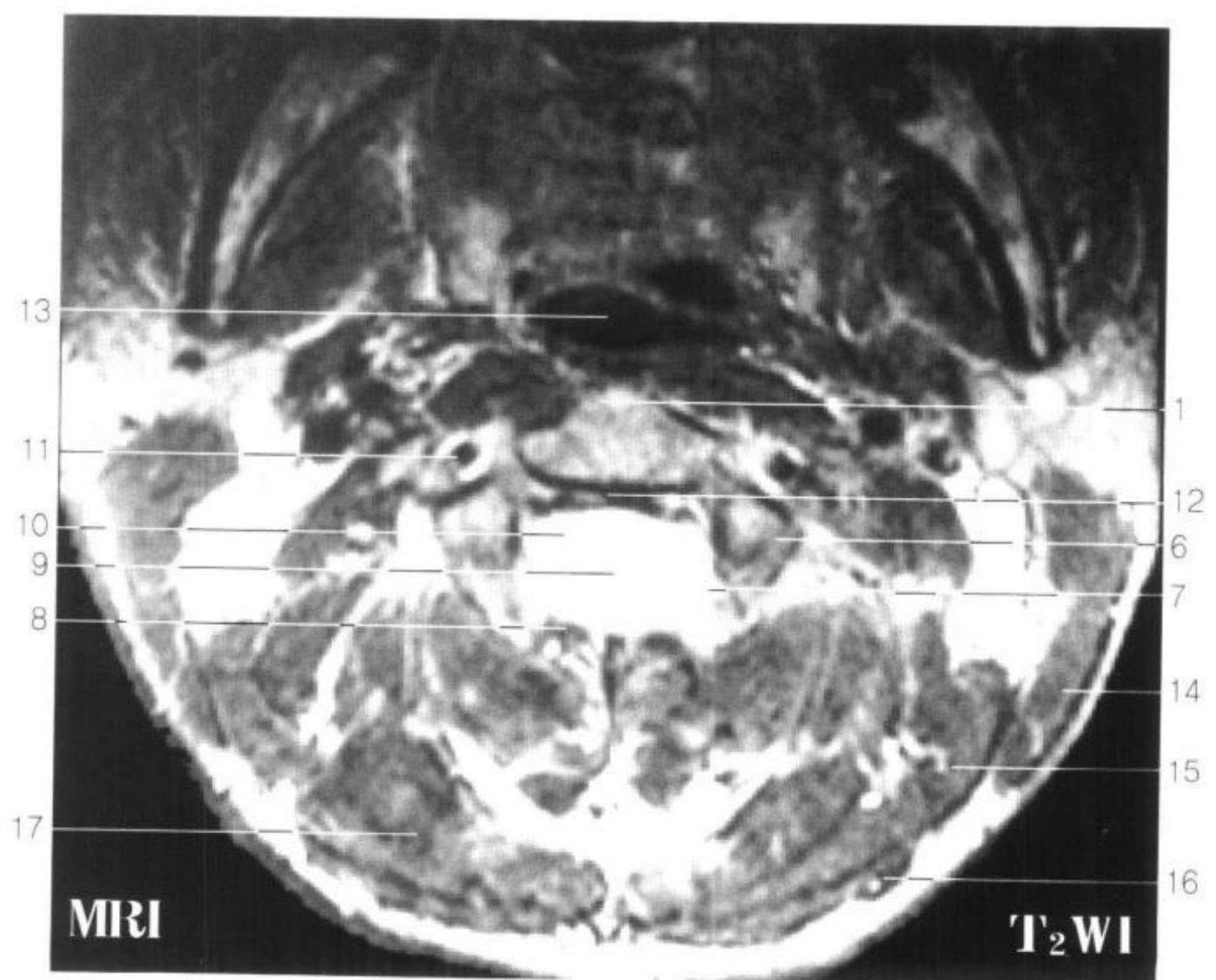
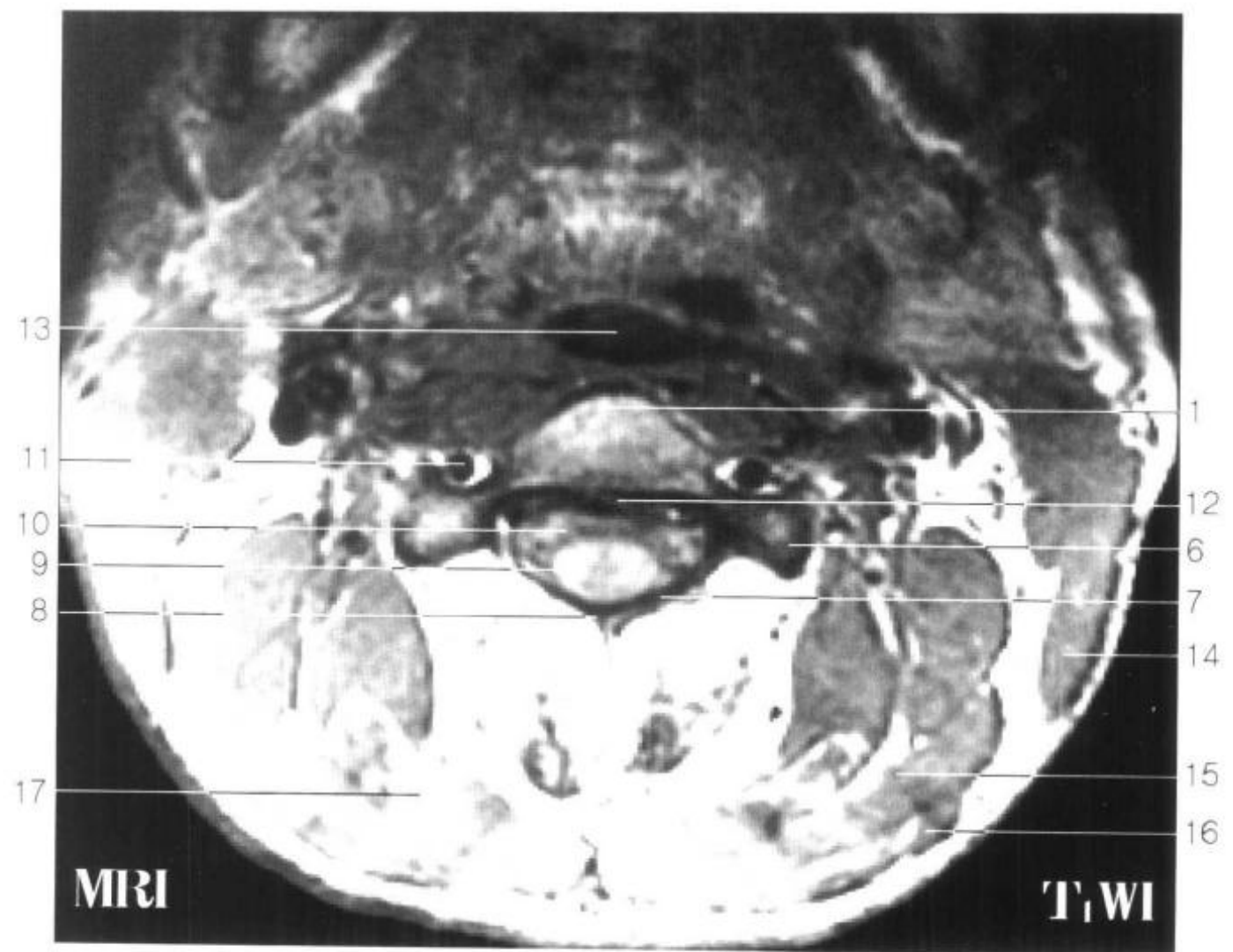


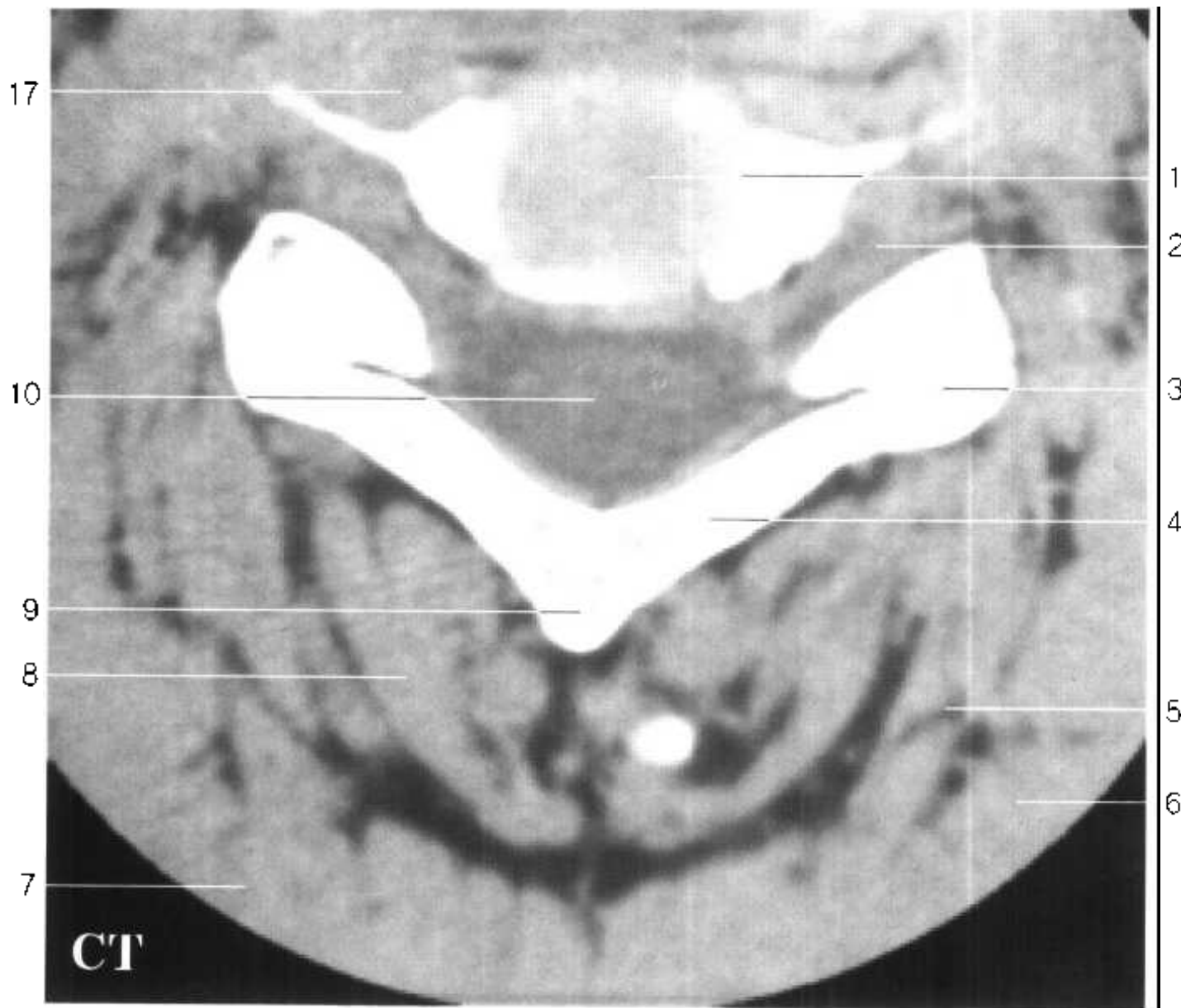


第3颈椎水平断面图 HC₃

- | | |
|---|--|
| 1. 椎体 vertebral body | 9. 脊髓 spinal cord |
| 2. 横突孔 transverse foramen | 10. 蛛网膜下隙 subarachnoid space |
| 3. 椎管 vertebral canal | 11. 椎动脉 vertebral a. |
| 4. 棘突 spinous process | 12. 椎内前静脉丛 anterior internal vertebral venous plexus |
| 5. 横突前结节 anterior tubercle of transverse process | 13. 咽腔 cavity of pharynx |
| 6. 横突后结节 posterior tubercle of transverse process | 14. 胸锁乳突肌 sternocleidomastoid |
| 7. 硬脊膜 spinal dura mater | 15. 头夹肌 splenius capitis |
| 8. 硬膜外隙 epidural space | 16. 斜方肌 trapezius |
| | 17. 头半棘肌 semispinalis capitis |

Fig. HC₃

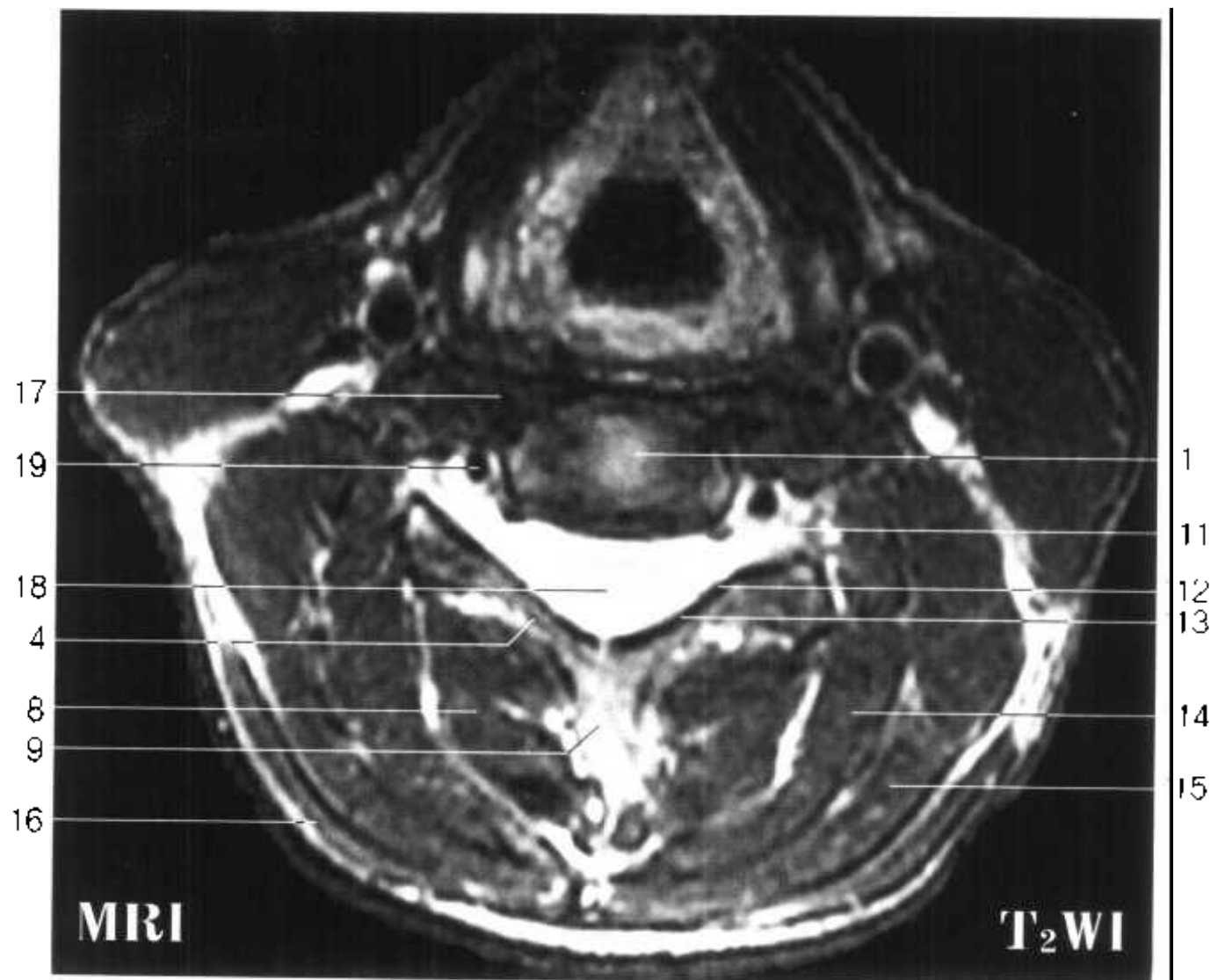
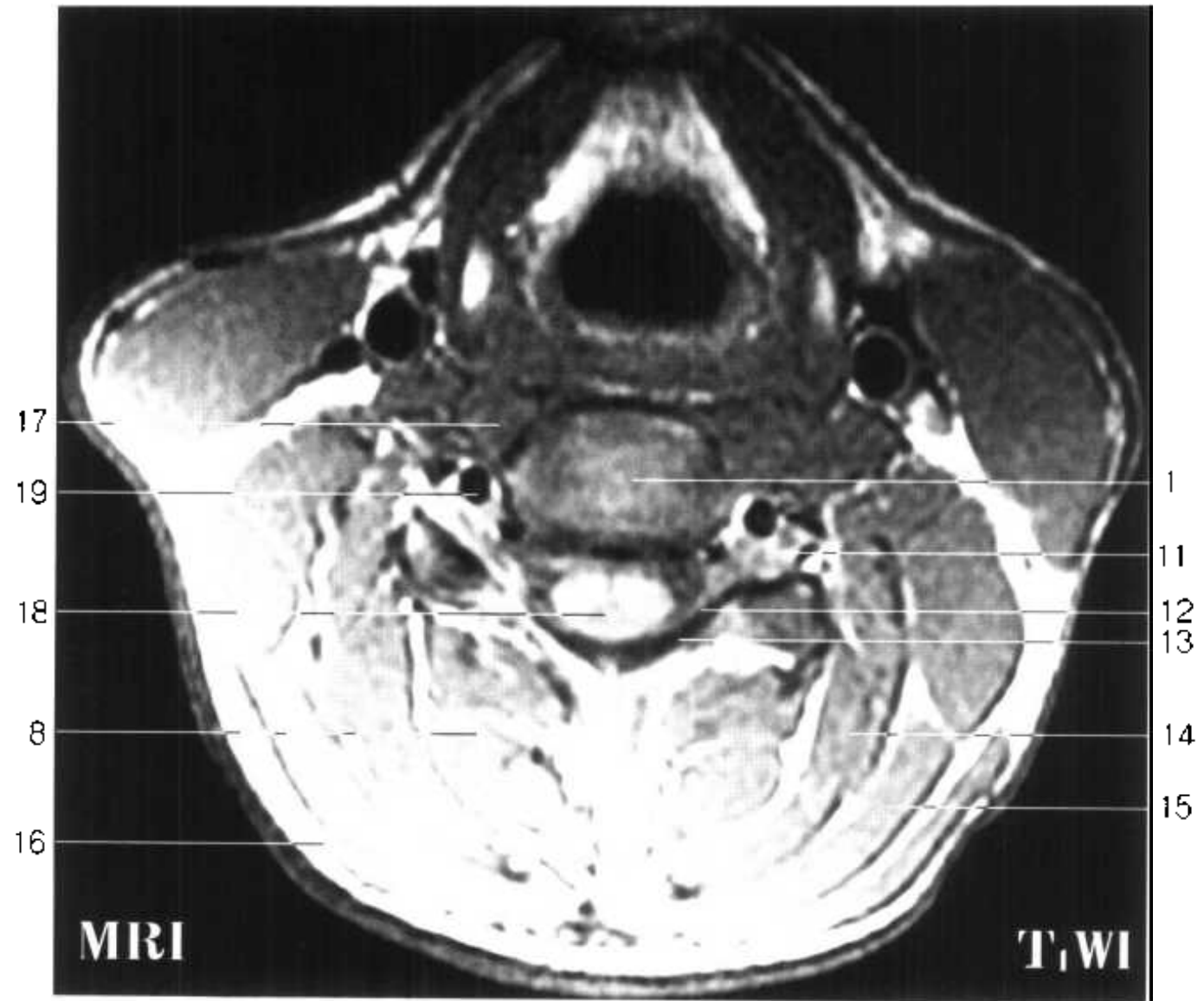


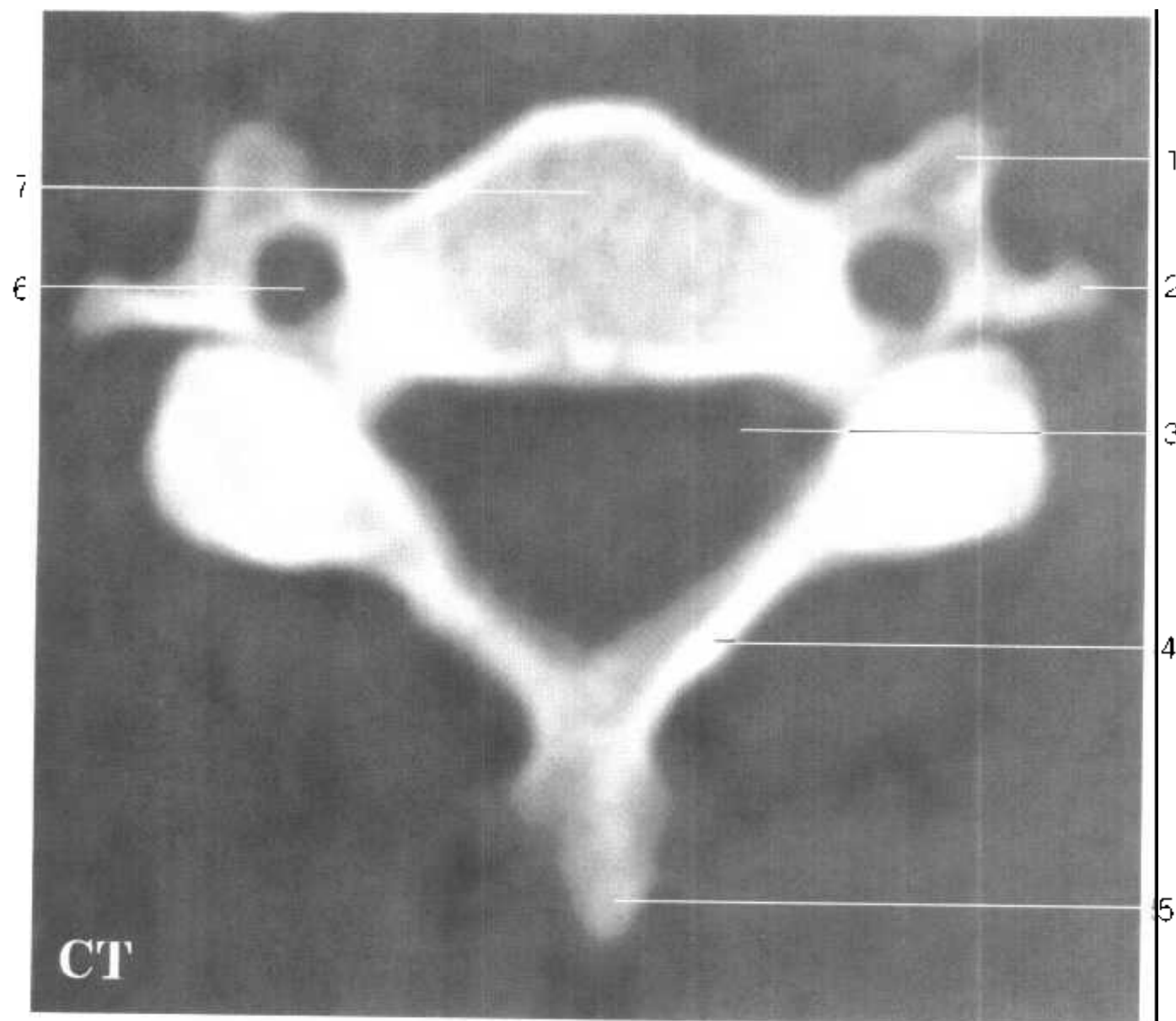


第 4、5 颈椎间盘水平断面图 HC₄₋₅

- | | |
|---|-------------------------------|
| 1. 4、5 颈椎间盘 intervertebral disc (C ₄ - C ₅) | 10. 椎管 vertebral canal |
| 2. 椎间孔 intervertebral foramen | 11. 脊神经 spinal nerve |
| 3. 4、5 颈椎关节突关节 zygapophysial joint (C ₄ - C ₅) | 12. 硬脊膜 spinal dura mater |
| 4. 椎弓板 lamina of vertebral arch | 13. 硬膜外隙 epidural space |
| 5. 头半棘肌 semispinalis capitis | 14. 头半棘肌 semispinalis capitis |
| 6. 头夹肌 splenius capitis | 15. 头夹肌 splenius capitis |
| 7. 斜方肌 trapezius | 16. 斜方肌 trapezius |
| 8. 颈半棘肌 semispinalis cervicis | 17. 颈长肌 longus colli |
| 9. 棘突 spinous process | 18. 脊髓 spinal cord |
| | 19. 椎动脉 vertebral a. |

Fig. HC₄₋₅

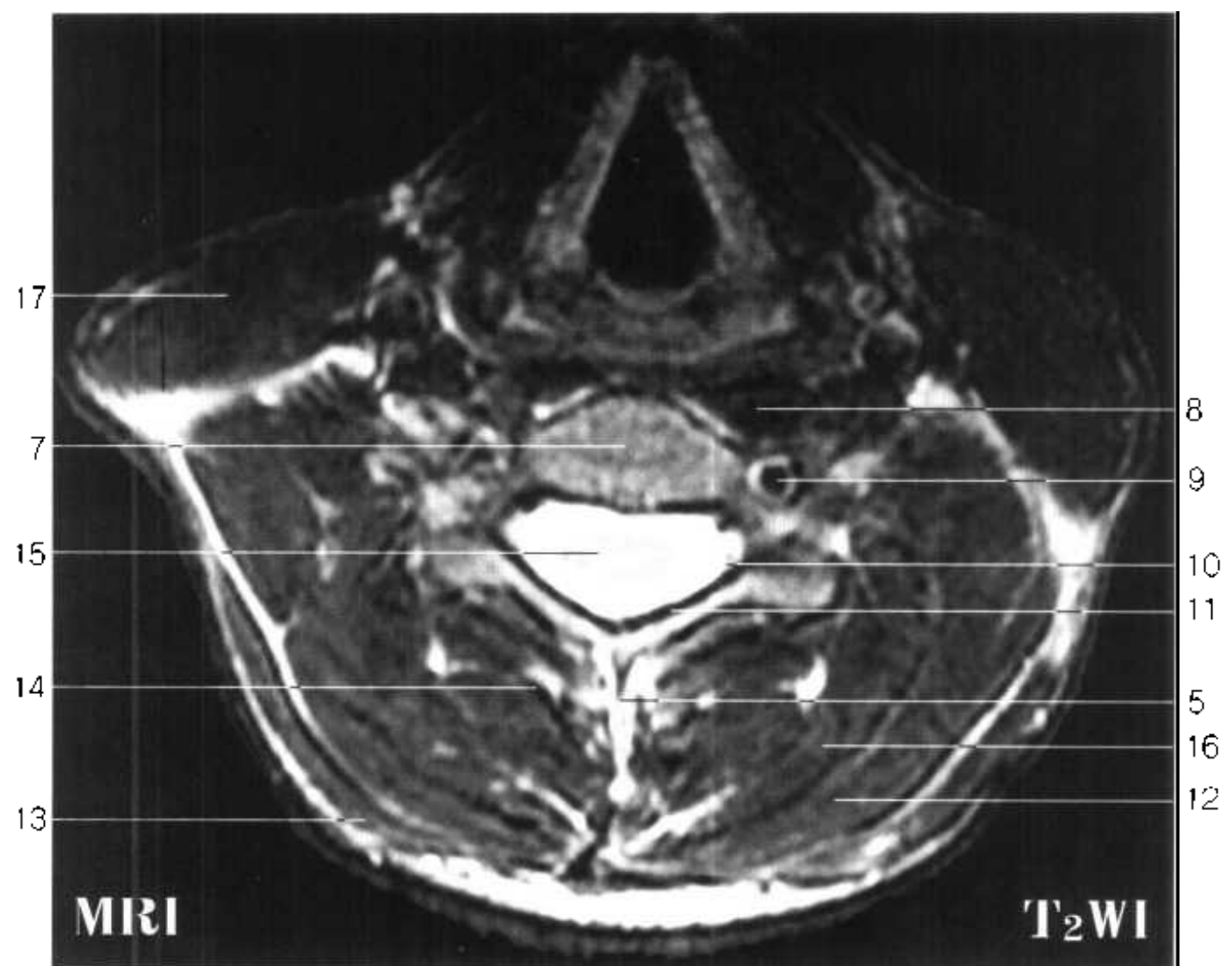
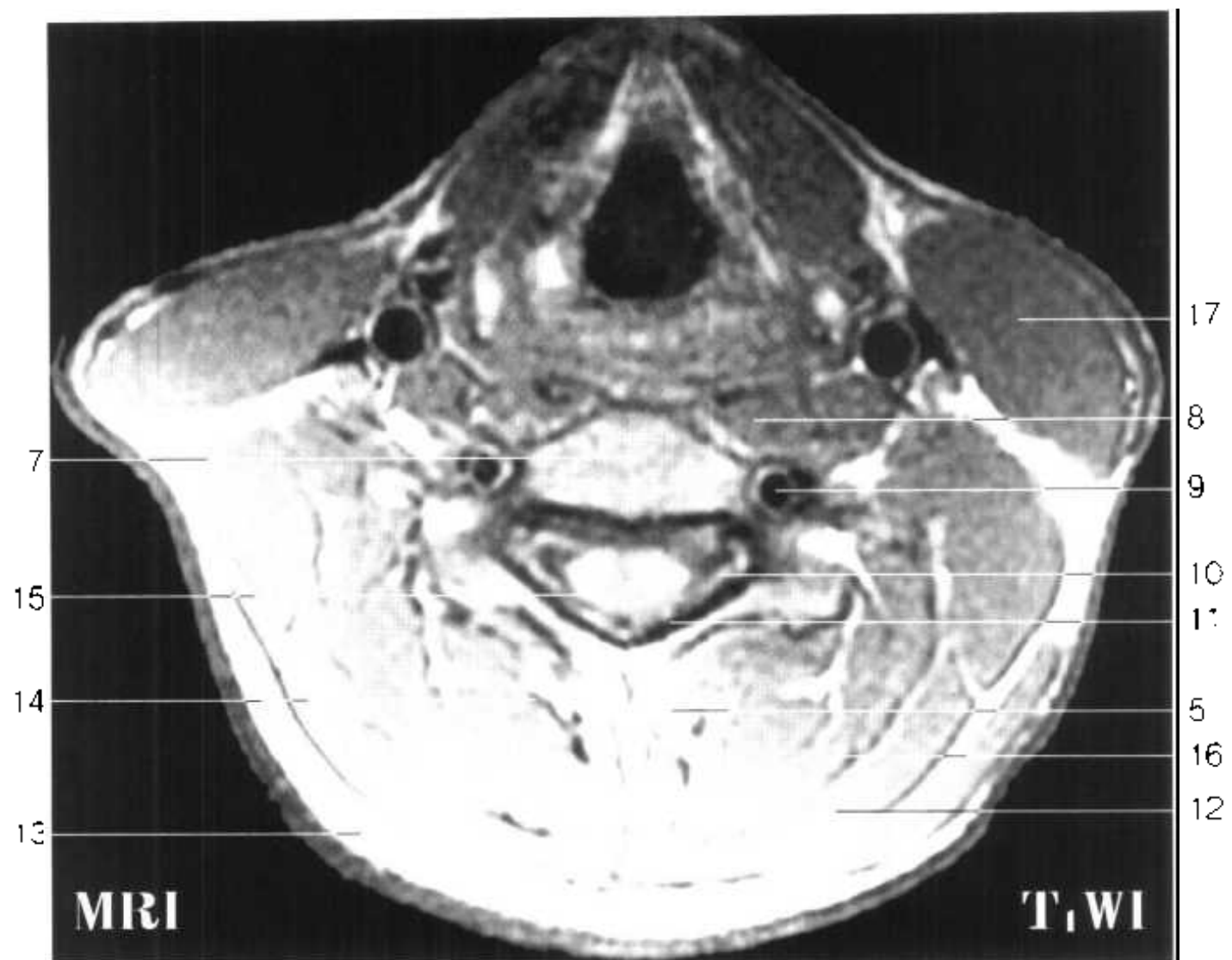


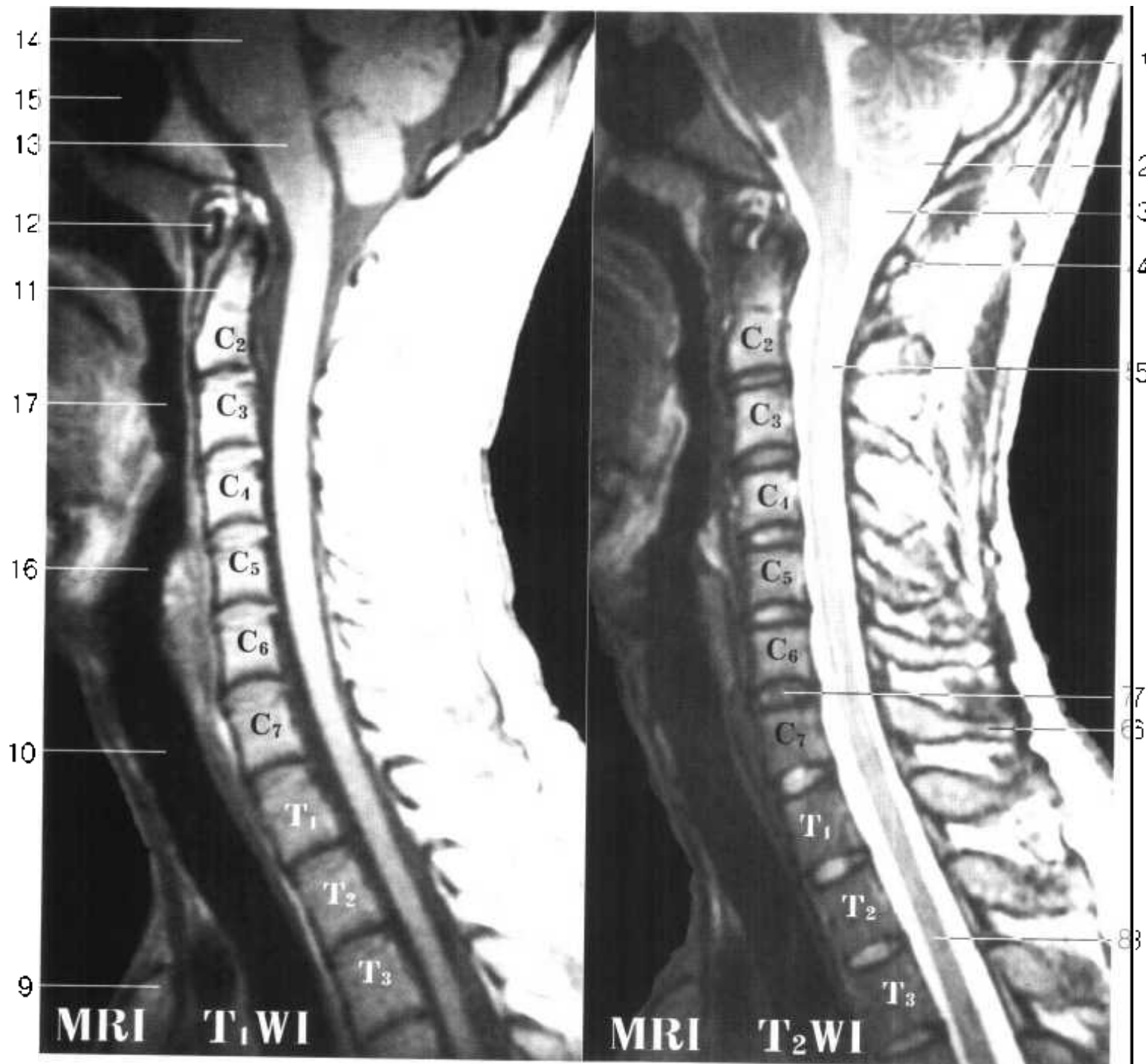


第5颈椎水平断面图 HC₅

- | | |
|---------------------------------|--------------------------------|
| 1. 前结节 anterior tubercle | 10. 硬脊膜 spinal dura mater |
| 2. 后结节 posterior tubercle | 11. 硬膜外隙 epidural space |
| 3. 椎管 vertebral canal | 12. 头夹肌 splenius capitis |
| 4. 椎弓板 lamina of vertebral arch | 13. 斜方肌 trapezius |
| 5. 棘突 spinous process | 14. 颈半棘肌 semispinalis cervicis |
| 6. 横突孔 transverse foramen | 15. 脊髓 spinal cord |
| 7. 椎体 vertebral body | 16. 头半棘肌 semispinalis capitis |
| 8. 颈长肌 longus colli | 17. 胸锁乳突肌 sternocleidomastoid |
| 9. 椎动脉 vertebral a. | |

Fig. HC₅



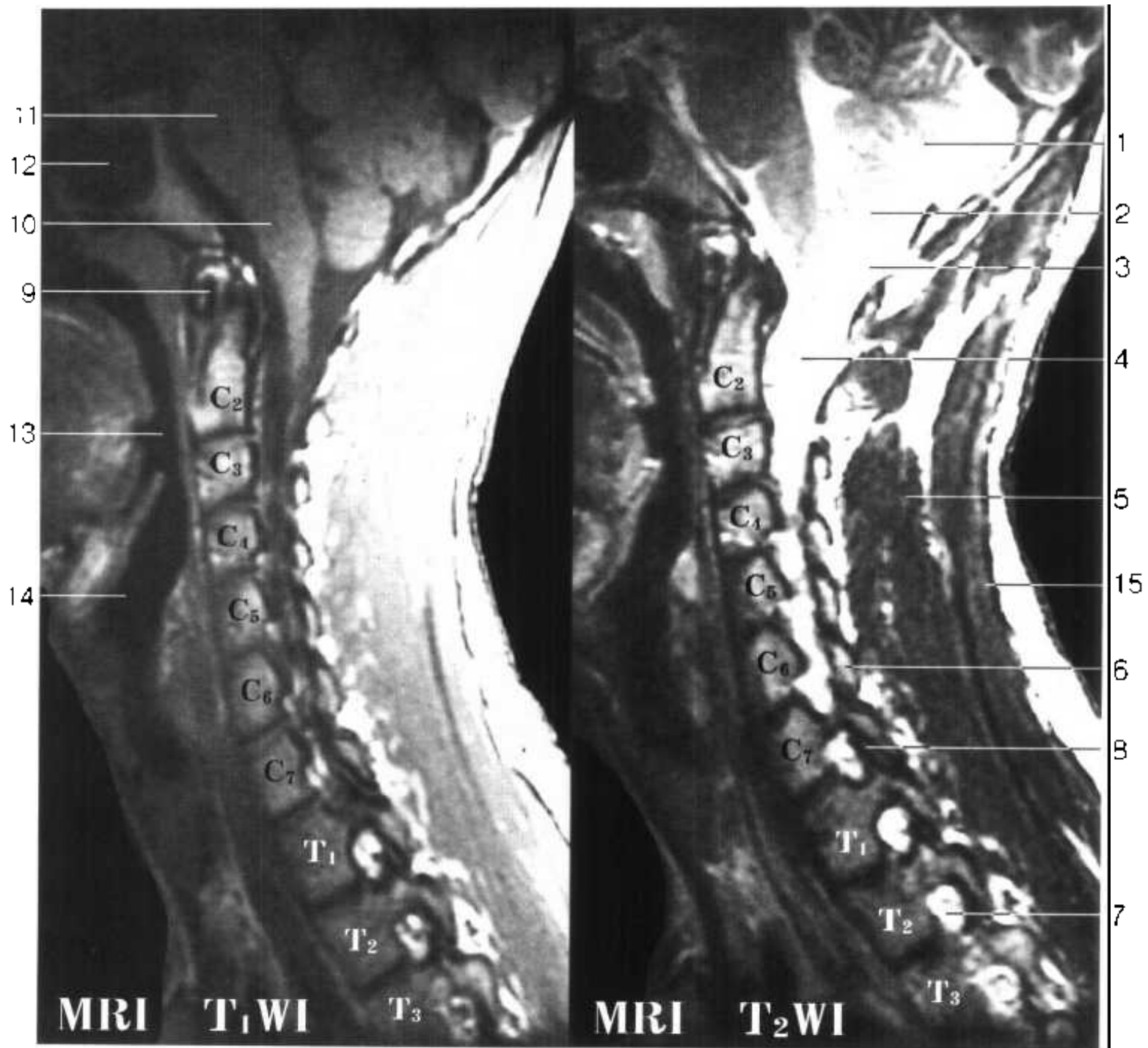


颈椎正中矢状断面图 MSC

- | | |
|---|---------------------------------|
| 1. 小脑 cerebellum | 9. 胸骨柄 manubrium sterni |
| 2. 小脑扁桃体 tonsil of cerebellum | 10. 气管 trachea |
| 3. 小脑延髓池 cerebellomedullary cistern | 11. 枢椎齿突 dens of axis |
| 4. 寰椎后弓 posterior arch of atlas | 12. 寰椎前弓 anterior arch of atlas |
| 5. 脊髓 spinal cord | 13. 延髓 medulla oblongata |
| 6. 第7颈椎棘突 spinal process(C ₇) | 14. 脑桥 pons |
| 7. 6、7颈椎间盘 intervertebral disc (C ₆ ~ C ₇) | 15. 蝶窦 sphenoidal sinus |
| 8. 脊髓 spinal cord | 16. 喉腔 laryngeal cavity |
| | 17. 咽腔 cavity of pharynx |

Fig. MSC

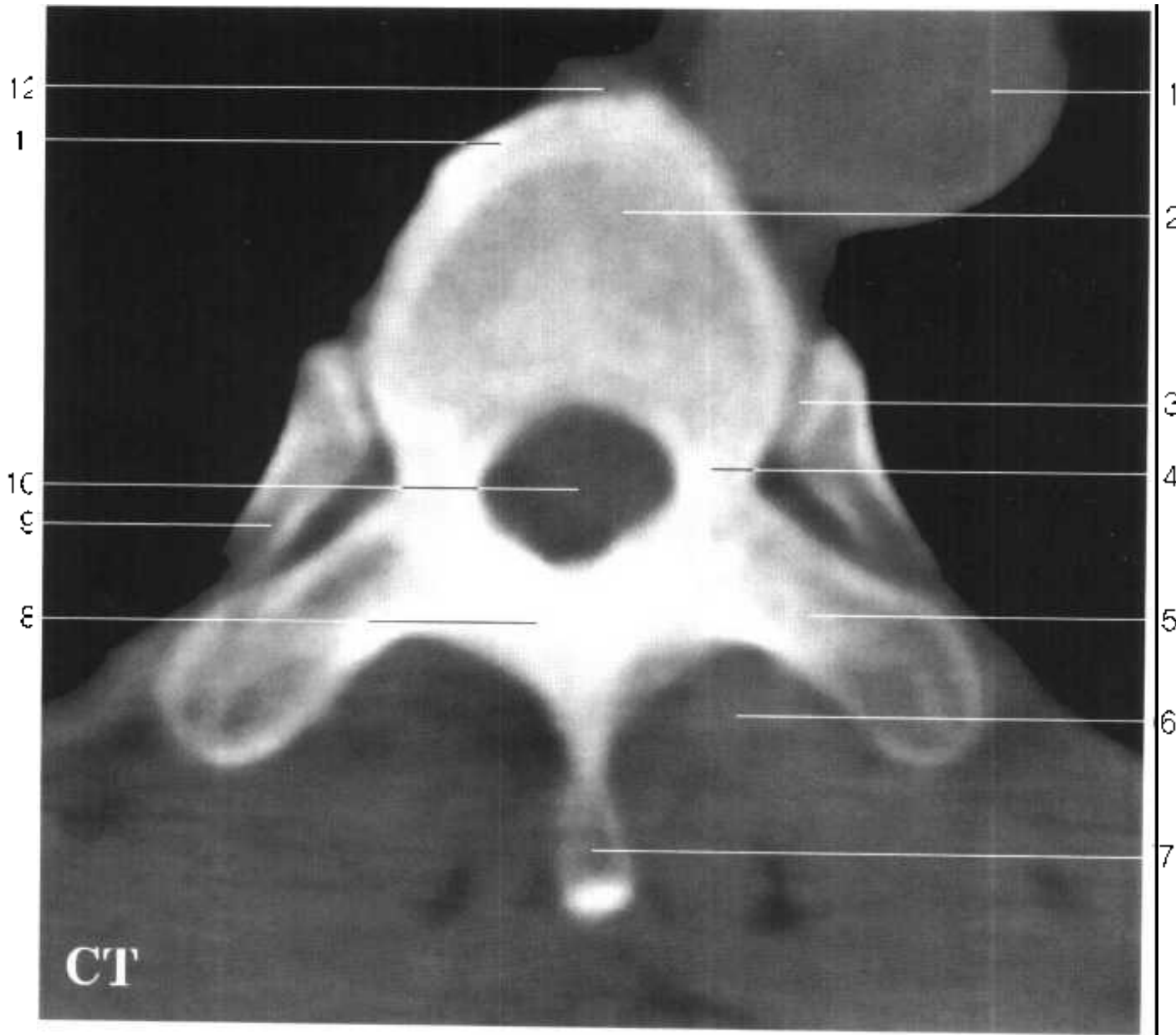
428



颈椎旁正中矢状断面图 PSC

- | | |
|-------------------------------------|--------------------------------|
| 1. 小脑 cerebellum | 9. 寰椎前弓 anterior arch of atlas |
| 2. 小脑扁桃 tonsil of cerebellum | 10. 延髓 medulla oblongata |
| 3. 小脑延髓池 cerebellomedullary cistern | 11. 脑桥 pons |
| 4. 椎管 vertebral canal | 12. 蝶窦 sphenoidal sinus |
| 5. 竖脊肌 erector spinae | 13. 咽 pharynx |
| 6. 椎弓 vertebral arch | 14. 喉 larynx |
| 7. 椎间孔 intervertebral foramen | 15. 斜方肌 trapezius |
| 8. 颈神经 cervical n. | |

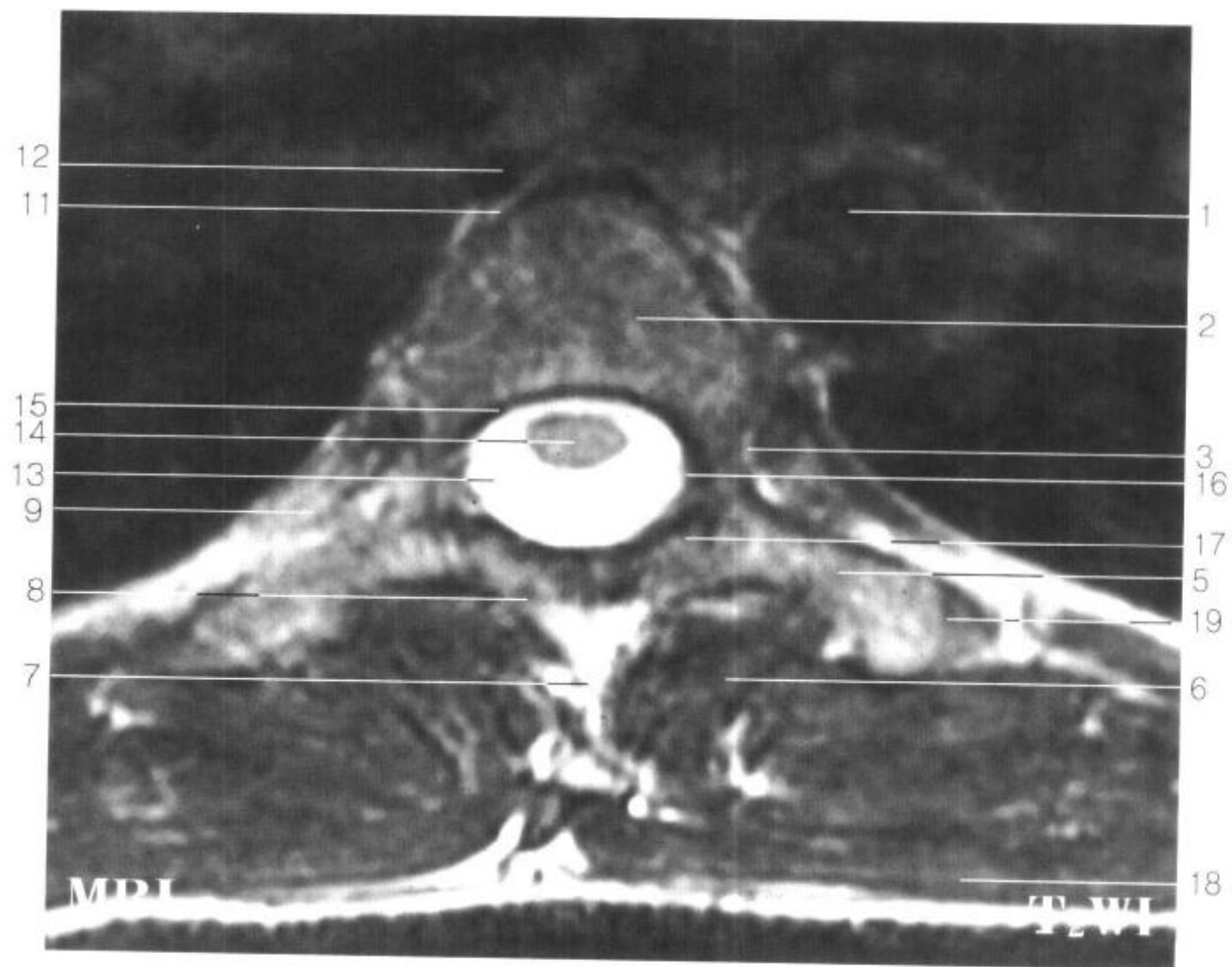
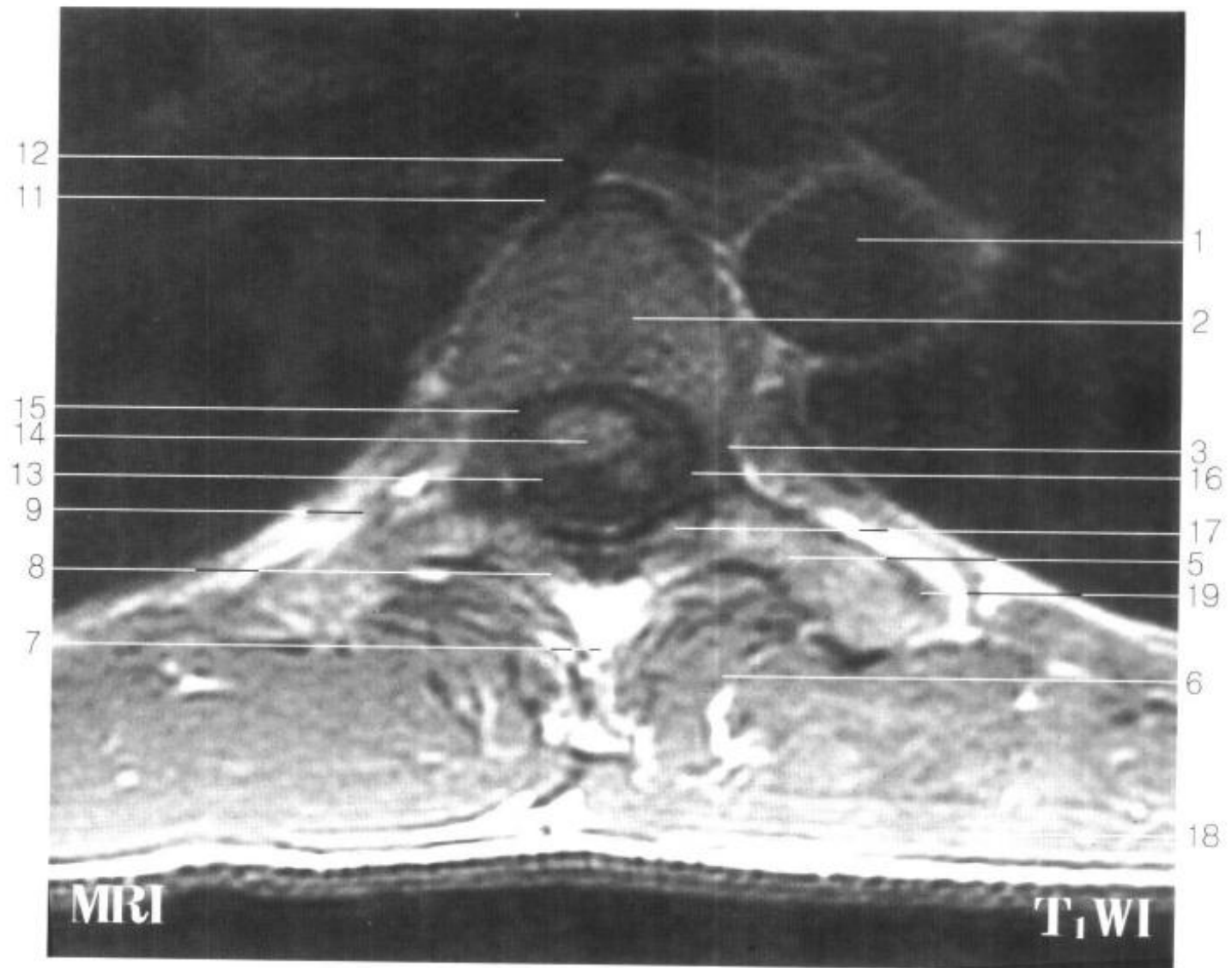
Fig. PSC

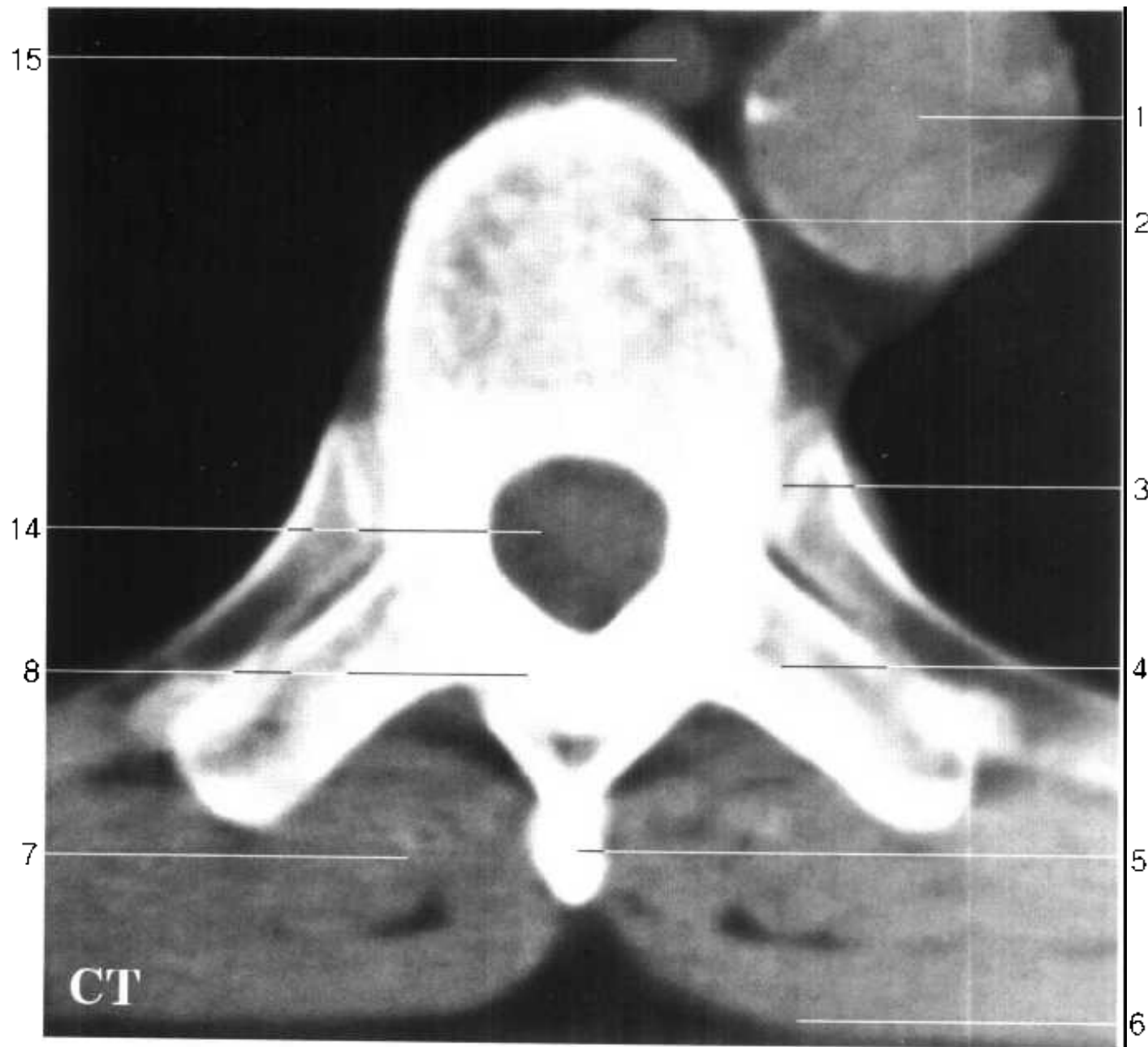


第5胸椎水平断面图 HT₅

- | | |
|----------------------------------|---|
| 1. 胸主动脉 thoracic aorta | 11. 前纵韧带 anterior longitudinal ligament |
| 2. 椎体 vertebral body | 12. 奇静脉 azygos v. |
| 3. 肋头关节 joint of costal head | 13. 蛛网膜下隙 subarachnoid space |
| 4. 椎弓根 pedicle of vertebral arch | 14. 脊髓 spinal cord |
| 5. 横突 transverse process | 15. 硬膜外隙 epidural space |
| 6. 竖脊肌 erector spinae | 16. 硬脊膜 spinal dura mater |
| 7. 棘突 spinous process | 17. 黄韧带 ligamenta flava |
| 8. 椎弓板 lamina of vertebral arch | 18. 斜方肌 trapezius |
| 9. 肋骨 costal bone | 19. 肋横突关节 costotransverse joint |
| 10. 椎管 vertebral canal | |

Fig. HT₅

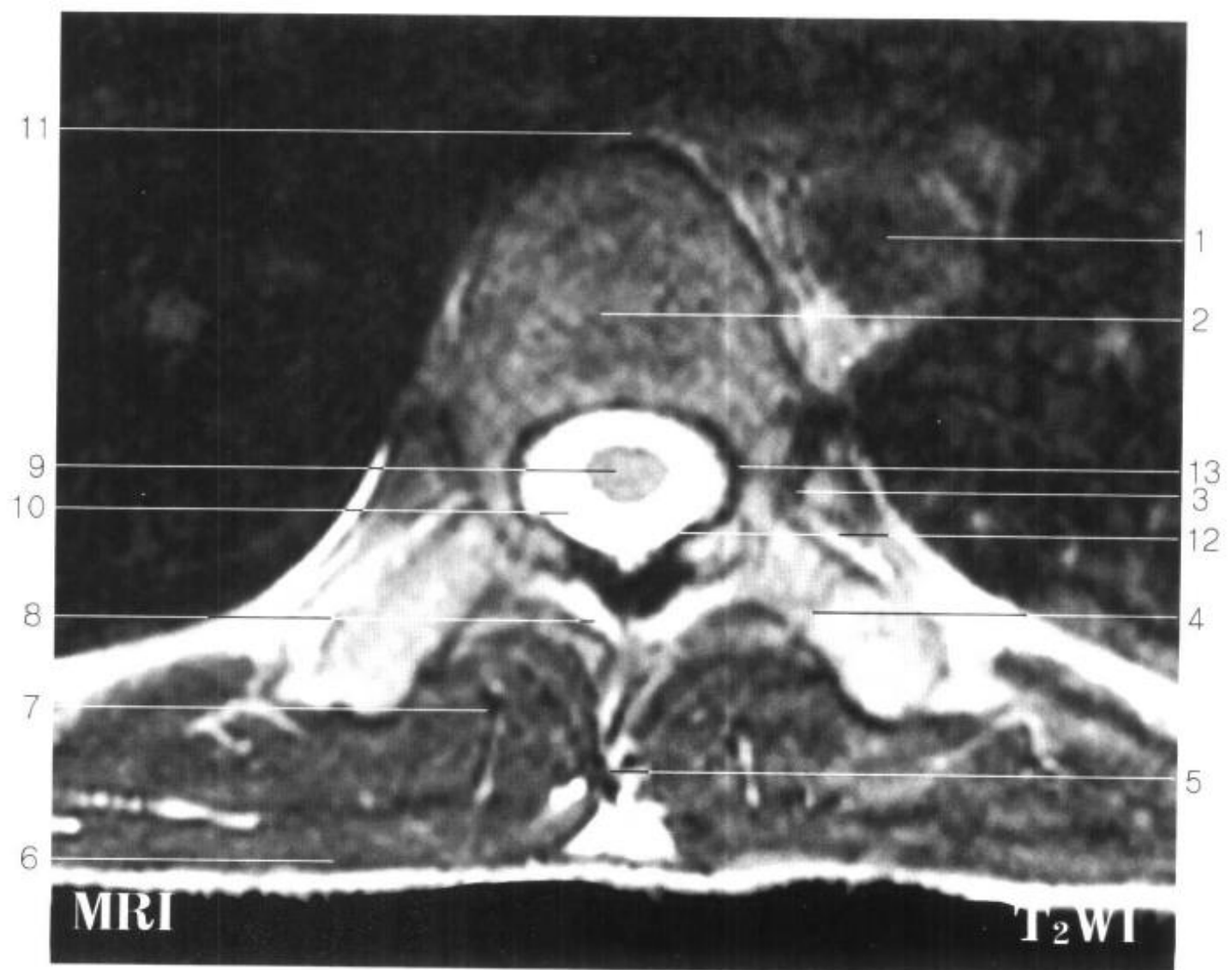
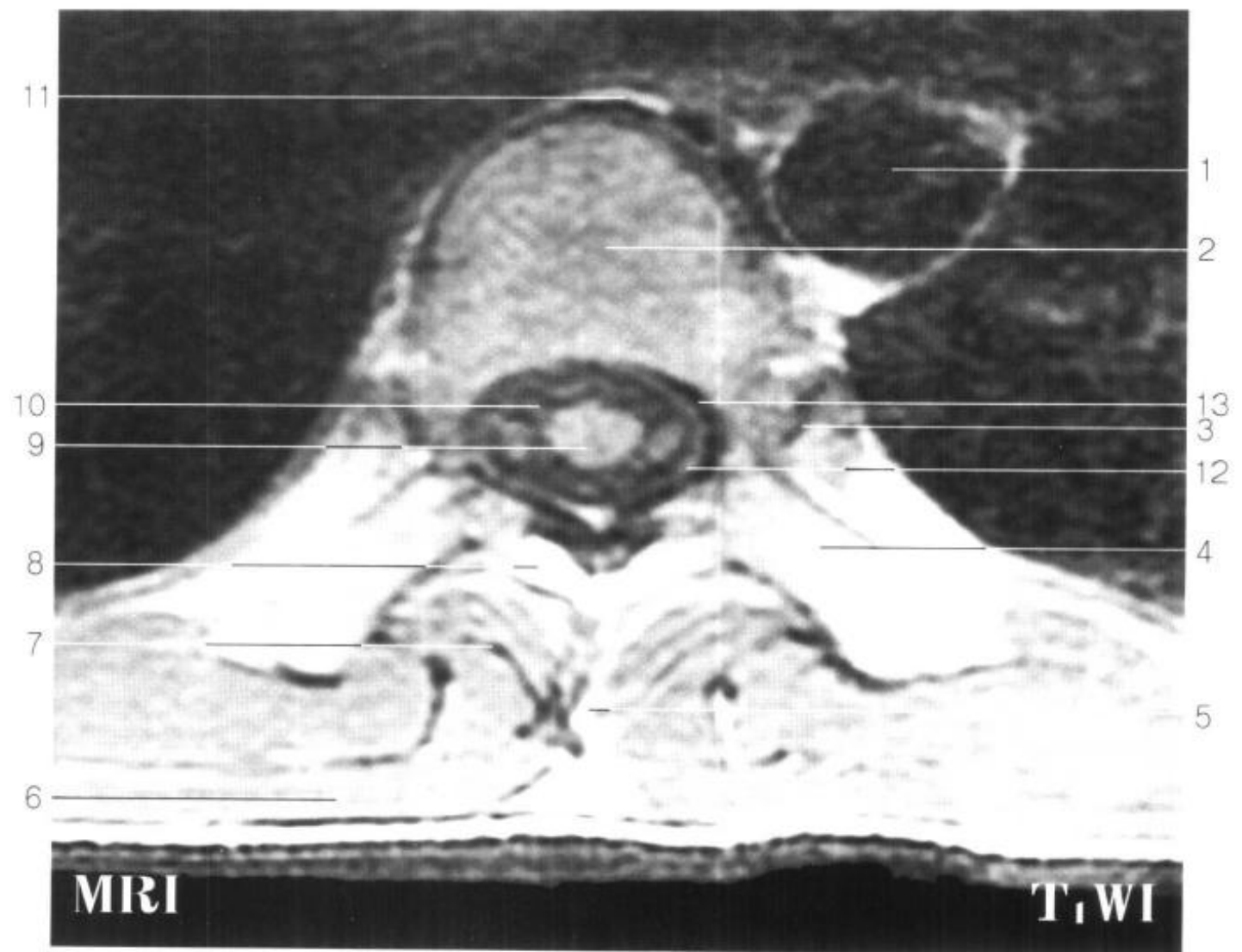


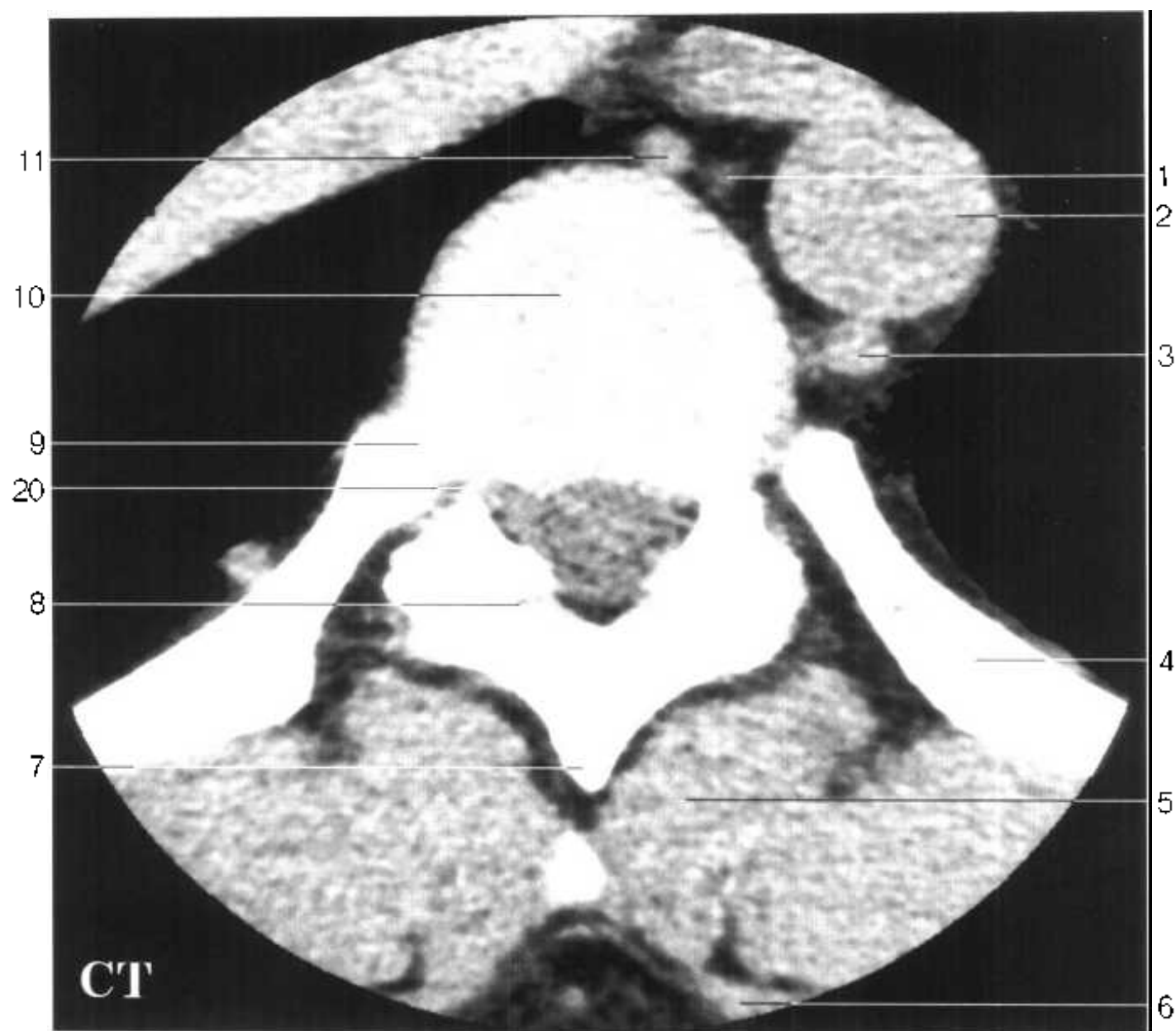


第8胸椎水平断面图 HT₈

- | | |
|---------------------------------|---|
| 1. 胸主动脉 thoracic aorta | 9. 脊髓 spinal cord |
| 2. 椎体 vertebral body | 10. 蛛网膜下隙 subarachnoid space |
| 3. 肋头关节 joint of costal head | 11. 前纵韧带 anterior longitudinal ligament |
| 4. 横突 transverse process | 12. 硬脊膜 spinal dura mater |
| 5. 棘突 spinous process | 13. 硬膜外隙 epidural space |
| 6. 斜方肌 trapezius | 14. 椎管 vertebral canal |
| 7. 竖脊肌 erector spinae | 15. 奇静脉 azygos v. |
| 8. 椎弓板 lamina of vertebral arch | |

Fig. HT₈

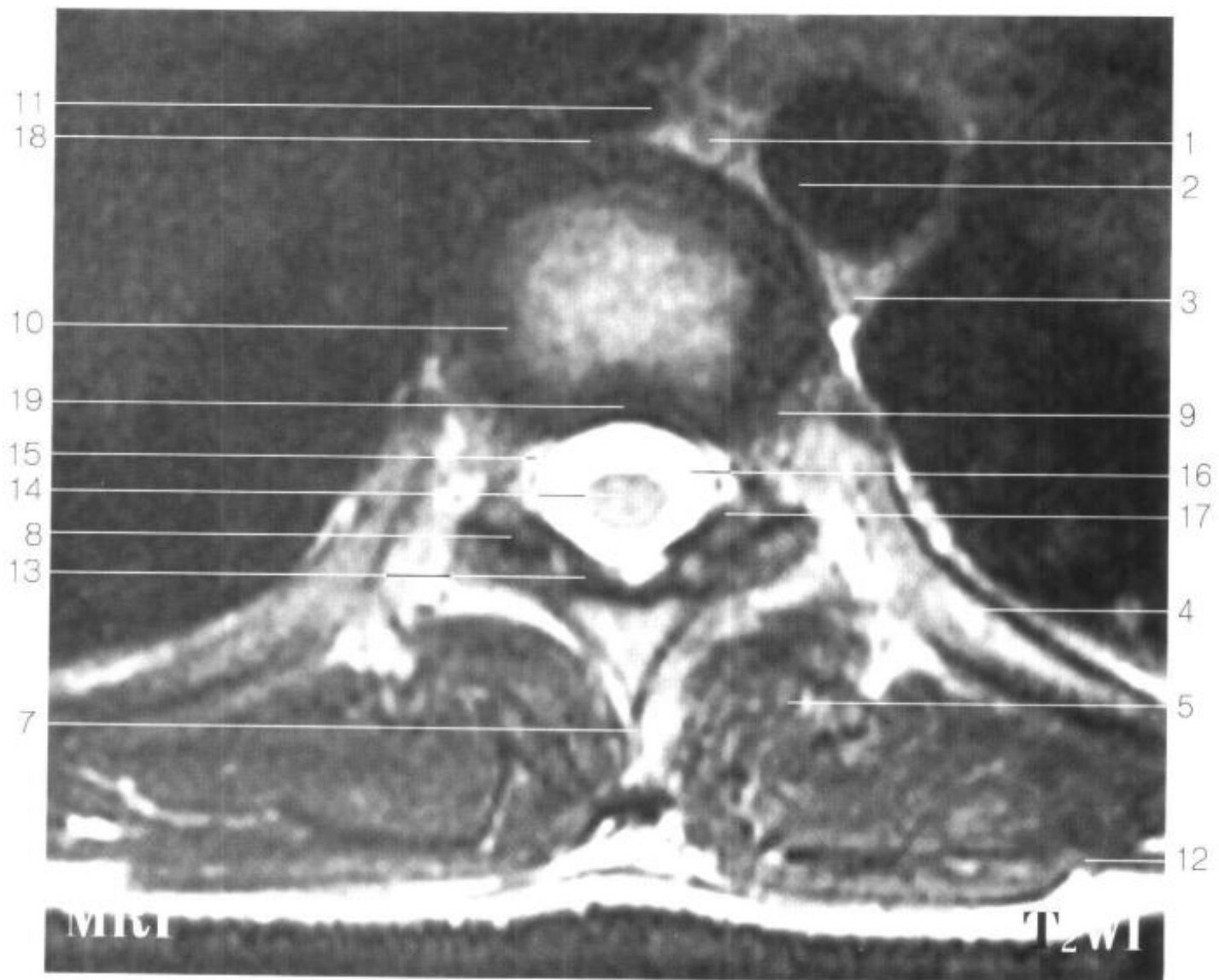
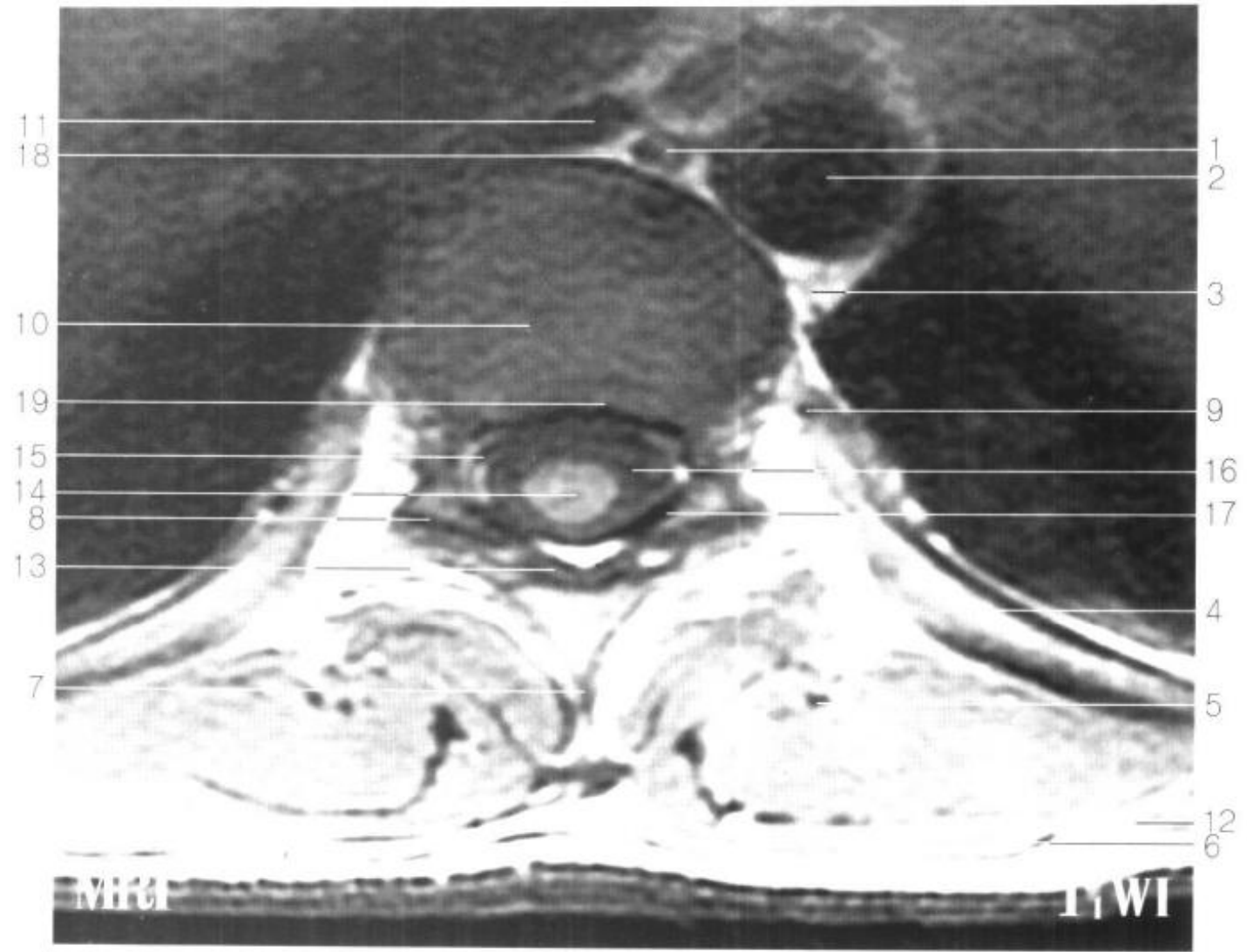


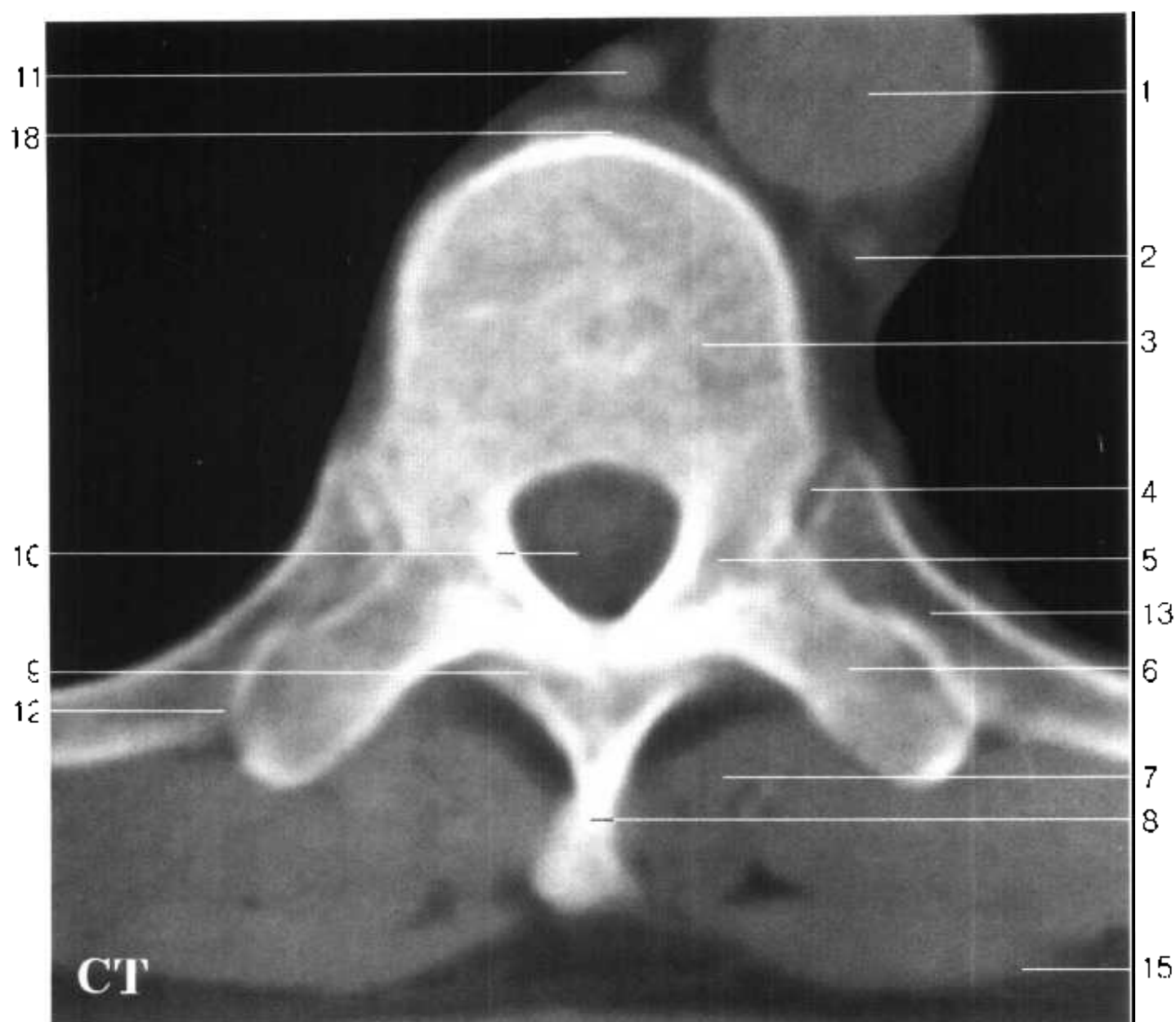

第 9、10 胸椎间盘水平断面图 HT₉₋₁₀

- | | |
|---|--|
| 1. 胸导管 thoracic duct | 11. 奇静脉 azygos v. |
| 2. 胸主动脉 thoracic aorta | 12. 背阔肌 latissimus dorsi |
| 3. 半奇静脉 hemiazygos v. | 13. 黄韧带 ligamenta flava |
| 4. 肋骨 costal bone | 14. 脊髓 spinal cord |
| 5. 竖脊肌 erector spinae | 15. 硬脊膜 spinal dura mater |
| 6. 斜方肌 trapezius | 16. 蛛网膜下隙 subarachnoid space |
| 7. 棘突 spinous process | 17. 硬膜外隙 epidural space |
| 8. 9、10 胸椎关节突关节 zygapophysial joint(T ₉ ~T ₁₀) | 18. 前纵韧带 anterior longitudinal ligament |
| 9. 肋头关节 joint of costal head | 19. 后纵韧带 posterior longitudinal ligament |
| 10. 9、10 胸椎间盘 intervertebral disc(T ₉ ~T ₁₀) | 20. 椎间孔 intervertebral foramen |

Fig. HT₉₋₁₀






第 10 胸椎水平断面图 HT₁₀

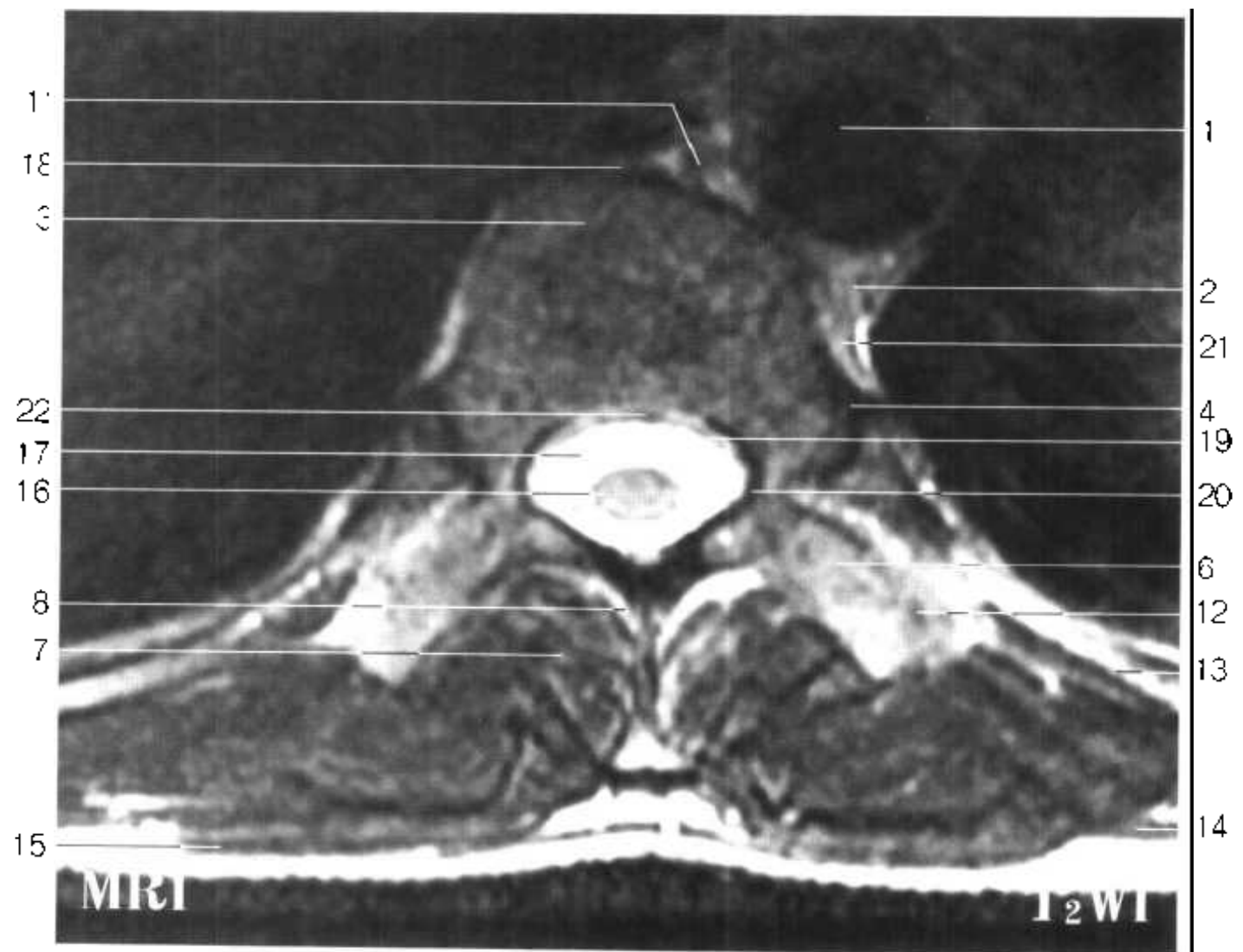
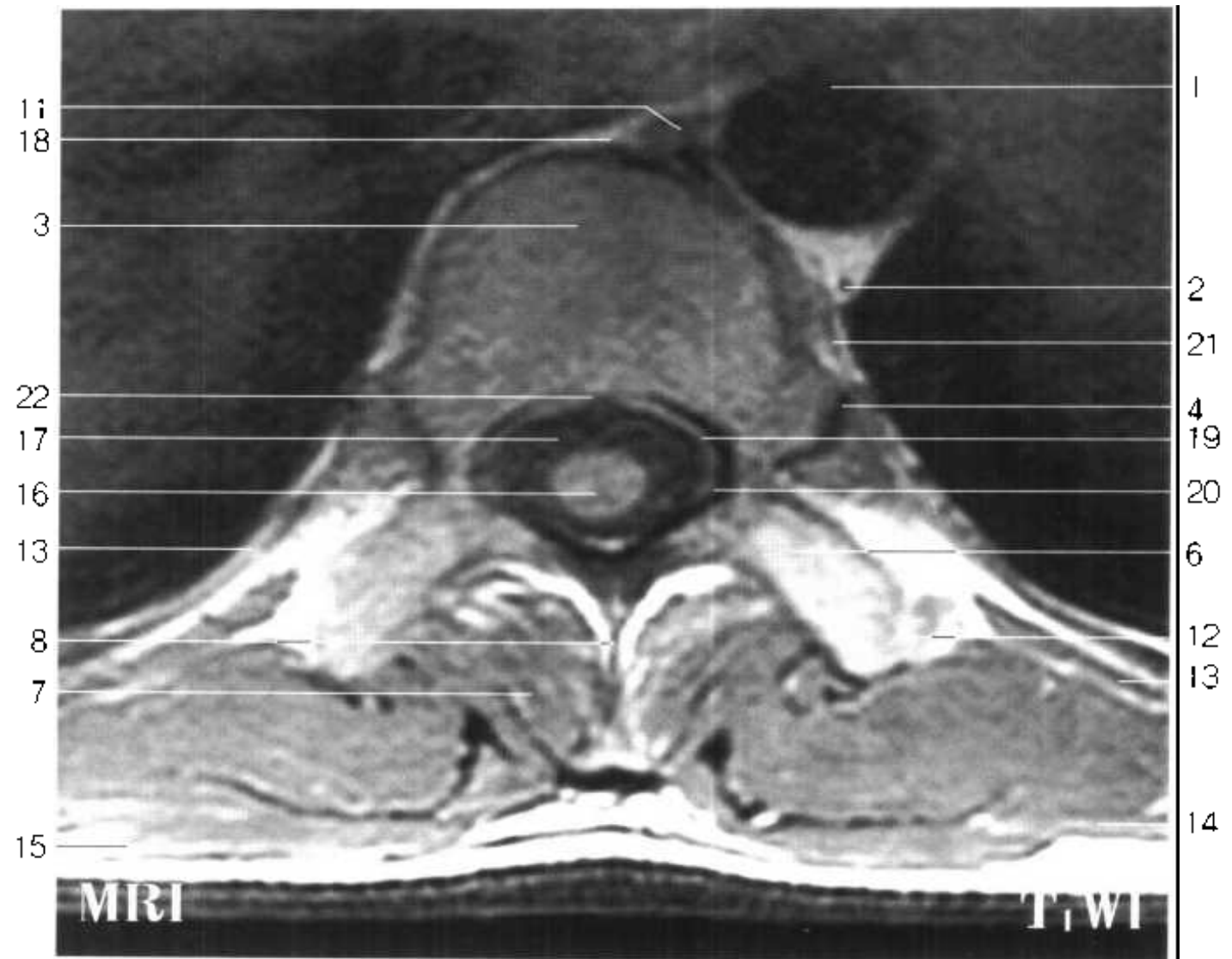
- | | |
|----------------------------------|--|
| 1. 胸主动脉 thoracic aorta | 13. 肋骨 costal bone |
| 2. 半奇静脉 hemiazygos v. | 14. 背阔肌 latissimus dorsi |
| 3. 椎体 vertebral body | 15. 斜方肌 trapezius |
| 4. 肋头关节 joint of costal head | 16. 脊髓 spinal cord |
| 5. 椎弓根 pedicle of vertebral arch | 17. 蛛网膜下隙 subarachnoid space |
| 6. 横突 transverse process | 18. 前纵韧带 anterior longitudinal ligament |
| 7. 竖脊肌 erector spinae | 19. 硬脊膜 spinal dura mater |
| 8. 棘突 spinous process | 20. 硬膜外隙 epidural space |
| 9. 椎弓板 lamina of vertebral arch | 21. 肋间后动脉 posterior intercostal a. |
| 10. 椎管 vertebral canal | 22. 后纵韧带 posterior longitudinal ligament |
| 11. 奇静脉 azygos v. | |
| 12. 肋横突关节 costotransverse joint | |

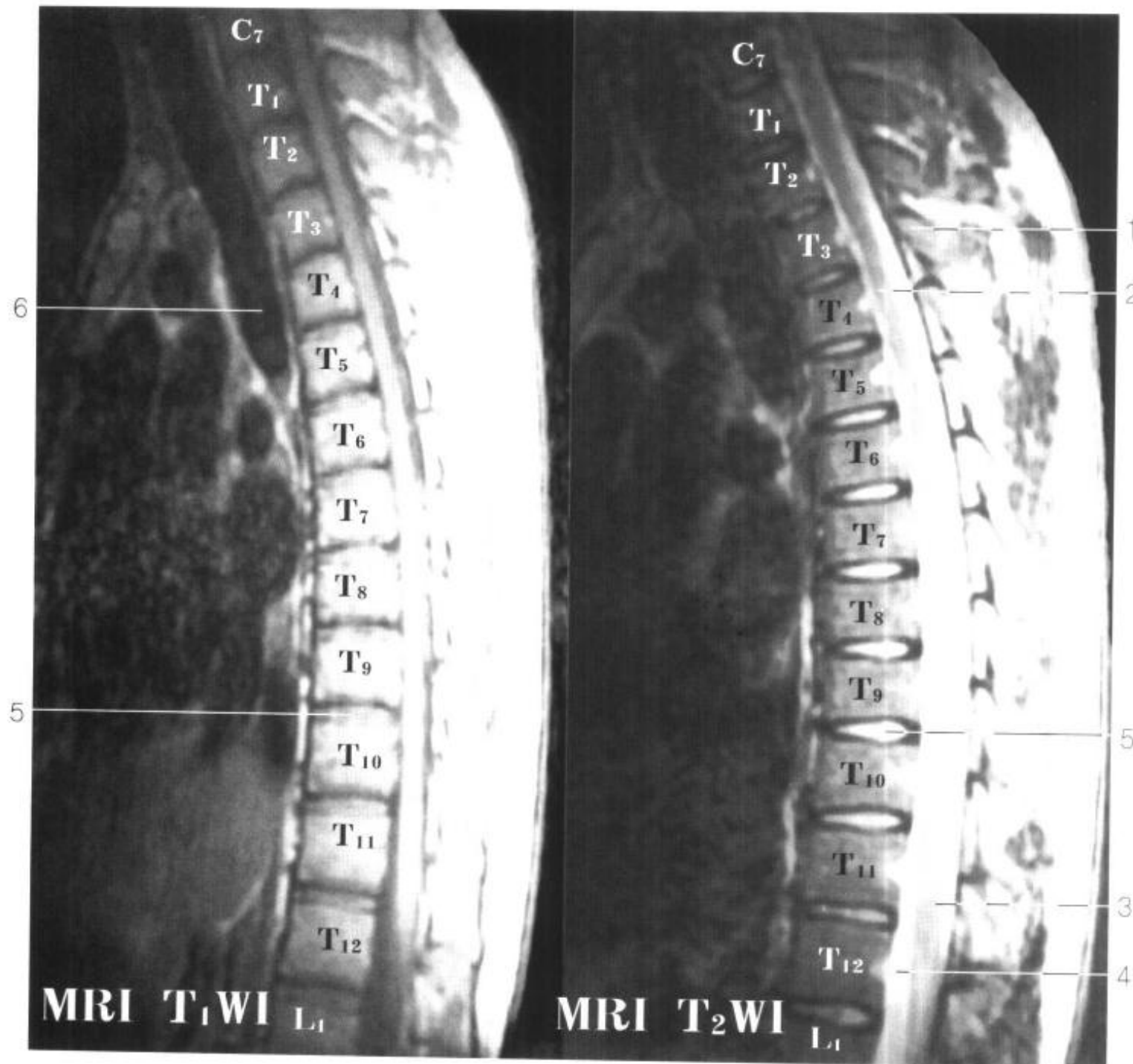
Fig. HT₁₀



脊柱区

VERTEBRAL REGION

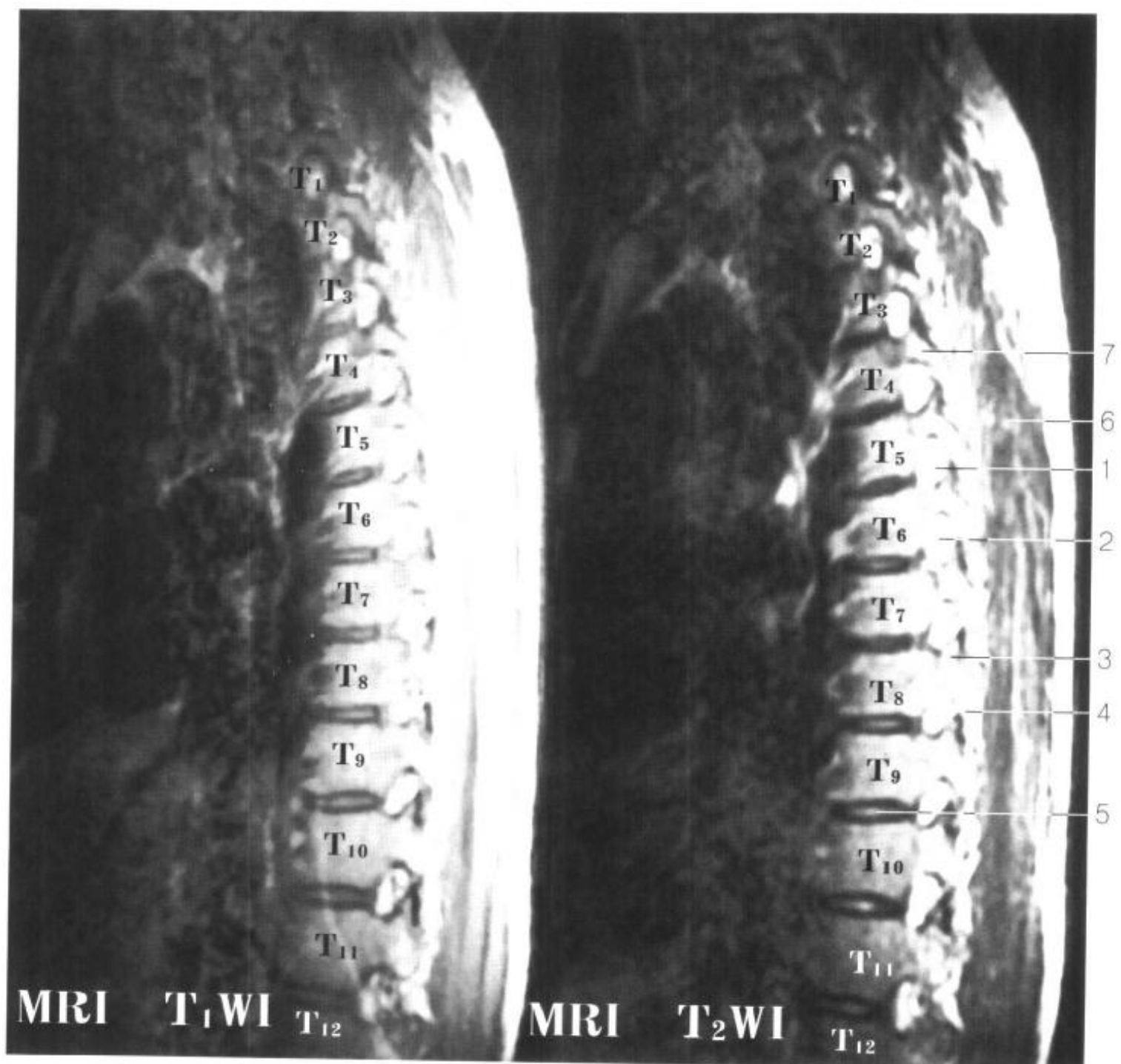




胸椎正中矢状断面图 MST

1. 棘突 spinous process
2. 脊髓 spinal cord
3. 腰骶膨大 lumbosacral enlargement
4. 蛛网膜下隙 subarachnoid space
5. 9、10 胸椎间盘 intervertebral disc(T₉ ~ T₁₀)
6. 气管 trachea

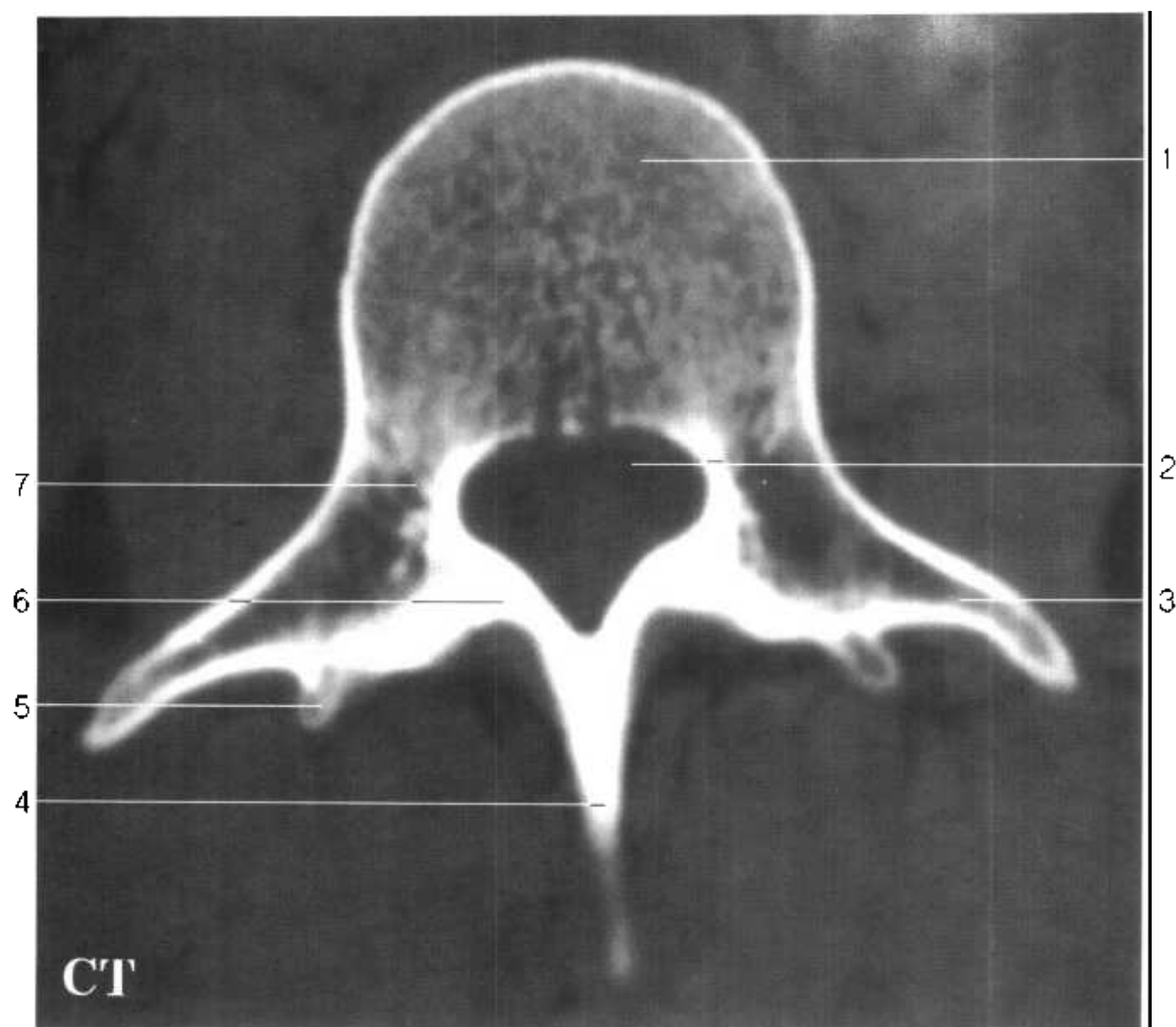
Fig. MST



胸椎旁正中矢状断面图 PST

1. 椎间孔 intervertebral foramen
2. 胸神经 thoracic n.
3. 上关节突 superior articular process
4. 下关节突 inferior articular process
5. 9、10 胸椎间盘 intervertebral disc(T₉~T₁₀)
6. 竖脊肌 erector spinae
7. 椎弓 vertebral arch

Fig. PST

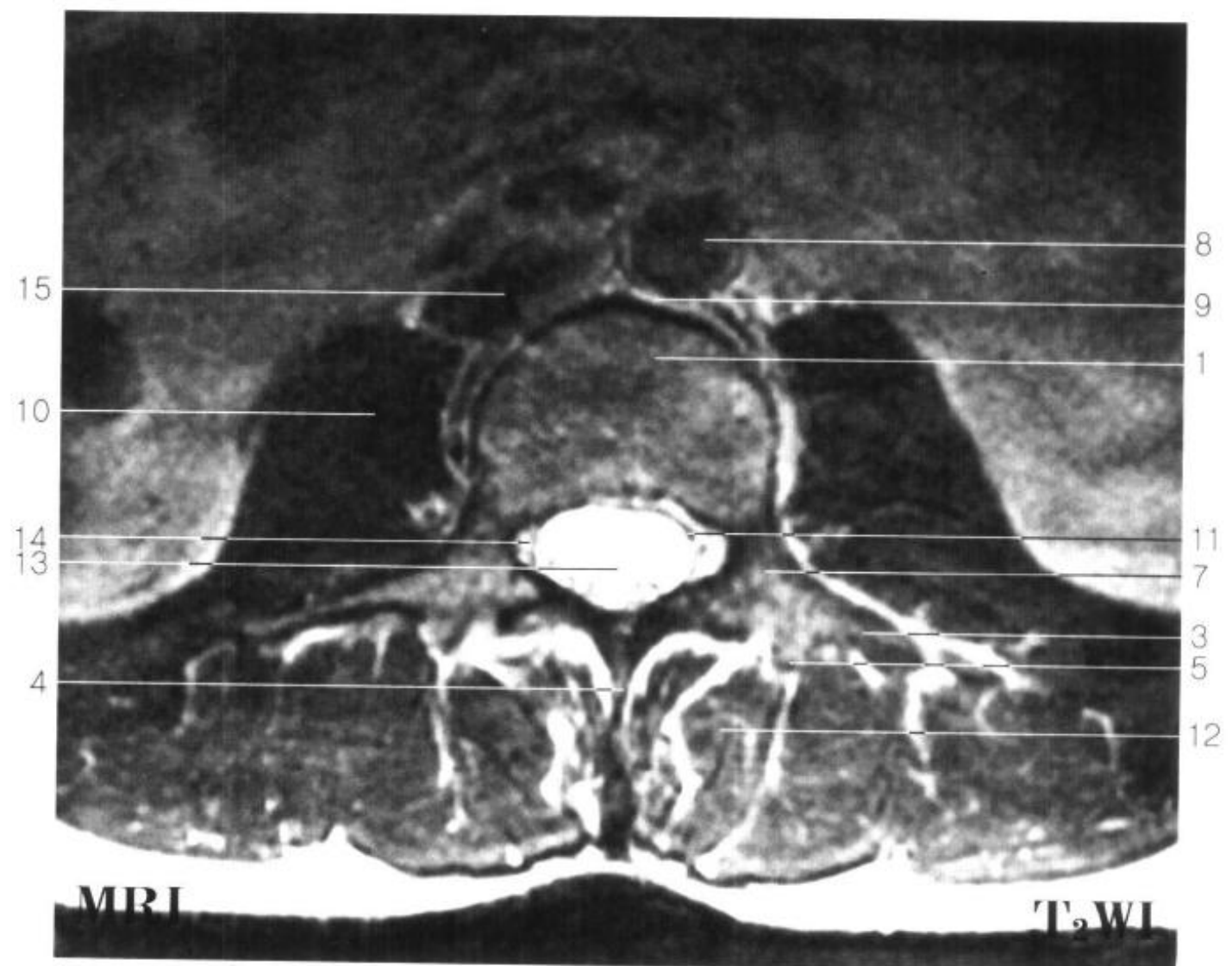
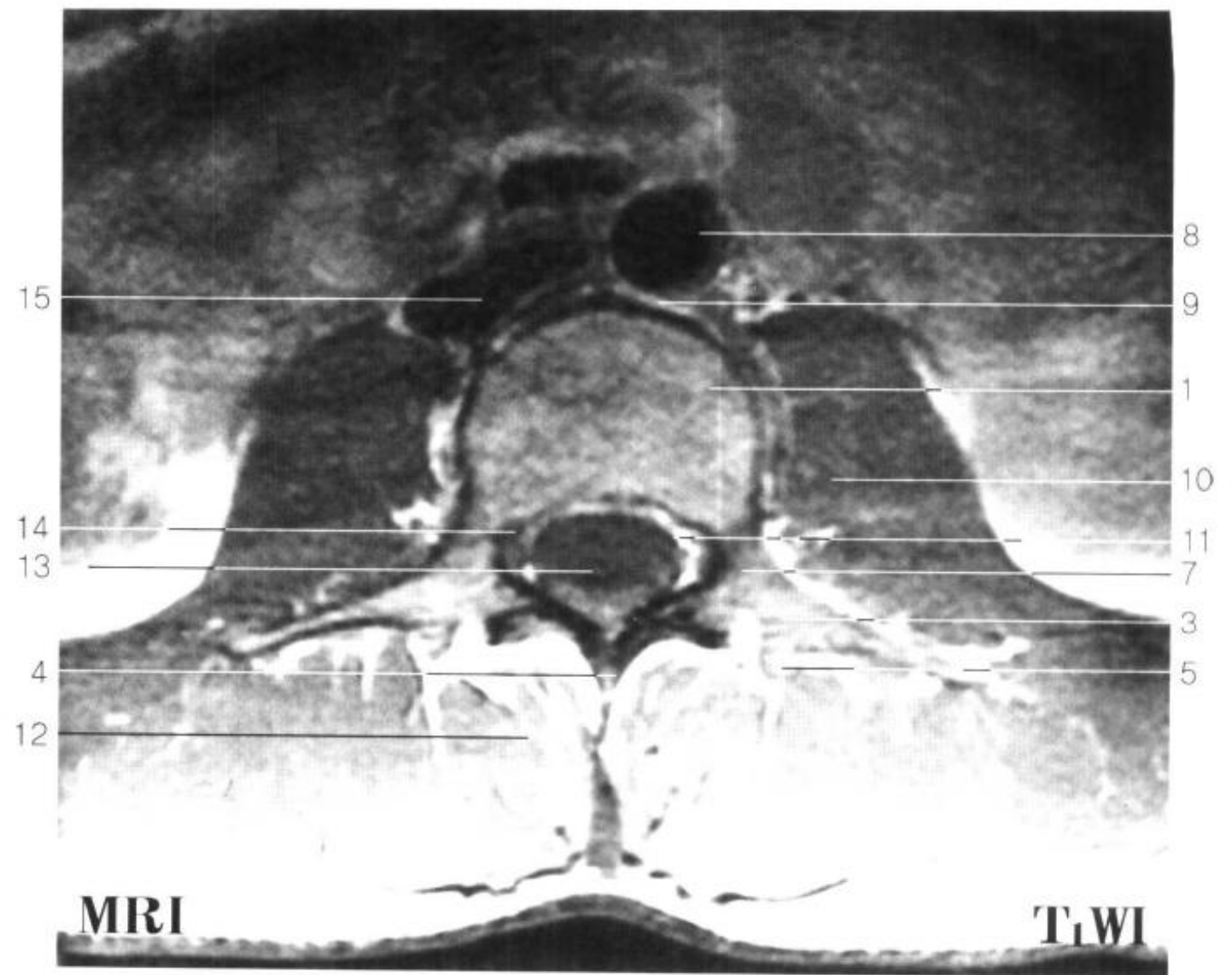


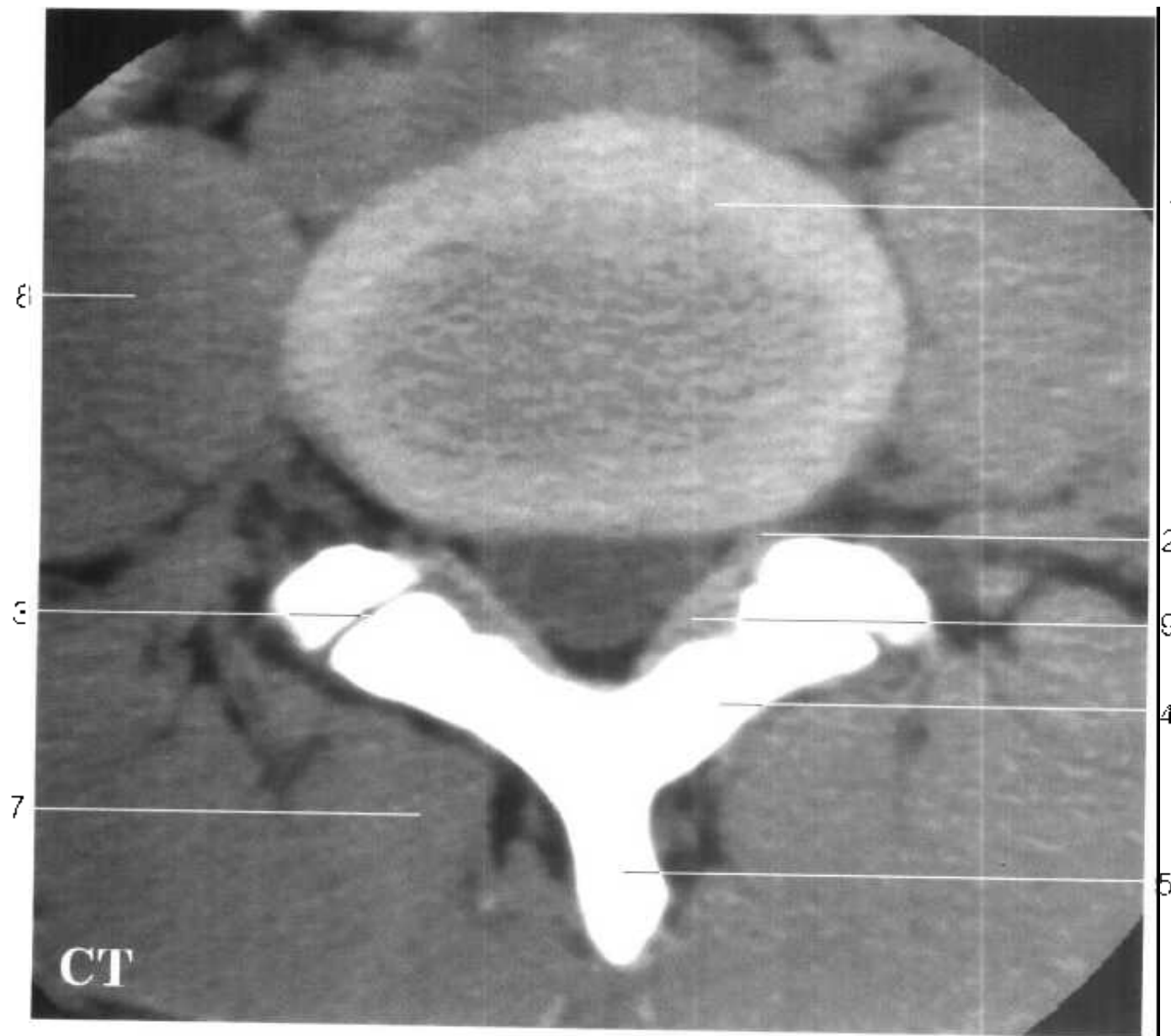
第3腰椎水平断面图 HL₃

- | | |
|------------------------------------|--|
| 1. 椎体 vertebral body | 9. 前纵韧带 anterior longitudinal ligament |
| 2. 椎管 vertebral canal | 10. 腰大肌 psoas major |
| 3. 横突 transverse process | 11. 硬脊膜 spinal dura mater |
| 4. 棘突 spinous process | 12. 竖脊肌 erector spinae |
| 5. 上关节突 superior articular process | 13. 马尾 cauda equina |
| 6. 椎弓板 lamina of vertebral arch | 14. 硬膜外隙 epidural space |
| 7. 椎弓根 pedicle of vertebral arch | 15. 下腔静脉 inferior vena cave |
| 8. 腹主动脉 abdominal aorta | |

Fig. HL₃

图 10-1-1

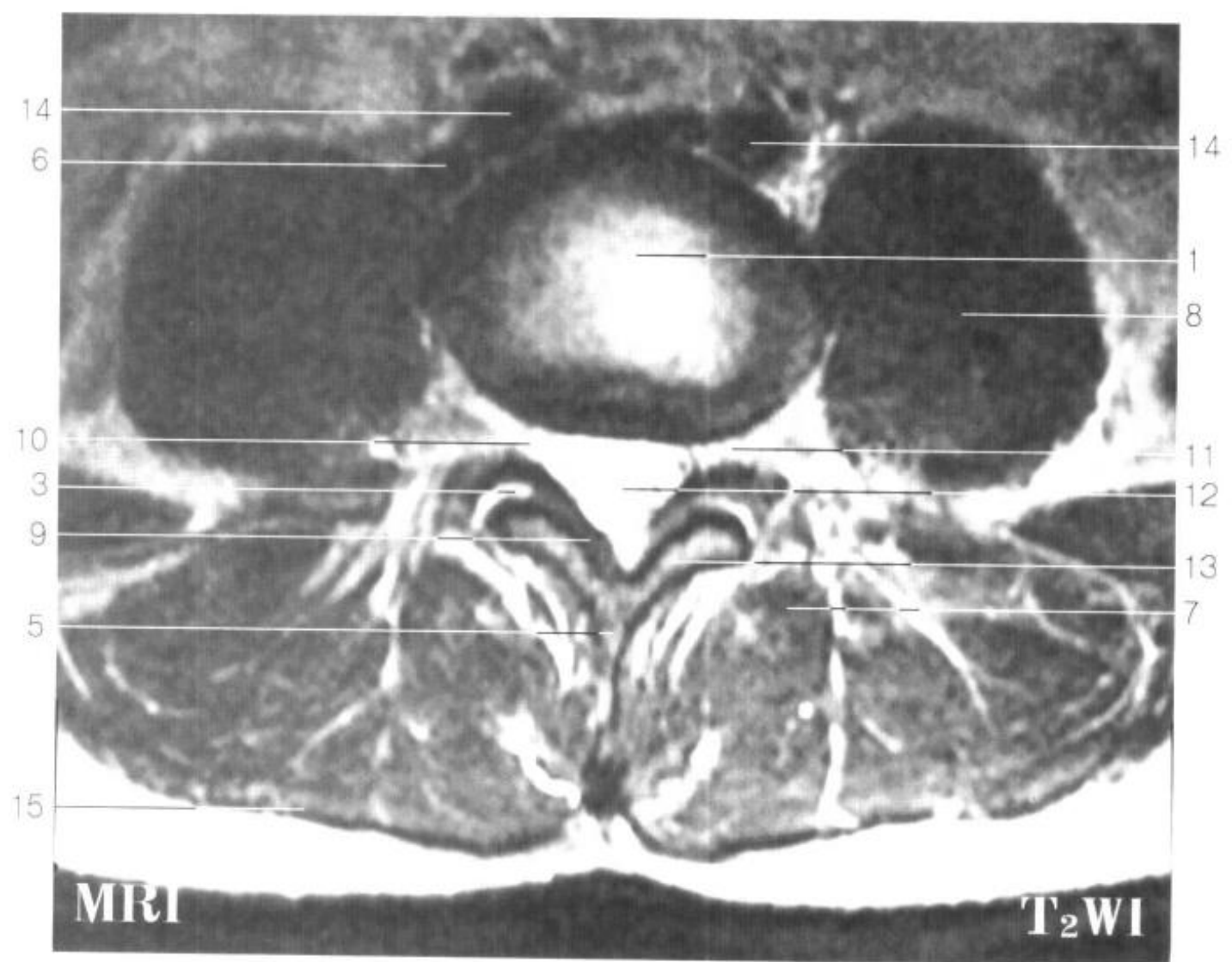
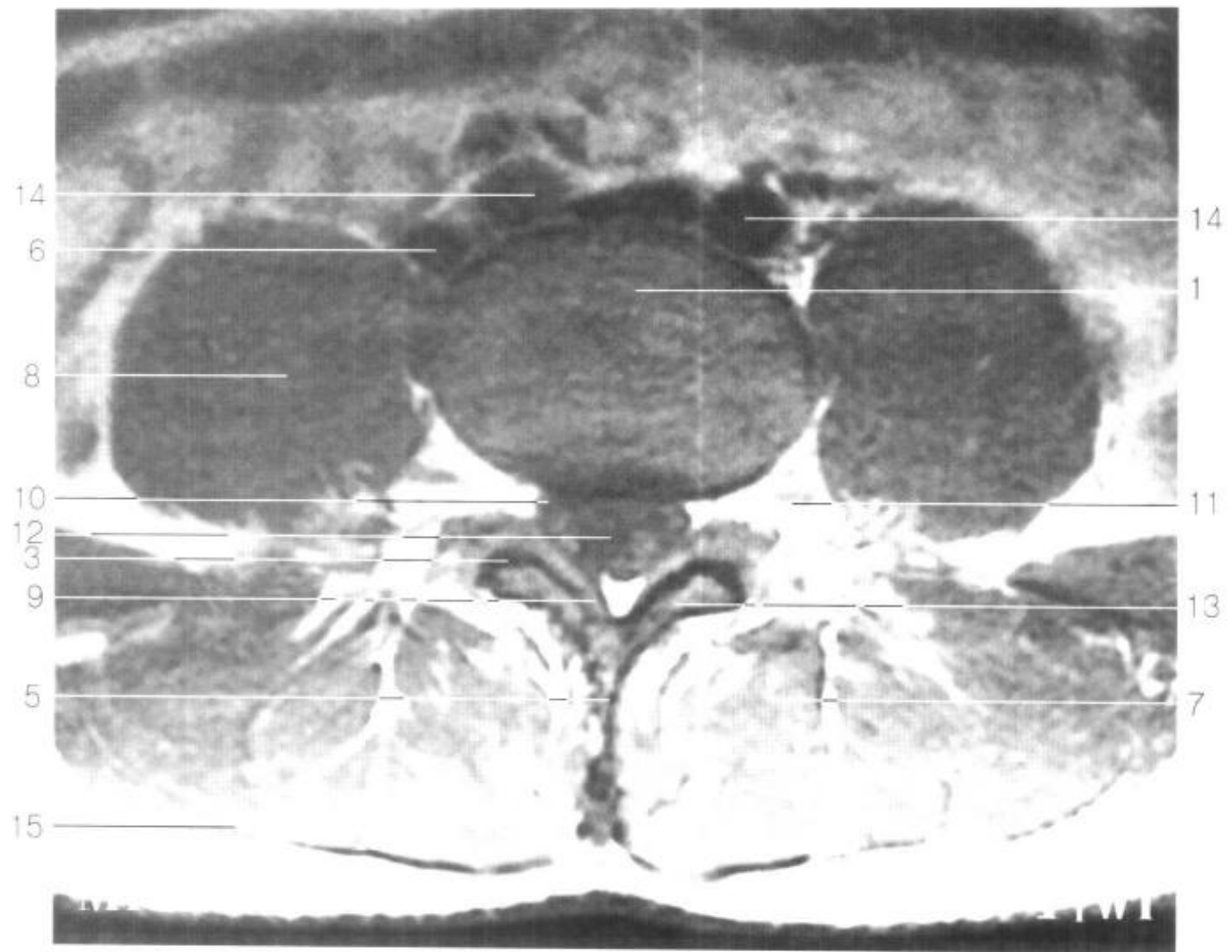


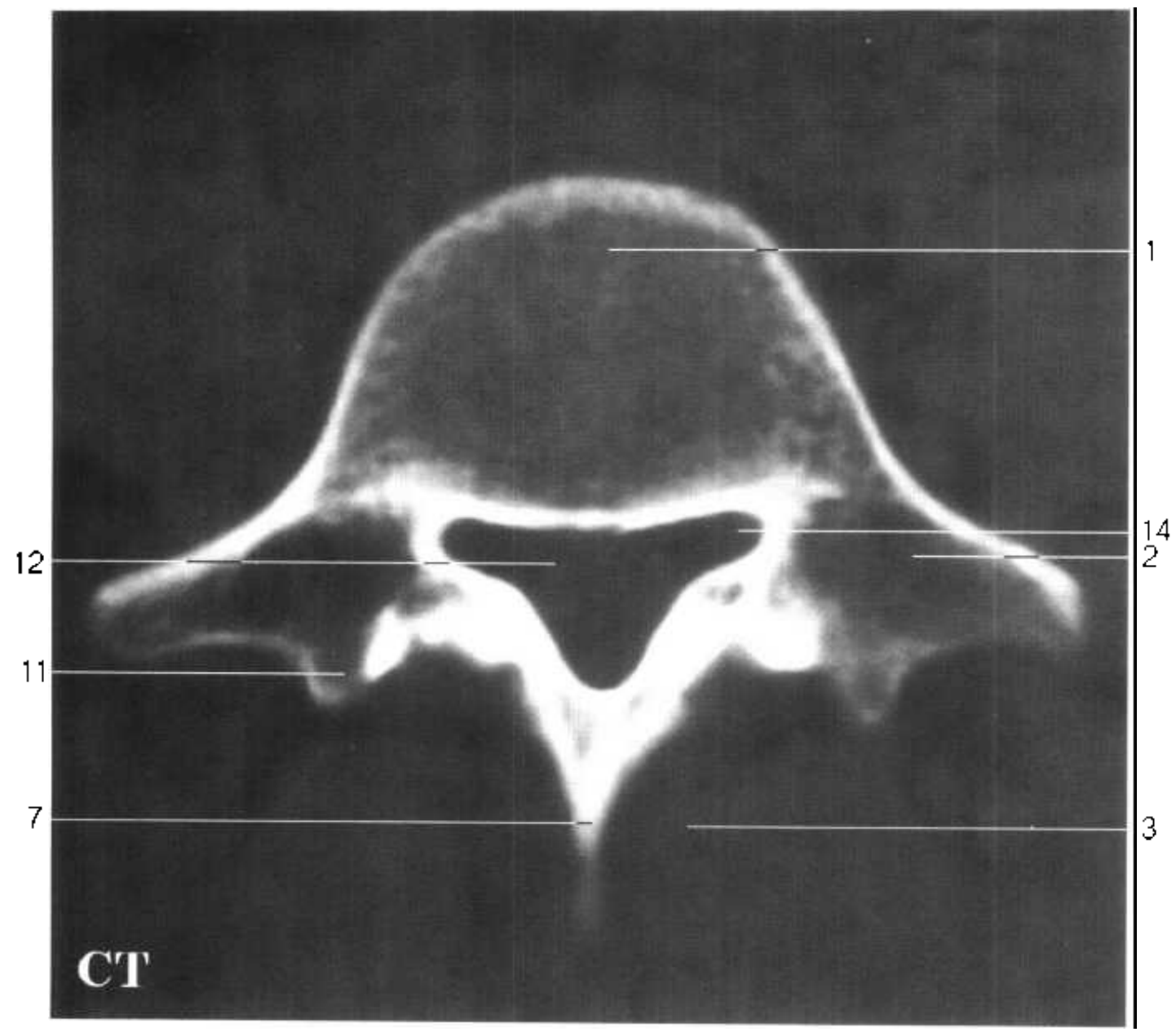


第 4、5 腰椎间盘水平断面图 HL₄₋₅

- | | |
|---|----------------------------------|
| 1. 4、5 腰椎间盘 intervertebral disc(L ₄ ~L ₅) | 8. 腰大肌 psoas major |
| 2. 椎间孔 intervertebral foramen | 9. 黄韧带 ligamenta flava |
| 3. 4、5 腰椎关节突关节 zygapophysial joint(L ₄ ~L ₅) | 10. 硬脊膜 spinal dura mater |
| 4. 椎弓板 lamina of vertebral arch | 11. 脊神经 spinal nerve |
| 5. 棘突 spinous process | 12. 马尾 cauda equina |
| 6. 下腔静脉 inferior vena cava | 13. 椎弓板 lamina of vertebral arch |
| 7. 竖脊肌 erector spinae | 14. 髂总动脉 common iliac a. |
| | 15. 背阔肌 latissimus dorsi |

Fig. HL 4-5

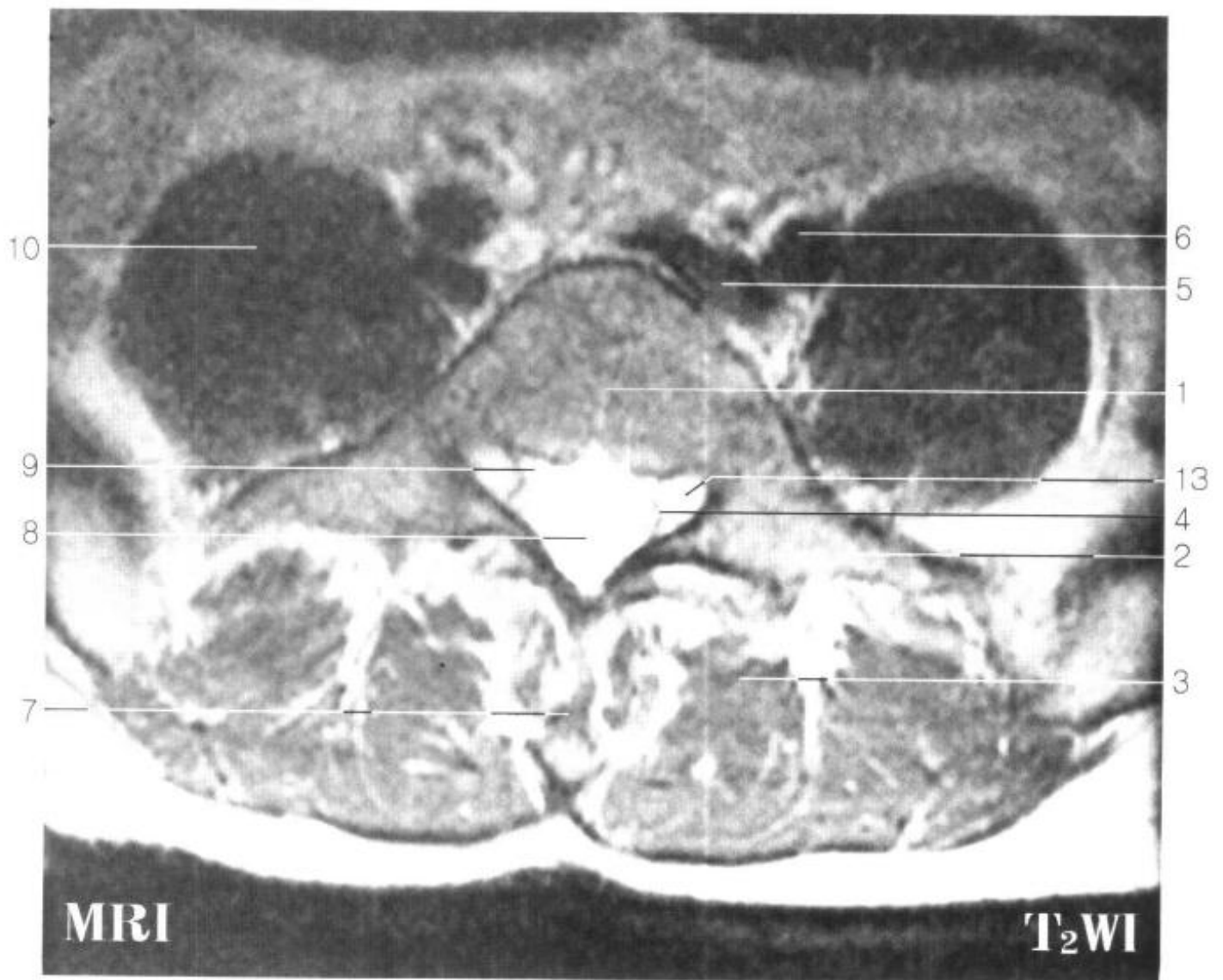
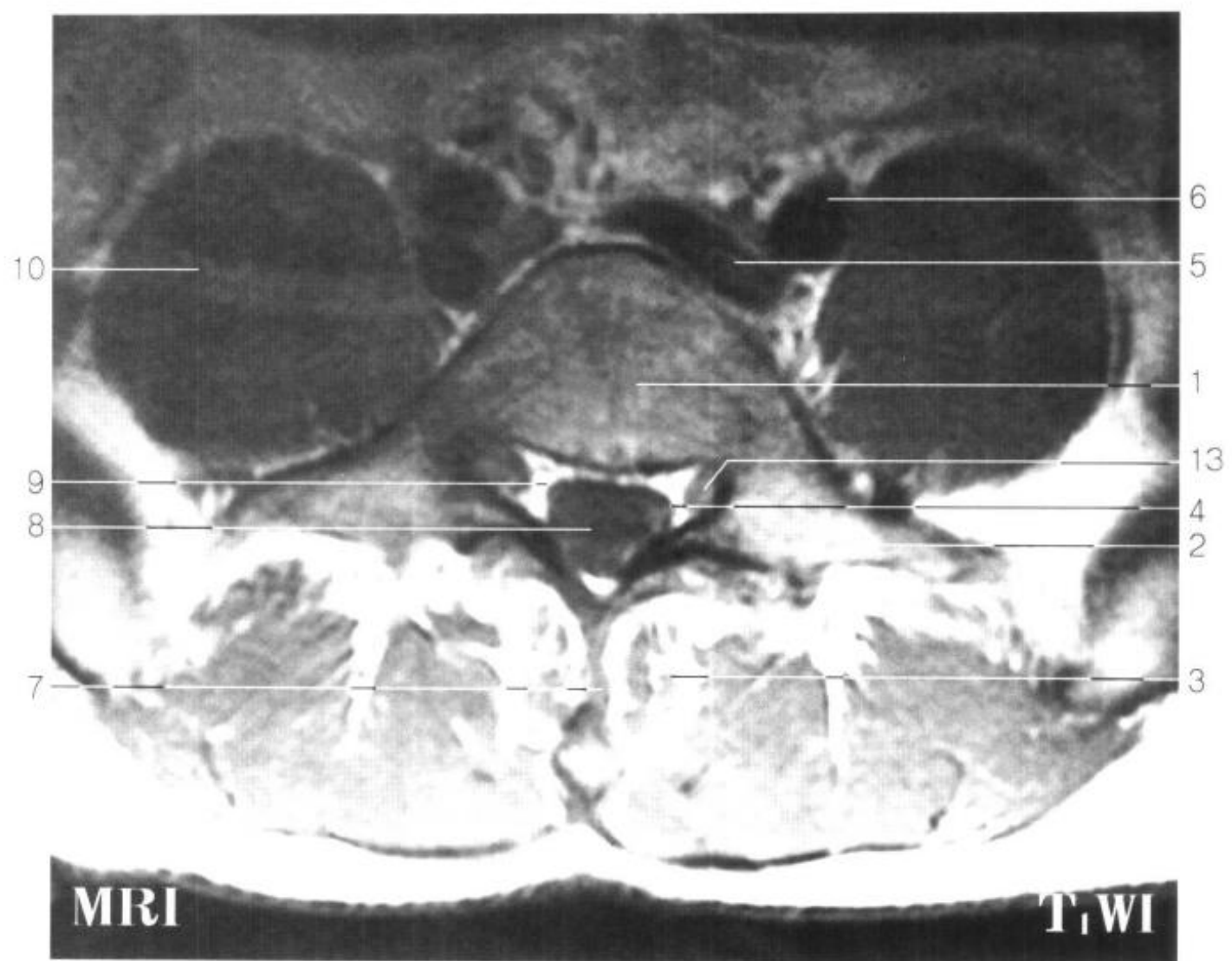


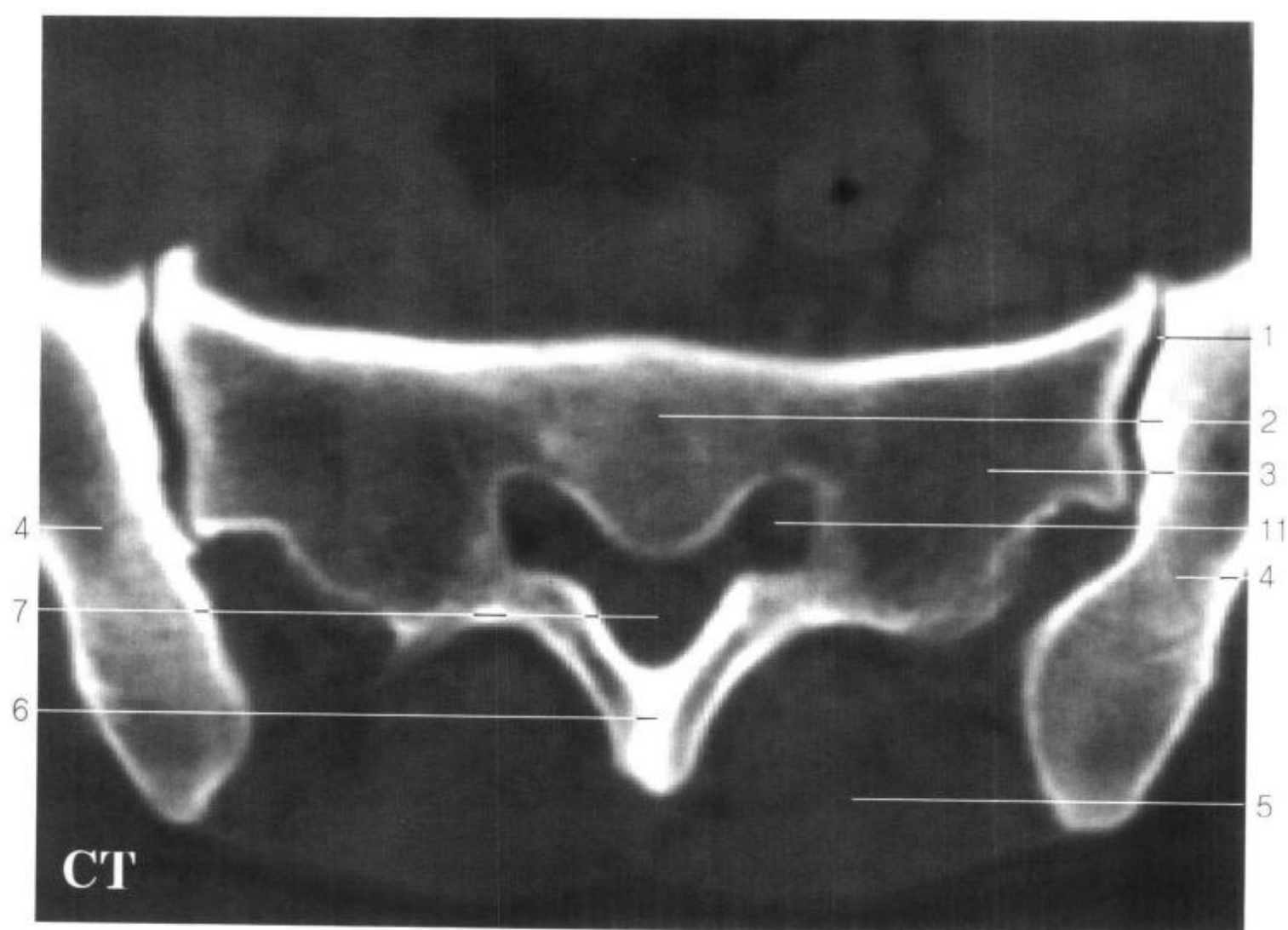


第5腰椎水平断面 HL₅

- | | |
|--------------------------|-------------------------------------|
| 1. 椎体 vertebral body | 8. 马尾 cauda equina |
| 2. 横突 transverse process | 9. 硬膜外隙 epidural space |
| 3. 竖脊肌 erector spinae | 10. 腰大肌 psoas major |
| 4. 硬脊膜 spinal dura mater | 11. 上关节突 superior articular process |
| 5. 髂总静脉 common iliac v. | 12. 椎管 vertebral canal |
| 6. 髂总动脉 common iliac a. | 13. 腰神经 lumbar n. |
| 7. 棘突 spinous process | 14. 外侧隐窝 lateral recess |

Fig. HL₅

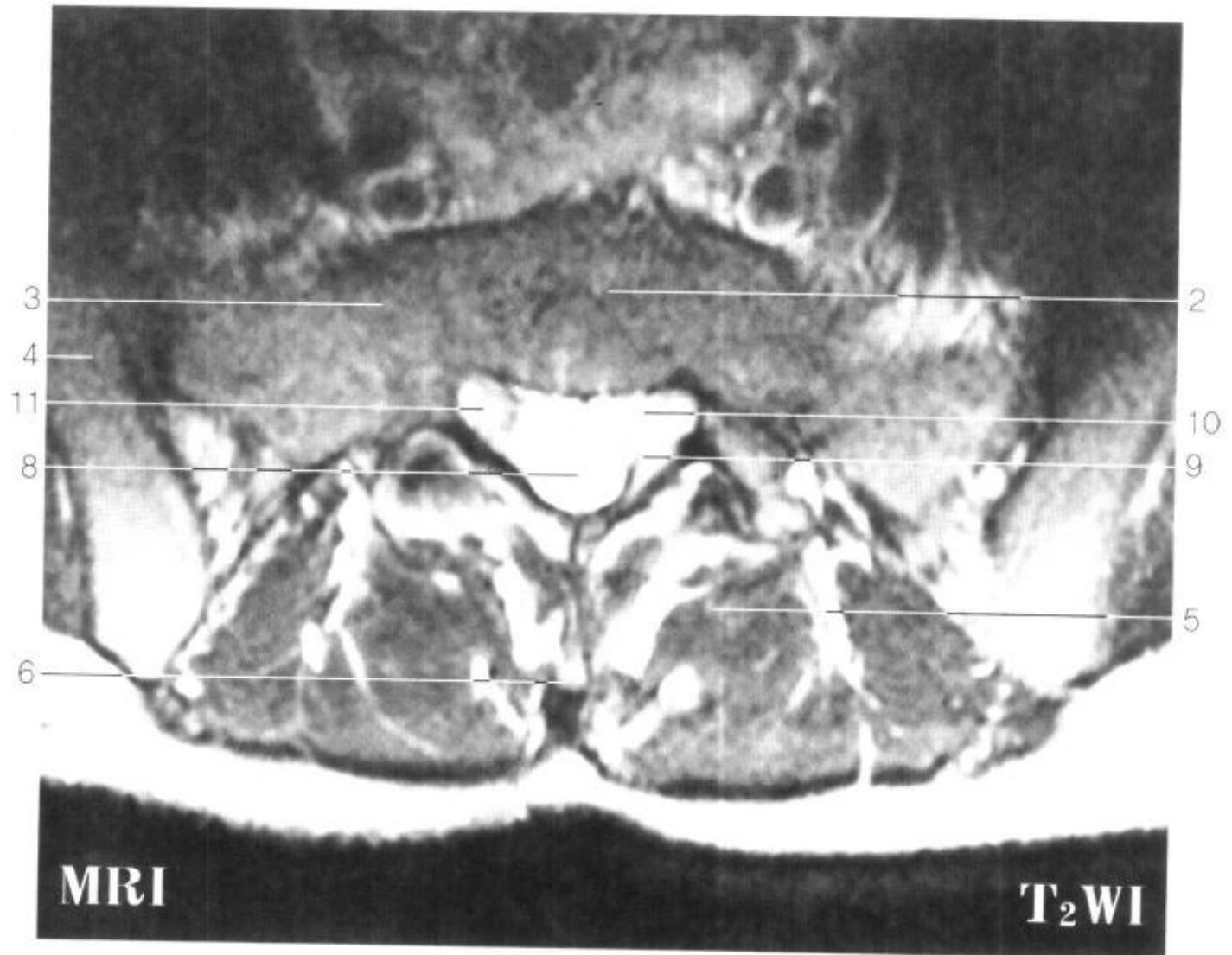
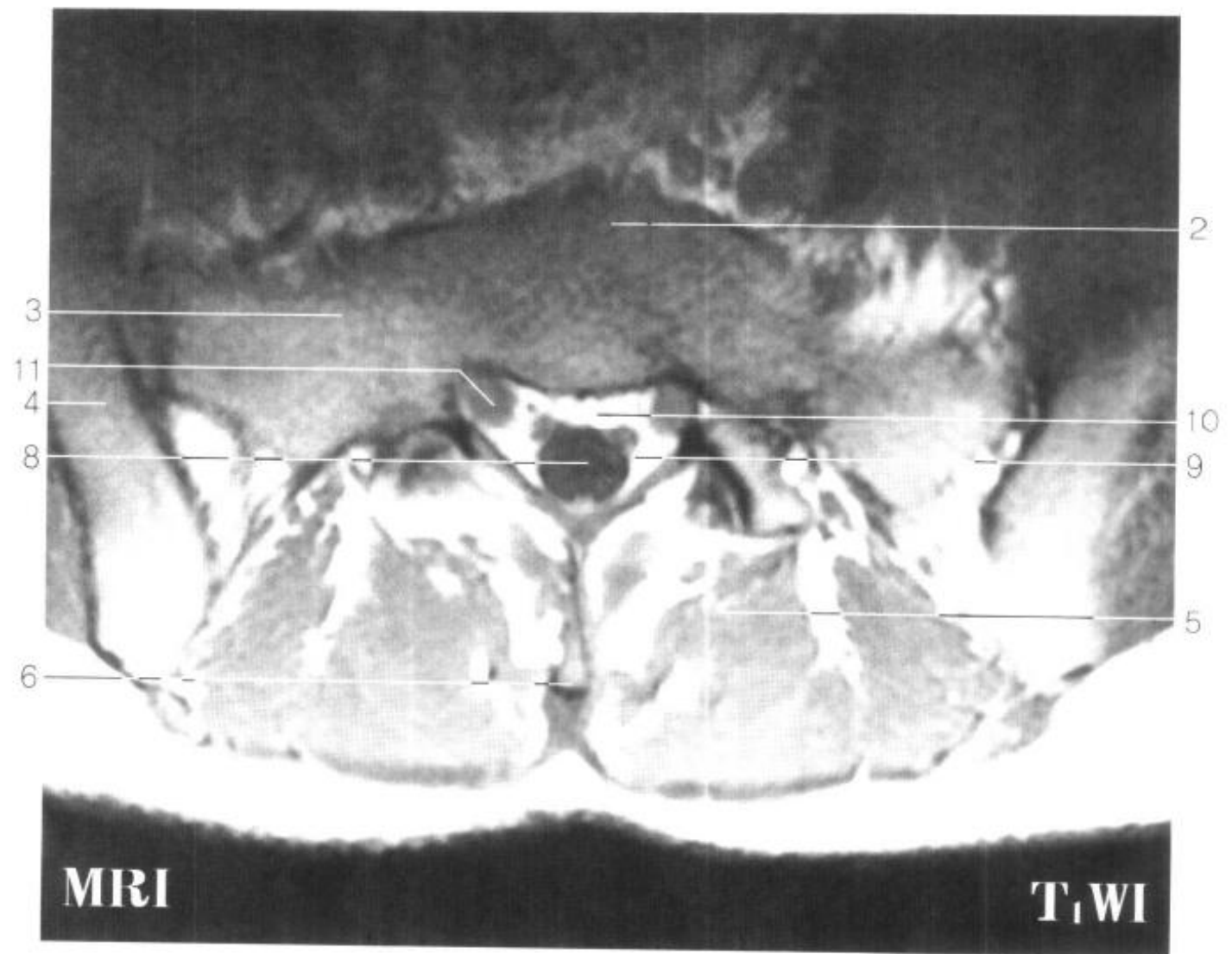


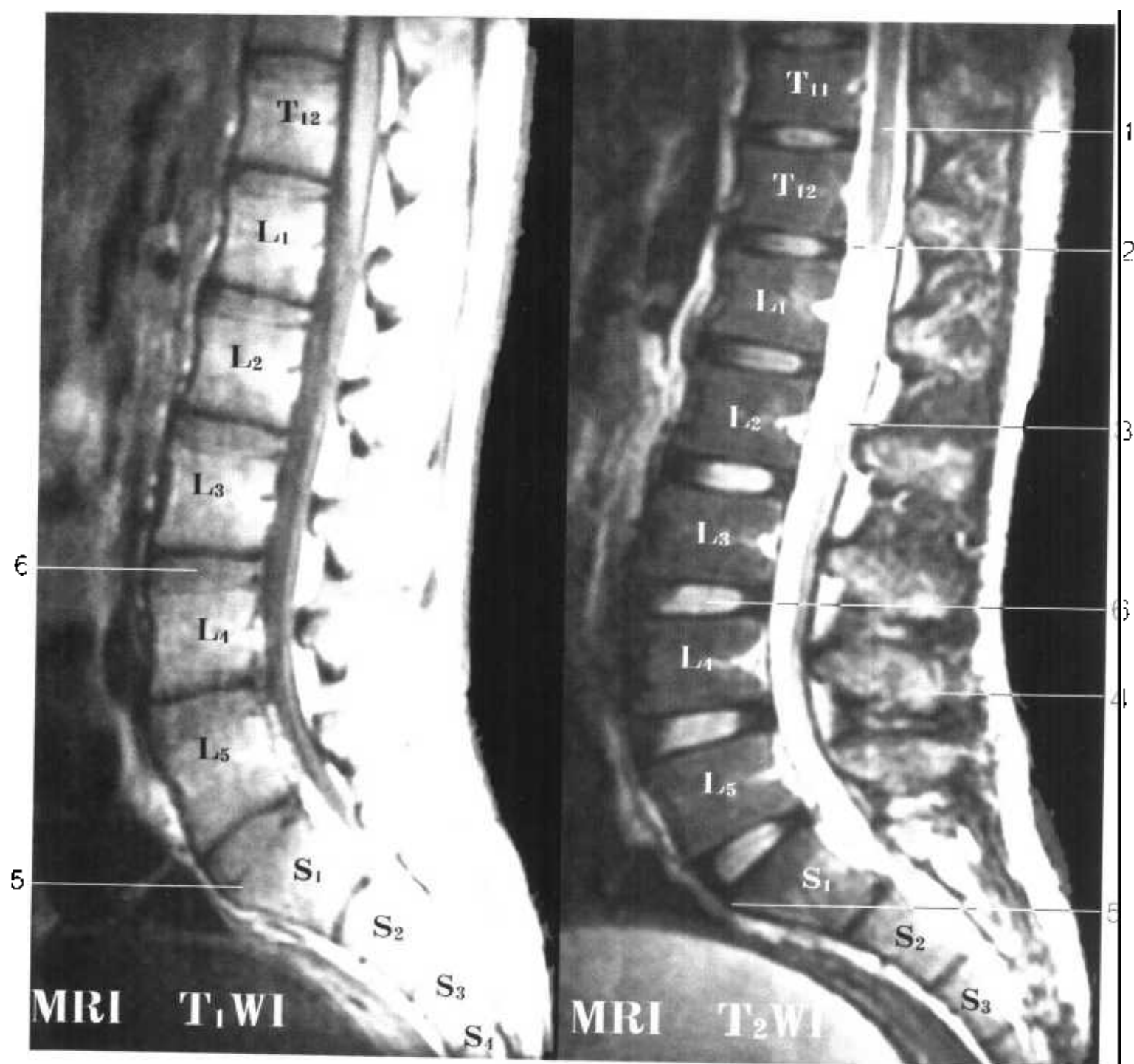


第1 骶椎水平断面图 HS,

- | | |
|-----------------------------|--------------------------|
| 1. 骶髂关节 sacroiliac joint | 7. 骶管 sacral canal |
| 2. 椎体 vertebral body | 8. 马尾 cauda equina |
| 3. 骶翼 ala of sacrum | 9. 硬脊膜 spinal dura mater |
| 4. 髌骨 ilium | 10. 硬膜外隙 epidural space |
| 5. 竖脊肌 erector spinae | 11. 第1 骶神经 1st sacral n. |
| 6. 骶正中嵴 median sacral crest | |

Fig. HS,

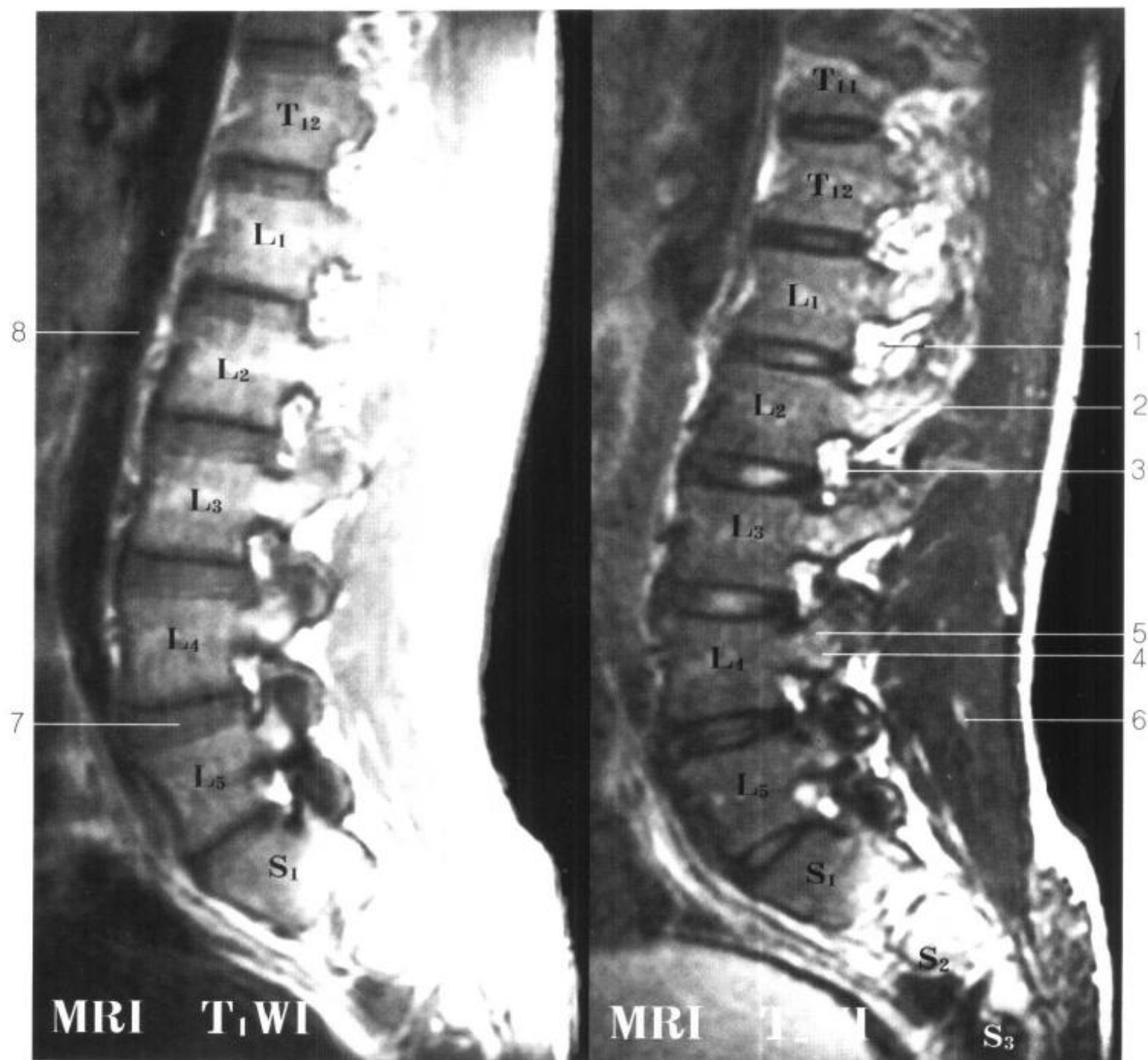




腰骶部正中矢状断面图 MSL

1. 腰骶膨大 lumbosacral enlargement
2. 蛛网膜下隙 subarachnoid space
3. 马尾 cauda equina
4. 棘突 spinous process
5. 岬 promontory
6. 3、4腰椎间盘 intervertebral disc (L₃~L₄)

Fig. MSL

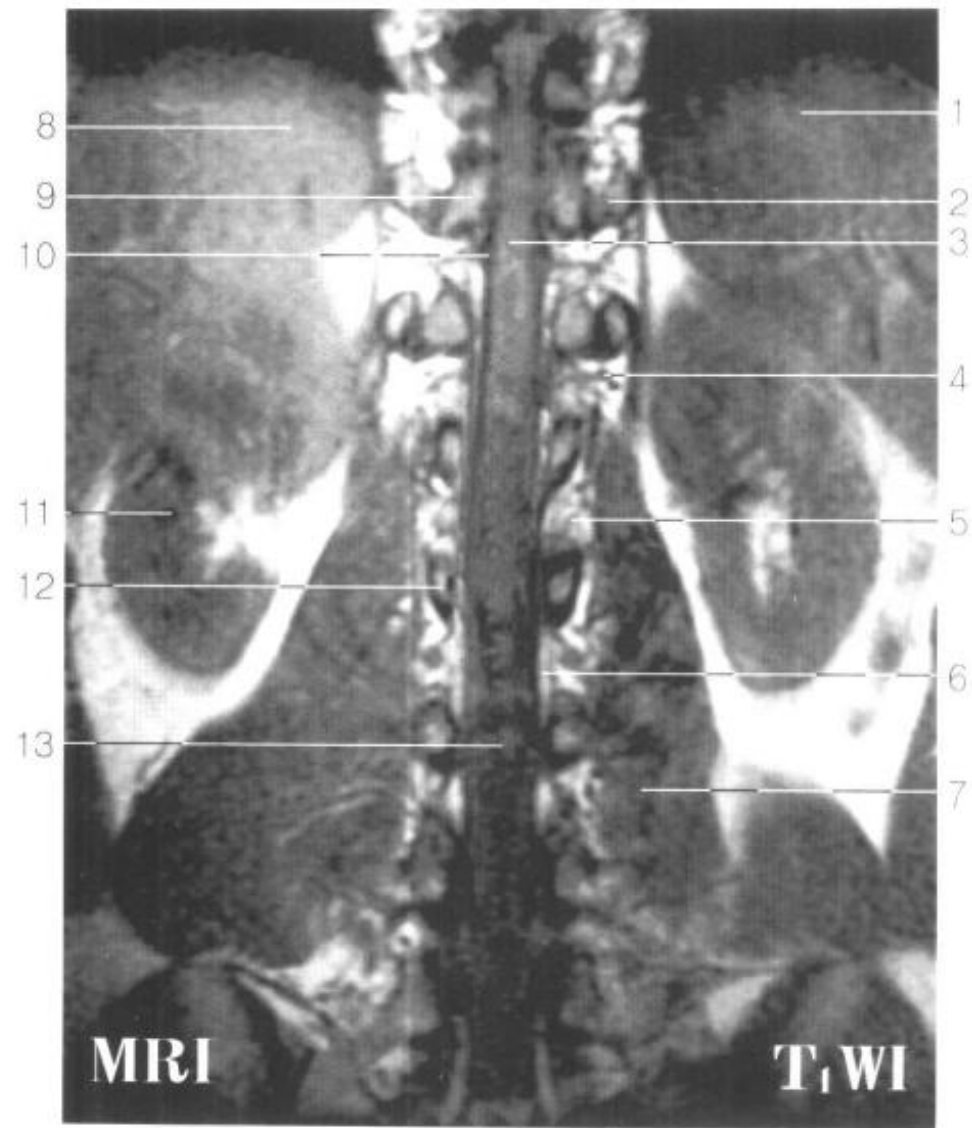


腰骶部旁正中矢状断面图 PSL

1. 椎间孔 intervertebral foramen
2. 椎弓 vertebral arch
3. 腰神经 lumbar n.
4. 下关节突 inferior articular process
5. 上关节突 superior articular process
6. 竖脊肌 erector spinea
7. 4、5腰椎间盘 intervertebral disc (L₄-L₅)
8. 腹主动脉 abdominal aorta

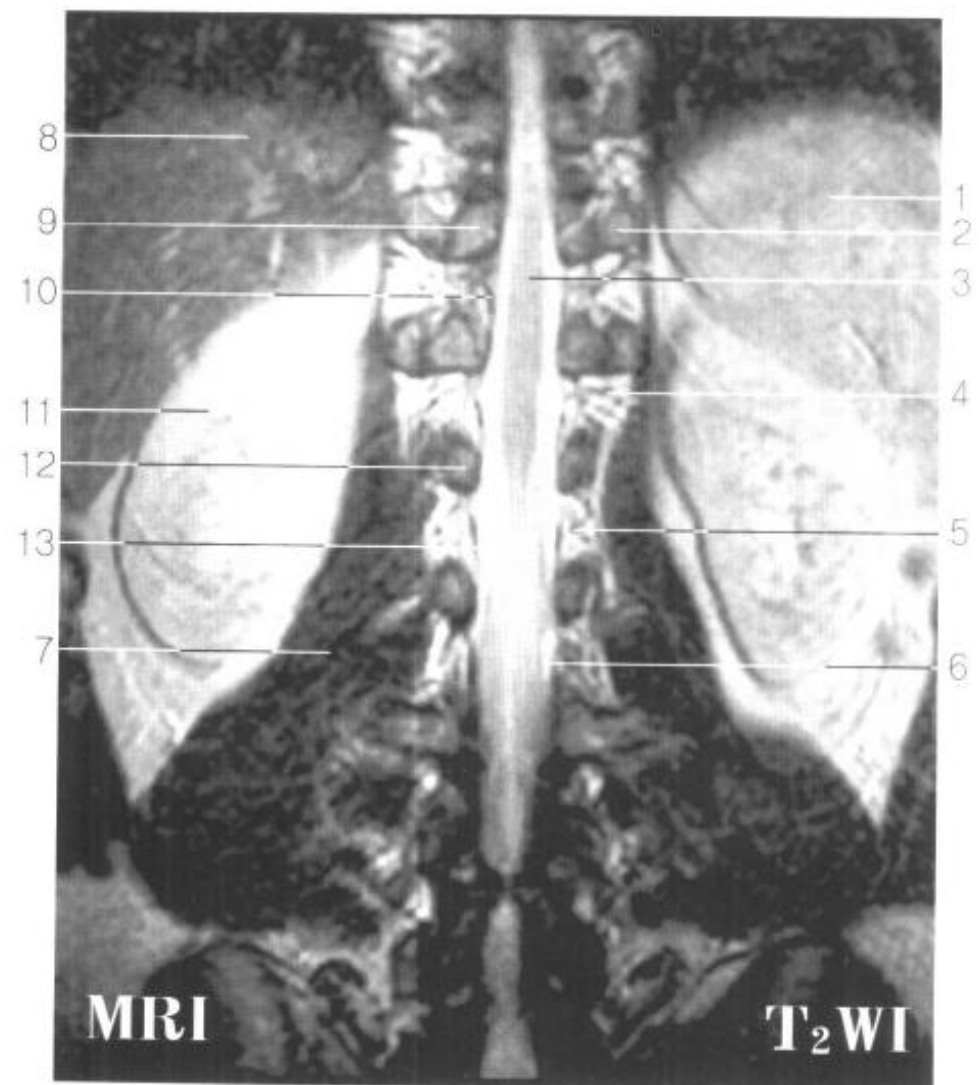
Fig. PSL

图 4-2-20



脊柱额状断面图 FVR

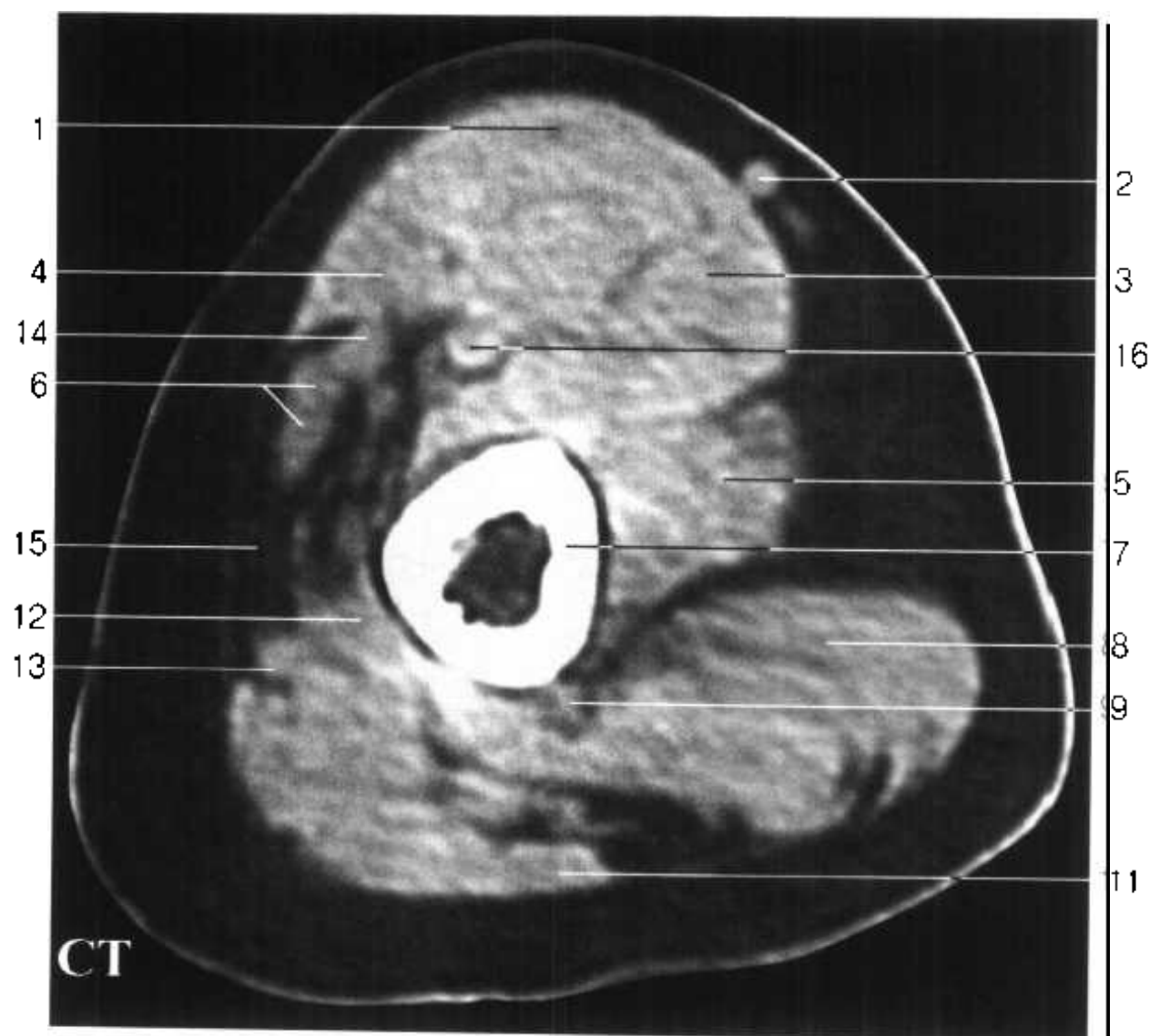
1. 脾 spleen
2. 上关节突 superior articular process
3. 脊髓 spinal cord
4. 脊神经 spinal nerve
5. 椎间孔 intervertebral foramen
6. 硬膜外隙 epidural space
7. 腰大肌 psoas major
8. 肝 liver
9. 下关节突 inferior articular process
10. 硬脊膜 spinal dura mater
11. 右肾 right kidney
12. 椎弓根 pedicle of vertebral arch
13. 马尾 cauda equina



Sig. FVR

四肢部

LIMBS



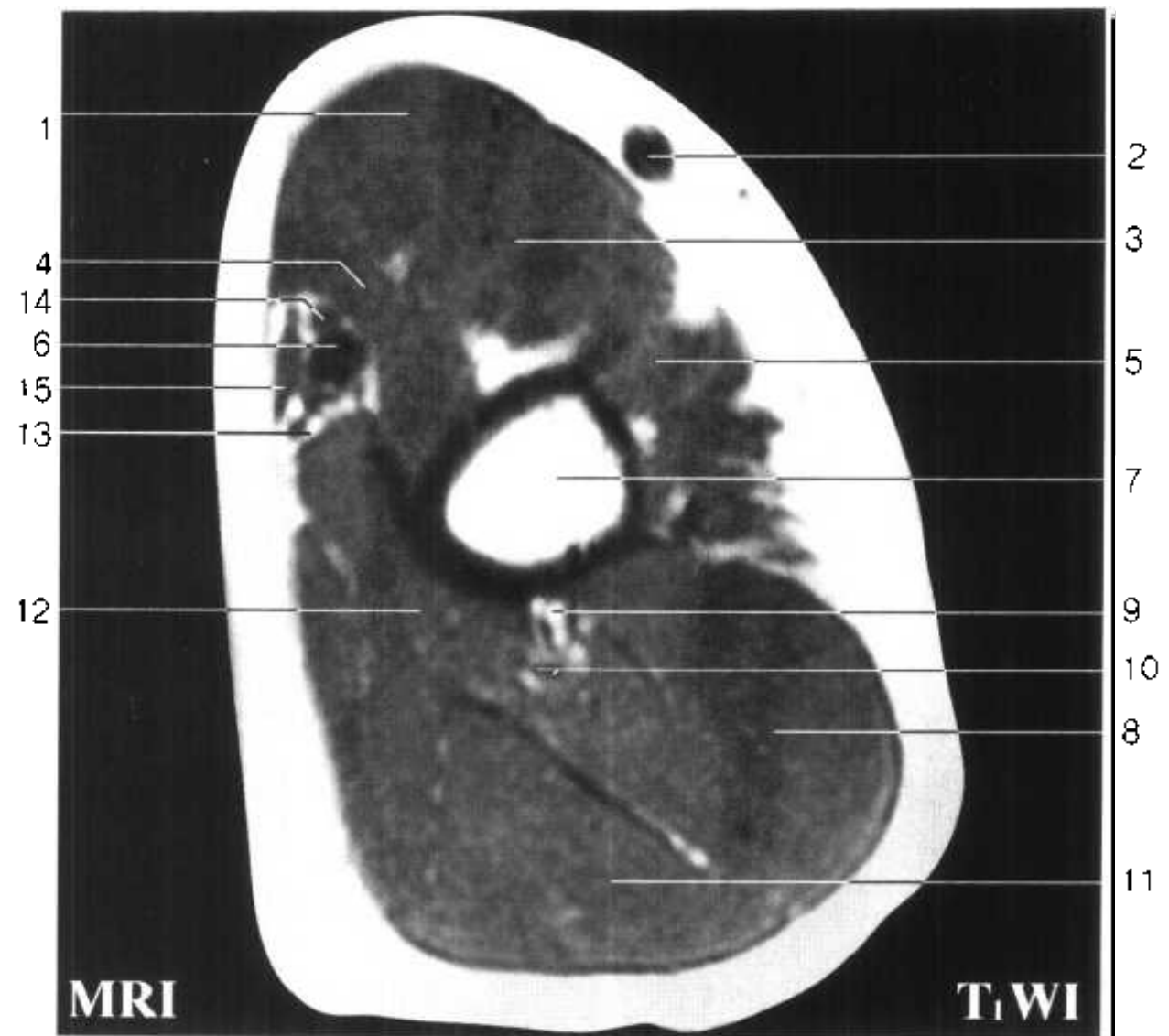
左上肢水平断面图 HUL

Fig. HUL 1

1. 肱二头肌短头 short head of biceps brachii
2. 头静脉 cephalic v.
3. 肱二头肌长头 long head of biceps brachii
4. 喙肱肌 coracobrachialis
5. 三角肌 deltoid
6. 肱动、静脉 brachial a.and v.
7. 肱骨 humerus
8. 肱三头肌外侧头 lateral head of triceps brachii

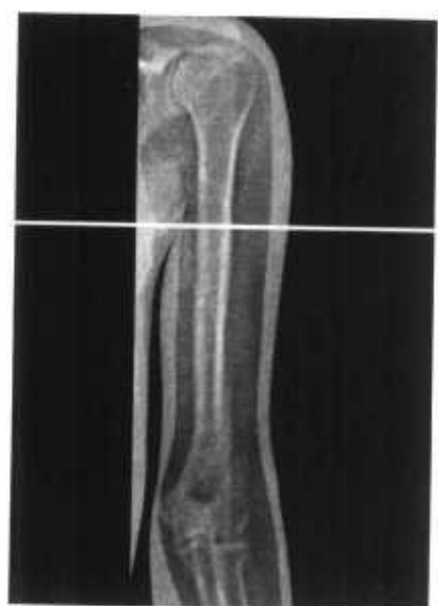

Fig. HUL 1



9. 桡神经 radial n.
10. 肱深动、静脉 deep brachial a.and v.
11. 肱三头肌长头 long head of triceps
brachii
12. 肱三头肌内侧头 medial head of triceps
brachii
13. 尺神经 ulnar n.
14. 正中神经 median n.
15. 贵要静脉 basilic v.
16. 肌皮神经 musculocutaneous n.

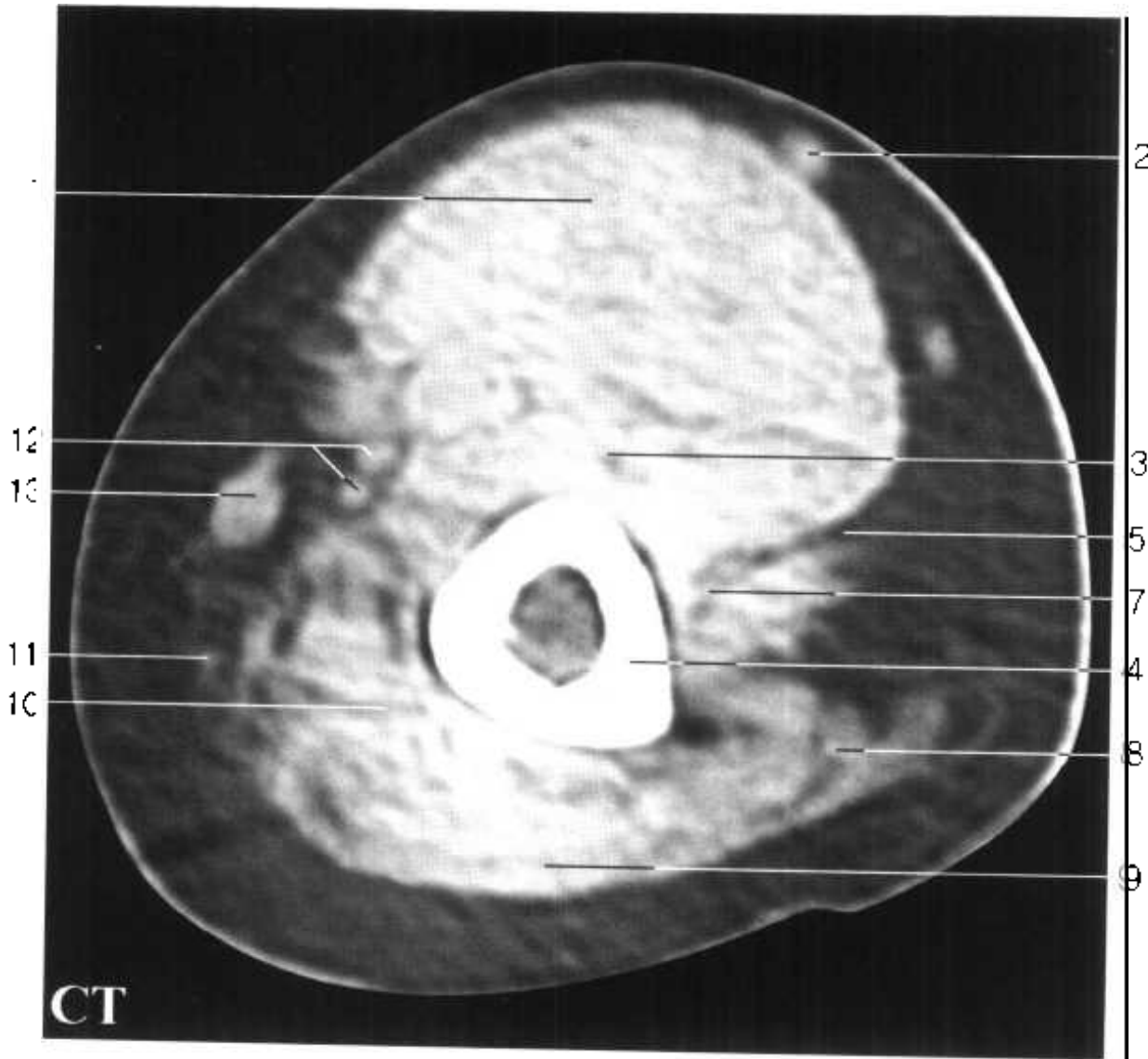
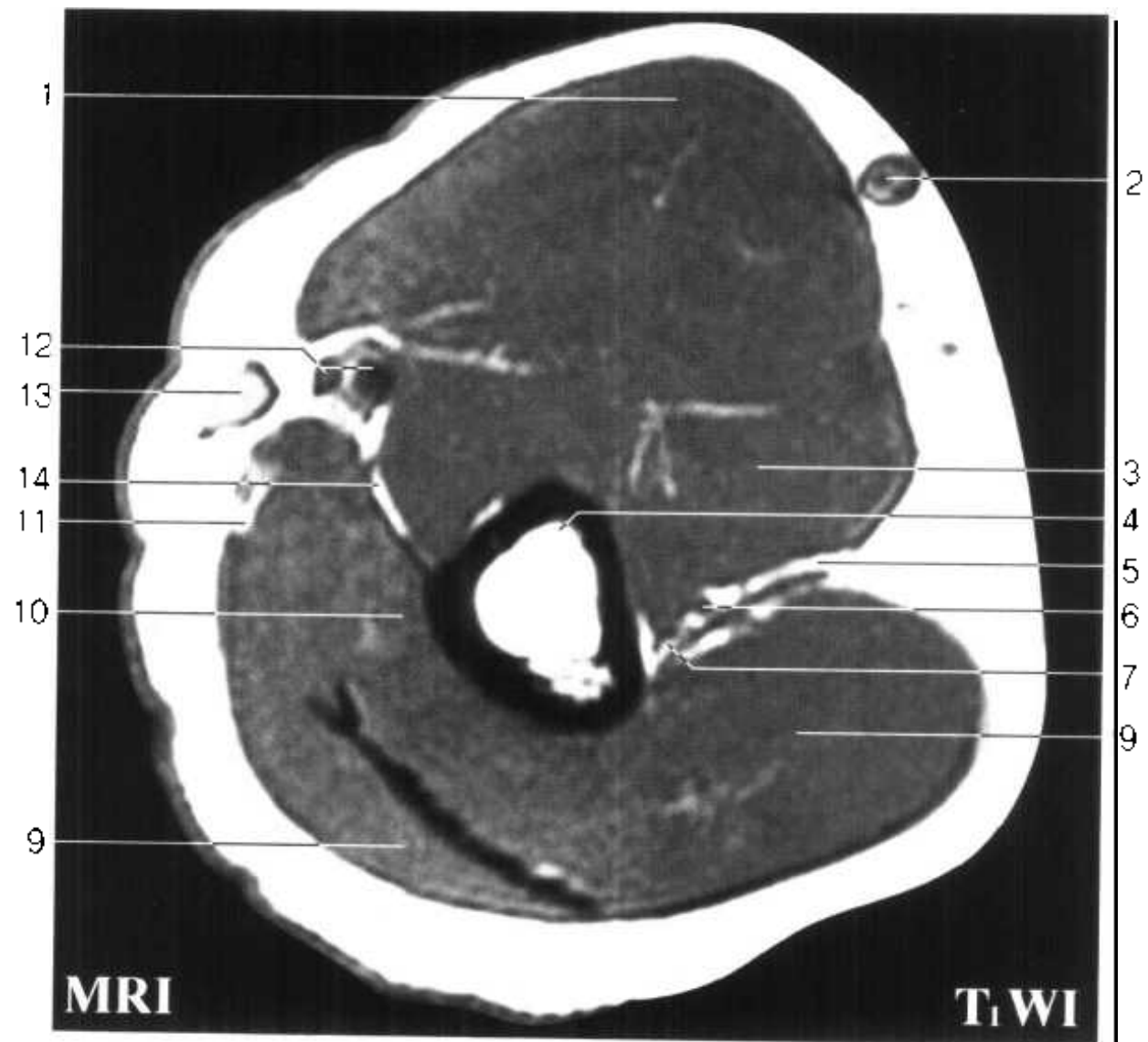


Fig. HUL 2

- 1. 肱二头肌 biceps brachii
- 2. 头静脉 cephalic v.
- 3. 肱肌 brachialis
- 4. 肱骨 humerus
- 5. 臂外侧肌间隔 lateral brachial intermuscular septum
- 6. 肱深动、静脉 deep brachial a.and v.
- 7. 桡神经 radial n.
- 8. 肱三头肌外侧头 lateral head of triceps brachii
- 9. 肱三头肌长头 long head of triceps brachii

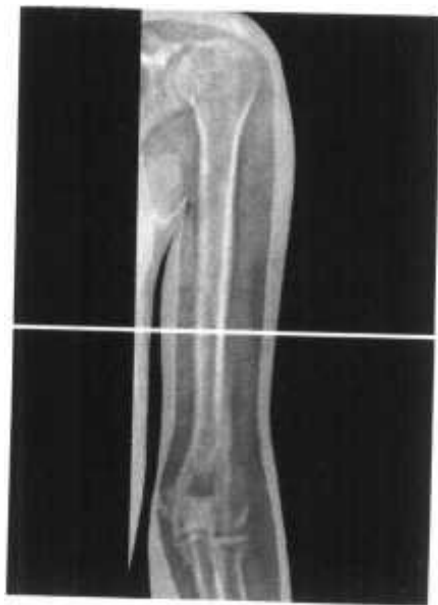

Fig. HUL 2



- 10. 肱三头肌内侧头 medial head of triceps brachii
- 11. 尺神经 ulnar n.
- 12. 肱动、静脉 brachial a.and v.
- 13. 贵要静脉 basilic v.
- 14. 臂内侧肌间隔 medial brachial intermuscular septum

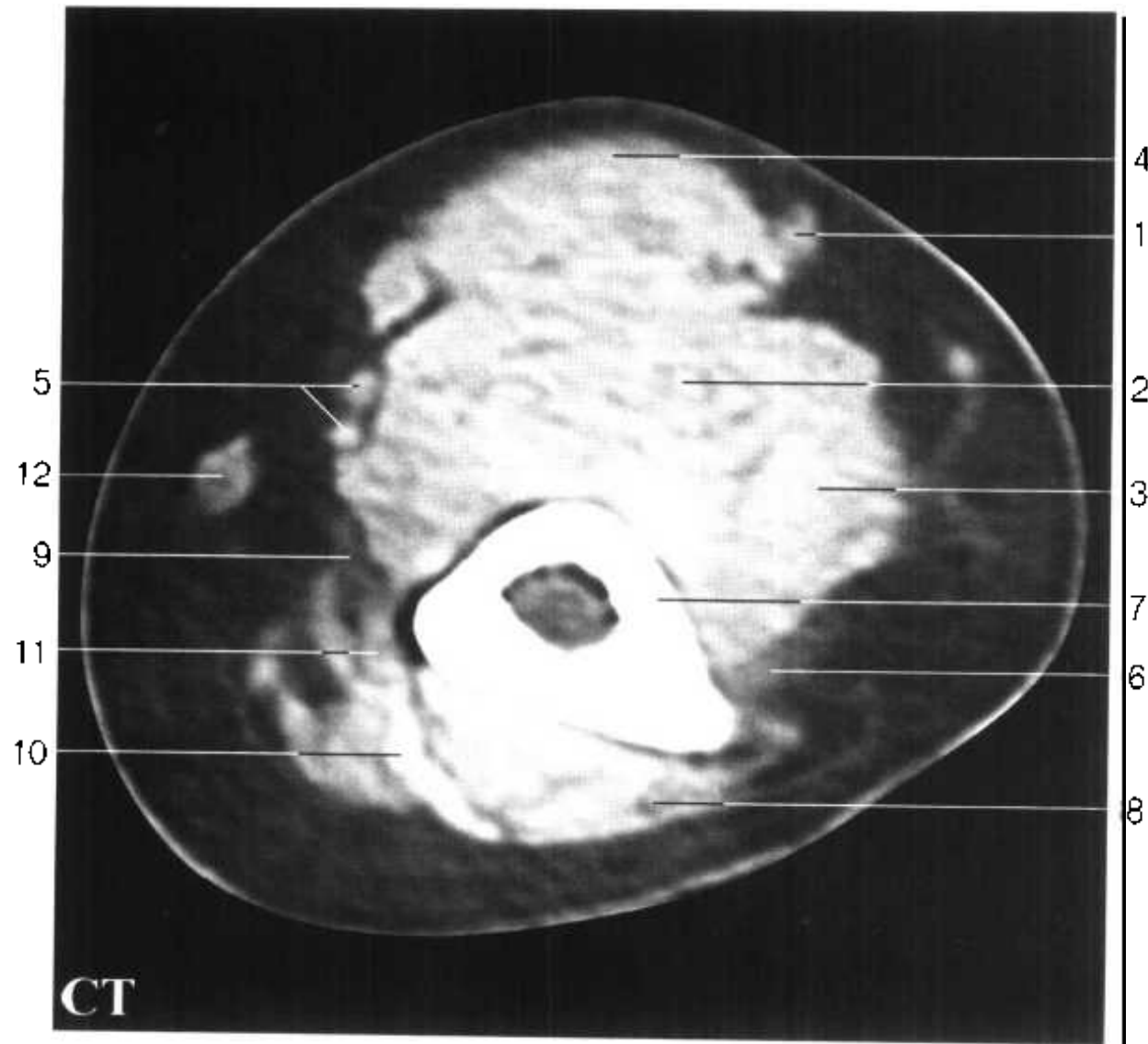
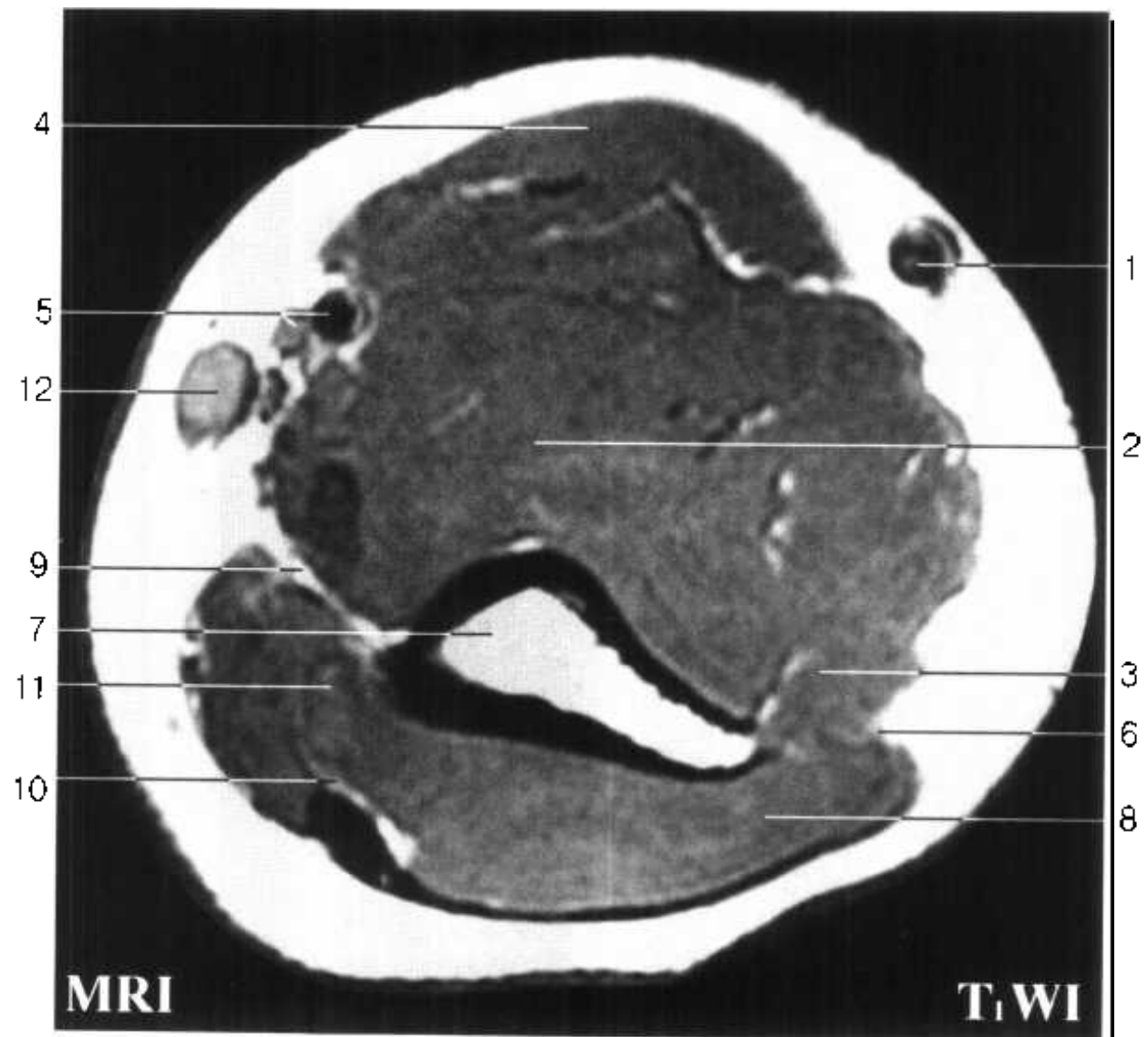


Fig. HUL 3

- 1. 头静脉 cephalic v.
- 2. 肱肌 brachialis
- 3. 肱桡肌 brachioradialis
- 4. 肱二头肌 biceps brachii
- 5. 肱动、静脉 brachial a.and v.
- 6. 臂外侧肌间隔 lateral brachial intermuscular septum
- 7. 肱骨 humerus
- 8. 肱三头肌外侧头 lateral head of triceps brachii
- 9. 臂内侧肌间隔 medial brachial intermuscular septum

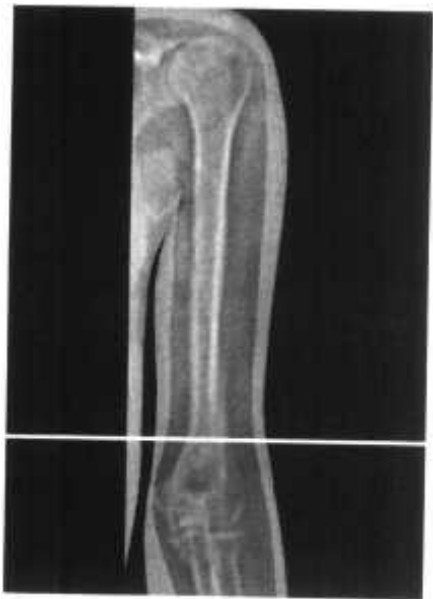

Fig. HUL 3



- 10. 肱三头肌腱 tendon of triceps brachii
- 11. 肱三头肌内侧头 medial head of triceps brachii
- 12. 贵要静脉 basilic v.

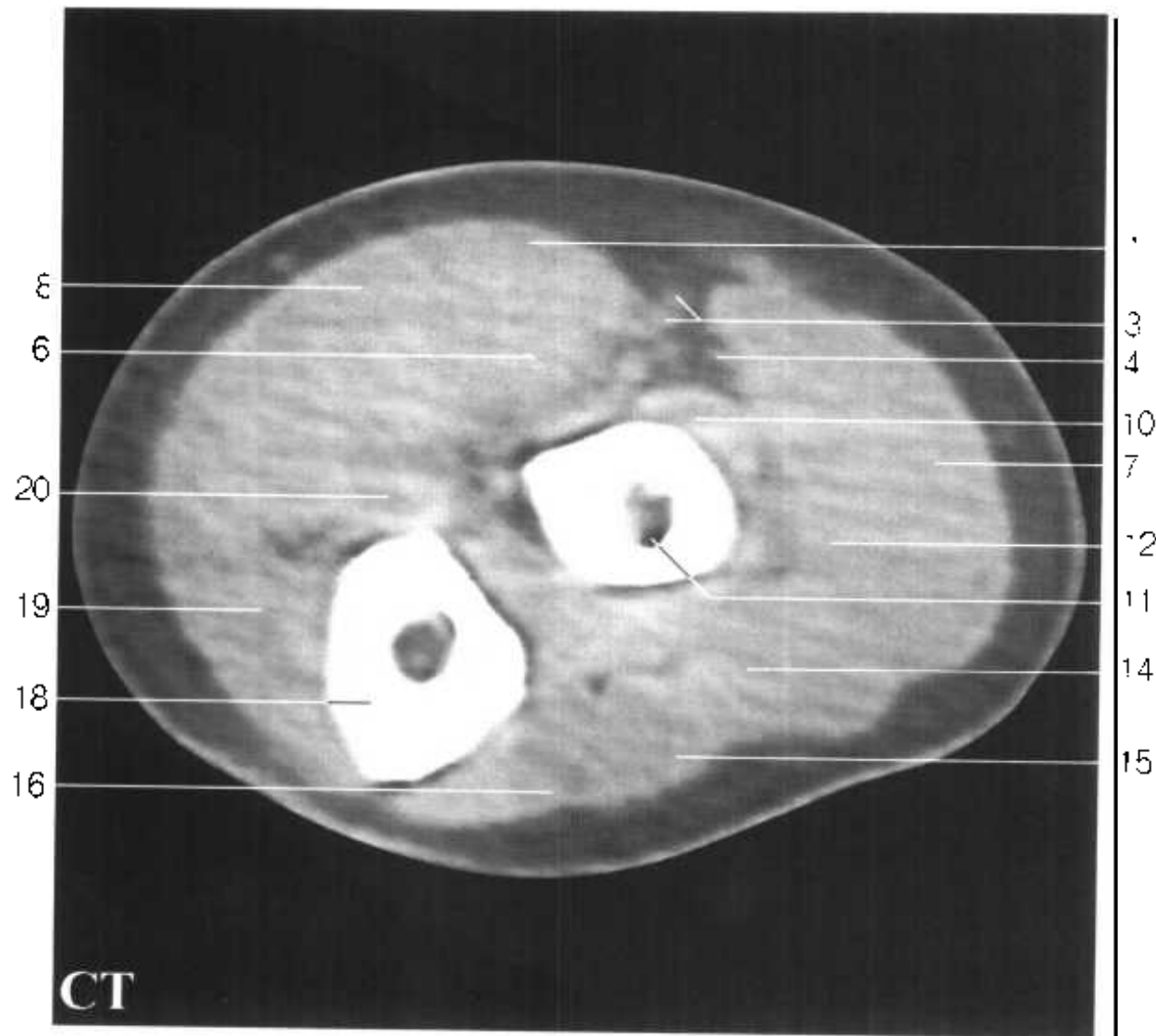
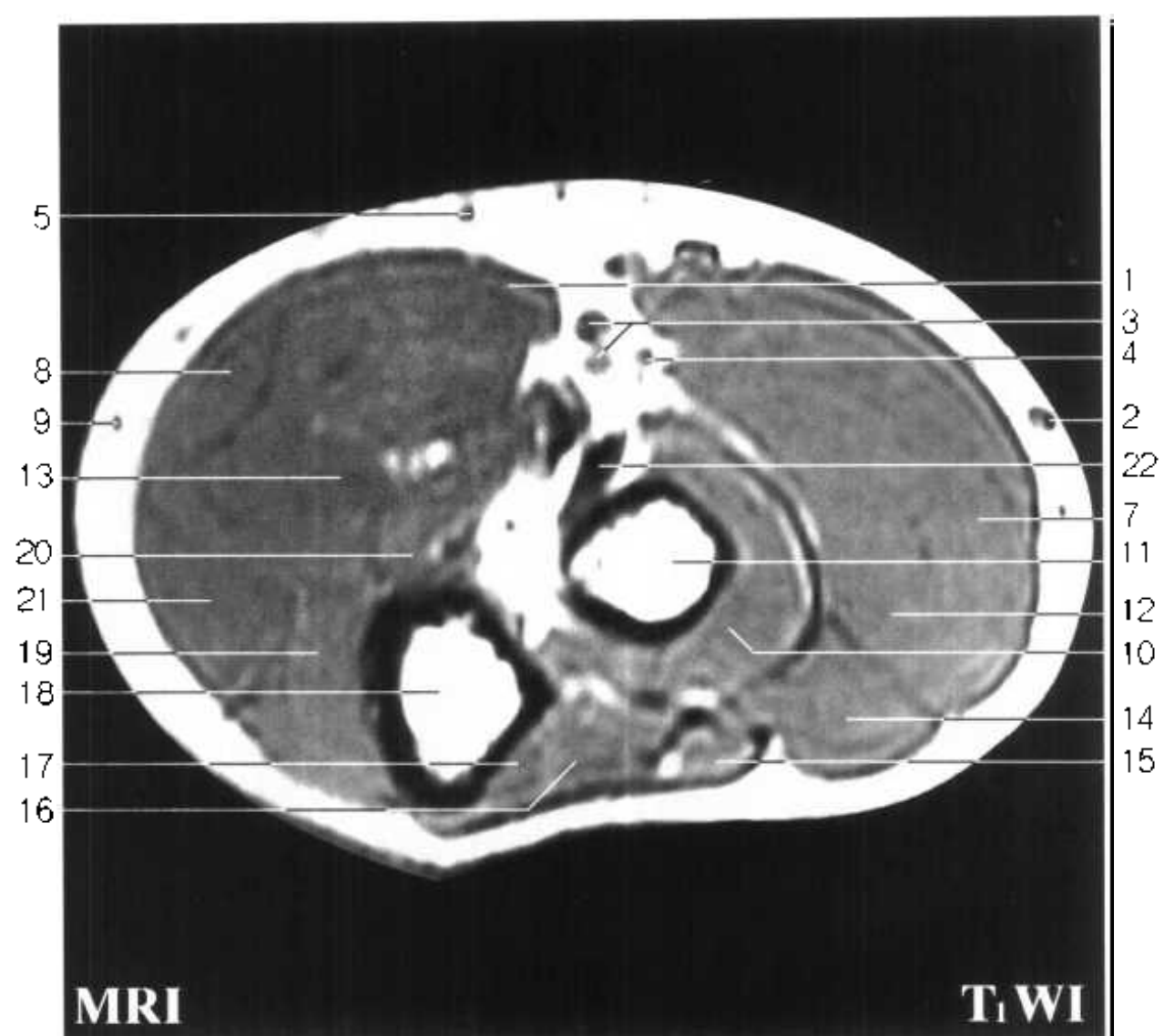


Fig. HUL 4

1. 桡侧腕屈肌 flexor carpi radialis
2. 头静脉 cephalic v.
3. 桡动、静脉 radial a.and v.
4. 桡神经浅支 superficial branch of radial n.
5. 前臂正中静脉 median antebrachial v.
6. 旋前圆肌 pronator teres
7. 桡侧腕长伸肌 extensor carpi radialis longus
8. 掌长肌 palmaris longus
9. 贵要静脉 basilic v.
10. 旋后肌 supinator
11. 桡骨 radius

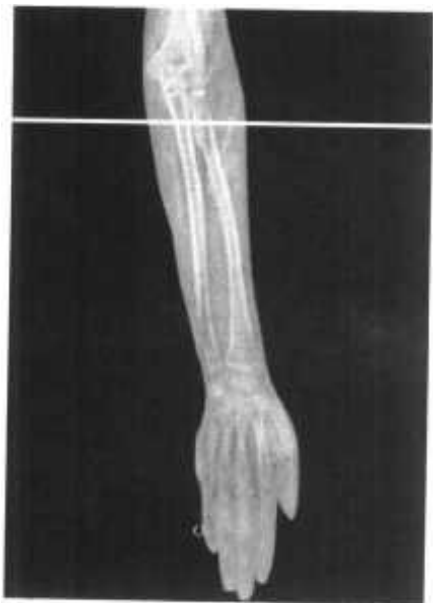

Fig. HUL 4



12. 桡侧腕短伸肌 extensor carpi radialis
brevis
13. 指浅屈肌 flexor digitorum superficialis
14. 指伸肌 extensor digitorum
15. 小指伸肌 extensor digiti minimi
16. 尺侧腕伸肌 extensor carpi ulnaris
17. 肘肌 anconeus
18. 尺骨 ulna
19. 指深屈肌 flexor digitorum profundus
20. 肱肌 brachialis
21. 尺侧腕屈肌 flexor carpi ulnaris
22. 肱二头肌 biceps brachii

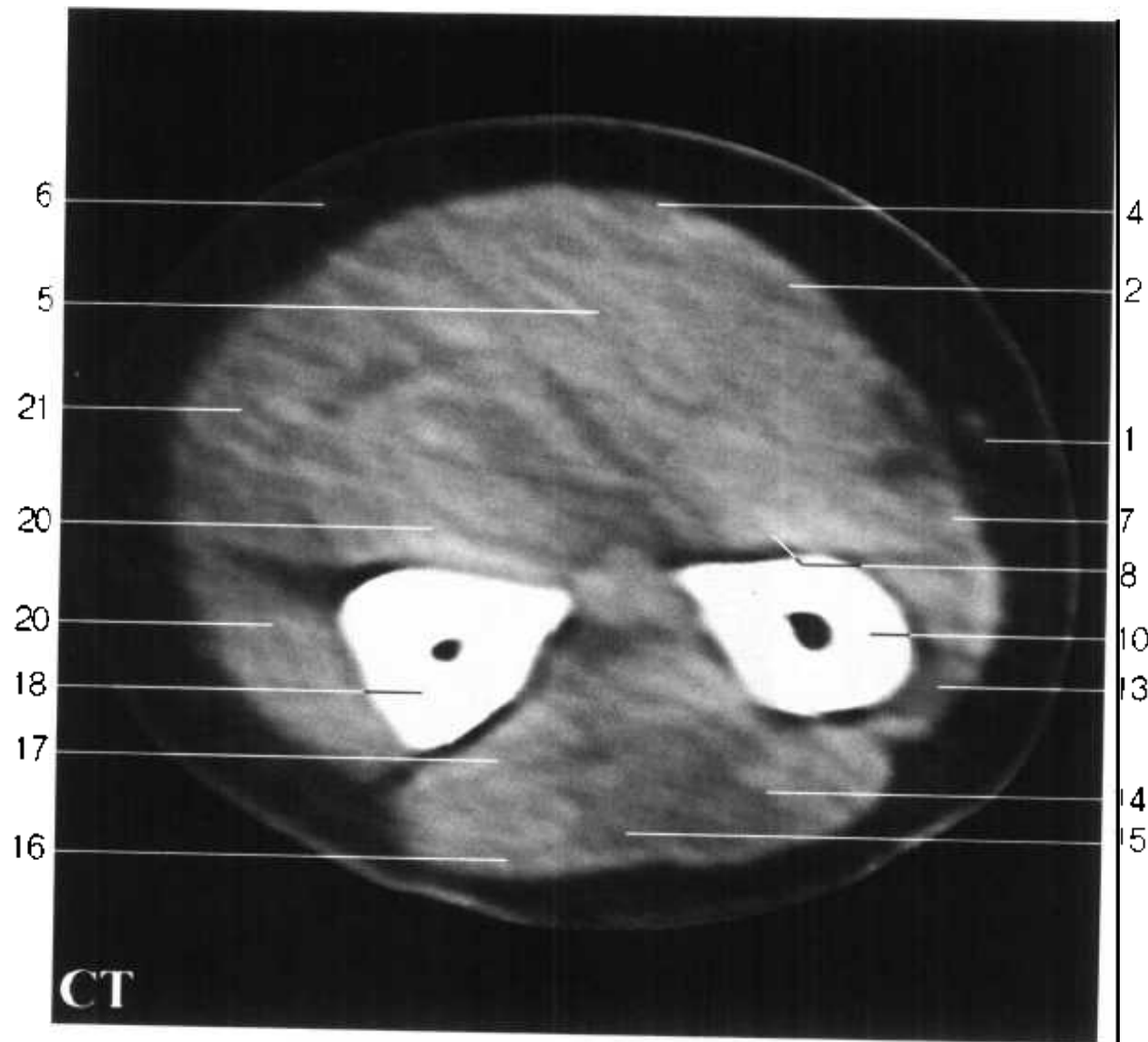
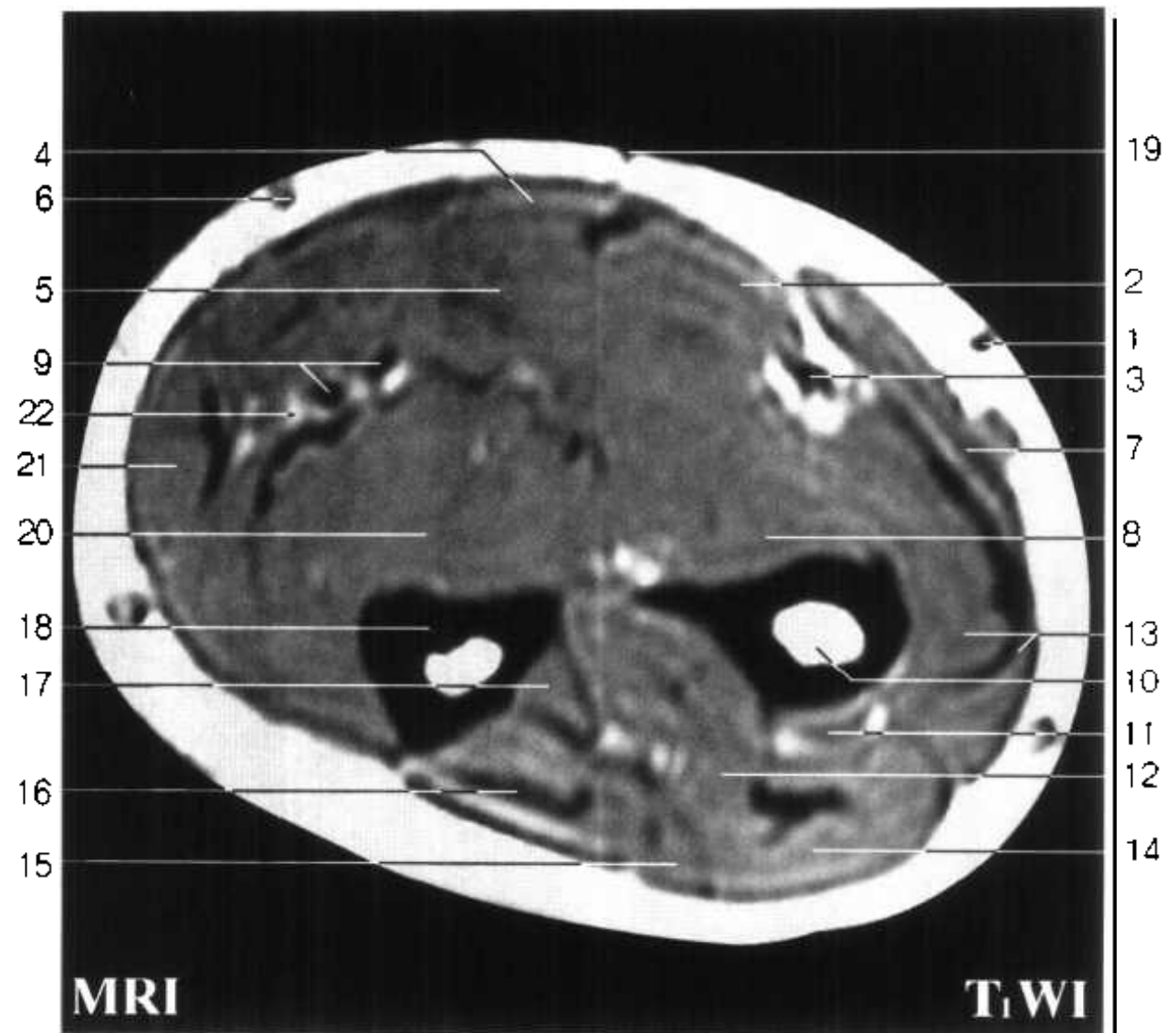


Fig. HUL 5

1. 头静脉 cephalic v.
2. 桡侧腕屈肌 flexor carpi radialis
3. 桡动、静脉 radial a. and v.
4. 掌长肌 palmaris longus
5. 指浅屈肌 flexor digitorum superficialis
6. 贵要静脉 basilic v.
7. 肱桡肌 brachioradialis
8. 拇长屈肌 flexor pollicis longus
9. 尺动、静脉 ulnar a. and v.
10. 桡骨 radius
11. 旋后肌 supinator
12. 拇长展肌 abductor pollicis longus

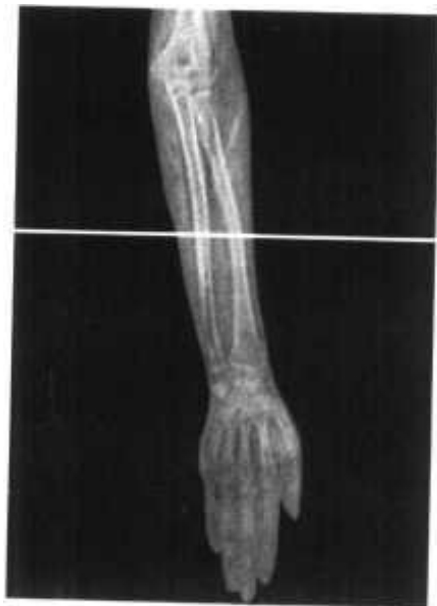

Fig. HUL 5



- 13. 桡侧腕长、短伸肌 *extensor carpi radialis longus and brevis*
- 14. 指伸肌 *extensor digitorum*
- 15. 小指伸肌 *extensor digiti minimi*
- 16. 尺侧腕伸肌 *extensor carpi ulnaris*
- 17. 拇长伸肌 *extensor pollicis longus*
- 18. 尺骨 *ulna*
- 19. 前臂正中静脉 *median antebrachial v.*
- 20. 指深屈肌 *flexor digitorum profundus*
- 21. 尺侧腕屈肌 *flexor carpi ulnaris*
- 22. 尺神经 *ulnar n.*

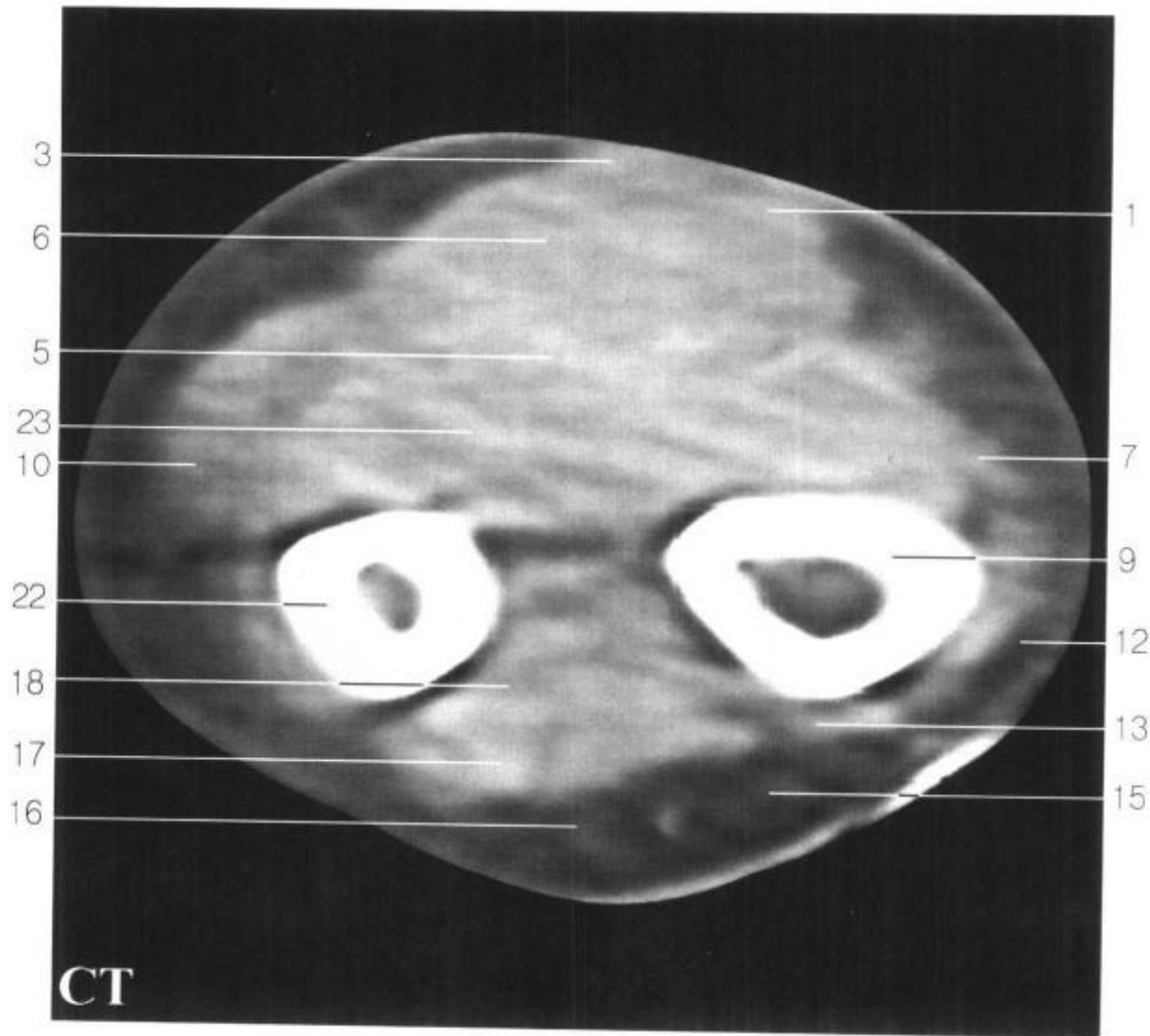
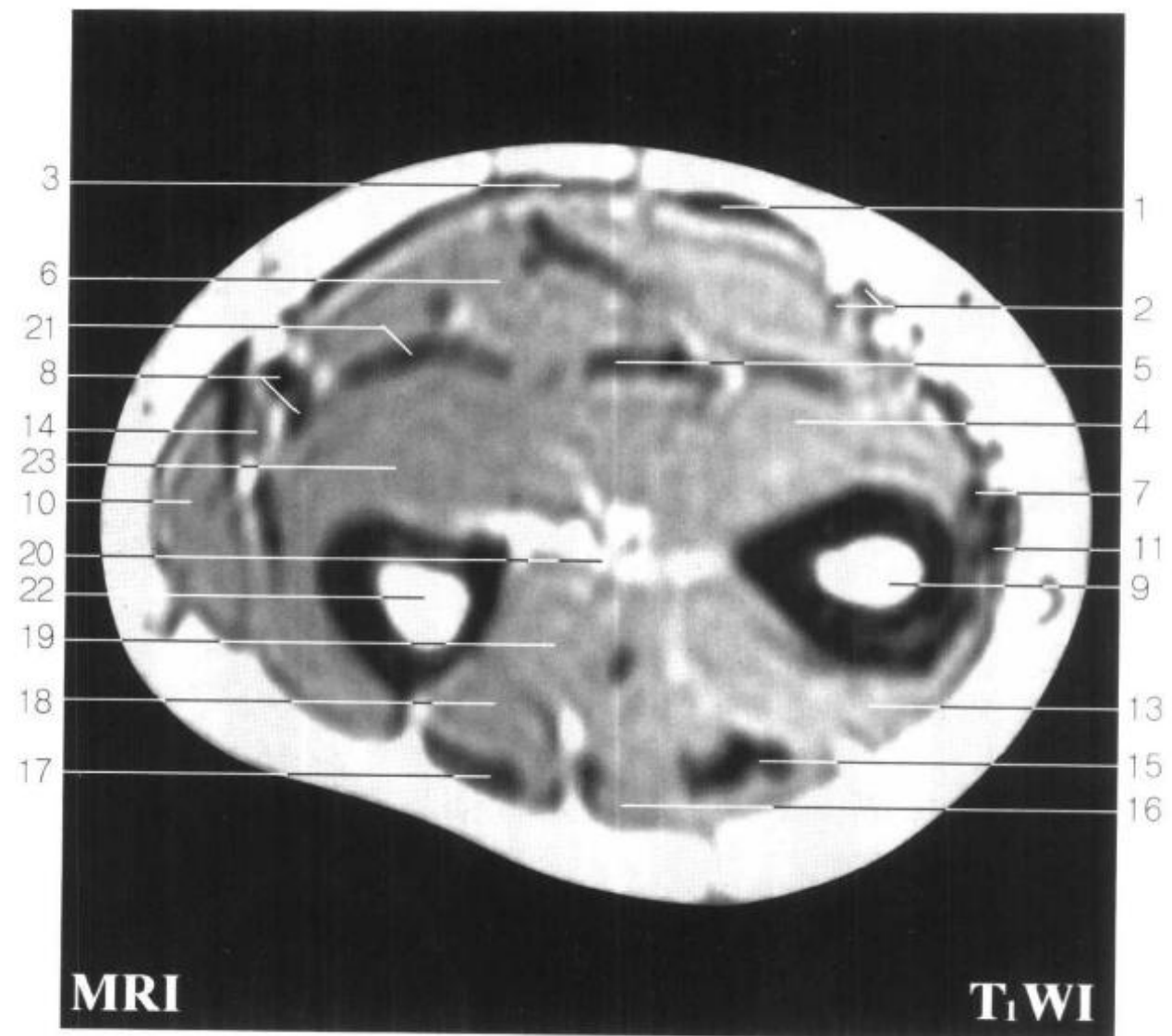


Fig. HUL 6

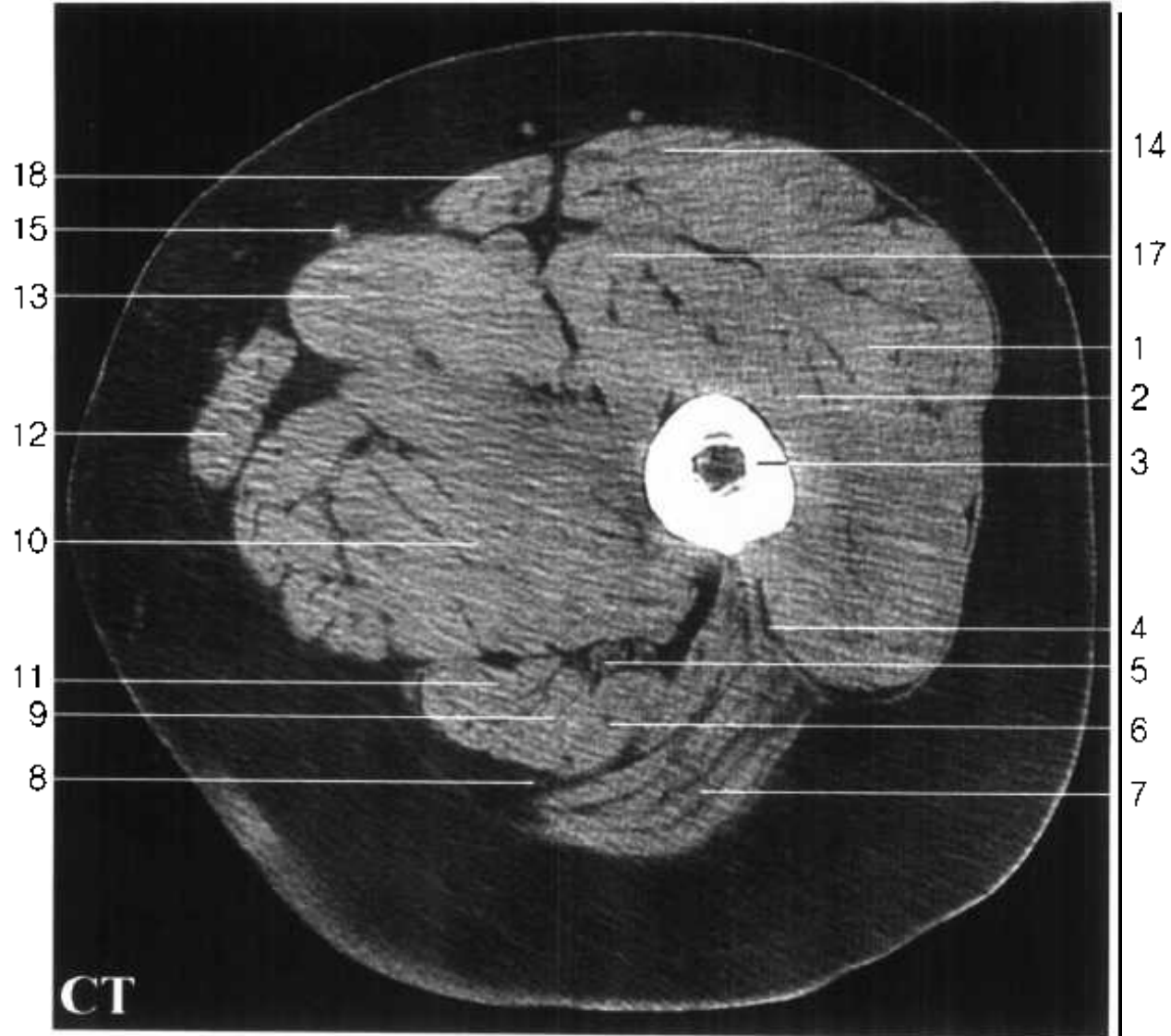
1. 桡侧腕屈肌 flexor carpi radialis
2. 桡动、静脉 radial a.and v.
3. 掌长肌腱 tendon of palmaris longus
4. 拇长屈肌 flexor pollicis longus
5. 指深屈肌 flexor digitorum profundus
6. 指浅屈肌 flexor digitorum superficialis
7. 肱桡肌腱 tendon of brachioradialis
8. 尺动、静脉 ulnar a.and v.
9. 桡骨 radius
10. 尺侧腕屈肌 flexor carpi ulnaris
11. 桡侧腕长伸肌腱 tendon of extensor carpi radialis longus
12. 桡侧腕短伸肌腱 tendon of extensor carpi radialis brevis
13. 拇长展肌腱 tendon of abductor pollicis longus

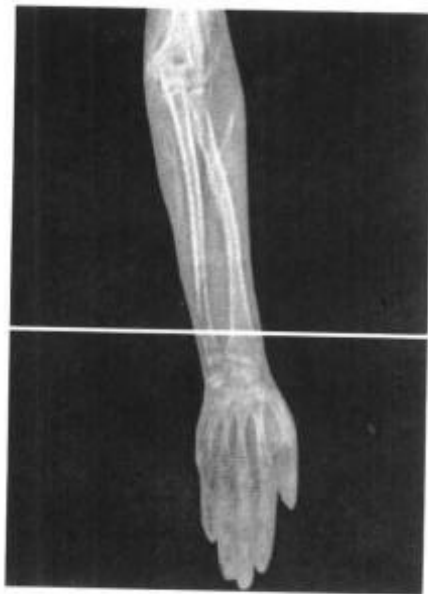

Fig. HUL 6



- 14. 尺神经 ulnar n.
- 15. 指伸肌腱 tendon of extensor digitorum
- 16. 小指伸肌腱 tendon of extensor digiti minimi
- 17. 尺侧腕伸肌 extensor carpi ulnaris
- 18. 拇长伸肌 extensor pollicis longus
- 19. 食指伸肌 extensor indicis
- 20. 前臂骨间膜 interosseous membrane of forearm
- 21. 指深屈肌 flexor digitorum profundus
- 22. 尺骨 ulna
- 23. 旋前方肌 pronator quadratus



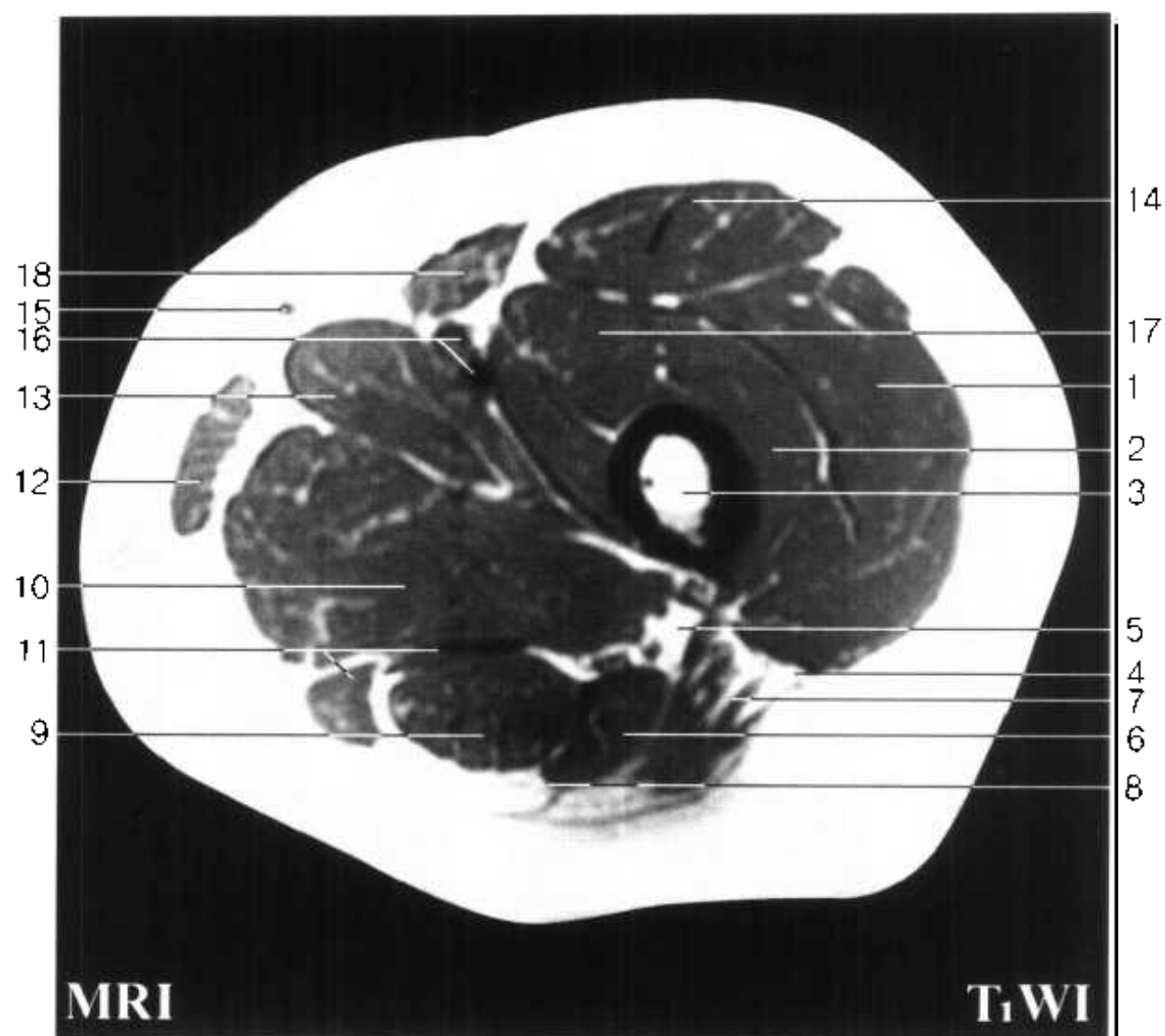
左下肢水平断面图 HLL

Fig. HLL 1

- 1. 股外侧肌 vastus lateralis
- 2. 股中间肌 vastus intermedius
- 3. 股骨 femur
- 4. 股外侧肌间隔 lateral femoral intermuscular septum
- 5. 坐骨神经 sciatic n.
- 6. 股二头肌长头 long head of biceps femoris
- 7. 臀大肌 gluteus maximus
- 8. 股后皮神经 posterior femoral cutaneous n.

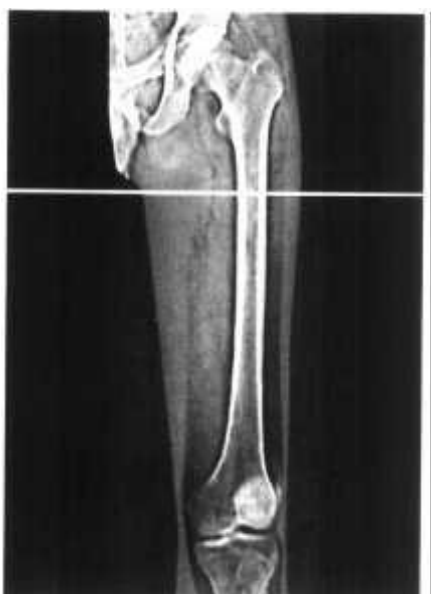

Fig. HLL 1



9. 半腱肌 semitendinosus
10. 大收肌 adductor magnus
11. 半膜肌 semimembranosus
12. 股薄肌 gracilis
13. 长收肌 adductor longus
14. 股直肌 rectus femoris
15. 大隐静脉 great saphenous v.
16. 股动、静脉 femoral a.and v.
17. 股内侧肌 vastus medialis
18. 缝匠肌 sartorius

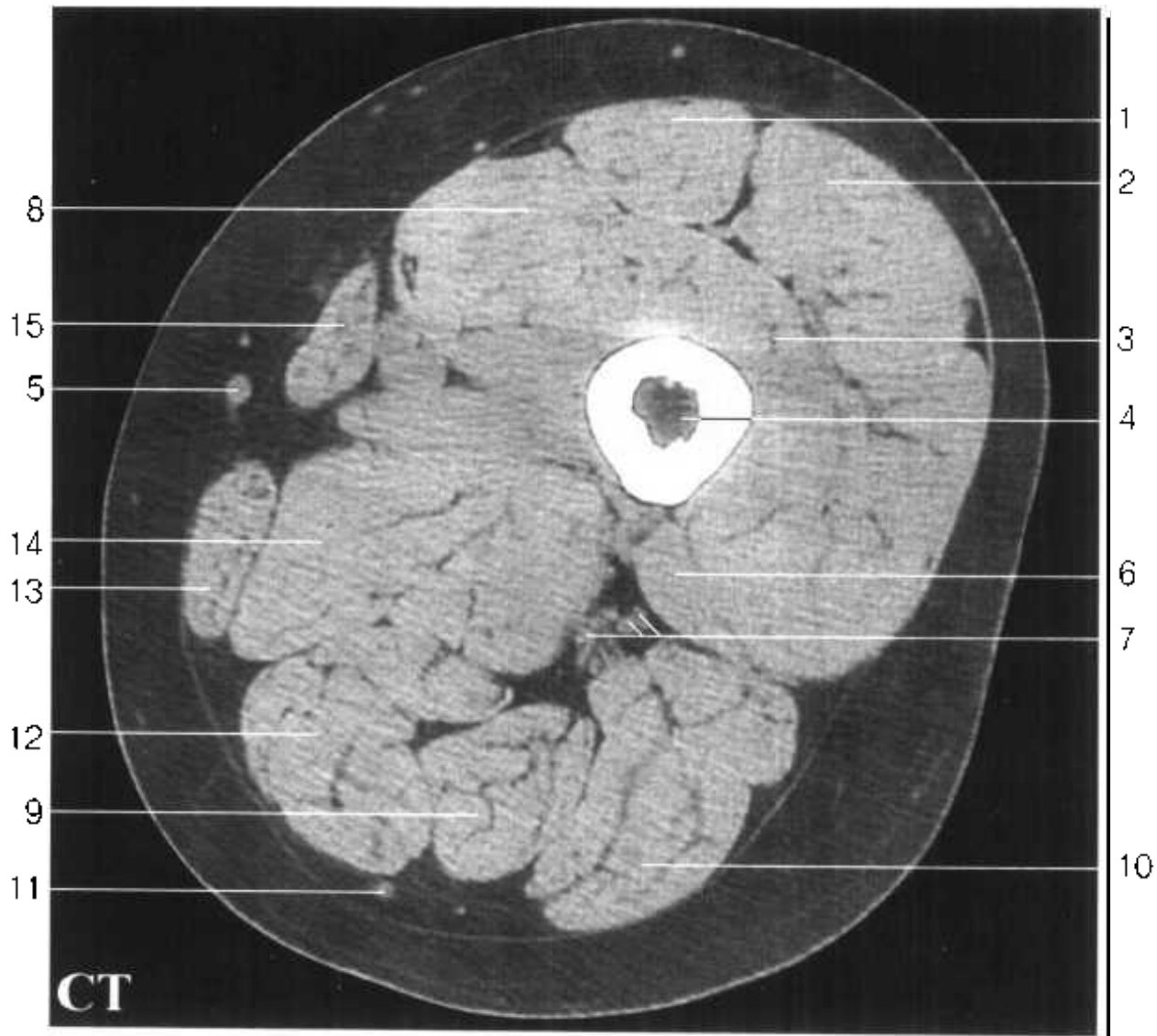
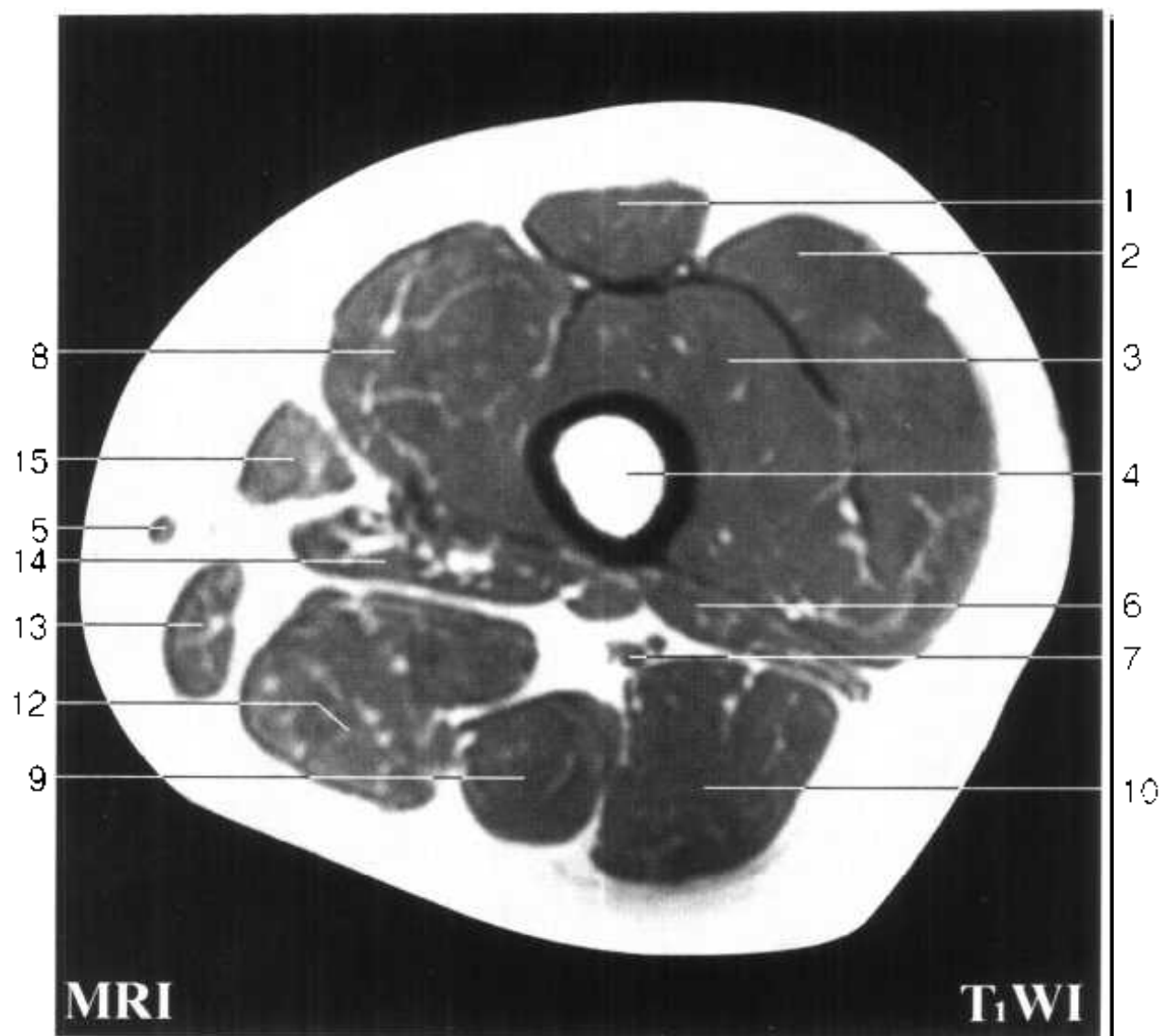


Fig. HLL 2

1. 股直肌 rectus femoris
2. 股外侧肌 vastus lateralis
3. 股中间肌 vastus intermedius
4. 股骨 femur
5. 大隐静脉 great saphenous v.
6. 股二头肌短头 short head of biceps femoris
7. 坐骨神经及坐骨神经伴行动、静脉 sciatic n. and accompanying a.and v.
8. 股内侧肌 vastus medialis

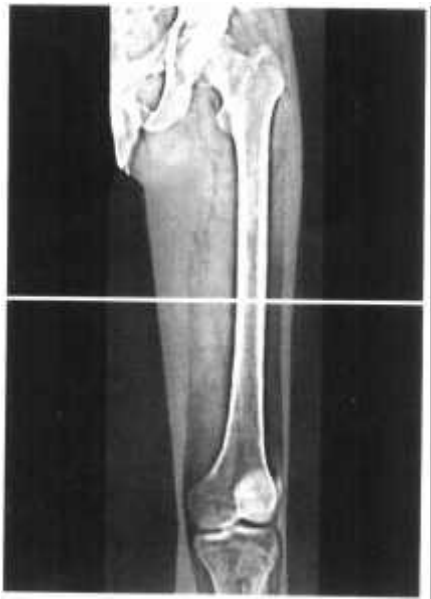

Fig. HLL 2



- 9. 半腱肌 semitendinosus
- 10. 股二头肌长头 long head of biceps femoris
- 11. 股后皮神经 posterior femoral cutaneous n.
- 12. 半膜肌 semimembranosus
- 13. 股薄肌 gracilis
- 14. 大收肌 adductor magnus
- 15. 缝匠肌 sartorius

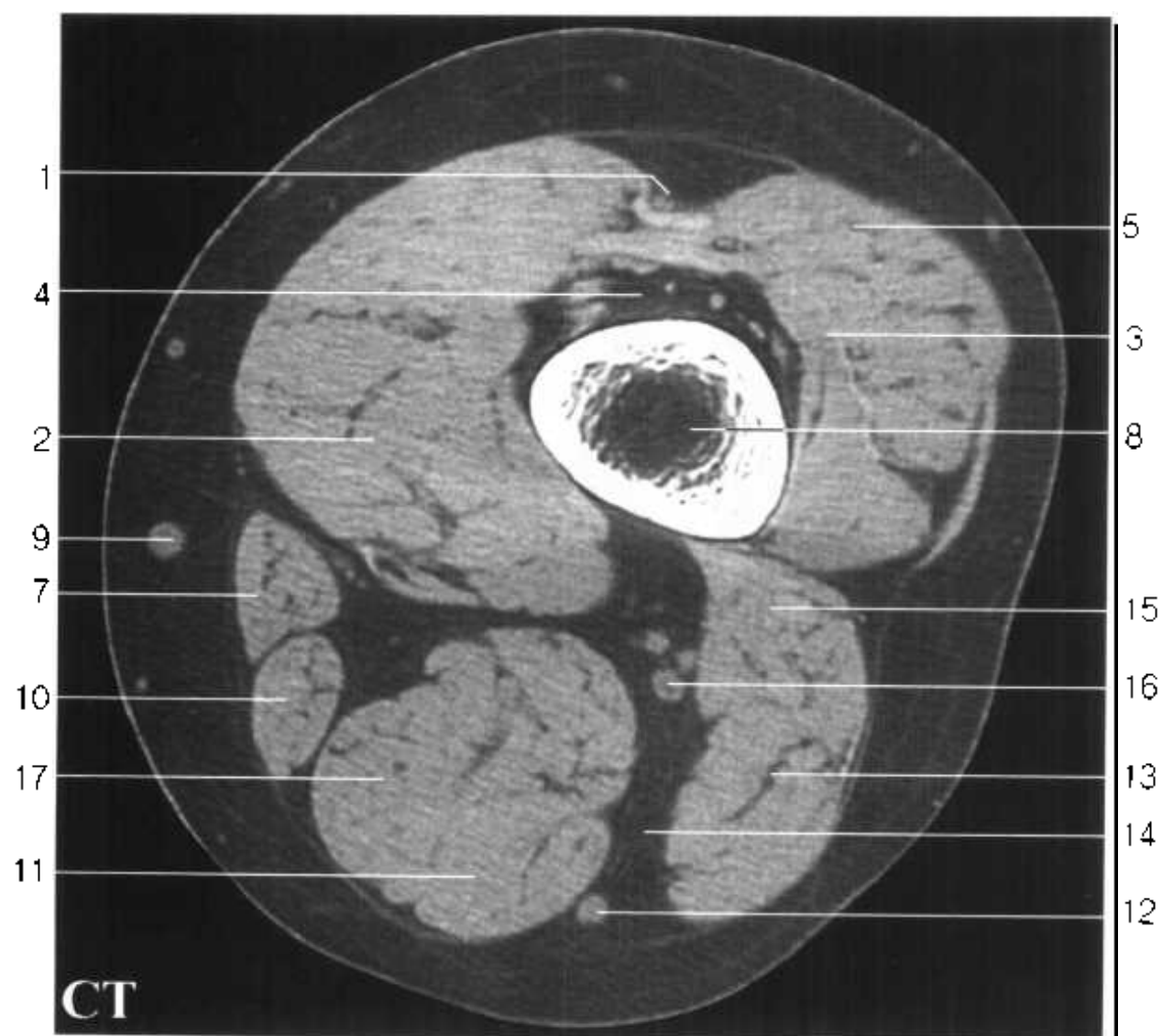
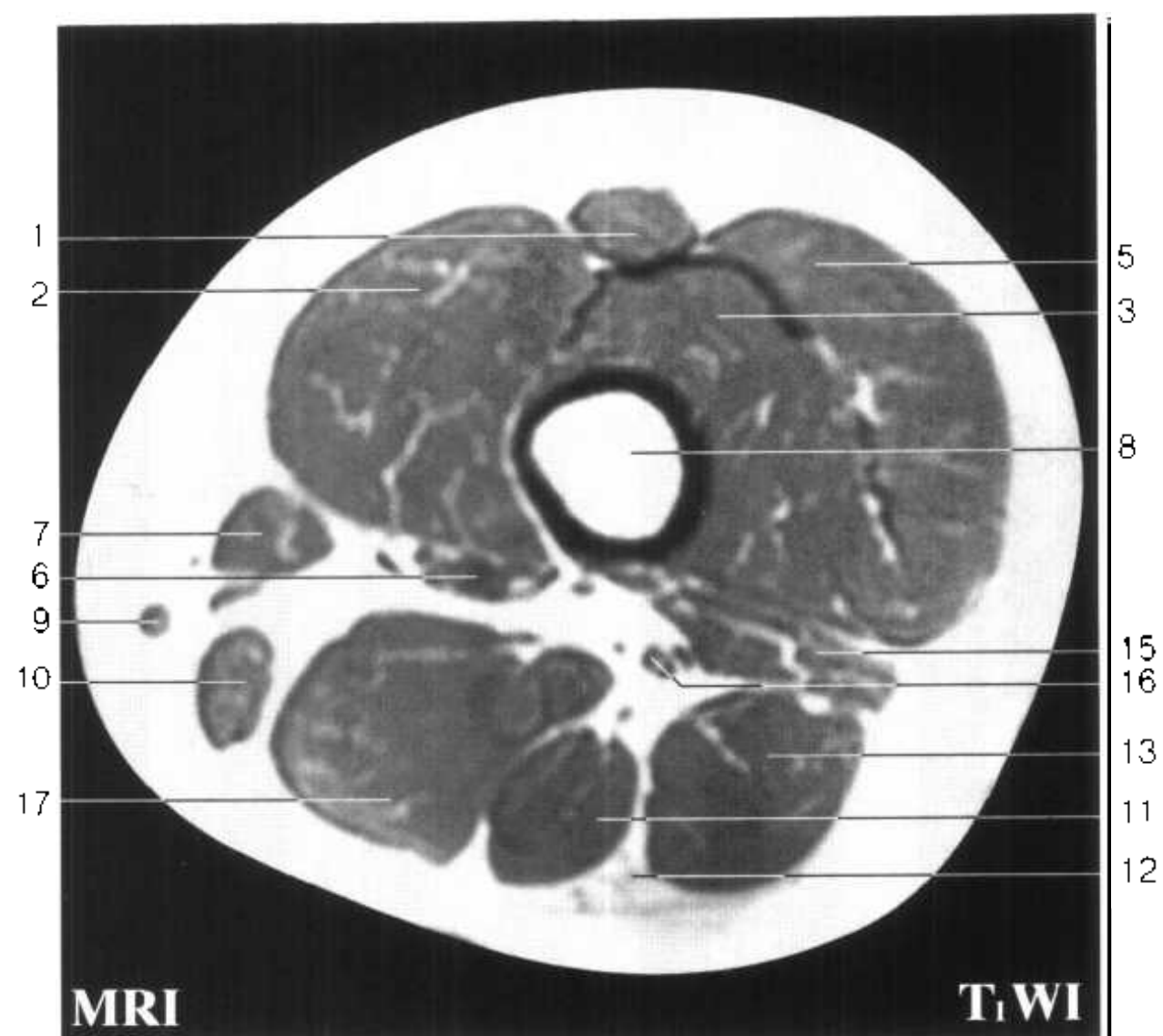


Fig. HLL 3

1. 股直肌 rectus femoris
2. 股内侧肌 vastus medialis
3. 股中间肌 vastus intermedius
4. 髌上囊 suprapatellar bursa
5. 股外侧肌 vastus lateralis
6. 大收肌 adductor magnus
7. 缝匠肌 sartorius
8. 股骨 femur
9. 大隐静脉 great saphenous v.
10. 股薄肌 gracilis
11. 半腱肌 semitendinosus

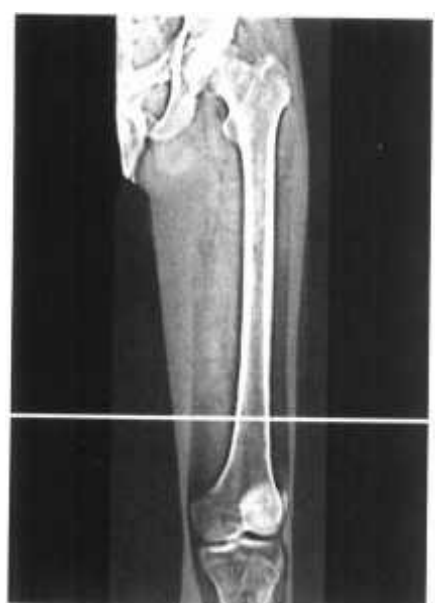

Fig. HLL 3



12. 股后皮神经 posterior femoral cutaneous n.
13. 股二头肌长头 long head of biceps femoris
14. 股后肌间隔 posterior femoral intermuscular septum
15. 股二头肌短头 short head of biceps femoris
16. 坐骨神经 sciatic n.
17. 半膜肌 semimembranosus

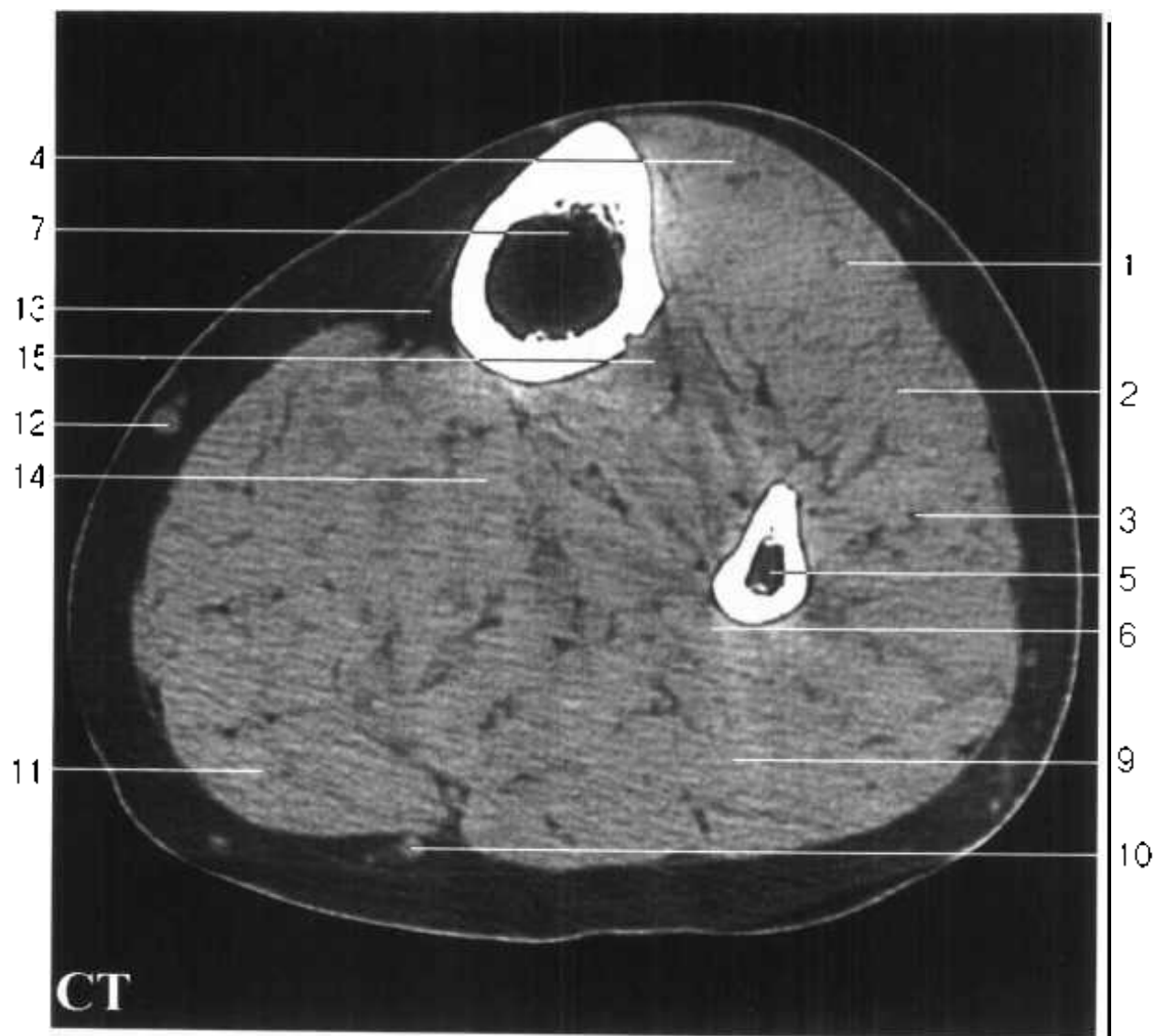
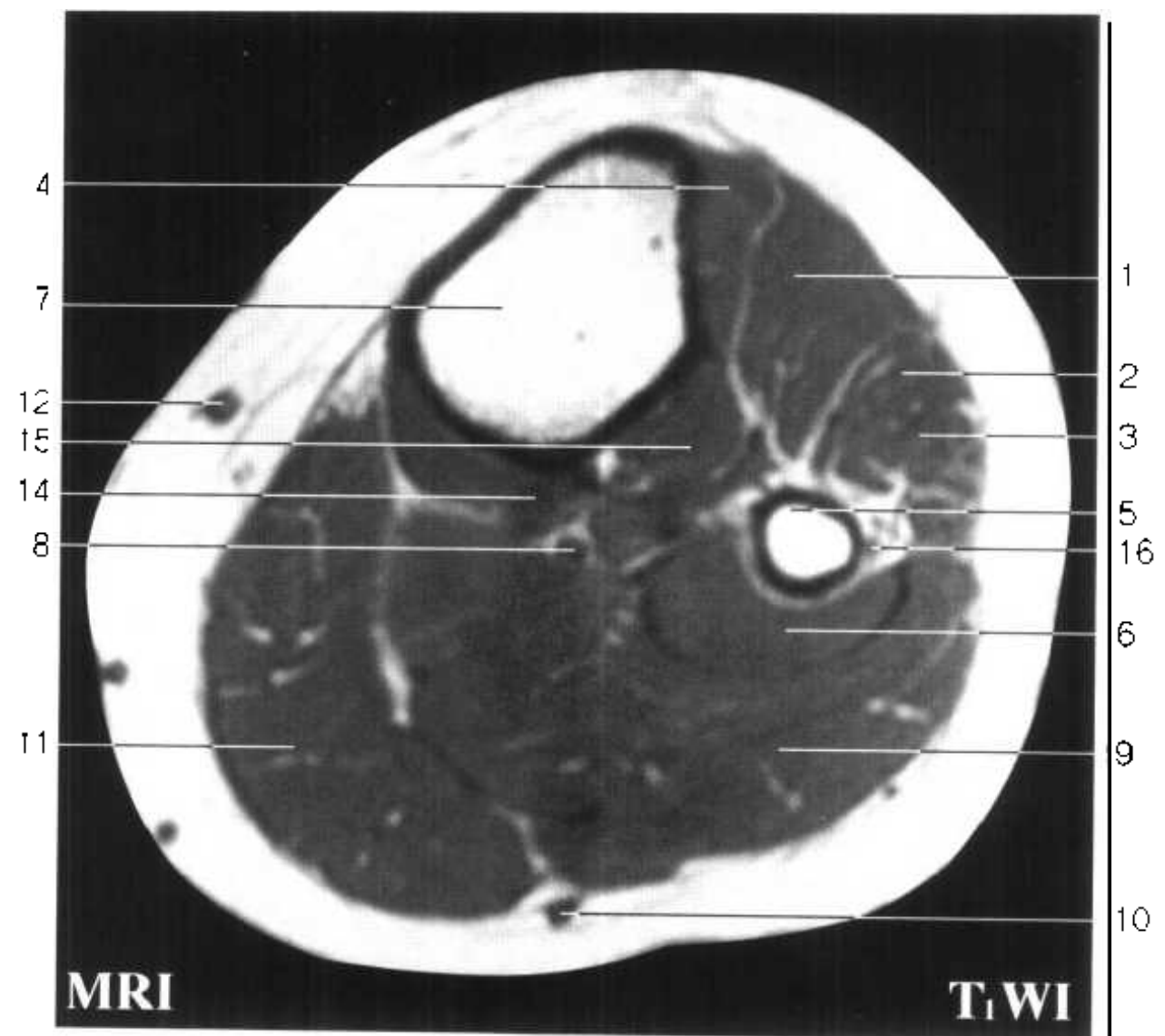


Fig. HLL 4

1. 趾长伸肌 extensor digitorum longus
2. 腓骨长肌 peroneus longus
3. 腓骨短肌 peroneus brevis
4. 胫骨前肌 tibialis anterior
5. 腓骨 fibula
6. 比目鱼肌 soleus
7. 胫骨 tibia
8. 胫神经 tibial n.
9. 腓肠肌外侧头 lateral head of gastrocnemius

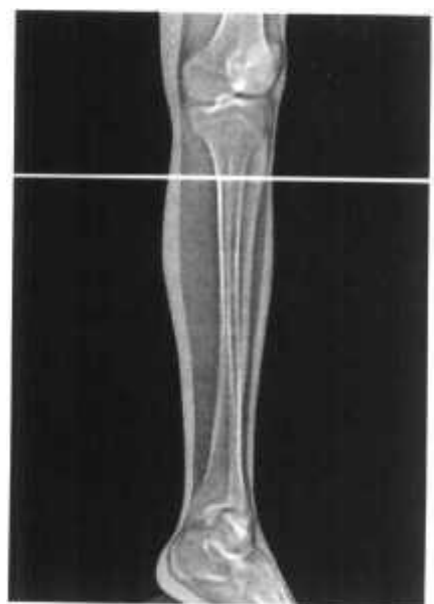

Fig. HLL 4



10. 小隐静脉 small saphenous v.
11. 腓肠肌内侧头 medial head of gastrocnemius
12. 大隐静脉 great saphenous v.
13. 鹅足囊 anserine bursa
14. 腓肌 popliteus
15. 胫骨后肌 tibialis posterior
16. 腓总神经 common peroneal n.

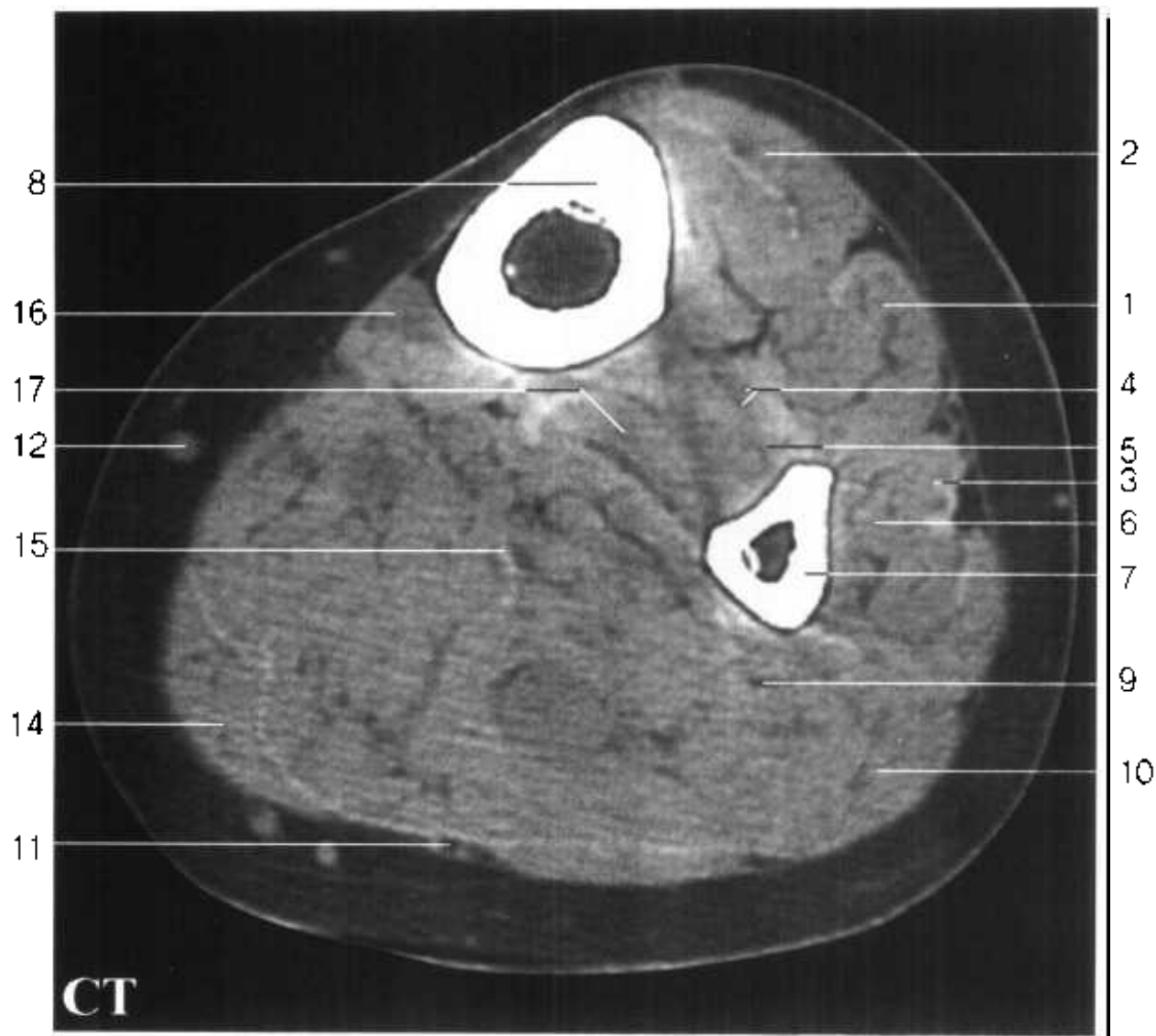
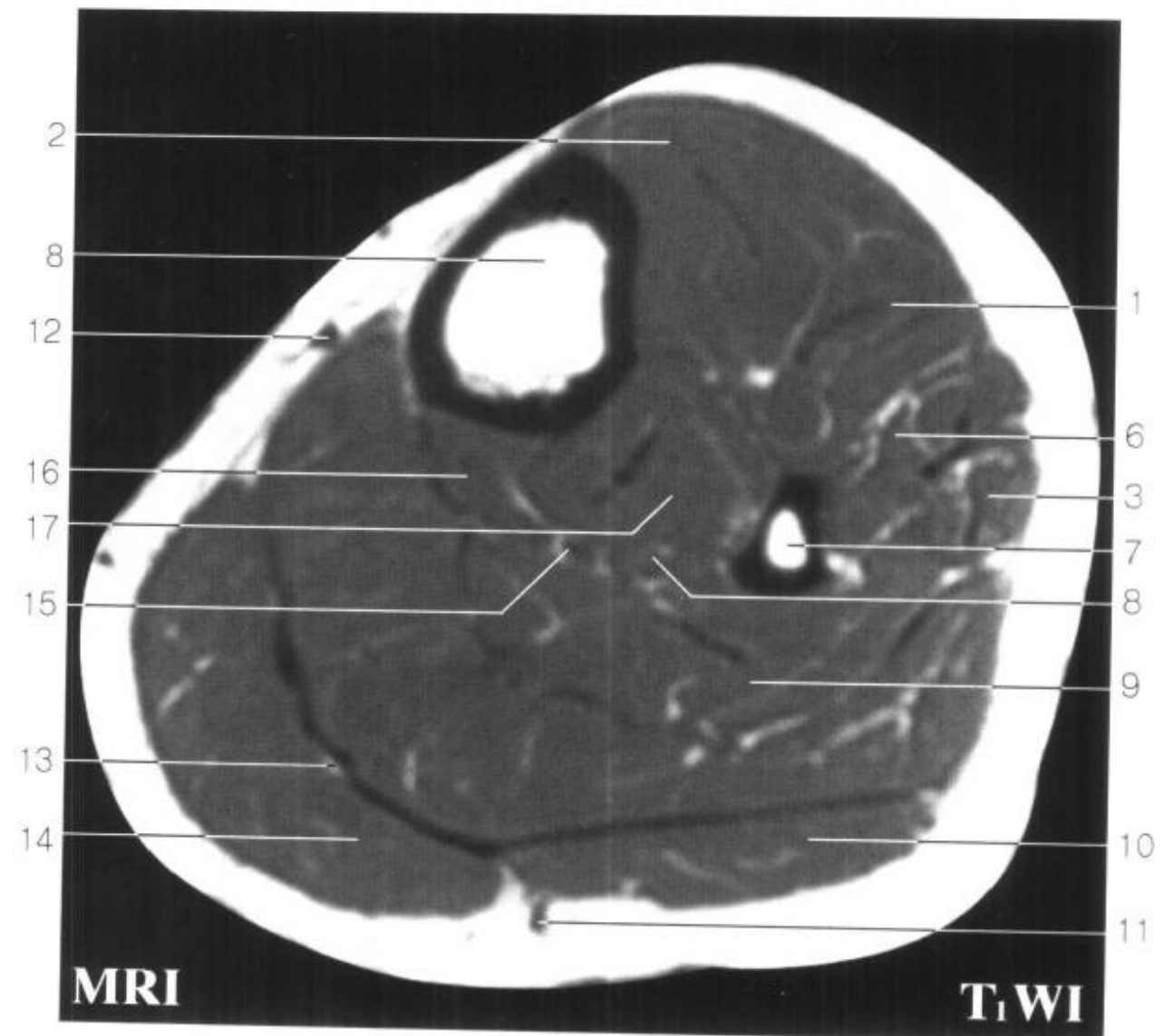


Fig. HLL 5

1. 趾长伸肌 extensor digitorum longus
2. 胫骨前肌 tibialis anterior
3. 腓骨长肌 peroneus longus
4. 胫前动、静脉 anterior tibial a.and v.
5. 小腿骨间膜 crural interosseous membrane
6. 腓骨短肌 peroneus brevis
7. 腓骨 fibula
8. 胫骨 tibia
9. 比目鱼肌 soleus

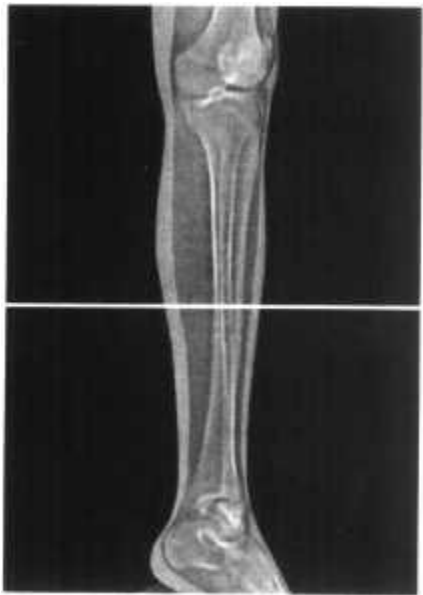

Fig. HLL 5



10. 腓肠肌外侧头 lateral head of gastrocnemius
11. 小隐静脉 small saphenous v.
12. 大隐静脉 great saphenous v.
13. 跖肌腱 tendon of plantaris
14. 腓肠肌内侧头 medial head of gastrocnemius
15. 胫神经 tibial n.
16. 趾长屈肌 flexor digitorum longus
17. 胫骨后肌 tibialis posterior

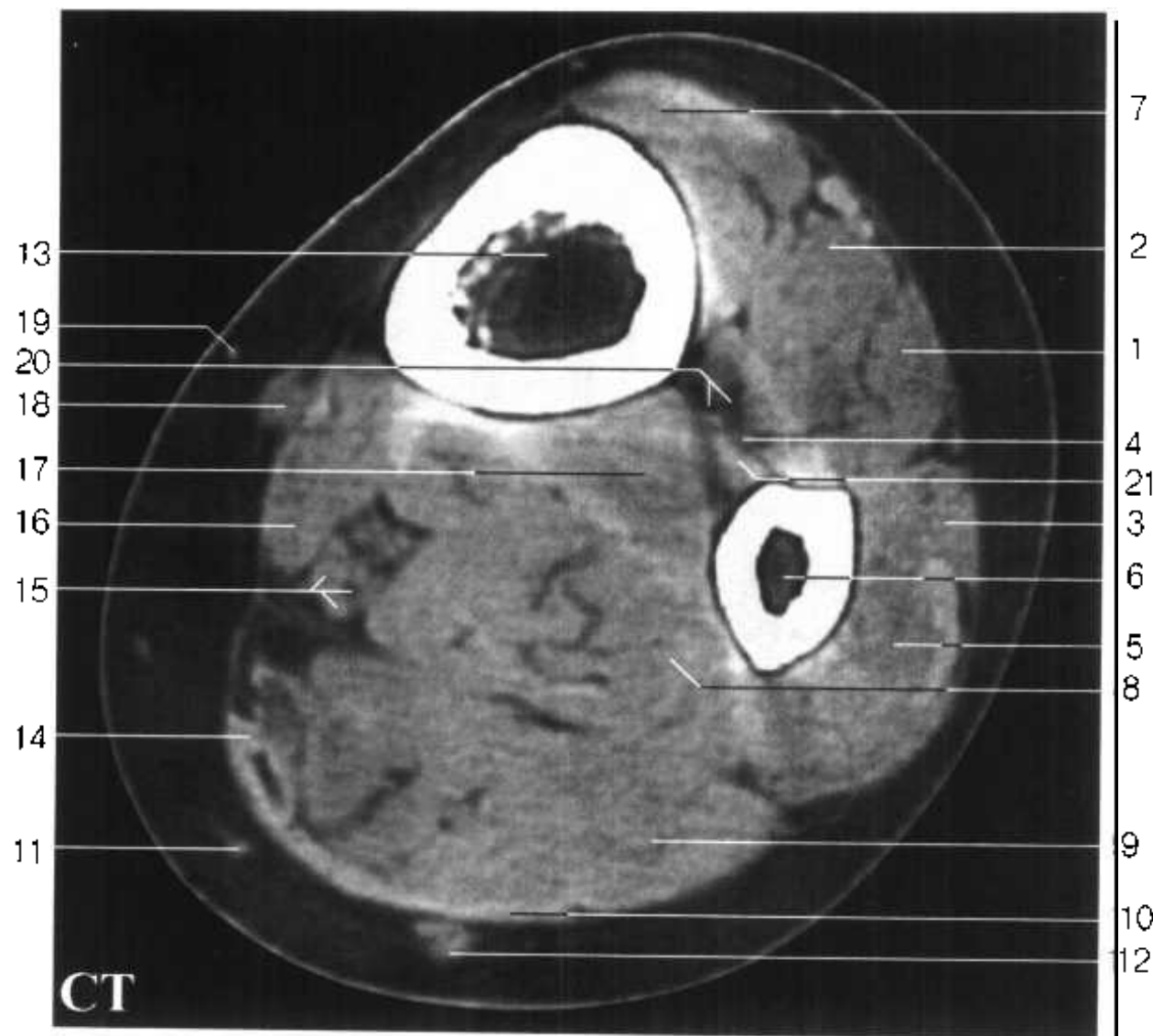


Fig. HLL 6

1. 趾长伸肌 extensor digitorum longus
2. 踇长伸肌 extensor hallucis longus
3. 腓骨长肌 peroneus longus
4. 腓深神经 deep peroneal n.
5. 腓骨短肌 peroneus brevis
6. 腓骨 fibula
7. 胫骨前肌 tibialis anterior
8. 踇长屈肌 flexor hallucis longus
9. 比目鱼肌 soleus
10. 腓肠肌腱 tendon of gastrocnemius
11. 腓肠神经 sural n.
12. 小隐静脉 small saphenous v.

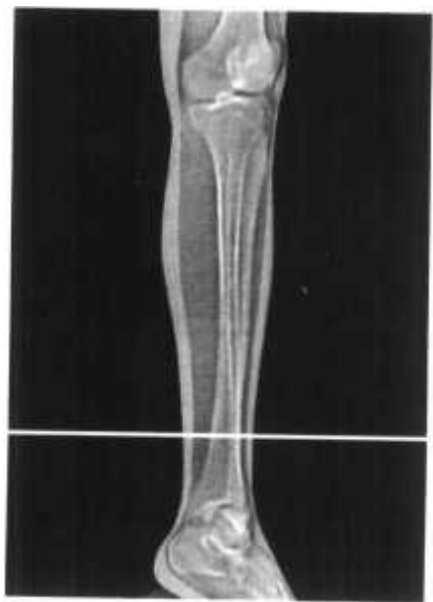
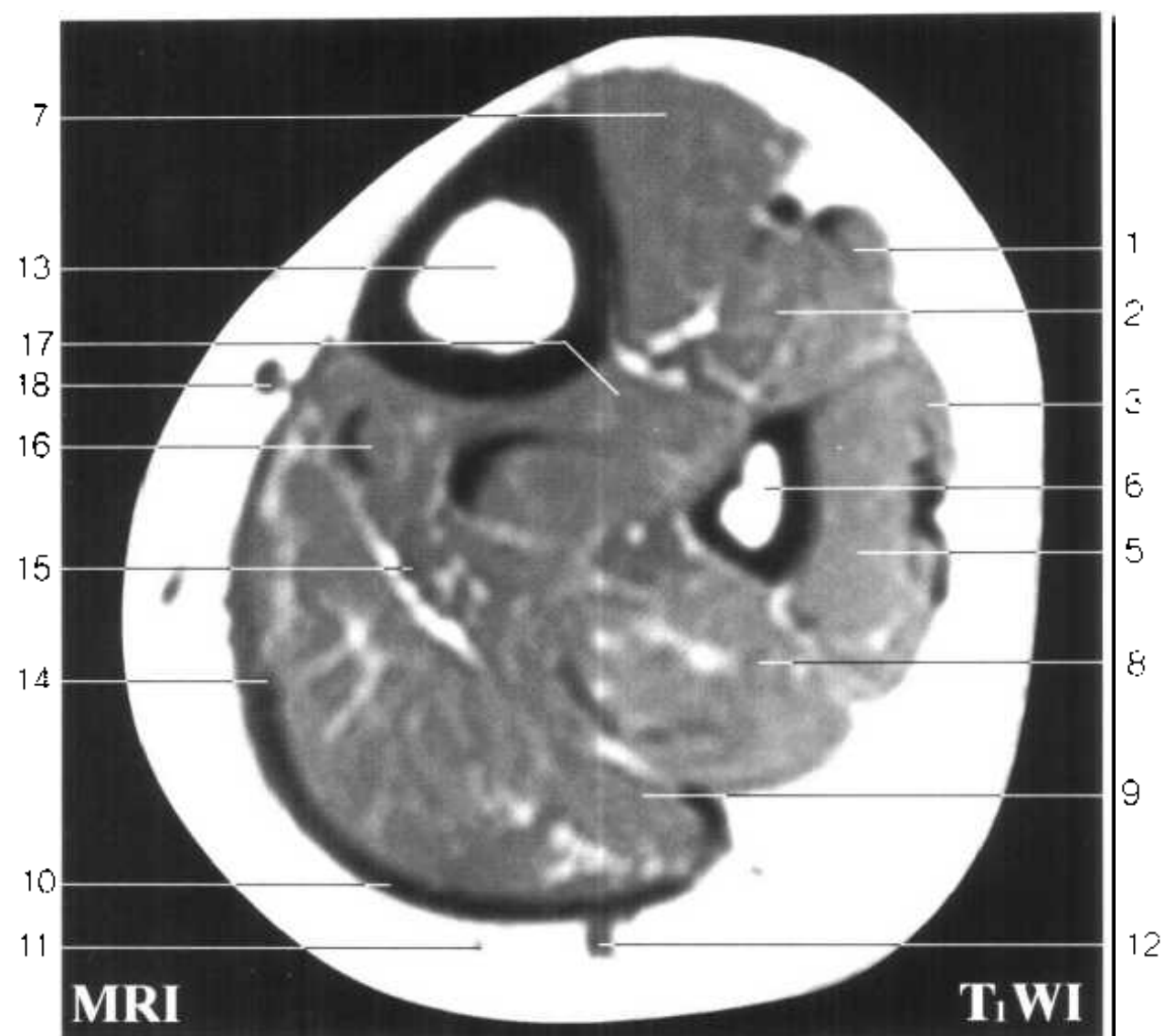
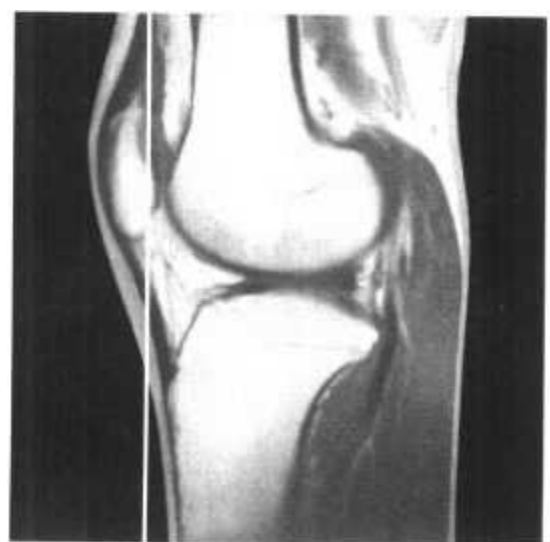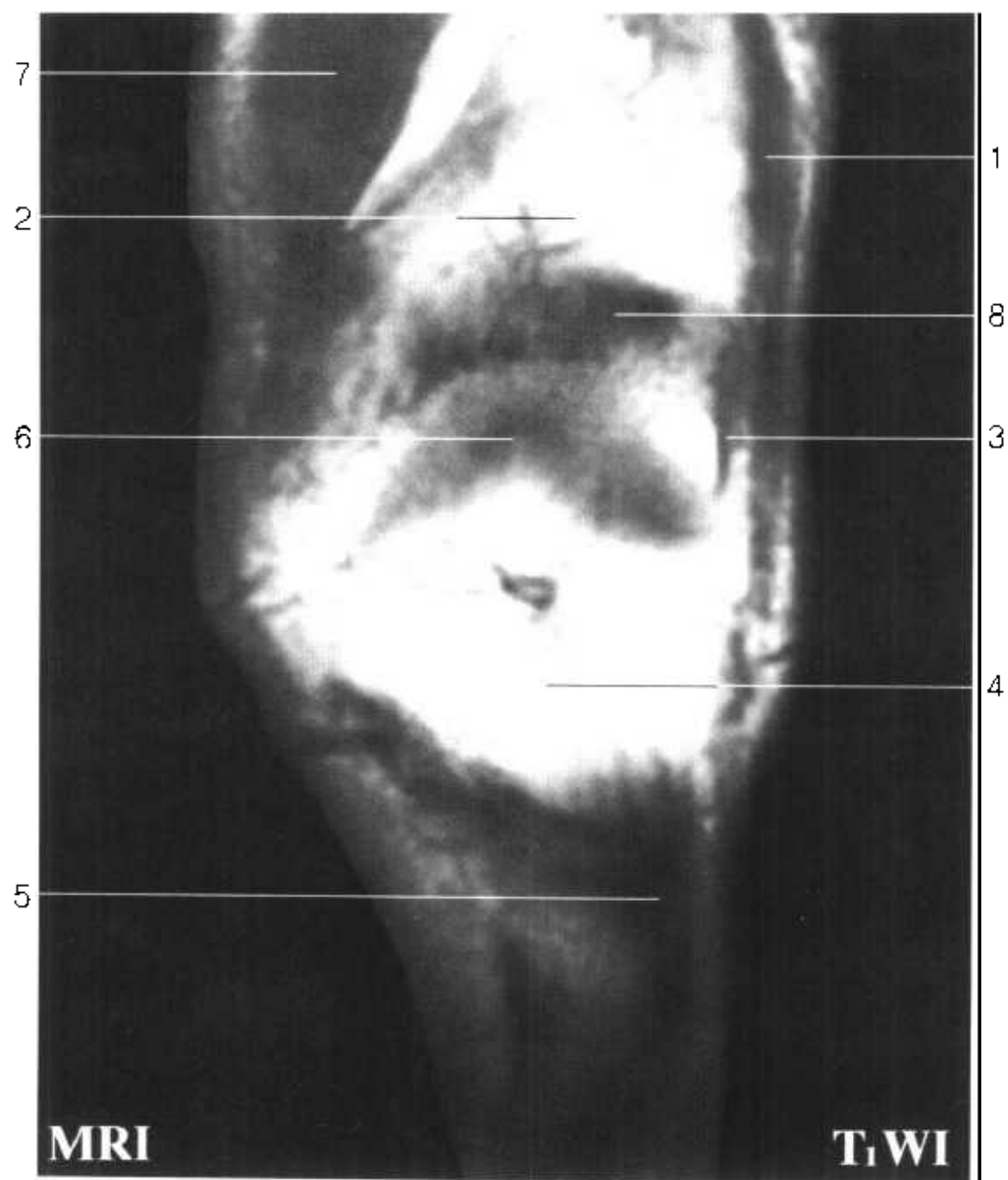Fig. HLL 6



13. 胫骨 tibia
14. 跖肌腱 tendon of plantaris
15. 胫神经与胫后动、静脉 tibial n.and posterior tibial a., v.
16. 趾长屈肌 flexor digitorum longus
17. 胫骨后肌 tibialis posterior
18. 大隐静脉 great saphenous v.
19. 隐神经 saphenous n.
20. 胫前动、静脉 anterior tibial a.and v.
21. 小腿骨间膜 crural interosseous membrane

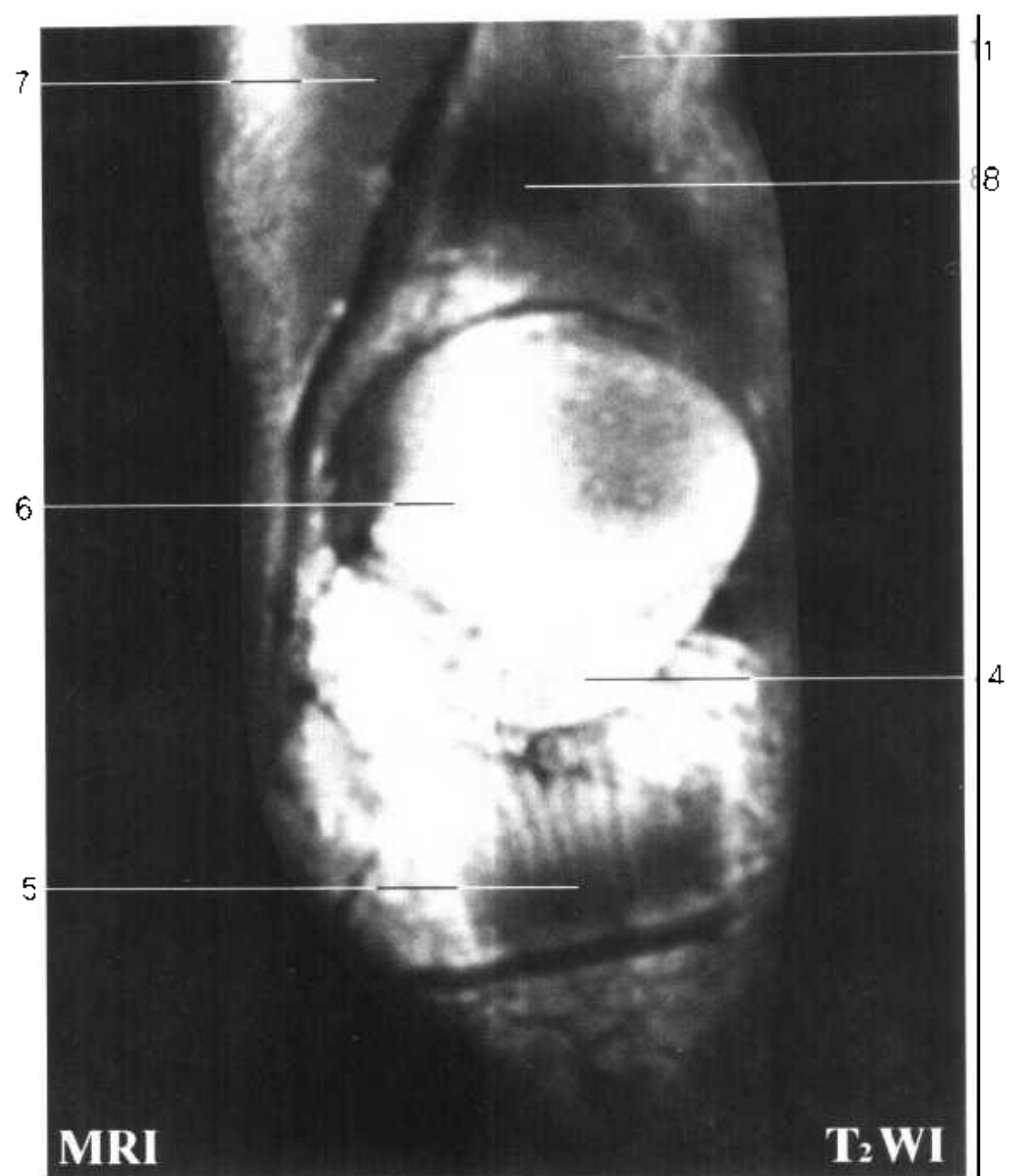

左膝关节额状断面图 FK(L)

Fig. FK(L) 1

- 1. 股外侧肌 vastus lateralis
- 2. 髌上脂体 suprapatellar fat pad
- 3. 膝关节腔 articular cavity of knee joint
- 4. 髌下脂体 infrapatellar fat pad
- 5. 髌韧带 patellar ligament
- 6. 髌骨 patella

Fig. FK(L) 1



- 7. 股内侧肌 vastus medialis
- 8. 股四头肌腱 tendon of quadriceps femoris

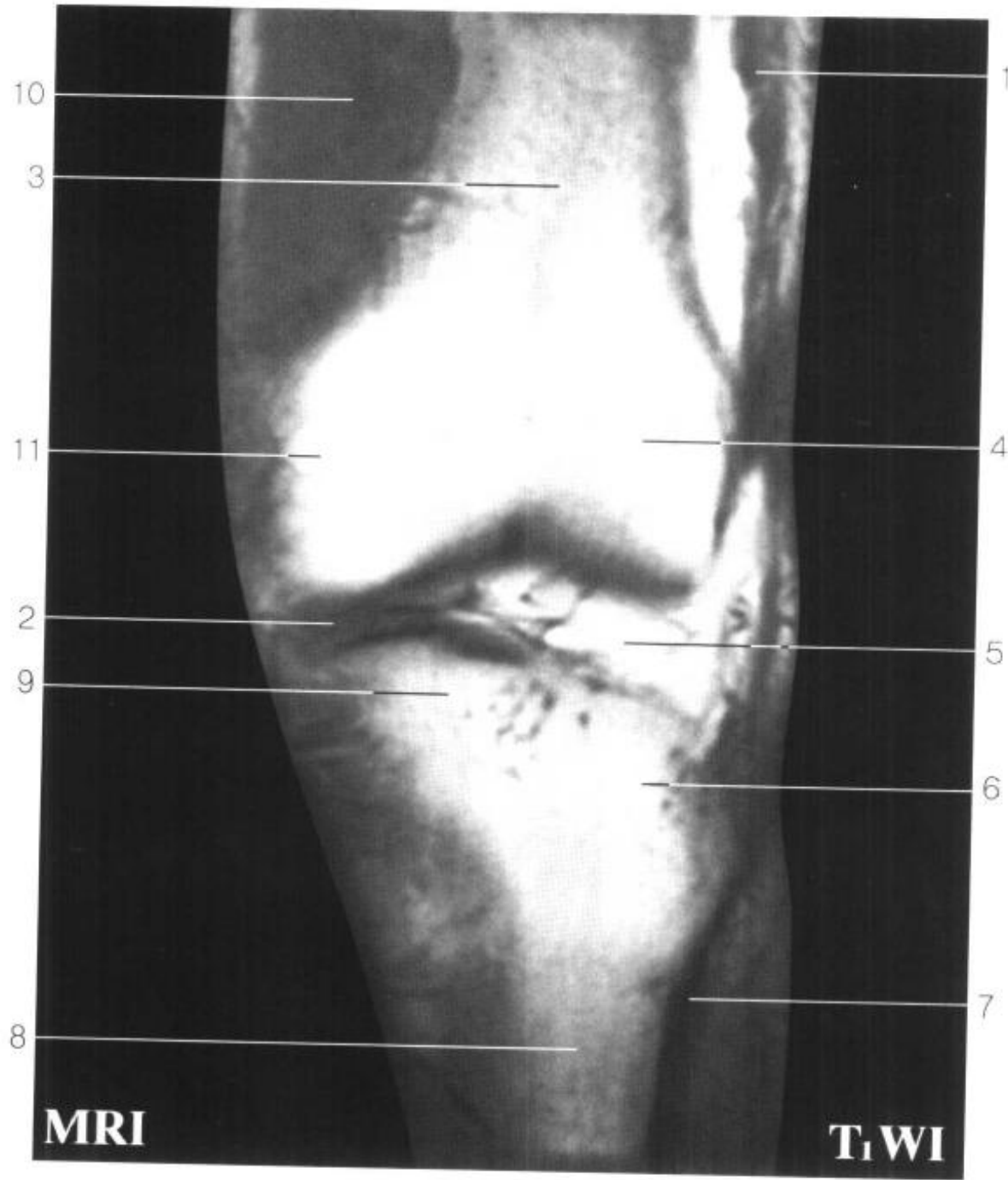
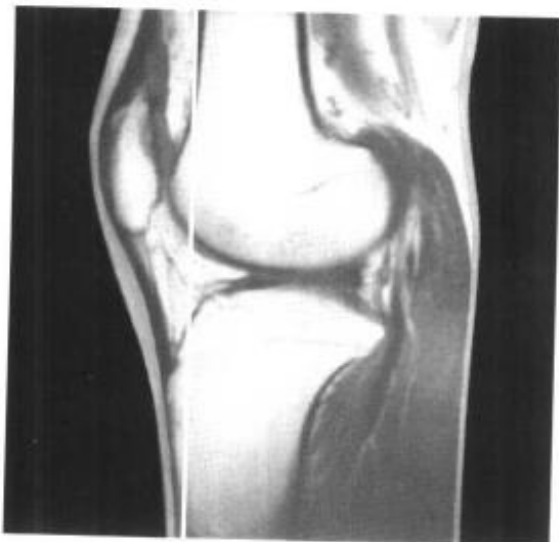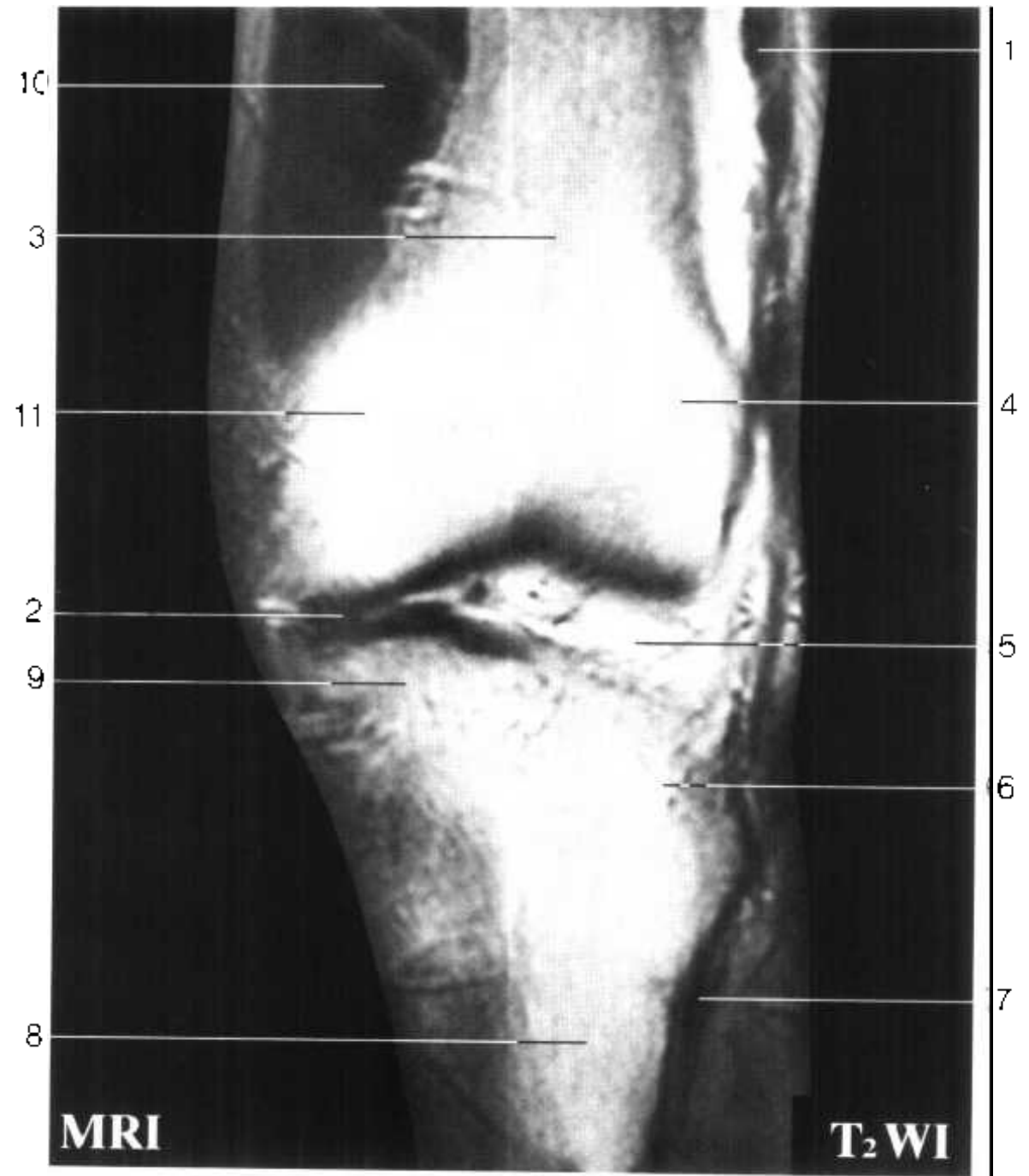


Fig. FK(L) 2



- 1. 股外侧肌 vastus lateralis
- 2. 内侧半月板 medial meniscus
- 3. 股骨 femur
- 4. 股骨外侧髁 lateral condyle of femur
- 5. 髌下脂体 infrapatellar fat pad
- 6. 胫骨外侧髁 lateral condyle of tibia

Fig. FK(L) 2



- 7. 胫骨前肌 tibialis anterior
- 8. 胫骨 tibia
- 9. 胫骨内侧髁 medial condyle of tibia
- 10. 股内侧肌 vastus medialis
- 11. 股骨内侧髁 medial condyle of femur

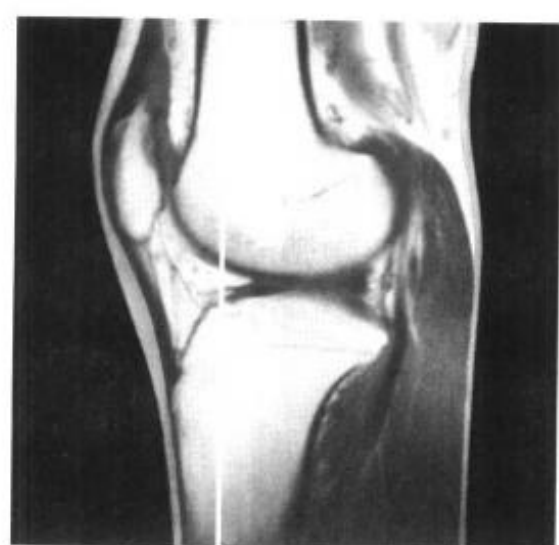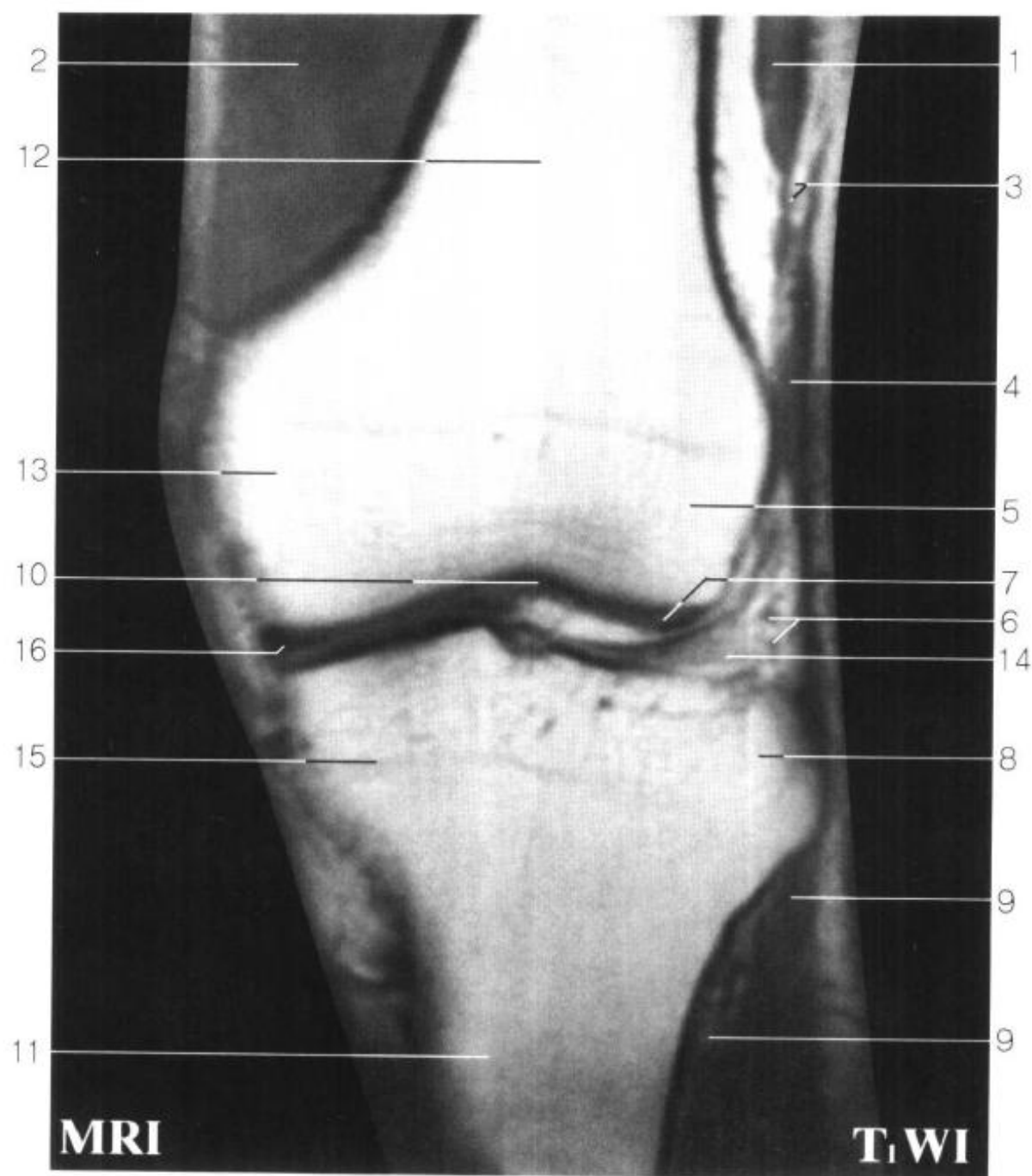
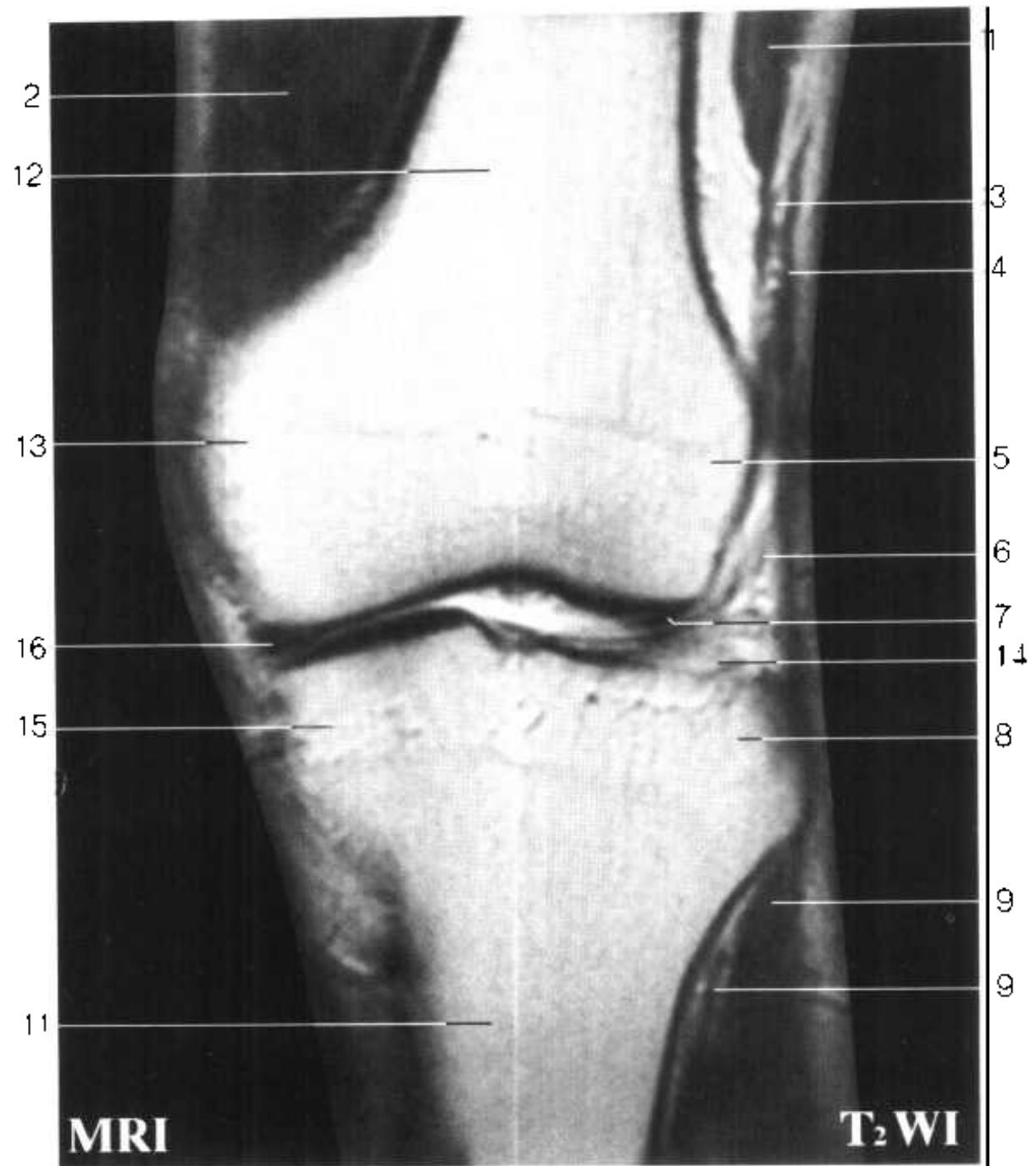


Fig. FK(L) 3

1. 股外侧肌 vastus lateralis
2. 股内侧肌 vastus medialis
3. 膝上外侧动、静脉 lateral superior genicular a.and v.
4. 髂胫束 iliotibial tract
5. 股骨外侧髁 lateral condyle of femur
6. 膝下外侧动、静脉 lateral inferior genicular a.and v.
7. 外侧半月板 lateral meniscus

Fig . FK(L) 3



- 8. 胫骨外側髁 lateral condyle of tibia
- 9. 胫骨前肌 tibialis anterior
- 10. 膝橫切帶 transverse ligament of knee
- 11. 胫骨 tibia
- 12. 股骨 femur
- 13. 股骨內側髁 medial condyle of femur
- 14. 髌下脂體 infrapatellar fat pad
- 15. 胫骨內側髁 medial condyle of tibia
- 16. 內側半月板 medial meniscus

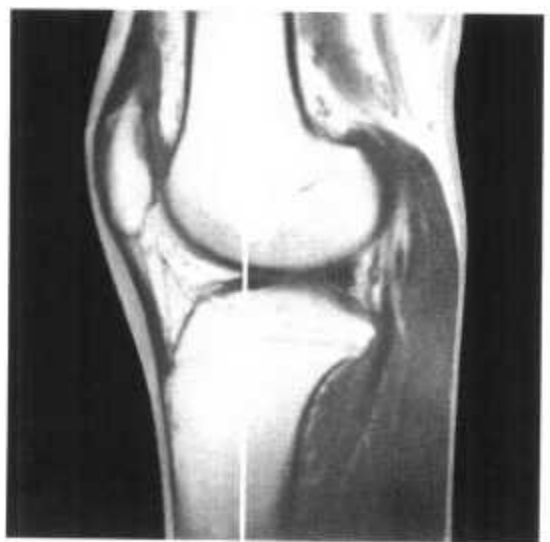
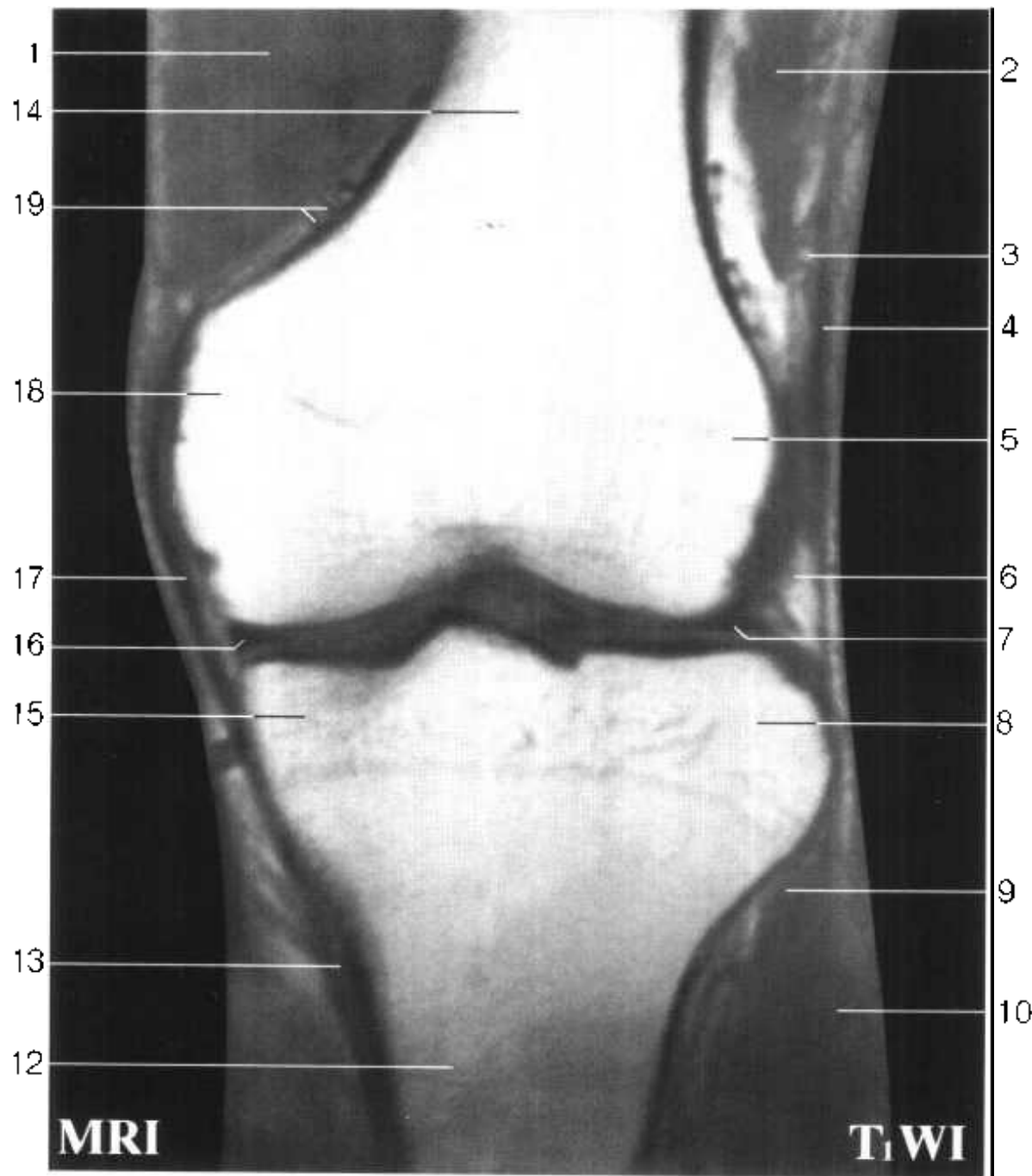
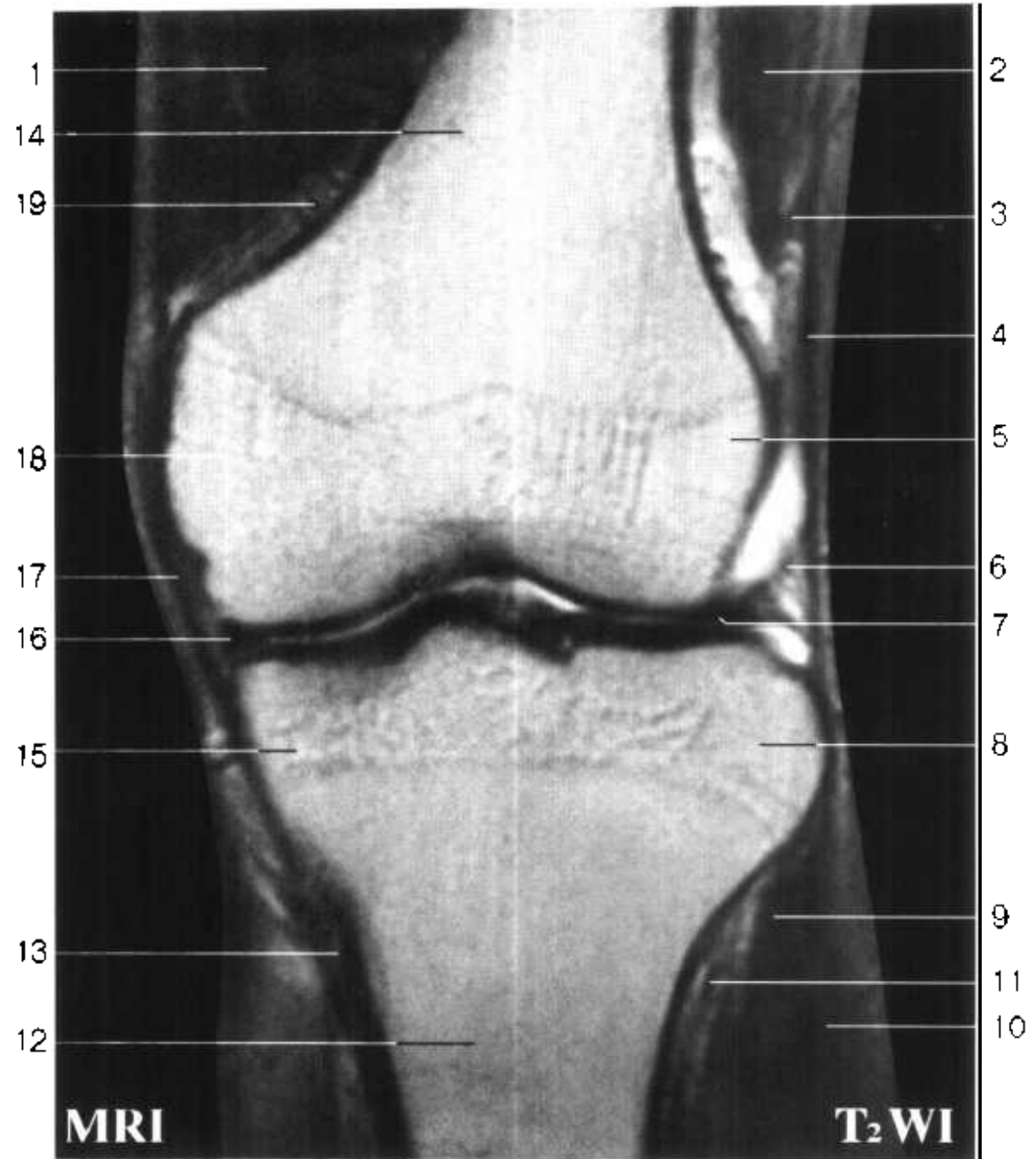Fig. FK(L) 4

1. 股内侧肌 vastus medialis
2. 股外侧肌 vastus lateralis
3. 膝上外侧动、静脉 lateral superior genicular a.and v.
4. 髂胫束 iliotibial tract
5. 股骨外侧髁 lateral condyle of femur
6. 膝下外侧动、静脉 lateral inferior genicular a.and v.
7. 外侧半月板 lateral meniscus
8. 胫骨外侧髁 lateral condyle of tibia
9. 胫骨前肌 tibialis anterior

Fig. FK(L) 4



10. 趾长伸肌 extensor digitorum longus
11. 胫前动、静脉 anterior tibial a.and v.
12. 胫骨 tibia
13. 半膜肌与半腱肌腱 tendon of semimembranosus and semitendinosus
14. 股骨 femur
15. 胫骨内侧髁 medial condyle of tibia
16. 内侧半月板 medial meniscus
17. 胫侧副韧带 tibial collateral ligament
18. 股骨内侧髁 medial condyle of femur
19. 膝上内侧动、静脉 medial superior genicular a.and v.

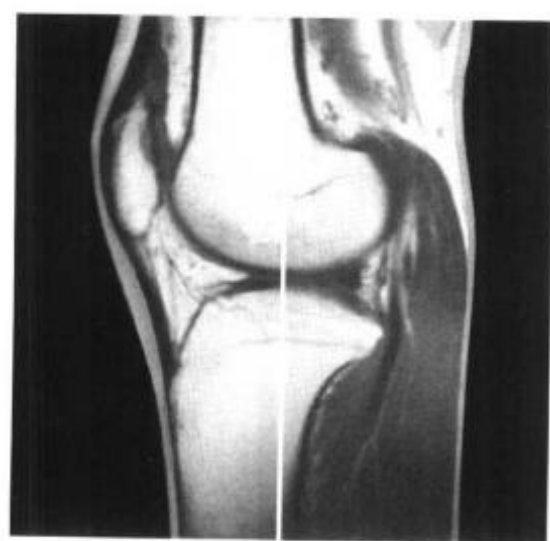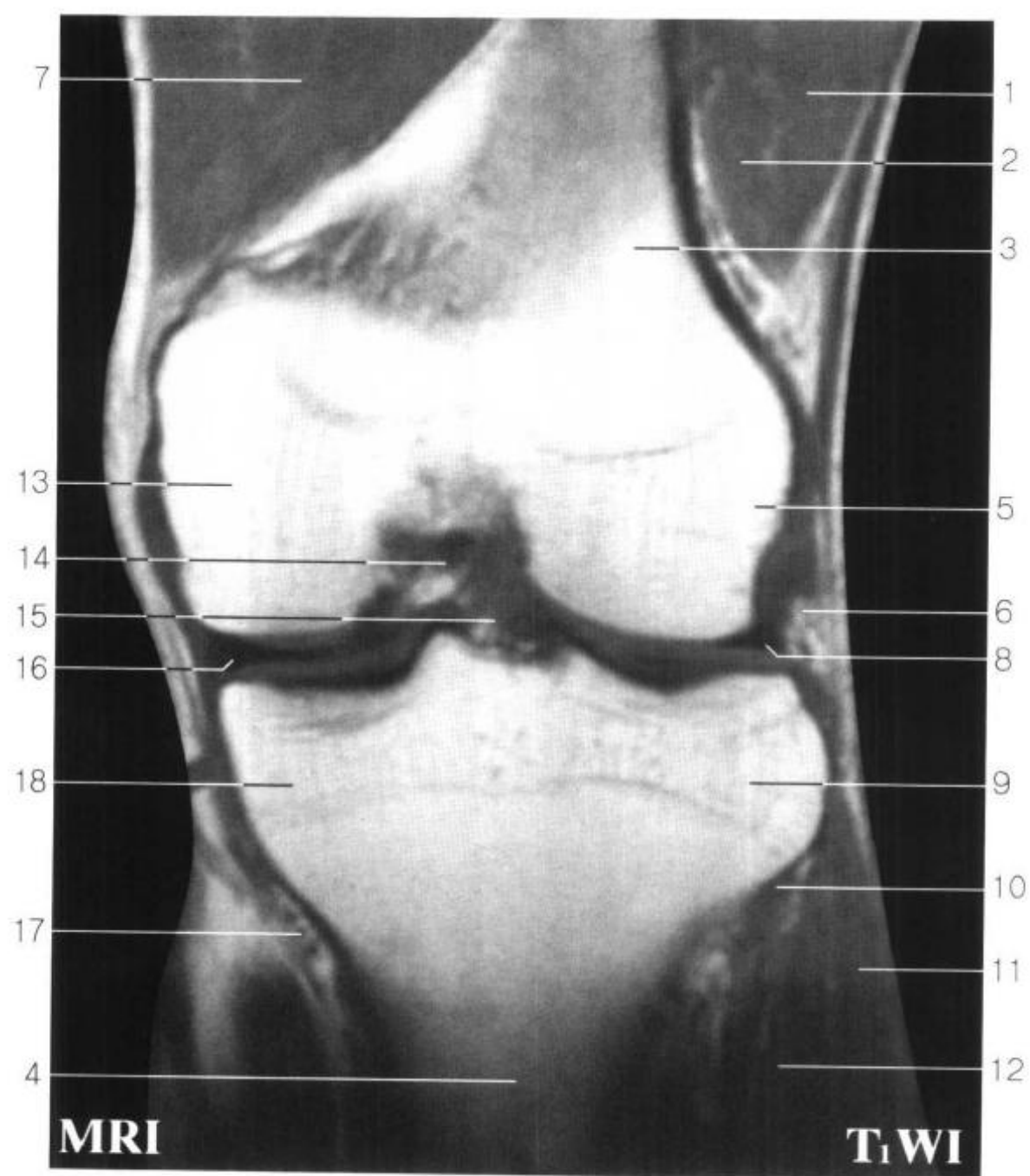
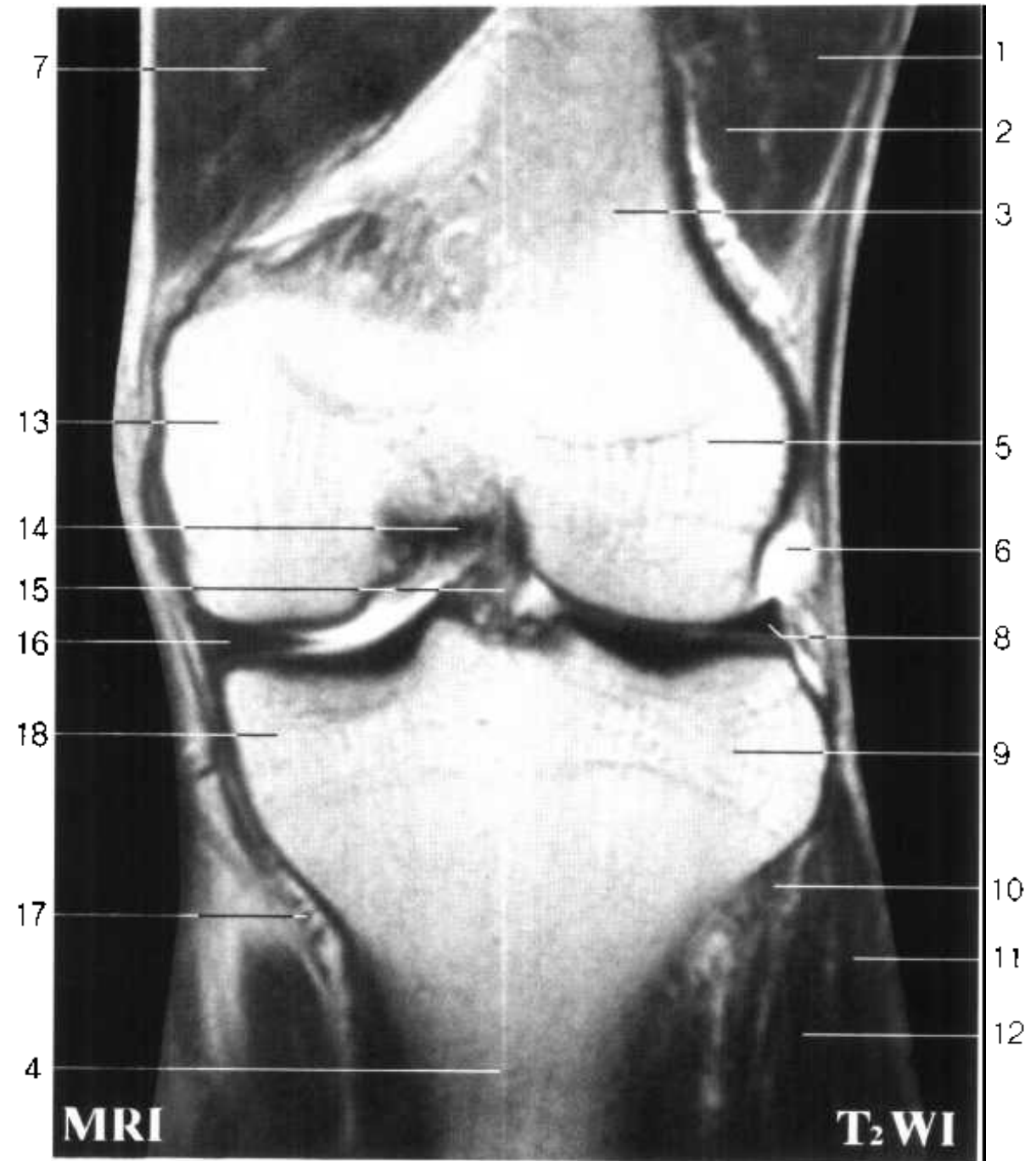


Fig. FK(L) 5

1. 股外侧肌 vastus lateralis
2. 股中间肌 vastus intermedius
3. 股骨 femur
4. 胫骨 tibia
5. 股骨外侧髁 lateral condyle of femur
6. 腓肌腱 tendon of popliteus
7. 股内侧肌 vastus medialis
8. 外侧半月板 lateral meniscus
9. 胫骨外侧髁 lateral condyle of tibia

Fig. FK(L) 5



10. 股二头肌腱 tendon of biceps femoris
11. 趾长伸肌 extensor digitorum longus
12. 胫骨前肌 tibialis anterior
13. 股骨内侧髁 medial condyle of femur
14. 后交叉韧带 posterior cruciate ligament
15. 前交叉韧带 anterior cruciate ligament
16. 内侧半月板 medial meniscus
17. 膝下内侧动、静脉 medial inferior genicular a.and v.
18. 胫骨内侧髁 medial condyle of tibia

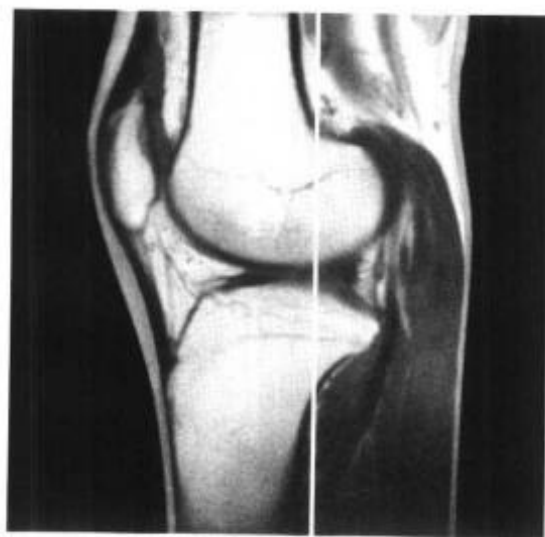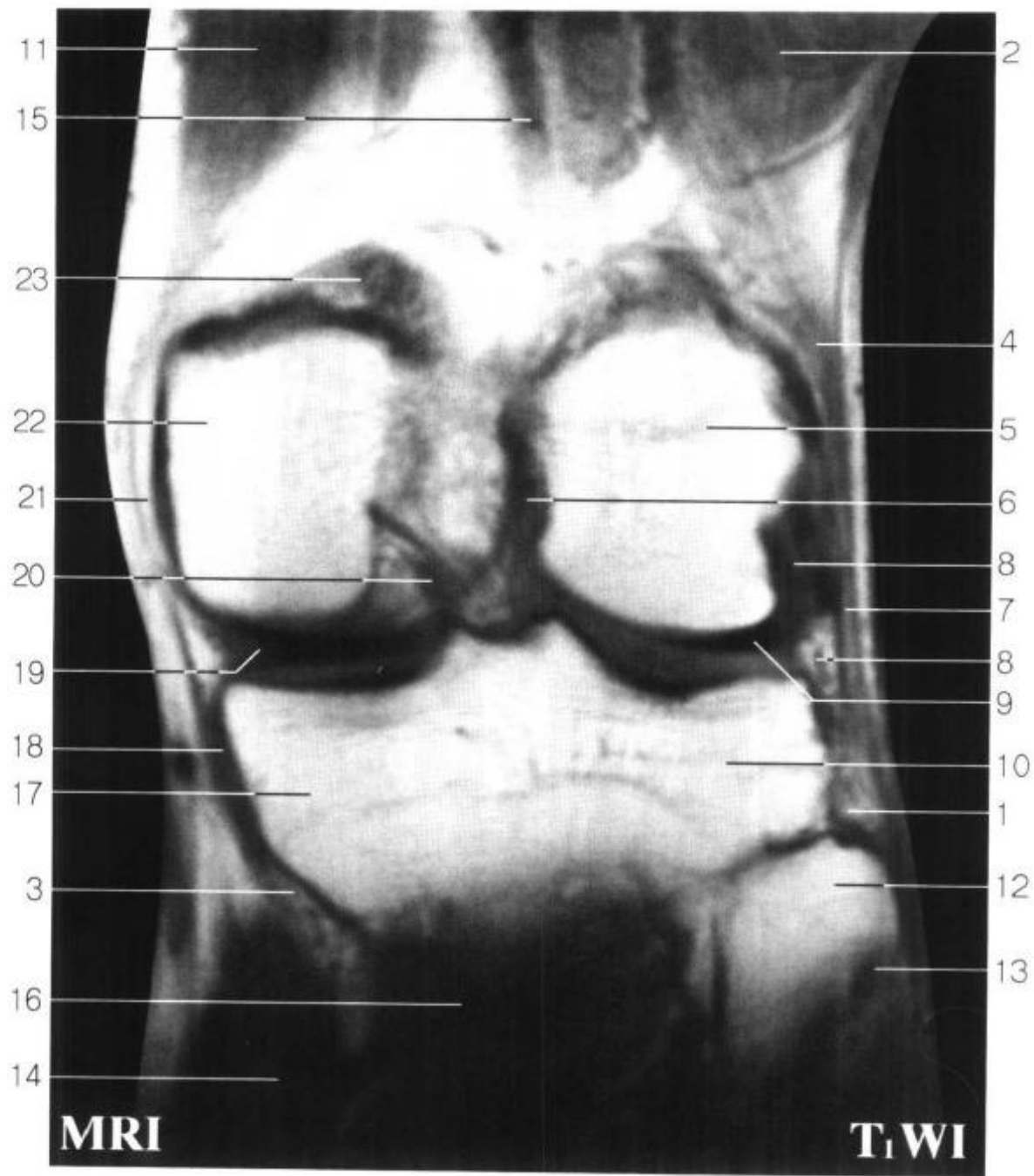
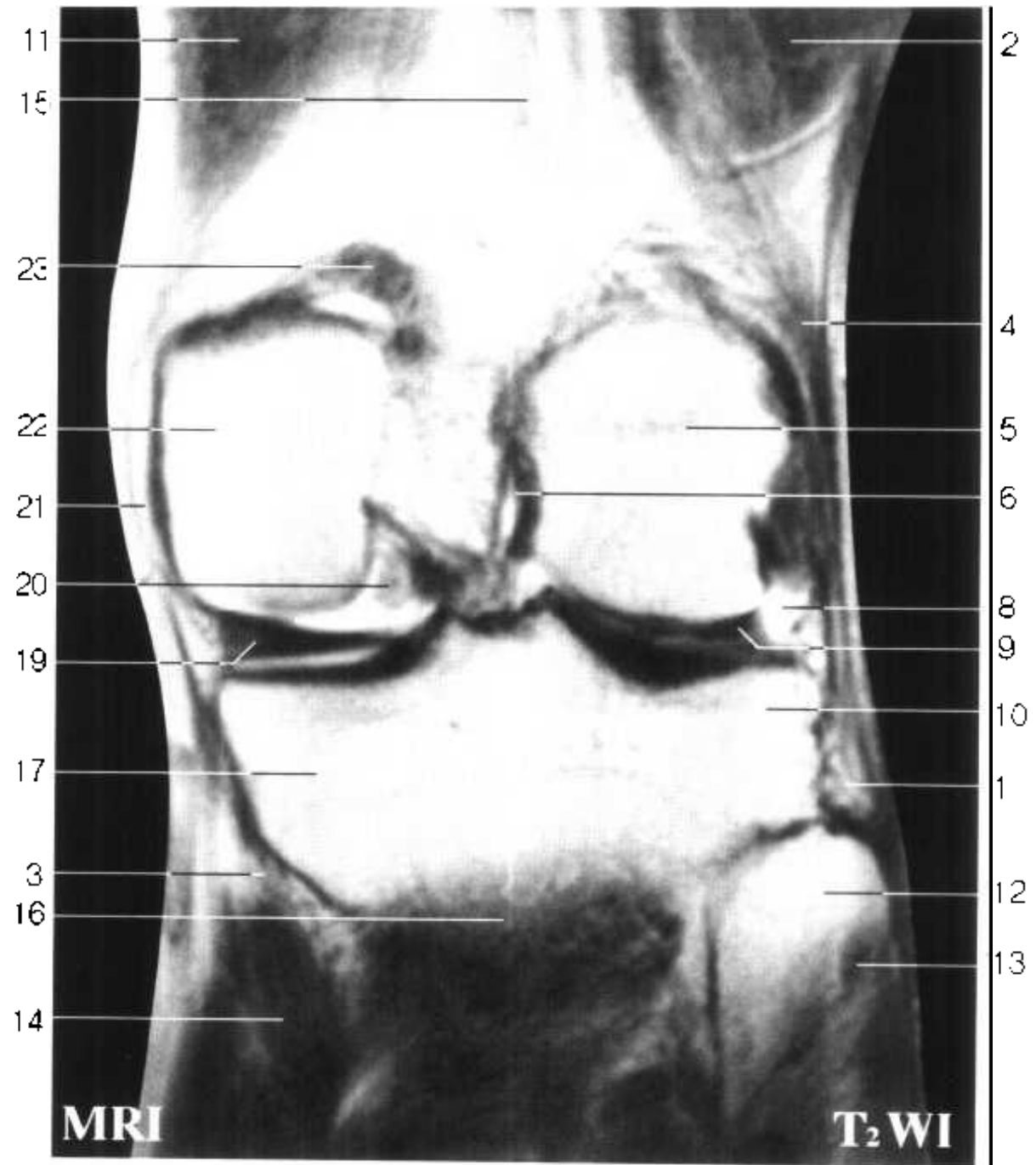


Fig. FK(L) 6

1. 股二头肌腱 tendon of biceps femoris
2. 股外侧肌 vastus lateralis
3. 半膜肌腱 tendon of semimembranosus
4. 股二头肌 biceps femoris
5. 股骨外侧髁 lateral condyle of femur
6. 前交叉韧带 anterior cruciate ligament
7. 腓侧副韧带 fibular collateral ligament
8. 腘肌腱 tendon of popliteus
9. 外侧半月板 lateral meniscus
10. 胫骨外侧髁 lateral condyle of tibia
11. 缝匠肌 sartorius
12. 腓骨头 fibular head

Fig. FK(L) 6



13. 腓骨长肌 peroneus longus
14. 比目鱼肌 soleus
15. 腘动脉 popliteal a.
16. 腘肌 popliteus
17. 胫骨内侧髁 medial condyle of tibia
18. 缝匠肌腱 tendon of sartorius
19. 内侧半月板 medial meniscus
20. 后交叉韧带 posterior cruciate ligament
21. 胫侧副韧带 tibial collateral ligament
22. 股骨内侧髁 medial condyle of femur
23. 腓肠肌内侧头 medial head of gastrocnemius

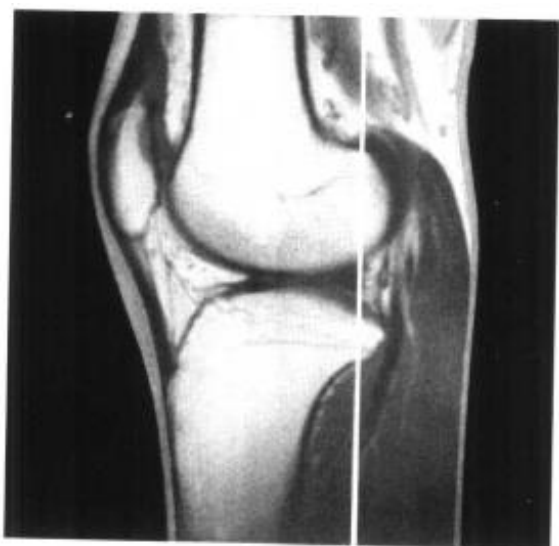
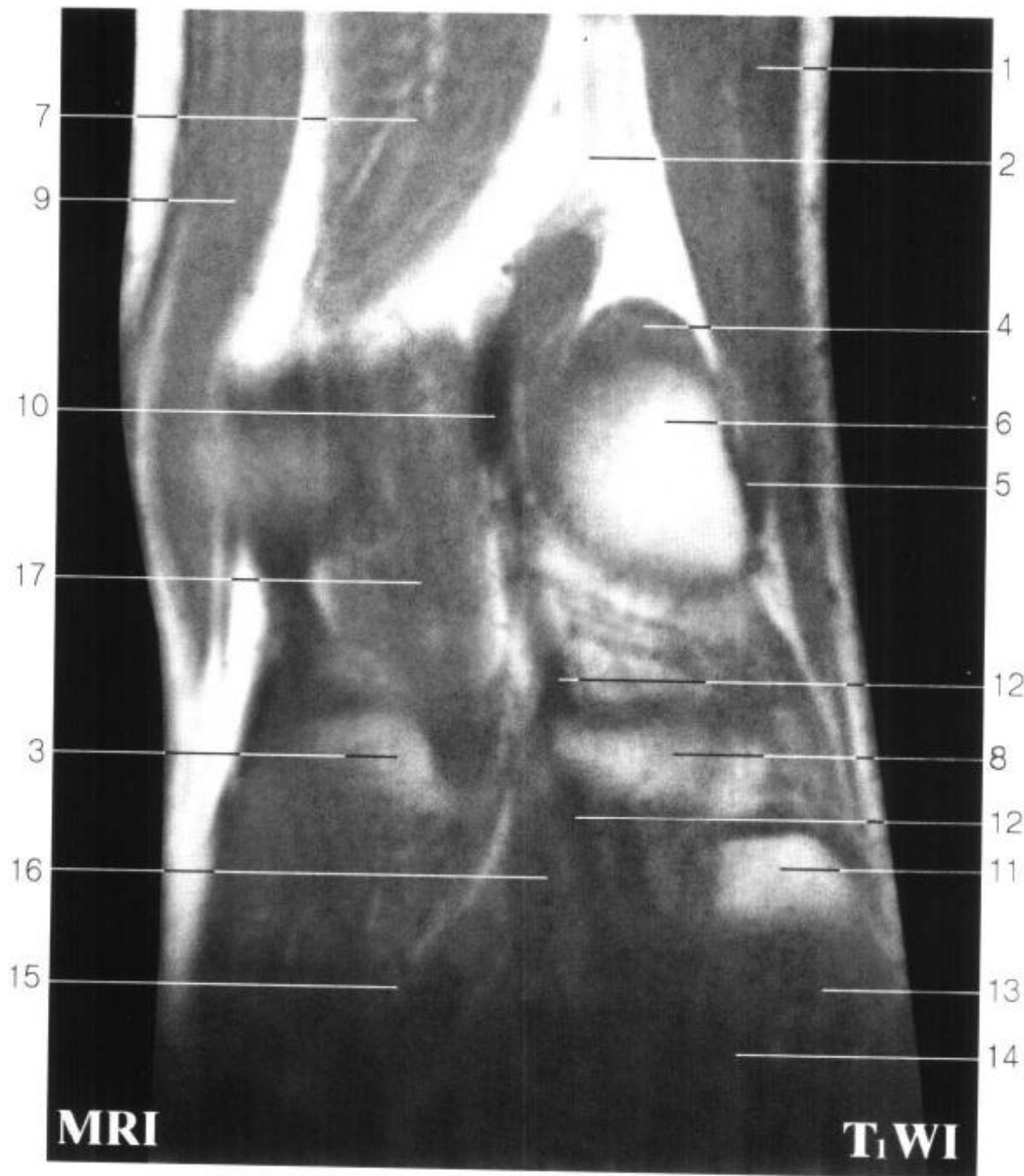
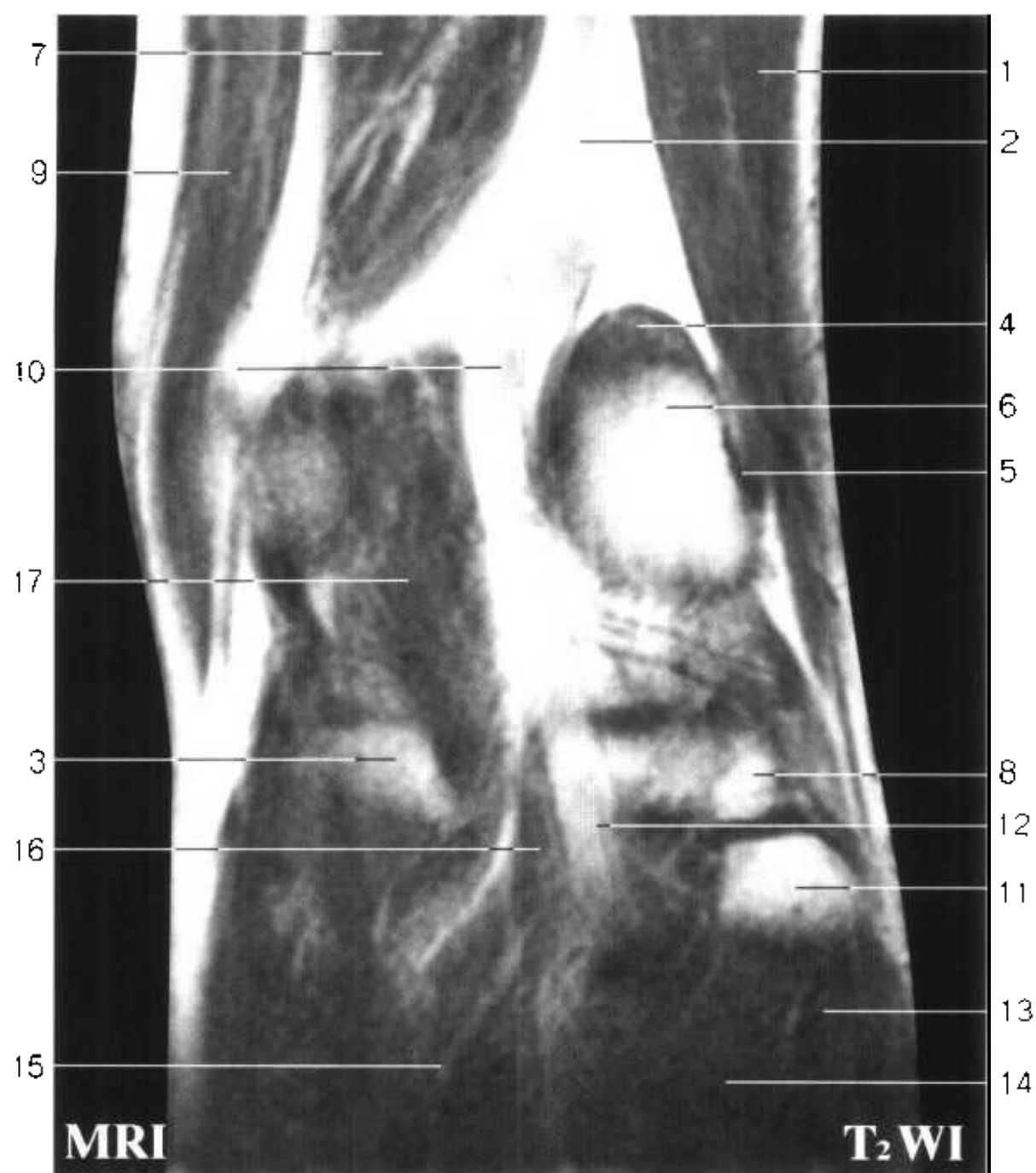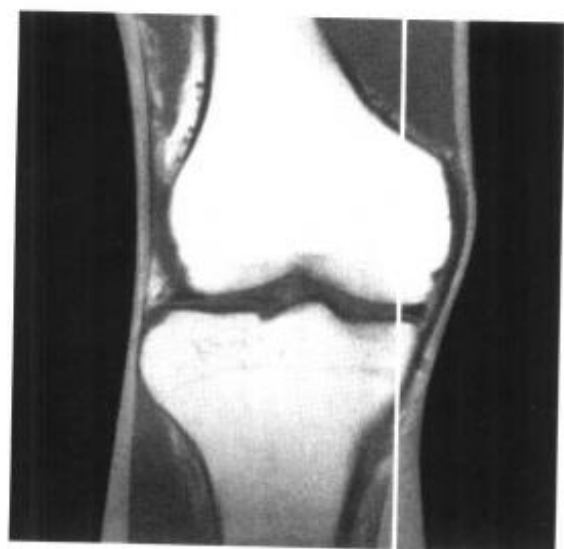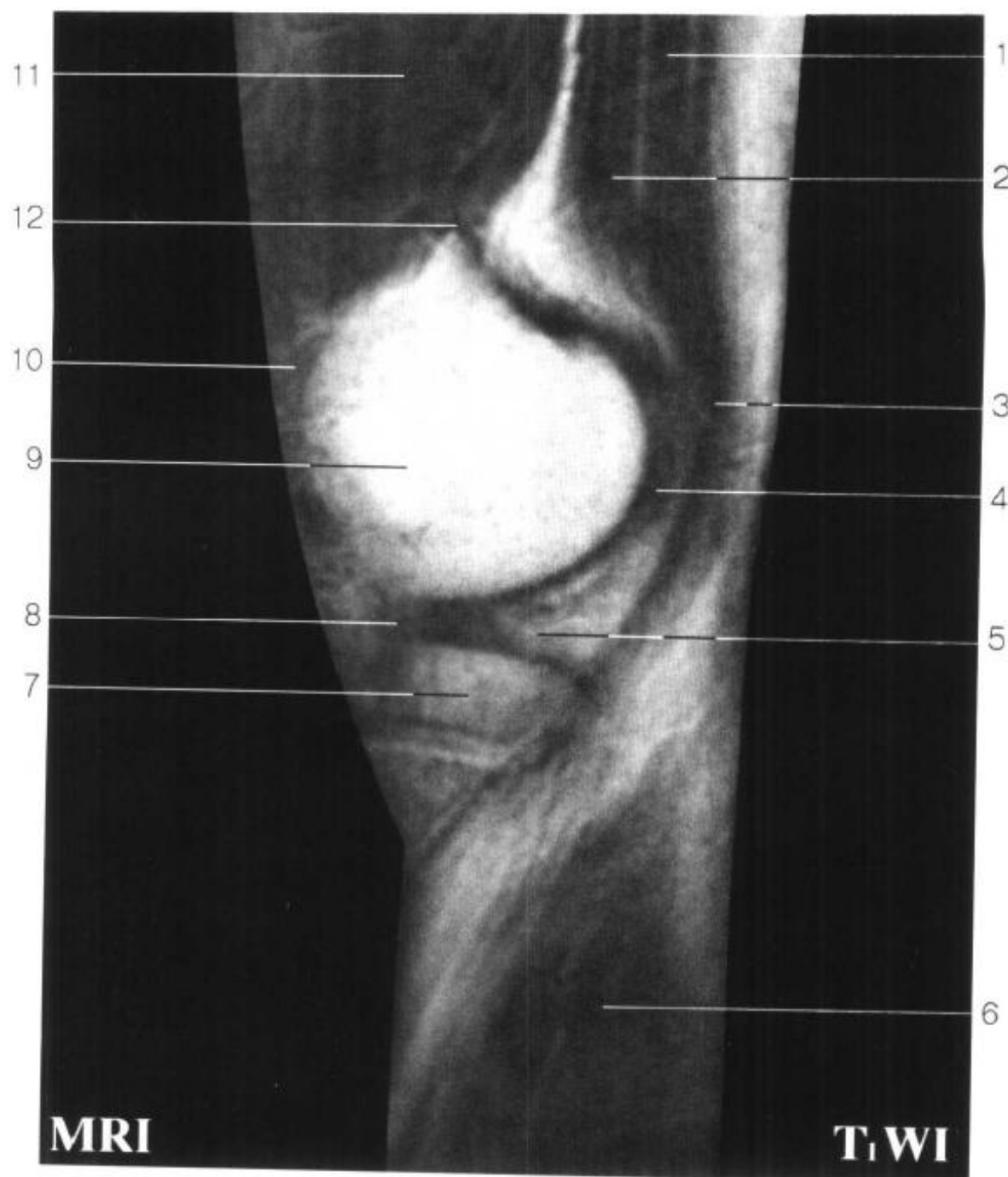Fig. FK(L) 7

- 1. 股二头肌 biceps femoris
- 2. 腘窝 popliteal fossa
- 3. 胫骨内侧髁 medial condyle of tibia
- 4. 腓肠肌外侧头 lateral head of gastrocnemius
- 5. 腘肌腱 tendon of popliteus
- 6. 股骨外侧髁 lateral condyle of femur
- 7. 大收肌 adductor magnus
- 8. 胫骨外侧髁 lateral condyle of tibia
- 9. 缝匠肌 sartorius

Fig. FK(L) 7



- 10. 腘动脉 popliteal a.
- 11. 腓骨头 fibular head
- 12. 腘静脉 popliteal v.
- 13. 腓骨长肌 peroneus longus
- 14. 腓骨短肌 peroneus brevis
- 15. 腓肠肌 gastrocnemius
- 16. 腘静脉 popliteal v.
- 17. 腓肠肌内侧头 medial head of gastrocnemius

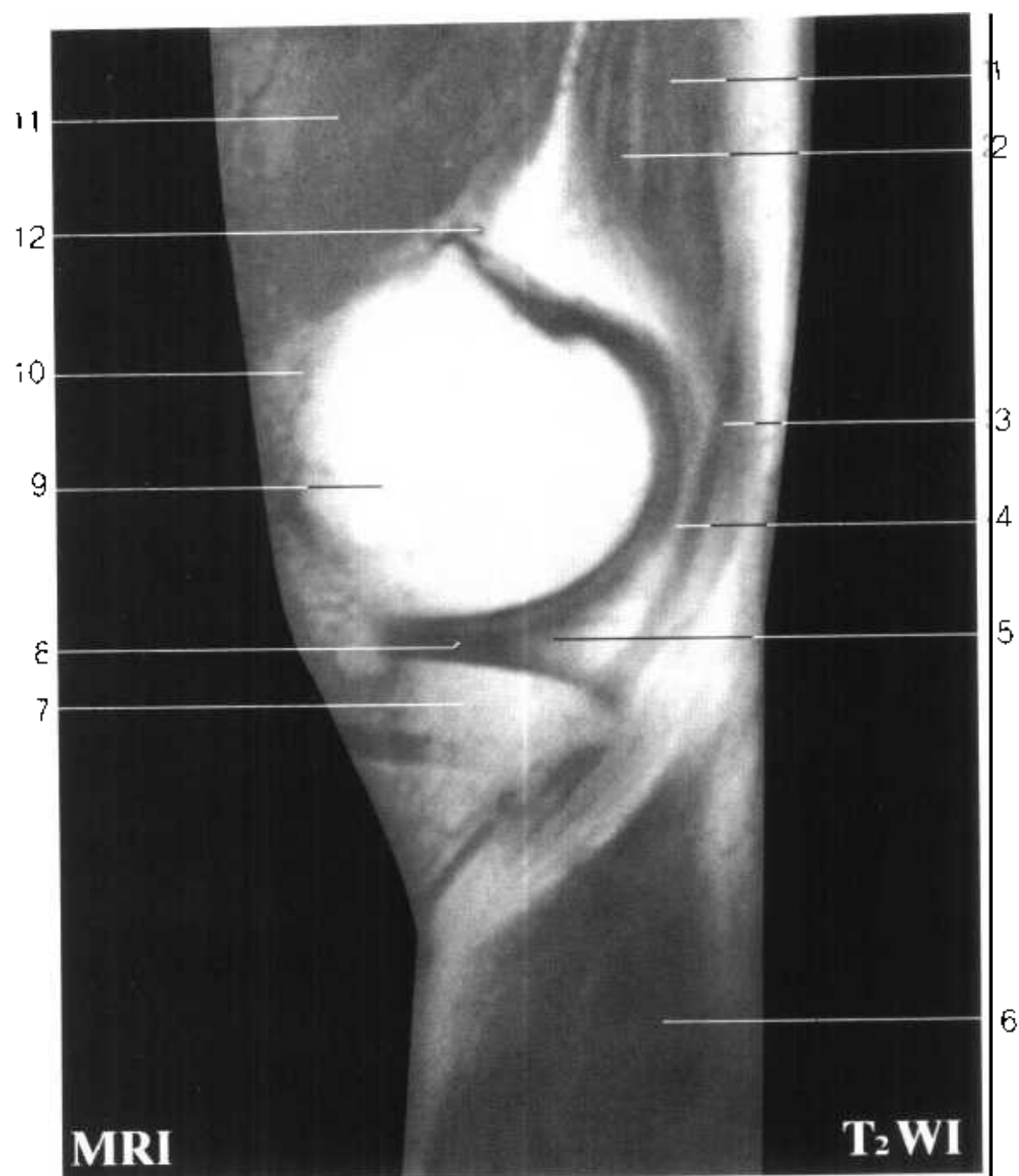

右膝关节矢状断面图 SK(R)

Fig. SK(R) 1

- 1. 股薄肌 gracilis
- 2. 缝匠肌 sartorius
- 3. 半腱肌腱 tendon of semitendinosus
- 4. 关节囊 articular capsule
- 5. 内侧半月板后部 posterior part of medial meniscus
- 6. 腓肠肌内侧头 medial head of gastrocnemius
- 7. 胫骨内侧髁 medial condyle of tibia

Fig. SK(R) 1



- 8. 内侧半月板前部 anterior part of medial meniscus
- 9. 股骨内侧髁 medial condyle of femur
- 10. 髌内侧支持带 medial patellar retinaculum
- 11. 股内侧肌 vastus medialis
- 12. 膝上内侧动脉 medial superior genicular a.

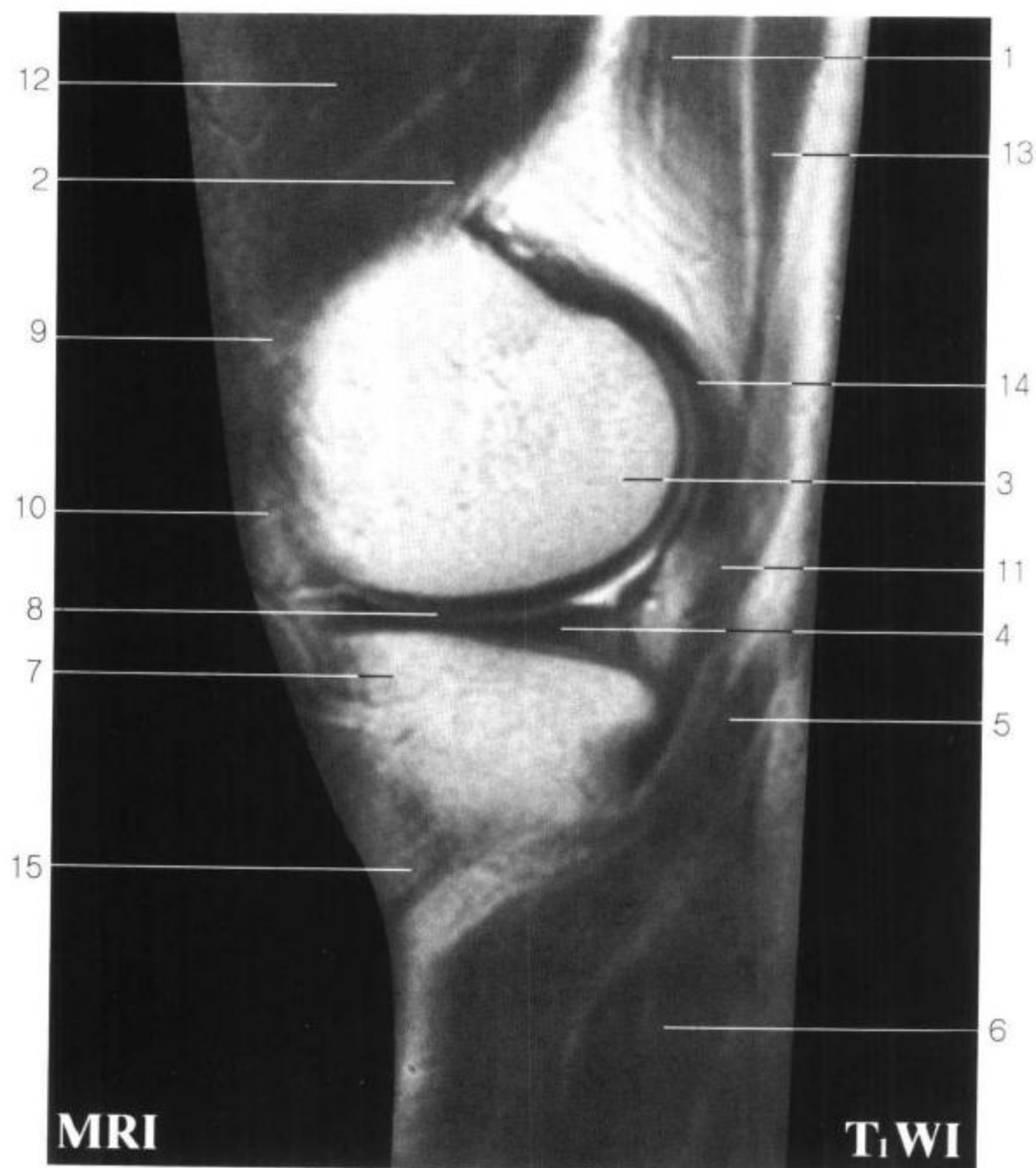

Fig. SK(R) 2

1. 半膜肌 semimembranosus
2. 膝上内侧动脉 medial superior genicular a.
3. 股骨内侧髁 medial condyle of femur
4. 内侧半月板后部 posterior part of medial meniscus
5. 腓肠肌内侧头 medial head of gastrocnemius
6. 比目鱼肌 soleus
7. 胫骨内侧髁 medial condyle of tibia
8. 关节腔 articular cavity

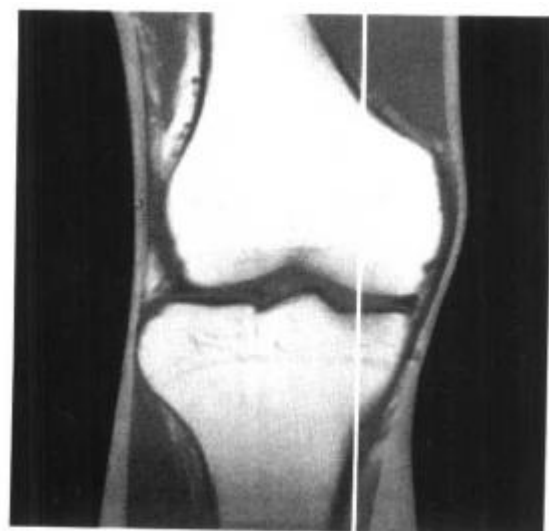
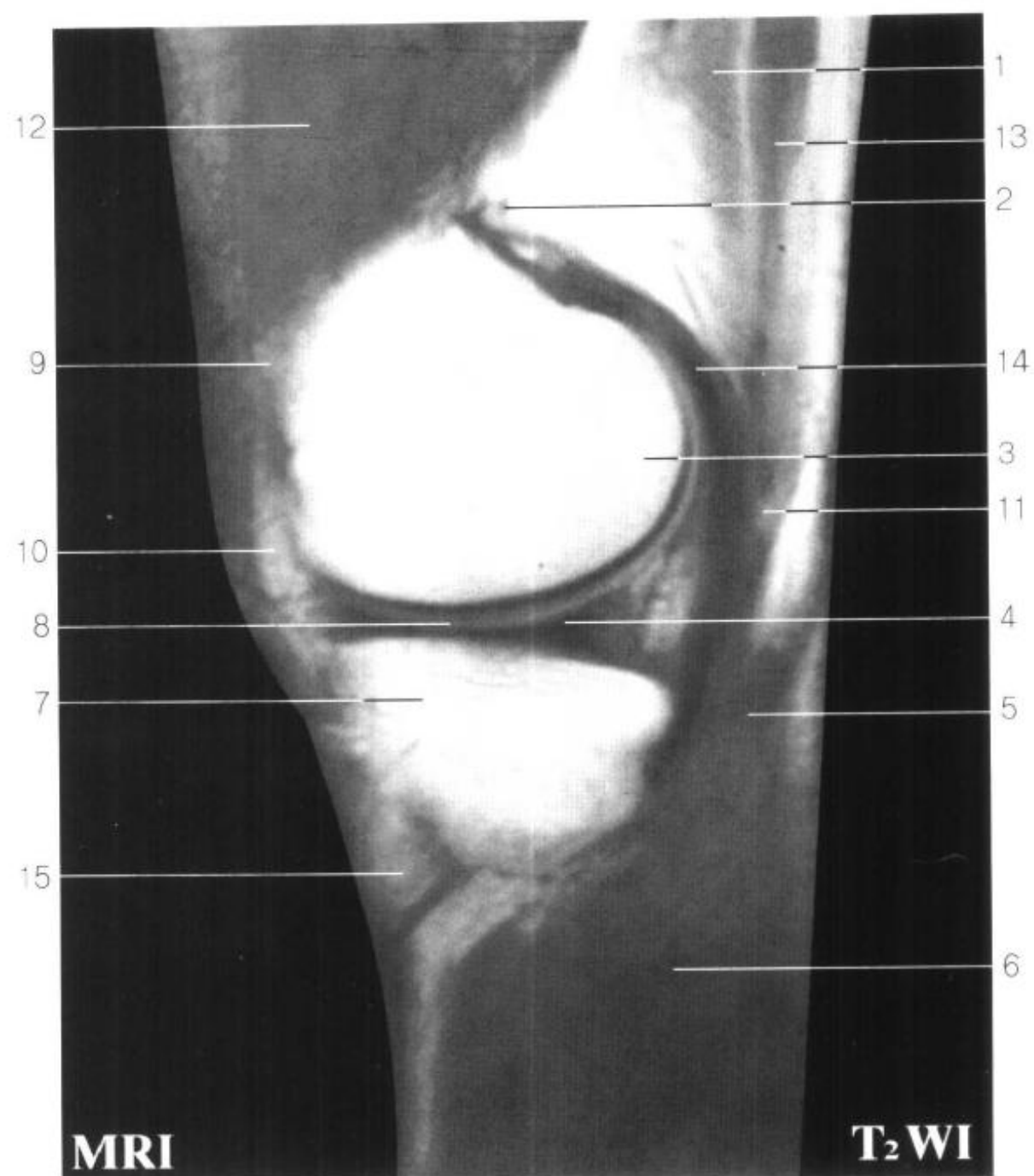

Fig. SK(R) 2



- 9. 髌韧带 patellar ligament
- 10. 髌内侧支持带 medial patellar retinaculum
- 11. 半膜肌腱 tendon of semimembranosus
- 12. 股内侧肌 vastus medialis
- 13. 半腱肌 semitendinosus
- 14. 关节囊 articular capsule
- 15. 缝匠肌腱 tendon of sartorius

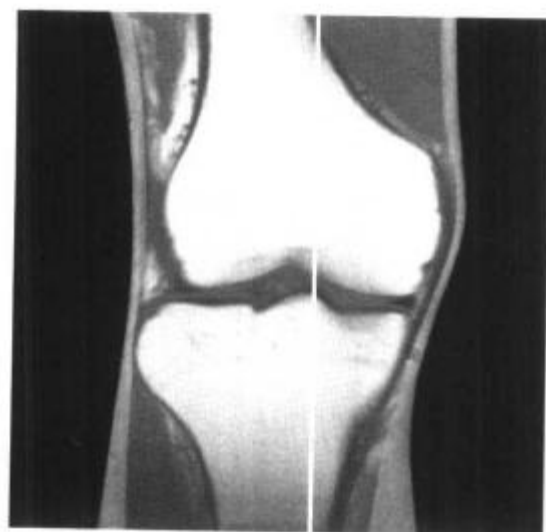
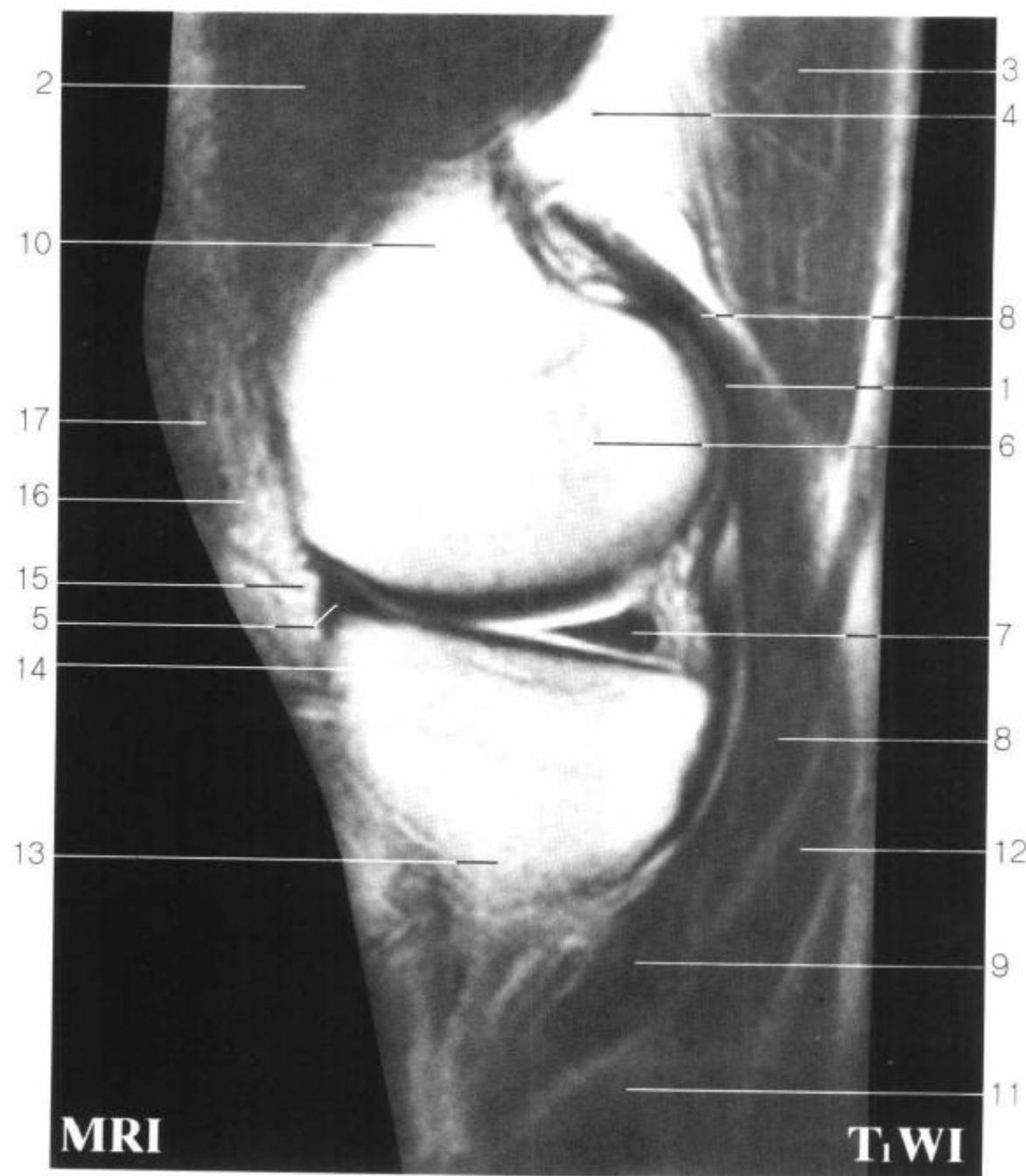
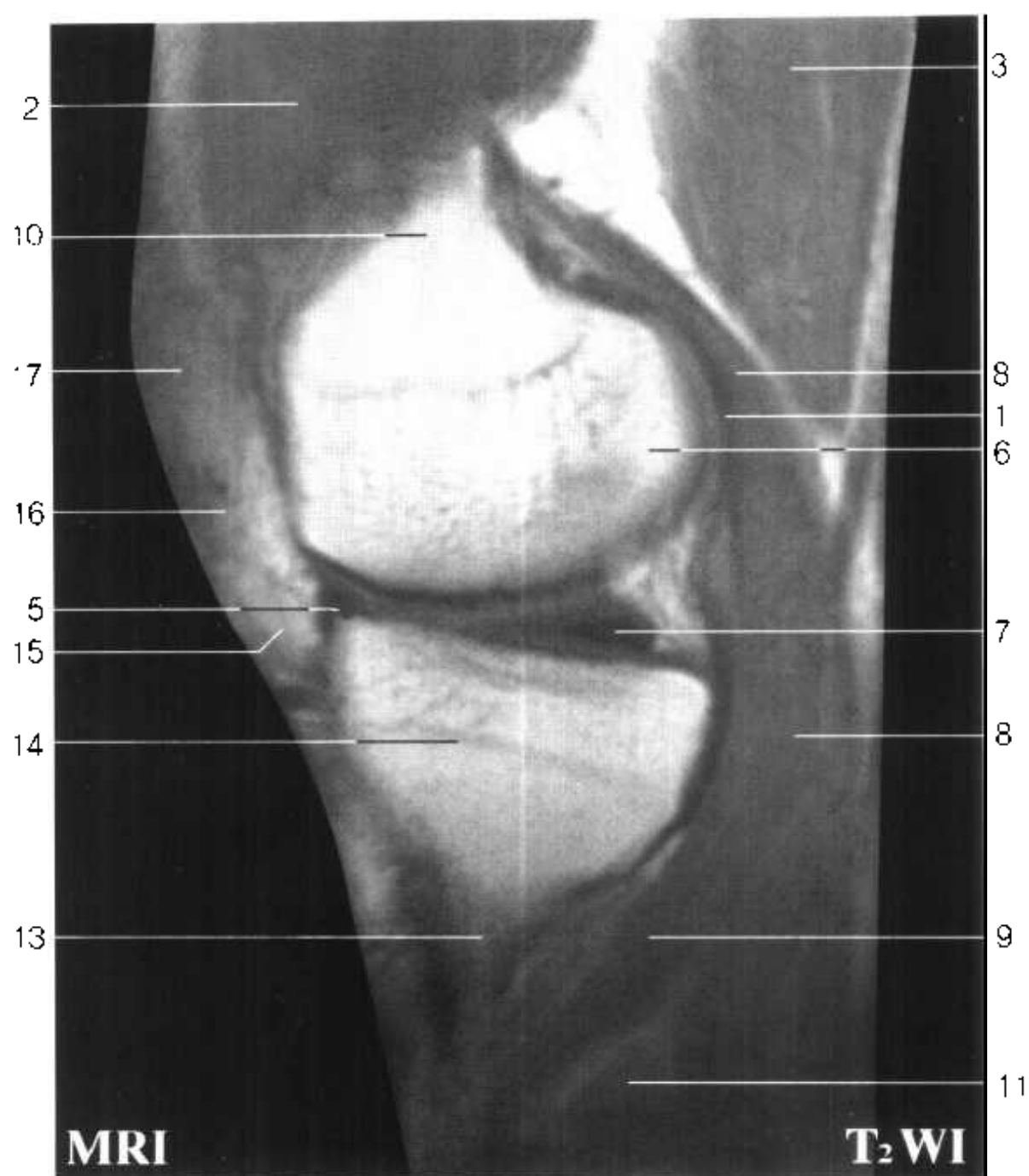Fig. SK(R) 3

1. 关节囊 articular capsule
2. 股内侧肌 vastus medialis
3. 半膜肌 semimembranosus
4. 膝上内侧动脉 medial superior genicular a.
5. 内侧半月板前部 anterior part of medial meniscus
6. 股骨内侧髁 medial condyle of femur
7. 内侧半月板后部 posterior part of medial meniscus

Fig. SK(R) 3



8. 腓肠肌内侧头 medial head of gastrocnemius
9. 腓肌 popliteus
10. 股骨 femur
11. 比目鱼肌 soleus
12. 腓肠肌 gastrocnemius
13. 胫骨 tibia
14. 胫骨内侧髁 medial condyle of tibia
15. 翼状襞 alar fold
16. 髌韧带 patellar ligament
17. 髌骨 patella

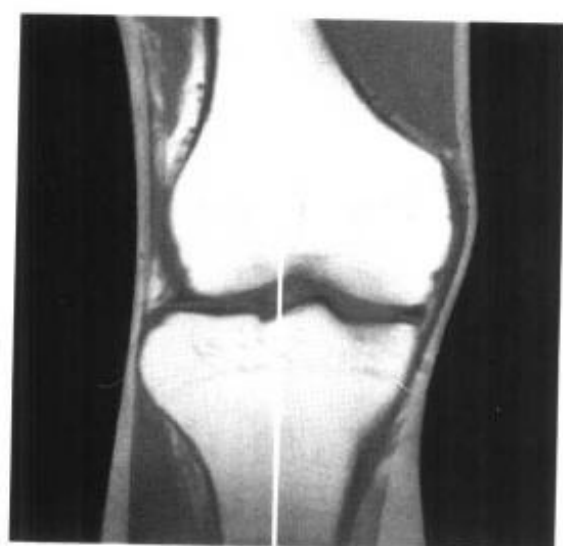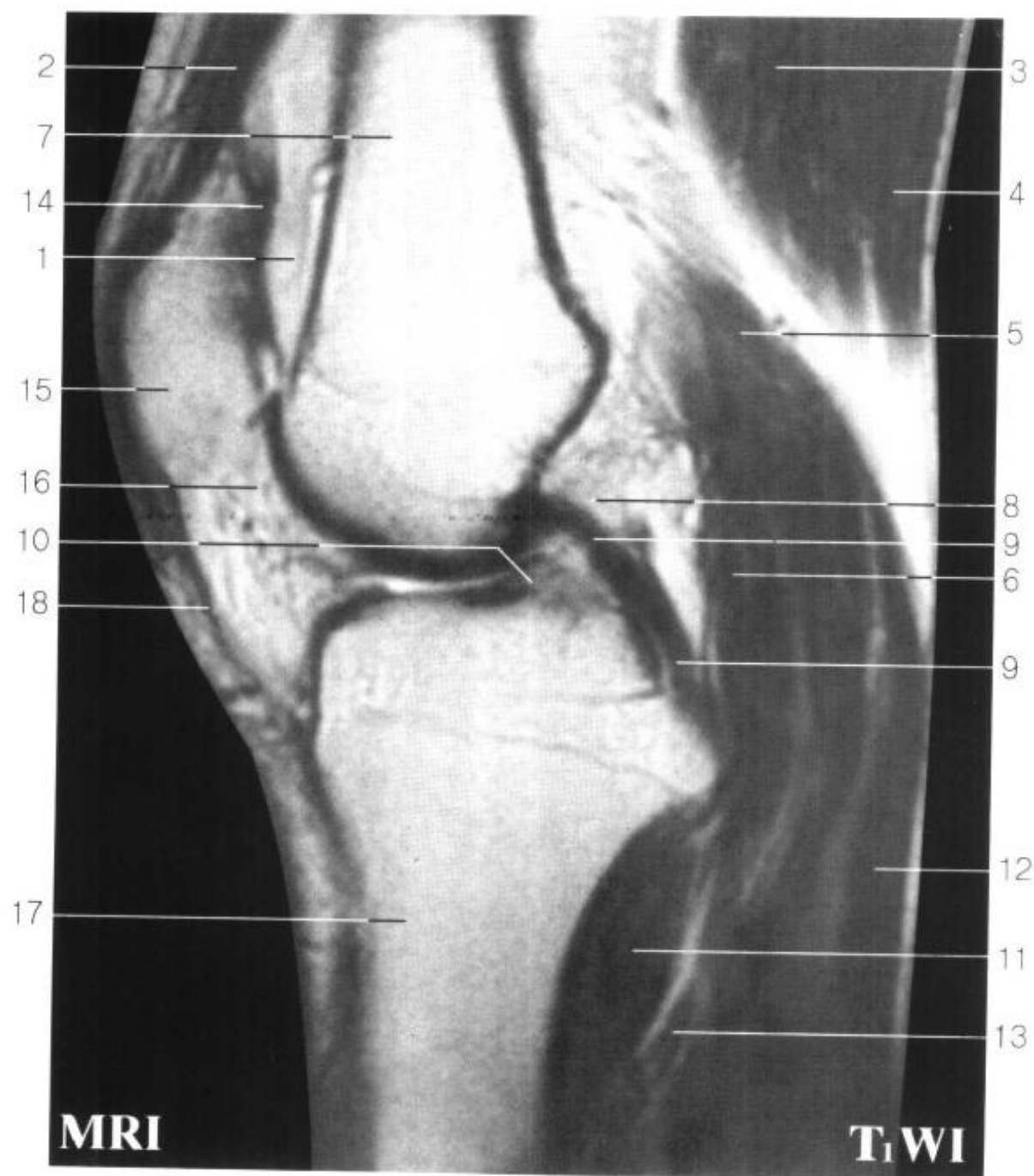
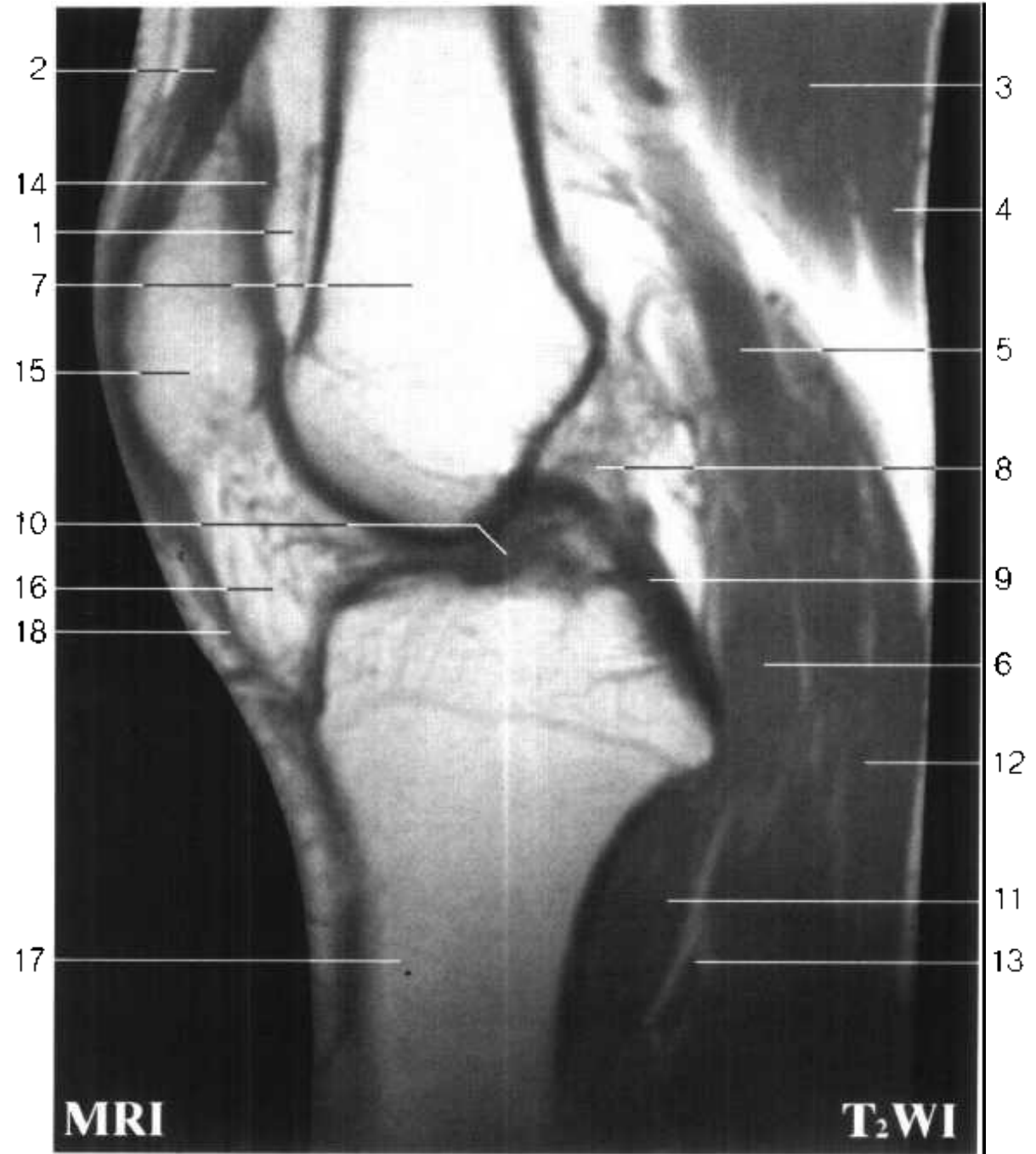


Fig. SK(R) 4

1. 股前脂体 prefemoral fat pad
2. 股直肌 rectus femoris
3. 半膜肌 semimembranosus
4. 半腱肌 semitendinosus
5. 腘静脉 popliteal v.
6. 腘动脉 popliteal a.
7. 股骨 femur
8. 板股后韧带 posterior meniscofemoral ligament
9. 后交叉韧带 posterior cruciate ligament

Fig. SK(R) 4



- 10. 前交叉韧带 anterior cruciate ligament
- 11. 腘肌 popliteus
- 12. 腓肠肌 gastrocnemius
- 13. 胫后静脉 posterior tibial v.
- 14. 髌上囊 suprapatellar bursa
- 15. 髌骨 patella
- 16. 翼状襞 alar fold
- 17. 胫骨 tibia
- 18. 髌韧带 patellar ligament

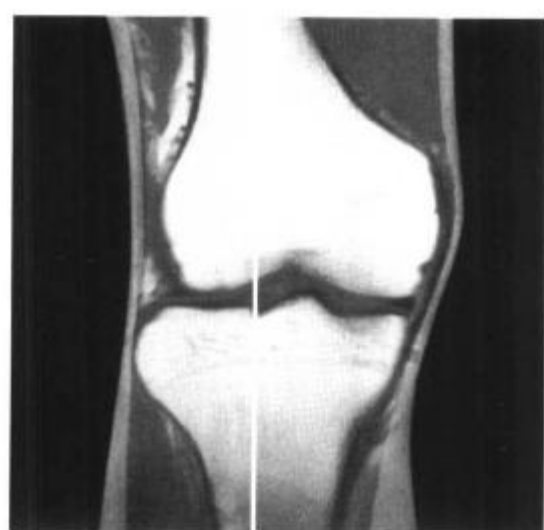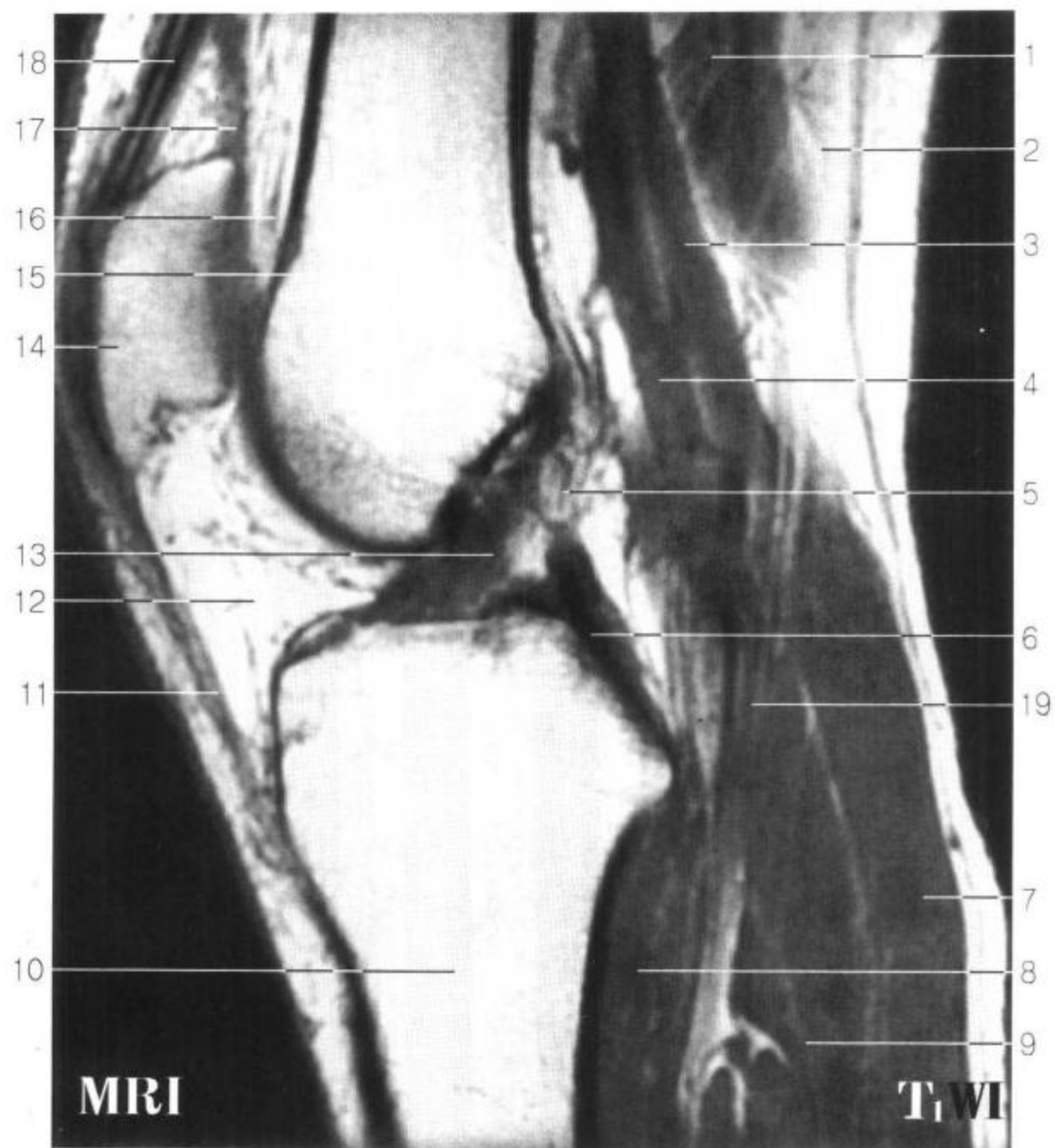

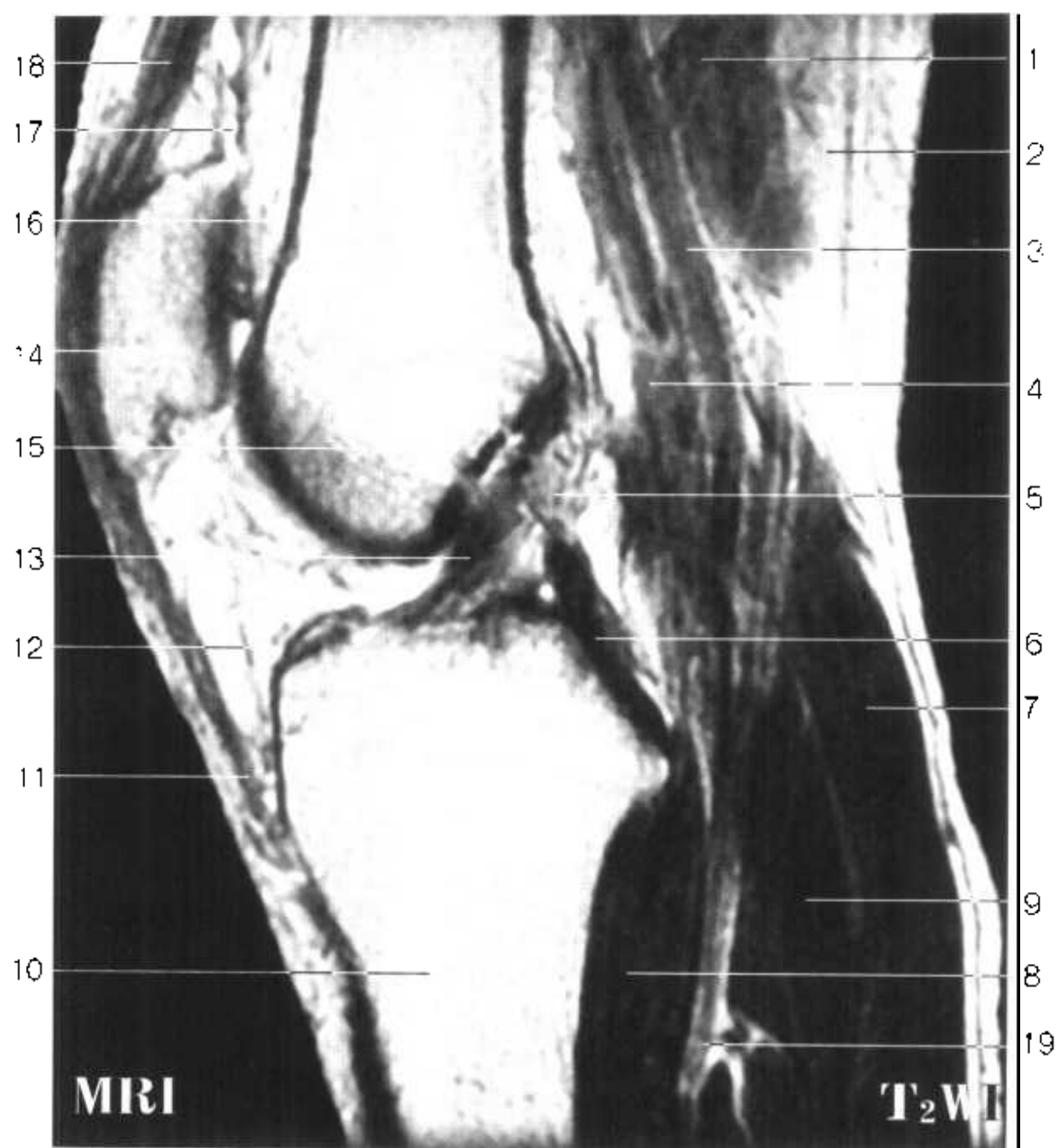
Fig.SK (R) 5

1. 半膜肌 semimembranosus
2. 半腱肌 semitendinosus
3. 腘静脉 popliteal v.
4. 腘动脉 popliteal a.
5. 板股后韧带 posterior meniscofemoral ligament
6. 后交叉韧带 posterior cruciate ligament
7. 腓肠肌 gastrocnemius
8. 腘肌 popliteus
9. 比目鱼肌 soleus

Fig. SK (R) 5



- 10. 胫骨 tibia
- 11. 髌韧带 patellar ligament
- 12. 翼状襞 alar folds
- 13. 前交叉韧带 anterior cruciate ligament
- 14. 髌骨 patella
- 15. 股骨 femur
- 16. 股前脂体 prefemoral fat pad
- 17. 髌上囊 suprapatellar bursa
- 18. 股直肌 rectus femoris
- 19. 胫后静脉 posterior tibial v.

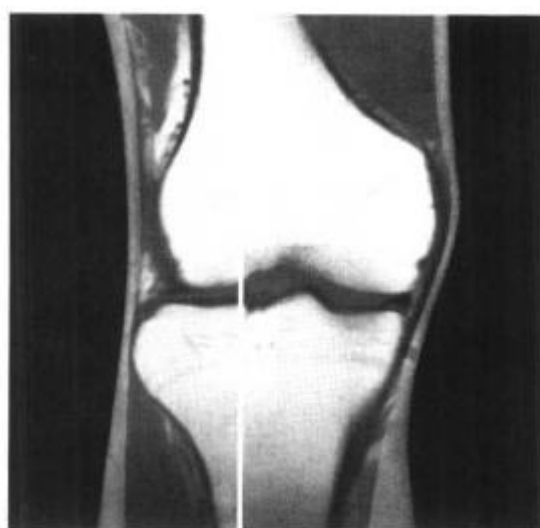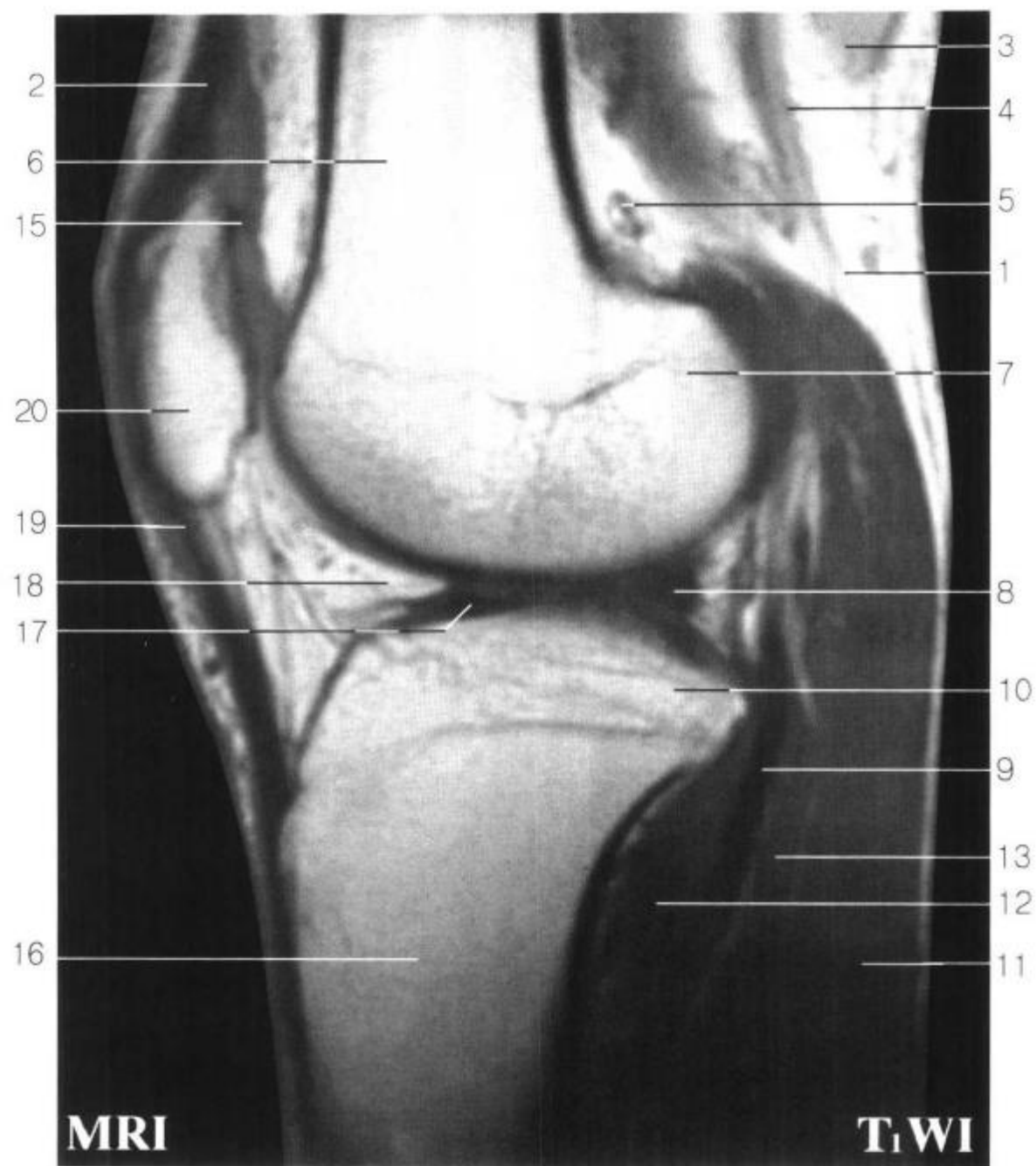
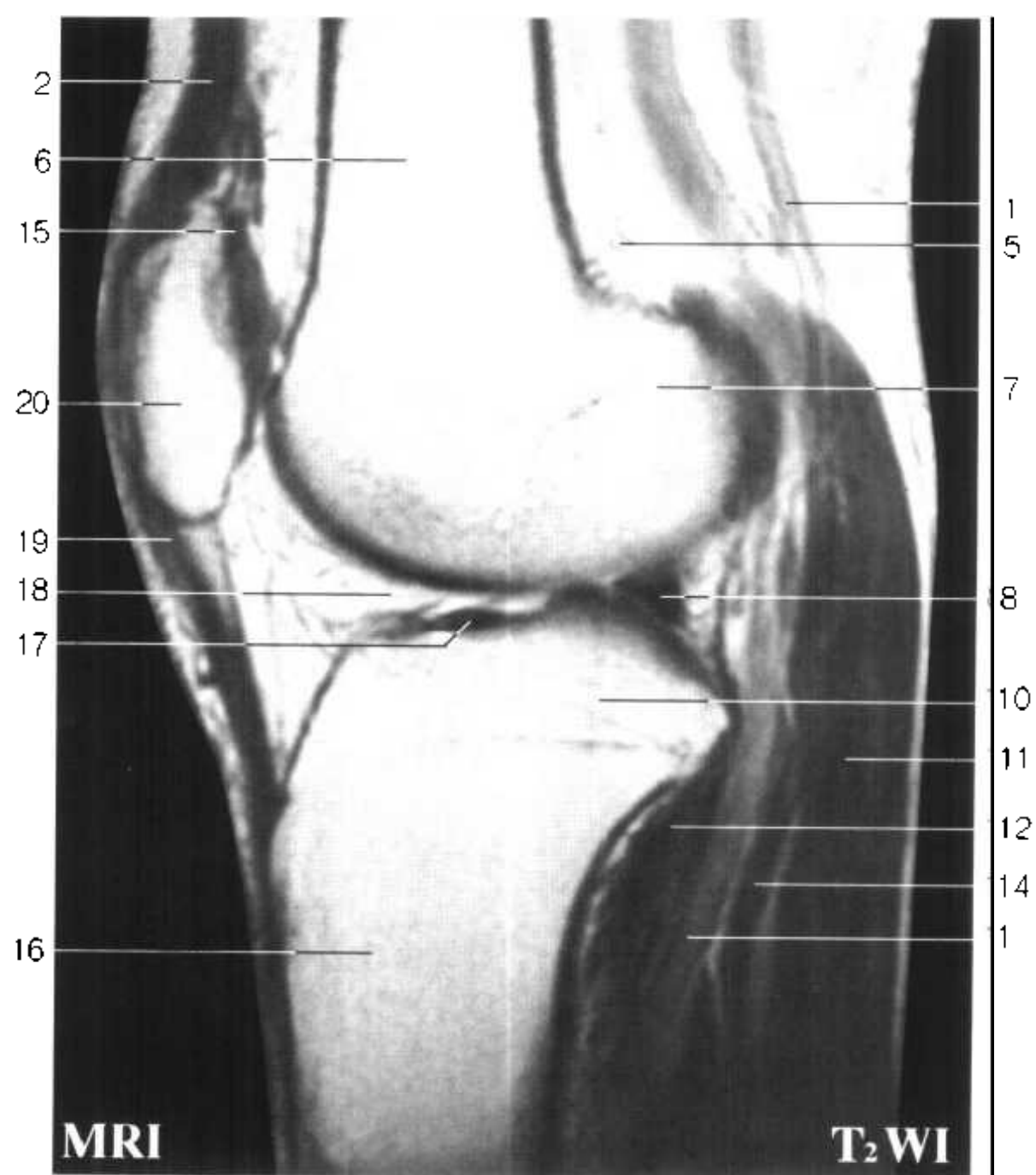


Fig. SK(R) 6

1. 胫神经 tibial n.
2. 股直肌腱 tendon of rectus femoris
3. 半膜肌 semimembranosus
4. 坐骨神经 sciatic n.
5. 膝上外侧动、静脉 lateral superior genicular a. and v.
6. 股骨 femur
7. 股骨外侧髁 lateral condyle of femur
8. 外侧半月板后部 posterior part of lateral meniscus
9. 腘动脉 popliteal a.

Fig. SK(R) 6



- 10. 胫骨外侧髁 lateral condyle of tibia
- 11. 腓肠肌 gastrocnemius
- 12. 腓肌 popliteus
- 13. 比目鱼肌 soleus
- 14. 胫后动脉 posterior tibial a.
- 15. 髌上囊 suprapatellar bursa
- 16. 胫骨 tibia
- 17. 前交叉韧带 anterior cruciate ligament
- 18. 髌下滑膜襞 infrapatellar synovial fold
- 19. 髌韧带 patellar ligament
- 20. 髌骨 patella

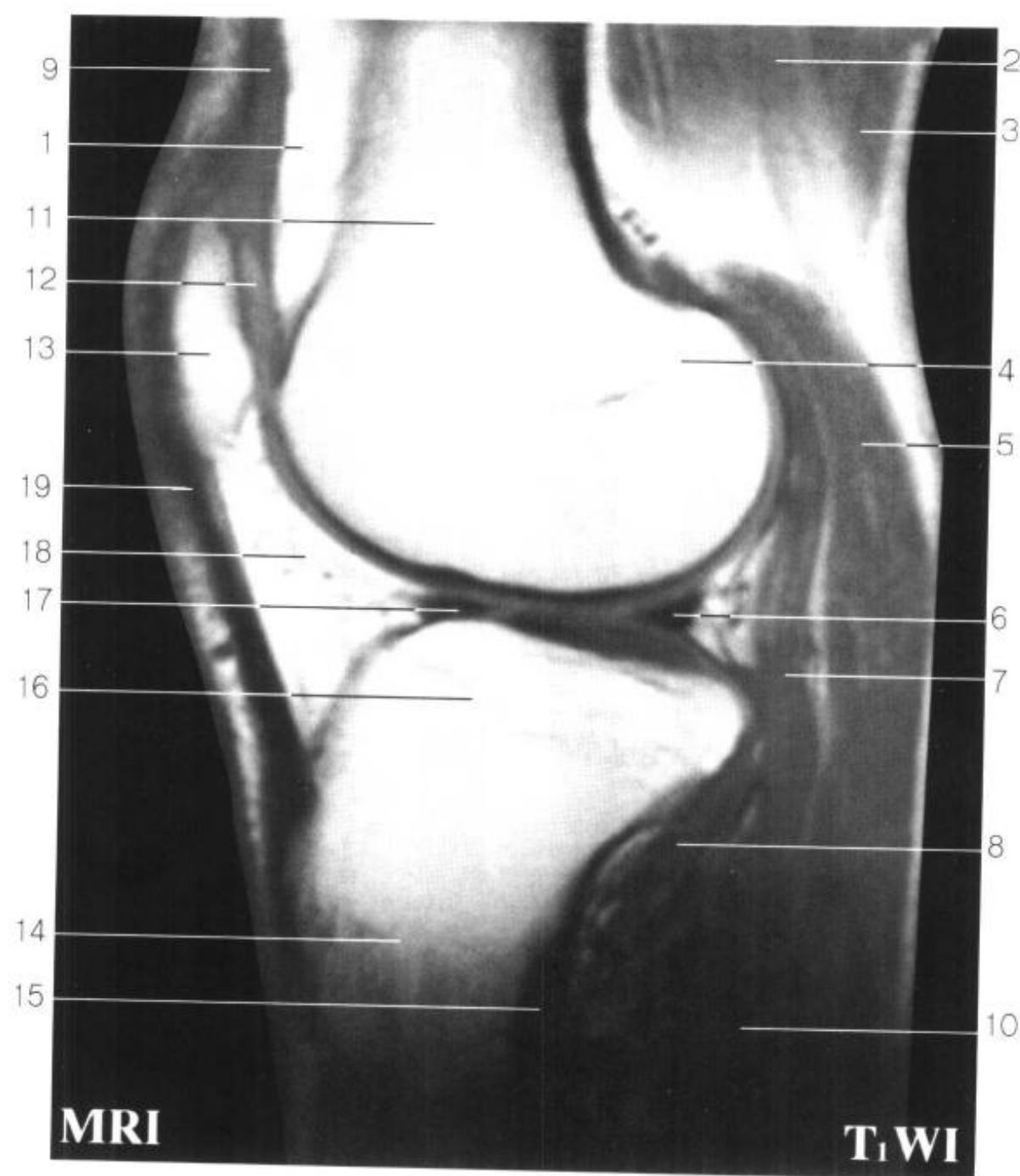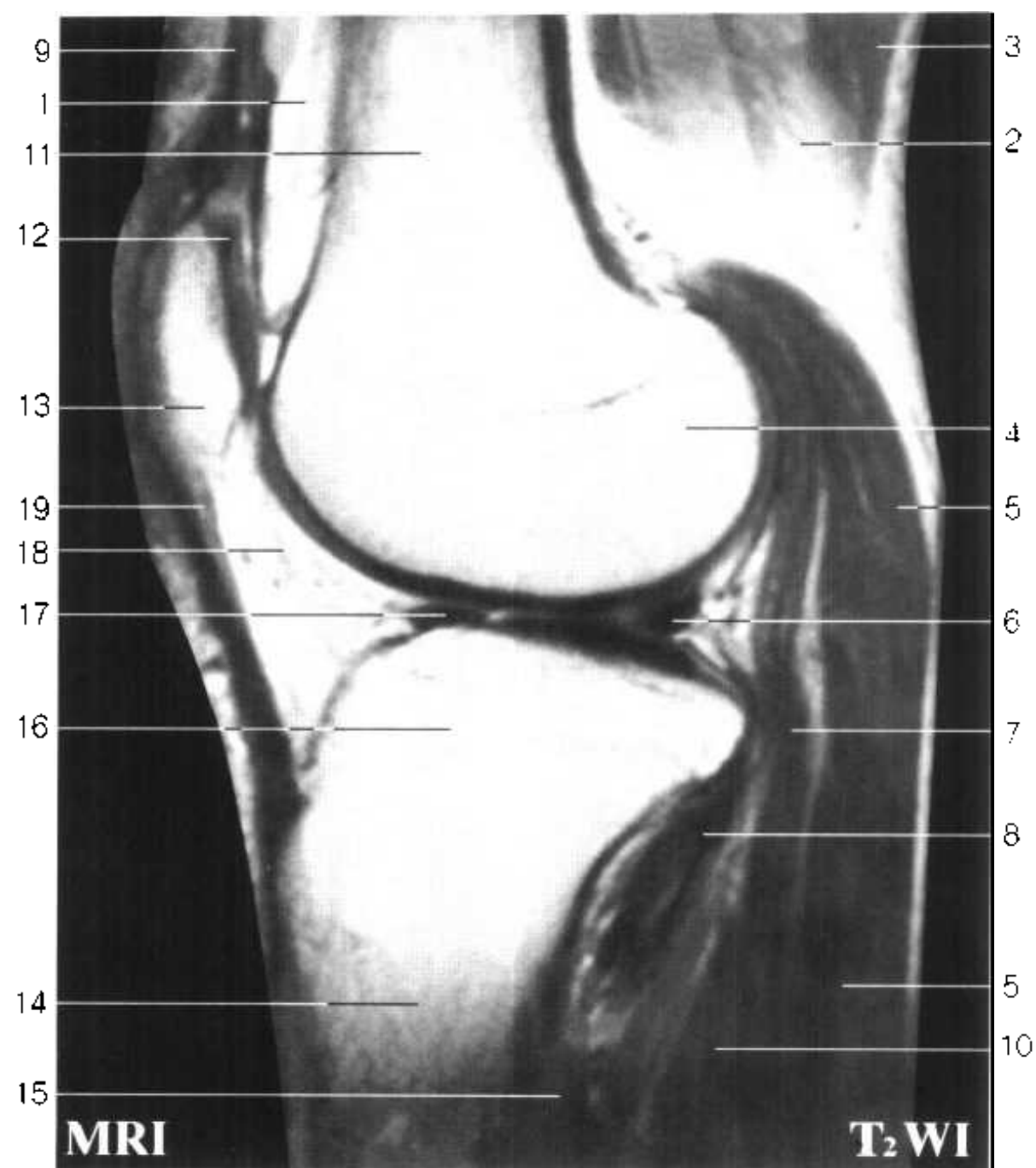


Fig. SK(R) 7

1. 股前脂体 prefemoral fat pad
2. 股二头肌短头 short head of biceps femoris
3. 股二头肌长头 long head of biceps femoris
4. 股骨外侧髁 lateral condyle of femur
5. 腓肠肌外侧头 lateral head of gastrocnemius
6. 外侧半月板后部 posterior part of lateral meniscus
7. 跖肌 plantaris
8. 腓肌 popliteus
9. 股直肌 rectus femoris

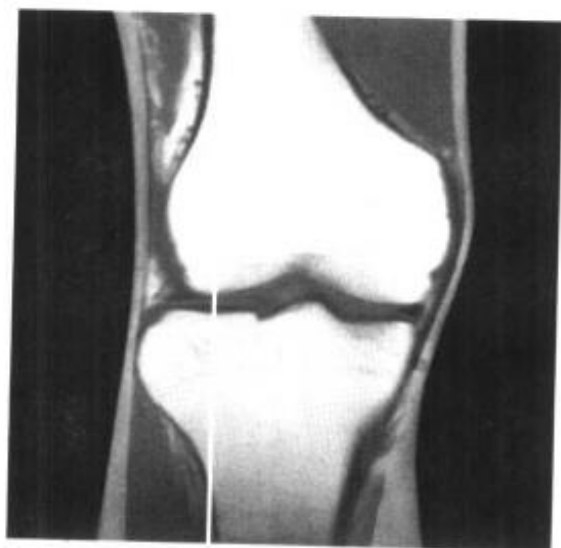

Fig. SK(R) 7



- 10. 比目鱼肌 soleus
- 11. 股骨 femur
- 12. 髌上囊 suprapatellar bursa
- 13. 髌骨 patella
- 14. 胫骨 tibia
- 15. 胫骨后肌 tibialis posterior
- 16. 胫骨外侧髁 lateral condyle of tibia
- 17. 外侧半月板前部 anterior part of lateral meniscus
- 18. 翼状襞 alar fold
- 19. 髌韧带 patellar ligament

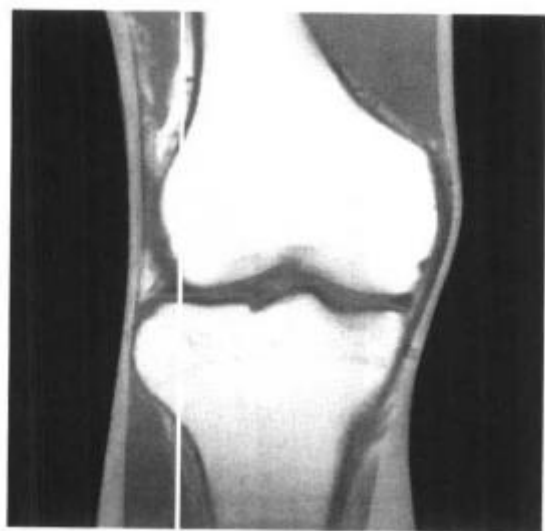
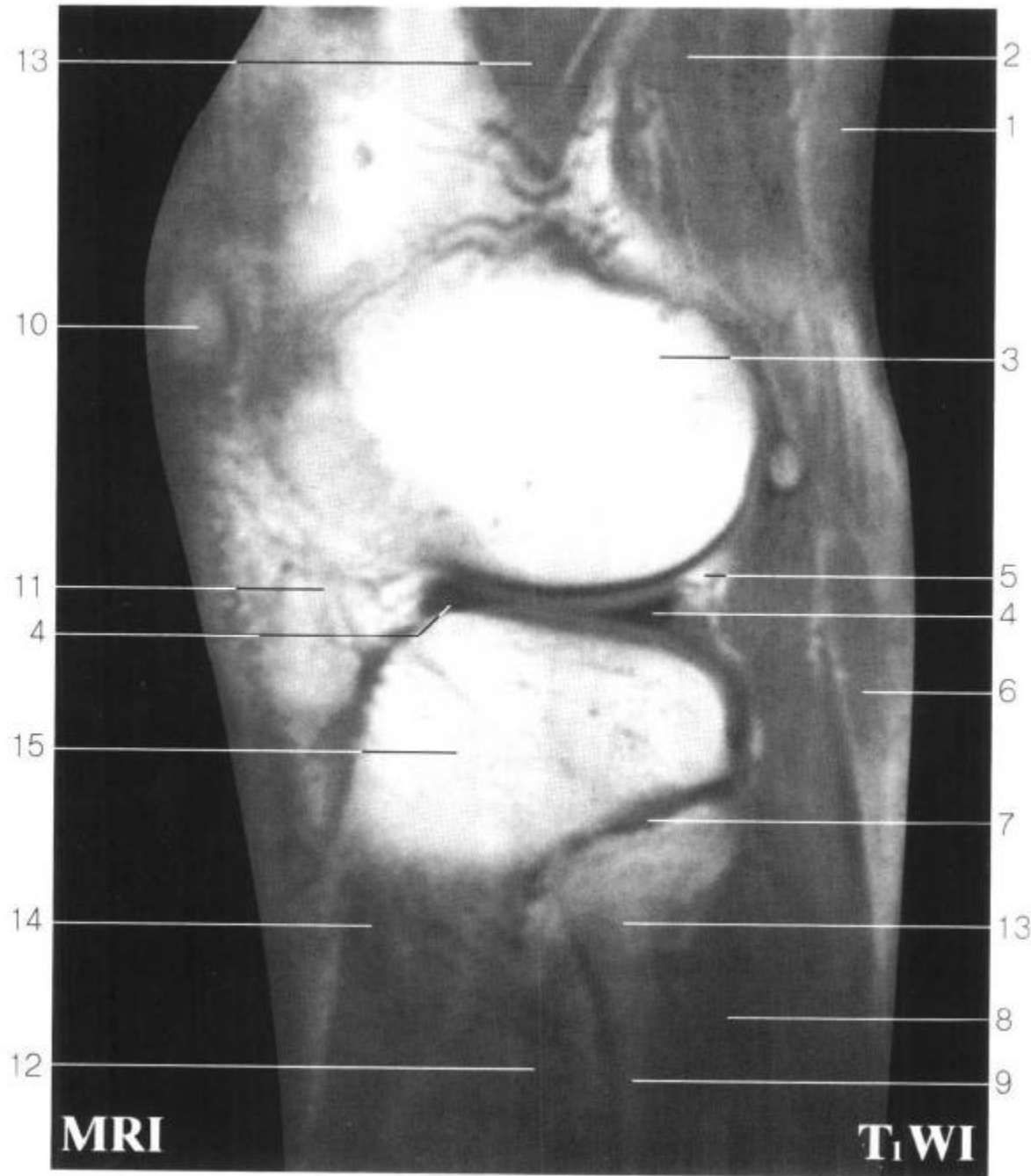
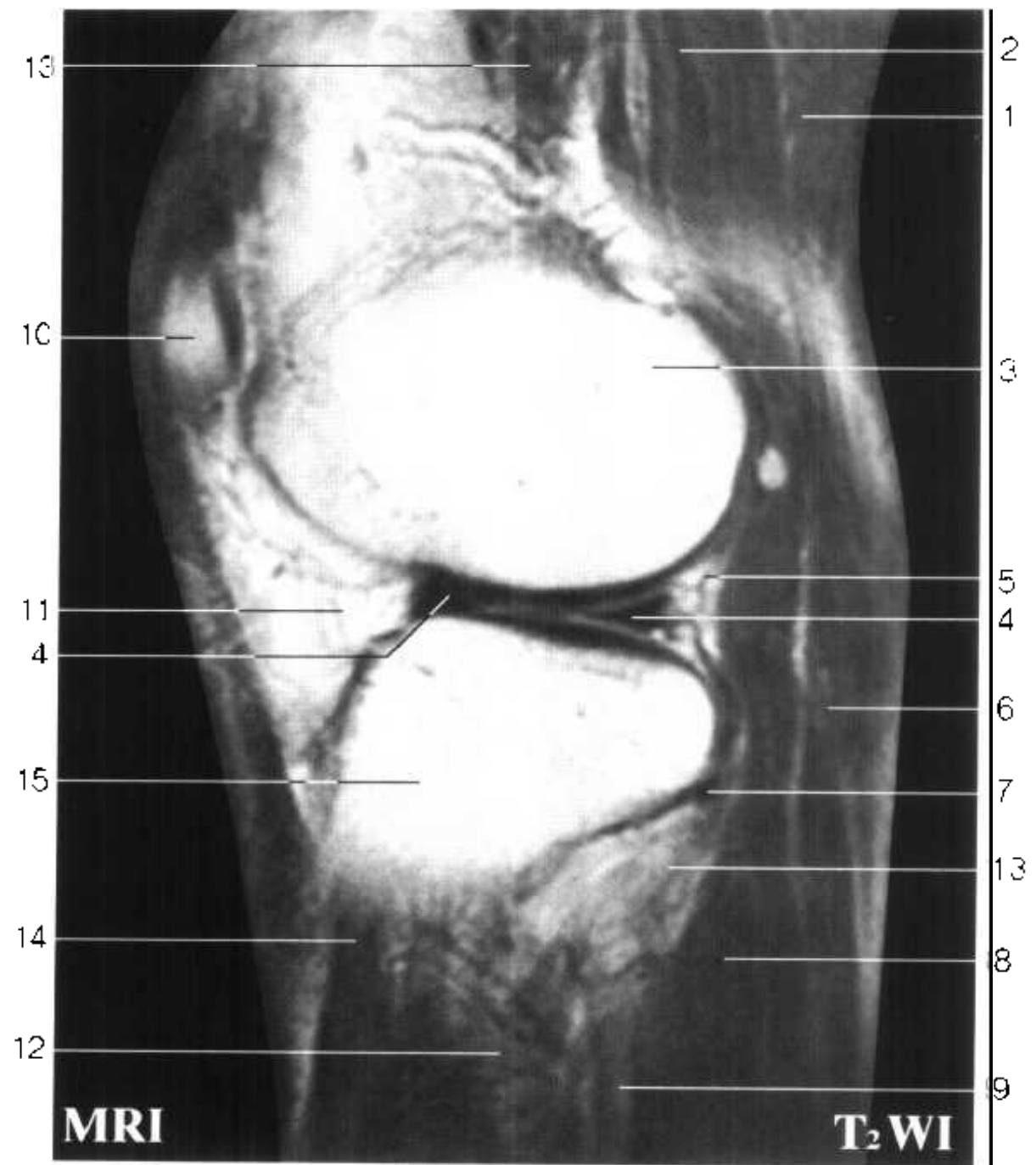Fig. SK(R) 8

- 1. 股二头肌长头 long head of biceps femoris
- 2. 股二头肌短头 short head of biceps femoris
- 3. 股骨外侧髁 lateral condyle of femur
- 4. 外侧半月板 lateral meniscus
- 5. 腓肌腱 tendon of popliteus
- 6. 腓肠肌外侧头 lateral head of gastrocnemius
- 7. 胫腓关节 tibiofibular joint

Fig. SK(R) 8



- 8. 比目鱼肌 soleus
- 9. 腓骨 fibula
- 10. 髌骨 patella
- 11. 翼状襞 alar fold
- 12. 趾长伸肌 extensor digitorum longus
- 13. 股中间肌 vastus intermedius
- 14. 胫骨前肌 tibialis anterior
- 15. 胫骨外侧髁 lateral condyle of tibia